Copyrighted Material

OBSTETRIC IMAGING

Fetal Diagnosis and Care

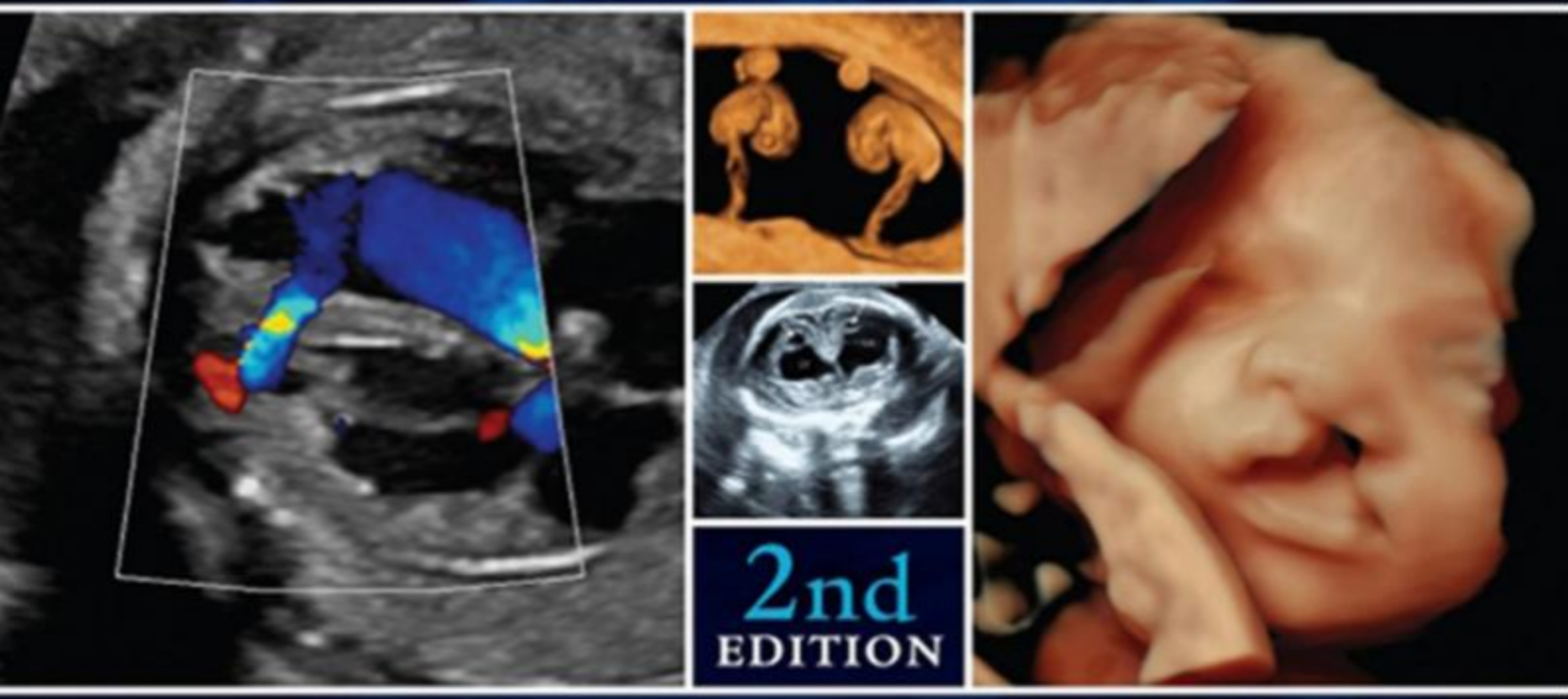

COPEL | D'ALTON | FELTOVICH | GRATACÓS
KRAKOW | ODIBO | PLATT | TUTSCHEK

ELSEVIER

ExpertRadiologySeries

Copyrighted Material

OBSTETRIC IMAGING

Fetal Diagnosis and Care

2nd
EDITION

OBSTETRIC IMAGING

Fetal Diagnosis and Care

JOSHUA A. COPEL, MD
Professor and Vice Chair
Clinical Operations
Obstetrics, Gynecology, and Reproductive Sciences
Professor of Pediatrics
Yale School of Medicine
New Haven, Connecticut

MARY E. D'ALTON, MB, BCh, BAO
Willard C. Rappleye Professor and Chair
Department of Obstetrics and Gynecology
Columbia University College of Physicians and Surgeons
Director
Obstetrics and Gynecology Services
Columbia University Medical Center
New York, New York

HELEN FELTOVICH, MD, MS
Physician
Maternal-Fetal Medicine
Department of Obstetrics and Gynecology
Intermountain Healthcare
Provo, Utah

EDUARD GRATACÓS, MD, PhD
Director
Barcelona Center for Maternal-Fetal and Neonatal Medicine
Hospital Clinic and Hospital Sant Joan de Deu
Clinical Institute of Gynecology, Obstetrics, and Neonatology
Professor of Obstetrics and Gynecology
University of Barcelona
Barcelona, Spain

DEBORAH KRAKOW, MD
Professor
Obstetrics and Gynecology, Orthopaedic Surgery, and Human Genetics
David Geffen School of Medicine at UCLA
Los Angeles, California

ANTHONY O. ODIBO, MD, MSCE
Professor
Fetal Care Center
Division of Maternal-Fetal Medicine
Department of Obstetrics and Gynecology
Morsani College of Medicine
University of South Florida
Tampa, Florida

LAWRENCE D. PLATT, MD
Professor
Department of Obstetrics and Gynecology
David Geffen School of Medicine at UCLA
Center for Fetal Medicine and Women's Ultrasound
Los Angeles, California

BORIS TUTSCHEK, MD, PhD
Consultant Obstetrician and Gynecologist
Prenatal Zurich
Zürich, Switzerland
Professor of Obstetrics and Gynecology
Medical Faculty
Heinrich Heine University
Düsseldorf, Germany

ELSEVIER

ELSEVIER

1600 John F. Kennedy Blvd.
Ste 1800
Philadelphia, PA 19103-2899

OBSTETRIC IMAGING: FETAL DIAGNOSIS AND CARE
SECOND EDITION

ISBN: 978-0-323-44548-1

Copyright © 2018 by Elsevier, Inc. All rights reserved.

No part of this publication may be reproduced or transmitted in any form or by any means, electronic or mechanical, including photocopying, recording, or any information storage and retrieval system, without permission in writing from the Publisher. Details on how to seek permission, further information about the Publisher's permissions policies, and our arrangements with organizations such as the Copyright Clearance Center and the Copyright Licensing Agency can be found at our website: www.elsevier.com/permissions.

This book and the individual contributions contained in it are protected under copyright by the Publisher (other than as may be noted herein).

Notices

Knowledge and best practice in this field are constantly changing. As new research and experience broaden our understanding, changes in research methods, professional practices, or medical treatment may become necessary.

Practitioners and researchers must always rely on their own experience and knowledge in evaluating and using any information, methods, compounds, or experiments described herein. In using such information or methods, they should be mindful of their own safety and the safety of others, including parties for whom they have a professional responsibility.

With respect to any drug or pharmaceutical products identified, readers are advised to check the most current information provided (i) on procedures featured or (ii) by the manufacturer of each product to be administered, to verify the recommended dose or formula, the method and duration of administration, and contraindications. It is the responsibility of practitioners, relying on their own experience and knowledge of their patients, to make diagnoses, to determine dosages and the best treatment for each individual patient, and to take all appropriate safety precautions.

To the fullest extent of the law, neither the Publisher nor the authors, contributors, or editors assume any liability for any injury and/or damage to persons or property as a matter of products liability, negligence, or otherwise or from any use or operation of any methods, products, instructions, or ideas contained in the material herein.

Previous edition copyrighted 2012

Library of Congress Cataloging-in-Publication Data
Names: Copel, Joshua A., editor.
Title: Obstetric imaging : fetal diagnosis and care / [edited by] Joshua A. Copel, Mary E. D'Alton, Helen Feltovich, Eduard Gratacós, Deborah Krakow, Anthony O. Odibo, Lawrence D. Platt, Boris Tutschek.
Description: Second edition. | Philadelphia, PA : Elsevier, [2018] | Includes bibliographical references and index.
Identifiers: LCCN 2017029132 | ISBN 9780323445481 (hardcover)
Subjects: | MESH: Congenital Abnormalities—diagnostic imaging | Fetus—abnormalities | Prenatal Diagnosis
Classification: LCC RG626 | NLM QS 675 | DDC 618.3/2075—dc23
LC record available at https://lccn.loc.gov/2017029132

Senior Content Strategist: Robin Carter
Senior Content Development Specialist: Anne Snyder
Publishing Services Manager: Catherine Albright Jackson
Senior Project Manager: Doug Turner
Designer: Renee Duenow

Printed in China

Last digit is the print number: 9 8 7 6 5 4 3 2 1

Working together to grow libraries in developing countries
www.elsevier.com • www.bookaid.org

CONTRIBUTORS

Sonya S. Abdel-Razeq, MD
Assistant Professor
Maternal-Fetal Medicine
Obstetrics, Gynecology, and Reproductive Sciences
Yale School of Medicine
New Haven, Connecticut
Cytomegalovirus, Rubella, Toxoplasmosis, Herpes Simplex Virus, and Varicella

Yalda Afshar, MD, PhD
Department of Obstetrics and Gynecology
Division of Maternal-Fetal Medicine
University of California, Los Angeles
Los Angeles, California
Turner Syndrome (Monosomy X)

Marta Arigita, MD
Obstetric and Gynecologic Resident
Fetal I+D Fetal Medicine Research Center
Center for Maternal-Fetal and Neonatal Medicine
Hospital Clínic and Hospital Sant Joan de Déu
Clinical Institute of Gynecology, Obstetrics, and Neonatology
Barcelona, Spain
Cystic Hygroma

Abigail A. Armstrong, MD
Department of Obstetrics and Gynecology
University of California, Los Angeles
Los Angeles, California
Mosaic Trisomies 8, 9, and 16

Mert Ozan Bahtiyar, MD
Director, Fetal Care Center
Associate Professor
Obstetrics, Gynecology, and Reproductive Sciences and Nursing
Yale School of Medicine
New Haven, Connecticut
Atlas of Selected Normal Images
Parvovirus B19 Infection During Pregnancy

Ahmet Baschat, MD
Professor of Gynecology and Obstetrics
The Johns Hopkins Center for Fetal Therapy
Baltimore, Maryland
Doppler Ultrasound Evaluation of the Fetus and Placenta

Marc U. Baumann, MD, PhD
Consultant Obstetrician and Gynecologist
University Hospital of Bern
Bern, Switzerland
Hepatic Anomalies

Mar Bennasar, MD
Maternal-Fetal Senior Specialist
Fetal I+D Fetal Medicine Research Center
Barcelona Center for Maternal-Fetal and Neonatal Medicine
Hospital Clínic and Hospital Sant Joan de Déu
Clinical Institute of Gynecology, Obstetrics, and Neonatology
Augus Pi i Sunyer Biomedical Research Institute
University of Barcelona
Center for Biomedical Research on Rare Diseases
Barcelona, Spain
Cystic Hygroma
Aortic Stenosis and Aortic Atresia
Hypoplastic Left Heart Syndrome and Mitral Atresia
Aortic Coarctation
Interruption of the Aortic Arch
Aortic Arch Anomalies
Tetralogy of Fallot
Transposition of Great Arteries
Double-Outlet Right Ventricle
Common Arterial Trunk

Richard L. Berkowitz, MD
Professor
Maternal-Fetal Medicine
Columbia University Medical Center
New York, New York
Cordocentesis and Fetal Transfusion
Multifetal Pregnancy Reduction

Amar Bhide, MD
Consultant in Fetal Medicine
Fetal Medicine Unit
St. George's Hospital
London, United Kingdom
Vascular Cerebral Anomalies

Harm-Gerd K. Blaas, MD, PhD
Department of Laboratory Medicine
Children's and Women's Health
Norwegian University of Science and Technology
National Center for Fetal Medicine
St Olavs Hospital
Trondheim, Norway
Holoprosencephaly

April T. Bleich, MD
Maternal-Fetal Medicine
Obstetrix Medical Group
Fort Worth, Texas
Abnormal Kidney Location
Multicystic Dysplastic Kidney
Autosomal Recessive (Infantile) Polycystic Kidney Disease

Thorsten Braun, MD, PhD
Consultant Obstetrician and Gynecologist
Charité—University Medicine Berlin
Department of Obstetrics
Campus Virchow Klinikum
Berlin, Germany
Intestinal Obstruction

Fallon R. Brewer, MS, CGC
Genetic Counselor
Department of Genetics
University of Alabama at Birmingham
Birmingham, Alabama
Goldenhar Syndrome
Pierre Robin Sequence
Prune-Belly Syndrome
Sirenomelia
VATER Association

Angela Burgess, MD, PhD
Richmond University Medical Center
Mount Sinai Consortium
Department of Obstetrics and Gynecology
Staten Island, New York
Lymphedema and Lymphatic Malformations

Alison G. Cahill, MD, MSCI
Associate Professor
Department of Obstetrics and Gynecology
Washington University School of Medicine
St. Louis, Missouri
Miller-Dieker Syndrome (17p13.3 Deletion Syndrome)

Katherine H. Campbell, MD, MPH
Assistant Professor
Obstetrics, Gynecology, and Reproductive Sciences
Yale School of Medicine
New Haven, Connecticut
Gastroschisis
Omphalocele

Frederic Chantraine, MD, PhD
Consultant Obstetrician and Gynecologist
Department of Obstetrics and Gynecology
CHR Citadelle
University of Liege
Liege, Belgium
Abdominal Cysts

Tamara T. Chao, MD
Maternal-Fetal Medicine
MultiCare Health System
Tacoma, Washington
Abnormal Kidney Size
Duplicated Collecting System
Posterior Urethral Valves

Debnath Chatterjee, MD
Associate Professor of Anesthesiology
Children's Hospital Colorado/University of Colorado School of Medicine
Director of Fetal Anesthesia
Colorado Fetal Care Center
Aurora, Colorado
Open Fetal Surgery

Jaclyn M. Coletta, MD
Assistant Professor
Maternal-Fetal Medicine
Columbia University Medical Center
New York, New York
Chorioangioma
Choriocarcinoma
Gestational Trophoblastic Disease
Vasa Previa

Elena Contro, MD, PhD
Consultant in Obstetrics and Gynecology
S. Orsola-Malpighi University Hospital
Bologna, Italy
Intracranial Hemorrhage, Cysts, Tumors, and Destructive Lesions
Neural Tube Defects

Joshua A. Copel, MD
Professor and Vice Chair
Clinical Operations
Obstetrics, Gynecology, and Reproductive Sciences
Professor of Pediatrics
Yale School of Medicine
New Haven, Connecticut
Thymus
Fetal Adrenal Abnormalities
Gastroschisis
Omphalocele
Cytomegalovirus, Rubella, Toxoplasmosis, Herpes Simplex Virus, and Varicella

Fatima Crispi, MD, PhD
Department of Maternal-Fetal Medicine
BCNatal, Hospital Clínic and Hospital Sant Joan de Déu
University of Barcelona
Barcelona, Spain
Choanal Atresia
Double-Inlet Single Ventricle
Atrial Isomerism
Anomalies of Pulmonary Venous Return
Anomalies of Systemic Venous Return
Cardiomyopathy
Cardiac Tumors
Arrhythmias

Timothy M. Crombleholme, MD
Professor of Pediatric Surgery
Children's Hospital Colorado/University of Colorado School of Medicine
Aurora, Colorado
Open Fetal Surgery

Sarah N. Cross, MD
Assistant Professor
Division of Maternal-Fetal Medicine
Department of Obstetrics, Gynecology, and Women's Health
University of Minnesota
Minneapolis, Minnesota
Cytomegalovirus, Rubella, Toxoplasmosis, Herpes Simplex Virus, and Varicella

Mónica Cruz-Lemini, MD, PhD
Clinical Researcher
Fetal Medicine and Surgery Research Unit
Neurodevelopmental Research Unit "Dr. Augusto Fernández Guardiola"
Neurobiology Institute
National Autonomous University of Mexico—Campus Juriquilla
Querétaro, Mexico
Congenital Cystic Adenomatoid Malformation of the Lung
Hydrothorax
Other Thoracic Tumors and Masses

Rogelio Cruz-Martínez, MD, PhD
Head and Professor
Fetal Medicine and Surgery Research Unit
Women and Children's Specialty Hospital of Querétaro
Neurodevelopmental Research Unit
Neurobiology Institute
National Autonomous University of Mexico—Campus Juriquilla
Querétaro, Mexico
Congenital Cystic Adenomatoid Malformation of the Lung
Bronchopulmonary Sequestration
Hydrothorax
Scimitar Syndrome
Congenital High Airways Obstruction Syndrome (CHAOS) and Bronchial Atresia

Andrea Dall'Asta, MD
Obstetrics and Gynecology Unit
University of Parma
Parma, Italy
Neural Tube Defects

Mary E. D'Alton, MB, BCh, BAO
Willard C. Rappleye Professor and Chair
Department of Obstetrics and Gynecology
Columbia University College of Physicians and Surgeons
Director
Obstetrics and Gynecology Services
Columbia University Medical Center
New York, New York
Nuchal Translucency
Placental Abruption
Placenta Accreta
Chorioangioma
Choriocarcinoma
Placenta Circumvallata
Gestational Trophoblastic Disease
Placenta Previa
Vasa Previa
Chorionicity of Multiple Gestations
Monochorionic Monoamniotic Twin Gestations
Monochorionic Diamniotic Twin Gestations
Dichorionic Diamniotic Twin Gestations

Francesco D'Antonio, MD, PhD
Department of Clinical Medicine
Faculty of Health Sciences
UiT/The Arctic University of Norway
Department of Obstetrics and Gynaecology
University Hospital of Northern Norway
Tromsø, Norway
Ventriculomegaly

Jodi S. Dashe, MD
Professor of Obstetrics and Gynecology
University of Texas Southwestern Medical Center
Director of Prenatal Diagnosis
Parkland Health and Hospital Systems
Dallas, Texas
Abnormal Kidney Location
Abnormal Kidney Size
Bilateral Renal Agenesis
Unilateral Renal Agenesis
Renal Pelvis Dilatation
Duplicated Collecting System
Posterior Urethral Valves
Multicystic Dysplastic Kidney
Autosomal Recessive (Infantile) Polycystic Kidney Disease

Luc De Catte, MD, PhD
Consultant
Fetal Medicine
Department of Obstetrics and Gynecology
University Hospitals Leuven
Leuven, Belgium
Congenital Diaphragmatic Hernia

Francesca De Musso, MD
Hopital Delafontaine
Saint-Denis, France
Intracranial Hemorrhage, Cysts, Tumors, and Destructive Lesions
Neural Tube Defects

Valentina De Robertis, MD
Fetal Medicine Unit
Di Venere and Sarcone Hospitals
Bari, Italy
Corpus Callosum and Septum Pellucidum Anomalies

Jan Deprest, MD, PhD
Department of Obstetrics and Gynecology
University Hospitals Leuven
Leuven, Belgium
Congenital Diaphragmatic Hernia

Roland Devlieger, MD, PhD
Professor
Department of Obstetrics and Gynecology
University Hospitals Leuven
Leuven, Belgium
Congenital Diaphragmatic Hernia

Anke Diemert, MD
Department of Obstetrics and Fetal Medicine
University Medical Center—Hamburg
Hamburg, Germany
Fetal Spleen

Lindsey Drehfal, MS
Research Assistant
Quantitative Ultrasound Laboratory
Department of Medical Physics
University of Wisconsin
Madison, Wisconsin
Elasticity Imaging in Obstetrics

Elisenda Eixarch, MD, PhD
Maternal-Fetal Consultant
Department of Maternal-Fetal and Neonatal Medicine
BCNatal, Hospital Clínic and Hospital Sant Joan de Déu
University of Barcelona
Barcelona, Spain
Orbital Defects: Hypertelorism and Hypotelorism
Facial Dysmorphism
Neck Teratoma

Alexander Engels, MD
Department of Development and Regeneration
University Hospitals Leuven
Leuven, Belgium
Congenital Diaphragmatic Hernia

Jakob Evers, MD
Chief Physician
Luzerner Kantonsspital
Obstetrics and Gynecology
Departement Sursee
Sursee, Switzerland
Megacystis-Microcolon-Intestinal Hypoperistalsis Syndrome

Tiziana Fanelli, MD
Fetal Medicine Unit
Di Venere and Sarcone Hospitals
Bari, Italy
Corpus Callosum and Septum Pellucidum Anomalies

Helen Feltovich, MD, MS
Physician
Maternal-Fetal Medicine
Department of Obstetrics and Gynecology
Intermountain Healthcare
Provo, Utah
Cervical Length and Spontaneous Preterm Birth
Doppler Ultrasound Evaluation of the Fetus and Placenta

Susana Fernández, MD
Fetal Thyroid Masses and Fetal Goiter

Francesc Figueras, MD
Associate Professor
Obstetrics and Gynecology Department
University of Barcelona
Head of High-Risk Obstetrics
Department of Maternal-Fetal Medicine
BCNatal, Hospital Clínic and Hospital Sant Joan de Déu
University of Barcelona
Barcelona, Spain
Facial Dysmorphism

Perry Friedman, MD
MFM Fellow
Beaumont Hospital
Royal Oak, Michigan
Polyhydramnios
Oligohydramnios

Tiziana Frusca, MD
Obstetrics and Gynecology Unit
University of Parma
Parma, Italy
Neural Tube Defects

Karin M. Fuchs, MD
Assistant Professor
Department of Obstetrics and Gynecology
Division of Maternal-Fetal Medicine
Columbia University Medical Center
New York, New York
Amniotic Band Sequence
Cord Cyst
Cord Varix
Limb–Body Wall Complex
Chorionicity of Multiple Gestations
Monochorionic Monoamniotic Twin Gestations
Monochorionic Diamniotic Twin Gestations
Dichorionic Diamniotic Twin Gestations

Julie A. Gainer, DO
Utah Valley Regional Medical Center
Maternal Fetal Medicine
Intermountain Healthcare
Provo, Utah
Triploidy

France Galerneau, MD, FRCS(C)
Associate Professor
Obstetrics, Gynecology, and Reproductive Sciences
Yale University School of Medicine
New Haven, Connecticut
Fetal Hepatic Calcification
Beckwith-Wiedemann Syndrome

Stephanie L. Gaw, MD, PhD
Assistant Professor
Division of Maternal-Fetal Medicine
Department of Obstetrics, Gynecology, and Reproductive Sciences
University of California, San Francisco
San Francisco, California
Trisomy 13
Trisomy 18
Trisomy 21
Mosaic Trisomies 8, 9, and 16

Kobina Ghartey, MD
Twin Reversed Arterial Perfusion Sequence

Tullio Ghi, MD, PhD
Department of Obstetrics
University of Parma
Parma, Italy
Intracranial Hemorrhage, Cysts, Tumors, and Destructive Lesions
Neural Tube Defects

Katherine R. Goetzinger, MD, MSCI
Assistant Professor
Department of Obstetrics, Gynecology, and Reproductive Sciences
University of Maryland School of Medicine
Baltimore, Maryland
Fryns Syndrome
Pentalogy of Cantrell
Cystic Fibrosis
Tuberous Sclerosis
Miller-Dieker Syndrome (17p13.3 Deletion Syndrome)

Olga Gómez, MD, PhD
Maternal-Fetal Consultant
Department of Maternal-Fetal Medicine
Barcelona Center for Maternal-Fetal and Neonatal Medicine
Hospital Clínic and Hospital Sant Joan de Déu
University of Barcelona
Center for Biomedical Research on Rare Diseases
Barcelona, Spain
Cleft Lip and Palate
Micrognathia and Retrognathia
Facial Dysmorphism
Ultrasound of Normal Fetal Heart
Ventricular Septal Defect
Atrioventricular Septal Defect
Tricuspid Atresia
Ebstein Anomaly and Tricuspid Dysplasia
Pulmonary Stenosis and Atresia

Eduard Gratacós, MD, PhD
Director
Barcelona Center for Maternal-Fetal and Neonatal Medicine
Hospital Clinic and Hospital Sant Joan de Deu
Clinical Institute of Gynecology, Obstetrics, and Neonatology
Professor of Obstetrics and Gynecology
University of Barcelona
Barcelona, Spain
Congenital Cystic Adenomatoid Malformation of the Lung
Bronchopulmonary Sequestration
Hydrothorax
Scimitar Syndrome
Other Thoracic Tumors and Masses

Carole Gravino, RDMS, FE
Yale-New Haven Hospital
New Haven, Connecticut
Atlas of Selected Normal Images

Maureen S. Hamel, MD
Division of Maternal Fetal Medicine
Department of Obstetrics and Gynecology
Women & Infants Hospital of Rhode Island
Providence, Rhode Island
Cloacal Abnormalities

Christina S. Han, MD
Department of Obstetrics and Gynecology
David Geffen School of Medicine at UCLA
University of California, Los Angeles
Center for Fetal Medicine and Women's Ultrasound
Los Angeles, California
Fetal Adrenal Abnormalities
Fetal Biophysical Profile

Lorie M. Harper, MD, MSCI
Associate Professor
Division of Maternal Fetal Medicine
Department of Obstetrics and Gynecology
University of Alabama at Birmingham
Birmingham, Alabama
Goldenhar Syndrome
Pierre Robin Sequence
Prune-Belly Syndrome
Sirenomelia
VATER Association

Wolfgang Henrich, MD, PhD
Professor and Head
Department of Obstetrics
Charité—University Medicine Berlin
Berlin, Germany
Intestinal Obstruction
Choroid Plexus Anomalies: Cysts and Papillomas

Jennifer S. Hernandez, MD
Maternal-Fetal Medicine
Obstetrix Medical Group
Fort Worth, Texas
Bilateral Renal Agenesis
Unilateral Renal Agenesis
Renal Pelvis Dilatation

Mauricio Herrera, MD
Director
Department of Maternal Fetal Medicine
Colombia University Clinic
Colsánitas Clinic
Bogotá, Colombia
Congenital Zika Virus Syndrome

Cara C. Heuser, MD
Division of Maternal-Fetal Medicine
Intermountain Healthcare
Department of Obstetrics and Gynecology
University of Utah School of Medicine
Salt Lake City, Utah
Caudal Regression Syndrome

June Y. Hou, MD
Assistant Professor
Division of Gynecologic Oncology
Department of Obstetrics and Gynecology
Columbia University Medical Center/New York Presbyterian Hospital
New York, New York
Choriocarcinoma
Gestational Trophoblastic Disease

Michael House, MD
Associate Professor
Division of Maternal Fetal Medicine
Tufts Medical Center
Boston, Massachusetts
Cervical Length and Spontaneous Preterm Birth

Lisa W. Howley, MD
Co-Director, Fetal Cardiology Program
Assistant Professor of Pediatrics
Children's Hospital Colorado/University of Colorado School of Medicine
Aurora, Colorado
Open Fetal Surgery

Rebecca S. Hulinsky, MS, CGC
Intermountain Healthcare
Salt Lake City, Utah
Caudal Regression Syndrome

Jon A. Hyett, MBBS, BSc, MD, MRCOG, FRANZCOG
Head of Department
High-Risk Obstetrics
Royal Prince Alfred Hospital
Head of Discipline
Obstetrics, Gynecology, and Neonatology
University of Sydney
Sydney, Australia
Intraabdominal Masses

G. Marc Jackson, MD
Division of Maternal-Fetal Medicine
Intermountain Healthcare
Department of Obstetrics and Gynecology
University of Utah School of Medicine
Salt Lake City, Utah
Caudal Regression Syndrome

Joses A. Jain, MD
Clinical Fellow
Department of Obstetrics and Gynecology
Division of Maternal Fetal Medicine
Columbia University Medical Center
New York, New York
Amniotic Band Sequence
Cord Cyst
Cord Varix
Limb–Body Wall Complex

Anthony Johnson, DO
Professor of Obstetrics, Gynecology, and Reproductive Sciences
Professor of Pediatric Surgery
University of Texas School of Medicine at Houston
McGovern Medical School
Co-Director, The Fetal Center
Memorial Hermann Children's Hospital
Houston, Texas
Nonimmune Hydrops Fetalis
Immune Hydrops Fetalis

Clark T. Johnson, MD, MPH
Assistant Professor
Department of Gynecology and Obstetrics
Johns Hopkins Medicine
Baltimore, Maryland
Congenital Syphilis

Franz Kainer, MD, PhD
Professor
Department of Perinatal Medicine and Obstetrics
Clinic Hallerwiese
Nürnberg, Germany
Sacrococcygeal Teratoma and Fetus in Fetu

Karim D. Kalache, MD, PhD
Professor of Obstetrics and Gynecology
Weill Cornell Medical College—Qatar
Obstetrics and Gynecology Department
Sidra Medical and Research Center
Doha, Qatar
Biliary Anomalies

Katherine S. Kohari, MD
Assistant Professor
Department of Obstetrics, Gynecology, and Reproductive Sciences
Yale University School of Medicine
New Haven, Connecticut
Echogenic Bowel

Deborah Krakow, MD
Professor
Obstetrics and Gynecology, Orthopedic Surgery, and Human Genetics
David Geffen School of Medicine at UCLA
Los Angeles, California
Skeletal Dysplasias: An Overview
Atelosteogenesis Disorders
Campomelic Dysplasia
Chondrodysplasia Punctata
DTDST Dysplasia (Including AOII and Achondrogenesis IB)
FGFR3 Disorders: Thanatophoric Dysplasia, Achondroplasia, and Hypochondroplasia
Hypophosphatasia
Osteogenesis Imperfecta
Radial Ray Deficiency
Russell-Silver Syndrome
Short Rib Thoracic Dysplasia With or Without Polydactyly
Spondyloepiphyseal Dysplasia Congenita
Other Type II Collagen Disorders
Acrofacial Dysostosis
Spinal Abnormalities and Klippel-Feil Syndrome
Abnormal Hands: Focus on the Thumbs
Craniosynostosis
Clubfoot (Talipes Equinovarus) and Clenched Hands

Wesley Lee, MD
Division Director
Women's and Fetal Imaging
Professor
Department of Obstetrics and Gynecology
Baylor College of Medicine
Texas Children's Hospital
Houston, Texas
22q11.2 Deletion Syndrome
Chromosome 4p Deletion Syndrome (Wolf-Hirschhorn Syndrome)
Chromosome 5p Deletion Syndrome (Cri du Chat Syndrome)

Tally Lerman-Sagie, MD
Professor of Pediatrics and Child Neurology
Sackler School of Medicine
Tel Aviv University
Head, Pediatric Neurology Unit
Co-Director, Metabolic Neurogenetic Clinic
Co-Director, Fetal Neurology Clinic
Wolfson Medical Center
Holon, Israel
Cerebellar Anomalies

Liesbeth Lewi, MD, PhD
Professor
Department of Obstetrics and Gynecology
University Hospitals Leuven
Leuven, Belgium
Congenital Diaphragmatic Hernia

Ling Li, MD, PhD
University of Nebraska Medical Center
Pediatric Cardiology
Omaha, Nebraska
Thymus

Heather S. Lipkind, MD, MS
Associate Professor
Department of Obstetrics, Gynecology, and Reproductive Sciences
Yale University School of Medicine
New Haven, Connecticut
Cytomegalovirus, Rubella, Toxoplasmosis, Herpes Simplex Virus, and Varicella

Ryan E. Longman, MD
Director, Reproductive Genetics
Department of Obstetrics and Gynecology
University of Miami Miller School of Medicine
Miami, Florida
CHARGE Syndrome
Klippel-Trénaunay-Weber Syndrome
Neu-Laxova Syndrome
Poland Sequence

Adetola F. Louis-Jacques, MD
Fellow
Division of Maternal-Fetal Medicine
Department of Obstetrics and Gynecology
Morsani College of Medicine
University of South Florida
Tampa, Florida
Meckel-Gruber Syndrome
Smith-Lemli-Opitz Syndrome

Lindsay Maggio, MD, MPH
Division of Maternal-Fetal Medicine
Department of Obstetrics and Gynecology
Morsani College of Medicine
University of South Florida
Tampa, Florida
Holt-Oram Syndrome

Urania Magriples, MD
Associate Professor
Maternal-Fetal Medicine
Yale School of Medicine
New Haven, Connecticut
Intrauterine Growth Restriction

Gustavo Malinger, MD
Director
Division of Ultrasound in Obstetrics and Gynecology
Lis Maternity Hospital
Tel Aviv Sourasky Medical Center
Associate Clinical Professor
Sackler School of Medicine
Tel Aviv University
Tel Aviv, Israel
Cortical Development and Disorders
Cerebellar Anomalies
Congenital Zika Virus Syndrome

Stephanie Martin, DO
Director, Southern Colorado Maternal-Fetal Medicine
Director, Maternal-Fetal Medicine/Centura Southstate
Colorado Springs, Colorado
Clubfoot (Talipes Equinovarus)

Josep M. Martinez, MD, PhD
Senior Consultant in Fetal Medicine
Department of Maternal-Fetal Medicine
BCNatal, Hospital Clínic and Hospital Sant Joan de Déu
University of Barcelona
Barcelona, Spain
Ultrasound of Normal Fetal Heart
Ventricular Septal Defect
Atrioventricular Septal Defect
Tricuspid Atresia
Ebstein Anomaly and Tricuspid Dysplasia
Pulmonary Stenosis and Atresia
Aortic Stenosis and Aortic Atresia
Hypoplastic Left Heart Syndrome and Mitral Atresia
Aortic Coarctation
Interruption of the Aortic Arch
Aortic Arch Anomalies
Tetralogy of Fallot
Transposition of Great Arteries
Double-Outlet Right Ventricle
Common Arterial Trunk
Double-Inlet Single Ventricle
Atrial Isomerism
Anomalies of Pulmonary Venous Return
Anomalies of Systemic Venous Return
Cardiomyopathy
Cardiac Tumors
Arrhythmias

Ahmed I. Marwan, MD
Assistant Professor of Surgery and Pediatrics
Colorado Fetal Care Center
Division of Pediatric Surgery
Children's Hospital Colorado/University of Colorado School of Medicine
Aurora, Colorado
Open Fetal Surgery

Audrey Merriam, MD
Maternal-Fetal Medicine Fellow
Obstetrics and Gynecology
Columbia University
New York, New York
Placental Abruption
Placenta Circumvallata
Placenta Previa

Silke A. M. Michaelis, MD
Obstetrics
Spitalzentrum Biel—Centre Hospitalier Bienne
Biel-Bienne, Switzerland
Biliary Anomalies

Jena Miller, MD
Assistant Professor
The Johns Hopkins Center for Fetal Therapy
Baltimore, Maryland
Doppler Ultrasound Evaluation of the Fetus and Placenta

Russell S. Miller, MD
Assistant Professor
Obstetrics and Gynecology
Columbia University Medical Center
New York, New York
Radiofrequency Ablation
Selective Laser Photocoagulation
Fetal Shunts
Twin-Twin Transfusion Syndrome
Twin Reversed Arterial Perfusion Sequence

Anne-Elodie Millischer, MD
Pediatric Imaging and Maternal-Fetal Center
Necker Hospital—Sick Children
AP-HP
Paris Descartes University
Paris, France
Magnetic Resonance Imaging in Obstetrics

Ana Monteagudo, MD
Clinical Professor of Obstetrics and Gynecology
New York University School of Medicine and Icahn School of Medicine at Mount Sinai
Carnegie Imaging for Women
New York, New York
Pregnancy of Unknown Location, Early Pregnancy Loss, Ectopic Pregnancy, and Cesarean Scar Pregnancy

Leslie Moroz, MD, MSc
Clinical Fellow
Critical Care and Maternal-Fetal Medicine
New York Presbyterian/Columbia University Medical Center
New York, New York
Placenta Accreta

Claudia Mosquera, MD
Physician
The Valley Hospital
Ridgewood, New Jersey
Radiofrequency Ablation

Unzila A. Nayeri, MD
Assistant Professor Obstetrics and Gynecology
University of Miami Miller School of Medicine
Miami, Florida
Parvovirus B19 Infection During Pregnancy

Sarah Običan, MD
Assistant Professor
Division of Maternal-Fetal Medicine
Department of Obstetrics and Gynecology
Morsani College of Medicine
University of South Florida
Tampa, Florida
Holt-Oram Syndrome

Anthony O. Odibo, MD, MSCE
Professor
Fetal Care Center
Division of Maternal-Fetal Medicine
Department of Obstetrics and Gynecology
Morsani College of Medicine
University of South Florida
Tampa, Florida
Septooptic Dysplasia
Walker-Warburg Syndrome
Cornelia de Lange Syndrome
Fraser Syndrome
Meckel-Gruber Syndrome
Noonan Syndrome
Roberts Syndrome
Pontocerebellar Disorders
Smith-Lemli-Opitz Syndrome

Dotun Ogunyemi, MD
System Vice Chair
Beaumont Health
MFM Fellowship Director
Beaumont Hospital
Royal Oak, Michigan
Professor
William Beaumont School of Medicine
Oakland University
Rochester Hills, Michigan
Polyhydramnios
Oligohydramnios

Aris T. Papageorghiou, MD
Consultant in Obstetrics and Fetal Medicine
Fetal Medicine Unit
St. George's Hospital
University of London
London, United Kingdom
Ventriculomegaly

Felicity J. Park, BAppSci, MBBS, FRANZCOG, cMFM
Senior Staff Specialist
Department of Obstetrics and Gynecology
John Hunter Hospital
Newcastle, Australia
Intraabdominal Masses

Christian M. Pettker, MD
Assistant Professor
Department of Obstetrics, Gynecology, and Reproductive Sciences
Yale School of Medicine
New Haven, Connecticut
Ambiguous Genitalia

Gianluigi Pilu, MD
Associate Professor
Department of Medical and Surgical Sciences
University of Bologna
Bologna, Italy
Intracranial Hemorrhage, Cysts, Tumors, and Destructive Lesions
Neural Tube Defects

Lawrence D. Platt, MD
Professor
Department of Obstetrics and Gynecology
David Geffen School of Medicine at UCLA
Center for Fetal Medicine and Women's Ultrasound
Los Angeles, California
Fetal Biophysical Profile
Introduction to Aneuploidy
Trisomy 13
Trisomy 18
Trisomy 21
Turner Syndrome (Monosomy X)
Mosaic Trisomies 8, 9, and 16

Bienvenido Puerto, PhD
Maternal-Fetal Senior Consultant
Fetal I+D Fetal Medicine Research Center
Barcelona Center for Maternal-Fetal and Neonatal Medicine
Hospital Clínic and Hospital Sant Joan de Déu
Clinical Institute of Gynecology, Obstetrics, and Neonatology
August Pi i Sunyer Biomedical Research Institute
University of Barcelona
Center of Biomedical Research on Rare Diseases
Barcelona, Spain
Cleft Lip and Palate
Orbital Defects: Hypertelorism and Hypotelorism
Choanal Atresia
Micrognathia and Retrognathia
Facial Dysmorphism
Cystic Hygroma
Neck Teratoma
Fetal Thyroid Masses and Fetal Goiter
Congenital High Airways Obstruction Syndrome (CHAOS) and Bronchial Atresia

Melissa Quinn, MBA, RDMS
Division Administrator
Division of Maternal-Fetal Medicine
Department of Obstetrics and Gynecology
Columbia University Medical Center
New York, New York
Amniocentesis
Chorionic Villus Sampling

Luigi Raio, MD
Professor
Department of Obstetrics and Gynecology
University of Bern, Inselspital
Bern, Swizerland
Megacystis-Microcolon-Intestinal Hypoperistalsis Syndrome

Georgios Rembouskos, MD
Fetal Medicine Unit
Di Venere and Sarcone Hospitals
Bari, Italy
Corpus Callosum and Septum Pellucidum Anomalies

Ivan M. Rosado-Mendez, PhD, MSc
Associate Investigator
Institute of Physics
National Autonomous University of Mexico
Mexico City, Mexico
Ultrasound Physics for the Clinician

Andrea Rossi, MD
Department of Pediatric Neurology
G. Gaslini Children's Research Hospital
Genoa, Italy
Corpus Callosum and Septum Pellucidum Anomalies

Francesca Maria Russo, MD
Research Fellow
Department of Obstetrics and Gynecology
University Hospitals Leuven
Leuven, Belgium
Congenital Diaphragmatic Hernia

Laura Salazar, MD
Maternal-Fetal Fellow Researcher
Fetal I+D Fetal Medicine Research Center
Barcelona Center for Maternal-Fetal and Neonatal Medicine
BCNatal, Hospital Clínic and Hospital Sant Joan de Déu
Clinical Institute of Gynecology, Obstetrics, and Neonatology
August Pi i Sunyer Biomedical Research Institute
University of Barcelona
Center for Biomedical Research on Rare Diseases
Barcelona, Spain
Cystic Hygroma

Laurent J. Salomon, MD, PhD
Pediatric Imaging and Maternal-Fetal Center
Necker Hospital—Sick Children
AP-HP
Paris Descartes University
Paris, France
Magnetic Resonance Imaging in Obstetrics

Amber Samuel, MD
Physician
Obstetrix Medical Group of Houston
Houston, Texas
Selective Laser Photocoagulation

Magdalena Sanz-Cortés, MD, PhD
Associate Professor
Obstetrics and Gynecology
Baylor College of Medicine
Houston, Texas
Micrognathia and Retrognathia
Neck Teratoma
Fetal Thyroid Masses and Fetal Goiter

Anna Katerina Sfakianaki, MD, MPH
Associate Professor
Maternal-Fetal Medicine and Family Planning
Department of Obstetrics, Gynecology, and Reproductive Sciences
Yale School of Medicine
New Haven, Connecticut
Pregnancy of Unknown Location, Early Pregnancy Loss, Ectopic Pregnancy, and Cesarean Scar Pregnancy

Jeanne S. Sheffield, MD
Professor of Gynecology and Obstetrics
Director of the Division of Maternal-Fetal Medicine
Johns Hopkins Medicine
Baltimore, Maryland
Congenital Syphilis

Sara Shelley, MGC
Instructor
Department of Obstetrics, Gynecology, and Reproductive Sciences
University of Maryland School of Medicine
Baltimore, Maryland
Fryns Syndrome
Tuberous Sclerosis

Michelle Silasi, MD
Assistant Professor
Department of Obstetrics, Gynecology, and Reproductive Sciences
Yale School of Medicine
New Haven, Connecticut
Fetal Macrosomia

Robert Silver, MD
Professor
Department of Obstetrics and Gynecology
University of Utah School of Medicine
Salt Lake City, Utah
Lymphedema and Lymphatic Malformations

Lynn L. Simpson, MD
Professor
Obstetrics and Gynecology
Columbia University Medical Center
New York, New York
Radiofrequency Ablation
Selective Laser Photocoagulation
Fetal Shunts
Twin-Twin Transfusion Syndrome
Twin Reversed Arterial Perfusion Sequence

Rachel G. Sinkey, MD
Department of Obstetrics and Gynecology
Division of Maternal-Fetal Medicine
Morsani College of Medicine
University of South Florida
Tampa, Florida
Cornelia de Lange Syndrome
Noonan Syndrome
Pontocerebellar Disorders

Saul Snowise, MD
Assistant Professor of Obstetrics, Gynecology, and Reproductive Sciences
University of Texas School of Medicine at Houston
McGovern Medical School
Houston, Texas
Nonimmune Hydrops Fetalis
Immune Hydrops Fetalis

Pascale Sonigo, MD
Pediatric Imaging and Maternal-Fetal Center
Necker Hospital—Sick Children
AP-HP
Paris Descartes University
Paris, France
Magnetic Resonance Imaging in Obstetrics

Hindi E. Stohl, MD, JD
Director, Division of Maternal-Fetal Medicine
Harbor–UCLA Medical Center
Torrance, California
Introduction to Aneuploidy

Jens H. Stupin, MD
Departments of Gynecology and Obstetrics
Charité—University Medicine Berlin
Berlin, Germany
Choroid Plexus Anomalies: Cysts and Papillomas

Ilan E. Timor-Tritsch, MD
Professor of Obstetrics and Gynecology
New York University School of Medicine
New York, New York
Pregnancy of Unknown Location, Early Pregnancy Loss, Ectopic Pregnancy, and Cesarean Scar Pregnancy
Congenital Zika Virus Syndrome

Ants Toi, MD
Professor of Radiology
Professor of Obstetrics and Gynecology
University of Toronto
Radiologist
Department of Medical Imaging
Mt. Sinai Hospital
Toronto, Ontario, Canada
Cortical Development and Disorders

Gloria Too, MD
Maternal-Fetal Medicine Clinical Fellow
Columbia University Medical Center
New York, New York
Cordocentesis and Fetal Transfusion
Multifetal Pregnancy Reduction

Boris Tutschek, MD, PhD
Consultant Obstetrician and Gynecologist
Prenatal Zurich
Zürich, Switzerland
Professor of Obstetrics and Gynecology
Medical Faculty
Heinrich Heine University
Düsseldorf, Germany
Abdominal Cysts
Hepatic Anomalies
Fetal Spleen
Three-Dimensional Ultrasound: Techniques and Clinical Applications

Methodius G. Tuuli, MD, MPH
Associate Professor
Department of Obstetrics and Gynecology
Washington University School of Medicine
St. Louis, Missouri
Septooptic Dysplasia
Walker-Warburg Syndrome
Fraser Syndrome
Roberts Syndrome

Ignatia B. Van den Veyver, MD
Professor
Department of Obstetrics and Gynecology
Professor and Director
Clinical Prenatal Genetics Service
Department of Molecular and Human Genetics
Baylor College of Medicine
The Jan and Dan Duncan Neurological Research Institute
Texas Children's Hospital
Houston, Texas
22q11.2 Deletion Syndrome
Chromosome 4p Deletion Syndrome (Wolf-Hirschhorn Syndrome)
Chromosome 5p Deletion Syndrome (Cri du Chat Syndrome)

Tim Van Mieghem, MD, PhD
Department of Obstetrics and Gynecology
Mount Sinai Hospital and University of Toronto
Toronto, Canada
Congenital Diaphragmatic Hernia

Joy Vink, MD
Assistant Professor
Co-Director, Preterm Birth Prevention Center
Division of Maternal-Fetal Medicine
Department of Obstetrics and Gynecology
Columbia University Medical Center
New York, New York
Amniocentesis
Chorionic Villus Sampling
Diagnostic Procedures in Multiples

Paolo Volpe, MD
Fetal Medicine Unit
Di Venere and Sarcone Hospitals
Bari, Italy
Corpus Callosum and Septum Pellucidum Anomalies

Carmela Votino, MD
Fetal Medicine Unit
Di Venere and Sarcone Hospitals
Bari, Italy
Corpus Callosum and Septum Pellucidum Anomalies

Jennifer M. Walsh, MB, BCh, BAO, PhD, MRCOG, FRCPI
Department of Obstetrics and Gynecology
Columbia University Medical Center
New York, New York
Nuchal Translucency

Erika F. Werner, MD, MS, FACOG
Division of Maternal Fetal Medicine
Department of Obstetrics and Gynecology
Women & Infants Hospital of Rhode Island
Providence, Rhode Island
Cloacal Abnormalities

Lisa C. Zuckerwise, MD
Clinical Instructor/Maternal Fetal Medicine Fellow
Department of Obstetrics, Gynecology, and Reproductive Sciences
Division of Maternal-Fetal Medicine
Yale University School of Medicine
New Haven, Connecticut
Thymus

PREFACE

Since the publication of the first edition of this text 5 years ago, we have seen many improvements in the quality of fetal imaging, as well as an explosion in related knowledge of the genetics underlying so much of what we do. This edition features new images and videos and a reorganization of the genetics information sections, including skeletal dysplasias. We also have a unique new section on the latest technologies used in our field.

The changes in this edition arise from the creative thinking and persistence of my fellow editors. I was fortunate that all of the editors from the first edition agreed to a reprise and that Deborah Krakow agreed to join the team to supervise the genetics and skeletal dysplasia sections. Even more than in the first edition, the format of the book is intended for both print and web access. All of the references for the book are in the web version, as are the video clips that add so much more in many diagnoses.

My deep thanks to our editor at Elsevier, Robin Carter, as well as our content specialist, Anne Snyder, who did so much day to day to keep the project moving. Finally, the authors of all the chapters deserve recognition for their work in producing outstanding contributions. All of the editors share my gratitude—and frankly my awe—at what came from our colleagues in producing this volume.

Joshua A. Copel, MD

VIDEO CONTENTS

CHAPTER 4 HYDROTHORAX

VIDEO 4.1 Bilateral Fetal Pleural Effusion or Hydrothorax

VIDEO 4.2 Massive Fetal Pericardial Effusion

CHAPTER 20 GASTROSCHISIS

VIDEO 20.1 Color Doppler Image of the Umbilical Cord Insertion Into the Abdomen Adjacent to the Herniated Bowel in a Fetus With Gastroschisis

VIDEO 20.2 Four-Dimensional Ultrasound of Fetal Torso With Gastroschisis

CHAPTER 21 OMPHALOCELE

VIDEO 21.1 Omphalocele With Levorotated Heart

CHAPTER 24 ABDOMINAL CYSTS

VIDEO 24.1 Partial Resection of Ovarian Cyst in a Neonate

VIDEO 24.2 Endoscopic Retrieval of a Detached Right Ovary With Hemorrhagic Cyst in a Neonate

VIDEO 24.3 Endoscopic Resection of Gastric Duplication in a Neonate

VIDEO 24.4 Normal Fetal Small Bowel Mesentery

CHAPTER 27 CONGENITAL DIAPHRAGMATIC HERNIA

VIDEO 27.1 Ultrasound of Isolated Left-Sided Congenital Diaphragmatic Hernia

VIDEO 27.2 Fetoscopic Removal of Tracheal Balloon in a Fetus With Isolated Congenital Diaphragmatic Hernia

CHAPTER 28 HEPATIC ANOMALIES

VIDEO 28.1 Gray Scale Imaging of Hepatic Hemangioma

VIDEO 28.2 Power Doppler Imaging of a Hepatic Hemangioma

CHAPTER 32 FETAL SPLEEN

VIDEO 32.1 Double Vessel Sign in Left-Isomerism: Transverse View

VIDEO 32.2 Double Vessel Sign in Left-Isomerism: Sagittal View

CHAPTER 39 HOLOPROSENCEPHALY

VIDEO 39.1 Coronar Slices Through the Monocavity of the HPE-Brain in an 18-Week-Old Fetus

VIDEO 39.2 Approximately 13-Week-Old Fetus With Alobar HPE: Horizontal Slices Through the Brain

VIDEO 39.3 Approximately 13-Week-Old Fetus With Alobar HPE: Coronar Slices Through the Brain

VIDEO 39.4 Approximately 13-Week-Old Fetus With Alobar HPE: Coronar Slices Through the Brain

CHAPTER 65 CLEFT LIP AND PALATE

VIDEO 65.1 Three-Dimensional Multiplanar Mode of a Fetus With a Bilateral Cleft Lip and Palate at 21 Weeks' Gestation

CHAPTER 68 MICROGNATHIA AND RETROGNATHIA

VIDEO 68.1 Agnathia

VIDEO 68.2 Three-Dimensional Reconstruction of a Fetus With Micrognathia

VIDEO 68.3 Four-Dimensional Reconstruction of a Fetus With Micrognathia

CHAPTER 69 FACIAL DYSMORPHISM

VIDEO 69.1 Otocephaly and Micrognathia

CHAPTER 71 NECK TERATOMA

VIDEO 71.1 Unilocular, Encapsulated Complex Tumor of Fetal Neck

VIDEO 71.2 Primarily Solid Neck Tumor

VIDEO 71.3 Neck Teratoma

CHAPTER 74 ULTRASOUND OF NORMAL FETAL HEART

VIDEO 74.1 Normal Drainage of Superior Pulmonary Veins to the Left Atrium

VIDEO 74.2 Normal View of Right Ventricle, Pulmonary Valve, and Ductal Arch

VIDEO 74.3 Normal Ductal Arch

VIDEO 74.4 Normal Aortic Arch

VIDEO 74.5 Normal Aortic Arch

VIDEO 74.6 Drainage of the Superior and Inferior Vena Cava Into the Right Atrium

VIDEO 74.7 Presence of a Normal Ductus Venosus

VIDEO 74.8 Normal Heart Evaluated by Transvaginal Route

VIDEO 74.9 Transposition of Great Arteries

VIDEO 74.10 Examination of a Normal Heart by the Five Short-Axis Views

CHAPTER 75 VENTRICULAR SEPTAL DEFECT

VIDEO 75.1 Small Apical Ventricular Septal Defects

VIDEO 75.2 Large Perimembranous Ventricular Septal Defects

CHAPTER 76 ATRIOVENTRICULAR SEPTAL DEFECT

VIDEO 76.1 Unbalanced Complete Atrioventricular Septal Defects

VIDEO 76.2 Unbalanced Complete Atrioventricular Septal Defects

VIDEO 76.3 Incomplete Atrioventricular Septal Defects

VIDEO 76.4 Incomplete Atrioventricular Septal Defects

CHAPTER 77 TRICUSPID ATRESIA

VIDEO 77.1 Gray Scale Imaging of Tricuspid Atresia With Ventricular Septal Defect

VIDEO 77.2 Gray Scale and Color Doppler Imaging of Tricuspid Atresia With Ventricular Septal Defect

VIDEO 77.3 Tricuspid Atresia Without Ventricular Septal Defect

CHAPTER 78 EBSTEIN ANOMALY AND TRICUSPID DYSPLASIA

VIDEO 78.1 Gray Scale and Color Doppler Images of Ebstein Anomaly of Tricuspid Valve

VIDEO 78.2 Ebstein Anomaly of Tricuspid Valve

CHAPTER 79 PULMONARY STENOSIS AND ATRESIA

VIDEO 79.1 Fetus With Pulmonary Stenosis and Intact Interventricular Septum

VIDEO 79.2 Pulmonic Stenosis

CHAPTER 81 HYPOPLASTIC LEFT HEART SYNDROME AND MITRAL ATRESIA

VIDEO 81.1 Hypoplastic Left Heart Syndrome in a Case of Aortic Atresia

CHAPTER 82 AORTIC COARCTATION

VIDEO 82.1 Fetal Aortic Coarctation

CHAPTER 83 INTERRUPTION OF THE AORTIC ARCH

VIDEO 83.1 Fetus With Interrupted Aortic Arch

CHAPTER 84 AORTIC ARCH ANOMALIES

VIDEO 84.1 Right Aortic Arch

VIDEO 84.2 Aberrant Right Subclavian Artery

CHAPTER 85 TETRALOGY OF FALLOT

VIDEO 85.1 Tetralogy of Fallot

VIDEO 85.2 Tetralogy of Fallot/Absent Pulmonary Valve Syndrome

CHAPTER 86 TRANSPOSITION OF GREAT ARTERIES

VIDEO 86.1 Transposition of the Great Arteries and an Intact Ventricular Septum

VIDEO 86.2 Corrected Transposition of the Great Vessels

CHAPTER 87 DOUBLE-OUTLET RIGHT VENTRICLE

VIDEO 87.1 Double-Outlet Right Ventricle With Subpulmonary Ventricular Septal Defect

CHAPTER 88 COMMON ARTERIAL TRUNK

VIDEO 88.1 Truncus Arteriosus

CHAPTER 89 DOUBLE-INLET SINGLE VENTRICLE

VIDEO 89.1 Four-Chamber and Outflow Views of Single Ventricle With Transposition

CHAPTER 90 ATRIAL ISOMERISM

VIDEO 90.1 Sweep of Abdomen and Thorax Showing Stomach on One Side and Apex of the Heart on the Opposite Side

VIDEO 90.2 Stomach on the Right Side and Apex of the Heart on the Opposite Side

CHAPTER 91 ANOMALIES OF PULMONARY VENOUS RETURN

VIDEO 91.1 Anomalous Pulmonary Venous Return

CHAPTER 92 ANOMALIES OF SYSTEMIC VENOUS RETURN

VIDEO 92.1 Extrahepatic Agenesis of the Ductus Venosus

CHAPTER 93 CARDIOMYOPATHY

VIDEO 93.1 Cardiomegaly With Dilated Myocardiopathy

VIDEO 93.2 Noncompacted Cardiomyopathy

CHAPTER 94 CARDIAC TUMORS

VIDEO 94.1 Multiple Rhabdomyomata

VIDEO 94.2 Huge Pericardial Teratoma

CHAPTER 95 ARRHYTHMIAS

VIDEO 95.1 Fetal Tachycardia

VIDEO 95.2 Fetal Tachycardia

VIDEO 95.3 Fetal Atrial Flutter With Variable Block

VIDEO 95.4 Fetal Complete Heart Block

CHAPTER 103 CORD VARIX

VIDEO 103.1 Umbilical Vein Varix

VIDEO 103.2 Umbilical Vein Varix

CHAPTER 115 SELECTIVE LASER PHOTOCOAGULATION

VIDEO 115.1 Fetoscopic Selective Laser Photocoagulation

VIDEO 115.2 Fetoscopic View of Recipient Twin Within a Polyhydramniotic Sac

VIDEO 115.3 Fetoscopic View of a "Stuck" Donor Twin

CHAPTER 118 OPEN FETAL SURGERY

VIDEO 118.1 Open Fetal Repair of a Myelomeningocele

CHAPTER 125 FETAL BIOPHYSICAL PROFILE

VIDEO 125.1 Altered Fetal Breathing

CHAPTER 143 TUBEROUS SCLEROSIS

VIDEO 143.1 Third Trimester Fetal Heart With Multiple Echogenic Rhabdomyomas

CHAPTER 163 TWIN REVERSED ARTERIAL PERFUSION SEQUENCE

VIDEO 163.1 Ultrasound Cine Video of an Acardiac Fetus

VIDEO 163.2 Ultrasound Doppler Cine Video of an Acardiac Fetus

CHAPTER 170 ELASTICITY IMAGING IN OBSTETRICS

VIDEO 170.1 Video of Shear Wave Displacement and Wave Front Propagation

CHAPTER 173 THREE-DIMENSIONAL ULTRASOUND: TECHNIQUES AND CLINICAL APPLICATIONS

VIDEO 173.1 Median Section of a Normal Fetal Trunk at 20 Weeks' Gestation

VIDEO 173.2 Tomographic Imaging From a STIC Volume, Acquired With Power Doppler Information, of a 23-Week-Old Fetus With d-Transposition of the Great Arteries

VIDEO 173.3 Tomographic Imaging From a STIC Volume, Acquired With Power Doppler Information, of a Normal 23-Week-Old Fetus

VIDEO 173.4 Multiplanar Reconstruction and Three-Dimensional *en face* View of the Atrioventricular Valve Plane of a 24-Week-Old Fetus With Bradycardia

VIDEO 173.5 Three-Dimensional Power Doppler Angiogram (Reconstruction of the Normal Main Vessels) of the Fetal Trunk at 21 Weeks

VIDEO 173.6 Three-Dimensional Power Doppler Angiogram (Reconstruction of the Normal Main Vessels of the Fetal Trunk) at 21 Weeks

1 Atlas of Selected Normal Images

MERT OZAN BAHTIYAR | CAROLE GRAVINO



Fig. 1.1 The crown-rump length is a measurement of the length of human fetuses from the top of the crown to the bottom of the rump. It is used to estimate gestational age.



Fig. 1.2 Transvaginal ultrasound and sagittal long-axis view of the endocervical canal. Both the internal os and the external os are well visualized. The cervical length is measured from the internal os to the external os along the endocervical canal.



Fig. 1.3 Sagittal view of the uterus with an anterior *(Ant)* placenta.



Fig. 1.4 Sagittal view of the uterus showing a posterior *(Post)* placenta.



Fig. 1.5 Normal umbilical cord insertion into the placenta.

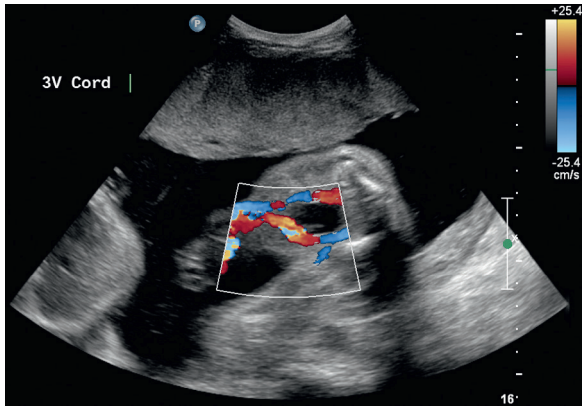

Fig. 1.6 Fetal umbilical cord insertion site. The umbilical arteries emerge caudally—originating at the iliac arteries and coursing along the margin of the urinary bladder. The umbilical vein proceeds cephalad and joins the fetal portal circulation. *3V,* Three-vessel.



Fig. 1.7 Transverse view of the umbilical cord. The umbilical cord is composed of a vein and two smaller arteries.

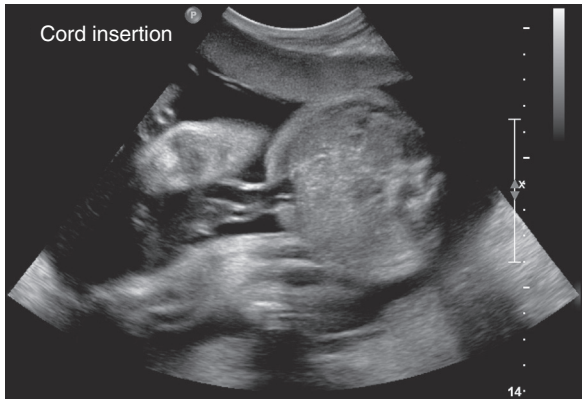

Fig. 1.8 Transverse view of the fetal abdomen and the umbilical cord insertion site showing integrity of the central abdominal wall.

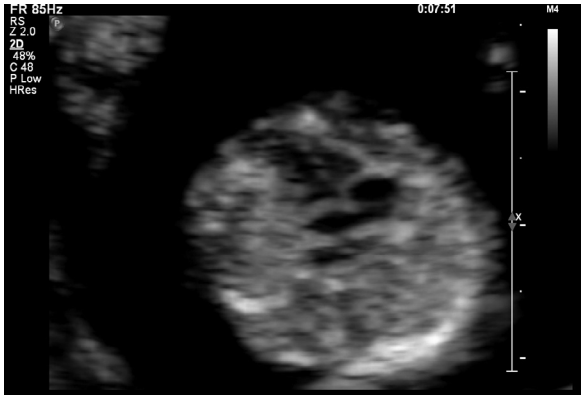

Fig. 1.9 Four-chamber view of the fetal heart at 12 weeks of gestation.



Fig. 1.10 Interventricular septum at 12 weeks of gestation.



Fig. 1.11 Left ventricular outflow at 12 weeks of gestation. *LVOT*, Left ventricular outflow tract.

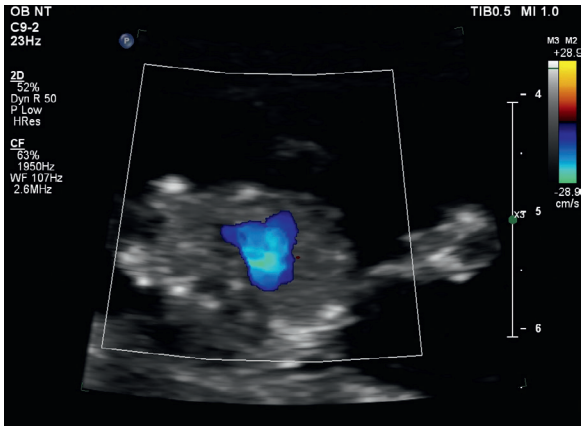

Fig. 1.12 Three-vessel view shown by color Doppler at 12 weeks of gestation.



Fig. 1.13 Aortic arch *(Ao Arch)* at 12 weeks of gestation.



Fig. 1.14 Four-chamber view obtained with a transverse axial view through the fetal thorax. This view provides information on the size of the heart and its chambers; the pulmonary venous connections to the atrial segment; the morphology of the ventricles; the type of atrioventricular (AV) connection; and the integrity of the atrial, AV, and ventricular septa.



Fig. 1.15 Four-chamber view with the fetus in the left decubitus position. The interventricular septum is clearly visualized and appears intact.



Fig. 1.16 The left ventricular outflow tract *(LVOT)* view is initially obtained with the ventricular septum horizontal to the transducer in the four-chamber view followed by clockwise or counterclockwise rotation of the transducer. The LVOT view also shows the left ventricular inlet with the anterior leaflet of the mitral valve demarcating both the inlet and the outflow tract.

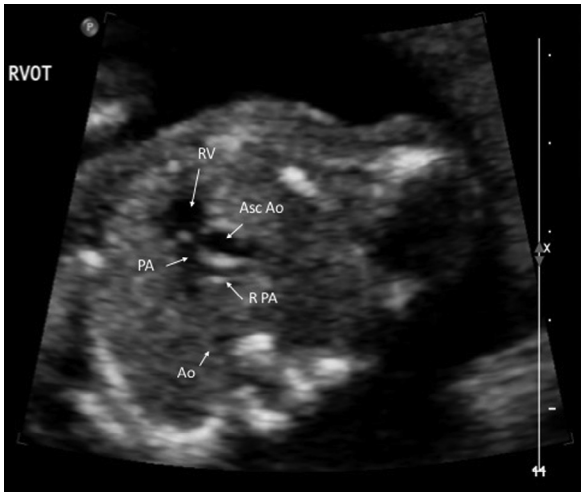

Fig. 1.17 The right ventricular outflow tract *(RVOT)* view is obtained by starting from the four-chamber view and sliding the transducer toward the fetal head. The RVOT leads to the main pulmonary artery traveling superiorly and posteriorly. *Ao,* Aorta; *Asc Ao,* ascending aorta; *PA,* main pulmonary artery; *R PA,* right pulmonary artery; *RV,* right ventricle.



Fig. 1.18 Three-vessel view *(3VV)* is obtained by sliding the transduced further toward the fetal head after visualization of RVOT. *Ao*, Aorta; *DA,* ductus arteriosus; *PA*, pulmonary artery; *SVC*, superior vena cava.



Fig. 1.19 Sagittal view of the aortic arch. The aortic arch gives rise to the right innominate or brachiocephalic artery, the left common carotid artery, and the left subclavian artery.

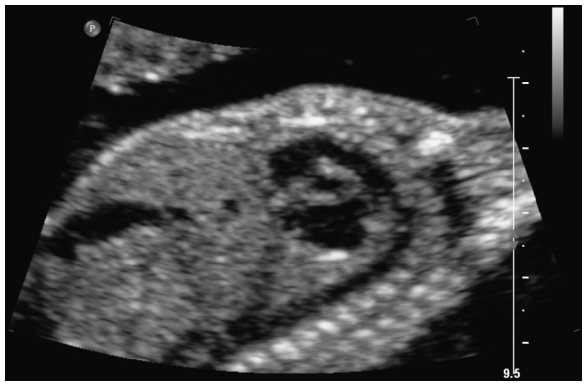

Fig. 1.20 Parasagittal view of the ductal arch. The ductal arch appears as a hockey stick–type structure with no branching head vessels.

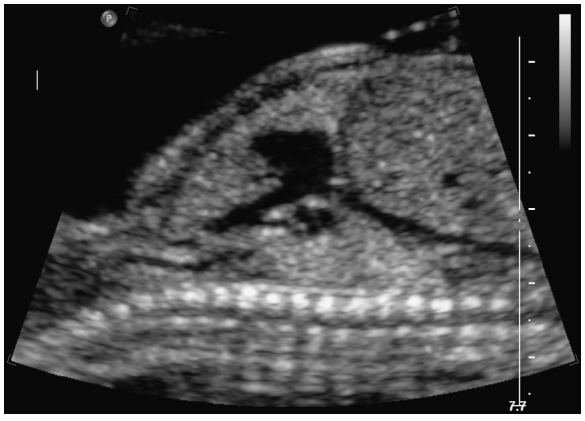

Fig. 1.21 Sagittal view of the inferior vena cava and superior vena cava, which are draining into the right atrium.



Fig. 1.22 Parasagittal view of the fetal aorta and inferior vena cava.

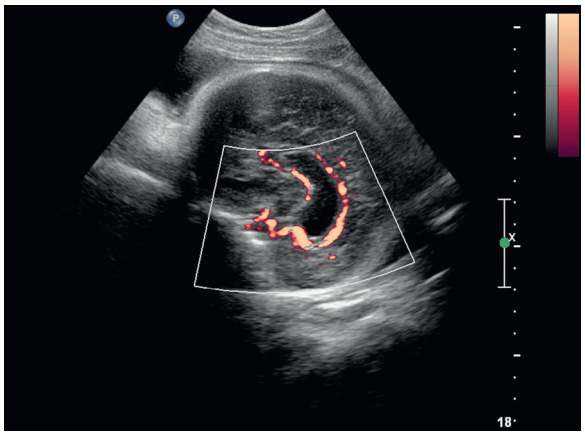

Fig. 1.23 Sagittal view of the corpus callosum. Power Doppler shows branching of the anterior cerebral artery, which gives rise to the pericallosal artery.



Fig. 1.24 View of the posterior fossa in the second trimester. The shape and size of the cerebellum, in addition to the cisterna magna and nuchal fold, are assessed in this view. The cavum septi pellucidi is seen anteriorly.



Fig. 1.25 Axial sonogram through the lateral ventricles of a second-trimester fetus showing the choroid plexus.



Fig. 1.26 Axial sonogram through the lateral ventricles of a first-trimester fetus showing the choroid plexus.



Fig. 1.27 Transverse intracranial view at the level of the ventricles. The atrium of the lateral ventricle *(Lat Vent)* is measured at the level of the choroid plexus. An atrial measurement of less than 10 mm is considered normal.



Fig. 1.28 Transcerebellar view of the fetal head showing the posterior fossa. The cerebellum, cisterna magna *(Cist Mag)*, and nuchal fold *(Nuch Fold)* are measured in this view.

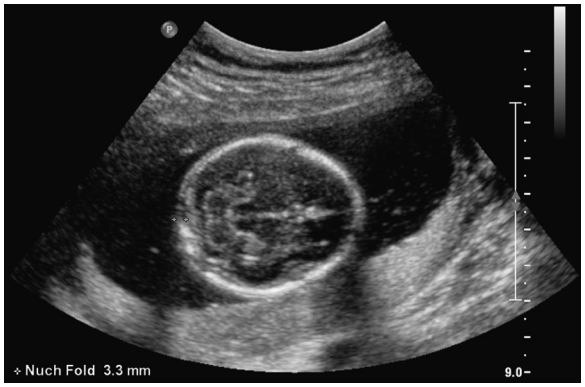

Fig. 1.29 The transcerebellar view of the fetal head allows measurement of the nuchal fold *(Nuch Fold)*. To obtain this measurement, calipers are placed at the outer edge of the occipital bone and the outer skin edge.



Fig. 1.30 Transcerebellar view of the fetal head showing the posterior fossa, which consists of the cerebellum and cisterna magna *(Cist Mag)*.

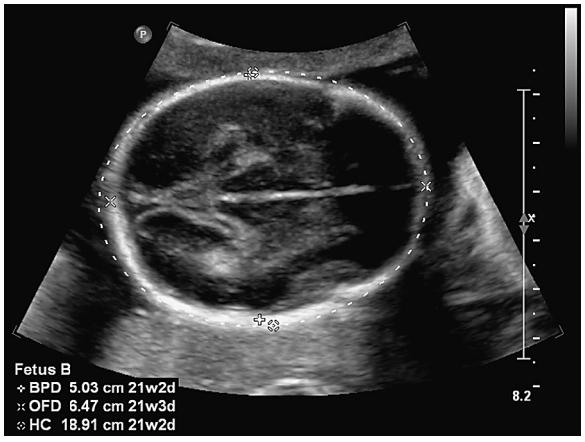

Fig. 1.31 Transverse view of the fetal head at the level of the biparietal diameter *(BPD)*. To obtain the BPD, the view must include the third ventricle, thalamus, and cavum septi pellucidi. The measurements are obtained by placing cursors at the outer edge of one calvarial wall to the inner edge of the opposite calvarial wall. The head circumference *(HC)* is measured by placing the cursors at the outer edges of the near and far calvarial walls. *OFD*, Occipitofrontal diameter.



Fig. 1.32 Midsagittal view of the fetal face showing the profile. The nasal bone, mandible, and maxilla are seen along with the upper and lower lips.

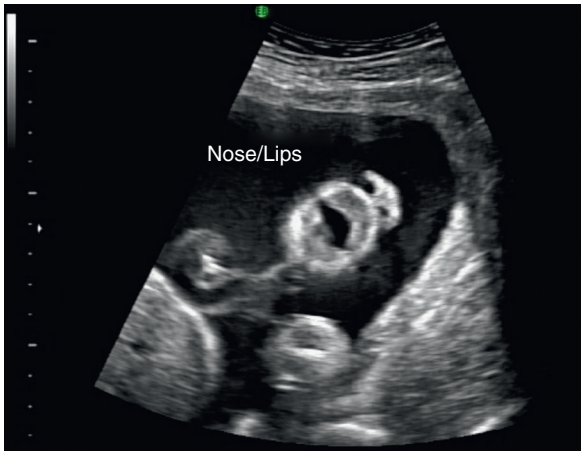

Fig. 1.33 Coronal view of the anterior face displaying the tip of the nose, nostrils, and upper lip shows the integrity of the upper lip.



Fig. 1.34 Coronal view of the anterior face showing the fetal tongue.

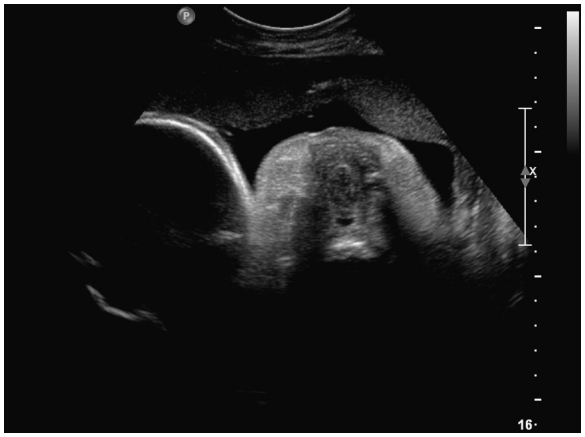

Fig. 1.35 Axial view of the fetal head showing the fetal palate as a semicircular echogenic structure.



Fig. 1.36 Coronal view of the fetal face showing the fetal orbits.

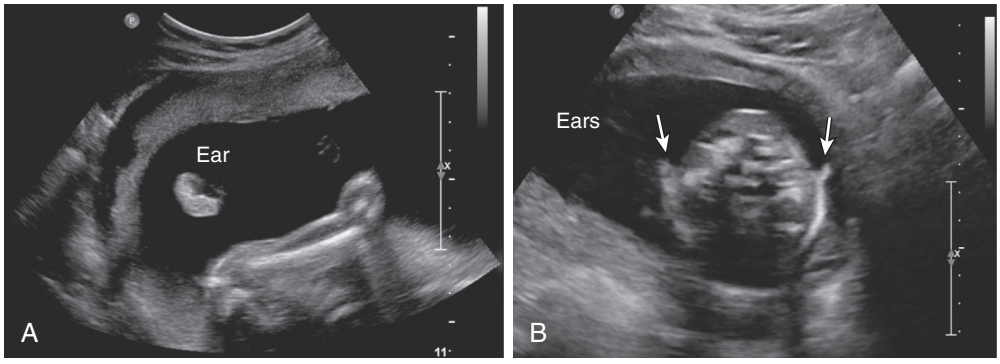

Fig. 1.37 Parasagittal (A) and axial (B) views of the fetal ear.

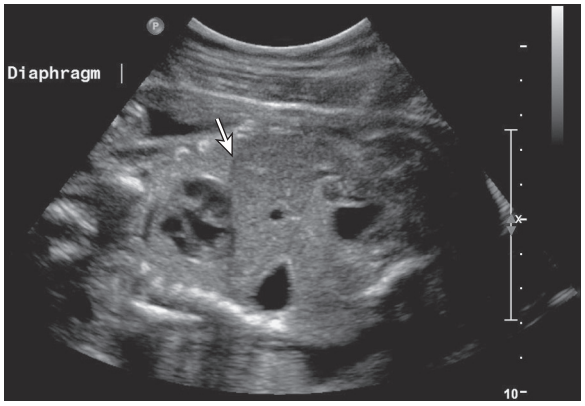

Fig. 1.38 Sagittal view of the fetal diaphragm. The fetal diaphragm is seen as a curvilinear hypoechoic structure separating the abdominal and thoracic cavities.



Fig. 1.39 Sagittal view of the fetal lung and diaphragm. The lung is slightly more echogenic than the liver. The hypoechoic diaphragm is seen separating these structures.

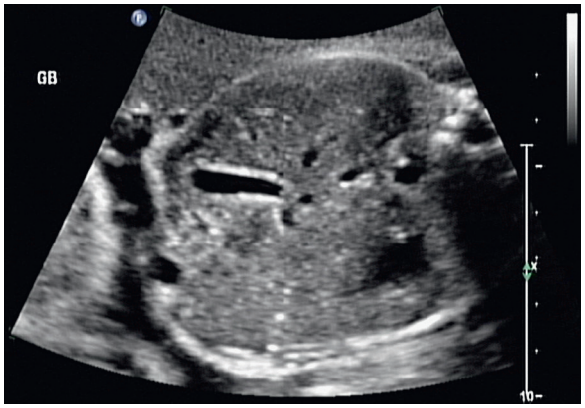

Fig. 1.40 Transverse view through the fetal abdomen. The fetal gallbladder *(GB)* appears as a teardrop-shaped, fluid-filled structure between 7 and 15 weeks' gestation. A normal gallbladder can assume various shapes and sizes during pregnancy.



Fig. 1.41 Transverse view of the fetal abdomen. To measure the abdominal circumference *(AC)* accurately, the stomach and umbilical segment of the left portal vein should be visualized. Cursors are placed to fit the edges of the skin.

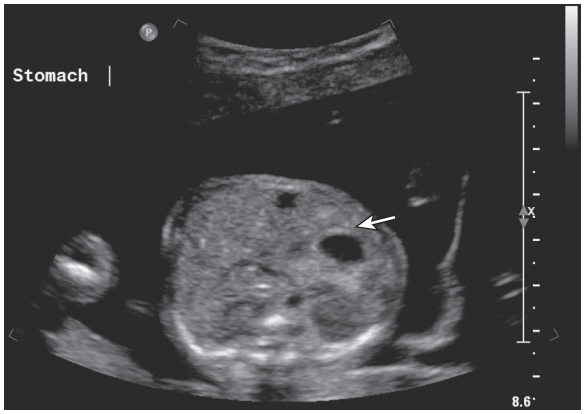

Fig. 1.42 Transverse view of the fetal abdomen showing the fluid-filled fetal stomach.



Fig. 1.43 Coronal view of the fetal kidneys.

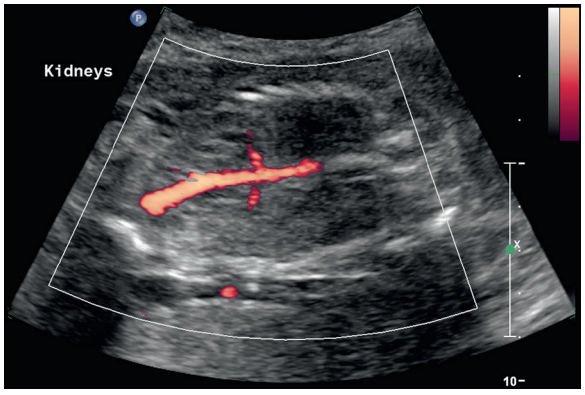

Fig. 1.44 Coronal view of the renal arteries supplying both fetal kidneys.

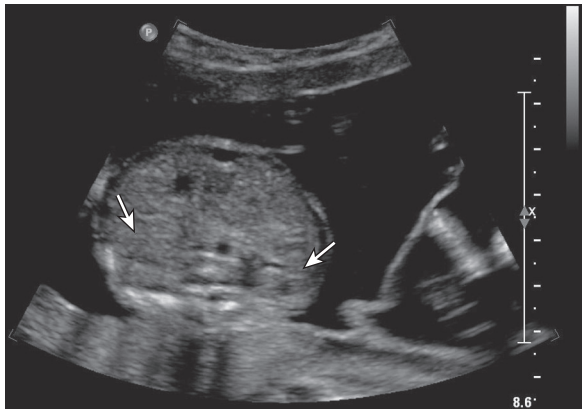

Fig. 1.45 Transverse view of the fetal kidneys. The fetal kidneys *(arrows)* are visualized as circular structures adjacent to the lumbar spinal ossification centers bilaterally.

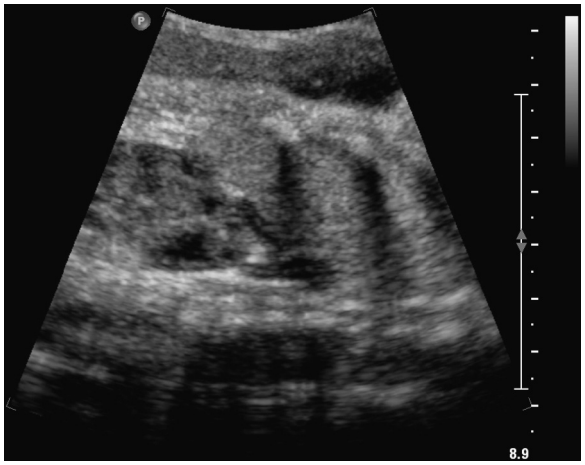

Fig. 1.46 Sagittal view through either the right flank or the left flank. The triangle-shaped adrenal gland is seen adjacent to the superior pole of the kidney.



Fig. 1.47 Sagittal view of the fetal spine at the level of the lumbosacral spine. The overlying skin is intact and helps rule out large neural tube defects.



Fig. 1.48 Sagittal view of the fetal spine.



Fig. 1.49 Coronal view of the fetal spine shows the parallel vertebral columns and ossification centers.

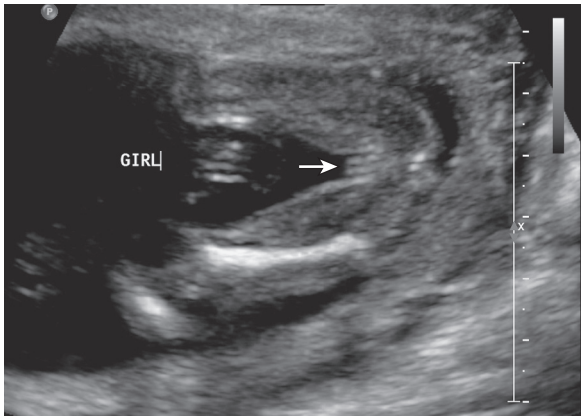

Fig. 1.50 Coronal view of the female external genitalia. The labia majora and labia minora are clearly identified.



Fig. 1.51 Sonogram of the fetal penis. The penis and scrotum are clearly visualized.



Fig. 1.52 Longitudinal view of the fetal humerus. Measurements are taken from each end of the diaphysis and include only the ossified portion of the bone.

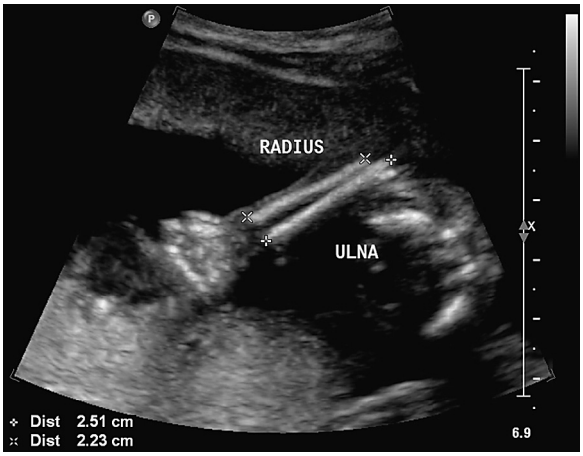

Fig. 1.53 Longitudinal view of the fetal forearm. Although the ulna and radius end at the same distal level, the ulna is longer than the radius proximally.



Fig. 1.54 Longitudinal view of the fetal femur. Measurements are taken from each end of the diaphysis. Only the ossified portion of the bone is measured. *FL,* Femur length.

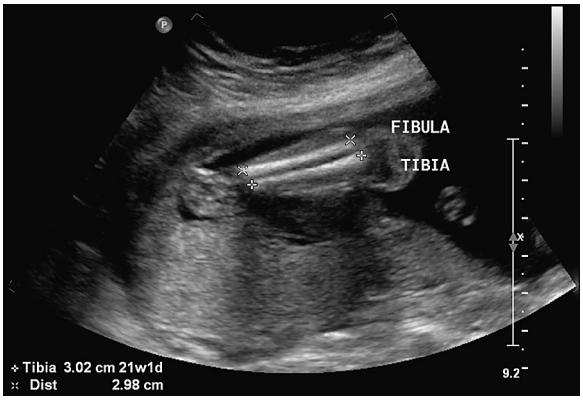

Fig. 1.55 Longitudinal view of the fetal lower leg. The tibia is more medial and is longer than the fibula proximally.

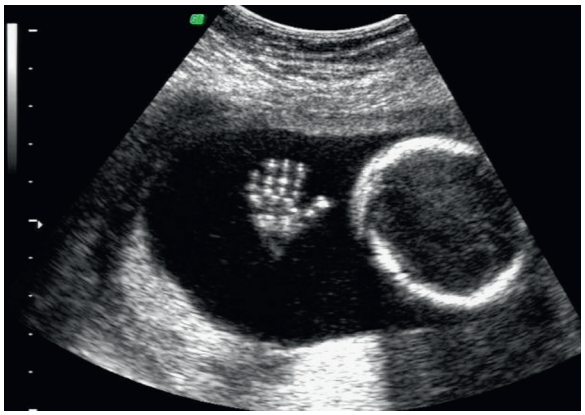

Fig. 1.56 Coronal view of the fetal hand showing the bony details of the developing phalanges.

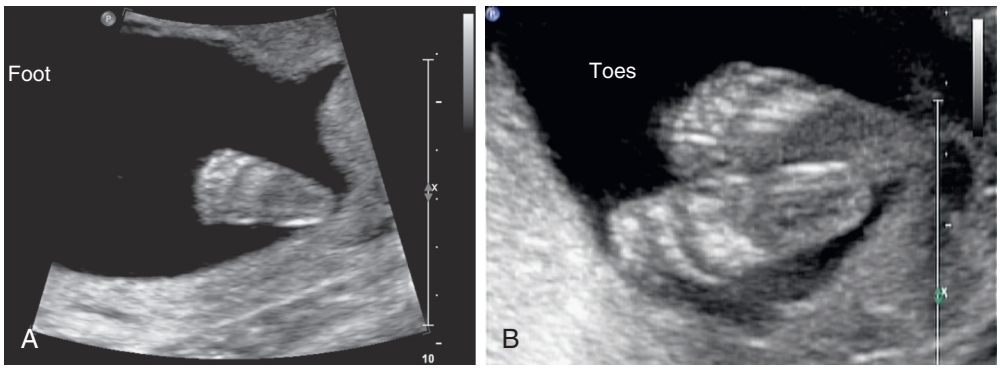

Fig. 1.57 Transverse axial view of a fetal foot (A) and fetal toes (B) where the proximal phalangeal ossification centers and metatarsal ossification centers are also visualized.

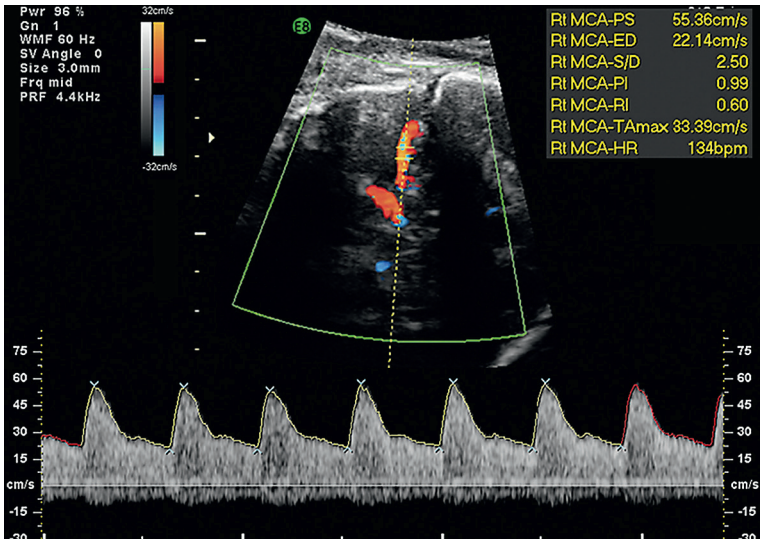

Fig. 1.58 The middle cerebral artery, a major branch of the circle of Willis, plays an important role in fetal adaptation to oxygenation. In the setting of fetal hypoxia, blood flow is centrally redistributed with increased blood flow to the brain. In a transverse view of the fetal head, the middle cerebral arteries are seen in the long axis with their course parallel to the ultrasound beam. The measured velocity is most accurate if measured at the proximal portion of the vessel adjacent to its origin at the circle of Willis.

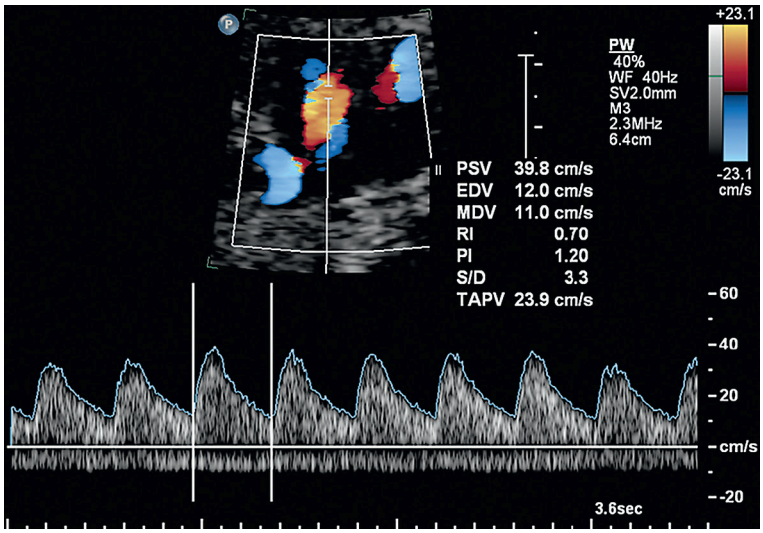

Fig. 1.59 Umbilical artery Doppler velocimetry, which is obtained from a floating segment of the umbilical cord, reflects placental impedance. Normally, the umbilical arterial circulation is a low-impedance circulation. *EDV*, End diastolic velocity; *MDV*, mean diastolic velocity; *RI*, resistive index; *PI*, pulsatility index; *PSV*, peak systolic velocity; *S/D*, peak systolic velocity/end diastolic velocity; *TAPV*, time averaged peak velocity.

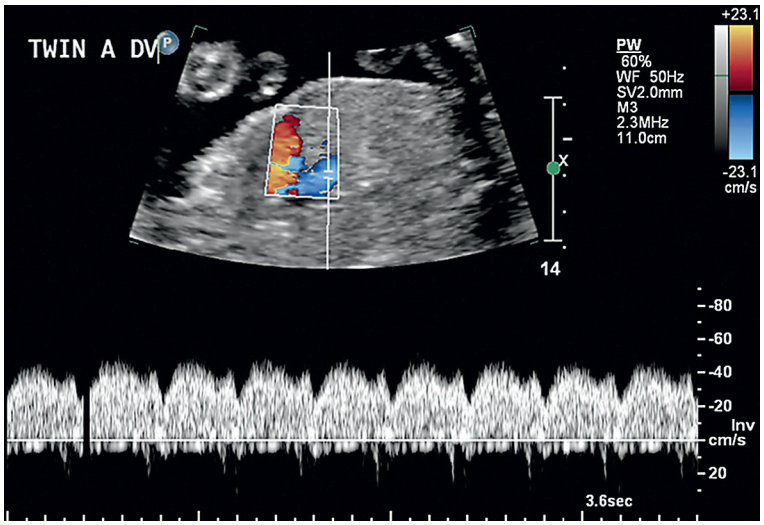

Fig. 1.60 The fetal ductus venosus *(DV)* shunts most of the blood flow from the umbilical vein directly to the inferior vena cava, bypassing the fetal liver. Blood flow through the ductus venosus is used to predict compromised states in fetuses with growth restriction.

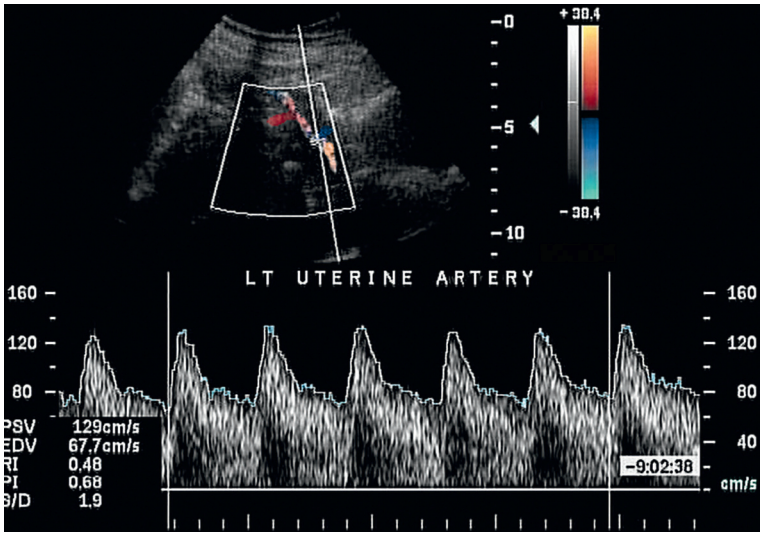

Fig. 1.61 Doppler velocimetry of the uterine artery is measured as the vessel crosses over the hypogastric artery and vein before entering the uterus at the uterine-cervical junction. In a normal state, uterine vasculature displays low impedance. The presence of a notch in the waveform and an increase in impedance characterizes an abnormal uterine circulation and may be associated with complications such as growth restriction, preeclampsia, and preterm delivery. *LT*, Left.

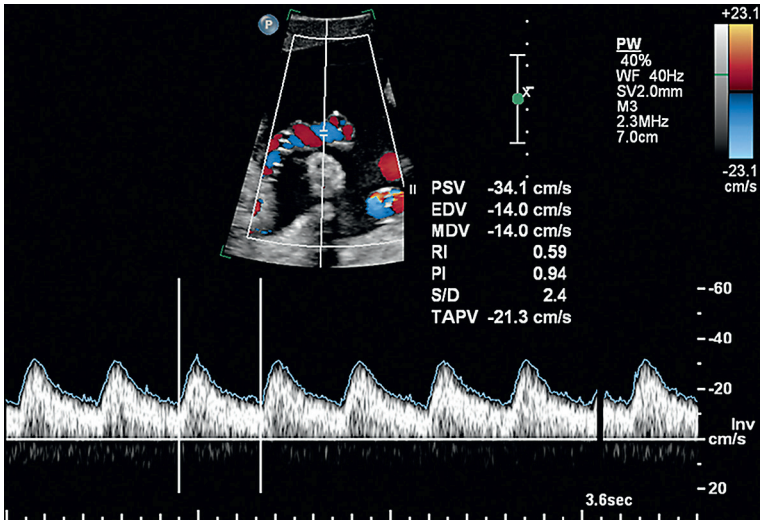

Fig. 1.62 Umbilical artery Doppler velocimetry (UADV) in the third trimester. Normally, an increase in end-diastolic flow is seen with advancing gestation. UADV is commonly used to assess the intrauterine and placental environment in the setting of intrauterine growth restriction and oligohydramnios. *EDV*, End diastolic velocity; *MDV*, mean diastolic velocity; *RI*, resistive index; *PI*, pulsatility index; *PSV*, peak systolic velocity; *S/D*, peak systolic velocity/end diastolic velocity; *TAPV*, time averaged peak velocity.

2 Congenital Cystic Adenomatoid Malformation of the Lung

ROGELIO CRUZ-MARTÍNEZ | MÓNICA CRUZ-LEMINI | EDUARD GRATACÓS

Introduction

Congenital cystic adenomatous malformations (CCAMs) of the lung represent the most common lung defect diagnosed prenatally.

CCAMs are intrapulmonary lesions with a typical hyperechoic appearance on ultrasound (US), with or without cystic components. Both sides of the lung, both sexes, and all races are equally affected. Most fetuses with CCAM are detected prenatally and have a good outcome, but appropriate identification and ongoing surveillance are required because of the unpredictability of growth patterns for CCAM masses.

Disorder

DEFINITION

CCAM is a developmental, nonhereditary, usually mixed (solid and cystic) lung mass consisting of abnormal hamartomatous or dysplastic lung tissue and bronchoalveolar structures thought to result from abnormal branching of the immature bronchioles during early stages of lung morphogenesis.[1]

PREVALENCE AND EPIDEMIOLOGY

CCAM is the most common fetal hyperechogenic lung lesion and accounts for 50% to 75% of detected fetal lung abnormalities.[2] These lesions may display dramatic changes during pregnancy, with spontaneous regression and total resolution in more than half of cases.[3,4] Thus, postnatal studies probably underestimate the real incidence of lung lesions, with a commonly quoted incidence of 1:25,000 to 1:35,000.[5] In prenatal studies performed in nonreferred populations, an incidence of 1:4000 to 1:6000 has been reported.[6] Prenatal diagnosis has dramatically increased as a result of improvement of US equipment over time, so the precise prevalence of prenatal CCAM is still unknown and might change in the future.

ETIOLOGY AND PATHOPHYSIOLOGY

CCAM is characterized by lack of normal alveoli and originates from a dysplastic overgrowth and cystic dilatation of terminal bronchioles with various types of epithelial lining.

CCAM may have a mainly solid, mainly cystic, or mixed appearance. Stocker et al.[7] described three types of lung lesions based on cyst diameter, which probably represent differences in the origin of the dysplastic lesion in the bronchial tree levels.

- *Type I* macrocystic CCAMs are characterized by single or multiple cysts greater than 2 cm in diameter, lined by ciliated pseudostratified columnar epithelium. These represent nearly 50% of CCAM cases in postnatal series. They frequently cause mediastinal compression, are rarely associated with other anomalies, and generally have a good prognosis.
- *Type II* lesions account for up to 40% of CCAMs, are single or multiple cysts less than 2 cm in diameter, and are lined with mixed ciliary, columnar, and cuboidal epithelium, with a thin underlying fibromuscular layer.
- *Type III* lesions are microcystic, predominantly solid lesions, with small cysts (<0.5 cm). These lesions represent 10% of CCAM lesions and are histologically composed of alveoluslike structures lined by ciliated cuboidal epithelium separated by microscopic masses lined with nonciliated cuboidal epithelium.

Thus, type I represents an anomaly of the more proximal part of bronchial tree, the principal bronchioles, whereas type III represents changes in the distal most peripheral alveolar tissues. Types II and III are more frequently associated with other anomalies and have graver prognosis.

Stocker et al.[7] later expanded his classification to include another two types. Type 0, acinar dysplasia or agenesis, is very rare, involves all the lung lobes, and is incompatible with life. Type IV CCAM lesions are represented by large, thin-walled peripheral cysts caused by hamartomatous malformation of the distal acinus.

Another, more clinically appropriate classification, based on US appearance, was introduced by Adzick et al.,[8] who divided prenatally diagnosed lung lesions into two groups: *macrocystic* (type I), with cysts greater than 5 mm, which is seen on US as a cystic mass, and *microcystic* (type II) with cysts smaller than 5 mm, which appear as solid echogenic lesions on US. The presence or absence of cysts is important because this determines options for therapy in cases of fetal hydrops.

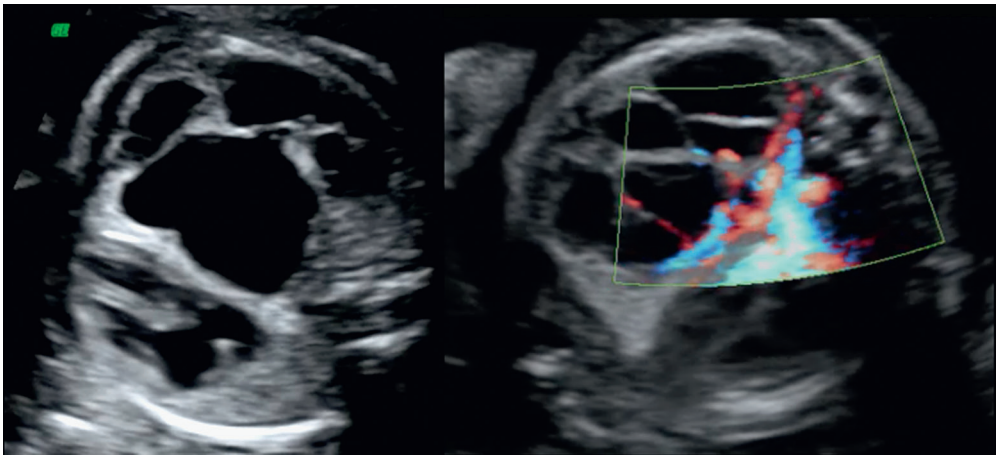

Fig. 2.1 US image of a 22-week fetus with a large macrocystic CCAM in the left lung. Significant mediastinal shift and pulmonary blood supply is note.

MANIFESTATIONS OF DISEASE

Clinical Presentation

A CCAM appears as a hyperechoic solid or cystic thoracic mass. Cysts may be single or multiple, small or occupying the entire volume of the mass. CCAM is usually unilateral and unilobar, with a slight predilection for the lower lobes of the lung. The mass is usually detected in the second trimester, commonly showing slight growth at the beginning. In half of cases, there is apparent prenatal resolution of the hyperechoic lesion, usually by around 32 weeks' gestation.[3] Large tumors are associated with mediastinal shift with displacement of the heart to the contralateral part of the thorax, flattening of the diaphragm, esophageal compression resulting in polyhydramnios, and direct cardiac compression and obstruction of venous return resulting in rare cases in hydrops fetalis.

The risk of chromosomal abnormalities is not increased significantly in isolated CCAM.[3,8] Associated anomalies are detected in 8%–12% of cases.[9,10] Commonly reported associated anomalies are renal defects, congenital diaphragmatic hernia, tracheoesophageal fistula, and congenital heart defects.[3,11,12]

The prognosis of prenatally diagnosed CCAM lesions depends on the size of the lesion and the degree of pulmonary hypoplasia, existence of associated anomalies, and development of fetal hydrops. Evaluation of the size of the lung mass by means of the *c*ystic adenomatoid malformation *v*olume *r*atio (CVR = length × height × width × 0.52 divided by the head circumference) is useful for predicting the development of hydrops.[13] A CVR greater than 1.6 presents a 75% risk to develop hydrops, whereas a CVR less than 1.5 has a 3% risk of hydrops.

Imaging Technique and Findings

Ultrasound. An echogenic cystic lung mass. The location, size, and existence of discrete lung cysts and blood supply must be evaluated using conventional spectral, color, or power Doppler US. Type I lesions are predominantly cystic masses with large cysts (Fig. 2.1), type II lesions are predominantly solid masses with small cysts (Fig. 2.2), and type III lesions are solid, homogeneous, hyperechoic masses (Fig. 2.3).

In all CCAM types, blood supply is classically from pulmonary vessels, but sometimes the masses may have a systemic vascular supply, similarly to bronchopulmonary sequestration (BPS)



Fig. 2.2 Sagittal section of a large CCAM with a mostly solid component but two medium-sized cysts.



Fig. 2.3 Axial section of a large microcystic CCAM. There is a uniformly hyperechoic solid mass in the left lung, which creates a significant mediastinal shift. The right normal lung is virtually invisible behind the heart.

(Chapter 3), and these are termed *hybrid CCAM-BPS lesions* (Fig. 2.4).

The work-up should include fetal echocardiography and comprehensive sonographic evaluation to rule out associated anomalies, hydrops and early manifestations of cardiac decompensation, such as appearance of tricuspid regurgitation, Doppler abnormalities of ductus venosus flow, and polyhydramnios. Karyotyping should be seriously considered, especially in cases with associated anomalies.

Fetuses with CCAM must be followed closely. Depending on the type and size of the lung lesion, US surveillance should be scheduled biweekly or weekly.

Magnetic Resonance Imaging. Magnetic resonance imaging (MRI) has been used to evaluate fetal lung masses but has not shown a substantial advantage over US (Fig. 2.5).

CLASSIC SIGNS

Echogenic unilateral, well-defined, solid or cystic lung lesion
Involves part of the lung, with predilection to the lower lobe
Absence of feeding arterial vessels arising from the systemic circulation

Differential Diagnosis From Imaging Findings

Several lung lesions should be considered in the differential diagnosis of CCAM:

1. *Intralobar bronchopulmonary sequestration*. A BPS is usually a well-circumscribed, echogenic solid mass that receives arterial blood from the systemic circulation. This feature is pathognomonic for this condition, but not always easily found. On US, BPS is indistinguishable from microcystic CCAM. As mentioned, cystic lesions clinically and histologically apparent as CCAM may have a systemic blood supply. There is no clear histologic distinction between these two entities and mixed forms (hybrids) are common.[14,15]
2. *Congenital lobar emphysema (CLE)*. CLE is lobar overinflation without destruction of the alveoli, usually located in the upper lobe of the lung. On US, CLE is indistinguishable from microcystic CCAM, and the nature of solid lesions sometimes can only be proven pathologically.
3. *Peripheral bronchial obstruction caused by bronchial atresia or bronchogenic cyst*. This lesion also appears as a solid, echogenic mass, involving a lobe or the entire lung. Dilatation of the

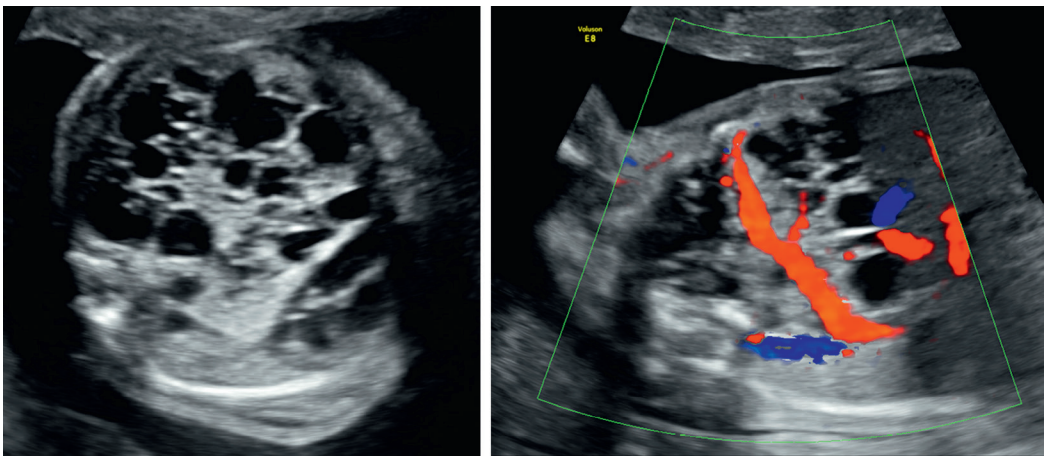

Fig. 2.4 Solid cystic mass in the left lung. Use of color Doppler allows visualization of an arterial supply vessel, which originates directly from the aorta leading to a diagnosis of CCAM-BPS hybrid.

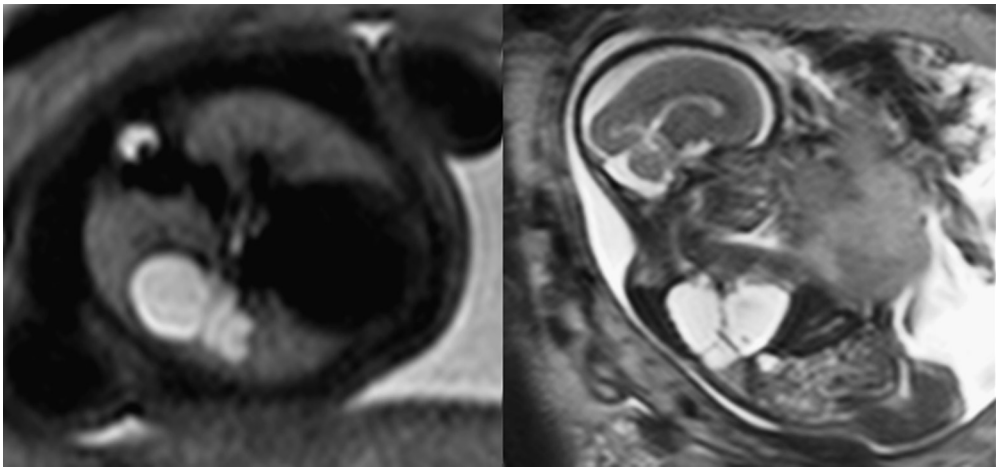

Fig. 2.5 MRI of a 29-week fetus with macrocystic CCAM. The transverse and sagittal views of the fetal thorax show hyperintensive cystic lesions in the right lung.

bronchial tree secondary to bronchial obstruction may help differentiate between bronchial atresia and CCAM.[16]

4. *Congenital diaphragmatic hernia (CDH)*. Evaluation of stomach position, observation of peristalsis of the loop of herniated intestine, and direct visualization of the diaphragm can be very useful in making the distinction.

Synopsis of Treatment Options

PRENATAL

Prenatal intervention should only be considered in selected cases with hydrops fetalis, normal karyotype and absence of associated anomalies. Significant mediastinal shift, polyhydramnios, or abnormal venous Doppler may indicate a very high risk of hydrops, but it is unclear whether fetal therapy should be indicated on these grounds.

Invasive Fetal Therapy

The spectrum of fetal interventions includes open fetal surgery,[17] cyst aspiration,[18] placement of thoracoamniotic shunt,[19,20] percutaneous laser ablation,[21] and fetal bronchoscopy.[16] Although a 50% success rate has been reported, open fetal surgical resection is controversial because of associated complications and the aggressiveness of the procedure.

The placement of a thoracoamniotic shunt is the technique of choice. The shunt is placed in the dominant cyst or in an area where the presence of cysts is most prominent.

If the shunt is correctly placed, CCAM volume reduction and rapid improvement in hydrops are observed in most cases.[12]

For cases of CCAM and hydrops diagnosed after 34 weeks' gestation, weekly aspirations might be an option to prolong pregnancy and improve fetal lung maturation with corticosteroids. The main goal in these cases would be to reach a sufficient weight to allow postnatal extracorporeal membrane oxygenation, usually 2 kg, which may be critical to ensure postnatal survival.

For microcystic lesions, where shunt placement or percutaneous aspiration is impossible, percutaneous laser ablation[21] or fetal bronchoscopy[16] has been proposed. Further studies are necessary to consider these techniques as a therapeutic option.

Medical Therapy

Maternal administration of betamethasone at doses normally used for fetal lung maturation has been reported to decrease the mass size and improve hydrops in a proportion of large complicated CCAM masses.[22,23] The mechanism is unknown, but it is postulated that steroids might accelerate lesion maturation or involution. Although the reported series are small, it seems reasonable that corticosteroids could be attempted as a first-line therapy, so that invasive treatment could be reserved for those cases progressing despite corticosteroid therapy.

POSTNATAL

Postnatal resection is the rule, although timing depends on any respiratory compromise. Resection can be deferred for weeks or months after birth if the infant is stable.

WHAT THE REFERRING PHYSICIAN NEEDS TO KNOW

CCAM is the most common cause of thoracic masses in the fetus. Prognosis is generally good as long as there is adequate residual normal lung tissue.

In the presence of hydrops, the perinatal mortality is almost 100%. Such cases should be referred to centers with experience in fetal interventions.

KEY POINTS

- The most common cause of fetal thoracic masses
- Often regress significantly before birth
- Characterized by a lack of normal alveoli and originates from a dysplastic overgrowth and cystic dilatation of terminal bronchioles with various types of epithelial lining
- Pulmonary arterial supply
- May overlap histologically with lung sequestration
- Common classifications systems based on size of visible cyst
- Prognosis depends on the size of the lung mass

SUGGESTED READING

Achiron R, Hegesh J, Yagel S. Fetal lung lesions: a spectrum of disease. New classification based on pathogenesis, two-dimensional and color Doppler ultrasound. *Ultrasound Obstet Gynecol*. 2004;24:107-114.

Achiron R, Zalel Y, Lipitz S, et al. Fetal lung dysplasia: clinical outcome based on a new classification system. *Ultrasound Obstet Gynecol*. 2004;24:127-133.

Adzick NS. Management of fetal lung lesions. *Clin Perinatol*. 2009;36:363-376.

Azizkhan RG, Chrombleholme TM. Congenital cystic lung disease: contemporary antenatal and postnatal management. *Pediat Surg Int*. 2008;24:643-657.

Cavoretto P, Molina F, Poggi S, et al. Prenatal diagnosis and outcome of echogenic fetal lung lesions. *Ultrasound Obstet Gynecol*. 2008;32:769-783.

Illanes S, Hunter A, Evans M, et al. Prenatal diagnosis of echogenic lung: evolution and outcome. *Ultrasound Obstet Gynecol*. 2005;26:145-149.



All references are available online at www.expertconsult.com.

REFERENCES

1. Harrison MR, Adzick NS, Jennings RW, et al. Antenatal intervention for congenital cystic adenomatoid malformation. *Lancet*. 1990;336:965-967.
2. Lecomte B, Hadden H, Coste K, et al. Hyperechoic congenital lung lesions in a non-selected population: from prenatal detection till perinatal management. *Prenat Diagn*. 2009;29:1222-1230.
3. Cavoretto P, Molina F, Poggi S, et al. Prenatal diagnosis and outcome of echogenic fetal lung lesions. *Ultrasound Obstet Gynecol*. 2008;32:769-783.
4. Laberge JM, Flageole H, Pugash D, et al. Outcome of the prenatally diagnosed congenital cystic adenomatoid lung malformation: a Canadian experience. *Fetal Diagn Ther*. 2001;16:178-186.
5. Laberge JM, Puligandla P, Flageole H. Asymptomatic congenital lung malformations. *Semin Pediatr Surg*. 2005;14:16-33.
6. Burge D, Wheeler R. Increasing incidence of detection of congenital lung lesions. *Pediatr Pulmonol*. 2010;45:103, author reply 104.
7. Stocker JT, Madewell JE, Drake RM. Congenital cystic adenomatoid malformation of the lung. Classification and morphologic spectrum. *Hum Pathol*. 1977;8:155-171.
8. Adzick NS, Harrison MR, Glick PL, et al. Fetal cystic adenomatoid malformation: prenatal diagnosis and natural history. *J Pediatr Surg*. 1985;20:483-488.
9. Bromley B, Parad R, Estroff JA, et al. Fetal lung masses: prenatal course and outcome. *J Ultrasound Med*. 1995;14:927-936, quiz p1378.
10. Thorpe-Beeston JG, Nicolaides KH. Cystic adenomatoid malformation of the lung: prenatal diagnosis and outcome. *Prenat Diagn*. 1994;14:677-688.
11. Husler MR, Wilson RD, Rychik J, et al. Prenatally diagnosed fetal lung lesions with associated conotruncal heart defects: is there a genetic association? *Prenat Diagn*. 2007;27:1123-1128.
12. Wilson RD, Hedrick HL, Liechty KW, et al. Cystic adenomatoid malformation of the lung: review of genetics, prenatal diagnosis, and in utero treatment. *Am J Med Genet A*. 2006;140:151-155.
13. Crombleholme TM, Coleman B, Hedrick H, et al. Cystic adenomatoid malformation volume ratio predicts outcome in prenatally diagnosed cystic adenomatoid malformation of the lung. *J Pediatr Surg*. 2002;37:331-338.
14. Hirose R, Suita S, Taguchi T, et al. Extralobar pulmonary sequestration mimicking cystic adenomatoid malformation in prenatal sonographic appearance and histological findings. *J Pediatr Surg*. 1995;30:1390-1393.
15. Rashad F, Grisoni E, Gaglione S. Aberrant arterial supply in congenital cystic adenomatoid malformation of the lung. *J Pediatr Surg*. 1988;23:1007-1008.
16. Cruz-Martinez R, Mendez A, Perez-Garcilita O, et al. Fetal bronchoscopy as a useful procedure in a case with prenatal diagnosis of congenital microcystic adenomatoid malformation. *Fetal Diagn Ther*. 2015;37:75-80.
17. Adzick NS. Open fetal surgery for life-threatening fetal anomalies. *Semin Fetal Neonatal Med*. 2010;15:1-8.
18. Brown MF, Lewis D, Brouillette RM, et al. Successful prenatal management of hydrops, caused by congenital cystic adenomatoid malformation, using serial aspirations. *J Pediatr Surg*. 1995;30:1098-1099.
19. Wilson RD, Baxter JK, Johnson MP, et al. Thoracoamniotic shunts: fetal treatment of pleural effusions and congenital cystic adenomatoid malformations. *Fetal Diagn Ther*. 2004;19:413-420.
20. Yokoyama T, Yamashita K, Nishiyama T, et al. A case of thoraco-amniotic shunt for congenital cystic adenomatoid malformation. *Masui*. 2005;54:287-290.
21. Bruner JP, Jarnagin BK, Reinisch L. Percutaneous laser ablation of fetal congenital cystic adenomatoid malformation: too little, too late? *Fetal Diagn Ther*. 2000;15:359-363.
22. Peranteau WH, Wilson RD, Liechty KW, et al. Effect of maternal betamethasone administration on prenatal congenital cystic adenomatoid malformation growth and fetal survival. *Fetal Diagn Ther*. 2007;22:365-371.
23. Tsao K, Hawgood S, Vu L, et al. Resolution of hydrops fetalis in congenital cystic adenomatoid malformation after prenatal steroid therapy. *J Pediatr Surg*. 2003;38:508-510.

3 Bronchopulmonary Sequestration

ROGELIO CRUZ-MARTÍNEZ | EDUARD GRATACÓS

Introduction

Bronchopulmonary sequestration (BPS) is a solid lung lesion of nonfunctioning pulmonary tissue, a supernumerary lobe of the lung, which lacks connection to the tracheobronchial tree and receives its blood supply from an aberrant systemic feeding artery, originating commonly from the descending aorta. Two forms are recognized: intralobar sequestration (ILS), which is

incorporated into normal lung tissue, and extralobar sequestration (ELS), which has its own pleural cover and is completely separated from the normal lung. ELS may also be outside the thoracic cavity.

Disorder

PREVALENCE AND EPIDEMIOLOGY

Bronchopulmonary sequestration is the second most common congenital lung anomaly after congenital cystic adenomatoid malformation (CCAM). ELS accounts for most cases of BPS diagnosed prenatally and 25% to 50% of cases of BPS diagnosed postnatally.[1] This difference in prenatal and postnatal prevalence is thought to be explained by the fact that many instances of ILS could be acquired postnatally.[2] ELS was reported to have 4:1 male predominance,[3] but recent series report a similar prevalence in both sexes.[4]

ETIOLOGY AND PATHOPHYSIOLOGY

Bronchopulmonary sequestration frequently occurs in the lower left lung. It is thought to originate from a supernumerary caudally positioned lung bud that migrated caudally during lung development together with the esophagus. Development before or after formation of the pleura leads to ILS or ELS, respectively.[3] ELS can be intrathoracic (usually on the left, comprising up to 50% of all cases); located in the anterior and posterior mediastinum (8% and 6%); or outside the chest cavity, most frequently below the diaphragm (up to 18% of cases).[4] ELS and ILS forms of BPS can coexist.[5] ELS has a systemic arterial blood supply from supradiaphragmatic or infradiaphragmatic vessels, normally originating directly from the aorta.[4] ELS masses usually, but not always, have venous connection to systemic vessels (superior vena cava, azygous vein, and hemiazygous vein), while ILS always drains to pulmonary veins.

MANIFESTATIONS OF DISEASE

Clinical Presentation

Extralobar sequestration is usually diagnosed prenatally as an intrathoracic or abdominal mass, with characteristic ultrasound (US) and Doppler features. The prenatal prognosis depends on the mass size and the presence of hydrothorax or hydrops. BPS generally has a good prognosis and a high rate of spontaneous resolution. Of BPS diagnosed prenatally, 75% of masses dramatically regress on serial prenatal US scanning, being detectable only by postnatal cross-sectional imaging studies.[6] The mechanism of regression could relate to spontaneous thrombosis of the systemic feeding artery.

A small proportion of cases show large masses that can cause massive hydrothorax and severe mediastinal shift with fetal hydrops. A possible additional mechanism for fetal hydrops is arteriovenous shunting through the lung mass and high-output cardiac failure. Compression of the esophagus can also cause polyhydramnios and preterm delivery in some cases.[7]

Neonatal outcome depends on several factors, as follows:

- Mass size and position. Large intrathoracic masses may lead to lung hypoplasia, mediastinal shift, and fetal hydrops owing to blood vessel compression. Intraabdominal ELS generally has a good prognosis.
- Development of massive pleural effusion and/or fetal hydrops. Those cases are usually at risk of intrauterine fetal demise.
- Associated anomalies.

Postnatally, ELS may be asymptomatic or manifest with respiratory distress, pneumonia, feeding difficulties, or high-output congestive heart failure owing to arteriovenous shunting through pathologic tissue.[8] The most common problem is repeated infections of the sequestered segment, which can require emergency resection of the sequestered lobe.[1] Clinical presentation is also influenced by associated anomalies, which are rare in cases of ELS.[6] Gastrointestinal tract anomalies, congenital heart disease, chest wall anomalies, diaphragmatic hernia, and vertebral deformities are most commonly described.[2,9,10]

The risk of chromosomal abnormalities has not been found to be significantly increased in isolated BPS.

Imaging Technique and Findings

Ultrasound. Bronchopulmonary sequestration typically appears as a hyperechogenic, mostly solid, homogeneous, well-defined lesion (Fig. 3.1). Usually detected in the second trimester, it commonly shows slight growth at the beginning and subsequent, sometimes dramatic, regression later during the pregnancy.[6] If ELS is situated below the diaphragm, it may be indistinguishable from a suprarenal mass. The pathognomonic sign of BPS is the presence of a systemic feeding artery that can be identified by using color or power Doppler US as arising from the descending aorta and entering into the lung mass (Fig. 3.2).

Hydrothorax may occur in rare cases of ELS. If large in size, the lung mass and hydrothorax can cause mediastinal shift and hydrops (Fig. 3.3). The mechanism for hydrothorax has been speculated to include also increased venous return because of shunting through the affected lung.[11]

Magnetic Resonance Imaging (MRI). Demonstration of the feeding vessel and differential diagnosis with other lung lesions can be also done using fetal MRI.[12,13] The initial MRI appearance in cases of BPS is a well-defined, triangular, homogeneous mass with a higher signal intensity than a normal lung on T2-weighted imaging and lower intensity than amniotic fluid. After partial regression, BPS lesions tend to decrease in signal intensity.

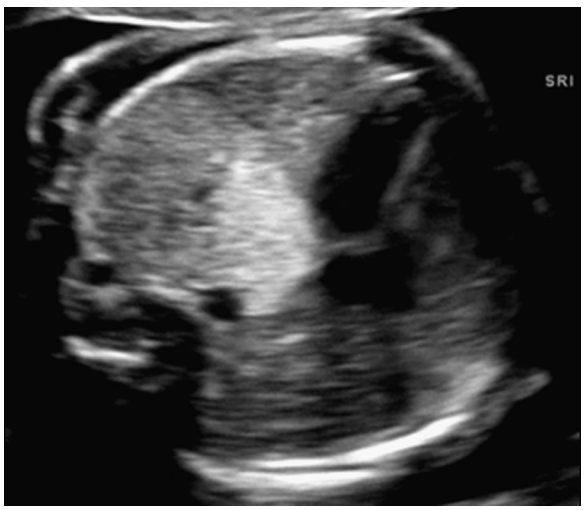

Fig. 3.1 Illustrative US image obtained in a 27-week fetus with BPS. The image demonstrates a transverse view of the fetal thorax showing a uniformly echogenic lesion that involves the inferior lobe of the left lung.

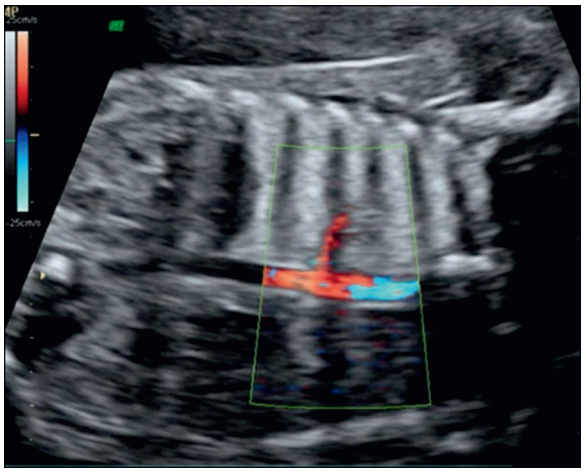

Fig. 3.2 Using color Doppler ultrasound, an aberrant branch of the aorta supplying the lung mass is visualized. Such finding is considered as pathognomonic sign of the BPS.

Visualization of the draining vein is more difficult because of poor resolution and tortuosity of the small veins.

CLASSIC SIGNS

Hyperechogenic solid lung mass or subdiaphragmatic abdominal mass
Systemic arterial blood support directly from aorta

Differential Diagnosis From Imaging Findings

1. *CCAM.* Appearance can occasionally be the same, but CCAM will not show the feeding vessel. However, in up to 40% of cases the mass is a CCAM-BPS hybrid, so that a cystic mass presents a systemic feeding artery.[14,15]
2. *Bronchial atresia (BA).* BA lesions commonly involve the whole lung, which appears hyperinflated and very echogenic, with eversion of the diaphragm. A clearly visible dilated bronchial tree distal to the obstruction is a clue for diagnosis of BA. Contrary to BPS, BA has blood support from pulmonary vessels.
3. *Scimitar syndrome.* This entity is characterized by hypoplasia of all or part of the right lung with abnormal pulmonary venous drainage into the inferior vena cava. An abnormal arterial supply to the hypoplastic lung from the aorta may be present, making this entity resemble BPS. In BPS, the mass is echogenic with sometimes contralateral mediastinal shift, whereas in scimitar syndrome, the lung is hypoplastic, not echogenic, and mediastinal shift is to the right (ipsilateral to the affected lung).[16]
4. *Suprarenal masses.* Subdiaphragmatic ELS may be very similar to rare suprarenal masses, such as neuroblastoma, mesonephric blastoma, or adrenal hemorrhage by identifying in ELS a systemic aberrant feeding artery. The US solid, echogenic appearance of ELS should help the distinction, and the contribution of MRI is normally very helpful for the differential diagnosis.[17] Careful outlining of the margins of the kidney and adrenal can help exclude those organs from involvement in suspected infradiaphragmatic sequestration.

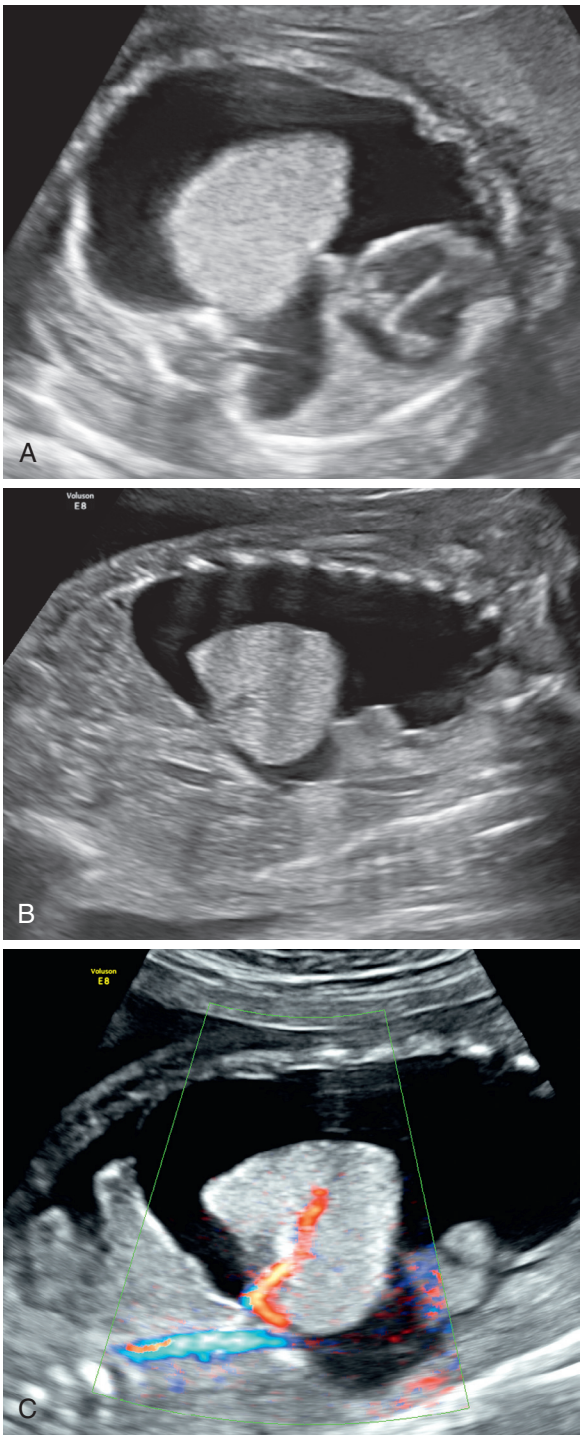

Fig. 3.3 US images obtained in a 26-week fetus with BPS and hydrops. Transverse (A) and sagittal (B) view of the fetal thorax show a hyperechogenic mass with massive hydrothorax and bilateral lung compression. A systemic feeding artery arising from the descending aorta is observed with power Doppler ultrasound (C).

Synopsis of Treatment Options

PRENATAL

A significant proportion of BPS cases regress prenatally. Thus, BPS with no evidence of fetal hydrothorax or hydrops can be managed expectantly, with biweekly prenatal follow-up evaluations assessing lung mass growth and early signs of complications,

such as polyhydramnios, pleural effusion, Doppler abnormalities in the ductus venosus, or hydrops. Development of hydrops earlier than 32–34 weeks' gestation may be an indication for fetal therapy. Open fetal surgery with intrauterine resection of the enlarged pulmonary lobe (lobectomy) has been offered showing a survival rate of about 50%,[18] but because of the high risks, it is virtually never done. Thoracoamniotic shunt is another option, particularly if there is massive pleural effusion,[19,20] but in very large masses the improvement could be limited. Percutaneous sclerotherapy with polidocanol injection into the feeding artery has also been performed.[21] However, this procedure carries the potential risk of alcohol dispersion into the systemic vasculature, and therefore further studies are necessary to consider this technique as a therapeutic option.[19] Other fetal interventions such as radiofrequency ablation of the feeding artery, interstitial laser therapy, and coil embolization have also been reported with variable results.[22] Percutaneous laser ablation of the feeding artery has recently been reported in one series, showing resolution of hydrops and hydrothorax, lung mass regression, and a survival rate in up to 100% with no need of neonatal surgery in virtually all cases.[23] Further studies may clarify the best therapeutic option for complicated BPS.

POSTNATAL

Aside from very rare complicated cases, the prognosis of BPS is in general excellent, with survival approaching 100%.[24] Delivery of fetuses with large masses or signs of cardiac compromise should be performed in centers with appropriate facilities for treatment of neonates with lung hypoplasia. The degree of pulmonary hypoplasia is the most important determinant for neonatal outcome. Different levels of ventilator support or extracorporeal membrane oxygenation and immediate thoracic surgery may be needed in some severe cases.

The initial method for evaluating pediatric chest disease remains the plain chest radiograph. When more precise description of a chest mass is required, pulmonary computed tomography (CT) with angiography is the best option.[25] CT offers the widest spectrum of applicability and CT angiography is also valuable in evaluating the feeding systemic vessel.

Virtually all cases of pulmonary sequestration in the long term require postnatal surgery with mass resection[1] to minimize the risk for infection and hemorrhage. Malignant transformation is not increased in cases of BPS.[4] Removal of the sequestration in the long-term follow-up allows compensatory lung growth in the remaining lung tissue.[26] Treatment with arterial embolization of the systemic feeding vessel has also been described, although this is not always successful.[27]

WHAT THE REFERRING PHYSICIAN NEEDS TO KNOW

Spontaneous regression can occur in the presence of small lung masses. Extensive fetal follow-up assessing lung mass growth and the presence of fetal effusions is required. Isolated cases are not at higher risk of chromosomal abnormalities. Large masses with hydrothorax or hydrops are associated with high perinatal mortality and should be referred to an experienced fetal surgery center. Delivery should occur at a tertiary center with neonatal surgery capabilities.

KEY POINTS

- BPS is a solid hyperechogenic mass
- Most cases occur above the diaphragm in the left lower lobe.
- BPS has a systemic feeding artery, which may be identified on prenatal ultrasound using color Doppler
- Hydrothorax or hydrops are indications for fetal intervention

SUGGESTED READING

Achiron R, Hegesh J, Yagel S. Fetal lung lesions: a spectrum of disease. New classification based on pathogenesis, two-dimensional and color Doppler ultrasound. *Ultrasound Obstet Gynecol*. 2004;24:107-114.

Adzick NS. Management of fetal lung lesions. *Clin Perinatol*. 2009;36:363-376.

Azizkhan RG, Crombleholme TM. Congenital cystic lung disease: contemporary antenatal and postnatal management. *Pediatr Surg Int*. 2008;24(6):643-657.

Cavoretto P, Molina F, Poggi S, et al. Prenatal diagnosis and outcome of echogenic fetal lung lesions. *Ultrasound Obstet Gynecol*. 2008;32:769-783.

Illanes S, Hunter A, Evans M, et al. Prenatal diagnosis of echogenic lung: evolution and outcome. *Ultrasound Obstet Gynecol*. 2005;26:145-149.

Witlox RS, Lopriore E, Oepkes D. Prenatal interventions for fetal lung lesions. *Prenat Diagn*. 2011;31:628-636.



All references are available online at www.expertconsult.com.

REFERENCES

1. Collin PP, Desjardins JG, Khan AH. Pulmonary sequestration. *J Pediatr Surg*. 1987;22:750-753.
2. Stocker JT. Sequestrations of the lung. *Semin Diagn Pathol*. 1986;3:106-121.
3. Carter R. Pulmonary sequestration. *Ann Thorac Surg*. 1969;7:68-88.
4. Conran RM, Stocker JT. Extralobar sequestration with frequently associated congenital cystic adenomatoid malformation, type 2: report of 50 cases. *Pediatr Dev Pathol*. 1999;2:454-463.
5. Wesley JR, Heidelberger KP, DiPietro MA, et al. Diagnosis and management of congenital cystic disease of the lung in children. *J Pediatr Surg*. 1986;21:202-207.
6. Adzick NS, Harrison MR, Crombleholme TM, et al. Fetal lung lesions: management and outcome. *Am J Obstet Gynecol*. 1998;179:884-889.
7. Dolkart LA, Reimers FT, Helmuth WV, et al. Antenatal diagnosis of pulmonary sequestration: a review. *Obstet Gynecol Surv*. 1992;47:515-520.
8. Landing BH, Dixon LG. Congenital malformations and genetic disorders of the respiratory tract (larynx, trachea, bronchi, and lungs). *Am Rev Respir Dis*. 1979;120:151-185.
9. Azizkhan RG, Crombleholme TM. Congenital cystic lung disease: contemporary antenatal and postnatal management. *Pediatr Surg Int*. 2008;24:643-657.
10. Ryckman FC, Rosenkrantz JG. Thoracic surgical problems in infancy and childhood. *Surg Clin North Am*. 1985;65:1423-1454.
11. Sade RM, Clouse M, Ellis FH Jr. The spectrum of pulmonary sequestration. *Ann Thorac Surg*. 1974;18:644-658.
12. Chen CP, Liu YP, Lin SP, et al. Prenatal magnetic resonance imaging demonstration of the systemic feeding artery of a pulmonary sequestration associated with in utero regression. *Prenat Diagn*. 2005;25:721-723.
13. Dhingsa R, Coakley FV, Albanese CT, et al. Prenatal sonography and MR imaging of pulmonary sequestration. *AJR Am J Roentgenol*. 2003;180:433-437.
14. Cass DL, Crombleholme TM, Howell LJ, et al. Cystic lung lesions with systemic arterial blood supply: a hybrid of congenital cystic adenomatoid malformation and bronchopulmonary sequestration. *J Pediatr Surg*. 1997;32:986-990.
15. Hirose R, Suita S, Taguchi T, et al. Extralobar pulmonary sequestration mimicking cystic adenomatoid malformation in prenatal sonographic appearance and histological findings. *J Pediatr Surg*. 1995;30:1390-1393.
16. Bhide A, Murphy D, Thilaganathan B, et al. Prenatal findings and differential diagnosis of scimitar syndrome and pulmonary sequestration. *Ultrasound Obstet Gynecol*. 2010;35:398-404.
17. Curtis MR, Mooney DP, Vaccaro TJ, et al. Prenatal ultrasound characterization of the suprarenal mass: distinction between neuroblastoma and subdiaphragmatic extralobar pulmonary sequestration. *J Ultrasound Med*. 1997;16:75-83.
18. Adzick NS. Open fetal surgery for life-threatening fetal anomalies. *Semin Fetal Neonatal Med*. 2010;15:1-8.
19. Cavoretto P, Molina F, Poggi S, et al. Prenatal diagnosis and outcome of echogenic fetal lung lesions. *Ultrasound Obstet Gynecol*. 2008;32:769-783.
20. Salomon LJ, Audibert F, Dommergues M, et al. Fetal thoracoamniotic shunting as the only treatment for pulmonary sequestration with hydrops: favorable long-term outcome without postnatal surgery. *Ultrasound Obstet Gynecol*. 2003;21:299-301.
21. Nicolini U, Cerri V, Groli C, et al. A new approach to prenatal treatment of extralobar pulmonary sequestration. *Prenat Diagn*. 2000;20:758-760.
22. Baud D, Windrim R, Kachura JR, et al. Minimally invasive fetal therapy for hydropic lung masses: three different approaches and review of the literature. *Ultrasound Obstet Gynecol*. 2013;42:440-448.
23. Cruz-Martinez R, Mendez A, Duenas-Riano J, et al. Fetal laser surgery prevents fetal death and avoids the need for neonatal sequestrectomy in cases with bronchopulmonary sequestration. *Ultrasound Obstet Gynecol*. 2015;46:627-628.
24. Lopoo JB, Goldstein RB, Lipshutz GS, et al. Fetal pulmonary sequestration: a favorable congenital lung lesion. *Obstet Gynecol*. 1999;94:567-571.
25. Stein SM, Cox JL, Hernanz-Schulman M, et al. Pediatric chest disease: evaluation by computerized tomography, magnetic resonance imaging, and ultrasonography. *South Med J*. 1992;85:735-742.
26. Corbett HJ, Humphrey GM. Pulmonary sequestration. *Paediatr Respir Rev*. 2004;5:59-68.
27. Curros F, Chigot V, Emond S, et al. Role of embolisation in the treatment of bronchopulmonary sequestration. *Pediatr Radiol*. 2000;30:769-773.

To access the videos in this chapter, scan this QR code or visit expertconsult.com

4 Hydrothorax

MÓNICA CRUZ-LEMINI | ROGELIO CRUZ-MARTÍNEZ | EDUARD GRATACÓS

Introduction

Fetal hydrothorax is an intrathoracic effusion arising in the fetus, which may occur unilaterally or bilaterally, and may be primary or secondary.[1,2]

Disease

DEFINITION

Fetal hydrothorax (also pleural effusion) is an intrathoracic effusion, which may occur unilaterally or bilaterally.[3,4] It constitutes a nonspecific finding, since it generally is the clinical manifestation of subjacent pathology.[4] If primary and isolated, it is termed *primary fetal hydrothorax*, and postnatally *chylothorax*.[5]

PREVALENCE AND EPIDEMIOLOGY

An uncommon finding, occurring in 1:8600 to 1:15,000 pregnancies,[1,6] with male fetuses affected more frequently than female (2:1).[7]

ETIOLOGY AND PATHOPHYSIOLOGY

There is a wide range of potential etiologies.[2–4,8] Hydrothorax is more commonly part of a more complex disease, and frequently associated with hydrops:

- cardiovascular disease (50%) and fetal arrhythmias
- structural malformations (25%), particularly pulmonary abnormalities such as congenital cystic adenomatoid malformation (CCAM), bronchopulmonary sequestration (BPS), or congenital diaphragmatic hernia (CDH)[4,9–11]
- chromosomal defects (6%–17%), most commonly trisomy 21 and Turner syndrome
- hematologic conditions (alloimmunization)
- infections (toxoplasmosis, rubella, cytomegalovirus, syphilis, herpes, and parvovirus B19)
- lung and digestive disorders
- metabolic disorders (congenital goiter)
- anomalies in the umbilical cord and placenta

Primary fetal hydrothorax is a diagnosis of exclusion,[5] which cannot conclusively be confirmed prenatally.[6,12]

The main pathophysiologic consequences of hydrothorax are lung hypoplasia and hydrops due to mediastinal shift,[12] caused by compression of the heart and obstruction of venous return. Additionally, compression of the esophagus may lead to polyhydramnios.[4,9,13]

The diagnosis of hydrothorax warrants a thorough investigation of potential causes. Detailed ultrasound (US) and karyotyping, primarily looking for trisomy 21, Turner syndrome, and other aneuploidies, are mandatory.[14] More advanced genetic testing may help in isolated cases, and potential genes associated with the disease have been described.[15] As mentioned, primary hydrothorax is an exclusion diagnosis that can only be confirmed postnatally.[12,16]

MANIFESTATIONS OF DISEASE

Clinical Presentation

The diagnosis can be made by identification of isolated fluid effusion surrounding one or both fetal lungs, under variable forms, from a mild unilateral effusion to massive bilateral effusion. A proportion of cases present as fetal hydrops, which may hamper discerning whether hydrothorax was first, and thus the cause of hydrops, or whether it is part of a general problem.

For isolated hydrothorax, when the onset is in the form of a mild pleural effusion, the evolution is hard to predict. Some cases remain stable for the remainder of the pregnancy whereas some evolve to severe hydrothorax.[5,12] Severe cases virtually always evolve to hydrops.

One of the main concerns is the underlying disease causing the problem. Bilateral effusions, severe hydrothorax with significant lung/mediastinal compression and hydrops constitute poor prognostic signs.[3,8–11,17] Parents must be warned that even in the event of successful prenatal therapy, there remains a risk of underlying potentially severe diseases, which will become evident only after birth. Chylothorax has been associated with mosaicism and various genetic disorders, some of which have recently been described, associated to gene mutations.[14,15]

Imaging Technique and Findings

Ultrasound. The diagnosis is made based on the presence of free fluid in the thoracic cavity, unilaterally or bilaterally.[4,18] The lung floats freely in the pleural cavity. In severe cases, the lung is much reduced in size and has a characteristic butterfly appearance,

floating in free fluid and moving with the heart beats. Unilateral severe cases present with severe mediastinal shift and compression of the contralateral lung.[17] Defining hydrothorax as mild, moderate, or severe is based on subjective factors including the degree of lung compression and mediastinal shift (Figs. 4.1 and 4.2).

As mentioned, when the diagnosis is first made in the context of fetal hydrops, it is difficult to discern whether the thoracic effusion is the cause or consequence of hydrops.[5,11,17,19]

Magnetic Resonance Imaging. Magnetic Resonance Imaging (MRI) does not provide additional information in primary fetal hydrothorax, but it may help ruling out associated abnormalities, such as CCAM, BPS, or CDH, where the primary pathology dictates management.[9]



Fig. 4.1 Unilateral right hydrothorax. Note the significant mediastinal shift and the compression of the contralateral lung. In spite of the unilateral presentation, the fetus presents subcutaneous edema, which in most cases will evolve rapidly to generalized hydrops fetalis.



Fig. 4.2 Bilateral severe hydrothorax in a hydropic fetus at 33 weeks. Note the typical compressed appearance of the lungs, floating in the free fluid. There is no mediastinal shift because the pressure at each hemithorax is mutually compensated.

CLASSIC SIGNS

Presence of free fluid surrounding the lung, either unilaterally or bilaterally.

Differential Diagnosis From Imaging Findings

Diagnosis is normally very straightforward.

Differential diagnosis can only be challenging in rare cases of massive pericardial effusion, which in some cases may be large enough to occupy half of the thoracic area. However, in such cases, free fluid surrounds the heart, with the lungs being compressed posteriorly and in close contact with the thoracic wall[4,8–10] (Videos 4.1 and 4.2).

Synopsis of Treatment Options

PRENATAL

Prenatal evolution is variable, with 10% to 20% of isolated hydrothorax resolving spontaneously and with good postnatal outcome.[20] This is also true for mild to moderate effusions that remain stable during pregnancy, with a fair number of cases presenting a good outcome with postnatal treatment.[5,20]

Invasive fetal therapy for fetal hydrothorax should be reserved for severe isolated cases.[12,17,19] Treatment aims at reducing the risk of lung hypoplasia and preventing hydrops, which are substantial in such cases. Therefore even in the absence of hydrops, treatment is normally considered in unilateral cases with very significant mediastinal shift, particularly if there is accompanying polyhydramnios.

It can be controversial whether to place a shunt in a severely hydropic fetus. A reasonable approach would be that once other causes have been ruled out, and if there is clear presence of severe hydrothorax, shunt placement could be discussed with parents as an option, which might substantially improve the situation if the primary cause of the hydrops was the pleural effusion. Treating hydropic fetuses with mild or moderate forms of pleural effusion should be strongly discouraged.[5,11,12,20–23]

Some centers perform a single drainage by thoracocentesis before placing a thoracoamniotic shunt. This allows detailed examination of the heart after decompression, as well as evaluation of the ability to reinflate the lungs. It also allows characterization of the lung fluid, although in most cases the results are nonspecific. Lung fluid can also be used for karyotyping due to the elevated amount of leukocytes. Although pressure might be adequately relieved, in most cases the fluid is restituted within 24 hours, so that prolonged decompression is required.[5,11,21,22] Pleuroamniotic shunting comprises the introduction of a double pigtail catheter into the thoracic cavity by US guidance and allows permanent thoracic decompression. In bilateral cases, one shunt must be placed at each hemithorax.[1,5,11,13,21,22] Perinatal mortality without treatment may be greater than 90% if cases are properly selected.[7,24] Mortality rates are reduced but remain high, about 10% to 30% for nonhydropic and as high as 50% to 60% in bilateral hydropic cases.[5,12,13,17,25] This high mortality is explained by a combination of prematurity as a complication of the fetal intervention, lung hypoplasia that could not be reversed in spite of decompression, underlying severe diseases, and/or suboptimal shunt placement and thoracic decompression.[5,12,13,17]

The use of OK-432, a lyophilized incubation mixture of group A *Streptococcus pyogenes* of human origin, has been described to treat fetal chylothorax, with promising results.[26,27] OK-432 is a biologic modifier hypothesized to directly inhibit and cease fluid production by lymphatic vessels, and additionally generate pleural adherence (pleurodesis). A recent review has reported survival rates of 78% in hydropic fetuses with this treatment, but further studies are required to compare its use to pleuroamniotic shunting.[28]

For very late diagnosis beyond term, scheduled cesarean section with previous US-guided thoracic drainage just before fetal extraction could be considered. This intervention allows lung expansion and reduces the need of emergency drainage by the neonatologist, thereby preventing delays in proper neonatal respiratory support.[29] There is no published data to support the benefit of this strategy, but it is commonly followed at many centers.

POSTNATAL

Severe hydrothorax requires immediate neonatal care. In cases treated with pleuroamniotic shunting the catheter must be immediately clamped after fetal extraction to avoid neonatal pneumothorax at birth.[12]

A prenatal diagnosis of primary fetal hydrothorax must be confirmed in the newborn. Neonatal terminology usually refers to pleural effusion as *chylothorax*, a term that strictly speaking must be reserved for the postnatal period, since in the absence of nutrition there is no production of chyle.

The presence or absence of an underlying disease will determine postnatal evolution. In isolated cases, postnatal management is normally conservative and is based on the use of thoracic drainage if required, triglyceride-deprived diet, and occasionally somatostatin analogs (octreotide). In most cases, the effusion resolves over time, and only in rare persisting cases ligation of the thoracic duct is required.[16,30]

WHAT THE REFERRING PHYSICIAN NEEDS TO KNOW

- Fetal hydrothorax is a sign with multiple potential etiologies.
- In general, unilateral mild cases are primary abnormalities of the lymphatic drainage system and have good prognosis.
- Severe cases are associated with a poor prognosis, and pleuroamniotic shunting should be offered. Prenatal therapy improves the mortality rate substantially, but bilateral hydropic cases will present high mortality rates.

KEY POINTS

- Accumulation of fluid in the pleural space, which may occur unilaterally or bilaterally, and may be primary or secondary.
- Cardiac, pulmonary, or chromosomal abnormalities associated with 80% of cases.
- Primary fetal hydrothorax is an exclusion diagnosis.
- A common indication for fetal therapy, which may substantially improve prognosis, particularly in severe nonhydropic and/or unilateral cases.

SUGGESTED READINGS

Deurloo KL, Devlieger R, Lopriore E, et al. Isolated fetal hydrothorax with hydrops: a systematic review of prenatal treatment options. *Prenat Diagn*. 2007;27(10):893-899.

Gratacós E, et al. *Medicina Fetal*. 1st ed. Barcelona: Médica Panamericana (ME); 2007.

Ruano R, Ramalho AS, Cardoso AK, et al. Prenatal diagnosis and natural history of fetuses presenting with pleural effusion. *Prenat Diagn*. 2011;5:496-499.

Yinon Y, Kelly E, Ryan G. Fetal pleural effusions. *Best Pract Res Clin Obstet Gynaecol*. 2008;22(1):77-96.



All references are available online at www.expertconsult.com.

REFERENCES

1. Yinon Y, Grisaru-Granovsky S, Chaddha V, et al. Perinatal outcome following fetal chest shunt insertion for pleural effusion. *Ultrasound Obstet Gynecol*. 2010;36:58-64.
2. Ruano R, Ramalho AS, Cardoso AK, et al. Prenatal diagnosis and natural history of fetuses presenting with pleural effusion. *Prenat Diagn*. 2011;31:496-499.
3. Gratacós E, et al. *Medicina Fetal*. 1st ed. Barcelona: Médica Panamericana (ME); 2007.
4. Yinon Y, Kelly E, Ryan G. Fetal pleural effusions. *Best Pract Res Clin Obstet Gynaecol*. 2008;22:77-96.
5. Deurloo KL, Devlieger R, Lopriore E, et al. Isolated fetal hydrothorax with hydrops: a systematic review of prenatal treatment options. *Prenat Diagn*. 2007;27:893-899.
6. Bellini C, Ergaz Z, Boccardo F, et al. Dynamics of pleural fluid effusion and chylothorax in the fetus and newborn: role of the lymphatic system. *Lymphology*. 2013;46:75-84.
7. Derderian SC, Trivedi S, Farrell J, et al. Outcomes of fetal intervention for primary hydrothorax. *J Pediatr Surg*. 2014;49:900-903, discussion 903-904.
8. Paladini D. Ultrasound of congenital fetal anomalies. *Differential diagnosis and prognostic indicators.* Informa UK Ltd, 2007.
9. Pumberger W, Hormann M, Deutinger J, et al. Longitudinal observation of antenatally detected congenital lung malformations (CLM): natural history, clinical outcome and long-term follow-up. *Eur J Cardiothorac Surg*. 2003;24:703-711.
10. Knox EM, Kilby MD, Martin WL, et al. In-utero pulmonary drainage in the management of primary hydrothorax and congenital cystic lung lesion: a systematic review. *Ultrasound Obstet Gynecol*. 2006;28:726-734.
11. Hayashi S, Sago H, Kitano Y, et al. Fetal pleuroamniotic shunting for bronchopulmonary sequestration with hydrops. *Ultrasound Obstet Gynecol*. 2006;28:963-967.
12. Bianchi S, Lista G, Castoldi F, et al. Congenital primary hydrothorax: effect of thoracoamniotic shunting on neonatal clinical outcome. *J Matern Fetal Neonatal Med*. 2010;23:1225-1229.
13. Hache JJ, Emery SP, Vallejo MC. Bilateral fetal hydrothorax requiring intrauterine fetal thoracoamniotic shunts: anesthetic considerations and management. *ScientificWorldJournal*. 2009;9:435-440.
14. Cremonini G, Poggi A, Capucci R, et al. Rare case of massive congenital bilateral chylothorax in a hydropic fetus with true mosaicism 47,XXX/46,XX. *J Obstet Gynaecol Res*. 2014;40:259-262.
15. Bulow L, Lissewski C, Bressel R, et al. Hydrops, fetal pleural effusions, and chylothorax in three patients with CBL mutations. *Am J Med Genet A*. 2015;167A:394-399.
16. Siu SL, Lam DS. Spontaneous neonatal chylothorax treated with octreotide. *J Paediatr Child Health*. 2006;42:65-67.
17. Alkazaleh F, Saleem M, Badran E. Intrathoracic displacement of pleuroamniotic shunt after successful in utero treatment of fetal hydrops secondary to hydrothorax. Case report and review of the literature. *Fetal Diagn Ther*. 2009;25:40-43.
18. Favre R. Diagnosis and treatment of fetal pleural effusions. *Arch Pediatr*. 2010;17:695-696.
19. Witlox RS, Lopriore E, Walther FJ, et al. Single-needle laser treatment with drainage of hydrothorax in fetal bronchopulmonary sequestration with hydrops. *Ultrasound Obstet Gynecol*. 2009;34:355-357.
20. Petersen S, Kaur R, Thomas JT, et al. The outcome of isolated primary fetal hydrothorax: a 10-year review from a tertiary center. *Fetal Diagn Ther*. 2013;34:69-76.
21. National Institute for Health and Clinical Excellence. *Insertion of pleuroamniotic shunt for fetal pleural effusion*. London: National Institute for Health and Clinical Excellence; 2006.
22. Picone O, Benachi A, Mandelbrot L, et al. Thoracoamniotic shunting for fetal pleural effusions with hydrops. *Am J Obstet Gynecol*. 2004;191:2047-2050.
23. Deurloo K, Devlieger R, Oepkes D. Maternal hydrops syndrome following successful treatment of fetal hydrops by shunting of bilateral hydrothorax. *Prenat Diagn*. 2003;23:944-945.
24. Pellegrinelli JM, Kohler A, Kohler M, et al. Prenatal management and thoracoamniotic shunting in primary fetal pleural effusions: a single centre experience. *Prenat Diagn*. 2012;32:467-471.
25. Miyoshi T, Katsuragi S, Ikeda T, et al. Retrospective review of thoracoamniotic shunting using a double-basket catheter for fetal chylothorax. *Fetal Diagn Ther*. 2013;34:19-25.
26. Tsukihara A, Tanemura M, Suzuki Y, et al. Reduction of pleural effusion by OK-432 in a fetus complicated with congenital hydrothorax. *Fetal Diagn Ther*. 2004;19:327-331.
27. Yang YS, Ma GC, Shih JC, et al. Experimental treatment of bilateral fetal chylothorax using in-utero pleurodesis. *Ultrasound Obstet Gynecol*. 2012;39:56-62.
28. O'Brien B, Kesby G, Ogle R, et al. Treatment of primary fetal hydrothorax with OK-432 (Picibanil): outcome in 14 fetuses and a review of the literature. *Fetal Diagn Ther*. 2015;37:259-266.
29. Henry PY, Aravindan CS, Sivakumar K, et al. Extrauterine intrapartum treatment (EXIT) in bilateral primary fetal hydrothorax. *Indian J Pediatr*. 2009;76:99-101.
30. Ergaz Z, Bar-Oz B, Yatsiv I, et al. Congenital chylothorax: clinical course and prognostic significance. *Pediatr Pulmonol*. 2009;44:806-811.

5 Scimitar Syndrome

ROGELIO CRUZ-MARTÍNEZ | EDUARD GRATACÓS

Introduction

Scimitar syndrome (SS) is a rare congenital anomaly characterized by a partial (usually the right lower lobe) or complete unilateral anomalous pulmonary venous drainage in association with ipsilateral lung hypoplasia.[1] The anomaly, also known as *pulmonary venolobar syndrome* or *hypogenetic lung syndrome*, was first described in 1836.[2] The term *scimitar* was first used by Halasz et al.[3] to describe the radiographic appearance of the anomalous pulmonary vein trajectory that drains into the inferior vena cava (IVC) just below or above the right hemidiaphragm as a broad, gently curved shadow resembling the silhouette of a short, curved Persian sword known as a *shimshir*. In 1960,[4] the familial occurrence and the clinical spectrum were defined first using the term *scimitar syndrome*.

Disorder

DEFINITION

SS is a congenital pulmonary anomaly consisting of an anomalous vein that drains part or all of the right lung blood flow into the systemic venous circulation, usually the IVC, associated with an ipsilateral pulmonary hypoplasia, underdevelopment of the right pulmonary artery, and sometimes an anomalous systemic arterial supply from the descending aorta to the hypoplastic lung.[5]

Although SS has been classically described as involving the right lung, this might be due to the extreme rarity of a left-sided vena cava, because some case reports of left-sided SS have also been described.[6–8]

PREVALENCE AND EPIDEMIOLOGY

Most cases reported were in adults or older children, accounting for 1:2000 cases of congenital heart disease.[9] Only a few prenatal cases have been reported,[10–12] with an estimated incidence of 1:100,000 to 3:100,000 live births and a clear female predominance.[9,13]

ETIOLOGY AND PATHOPHYSIOLOGY

Isolated SS is usually sporadic and not associated with chromosomal or genetic abnormalities, but in the presence of associated malformations, the risk of chromosomal defects increases to 50%. Association with other malformations is common, including congenital heart disease in 75%, lung congenital cystic malformations, congenital diaphragmatic hernia (CDH), and vertebral anomalies.[11,14–16] The most commonly reported congenital heart malformation is persistent left superior vena cava draining to the coronary sinus[17]; other abnormalities that have been described include tetralogy of Fallot, coarctation of the aorta, abnormalities of the aortic arch, atrial septal defects, absent IVC, and pulmonary vein stenosis contralateral to the hypoplastic lung.[11,12,14,18,19]

The pathogenetic mechanism of SS is unclear. It seems to originate from an abnormal lung development during embryogenesis.[20] It has been hypothesized that connections between the pulmonary and systemic plexus of capillaries normally present during embryonic development remain patent, leading to pulmonary hypoplasia and underdevelopment of the ipsilateral pulmonary artery. There is no evidence of the influence of common teratogens in the genesis of SS.

MANIFESTATIONS OF DISEASE

Clinical Presentation

There are often no prenatal manifestations. Hypoplasia of the right lung may cause a rightward shift of the heart. SS is usually a nonlethal anomaly. Although extremely rare, coexistence with stenosis of the pulmonary vein contralateral to the hypoplastic lung may be associated with a high neonatal mortality rate.[18]

In the absence of additional congenital malformations, the prognosis depends on the degree of lung hypoplasia and the presence of abnormal arterial blood supply to the affected lung, which can lead to pulmonary hypertension with a left-to-right cardiac shunt in 50% of the cases.[9] In cases with mild pulmonary hypoplasia and an absence of any abnormal systemic artery supplying the right lung, the prognosis is normally good. In many instances, the condition is asymptomatic after birth and remains clinically silent for a long time, sometimes to adulthood. In more severe cases manifesting in infancy and childhood, common clinical manifestations are dyspnea, cyanosis, respiratory distress or cardiac failure owing to increased pulmonary blood flow secondary to the aberrant pulmonary arterial supply, and recurrent respiratory tract infections during infancy.[9,21]

Diagnosis

Prenatal ultrasound (US) is characterized by anomalous drainage of any pulmonary vein (Figs. 5.1 and 5.2) together with ipsilateral lung hypoplasia and mediastinal shift. SS can usually be detected on US during the second trimester of pregnancy. The anomalous venous drainage is usually into the IVC below the diaphragm but may join with the hepatic vein, portal vein, coronary sinus, right atrium,[1,14] or more unusually, with the superior vena cava[22] or the left atrium.[23]

When SS is suspected prenatally, the diagnosis must be confirmed postnatally by radiography, angiography or transthoracic or transesophageal echocardiography, noninvasive computed tomography (CT), or magnetic resonance angiography (MRA). The most evident postnatal sign is the radiologic presence of the mediastinal shift. The typical pathognomonic finding is the postnatal radiographic identification of the classic *scimitar sign*—an anomalous pulmonary vein appearing as a curvilinear density in the right lower lobe directed toward the right hemidiaphragm.

Imaging Technique and Findings

Ultrasound. Several prenatal US findings of this entity have been described consisting of signs related to abnormal lung development.[11]

- In axial views, there is a clear mediastinal shift to the right, secondary to right-lung hypoplasia with normal abdominal situs. There is an apparent reduction in the size of the right lung but with no signs suggesting CDH or a pulmonary mass.[10]

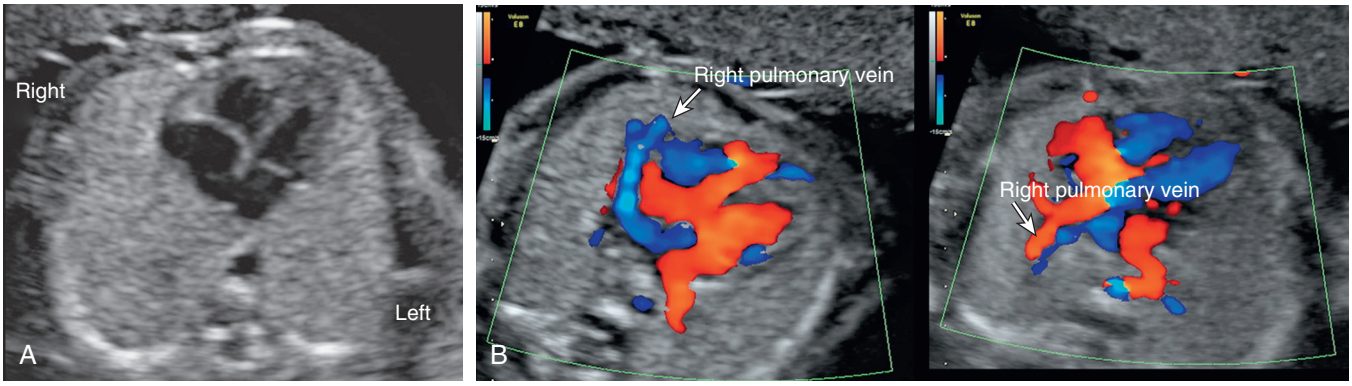

Fig. 5.1 Ultrasound images obtained from a normal fetus. (A) The right lung is normally higher than left lung. (B) Using spectral Doppler US, both right pulmonary veins *(arrows)* draining into the left atrium are observed.

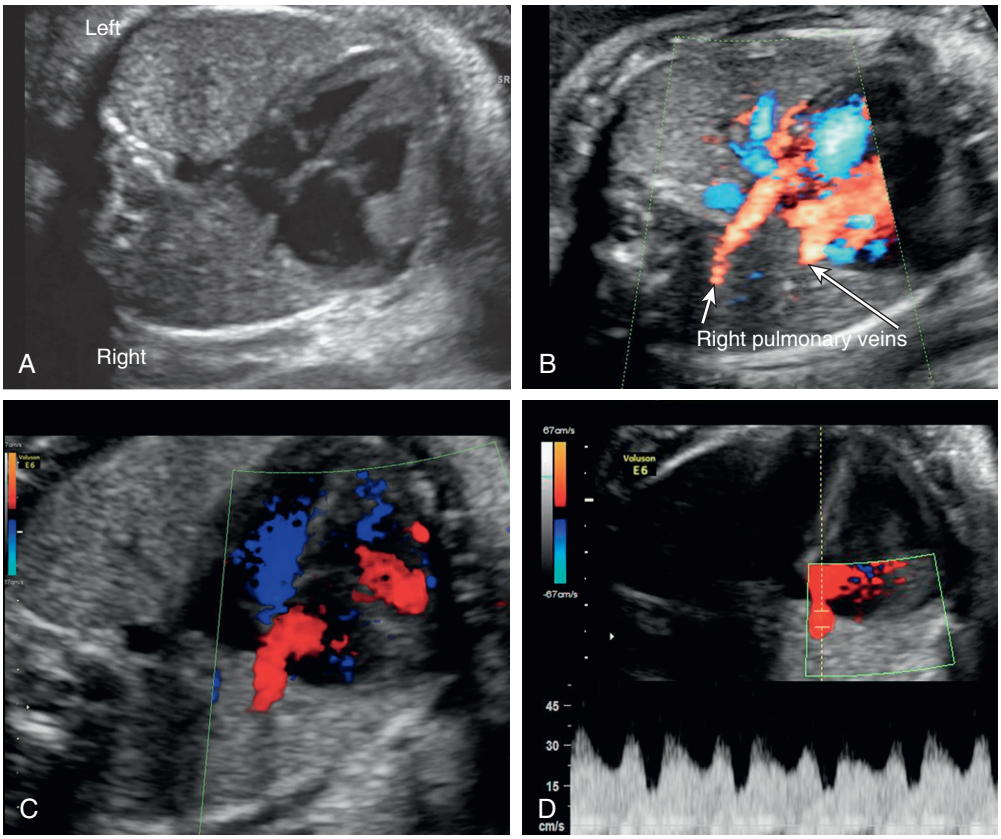

Fig. 5.2 Ultrasound image obtained in a 25-week fetus with SS. This transverse view of the fetal thorax shows mild dextroposition of the heart. (A) The affected lung appears decreased in size and with normal echogenicity compared to the left lung. (B) Using spectral Doppler US, anomalous pulmonary venous drainage into the right atrium is observed. (C, D) The anomalous right pulmonary vein draining into the right atrium (C) that is confirmed by visualization of a venous Doppler waveform (D).

- Anomalous drainage of a pulmonary vein to the IVC and mild narrowing of the right pulmonary artery can be detected using spectral or power Doppler US, but detection is extremely difficult or impossible in most cases because of the small size of the vessels, lower systemic blood pressure, and pulmonary impedance during fetal life.[10,12] Aberrant drainage can be shown in only 70% of the cases by postnatal cardiac catheterization.[10]

Magnetic Resonance Imaging. Postnatal magnetic resonance imaging (MRI) or computed tomography (CT) can confirm the anomalous pulmonary vein and can be useful in the differential diagnosis of other congenital lung lesions such as CDH, bronchopulmonary sequestration (BPS), or bronchial anomalies. In addition, MRI plays an important role in assessing the presence of an additional anomalous arterial blood supply into the fetal lung.[24] This information is clinically important in planning surgical treatment. Data on prenatal use of MRI are unavailable.

Differential Diagnosis From Imaging Findings

Differential diagnosis must be established with other pulmonary defects, including CDH and bronchopulmonary sequestration (BPS). PS shows overlapping features or may coexist in 50% to 60% of cases.[25] The differential diagnosis of CDH should be straightforward when the homogeneous US appearance of the lung parenchyma is confirmed. Regarding PS, the differential diagnosis should be easy in most cases when the following features are considered:

1. SS mainly affects the right lung, whereas BPS often affects the left lung.
2. Lung echogenicity in SS is not increased, whereas it tends to be increased in BPS.
3. Abnormal systemic arterial supply is normally not found in SS.[10]
4. Mediastinal shift is rare in BPS, and if present, it is contralateral to (i.e., away from) the affected lung.

Synopsis of Treatment Options

PRENATAL

None

POSTNATAL

SS seldom requires surgical correction. Surgery is indicated for cases with severe symptoms or cases with significant pulmonary hypertension with left-to-right shunt. If the anomalous systemic arterial blood supply to the hypoplastic lung is confirmed postnatally, embolization of the abnormal arteries is a postnatal management option. Similarly, cases with left-to-right shunt

could be surgically treated by redirecting the scimitar vein into the left atrium.[26] In addition, pulmonary lobectomy may be indicated for cases with repeated lung infections. In contrast, cases with isolated anomalous pulmonary venous drainage usually require no postnatal intervention.

WHAT THE REFERRING PHYSICIAN NEEDS TO KNOW

- SS is a rare fetal defect that must be considered on the list of possible diagnosis causing rightward mediastinal shift.
- Pulmonary venous drainage is often abnormal, but demonstration in utero is extremely challenging and may be impossible.
- The risk of associated anomalies is high. If SS is suspected, advanced echocardiography must be performed to exclude additional congenital heart malformations.

KEY POINTS

- Rare cause of right mediastinal shift.
- Right-lung hypoplasia together with anomalous right pulmonary venous drainage (normally not evident prenatally).
- High association with cardiac defects.
- Scimitar sign is a pathognomonic feature but refers to postnatal findings.

SUGGESTED READING

Bhide A, Murphy D, Thilaganathan B, et al. Prenatal findings and differential diagnosis of scimitar syndrome and pulmonary sequestration. *Ultrasound Obstet Gynecol*. 2010;35:398-404.

Grisaru D, Achiron R, Lipitz S, et al. Antenatal sonographic findings associated with scimitar syndrome. *Ultrasound Obstet Gynecol*. 1996;8:131-133.

Midyat L, Demir E, Askin M, et al. Eponym. Scimitar syndrome. *Eur J Pediatr*. 2010;169:1171-1177.



All references are available online at www.expertconsult.com.

REFERENCES

1. Biyyam DR, Chapman T, Ferguson MR, et al. Congenital lung abnormalities: embryologic features, prenatal diagnosis, and postnatal radiologic-pathologic correlation. *Radiographics*. 2010;30:1721-1738.
2. Cooper G. Case of malformation of the thoracic viscera consisting of imperfect development of the right lung and transposition of the heart. *London Med Gaz*. 1836;18:600-601.
3. Halasz NA, Halloran KH, Liebow AA. Bronchial and arterial anomalies with drainage of the right lung into the inferior vena cava. *Circulation*. 1956;14:826-846.
4. Neill CA, Ferencz C, Sabiston DC, et al. The familial occurrence of hypoplastic right lung with systemic arterial supply and venous drainage "scimitar syndrome". *Bull Johns Hopkins Hosp*. 1960;107:1-21.
5. Midyat L, Demir E, Askin M, et al. Eponym. Scimitar syndrome. *Eur J Pediatr*. 2010;169:1171-1177.
6. Agayev A, Yekeler E. Left-sided scimitar syndrome. *Pediatr Radiol*. 2009;39:191.
7. Juraszek AL, Cohn H, Van Praagh R, et al. Isolated left-sided scimitar vein connecting all left pulmonary veins to the right inferior vena cava. *Pediatr Cardiol*. 2005;26:846-847.
8. Rutledge JM, Hiatt PW, Wesley Vick G 3rd, et al. A sword for the left hand: an unusual case of left-sided scimitar syndrome. *Pediatr Cardiol*. 2001;22:350-352.
9. Wang CC, Wu ET, Chen SJ, et al. Scimitar syndrome: incidence, treatment, and prognosis. *Eur J Pediatr*. 2008;167:155-160.
10. Bhide A, Murphy D, Thilaganathan B, et al. Prenatal findings and differential diagnosis of scimitar syndrome and pulmonary sequestration. *Ultrasound Obstet Gynecol*. 2010;35:398-404.
11. Grisaru D, Achiron R, Lipitz S, et al. Antenatal sonographic findings associated with scimitar syndrome. *Ultrasound Obstet Gynecol*. 1996;8:131-133.
12. Michailidis GD, Simpson JM, Tulloh RM, et al. Retrospective prenatal diagnosis of scimitar syndrome aided by three-dimensional power Doppler imaging. *Ultrasound Obstet Gynecol*. 2001;17:449-452.
13. Gudjonsson U, Brown JW. Scimitar syndrome. *Semin Thorac Cardiovasc Surg Pediatr Card Surg Annu*. 2006;56-62.
14. Cirillo RL Jr. The scimitar sign. *Radiology*. 1998;206:623-624.
15. Gao YA, Burrows PE, Benson LN, et al. Scimitar syndrome in infancy. *J Am Coll Cardiol*. 1993;22:873-882.
16. Gikonyo DK, Tandon R, Lucas RV Jr, et al. Scimitar syndrome in neonates: report of four cases and review of the literature. *Pediatr Cardiol*. 1986;6:193-197.
17. Sun J, Zhang S, Jiang D, et al. Scimitar syndrome with the left persistent superior vena cava. *Surg Radiol Anat*. 2009;31:307-309.
18. Argueta-Morales IR, Meador LC, Nykanen DG, et al. Infantile form of scimitar syndrome with contralateral pulmonary vein stenosis. *Pediatr Cardiol*. 2010;31:550-552.
19. Khalilzadeh S, Hassanzad M, Khodayari AA. Scimitar syndrome. *Arch Iran Med*. 2009;12:79-81.
20. Healey JE Jr. An anatomic survey of anomalous pulmonary veins: their clinical significance. *J Thorac Surg*. 1952;23:433-444.
21. Ziora D, Kozielski J, Glowacki J, et al. Repeated lung infections. Scimitar syndrome. *Eur Respir J*. 1994;7:617-619.
22. Demir E, Askin M, Midyat L, et al. Scimitar syndrome associated with partial anomalous pulmonary venous draining into superior vena cava. *Eur J Pediatr*. 2010;169:1263-1265.
23. Holt PD, Berdon WE, Marans Z, et al. Scimitar vein draining to the left atrium and a historical review of the scimitar syndrome. *Pediatr Radiol*. 2004;34:409-413.
24. Khan MA, Torres AJ, Printz BF, et al. Usefulness of magnetic resonance angiography for diagnosis of scimitar syndrome in early infancy. *Am J Cardiol*. 2005;96:1313-1316.
25. Najm HK, Williams WG, Coles JG, et al. Scimitar syndrome: twenty years' experience and results of repair. *J Thorac Cardiovasc Surg*. 1996;112:1161-1168, discussion 1168-9.
26. Murphy JW, Kerr AR, Kirklin JW. Intracardiac repair for anomalous pulmonary venous connection of right lung to inferior vena cava. *Ann Thorac Surg*. 1971;11:38-42.

6 Thymus

LISA C. ZUCKERWISE | LING LI | JOSHUA A. COPEL

Introduction

The thymus is a lymphoepithelial organ with key adaptive immune functions during both intrauterine and extrauterine life.[1,2] The thymus develops from the third pharyngeal pouch, which gives rise to endodermal-derived thymic cortical epithelium, and the third pharyngeal cleft, which is thought to give rise to ectodermal-derived medullary thymic epithelium.[3,4]

The thymus enlarges in the ninth gestational week when lymphocytes and hematopoietic cells migrate from embryonal blood vessels to spaces between thymus epithelial cells. After the 12th gestational week, the thymus descends into the anterior mediastinum and becomes an encapsulated, lobulated organ with a cortex that is densely populated with lymphocytes and a medulla that appears more epithelial because of a relative paucity of lymphoid cells.[5] The thymus continues to grow throughout fetal life.[6]

Normal Anatomy

GENERAL ANATOMIC DESCRIPTIONS

The thymus consists of two lateral lobes placed in close contact along the midline, situated partly in the thorax and partly in the neck, and extending from the fourth costal cartilage upward, approaching the lower border of the thyroid gland (Fig. 6.1). It is covered by the sternum and by the origins of the sternohyoid and sternothyroid muscles.[7] Below, it rests on the pericardium, and is separated from the aortic arch and great vessels by a layer of fascia. In the neck, it lies on the anterior surface of the trachea, behind the sternohyoid and sternothyroid muscles.[7]

ULTRASOUND

The fetal thymus is visualized on ultrasound (US) as a homogeneous quadrangular structure in the anterior superior mediastinum, ventral to the pericardium and great vessels of the heart, and between both lungs. It is well visualized in the three-vessel view or the three-vessel–trachea view, lying anterior to the vessels (pulmonary artery, aorta, and superior vena cava, with the trachea to the right of the vessels) (Figs. 6.2–6.5).[8,9] It is most often identified between the sternum and great vessels of the heart in the axial view of the fetal chest. From the sagittal view, the thymus appears triangular or teardrop-shaped (Fig. 6.6). Compared with the lungs, it is similar in echogenicity or

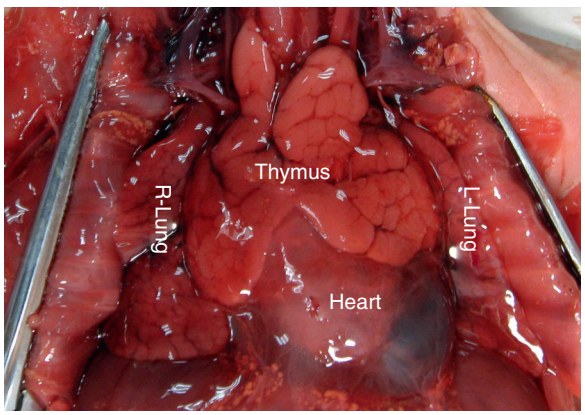

Fig. 6.1 Normal fetal thymus in a 26-week, 2-day gestation.

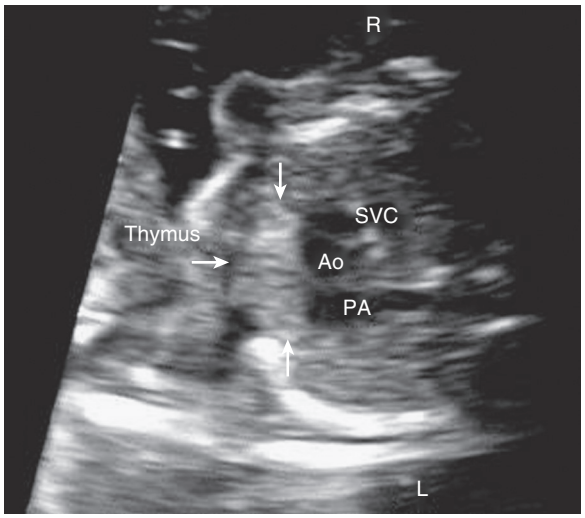

Fig. 6.2 Ultrasound (US) image (three-vessel view) in a 20-week fetus showing the thymus as a quadrangular structure in front of the three vessels (aorta *[Ao]*, pulmonary artery *[PA]*, superior vena cava *[SVC]*). The thymus is slightly more echogenic than the lungs. *L*, Left; *R*, right.

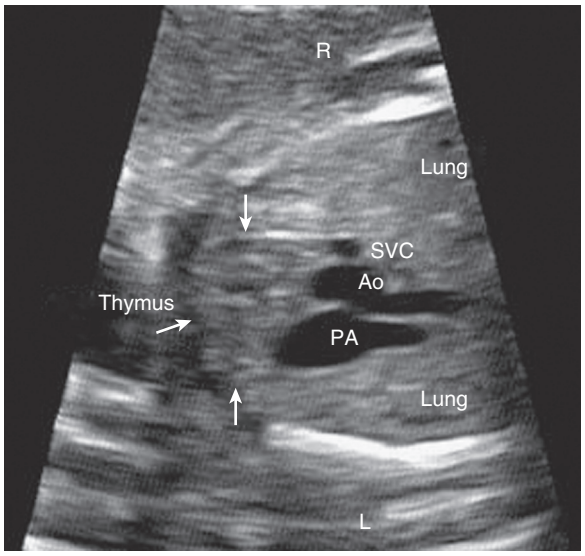

Fig. 6.3 Ultrasound (US) image (three-vessel view) in a 28-week fetus showing the thymus as a quadrangular structure in front of the three vessels (aorta *[Ao]*, pulmonary artery *[PA]*, superior vena cava *[SVC]*). The thymus is less echogenic than the lungs. *L*, Left; *R*, right.

slightly more echogenic in the early second trimester, between 17 weeks' and 22 weeks' gestation (see Figs. 6.2 and 6.4), and less echogenic in later pregnancy (see Figs. 6.3 and 6.5).[10]

With the development and application of three-dimensional (3D) US and four-dimensional (4D) US, the entire fetal thymus can be reconstructed and measured using a 3D model derived from multiple two-dimensional (2D) planes, which conquers the limitation of single-plane information from 2D US. Using off-line virtual organ computer-aided analysis (VOCAL) software, the 3D morphology of the fetal thymus can be evaluated from any orientation (Figs. 6.7–6.9).[11]

There are several studies of ultrasonic measurement data for normal fetal thymic size in the English literature: anterior-posterior thickness by Felker et al.,[9] perimeter by Zalel et al.,[8]

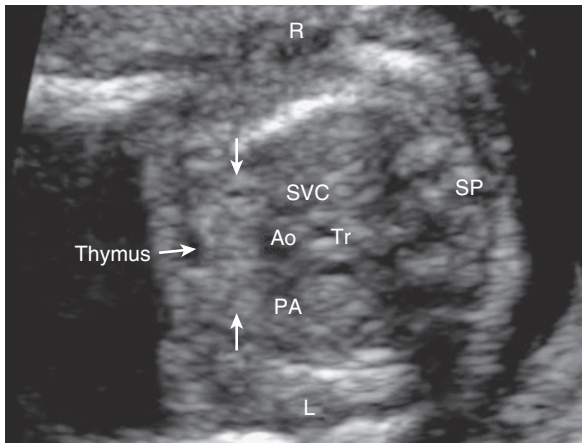

Fig. 6.4 Ultrasound (US) image (three-vessel–trachea view) in an 18-week, 3-day fetus showing the thymus as a quadrangular structure in front of the three vessels (aorta *[Ao]*, pulmonary artery *[PA]*, superior vena cava *[SVC]*, thymus *[Th]*). The thymus is slightly more echogenic than the lungs. *L*, Left; *R*, right; *SP*, spine; *Tr*, trachea.

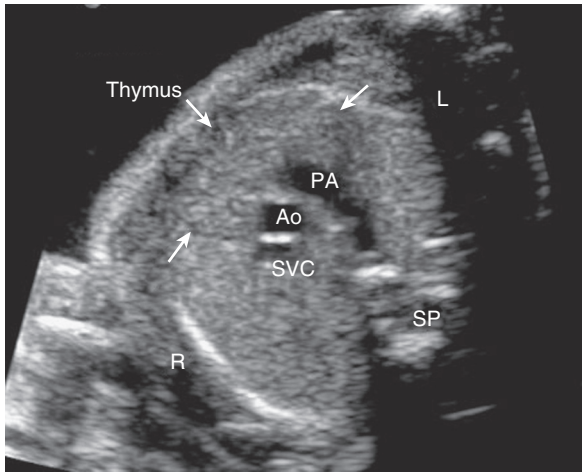

Fig. 6.5 Ultrasound (US) image (three-vessel view) in a 24-week, 6-day fetus showing the thymus as a quadrangular structure in front of the three vessels (aorta *[Ao]*, pulmonary artery *[PA]*, superior vena cava *[SVC]*). The thymus is less echogenic than the lungs. *L*, Left; *R*, right; *SP*, spine.

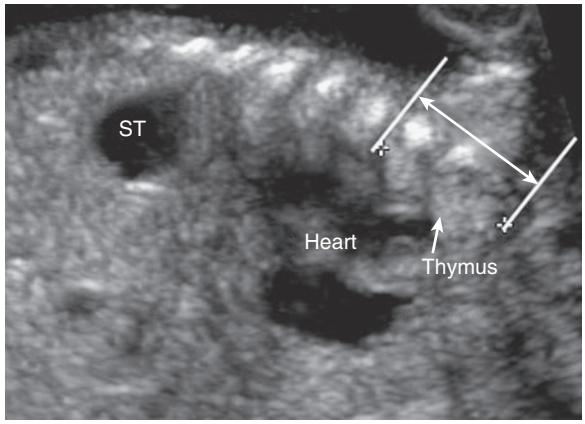

Fig. 6.6 Ultrasound (US) image (sagittal view) in a 21-week, 6-day fetus showing the thymus. *ST*, Stomach.

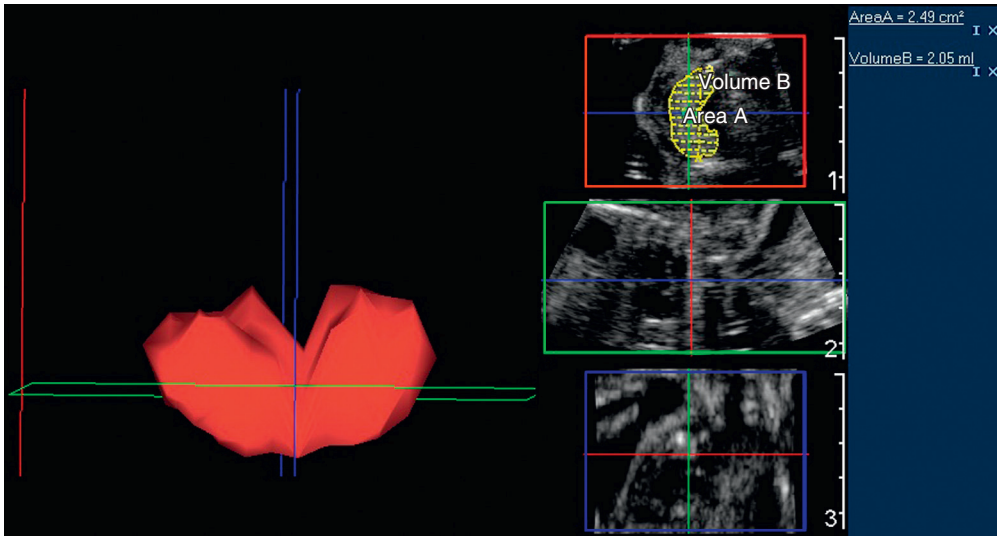

Fig. 6.7 Virtual organ computer-aided analysis (VOCAL) calculation of fetal thymus volume in 22-week gestation (QLAB software). Four images are shown: Right three images are three orthogonal planes; left image is reconstruction thymus volume. Upper right shows thymus volume = 2.05 mL.

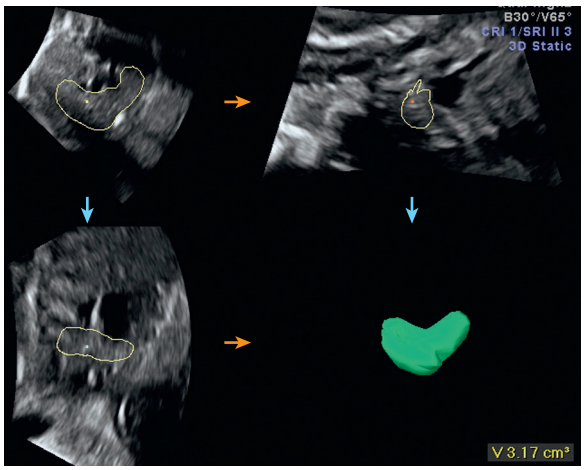

Fig. 6.8 Virtual organ computer-aided analysis (VOCAL) calculation of fetal thymus volume in 26-week gestation (4D view software). Four images are shown: Left two images and upper right are three orthogonal planes; lower right image is reconstruction thymus volume. Lower right shows thymus volume = 3.17 mL.

transverse diameter by Jeppesen et al.[6] and Cho et al.,[10] and 3D volume by Li et al.[11] The thy-box technique, which uses vascular boundaries with Doppler (internal mammary arteries laterally, three vessels posteriorly, and sternum anteriorly) to identify the thymus and produce measurements, was described by Paladini in 2011 and has demonstrated favorable feasibility and reproducibility for use into the early third trimester.[12,13]

DETAILED DESCRIPTION OF SPECIFIC AREAS

Normal Variants

The two lobes of the thymus generally differ in size. They are occasionally united to form a single mass and sometimes separated by an intermediate lobe.[7]

Differential Considerations

Thymic hypoplasia is a condition in which the thymus is underdeveloped or involuted. Thymic aplasia is congenital absence of the thymus. Thymic hypoplasia and thymic aplasia have been reported as an associated finding in various diseases, such as 22q11.2 deletion (DiGeorge syndrome),[14] Ellis-van Creveld syndrome,[15] severe combined immunodeficiency,[16] human immunodeficiency virus (HIV) infection,[17] fetal growth restriction (FGR),[18] acute illness,[19] exposure to ethanol,[20] and chorioamnionitis.[21]

Chaoui et al.[22] and Barrea et al.[23] investigated the fetal thymus and found that absent or hypoplastic thymus on US is a marker for deletion 22q11.2 in fetal cardiac defects, with a sensitivity of at least 90% and specificity of 98.5% in a group of fetuses with prenatally diagnosed cardiac defects. A larger study of 74 fetuses with confirmed 22q11.2 deletion by fluorescence in situ hybridization (FISH) analysis found that 86% of these fetuses had a thymic abnormality at autopsy, with 53.3% having complete thymic agenesis and 46.7% demonstrating thymic hypoplasia.[24] Taken together, these studies suggest that thymic evaluation by ultrasound can be useful to identify patients at risk for 22q11.2 deletion in the presence of small or absent thymus.

Cromi et al.[25] assessed fetal thymus size in growth-restricted fetuses and found that the vast majority of growth-restricted fetuses (58/60, 97%) demonstrated thymic size smaller than fifth percentile, compared with only 7/60 (11%) controls having small thymus. The authors postulated that a small fetal thymus is a marker of the fetal immune-endocrine response to malnutrition. A clinically relevant study by Ekin et al.[26] assessed the implication of small thymus in cases of growth-restricted fetuses and confirmed significantly smaller thymuses than in normally grown controls. Importantly, they also found that smaller thymus size within the growth-restricted fetuses was associated with significantly higher risk of perinatal morbidity including preterm delivery, respiratory distress syndrome, early neonatal sepsis, and longer intensive care unit stays.

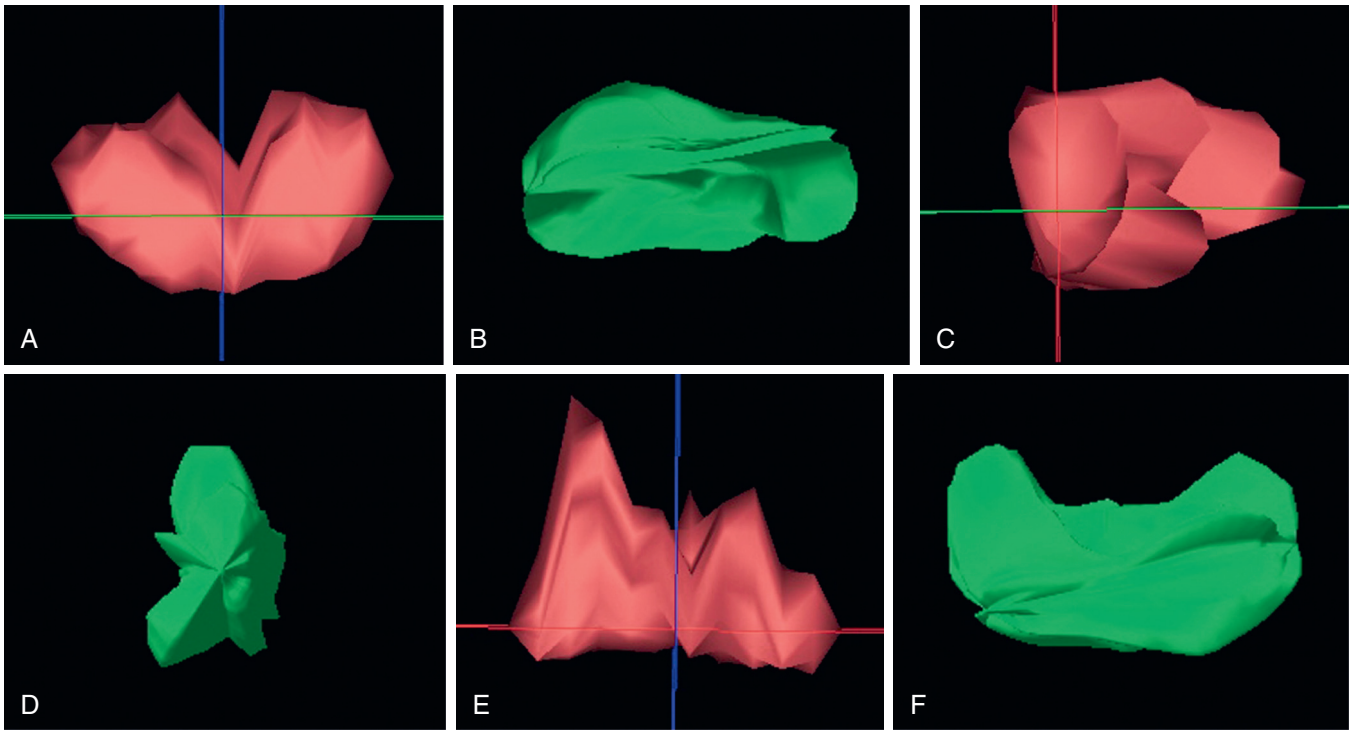

Fig. 6.9 Virtual organ computer-aided analysis (VOCAL) calculation of fetal thymus volume in 22-week gestation (different views). (A) Transverse view of fetal thymus (QLAB from Philips, Bothell, Washington). (B) Transverse view of fetal thymus (4D view from GE , Milwaukee, Wisconsin). (C) Sagittal view of fetal thymus (QLAB from Philips). (D) Sagittal view of fetal thymus (4D view from GE). (E) Coronal view of fetal thymus (QLAB from Philips). (F) Coronal view of fetal thymus (4D view from GE).

Yinon et al.,[27] Di Naro et al.,[28] and El-Haieg et al.[29] demonstrated that fetal thymic involution (as demonstrated by size smaller than fifth percentile) is a predictor of the fetal inflammatory response syndrome both in women with preterm labor and intact membranes and in women with preterm premature rupture of membranes. In fact, Cetin et al.[30] found reduced fetal thymus diameter below the fifth percentile to be a promising prenatal marker for predicting early neonatal sepsis in patients admitted for preterm premature rupture of membranes, with a sensitivity of 100% and specificity of 73% in their series of 40 consecutive cases.

Pertinent Imaging Considerations

Assessment of the fetal thymus may be indicated when DiGeorge syndrome (22q11.2 deletion), Ellis-van Creveld syndrome, severe combined immunodeficiency, HIV infection, FGR, acute illness, exposure to ethanol, or chorioamnionitis is suspected. If the fetal thymus is significantly decreased in size or absent on the anatomic survey US scan, careful assessment of fetal anatomy, including cardiac anatomy, is necessary, as is consideration of genetic counseling and testing. When fetal congenital heart disease is suspected, especially conotruncal anomalies, assessment of the fetal thymus may be helpful in stratifying risk for associated fetal conditions and counseling on diagnostic genetic testing.[11] In cases of FGR, preterm labor or preterm premature rupture of membranes, a small thymus may indicate thymic involution, representing a worse fetal prognosis.[26–30]

KEY POINTS

- On 2D US, the fetal thymus is visualized as a homogeneous structure in the anterior superior mediastinum.
- The thymus grows throughout fetal life.
- Thymic hypoplasia and thymic aplasia are associated findings in various diseases.

SUGGESTED READING

Hata T, Deter RL. A review of fetal organ measurements obtained with ultrasound: normal growth. *J Clin Ultrasound*. 1992;20:155-174.

Munoz-Chapuli M, Gamez F, Bravo C, et al. The thy-box for sonographic assessment of the fetal thymus: nomogram and review of the literature. *J Ultrasound Med*. 2015;34:853-858.

Haynes BF, Hale LP. The human thymus: a chimeric organ comprised of central and peripheral lymphoid components. *Immunol Res*. 1998;18:175-192.

Mastrolia SA, Erez O, Loverro G, et al. Ultrasonographic approach to diagnosis of Fetal Inflammatory Response Syndrome: a tool for at risk fetuses? *Am J Obstet Gynecol*. 2016;215:9-20.

All references are available online at www.expertconsult.com.

REFERENCES

1. Schwartz R. Acquisition of immunologic self-tolerance. *Cell*. 1989;57:1073-1081.
2. Haynes B, Hale L. The human thymus: a chimeric organ comprised of central and peripheral lymphoid components. *Immunol Res*. 1998;18:175-192.
3. Haynes B, Denning S, Le P, et al. Human intrathymic T cell differentiation. *Semin Immunol*. 1990;2:67-77.
4. Haynes B. Human thymic epithelium and T cell development: current issues and future directions. *Thymus*. 1990;16:143-157.
5. Von Gaudecker B. The development of the human thymus microenvironment. *Curr Top Pathol*. 1986;75:1-42.
6. Jeppesen DL, Hasselbalch H, Nielsen SD, et al. Thymic size in preterm neonates: a sonographic study. *Acta Paediatr*. 2003;92:817-822.
7. Gray H. The thymus. In: *Anatomy of the Human Body*. Philadelphia: Lea & Febiger; 1985.
8. Zalel Y, Gamzu R, Mashiach S, et al. The development of the fetal thymus: an in utero sonographic evaluation. *Prenat Diagn*. 2002;22:114-117.
9. Felker RE, Cartier MS, Emerson DS, et al. Ultrasound of the fetal thymus. *J Ultrasound Med*. 1989;8:669-673.
10. Cho JY, Min JY, Lee YH, et al. Diameter of the normal fetal thymus on ultrasound. *Ultrasound Obstet Gynecol*. 2007;29:634-638.
11. Li L, Bahtiyar M, Buhimschi C, et al. Assessment of the fetal thymus by 2D and 3D ultrasound during normal human gestation and in fetuses with congenital heart defects. *Ultrasound Obstet Gynecol*. 2011;37:404-409.
12. Paladini D. How to identify the thymus in the fetus: the thy-box. *Ultrasound Obstet Gynecol*. 2011;37:488-492.
13. Munoz-Chapuli M, Gamez F, Bravo C, et al. The thy-box for sonographic assessment of the fetal thymus: nomogram and review of the literature. *J Ultrasound Med*. 2015;34:853-858.
14. Dodson WE, Alexander D, Al-Aish M, et al. The DiGeorge syndrome. *Lancet*. 1969;1:574-575.
15. Ichijima K, Yamabe H, Kobashi Y, et al. An unusual case of metaphyseal chondrodysplasia with an abnormal perilacunar matrix associated with agranulocytosis and hypoplasia of the thymus. *Virchows Arch A Pathol Anat Histol*. 1981;391:275-289.
16. Martin JP, Aguilar FT. Thymic hypoplasia with severe combined immunodeficiency. *Ann Allergy*. 1977;39:196-200.
17. Zalel Y, Gamzu R, Mashiach S, et al. The development of the fetal thymus: an in utero sonographic evaluation. *Prenat Diagn*. 2002;22:114-117.
18. Hartge R, Jenkins DM, Kohler HG. Low thymic weight in small-for-dates babies. *Eur J Obstet Gynecol Reprod Biol*. 1978;8:153-155.
19. Van-Baarlen SJ, Achuurman HJ, Huber J. Acute thymic involution in infancy and childhood: a reliable marker for duration of acute illness. *Hum Pathol*. 1988;19:1155-1160.
20. Ewald SJ, Frost WW. Effect of prenatal exposure to ethanol on development of the thymus. *Thymus*. 1987;9:211-215.
21. Toti P, De Felice C, Stumpo M, et al. Acute thymic involution in fetuses and neonates with chorioamnionitis. *Hum Pathol*. 2000;31:1121-1128.
22. Chaoui R, Kalache KD, Heling KS, et al. Absent or hypoplastic thymus on ultrasound: a marker for deletion 22q11.2 in fetal cardiac defects. *Ultrasound Obstet Gynecol*. 2002;20:546-552.
23. Barrea C, Yoo SJ, Chitayat D, et al. Assessment of the thymus at echocardiography in fetuses at risk for 22q11.2 deletion. *Prenat Diagn*. 2003;23:9-15.
24. Noel A, Pelluard F, Delezoid A, et al. Fetal phenotype associated with 22q11 deletion. *Am J Med Genet A*. 2014;164:2724-2731.
25. Cromi A, Ghezzi F, Raffaelli R, et al. Ultrasonographic measurement of thymus size in IUGR fetuses: a marker of the fetal immunoendocrine response to malnutrition. *Ultrasound Obstet Gynecol*. 2009;33:421-426.
26. Ekin A, Gezer C, Taner CE, et al. Prognostic value of fetal thymus size in intrauterine growth restriction. *J Ultrasound Med*. 2016;35:511-517.
27. Yinon Y, Zalel Y, Weisz B, et al. Fetal thymus size as a predictor of chorioamnionitis in women with preterm premature rupture of membranes. *Ultrasound Obstet Gynecol*. 2007;29:639-643.
28. Di Naro E, Cromi A, Ghezzi F, et al. Fetal thymic involution: a sonographic marker of the fetal inflammatory response syndrome. *Am J Obstet Gynecol*. 2006;194:153-159.
29. El-Haieg DO, Zidan AA, El-Nemr MM. The relationship between sonographic fetal thymus size and the components of the systemic fetal inflammatory response syndrome in women with preterm prelabour rupture of membranes. *Br J Obstet Gynaecol*. 2008;115:836-841.
30. Cetin O, Dokurel Cetin I, Uludag S, et al. Serial ultrasonographic examination of the fetal thymus in the prediction of early neonatal sepsis in preterm premature rupture of membranes. *Gynecol Obstet Invest*. 2014;78:201-207.

7 Other Thoracic Tumors and Masses

MÓNICA CRUZ-LEMINI | EDUARD GRATACÓS

Introduction

Among rare thoracic tumors not described in previous chapters, two are the most common. *Bronchogenic cysts* are derived from abnormal budding of the ventricular diverticulum in the mediastinum or the lung.[1–4] *Lymphangiomas* arise from the lymphatic system and develop more frequently in the thorax, head, and neck.[5]

Bronchogenic Cyst

DEFINITION

A *bronchogenic cyst* is a cystic duplication of the tracheobronchial tree, derived from an abnormal budding of the ventricular diverticulum of the foregut.[4,6]

PREVALENCE AND EPIDEMIOLOGY

Bronchogenic cysts account for about 20% to 30% of congenital bronchopulmonary foregut cystic malformations.[7] Prevalence is reported as 1:42,000, although this could be underestimated because of the high rate of late diagnosis and hidden cases.[8] Half of these cases are diagnosed after 15 years of age. Prenatal diagnosis is only possible in large cysts. A 70% detection rate has been suggested, although the small numbers of cases render any meaningful estimate difficult.[3]

ETIOLOGY AND PATHOPHYSIOLOGY

Bronchogenic cysts result from abnormal budding of the ventral diverticulum of the primitive foregut. Most cysts develop between the 26th and 40th days of fetal life. If appearing during early bronchial development, the cyst is located in the mediastinum (30%), normally between the trachea and esophagus, and later it develops in the lung (70%).[4,9] The cyst wall resembles a bronchus with ciliated respiratory epithelial lining, smooth muscle, cartilaginous structures, and bronchial mucus glands, usually filled with thick mucus.[4]

MANIFESTATIONS OF DISEASE

Clinical Presentation

In children and adults, most cysts are asymptomatic and diagnosed at routine ultrasound or chest radiographs.[10] Prenatally, clinical manifestations will depend on the size, presence of bronchial obstruction or mediastinal shift, and location. Rarely, bronchogenic cysts may obstruct a large bronchus creating a similar effect to bronchial atresia, with impaired fluid drainage distal to the obstruction leading to enlarged hyperechogenic lungs, mediastinal shift, and high risk of lung hypoplasia, polyhydramnios, and hydrops.[4,11]

Imaging Technique and Findings

Ultrasound. A single, well-defined, unilocular, hypoechogenic intrathoracic mass within the lung parenchyma or mediastinum.[7,9] Mediastinal and large cysts tend to compress the trachea and esophagus, with subsequent polyhydramnios and/or hydrops.[11] (Fig. 7.1). Visualization of small mediastinal cysts can be challenging because of difficult differentiation from other structures, so they should be suspected in the presence of mediastinal enlargement without a clear mass.

Magnetic Resonance Imaging. Magnetic resonance imaging (MRI) can be helpful for confirming large and detecting smaller bronchogenic cysts.[9,11,12] It may aid in the differential diagnosis with other pulmonary malformations, providing better identification of congenital cystic adenomatoid malformation (CCAM) or bronchopulmonary sequestration, but reported error rates

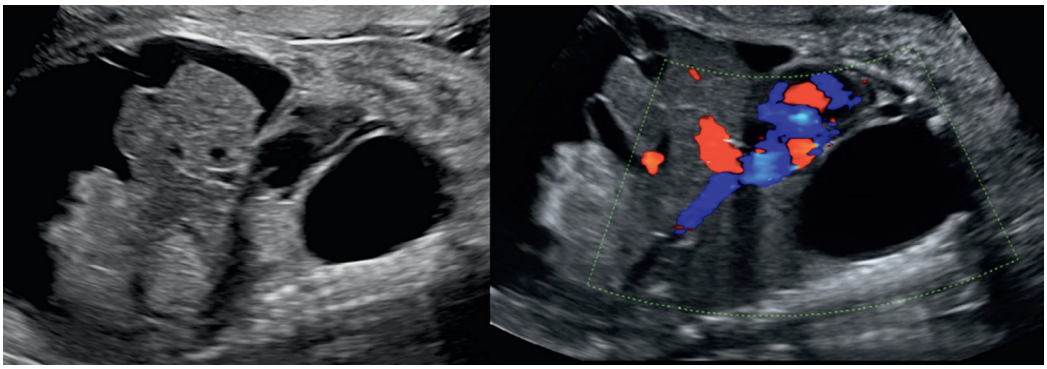

Fig. 7.1 Two-dimensional and color Doppler imaging of a large cystic lesion in a 25-week-old fetus corresponding to a bronchogenic cyst in the right hemithorax. Fetal hydrops is present, because of compression of venous return to the heart.

still range from 6% to 16%.[10] The cyst is markedly hyperintense on T2-weighted MR imaging, and may show a hyperintense signal on T1-weighted images caused by mucoid or hemorrhagic contents.[4,11,13]

CLASSIC SIGNS

- Single, well-defined, unilocular, hypoechogenic mass in the lung or mediastinum.
- Mediastinal shift may be associated, but is not mandatory for diagnosis.

Differential Diagnosis From Imaging Findings

The main differential diagnostic considerations are bronchopulmonary sequestration (BPS) and congenital cystic adenomatoid malformation (CCAM). Differentiation can be difficult or impossible prenatally with macrocystic CCAM lesions appearing as single cysts. Coexistence of these three separate anomalies in one lesion has been reported, suggesting a common embryologic link for these malformations.[7]

The differential diagnosis must also include duplication cysts and neurenteric cysts. Duplication cysts are usually located in the middle or posterior mediastinum whereas neurenteric cysts are found in the posterior mediastinum and are associated with vertebral defects in the region where the cyst communicates with the spinal canal.[13]

Synopsis of Treatment Options

PRENATAL

Prenatal intervention is only indicated in massive cysts producing mediastinal shift. In utero pulmonary drainage may be associated with improvement in perinatal survival, but there is scarce experience and fluid may reaccumulate.[6,7] There is no experience with thoracoamniotic shunts.[14] *Ex utero* intrapartum treatment (EXIT) with cyst resection by thoracotomy has been recently described to avoid acute respiratory decompensation at birth.[4]

POSTNATAL

Bronchogenic cysts may continue to grow slowly in the first months of life, but even in the absence of complications, size tends to increase constantly at an exponential rate, so resection is often recommended before 2 years of age,[10] to avoid recurrent respiratory infection. In cases where intraparenchymal cysts wedge resection, segmental resection, or lobectomy may be required, prognosis will depend on location and size of the mass.[7] Prenatally diagnosed cases may require urgent surgery at birth more often because of larger size.[15]

WHAT THE REFERRING PHYSICIAN NEEDS TO KNOW

- A very rare lesion appearing as a single cyst in the mediastinum or the lung.
- Prognosis depends on precise location and size, but is usually good.
- Large masses require planned delivery in a tertiary center.

KEY POINTS

- A benign tumor of the bronchial tree.
- With the rare exception of very large cysts, prognosis is generally good.

Lymphangioma

DEFINITION

Lymphangioma arises from the lymphatic system and presents more frequently in the thorax, head, and neck.[5] It is commonly subdivided into cystic and cavernous lymphangioma depending on its ultrasonographic characteristics. A cystic lymphangioma, also known as a *hygroma,* is described as a large singular or multilocular fluid-filled cavity, located commonly in the neck and thoracic area. The cavernous lymphangioma differs in that they are composed of innumerable cystic spaces, and occur more commonly in the trunk and forearms.[16]

PREVALENCE AND EPIDEMIOLOGY

The prevalence of lymphangioma is unknown. It is estimated to be around 1.1:10,000 to 5.3:10,000 live births, although series including miscarriages, stillbirths, and elective terminations estimate a higher prevalence of 30:10,000 births.[8,17] They account for 25% of benign vascular growths in children.[18] Pediatric series suggest that 50% of lymphangiomas are present at birth, and up to 90% become evident by the age of 2 years.

ETIOLOGY AND PATHOPHYSIOLOGY

The basic pathologic process is the collection of lymphatic cisterns in the deep subcutaneous plane. They are separated from the network of lymph vessels, but communicate with the superficial lymph vesicles through vertical, dilated lymph channels. This creates a "sequestration" of lymphatic tissue and fluid in early embryonic development, with local distention and development of thick and fibrotic walls surrounding the dilatation.[5,8,19]

Location and size determines gestational age at diagnosis, prognosis, and association with other anomalies.[5,16,20] About 70% to 80% occur in the neck (cystic hygromas, Chapter 70). The remaining 20% to 30% occur in the axillary region, mediastinum, extremities, trunk, retroperitoneal area, abdominal viscera, pelvis, and chest wall.

While nuchal cystic hygromas are commonly associated with karyotype defects and other malformations, this might not apply to nonnuchal lymphangiomas diagnosed in utero,[17] particularly those diagnosed later in pregnancy.[1,5,16,21]

Survival rate improves with a normal karyotype, atypical location, and in utero resolution of cystic lymphangioma. Thoracic lymphangiomas commonly do not increase in size and are rarely associated with other anomalies. Prognosis will depend on the location and extent of the lesion. In spite of a low risk, karyotype is normally recommended as part of the workup of any fetal malformation (Fig. 7.2).

MANIFESTATIONS OF DISEASE

Imaging Technique and Findings

Ultrasound. A thin-walled, multilocular or multiseptated cyst with variable echographic patterns, with no vascularization



Fig. 7.2 Ultrasound image of a thoracoabdominal lymphangioma affecting the thoracic and abdominal wall, axial plane.



Fig. 7.3 Parasagittal section of a large thoracic tumor, which occupies the thoracic cavity and inverts the normal shape of the diaphragm. The fetus has massive hydrops. The mass had the typical appearance of macrocystic congenital cystic adenomatoid malformation, and this was the prenatal diagnosis. Postnatal surgery and pathology confirmed the diagnosis of lung lymphangioma.

internally demonstrated by Doppler ultrasound.[16,20,21] Size and shape may vary, although walls may appear multilobular at times. Internal fluid may be anechoic, or there may be variable internal echoes or fluid-fluid levels, caused by bleeding and fibrin deposition.

Magnetic Resonance Imaging. Magnetic resonance imaging is useful to evaluate the precise location and full extent of the lesion, to characterize it better for postnatal treatment.[12,13,22,23] Multilocular high-signal, sharply defined cystic masses are observed, with thin- or thick-walled septa.[20,24,25]

Other Applicable Modality. Three-dimensional and four-dimensional imaging has been reported to aid in diagnosis and characterization of the extent of lesions in lymphangiomas compromising the fetal airway.[20,25,26] Assessment of the extent of the mass and of its relationships with the trachea, as well as visualization of swallowing movements, may provide useful information on the fetal airway and to plan delivery.

Differential Diagnosis From Imaging Findings

The most difficult differential diagnosis is with a large macrocystic CCAM (Fig. 7.3). Some cases may be impossible to differentiate, and this will only be done on open surgery and pathologic study. More rarely, lymphangiomas may resemble hemangiomas and teratomas.[19] Teratomas are usually hyperechogenic and mainly solid, so differentiation is generally possible. Hemangiomas can present identical features on ultrasound, although Doppler imaging of the vasculature might prove useful to differentiate these two entities. When CCAM is ruled out, lymphangioma is the most common cause of a heterogeneous polycystic mass.

Synopsis of Treatment Options

PRENATAL

Pediatric cases may be occasionally treated with sclerosing agents such as OK-432, a lyophilized incubation mixture of group A *Streptococcus pyogenes* of human origin.[17] There are recent experiences for prenatal treatment with this agent in fetal cystic hygromas, but there is no experience in thoracic lymphangioma.[17,27]

Very large lung lymphangiomas may induce a mass effect in the same way as CCAM, thereby resulting in lung hypoplasia, massive mediastinal shift, and hydrops.[28,29] It is unknown whether placement of a shunt or treatment with sclerosing agents might improve prognosis cases. Given the potential similarity by ultrasound imaging, it is also plausible that there are nonreported cases of large lung lymphangiomas treated with shunting, believing they were CCAM.

POSTNATAL

The success of surgical interventions and neonatal outcome mainly depends on the size, location, and type of tumor. Surgical excision is commonly the preferred treatment with local recurrences being common, because of the difficulty in removing the lesion entirely.[19] As with other fetal thoracic diseases, very large masses may induce lung hypoplasia to such extent that the neonate dies of lung insufficiency irrespective of intensive respiratory support.[30]

WHAT THE REFERRING PHYSICIAN NEEDS TO KNOW

- A very rare lesion with cystic heterogeneous appearance, which may resemble CCAM.
- Prognosis will depend on precise location and size.
- Large masses require planned delivery in a tertiary center.

KEY POINTS

- Benign tumor of the lymphatic system.
- Prognosis depends on location and size, but small thoracic lymphangiomas have generally good prognosis.
- Large masses may be associated with very poor prognosis caused by mediastinal shift and lung hypoplasia.

SUGGESTED READINGS

Maurin S, Hery G, Bourliere B, et al. Bronchogenic cyst: Clinical course from antenatal diagnosis to postnatal thoracoscopic resection. *J Minim Access Surg*. 2013;9:25-28.

Rasidaki M, Sifakis S, Vardaki E, et al. Prenatal diagnosis of a fetal chest wall cystic lymphangioma using ultrasonography and MRI: a case report with literature review. *Fetal Diagn Ther*. 2005;20:504-507.

Recio Rodriguez M, Martinez de Vega V, Cano Alonso R, et al. MR imaging of thoracic abnormalities in the fetus. *Radiographics*. 2012;32:E305-E321.

Surico D, Amadori R, D'Ajello P, et al. Antenatal diagnosis of fetal lymphangioma by ultrasonography. *Eur J Obstet Gynecol Reprod Biol*. 2013;168:236.



All references are available online at www.expertconsult.com.

REFERENCES

1. Gratacós E. *Medicina Fetal*. 1st ed. Barcelona, España: Ed Médica Panamericana (ME); 2007.
2. Paladini D. *Ultrasound of congenital fetal anomalies: differential diagnosis and prognostic indicators*. Informa UK Ltd.; 2007.
3. Sarper A, Ayten A, Golbasi I, et al. Bronchogenic cyst. *Tex Heart Inst J*. 2003;30:105-108.
4. Chatterjee D, Hawkins JL, Somme S, et al. Ex utero intrapartum treatment to resection of a bronchogenic cyst causing airway compression. *Fetal Diagn Ther*. 2014;35:137-140.
5. Comstock CH, Lee W, Bronsteen RA, et al. Fetal mediastinal lymphangiomas. *J Ultrasound Med*. 2008;27:145-148.
6. Bayar UO, Numanoglu V, Bektas S, et al. Management of fetal bronchogenic lung cysts: a case report and short review of literature. *Case Rep Med*. 2010;2010:751423.
7. Rios LT, Araujo Junior E, Nardozza LM, et al. Prenatal diagnosis and postnatal findings of bronchogenic cyst. *Case Rep Pulmonol*. 2013;2013:483864.
8. Chang TS, Ricketts R, Abramowksy CR, et al. Mesenteric cystic masses: a series of 21 pediatric cases and review of the literature. *Fetal Pediatr Pathol*. 2011;30:40-44.
9. Winters WD, Effmann EL. Congenital masses of the lung: prenatal and postnatal imaging evaluation. *J Thorac Imaging*. 2001;16:196-206.
10. Maurin S, Hery G, Bourliere B, et al. Bronchogenic cyst: clinical course from antenatal diagnosis to postnatal thoracoscopic resection. *J Minim Access Surg*. 2013;9:25-28.
11. Levine D, Jennings R, Barnewolt C, et al. Progressive fetal bronchial obstruction caused by a bronchogenic cyst diagnosed using prenatal MR imaging. *AJR Am J Roentgenol*. 2001;176:49-52.
12. Ward VL. MR imaging in the prenatal diagnosis of fetal chest masses: effects on diagnostic accuracy, clinical decision making, parental understanding, and prediction of neonatal respiratory health outcomes. *Acad Radiol*. 2002;9:1064-1069.
13. Recio Rodriguez M, Martinez de Vega V, Cano Alonso R, et al. MR imaging of thoracic abnormalities in the fetus. *Radiographics*. 2012;32:E305-E321.
14. Kyle PM, Lange IR, Menticoglou SM, et al. Intrauterine thoracentesis of fetal cystic lung malformations. *Fetal Diagn Ther*. 1994;9:84-87.
15. Dembinski J, Kaminski M, Schild R, et al. Congenital intrapulmonary bronchogenic cyst in the neonate–perinatal management. *Am J Perinatol*. 1999;16:509-514.
16. Goldstein I, Leibovitz Z, Noi-Nizri M. Prenatal diagnosis of fetal chest lymphangioma. *J Ultrasound Med*. 2006;25:1437-1440.
17. Lu D, Wang Y, Zeng W, et al. Giant fetal lymphangioma at chest wall and prognosis: case report and literature review. *Taiwan J Obstet Gynecol*. 2015;54:62-65.
18. Surico D, Amadori R, D'Ajello P, et al. Antenatal diagnosis of fetal lymphangioma by ultrasonography. *Eur J Obstet Gynecol Reprod Biol*. 2013;168:236.
19. McHoney M. Early human development: neonatal tumours: vascular tumours. *Early Hum Dev*. 2010;86:613-618.
20. Ono K, Kikuchi A, Miyashita S, et al. Fetus with prenatally diagnosed posterior mediastinal lymphangioma: characteristic ultrasound and magnetic resonance imaging findings. *Congenit Anom (Kyoto)*. 2007;47:158-160.
21. Arisoy R, Erdogdu E, Kumru P, et al. Prenatal diagnosis and outcome of lymphangiomas and its relationship with fetal chromosomal abnormalities. *J Matern Fetal Neonatal Med*. 2016;29:466-472.
22. Rha SE, Byun JY, Kim HH, et al. Prenatal sonographic and MR imaging findings of extensive fetal lymphangioma: a case report. *Korean J Radiol*. 2003;4:260-263.
23. Chen CP. Prenatal imaging of the fetal anterior chest wall cystic hygroma by magnetic resonance imaging. *Prenat Diagn*. 2003;23:1099-1100.
24. Cozzi DA, Olivieri C, Manganaro F, et al. Fetal abdominal lymphangioma enhanced by ultrafast MRI. *Fetal Diagn Ther*. 2010;27:46-50.
25. Rasidaki M, Sifakis S, Vardaki E, et al. Prenatal diagnosis of a fetal chest wall cystic lymphangioma using ultrasonography and MRI: a case report with literature review. *Fetal Diagn Ther*. 2005;20:504-507.
26. Paladini D, Vassallo M, Sglavo G, et al. Cavernous lymphangioma of the face and neck: prenatal diagnosis by three-dimensional ultrasound. *Ultrasound Obstet Gynecol*. 2005;26:300-302.
27. Mikovic Z, Simic R, Egic A, et al. Intrauterine treatment of large fetal neck lymphangioma with OK-432. *Fetal Diagn Ther*. 2009;26:102-106.
28. Mondal PC, Ghosh D, Mondal A, et al. Congenital fetal lymphangioma causing shoulder dystocia and uterine rupture. *Int J Gynaecol Obstet*. 2011;112:248.
29. Pascoli I, Gritti A, Cutrone C, et al. EXIT (Ex Utero Intrapartum Treatment) technique — management of a giant fetal lymphangioma. *J Matern Fetal Neonatal Med*. 2010;23:190-192.
30. Gedikbasi A, Gul A, Sargin A, et al. Cystic hygroma and lymphangioma: associated findings, perinatal outcome and prognostic factors in live-born infants. *Arch Gynecol Obstet*. 2007;276:491-498.

8 Abnormal Kidney Location

APRIL T. BLEICH | JODI S. DASHE

Introduction

There are three types of abnormalities of renal location: simple renal ectopia (e.g., pelvic kidney), crossed renal ectopia, and horseshoe kidney. They are collectively termed *renal ectopia*. During normal development, the metanephros migrates from the pelvis to the abdomen, and rotates about its longitudinal axis. Abnormalities of renal location may occur because of failure of ascent of the metanephric buds or because of fusion before ascent. Although renal ectopia is relatively benign, it is associated with an increased risk of complications, including vesicoureteral reflux (VUR), ureteropelvic junction (UPJ) obstruction, infection, and renal calculi.[1–4] Affected individuals are usually asymptomatic. If a prenatal diagnosis is not made, affected individuals may not receive medical attention until complications arise. Improvements in ultrasound (US) technology have made it easier to identify abnormalities of renal location; however, these anomalies are subtle, and an index of suspicion is required.

Disorder

DEFINITION

Pelvic kidney is also called *simple renal ectopia* and refers to a kidney that is on the correct side but has failed to migrate upward. A pelvic kidney is located opposite the sacrum and below the aortic bifurcation.[5]

Crossed renal ectopia occurs when both kidneys are located on the same side of the spine. In most cases, the kidney on the incorrect side is located below the normal kidney and is fused with it (termed *crossed-fused ectopia*). The ureter of the displaced kidney crosses the midline and inserts into the bladder in the normal location.[6,7]

Horseshoe kidney is a fusion of the lower poles of the kidneys, with an isthmus that crosses the midline, usually anterior to the great vessels, and just below the inferior mesenteric artery—preventing the horseshoe kidney from migrating upward to the normal location.[8,9]

PREVALENCE AND EPIDEMIOLOGY

Pelvic kidney occurs in 1:2000 to 1:3000 births.[10,11] It is slightly more common in males, and a left-sided predominance has been reported.[5] Pelvic kidney is bilateral in 12% of cases.[5]

The prevalence of crossed renal ectopia is 1:7500 individuals.[12] It is twice as common in males, and the left kidney is more often the one that is crossed, meaning that both kidneys are commonly found on the right side.[6,7,13] In approximately 75% of cases, the kidneys are fused (i.e., crossed-fused ectopia).[6,7]

Horseshoe kidney is the most common renal ectopia, with a reported prevalence of 1:400 individuals.[14] It is also twice as common in males.[1,8,14]

All forms of renal ectopia are associated with other renal abnormalities. Hydronephrosis has been reported in more than 50%; VUR and UPJ obstruction each occur in approximately 20% (see Chapter 12).[2,5] Renal calculi have been reported in 20% of cases of horseshoe kidney, postulated to be caused by a combination of stasis and infection.[1,3,9]

Renal ectopia is also associated with a high prevalence of anomalies of other organ systems. Reproductive tract abnormalities have been reported in approximately 25%, musculoskeletal anomalies in 25%, and cardiac malformations in 10%.[1,5] Horseshoe kidney is further associated with chromosomal abnormalities, including Turner syndrome and trisomies 21, 18, and 13.[9,15]

ETIOLOGY, PATHOPHYSIOLOGY, AND EMBRYOLOGY

During the sixth through ninth gestational weeks, the kidneys ascend from the pelvis to the lumbar region just below the adrenal glands.[16] Failure of ascent results in renal ectopia. The mechanism behind failed ascent is unknown. Theories include ureteral bud maldevelopment, defective metanephric tissue, genetic abnormalities, vascular obstruction, and teratogen exposure.[6,10,15,17,18] Ectopic kidneys are more likely to be hypoplastic (see Chapter 9), are abnormally shaped, and have an atypical blood supply.[19] Pelvic kidney represents complete failure of ascent. Crossed renal ectopia results from abnormal migration to the opposite side of the pelvis. With crossed renal ectopia, there is malrotation of both kidneys, which may lead to narrowing at the level of the ureteropelvic junction and subsequent obstruction.[6,18] The kidney that is crossed commonly fuses with the inferior pole of the normally located kidney, but there are also other variants, including kidneys that are S-shaped, L-shaped, lump-shaped, disk-shaped, and superiorly fused.[15] In each form of crossed renal ectopia, the ureter of the kidney that is on the abnormal side crosses the pelvis to insert normally into the bladder.

Horseshoe kidney is believed to result from fusion of the metanephric buds before the renal capsule has matured. The inferior poles are joined at an isthmus that is typically located below the inferior mesenteric artery, preventing their normal medial rotation as well as ascent. The isthmus may be composed of renal tissue but is often fibrous. The cause of the fusion is unknown. Theories include close approximation of metanephric tissue in early embryogenesis, excessive renal blastema, and a teratogenic event involving abnormal migration of posterior nephrogenic cells.[9,17] It is hypothesized that development of the isthmus through abnormal migration may account for the slightly increased incidence of associated renal malignancies.[17,20]

In one series, 10% of parents and 5% of offspring of individuals with horseshoe kidney were also found to have renal anomalies, and 80% of these were horseshoe kidney, suggesting autosomal dominant inheritance.[21]

MANIFESTATIONS OF DISEASE

Clinical Presentation

Prenatal diagnosis of renal ectopia is based on US findings, as discussed subsequently. These abnormalities commonly go undetected prenatally and postnatally. Children may be diagnosed during evaluation for urinary tract infection because of the association with VUR and UPJ obstruction. Some individuals with horseshoe kidney come to attention because of renal calculi.

Imaging Technique and Findings

Ultrasound. When there is a pelvic kidney or crossed renal ectopia, the initial US finding is often an inability to visualize a normal kidney in one renal fossa (see Fig. 11.1). If the diagnosis is suspected, it is important to image both renal fossae in multiple planes and to image the pelvis to determine whether the diagnosis is unilateral renal agenesis or renal ectopia. It is also important to assess for abnormalities of the contralateral kidney. When a kidney is not present in the renal fossa, the adrenal flattens and fills the fossa in what has been termed the *"lying-down" adrenal sign* (see Figs. 10.3 and 11.2).[22] The adrenal gland is suprarenal and almond-shaped, with a hypoechoic cortex and hyperechoic medulla.

Pelvic kidneys are usually located below the level of the aortic bifurcation and opposite the sacrum.[5] The pelvic kidney may be challenging to differentiate from surrounding structures, particularly in the second trimester when there is less perinephric fat. In addition, the pelvic kidney is frequently hypoplastic (Fig. 8.1). Hypoplasia may be diagnosed using reference tables (see Table 9.1). Abnormal orientation of the renal pelvis may predispose to obstruction, and hydronephrosis is common. As shown in Figs. 8.2 and 8.3, the degree of dilatation may range from mild to severe. With any degree of hydronephrosis, surveillance for worsening obstruction is recommended (see also Chapter 12).

When there is crossed renal ectopia, one kidney is usually at the normal level and the second is inferior to it, malrotated, and often fused with it (crossed-fused ectopia) (Fig. 8.4). Close attention to the contour of the kidneys and their orientation may be helpful. The fused kidneys may have a globular appearance that can mimic a solitary kidney with compensatory hypertrophy (see Chapter 9). As gestation advances, the two kidneys often become easier to visualize (Fig. 8.5). Color Doppler may demonstrate two separate vessels supplying the kidneys (Fig. 8.6).

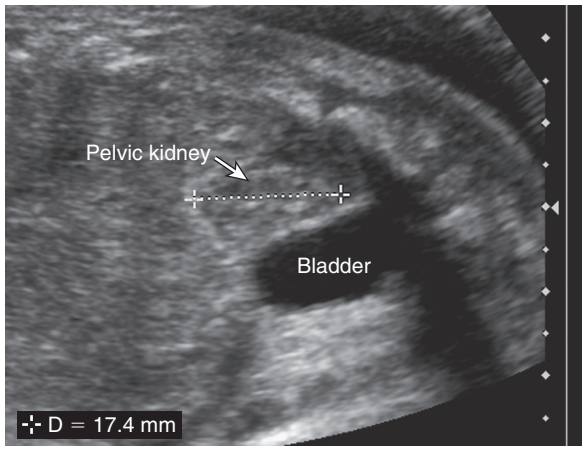

Fig. 8.1 Sagittal image of a pelvic kidney at 26 weeks' gestation. The kidney is posterior to the superior portion of the bladder and is hypoplastic, measuring 17.4 mm in length.

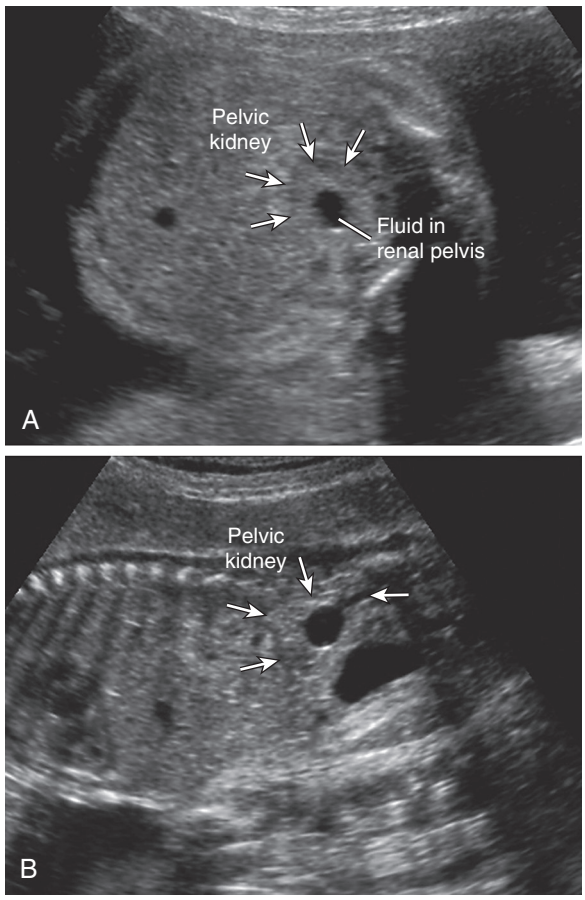

Fig. 8.2 Transverse (A) and sagittal (B) images of a pelvic kidney at 24 weeks' gestation. Mild renal pelvis dilation is visible.

With horseshoe kidney, the inferior poles fuse to form an isthmus that crosses the midline, anterior to the great vessels and just below the inferior mesenteric artery. Although the kidney is displaced inferiorly, this may not be appreciated if only the upper poles of the kidney are imaged. This anomaly is frequently undiagnosed in the absence of associated anomalies. The shape

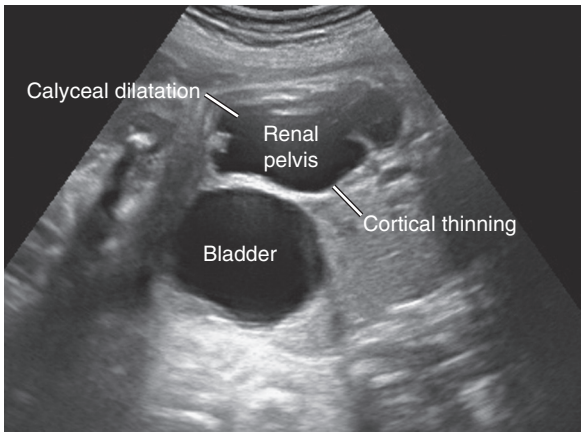

Fig. 8.3 Coronal image of a pelvic kidney at 35 weeks' gestation, showing marked calyceal dilation and cortical thinning (grade IV hydronephrosis).

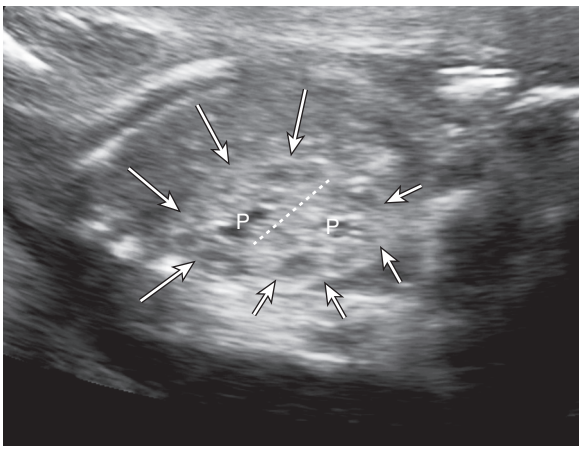

Fig. 8.4 Sagittal image depicting crossed-fused ectopia at 20 weeks' gestation. *Dotted line* indicates area of fusion. Two renal pelves *(P)* are visible. The kidneys are rotated, with medial deviation of their inferior poles. The renal contour has a globular appearance.

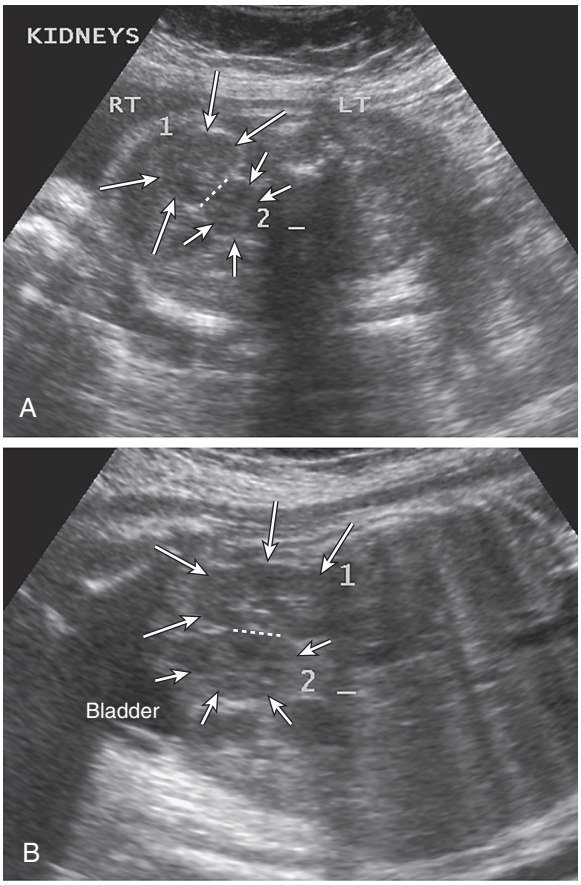

Fig. 8.5 Transverse (A) and sagittal (B) image at 38 weeks' gestation, showing two fused kidneys on the right side in a fetus with crossed-fused ectopia. *Dotted line* indicates area of fusion. No kidney is visible in the left renal fossa.

of a horseshoe ("U") is visualized in the coronal plane (Fig. 8.7), whereas in the transverse plane, a bridge of tissue may be seen to connect the two kidneys anteriorly, with subtle anterior displacement of the collecting system (Fig. 8.8). Because of the strong association with chromosomal abnormalities, amniocentesis should be offered in the setting of horseshoe kidney or when any form of renal ectopia is present in conjunction with other anomalies.

CLASSIC SIGNS

Pelvic kidney: "Lying-down" adrenal sign, with kidney located in the pelvis
Crossed renal ectopia: Both kidneys on one side, often fused together, with the "lying-down" adrenal sign on the contralateral side
Horseshoe kidney: An isthmus of tissue joining the inferior poles of the kidneys, which form the shape of a horseshoe in the coronal plane

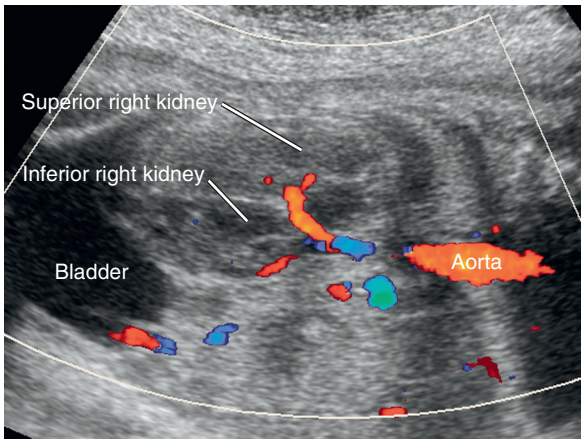

Fig. 8.6 Sagittal image at 38 weeks' gestation depicting crossed-fused ectopia. Two contiguous (fused) masses of renal tissue are visible, with the inferior one adjacent to the bladder. Color Doppler reveals a separate vessel supplying each mass.

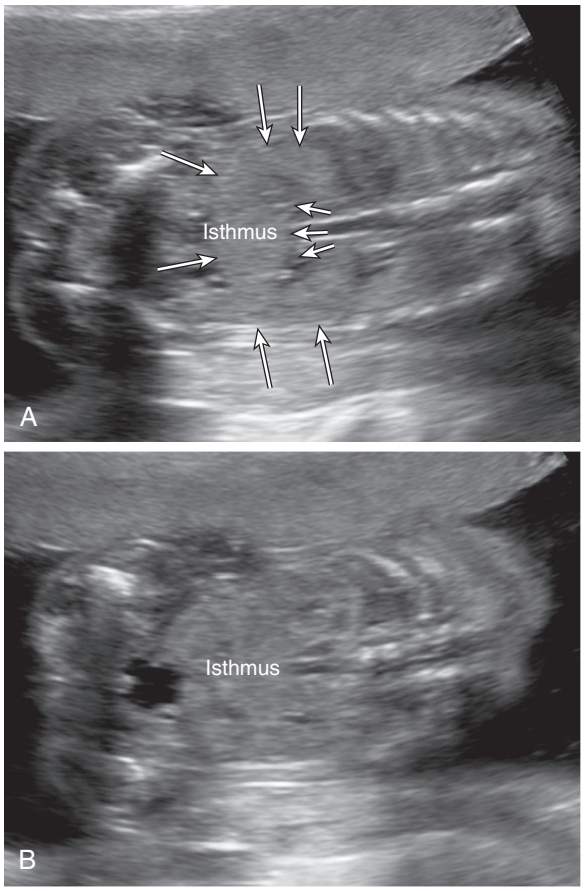

Fig. 8.7 (A, B) Coronal images of a horseshoe kidney at 20 weeks' gestation. There is a transverse band of renal tissue (the isthmus) that extends across the fetal pelvis, connecting the inferior poles. This fetus had trisomy 18.

Differential Diagnosis From Imaging Findings

1. Unilateral renal agenesis
2. Normal kidney
3. Normally located kidney with renal pelvis dilatation or multicystic dysplasia
4. Renal tumor

Synopsis of Treatment Options

POSTNATAL

US is performed in the neonatal period to confirm the diagnosis and evaluate for evidence of obstruction. Given the high incidence of VUR, voiding cystourethrogram may be considered.[4] Renal ectopia generally is associated with a benign clinical course. UPJ obstruction is the most common indication for surgical intervention. Horseshoe kidneys and crossed renal ectopia have been associated with a slight increase in the incidence of renal tumors, including renal cell carcinoma, Wilms tumor, and carcinoid.[1,17,20,23,24] Horseshoe kidneys are also more susceptible to traumatic injury because of low position and lack of bony protection.[9]

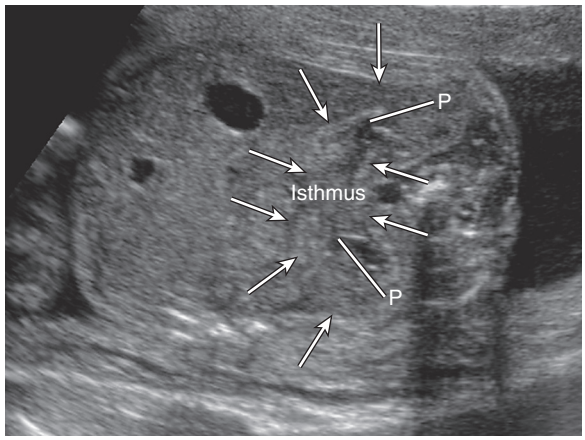

Fig. 8.8 Transverse image of horseshoe kidney at 28 weeks' gestation. There is a band of renal tissue crossing the midline anterior to the aorta (the isthmus). The medial aspects of the renal pelves *(P)* angle anteriorly.

WHAT THE REFERRING PHYSICIAN NEEDS TO KNOW

Compared with other fetal anomalies, the US findings in renal ectopia may be subtle. It is important to verify the presence of both kidneys in the renal fossae, and if one is absent, it is important to try to determine if it is in the pelvis or on the same side as the other kidney. Horseshoe kidney is much more common than other forms of renal ectopia but less likely to be detected prenatally. Any evidence of renal pelvic dilatation in an ectopic kidney should be followed for progression, and third-trimester evaluation (e.g., at 32 weeks) is suggested even in the absence of dilatation. Postnatal follow-up is necessary to avoid complications related to infection, reflux, and obstruction.

KEY POINTS

- There are three forms of renal ectopia: Pelvic kidney occurs in approximately 1:2000 to 1:3000 births; crossed renal ectopia, in 1:7500 births; and horseshoe kidney, in 1:400 births.
- Each type of renal ectopia is associated with an increased prevalence of VUR and UPJ obstruction. There is also a high prevalence of renal calculi in individuals with horseshoe kidney.
- Pregnancies complicated by renal ectopia should be evaluated for other anomalies and followed for development of hydronephrosis. Amniocentesis should be offered in the setting of horseshoe kidney or when any type of renal ectopia is present in conjunction with other anomalies.

SUGGESTED READING

Cinman NM, Okeke Z, Smith AD. Pelvic kidney: associated diseases and treatment. *J Endourol.* 2007;21:836-842.

Decter RM. Renal duplication and fusion anomalies. *Pediatr Clin North Am.* 1997;44:1323-1341.

Guarino N, Tadini B, Camardi P, et al. The incidence of associated urological abnormalities in children with renal ectopia. *J Urol.* 2004;172:1757-1759.

Natsis K, Piagkou M, Skotsimara A, et al. Horseshoe kidney: a review of anatomy and pathology. *Surg Radiol Anat.* 2014;36:517-526.

O'Brien J, Buckley O, Doody O, et al. Imaging of horseshoe kidneys and their complications. *J Med Imaging Radiat Oncol.* 2008;52:216-226.

All references are available online at www.expertconsult.com.

REFERENCES

1. Pitts WR, Muecke EC. Horseshoe kidneys: a 40-year experience. *J Urol*. 1975;113:743-746.
2. Cascio S, Sweeney B, Granata C, et al. Vesicoureteral reflux and ureteropelvic junction obstruction in children with horseshoe kidney: treatment and outcome. *J Urol*. 2002;167:2566-2568.
3. Raj GV, Auge BK, Weizer AZ, et al. Percutaneous management of calculi within horseshoe kidneys. *J Urol*. 2003;170:48-51.
4. Guarino N, Tadini B, Camardi P, et al. The incidence of associated urological abnormalities in children with renal ectopia. *J Urol*. 2004;172:1757-1759.
5. Gleason PE, Kelalis PP, Husmann DA, et al. Hydronephrosis in renal ectopia: incidence, etiology, and significance. *J Urol*. 1994;151:1660-1661.
6. Hertz M, Rubinstein J, Shahin N, et al. Crossed renal ectopia: clinical and radiological findings in 22 cases. *Clin Radiol*. 1977;28:339-344.
7. Baniel J, Glezerson G, Tobias M, et al. Renal ectopia. *Scand J Urol Nephrol*. 1991;25:241-244.
8. Kölln CP, Boatman L, Schmidt JD, et al. Horseshoe kidney: a review of 105 patients. *J Urol*. 1972;107:203-204.
9. O'Brien J, Buckley O, Doody O, et al. Imaging of horseshoe kidneys and their complications. *J Med Imaging Radiat Oncol*. 2008;52:216-226.
10. Malek RS, Kelalis PP, Burke EC. Ectopic kidney in children and frequency of association with other malformations. *Mayo Clin Proc*. 1971;46:461-467.
11. Zafar FS, Lingeman JE. Value of laparoscopy in the management of calculi complicating renal malformations. *J Endourol*. 1996;10:379-383.
12. Kretschmer HL. Unilateral fused kidney. *Surg Gynecol Obstet*. 1925;40:360-366.
13. Boatman DL, Culp DA Jr, Culp DA, et al. Crossed renal ectopia. *J Urol*. 1972;108:30-31.
14. Whitehouse GH. Some urographic aspects of the horseshoe kidney anomaly—a review of 59 cases. *Clin Radiol*. 1975;25:107-114.
15. Decter RM. Renal duplication and fusion anomalies. *Pediatr Clin North Am*. 1997;44:1323-1341.
16. Woolf AS, Price KL, Scambler PJ, et al. Evolving concepts in human renal dysplasia. *J Am Soc Nephrol*. 2004;15:998-1007.
17. Hohenfellner M, Schultz-Lampel D, Lampel A, et al. Tumor in the horseshoe kidney: clinical implications and review of embryogenesis. *J Urol*. 1992;147:1098-1102.
18. Felzenberg J, Nasrallah P. Crossed renal ectopia without fusion associated with hydronephrosis in an infant. *Urology*. 1991;38:450-452.
19. Hill LM, Grzybek P, Mills A, et al. Antenatal diagnosis of fetal pelvic kidneys. *Obstet Gynecol*. 1994;83:333-336.
20. Natsis K, Piagkou M, Skotsimara A, et al. Horseshoe kidney: a review of anatomy and pathology. *Surg Radiol Anat*. 2014;36:517-526.
21. McPherson E. Renal anomalies in families of individuals with congenital solitary kidney. *Genet Med*. 2007;9:298-302.
22. Hoffman CK, Filly RA, Callen PW. The "lying down" adrenal sign: a sonographic indicator of renal agenesis or ectopia in fetuses and neonates. *J Ultrasound Med*. 1992;11:533-536.
23. Buntley D. Malignancy associated with horseshoe kidney. *Urology*. 1976;8:146-148.
24. Glodny B, Peterson J, Hofmann KJ, et al. Kidney fusion anomalies revisited: clinical and radiological analysis of 209 cases of crossed fused ectopia and horseshoe kidney. *BJU Int*. 2008;103:224-235.

9 Abnormal Kidney Size

TAMARA T. CHAO | JODI S. DASHE

Introduction

The fetal kidneys are routinely imaged in the second and third trimester, but they are not usually measured unless an abnormality is suspected. Nomograms are available not only for kidney length (Table 9.1) but also for anterior-posterior diameter (Table 9.2) and transverse diameter (Table 9.3).[1,2] An abnormality of kidney size can occur as a normal variant, as a physiologic adaptation (i.e., compensatory hypertrophy), as a manifestation of a renal anomaly or tumor, or as a component of a genetic syndrome. If an abnormality of kidney size is suspected, further evaluation may reveal information about underlying pathology and assist with counseling about prognosis.

Normal Anatomy

GENERAL ANATOMIC DESCRIPTIONS

The kidneys are visible by 11 to 13 weeks' gestation, appearing as bilateral echogenic masses adjacent to the lumbar spine (Fig. 9.1).[3] They are circular in the transverse plane and elliptical when viewed longitudinally, spanning four to five spinal segments. As gestation advances, the relative echogenicity of the kidney decreases, and a rim of perinephric fat facilitates visualization of the kidney margins (Fig. 9.2). In addition, corticomedullary differentiation becomes visible, with the medulla less echogenic

TABLE 9.1 NOMOGRAM FOR KIDNEY LENGTH IN MILLIMETERS ACCORDING TO GESTATIONAL AGE

Weeks' Gestation	3rd	10th	50th	90th	97th
14	7.5	8.0	9.3	10.8	11.6
15	8.8	9.5	11.0	12.8	13.7
16	10.2	11.0	12.7	14.8	15.8
17	11.6	12.5	14.5	16.8	18.1
18	13.1	14.1	16.3	18.9	20.3
19	14.6	15.6	18.2	21.1	22.6
20	16.1	17.2	20.0	23.2	24.9
21	17.5	18.8	21.8	25.4	27.2
22	19.0	20.4	23.6	27.4	29.4
23	20.4	21.9	25.4	29.5	31.6
24	21.8	23.4	27.1	31.5	33.8
25	23.1	24.8	28.8	33.4	35.8
26	24.4	26.2	30.4	35.3	37.8
27	25.6	27.5	31.9	37.1	39.7
28	26.8	28.7	33.4	38.7	41.5
29	27.9	29.9	34.7	40.3	43.2
30	28.9	31.0	36.0	41.8	44.8
31	29.9	32.1	37.2	43.2	46.3
32	30.8	33.0	38.3	44.5	47.7
33	31.6	33.9	39.4	45.7	49.0
34	32.4	34.7	40.3	46.8	50.2
35	33.1	35.4	41.1	47.8	51.2
36	33.7	36.1	41.9	48.7	52.2
37	34.2	36.7	42.6	49.4	53.0
38	34.7	37.2	43.2	50.1	53.8
39	35.1	37.6	43.7	50.7	54.4
40	35.4	38.0	44.1	51.2	54.9
41	35.7	38.3	44.5	51.6	55.4
42	36.0	38.6	44.8	52.0	55.7

Data from Chitty LS, Altman DG: Charts of fetal size: kidney and renal pelvis measurements, *Prenat Diagn* 23:891–897, 2003.

TABLE 9.2 NOMOGRAM FOR KIDNEY ANTERIOR-POSTERIOR DIAMETER IN MILLIMETERS ACCORDING TO GESTATIONAL AGE

Weeks' Gestation	3rd	10th	50th	90th	97th
14	4.6	5.2	6.5	8.3	9.2
15	5.4	6.0	7.6	9.6	10.7
16	6.2	6.9	8.6	10.9	12.1
17	7.0	7.8	9.7	12.2	13.6
18	7.8	8.7	10.8	13.6	15.1
19	8.6	9.5	11.9	14.9	16.6
20	9.4	10.4	13.0	16.3	18.0
21	10.2	11.3	14.1	17.5	19.4
22	11.0	12.2	15.1	18.8	20.8
23	11.8	13.0	16.1	20.0	22.1
24	12.5	13.8	17.1	21.1	23.3
25	13.2	14.6	18.0	22.2	24.5
26	13.9	15.4	18.9	23.2	25.6
27	14.6	16.1	19.7	24.2	26.6
28	15.2	16.7	20.5	25.1	27.6
29	15.8	17.4	21.2	25.9	28.4
30	16.4	18.0	21.9	26.7	29.2
31	16.9	18.5	22.5	27.3	29.9
32	17.4	19.0	23.1	27.9	30.6
33	17.8	19.5	23.6	28.5	31.2
34	18.2	19.9	24.0	29.0	31.6
35	18.6	20.3	24.4	29.4	32.1
36	18.9	20.6	24.8	29.7	32.4
37	19.2	20.9	25.1	30.0	32.7
38	19.5	21.2	25.3	30.3	32.9
39	19.7	21.4	25.5	30.5	33.1
40	19.9	21.6	25.7	30.6	33.2
41	20.1	21.8	25.8	30.7	33.2
42	20.2	21.9	25.9	30.7	33.2

Data from Chitty LS, Altman DG: Charts of fetal size: kidney and renal pelvis measurements, *Prenat Diagn* 23:891–897, 2003.

TABLE 9.3 NOMOGRAM FOR KIDNEY TRANSVERSE DIAMETER IN MILLIMETERS ACCORDING TO GESTATIONAL AGE

Weeks' Gestation	3rd	10th	50th	90th	97th
14	4.4	5.0	6.3	8.0	8.9
15	5.1	5.7	7.3	9.2	10.2
16	5.9	6.5	8.3	10.4	11.6
17	6.6	7.4	9.3	11.7	13.0
18	7.4	8.2	10.3	12.9	14.4
19	8.1	9.0	11.3	14.2	15.7
20	8.9	9.9	12.3	15.4	17.1
21	9.7	10.7	13.3	16.6	18.4
22	10.4	11.5	14.3	17.8	19.7
23	11.2	12.3	15.3	18.9	20.9
24	11.9	13.1	16.2	20.1	22.1
25	12.6	13.9	17.1	21.1	23.3
26	13.3	14.7	18.0	22.1	24.4
27	14.0	15.4	18.9	23.1	25.4
28	14.6	16.1	19.7	24.0	26.4
29	15.2	16.7	20.4	24.9	27.3
30	15.8	17.4	21.1	25.7	28.2
31	16.4	18.0	21.8	26.5	29.0
32	17.0	18.5	22.4	27.2	29.7
33	17.5	19.1	23.0	27.8	30.4
34	17.9	19.6	23.6	28.4	31.0
35	18.4	20.1	24.1	29.0	31.6
36	18.8	20.5	24.6	29.4	32.1
37	19.2	20.9	25.0	29.9	32.5
38	19.6	21.3	25.4	30.3	32.9
39	19.9	21.6	25.7	30.6	33.2
40	20.3	21.9	26.0	30.9	33.5
41	20.5	22.2	26.3	31.1	33.7
42	20.8	22.5	26.5	31.3	33.9

Data from Chitty LS, Altman DG: Charts of fetal size: kidney and renal pelvis measurements, *Prenat Diagn* 23:891–897, 2003.

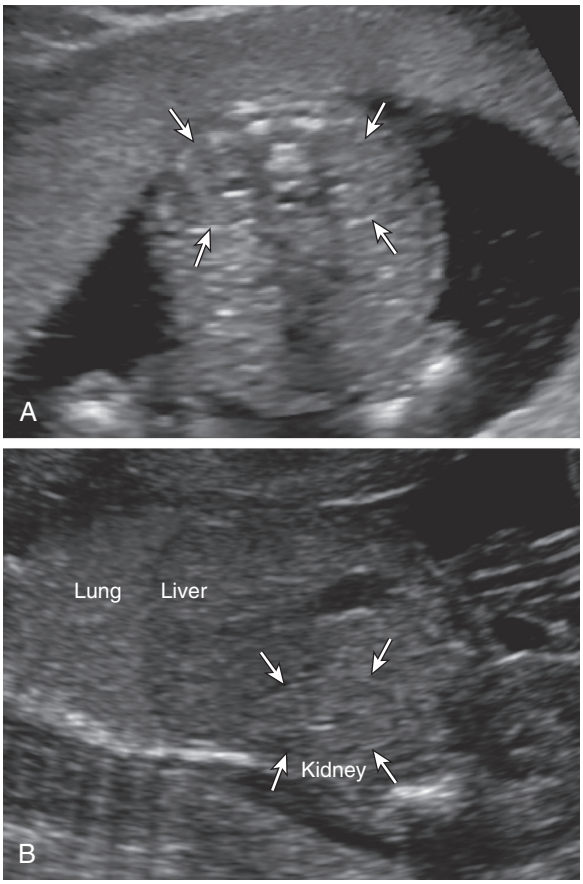

Fig. 9.2 (A) Transverse image of the fetal kidneys *(arrows)* at 18 weeks' gestation. They are readily visible by this gestational age. A physiologic amount of urine may be noted in the renal pelves. (B) Sagittal image at 18 weeks' gestation. At this gestational age, the fetal kidney *(arrows)* is less echogenic than the fetal lung and relatively isoechoic to the liver. Renal echogenicity continues to decrease as gestational age advances.

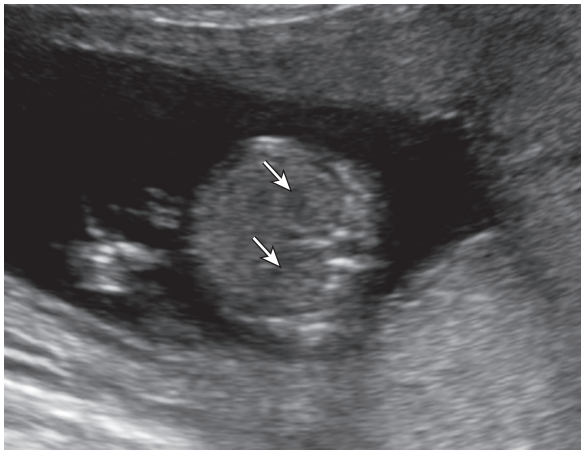

Fig. 9.1 Transverse image of fetal kidneys *(arrows)* at 13 weeks' gestation. The kidneys appear as mildly echogenic masses adjacent to the lumbar spine.

than the surrounding cortex. Echopenic (hypoechoic) renal pyramids, which are arranged in anterior and posterior rows, are also visible within the cortex, particularly by late pregnancy (Fig. 9.3). Absent or abnormal corticomedullary differentiation may be a sign of renal disease (see Chapter 16). By the third trimester, the kidneys should be less echogenic than the liver and spleen.

Kidney size increases linearly with gestational age.[4,5] The kidney length is measured in the sagittal plane and is evaluated using a gestational age–specific nomogram (see Table 9.1). The mean length is 20 mm at 20 weeks' gestation, increasing by approximately 1.1 mm per week thereafter.[1]

DETAILED DESCRIPTION OF SPECIFIC AREAS

Normal Variants

The normal range for kidney length (i.e., normal variation in size) also increases with advancing gestation, particularly in the third trimester. As a result, even when kidneys are enlarged and appear echogenic, if a thorough evaluation does not reveal other abnormalities and the family history is normal, the outcome may be normal.[6,7] A common cause of renal enlargement is compensatory hypertrophy, which may occur when the

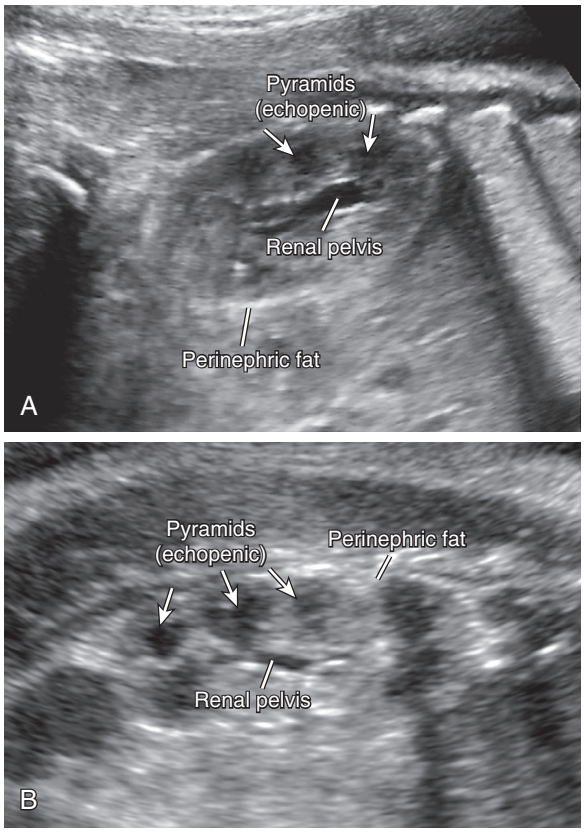

Fig. 9.3 Sagittal images of fetal kidneys at 32 weeks' gestation (A) and 36 weeks' gestation (B). Perinephric fat facilitates visualization of the kidney margins. As gestational age advances, the renal pyramids *(arrows)* become more hypoechoic. The amount of fluid within the renal pelves is physiologic.

contralateral kidney is absent, as in unilateral renal agenesis (see Chapter 11 and Fig. 11.4), or nonfunctioning, as with multicystic dysplastic kidney (see Chapter 15).

When there is compensatory hypertrophy, the kidney develops a globular appearance, and the ratio of the anterior-posterior diameter to the transverse diameter changes.[2] Cho et al.[2] reported that an anterior-posterior-to-transverse diameter ratio of 0.9 or greater has 100% accuracy for detecting compensatory hypertrophy, and that a ratio below this threshold increases the likelihood of a second functioning kidney in an ectopic location. The anterior-posterior and transverse diameters may also be abnormal in the setting of growth restriction, when length measurements may remain in the normal range.[8] Abnormalities of the anterior-posterior and transverse kidney diameters have been correlated with abnormalities in the renin-angiotensin system in fetuses with growth restriction.[8,9] In addition, fetal growth restriction may be associated with diminished nephron number.[10]

Pertinent Imaging Considerations

When the fetal kidneys are either abnormally large or small, "normal" should be a diagnosis of exclusion. The following may be considered in the evaluation of enlarged kidneys:

1. *Is the process unilateral or bilateral?* If unilateral, determine whether both kidneys are present, and verify that the contralateral kidney appears normal.
2. *Are there associated anomalies?* Findings may indicate an associated syndrome, such as Beckwith-Wiedemann (see Chapter 109), Meckel-Gruber (see Chapter 133), or even aneuploidy such as trisomy 13 (see Chapter 149).
3. *Is the amniotic fluid volume normal?* If the amniotic fluid volume is severely decreased before midgestation, the prognosis is poor. Increased amniotic fluid volume may be found with ureteropelvic junction obstruction (see Chapter 12) or with mesoblastic nephroma.
4. *Are the kidneys echogenic (i.e., subjectively more echogenic than liver)?* Conditions associated with enlarged, echogenic, noncystic kidneys may include autosomal recessive or autosomal dominant polycystic kidney disease (see Chapter 16); neoplasms, such as mesoblastic nephroma or Wilms tumor; overgrowth syndromes, such as Beckwith-Wiedemann syndrome (Chapter 109) or Perlman syndrome; or infection, such as cytomegalovirus (see Chapter 165).
5. *How significant is the enlargement?* Massive enlargement may be found with autosomal recessive polycystic kidney disease (see Chapter 16). Less severe enlargement is nonspecific.
6. *Is the collecting system normal?* Is the enlargement caused in the setting of hydronephrosis (see Chapter 12), with duplication of the renal collecting system (see Chapter 13), from cystic renal dysplasia (back-pressure damage) (see Fig. 14.5), or from bladder outlet obstruction (see Chapter 14).
7. *Are there cystic changes, and if so, are they confined to one kidney?* If unilateral, consider multicystic dysplastic kidney (see Chapter 15) or (rarely) mesoblastic nephroma with cystic degeneration. If bilateral, the differential diagnosis includes Meckel-Gruber syndrome and numerous other syndromes (see Chapters 16 and 133). Associated anomalies and amniotic fluid volume may have important prognostic implications.

Alternately, a small kidney may indicate renal hypoplasia. Kidneys that are small tend to be more difficult to evaluate with ultrasound. The differential diagnosis includes multicystic dysplastic kidney with regression (see Chapter 15) and cystic renal dysplasia from obstruction with back-pressure damage (e.g., from bladder outlet obstruction or vesicoureteral reflux). Growth-restricted fetuses also tend to have smaller kidneys. Hypoplastic kidneys are commonly found in an ectopic location in the pelvis (see Fig. 8.1).

KEY POINTS

- Measurement of kidney size can assist in the diagnosis when a renal abnormality is suspected. Nomograms are available for kidney length, anterior-posterior diameter, and transverse diameter.
- The average length of the kidney is 20 mm at 20 weeks' gestation and increases by approximately 1.1 mm per week thereafter.
- Abnormalities in size may be a normal variant; may represent compensatory hypertrophy; or may be a manifestation of a renal anomaly, infection, tumor, growth abnormality, or syndrome.
- Evaluation of an abnormality in renal size should include an assessment of the amniotic fluid volume, renal collecting system, cystic changes within the kidneys, abnormalities of echogenicity or corticomedullary differentiation, and any associated abnormalities in other organ systems. A careful family history is also important.

SUGGESTED READING

Chitty LS, Altman DG. Charts of fetal size: kidney and renal pelvis measurements. *Prenat Diagn*. 2003;23:891-897.

Cho JY, Moon MH, Lee YH, et al. Measurement of compensatory hyperplasia of the contralateral kidney: usefulness for differential diagnosis of fetal unilateral empty renal fossa. *Ultrasound Obstet Gynecol*. 2009;34:515-520.

Tsatsaris V, Gagnadoux MF, Aubrey MC, et al. Prenatal diagnosis of bilateral isolated fetal hyperechogenic kidneys: is it possible to predict long-term outcome? *BJOG*. 2002;109:1388-1393.



All references are available online at www.expertconsult.com.

REFERENCES

1. Chitty LS, Altman DG. Charts of fetal size: kidney and renal pelvis measurements. *Prenat Diagn*. 2003;23:891-897.
2. Cho JY, Moon MH, Lee YH, et al. Measurement of compensatory hyperplasia of the contralateral kidney: usefulness for differential diagnosis of fetal unilateral empty renal fossa. *Ultrasound Obstet Gynecol*. 2009;34:515-520.
3. Bronshtein M, Kushnir O, Ben-Rafael Z, et al. Transvaginal sonographic measurement of fetal kidneys in the first trimester of pregnancy. *J Clin Ultrasound*. 1990;18:299-301.
4. Grannum P, Bracken M, Silverman R, et al. Assessment of fetal kidney size in normal gestation by comparison of ratio of kidney circumference to abdominal circumference. *Am J Obstet Gynecol*. 1980;136:249-254.
5. Callan NA, Otis CS, Weiner S. Growth of the fetal kidney: ultrasonographic measurement of the ratio of average kidney diameter to biparietal diameter. *J Reprod Med*. 1985;30:485-488.
6. Tsatsaris V, Gagnadoux MF, Aubrey MC, et al. Prenatal diagnosis of bilateral isolated fetal hyperechogenic kidneys: is it possible to predict long-term outcome? *Br J Obstet Gynaecol*. 2002;109:1388-1393.
7. Mashiach R, Davidovits M, Eisenstein B, et al. Fetal hyperechogenic kidney with normal amniotic fluid volume: a diagnostic dilemma. *Prenat Diagn*. 2005;25:553-558.
8. Konje JC, Okaro CI, Bell SC, et al. A cross-sectional study of changes in fetal renal size with gestation in appropriate- and small-for-gestational-age fetuses. *Ultrasound Obstet Gynecol*. 1997;9:22-26.
9. Konje JC, Bell SC, Morton JJ, et al. Human fetal kidney morphometry during gestation and the relationship between weight, kidney morphometry and plasma active renin concentration at birth. *Clin Sci*. 1996;91:169-175.
10. Manalich R, Reyes L, Herrera M, et al. Relationship between weight at birth and the number and size of renal glomeruli in humans: a histomorphometric study. *Kidney Int*. 2000;58:770-773.

10 Bilateral Renal Agenesis

JENNIFER S. HERNANDEZ | JODI S. DASHE

Introduction

Bilateral renal agenesis is a uniformly lethal anomaly. Absence of the kidneys causes anhydramnios, resulting in pulmonary hypoplasia, characteristic facies, and positional extremity abnormalities (Fig. 10.1). This constellation of findings was first described by Edith Potter, and bilateral renal agenesis has been termed *Potter syndrome*.[1,2] The deformation sequence itself, which can occur following lack of amniotic fluid from any early insult (not merely from renal agenesis), is known as the *oligohydramnios sequence* or *Potter sequence*.

It is often challenging to diagnose absence of a structure, and bilateral renal agenesis can be particularly challenging because the lack of amniotic fluid impairs visualization. However, in population-based registries, renal agenesis has been diagnosed prenatally in about 90% of cases.[3,4]

Disorder

DEFINITION

Bilateral renal agenesis is the congenital absence of both kidneys and ureters.

PREVALENCE AND EPIDEMIOLOGY

In Potter's original series, the prevalence of bilateral renal agenesis was approximately 1:3000 births.[1] In population-based studies

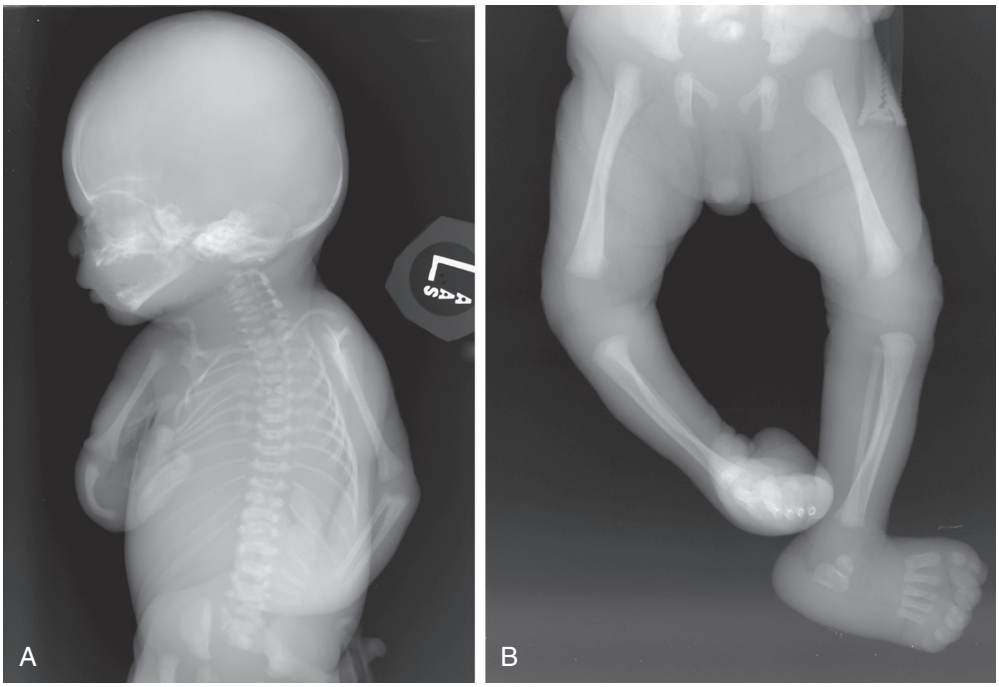

Fig. 10.1 Radiographs of a stillborn infant with bilateral renal agenesis, showing abnormal positioning of the hands and feet.

involving routine prenatal ultrasound (US), the prevalence is 1:8000 to 1:9000 pregnancies.[3,4] The actual birth prevalence is less common because approximately two-thirds of pregnancies with bilateral renal agenesis are terminated.[3,4]

Bilateral renal agenesis is three times more common in males.[5,6] It is also more common in the setting of pregestational diabetes.[7] Based on data from the National Birth Defects Prevention Study, obesity and cigarette smoking approximately double the risk for bilateral renal agenesis, and binge drinking in the second month may more than triple the risk.[8]

Associated anomalies have been reported in a high percentage of cases, including VACTERL (*v*ertebral, *a*nal, *c*ardiac, *t*racheal, *e*sophageal, *r*enal, and *l*imb anomalies; see Chapter 146) association in 48% and gastrointestinal atresia in 28%.[6] Partial laterality defects have been identified in more than 50% of cases, including intestinal malrotation, incomplete lobulation of the right lung, and persistence of the left superior vena cava.[6] Aneuploidy has been reported in 7%.[3,4] Bilateral renal agenesis is also a component of several syndromes, including branchiootorenal syndrome, Fraser syndrome (see Chapter 128), and sirenomelia (see Chapter 144).[9,10]

ETIOLOGY AND PATHOPHYSIOLOGY

Renal agenesis results when the ureteric bud either fails to develop from the mesonephric (Wolffian) duct or fails to induce the surrounding metanephric mesenchyme to form glomeruli and nephrons.[11] There is usually absence of the seminal vesicles and vas deferens in males, and a high incidence of müllerian anomalies and müllerian agenesis in females.[1,2]

There is a significant familial aggregation of cases, with a recurrence risk of 5% to 6% and an overall prevalence of renal anomalies of 15% among first-degree relatives.[5,6] The RET (Rearranged in Transfection) tyrosine kinase signaling system appears to be critical for normal nephron size and function.[12] In one series, about 30% of fetuses with bilateral renal agenesis had evidence of an RET gene mutation.[13]

MANIFESTATIONS OF DISEASE

Clinical Presentation

The fundal height may lag behind gestational age because of lack of amniotic fluid. The prenatal diagnosis is based on US findings, as discussed subsequently.

Imaging Technique and Findings

Ultrasound. Typically, the initial finding in the second trimester is a severe decrease or absence of the amniotic fluid volume. Fetal urine production is the major source of amniotic fluid after 16 to 18 weeks' gestation. Whenever oligohydramnios is encountered, particularly in the second trimester, it is important to image the fetal renal fossae and pelvis. In bilateral renal agenesis, the kidneys are not present in either the renal fossae or in an ectopic pelvic location, and there is no urine visible in the bladder (Fig. 10.2). However, the diagnosis may be challenging because lack of amniotic fluid can severely impair visualization.

When imaging the renal fossae, kidneys should be differentiated from the adrenal glands. The adrenal gland is suprarenal and almond-shaped, with a hypoechoic cortex and hyperechoic medulla. If a kidney is absent or in an ectopic location, the adrenal flattens and fills the fossa in what has been termed the "lying-down" adrenal sign (Fig. 10.3).[14] The adrenal is "lying down" on the psoas muscle, which is also hypoechoic.

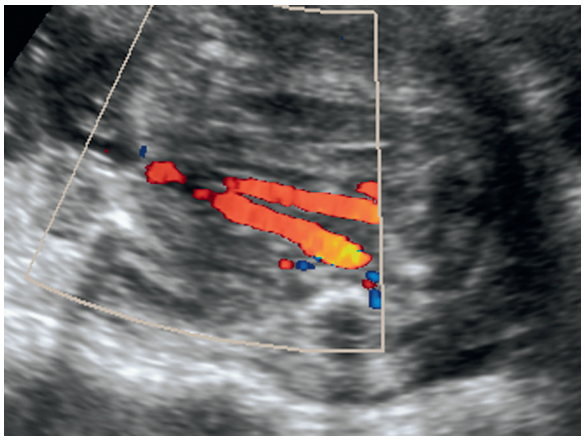

Fig. 10.2 The fetal bladder is outlined by the umbilical arteries. No urine is visible within the bladder. Note the lack of amniotic fluid surrounding the fetus.

Color Doppler imaging of the descending aorta is a useful adjunct because the renal arteries are reliably visualized when the kidneys are present, and they are absent in renal agenesis (Fig. 10.4).[15,16] The fetal abdomen is imaged in the coronal plane with the beam perpendicular to the aorta so that renal arteries arise at an angle of insonation below 20 degrees. If necessary, a nomogram is available to predict the location of the renal arteries, using the femur length as a reference.[15]

Before 16 weeks' gestation, and especially in the first trimester, the diagnosis of renal agenesis is possible but requires a high index of suspicion, because the amniotic fluid volume is often normal.[17,18] Fetal kidneys can be visualized, if present, by 11 to 13 weeks' gestation.[19,20] They appear as bilateral echogenic masses with the same density as fetal lungs (see Fig. 9.1).[18] Transvaginal US may be helpful if renal agenesis is suspected. A fluid collection may be visible in the pelvis, owing to retrograde filling of the bladder or a urachal cyst mimicking the bladder, and this may complicate the diagnosis.[18]

Despite these challenges, the diagnostic accuracy of second-trimester or third-trimester US is high. In two large, population-based registries involving multiple European countries (EUROCAT and EUROSCAN), the sensitivity of US for bilateral renal agenesis was approximately 90%, with median gestational age at diagnosis of 21 weeks and more than two-thirds diagnosed before 24 weeks.[3,4]

Magnetic Resonance Imaging. The diagnosis of bilateral renal agenesis is generally made with US. However, the prospect of pregnancy termination in the setting of poor visualization led to the investigation of fetal magnetic resonance imaging (MRI) as an adjunctive diagnostic modality for selected cases. Normally, the renal pelvis and bladder are bright and isointense to maternal fat on T2-weighted imaging. In renal agenesis, there is signal void (dark appearance) in the region of the bladder and, not unexpectedly, signal void in the region of the renal pelvis (Fig. 10.5).[21]

CLASSIC SIGNS

Absence of kidneys in the renal fossae bilaterally
"Lying down" adrenal sign
Absence of amniotic fluid beyond 18 weeks' gestation

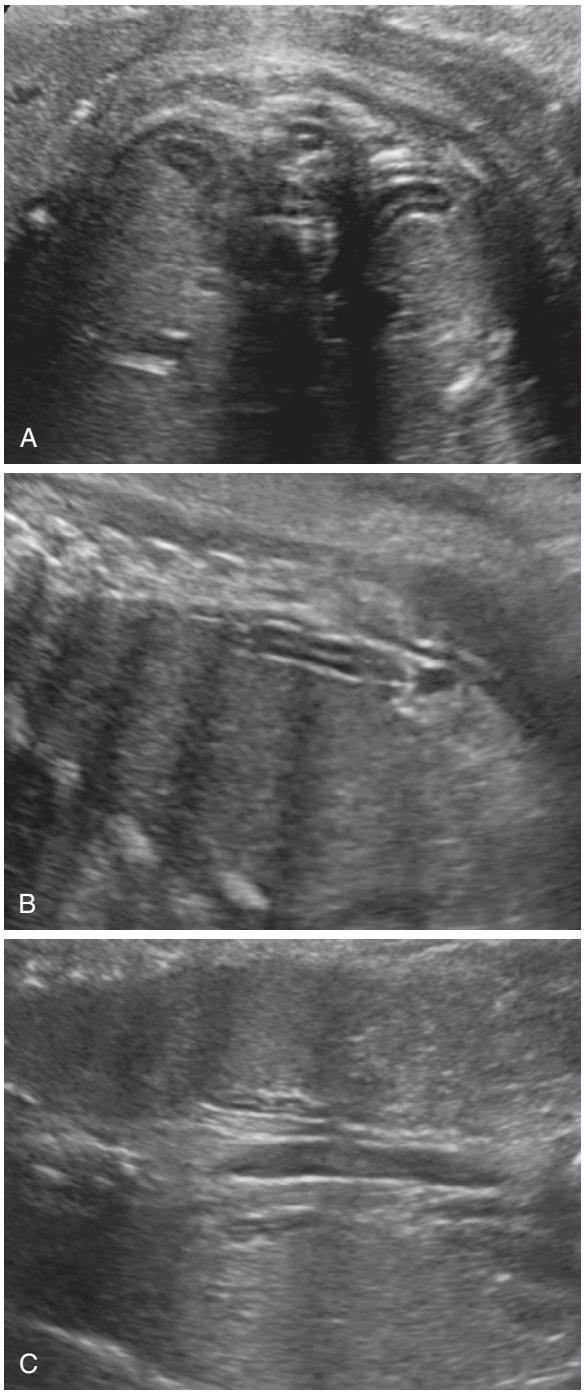

Fig. 10.3 Bilateral renal agenesis. In these transverse (A), sagittal (B), and coronal (C) images of the fetal abdomen, the adrenal gland occupies the renal fossa. The sagittal (B) and coronal (C) images depict the "lying down" adrenal sign.

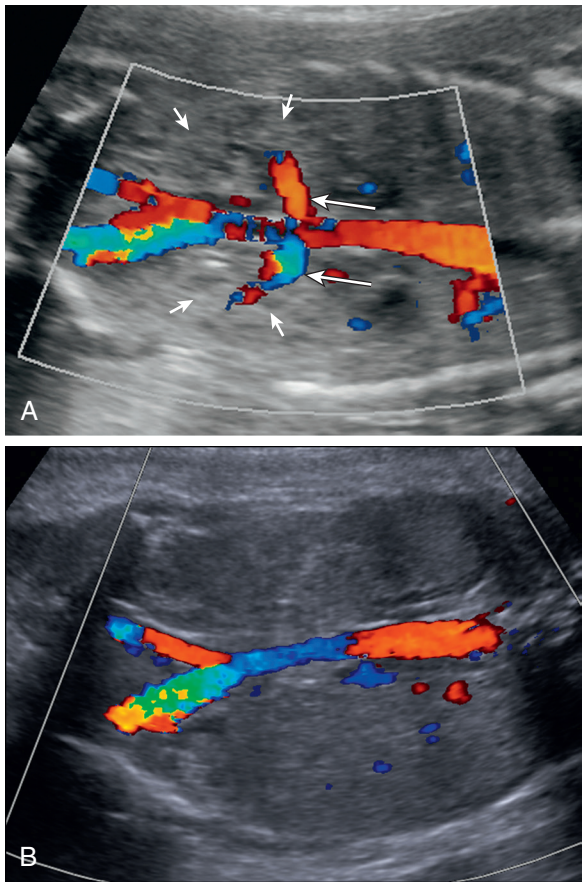

Fig. 10.4 (A) Color Doppler imaging of the descending aorta depicts the normal renal arteries *(long arrows). Short arrows* indicate fetal kidneys. (B) Renal agenesis. In this image, no renal arteries arise from the descending aorta.

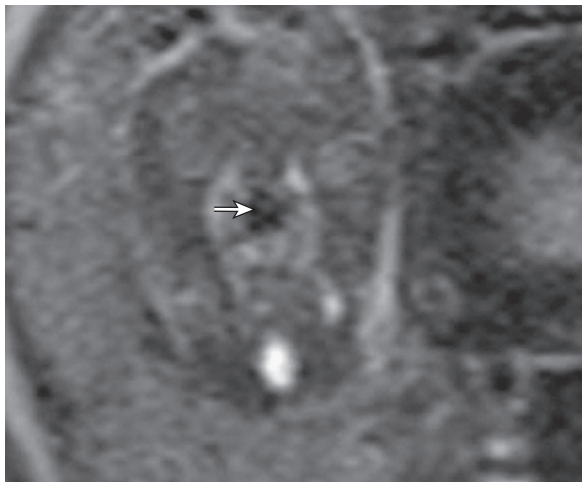

Fig. 10.5 Magnetic resonance imaging in a fetus with renal agenesis shows signal void (dark appearance) in the region of the bladder *(arrow).*

Differential Diagnosis From Imaging Findings

1. Syndromes that may include renal agenesis are as follows:
   - Branchiootorenal syndrome (autosomal dominant)
   - Fraser syndrome (autosomal recessive) (see Chapter 128)
   - Sirenomelia (see Chapter 144)
   - VACTERL association (see Chapter 146)
2. Lethal renal anomalies with abnormal appearance of the kidney are as follows:
   - Autosomal recessive (infantile) polycystic kidney disease (see Chapter 16)
   - Bilateral multicystic dysplastic kidneys (see Chapter 15)
   - Meckel-Gruber syndrome (autosomal recessive) (see Chapter 133)

3. Conditions in which lack of amniotic fluid may impair the diagnosis are the following:
   - Severe fetal growth restriction
   - Early rupture of membranes

Synopsis of Treatment Options

PRENATAL

A recent case report described in utero treatment for bilateral fetal renal agenesis with serial amniofusions, in an effort to avoid lethal pulmonary hypoplasia.[22] The neonate was delivered at 29 weeks because of preterm labor, initiated peritoneal dialysis at 36 hours of life, and despite requiring prolonged hospitalization, was able to achieve short-term survival—awaiting renal transplant at the time of the report's publication.[22] An accompanying editorial cautioned that long-term survival and quality of life in infancy and childhood must be considered before serial infusion can be considered as a potential therapy for bilateral renal agenesis.[23]

When unilateral renal agenesis is encountered, the pregnant woman should be counseled that first-degree relatives (of the fetus) may be at increased risk for unilateral renal agenesis and other renal anomalies.[24] Sonographic screening should be considered for parents and siblings, and is also indicated in future pregnancies.

WHAT THE REFERRING PHYSICIAN NEEDS TO KNOW

The finding of oligohydramnios or anhydramnios after 16 weeks' gestation should prompt a thorough evaluation of the fetal urinary system and a search for associated anomalies.

SUGGESTED READING

Bronshtein M, Amit A, Achiron R, et al. The early prenatal sonographic diagnosis of renal agenesis: techniques and pitfalls. *Prenat Diagn*. 1994;14:291-297.

Potter EL. Bilateral absence of ureters and kidneys: a report of 50 cases. *Obstet Gynecol*. 1965;25:3-8.

Toka HR, Toka O, Hariri A, et al. Congenital anomalies of kidney and urinary tract. *Semin Nephrol*. 2010;30:374-386.

Wiesel A, Queisser-Luft A, Clementi M, et al. Prenatal detection of congenital renal malformations by fetal ultrasonographic examination: an analysis of 709,030 births in 12 European countries. *Eur J Med Genet*. 2005;48:131-144.



All references are available online at www.expertconsult.com.

REFERENCES

1. Potter EL. Bilateral absence of ureters and kidneys: a report of 50 cases. *Obstet Gynecol*. 1965;25:3-8.
2. Potter EL. Bilateral renal agenesis. *J Pediatr*. 1946;29:68-76.
3. Wiesel A, Queisser-Luft A, Clementi M, et al. Prenatal detection of congenital renal malformations by fetal ultrasonographic examination: an analysis of 709,030 births in 12 European countries. *Eur J Med Genet*. 2005;48:131-144.
4. EUROCAT. European surveillance for congenital anomalies. Available at: www.eurocat-network.eu/. Accessed 4 April 2016.
5. Schwaderer AL, Bates CM, McHugh KM, et al. Renal anomalies in family members of infants with bilateral renal agenesis/adysplasia. *Pediatr Nephrol*. 2007;22:52-56.
6. Harewood L, Liu M, Keeling J, et al. Bilateral renal agenesis/hypoplasia/dysplasia (BRAHD): postmortem analysis of 45 cases with breakpoint mapping of two de novo translocations. *PLoS ONE*. 2010;5:e12375.
7. Nielsen BL, Norgard B, Puho E, et al. Risk of specific congenital anomalies in offspring of women with diabetes. *Diabet Med*. 2005;22:693-696.
8. Slickers JE, Olshan AF, Siega-Riz AM, et al. Maternal body mass index and lifestyle exposures and the risk of bilateral renal agenesis or hypoplasia. *Am J Epidemiol*. 2008;168:1259-1267.
9. Chen A, Francis M, Ni L, et al. Phenotypic manifestations of branchio-oto-renal syndrome. *Am J Med Genet*. 1995;58:365-370.
10. Prasun P, Pradhan M, Goel H. Intrafamilial variability in Fraser syndrome. *Prenat Diagn*. 2007;27:778-782.
11. Toka HR, Toka O, Hariri A, et al. Congenital anomalies of kidney and urinary tract. *Semin Nephrol*. 2010;30:374-386.
12. Davis TK, Hoshi M, Jain S. To bud or not to bud: the RET perspective in CAKUT. *Pediatr Nephrol*. 2014;29(4):597-608.
13. Skinner MA, Safford SD, Reeves JG, et al. Renal aplasia in humans is associated with RET mutations. *Am J Hum Genet*. 2008;82:344-351.
14. Hoffman CK, Filly RA, Callen PW. The "lying down" adrenal sign: a sonographic indicator of renal agenesis or ectopia in fetuses and neonates. *J Ultrasound Med*. 1992;11:533-536.
15. DeVore GR. The value of color Doppler sonography in the diagnosis of renal agenesis. *J Ultrasound Med*. 1995;14:443-449.
16. Sepulveda W, Stagiannis KD, Flack N. Accuracy of prenatal diagnosis of renal agenesis with color flow imaging in severe second-trimester oligohydramnios. *Am J Obstet Gynecol*. 1995;173:1788-1792.
17. Mackenzie FM, Kingston GO, Oppenheimer L. The early prenatal diagnosis of bilateral renal agenesis using transvaginal sonography and color Doppler ultrasonography. *J Ultrasound Med*. 1994;13:49-51.
18. Bronshtein M, Amit A, Achiron R, et al. The early prenatal sonographic diagnosis of renal agenesis: techniques and possible pitfalls. *Prenat Diagn*. 1994;14:291-297.
19. Bronshtein M, Kushnir O, Ben-Rafael Z, et al. Transvaginal sonographic measurements of fetal kidneys in the first trimester of pregnancy. *J Clin Ultrasound*. 1990;18:299-301.
20. Rosati P, Guariglia L. Transvaginal sonographic assessment of the fetal urinary tract in early pregnancy. *Ultrasound Obstet Gynecol*. 1996;7:95-100.
21. Hawkins JS, Dashe JS, Twickler DM. Magnetic resonance imaging diagnosis of severe fetal renal anomalies. *Am J Obstet Gynecol*. 2008;198:328.e1-328.e5.
22. Bienstock JL, Birsner ML, Coleman F, et al. Successful in utero intervention for bilateral renal agenesis. *Obstet Gynecol*. 2014;124:413-415.
23. Johnson A, Luks FI. A cautionary note on new fetal interventions. *Obstet Gynecol*. 2014;124:411-412.
24. McPherson E, Carey J, Kramer A, et al. Dominantly inherited renal adysplasia. *Am J Med Genet*. 1987;26:863-872.

11 Unilateral Renal Agenesis

JENNIFER S. HERNANDEZ | JODI S. DASHE

Introduction

Unilateral renal agenesis, also called *solitary kidney,* is a common congenital anomaly. Affected individuals are usually asymptomatic, and if a diagnosis is not made prenatally, they may not receive medical attention until complications arise. If unilateral renal agenesis is diagnosed in childhood, nearly 50% of affected children have an associated renal abnormality, including 30% with vesicoureteral reflux (VUR).[1,2] Being born with one kidney is not equivalent to reaching adulthood with two kidneys and subsequently undergoing a nephrectomy. Individuals with unilateral renal agenesis, even in the absence of reflux, have an increased risk of hypertension, renal insufficiency, and progression to end-stage renal disease requiring transplant.[3,4] Earlier identification of unilateral renal agenesis may forestall the development of these complications. Improvements in ultrasound (US) technology have made it easier to identify unilateral renal agenesis with prenatal US.

Disorder

DEFINITION

Unilateral renal agenesis is the congenital absence of one kidney and ureter.

PREVALENCE AND EPIDEMIOLOGY

Unilateral renal agenesis occurs in approximately 1:1000 to 1:2000 births, but it often goes undetected prenatally.[5–10] In a systematic review, unilateral renal agenesis was diagnosed prenatally in 1:8000 pregnancies, and in a population-based registry of European countries with routine sonography, unilateral renal agenesis was identified prenatally in only 1:20,000 pregnancies.[5,8] This is in contrast to the excellent detection of bilateral renal agenesis, and it highlights the importance of maintaining an index of suspicion. Male predominance of unilateral renal agenesis has been reported in some studies but not others.[2–4,11] The left kidney is absent more often than the right.[2,11,12] Unilateral renal agenesis is also more common in the setting of pregestational diabetes.[13]

Associated renal anomalies, including VUR, ureteropelvic junction (UPJ) obstruction, and ureterovesical junction obstruction, have been reported in 30% to 50% of children referred for evaluation.[2,5] In females, müllerian anomalies are common, particularly bicornuate uterus, uterus didelphys, and unicornuate uterus.[12] Occasionally, these associated anomalies are first identified in the setting of Herlyn-Werner-Wunderlich syndrome (uterus didelphys, obstructed hemivagina, and ipsilateral renal agenesis) because of hematocolpos at the time of initiation of menstruation during puberty.[14] In males, there is an increased incidence of

congenital absence of the vas deferens and cysts of the seminal vesicles.[15,16] Other associations include caudal dysgenesis, skeletal anomalies, and malformations of the central nervous system.[17] Unilateral renal agenesis is a component of several syndromes, including branchiootorenal syndrome,[18] 22q11.2 deletion syndrome (see Chapter 154),[19] and Fraser syndrome (see Chapter 128),[20] and it is one of several renal anomalies encountered in the VACTERL (*v*ertebral, *a*nal, *c*ardiac, *t*racheal, *e*sophageal, *r*enal, and *l*imb anomalies) association (see Chapter 146). The aneuploidy risk is increased in the setting of other anomalies.

ETIOLOGY AND PATHOPHYSIOLOGY

Renal agenesis results when the ureteric bud either fails to develop from the mesonephric (Wolffian) duct or fails to induce the surrounding metanephric mesenchyme to form glomeruli and nephrons.[21] There is a significant familial aggregation of cases. Offspring of individuals with unilateral renal agenesis have a 12% incidence of urogenital anomalies, more than 50% of which are renal agenesis; there is also an increased risk among other first-degree relatives.[17] In one series, 20% of cases of unilateral renal agenesis had evidence of a mutation in the RET (Rearranged in Transfection) gene.[22]

Individuals with unilateral renal agenesis are at increased risk of progression to end-stage renal disease, postulated to be caused by an overall reduction in their number of nephrons, with subsequent hyperfiltration and focal glomerulosclerosis.[3,4,23] From the standpoint of prenatal or postnatal imaging, it may be impossible to differentiate true renal agenesis from severe hypoplasia (see Chapter 9) or multicystic dysplasia with subsequent regression (see Chapter 15), and individuals with these lesions may have abnormalities of the contralateral, normal-appearing kidney as well.[16,24]

MANIFESTATIONS OF DISEASE

Clinical Presentation

The prenatal diagnosis of unilateral renal agenesis is based on US findings, as discussed subsequently. This anomaly commonly goes undetected prenatally and postnatally. Children may be diagnosed during evaluation for urinary tract infection because of the association with VUR. Adults may present with hypertension, proteinuria, or renal insufficiency. Unilateral renal agenesis may remain undiagnosed in many individuals throughout life.

Imaging Technique and Findings

Ultrasound. Typically, the initial US finding is an inability to visualize a normal kidney in the renal fossa (Fig. 11.1). When the diagnosis is suspected, it is important to image the renal fossae in multiple planes and to look for a pelvic kidney (see Chapter 8). If a kidney is not present in the renal fossa, the adrenal flattens and fills the fossa in what has been termed the "*lying-down*" *adrenal sign* (Fig. 11.2).[25] The adrenal gland is suprarenal and almond-shaped, with a hypoechoic cortex and hyperechoic medulla.

Color Doppler imaging of the descending aorta may be a useful adjunct. The fetal abdomen is imaged in the coronal plane with the beam perpendicular to the aorta so that renal arteries arise at an angle of insonation below 20 degrees. A renal artery is visible only on the side that has a kidney (Fig. 11.3).[26,27]

Often, there is also compensatory hypertrophy of the kidney on the contralateral side, which persists into childhood

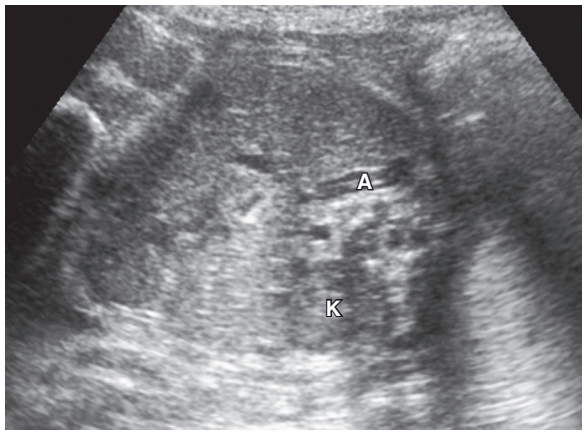

Fig. 11.1 When there is unilateral renal agenesis, only the adrenal is visible in one renal fossa, shown here in the transverse plane. *A*, Fetal adrenal gland; *K*, fetal kidney.

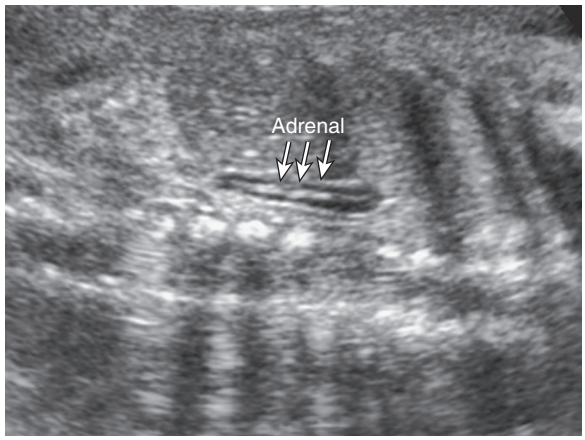

Fig. 11.2 In this coronal image of unilateral renal agenesis, the adrenal (*arrows*) flattens and fills the renal fossa, in what has been termed the "lying-down" adrenal sign. The cortex is hypoechoic cortex, and medulla is hyperechoic.

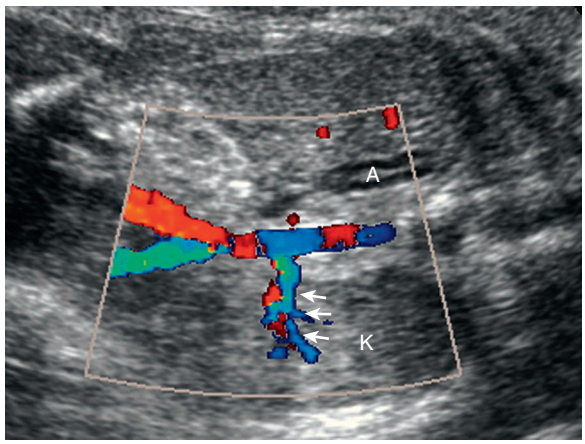

Fig. 11.3 Color Doppler imaging of the descending aorta shows that only one renal artery is present *(arrows)*. *A*, "Lying-down" adrenal gland; *K*, fetal kidney.

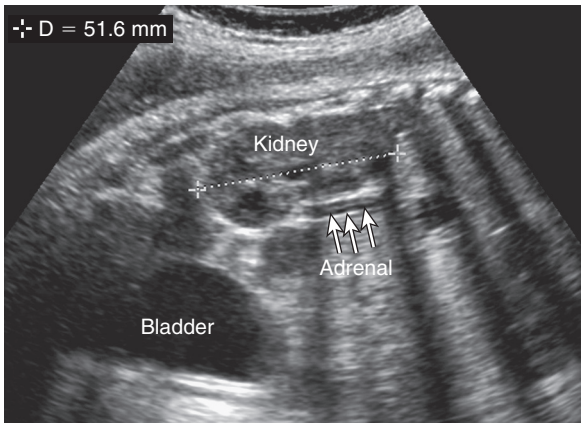

Fig. 11.4 Compensatory hypertrophy of the solitary kidney in unilateral renal agenesis. This kidney measures at the 97th percentile at 35 weeks' gestation.

(Fig. 11.4).[11,28] There is an increased risk of anomalies of the remaining kidney, particularly VUR and UPJ obstruction (see Chapter 12).[1,2] Because unilateral renal agenesis is associated with other genitourinary abnormalities and may be a component of various syndromes, targeted imaging is warranted, and amniocentesis may be offered.

CLASSIC SIGNS

Absence of one kidney
"Lying-down" adrenal sign
Color Doppler showing absence of a renal artery

Differential Diagnosis From Imaging Findings

1. Renal hypoplasia (see Chapter 9)
2. Multicystic dysplastic kidney with regression (see Chapter 15)
3. Pelvic kidney (see Chapter 8)
4. Crossed-fused renal ectopia (see Chapter 8)

Unilateral renal agenesis may occur as a component of the following syndromes:

1. Branchiootorenal syndrome (autosomal dominant)
2. 22q11.2 deletion syndrome, autosomal dominant (see Chapter 154)
3. Fraser syndrome (autosomal recessive) (see Chapter 128)
4. VACTERL association (see Chapter 146)
5. Herlyn-Werner-Wunderlich syndrome

Synopsis of Treatment Options

POSTNATAL

Most newborns with unilateral renal agenesis are asymptomatic. The diagnosis is confirmed with US, which also evaluates for the presence of associated genitourinary abnormalities. A voiding cystourethrogram is usually performed to evaluate for VUR, and a radionucleotide scan may be performed to assess renal function. Children are followed with serial assessments of growth, nutritional status, blood pressure, proteinuria or microalbuminuria, creatinine concentration, and occasionally additional imaging.[22]

Genitourinary imaging in a female patient with unilateral renal agenesis is ultimately recommended to determine if any müllerian anomalies are present.[29] First-degree relatives of an infant identified as having unilateral renal agenesis should be evaluated for renal anomalies as well.[29]

WHAT THE REFERRING PHYSICIAN NEEDS TO KNOW

Unilateral renal agenesis is an anomaly that frequently goes unrecognized, even though it is detectable with US. When unilateral renal agenesis is identified, it is important to evaluate the remaining kidney for evidence of pelvic dilatation or other abnormalities. In the absence of VUR, individuals born with one functioning kidney are usually asymptomatic, but they are at risk for long-term morbidity related to hypertension and renal insufficiency.

KEY POINTS

- Unilateral renal agenesis is a common anomaly, affecting 1:1000 to 1:2000 births.
- When the kidney is not present, the adrenal assumes a "lying-down" appearance in the renal fossa, and color Doppler reveals absence of one renal artery.
- The solitary kidney often shows compensatory hypertrophy.
- Individuals with unilateral renal agenesis require evaluation for associated anomalies and long-term follow-up for development of hypertension and renal insufficiency.

SUGGESTED READING

Argueso LR, Ritchey ML, Boyle ET, et al. Prognosis of patients with unilateral renal agenesis. *Pediatr Nephrol*. 1992;6:412-416.
Chevalier RL. When is one kidney not enough? *Kidney Int*. 2009;76:475-477.
McPherson E. Renal anomalies in families of individuals with congenital solitary kidney. *Genet Med*. 2007;9:298-302.
Sanna-Cherchi S, Ravani P, Corbani V, et al. Renal outcome in patients with congenital anomalies of the kidney and urinary tract. *Kidney Int*. 2009;76:528-533.
Westland R, Schreuder MF, Ket JCF, et al. Unilateral renal agenesis: a systematic review on associated anomalies and renal injury. *Nephrol Dial Transplant*. 2013;28:1844-1855.

All references are available online at www.expertconsult.com.

REFERENCES

1. Atiyeh B, Husmann D, Baum M. Contralateral renal abnormalities in patients with renal agenesis and noncystic renal dysplasia. *Pediatrics*. 1993; 91:812-815.
2. Cascio S, Paran S, Puri P. Associated urological anomalies in children with unilateral renal agenesis. *J Urol*. 1999;162:1081-1083.
3. Argueso LR, Ritchey ML, Boyle ET, et al. Prognosis of patients with unilateral renal agenesis. *Pediatr Nephrol*. 1992;6:412-416.
4. Sanna-Cherchi S, Ravani P, Corbani V, et al. Renal outcome in patients with congenital anomalies of the kidney and urinary tract. *Kidney Int*. 2009;76:528-533.
5. Westland R, Schreuder MF, Ket JCF, et al. Uniateral renal agenesis: a systematic review on associated anomalies and renal injury. *Nephrol Dial Transplant*. 2013;28:1844-1855.
6. Sheih CP, Liu MB, Hung CS, et al. Renal abnormalities in schoolchildren. *Pediatrics*. 1989;84:1086-1090.
7. Wiesel A, Queisser-Luft A, Clementi M, et al. Prenatal detection of congenital renal malformations by fetal ultrasonographic examination: an analysis of 709,030 births in 12 European countries. *Eur J Med Genet*. 2005;48: 131-144.
8. Halek J, Flogelova H, Michalkova K, et al. Diagnostic accuracy of postnatal ultrasound screening for urinary tract abnormalities. *Pediatr Nephrol*. 2010;25:281-287.
9. Bronshtein M, Bar-Hava I, Lightman A. The significance of early second-trimester sonographic detection of minor fetal renal anomalies. *Prenat Diagn*. 1995;15:627-632.
10. Spira EM, Jacobi C, Frankenschmidt A, et al. Sonographic long-term study: paediatric growth charts for single kidneys. *Arch Dis Child*. 2009; 94:693-698.
11. Acién P, Acién M. Unilateral renal agenesis and female genital tract pathologies. *Acta Obstet Gynaecol Scand*. 2010;89:1424-1431.
12. Nielsen GL, Norgard B, Puho E, et al. Risk of specific congenital abnormalities in offspring of women with diabetes. *Diabet Med*. 2005;22:693-696.
13. Fedele L, Motta F, Frontino G, et al. Double uterus with obstructed hemivagina and ipsilateral renal agenesis: pelvic anatomic variants in 87 cases. *Hum Reprod*. 2013;6:1580-1583.
14. Heaney JA, Pfister RC, Meares EM Jr. Giant cyst of the seminal vesicle with renal agenesis. *AJR Am J Roentgenol*. 1987;149:139-140.
15. Kolettis PN, Sandlow JI. Clinical and genetic features of patients with congenital unilateral absence of the vas deferens. *Urology*. 2002; 60:1073-1076.
16. McPherson E. Renal anomalies in families of individuals with congenital solitary kidney. *Genet Med*. 2007;9:298-302.
17. Kochhar A, Fischer SM, Kimberling WJ, et al. Branchio-oto-renal syndrome. *Am J Med Genet*. 2007;143A:1671-1678.
18. Sundaram UT, McDonald-McGinn DM, Huff D, et al. Primary amenorrhea and absent uterus in the 22q11.2 deletion syndrome. *Am J Med Genet*. 2007;143A:2016-2018.
19. Eskander BS, Shehata BM. Fraser syndrome: a new case report with review of the literature. *Fetal Pediatr Pathol*. 2008;27:99-104.
20. Toka HR, Toka O, Hariri A, et al. Congenital anomalies of kidney and urinary tract. *Semin Nephrol*. 2010;30:374-386.
21. Skinner MA, Safford SD, Reeves JG, et al. Renal aplasia in humans is associated with RET mutations. *Am J Hum Genet*. 2008;82:344-351.
22. Chevalier RL. When is one kidney not enough? *Kidney Int*. 2009; 76:475-477.
23. Mesrobian HG, Rushton HG, Bulas D. Unilateral renal agenesis may result from in utero regression of multicystic renal dysplasia. *J Urol*. 1993;150:793-794.
24. Hoffman CK, Filly RA, Callen PW. The "lying down" adrenal sign: a sonographic indicator of renal agenesis or ectopia in fetuses and neonates. *J Ultrasound Med*. 1992;11:533-536.
25. DeVore GR. The value of color Doppler sonography in the diagnosis of renal agenesis. *J Ultrasound Med*. 1995;14:443-449.
26. Sepulveda W, Stagiannis KD, Flack NJ. Accuracy of prenatal diagnosis of renal agenesis with color flow imaging in severe second-trimester oligohydramnios. *Am J Obstet Gynecol*. 1995;173:1788-1792.
27. Hartshorne N, Shepard T, Barr M Jr. Compensatory renal growth in human fetuses with unilateral renal agenesis. *Teratology*. 1991;44:7-10.
28. Hollander M, Verdonk P, Trap K. Unilateral renal agenesis and associated Mullerian anomalies: a case report and recommendations for pre-adolescent screening. *J Pediatr Adolesc Gynecol*. 2008;21:151-153.
29. McPherson E. Renal anomalies in families of individuals with congenital solitary kidney. *Genet Med*. 2007;5:298-302.

12 Renal Pelvis Dilatation

JENNIFER S. HERNANDEZ | JODI S. DASHE

Introduction

Fetal renal pelvis dilatation (or dilation) is a common ultrasound (US) finding, identified in 1% to 5% of pregnancies.[1–4] There is a strong correlation between the degree of renal pelvis dilatation and the likelihood of postnatal urinary pathology, particularly ureteropelvic junction (UPJ) obstruction and vesicoureteral reflux (VUR).[5,6] However, the normal renal pelvis diameter also increases with advancing gestation, and mild dilatation is a transient, normal variant in most cases.[1,5] The Society for Fetal Urology has termed *fetal renal pelvis dilatation* "a surrogate measurement of potential disease," to denote that it does not represent pathology.[4] Thresholds for renal pelvis dilatation in the second and third trimesters have been established to help in counseling families and guiding initial postnatal management (Table 12.1).[4–6]

Conditions associated with renal pelvis dilatation as an isolated finding include UPJ obstruction and VUR. Renal pelvis dilatation may also occur in the setting of ureteral obstruction, as with duplication of the renal collecting system (see Chapter 13), and with urethral obstruction, such as posterior urethral valves (see Chapter 14).

Disorder

DEFINITION

Fetal renal pelvis dilatation is also called *urinary tract dilation* or *hydronephrosis*, though these terms are less precise. It encompasses dilatation confined to the renal pelvis, termed *pyelectasis* or *pelviectasis,* and that which also involves the calyces, termed *caliectasis* or *pelvicaliectasis*. The pelvis is measured anterior to posterior in the transverse plane. Of the various thresholds used to diagnose dilatation, the most common are 4 mm in the second trimester (up to 20 weeks), and 7 mm at approximately 32 weeks in the third trimester.[4,7,8] The second-trimester threshold is used to identify fetuses that need additional US evaluation in the third trimester, and it is also considered a minor marker that confers slightly increased risk for trisomy 21 (see Chapter 152). The third-trimester threshold is used to identify cases that need postnatal evaluation. Criteria have been established for mild, moderate, and severe renal pelvis dilatation, based on the risk of neonatal renal abnormality in a metaanalysis of more than 100,000 screened pregnancies.[5] These definitions have been endorsed by the Society for Fetal Urology and are listed in Table 12.1.[4,5]

TABLE 12.1 DIAGNOSTIC CRITERIA FOR DEGREE OF RENAL PELVIS DILATATION

Degree of Dilatation	Second Trimester (mm)	Third Trimester (mm)
Mild	4 to <7	7 to <9
Moderate	7 to ≤10	9 to ≤15
Severe	>10	>15

From Nguyen HT, Herndon CDA, Cooper C, et al.: The Society for Fetal Urology consensus statement on the evaluation and management of antenatal hydronephrosis, *J Pediatr Urol* 6:212–231, 2010.

PREVALENCE AND EPIDEMIOLOGY

Renal pelvis dilatation is observed in 1% to 5% of second-trimester pregnancies.[1–4] The male-to-female ratio is 2:1.[3] In 1.5% of pregnancies, approximately one-third of pregnancies with renal pelvis dilatation, a urinary abnormality is confirmed in the neonatal period.[3] However, 40% to 90% of cases are transient and do not represent pathology.[4] The overall likelihood of an underlying abnormality increases with the degree of dilatation: 12% with mild, 45% with moderate, and 88% with severe hydronephrosis.[4,5]

The most common associated abnormality is UPJ obstruction, which occurs in 10% to 30% of cases.[4,5] UPJ obstruction is identified in approximately 1:1000 to 1:2000 births, has a male-to-female ratio between 3:1 and 4:1, and is predominantly left-sided.[9,10] The prevalence of UPJ obstruction increases with worsening dilatation, occurring in 5% with mild, 17% with moderate, and more than 50% with severe hydronephrosis.[4,5] It is bilateral in 20% to 25% of cases.[9]

VUR is also associated with renal pelvis dilatation. VUR occurs in approximately 4% with mild renal pelvis dilatation and 8% to 14% with moderate or severe pelvis dilatation.[4,5] Although VUR is a less common cause of fetal hydronephrosis than UPJ obstruction, it is more frequent in the general population, occurring in approximately 1% of individuals.[11] When VUR comes to attention in the neonatal period because renal pelvis dilatation was diagnosed prenatally, most affected infants are males, and VUR often resolves by early childhood. In contrast, when VUR is identified only after children have developed symptoms, the majority are females, and there is greater risk for renal insufficiency.[12]

ETIOLOGY, PATHOPHYSIOLOGY, AND EMBRYOLOGY

The etiology of transient renal pelvis dilatation is unknown. It is postulated that minor kinks or folds in the ureter during development may lead to transient obstruction or reflux, or that the fetus may be experiencing ureteral relaxation from the effects of maternal progesterone.[13] Mild renal pelvis dilatation up to

20 weeks of gestation is used as a minor marker that confers slightly increased risk for trisomy 21 (see Chapter 151).

The pathophysiology of UPJ obstruction is unknown and appears to be multifactorial.[10] Potential causes include incomplete recanalization resulting in stricture, compression from fetal vessels, and abnormal innervation or muscular discontinuity that compromises normal peristalsis.[10]

VUR is believed to occur when the ureteral bud develops at an abnormal location and makes contact with poorly differentiated portions of metanephric mesoderm, increasing the likelihood of hypoplasia or dysplasia.[11] The location of the ureteral bud results in a vesicoureteral valve that is also abnormal, causing the reflux.[11,14] VUR has been identified in up to 50% of parents and siblings of affected individuals, consistent with autosomal dominant inheritance.[11,15–17]

MANIFESTATIONS OF DISEASE

Imaging Technique and Findings

Ultrasound. The fetal renal pelvis is measured anterior to posterior in the transverse plane, with calipers placed on the inner border of the fluid collection (Fig. 12.1). Imaging should be performed in multiple planes, to identify the level of obstruction or any pathology along the course of the collecting system. In most cases, fetal renal pelvis dilatation is an isolated finding. The fetal ureter is not typically visible on US unless it is abnormal. Ureteral dilatation suggests reflux or obstruction at the level of the ureterovesical junction, as in the setting of a ureterocele (see Figs. 13.4 and 13.5). Marked hydronephrosis may also occur when there is obstruction at the level of the urethra, as with posterior urethral valves (see Fig. 14.6). A 2014 multidisciplinary consensus recommended that the sonographic description of renal pelvis dilatation include laterality, extent of calyceal dilatation, any parenchymal abnormality, bladder or urethral abnormalities, fetal sex, and assessment of amniotic fluid, and any abnormalities of other organ systems.[18]

The amniotic fluid volume is usually normal. However, UPJ obstruction is one of two renal abnormalities that may cause *paradoxical hydramnios*; the other is mesoblastic nephroma. Oligohydramnios is uncommon and usually occurs only in the setting of either severe bilateral UPJ or unilateral UPJ with a contralateral renal anomaly, such as multicystic dysplastic kidney (see Chapter 15).[19]

When mild renal pelvis dilatation is encountered in the second trimester, it is important to confirm that it appears isolated. If the fetal trisomy 21 risk is increased after taking renal pelvis dilatation into consideration, amniocentesis should be offered (see Chapter 111). We recommend an additional US evaluation at 32 weeks.[8] In 80% of cases, mild hydronephrosis in the second trimester resolves before delivery.[1] If dilatation is severe, or if there is calyceal dilatation or cortical thinning, more frequent imaging may be warranted. Neonatal evaluation is typically reserved for patients with fetal renal pelvis measurements of at least 7 mm in the third trimester.[1,4,7,8]

In 1993, the Society for Fetal Urology developed a grading system for hydronephrosis based on qualitative differences in renal morphology with worsening dilatation (Table 12.2).[20] This grading system was developed for use in children rather than fetuses, but it is often applied in the prenatal setting. If the dilatation is confined to the renal pelvis (pyelectasis), it is considered grade I hydronephrosis (see Fig. 12.1). As shown in Fig. 12.1B, by the third trimester the anechoic renal pelvis may be easily differentiated from the hypoechoic renal pyramids. If calyces are visible, the dilatation is considered grade II (Fig. 12.2). Rounding of the calyces (calyceal dilatation), indicates grade III hydronephrosis (Fig. 12.3). The calyces should be shown to

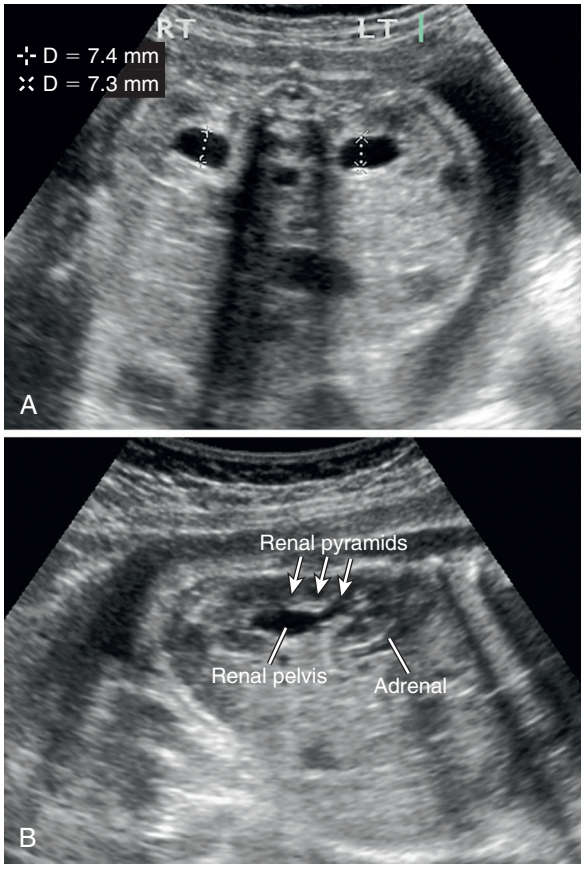

Fig. 12.1 Transverse (A) and sagittal (B) images depicting mild bilateral renal pelvis dilatation (grade I hydronephrosis) at 32 weeks' gestation. The anterior-posterior diameter of each renal pelvis measured 7 mm. Calipers are placed within the border of the fluid collection. In the sagittal image (B), the hypoechoic renal pyramids *(arrows)* are easily differentiated from the more echogenic cortex and the anechoic renal pelvis. The normal adrenal is also visible.

TABLE 12.2 SOCIETY FOR FETAL UROLOGY CLASSIFICATION OF HYDRONEPHROSIS

Grade	Central Renal Complex	Renal Parenchymal Thickness
0	Intact	Normal
I	Mild splitting of pelvis	Normal
II	Moderate splitting of pelvis and calyces but confined within renal border	Normal
III	Marked splitting, pelvis dilated outside renal border and calyces dilated	Normal
IV	Further pelvicalyceal dilatation	Thinned

From Fernbach SK, Maizels M, Conway JJ: Ultrasound grading of hydronephrosis: introduction to the system used by the Society for Fetal Urology, *Pediatr Radiol* 23:478–480, 1993.

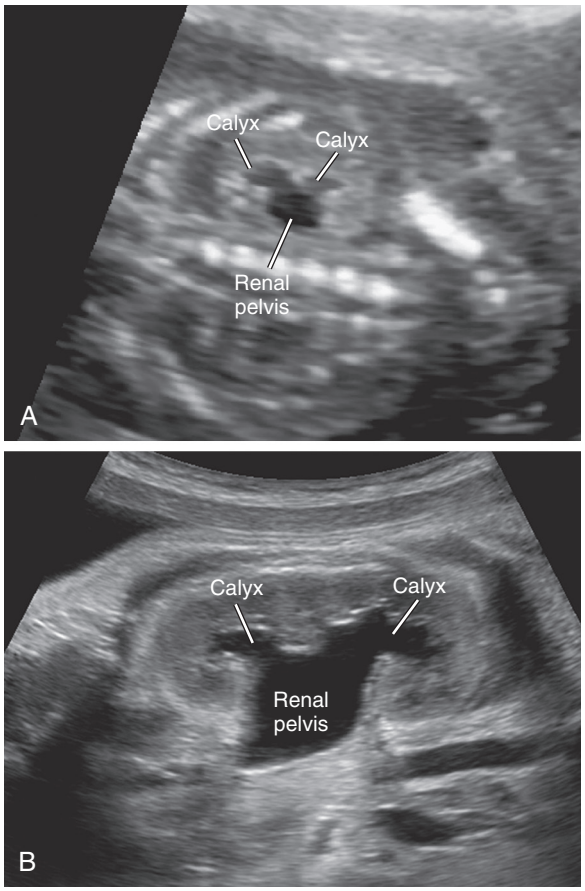

Fig. 12.2 Coronal images of grade II hydronephrosis at 18 weeks' gestation (A) and 34 weeks' gestation (B) in the same patient. The calyces are visible but not significantly dilated.

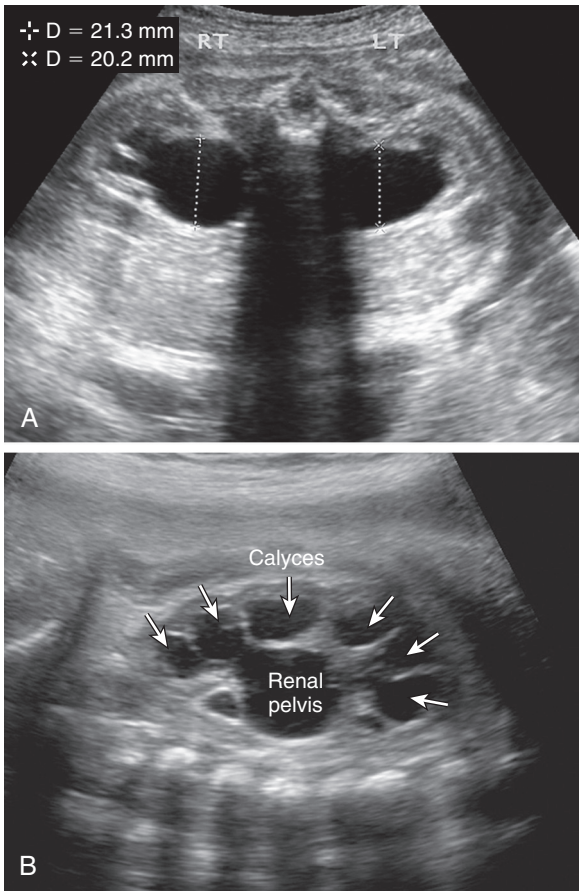

Fig. 12.3 Transverse (A) and sagittal (B) images depicting bilateral grade III hydronephrosis at 35 weeks' gestation. The anterior-posterior diameter of the renal pelves measured approximately 2 cm. Although the calyces *(arrows)* are rounded, cortex is readily visible.

communicate with the renal pelvis, to exclude the diagnosis of multicystic dysplastic kidney and other cystic renal anomalies (see Chapter 15). Grade IV hydronephrosis is diagnosed based on thinning of the renal parenchyma (Figs. 12.4 and 12.5; see also Fig. 8.3). Calyces may or may not be visible once cortical thinning has developed.

CLASSIC SIGNS

Enlargement of the renal pelvis, with or without calyceal dilatation

Differential Diagnosis From Imaging Findings

1. Transient (physiologic) hydronephrosis
2. UPJ obstruction
3. VUR
4. Megaureter
5. Ureterocele or duplicated collecting system
6. Posterior urethral valves (bladder outlet obstruction)
7. Multicystic dysplastic kidney

Synopsis of Treatment Options

POSTNATAL

Neonatal renal US is the initial imaging modality. It is usually performed on or after the second day of life, with the understanding that normal initial neonatal dehydration may mask hydronephrosis.[4] If the US examination is normal, a second US may be recommended at 1 month of age. If the second examination is normal, there is controversy over whether additional follow-up is needed because a small percentage of children (1%–5%) later present with recurrent and typically severe hydronephrosis.[4] There is a lack of agreement as to whether a voiding cystourethrogram is always necessary, and the Society for Fetal Urology has stated that there is no clear evidence to support or avoid postnatal imaging for VUR.[4] Patients at increased risk for urinary tract infection are typically treated with prophylactic antibiotics. Except in the most severe cases, most urologists initially follow the patient with radiologic examinations and consider surgical management

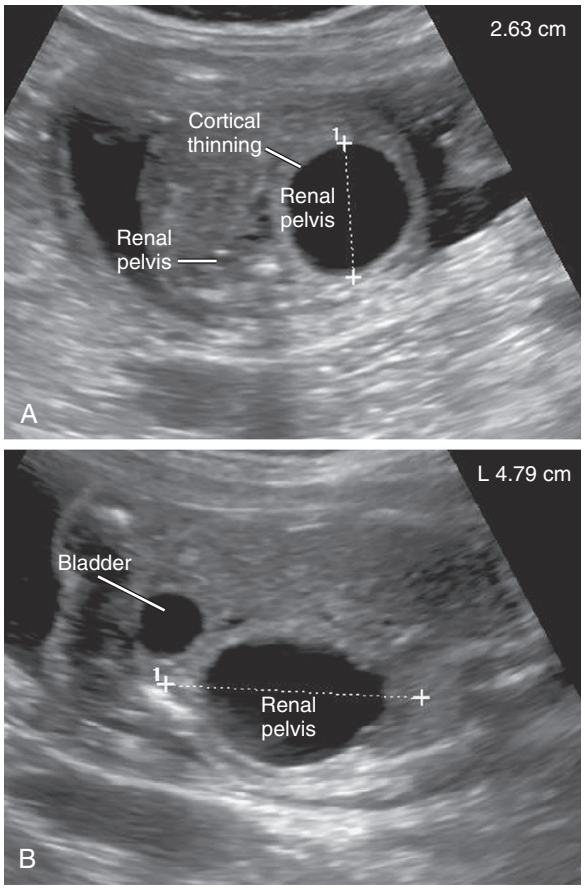

Fig. 12.4 Transverse (A) and coronal (B) images depicting unilateral grade IV hydronephrosis at 18 weeks' gestation. The anterior-posterior diameter of the affected kidney measured approximately 26 mm. Cortical thinning is appreciable, and the kidney is enlarged (length 48 mm). Note the physiologic amount of the fluid in the contralateral kidney.

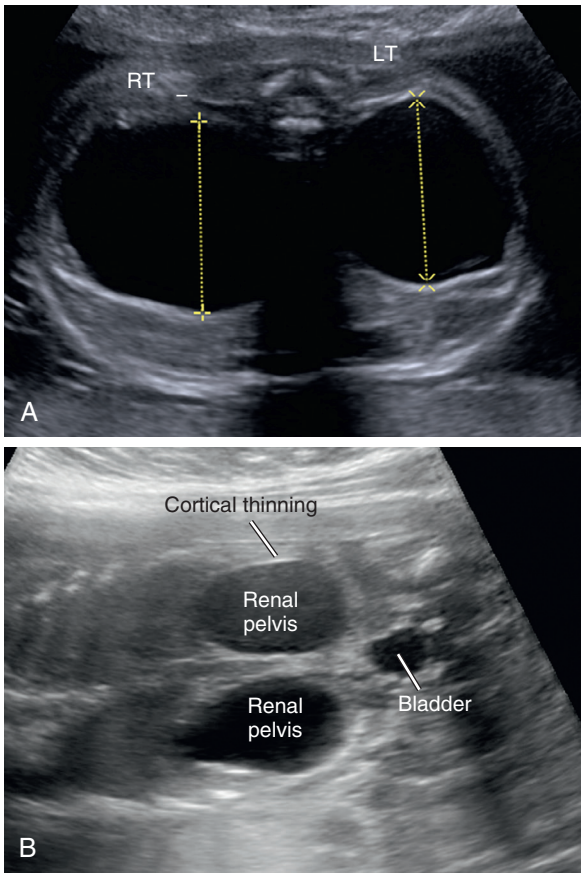

Fig. 12.5 Transverse (A) and coronal (B) images of bilateral grade IV hydronephrosis in the second trimester. Renal pelves measured more than 35 mm in anterior-posterior diameter at 26 weeks' gestation. The infant was confirmed to have UPJ obstruction. *LT,* Left; *RT,* right.

only in the setting of worsening hydronephrosis or decreasing differential renal function.[4,21] Operative repair of UPJ obstruction is eventually required in approximately 25% of cases.[4]

What the Referring Physician Needs to Know

Renal pelvis dilatation is a common finding that is usually transient, but there is a small risk of significant renal pathology, particularly with progressive or severe dilatation, caliectasis, or ureteral dilatation. It is important to reevaluate the pregnancy in the third trimester and to provide neonatal follow-up for patients with persistent hydronephrosis.

KEY POINTS

- Renal pelvis dilatation is identified in 1% to 5% of pregnancies.
- The three most common etiologies are transient (physiologic) hydronephrosis, UPJ obstruction, and VUR.
- If renal pelvis dilatation is diagnosed in the second trimester, follow-up US examination is performed in the third trimester to identify persistent or worsening hydronephrosis. Neonatal evaluation is typically reserved for patients with fetal renal pelvis measurements of at least 7 mm in the third trimester.
- Factors associated with increased likelihood of postnatal pathology include moderate or severe hydronephrosis (third-trimester renal pelvis diameter ≥ 10 mm), calyceal dilatation or cortical thinning, and ureteral dilatation.

SUGGESTED READING

Hothi DK, Wade AS, Gibert R, et al. Mild fetal renal pelvis dilatation—much ado about nothing? *Clin J Am Soc Nephrol.* 2009;4:168-177.

Lee RS, Cendron M, Kinnamon DD, et al. Antenatal hydronephrosis as a predictor of postnatal outcome: a meta-analysis. *Pediatrics.* 2006;118:586-593.

Nguyen HT, Herndon CDA, Cooper C, et al. The Society for Fetal Urology consensus statement on the evaluation and management of antenatal hydronephrosis. *J Pediatr Urol.* 2010;6:212-231.

Pates JA, Dashe JS. Prenatal diagnosis and management of hydronephrosis. *Early Hum Dev.* 2006;82:3-8.

Nguyen HT, Benson CB, Bromley B, et al. Multidisciplinary consensus on the classification of prenatal and postnatal urinary tract dilation (UTD classification system). *J Pediatr Urol.* 2014;10:982-999.



All references are available online at www.expertconsult.com.

REFERENCES

1. Sairam S, Al-Habib A, Sasson S, et al. Natural history of fetal hydronephrosis diagnosed on mid-trimester ultrasound. *Ultrasound Obstet Gynecol*. 2001;17:191-196.
2. Chudleigh T. Mild pyelectasis. *Prenat Diagn*. 2001;21:936-941.
3. Ismaili K, Hall M, Donner C, et al. Results of systematic screening for minor degrees of fetal renal pelvis dilatation in an unselected population. *Am J Obstet Gynecol*. 2003;188:242-246.
4. Nguyen HT, Herndon CDA, Cooper C, et al. The Society for Fetal Urology consensus statement on the evaluation and management of antenatal hydronephrosis. *J Pediatr Urol*. 2010;6:212-231.
5. Lee RS, Cendron M, Kinnamon DD, et al. Antenatal hydronephrosis as a predictor of postnatal outcome: a meta-analysis. *Pediatrics*. 2006;118: 586-593.
6. Hothi DK, Wade AS, Gibert R, et al. Mild fetal renal pelvis dilatation—much ado about nothing? *Clin J Am Soc Nephrol*. 2009;4:168-177.
7. Pates JA, Dashe JS. Prenatal diagnosis and management of hydronephrosis. *Early Hum Dev*. 2006;82:3-8.
8. Reddy UM, Abuhamad AZ, Levine D, et al. Fetal imaging: executive summary of a joint Eunice Kennedy Shriver National Institute of Child Health and Human Development, Society for Maternal-Fetal Medicine, American Institute of Ultrasound in Medicine, American College of Obstetricians and Gynecologists, American College of Radiology, Society for Pediatric Radiology, and Society of Radiologists in Ultrasound Fetal Imaging workshop. *Obstet Gynecol*. 2014;123:1070-1082.
9. Woodward M, Frank D. Postnatal management of antenatal hydronephrosis. *BJU Int*. 2002;89:149-156.
10. Williams B, Tareen B, Resnick M. Pathophysiology and treatment of ureteropelvic junction obstruction. *Curr Urol Rep*. 2007;8:111-117.
11. Mak RH, Kuo H. Primary ureteral reflux: emerging insights from molecular and genetic studies. *Curr Opin Pediatr*. 2003;15:181-185.
12. Mears AL, Raza SA, Sinha AK, et al. Micturating cystourethrograms are not necessary for all cases of antenatally diagnosed hydronephrosis. *J Pediatr Urol*. 2007;3:264-267.
13. Cendron M, D'Alton ME, Crombleholme TM. Prenatal diagnosis and management of the fetus with hydronephrosis. *Semin Perinatol*. 1994;18: 163-181.
14. Mackie GG, Stephens FD. Duplex kidneys: a correlation of renal dysplasia with position of the ureteral orifice. *J Urol*. 1975;61:274-280.
15. Van den Abbelle AD, Treves ST, Lebowitz RL, et al. Vesicoureteric reflux in asymptomatic siblings of patients with known reflux: radionuclide cystography. *Pediatrics*. 1987;79:147-153.
16. Noe NH, Wyatt RJ, Peeden JN Jr, et al. The transmission of vesicoureteric reflux from parent to child. *J Urol*. 1992;148:1869-1871.
17. Kaefer M, Curran M, Treves ST, et al. Sibling vesicoureteral reflux in multiple gestation births. *Pediatrics*. 2000;105:800-804.
18. Nguyen HT, Benson CB, Bromley B, et al. Multidisciplinary consensus on the classification of prenatal and postnatal urinary tract dilation (UTD classification system). *J Pediatr Urol*. 2014;10:982-999.
19. Flake AW, Harrison MR, Sauer L, et al. Ureteropelvic junction obstruction in the fetus. *J Pediatr Surg*. 1986;21:1058-1063.
20. Fernbach SK, Maizels M, Conway JJ. Ultrasound grading of hydronephrosis: introduction to the system used by the Society for Fetal Urology. *Pediatr Radiol*. 1993;23:478-480.
21. Onen A, Jayanthi VR, Koff SA. Long-term follow up of prenatally detected severe bilateral newborn hydronephrosis initially managed nonoperatively. *J Urol*. 2002;168:1118-1120.

13 Duplicated Collecting System

TAMARA T. CHAO | JODI S. DASHE

Introduction

Duplication of the renal collecting system, also termed *duplex kidney,* is one of the few renal anomalies more common in females. Duplex kidneys have an upper pole and a lower pole, called *moieties,* each drained by a ureter. Approximately one-third of the duplex kidney is drained by the upper pole ureter, with two-thirds drained by the lower pole ureter.[1]

Many individuals with duplex kidneys are asymptomatic and have no impairment of renal function. Those who come to attention prenatally or postnatally usually have a complication related to abnormal implantation of one or both ureters. The upper pole ureter may form a ureterocele within the bladder that causes obstruction, resulting in little or no function of the upper pole moiety.[2,3] The lower pole ureter may have a short intravesical segment that results in vesicoureteral reflux (VUR). Duplex systems that have these complications also have ultrasound (US) findings that facilitate their prenatal detection. Clinically significant duplication of the collecting system may manifest prenatally with upper pole hydronephrosis and dilatation of the upper pole ureter, lower pole hydronephrosis, or a ureterocele within the bladder.

Disorder

DEFINITION

Duplication of the renal collecting system is a condition in which a kidney is divided into separate upper and lower pole moieties, each drained by a ureter. If the duplication is complete, the upper and lower pole ureters drain separately. If the duplication is partial, the ureters fuse to form a bifid ureter before emptying into the bladder. Complete duplication is often associated with a ureterocele, which is a cystic dilatation of the distal end of the ureter, usually within the bladder but occasionally at other sites along the genitourinary tract.

PREVALENCE AND EPIDEMIOLOGY

The prevalence of duplicated collecting systems is difficult to estimate accurately because most cases are not identified either prenatally or in childhood. Prenatally detected renal duplication occurs in approximately 1:3000 to 1:5000 births, based on data from the 1990s.[4,5] In autopsy studies, the prevalence of a duplicated system (including partial duplication) is approximately 1:125.[6,7]

Renal duplication is twice as common in females, and 80% of cases complicated by a ureterocele occur in females.[1,8] The duplication is bilateral in 15% to 20%.[1,8] Unilateral cases are more likely to affect the left kidney.[9] Duplication is generally considered to be a sporadic anomaly, although an increased incidence has been described in some families, suggesting autosomal dominant inheritance with incomplete penetrance and variable expressivity.[10,11]

ETIOLOGY, PATHOPHYSIOLOGY, AND EMBRYOLOGY

Complete duplication occurs when an extra ureteric bud arises from the mesonephric (Wolffian) duct and fuses with the metanephric mesenchyme at a separate site from the original bud.[8] The ureteric bud closest to the urogenital sinus gives rise to the lower pole ureter, and the cephalad bud gives rise to the upper pole ureter.[12,13] Partial duplication occurs when a single ureteric bud divides before fusing with the metanephric mesenchyme.[2,8]

The anatomic relationship of the upper and lower pole ureters as they enter the bladder is called the *Weigert-Meyer rule*.[12,13] The upper pole ureter crosses the lower pole ureter and inserts medially and distally (inferiorly) to the lower pole ureter, either ectopically in the bladder or occasionally elsewhere along the genitourinary tract.[8] Sites include the uterus, vagina, urethra, ejaculatory ducts, vas deferens, epididymis, or seminal vesicles. The upper pole ureter often develops a ureterocele, a cystic dilatation of the intravesical portion of the ureter, with narrowing of the ureteral orifice. In the setting of obstruction from a ureterocele in a duplex system, two-thirds of individuals have poor function of the upper pole moiety.[3] The lower pole ureter drains laterally in the bladder trigone. The lower pole ureter has an intravesical portion that is shorter than normal, which may result in VUR and eventual cystic renal dysplasia.

MANIFESTATIONS OF DISEASE

Clinical Presentation

Prenatal diagnosis of a duplicated collecting system is based on US findings, as discussed subsequently. Most cases do not manifest prenatally, and many remain undiagnosed throughout life, with no renal impairment.[1,8] Affected children may present with urinary tract infection secondary to reflux. Less commonly, individuals may be found to have a duplex system during evaluation for hypertension or renal insufficiency. Rarely, symptoms may result from implantation of the upper pole ureter in a location other than the bladder, such as incontinence from ureteral implantation in the vagina.[14]

Imaging Technique and Findings

Ultrasound. The characteristic US finding is dilatation of the upper and lower pole pelves, with an intervening band of renal tissue (Fig. 13.1). The degree of hydronephrosis affecting each moiety can range from simple dilatation of the pelvis to marked calyceal dilatation with thinning of the renal cortex (see Fig. 13.1). Visualization of the intervening band of tissue

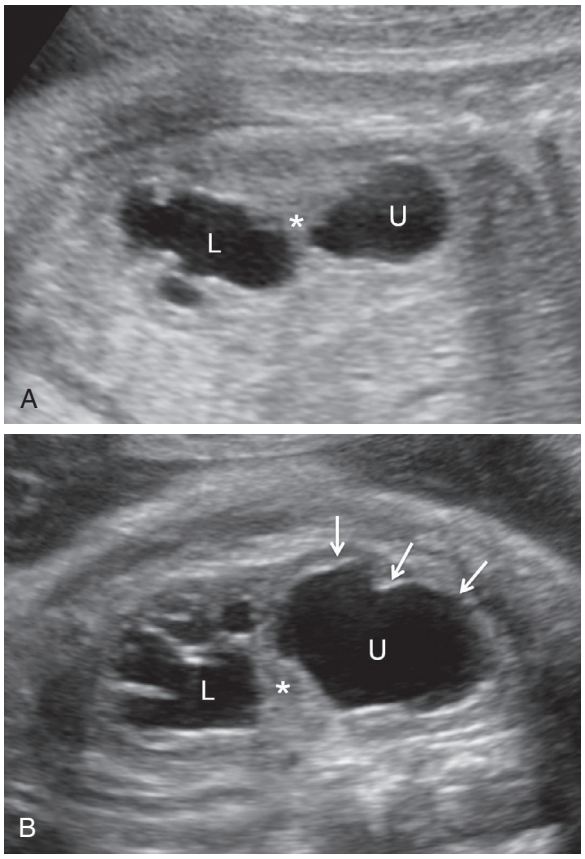

Fig. 13.1 (A, B) Dilatation of the upper *(U)* and lower *(L)* pole renal pelvis in a duplicated renal collecting system. The *asterisk* shows the intervening band of renal tissue. If hydronephrosis is present, the degree can range from simple dilatation of the pelvis to marked calyceal dilatation with thinning of the renal cortex *(arrows)*.

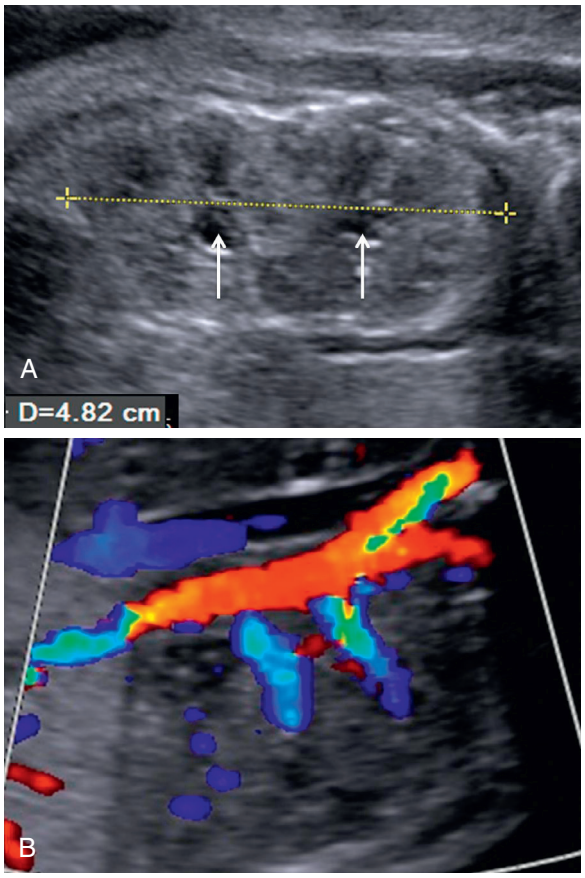

Fig. 13.2 Uncomplicated duplication. Two renal pelvis are visible in this duplex kidney, separated by an intervening band of normal renal tissue. (A) At 32 weeks, the kidney is enlarged, and there is a physiologic amount of fluid in each renal pelvis *(arrows)*. There is normal corticomedullary differentiation. (B) Color Doppler demonstrates two renal arteries perfusing the duplex kidney.

differentiates renal duplication from other causes of renal pelvis dilatation (see Chapter 12). With improvements in ultrasound technology, it may be possible to identify a duplex kidney when neither moiety is dilated – which is termed an *uncomplicated duplication* (Fig. 13.2). Identification of two renal arteries supplying the kidney further supports the diagnosis (see Fig. 13.2). The length of the kidney often exceeds the 95th percentile (see Fig. 13.2 and Table 9.1).[9,15] Whenever renal pelvis dilatation is encountered, it is important to image both kidneys in the sagittal and transverse planes, so that a duplex system is not missed. Eccentric location of a dilated single renal pelvis (high or low in the kidney) warrants a careful evaluation of the renal parenchyma, the ureter exiting the pelvis, and the bladder (Fig. 13.3).

Pelvic dilatation of the upper pole moiety is frequently more severe, with visible dilatation of the upper pole ureter (see Figs. 13.3 and 13.4). This dilatation is usually secondary to a ureterocele within the bladder (Fig. 13.5). Failure to visualize a ureterocele does not exclude the diagnosis. Occasionally, a ureterocele is compressed against the bladder wall or may be difficult to visualize because of its position in the bladder, because the bladder has just emptied, or because it drains into an ectopic location.[5] Rarely, a ureterocele within the bladder may obstruct the urethra and result in bladder outlet obstruction (see Chapter 14).[16,17] Duplication is bilateral in 15% to 20% of cases, and two ureteroceles may be visible in such cases (Fig. 13.6).[1,8]

CLASSIC SIGNS

The kidney contains two distinct renal pelves (upper and lower pole moieties), with an intervening band of renal tissue. There is often dilatation of one or both pelves, as well as ureteral dilatation—particularly dilatation of the upper pole ureter, accompanied by a ureterocele within the bladder.

Differential Diagnosis From Imaging Findings

1. Ureteropelvic junction obstruction
2. VUR
3. Multicystic dysplastic kidney
4. Solitary renal cyst
5. Congenital megaureter
6. Isolated ureterocele (20% of ureteroceles do not occur in conjunction with a duplicated system)

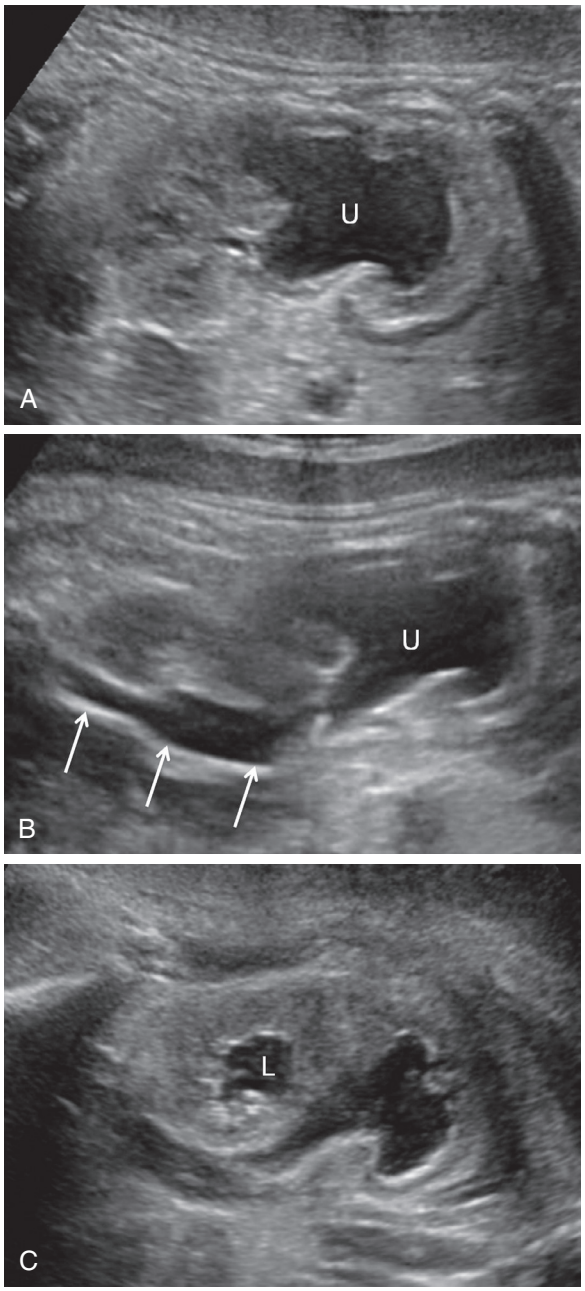

Fig. 13.3 (A) The apparent eccentrically-located dilated renal pelvis represents an obstructed upper pole moiety *(U)* of a duplex kidney. The degree of upper pole hydronephrosis is frequently more severe than that affecting the lower pole, because of obstruction from a ureterocele within the bladder. (B) The upper pole ureter *(arrows)* is dilated throughout its course. (C) Additional imaging demonstrates that the lower pole moiety *(L)* is also dilated.

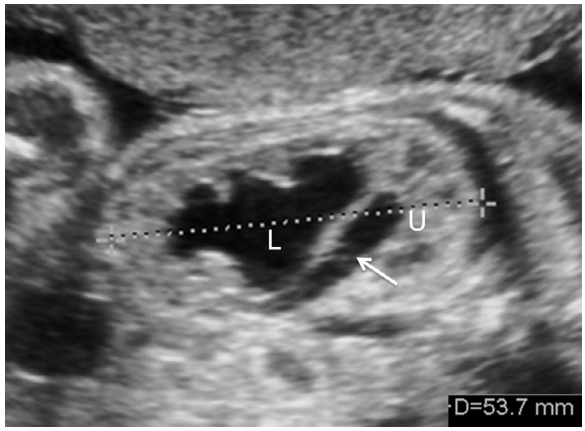

Fig. 13.4 Duplicated renal collecting system. There is dilatation of the upper pole ureter *(U)* and the lower pole renal pelvis *(L)*, with rounding of calyces. The length of the kidney typically exceeds the 95th percentile. This kidney was more than 5 cm long at 27 weeks' gestation.

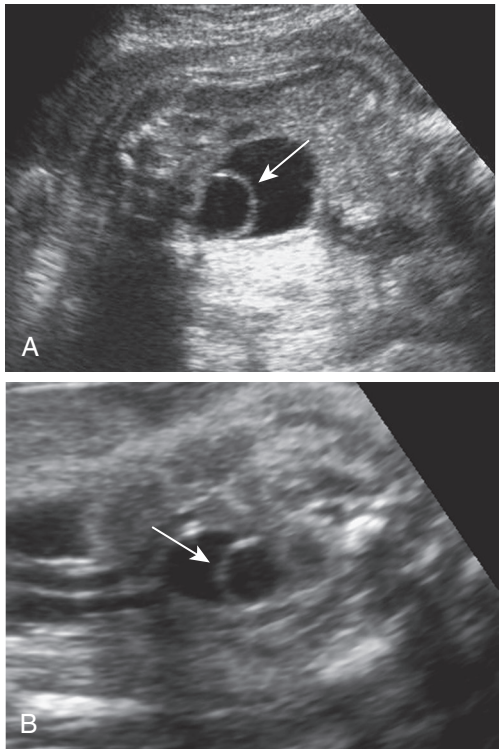

Fig. 13.5 (A, B) Ureterocele (*arrows*) within the bladder.

Synopsis of Treatment Options

POSTNATAL

If the diagnosis of a duplicated collecting system is made prenatally, neonatal evaluation typically includes US and a voiding cystourethrogram. Magnetic resonance urography (MRU) may provide valuable diagnostic information in complex duplications.[18] Approximately 70% of children who present with infection in the setting of a duplex kidney are found to have VUR.[1,3,19] The major benefit of prenatal diagnosis appears to be in the use of prophylactic antibiotics to prevent urinary tract infection, particularly in asymptomatic infants with no evidence of reflux or low-grade reflux.[20]

Upper pole obstruction secondary to a ureterocele results in a high rate of permanent damage to the upper pole moiety, regardless of whether the diagnosis was made prenatally or postnatally.[19] In the case of significant reflux, intravesical ureteroceles are often decompressed endoscopically.[2,3,19] Other treatment strategies include complete reconstruction at the bladder level if the upper tract is functional or heminephrectomy if the upper tract is nonfunctional.[2,3] The nonfunctioning moiety often involutes over time.

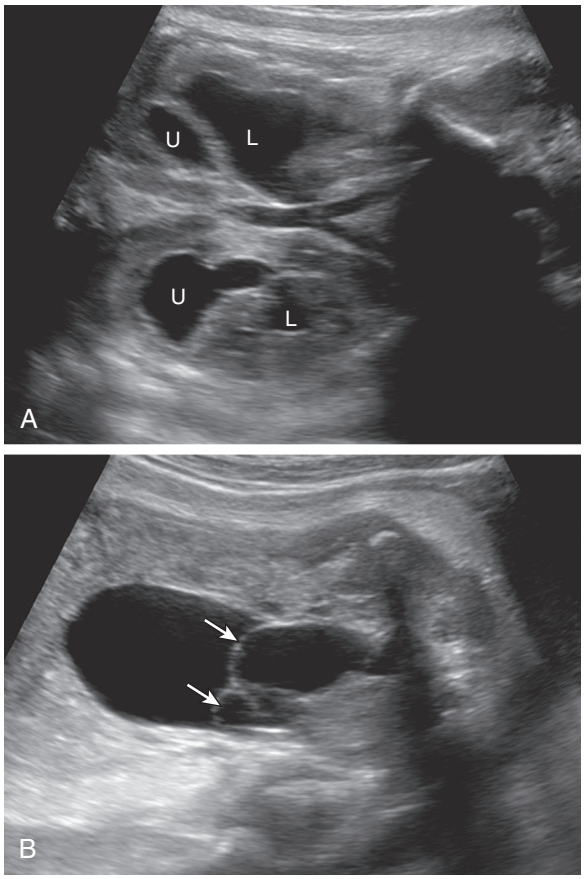

Fig. 13.6 (A) Duplication is bilateral in 15% to 20% of cases. Upper *(U)* and lower *(L)* pole renal pelvis are shown. (B) Bilateral ureteroceles *(arrows)* are visible within the bladder.

WHAT THE REFERRING PHYSICIAN NEEDS TO KNOW

Whenever renal pelvis dilatation is encountered, it is important to image the kidneys in the sagittal plane to exclude a duplicated system. Complications of a duplicated collecting system may include loss of function of the upper pole moiety from an obstructing ureterocele and renal dysplasia of the lower pole moiety from VUR.

KEY POINTS

- Duplication of the renal collecting system is recognized in approximately 1:4000 pregnancies.
- The condition is more frequent in females, disproportionately affects the left kidney, and is bilateral in 15% to 20% of cases.
- US may show dilatation of one or both renal pelves, with an intervening band of renal tissue. Ureteral dilatation may be evident, and there may be a ureterocele in the bladder.
- The Weigert-Meyer rule describes the relationship of the ureters. The upper pole ureter inserts medially and inferiorly to the lower pole ureter, with obstruction of the upper pole moiety secondary to a ureterocele. The lower pole ureter inserts laterally in the bladder trigone and has a shortened intravesical segment that leads to reflux.

SUGGESTED READING

Adiego B, Martinez-Ten P, Perez-Pedregosa J, et al. Antenatally diagnosed renal duplex anomalies: sonographic features and long-term postnatal outcome. *J Ultrasound Med*. 2011;30:809-815.

Castagnetti M, El-Ghoneimi A. Management of duplex system ureteroceles in neonates and infants. *Nat Rev Urol*. 2009;6:307-315.

Merlini E, Lelli Chiesa P. Obstructive ureterocele—an ongoing challenge. *World J Urol*. 2004;22:107-114.

Whitten SM, Wilcox DT. Duplex systems. *Prenat Diagn*. 2001;21:952-957.

All references are available online at www.expertconsult.com.

REFERENCES

1. Privett JT, Jeans WD, Roylance J. The incidence and importance of renal duplication. *Clin Radiol*. 1976;27:521-530.
2. Merlini E, Lelli Chiesa P. Obstructive ureterocele—an ongoing challenge. *World J Urol*. 2004;22:107-114.
3. Castagnetti M, El-Ghoneimi A. Management of duplex system ureteroceles in neonates and infants. *Nat Rev Urol*. 2009;6:307-315.
4. James CA, Watson AR, Twining P, et al. Antenatally detected urinary tract abnormalities: changing incidence and management. *Eur J Pediatr*. 1998;157:508-511.
5. Vergani P, Ceruti P, Locatelli A, et al. Accuracy of prenatal ultrasonographic diagnosis of duplex renal system. *J Ultrasound Med*. 1999;18:463-467.
6. Nation EF. Duplication of the kidney and ureter: a statistical study of 230 new cases. *J Urol*. 1944;51:456.
7. Campbell MF, Harrison JH. Anomalies of the ureter. In: Campbell MF, Harrison JH, eds. *Urology*. 3rd ed. Philadelphia: Saunders; 1970:1488.
8. Whitten SM, Wilcox DT. Duplex systems. *Prenat Diagn*. 2001;21:952-957.
9. Davidovits M, Einstein B, Ziv N, et al. Unilateral duplicated system: comparative length and function of kidneys. *Clin Nucl Med*. 2004;29:99-102.
10. Atwell D, Cook PL, Howell CJ, et al. Familial incidence of bifid and double ureters. *Arch Dis Child*. 1974;49:390-393.
11. Sözübir S, Ewalt D, Strand W, et al. Familial ureteroceles: an evidence for genetic background? *Turk J Pediatr*. 2005;47:255-260.
12. Weigert C. Über einige Bildungsfehler der Ureteren. *Virchows Arch Path Anat Physiol Klin Med*. 1877;70:490-501.
13. Meyer R. Normal and abnormal development of the ureter in the human embryo—a mechanistic consideration. *Anat Rec*. 1946;96:355-370.
14. Ahmed S, Morris LL, Byard RW. Ectopic ureter with complete ureteral duplication in the female child. *J Pediatr Surg*. 1992;27:1455-1460.
15. Abuhamad AZ, Horton CE Jr, Horton SH, et al. Renal duplication anomalies in the fetus: clues for prenatal diagnosis. *Ultrasound Obstet Gynecol*. 1996;7:174-177.
16. Gloor JM, Ogburn P, Matsumoto J. Prenatally diagnosed ureterocele presenting as fetal bladder outlet obstruction. *J Perinatol*. 1996;6:285-287.
17. Austin PF, Cain MP, Casale AJ, et al. Prenatal bladder outlet obstruction secondary to ureterocele. *Urology*. 1998;52:1132-1135.
18. Adeb M, Darge K, Dillman JR, et al. Magnetic resonance urography in evaluation of duplicated renal collecting systems. *Magn Reson Imaging Clin N Am*. 2013;21:717-730.
19. Chertin B, Rabinowitz R, Pollack A, et al. Does prenatal diagnosis influence the morbidity associated with left in situ nonfunctioning or poorly functioning renal moiety after endoscopic puncture of ureterocele? *J Urol*. 2005;173:1349-1352.
20. Upadhay J, Bolduc S, Braga L, et al. Impact of prenatal diagnosis on the morbidity associated with ureterocele management. *J Urol*. 2002;167:2560-2565.

14 Posterior Urethral Valves

TAMARA T. CHAO | JODI S. DASHE

Introduction

Posterior urethral valves (PUV) are the most common cause of fetal lower urinary tract obstruction, also called bladder outlet obstruction. Membranous tissue in the posterior urethra results in varying degrees of obstruction. The condition occurs only in males, although other etiologies of bladder outlet obstruction can affect females and males. There is a wide range of severity prenatally and postnatally. Lack of amniotic fluid during development may result in pulmonary hypoplasia, and many who survive have significant kidney and bladder damage. Severely affected fetuses, including those with oligohydramnios before midgestation, have a grim prognosis in the absence of therapy, with mortality from pulmonary hypoplasia as high as 95%.[1] In selected cases, placement of a fetal vesicoamniotic shunt can restore amniotic fluid volume and avoid lethal pulmonary hypoplasia. However, affected infants still require ablation of the valves, and more than 50% of survivors have renal insufficiency, chronic voiding problems, and other major morbidities.[2] Timely referral is crucial because therapy is not an option if renal function is already severely impaired. PUV have characteristic ultrasound (US) findings that permit prenatal diagnosis, often by the early second trimester and occasionally in the first trimester.

Disorder

DEFINITION

PUV refers to membranous tissue within the male posterior urethra resulting in varying degrees of lower urinary tract obstruction.

PREVALENCE AND EPIDEMIOLOGY

The reported prevalence of PUV is 1:8000 to 1:25,000 boys.[3,4] However, this range likely underestimates the number of affected fetuses. In the era before routine prenatal diagnosis, 45% of neonates with PUV died soon after birth from pulmonary hypoplasia.[5] This has been termed the "hidden mortality" of the condition, because affected infants did not survive to reach treatment centers.[6]

Associated anomalies have been reported in more than 40% of fetuses with PUV, including cardiac malformations, gastrointestinal abnormalities, and other genitourinary anomalies.[7,8] In addition, 5% to 8% of cases of bladder outlet obstruction are associated with aneuploidy.[9,10]

ETIOLOGY AND PATHOPHYSIOLOGY

The etiology of PUV is postulated to be failure of the urogenital membrane to disintegrate completely, leaving membranous tissue within the posterior urethra.[11] Endoscopic evaluation in affected infants demonstrates a simple mucosal membrane, with scant fibrous stroma, and a small eccentric opening.[11,12] The major risk is back-pressure damage, which may result in vesicoureteral reflux, cystic renal dysplasia, altered tubular function, and abnormal bladder function.[11,13]

MANIFESTATIONS OF DISEASE

Clinical Presentation

In the absence of US evaluation, the fundal height may lag behind gestational age owing to decreased amniotic fluid volume. The prenatal diagnosis is based on US findings.

Imaging Technique and Findings

Ultrasound. The initial US finding is typically a dilated, thick-walled bladder, which may be evident in the first trimester or early second trimester (Fig. 14.1). The bladder wall is considered abnormal if it measures more than 2 mm thick. Color Doppler of the umbilical arteries as they encircle the bladder may assist with accurate measurement of bladder wall thickness (Fig. 14.2). A characteristic finding is the "keyhole" sign, which refers to the appearance of the dilated proximal urethra contiguous with the bladder (see Fig. 14.2 and Fig. 14.3).

The amniotic fluid volume is often severely decreased. Fetal urine production is the major source of amniotic fluid after 16 to 18 weeks' gestation. If severity of disease is uncertain—which is common—it may be prudent to follow the pregnancy closely around this gestational age range because the amniotic fluid volume may precipitously decrease. Although fetuses with normal amniotic fluid are not at risk for pulmonary hypoplasia, or for the deformations of the face and extremities that characterize Potter sequence, affected infants remain at risk for renal insufficiency, and voiding difficulties.

PUV is characterized by a spectrum of renal findings that reflect both the severity and the timing of the obstructive process. Early and severe obstruction may result in kidneys that are small and echogenic (Fig. 14.4). Kidneys may also have cortical cysts or appear diffusely cystic secondary to obstructive cystic dysplasia, a function of back-pressure damage from obstruction (Figs. 14.5 and 14.6). Renal echogenicity and cystic dysplasia are almost

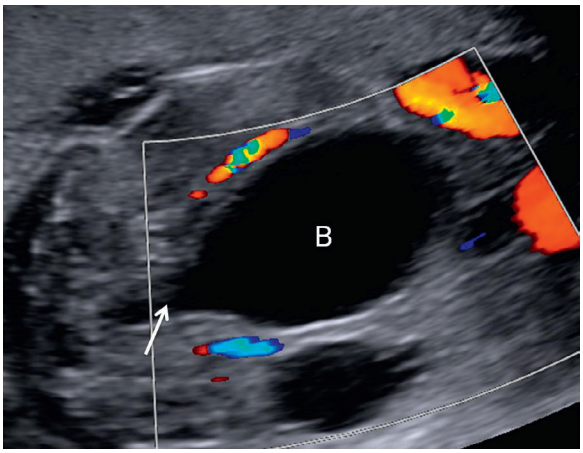

Fig. 14.2 At 20 weeks' gestation, the bladder *(B)* appears dilated and thick-walled. It is outlined by the umbilical (superior vesical) arteries, facilitating measurement of wall thickness, which was 3 mm. Dilatation of the proximal urethra *(arrow)* forms the characteristic "keyhole" sign. No amniotic fluid is visible. The cystic structure inferior to the bladder represents dilated ureter.

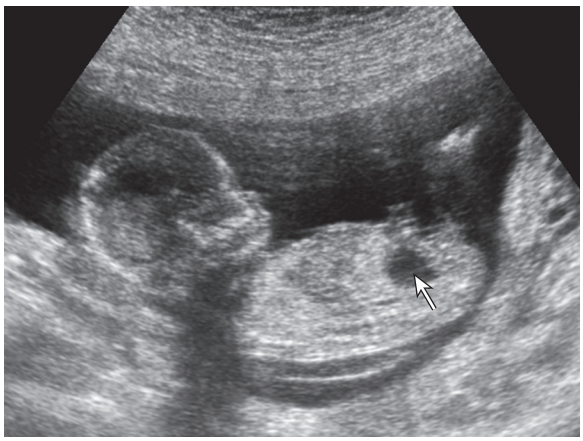

Fig. 14.1 Dilated fetal bladder *(arrow)* at 15 weeks' gestation. The amniotic fluid volume has not yet decreased.

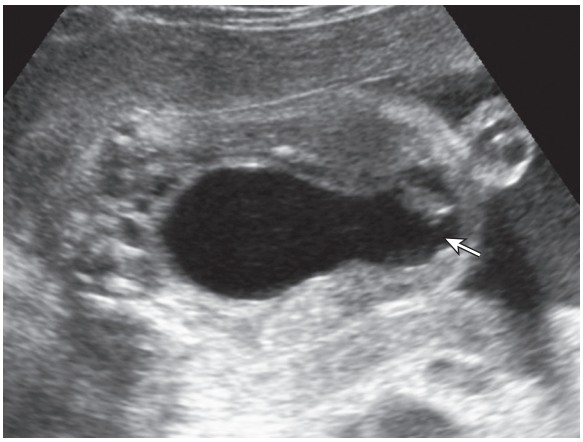

Fig. 14.3 "Keyhole" sign. Dilatation of the proximal urethra *(arrow)* anterior to the dilated bladder creates the appearance of an old-fashioned keyhole.

always found in the setting of severe oligohydramnios. In a metaanalysis of infants with bladder outlet obstruction, renal echogenicity, and cortical cysts were the US parameters most predictive of poor renal function, with a sensitivity of 57% and specificity of 84%.[14] Oligohydramnios was also associated with a poor prognosis.[14] Absence of these findings, however, does not guarantee a normal outcome.

Hydronephrosis is a common finding and is often accompanied by ureteral dilatation (see Fig. 14.6). It has limited accuracy in predicting outcome.[14] The degree of hydronephrosis may be asymmetric—one side may appear significantly more affected than the other (Fig. 14.7). Occasionally, pressure may cause a rupture along the urinary tract, resulting in a perinephric urinoma or, more commonly, urinary ascites (Fig. 14.8).

Magnetic Resonance Imaging. In cases in which visualization on US is severely limited, such as by lack of amniotic fluid or maternal obesity, the diagnosis of complex genitourinary abnormalities may be challenging. Magnetic resonance imaging (MRI) may be a useful adjunct in selected cases.[15] Particularly if the fetal sex cannot be visualized, MRI may be helpful in differentiating PUV from complex genitourinary abnormalities such as hydrometrocolpos or persistent cloaca (Fig. 14.9).

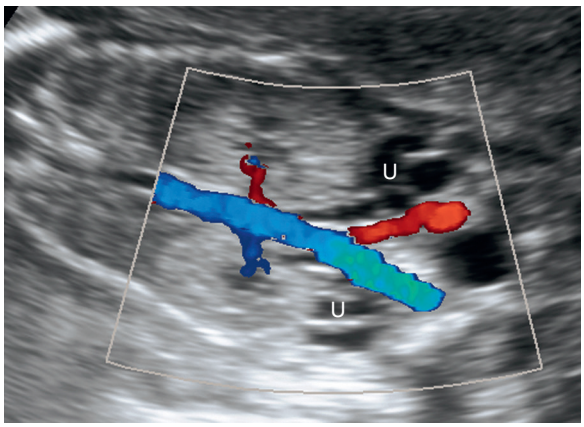

Fig. 14.4 The kidneys are small and echogenic in this fetus with severe posterior urethral valves. The ureters *(U)* are markedly dilated and tortuous.

CLASSIC SIGNS

The classic finding is the "keyhole" sign, which represents the appearance of the enlarged bladder and dilated posterior urethra. However, a keyhole sign is neither sensitive nor specific. In a series of 54 infants with obstructive uropathy, 90% of infants with PUV had a dilated, thick-walled bladder on prenatal US examination, but a keyhole sign had been noted in only 45%.[16] Among infants subsequently found to have other etiologies of bladder outlet obstruction, more than 25% had bladder findings characteristic of PUV.[16]

Differential Diagnosis From Imaging Findings

1. Urethral atresia
2. Meatal stenosis
3. Anterior urethral valves
4. Hypospadias (severe)
5. Megacystis microcolon intestinal hypoperistalsis syndrome (see Chapter 30)
6. Prune-belly syndrome or Eagle-Barrett syndrome (see Chapter 139)
7. Persistent cloaca
8. Hydrometrocolpos with resultant bladder compression
9. Ureterocele (rare, more commonly causes ureteral obstruction; see Chapter 13)

Synopsis of Treatment Options

PRENATAL

Although PUV may be strongly suspected based on US findings, it may be impossible to differentiate PUV from other causes of bladder outlet obstruction prenatally, particularly when visualization is limited.[16] Vesicoamniotic shunt therapy for bladder outlet obstruction is usually considered only if the following five conditions are present:

1. *The amniotic fluid volume is severely decreased, particularly before 24 weeks' gestation.* Although the prognosis of PUV with normal amniotic fluid volume is not always good, these fetuses are not at risk for pulmonary hypoplasia, and are not generally considered candidates for fetal therapy.

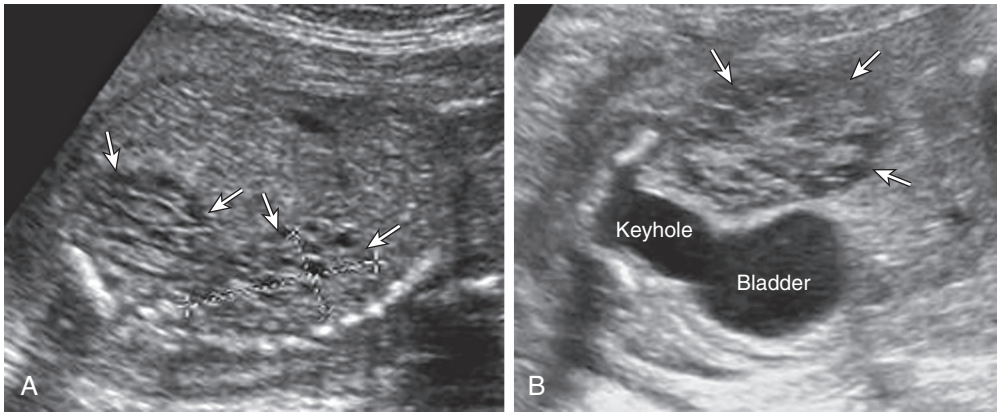

Fig. 14.5 (A,B). Diffuse cystic renal dysplasia secondary to severe posterior urethral valves. An enlarged, thick-walled bladder with a "keyhole" sign adjacent to the cystic kidney *(arrows)* is depicted in B.

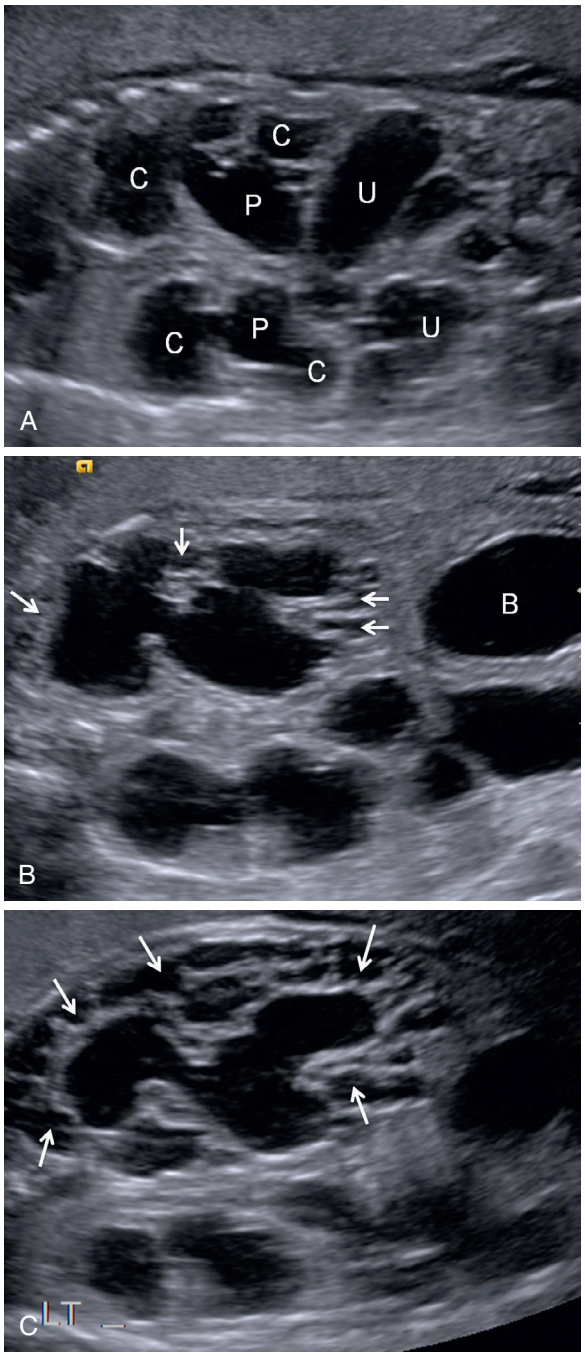

Fig. 14.6 Coronal images demonstrating progression of cystic renal dysplasia with advancing gestation in the setting of posterior urethral valves. (A) At 20 weeks, there is marked dilatation of the renal pelves *(P)* and calyces *(C)*, with prominently dilated loops of ureter *(U)* just inferior to the kidneys. Renal cortex appears normal, however. (B) At 22 weeks, cystic cortical changes are becoming evident *(arrows)*. The thick-walled bladder *(B)* is also shown in this image. (C) By 26 weeks, the renal cortical cysts *(arrows)* have become larger and more diffuse.

2. *The fetus is male.* If visualization of the fetal sex is limited by lack of amniotic fluid, karyotype may be needed (see later). Female fetuses with bladder outlet obstruction tend to have more severe genitourinary abnormalities that preclude therapy.
3. *There is no evidence of associated anomalies.* Approximately 40% of fetuses have other major malformations.[7,8] In such cases, the prognosis is generally so poor that therapy is not offered. Lack of amniotic fluid can hamper visualization considerably, so even if bladder outlet obstruction appears to be isolated, families should be counseled that all abnormalities may not be visible on US. During the procedure in which a vesicoamniotic shunt is placed, amnioinfusion is usually performed first, and this may be a good opportunity to look for anomalies again.
4. *The fetal karyotype and/or chromosomal microarray analysis are normal.* Bladder outlet obstruction is associated with aneuploidy in 5% to 8% of cases.[9,10] Amniocentesis can be performed if feasible, though it may be simpler to assay fetal urine at the initial vesicocentesis (see later). Alternately, chorionic villus sampling or fetal blood sampling can be performed.
5. *Serial fetal vesicocentesis results are consistent with a good prognosis.* Analysis of the fetal urine via US-guided vesicocentesis at 18 to 22 weeks' gestation has prognostic implications for renal function (Table 14.1). Vesicocentesis is usually performed up to three times, at approximately 48-hour intervals, to collect urine that has been produced recently and more accurately reflects renal function.[6] Normally, fetal urine is hypotonic, secondary to tubular reabsorption of sodium and chloride. In the setting of PUV, isotonic urine indicates renal tubular damage.[6] If urinary electrolyte and other analyte values on the last specimen obtained suggest that renal function may be preserved, which is termed "good prognosis," the fetus may be a candidate for therapy. Shunt therapy is not offered if the analytes confer poor prognosis

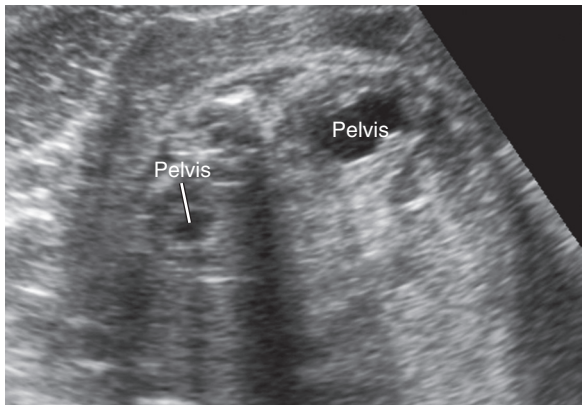

Fig. 14.7 Transverse image of the kidneys in a fetus with posterior urethral valves showing asymmetric renal pelvis dilatation. No amniotic fluid is visible.

TABLE 14.1 PROGNOSTIC URINARY ANALYTE VALUES BASED ON SERIAL VESICOCENTESES AT 18–22 WEEKS

Analyte	Good Prognosis	Poor Prognosis
Sodium (mg/dL)	<90	
Chloride (mg/dL)	<80	>90
Osmolality (mg/dL)	<180	>200
Calcium (mg/dL)	<7	>8
Phosphate (mmol/L)	<2	>2
β_2-Microglobulin (mg/L)	<4.0	>4.0
Total protein (mg/dL)	<20	>40

Data from Mann S, Johnson MP, Wilson RD: Fetal thoracic and bladder shunts, *Semin Fetal Neonatal Med* 15:28–33, 2010.

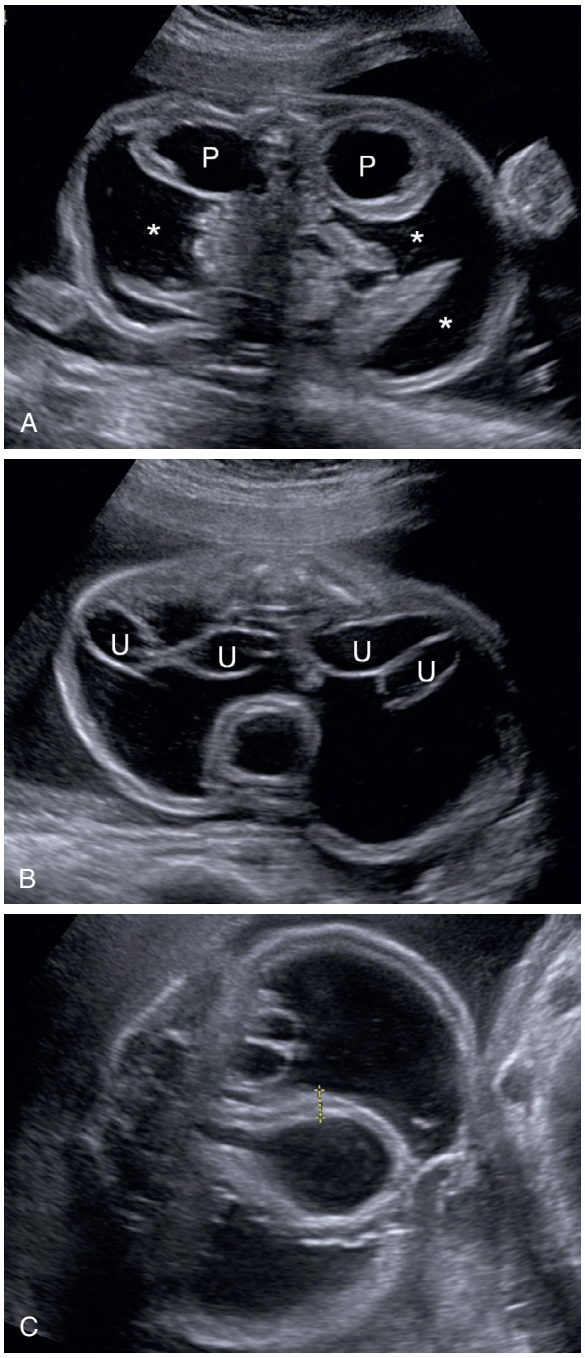

Fig. 14.8 Urinary ascites at 25 weeks. (A) Transverse image at the level of the kidneys, with dilated renal pelves *(P)* and urinary ascites *(asterisks)* outlining the small bowel and liver edge. (B) Transverse image at the level of the pelvis, showing dilated loops of ureter *(U)* and a dilated, thick-walled bladder. (C) The bladder wall thickness measured 6 mm in this image.

because it has not been found to improve outcome in these cases.[10]

Vesicoamniotic Shunt Placement

A vesicoamniotic shunt is placed under US guidance using a double-pigtail catheter inserted through a narrow trocar. Amnioinfusion of warmed lactated Ringer solution is often performed before the procedure to allow placement of the distal end of the catheter within the amniotic cavity. It may be prudent to repeat the anatomic survey after amnioinfusion because lack of fluid can significantly limit visualization of fetal abnormalities. Placement of the catheter is as low as possible in the fetal bladder, to avoid displacement after decompression, and color Doppler may be used to outline the umbilical arteries to avoid vascular trauma during catheter placement.[17]

Complications include displacement of the shunt out of the bladder in about 40% of cases; urinary ascites in 20%; and incidental gastroschisis after shunt displacement, in which bowel herniates through the shunt site, in 10%.[6,10] In addition, 70% of pregnancies have delivered preterm, with preterm rupture of membranes in more than 30%.[6] Long-term complications include end-stage renal disease in approximately one-third, milder renal impairment in another 20%, and respiratory problems in almost half of surviving children.[2]

Recently, investigators in 21 European centers reported results of the PLUTO study,[18] a randomized controlled trial of shunt placement versus conservative management in pregnancies with fetal bladder outlet obstruction in which the clinician was uncertain about optimal management. Although planned enrollment was 150 pregnancies, only 31 were recruited, and of 24 live births, there were 12 early neonatal deaths because of pulmonary hypoplasia (attesting to the severity of the condition).[18] When analyzed according to the treatment received, shunted infants demonstrated improved survival; nonetheless, the long-term outlook was poor; only two children in the study had normal renal function at 2 years of age.[18]

Fetal Cystoscopy

Fetal cystoscopy is an investigational therapy used to ablate PUV prenatally and potentially improve outcomes. In this procedure, a narrow trocar is inserted through the fetal abdominal wall and into the superior aspect of the fetal bladder. Using a fetoscope, the posterior urethra is entered, and attempts are made to relieve the obstruction. Techniques have included hydroablation with warmed normal saline, mechanic disruption with a guide wire, or, most recently, fulguration with a neodymium:yttrium-aluminum-garnet (Nd:YAG) laser.[19,20] Although the Nd:YAG laser approach appears promising,[21] its efficacy has yet to be shown in large series, and it is currently available only at highly specialized centers.

POSTNATAL

After birth, the infant is assessed for pulmonary hypoplasia, and if the infant is stable, US examination is performed to confirm the diagnosis. The bladder is initially drained with a urethral or suprapubic catheter, and a voiding cystourethrogram is performed. Serum creatinine assessed after 48 hours of life reflects renal function in the neonate. Valve ablation is usually performed early in the neonatal period to preserve bladder function.[22] Serum creatinine greater than 1.0 mg/dL and bladder dysfunction are risk factors for progression of renal disease.[23] Children with PUV need close surveillance throughout life to assess the completeness of valve resection, urethral patency, renal function, bladder drainage and function, and urinary tract infections. Overall, the prevalence of renal insufficiency among children with a prenatal diagnosis of PUV ranges from approximately 20% to 60%,[24–26] and the rate of progression to end-stage renal disease—requiring dialysis or transplant—is approximately 15%.[23,27] Because of improvements in nephrology and prenatal care, the life expectancy of children with PUV can extend into adolescence and adult life.[28]

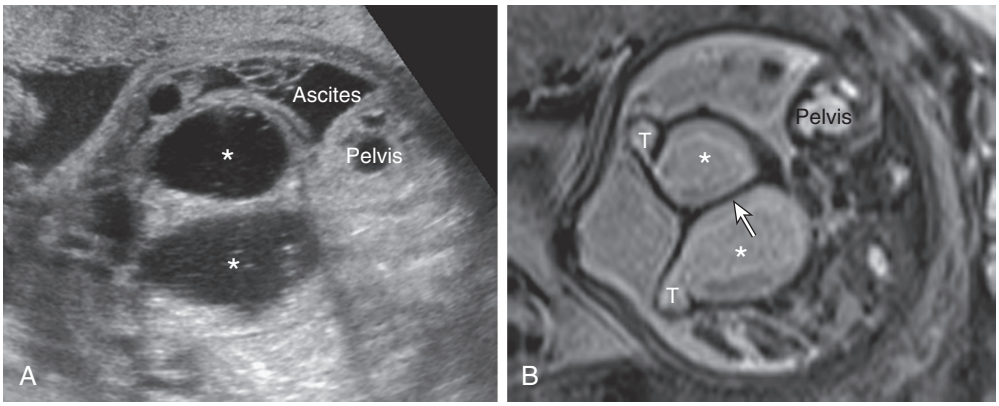

Fig. 14.9 (A) Transverse ultrasound image of a fetus with a complex genitourinary anomaly that resulted in urinary ascites, renal pelvis dilatation, and thick-walled cystic pelvic structures *(asterisks)*. (B) Fetal MRI showed that the cystic pelvic structures *(asterisks)* represented hydrometrocolpos, with dilated fallopian tubes *(T)* and a prominent uterine septum *(arrow)*. The fetus had a persistent cloaca.

WHAT THE REFERRING PHYSICIAN NEEDS TO KNOW

- The diagnosis of PUV should be considered whenever the bladder appears dilated, particularly in the setting of severely decreased amniotic fluid.
- Because findings such as the keyhole sign and bilateral hydronephrosis are not always apparent, a high index of suspicion may be needed to avoid delays in diagnosis.
- Families need to be counseled about the high rates of acute and chronic morbidity associated with this condition.

KEY POINTS

- The most common cause of fetal bladder outlet obstruction is PUV.
- US examination shows a dilated, thick-walled bladder, often with dilatation of the proximal urethra—the "keyhole" sign. Renal findings may include hydronephrosis, cortical cysts, or kidneys that are small and echogenic. Ureteral dilatation is also common.
- Oligohydramnios before midgestation confers an extremely poor prognosis and prompts consideration for fetal vesicoamniotic shunt therapy.
- Important factors before vesicoamniotic shunt placement are that the anomaly appears isolated, genetic studies are normal, and urinary analyte values obtained via serial vesicocentesis suggest relatively preserved renal function

SUGGESTED READING

Bernardes LS, Aksnes G, Saada J, et al. Keyhole sign: how specific is it for the diagnosis of posterior urethral valves? *Ultrasound Obstet Gynecol*. 2009;34:419-423.

Mann S, Johnson MP, Wilson RD. Fetal thoracic and bladder shunts. *Semin Fetal Neonatal Med*. 2010;15:28-33.

Morris RK, Malin GK, Khan KS, et al. Antenatal ultrasound to predict postnatal renal function in congenital lower urinary tract obstruction: systematic review of test accuracy. *Br J Obstet Gynaecol*. 2009;116:1290-1299.

Yohannes P, Hanna M. Current trends in the management of posterior urethral valves in the pediatric population. *Urology*. 2002;60:947-953.

Lopez Pereira P, Martinez Urrutia MJ, Espinosa L, et al. Long-term consequences of posterior urethral valves. *J Ped Urol*. 2013;9:590-596.

All references are available online at www.expertconsult.com.

REFERENCES

1. Mahoney BS, Callen PW, Filly RA. Fetal urethral obstruction: US evaluation. *Radiology*. 1985;157:221-224.
2. Biard J, Johnson MP, Carr MC, et al. Long-term outcomes in children treated by prenatal vesicoamniotic shunting for lower urinary tract obstruction. *Obstet Gynecol*. 2005;106:503-508.
3. Casale AJ. Early ureteral surgery for posterior urethral valves. *Urol Clin North Am*. 1990;17:361-372.
4. Atwell JD. Posterior urethral valves in the British Isles: a multicenter BAPS review. *J Paediatr Surg*. 1983;18:70-74.
5. Nakayama DK, Harrison MR, de Lorimier AA. Prognosis of posterior urethral valves presenting at birth. *J Pediatr Surg*. 1986;21:43-45.
6. Freedman AL, Johnson MP, Gonzalez R. Fetal therapy for obstructive uropathy: past, present... future? *Pediatr Nephrol*. 2000;14:167-176.
7. Hayden SA, Russ PD, Pretorius DH, et al. Posterior urethral obstruction: prenatal sonographic findings and clinical outcome in fourteen cases. *J Ultrasound Med*. 1988;7:371-375.
8. Hobbins JC, Robero R, Grannum P, et al. Antenatal diagnosis of renal anomalies with ultrasound. I. Obstructive uropathy. *Am J Obstet Gynecol*. 1984;148:868-877.
9. Manning FA, Harrison MR, Rodeck C. Catheter shunts for fetal hydronephrosis and hydrocephalus: report of the International Fetal Surgery Registry. *N Engl J Med*. 1986;315:336-340.
10. Mann S, Johnson MP, Wilson RD. Fetal thoracic and bladder shunts. *Semin Fetal Neonatal Med*. 2010;15:28-33.
11. Dinneen MD, Duffy PG. Posterior urethral valves. *Br J Urol*. 1996;78:275-281.
12. Dewan PA, Zappala SM, Ransley PG, et al. Endoscopic reappraisal of the morphology of congenital obstruction of the posterior urethra. *Br J Urol*. 1992;70:439-444.
13. Holmes N, Harrison MR, Baskin LS. Fetal surgery for posterior urethral valves: long-term postnatal outcomes. *Pediatrics*. 2001;108:E7.
14. Morris RK, Malin GK, Khan KS, et al. Antenatal ultrasound to predict postnatal renal function in congenital lower urinary tract obstruction: systematic review of test accuracy. *Br J Obstet Gynaecol*. 2009;116:1290-1299.
15. Hawkins JS, Dashe JS, Twickler DM. MRI diagnosis of severe fetal renal anomalies. *Am J Obstet Gynecol*. 2008;198:328.e1-328.e5.
16. Bernardes LS, Aksnes G, Saada J, et al. Keyhole sign: how specific is it for the diagnosis of posterior urethral valves? *Ultrasound Obstet Gynecol*. 2009;34:419-423.
17. Agarwal SK, Fisk NM. In utero therapy for lower urinary tract obstruction. *Prenat Diagn*. 2001;21:970-976.
18. Morris RK, Malin GL, Quinlan-Jones E, et al. Percutaneous vesicoamniotic shunting versus conservative management for fetal lower urinary tract obstruction (PLUTO): a randomized trial. *Lancet*. 2013;382:1496-1506.
19. Welsh A, Agarwal S, Kumar S, et al. Fetal cystoscopy in the management of fetal obstructive uropathy: experience in a single European centre. *Prenat Diagn*. 2003;23:1033-1041.
20. Ruano R, Duarte S, Bunduki V, et al. Fetal cystoscopy for severe lower urinary tract obstruction—initial experience of a single center. *Prenat Diagn*. 2010;30:30-39.
21. Ruano R, Sanagess N, Sangi-Haghpeykar H, et al. Fetal intervention for severe lower urinary tract obstruction: a multicenter case-control study comparing fetal cystoscopy with vesicoamniotic shunting. *Ultrasound Obstet Gynecol*. 2015;45:452-458.
22. Youssif M, Dawood W, Shabaan S, et al. Early valve ablation can decrease the incidence of bladder dysfunction in boys with posterior urethral valves. *J Urol*. 2009;182:1765-1768.
23. DeFoor W, Clark C, Jackson E, et al. Risk factors for end stage renal disease in children with posterior urethral valves. *J Urol*. 2008;180:1705-1708.
24. Reinberg Y, de Castano I, Gonzalez R. Prognosis for patients with prenatally diagnosed posterior urethral valves. *J Urol*. 1992;148:125-126.
25. El-Ghoneimi A, Desgrippes A, Luton D, et al. Outcome of posterior urethral valves: to what extent is it improved by prenatal diagnosis? *J Urol*. 1999;162:849-853.
26. Oliveira EA, Rabelo EAS, Pereira AK, et al. Prognostic factors in prenatally-detected posterior urethral valves: a multivariate analysis. *Pediatr Surg Int*. 2002;18:662-667.
27. Ylinen E, Ala-Houhala M, Wikström S. Prognostic factors of posterior urethral valves and the role of antenatal detection. *Pediatr Nephrol*. 2004;19:875-879.
28. Lopez Pereira P, Martinez Urrutia MJ, Espinosa L, et al. Long-term consequences of posterior urethral valves. *J Ped Urol*. 2013;9:590-596.

15 Multicystic Dysplastic Kidney

APRIL T. BLEICH | JODI S. DASHE

Introduction

Multicystic dysplastic kidney (MCDK) is a form of severe renal dysplasia that typically results in a nonfunctioning kidney. The parenchyma is replaced by numerous cysts of varying size, with echogenic intervening tissue and an atretic ureter. Microscopically, undifferentiated epithelium and primitive ducts are surrounded by fibromuscular connective tissue.[1] Bilateral MCDK usually results in Potter sequence (see Chapter 10), with early and severe oligohydramnios conferring an extremely poor prognosis secondary to pulmonary hypoplasia along with renal failure. When MCDK is unilateral, contralateral renal anomalies, in particular vesicoureteral reflux (VUR), may complicate the prognosis. The phenotypic presentation is variable, with some kidneys massively enlarged and others hypoplastic; over the course of gestation, the dysplastic kidney may enlarge, become smaller, or regress completely. Prenatal ultrasound (US) is useful for identification of this renal anomaly and, if unilateral, for

surveillance of kidney size and detection of any associated abnormalities.

Disorder

DEFINITION

MCDK is a form of severe renal dysplasia in which the kidney contains numerous smooth-walled cysts of varying size that do not communicate with a renal pelvis, surrounded by an echogenic cortex. The ureter is atretic, and the kidney is generally nonfunctioning.

PREVALENCE AND EPIDEMIOLOGY

In prenatal series, the prevalence of unilateral MCDK is about 1:4000 births, with a reported range of 1:2000 to 1:7000.[2–4] The variation likely reflects the difficulty identifying dysplastic kidneys that are small or contain few cysts. Bilateral MCDK accounts for 25% of cases, a prevalence of about 1:12,000 births.[5] There is a slight male predominance for unilateral MCDK—60% of cases occur in males.[4] When the disease is unilateral, the left kidney is more commonly affected.[4,6] Bilateral MCDK is more common in females.[5]

Unilateral MCDK is associated with contralateral renal anomalies in 30% to 40% of cases, which may have important prognostic implications because the contralateral kidney is often the only functioning kidney.[4] The most common contralateral renal abnormality is VUR in 20% of cases, followed by ureteropelvic junction (UPJ) obstruction in 12% of cases (see Chapter 12).[1,4,7] Nonrenal anomalies have also been reported in 25% of cases, including cardiac anomalies (particularly ventricular septal defects), central nervous system anomalies, spinal malformations, and gastrointestinal obstructions.[4,5] Cystic dysplasia may also occur as a component of numerous syndromes, including Meckel-Gruber syndrome and Kallmann syndrome.[8,9] When MCDK is found in the setting of other abnormalities, the aneuploidy risk is as high as 25%.[5] As an isolated anomaly, unilateral MCDK is not strongly associated with aneuploidy;[5] however, recent series have described an increased risk for pathogenic copy number variants using chromosomal microarray analysis.[10,11]

ETIOLOGY AND PATHOPHYSIOLOGY

MCDK is a severe form of renal dysplasia, which comprises of a group of disorders in which nephrons and collecting ducts do not form properly, with undifferentiated epithelium, and primitive ducts surrounded by fibromuscular connective tissue.[1,9] Potter[12] proposed that MCDK was the result of a primary defect in the ureteric bud and that failure of coordination between the ureteric bud and metanephric mesenchyme resulted in abnormal development of collecting duct, loss of functional nephrons, and cyst formation.[13,14] However, pathologic evaluation has shown that some fetal kidneys contain normal-appearing nephrons along with cystic dysplastic tissue, and it has been proposed that MCDK may result from impairment of urine flow early in development.[12,15] This impairment may account for the association between dysplasia and contralateral renal anomalies, such as VUR.

Most cases of MCDK are sporadic, but a familial link has been reported. Ten percent of affected individuals have a first-degree relative with a renal or urinary tract malformation, or both, similar to the association found in renal agenesis.[14,16,17] Several genes have been identified that may have important roles in the development of MCDK, including *PAX2, TCF2,* and uroplakins.[14]

MANIFESTATIONS OF DISEASE

Clinical Presentation

Prenatal diagnosis is based on US findings, as discussed subsequently. In the absence of US evaluation, bilateral MCDK may manifest with lagging fundal height secondary to oligohydramnios. Historically, unilateral MCDK was a common cause of a flank mass in an infant, and diagnosis was not made in some cases until adulthood.[1]

Imaging Technique and Findings

Ultrasound. The characteristic US appearance is an enlarged kidney (or kidneys) filled with smooth-walled cysts of varying size. The cysts do not communicate, there is no normal renal pelvis, and the stroma is abnormally echogenic. In some cases, large cysts fill the cortex, and the kidney may be markedly enlarged (Fig. 15.1). In others, small and medium-sized cysts are interspersed throughout the echogenic cortex (Figs. 15.2 and 15.3). Rarely, MCDK may present as a single large cyst.[18] Although the kidney may be markedly enlarged, it may also be hypoplastic and difficult to visualize, and its size may increase or decrease over time. In prenatal series of unilateral MCDK, approximately 5% of cases had completely involuted by the time of postnatal US examination.[4] Postnatally, more than half will demonstrate partial or complete regression over time.[19,20]

When MCDK is bilateral, the amniotic fluid volume is usually severely decreased from early in gestation (see Figs. 15.1–15.3), resulting in Potter sequence—similar to bilateral renal agenesis (see Chapter 10). In such cases the resultant pulmonary hypoplasia confers a lethal prognosis. In rare cases of bilateral MCDK, both kidneys are not completely involved, the amniotic fluid volume is relatively preserved until the third trimester, and children may survive to receive postnatal renal transplant.[21]

Unilateral MCDK is associated with a high incidence of contralateral renal anomalies, and renal pelvis dilation may indicate either VUR or UPJ obstruction. Mild renal pelvis dilation in the contralateral kidney should be followed for progression during the course of gestation (Fig. 15.4). Compensatory hypertrophy of the contralateral kidney is common (see Fig. 15.3), as it is with unilateral renal agenesis (see Chapter 11 and Fig. 11.4). In prenatal series of unilateral MCDK, approximately 33% have contralateral compensatory hypertrophy, and this increases to 77% by 10 years of age.[4] The amniotic fluid volume is typically normal. Targeted imaging for associated anomalies is warranted, and amniocentesis should be offered.

CLASSIC SIGNS

Kidney containing smooth-walled cysts of varying size that do not communicate with a renal pelvis, with abnormally echogenic intervening stroma.

Differential Diagnosis From Imaging Findings

1. Severe hydronephrosis in the setting of obstruction
2. Autosomal recessive polycystic kidney disease

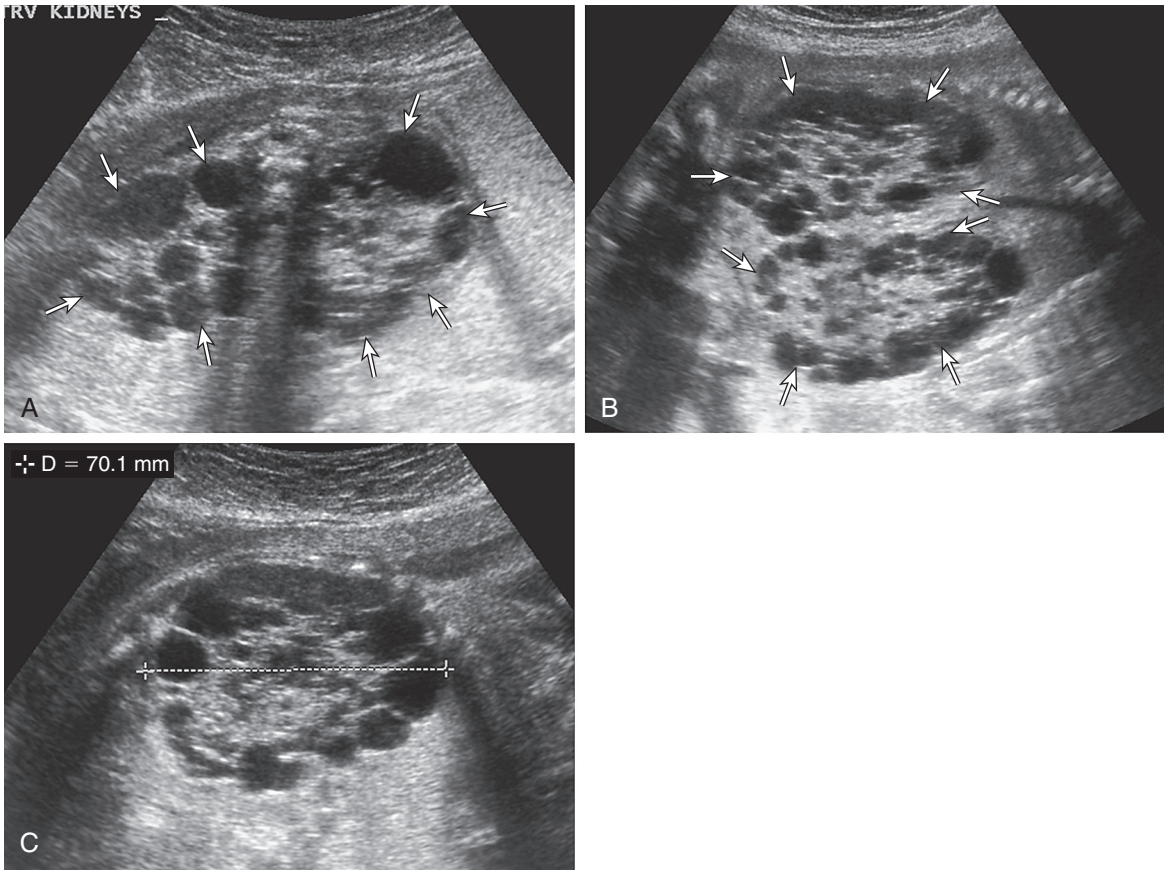

Fig. 15.1 Transverse (A), coronal (B), and sagittal (C) images of a fetus with bilateral multicystic dysplastic kidney. The kidneys are markedly enlarged, filling the pelvis and abdomen. Large, smooth-walled cysts *(arrows)* fill the kidneys and are particularly prominent in the periphery. There is no normal renal pelvis, and the visible stroma is echogenic and interspersed with smaller cysts. No amniotic fluid is visible. The kidney length is 7 cm at 26 weeks' gestation (C). *(B, From Fetal imaging. In Cunningham FG, Leveno KJ, Bloom SL, et al., editors:* Williams obstetrics, *ed 23, New York, 2010, McGraw Hill, p 360.)*

3. Mesoblastic nephroma with cystic degeneration
4. Cystic dysplasia may occur as a component of other syndromes
   - Bardet-Biedl syndrome (autosomal recessive)
   - Beckwith-Wiedemann syndrome (sporadic and autosomal dominant) (see Chapter 109)
   - Branchiootorenal syndrome (autosomal dominant)
   - Meckel-Gruber syndrome (autosomal recessive) (see Chapter 133)
   - Oral-facial-digital syndrome, type I (X-linked dominant)
   - Skeletal dysplasias: asphyxiating thoracic dysplasia or Jeune syndrome (autosomal recessive), and short-rib polydactyly (autosomal recessive) (see Chapter 55)
   - Smith-Lemli-Opitz syndrome (autosomal recessive) (see Chapter 145)
   - Zellweger syndrome (autosomal recessive)

SYNOPSIS OF TREATMENT OPTIONS

Postnatal

After birth, postnatal US is typically performed to confirm the diagnosis and evaluate the contralateral kidney for evidence of VUR or UPJ obstruction. A radionucleotide scan may be performed to assess renal function. In the past, nephrectomy was often performed for MCDK because of concern for early-onset hypertension and malignant transformation to Wilms tumor. However, it is now believed that the risk of hypertension is no greater than in the general population and that the risk of malignant transformation to Wilms tumor is minimal.[19,22,23] For this reason, most cases are managed nonsurgically.[19] In most cases, MCDK regresses over time, and the contralateral kidney shows compensatory hypertrophy.[4,19,20] In the absence of VUR or other abnormality of the contralateral kidney, surveillance may include serial abdominal examination, assessment of blood pressure, urinalysis, serum creatinine concentration, and renal US evaluation.[1]

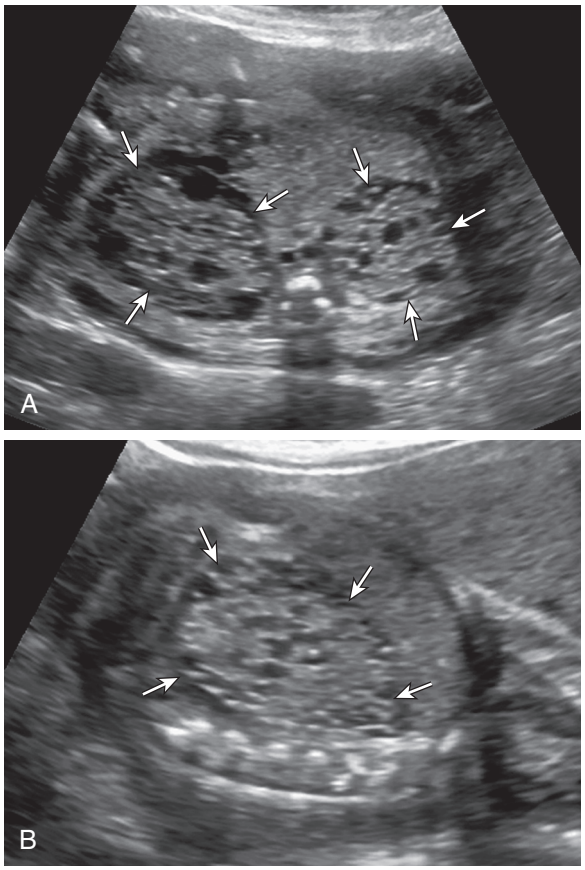

Fig. 15.2 Transverse (A) and sagittal (B) images of a fetus with bilateral multicystic dysplastic kidney at 28 weeks' gestation. Compared with the fetus shown in Fig. 15.1, the cysts (*arrows*) are smaller, and more abnormally echogenic renal parenchyma is visible. The kidneys are enlarged but do not fill the abdomen. There is no normal renal pelvis or corticomedullary differentiation, and amniotic fluid is absent.

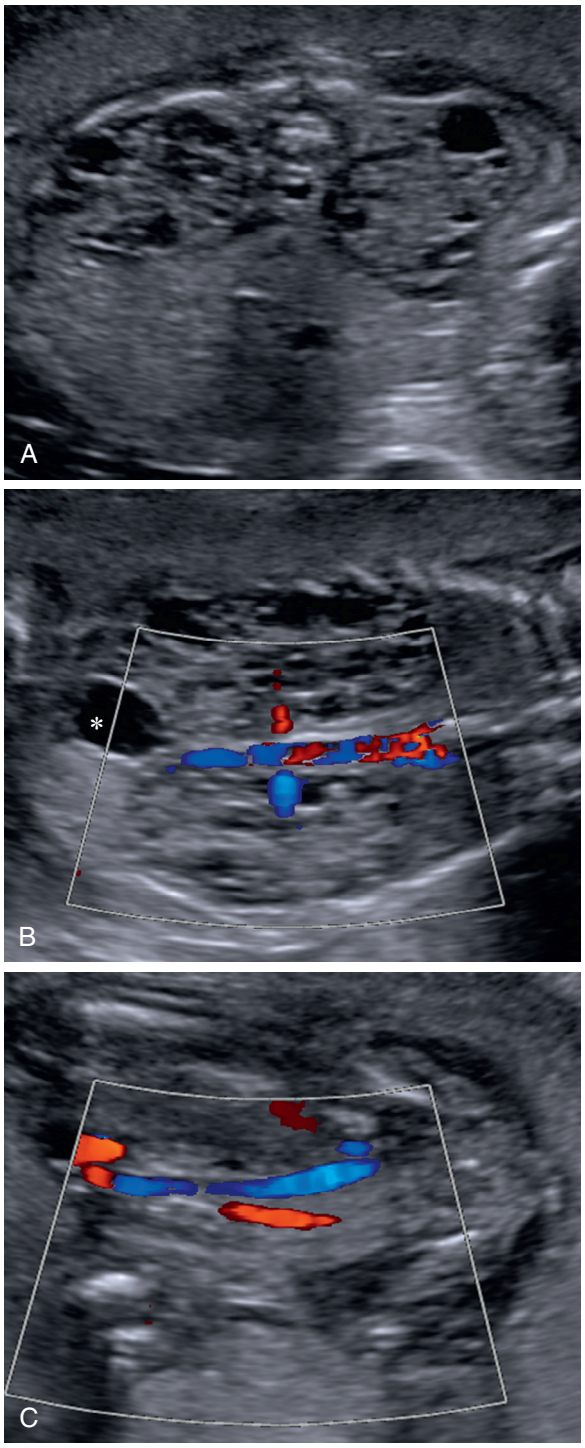

Fig. 15.3 Transverse (A) and coronal (B) images of a fetus with bilateral multicystic dysplastic kidney at 21 weeks' gestation. Small and medium-sized cysts are dispersed throughout the echogenic renal cortex, with no visible renal pelvis or corticomedullary differentiation. The *asterisk* indicates a single prominent inferior pole cyst and (C) depicts the empty fetal bladder, outlined by the umbilical arteries.

WHAT THE REFERRING PHYSICIAN NEEDS TO KNOW

When bilateral MCDK is encountered or suspected, a careful search for associated anomalies is important. Although MCDK is usually a sporadic anomaly, many syndromes may include renal cystic dysplasia, and they often have mendelian inheritance.[11] Bilateral MCDK usually manifests with severe oligohydramnios by 16 to 18 weeks' gestation, similar to other etiologies of Potter sequence (see Chapter 10). If the amniotic fluid volume is preserved, this suggests either another etiology or, rarely, that the kidneys contain some normal tissue. In such cases, renal function is likely to be poor but cannot be accurately predicted, and pulmonary hypoplasia would be less likely.

When unilateral MCDK is encountered or suspected, an evaluation for associated anomalies and aneuploidy is also important, and attention should focus on the size, appearance, and any degree of hydronephrosis of the contralateral kidney. The prognosis for unilateral MCDK is generally good, but contralateral VUR is common and can be a major source of morbidity.

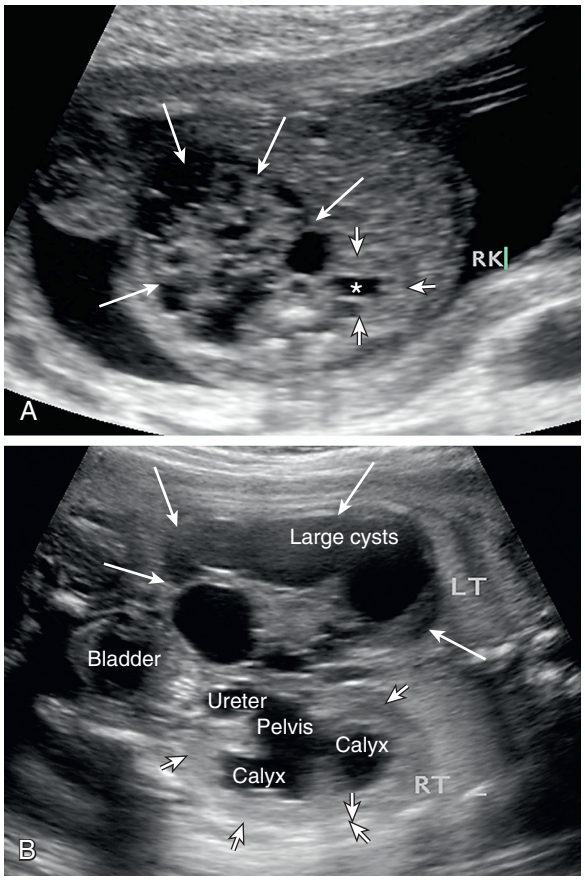

Fig. 15.4 Transverse image of a unilateral, left-sided multicystic dysplastic kidney at 20 weeks' gestation. The kidney is markedly enlarged, reaching the anterior abdominal wall and crossing the midline *(long arrows)*. The contralateral kidney is not enlarged *(short arrows)*, but mild renal pelvis dilatation may be appreciated (4 mm *[asterisk]*). The amniotic fluid volume is normal. (B) By 28 weeks' gestation, the cysts in the left kidney have increased in size. Even more impressive is that the right (normal) kidney is now almost as large as the left multicystic kidney (compensatory hypertrophy) and has developed grade III hydronephrosis, with prominent rounding of calyces. Findings are concerning for vesicoureteral reflux (VUR). *RK*, Right kidney.

KEY POINTS

- Unilateral MCDK complicates 1:4000 births, is slightly more common in males, and is associated with a contralateral renal anomaly in 30% to 40% of cases, in particular, VUR or UPJ obstruction.
- Bilateral MCDK complicates approximately 1:12,000 births and confers an extremely poor prognosis.
- Approximately 25% of cases of MCDK are associated with nonrenal anomalies. Numerous syndromes are characterized by cystic renal dysplasia, and associated anomalies may provide clues to their diagnosis.
- There is an increased risk for chromosomal abnormalities, particularly in the setting of associated anomalies, and prenatal diagnosis with chromosomal microarray analysis should be considered.
- The phenotypic presentation of MCDK varies over time. Some kidneys are markedly enlarged, whereas others are hypoplastic. Most tend to regress and even involute after birth.
- In the past, a unilateral MCDK was often surgically removed, owing to concerns about early-onset hypertension and malignant potential. However, these complications have not been shown to be significantly increased, and most children are now followed expectantly.

SUGGESTED READING

Hains DS, Bates CM, Ingraham S, et al. Management and etiology of the unilateral multicystic dysplastic kidney: a review. *Pediatr Nephrol*. 2009;24:233-241.

Schreuder MF, Westland R, van Wijk JA. Unilateral multicystic dysplastic kidney: a meta-analysis of observational studies on the incidence, associated urinary tract malformations and the contralateral kidney. *Nephrol Dial Transplant*. 2009;24:1810-1818.

Winyard P, Chitty LS. Dysplastic kidneys. *Semin Fetal Neonatal Med*. 2008;13:142-151.

All references are available online at www.expertconsult.com.

REFERENCES

1. Hains DS, Bates CM, Ingraham S, et al. Management and etiology of the unilateral multicystic dysplastic kidney: a review. *Pediatr Nephrol*. 2009;24:233-241.
2. Wiesel A, Queisser-Luft A, Clementi M, et al. Prenatal detection of congenital renal malformations by fetal ultrasonographic examination: analysis of 709,030 births in 12 European countries. *Eur J Med Genet*. 2005;48:131-144.
3. Mallik M, Watson AR. Antenatally detected urinary tract abnormalities: more detection but less action. *Pediatr Nephrol*. 2008;23:897-904.
4. Schreuder MF, Westland R, van Wijk JA. Unilateral multicystic dysplastic kidney: a meta-analysis of observational studies on the incidence, associated urinary tract malformations and the contralateral kidney. *Nephrol Dial Transplant*. 2009;24:1810-1818.
5. Lazebnik N, Bellinger MF, Ferguson JE, et al. Insights into the pathogenesis and natural history of fetuses with multicystic dysplastic kidney disease. *Prenat Diagn*. 1999;19:418-423.
6. Weinstein A, Goodman TR, Iragorri S. Simple multicystic dysplastic kidney disease: end points for subspecialty follow up. *Pediatr Nephrol*. 2008;23:111-116.
7. Atiyeh B, Husmann D, Baum M. Contralateral renal abnormalities in multicystic-dysplastic kidney disease. *J Pediatr*. 1992;121:65-67.
8. Deeb A, Robertson A, MacColl G, et al. Multicystic dysplastic kidney and Kallmann's syndrome: a new association. *Nephrol Dial Transplant*. 2001;16:1170-1175.
9. Bisceglia M, Galliani CA, Senger C, et al. Renal cystic diseases: a review. *Adv Anat Pathol*. 2006;13:26-56.
10. Fu F, Chen F, Li R, et al. Prenatal diagnosis of fetal multicystic dysplastic kidney via high-resolution whole-genome array. *Nephrol Dial Transplant*. 2016;0:1-6. doi:10.1093/ndt/gfv465.
11. Xi Q, Zhu X, Wang Y, et al. Copy number variations in multicystic dysplastic kidney: an update for prenatal diagnosis and genetic counseling. *Prenat Diagn*. 2016;36:1-6.
12. Woolf AS, Price KL, Scambler PJ, et al. Evolving concepts in human renal dysplasia. *J Am Soc Nephrol*. 2004;15:998-1007.
13. Potter EL. *Normal and Abnormal Development of the Kidney*. Chicago: Year Book Medical Publishers; 1972.
14. Winyard P, Chitty LS. Dysplastic kidneys. *Semin Fetal Neonatal Med*. 2008;13:142-151.
15. Matsell DG, Bennett T, Goodyer P, et al. The pathogenesis of multicystic dysplastic kidney disease: insights from the study of fetal kidneys. *Lab Invest*. 1996;74:883-893.
16. Sekine T, Namai Y, Yanagisawa A, et al. A familial case of multicystic dysplastic kidney. *Pediatr Nephrol*. 2005;20:1245-1248.
17. McPherson E. Renal anomalies in families of individuals with congenital solitary kidney. *Genet Med*. 2007;9:298-302.
18. Lim F, Tsao T, Chang H, et al. Multicystic dysplastic kidney disease presenting with a single large cyst in a fetus-anatomical basis and radiological aspects. *Pediatr Neonatol*. 2011;52:227-231.
19. Cambio AJ, Evans CP, Kurzrock EA. Non-surgical management of multicystic dysplastic kidney. *Br J Urol*. 2008;101:804-808.
20. Kiyak A, Yilmaz A, Turhan P, et al. Unilateral multicystic dysplastic kidney: single-center experience. *Pediatr Nephrol*. 2009;24:99-104.
21. Klaassen I, Neuhaus TJ, Mueller-Wiefel DE, et al. Antenatal oligohydramnios of renal origin: long-term outcome. *Nephrol Dial Transplant*. 2007;22:432-439.
22. Narchi H. Risk of hypertension with multicystic kidney disease: a systematic review. *Arch Dis Child*. 2005;90:921-924.
23. Narchi H. Risk of Wilms' tumour with multicystic kidney disease: a systematic review. *Arch Dis Child*. 2005;90:147-149.

16 Autosomal Recessive (Infantile) Polycystic Kidney Disease

APRIL T. BLEICH | JODI S. DASHE

Introduction

Autosomal recessive polycystic kidney disease (ARPKD) is a chronic, progressive condition that affects the kidneys and liver, causing cystic dilatation of the renal collecting ducts and congenital hepatic fibrosis (CHF), or Caroli disease.[1] ARPKD is also called *infantile polycystic kidney disease* and ARPKD/CHF. ARPKD is caused by mutations of a large, complex gene, *PKHD1,* and it has an unusually wide spectrum of phenotypic variability. Diagnosis is made prenatally or soon after birth in approximately 30% of patients,[2–4] and neonatal mortality from pulmonary hypoplasia occurs in approximately 15% of cases—up to half of cases with prenatal diagnosis.[3,5,6] Among children who survive infancy, morbidity is determined by the degree of renal

insufficiency, with current 5-year and 10-year survival rates between 80% and 90%.[3,6] Some individuals do not come to medical attention until later in childhood or adulthood and have both renal and hepatic manifestations, including early-onset hypertension, renal failure, portal hypertension, and recurrent cholangitis.[4] The varying phenotypic manifestations of ARPKD can pose unique challenges from the standpoint of prenatal diagnosis, particularly in absence of an informative family history.

Disorder

DEFINITION

Infantile polycystic kidney disease is an autosomal recessive disease that causes cystic dilatation of the renal collecting ducts and CHF.

PREVALENCE AND EPIDEMIOLOGY

The prevalence of ARPKD is estimated to be 1:20,000 births.[7] Inheritance is autosomal recessive, with complete penetrance but variable expressivity even within a family.[6] Carrier frequency of a disease-causing *PKHD1* mutation is estimated to be 1:70 in the general population.[7] Family members of affected individuals should be counseled about inheritance patterns and recurrence risk.

ETIOLOGY AND PATHOPHYSIOLOGY

Historically, ARPKD was divided into four subtypes, based on timing of presentation and degree of renal and hepatic involvement: perinatal, neonatal, infantile, and juvenile.[8] It is now viewed as a spectrum of disease. Renal involvement is characterized by dilatation and elongation of the cortical collecting ducts, resulting in a uniform distribution of radially arranged fusiform cysts.[8] The outer renal cortex is spared because it contains no tubules.[9] In the liver, proliferation and dilatation of portal bile ducts are responsible for development of periportal fibrosis.[8] ARPKD is caused by mutations of the *PKHD1* gene, which is located on the short arm of chromosome 6. *PKHD1* is one of the largest human genes, possessing a complex splicing pattern that results in multiple transcripts, the largest of which is fibrocystin/polyductin. This gene product is expressed in the kidney and, to a lesser extent, in the liver, and it is believed to play a role in regulation of cell proliferation, adhesion, and repulsion.[10–12]

Molecular genetic testing is available for affected families. *PKHD1* mutation screening using denaturing high-performance liquid chromatography has identified mutations in more than 75% of cases, including 85% of patients with perinatal or neonatal demise.[6,13] However, because most affected children are compound heterozygotes (inheriting a different mutation from each parent) and because most mutations are unique to individual families, genotype-phenotype correlations pose a challenge.[13,14] In general, inheritance of two truncating mutations is more strongly associated with perinatal mortality, whereas those with missense mutations tend to display a milder phenotype.[6] Prenatal diagnosis is available using single gene molecular genetic analysis, as is preimplantation genetic diagnosis. Indirect, haplotype-based linkage analysis is no longer the preferred method because of the possibility of misdiagnosis.[14]

MANIFESTATIONS OF DISEASE

Clinical Presentation

The clinical presentation is highly variable. Diagnosis may be made in affected individuals before birth, in the neonatal period, in childhood, or in young adulthood. Manifestations may include pulmonary hypoplasia, early-onset hypertension, renal insufficiency, portal hypertension, esophageal varices, and recurrent cholangitis. Approximately 50% of patients require dialysis by age 20.[6] Prenatally, the diagnosis is suspected based on ultrasound (US) findings and may be confirmed in an informative family by the identification of disease-causing mutations.

Imaging Technique and Findings

Ultrasound. The characteristic US finding is massive, symmetrically enlarged, echogenic kidneys, which fill and distend the fetal abdomen, measuring between 4 and 15 standard deviations above the mean for gestational age.[9] Normal corticomedullary differentiation is not visible. In some cases, these findings may be apparent in the first trimester (Fig. 16.1).[15] When ARPKD manifests early in gestation, amniotic fluid volume is usually severely decreased, with no urine visible in the bladder (Fig. 16.2). As with other causes of severe, prolonged oligohydramnios, there is significant risk for pulmonary hypoplasia secondary to Potter sequence (see Chapter 10). With advancing gestation, the appearance of the kidney becomes more inhomogeneous, and tiny cysts may be visible (Fig. 16.3).

In many cases, the diagnosis of ARPKD is not so straightforward. Another presentation involves kidneys that are echogenic but only mildly enlarged, measuring between 2 and 4 standard deviations above the mean, with preserved amniotic fluid volume (Fig. 16.4). The kidneys may not appear noticeably abnormal until after midgestation.[9] In the absence of an informative family history, counseling for such cases is problematic.[16,17] Although the differential diagnosis includes ARPKD, it also includes genetic syndromes such as Bardet-Biedl syndrome and glutaric aciduria type II, aneuploidy such as trisomy 13 (Fig. 16.5), and especially, normal kidneys.[9,18,19] A careful family history, diligent search for other anomalies, and consideration of amniocentesis are important.

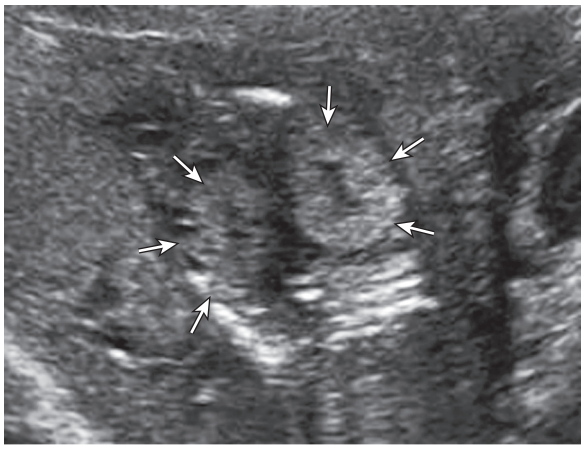

Fig. 16.1 Coronal image of a fetus with autosomal recessive polycystic kidney disease (ARPKD) at 14 weeks' gestation. The kidneys *(arrows)* appear massively enlarged and echogenic, and there is no visible amniotic fluid.

When the fetal kidneys are mildly enlarged and echogenic, and amniotic fluid volume is normal, the differential diagnosis also includes autosomal dominant polycystic kidney disease (ADPKD) (Fig. 16.6). ADPKD usually has no prenatal manifestations; patients typically present in the fourth decade of life. However, ADPKD is much more common than ARPKD, occurring in 1:800 births rather than 1:20,000. In the absence of a family history or other fetal abnormalities, consideration may be given to US evaluation of the parents' kidneys (Fig. 16.7).

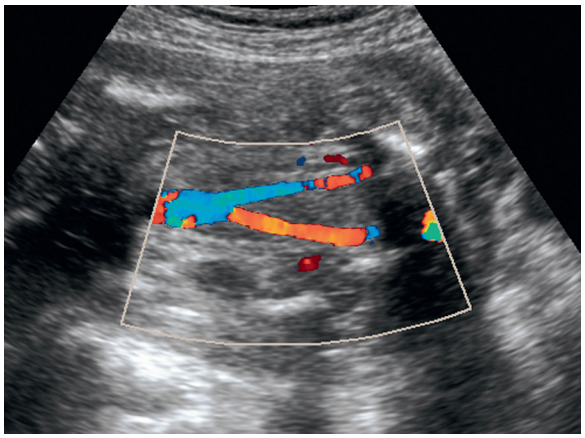

Fig. 16.2 Transverse image at the level of the bladder in a fetus with autosomal recessive polycystic kidney disease (ARPKD) at 24 weeks' gestation. No urine is visible.

Although rare, there have been case reports of fetal hepatic fibrosis secondary to ARPKD manifesting with cystic dilatation of intrahepatic bile ducts in the setting of echogenic kidneys in the third trimester.[20] Also, because of variable expressivity, normal-appearing kidneys do not preclude a diagnosis of ARPKD in an at-risk pregnancy. Renal manifestations may not be visible until childhood or even later.

CLASSIC SIGNS

Bilaterally enlarged echogenic kidneys without corticomedullary differentiation, often associated with oligohydramnios.

Differential Diagnosis From Imaging Findings

1. Normal variant (provided amniotic fluid volume is normal beyond 18 weeks)
2. ADPKD
3. Trisomy 13 (see Chapter 149)
4. Multicystic dysplastic kidneys (see Chapter 15)
5. Meckel-Gruber syndrome (autosomal recessive) (see Chapter 133)
6. Bardet-Biedl syndrome (autosomal recessive)
7. Glutaric aciduria type II (autosomal recessive)
8. Perlman syndrome (autosomal recessive)
9. Beckwith-Wiedemann syndrome (see Chapter 109)

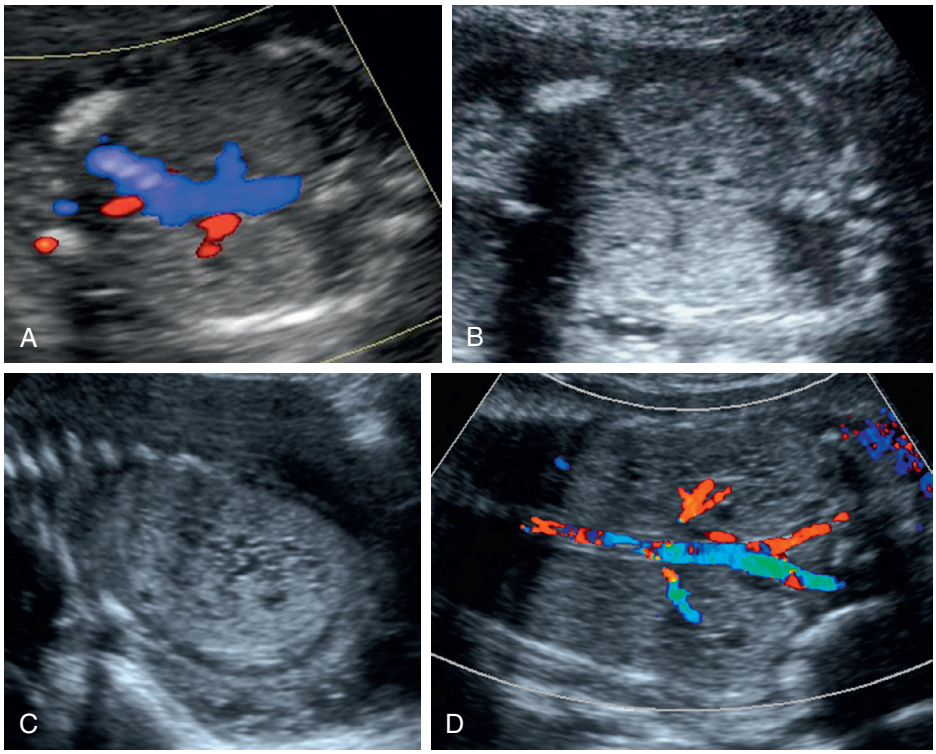

Fig. 16.3 Coronal images of a fetus with severe autosomal recessive polycystic kidney disease (ARPKD) at 18 weeks (A) and at 20 weeks (B), showing enlarged, echogenic, and inhomogeneous kidneys. There is no measurable pocket of amniotic fluid. By 26 weeks, sagittal (C) and coronal (D) images demonstrate diffuse tiny cysts within kidneys that are globular, echogenic, and fill the abdomen and pelvis.

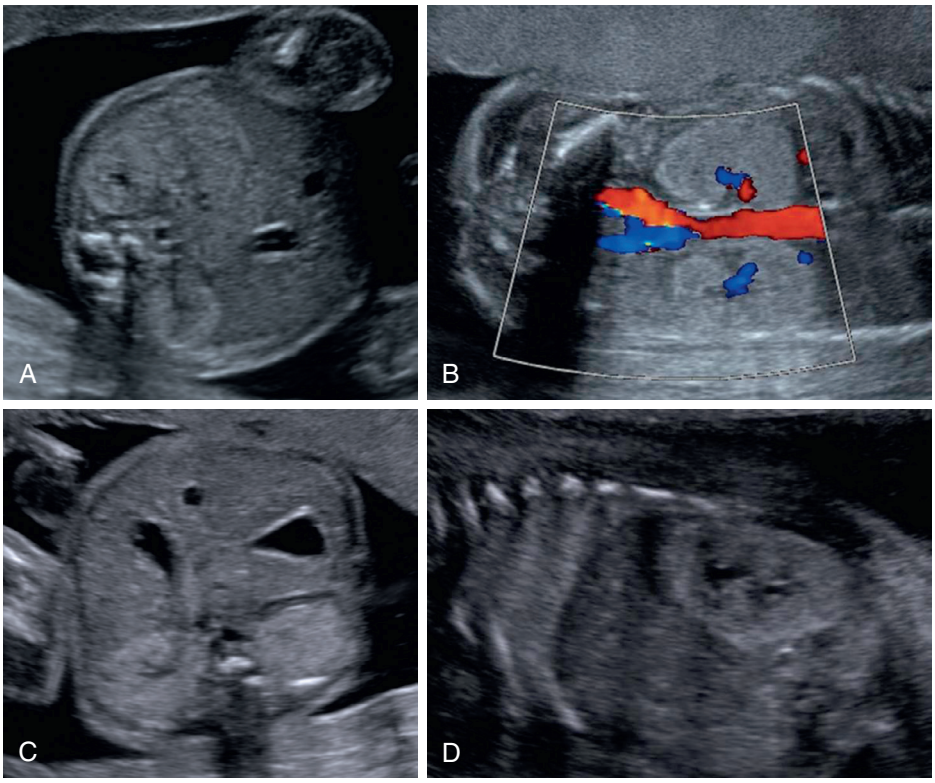

Fig. 16.4 At 21 weeks, transverse (A) and coronal (B) images demonstrate kidneys that are echogenic, mildly enlarged, and slightly globular in appearance. Images (C) and (D) are transverse and sagittal views of the same fetus at 25 weeks. The amniotic fluid volume is normal. The differential diagnosis is broad in this situation.

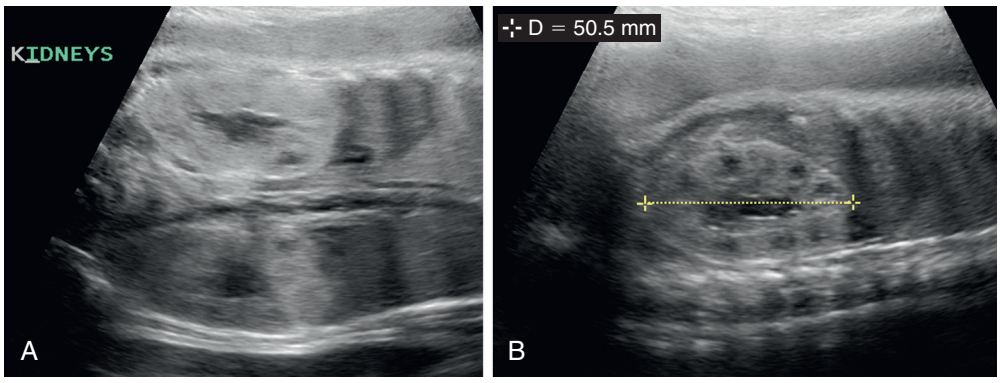

Fig. 16.5 Coronal (A) and sagittal (B) images of enlarged, echogenic kidneys in a fetus with trisomy 13. The kidneys measured 5 cm in length at 28 weeks' gestation.

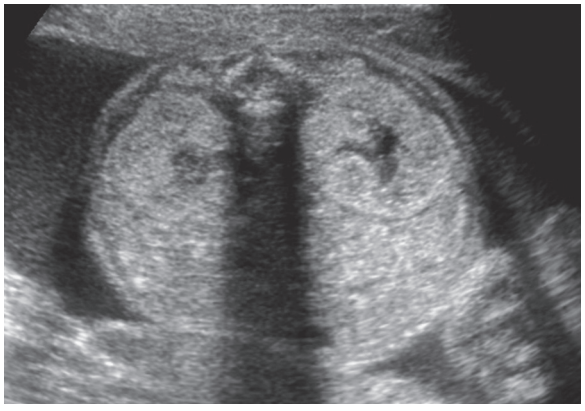

Fig. 16.6 Transverse image of echogenic, mildly enlarged kidneys in a fetus with autosomal dominant polycystic kidney disease. Cysts are not visible prenatally.

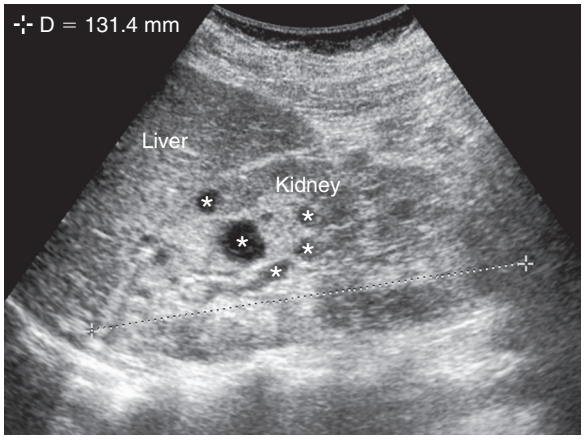

Fig. 16.7 Maternal right kidney, showing autosomal dominant polycystic kidney disease. Cysts are indicated by *asterisks*.

Synopsis of Treatment Options

POSTNATAL

When the amniotic fluid volume is severely decreased before 20 weeks, the prognosis is so poor that (if the pregnancy is continued) many families plan comfort care. In the absence of lethal pulmonary hypoplasia, initial postnatal management consists of evaluation of pulmonary and renal function. The growth and development of the infant are followed closely, with surveillance for hypertension, hyponatremia, renal insufficiency, cholangitis, and portal hypertension.

WHAT THE REFERRING PHYSICIAN NEEDS TO KNOW

ARPKD, which is caused by mutations in the *PKHD1* gene, is characterized by progressive renal failure and hepatic fibrosis. Cases that manifest prenatally show varying degrees of renal enlargement. Massively enlarged, echogenic kidneys, together with severely decreased amniotic fluid before midgestation, confer significant risk for pulmonary hypoplasia. However, in other cases, the kidneys are enlarged to a lesser degree, and amniotic fluid is preserved; these findings are not specific for ARPKD and may occur in ADPKD, trisomy 13, other syndromes, and normal pregnancy. Molecular genetic testing may be helpful in affected families.

KEY POINTS

- ARPKD affects 1:20,000 pregnancies and has a wide spectrum of phenotypic variability.
- Approximately 30% of cases are diagnosed prenatally or soon after birth; some prenatal cases have lethal pulmonary hypoplasia.
- US findings include echogenic kidneys that are variably enlarged, with early oligohydramnios in the most severe cases.
- For patients who survive infancy, 10-year survival is greater than 80%, but morbidity is significant, with hypertension, ascending cholangitis, portal hypertension, and renal insufficiency. Approximately 50% require dialysis by age 20.

SUGGESTED READING

Avni FE, Garel L, Cassart M, et al. Perinatal assessment of hereditary cystic renal diseases: the contribution of sonography. *Pediatr Radiol*. 2006;36:405-414.

Guay-Woodford L, Bissler J, Braun M, et al. Consensus expert recommendations for the diagnosis and management of autosomal recessive polycystic kidney disease: report of an international conference. *J Pediatr*. 2014;165:611-617.

Guay-Woodford LM, Desmond RA. Autosomal recessive polycystic kidney disease: the clinical experience in North America. *Pediatrics*. 2003;111:1072-1080.

Gunay-Aygun M, Avner ED, Ballacao RL, et al. Autosomal recessive polycystic kidney disease and congenital hepatic fibrosis: summary statement of a first National Institutes of Health/Office of Rare Diseases conference. *J Pediatr*. 2006;149:159-164.

Turkbey B, Ocak I, Daryanani K, et al. Autosomal recessive polycystic kidney disease and congenital hepatic fibrosis (ARPKD/CHF). *Pediatr Radiol*. 2009;39:100-111.



All references are available online at www.expertconsult.com.

REFERENCES

1. Turkbey B, Ocak I, Daryanani K, et al. Autosomal recessive polycystic kidney disease and congenital hepatic fibrosis (ARPKD/CHF). *Pediatr Radiol*. 2009;39:100-111.
2. Zerres K, Rudnik-Schoneborn S, Deget F, et al. Clinical course of 115 children with autosomal recessive polycystic kidney disease. *Acta Pediatr*. 1996;85:437-445.
3. Guay-Woodford LM, Desmond RA. Autosomal recessive polycystic kidney disease: the clinical experience in North America. *Pediatrics*. 2003;111:1072-1080.
4. Gunay-Aygun M, Avner ED, Ballacao RL, et al. Autosomal recessive polycystic kidney disease and congenital hepatic fibrosis: summary statement of a first National Institutes of Health/Office of Rare Diseases conference. *J Pediatr*. 2006;149:159-164.
5. Roy S, Dillon MJ, Trompeter RS, et al. Autosomal recessive polycystic kidney disease: long-term outcome of neonatal survivors. *Pediatr Nephrol*. 1997;11:302-306.
6. Bergmann C, Senderek J, Windelen E, et al. Clinical consequences of PKHD1 mutations in 164 patients with autosomal-recessive polycystic kidney disease (ARPKD). *Kidney Int*. 2005;67:829-848.
7. Zerres K, Mücher G, Becker J, et al. Prenatal diagnosis of autosomal recessive polycystic kidney disease (ARPKD): molecular genetics, clinical experience, and fetal morphology. *Am J Med Genet*. 1998;6:137-144.
8. Blyth H, Ockenden BH. Polycystic disease of kidneys and liver presenting in childhood. *J Med Genet*. 1971;8:257-284.
9. Avni FE, Garel L, Cassart M, et al. Perinatal assessment of hereditary cystic renal diseases: the contribution of sonography. *Pediatr Radiol*. 2006;36:405-414.
10. Al-Bhalal L, Akhtar M. Molecular basis of autosomal recessive polycystic kidney disease (ARPKD). *Adv Anat Pathol*. 2008;15:54-58.
11. Deltas C. Papagregoriou G. Cystic diseases of the kidney. *Arch Pathol Lab Med*. 2010;134:569-582.
12. Zerres K, Senderek J, Rudnik-Schöneborn S, et al. New options for prenatal diagnosis in autosomal recessive polycystic kidney disease by mutation analysis of the PKHD1 gene. *Clin Genet*. 2004;66:53-57.
13. Bergmann C, Senderek J, Kupper F, et al. PKHD1 mutations in autosomal recessive polycystic kidney disease (ARPKD). *Hum Mutat*. 2004;23:453-463.
14. Guay-Woodford L, Bissler J, Braun M, et al. Consensus expert recommendations for the diagnosis and management of autosomal recessive polycystic kidney disease: report of an international conference. *J Pediatr*. 2014;165:611-617.
15. Bronshtein M, Kushnir O, Ben-Rafael Z, et al. Transvaginal sonographic measurement of fetal kidneys in the first trimester of pregnancy. *J Clin Ultrasound*. 1990;18:299-301.
16. Lilford RJ, Irving HC, Allibone EB. A tale of two prior probabilities—avoiding the false positive antenatal diagnosis of autosomal recessive polycystic kidney disease. *Br J Obstet Gynaecol*. 1992;99:216-219.
17. Mashiach R, Davidovits M, Eisenstein B. Fetal hyperechogenic kidney with normal amniotic fluid volume: a diagnostic dilemma. *Prenat Diagn*. 2005;25:553-558.
18. Whitfield J, Hurst D, Bennett MJ, et al. Fetal polycystic kidney disease associated with glutaric aciduria type II: an inborn error of energy metabolism. *Am J Perinat*. 1996;13:131-134.
19. Kjaergaard S, Graem N, Larsen T, et al. Recurrent fetal polycystic kidneys associated with glutaric aciduria type II. *APMIS*. 1998;106:1188-1193.
20. Sgro M, Rossetti S, Barozzino T. Caroli's disease: prenatal diagnosis, postnatal outcome and genetic analysis. *Ultrasound Obstet Gynecol*. 2004;23:73-76.

SECTION TWO
Other

17 Fetal Adrenal Abnormalities

CHRISTINA S. HAN | JOSHUA A. COPEL

Introduction

The fetal adrenal glands can be reliably imaged on prenatal ultrasound. The adrenal glands are located in a retroperitoneal, paraspinous location, cephalad to the upper renal poles. The gland is composed of a hypoechogenic cortex and a thin echogenic medulla (Fig. 17.1).

Adrenal abnormalities can be divided into three categories and are listed in Table 17.1:

1. masses (neuroblastoma)
2. bleeding (hemorrhage or hematoma)
3. congenital adrenal hyperplasia

Neuroblastoma

DEFINITION

Neuroblastomas are a clinically heterogeneous group of malignant neuroendocrine tumors arising from pluripotent embryonic neuroectodermal cells. They are found in the adrenal glands in 40% of cases, but may also be found anywhere throughout the sympathetic nervous system (e.g., abdomen in 25%, thorax in 15%, neck in 5%, and retroperitoneal sympathetic ganglia in 5%).[1] Of cases that are diagnosed prenatally, approximately 93% of cases are adrenal in origin.[2]

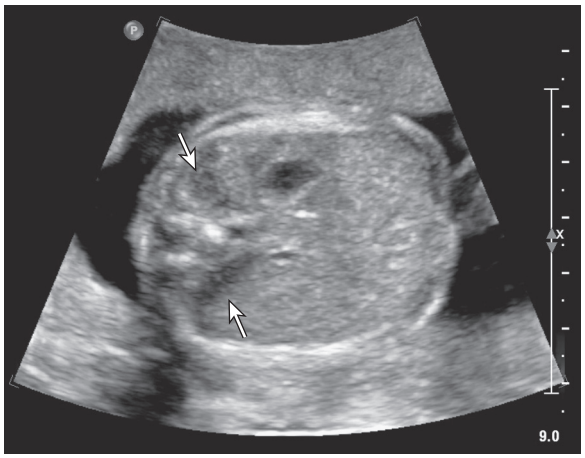

Fig. 17.1 Normal fetal adrenal gland *(arrows)*.

TABLE 17.1 FETAL ADRENAL MASSES

Intrinsic Adrenal Anomalies	Differential Diagnoses
1. Adrenal neuroblastoma 2. Adrenal hemorrhage or hematoma 3. Congenital adrenal hyperplasia	1. Duplicated urinary collection system 2. Renal dysplasia 3. Mesoblastic nephroma 4. Lymphangioma 5. Teratoma 6. Extralobar pulmonary sequestration

PREVALENCE AND EPIDEMIOLOGY

Neuroblastoma is the most common extracranial malignant solid tumor in infants younger than 1 year old, with an incidence rate of 60 per million live births.[3] The median age at diagnosis is 17.3 months of age, and 40% of patients are diagnosed before 1 year of age.[4]

The prognosis of neuroblastoma is inversely related to the age at diagnosis.[5] Prenatal diagnosis of neuroblastoma allows detection at the earliest stages, enables prompt postnatal therapy with surgical resection and chemotherapy, and confers a survival advantage.[6] They are accountable for 15% of pediatric oncologic fatalities.[7]

ETIOLOGY AND PATHOPHYSIOLOGY

During embryogenesis, pluripotent neuroblasts migrate from the neural crest to form primitive sympathetic ganglia and adrenal medulla. Between 15 and 20 weeks of gestation, neuroblasts undergo an obligatory transition through a stage that is histologically similar to an in situ neuroblastoma.[8] These lesions may follow a natural course of spontaneous regression by birth, or develop into clinically pathologic lesions via an oncogenic defect in control of cell division.

Chromosomal deletions of 1p, 11q, and 14q are found in approximately 50% of neuroblastomas.[9] Neuroblastomas are also found to have a higher incidence rate in fetuses with Turner syndrome,[10] and in disorders affecting neural crest cells, known collectively as neurocristopathies (Hirschsprung disease, central hypoventilation, and neurofibromatosis type 1).[11] Folate has also been implicated in a population-based study investigating the effect of dietary folate fortification. The incidence of neuroblastoma declined from 1.6 to 0.6 cases per 10,000 births before and after folate fortification, respectively.[12] In 1% to 2% of cases, neuroblastoma may exhibit a familial pattern, with autosomal dominant inheritance, incomplete penetrance, and a broad spectrum of clinical behaviors.[13]

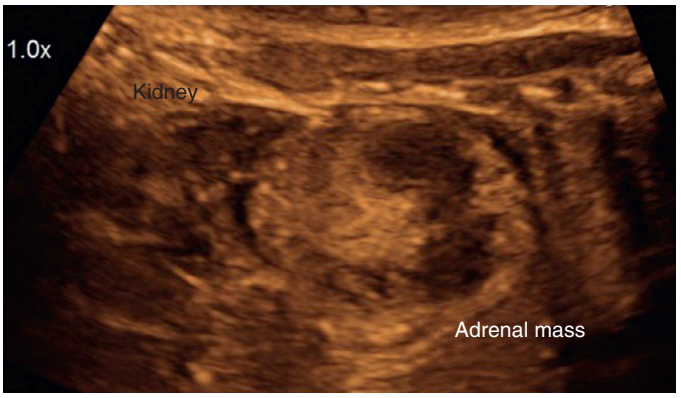

Fig. 17.2 Fetal adrenal mass, suspicious for neuroblastoma.

MANIFESTATIONS OF DISEASE

Clinical Presentation

Neuroblastomas have a wide spectrum of clinical presentations in the neonate, and may be difficult to diagnose. Signs and symptoms can be localized (e.g., palpable mass, pain, bowel or bladder compression, respiratory compromise, Horner syndrome) or systemic (e.g., hypertension, secretory diarrhea, anemia, vague systemic symptoms). Neuroblastomas can metastasize via the hematogenous or lymphatic routes to bone, bone marrow, skin, liver, lung, brain, and placenta.[14] In advanced stages of disease in the fetus, the mother may also display signs of elevated catecholamine, including hypertension, tachycardia, or preeclampsia. Neonatal imaging and laboratory correlation, with urinary homovanillic acid (HVA) and vanillylmandelic acid (VMA), are helpful in the confirmation of diagnosis. In children with neuroblastoma, 90% will have abnormal HVA, while 72.5% will have abnormal VMA.[15]

Imaging Technique and Findings

Ultrasound. The fetal adrenal glands can be easily identified on ultrasound (US) imaging. They have a discoid shape on a transverse view, and appear as Y- or V-shaped structures at the superior border of the kidney on an axial view. They can be imaged from the end of the first trimester.[16]

Prenatal diagnosis of neuroblastoma by ultrasound was first reported in 1983.[17,18] Adrenal neuroblastoma is typically seen as a suprarenal or paraspinal mass with cystic, solid, or mixed echogenicity. The kidney may be displaced inferiorly. Associated focal hemorrhage or calcification can be seen. Ultrasound detection usually happens during the third trimester. The right side appears to be affected more often,[16] with 90% of right-sided suprarenal masses proving to be neuroblastoma.[19] The presence of a systemic arterial supply on Doppler US may suggest a diagnosis of bronchopulmonary sequestration over a neuroblastoma. A fetal adrenal mass suspicious for neuroblastoma is seen in Fig. 17.2.

Magnetic Resonance Imaging. Adrenal glands present with marked hypointense signals on T2-weighted sequences and are demarcated from the adjacent organs by the hyperintense perirenal adipose tissues. Fetal magnetic resonance imaging (MRI) can be used as an adjunct to better localize and characterize tissue

TABLE 17.2 TYPICAL US AND MRI CHARACTERISTICS OF SUPRARENAL MASSES

Lesion	US Characteristics	MRI Characteristics
Neuroblastoma	Variable (echogenic, solid, cystic, or heterogeneous)	Heterogeneous or high T2 signal intensity (SI)
Extralobar sequestration	Solid, echogenic, "reverse teardrop" appearance	High T2 SI
Adrenal hemorrhage	Cystic or complex with septations	Heterogeneous SI on T1 and T2
Lymphatic malformation	Cystic with septations	High T1, infiltrating the retroperitoneum
Dysplastic duplex kidney	Heterogeneous, echogenic mass with cysts	Cystic changes in the upper pole of a duplex kidney
Adrenal hyperplasia	Bilateral masslike adrenals	Bilateral, same SI as adrenals

characteristics of fetal abdominal masses and presence of hepatic metastases, although this may also be delayed until the postnatal period.[20,21] Table 17.2 describes the differences between MRI and US findings in various adrenal pathologies.

CLASSIC SIGNS

The classic ultrasound findings of neuroblastoma are a suprarenal mass of solid, cystic, or mixed echogenicity. Rarely, maternal signs and symptoms of elevated circulating catecholamines may be present, including hypertension, tachycardia, preeclampsia, and mirror syndrome.[16]

Differential Diagnosis From Imaging Findings

1. Adrenal hematoma
2. Adrenal cyst
3. Renal mass
4. Dysplastic duplex kidney
5. Lymphatic malformation
6. Subdiaphragmatic bronchopulmonary sequestration

Synopsis of Treatment Options

PRENATAL

In utero fetal survival rate is high. Spontaneous regression is seen in 40% of cases.[2] Expectant management is recommended, with serial fetal ultrasounds to screen for fetal hydrops, adrenal enlargement, or metastases. Mode and timing of delivery is dictated by size of adrenal mass, as abdominal dystocia and fetal hemoperitoneum have been reported after vaginal delivery.[16] Mothers should also be monitored for development of hypertensive disorders or mirror syndrome.

POSTNATAL

Surgery alone is the primary therapy for adrenal neuroblastoma. Neoadjuvant chemotherapy may be used in cases whose tumors cannot be resected, such as spinal cord or respiratory tract involvement. Given the possibility of regression, some specialized centers allow for needle biopsy to select for lower grade, less aggressive tumors that may be amenable to expectant management and observation over a 4–6 week period.[16]

WHAT THE REFERRING PHYSICIAN NEEDS TO KNOW

All fetal intraabdominal masses need to undergo thorough evaluation to determine regional anatomy and associated anomalies. Serial surveillance and prenatal consultation with a pediatric surgeon may be necessary.

Adrenal Hemorrhage

DEFINITION

Adrenal hemorrhage is not uncommon in neonates.[22] The adrenal glands are encased in the perirenal fascia and are relatively large in the fetal period, weighing 2–4 grams at birth (10–20 times larger than adult adrenal glands relative to body weight). The adrenal vascular supply arises from the inferior phrenic, aortic, and renal arteries and divides into three major arteries that supply the delicate subcapsular vascular plexus. The right suprarenal vein drains into the inferior vena cava, whereas the left suprarenal vein drains into the renal or inferior phrenic veins. Hemorrhage can occur in the subcapsular space and, when severe, can rarely result in fetal hypotension and death. Smaller bleeds may present as incidental findings on routine fetal ultrasound.

PREVALENCE AND EPIDEMIOLOGY

Neonatal adrenal hemorrhage occurs at an incidence rate of 1.7–1.9 per 1000.[23] The right adrenal gland is involved in 75% of cases, possibly because of the relatively shorter adrenal vein.

ETIOLOGY AND PATHOPHYSIOLOGY

The etiology of fetal adrenal hemorrhage is not clearly understood. Associated factors include birth trauma, perinatal asphyxia, septicemia, hemorrhagic disorders, or hypoprothrombinemia, although spontaneous hemorrhage has also been reported. The majority of adrenal hemorrhages remain intracapsular with subsequent spontaneous resolution. An autopsy review found renal vein thrombosis in nearly 50% of cases with adrenal hemorrhage.[24]

MANIFESTATIONS OF DISEASE

Clinical Presentation

Adrenal hematoma and hemorrhage are often incidental findings on prenatal ultrasound, but may be associated with intrauterine demise. In the neonate, ischemic damage to bilateral adrenal glands can manifest as acute adrenal insufficiency.

Imaging Technique and Findings

Ultrasound. Adrenal hemorrhage, unlike neuroblastomas, will demonstrate an evolution in sonographic appearance over time. A new clot will initially be seen as a hyperechogenic irregular mass. As the clot organizes, internal echoes can be seen, producing a heterogeneous appearance with mixed echogenicity (Fig. 17.3). The mass can be differentiated from neuroblastoma by the absence of vascular flow on Doppler US in a hematoma.[21] Lastly, hematoma resolution is seen as an anechoic cyst (Fig. 17.4), which

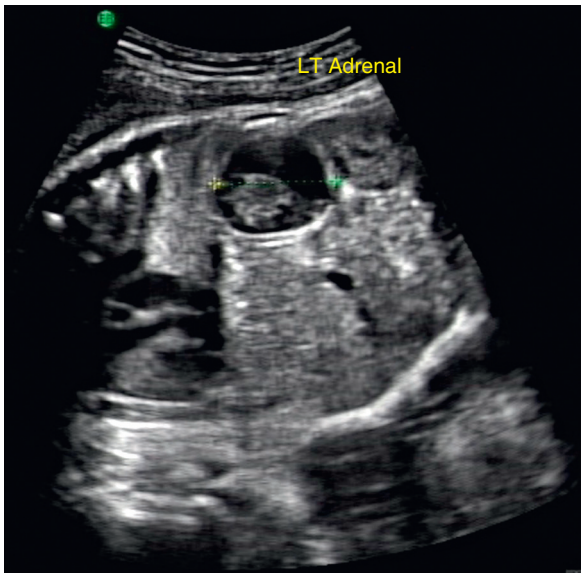

Fig. 17.3 Fetal adrenal cyst, suspicious for hematoma.



Fig. 17.5 Fetal adrenal cyst in the same patient, now with collapsing cyst.



Fig. 17.4 Fetal adrenal cyst in the same patient, indicating resolved hematoma.

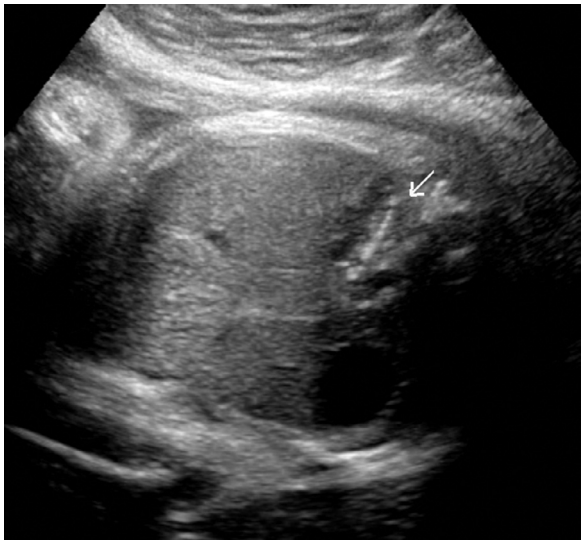

Fig. 17.6 Fetal adrenal calcifications *(arrow)* after resolution of an adrenal hematoma.

may decrease in size in subsequent ultrasounds (Fig. 17.5).[25] Calcification of the adrenal gland may be a sequela of prior adrenal hemorrhage (Fig. 17.6), but can also be seen in adrenal neuroblastomas. The changes in appearance may continue into the postnatal period.

Magnetic Resonance Imaging. Fetal MRI may aid in characterization of fetal abdominal masses and may aid in the diagnosis of adrenal hemorrhage. Table 17.2 describes the differences between MRI and US findings in various adrenal pathologies.

Differential Diagnosis From Imaging Findings

1. Adrenal neuroblastoma
2. Adrenal cyst
3. Renal mass
4. Dysplastic duplex kidney
5. Lymphatic malformation
6. Subdiaphragmatic bronchopulmonary sequestration

Synopsis of Treatment Options

PRENATAL

No prenatal therapy exists for adrenal hemorrhage. Serial fetal surveillance can be performed for fetal growth, changes in sonographic appearance, and maternal reassurance. Adrenal hematoma and hemorrhage are often incidental findings on prenatal ultrasound, but may be associated with intrauterine demise.

POSTNATAL

Fetal adrenal hematoma often spontaneously resolve and rarely require postnatal surgical intervention.[21] Pediatricians should monitor for signs of adrenal insufficiency.

WHAT THE REFERRING PHYSICIAN NEEDS TO KNOW

Adrenal hematomas are not uncommon in fetuses and neonates and often do not require surgical intervention. However, medical management of adrenal insufficiency may be required.

Congenital Adrenal Hyperplasia

DEFINITION

Congenital adrenal hyperplasia (CAH) is a group of autosomal recessive disorders involving inborn errors of steroid biosynthesis. Enzymatic mutations decrease conversion of cholesterol in the adrenal cortex to cortisol, aldosterone, or sex steroids. Compensatory excessive synthesis of precursor steroids results in diffuse enlargement and hyperplasia of the adrenals.

PREVALENCE AND EPIDEMIOLOGY

More than 90% of CAH cases result from 21-hydroxylase deficiency, whereas 5% to 8% result from 11-beta-hydroxylase deficiency. Carrier rates for mutations or partial deletions of the *CYP21A* gene, which codes for the 21-hydroxylase enzyme, range from 1:60 individuals in the general population to 1:3 individuals in Ashkenazi Jewish population. Population-based data shows an estimated disease prevalence of approximately 1:15,000 live births.[26] Prevalence rates vary by geography and ethnicity (e.g., African-Americans with 1:42,000 live births, Chinese with 1:28,000 live births, and Yupik Eskimo in Alaska with 1:280 live births).[27]

ETIOLOGY AND PATHOPHYSIOLOGY

The steroid biosynthesis pathway can be seen in Fig. 17.7. The conversion of 17-hydroxyprogesterone to 11-deoxycortisol is prevented by 21-hydroxylase deficiency, and manifests with various degrees of severity. Rarer causes of CAH include 11-beta-hydroxylase deficiency, 17-alpha-hydroxylase deficiency, 17,20-lyase deficiency, 3-beta-hydroxysteroid deficiency, congenital lipoid adrenal hyperplasia, and CYP11A1 side-chain cleavage deficiency.

Deficiencies in the steroidogenesis pathway result in deficient levels of cortisol, aldosterone, or sex steroids. Failure of the negative feedback mechanism from cortisol causes unabated release of adrenocorticotropic hormone (ACTH) and hyperplasia of the adrenal cortex.

MANIFESTATIONS OF DISEASE

Clinical Presentation

The classic form of 21-hydroxylase deficiency presents in the neonate as adrenal insufficiency with or without salt-wasting. In female infants, virilization and/or ambiguous genitalia may be seen (Fig. 17.8). The salt-wasting form results in neonatal failure to thrive, dehydration, hyponatremia, and hyperkalemia within the first 1–2 weeks of life. The nonclassic or late-onset form of 21-hydroxylase deficiency manifests later in life with signs of androgen excess, such as premature pubarche, hirsutism, early body odor, sexual precocity, menstrual irregularity, infertility, acne, and accelerated skeletal maturation. Some patients with late-onset CAH remain asymptomatic.

When a family history of CAH exists, prenatal diagnosis can be performed using DNA extracted from fetal tissues by chorionic villus sampling. Many states have mandatory newborn screening for CAH by detection of elevated levels of 17-hydroxyprogesterone levels.

Imaging Technique and Findings

Ultrasound. Ambiguous genitalia is often the only ultrasonographic sign of CAH. A female fetus may exhibit clitoromegaly and prominent, fused labia, consistent with female pseudohermaphroditism. A male fetus may not exhibit any abnormal findings. Enlargement of the adrenal glands to greater than 95th percentile and a cerebriform pattern can also be seen in CAH[28] (see Fig. 17.6).

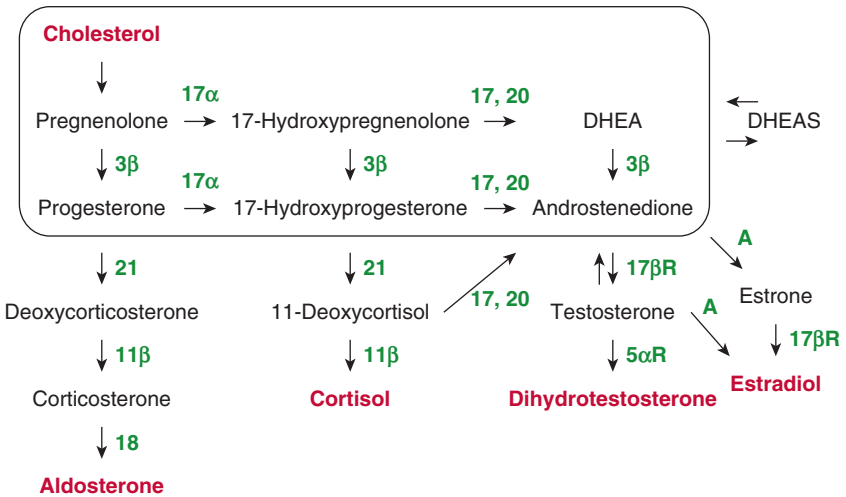

Fig. 17.7 The synthetic pathways for adrenal steroid synthesis. Enzymatic defects in this pathway result in decreased levels of cortisol, aldosterone, and sex steroids. *DHEA*, Dehydroepiandrosterone; *DHEAS*, dehydroepiandrosterone sulfate.

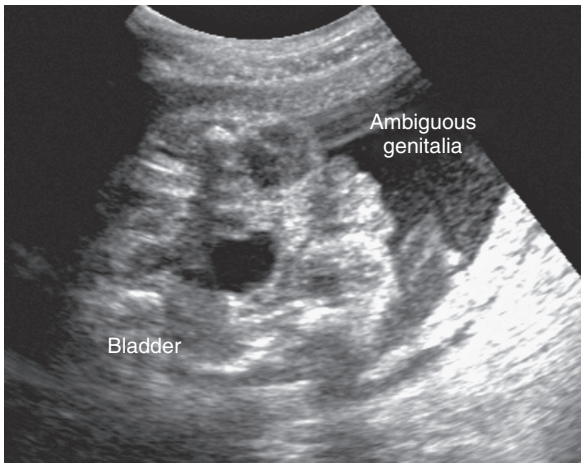

Fig. 17.8 Ambiguous genitalia in a fetus affected by congenital adrenal hyperplasia.

CLASSIC SIGNS

Classic ultrasound findings of CAH include ambiguous genitalia and enlarged adrenal glands.

Differential Diagnosis From Imaging Findings

1. Disorders of sexual differentiation
2. Adrenal neuroblastoma
3. Renal mass
4. Subdiaphragmatic bronchopulmonary sequestration

Synopsis of Treatment Options

PRENATAL

Prenatal therapy for CAH should only be used in consultation with an experienced maternal-fetal medicine, genetics, and endocrinology team. In patients with a family history of CAH, treatment with dexamethasone can be initiated in early gestation to prevent virilization and ambiguous genitalia in a female fetus. Treatment should be initiated by 6–8 weeks of gestation, well before the ability to perform invasive testing or noninvasive prenatal screening (NIPS) for sex or presence of enzymatic deficiencies. Chorionic villus sampling or NIPS may be performed after 10 weeks in pregnancies at risk for CAH, and treatment is discontinued if genetic testing reveals a male fetus or if chorionic villus sampling (CVS) reveals an unaffected female.

POSTNATAL

Female infants with CAH can be diagnosed via ambiguous genitalia, whereas male infants often present via diagnosis by newborn screening or in adrenal crisis. Either case should prompt immediate treatment with exogenous corticosteroids. Long-term management involves glucocorticoid, mineralocorticoid therapy, and salt supplementation. Ambiguous genitalia can be corrected surgically with clitoroplasty and vaginoplasty, but the timing of therapy remains controversial and requires a complex team well versed in the management of disorders of sexual development.

WHAT THE REFERRING PHYSICIAN NEEDS TO KNOW

A patient with a family history of CAH should ideally undergo preconceptional consultation with maternal-fetal medicine and geneticists, to optimize dexamethasone treatment in early gestation and arrange invasive or noninvasive genetic testing.

KEY POINTS

- The adrenal glands are located in a retroperitoneal, paraspinous location, cephalad to the upper renal poles.
- Neuroblastoma is the most common extracranial malignant solid tumor in infants younger than 1 year old. Prognosis of neuroblastoma is inversely related to the age at diagnosis, therefore prenatal diagnosis may provide survival advantage.
- Neuroblastomas are also found to have a higher incidence rate in fetuses with Turner syndrome, Hirschsprung disease, central hypoventilation, and neurofibromatosis type 1.
- Adrenal hemorrhage can occur in the subcapsular space and, when severe, can result in fetal hypotension and death.
- A patient with a family history of CAH should ideally undergo preconceptional consultation with maternal-fetal medicine and geneticists, to optimize dexamethasone treatment in early gestation and arrange invasive genetic testing.

SUGGESTED READING

Barwick TD, Malhotra A, Webb JAW, et al. Embryology of the adrenal glands and its relevance to diagnostic imaging. *Clin Radiol*. 2005;60:953-959.

Heaton TE, Liechty KW. Postnatal management of prenatally diagnosed abdominal masses and anomalies. *Prenat Diagn*. 2008;28(7):656-666.

Levine LS. Congenital adrenal hyperplasia. *Pediatr Rev*. 2000;21(5):159-170.

Schwarzler P, Bernard JP, Senat MV. Prenatal diagnosis of fetal adrenal masses: differentiation between hemorrhage and solid tumor by color Doppler sonography. *Ultrasound Ob Gyn*. 1999;13:351-355.

Van Vuuren SH, Damen-Elias HA, Stigter RH, et al. Size and volume charts of fetal kidney, renal pelvis and adrenal gland. *Ultrasound Ob Gyn*. 2012;40(6):659-664.

All references are available online at www.expertconsult.com.

REFERENCES

1. Schwab M, Shimada H, Joshi V, et al. Neuroblastic tumours of adrenal gland and sympathetic nervous system. In: Kleihues P, Cavenee WK, eds. *Pathology and Genetics of Tumours of the Nervous System*. Lyon, France: World Health Organization, IARC; 2000:153.
2. Acharya S, Jayabose S, Kogan S, et al. Prenatally diagnosed neuroblastoma. *Cancer*. 1997;80:304-310.
3. Bader J, Miller R. US cancer incidence and mortality in the first year of life. *Am J Dis Child*. 1979;133:157-159.
4. Brodeur GM, Maris JM. Neuroblastoma. In: Pizzo PA, Poplack DG, eds. *Principles and Practice of Pediatric Oncology*. Philadelphia: Lippincott Williams & Wilkins; 2002:895.
5. Jennings RW, LaQuaglia MP, Leong K, et al. Fetal neuroblastoma: prenatal diagnosis and natural history. *J Ped Surg*. 1993;28(9):1168-1774.
6. Sawada T, Kidowaki T, Sakamoto I, et al. Neuroblastoma: mass screening for early detection and its prognosis. *Cancer*. 1984;53:2731-2735.
7. Goodman MT, Gurney JG, Smith MA, et al. Sympathetic nervous system tumors. In: Ries LA, Smith MA, Gurney JG, et al, eds. *Cancer Incidence and Survival Among Children and Adolescents: United States SEER Program, 1975-1995*. Bethesda, MD: National Cancer Institute; 1999:35.
8. Turkel SB, Itabashi HH. The natural history of neuroblastic cells in the fetal adrenal gland. *Am J Pathol*. 1974;76:225-243.
9. Attiyeh EF, London WB, Mosse YP, et al. Chromosome 1p and 11q deletions and outcome in neuroblastoma. *N Engl J Med*. 2005;353(21):2243-2253.
10. Blatt J, Olshan AF, Lee PA, et al. Neuroblastoma and related tumors in Turner's syndrome. *J Pediatr*. 1997;131(5):666-670.
11. Stovroff M, Dykes F, Teague WG. The complete spectrum of neurocristopathy in an infant with congenital hypoventilation, Hirschsprung's disease, and neuroblastoma. *J Pediatr Surg*. 1995;30(8):1218-1221.
12. French AE, Grant R, Weitzman S, et al. Folic acid food fortification is associated with a decline in neuroblastoma. *Clin Pharmacol Ther*. 2003;74(3):288-294.
13. Perri P, Longo L, McConville C, et al. Linkage analysis in families with recurrent neuroblastoma. *Ann N Y Acad Sci*. 2002;963:74-84.
14. Kume A, Morikawa T, Ogawa M, et al. Congenital neuroblastoma with placental involvement. *Int J Clin Exp Pathol*. 2014;7(11):8198-8204.
15. Tuchman M, Ramnaraine MLR, Woods WG, et al. Three years of experience with random urinary homovanillic and vanillylmandelic acid levels in the diagnosis of neuroblastoma. *Pediatrics*. 1987;79:203.
16. Kesrouani A, Duchatel F, Seilanian M, et al. Prenatal diagnosis of adrenal neuroblastoma by ultrasound: a report of two cases and review of the literature. *Ultrasound Obstet Gynecol*. 1999;13:446-449.
17. Fenart D, Deville A, Donzeau M, et al. Neuroblastome retroperitoneal diagnostique in utero. *J Radiol*. 1983;64:359-361.
18. Sones PJ. Sonography case of the day. *Am J Roentgenol*. 1983;140:1024-1029.
19. Curtis M, Mooney D, Vaccaro T, et al. Prenatal ultrasound characterization of the suprarenal mass: distinction between neuroblastoma and subdiaphragmatic extralobar pulmonary sequestration. *J Ultrasound Med*. 1997;16:75-83.
20. Hill BJ, Joe BN, Qayyum A, et al. Supplemental value of MRI in fetal abdominal disease detected on prenatal sonography: preliminary experience. *Am J Roentgenol*. 2005;184:993-998.
21. Flanagan SM, Robesova E, Jaramillo D, et al. Fetal suprarenal masses—assessing the complementary role of magnetic resonance and ultrasound for diagnosis. *Pediatr Radiol*. 2016;46(2):246-254.
22. Schwarzler P, Bernard JP, Senat MV. Prenatal diagnosis of fetal adrenal masses: differentiation between hemorrhage and solid tumor by color Doppler sonography. *Ultrasound Obstet Gynecol*. 1999;13:351-355.
23. DeSa DJ, Nicholls S. Haemorrhagic necrosis of the adrenal gland in perinatal infants: a clinicopathological study. *J Pathol*. 1972;106:133.
24. Fox B. Venous infarction of the adrenal glands. *J Pathol*. 1976;119(2):65-89.
25. Strouse PJ, Bowerman RA, Schlesinger AE. Antenatal sonographic findings of fetal adrenal hemorrhage. *J Clin Ultrasound*. 1995;23:442-446.
26. Therrell BL. Newborn screening for congenital adrenal hyperplasia. *Endocrinol Metab Clin North Am*. 2001;30(1):15-30.
27. Pang S, Murphey W, Levine LS, et al. A pilot newborn screening for congenital adrenal hyperplasia in Alaska. *J Clin Endocrinol Metab*. 1982;55:413.
28. Saada J, Grebille AG, Aubry MC, et al. Sonography in prenatal diagnosis of congenital adrenal hyperplasia. *Prenat Diagn*. 2004;24:627-630.

18 Ambiguous Genitalia

CHRISTIAN M. PETTKER

INTRODUCTION

While not of primary focus for the medically minded sonographer or sonologist, sex determination is often the most important question for parents during a fetal ultrasound (US) examination. Sex determination, however, can be medically important in the diagnosis of zygosity or chorionicity in multiple gestations, for counseling regarding X-linked diseases, and in cases of ambiguous genitalia. The diagnosis of ambiguous genitalia, which has various causes, can be confusing for any specialist. Uncertainty in the ability to assign a fetal sex can be traumatizing for parents. Attention in explaining and investigating the findings and the differential diagnosis is critical. For both medical and psychologic reasons, ambiguous genitalia in a newborn requires timely diagnosis and management.

Disease

DEFINITION

Ambiguous genitalia, a subclassification of the *disorders of sex development (DSDs),* is defined as the unclear appearance of the fetal external genitalia, leading to unsuccessful phenotypic determination of fetal sex. In essence, there is confusion between the presence of a clitoris or penis and between the presence of a scrotum or labia. DSDs are divided into five classifications according to the Lawson Wilkins Pediatric Endocrine Society and the European Society for Pediatric Endocrinology (Table 18.1); ambiguous genitalia can fall within any of these classes.[1,2] Other terms used to describe these disorders are *intersex conditions* and *genital anomalies.* Ambiguous genitalia is a physical or morphologic diagnosis because there are many different underlying causes.

PREVALENCE AND EPIDEMIOLOGY

Abnormalities of the external genitalia that warrant further workup occur in 1:4500 births.[3] The frequency of the most common cause of ambiguous genitalia, classic congenital adrenal hyperplasia (CAH), is estimated to be 1:15,000.[4]

ETIOLOGY AND PATHOPHYSIOLOGY

The external genitalia become differentiated at approximately 9 weeks of gestation, and genital development is typically complete by 12 weeks for females and 14 to 16 weeks for males. Successful morphogenesis of the external genitalia depends on dihydrotestosterone (DHT) exposure for males; in females, vulvar and vaginal differentiation is not hormone-dependent. Without DHT action (because of either a lack of DHT or a failure of DHT to function), a 46,XY fetus could have phenotypically female external genitalia. On the other hand, androgen exposure before 12 weeks' gestation can cause labial fusion or a virilized urogenital sinus, whereas exposure after 12 weeks typically causes only clitoromegaly and labial enlargement (scrotalization). Androgen exposure may occur from maternal ingestion, maternal or fetal ovarian or adrenal tumors, or placental P450 aromatase deficiency. The last-mentioned condition can cause virilization of a female fetus by not allowing circulating fetal androgens to be converted to estrogens.[5]

The most common cause of ambiguous genitalia is CAH. CAH is a 46,XX DSD (masculinization of a female fetus) caused by an enzymatic deficiency that disrupts steroidogenesis. In 90% of cases, the deficiency is in CYP21 (21-hydroxylase), which causes an excess of 17-hydroxyprogesterone. Excess 17-hydroxyprogesterone is shunted toward the androgen production pathway of steroidogenesis; this androgenization causes virilization of the female. Male genitalia are unaffected with the exception of possible hyperpigmentation and penile enlargement.[6] The shunt also reduces aldosterone and cortisol production, which can produce life-threatening salt-wasting (hyponatremia and hyperkalemia) in the neonatal period. Nonclassic forms of CAH also exist, which generally cause androgenizing features only in adolescent girls or women. The presence of classic and nonclassic forms of CAH can make counseling patients who are affected or are carriers difficult; experienced specialists generally should counsel such patients.

Other causes of ambiguous genitalia include the various DSDs (see Table 18.1), aneuploidy (especially trisomy 13), triploidy, Prader-Willi syndrome, velocardiofacial syndrome, and Smith-Lemli-Opitz syndrome. More complete reviews of the various causes are available.[7]

MANIFESTATIONS OF DISEASE

Clinical Presentation

Ambiguous genitalia is often diagnosed postnatally, although prenatal diagnosis arises when sex cannot be determined on anatomic US examination. A discrepancy between genotype (from chorionic villus sampling [CVS] or amniocentesis, or from that predicted from fetal cell-free DNA [cfDNA] screening) and phenotype (from US) often initiates an investigation to consider a fetal genital anomaly.[8] The use of fetal cfDNA testing may

TABLE 18.1 DISORDERS OF SEXUAL DEVELOPMENT (DSDs)

	Old Nomenclature	Description	Common Examples
46,XY DSD	Male pseudohermaphrodite	Ambiguous or female genitalia, male gonads	Androgen insensitivity, 5α-reductase deficiency, Smith-Lemli-Opitz syndrome
46,XX DSD	Female pseudohermaphrodite	Ambiguous or male genitalia, female gonads	Congenital adrenal hyperplasia, maternal ovarian or adrenal tumor, placental P450 aromatase deficiency
Ovotesticular DSD	True hermaphrodite	Ambiguous genitalia, male and female gonads	Chimeric, mixed gonadal dysgenesis
46,XX testicular DSD	XX male	Ambiguous or male genitalia, male gonads	Sex-determining-region (SRY) translocation
46,XY complete gonadal dysgenesis	XY sex reversal	Female genitalia, undeveloped ("streak") gonads	Swyer syndrome

Adapted from Lee PA, Houk CP, Ahmed SF, et al.: Consensus statement on management of intersex disorders. *Pediatrics.* 2006;118:e488–e500.

make the prenatal diagnosis of ambiguous genitalia more common, as there are more opportunities to note discrepancies between karyotype and phenotype, such as an enlarged clitoris and labia in a pregnancy where cfDNA suggested a male fetus. At present, data are not available to describe a clear role for cfDNA testing in pregnancies with ambiguous genitalia beyond case reports. For instance, androgen insensitivity syndrome was diagnosed after a female phenotype was identified at the detailed anatomic screen, in a woman of advanced maternal age who had cfDNA screening that revealed the presence of a Y chromosome.[9]

Imaging Technique and Findings

Ultrasound. Normal female genitalia are characterized by two echogenic parallel lines in a transverse section in the midtrimester. A clitoris may be seen between these labia and should be directed caudally. The uterus occasionally can be seen in the second half of gestation as a mass between the bladder and rectum, but its absence is an unreliable indicator for sex determination. Normal male genitalia are characterized by the presence of a scrotum, which may not be seen prominently until the third trimester when testicular descent occurs. The phallus is usually seen pointing cranially. Color Doppler can be used to see urine streaming from the tip of the penis. Nomograms for scrotal diameter, penile length, and bilabial diameter have been published.[10]

By definition, ambiguous genitalia is shown when the aforementioned signs are mixed or not identified. Specifically, ambiguous genitalia is often seen as a short phallus (or, conversely, clitoromegaly) with bifid scrotum (or, conversely, labial swelling) (Figs. 18.1 and 18.2). Because of confusion, US fetal sex determination generally should not be attempted before the second trimester.[11,12] In a case where ambiguous genitalia is considered, imaging in the late second and early third trimesters can allow for assessment of testes descent or the internal reproductive organs (e.g., uterus).

CAH is usually diagnosed through invasive genetic testing (for instance, of the 21-hydroxylase gene), although US visualization of adrenal hypertrophy has been reported.[13] Three-dimensional (3D) US may be helpful in the diagnosis of fetal sex; one case report in the literature described prenatal diagnosis using 3D US in a case where there was a discordance between sex on US and the karyotype results.[14] This karyotypic male had a bifid scrotum and small phallus with hypospadias on 3D US; the diagnosis was confirmed postnatally (Figs. 18.3 and 18.4).

Magnetic Resonance Imaging. Few published reports of using magnetic resonance imaging (MRI) for fetal sex determination exist. A descriptive case series of fetal MRI from one center showed good confidence for determining fetal sex, although these studies did not involve any cases of ambiguous genitalia and were not performed for fetal sex determination.[15] In a case of bladder exstrophy, MRI was used to confirm the genitourinary

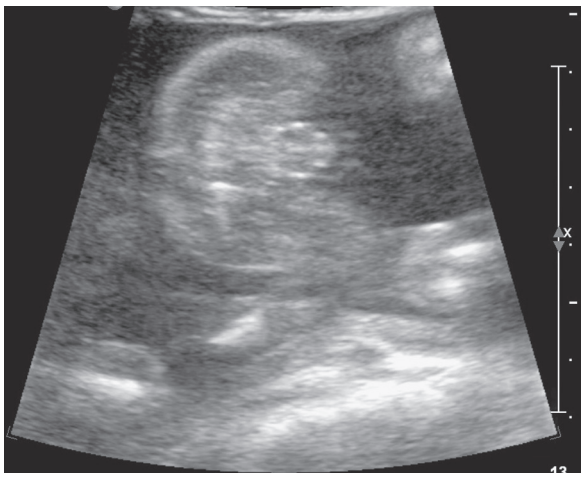

Fig. 18.1 Ultrasound of ambiguous genitalia in a triplet pregnancy. Karyotype 46,XY. Postnatal examination showed hypospadias and bifid scrotum.

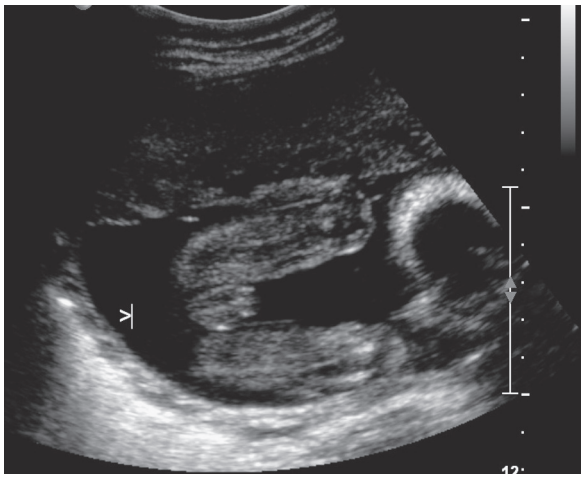

Fig. 18.2 Two-dimensional ultrasound of the same fetus shown in Fig. 18.1.



Fig. 18.3 Three-dimensional image showing ambiguous genitalia.



Fig. 18.4 Three-dimensional image showing ambiguous genitalia.

diagnosis and clarify sex phenotype when US was unable to do so.[16] Another case of suspected ambiguous genitalia was correctly determined to be a perineal lipoma with other genitourinary abnormalities with the aid of MRI.[17] The strength of MRI is in the possible ability to delineate internal genital structures better, such as the gonads and müllerian duct structures (e.g., uterus).

Other Applicable Modality. Chorionic villus sampling and amniocentesis can be performed for karyotypic determination of sex. CVS is often used in patients with a history of a prior child with CAH to determine the genotypic status and the fetal sex.

Differential Diagnosis From Imaging Findings

Hypospadias can cause a downward orientation of the phallus, which may confuse the observer in thinking that there is a female fetus. The presence of a scrotum and the visualization of a urine stream on Doppler would aid in differentiation of hypospadias from ambiguous genitalia. Bladder exstrophy is diagnosed when the bladder is invisible or there is a lower abdominal hernia. Other diagnostic considerations include the following:

1. microphallus
2. epispadias
3. cryptorchidism
4. incomplete scrotal fusion
5. perineal lipoma

Synopsis of Treatment Options

PRENATAL

There are no prenatal treatments for ambiguous genitalia in general. However, prenatal treatment in cases of CAH is integral in the prevention of a DSD. Mothers known to be at risk for having a fetus with CAH (known affected, known carrier, or prior infant with CAH) are treated with oral dexamethasone in the first trimester (if not preconceptionally), and invasive diagnosis of gender and genotype is offered. Steroid supplementation suppresses the fetal adrenal gland, causing a reduction in androgen production. Given the early period of phenotypic sex development, treatment must be initiated early. Eventually, if the fetus is determined not to be affected with the gene mutation or if the fetus is male, treatment is usually stopped. In cases where the parents are both known carriers, only 1 : 8 of fetuses are affected and female—the target population for therapy. However, treatment is effective in preventing masculinization in 85% of affected female fetuses.[17]

POSTNATAL

Postnatal management of ambiguous genitalia requires a multidisciplinary approach involving specialists in endocrinology, radiology, genetics, surgery, and often psychiatry. The diagnosis of CAH is particularly noteworthy because the classic salt-wasting form is associated with a life-threatening neonatal course if not identified and treated.

KEY POINTS

- Ambiguous genitalia is a morphologic diagnosis, with various underlying genetic and hormonal etiologies.
- Because of the complex genetic, hormonal, physical, and social factors involved, determination of fetal sex in cases of ambiguous genitalia is best done postnatally, incorporating an array of clinical consultants.
- CAH is the most common cause of ambiguous genitalia; timely diagnosis in the postnatal period is important because of the life-threatening consequences of the classic salt-wasting form.
- In cases of ambiguous genitalia, invasive diagnosis with CVS or amniocentesis can be helpful in reconciling US findings, determining genetic sex, and diagnosing CAH.
- Karyotypic results do not always determine sex assignment, given the complex hormonal and social issues involved in sex determination.

SUGGESTED READING

Hughes IA. Disorders of sex development: a new definition and classification. *Best Pract Res Clin Endocrinol Metab*. 2008;22:119-134.

McGillivray BC. Genetic aspects of ambiguous genitalia. *Pediatr Clin North Am*. 1992;39:307-317.

Merke DP, Bornstein SR. Congenital adrenal hyperplasia. *Lancet*. 2005;365:2125-2136.

Odeh M, Granin V, Kais M, et al. Sonographic fetal sex determination. *Obstet Gynecol Surv*. 2009;64:50-57.

Pinette MG, Wax JR, Blackstone J, et al. Normal growth and development of fetal external genitalia demonstrated by sonography. *J Clin Ultrasound*. 2003;30:465-472.

Sultan C, Paris F, Jeandel C, et al. Ambiguous genitalia in the newborn. *Semin Reprod Med*. 2002;20:181-188.

All references are available online at www.expertconsult.com.

REFERENCES

1. Hughes IA. Disorders of sex development: a new definition and classification. *Best Pract Res Clin Endocrinol Metab*. 2008;22:119-134.
2. Lee PA, Houk CP, Ahmed SF, et al. Consensus statement on management of intersex disorders. *Pediatrics*. 2006;118:e488-e500.
3. Hughes IA, Nihoul-Fekete C, Thomas B, et al. Consequences of the ESPE/LWPES guidelines for diagnosis and treatment of disorders of sex development. *Best Pract Res Clin Endocrinol Metab*. 2007;21:351-365.
4. Pang S, Clark A. Congenital adrenal hyperplasia due to 21-hydroxylase deficiency: newborn screening and its relationship to the diagnosis and treatment of the disorder. *Screening*. 1993;2:105.
5. Meinhardt U, Mullis PE. The essential role of the aromatase/P450arom. *Semin Reprod Med*. 2000;20:255-276.
6. Merke DP, Bornstein SR. Congenital adrenal hyperplasia. *Lancet*. 2005;365:2125-2136.
7. Sultan C, Paris F, Jeandel C, et al. Ambiguous genitalia in the newborn. *Semin Reprod Med*. 2002;20:181-188.
8. Bretelle F, Salomon L, Senat MF, et al. Fetal gender: antenatal discrepancy between phenotype and genotype. *Ultrasound Obstet Gynecol*. 2002;20:286-289.
9. Zilberman D, Parikh LI, Skinner M, et al. Prenatal diagnosis of androgen insensitivity syndrome using cell-free fetal DNA testing. *Ultrasound Obstet Gynecol*. 2015;45:112-116.
10. Pinette MG, Wax JR, Blackstone J, et al. Normal growth and development of fetal external genitalia demonstrated by sonography. *J Clin Ultrasound*. 2003;30:465-472.
11. Odeh M, Granin V, Kais M, et al. Sonographic fetal sex determination. *Obstet Gynecol Surv*. 2009;64:50-57.
12. Saada J, Brebille A, Aubry M, et al. Sonography in prenatal diagnosis of congenital adrenal hyperplasia. *Prenat Diagn*. 2004;24:627-630.
13. Naylor CS, Carlson DE, Santulli T, et al. Use of three-dimensional ultrasonography for prenatal diagnosis of ambiguous genitalia. *J Ultrasound Med*. 2001;20:1365-1367.
14. Trop I, Levine D. Normal fetal anatomy as visualized with fast magnetic imaging. *Top Magn Reson Imaging*. 2001;12:3-17.
15. Hsieh K, O'Loughlin MT, Ferrer FA. Bladder exstrophy and phenotypic gender determination on fetal magnetic resonance imaging. *Urology*. 2005;65:998-999.
16. Nakamura Y, Jennings RW, Connolly S, et al. Fetal diagnosis of penoscrotal transposition associated with perineal lipoma in one twin. *Fetal Diagn Ther*. 2010;27:164-167.
17. Speiser PW, Azziz R, Baskin LS, et al. Congenital adrenal hyperplasia due to steroid 21-hydroxylase deficiency: an Endocrine Society clinical practice guideline. *J Clin Endocrinol Metab*. 2010;95:4133-4160.

19 Cloacal Abnormalities

ERIKA F. WERNER | MAUREEN S. HAMEL

INTRODUCTION

Cloaca is derived from the Latin word for sewer or drain. Anatomically, it is used to describe a confluence of the urinary, genital, and gastrointestinal (GI) tracts. While this is the norm in birds, reptiles, and amphibians, most mammals have separate outlets for each system. In humans, there is a wide range of cloacal abnormalities. Mild forms may involve only a persistent urogenital sinus opening in combination with an anteriorly displaced anus. More severe varieties involve all three tracts converging in the pelvis. The most extreme type of cloacal anomaly is termed cloacal exstrophy, and includes a large midline abdominal defect.[1]

Cloacal abnormalities were first described in humans over 300 years ago.[1,2] Historically, these anomalies were fatal because of GI and/or urinary obstruction. With advancements in neonatal management and surgical intervention, children born with these anomalies are now able to survive, and often thrive.[1,3]

Disease

DEFINITION

A cloaca is a common chamber into which some or all of the digestive, urinary, and reproductive tracts discharge their contents. Cloacal abnormalities present in a spectrum of mild to severe forms and all share a common etiology (see later section).[4] In humans, the most extreme cloacal abnormality, cloacal exstrophy, is often referred to as the OEIS complex. The OEIS complex includes the midline abdominal defect of omphalocele (O), exstrophy of the bladder (E), imperforate anus (I), and spine (S) abnormalities.[1,5]

PREVALENCE AND EPIDEMIOLOGY

The prevalence of cloacal exstrophy was initially estimated as 1:200,000–1:250,000 births[5] and all cloacae as 1:50,000 births.[4,6] More recent studies have found a significantly higher prevalence, ranging from 1:9715 births[7] to 1:27,174 births.[8,9] The increased incidence may be caused by more accurate diagnosis and record keeping.

Males seem equally affected compared to females (Table 19.1).[6–12] Cloacal malformations are nonhereditary, as no familial cases have been described. Large cohort studies have not elicited any epidemiologic trends.[5,8] In particular, no maternal factors, including maternal age, appear to increase the risk for cloaca.[9] Of note, more cases are seen in twin pregnancies than might be expected.[7,9,12]

ETIOLOGY AND PATHOPHYSIOLOGY

A cloaca exists in all human embryos up to 4–6 weeks, at which time it becomes partitioned into the urogenital sinus and the rectum.[4] Failure of this partitioning is one reason the term "persistent cloaca" is sometimes used for fetuses and newborns. The cloacal membrane is a transitory bilaminar structure composed of endoderm and ectoderm.[13] As the embryo develops, mesodermal in-growth leads to the cloacal membrane receding and the formation of the urorectal septum. The posterior area of the cloaca becomes the anus and the anterior portion becomes the urogenital sinus. When the cloacal membrane does not recede and/or the mesoderm does not invade, or if the cloacal membrane is too large, cloacae form.[4,14] The exact cause of the interruption in normal development is unknown, but it does not appear to be teratogenic or familial; some evidence suggests disruptions in hormonal signaling as well as with homeobox and sonic hedgehog gene signaling.[15,16]

As noted in Table 19.1, a cloaca frequently occurs in one embryo of twin gestations. It has been theorized that a cytoplasmic deficiency associated with asymmetric splitting may place these fetuses at increased risk for midline defects.[9] It has also been suggested that a single embryonic disc may increase the risk of mesodermal insufficiency.[17]

MANIFESTATIONS OF DISEASE

Clinical Presentation

The majority of fetuses with cloacal anomalies have abnormalities noted on ultrasound (US).[4] However, definitive diagnosis can be difficult. In fact, retrospective analyses suggest that among patients with a diagnosis of cloaca at birth, as few as 6% are suspected prenatally.[18,19] Mild forms of cloaca may be the most difficult to diagnose prenatally.[20] Patients may be referred secondary to a pelvic mass formed by the confluence of the genital, urinary, and GI tracts. This mass can be septated or can mimic a hydrocolpos (Fig. 19.1).[21] Because the urogenital and GI tracts drain into a common chamber, urine and meconium collect in the tract and this can result in an apparent hydrocolpos. The common channel is usually patent but with varying degrees of obstruction at the perineum. In a published series of six proven cases of cloacal malformation, on prenatal imaging, a central cystic pelvic mass with a fluid-debris level was seen in all six cases, and in all but one case this mass was septated. Because of the variability of perineal outlet obstruction, in total, only 30% to 50% of fetuses will have the apparent hydrocolpos on ultrasound.[22]

Cloacal anomalies may also be suspected in cases of ambiguous genitalia. Some patients do not present until the late second or early third trimester when ascites is identified. In these patients, the cloacal anomaly is thought to be obstructive, resulting in the urine escaping through the fallopian tubes and creating ascites.[23] Urologic anomalies are frequent, with up to 90% of patients with cloacal anomalies having concurrent urologic abnormalities; hydronephrosis is most common.[22]

TABLE 19.1 INCIDENCE OF CLOACAL ABNORMALITIES

Study	Total With Cloacae (*n*)	Male (%)	Twins (%)	Percent Genetically Normal
Evans et al.[8]	10	50	NA	NA
Mathews et al.[10]	38	53	NA	NA
Lund and Hendren[11]	20	65	NA	NA
Ricketts et al.[12]	12	50	17	NA
Hendren[6]	41	59	NA	NA
Keppler-Noreuil et al.[9]	15	42	20	100
Meizner et al.[7]	6	66	33	100
Total, % (95% CI)	139	55 (47–63)	21 (11–38)	100

CI, Confidence interval; *NA*, not available.

TABLE 19.2 ANOMALIES ASSOCIATED WITH CLOACAL EXSTROPHY (LISTED BY FREQUENCY)

Gastrointestinal Anomalies	Genital Anomalies	Urinary Anomalies	CNS Anomalies	Skeletal Anomalies
Omphalocele	Undescended testes	Bladder exstrophy	Lipomeningocele	Clubfeet
Imperforate anus	Bifid phallus	Hydronephrosis	Myelomeningocele	Extra vertebrae
Malrotation	Absent uterus	Unilateral renal agenesis	Spina bifida occulta	
Short gut syndrome	Rudimentary phallus	Pelvic kidney	Cord tethering	
Duodenal atresia	Bifid uterus	Ureteral duplication		
	Double vagina	Megaureter		

CNS, Central nervous system.

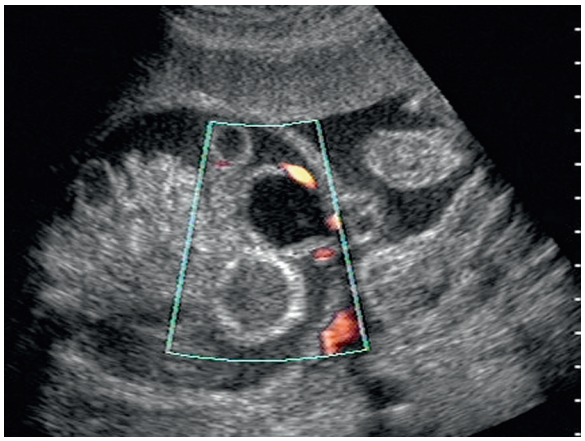

Fig. 19.1 A mild cloaca in the second trimester.

Cloacal exstrophy or OEIS typically presents as a constellation of anomalies on ultrasound. The most common clinical findings are listed by frequency in Table 19.2. Omphalocele is present in 100% of cloacal exstrophies.[9,10,12] Imperforate anus is also present in almost all cases, although this diagnosis is usually not made until after birth.[7] Spinal anomalies are present in 64% to 100% of cases.[9,11,24] However, there is significant variability in the literature regarding long-term neurologic outcomes. Much of this variability may be caused by the morbidity historically associated with the treatment of these children, among whom preterm birth and sepsis were common. Lower extremity abnormalities are also frequent, including clubbing. In one review of 38 patients, 9 were wheelchair-bound and 19 required orthopedic devices.[10] Upper urinary tract and renal anomalies are common and diverse, as are genital anomalies.[3,10–12] Genetically male neonates have sometimes been raised as females because of the severity of their genital abnormalities, though this strategy is controversial.[10]

Imaging Technique and Findings

While cloaca represents a range of abnormal connections with a myriad of different surgical treatments, many have similar prenatal imaging features. Prenatal recognition of abnormalities may impact prenatal and neonatal care and has the potential to improve outcomes.[22]

Ultrasound. Diagnosis by ultrasound was first described by Meizner et al. in 1985.[25] While cloacae are rarely diagnosed in the first trimester, approximately one-fifth of cloacae have an increased nuchal translucency.[9] This may be because of abdominal wall defects leading to increased intrathoracic compression resulting in jugular lymphatic obstruction early in embryologic development.[9]

In the second trimester, many of the anatomic defects listed in Table 19.2 are visible. In one small study, 83% of cloacal anomalies were detected at 16–18 weeks.[7] In addition to the previously mentioned anomalies, a two-vessel cord is seen in one-third of cases[9] and oligohydramnios is present in approximately one-half of cases.[23] Fig. 19.2 shows a typical sonographic image of a fetus with cloacal exstrophy. As the pregnancy progresses, oligohydramnios, ascites, and hydronephrosis become more prominent.[23,26] Intrauterine growth restriction also has been reported in some series[9] although not in others.[24]

Magnetic Resonance Imaging. Severe forms of cloacae, such as cloacal exstrophy, rarely need additional imaging for diagnosis, but magnetic resonance imaging (MRI) can be helpful in distinguishing milder forms of cloaca from other anomalies. The meconium in the distal digestive tract appears dark with low signals on T2-weighted sequences and bright on T1-weighted sequences. Thus, absence of meconium alongside the bladder



Fig. 19.2 Cloacal exstrophy with a prominent omphalocele identified at 14 weeks' gestation.

can indicate cloaca rather than isolated hydrocolpos.[21] MRI can also better characterize spinal anomalies.[24]

CLASSIC SIGNS

Nonvisualization of the bladder (caused by bladder exstrophy) and an infraumbilical anterior abdominal wall defect are classic findings of cloacal exstrophy. When these two findings are found together, 100% of infants have a third anomaly found in the OEIS complex.[9] More subtle cloacal anomalies classically have an enlarged fluid-filled cavity (see Fig. 19.1), and it is difficult to identify genitalia.

Differential Diagnosis From Imaging Findings

Cloacal exstrophy can be confused with any of the individual findings that classically comprise the OEIS complex. Thus patients may be incompletely diagnosed and told their fetus has an omphalocele, spina bifida, bladder exstrophy, or hydronephrosis rather than cloacal exstrophy. One small study estimated that the diagnosis was correctly made 8 in 15 times.[9] The differential diagnosis also frequently includes the following:

- pentalogy of Cantrell
- limb-body wall complex
- VATER syndrome (vertebral defects, imperforate anus, tracheoesophageal fistula, radial and renal dysplasia) association
- CHARGE syndrome (coloboma, heart disease, choanal atresia, retardation, genital hypoplasia, and ear anomalies)

Cloacae can also be mistaken for ambiguous genitalia, hydrocolpos, pelvic masses, and bladder obstruction.

Synopsis of Treatment Options

PRENATAL

As in all pregnancies complicated by anomalies, women carrying a fetus with a cloaca often undergo an amniocentesis to rule out karyotypic anomalies, although thus far cloaca has not been associated with any specific genetic anomaly (see Table 19.1). Karyotype can aid in assignment of sex in ambiguous cases, but amniocentesis would not necessarily be indicated for this purpose as karyotype can be obtained postnatally. In addition, patients should be offered termination. Two studies have found that one-third of patients found to have a fetus with cloaca choose to terminate.[4,6]

Patients who continue their pregnancies should be followed with serial biometric growth ultrasounds given the potential for intrauterine growth restriction (IUGR). Many of these pregnancies are complicated by oligohydramnios and thus are delivered before term. As fetuses with cloacae approach term, prenatal testing may be warranted as the stillbirth rates range from 6% to 30%.[9,23]

POSTNATAL

Before 1960, the majority of cloacal anomalies were fatal and no neonates with cloacal exstrophy survived. Recent studies cite greater than 85% survival.[12,24] The majority of deaths are because of GI complications.[24] Outcomes are directly related to the severity of the malformation, with a persistent urogenital sinus representing a mild manifestation as compared to complete cloacal dysgenesis, which is severe and usually lethal.[22]

The initial surgery is undertaken in the first week of life and typically includes an ileostomy[10] or right transverse colostomy.[6] In the case of cloacal exstrophy, the omphalocele is also closed and the medial edges of the bladder are reapproximated.[6,10,27] Exploration should be minimized during this initial surgery to avoid adhesion formation, given the need for future surgeries.[6] Definitive correction of the cloaca typically occurs between 6 and 24 months.

As the majority of these neonates now survive into childhood, recent studies have focused on the morbidity associated with cloacal anomalies. Because of short gut syndrome, as many as one-third of children with cloacae have failure to thrive at age 5.[24] Virtually no patient with cloacal exstrophy has full control of his/her bladder or bowel function.[12] Even in patients with milder cloacal anomalies, significant bowel and bladder deficits are common. In one study of 141 children with mild cloacae, only 82 had spontaneous bowel movements and only 83 could void spontaneously.[6] The two factors that most predict functional outcome are anal position and cloacal length, with a short cloaca (<3 cm) and a normally positioned anus imparting better long-term functional outcomes.[19,26] Children also face significant psychologic stress, particularly male infants who have been raised as females because of surgical gender reassignment.[28]

There are several documented cases of patients with cloacae who have themselves become pregnant. While the majority of these patients undergo cesarean delivery, vaginal delivery has been reported. Vaginal delivery may be limited by vaginal elasticity, so abdominal delivery can be required.[29]

WHAT THE REFERRING PHYSICIAN NEEDS TO KNOW

- Cloacal anomalies should be considered in any fetus found to have bladder exstrophy, omphalocele, an enlarged or septated bladder, ambiguous genitalia, or unexplained ascites.
- The survival for infants born with cloacal anomalies is now approximately 90%.
- The majority of these patients have some long-term deficits with regard to bladder and bowel control. Cloacal length and anal position best predict long-term functional outcomes.
- Any fetus thought to have a cloacal anomaly needs to be delivered at a tertiary care center with multiple surgical subspecialties available for neonatal intervention.

KEY POINTS

- Cloacal anomalies involve the urinary, genital, and GI tracts emptying into a common area.
- Cloacal anomalies are typically diagnosed in the second and third trimester.
- They can manifest as a wide range of findings on US but should be considered in all cases involving abnormal bladders and omphaloceles.
- Ultrasound is the best modality for diagnosis, but MRI may be useful for distinguishing hydrocolpos from cloacal anomalies.
- Advancements in neonatal care and surgical techniques have greatly improved the mortality, but there is still significant morbidity associated with cloacae.

SUGGESTED READINGS

Bischoff A. The surgical treatment of cloaca. *Semin Pediatr Surg*. 2016;25:102-107.

Keppler-Noreuil K, Gorton S, Foo F, et al. Prenatal ascertainment of OEIS complex/cloacal exstrophy—15 new cases and literature review. *Am J Med Genet A*. 2007;143A(18):2122-2128.

Mathews R, Jeffs R, Reiner W, et al. Cloacal exstrophy—improving the quality of life: the Johns Hopkins experience. *J Urol*. 1998;160(6 Pt 2):2452-2456.

McHoney M, Ransley PG, Duffy P, et al. Cloacal exstrophy: morbidity associated with abnormalities of the gastrointestinal tract and spine. *J Pediatr Surg*. 2004;39(8):1209-1213.

Peiro JL, Scorletti F, Sbragia L. Prenatal diagnosis of cloacal malformation. *Semin Pediatr Surg*. 2016;25:71-75.

Schober JM, Carmichael PA, Hines M, et al. The ultimate challenge of cloacal exstrophy. *J Urol*. 2002;167(1):300-304.



All references are available online at www.expertconsult.com.

REFERENCES

1. Pena A. Cloaca—historical aspects and terminology. *Semin Pediatr Surg*. 2016;25:62-65.
2. Littre A. *Med Acad R Sci*. 1709;4:9.
3. Caldwell BT, Wilcox DT. Long-term urological outcomes in cloacal anomalies. *Semin Pediatr Surg*. 2016;25:108-111.
4. Peiro JL, Scorletti F, Sbragia L. Prenatal diagnosis of cloacal malformation. *Semin Pediatr Surg*. 2016;25:71-75.
5. Carey JC, Greenbaum B, Hall BD. The OEIS complex (omphalocele, exstrophy, imperforate anus, spinal defects). *Birth Defects Orig Artic Ser*. 1978;14(6 B):253-263.
6. Hendren W. Cloaca, the most severe degree of imperforate anus: experience with 195 cases. *Ann Surg*. 1998;228(3):331-346.
7. Meizner I, Levy A, Barnhard Y. Cloacal exstrophy sequence: an exceptional ultrasound diagnosis. *Obstet Gynecol*. 1995;86(3):446-450.
8. Evans JA, Darvill KD, Trevenen C, et al. Cloacal exstrophy and related abdominal wall defects in Manitoba: incidence and demographic factors. *Clin Genet*. 1985;27(3):241-251.
9. Keppler-Noreuil K, Gorton S, Foo F, et al. Prenatal ascertainment of OEIS complex/cloacal exstrophy—15 new cases and literature review. *Am J Med Genet A*. 2007;143A(18):2122-2128.
10. Mathews R, Jeffs R, Reiner W, et al. Cloacal exstrophy—improving the quality of life: the Johns Hopkins experience. *J Urol*. 1998;160(6 Pt 2):2452-2456.
11. Lund D, Hendren W. Cloacal exstrophy: experience with 20 cases. *J Pediatr Surg*. 1993;28(10):1360-1368, discussion 1368-1369.
12. Ricketts RR, Woodard JR, Zwiren GT, et al. Modern treatment of cloacal exstrophy. *J Pediatr Surg*. 1991;26(4):444-450.
13. Marshall VF, Muecke EC. Variations in exstrophy of the bladder. *J Urol*. 1962;88:766.
14. McLaughlin KP, Rink RC, Kalsbeck JE, et al. Cloacal exstrophy: the neurological implications. *J Urol*. 1995;154(2):782-784.
15. Williams DH IV, Fitchev P, Policarpio-Nicolas ML, et al. Urorectal septum malformation sequence. *Urology*. 2005;66:657.e5-657.e7.
16. Wheeler PG, Weaver DD. Partial urorectal septum malformation sequence: a report of 25 cases. *Am J Med Genet*. 2001;103:99-105.
17. Siebert J, Rutledge J, Kapur R. Association of cloacal anomalies, caudal duplication, and twinning. *Pediatr Dev Pathol*. 2005;8(3):339-354.
18. Bischoff A, Levitt MA, Lim FY, et al. Prenatal diagnosis of cloacal malformations. *Pediatr Surg Int*. 2010;26:1071-1075.
19. Livingston JC, Elicevik M, Breech L, et al. Persistent cloaca: a 10 year review of prenatal diagnosis. *J Ultrasound Med*. 2012;31:403-407.
20. Bischoff A, Calvo-Garcia MA, Baregamian N, et al. Prenatal counseling for cloaca and cloacal exstrophy—challenges faced by pediatric surgeons. *Pediatr Surg Int*. 2012;28:781-788.
21. Picone O, Laperelle J, Sonigo P, et al. Fetal magnetic resonance imaging in the antenatal diagnosis and management of hydrocolpos. *Ultrasound Obstet Gynecol*. 2007;30(1):105-109.
22. Winkler NS, Kennedy AM, Woodward PJ. Cloacal malformation: embryology, anatomy, and prenatal imaging features. *J Ultrasound Med*. 2012;31:1843-1855.
23. Petrikovsky B, Walzak MJ, D'Addario P. Fetal cloacal anomalies: prenatal sonographic findings and differential diagnosis. *Obstet Gynecol*. 1988;72(3 Pt 2):464-469.
24. McHoney M, Ransley PG, Duffy P, et al. Cloacal exstrophy: morbidity associated with abnormalities of the gastrointestinal tract and spine. *Pediatr Surg*. 2004;39(8):1209-1213.
25. Meizner I, Bar-Ziv J. Prenatal ultrasonic diagnosis of cloacal exstrophy. *Am J Obstet Gynecol*. 1985;153(7):802-803.
26. Bischoff A. The surgical treatment of cloaca. *Semin Pediatr Surg*. 2016;25:102-107.
27. Ohno Y, Koyama N, Tsuda M, et al. Antenatal ultrasonographic appearance of a cloacal anomaly. *Obstet Gynecol*. 2000;95(6 Pt 2):1013-1015.
28. Yiee J, Wilcox D. Abnormalities of the fetal bladder. *Semin Fetal Neonatal Med*. 2008;13(3):164-170.
29. Greenberg JA, Hardy Hendren W. Vaginal delivery after cloacal malformation repair. *Obstet Gynecol*. 1997;90(4 Pt 2):666-667.

To access the videos in this chapter, scan this QR code or visit expertconsult.com

20 Gastroschisis

KATHERINE H. CAMPBELL | JOSHUA A. COPEL

Introduction

Gastroschisis, a full thickness paraumbilical defect in the abdominal wall that results in herniation of the fetal midgut, has been considered an entity embryologically distinct from omphalocele since the mid-1950s.[1] The widespread availability of prenatal ultrasound (US) and of maternal serum alpha-fetoprotein screening allows for routine antepartum diagnosis of gastroschisis with high accuracy.[2,3] For reasons not well defined, the prevalence of gastroschisis has continued to increase both in the United States and internationally.[4] The defect is usually isolated, without chromosomal abnormalities, but it carries a significant mortality rate of 5% to 10%.[2,5] Infants with gastroschisis are more likely to be born prematurely and to be affected by intrauterine growth restriction.[6–11] Bowel atresia and damage to the bowel secondary to persistent intrauterine contact with amniotic fluid is also implicated in neonatal morbidity and mortality. Because serial prenatal surveillance of affected fetuses is possible and the short-term and long-term neonatal sequelae are recognized, many practitioners have studied how to optimize fetal maturity while minimizing ongoing damage to the fetal bowel.

Disease

DEFINITION

Gastroschisis (Greek for "abdominal cleft") is a full-thickness paraumbilical defect in the abdominal wall. In most cases, the defect lies to the right of a normally inserted umbilical cord. Fetal bowel herniates through this defect and can be seen floating freely in the amniotic fluid (Fig. 20.1 and Video 20.2). The defect is usually small (<4 cm), and, by definition, there is no peritoneal membrane covering the herniated abdominal contents (Fig. 20.2). Although it is possible to see herniation of additional organs, such as the stomach, liver, spleen, or genitourinary tract, this is less common. The diagnosis is easily made with US scanning starting at the end of the first trimester.[11,12]

In contrast to omphalocele, the loops of exposed bowel are not protected from the amniotic fluid by the peritoneum. In addition, the blood supply to the herniated gut can be disrupted if there is kinking or compression of the bowel as it passes through the abdominal wall defect. These mechanisms can lead to an array of fetal and neonatal complications, including volvulus, bowel atresia, stenosis, or necrosis, hypoperistalsis, and short gut syndrome.

PREVALENCE AND EPIDEMIOLOGY

The incidence of gastroschisis has been increasing worldwide for the past 2 to 3 decades.[2,4,13,14] Reported rates of gastroschisis have increased over the past 25 years from 0.1:10,000 to 1.0:10,000 live births in developed countries, and from 3.0:10,000 to 5.0:10,000 births in underdeveloped countries.[2,13,14] The variation in incidence is attributed to geographic distribution and maternal age. Studies have consistently reported a several-fold higher rate

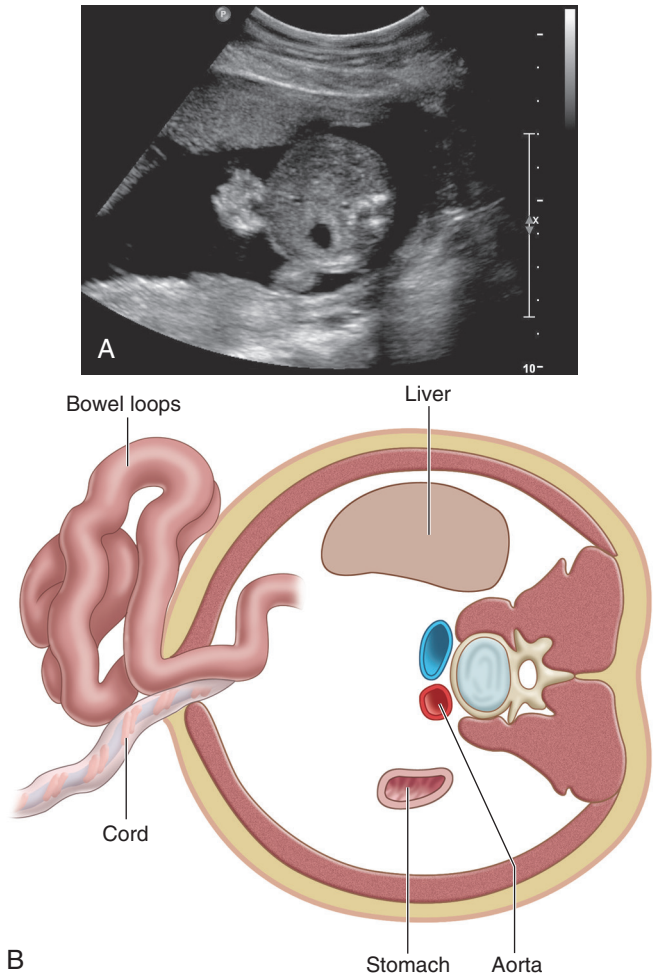

Fig. 20.1 (A) Gastroschisis at estimated gestational age of 20 weeks, 3 days. (B) Line drawing denoting size and location of gastroschisis defect.



Fig. 20.2 Normal cord insertion with the abdominal wall defect noted to the right.

of gastroschisis in pregnancies of women younger than 20 years old.[2] Mastroiacovo et al.[14] evaluated the data of 25 registries of members of the International Clearinghouse for Birth Defects Surveillance and Research with 7 years of data and found 14 registries with a significantly increasing temporal trend of gastroschisis. No similar trend was observed in 36 other malformations analyzed. The increasing trend is worldwide but not universal.

TABLE 20.1 ASSOCIATIONS LINKED TO GASTROSCHISIS AND THE WEIGHT OF EVIDENCE

Association	Weight of Evidence
TERATOGENIC	
Tobacco	Weak
Alcohol	Weak
Cocaine	Very weak
Aspirin	Weak
Ibuprofen	Weak
Pseudoephedrine	Weak
Acetaminophen	Weak
EPIDEMIOLOGIC	
Young maternal age	Strong
Low maternal body mass	Weak
Short interval between menarche and first pregnancy	Weak
Low socioeconomic status	Weak
Poor maternal education	Weak
INFECTIONS	
Genitourinary infections	Weak

Increased incidence is seen in Japan; Australia; North, Central, and South America; and North-Central Europe. United States Centers for Disease Control and Prevention (CDC) data from 1995 to 2012 revealed a 30% increase in the prevalence of gastroschisis when comparing the time periods 1995–2005 and 2006–2012, with the prevalence increasing from 3.6:10,000 to 4.9:10,000 live births.[4] All studies consistently found a strong association between young maternal age and fetal gastroschisis.

The disproportionate number of young women whose pregnancies are complicated by gastroschisis and the overall increase in incidence worldwide suggest a role for underlying environmental causes, such as infection, nutrition, or medication use. Researchers have linked smoking, alcohol use, and use of common medications such as acetaminophen, aspirin, ibuprofen, and pseudoephedrine to gastroschisis. However, it is unclear if these associations are causal or sufficient to explain the increasing rates seen worldwide (Table 20.1). Researchers have also found a significant association between mothers who reported both urinary tract infection and sexually transmitted infection in the month before conception or during the first trimester and fetal gastroschisis (adjusted odds ratio 4.0, 95% confidence interval 1.4–11.6).[15] A more recent study evaluating smoking as a risk factor for gastroschisis found first-trimester cigarette exposure was more common in mothers with infants diagnosed with gastroschisis. However, after controlling for confounding variables (maternal age, preconception body mass index), the association between smoking and development of gastroschisis was determined to be weak, with an adjusted odds ratio of 1.6 (95% confidence interval 1.1–2.3).[16]

Gastroschisis is rarely associated with aneuploidy and uncommonly linked to additional anomalies. There are isolated reports of gastroschisis in association with trisomies 13, 18, and 21 and monosomy 22. In the European surveillance of congenital anomalies (EUROCAT) registry of live births, stillbirths after 20 weeks' gestation, and terminations, 3% of cases of gastroschisis had a chromosomal anomaly; however, the definition of gastroschisis included various abdominal wall defects.[17,18] In a population-based

study, after excluding other abdominal wall defects, 14% of cases of gastroschisis were associated with additional defects (central nervous system being the most common at 4.5%), and 1.2% of cases of gastroschisis were associated with abnormal chromosomes.[19] Traditionally, gastroschisis is regarded as a nonfamilial anomaly; however, authors have reported familial recurrences of gastroschisis. In a population-based study in California that included an extended pedigree of all probands, six (4.7%) of 127 families had more than one affected relative, and the sibling recurrence rate was 3.5%.[20] The incidence of gastroschisis in offspring of affected individuals is unknown, and the role of genetic, epigenetic, and environmental factors on the development of gastroschisis is also undetermined.

ETIOLOGY AND PATHOPHYSIOLOGY

Gastroschisis has been regarded as a disruption (i.e., an abnormality produced after initial normal development) rather than a malformation (i.e., an abnormality occurring during early embryonic development). However, emerging evidence suggests that gastroschisis may be a malformation. Several hypotheses have been proposed to describe events leading to the development of gastroschisis.[21,22] All hypotheses involve defective formation or disruption of the body wall, leading to subsequent herniation of bowel (Table 20.2).

Because a disproportionate number of fetuses with gastroschisis are carried by younger women, research has focused on factors thought to be more prevalent in this group, such as nutritional patterns and drug use. The generally accepted vascular pathogenesis of gastroschisis has prompted a focus on vasoactive factors such as cocaine use, smoking, and use of cold remedies. Study results have been largely contradictory, with weak or modest associations found between various environmental factors. More recently, other new theories have been presented to explain the mechanism behind the defect.

The first proposes that gastroschisis is the consequence of failure of one or more of the folds responsible for abdominal wall closure.[21] This failure is the proposed mechanism for other ventral wall defects (e.g., ectopia cordis, cloacal exstrophy). The proposed mechanism states that the body fold failure impedes the merging of the yolk sac with the body stalk. As development of the gut continues, part of the primary intestinal loop attached to the vitelline duct herniates through the body fold defect and into the amniotic cavity instead of the umbilical cord. An alternative scenario is proposed in which the primary intestinal loop herniates normally into the umbilical cord, with another part of the gut herniating through the unclosed portion of the ventral wall.

Another proposed mechanism explaining development of gastroschisis was presented in an article by Stephenson et al. in 2009.[23] These authors hypothesized that the determining defect in gastroschisis is failure of the yolk sac and related vitelline structures to be incorporated into the umbilical stalk. This failure leads to persistence of the vitelline duct and yolk sac outside the main body stalk and abdominal wall, whereas the lateral abdominal walls close normally. The developing midgut has two points of egress from the abdominal cavity; this leads to abnormal herniation of the expanding midgut into the amniotic cavity and subsequent development of gastroschisis.

TABLE 20.2 PROPOSED HYPOTHESES DESCRIBING EVENTS LEADING TO DEVELOPMENT OF GASTROSCHISIS

Year	Author	Hypothesis
1963	Duhamel	Failure of embryonic mesenchyme to form the abdominal wall because of teratogen exposure
1975	Shaw	Rupture of amnion around the umbilical ring during the time of physiologic herniation or later
1980	deVries	Abnormal involution of right umbilical vein leading to weakening of the body wall and subsequent gut herniation
1981	Hoyme et al.	Disruption of right omphalomesenteric (vitelline or yolk sac) artery leading to infarction and necrosis at the base of the cord with subsequent body wall damage
2007	Feldkamp et al.	Abnormal folding of body wall resulting in a ventral body wall malformation leading to herniation of fetal gut
2009	Stevenson et al.	Failure of yolk sac and related vitelline structures to become incorporated into the body stalk, orphaning the vitelline duct and yolk sac outside both the main body stalk and the abdominal wall

MANIFESTATIONS OF DISEASE

Clinical Presentation

Nearly all cases of gastroschisis are associated with elevated levels of maternal serum alpha-fetoprotein (MSAFP).[24] Before routine US screening, MSAFP may have been the sole prenatal indicator of gastroschisis. In a series of 23 cases of gastroschisis, the average MSAFP was 9.42 multiples of the median; MSAFP was elevated in every case.[2,5]

Most cases of gastroschisis are now diagnosed prenatally with US. The EUROCAT study reported a 90% detection rate of gastroschisis on prenatal US. A subsequent population-based study detected 97.7% of cases during prenatal US.[2,3,13] There are reports of diagnosis of gastroschisis during the late first trimester.[11,19] However, most cases are diagnosed during routine anatomy US performed at 18 to 20 weeks' gestation.

Imaging Technique and Findings

Ultrasound. The classic appearance of fetal gastroschisis on US is free-floating loops of bowel within the amniotic fluid (Fig. 20.3). On closer examination, a defect is seen to the right (in most cases) of a normally inserted umbilical cord (Video 20.1). The intestine is usually the only herniated organ. It is rare to see concomitant herniation of additional abdominal organs in



Fig. 20.3 Free-floating loops of fetal bowel.

cases of isolated gastroschisis.[19] There is no peritoneal covering of the intestinal mass, and the exteriorized mass has a "cauliflower" appearance because the fluid between loops of bowel results in acoustic interfaces at both near and far bowel walls (Fig. 20.4). Visualization of free-floating bowel loops is enhanced secondary to echogenic bowel wall edema and inflammation in addition to the dilated intestinal lumen (Fig. 20.5). The stomach and intestine may become dilated because of obstruction (volvulus, atresia or stenosis, or malrotation) or hypoperistalsis.

Gastroschisis may be seen on US beginning after 11 weeks of gestation when the physiologic gut herniation resolves and returns to the abdominal cavity (Figs. 20.6 and 20.7).[11,19] The main differential diagnosis at that point in time is omphalocele, in which herniated abdominal contents protrude through a ventral wall defect and into the base of the umbilical cord (Chapter 21). By definition, omphalocele has a peritoneal covering except in the rare case in which the covering is ruptured. Additional differential diagnoses are described in the next section. It is crucial to exclude omphalocele as a diagnosis because additional structural abnormalities are seen more often with omphalocele (50% to 70% of cases), and approximately 20% to 40% of cases of omphalocele are associated with chromosomal abnormalities.[18]

In contrast to omphalocele, gastroschisis is not generally associated with chromosomal abnormalities or malformations outside the gastrointestinal tract. A review of 3322 cases of gastroschisis from 24 international registries of congenital malformations found 12% to have additional unrelated malformations, 2% to be part of a known syndrome, and 1.2% to have chromosomal abnormalities.[19] However, one-quarter of cases of gastroschisis have associated gastrointestinal problems, including malrotation, atresia, and stenosis.[5]

Oligohydramnios is the most common amniotic fluid abnormality seen in gastroschisis. Polyhydramnios is present less frequently.[25,26]

Because most cases of gastroschisis are diagnosed prenatally, various management algorithms have been proposed, with differing opinions and supporting literature regarding optimal prenatal surveillance, delivery time, and mode of delivery. Approximately one-third to two-thirds of neonates born with gastroschisis have impaired prenatal growth.[6,8] The fetal growth restriction appears to be symmetric and does not seem to be progressive throughout gestation. Because the abdominal circumference routinely lags in affected fetuses, a specific formula for estimating weight in fetuses with abdominal wall defects has been proposed.[27] Measurements used include biparietal diameter, occipitofrontal diameter, and femur length. In a retrospective cohort study, Nicholas et al.[7] found growth restriction to be predictive of adverse neonatal outcome.

Dilated extraabdominal fetal bowel has been used as a marker for possible poor postnatal prognosis since the 1980s, and it is often cited as a factor in the decision for early delivery. In an



Fig. 20.4 Characteristic "cauliflower" appearance of free-floating loops of bowel.



Fig. 20.5 Free-floating loops of bowel at estimated gestational age of 33 weeks, 3 days.

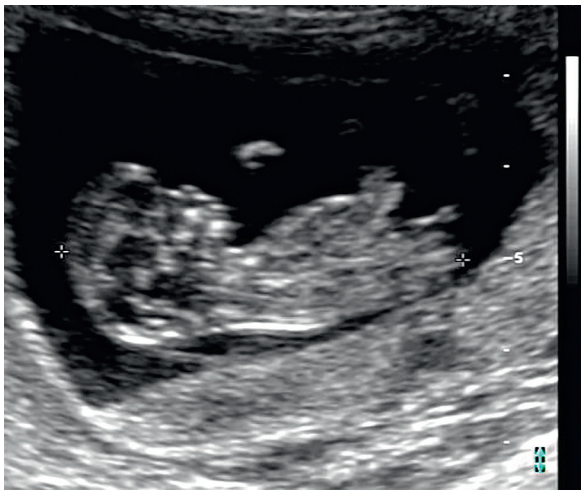

Fig. 20.6 Physiologic gut herniation at estimated gestational age of 11 weeks, 2 days, seen in sagittal view.



Fig. 20.7 Physiologic gut herniation at estimated gestational age of 11 weeks, 2 days, seen in transverse view.

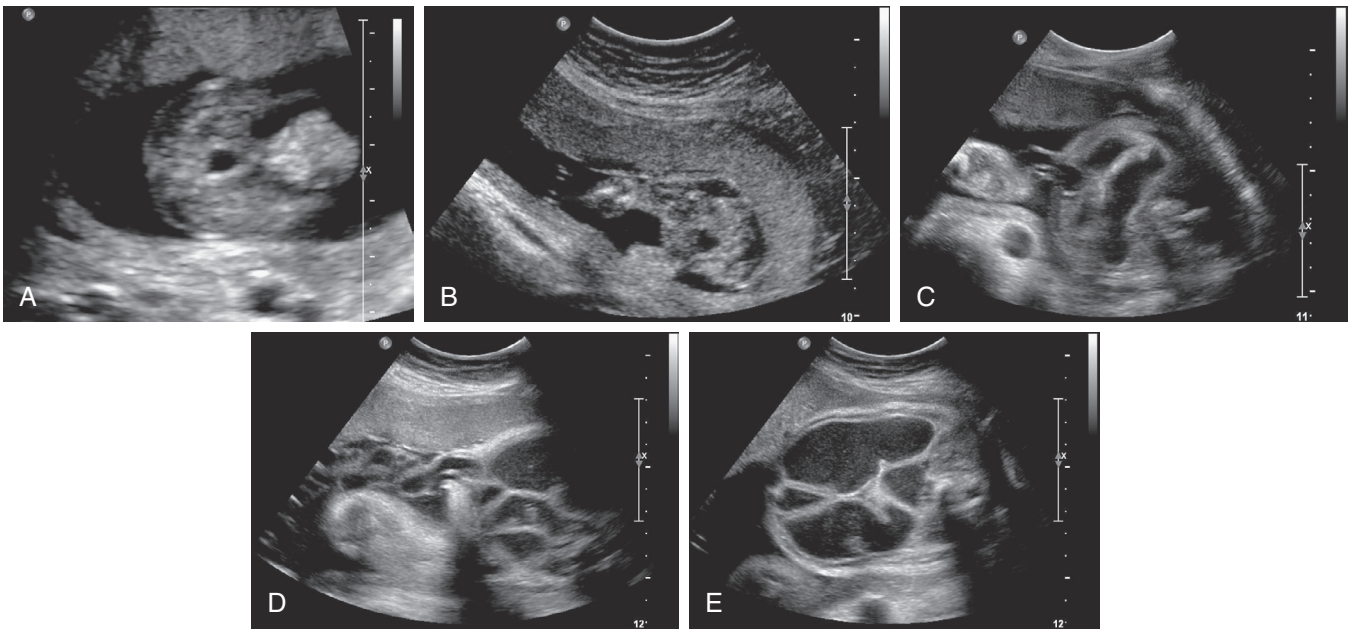

Fig. 20.8 (A) Gastroschisis diagnosed at estimated gestational age of 15 weeks, 6 days. (B) Repeat ultrasound (US) at 21 weeks, 6 days revealed a small amount of gastroschisis and dilated intraabdominal bowel. (C) Repeat US at 25 weeks, 6 days revealed no extraabdominal bowel but worsening intraabdominal bowel dilatation. (D) At 31 weeks, 6 days, no abdominal defect was appreciated, and the intraabdominal bowel dilatation persisted. (E) Significantly dilated loops of intraabdominal bowel in a case of "vanishing gastroschisis."

analysis of a retrospective cohort by Mears et al.,[28] 81% of 60 cases of gastroschisis had prenatal bowel dilatation (defined as diameter >10 mm). The authors found correlation between bowel dilatation and earlier diagnosis of dilatation with the type of postnatal repair required. However, this finding did not predict an increase in mortality, complex postnatal course, or prolonged time on parenteral nutrition. A systematic review of 10 observational studies concluded that fetuses with isolated gastroschisis and bowel dilatation are not at increased risk of adverse perinatal outcome compared with fetuses without dilatation.[29] When intraabdominal bowel dilatation is present, intestinal stenosis or atresia should be suspected.

Cases of "vanishing gastroschisis" have been presented in the literature.[30] This phenomenon was first described in 1957 by Kiesewetter. Widespread use of prenatal US has allowed documentation of the natural history of this phenomenon (Figs. 20.8 and 20.9). Typical presentation is a diagnosis of gastroschisis in the late first or early second trimester, with subsequent US examinations revealing a spectrum of findings from shrinkage of the amount of extraabdominal intestine to complete absence of extraabdominal intestine. There is some degree of atresia and stenosis of the affected bowel, resulting in intraabdominal bowel dilatation.

Magnetic Resonance Imaging. Magnetic resonance imaging (MRI) is traditionally not used to augment US diagnosis or characterize fetal gastroschisis further.

CLASSIC SIGNS

Free-floating loops of fetal intestine with no amnioperitoneal covering arise from a small abdominal wall defect usually to the right of a normal umbilical cord insertion. The extraabdominal mass of fetal bowel is classically described as having a "cauliflower" appearance.



Fig. 20.9 An unusual case of gastroschisis. Note small abdominal wall defect and dusky appearance of the bowel. *(Courtesy of Milissa McKee, MD, Yale School of Medicine.)*

Differential Diagnosis From Imaging Findings

1. Physiologic gut herniation. This is normally resolved after 11 weeks' gestation and is found within the base of the umbilical cord.[31]
2. Omphalocele. Defined as an anterior ventral wall defect through which intraabdominal contents are extruded into the base of the umbilical cord. By definition, an amnioperitoneal membrane covers the hernia. Although possible, it is rare for the membrane to rupture.
3. Amniotic bands.
4. Limb-body wall complex (body stalk abnormalities). This group of abdominal wall defects is thought to be the result

of complete failure of body wall folding. The result is herniation of the abdominal organs in a sac of amnioperitoneum. The defect leads to an absence of the umbilicus and true cord.
5. Bladder or cloacal exstrophy. This can include exstrophy of the bladder and small or large intestine, anal atresia, hypoplasia of the colon, omphalocele, and anomalous genitalia.
6. Ectopia cordis. The heart is partially or completely exposed from the confines of the thoracic cavity as a result of failure of fusion of the lateral folds of the thorax and the cephalic fold.
7. Pentalogy of Cantrell. Complex ventral wall malformation, which includes an epigastric abdominal defect, defect of the lower sternum, deficiency of the diaphragmatic pericardium, deficiency of the anterior diaphragm, and cardiac abnormality.
8. Urachal abnormalities.
9. Umbilical cord cyst.

Synopsis of Treatment Options

PRENATAL

There are presently no prenatal treatment options for fetal gastroschisis. It has been suggested that prolonged exposure of the fetal bowel to the amniotic fluid and progressive mechanic constriction of the herniated intestine are the two main mechanisms behind intestinal damage.[32] In addition, 25% of cases of gastroschisis can be complicated by oligohydramnios. Some investigators have presented case reports using amnioinfusion to alleviate oligohydramnios, while minimizing continued intestinal damage from putative toxic mediators in the amniotic fluid.[32,33] This therapy is currently limited to investigational settings only and is not standard care in the management of gastroschisis.

More recently, in utero anatomic repair of gastroschisis was performed in midgestation in a fetal lamb model. Successful repair of surgically created gastroschisis alleviated the progressive signs of inflammation and peel development seen in the cases of the unrepaired defect.[23]

Coordination of delivery at a tertiary care facility is preferable because it allows optimal conditions for the neonate with the availability of maternal-fetal medicine, neonatology, and pediatric surgery. Current practice is to allow women carrying fetuses with gastroschisis to undergo vaginal delivery with cesarean section reserved for routine obstetric indications because there is no clear evidence that mode of delivery alters the outcome.[9,10] There is evidence that vaginal delivery with cesarean reserved for routine obstetric indications is becoming the more prevalent in pregnancies affected by gastroschisis.[34]

POSTNATAL

Secondary to the exposure of the eviscerated bowel, the neonate is at risk for insensible losses of fluid and heat. Immediately after delivery, the herniated bowel is wrapped with sterile saline dressings and covered in plastic wrap (Fig. 20.10). If pediatric surgery is not immediately available for evaluation, the neonate should be placed on the right side to avoid kinking of the blood supply as it traverses through the abdominal defect. A nasogastric tube is placed to decompress the bowel maximally, and intravenous access is obtained for fluid resuscitation. The preferable method of closure for routine gastroschisis is by bedside placement of a Silastic spring-loaded silo (Fig. 20.11). The advantages of this method include minimal need for fluid resuscitation and avoidance of general anesthesia and intubation. Defects are usually reduced in 1 to 3 days (Fig. 20.12). If the gastroschisis is complicated (e.g., bowel atresia, perforation, ischemia, or vanishing gastroschisis), the neonate requires exploration in the operating room with subsequent placement of a silo. Approximately 10% of gastroschisis cases are complicated by intestinal atresia. Gastroschisis can also be reduced via primary closure or by staged closure. Once the reduction is performed, the skin defect may be closed with traditional suture closure, or with a biologic closure using the remnant of umbilical cord. The major postnatal morbidity is overcoming poor mucosal function and hypoperistalsis.

WHAT THE REFERRING PHYSICIAN NEEDS TO KNOW

- Gastroschisis can usually be diagnosed during second-trimester routine US scans, and there is usually an elevated MSAFP.
- Fetuses with gastroschisis should be delivered at tertiary care centers.
- Associated defects are present less commonly than with omphalocele but should still be sought.
- Accurate estimation of fetal weight is difficult in the setting of gastroschisis.



Fig. 20.10 Neonate with gastroschisis. Note presence of a herniated fallopian tube. *(Courtesy Milissa McKee, MD, Yale School of Medicine.)*



Fig. 20.11 Silastic silo in place on day 1 of life. *(Courtesy Milissa McKee, MD, Yale School of Medicine.)*

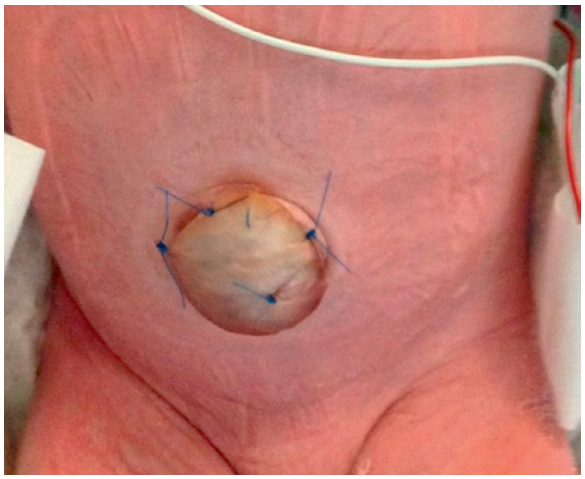

Fig. 20.12 Biologic closure of residual skin defect after successful reduction of gastroschisis *(Courtesy David Stitelman, MD, Yale School of Medicine.)*

KEY POINTS

- Gastroschisis is a result of a full-thickness paraumbilical (usually right-sided) defect that allows herniation of free-floating fetal bowel into the amniotic cavity.
- The incidence of gastroschisis is increasing worldwide.
- Young mothers have higher rates of gastroschisis.
- Approximately 10% of cases of gastroschisis have additional unrelated malformations.
- Gastroschisis is rarely associated with aneuploidy (<2% of cases); cases with aneuploidy are frequently associated with additional fetal malformations.
- Several hypotheses for etiology exist; the most recent hypothesis describes a failure of the vitelline structures to be incorporated into the umbilical stalk.
- Nearly all cases of gastroschisis are associated with elevations in MSAFP.
- The rate of prenatal detection is 90% to 97%.
- The characteristic US appearance is of free-floating loops of fetal bowel in the amniotic cavity. The bowel is typically described as having a "cauliflower" appearance.
- Rarely, herniation of additional fetal organs is present.
- Differential diagnosis includes omphalocele, ruptured omphalocele, limb–body wall complex, bladder exstrophy, cloacal exstrophy, ectopia cordis, pentalogy of Cantrell, umbilical cord cysts, and urachal abnormalities.
- No prenatal therapy is available at the present time.
- Postnatal therapy includes primary closure, use of a Silastic spring-loaded silo, or staged closure.
- Overall survival rate is greater than 90% in developed countries.
- Long-term complications include bowel dysmotility, short gut syndrome, and complications from long-term total parenteral nutrition including liver failure.

SUGGESTED READING

Bronshtein M, Blazer S, Zimmer E. The gastrointestinal tract and abdominal wall. In: Callen PW, ed. *Ultrasonography in obstetrics and gynecology*. 5th ed. Philadelphia: Saunders; 2008:587-639.

David AL, Tan A, Curry J. Gastroschisis: sonographic diagnosis, associations, management and outcome. *Prenat Diagn*. 2008;28:633-644.

Ledbetter DJ. Gastroschisis and omphalocele. *Surg Clin North Am*. 2006;86:249-260.

Nick AM, Bruner JP, Moses R, et al. Second-trimester intra-abdominal bowel dilation in fetuses with gastroschisis predicts neonatal bowel atresia. *Ultrasound Obstet Gynecol*. 2006;28:821-825.

Saada J, Oury JF, Vuillard E, et al. Gastroschisis. *Clin Obstet Gynecol*. 2005;48:964-972.

Sanders RC. *Structural fetal abnormalities: The total picture*. 2nd ed. St. Louis: Mosby; 2002.

Schlatter M, Norris K, Uitvlugt N, et al. Preformed silos in the management of gastroschisis: new progress with an old idea. *J Pediatr Surg*. 2003;38:459-464.

Tower C, Ong SS, Ewer AK, et al. Prognosis in isolated gastroschisis with bowel dilatation: a systematic review. *Arch Dis Child Fetal Neonatal Ed*. 2009;94:F268-F274.

Wilson RD, Johnson MP. Congenital abdominal wall defects: an update. *Fetal Diagn Ther*. 2004;19:385-398.

All references are available online at www.expertconsult.com.

REFERENCES

1. Moore TC, Stokes GE. Gastroschisis: report of two cases treated by a modification of the gross operation for omphalocele. *Surgery*. 1953;33:112-120.
2. Fillingham A, Rankin J. Prevalence, prenatal diagnosis and survival of gastroschisis. *Prenat Diagn*. 2008;28:1232-1237.
3. Barisic I, Clementi M, Husler M, et al. Evaluation of prenatal ultrasound diagnosis of fetal abdominal wall defects by 19 European registries. *Ultrasound Obstet Gynecol*. 2001;18:309-316.
4. Jones AM, Isenburg J, Salemi JL, et al. Increasing prevalence of gastroschisis—14 states, 1995–2012. *MMWR*. 2016.
5. Abdullah F, Arnold MA, Nabaweesi R, et al. Gastroschisis in the United States, 1988–2003: analysis and risk categorization of 4344 patients. *J Perinatol*. 2007;27:50-55.
6. Horton A, Powell M, Wolfe H. Intrauterine growth patterns in fetal gastroschisis. *Am J Perinatol*. 2010;27:211-217.
7. Nicholas S, Stamilio D, Dicke J, et al. Predicting adverse neonatal outcomes in fetuses with abdominal wall defects using prenatal risk factors. *Obstet Gynecol*. 2009;201:383.e1-383.e6.
8. Netta D, Wilson RD, Visintainer P, et al. Gastroschisis: growth patterns and a proposed prenatal surveillance protocol. *Fetal Diagn Ther*. 2007;22:352-357.
9. How HY, Harris BJ, Pietrantoni M, et al. Is vaginal delivery preferable to elective cesarean delivery in fetuses with a known ventral wall defect? *Obstet Gynecol*. 2000;182:1527-1534.
10. Salihu H, Emusu D, Aliyu Z, et al. Mode of delivery and neonatal survival of infants with isolated gastroschisis. *Obstet Gynecol*. 2004;104:678-683.
11. Souka AP, Nicolaides KH. Diagnosis of fetal abnormalities at the 10–14-week scan. *Ultrasound Obstet Gynecol*. 1997;10:429-442.
12. Cullen MT, Green J, Whetham J, et al. Transvaginal ultrasonographic detection of congenital anomalies in the first trimester. *Obstet Gynecol*. 1990;163:466-476.
13. Loane M, Dolk H, Bradbury I. Increasing prevalence of gastroschisis in Europe, 1980–2002: a phenomenon restricted to younger mothers? *Paediatr Perinat Epidemiol*. 2007;21:363-369.
14. Mastroiacovo P, Lisi A, Castilla E. The incidence of gastroschisis: research urgently needs resources. *BMJ (Clin Res Ed)*. 2006;332:423-424.
15. Feldkamp M, Reefhuis J, Kucik J, et al. Case-control study of self-reported genitourinary infections and risk of gastroschisis: findings from the National Birth Defects Prevention Study, 1997–2003. *BMJ*. 2008;336:1420-1423.
16. Feldkamp M, Alder S, Carey J. A case control population-based study investigating smoking as a risk factor for gastroschisis in Utah, 1997–2005. *Birth Defects Res A Clin Mol Teratol*. 2008;82:768-775.
17. Curry JI, McKinney P, Thornton JG, et al. The aetiology of gastroschisis. *Br J Obstet Gynaecol*. 2000;107:1339-1346.
18. Calzolari E, Bianchi F, Dolk H, et al. Omphalocele and gastroschisis in Europe: a survey of 3 million births, 1980–1990. EUROCAT Working Group. *Am J Med Genet A*. 1995;58:187-194.
19. Mastroiacovo P, Lisi A, Castilla E, et al. Gastroschisis and associated defects: an international study. *Am J Med Genet*. 2007;143:660-671.
20. Salinas CF, Bartoshesky L, Othersen HB, et al. Familial occurrence of gastroschisis: four new cases and review of the literature. *Am J Dis Child*. 1979;133:514-517.
21. Feldkamp M, Carey J, Sadler T. Development of gastroschisis: review of hypotheses, a novel hypothesis, and implications for research. *Am J Med Genet A*. 2007;143:639-652.
22. Stevenson RE, Rogers RC, Chandler JC, et al. Escape of the yolk sac: a hypothesis to explain the embryogenesis of gastroschisis. *Clin Genet*. 2009;75:326-333.
23. Stephenson J, Pichakron K, Vu L, et al. In utero repair of gastroschisis in the sheep *(Ovis aries)* model. *J Pediatr Surg*. 2010;45:65-69.
24. Douglas DL. Gastroschisis and alpha-fetoprotein. *Lancet*. 1977;1:42.
25. Saller DN, Canick JA, Palomaki GE, et al. Second-trimester maternal serum alpha-fetoprotein, unconjugated estriol, and hCG levels in pregnancies with ventral wall defects. *Obstet Gynecol*. 1994;84:852-855.
26. Crawford RA, Ryan G, Wright VM, et al. The importance of serial biophysical assessment of fetal wellbeing in gastroschisis. *Br J Obstet Gynaecol*. 1992;99:899-902.
27. Siemer J, Hilbert A, Hart N, et al. Specific weight formula for fetuses with abdominal wall defects. *Ultrasound Obstet Gynecol*. 2008;31:397-400.
28. Mears A, Sadiq J, Impey L, et al. Antenatal bowel dilatation in gastroschisis: a bad sign? *Pediatr Surg Int*. 2010;26:581-588.
29. Tower C, Ong SSC, Ewer AK, et al. Prognosis in isolated gastroschisis with bowel dilatation: a systematic review. *Arch Dis Child Fetal Neonatal Ed*. 2009;94:F268-F274.
30. Davenport M, Haugen S, Greenough A, et al. Closed gastroschisis: antenatal and postnatal features. *J Pediatr Surg*. 2001;36:1834-1837.
31. Timor-Tritsch IE, Warren WB, Peisner DB, et al. First-trimester midgut herniation: a high-frequency transvaginal sonographic study. *Obstet Gynecol*. 1989;161:831-833.
32. Burc L, Volumenie J, de Lagausie P, et al. Amniotic fluid inflammatory proteins and digestive compounds profile in fetuses with gastroschisis undergoing amnioexchange. *Br J Obstet Gynaecol*. 2004;111:292-297.
33. Sapin E, Mahieu D, Borgnon J, et al. Transabdominal amnioinfusion to avoid fetal demise and intestinal damage in fetuses with gastroschisis and severe oligohydramnios. *J Pediatr Surg*. 2000;35:598-600.
34. Friedman AM, Ananth CV, Siddiq Z, et al. Gastroschisis: epidemiology and mode of delivery, 2005-2013. *Am J Obstet Gynecol*. 2016;215:348 e1-348 e9.

To access the videos in this chapter, scan this QR code or visit expertconsult.com

21 Omphalocele

KATHERINE H. CAMPBELL | JOSHUA A. COPEL

Introduction

Omphalocele is classified as a ventral wall defect in which there is midline herniation of abdominal viscera into the base of the umbilical cord. Before the 1950s, gastroschisis was considered a variant of omphalocele. It is now known that each entity has a separate etiology, unique risk factors, and distinct outcomes. As a result of widespread use of prenatal screening with maternal

serum alpha-fetoprotein (MSAFP) and second-trimester ultrasound (US) examination, omphalocele is commonly diagnosed during pregnancy.[1–3] Fetuses with a diagnosis of omphalocele are at a significantly increased risk for having additional structural or chromosomal abnormalities, or associated conditions such as Beckwith-Wiedemann syndrome (Chapter 109).[1,4–8] Because of these associations, there is an elevated risk of subsequent fetal loss in affected pregnancies. Early and accurate identification of omphalocele is the critical first step in providing appropriate prenatal counseling for families affected by this congenital anomaly. Detection of additional abnormalities, appropriate genetic counseling, and involvement of appropriate pediatric specialties are critical components of the optimal antepartum management of omphalocele.

Disease

DEFINITION

Omphalocele, also known as *exomphalos,* is a midline abdominal wall defect of variable size in which bowel or liver or both herniate into the base of the umbilical cord. Although possible, it is less common for other abdominopelvic organs to be present in an omphalocele (Figs. 21.1, 21.2). The defect is characterized by the absence of fascia, abdominal muscles, and skin. The herniated abdominal contents are covered by a membrane consisting of peritoneum on the inner surface, Wharton jelly in the center, and amnion on the outer surface. The umbilical vessels insert into the membrane, distal from the body wall, and the umbilical vein can be seen coursing through the omphalocele sac (Figs. 21.3, 21.4).[9]

Identification of the covering membrane and abnormal location of the umbilical cord insertion are two of the key anatomic features of omphalocele. Correct detection allows for differentiation from gastroschisis. Although rare, as documented by case reports, it is possible for the amnioperitoneal covering to rupture in utero. If rupture occurs, differentiation from gastroschisis becomes difficult, especially in the setting of advanced gestational age. The presence of extracorporeal liver may help identify a ruptured omphalocele accurately because liver is rarely herniated in isolated gastroschisis.

PREVALENCE AND EPIDEMIOLOGY

The reported incidence of omphalocele ranges from 1.0:10,000 to 2.5:10,000 live births.[1,6,8] The incidence ranges from 2.5:10,000 to 4.0:10,000 when stillbirths and abortions are considered.[1,8,10,11] In contrast to gastroschisis, the incidence of omphalocele does not seem to be increasing. A retrospective review of cases of prenatally diagnosed omphalocele in the state of Western Australia



Fig. 21.1 Omphalocele with extracorporeal liver seen in transverse view at 21 weeks' estimated gestational age. The diagnosis was Beckwith-Wiedemann syndrome.



Fig. 21.3 Umbilical vessels coursing through the fetal omphalocele seen in transverse view at 19 weeks' estimated gestational age.

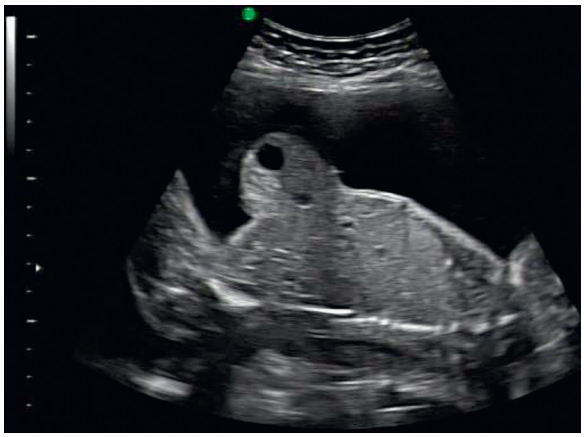

Fig. 21.2 Omphalocele with extracorporeal liver seen in sagittal view at 21 weeks' estimated gestational age.

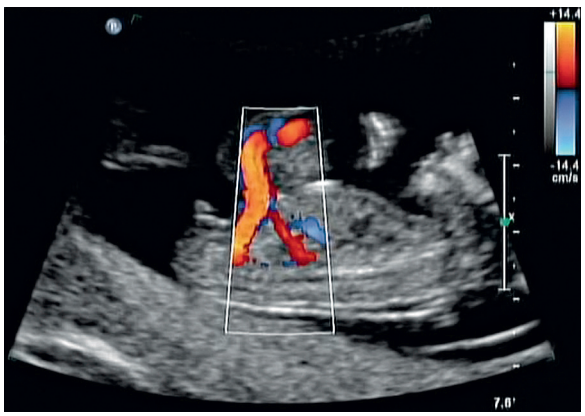

Fig. 21.4 Umbilical vessels coursing through the fetal omphalocele seen in sagittal view at 13 weeks' estimated gestational age.

TABLE 21.1 PREVALENCE OF ASSOCIATED ANOMALIES

Study	Year Published	Associated Anomalies, % (*n*/*N*)	Karyotype Abnormality, % (*n*/*N*) (% Trisomy 18)	Recognized Syndrome, % (*n*/*N*)
EUROCAT[28]	1995	54 (397/732)	12 (94/732) (64)	9 (66/732)
EUROSCAN[1]	2001	56 (77/137)	25 (34/137) (62)	10 (14/137)
Western Australia[10]	2009	74 (66/89)	43 (40/89) (78)	5 (4/89)
US National Birth Defects Prevention Network[11]	2015	62 (1421/2308)	17 (385/2308) (50)	

n, Number of cases; *N*, total study size.

from 1998–2007 identified 107 cases of omphalocele in live births, stillbirths, and terminations of pregnancy from 256,500 registered births. The average rate of omphalocele was 4 : 10,000 births (range 2.3–7.8 : 10,000 births).[10] In the 1995 EUROCAT survey of 3 million births from 1980 to 1990, 732 cases of omphalocele were registered. The average total prevalence rate was 2.53 : 10,000 births (range 1.11–4.79 : 10,000 births).[8] Significant heterogeneity was observed in rates of omphalocele in Europe. One possible explanation for the observed regional differences may be the underregistration of some types of births, notably terminations. The 2001 survey from the EUROSCAN study group found a prevalence of 1.98 : 10,000 births. There was a considerable amount of heterogeneity between the rates in different geographic regions, ranging from 0.15 : 10,000 to 6.09 : 10,000 births.[1] The National Birth Defects Prevention Network in the United States examined 2308 cases of omphalocele over 11 years (1995–2005) and found that the prevalence of omphalocele remained constant over this time span.[11]

The association between omphalocele and chromosomal abnormalities is well characterized, with published rates of chromosomal abnormalities in omphalocele ranging from 13% to 42%.[4,6,8,10] The wide range may be explained by the high rate of intrauterine lethality for many chromosomal abnormalities, resulting in the observed decrease in prevalence with advancing gestational age. This effect is described in a US screening study of 15,726 women, which estimated the prevalence of chromosomal defects in 153 fetuses with omphalocele to decrease from 39.4% at 12 weeks' gestation to 27.5% at 20 weeks' gestation and 14.4% at live birth.[12] The most commonly associated aneuploidy is trisomy 18.[4,5,8,10,12,13] Approximately 9% to 15% of fetuses with omphalocele have a recognized syndrome,[6,8] and many fetuses with omphalocele have additional structural abnormalities, with incidence ranging from 54% to 78% (Table 21.1).[8,14]

There are minimal racial and ethnic differences in the incidence of other anomalies with omphalocele. Of black infants with omphalocele, 38% had associated anomalies, whereas 41.7% of whites and 40.6% of Hispanics had associated anomalies. Survival was better among black infants (adjusted hazard ratio 0.52, 95% confidence interval [CI] 0.37–0.74).[15]

Women at the extremes of reproductive age (younger than 20 and older than 35), multiple gestation, and male sex are associated with increased risk of omphalocele.[8,11,12] Maternal obesity is also a risk factor for fetal omphalocele. In a population-based case-control study from the Atlanta Birth Defects Risk Factor Surveillance Study,[16] obese women (body mass index ≥30) were more likely than women of average weight to have an infant with omphalocele (odds ratio 3.3, 95% CI 1.0–10.3). Additional maternal risk factors for the development of omphalocele identified in the National Birth Defects Prevention Study[17] included alcohol consumption (adjusted odds ratio 1.53, 95% CI 1.04–2.25) and heavy smoking (adjusted odds ratio 4.26, 95% CI 1.58–11.52).

ETIOLOGY AND PATHOPHYSIOLOGY

Omphalocele is considered a sporadically occurring defect. However, familial recurrence of these birth defects is more common compared with gastroschisis.[17] Ventral wall defects are a result of disturbances during embryonic development. The anterior abdominal or ventral wall develops between gestational weeks 5 and 12. This process involves the folding of the embryonic disk in a cranial-caudad direction and lateral direction. The resulting umbilical ring contains the allantois, umbilical vessels, extraembryonic coelom, vitelline duct, and associated vitelline vessels.[3]

As the abdomen develops, there are different rates of development of the enclosed organs and the abdominal cavity itself. By gestational week 8, the embryonic liver begins to expand rapidly, and the elongating fetal midgut herniates into the extraembryonic coelom in the umbilical cord owing to the lack of sufficient intraabdominal space. This phenomenon is termed *physiologic midgut herniation*. The allantois, vitelline duct, and accompanying vessels are obliterated as they are incorporated into the umbilical cord. By gestational week 12, the midgut rotates, the extraembryonic coelom becomes progressively obliterated, and the embryonic bowel is directed back into the abdominal cavity. At the same time, the heart and the pericardium, which lie on the ventral surface of the embryo, are incorporated into the chest by the lateral and cephalic folds. Missteps during this critical period of embryonic development may result in anterior abdominal wall defects of varying severity or cardiac defects, or both.[18]

In general, the earlier the embryologic abnormality occurs, the more complex the structural abnormality will be. Omphalocele is proposed to be a result of one or both of the following developmental errors: (1) failure of closure of the extraembryonic coelom with persistent herniation of abdominal contents or (2) defective fusion of the embryonic folds in the midline. The latter mechanism is also thought to be responsible for other ventral wall defects, including cloacal exstrophy and pentalogy of Cantrell.

As previously mentioned, omphalocele is strongly associated with other structural and chromosomal abnormalities. However, fetuses with omphalocele constitute a heterogeneous group. It is possible to have a karyotypically normal fetus with isolated omphalocele grow and develop into a healthy child with no additional complications.[4] In many cases, omphalocele may be only a marker of a more serious developmental abnormality that can involve a chromosome aberration, syndrome, or additional anomalies.

The most commonly reported associated congenital abnormality is congenital heart disease, which accounts for 35% to 63% of identified malformations.[1,4,6,10,11,18–21] Specific defects include ventricular septal defect, atrial septal defect, tetralogy of Fallot, dextrocardia, and ectopia cordis. Levorotation of the cardiac axis is commonly seen in omphalocele and its presence is not always correlated with congenital heart disease (Video 21.1). A case series in 2006 found 59% of fetuses with omphalocele to have an abnormal cardiac axis, but only 35% had a congenital heart defect (Fig. 21.5).[22] Isolated cardiac levorotation is likely because of the downward and outward displacement of abdominal contents. Additional associated abnormalities include central nervous system defects, craniofacial defects, esophageal atresia, diaphragmatic defect, limb abnormalities, genitourinary anomalies, and gastrointestinal defects (Table 21.2).



Fig. 21.5 Levorotated cardiac axis in a 29-week fetus with omphalocele and extracorporeal liver.

TABLE 21.2 ANOMALIES ASSOCIATED WITH OMPHALOCELE

MUSCULOSKELETAL	Clubfoot, polydactyly, limb deficiency, vertebral anomalies, rib anomalies
URINARY	Renal agenesis, polycystic kidney, hydronephrosis, ureteral anomalies, vesicoureteral reflux, duplication of kidney and renal pelvis, agenesis of urethra or bladder, bladder exstrophy
CARDIOVASCULAR	Ventricular septal defect, atrial septal defect, tetralogy of Fallot, patent ductus arteriosus, tricuspid valve abnormality, ectopia cordis
GASTROINTESTINAL	Anal atresia, ileal atresia, malrotation
CENTRAL NERVOUS	Spina bifida, anencephaly, hydrocephaly
DIAPHRAGMATIC	Hernia
HEAD AND FACE	Cleft lip/palate, facial anomalies
GENITAL	Absence of uterus, hypospadias, ambiguous genitalia
RESPIRATORY	Laryngeal anomalies, pulmonary agenesis, cystic lung

The most common aneuploidy seen in omphalocele is trisomy 18 (Chapter 150). Additional chromosome abnormalities include trisomy 13 (Chapter 149), trisomy 16, trisomy 21 (uncommon) (Chapter 151), Turner syndrome (uncommon) (Chapter 152), and triploidy (Chapter 148) (Table 21.3).[1,3,8,10,20] Many syndromes are associated with the presence of omphalocele. The classic association is Beckwith-Wiedemann syndrome (Chapter 109).[7,23] Table 21.4 lists other associated syndromes.

MANIFESTATIONS OF DISEASE

Clinical Presentation

Elevated MSAFP may be the first indication of fetal omphalocele. Median MSAFP levels are significantly elevated in pregnancies affected by omphalocele compared with unaffected pregnancies. However, median MSAFP levels are lower in cases of omphalocele compared with gastroschisis, and some women carrying fetuses affected by omphalocele have a normal MSAFP, perhaps secondary to the covering membrane. In a case-control study, the median MSAFP in omphalocele was 4.18 multiples of the median. Of the 17 cases of omphalocele, 11 (64%) had MSAFP values greater than 2.0 multiples of the median.[24]

Because of the widespread application of routine second-trimester anatomy US examinations and improved image resolution, most omphaloceles are diagnosed prenatally in the second trimester. Published detection rates range from 75% to 86%.[1,2] There are also reports of late first-trimester detection, although care must be taken to distinguish suspected omphalocele from physiologic midgut herniation when making an early diagnosis.[25,26]

TABLE 21.3 CHROMOSOME ANOMALIES ASSOCIATED WITH OMPHALOCELE

Trisomy 18 (Edward syndrome)
Trisomy 13 (Patau syndrome)
Trisomy 16
Trisomy 21 (Down syndrome)—uncommon
45,X (Turner syndrome)
Triploidy

TABLE 21.4 SHORT LIST OF SYNDROMES ASSOCIATED WITH OMPHALOCELE

Syndrome	Associated Findings
Amniotic band syndrome	Absent digits, swollen distal limb, facial problems, encephalocele, anencephaly, clubfeet or clubhands, gastroschisis or omphalocele
Beckwith-Wiedemann syndrome	Macroglossia; enlarged, echogenic kidneys; enlarged liver and spleen; cardiomegaly
Pentalogy of Cantrell	Ectopia cordis, cleft sternum, pericardial defect, congenital heart defect
OEIS complex[a]	Exstrophy of bladder, imperforate anus, spinal defects
Lethal omphalocele–cleft palate syndrome	Omphalocele, cleft palate

[a]OEIS complex comprises omphalocele, exstrophy of the bladder, imperforate anus, and spine abnormalities.

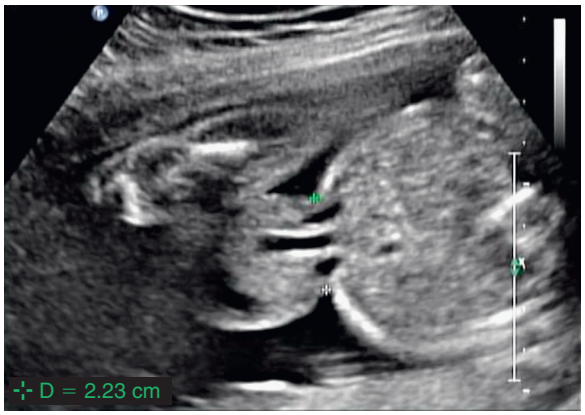

Fig. 21.6 Ventral wall defect of 2.23 cm seen at 25 weeks' estimated gestational age.

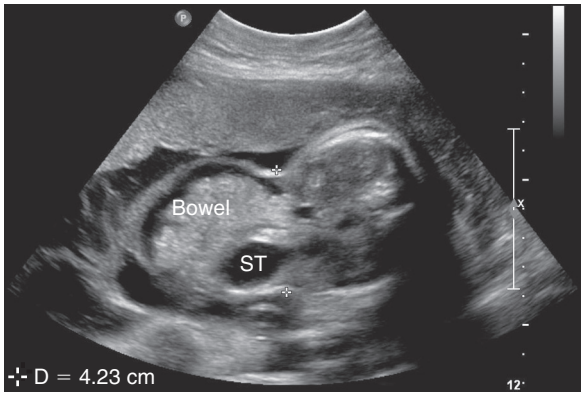

Fig. 21.7 Ventral wall defect of 4.23 cm seen at 28 weeks' estimated gestational age. *ST*, Stomach.



Fig. 21.8 Omphalocele with intracorporeal liver seen at 22 weeks' estimated gestational age. This fetus had a known diagnosis of trisomy 18.



Fig. 21.9 Large omphalocele with ascites seen at 29 weeks' estimated gestational age.



Fig. 21.10 Likely ruptured omphalocele seen at 23 weeks' estimated gestational age.

Imaging Technique and Findings

Ultrasound. The classic appearance of omphalocele on US is an anterior abdominal mass at the site of cord insertion with a covering membrane. This defect is usually identified during routine anatomy US. However, identification in the late first trimester is possible. Before 12 weeks' gestation, large, liver-containing omphaloceles can be accurately detected.[25,26] Diagnosis of small omphaloceles should be confirmed after 12 weeks' gestation, when physiologic midgut herniation has resolved.[13] Increased nuchal translucency is a commonly associated finding, especially in cases with aneuploidy (Chapter 45).[26] Umbilical vessels can be seen coursing through a rounded, smooth mass. The abdominal wall defect can be variable in size—large omphaloceles may have defects greater than 5 cm (Figs. 21.6 and 21.7). Small defects usually contain only small bowel (Fig. 21.8). Larger defects frequently contain liver, and other abdominopelvic viscera may be present as well (Fig. 21.9). Ascites can be present in the omphalocele sac or fetal abdomen and does not imply onset of hydrops fetalis.[20,21]

Omphalocele can be divided into two groups: omphaloceles with herniated liver and omphaloceles without herniated liver. Approximately 40% to 50%[20,21] of omphaloceles contain liver. Chromosome abnormalities and syndromes occur more commonly in smaller omphaloceles without liver herniation. In one case series of 72 neonates with omphalocele, 39% (17 of 44) of neonates with small, nonliver-containing omphaloceles had an abnormal karyotype, Beckwith-Wiedemann syndrome, or dysmorphism. Only 14% (4 of 28) of infants born with large, liver-containing omphaloceles had an associated abnormality or syndrome.[20] Although fetuses with large, liver-containing omphaloceles may be at lower risk of karyotypic abnormalities or syndromes, these fetuses are at risk for significant morbidity and mortality secondary to the omphalocele itself or the presence of additional malformations. Rarely, the omphalocele membrane ruptures before delivery (Figs. 21.10–21.13).

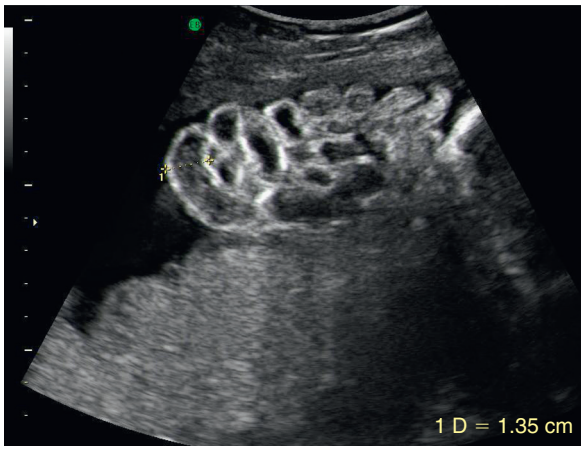

Fig. 21.11 Free-floating bowel seen in a case of ruptured omphalocele at 32 weeks' estimated gestational age.

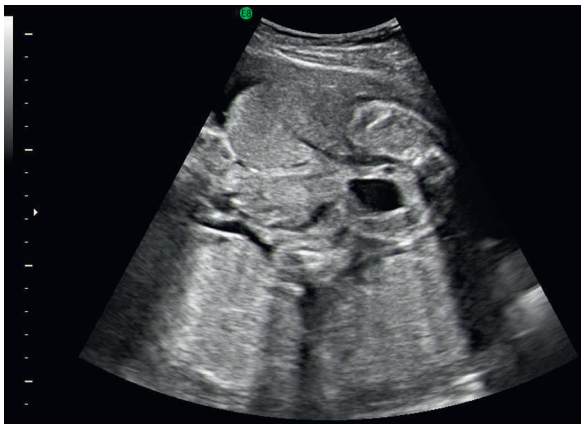

Fig. 21.12 Extracorporeal liver and bowel without covering membrane at 32 weeks' estimated gestational age.

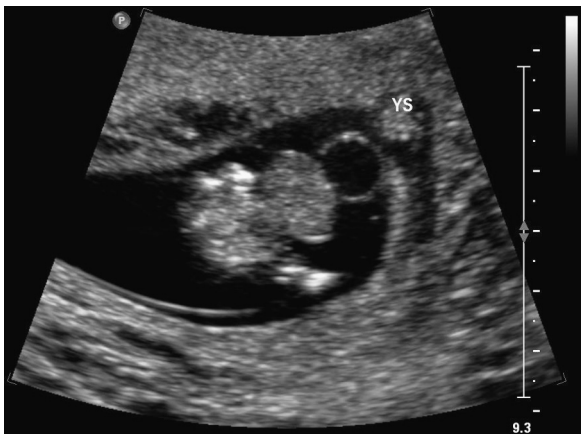

Fig. 21.13 Large omphalocele seen at 11 weeks' estimated gestational age; note presence of yolk sac *(YS)*.

Because of the high risk of associated abnormalities, fetuses with omphalocele should have a targeted anatomy US and fetal echocardiogram. The presence of additional anomalies, especially major malformations, places the fetus at high risk for karyotypic abnormalities and subsequent pregnancy loss. Women carrying affected fetuses should be offered invasive fetal testing by chorionic villus sampling or amniocentesis.

Beckwith-Wiedemann syndrome is the most common syndrome associated with omphalocele. It is a rare congenital overgrowth condition characterized by macroglossia, gigantism, omphalocele, visceromegaly, hemihypertrophy, renal malformations, and distinctive earlobe creases. Most cases are diagnosed postpartum, and there are no official antepartum diagnostic criteria. However, it is technically possible to make the diagnosis prenatally. A 2008 review of a hospital database revealed 20% of patients with isolated omphalocele ultimately received a diagnosis of Beckwith-Wiedemann syndrome.[7] Prenatal US findings include macroglossia, omphalocele, polyhydramnios, increased abdominal circumference, and renal or liver enlargement. Approximately 50% of patients with Beckwith-Wiedemann syndrome have omphalocele.[23]

The reported risk of fetal and neonatal death among euploid fetuses with omphalocele is approximately 30%.[5] In a retrospective cohort study, the only predictor of adverse neonatal outcome was exteriorization of the fetal liver.[27] Fetuses with omphalocele are at risk for growth restriction and preterm labor and delivery. However, the underlying etiology of omphalocele correlates with the birth weight and gestational age at delivery. Fetuses with karyotypic abnormalities, such as trisomy 18, are at significant risk for growth restriction, whereas fetuses with Beckwith-Wiedemann syndrome are at risk for macrosomia.[4] Serial growth US scans are warranted. The mean gestational age at delivery in a population-based cohort was 38.3 weeks' estimated gestational age; 16% of the omphalocele cohort was born before 37 weeks' gestational age. In a separate population-based cohort, mean gestational age at delivery was 36.5 weeks, but if the fetus had multiple malformations or a genetic or syndromic condition, the estimated gestational age at delivery was 34.5 weeks.[8] Depending on the associated anomalies, a pregnancy affected by omphalocele may have oligohydramnios (i.e., associated renal anomalies) or polyhydramnios (i.e., tracheoesophageal fistula).

Magnetic Resonance Imaging. Magnetic resonance imaging (MRI) is traditionally not used to augment US diagnosis or characterize fetal omphalocele further.

CLASSIC SIGNS

A circular, echogenic mass anterior to the fetal abdomen can be seen at 10 weeks' estimated gestational age (see Fig. 21.13). The centrally herniated abdominal contents protrude into the base of the umbilical cord and are covered by an amnioperitoneal membrane. Characteristically, the umbilical cord inserts on the apical portion of the membrane, and the intrahepatic portion of the umbilical vein can be seen coursing through the central portion of the defect.

Differential Diagnosis From Imaging Findings

1. Physiologic gut herniation. This is normally resolved by 12 weeks' gestation.
2. Gastroschisis. An abdominal wall defect located lateral to a normal umbilicus but not involving the umbilical ring. No membrane covers the intestine, and loops of bowel can be seen free-floating in the amniotic fluid.
3. Amniotic bands.
4. Limb-body wall complex (body stalk abnormalities). This group of abdominal wall defects is thought to be the result



Fig. 21.14 Large umbilical cord cyst seen in conjunction with a large extracorporeal omphalocele.



Fig. 21.15 Neonate with intact covering membrane. The omphalocele contains liver and bowel.

of complete failure of body wall folding. The result is herniation of the abdominal organs in a sac of amnioperitoneum. The defect leads to an absence of the umbilicus and true cord.

5. Bladder or cloacal exstrophy. This can include exstrophy of the bladder and small or large intestine, anal atresia, hypoplasia of the colon, omphalocele, and anomalous genitalia.
6. Ectopia cordis. The heart is partially or completely exposed to the surface of the thorax and is a result of failure of fusion of the lateral folds of the thorax area and cephalic fold.
7. Pentalogy of Cantrell. Complex ventral wall malformation, which includes an epigastric abdominal defect, defect of the lower sternum, deficiency of the diaphragmatic pericardium, deficiency of the anterior diaphragm, and cardiac abnormality.
8. Urachal abnormalities.
9. Umbilical cord cyst (Fig. 21.14).

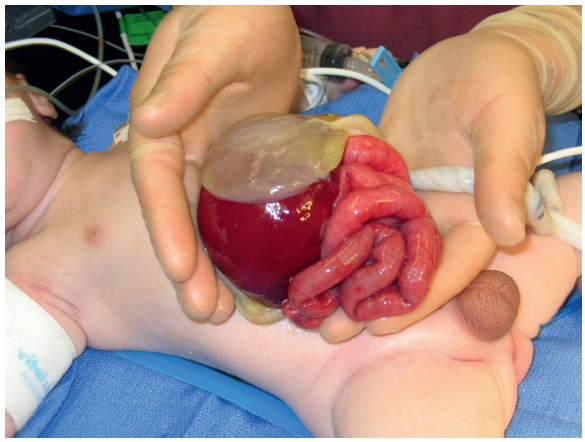

Fig. 21.16 Neonate with ruptured covering membrane; note liver and bowel. The rupture occurred during delivery.

Synopsis of Treatment Options

PRENATAL

There are no prenatal treatment options for omphalocele at the present time. Given the strong association of omphalocele with additional congenital defects, chromosome abnormalities, and syndromes, it is common for women to undergo invasive testing (i.e., chorionic villus sampling or amniocentesis) of pregnancies affected by omphalocele. Spontaneous termination occurs in many pregnancies. Elective termination is an option for affected pregnancies. The current practice is to allow women carrying fetuses with omphalocele to undergo vaginal delivery with cesarean section reserved for routine obstetric indications, as there is no clear evidence that mode of delivery alters outcome.[9,28]

POSTNATAL

Delivery of fetuses with known ventral wall defects should occur at a hospital with neonatology and pediatric surgery services immediately available for neonatal care. Initial management starts with the ABCs (airway, breathing, and circulation) of resuscitation. Secondary to exposure of the amnioperitoneal membrane, the neonate is at risk for insensible losses of fluid and heat. The defect is inspected immediately after delivery to ensure the covering membrane is intact, and nonadherent dressings are applied to stabilize and prevent trauma to the sac. If the sac is ruptured, the exposed bowel should be treated in a similar fashion to gastroschisis. A nasogastric tube is placed to decompress the bowel, and intravenous access is obtained for fluid resuscitation. Because of the association of omphalocele with various syndromes and additional anomalies, a prompt detailed physical examination of the neonate is warranted. As long as the membranous sac remains intact, there is no urgency to perform operative closure, and time can be taken to complete the evaluation for associated defects (Figs. 21.15 and 21.16).

When the neonate is stable, and if the defect is relatively small, a primary closure can be done. If the defect is large, various closure techniques have been used. The herniated contents may be placed in a Silastic silo for reduction and subsequent closure. In contrast to gastroschisis, silos for omphalocele are placed in the operating room under general anesthesia. Defects are usually closed in 1 to 3 days. Alternatively, large defects may be treated with topical silver sulfadiazine to allow for epithelialization of the membrane over weeks to months. When the membrane is strong enough to withstand external pressure, an abdominal binder is placed until the herniated abdominal contents are successfully reduced. The infant is then taken to the operating room for a delayed primary closure. Major postnatal morbidity and mortality directly correlates with the presence of global defects such as aneuploidy or specific syndromes and concomitant structural anomalies.[11]

KEY POINTS

- Omphalocele is a result of a full-thickness midline defect of variable size that allows herniation of fetal bowel or liver or both into an amnioperitoneal sac at the level of the umbilicus.
- The reported incidence of omphalocele ranges from 1:10,000 to 2.5:10,000 live births; when stillbirths and abortions are considered, the incidence ranges from 2.5:10,000 to 4:10,000.
- Omphalocele is more common in women at the extremes of reproductive age.
- Approximately 55% to 80% of cases of omphalocele are associated with additional fetal anomalies.
- Approximately 13% to 43% of cases of omphalocele are associated with fetal karyotype abnormalities, most of which have associated anomalies.
- Omphalocele results when the physiologic herniation of the embryonic gut into the umbilical cord fails to return to the abdominal cavity. There may also be a concomitant defect in lateral body fold migration and body wall closure; this may explain the various sizes of omphalocele defects.
- Approximately 70% of omphaloceles are associated with elevations in MSAFP.
- Prenatal detection ranges from 75% to 85%.
- The classic appearance of omphalocele on US is an anterior abdominal mass at the site of cord insertion with a covering membrane. The umbilical cord is inserted into the apex of the sac, and the umbilical vein may be seen traversing through the center.
- Smaller defects, not containing fetal liver, have a higher incidence of karyotype abnormalities compared with larger, liver-containing defects.
- Differential diagnosis includes gastroschisis, limb–body wall complex, bladder exstrophy, cloacal exstrophy, ectopia cordis, pentalogy of Cantrell, umbilical cord cysts, and urachal abnormalities.
- Delivery can be vaginal and should occur at a center able to care for the neonate.
- Postnatal therapy includes primary closure, use of a Silastic spring-loaded silo, or staged closure.
- Overall survival rate directly correlates with the presence of additional structural and chromosomal abnormalities.

SUGGESTED READING

Kilby MD, Lander A, Usher-Somers M. Exomphalos (omphalocele). *Prenat Diagn*. 1998;18:1283-1288.

Ledbetter DJ. Gastroschisis and omphalocele. *Surg Clin North Am*. 2006;86:249-260.

Mann S, Blinman TA, Douglas Wilson R. Prenatal and postnatal management of omphalocele. *Prenat Diagn*. 2008;28:626-632.

Marven S, Owen A. Contemporary postnatal surgical management strategies for congenital abdominal wall defects. *Semin Pediatr Surg*. 2008;17:222-235.

Robinson JN, Abuhamad AZ. Abdominal wall and umbilical cord anomalies. *Clin Perinatol*. 2000;27:947-978.

Sanders RC. *Structural fetal abnormalities: the total picture*. 2nd ed. St. Louis: Mosby; 2002.



All references are available online at www.expertconsult.com.

REFERENCES

1. Barisic I, Clementi M, Husler M, et al. Evaluation of prenatal ultrasound diagnosis of fetal abdominal wall defects by 19 European registries. *Ultrasound Obstet Gynecol*. 2001;18:309-316.
2. Salihu HM, Boos R, Schmidt W. Omphalocele and gastroschisis. *J Obstet Gynaecol*. 2002;22:489-492.
3. Robinson JN, Abuhamad AZ. Abdominal wall and umbilical cord anomalies. *Clin Perinatol*. 2000;27:947-978.
4. Brantberg A, Blaas HK, Haugen SE, et al. Characteristics and outcome of 90 cases of fetal omphalocele. *Ultrasound Obstet Gynecol*. 2005;26: 527-537.
5. Fratelli N, Papageorghiou AT, Bhide A, et al. Outcome of antenatally diagnosed abdominal wall defects. *Ultrasound Obstet Gynecol*. 2007;30:266-270.
6. Stoll C, Alembik Y, Dott B, et al. Omphalocele and gastroschisis and associated malformations. *Am J Med Genet A*. 2008;146A:1280-1285.
7. Wilkins-Haug L, Porter A, Hawley P, et al. Isolated fetal omphalocele, Beckwith-Wiedemann syndrome, and assisted reproductive technologies. *Birth Defects Res A Clin Mol Teratol*. 2009;85:58-62.
8. Calzolari E, Bianchi F, Dolk H, et al. Omphalocele and gastroschisis in Europe: a survey of 3 million births 1980–1990. EUROCAT Working Group. *Am J Med Genet*. 1995;58:187-194.
9. Bianchi DW, D'Alton ME, Crombleholme TM. *Fetology: Diagnosis and Management of the Fetal Patient*. New York: McGraw-Hill; 2000.
10. Calvert N, Damiani S, Sunario J, et al. The outcomes of pregnancies following a prenatal diagnosis of fetal exomphalos in Western Australia. *Aust N Z J Obstet Gynaecol*. 2009;49:371-375.
11. Marshall J, Salemi JL, Tanner JP, et al. Prevalence, correlates, and outcomes of omphalocele in the United States, 1995–2005. *Obstet Gynecol*. 2015;126(2):284-293.
12. Snijders RJ, Sebire NJ, Souka A, et al. Fetal exomphalos and chromosomal defects: relationship to maternal age and gestation. *Ultrasound Obstet Gynecol*. 1995;6:250-255.
13. Timor-Tritsch IE, Warren WB, Peisner DB, et al. First-trimester midgut herniation: a high-frequency transvaginal sonographic study. *Obstet Gynecol*. 1989;161:831-833.
14. Porter A, Benson C, Hawley P, et al. Outcome of fetuses with a prenatal ultrasound diagnosis of isolated omphalocele. *Prenat Diagn*. 2009;29:668-673.
15. Salihu H, Aliyu Z, Pierre-Louis B, et al. Omphalocele and gastroschisis: black-white disparity in infant survival. *Birth Defects Res A Clin Mol Teratol*. 2004;70:586-591.
16. Watkins M, Rasmussen S, Honein M, et al. Maternal obesity and risk for birth defects. *Pediatrics*. 2003;111(5 Pt 2):1152-1158.
17. Bird TM, Robbins J, Druschel C, et al. Demographic and environmental risk factors for gastroschisis and omphalocele in the National Birth Defects Prevention Study. *J Pediatr Surg*. 2009;44:1546-1551.
18. Gibbin C, Touch S, Broth RE, et al. Abdominal wall defects and congenital heart disease. *Ultrasound Obstet Gynecol*. 2003;21:334-337.
19. Heider A, Strauss R, Kuller J. Omphalocele: clinical outcomes in cases with normal karyotypes. *Obstet Gynecol*. 2004;190:135-141.
20. Groves R, Sunderajan L, Khan A, et al. Congenital anomalies are commonly associated with exomphalos minor. *J Pediatr Surg*. 2006;41:358-361.
21. Kumar H, Jester A, Ladd A. Impact of omphalocele size on associated conditions. *J Pediatr Surg*. 2008;43:2216-2219.
22. Boulton SL, McKenna DS, Cly GC, et al. Cardiac axis in fetuses with abdominal wall defects. *Ultrasound Obstet Gynecol*. 2006;28:785-788.
23. Williams D, Gauthier D, Maizels M. Prenatal diagnosis of Beckwith-Wiedemann syndrome. *Prenat Diagn*. 2005;25:879-884.
24. Saller DN, Canick JA, Palomaki GE, et al. Second-trimester maternal serum alpha-fetoprotein, unconjugated estriol, and hCG levels in pregnancies with ventral wall defects. *Obstet Gynecol*. 1994;84:852-855.
25. Souka AP, Nicolaides KH. Diagnosis of fetal abnormalities at the 10–14-week scan. *Ultrasound Obstet Gynecol*. 1997;10:429-442.
26. van Zalen-Sprock RM, Vugt JM, van Geijn HP. First-trimester sonography of physiological midgut herniation and early diagnosis of omphalocele. *Prenat Diagn*. 1997;17:511-518.
27. Nicholas S, Stamilio D, Dicke J, et al. Predicting adverse neonatal outcomes in fetuses with abdominal wall defects using prenatal risk factors. *Obstet Gynecol*. 2009;201:383.e1-383.e6.
28. How HY, Harris BJ, Pietrantoni M, et al. Is vaginal delivery preferable to elective cesarean delivery in fetuses with a known ventral wall defect? *Obstet Gynecol*. 2000;182:1527-1534.

22 Echogenic Bowel

KATHERINE S. KOHARI

Introduction

Fetal echogenic bowel (FEB) is typically seen during second trimester prenatal ultrasound. FEB occurs when the fetal bowel appears with the same or greater echogenicity than do surrounding bony structures. When seen in the second trimester, FEB has been associated with increased risk for fetal cystic fibrosis, aneuploidy, gastrointestinal abnormalities, growth restriction, and viral infections.[1] However, it is important to realize that the majority of patients with isolated FEB will have no associated adverse outcomes.

Disorder

DEFINITION

While there is no standard definition for FEB, most practitioners use bowel that appears as bright as bone when minimal gain is used. Typically, the iliac wing is used as the bony reference point. The area may be singular or multifocal within the fetal abdomen, and should be homogeneously hyperechoic. Echogenic areas that create distal shadowing are suggestive of calcification.[2] It is important to recognize that high frequency transducers can create the appearance of echogenicity, so consider using a lower frequency (e.g., 5 MHz) transducer to avoid overdiagnosis.[3] Furthermore, newer machines with improved penetration often lead to an increase in the diagnosis of echogenic lesions. Similarly, women with lower body mass index (BMI) appear to be more often diagnosed with echogenic bowel.[4] Therefore, care should be taken to adjust the gain to avoid overdiagnosis.

PREVALENCE AND EPIDEMIOLOGY

The reported prevalence of FEB ranges from 0.2% to 1.4% during the second trimester.[5]

ETIOLOGY AND PATHOPHYSIOLOGY

FEB is a nonspecific ultrasound finding that confers an increased risk for a range of pathologies. In many cases FEB is considered a normal variant, especially when isolated; however, one-third of cases may have a pathologic cause.[2] Each pathologic entity has differing theories of the pathophysiology resulting in FEB, which will be addressed subsequently.

Bleeding

A bleeding event during pregnancy may result in blood in the amniotic cavity. The fetus then swallows and digests the blood, resulting in deposition of blood components into the gastrointestinal system. As blood is echogenic, the presence of blood in the fetal gastrointestinal system can increase its echogenicity. FEB can persist beyond 2 weeks after a bleeding event, therefore assessing the patient's recent history is important.[6] Additional findings more consistent with a bleeding cause would be the presence of echogenic material in the fetal stomach or visualization of a subchorionic fluid collection.

Aneuploidy

FEB is considered a soft marker for fetal aneuploidy, most commonly trisomy 21. In some studies it increases the likelihood for trisomy 21 by 6.1-fold.[7] FEB has been associated with other aneuploidies as well, with an overall aneuploidy risk of 6.7% in isolated FEB.[8] In one retrospective cohort, the presence of FEB, when combined with other soft markers and major structural abnormalities, increased the chromosomal abnormality rate to 7.7% and 17.4%, respectively.[8] The pathophysiology of FEB in aneuploidy is unclear. Fetuses with genetic abnormalities may have gastrointestinal complications, such as decreased intestinal motility or malformation. The likelihood ratio of 6.1 can be used to recalculate a patient's aneuploidy risk from their a priori age-related risk or from the results of analyte screening. It is unclear whether the results of cell-free DNA (cfDNA) screening should be adjusted based on the finding of FEB.

Cystic Fibrosis

There is a well-established correlation between FEB and fetal cystic fibrosis. Cystic fibrosis, a malfunction of an important chloride channel, results in pancreatic insufficiency and hypomotility. This leads to increased secretions and thicker meconium, which is thought to be the etiology for FEB in these patients. In a large French cohort, FEB was seen in 10% of infants with genetic diagnosis of cystic fibrosis.[9] Conversely, 3% of all fetuses with FEB had cystic fibrosis.[9] This incidence is much higher than the expected incidence of 1:2000–1:3000 live births in a Caucasian population.

Growth Restriction

FEB has been associated with fetal growth restriction. The etiology is unknown, but has been postulated to be related to reduced blood flow to the intestine with preferential shunting to vital organs such as the brain. However, one study indicated the opposite, demonstrating vasodilation in the superior mesenteric and celiac trunks in growth-restricted fetuses.[10] Fourteen percent to 23% of fetuses with FEB are also growth restricted.[11] The presence of growth restriction and FEB increases the risk for fetal demise. This risk is further increased by the presence of elevated maternal alpha-fetoprotein and/or oligohydramnios.[12]

Digestive Tract Malformations

Disorders of the gastrointestinal system have been associated with the presence of FEB. FEB may be one of the earliest signs of small or large bowel obstruction.[13] The etiology behind this is that decreased transit time allows for increased fluid reabsorption, resulting in increased density of intestinal contents. With continued observation, more characteristic findings of bowel obstruction, such as dilation, become apparent. Additional disorders of the gastrointestinal system reported in case reports/series associated with FEB include imperforate anus, intestinal atresias, volvulus, Hirschprung disease, and Zellweger Syndrome.[13–15]

Infection

Congenital infection may result in FEB, possibly because of direct bowel damage. The most common prenatal infection related to FEB is cytomegalovirus (CMV). It is estimated that 3% of fetuses with FEB have CMV infection.[13] However, this association is controversial, as it has not been demonstrated in all studies. Other potential infectious etiologies include toxoplasmosis, varicella, herpes, and parvovirus.

MANIFESTATIONS OF DISEASE

Clinical Presentation

FEB is typically seen at a second trimester ultrasound and is considered a sign of potential pathologic conditions. In a large cohort study, FEB was associated with chromosomal abnormalities in 4.3% of cases, cystic fibrosis in 3.1%, digestive tract abnormalities in 2.9%, infectious disease 2.8%, intrauterine growth restriction in 2.3% and fetal death in 1.9%.[13] A risk of poor perinatal outcome of 33% was demonstrated in one large series.[16]

After birth, the majority of neonates with prenatal isolated FEB have no major sequelae. Interestingly, only 11% of children were identified as having any intestinal symptoms of constipation, chronic abdominal pain, milk intolerance, or reflux after having FEB.[17]

Imaging Technique and Findings

Ultrasound. FEB is suspected during ultrasound evaluation of the fetal abdomen. If one or more areas appear particularly echogenic, the gain should be reduced until nearby bone is nearly visible (Figs. 22.1 and 22.2). If the area in question is still visible, either as bright or brighter than the bone, FEB is diagnosed. Typically, the iliac wing is used as the bony reference. There are no diagnostic requirements related to size, number, or shape of the echogenicities.

It is important to use a low frequency ultrasound probe to avoid overdiagnosing FEB in the absence of clinical sequelae. A study evaluating the use of both 8-MHz and 5-MHz transducers demonstrated an increase in the diagnosis of FEB in the 8-MHz group (31% versus 3%).[3] This increase was not associated with any meaningful effects on outcome. An additional study demonstrated that women with a lower BMI were more likely to

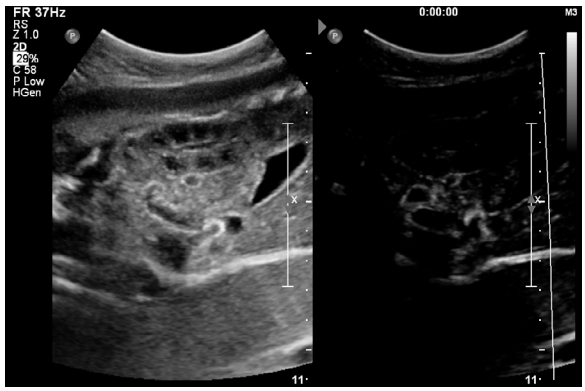

Fig. 22.1 Example of fetal echogenic bowel (FEB) diagnosed at 18 weeks' gestation. *Left panel,* normal gain; *right panel,* proper use of reduced gain to show comparison to adjacent bone.

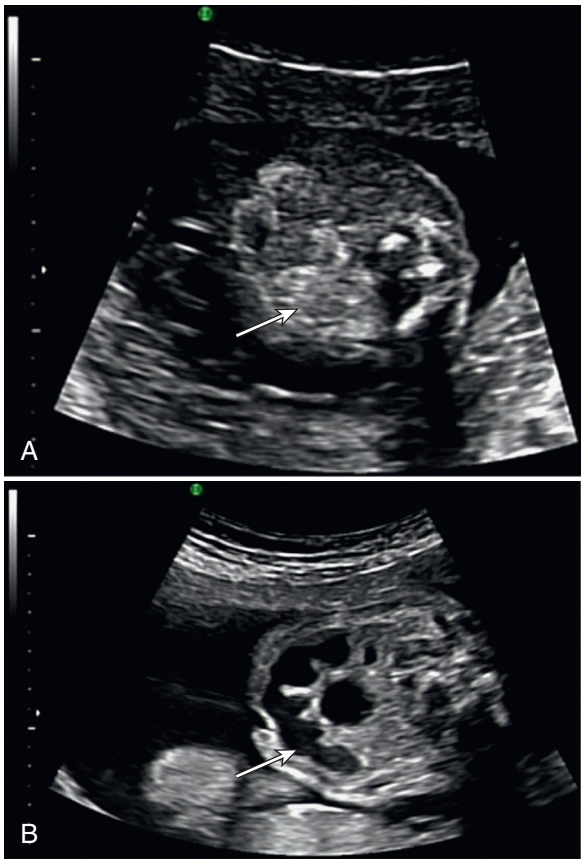

Fig. 22.2 (A) Echogenic bowel (EB) *(arrow)* at 20 weeks' gestation. (B) Progression of EB *(arrow)* at 27 weeks' gestation. Intestinal dilatation at 27 weeks' gestation subsequently was diagnosed as jejunal atresia.

have FEB diagnosed than their larger counterparts.[4] Therefore, proper and consistent technique in diagnosing FEB is important for patient counseling and prediction of outcomes.

Magnetic Resonance Imaging. Ultrasonography remains the mainstay of diagnosis of FEB. However, if there is elevated concern for a bowel malformation, fetal magnetic resonance imaging (MRI) may provide a useful diagnostic adjunct. T1-weighted MRI can evaluate location of meconium, which follows a normal progression throughout gestation. Absence of meconium in a distal portion of the intestine may be more consistent with a proximal obstruction, for example.[18] In addition, comparison of T1- and T2-weighted sequences, with varied distribution of increased intensity, may help more closely identify potential area of obstruction.[19] While MRI technology continues to improve, it is not yet capable to pinpoint the level of obstruction; therefore it should be used judiciously in the setting of FEB.

Differential Diagnosis From Imaging Findings

FEB has many potential causes and is an ultrasonographic sign. The most common pathologies include:

1. pregnancy bleeding
2. aneuploidy
3. cystic fibrosis
4. digestive tract malformations
5. fetal growth restriction
6. congenital infection

Synopsis of Treatment Options

PRENATAL

The suspected etiology of FEB dictates the management strategies available. Therefore, thorough evaluation with a detailed medical history, genetic history, pregnancy history, and a targeted anatomy ultrasound should be routine when FEB is seen. In addition, if available, the patient should be seen by a genetic counselor to review the association between FEB and aneuploidy and cystic fibrosis. If desired, the patient should undergo diagnostic genetic testing. If not already performed, parental carrier screening for cystic fibrosis should be offered.

At the time of amniocentesis, the fluid may be sent for infectious evaluation by polymerase chain reaction (PCR) for cytomegalovirus, and possibly toxoplasmosis. If amniocentesis is declined, maternal serum can also be sent, although less specific.

Continued surveillance throughout the pregnancy includes serial growth ultrasounds to evaluate for growth restriction or evolving intestinal pathology.

POSTNATAL

Postnatal evaluation is dictated by any pathologic findings found in the prenatal period. Routine evaluation by pediatrics should be performed.

WHAT THE REFERRING PHYSICIAN NEEDS TO KNOW

- FEB is usually idiopathic, but has been associated with aneuploidy, cystic fibrosis, intestinal malformation, and growth restriction
- Evaluation includes detailed anatomic survey, parental testing for cystic fibrosis, genetics referral and possible amniocentesis
- Fetuses are surveilled with serial growth ultrasounds

KEY POINTS

- FEB is a common and usually benign finding
- There is an increased association with aneuploidy, bleeding, gastrointestinal abnormalities, fetal cystic fibrosis, and growth restriction
- Isolated FEB increases the likelihood of trisomy 21 by sixfold over baseline
- Serial growth ultrasounds are used to monitor fetal growth and development of sonographic findings consistent with intestinal abnormalities
- MRI may be used adjunctively if bowel obstruction is suspected
- Overdiagnosis of FEB can be avoided with selection of the appropriate probe

SUGGESTED READING

Goetzinger KR, Cahill AG, Macones GA, et al. Echogenic bowel on second-trimester ultrasonography: evaluating the risk of adverse pregnancy outcome. *Obstet Gynecol*. 2011;117(6):1341-1348.

Smith-Bindman R, Hosmer W, Feldstein VA, et al. Second-trimester ultrasound to detect fetuses with Down syndrome: a meta-analysis. *JAMA*. 2001;285:1044-1055.

Simon-Bouy B, Satre V, Ferec C, et al. Hyperechogenic fetal bowel: a large French collaborative study of 682 cases. *Am J Med Genet A*. 2003;121A:209-213.

All references are available online at www.expertconsult.com.

REFERENCES

1. Al-Kouatly HB, Chasen ST, Streltzoff J, et al. The clinical significance of fetal echogenic bowel. *Am J Obstet Gynecol.* 2001;185(5):1035.
2. Sepulveda W, Sebire NJ. Fetal echogenic bowel: a complex scenario. *Ultrasound Obstet Gynecol.* 2000;16:510-514.
3. Vincoff NS, Callen PW, Smith-Bindman R, et al. Effect of ultrasound transducer frequency on the appearance of the fetal bowel. *J Ultrasound Med*. 1999;18:799-803.
4. Bornstein E, Sheiner E, Barnhard Y, et al. The association of maternal BMI with fetal echogenic intracardiac foci and echogenic bowel. *J Matern Fetal Neonatal Med*. 2010;23:781-784.
5. Hurt L, Wright M, Dunstan F, et al. Prevalence of defined ultrasound findings of unknown significance at the second trimester fetal anomaly scan and their association with adverse pregnancy outcomes: the Welsh study of mothers and babies population-based cohort. *Prenat Diagn*. 2016;36(1):40-48.
6. Petrikovsky B, Smith-Levitin M, Holsten N. Intra-amniotic bleeding and fetal echogenic bowel. *Obstet Gynecol*. 1999;93(5 Pt 1):684-686.
7. Smith-Bindman R, Hosmer W, Feldstein VA, et al. Second-trimester ultrasound to detect fetuses with Down syndrome: a meta-analysis. *JAMA*. 2001;285:1044-1055.
8. Ekin A, Gezer C, Eftal Taner C, et al. The effect of associated structural malformations in the prediction of chromosomal abnormality risk of fetuses with echogenic bowel. *J Matern Fetal Neonatal Med*. 2016;26:41.
9. Muller F, Simon-Bouy B, Girodon E, et al. Predicting the risk of cystic fibrosis with abnormal ultrasound signs of fetal bowel: results of a French molecular collaborative study based on 641 prospective cases. *Am J Med Genet*. 2002;110:109-115.
10. Achiron R, Mazkereth R, Orvieto R, et al. Echogenic bowel in intrauterine growth restriction fetuses: does this jeopardize the gut? *Obstet Gynecol*. 2002;100:120-125.
11. Goetzinger KR, Cahill AG, Macones GA, et al. Echogenic bowel on second-trimester ultrasonography: evaluating the risk of adverse pregnancy outcome. *Obstet Gynecol*. 2011;117(6):1341-1348.
12. Achiron R, Seidman DS, Horowitz A, et al. Hyperechogenic fetal bowel and elevated serum alpha-fetoprotein: a poor fetal prognosis. *Obstet Gynecol*. 1996;88:368-371.
13. Simon-Bouy B, Satre V, Ferec C, et al. Hyperechogenic fetal bowel: a large French collaborative study of 682 cases. *Am J Med Genet A*. 2003;121A:209-213.
14. Bashiri A, Burstein E, Hershkowitz R, et al. Fetal echogenic bowel at 17 weeks' gestational age as the early and only sign of a very long segment of Hirschsprung disease. *J Ultrasound Med*. 2008;27:1125-1126.
15. Aydemir O, Kavurt S, Esin S, et al. Fetal echogenic bowel in association with Zellweger syndrome. *J Obstet Gynaecol Res*. 2014;40:1799-1802.
16. Carcopino X, Chaumoitre K, Shojai R, et al. Foetal magnetic resonance imaging and echogenic bowel. *Prenat Diagn*. 2007;27:272-288.
17. Patel Y, Boyd PA, Chamberlain P, et al. Follow-up of children with isolated fetal echogenic bowel with particular reference to bowel-related symptoms. *Prenat Diagn*. 2004;24:35-37.
18. Rubesova E. Fetal bowel abnormalities: UA and MRI assessment. *Pediatr Radiol*. 2012;42:S101-S106.
19. Furey E, Bailey A, Twickler D. Fetal MRI imaging of gastrointestinal abnormalities. *Radiographics*. 2016;36:904-917.

23 Fetal Hepatic Calcification

FRANCE GALERNEAU

Introduction

Fetal hepatic calcifications are divided into three categories: peritoneal, parenchymal, and vascular. This chapter addresses parenchymal hepatic calcifications and, to a lesser degree, vascular calcifications, which may be included in the differential diagnosis of parenchymal calcifications.

Disorder

DEFINITION

Fetal hepatic calcifications are single or multiple echogenic areas of various sizes (usually small, punctate) within the fetal hepatic parenchyma detected by ultrasound (US). They can be isolated or associated with other anomalies.

PREVALENCE AND EPIDEMIOLOGY

In autopsy studies, intrahepatic calcifications (IHCs) are found in 2.2%[1] to 4.2%[2] of cases, and are often associated with aneuploidy and/or fetal anomalies. Most cases included in these studies are the result of spontaneous abortions, fetal demises, or termination of pregnancies for fetal anomalies. In contrast, and despite the near routine use of prenatal ultrasound, prenatal diagnosis of fetal IHC is less common, with an incidence of 1:260[3] to 1:1750.[4] In a retrospective study of 24,600 routine US scans done between 14 weeks' and 26 weeks' gestation, Bronshtein and Blazer[4] identified 14 cases of intrahepatic calcifications for an incidence of 1:1750 (0.057%). In another retrospective study, Achiron et al.[5] reviewed 7500 routine US scans from 14 to 24 weeks' gestation and reported five fetuses with liver calcifications (0.06% or 1:1666). Pata et al, reported a higher incidence (1:260) from a referral center where most ultrasounds are done for suspected fetal anomalies.[3]

ETIOLOGY AND PATHOPHYSIOLOGY

Fetal intrahepatic parenchymal calcifications have classically been attributed to transplacental infection, vascular events, or hepatic tumors (primary or metastatic, benign or malignant); however, this was based on studies in neonates and a few prenatal case reports. With the now almost universal use of prenatal US, IHCs are often diagnosed prenatally either as an isolated finding or in association with other anomalies. Parenchymal liver calcifications have been linked to aneuploidy, particularly if other anomalies are present.[6,17] In a large retrospective case-control study of autopsy specimens, 51% of the 85 fetuses with IHCs were aneuploid in contrast to 21% of those without IHCs.[17] Seventy-two percent of the fetuses with IHCs had associated anomalies, compared to 55% of the controls. In that study, the presence of a calcification in a fetus with malformation doubled the likelihood of aneuploidy compared to those without calcification. Vascular calcifications may result from calcified portal or venous clots secondary to either hypoperfusion or thromboembolism.[1] The causes, outcome, and prognosis of prenatally diagnosed IHCs were not well established until studies of prenatal US were published.

In the largest six studies of prenatal diagnosis of fetal IHCs published in the literature since 1990,[3–8] 44% of cases had associated anomalies, at least 11% were shown to have an abnormal karyotype (karyotypes were unavailable in one study[7] and universally obtained in only one[3]), and 2.3% had a proven transplacental infection (Table 23.1). At neonatal follow-up, 57% had a normal outcome. The prognosis was better in cases of isolated IHCs, with a survival rate of 90% to 100%.[3,6–8] In cases of isolated IHCs, postnatal follow-up, when available, either confirmed the presence of calcifications or showed their disappearance. The etiology of isolated IHCs is unclear and has been attributed to vascular events or fibrosis by exclusion of other mechanisms such as infection or aneuploidy. Because viral serologies are not universally obtained in cases of isolated IHCs, it is also possible that transient infection from which the fetus may have recovered are underestimated. That question could be answered by a prospective trial.

Bronshtein and Blazer[4] suggested that scattered nodular calcifications may indicate local hemorrhage rather than a thrombus, given the fact that even a small calcification in a 15-week fetal liver is much larger than the vascular diameter. These authors raised the possibility that regeneration of the liver and hepatic growth may explain the decrease in size and even disappearance of IHCs in some cases. This theory could explain why calcifications that are visible in a fetus are often no longer visible in the neonate.

In contrast to the aforementioned prenatal studies, one pathologic study of 1500 cases of spontaneous abortions[1] showed a high incidence (90%) of vascular IHCs in the 33 cases reported (Table 23.2). Of these fetuses, 85% had associated anomalies, in particular, "meconium intraluminal calcifications (27%), cystic hygromas (18%), and metaphyseal defects (18%)."[1] Parenchymal or mixed (parenchymal and vascular) IHCs were present in only 9% of abortuses. Chromosomal studies were unavailable. Kidron and Sharony[2] confirmed these findings in their retrospective review of 827 fetal autopsies, where the majority of the 35 cases of IHCs were of the vascular type. They suggest that fetal IHCs may be the result of circulatory compromise preceding death.

Although multiple studies[3,4,6,8] and case reports have linked IHCs to aneuploidy, the mechanism by which calcifications are formed in aneuploid fetuses has not been clearly elucidated. This mechanism could involve a vascular event. Three possible

TABLE 23.1 SUMMARY OF STUDIES OF PRENATALLY DETECTED INTRAHEPATIC CALCIFICATIONS PUBLISHED SINCE 1990

First Author (Year), Location	No. Cases	Incidence	GA at Diagnosis (weeks)	Associated Anomalies, *n* (%)	Aneuploidy, *n* (%)	Infection, *n* (%)	Normal Outcome, *n* (%)
Bronshtein[4] (1995), Israel	14	1:1750	14–26	3 (21)	2 (14) trisomy 18	0	10 (71)
Achiron[5] (1996), Israel	5	1:2000	14–24	1 (20), attributed to vascular accident	0	0	4 (80)
Simchen[6] (2002), Canada	61	?	?	40 (65)	11 (18); 4 trisomy13, 2 trisomy 21, 2 trisomy 18, 1, 45,XO, 2 other	2 (3.2); 1 CMV, 1 parvovirus B19	19 (31); 90% (19/21) if isolated
Stein[7] (1995), United States	33	?	16–38	8 (24)	Unknown	1 (3); CMV, NND at 3 months	29 (87); 96% (24/25) if isolated
Koopman[8] (1998), the Netherlands	7	1:1037	20–32	2 (28)	1 (14); trisomy 18	0; only 1 tested	5 (71); 100% if isolated
Pata[3] (2012), Turkey	7	1:260	18–23	2 (28)	2 (28) 1 Tri 18 1 Tri 21	0 all tested	5 (71) 100% if isolated (5/5)
Total	127		14–38	56 (44)	14 (11)	3 (2.3)	72 (57) Higher if isolated

[a]Note: Studies 4, 5, 7, and 8 are retrospective reviews of prenatal diagnosis of intrahepatic calcifications; studies 4 and 5 are general population studies. In studies 3 and 6, cases of intrahepatic calcifications in a referral population were followed prospectively.
CMV, Cytomegalovirus; *GA*, gestational age; *NND*, neonatal death.

TABLE 23.2 TABLE 1500 CASES OF SPONTANEOUS MISCARRIAGES

Type of Intrahepatic Calcifications	No. (%)
Hepatic vein thrombosis	18 (54)
Portal vein thrombosis	12 (36)
Parenchymal	2 (6)
Mixed	1 (3)
Total	33

Data from Hawass NS, el Badawi MG, Fatani JA, et al: Fetal hepatic calcification. *Pediatr Radiol* 20:528–535, 1990.

mechanisms for vascular events resulting in IHCs have been proposed[1,4,9,10]:

- Embolization to the fetal liver from a placental vein thrombus.
- Intravascular fibrin formation after maternal or fetal release of thromboplastin.
- Ischemic infarction after placental accident or vascular thrombosis.

Vascular events may be associated with aneuploidy, infection, or transient in utero vascular accidents. At the present time, it is impossible to differentiate small calcified hepatic or portal vein thrombus from intraparenchymal calcifications with prenatal US.

Cytomegalovirus (CMV) is the most common infection associated with fetal or neonatal IHCs.[11] Other pathogens[11–16] reported include syphilis, parvovirus B19, herpes simplex type II, adenovirus, varicella zoster, rubella, echovirus 11, and toxoplasmosis. In most cases of IHCs proven to be the result of transplacental infection, other US findings are present, such as intracranial calcifications, ventriculomegaly, hepatomegaly, ascites, hydrops, placentomegaly, and placental calcifications. The mechanism of IHCs with transplacental infection is unclear but has been attributed to an intense inflammatory response[8] with or without resulting vascular accidents or fibrosis.

Hepatic tumors usually manifest as larger, complex masses that may contain areas of punctate calcifications. The most common are hepatoblastoma and metastatic adrenal neuroblastoma.

MANIFESTATIONS OF DISEASE

Clinical Presentation

Most commonly, hepatic calcifications are an incidental finding on routine prenatal US. Alternatively, they may be detected at the time of an anatomy scan done for the usual indications (e.g., advanced maternal age) or because of suspected fetal anomalies, abnormal maternal serum screening, particularly elevated alpha-fetoprotein,[1] or a maternal history of possible perinatal viral infection, such as syphilis, varicella, parvovirus B19,[6] or TORCH (*t*oxoplasmosis, *o*ther [congenital syphilis and viruses], *r*ubella, *C*MV, and *h*erpes simplex virus). In most cases, IHCs are visible by 25 weeks' gestation[1]; sometimes they are visible by the beginning of the second trimester. IHCs may be single or multiple.

Imaging Technique and Findings

Ultrasound. Single or multiple echogenic areas, often punctate, are visible within the liver parenchyma (Figs. 23.1–23.5). Multiple scattered nodular calcifications are most consistent with viral infections, whereas tumors usually manifest as a single, larger, complex mass with areas of echogenicity. Fetal IHCs may be detected by the second trimester.

Magnetic Resonance Imaging. Magnetic resonance imaging (MRI) is usually unnecessary, unless associated central nervous system anomalies are suspected that require further imaging.



Fig. 23.1 Scattered parenchymal intrahepatic calcifications in a 22-week singleton. Viral studies were negative, and karyotype was normal.

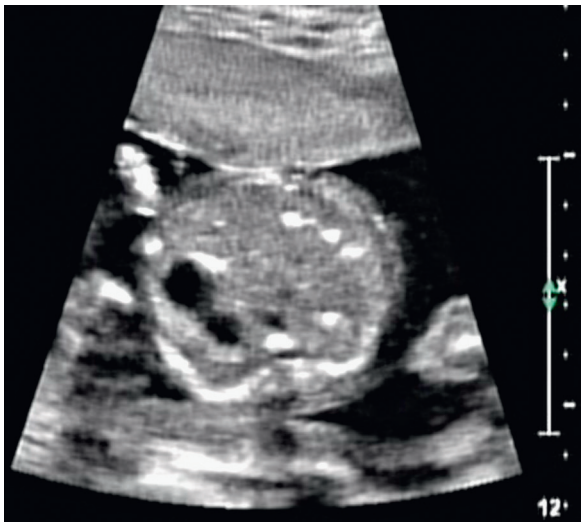

Fig. 23.2 Transverse view of the abdomen (same fetus as in Fig. 23.1 at 22 weeks).

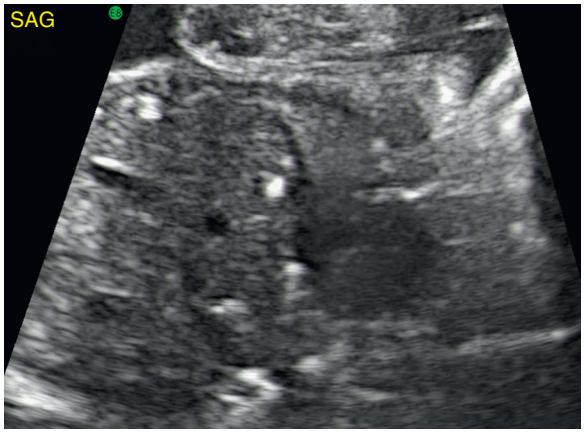

Fig. 23.3 Sagittal view of the abdomen (same fetus at 28 weeks). Some calcifications are near the liver dome but still within the parenchyma.

CLASSIC SIGNS

Single or multiple scattered echogenic areas within the liver parenchyma

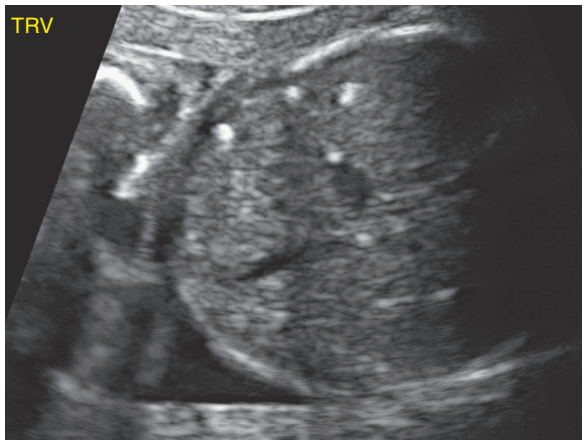

Fig. 23.4 Transverse view of the abdomen (same fetus at 28 weeks). Note the acoustic shadowing of some calcifications. The patient was admitted with preterm premature rupture of membranes at 31 weeks and delivered at 34 weeks a live 1820-g boy. Multiple liver calcifications were confirmed by ultrasound (US). Laboratory tests were normal except for mild elevation of aspartate aminotransferase (69 U/L). Cytomegalovirus urine culture was negative. Presumed diagnosis was TORCH infection. The infant was discharged home on day 7 with plan for follow-up US at 3 months. *TORCH, T*oxoplasmosis, *o*ther [congenital syphilis and viruses], *r*ubella, *c*ytomegalovirus, and *h*erpes simplex virus.

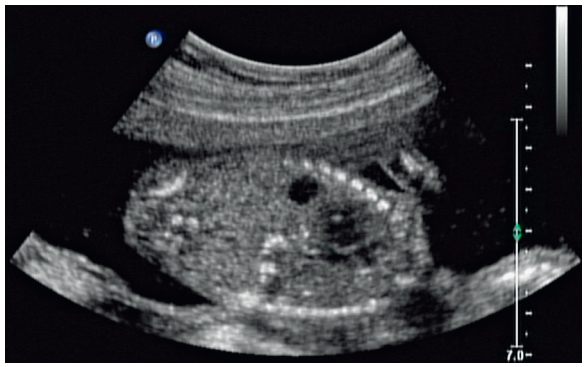

Fig. 23.5 Intrahepatic calcifications in a 19-week twin, 2 weeks after the death of the cotwin in a monochorionic-diamniotic pregnancy. The liver (and bowel) calcifications were not noted in prior ultrasound scans, suggesting the possibility of a vascular event after the cotwin's demise. Viral studies were negative. At birth (normal spontaneous vaginal delivery at term), the neonate was found to have lesions consistent with epidermolysis bullosa and aplasia cutis on the dorsal aspect of the knees, hands, and groin area. Liver studies were not done before discharge.

Differential Diagnosis From Imaging Findings

1. Isolated intraparenchymal IHCs may be associated with aneuploidy, transplacental infection, or vascular events. The presence of other anomalies is strongly suggestive of aneuploidy. Infections are usually associated with multiple calcifications and other findings such as ventriculomegaly (CMV, toxoplasmosis) and fetal hydrops (parvovirus). Gallstones may appear similar to IHCs but are usually arranged linearly and located at the site of the gallbladder. Liver masses with calcifications are usually larger complex masses.

2. Surface IHCs are usually the result of meconium peritonitis. Calcifications should also be considered in adjacent organs such as the bowel, lung (echogenic lung mass), right adrenal (hemorrhage, neuroblastoma), or kidney (dysplastic kidney, Wilms tumor).
3. Idiopathic arterial calcifications of infancy is a rare autosomal recessive syndrome with a poor prognosis characterized by abnormal arterial walls with calcifications.

Synopsis of Treatment Options

PRENATAL

No treatment is available unless a transplacental infection such as toxoplasmosis is diagnosed (see chapters on individual infections). Investigations should include the following:

- Comprehensive fetal anatomy survey to clarify the number and location of the calcifications and look for associated anomalies; a fetal echocardiogram may be considered.
- Amniocentesis for karyotyping and viral polymerase chain reaction (PCR) if infection is suspected.
- Maternal viral serology for STORCH (syphilis, toxoplasmosis, rubella, CMV, herpesvirus), parvovirus B19, and varicella.
- Serial US for follow-up during the pregnancy; lesions that remain unchanged or decrease in size or number after a negative workup are usually associated with a good prognosis and are likely not clinically significant.

Consider delivery in a tertiary center, particularly if there are associated anomalies, aneuploidy, or proven infection.

POSTNATAL

Investigations should include the following:

- careful examination of neonate looking for dysmorphism or stigmata of transplacental infection
- neonatal imaging (abdominal US, radiograph)
- liver function tests
- viral PCR studies as needed

WHAT THE REFERRING PHYSICIAN NEEDS TO KNOW

- Fetal intrahepatic calcifications may be associated with aneuploidy, fetal infections, and less often, hepatic tumors.
- The risk of aneuploidy is highest when there are associated anomalies. Referral should be made for comprehensive fetal anatomy survey.
- Amniocentesis should be offered for karyotyping and viral studies.
- In the absence of aneuploidy or perinatal infections, isolated fetal IHCs are usually benign and have a good prognosis.

KEY POINTS

- IHCs are present in 0.06% to 0.38% of pregnancies.
- IHCs are associated with aneuploidy in 10% of cases (mostly trisomies 18 and 13) and transplacental infections (CMV, parvovirus, and others) in 2% to 3% of cases.
- Isolated parenchymal IHCs are usually benign and have an excellent prognosis (90% to 100% survival).
- When aneuploidy and transplacental infections have been ruled out, isolated IHCs are of no clinical significance and should be followed expectantly.

SUGGESTED READING

Bromley B, Benacerraf BR. Differential diagnosis. In: Benacerraf B, ed. *Ultrasound of fetal syndromes*. 2nd ed. Philadelphia: Churchill Livingstone; 2008.

Bromley B, Benacerraf BR. Sonographic fetal findings with borderline significance: the grey zone in fetal diagnosis. In: Benacerraf B, ed. *Ultrasound of fetal Syndromes*. 2nd ed. Philadelphia: Churchill Livingstone; 2008.

Degani S. Sonographic findings in fetal viral infections: a systematic review. *Obstet Gynecol Surv*. 2006;61:329-336.

Echogenic mass in abdomen. In: Benacerraf B, ed. *Ultrasound of fetal syndromes*. 2nd ed. Philadelphia: Churchill Livingstone; 2008:68-70.

Intra-abdominal calcifications—hepatic. In: Bianchi DW, Crumblehome TM, D'Alton ME, et al., eds. *Fetology: diagnosis and management of the fetal patient*. 2nd ed. McGraw Hill Professional; 2010:478-481.

Levine D. Overview of echogenic masses and calcification in the fetal abdomen. In: Basow DS, ed. *UpToDate*. Waltham, MA: Wolters Kluwer; 2017.



All references are available online at www.expertconsult.com.

REFERENCES

1. Hawass NS, el Badawi MG, Fatani JA, et al. Fetal hepatic calcification. *Pediatr Radiol*. 1990;20:528-535.
2. Kidron D, Sharony R. Fetal liver calcifications: an autopsy study. *Virchows Arch*. 2012;460(4):399-406.
3. Pata O, Gunduz NM, Unlu C. Isolated fetal liver calcifications. *J Turk Ger Gynecol Assoc*. 2012;13(1):67-69.
4. Bronshtein M, Blazer S. Prenatal diagnosis of liver calcifications. *Obstet Gynecol*. 1995;86:739-743.
5. Achiron R, Seidman DS, Afek A, et al. Prenatal ultrasonographic diagnosis of fetal hepatic hyperechogenicities: clinical significance and implications for management. *Ultrasound Obstet Gynecol*. 1996;7:251-255.
6. Simchen MJ, Toi A, Bona M, et al. Fetal intra-hepatic calcifications: prenatal diagnosis and outcome. *Am J Obstet Gynecol*. 2002;187:1617-1622.
7. Stein B, Bromley B, Michlewitz H, et al. Fetal liver calcifications: sonographic appearance and postnatal outcome. *Radiology*. 1995;197:489-492.
8. Koopman E, Wladimiroff JW. Fetal intrahepatic hyperechogenic foci: prenatal ultrasound diagnosis and outcome. *Prenat Diagn*. 1998;18:339-342.
9. Blanc WA, Berdon WE, Baker DH, et al. Calcified portal vein thromboemboli in newborn and stillborn infants. *Radiology*. 1967;88:287-292.
10. Friedman AP, Haller JO, Boyer B, et al. Calcified portal vein thromboemboli in infants: radiology and ultrasonography. *Radiology*. 1981;140:381-382.
11. Degani S. Sonographic findings in fetal viral infections: a systematic review. *Obstet Gynecol Surv*. 2006;61:329-336.
12. Rigsby CK, Donnelly LF. Fetal varicella syndrome: association with multiple hepatic calcifications and intestinal atresia. *Pediatr Radiol*. 1997;27:779.
13. Shackelford GD, Kirks DR. Neonatal hepatic calcification secondary to transplacental infection. *Radiology*. 1977;122:753-757.
14. Meyberg-Solomayer GC, Fehm T, Muller-Hansen I, et al. Prenatal ultrasound diagnosis, follow-up and outcome of congenital varicella syndrome. *Fetal Diagn Ther*. 2006;21:296-301.
15. Herman TE. Extensive hepatic calcification secondary to fulminant neonatal syphilitic hepatitis. *Pediatr Radiol*. 1995;25:120-122.
16. Tongsong T, Srisupundit K, Traisrisilp K. Prenatal sonographic diagnosis of congenital varicella syndrome. *J Clin Ultrasound*. 2012;40(3):176-178.
17. Sahlin E, Sirotkina M, Marnerides A, et al. Fetal calcifications are associated with chromosomal abnormalities. *PLOS ONE*. 2015;10:e0123343.

To access the videos in this chapter, scan this QR code or visit expertconsult.com

24 Abdominal Cysts

FREDERIC CHANTRAINE | BORIS TUTSCHEK

Introduction

Different organ systems can give rise to abdominal cysts that can be detected on prenatal ultrasound (US) (Table 24.1). Depending on the location, gestational age, gender, and US appearance of the cyst, a limited differential diagnosis or the correct diagnosis can often be achieved. Intraabdominal cysts may develop from many organs. The most frequent origins are the urinary system (hydronephrosis, multicystic dysplastic kidneys, polycystic kidneys, hydroureter, megacystis; see Chapters 12–16) or dilated bowel

(see Chapter 26). Other origins of abdominal cysts include the biliary system (see Chapter 25), liver (see Chapter 28), and spleen (see Chapter 32). This chapter addresses ovarian cysts, enteric duplication cysts, mesenteric cysts/mesenteric lymphangioma, hydrocolpos, urachal cysts, and umbilical vein varix.

First Trimester

Fetal abdominal cysts at 11–14 weeks are rare. In the majority of cases cysts are an isolated finding and 60% to 80% resolve spontaneously.[1,2] In cases of persistence or when the cyst is not completely anechoic, close follow-up is recommended, because of the association with anorectal or other gastrointestinal malformations.

Ovarian Cysts

DEFINITION

Ovarian cysts are fluid-filled sacs arising from the ovary.

TABLE 24.1 FETAL ABDOMINAL CYSTS BY ORGAN SYSTEMS

Gastrointestinal tract	Dilated stomach, dilated proximal duodenum, dilated jejunum or ileum, dilated colon, meconium pseudocysts
	Mesenteric cysts/lymphangioma, enteric duplication cysts
	Hepatic cysts, cystic hepatic tumors, biliary cysts
	Splenic cyst
Urinary tract	Renal cysts, (macro-)cystic kidneys, multicystic-dysplastic kidneys, hydronephrosis, dilated upper pole in duplex kidney, dilated ureter, dilated bladder, ureterocele
	Urachal cyst, persistent cloaca
Genital	Ovarian cysts
	Hydrocolpos, hydrometrocolpos
Others	Umbilical vein varix

PREVALENCE AND EPIDEMIOLOGY

After the kidneys and bowel, the ovaries are the third most frequent organ giving rise to abdominal cysts. The first case was reported by Valenti et al. in 1975.[3] The incidence was initially estimated to be 1:2625 pregnancies.[4] With improving image quality the number of cases diagnosed prenatally might have increased, but the incidence of 1:2500 is confirmed in more recent reports.[5,6]

ETIOLOGY AND PATHOPHYSIOLOGY

The fetal ovary is sensitive to the maternal gonadotropins. Fetal ovarian cysts are usually functional, mostly follicles enlarged as a result of stimulation by maternal and placental hormones.[7] A higher prevalence of these cysts is noted in pregnancies complicated by diabetes, preeclampsia, and rhesus immunization, i.e., in pregnancies with an increased release of placental human chorionic gonadotropin.[8]

MANIFESTATIONS OF DISEASE

Clinical Presentation

Ovarian cysts are usually detected in the second or third trimester, mostly as incidental findings. Postnatal regression is common because of a lack of stimulating maternal hormones.[9] Most ovarian cysts are unilateral.

Imaging Technique and Findings

Ultrasound. The ultrasound (US) appearance depends on the size of the cyst and the possible complications, such as torsion of the ovary or intracystic bleeding. Uncomplicated cysts typically appear as a unilocular, thin-walled cystic mass (Fig. 24.1). Ovarian cysts may appear as a complex mass (with internal echoes, septations, or debris; Fig. 24.2) or as a solid mass when complicated by torsion or internal bleeding.

Magnetic Resonance Imaging. Magnetic resonance imaging (MRI) is not required to diagnose ovarian cysts. An ovarian cyst can be an incidental finding on fetal MRI; in T2-weighted images it appears as a white cystic structure.

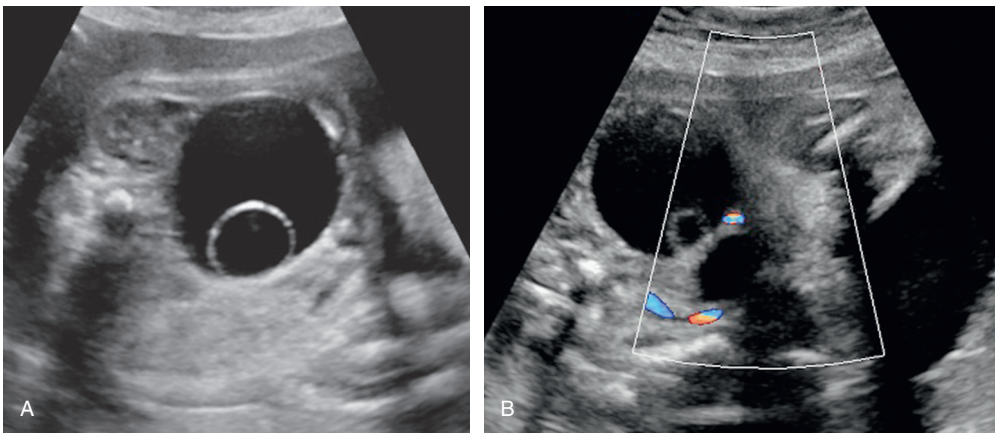

Fig. 24.1 Ovarian cyst in a female fetus at 31 weeks' gestation. (A) Transverse view of the fetal abdomen at the level of the kidney shows an anechoic cyst with another internal cyst, next to the normal ipsilateral kidney. (B) Color Doppler image shows the fetal bladder identified by the two vesical arteries.

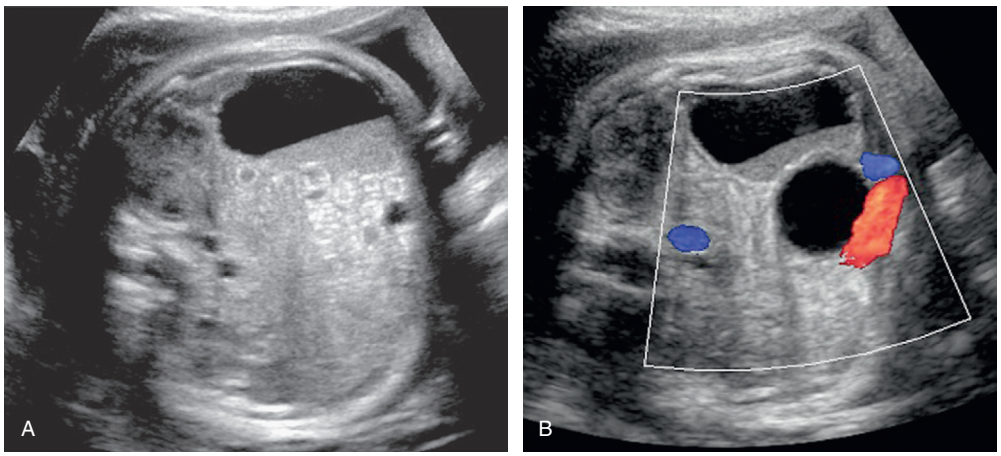

Fig. 24.2 US images of a fetal ovarian cyst with mild echogenic sediment (after internal bleeding). (A) Cross-section at the level of the ipsilateral kidney. (B) Cross-section near the fetal pelvis, next to the fetal bladder indicated by the bladder vessels.

CLASSIC SIGNS

A simple intraabdominal cystic structure (2 to 5 cm) in a female fetus, typically unilateral, with normal urinary tract (kidneys and bladder clearly seen) and intestinal tract (no dilated bowel).

Differential Diagnosis From Imaging Findings

The US appearance of a fetal ovarian cyst may be indistinguishable from mesenteric or enteric duplication cysts. The identification of a male gender can help exclude ovarian cyst or hydrocolpos and to make persistent cloaca or megacystis-microcolon-intestinal hypoperistalsis syndrome (see Chapters 19 and 30) unlikely. Other considerations in both sexes include urachal cyst (located in the midline and above the bladder, in contact with the abdominal wall and not mobile), mesenteric cyst (generally multiloculated), and enteric duplication cyst (thicker wall owing to the presence of mucosa). A complicated ovarian cyst (torsion with thickened "wall") can also imitate a meconium pseudocyst (see Chapter 26).

Synopsis of Treatment Options

PRENATAL

Options for prenatal management include observation and, in the case of a simple cyst, aspiration. The conservative approach is usually preferred. Authors favoring prenatal aspiration claim to prevent ovarian torsion and its complications (i.e., necrosis and intraabdominal inflammation).[10,11] The procedure has to be weighed against the risk of complications (i.e., preterm rupture of membranes, infection, and bleeding).[7] No randomized trial comparing invasive and conservative approaches exists. Periodic follow-up to check the size and appearance of the cyst can be recommended. A puncture with aspiration of the cyst may be reasonable for very large cysts likely to impair vaginal delivery.[12] Otherwise fetal ovarian cysts do not present a contraindication for vaginal delivery.

POSTNATAL

Postnatal US confirms the diagnosis. Other imaging modalities (MRI or computed tomography [CT]) are usually not required. Depending on the size and the appearance of the cyst, the choice is between conservative and invasive management. A recent metaanalysis including 34 studies with a total of 954 fetuses showed that 54.6% (95% confidence interval [CI] 47.0–62.0) of the cysts regressed either during pregnancy or after birth. Resolution occurred significantly less often in complex versus simple cysts (odds ratio [OR]: 0.15, 95% CI 0.10–0.23) and in cysts ≥ 40 mm compared to smaller ones (OR: 0.03, 95% CI 0.01–0.06). An observed change in ultrasound pattern on follow-up examination was associated with an increased risk of eventual ovarian loss (positive predictive value [PP]: 57.7%, 95% CI 42.9–71.8). The risk of ovarian torsion was also significantly higher in cysts ≥ 40 mm (OR: 30.8, 95% CI 8.6–110). Larger and complex cysts tended to have surgery more often. In cases with prenatal aspiration 38% recurred (95% CI 14.8–64.3), torsion and hemorrhage (diagnosed after birth) complicated 10.8% (95% CI 4.4–19.7), and 9.7% (95% CI 3.7–18.3), respectively. Eighteen percent of fetuses undergoing prenatal aspiration also had surgery after birth.[13]

In the neonate it seems reasonable to operate (laparoscopically, if possible) on cysts larger than 40 mm, or complex and symptomatic cysta.[14] Cystectomy is preferred over oophorectomy. Large simple ovarian cysts in neonates can also be aspirated under US guidance.[15] Smaller cysts and simple cysts are often managed conservatively. Accompanying videos show a laparoscopic marsupialization of a simple ovarian cyst in a neonate (Video 24.1) and a laparoscopic retrieval of a spontaneously detached ovarian cyst (Video 24.2).

Enteric Duplication Cysts

DEFINITION

Enteric duplications comprise two layers of epithelium and share the vascular supply with the adjacent intestinal tract. They are typically in immediate contact, but not in continuity, with the intestinal tract.[16]

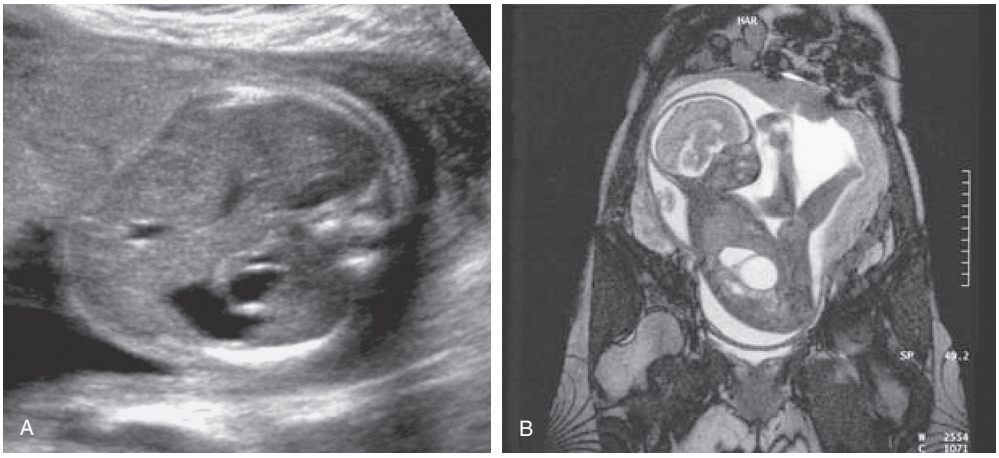

Fig. 24.3 Enteric duplication cyst. (A) US image of an enteric duplication cyst close to the fetal stomach in a fetus at 24 weeks; the accompanying Video 24.1 shows part of the neonatal endoscopic procedure to remove this duplication cyst. (B) T2-weighted MRI (sagittal section) from a similar case at 27 weeks shows a thick-walled, fluid-filled cyst juxtaposed to, but not in continuity with, the fetal stomach. *(B, from Okamoto et al.[18] with permission)*

PREVALENCE AND EPIDEMIOLOGY

Enteric duplication cysts are commonly found postnatally[17] but are rarely detected prenatally.[16,18] Males are affected twice as often as females.[19]

ETIOLOGY AND PATHOPHYSIOLOGY

There are multiple theories that explain the development of enteric duplications, but no definitive theory accounts for all known variants. Theories involve partial or abortive twinning, the split notochord theory and anomalous adhesion occurring in the third week of gestation, diverticula and canalization defects between 6 to 8 weeks of life, and even environmental factors such as trauma and hypoxia.[20]

Histologic evaluation of the cysts shows full replication of the mucosal, muscular, and serosal layers.[21]

MANIFESTATIONS OF DISEASE

Clinical Presentation

Enteric duplication cysts can originate from any part of the gastrointestinal tract. Jejuno-ileal duplications are the most common; in one large series, they accounted for 61% of duplication cysts.[22] The cysts are found on the mesenteric side of the bowel and are often difficult to differentiate from a mesenteric cyst. Most of these anomalies become symptomatic at some stage later in life, owing to pain, bleeding, or intussusceptions, and require surgical resection.[17]

Imaging Technique and Findings

Ultrasound. Enteric duplication cysts are elongated, tubular, or spherical cystic masses, usually unilocular and anechoic (Fig. 24.3). Multiple septations and "sludge" may be seen (Table 24.2). The location and mass effect on adjacent bowel can suggest the diagnosis. If present, peristaltic movement of the muscular wall can aid in the diagnosis.[16]

Magnetic Resonance Imaging. MRI can provide a global overview of the abdomen and can be helpful in the differential diagnosis, enabling better tissue differentiation.[18,23]

TABLE 24.2. ULTRASOUND CRITERIA OF AN OVARIAN CYST VERSUS AN ENTERIC DUPLICATION CYST

	Ovarian Cyst	Enteric Duplication Cyst
Gender	Female	Male and female (ratio 2:1)
Location	Lower abdomen	Entire abdomen
Structure	Cystic	Elongated, thick-walled
Internal structure	Smooth, isolated or heterogeneous	Smooth, "sludge"
Kidneys and bladder	Visible	Visible
Peristalsis	No	Possible

Modified after Giorlandino C, Rivosecchi M, Bilancioni E, et al.: Successful intrauterine therapy of a large fetal ovarian cyst. *Prenat Diagn* 10:473–475(10), 1990.

CLASSIC SIGNS

Anechoic, unilocular, tubular, or spherical cystic mass close in relationship with adjacent bowel

Differential Diagnosis From Imaging Findings

The differential diagnosis of ovarian and mesenteric cysts is difficult and includes mesenteric cysts and mesenteric lymphangioma. Possible cystic structures in the right upper quadrant include duodenal or antral duplication cysts, choledochal cysts, and hepatic cysts. Urachal cysts, renal cysts, and dilated bowel can usually be excluded based on their location and appearance.

Synopsis of Treatment Options

PRENATAL

No prenatal treatment such as aspiration is described for these cysts. Mode and timing of delivery should not be influenced by

the suspicion of an enteric duplication cyst if there is no sign of bowel obstruction.

POSTNATAL

Nearly 85% of patients with enteric duplication cysts become symptomatic and require surgery, which is usually curative.[24] Foley et al.[17] reported the outcome with delayed resection in asymptomatic patients as excellent, but 25% of the patients in this series had obstructive symptoms necessitating surgery in the first days of life. In cases with prenatal suspicion of enteric duplication, neonatal clarification by US and contrast studies and evaluation by a pediatric surgeon are required. Video 24.3 shows laparoscopic resection of a gastric duplication cyst.

Mesenteric Cysts and Cystic Lymphangioma

PREVALENCE AND EPIDEMIOLOGY

Mesenteric cysts represent a small proportion of abdominal cysts in neonates and infants[25] but can also be diagnosed prenatally. They are estimated to occur in 1:20,000 pediatric admissions.[21] The prevalence in fetuses is unknown.

ETIOLOGY AND PATHOPHYSIOLOGY

Mesenteric cysts comprise multiloculated dilated channels on the serosal surface of the mesentery and represent abdominal lymphangiomas.[25] They arise from abnormal lymphatic channels that fail to connect properly in the lymphatic system.[26] Mesenteric and retroperitoneal lymphangiomas represent only 2% of all lymphangiomas detected prenatally.[27] They occur mostly in the mesentery of the small bowel and less commonly in the retroperitoneum.

MANIFESTATIONS OF DISEASE

Clinical Presentation

Mesenteric cysts/mesenteric lymphangiomas are often asymptomatic and may be an incidental finding at surgery, but infants presenting with abdominal pain, obstructive symptoms, or anemia from intracystic bleeding have been reported.[21]

Imaging Technique and Findings

Ultrasound. The normal mesentery of the bowel can be visualized in the third trimester (Fig. 24.4A) when fetal breathing movements shift the abdominal organs relative to each other (Video 24.4). US findings of mesenteric cysts (see Fig. 24.4B) are variable. The cysts are often septated but can be unilocular, are variable in size, and are usually thin-walled. In cases of intracystic bleeding, they appear heterogeneous or even solid. These cysts are located within the midabdomen and are mobile, so their position can vary on serial US examinations.[24]

Magnetic Resonance Imaging. In a case report of a mesenteric cyst,[23] US and MRI findings were the same, and MRI did not alter prenatal or postnatal management or counseling.

CLASSIC SIGNS

Diagnosed in the second or third trimester, in either male or female fetuses, as a mobile multilocular cystic structure

Differential Diagnosis From Imaging Findings

The differential diagnosis includes enteric duplication or ovarian cysts. Because of their specific findings, the following types of cysts are less likely:

1. pancreatic cyst (location)
2. urachal cyst (fixed to the abdominal wall, just over the bladder)
3. renal cyst (lateral position, kidney included)
4. bowel dilatation (peristalsis)

Synopsis of Treatment Options

PRENATAL

Serial US examinations allow the clinician to follow the size of the cyst.

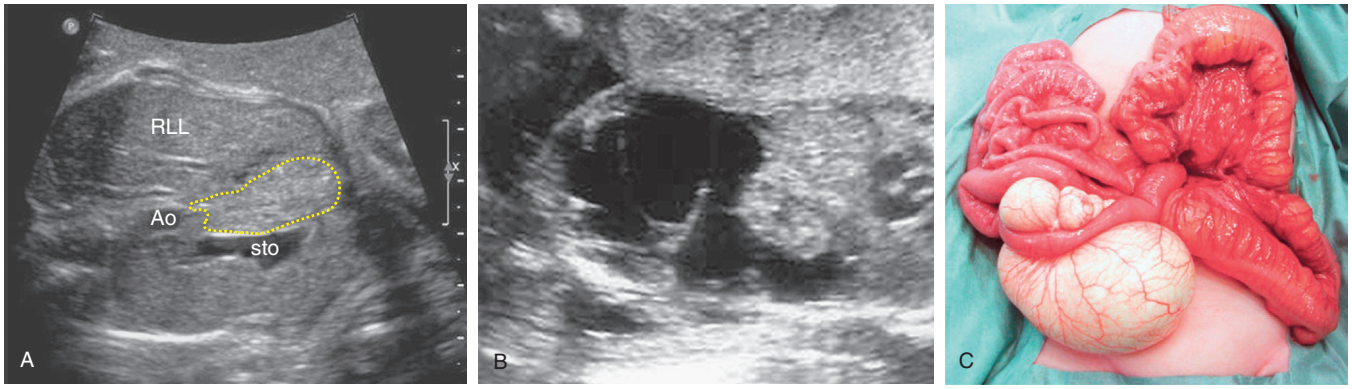

Fig. 24.4 Normal fetal small bowel mesentery and mesenteric cysts/mesenteric lymphangioma. (A) Transverse section of the fetal abdomen shows a normal small bowel mesentery at 28 weeks (outlined by a *dotted line*; see also Video 24.1). (B) Longitudinal section of the fetal abdomen at 20 weeks (diaphragm and heart on the right side of the image) shows a left-sided retroperitoneal abdominopelvic mass associated with anterior displacement of the ipsilateral kidney. (C) Surgical image in a neonate shows a multilocular, whitish mesenteric cyst/mesenteric lymphangioma in between otherwise normal small bowel loops and colon. *Ao*, Aorta; *RLL*, right lobe of the liver; *sto*, stomach. *(B, From Deshpande[56] with permission.)*

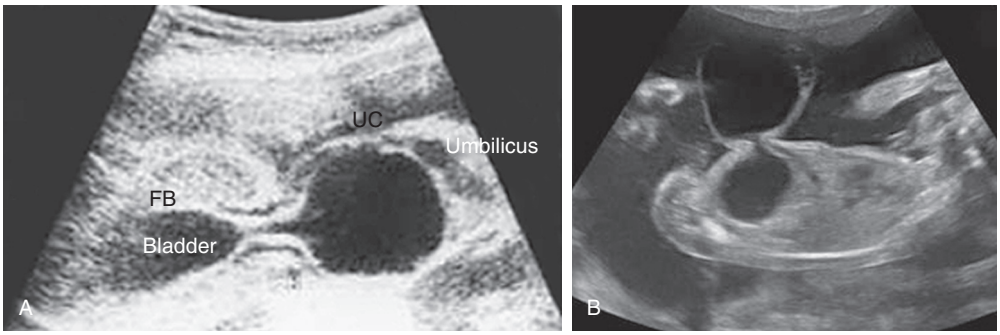

Fig. 24.5 Urachal cysts. (A) Vesicoallantoic cyst at 29 weeks. This entity represents a single communicating cavity of bladder, patent urachus, and umbilical cord cyst. (B) Patent urachus at 13 weeks, extending into the umbilical cord. *FB*, Fetal bladder; *UC*, umbilical cord. *(A, From Shukunami et al.[57]; B, from Weichert et al.[58] with permission.)*

POSTNATAL

US as first-line modality can be augmented by MRI or CT scan to define the relationship with the surrounding organs.[21] Surgical resection is recommended because of the acute complications and the small risk of malignant degeneration later in life.[28] Postsurgical recurrence is more likely in retroperitoneal than in mesenteric cysts.[29]

Urachal Cysts

DEFINITION

Urachal abnormalities, including cysts, are the result of the abnormal persistence of the embryologic urachus.

PREVALENCE AND EPIDEMIOLOGY

Urachal abnormalities are rare[30]; they occur three times more frequently in male fetuses.[31]

ETIOLOGY AND PATHOPHYSIOLOGY

The urachus is an embryonic communication between the allantois and the cloaca and normally involutes, resulting in a fibrous cord between the umbilicus and the bladder.[32] Failure in closure of the entire urachus or some portion results in different anomalies, as follows (modified after[33]):

- *Urachal cyst:* patent midduct with closure at both ends (umbilicus and bladder).
- *Urachal sinus:* persistent tissue at the umbilicus, no connection to the bladder.
- *Urachal diverticulum:* persistent tissue at the bladder, no connection to the umbilicus.
- *Patent urachus:* complete patency, free communication between bladder and "umbilical cord cyst."

MANIFESTATIONS OF DISEASE

Clinical Presentation

Urachal cysts are located close to the ventral wall between the umbilical cord insertion and the bladder. The two umbilical arteries surround the cyst.

Imaging Technique and Findings

Ultrasound. Urachal cysts are detectable in the second trimester. Cases are often referred for suspected omphalocele because urachal anomalies can have a very similar appearance.[34] The location close to the umbilicus and the umbilical arteries and in some cases the communication with the bladder and the absence of internal blood flow suggest the prenatal diagnosis of urachal cyst (Fig. 24.5). Matsui et al.[31] reported the sign of "disappearance of the cyst" in the third trimester on prenatal US in cases of patent urachus with bladder prolapse. Riddell et al. reported the finding of an "hourglass communication" between the fetal bladder and a cyst of the umbilical cord, which should be considered indicative of a patent urachus with varying degrees of umbilical bladder prolapse (Fig. 24.6).[35]

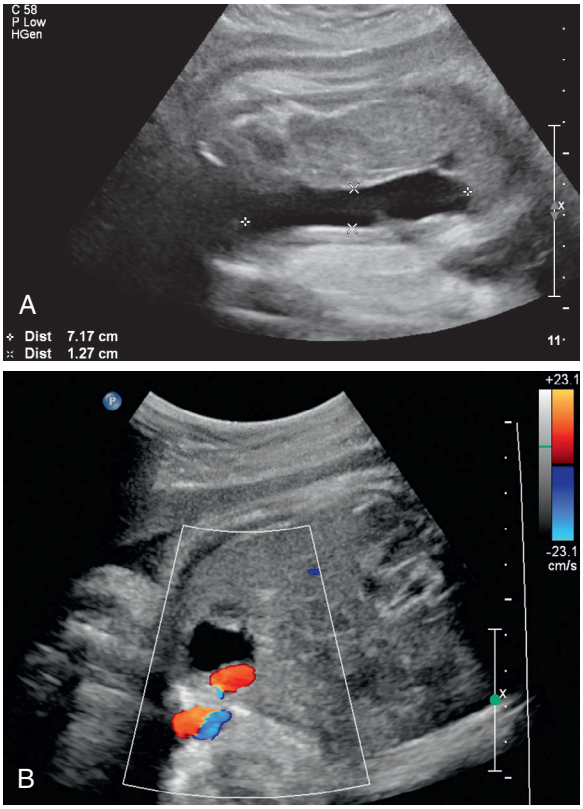

Fig. 24.6 Pelvic mass from a third-trimester fetus with a patient urachus. (A) Coronal view of anterior abdomen showing elongated mass extending from pelvis to level of kidneys. (B) Axial view at level of umbilical cord insertion showing apex of the mass approaching the anterior abdominal wall. *(Courtesy Joshua A. Copel, Yale School of Medicine.)*

CLASSIC SIGNS

Second-trimester scan of a fetus presenting a median intraabdominal anechoic cyst located between the bladder and umbilicus, surrounded by the umbilical arteries

Differential Diagnosis From Imaging Findings

The differential diagnosis includes ventral wall defects, such as omphalocele and cloacal or bladder exstrophy (see Chapters 19 and 21). In bladder exstrophy, there is nonvisualization of a normally filled bladder, and its wall can be seen as an open plate on the anterior wall of the fetal abdomen. Other considerations are lesions of the umbilical cord (cysts or umbilical vein varix). Color Doppler can clarify the anatomy by demonstrating the surrounding vessels.

Synopsis of Treatment Options

PRENATAL

If urachal cyst is suspected prenatally, a detailed anomaly scan should be performed. Urachal anomalies are generally isolated, but associations with other genitourinary conditions, such as cryptorchidism, unilateral kidney, and hydronephrosis, and with omphalocele, myelomeningocele, and cerebral anomalies have been reported.[30,36,37] Serial US scans can help follow the prenatal evolution of the urachal cyst.[31] Fetal karyotyping is not mandatory solely because of an isolated urachal cyst.[32] Vaginal delivery is not contraindicated. Care must be taken when clamping and cutting the umbilical cord to ensure that the cyst is not damaged.

POSTNATAL

Postnatal US followed by cystourethrogram and contrast injection studies (into the urachal opening) can clarify urachal anomalies suspected prenatally. Undetected urachal cysts are usually asymptomatic but may manifest with pain, infection, or malignancy later in life (urachal adenocarcinoma).[33] Surgical resection of urachal cysts is indicated, including a cuff of the bladder. Prognosis is excellent, and bladder function after surgery is usually good.[31]

Hydrocolpos and Hydrometrocolpos

DEFINITION

Hydrocolpos is cystic dilatation of the vagina. The term *hydrometrocolpos* describes distention of the vagina and uterus. Both conditions are caused by the combination of distal obstruction and significant fluid secretion from the genital tract.[8]

PREVALENCE AND EPIDEMIOLOGY

The prevalence of congenital hydrocolpos is less than 1:30,000.[38] In contrast, hydrocolpos at puberty is much more common, with a prevalence of 1:1000.[39]

ETIOLOGY AND PATHOPHYSIOLOGY

The less severe isolated hydrocolpos should be differentiated from the complicated hydrocolpos secondary to a urogenital sinus, in which other abnormalities are present (cloacal malformation; see Chapter 19).

MANIFESTATIONS OF DISEASE

Clinical Presentation

Congenital hydrocolpos and hydrometrocolpos are extremely rare. They are usually diagnosed in the third trimester, probably because maternal hormonal stimulation is insufficient for glandular secretion before this age. Hydrometrocolpos has been reported after prenatal dexamethasone treatment for congenital adrenal hyperplasia[40] or in association with ambiguous genitalia in 45,X/46,XY mosaicism.[41] The combination of hydrocolpos, polydactyly, and a congenital heart defect is known as *McKusick-Kaufman syndrome*.[42] Persistent urogenital sinus is associated with uterine anomalies, vaginal atresia or duplication, renal anomalies (hydronephrosis, renal agenesis, polycystic kidney), imperforate anus, esophageal atresia, and sacral hypoplasia.[43]

Imaging Technique and Findings

Ultrasound. Presentation on US is a cystic or solid pelvic mass located just behind the bladder in a female fetus (Fig. 24.7). Associated genitourinary anomalies occur. The dilated vagina or uterus can cause urinary tract obstruction. The presence of a fluid-debris level inside the mass can differentiate this cyst from the fetal urinary bladder. In cases with cloacal anomaly, ascites is possible because urine can pass through the fallopian tubes into the abdominal cavity.[44]

Magnetic Resonance Imaging. One study reported MRI to be superior to US in clarifying the relationship of hydrocolpos with bladder and rectum.[23,45]

CLASSIC SIGNS

Hydrocolpos suspected with an oval cystic mass in the mid-to-lower abdomen of a female fetus

Differential Diagnosis From Imaging Findings

The differential diagnosis of a pelvic cystic mass includes the following:

1. ovarian cyst in a female fetus
2. megacystis
3. dilated bowel
4. enteric duplication
5. mesenteric cyst
6. sacrococcygeal teratoma
7. anterior meningocele

Synopsis of Treatment Options

PRENATAL

Associated abnormalities (localized in the pelvis such as persistent cloaca or peripheral such as polydactyly) should be sought. An isolated hydrocolpos should be differentiated from a secondary, more complex one associated with cloacal anomaly (elevated morbidity and possibility of a syndrome). Because of the rarity of hydrocolpos, no consensus about the timing and mode of delivery is available.

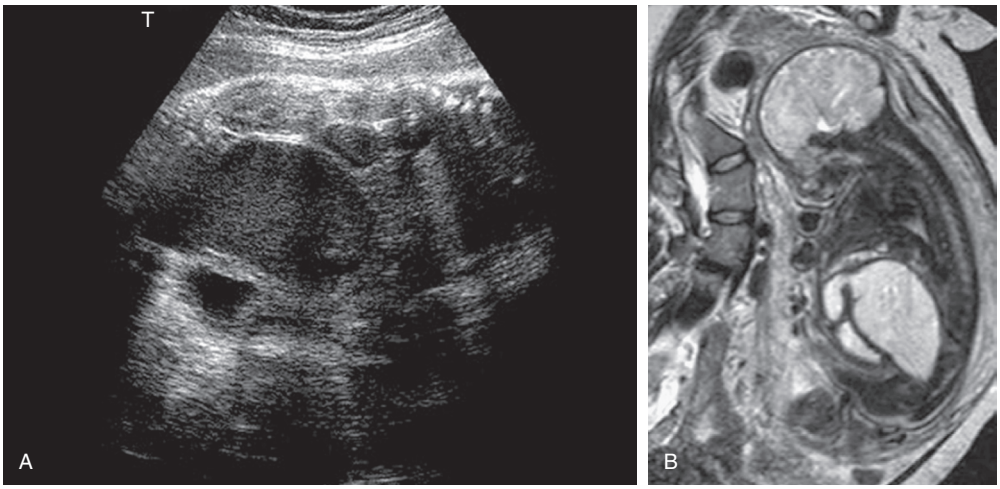

Fig. 24.7 Hydrocolpos at 37 weeks (in this case in the presence of cloacal anomaly). (A) US image of the fetal trunk (dorsoanterior fetal position, longitudinal section) shows a large cyst with a maximum diameter of 77 mm, posterior to the bladder and anterior to the kidney. (B) Sagittal MRI of the same fetus. There is a normal appearance of the fetal bladder anterior but a larger cystic mass posterior to it. *(From Hayashi et al.[59] with permission.)*

POSTNATAL

Prognosis depends on the presence and severity of associated disorders.[24] Advanced radiologic studies of the internal genitalia may be required in the early postnatal phase to clarify the severity of the lesion.

Umbilical Vein Varix

DEFINITION

Varix refers to the focal dilatation of the umbilical vein, located in its intraabdominal part.

PREVALENCE AND EPIDEMIOLOGY

This entity is rare.[46] In larger series, 13 cases of umbilical vein varix were diagnosed among 50,000 deliveries, and 28 cases in approximately 65,000 pregnancies were reported.[47,48]

ETIOLOGY AND PATHOPHYSIOLOGY

The developmental origin of the umbilical vein varix is unknown. The most frequent location of umbilical vein varix is the intraabdominal extrahepatic part of this vessel, which is not surrounded by dense liver tissue. Any increase in venous pressure could dilate the vein at this level and cause the varix. Associations of this condition and cardiomegaly and hydrops have been described.[49]

MANIFESTATIONS OF DISEASE

Clinical Presentation

An umbilical vein varix can be detected in the second and third trimester. In 91 fetuses with umbilical vein varix, additional US findings were detected in 32% (most commonly cardiovascular system anomalies, hydrops, and anemia); 10% of the cases had chromosomal abnormalities. The perinatal loss rate was 13%. The rate of complications (including intrauterine death, thrombosis of the umbilical vein, and abnormal prenatal cardiotocogram) was higher if diagnosis of umbilical vein varix was made before 26 weeks' gestation.[47] Intrauterine death can occur secondary to thrombosis of the varix.[50,51]

If detailed US examination does not reveal other anomalies, there does not seem to be an increased fetal risk.[48] However, closer fetal surveillance (growth and well-being, possible development of associated anomalies) should be offered.

Imaging Technique and Findings

Ultrasound. Diagnostic criteria are an umbilical vein diameter greater than 9 mm,[52] or enlargement of the diameter of the vein by at least 50% compared with the remainder of the intrahepatic umbilical vein,[53] or a width greater than 2 standard deviations above the norm.[47] Color Doppler shows venous blood flow in the "cyst" and its continuity with the umbilical vein (Fig. 24.8).

If umbilical vein varix is suspected, a detailed anomaly scan is mandatory. Associated structural abnormalities are frequent and have to be ruled out. Possibly associated anomalies include cardiovascular malformations, aneuploidies, diaphragmatic hernia, ventriculomegaly, short long bones, and other abnormalities of the umbilical vessels and placenta.[47]

CLASSIC SIGNS

Enlargement of the intraabdominal part of the umbilical vein is main US finding. Venous blood flow can be confirmed using Doppler US.

Differential Diagnosis From Imaging Findings

The differential diagnosis includes other intraabdominal cysts such as ovarian, enteric duplication, and mesenteric cysts, and cystic masses of the umbilical cord. Color Doppler provides relevant information.

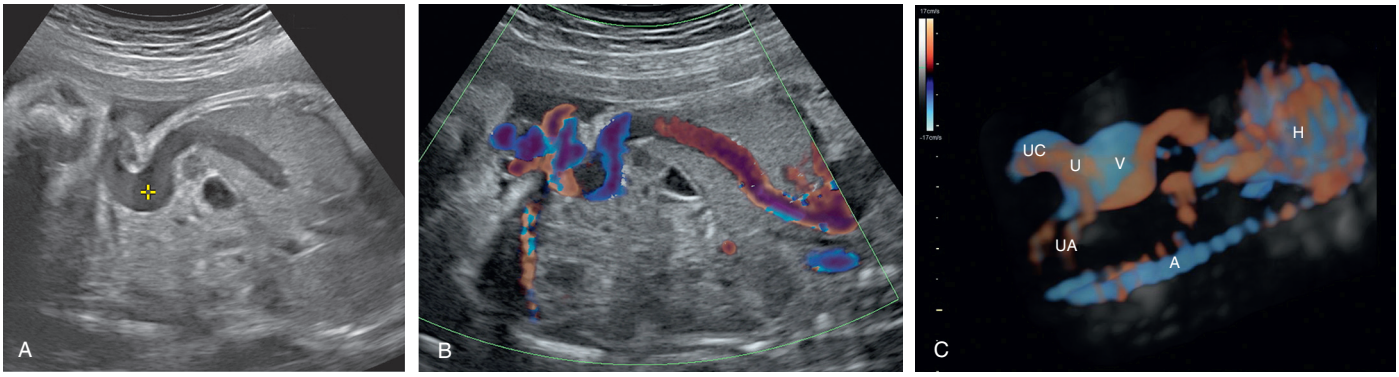

Fig. 24.8 US images of an intraabdominal umbilical vein varix. (A) Dilated proximal portion next to the umbilical ring in a 28-week fetus. Oblique view of the fetal abdomen shows a torqued course of a varicose umbilical vein (*yellow caliper mark*). (B) Color Doppler longitudinal section of the same fetus shows the umbilical part and the entire course of the umbilical vein from the varix leading into the ductus venosus. Note the loss of color signal at the varix where the blood flow velocity is decreased, the angle of insonation is 90 degrees, and the velocities are below the threshold of the color Doppler. (C) Three-dimensional reconstruction of the main fetal vessels, highlighting the markedly dilated proximal part of the intraabdominal umbilical vein.

Synopsis of Treatment Options

PRENATAL

An umbilical vein varix is associated with a high incidence of adverse fetal outcome (32%), including associated fetal abnormalities, fetal anemia, chromosomal abnormalities, and intrauterine death.[46] In a review of 91 cases, there was a normal outcome for only 59% of the fetuses.[47] Careful US examination of the whole fetus is mandatory if umbilical vein varix is diagnosed. If other abnormal findings are detected, karyotyping should be offered. If fetal anemia is suspected,[47] cordocentesis may be required. Some authors propose to deliver prematurely to avoid intrauterine demise.[38,42] For an isolated umbilical vein varix, however, premature delivery is usually not required, and the prognosis is generally good.[46,48,49]

POSTNATAL

Melcer et al. observed a possible association between umbilical vein varix and childhood developmental delay. However, the authors concluded that the clinical implications of these findings are still premature and additional studies are needed.[54]

KEY POINTS

- Prenatal ultrasound is a very effective tool to diagnose and classify fetal intraabdominal cysts.[55]
- Intraabdominal cysts are findings of the late second and third trimesters.
- Ovarian cysts are the most frequent diagnosis, and follow-up during pregnancy is needed to exclude complications.
- Fetal MRI can be helpful but is usually not required.
- In general, if an intraabdominal cyst is an isolated finding, there is no need for karyotyping.
- Most affected fetuses can be delivered vaginally and at term.
- Postnatal US imaging is recommended.

SUGGESTED READING

Heaton TE, Liechty KW. Postnatal management of prenatally diagnosed abdominal masses and anomalies. *Prenat Diagn*. 2008;28:656-666.

Hyett J. Intraabdominal masses: prenatal differential diagnosis and management. *Prenat Diagn*. 2008;28:645-655.

All references are available online at www.expertconsult.com.

REFERENCES

1. Khalil A, Cooke PC, Mantovani E, et al. Outcome of first-trimester fetal abdominal cysts: cohort study and review of the literature. *Ultrasound Obstet Gynecol*. 2014;43(4):413-419.
2. Dhombres F, Friszer S, Castaing O, et al. Fetal abdominal cysts at the first trimester scan. *Gynecol Obstet Fertil*. 2015;43(7-8):491-495.
3. Valenti C, Kassner G, Yermakov V, et al. Antenatal diagnosis of a fetal ovarian cyst. *Am J Obstet Gynecol*. 1975;15:216-219.
4. Kirkinen P, Jouppila P. Perinatal aspects of pregnancy complicated by fetal ovarian cyst. *J Perinat Med*. 1985;13(5):245-251.
5. Bryant AE, Laufer MR. Fetal ovarian cysts: incidence, diagnosis and management. *J Reprod Med*. 2004;49(5):329-337.
6. Trinh TW, Kennedy AM. Fetal ovarian cysts: review of imaging spectrum, differential diagnosis, management, and outcome. *Radiographics*. 2015;35(2):621-635.
7. Meizner I, Levy A, Katz M, et al. Fetal ovarian cysts: prenatal ultrasonographic detection and postnatal evaluation and treatment. *Am J Obstet Gynecol*. 1991;164(3):874-878.
8. Nyberg DNI. *Abdomen and Gastrointestinal Tract. Diagnostic Imaging of Fetal Anomalies*. Philadelphia: Lippincott Williams & Wilkins; 2003:547-602.
9. Crombleholme TM, Craigo SD, Garmel S, et al. Fetal ovarian cyst decompression to prevent torsion. *J Pediatr Surg*. 1997;32(10):1447-1449.
10. Giorlandino C, Rivosecchi M, Bilancioni E, et al. Successful intrauterine therapy of a large fetal ovarian cyst. *Prenat Diagn*. 1990;10(7):473-475.
11. Perrotin F, Potin J, Haddad G, et al. Fetal ovarian cysts: a report of three cases managed by intrauterine aspiration. *Ultrasound Obstet Gynecol*. 2000;16(7):655-659.
12. Heling KS, Chaoui R, Kirchmair F, et al. Fetal ovarian cysts: prenatal diagnosis, management and postnatal outcome. *Ultrasound Obstet Gynecol*. 2002;20(1):47-50.
13. Bascietto F, Liberati M, Marrone L, et al. Outcome of ovarian cysts diagnosed on prenatal ultrasound: a systematic review and meta-analysis. *Ultrasound Obstet Gynecol*. 2016;http://dx.doi.org/10.1002/uog.16002. [epub ahead of print].
14. Monnery-Noche ME, Auber F, Jouannic JM, et al. Fetal and neonatal ovarian cysts: is surgery indicated? *Prenat Diagn*. 2008;28(1):15-20.
15. Pienkowski C, Cartault A, Carfagna L, et al. Fetal ovarian cysts: preliminary results of a prospective study of neonatal management. *Arch Pediatr*. 2009;16(6):583-584.
16. Richards DS, Langham MR, Anderson CD. The prenatal sonographic appearance of enteric duplication cysts. *Ultrasound Obstet Gynecol*. 1996;7(1):17-20.
17. Foley PT, Sithasanan N, McEwing R, et al. Enteric duplications presenting as antenatally detected abdominal cysts: is delayed resection appropriate? *J Pediatr Surg*. 2003;38(12):1810-1813.
18. Okamoto T, Takamizawa S, Yokoi A, et al. Completely isolated alimentary tract duplication in a neonate. *Pediatr Surg Int*. 2008;24(10):1145-1147.
19. Gray SWSJ. *The small intestines: embryology for surgeons*. Baltimore: Williams and Wilkins; 1994.
20. Nishizawa C, Cajusay-Velasco S, Mashima M, et al. HD live imaging of fetal enteric duplication cyst. *J Med Ultrasonics*. 2014;41(4):511-514.
21. Heaton TE, Liechty KW. Postnatal management of prenatally diagnosed abdominal masses and anomalies. *Prenat Diagn*. 2008;28(7):656-666.
22. Holcomb GW 3rd, Gheissari A, O'Neill JA Jr, et al. Surgical management of alimentary tract duplications. *Ann Surg*. 1989;209(2):167-174.
23. Gupta P, Sharma R, Kumar S, et al. Role of MRI in fetal abdominal cystic masses detected on prenatal sonography. *Arch Gynecol Obstet*. 2010;281(3):519-526.
24. McEwing R, Hayward C, Furness M. Foetal cystic abdominal masses. *Australas Radiol*. 2003;47(2):101-110.
25. Chang TS, Ricketts R, Abramowsky CR, et al. Mesenteric cystic masses: a series of 21 pediatric cases and review of the literature. *Fetal Pediatr Pathol*. 2011;30(1):40-44.
26. Mostofian E, Ornvold K, Latchaw L, et al. Prenatal sonographic diagnosis of abdominal mesenteric lymphangioma. *J Ultrasound Med*. 2004;23(1):129-132.
27. Ho M, Lee CC, Lin TY. Prenatal diagnosis of abdominal lymphangioma. *Ultrasound Obstet Gynecol*. 2002;20(2):205-206.
28. Wilson SR, Bohrer S, Losada R, et al. Retroperitoneal lymphangioma: an unusual location and presentation. *J Pediatr Surg*. 2006;41(3):603-605.
29. Kurtz RJ, Heimann TM, Holt J, et al. Mesenteric and retroperitoneal cysts. *Ann Surg*. 1986;203(1):109-112.
30. Cilento BG Jr, Bauer SB, Retik AB, et al. Urachal anomalies: defining the best diagnostic modality. *Urology*. 1998;52(1):120-122.
31. Matsui F, Matsumoto F, Shimada K. Prenatally diagnosed patent urachus with bladder prolapse. *J Pediatr Surg*. 2007;42(12):e7-e10.
32. Lugo B, McNulty J, Emil S. Bladder prolapse through a patent urachus: fetal and neonatal features. *J Pediatr Surg*. 2006;41(5):e5-e7.
33. Palazzi D, Brandt M. Care of the umbilicus and management of umblical disorders. In:Basow DS, ed. *UpToDate*. Waltham, MA: UpToDate; 2010.
34. Tolaymat LL, Maher JE, Kleinman GE, et al. Persistent patent urachus with allantoic cyst: a case report. *Ultrasound Obstet Gynecol*. 1997;10(5):366-368.
35. Riddell JV, Houle AM, Franc-Guimond J, et al. Prenatal vesico-allantoic cyst outcome — a spectrum from patent urachus to bladder exstrophy. *Prenat Diagn*. 2015;35(13):1342-1346.
36. Rich RH, Hardy BE, Filler RM. Surgery for anomalies of the urachus. *J Pediatr Surg*. 1983;18(4):370-372.
37. Fuchs F, Picone O, Levaillant JM, et al. Prenatal diagnosis of a patent urachus cyst with the use of 2D, 3D, 4D ultrasound and fetal magnetic resonance imaging. *Fetal Diagn Ther*. 2008;24(4):444-447.
38. Taori K, Krishnan V, Sharbidre KG, et al. Prenatal sonographic diagnosis of fetal persistent urogenital sinus with congenital hydrocolpos. *Ultrasound Obstet Gynecol*. 2010;36(5):641-643.
39. Winderl LM, Silverman RK. Prenatal diagnosis of congenital imperforate hymen. *Obstet Gynecol*. 1995;85(5 Pt 2):857-860.
40. Couper JJ, Hutson JM, Warne GL. Hydrometrocolpos following prenatal dexamethasone treatment for congenital adrenal hyperplasia (21-hydroxylase deficiency). *Eur J Pediatr*. 1993;152(1):9-11.
41. Moore K. *The Urogenital System. The Developing Human: Clinically Oriented Embryology*. Philadelphia, London: WB Saunders; 1988:246-284.
42. Arena F, Cordaro S, Romeo C, et al. McKusick-Kaufman syndrome: diagnostic and therapeutic problems. *Pediatr Med Chir*. 1999;21(2):67-71.
43. Muller R, Dohmann S. Hydrometrocolpos causing progressive unilateral hydronephrosis in agenesis of the contralateral kidney. *Zentralbl Gynakol*. 2000;122(11):581-584.
44. Nigam A, Kumar M, Gulati S. Fetal ascites and hydrometrocolpos due to persistent urogenital sinus and cloaca: a rare congenital anomaly and review of literature. *BMJ Case Rep*. 2014;2014.
45. Calvo-Garcia MA, Kline-Fath BM, Levitt MA, et al. Fetal MRI clues to diagnose cloacal malformations. *Pediatr Radiol*. 2011;41(9):1117-1128.
46. Zalel Y, Lehavi O, Heifetz S, et al. Varix of the fetal intra-abdominal umbilical vein: prenatal sonographic diagnosis and suggested in utero management. *Ultrasound Obstet Gynecol*. 2000;16(5):476-478.
47. Fung TY, Leung TN, Leung TY, et al. Fetal intra-abdominal umbilical vein varix: what is the clinical significance? *Ultrasound Obstet Gynecol*. 2005;25(2):149-154.
48. Mankuta D, Nadjari M, Pomp G. Isolated fetal intra-abdominal umbilical vein varix: clinical importance and recommendations. *J Ultrasound Med*. 2011;30(2):273-276.
49. Sepulveda W, Sebire N, Harris R, et al. *The Placenta, Umbilical Cord and Membranes. Diagnostic Imaging of Fetal Anomalies*. Philadelphia: Lippincott Williams & Wilkins; 2003:85-132.
50. Huber G. Title page—intrahepatic umbilical vein varix with postnatal complication in the newborn. *Ultraschall Med*. 2010;31(1):1-3.
51. Viora E, Sciarrone A, Bastonero S, et al. Thrombosis of umbilical vein varix. *Ultrasound Obstet Gynecol*. 2002;19(2):212-213.
52. Allen SL, Bagnall C, Roberts AB, et al. Thrombosing umbilical vein varix. *J Ultrasound Med*. 1998;17(3):189-192.
53. Sepulveda W, Mackenna A, Sanchez J, et al. Fetal prognosis in varix of the intrafetal umbilical vein. *J Ultrasound Med*. 1998;17(3):171-175.
54. Melcer Y, Ben-Ami I, Wiener Y, et al. Long-term outcomes of children with umbilical vein varix diagnosed prenatally. *Prenat Diagn*. 2013;33(5):492-496.
55. Marchitelli G, Stirnemann J, Acanfora MM, et al. Prenatal diagnosis of intra-abdominal cystic lesions by fetal ultrasonography: diagnostic agreement between prenatal and postnatal diagnosis. *Prenat Diagn*. 2015;35(9):848-852.
56. Deshpande P, Twining P, O'Neill D. Prenatal diagnosis of fetal abdominal lymphangioma by ultrasonography. *Ultrasound Obstet Gynecol*. 2001;17(5):445-448.
57. Shukunami K, Tsuji T, Kotsuji F. Prenatal sonographic features of vesicoallantoic cyst. *Ultrasound Obstet Gynecol*. 2000;15(6):545-546.
58. Weichert J, Chiriac A, Kaiser M, et al. Prenatal management of an allantoic cyst with patent urachus. *Arch Gynecol Obstet*. 2009;280(2):321-323.
59. Hayashi S, Sago H, Kashima K, et al. Prenatal diagnosis of fetal hydrometrocolpos secondary to a cloacal anomaly by magnetic resonance imaging. *Ultrasound Obstet Gynecol*. 2005;26(5):577-579.

25 Biliary Anomalies

SILKE A. M. MICHAELIS | KARIM D. KALACHE

Introduction

The diagnosis and detection of some forms of bile duct disease have become possible with routine prenatal ultrasound. However, it remains difficult to offer a specific diagnosis or even prognosis in most cases. The most common finding is probably cystic dilatation of the biliary tree, mainly because of choledochal cysts or biliary atresia. In this chapter, biliary atresia, choledochal cysts, and gallstones will be discussed, as they are amenable to prenatal diagnosis.

The gallbladder and the cystic duct begin to form during the fourth week of embryonic development as a cystic diverticulum situated below the hepatic diverticulum at the level of the duodenum. As soon as development of the cystic diverticulum is completed, cell proliferation at the junction of the cystic and hepatic ducts lead to formation of the intra- and extrahepatic biliary tracts. Bile excretion starts around the 12th week of gestation.[1] At around the same time, the gallbladder and the cystic duct are completely formed and the cystic duct joins the common hepatic duct to form the biliary duct. The biliary tract is patent allowing bile secretion into the intestinal tract.

The fetal gallbladder can be visualized from the 14th–16th week onward[2] and it is seen in 65% to 82% of fetuses at 24–27 weeks' gestation.[3] Its size increases continuously until 30–34 weeks' gestation and then remains unchanged until term.[4]

On ultrasound, the gallbladder appears as a small, hypoechoic, oval cystic structure located at the lower border of the liver, close to the intestinal loops, and to the right of the intraabdominal umbilical vein. It is smaller than the stomach. Its shape and volume can vary from one fetus to another.

Biliary Atresia

DEFINITION

Biliary atresia (BA) is the destructive inflammatory obliterative cholangiopathy of neonates. BA is not associated with calculi, neoplasm, or rupture.

It is a life-threatening condition in infants, one of the most common causes of neonatal cholestasis and the most frequent indication for liver transplantation in childhood.[5] If untreated, progressive liver cirrhosis leads to death by the age of 2 years. Early diagnosis and intervention are important for a better outcome. The disease is classified based on the anatomic pattern of the extrahepatic biliary tract remnant (Fig. 25.1 and Table 25.1).

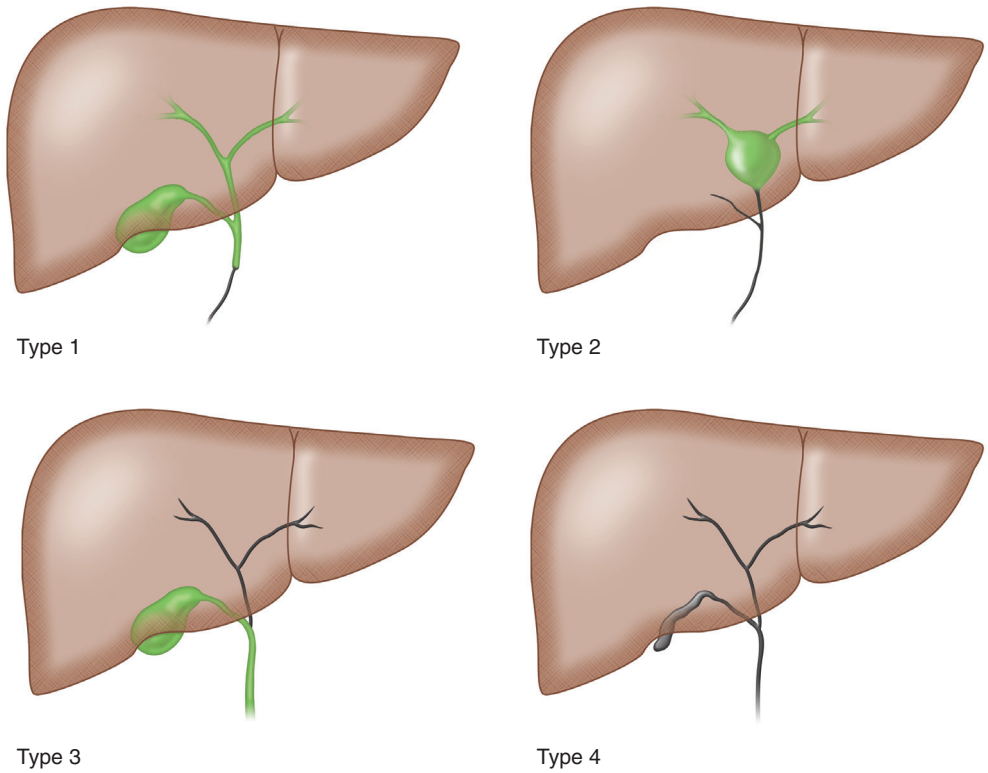

Fig. 25.1. French classification of biliary atresia. *Type 1,* Atresia limited to common bile duct; *type 2,* cyst in the liver hilum communicating with dystrophic intrahepatic bile ducts; *type 3,* hepatic duct atresia; gallbladder, cystic duct, and common bile duct patent; *type 4,* complete extrahepatic biliary atresia. *(Redrawn from Callen PW:* Ultrasonography in obstetrics and gynaecology, *ed 5, Philadelphia, Saunders, 2008.)*

TABLE 25.1 ANATOMIC TYPES OF BILIARY ATRESIA

French Classification	Frequency (%)	Description	Upper Level of Obstruction of the Extrahepatic Bile Ducts
Type 1	3	Atresia limited to the common bile duct	Common bile duct
Type 2	6	Cyst in the liver hilum communicating with dystrophic intrahepatic bile ducts	Hepatic duct
Type 3	19	Gallbladder, cystic duct, and common bile duct patent	Porta hepatis
Type 4	72	Complete extrahepatic biliary atresia	Porta hepatis

Derived from Chardot C: Biliary atresia. *Orphanet J Rare Dis* 1:28, 2006.

PREVALENCE AND EPIDEMIOLOGY

Biliary atresia (BA) is a rare disorder with estimates of national prevalence ranging from 0.2:10,000 to 0.5:10,000 in the UK and France.[6,7] It is more common in East Asia and has a prevalence of 2:10,000 in Taiwan.[6] There is no sex predilection in Caucasians, although in Japan there is a female predominance.[8] BA is rarely familial and in twins is usually discordant.

Associated congenital anatomic abnormalities are found in up to 20% of neonates, the most common being biliary atresia-splenic malformation syndrome (BASM syndrome), reported in about 10% of a European series.[9] Clinical features of the laterality defect sequence, such as asplenia, polysplenia, and situs inversus, can be present. Cardiac, gastrointestinal, renal, and urinary tract anomalies have also been described (Table 25.2).[9] BA has also been seen in trisomies 18 and 21.

In 80% to 90% the disorder seems to be isolated. It is thought that the obliterative process begins in the perinatal period in this group of patients ("perinatal" or "acquired form"), whereas it is believed to begin in the embryonic phase in the syndromic cases ("congenital" or "embryonic form").[5] In some cases of isolated BA, cystic changes are observed within the obliterated biliary tree (cystic biliary atresia) and can also be detected on prenatal ultrasound examination.[9,10]

ETIOLOGY AND PATHOPHYSIOLOGY

The cause of BA remains unknown, and the disease is believed to be multifactorial in nature. Some cases seem to be related to abnormal morphogenesis of the bile ducts early in gestation, whereas others seem to result from later damage to normally developing bile ducts.[5,11] Genetic, vascular, inflammatory, and toxic insults might contribute to the obliterative cholangiopathy observed in BA.[11]

MANIFESTATIONS OF DISEASE

Clinical Presentation

BA typically presents shortly after birth with persistent jaundice, pale stools, and dark urine in term infants with normal birth weights.[7] Initially the child is in good condition. Weight loss, irritability, and increasing levels of jaundice develop later. Splenomegaly, ascites, and hemorrhage (impaired absorption of vitamin K) develop. Untreated, this condition leads to cirrhosis and death within the first years of life.[5,7,12]

TABLE 25.2 CONGENITAL ANOMALIES ASSOCIATED WITH SYNDROMIC BILIARY ATRESIA

	Frequency (%)
Splenic malformation (e.g., polysplenia, asplenia, double spleen)	100
Situs inversus	37
Intestinal malrotation	60
Absent inferior vena cava	70
Cardiac anomalies (e.g., ventricular or atrial septal defect, hypoplastic left heart)	45
Pancreatic anomalies (e.g., annular pancreas)	11

From Hartley JL, Davenport M, Kelly DA: Biliary atresia. *Lancet* 374:1704–1713, 2009.

Imaging Technique and Findings

Ultrasound. The prenatal diagnosis of BA is difficult and remains exceptional (about 5%).[10,13] On prenatal ultrasound, it is suspected when the fetal gallbladder cannot be seen on any occasion, which is sometimes associated with a small cystic structure in the liver hilum.[9,10,13] (Fig. 25.2).

Mainly BA types 1 and 2, which occur less frequently, can be suspected on prenatal sonography. In such cases amniocentesis is recommended for cystic fibrosis screening, hepatic enzyme tests, and karyotyping.[14] Digestive enzymes are present in the amniotic fluid (AF) from the 12th week onward and will increase until the 18th week, after which maturation of the anal sphincter progressively impairs this. After 22 weeks, there are normally only very low levels of digestive enzyme activities in AF, making it difficult to discern between physiologically and abnormally low levels. Therefore, it is only useful to measure digestive enzymes in the amniotic fluid before the 22nd week. Biliary atresia is associated with a very low level of only the hepatic enzyme gamma-glutamyl-transpeptidase (GGTP), which is secreted from the biliary epithelium,[15] while in cystic fibroses there is a very low level of all digestive enzymes including alkaline phosphatase (AP), which is secreted by the enterocytes.[14,16,17] High level of GGTP at 22 weeks is considered as a reassuring sign.

CLASSIC SIGNS

After birth, the clinical triad of BA is jaundice, acholic stools, and dark urine, as well as hepatomegaly.[7]

Choledochal Cysts

DEFINITION

Choledochal cysts (CC) are rare congenital anomalies of the biliary tract that are the result of an abnormally long common pancreaticobiliary duct allowing reflux of pancreatic enzymes into the biliary ducts. It is four times more common in girls and considered a disease of infancy, with 40% to 60% of cases being diagnosed before the age of 10. The Todani classification is descriptive and distinguishes five types of CC (Fig. 25.3 and Table 25.3). Type I is the most common type with a saclike dilatation of the common bile duct. Type V, also known as the autosomal recessive *Caroli disease*, shows cystic dilatations of the intrahepatic biliary duct.[18]

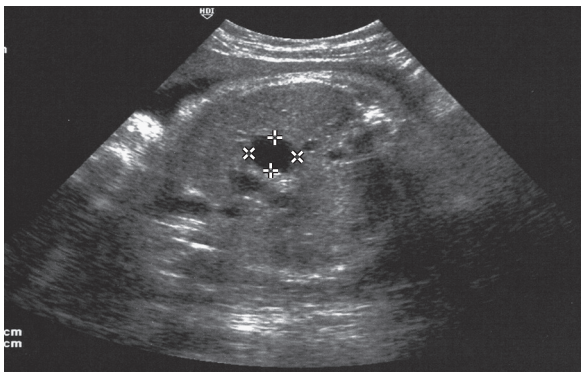

Fig. 25.2. Biliary atresia. Prenatal ultrasound at 31 weeks' gestation with a cystic structure on the caudal surface of the liver (calipers indicating size of 15 mm × 16 mm). *(From Davenport M, Hadzic N: Prenatal diagnosis of liver and biliary tract disease.* Semin Neonatol *8:347–355, 2003.)*

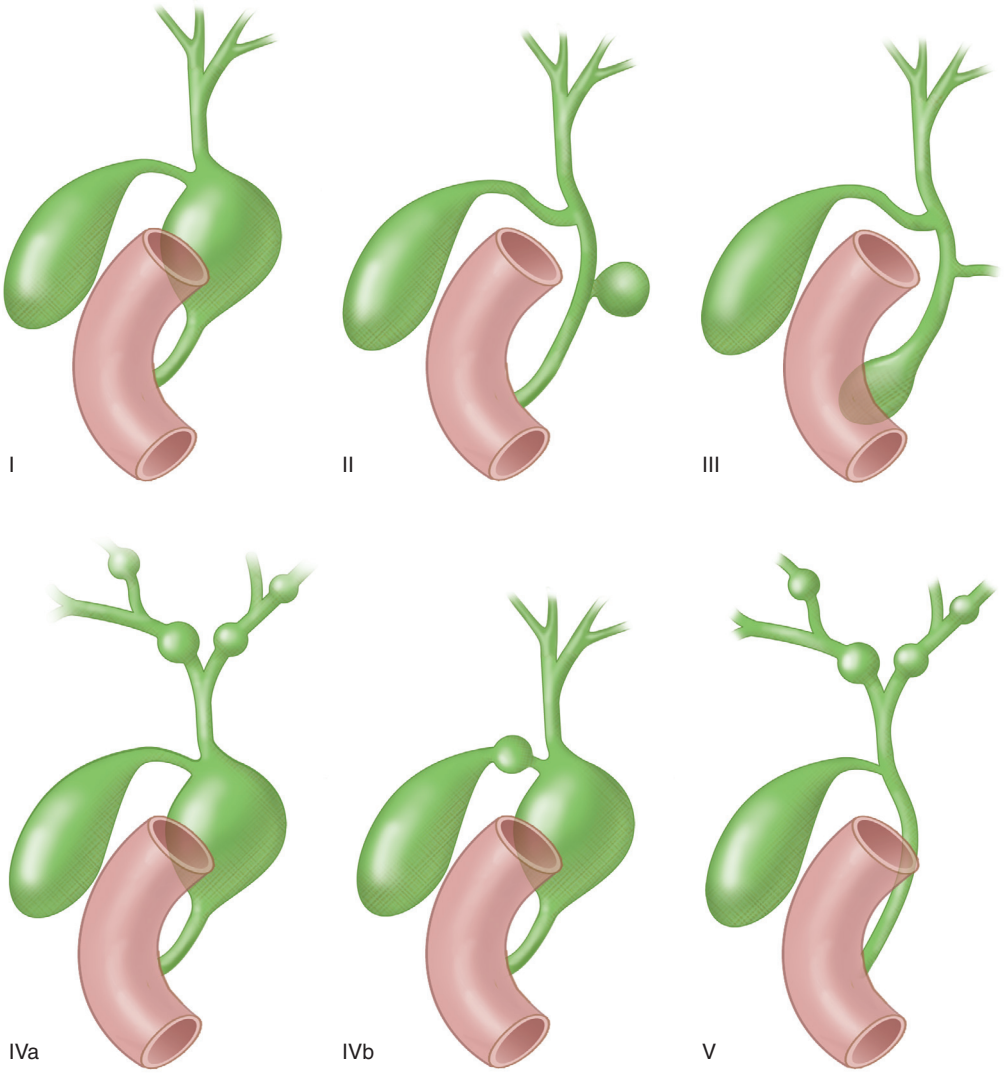

Fig. 25.3. Choledochal cyst classification (Todani classification[18]). See Table 25.3 for an explanation of the various types of cysts. *(Redrawn from Callen PW:* Ultrasonography in obstetrics and gynaecology, *ed 5, Philadelphia, Saunders, 2008.)*

TABLE 25.3 CLASSIFICATION SCHEMES FOR CHOLEDOCHAL CYSTS

	Type I	Type II	Type III	Type IV	Type V
Alonso-Lej	Congenital cystic dilatation of common bile duct	Congenital diverticulum of common bile duct	Congenital choledochocele		
Todani	(a) Common type, (b) segmental dilatation, (c) diffuse/cylindric dilatation	Diverticulum type in any part of extrahepatic duct	Choledochocele	(a) Multiple cysts in intra- and extrahepatic ducts, (b) multiple cysts in extrahepatic ducts only	Intrahepatic bile duct cyst (single or multiple)
Visser	Choledochal cyst	Choledochal diverticulum	Choledochocele	Choledochal cyst	Caroli disease

Derived from Clifton MS, et al.: *Pediatrics* 117:e596-e600, 2006.

PREVALENCE AND EPIDEMIOLOGY

The incidence in Western countries is 1 : 100,000 live births, but is much higher in Asian populations. Choledochal cysts are four to five times more common in females among whites.[19]

ETIOLOGY AND PATHOPHYSIOLOGY

The etiology of CC remains unknown. Several mechanisms have been postulated: a failure of recanalization of the primitive biliary tree, the theory of a long common channel allowing free mixing of pancreatic and biliary juices, and the theory of distal obstruction.[19–21]

MANIFESTATION OF DISEASE

Clinical Presentation

Most patients present with abdominal pain, fever and/or nausea, and vomiting.[22] Twenty percent of cases are diagnosed within the first 6 months of life, mainly with jaundice. Most CC become apparent in children between 6 months and 10 years of age, and symptoms may be present for 2–3 years before the establishment of the diagnosis. Diagnostic delay appears to be common and may have fatal consequences, such as pancreatitis, spontaneous perforation, cholelithiasis, cholangitis, secondary liver cirrhosis, portal hypertension, and malignancy. Early treatment and early diagnosis can reduce the incidence of serious complications.[19,22,23]

Imaging Technique and Findings

Ultrasound. Despite advances in obstetric ultrasonography, it is difficult to make a correct prenatal diagnosis. Fetal choledochal cysts usually appear as a fluidfilled, anechoic mass in the region of the porta hepatis (Fig. 25.4). They have been described as early as in the first trimester, but usually are seen at routine morphology scan around 20 weeks.[10,24] Demonstration of continuity with the gallbladder or hepatic ducts can facilitate the diagnosis. Occasionally, associated biliary duct dilation can be observed. The cystic lesion is immobile and can increase in size as pregnancy progresses. Color Doppler can be helpful in demonstrating the closeness to the portal vein and hepatic artery.[10,19] The use of three-dimensional (3D) tomographic display has been reported to be of use in establishing the location and anatomic relation of the cyst.[24]

Magnetic Resonance Imaging. Magnetic resonance imaging (MRI) used in the late third trimester has been described to delineate the spatial anatomic relationship of the CC with other internal organs. This information is very useful to identify the type of CC and for differential diagnosis. Owing to its excellent anatomic and contrast resolution, valuable additional information can be provided using T1- and T2-weighted MRI in addition to ultrasound.[25,26] (Fig. 25.5).

CLASSIC SIGNS

The classic presentation of a choledochal cyst is that of pain, jaundice, and right hypochondrial mass, which is rare in children.[20,21]

Gallstones

DEFINITION

The presence of echogenic material, sludge, or formation of calculi within the fetal gallbladder can be visualized on prenatal ultrasound in the third trimester.[27,28]

PREVALENCE AND EPIDEMIOLOGY

Detection of echogenic foci in the gallbladder is unusual in prenatal life, but not rare. Although the exact incidence is unknown, Kiserud observed echogenic material in nearly 1% of referred patients after 28 weeks,[28] and Cancho Candela observed a rate of 0.45%.[29] Reports on possible associated anomalies with echodensity in the gallbladder are conflicting. Kiserud described associations with intrauterine growth restriction (IUGR), tetralogy of Fallot, trisomy 21, and gastroschisis.[28] Other authors described echogenic foci in the gallbladder as benign and without associated

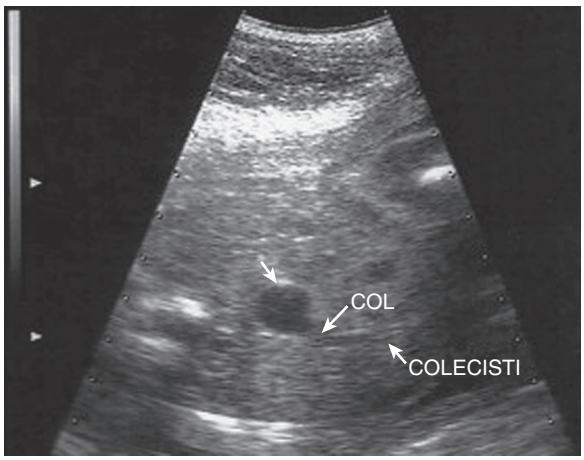

Fig. 25.4. Choledochal cyst. A subhepatic cystic lesion is communicating with the choledochal duct *(arrow)* at 23 weeks' gestation. *COL,* Choledochal duct; *COLECISTI,* gallbladder. *(From Casaccia G, Bilancioni E, Nahom A, et al.: Cystic anomalies of biliary tree in the fetus: is it possible to make a more specific prenatal diagnosis?* J Pediatr Surg *37:1191–1194, 2002.)*

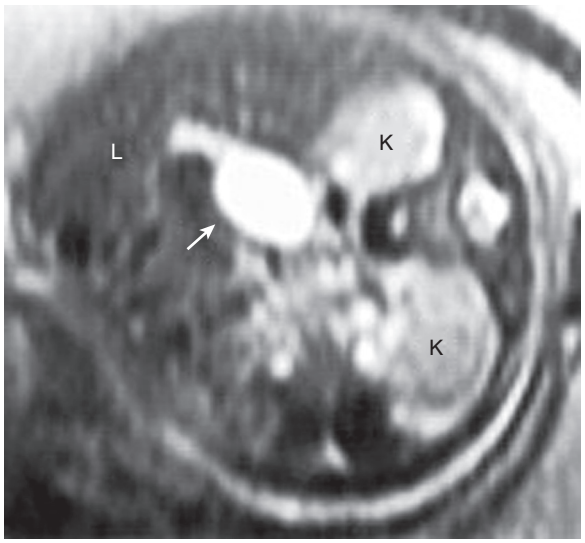

Fig. 25.5. Prenatal ultrafast MRI showing a large cyst in the fetal abdomen *(arrow). K,* Kidney; *L,* liver. *(From MacKenzie TC, Howell LJ, Flake AW, et al.: The management of prenatally diagnosed choledochal cysts.* J Pediatr Surg *36:1241–1243, 2001.)*

anomalies. Most gallstones resolve spontaneously either pre- or postnatally.[27,29–31]

ETIOLOGY AND PATHOPHYSIOLOGY

The cause or natural history of sludge or stones in the fetal gallbladder is unknown and they often are incidental findings in the third trimester. Brown proposed that an increase in cholesterol level and depressed bile acid synthesis caused by estrogen might be responsible for the formation of gallstones.[27] In neonates, possible causes of gallstones include hemolytic disorders (e.g., thalassemia, sickle cell anemia) and nonhemolytic disorders (e.g., pancreatitis, cystic fibrosis, hyperalimentation).[27,32]

MANIFESTATION OF DISEASE

Imaging Technique and Findings

Ultrasound. Stones and sludge in the fetal gallbladder are mainly observed in the third trimester and produce a variety of sonographic appearances.[29,31] There is a wide range regarding homogeneity, echogenicity, and degree of acoustic shadowing. Using a transverse section through the fetal abdomen, single, multiple, or diffuse echogenic foci (filling the complete gallbladder lumen) with or without acoustic shadowing can be observed (Fig. 25.6).

Differential Diagnosis From Imaging Findings

Despite advances in obstetric ultrasonography, it is still difficult to make a correct prenatal diagnosis of the different types of biliary cystic malformations. Frequently the correct diagnosis is missed.[33] CC and BA share the same ultrasound patterns, and no sonographic differential parameter is unequivocally accepted.[10,13,34] Some authors suggest that an increase in size of the cyst as well as echogenicity suggesting bile flow might indicate a CC. In contrast, a cyst with an anechoic pattern and small dimensions remaining stable in size, suggesting of absence of bile flow into the cyst, favors the diagnosis of BA.[10]

The differential diagnosis of cystic biliary malformations includes duodenal atresia, enteric duplication cyst, ovarian cyst, liver cyst, and gallbladder duplication.[30] Gallbladder echogenic foci could mimic intrahepatic or peritoneal calcifications, especially in a contracted gallbladder, or hyperechogenic bowel.[27]



Fig. 25.6. Sludge in the fetal gallbladder. *(Courtesy Dr. H. G. Blaas, Trondheim University Hospital, Norway.)*

Synopsis of Treatment Options: Biliary Atresia

PRENATAL

There is no prenatal treatment for BA. Timely referral for an ultrasound evaluation of the liver and biliary tree to evaluate the lesion precisely is important.

POSTNATAL

Infants in whom a prenatal suspicion of BA have been made or infants with persistent jaundice and acholic stools must be promptly investigated. This includes postnatal ultrasound of the abdomen and may include percutaneous liver biopsy, endoscopic retrograde cholangiopancreatography, and magnetic resonance cholangiopancreatography for noninvasive definition of biliary anatomy.[5,7,35] Early diagnosis is essential to avoid liver damage and cirrhosis. Occasionally, operative cholangiography may be essential. The treatment of choice is surgical and consists of a Kasai portoenterostomy to achieve clearance of jaundice and restore liver function. This should be performed as soon as possible (not after 60 days of age) to be successful.[12] Liver transplantation may be needed later if the Kasai operation fails or if cirrhosis occurs. Approximately 90% of patients survive and most have a normal quality of life.

Synopsis of Treatment Options: Choledochal Cyst

PRENATAL

As with BA, specialist referral is essential. The size of the cyst should be monitored, as cysts can grow.

POSTNATAL

In cases of suspected cystic anomalies of the biliary tree, a confirmatory postnatal ultrasound has to be done and the same diagnostic steps and interventions as described with BA must be made to establish an accurate diagnosis. The treatment of choice is surgical: complete excision of the extrahepatic bile ducts including the gallbladder and a biliary-enteric reconstruction, most commonly a Roux-en-Y hepaticojejunostomy. The optimal time for surgery is about 3–6 months of age. In cases of an obstructed CC, early laparotomy needs to be considered to avoid late sequelae.[19,21]

Synopsis of Treatment Options: Gallstones

PRENATAL

There is no prenatal treatment for gallstones. Serial evaluations of the echogenic material as well as a detailed morphology scan are warranted.

POSTNATAL

Most fetal and neonatal gallstones resolve spontaneously. A postnatal sonographic follow-up can be considered.

WHAT THE REFERRING PHYSICIAN NEEDS TO KNOW

Biliary atresia and choledochal cysts are rare diseases, often missed on prenatal ultrasound examination. Infants with persisting jaundice and acholic stools must be regarded as having BA and hence urgently need to be referred to a specialist center to establish a correct diagnosis and for early surgical intervention.

KEY POINTS

- The correct prenatal diagnosis in cases with cystic biliary malformation is often imprecise.
- A distinction between CC and BA is extremely difficult and not always possible.
- Third-trimester MRI and 3D ultrasound can provide additional useful information in cases of suspected CC.
- Postnatal investigation usually allows a specific diagnosis and therefore treatment.
- Therefore, early referral to a specialized center is advised in cases of suspected cystic hepatic lesions.
- Early surgical intervention in cases of BA and CC diminishes the risks of long-term liver sequelae.
- Fetal gallstones are rare and mostly resolve spontaneously.

SUGGESTED READINGS

Chardot C. Biliary atresia. *Orphanet J Rare Dis*. 2006;1:28.

Davenport M, Hadzic N. Prenatal diagnosis of liver and biliary tract disease. *Semin Neonatol*. 2003;8:347-355.

Hartley JL, Davenport M, Kelly DA. Biliary atresia. *Lancet*. 2009;374:1704-1713.

Nyberg DA, Neilsen IR. Abdomen and gastrointestinal tract: gallbladder echogenic foci. In: Nyberg DA, McGahan JP, Pretorius DH, et al, eds. *Diagnostic imaging of fetal anomalies*, edition. Philadelphia: Lippincott, Williams & Wilkins; 2003:591-592.

Singham J, Yoshida EM, Scudamore C. Choledochal cysts. Part 1: Classification and pathogenesis. *Can J Surg*. 2009;52:434-440.

Singham J, Yoshida EM, Scudamore CH. Choledochal cysts. Part 2: Diagnosis. *Can J Surg*. 2009;52:506-511.

Singham J, Yoshida EM, Scudamore CH. Choledochal cysts. Part 3: Management. *Can J Surg*. 2010;53:51-56.



All references are available online at www.expertconsult.com.

REFERENCES

1. Sadler TW. Digestive system. In: *Langman's medical embryology*. 5th ed. Baltimore: Williams & Wilkins; 1985.
2. Blazer S, Zimmer EZ, Bronshtein M. Nonvisualization of the fetal gallbladder in early pregnancy: comparison with clinical outcome. *Radiology*. 2002;224(2):379-382.
3. Hata K, Aoki S, Hata T, et al. Ultrasonographic identification of the human fetal gallbladder in utero. *Gynecol Obstet Invest*. 1987;23(2):79-83.
4. Goldstein I, Tamir A, Weisman A, et al. Growth of the fetal gall bladder in normal pregnancies. *Ultrasound Obstet Gynecol*. 1994;4(4):289-293.
5. Chardot C, Debray D. Biliary atresia: a condition requiring urgent diagnosis and treatment. *Arch Pediatr*. 2011;18(4):476-481.
6. Chardot C, Carton M, Spire-Bendelac N, et al. Epidemiology of biliary atresia in France: a national study 1986-96. *J Hepatol*. 1999;31(6):1006-1013.
7. McKiernan PJ, Baker AJ, Kelly DA. The frequency and outcome of biliary atresia in the UK and Ireland. *Lancet*. 2000;355(9197):25-29.
8. Ohi R. Surgery for biliary atresia. *Liver*. 2001;21(3):175-182.
9. Tanaka N, Ueno T, Takama Y, et al. Diagnosis and management of biliary cystic malformations in neonates. *J Pediatr Surg*. 2010;45(11):2119-2123.
10. Casaccia G, Bilancioni E, Nahom A, et al. Cystic anomalies of biliary tree in the fetus: is it possible to make a more specific prenatal diagnosis? *J Pediatr Surg*. 2002;37(8):1191-1194.
11. Mack CL, Sokol RJ. Unraveling the pathogenesis and etiology of biliary atresia. *Pediatr Res*. 2005;57(5 Pt 2):87R-94R.
12. Hsiao CH, Chang MH, Chen HL, et al. Universal screening for biliary atresia using an infant stool color card in Taiwan. *Hepatology*. 2008;47(4):1233-1240.
13. Hinds R, Davenport M, Mieli-Vergani G, et al. Antenatal presentation of biliary atresia. *J Pediatr*. 2004;144(1):43-46.
14. Boughanim M, Benachi A, Dreux S, et al. Nonvisualization of the fetal gallbladder by second-trimester ultrasound scan: strategy of clinical management based on four examples. *Prenat Diagn*. 2008;28(1):46-48.
15. Muller F, Gauthier F, Laurent J, et al. Amniotic fluid GGT and congenital extrahepatic biliary damage. *Lancet*. 1991;337(8735):232-233.
16. Ochshorn Y, Rosner G, Barel D, et al. Clinical evaluation of isolated nonvisualized fetal gallbladder. *Prenat Diagn*. 2007;27(8):699-703.
17. Chalouhi GE, Muller F, Dreux S, et al. Prenatal non-visualization of fetal gallbladder: beware of biliary atresia! *Ultrasound Obstet Gynecol*. 2011;38(2):237-238, author reply 8-40.
18. Sgro M, Rossetti S, Barozzino T, et al. Caroli's disease: prenatal diagnosis, postnatal outcome and genetic analysis. *Ultrasound Obstet Gynecol*. 2004;23(1):73-76.
19. Couto JC, Leite JM, Machado AV, et al. Antenatal diagnosis of a choledocal cyst. *J Radiol*. 2002;83(5):647-649.
20. Stringer MD, Dhawan A, Davenport M, et al. Choledochal cysts: lessons from a 20 year experience. *Arch Dis Child*. 1995;73(6):528-531.
21. Clifton MS, Goldstein RB, Slavotinek A, et al. Prenatal diagnosis of familial type I choledochal cyst. *Pediatrics*. 2006;117(3):e596-e600.
22. Alonso-Lej F, Rever WB Jr, Pessagno DJ. Congenital choledochal cyst, with a report of 2, and an analysis of 94, cases. *Int Abstr Surg*. 1959;108(1):1-30.
23. Vijayaraghavan P, Lal R, Sikora SS, et al. Experience with choledochal cysts in infants. *Pediatr Surg Int*. 2006;22(10):803-807.
24. Lee IH, Kim GJ. Fetal choledochal cyst diagnosed at 22 weeks of gestation by three-dimensional ultrasonography: a case report. *J Korean Med Sci*. 2008;23(5):909-911.
25. Chen CP, Cheng SJ, Chang TY, et al. Prenatal diagnosis of choledochal cyst using ultrasound and magnetic resonance imaging. *Ultrasound Obstet Gynecol*. 2004;23(1):93-94.
26. Wong AM, Cheung YC, Liu YH, et al. Prenatal diagnosis of choledochal cyst using magnetic resonance imaging: a case report. *World J Gastroenterol*. 2005;11(32):5082-5083.
27. Brown DL, Teele RL, Doubilet PM, et al. Echogenic material in the fetal gallbladder: sonographic and clinical observations. *Radiology*. 1992;182(1):73-76.
28. Kiserud T, Gjelland K, Bogno H, et al. Echogenic material in the fetal gallbladder and fetal disease. *Ultrasound Obstet Gynecol*. 1997;10(2):103-106.
29. Cancho Candela R, Diaz Gonzalez J, Perandones Fernandez C, et al. Echogenic material in fetal gallbladder: prenatal diagnosis and postnatal follow-up. *An Pediatr (Barc)*. 2004;61(4):326-329.
30. Stringer MD, Lim P, Cave M, et al. Fetal gallstones. *J Pediatr Surg*. 1996;31(11):1589-1591.
31. Suma V, Marini A, Bucci N, et al. Fetal gallstones: sonographic and clinical observations. *Ultrasound Obstet Gynecol*. 1998;12(6):439-441.
32. Munjuluri N, Elgharaby N, Acolet D, et al. Fetal gallstones. *Fetal Diagn Ther*. 2005;20(4):241-243.
33. Davenport M, Hadzic N. Prenatal diagnosis of liver and biliary tract disease. *Semin Neonatol*. 2003;8(5):347-355.
34. Redkar R, Davenport M, Howard ER. Antenatal diagnosis of congenital anomalies of the biliary tract. *J Pediatr Surg*. 1998;33(5):700-704.
35. Todani T, Watanabe Y, Narusue M, et al. Congenital bile duct cysts: classification, operative procedures, and review of thirty-seven cases including cancer arising from choledochal cyst. *Am J Surg*. 1977;134(2):263-269.

26 Intestinal Obstruction

THORSTEN BRAUN | WOLFGANG HENRICH

Introduction

The fetal intestinal tract can be altered by numerous pathologic processes. Typical ultrasound (US) findings of bowel obstruction are dilated bowel loops in the fetal abdomen proximal to the obstruction. Although large bowel dilatation occasionally can be observed, most cases of bowel dilatation are in the small intestine.[1] Early diagnosis is possible for some proximal obstructions, such as duodenal atresia and esophageal atresia. In this chapter, we describe bowel disorders that can be diagnosed by prenatal US in anatomic sequence from the proximal to the distal segments of the gastrointestinal (GI) tract.

Esophageal Obstruction

DEFINITION

Esophageal obstruction is a malformation in which the esophagus is interrupted and forms a blind-ending pouch rather than connecting normally to the stomach. The interrupted esophagus may or may not communicate with the trachea, forming different types of trache-esophageal fistulae (TEFs).[2]

PREVALENCE AND EPIDEMIOLOGY

The incidence is between 1 : 3000 and 1 : 4000 live births.[3–6] Males are slightly more often affected than females.[1]

ETIOLOGY AND PATHOPHYSIOLOGY

The etiologies include genetic and environmental factors.[7–9] Esophageal obstruction with or without TEF[2] results from incomplete division by the tracheoesophageal septum of the foregut into the ventral respiratory portion and the dorsal digestive portion. This process is normally completed by 8 weeks' gestation. The most common variation is a proximal esophageal obstruction with a distal TEF, found in 86% of affected cases.[10] Isolated esophageal atresia (upper and lower pouch esophageal obstruction) accounts for 7% to 8% of cases.[10] The pathologic classification of esophageal malformations according to Gross[11] is shown in Table 26.1.

MANIFESTATIONS OF DISEASE

Clinical Presentation

Postnatal signs of esophageal atresia are respiratory distress, excessive salivation, "blowing bubbles," and feeding difficulties.

Imaging Technique and Findings

Ultrasound. Prenatal detection of esophageal obstruction is difficult; a suspicious prenatal US scan may show both polyhydramnios and a small or invisible fetal stomach (Figs. 26.1 and 26.2). The reported sensitivity of detecting esophageal obstruction with US ranges from 24% to 42%.[12] Polyhydramnios combined

TABLE 26.1 Different Types of Esophageal Atresia

Type	Name(s)	Description
A	"Long gap," "pure" or "isolated" esophageal atresia	Esophageal atresia without fistula; characterized by the presence of a "gap" between the two esophageal blind pouches
B	Esophageal atresia with proximal TEF	Esophageal atresia where the upper esophageal pouch connects abnormally to the trachea (fistula); lower esophageal pouch ends blindly
C	Esophageal atresia with distal TEF	Esophageal atresia where the lower esophageal pouch connects abnormally with the trachea (fistula); upper esophageal pouch ends blindly
D	Esophageal atresia with both proximal and distal TEFs (two TEFs)	Esophageal atresia where the upper and lower esophageal pouches make an abnormal connection with the trachea in two separate, isolated places; upper esophageal atresia also still ends in a blind pouch
E	TEF *only* with no esophageal atresia plus blind pouch over esophageal atresia	Rare form of esophageal atresia with esophagus fully intact and capable of normal functions, but there is an abnormal connection between the esophagus and the trachea, called a *fistula*
F	Esophageal stenosis; also known as *esophageal stricture*	Rare form of esophageal atresia with esophagus fully intact and connected to the stomach, but the esophagus gradually narrows, causing food and saliva to become "caught" in the esophagus; this type occasionally can go undiagnosed until adulthood

TEF, Trache-esophageal fistula.
Adapted from Gross RE: *The surgery of infancy and childhood,* Philadelphia, 1953, Saunders.

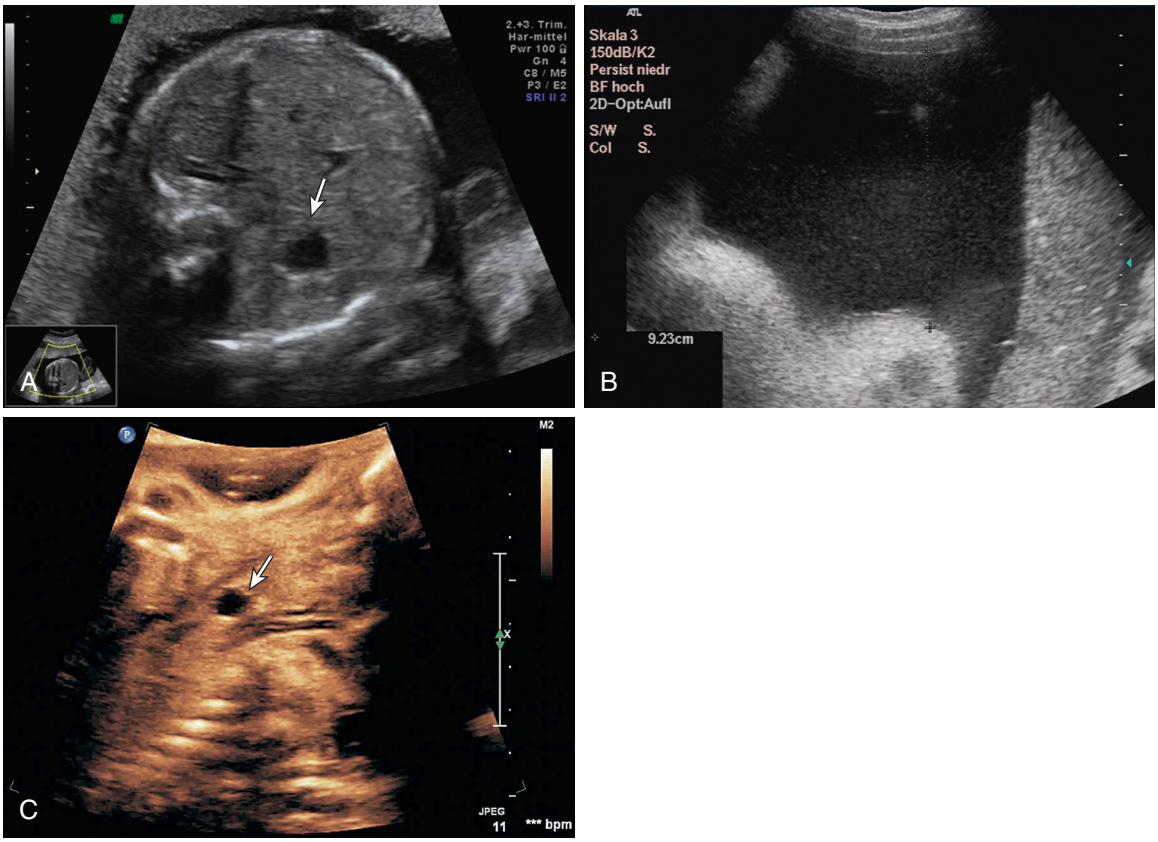

Fig. 26.1 Esophageal obstruction. (A) Small stomach at 27 weeks' gestation. (B) Polyhydramnios. (C) Esophageal obstruction with visible pouch *(arrow)* in a longitudinal section of the fetal neck.

with a small or invisible stomach increases the positive predictive value to 39% to 56%.[12–15] This combination lacks specificity, because amniotic fluid may flow into the stomach through a TEF. Because polyhydramnios usually does not occur before 20 weeks' gestation, the diagnosis of esophageal obstruction is often made later. Efforts to improve the detection rate have focused on demonstration on US or magnetic resonance imaging (MRI) of an esophageal pouch, representing the dilatation of the blind-ending upper esophagus,[15–20] which may be a transient finding. High-resolution US can sometimes visualize the fetal esophagus between the heart and the aorta.[21] Esophageal obstruction is often associated with intrauterine growth restriction,[3,22] a combination suggestive of syndromic association.[23–25]

Magnetic Resonance Imaging. On MRI, a TEF postnatally appears as a linear hypointense structure between the trachea and the esophagus, typically about 1 cm above the carina.[26] Postnatal MRI can show air between the trachea and the esophagus, caused by an E-type TEF, which is beneficial with no need

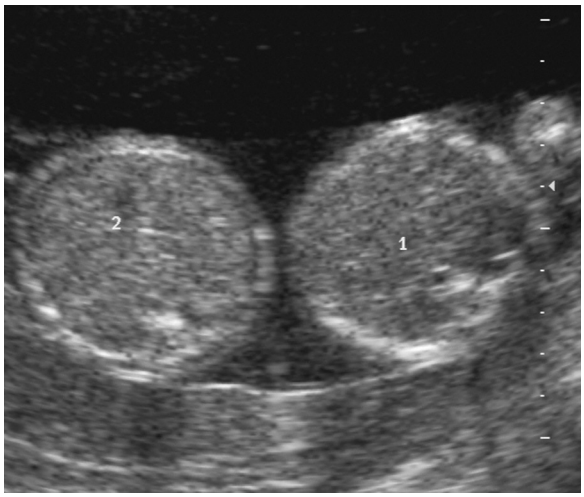

Fig. 26.2 Dichorionic twin pregnancy with one fetus with a visible but small stomach (esophageal atresia) *(2)* and one fetus with a physiologic, transiently nonvisible stomach at 18 weeks' gestation *(1)*.

for swallowing during the study and without risk of aspiration as in a contrast work-up that is otherwise required.[26]

CLASSIC SIGNS

Absent or very small stomach in combination with polyhydramnios

Differential Diagnosis From Imaging Findings

Lack of visualization of a fluid-filled stomach in the abdomen also occurs in diaphragmatic hernia, cleft lip/palate, arthrogryposis, twin-to-twin transfusion syndrome, trisomy 18, renal agenesis, and central nervous system disorders with impairment of swallowing (Fig. 26.3), and in normal fetuses, although only transiently. Of infants with esophageal obstruction diagnosed postnatally, 6% to 10% have chromosomal abnormalities or genetic syndromes.[27,28] Associated malformations are found in 50% to 70%[3] and include GI (28%), cardiac (24%), genitourinary (13%), musculoskeletal (11%), central nervous system (7%), facial anomalies (6%), and other anomalies (12%).[29] In about 10% of cases, esophageal obstruction is part of the VACTERL (*v*ertebral, *a*nal, *c*ardiac, *t*racheal, *e*sophageal, *r*enal, and *l*imb anomalies) association, which is defined as esophageal obstruction (tracheoesophageal fistula) associated with at least two anomalies affecting the other listed regions.[27–30]

Synopsis of Treatment Options

The prognosis of esophageal obstruction has improved because of better diagnostic techniques and preoperative and postoperative care.[31–33] Mortality rates are related to additional congenital malformations and prematurity.[6,34,35] In one study, children with esophageal obstruction diagnosed prenatally were born 2 weeks earlier than children with esophageal obstruction diagnosed postnatally (36.4 weeks versus 38.2 weeks; $P = .02$), had a higher mortality (30% versus 12%; $P = .05$), and had more associated anomalies (80% versus 59%; $P = .04$). Morbidity largely results

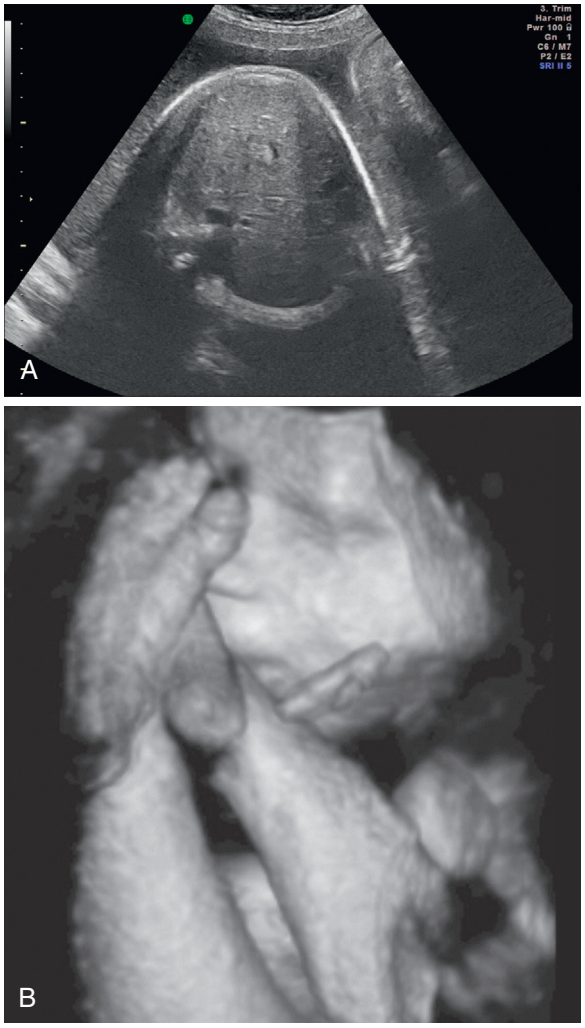

Fig. 26.3 Fetal akinesia syndrome. (A) No visible stomach at 41 weeks' gestation, polyhydramnios. (B) Extended legs and polyhydramnios at 41 weeks' gestation.

from postoperative complications, structural abnormalities of the airways, and the presence of additional congenital anomalies.[6,27,36–38] Morbidity in survivors is independent of the time of diagnosis and of the presence of associated anomalies. Other investigators reported a perinatal and infant mortality rate of about 22%[3]; 82% of the survivors underwent primary surgery, with a postoperative mortality rate of 9%.[3] The prognosis of isolated esophageal obstruction is generally good.

Gastric Obstruction

DEFINITION

Although pyloric stenosis is a relatively frequent finding after birth, gastric outlet obstruction rarely manifests in fetuses.

PREVALENCE AND EPIDEMIOLOGY

Gastric outlet obstruction or pyloric stenosis is a rare condition representing 1% of all fetal GI obstructions. Congenital gastric outlet obstruction is commonly found as an isolated anomaly with an excellent prognosis.[39]

ETIOLOGY AND PATHOPHYSIOLOGY

The etiology of pyloric stenosis is not known. The theory of a congenital inability of the pyloric sphincter to relax with subsequent hypertrophy of the pyloric musculature proximal to the sphincter forming the pyloric tumor was supported in independent studies, showing degenerated cells of the myenteric plexus in the pylorus.[40]

MANIFESTATIONS OF DISEASE

Clinical Presentation

Projectile vomiting is present at birth or shortly after when the infant attempts to feed.

Imaging Technique and Findings

Ultrasound. Prenatal diagnosis is rare but can be made mostly in the third trimester in cases with a combination of polyhydramnios and dilated stomach.[41–43] Difficulties in prenatal detection are caused by physiologic variations of the fetal stomach size[44] and the inconsistent, late development of polyhydramnios, which has been reported in only 50% of cases.[39]

Differential Diagnosis From Imaging Findings

In about half of cases of gastric obstruction, associated anomalies have been described, including other intestinal anomalies and epidermolysis bullosa.[42,43] Antral pyloric membranes, consisting of two layers of mucosa with one layer of submucosa in between, usually occur 1- to 7-cm proximal to the pylorus.[40] On radiographs, a thin linear filling defect is seen, usually 2 to 3 mm in thickness and running perpendicular to the long axis of the antrum and 2- to 3-cm proximal to the pylorus, and a "double bulb" deformity with barium in the bulb and in the pyloric channel distal to the web is sometimes observed.[40] Infants with antral webs may develop postprandial vomiting as thicker foods are added to the diet; however, nonobstructive webs are usually completely asymptomatic unless a large object, such as a foreign body, is swallowed.

Synopsis of Treatment Options

The surgical treatment for a pyloric membrane is a simple excision of the web, in some cases, in combination with laparoscopic pyloroplasty.[42,43,45] Early diagnosis and treatment are important because the main causes of death in isolated cases are infectious complications or associated anomalies.[39]

Duodenal Obstruction

DEFINITION

Duodenal obstruction or duodenal atresia is a complete or partial obstruction of the duodenum.

PREVALENCE AND EPIDEMIOLOGY

Duodenal atresia affects 1:5000 to 1:10,000 live births.[46]

ETIOLOGY AND PATHOPHYSIOLOGY

Typically, 80% of the obstruction is distal to the ampulla of Vater and 20% proximal, and is usually a blind-end atresia that interrupts the duodenal lumen. One theory to explain duodenal atresia is failure to recanalize the duodenal lumen after being in a temporary solid state during early embryologic development; other authors have suggested an impairment of angiogenesis during gut development.[47] Duodenal obstruction occurs more commonly in fetuses with trisomy 21 (30%) and is associated with other structural malformations (20%). In about 20% of patients, duodenal obstructions are associated with an annular pancreas, a ring of pancreatic tissue encircling the distal portion of the duodenum[46,48]; another suggests that the annular pancreas does not have a role in the genesis of the lesion but rather is a consequence of a common developmental field defect.[49]

MANIFESTATIONS OF DISEASE

Clinical Presentation

Vomiting is the prevailing symptom of duodenal obstruction and may occur on the first day of life. The vomitus is bilious; the infant vomits feedings, loses weight, and is restless and irritable. Other symptoms include difficulty breathing, excessive salivation and drooling, a palpable mass in the abdomen, jaundice, and lethargy.

Imaging Technique and Findings

Ultrasound. Duodenal atresia is typically diagnosed after 20 weeks' gestation but can be found in the first trimester.[47] Duodenal atresia is seen on US as a typical "double-bubble" sign, representing a fluid-filled stomach and proximal duodenum separated by a narrowing at the site of the pylorus that is much wider than normal and crossed by back-and-forth peristalsis of intestinal fluid. Rarely, a double-bubble sign can be seen in duodenal duplication, mimicking duodenal atresia (Fig. 26.4).[50] A C-shaped loop of dilated bowel may occur in combination with esophageal atresia (Fig. 26.5). The increased amount of amniotic fluid in the stomach is related to the obstruction, despite regurgitation; this results in a characteristic C-shaped fluid collection in the upper fetal abdomen.[51] Polyhydramnios occurs in the third trimester in virtually all cases of duodenal atresia.

Magnetic Resonance Imaging. On MRI, the signal intensity differences of the dilated bowel may provide information in addition to US findings in identifying the site of the obstruction. The proximal small bowel appears hyperintense on single shot fast spin echo (SSFSE) sequence and hypointense on T1-weighted fast spin echo (FSE) sequence. In contrast, the distal small bowel and colon appear intermediate to hypointense on SSFSE sequence and hyperintense on T1-weighted FSE sequence. Hyperintense bowel dilatation on SSFSE sequence suggests jejunal atresia, and bowel dilatation of intermediate intensity on SSFSE sequence and hyperintensity on T1-weighted FSE sequence suggests distal ileal atresia.[52]

CLASSIC SIGNS

Typical double-bubble sign on US, representing a fluid-filled stomach and proximal duodenum.

Differential Diagnosis From Imaging Findings

Visualization of a pseudo–double bubble in an oblique plane of the fetal trunk as a consequence of a prominent incisura angularis of the stomach or a peristaltic wave of the stomach can be

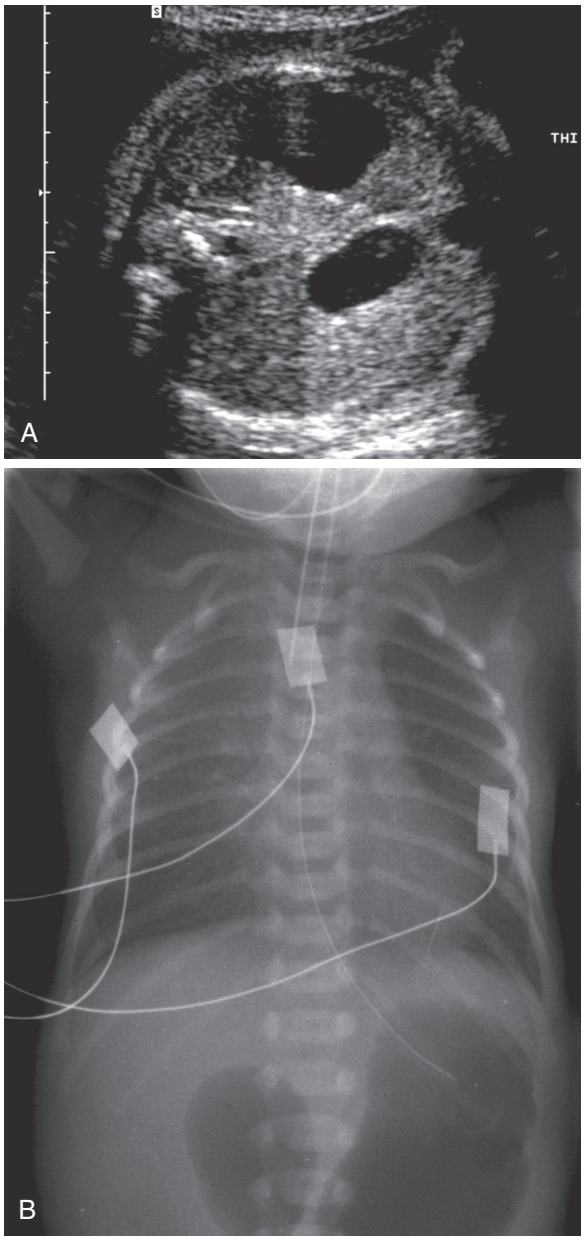

Fig. 26.4 Duodenal obstruction. (A) Double-bubble sign at 31 weeks' gestation. (B) Duodenal obstruction with double-bubble sign on neonatal radiograph.

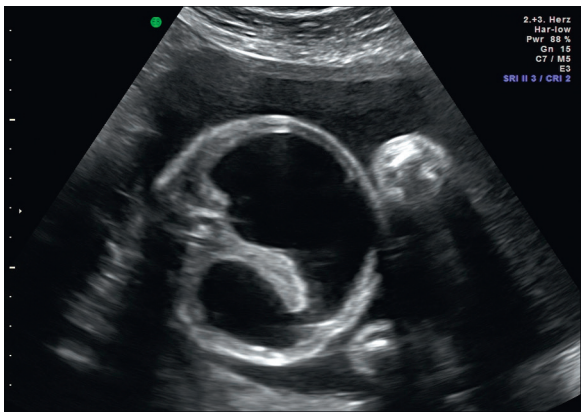

Fig. 26.5 Esophageal and duodenal obstruction. Loop of dilated bowel with increased amount of amniotic fluid in the stomach (C-shaped sign).

mistaken for duodenal atresia. To avoid this error, the abdomen should be scanned repeatedly in a transverse plane.[53,54]

Synopsis of Treatment Options

Because significant fluid and electrolyte imbalances develop in neonates with duodenal atresia soon after birth, surgical bypass with a duodeno-duodenostomy or gastro-jejunostomy should be performed as soon as possible. Prenatal diagnosis of duodenal obstruction provides an opportunity for a delivery in an appropriate setting and reduces morbidity and hospitalization time.[55–57] The overall survival rate is 57%.[58]

Jejunal Obstruction

DEFINITION

Jejuno-ileal atresia and stenosis are among the most common causes of neonatal intestinal obstruction. Atresia is a complete obstruction of the lumen of the bowel and is more common than stenosis.

PREVALENCE AND EPIDEMIOLOGY

The jejunum and ileum account for 39% of intestinal atresias,[59] with an incidence of 1:3000 to 1:5000 live births.[1]

ETIOLOGY AND PATHOPHYSIOLOGY

Jejunal and ileal atresias may result from incomplete embryonic recanalization, but most cases are thought to result from intestinal vascular impairment during embryologic development.[59,60] An inadequate blood supply may be the primary cause or secondary to associated disease such as gastroschisis or volvulus.[16,59] Jejunal and ileal obstruction can be divided into five types according to Grosfeld,[61] representing a spectrum of severity from a simple web to full atresia with loss of bowel length. Obstruction occurs in the proximal jejunum in 31%, the distal jejunum in 20%, the proximal ileum in 13%, and the distal ileum in 36% of cases.[62] In about 6% of cases multiple atretic sites are present.[63]

MANIFESTATIONS OF DISEASE

Clinical Presentation

The neonatal symptoms of jejunal atresia depend on how long the condition is left untreated. Classic symptoms include failure to tolerate feedings, nausea and vomiting, intermittent abdominal pain, and sometimes abdominal distention.

Imaging Technique and Findings

Ultrasound. Jejunal and ileal atresias are diagnosed by prenatal US typically in the third trimester.[59] The diagnosis is challenging, and a recent review demonstrated a wide range in sensitivity and specificity.[64] Dilated jejunal and ileal bowel segments proximal to the site of atresia are rarely diagnosed before 24 weeks' gestation.[1] Follow-up US examinations for suspected intestinal atresia should be performed at 28 to 32 weeks' gestation.[59] Polyhydramnios is a common associated finding in small bowel obstruction during the third trimester and appears to be more likely with proximal atresia (Fig. 26.6)[65]; its presence in combination with dilated bowel loops is associated with more severe obstruction.[66]

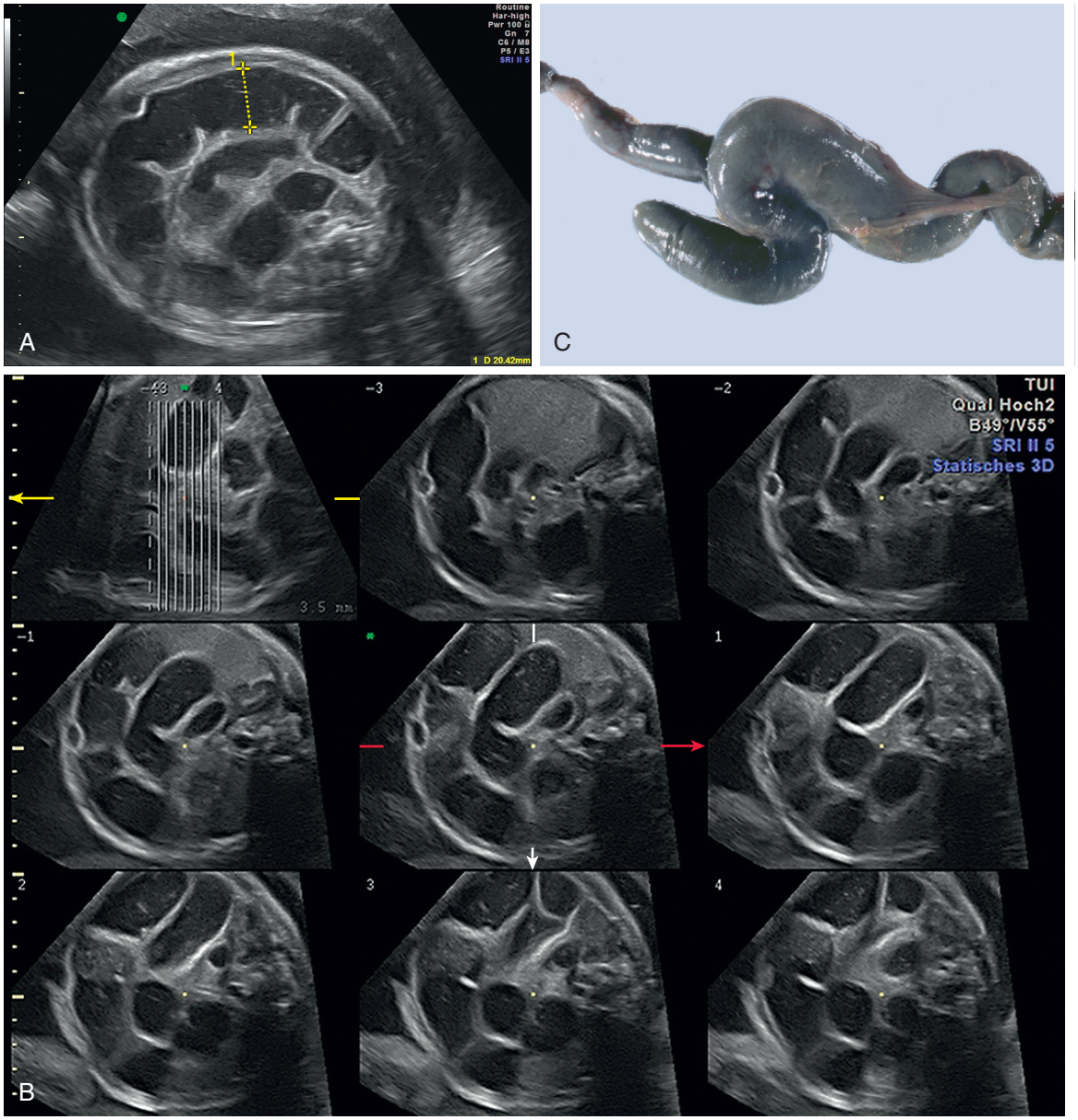

Fig. 26.6 Jejunal obstruction. (A) Massively dilated jejunal loops at 35 weeks' gestation. (B) Massively dilated jejunal loops at 35 weeks' gestation (tomographic US imaging). (C) Bowel correlate after surgery.

Magnetic Resonance Imaging. The diagnosis of small bowel atresia is feasible by US, although it may be difficult to distinguish between the colon and the small bowel. With MRI, however, these intestinal parts have specific prenatal appearances. The small bowel has a hypointense signal on T1-weighted images but a hyperintense signal on T2-weighted images because the small intestine is fluid filled. The colon displays easily recognizable and spontaneous hyperintense signals on T1-weighted images and hypointense signals on T2-weighted images. With MRI, it is possible to determine the site of occlusion prenatally and to establish whether there is some remaining normal small bowel.[67–69]

Differential Diagnosis From Imaging Findings

Meconium ileus, volvulus, Hirschsprung disease, hyperperistalsis syndrome, and congenital chloridorrhea should be considered in fetuses with dilated small bowel segments. Urinary tract obstruction with hydroureter and hydronephrosis can be associated with oligohydramnios, which may help distinguish it from dilated small bowel segments proximal to the atresia.[70] Approximately one-third of prenatally recognized abdominal cysts are associated with intestinal atresia. Other cystic masses, such as ovarian cysts, enteric duplication cysts, or mesenteric cysts, have to be distinguished from small bowel atresia (see Chapter 24). In 27% of cases of small bowel atresia, there is an association with one of the following anomalies: volvulus, malrotation, intestinal duplications, meconium ileus, or gastroschisis. Meconium peritonitis complicates 6% of cases of atresia, and concurrent bowel abnormalities are present in 5%, including colon atresia, esophageal atresia, anorectal atresia, and enteric duplications.[62] Even placental vascular abnormalities have been found in cases with small bowel atresia.[71]

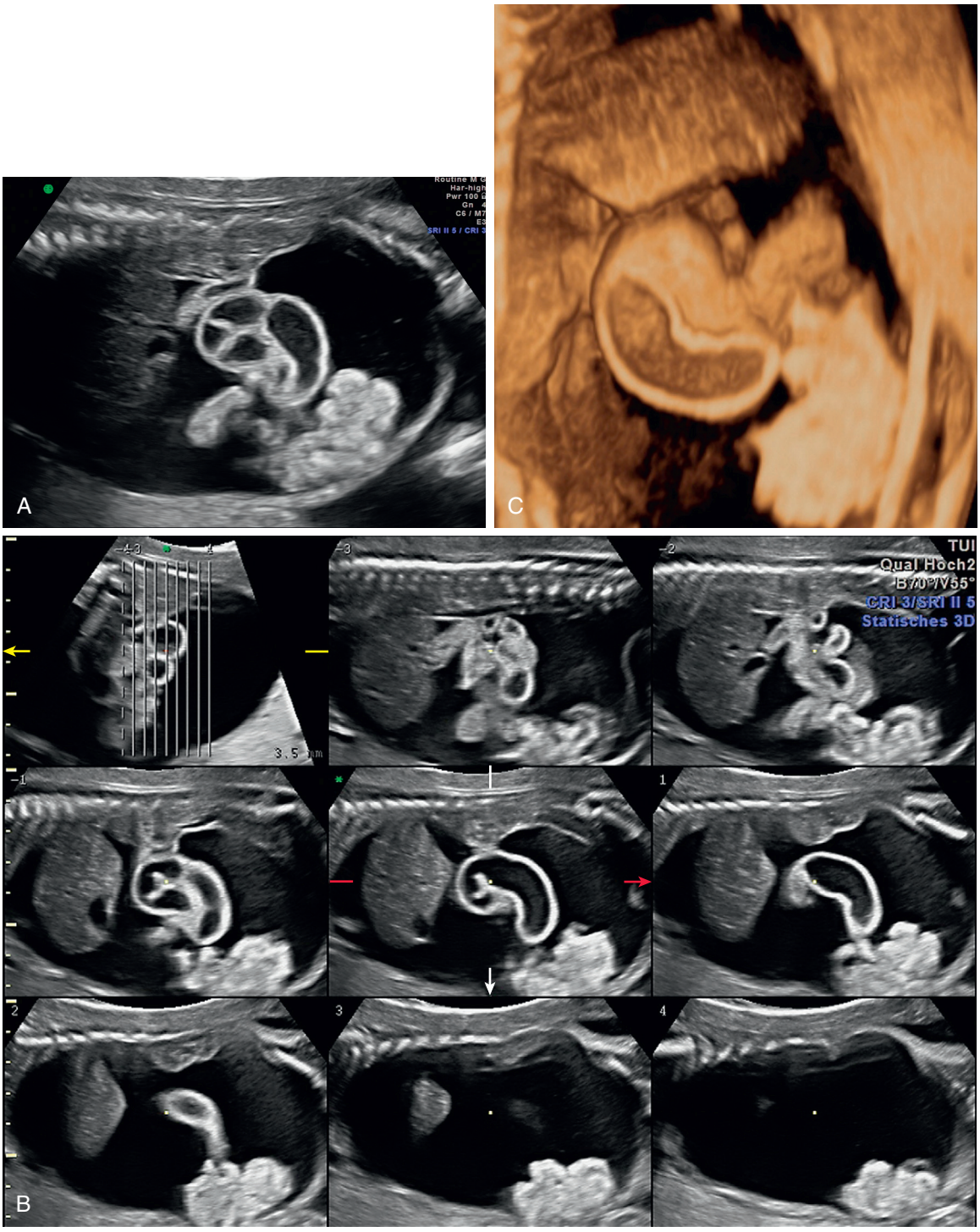

Fig. 26.7 "Apple peel" sign with ascites, echogenic bowel. (A) Jejunum at 25 weeks' gestation. (B) Jejunum at 25 weeks' gestation (tomographic US imaging). (C) Jejunum at 25 weeks' gestation (three-dimensional mode).

Synopsis of Treatment Options

The prognosis depends on the site and the extent of the atresia. In 6% of cases, ischemia and infarction lead to intrauterine perforation of small bowel and meconium peritonitis.[1] A rare form of inherited jejunal atresia is the "apple peel" small bowel, which consists of proximal jejunal atresia with absence of the distal superior mesenteric artery, shortening of the small bowel distal to the atresia, and absence of the dorsal mesentery. The distal small intestine spirals around its vascular supply and resembles an apple peel. The result is a very short intestine with a propensity toward necrotizing enterocolitis.[72] This defect has historically been associated with high mortality, although more recent reports suggest an improved prognosis (Fig. 26.7).[73]

Imperforate Anus

DEFINITION

Large bowel anomalies are rare and less frequent than small bowel anomalies. Large bowel anomalies include anorectal atresia, persistent common cloaca as a complicated form of anorectal atresia, and Hirschsprung disease. Synonyms for anorectal atresia are *anal atresia* and *imperforate anus*. In its simplest form, imperforate anus results from a failure of the anal canal to perforate during bowel development.

PREVALENCE AND EPIDEMIOLOGY

The reported incidence of anorectal malformations ranges from 1:1500 to 1:5000 newborns.[74–76]

ETIOLOGY AND PATHOPHYSIOLOGY

During the ninth week of gestation, the downward-growing urogenital septum separates the cloaca into the ventral urogenital sinus (which develops into the urinary bladder and urethra) and the dorsal rectum. Anorectal malformations occur by the 10th week from an abnormal partitioning of the cloaca by the urogenital septum. Imperforate anus appears if the membrane of the anal pouch does not perforate.

Anorectal malformations are classified by their termination in relation to the levator sling into high (supralevator) and low (infralevator) lesions. High lesions have a higher incidence of associated fistulas and genitourinary malformations and are more frequent.

MANIFESTATIONS OF DISEASE

Clinical Presentation

Passage of the first stool does not occur within 24 to 48 hours after birth.

Imaging Technique and Findings

Ultrasound. The prenatal diagnosis of an imperforate anus is difficult and is seldom been made by prenatal US.[77] Reports of prenatal diagnosis are from the third trimester; possible signs are dilated colon in the lower abdomen[78–80] or intraluminal meconium calcifications proximal or distal to the site of obstruction (Fig. 26.8).[81–83] These calcifications differ from linear

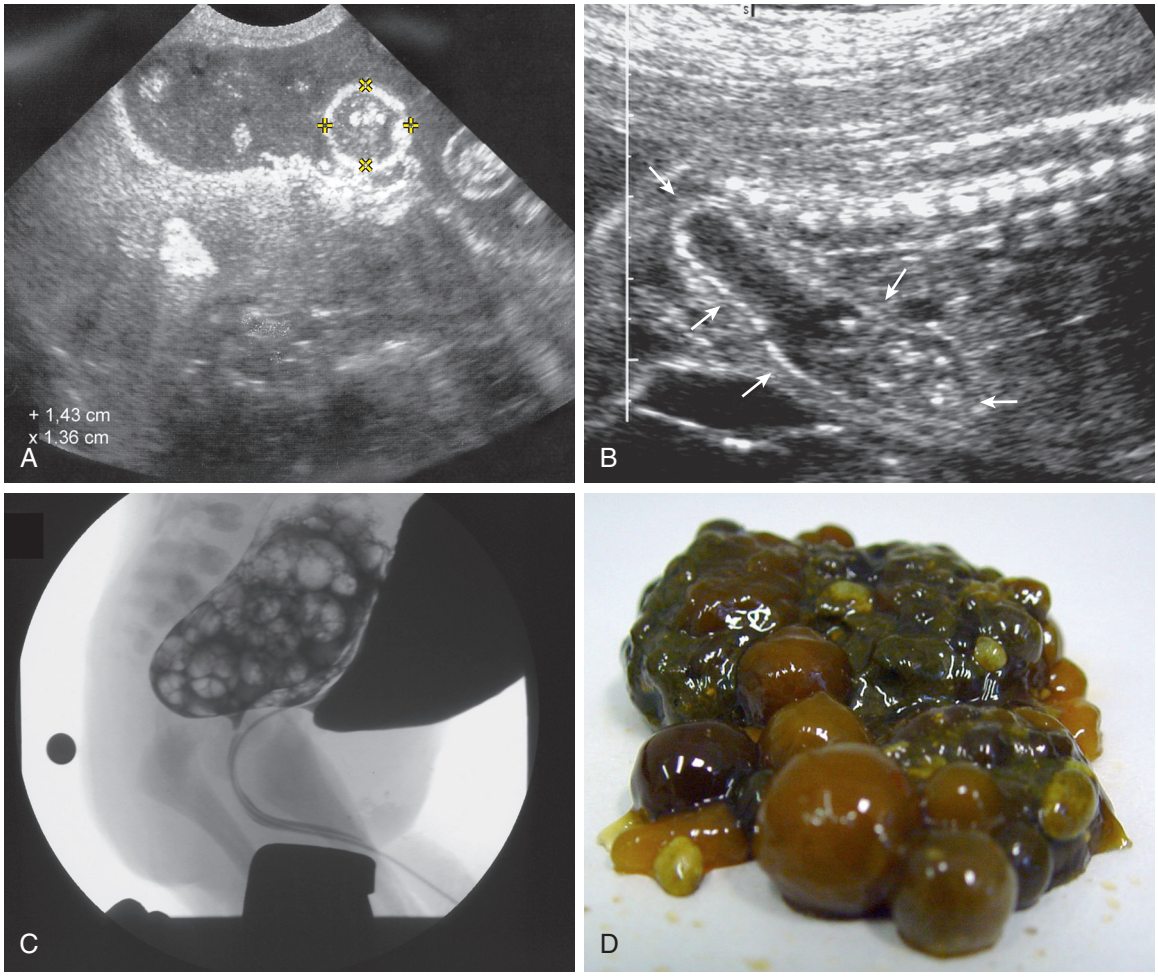

Fig. 26.8 (A) Enterolithiasis at 21 weeks' gestation showing a blind-ending distended rectum *(arrows)* with intraluminal echogenic foci (coproliths). (B) Voiding cystourethrogram showing high type of imperforate anus, rectourethral fistula, and multiple round calculi (coproliths) in the dilated large intestine. (C) One day after delivery. (D) Calcified enteroliths after colostomy. *(From Pohl-Schickinger A, Henrich W, Degenhardt P, et al: Echogenic foci in the dilated fetal colon may be associated with the presence of a rectourinary fistula.* Ultrasound Obstet Gynecol *28:341–344, 2006.)*

calcifications seen in meconium peritonitis, which can occur in the upper abdominal cavity, often adjacent to the liver, and sometimes are seen in the scrotum.[84] However, more recent reports show that US findings can be observed at 12 weeks' gestation.[85–87] In the presence of associated urogenital malformations with bilateral renal obstruction, amniotic fluid can be decreased. Fetuses with imperforate anus tend to be small for gestational age.[88] In maternal plasma, decreased alpha-fetoprotein levels have been observed in cases of imperforate anus.[89]

Magnetic Resonance Imaging. MRI findings include pathologic dilatation of the distal colon and rectum.[90]

Differential Diagnosis From Imaging Findings

Additional malformations are present in 70% of neonates with imperforate anus. When imperforate anus was diagnosed prenatally, 90% of fetuses had additional malformations, presumably making the diagnosis easier.[1] The most common associated malformations are seen with the VACTERL association and caudal regression syndrome (renal agenesis or dysplasia, sacral agenesis, lower limb hypoplasia, sirenomelia).

Synopsis of Treatment Options

The overall prognosis of imperforate anus is poor because of the high rate of associated malformations, but the survival of infants with isolated imperforate anus and with only one additional anomaly is high.[91] The aims of surgical treatment are to provide a normal-site anus of adequate caliber and appearance, while preserving as much of the normal intrinsic anorectal anatomy and function as possible. Posterior sagittal anorectoplasty has become the most frequently performed surgical procedure in the reconstruction of anorectal malformations,[92] and in recent years laproscopic approaches have been developed.[93]

Hirschsprung Disease

DEFINITION

Hirschsprung disease, or congenital aganglionic megacolon, is a neuromotor disorder of the gut in which a failure of relaxation of bowel musculature causes a functional obstruction in the affected segment and dilatation in the segment proximal to it (Fig. 26.9).

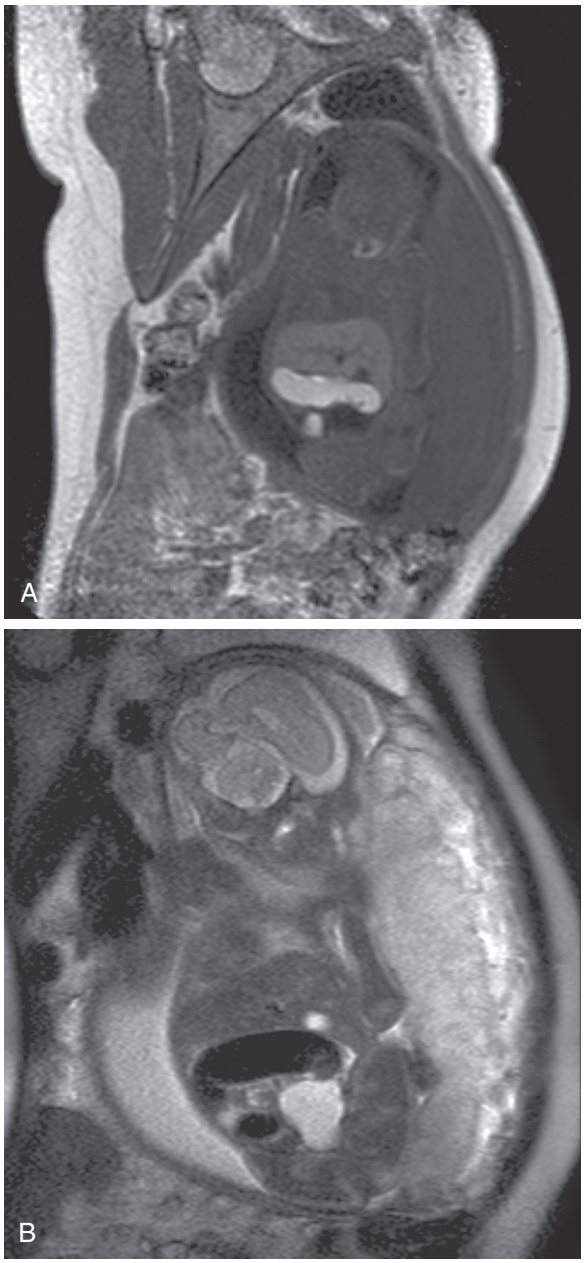

Fig. 26.9 Hirschsprung disease. (A) MRI at 30 weeks' gestation. Coronal T1-weighted sequences show meconium-filled (hyperintense) dilated colon with atresia at the hepatic flexure. (B) Corresponding T2-weighted image with hypointense appearance of dilated colon loops. *(Courtesy D. Prayer, Vienna.)*

PREVALENCE AND EPIDEMIOLOGY

The incidence is 1:5000 live births, with a male predominance of about 80%.[94–96]

ETIOLOGY AND PATHOPHYSIOLOGY

Hirschsprung disease is thought to be caused by a defect in the craniocaudal migration during the first 12 weeks of gestation of motor neuroblasts originating from the neural crest. Other authors suggested accelerated ganglion cell destruction within the intestine or defects in differentiation of neuroblasts into ganglion cells.[97] The disorder is characterized by aganglionosis in the myenteric (Auerbach) and submucous (Meissner) plexus of the distal colon. Hirschsprung disease is a heterogeneous genetic disorder with autosomal dominant, autosomal recessive, and polygenic forms.[98] Eight mutations in the *RET* proto-oncogene, a receptor tyrosine kinase that transduces growth and differentiation signals in neural crest cells, account for at least 50% of familial cases and 20% of sporadic cases.[99–102]

MANIFESTATIONS OF DISEASE

Clinical Presentation

Diagnosis in most patients is made in the neonatal period based on symptoms of distal intestinal obstruction, including bilious emesis, abdominal distention or enterocolitis, or a failure to pass stool within 48 hours of birth.[97,103] The major complication is perforation of bowel proximal to the obstruction. At the time of birth, 10% of fetuses have developed meconium peritonitis.[104,105]

The clinical diagnosis is made by rectal examination and contrast radiography (contrast enema). In 90% of cases, the bowel involvement is distal to the splenic flexure; in 74% of cases, it is limited to the rectosigmoid. The entire colon or distal ileum is involved in less than 10% of cases.

Imaging Technique and Findings

Ultrasound. The prenatal diagnosis of Hirschsprung disease is limited, probably because signs such as small bowel dilatation and polyhydramnios in the third trimester are present only in cases of total aganglionosis of the colon.[106] Another (nonspecific) US marker is increased bowel echogenicity. Nyberg et al.[107] and Sepulveda and Sebire[108] suggested that the aganglionic segment is unable to transmit a peristaltic wave and that the US features of echogenic bowel are caused by abnormal echogenicity of the meconium inside the small bowel lumen.

Differential Diagnosis From Imaging Findings

Hirschsprung disease is associated with several chromosomal anomalies, such as trisomy 21 (10% of the cases), congenital central hypoventilation syndrome, Bardet-Biedl syndrome, Waardenburg syndrome, Mowat-Wilson syndrome, Smith-Lemli-Opitz syndrome, and cardiac disease (especially septal defects).[100,109,110] Congenital anomalies of the urinary tract, such as hydronephrosis and renal hypoplasia, can be present in 25% of patients with Hirschsprung disease.[111,112]

Synopsis of Treatment Options

The goal of treatment is to resect the affected, functionally obstructed bowel segment and to attach the normal ganglionic bowel close to the anus, preserving normal sphincter function. Different surgical procedures have been described, ranging from traditionally open abdomino-perineal pull-through procedures to laparoscopically assisted transanal repair.[113–116] The mortality rate in infancy varies between 20% and 40% in cases of total aganglionosis.[117,118]

Volvulus

DEFINITION

The term *volvulus* refers to an abnormal twisting of the intestine that can impair the blood flow to the intestine. Volvulus can lead to gangrene and death of that segment of the GI tract, intestinal obstruction, perforation of the intestine, and peritonitis. The stomach, small intestine, cecum, and sigmoid colon can all be subject to volvulus. Malrotation of the bowel during fetal development can predispose to volvulus (Fig. 26.10).[119]

PREVALENCE AND EPIDEMIOLOGY

Midgut volvulus rarely occurs prenatally. Cases of intrauterine fetal death caused by midgut volvulus have been reported in the literature.[2]

ETIOLOGY AND PATHOPHYSIOLOGY

Small bowel volvulus occurs when a bowel loop rotates around its mesenteric pedicle. The axis of rotation is the superior mesenteric artery and the mesentery along with the superior mesenteric vein twists around it. Volvulus is associated with intestinal malrotation secondary to a lack of the broad mesenteric attachment that fixes it to the posterior abdominal wall.

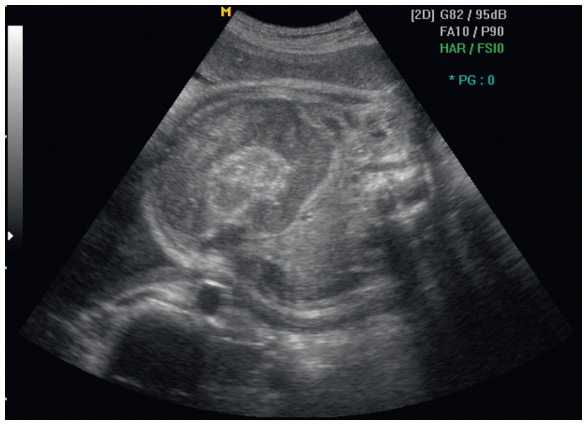

Fig. 26.10 Volvulus at 33 weeks' gestation. *(Courtesy K. Kalache, Berlin.)*

MANIFESTATIONS OF DISEASE

Clinical Presentation

The signs and symptoms depend on the degree of ischemia. When intestinal ischemia develops, pain becomes more pronounced. The neonate may have signs of an acute abdomen with rigidity and tenderness to palpation.

Imaging Technique and Findings

Ultrasound. Historically, volvulus has been described in pediatric cohorts. As a result of advances in prenatal US and other imaging techniques, several reports have described intestinal volvulus that occurred in utero, but the condition was diagnosed postnatally, and no suspicion was raised prenatally.[120–123] Nonspecific signs on US include polyhydramnios, ascites, dilated bowel loops, peritoneal calcifications, and meconium pseudocysts. Apart from polyhydramnios, Crisera et al.[120] described the following signs for fetal volvulus: the presence of a static abdominal mass with dilated intestinal loops and decreased fetal movements. A more recently reported sign is the typical appearance of the twisting around the superior mesenteric vessels, the so-called whirlpool sign, first described by Pracros et al.[124] in 15 of 18 affected infants. Since then, several reports have shown the accuracy of this sign.[125–129] Shimanuki et al.[127] showed that among 13 pediatric patients with surgically confirmed midgut volvulus, 12 had a clockwise whirlpool sign, indicating a sensitivity of 92%. They reported specificity and positive predictive values of 100%. In addition, among three patients with a counterclockwise whirlpool sign, none had intestinal volvulus during laparotomy, emphasizing the importance of the direction of rotation.

The three-dimensional counterpart of the whirlpool sign is the so-called barber pole sign in infants, describing the spiral appearance of the superior mesenteric vessels along with their branches caused by the twisted mesentery that embeds them. It was first described as an angiographic sign,[130] but since then it has been shown with other modalities that visualize vascular anatomy, such as computed tomography (CT),[131] Doppler US,[132] and three-dimensional power Doppler US in infants and adults.[133]

Magnetic Resonance Imaging. A case report is available on the prenatal diagnosis of midgut volvulus by US and MRI.[134]

Other Applicable Modality. In case reports of confirmed fetal diagnoses of intestinal volvulus, pathologic fetal heart rate tracing patterns have been described.[135,136]

Synopsis of Treatment Options

In cases with a high suspicion for the diagnosis, preterm delivery may be considered, followed by prompt surgical intervention, in an attempt to avoid intrauterine demise.

Echogenic Bowel

DEFINITION

Hyperechogenic bowel is a nonspecific marker and most commonly observed in normal fetuses. *Fetal echogenic bowel* refers to increased echogenicity or brightness of the fetal bowel. It can be diffuse or focal, and is uniform over a well-defined area that does not shadow. To reduce subjectivity in diagnosis, echogenic bowel should be considered only when it appears as bright as fetal bone (Fig. 26.11).

PREVALENCE AND EPIDEMIOLOGY

Echogenic bowel is diagnosed in 0.2% to 1.4% of second-trimester US examinations.[137–139] The prevalence of fetal echogenic bowel varies in the second trimester from 0.5% to 1%.[108,140] This finding typically occurs as a normal variant but also has been associated with cystic fibrosis (CF),[137,141] chromosomal abnormalities,[139,141] structural abnormalities, and fetal cytomegalovirus infection.[142] In first-trimester US examination, echogenic bowel occurs as a soft marker for trisomy 21.[143]

ETIOLOGY AND PATHOPHYSIOLOGY

The etiology is unclear, but explanations include bowel wall edema in cases of thalassemia, hypoxemia or anemia, and changes in water or protein content of the meconium.[144] Swallowing of amniotic fluid after intraamniotic bleeding is implicated in some cases of second-trimester echogenic bowel.[145]

MANIFESTATIONS OF DISEASE

Clinical Presentation

The clinical presentation depends on the etiology of echogenic bowel.

Imaging Technique and Findings

Ultrasound. US assessment of bowel echogenicity is subjective, comparing the echogenicity with that of adjacent structures. A score using bone or liver density has been suggested.[107] Others defined grade 1 (moderate) to grade 3 (severe, as bright as bone) echogenicity.[107] Transducer frequency should be 5 MHz or less. Transducers with higher frequency lead to "overdiagnosis" of fetal bowel echogenicity.[146]

Differential Diagnosis From Imaging Findings

In a review of 804 fetuses with echogenic bowel, 9% had chromosomal anomalies, 2.1% had cystic fibrosis (CF), and 3.5% had congenital infections. The rates of intrauterine growth restriction in chromosomally normal fetuses was 7.7%, and the perinatal mortality (excluding aneuploidy and terminations) was 8%.[108] Most fetuses with isolated echogenic bowel are normal.

Synopsis of Treatment Options

After prenatal diagnosis of echogenic bowel, a detailed fetal anatomic survey is recommended to exclude other fetal malformations or genetic anomalies and to evaluate amniotic fluid, look for intraamniotic or subchorionic bleeding, and examine placenta morphology for insufficiency. Further investigations to determine fetal karyotype and parental CF carrier status and screening for maternal serologic infections can be offered.

Meconium Ileus

DEFINITION

Meconium peritonitis is a sterile, chemical peritonitis induced by meconium in the peritoneal cavity, most commonly seen in perforation of the ileum (Fig. 26.12).

PREVALENCE AND EPIDEMIOLOGY

Meconium ileus is a rare condition with an estimated incidence of 1:35,000 live births.[147]

ETIOLOGY AND PATHOPHYSIOLOGY

Nearly all patients with meconium ileus prove to have CF,[148] but only 10% to 15% of patients with CF are affected by meconium ileus as an earliest clinical sign. CF is the most common autosomal recessive disorder in the United States: 1:29 Americans is a carrier, and 1:3000 newborns have the disease. In most cases, the disorder can be diagnosed genetically and prenatally.

MANIFESTATIONS OF DISEASE

Clinical Presentation

After 20 weeks' gestation, bowel peristalsis starts, and meconium peritonitis may occur secondary to the bowel rupture with expulsion of meconium into the peritoneal cavity.[149]

Imaging Technique and Findings

Ultrasound. A packed ileum with abnormally thick and sticky meconium produces a functional obstruction without any obvious anatomic cause.[150] A dilated ileum with hyperperistalsis, a relatively normal jejunum and a collapsed empty colon, and polyhydramnios are the most common US signs.[148] Resulting adhesions between bowel loops and omentum can result in cystic masses.[151,152] In rare cases in which the processus vaginalis is patent, meconium may pass down into the external genitalia to form bilateral hydroceles or swelling of the vulva.[148] In high-risk patients, genetic diagnosis of CF by amniocentesis or chorionic villus sampling is highly accurate (98%).[153]

Magnetic Resonance Imaging. Meconium peritonitis is a chemical peritonitis that results from perforation of the bowel and should be diagnosed on US with the finding of peritoneal calcification. Other findings associated with meconium peritonitis include ascites and meconium pseudocysts (see Chapter 24). MRI may be useful to distinguish meconium pseudocysts from other abdominal cystic masses.[52]

Differential Diagnosis From Imaging Findings

Dilated bowel is also seen in jejunal atresia, hyperechogenic bowel, and mucous plug syndrome of the colon. Of patients with meconium ileus, 50% have other GI complications such as bowel atresia, volvulus, perforation, or meconium peritonitis.

Synopsis of Treatment Options

In the presence of increasing fetal ascites, progressive fetal abdominal distention, and worsening polyhydramnios, delivery should be considered.[148] Pregnancies without any progression of US signs can continue until term. Nonsurgical therapy includes a radiologic enema and enterotomy and irrigation only if the enema fails. The prognosis of meconium ileus in patients with CF has been dramatically improved as a result of advances in pediatric care, but 80% of patients develop pancreatic insufficiency, 95% develop recurrent respiratory infections and chronic lung disease, and 70% develop male infertility.[1]

WHAT THE REFERRING PHYSICIAN NEEDS TO KNOW

Cystic or echogenic intraabdominal findings, perhaps accompanied by increased amount of amniotic fluid, warrant detailed study of the GI tract to rule out an intestinal obstruction. Intestinal loops show typical peristalsis particularly in the third trimester, but pronounced back-and-forth movements of dilated loops and content may indicate stenosis or atresia. There is an increased prevalence of chromosomal abnormalities in cases with proximal stenosis and with CF in lower obstructions (Table 26.2).

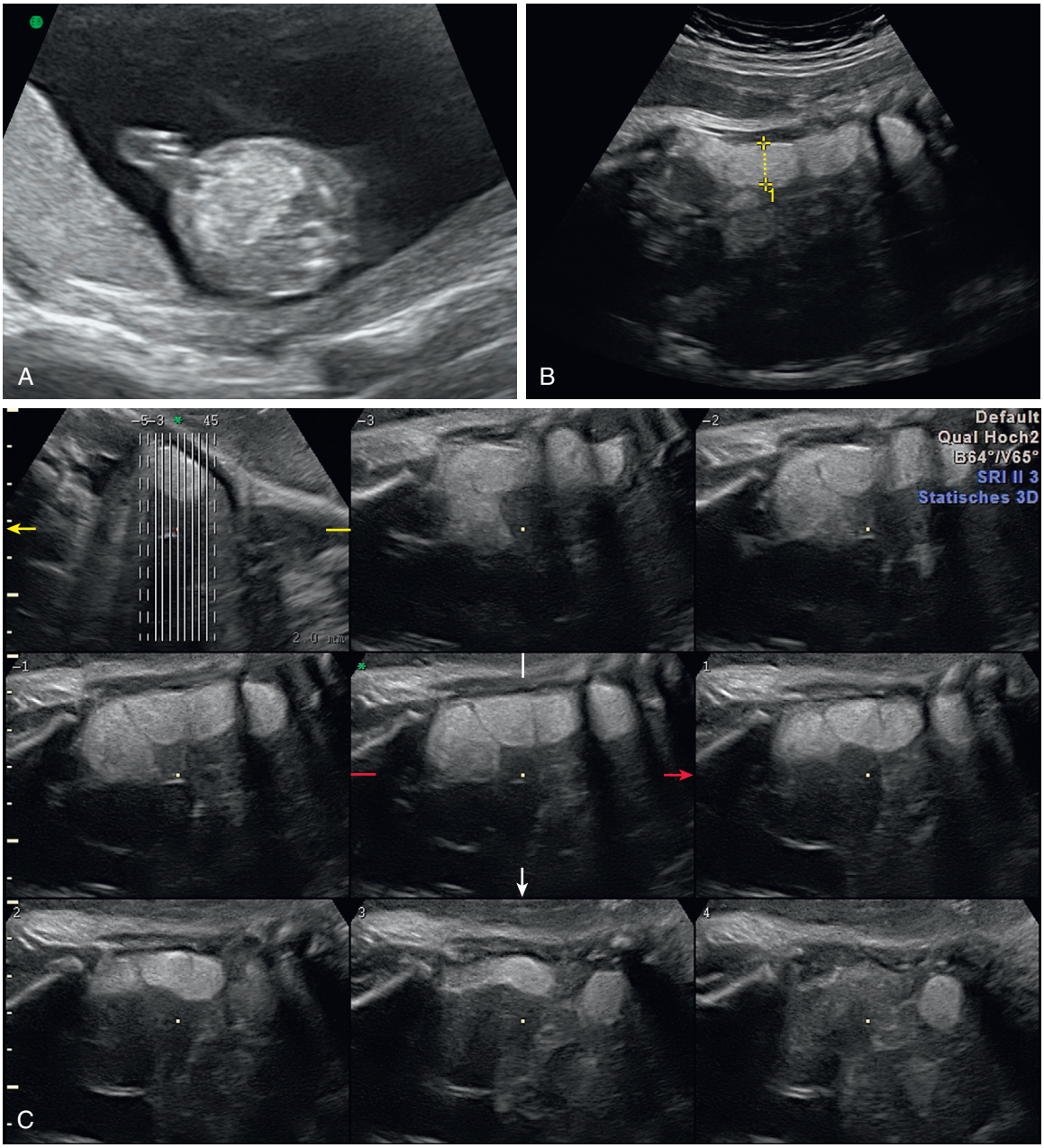

Fig. 26.11 Echogenic bowel. (A) Jejunum at 16 weeks' gestation. (B) Echogenic bowel content at 40 weeks' gestation. (C) Jejunum at 40 weeks' gestation (tomographic US imaging).

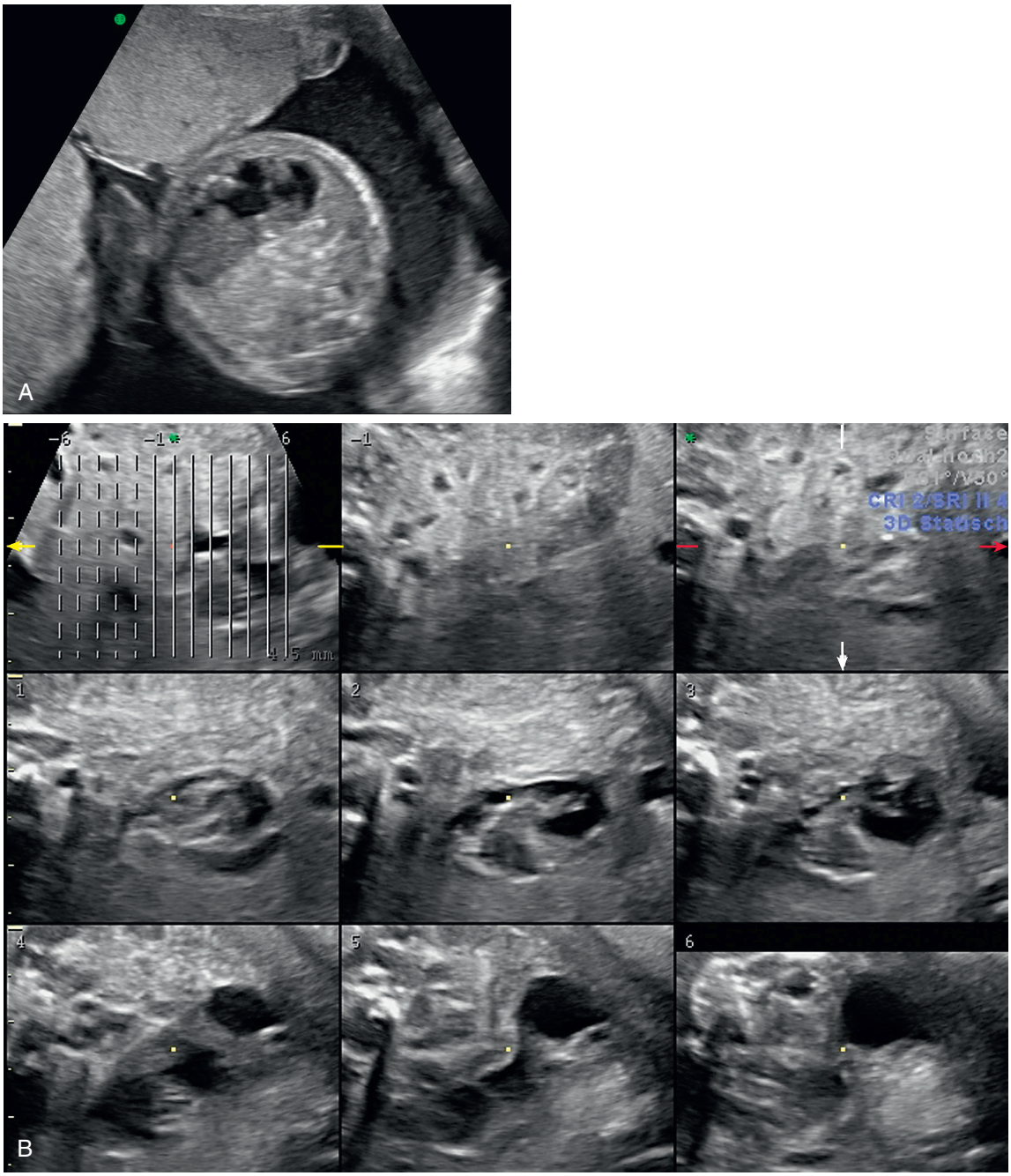

Fig. 26.12 Meconium peritonitis. (A) At 25 weeks' gestation. (B) At 35 weeks' gestation (tomographic US imaging).

TABLE 26.2 Ultrasound Features of Common Gastrointestinal Abnormalities

Abnormality	Typical Ultrasound Findings	Associated Abnormalities
Esophageal atresia	Stomach not visible, later polyhydramnios	Increased risk for trisomies 21 and 18
Duodenal atresia	Double-bubble sign	Trisomy 21 in >50% of cases
Jejunal atresia	Dilated small bowel	Usually isolated
Meconium ileus	Hyperechoic bowel, dilated bowel	CF
Imperforate anus	Occasionally dilated colon	VATER association

CF, Cystic fibrosis; *VATER*, vertebral, anal, tracheo-esophageal, and radial and renal anomalies.
From Nyberg DA, Neilson IR: Abdomen and gastrointestinal tract. In Nyberg DA, McGahan JP, Pretorius DH, et al., editors: *Diagnostic imaging of fetal anomalies,* Philadelphia, 2003, Lippincott Williams & Wilkins, pp 549–572.

KEY POINTS

- Upper GI obstructions with esophageal and duodenal atresia are associated with aneuploidy.
- In cases of GI malformations associated anomalies, such as trisomy 21, cardiac anomalies, and CF, should be ruled out.
- Lower intestinal obstructions can be associated with aneuploidy, CF, or meconium peritonitis.
- The degree of polyhydramnios correlates with the site of obstruction—the more proximal the obstruction, the more intense the polyhydramnios.
- US findings of hyperechogenic bowel mandates work-up for maternal or fetal infections; chromosomal anomalies; CF; and, in late gestation, placental insufficiency.
- Referral to a perinatal center with immediate neonatal care unit and prenatal interdisciplinary counseling with a neonatologist and pediatric surgeon is recommended.

SUGGESTED READING

Biyyam DR, Dighe M, Siebert JR. Antenatal diagnosis of intestinal malrotation on fetal MRI. *Pediatr Radiol*. 2009;39:847-849.

Choudhry MS, Rahman N, Boyd P, et al. Duodenal atresia: associated anomalies, prenatal diagnosis and outcome. *Pediatr Surg Int*. 2009;25:727-730.

Frisova V, Kavalcova L, Kyncl M, et al. Congenital gastric outlet obstruction by pyloric membrane: prenatal and postnatal diagnosis and management. *Fetal Diagn Ther*. 2009;26:98-101.

Houben CH, Curry JI. Current status of prenatal diagnosis, operative management and outcome of esophageal atresia/tracheo-esophageal fistula. *Prenat Diagn*. 2008;28:667-675.

Spitz L. Oesophageal atresia. *Orphanet J Rare Dis*. 2007;2:24.



All references are available online at www.expertconsult.com.

REFERENCES

1. Nyberg DA, Neilson IR. Abdomen and gastrointestinal tract. In: Nyberg DA, McGahan JP, Pretorius DH, et al, eds. *Diagnostic Imaging of Fetal Anomalies*. Philadelphia: Lippincott Williams & Wilkins; 2003:549-572.
2. Steffensen TS, Gilbert-Barness E, DeStefano KA, et al. Midgut volvulus causing fetal demise in utero. *Fetal Pediatr Pathol*. 2008;27:223-231.
3. Sparey C, Jawaheer G, Barrett AM, et al. Esophageal atresia in the Northern Region Congenital Anomaly Survey, 1985-1997: prenatal diagnosis and outcome. *Am J Obstet Gynecol*. 2000;182:427-431.
4. Depaepe A, Dolk H, Lechat MF. The epidemiology of tracheo-oesophageal fistula and oesophageal atresia in Europe. EUROCAT Working Group. *Arch Dis Child*. 1993;68:743-748.
5. Shaw-Smith C. Oesophageal atresia, tracheo-oesophageal fistula, and the VACTERL association: review of genetics and epidemiology. *J Med Genet*. 2006;43:545-554.
6. Spitz L. Oesophageal atresia. *Orphanet J Rare Dis*. 2007;2:24.
7. Felix JF, Steegers-Theunissen RP, de Walle HE, et al. Esophageal atresia and tracheoesophageal fistula in children of women exposed to diethylstilbestrol in utero. *Am J Obstet Gynecol*. 2007;197:38 e31-38 e35.
8. Felix JF, Tibboel D, de Klein A. Chromosomal anomalies in the aetiology of oesophageal atresia and tracheo-oesophageal fistula. *Eur J Med Genet*. 2007;50:163-175.
9. Felix JF, de Jong EM, Torfs CP, et al. Genetic and environmental factors in the etiology of esophageal atresia and/or tracheoesophageal fistula: an overview of the current concepts. *Birth Defects Res A Clin Mol Teratol*. 2009;85:747-754.
10. Spitz L. Esophageal atresia and tracheoesophageal malformations. In: Ashcraft K, Holcomb G, Murphy JP, eds. *Pediatric Surgery*. Philadelphia: Saunders; 2005:352-370.
11. Gross RE. *The surgery of infancy and childhood*. Philadelphia: Saunders; 1953.
12. Stringer MD, McKenna KM, Goldstein RB, et al. Prenatal diagnosis of esophageal atresia. *J Pediatr Surg*. 1995;30:1258-1263.
13. McKenna KM, Goldstein RB, Stringer MD. Small or absent fetal stomach: prognostic significance. *Radiology*. 1995;197:729-733.
14. Choudhry M, Boyd PA, Chamberlain PF, et al. Prenatal diagnosis of tracheo-oesophageal fistula and oesophageal atresia. *Prenat Diagn*. 2007;27:608-610.
15. Houben CH, Curry JI. Current status of prenatal diagnosis, operative management and outcome of esophageal atresia/tracheo-esophageal fistula. *Prenat Diagn*. 2008;28:667-675.
16. Kalache KD, Wauer R, Mau H, et al. Prognostic significance of the pouch sign-in fetuses with prenatally diagnosed esophageal atresia. *Am J Obstet Gynecol*. 2000;182:978-981.
17. Langer JC, Hussain H, Khan A, et al. Prenatal diagnosis of esophageal atresia using sonography and magnetic resonance imaging. *J Pediatr Surg*. 2001;36:804-807.
18. Shulman A, Mazkereth R, Zalel Y, et al. Prenatal identification of esophageal atresia: the role of ultrasonography for evaluation of functional anatomy. *Prenat Diagn*. 2002;22:669-674.
19. Centini G, Rosignoli L, Kenanidis A, et al. Prenatal diagnosis of esophageal atresia with the pouch sign. *Ultrasound Obstet Gynecol*. 2003;21:494-497.
20. Yagel S, Sonigo P, Rousseau V, et al. Esophageal atresia diagnosed with three-dimensional ultrasonography. *Ultrasound Obstet Gynecol*. 2005;26:307-308.
21. Develay-Morice JE, Rathat G, Duyme M, et al. [Ultrasonography of fetal esophagus: healthy appearance and prenatal diagnosis of a case of esophagus atresia with esotracheal fistula. *Gynecol Obstet Fertil*. 2007;35:249-257.
22. Surana R, Puri P. Small intestinal atresia: effect on fetal nutrition. *J Pediatr Surg*. 1994;29:1250-1252.
23. Sickler GK, Nyberg DA, Sohaey R, et al. Polyhydramnios and fetal intrauterine growth restriction: ominous combination. *J Ultrasound Med*. 1997;16:609-614.
24. Furman B, Erez O, Senior L, et al. Hydramnios and small for gestational age: prevalence and clinical significance. *Acta Obstet Gynecol Scand*. 2000;79:31-36.
25. Lazebnik N, Many A. The severity of polyhydramnios, estimated fetal weight and preterm delivery are independent risk factors for the presence of congenital malformations. *Gynecol Obstet Invest*. 1999;48:28-32.
26. Gunlemez A, Anik Y, Elemen L, et al. H-type tracheoesophageal fistula in an extremely low-birth weight premature neonate: appearance on magnetic resonance imaging. *J Perinatol*. 2009;29:393-395.
27. Genevieve D, de Pontual L, Amiel J, et al. An overview of isolated and syndromic oesophageal atresia. *Clin Genet*. 2007;71:392-399.
28. Smith N. Oesophageal atresia and tracheo-oesophageal fistula. *Early Hum Dev*. 2014;90(12):947-950.
29. Holder TM, Cloud DT, Lewis JE Jr, et al. Esophageal atresia and tracheoesophageal fistula. A survey of its members by the Surgical Section of the American Academy of Pediatrics. *Pediatrics*. 1964;34:542-549.
30. Pohl-Schickinger A, Henrich W, Degenhardt P, et al. Echogenic foci in the dilated fetal colon may be associated with the presence of a rectourinary fistula. *Ultrasound Obstet Gynecol*. 2006;28:341-344.
31. Garabedian C, Sfeir R, Langlois C, et al. Does prenatal diagnosis modify neonatal treatment and early outcome of children with esophageal atresia? *Am J Obstet Gynecol*. 2015;212:340.e1.
32. Brantberg A, Blaas HG, Haugen SE, et al. Esophageal obstruction-prenatal detection rate and outcome. *Ultrasound Obstet Gynecol*. 2007;30:180.
33. de Jong EM, de Haan MA, Gischler SJ, et al. Pre- and postnatal diagnosis and outcome of fetuses and neonates with esophageal atresia and tracheoesophageal fistula. *Prenat Diagn*. 2010;30:274.
34. Lopez PJ, Keys C, Pierro A, et al. Oesophageal atresia: improved outcome in high-risk groups? *J Pediatr Surg*. 2006;41:331-334.
35. Sinha CK, Haider N, Marri RR, et al. Modified prognostic criteria for oesophageal atresia and tracheo-oesophageal fistula. *Eur J Pediatr Surg*. 2007;17:153-157.
36. Deurloo JA, de Vos R, Ekkelkamp S, et al. Prognostic factors for mortality of oesophageal atresia patients: Waterston revived. *Eur J Pediatr*. 2004;163:624-625.
37. Deurloo JA, Smit BJ, Ekkelkamp S, et al. Oesophageal atresia in premature infants: an analysis of morbidity and mortality over a period of 20 years. *Acta Paediatr*. 2004;93:394-399.
38. Gischler SJ, van der Cammen-van Zijp MH, Mazer P, et al. A prospective comparative evaluation of persistent respiratory morbidity in esophageal atresia and congenital diaphragmatic hernia survivors. *J Pediatr Surg*. 2009;44:1683-1690.
39. Frisova V, Kavalcova L, Kyncl M, et al. Congenital gastric outlet obstruction by pyloric membrane: prenatal and postnatal diagnosis and management. *Fetal Diagn Ther*. 2009;26:98-101.
40. Mandell GA. Association of antral diaphragms and hypertrophic pyloric stenosis. *AJR Am J Roentgenol*. 1978;131:203-206.
41. Okoye BO, Parikh DH, Buick RG, et al. Pyloric atresia: five new cases, a new association, and a review of the literature with guidelines. *J Pediatr Surg*. 2000;35:1242-1245.
42. Ilce Z, Erdogan E, Kara C, et al. Pyloric atresia: 15-year review from a single institution. *J Pediatr Surg*. 2003;38:1581-1584.
43. Al-Salem AH. Congenital pyloric atresia and associated anomalies. *Pediatr Surg Int*. 2007;23:559-563.
44. Bonin B, Gruslin A, Simpson NA, et al. Second trimester prenatal diagnosis of congenital gastric outlet obstruction. *J Ultrasound Med*. 1998;17:403-406.
45. Biyyam DR, Dighe M, Siebert JR. Antenatal diagnosis of intestinal malrotation on fetal MRI. *Pediatr Radiol*. 2009;39:847-849.
46. Fonkalsrud EW, DeLorimier AA, Hays DM. Congenital atresia and stenosis of the duodenum: a review compiled from the members of the Surgical Section of the American Academy of Pediatrics. *Pediatrics*. 1969;43:79-83.
47. Choudhry MS, Rahman N, Boyd P, et al. Duodenal atresia: associated anomalies, prenatal diagnosis and outcome. *Pediatr Surg Int*. 2009;25:727-730.
48. Kirillova IA, Kulazhenko VP, Kulazhenko LG, et al. Pancreas annulare in human embryos. *Acta Anat (Basel)*. 1984;118:214-217.
49. Merrill JR, Raffensperger JG. Pediatric annular pancreas: twenty years' experience. *J Pediatr Surg*. 1976;11:921-925.
50. Malone FD, Crombleholme TM, Nores JA, et al. Pitfalls of the "double bubble" sign: a case of congenital duodenal duplication. *Fetal Diagn Ther*. 1997;12:298-300.
51. Estroff JA, Parad RB, Share JC, et al. Second trimester prenatal findings in duodenal and esophageal atresia without tracheoesophageal fistula. *J Ultrasound Med*. 1994;13:375-379.
52. Shinmoto H, Kuribayashi S. MRI of fetal abdominal abnormalities. *Abdom Imaging*. 2003;28:877-886.
53. Gross BH, Filly RA. Potential for a normal fetal stomach to simulate the sonographic "double bubble" sign. *J Can Assoc Radiol*. 1982;33:39-40.
54. Gilbertson-Dahdal DL, Dutta S, Varich LJ, et al. Neonatal malrotation with midgut volvulus mimicking duodenal atresia. *AJR Am J Roentgenol*. 2009;192:1269.
55. Aite L, Trucchi A, Nahom A, et al. Antenatal diagnosis of surgically correctable anomalies: effects of repeated consultations on parental anxiety. *J Perinatol*. 2003;23:652.

56. Bittencourt DG, Barini R, Marba S, et al. Congenital duodenal obstruction: does prenatal diagnosis improve the outcome? *Pediatr Surg Int*. 2004;20:582.
57. Cohen-Overbeek TE, Grijseels EW, Niemeijer ND, et al. Isolated or non-isolated duodenal obstruction: perinatal outcome following prenatal or postnatal diagnosis. *Ultrasound Obstet Gynecol*. 2008;32:784.
58. Nicolaides KH, Snijders RJ, Cheng HH, et al. Fetal gastro-intestinal and abdominal wall defects: associated malformations and chromosomal abnormalities. *Fetal Diagn Ther*. 1992;7:102-115.
59. Trautner MC, Aladangady N, Maalouf E, et al. Jejunal atresia in an infant with triple-X syndrome. *J Matern Fetal Neonatal Med*. 2004;16:198-200.
60. Admas SD, Stanton MP. Malrotation and intestinal atresias. *Early Hum Dev*. 2014;90:921-925.
61. Grosfeld JL, Ballantine TVN, Shoemaker R. Operative management of ointestinal atresia and stenosis based on pathologic findings. *J Pediatr Surg*. 1979;14:368-375.
62. Touloukian RJ. Intestinal atresia. *Clin Perinatol*. 1978;5:3-18.
63. Baglaj M, Carachi R, Lawther S. Multiple atresia of the small intestine: a 20-year review. *Eur J Pediatr Surg*. 2008;18:13.
64. Virgone C, D'antonio F, Khalil A, et al. Accuracy of prenatal ultrasound in detecting jejunal and ileal atresia: systematic review and meta-analysis. *Ultrasound Obstet Gynecol*. 2015;45:523.
65. Cheng W, Mya GH, Saing H. Does the amniotic fluid protein absorption contribute significantly to the fetal weight? *J Paediatr Child Health*. 1996;32:39-41.
66. Iacobelli BD, Zaccara A, Spirydakis I, et al. Prenatal counselling of small bowel atresia: watch the fluid! *Prenat Diagn*. 2006;26:214.
67. Benachi A, Sonigo P, Jouannic JM, et al. Determination of the anatomical location of an antenatal intestinal occlusion by magnetic resonance imaging. *Ultrasound Obstet Gynecol*. 2001;18:163-165.
68. Garel C, Dreux S, Philippe-Chomette P, et al. Contribution of fetal magnetic resonance imaging and amniotic fluid digestive enzyme assays to the evaluation of gastrointestinal tract abnormalities. *Ultrasound Obstet Gynecol*. 2006;28:282.
69. Wax JR, Hamilton T, Cartin A, et al. Congenital jejunal and ileal atresia: natural prenatal sonographic history and association with neonatal outcome. *J Ultrasound Med*. 2006;25:337.
70. Colombani M, Ferry M, Toga C, et al. Magnetic resonance imaging in the prenatal diagnosis of congenital diarrhea. *Ultrasound Obstet Gynecol*. 2010;35:560.
71. Komuro H, Amagai T, Hori T, et al. Placental vascular compromise in jejunoileal atresia. *J Pediatr Surg*. 2004;39:1701.
72. Berrocal T, Lamas M, Gutierrez J, et al. Congenital anomalies of the small intestine, colon, and rectum. *Radiographics*. 1999;19:1219-1236.
73. Waldhausen JH, Sawin RS. Improved long-term outcome for patients with jejunoileal apple peel atresia. *J Pediatr Surg*. 1997;32:1307-1309.
74. Christensen K, Madsen CM, Hauge M, et al. An epidemiological study of congenital anorectal malformations: 15 Danish birth cohorts followed for 7 years. *Paediatr Perinat Epidemiol*. 1990;4:269-275.
75. Stoll C, Alembik Y, Roth MP, et al. Risk factors in congenital anal atresias. *Ann Genet*. 1997;40:197-204.
76. Cho S, Moore SP, Fangman T. One hundred three consecutive patients with anorectal malformations and their associated anomalies. *Arch Pediatr Adolesc Med*. 2001;155:587-591.
77. Brantberg A, Blaas HG, Haugen SE, et al. Imperforate anus: a relatively common anomaly rarely diagnosed prenatally. *Ultrasound Obstet Gynecol*. 2006;28:904-910.
78. Bean WJ, Calonje MA, Aprill CN, et al. Anal atresia: a prenatal ultrasound diagnosis. *J Clin Ultrasound*. 1978;6:111-112.
79. Harris RD, Nyberg DA, Mack LA, et al. Anorectal atresia: prenatal sonographic diagnosis. *AJR Am J Roentgenol*. 1987;149:395-400.
80. Auslander R, Nevo O, Diukman R, et al. Johanson-Blizzard syndrome: a prenatal ultrasonographic diagnosis. *Ultrasound Obstet Gynecol*. 1999;13:450-452.
81. Berdon WE, Baker DH, Wigger HJ, et al. Calcified intraluminal meconium in newborn males with imperforate anus: enterolithiasis in the newborn. *Am J Roentgenol Radium Ther Nucl Med*. 1975;125:449-455.
82. Mandell J, Lillehei CW, Greene M, et al. The prenatal diagnosis of imperforate anus with rectourinary fistula: dilated fetal colon with enterolithiasis. *J Pediatr Surg*. 1992;27:82-84.
83. Shalev E, Weiner E, Zuckerman H. Prenatal ultrasound diagnosis of intestinal calcifications with imperforate anus. *Acta Obstet Gynecol Scand*. 1983;62:95-96.
84. Duncan AW. Quiz case. Multiple calcifications of intraluminal meconium enterolithiasis. *Eur J Radiol*. 2001;37:120-122.
85. Kaponis A, Paschopoulos M, Paraskevaidis E, et al. Fetal anal atresia presenting as transient bowel dilatation at 16 weeks of gestation. *Fetal Diagn Ther*. 2006;21:383.
86. Taipale P, Rovamo L, Hiilesmaa V. First-trimester diagnosis of imperforate anus. *Ultrasound Obstet Gynecol*. 2005;25:187-188.
87. Gilbert CE, Hamill J, Metcalfe RF, et al. Changing antenatal sonographic appearance of anorectal atresia from first to third trimesters. *J Ultrasound Med*. 2006;25:781-784.
88. Stoll C, Alembik Y, Dott B, et al. Evaluation of prenatal diagnosis of congenital gastro-intestinal atresias. *Eur J Epidemiol*. 1996;12:611-616.
89. Van Rijn M, Christaens GC, Hagenaars AM, et al. Maternal serum alpha-fetoprotein in fetal anal atresia and other gastro-intestinal obstructions. *Prenat Diagn*. 1998;18:914-921.
90. Chen CP, Chang TY, Liu YP, et al. Prenatal 3-dimensional sonographic and MRI findings in omphalocele-exstrophy-imperforate anus-spinal defects complex. *J Clin Ultrasound*. 2008;36:308-311.
91. Khatib N, Belossesky R, Marwan O, et al. Fetal bowel calcifications: a sign of anal atresia with rectourethral fistula. *J Clin Ultrasound*. 2010;38:332-334.
92. Pena A. Anorectal malformations. *Semin Pediatr Surg*. 1995;4:35-47.
93. Bischoff A, Martinez-Leo B, Pena A. Laparoscopic approach in the management of anorectal malformations. *Pediatr Surg Int*. 2015;31:431-437.
94. Keckler SJ, St Peter SD, Spilde TL, et al. Current significance of meconium plug syndrome. *J Pediatr Surg*. 2008;43:896-898.
95. Kleinhaus S, Boley SJ, Sheran M, et al. Hirschsprung's disease. A survey of the members of the Surgical Section of the American Academy of Pediatrics. *J Pediatr Surg*. 1979;14:588-597.
96. Suita S, Taguchi T, Ieiri S, et al. Hirschsprung's disease in Japan: analysis of 3852 patients based on a nationwide survey in 30 years. *J Pediatr Surg*. 2005;40:197-201.
97. Kays DW. Surgical conditions of the neonatal intestinal tract. *Clin Perinatol*. 1996;23:353-375.
98. Russell MB, Russell CA, Fenger K, et al. Familial occurrence of Hirschsprung's disease. *Clin Genet*. 1994;45:231-235.
99. Martucciello G, Ceccherini I, Lerone M, et al. Pathogenesis of Hirschsprung's disease. *J Pediatr Surg*. 2000;35:1017-1025.
100. Parisi MA, Kapur RP. Genetics of Hirschsprung disease. *Curr Opin Pediatr*. 2000;12:610-617.
101. Uesaka T, Nagashimada M, Yonemura S, et al. Diminished Ret expression compromises neuronal survival in the colon and causes intestinal aganglionosis in mice. *J Clin Invest*. 2008;118:1890-1898.
102. Tam PK. Hirschsprung's disease: a bridge for science and surgery. *J Pediatr Surg*. 2016;51:18-22.
103. Khan AR, Vujanic GM, Huddart S. The constipated child: how likely is Hirschsprung's disease? *Pediatr Surg Int*. 2003;19:439-442.
104. Sullivan PB. Hirschsprung's disease. *Arch Dis Child*. 1996;74:5-7.
105. Ikeda K, Goto S. Diagnosis and treatment of Hirschsprung's disease in Japan: an analysis of 1628 patients. *Ann Surg*. 1984;199:400-405.
106. Jakobson-Setton A, Weissmann-Brenner A, Achiron R, et al. Retrospective analysis of prenatal ultrasound of children with Hirschsprung disease. *Prenat Diagn*. 2015;35:699.
107. Nyberg DA, Dubinsky T, Resta RG, et al. Echogenic fetal bowel during the second trimester: clinical importance. *Radiology*. 1993;188:527-531.
108. Sepulveda W, Sebire NJ. Fetal echogenic bowel: a complex scenario. *Ultrasound Obstet Gynecol*. 2000;16:510-514.
109. Flori E, Girodon E, Samama B, et al. Trisomy 7 mosaicism, maternal uniparental heterodisomy 7 and Hirschsprung's disease in a child with Silver-Russell syndrome. *Eur J Hum Genet*. 2005;13:1013-1018.
110. Mueller C, Patel S, Irons M, et al. Normal cognition and behavior in a Smith-Lemli-Opitz syndrome patient who presented with Hirschsprung disease. *Am J Med Genet A*. 2003;123A:100-106.
111. Sarioglu A, Tanyel FC, Buyukpamukcu N, et al. Hirschsprung-associated congenital anomalies. *Eur J Pediatr Surg*. 1997;7:331-337.
112. Pini Prato A, Musso M, Ceccherini I, et al. Hirschsprung disease and congenital anomalies of the kidney and urinary tract (CAKUT): a novel syndromic association. *Medicine (Baltimore)*. 2009;88:83-90.
113. Lall A, Gupta DK, Bajpai M. Neonatal Hirschsprung's disease. *Indian J Pediatr*. 2000;67:583-588.
114. Teitelbaum DH, Cilley RE, Sherman NJ, et al. A decade of experience with the primary pull-through for Hirschsprung disease in the newborn period: a multicenter analysis of outcomes. *Ann Surg*. 2000;232:372-380.
115. So HB, Becker JM, Schwartz DL, et al. Eighteen years' experience with neonatal Hirschsprung's disease treated by endorectal pull-through without colostomy. *J Pediatr Surg*. 1998;33:673-675.

116. Ramesh JC, Ramanujam TM, Yik YI, et al. Management of Hirschsprung's disease with reference to one-stage pull-through without colostomy. *J Pediatr Surg*. 1999;34:1691-1694.
117. Pingault V, Bondurand N, Kuhlbrodt K, et al. SOX10 mutations in patients with Waardenburg-Hirschsprung disease. *Nat Genet*. 1998;18:171-173.
118. N-Fekete C, Ricour C, Martelli H, et al. Total colonic aganglionosis (with or without ileal involvement): a review of 27 cases. *J Pediatr Surg*. 1986;21:251-254.
119. Admas SD, Stanton MP. Malrotation and intestinal atresias. *Early Hum Dev*. 2014;90:921-925.
120. Crisera CA, Ginsburg HB, Gittes GK. Fetal midgut volvulus presenting at term. *J Pediatr Surg*. 1999;34:1280-1281.
121. Di Maggio G, De Felice C, Messina M, et al. Intrauterine volvulus without malrotation in a very low-birth-weight preterm infant. *Eur J Pediatr Surg*. 1997;7:364-366.
122. Allahdin S, Kay V. Ischaemic haemorrhagic necrosis of the intestine secondary to volvulus of the midgut: a silent cause of intrauterine death. *J Obstet Gynaecol*. 2004;24:310.
123. Morikawa N, Namba S, Fujii Y, et al. Intrauterine volvulus without malrotation associated with segmental absence of small intestinal musculature. *J Pediatr Surg*. 1999;34:1549-1551.
124. Pracros JP, Sann L, Genin G, et al. Ultrasound diagnosis of midgut volvulus: the "whirlpool" sign. *Pediatr Radiol*. 1992;22:18-20.
125. Taori K, Sanyal R, Attarde V, et al. Unusual presentations of midgut volvulus with the whirlpool sign. *J Ultrasound Med*. 2006;25:99-103.
126. Epelman M. The whirlpool sign. *Radiology*. 2006;240:910-911.
127. Shimanuki Y, Aihara T, Takano H, et al. Clockwise whirlpool sign at color Doppler US: an objective and definite sign of midgut volvulus. *Radiology*. 1996;199:261-264.
128. Vijayaraghavan SB, Ravikumar VR, Srimathy G. Whirlpool sign in small-bowel volvulus due to a mesenteric cyst. *J Ultrasound Med*. 2004;23:1375-1377.
129. Chao HC, Kong MS, Chen JY, et al. Sonographic features related to volvulus in neonatal intestinal malrotation. *J Ultrasound Med*. 2000;19:371-376.
130. Buranasiri SI, Baum S, Nusbaum M, et al. The angiographic diagnosis of midgut malrotation with volvulus in adults. *Radiology*. 1973;109:555-556.
131. Clark P, Ruess L. Counterclockwise barber-pole sign on CT: SMA/SMV variance without midgut malrotation. *Pediatr Radiol*. 2005;35:1125-1127.
132. Hsu CY, Chiba Y, Fukui O, et al. Counterclockwise barber-pole sign on prenatal three-dimensional power Doppler sonography in a case of duodenal obstruction without intestinal malrotation. *J Clin Ultrasound*. 2004;32:86-90.
133. Chaoui R, Kalache KD, Hartung J. Application of three-dimensional power Doppler ultrasound in prenatal diagnosis. *Ultrasound Obstet Gynecol*. 2001;17:22-29.
134. Miyakoshi K, Ishimoto H, Tanigaki S, et al. Prenatal diagnosis of midgut volvulus by sonography and magnetic resonance imaging. *Am J Perinatol*. 2001;18:447-450.
135. Schiermeier S, Reinhard J, Westhof G, et al. The significance of electronic CTG for intrauterine volvulus in the 32nd week of gestation. *Z Geburtshilfe Neonatol*. 2008;212:30-33.
136. Lyrenas S, Cnattingius S, Lindberg B. Fetal jejunal atresia and intrauterine volvulus—a case report. *J Perinat Med*. 1982;10:247-248.
137. Dicke JM, Crane JP. Sonographically detected hyperechoic fetal bowel: significance and implications for pregnancy management. *Obstet Gynecol*. 1992;80:778-782.
138. Bromley B, Doubilet P, Frigoletto FD Jr, et al. Is fetal hyperechoic bowel on second-trimester sonogram an indication for amniocentesis? *Obstet Gynecol*. 1994;83:647-651.
139. Berlin BM, Norton ME, Sugarman EA, et al. Cystic fibrosis and chromosome abnormalities associated with echogenic fetal bowel. *Obstet Gynecol*. 1999;94:135-138.
140. Al-Kouatly HB, Chasen ST, Streltzoff J, et al. The clinical significance of fetal echogenic bowel. *Am J Obstet Gynecol*. 2001;185:1035-1038.
141. Muller F, Dommergues M, Aubry MC, et al. Hyperechogenic fetal bowel: an ultrasonographic marker for adverse fetal and neonatal outcome. *Am J Obstet Gynecol*. 1995;173:508-513.
142. Duchatel F, Muller F, Oury JF, et al. Prenatal diagnosis of cystic fibrosis: ultrasonography of the gallbladder at 17 to 19 weeks of gestation. *Fetal Diagn Ther*. 1993;8:28-36.
143. Dagklis A, Fazi C, Sala C, et al. The immunoglobulin gene repertoire of low-count chronic lymphocytic leukemia (CLL)-like monoclonal B lymphocytosis is different from CLL: diagnostic implications for clinical monitoring. *Blood*. 2009;114:26-32.
144. Ewer AK, McHugo JM, Chapman S, et al. Fetal echogenic gut: a marker of intrauterine gut ischaemia? *Arch Dis Child*. 1993;69:510-513.
145. Sepulveda W, Reid R, Nicolaidis P, et al. Second-trimester echogenic bowel and intra-amniotic bleeding: association between fetal bowel echogenicity and amniotic fluid spectrophotometry at 410 nm. *Am J Obstet Gynecol*. 1996;174:839-842.
146. Vincoff NS, Callen PW, Smith-Bindman R, et al. Effect of ultrasound transducer frequency on the appearance of the fetal bowel. *J Ultrasound Med*. 1999;18:799-803.
147. Zangheri G, Andreani M, Ciriello E, et al. Fetal intra-abdominal calcifications from meconium peritonitis: sonographic predictors of postnatal surgery. *Prenat Diagn*. 2007;27:960-963.
148. Konje JC, de Chazal R, MacFadyen U, et al. Antenatal diagnosis and management of meconium peritonitis: a case report and review of the literature. *Ultrasound Obstet Gynecol*. 1995;6:66-69.
149. Forouhar F. Meconium peritonitis: pathology, evolution, and diagnosis. *Am J Clin Pathol*. 1982;78:208-213.
150. Park RW, Grand RJ. Gastrointestinal manifestations of cystic fibrosis: a review. *Gastroenterology*. 1981;81:1143-1161.
151. Schwimer SR, Vanley GT, Reinke RT. Prenatal diagnosis of cystic meconium peritonitis. *J Clin Ultrasound*. 1984;12:37-39.
152. Fleischer AC, Davis RJ, Campbell L. Sonographic detection of a meconium-containing mass in a fetus: a case report. *J Clin Ultrasound*. 1983;11:103-105.
153. Boue A, Muller F, Nezelof C, et al. Prenatal diagnosis in 200 pregnancies with a 1-in-4 risk of cystic fibrosis. *Hum Genet*. 1986;74:288-297.

To access the videos in this chapter, scan this QR code or visit expertconsult.com

27 Congenital Diaphragmatic Hernia

TIM VAN MIEGHEM | FRANCESCA MARIA RUSSO | ALEXANDER ENGELS | LUC DE CATTE | ROLAND DEVLIEGER | LIESBETH LEWI | JAN DEPREST

Introduction

Incomplete formation of the fetal diaphragm early in gestation results in a diaphragmatic defect allowing abdominal organs to herniate into the chest. These organs compete for space with the growing lungs, leading to inadequate pulmonary development and to respiratory failure and pulmonary hypertension at birth. Even with the advances made in the neonatal management of congenital diaphragmatic hernia (CDH), the postnatal mortality of this condition remains at 30% to 40%, even in cases without major associated anomalies (isolated CDH).

With the advent of general screening strategies using high-resolution ultrasound, CDH is now diagnosed prenatally in 50% to 60%,[1] allowing referral of patients to high-volume tertiary care centers for prenatal management, delivery, and neonatal care. Prenatal lung measurements, based on ultrasound (US) and magnetic resonance imaging (MRI), allow clinicians to assess the degree of pulmonary hypoplasia and to identify cases at high risk of postnatal mortality and morbidity. With the prenatal information available, the patient can be counseled about the prognosis of the fetus, and a fetus with a dismal prognosis can be referred for prenatal interventions. In this chapter, we review the practical aspects and clinical implications of the diagnosis of CDH.

Disorder

DEFINITION

In CDH, the continuity of the diaphragm is interrupted. This interruption can be situated either in the posterolateral part of the diaphragm (Bochdalek type) or in the retrosternal region (Morgagni type). Rarely, the defect is central involving the tendinous part of the diaphragm.

PREVALENCE AND EPIDEMIOLOGY

CDH complicates about 1:2500 pregnancies and 1:5000 live births. The Bochdalek type accounts for 80% to 90% of all congenital diaphragmatic defects. Of CDHs, 85% occur on the left side, 13% occur on the right side, and about 2% are bilateral. Most cases are sporadic; familial cases constitute less than 5% of CDHs.

Most CDH cases (60%) are isolated (i.e., they occur without any other anatomic or chromosomal defect); however, 40% are complex and show some associated anomaly (Table 27.1). The risk of spontaneous intrauterine fetal demise is low (2%), although slightly higher than the background risk. Many pregnancies are terminated after the prenatal diagnosis of CDH: depending on

TABLE 27.1 ASSOCIATED ANOMALIES COMMONLY FOUND IN COMPLEX CONGENITAL DIAPHRAGMATIC HERNIA

	Common Additional Findings
GENETIC	
Trisomy 18 (Edwards syndrome)	IUGR, clenched hands, cardiac defects, CNS anomalies, micrognathia, microphthalmia, omphalocele
Tetrasomy 12p (Pallister-Killian syndrome)	Brachycephaly, low-set ears, coarse facies, micromelia, CNS anomalies, nuchal edema, cardiac defects
Trisomy 21 (Down syndrome)	Nuchal edema, ventriculomegaly, nasal bone hypoplasia, flat face, cardiac defects, pyelectasis, clinodactyly, short upper limbs, sandal foot
Deletion 4p (Wolf-Hirschhorn syndrome)	IUGR, facial dysmorphology, cardiac defects, hypospadias
Deletion 15q	Craniofacial anomalies, cardiac defects, hypoplastic genitalia, cryptorchidism
SYNDROMAL	
Denys-Drash syndrome	Genital anomalies, Wilms tumors
Donnai-Barrow syndrome	Hypertelorism, omphalocele, agenesis of corpus callosum
Fryns syndrome	Micrognathia, cleft palate, nail hypoplasia, cardiac defects, renal malformations, genital anomalies, cystic hygroma, ventriculomegaly, agenesis of corpus callosum
Jarcho-Levin syndrome	Hemivertebrae, vertebral fusion, scoliosis, rib anomalies, cleft palate, hydronephrosis
Simpson-Golabi-Behmel syndrome	Macrosomia, macroglossia, omphalocele, skeletal anomalies, accessory nipples, coarse face, hypertelorism, renal anomalies
Matthew-Wood syndrome	Anophthalmia or microphthalmia, pulmonary agenesis
Goldenhar syndrome	Unilateral hypoplasia of the mandible and ear, skin tags, microphthalmia, hemivertebrae
Poland syndrome	Unilateral symbrachydactyly, ipsilateral aplasia of the sternal head of the pectoralis major muscle
Pentalogy of Cantrell	Ectopia cordis, cardiac defects, supraumbilical abdominal wall defect, defect of lower sternum
Beckwith-Wiedemann syndrome	Organ hypertrophy, macrosomia, macroglossia, omphalocele
NONSYNDROMIC, NONCHROMOSOMAL ASSOCIATIONS	
Cardiovascular	Septal defects, conotruncal anomalies
CNS	Neural tube defects, ventriculomegaly
Musculoskeletal and limb defects	Absence defects, polydactyly, syndactyly, rib and vertebral anomalies
Genitourinary defects	Cryptorchidism, ectopic kidney, horseshoe kidney

CNS, Central nervous system; *IUGR,* intrauterine growth restriction.

the region, overall termination rates approach 20% to 30%, and 50% in those with complex CDH.[2]

Reported survival rates of neonates with isolated CDH are severely biased by the high rate of terminations but are consistently around 60% to 70% in unselected cohorts. A more precise estimation of survival for an individual case can be made prenatally. The presence of other major associated anomalies affects the outcome, and the prognosis of complex cases is poor (survival rates is less than 15%).

ETIOLOGY, PATHOPHYSIOLOGY, AND EMBRYOLOGY

Very little is known about the etiology of CDH. The diaphragm forms during the sixth week of gestation from the fusion of four structures: the transverse septum, the pleuroperitoneal membranes, the dorsal mesentery of the esophagus, and the body wall.

The transverse septum, which forms the central tendon, separates the thoracic and abdominal cavities. The septum fuses dorsally with the primitive mediastinal mesenchyme and with the pleuroperitoneal membranes. Although any defect in the fusion process could be responsible for the development of CDH, the defective fusion between septum and pleuroperitoneal membranes is probably at the origin of most cases.[3]

CDH causes pathologic changes in the lungs, mainly in the lung adjacent to the defect, including a reduced number of conducting and respiratory airways, thickened alveolar septa, increased arterial wall thickness, and extension of the muscle layer in the preacinar arteries. These changes can be secondary to pulmonary compression by the herniated organs; however, based on experimental data in an animal model of CDH, some research groups suggest that the primary insult may be located in the lung itself [4] rather than in the diaphragm. This hypothesis is supported further by experimental data in a rat model of CDH using the herbicide nitrofen.

MANIFESTATIONS OF DISEASE

Clinical Presentation

Although the finding of fetal CDH in most cases is incidental on a routine screening US, some cases are diagnosed due to polyhydramnios. Most cases of CDH are associated with a mild degree of polyhydramnios, probably secondary to impaired fetal swallowing as a consequence of the altered position of the esophagus and the stomach. Rarely, polyhydramnios becomes excessive and results in preterm rupture of the membranes and preterm labor.

CDH is often still diagnosed only after birth by the obstetrician or pediatrician confronted with a neonate with severe respiratory

distress and a scaphoid abdomen. On auscultation, breath sounds are diminished on the side of the hernia, and heart sounds are best heard on the side contralateral to the hernia. A chest radiograph can confirm the diagnosis.

Imaging Technique and Findings

Ultrasound

The fetal diaphragm and eventual diaphragmatic defects can be visualized by US from the first trimester of gestation on, but usually the altered position of the abdominal and thoracic organs alerts the sonographer. In left-sided CDH, herniated bowels are seen in the left hemithorax. In more severe cases, the stomach, spleen, or part of the liver is also in the thorax ("up"; Fig. 27.1, Video 27.1). In association with these primary findings, the left lung is hypoplastic and displaced anteriorly and upward. The right lung is usually also smaller than normal but to a lesser degree than the left. Mediastinal shift and hypoplasia of the left cardiac ventricle are frequently observed.[5] When the left liver lobe is herniated, it is most commonly situated in front of the stomach, and its aberrant position leads to a typical S-shaped kinking pattern in the intraabdominal part of the umbilical vein, which is striking when using color Doppler imaging. Malposition of the gallbladder to the left side of the abdomen is a finding commonly associated with liver herniation.

When the diaphragmatic defect is situated on the right side, the only herniated organ is often the liver (Fig. 27.2). The heart is shifted to the left side and squeezed between the chest wall and the liver, leading to a shortening of its long axis. About one in three cases of right-sided CDH will have associated ascites and pleural effusion, probably due to abnormalities in lymphatic drainage through the thoracic duct.[6] In bilateral diaphragmatic hernia, both the stomach and the liver are herniated. Mediastinal shift may be minimal (Fig. 27.3).

In addition to these direct findings, most cases of CDH have a mild degree of polyhydramnios caused by the aberrant

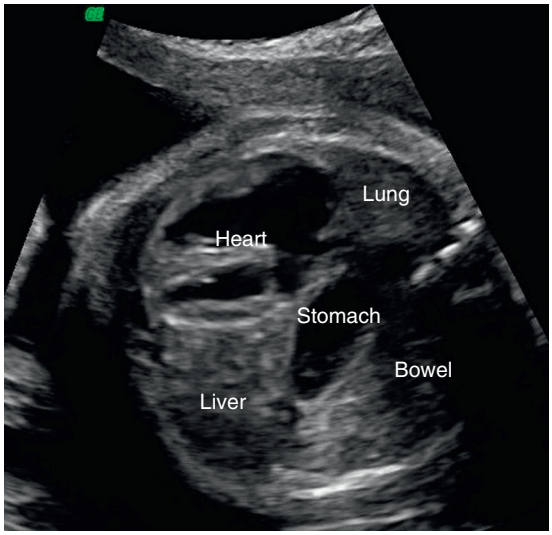

Fig. 27.1 US image showing a transverse section through the chest of a fetus with left-sided CDH at 26 weeks' gestation. Mediastinal shift and herniation of liver, stomach, and bowel into the chest are noted.

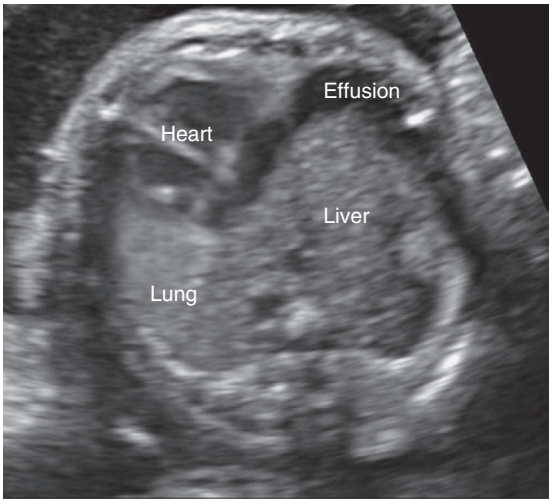

Fig. 27.2 US image showing a transverse section through the chest of a fetus with right-sided CDH at 23 weeks' gestation. Mediastinal shift and presence of liver in the chest are noted. There is a small pleural effusion.

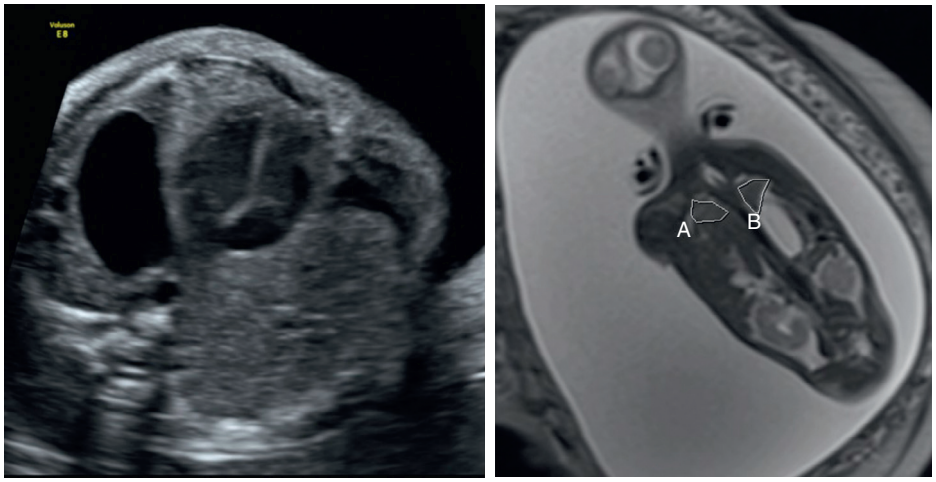

Fig. 27.3 US (*left*) and MRI (*right*) images of a fetus with bilateral diaphragmatic hernia at 28 weeks' gestation. Note on the US the presence of stomach and liver besides the heart. There is a small effusion. On MRI, the lungs (traced and labelled *A* and *B*) are extremely hypoplastic.

position of the stomach and esophagus and ensuing swallowing difficulties. In the first trimester, contact between fetal stomach and bladder may also be an indirect sign of diaphragmatic hernia.[7]

The main aim of all prenatal imaging techniques in CDH is to predict the outcome of the individual fetus. The first step is to look for associated anatomic anomalies and to exclude chromosomal anomalies. Next, the severity of pulmonary hypoplasia is assessed using US, MRI, or both. We describe both tools, and other reviews are available.[8]

On US, the fetal lungs are best assessed in the axial section. The cross-sectional area of the lung opposite to the side of the diaphragmatic defect (contralateral lung) can be used to predict the outcome in fetuses with CDH. The measurement should be performed at the level of the four-chamber view and related to the head circumference measured at the same visit (lung-to-head ratio [LHR]). Peralta et al.[9] showed that the most accurate method for measuring lung size in normal lungs is to trace the lung contours rather than multiplying the lung diameters (Fig. 27.4). Although this method may seem easy, a trainee needs an experience of about 70 to 80 measurements before being able to measure the LHR reliably. As the lung area in normal fetuses increases 16-fold compared with only a fourfold increase in head circumference between 12 and 32 weeks' gestation, the LHR of a healthy fetus increases, making comparison of LHRs measured at different gestational ages difficult. To overcome this problem, we suggested accounting for the effect of gestational age on LHR by expressing the measured (or "observed") LHR as a percentage of the mean ("expected") LHR of the same lung in healthy gestational age–matched fetuses (observed/expected [O/E] LHR).[10] An automated LHR calculator is freely available on http://www.euroCDH.org. Another proposed method to account for the effect of gestational age is the quantitative lung index.[11] This method, however, has not undergone the same extensive evaluation and validation as the O/E LHR.

Both O/E LHR and liver herniation have been shown to be predictive of neonatal mortality and morbidity,[12] but not of long-term morbidity.[13] For clinical use, a classification tool based on US assessment of O/E LHR and liver position has been developed, permitting assignment to groups with expected extreme, severe, moderate, or mild pulmonary hypoplasia (Fig. 27.5).[14]

Recent studies have also shown that fetal stomach position (graded as "intraabdominal," "anterior left chest," "mid-left chest," "posterior right chest") correlates with neonatal mortality[15] and morbidity.[16] It still needs to be confirmed whether this is truly independent of lung size and liver position.

In an attempt to quantify the severity of lung hypoplasia and predict the second major negative factor in CDH, pulmonary hypertension, we and others have been investigating prenatal lung vascularity using Doppler US. Different indices of lung blood flow and the reactivity to oxygen of the pulmonary artery and its branches may help in predicting outcome, but these tools are still investigational.

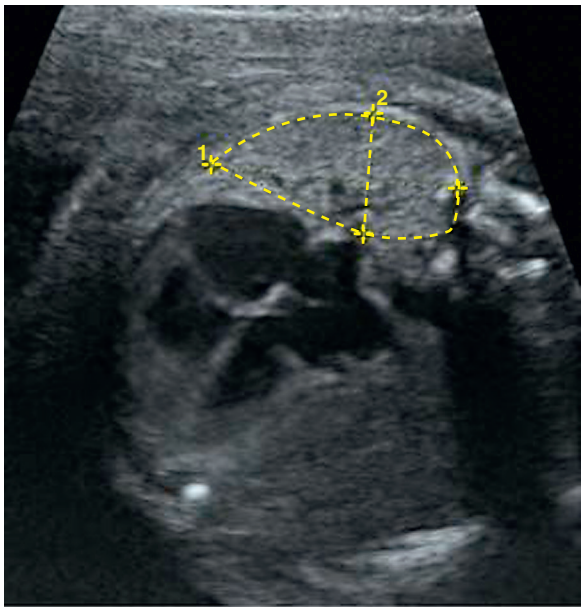

Fig. 27.4 US measurement of the lung area to calculate lung-to-head ratio. We preferentially use a transverse section at the level of the four-chamber view with the lung in the anterior field, and we use the "tracing method."

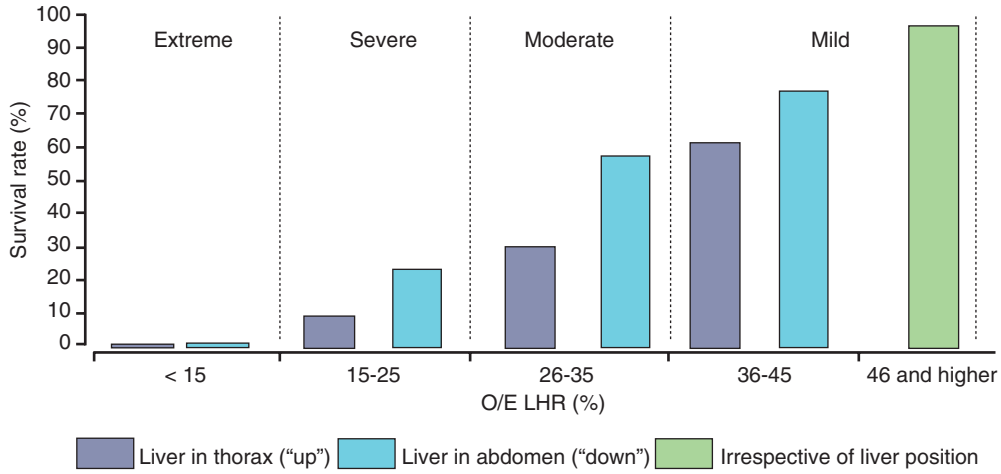

Fig. 27.5 Graph plotting neonatal survival versus fetal lung size as measured by US (observed/expected LHR) in fetuses with and without liver herniation. *(From Deprest J, Flemmer A, Gratacos E, et al: Antenatal prediction of lung volume and in utero treatment by fetal endoscopic tracheal occlusion in severe isolated congenital diaphragmatic hernia.* Semin Fetal Neonat Med *14:8–13, 2009.)*

Magnetic Resonance Imaging

MRI is an excellent imaging modality for morphologic and volumetric evaluation of the fetal lung because the high water content of the lung results in a high signal intensity on T2-weighted images and provides superior contrast resolution in the fetal chest (Fig. 27.6).[8] MRI sequences typically used for fetal studies include single-shot turbo spin echo (SSTSE), balanced gradient echo (BGE), and volume-integrated gradient echo (VIGE) sequences. SSTSE and BGE sequences generate T2-weighted images and allow evaluation of the fluidfilled lungs. VIGE is a T1-weighted sequence and is ideal to outline the liver and the intestines. MRI slice thickness ranges between 2 mm and 4 mm. As with US, volumes should be compared with gestational age–matched or fetal weight–matched normal fetal lungs.[17]



Fig. 27.6 MRI (T2 sequence) of a fetus with left-sided CDH at 28 weeks' gestation. The presence of stomach *(S)* and bowels *(B)* is noted in the left chest. We delineated the contour of the right lung.

MRI can also show the presence of liver herniation and may allow a more precise quantification of the amount of liver herniated.[18]

Differential Diagnosis From Imaging Findings

The differential diagnosis of CDH includes mainly other pulmonary or thoracic pathologies, such as cystic lesions (i.e., cystic adenomatoid malformation; bronchogenic, enteric, and neuroenteric cysts; mediastinal teratoma; and thymic cysts); bronchopulmonary sequestrations; and bronchial or pulmonary atresia. In these conditions, the intraabdominal organs are not displaced.

Diaphragmatic eventration, characterized by defective diaphragmatic muscularization, can be more challenging to differentiate prenatally from other forms of CDH and, in our experience, is virtually impossible in the prenatal period. Nevertheless, US markers have been described (cephalic displacement of the diaphragm and pleural or pericardial effusions).[19]

Synopsis of Treatment Options

PRENATAL

Because of the high mortality in cases of severe CDH managed (only) postnatally, different groups explored the potential benefits of prenatal intervention. Open fetal surgery and diaphragmatic repair, as done in the postnatal period, is not a valid option as this kinks the ductus venosus in fetuses with liver herniation and leads to intrauterine death.

Subsequent interventions were based on the observation that fetal tracheal occlusion prevents the egress of lung fluid, stretches the lung, and promotes lung growth. Fetal endoluminal tracheal occlusion (FETO) is now a clinically feasible, minimally invasive procedure performed under maternal local anesthesia. The fetus is anesthetized and immobilized through an in utero intramuscular injection. A 1.3-mm fetoscope within a 3-mm sheath (Karl Storz, Tüttlingen, Germany) is inserted into the fetal trachea via the mouth and pharynx, and a detachable balloon is inflated between the carina and the vocal cords (Fig. 27.7, Video 27.2).

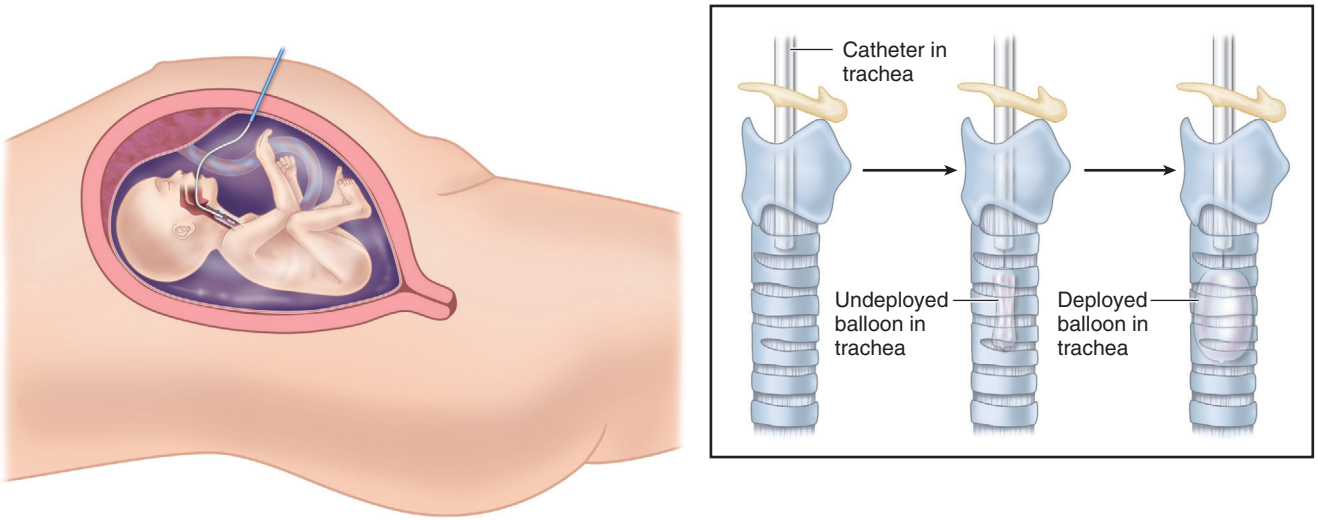

Fig. 27.7 Image depicting the fetoscopic delivery of an endoluminal tracheal balloon in the fetus.

FETO is typically done between 28 to 30 weeks' gestation. The balloon is preferentially removed prenatally by US-guided puncture or with fetoscopy around 34 to 35 weeks' gestation, but in case of unexpected preterm delivery, tracheoscopy during an ex utero intrapartum (EXIT) procedure is an option. A cohort series in over 200 fetuses with isolated severe diaphragmatic hernia showed a survival rate twice as expected compared to a historical cohort of 354 expectantly managed fetuses (50% rather than 25%).[20]

Improved survival after FETO was also confirmed by a recent metaanalysis of case-control and small (pseudo) randomized studies[21] and is now being formally validated in the randomized TOTAL trial (http://www.eurocdh.org [clinicaltrials.gov registry NCT01240057]).

The most important complications of FETO are preterm premature rupture of membranes and preterm delivery. Premature rupture of membranes occurs in close to 50% but only in 15% within 3 weeks after the first fetoscopy. On average, the gestational age at delivery after FETO is 35.3 weeks.

POSTNATAL

As many variations in the treatment of a neonate with CDH existed, a European consensus on the postnatal management of CDH was sought.[22]

Fetuses with prenatally diagnosed CDH should be delivered in expert tertiary care centers. The morphologic alterations caused by CDH result in insufficient respiratory capacity and severe pulmonary hypertension soon after birth. Historically, newborns with CDH were managed with aggressive ventilation and immediate reconstructive surgery. However, to reduce the risk of ventilation-induced lung injury, "gentle ventilation" or spontaneous breathing followed by delayed surgical repair of the diaphragm has become the preferred strategy.[23] In case of persistent hypercapnia, high-frequency oscillating ventilation has been proposed as a rescue strategy. If conventional therapy fails to stabilize the neonate, extracorporeal membrane oxygenation (ECMO) is an additional option.

Severe pulmonary hypertension usually occurs several hours after birth and is often reversible, but it may become chronic and result in right cardiac failure and death despite adequate treatment. To facilitate lung perfusion, different potent vasodilators that regulate pulmonary vascular tone have been suggested, of which inhaled nitric oxide is the most common. Sildenafil, a phosphodiesterase-5 inhibitor, can be synergistic with inhaled nitric oxide to improve therapeutic efficacy and prevent rebound hypertension. Other potential vasodilators can be used as a rescue therapy; however, their effectiveness and safety in CDH have yet to be proven.

Diaphragmatic repair is performed when the neonate is sufficiently stabilized, typically in the first week of life. The repair is done by an open thoracic or abdominal approach, but in milder cases a thoracoscopic approach may also be an option. If the diaphragmatic defect cannot be closed using the native tissue, a patch can be used.

After discharge from the neonatal intensive care unit, long-term multidisciplinary follow-up is required as CDH infants commonly have bronchopulmonary dysplasia, failure to thrive, gastroesophageal reflux, nutrition disorders, neurodevelopmental delay, and musculoskeletal problems.[24]

WHAT THE REFERRING PHYSICIAN NEEDS TO KNOW

CDH is a rare disease with a broad outcome spectrum. In expert centers, the prognosis of the individual fetus can be estimated prenatally only after a comprehensive assessment.

Associated anomalies and aneuploidies should be excluded. If CDH is isolated, the postnatal outcome depends on liver position and lung size. Both can be assessed by US or MRI. In more severe cases, with poor predicted postnatal survival, a prenatal intervention (fetoscopic tracheal occlusion) can potentially improve the outcome; this is currently being tested in randomized trials. All fetuses with prenatally diagnosed CDH should be delivered in tertiary care centers to allow for optimal neonatal care.

KEY POINTS

- The most striking US signs are mediastinal shift and presence of bowel, stomach, spleen, or liver in the chest.
- Associated anomalies and aneuploidies should be excluded.
- In isolated CDH, the prognosis depends on lung size and liver position, which can be assessed quantitatively by US and MRI.
- Fetal tracheal occlusion is an experimental prenatal therapy with the potential of increasing survival; it is currently being tested in a randomized trial.
- All fetuses with CDH should be evaluated and delivered in tertiary care centers.

SUGGESTED READING

Chiu P, Hedrick HL. Postnatal management and long-term outcome for survivors with congenital diaphragmatic hernia. *Prenat Diagn*. 2008;28:592-603.

Claus F, Sandaite I, DeKoninck P, et al. Prenatal anatomical imaging in fetuses with congenital diaphragmatic hernia. *Fetal Diagn Ther*. 2011;29:88-100.

Dekoninck P, Gratacos E, Van Mieghem T, et al. Results of fetal endoscopic tracheal occlusion for congenital diaphragmatic hernia and the set-up of the randomized controlled TOTAL trial. *Early Hum Dev*. 2011;87:619-624.

All references are available online at www.expertconsult.com.

REFERENCES

1. Gallot D, Boda C, Ughetto S, et al. Prenatal detection and outcome of congenital diaphragmatic hernia: a French registry-based study. *Ultrasound Obstet Gynecol*. 2007;29:276-283.
2. Stege G, Fenton A, Jaffray B. Nihilism in the 1990s: the true mortality of congenital diaphragmatic hernia. *Pediatrics*. 2003;112:532-535.
3. http://discovery.lifemapsc.com/library/review-of-medical-embryology/chapter-48-development-of-the-diaphragm. Last accessed on April 29, 2016.
4. Keijzer R, Liu J, Deimling J, et al. Dual-hit hypothesis explains pulmonary hypoplasia in the nitrofen model of congenital diaphragmatic hernia. *Am J Pathol*. 2000;156:1299-1306.
5. Van Mieghem T, Gucciardo L, Doné E, et al. Left ventricular cardiac function in fetuses with congenital diaphragmatic hernia and the effect of fetal endoscopic tracheal occlusion. *Ultrasound Obstet Gynecol*. 2009;34:424-429.
6. Van Mieghem T, Cruz-Martinez R, Allegaert K, et al. Outcome of fetuses with congenital diaphragmatic hernia and associated intrafetal fluid effusions managed in the era of fetal surgery. *Ultrasound Obstet Gynecol*. 2012;39:50-55.
7. Aiello H, Meller C, Vázquez L, et al. Stomach in contact with the bladder: a sonographic sign of left congenital diaphragmatic hernia. *Fetal Diagn Ther*. 2016;40:231-234.
8. Claus F, Sandaite I, DeKoninck P, et al. Prenatal anatomical imaging in fetuses with congenital diaphragmatic hernia. *Fetal Diagn Ther*. 2011;29:88-100.
9. Peralta CF, Cavoretto P, Csapo B, et al. Assessment of lung area in normal fetuses at 12-32 weeks. *Ultrasound Obstet Gynecol*. 2005;26:718-724.
10. Jani J, Nicolaides KH, Keller RL, et al. Observed to expected lung area to head circumference ratio in the prediction of survival in fetuses with isolated diaphragmatic hernia. *Ultrasound Obstet Gynecol*. 2007;30:67-71.
11. Quintero RA, Quintero LF, Chmait R, et al. The quantitative lung index (QLI): a gestational age-independent sonographic predictor of fetal lung growth. *Am J Obstet Gynecol*. 2011;205:544.e1-544.e8.
12. Alfaraj MA, Shah PS, Bohn D, et al. Congenital diaphragmatic hernia: lung-to-head ratio and lung volume for prediction of outcome. *Am J Obstet Gynecol*. 2011;205:43.e1-43.e8.
13. King SK, Alfaraj M, Gaiteiro R, et al. Congenital diaphragmatic hernia: observed/expected lung-to-head ratio as a predictor of long-term morbidity. *J Pediatr Surg*. 2016;51:699-702.
14. Deprest JA, Hyett JA, Flake AW, et al. Current controversies in prenatal diagnosis 4: should fetal surgery be done in all cases of severe diaphragmatic hernia? *Prenat Diagn*. 2009;29:15-19.
15. Cordier AG, Jani JC, Cannie MM, et al. Stomach position in prediction of survival in left-sided congenital diaphragmatic hernia with or without fetoscopic endoluminal tracheal occlusion. *Ultrasound Obstet Gynecol*. 2015;46:155-161.
16. Lusk LA, Wai KC, Moon-Grady AJ, et al. Fetal ultrasound markers of severity predict resolution of pulmonary hypertension in congenital diaphragmatic hernia. *Am J Obstet Gynecol*. 2015;213:216.e1-216.e8.
17. Nawapun K, Sandaite I, Dekoninck P, et al. Comparison of matching by body volume or gestational age for calculation of observed to expected total lung volume in fetuses with isolated congenital diaphragmatic hernia. *Ultrasound Obstet Gynecol*. 2014;44:655-660.
18. Cannie M, Jani J, Chaffiotte C, et al. Quantification of intrathoracic liver herniation by magnetic resonance imaging and prediction of postnatal survival in fetuses with congenital diaphragmatic hernia. *Ultrasound Obstet Gynecol*. 2008;32:627-632.
19. Jeanty C, Nien JK, Espinoza J, et al. Pleural and pericardial effusion: a potential ultrasonographic marker for the prenatal differential diagnosis between congenital diaphragmatic eventration and congenital diaphragmatic hernia. *Ultrasound Obstet Gynecol*. 2007;29:378-387.
20. Jani JC, Nicolaides KH, Gratacós E, et al. Severe diaphragmatic hernia treated by fetal endoscopic tracheal occlusion. *Ultrasound Obstet Gynecol*. 2009;34:304-310.
21. Al-Maary J, Eastwood MP, Russo FM, et al. Fetal tracheal occlusion for severe pulmonary hypoplasia in isolated congenital diaphragmatic hernia: a systematic review and meta-analysis of survival. *Ann Surg*. 2016;264:929-933.
22. Reiss I, Schaible T, van den Hout L, et al. Standardized postnatal management of infants with congenital diaphragmatic hernia in Europe: the CDH EURO Consortium consensus. *Neonatology*. 2010;98(4):354-364.
23. Chiu P, Hedrick HL. Postnatal management and long-term outcome for survivors with congenital diaphragmatic hernia. *Prenat Diagn*. 2008;28:592-603.
24. Safavi A, Synnes AR, O'Brien K, et al. Multiinstitutional follow-up of patients with congenital diaphragmatic hernia reveals severe disability and variations in practice. *J Pediatr Surg*. 2012;47:836-841.

To access the videos in this chapter, scan this QR code or visit expertconsult.com

28 Hepatic Anomalies

MARC U. BAUMANN | BORIS TUTSCHEK

Introduction

Structural fetal hepatic anomalies include tumors (usually primary, rarely metastatic), calcifications, cysts, hepatomegaly, and biliary anomalies. Fetal biliary anomalies are discussed in Chapter 25. Many of these conditions can be diagnosed prenatally by ultrasound (US).

Hepatic Tumors, Calcifications, and Cysts

Solid hepatic tumors are rare, accounting for approximately 5% of perinatal neoplasms.[1] They include benign and malignant primary neoplasms and metastases of nonhepatic cancers.[2] Hepatic tumors appear as intraperitoneal masses, detected prenatally by US and postnatally by palpation. The main tumors are hemangioma, mesenchymal hamartoma, and hepatoblastoma.

Hemangioma

DEFINITION

Hemangioma is a benign tumor characterized by increased angiogenesis. It may occur in various organs.

PREVALENCE AND EPIDEMIOLOGY

Hemangioma is the most common primary fetal hepatic tumor and accounts for about 60% of all fetal hepatic tumors.[1]

ETIOLOGY AND PATHOPHYSIOLOGY

Hemangioma is a benign vascular tumor characterized by substantial perinatal growth of single or multiple nodules, followed by slow involution during childhood.

Mesenchymal Hamartoma

DEFINITION

Mesenchymal hamartomas are composed of hepatocytes, biliary elements, and connective tissue. This hepatic tumor has traditionally been regarded as a hamartoma. However, cytogenetic studies have suggested that this tumor should be considered a true neoplasm.[3] Biochemical markers such as maternal serum alpha-fetoprotein and beta-human chorionic gonadotropin may be elevated.

PREVALENCE AND EPIDEMIOLOGY

Mesenchymal hamartoma is the second most common liver tumor. About one-third of all perinatal hepatic tumors are hamartomas.

ETIOLOGY AND PATHOPHYSIOLOGY

Mesenchymal hamartoma is a benign tumor that consists of hepatocytes, biliary components, and fibrous tissue and may form a solid or multicystic mass.

Hepatoblastoma

DEFINITION

Fetal hepatoblastoma arises from undifferentiated embryonal tissue and occurs as epithelial or epithelial/mesenchymal.

PREVALENCE AND EPIDEMIOLOGY

Hepatoblastoma is the most common malignant fetal tumor.[4] About 16% of perinatal hepatic tumors are hepatoblastoma.[1] The female-to-male ratio is 1.6:6.

ETIOLOGY AND PATHOPHYSIOLOGY

Most hepatoblastomas are found in the right lobe; a few arise from both lobes with a multiple nodule aspect. This preference for the right lobe might be explained by the different blood oxygen tensions of the vessels supplying the two lobes.[5,6] The hepatic vein delivers oxygen-saturated blood to the left lobe, whereas the portal vein supplies less saturated blood to the right lobe, which facilitates the development of hepatoblastoma.

Hepatic Calcifications

DEFINITION

Calcifications represent local accumulations of calcium, usually caused by infection or inflammation, hypoxia, or necrosis.

PREVALENCE AND EPIDEMIOLOGY

The incidence of fetal hepatic calcifications has been reported to be 1:1750 at 15 to 26 gestational weeks.[7]

ETIOLOGY AND PATHOPHYSIOLOGY

Hepatic calcifications usually have a peritoneal (infection, meconium peritonitis), parenchymal (infection, tumor), or vascular origin or cause. Other malformations are present in 21% of fetuses with hepatic calcifications.[7]

Hepatic Cysts

Hepatic cysts occur in isolation, as part of genetic syndromes such as autosomal dominant polycystic kidney disease, or as manifestations of biliary anomalies (see Chapter 25).

DEFINITION

A cyst is a structure composed of a distinct wall with a liquid or solid content. In adults, hepatic cysts include parasitic and nonparasitic cysts, but fetal parasitic cysts have not yet been reported. Hepatic cysts may be solitary or multiple, such as in congenital polycystic disease of the kidney and liver, congenital dilatation of intrahepatic bile ducts (Caroli disease), and congenital hepatic fibrosis.[8,9]

PREVALENCE AND EPIDEMIOLOGY

The incidence of hepatic cysts is low in neonates and increases with age. Approximately 2.5% of the general population is affected. The female-to-male ratio is 4:1.[8] The incidence of fetal hepatic cysts has been reported as 1:7786 fetuses at 13 to 17 weeks' gestation.[10]

ETIOLOGY AND PATHOPHYSIOLOGY

The etiology of isolated solitary hepatic cysts is unknown. Aberrant bile ducts may cause accumulations of bile, leading to hepatic cysts (see also Chapter 25).[11]

Congenital Intrahepatic Shunts

DEFINITION

Congenital intrahepatic shunts are characterized by anomalous communications among hepatic vessels.

PREVALENCE AND EPIDEMIOLOGY

Intrahepatic arteriovenous shunts are exceedingly rare, and their prevalence is unknown.

ETIOLOGY AND PATHOPHYSIOLOGY

Anomalous communications among hepatic artery, vein, and portal vein account for arteriovenous, arterioportal, and portosystemic shunts.[12]

Hereditary hemorrhagic telangiectasia (HHT), an autosomal dominant condition, leads to mucocutaneous telangiectasias and visceral arteriovenous malformations (AVMs) commonly detected in the cerebral, pulmonary, and hepatic circulation, which might be revealed antenatally. When fetal hepatic AVMs are suspected in HHT patients, genetic testing should be offered.[13]

MANIFESTATIONS OF DISEASE

Clinical Presentation

Hemangioma. The growth of nodules may cause hepatic (subcapsular) hematoma due to spontaneous bleeding during involution,[14] anemia, hydrops, hydramnios, thrombocytopenia, disseminated intravascular coagulation and localized consumption coagulopathy (Kasabach-Merritt syndrome), and neonatal cardiac failure secondary to massive arteriovenous shunting inside the tumor.[1]

Fetal blood sampling may be useful to test for thrombocytopenia, allowing optimal perinatal management such as intrauterine platelet transfusion before delivery.[15] Postnatal treatment strategies consist of medical management (steroids and interferon alfa) and interventional modalities (hepatic artery ligation or embolization, surgical resection, or liver transplantation).[2,16] In prenatally diagnosed liver hemangiomas, treatment with corticosteroids has been attempted.[17] However, spontaneous remission of a hemangioma after birth is common.[18] Half of the affected cases also had hemangiomas of the skin and other organs.[1] Hemangiomas and concomitant chorioangioma or other impairment of the placental architecture have also been reported.[19]

Mesenchymal Hamartoma. Mesenchymal hamartomas usually increase in size, which necessitates surgery. A few cases show incomplete spontaneous regression, whereas some undergo malignant transformation to undifferentiated (embryonal) sarcoma, although this occurs very rarely.[20] Large tumors may compress the inferior vena cava and the umbilical vein, leading to polyhydramnios and fetal hydrops. Associations with placental pathology[21] and Beckwith-Wiedemann syndrome (BWS)[22] have been reported (see also Chapter 109).

Hepatoblastoma. During labor, the fetus is at risk for intraabdominal hemorrhage owing to rupture of hepatoblastoma.[23] Hepatoblastomas can be associated with genetic anomalies and malformation syndromes such as BWS, familial adenomatous polyposis coli, fetal alcohol syndrome, and trisomy 18.[24–28]

Hepatic Calcifications. In the presence of hepatic calcifications, a detailed US examination should seek additional structural anomalies, and serologic testing for infections including TORCH (*t*oxoplasmosis, *o*ther [congenital syphilis and viruses], *r*ubella, *c*ytomegalovirus, and *h*erpes simplex virus) and amniocentesis for karyotyping and viral polymerase chain reaction (PCR) testing should be discussed. Isolated hepatic calcifications have a good prognosis.[7] The combination of hepatic calcifications with other sonographic abnormalities are associated with increased risk for chromosomal abnormalities, mainly trisomy 13.[29]

Hepatic Cysts. Most hepatic cysts detected during the early second trimester disappear spontaneously, particularly when the cysts are initially small and peripheral.[10,30] Most persistent hepatic cysts are asymptomatic and do not need a neonatal surgical intervention. Complications may arise from pressure effects.[31] US-guided in utero needle drainage of hepatic cysts has been reported,[32,33] but postnatal procedures may still be necessary in symptomatic cysts.[11] Postnatal surgical interventions include total excision, partial excision with marsupialization of the cyst wall, and Roux-en-Y hepatojejunostomy.[34,35]

Intrahepatic Arteriovenous Shunts. Arteriovenous shunts in the liver are associated with a high mortality rate. Clinical

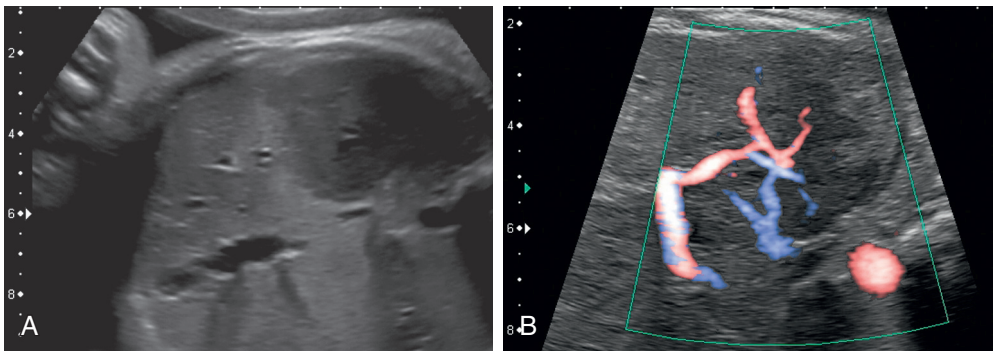

Fig. 28.1 US appearance of hepatic hemangioma at 36 weeks' gestation. (A) Grayscale imaging shows hypoechoic tumor in the right lobe of the liver. (B) Perfusion imaging (directional power Doppler) of the same tumor, indicating the presence of large feeding and draining vessels (see also Videos 28.1 and 28.2).

symptoms depend on the size, type and site of the shunts. Clinically significant arteriovenous shunts result in high-output heart failure. Congenital intrahepatic arterioportal shunts lead to portal hypertension and subsequently to gastrointestinal bleeding, anemia, ascites, diarrhea, and malabsorption. Portosystemic shunts lead to hypergalactosemia, increased bile acid, hepatopulmonary shunt, portopulmonary hypertension, and focal hepatic nodular hyperplasia.[12]

In complex intrahepatic shunts, hepatic resection is the treatment of choice since embolization is associated with increased risk of adverse outcome and might not provide an efficient therapy.[12,36]

Imaging Technique and Findings

Ultrasound

Hemangioma. On prenatal US, fetal hepatic hemangiomas may be heterogeneous, but they are usually mixed solid/cystic and hypoechoic compared with normal liver tissue (Fig. 28.1A). They typically show increased vascularity on color Doppler examination (see Fig. 28.1B).

Mesenchymal Hamartoma. Mesenchymal hamartoma appears as a multiloculated cystic mass with different-sized, thin-walled cysts and an anechoic and hypovascular aspect.[37] Color Doppler usually shows no increased vascularity. Hamartomas have been detected by prenatal US, typically in the third trimester of pregnancy.[3,37,38] Some fetuses also have polyhydramnios.

Hepatoblastoma. The US appearance of fetal hepatoblastoma is more irregular and mostly solid, and these lesions show calcifications. On prenatal US, hepatoblastoma appears as a usually single, heterogeneous, circumscribed, echogenic solid mass within the liver with a spoke-wheel appearance (Fig. 28.2).[6] Possible associated US findings are hydramnios and fetal hydrops, which may lead to prenatal or postnatal death.[39]

Hepatic Calcifications. Hepatic calcifications appear as isolated or sporadic bright echogenic foci (Fig. 28.3).

Hepatic Cysts. Most fetal hepatic cysts are detected in the third trimester, but they also may be identified in the first trimester (Figs. 28.4 and 28.5).[11] Hepatic cysts are usually anechoic spaces surrounded by liver parenchyma. Color Doppler may show vessels in the vicinity of the cyst and the hepatic artery or the portal vein, indicating a biliary origin (see Chapter 25).

If multiple hepatic cysts are detected by US, the differential diagnosis includes congenital polycystic disease of the liver and kidney, congenital dilatation of intrahepatic bile ducts (Caroli disease), and congenital hepatic fibrosis. Cystic kidney diseases are discussed in Chapters 15 and 16.



Fig. 28.2 Fetal hepatoblastoma. *(From Shih JC, Tsao PN, Huang SF, et al: Antenatal diagnosis of congenital hepatoblastoma in utero.* Ultrasound Obstet Gynecol *16:94–97, 2000.)*

Intrahepatic Shunts. In large congenital intrahepatic shunts, considerable dilatation of the suprarenal aorta and hepatic vessels, along with mild cardiomegaly, may be observed at prenatal ultrasound.[36] Doppler spectral analysis of intrahepatic vessels may show arterial traces with little systolic-diastolic flow variation and high-velocity venous signals.[40]

Magnetic Resonance Imaging. Magnetic resonance imaging (MRI) in addition to fetal echocardiography in late gestation may help assess the functional relevance of large hemangiomas.[2] For the diagnosis of mesenchymal hamartoma, fetal MRI may be of additional value.[37]

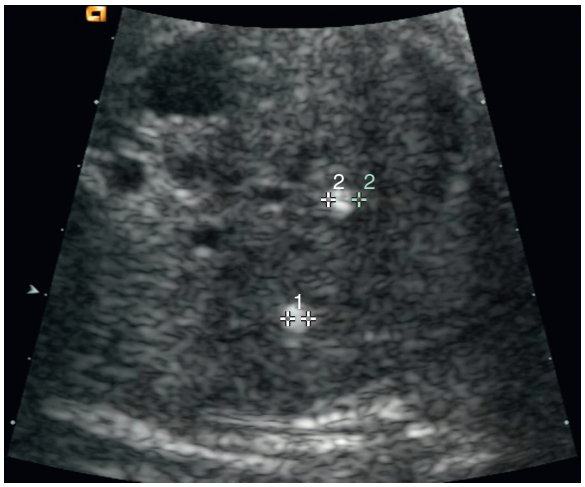

Fig. 28.3 US appearance of fetal hepatic calcifications at 33 weeks' gestation.

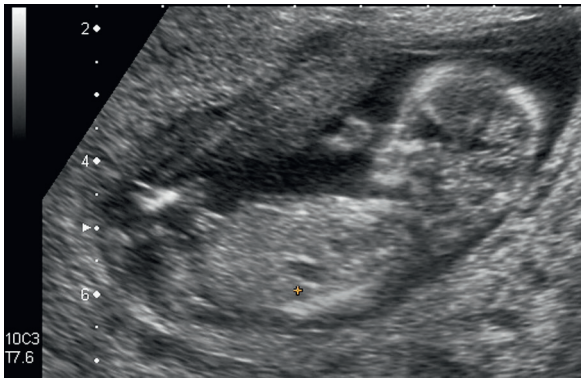

Fig. 28.5 US appearance of a fetal hepatic cyst at 13 weeks' gestation.

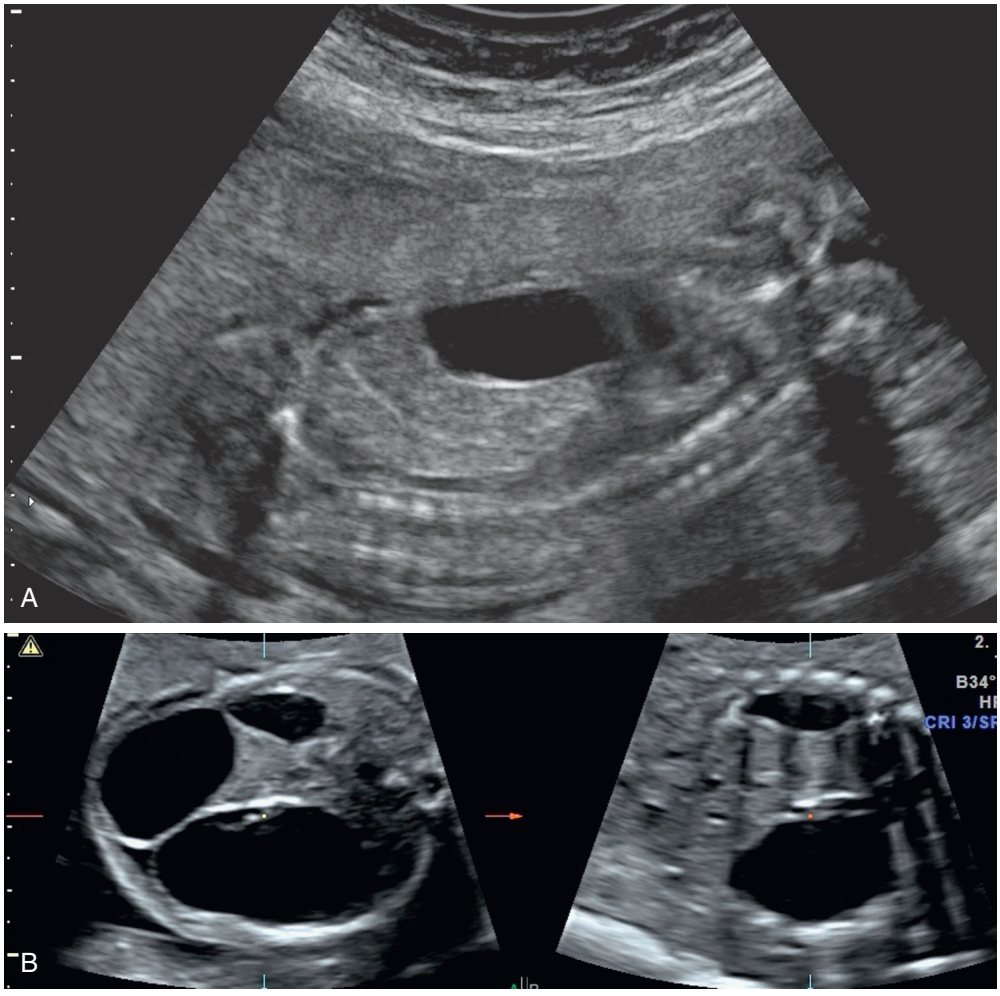

Fig. 28.4 US appearance of fetal hepatic cysts at 20 weeks' gestation. (A) Longitudinal section shows a single cyst. (B) Multiplanar reconstruction of multiple hepatic cysts at 20 weeks.

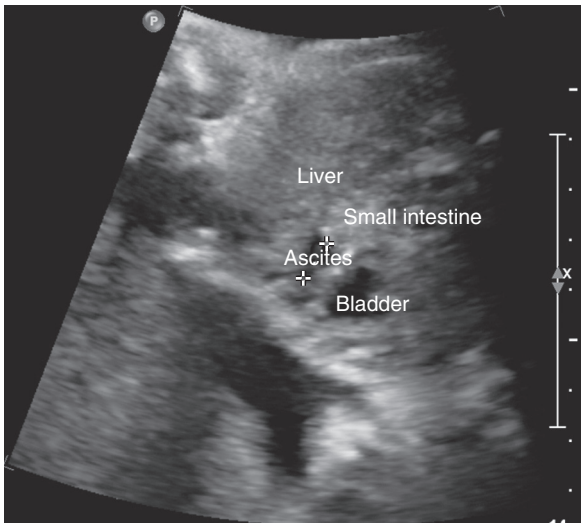

Fig. 28.6 Fetal hepatomegaly at 27 weeks' gestation with the liver reaching down into the fetal pelvis.

Hepatomegaly

Fetal hepatomegaly occurs in the context of infection, metabolic or genetic diseases, or hematologic alterations and often accompanies fetal hydrops (immune and nonimmune). Localized or overall fetal hepatomegaly is also typical for hepatic tumors.

Hepatomegaly and Fetal Infections

Human cytomegalovirus (CMV) is the most common congenital viral infection and, in the acute phase, manifests with hepatomegaly. Toxoplasmosis, syphilis, and rubella also can cause hepatomegaly. Parvovirus infection is another possible cause of hepatomegaly; it is generally accompanied by splenomegaly and accelerated cerebral peak systolic velocities owing to hyperdynamic fetal circulation caused by fetal anemia and hydrops. Fetal infections are described in detail in Chapters 165 to 168.

DEFINITION

Hepatomegaly means enlargement of the fetal liver. Enlargement can be judged subjectively (e.g., when the liver reaches into the fetal pelvis adjacent to the fetal bladder) (Fig. 28.6). For a more objective and quantifiable assessment, the length of the right lobe of the liver can be measured from the dome of the diaphragm to the tip of the right lobe parallel to the long axis of the fetal trunk (Fig. 28.7).[41,42] Normal ranges have been reported for fetal liver length (Fig. 28.8).

PREVALENCE AND EPIDEMIOLOGY

CMV infection is the most common perinatal viral infection with a birth prevalence of about 0.5%.[43] Maternal parvovirus infection occurs in 3.5% of pregnancies.[44,45] The prevalence of syphilis has increased from 15:100,000 to 20:100,000 between 2010 and 2014 in the United States.[46]

ETIOLOGY AND PATHOPHYSIOLOGY

Fetal hepatomegaly infection is caused by local inflammation, hyperperfusion, and infiltration with leukocytes.

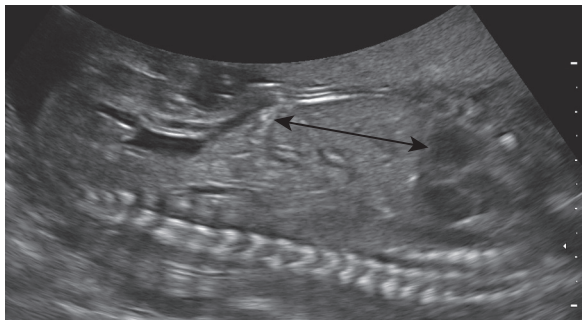

Fig. 28.7 US appearance of a normal fetal liver length (longitudinal section of fetal trunk) at 22 weeks' gestation.

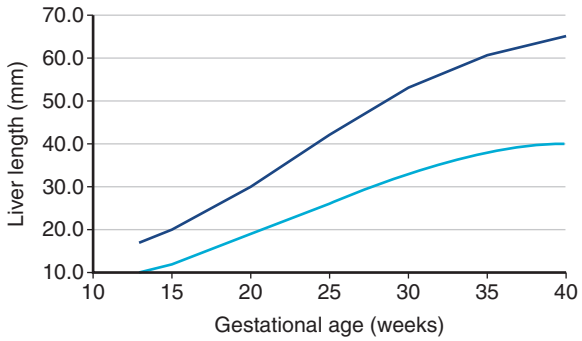

Fig. 28.8 Normal values for fetal liver length as determined by US. *(Modified from Roberts AB, Mitchell JM, Pattison NS: Fetal liver length in normal and isoimmunized pregnancies.* Am J Obstet Gynecol *161:42–46, 1989.)*

Hepatomegaly in Metabolic or Genetic Diseases

DEFINITION

Gestational diabetes may be complicated by fetal overgrowth and organomegaly. Hepatomegaly occurs in fetuses exposed to maternal diabetes.[42,47]

Beckwith-Wiedemann syndrome (BWS) is a genetic syndrome (variable modes of inheritance) characterized by impaired growth regulation, subsequent overgrowth, and a predisposition for distinct tumors. It typically manifests with omphalocele, organomegaly including hepatomegaly and macroglossia, and polyhydramnios (Chapter 109).[48]

Storage and other metabolic diseases can also exhibit hepatomegaly. Zellweger syndrome, or cerebro-hepato-renal syndrome, is a peroxisomal disorder. This peroxisome deficiency leads to impaired metabolism of fatty acids.

Niemann-Pick disease comprises a heterogeneous group of lysosomal lipid storage diseases. Gaucher disease, also known as *glucocerebrosidase deficiency*, includes type 1 (common), type 2, and type 3 (rare).

PREVALENCE AND EPIDEMIOLOGY

Gestational diabetes has a variable prevalence and complicates 18% of pregnancies.[49] It constitutes a common cause of fetal hepatomegaly.

BWS is the most common overgrowth syndrome. The incidence of BWS is approximately 1:13,700.[50,51] The true incidence may

be higher because mild cases escape detection. Females and males show an equal incidence of BWS. Most cases are sporadic (85%), but 15% show a familial pattern. US examination should be offered to families of members with BWS because it can be diagnosed prenatally, even before 20 weeks' gestation.[52] For a detailed description of BWS, see Chapter 109.

The incidence of Zellweger syndrome is about 1:100,000 newborns.[53] Incidence of Niemann-Pick disease type A and type B ranges from 0.5:100,000 to 1:100,000 births,[54] whereas incidence of type C is approximately 1:150,000 births.[55]

Prenatal-onset of Niemann-Pick disease type C has been reported in the literature in very few cases.[56]

ETIOLOGY AND PATHOPHYSIOLOGY

BWS can be caused by various epigenetic or genetic alterations affecting imprinted genes on chromosome 11p15.5.[48] Zellweger syndrome is a rare and lethal autosomal recessive disease of peroxisomal metabolism with variable expression that shows hepatomegaly in homozygous fetuses.

Patients with Niemann-Pick disease type A and type B show a deficiency of sphingomyelinase and a subsequent accumulation of sphingomyelin in liver and spleen. Type C is characterized by altered intracellular transport of low-density lipoprotein cholesterol resulting in lysosomal accumulation of lipid molecules. The mode of inheritance of all three types of Niemann-Pick disease is autosomal recessive.

The underlying pathologic mechanisms of all three types of Gaucher disease are mutations in the gene encoding acid beta-glucosidase, leading to impaired function of lysosomal enzyme beta-glucocerebrosidase, which leads to an accumulation of glucosylceramide in hepatic, bone marrow, and splenic cells. Prenatally, glucocerebrosidase activity may be assessed in chorionic villi and amniocytes.

Hepatomegaly in Hematologic Diseases

DEFINITION

Anemia, such as in hemolytic disease of the fetus and newborn or in alpha-thalassemia, can cause fetal hepatosplenomegaly and hydrops. Myeloproliferative disorder is a transient hematologic condition with excessive leukocytosis.[57] Fetal leukemia is exceedingly rare.[58]

PREVALENCE AND EPIDEMIOLOGY

Hemolytic disease of the fetus and newborn is caused by red blood cell antigens leading to fetal anemia. With the introduction of anti-D prophylaxis, an incidence of only 0.1% of rhesus D–negative women can be achieved.[59] Alpha-thalassemia is the most common cause of fetal hydrops in Southeast Asia.[60] Transient myeloproliferative disorder may be present in 14% of fetuses with trisomy 21.[57] In infants younger than 1 year, the annual incidence of leukemia is 1:25,000.[61]

ETIOLOGY AND PATHOPHYSIOLOGY

Isoimmunization with red blood cell antigens leads to destruction of fetal red blood cells, anemia, and eventually hydrops (see Chapter 123). In homozygous thalassemia, diminished production of red blood cells is the cause of anemia (see Chapter 122). Both conditions are associated with hepatomegaly and splenomegaly and may lead to frank hydrops.

The most common genetic characteristics in de novo leukemia in infants are translocations of the *MLL* gene at the chromosome band 11q23. Fetal leukemic reactions can occur as a complication of chromosomal anomalies such as trisomy 21, Turner syndrome, and chromosome 7p deletion. Congenital leukemia generally shows a rapid deterioration,[62] but spontaneous remissions have also been reported.[63]

MANIFESTATIONS OF DISEASE

Clinical Presentation

Fetal Infections. In fetal CMV infection, sonographic findings include hepatic calcifications and mild to moderate hepatomegaly, splenomegaly, echogenic bowel ascites, and hydrops. In fetal parvovirus infection, the accelerated fetal circulatory system is most apparent in the elevated peak systolic velocity in the middle cerebral artery and effusion or even hydrops. Hepatomegaly and hepatic calcifications occur.[64]

In congenital syphilis, prenatal sonographic findings include hepatomegaly, placentomegaly, Doppler abnormalities in the middle cerebral artery, and less commonly ascites and polyhydramnios (Chapter 168).[65]

Metabolic or Genetic Diseases. Fetal hepatomegaly has been quantified in patients with gestational diabetes. Fetal liver length was significantly greater by 18 weeks' gestation (12% above normal mean values) and even greater by 36 weeks (19%; $P < .02$). The major increase in liver size occurs early in pregnancy but seems to be modifiable by glycemic control later in gestation. In nondiabetic pregnant obese controls, fetal liver length was also increased, but less than in the diabetic mothers.[42]

In BWS the phenotype varies considerably. The typical characteristics—macrosomia, macroglossia, and omphalocele—may not always all be present. Major findings include abdominal wall defect, macroglossia, macrosomia, anterior earlobe creases or posterior helical pits, visceromegaly (liver, kidney, spleen, pancreas, and adrenal glands), embryonal tumor in childhood, hemihyperplasia, adrenocortical cytomegaly, renal abnormalities, positive family history of BWS, and cleft palate. Findings in pregnancy include polyhydramnios, enlarged placenta or thickened umbilical cord (or both), premature onset of labor and delivery, neonatal hypoglycemia, and cardiomegaly, structural cardiac anomalies, or cardiomyopathy. Findings in neonates include characteristic facies, diastasis recti abdominis, nevus flammeus, and advanced bone age. In children with BWS, risk of tumor development is 7.5%. Tumors associated with BWS are most commonly Wilms tumor and hepatoblastoma. Other embryonal tumors that may occur in BWS include rhabdomyosarcoma, adrenocortical carcinoma, and neuroblastoma.[48]

Patients with type A Niemann-Pick disease have severe neurovisceral manifestations, whereas in patients with type B, the disease is limited to visceral organs and has a chronic course. Patients with type C Niemann-Pick disease have subacute neurologic complications and less pronounced organomegaly than that associated with type A.

Among the glucocerebrosidases, nonneurologic Gaucher disease type 1 is most common, accounting for about 95% of all patients with Gaucher disease. The neuronopathic forms (types 2 and 3) are rare. Gaucher disease type 1 shows variable hepatomegaly and splenomegaly and other organ manifestations.

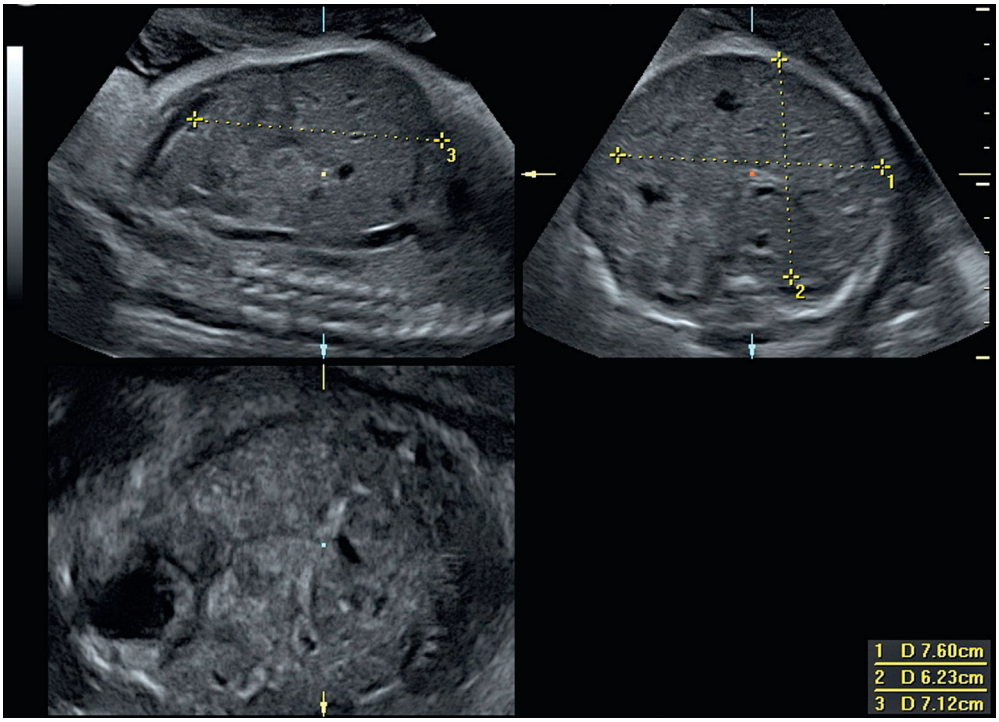

Fig. 28.9 Multiplanar US imaging (longitudinal, axial, and coronal) of fetal hepatomegaly in a fetus with metabolic disease at 31 weeks' gestation.

The clinical manifestation of Zellweger syndrome is characterized by a heterogeneous pattern of structural aberrations secondary to the variable expression of this lethal autosomal recessive disease. Most infants do not survive the first year of life.

Hematologic Diseases. Neonatal and fetal leukemia is very rare. Congenital leukemia generally shows a rapid deterioration,[62] but spontaneous remissions have also been reported.[63] In particular, in fetuses with trisomy 21, there is a similar entity with hepatomegaly and splenomegaly, called *transient myeloproliferative disorder,* which may affect 14% of fetuses with trisomy 21.[57] Fetal anemia leads to extramedullary erythropoiesis, resulting in hepatosplenomegaly in addition to other signs of anemia (elevated peak systolic velocity in the middle cerebral artery).

Imaging Technique and Findings

Ultrasound. The size of the fetal liver can be assessed subjectively by judging how far the liver reaches toward the fetal pelvis (see Fig. 28.6) or objectively by measuring the greatest length in the long axis of the fetal body (see Figs. 28.7 and 28.8) or from three-dimensional US hepatic volume.[41,66]

Fetal Infections. Hepatomegaly in fetal infection can be accompanied by splenomegaly, accelerated flow velocities and tissue hyperperfusion, ascites, and frank hydrops.

Metabolic or Genetic Diseases. In gestational diabetes, measurement of fetal liver length shows an increased liver size.[42] Because fetuses of diabetic mothers have disproportionate growth of the liver and subcutaneous fat, fetal abdominal circumference, which is mainly determined by liver size, has been suggested rather than estimated fetal weight as the measure on US of fetal response to diabetes.[67] Hepatomegaly in fetal metabolic disease is shown in Fig. 28.9.

US signs of fetal BWS include polyhydramnios; enlarged placenta and thickened umbilical cord; cardiomegaly or structural cardiac anomalies; and the triad omphalocele, macroglossia, and macrosomia (hepatomegaly or hepatosplenomegaly and organomegaly of the kidney, pancreas, and adrenal glands).[68–71] In fetuses with Niemann-Pick disease type C, ascites, hepatosplenomegaly, intrauterine growth restriction, oligohydramnios, and placental thickening can be found.[72,73] US studies of fetuses with Niemann-Pick disease type A and type B are scarce. In Niemann-Pick disease type A, there is a characteristic US appearance of the placenta that correlates with histochemical localization of sphingomyelin in the placenta.[74]

US findings in Gaucher disease include hepatomegaly, hydrops, polyhydramnios, and a small or absent stomach bubble owing to swallowing palsy.[75,76] In Zellweger syndrome, reported US findings include increased nuchal translucency, intrauterine growth restriction, hypokinesia, abnormal skull shape, micrognathia, buphthalmos, clinodactyly, hepatomegaly, cardiac anomalies, central nervous system anomalies such as hydrocephalus, ventriculomegaly, and periventricular cysts.[77]

Hematologic Diseases. In fetuses with trisomy 21, hydrops or hepatosplenomegaly can be a sign of transient myeloproliferative disorder; the US appearance mimics fetal infection (Fig. 28.10).[58,78] In fetal leukemia associated with trisomy 21, the predominant US characteristics are hepatosplenomegaly and, possibly, hydrops.[58] Fetal leukemia without chromosomal aberration is exceedingly rare. One study reported prenatal US findings of elevated amniotic fluid index and fetal hepatomegaly.[79]

In severe fetal anemia, such as isoimmunization or homozygous alpha-thalassemia, hepatosplenomegaly, thickened placenta, fetal hydrops, and other signs of anemia can be detected by prenatal US.[41,80–84] Besides hepatomegaly, splenomegaly is also closely associated with fetal anemia, probably owing to extramedullary erythropoiesis, and can be assessed by measuring splenic circumference.[85]

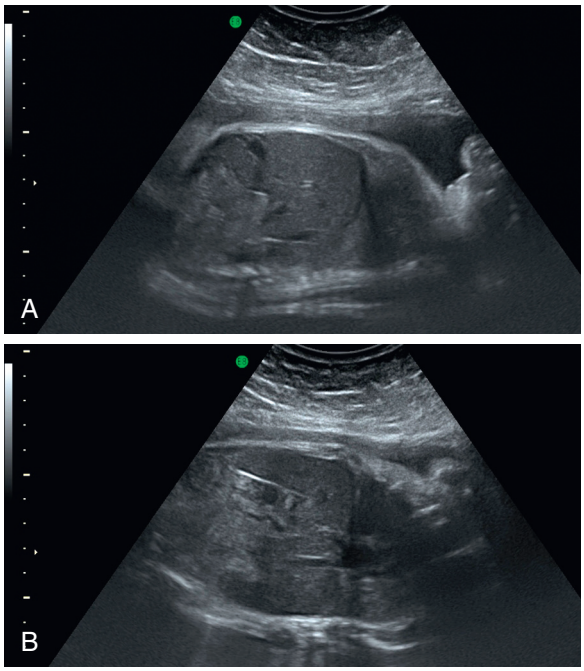

Fig. 28.10 US appearance of the liver length in a fetus with trisomy 21 at 29 weeks' gestation with myeloproliferative disorder. (A) Longitudinal view. (B) Coronal view.

Magnetic Resonance Imaging

Fetal Infections. In fetuses with CMV infection, MRI seems to have higher sensitivity than transabdominal US in the detection of associated brain anomalies.[72,73]

Metabolic or Genetic Diseases. MRI may be useful to complement US investigations in suspected BWS and Zellweger syndrome.[71,74] In Zellweger syndrome, MRI can reveal characteristic abnormal cortical gyration, impaired myelination, and cerebral periventricular pseudocysts; renal microcysts; and hepatosplenomegaly.[75,76]

CLASSIC SIGNS

Hepatic tumors in fetuses are very rare and heterogeneous.
Hepatic calcifications can be associated with anomalies and infection.
Macrosomia, organomegaly, and polyhydramnios are fetal manifestations of gestational diabetes.
In BWS, the typical triad comprises omphalocele, macroglossia, and organomegaly; however, it may be incomplete.

WHAT THE REFERRING PHYSICIAN NEEDS TO KNOW

Fetal hepatomegaly is a nonspecific finding that warrants detailed examination. The most common cause is probably poor maternal glycemic control in diabetic pregnancies.

KEY POINTS

- Hepatomegaly can be caused by metabolic, hematologic, or genetic diseases; fetal infection; or hepatic tumors. The most common cause is probably gestational diabetes.
- Hemangioma is the most common fetal hepatic tumor.
- CMV is the most common fetal viral infection and in the acute phase is associated with hepatomegaly, ascites, possible abdominal calcifications, and abnormal cerebral echogenicities.

SUGGESTED READING

Isaacs H Jr. Fetal and neonatal hepatic tumors. *J Pediatr Surg*. 2007;42:1797-1803.
Ishak KG, Sharp HL. Developmental abnormalities and liver diseases in childhood. In: MacSween NM, Anthony PP, Scheurer PJ, eds. *Pathology of the liver*. 3rd ed. Edinburgh: Churchill Livingstone; 1994:83-122.
Smrcek JM, Baschat AA, Germer U, et al. Fetal hydrops and hepatosplenomegaly in the second half of pregnancy: a sign of myeloproliferative disorder in fetuses with trisomy 21. *Ultrasound Obstet Gynecol*. 2001;17:403-409.
Weksberg R, Shuman C, Smith AC. Beckwith-Wiedemann syndrome. *Am J Med Genet C Semin Med Genet*. 2005;137C:12-23.

All references are available online at www.expertconsult.com.

REFERENCES

1. Isaacs H Jr. Fetal and neonatal hepatic tumors. *J Pediatr Surg*. 2007;42(11):1797-1803.
2. Makin E, Davenport M. Fetal and neonatal liver tumours. *Early Hum Dev*. 2010;86(10):637-642.
3. Stringer MD, Alizai NK. Mesenchymal hamartoma of the liver: a systematic review. *J Pediatr Surg*. 2005;40(11):1681-1690.
4. Orbach D, Sarnacki S, Brisse HJ, et al. Neonatal cancer. *Lancet Oncol*. 2013;14(13):e609-e620.
5. Kiserud T, Eik-Nes SH, Blaas HG, et al. Foramen ovale: an ultrasonographic study of its relation to the inferior vena cava, ductus venosus and hepatic veins. *Ultrasound Obstet Gynecol*. 1992;2(6):389-396.
6. Shih JC, Tsao PN, Huang SF, et al. Antenatal diagnosis of congenital hepatoblastoma in utero. *Ultrasound Obstet Gynecol*. 2000;16(1):94-97.
7. Bronshtein M, Blazer S. Prenatal diagnosis of liver calcifications. *Obstet Gynecol*. 1995;86(5):739-743.
8. Ishak KG, Sharp HL. Developmental abnormalities and liver diseases in childhood. In: MacSween NM, Anthony PP, Scheurer PJ, eds. *Pathology of the Liver*. 3rd ed. Edinburgh: Churchill Livingstone; 1994:83-122.
9. Macken MB, Wright JR Jr, Lau H, et al. Prenatal sonographic detection of congenital hepatic cyst in third trimester after normal second-trimester sonographic examination. *J Clin Ultrasound*. 2000;28(6):307-310.
10. Bronstein M, Nizar K, Weiner Z. Significance of early prenatal diagnosis of fetal hepatic cyst. *J Clin Ultrasound*. 2009;37(2):65-68.
11. Berg C, Baschat AA, Geipel A, et al. First-trimester diagnosis of fetal hepatic cyst. *Ultrasound Obstet Gynecol*. 2002;19(3):287-289.
12. Wu L, Zhao L, Lu Y, et al. Interventional embolization of congenital intrahepatic shunts in children. *Pediatr Radiol*. 2016;46(4):541-547.
13. Saleh M, Miron I, Al-Rukban H, et al. Prenatal presentation of hereditary hemorrhagic telangiectasia—a report of two sibs. *Prenat Diagn*. 2016;36(9):891-893.
14. Maher JE, Van Beek B, Kelly RT, et al. Spontaneous subcapsular hematoma of the fetal liver: a case report and review of literature. *AJP Rep*. 2015;5(2):e203-e206.
15. Gembruch U, Baschat AA, Gloeckner-Hoffmann K, et al. Prenatal diagnosis and management of fetuses with liver hemangiomata. *Ultrasound Obstet Gynecol*. 2002;19(5):454-460.
16. Daller JA, Bueno J, Gutierrez J, et al. Hepatic hemangioendothelioma: clinical experience and management strategy. *J Pediatr Surg*. 1999;34(1):98-105, discussion 6.
17. Schmitz R, Heinig J, Klockenbusch W, et al. Antenatal diagnosis of a giant fetal hepatic hemangioma and treatment with maternal corticosteroid. *Ultraschall Med*. 2009;30(3):223-226.
18. Chan KL, Tang MH, Tse HY, et al. Factors affecting outcomes of prenatally-diagnosed tumours. *Prenat Diagn*. 2002;22(5):437-443.
19. Marton T, Silhavy M, Csapo Z, et al. Multifocal hemangioendothelioma of the fetus and placenta. *Hum Pathol*. 1997;28(7):866-869.
20. Ramanujam TM, Ramesh JC, Goh DW, et al. Malignant transformation of mesenchymal hamartoma of the liver: case report and review of the literature. *J Pediatr Surg*. 1999;34(11):1684-1686.
21. Kitano Y, Ruchelli E, Weiner S, et al. Hepatic mesenchymal hamartoma associated with mesenchymal stem villous hyperplasia of the placenta. *Fetal Diagn Ther*. 2000;15(3):134-138.
22. Cajaiba MM, Sarita-Reyes C, Zambrano E, et al. Mesenchymal hamartoma of the liver associated with features of Beckwith-Wiedemann syndrome and high serum alpha-fetoprotein levels. *Pediatr Dev Pathol*. 2007;10(3):233-238.
23. von Schweinitz D. Neonatal liver tumours. *Semin Neonatol*. 2003;8(5):403-410.
24. Mamlok V, Nichols M, Lockhart L, et al. Trisomy 18 and hepatoblastoma. *Am J Med Genet*. 1989;33(1):125-126.
25. Khan A, Bader JL, Hoy GR, et al. Hepatoblastoma in child with fetal alcohol syndrome. *Lancet*. 1979;1(8131):1403-1404.
26. Orozco-Florian R, McBride JA, Favara BE, et al. Congenital hepatoblastoma and Beckwith-Wiedemann syndrome: a case study including DNA ploidy profiles of tumor and adrenal cytomegaly. *Pediatr Pathol*. 1991;11(1):131-142.
27. Giardiello FM, Offerhaus GJ, Krush AJ, et al. Risk of hepatoblastoma in familial adenomatous polyposis. *J Pediatr*. 1991;119(5):766-768.
28. von Schweinitz D. Hepatoblastoma: recent developments in research and treatment. *Semin Pediatr Surg*. 2012;21(1):21-30.
29. Simchen MJ, Toi A, Bona M, et al. Fetal hepatic calcifications: prenatal diagnosis and outcome. *Am J Obstet Gynecol*. 2002;187(6):1617-1622.
30. Charlesworth P, Ade-Ajayi N, Davenport M. Natural history and long-term follow-up of antenatally detected liver cysts. *J Pediatr Surg*. 2007;42(3):494-499.
31. Merine D, Nussbaum AR, Sanders RC. Solitary nonparasitic hepatic cyst causing abdominal distension and respiratory distress in a newborn. *J Pediatr Surg*. 1990;25(3):349-350.
32. Arzt WSM, Yaman C. Prenatal diagnosis and therapy of a fetal hepatic cyst in the 2nd trimester. *Geburtshilfe Frauenheilkd*. 1998;58:129-131.
33. Ito M, Yoshimura K, Toyoda N, et al. Aspiration of giant hepatic cyst in the fetus in utero. *Fetal Diagn Ther*. 1997;12(4):221-225.
34. Jojart G, Verebely T. [Primary neonatal liver cyst]. *Orv Hetil*. 1992;133(33):2101-2102.
35. Tsao L, Jeanty P. Liver cyst. *The Fetus*. 1993;3:75164-75166.
36. Lima M, Lalla M, Aquino A, et al. Congenital symptomatic intrahepatic arteriovenous fistulas in newborns: management of 2 cases with prenatal diagnosis. *J Pediatr Surg*. 2005;40(10):e1-e5.
37. Cornette J, Festen S, van den Hoonaard TL, et al. Mesenchymal hamartoma of the liver: a benign tumor with deceptive prognosis in the perinatal period. Case report and review of the literature. *Fetal Diagn Ther*. 2009;25(2):196-202.
38. Tovbin J, Segal M, Tavori I, et al. Hepatic mesenchymal hamartoma: a pediatric tumor that may be diagnosed prenatally. *Ultrasound Obstet Gynecol*. 1997;10(1):63-65.
39. Ammann RA, Plaschkes J, Leibundgut K. Congenital hepatoblastoma: a distinct entity? *Med Pediatr Oncol*. 1999;32(6):466-468.
40. Adaletli I, Kurugoglu S, Kilic F, et al. Radiological evaluation with Doppler sonography and multidetector CT angiography in congenital hepatic arteriovenous malformation in a newborn. *Pediatr Radiol*. 2006;36(11):1204-1207.
41. Vintzileos AM, Neckles S, Campbell WA, et al. Fetal liver ultrasound measurements during normal pregnancy. *Obstet Gynecol*. 1985;66(4):477-480.
42. Roberts AB, Mitchell J, Murphy C, et al. Fetal liver length in diabetic pregnancy. *Am J Obstet Gynecol*. 1994;170(5 Pt 1):1308-1312.
43. Kenneson A, Cannon MJ. Review and meta-analysis of the epidemiology of congenital cytomegalovirus (CMV) infection. *Rev Med Virol*. 2007;17(4):253-276.
44. Rodis JF, Quinn DL, Gary GW Jr, et al. Management and outcomes of pregnancies complicated by human B19 parvovirus infection: a prospective study. *Am J Obstet Gynecol*. 1990;163(4 Pt 1):1168-1171.
45. Gratacos E, Torres PJ, Vidal J, et al. The incidence of human parvovirus B19 infection during pregnancy and its impact on perinatal outcome. *J Infect Dis*. 1995;171(5):1360-1363.
46. Prevention CfDCa: STD surveillance 2014. http://www.cdc.gov/std/stats14/surv-2014-print.pdf.
47. Perovic M, Gojnic M, Arsic B, et al. Relationship between mid-trimester ultrasound fetal liver length measurements and gestational diabetes mellitus. *J Diabetes*. 2015;7(4):497-505.
48. Weksberg R, Shuman C, Smith AC. Beckwith-Wiedemann syndrome. *Am J Med Genet C Semin Med Genet*. 2005;137C(1):12-23.
49. Metzger BE, Gabbe SG, Persson B, et al. International association of diabetes and pregnancy study groups recommendations on the diagnosis and classification of hyperglycemia in pregnancy. *Diabetes Care*. 2010;33(3):676-682.
50. Engstrom W, Lindham S, Schofield P. Wiedemann-Beckwith syndrome. *Eur J Pediatr*. 1988;147(5):450-457.
51. Choufani S, Shuman C, Weksberg R. Beckwith-Wiedemann syndrome. *Am J Med Genet C Semin Med Genet*. 2010;154C(3):343-354.
52. Winter SC, Curry CJ, Smith JC, et al. Prenatal diagnosis of the Beckwith-Wiedemann syndrome. *Am J Med Genet*. 1986;24(1):137-141.
53. Danks DM, Tippett P, Adams C, et al. Cerebro-hepato-renal syndrome of Zellweger. A report of eight cases with comments upon the incidence, the liver lesion, and a fault in pipecolic acid metabolism. *J Pediatr*. 1975;86(3):382-387.
54. Schuchman EH. The pathogenesis and treatment of acid sphingomyelinase-deficient Niemann-Pick disease. *J Inherit Metab Dis*. 2007;30(5):654-663.
55. Vanier MT, Millat G. Niemann-Pick disease type C. *Clin Genet*. 2003;64(4):269-281.
56. Colin E, Barth M, Boussion F, et al. In utero diagnosis of Niemann-Pick type C in the absence of family history. *JIMD Rep*. 2016;28:105-110.
57. Smrcek JM, Baschat AA, Germer U, et al. Fetal hydrops and hepatosplenomegaly in the second half of pregnancy: a sign of myeloproliferative disorder in fetuses with trisomy 21. *Ultrasound Obstet Gynecol*. 2001;17(5):403-409.
58. Robertson M, De Jong G, Mansvelt E. Prenatal diagnosis of congenital leukemia in a fetus at 25 weeks' gestation with Down syndrome: case report and review of the literature. *Ultrasound Obstet Gynecol*. 2003;21(5):486-489.
59. Bowman JM. The prevention of Rh immunization. *Transfus Med Rev*. 1988;2(3):129-150.

60. Liang ST, Wong VC, So WW, et al. Homozygous alpha-thalassaemia: clinical presentation, diagnosis and management. A review of 46 cases. *Br J Obstet Gynaecol*. 1985;92(7):680-684.
61. Linabery AM, Ross JA. Trends in childhood cancer incidence in the U.S. (1992–2004). *Cancer*. 2008;112(2):416-432.
62. Siegel SE, Moran RG. Problems in the chemotherapy of cancer in the neonate. *Am J Pediatr Hematol Oncol*. 1981;3(3):287-296.
63. Lampkin BC, Peipon JJ, Price JK, et al. Spontaneous remission of presumed congenital acute nonlymphoblastic leukemia (ANLL) in a karyotypically normal neonate. *Am J Pediatr Hematol Oncol*. 1985;7(4):346-351.
64. Savarese I, De Carolis MP, Costa S, et al. Atypical manifestations of congenital parvovirus B19 infection. *Eur J Pediatr*. 2008;167(12):1463-1466.
65. Rac MW, Bryant SN, McIntire DD, et al. Progression of ultrasound findings of fetal syphilis after maternal treatment. *Am J Obstet Gynecol*. 2014;211(4):426 e1-426 e6.
66. Laudy JA, Janssen MM, Struyk PC, et al. Fetal liver volume measurement by three-dimensional ultrasonography: a preliminary study. *Ultrasound Obstet Gynecol*. 1998;12(2):93-96.
67. Anderson NG, Notley E, Graham P, et al. Reproducibility of sonographic assessment of fetal liver length in diabetic pregnancies. *Ultrasound Obstet Gynecol*. 2008;31(5):529-534.
68. Nowotny T, Bollmann R, Pfeifer L, et al. Beckwith-Wiedemann syndrome: difficulties with prenatal diagnosis. *Fetal Diagn Ther*. 1994;9(4):256-260.
69. Hamada H, Fujiki Y, Obata-Yasuoka M, et al. Prenatal sonographic diagnosis of Beckwith-Wiedemann syndrome in association with a single umbilical artery. *J Clin Ultrasound*. 2001;29(9):535-538.
70. Mulik V, Wellesley D, Sawdy R, et al. Unusual prenatal presentation of Beckwith-Wiedemann syndrome. *Prenat Diagn*. 2004;24(7):501-503.
71. Williams DH, Gauthier DW, Maizels M. Prenatal diagnosis of Beckwith-Wiedemann syndrome. *Prenat Diagn*. 2005;25(10):879-884.
72. Moreno R, Lardennois C, Drouin-Garraud V, et al. Prenatal revelation of Niemann-Pick disease type C in siblings. *Acta Paediatr*. 2008;97(8):1136-1139.
73. Spiegel R, Raas-Rothschild A, Reish O, et al. The clinical spectrum of fetal Niemann-Pick type C. *Am J Med Genet A*. 2009;149A(3):446-450.
74. Schoenfeld A, Abramovici A, Klibanski C, et al. Placental ultrasonographic biochemical and histochemical studies in human fetuses affected with Niemann-Pick disease type A. *Placenta*. 1985;6(1):33-43.
75. Sarfati R, Hubert A, Dugue-Marechaud M, et al. Prenatal diagnosis of Gaucher's disease type 2. Ultrasonographic, biochemical and histological aspects. *Prenat Diagn*. 2000;20(4):340-343.
76. Rowlands S, Murray H. Prenatal ultrasound findings in a fetus diagnosed with Gaucher's disease (type 2) at birth. *Prenat Diagn*. 1997;17(8):765-769.
77. Johnson JM, Babul-Hirji R, Chitayat D. First-trimester increased nuchal translucency and fetal hypokinesia associated with Zellweger syndrome. *Ultrasound Obstet Gynecol*. 2001;17(4):344-346.
78. Hartung J, Chaoui R, Wauer R, et al. Fetal hepatosplenomegaly: an isolated sonographic sign of trisomy 21 in a case of myeloproliferative disorder. *Ultrasound Obstet Gynecol*. 1998;11(6):453-455.
79. Shibasaki T, Matsuda H, Kawakami Y, et al. Fetal leukemia with umbilical artery embolism and circulatory failure. *Obstet Gynecol*. 2007;109(2 Pt2):521-523.
80. Roberts AB, Mitchell JM, Pattison NS. Fetal liver length in normal and isoimmunized pregnancies. *Am J Obstet Gynecol*. 1989;161(1):42-46.
81. Roberts AB, Mitchell JM, Lake Y, et al. Ultrasonographic surveillance in red blood cell alloimmunization. *Am J Obstet Gynecol*. 2001;184(6):1251-1255.
82. Luewan S, Tongprasert F, Piyamongkol W, et al. Fetal liver length measurement at mid-pregnancy among fetuses at risk as a predictor of hemoglobin Bart's disease. *J Perinatol*. 2011;31(3):157-160.
83. Leung KY, Cheong KB, Lee CP, et al. Ultrasonographic prediction of homozygous alpha0-thalassemia using placental thickness, fetal cardiothoracic ratio and middle cerebral artery Doppler: alone or in combination? *Ultrasound Obstet Gynecol*. 2010;35(2):149-154.
84. Srisupundit K, Tongprasert F, Luewan S, et al. Splenic circumference at midpregnancy as a predictor of hemoglobin Bart's disease among fetuses at risk. *Gynecol Obstet Invest*. 2011;72(1):63-67.
85. Bahado-Singh R, Oz U, Mari G, et al. Fetal splenic size in anemia due to Rh-alloimmunization. *Obstet Gynecol*. 1998;92(5):828-832.

29 Intraabdominal Masses

JON A. HYETT | FELICITY J. PARK

Introduction

Intraabdominal solid masses and cystic lesions are not commonly identified during the routine 20-week anomaly ultrasound (US) scan and are uncommon findings at later gestations. However, intraabdominal masses occasionally are seen as an incidental finding during a third-trimester US scan assessing fetal growth and wellbeing. Potential differential diagnoses are numerous, but the differential diagnosis typically can be restricted through a detailed assessment of the site and appearance of the lesion. Prenatal intervention is not indicated in most circumstances, but further postnatal investigation or surgical repair may be required shortly after birth, so effective prenatal diagnosis avoids delay in treating the neonate.

Disease

DEFINITION

An intraabdominal mass is a space-occupying lesion within the abdominal cavity that appears either cystic or solid.

PREVALENCE AND EPIDEMIOLOGY

Intraabdominal masses are rare. The prevalence of congenital anomalies, such as bowel atresias, is low. Duodenal, small and large bowel, and rectoanal atresias affect 5.1 : 10,000 births, accounting for 2.2% of congenital anomalies.[1,2] The prevalence of atresia of the common bile duct is even lower (0.3 : 10,000 births).[1]

Some lesions, such as ovarian cyst or hydrometrocolpos, affect only female fetuses. A significant ovarian cyst is subjectively defined as greater than 2 cm in diameter and occurs approximately in 4 : 10,000 female live births.[3] Choledochal cysts are more common in females (4 : 1 prevalence) and in Asian populations. Other anomalies, such as enteric duplication cysts, are more common in males than in females (2 : 1).[4] However, because of the low birth prevalence, it is often difficult to determine accurate epidemiologic differences between populations. Abdominal cysts are discussed in more detail in Chapter 24.

The most common echogenic intraabdominal mass is echogenic bowel (Chapter 22). In contrast to other intraabdominal masses, this acquired anomaly may be seen at the 20-week scan and has a prevalence of 0.3% at this gestation. Greater than 80% of fetuses with echogenic bowel have no underlying pathology, but there are associations with chromosomal abnormality, cystic fibrosis, fetal infection, and intrauterine growth restriction.[5,6]

ETIOLOGY AND PATHOPHYSIOLOGY

The etiology of intraabdominal masses varies widely depending on the organ or system involved. Numerous abnormalities, in particular, cystic masses, are truly congenital with failure in the development of hollow viscera, such as a portion of the bowel (e.g., duodenum, small or large bowel, rectum-anus; Chapter 26), or of drainage channels (e.g., common bile duct; Chapter 25). Most of these anomalies, with the exception of duodenal atresia, are not associated with chromosomal abnormality.[7]

Small bowel atresia is thought to result from an episode of vascular impairment during embryologic development.[8] It may occur in isolation or in association with gastroschisis (the cause of which is also considered to be a vascular accident), or a volvulus. In contrast, enteric duplication cysts appear to arise from a failure of separation between the notochord and endoderm, which explains an association with vertebral anomalies.[4] Some congenital anomalies, such as cystic fibrosis, cause secondary changes that are visible as an intraabdominal mass. The increased echogenicity of the bowel is acquired owing to thick, abnormally viscous meconium, and the development of a pseudoobstruction.[9]

Some intraabdominal masses are acquired rather than congenital. The inflammatory response to fetal infection can lead to the development of echogenic bowel and foci of calcification. The obstructed or hypoxic small bowel may become distended, and perforation may lead to a sterile chemical peritonitis with calcified foci being seeded through the peritoneal cavity as part of the inflammatory response. These foci represent a subacute sign of injury that may take a few weeks to evolve (see Chapters 22 and 26).

Focal calcification is also occasionally seen within the liver, with a prevalence of approximately 6 : 10,000 fetuses (see Chapters 23 and 28). These calcifications may result from localized vascular disruption within the liver causing infarction or ischemia and subsequent fibrosis and calcification.[10] Calcifications are generally found in three sites: on the surface of the liver, where they may be associated with meconium peritonitis; as discrete lesions within the liver capsule, associated with vascular emboli; or more diffusely throughout the liver parenchyma as a result of more widespread ischemia and necrosis that may occur secondary to fetal infection.[11]

Ovarian folliculogenesis occurs from 20 weeks' gestation, and fetal ovarian cysts are often not recognized until the third trimester. The hypothalamic-pituitary-ovarian endocrine axis is active from the end of the first trimester, and cyst formation is thought to be related to gonadotropin, placental human chorionic gonadotropin, or placental estrogen release.[12]

Tumors are rarely seen in the fetus, but hemangioma (60%), mesenchymal hamartoma (23%), and hepatoblastoma (17%) are the most common among perinatal hepatic tumors (see Chapter 28).[13] Neuroblastoma and teratoma have also been reported, but are rare, except for sacrococcygeal teratomas that often have a pelvic component (Chapter 31). Hepatic tumors may manifest as a solitary or multifocal hypoechoic or hyperechoic mass within the liver and may have associated areas of calcification.[14] Hepatoblastoma is associated with increased alpha-fetoprotein, and this may be reflected in maternal serum alpha-fetoprotein levels.[15]

MANIFESTATIONS OF DISEASE

Clinical Presentation

Because the gastrointestinal (GI) tract does not reach functional maturity until the third trimester, pathology is often not recognizable before this stage. The fetus swallows two to seven mL of amniotic fluid every 24 hours at 16 to 17 weeks' gestation, and this increases to 13 to 16 mL at 20 weeks, and 450 mL at term.[16] Fetal bowel motility also increases with gestational age. Consequently, anomalies such as duodenal atresia can be identified when the proximal duodenum fills with amniotic fluid and becomes distended, developing the characteristic double bubble sign in the late second or early third trimester of pregnancy (Fig. 29.1).[4] Generally, the lower an obstruction is in the GI tract,



Fig. 29.1 Axial section of upper abdomen at 28 weeks' gestation. The stomach (lying laterally at the bottom of the image) is distended, as is the proximal third of the duodenum (centrally placed). These features are typical of duodenal atresia.

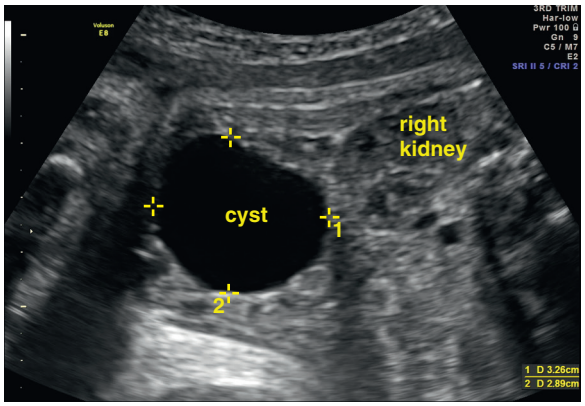

Fig. 29.2 Right parasagittal section showing a 3-cm-diameter simple cyst, separate to and below the right kidney. Postnatal US confirmed that this was a simple ovarian cyst in this 33-week female fetus.

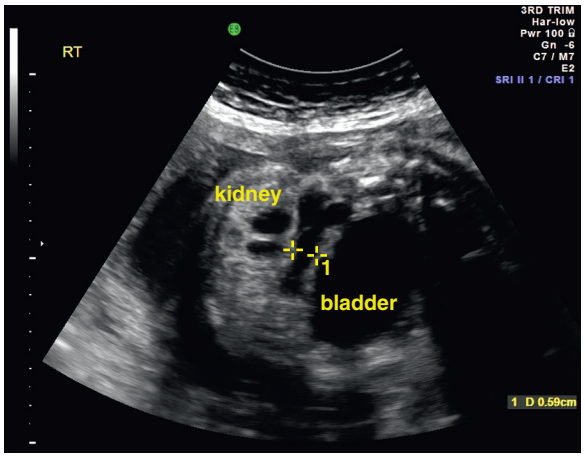

Fig. 29.3 This dilated tubular structure, marked by calipers, lies between the kidney (with evidence of hydronephrosis) and bladder (which is distended). Localization allows the differential diagnosis to be narrowed to a hydroureter.

the later and more subtle its presentation. Anomalies such as Hirschsprung disease and anal atresia are rarely diagnosed before birth.[17] Similarly, pathologies such as ovarian cysts become visible only in the third trimester of pregnancy, owing to the normal developmental process (Fig. 29.2).[12]

Imaging Technique and Findings

Ultrasound. A fetal morphology scan is typically performed at 18 to 23 weeks' gestation and includes standard views of the abdomen and abdominal contents (Chapter 1).[18,19] This examination is designed to detect mainly more common, major structural anomalies, such as omphalocele, gastroschisis, diaphragmatic hernia, and significant urogenital abnormalities. The abdominal circumference is measured in an axial section at a level where the stomach and intrahepatic portion of the umbilical vein can be seen. Careful examination of this and adjacent sections, reveals most of the anomalies mentioned when they are large enough for detection on US. The bowel should be visualized to check for evidence of echogenicity (being as bright as bone) or dilatation (which should be formally measured in transverse diameter).

At more advanced gestational ages, when fetal growth is assessed, the biometry of the abdomen is measured using the same previously described landmarks. Although morphology is not systematically reviewed in the third trimester, if it has been assessed at the second-trimester scan, the sonographer should be aware of the potential for intraabdominal pathology to become apparent at later gestations, and should note the presence of any cystic or solid masses while scanning through the abdomen to assess biometry.

When a cystic or solid mass is shown, it is important to extend the examination to characterize it in more detail. By changing the insonation angle (i.e., by rotating the US probe around the maternal abdomen), it is normally possible to image the mass from different angles, which may help to delineate its border and define whether it is contained within a single viscus, or is more diffuse. Similarly, visualization in different fetal planes (axial/coronal and sagittal) allows localization (Figs. 29.3 and 29.4). Adapting the settings of the US system (gain, contrast, gray mapping, speckle reduction imaging, tissue harmonics, real-time compounding) may help to define the border of the mass more clearly, and allow better contrast between adjacent soft tissue structures. Cystic lesions may be simple or complex, and solid lesions may be homogeneous or heterogeneous. Areas of calcification may be identified by loss of

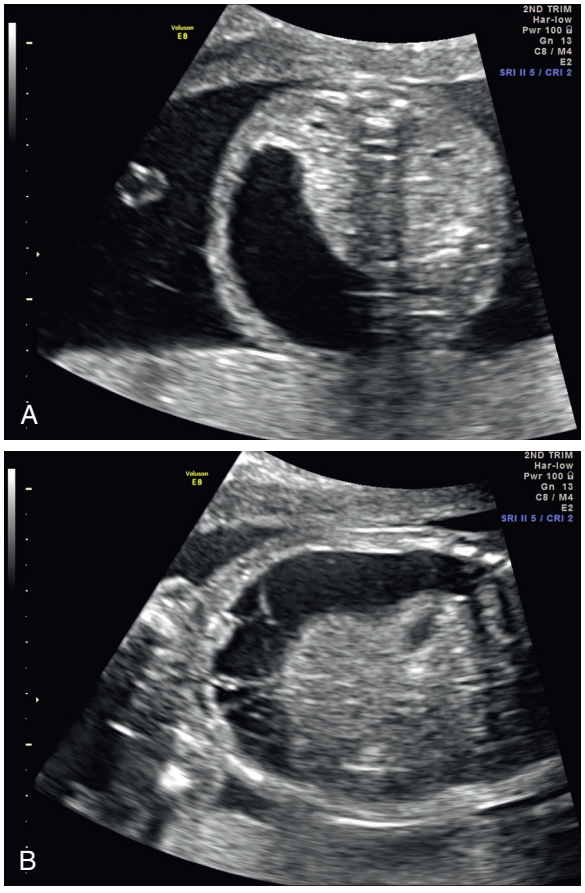

Fig. 29.4 (A) Axial section of the fetal abdomen, at the level of the kidneys, shows a single cystic tubular structure running behind the anterior abdominal wall. (B) Further examination in the coronal section shows that this cystic area extends around the periphery of the abdomen and pelvis, and contains some fine loculation in the pelvic component. A postnatal diagnosis of abdominal lymphangioma was made. These rare benign tumors can arise from the anterior abdominal wall, the mesentery of small bowel, or the omentum, or may be retroperitoneal.

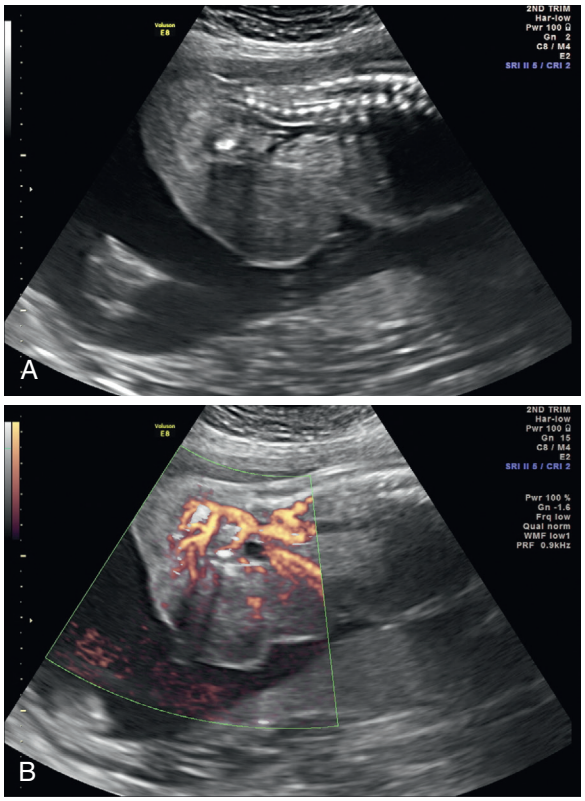

Fig. 29.5 (A) This mass of mixed echogenicity has disrupted the contour of the lower abdominal and pelvic wall. It was found to extend around the buttock to the sacral and gluteal areas, but was predominantly intraabdominal. (B) This teratoma was highly vascular, which eventually led to fetal hydrops.

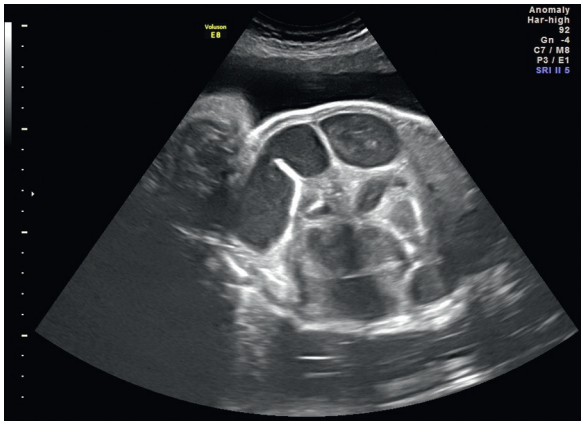

Fig. 29.6 Loops of dilated large bowel (note visible haustra). This was an incidental finding found in a 34-week fetus being scanned to estimate fetal weight.

acoustic signal behind the mass (shadowing). Color or power Doppler can be used to identify a vascular pedicle or more widespread perfusion (Fig. 29.5).

Certain anomalies have defining characteristics: objective assessment of the bowel relies on normative data produced by two studies involving 430 fetuses.[20,21] Dilatation of the small or large bowel is defined by a maximal luminal diameter greater than 7 mm for the small bowel, and greater than 18 mm for the large bowel (Fig. 29.6). Similarly, an ovarian cyst is considered relevant if it is more than 2 cm in diameter (Fig. 29.7) and may

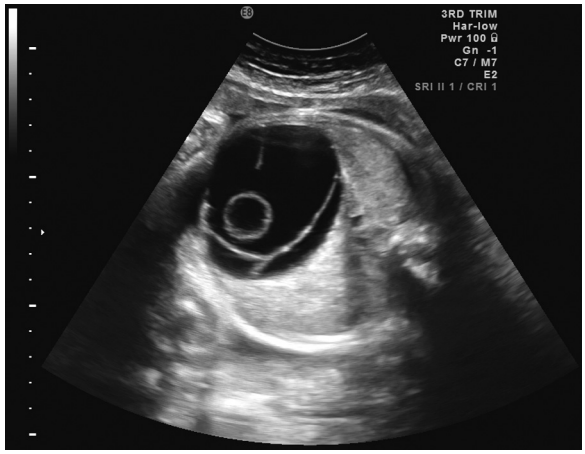

Fig. 29.7 A 4-cm-diameter complex right ovarian cyst seen at 32 weeks' gestation. This cystic mass lay lateral to, and was separate from, the bladder.



Fig. 29.8 Axial section of upper abdomen showing an area of calcification within the liver parenchyma. Other views showed the calcifications within the parenchyma but just below the diaphragm. Note the acoustic shadow caused by the lesion.

have simple septations or daughter cysts, which are considered to be pathognomonic.[12,22] Whilst identification of an abdominal or pelvic cystic mass is the most common feature of a cloacal abnormality, it is often associated with other intraabdominal pathologies including hydronephrosis and hydroureter, oligohydramnios, distended bowel, and ascites.[23] Calcified foci are defined as discrete areas of echogenicity with acoustic shadowing. These may be free within the peritoneum, within the stomach or bowel wall, or within the liver (Fig. 29.8) or spleen, or associated with the biliary tree.

The differential diagnosis depends on the site and character of the lesion (Table 29.1). Other considerations include the anticipated prevalence of anomalies, the gestational age at diagnosis, and the sex of the fetus. A recent retrospective review of 354 fetuses that had intraabdominal masses, predominantly urinary, gastrointestinal or genital in nature, reported associated anomalies in 40% of cases; so a thorough sequential US assessment

TABLE 29.1 DIFFERENTIAL DIAGNOSIS OF FETAL INTRAABDOMINAL MASSES IDENTIFIED BY PRENATAL US: MAIN AND ASSOCIATED FINDINGS, DIFFERENTIAL DIAGNOSIS, AND TYPICAL ADDITIONAL INVESTIGATIONS

Presenting Finding	Associated Features	Differential Diagnosis	Other Investigations
SIMPLE CYST			
Retroperitoneal	Lateral or lower abdomen within renal pelvis	Hydronephrosis	Urinary electrolytes where functional assessment necessary
	Within renal parenchyma	Renal cyst	
	Possible association with duplex kidney or double ureter		
Within bladder		Ureterocele	
Within liver	May be complex	Subcapsular hematoma	Doppler to check for vascularity of hemangioma
Below liver		Choledochal cyst	
Lateral or lower abdomen	Female fetus; may be complex or have solid component	Ovarian cyst	Doppler to show blood flow
Any abdominal site		Mesenteric cyst	Fetal MRI may differentiate by characterizing contents
		Duplication cyst	
		Enteric cyst	
		Meconium pseudocyst	
DOUBLE CYST			
Double bubble	Localized to upper abdomen	Duodenal atresia	Karyotype for association with trisomy 21; check for other structural anomalies, including cardiac defects, vertebral and radial anomalies, other bowel atresias
	Can show continuity with stomach or duodenum	Volvulus	
		Intussusception	
COMPLEX CYST			
Retroperitoneal or upper abdomen	Separate from or above kidney	Adrenal hemorrhage	
		Neuroblastoma	
		Lymphangioma	
		Hydroureter	
Lateral or lower abdomen	Female	Ovarian cyst	
DILATED TUBULAR STRUCTURE			
Contains clear fluid	Dilated bowel	Gastroschisis or exomphalos	Karyotype for association with trisomy 18
		Cloacal anomalies	
		Volvulus	
		Intussusception	
		Hirschsprung disease	Karyotype for association with trisomy 18
		Megacystis microcolon	
	Dilated ureter	Bladder outflow obstruction or vesicoureteric reflux	
Contains echogenic material		Meconium ileus	Can be confirmed by MRI
			Karyotype
			DNA analysis for cystic fibrosis
Associated with blood flow		Arteriovenous malformation	Doppler to show blood flow
		Abnormal ductus venosus	
HYPERECHOGENIC BOWEL			
	With dilated loops of bowel	Bowel obstruction	DNA analysis for cystic fibrosis
	With other structural anomalies or markers of aneuploidy	Chromosomal abnormality	Karyotype
	CNS anomaly or IUGR	Fetus affected by infection	Maternal TORCH screen or amniocentesis PCR
	Abnormal biometry	IUGR or placental insufficiency	Doppler to show maternal and fetal placentation or fetal compensation
	Intraamniotic bleeding	Ingestion of intraamniotic blood	
Intraabdominal calcification	Within biliary tree	Biliary atresia	
	Peritoneal with or without ascites	Bowel perforation	Cystic fibrosis
		Meconium peritonitis	
Intrahepatic calcification	CNS anomaly or IUGR	Fetal infection	Maternal CMV or toxoplasmosis TORCH screen or amniocentesis PCR

CMV, Cytomegalovirus; *CNS*, central nervous system; *IUGR*, intrauterine growth restriction; *PCR*, polymerase chain reaction; *TORCH*, *t*oxoplasmosis, *o*ther [congenital syphilis and viruses], *r*ubella, *c*ytomegalovirus, and *h*erpes simplex virus.

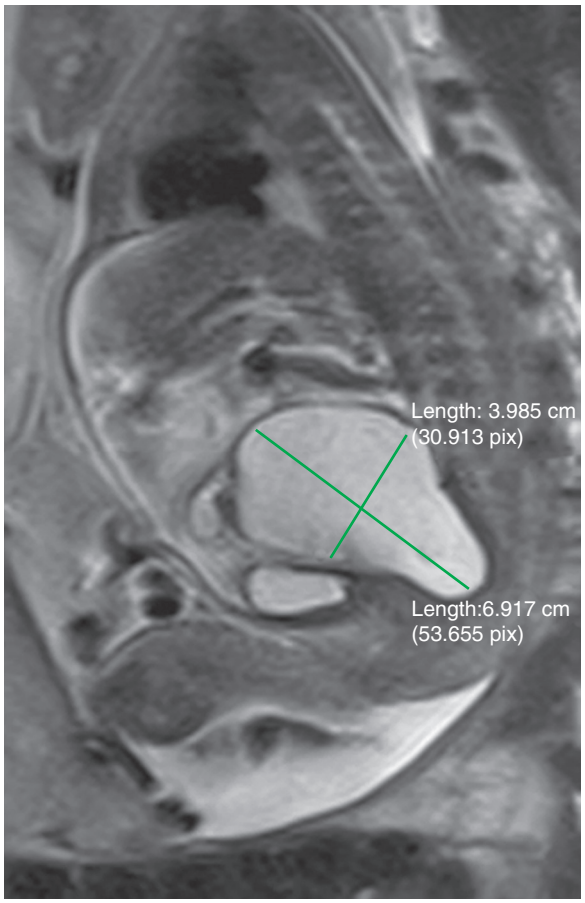

Fig. 29.9 Panoramic view provided by fetal MRI assists diagnosis. The echogenic cystic lesion seen on this T2-weighted image is posterior to the bladder. Diagnosis of a hydrometrocolpos was made.

of fetal anatomy should be completed.[24] Further investigations, such as maternal serology, genetic testing for cystic fibrosis, amniocentesis (15% anomaly rate reported),[24] and fetal magnetic resonance imaging (MRI), may help reach a formal diagnosis. Postnatal imaging is required in many circumstances, allowing the lesion to be visualized in higher resolution, and enabling the clinician to assess changes over time.

Magnetic Resonance Imaging. Data supporting the use of MRI as an adjunct to US for prenatal diagnosis of intraabdominal masses are limited. Image acquisition has improved with the use of rapid single shot fast spin echo (SSFSE) sequences. This imaging modality has several potential advantages for fetal assessment, and with regard to abdominal examination, the ability to capture panoramic images with good soft tissue contrast in any orientation is proving to be valuable (Fig. 29.9).[25–27] Meconium has a high protein and mineral content that is readily distinguished by its high signal intensity on T1-weighted imaging, effectively acting as a contrast agent for the GI tract.[28]

In one series of 32 cases, various intraabdominal pathologies were imaged using T1-weighted and T2-weighted sequences at 23 to 38 weeks' gestation. MRI was valuable in delineating the site and severity of bowel anomalies, and was able to differentiate between meconium pseudocysts and enteric cysts.[29] MRI was also useful for defining planes, improving diagnostic accuracy for anorectal and pelvic malformations, sacrococcygeal teratoma, and congenital diaphragmatic hernia. Another group recently reported that, in a prospective study of 38 fetuses referred for MRI due after an intraabdominal mass had been detected on US, additional information was identified through MRI in 60% of cases.[30] In 10% of cases, the US diagnosis changed significantly, and in 5% the anomaly could not be effectively demonstrated by MRI.[30]

Differential Diagnosis From Imaging Findings

Because almost all intraabdominal organs can give rise to cystic or solid masses, the list of differential diagnoses is typically long. Possible diagnoses and their salient features are shown in Table 29.1. However, for any particular intraabdominal anomaly, the sensitivity and specificity of prenatal US are not high.[17,31–33] Because most of these conditions are rare, the positive predictive value of screening is poor. The subjective or objective cutoffs used to define an abnormality were typically defined without formal assessment of their effectiveness. In view of the poor sensitivity and the lack of data to show improvements in neonatal outcome, it could be argued that one should often refrain from attempting to make a formal "definitive" prenatal diagnosis of intraabdominal pathology.

Synopsis of Treatment Options

PRENATAL

Because a precise prenatal diagnosis is often impossible, planning further prenatal management and counseling for long-term prognosis can be challenging.[34] It often may be more appropriate to stop short of a specific diagnosis, and to use the prenatal findings to identify fetuses that need delivery and further postnatal assessment in an appropriate facility. In view of the limited positive predictive value and lack of data showing clinical value, it is difficult to advocate either fetal intervention or early delivery in most cases. Preterm delivery may merely make postnatal management more complicated.

Intrauterine intervention for some anomalies such as ovarian cyst has been advocated by some authors, with the aim of preventing torsion and postnatal resection, but this must be balanced against good experiences by others with a noninterventional approach.[35] For fetal hepatic hemangioma, maternal corticosteroid therapy has been successfully used to prevent the development of fetal hydrops.[36] In the rare case of a fetus with a large teratoma, cesarean section may be the preferred mode of delivery to prevent dystocia, tumor rupture, and exsanguination.

POSTNATAL

In some circumstances, prenatal diagnosis is likely to improve postnatal outcome. Duodenal atresia may be associated with severe fluid and electrolyte imbalance; early recognition prevents deterioration of the neonate. Because the natural course of infants who had prenatal features of intraabdominal pathologies is poorly described, the type and timing of postnatal intervention is often also controversial. The principles of management should be to deliver the infant in an environment where the infant can be stabilized and supported, to perform appropriate investigations to make a firm diagnosis, and to plan any intervention on the basis of the risks associated with expectant or active management.

WHAT THE REFERRING PHYSICIAN NEEDS TO KNOW

The finding of an intraabdominal mass is usually incidental to the indication for referral. In most cases, the fetus is in no immediate danger, and the mass can be followed with serial US scans. The referring physician needs to be advised about the appropriate site for delivery. Sensitivity, specificity, and positive predictive value of prenatal US for intraabdominal masses are limited.

KEY POINTS

- Intraabdominal masses are rare, accounting for less than 2% of all congenital abnormalities.
- Most intraabdominal organs can give rise to a mass, and it is often difficult to make a precise diagnosis.
- Data on sensitivity, specificity, and positive predictive value of prenatal diagnosis of intraabdominal masses are limited.
- Occasionally, prenatal diagnosis of an intraabdominal mass may improve infant outcomes, mainly by indicating the appropriate setting for delivery and neonatal care.

SUGGESTED READING

McEwing R, Hayward C, Furness M. Foetal cystic abdominal masses. *Australasian Radiol.* 2003;47:101-110.

McNamara A, Levine D. Intraabdominal fetal masses: a practical guide to diagnosis and management. *Radiographics*. 2005;25:633-645.



All references are available online at www.expertconsult.com.

REFERENCES

1. European Surveillance of Congenital Anomalies. http://www.eurocat-network.eu/accessprevalencedata/prevalencetables.
2. Safra MJ, Oakley GP, Erikson JD. Descriptive epidemiology of small bowel atresias in metropolitan Atlanta. *Teratology*. 1976;14:143-149.
3. Sakala EP, Leon ZA, Rouse GA. Management of antenatally diagnosed fetal ovarian cysts. *Obstet Gynecol Surv*. 1991;46:407-511.
4. Gray SW, Skandalakis JE. The small intestines. In: Gray SW, Skandalakis JE, eds. *Embryology for surgeons*. Baltimore: Williams & Wilkins; 1994:63-100.
5. Ghose I, Mason GC, Martinez D, et al. Hyperechogenic fetal bowel: a prospective analysis of sixty consecutive cases. *Br J Obstet Gynaecol*. 2000;107:426-429.
6. Simon-Bouy B, Satre V, Ferec C, et al. Hyperechogenic fetal bowel: a large French collaborative study of 682 cases. *Am J Med Genet*. 2003;121A:209-213.
7. Grosfeld JL, Rescorla FJ. Duodenal atresia and stenosis: reassessment of treatment and outcome based on antenatal diagnosis, pathologic variance and long term follow-up. *World J Surg*. 1993;17:301-309.
8. Touloukian RJ. Intestinal atresia. *Clin Perinatol*. 1978;5:3-18.
9. Hill LM, Fries J, Hecker J, et al. Second trimester echogenic small bowel: an increased risk for adverse perinatal outcome. *Prenat Diagn*. 1994;14:845-850.
10. Achiron R, Seidman DS, Afek A, et al. Prenatal diagnosis of liver calcifications. *Obstet Gynecol*. 1995;86:739-743.
11. Yamashita Y, Iwanaga R, Goto A, et al. Congenital cytomegalovirus infection associated with fetal ascites and intrahepatic calcifications. *Acta Pediatr Scand*. 1989;78:965-967.
12. Sedin G, Bergquist C, Lindgren PG. Ovarian hyperstimulation syndrome in preterm infants. *Pediatr Res*. 1985;19:548-552.
13. Isaacs H. Fetal and neonatal hepatic tumors. *J Pediatr Surg*. 2007;42:1797-1803.
14. Chalubinski K, Deutinger J, Bernaschek G. Meconium peritonitis: extrusion of meconium and different sonographic appearances in relation to the stage of the disease. *Prenat Diagn*. 1992;12:631-636.
15. Chuileannain FN, Rowlands S, Sampson A. Ultrasonographic appearances of fetal hepatic hemangioma. *J Ultrasound Med*. 1999;18:379-381.
16. Loveday BJ, Barr JA, Aitken J. The intra-uterine demonstration of duodenal atresia by ultrasound. *Br J Radiol*. 1975;48:1031-1032.
17. Corteville JE, Gray DL, Langer JC. Bowel abnormalities in the fetus: correlation of prenatal ultrasonographic findings with outcome. *Am J Obstet Gynecol*. 1996;72:175.
18. Australasian Society of Ultrasound in Medicine. Policies and statements. D2. Guidelines for the mid trimester obstetric scan. http://www.asum.com.au/open/P&S/D2_policy.pdf.
19. Kirwan D: NHS Fetal Anomaly Screening Program: 18+0 to 20+6 weeks fetal anomaly scan: national standards and guidance for England. http://www.fetalanomalyscreening.nhs.uk.
20. Nyberg DA, Mack LA, Patten RM, et al. Fetal bowel: normal sonographic findings. *J Ultrasound Med*. 1987;6:3-6.
21. Parulekar SG. Sonography of normal fetal bowel. *J Ultrasound Med*. 1991;10:211-220.
22. Trinh TW, Kennedy AM. Fetal ovarian cysts: review of imaging spectrum, differential diagnosis, management and outcome. *Radiographics*. 2015;35:621-635.
23. Bischoff A, Levitt MA, Lim FY, et al. Prenatal diagnosis of cloacal malformations. *Pediatr Surg Int*. 2010;26:1071-1075.
24. Amari F, Beyer DA, Diedrich K, et al. Fetal intra-abdominal tumors: assessment of spectrum, accuracy of prenatal diagnosis, perinatal outcome, and therapy at a tertiary referral centre. *Eur J Obstet Gynecol Repro Biol*. 2013;167:166.
25. Saguintaah M, Couture A, Veyrac C, et al. MRI of the fetal gastrointestinal tract. *Pediatr Radiol*. 2002;32:395-404.
26. Breysem L, Bosmans H, Dymarkowski S, et al. The value of fast MR imaging as an adjunct to ultrasound in prenatal diagnosis. *Eur Radiol*. 2003;13:1538-1548.
27. Hill BJ, Joe BN, Qayyum A, et al. Supplemental value of MRI in fetal abdominal disease detected on prenatal sonography: preliminary experience. *AJR Am J Roentgenol*. 2005;184:993-998.
28. Brugger PC, Prayer D. Fetal abdominal magnetic resonance imaging. *Eur J Radiol*. 2006;57:278-293.
29. Veyrac C, Couture A, Saguintaah M, et al. MRI of fetal GI tract abnormalities. *Abdom Imaging*. 2004;29:411-420.
30. Manganaro L, Saldari M, Bernardo S, et al. Role of magnetic resonance imaging in the prenatal diagnosis of gastrointestinal fetal anomalies. *Radiol Med*. 2015;120:393-403.
31. Borsellino A, Zaccara A, Nahom A, et al. False-positive rate in prenatal diagnosis of surgical anomalies. *J Pediatr Surg*. 2006;41:826-829.
32. Stoll C, Alembik Y, Dott B, et al. Evaluation of prenatal diagnosis of congenital gastro-intestinal atresias. *Eur J Epidemiol*. 1996;12:611-616.
33. Casaccia G, Bilancioni E, Nahom A, et al. Cystic anomalies of biliary tree in the fetus: is it possible to make a more specific prenatal diagnosis? *J Pediatr Surg*. 2002;37:1191-1194.
34. Aite L, Zaccara A, Nahom A, et al. Mothers' adaptation to antenatal diagnosis of surgically correctable anomalies. *Early Hum Dev*. 2006;82:649-653.
35. Foley PT, Ford WDA, McEwing R, et al. Is conservative management of prenatal and neonatal cysts justifiable? *Fetal Diagn Ther*. 2005;20:454-458.
36. Morris J, Abbott J, Burrows P, et al. Antenatal diagnosis of fetal hepatic hemangioma treated with maternal corticosteroids. *Obstet Gynecol*. 1999;94:813-815.

30 Megacystis-Microcolon-Intestinal Hypoperistalsis Syndrome

JAKOB EVERS | LUIGI RAIO

Introduction

Megacystis-microcolon-intestinal hypoperistalsis syndrome (MMIHS) is a rare and severe condition that is characterized by functional intestinal obstruction with dilated small intestine, microcolon, malrotation, decreased or absent bowel movement, and, prenatally, a massively enlarged nonobstructive urinary bladder often associated with hydroureteronephrosis. The anomaly was first described by Berdon et al. in 1976[1] and is also termed *neonatal hollow visceral myopathy*. Female fetuses are affected four to five times more often than male fetuses.[2] In the neonate, the predominant problem is the reduced or absent bowel function and the impossibility of enteral nutrition. Kidneys and the lower urinary tract are not dysfunctional in most cases; however, secondary impairment of the urinary system owing to urethral reflux is frequent.

The usual postnatal therapeutic approaches are total parenteral nutrition combined with a trial of various prokinetic agents (which remain ineffective in most cases). Transabdominal drainage of the urinary bladder is frequently applied to preserve kidney function. Further steps are laparotomy, attempts to milk out or resect dysfunctional parts of the intestine, or drain them via ileostomy. Multiorgan transplantation is a desperate therapeutic effort to provide a viable intestine in these children.[3] Although most authors describe MMIHS as a fatal condition with newborns surviving for only a few months with all therapeutic efforts being made, there are reports of prolonged survival up to the age of 18 years.[4]

Disease

DEFINITION

MMIHS is defined by the presence of a massively distended urinary bladder without lower urinary tract obstruction, a dilated small bowel, and microcolon with decreased or absent peristalsis.

PREVALENCE AND EPIDEMIOLOGY

From the first description in 1976 until 2011, more than 227 cases were reported.[3] Females are affected more often than males.[2] Although a possible autosomal recessive inheritance pattern has been suggested based on cases with a family history or consanguinity,[5] most cases seem to be sporadic. Whole-exome sequencing recently showed that a relevant proportion of MMIHS is caused by *de novo* heterozygous mutations of the gene encoding the smooth muscle gamma-2 actin, ACTG2. In this case, a recurrence risk would be approximately 1%, while in the majority of familial disease an autosomal dominant inheritance pattern has been postulated.[6–8]

Moreover, these studies show that the different clinical manifestations depend on the degree of protein malfunction and differential expression of smooth muscle actins.[7]

ETIOLOGY AND PATHOPHYSIOLOGY

Recent findings suggest that the loss of intestinal function is related to intestinal smooth muscle myopathy.[9] Reduction or absence of actin in the circular layer of the small intestine, and vacuolic degeneration of smooth muscle cells[10] with reduction of contractile and cytoskeleton proteins, have also been described. A dysfunctional neuronal nicotinic acetylcholine receptor and an association with chromosome 15q11 deletion[9] are being discussed. Earlier reports suggested various changes in ganglion cells and axons of the myenteric plexus as a reason for intestinal malfunction.[3] An inflammatory process of the intestine and urinary tract, and defects in the synthesis of collagen fibers, are

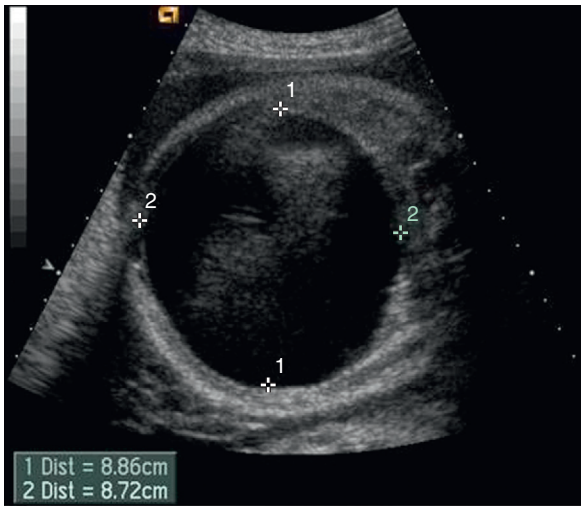

Fig. 30.1 US image of dilated fetal bladder without dilatation of the proximal urethra at 36 weeks' gestation.

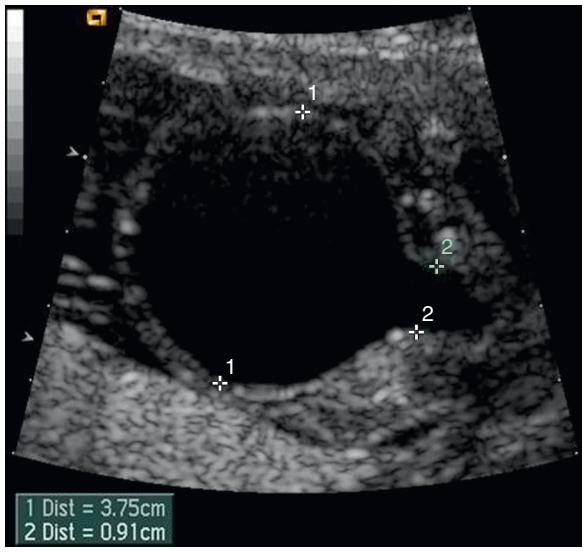

Fig. 30.2 US image of a dilated fetal bladder at 17 weeks' gestation with characteristic appearance of the dilated proximal urethra (so-called keyhole appearance).

other hypotheses. Similar findings have been described in megacystis, megaureter, and fetal hydronephrosis.[11]

MANIFESTATIONS OF DISEASE

Clinical Presentation

The diagnosis of MMIHS is usually made in neonates with functional intestinal and urinary tract obstruction. Clinical signs may be a distended abdomen, malrotation of the colon, and absent bowel sounds.[12] Feeding intolerance and emesis may be found, and enlarged kidneys may be palpated. In contrast to megacystis secondary to urethral valve or other lower urinary tract obstructions (LUTO),[13] a transurethral drainage of the bladder is possible. Cases resemble neuropathic bladder outlet obstruction, but without any form of meningomyelocele. Maldescent of the testes is common in affected males.

Abdominal surgery to correct malrotation, remove adhesions, and rinse the intestinal lumen via intraoperative catheterization of the intestine is frequently performed. Total parenteral nutrition is necessary in most cases, often followed by liver failure owing to chronic cholestasis. Because of the dysfunctional bladder, repeated urinary tract infections and eventual renal failure can occur. Affected children often die of multiorgan failure after sepsis in the first months of their lives.[3]

Imaging Technique and Findings

Ultrasound. The leading sign of MMIHS is a massively distended bladder (megacystis) (Fig. 30.1), combined with a normal or increased amount of amniotic fluid.[14,15]

Additionally, mild bilateral hydronephrosis and isolated dilated stomach, or both, are often present. These signs may precede the development of megacystis and should be an indication for follow-up examinations. The bladder wall is usually not thickened. When fetal abdominal cysts are detected, MMIHS should be part of the differential diagnosis. Megacystis may develop only after 20 weeks' gestation, in contrast to LUTO, in which megacystis is often detected in the first trimester (Fig. 30.2). Because there is a predilection for female infants, knowledge of fetal gender may be valuable. Additional US findings may be a distended stomach (Fig. 30.3), possibly in combination with a

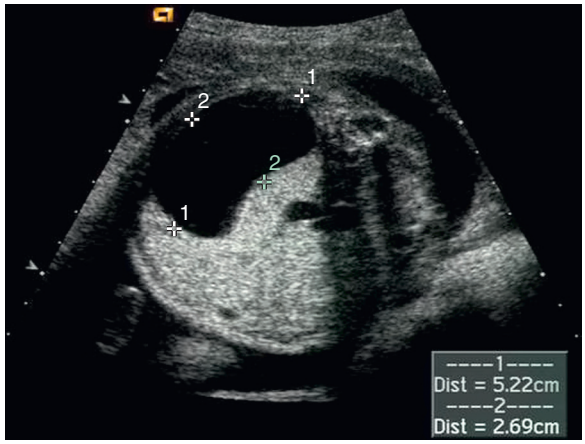

Fig. 30.3 US cross section of a fetal abdomen at 31 weeks' gestation showing a markedly dilated fetal stomach.

dilated duodenum and esophagus. Structural anomalies of the abdominal wall such as omphalocele, hydrometrocolpos, and segmental colonic dilatation can be additional features.[16] In a recent review of prenatal diagnosed MMIHS cases, gastrointestinal abnormalities were noted in 24% of pregnancies complicated by MMIHS.[15]

Magnetic Resonance Imaging. Magnetic resonance imaging (MRI) can be useful to detect or confirm intestinal abnormalities and obstructions suspected at prenatal US examination (Fig. 30.4).[17] Complete or partial intestinal malrotation, short bowel with microileum, and microcolon are possible MRI findings. Maldescent of the testes in males and a patent urachal remnant are further signs.

Other Applicable Modalities. Amniotic fluid digestive enzyme assay and fetal urine analysis by vesicocentesis are promising additional new prenatal diagnostic approaches.[18,19] Indeed, the combination of megacystis, abnormally high amniotic fluid digestive enzyme levels, and normal urinalysis, except for high calcium levels, is indicative of MMIHS.[19]



Fig. 30.4 T2-weighted sagittal MRI of a 32-week fetus with megacystis, microcolon, dilated esophagus, and abdominal wall defect. *(From Munch EM, Cisek LJ Jr, Roth DR, et al.: Magnetic resonance imaging for prenatal diagnosis of multisystem disease: megacystis microcolon intestinal hypoperistalsis syndrome.* Urology *74:592, 2009.)*

CLASSIC SIGNS

The classic presentation on prenatal US examination is a fetus with a cystic intraabdominal mass (see Fig. 30.1), representing the massively enlarged urinary bladder, whereas there is a normal or increased amount of amniotic fluid, typically in a female fetus.[3] A dilated stomach and distended duodenum are additional signs of intestinal obstruction (see Figs. 30.3 and 30.4).

Differential Diagnosis From Imaging Findings

The main differential diagnosis is lower urinary tract malformation with megacystis.[20] In male (and seldom in female) fetuses, posterior urethral valve and urethral agenesis (see Fig. 30.2)[21] lead to an enlarged bladder and classic prune-belly syndrome,[22] although the presentations of MMIHS and prune-belly syndrome may overlap.[12,23] The forms of LUTO are usually associated with a reduced amount of amniotic fluid in early gestation or anhydramnios later on.

Synopsis of Treatment Options

PRENATAL

In MMIHS, the reason for the megacystis is not obstruction, as opposed to LUTO, but is a disturbed neuronal or muscular function of the detrusor vesicae. Vesicoamniotic shunting (VAS) in cases with LUTO may reduce morbidity or mortality by improvement of pulmonary and renal function; however, this is not the case in MMIHS. Although the therapeutic effect of VAS is controversial,[24] there may be diagnostic advantages because image quality increases after VAS[25] and facilitates assessment of the intestine.

In case of definite prenatal diagnosis of MMIHS, an offer of termination of the pregnancy is reasonable because prognosis is very poor. Prenatal diagnosis often cannot be achieved early in pregnancy.

POSTNATAL

Transabdominal drainage of the bladder is used in most cases to preserve renal function. Total parenteral nutrition is the only possible form of nutrition for affected neonates. Various prokinetic agents are in use, with only a mild effect at best. Multiorgan transplantation[26] or combined living-related segmental liver and bowel transplantation[8] have been used.

WHAT THE REFERRING PHYSICIAN NEEDS TO KNOW

MMIHS should be suspected in fetuses with megacystis (see Fig. 30.1) and normal or increased amniotic fluid, particularly in the second or third trimester, especially in combination with dilated stomach and duodenum (see Fig. 30.4). If there are affected siblings, additional fetal US examinations in a center are prudent. In general, neonatal prognosis is poor. Because prenatal diagnosis is difficult and definite diagnosis is possible only late in pregnancy, if it all, parents should be transferred to a specialist center for prenatal counseling.

KEY POINTS

- Classic megacystis combined with normal or increased amniotic fluid is suggestive of MMIHS.
- Distended or partially distended upper gastrointestinal tract (dilated esophagus, dilated stomach or dilated duodenum) may be present.
- Typically, females are affected.
- Affected siblings should prompt assessment of pregnancy.
- Referral to a specialized center is mandatory.

SUGGESTED READING

Anneren G, Meurling S, Olsen L. Megacystis-microcolon-intestinal hypoperistalsis syndrome (MMIHS), an autosomal recessive disorder: clinical reports and review of the literature. *Am J Med Genet*. 1991;41:251.

Dewan PA, Brown N, Murthy DP, et al. Hydrometrocolpos and segmental colonic dilatation in a girl with megacystis-microcolon-intestinal hypoperistalsis syndrome. *J Paediatr Child Health*. 1995;31:479.

Garber A, Shohat M, Sarti D. Megacystis-microcolon-intestinal hypoperistalsis syndrome in two male siblings. *Prenat Diagn*. 1990;10:377.

Kohler M, Pease PW, Upadhyay V. Megacystis-microcolon-intestinal hypoperistalsis syndrome (MMIHS) in siblings: case report and review of the literature. *Eur J Pediatr Surg*. 2004;14:362.

Turner CD, Jeanty P Intestinal hypoperistalsis, megacystis-microcolon. http://www.thefetus.net.

Vintzileos AM, Eisenfeld LI, Herson VC, et al. Megacystis-microcolon-intestinal hypoperistalsis syndrome: prenatal sonographic findings and review of the literature. *Am J Perinatol*. 1986;3:297.

White SM, Chamberlain P, Hitchcock R, et al. Megacystis-microcolon-intestinal hypoperistalsis syndrome: the difficulties with antenatal diagnosis. Case report and review of the literature. *Prenat Diagn*. 2000;20:697.

Soh H, Fukuzawa M, Kubota A, et al. Megacystis microcolon intestinal hypoperistalsis syndrome: a report of a nationwide survey in Japan. *J Pediatr Surg*. 2015;50:2048.

Lu W, Xiao Y, Wang J, et al. Mutation in actin γ-2 responsible for megacystis microcolon intestinal hypoperistalsis syndrome in four Chinese patients. *J Pediatr Gastroenterol Nutr*. 2016.

Mc Laughlin D, Puri P. Familial megacystis microcolon intestinal hypoperistalsis syndrome: a systematic review. *Pediatr Surg Int*. 2013;29:947.

All references are available online at www.expertconsult.com.

REFERENCES

1. Berdon WE, Baker DH, Blanc WA, et al. Megacystis-microcolon-intestinal hypoperistalsis syndrome: a new cause of intestinal obstruction in the newborn. Report of radiologic findings in five newborn girls. *AJR Am J Roentgenol*. 1976;126:957.
2. White SM, Chamberlain P, Hitchcock R, et al. Megacystis-microcolon-intestinal hypoperistalsis syndrome: the difficulties with antenatal diagnosis. Case report and review of the literature. *Prenat Diagn*. 2000;20:697.
3. Gosemann JH, Puri P. Megacystis microcolon intestinal hypoperistalsis syndrome: systematic review of outcome. *Pediatr Surg Int*. 2011;27:1041-1046.
4. Jimenez Gil de Muro ST, Moros Pena M, Gimeno Pita P, et al. Megacystis-microcolon-intestinal hypoperistalis syndrome: a case of prolonged survival. *An Pediatr*. 2004;61:453-454.
5. Anneren G, Meurling S, Olsen L. Megacystis-microcolon-intestinal hypoperistalsis syndrome (MMIHS), an autosomal recessive disorder: clinical reports and review of the literature. *Am J Med Genet*. 1991;41:251.
6. Wangler MF, Beaudet AL. ACTG2-related disorders. In: Pagon RA, Adam MP, Ardinger HH, et al, eds. *GeneReviews [Internet]*. Seattle: University of Washington Press; 1993–2016. Posted June 11, 2015.
7. Thorson W, Diaz-Horta O, Foster J 2nd, et al. De novo ACTG2 mutations cause congenital distended bladder, microcolon, and intestinal hypoperistalsis. *Hum Genet*. 2014;133:737.
8. Raofi V, Beatty E, Testa G, et al. Combined living-related segmental liver and bowel transplantation for megacystis-microcolon-intestinal hypoperistalsis syndrome. *J Pediatr Surg*. 2008;43:e9.
9. Szigeti R, Chumpitazi BP, Finegold MJ, et al. Absent smooth muscle actin immunoreactivity of the small bowel muscularis propria circular layer in association with chromosome 15q11 deletion in megacystis-microcolon-intestinal hypoperistalsis syndrome. *Pediatr Dev Pathol*. 2010;13:322.
10. Rolle U, O'Briain S, Pearl RH, et al. Megacystis-microcolon-intestinal hypoperistalsis syndrome: evidence of intestinal myopathy. *Pediatr Surg Int*. 2002;18:2.
11. Rolle U, Puri P. Structural basis of voiding dysfunction in megacystis microcolon intestinal hypoperistalsis syndrome. *J Pediatr Urol*. 2006;2:277.
12. Levin TL, Soghier L, Blitman NM, et al. Megacystis-microcolon-intestinal hypoperistalsis and prune belly: overlapping syndromes. *Pediatr Radiol*. 2004;34:995.
13. McHugo J, Whittle M. Enlarged fetal bladders: aetiology, management and outcome. *Prenat Diagn*. 2001;21:958.
14. Chen CP, Wang TY, Chuang CY. Sonographic findings in a fetus with megacystis-microcolon-intestinal hypoperistalsis syndrome. *J Clin Ultrasound*. 1998;26:217.
15. Tuzovic L, Tang S, Miller RS, et al. New insights into the genetics of fetal megacystis: ACTG2 mutations, encoding γ-2 smooth muscle actin in megacystis microcolon intestinal hypoperistalsis syndrome (Berdon syndrome). *Fetal Diagn Ther*. 2015;38:296.
16. Dewan PA, Brown N, Murthy DP, et al. Hydrometrocolpos and segmental colonic dilatation in a girl with megacystis-microcolon-intestinal hypoperistalsis syndrome. *J Paediatr Child Health*. 1995;31:479.
17. Munch EM, Cisek LJ Jr, Roth DR. Magnetic resonance imaging for prenatal diagnosis of multisystem disease: megacystis microcolon intestinal hypoperistalsis syndrome. *Urology*. 2009;74:592.
18. Garel C, Dreux S, Philippe-Chomette P, et al. Contribution of fetal magnetic resonance imaging and amniotic fluid digestive enzyme assays to the evaluation of gastrointestinal tract abnormalities. *Ultrasound Obstet Gynecol*. 2006;28:282.
19. Muller F, Dreux S, Vaast P, et al. Prenatal diagnosis of megacystis-microcolon-intestinal hypoperistalsis syndrome: contribution of amniotic fluid digestive enzyme assay and fetal urinalysis. *Prenat Diagn*. 2005;25:203.
20. Kohler M, Pease PW, Upadhyay V. Megacystis-microcolon-intestinal hypoperistalsis syndrome (MMIHS) in siblings: case report and review of the literature. *Eur J Pediatr Surg*. 2004;14:362.
21. Robyr R, Benachi A, Daikha-Dahmane F, et al. Correlation between ultrasound and anatomical findings in fetuses with lower urinary tract obstruction in the first half of pregnancy. *Ultrasound Obstet Gynecol*. 2005;25:478.
22. Liao AW, Sebire NJ, Geerts L, et al. Megacystis at 10 to 14 weeks of gestation: chromosomal defects and outcome according to bladder length. *Ultrasound Obstet Gynecol*. 2003;21:338.
23. Giuliani S, Vendryes C, Malhotra A, et al. Prune belly syndrome associated with cloacal anomaly, patent urachal remnant, and omphalocele in a female infant. *J Pediatr Surg*. 2010;45:e39.
24. Morris RK, Malin GL, Khan KS, et al. Systematic review of the effectiveness of antenatal intervention for the treatment of congenital lower urinary tract obstruction. *BJOG*. 2010;117:382.
25. Hidaka N, Kawamata K, Chiba Y. Megacystis-microcolon-intestinal hypoperistalsis syndrome: in utero sonographic appearance and the contribution of vesicocentesis in antenatal diagnosis. *J Ultrasound Med*. 2006;25:765.
26. Masetti M, Rodriguez MM, Thompson JF, et al. Multivisceral transplantation for megacystis-microcolon-intestinal hypoperistalsis syndrome. *Transplantation*. 1999;68:228.

31 Sacrococcygeal Teratoma and Fetus in Fetu

FRANZ KAINER

Introduction

Sacrococcygeal teratoma (SCT) is the most common tumor in newborns. Fetal SCT diagnosed in utero is associated with a 50% risk of preterm delivery, a mortality rate of 15% to 35%, and a morbidity rate of 12% to 68%.[1–3]

Perinatal mortality and morbidity are high because of high-output cardiac failure, fetal hydrops, preterm delivery, anemia, dystocia, and tumor rupture. The intrapelvic and intraabdominal extent of SCT and its compressive effect on the urinary tract also affect perinatal morbidity. The prognosis is excellent in cases with uneventful gestation and if the tumor can be resected entirely and successfully after delivery. Identification of fetuses at risk for perinatal complications is important in order to counsel the parents and to plan perinatal management. The ultrasound (US) morphologic differentiation into predominantly solid and predominantly cystic tumors is an important prognostic factor (Fig. 31.1).[4]

Cystic tumors tend not to compromise intrauterine development even when the diagnosis is made in the second trimester. Predominantly solid tumors may lead to cardiac failure and fetal hydrops. The value of the Surgical Section classification of the American Academy of Pediatrics is that it incorporates the ease of surgical resection, prenatal detection, and the likelihood of malignancy (Fig. 31.2).[1]

Disease

DEFINITION

An SCT is a tumor that develops at the base of the coccyx and is derived from all three germ cell layers. Fetus in fetu (or "inclusion twin") involves a malformed parasitic monozygotic twin found inside the body of its co-twin, usually in the abdominal cavity or in the sacrococcygeal region.[5]

PREVALENCE AND EPIDEMIOLOGY

The incidence of SCT is 1:40,000 live births. Females are four times more commonly affected, but malignancy is more common in males. Malignant elements are generally not seen in fetal SCT. However, because small, predominantly intrapelvic SCT may go undiagnosed for years, until they grow large enough to cause pain, constipation, or other tumor-associated symptoms, the incidence of malignancy within SCT increases with age.

Fetus in fetu is a very rare condition. The overall incidence is 1:500,000 live births. The embryopathogenesis and differentiation from teratoma have not been well established.[5]

Embryology

SCTs originate from primitive pluripotent cells at the primitive knot (Hensen's node) during their migration from the yolk sac to the genital ridge (gestational weeks 4 to 6). These cells normally degenerate and disappear; however, if they escape the control of embryonic inductors and organizers, a teratoma results. Extragonadal teratomas tend to occur in the midline (anterior mediastinum, retroperitoneum, sacrococcygeal region), are composed of mixed dermal elements derived from all three germ layers, and contain neural elements, squamous and intestinal epithelium, skin appendages, teeth, and sometimes calcium. The sacrococcygeal region is the most frequent site.

ETIOLOGY AND PATHOPHYSIOLOGY

Sacrococcygeal Teratoma

The exact etiology of SCT is unknown; most are thought to be sporadic, but some cases are familial with autosomal dominant inheritance. There is no increased occurrence of chromosomal anomalies in fetuses if there are no associated malformations. In 15% of patients, associated congenital anomalies are present, such as imperforate anus, sacral bone defects, duplication of the uterus or vagina, spina bifida, and meningomyelocele.[1,2]

Most SCTs are benign. If the tumor is resectable after birth, there is no significant morbidity. Perinatal mortality and morbidity are attributed to various mechanisms.[6–9] The main perinatal risk factor besides prematurity is the morphology and vascularity of the tumor.[10,11]

Morphologic Classification by Ultrasound

Predominantly Cystic Tumor (Type A). Cystic tumors (15% of cases) with low vascularity do not compromise intrauterine development even when diagnosis is established in the second trimester. Polyhydramnios is frequent in large cystic tumors, which may be due to direct transudation into the amniotic fluid. Vaginal delivery is possible if the tumor size is smaller than 5 cm. For tumors larger than 5 cm, aspiration of cystic lesions may allow vaginal delivery.

Cystic-Solid Tumors (Type B). Keslar et al.[12] reported that 71% of 96 SCTs in their series were composed of both solid and cystic elements. Solid tumors with low vascularization of the tumor may not influence fetal well-being, but high blood flow to the tumor typically leads to hemodynamic compromise. In these cases, high-velocity arterial flow signals can be found within the tumor. The tumor acts as a large arteriovenous shunt. The increased blood flow results in high-output cardiac failure with cardiomegaly, pericardial effusions, dilated inferior vena cava,



Fig. 31.1 Predominantly cystic SCT (type A) at 19 weeks' gestation.

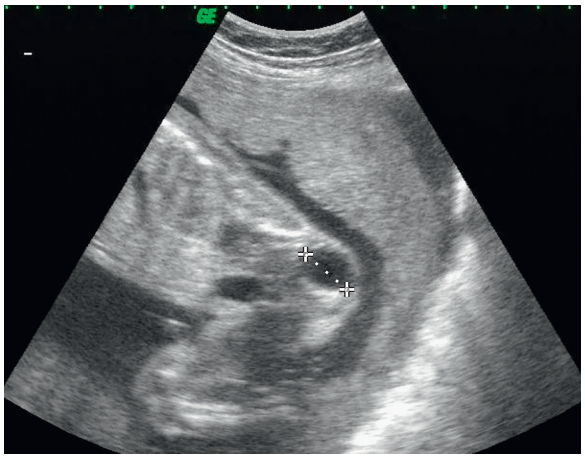

Fig. 31.2 Predominantly cystic SCT (type A) and normal bladder with completely internal component at 21 weeks' gestation. Vaginal delivery occurred, and the outcome was uneventful after complete surgical resection.

TABLE 31.1 PROGNOSTIC AFTER PRENATAL DIAGNOSIS OF SACROCOCCYGEAL TERATOMA

	Low Risk	Intermediate Risk	High Risk
US morphology	Type A (cystic)	Type B (cystic-solid)	Type C (solid with fetal hydrops)
Tumor size	<5 cm	5–10 cm	>10 cm
Associated malformations	No	Renal pyelectasis	Chromosomal anomalies, spina bifida
Gestational age at delivery	>32 weeks	28–32 weeks	<28 weeks
Cardiovascular examination	Normal	Myocardial hypertrophy	Impairment of myocardial function; abnormal venous Doppler

Data from references 4, 7, 8, 10, and 11.

and increased preload indices of the fetal venous system. Reversal of diastolic flow in the umbilical arteries can be observed as the lower resistance in the tumor "steals" blood flow from the placenta. Severe anemia may result from hemorrhage into the tumor; anemia can be diagnosed by demonstrating increased peak blood flow velocity in the middle cerebral artery. Placentomegaly and polyhydramnios relate to the size and vascularization of the tumor. Tumor rupture may be caused by uncontrolled labor or delivery complications. Cesarean section is recommended if the tumor size is larger than 5 cm.[4,7,8,10,11]

Solid Tumor With Fetal Hydrops (Type C). Perinatal mortality and morbidity are high in fetuses with hydrops. In fetal hydrops, there is high-output heart failure, which is associated with a dismal prognosis. Hydrops and tumor hemorrhage are associated with the highest risk of fetal death. For this small subgroup, fetal therapy with surgical removal of the teratoma in a previable fetus may prove to be the most effective treatment, but this approach is still investigational. Severe cases may also lead to maternal "mirror syndrome", manifesting as severe preeclampsia. In fetuses with solid, highly vascularized SCT, percutaneous radiofrequency ablation of the feeding tumor vessels may diminish blood flow sufficiently to reverse high-output fetal heart failure.[13]

The individual risk can be established with US morphologic classification and other fetal and tumor characteristics (Table 31.1).

Surgical Classification. The American Academy of Pediatrics Surgical Section classification scores the extent of SCT for postnatal surgical management (Table 31.2).[14] The tumor also can be graded histologically (Table 31.3),[15] but grading of SCT does not seem to correlate with prognosis.

TABLE 31.2 CLASSIFICATION OF EXTENT OF SACROCOCCYGEAL TERATOMAS ACCORDING TO THE AMERICAN ACADEMY OF PEDIATRICS SURGICAL SECTION

Type	
I	Predominantly external with minimal presacral component
II	External but with significant intrapelvic extension
III	External but with a predominantly pelvic mass extending into the abdomen
IV	Presacral with no external presentation

From Altman RP, Randolph JG, Lilly JR: Sacrococcygeal teratoma: American Academy of Pediatrics Surgical Section survey—1973. *J Pediatr Surg* 9:389–398, 1974.

Fetus in Fetu. Several developmental hypotheses have been proposed for fetus in fetu; the most accepted one postulates the inclusion of a monozygotic diamniotic twin.[16] Although the most frequent site is the abdominal cavity, fetus in fetu has also been found in the posterior mediastinum, neck, and sacrococcygeal region. In 80% of cases, it develops in the retroperitoneum. Most cases manifest in infancy, but it can be detected at any age. Organs

TABLE 31.3 GRADING OF SACROCOCCYGEAL TERATOMAS

Grade	
0	Tumor contains only mature tissue
1	Tumor contains rare foci of immature tissues
2	Tumor contains moderate quantities of immature tissues
3	Tumor contains large quantities of immature tissue with or without malignant yolk sac elements

present can include the vertebral column, limbs, central nervous system, gastrointestinal tract, vessels, and genitourinary tract. Classically, a fetus in fetu is anencephalic. Hemodynamic compromise may be similar to fetal hydrops occurring in large, solid fetal SCT.[16]

MANIFESTATIONS OF DISEASE

Clinical Presentation

- Polyhydramnios is frequent; this may be due to direct transudation into the amniotic fluid or to fetal polyuria, secondary to the hyperdynamic circulation, which is the consequence of arteriovenous shunting.
- Premature labor and premature rupture of membranes are associated with the amount of amniotic fluid and the size of the tumor.
- Without prenatal diagnosis, a large tumor may result in obstructed labor and intrauterine death.
- After delivery, SCT type A, B, or C can easily be diagnosed by clinical inspection.

Imaging Technique and Findings

Ultrasound

Grayscale Ultrasound. An exophytic mass extending from the sacrum can be visualized in types A through C. The amount of solid and vascularized component is an important prognostic sign. The differentiation into three types can be done easily with grayscale US. Predominantly cystic SCT may be misdiagnosed as anterior sacral meningomyelocele (see Figs. 31.1 and 31.2).

Even in predominantly cystic tumors, the production of fluid may lead to large tumors (Fig. 31.3). Antepartum US is important to plan the mode of delivery (Fig. 31.4). Solid exophytic tumors (Figs. 31.5 and 31.6) can be detected easily in the second trimester. Increased blood flow to the tumor may lead to typically hemodynamic effects with cardiomegaly (Fig. 31.7) and cardiac failure. A "tumor to fetal weight ratio" has been proposed, with encouraging results in one study of 68 continuing pregnancies with fetal SCT.[17]

US findings in fetus in fetu are usually a complex cystic mass with ill-defined solid internal components. Most commonly, fetus in fetu is found in the upper retroperitoneum. Uncommon sites are the oral cavity, sacrococcygeal region, and scrotum.[18]

Three-Dimensional Ultrasound. Three-dimensional (3D) US visualization may be helpful for interdisciplinary cooperation between obstetricians, neonatologists, pediatric surgeons, and also for counseling of the parents (Fig. 31.8).

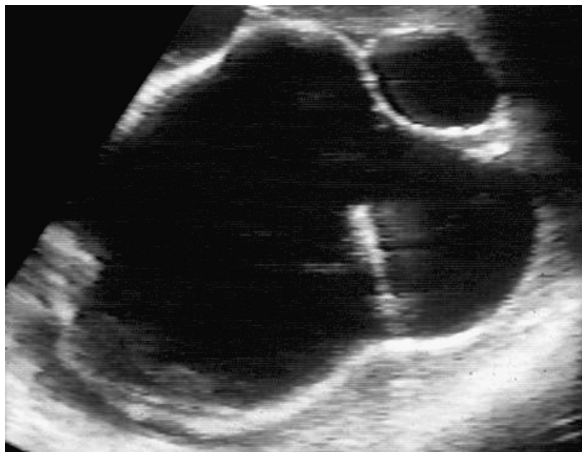

Fig. 31.3 Increase of predominantly cystic SCT (diameter of 14 cm) at 36 weeks' gestation (same fetus as in Fig. 31.1).



Fig. 31.4 Neonate at vaginal delivery after fetal puncture of cystic component of SCT (1300 mL had been drained) (same fetus as in Fig. 31.1). Complete surgical resection was eventually performed, and the outcome was uneventful.



Fig. 31.5 Predominantly solid SCT at 21 weeks' gestation.

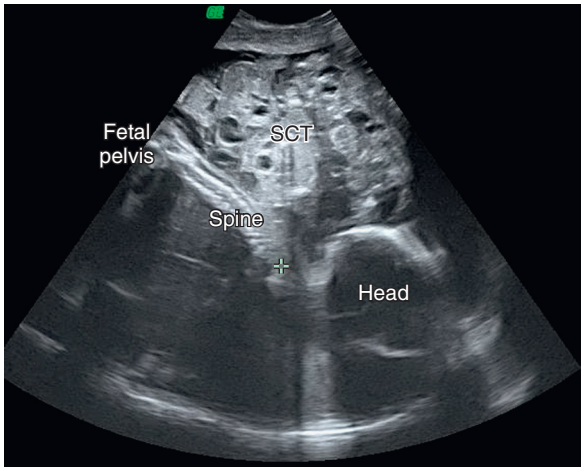

Fig. 31.6 Large, predominantly solid SCT at 28 weeks' gestation. In this image, the large tumor, almost the same size as the fetal trunk, is folded back over the fetal spine. Fetal compromise with cardiac failure and pathologic fetal heart rate tracing occurred.

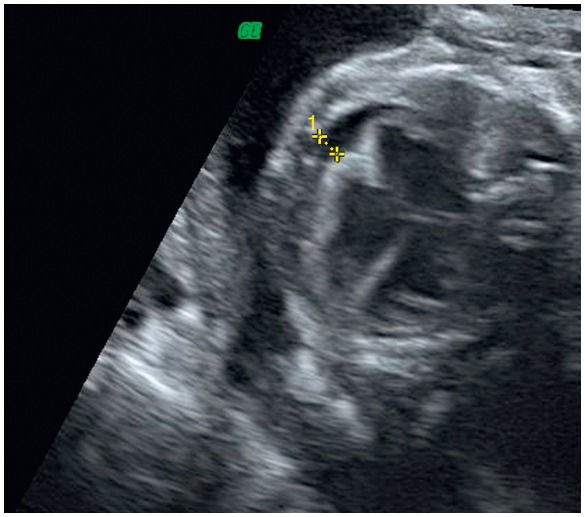

Fig. 31.7 Cardiomegaly in a 26-week fetus with highly vascularized SCT; intrauterine fetal death eventually occurred.

Doppler Flow Velocimetry. The vascularization of the tumor can be visualized with color Doppler flow velocimetry. Three-dimensional power Doppler US can help show smaller feeding arteries of the tumor. The appearance of pulsatile flow in the umbilical vein is a marker for circulatory compromise and cardiac failure. Additionally, changes in the ductus venosus (absent or reversed flow during atrial contraction) indicates impaired cardiac function. Increased resistance of umbilical arteries in fetuses with SCT may predict impending death.[19]

Magnetic Resonance Imaging. Fetal MRI is helpful in SCT to evaluate any intrapelvic extension, to determine possible involvement of the spinal canal, and to diagnose hemorrhage inside the tumor. The additional anatomic resolution provided by MRI results in more accurate prenatal counseling and improved preoperative planning for surgical resection.[20,21]

MRI has been proven helpful in suggesting a specific preoperative diagnosis of fetus in fetu.[21]



Fig. 31.8 Cesarean section performed at 28 weeks' gestation of a fetus with SCT (birth weight 980 g). The main tumor mass could be resected immediately after delivery. The outcome was uneventful after complete surgical resection 6 weeks after delivery.

Other Applicable Modality. Screening methods such as amniotic fluid alpha-fetoprotein level or maternal serum screening have proven effective, but they can be used postnatally to differentiate between benign and malignant SCT.

Differential Diagnosis From Imaging Findings

SACROCOCCYGEAL TERATOMA

1. Myelomeningocele
2. Fetal ovarian cyst
3. Dilated bowel
4. Mesenteric cyst
5. Bladder duplication
6. Hydrocolpos
7. Cystic neuroblastoma
8. Lymphangioma
9. Hemangioma
10. Lipoma
11. Ependymoma

FETUS IN FETU

Calcifications in the neonatal abdomen are commonly seen in meconium peritonitis, often with ascites. Other causes of calcifications include neuroblastoma, viral infections, and adrenal hemorrhage.

Synopsis of Treatment Options

PRENATAL

Amnioreduction

Indications for amnioreduction are the following:

- Maternal discomfort
- Preterm labor

Cyst Aspiration

Cyst aspiration is performed before delivery to prevent birth trauma.

Fetal Surgery

Intrauterine therapy with fetal surgery is currently reserved for a small subgroup of patients with predominantly solid tumors with fetal hydrops.[13] Options for fetal surgery are as follows:

- Open fetal surgery for debulking
- Tumor embolization
- Radiofrequency ablation
- Laser ablation

Delivery

Dystocia of large tumors can be prevented by elective cesarean section. Trauma to solid tumors during delivery should be avoided because of entry of tissue thrombogenic material into the bloodstream, resulting in activation of the coagulation cascade.

POSTNATAL

Sacrococcygeal Teratoma

After delivery, teratomas should be handled very carefully and protected from mechanical harm, because erosion of the surface may precipitate life-threatening bleeding even before surgical resection begins (Fig. 31.9). The treatment of choice is early surgical resection with complete excision of the coccyx. A recurrence rate of 8% to 22% was reported when the coccyx was not removed completely.[22]



Fig. 31.9 Three-dimensional (3D) US surface rendering at 18 weeks' gestation of a predominantly solid SCT (type C).

Fetus in Fetu

Complete excision of the mass is curative and confirmatory.[23]

WHAT THE REFERRING PHYSICIAN NEEDS TO KNOW

- Fetuses with a prenatal diagnosis of SCT can be treated at an appropriate center with planned delivery and prompt therapy after birth.
- For fetal SCT, cardiac compromise and obstetric complications can develop rapidly, warranting close prenatal surveillance.
- Consideration of intrauterine therapy (fetal surgery) is currently reserved for a small subgroup of patients with predominately solid tumors with fetal hydrops.

KEY POINTS

- Prenatal diagnosis is essential for optimal perinatal management.
- An exophytic mass extending from the sacrum is a diagnostic clue.
- The main prognostic factors are vascularization and size of the tumor.
- MRI is helpful for determining the intrapelvic extent and evaluating the spine and tumor hemorrhage.

SUGGESTED READING

Ayed A, Tonks AM, Lander A, et al. A review of pregnancies complicated by congenital sacrococcygeal teratoma in the West Midlands region over an 18-year period: population-based, cohort study. *Prenat Diagn*. 2015;35(11):1037-1047.

Barksdale EM Jr, Obokhare I. Teratomas in infants and children. *Curr Opin Pediatr*. 2009;21:344-349.

Holcroft CJ, Blakemore KJ, Gurewitsch ED, et al. Large fetal sacrococcygeal teratomas: could early delivery improve outcome? *Fetal Diagn Ther*. 2008;24:55-60.

Ng EW, Porcu P, Loehrer PJ Sr. Sacrococcygeal teratoma in adults: case reports and a review of the literature. *Cancer*. 1999;86:1198.

Sebire NJ, Fowler D, Ramsay AD. Sacrococcygeal tumors in infancy and childhood: a retrospective histopathological review of 85 cases. *Fetal Pediatr Pathol*. 2004;23:295-303.

All references are available online at www.expertconsult.com.

REFERENCES

1. Holtermann AX, Filiatrault D, Lallier M, et al. The natural history of sacrococcygeal teratomas diagnosed through routine obstetric sonogram: a single institution experience. *J Pediatr Surg*. 1998;33:899-903.
2. Pauniaho SL, Heikinheimo O, Vettenranta K, et al. High prevalence of sacrococcygeal teratoma in Finland – a nationwide population-based study. *Acta Paediatr*. 2013;102:e251-e256.
3. Swamy R, Embleton N, Hale J. Sacrococcygeal teratoma over two decades: birth prevalence, prenatal diagnosis and clinical outcomes. *Prenat Diagn*. 2008;28:1048-1051.
4. Sheth S, Nussbaum AR, Sanders RC, et al. Prenatal diagnosis of sacrococcygeal teratoma: sonographic-pathologic correlation. *Radiology*. 1988;169:131-136.
5. Grant P, Pearn JH. Foetus in foetu. *Med J Aust*. 1969;1:1016-1020.
6. Rodriguez MA, Cass DL, Lazar DA, et al. Tumor volume to fetal weight ratio as an early prognostic classification for fetal sacrococcygeal teratoma. *J Pediatr Surg*. 2011;46:1182-1185.
7. Sy ED, Filly RA, Cheong ML, et al. Prognostic role of tumor-head volume ratio in fetal sacrococcygeal teratoma. *Fetal Diagn Ther*. 2009;26:75-80.
8. Neubert S, Trautmann K, Tanner B, et al. Sonographic prognostic factors in prenatal diagnosis of SCT. *Fetal Diagn Ther*. 2004;19:319-326.
9. Wilson RD, Hedrick H, Flake AW, et al. Sacrococcygeal teratomas: prenatal surveillance, growth and pregnancy outcome. *Fetal Diagn Ther*. 2009;25:15-20.
10. Westerburg B, Feldstein VA, Sandberg PL, et al. Sonographic prognostic factors in fetuses with sacrococcygeal teratoma. *J Pediatr Surg*. 2000;35:322-325.
11. Benachi A, Durin L, Maurer SV, et al. Prenatally diagnosed sacrococcygeal teratoma: a prognostic classification. *J Pediatr Surg*. 2006;41:1517-1521.
12. Keslar PJ, Buck JL, Suarez ES. Germ cell tumors of the sacrococcygeal region: radiologic-pathologic correlation. *Radiographics*. 1994;14:607-622.
13. van Mieghem T, Al-Ibrahim A, Deprest J, et al. Minimally invasive therapy for fetal sacrococcygeal teratoma: case series and systematic review of the literature. *Ultrasound Obstet Gynecol*. 2014;43:611-619.
14. Altman RP, Randolph JG, Lilly JR. Sacrococcygeal teratoma: American Academy of Pediatrics Surgical Section survey—1973. *J Pediatr Surg*. 1974;9:389-398.
15. Graf JL, Housely HT, Albanese CT, et al. A surprising histological evolution of preterm sacrococcygeal teratoma. *J Pediatr Surg*. 1998;33:177-179.
16. Ji Y, Chen S, Zhong L, et al. Fetus in fetu: two case reports and literature review. *BMC Pediatr*. 2014;14:88-94.
17. Akinkuotu AC, Coleman A, Shue E, et al. Predictors of poor prognosis in prenatally diagnosed sacrococcygeal teratoma: a multiinstitutional review. *J Pediatr Surg*. 2015;50:771-774. doi:10.1016/j.jpedsurg.2015.02.034.
18. Gerber RE, Kamaya A, Miller SS, et al. Fetus in fetu: 11 fetoid forms in a single fetus: review of the literature and imaging. *J Ultrasound Med*. 2008;27:1381-1387.
19. Olutoye OO, Johnson MP, Coleman BG, et al. Abnormal umbilical cord Doppler sonograms may predict impending demise in fetuses with sacrococcygeal teratoma: a report of two cases. *Fetal Diagn Ther*. 2004;19:35-39.
20. Danzer E, Hubbard AM, Hedrick HL, et al. Diagnosis and characterization of fetal sacrococcygeal teratoma with prenatal MRI. *AJR Am J Roentgenol*. 2006;187:W350-W356.
21. Avni FE, Guibaud L, Robert Y, et al. MR imaging of fetal sacrococcygeal teratoma: diagnosis and assessment. *AJR Am J Roentgenol*. 2002;178:179-183.
22. Bilik R, Shandling B, Pope M, et al. Malignant benign neonatal sacrococcygeal teratoma. *J Pediatr Surg*. 1993;28:1158-1160.
23. Crussi FG, Winkler RF, Mirkin DL. Sacrococcygeal teratoma in infants and children. *Arch Pathol Lab Med*. 1978;102:420-425.

To access the videos in this chapter, scan this QR code or visit expertconsult.com

32 Fetal Spleen

ANKE DIEMERT | BORIS TUTSCHEK

Introduction

The fetal spleen is an important center of hematopoiesis until the late fetal period. In postnatal life, the function of the spleen is mainly as an immune organ, with lymphocyte and monocyte production continuing throughout adult life. During fetal development, the spleen appears between the fifth and eighth gestational weeks as an aggregation of reticular mesenchymal cells in the dorsal epigastrium of the stomach. The gastrosplenic ligament connects the spleen to the greater curvature of the stomach, and the splenorenal ligament connects the spleen to the dorsal abdominal wall. The fetal spleen shows distinct lobules that disappear before birth.[1] The developing spleen acquires its characteristic "coffee bean" shape early in the fetal period.

The fetal spleen is usually not seen on ultrasound (US) before 18 weeks, and absence of the spleen may be very difficult to prove by US. Several prospective observational studies have measured fetal spleen size and volume according to gestational age. Normal values for fetal spleen dimensions have been proposed.[2–6] From a clinical point of view, the rationale for developing normal values is the association of splenic size with hematologic and infectious diseases and developmental syndromes. The proposed normal ranges for size and volume of the fetal spleen according to gestational age are summarized in Table 32.1.

Doppler measurements of the splenic artery are another potentially clinically useful aspect of US assessment of the fetal spleen. Several groups reported the association of splenic artery pulsatility and flow velocities with fetal growth restriction and anemia.[7–11] The splenic artery is usually visualized in an axial plane and can be identified by its course originating from the celiac trunk in front of the aorta and running behind the stomach to the spleen (Fig. 32.1). Ebbing et al.[12] published the first systematic longitudinal study of Doppler measurements in the fetal splenic artery and the celiac artery and proposed reference ranges for splenic artery pulsatility indices (PI) and peak systolic velocity (PSV). PI and PSV in the splenic artery were strongly and positively correlated with PI in the middle cerebral artery and the umbilical artery. Because Doppler measurements of the middle cerebral artery PI are widely used to assess potential anemic conditions of the fetus,[13] Doppler velocimetry of the splenic artery could be useful as an additional tool to establish or confirm diagnosis. The study by Ebbing et al.[12] also showed that splenic artery flow and celiac artery flow correlate with portocaval pressure and umbilical venous supply to the right liver lobe. For this reason, Doppler measurements of the splenic artery may provide a method for the differential assessment of splanchnic circulation in the fetus. Reference values for splenic artery Doppler measurements are provided in Fig. 32.2.

The splenic vein can also be visualized in an oblique abdominal plane using Doppler. The flow pattern of the splenic vein is not pulsatile in normal conditions. Using Doppler, Musilova analyzed the flow pattern of the splenic vein in women with preterm prelabor rupture of membranes (PPROM), reporting that a pulsatile flow pattern in the splenic vein was predominantly observed in PPROM with chorioamnionitis (likelihood ratio 13.2), and with funisitis (likelihood ratio 5.7).[14] They suggested that Doppler evaluation of the splenic vein could be a noninvasive tool for the prediction of these inflammatory complications. However, this single report lacks confirmation from other studies.

Pathologic findings of the spleen discovered during prenatal US screening examinations are mostly related to the location or size of the organ and the occurrence of malformations. Accessory spleens are a common finding in adults and are usually spherical homogeneous masses a few centimeters or less in size and with smooth borders. They are typically located near the splenic hilus or the tail of the pancreas but can be found anywhere else in the abdomen, where they can be mistaken for tumors. The complete absence of the spleen (asplenia) and a condition with multiple small spleens (polysplenia) are rare anomalies and should raise the suspicion for associated laterality and cardiac defects. US evaluation of the spleen can be important to establish the diagnosis or aid in the identification of numerous rare developmental disorders, such as cardiosplenic syndromes, polysplenia and situs inversus, and splenogonadal fusion limb defect.

Congenital Splenic Cysts

DEFINITION

Depending on histology and suspected etiology, splenic cysts can be divided into two types: primary cysts (approximately 25% of all splenic cysts), which are formed by cellular layers and have an inner epithelium; and secondary cysts or pseudocysts, which consist of a fibrous capsule. Primary cysts can be neoplastic and originate as dermoids, epidermoids, hemangiomas, or lymphangiomas. Secondary cysts are believed to be of posttraumatic, inflammatory, or degenerative origin.

TABLE 32.1 REFERENCE VALUES FOR NORMAL SPLENIC MEASUREMENTS OBTAINED BY ULTRASOUND (FETAL ABDOMINAL CROSS SECTIONS) BY GESTATIONAL AGE

Gestational Age (Completed Weeks)	Width Measured From Side to Side (cm)				Circumference (cm)				Area (cm^2)			Volume (cm^3)
	Schmidt et al.[3]	Hata et al.[6]	Aoki et al.[2]	You et al.[5]	Schmidt et al.[3]	Aoki et al.[2]	You et al.[5]	Srisupundit et al.[4]	Hata et al.[6]	Aoki et al.[2]	You et al.[5]	You et al.[5]
16								2.8				
20	1.3	1.4	1.5	2.0	4.5	4.2	S.2	4.4	0.6	1.0	1.3	0.7
24	2.5	2.0	2.2	2.3	6.1	6.1	6.2	6.0	1.9	2.2	1.9	1.2
28	3.1	2.5	2.9	3.0	7.4	79	79	7.6	3.2	3.6	3 1	2.3
32	3.8	3.1	3.5	3.5	8.9	9.5	9.6	9.1	4.5	5.2	4.7	4.0
36	4.8	3.6	4.0	4.1	10.9	11.0	11.2	10.6	5.8	70	6.4	6.3
40	6.2	4.2	4.3		13.8	12.3		12.0	71	9.0	7.2	

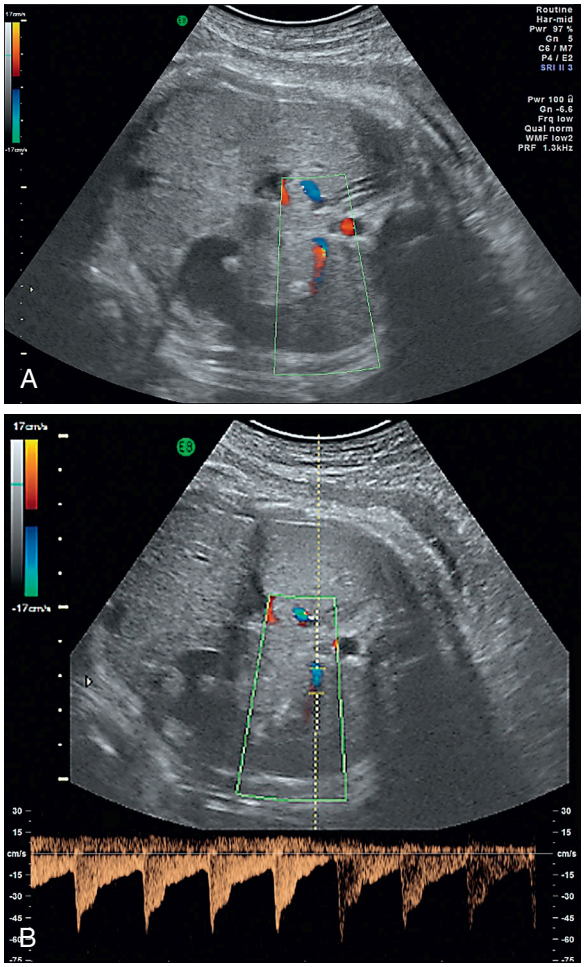

Fig. 32.1 (A) Localization of splenic artery in the abdomen. (B) Splenic vessel color Doppler assessment. Note the normal nonpulsatile venous flow and the normal flow pattern and peak velocity in the splenic artery.

PREVALENCE AND EPIDEMIOLOGY

Congenital splenic cysts are generally considered to be rare. However, since the advent of high-resolution fetal US scans, splenic cysts have been regularly detected and reported. The exact prevalence of congenital splenic cysts is unknown. A review of 13 cases was published by Kabra.[15]

ETIOLOGY AND PATHOPHYSIOLOGY

The exact origin of congenital splenic cysts is unclear. However, several etiologic mechanisms have been proposed, such as invasion of pluripotent stem cells into the fetal spleen, invagination of peritoneal endothelial cells during development, inclusion of cellulous mesothelium during organogenesis, or dilatation of normal lymphatic areas within the spleen.[12]

MANIFESTATIONS OF DISEASE

Clinical Presentation

Congenital splenic cysts are usually diagnosed during prenatal US from week 20 onward, typically as chance findings. In postnatal life, larger congenital splenic cysts can become symptomatic because of expansion, rupture, and bleeding, manifesting as sudden abdominal incidents.

Imaging Technique and Findings

Ultrasound. The typical US pattern of a congenital cyst is an anechoic cyst with smooth walls. Epidermoid cysts have a complex pattern with irregularities and thickness of the posterior walls because of epithelial peripheral trabeculations and internal echoes from blood clots. Pseudocysts occasionally may be sonolucent, but calcifications are more frequently observed. Infarcts are characteristically triangular. Fresh hematomas appear hyperechoic, with subcapsular fluid collection.[16,17]

Magnetic Resonance Imaging. There are only few reports on the use of magnetic resonance imaging (MRI) for the diagnosis of splenic cysts. On both T1-weighted and T2-weighted scans, splenic cysts usually have signal intensity equal to that of water; however, depending on the composition of the cystic fluid, the signal intensity in T1-weighted images may increase.

Differential Diagnosis From Imaging Findings

The differential diagnosis of a fetal abdominal cystic mass includes the following:

1. splenic cyst
2. renal cyst
3. hydronephrosis (see Chapter 12)
4. cystic dysplasia of the kidneys (see Chapters 15 and 16)
5. obstruction-duplication of the urinary tract (see Chapters 12 and 13)

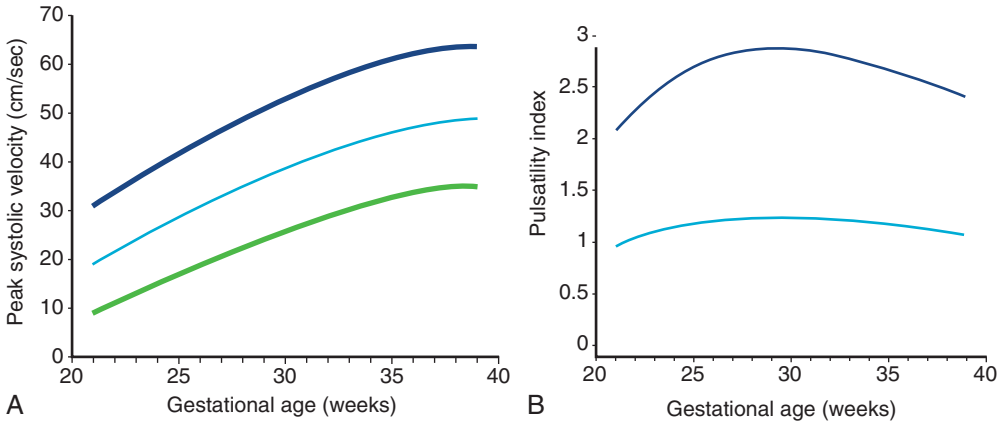

Fig. 32.2 (A) Reference values for splenic artery PSV (cm/s; y-axis), 5th, 50th, and 95th percentiles. Gestational weeks on x-axis. (B) Reference values for splenic artery PI (y-axis), 5th and 95th percentiles. Gestational weeks on x-axis. *(B, Modified from Ebbing C, Rasmussen S, Godfrey KM, Hanson MA, Kiserud T: Fetal celiac and splenic artery flow velocity and pulsatility index: longitudinal reference ranges and evidence for vasodilation at a low portocaval pressure gradient.* Ultrasound Obstet Gynecol *32(5):663–72, 2008.)*

6. adrenal cyst (see Chapter 17)
7. hepatic cyst (see Chapters 24, 25, and 28)
8. choledochal cyst (see Chapter 25)
9. pancreatic pseudocyst
10. mesenteric cyst (see Chapter 24)
11. urachal cyst
12. omental cyst (see Chapter 24)
13. congenital duplication of stomach
14. duodenal atresia (see Chapter 26)
15. ovarian cysts (see Chapter 24)
16. giant hydrosalpinx

Synopsis of Treatment Options

PRENATAL

No prenatal treatment of congenital splenic cysts has been reported.

POSTNATAL

Most authors agree that congenital splenic cysts have a good prognosis; spontaneous regression of the cysts occurs in many cases.[15] For this reason, most authors recommend an expectant approach. In the rare cases in which congenital splenic cysts become symptomatic—most often through progressive enlargement, infection, bleeding, or rupture—various interventional procedures have been suggested. Besides surgical options, percutaneous drainage and sclerotherapy with alcohol have been applied successfully.[18]

WHAT THE REFERRING PHYSICIAN NEEDS TO KNOW

Congenital splenic cysts are usually incidental findings with a good prognosis. However, the detection of congenital splenic cysts should prompt an evaluation for cystic structures in other organs—in particular, kidney, liver, pancreas, and lungs—to rule out the possibility of polycystic disease.

Cardiosplenic Syndromes

DEFINITION

Defects in the development of normal human left-right asymmetry result in so-called heterotaxy syndromes (see Chapter 91). The best-known heterotaxy syndrome is situs inversus, in which unpaired thoracic and abdominal organs are positioned in a mirror-image fashion but are otherwise structurally normal. The more common partial defects in left-right asymmetry result in so-called situs ambiguus or cardiosplenic syndromes. Situs ambiguus or cardiosplenic syndromes are divided into two distinct conditions: polysplenia syndrome/left isomerism and asplenia syndrome/right isomerism.

Polysplenia syndrome, or left isomerism (bilateral left-sidedness, also known as *Ivemark syndrome*), is characterized by paired left-sided viscera. The hallmark findings of this condition are multiple spleens associated with cardiac anomalies (often ventricular or atrioventricular septal defects and outflow tract abnormalities) and heart block. Also typical of this condition are bilateral bilobed lungs, a malpositioned stomach, a midline liver, and interruption of the inferior vena cava with the venous return from the lower body occurring over the prominent azygos vein (right to the aorta) or hemiazygos vein (left to the aorta), running parallel to the descending aorta (Fig. 32.3 and Videos 32.1 and 32.2).

Asplenia syndrome, or right isomerism (bilateral right-sidedness), is characterized by agenesis of the spleen in combination with paired right-sided viscera. Typical findings are right atrial isomerism with bilateral superior vena cava, multiple and more severe cardiac anomalies (including anomalous pulmonary venous connections, often atrioventricular septal defects, and outflow tract abnormalities), bilateral trilobed lungs, and a midline liver. The association of asplenia with cardiovascular anomalies was first described by Ivemark.[19]

PREVALENCE AND EPIDEMIOLOGY

In the Baltimore-Washington Infant Study, the incidence of cardiac defects associated with left-right asymmetry

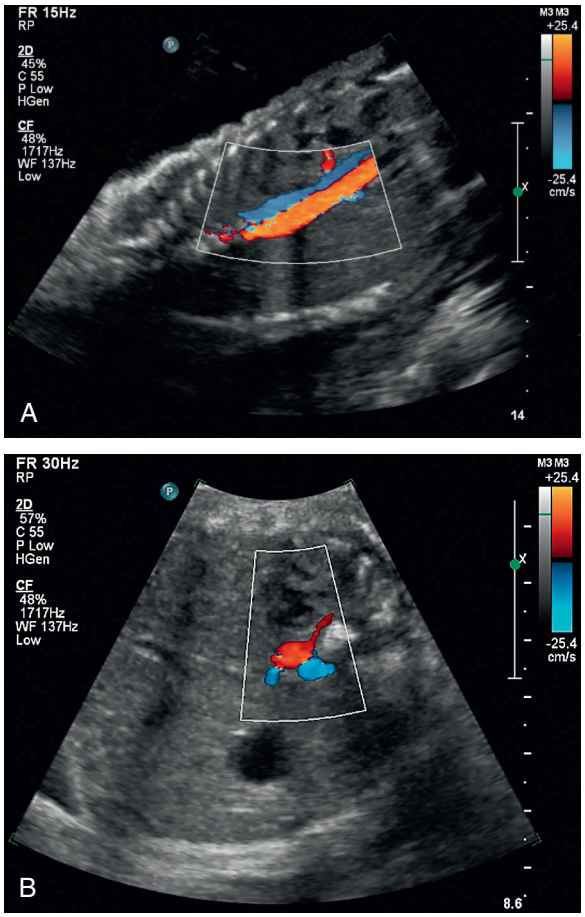

Fig. 32.3 (A) Double-vessel sign in heterotaxy syndrome (left isomerism; sagittal view). (B) Double-vessel sign in heterotaxy syndrome (left isomerism; transverse view).

malformations was estimated at 1.44:10,000.[20] This figure might be an underestimation because not all left-right asymmetry malformations are deleterious, and malformations without severe cardiac defects might go undiagnosed for a long time.

ETIOLOGY AND PATHOPHYSIOLOGY

The heterotaxy syndromes are genetically heterogeneous conditions with different modes of transmission and a wide phenotypic spectrum. Although some sporadic cases associated with translocations or deletions have been reported, a familial pattern with autosomal recessive inheritance also exists. Linkage studies have yielded numerous candidate genes controlling left-right asymmetry.[21] Some authors have also speculated on the involvement of teratogenic factors; in animal models, heterotaxy can be induced by retinoic acid.

MANIFESTATIONS OF DISEASE

Clinical Presentation

The suspicion of cardiosplenic syndromes usually arises from pathologic findings on fetal echocardiography or the incidental finding of visceral lateralization defects. Because of the complexity and severity of these defects, they may be associated with small-for-gestational-age fetuses or fetal demise.

Imaging Technique and Findings

Ultrasound. The largest series of prenatal US evaluations in cases with cardiosplenic syndromes was reported by Berg.[22] In cases with polysplenia/left isomerism, the most consistent finding was interruption of the inferior vena cava with azygos continuation (observed in 21 of 22 fetuses in this series). A characteristic sign for the interruption of the inferior vena cava is the "double-vessel" sign (see Fig. 32.3) in the thorax (descending aorta and prominent azygos vein behind the heart) and absence of the cranial part of the inferior vena cava with umbilical drainage into the right atrium as first suggested by Sheley.[23] Another characteristic US sign of the viscera-cardiac heterotaxy in left isomerism is the visualization of the stomach contralateral to the cardiac apex. Diagnosis of asplenia syndrome/right isomerism is usually made on US by findings of complete atrioventricular septal defect with viscera-cardiac heterotaxy or juxtaposition of the inferior vena cava and aorta on the same side of the spine, or both.[22]

Magnetic Resonance Imaging. Because of its small size, the fetal spleen is often difficult to see by US. The detection of the spleen becomes particularly difficult in cases of polysplenia/left isomerism, where multiple small splenules can be located in the abdomen, making a definitive diagnosis of asplenia on US challenging. Fetal MRI is increasingly being used as an investigation method for heterotaxy syndromes. As the number of scans increases, so is the variety of congenital malformations being recognized. Many cases of heterotaxy will also involve the central nervous system and produce pulmonary, gastrointestinal, immunologic, and genitourinary malformations. One group has even suggested that fetal MRI is the imaging modality of choice for a comprehensive assessment of complex heterotaxy syndromes.[24]

Differential Diagnosis From Imaging Findings

The differential diagnosis between right and left isomerism can be particularly challenging because there is considerable overlap of the two syndromes, particularly concerning the cardiac defects. None of the features seen in the cardiosplenic syndromes are mandatory. Although polysplenia is considered the hallmark of left isomerism, asplenia or even a normal spleen do not rule out the diagnosis. Also, the presence of a spleen has been reported in right isomerism.[25]

Synopsis of Treatment Options

PRENATAL

There is no specific treatment for heterotaxy syndromes in the prenatal period. When complex malformations are present, delivery should occur at a center capable of caring for the newborn.

POSTNATAL

Morbidity and mortality of infants with heterotaxy syndromes are mostly determined by the severity of the cardiac defects and the susceptibility to infection. However, with more recent improvements in pediatric cardiac surgery, the survival prospects of affected children have improved so that the intraabdominal anomalies have become increasingly important.

WHAT THE REFERRING PHYSICIAN NEEDS TO KNOW

Cardiac defects paired with situs anomalies are characteristic of the heterotaxy syndromes. The phenotypic spectrum and the differential diagnosis of these syndromes can be challenging.

Splenogonadal Fusion–Limb Defect Syndrome

DEFINITION

In splenogonadal fusion the spleen is abnormally connected to the gonad or, even rarer, remnants of the mesonephros. The syndrome is often associated with limb defects (amelia), cryptorchidism, and other fetal malformations.[26]

PREVALENCE AND EPIDEMIOLOGY

Splenogonadal fusion is a very rare condition, with roughly 150 postnatally confirmed cases in the literature and very few reports in which a prenatal diagnosis was made.[27]

ETIOLOGY AND PATHOPHYSIOLOGY

In the early embryo the spleen develops near the left gonad. If a fusion occurs, the gonad pulls the splenic tissue downward, and the gonadal descent may be prevented. For this reason, splenogonadal fusion is often associated with cryptorchidism.

MANIFESTATIONS OF DISEASE

Clinical Presentation

The diagnosis of a pelvis mass on US paired with amelia should raise suspicion for splenogonadal fusion limb defect syndrome.

Imaging Technique and Findings

Ultrasound. Isolated pelvic or scrotal masses of splenic tissue attached to the testis or ovary might be detected on US examination. A wide range of additional malformations, such as amelia, anal atresia, mechanical bowel obstruction, micrognathia, and others, usually accompanies the syndrome.

Magnetic Resonance Imaging. There are no reports on the use of fetal MRI in this syndrome.

Differential Diagnosis From Imaging Findings

Some authors distinguish between splenogonadal fusion as an isolated condition and splenogonadal fusion with limb defects as a distinct entity.

Synopsis of Treatment Options

PRENATAL

No prenatal treatment options exist.

POSTNATAL

The postnatal prognosis of splenogonadal fusion–limb defect syndrome depends on the concomitant malformations.

WHAT THE REFERRING PHYSICIAN NEEDS TO KNOW

Splenogonadal fusion defects should be considered when limb defects are diagnosed on prenatal US examination.

Fetal Splenomegaly and Hypoplastic Spleen

DEFINITION

Enlargement of the fetal spleen is usually found secondary to numerous systemic diseases and is often concomitant with hepatomegaly. A hypoplastic fetal spleen is much rarer and has been described in cases of DiGeorge syndrome and sickle cell anemia.[3] Normal values for fetal spleen size have been proposed by several groups[2–6] and can be used as a reference to define splenomegaly or a hypoplastic spleen according to the gestational age.

PREVALENCE AND EPIDEMIOLOGY

No reliable figures for the incidence of fetal splenomegaly or hypoplastic spleen are available.

ETIOLOGY AND PATHOPHYSIOLOGY

Fetal splenomegaly is associated with numerous heterogeneous conditions usually affecting hematopoiesis and the reticuloendothelial system.

MANIFESTATIONS OF DISEASE

Clinical Presentation

Fetal splenomegaly is a classic sign of fetal anemia.[3] In addition to splenomegaly, fetal anemia leads to decreased blood viscosity and increased cardiac output, resulting in a hyperdynamic state that can be shown by Doppler velocimetry of the middle cerebral artery or the splenic artery. Fetal anemia with marked enlargement of the spleen has been described in the setting of Rhesus incompatibility or after serial intrauterine transfusions.[3,28] Srisupundit and coworkers have reported that splenic size at midpregnancy could be used as a US marker in predicting fetal Hb Bart disease before the appearance of classic ultrasound findings of fetal hydrops.[29] Since Hemoglobin (Hb) Bart disease (homozygous alpha-thalassemia 1) is the most common cause of fetal hydrops in southeast Asia, routine measurement of the fetal spleen size could emerge as a screening tool for this common condition. However, the single study published so far needs independent confirmation. In principle, any condition leading to fetal anemia might lead to spleen enlargement.

Marked fetal splenomegaly has also been described as a sign of fetal infection, such as cytomegalovirus infection.[30] In this situation, other signs suggestive of cytomegalovirus infection, such as ventriculomegaly, calcifications, or abnormal cerebral echogenicities, usually accompany fetal splenomegaly. Trisomy 21[31] or certain storage diseases such as Niemann-Pick disease type C or glycogen storage disease can also cause splenomegaly.

In contrast, there are only few reports of a hypoplastic fetal spleen.[3] This condition can occur in conjunction with polysplenia/left isomerism syndrome (see previous section on cardiosplenic syndrome) or in DiGeorge syndrome.

Imaging Technique and Findings

Ultrasound. Diagnosis of fetal splenomegaly on US can be challenging because the spleen can be shadowed by the spine if the fetal left side is posterior and because liver and spleen have similar echogenicities and can be hard to distinguish when both organs are enlarged.

Secondary signs of splenic enlargement are displacement of the stomach from the left side of the abdomen to the midline or anterior abdominal cavity. Sometimes the lower border of the spleen can be detected as low as the lower pole of the left kidney. The spleen is well arterialized, and the splenic artery and vein can easily be located in most cases using color Doppler, confirming the presence and location of the spleen, its relationship to the adjacent abdominal organs,[30] and the arterial and in particular venous flow patterns; under normal conditions, splenic vein flow was continuous in 96% of fetuses, but pulsatile in 47% of pregnancies with histological evidence of chorioamnionitis.[32]

Magnetic Resonance Imaging. No specific reports on the use of MRI in fetal splenomegaly have been published.

Differential Diagnosis From Imaging Findings

Because both fetal splenomegaly and hypoplastic spleen are mostly secondary and not found in isolation, it is important to look for possible associated imaging findings. Fetal anemia is readily diagnosed using Doppler velocimetry of the middle cerebral artery.[13] Other conditions such as cytomegalovirus infection, storage diseases, and trisomies have further characteristic imaging findings.

Synopsis of Treatment Options

Treatment options depend on the cause of fetal splenomegaly, so no general recommendations can be given.

WHAT THE REFERRING PHYSICIAN NEEDS TO KNOW

Splenomegaly is a classic sign of fetal anemia but can also occur in other conditions, such as infection, storage diseases, and trisomy 21.

KEY POINTS

- The fetal spleen is usually not seen on US before 18 weeks' gestation.
- On an axial abdominal section, the normal fetal spleen can be seen dorsal to the stomach and caudal to the left lung; it is less echogenic than the lung.
- Doppler US of the splenic artery can be helpful to locate the fetal spleen.
- Altered splenic artery pulsatility and flow velocities are associated with fetal growth restriction and anemia, and splenic venous flow may be pulsatile in fetal inflammation.
- Splenomegaly is a classic sign of fetal anemia but can also be associated with other conditions such as fetal infection or storage diseases.
- The complete absence of the spleen (asplenia) and the presence of multiple small spleens (polysplenia) are rare anomalies and should raise the suspicion for associated congenital defects, especially of the fetal heart.

SUGGESTED READING

Berg C, Geipel A, Smrcek J, et al. Prenatal diagnosis of cardiosplenic syndromes: a 10-year experience. *Ultrasound Obstet Gynecol.* 2003;22:451.

Ebbing C, Rasmussen S, Godfrey KM, et al. Fetal celiac and splenic artery flow velocity and pulsatility index: longitudinal reference ranges and evidence for vasodilation at low portocaval pressure gradient. *Ultrasound Obstet Gynecol.* 2008;32:663.

Hata T, Kuno A, Day SY, et al. Three-dimensional sonographic volume measurement of the fetal spleen. *J Obstet Gynaecol Res.* 2007;33:600.

Loomba R, Shah PH, Anderson RH. Fetal magnetic resonance imaging of malformations associated with heterotaxy. *Cureus.* 2015;7(5):e269.

All references are available online at www.expertconsult.com.

REFERENCES

1. Moore KL, Persaud T: Before we are born: essentials of embryology and birth defects. Philadelphia: Saunders; 1999.
2. Aoki S, Hata T, Kitao M. Ultrasonographic assessment of fetal and neonatal spleen. *Am J Perinatol*. 1992;5-6:361-367.
3. Schmidt W, Yarkoni S, Jeanty P, et al. Sonographic measurements of the fetal spleen: clinical implications. *J Ultrasound Med*. 1985;4(12):667-672.
4. Srisupundit K, Piyamongkol W, Tongprasert F, et al. Reference range of fetal splenic circumference from 14 to 40 weeks of gestation. *Arch Gynecol Obstet*. 2011;283(3):449-453.
5. You J-H, Lv G-R, Liu X-L, et al. Reference ranges of fetal spleen biometric parameters and volume assessed by three-dimensional ultrasound and their applicability in spleen malformations. *Prenat Diagn*. 2014;34(12): 1189-1197.
6. Hata T, Kuno A, Dai S-Y, et al. Three-dimensional sonographic volume measurement of the fetal spleen. *J Obstet Gynaecol Res*. 2007;33(5): 600-605.
7. Abuhamad AZ, Mari G, Bogdan D, et al. Doppler flow velocimetry of the splenic artery in the human fetus: is it a marker of chronic hypoxia? *Am J Obstet Gynecol*. 1995;172(3):820-825.
8. Bahado-Singh R, Oz U, Deren O, et al. A new splenic artery Doppler velocimetric index for prediction of severe fetal anemia associated with Rh alloimmunization. *Am J Obstet Gynecol*. 1999;180(1 Pt 1):49-54.
9. Capponi A, Rizzo G, Arduini D, et al. Splenic artery velocity waveforms in small-for-gestational-age fetuses: relationship with pH and blood gases measured in umbilical blood at cordocentesis. *Am J Obstet Gynecol*. 1997;176(2):300-307.
10. Oz U, Kovanci E, Jeffress A, et al. Splenic artery Doppler in the prediction of the small-for-gestational age infant. *Ultrasound Obstet Gynecol*. 2002;20(4):346-350.
11. Dubiel M, Kozber H, Debniak B, et al. Fetal and placental power Doppler imaging in normal and high-risk pregnancy. *Eur J Ultrasound*. 1999;9(3): 223-230.
12. Ebbing C, Rasmussen S, Godfrey KM, et al. Fetal celiac and splenic artery flow velocity and pulsatility index: longitudinal reference ranges and evidence for vasodilation at a low portocaval pressure gradient. *Ultrasound Obstet Gynecol*. 2008;32(5):663-672.
13. Mari G, Adrignolo A, Abuhamad AZ, et al. Diagnosis of fetal anemia with Doppler ultrasound in the pregnancy complicated by maternal blood group immunization. *Ultrasound Obstet Gynecol*. 1995;5(6):400-405.
14. Musilova I, Kacerovsky M, Hornychova H, et al. Pulsation of the fetal splenic vein—a potential ultrasound marker of histological chorioamnionitis and funisitis in women with preterm prelabor rupture of membranes. *Acta Obstet Gynecol Scand*. 2012;91(9):1119-1123.
15. Kabra NS, Bowen JR. Congenital splenic cyst: a case report and review of the literature. *J Paediatr Child Health*. 2001;37(4):400-402.
16. Solbiati L, Bossi MC, Bellotti E, et al. Focal lesions in the spleen: sonographic patterns and guided biopsy. *AJR Am J Roentgenol*. 1983;140(1):59-65.
17. Dankovcik R, Urdzik P, Lazar I, et al. Conservative management in three cases of prenatally recognized splenic cyst using 2D, 3D, multi-slice and Doppler ultrasonography. *Fetal Diagn Ther*. 2009;26(3):177-180.
18. Goktay AY, Secil M, Ozcan MA, et al. Percutaneous treatment of congenital splenic cysts: drainage and sclerotherapy with polidocanol. *Cardiovasc Intervent Radiol*. 2006;29(3):469-472.
19. Ivemark BI. Implications of agenesis of the spleen on the pathogenesis of conotruncus anomalies in childhood; an analysis of the heart malformations in the splenic agenesis syndrome, with fourteen new cases. *Acta Paediatr Suppl*. 1955;44(suppl 104):7-110.
20. Ferencz C, Loffredo C, Correa-Villasenor A, et al. *Genetic and environmental risk factors of major cardiovascular malformations*. Hoboken, NJ, Wiley-Blackwell; 1997:1.
21. Casey B. Genetics of human situs abnormalities. *Am J Med Genet*. 2001;101(4):356-358.
22. Berg C, Geipel A, Smrcek J, et al. Prenatal diagnosis of cardiosplenic syndromes: a 10-year experience. *Ultrasound Obstet Gynecol*. 2003; 22(5):451-459.
23. Sheley RC, Nyberg DA, Kapur R. Azygous continuation of the interrupted inferior vena cava: a clue to prenatal diagnosis of the cardiosplenic syndromes. *J Ultrasound Med*. 1995;14(5):381-387.
24. Loomba R, Shah PH, Anderson RH. Fetal magnetic resonance imaging of malformations associated with heterotaxy. *Cureus*. 2015;7(5):e269-9.
25. Winer-Muram HT, Tonkin IL. The spectrum of heterotaxic syndromes. *Radiol Clin North Am*. 1989;27(6):1147-1170.
26. McPherson F, Frias JL, Spicer D, et al. Splenogonadal fusion-limb defect "syndrome" and associated malformations. *Am J Med Genet A*. 2003;120A(4):518-522.
27. Basbug M, Akgun H, Ozgun MT, et al. Prenatal sonographic findings in a fetus with splenogonadal fusion limb defect syndrome. *J Clin Ultrasound*. 2009;37(5):298-301.
28. Correa MD, Castro MJBV, Cabral ACV, et al. Influence of fetal anemia on fetal splenic artery Doppler in Rh-alloimmunized pregnancies. *Fetal Diagn Ther*. 2009;25(1):3-7.
29. Srisupundit K, Tongprasert F, Luewan S, et al. Splenic circumference at midpregnancy as a predictor of hemoglobin Bart's disease among fetuses at risk. *Gynecol Obstet Invest*. 2011;72(1):63-67.
30. Chaoui R, Zodan-Marin T, Wisser J. Marked splenomegaly in fetal cytomegalovirus infection: detection supported by three-dimensional power Doppler ultrasound. *Ultrasound Obstet Gynecol*. 2002;20(3):299-302.
31. Hartung J, Chaoui R, Wauer R, et al. Fetal hepatosplenomegaly: an isolated sonographic sign of trisomy 21 in a case of myeloproliferative disorder. *Ultrasound Obstet Gynecol*. 1998;11(6):453-455.
32. Musilova I, Kacerovsky M, Hornychova H, et al. Pulsation of the fetal splenic vein: a potential ultrasound marker of histological chorioamnionitis and funisitis in women with preterm prelabor rupture of membranes. *Acta Obstet Gynecol Scand*. 2012;91:1119-1123.

33 Choroid Plexus Anomalies: Cysts and Papillomas

JENS H. STUPIN | WOLFGANG HENRICH

INTRODUCTION

The choroid plexus is a vascular convolute, consisting of epithelial cells (a type of microglia), fenestrated blood vessels, and stroma, which lie in the ventricular system of the brain. It is the main source of cerebrospinal fluid (CSF) and actively regulates the constituents in CSF. The choroid plexus epithelial cells and the tanycytes, special ependymal cells located in the floor of the third ventricle, constitute the blood-CSF-brain barrier that separates blood and CSF compartments.[1] The choroid plexus begins to differentiate as a bulge of the pia mater into the ventricular ependyma in week 6 of gestation, shortly after closure of the neural tube. The choroid plexus is derived from an invagination of the neuroepithelium and is located within the brain substance, but in continuity with the meninges. It first appears on the roof of the fourth ventricle, then in the lateral ventricles, and finally in the third ventricle.[2,3] The two main components of the choroid plexus are the epithelium derived from the neural tube epithelium and mesenchyme derived from the meninges.[1,4]

Choroid plexus cysts (CPCs) form most likely due to aberrant growth during the ninth week of gestation of either neuroepithelium or angiomatous, interconnecting thin-walled capillaries within the matrix of the immature choroid plexus.[1] CPCs appear as fluid-filled areas in the choroid plexus and are the most common congenital abnormalities of the choroid plexus. They are easily detectable on prenatal ultrasound (US).

The choroid plexus can also be affected by acquired disease processes, such as primary or secondary neoplasms, infections, and hemorrhage. Intracranial tumors arising from the choroid plexus such as choroid plexus papillomas (CPPs) are extremely rare congenital anomalies.[3,5,6]

Disease

DEFINITION

Choroid plexus cysts (CPCs) are most frequently transient and benign, often round and sonolucent spaces within the developing choroid plexus of the lateral ventricles. They were first described by Chudleigh et al.[7] and were found to be associated with aneuploidy, especially trisomy 18.[8]

Choroid plexus papilloma (CPP) is a very rare, usually benign, fetal intracranial tumor. According to the World Health Organization classification of tumors of the nervous system, this more differentiated tumor is classified as a primary tumor of the choroid plexus grade I, as distinguished from atypical choroid plexus papilloma (grade II) and choroid plexus carcinoma (grade III).[3]

PREVALENCE AND EPIDEMIOLOGY

CPCs are frequently detected during the second-trimester US screening examination. The reported prevalence of fetal CPC ranges from 0.18% to 3.6%, independent of fetal sex.[3,9]

CPPs represent 0.5% to 3% of intracranial tumors in children and 5% to 20% of all perinatal brain tumors.[10] They are the most common brain tumors in the first year of life (up to 20%).[1] Postnatally there is a male predilection, but a higher incidence in girls with Aicardi syndrome.[3]

ETIOLOGY AND PATHOPHYSIOLOGY

CPCs are thought to originate from neuroepithelial folds of the choroid plexus filling with CSF and debris. The collection of fluid is surrounded by choroid plexus tissue. At 6 weeks' gestation, the onset of the development of choroid plexus, a bulge from the medial wall of the lateral ventricle, becomes covered with pseudostratified epithelium, and then lobulated with villi. The cells change from cuboid to columnar epithelium. The choroid plexus produces CSF beginning from ninth week of gestation, leading to expansion of the ventricular system. As the villi grow and become entangled, a cystic space is formed, which traps CSF. Most villi form at 13 to 18 weeks' gestation. Fluid accumulates and results in the formation of CPCs, which can be detected by prenatal US.[1] Usually, the CSF is released and the cysts resolve as the stroma decreases with increasing gestational age, mostly between 26 to 28 weeks' gestation.[11]

Choroid plexus and CPCs differ in vascularity. Kraus and Jirasek[4] showed typical wavy longitudinal nonbranching capillary loops under the surface epithelium of the choroid plexus. In contrast, there is a net of interconnecting angiomatous irregular capillaries (capillary plexus) with variable volumes in the walls of CPCs.

CPCs are typically transient and benign findings. Without associated anomalies they should be considered normal variants.[12] CPCs in low-risk populations confer a 1% aneuploidy risk, mostly for trisomy 18, but occasionally also for trisomy 21 and triploidy.[8,9,12] CPCs are found in 30% to 53% of fetuses with trisomy 18 in the second trimester.[13,14] In trisomy 18, CPCs are associated with other sonographic anomalies in the majority (80%–90%) of these cases, but in 11% of pregnancies with trisomy 18 CPCs, they were the only detected sign.[14] They have no known association with other adverse outcomes when the karyotype is normal. Long-term outcome studies have shown that the prenatal finding of isolated CPC, in the absence of aneuploidy, was not associated with altered fetal growth and development,[15,16] delayed infant and early childhood development, or significant neurocognitive or neurobehavioral delays.[17] Even in a case series of fetal ventriculomegaly secondary to large CPCs, in all cases the lateral ventricles became normal or decreased in size during pregnancy, resulting in normal growth and development on long-term follow-up (4–6 years).[18]

No other known fetal anomalies are linked to CPCs. All studies so far have shown that the presence of associated anomalies, but not of CPCs per se, are the most important predictor of a fetal chromosomal defect,[11] followed by increased maternal age.[12]

When isolated CPCs are found in a low-risk population, the likelihood of trisomy 18 increases 3.5-fold to 9-fold when assessing only this single marker.[19] In a metaanalysis of 13 prospective studies involving 1346 second-trimester fetuses with isolated CPC, Yoder et al.[20] found a significant association between isolated CPC and trisomy 18, with a likelihood ratio of 13.8. In association with a structural abnormality, the risk increase above baseline was almost 1800-fold.[19] The risk of chromosomal abnormalities in the presence of isolated CPCs depends on the *a priori* risk. For example, based on maternal age alone, the risk changes from less than 1:2500 if the mother is 20 years old to about 1:50 if the maternal age is 45 years (Table 33.1).[12]

Other factors, such as serum analyte screening, can alter the calculated *a priori* risk. Gupta[19] used data from 200,000 US examinations to calculate aneuploidy risk in pregnancies with fetal CPC. In women who had multiple-marker screening tests indicating no increased risk, who had otherwise normal-appearing fetuses, and who were younger than 32 years, isolated CPCs did not increase the risk of trisomy 18 sufficiently to indicate fetal karyotyping. From a metaanalysis of eight prospective trials published between 1990 and 2000, Demasio et al.[21] concluded that there is no evidence that detection of isolated CPC in women younger than 35 years increases the risk of trisomy 18. CPCs were suggested as a possible minor marker of trisomy 21, but the prevalence of CPCs in fetuses with trisomy 21 and in the general population is the same (1.4%), so they should not be considered to increase the risk of trisomy 21.[9,20]

TABLE 33.1 APPROXIMATE RISK OF TRISOMY 18 IN FETUSES WITH CHOROID PLEXUS CYSTS

Maternal Age (years)	RISK		
	Overall	Isolated Cyst	Plus One Other Abnormality
20–24	1:4500	1:2950	1:225
25–29	1:3600	1:2300	1:175
30–34	1:2000	1:1300	1:100
35–39	1:750	1:470	1:35
40–44	1:400	1:100	1:10

Data from Snijders RJM, Shawa L, Nicolaides KH: Fetal choroid plexus cysts and trisomy 18: assessment of risk based on ultrasound findings and maternal age. *Prenat Diagn* 14:1119–1127, 1994.

CPP is a polygenetic disorder. Different genetic loci have been implicated, and chromosomal alterations such as +7q (65%), +5q (62%), +7p (59%), and +5p (56%) have been reported.[22] Different pathways in tumorigenesis of CPPs are active, such as platelet-derived growth factor receptor (PDGFR), the tumor necrosis factor–related apoptosis-inducing ligand (TRAIL) pathways (CASP8, TFRSF10C, and TFRSF10D), Notch3 signaling, and the transcription factor TWIST1.[5]

CPP is usually a benign tumor of ependymal origin, arising from the neuroepithelial cells of the choroid plexus, most commonly at the level of the atria of the lateral ventricles (70%–80%) but also from the third ventricle (14%), fourth ventricle (7%), and interventricular foramen.[23]

CPP histologically resembles the nonneoplastic choroid plexus, with highly differentiated cuboidal epithelial cells based on papillary fibrovascular tissue, without signs of increased mitotic activity, nuclear atypia, or altered vascularization, but higher cellular density. These tumors are classified as choroid plexus papilloma World Health Organization grade I. The noninvasive and slow-growing tumor blocks the physiologic drainage of the CSF in the subarachnoid cisterns and secretes additional CSF, causing ventriculomegaly.[2,5]

Malignant transformation of CPPs is rare (5%–10%). The 5-year survival rate after surgery of CPP has improved from 50% in early studies to approximately 100% in more recent reports, due to advances in imaging, surgical approaches, and quality of intensive care.[5,24] There is no established association between fetal and neonatal tumors and chromosomal aberrations, other than in two syndromes, Aicardi-Goutières syndrome and hypomelanosis of Ito.[3]

MANIFESTATIONS OF DISEASE

Clinical Presentation

CPCs are single or multiple round hypoechogenic cystic structures usually in the body and atrium of the lateral ventricles, with diameters ranging from 3 mm to 20 mm. CPCs may be unilateral, bilateral, or multiple. Their appearance and laterality have no clinical relevance. Their cystic structure appears simple or septated; 95% of CPCs are isolated. The cysts do not cause any local damage or effect.[7,19] Fetal CPCs may be detected by US as early as 11 to 12 weeks' gestation. They resolve at the end of the second trimester in more than 95% of cases.[8,11]

The prenatal diagnosis of CPP relies on the demonstration of an echogenic solid intraventricular mass at the level of the choroid plexus in the presence of ventriculomegaly, the main presenting finding in the fetus. Ventriculomegaly is present in 85% to 87% of affected cases, but correlates poorly with the size and pathologic features of the tumor. Affected children typically become symptomatic during the first year of life with signs of increased intracranial pressure. They usually experience headaches, nausea and vomiting, focal neurologic impairments, macrocephaly, and epileptic seizures. In rare cases, CPP can be a cause of intracranial hemorrhages.[3,5,25]

Imaging Technique and Findings

Ultrasound. The transventricular view is the first choice to visualize the normal choroid plexus. The plane lies superior and

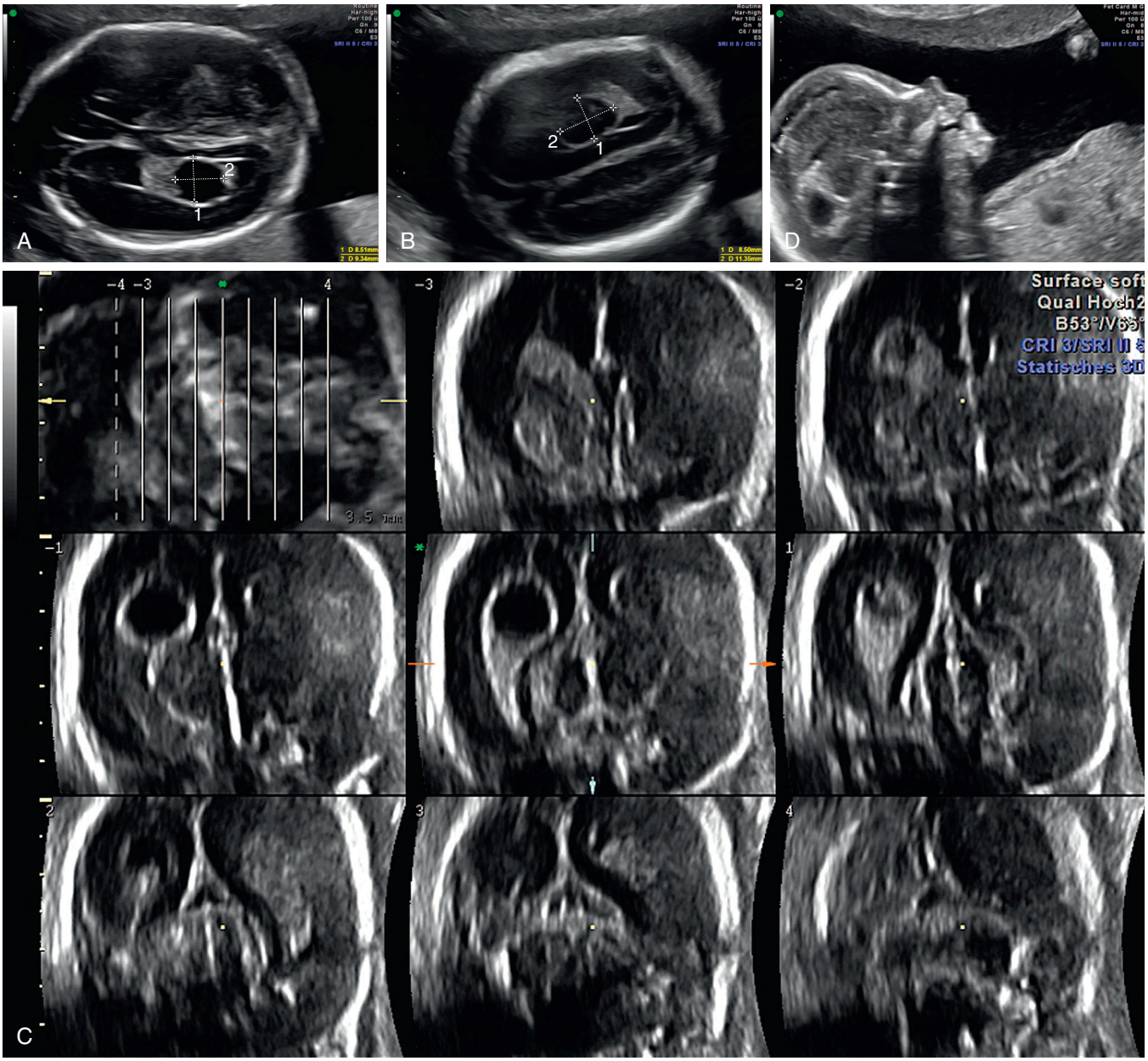

Fig. 33.1 Bilateral CPC in a 20-week fetus without any chromosomal abnormality. (A, B) Transverse views show a CPC measuring 9 mm (calipers) in left lateral ventricle (A), and a CPC measuring 11 mm (calipers) in right lateral ventricle (B). (C) Coronal view in tomographic US imaging shows bilateral CPCs. (D) Parasagittal view shows CPC in right lateral ventricle.

parallel to the transthalamic biparietal diameter plane. Before 16 weeks' gestation, the choroid plexus fills most of the volume of the lateral ventricles with its typical symmetric butterfly appearance. The normal choroid plexus occupies the lateral ventricles from side to side.

CPCs can occur throughout the ventricular system, but they are typically found at the level of the atrium of the lateral ventricles. They are located in the body of the plexus, and may protrude into the ventricular cavity. They appear as sonolucent (black) spaces within the choroid plexus. CPCs show echogenic, well-defined walls and, occasionally, internal septations (Figs. 33.1–33.3 and Table 33.2).[3]

A CPP appears as a well-defined, lobular, hyperechogenic intraventricular mass, adjacent to normal choroid plexus. The diagnosis of ventriculomegaly combined with an intraventricular hypervascularized tumor without infiltrative growth is pathognomonic (Figs. 33.4A,B). CPPs are highly vascular tumors and receive blood supply from the choroidal arteries. Prenatal color Doppler flow imaging can show the characteristic vascularity and feeding vessels at the base of the mass (see Fig. 33.4C; see Table 33.2).[26]

Magnetic Resonance Imaging. CPC usually have the same signal intensity on magnetic resonance imaging (MRI) as CSF. They show high signal intensity on diffusion-weighted images. The signal intensity of cystic fluid may be higher on T1-weighted and T2-weighted images and lower on apparent diffusion coefficient maps, which may be partially explained by slower water diffusion rate because of higher protein content.[2,3]

CPPs appear on MRI as a homogeneous intraventricular cauliflower-like mass on T1-weighted sequences. The mass may adhere to the ventricular wall, but usually it is well delineated from brain tissue. Characteristically, the central portions of the papilloma are isointense to hypointense on T1-weighted images, and isointense to hyperintense compared with gray matter on T2-weighted images. Because of rich vascularity and enlarged feeding arteries, there is an intense and homogeneous contrast enhancement. Calcifications and hemorrhages may locally modify the signal intensities of the tumor. Calcification and vascularity may be seen as regions of marked hypointensity.[2,5,25]

TABLE 33.2 ULTRASOUND FINDINGS

Ultrasound Findings in Choroid Plexus Cyst[3]	Ultrasound Findings in Choroid Plexus Papilloma[26]
Simple round hypoechogenic cystic structure	Hyperechoic intraventricular mass
Thick echogenic wall	Hydrocephalus and dilatation of fetal subarachnoid cisterns secondary to CSF overproduction
Internal septations	Color Doppler flow shows feeder arteries with resistance of flow and nonvisualization of vascularity within tumor mass

CSF, Cerebrospinal fluid.

Differential Diagnosis From Imaging Findings

1. CPC: other cystic abnormalities within the brain include arachnoid cysts, porencephaly, cystic tumors, and intracranial hemorrhage (Table 33.3). Large unilocular CPCs can appear as a ventricular dilatation. Blood clots from localized intraventricular bleeding can be mistaken for CPC.
2. CPP: the differential diagnosis of fetal intracranial masses includes intraventricular hemorrhage, choroid plexus carcinoma, and other brain tumors (e.g., thalamic cavernous angioma).[27] Intraventricular bleeding with clot formation and secondary irritation of the arachnoid granulations, causing diminished CSF reabsorption, can mimic CPPs. Because intraventricular clots do not have feeding arteries, the use of

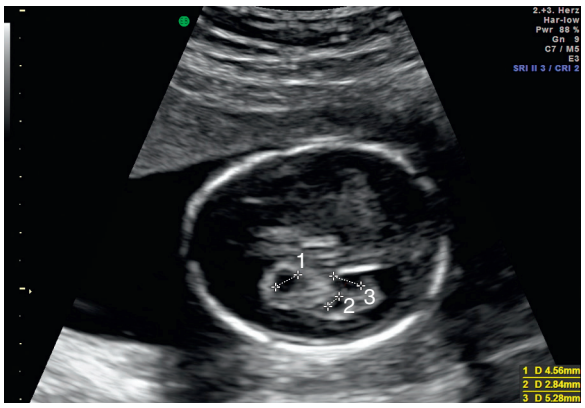

Fig. 33.2 Multiple unilateral CPCs in a 17-week fetus without any chromosomal abnormality. Transverse view shows three cysts (calipers) in the left lateral ventricle.

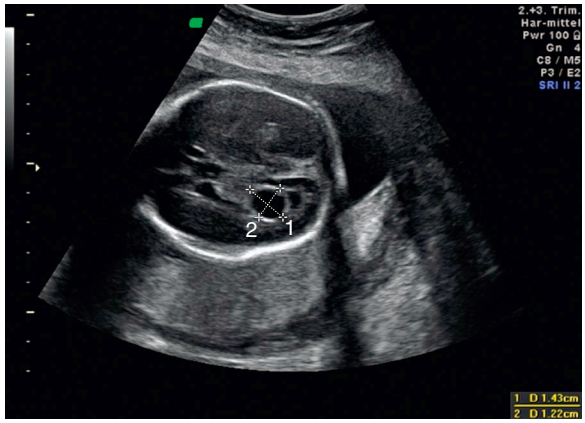

Fig. 33.3 Trisomy 18 and CPC in a 24-week fetus. Transverse view shows unilateral CPC measuring 14 mm (calipers) in left lateral ventricle. Other abnormalities in this case included a cardiac defect (atrioventricular septal defect), hydronephrosis, and clenched hands.

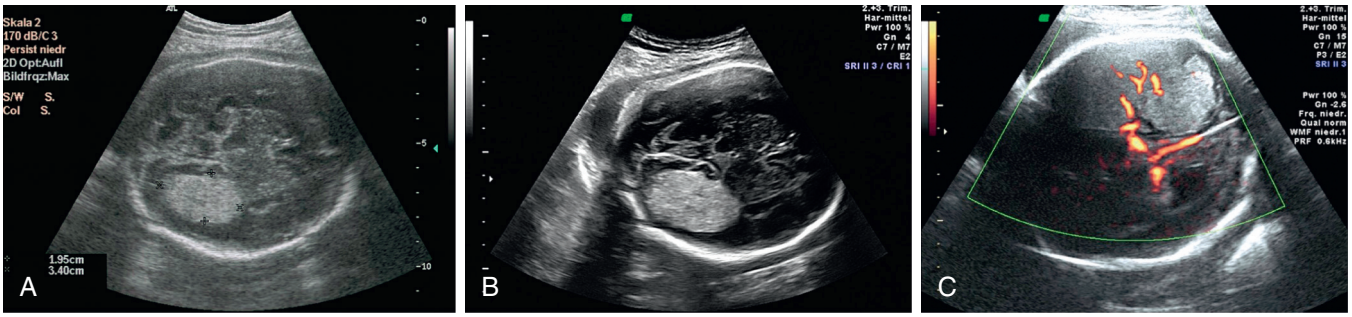

Fig. 33.4 (A) CPP in fetus at 31 weeks' gestation. Transverse view shows echogenic tumor measuring about 10 mm in the right lateral ventricle and moderate ipsilateral ventriculomegaly without any additional anomalies. (B) CPP in the same fetus at 32 weeks' gestation. Transverse view shows tumor growth in the lateral ventricle, which begins to cause midline shift. (C) Transverse view (power Doppler) shows the feeding vessel of the tumor in the right ventricle. *(From Hartge DR, Axt-Fliedner R, Weichert J: Prenatal diagnosis and successful postnatal therapy of an atypical choroid plexus papilloma—case report and review of literature.* J Clin Ultrasound *38:377–383, 2010)*

TABLE 33.3 DISTINGUISHING FEATURES OF LATERAL INTRACRANIAL CYSTS

Choroid plexus cyst	Cyst present within choroid plexus of lateral ventricle
	Bilateral or unilateral
Arachnoid cyst	Smooth wall
	Asymmetric
	Mass effect
	Possible hydrocephalus (dependent on location)
Porencephaly	Usually unilateral
	Communicates with ventricle
	Cavity size increases with distance from ventricle
	Cavity lined by white matter
Cystic neoplasm	Mass effect
	Solid or irregular with cystic components
Intracranial hemorrhage	Initial echogenic clot in ventricle
	Later echogenic clot plus ventriculomegaly on side of hemorrhage

Data from McGahan J, Thurmond A: The fetal head. In McGahan J, Porto M, editors: *Diagnostic obstetrical ultrasound.* Philadelphia, 1994, Lippincott.

Doppler color flow can help differentiate them from a solid tumor. The sonographic features (volume of the mass, and findings on color Doppler imaging) do not allow discrimination between benign (CPPs) and malignant (choroid plexus carcinoma) tumors. The final diagnosis can only be known after surgical excision of the tumor.[25]

Synopsis of Treatment Options

PRENATAL

Choroid Plexus Cysts

Controversy still remains concerning appropriate management. Some studies concluded that an isolated CPC is not an indication for genetic testing, whereas some others recommended it.[13,28] Based on the metaanalyses by Yoder et al.[20] and Demasio et al.,[21] we suggest the following protocol for the management of a CPC according to the American College of Obstetricians and Gynecologists[29] and the World Association of Perinatal Medicine Working Group on Ultrasound in Obstetrics:[30]

1. When a CPC is identified, a targeted US examination of the entire fetus should be performed. Routine follow-up scans may be considered during the course of the pregnancy to confirm the disappearance of CPCs.[28] Larger cysts (greater than 10 mm) may carry an increased risk for trisomy 18 compared with smaller cysts. Other US characteristics, such as bilaterality, number, complexity, and delayed resolution, seem to be unrelated to the risk of aneuploidy.[9,11] Standard obstetric management is indicated in isolated CPC.
2. Genetic counseling and karyotyping should be offered if any other sonographic abnormalities are seen. If the CPCs are isolated, the prior risk (maternal age or previous risk assessment; Table 33.1) should be a major factor in deciding whether to offer karyotyping, possible noninvasive prenatal testing, or simple observation.[12,20]
3. The parents should be informed and reassured about the usually favorable natural history (spontaneous resolution) of CPCs.

Choroid Plexus Papilloma

Valid recommendations are lacking for prenatal treatment management of CPPs. Timely prenatal recognition and diagnosis of CPP may assist in a planned atraumatic delivery. If ventriculomegaly worsens, an elective cesarean delivery is the treatment of choice.[5,6,24]

POSTNATAL

In isolated CPCs, neonatal cranial US should be offered to confirm cerebral normality. Parents should be reassured regarding the prognosis of isolated CPCs. The presence of isolated cysts does not warrant intensive infant and early childhood follow-up.[17,28,29]

CPPs can usually be cured by surgical resection. The treatment of choice in the neonate is surgical resection of the tumor. Intraoperatively, the neoplasm should be excised totally after carefully securing the vascular pedicle.[5,24] However, the procedure may be technically difficult and complicated by hemorrhage.[10] Because the risk of recurrence or malignant transformation is low, radiotherapy to the developing brain should be avoided.[5]

WHAT THE REFERRING PHYSICIAN NEEDS TO KNOW

Prospective parents should be reassured regarding the prognosis for isolated CPCs. The natural course of the cysts and the risk for an aneuploidy, especially trisomy 18, should be explained to the parents. If CPC is detected, the fetus needs a comprehensive anatomic US examination by an experienced examiner to search for other abnormalities. The option for genetic testing should be explained, along with its risks and benefits.[11,29,30]

In fetuses with CPP, the parents should be informed about the benign nature of the tumor and the possibility to cure it by surgical resection after delivery. Serial fetal US examinations may be necessary to follow the development of hydrocephalus. An atraumatic delivery should be planned.[5,6,24]

KEY POINTS

CHOROID PLEXUS CYSTS

- CPC usually are benign, transient findings.
- The typical US finding is a round hypoechogenic cyst in the echogenic choroid plexus.
- CPC are typically seen during the second-trimester screening examination.
- Cysts decrease rapidly in size and mostly disappear before birth.
- CPC are associated with an increased likelihood of trisomy 18 if other anomalies are present, or if the patient has a high *a priori* risk.
- When isolated CPC are detected, the prior risk (maternal age or prior risk assessment) should be the major factor in deciding whether to offer genetic testing.
- If associated anomalies are seen, fetal karyotyping should be offered.

CHOROID PLEXUS PAPILLOMA

- CPPs are very rare and, usually, histologically benign fetal intracranial tumors.
- The typical US finding is a hyperechoic intraventricular mass.
- The tumor causes ventriculomegaly in most cases.
- A planned cesarean section is the delivery mode of choice in severe hydrocephaly.
- Affected children typically become symptomatic during the first year of life with signs of increased intracranial pressure.
- CPPs can be cured by surgical resection with favorable outcomes.

SUGGESTED READING

Anselem O, Mezzetta L, Grangé G, et al. Fetal tumors of the choroid plexus: is differential diagnosis between papilloma and carcinoma possible? *Ultrasound Obstet Gynecol*. 2011;38:229-232.

Guermazi A, De Kerviler E, Zagdanski AM, et al. Diagnostic imaging of choroid plexus disease. *Clin Radiol*. 2000;55:503-516.

Gupta JK, Khan KS, Thornton JG, et al. Management of fetal choroid plexus cysts. *Br J Obstet Gynaecol*. 1997;104:881-886.

Kraus I, Jirasek JE. Some observations of the structure of the choroid plexus and its cysts. *Prenat Diagn*. 2002;22:1223-1228.

Lopez JA, Reich D. Choroid plexus cysts. *J Am Board Fam Med*. 2006;19:422-425.

Naeini RM, Yoo JH, Hunter JV. Spectrum of choroid plexus lesions in children. *AJR Am J Roentgenol*. 2009;192:32-40.

Safaee M, Oh MC, Bloch O, et al. Choroid plexus papillomas: advances in molecular biology and understanding of tumorigenesis. *Neuro Oncol*. 2013;15:255-267.

Severino M, Schwartz ES, Thurnher MM, et al. Congenital tumors of the central nervous system. *Neuroradiology*. 2010;52:531-548.

Walkinshaw SA. Fetal choroid plexus cysts: are we there yet? *Prenat Diagn*. 2000;20:657-662.

Wolburg H, Paulus W. Choroid plexus: biology and pathology. *Acta Neuropathol*. 2010;119:75-88.



All references are available online at www.expertconsult.com.

REFERENCES

1. Wolburg H, Paulus W. Choroid plexus: biology and pathology. *Acta Neuropathol*. 2010;119:75-88.
2. Guermazi A, De Kerviler E, Zagdanski AM, et al. Diagnostic imaging of choroid plexus disease. *Clin Radiol*. 2000;55:503-516.
3. Naeini RM, Yoo JH, Hunter JV. Spectrum of choroid plexus lesions in children. *AJR Am J Roentgenol*. 2009;192:32-40.
4. Kraus I, Jirasek JE. Some observations of the structure of the choroid plexus and its cysts. *Prenat Diagn*. 2002;22:1223-1228.
5. Safaee M, Oh MC, Bloch O, et al. Choroid plexus papillomas: advances in molecular biology and understanding of tumorigenesis. *Neuro Oncol*. 2013;15:255-267.
6. Hartge DR, Axt-Fliedner R, Weichert J. Prenatal diagnosis and successful postnatal therapy of an atypical choroid plexus papilloma—case report and review of literature. *J Clin Ultrasound*. 2010;38:377-383.
7. Chudleigh P, Pearce JM, Campbell S. The prenatal diagnosis of transient cysts of the fetal choroid plexus. *Prenat Diagn*. 1984;4:135-137.
8. Nicolaides KH, Rodeck CH, Gosden CM. Rapid karyotyping in non-lethal fetal malformations. *Lancet*. 1986;8476:283-287.
9. Gupta JK, Cave M, Lilford RJ, et al. Clinical significance of fetal choroid plexus cysts. *Lancet*. 1995;346:724-729.
10. Isaacs H. Fetal brain tumors: a review of 154 cases. *Am J Perinatol*. 2009;26:453-466.
11. Walkinshaw SA. Fetal choroid plexus: are we there yet? *Prenat Diagn*. 2000;20:657-662.
12. Snijders RJM, Shawa L, Nicolaides KH. Fetal choroid plexus cysts and trisomy 18: assessment of risk based on ultrasound findings and maternal age. *Prenat Diagn*. 1994;14:1119-1127.
13. Coco C, Jeanty P. Karyotyping of fetuses with isolated choroid plexus cysts is not justified in an unselected population. *J Ultrasound Med*. 2004;23:899-906.
14. Cho RC, Chu P, Smith-Bindman R. Second trimester prenatal ultrasound for the detection of pregnancies at increased risk of trisomy 18 based on serum screening. *Prenat Diagn*. 2009;29:129-139.
15. Irani S, Ahmadi F, Javam M, et al. Outcome of isolated fetal choroid plexus cyst detected in prenatal sonography among infertile patients referred to Royan Institute: a 3-year study. *Iran J Reprod Med*. 2015;13:571-576.
16. DiPietro JA, Costigan KA, Cristofalo EA, et al. Choroid plexus cysts do not affect fetal neurodevelopment. *J Perinatol*. 2006;26:622-627.
17. Bernier FP, Crawford SG, Dewey D. Developmental outcome of children who had choroid plexus cysts detected prenatally. *Prenat Diagn*. 2005;25:322-326.
18. Fong K, Chong K, Toi A, et al. Fetal ventriculomegaly secondary to isolated large choroid plexus cyst: prenatal findings and postnatal outcome. *Prenat Diagn*. 2011;31:395-400.
19. Gupta JK, Khan KS, Thornton JG, et al. Management of fetal choroid plexus cysts. *Br J Obstet Gynaecol*. 1997;104:881-886.
20. Yoder PR, Sabbagha RE, Gross SJ, et al. The second trimester fetus with isolated choroid plexus cysts: a meta-analysis of risk of trisomies 18 and 21. *Obstet Gynecol*. 1999;93:869-872.
21. Demasio K, Canterino J, Ananth C, et al. Isolated choroid plexus cyst in low-risk women less than 35 years old. *Am J Obstet Gynecol*. 2002;187:1246-1249.
22. Rickert CH, Wiestler OD, Paulus W. Chromosomal imbalances in choroid plexus tumors. *Am J Pathol*. 2002;160:1105-1113.
23. Strojan P, Popovic M, Surlan K, et al. Choroid plexus tumors: a review of 28-year experience. *Neoplasma*. 2004;51:306-312.
24. Verma SK, Satyarthee GD, Sharma BS. Giant choroid plexus papilloma of the lateral ventricle in fetus. *J Pediatr Neurosci*. 2014;9:185-187.
25. Anselem O, Mezzetta L, Grangé G, et al. Fetal tumors of the choroid plexus: is differential diagnosis between papilloma and carcinoma possible? *Ultrasound Obstet Gynecol*. 2011;38:229-232.
26. Adra AM, Mejides AA, Salman FA, et al. Prenatal sonographic diagnosis of a third ventricle choroid plexus papilloma. *Prenat Diagn*. 1994;14:865-867.
27. Henrich W, Stupin JH, Bühling KJ, et al. Prenatal sonographic findings of thalamic cavernous angioma. *Ultrasound Obstet Gynecol*. 2002;19:518-522.
28. Lopez JA, Reich D. Choroid plexus cysts. *J Am Board Fam Med*. 2006;19:422-425.
29. American College of Obstetricians and Gynecologists. ACOG Practice Bulletin No. 163: Screening for fetal aneuploidy. *Obstet Gynecol*. 2016;127:e123-e137.
30. Ebrashy A, Kurjak A, Adra A, et al. Controversial ultrasound findings in midtrimester pregnancy. Evidence based approach. Recommendation and guidelines for perinatal practice. *J Perinat Med*. 2016;44:131-137.

34 Corpus Callosum and Septum Pellucidum Anomalies

PAOLO VOLPE | CARMELA VOTINO | TIZIANA FANELLI | VALENTINA DE ROBERTIS | GEORGIOS REMBOUSKOS | ANDREA ROSSI

Introduction

Anomalies of the corpus callosum and septum pellucidum are disorders of prosencephalic midline development. Midline prosencephalic development peaks at 7 to 12 weeks' gestation and includes the formation of the chiasmatic, commissural, and hypothalamic plates, enabling formation of the corpus callosum (12 to 20 weeks) and septum pellucidum. Corpus callosum and septum pellucidum anomalies are often associated with other brain abnormalities.

Corpus Callosum Anomalies

DEFINITION

The corpus callosum represents the major telencephalic commissure. The telencephalic commissures are corticocortical bundles of white matter extending from one hemisphere to the other, typically in a symmetric fashion.[1,2] The other interhemispheric commissures are the anterior and the hippocampal commissures. The corpus callosum is composed of four parts (from front to back): rostrum, genu, body, and splenium (Fig. 34.1). Developmental abnormalities of the corpus callosum include complete or partial agenesis of the corpus callosum (ACC); partial ACC is also referred to as *hypogenesis* (or *dysgenesis*).

PREVALENCE AND EPIDEMIOLOGY

The prevalence of corpus callosum anomalies varies significantly in different studies. Depending on the population and the diagnostic criteria, 0.3% to 0.7% in the general population and 2% to 3% in developmentally disabled individuals have been reported.[3]

ETIOLOGY AND PATHOPHYSIOLOGY

The anterior part of the corpus callosum develops along a fusion line composed of specialized groups of glial cells, the glial sling, that guide commissural axons of the frontal lobes through the interhemispheric meninges toward the contralateral hemisphere. Commissural fibers from the temporooccipital lobes cross the midline along the anterior commissure, while posterior occipitoparietal fibers cross along the scaffold provided by the hippocampal commissure, resulting in the callosal splenium. Thus, contrary to common misconception, there is no anteroposterior growth of the corpus callosum; rather the corpus callosum forms by two separate segments that eventually coalesce to fuse the complete commissural plate.[2] If the normal developmental process is disturbed, the corpus callosum may be completely or partially absent (hypogenetic).[1,2,4]

The knowledge of the organogenetic process helps differentiate a developmental injury (hypogenesis) from an acquired one (destruction). The latter mechanism usually occurs in association with hypoxic-ischemic injury and infectious causes.[4] Two types of congenital callosal abnormalities can then be distinguished. In the first type, the axons are present but are unable to cross the midline; they form large aberrant fiber bundles ("Probst bundles") along the medial hemispheric walls. In the second type, which is less frequent, the axons fail to form, and no Probst bundles are found. The etiology of ACC is very heterogeneous. Identified causes are chromosomal, monogenic, and teratogenic. Chromosomal abnormalities are present in 20% of ACC, especially trisomies 18 and 13. More than 250 syndromes involving ACC

have been reported and about 15 genes have been identified as responsible for AAC.[5] Some environmental and metabolic factors also have been implicated in ACC, such as fetal cytomegalovirus and rubella infections and fetal alcohol exposure.[6] Most isolated ACC cases are sporadic. However, autosomal recessive or dominant transmission occurs in about 3% (personal data), which may justify magnetic resonance imaging (MRI) assessment of the parents' corpus callosum.

MANIFESTATIONS OF DISEASE

Clinical Presentation

Clinical features of ACC include mental retardation, easily controlled epilepsy, and behavioral disorders. Clinical findings vary widely, ranging from asymptomatic with normal intellectual capacities to severe mental retardation.[7]

Although the overall prognosis of ACC is controversial, several studies reported a worse prognosis in the presence of additional anomalies.[7] Cases of isolated ACC seem to carry a better prognosis,[8] but the clinician must be cautious when assessing the fetal and neonatal prognosis considering the small number of fetal series reported in the literature.[6] Even with extensive prenatal analysis it is difficult to ascertain whether the malformation is truly isolated.[6–8]

A review article was recently dedicated to neurodevelopmental outcome in truly isolated ACC[9] found only six studies using appropriate data (MRI before and after birth, neurodevelopmental assessment with standardized tests). The outcome was favorable in 75.4% of cases, with moderate disability in 13% and severe disability in 11.6% of cases. The prognosis of partially isolated ACC was not significantly different from that of isolated complete forms.[9]

In individuals with ACC, subtle neuropsychologic, perceptual, and motor defects can emerge later in life. Long-term follow-up is important, especially with regard to social interactions and school performance, to provide better prognostic information to families.[6,7]

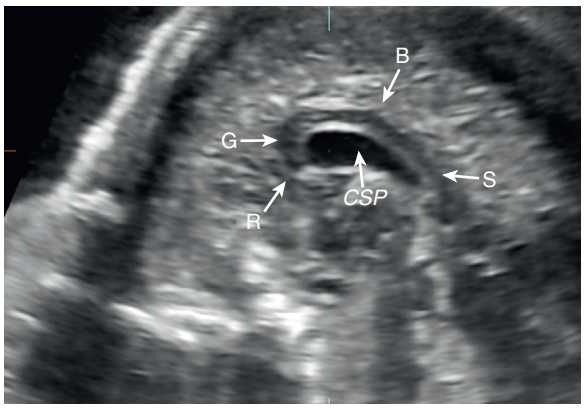

Fig. 34.1 Midsagittal (or median) plane of the brain in a 22-week fetus showing the entire corpus callosum. *B,* Body; *CSP,* cavum septi pellucidi; *G,* genu; *R,* rostrum; *S,* splenium.

Imaging Technique and Findings

Ultrasound. The corpus callosum can be shown with ultrasound (US),[10] but some degree of technical skill is required because it is not apparent in the standard axial planes, and additional coronal and particularly sagittal planes are required. In fetuses in cephalic presentation, the transvaginal approach is preferred;[11,12] in fetuses in breech presentation, a transfundal approach is suggested. Using a three-dimensional multiplanar technique can also be helpful because it offers a more accurate identification of the midsagittal plane, and navigation in the other two simultaneous orthogonal planes may permit a better evaluation of the midline prosencephalic structures (Fig. 34.2).[13] In axial planes, the diagnosis is based on the presence of indirect signs. Because the corpus callosum shares a common anatomic and embryogenetic formation with the septum pellucidum, complete ACC is commonly associated with a hypoplastic or absent cavum septi pellucidi (CSP).

Complete Corpus Callosum Agenesis. At the second-trimester anomaly scan, ACC may be suspected when the CSP is not visualized on the axial transventricular view (Fig. 34.3). The suspicion of ACC is supported further by the recognition of other indirect signs, such as (1) colpocephaly (dilatation of the atria and occipital horns of the lateral ventricles, owing to the

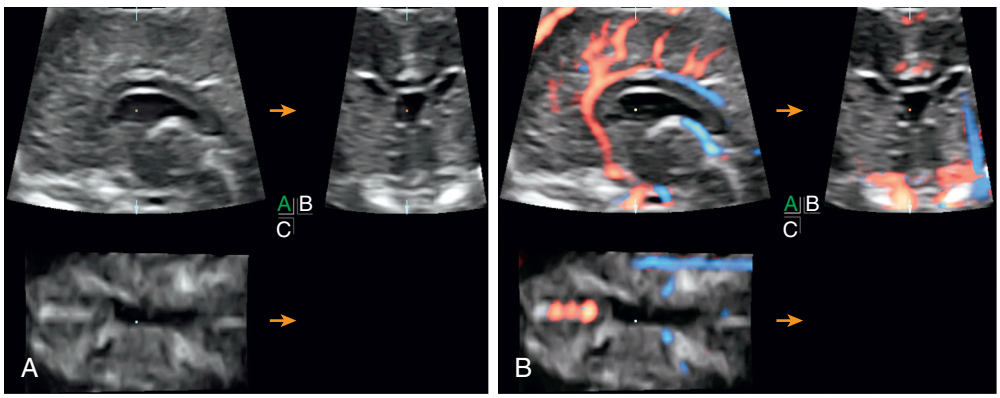

Fig. 34.2 (A) Multiplanar analysis of US volume of a 22-week fetal brain, obtained with a transvaginal approach from the sagittal plane. The *A* plane corresponds to the sagittal plane; *B,* to the coronal plane; and *C,* to the axial plane. The position of the reference dot is within the cavum septi pellucidi. To better assess the relationship between different brain structures, it is possible to move the dot on one plane and evaluate the corresponding changes on the other two planes. (B) Color Doppler acquisition of US volume of a 22-week fetal brain, displayed in the multiplanar mode, enabling detailed visualization of the anterior cerebral artery and pericallosal artery.

absence of the splenium and to a defect of the intrinsic association bundles of the occipital lobe) (Fig. 34.4) and (2) increased separation of the hemispheres with the bodies of the lateral ventricles parallel to each other and shifted laterally (see Fig. 34.4). Dorsal elevation of the third ventricle can be also present. On coronal sections of the fetal brain, the indirect signs are mainly apparent in the frontal horns, which are separated more than usual and show concave medial borders (Fig. 34.5). This appearance is due to the compression exerted by a large longitudinal bundle of fibers representing the callosal fibers that fail to cross the hemispheres, are rerouted parasagittally, and run parallel to the midline. This abnormal bundle, the *longitudinal bundle of Probst,* runs parallel to the medial walls of the lateral ventricles and enlarges and deforms their medial borders, especially at the level of the frontal horns. Each of these indirect signs can be present in isolation, which in part explains the frequently missed diagnosis of ACC.

A definitive diagnosis of ACC relies on direct visualization[6,10]: demonstration of the absence of the corpus callosum on midsagittal and coronal views of the fetal brain. In particular, the midsagittal plane shows absence of the corpus callosum (Fig. 34.6A) and, in advanced gestation or postnatally, an atypical radiating appearance of the median sulci, which converge toward the third ventricle (see Fig. 34.6B). In this view, the cingulate gyrus can be recognized, or appears incomplete.

Partial Corpus Callosum Agenesis. ACC may also be partial (pACC), resulting in more subtle US findings than are associated with complete ACC. When the corpus callosum is incompletely formed, usually the posterior portion is affected (the posterior body and the splenium); in this situation, the CSP can be present, and often the only indirect US sign is colpocephaly. Identifying pACC is important because approximately one third of apparently isolated cases are associated with moderate or severe neurological morbidity.[9] In up to one-third of cases there are no indirect signs, and consequently the diagnosis may be missed unless direct demonstration of the corpus callosum (CC) in the midsagittal plane is attempted.[4,6,14] In cases of pACC without indirect signs, the shape of CSP is also abnormal.[15] A sagittal view is the only

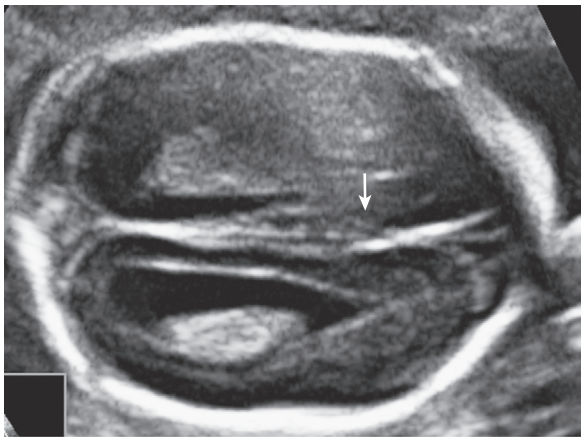

Fig. 34.3 Indirect signs of ACC. Axial scan of a 22-week fetal brain shows the absence of the CSP *(arrow)* and the teardrop shape of the lateral ventricle owing to dilatation of the atria and occipital horns (colpocephaly).

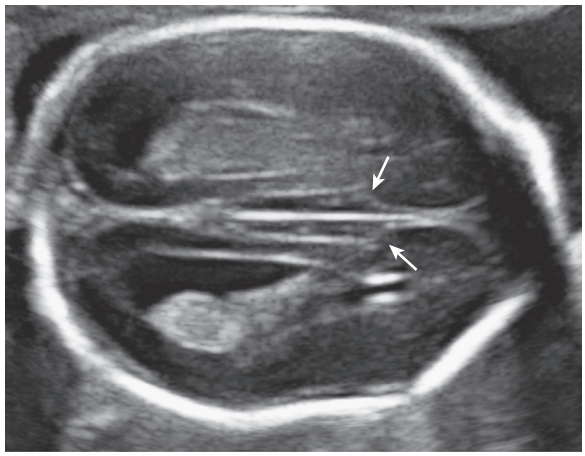

Fig. 34.4 Indirect signs of ACC. Axial scan of a 22-week fetal brain. *Arrows* indicate increased separation of the hemispheres with the bodies of the lateral ventricles parallel to each other and shifted laterally. Colpocephaly is also present.

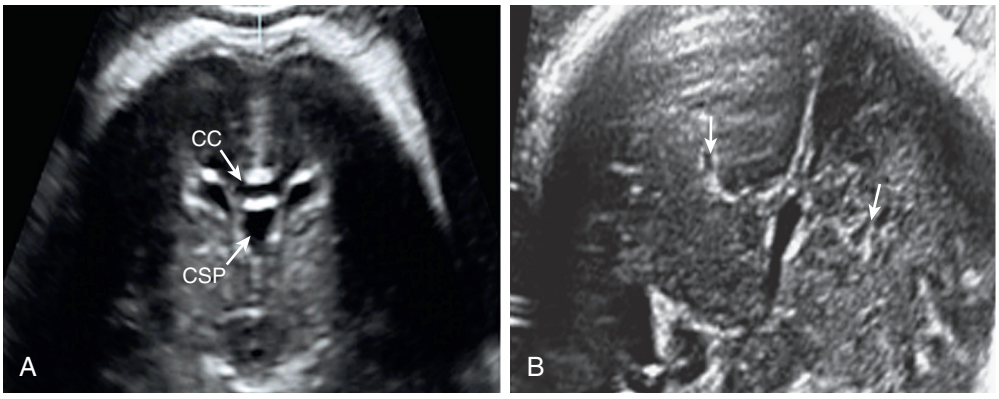

Fig. 34.5 (A) Midcoronal view of the brain in a 23-week normal fetus shows the normally developed frontal horns, genu *(CC),* and cavum septi pellucidi *(CSP).* (B) ACC. Coronal scan of a 29-week fetal brain shows absence of the genu and increased distance between the frontal horns *(arrows).* The inner walls of the frontal horns are concave medially because of the medial compression exerted by the Probst bundles. Together with the lumen of the third ventricle, this makes up the typical appearance of a "bull's head".

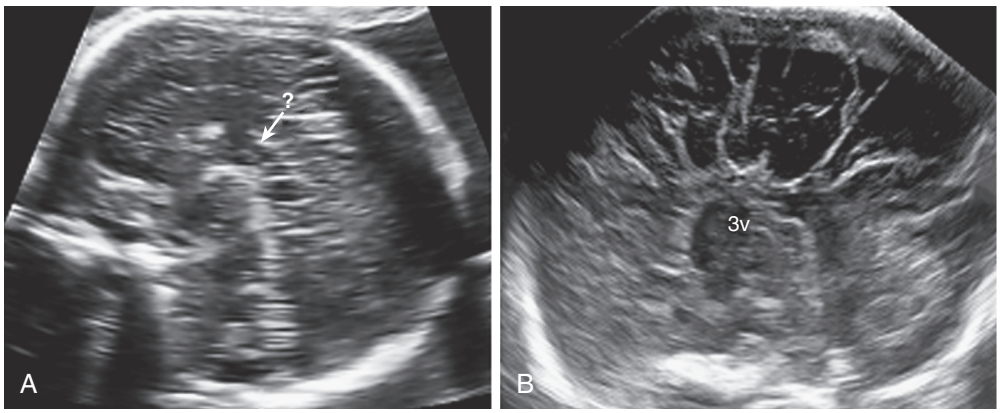

Fig. 34.6 (A) Midsagittal scan of the brain in a 22-week fetus with ACC shows the absence of the corpus callosum *(?)* and of the CSP. (B) ACC at 31 weeks' gestation. At this advanced gestational age, an atypical radiating appearance of the median sulci, which converge toward the third ventricle *(3v)*, can also be seen.

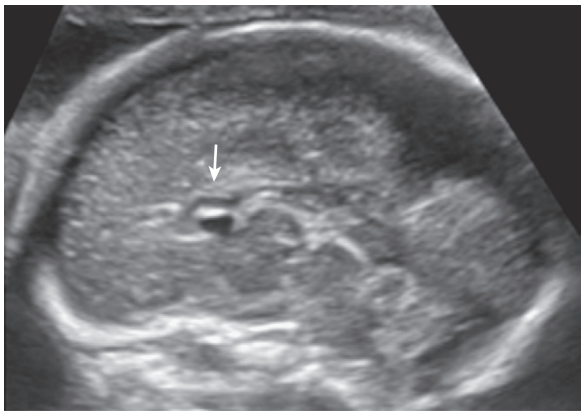

Fig. 34.7 Partial ACC. Midsagittal scan of the brain in a 24-week fetus with partially absent corpus callosum. Genu and a small anterior part of the body are present *(arrow)*, whereas the posterior part of the body and the splenium are absent.

way to make the diagnosis, visualizing a small corpus callosum that is lacking the posterior part (Fig. 34.7) and only partially surrounds the third ventricle. Less frequently, the remaining structure in pACC is the genu; it can appear thin and barely discernible with grayscale imaging and can be identified only when highlighted by the course of the pericallosal artery.

In ACC, color Doppler demonstrates that the normal semicircular arterial loop, formed by the pericallosal artery along the superior surface of corpus callosum, is missing or distorted (Fig. 34.8). This sign may help make the diagnosis of ACC, with even greater value in partial ACC; in partial ACC, the pericallosal artery closely follows and outlines the small anterior part of the corpus callosum, which is difficult to delineate with grayscale imaging alone.[4,6] In pACC this course is then lost and usually absent in the posterior part of corpus callosum.

Midline interhemispheric cysts associated with ACC are considered extensions of the ventricular system (see Fig. 34.8C). Intracranial lipoma is another median anomaly that may be associated with ACC. This anomaly is visible only in the third trimester as a hyperechoic structure under the inferior part of the interhemispheric fissure (Fig. 34.9).

Magnetic Resonance Imaging. Fetal MRI allows good visualization of the corpus callosum and other midline structures. MRI is usually performed acquiring T2-weighted sequences with ultrafast techniques (such as single-shot fast-spin echo), which provide images without motion artifacts and with good resolution.[16] The normal corpus callosum is displayed as a low-signal intensity stripe arching between the two hemispheres (Fig. 34.e1). The genu and body of the corpus callosum are visible above the CSP, whose splayed leaves are visible on coronal and axial slices. Regardless of the gestational age, the posterior callosal portion (body to splenium) is invariably better seen than the anterior portion (rostrum and genu) (Fig. 34.10) because of the larger degree of separation of the two hemispheres and extension of the interhemispheric fissure posteriorly. Therefore, any evaluation of the commissural plate must also include orthogonal (axial and coronal) slices. The length of the corpus callosum is easily measurable on midsagittal scans; normal ranges across gestation are available (Fig. 34.e2).[17] Standards of corpus callosum thickness by fetal MRI are still lacking.

The US diagnosis of ACC is associated with a false-positive rate of 0% to 20%, underlining the contribution of MRI.[18] Complete ACC is clearly demonstrable on MRI (Fig. 34.11) by the absence of the commissural plate and abnormal configuration of the lateral ventricles, which are oriented parallel to the interhemispheric fissure and dilated posteriorly (colpocephaly). The interhemispheric fissure is wide and may be occupied by an upward expansion of the third ventricle. On parasagittal views, the cyngulate gyrus is not visible. In the third trimester (i.e., with advanced sulcation), the mesial sulci are oriented radially in a spoke-wheel pattern (Fig. 34.e3). The longitudinal Probst bundles can be seen as they course along the medial walls of the lateral ventricles (Fig. 34.e4). Associated features may include complex interhemispheric cysts or interhemispheric lipomas. The use of T1-weighted images may increase the sensitivity for lipomas (Fig. 34.e5), although obtaining such sequences on fetal MRI may be technically challenging. pACC is also usually detected using MRI. Various degrees of hypogenesis are possible, and individual cases may differ significantly (Fig. 34.e6).

The main advantage of MRI is the recognition of additional cerebral anomalies, such as abnormal sulcation, migration anomalies, and heterotopias. For these pathologies MRI is more sensitive than US.[19] The presence of cortical abnormalities, such as polymicrogyria, are more easily recognizable from the late second trimester onward, when advanced development of the



Fig. 34.e1 Normal MRI in a 21-week fetus: (A) sagittal, (B) coronal, and (C) axial single-shot fast-spin-echo T2-weighted images. The corpus callosum *(arrows)*, leaves of the septum pellucidum *(arrowheads)*, and cavum septi pellucidi *(asterisk)* are displayed.

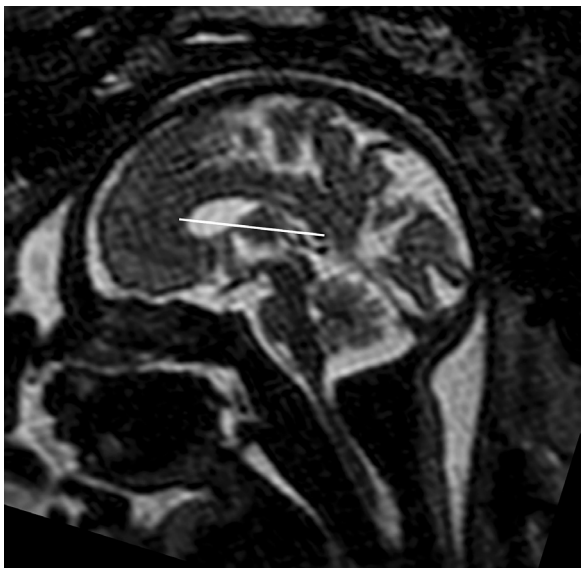

Fig. 34.e2 Normal MRI, sagittal single-shot fast-spin-echo T2-weighted images at 32 weeks' gestation shows method for assessment of longitudinal callosal length according to Harreld et al.[17]

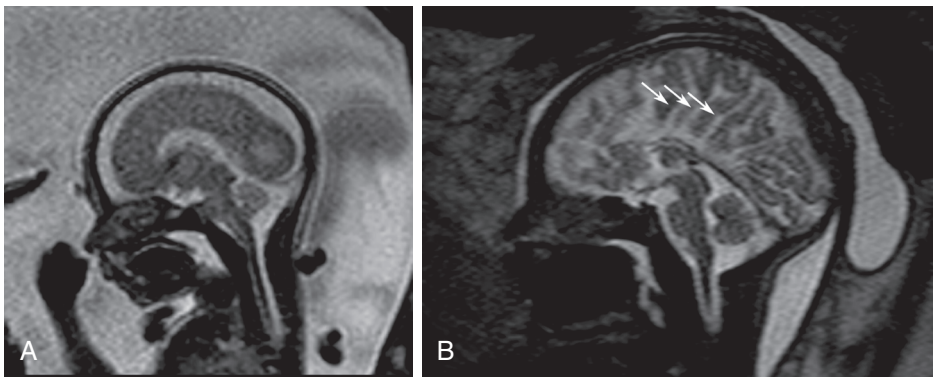

Fig. 34.e3 Appearance of mesial hemispheric sulci in complete agenesis of corpus callosum. (A) Sagittal single-shot fast-spin-echo T2-weighted image in a 20-week fetus shows flat mesial hemispheric surface, consistent with physiological absent sulcation at this gestational age. (B) Sagittal single-shot fast-spin-echo T2-weighted image in a 30-week fetus shows absent cingulate gyrus and sulcus and also reveals typical radial arrangement of mesial hemispheric sulci *(arrows).*

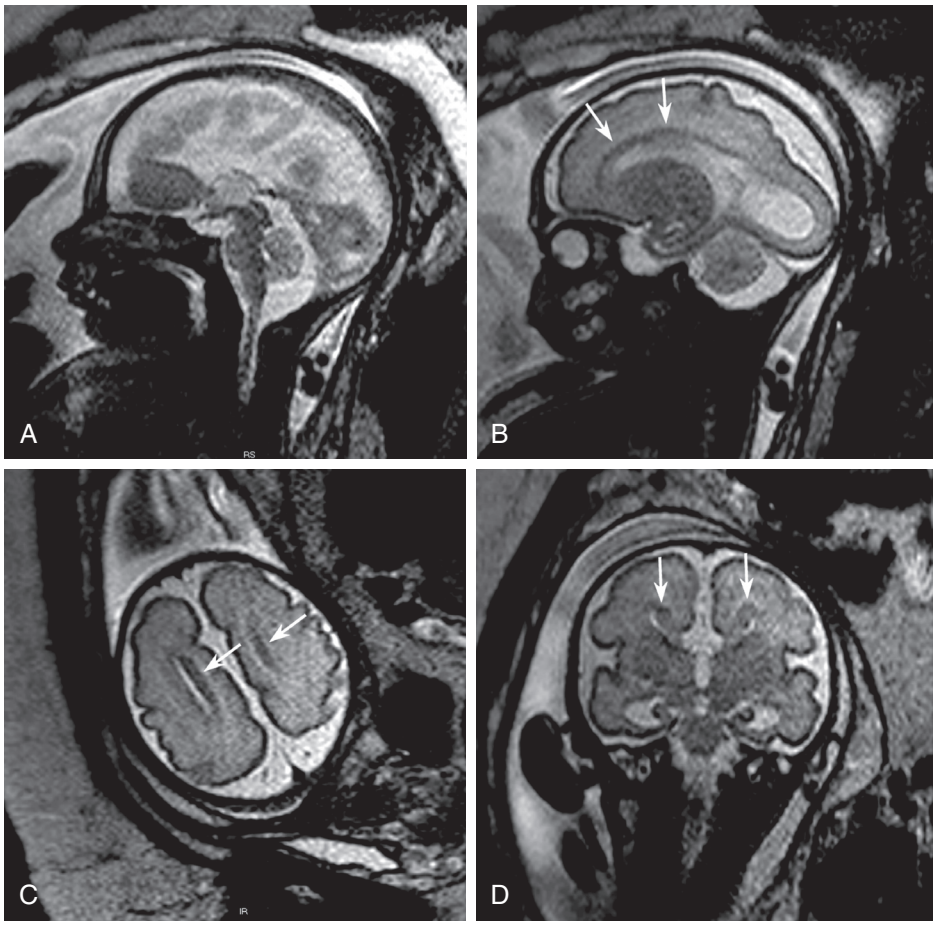

Fig. 34.e4 Longitudinal Probst bundles in a 28-week fetus with complete agenesis of the corpus callosum. (A) Midsagittal single-shot fast-spin-echo T2-weighted image shows complete callosal agenesis. (B) Parasagittal, (C) axial, and (D) coronal single-shot fast-spin-echo T2-weighted images show hypointense stripes bordering the medial aspect of the lateral ventricles *(arrows),* consistent with heterotopic course of axons that should have formed the corpus callosum.

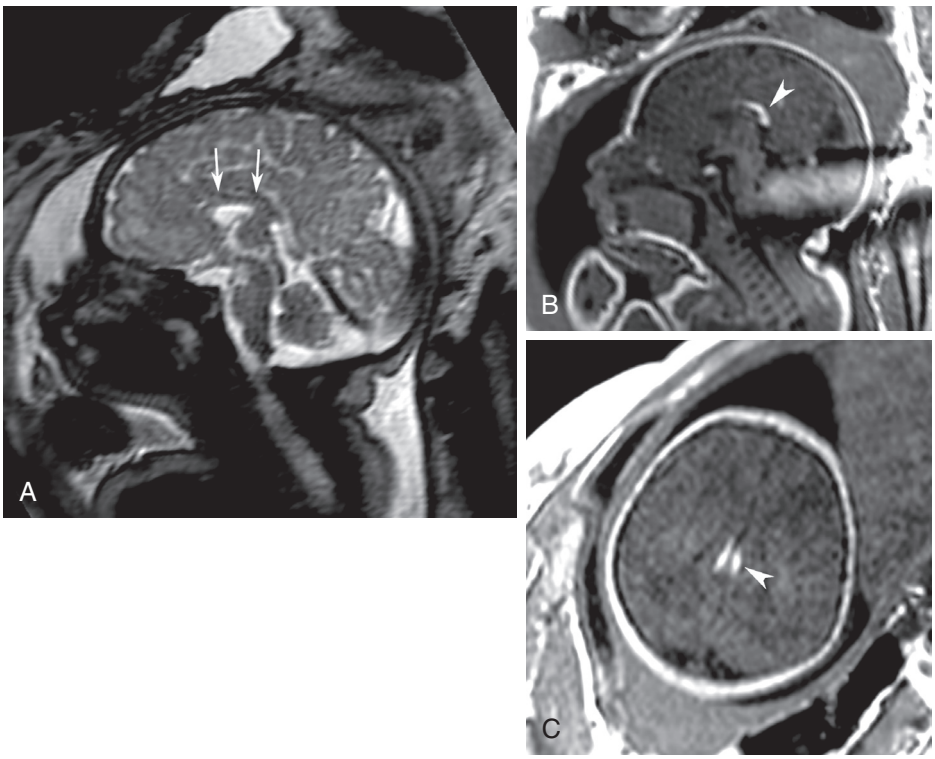

Fig. 34.e5 Callosal lipoma in a 34-week fetus. (A) Sagittal single-shot fast-spin-echo T2-weighted image shows hypoplastic corpus callosum *(arrows)*. (B) Sagittal and (C) axial turbo-spin-echo T1-weighted images show hyperintense midline structure *(arrowheads)* corresponding to a lipoma overlying the hypoplastic callosal splenium.

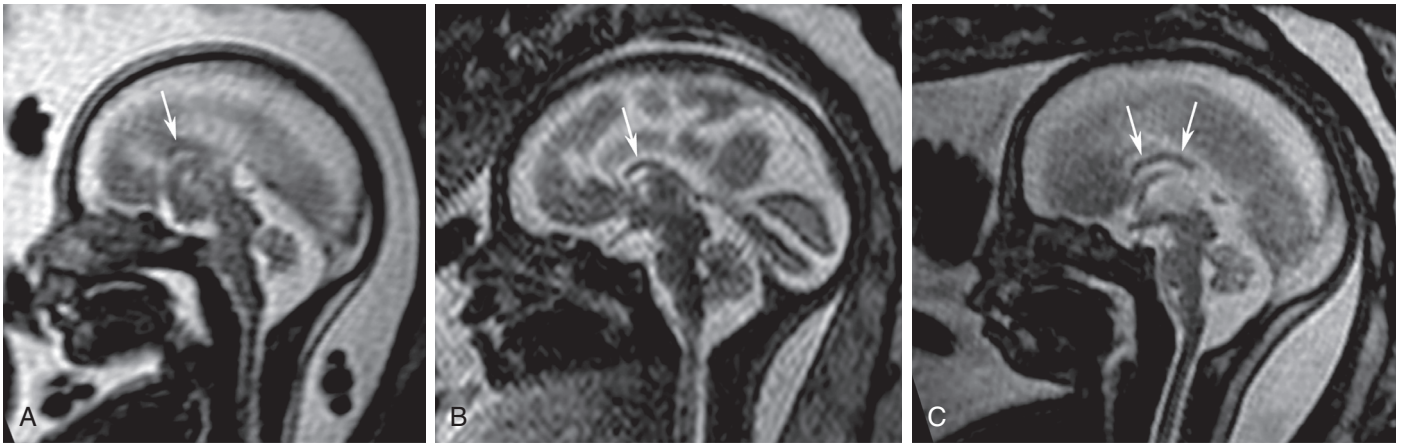

Fig. 34.e6 Various degrees of corpus callosum hypogenesis. (A–C) Sagittal single-shot fast-spin-echo T2-weighted images in three different fetuses (A, 21 weeks'; B, 26 weeks'; C, 22 weeks' gestation) show variable degrees of hypogenesis of the corpus callosum *(arrows)*.

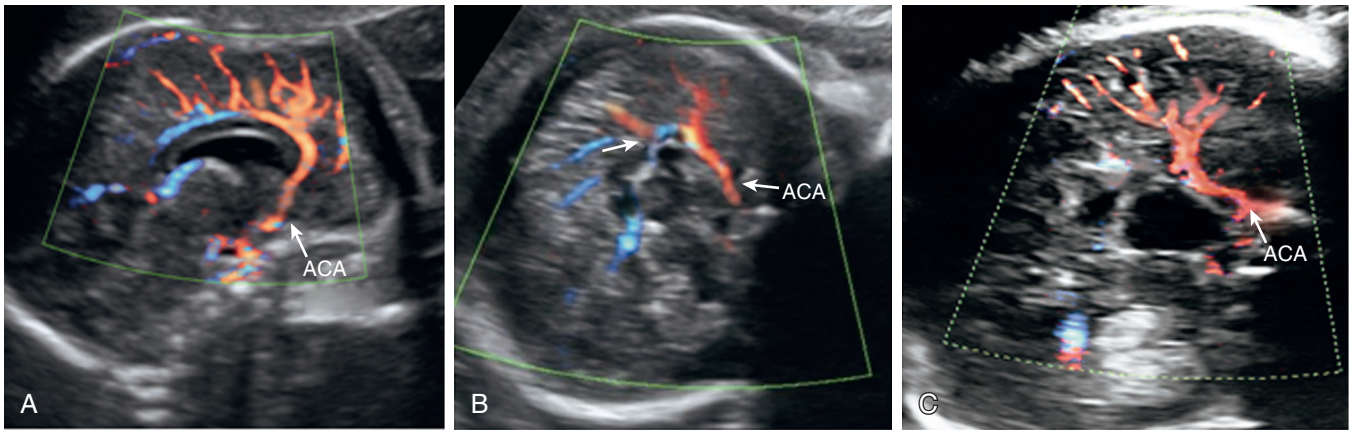

Fig. 34.8 (A) Midsagittal view of a 22-week normal fetal brain. Color Doppler shows anterior cerebral artery *(ACA)* branching giving rise to the pericallosal artery (PA). (B) Partially absent corpus callosum. Midsagittal view of a 22-week fetal brain. The small corpus callosum *(arrow)* is highlighted by the course of the PA. The PA closely follows the genu but loses its normal course where the corpus callosum disappears; it takes an upward posterior oblique direction. (C) Complete agenesis of the corpus callosum associated with a midline interhemispheric cyst. Midsagittal view of a 30-week fetal brain shows the absence of the PA; its classic loop is not seen. In addition, a midline interhemispheric cyst is clearly seen.

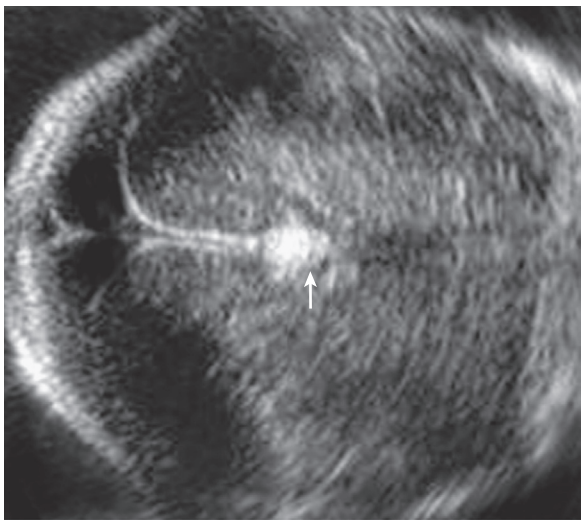

Fig. 34.9 ACC associated with lipoma. A hyperechogenic image under the interhemispheric fissure is clearly seen *(arrow)*.

sulci and gyri has occurred.[6] However, abnormally early or aberrant sulcation can already provide evidence of polymicrogyria on early second-trimester scans (Fig. 34.e7).[20]

The association with other cerebral anomalies may narrow the differential diagnoses and in some cases provide a specific syndromic diagnosis. For example, the association of ACC, polymicrogyria involving the two cerebral hemispheres asymmetrically, and choroid plexus cyst in a female fetus is pathognomonic for the Aicardi syndrome (Fig. 34.e8).[21]

Differential Diagnosis From Imaging Findings

Holoprosencephaly and septooptic dysplasia (SOD) are also characterized by the absence of CSP (see Fig. 34.12) and need to be distinguished from ACC. The presence of fused or communicating frontal horns (Fig. 34.12) and of the corpus callosum (sometimes thinned) helps differentiate between absence of the septum pellucidum and ACC. Fused frontal horns, an abnormal anterior cerebral artery (azygos anterior cerebral artery), and absence of a normally developed interhemispheric fissure anteriorly (Figs. 34.12 and 34.13) in holoprosencephaly distinguish it from isolated and complete ACC.

Synopsis of Treatment Options

PRENATAL

No prenatal treatment is available. When ACC is diagnosed in a fetus, karyotyping should be offered because of the high risk of chromosomal anomalies. In addition, the high rate of association with Mendelian disorders underlines the importance of a full family history and a careful search for additional structural anomalies.

POSTNATAL

Treatment is symptomatic and includes physiotherapy, psychotherapy, speech therapy, and antiepileptic drugs for seizures.

WHAT THE REFERRING PHYSICIAN NEEDS TO KNOW

- Diagnosis of ACC is usually impossible before 18 to 20 weeks' gestation because the formation of the corpus callosum is incomplete.
- ACC is often associated with other brain and systemic anomalies and may be part of a syndrome.
- Other central nervous system malformations (i.e., gyral anomalies) or extra–central nervous system anomalies can be present even when ACC is apparently isolated on ultrasound or MRI, especially if performed at 20 to 22 weeks' gestation.
- Genetic counseling is indicated.

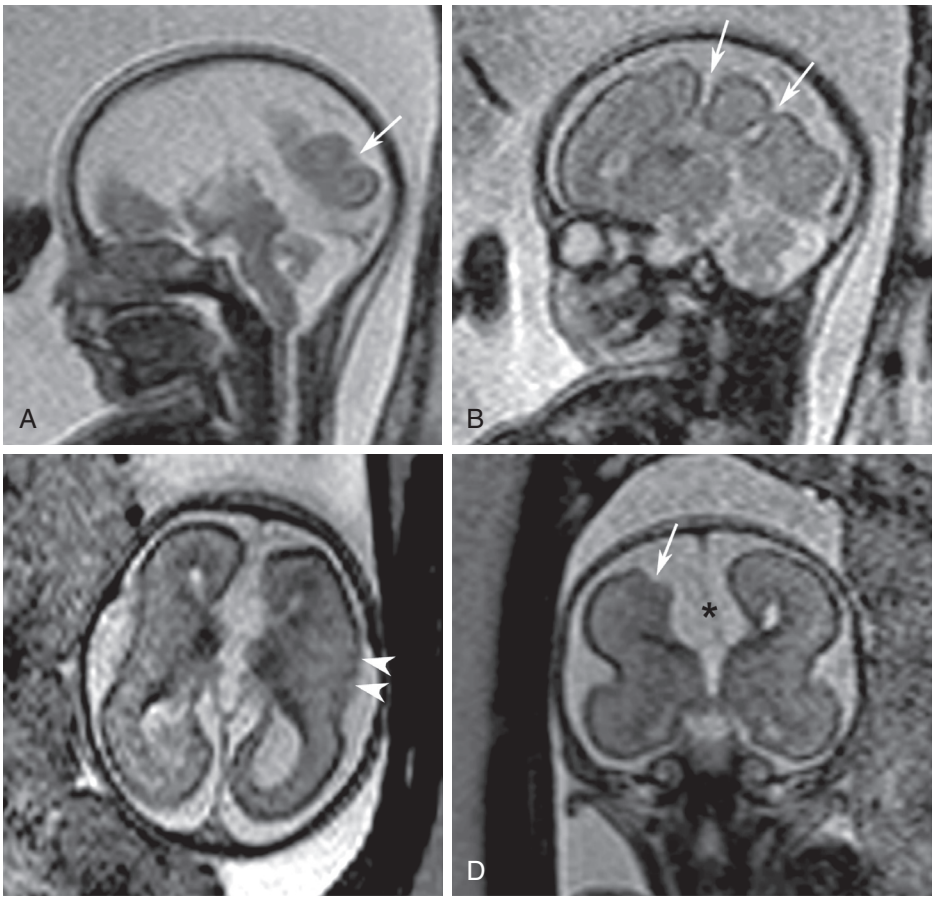

Fig. 34.e7 Abnormal sulcation in a 21-week fetus with acrocallosal syndrome. (A, B) Sagittal single-shot fast-spin-echo T2-weighted images show corpus callosum agenesis associated with aberrant sulcation, consistent with developing polymicrogyria *(arrows)*. (C) Axial single-shot fast-spin-echo T2-weighted image shows seesaw cortical pattern *(arrowheads)*, also an early feature of polymicrogyria. (D) Coronal single-shot fast-spin-echo T2-weighted image shows markedly enlarged interhemispheric fissure *(asterisk)* and, again, abnormal hemispheric sulcation *(arrow)*.

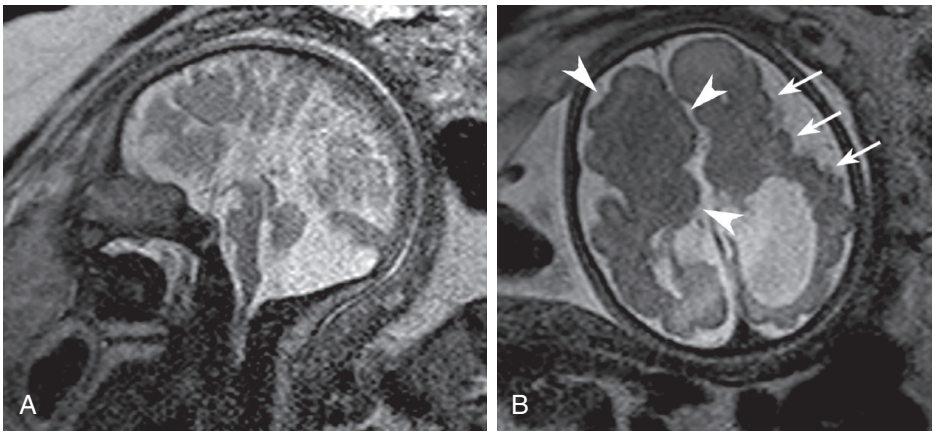

Fig. 34.e8 Aicardi syndrome in a 33-week female fetus. (A) Sagittal single-shot fast-spin-echo T2-weighted image shows typical features of complete callosal agenesis and incidental mega cisterna magna. (B) Axial single-shot fast-spin-echo T2-weighted image shows asymmetric cerebral hemispheres, with a megalic appearance of the right frontal lobe *(arrowheads)* and associated left-sided polymicrogyria *(arrows)*.

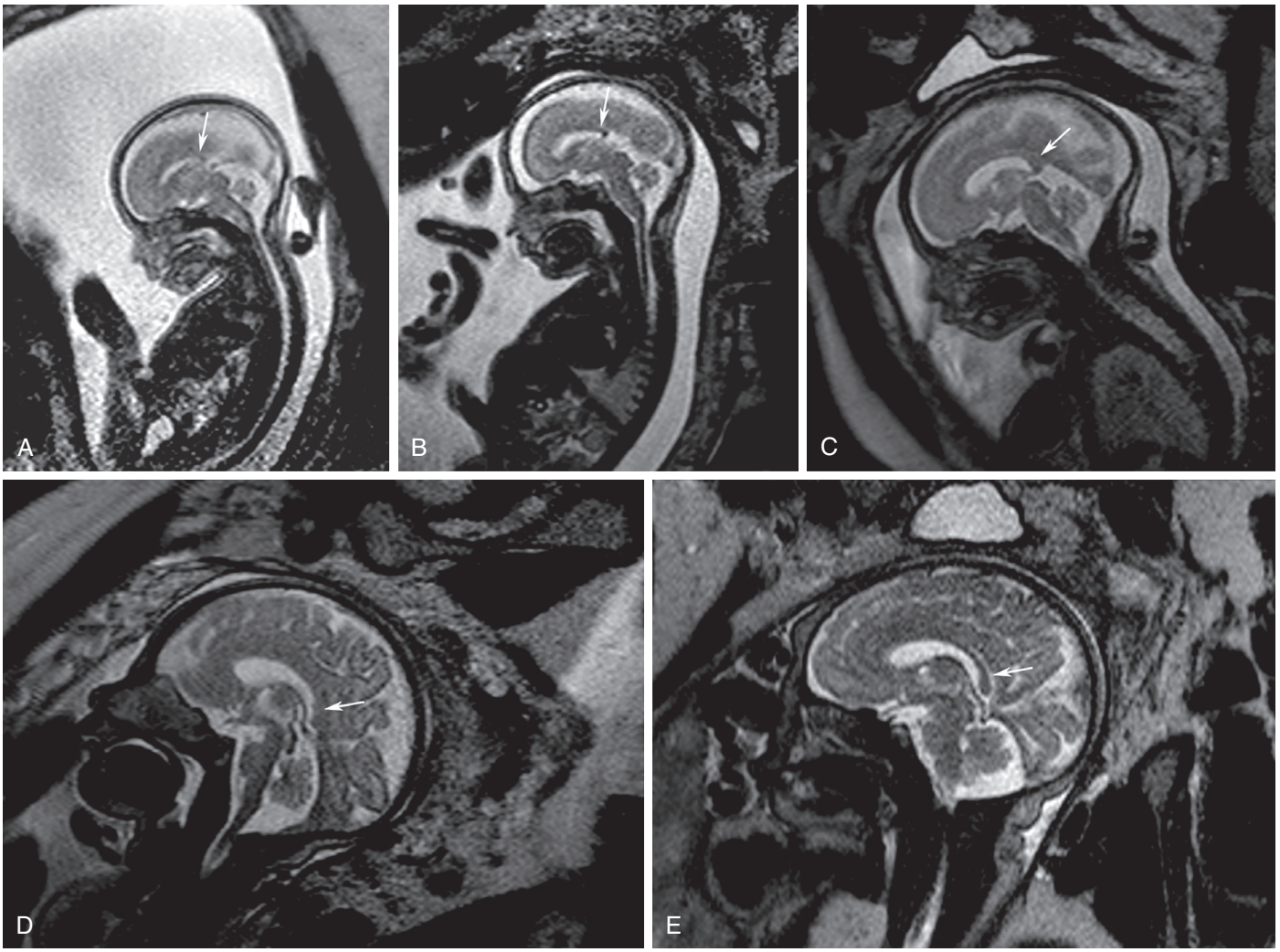

Fig. 34.10 Normal MRI, sagittal single-shot fast-spin-echo T2-weighted images at 21 (A), 24 (B), 28 (C), 32 (D), and 36 (E) weeks' gestation. Notice that the splenium of the corpus callosum *(arrows)* is always better seen than the anterior callosal portions.

KEY POINTS

- The main US indirect signs of complete ACC include colpocephaly, absent CSP, and increased separation of the hemispheres.
- A definitive diagnosis of ACC relies on recognition of direct signs, which consist of the demonstration of the absence of the corpus callosum on midsagittal and coronal views of the fetal brain.
- Partial ACC can be difficult to identify as a third of the cases lacks indirect signs. The outcome of pACC is similar to that of complete ACC
- Fetal MRI is more sensitive than US to diagnose possible additional cerebral anomalies, such as delayed sulcation, migration anomalies, and heterotopias.
- The overall prognosis of ACC is controversial. Several studies have reported a worse prognosis in the presence of additional anomalies. Truly isolated ACC appears to have a better prognosis (neurodevelopmental delay at three years in 25% of cases).
- Also in isolated ACC, despite the combined use of MRI and US, strong prognostic markers are missing, making prenatal genetic counseling difficult.

Absent Septum Pellucidum and Septooptic Dysplasia

DEFINITION

The septum pellucidum (SP) is a structure between the medial border of the frontal horns and the bodies of the lateral ventricles. It is intimately related to the corpus callosum, which provides its rostral and superior boundaries. The body of the fornix forms its posterior-inferior floor. The septum pellucidum does not contain organized gray matter, yet it is not simply a membrane. It is made of two sheaths of white matter apposed to each other along the midline and has been shown to carry fibers. In the fetus, the space between its two sheaths is the *cavum septi pellucidi (CSP)* (see Fig. 34.12), and its occasional posterior recess between the splenium and hippocampal commissure is the *cavum vergae*.

Agenesis of the septum pellucidum (ASP) is a rare brain anomaly that can be isolated or be part of cortical abnormalities, ACC, holoprosencephaly, or SOD (Table 34.1).[6,22–24] These anomalies can be subtle, leading to difficulties in prenatal diagnosis and management. In addition, secondary disruption of the septum pellucidum due to severe hydrocephalus has been reported.[23] When

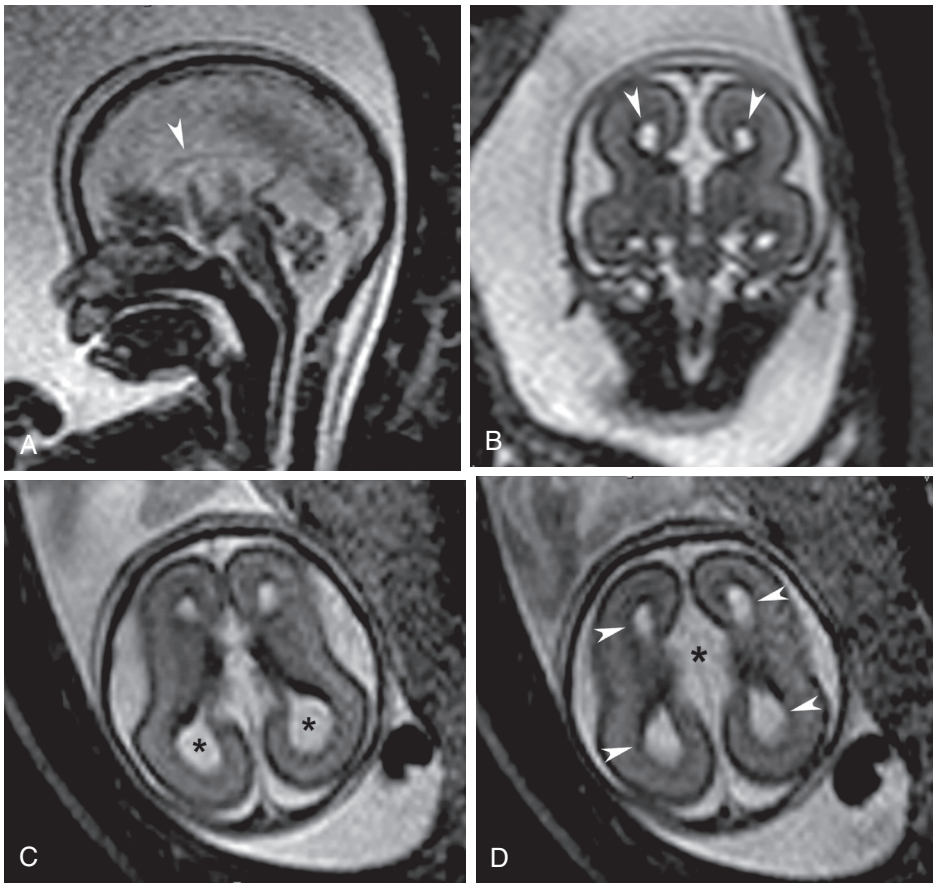

Fig. 34.11 Complete agenesis of the corpus callosum in a 20-week fetus. (A) Sagittal single-shot fast-spin-echo T2-weighted image shows complete absence of the corpus callosum: the tela choroidea of the third ventricle is faintly visible (*arrowhead*). (B) Coronal single-shot fast-spin-echo T2-weighted image shows abnormal orientation of the frontal horns (*arrowheads*), resulting in a "bull's head" appearance when viewed together with the third ventricle. (C, D) Axial single-shot fast-spin-echo T2-weighted images show dilated ventricular atria (*asterisks*, C) and parallel orientation of the ventricular bodies to the midline (*arrowheads*, D), producing the so-called colpocephaly. Also notice widened interhemispheric fissure (*asterisk*, D).

TABLE 34.1 FETAL BRAIN ANOMALIES ASSOCIATED WITH ABSENT CAVUM SEPTI PELLUCIDI

Septooptic dysplasia (SOD)
Holoprosencephaly
Complete agenesis of corpus callosum (ASP)
Bilateral polymicrogyria
Bilateral schizencephaly
Severe hydrocephaly

associated with optic nerve hypoplasia, ASP is a classic feature of SOD. SOD was first described by De Morsier[25] in an autopsy series of 36 patients; it is a highly heterogeneous condition that comprises a variable combination of optic nerve hypoplasia, absent septum pellucidum, and hypothalamic-pituitary dysfunction. SOD can be also associated with cortical abnormalities ("SOD-plus"), especially bilateral schizencephaly and polymicrogyria.

PREVALENCE AND EPIDEMIOLOGY

The septum pellucidum is partly or completely absent in 2 to 3:100,000 individuals.[23] However, this rate does not include asymptomatic cases. This anomaly can be isolated or associated with additional brain malformations.

ETIOLOGY AND PATHOPHYSIOLOGY

Most cases of SOD are sporadic, and several etiologies have been suggested. However, numerous familial cases have been described, and the identification of mutations in key developmental genes, including *HESX1, SOX2, SOX3*, and *OTX2* in patients with SOD and associated phenotypes suggests that a genetic cause exists also in sporadic cases. The precise etiology of SOD is likely multifactorial, involving contributions from environmental factors (drug and alcohol abuse, young maternal age) in addition to an important role for crucial developmental genes.[26]

MANIFESTATIONS OF DISEASE

Clinical Presentation

Severity varies; only 30% of patients manifest the complete clinical triad, with many patients having associated findings. Children with isolated ASP often have a favorable neurological outcome, but 18% of fetuses diagnosed with ASP are at risk for SOD.[27,28] The long-term neurological outlook is difficult to predict due to very short-term follow-up data available in literature. Some SOD patients present at birth with multiple congenital anomalies, whereas others show growth failure and/or visual anomalies (most frequently strabismus or nystagmus) during childhood. The

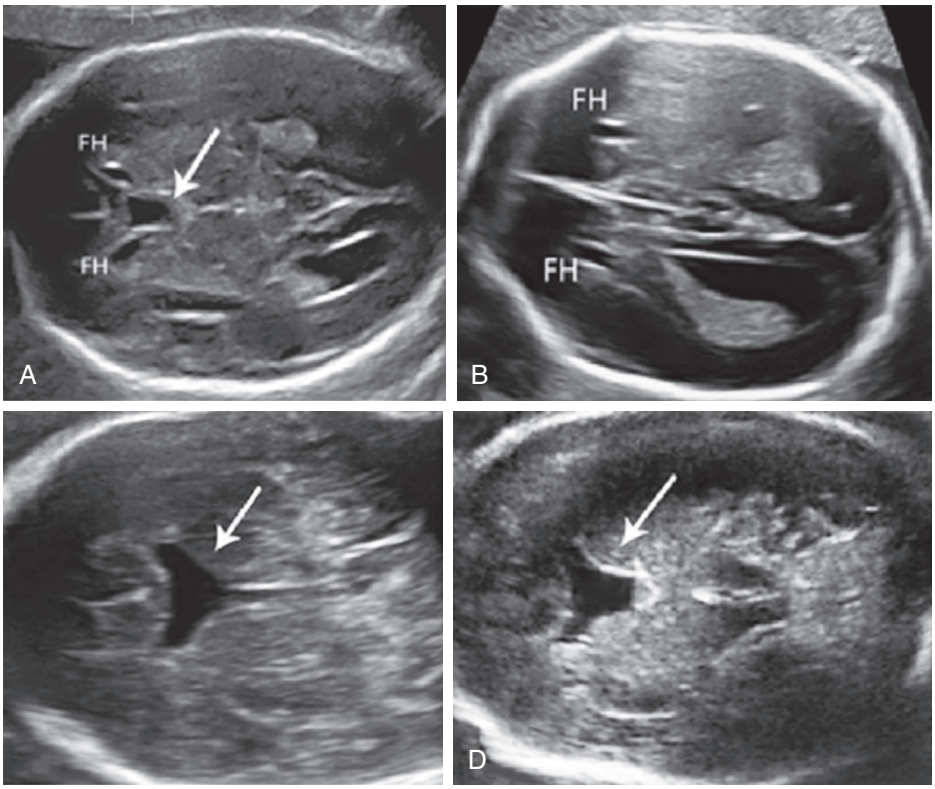

Fig. 34.12 (A) Axial scan of a 22-week normal fetal brain. Cavum septi pellucidi (CSP) is a square-shaped structure that entirely fills the space between the frontal horns *(FH)*. (B) Complete ACC. CSP is absent: no boxlike structure is seen between FH. (C) Absent Septum Pellucidum. *Arrow* indicates communicating FH (and absence of CSP). (D) Lobar holoprosencephaly. *Arrow* indicates fused FH (and absence of CSP). A normal interhemispheric fissure in between the anterior hemispheres cannot be seen.

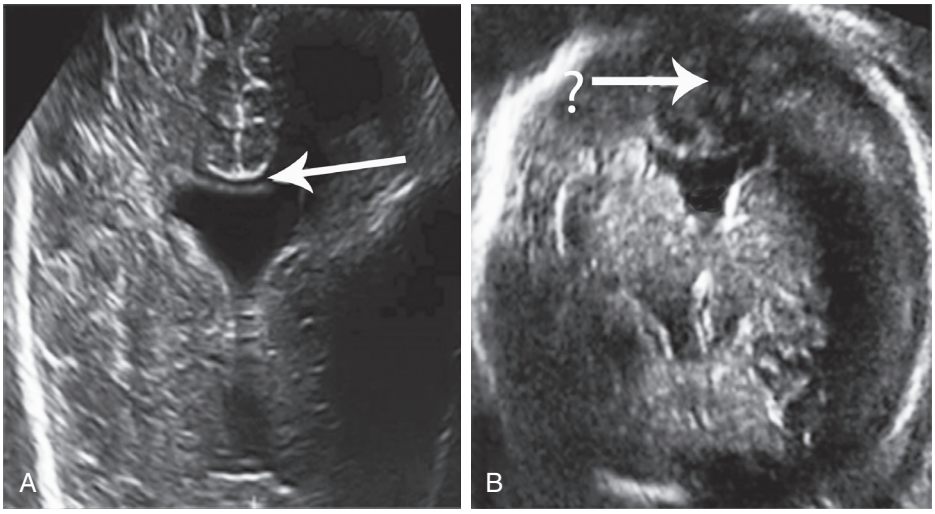

Fig. 34.13 (A) Absent septum pellucidum. Midcoronal plane of a 34-week fetal brain shows the absence of CSP with communicating frontal horns. The genu *(arrow)* is normally developed. (B) Lobar holoprosencephaly. Midcoronal plane of a 30-week fetal brain shows the absence of CSP and of a normally developed interhemispheric fissure in between the anterior hemispheres *(?)*. The genu is absent and the frontal horns are fused.

optic nerve hypoplasia can be unilateral or bilateral (57% and 32% of cases, respectively), and significant visual impairment occurs in 23% of patients. Hypopituitarism is present in 62% to 80% of patients, and although growth hormone deficiency (leading to short stature in childhood) is the most frequent endocrine anomaly, additional hormone insufficiencies may develop (thyroid-stimulating, adrenocorticotropic, and gonadotropin-releasing hormone deficiencies). Midline brain defects include agenesis of the septum pellucidum (60% of cases) and/or corpus callosum. Associated cortical malformations have also been reported ("SOD-plus"). Intellectual deficit, developmental delay, seizures, and cerebral palsy may be present. Additional findings can include diabetes insipidus, sleep disorders, autism, precocious puberty, obesity, thermoregulatory disturbances, anosmia, sensorineural hearing loss, and cardiac and digital anomalies.

The clinical presentation of SOD is variable. Visual disturbances may range from blindness to almost normal vision; hypothalamic-pituitary insufficiency, mainly characterized by growth deficit and diabetes insipidus, is seen in two-thirds of patients. Microphallus (in males) can also be present. In cases of SOD-plus, seizures or spastic motor deficit or both are also present. The prognosis of SOD is variable, depending on the severity of the disease.

Isolated ASP is more frequent than SOD and thought to be asymptomatic. However, prenatal detection of an isolated ASP does not guarantee normal neurologic clinical status due to the presence of brain anomalies not detectable by US and MRI.[29] Isolated ASP can be associated with behavioral and neuropsychological disorders.[27]

Imaging Technique and Findings

Ultrasound. ASP can be diagnosed by US in the second trimester of pregnancy. The US findings are the absence of the CSP and communicating frontal horns. On the coronal view, absence of the septum pellucidum results in a squared appearance of the frontal horns with inferior pointing (Figs. 34.13 and 34.14). The corpus callosum usually is present. The differential diagnosis between SOD and isolated ASP may be attempted by evaluation of (1) maternal urine and serum estriol levels; (2) fetal blood assays for growth hormone, adrenocorticotropic hormone, and prolactin; and (3) measurement of optic nerves and chiasma sizes in the third trimester, using MRI and three-dimensional US.[6,22,30]

Magnetic Resonance Imaging. Fetal MRI allows an optimal visualization of the septum pellucidum and CSP (see Fig. 34.e1). ASP on MRI exhibits a midline fusion of the frontal horns (Fig. 34.e9). Patients with septooptic dysplasia typically show fusion of the pillars of the fornix producing an intraventricular bundle sagittally in the midline, well visible on coronal sections. This finding is particularly useful to diagnose this condition in case of associated hydrocephalus (Fig. 34.15).

Evaluation of the size of the optic nerves and chiasm is difficult even on third-trimester MRI and often diagnosed only after birth. However, in the presence of hypoplastic optic chiasm (and cortical abnormalities), the diagnosis of SOD should be suspected and can be corroborated by maternal and fetal endocrinologic deficiencies.[6,22] MRI also is used to detect possible associated cortical abnormalities, such as polymicrogyria and schizencephaly. However, cortical malformation can be difficult to rule out on early second trimester scans, when sulcation is yet to develop.

Other Applicable Modality. The onset and extent of hormonal disorders in patients with SOD vary considerably. Endocrinologic deficiencies are found in 50% to 90% of cases during infancy.[31] For this reason, despite normal fetal pituitary function (and normal appearance of the optic tract on fetal MRI), SOD cannot be completely ruled out prenatally. However, the assessment of fetal pituitary function should be incorporated into the diagnostic work-up because pituitary dysfunction, when present, represents a typical sign of SOD.

CLASSIC SIGNS

Classic signs suggesting ASP include:
Absent CSP
Fused fornices in the midline
Anterior horns connected across the midline
Squared-off appearance of frontal horns

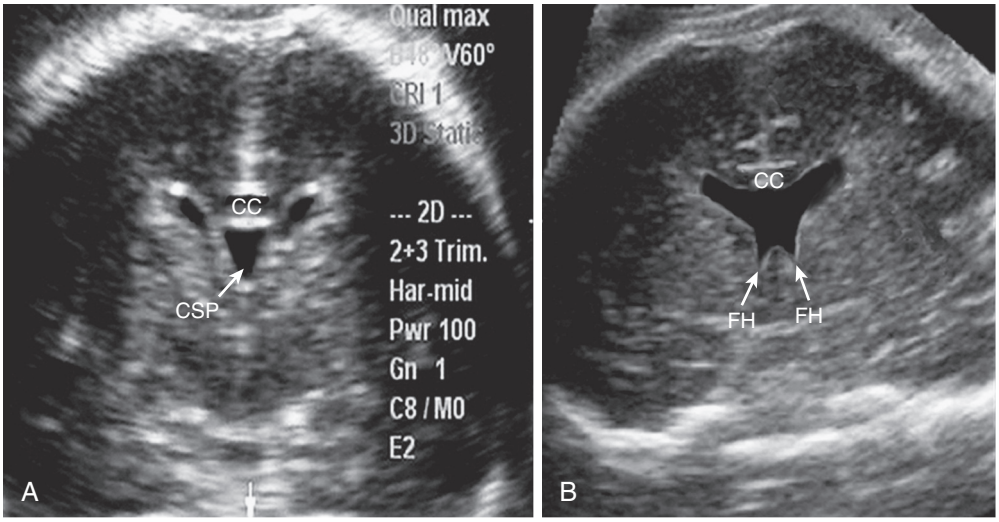

Fig. 34.14 (A) Midcoronal view of the brain in a 23-week normal fetus shows the normally developed frontal horns, genu *(CC)*, and cavum septi pellucidi *(CSP)*. (B) Absent septum pellucidum. Midcoronal plane of a 29-week fetal brain shows the absence of the CSP with communicating frontal horns *(FH)*. The typical aspect of the downward point of the frontal horns is clearly seen *(arrows)*. The genu is normally developed *(CC)*.

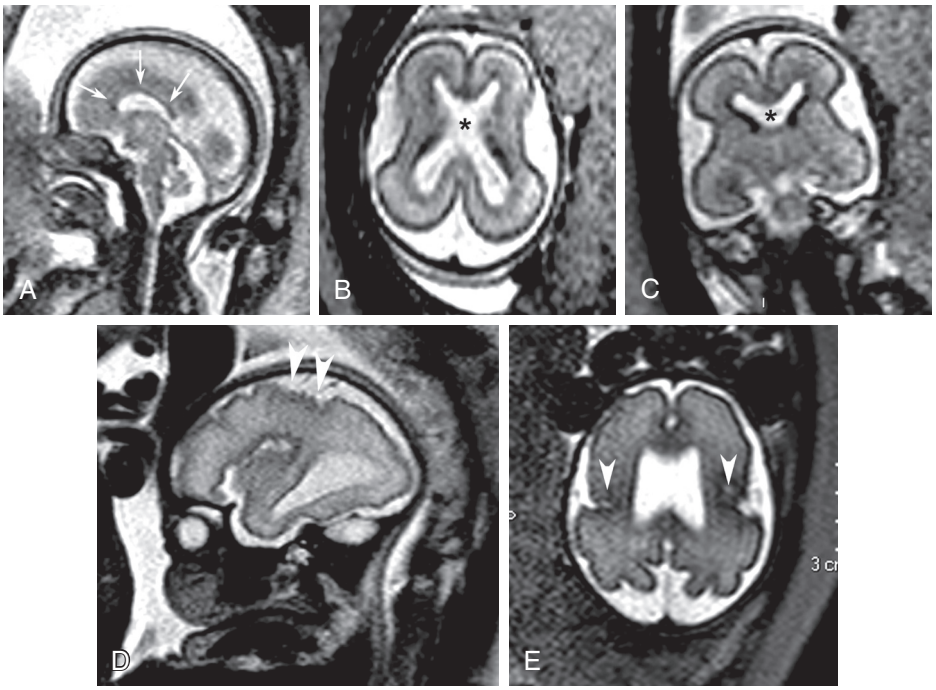

Fig. 34.e9 Agenesis of the septum pellucidum. (A) Sagittal single-shot fast-spin-echo T2-weighted images obtained at 20 weeks' gestation shows normal corpus callosum (*arrows*, A), while (B) axial and (C) coronal single-shot fast-spin-echo T2-weighted images show absent septum pellucidum resulting in a midline fusion of the frontal horns (*asterisk*, B, C). Note that the cortical mantle is flat, consistent with the physiological immaturity of sulcation at that age. (D) Parasagittal single-shot fast-spin-echo T2-weighted image and (E) axial single-shot fast-spin-echo T2-weighted image obtained at 30 weeks' gestation in the same fetus show abnormal sulcation *(arrowheads),* consistent with bilateral perisylvian polymicrogyria.

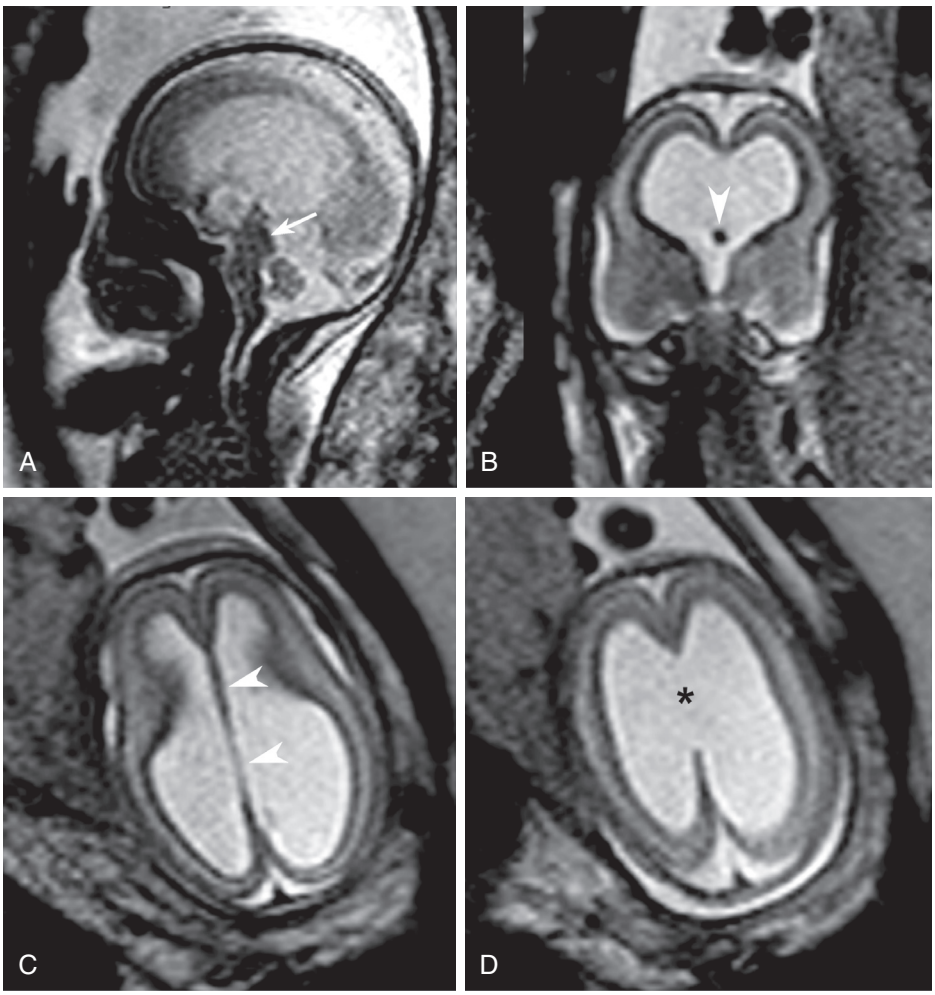

Fig. 34.15 Septooptic dysplasia in a 21-week fetus. (A) Sagittal single-shot fast-spin-echo T2-weighted image shows marked ventricular dilatation and aqueductal stenosis *(arrow)*. (B) Coronal single-shot fast-spin-echo T2-weighted image shows fused pillars of the fornix *(arrowhead)* coursing on the midline. Notice ventricular dilatation with squared frontal horns. (C) Axial single-shot fast-spin-echo T2-weighted image at level of the fused fornices *(arrowheads)* provides a false impression of presence of the septum pellucidum; however, (D) axial single-shot fast-spin-echo T2-weighted image obtained at a slightly more cranial level shows the two lateral ventricles are widely communicating on the midline *(asterisk)*.

Differential Diagnosis From Imaging Findings

On US coronal view, the absence of the septum pellucidum results in a squared-off appearance of the lateral ventricles that resembles holoprosencephaly (Figs. 34.13 and 34.16). However, if the interhemispheric fissure is normally developed and the anterior corpus callosum and anterior cerebral arteries are normal in shape and position, this is suggestive of ASP without holoprosencephaly (see Fig. 34.13). In addition, MRI can be useful in clearly showing ventral fusion of the frontal lobes in holoprosencephaly and a caudally displaced fornix in SOD and isolated ASP.

Synopsis of Treatment Options

PRENATAL

No prenatal treatment is available.

POSTNATAL

Postnatal treatment is symptomatic, and a multidisciplinary team with regular follow-up should manage patients with SOD. Hormone insufficiencies can be treated with hormone replacement therapy, but close monitoring is required as the hormone deficiencies evolve with age. Children may benefit from developmental programs for visually impaired individuals and from physical and occupational therapies.

WHAT THE REFERRING PHYSICIAN NEEDS TO KNOW

- US and MRI can diagnose absence of the septum pellucidum in the second trimester of pregnancy.
- Some associated brain abnormalities are not detectable before the third trimester.
- In most cases, it is impossible to determine the presence of SOD before birth.

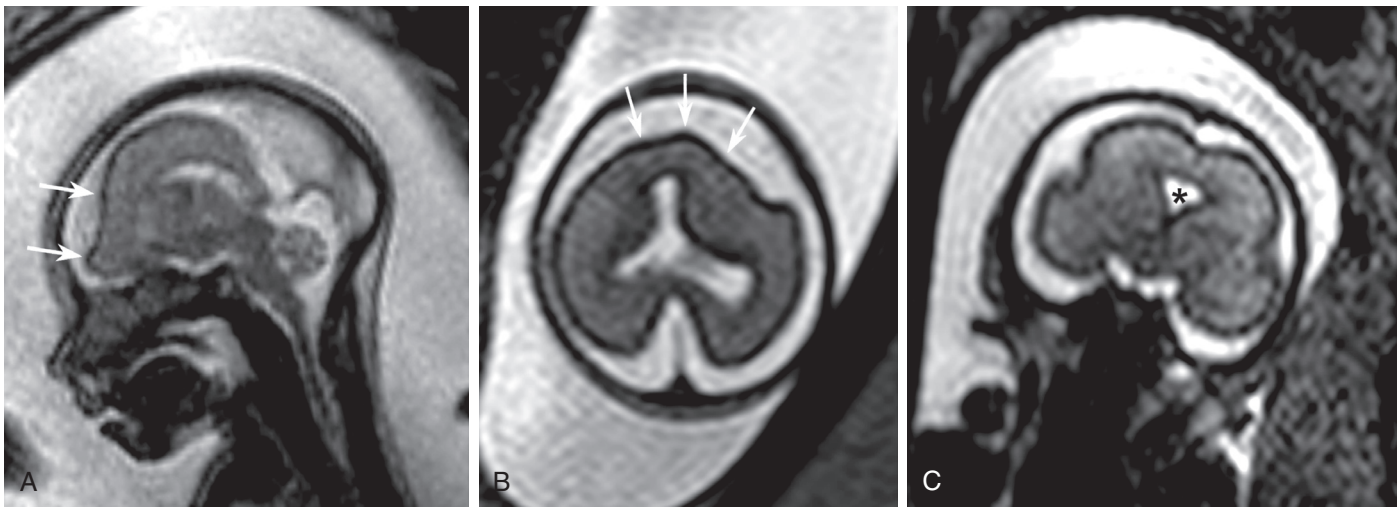

Fig. 34.16 Semilobar holoprosencephaly in a 23-week fetus. (A) Sagittal single-shot fast-spin-echo T2-weighted image shows abnormal nervous structure bridging the midline anteriorly *(arrows)*. (B) Axial single-shot fast-spin-echo T2-weighted image confirms lack of cleavage of the frontal lobes *(arrows)*. The septum pellucidum is absent. (C) Coronal single-shot fast-spin-echo T2-weighted image shows midline fusion of the lateral ventricles *(asterisk)*, reminiscent of septooptic dysplasia.

KEY POINTS

- US can diagnose absence of the septum pellucidum in the second trimester of pregnancy.
- MRI can visualize the size of the optic nerves and chiasma (in late pregnancy) to search for optic nerve or chiasma hypoplasia (SOD) and to show possible associated cortical abnormalities (SOD-plus).
- Assessment of fetal pituitary function should be incorporated into the diagnostic work-up because pituitary dysfunction, when present, represents a typical sign of SOD.
- The clinical presentation of SOD is variable; only 30% of patients present with the complete clinical triad with many patients having associated findings.

SUGGESTED READING

Malinger G, Lev D, Kidron D, et al. Differential diagnosis in fetuses with absent septum pellucidum. *Ultrasound Obstet Gynecol*. 2005;25:42-49.

Pilu G, Segata M, Ghi T, et al. Diagnosis of midline anomalies of the fetal brain with the three dimensional median view. *Ultrasound Obstet Gynecol*. 2006;27:522-529.

Volpe P, Campobasso G, De Robertis V, et al. Disorders of prosencephalic development. *Prenat Diagn*. 2009;29:340-354.

All references are available online at www.expertconsult.com.

REFERENCES

1. Barkovich AJ. Magnetic resonance imaging: role in the understanding of cerebral malformations. *Brain Dev*. 2002;224:2-12.
2. Raybaud C. The corpus callosum, the other great forebrain commissures, and the septum pellucidum: anatomy, development, and malformation. *Neuroradiology*. 2010;52:447-477.
3. Jeret JS, Serur D, Wisniewski K. Frequency of agenesis of the corpus callosum in the developmentally disabled population as determined by computerized tomography. *Pediatr Neurosci*. 1985-1986;12:101-103.
4. Volpe P, Paladini D, Resta M, et al. Characteristics, associations and outcome of partial agenesis of the corpus callosum in the fetus. *Ultrasound Obstet Gynecol*. 2006;27:509-516.
5. Paul LK, Brown WS, Adolphs R, et al. Agenesis of the corpus callosum: genetic, developmental and functional aspects of connectivity. *Nat Rev Neurosci*. 2007;8:287-299.
6. Volpe P, Campobasso G, De Robertis V, et al. Disorders of prosencephalic development. *Prenat Diagn*. 2009;29:340-354.
7. Moutard ML, Kieffer V, Feingold J, et al. Agenesis of corpus callosum: prenatal diagnosis and prognosis. *Childs Nerv Syst*. 2003;19:471-476.
8. Moutard ML, Kieffer V, Feingold J, et al. Isolated corpus callosum agenesis: a ten-year follow-up after prenatal diagnosis (how are the children without corpus callosum at 10 years of age? *Prenat Diagn*. 2012;32:277-283.
9. Sotiriadis A, Makrydimas G. Neurodevelopment after prenatal diagnosis of isolated agenesis of the corpus callosum: an integrative review. *Am J Obstet Gynecol*. 2012;206:337.e1-337.e5.
10. Pilu G, Sandri F, Perolo A, et al. Sonography of fetal agenesis of the corpus callosum: a survey of 35 cases. *Ultrasound Obstet Gynecol*. 1993;3:318-329.
11. Malinger G, Zakut H. The corpus callosum: normal fetal development as shown by transvaginal sonography. *AJR Am J Roentgenol*. 1993;161:1041-1043.
12. Timor-Tritsch IE, Monteagudo A. Transvaginal fetal neurosonography: standardization of the planes and sections by anatomic landmarks. *Ultrasound Obstet Gynecol*. 1996;8:42-47.
13. Pilu G, Segata M, Ghi T, et al. Diagnosis of midline anomalies of the fetal brain with the three dimensional median view. *Ultrasound Obstet Gynecol*. 2006;27:522-529.
14. Paladini D, Pastore G, Cavallaro A, et al. Agenesis of the fetal corpus callosum: sonographic signs change with advancing gestational age. *Ultrasound Obstet Gynecol*. 2013;42:687-690.
15. Shen O, Gelot AB, Moutard ML, et al. Abnormal shape of the cavum septi pellucidi: an indirect sign of partial agenesis of the corpus callosum. *Ultrasound Obstet Gynecol*. 2015;46:595-599.
16. Perrone A, Savelli S, Maggi C, et al. Magnetic resonance imaging versus ultrasonography in fetal pathology. *Radiol Med*. 2008;113:225-241.
17. Harreld JH, Bhore R, Chason DP, et al. Corpus callosum length by gestational age as evaluated by fetal MR imaging. *AJNR Am J Neuroradiol*. 2011;32:490-494.
18. Santo S, D'Antonio F, Homfray T, et al. Counseling in fetal medicine: agenesis of the corpus callosum. *Ultrasound Obstet Gynecol*. 2012;40:513-521.
19. Triulzi F, Manganaro L, Volpe P. Fetal magnetic resonance imaging: indications, study protocols and safety. *Radiol Med*. 2011;116:337-350.
20. Righini A, Parazzini C, Doneda C, et al. Early formative stage of human focal cortical gyration anomalies: fetal MRI. *AJR Am J Roentgenol*. 2012;198:439-447.
21. Hergan B, Atar OD, Poretti A, et al. Serial fetal MRI for the diagnosis of Aicardi syndrome. *Neuroradiol J*. 2013;26:380-384.
22. Lepinard C, Coutant R, Boussion F, et al. Prenatal diagnosis of absence of the septum pellucidum associated with septo-optic dysplasia. *Ultrasound Obstet Gynecol*. 2005;25:73-75.
23. Barkovich AJ, Norman D. Absence of the septum pellucidum: a useful sign in the diagnosis of congenital brain malformations. *AJR Am J Roentgenol*. 1989;152:353-360.
24. Malinger G, Lev D, Kidron D, et al. Differential diagnosis in fetuses with absent septum pellucidum. *Ultrasound Obstet Gynecol*. 2005;25:42-49.
25. De Morsier G. Etudes sur les dystrophies cranio-encephaliques III. Agenesie du septum pellucidum avec malformation du tractus optique: la dysplasie septo-optique. *Schweiz Arch Neurol Psychiatr*. 1956;77:267-292.
26. Kelberman D, Dattani MT. Septo-optic dysplasia: novel insights into the aetiology. *Horm Res*. 2008;69:257-265.
27. Damaj L, Bruneau B, Ferry M, et al. Pediatric outcome of children with the prenatal diagnosis of isolated septal agenesis. *Prenat Diagn*. 2010;30:1143-1150.
28. Garcia-Arreza A, Garcia-Diaz L, Fajardo M, et al. Isolated absence of septum pellucidum: prenatal diagnosis and outcome. *Fetal Diagn Ther*. 2013;33:130-132.
29. Belhocine O, Andre C, Kalifa G, et al. Does asymptomatic septal agenesis exist? A review of 34 cases. *Pediatr Radiol*. 2005;35:410-418.
30. Bault JP, Salomon LJ, Guibaud L, et al. Role of three-dimensional ultrasound measurement of the optic tract in fetuses with agenesis of the septum pellucidum. *Ultrasound Obstet Gynecol*. 2011;37:570-575.
31. Willnow S, Kiess W, Butenandt O, et al. Endocrine disorders in septo-optic dysplasia (De Morsier syndrome)—evaluation and follow up of 18 patients. *Eur J Pediatr*. 1996;155:179-184.

35 Septooptic Dysplasia

METHODIUS G. TUULI | ANTHONY O. ODIBO

Introduction

Septooptic dysplasia (SOD), also known as *de Morsier syndrome,* is a rare heterogeneous disorder. It is characterized by optic nerve hypoplasia and midline forebrain abnormalities, such as agenesis of the corpus callosum, absence of the cavum septi pellucidi, and pituitary hypoplasia with consequent panhypopituitarism.[1] It has been proposed that the terms *SOD* and *de Morsier syndrome* should be abandoned, as they are not independent entities.[2]

Disease

DEFINITION

Diagnosis of SOD requires the presence of any two of the classic features: (1) optic nerve hypoplasia, (2) midline forebrain abnormalities, or (3) pituitary hypoplasia.[1]

PREVALENCE AND EPIDEMIOLOGY

The reported incidence is 1 : 10,000 live births,[3] equally prevalent in males and females. Some studies suggest SOD is more common

in younger mothers and primigravidas.[3] It has also been shown to occur more frequently in areas with high population density, inner-city areas with high rates of unemployment, and areas with high rates of teenage pregnancy.

ETIOLOGY AND PATHOPHYSIOLOGY

The etiology of SOD is uncertain. It may be the result of mutations in the homeobox gene *HESX1,* or a possible autosomal recessive inheritance.[4] Sporadic cases are thought to be the result of vascular disruption, exposure to teratogens such as valproic acid and ethanol, viral infections such as cytomegalovirus, or maternal drug abuse with cocaine and amphetamines.[5,6]

MANIFESTATIONS OF DISEASE

Clinical Presentation

Clinical manifestation of SOD is variable and depends on the extent of the anatomic defects and the degree of pituitary involvement. Most affected individuals exhibit neurodevelopmental disability, visual deficits, and seizures. Associated eye abnormalities include nystagmus, microphthalmia, and colobomas of the iris, choroids, and retina. Associated cranial anomalies include ventriculomegaly, agenesis of the corpus callosum, and schizencephaly. Craniofacial anomalies include bilateral cleft lip/palate, high arched palate, and flat nasal bridge. Mental retardation is common.

Signs of anterior and posterior pituitary deficiency are present in approximately 45% to 60% of affected individuals.[4,6] Low levels of growth hormone and antidiuretic hormone may result in pituitary dwarfism and diabetes insipidus. Pubertal delay or precocious puberty may also occur. Another endocrine manifestation is secondary hypothyroidism, a condition characterized by low levels of thyroid hormones, with concomitant low levels of thyroid-stimulating hormone.

Imaging Technique and Findings

Ultrasound. The classic ultrasound (US) finding is absence of the cavum septi pellucidi, with communication between the two frontal horns across the midline. This gives a typical "squared roof" appearance (Fig. 35.1). The corpus callosum may be present, thinned, or absent. Mild ventriculomegaly is commonly seen.

Based on prenatal diagnostic imaging, SOD was originally divided into two distinct anatomic subgroups[6]: (1) presence of schizencephaly, normal-sized ventricles, a remnant of the cavum septi pellucidi, and normal-appearing optic radiations, and (2) absence of schizencephaly but absent cavum septi pellucidi and white matter hypoplasia, resulting in ventriculomegaly. Advances in technology and knowledge of the disorder suggest that SOD is a constellation of lesions of varying severity, and not two distinct subtypes.

Magnetic Resonance Imaging. Fetal magnetic resonance imaging (MRI) may be performed to confirm the absence of the cavum septi pellucidi and the other associated brain malformations. However, MRI lacks sufficient resolution to detect abnormalities of the optic chiasm and tracts.



Fig. 35.1 Intracranial anatomy at 35 weeks' gestation. There is absence of the cavum septi pellucidi, and the frontal horns are fused in the midline, giving the typical "squared roof" appearance.

Differential Diagnosis From Imaging Findings

1. Holoprosencephaly (lobar and alobar)
2. Schizencephaly
3. Agenesis of the corpus callosum

Synopsis of Treatment Options

PRENATAL

No special obstetric management is required for patients carrying a fetus with suspected SOD. Genetic amniocentesis may be helpful to rule out aneuploidy and to facilitate parental counseling. Termination of pregnancy is an option when the diagnosis is certain and made early. Prenatal care should not be altered when continuation of the pregnancy is chosen. Neonatology or pediatric neurology consultation is beneficial to prepare parents regarding follow-up in the neonatal period and long-term prognosis.

POSTNATAL

Postnatally, infants should undergo imaging (computed tomography [CT] or MRI), endocrine evaluation, and visual assessment to confirm the diagnosis. Prognosis depends on the severity of the associated abnormalities and the degree of pituitary insufficiency. Prevention of hypoglycemic episodes, seizures, and hormonal imbalances is crucial for long-term survival and overall prognosis. Parents should be counseled that the recurrence risk in future pregnancies is generally low. However, a few cases have displayed autosomal dominant and autosomal recessive transmission patterns.

WHAT THE REFERRING PHYSICIAN NEEDS TO KNOW

SOD is a rare heterogeneous disorder characterized by (1) optic nerve hypoplasia, (2) midline forebrain abnormalities, and (3) pituitary hypoplasia. It may be the result of a specific *de novo* gene mutation or a possible autosomal recessive inheritance. The classic US finding is absence of the cavum septi pellucidi.

KEY POINTS

- Diagnosis of SOD requires documentation of any two of three features:
  - Optic nerve hypoplasia
  - Midline forebrain abnormalities
  - Pituitary hypoplasia
- Diagnostic clues on US include absence of the cavum septi pellucidi, agenesis of the corpus callosum, and ventriculomegaly.

- Clinical manifestations are variable and depend on the extent of the anatomic defects and the degree of pituitary involvement.
- No special obstetric management is required for patients carrying a fetus with suspected SOD.

SUGGESTED READING

Kelberman D, Dattani MT. Genetics of septo-optic dysplasia. *Pituitary*. 2007;10:393-407.

Polizzi A, Pavone P, Iannetti P, et al. Septo-optic dysplasia complex: a heterogeneous malformation syndrome. *Pediatr Neurol*. 2006;34:66-71.

Webb EA, Dattani MT. Septo-optic dysplasia. *Eur J Hum Genet*. 2010;18(4):393-397.



All references are available online at www.expertconsult.com.

REFERENCES

1. Roessmann U. Septo-optic dysplasia (SOD) or De Morsier syndrome. *J Clin Neuroophthalmol*. 1989;9:156-159.
2. Garcia-Filion P, Borchert M. Prenatal determinants of optic nerve hypoplasia: review of suggested correlates and future focus. *Surv Ophthalmol*. 2013;58:610-619.
3. Patel L, McNally RJ, Harrison E, et al. Geographical distribution of optic nerve hypoplasia and septo-optic dysplasia in Northwest England. *J Pediatr*. 2006;148:85-88.
4. Kelberman D, Dattani MT. Genetics of septo-optic dysplasia. *Pituitary*. 2007;10:393-407.
5. Orrico A, Galli L, Zappella M, et al. Septo-optic dysplasia with digital anomalies associated with maternal multidrug abuse during pregnancy. *Eur J Neurol*. 2002;9:679-682.
6. Polizzi A, Pavone P, Iannetti P, et al. Septo-optic dysplasia complex: a heterogeneous malformation syndrome. *Pediatr Neurol*. 2006;34:66-71.

36 Cortical Development and Disorders

ANTS TOI | GUSTAVO MALINGER

Introduction

Cortical neuronal cell development starts at about 7 weeks' gestation from stem cells in the germinal matrix that line the ventricles. The stem cells proliferate and differentiate into glial cells and neurons. The glial cells migrate radially to the brain surface and create a scaffold for the neurons to follow to the outer cortex, where the neurons organize connections and commissures. Other neurons derived from the ganglionic eminence migrate tangentially to form inhibitory neurons and basal ganglia. Rapid development occurs at about 15 to 20 weeks' gestation. By about 30 weeks' gestation, neuron development is completed, resulting in the six cortical layers. Neurons are formed in larger numbers than needed, and more than half undergo apoptosis.[1]

At the same time as the cortex is being formed, other brain structures develop, including the commissures (e.g., corpus callosum), cerebellum, and eyes. Interruption in normal neurodevelopment from any cause can result in abnormalities of any of these structures, and the final clinical manifestations often reflect the timing rather than the nature of the insult.[2]

Migration and development are controlled by complicated gene-protein interactions.[3] Genes controlling neural development often also control the development of other body organs such as muscles and bones. Mutations or disturbances to genes involved in neurogenesis can result in abnormal somatic development. For example, mutation in the *FGRF3* gene associated with thanatophoric dysplasia results in both skeletal abnormality and cerebral pachygyria.[4,5]

Disease

DEFINITION

Disturbances of cortical development are collectively called *malformations of cortical development*. They are very diverse, and there is no single or complete classification. A commonly used classification by Barkovich et al.[2] classifies malformations of cortical development according to time of insult and genetic abnormality (Table 36.1).

PREVALENCE AND EPIDEMIOLOGY

Malformations of cortical development are uncommon. However, about 25% of children and young adults with intractable epilepsy are found to have malformations of cortical development.

ETIOLOGY AND PATHOPHYSIOLOGY

The basic abnormality is a disturbance in normal proliferation, migration, and organization of neurons from any cause.[2,5,6] The age when the insult occurs and disturbs a specific development phase can be more important than the specific nature of the insult in determining the type of malformations that occur. The etiology of malformations is varied. About half result from as yet unknown intrinsic fetal causes; the remainder include single gene disorders, and inborn errors of metabolism (peroxisomal disorders, organic acidopathies, mitochondrial disorders).[7]

TABLE 36.1 CLASSIFICATION OF MALFORMATIONS OF CORTICAL DEVELOPMENT

1. Abnormal neuronal proliferation, differentiation apoptosis
   a. Abnormal brain size (microcephaly, macrocephaly, hemimegalencephaly)
   b. Abnormal neuronal proliferation (tumor like conditions)
2. Abnormal neuronal migration
   a. Lissencephaly type1/subcortical band heterotopia
   b. Lissencephaly type 2 (cobblestone cortex/congenital muscular dystrophy)
   c. Heterotopia
3. Abnormal postmigrational development
   a. Polymicrogyria
   b. Schizencephaly

Modified from Barkovich AJ,Guerrini R, Kuzniecky RI, et al.: A developmental and genetic classification for malformations of cortical development: update 2012. *Neurology* 135:1348–1369, 2012.

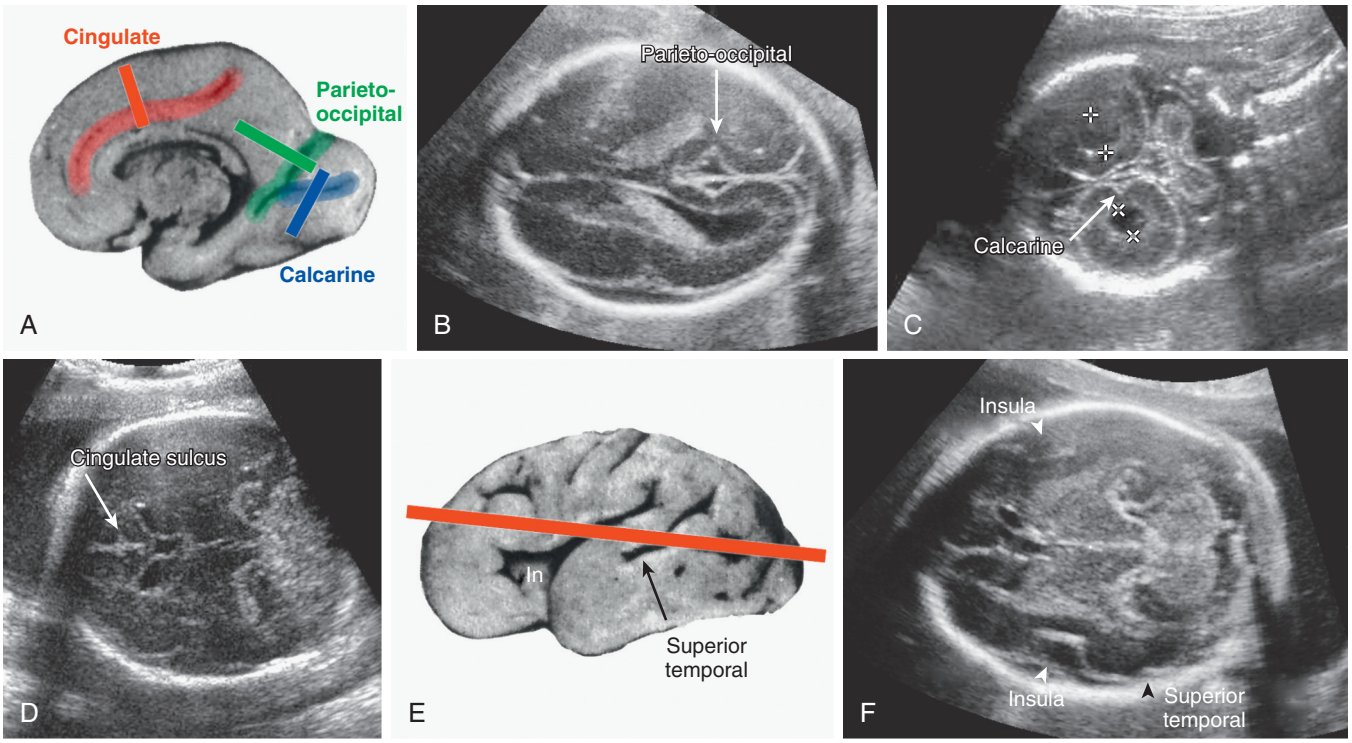

Fig. 36.1 US views used to show early-appearing sulci and fissures. (A) Medial hemispheric sulci at 26 weeks' gestation. Sulci indicated by color. *Solid bars* indicate scan orientation that is used to show each sulcus.[40] (B) Normal diamond-shaped appearance of parietooccipital fissure at 24 weeks' gestation *(arrow)*. (C) Calcarine fissure notch in medial occipital lobe at 22 weeks' gestation *(arrow)*. (D) Cingulate sulcus at 26 weeks' gestation *(arrow)*. (E) Early-appearing sulci on lateral brain surface at 28 weeks' gestation, and scan plane used to show sylvian fissure and insula *(In)*, and superior temporal sulcus. (F) Normal US appearance of early lateral sulci. *White arrow* points to angular plateau shape of insula; *black arrow* indicates superior temporal sulcus. *(A, Modified from Dorovini-Zis K, Dolman CL: Gestational development of brain.* Arch Pathol Lab Med *101:192–195, 1977. Copyright © American Medical Association. All rights reserved.)*

Extrinsic (acquired) insults include hypoxia, maternal diseases (diabetes, phenylketonuria), and maternal exposures (teratogens).

MANIFESTATIONS OF DISEASE

Clinical Presentation

There is a large range of presentation from normal function to severe developmental delay or death. Epilepsy is common. Many individuals have additional problems related to associated anomalies and syndromes.

Imaging Technique and Findings

The brain undergoes significant morphologic changes throughout gestation. It is important to be aware of normal appearances at each age.

Ultrasound. Ultrasound (US) is the mainstay of prenatal fetal central nervous system (CNS) evaluation.[8–10] Additional information can be obtained using Doppler and three-dimensional (3D) evaluation. Cortical sulci and the insula follow a regular pattern of maturation that can be assessed by 18 weeks' gestation. The medial hemispheric sulci are more readily assessed with US (Fig. 36.1 and Table 36.2).[11–14]

Magnetic Resonance Imaging. Magnetic resonance imaging (MRI) is the second line of investigation and allows more complete anatomic delineation (Fig. 36.2). MRI can be more effective in evaluation of cortical surfaces and gray and white matter differentiation, and can detect hypoxic and hemorrhagic changes.[5,6,8,15,16] Increasingly sophisticated MRI sequences are being developed to evaluate metabolic and microstructural changes in the cortex.[17] Currently MRI effectiveness in the diagnosis of cortical malformations remains limited before 24 weeks.

TABLE 36.2 GESTATIONAL AGES WHEN CEREBRAL SULCI BECOME VISIBLE ON ULTRASOUND AND MAGNETIC RESONANCE IMAGING

	US		MRI	
Fissure or Sulcus	First Seen	Always Seen	First Seen	Always Seen
Parietooccipital fissure	18.5	20.5	18–19	23–23
Calcarine fissure	18.5	21.9	18–19	22–23
Cingulate fissure	23.2	24.3	24–25	28–29
Central sulcus			26–27	26–27
Convexity sulci	23.2	27.9	26–27	28–29

Modified from Ghai S, Fong KW, Toi A, et al.: Prenatal US and MR imaging findings of lissencephaly: review of fetal cerebral sulcal development. *Radiographics* 26:389–405, 2006.

Specific Malformations of Cortical Development

Microcephaly

DEFINITION

Microcephaly is defined, in the pediatric population, as occipitofrontal head circumference less than 2 standard deviations (SD) below the mean for age and gender. Some authors believe less than 3 SD is more appropriate, and likely to be of clinical significance in the diagnosis of fetal microcephaly.[18–21] *Microcephaly* is a descriptive term; it does not refer to a specific pathologic condition. The intention is to identify infants with small heads who are at risk for mental retardation.

PREVALENCE AND EPIDEMIOLOGY

Prevalence is estimated at 1:10,000 to 1.6:10,000 births. Microcephaly is commonly seen in association with other conditions. The incidence is likely higher if spontaneous abortions, stillbirths, and neonatal deaths are included.[20,22] Depending on etiology, failure of head growth may manifest in early or late pregnancy, but in the vast majority of cases it only becomes evident during the first year of life.

ETIOLOGY AND PATHOPHYSIOLOGY

The etiology is very heterogeneous (Table 36.3). The change in head size reflects failure of brain growth. Smaller heads are more likely to be associated with neurodevelopmental deficiency. Online Mendelian Inheritance in Man (OMIM) lists 680 conditions associated with microcephaly (www.ncbi.nlm.nih.gov/sites/omim). There are two main categories: primary (congenital) and secondary (acquired) (see Table 36.3).[18,21,22]

MANIFESTATIONS OF DISEASE

Clinical Presentation

The head appears small; in the fetus the occipitofrontal circumference is less than 3 SD below the mean for gestational age. Microcephaly may manifest at any age ranging from early second trimester to after delivery.[23] Often there is a suspicious pregnancy or family history. In one group of 33 affected children, findings

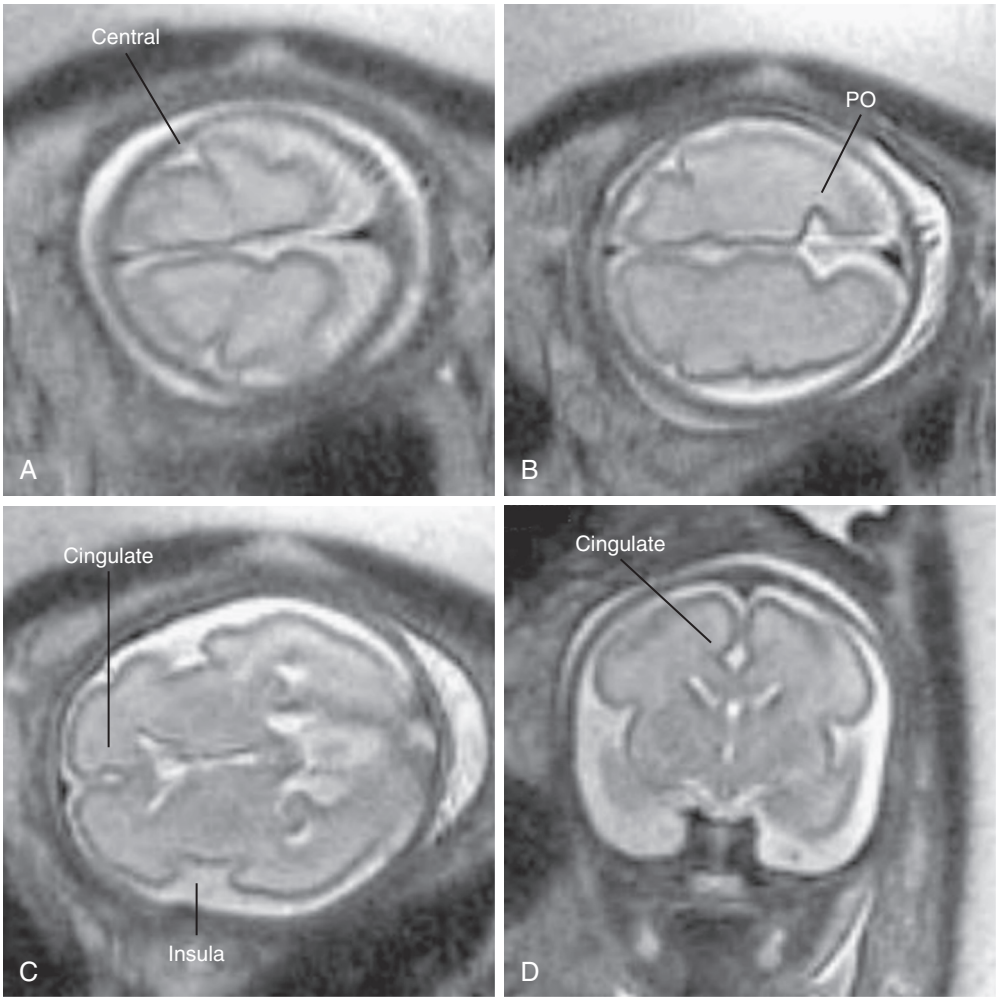

Fig. 36.2 MRI appearance of normal sulci in a 28-week fetus. (A) Central sulcus (this is very poorly seen with US). (B) Parietooccipital *(PO)*. (C) Cingulate sulcus and insula. Acute angles at margins of insula indicate normal operculization. (D) Cingulate sulcus.

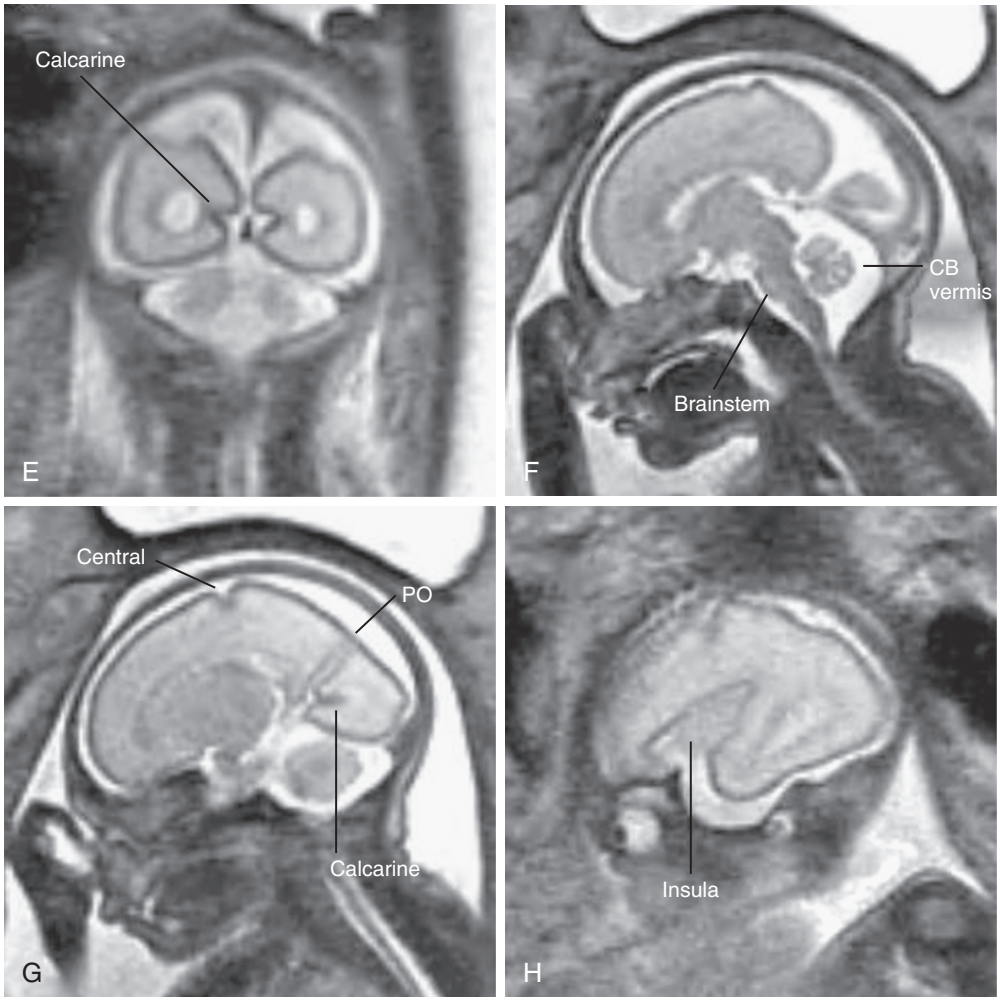

Fig. 36.2, cont'd (E) Calcarine fissure. (F) Midsagittal view shows essentially straight brainstem and normal appearance of cerebellar vermis *(CB vermis)*, and triangular fourth ventricle. (G) Parasagittal view shows central sulcus and parietooccipital fissure *(PO)*, with calcarine fissure intersecting with it. (H) Normal triangular shape of insula and sylvian fissure.

TABLE 36.3 ETIOLOGIES OF MICROCEPHALY

PRIMARY (CONGENITAL)
Multifactorial (some cases are familial)
Genetic
  Isolated
Syndromic
  Chromosome abnormalities (trisomies 21, 18, 13)
  Contiguous gene deletion syndromes
Syndromes with multiple anomalies
  Holoprosencephaly
  Smith-Lemli-Opitz syndrome
  Cornelia de Lange syndrome
Many other syndromes

SECONDARY (ACQUIRED OR ENVIRONMENTAL)
Hypoxic-ischemic encephalopathy
Intrauterine growth restriction
Disruptions (twin death, vascular accidents, trauma)
Infections (especially CMV, Zika)
Maternal exposures or teratogens (alcohol, hydantoin, radiation)
Maternal diseases (maternal phenylketonuria, poorly controlled diabetes)

Modified from Dahlgren and Wilson,[22] Abuelo,[18] and Tarrant et al.[21]

were as follows: 48% had distinct cerebral malformations, 18% had findings of cytomegalovirus (CMV), 24% had nonspecific brain abnormalities, and 10% had no overt brain abnormality. Of the 90% of children with identifiable brain abnormalities, 93% were neurodevelopmentally abnormal.[24] Other infections such Zika virus (ZIKV) can cause cerebral disturbances and microcephaly.[25]

Imaging Technique and Findings

Ultrasound. Head circumference is small for age (less than 3 SD below the mean for gestational age). As a rule of thumb, generally the biparietal diameter is about 10 mm smaller than expected, and age estimated from biparietal diameter is about 4 weeks too small.[20,21,26] In some cases, there is an abnormal head-to-abdomen ratio or head-to-femur ratio, or both.[20] The forehead is short and slopes backward (Fig. 36.3), and there is an increased subarachnoid space. Brain structures are poorly visible (owing to decreasing US windows, as calvarial collapse narrows sutures and fontanelles), requiring scanning in atypical planes to see intracranial structures (see Fig. 36.3). Overall, the brain usually appears abnormal (e.g., structural abnormalities, abnormal sulcation [often simplified], holoprosencephaly,

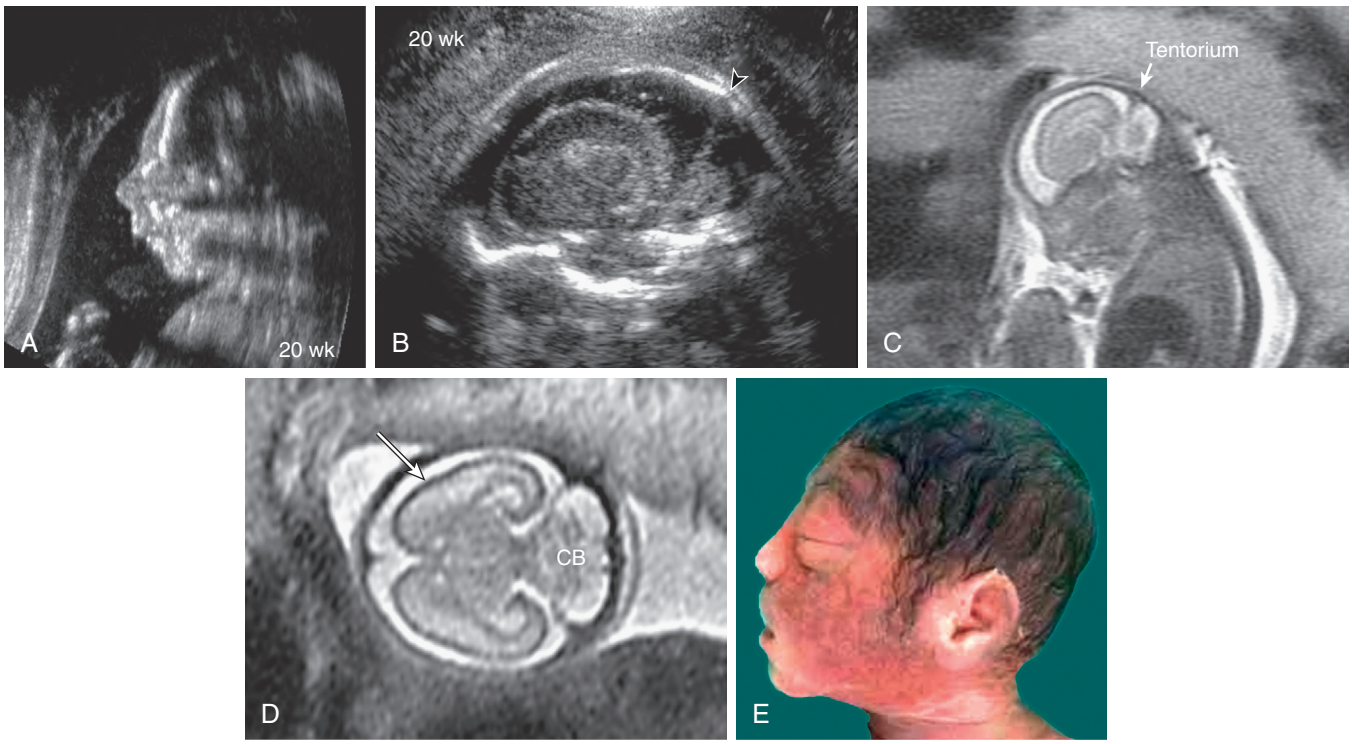

Fig. 36.3 Microcephaly at 20 weeks' gestation. (A) Profile shows posteriorly sloping short forehead and micrognathia. (B) Parasagittal US shows small calvaria and small smooth cerebrum above the tentorium *(arrow)*. (C) Corresponding MRI. (D) Axial MRI shows small agyric cerebrum *(arrow)* surrounded by excess extraaxial fluid. *CB,* Cerebellum. (E) Profile of different fetus shows characteristic sloping forehead.

calcifications with infections). There may be other fetal findings related to possibly associated syndromes. In the absence of associated anomalies, the diagnosis of microcephaly is rarely suspected before delivery.

Magnetic Resonance Imaging. MRI findings are similar to those of US and include (see Fig. 36.3) brain smaller than expected for skull (wide subarachnoid spaces); abnormal gyration pattern, often simplified; and possibly signs of infection (calcifications, stranding in ventricles).[5] However, MRI allows more detailed evaluation of sulci and gyri for abnormality and may show areas of hemorrhage or ischemia that are not evident on US. In addition, noncerebral findings may suggest an etiology and associated syndromes.

CLASSIC SIGNS

Small head
Short and sloping forehead
Brain structures hard to see with US and usually dysmorphic
Other anomalies

KEY POINTS

- Head circumference less than 3 SD below mean for gestational age
- If head circumference is less than 2 SD below mean for gestational age, repeat the examination in 3 weeks
- Head growth failure may appear late
- Multiple etiologies
- Multidisciplinary investigations and counseling useful

Macrocephaly and Hemimegalencephaly

DEFINITION

Macrocephaly refers to head enlargement from any cause, including abnormalities of the scalp, cranial bones, and intracranial structures. It is a descriptive term and is defined as occipitofrontal circumference greater than 2 SD above the mean for gestational age and sex. Some authors use 98th centile or greater than 3 SD above the mean for gestational age. The term *megalencephaly* describes a brain that is large. Macrocephaly may be due to megalencephaly (true enlargement of brain parenchyma) or many other conditions that cause an enlarged head.[27] Usually obvious conditions that can cause head enlargement, such as hydrocephaly and brain tumors, are not included. *Hemimegalencephaly* is a malformation of cortical development that manifests as a hamartomatous enlargement of one hemisphere.[5,28]

PREVALENCE AND EPIDEMIOLOGY

Prevalence is not quoted, but by definition would include about 2% of the population; in these cases, most of the macrocephalic individuals will be normal. Macrocephaly is a finding associated with various conditions (Table 36.4). OMIM lists 218 conditions associated with macrocephaly and 27 associated with megalencephaly (http://www.ncbi.nlm.nih.gov/omim).

Benign familial macrocephaly (external hydrocephalus) accounts for about 50% of cases. It is an autosomal dominant condition that is four times more common in boys. Most affected individuals are developmentally normal. Other family members also have large heads. The first question on discovery of an

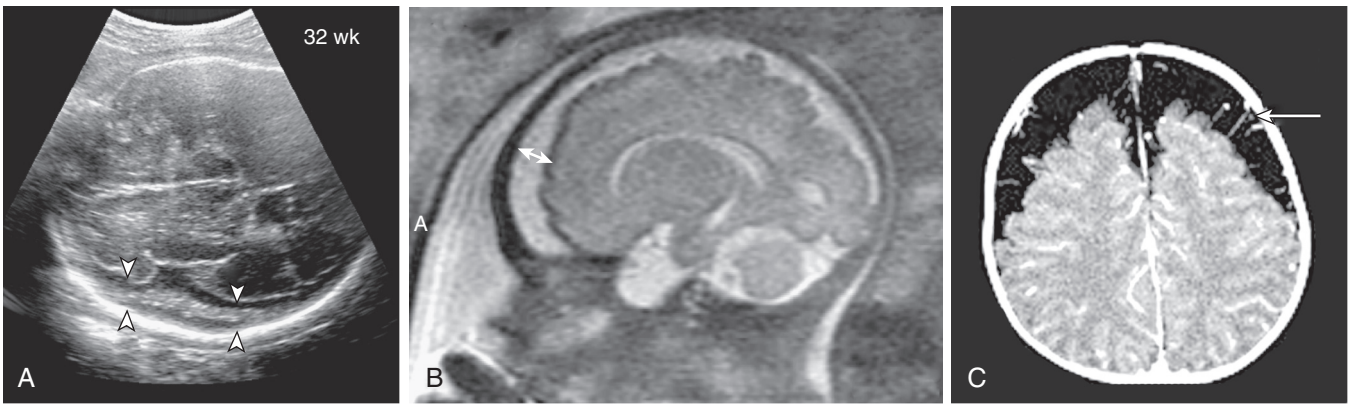

Fig. 36.4 Familial autosomal dominant macrocephaly. (A) Axial view shows wide subarachnoid fluid space *(between arrowheads)* and normal underlying brain. (B) Parasagittal MRI shows wide subarachnoid space anteriorly *(arrowheads)*. (C) Postnatal computed tomography scan in a different patient shows increased subarachnoid fluid traversed by normal undisplaced arachnoid vessels *(arrow)*.

TABLE 36.4 CONDITIONS ASSOCIATED WITH MACROCEPHALY

GENETIC
Familial macrocephaly ("benign")
Autism
Syndrome associations
- With cutaneous findings
  - *PTEN* hamartoma, neurofibromatosis
- Overgrowth syndromes
  - Sotos, Weaver, fragile X, many others
- Neuro-cardio-facial-cutaneous syndromes
  - Noonan, Costello, others
- Metabolic types
  - With leukodystrophy (Alexander, Canavan, others)
  - With organic aciduria
  - Storage diseases
- Skeletal dysplasia
  - Thanatophoric
- Hydrocephalus

NONGENETIC
Hydrocephalus
- Secondary to hemorrhage, infections, others

Subdural collections
Arachnoid cysts

Modified from Olney[31] and Williams et al.[27]

TABLE 36.5 SYNDROMES ASSOCIATED WITH HEMIMEGALENCEPHALY

Isolated (about 50% of cases)
Syndromic
- Cutaneous syndromes
  - Epidermal nevus syndrome
  - Proteus syndrome
  - Hypermelanosis of Ito
  - Unilateral hypomelanosis
  - Neurofibromatosis type 1
  - Tuberous sclerosis
  - Klippel-Trénaunay-Weber syndrome
  - Others

Total hemimegalencephaly (also involves brainstem and cerebellum)

Modified from Flores-Sarnat[29] and Tinkle et al.[28]

enlarged but otherwise normal-appearing head should be, "Does anyone else in the family have a large head?"

Hemimegalencephaly is sporadic. It may be isolated or associated with neurocutaneous or somatic hemihypertrophy syndromes. Outcome is poor in most cases, especially if hemimegalencephaly is syndromic.[28,29]

ETIOLOGY AND PATHOPHYSIOLOGY

Head enlargement can occur as an isolated condition, or it can be associated with many genetic, syndromic, and nonsyndromic conditions (see Table 36.4). Benign familial macrocephaly is the most common cause of macrocephaly and is associated with increased subarachnoid fluid. Hemimegalencephaly is a malformation of cortical development that is isolated in about 50% of cases but is also associated with other abnormalities and syndromes (Table 36.5).[5,28,29]

MANIFESTATIONS OF DISEASE

Clinical Presentation

In macrocephaly, there is head enlargement, usually manifesting late in pregnancy or in childhood.[27,30,31] In hemimegalencephaly, there is asymmetric head and brain enlargement. Some patients also have somatic hemihypertrophy; seizures, developmental delay, and hemiparesis are common.[29] Both macrocephaly and hemimegalencephaly can have diverse manifestations related to associated conditions and syndromes (see Tables 36.4 and 36.5).

Imaging Technique and Findings

Ultrasound. Head circumference is greater than 2 SD above the mean for gestational age. However, macrocephaly may not develop until the third trimester or after delivery.[30] The most common etiology, benign familial macrocephaly, has a wide subarachnoid space and cortical vein sign (undisplaced bridging cortical veins in widened subarachnoid space) (Fig. 36.4).[32,33] A family history should be obtained because most of these cases have functionally normal outcomes.

Somatic abnormalities involve any body part related to associated syndromes. The brain may appear normal, large, or dysmorphic depending on the underlying condition. Hemimegalencephaly shows hemispheric asymmetry with the larger hemisphere having abnormal texture, gyration, and often

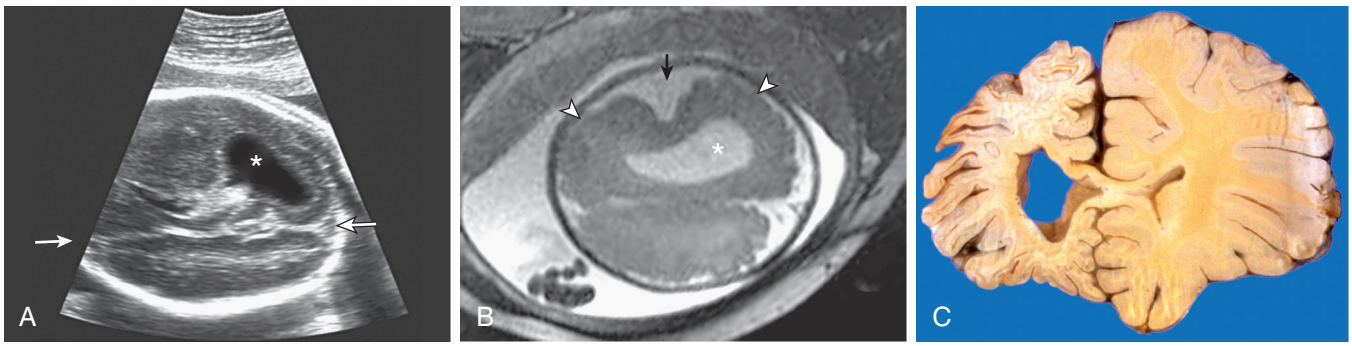

Fig. 36.5 Hemimegalencephaly in a fetus at 26 weeks' gestation. (A) US shows a large hemisphere with dilated ventricle *(asterisk)*. Note asymmetric position of falx between *arrows*.[40] (B) MRI in a different patient. Abnormal large upper hemisphere shows altered signal texture, abnormal sylvian fissure *(black arrow)*, and abnormal gyration pattern *(arrowheads)*. (C) Pathology specimen of a different fetus shows asymmetric enlargement and abnormal texture in the larger hemisphere. The smaller hemisphere shows ventriculomegaly and abnormal gyration. *(A, From Toi A, Chitayat D, Blaser S: Abnormalities of the foetal cerebral cortex.* Prenat Diagn *29:355–371, 2009. Used by permission.)*

ventriculomegaly (Fig. 36.5). Somatic and posterior fossa asymmetry may occur.

Magnetic Resonance Imaging. In macrocephaly, MRI is helpful after the diagnosis is suspected on US. The brain may appear normal, enlarged, or dysmorphic depending on the underlying condition (see Fig. 36.4).[27] In hemimegalencephaly, the affected hemisphere is variably enlarged and dysmorphic, and shows poor gray and white matter differentiation, abnormal gyration, and ventricular enlargement; the other hemisphere is compressed (see Fig. 36.5).[29]

Other Applicable Modality. Multidisciplinary counseling and investigations are important to try to establish diagnosis and prognosis with macrocephaly and hemimegalencephaly.

CLASSIC SIGNS

Classic signs of macrocephaly include:
- Head circumference greater than 2 SD above mean for gestational age
- Family history of large head

Classic signs of hemimegalencephaly include:
- Cranial asymmetry
- Epilepsy
- Contralateral hemiparesis

KEY POINTS

- Head circumference greater than 2 SD above mean for gestational age
- Isolated benign macrocephaly, the most common etiology, has favorable outcome and can be familial; head circumference of the parents should be measured
- May not manifest until third trimester or later after birth
- Many associated syndromes and abnormalities
- Detailed US, MRI, multidisciplinary investigations and counseling are useful

Migration Abnormalities (Lissencephaly, Agyria, Heterotopia, and Pachygyria)

DEFINITION

Neuron migration abnormalities are characterized by disturbed migration of neurons from the ventricular germinal matrix to the cortex, manifesting as abnormalities of gyration, abnormalities of sulcation (agyria, pachygyria, cortical thickening), and ectopic collections of neurons in abnormal locations (heterotopia). Three major groups are usually considered (see Table 36.1)[2]:
- Lissencephaly type 1 (failure of migration—e.g., Miller-Dieker syndrome; Chapter 157)
- Lissencephaly type 2 (overmigration—e.g., congenital muscular dystrophy, Walker-Warburg syndrome [Chapter 38])
- Heterotopia (variable abnormal migration leaving collections of neurons in abnormal locations)

PREVALENCE AND EPIDEMIOLOGY

Type 1 and type 2 are uncommon, estimated at 1:100,000 to 4:100,000 births. Heterotopia is more common and found in about 40% of individuals with intractable epilepsy.

ETIOLOGY AND PATHOPHYSIOLOGY

Lissencephaly is associated with mutations in several genes, but mutations are not found in every case.[1,3] In type 1, mutations have been found in *LIS-1*, doublecortin (*DCX*), *ARX*, and *RELIN;* in type 2, mutations are reported in *POMT1, POMT2, FKTN,* and other genes that also have important functions in the development of other organs such as eyes, peripheral nerves, and skeletal and cardiac muscle. Environmental effects such as infection (especially CMV), teratogens, and hypoxia that occur at critical times in fetal development can result in similar cerebral abnormalities.[2] Final outcomes can range from normal to lethal depending on the specific genetic mutation or severity of environmental insult. Survivors typically have epilepsy and developmental delays.[3,12] Heterotopia may be sporadic and isolated, or associated with genetic abnormality or any insult to normal growth and development.

MANIFESTATIONS OF DISEASE

Clinical Presentation

Presentation depends on the severity of cortical malformation and associated somatic abnormalities. Epilepsy, developmental delay, and somatic abnormalities are common. Mild cases, especially cases with acquired heterotopias, may escape prenatal

detection, and the individuals may function normally after birth.[3,5,34]

Type 1 Miller-Dieker syndrome typically has associated congenital heart disease, omphalocele, genitourinary abnormalities, IUGR, and dysmorphic facies.[12] The *DCX* mutation is X-linked. Females with the mutation do well, although MRI examinations are abnormal, showing double-layer cortex; males are severely disabled.

Type 2 is grouped with congenital muscular dystrophies. There are several phenotypes including Walker-Warburg syndrome, Fukuyama syndrome, muscle-eye-brain disease, and others. The most severe, Walker-Warburg syndrome (also called *HARD-E*), is characterized by hydrocephalus, agyria, retinal or eye dysplasia, and encephalocele, and affected individuals exhibit very poor tone at birth ("floppy baby") owing to muscle abnormality (Chapter 38).[12]

Imaging Technique and Findings

Ultrasound. Mild cases have no cerebral or somatic abnormality that can be detected prenatally. Early detection is difficult because the normal brain is agyric and smooth until the middle of the second trimester. Sulcal delay may start becoming apparent after 23 weeks.[10,12] Type 1 typically shows mild ventriculomegaly and failed, delayed, or abnormal sulcation (Fig. 36.6); type 2 can have early onset of ventriculomegaly, failed or abnormal sulcation, and eye abnormalities with or without encephalocele (called *HARD±E*). Other findings include abnormal corpus callosum, abnormally kinked brainstem, vermian hypoplasia, and somatic abnormalities (Fig. 36.7). Heterotopia can manifest as nodularity lining the ventricles (periventricular heterotopia) (Fig. 36.8), but lesions within the cortex generally escape detection.[5]

Magnetic Resonance Imaging. MRI is more sensitive than US in showing abnormal gray matter (neurons) as thickening nodules or bands in abnormal locations, and is useful in late pregnancy to assess gyration (see Fig. 36.7). Brainstem kinking, callosal abnormality, cerebellar hypoplasia, and cysts as seen with severe type 2 lissencephaly can be more readily apparent on MRI (see Fig. 36.8). Examination of the parents can help identify syndromes in familial cases.[3,5,35,36]

Other Applicable Modality. Carrier status investigation for Walker-Warburg syndrome, FKTN related, is currently available.

CLASSIC SIGNS

Ventriculomegaly
Delayed or absent development of sulci and insula
Abnormal cortical gray matter pattern
Kinked brainstem
Cerebellar and eye abnormalities
Family history

Differential Diagnosis From Imaging Findings

1. Aqueduct stenosis (ventriculomegaly)
2. Infections (CMV)
3. Teratogens (alcohol, radiation)
4. Hypoxic injury

KEY POINTS

- Early ventriculomegaly may be first clue
- Sulcal and sylvian fissure development delayed or absent
- Additional abnormalities seen in hindbrain, eyes, encephalocele, and somatic anomalies
- Genetic confirmation possible in some instances

Disorders of Cortical Organization: Polymicrogyria and Schizencephaly

DEFINITION

In disorders of cortical organization, neurons that have reached the cortex fail to organize normal connections.[2,3,5] The term *polymicrogyria* describes a brain surface with an excessive number of abnormally small gyri producing an irregular cortical surface. The term *schizencephaly* (split brain) describes an abnormality of the brain in which cortical gray matter spans the cortex from ventricle to surface. The defect may be an open communicating cleft (open lip) lined by abnormal gray matter, or a closed noncommunicating column of gray matter (closed lip).[37] In contrast, in porencephaly, brain clefts are lined by white matter, not gray matter (Chapter 40).

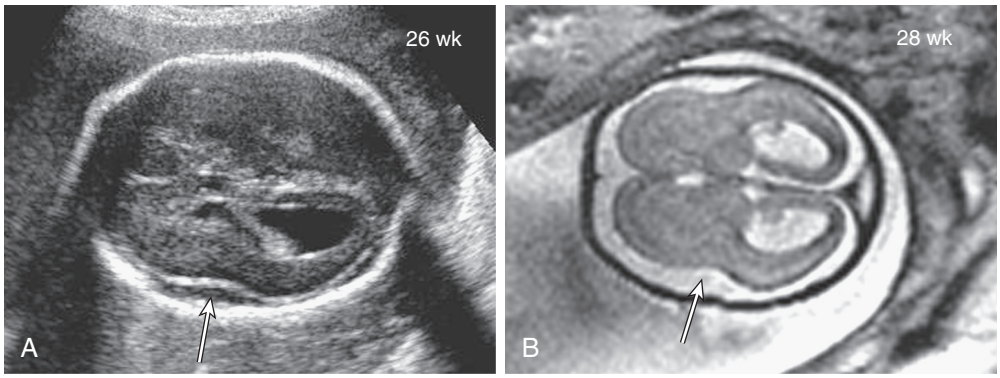

Fig. 36.6 Lissencephaly type 1 (Miller-Dieker syndrome) at 26 weeks' gestation. (A) Mild ventriculomegaly (11 mm) and agyric cortical surface. Note flattening of sylvian fissure *(arrow)*. (B) Corresponding MRI shows agyria and flattened unformed sylvian fissure *(arrow)*.[41] *(B, From Toi A, Chitayat D, Blaser S: Abnormalities of the foetal cerebral cortex.* Prenat Diagn *2009;29:355–371. Used by permission.)*

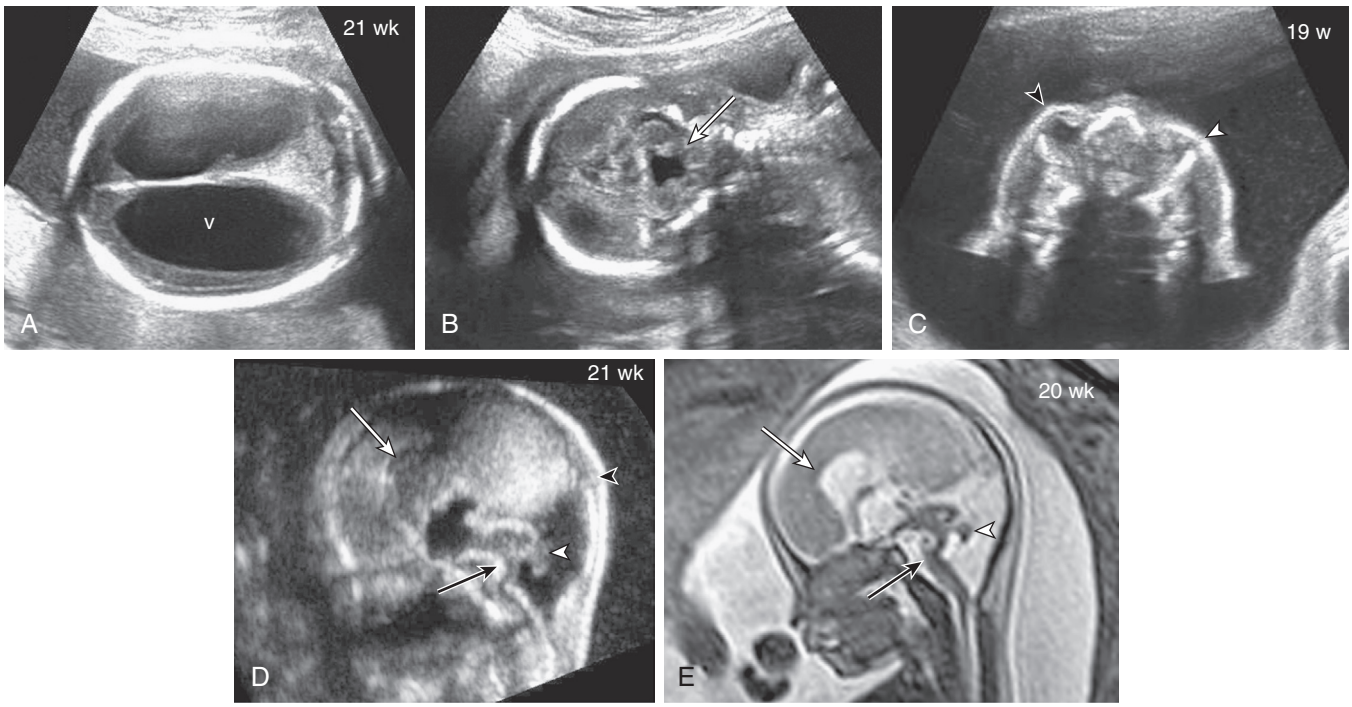

Fig. 36.7 Lissencephaly type 2 (Walker-Warburg syndrome) at 19 weeks' gestation. (A) Prominent ventriculomegaly *(V)* in agyric brain. (B) Cerebellar vermian hypoplasia *(arrow)*. (C) Eye abnormalities: microophthalmia and cataract *(black arrow)*, anophthalmia *(white arrow)*.[40] (D) Kinked, Z-shaped brainstem *(black arrow)*; small vermis *(white arrowhead)*; and abnormally elevated corpus callosum *(white arrow)*. *Black arrowhead* indicates encephalocele. (E) MRI in different fetus with the same condition. *(C, From Toi A, Chitayat D, Blaser S: Abnormalities of the foetal cerebral cortex.* Prenat Diagn *29:355–371, 2009. Used by permission.)*

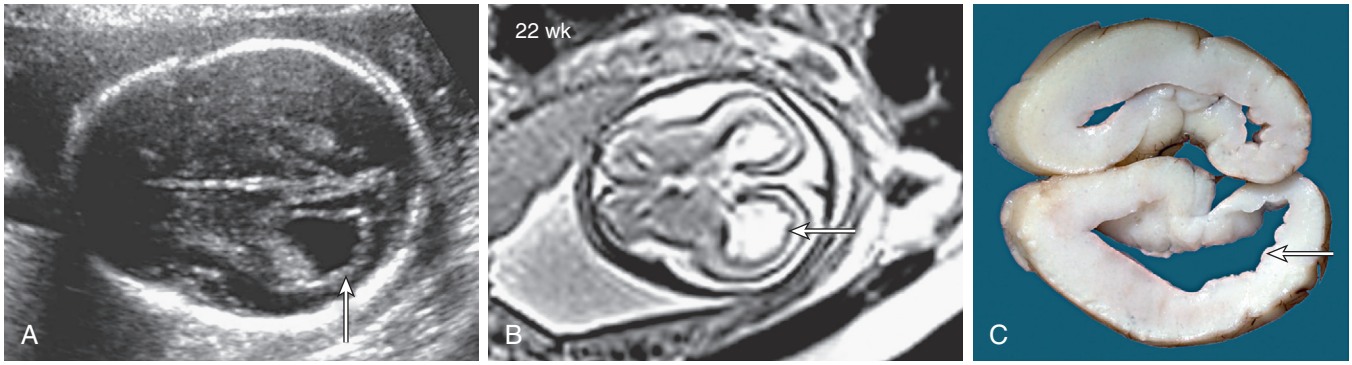

Fig. 36.8 Periventricular nodular heterotopia at 21 weeks' gestation. (A) Ventriculomegaly with nodules on ventricle surface *(arrow)*. (B) Corresponding T2-weighted MRI shows low signal intensity (dark) heterotopic nodules lining the ventricles. (C) Pathology specimen shows periventricular heterotopic nodules. *(A,C, From Toi A, Chitayat D, Blaser S: Abnormalities of the foetal cerebral cortex.* Prenat Diagn *29:355–371, 2009. Used by permission.)*

PREVALENCE AND EPIDEMIOLOGY

These conditions are uncommonly seen prenatally, but polymicrogyria is likely the most common malformation of cortical development seen on imaging postnatally.[5,38]

ETIOLOGY AND PATHOPHYSIOLOGY

Polymicrogyria may be isolated or associated with other brain or somatic abnormalities. It can arise from genetic or environmental causes, including infectious, toxic, hypoxic, and metabolic, and it can be part of various single gene disorders.[2,3,5,39] Schizencephaly can also have genetic or environmental causes and often accompanies hypoxic and disruptive vascular abnormalities, teratogens (warfarin, alcohol, cocaine), infection, and twin interactions.[3,38,39] Both conditions are commonly associated with other CNS and somatic abnormalities.

MANIFESTATIONS OF DISEASE

Clinical Presentation

Clinical manifestation varies depending on the extent and location of cerebral involvement and associated anomalies. Mental and motor deficiencies and seizures are common.[5,38,39]

Imaging Technique and Findings

Ultrasound. Both polymicrogyria and schizencephaly can be difficult to detect with US, especially if small cortical areas are involved because of their late appearance and location in the cortex. Associated somatic and CNS abnormalities are more likely to be detected, including ventriculomegaly, abnormal corpus callosum, and cavum septi pellucidi and cerebellum.[10] In polymicrogyria, the gyral abnormality can occur in different parts of the cortex where US visibility is very restricted (Fig. 36.9). The sylvian fissure is involved in about 80% of cases. A few cases have been detected by US.[5,10] Schizencephaly with open clefts can be seen as cerebrospinal fluid-containing clefts usually in the posterior parietal regions. In severe cases, the appearance can be very similar to hydranencephaly (Fig. 36.10).[10,37]

Magnetic Resonance Imaging. Polymicrogyria is more readily detected by MRI than US, and manifests as abnormally fine gyration and gray matter abnormality. Changes are not apparent until late pregnancy and involve the peripheral cortex (see Fig. 36.9).[36] Schizencephaly shows abnormal gray matter spanning brain from ventricle to cortex, with or without open communication (see Fig. 36.10).[36–38] Additional cerebral abnormalities are common and may be more completely defined by MRI because changes often appear in later pregnancy, involve the brain cortex, and are related to gray and white matter abnormalities such as heterotopias and gyral abnormality.[5,37,38]

CLASSIC SIGNS

Polymicrogyria—small abnormal gyri
Schizencephaly—cortical clefts
Both commonly associated with additional cerebral abnormalities

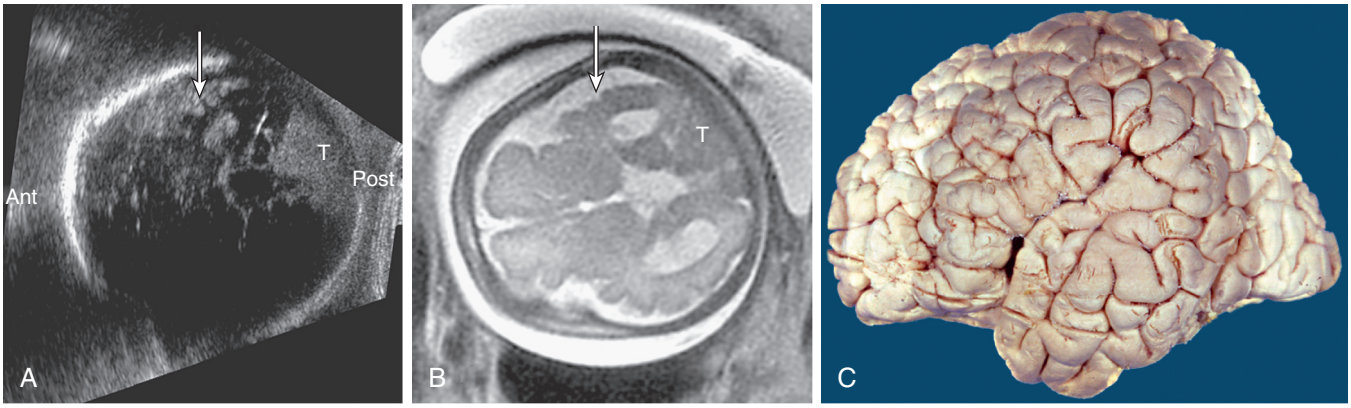

Fig. 36.9 Polymicrogyria at 30 weeks' gestation. Abnormal cortical development in a fetus with sagittal sinus thrombosis *(T)* and subarachnoid bleed. It can be difficult to detect such peripheral cortical changes on US. (A) Axial US shows small abnormal gyri *(arrow)* in the region of the subarachnoid bleed (bleeding is visible as the adjacent echogenic area). *T,* Thrombosed enlarged sagittal sinus. *Ant/Post* indicates forehead and occiput for orientation. (B) Corresponding MRI confirms small abnormal sulci *(arrow). T,* Thrombus. (C) Pathologic specimen shows all gyri are small and disarrayed. *(Courtesy Neuropathology Unit, University of California, San Francisco School of Medicine.)*

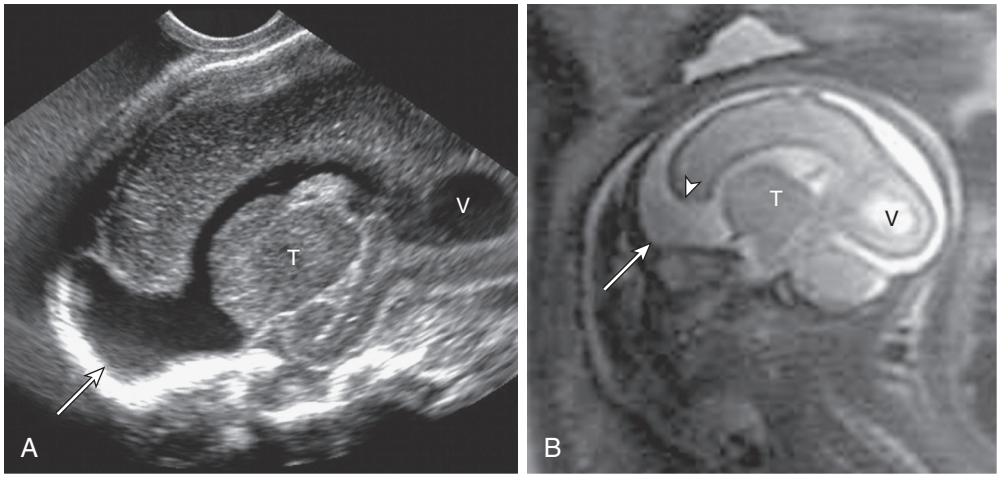

Fig. 36.10 Open lip schizencephaly in an atypical anterior location. (A) Large defect in the anterior cortex *(arrow)* allows cerebrospinal fluid communication between the subarachnoid space and ventricle *(V).* (B) Corresponding MRI. Note dark, low signal at the surface of the defect *(arrowhead)* implying that cortical tissue lines the defect. This differentiates schizencephaly from acquired defects such as porencephaly, where white matter lines the cleft margin.

Differential Diagnosis From Imaging Findings

Very large schizencephalic clefts can mimic hydranencephaly and ventriculomegaly with cortical rupture.[5]

KEY POINTS

- Late presentation, often in childhood or later
- US can detect some lesions, but MRI is required for more complete evaluation

Synopsis of Treatment Options for Abnormalities of Cortical Development

For all conditions discussed in this chapter, the prenatal and postnatal treatment options and advice to the referring physician are similar.

PRENATAL

Prenatal treatment options depend on the specific condition and associated findings. Pregnancy termination can be offered if appropriate.

POSTNATAL

Postnatal treatment is symptomatic. Epilepsy is common.

WHAT THE REFERRING PHYSICIAN NEEDS TO KNOW

- Cortical malformations have various etiologies and appearances.
- Many malformations manifest in late pregnancy, but symptoms may not appear until after birth and sometimes not until adult life.
- Developmental delay and epilepsy are common.
- Prognosis is generally poor with prenatally diagnosed and severe conditions.
- Detailed neurosonography examinations followed by MRI are useful for evaluation.
- Additional somatic abnormalities and syndromes are common.
- Multidisciplinary specialty counseling is important.

Acknowledgments

The authors wish to thank Dr. David Chitayat, Dr. Katherine Fong, Dr. Patrick Shannon, Dr. Susan Blaser, Dr. Charles Raybaud, Dr. Phyllis Glanc, and the Fetal Medicine Unit at the University of Toronto for some of the illustrative materials and assistance with the manuscript.

SUGGESTED READING

Barkovich AJ. Magnetic resonance imaging: role in the understanding of cerebral malformations. *Brain Dev*. 2002;24:2-12.

Barkovich AJ. *Pediatric neuroimaging*. Philadelphia: Lippincott Williams & Wilkins; 2005.

Flores-Sarnat L. Hemimegalencephaly syndrome. *Handb Clin Neurol*. 2007;87:153-176.

Fogliarini C, Chaumoitre K, Chapon F, et al. Assessment of cortical maturation with prenatal MRI. Part I: Normal cortical maturation. *Eur Radiol*. 2005;15:1671-1685.

Oliveira Melo AS, Malinger G, Ximenes R, et al. Zika virus intrauterine infection causes fetal brain abnormality and microcephaly: tip of the iceberg? *Ultrasound Obstet Gynecol*. 2016;47:6-7. doi:10.1002/uog.15831.

Panigrahy A, Borzage M, Bluml S. Basic principles and concepts underlying recent advances in magnetic resonance imaging of the developing brain. *Semin Perinatol*. 2010;34:3-19.

Raybaud C, Levrier O, Brunel H, et al. MR imaging of fetal brain malformations. *Childs Nerv Syst*. 2003;19:455-470.

Salomon LJ, Garel C. Magnetic resonance imaging examination of the fetal brain. *Ultrasound Obstet Gynecol*. 2007;30:1019-1032.



All references are available online at www.expertconsult.com.

REFERENCES

1. Gupta A, Tsai LH, Wynshaw-Boris A. Life is a journey: a genetic look at neocortical development. *Nat Rev Genet*. 2002;3:342-355.
2. Barkovich AJ, Guerrini R, Kuzniecky RI, et al. A developmental and genetic classification for malformations of cortical development: update 2012. *Neurology*. 2012;135:1348-1369.
3. Guerrini R, Dobyns WB, Barkovich AJ. Abnormal development of the human cerebral cortex: genetics, functional consequences and treatment options. *Trends Neurosci*. 2008;31:154-162.
4. Hevner RF. The cerebral cortex malformation in thanatophoric dysplasia: neuropathology and pathogenesis. *Acta Neuropathol*. 2005;110:208-221.
5. Barkovich AJ, Raybaud CA. Malformations of cortical development. *Neuroimaging Clin N Am*. 2004;14:401-423.
6. Raybaud C, Levrier O, Brunel H, et al. MR imaging of fetal brain malformations. *Childs Nerv Syst*. 2003;19:455-470.
7. Nissenkorn A, Michelson M, Ben-Zeev B, et al. Inborn errors of metabolism: a cause of abnormal brain development. *Neurology*. 2001;56:1265-1272.
8. Reddy UM, Filly RA, Copel JA. Prenatal imaging: ultrasonography and magnetic resonance imaging. *Obstet Gynecol*. 2008;112:145-157.
9. Malinger G, Monteagudo A, Pilu G, et al. Sonographic examination of the fetal central nervous system: guidelines for performing the "basic examination" and the "fetal neurosonogram. *Ultrasound Obstet Gynecol*. 2007;29:109-116.
10. Malinger G, Kidron D, Schreiber L, et al. Prenatal diagnosis of malformations of cortical development by dedicated neurosonography. *Ultrasound Obstet Gynecol*. 2007;29:178-191.
11. Toi A, Lister WS, Fong KW. How early are fetal cerebral sulci visible at prenatal ultrasound and what is the normal pattern of early fetal sulcal development? *Ultrasound Obstet Gynecol*. 2004;24:706-715.
12. Ghai S, Fong KW, Toi A, et al. Prenatal US and MR imaging findings of lissencephaly: review of fetal cerebral sulcal development. *Radiographics*. 2006;26:389-405.
13. Cohen-Sacher B, Lerman-Sagie T, Lev D, et al. Sonographic developmental milestones of the fetal cerebral cortex: a longitudinal study. *Ultrasound Obstet Gynecol*. 2006;27:494-502.
14. Quarello E, Stirnemann J, Ville Y, et al. Assessment of fetal Sylvian fissure operculization between 22 and 32 weeks: a subjective approach. *Ultrasound Obstet Gynecol*. 2008;32:44-49.
15. Guibaud L. Contribution of fetal cerebral MRI for diagnosis of structural anomalies. *Prenat Diagn*. 2009;29:420-433.
16. Garel C. New advances in fetal MR neuroimaging. *Pediatr Radiol*. 2006;36:621-625.
17. Pugash D, Krssak M, Kulemann V, et al. Magnetic resonance spectroscopy of the fetal brain. *Prenat Diagn*. 2009;29:434-441.
18. Abuelo D. Microcephaly syndromes. *Semin Pediatr Neurol*. 2007;14:118-127.
19. Stoler-Poria S, Lev D, Schweiger A, et al. Developmental outcome of isolated fetal microcephaly. *Ultrasound Obstet Gynecol*. 2010;36:154-158.
20. den Hollander NS, Wessels MW, Los FJ, et al. Congenital microcephaly detected by prenatal ultrasound: genetic aspects and clinical significance. *Ultrasound Obstet Gynecol*. 2000;15:282-287.
21. Tarrant A, Garel C, Germanaud D, et al. Microcephaly: a radiological review. *Pediatr Radiol*. 2009;39:772-780.
22. Dahlgren L, Wilson RD. Prenatally diagnosed microcephaly: a review of etiologies. *Fetal Diagn Ther*. 2001;16:323-326.
23. Bromley B, Benacerraf BR. Difficulties in the prenatal diagnosis of microcephaly. *J Ultrasound Med*. 1995;14:303-306.
24. Persutte WH. Microcephaly—no small deal. *Ultrasound Obstet Gynecol*. 1998;11:317-318.
25. Soares de Oliveira-Szejnfeld P, Levine D, Melo AS, et al. Congenital brain abnormalities and Zika virus: what the radiologist can expect to see prenatally and postnatally. *Radiology*. 2016;281:203-218.
26. Pilu G, Falco P, Milano V, et al. Prenatal diagnosis of microcephaly assisted by vaginal sonography and power Doppler. *Ultrasound Obstet Gynecol*. 1998;11:357-360.
27. Williams CA, Dagli A, Battaglia A. Genetic disorders associated with macrocephaly. *Am J Med Genet A*. 2008;146A:2023-2037.
28. Tinkle BT, Schorry EK, Franz DN, et al. Epidemiology of hemimegalencephaly: a case series and review. *Am J Med Genet A*. 2005;139:204-211.
29. Flores-Sarnat L. Hemimegalencephaly, part 1: genetic, clinical, and imaging aspects. *J Child Neurol*. 2002;17:373-384.
30. Malinger G, Lerman-Sagie T, Watemberg N, et al. A normal second-trimester ultrasound does not exclude intracranial structural pathology. *Ultrasound Obstet Gynecol*. 2002;20:51-56.
31. Olney AH. Macrocephaly syndromes. *Semin Pediatr Neurol*. 2007;14:128-135.
32. Malinger G, Lerman-Sagie T, Achiron R, et al. The subarachnoid space: normal fetal development as demonstrated by transvaginal ultrasound. *Prenat Diagn*. 2000;20:890-893.
33. Alper G, Ekinci G, Yilmaz Y, et al. Magnetic resonance imaging characteristics of benign macrocephaly in children. *J Child Neurol*. 1999;14:678-682.
34. Gleeson JG. Neuronal migration disorders. *Ment Retard Dev Disabil Res Rev*. 2001;7:167-171.
35. Fogliarini C, Chaumoitre K, Chapon F, et al. Assessment of cortical maturation with prenatal MRI, part II: abnormalities of cortical maturation. *Eur Radiol*. 2005;15:1781-1789.
36. Salomon LJ, Garel C. Magnetic resonance imaging examination of the fetal brain. *Ultrasound Obstet Gynecol*. 2007;30:1019-1032.
37. Oh KY, Kennedy AM, Frias AE Jr, et al. Fetal schizencephaly: pre- and postnatal imaging with a review of the clinical manifestations. *Radiographics*. 2005;25:647-657.
38. Curry CJ, Lammer EJ, Nelson V, et al. Schizencephaly: heterogeneous etiologies in a population of 4 million California births. *Am J Med Genet A*. 2005;137:181-189.
39. Montenegro MA, Guerreiro MM, Lopes-Cendes I, et al. Interrelationship of genetics and prenatal injury in the genesis of malformations of cortical development. *Arch Neurol*. 2002;59:1147-1153.
40. Dorovini-Zis K, Dolman CL. Gestational development of brain. *Arch Pathol Lab Med*. 1977;101:192-195.
41. Toi A, Chitayat D, Blaser S. Abnormalities of the foetal cerebral cortex. *Prenat Diagn*. 2009;29:355-371.

37 Cerebellar Anomalies

GUSTAVO MALINGER | TALLY LERMAN-SAGIE

Introduction

The fetal cerebellum develops throughout pregnancy and may be visualized starting from the first trimester. By the seventh week of gestation, the rhombencephalic vesicle, the precursor of the fourth ventricle and cisterna magna, is the most prominent structure of the brain. By the eighth week, the cerebellar hemispheres may be seen lateral to the fourth ventricle; the choroid plexus of the fourth ventricle is also present. The cerebellar hemispheres grow and develop toward the midline, and by 12 to 13 weeks' gestation, the superior portion of the vermis appears in the midline between them. The vermis develops caudocranially

and usually, but not always, finishes this "rotation" before 20 weeks' gestation.

Disease

Anomalies of the posterior fossa typically manifest either by cystic dilatation or by an obliterated cisterna magna on prenatal ultrasound (US). Biometry of the cerebellum and, in particular, the cerebellar vermis measured by US or magnetic resonance imaging (MRI) often reveals specific cerebellar or vermian variants or anomalies, many of them with well-known prognoses. Possible fetal anomalies include cerebellar hypoplasia (CH) (isolated, or in fetuses with intrauterine growth restriction [IUGR]), rhombencephalosynapsis, Dandy-Walker malformation (DWM), cerebellar hemispheric asymmetry, vermian agenesis, pontocerebellar hypoplasia, and other syndromes associated with a small vermis.

DEFINITION

The transverse cerebellar diameter (TCD) (Fig. 37.1A) is a well-established measurement used for estimation of gestational age because it is less affected by IUGR than other parameters.[1] The main differential diagnoses of a too-small TCD are two rare conditions: CH (see Figs. 37.1B and 37.2B) and rhombencephalosynapsis (Fig. 37.2A). The TCD may also be small in 26% of fetuses with IUGR.[1]

Cerebellar hypoplasia (CH) is essentially a growth disorder with intact major subdivisions of the cerebellum but reduced number of folia.[2] In some cases, the pons may be also involved; this condition is called *pontocerebellar hypoplasia* and is usually transmitted as an autosomal recessive trait. CH is rarely diagnosed in utero and is usually associated with the presence of other anomalies[3] or chromosomal defects, in particular, trisomy 18 (see Figs. 37.1B and 37.2.B).[4] In the fetus, CH cannot be differentiated from cerebellar atrophy, and it is usually not present or not diagnosed by the time of second-trimester anatomy screening scans, and sometimes even during third-trimester US examinations.[5–7] When TCD is in the low-normal range or when there is a familial risk of CH, follow-up interval measurements should be performed until close to term; however, even this approach, including neurosonography and T2-weighted MRI sequences, may fail to reveal cases with proven molecular diagnosis.[7]

Rhombencephalosynapsis is an even rarer condition; less than 200 cases have been reported in the world literature. It is defined

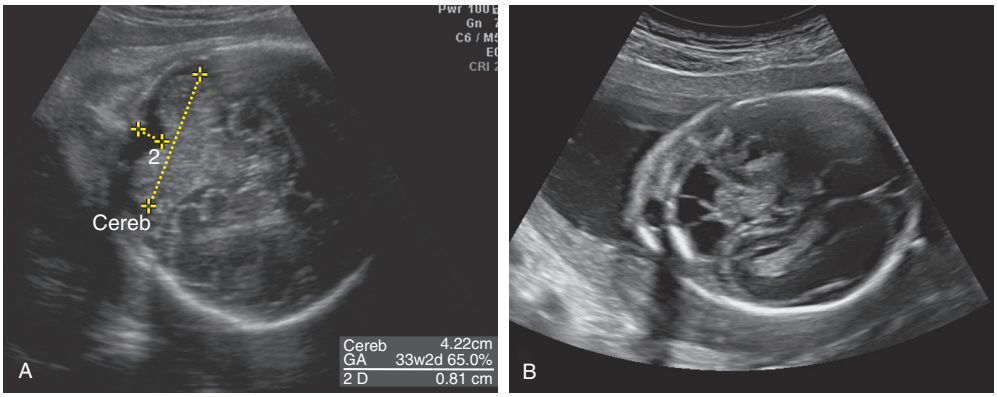

Fig. 37.1 (A) Measurement of TCD at 32 weeks' gestation (between calipers, *Cereb*). The cisterna magna is measured in the same plane (between calipers, *2*). (B) Marked CH at 23 weeks' gestation with associated malformation of cortical development and nuchal cysts.

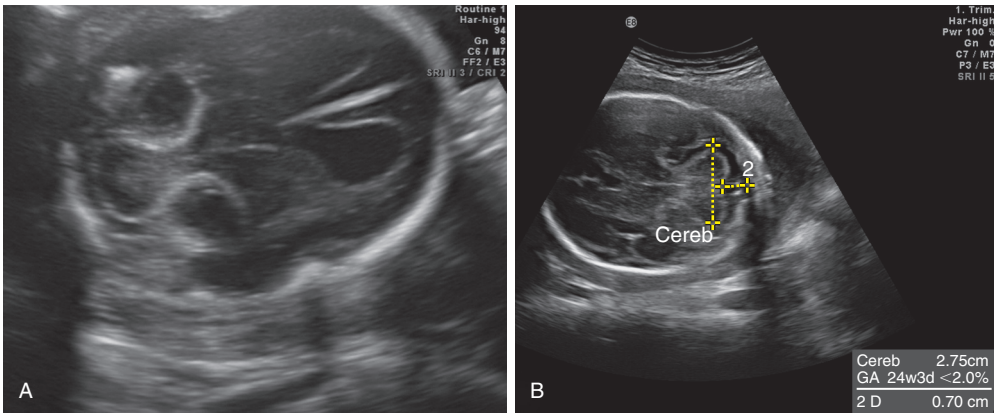

Fig. 37.2 (A) Rhombencephalosynapsis in a 21-week, 6-day fetus. The reduced size of the cerebellum is readily apparent. The cerebellum has a rounded shape, and there is a lack of hyperechogenicity in the midline owing to agenesis of the vermis. This fetus was referred because of severe ventriculomegaly with disruption of the septum pellucidum (not shown). (B) CH in a 28-week, 4-day fetus. TCD is 4 weeks smaller than expected, but the anatomy is conserved.

as a total or partial agenesis of the vermis with fusion of the cerebellar hemispheres. The degree to which TCD is reduced varies, but usually a small TCD is clearly apparent (see Fig. 37.2A). The diagnosis is confirmed if continuity of the folia from one hemisphere to the other (in axial and coronal planes) can be shown, and the vermis and a normal, triangular fourth ventricle (in coronal and midsagittal planes) cannot be seen. Rhombencephalosynapsis may occur as an isolated finding, or as a part of malformative syndromes; the best-known syndrome is Gomez-Lopez-Hernandez syndrome characterized by rhombencephalosynapsis, parietooccipital alopecia, trigeminal nerve anesthesia, intellectual impairment, craniosynostosis, short stature, and craniofacial anomalies.[8] Prenatal diagnosis of this condition has been reported in at least 40 cases.[9,10] Patients without associated malformations may have normal, or almost normal, neurodevelopment.[11]

IUGR may present a diagnostic challenge when gestational age is unknown. Fetuses with a well-established diagnosis of IUGR and a small cerebellum have a twofold increase in perinatal mortality compared with other fetuses with IUGR.[1]

Cerebellar hemispheric asymmetry is being diagnosed with increasing frequency in fetuses and newborns. Data obtained from the follow-up of children with cerebellar hemispheric asymmetry indicate that most cases are due to disruptive prenatal cerebellar insults, most likely hemorrhagic, leading to the development of unilateral hypoplasia.[12,13] Other possible etiologies include cerebellar infarction, infection, and bleeding in a cavernous angioma or tumor. Regardless of etiology, it is believed that unilateral CH originates in the prenatal period. The clinical picture ranges from asymptomatic cases to severe impairment; patients with involvement of the vermis or the pons probably have a poorer prognosis.[14] The natural history in cases diagnosed in utero may be dynamic over time, with intracerebellar hyperechogenicities that gradually develop into a cystic lesion leading to a small cerebellar hemisphere (Fig. 37.3).[15]

A small cisterna magna (less than 2 mm) should raise the suspicion of Chiari II malformation with open spinal dysraphism (see Chapter 41). This finding is usually associated with ventriculomegaly, abnormal skull shape, and disappearance of the subarachnoid spaces around the brain. Although identification of spinal dysraphism may be difficult, it almost always can be shown eventually using either a transabdominal or a transvaginal approach.

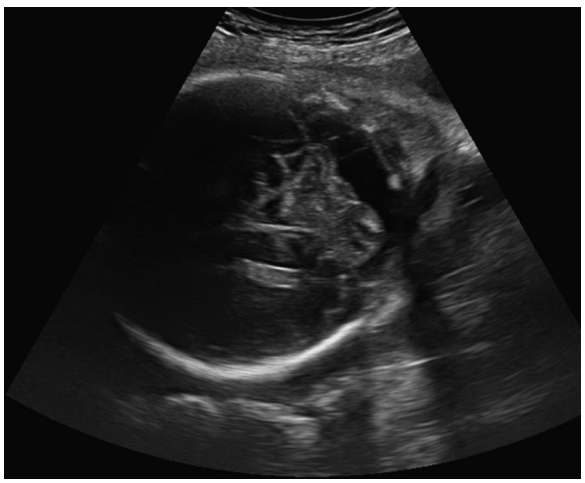

Fig. 37.3 Cerebellar asymmetry at 32 weeks' gestation after cerebellar hemorrhage.

Identification of a large cisterna magna (greater than 10 mm) is an indication for a detailed examination of the vermis using orthogonal planes. A persistent Blake pouch may produce the false impression that the vermis is not completely formed, but in these cases the posterior fossa is usually of normal size, and the tentorium is not elevated. The differential diagnoses in patients with a large cisterna magna include mega cisterna magna, retrocerebellar arachnoid cyst, DWM, and other conditions affecting the vermis. In these patients, the first step is to study the normality of the vermis (see Imaging Technique and Findings). Although difficult to establish using US or MRI, a morphologically normal vermis reduces the differential diagnoses to only two entities: mega cisterna magna or retrocerebellar arachnoid cyst. When the vermis seems abnormal, DWM should be suspected.

Mega cisterna magna is defined as a cisterna magna larger than 10 mm. In many cases of apparent large cisterna magna (greater than 10 mm), a measurement in a wrong plane with the transducer in a plane between the axial and the coronal plane is the cause. Mega cisterna magna does not exert pressure on the adjacent cerebellum or cause ventriculomegaly. A large cisterna magna may be associated with macrocephaly. Isolated mega cisterna magna may be considered a normal variant and is not associated with neurodevelopmental delay.[16]

Arachnoid cysts may be present at different locations in the fetal brain, but infratentorial retrocerebellar cysts are the most common arachnoid cyst diagnosed in utero. These cysts rarely may cause pressure on the cerebellum and brainstem; these fetuses may develop progressive ventriculomegaly and need surgical treatment comprising decompression of the cyst or ventriculoperitoneal shunt. Generally, the prognosis is similar to mega cisterna magna.[16]

Dandy-Walker malformation (DWM) is defined by the presence of a cystic dilatation of the posterior fossa communicating with the fourth ventricle with varying degrees of hypoplasia or agenesis of the vermis and elevation of the tentorium (Fig. 37.4). DWM may be accompanied by ventriculomegaly of different degrees of severity. The prevalence of DWM is unknown; its incidence has been reported to be 1:100,000 live births.[17] An unusually wide communication between the fourth ventricle and the cisterna magna, and elevation of the tentorium are the additional required US signs of DWM. The degree of development of the vermis, in particular the presence of normal primary and secondary fissures, is important in establishing the prognosis (see Imaging Technique and Findings). The mass effect produced by dilatation of the fourth ventricle and cisterna magna makes the task of measuring the vermis and assessing its structure difficult even by MRI; in these patients, the presence of a normal or abnormal pons may be important (see subsequent discussion of pontocerebellar hypoplasia). Prognosis is related not only to the presence of associated malformations[18] but also to degree of hypoplasia of the vermis.[19] Survival rates range from 6%[20] to 75%[18] of affected newborns.

The terms *vermian agenesis* and *isolated vermian hypoplasia* describe a heterogeneous group of conditions with confusing definitions and terminologies.[21] In the prenatal literature, *Dandy-Walker variant, isolated vermian hypoplasia, inferior vermian hypoplasia,* and *vermian dysgenesis* or *agenesis* as part of molar tooth–related syndromes are inaccurately used

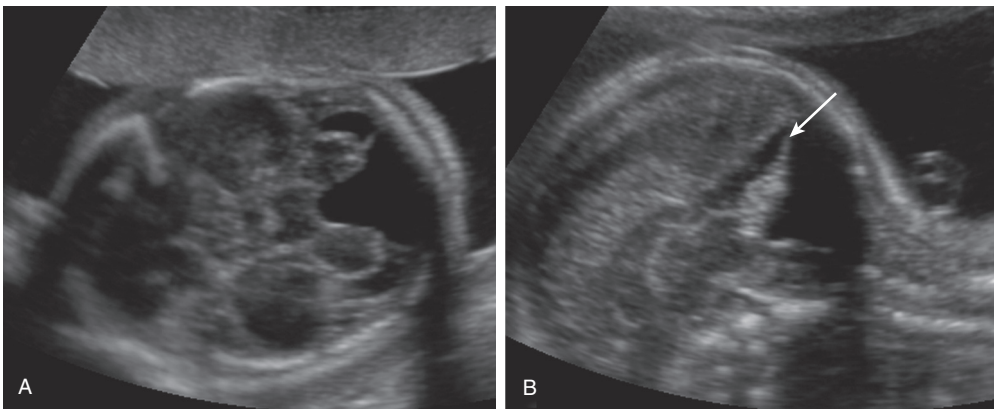

Fig. 37.4 Classic DWM at 22 weeks' gestation. Axial (A) and sagittal (B) planes show the large fourth ventricle communicating with a large cisterna magna. The abnormal vermis is depicted only in B. The tentorium is elevated *(arrow)*.

as synonymous. Using the multiplanar approach, it is possible in most, but not all, cases to differentiate among these entities.[22]

The presence of a wide communication between the fourth ventricle and a normal-sized cisterna magna with normal vermian biometry, normal ratio between the superior and inferior portions of the vermis, and normal fissures is indicative of delayed closure of the vermis, probably secondary to a persistent Blake pouch. This condition is also called *Blake pouch cyst* and usually has a good prognosis.

An apparently isolated small vermis with all the lobules present should raise the suspicion of vermian hypoplasia. For these patients, a prognosis usually cannot be made in utero because this condition can be found as a dominant benign trait or as part of genetic syndromes such as fragile X syndrome.

A complete or partially missing vermis is indicative of *vermian agenesis*. If the cerebellar hemispheres are wide apart, the diagnosis may be straightforward, but in some cases the missing vermis permits the hemispheres to "invade" the midline, giving the false appearance of the vermis being present. This potential pitfall may be avoided by failure to visualize midline hyperechogenicity that is characteristic of the normal vermis in axial and coronal planes; by observing that, in the sagittal plane, the folia of the hemispheres are present instead of the vermian fissures; and by showing that the fourth ventricle does not have its usual triangular shape. In these cases, a search for "molar tooth" (a descriptive term borrowed from MRI) features, including the visualization of the interpeduncular fossa, cerebellar peduncles, and brainstem to diagnose the so-called molar tooth–related syndromes, is indicated.

The absence of normal anterior protrusion of the pons together with abnormal cerebellar findings is frankly pathologic (e.g., pontocerebellar hypoplasia). This finding is associated with a poor prognosis.

MANIFESTATIONS OF DISEASE

Clinical Presentation

The clinical presentation includes abnormal US appearance of the posterior fossa, either enlarged cisterna magna (in cerebellar vermian anomalies), or small or absent cisterna magna (in open spinal dysraphism).

Imaging Technique and Findings

Ultrasound and Magnetic Resonance Imaging. The relatively late development of the cerebellum, the possibility that cerebellar pathologies are due to an arrest of development in many cases, and technical difficulties in the visualization of the infratentorial structures make prenatal diagnosis of cerebellar diseases very challenging even for experts using neurosonography[22] or MRI.[23] Because of these factors, we and others[24] believe that the approach for the diagnosis of suspected cerebellar anomalies should be a stepwise description of important infratentorial landmarks, including the following:

1. Measurement of TCD (see Fig. 37.1)[1,25]
2. Assessment of hemispheric symmetry (see Fig. 37.3) (marked asymmetry is due to unilateral hypoplasia)
3. Measurement of the width of the cisterna magna (see Fig. 37.1A)[26]
4. Evaluation of the vermis, including size, presence of fissures, and shape of the fourth ventricle (Fig. 37.5)[27]
5. Evaluation of the pons (see Fig. 37.5)[28]

In all cases, a search for associated central nervous system and noncentral nervous system anomalies should be attempted because any additional pathologic finding indicates a poorer prognosis.

The measurement of the width of the cisterna magna is part of the minimal requirements of any fetal anatomic US scan (see Fig. 37.1).[29] The measurement is usually performed in the axial transcerebellar plane, but the midsagittal plane is considered more accurate. A width of 2 to 10 mm is considered normal.[26]

Evaluation of the vermis is probably the most difficult and tricky task in fetal brain imaging and is associated with numerous false-negative and false-positive diagnoses.[30] This difficulty is due to a combination of technical and developmental factors, including mainly that axial planes are insufficient for diagnosis, difficulties in obtaining true sagittal planes, differentiation between the vermis and the hemispheres in this plane, late development of the vermis, and late disappearance of Blake pouch.[22] The risk of clinical significance of a suspicious vermis is increased when the fetus has associated anomalies or an abnormal karyotype. A complete evaluation of the vermis includes visualization in orthogonal planes with particular attention to the size and presence of primary and secondary fissures reaching the fastigium and the shape of the fourth ventricle (see Fig. 37.5).[19,22,27,31]

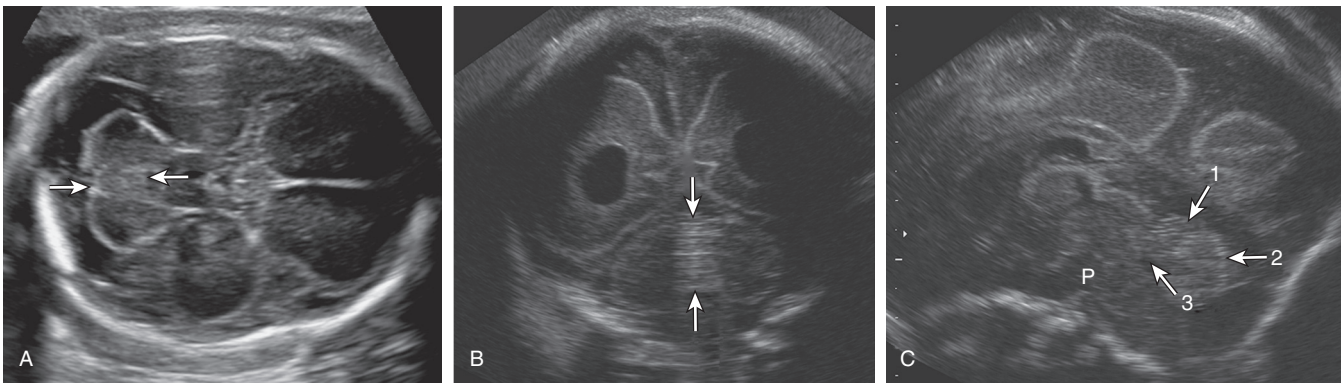

Fig. 37.5 Orthogonal planes show a normal fetal vermis at 25 weeks' gestation. Axial (A) and coronal (B) planes show the echogenic vermis *(arrows)*. In the midsagittal plane (C), the primary *(1)* and secondary *(2)* fissures are observed ending close to the fastigium of the fourth ventricle *(3)*. The pons is also observed in this plane *(P)*.

In the midsagittal plane, the pons can be seen as a hypoechogenic structure protruding anteriorly. Evaluation of the pons by biometric assessment can aid in questionable cases.[28]

CLASSIC SIGNS

Enlarged cisterna magna (apparent on an axial scan) in Blake pouch cyst, mega cisterna magna, retrocerebellar arachnoid cyst, or DWM.
Small or not measureable cisterna magna in Chiari II malformation associated with spinal dysraphism.
Absence of echogenic vermian tissue and fusion of the hemispheres in the midline in rhombencephalosynapsis.
Hypoplasia of the cerebellar vermis without the other signs of DWM—various entities formerly termed *Dandy-Walker variants*.

Differential Diagnosis From Imaging Findings

The differential diagnosis for a large cisterna magna includes Blake pouch cyst, retrocerebellar arachnoid cyst, and mega cisterna magna (normal-sized cerebellar vermis) versus DWM (missing lower part and upward rotation of the vermis, elevated tentorium), or vermian hypoplasia or agenesis.

Synopsis of Treatment Options

PRENATAL

In conditions with a known poor prognosis, the offer of pregnancy termination can be considered. However, the normal variants or more benign alterations such as Blake pouch cyst or mega cisterna magna that may imitate severe cerebellar anomalies must be confidently excluded.

POSTNATAL

Postnatal treatment is determined by neuropediatric findings.

WHAT THE REFERRING PHYSICIAN NEEDS TO KNOW

- Various anomalies in the posterior fossa can alter the appearance of the fetal cerebellum and cisterna magna.
- Often, but not always, a detailed neurosonography examination can differentiate between these anomalies prenatally.
- The most common anomaly of the posterior fossa is the Chiari II malformation in open spina bifida.
- Normal variants or milder forms that may imitate more severe anomalies must be kept in mind.

KEY POINTS

- Fetal cerebellar anomalies may be diagnosed using a stepwise approach.
- Abnormal conditions affecting the cerebellum, in particular the vermis, may not be diagnosed during pregnancy, even in high-risk patients.

SUGGESTED READING

D'Antonio F, Khalil A, Garel C, et al. Systematic review and meta-analysis of isolated posterior fossa malformations on prenatal ultrasound imaging (part 1): nomenclature, diagnostic accuracy and associated anomalies. *Ultrasound Obstet Gynecol*. 2016;47:690-697. doi:10.1002/uog.14900.
D'Antonio F, Khalil A, Garel C, et al. Systematic review and meta-analysis of isolated posterior fossa malformations on prenatal imaging (part 2): neurodevelopmental outcome. *Ultrasound Obstet Gynecol*. 2016;48:28-37. doi:10.1002/uog.15755.
Guibaud L, des Portes V. Plea for an anatomical approach to abnormalities of the posterior fossa in prenatal diagnosis. *Ultrasound Obstet Gynecol*. 2006;27:477-481.
ISUOG guidelines. Sonographic examination of the fetal central nervous system: guidelines for performing the basic examination and the fetal neurosonogram. *Ultrasound Obstet Gynecol*. 2007;29:109-116.
Limperopoulos C, Robertson RL Jr, Khwaja OS, et al. How accurately does current fetal imaging identify posterior fossa anomalies? *AJR Am J Roentgenol*. 2008;190:1637-1643.
Malinger G, Lev D, Lerman-Sagie T. The fetal cerebellum: pitfalls in diagnosis and management. *Prenat Diagn*. 2009;29:372-380.

All references are available online at www.expertconsult.com.

REFERENCES

1. Vinkesteijn AS, Mulder PG, Wladimiroff JW. Fetal transverse cerebellar diameter measurements in normal and reduced fetal growth. *Ultrasound Obstet Gynecol*. 2000;15:47-51.
2. Barth PG. Pontocerebellar hypoplasias: an overview of a group of inherited neurodegenerative disorders with fetal onset. *Brain Dev*. 1993;15: 411-422.
3. Mitra AG, Salvino AR, Spence JE. Prenatal diagnosis of fatal infantile olivopontocerebellar hypoplasia syndrome. *Prenat Diagn*. 1999;19: 375-378.
4. Vinkesteijn AS, Jansen CL, Los FJ, et al. Fetal transcerebellar diameter and chromosomal abnormalities. *Ultrasound Obstet Gynecol*. 2001;17: 502-505.
5. Garel C. *MRI of the fetal brain: normal development and cerebral pathologies*. Berlin: Springer; 2004.
6. Goasdoue P, Rodriguez D, Moutard ML, et al. Pontoneocerebellar hypoplasia: definition of MR features. *Pediatr Radiol*. 2001;31:613-618.
7. Graham JM Jr, Spencer AH, Grinberg I, et al. Molecular and neuroimaging findings in pontocerebellar hypoplasia type 2 (PCH2): is prenatal diagnosis possible? *Am J Med Genet A*. 2010;152A:2268-2276.
8. Tan TY, McGillivray G, Goergen SK, et al. Prenatal magnetic resonance imaging in Gomez-Lopez-Hernandez syndrome and review of the literature. *Am J Med Genet A*. 2005;138:369-373.
9. McAuliffe F, Chitayat D, Halliday W, et al. Rhombencephalosynapsis: prenatal imaging and autopsy findings. *Ultrasound Obstet Gynecol*. 2008;31: 542-548.
10. Napolitano M, Righini A, Zirpoli S, et al. Prenatal magnetic resonance imaging of rhombencephalosynapsis and associated brain anomalies: report of 3 cases. *J Comput Assist Tomogr*. 2004;28:762-765.
11. Poretti A, Alber FD, Burki S, et al. Cognitive outcome in children with rhombencephalosynapsis. *Eur J Paediatr Neurol*. 2009;13:28-33.
12. Poretti A, Boltshauser E, Huisman TA. Prenatal cerebellar disruptions: neuroimaging spectrum of findings in correlation with likely mechanisms and etiologies of injury. *Neuroimaging Clin N Am*. 2016;26:359-372.
13. Poretti A, Limperopoulos C, Roulet-Perez E, et al. Outcome of severe unilateral cerebellar hypoplasia. *Dev Med Child Neurol*. 2010;52:718-724.
14. Benbir G, Kara S, Yalcinkaya BC, et al. Unilateral cerebellar hypoplasia with different clinical features. *Cerebellum*. 2011;10:49-60.
15. Malinger G, Zahalka N, Kidron D, et al. Fatal outcome following foetal cerebellar haemorrhage associated with placental thrombosis. *Eur J Paediatr Neurol*. 2006;10:93-96.
16. Dror R, Malinger G, Ben-Sira L, et al. Developmental outcome of children with enlargement of the cisterna magna identified in utero. *J Child Neurol*. 2009;24:1486-1492.
17. Ohaegbulam SC, Afifi H. Dandy-Walker syndrome: incidence in a defined population of Tabuk, Saudi Arabia. *Neuroepidemiology*. 2001;20:150-152.
18. Salihu HM, Kornosky JL, Druschel CM. Dandy-Walker syndrome, associated anomalies and survival through infancy: a population-based study. *Fetal Diagn Ther*. 2008;24:155-160.
19. Adamsbaum C, Moutard ML, Andre C, et al. MRI of the fetal posterior fossa. *Pediatr Radiol*. 2005;35:124-140.
20. Has R, Ermis H, Yuksel A, et al. Dandy-Walker malformation: a review of 78 cases diagnosed by prenatal sonography. *Fetal Diagn Ther*. 2004;19: 342-347.
21. Parisi MA, Dobyns WB. Human malformations of the midbrain and hindbrain: review and proposed classification scheme. *Mol Genet Metab*. 2003;80:36-53.
22. Malinger G, Lev D, Lerman-Sagie T. The fetal cerebellum: pitfalls in diagnosis and management. *Prenat Diagn*. 2009;29:372-380.
23. Limperopoulos C, Robertson RL Jr, Khwaja OS, et al. How accurately does current fetal imaging identify posterior fossa anomalies? *AJR Am J Roentgenol*. 2008;190:1637-1643.
24. Guibaud L, des Portes V. Plea for an anatomical approach to abnormalities of the posterior fossa in prenatal diagnosis. *Ultrasound Obstet Gynecol*. 2006;27:477-481.
25. Campbell WA, Nardi D, Vintzileos AM, et al. Transverse cerebellar diameter/abdominal circumference ratio throughout pregnancy: a gestational age-independent method to assess fetal growth. *Obstet Gynecol*. 1991;77: 893-896.
26. Filly RA, Cardoza JD, Goldstein RB, et al. Detection of fetal central nervous system anomalies: a practical level of effort for a routine sonogram. *Radiology*. 1989;172:403-408.
27. Malinger G, Ginath S, Lerman-Sagie T, et al. The fetal cerebellar vermis: normal development as shown by transvaginal ultrasound. *Prenat Diagn*. 2001;21:687-692.
28. Achiron R, Kivilevitch Z, Lipitz S, et al. Development of the human fetal pons: in utero ultrasonographic study. *Ultrasound Obstet Gynecol*. 2004; 24:506-510.
29. ISUOG guidelines. Sonographic examination of the fetal central nervous system: guidelines for performing the basic examination and the fetal neurosonogram. *Ultrasound Obstet Gynecol*. 2007;29:109-116.
30. Phillips JJ, Mahony BS, Siebert JR, et al. Dandy-Walker malformation complex: correlation between ultrasonographic diagnosis and postmortem neuropathology. *Obstet Gynecol*. 2006;107:685-693.
31. Malinger G, Lev D, Lerman-Sagie T. Normal and abnormal fetal brain development during the third trimester as demonstrated by neurosonography. *Eur J Radiol*. 2006;57:226-232.

38 Walker-Warburg Syndrome

METHODIUS G. TUULI | ANTHONY O. ODIBO

Introduction

Walker-Warburg syndrome (WWS) is a rare, lethal congenital diffuse neurodysplasia, characterized by variable ocular and cerebral abnormalities. Cerebral findings include ventriculomegaly, encephalocele, and Dandy-Walker malformation. Ocular findings are varied, may occur in the posterior or anterior segments of the eye, or both, and include microphthalmia, congenital cataracts, corneal opacities, nonreactive pupils, iris synechiae, optic disk colobomas, and retinal dysplasia or detachment.[1]

Disease

DEFINITION

The principal morphologic diagnostic criteria of WWS are lissencephaly, cerebellar and ocular abnormalities, and congenital muscular dystrophy.[2]

PREVALENCE AND EPIDEMIOLOGY

WWS is a rare disease with a worldwide distribution. Although the overall incidence is unknown, a survey in Italy reported an incidence of 1.2:100,000 live births.[3] WWS has been noted to recur in siblings, especially in consanguineous families, suggesting an autosomal recessive mode of inheritance.[4,5]

ETIOLOGY AND PATHOPHYSIOLOGY

Several genes have been implicated in the etiology of WWS with considerable heterogeneity. Approximately 20% of patients have mutations in the protein *O*-mannosyltransferase 1 and 2 (*POMT1* and *POMT2*) genes, which are essential for muscle and neuronal development.[6,7] The neurodysplasia has been attributed to failure of neuronal migration between the sixth and ninth weeks of gestation[8]; this may result from toxins, drugs, infections, radiation, or chromosomal aberrations. The ocular abnormalities are considered the result of abnormal differentiation of eye structures.

MANIFESTATIONS OF DISEASE

Clinical Presentation

A family history of the disorder or ultrasound (US) findings of lissencephaly, cerebral and cerebellar abnormalities, and ocular defects should raise suspicion of WWS prenatally. Clinical manifestations at birth include generalized hypotonia, muscle weakness, developmental delay, mental retardation, and occasional seizures. Laboratory investigations usually show elevated creatine kinase, and muscle pathology reveals a myopathic or dystrophic pattern and altered alpha-dystroglycan.

Imaging Technique and Findings

Ultrasound. Although it is possible to look for a wide range of diagnostic signs in the neonate, it is not feasible to identify all the signs on US. Findings include ventriculomegaly (Fig. 38.1), encephalocele (Fig. 38.2), and Dandy-Walker malformation.



Fig. 38.1 Midsagittal sonographic image, demonstrating Z-shaped appearance of the brainstem *(dotted line)*, surrounded by an echogenic band *(arrows)*, associated with a posterior fossa cyst *(C)* causing upward displacement of the small vermis *(V)*. This is classic in cases of cobblestone lissencephaly. *(From Lacalm A, Nadaud B, Massoud M, et al.: Prenatal diagnosis of cobblestone lissencephaly associated with Walker-Warburg syndrome based on a specific sonographic pattern.* Ultrasound Obstet Gynecol. *47:117– 122, 2016)*

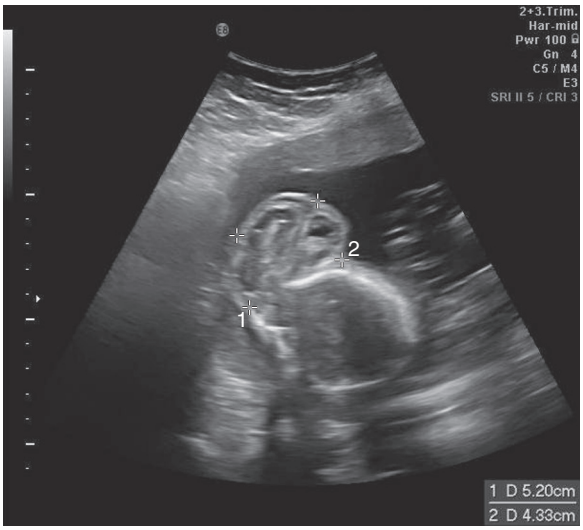

Fig. 38.2 Encephalocele.

Dandy-Walker malformation can be diagnosed at 14 weeks' gestation, and ventriculomegaly can be seen by 15 to 17 weeks' gestation.[9,10] Lissencephaly cannot be reliably diagnosed until after 28 weeks, but a recent report describes making this diagnosis as early as 14 weeks.[11] Lissencephaly may also be seen from a transvaginal view of the brain as a cobblestone appearance.[12]

Magnetic Resonance Imaging. Magnetic resonance imaging (MRI) may be used to confirm the intracranial findings, especially lissencephaly.[13]

CLASSIC SIGNS

Lissencephaly
Cerebellar and ocular abnormalities
Congenital muscular dystrophy

Differential Diagnosis From Imaging Findings

Differential diagnosis of the common findings (ventriculomegaly, encephalocele, and lissencephaly) include the following[14]:

1. *Aneuploidy*—trisomy 13 and trisomy 18
2. *Congenital infections*—toxoplasmosis, rubella, cytomegalovirus, herpes
3. *Nonchromosomal syndromes*—Meckel-Gruber syndrome, Miller-Dieker syndrome, Fryns syndrome, Neu-Laxova syndrome

Synopsis of Treatment Options

PRENATAL

WWS is a lethal disorder. Genetic counseling should be offered to parents, and amniocentesis should be recommended to exclude aneuploidy. Prenatal testing is possible in families with known mutations.[15]

POSTNATAL

In most reported cases of WWS, infants have died within the first few months of life, with almost all affected children dying by age 3 years. Because no specific treatment is available, management is supportive and preventive. Nutrition should be monitored and supplemented via tube feeding as needed. Anticonvulsants may be used as needed if seizures occur. Some children require shunt placement for hydrocephalus or encephalocele.

WHAT THE REFERRING PHYSICIAN NEEDS TO KNOW

It is not feasible to identify all the signs of WWS on US. Common findings include ventriculomegaly, encephalocele, and Dandy-Walker malformation. Lissencephaly can be diagnosed only after 28 weeks' gestation and is often best seen using transvaginal US to view the fetal brain.

KEY POINTS

- WWS is a rare lethal congenital diffuse neurodysplasia characterized by variable ocular and cerebral abnormalities.
- The principal morphologic diagnostic criteria are lissencephaly, cerebellar and ocular abnormalities, and congenital muscular dystrophy.
- Several genes have been implicated in the etiology of WWS, including the *POMT1* and *POMT2* genes, with an autosomal recessive pattern of inheritance.
- No specific treatment is available for WWS; management is supportive and preventive.

SUGGESTED READING

Lacalm A, Nadaud B, Massoud M, et al. Prenatal diagnosis of cobblestone lissencephaly associated with Walker-Warburg syndrome based on a specific sonographic pattern. *Ultrasound Obstet Gynecol*. 2016;47:117-122.

Vajsar J, Schachter H. Walker-Warburg syndrome. *Orphanet J Rare Dis*. 2006;1:29.



All references are available online at www.expertconsult.com.

REFERENCES

1. Murphy KJ, PeBenito R, Storm RL, et al. Walker-Warburg syndrome: case report and literature review. *Ophthalmic Paediatr Genet*. 1990;11:103-108.
2. Dobyns WB, Kirkpatrick JB, Hittner HM, et al. Syndromes with lissencephaly. II. Walker-Warburg and cerebro-oculo-muscular syndromes and a new syndrome with type II lissencephaly. *Am J Med Genet*. 1985;22:157-195.
3. Mostacciuolo ML, Miorin M, Martinello F, et al. Genetic epidemiology of congenital muscular dystrophy in a sample from north-east Italy. *Hum Genet*. 1996;97:277-279.
4. Warburg M. Hydrocephaly, congenital retinal nonattachment, and congenital falciform fold. *Am J Ophthalmol*. 1978;85:88-94.
5. Chemke J, Czernobilsky B, Mundel G, et al. A familial syndrome of central nervous system and ocular malformations. *Clin Genet*. 1975;7:1-7.
6. Beltran-Valero de Bernabe D, Currier S, Steinbrecher A, et al. Mutations in the O-mannosyltransferase gene POMT1 give rise to the severe neuronal migration disorder Walker-Warburg syndrome. *Am J Hum Genet*. 2002;71:1033-1043.
7. van Reeuwijk J, Janssen M, van den Elzen C, et al. POMT2 mutations cause alpha-dystroglycan hypoglycosylation and Walker-Warburg syndrome. *J Med Genet*. 2005;42:907-912.
8. Miller G, Ladda RL, Towfighi J. Cerebro-ocular dysplasia—muscular dystrophy (Walker-Warburg) syndrome: findings in 20-week-old fetus. *Acta Neuropathol*. 1991;82:234-238.
9. Achiron R, Achiron A. Transvaginal ultrasonic assessment of the early fetal brain. *Ultrasound Obstet Gynecol*. 1991;1:336-344.
10. Friedman JM, Santos-Ramos R. Natural history of X-linked aqueductal stenosis in the second and third trimesters of pregnancy. *Am J Obstet Gynecol*. 1984;150:104-106.
11. Lacalm A, Nadaud B, Massoud M, et al. Prenatal diagnosis of cobblestone lissencephaly associated with Walker-Warburg syndrome based on a specific sonographic pattern. *Ultrasound Obstet Gynecol*. 2016;47:117-122.
12. Monteagudo A, Timor-Tritsch IE. Development of fetal gyri, sulci and fissures: a transvaginal sonographic study. *Ultrasound Obstet Gynecol*. 1997;9:222-228.
13. Okamura K, Murotsuki J, Sakai T, et al. Prenatal diagnosis of lissencephaly by magnetic resonance image. *Fetal Diagn Ther*. 1993;8:56-59.
14. Monteagudo A, Alayon A, Mayberry P. Walker-Warburg syndrome: case report and review of the literature. *J Ultrasound Med*. 2001;20:419-426.
15. Vajsar J, Schachter H. Walker-Warburg syndrome. *Orphanet J Rare Dis*. 2006;1:29.

To access the videos in this chapter, scan this QR code or visit expertconsult.com

39 Holoprosencephaly

HARM-GERD K. BLAAS

Introduction

Holoprosencephaly (HPE) has been known since antiquity through the figure of the cyclopean shepherd Polyphemos in Homer's *Odyssey* (circa 800 BC). Until the 17th century, a cyclopic newborn, whether it was a human or an animal, was associated with mystic and fabulous narrations.[1,2] In the 18th century, HPE and other anomalies were recognized as congenital conditions, and cases of HPE were collected and described scientifically.[1,2] Recently, a 1500-year-old skull of a 5-year-old child (based on ossification and tooth eruption) who had a premaxillary agenesis and ocular hypotelorism was found in Peru.[3]

Recognition of HPE prenatally by two-dimensional (2D) ultrasound (US) was first described by Kurtz et al. in 1980[4] and has since been described in many case reports and studies. Alobar HPE is the most severe form of HPE and can be diagnosed with 2D and three-dimensional (3D) US in the embryonic period at 9 weeks' gestational age.[5] Although magnetic resonance imaging (MRI) was introduced into fetal imaging in 1984, and fetal HPE was described by MRI in 1991,[6] this imaging modality still has limited application in diagnosis of fetal HPE because MRI investigations require resources. Neuroimaging studies of postnatal HPE are mainly based on MRI and have shown an extensive variety of expression.[7] The full range of the variety of expression of HPE and associated anomalies has not yet been described in prenatal studies.

Disease

DEFINITION

HPE is a heterogeneous central nervous system (CNS) anomaly that results from a primary defect in induction and patterning of the rostral neural tube (basal forebrain), leading to varying degrees of incomplete separation of the cerebral hemispheres. The categorization of HPE introduced by DeMyer and Zeman in 1963 and modified by DeMyer in 1977[8] is still generally accepted. HPE is graded according to the severity of the brain anomaly as *alobar, semilobar,* and *lobar*. A mild version of HPE called *middle interhemispheric variant of HPE* has also been identified.[9]

PREVALENCE AND EPIDEMIOLOGY

Embryo

In 2004, a large embryonic study of HPE from Japan was published.[10] Embryos were diagnosed with HPE if they had characteristic craniofacial features, such as closely apposed or fused eyes, proboscis, and abnormally narrow heads. They found 201 HPE cases among 44,000 human embryos ranging from Carnegie stages 13 to 23, which corresponds approximately to 6 to 10 completed weeks based on last menstrual period. The prevalence of severe HPE in this embryonic population was 50:10,000. The actual prevalence is probably higher because mild forms of HPE could have escaped detection, particularly in the early stages of craniofacial development. This Japanese study did not classify the types of HPE according to brain anomalies, and karyotype was unknown.

Fetus

Many US reports describe the diagnosis of fetal HPE. A few fetal studies allow some epidemiologic conclusions.[11–13] Kagan[12] reported 57,119 pregnancies at 11 to 13 weeks' gestation, in which 44 cases of alobar HPE were detected, a prevalence of alobar HPE of 7.7:10,000. Of the 44 cases, 29 (66%) were aneuploid. Two likely reasons account for the high prevalence in this study: (1) early pregnancy losses in HPE fetuses, especially among fetuses associated with presumptive lethal chromosome defects, would not appear in series ascertained at birth, and (2) this may have been a selected population.

Blaas et al.[11] reported 17 fetuses from a referral population and 13 fetuses from a nonselected population of 119,411 deliveries (greater than or equal to 16 weeks' gestation). The mean age of detection of the cases was 21 ± 3 weeks' gestation. After reviewing records at all hospitals with departments of obstetrics, pediatrics, and pathology within the catchment area, two further HPE cases (one alobar and one semilobar) were identified that had not been diagnosed before delivery and resulted in death shortly after birth. Cases with lobar HPE were not identified. The prevalence of HPE in the nonselected fetal population was 1.26:10,000. Chromosome aberrations were present in 37% (11 of 30) of the whole study group. The brain anomalies consisted of 18 lobar HPE (60%), 5 semilobar HPE (17%), 4 lobar HPE (13%), and 3 anencephalic HPE (10%; see later).

A study from Taiwan[13] was based on HPE cases that were detected by US among cases referred for fetal karyotyping (Chen C, personal communication). A high prevalence of 6:10,000 could be the result of selection bias of pregnancies at risk for abnormal chromosomes.[13] Only alobar HPE types were diagnosed, and 34 (58%) had abnormal chromosomes.

A perinatal study from California (121 HPE diagnoses in 1,035,386 live births and fetal death deliveries, registered from greater than or equal to 20 weeks' gestational age to 1 year after delivery) reported a prevalence of 1.2:10,000.[14] The investigators found 56 alobar (46%), 24 semilobar (20%), and 11 lobar (9%) HPE cases, and 30 specimens (25%) had undetermined HPE type.[14]

International Studies

Large international studies including termination of pregnancies, stillbirths, and live births have found relatively high prevalences of HPE.[15,16] The prevalence of HPE cases ascertained was 2.16:10,000 in a hospital-based population of 179 cases from South America (during 2000 to 2003).[17] In the International Clearinghouse Birth Defects Surveillance Registry, the prevalence was 1.31:10,000, based on 963 HPE cases from 2000 to 2004.[16] A similar prevalence of 1.33:10,000 was observed in the EUROCAT registry in 2010,[15] which included 827 cases of arrhinencephalia or HPE in approximately 6,218,000 deliveries occurring from 2000 to 2008.

HPE study populations differ depending on the age of the specimens, the time of the detection of HPE, the number of cases, identified subgroups (e.g., chromosomal, nonchromosomal, not karyotyped), and the type of population (selected or nonselected). Substantial variations also exist in the identified cerebral defects and accompanying facial anomalies that generate differences in the ascertainment and categorizing of HPE cases. The discrepancy between embryonic and early fetal populations versus perinatal populations indicates a high loss rate of fetuses with HPE early in the first trimester. In addition, it is probable that some HPE cases are not recognized perinatally and not registered. Newborns with HPE and normal faces and infants with mild cerebral HPE types are especially prone to being missed. The inclusion of diagnoses until age 1 year in the postnatal study in California probably explains the relatively high prevalence and large share of mild HPE types. HPE features in conditions such as anencephaly and agnathia can also be overlooked or ignored in some studies.

ETIOLOGY AND PATHOPHYSIOLOGY

Etiologic heterogeneity contributes to the noticeable differences among HPE studies. Environmental, genetic, multifactorial, and unknown causes seem to be involved in the origin of this condition. HPE is an example of a multifactorial trait that may require synergy between mutations in key genes, interaction of these

mutations with endogenous variants, and additional environmental effects.[18]

Embryology

A common denominator for the large variety of the HPE spectrum is a defective induction of the prosencephalic neuroepithelium, including neural crest population by the prechordal plate during embryonic development, which may lead to HPE with its variable facial and cerebral appearances.[19] The mesendodermal prechordal plate is usually detectable in human embryos at Carnegie stages 7 and 8 rostral to the notochordal process in contact with the floor of the neural groove. At stages 9 and 10, the plate is related to neuromere D1, which consists of thick neural ectoderm and comprises the optic primordium.[19] In humans, the critical time period for teratogenic induction of HPE is in "the [embryologic] 3rd to early 4th week" of human development,[20] which corresponds approximately to Carnegie stages 9 and 10, or 4 weeks, 6 days to 5 weeks, 2 to 3 days, based on the last menstrual period.

Environmental Influences

Maternal factors such as diabetes have been associated with HPE. According to a study from 1983, the approximate risk to infants of diabetic mothers is 1% to 2%, which is a 200-fold greater risk than the general population.[20,21] The pathogenetic factors and their effects could be summarized as the result of any interference with the glycolytic pathway leading to a decreased rate of glycolysis and conversion of glucose to pyruvate.[22]

Animal studies have revealed that numerous teratogens may be involved in the development of HPE.[21] In a review of teratogenesis of HPE, Cohen and Shiota[21] summarized that various factors may be involved in the development of HPE, such as maternal alcohol consumption during early pregnancy, the influence of isotretinoin and etretinate on neural crest cells, mutated genes, and teratogens involving the Sonic Hedgehog (SHH) signaling pathway including perturbations in cholesterol homeostasis, which is an important part of this pathway. Two known causes of HPE in humans, fetal alcohol exposure and maternal diabetes, are both associated with elevated levels of reactive oxygen species.[21] The possible involvement of oxidative stress in the pathogenesis of HPE was shown by treating pregnant mice with antioxidants (vitamins C and E) to reduce oxidative stress. They partly prevented ethanol-induced apoptosis in the prechordal mesendoderm and HPE malformations.[23] This study may have important implications to the pathogenetic mechanisms and gene-environmental interaction in the genesis of HPE.

Abnormal Karyotype

The most frequently identified etiology of HPE is an abnormality of chromosome numbers. These abnormalities include trisomy 13, trisomy 18, and triploidy, although several other aberrations have been reported. Such chromosome aberrations are almost universally fatal in gestation or in infancy.[24] Trisomy 13 accounts for 75% of HPE cases caused by chromosomal anomalies (including cryptic rearrangements). Triploidy accounts for 20% of HPE cases. Trisomy 18 is less commonly seen in conjunction with HPE and accounts for 1% to 2% of the cases. HPE has also been reported in patients with trisomies other than trisomies 13 and 18. Overall, the recurrence risk of HPE secondary to cytogenetic anomalies is approximately 1%.[25]

Previous research on the genetic etiology of HPE showed at least 12 HPE candidate loci on 11 chromosomes, designated HPE 1 through 12.[26] Advances in cytogenetic techniques have enabled higher resolution and improved descriptions of chromosome aberrations in cases with HPE and have identified at least 14 genes where heterozygous mutations cause HPE, and even suggest that in some families several genetic events are necessary to cause HPE.[27]

Syndromes and Associations

HPE may be associated with numerous syndromes such as Meckel syndrome, Martin syndrome, Fitch syndrome, Pallister-Hall syndrome, Steinfeld syndrome, hypertelorism and ectrodactyly syndrome, velocardiofacial syndrome, pseudo–trisomy 13 syndrome, Lambotte syndrome, Genoa syndrome, Goldenhar syndrome, acrocallosal syndrome, and Smith-Lemli-Opitz syndrome.[11] Smith-Lemli-Opitz syndrome is due to a deficiency in the final step in the cholesterol biosynthetic pathway, 3β-hydroxy-steroid-Δ^7-reductase,[28] and cholesterol is an essential part of the SHH signaling network.[29]

Associated Anomalies

Depending on the etiology, either chromosome aberrations or nonchromosomal syndromes, a wide range of associated anomalies have been reported.

MANIFESTATIONS OF DISEASE

Clinical Presentation

Brain. In *alobar* HPE, only a single ventricle (holosphere) of variable size is present, lacking interhemispheric division (see Videos 39.1–39.4). Posteriorly, a membrane usually closes the holosphere. This membrane may bulge dorsally and form a fluid-filled "dorsal sac" (Fig. 39.1). The thalami and corpora striata are undivided across the midline; the olfactory tracts and bulbs and the corpus callosum are always absent (Fig. 39.2).

In *semilobar* HPE, there are rudimentary cerebral lobes, and an interhemispheric fissure may be present posteriorly (Fig. 39.3). The olfactory tracts and bulbs are absent or hypoplastic, and the corpus callosum is rudimentary.

In *lobar* HPE, some midline continuity may be present despite a distinct interhemispheric fissure. The olfactory tracts and bulbs may be absent, hypoplastic, or normal. Midline cleavage of the thalami and the corpora striata may be incomplete.

In the *middle interhemispheric variant* of HPE, the posterior frontal and parietal lobes fail to separate.[7] Hahn and Barnes[7] presented a detailed overview of the neuroimaging features of HPE based on postnatal high-resolution brain MRI studies (Table 39.1).

The HPE spectrum extends further into microforms with interhemispheric separation and only subtle midline brain defects (e.g., agenesis of corpus callosum).[30] Microforms may have normal brains by conventional neuroimaging, but display subtle craniofacial anomalies consistent with a midline defect, including hypotelorism (closely spaced eyes), a flat or sharp nasal bridge, choanal stenosis, or a single maxillary central incisor (SMCI).[31,32] Recently Solomon et al. presented five cases of microform HPE, four of whom had identified mutations in HPE-associated genes, who all had evidence for above-normal intelligence. This report expands the phenotypic spectrum of holoprosencephaly and is important in the counseling of patient and affected families.[32]

Face. The primary defect in induction and patterning of the rostral neural tube (basal forebrain, neural crest cells) also leads to variable facial anomalies (Fig. 39.4), which usually are

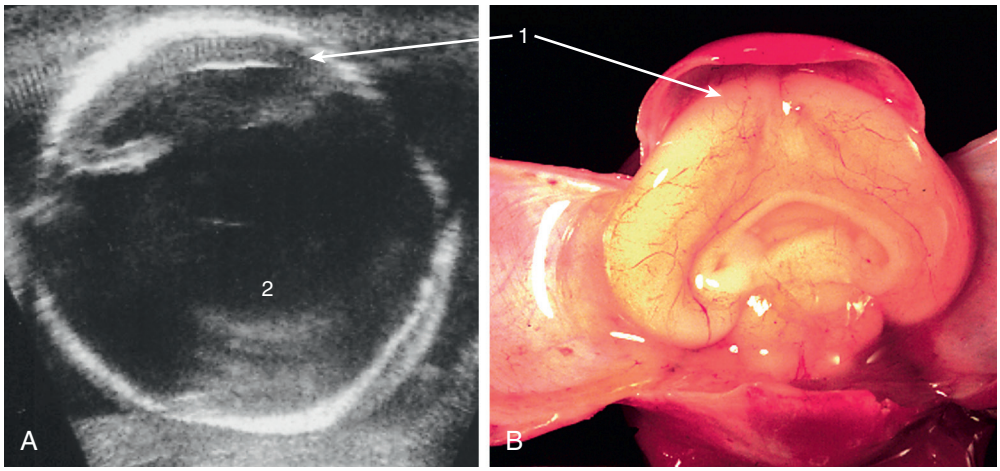

Fig. 39.1 Fetal alobar HPE at 18 weeks' gestation. (A) There is a small monocavity *(1)* and a large dorsal cyst *(2)*. (B) The membrane of the dorsal cyst collapsed at autopsy and cannot be seen in the macroscopic image.

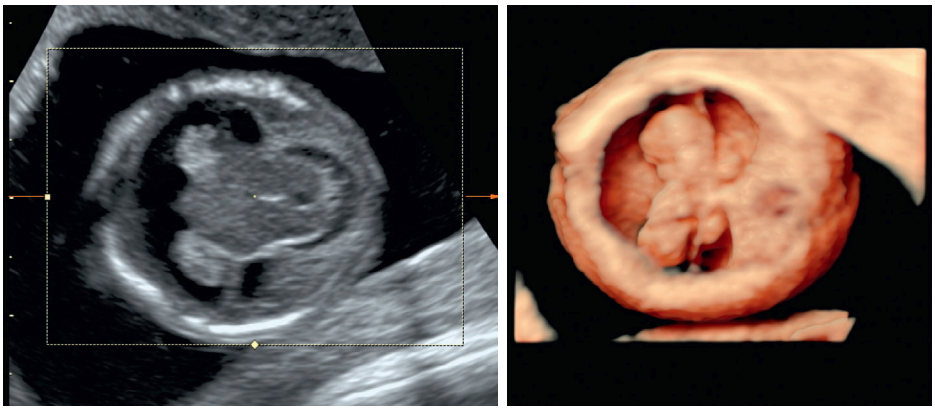

Fig. 39.2 Fetal alobar HPE at 13 weeks' gestation. The monocavity and the choroid plexuses are clearly visible in the 2D *(left)* and 3D *(right)* mode. *(Courtesy Rabih Chaoui.)*



Fig. 39.3 Autopsy images of a brain with semilobar HPE seen from cranial *(left)* and caudal *(right)*. The frontal part is fused, whereas the posterior part of the brain is clearly separated.

TABLE 39.1 MAGNETIC RESONANCE IMAGING NEUROIMAGING FEATURES OF HOLOPROSENCEPHALY TYPES

	Alobar	Semilobar	Lobar	MIH
Cortical nonseparation	Diffuse (holosphere)	Frontal	Basal frontal	Posterior frontal and parietal
Corpus callosum	Absent	Rostrum, genu, and body absent; splenium present	Rostrum and genu absent; anterior body variably present; splenium present	Body absent; genu variably present; splenium present
IHF and falx	Completely absent anteriorly and posteriorly	Present posteriorly only	Hypoplastic anteriorly and present posteriorly	Absent in posterior frontal and parietal region
Ventricles	Monoventricle communicating widely with dorsal cyst	Anterior horns absent; posterior horns present; small third ventricle	Rudimentary anterior horns; third ventricle formed	Normal or hypoplastic anterior horns; third ventricle formed
Dorsal cyst[a]	Usually present	Variably present	Absent	Present in ¼
Septum pellucidum	Absent	Absent	Absent or dysplastic	Absent
Thalamus	Often fused	Partial fusion	Usually fully separated	Fused in ⅓ to ½
Basal ganglia	Often fused (may form single mass with thalami)	Partial fusion (especially head of caudate)	Variable degree of fusion	Separated
Hypothalamus	Always fused to some degree (100%)	Very often fused to some degree (98%)	Often fused to some degree (83%)	Separated
Sylvian fissure	Often absent	Anteriorly and medially displaced (wide sylvian fissure) with fused frontal lobe	Anteriorly and medially displaced (wide sylvian fissure) with small frontal lobes	Often abnormally connected across the midline over the vertex
Cortical dysplasia and heterotopic gray matter	Frequent presence of diffuse broad gyri with too few sulci	Occasional broad gyri with too few sulci	Rare midline subcortical heterotopias in frontal regions	Very common
Cerebral vasculature	Rete of vessels branching from the internal cerebral arteries	Azygos anterior cerebral artery	Azygos anterior cerebral artery	Azygos anterior cerebral artery

The presence of a dorsal cyst is strongly correlated with lack of separation of the thalami and development of hydrocephaly.[34]
IHF, Interhemispheric fissure; *MIH*, middle interhemispheric variant of holoprosencephaly.
[a]From Hahn JS, Barnes PD. Neuroimaging advances in holoprosencephaly: refining the spectrum of the midline malformation. *Am J Med Genet Part C Semin Med Genet* 154C:120–132, 2010.

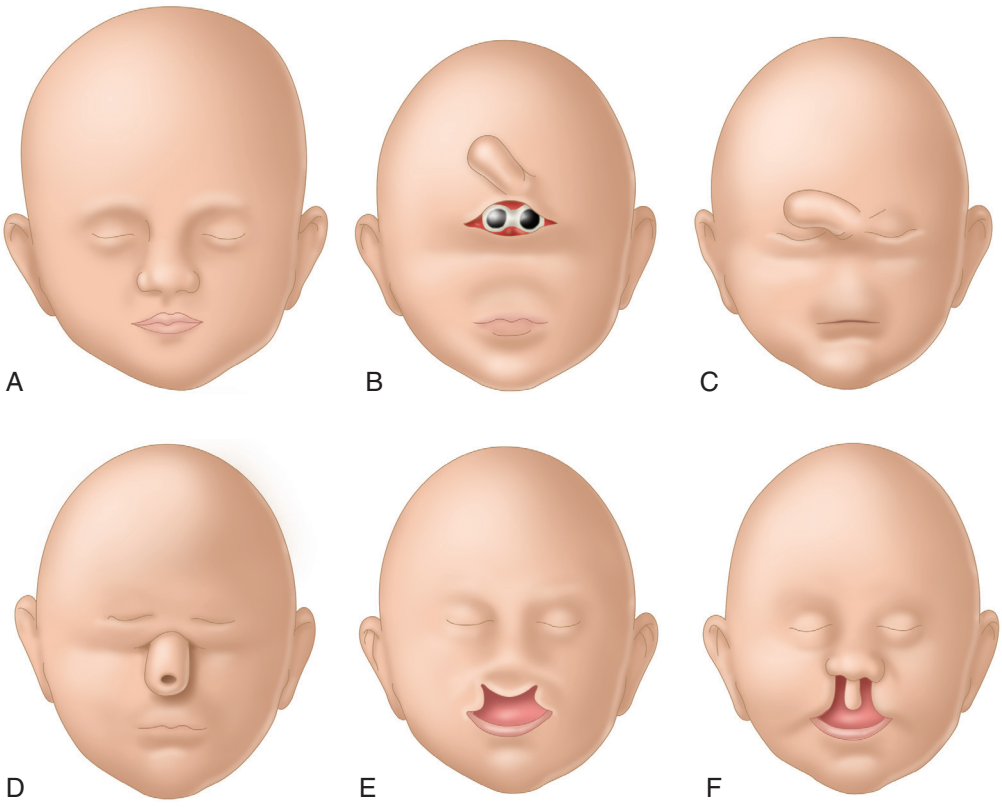

Fig. 39.4 Possible facial features in HPE. (A) Normal face. (B) Cyclops with two eye anlagen. (C) Ethmocephaly. (D) Cebocephaly with single nostril. (E) Premaxillary agenesis, or midline cleft. (F) Bilateral cleft lip and palate. *(Redrawn from Nyberg DA, Pretorius DH: Cerebral malformations. In Nyberg DA, Mahoney BS, Pretorius DH, editors:* Diagnostic ultrasound of fetal anomalies. *St. Louis, 1990, Mosby Year Book, pp 83–145.)*

categorized in four main types: (1) *cyclopia* with a single eye or various degrees of doubling of the eye anlage, with or without *proboscis* (Fig. 39.5); (2) *ethmocephaly* with *ocular hypotelorism* and *proboscis* located between the eyes; (3) *cebocephaly* with *ocular hypotelorism* and *single-nostril* nose (Fig. 39.6); and (4) *median cleft lip/palate (premaxillary agenesis)* and *ocular hypotelorism* (Fig. 39.7).

In addition, various facial phenotypes are described. Milder types of facial clefts or other anomalies are possible. Highly variable intrafamilial phenotypes in human SHH heterozygous patients are described, ranging from severe cyclopia to very mild clinical signs of HPE such as fused upper incisors.[33]

Other Possible Associated Cerebral and Facial Anomalies. Facial anomalies that usually are part of the HPE spectrum can be found in association with anencephaly (Fig. 39.8).[11] This association seems to be rare, but it is possible that most cases of anencephaly with facial HPE are not recognized as being part of the HPE spectrum. None of the large perinatal studies described anencephalic cases.[14–16,34]

Agnathia. HPE is occasionally associated with the spectrum of agnathia, including isolated agnathia; otocephaly, which refers to a broader malformation of mandibular hypoplasia or agnathia; and displacement of the ears or synotia, with or without aglossia (no tongue), and microstomia (small mouth) (Fig. 39.9). Many

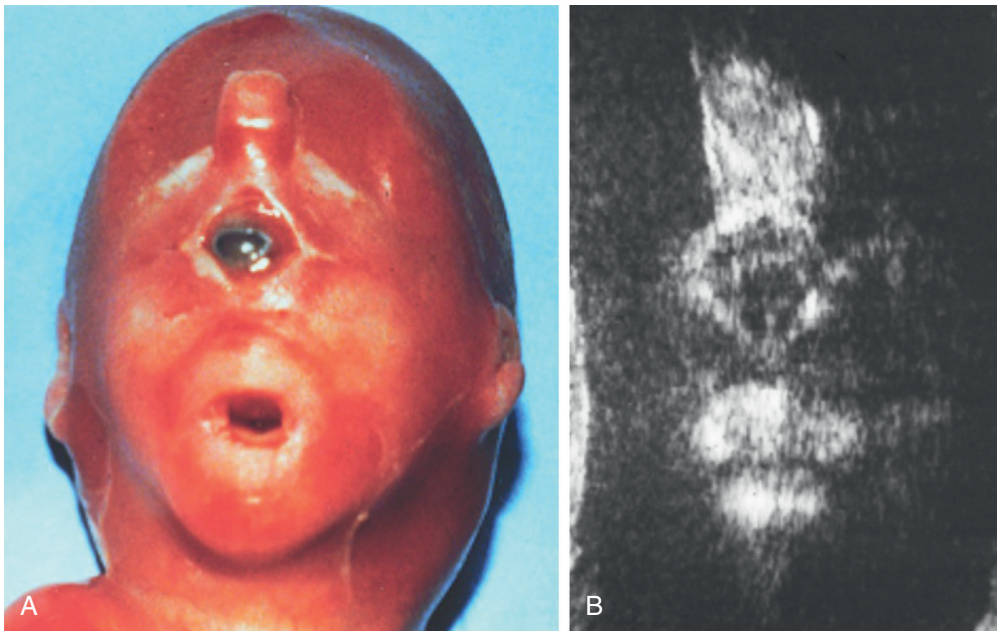

Fig. 39.5 Cyclopia (single eye anlage) (A) and proboscis in a fetus with alobar HPE (B). US image is a tangential section of the face that shows the proboscis, single orbit, and lips. *(From Blaas H-GK, Eriksson AG, Salvesen KA, et al: Brains and faces in holoprosencephaly: pre- and postnatal description of 30 cases.* Ultrasound Obstet Gynecol *19:24–38, 2002.)*

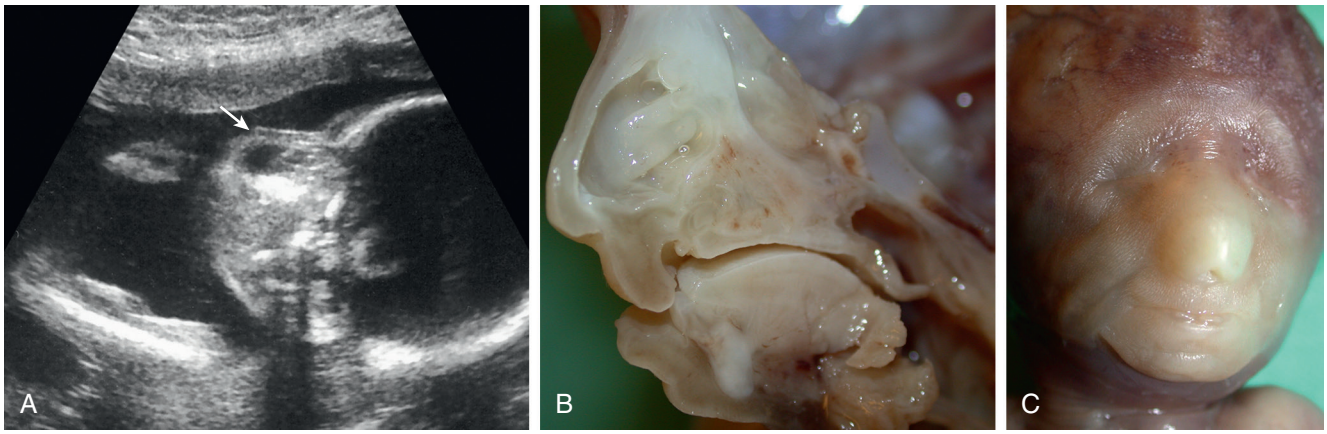

Fig. 39.6 An 18-week fetus with ethmocephaly. Alobar HPE was diagnosed based on US examination. (A, B) There was a single nostril with a large common nasal cavity (*arrow* in A), which was verified at autopsy (B). (C) The cebocephalic face with hypotelorism and single nostril nose.

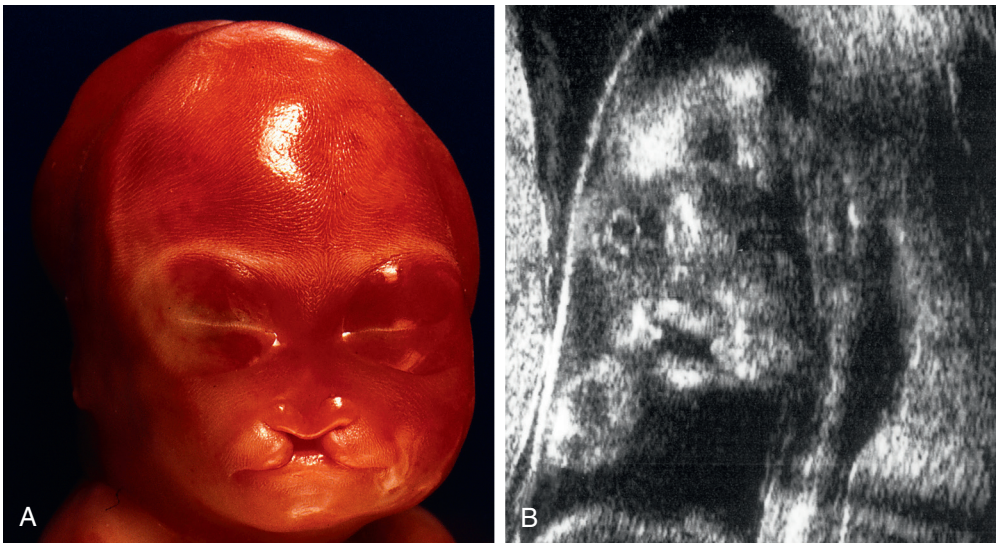

Fig. 39.7 Premaxillary agenesis in fetuses with alobar HPE. (A) Face at autopsy. (B) US image (in a twin pregnancy) at 18 weeks' gestation.



Fig. 39.8 Anencephalic fetus at 18 weeks' gestation with a single nostril and abnormal orbit and eye anlagen as part of the HPE spectrum. *(From Blaas H-GK, Eriksson AG, Salvesen KA, et al: Brains and faces in holoprosencephaly: pre- and postnatal description of 30 cases.* Ultrasound Obstet Gynecol *19:24–38, 2002.)*

patients have additional anomalies, particularly situs anomalies.[35] The prevalence in cohort studies of cases of HPE ranges from 1:121 (0.8%) (14) to 3:30 (10%).[11] Approximately 100 cases are published, of which 32 were collected more recently and described in detail in a review.[35]

Detection and Outcome. Estimates of the prevalence of HPE in embryos,[10] fetuses,[11–13] and infants[14] show a higher prevalence and more serious types of the HPE spectrum in early pregnancy. Mild variants such as lobar HPE and middle interhemispheric variant of holoprosencephaly (MIH) are often detected late in pregnancy or after birth. Severe isolated HPE exhibits high prenatal and perinatal mortality. Of 24 live-born infants with HPE, only 29% survived the first year.[36] Despite a high early mortality rate, some children with alobar HPE and many children with milder forms may survive beyond infancy.[37] Levey from the Carter Centers for Brain Research in Holoprosencephalies and Related Malformations assessed 182 children with HPE (15% alobar, 54% semilobar, 18% lobar, and 15% MIH type HPE). The developmental disabilities of children with HPE correlate with the severity of the brain malformation.[37]

Imaging Technique and Findings

Ultrasound. By performing the standard measurement of the head (biparietal diameter or head circumference), the sonographer usually can detect serious forms of HPE in the second trimester.

First-Trimester

Approach. A prerequisite for the early US assessment of HPE is the knowledge of the normal US development of the brain from the embryonic period and onward.[38,39] If possible, the transvaginal approach is preferable using a high-resolution transducer for a better assessment of the intracerebral and facial anatomy. Three-dimensional (3D) US can be used to acquire and generate US images in planes unavailable in the scan plane to assess the form and shape of an object of interest and calculate volumes. The basis and prerequisite for all 3D imaging are clear 2D tomograms. Transvaginal 2D and 3D US can be used throughout pregnancy for fetal neurosonography. In the selection of transvaginal versus transabdominal US, a trade-off between resolution and penetration must be made.

Findings. Since the 1980s, many HPE diagnoses have been reported between 10 and 14 weeks' gestation.[5,11,12,40,41] The earliest diagnosis of embryonic alobar HPE was made at 9 weeks, 2 days.[5] In this embryo with a crown-rump length of 23 mm, the monoventricular cavity of the endbrain was very small. Diagnostic clues included the lack of lateral ventricles and an obvious proboscis (Figs. 39.10A,B). Although the primary diagnosis was

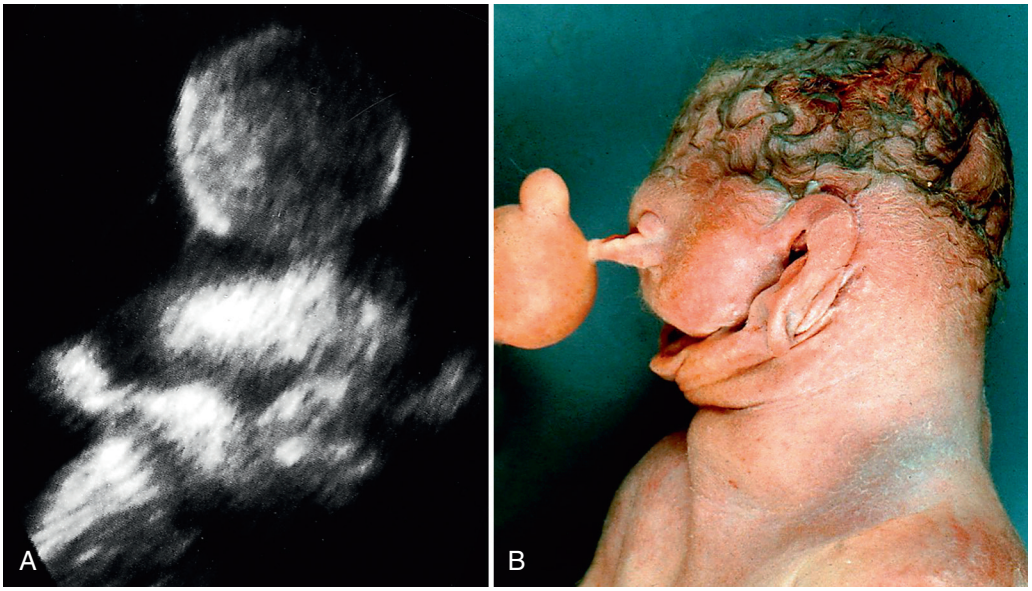

Fig. 39.9 Third-trimester fetus with alobar HPE and an unusual agnathia-otocephaly variant (B). US image is a section through the ears, maxilla, and ball-like proboscis (A). *(From Blaas H-GK, Eriksson AG, Salvesen KA, et al: Brains and faces in holoprosencephaly: pre- and postnatal description of 30 cases.* Ultrasound Obstet Gynecol *19:24–38, 2002.)*

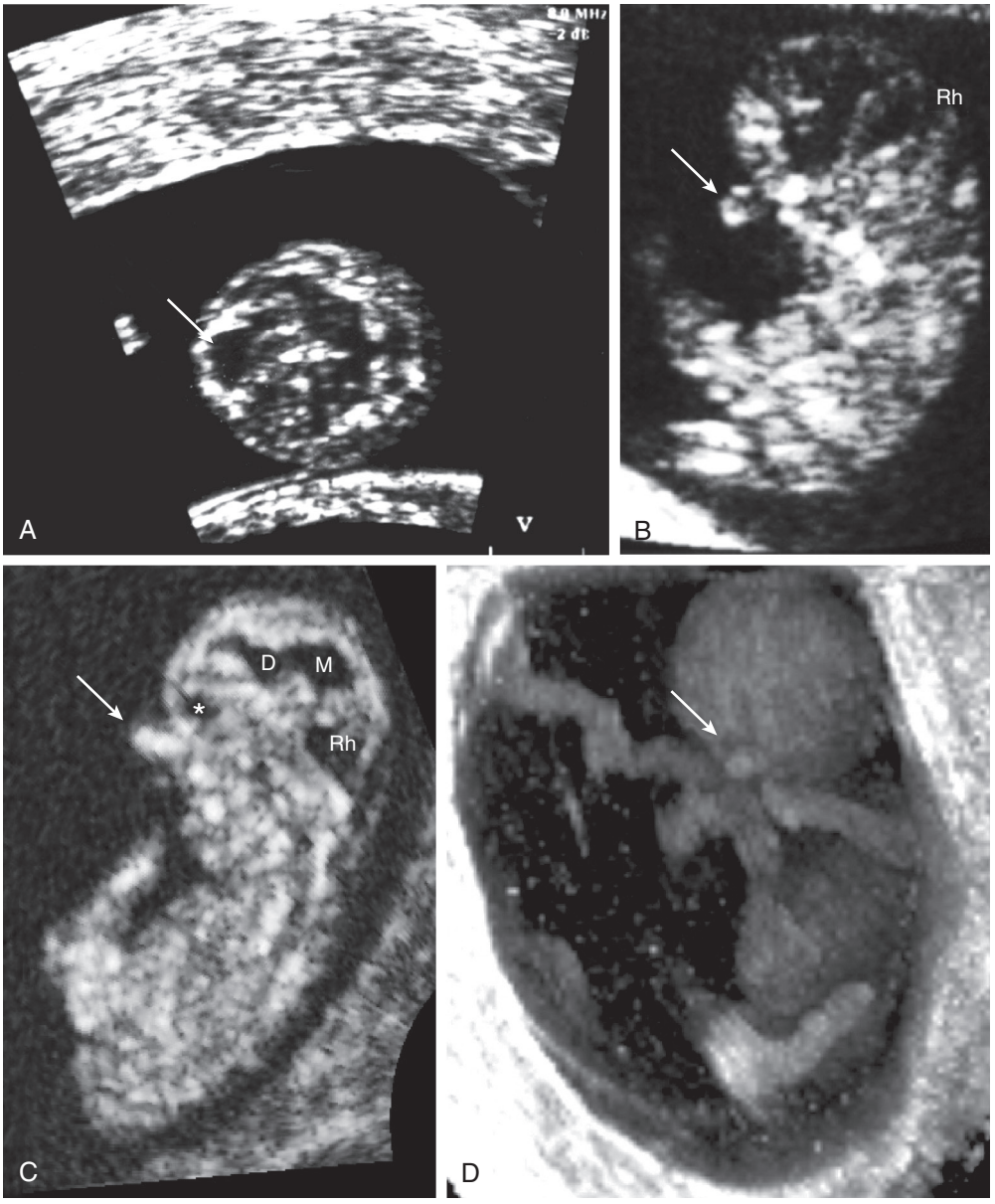

Fig. 39.10 2D and 3D images of alobar HPE at embryonic and early fetal period. (A) Horizontal transvaginal US image through the head of the embryo (crown-rump length, 23 mm) with a small monoventricle behind the forehead *(arrow)*. (B) Sagittal section of the same embryo; the proboscis can be clearly identified *(arrow)*. (C) Sagittal section from 3D reconstruction of the same fetus at 10 weeks' gestation (crown-rump length, 33 mm). *Arrow* indicates proboscis. (D) 3D surface rendering of the fetus at 10 weeks' gestation. *Arrows* point at the proboscis. *D,* Diencephalon; *M,* mesencephalon; *Rh,* rhombencephalon. *(C, From Blaas H-GK, Eik-Nes SH, Vainio T, et al: Alobar holoprosencephaly at 9 weeks gestational age visualized by two- and three-dimensional ultrasound.* Ultrasound Obstet Gynecol *15:62–65, 2000.)*

made using 2D US, the 3D volume analysis helped reconstruct sections of the face not obtainable by 2D US. Two hypoechogenic eye anlagen could be identified, and the brain volume could be evaluated. The monoventricular cavity of the endbrain was very small, less than one-tenth of the normal volume of the lateral ventricles.[5] In another case, a large monoventricular cavity of the endbrain was diagnostic at 9 weeks, 6 days.[42] The earliest reported diagnosis of semilobar HPE was made at 13 weeks' gestation.[43]

In two reports, 3D inversion rendering (Fig. 39.11) was used for diagnosis of HPE early in the first trimester.[40,41] Kim et al.[40] published a case of the abnormal cavities of a fetus at 12 ± 4 weeks with alobar HPE, and Timor-Tritsch et al.[41] described the abnormal brains of four fetuses with HPE, ranging from 9 ± 2 weeks to 14 ± 5 weeks.

As known from second trimester studies,[11,44] a relatively small head is a common feature of late first-trimester HPE-fetuses, too.[45,46] The BPD was below the 5th percentile in 32% of HPE cases.

Second and Third Trimesters

Approach. In midpregnancy, the transabdominal route with a 5-MHz transducer usually gives acceptable images of the growing fetal brain. In vertex presentations, the transvaginal approach makes it possible to obtain very detailed information of the neuroanatomy. At the end of pregnancy, the increasing ossification of the skull impairs the examination of the brain, especially when the head is positioned low in the maternal pelvis. Low frequencies such as 3.5 to 5 MHz have to be used for the transabdominal approach. As always in vertex presentations, the transvaginal route improves imaging,[47] although it may be very difficult to obtain the classic standard scan planes for the neuroanatomic examination as is done in the newborn.[47] Because of the large size of the head, lower frequencies are appropriate. The access through the fetal fontanelle as an acoustic window can be difficult in asynclitic positions of the head.

Findings. Microcephaly is a common feature in HPE in fetuses with normal and abnormal karyotypes. Increased size of the head may also occur, usually in fetuses in the third trimester. About 80% of fetuses with HPE have an abnormal shape or size of the head. US findings of an abnormal size of the head, hydrocephaly, microcephaly, or anencephaly should prompt the sonographer to rule out HPE.[11] The sutures of the skull in microcephalic fetuses with HPE and the sonographic windows often are narrow, making it more difficult to study cerebral anatomy.

In the standard transverse view of the fetal head for measurement of the biparietal diameter, there is a single dilated midline ventricle replacing the two lateral ventricles, or partial segmentation of the ventricles (Fig. 39.12). A confident diagnosis can be made using a midcoronal view, demonstrating absence of the cavum septi pellucidi, with fusion and squaring of the frontal horns.

Pilu[48,49] described US signs for the diagnosis of lobar HPE (Figs. 39.13 and 39.14). The earliest case was detected at 21 weeks' gestation. Volpe[50] pointed out the difficult differential diagnosis including septooptic dysplasia and isolated agenesis of the cavum septi pellucidi. A clue is the appearance of the frontal horns in the midcoronal (transthalamic) view, with absent cavum septi pellucidi, absent corpus callosum, and fused fornices. 3D US is well suited to enhance imaging also of facial anomalies of HPE (Fig. 39.15; see Fig. 39.10D).

Magnetic Resonance Imaging. US remains the primary imaging modality for examination of the fetal brain, but it may be limited by reverberation artifacts, poor penetration through the ossified skull with narrow sutures and fontanelles, oligohydramnios, and unfavorable fetal position, particularly in late pregnancy. MRI can be an important supplement in suspected fetal CNS anomalies.[51] MRI has a large field of view and a superior contrast resolution of soft tissue and is particularly suited to visualize CNS structures, including migration, myelination, and gyration of the developing brain in vivo. In addition, true multiplanar imaging in the 3D mode makes it easier to achieve optimal sections through brain structures. One of the first MRI examinations of fetal alobar HPE was performed using fetal anesthesia.[52] Today, technical advances allow MRI to be performed in milliseconds, reducing the difficulties caused by fetal movements. MRI can also be applied

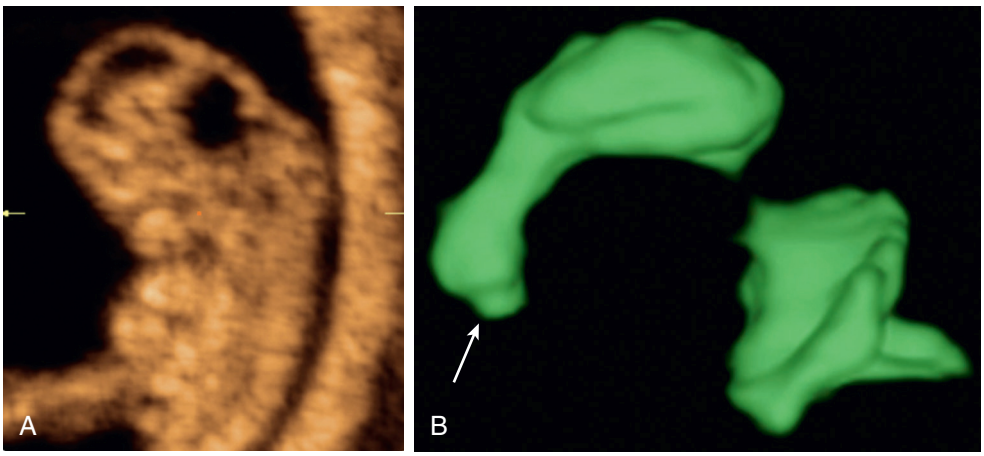

Fig. 39.11 3D reconstruction and inversion mode of the brain vesicles of an embryo with alobar HPE. (A) In the sagittal section, reconstructed from 3D US, absence of the third ventricle and a flat profile can be recognized. (B) *Arrow* points at the very small prosencephalic cavity (cavity corresponding to diencephalon and telencephalon). *(Images courtesy Bernard Benoit.)*

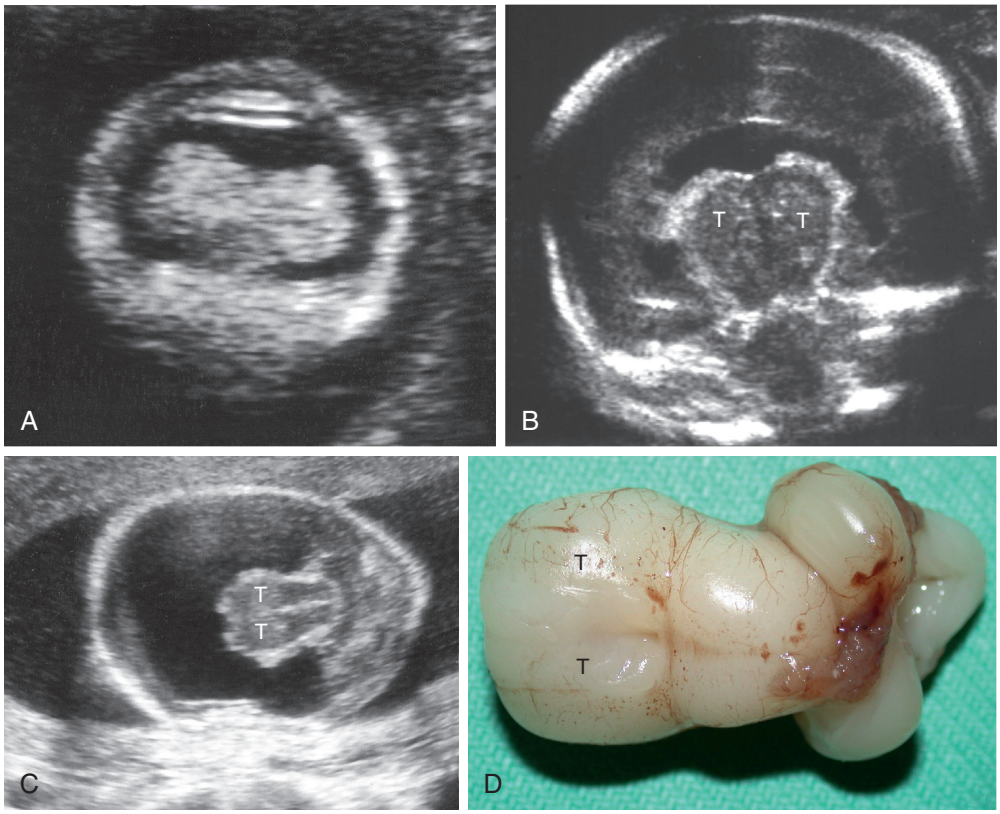

Fig. 39.12 Fetuses with alobar HPE at 12 weeks' gestation (A), 18 weeks' gestation (B), and 19 weeks' gestation (C and D). A and B, Coronal sections through the head with continuation of the cerebral cortex across the midline. The thalami (*T* in B) are not separated. The monocavity contains a small amount of fluid. (C) Horizontal section through the head (biparietal diameter plane) where a large fluid-filled cavity can be identified. This cavity represents both the monocavity of the holoprosencephalon and a large dorsal sac. The thalami (*T*) are not separated. (D) Brain of the same fetus shown in C without telencephalon.

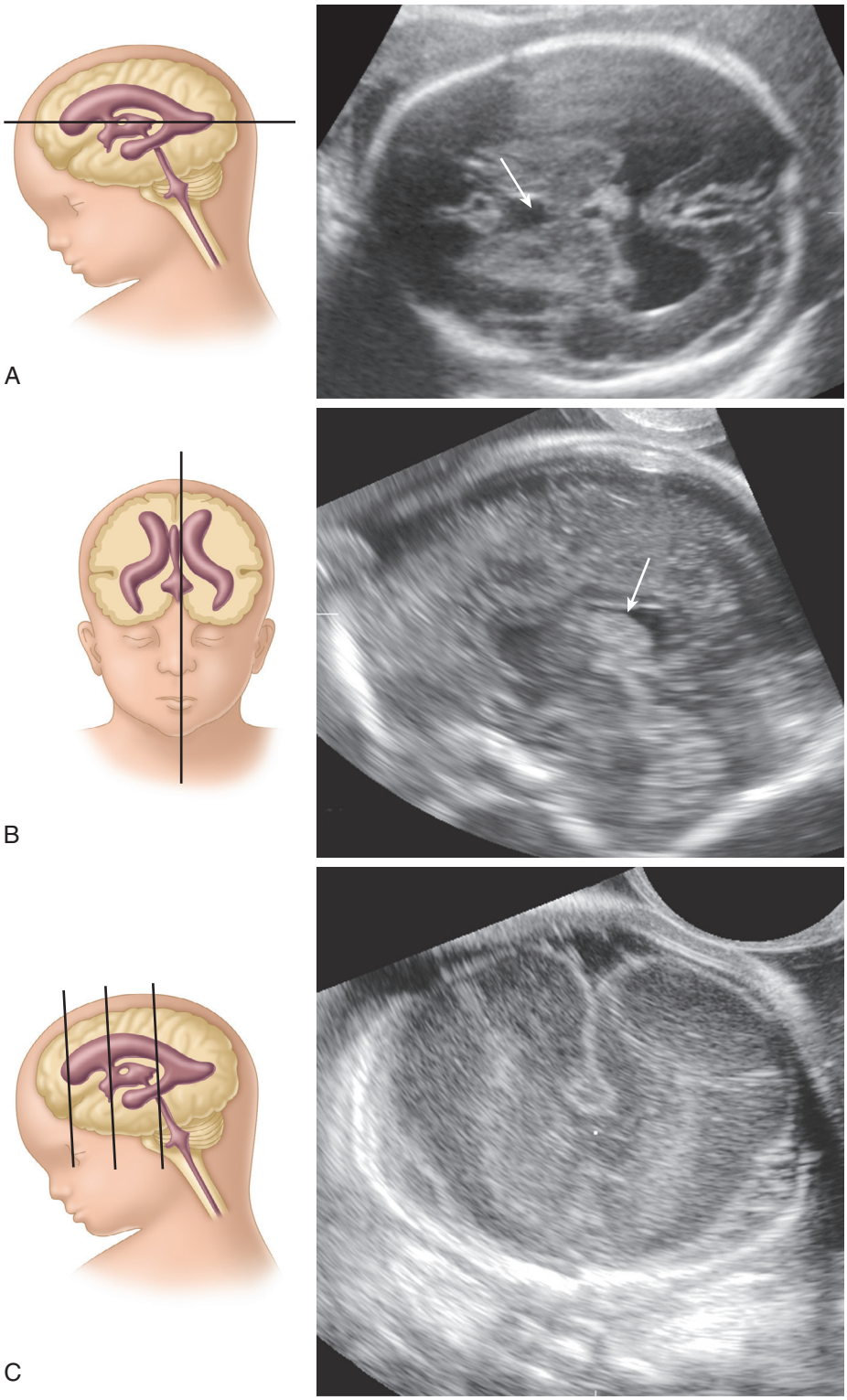

Fig. 39.13 Lobar HPE. (A) The cavum septi pellucidi is absent and the lateral ventricles appear significantly dysmorphic and fused from the level of the frontal horns to the bodies. (B) In the sagittal plane, the corpus callosum is seen in the typical fashion, but an irregular ridge of tissue is seen bridging between the hemispheres posteriorly *(arrow)*. (C–E) Coronal sections are most useful for the diagnosis because they show inferior fusion of the frontal lobes, poorly developed fused frontal horns, and communication between the bodies of the lateral ventricles. *(Reproduced with permission from Visual Encyclopedia of Ultrasound in Obstetrics and Gynecology, International Society of Ultrasound in Obstetrics and Gynecology. 2010.* http://www.isuog.org.*)*

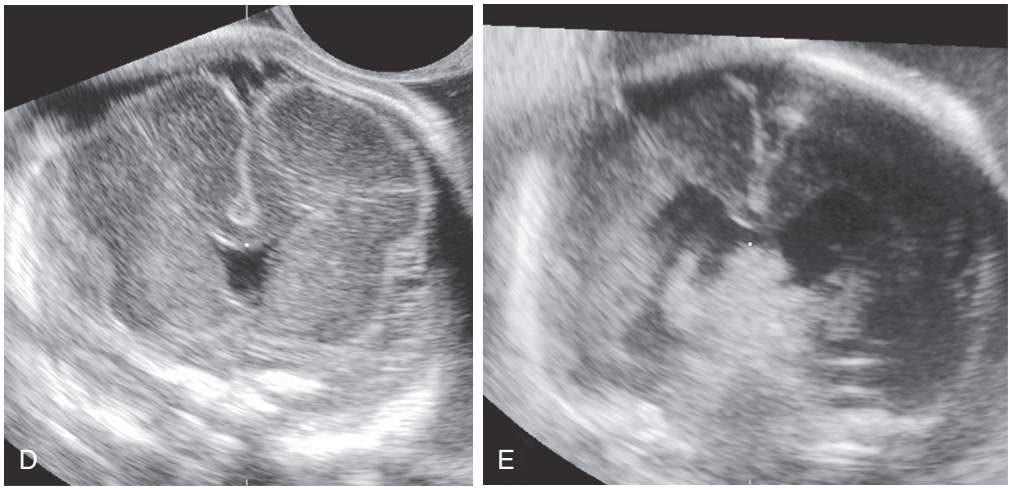

Fig. 39.13, cont'd

postmortem ("virtopsy") in cases where parents refuse autopsy.[53]

MRI of live-born infants has yielded detailed information on milder forms of HPE, in particular the distinction of lobar HPE and middle interhemispheric variant of HPE (Figs. 39.16 and 39.17).[54,55] Middle interhemispheric variant of HPE was first visualized by MRI prenatally in a 22-week fetus in 2004.[55]

Differential Diagnosis From Imaging Findings

Mild types of HPE can be mistaken for midline CNS anomalies that are not part of the HPE spectrum, such as septooptic dysplasia and agenesis of the cavum septi pellucidi. The differential diagnosis of lobar HPE and these conditions is described in Chapters 34 and 35.

Synopsis of Treatment Options

PRENATAL

There is a high prenatal and perinatal mortality rate of severe cases of isolated HPE. No treatment options are available. Because of the poor prognosis, the offer of termination of the pregnancy is indicated. If the parents do not wish termination, they need adequate counseling about the prognosis and eventual therapeutic possibilities.

POSTNATAL

Infants with HPE have multiple medical problems, of which many are typical for children with cerebral palsy. Because HPE is a midline defect, which commonly involves the hypothalamus, it is associated with endocrine dysfunction, temperature instability, and disturbed sleep-wake cycles in a high percentage of patients.[37] Survival of newborns with HPE is often uncertain after discharge. Parents are often desperate for the support and guidance of medical providers who are familiar with the natural history and common medical problems associated with HPE. Parents also need a clinician who can serve as a contact person after discharge.[37] Medical care of a child with HPE often requires coordination of multiple medical and rehabilitative specialists and a care plan based on the outlook, treatment goals, and parents' priorities.

WHAT THE REFERRING PHYSICIAN NEEDS TO KNOW

HPE can be viewed from two different perspectives: anatomic and genetic. When the main interest is description, the anatomic perspective is appropriate. From the genetic perspective, a fixed definition of HPE is inappropriate because the same cause may result in either severe HPE or a microform of HPE.[56] The clinician must consider both aspects because he or she has to diagnose the condition and provide optimal consultation with potential future pregnancies in mind.

KEY POINTS

- Varying degrees of nonseparation of the prosencephalon lead to a spectrum of midline anomalies involving the falx, corpus callosum, cavum septi pellucidi, thalami, and face.
- An abnormal communication between the cerebral hemispheres is suspicious for HPE.
- A dorsal cyst of variable size is often found in severe types of HPE and is strongly related to lack of separation of the thalami and development of hydrocephaly.
- Severe types of HPE usually have facial anomalies (e.g., cyclopia, ethmocephaly, cebocephaly, premaxillary agenesis, cleft lip/palate), but a normal face also can be present in HPE.
- Chromosome aberrations are frequent in HPE.
- MRI of the CNS is a supplement to US, particularly in the differential diagnosis of mild variants of HPE.
- The prenatal and perinatal mortality rate in severe isolated HPE is high.
- Surviving children with HPE have developmental disabilities correlating with the severity of brain malformation.

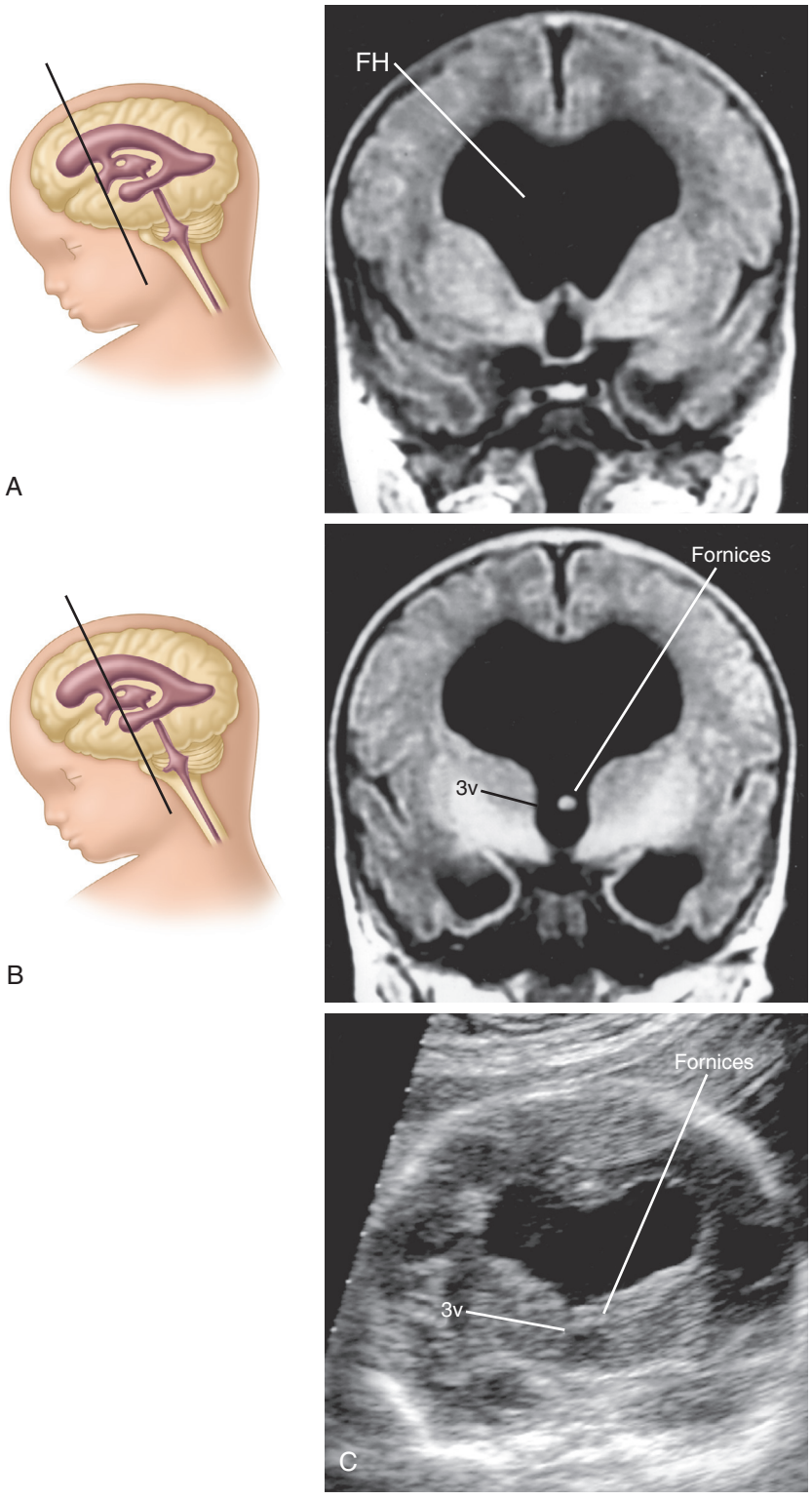

Fig. 39.14 Frontal sections through the brain in lobar holoprosencephaly. (A) and (B) MRI images of a newborn. (C) Ultrasound image of a third-trimester fetus. The well-developed frontal cortex and ventricular system associated with obstructive dilatation favor the diagnosis of HPE. The fornices *(arrow)* are fused and form a thick fascicle running in the floor of the ventricular cavity. *3v*, Third ventricle; *FH*, frontal horns. *(Reproduced with permission from Pilu G, Ambrosetto P, Sandri F, et al: Intraventricular fused fornices: a specific sign of fetal lobar holoprosencephaly*. Ultrasound Obstet Gynecol *4:65–67, 1994.)*

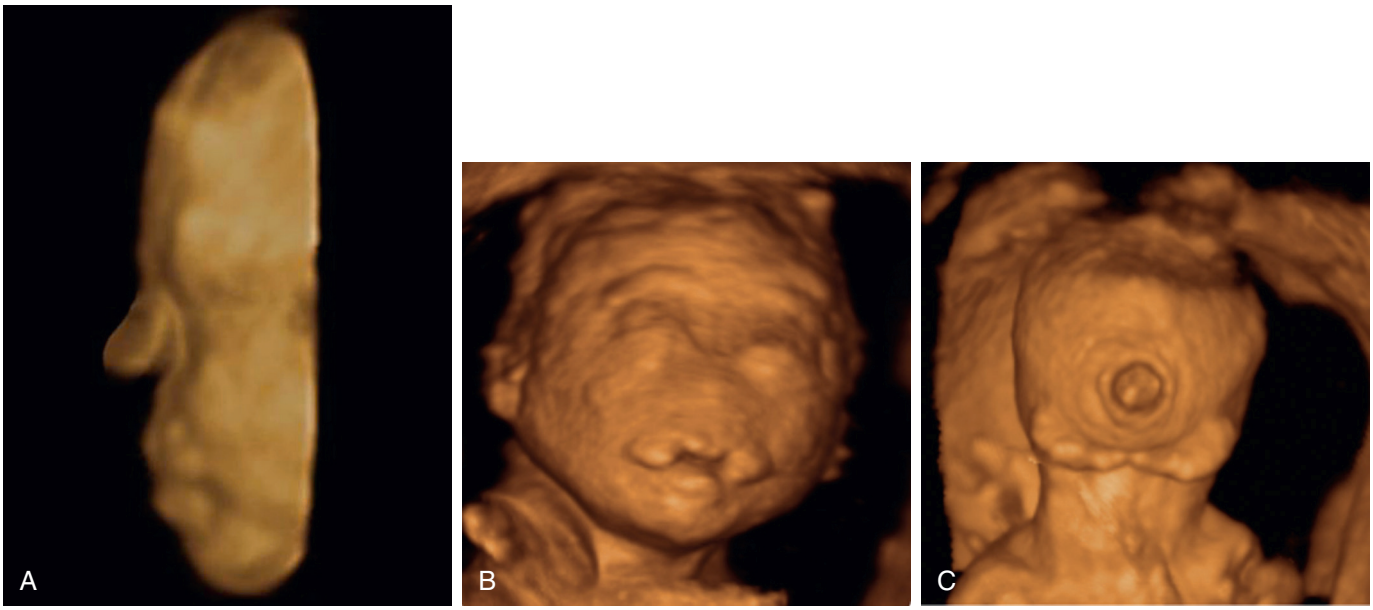

Fig. 39.15 Surface rendering (3D US) of facial features of alobar HPE. (A) Profile of fetus with ethmocephaly. (B) Frontal view of fetus with trisomy 13 with hypotelorism and premaxillary agenesis. (C) Frontal view of fetus with cyclopia and agnathia-otocephaly. *(A, Image courtesy Eberhard Merz; B and C, image courtesy Rabih Chaoui.)*

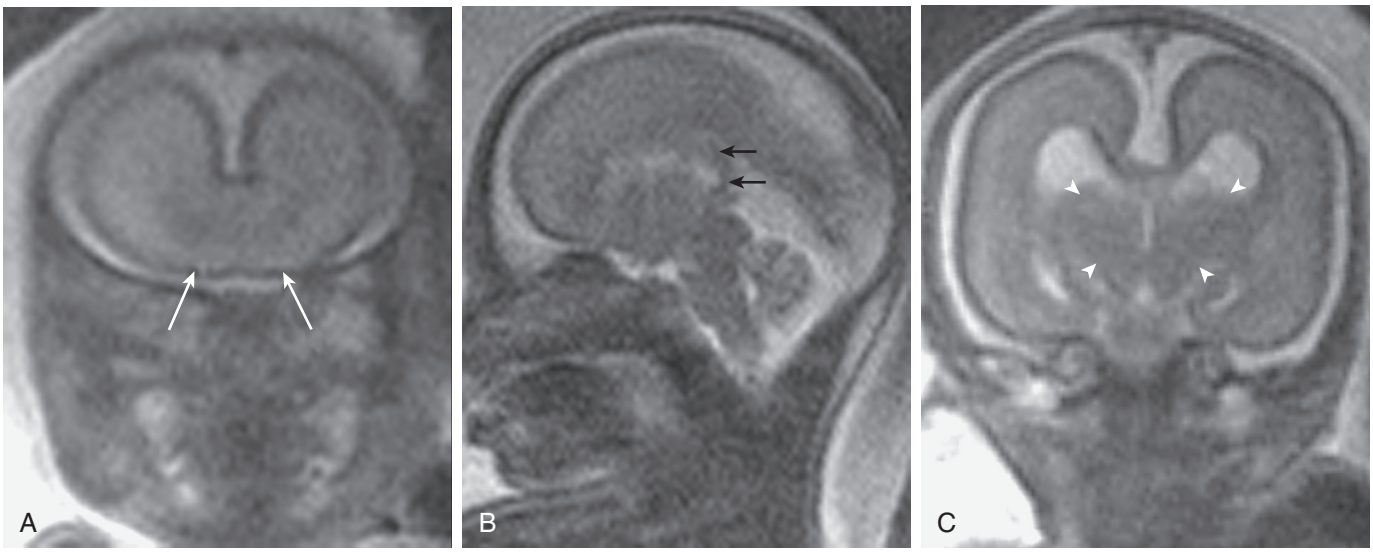

Fig. 39.16 MRI performed at 24 weeks' gestation. Coronal (A), sagittal (B), and coronal (C) T2-weighted images. MRI shows lack of separation of the inferior frontal lobes *(arrows)* with hypoplastic anterior falx (A) and what appears to be splenium *(arrows)* of the corpus callosum (B). The thalami and basal ganglia *(arrowheads)* appear separated (C). *(From Wong AM, Bilaniuk LT, Ng KK, et al: Lobar holoprosencephaly: prenatal MR diagnosis with postnatal MR correlation.* Prenat Diagn *25:296–299, 2005.)*

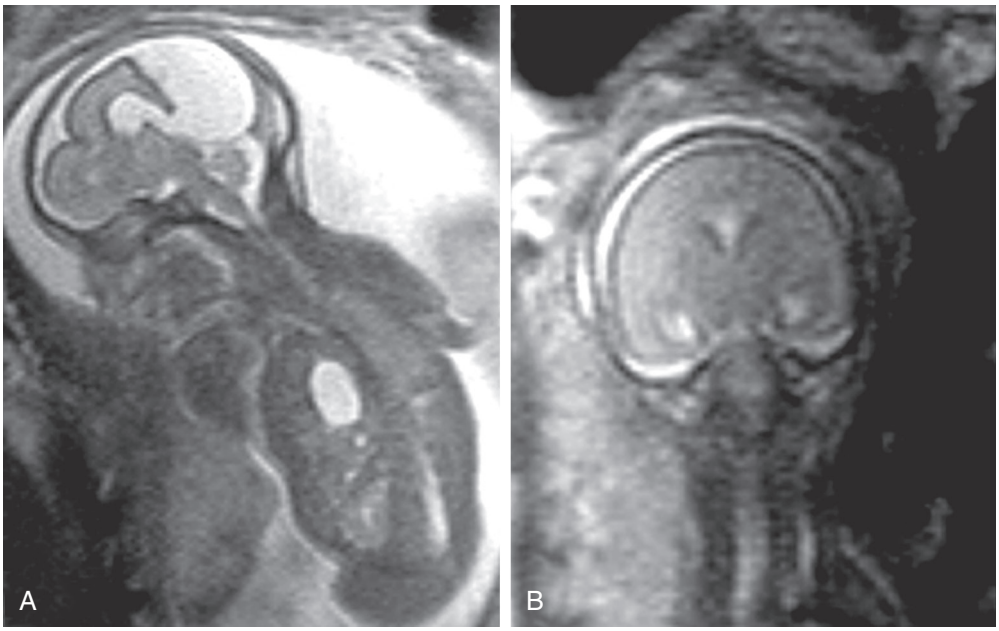

Fig. 39.17 Fetal MRI obtained at 22 weeks' gestation. (A) Sagittal half-Fourier single shot turbo spin echo (HASTE) (TR/TE/NA, 1000/95/1) image obtained through the midline reveals the dorsal cyst and cleft formed by communication of the sylvian fissures over the vertex. Herniation of the stomach into the chest is also apparent. (B) Coronal HASTE image obtained through the midportion of the brain depicts the lack of separation of the hemispheres and absent interhemispheric fissure more dorsally. *(From Pulitzer SB, Simon EM, Crombleholme TM, et al: Prenatal MR findings of the middle interhemispheric variant of holoprosencephaly.* AJNR Am J Neuroradiol *25:1034–1036, 2004.)*

SUGGESTED READING

Muenke M, Solomon B, Odent S, eds. Special issue: holoprosencephaly. *Am J Med Genet C Semin Med Genet*. 2010;154C:1-201.

All references are available online at www.expertconsult.com.

REFERENCES

1. Cohen MM Jr. Holoprosencephaly: a mythologic and teratologic distillate. *Am J Med Genet C Semin Med Genet*. 2010;154C:8-12.
2. Saint-Hilaire IG. *Histoire générale et particulière des anomalies de l'organisation chez l'homme et les animaux*. Paris: J-B Baillière; 1832.
3. Pachajoa H, Rodriguez C. Holoprosencephaly with premaxillary agenesis in a prehistoric skull. *Arch Dis Child Fetal Neonatal Ed*. 2013;98:e1. doi:10.1136/archdischild-2012-302123.
4. Kurtz AB, Wapner RJ, Rubin CS, et al. Ultrasound criteria for in utero diagnosis of microcephaly. *J Clin Ultrasound*. 1980;8:11-16.
5. Blaas H-GK, Eik-Nes SH, Vainio T, et al. Alobar holoprosencephaly at 9 weeks gestational age visualized by two- and three-dimensional ultrasound. *Ultrasound Obstet Gynecol*. 2000;15:62-65.
6. Wenstrom KD, Williamson RA, Weiner CP, et al. Magnetic resonance imaging of fetuses with intracranial defects. *Obstet Gynecol*. 1991;77:529-532.
7. Hahn JS, Barnes PD. Neuroimaging advances in holoprosencephaly: refining the spectrum of the midline malformation. *Am J Med Genet C Semin Med Genet*. 2010;154C:120-132.
8. DeMyer W. Holoprosencephaly (cyclopia-arhinencephaly). In: Vinken P, Bruyn G, eds. *Handbook of clinical neurology*. Chapter 18. Amsterdam: North-Holland Publishing Co; 1977:431-478.
9. Barchovich AJ, Quint DJ. Middle interhemispheric fusion: an unusual variant of holoprosencephaly. *AJNR Am J Neuroradiol*. 1993;14:431-440.
10. Yamada S, Uwabe C, Fujii S, et al. Phenotypic variability in human embryonic holoprosencephaly in the Kyoto Collection. *Birth Defects Res Part A Clin Mol Teratol*. 2004;70:495-508.
11. Blaas H-GK, Eriksson AG, Salvesen KÅ, et al. Brains and faces in holoprosencephaly: pre- and postnatal description of 30 cases. *Ultrasound Obstet Gynecol*. 2002;19(2):24-38.
12. Kagan KO, Staboulidou I, Syngelaki A, et al. The 11–13 week scan: diagnosis and outcome of holoprosencephaly, exomphalos and megacystis. *Ultrasound Obstet Gynecol*. 2010;36:10-14.
13. Chen C, Chern S, Lin C, et al. A comparison of maternal age, sex ratio and associated anomalies among numerically aneuploid, structurally aneuploid and euploid holoprosencephaly. *Genet Couns*. 2005;16:49-57.
14. Croen LA, Shaw GM, Lammer EJ. Holoprosencephaly: epidemiologic and clinical characteristics of a California population. *Am J Med Genet*. 1996;64:465-472.
15. EUROCAT. Arrhinencephaly/holoprosencephaly: http://www.eurocat-network.eu/; 2010.
16. Leoncini E, Baranello G, Orioli IM, et al. Frequency of holoprosencephaly in the International Clearinghouse Birth Defects Surveillance Systems: searching for population variations. *Birth Defects Res Part A Clin Mol Teratol*. 2008;82:585-591.
17. Orioli IM, Castilla EE. Epidemiology of holoprosencephaly: Prevalence and risk factors. *Am J Med Genet C Semin Med Genet*. 2010;154C:13-21.
18. Roessler E, Muenke M. The molecular genetics of holoprosencephaly. *Am J Med Genet C Semin Med Genet*. 2010;154C:52-61.
19. Müller F, O'Rahilly R. The prechordal plate, the rostral end of the notochord and nearby median features in staged human embryos. *Cells Tissues Organs*. 2003;173:1-20.
20. Lipinski RJ, Godin EA, O'Leary-Moore SK, et al. Genesis of teratogen-induced holoprosencephaly in mice. *Am J Med Genet C Semin Med Genet*. 2010;154C:29-42.
21. Cohen M Jr, Shiota K. Teratogenesis of holoprosencephaly. *Am J Med Genet*. 2002;109:1-15.
22. Kousseff BG. Gestational diabetes mellitus (class A): a human teratogen? *Am J Med Genet*. 1999;83(5):402-408.
23. Aoto K, Shikata Y, Higashiyama D, et al. Fetal ethanol exposure activates protein kinase A and impairs Shh expression in prechordal mesendoderm cells in the pathogenesis of holoprosencephaly. *Birth Defects Res A Clin Mol Teratol*. 2008;82:224-231.
24. Solomon BD, Rosenbaum KN, Meck JM, et al. Holoprosencephaly due to numeric chromosome abnormalities. *Am J Med Genet C Semin Med Genet*. 2010;154C:146-148.
25. Peebles DM. Holoprosencephaly. *Prenat Diagn*. 1998;18:477-480.
26. Roessler E, Muenke M. Holoprosencephaly: a paradigm for the complex genetics of brain development. *J Inherit Metab Dis*. 1998;21:481-497.
27. Mouden C, Dubourg C, Carré W, et al. Complex mode of inheritance in holoprosencephaly revealed by whole exome sequencing. *Clin Genet*. 2016. doi:10.1111/cge.12722.
28. Tint OS, Irons M, Elias ER, et al. Defective cholesterol biosynthesis associated with Smith-Lemli-Opitz syndrome. *N Engl J Med*. 1994;330:107-113.
29. Cohen MM Jr. Hedgehog signaling update. *Am J Med Genet A*. 2010;152A:1875-914.
30. Solomon BD, Pineda-Alvarez DE, Mercier S, et al. Holoprosencephaly flashcards: a summary for the clinician. *Am J Med Genet C Semin Med Genet*. 2010;154C:3-7.
31. Solomon BD, Mercier S, Vélez JI, et al. Analysis of genotype–phenotype correlations in human holoprosencephaly. *Am J Med Genet C Semin Med Genet*. 2010;154C:133-141.
32. Solomon BD, Pineda-Alvarez DE, Gropman AL, et al. High intellectual function in individuals with mutation-positive microform holoprosencephaly. *Mol Syndromol*. 2012;3:140-142.
33. Roessler E, Belloni E, Gaudenz K, et al. Mutations in the human Sonic Hedgehog gene cause holoprosencephaly. *Nat Genet*. 1996;14(3):357-360.
34. Whiteford ML, Tolmie JL. Holoprosencephaly in the west of Scotland 1975–1994. *J Med Genet*. 1996;33:578-584.
35. Kauvar EF, Solomon BD, Curry CJR, et al. Holoprosencephaly and agnathia spectrum: presentation of two new patients and review of the literature. *Am J Med Genet C Semin Med Genet*. 2010;154C:158-169.
36. Bullen PJ, Rankin JM, Robson SC. Investigation of the epidemiology and prenatal diagnosis of holoprosencephaly in the North of England. *Am J Obstet Gynecol*. 2001;184(6):1256-1262.
37. Levey EB, Stashinko E, Clegg NJ, et al. Management of children with holoprosencephaly. *Am J Med Genet C Semin Med Genet*. 2010;154C:183-190.
38. Blaas H-G, Eik-Nes SH, Kiserud T, et al. Early development of the forebrain and midbrain: a longitudinal ultrasound study from 7 to 12 weeks of gestation. *Ultrasound Obstet Gynecol*. 1994;4:183-192.
39. Blaas H-G, Eik-Nes SH, Berg S, et al. In-vivo three-dimensional ultrasound reconstructions of embryos and early fetuses. *Lancet*. 1998;352(9135):1182-1186.
40. Kim MS, Jeanty P, Turner C, et al. Three-dimensional sonographic evaluation of embryonic brain development. *J Ultrasound Med*. 2008;27:119-124.
41. Timor-Tritsch I, Monteagudo A, Santos R. Three-dimensional inversion rendering in the first- and early second-trimester fetal brain: its use in holoprosencephaly. *Ultrasound Obstet Gynecol*. 2008;32:744-750.
42. Sepulveda W, Lutz I, Be C. Holoprosencephaly at 9 weeks 6 days in a triploid fetus. *J Ultrasound Med*. 2007;26:411-414.
43. Wong HS, Lam YH, Tang MHY, et al. First-trimester ultrasound diagnosis of holoprosencephaly: three case reports. *Ultrasound Obstet Gynecol*. 1999;13:356-359.
44. Berry SM, Gosden C, Snijders RJM, et al. Fetal holoprosencephaly: associated malformations and chromosomal defects. *Fetal Diagn Ther*. 1990;5:92-99.
45. Khalil A, Papageorghiou A, Bhide A, et al. Biparietal diameter at 11 to 13 weeks' gestation in holoprosencephaly. *Prenat Diagn*. 2014;34:134-138.
46. Sepulveda W, Wong AE, Andreeva E, et al. Biparietal diameter–to–crown-rump length disproportion in first-trimester fetuses with holoprosencephaly. *J Ultrasound Med*. 2014;33:1165-1169.
47. ISUOG Guidelines. Sonographic examination of fetal central nervous system: guidelines for performing the 'basic examination' and the 'fetal neurosonogram'. *Ultrasound Obstet Gynecol*. 2007;29:109-116.
48. Pilu G, Ambrosetto P, Sandri F, et al. Intraventricular fused fornices: a specific sign of fetal lobar holoprosencephaly. *Ultrasound Obstet Gynecol*. 1994;4:65-67.
49. Pilu G, Sandri F, Perolo A, et al. Prenatal diagnosis of lobar holoprosencephaly. *Ultrasound Obstet Gynecol*. 1992;2:88-94.
50. Volpe P, Campobasso G, De Robertis V, et al. Disorders of prosencephalic development. *Prenat Diagn*. 2009;29:340-354.
51. Griffiths P, Jarvis D. In utero MR imaging of fetal holoprosencephaly: a structured approach to diagnosis and classifcation. *AJNR Am J Neuroradiol*. 2016. doi:10.3174/ajnr.A4572.
52. Tomà P, Costa A, Magnano GM, et al. Holoprosencephaly: prenatal diagnosis by sonography and magnetic resonance imaging. *Prenat Diagn*. 1990;10(7):429-436.
53. Griffith P, Paley M, Whitby E. Post-mortem MRI as an adjunct to fetal or neonatal autopsy. *Lancet*. 2005;365:1271-1273.
54. Lewis A, Simon E, Barkowich A, et al. Middle interhemispheric variant of holoprosencephaly: a distinct cliniconeuroradiologic subtype. *Neurology*. 2002;59:1860-1865.
55. Pulitzer SB, Simon EM, Crombleholme TM, et al. Prenatal MR findings of the middle interhemispheric variant of holoprosencephaly. *AJNR Am J Neuroradiol*. 2004;25:1034-1036.
56. Cohen MM. Problems in the definition of holoprosencephaly. *Am J Med Genet*. 2001;103:183-187.

40 Intracranial Hemorrhage, Cysts, Tumors, and Destructive Lesions

ELENA CONTRO | FRANCESCA DE MUSSO | GIANLUIGI PILU | TULLIO GHI

Introduction

Destructive cerebral lesions are not embryonic malformations, but rather the result of an insult to a normally developed fetal brain. The most common causes are hemorrhage, hypoxia-ischemia, and infections, but the pathophysiology is unclear in many cases. The prognosis is usually poor. This chapter describes the main features of fetal intracranial destructive lesions, including intracranial hemorrhages, porencephaly, hydranencephaly, and schizencephaly. Other intracranial lesions that develop late in gestation, including intracranial cysts and intracranial tumors, are also described. Fetal cerebral infections are discussed in Chapters 165 to 168.

Intracranial Hemorrhage

DEFINITION

An intracranial hemorrhage (ICH) is a collection of extravasated blood occurring in the fetal brain, usually affecting the lateral ventricles, although it can occasionally be found in other parts of the brain. Synonyms include *germinal matrix hemorrhage,*

intraventricular hemorrhage, intraparenchymal hemorrhage, and *subdural hematoma.*

PREVALENCE AND EPIDEMIOLOGY

Postnatal ICH is common in preterm neonates. In neonates weighing less than 1500 g or younger than 32 weeks' gestational age, the incidence is 40%.[1] ICH has been reported rarely in utero,[2,3] with an overall estimated incidence of 1:10,000 pregnancies.[2]

ETIOLOGY AND PATHOPHYSIOLOGY

There are numerous well-demonstrated and postulated causes of in utero ICH, including maternal hemorrhagic disorders, coagulopathy, maternal hypotension, preeclampsia, severe fetal growth restriction, placental abruption, infections, nonimmune hydrops, fetomaternal hemorrhage, complications of monochorionic twin pregnancies, and maternal cocaine abuse.[4] Platelet disorders (immune thrombocytopenic purpura, alloimmune thrombocytopenia, and hidden antiplatelet autoantibodies) can cause fetal platelet destruction and have been associated with ICH before the onset of labor.[5] Fetal alloimmune thrombocytopenia is caused in most cases by maternal alloimmunization against the human antigen HPA-1a and may cause ICH in the third trimester. A fetal platelet count is difficult to obtain, because invasive procedures are normally avoided in these cases. A recent report suggests that the number of previous gestations, which relates with the grade of exposure and immunization to the antigen, is the best indicator to predict ICH.[6] Fetal subdural hematomas can be caused by trauma.[7] At least one predisposing factor can be identified in about half of cases.[8]

Postnatally, most intraventricular hemorrhages originate in the subependymal germinal matrix region. In the premature brain, the germinal matrix contains thin-walled friable vessels supported by a delicate matrix that is easily injured by any elevation of the cerebral blood pressure, as in fetal hypoxia or thrombosis. It is unclear whether the pathophysiology is the same in intrauterine hemorrhage.

MANIFESTATIONS OF DISEASE

Clinical Presentation

ICH is more frequently detected in the third trimester, but it can be detected as early as 20 weeks. Only major ICH can be easily recognized prenatally. Small hemorrhages may resolve or leave a small residual cyst. In massive ICH, blood initially accumulates in the lateral ventricles and migrates into the third ventricle or the aqueduct of Sylvius, causing hydrocephalus. Finally, a porencephalic cyst may originate from the destructive process of the periventricular white matter.

ICH is commonly classified by severity into four grades:

- *Grade I:* Limited to the subependymal matrix
- *Grade II:* Clear spillover to the ventricles but filling less than 50% of the lateral ventricle (without acute ventriculomegaly)
- *Grade III:* Spillover to the ventricles with filling more than 50% of the lateral ventricle (with acute ventriculomegaly)
- *Grade IV:* Characteristics of grades I to III with destruction of periventricular parenchyma

Imaging Technique and Findings

Ultrasound. Most ICH is intraventricular and appears as an irregular echogenic mass on ultrasound (US) (Fig. 40.1). The lateral ventricles frequently dilate after hemorrhage (grade III) (Fig. 40.2), and in some cases an infarct may develop in the periventricular cortex (grade IV) (Fig. 40.3). Subdural hematomas appear as echogenic collections displacing brain tissue, but a specific diagnosis is frequently difficult (Fig. 40.4).

CLASSIC SIGNS

- Bilateral ventriculomegaly with irregular echogenic areas within the ventricles
- Echogenic lesions developing a hypoechogenic core over 1 to 2 weeks

Four clinical phases can be observed in the ultrasound features of ICH.[8] The time for the development of each phase after the initial event is variable.

1. Fresh hemorrhagic phase: presence of echogenic blood filling the lateral ventricles (3–8 days)
2. Liquefying phase: presence of a mass with external echogenic lining and internal anechoic core (3–8 days)
3. Complete liquefying phase: presence of a cystic hypoechoic mass (7–28 days)
4. Resolution phase: disappearance of ventriculomegaly and blood clots (7–105 days).

Doppler velocimetry of the middle cerebral artery (MCA) is a useful additional tool in the diagnosis of ICH. An increased

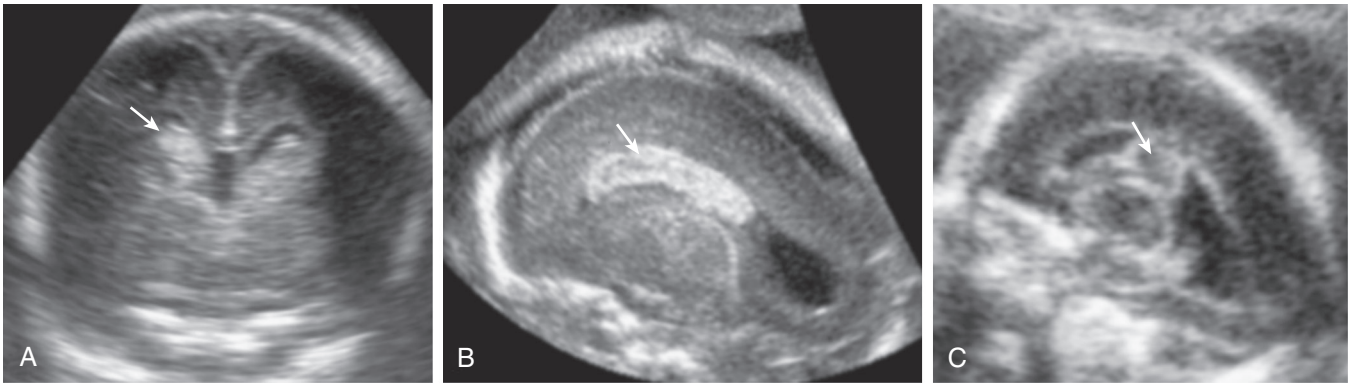

Fig. 40.1 Grade II intraventricular hemorrhage. (A, B) Recent hemorrhage. *Arrow* indicates intraventricular hyperechogenic area in the frontal horn and body of one lateral ventricle. (C) Old hemorrhage. *Arrow* indicates blood clot with a sonolucent core. *(Reproduced with permission from* Visual encyclopedia of ultrasound in obstetrics and gynecology, *2011. Available from* http://www.isuog.org.*)*

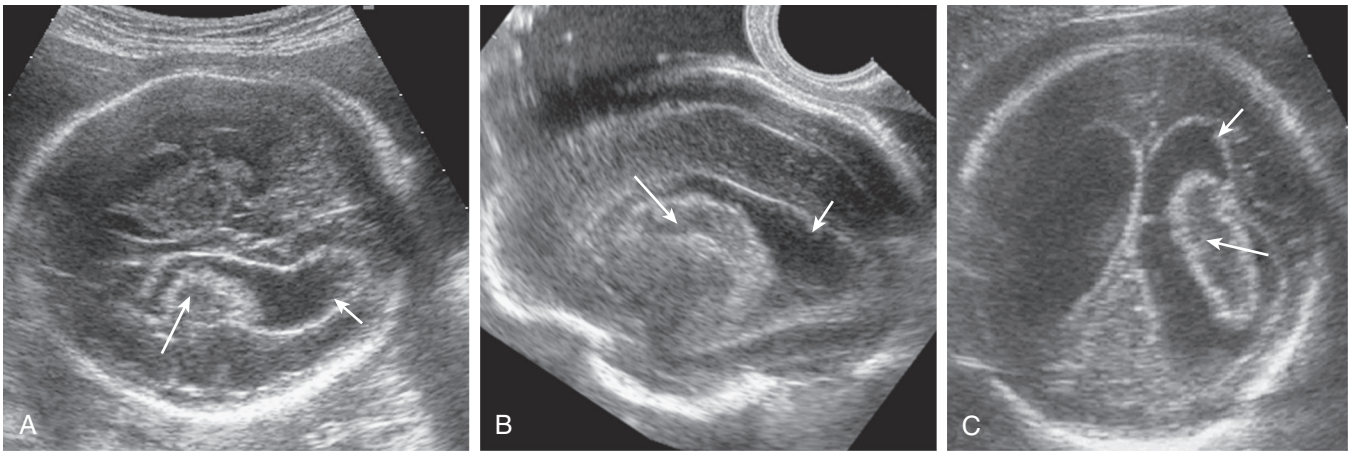

Fig. 40.2 Grade III intraventricular hemorrhage in the axial (A), sagittal (B), and coronal (C) views. The enlarged lateral ventricle has a hyperechogenic lining (*short arrows*) and contains a large blood clot (*long arrows*). *(Reproduced with permission from* Visual encyclopedia of ultrasound in obstetrics and gynecology, *2011. Available from* http://www.isuog.org.*)*

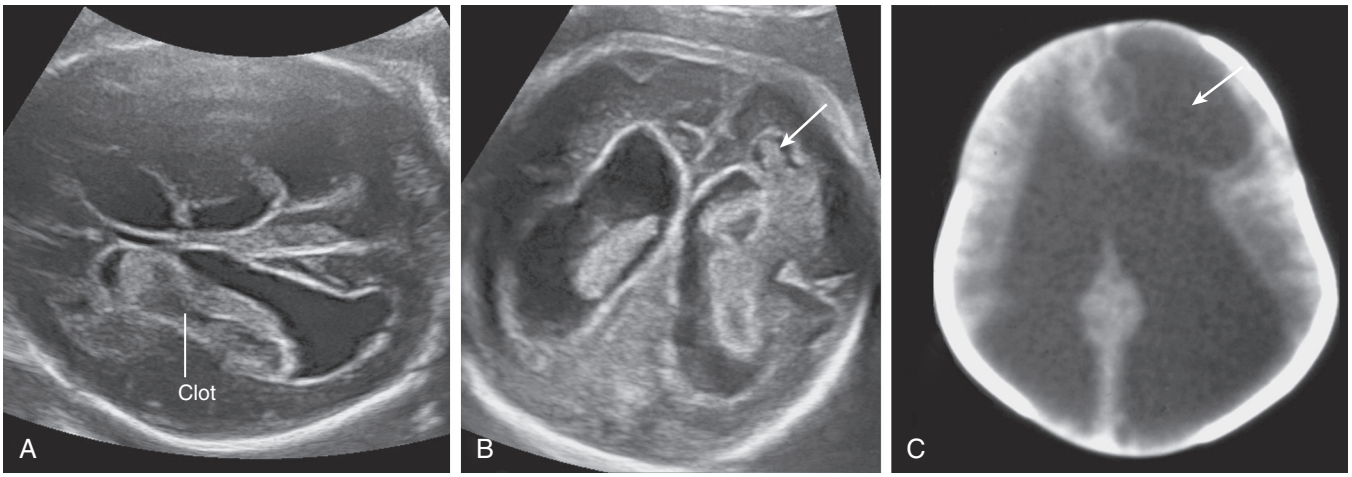

Fig. 40.3 Grade IV intraventricular and periventricular hemorrhage. (A) Enlarged lateral ventricle with echogenic lining containing a blood clot. (B) In the frontal lobe, an irregular sonolucent area suggests a white matter infarct *(arrow)*. (C) Postnatal MRI. Severe ventriculomegaly and destruction of periventricular white matter *(arrow)* are noted. *(Reproduced with permission from* Visual encyclopedia of ultrasound in obstetrics and gynecology, *2011. Available from* http://www.isuog.org.*)*

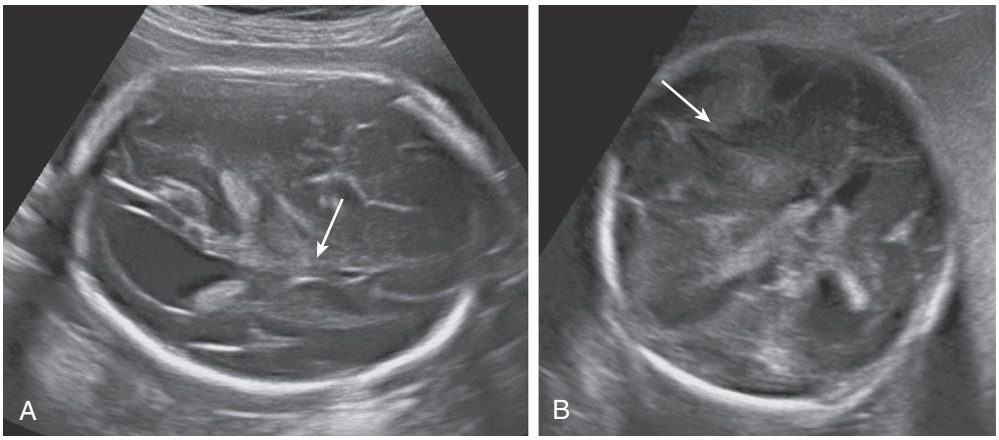

Fig. 40.4 Subdural hematoma. (A) Mass effect with midline shift *(arrow)*. (B) In the coronal view, most of the intracranial cavity is occupied by low-level echoes, and the cerebral architecture is distorted. The diagnosis of an ICH is not obvious on US and was mostly suggested by the medical history of anticoagulant use. *(Reproduced with permission from* Visual encyclopedia of ultrasound in obstetrics and gynecology, *2011. Available from* http://www.isuog.org.*)*

velocity in the MCA can document fetal anemia in case of massive hemorrhage, whereas the increased intracranial pressure impairs cerebral blood flow with increased resistance to flow in cerebral vessels.[9]

Differential Diagnosis From Imaging Findings

In massive ICH, there may be a mass effect that can be mistaken for a brain tumor. A hint for differential diagnosis is that fetal tumors grow or remain stable, whereas blood clots shrink and change appearance during pregnancy.

Other causes of ventriculomegaly (infections, brain structural abnormalities, genetic conditions) must be considered in the differential diagnosis. In unclear cases, serial US scans and fetal magnetic resonance imaging (MRI) should be performed.

Synopsis of Treatment Options

PRENATAL

Prenatal treatment considerations include the following:

- Identification of the cause (thorough maternal history, maternal platelet count, testing for maternal alloimmunization and isoimmunization)
- Maternal administration of steroids or intravenous immunoglobulin, fetal platelet transfusion if there is alloimmune fetal thrombocytopenia
- US monitoring
- Mode of delivery independent of the presence of platelet disorders
- Offer of termination of pregnancy if appropriate

WHAT THE REFERRING PHYSICIAN NEEDS TO KNOW

The prognosis for ICH largely depends on the severity of the condition, which ranges from mild neurologic deficits to neonatal death. A 50% perinatal death rate and 50% neurologic compromise in survivors have been reported. The grade of hemorrhage correlates with the severity of the prognosis.[8] The risk of recurrence depends on the underlying cause. Patients with alloimmune thrombocytopenia carry a very high (85%–90%) recurrence risk of ICH.[10]

KEY POINTS

- ICH usually affects lateral ventricles.
- ICH is common in premature newborns; it is rarely found prenatally.
- Fetuses with alloimmune thrombocytopenia have a high incidence of fetal hemorrhage, and there is a very high risk of recurrence in subsequent pregnancies.
- Fetal ICH has a poor prognosis.

Porencephaly

DEFINITION

Porencephaly is defined as the presence of cystic cavities within the brain matter. The cavities usually communicate with the ventricular system, the subarachnoid space, or both.[3] In contrast to schizencephaly, the lining of the cavity usually contains white matter. Synonyms include *encephaloclastic porencephaly* and *porencephalic cyst*.

PREVALENCE AND EPIDEMIOLOGY

Porencephaly is very rare with only isolated case reports in utero.[11]

ETIOLOGY AND PATHOPHYSIOLOGY

An ischemic insult is thought to cause this type of brain damage. It can be considered the result of a fetal ischemic stroke. Middle cerebral artery occlusion is postulated to be the main cause of porencephaly.[12] Birth trauma, inflammatory diseases, amniocentesis complications, and twin-to-twin transfusion syndrome are also recognized as possible causes.[13] In addition, familial and chromosomal types of porencephaly have been described.[14]

MANIFESTATIONS OF DISEASE

Clinical Presentation

The neuropathologic feature of porencephaly is a usually unilateral intrahemispheric cleft. The cleft is a fluid-filled cavity that usually communicates with the cerebral ventricles internally and the subarachnoid space externally and usually is lined with white matter. In contrast to schizencephaly, porencephaly is not associated with neuronal migration abnormalities.

Imaging Technique and Findings

Porencephaly is a lateralized lesion that appears as a cystic cavity within the brain, usually communicating with the lateral ventricle, the subarachnoid space, or both (Fig. 40.5A).

CLASSIC SIGNS

- Unilateral cystic cavity in the brain communicating with the ipsilateral ventricle

Differential Diagnosis From Imaging Findings

1. Distinction from unilateral schizencephaly may be difficult. In schizencephaly, clefts usually show smooth contours, whereas in porencephaly, the cavities tend to be rounder and with jagged contour. Fetal MRI can be useful in the third trimester by showing whether the defect is lined with white matter (porencephaly) or gray matter (schizencephaly).
2. Arachnoid cysts are usually smooth-walled, do not communicate with the ventricular system, and, in contrast to porencephaly, have a mass effect on the adjacent brain.

Synopsis of Treatment Options

Treatment considerations include the following:

- Similar diagnostic work-up as for ICH
- Offer of termination of pregnancy if appropriate, or conservative management

WHAT THE REFERRING PHYSICIAN NEEDS TO KNOW

Porencephaly is a rare destructive lesion of the fetal brain probably correlated with vascular occlusion and infarction. The prognosis is poor, and termination of pregnancy should be offered before the fetus is viable. Seizures, developmental delay, hemiparesis, and intellectual impairment are usually present in patients with this kind of lesion.

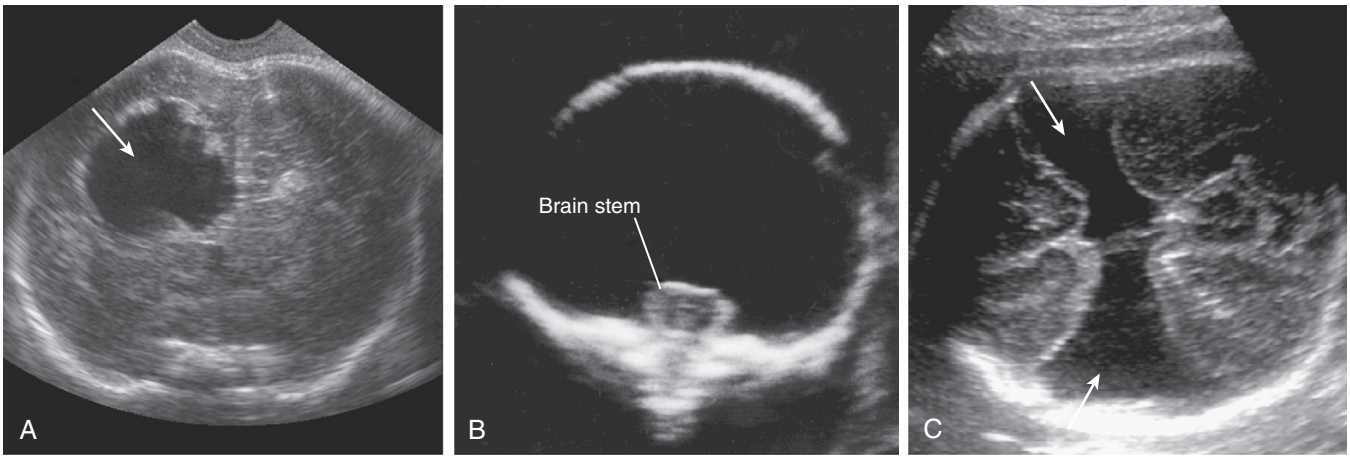

Fig. 40.5 Destructive lesions of the fetal brain. (A) In porencephaly, an irregular cavity is seen within one cerebral hemisphere *(arrow)*. (B) In hydranencephaly, the brain is entirely replaced by a fluid collection. (C) Bilateral clefts *(arrows)* suggest schizencephaly. *(Reproduced with permission from* Visual encyclopedia of ultrasound in obstetrics and gynecology, *2011. Available from* http://www.isuog.org.*)*

KEY POINTS

- Porencephaly is a rare destructive lesion of the fetal brain, probably secondary to vascular occlusion.
- It appears as a unilateral, white matter–lined cystic cavity communicating with the ipsilateral ventricle, with no mass effect.
- The prognosis is very poor, and termination of pregnancy should be offered.

Hydranencephaly

DEFINITION

Hydranencephaly is defined as the absence of the cerebral hemispheres; the hemispheres are replaced by a fluid-filled sac.

Synonyms include *hydrocephalic anencephaly, hydroencephalodysplasia*, and *cystencephaly*.

PREVALENCE AND EPIDEMIOLOGY

Hydranencephaly is rare; it occurs in about 1:10,000 to 2.5:10,000 births.[15]

ETIOLOGY AND PATHOPHYSIOLOGY

Hydranencephaly is the consequence of a destructive process of the fetal brain, which can be caused by vascular occlusion of the anterior or middle cerebral arteries;[16] confluence of multiple cystic leukomalacia cavities;[15] diffuse hypoxic-ischemic brain necrosis secondary to maternal exposure to butane or carbon monoxide;[17] infection by *Toxoplasma*, cytomegalovirus, or herpes simplex.[18] A recent case of hydranencephaly and hydrops fetalis secondary to maternal infection with Zika virus has been reported.[19] Finally, intrauterine demise of a twin from a monochorionic pair can lead to hydranencephaly.[20] Hydranencephaly can be considered as an extreme form of porencephaly.

MANIFESTATIONS OF DISEASE

Clinical Presentation

Hydranencephaly is characterized by the absence of the cerebral hemispheres, with incomplete or absent cerebral falx. The fluid-filled sac that replaces the brain is formed by the leptomeninges and the cerebrospinal fluid.

Imaging Technique and Findings

Ultrasound. On US, hydranencephaly appears as a large cystic structure replacing the fetal brain, with interruption or absence of the cerebral falx (see Fig. 40.5B). The brainstem and rhombencephalic structures are usually spared. Although normally visible in the second trimester when present, hydranencephaly is the consequence of a destructive process that can occur later in gestation.

CLASSIC SIGNS

- No cerebral hemispheres
- Thalami and brainstem protruding inside a cystic structure

Differential Diagnosis From Imaging Findings

Hydranencephaly must be distinguished from extreme hydrocephalus, porencephaly, and alobar holoprosencephaly. The presence of even minimal frontal cerebral cortex is indicative of hydrocephalus. Color Doppler may be useful for differential diagnosis because anterior and middle cerebral arteries are not visualized in hydranencephaly.

Synopsis of Treatment Options

PRENATAL

Prenatal treatment considerations include the following:

- Karyotyping

- Maternal serology or amniotic fluid polymerase chain reaction for cytomegalovirus, *Toxoplasma*, herpes, and Zika
- Offer of termination of pregnancy, if appropriate, or conservative management is indicated.

WHAT THE REFERRING PHYSICIAN NEEDS TO KNOW

Hydranencephaly is a severe destructive cerebral lesion, with the fetal brain replaced by a fluid-filled sac. The prognosis is universally poor, and death usually occurs within the first year of life. Termination of pregnancy should be advised if possible. Hydranencephaly is considered to be sporadic, with a certain degree of recurrence only in cases of infectious disorders.[2]

KEY POINTS

- Hydranencephaly is a severe destructive cerebral lesion with absence of the cerebral hemispheres.
- It can be the consequence of a vascular accident, other ischemic insults, infection, maternal exposure to toxins, or death of a co-twin in a monochorionic pregnancy.
- The typical US appearance is a large cystic structure replacing the fetal brain, but the brainstem and the thalami are preserved.
- It is usually identified at midgestation, but it also can occur later in pregnancy.
- The prognosis is very poor, and termination of pregnancy should be considered if possible.

Schizencephaly

DEFINITION

Schizencephaly is a disorder characterized by full-thickness, gray matter–lined clefts of the cerebral mantle. The clefts are often bilateral and symmetric, providing communication between the lateral ventricles and the external subarachnoid space. A synonym is *true porencephaly*.

PREVALENCE AND EPIDEMIOLOGY

Schizencephaly is very rare.

ETIOLOGY AND PATHOPHYSIOLOGY

The etiology of schizencephaly is unknown. It is probably not the result of a destructive process of the fetal brain, but rather a morphogenetic disorder. According to the most accepted theory, the cerebral clefts are the result of an alteration in neuronal migration from the germinal matrix.[21,22] A vascular etiology, similar to that postulated for porencephaly, has also been considered.[23] Finally, a genetic origin of the disease has recently been proposed, with the involvement of COL4A1 mutation, responsible for hemolytic anemia.[24]

MANIFESTATIONS OF DISEASE

Clinical Presentation

The neuropathologic features of schizencephaly include (1) hemispheric clefts, lined with pia-ependyma, usually bilateral, in the area of the Sylvian fissure; (2) communication of the subarachnoid space with the lateral ventricle, with infolding of gray matter along the cleft; and (3) multiple associated intracranial malformations (polymicrogyria, gray matter heterotopias, absent septum pellucidum, optic nerve hypoplasia, and agenesis of the corpus callosum).[22,23,25] The following classification into two variants has been proposed:

- *Type I:* Fused clefts in the cerebral mantle
- *Type II:* Separated clefts in the cerebral mantle with associated ventriculomegaly

Imaging Technique and Findings

Prenatal diagnosis of schizencephaly has been reported in few cases, always of the type II variety; type I variety would be very difficult to diagnose prenatally. Schizencephaly must be considered when clefts are found in the area of the Sylvian fissures, establishing a communication between the enlarged lateral ventricle medially and the subarachnoid space laterally (Fig. 40.5C). The two frontal horns may be fused as well, with absent septum pellucidum.

CLASSIC SIGNS

- Bilateral full-thickness and gray matter–lined clefts providing a communication between the lateral ventricle and the subarachnoid space

Differential Diagnosis From Imaging Findings

1. Distinguishing a large porencephalic cyst in the area of the Sylvian fissure from schizencephaly may be impossible; however, large porencephalic cysts are usually unilateral with jagged contours.
2. In lobar holoprosencephaly and septooptic dysplasia, the septum pellucidum is absent, and the frontal horns are fused, but usually there are no cortical defects.
3. Intracranial cysts may occur in the area of the Sylvian fissure, but they do not communicate with the ventricles.

Synopsis of Treatment Options

Termination of pregnancy should be offered if appropriate, or conservative management is indicated.

WHAT THE REFERRING PHYSICIAN NEEDS TO KNOW

Schizencephaly is a rare disorder characterized by loss of cerebral tissue, probably secondary to an alteration in the neuronal migration process. The prognosis is usually poor; children usually have various degrees of mental retardation and developmental delay, seizures, and motor abnormalities; rarely, asymptomatic cases with type I have been reported.[26] The recurrence risk of schizencephaly is unknown; however, neuronal migration disorders have been reported to be associated with a 5% to 20% chance of cerebral malformations in siblings.[27]

KEY POINTS

- Schizencephaly is a rare disorder characterized by bilateral full-thickness clefts, providing a communication between the lateral ventricle and the subarachnoid space.
- It is probably a neuronal migration disorder.
- It is not always possible to diagnose schizencephaly prenatally, especially with type I.
- The prognosis is poor, and termination of pregnancy should be offered.

Intracranial Cysts

DEFINITION

Intracranial cysts are fluid-filled, round lesions observed in the fetal brain. Choroid plexus cysts are the most common intracranial cysts; they are discussed in Chapter 33. Arachnoid and glioependymal cysts are also quite common in the fetus. Arachnoid cysts are the result of an accumulation of cerebrospinal-like fluid between the cerebral meninges. Glioependymal cysts are intracranial cysts lined with ependyma. They differ from arachnoid cysts, which have fibrous walls with no ependyma. No synonyms exist for arachnoid cysts. Synonyms for glioependymal cysts include *ependymal cysts, neuroepithelial cysts, epithelial cysts, choroidal epithelial cysts,* and *interhemispheric cysts* (occasionally associated with agenesis of the corpus callosum).

PREVALENCE AND EPIDEMIOLOGY

Intracranial cysts other than choroid plexus cysts are rare. The exact incidence is unknown.

ETIOLOGY AND PATHOPHYSIOLOGY

From external to internal, the meninges are composed of the dura mater, arachnoid, and pia mater. Arachnoid cysts originate from a fluid collection between the dura mater and the arachnoid, between the two layers of the arachnoid (intraarachnoid cysts), or between the arachnoid and the pia mater (subarachnoid cysts). They can be primary (maldevelopment of the meninges) or secondary (result of trauma, hemorrhage, or infection).[28] Arachnoid cysts may communicate with the subarachnoid space. Glioependymal cysts are thought to arise from displaced neuroectodermal tissue.[29]

MANIFESTATIONS OF DISEASE

Clinical Presentation

Arachnoid cysts are fluid-filled lesions usually located in the major cerebral fissures (Sylvian, Rolandic, and interhemispheric), in the sella turcica, in the anterior and middle fossa, and rarely in the posterior fossa. A recent systematic review has demonstrated that arachnoid cysts are often associated with anomalies (73% of cases) and extra central nervous system (CNS) anomalies (14% of cases), the most common cerebral associated findings being ventriculomegaly and callosal abnormalities. In 6% of cases chromosomal anomalies may be present, even if it is unlikely in isolated cases.[30]

Glioependymal cysts are usually located in the midline and are frequently associated with agenesis of the corpus callosum. Very large intracranial cysts can cause obstructive ventriculomegaly.

Imaging Technique and Findings

Ultrasound. On US, intracranial cysts appear as well-defined anechoic lesions with mass effect and are frequently associated with ventriculomegaly (Fig. 40.6). Midline cysts may be associated with agenesis of the corpus callosum. Differentiation between arachnoid and glioependymal cysts is impossible prenatally, although the latter condition is more likely when the lesion is in the midline. Apart from choroid plexus cysts, most other intracranial cysts are evident only in the third trimester.

CLASSIC SIGNS

Classic signs of arachnoid cysts include the following:
- Regular, anechoic cyst located in the midline supratentorial area, in the Sylvian fissure, or in the ambient cisterna usually at the brain surface with mass effect

Classic signs of glioependymal cysts include the following:
- Midline anechoic cyst displacing the hemispheres to the side
- Corpus callosum agenesis

Differential Diagnosis From Imaging Findings

Intracranial cysts must be distinguished from other fluid collections.

1. Porencephalic cysts and schizencephalic clefts are located inside the brain mass, whereas arachnoid cysts are external to the brain and show no communication with the lateral ventricles.
2. Brain tumors lie within the cortex and usually show solid or mixed echogenicity.
3. When a midline cyst is identified, it is important to rule out associated agenesis of the corpus callosum.
4. A posterior fossa arachnoid cyst is usually difficult to differentiate from primary cerebellar anomalies such as Dandy-Walker malformation (Chapter 37).
5. Vein of Galen aneurysms are easily shown by color flow mapping (Chapter 42).

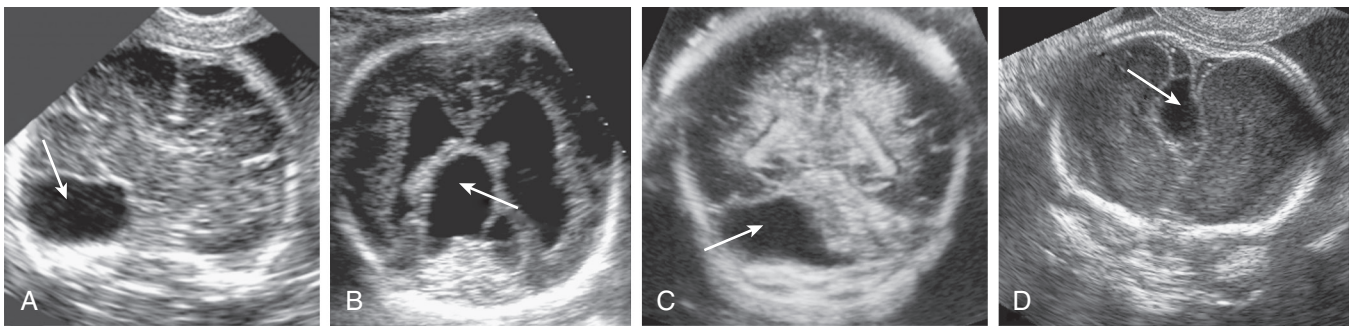

Fig. 40.6 Intracranial cysts *(arrows)*. (A) Cyst interposed between the skull base and the temporal lobe. (B) Interhemispheric cyst associated with ventriculomegaly. (C) Posterior fossa cyst. (D) Interhemispheric cyst associated with agenesis of corpus callosum. *(Reproduced with permission from* Visual encyclopedia of ultrasound in obstetrics and gynecology, *2011. Available from* http://www.isuog.org.*)*

6. Differential diagnosis between arachnoid cysts and glioependymal cysts may be possible only by histology and not by US; however, arachnoid cysts are usually located at the brain surface, whereas the midline location and association with agenesis of the corpus callosum indicate a glioependymal cyst.

Synopsis of Treatment Options

PRENATAL

Prenatal treatment considerations include the following:
- US monitoring
- Standard obstetric care

WHAT THE REFERRING PHYSICIAN NEEDS TO KNOW

Intracranial cysts are benign intracranial lesions and usually have a good prognosis. They are asymptomatic in most cases, although they may cause epilepsy, mild motor or sensory abnormalities, as well as hydrocephalus in children.[30] Management should be conservative with US monitoring. Standard obstetric care is advised, unless hydrocephalus or macrocrania occurs. In these cases, a cesarean section may be appropriate. Glioependymal and arachnoid cysts are similar in appearance and clinical outcome; it is uncertain whether these two entities should be kept separated. A worse outcome may be anticipated in case of associated obstructive hydrocephalus or agenesis of the corpus callosum.

KEY POINTS

- Arachnoid cysts are an accumulation of cerebrospinal-like fluid between the cerebral meninges. They appear on US as well-defined anechoic lesions with mass effect.
- Glioependymal cysts are fluid-filled lesions with an ependymal lining. Their distinction from arachnoid cyst is often histologic only. They are benign, but they may be associated with agenesis of the corpus callosum.
- Intracranial cysts usually have a good prognosis and should be managed conservatively, although they may be associated with obstructive hydrocephalus.

Intracranial Tumors

DEFINITION

The most common intracranial tumors are embryonic tumors (teratomas, epidermoid tumors, dermoid tumors), followed by germinal tumors (germinomas, choriocarcinomas, embryonal carcinomas) and neuroblastic tumors (medulloblastomas, neuroblastomas, retinoblastomas). Rare forms include tumors related to embryonal remnant tissues (craniopharyngiomas) and tumors of ependymal origin (glioblastoma multiforme, choroid plexus papillomas). Finally, there are tumors associated with genetic conditions (tuberous sclerosis, neurofibromatosis, systemic angiomatosis of the CNS and the eye), lipomas, and choroid plexus papillomas. Choroid plexus papillomas are discussed in Chapter 33. A synonym for intracranial tumor is *brain tumor*.

PREVALENCE AND EPIDEMIOLOGY

Fetal intracranial tumors are rare, with an estimated incidence of 0.34:1 million live births.[31]

ETIOLOGY AND PATHOPHYSIOLOGY

The exact cause of malignancy in early life is unknown. Embryonic tumors are thought to derive from embryologically displaced cells. Normal embryonic cells share some aspects with neoplastic cells (rapid growth, transforming capacity). Fetal exposure to exogenous factors such as drugs, viruses, and ionizing irradiation can lead to uncontrolled cell duplication leading to malignancy. In animal models, brain tumors have been produced by the use of chemical or viral teratogens.

MANIFESTATIONS OF DISEASE

Clinical Presentation

Most brain tumors (70%) are supratentorial, the others are infratentorial.[32]

Teratomas may contain well-differentiated structures (hair, bone) or undifferentiated tissues with a higher tendency toward malignancy. They are usually observed in the pineal region, the suprasellar region, or the fourth ventricle, with mass effect and distortion of the surrounding brain architecture.

Epidermoid tumors derive from epithelial cells and appear as cystic lesions containing desquamation of the internal epithelial lining. They are mostly located in the suprasellar region, in the temporal lobe, or at the level of the cerebello-pontine angle.

Germinomas originate from germ cells and are solid lesions occurring in the pineal and suprasellar region. Medulloblastomas appear as friable masses with internal necrosis, growing in the posterior fossa. Craniopharyngiomas derive from remnants of the craniopharyngeal duct and are solid-cystic lesions usually located in the suprasellar region. Although histologically benign, tumor expansion can cause displacement and damage of the surrounding brain parenchyma.

Tuberous sclerosis, neurofibromatosis, and systemic angiomatosis of the CNS and the eye are autosomal dominant conditions associated with brain tumors. Tuberous sclerosis is associated with multiple neuroglial nodules occurring in the cerebral cortex and the ventricular system; acoustic neurinomas are observed in association with neurofibromatosis; cerebellar hemangioblastomas occur in systemic angiomatosis of the CNS and the eye.

Lipomas are benign lesions usually located in the interhemispheric area or in the ventricles. There is a well-established association between interhemispheric lipomas and agenesis of the corpus callosum (Chapter 34).[31]

Macrocephaly, obstructive ventriculomegaly, intracranial calcifications, and hemorrhages are often associated with fetal brain tumors.

Imaging Technique and Findings

Ultrasound. Fetal brain tumors appear on US as solid or mixed lesions with mass effect and distortion of the surrounding brain architecture (Fig. 40.7). Asymmetry of the lesion is typical and may cause shifting of the midline. Macrocrania or skull swelling, hydrocephalus, epignathus, polyhydramnios, heart failure, and hydrops are also common findings. Histologic characterization of the lesion is usually impossible by US. However, teratomas are most frequently encountered and should be suspected particularly when they are associated with extracranial outgrowth (Fig. 40.8). MRI may be useful in defining the exact contours of the tumor (see Fig. 40.8).

CLASSIC SIGNS

Mass-occupying lesion with cystic and solid areas with distortion of the normal intracranial anatomy

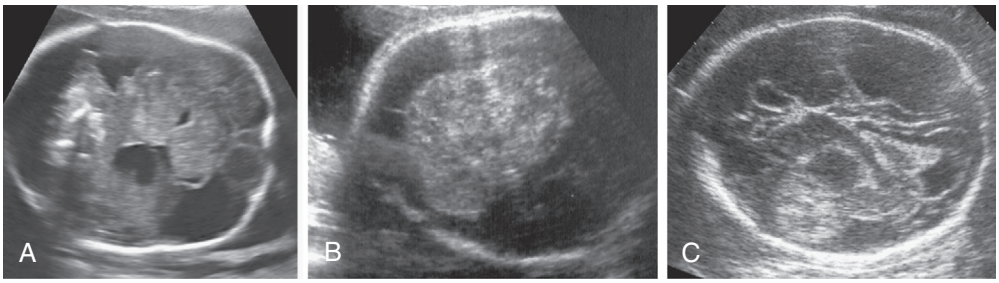

Fig. 40.7 Fetal intracranial tumors include teratoma (A), craniopharyngioma (B), and astrocytoma (C). Despite the different histologic types, US findings are similar. The cerebral architecture is subverted by the presence of a large solid or complex mass. *(Reproduced with permission from* Visual encyclopedia of ultrasound in obstetrics and gynecology, *2011. Available from* http://www.isuog.org.*)*

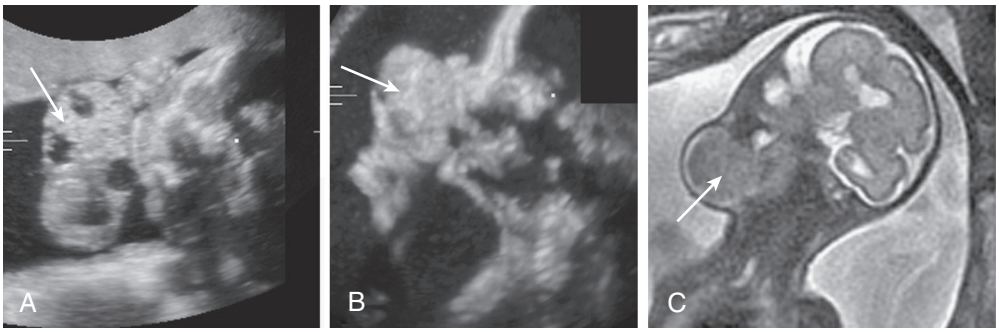

Fig. 40.8 Intracranial teratomas are frequently associated with external outgrowth of the tumor *(arrows)*, which may occur through the orbits (A), mouth (B), or skull base (C). *(Reproduced with permission from* Visual encyclopedia of ultrasound in obstetrics and gynecology, *2011. Available from* http://www.isuog.org.*)*

Differential Diagnosis From Imaging Findings

The main diagnostic problem is the differentiation between brain tumors and recent intracranial hemorrhages, although the latter result in cavitation and blood clot formation in about 2 weeks' time. Prenatal MRI may be useful in these cases.

Synopsis of Treatment Options

PRENATAL

Treatment considerations include the following:

- US monitoring
- Offer of termination of pregnancy if appropriate

WHAT THE REFERRING PHYSICIAN NEEDS TO KNOW

Intracranial tumors are very rare in the fetus. The most frequent lesions are teratomas. In postnatal series, the survival rate for this kind of tumor was only 7% at 1-year follow-up.[33] Generally, the prognosis is very poor, with an overall mortality rate of about 77%.[34] Only lipomas, unless associated with agenesis of the corpus callosum, have a good prognosis with a survival rate of 100% and no neurologic impairment.[34]

KEY POINTS

- Fetal brain tumors are rare.
- They appear on US as mass effect lesions with distortion of the surrounding brain architecture.
- Prenatal characterization of the histologic type of tumor may be impossible.
- The prognosis is poor, with the exception of lipomas with normal corpus callosum.

SUGGESTED READINGS

Delbos F, Bertrand G, Croisille L, et al. Fetal and neonatal alloimmune thrombocytopenia: predictive factors for intracranial hemorrhage. *Transfusion*. 2016;56:59-66.

Ghi T, Simonazzi G, Perolo A, et al. Outcome of antenatally diagnosed intracranial hemorrhage: case series and review of the literature. *Ultrasound Obstet Gynecol*. 2003;22:121-130.

Youssef A, D'Antonio F, Khalil A, et al. Outcome of fetuses with supratentorial extra-axial intracranic cysts: a systematic review. *Fetal Diagn and Ther*. 2016;40(1):1-12.

All references are available online at www.expertconsult.com.

REFERENCES

1. Papile LA, Burstein J, Burstein R, et al. Incidence and evolution of subependymal and intraventricular hemorrhage: a study of infants with birth weights less than 1,500 gm. *J Pediatr*. 1978;92:529-534.
2. Vergani P, Strobelt N, Locatelli A, et al. Clinical significance of fetal intracranial hemorrhage. *Am J Obstet Gynecol*. 1996;175(3 Pt 1):536-543.
3. Pilu G, Falco P, Perolo A, et al. Differential diagnosis and outcome of fetal intracranial hypoechoic lesions: report of 21 cases. *Ultrasound Obstet Gynecol*. 1997;9:229-236.
4. Frank DA, McCarten KM, Robson CD, et al. Level of in utero cocaine exposure and neonatal ultrasound findings. *Pediatrics*. 1999;104(5 Pt 1):1101-1105.
5. Zalneraitis EL, Young RS, Krishnamoorthy KS. Intracranial hemorrhage in utero as a complication of isoimmune thrombocytopenia. *J Pediatr*. 1979;95:611-614.
6. Delbos F, Bertrand G, Croisille L, et al. Fetal and neonatal alloimmune thrombocytopenia: predictive factors for intracranial hemorrhage. *Transfusion*. 2016;56:59-66.
7. Sokal MM, Katz M, Lell ME, et al. Neonatal survival after traumatic fetal subdural hematoma. *J Reprod Med*. 1980;24:131-133.
8. Ghi T, Simonazzi G, Perolo A, et al. Outcome of antenatally diagnosed intracranial hemorrhage: case series and review of the literature. *Ultrasound Obstet Gynecol*. 2003;22:121-130.
9. Sibony O, Fondacci C, Oury JF, et al. In utero cerebral intraparenchymal hemorrhage associated with an abnormal cerebral Doppler. *Fetal Diagn Ther*. 1993;8:126-128.
10. Johnson JA, Ryan G, al-Musa A, et al. Prenatal diagnosis and management of neonatal alloimmune thrombocytopenia. *Semin Perinatol*. 1997; 21:45-52.
11. Vintzileos AM, Hovick TJ, Escoto DT, et al. Congenital midline porencephaly: prenatal sonographic findings and review of the literature. *Am J Perinatol*. 1987;4:125-128.
12. Jung JH, Graham JM, Schultz N, et al. Congenital hydranencephaly/porencephaly due to vascular disruption in monozygotic twins. *Pediatrics*. 1984;73:467-469.
13. Eller KM, Kuller JA. Fetal porencephaly: a review of etiology, diagnosis, and prognosis. *Obstet Gynecol Surv*. 1995;50:684-687.
14. Berg RA, Aleck KA, Kaplan AM. Familial porencephaly. *Arch Neurol*. 1983;40:567-569.
15. Larroche JC, Droulle P, Delezoide AL, et al. Brain damage in monozygous twins. *Biol Neonate*. 1990;57:261-278.
16. Myers RE. Brain pathology following fetal vascular occlusion: an experimental study. *Invest Ophthalmol*. 1969;8:41-50.
17. Fernandez F, Perez-Higueras A, Hernandez R, et al. Hydranencephaly after maternal butane-gas intoxication during pregnancy. *Dev Med Child Neurol*. 1986;28:361-363.
18. Christie JD, Rakusan TA, Martinez MA, et al. Hydranencephaly caused by congenital infection with herpes simplex virus. *Pediatr Infect Dis*. 1986;5:473-478.
19. Sarno M, Sacramento GA, Khouri R, et al. Zika virus infection and stillbirths: a case of hydrops fetalis, hydranencephaly and fetal demise. *PLoS Neglected Tropical Diseases*. 2016;10(2):e0004517.
20. Fusi L, McParland P, Fisk N, et al. Acute twin-twin transfusion: a possible mechanism for brain-damaged survivors after intrauterine death of a monochorionic twin. *Obstet Gynecol*. 1991;78(3 Pt 2):517-520.
21. Bordarier C, Robain O. Familial occurrence of prenatal encephaloclastic damage: anatomoclinical report of two cases. *Neuropediatrics*. 1989;20:103-106.
22. Yakovlev WR. Schizencephalies: a study of congenital clefts in the cerebral mantle. I. Clefts with fused lips. *J Neuropatol Exp Neurol*. 1946;5:116-130.
23. Yakovlev WR. Schizencephalies: a study of congenital clefts in the cerebral mantle. II: Clefts with hydrocephalus and lips separated. *J Neuropatol Exp Neurol*. 1946;5:169-206.
24. Matsumoto T, Miyakoshi K. Intracranial sonographic features demonstrating in utero development of hemorrhagic brain damage leading to schizencephaly-associated COL4A1 mutation. *J Med Ultrasonics*. 2015;42:445-446.
25. Barkovich AJ, Norman D. MR imaging of schizencephaly. *AJR Am J Roentgenol*. 1988;150:1391-1396.
26. McGahan JP, Ellis W, Lindfors KK, et al. Congenital cerebrospinal fluid-containing intracranial abnormalities: a sonographic classification. *J Clin Ultrasound*. 1988;16:531-544.
27. Dobyns WB, Kirkpatrick JB, Hittner HM, et al. Syndromes with lissencephaly. II. Walker-Warburg and cerebro-oculo-muscular syndromes and a new syndrome with type II lissencephaly. *Am J Med Genet*. 1985;22:157-195.
28. Oliver LC. Primary arachnoid cysts; report of two cases. *BMJ*. 1958;1:1147-1149.
29. Friede RL, Yasargil MG. Supratentorial intracerebral epithelial (ependymal) cysts: review, case reports, and fine structure. *J Neurol Neurosurg Psychiatry*. 1977;40:127-137.
30. Youssef A, D'Antonio F, Khalil A, et al. Outcome of fetuses with supratentorial extra-axial intracranic cysts: a systematic review. *Fetal Diagn and Ther*. 2016;40(1):1-12.
31. Pilu G, Sandri F, Perolo A, et al. Sonography of fetal agenesis of the corpus callosum: a survey of 35 cases. *Ultrasound Obstet Gynecol*. 1993;3:318-329.
32. Cavalheiro S, Moron AF, Hisaba W, et al. Fetal brain tumors. *Childs Nerv Syst*. 2003;19:529-536.
33. Wakai S, Arai T, Nagai M. Congenital brain tumors. *Surg Neurol*. 1984;21:597-609.
34. Schlembach D, Bornemann A, Rupprecht T, et al. Fetal intracranial tumors detected by ultrasound: a report of two cases and review of the literature. *Ultrasound Obstet Gynecol*. 1999;14:407-418.

41 Neural Tube Defects

TULLIO GHI | ANDREA DALL'ASTA | GIANLUIGI PILU | ELENA CONTRO | FRANCESCA DE MUSSO | TIZIANA FRUSCA

Introduction

Neural tube defects (NTD) are the consequence of a failure in the closure of the neural tube, and differ depending on their localization and extent.

The term "neural tube defects" includes defects of the cranial vault, including the spectrum of acrania, exencephaly, and anencephaly, and encephaloceles, spinal defects ("spina bifida" or myelomeningocele), and combined cranial and spinal defects such as craniorachischisis. These defects, as well as hemivertebrae, are discussed in this chapter.

Embryology

Neural tube defects (NTDs) arise from the disruption occurring during several different stages of the neurulation process leading to the development of the central nervous system (CNS).[1] The cause is multifactorial, due to the complex interaction between genetic and environmental factors.

Neurulation origins from epiblastic cells migrate toward the primitive streak and form the neuroectodermal tissue of the neural plate as early as postovulatory day 16.[2] At this stage the neural plate is surrounded by paraxial mesodermal cells, which will develop into paired somites. These represent the mesodermal precursors of the vertebral bodies and of the ribs.[3]

Complex interactions involving neural ectodermal cells of the neural plate and nonneural ectoderm, which will develop into the overlying skin layer, are responsible for the induction of the neural plate. The borders of the neural plate elevate into the neural folds, move toward the midline, fuse, and form the neural tube.[1] Although the neural tube was previously thought to close from cranial to caudal in a zipper-like fashion, and starting from the level of the fifth somite,[4] more recent evidence suggests that neurulation proceeds through progressive waves of closure along the craniocaudal neuraxis.[5,6] After the process of closure has started, the open regions of the neural tube are called the anterior (cranial) and posterior (caudal) neuropores. Once closure is initiated at a site, neuroectodermal cells reorganize to form the roof of the neural tube, while overlying epidermal cells form the ectodermal layer of the skin.

Caudally, the process of closure of the neural tube continues until the posterior neuropore is closed,[1] whereas in the cranial region a second site of temporary closure appears in the forebrain at level of the ninth somite. This process, termed *occlusion*, is responsible for the spacing of the cranial vesicles and for the prevention of fluid drainage from the vesicles, which remain fluidfilled, forming the neurocele.[7] The cranial neuropore is closed on day 25, whereas the caudal neuropore closes by day 28. At this stage, the neurocele reopens without loss of fluid from the cranial vesicles.

The neurulation process described previously is called primary neurulation, and it is responsible for the development of the brain and of the spinal cord down to the sacral region (probably S4–S5).[1] From this level downward secondary neurulation, which occurs between approximately postovulatory days 23 to 32, forms the caudal end of the cord. Because this process takes place below the surface ectoderm, abnormalities of secondary neurulation produce lesions that are covered by skin and are not involved in the pathogenesis of open spina bifida.

When the cranial neuropore fails to close, the bony tissue covering the brain does not develop, and the unprotected neural tissue is destroyed. This represents the embryologic origin of major brain malformations such as acrania-exencephaly and acrania-anencephaly sequences. Acrania is characterized by the partial or complete absence of the cranial vault. This open defect of the calvaria and the skin results in the exposure of the neural tube, which defines exencephaly. Exencephaly is considered an early stage of anencephaly given that the "external" (intraamniotic) location of the brain tissue results in the abnormal development and regression of the forebrain and the diencephalon, leading to anencephaly. On the other hand, the hindbrain proceeds to develop normally, allowing for the fetus to survive until term.[8–10]

The development of congenital encephalocele is uncertain, although it seems to depend on defective closure of the anterior wall of the neural tube. The onset of the most severe lesions likely occurs before day 26 (after conception) whereas less severe lesions that primarily involve skull or meninges may occur later.[11] Anterior encephaloceles (sincipital and basal) probably result from defective development of the prosencephalic neural crest tissue; occipital encephaloceles probably arise from abnormal segmentation of the bones of the posterior cranium (supraoccipital, exoccipital, and basioccipital, and the posterior part of the parietal bones).[12]

Myelomeningoceles result either from the failure of closure of the neural tube prior to the reopening of the neurocele, which can also explain the collapse of the cranial vesicles and the development of the Chiari II malformation,[13,14] or from an overdistension and rupture of a previously normally closed neural tube. More recently it has been hypothesized that in some cases myelomeningoceles may be caused by abnormalities in midline axial integration occurring during the gastrulation process.[15,16]

Craniorachischisis represents the most extensive NTD characterized by failed closure of both the cranial and the caudal neural tube. The recent hypothesis of "multiple sites of neural tube fusion" explains the pathogenesis of this defect best, in which the calvaria and vertebrae fail to form correctly, exposing the neural tissue to further insult and destruction.[17]

Vertebral defects may arise from the disruption of normally formed anatomic structures, i.e., in the case of amniotic band

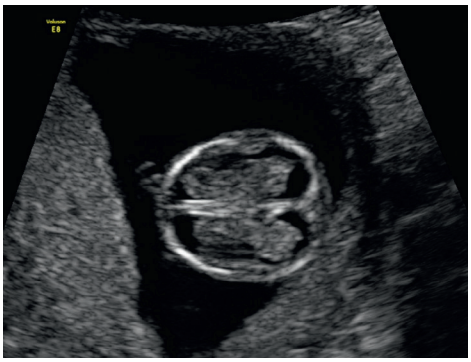

Fig. 41.1 Normal fetal head at 12 weeks of gestation: normal ossification of the skull, two hemispheres, both choroid plexus and the falx cerebri are visible.

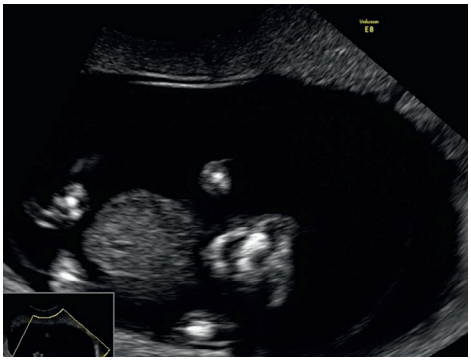

Fig. 41.2 Anencephaly at 13 weeks of gestation: coronal plane showing the absent calvarium.

syndrome, or from failure of the embryologic differentiation or development of a specific anatomic structure. Hemivertebrae, or wedge-shaped vertebrae, are caused by abnormal development or segmentation of somites during osteogenesis, most likely due to insufficient blood supply to the vertebrae. Hemivertebrae and other vertebral abnormalities such as block vertebrae, butterfly vertebrae, transitional vertebrae and spina bifida can cause compression of the spinal cord due to deformation of the vertebral canal, spinal curvature, and alterations of the shape and number of vertebrae.[18,19]

Acrania, Exencephaly, Anencephaly

DEFINITION

Acrania is the absence of the ossified cranial vault above the orbits, resulting in abnormal brain tissue that is exposed to amniotic fluid.

Because observational ultrasound (US) studies in human embryos indicate a progression from acrania to anencephaly, it was hypothesized that exencephaly is a precursor of anencephaly.[20] The initial defect is the absence of the cranium (acrania), resulting in exposure of brain tissue (exencephaly) with subsequent degeneration. Ossification of the skull vault as a continuous process (Fig. 41.1) is complete at 12 + 0 weeks.[21] By 12 weeks, the sonographic diagnosis of deficient ossification is based on the absence of the bony part of the neurocranium (calvarium) with the orbits (Fig. 41.2) visible as the most cranial bony structure (Fig. 41.3).

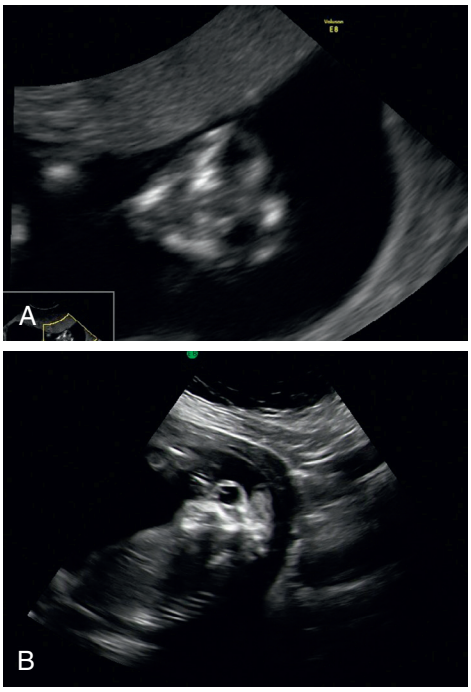

Fig. 41.3 Anencephaly at 12 weeks of gestation: (A) Coronal plane, showing the absent border of the orbits. (B) Exencephaly visible above the bony margins of the orbits.

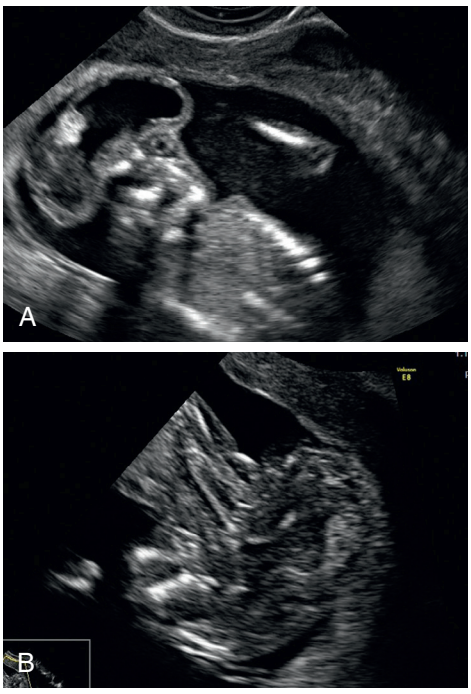

Fig. 41.4 Exencephaly at 13 weeks. (A) Abdominal ultrasound shows abnormal contours of the head, outwardly extruding brain tissue. (B) Vaginal ultrasound shows distorted remnants of normal brain structures.

In exencephaly, the area cerebrovasculosa (i.e, the abnormal disorganized central nervous tissue that replaces the cerebral hemispheres) is prominent as outwardly extruding brain tissue (Figs. 41.4A,B). The absence of the cranial bone and the abnormal shape of the exposed brain help distinguish between a normal immature brain and exencephaly.

ETIOLOGY

In the majority of NTDs, the exact etiology is not known. Most NTDs occur sporadically, indicating heterogeneity, and in most affected pregnancies there are no recognizable risk factors.

Genetic and nongenetic factors such as parental socioeconomic status; exposure to teratogens, such as valproic acid, folic acid antagonists, vitamin A, and alcohol; and maternal diabetes, maternal obesity, and hyperthermia during early pregnancy have been discussed as risk factors.

Epidemiologic studies in the early 1990s showed a correlation between maternal folate status and neural tube defects.[11,22] Subsequent studies confirmed that the recurrence risk for NTDs could be reduced by periconceptional supplementation with folic acid. Administration of folic acid before and during the first weeks of gestation can reduce the incidence of NTDs by 30% to 50%,[11,23] but cannot completely prevent it; other factors must be involved. The etiology of NTDs is thought to be multifactorial, that is, with significant genetic components[24] in combination with environmental risk factors.[25,26]

The aneuploidy rate in fetuses with NTDs has been reported to be between 2% and 25%, including trisomy 18, partial trisomy of the long arm of chromosome 2, structural anomalies of chromosome 11, 13, and duplication of chromosome 11,13, tetraploidy, and triploidy.[27] The rate of aneuploidy depends on the type of NTD: It is lower for anencephaly and meningomyelocele, with about 0.6% to 5%, and higher for encephaloceles with about 6% to 9%.[27,28] Aneuploidy risks in NTDs are even higher if there are additional structural anomalies.

Anencephaly

DEFINITION

Anencephaly is the absence of the cranial vault above the bony orbits, associated with the absence of the cerebral hemispheres and midbrain.

PREVALENCE AND EPIDEMIOLOGY

The incidence of anencephaly in Europe is about 0.3:1000,[29] but shows a wide regional variation. For example, in the United States, Denmark, South Africa, Taiwan, and India the average incidence is 1:1000 pregnancies, 3:1000 to 7:1000 in Ireland and Wales, but only 0.1:1000 to 0.6:1000 in France, Japan, Hungary, and former Yugoslavia.[30] Similarly to spina bifida, the incidence is particularly high in the United Kingdom and low in Asia.[31] The female-to-male ratio is about 4:1.[29]

ETIOLOGY AND PATHOPHYSIOLOGY

Closure of the cranial neuropore normally occurs between 23 and 28 days. A failure in this process eventually leads to anencephaly, with incomplete development of the brain and lack of formation of the cranial bones above the orbits. Some consider anencephaly as an extreme form or end-stage of acrania, with the cerebral hemispheres having been destroyed by direct exposure to the amniotic cavity and constant trauma from fetal movements, bringing the brain tissue into contact with the uterine walls.[32]

Clinical Presentation

Anencephaly is characterized by the absence of the cerebral hemispheres and the cranial vault. A layer of angiomatous stroma, but no skin, covers the defect. Brain development is incomplete: the brainstem and part of the midbrain are present. A part of the cerebral hemispheres may sometimes be observed in the first trimester; this condition is usually called exencephaly. Anencephaly may be associated with spina bifida, urinary tract abnormalities, cleft lip and palate, gastrointestinal, and cardiac abnormalities.[33]

The majority of neonates with anencephaly die within hours or a few days of birth. The mortality in utero is 23%, and approximately 35% during labor; neonatal survival up to 8 days has been reported.[34] An observational study of the natural history of anencephaly showed that about 25% of ongoing pregnancies are complicated by polyhydramnios, and nearly 20% of deliveries are complicated by shoulder dystocia. Furthermore, this study reported an increased rate of other complications including prolonged induction and delay in the second stage of labor.[34]

Imaging Technique and Findings

Anencephaly was the first fetal anomaly diagnosed by antenatal US in 1972.[35] Nowadays, exencephaly is often diagnosed in the first trimester, by demonstrating the irregularity of the cephalic pole with protrusion of the brain mass and irregular shape of the cranial pole, resulting in a characteristic image in the coronal plane that has been called the "*Mickey Mouse sign*" (Figs. 41.5 and 41.6).[36]

In the second trimester, the absence of the calvarium is easily recognized above the orbits, which look prominent (Figs. 41.7A,B). There is little or no brain remaining above the base of the skull.

CLASSIC SIGNS

"Mickey Mouse" face in the first trimester. Absence of the calvarium above the bony orbits in the second trimester.

Differential Diagnosis From Imaging Findings

Extreme microcrania or large encephaloceles can be confused with anencephaly, but in microcrania the calvarium is present and not interrupted. Amniotic band syndrome may cause destruction of the cranial vault, but usually this is accompanied by other abnormalities, such as limb amputation. Acrania, exencephaly, and anencephaly may be part of the same spectrum of abnormalities.[32]

Other Imaging Modalities

Magnetic resonance imaging (MRI) can be a sensitive tool for certain aspects of brain anomalies, mainly maturation of the brain, but in fetal anencephaly or exencephaly, MRI usually does not provide additional information. Fetal MRI as an adjunct to US may help identify topography, to add CNS and non-CNS findings, and may be helpful in the evaluation of complex forms of encephaloceles.[37] Its value is questionable with regard to changing the detailed sonographic diagnosis, or in particular the management in anencephaly of encephaloceles.[38]

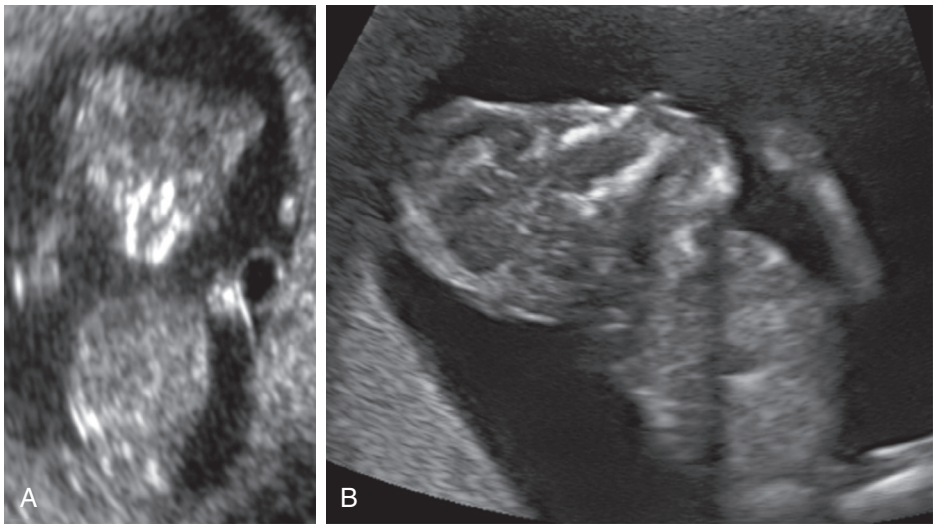

Fig. 41.5 Anencephaly in the first trimester: a cephalic pole is present but it is greatly distorted and floats freely in the amniotic fluid. (A) At 10 weeks' gestation, a coronal section demonstrates the "Mickey Mouse" sign. (B) Sagittal section at 13 weeks' gestation. *(Courtesy* Visual encyclopedia of ultrasound in obstetrics and gynecology, *2011*, http://www.isuog.org.*)*

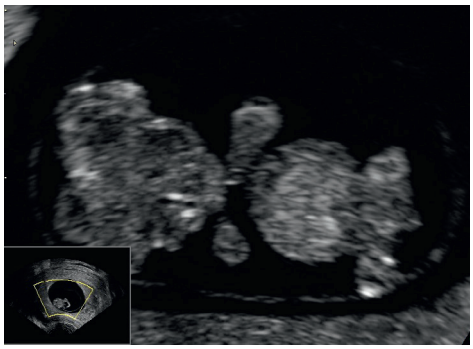

Fig. 41.6 Exencephaly at 9 weeks: the coronal plane shows the "Mickey Mouse" sign.

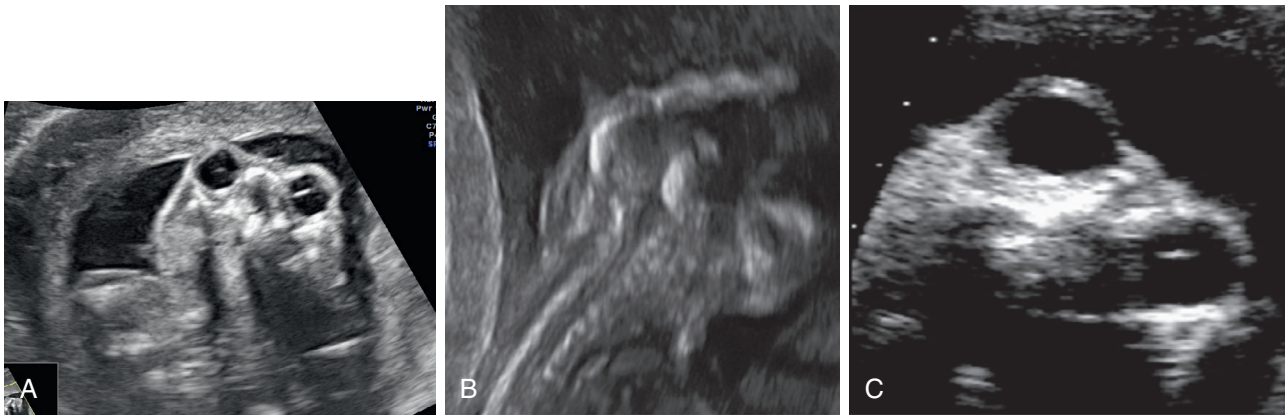

Fig. 41.7 (A) Classical appearance of anencephaly in the second trimester: the orbits are marking the upper limit of fetal face. (B, C) Anencephaly in the second trimester. Sonography shows the absence of the cranial vault and brain above the level of the skull base: (B) longitudinal view; (C) axial view. *(Courtesy* Visual encyclopedia of ultrasound in obstetrics and gynecology, *2011*, http://www.isuog.org.*)*

Other Applicable Modalities

Maternal serum alpha-fetoprotein (MSAFP) is increased in open NTDs, and has been used for NTD screening for more than 30 years. Using MSAFP cut-off levels of 2 or 2.5 multiples of the median for a given gestational age in singleton pregnancies, the detection rates are about 95%, and between 70% and 85% for anencephaly and open NTD, respectively.[39] The proper cut-off to use can vary between labs, and practitioners should be familiar with the standards of their local labs. The cut-off will usually correspond to about the 95th centile for the normal population, so there will be a 5% screen positive rate (i.e., 5% of normal pregnancies will have a value above the cut-off).

Many centers use high-resolution US in conjunction with MSAFP screening, and detection rates depend on the gestational age, and the type and severity of the NTD. First-trimester studies showed high detection rates of >90% for anencephaly and encephalocele (80%), but much lower detection rates for open spina bifida[40]; at least before the introduction of a detailed anatomic assessment of the posterior fossa during the early anomaly scan.[41,42]

Synopsis of Treatment Options

Termination of pregnancy should be offered.

In monochorionic twins, selective termination of the anencephalic fetus may be more harmful to the unaffected twin than expectant management due to complications, such as preterm labor and preterm ruptured membranes, although radiofrequency or microwave interruption of circulation to the affected fetus can be considered, especially in the setting of severe polyhydramnios.

PRENATAL

There are no prenatal treatment options. Women who continue pregnancies with exencephaly or anencephaly must be informed about the higher risk of pregnancy complications including preeclampsia, polyhydramnios, and antepartum hemorrhage.[43]

POSTNATAL

Anencephaly and exencephaly are uniformly lethal and cannot be treated.

WHAT THE REFERRING PHYSICIAN NEEDS TO KNOW

Most NTDs occur sporadically and are multifactorial in origin. Anencephaly is a lethal condition characterized by the absence of the cranial vault above the bony orbits and absence of the cerebral hemispheres. Termination of pregnancy should be offered.

Generally, fetuses with anencephaly, exencephaly, and most of the fetuses with encephaloceles are detectable early, many even at the time of first screening for fetal anomalies between 11 and 14 weeks. Altered anatomy of the posterior fossa may indicate open spina bifida during an early anomaly scan.

Folic acid supplementation before, and around the time of conception may reduce the risk of occurrence and recurrence of NTDs by two-thirds.[26] The standard dose is 0.4 mg daily, which can be increased to 4 mg daily in high-risk pregnancies (previous NTD).

KEY POINTS

- Anencephaly is a NTD characterized by the absence of the cranial vault above the bony orbits and absent cerebral hemispheres.
- Diagnosis can be difficult in the first trimester but is usually easy in the second trimester.
- Anencephaly is always fatal, and termination of pregnancy should be offered.
- Folic acid supplementation around the time of conception can be useful for reducing the risk of an affected fetus.

Encephalocele

DEFINITION

Encephalocele is the protrusion of intracranial structures through a defect in the skull. The herniated sac may contain meninges and brain tissue (encephalocele) or only meninges (meningocele).

Synonyms: cephalocele, cranial or occipital meningocele, cranium bifidum, encephalomeningocele, encephalomeningocystocele.

PREVALENCE AND EPIDEMIOLOGY

Encephaloceles account for 10% to 20% of all craniospinal dysraphisms. The prevalence of encephalocele is approximately 0.8:10,000 to 4:10,000 live births,[44–46] and is higher in Southeast Asia (2:10,000).[47] Overall, posterior encephaloceles are more common than anterior defects [44,48] but substantial ethnic differences exist: occipital cephalocele is more common in the Western hemisphere, whereas frontal cephalocele is more frequent in Asia, especially Thailand.

ETIOLOGY AND PATHOPHYSIOLOGY

Occipital encephaloceles are usually considered part of the spectrum of NTDs, which are thought to have a multifactorial origin. An environmental cause has been postulated for frontal encephaloceles. The two main etiologic theories include a failure of anterior fusion of the neural folds (with resulting failure of skull development) or the herniation of the brain through a bony malformation.[49] The insult is thought to occur around day 50 of gestation.

Encephaloceles may be isolated, but are often (23% to 37.5%) associated with other structural anomalies, including other CNS and extra-CNS abnormalities, and genetic syndromes, most commonly Meckel-Gruber syndrome (Chapter 133), an autosomal recessive disorder with a 25% recurrence risk.[50–52] Another typical anomaly that occurs associated with encephalocele is the consequence of an embryonic rupture of the amniotic membrane, the so-called amnion rupture sequence (Chapter 98).[53,54]

The recurrence risk of isolated encephalocele is 2% to 5%, but 10% if there are two affected siblings.[26,55]

Clinical Presentation

Encephaloceles may be classified as occipital (between the lambdoid suture and foramen magnum), parietal (between the bregma and the lambdoid suture), or anterior (between the bregma and the ethmoid bone). Anterior encephaloceles are further divided in frontal (external lesions near the root of the nose) and basal (internal lesions within the nose, the pharynx or the orbit). Three out of four encephaloceles are occipital.

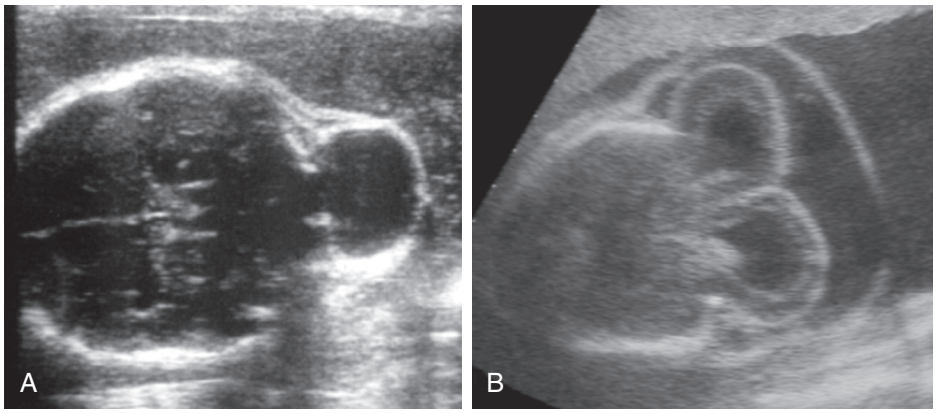

Fig. 41.8 Encephalocele and cranial meningocele: (A) cranial meningocele; (B) encephalocele. *(Courtesy* Visual encyclopedia of ultrasound in obstetrics and gynecology, *2011*, http://www.isuog.org.*)*

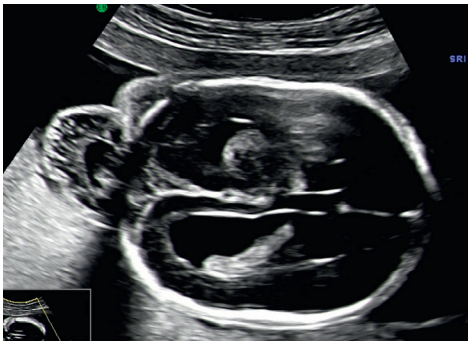

Fig. 41.9 Encephalocele at 24 weeks.



Fig. 41.10 Encephalocele at 12 weeks.

Parietal and frontal encephaloceles are more common in some regions in Asia.[44,45,46]

The prognosis of fetuses with encephalocele is poor. The survival rate is decreased and the prevalence of mental retardation is significant. The prognosis of an encephalocele depends on the size of the defect, the presence of herniated brain tissue, and on associated anomalies or syndromes.[52] An isolated encephalocele has a better prognosis.[56–59]

Imaging Technique and Findings

Antenatal diagnosis of encephalocele is usually easy. On US, it appears as a paracranial mass with brain tissue inside the herniated sac (Figs. 41.8–41.10). The skin is usually intact above the defect. Internal encephaloceles may not be diagnosable by prenatal ultrasound.

CLASSIC SIGNS

Skull defect with herniation of a sac filled with brain tissue.

Differential Diagnosis From Imaging Findings

Occipital meningocele must be differentiated from cystic hygroma. The demonstration of the skull defect can be difficult, as the bony discontinuity is usually small. Encephaloceles have a small base and are usually accompanied by other intracranial findings (ventriculomegaly, obliterated cisterna magna, frontal bossing), whereas cystic hygroma originates from the neck and has a large base.

Frontal encephalocele must be differentiated from a dermoid cyst of the anterior fontanel and dacryocystocele.

TREATMENT OPTIONS

Determining factors are the size, the amount of herniated neural tissue, and the presence of hydrocephalus or other anomalies.[60] Occipital encephaloceles are associated with higher rates of hydrocephalus and seizures, whereas anterior encephaloceles carry a better prognosis. However, surgery of anterior encephalocele is more challenging.[61,62]

Synopsis of Treatment Options

- Anatomic survey for associated anomalies
- Karyotyping
- Offer of termination of pregnancy if appropriate
- Mode and time of delivery depending on the size of the defect

WHAT THE REFERRING PHYSICIAN NEEDS TO KNOW

Encephalocele is a skull defect with protrusion of the meninges and brain tissue. It can be isolated, but also can be part of multiple fetal abnormalities. The prognosis depends on the site and size of the lesion, but is usually poor. Meningoceles have a better outcome than encephaloceles, frontal defects a better outcome than occipital ones. Like other NTDs, folic acid supplementation

may be useful in the prevention of occurrence and recurrence of encephalocele.

Exencephaly, certainly anencephaly, and most of the fetuses with encephaloceles can be detected early, many at the time of first screening examination.

KEY POINTS

- Encephalocele is the protrusion of intracranial structures through a skull defect.
- It is often associated with other structural abnormalities or genetic disorders.
- The prognosis is often poor, and the offer of termination of pregnancy should be considered.

Craniorachischisis

DEFINITION

Craniorachischisis results from a complete failure of neural tube formation, without development of the skull, and extensive vertebral and skin defect. A synonym is rachischisis.

PREVALENCE AND EPIDEMIOLOGY

Craniorachischisis is rare. The estimated incidence ranges from 10.7:10,000 births in Northern China to 0.5:10,000 births in Texas, and 0.1:10,000 births in Atlanta, Georgia.[63]

ETIOLOGY AND PATHOPHYSIOLOGY

Craniorachischisis is the most severe disorder of primary neurulation. Primary neurulation refers to the formation of the neural structures into a tube, forming the brain and spinal cord. Secondary neurulation refers to the formation of the lower spinal cord, which gives rise to the lumbar and sacral elements. The neural plate is formed around days 17 to 19 of gestation, the neural fold is formed around days 19 to 21, and the fusion of the neural folds occurs by day 23. Any disruption occurring in this delicate period—from when the neural plate begins its first fold until it fuses to form the neural tube—can cause craniorachischisis. Folic acid deficiency plays a role in craniorachischisis, as in other NTDs, but a combination of genetic, nutritional, and environmental factors is thought to be involved.[30]

MANIFESTATIONS OF DISEASE

Clinical Presentation

Craniorachischisis is characterized by complete absence of the skull and extensive defects in the vertebrae and skin. The brain is completely absent. Most cases of craniorachischisis are associated with multiple abnormalities and undergo spontaneous abortion early in pregnancy.[64]

Imaging Technique and Findings

Ultrasound. Absence of the skull, vertebrae, and skin results in a profound alteration of the normal fetal appearance (Fig. 41.11A), and this is easily recognized on prenatal US (Fig. 41.11B). Early prenatal diagnosis of craniorachischisis has been reported.[65]

CLASSIC SIGNS

Complete absence of the skull, vertebrae, and skin.

Differential Diagnosis From Imaging Findings

The differential diagnosis involves acrania-anencephaly, myeloschisis, and iniencephaly (Fig. 41.12).[66] Myeloschisis and

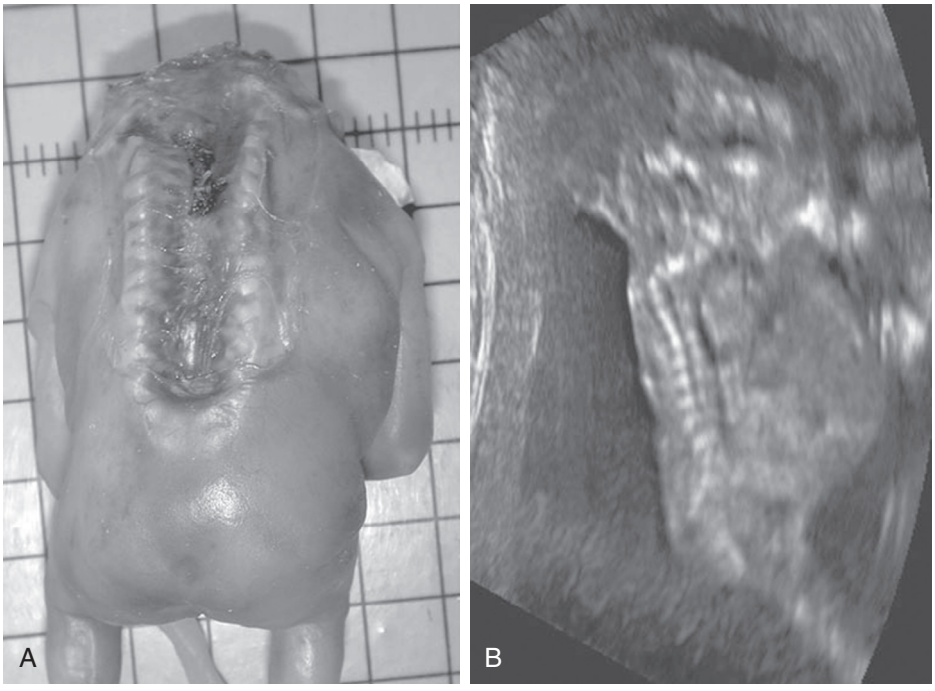

Fig. 41.11 Craniorachischisis. (A) Postnatal appearance. The cranial vault and brain are missing; the spine is short and split open. (B) US at 13 weeks' gestation. *(Courtesy* Visual encyclopedia of ultrasound in obstetrics and gynecology, *2011*, http://www.isuog.org.*)*

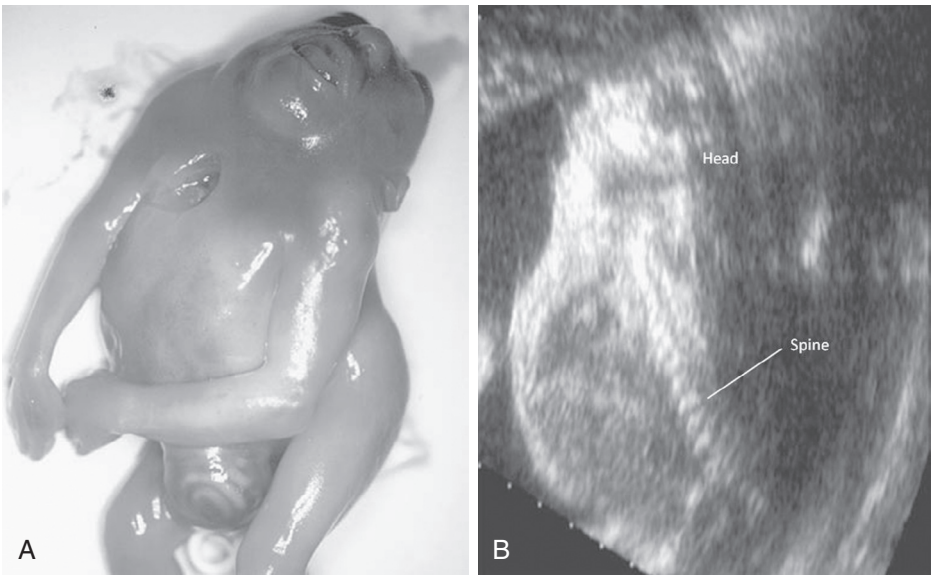

Fig. 41.12 Iniencephaly. (A) Postnatal appearance. There is extreme retroflexion of the head. A small omphalocele is seen, and spina bifida was present. (B) US at 20 weeks' gestation shows retroflexion of the head and short spine. Open spina bifida was also present. *(Courtesy* Visual encyclopedia of ultrasound in obstetrics and gynecology, *2011,* http://www.isuog.org.*)*

iniencephaly show similar patterns, but only the posterior neural tube is involved in myeloschisis, whereas there is also involvement of the base of the cranium and cervical vertebrae in iniencephaly, with normal closure of the anterior portion of the neural tube.

Synopsis of Treatment Options

Termination of pregnancy should be offered because craniorachischisis is always lethal.

WHAT THE REFERRING PHYSICIAN NEEDS TO KNOW

Craniorachischisis is the most severe NTD, resulting from a complete failure of neural tube formation. The condition is always lethal and often associated with multiple abnormalities. Most pregnancies spontaneously abort very early; otherwise, termination of pregnancy should be offered.

KEY POINTS

- Craniorachischisis is the most severe NTD, and it is incompatible with life.
- It is rare and often associated with other abnormalities.
- It can be diagnosed early in pregnancy.

Spina Bifida or Myelomeningocele

DEFINITION

Spina bifida is a midline defect of the vertebrae, with consequent exposure of the neural canal contents. Synonyms include spinal dysraphism, rachischisis, myelomeningocele, myelocele, and meningocele.

PREVALENCE AND EPIDEMIOLOGY

Spina bifida is one of the most common malformations of the CNS. The incidence varies according to geographic areas; it is particularly high in the United Kingdom and low in Asia.[32] The incidence is also high in the Mexican population, although it has decreased among Mexican women who immigrated to the United States, possibly related to nutritional factors. The risk of NTD among second-generation Mexican-American women is comparable to white women.[67] The overall incidence of NTD has decreased dramatically in the United States and Canada since the introduction of mandatory folic acid supplementation of breads, grains, and cereals.[68]

ETIOLOGY AND PATHOPHYSIOLOGY

The neural canal develops from the closure of the neural groove. The rostral opening of the spine (anterior neuropore) closes at about 24 days of gestation, and the posterior opening closes at about 28 days. Primary closure failure and secondary reopening of the distal neuropore have been postulated as possible causes of spina bifida.[69] Failure of induction of the ectodermal and mesodermal tissues results in an absence of skin and muscles above the defect.

MANIFESTATIONS OF DISEASE

Clinical Presentation

The term "Spina bifida" refers to the bony defect and is a generic classification for a wide spectrum of abnormalities.[70] Ventral defects are very rare; dorsal defects are more common. Ventral defects are caused by the splitting of the vertebral body. A cyst of neuroenteric origin, located anteriorly to the spine, can be observed in these cases. Ventral defects are usually found in the cervical or upper thoracic areas, but also can be found in the lower segment of the spine as part of multiple fetal abnormalities (Currarino syndrome).

Dorsal defects can be open (neural tissue exposed) or closed (neural defect skin-covered; Figs. 41.13 and 41.14). Open spina bifida accounts for 85% of dorsal defects. In open spina bifida, the neural tube is herniated in the amniotic cavity through a

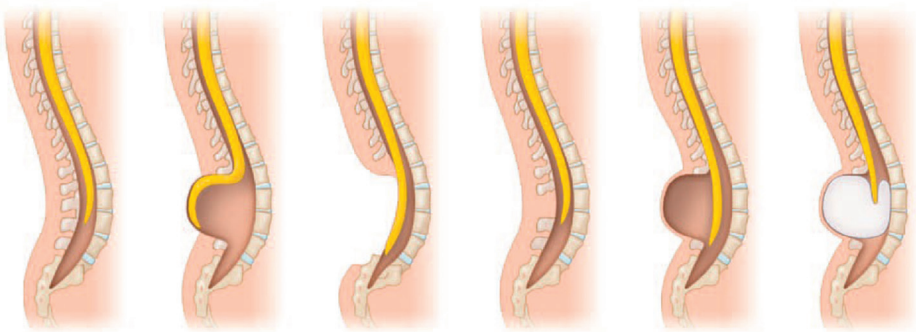

Fig. 41.13 Schematic representation of the spectrum of spina bifida. (A) Intact neural tube. (B) Open spina bifida—myelomeningocele. (C) Open spina bifida—myelocele. (D) Noncystic closed spina bifida. (E) Closed spina bifida with meningocele. (F) Closed spina bifida with lipoma. *(Courtesy* Visual encyclopedia of ultrasound in obstetrics and gynecology, *2011*, http://www.isuog.org.*)*

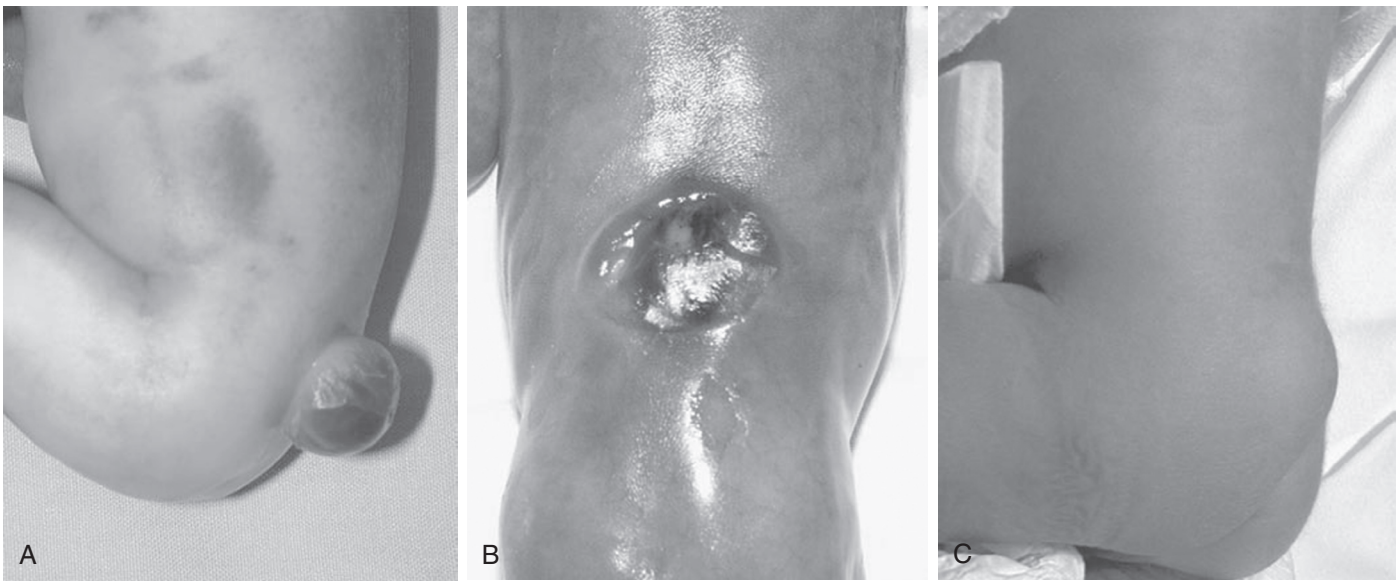

Fig. 41.14 Postnatal appearance of spina bifida. (A) Myelomeningocele. (B) Myelocele. (C) Closed spina bifida. *(Courtesy* Visual encyclopedia of ultrasound in obstetrics and gynecology, *2011*, http://www.isuog.org.*)*

vertebral and skin defect of variable size. The canal may be exposed or covered by a thin meningeal membrane. Neural tissue can also protrude through the skin defect and appear as a cystic tumor. If the mass is formed solely by the meninges, it is called meningocele; if neural tissue is also present, it is called myelomeningocele.

Associated anomalies are common in open spina bifida. They mainly include posterior fossa abnormalities, lower limb deformities, and, in postnatal life, variable degrees of incontinence. Chiari type II (or Arnold-Chiari) malformation is characterized by herniation of the cerebellar vermis through the foramen magnum, with downward displacement of the fourth ventricle and tentorium, and obliteration of the cisterna magna. Obstructive hydrocephalus can occur in these cases. Dislocation of the hips, bilateral clubfoot, or rocker-bottom feet are frequently associated with open spina bifida; they are caused by a defect of the peripheral nerves leading to unopposed action of certain muscle groups.

Closed spina bifida is a neural tube anomaly in which the vertebral defect is covered by the skin, often associated with a pigmented or haired area of the skin directly above the defect; a meningocele or a subcutaneous lipoma can sometimes be observed. Lower limb dysfunction and incontinence are often present in cases of closed spina bifida, but Chiari II malformation and obstructive hydrocephalus are absent. Closed spina bifida is classified as occult if the spinal cord does not herniate through the bony defect. Occult spina bifida is usually a postnatal finding and is commonly asymptomatic in the neonate, although neurologic sequelae secondary to tethered cord, or infection of an associated fistula are described. Finally, spina bifida can be found as part of chromosomal abnormalities (especially trisomy 13 or trisomy 18) or syndromes (Meckel syndrome, Jarcho-Levin syndrome).

Imaging Technique and Findings

Ultrasound. In the midsagittal plane, the normal spine appears as two parallel lines, one highly echogenic, formed by the vertebral bodies anteriorly, and one faint dotted line representing the connective tissue joining the two lateral processes posteriorly. In open spina bifida, the posterior line and overlying soft tissues are absent at the level of the lesion.

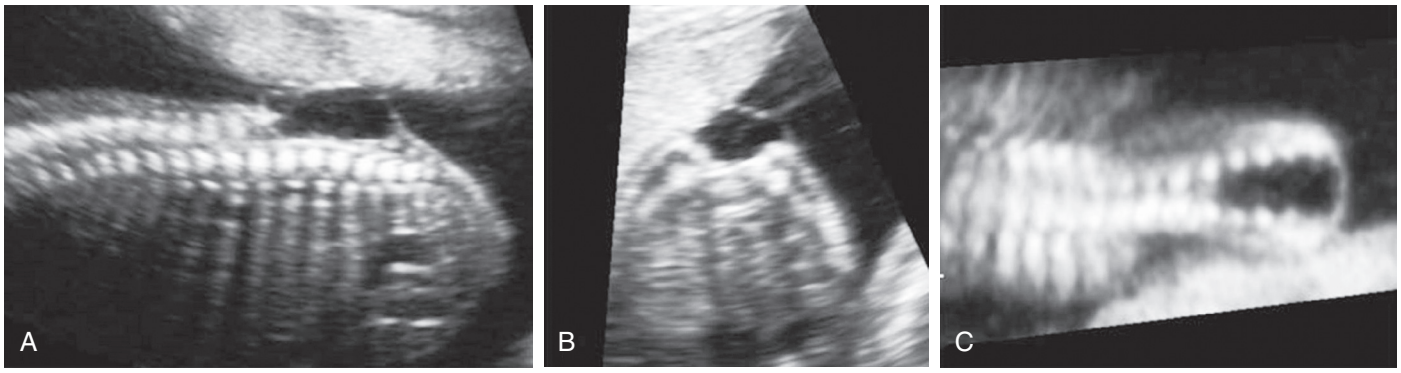

Fig. 41.15 Myelomeningocele. (A) Sagittal plane showing interruption of the double railway appearance of the spine, with a thin-walled cyst covering the defect. (B) Axial plane showing the U-shaped appearance of the open vertebra; a cyst is seen atop the lesion. (C) Coronal plane showing irregular widening of the ossification centers of the vertebrae in the area of the lesion. *(Courtesy* Visual encyclopedia of ultrasound in obstetrics and gynecology, *2011*, http://www.isuog.org.*)*

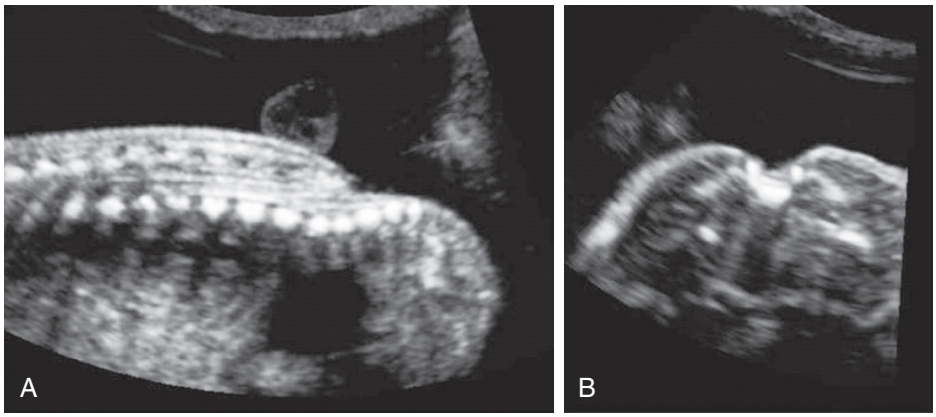

Fig. 41.16 Myelocele. (A, B) Sagittal and axial views. There is opening of the neural tube without a posterior cyst. *(Courtesy* Visual encyclopedia of ultrasound in obstetrics and gynecology, *2011*, http://www.isuog.org.*)*

If myelomeningocele is present, a thin-walled cyst is seen on top of the lesion (Fig. 41.15). In a few cases, myelocele is present, and this is more difficult to recognize because there is no cyst signaling the NTD (Fig. 41.16). Prenatal recognition of open spina bifida is usually achieved using its cranial signs (Fig. 41.17). These are easily detectable and include frontal bone scalloping (lemon sign), and most importantly, obliteration of the cisterna magna, with abnormal shape of the cerebellum (banana sign).[71] A variable degree of ventriculomegaly is present in almost all cases of open spina bifida in the third trimester, but only in 50% of cases at midgestation.[72] A clue for diagnosis of open spina bifida in the first trimester is the failure of visualization of the fourth ventricle (the so-called intracranial translucency), or the cisterna magna in the sagittal view, used to measure the nuchal translucency (Fig. 41.18).[73–75]

Diagnosis of closed spina bifida is difficult prenatally because it relies entirely on spinal findings. The spinal defect is always small but occasionally can be covered by a cystic structure or a lipoma. Continuity of the fetal skin is always present in these cases, but it is difficult to demonstrate. The most important sign in differentiating open from closed spina bifida is the absence of cranial signs in closed spina bifida (Figs. 41.19 and 41.20).[72]

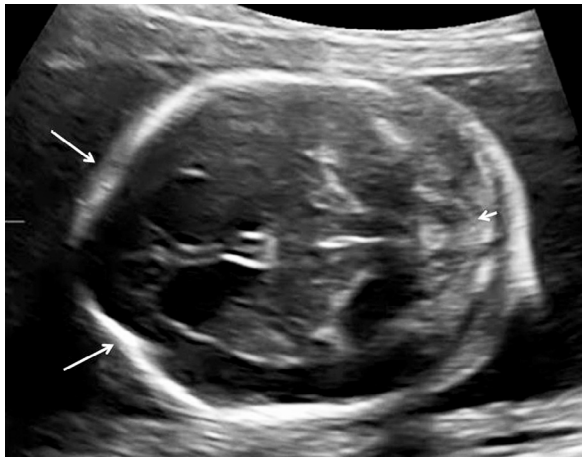

Fig. 41.17 Cranial signs of spina bifida. *Long arrows* indicate frontal bone scalloping (also referred to as lemon sign), and the *short arrow* indicates obliteration of the cisterna magna with distortion of cerebellar shape (also referred to as banana sign). *(Courtesy* Visual encyclopedia of ultrasound in obstetrics and gynecology, *2011*, http://www.isuog.org.*)*

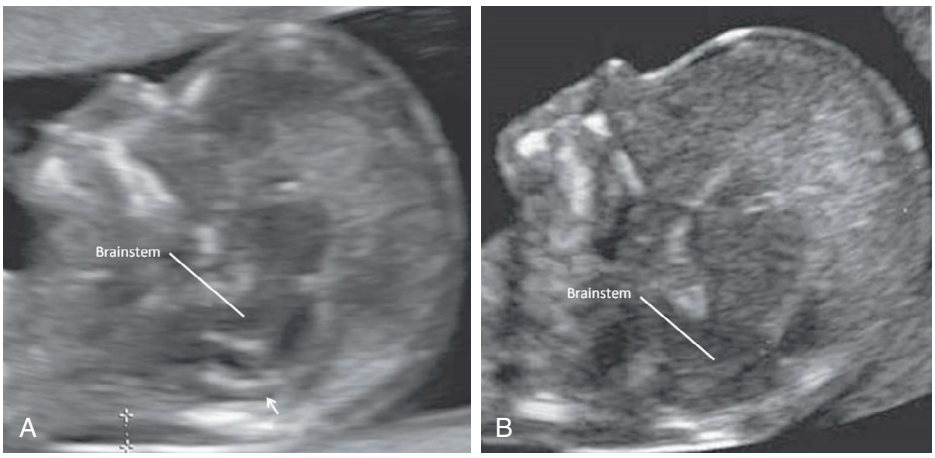

Fig. 41.18 (A) Normal appearance of the posterior fossa at 12 weeks' gestation includes the presence of a fluid-filled layer posterior to the brainstem that is commonly referred to as the intracranial translucency *(arrow)*. (B) In a fetus with spina bifida, the intracranial translucency is absent. *(Courtesy R. Chaoui, Berlin.)*

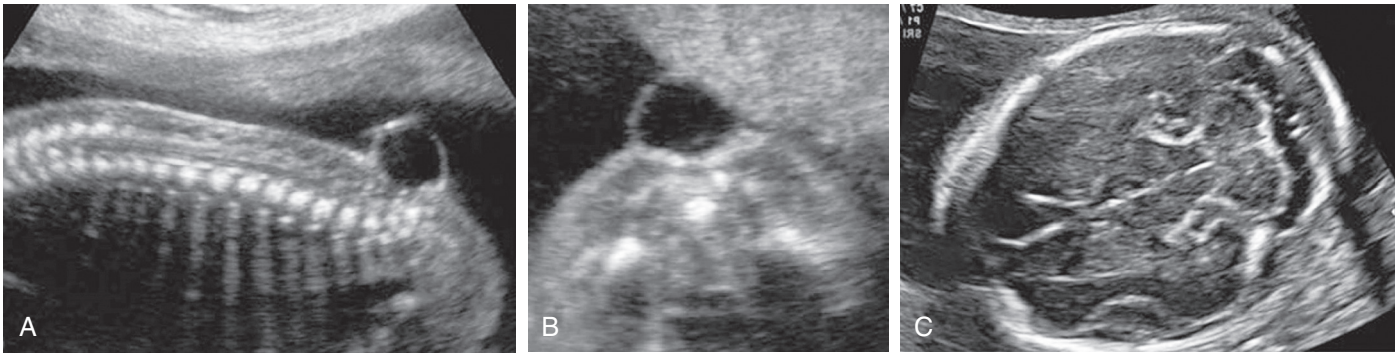

Fig. 41.19 Closed spina bifida with meningocele. (A, B) Sagittal and axial planes reveal images that are similar to the ones encountered with open defects. (C) The most important finding for the differential diagnosis is the integrity of intracranial anatomy. *(Courtesy* Visual encyclopedia of ultrasound in obstetrics and gynecology, *2011*, http://www.isuog.org.*)*

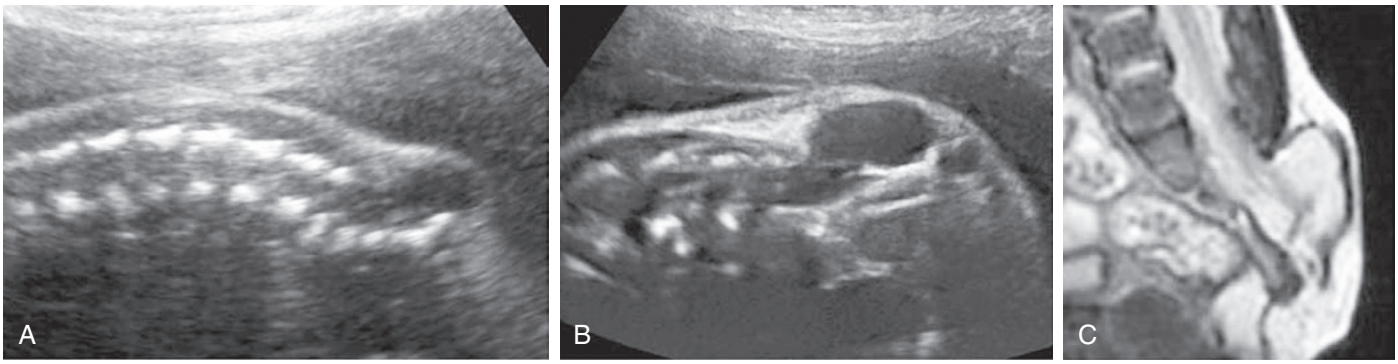

Fig. 41.20 Closed spina bifida with lipoma. (A, B) US appearance is similar to a meningocele. (C) Postnatal magnetic resonance imaging. *(Courtesy* Visual encyclopedia of ultrasound in obstetrics and gynecology, *2011*, http://www.isuog.org.*)*

In both open and closed spina bifida, when the defect is found, characterization of its position in the spine should be attempted. Three-dimensional (3D) US can be helpful in determining the anatomic level of the bony defect.

CLASSIC SIGNS

Classic signs of open spina bifida include:
Lemon sign
Banana sign
Obliterated cisterna magna
Absence of the skin and muscles above the defect
Classic signs of closed spina bifida include:
Small spinal defect with intact skin
Anechoic cystic lesion if present

Differential Diagnosis From Imaging Findings

The differential diagnosis is mainly between open and closed defects, which may have a similar US appearance, but carry a very different prognosis. Intracranial findings and skin discontinuity are the most important differences between these two entities and should be used as a diagnostic clue. Differential diagnosis of a cystic mass in the lower part of the spine also includes sacrococcygeal teratoma, although in the latter there is no discontinuity of the neural canal. Finally, closed spina bifida may be confused with a lipoma in the sacral area, which can also be found in association with the defect. Hemivertebrae may also distort the appearance of the spine (Fig. 41.21) but does not cause intracranial findings, and the skin over the lesion is intact.

Synopsis of Treatment Options

Treatment options are as follows:
- Standard obstetric care in cases with closed defects.
- Offer of termination of pregnancy should be considered in open spina bifida.
- Term delivery unless hydrocephalus occurs; in cases of hydrocephalus, the timing and the type of birth (cesarean versus vaginal) have to be evaluated according to the extent of intracranial fluid collection.
- Cesarean birth to limit neural cord damage (this is controversial).
- In utero closure of the defect to limit progressive damage to the neural cord.

The efficacy of intrauterine skin closure in fetuses with isolated open spina bifida was the subject of a large randomized controlled trial.[76] The authors reported lower perinatal mortality, a lower rate of shunt placement, and a higher score for mental development and motor function at 30 months in cases in which prenatal surgery before 26 weeks' gestation was performed, compared with cases in which standard postnatal repair only was performed. The trial was stopped for efficacy of prenatal surgery before reaching the planned number of cases.

WHAT THE REFERRING PHYSICIAN NEEDS TO KNOW

Spina bifida is a common defect of the neural canal. Closed defects generally have a good prognosis, whereas open defects are associated with high rates of mortality and handicap. About 20% of live-born infants undergoing surgery die in the first year of life, and about 35% die within the first 5 years.[77] Among survivors, 25% are totally paralyzed, 25% are partially paralyzed, and 25% require intensive rehabilitation programs. Only 17% of survivors have normal continence.[78] Standard obstetric care should be offered in cases of closed defects; accurate tailoring of timing and mode of delivery is necessary in cases of open defects. Folic acid supplementation around the time of conception may reduce the risk of spina bifida by two-thirds and prevent 70% of recurrent cases.[79] Reduction in the risk of spina bifida in low-risk pregnancies is possible through daily intake of 0.4 mg of folic acid from 1 month before conception until 3 months after. High-dose folic acid supplementation (4 mg) can be used to reduce the risk of recurrences.[79]

KEY POINTS

- Open spina bifida carries a poor prognosis, whereas closed spina bifida usually has a good outcome.
- Intracranial signs (lemon sign and banana sign) may help in the diagnosis of open defects.
- Intake of folic acid before conception may reduce the risk of spina bifida and reduce the chance of a recurrence.

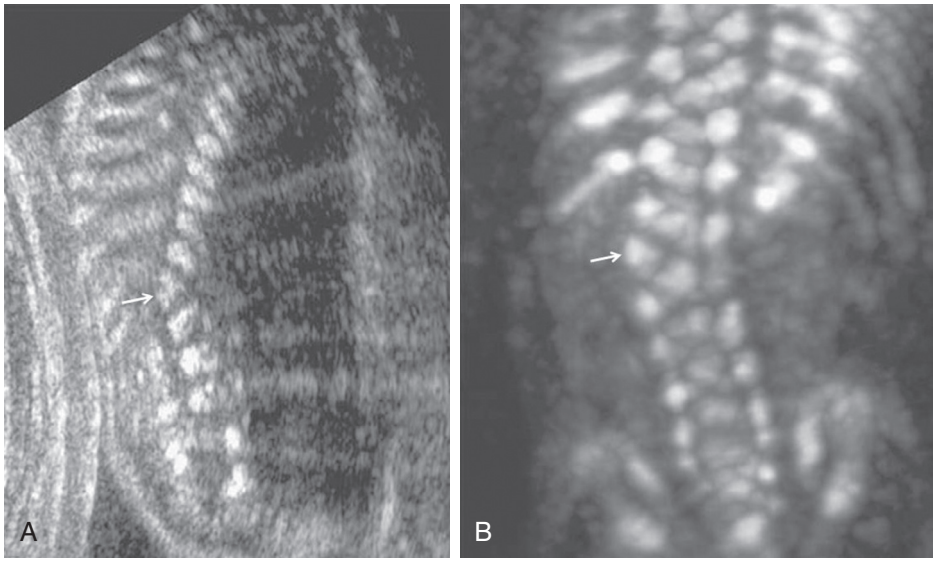

Fig. 41.21 Coronal scan (A) of the spine of a second-trimester fetus with hemivertebra *(arrow)* compared with a three-dimensional maximum mode reconstruction of the same case (B).

Hemivertebra

DEFINITION

Hemivertebra is a congenital anomaly of the spine in which only one-half of the vertebral body develops. Synonyms include congenital scoliosis (one of the causes), unilateral aplasia of the vertebral body, and complete unilateral failure of formation of the vertebral body.

PREVALENCE AND EPIDEMIOLOGY

The incidence of hemivertebra is estimated at 5:10,000 to 10:10,000 births with a male-to-female ratio of 0.31 for multiple vertebral anomalies, and 0.68 for solitary vertebral anomalies.[80]

ETIOLOGY AND PATHOPHYSIOLOGY

The etiology is unknown. The role of a genetic factor is controversial. The occurrence of isolated hemivertebra in siblings is very rare. An association of hemivertebra with neural defects in siblings has been reported. Wynne-Davies[80] performed a family survey of 337 patients with congenital scoliosis, and found that 5% to 10% of siblings of patients with multiple vertebral anomalies with or without spina bifida, had either vertebral anomalies or spina bifida. These authors found only 1 of 245 siblings among 101 infants with a solitary vertebral defect (including isolated hemivertebra) that had a spinal defect; they concluded that isolated defects were sporadic (nonfamilial) in nature, and carried no risk to subsequent siblings. Connor et al.[81] found an incidence of 4% of NTDs among siblings with congenital scoliosis. In contrast to the previous report, they found an increased incidence of NTDs in siblings of patients with single hemivertebra, and patients with multiple vertebral defects.

MANIFESTATIONS OF DISEASE

Clinical Presentation

Usually only one lateral part of the vertebral body is present, causing a deformation in the shape of the spine. Occasionally, the absent part of the vertebra may be located anteriorly. Hemivertebra is frequently seen in the lower thoracic part of the spine.[82] Hemivertebra generally involves a single vertebra[19] but multiple levels should always be sought.

Hemivertebra is commonly associated with other musculoskeletal anomalies, including anomalies of the spine, ribs, and limbs. Cardiac and genitourinary tract anomalies are common associated anomalies in hemivertebra; anomalies of the CNS and gastrointestinal tract have also been reported. Hemivertebra may be part of a syndrome including Jarcho-Levin syndrome, Klippel-Feil syndrome, and VACTERL (vertebral, anal, cardiac, tracheal, esophageal, renal, and limb anomalies) association.[19,81] The incidence of karyotypic abnormalities in fetuses with isolated vertebral anomalies is thought to be small. Zelop et al.[82] obtained normal karyotypes in all of 18 infants with isolated hemivertebra.

Imaging Technique and Findings

Ultrasound. The US findings associated with fetal hemivertebra include a distortion in the shape of the spine, which can be assessed by both sagittal and coronal scans. A specific diagnosis requires meticulous scanning, but it is usually possible by showing, usually in coronal scans, a triangular bony structure, which is smaller than a vertebra, at the level of the spinal distortion, wedging between the normal vertebral bodies. We have found that the diagnosis is greatly facilitated by the use of 3D US (see Fig. 41.21).

Differential Diagnosis From Imaging Findings

Hemivertebra may appear on US similar to other vertebral abnormalities (wedge vertebra, butterfly vertebra, block vertebra, bar vertebra, or any combination) that cause congenital scoliosis, and in some cases hemivertebra may be differentiated only after careful neonatal radiologic evaluation. Open NTDs may also be associated with abnormal curvature of the spine but should have other findings to distinguish it from hemivertebra. These findings include the cranial signs of open NTDs, disruption of the skin over the defect, and possibly the presence of a meningocele or myelomeningocele sac.

Diastematomyelia may be present US findings very similar to hemivertebra. A specific diagnosis sometimes can be difficult, but it is usually possible because in a transverse view diastematomyelia results in a typical image: a vertebra with three posterior ossification centers, with the central one protruding toward both the skin and the neural canal.

Synopsis of Treatment Options

Treatment options include:

- detailed anomaly scan
- karyotyping
- amniotic fluid alpha-fetoprotein concentration if there is a question of an open NTD
- serial US evaluation
- standard management of labor and delivery if there are no other complicating factors
- careful neonatal assessment for associated cardiac and genitourinary anomalies
- long-term orthopedic follow-up if necessary, before development of a serious deformity

WHAT THE REFERRING PHYSICIAN NEEDS TO KNOW

Hemivertebra is a common spinal deformity and is often associated with other anomalies. The prognosis is directly related to the presence of associated anomalies and the site, and the number of affected vertebrae.[83] The prognosis of isolated hemivertebra is usually good. Left untreated, 25% of patients with congenital scoliosis show no progression, 50% progress slowly, and 25% progress rapidly during postnatal growth.[19] Spinal fusion is the treatment of choice for cases of congenital scoliosis that are progressive or are of the short, rigid type. Infants with isolated hemivertebra usually are asymptomatic in the first 2 years of life.[83] Prenatal diagnosis is important for intervening in cases of congenital scoliosis before the development of a significant deformity.

KEY POINTS

- Hemivertebra is a common spinal deformity that is often associated with multiple fetal anomalies.
- If isolated, the prognosis is usually good.
- A detailed anomaly scan, karyotyping, and ruling out of an open defect should be performed.

SUGGESTED READINGS

Au KS, Ashley-Koch A, Northrup H. Epidemiologic and genetic aspects of spina bifida and other neural tube defects developmental disabilities. *Dev Disabil Res Rev*. 2010;16:6-15.

Cameron M, Moran P. Prenatal screening and diagnosis of neural tube defects. *Prenat Diagn*. 2009;29:402-411.

Kotil K, Kilinc B, Bilge T. Diagnosis and management of large occipito-cervical cephaloceles: a 10-year experience. *Pediatr Neurosurg*. 2008;44: 193Y19.

Obeidi N, Russell N, Higgins JR, et al. The natural history of anencephaly. *Prenat Diagn*. 2010;30:357-360.

Shaer CM, Chescheir N, Schulkin J. Myelomeningocele: a review of the epidemiology, genetics, risk factors for conception, prenatal diagnosis, and prognosis for affected individuals. *Obstet Gynecol Surv*. 2007;62(7):471-479.

Simpson JL, Mills J, Rhoads GG, et al. Genetic heterogeneity in neural tube defects. *Ann Genet*. 1991;34(3-4):279-286.

Stoll C, Alembik Y, Dott B. Associated malformations in cases with neural tube defects. *Genet Couns*. 2007;18(2):209-215.



All references are available online at www.expertconsult.com.

REFERENCES

1. Sadler TW. Embryology of neural tube development. *Am J Med Genet C Semin Med Genet*. 2005;135C(1):2-8.
2. Dias MS, Partington M. Embryology of myelomeningocele and anencephaly. *Neurosurg Focus*. 2004;16(2):E1.
3. Swinyard A, Nishimura H, Chaube S. Embryology and prenatal development of human spina bifida manifesta. *ICIB*. 1971;10(7):1-8.
4. O'Rahilly R, Muller F. The two sites of fusion of the neural folds and the two neuropores in the human embryo. *Teratology*. 2002;65:162-170.
5. Gilbert SF. *Developmental biology*. 7th ed. Sunderland, MA: Sinauer Associates; 2003.
6. Golden JA, Chernoff GF. Multiple sites of anterior neural tube closure in humans: evidence from anterior neural tube defects (anencephaly). *Pediatrics*. 1995;95:506-510.
7. Desmond ME, Jacobson AG. Embryonic brain enlargement requires cerebrospinal fluid pressure. *Dev Biol*. 1977;57:188.
8. O'Rahilly M, Muller F. *Human embryology & teratology*. New York: Wiley-Liss, Inc; 1992:253.
9. Jones KL. *Smith's recognizable patterns of human malformation*. 6th ed. Philadelphia: Saunders Elsevier; 2006:704.
10. Stone DH. The declining prevalence of anencephalus and spina bifida: its nature, causes and implications. *Dev Med Child Neurol*. 1987;29(4):541.
11. Czeizel AE, Dudás I. Prevention of the first occurrence of neural-tube defects by periconceptional vitamin supplementation. *N Engl J Med*. 1992; 327(26):1832-1835.
12. Francis-West PH, Robson L, Evans DJ. Craniofacial development: the tissue and molecular interactions that control development of the head. *Adv Anat Embryol Cell Biol*. 2003;169:III-VI, 1-138.
13. Sutton LN, Adzick NS, Bilaniuk LT, et al. Improvement in hindbrain herniation demonstrated by serial fetal magnetic resonance imaging following fetal surgery for myelomeningocele. *JAMA*. 1999;282:1826.
14. Tulipan N, Hernanz-Schulman M, Lowe LH, et al. Intrauterine myelomeningocele repair reverses preexisting hindbrain herniation. *Pediatr Neurosurg*. 1999;31:137.
15. Dias MS, Pang D. Split cord malformations. *Neurosurg Clin N Am*. 1995;6:339-358.
16. Dias MS, Walker ML. The embryogenesis of complex dysraphic malformations: a disorder of gastrulation? *Pediatr Neurosurg*. 1992;18:229-253.
17. Van Allen MI, Kalousek DK, Chernoff GF, et al. Evidence for multi-site closure of the neural tube in humans. *Am J Med Genet*. 1993;47(5): 723-743.
18. Moore KL, Persaud TVN. *The developing human*. 5th ed. Philadelphia: WB Saunders; 1993:358-364.
19. McMaster MJ, David CV. Hemivertebra as a cause of scoliosis. *J Bone Joint Surg Br*. 1986;68:588-595.
20. Wood LR, Smith MT. Generation of anencephaly: 1. aberrant neurulation and 2. conversion of exencephaly to anencephaly. *J Neuropathol Exp Neurol*. 1984;43:620-633.
21. Coady AM, Bower S. *Twining's Textbook of Fetal Abnormalities*. 3rd ed. Oxford, UK: Elsevier; 2015.
22. MRC Vitamin Study Research Group. Prevention of neural tube defects: results of the Medical Research Council vitamin study. *Lancet*. 1991; 338:131-137.
23. Au KS, Ashley-Koch A, Northrup H. Epidemiologic and genetic aspects of spina bifida and other neural tube defects developmental disabilities, research reviews. *Dev Disabil Res Rev*. 2010;16:6-15.
24. Copp AJ, Greene N. Genetics and development of neural tube defects. *J Pathol*. 2010;220:217-230.
25. Moretti ME, Bar-Oz B, Fried S, et al. Maternal hyperthermia and the risk for neural tube defects in offspring: systematic review and meta-analysis. *Epidemiology*. 2005;16:216-219.
26. Padmanabhan R. Etiology, pathogenesis and prevention of neural tube defects. *Congenit Anom (Kyoto)*. 2006;46(2):55-67.
27. Kennedy D, Chitayat D, Winsor EJ, et al. Prenatally diagnosed neural tube defects: ultrasound, chromosome, and autopsy or postnatal findings in 212 cases. *Am J Med Genet*. 1998;77(4):317-321.
28. Chen CP. Chromosomal abnormalities associated with neural tube defects (I): full aneuploidy. *Taiwan J Obstet Gynecol*. 2007;46(4):325-335.
29. Seller MJ. Sex, neural tube defects, and multisite closure of the human neural tube. *Am J Med Genet*. 1995;58(4):332-336.
30. Mitchell LE. Epidemiology of neural tube defects. *Am J Med Genet C Semin Med Genet*. 2005;135:88-94.
31. Busby A, Abramsky L, Dolk H, et al. Preventing neural tube defects in Europe: a missed opportunity. *Reprod Toxicol*. 2005;20(3):393-402.
32. Timor-Tritsch IE, Greenbaum E, Monteagudo A, et al. Exencephaly-anencephaly sequence: proof by ultrasound imaging and amniotic fluid cytology. *J Matern Fetal Med*. 1996;5(4):182-185.
33. David TJ, Nixon A. Congenital malformations associated with anencephaly and iniencephaly. *J Med Genet*. 1976;13(4):263-265.
34. Obeidi N, Russell N, Higgins JR, et al. The natural history of anencephaly. *Prenat Diagn*. 2010;30:357-360.
35. Campbell S, Johnstone FD, Holt EM, et al. Anencephaly: early ultrasonic diagnosis and active management. *Lancet*. 1972;2(7789):1226-1227.
36. Chatzipapas IK, Whitlow BJ, Economides DL. The 'Mickey Mouse' sign and the diagnosis of anencephaly in early pregnancy. *Ultrasound Obstet Gynecol*. 1999;13(3):196-199.
37. Rohrbach M, Chitayat D, Drake J, et al. Prenatal diagnosis of fetal exencephaly associated with amniotic band sequence at 17 weeks of gestation by fetal magnetic resonance imaging. *Fetal Diagn Ther*. 2007;22(2):112-115.
38. Peruzzi P, Corbitt RJ, Raffel C. Magnetic resonance imaging versus ultrasonography for the in utero evaluation of central nervous system anomalies. *J Neurosurg Pediatr*. 2010;6(4):340-345.
39. Wald NJ, Cuckle H, Brock JH, et al. Maternal serum-alpha-fetoprotein measurement in antenatal screening for anencephaly and spina bifida in early pregnancy. Report of U.K. collaborative study on alpha-fetoprotein in relation to neural-tube defects. *Lancet*. 1977;1(8026):1323-1332.
40. Whitlow BJ, Chatzipapas IK, Lazanakis ML, et al. The value of sonography in early pregnancy for the detection of fetal abnormalities in an unselected population. *Br J Obstet Gynaecol*. 1999;106(9):929-936.
41. Mangione R, Dhombres F, Lelong N, et al. Screening for fetal spina bifida at the 11-13-week scan using three anatomical features of the posterior brain. *Ultrasound Obstet Gynecol*. 2013;42(4):416-420.
42. Chaoui R, Benoit B, Heling KS, et al. Prospective detection of open spina bifida at 11-13 weeks by assessing intracranial translucency and posterior brain. *Ultrasound Obstet Gynecol*. 2011;38(6):722-726.
43. Cameron M, Moran P. Prenatal screening and diagnosis of neural tube defects. *Prenat Diagn*. 2009;29:402-411.
44. Rutka JT, Carlotti C, Iantosca M. Encephaloceles. In: Winn HR, ed. *Youmans neurological surgery*. 5th ed. Philadelphia: WB Saunders; 2004: 3198-3213.
45. Monteagudo A, Timor-Trisch IE. Cephalocele, anterior. http://www.TheFetus.net.1992-09-08-11.
46. Tsai PY, Chang CH, Chang FM. Prenatal diagnosis of the fetal frontal encephalocele by three-dimensional ultrasound. *Prenat Diagn*. 2006; 26:373-394.
47. David DJ, Proudman TW. Cephaloceles: classification, pathology, and management. *World J Surg*. 1989;13(4):349-357.
48. Mahapatra AK, Agrawal D. Anterior encephaloceles: a series of 103 cases over 32 years. *J Clin Neurosci*. 2006;13:536-539.
49. Rapport RL 2nd, Dunn RC Jr, Alhady F. Anterior encephalocele. *J Neurosurg*. 1981;54(2):213-219.
50. Stoll C, Alembik Y, Dott B. Associated malformations in cases with neural tube defects. *Genet Couns*. 2007;18(2):209-215.
51. Simpson JL, Mills J, Rhoads GG, et al. Genetic heterogeneity in neural tube defects. *Ann Genet*. 1991;34(3-4):279-286.
52. Baradaran N, Nejat F, Baradaran N, et al. Cephalocele: report of 55 Cases over 8 years. *Pediatr Neurosurg*. 2009;45:461-466.
53. Seeds JW, Cefalo RC, Herbert WNP. Amniotic band syndrome. *Am J Obstet Gynecol*. 1982;144:243-248.
54. Rushton DJ. Amniotic band syndrome. *Br Med J*. 1983;286:919-920.
55. Shaer CM, Chescheir N, Schulkin J. Myelomeningocele: a review of the epidemiology, genetics, risk factors for conception, prenatal diagnosis, and prognosis for affected individuals. *Obstet Gynecol Surv*. 2007;62(7):471-479.
56. Docherty JG, Daly JC, Carachi R. Encephaloceles: a review 1971–1990. *Eur J Pediatr Surg*. 1991;1(suppl 1):11-13.
57. Chervenak FA, Isaacson G, Mahoney MJ, et al. Diagnosis and management of fetal cephalocele. *Obstet Gynecol*. 1984;64:86-91.
58. Naidich TP, Altman NR, Braffman BH, et al. Cephaloceles and related malformations. *AJNR Am J Neuroradiol*. 1992;13:655-690.
59. Dadmehr M, Nejat F, El Khashab M, et al. Risk factors associated with occipital encephalocele: a case-control study. Clinical article. *J Neurosurg Pediatr*. 2009;3(6):534-537.
60. Kotil K, Kilinc B, Bilge T. Diagnosis and management of large occipitocervical cephaloceles: a 10-year experience. *Pediatr Neurosurg*. 2008;44:193Y19.
61. Bui CJ, Tubbs RS, Shannon CN, et al. Institutional experience with cranial vault encephaloceles. *J Neurosurg*. 2007;107:22Y25.
62. Sanna M, Fois P, Russo A, et al. Management of meningoencephalic herniation of the temporal bone: personal experience and literature review. *Laryngoscope*. 2009;119(8):1579-1585.

63. Johnson K, Suarez L, Felkner M, et al. Prevalence of craniorachischisis in a Texas-Mexico border population. *Birth Defects Res A Clin Mol Teratol*. 2004;70:92-94.
64. Polat I, Gul A, Aslan H, et al. Prenatal diagnosis of pentalogy of Cantrell in three cases, two with craniorachischisis. *J Clin Ultrasound*. 2005;33: 308-311.
65. Grange G, Favre R, Gasse B. Endovaginal sonographic diagnosis of craniorachischisis at 13 weeks of gestation. *Fetal Diagn Ther*. 1994;9: 391-394.
66. Sahid S, Sepulveda W, Dezerega V, et al. Iniencephaly: prenatal diagnosis and management. *Prenat Diagn*. 2000;20:202-205.
67. Velie EM, Shaw GM, Malcoe LH, et al. Understanding the increased risk of neural tube defect-affected pregnancies among Mexico-born women in California: immigration and anthropometric factors. *Paediatr Perinat Epidemiol*. 2006;20:219-230.
68. Canfield MA, Anderson JL, Waller DK, et al. Folic acid awareness and use among women with a history of a neural tube defect pregnancy—Texas, 2000–2001. *MMWR Recomm Rep*. 2002;51:16-19.
69. Gardner WJ. Myelomeningocele, the result of rupture of the embryonic neural tube. *Cleve Clin Q*. 1960;27:88-100.
70. Tortori-Donati P, Rossi A, Cama A. Spinal dysraphism: a review of neuroradiological features with embryological correlations and proposal for a new classification. *Neuroradiology*. 2000;42:471-491.
71. Nicolaides KH, Campbell S, Gabbe SG, et al. Ultrasound screening for spina bifida: cranial and cerebellar signs. *Lancet*. 1986;2:72-74.
72. Ghi T, Pilu G, Falco P, et al. Prenatal diagnosis of open and closed spina bifida. *Ultrasound Obstet Gynecol*. 2006;28:899-903.
73. Chaoui R, Benoit B, Mitkowska-Wozniak H, et al. Assessment of intracranial translucency (IT) in the detection of spina bifida at the 11-13-week scan. *Ultrasound Obstet Gynecol*. 2009;34:249-252.
74. Chaoui R, Nicolaides KH. From nuchal translucency to intracranial translucency: towards the early detection of spina bifida. *Ultrasound Obstet Gynecol*. 2010;35:133-138.
75. Chen FC, Gerhardt J, Entezami M, et al. Detection of spina bifida by first trimester screening—results of the prospective multicenter Berlin IT-study. *Ultraschall Med*. 14 April 2015. [epub ahead of print].
76. Adzick NS, Thom EA, Spong CY, et al; MOMS Investigators. A randomized trial of prenatal versus postnatal repair of myelomeningocele. *N Engl J Med*. 2011;364:993-1004.
77. Hunt GM. Open spina bifida: outcome for a complete cohort treated unselectively and followed into adulthood. *Dev Med Child Neurol*. 1990;32:108-118.
78. Main DM, Mennuti MT. Neural tube defects: issues in prenatal diagnosis and counselling. *Obstet Gynecol*. 1986;67:1-16.
79. Prevention of neural tube defects: results of the Medical Research Council vitamin study. MRC Vitamin Study Research Group. *Lancet*. 1991;338: 131-137.
80. Wynne-Davies R. Congenital vertebral anomalies: aetiology and relationship to spina bifida cystica. *J Med Genet*. 1975;12:280-288.
81. Connor JM, Conner AN, Connor RAC, et al. Genetic aspects of early childhood scoliosis. *Am J Med Genet*. 1987;27:419-424.
82. Zelop CM, Pretorius DH, Benacerraf BR. Fetal hemivertebrae: associated anomalies, significance, and outcome. *Obstet Gynecol*. 1993;81:412-416.
83. Winter RB. Congenital scoliosis. *Orthop Clin North Am*. 1988;19:395-408.

42 Vascular Cerebral Anomalies

AMAR BHIDE

Introduction

Cerebral vascular malformations are rare but potentially disastrous abnormalities. Aneurysm of the vein of Galen is the most common abnormality described in prenatal series.[1] Other types of intracranial vascular malformations are diagnosed prenatally only rarely. In the neonatal period, the clinical features include cyanosis, systolic murmur secondary to hyperdynamic circulation, cardiomegaly, and increased intracranial pressure.[2] Before the availability of ultrasound (US) diagnosis, most cerebral vascular malformations were diagnosed only at postmortem examination. These are serious abnormalities with a high risk of mortality. The mortality rate of aneurysms of the vein of Galen is nearly 90%, with most deaths occurring within 1 week of birth.[3] The various types of vascular malformations can be categorized as:

- Venous anomalies
  - Aneurysm of the vein of Galen
  - Dural sinus malformation (DSM)
- Arterial anomalies
  - Pial arteriovenous (AV) fistulas
- Mixed anomalies
  - Hemangiomas

Aneurysm of the Vein of Galen

DEFINITION

Aneurysm of the vein of Galen is a complex arteriovenous malformation (AVM) characterized by multiple communications between the system of the vein of Galen and the cerebral arteries.[1] Fig. 42.1 is a diagrammatic representation of the cerebral venous system. This anomaly consists of dilatation of the median prosencephalic vein in association with AV fistulas within the wall of the vein, or multiple shunts communicating with the anterior part of the vein.

PREVALENCE AND EPIDEMIOLOGY

Aneurysm of the vein of Galen is a rare vascular malformation; it represents less than 1% of all intracranial AVMs.[2]

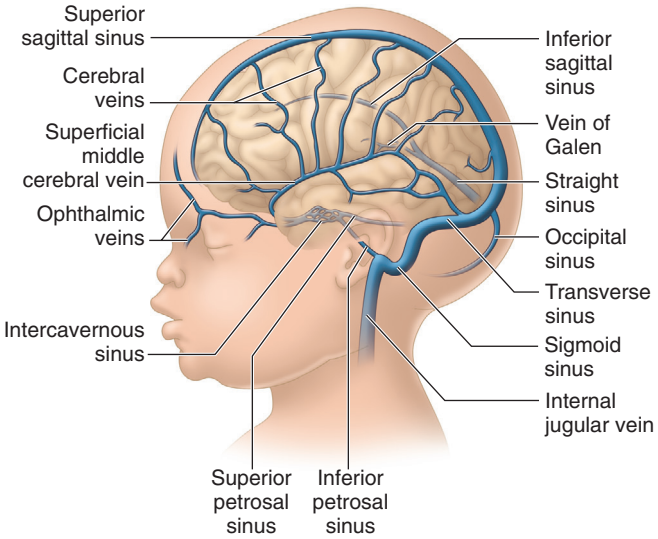

Fig. 42.1 Cerebral venous system.

ETIOLOGY AND PATHOPHYSIOLOGY

Aneurysm of the vein of Galen is thought to be a developmental abnormality. However, several previous publications reported normal cranial US scans in the early second trimester, but a vein of Galen malformation was detected later on in the pregnancy.[4,5]

Consequences of a vein of Galen malformation include the following[1]:

1. Cardiac failure: high-velocity left-to-right shunt through the AV communication causes cardiac failure. Left-to-right shunt leads to an increase in the workload of the heart, of the cardiothoracic ratio, and often of the heart rate. Postnatally, infants often have pulmonary hypertension.
2. Vascular steal: AV shunt in the brain can result in a vascular steal from other arteries in the brain. The result is progressive cerebral atrophy.
3. Venous hypertension: Increase in the venous pressure can lead to a reduction in the absorption of cerebrospinal fluid and progressive ventriculomegaly.

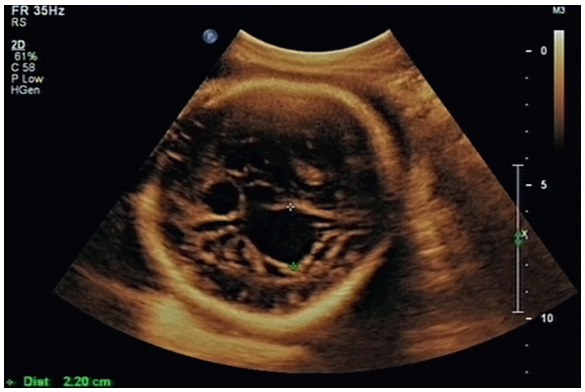

Fig. 42.2 Grayscale image of vein of Galen malformation.

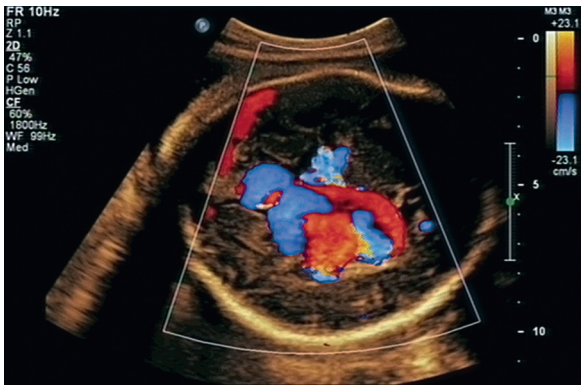

Fig. 42.3 Color flow mapping of vein of Galen malformation. Note high-velocity turbulent flow showing aliasing.

MANIFESTATIONS OF DISEASE

Imaging Technique and Findings

Ultrasound. Prenatal diagnosis of the vein of Galen malformation has been made on several occasions.[2,6–8] A classic finding is an echo-poor structure in the posterior region of the midline superior to the tentorium cerebelli and superior to the thalamus (Fig. 42.2).

The sagittal sinus is dilated in most cases. US with color flow mapping and Doppler interrogation reveals the presence of the turbulent flow typical of an AV malformation (Fig. 42.3). However, the flow may be absent if the lesion has undergone thrombosis.[9] Three-dimensional (3D) power angiography has been used to define the structure of the malformation.[10]

Magnetic Resonance Imaging. Prenatal magnetic resonance imaging (MRI) has been used to assess vascular connections and explore cerebral damage. Many associated anomalies have been described with the vein of Galen malformation. Table 42.1 lists commonly associated abnormalities. Fig. 42.4 shows cardiomegaly in a case of an aneurysm of the vein of Galen.

Differential Diagnosis From Imaging Findings

1. Arachnoid cyst or pseudocyst
2. Porencephalic cyst
3. Intracerebral hematoma
4. Dandy-Walker malformation

TABLE 42.1 ASSOCIATED ANOMALIES IN VEIN OF GALEN MALFORMATION (*N* = 25)

Ultrasound Finding	*n* (%)
Cardiomegaly	16 (64)
Enlarged neck veins	8 (32)
Ventriculomegaly	6 (24)
Polyhydramnios	4 (16)
No associated findings	6 (24)

Data from Sepulveda W, Platt C, Fisk N: Prenatal diagnosis of cerebral arteriovenous malformation using color Doppler ultrasonography: case report and review of the literature. *Ultrasound Obstet Gynecol* 6:282–286, 1995.

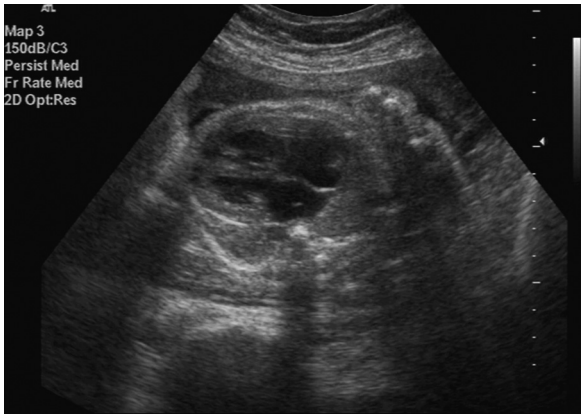

Fig. 42.4 Cardiomegaly associated with vein of Galen malformation. The heart occupies a large area of the chest.

Synopsis of Treatment Options

POSTNATAL

Most affected newborns show features of cardiac failure. Control of cardiac failure is the most immediate postnatal intervention. Definitive postnatal treatment consists of total excision of the lesion, surgical ligation, or embolization. Lasjaunias et al.[11] reported their experience of 317 cases with vein of Galen aneurysms. Initial management involved control of heart failure with diuretics and digitalis. Endovascular embolization was successfully employed as the first-line definitive treatment in 233 of 317 infants. Despite treatment, 23 (10.6%) newborns died. Severe mental retardation was reported in 20 infants, and moderate mental retardation was reported in 30 infants. Normal neurologic development was reported in 74% of survivors.

Spontaneous thrombosis of the malformation in the postnatal period has been reported.[12,13] In these cases, the thrombosed lesion was seen as a mass of high density or intensity values on computed tomography (CT) or MRI. However, in most cases, the lesion does not resolve spontaneously, and definitive postnatal treatment is required.

Dural Sinus Malformation (DSM)

DEFINITION

DSM is a rare disorder, and reported prognosis is poor, with a mortality rate of 38%.[14] These malformations are rarer than

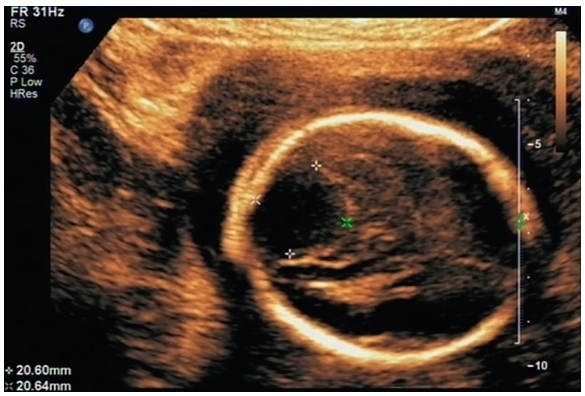

Fig. 42.5 Grayscale image of dural sinus malformation *(DSM)* detected at 22 weeks' gestation.

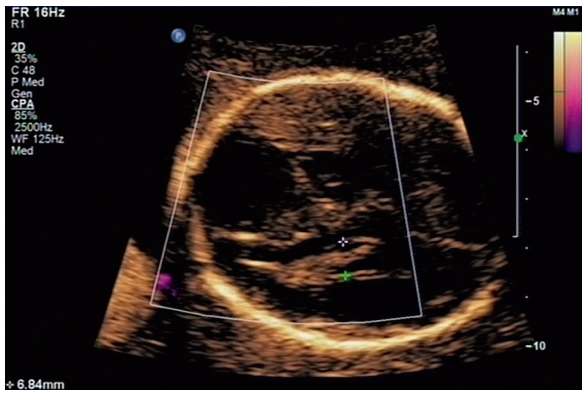

Fig. 42.6 Color flow mapping of dural sinus malformation *(DSM)*. No flow is seen owing to thrombosis.

vein of Galen aneurysms.[1] DSM often manifests in the prenatal period.

PREVALENCE AND EPIDEMIOLOGY

No robust data are available on the prevalence of DSM.

ETIOLOGY AND PATHOPHYSIOLOGY

DSM is caused by the persistence of an embryonic sinus or persistent enlargement of a sinus with secondary AV shunt within the wall of the dural lake. Other possible explanations include embryonic venous channel occlusion or temporary sinus occlusion. These lesions have been identified using US from 22 weeks' gestation.

MANIFESTATIONS OF DISEASE

Imaging Technique and Findings

Ultrasound. Although DSM can occur at all sites of dural sinuses in the skull, they occur mostly in the posterior cranial fossa. They are assumed to be congenital in origin. Morita et al.[14] described AV fistula of the posterior dural sinuses in three cases and conducted a literature search that revealed 21 additional cases. Komiyama et al.[15] reported an echo-poor lesion in the posterior cranial fossa, posterior to the cerebellum in the region of the torcular Herophili, the connecting point of the superior sagittal, straight, and occipital sinuses (see Fig. 42.1).

Color flow mapping can be used to look for turbulent blood flow in the lesion, but blood flow in a DSM is generally slower than in an aneurysm of the vein of Galen and may not be detected with color Doppler. Fig. 42.5 shows a fetus with a thrombosed DSM. No flow is shown on color Doppler or power angiography (Fig. 42.6).

Magnetic Resonance Imaging. Fetal MRI is very useful in assessing brain white matter and gray matter. It is also useful to detect a thrombus. Fig. 42.7 shows MRI findings of the fetus shown in Fig. 42.6. The falx cerebri is expanded posteriorly by a mass symmetric around the midline and inferiorly restrained by the tentorium cerebelli; the occipital poles are slightly splayed as a result. The parents requested pregnancy termination. Prenatal diagnosis was confirmed on autopsy. Fig. 42.8 shows the autopsy finding in the fetus.

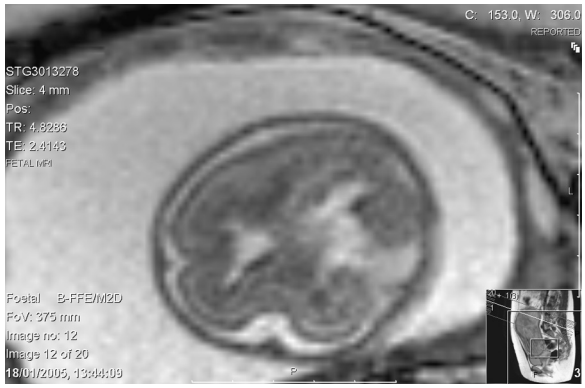

Fig. 42.7 MRI of dural sinus malformation *(DSM)* (the same fetus is shown as in Fig. 42.6).

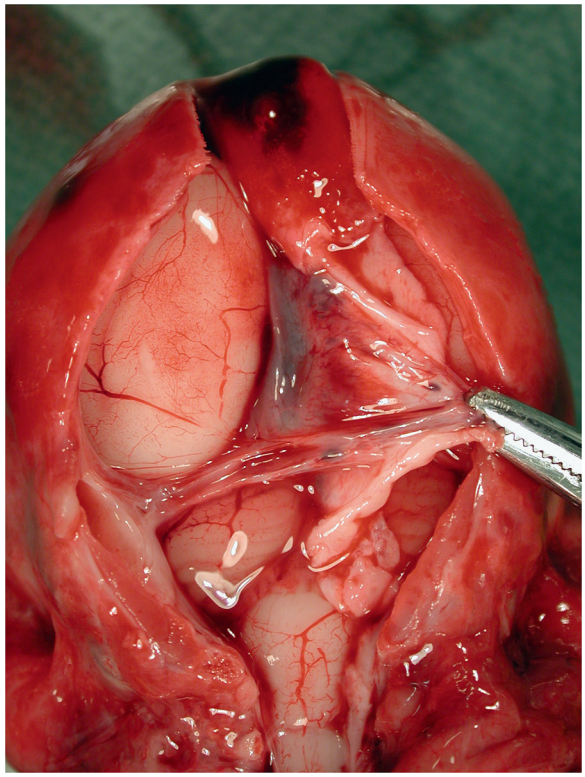

Fig. 42.8 Autopsy image of dural sinus malformation *(DSM)*. The clot in DSM has been removed.

DSM have also been reported in the anterior cranial fossa[16] and frontoparietal region.[17]

Differential Diagnosis From Imaging Findings

1. Dandy-Walker malformation
2. Arachnoid cyst
3. Blake pouch cyst

Synopsis of Treatment Options

POSTNATAL

Progressive heart failure has been reported in a case of DSM.[18] Morita et al.[14] reported 67% mortality. In their series, the outcome for pediatric patients with DSM was not satisfactory, with an overall mortality of 38%. Direct surgical resection or sinus isolation was attempted for eight patients, but anatomic cure was achieved in only two patients. Given the guarded prognosis, pregnancy termination can be offered as an option when prenatal diagnosis is made early.

Pial Arteriovenous Fistulas

DEFINITION

Pial AV fistulas correspond to an abnormal communication between arteries and veins. Most of the arteries feeding the pial AV fistula open into a single ectatic draining vein. Pial AV fistulas may be located in the posterior fossa or more commonly in the supratentorial space.

PREVALENCE AND EPIDEMIOLOGY

Prenatal diagnosis has been reported in one report of three cases.[19] Some isolated case reports have also appeared.

ETIOLOGY AND PATHOPHYSIOLOGY

Pial AV fistulas correspond to an abnormal communication between superficial arteries and usually with a single ectatic vein. They are located most commonly in the supratentorial space but can also be in the posterior fossa. Supratentorial AV fistulas are always superficial and are fed by pial (cortical) arteries. The low-resistance AVM often leads to hyperdynamic circulation, cardiac overload, and cardiac failure.

MANIFESTATIONS OF DISEASE

Imaging Technique and Findings

Ultrasound. US features leading to the suspicion of a pial AVM are as follows:

1. Unexplained cardiomegaly without a structural cardiac abnormality (may be due to high-output cardiac failure).
2. Dilatation of the vein of Galen may be due to the pial AVM emptying into the vein. This should not be confused with aneurysm of the vein of Galen. In cases with aneurysm of the vein of Galen, color flow mapping reveals turbulent flow not seen with pial AVM.
3. Visualization of the site of the pial AV fistula is the main diagnostic feature of this condition. Fistulas may be close to the midline or may be located more laterally.

Magnetic Resonance Imaging. MRI is particularly useful for detecting pial AVMs close to the cranium because these lesions may not be detected by US. The feeding and draining vessels are more clearly visible with MRI than with US.

Synopsis of Treatment Options

POSTNATAL

The prognosis depends on the presence of congestive cardiac failure and associated cerebral ischemic lesions. Differentiation between the vein of Galen malformation and pial AVM is very important in regard to treatment options. Treatment for the vein of Galen aneurysm is delayed until the infant is 5 to 6 months old, whereas pial AVMs warrant treatment soon after birth. Loss of brain tissue can occur rapidly even in asymptomatic newborns with a pial AVM. Embolization is the treatment of choice and should be performed in highly specialized centers.

Hemangiomas

DEFINITION

Hemangioma is a collection of blood vessels. The most common form is often called a "*strawberry mark*" as it looks like the surface of a strawberry. Hemangiomas can sometimes be located intracranially.

PREVALENCE AND EPIDEMIOLOGY

Intracranial hemangiomas are rare tumors.

ETIOLOGY AND PATHOPHYSIOLOGY

They are not true neoplasms and do not show potential for metastasis. Their natural history is unpredictable due to their tendency for recurrent hemorrhage and progressive growth with local destruction.

MANIFESTATIONS OF DISEASE

The hemangioma per se is often invisible. Hemorrhage leads to an increase in the echogenicity, which can attract attention and lead to the diagnosis. Tissue destruction resulting from hemorrhage and the loss of blood supply can lead to hypoplasia of the intracranial structures, which are often asymmetrical. Unilateral cerebellar hypoplasia may be a clue for the prenatal diagnosis of PHACE syndrome (posterior fossa malformations, hemangiomas, arterial anomalies, coarctation of the aorta and cardiac defects, and eye abnormalities).

Imaging Technique and Findings

Ultrasound. Prenatal detection of a cavernous hemangioma of the cerebellum has been reported.[20] It is the resulting hemorrhage that was detected as a hyperechoic area in the fetal brain.

Magnetic Resonance Imaging. Postnatal MRI is very accurate in the identification of cerebral cavernous angioma, but exact prenatal diagnosis can be difficult.

Differential Diagnosis

The differential diagnosis includes parenchymal hemorrhage, possibly from vascular anomaly, space-occupying lesion, or as a result of a viral infection.

Synopsis of Treatment Options

Intracranial hemorrhage is associated with a poor outlook. Identification of intracranial hemorrhage is a reasonable justification for an offer of pregnancy termination if legally possible.

POSTNATAL

The risk of hemorrhage (50%) is higher in the fetal group than it is in all other age groups (10%–45%). Three out of the four cases that presented with hemorrhage ended in either death or moderate mental retardation.[21] Infantile hemangiomas predominantly involute without significant residua and the majority do not require treatment.[22]

WHAT THE REFERRING PHYSICIAN NEEDS TO KNOW

- Vascular brain malformations are rare anomalies.
- The role of prenatal intervention is limited.
- Intracranial lesions detected on US without internal echoes should be examined with color flow or power Doppler.
- Many cases have indirect findings, such as cardiomegaly.
- Postnatally, minimally invasive treatment such as endovascular embolization has improved the prognosis considerably.

KEY POINTS

- Vascular cerebral malformations are rare congenital abnormalities.
- Many malformations manifest as echo-poor areas in the brain resembling cysts; color flow mapping of intracranial "cysts" is important for correct diagnosis.
- Most malformations are associated with a guarded prognosis because of cerebral damage, associated abnormalities, and circulatory compromise.
- If early prenatal detection is achieved, the offer of pregnancy termination can be considered.
- Definitive treatment in most lesions is postnatal.
- Referral to a specialized pediatric neurosurgery department is essential.

SUGGESTED READING

Karl K, Heling KS, Chaoui R. Ultrasound of the fetal veins part 3: the fetal intracerebral venous System. *Ultraschall Med*. 2016;37:6-26.

Lasjaunias PL, Chng SM, Sachet M, et al. The management of vein of Galen aneurysmal malformations. *Neurosurgery*. 2006;59(5 suppl 3):S184-S194.

Pilu G, Falco P, Sandri F, et al. Differential diagnosis and outcome of fetal intracranial hypoechoic lesions: report of 21 cases. *Ultrasound Obstet Gynecol*. 1997;9:229-236.

Sepulveda W, Platt C, Fisk N. Prenatal diagnosis of cerebral arteriovenous malformation using color Doppler ultrasonography: case report and review of the literature. *Ultrasound Obstet Gynecol*. 1995;6:282-286.



All references are available online at www.expertconsult.com.

REFERENCES

1. Brunelle F. Brain vascular malformations in the fetus: diagnosis and prognosis. *Childs Nerv Syst*. 2003;19:524-528.
2. Sepulveda W, Platt C, Fisk N. Prenatal diagnosis of cerebral arteriovenous malformation using color Doppler ultrasonography: case report and review of the literature. *Ultrasound Obstet Gynecol*. 1995;6:282-286.
3. Johnston I, Whittle I, Besser M, et al. Vein of Galen malformation: diagnosis and management. *Neurosurgery*. 1987;20:747-758.
4. Ordorica SA, Marks F, Frieden FJ, et al. Aneurysm of the vein of Galen: a new cause for Ballantyne syndrome. *Am J Obstet Gynecol*. 1990;162: 1166-1167.
5. Worswick L, Lamont RF, Thomas R, et al. Prenatal ultrasonographic diagnosis of an aneurysm of the vein of Galen. *Br J Radiol*. 1992;65:609-610.
6. Doren M, Tercanli S, Holzgreve W. Prenatal sonographic diagnosis of a vein of Galen aneurysm: relevance of associated malformations for timing and mode of delivery. *Ultrasound Obstet Gynecol*. 1995;6:287-289.
7. Mai R, Rempen A, Kristen P. Prenatal diagnosis and prognosis of a vein of Galen aneurysm assessed by pulsed and color Doppler sonography. *Ultrasound Obstet Gynecol*. 1996;7:228-229.
8. Pilu G, Falco P, Sandri F, et al. Differential diagnosis and outcome of fetal intracranial hypoechoic lesions: report of 21 cases. *Ultrasound Obstet Gynecol*. 1997;9:229-236.
9. Vijayaraghavan SB, Vijay S, Kala MR, et al. Prenatal diagnosis of thrombosed aneurysm of vein of Galen. *Ultrasound Obstet Gynecol*. 2006;27:81-83.
10. Heling KS, Chaoui R, Bollmann R. Prenatal diagnosis of an aneurysm of the vein of Galen with three-dimensional color power angiography. *Ultrasound Obstet Gynecol*. 2000;15:333-336.
11. Lasjaunias PL, Chng SM, Sachet M, et al. The management of vein of Galen aneurysmal malformations. *Neurosurgery*. 2006;59(5 suppl 3):S184-S194.
12. Beltramello A, Perini S, Mazza C. Spontaneously healed vein of Galen aneurysms: clinical and radiological features. *Childs Nerv Syst*. 1991;7: 129-134.
13. Nikas DC, Proctor MR, Scott RM. Spontaneous thrombosis of vein of Galen aneurysmal malformation. *Pediatr Neurosurg*. 1999;31: 33-39.
14. Morita A, Meyer FB, Nichols DA, et al. Childhood dural arteriovenous fistulae of the posterior dural sinuses: three case reports and literature review. *Neurosurgery*. 1995;37:1193-1199.
15. Komiyama M, Ishiguro T, Kitano S, et al. Serial sonographic observation of cerebral dural sinus malformation. *AJNR Am J Neuroradiol*. 2005; 25:1446-1448.
16. Gliemroth J, Nowak G, Arnold H. Dural arteriovenous malformation in the anterior cranial fossa. *Clin Neurol Neurosurg*. 1999;101:37-43.
17. Lee W, Kirk JS, Pryde P, et al. Atypical presentation of fetal arteriovenous malformation. *J Ultrasound Med*. 1994;13:645-647.
18. Ballester MJ, Raga F, Serra-Serra V, et al. Early prenatal diagnosis of an ominous aneurysm of the vein of Galen by color Doppler ultrasound. *Acta Obstet Gynecol Scand*. 1994;73:592-595.
19. Garel C, Azarian M, Lasjaunias P, et al. Pial arteriovenous fistulas: dilemmas in prenatal diagnosis, counseling and postnatal treatment: report of three cases. *Ultrasound Obstet Gynecol*. 2005;26:293-296.
20. Lerner A, Gilboa Y, Gerad L, et al. Sonographic detection of fetal cerebellar cavernous hemangioma with in-utero hemorrhage leading to cerebellar hemihypoplasia. *Ultrasound Obstet Gynecol*. 2006;28:968-971.
21. Leung KY, Tang MH, Lam TP, et al. Prenatal diagnosis of a cavernous angioma associated with intracranial hemorrhage: report of one case and review of the literature. *Ultrasound Obstet Gynecol*. 2004;24:800-803.
22. Liang MG, Frieden IJ. Infantile and congenital hemangiomas. *Semin Pediatr Surg*. 2014;23:162-167.

43 Ventriculomegaly

FRANCESCO D'ANTONIO | ARIS T. PAPAGEORGHIOU

Introduction

Ventriculomegaly (VM) is a nonspecific term, describing dilatation of the lateral cerebral ventricles, usually defined as greater than 10 mm at the level of the atria. VM is the most frequent abnormal central nervous system (CNS) finding detected with prenatal imaging techniques.[1] It is not a disease, but rather a sign that represents a common endpoint of various pathologic processes with different outcomes and prognosis; it may also be a physiologic finding representing an extreme normal variation.

The prognosis depends to a large degree on the underlying cause, the coexistence of other anomalies, and eventual progression. Because these cannot always be determined with confidence, counseling for VM can be difficult. It can be a benign finding, but it can also be associated with aneuploidies, congenital infections, cerebral vascular accidents or hemorrhage, and other fetal cerebral or extracerebral abnormalities, with different implications for long-term neurodevelopmental outcome.[2]

Disease

DEFINITION

Fetal VM is an ultrasound (US) finding that refers to dilatation of the lateral ventricles of the brain, typically defined as greater than 10 mm at the level of the atria, with or without dilatation of the third or fourth ventricles.[1] In the pediatric literature, the term *hydrocephalus* usually refers to expansion of the ventricular system associated with increased cerebrospinal fluid (CSF) pressure, secondary to a disturbance in the dynamics of CSF circulation.[3] Because it is impossible to measure CSF pressure in utero prenatally, this condition is preferably referred to as VM.[4]

The ventricular atrial width is roughly constant after 15 weeks' gestation. VM is defined as a width at the level of the atria of the lateral ventricle greater than 10 mm; this corresponds to about 4 standard deviations above the mean of 7.6 mm.[5] Most authors consider an atrial width of less than 10 mm normal, a width between 10.0 and 15.0 mild VM, and a width greater than

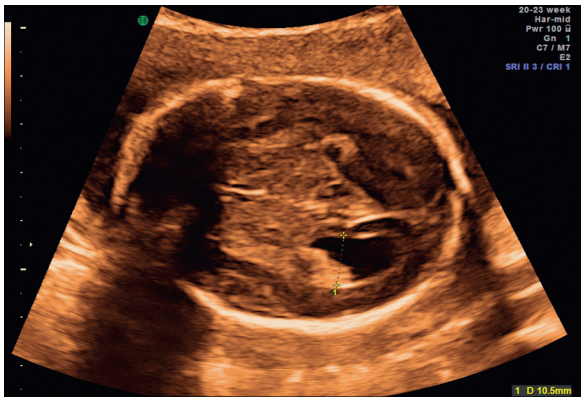

Fig. 43.1 Mild isolated fetal VM at 22 weeks' gestation.

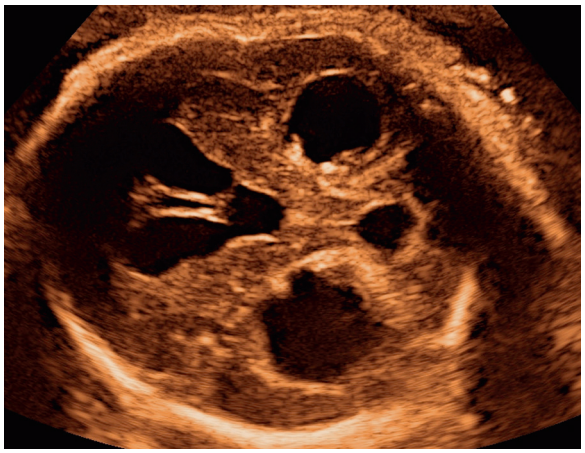

Fig. 43.2 Severe tetraventricular VM with dilatation of posterior, anterior, third, and fourth ventricles in a 30-week fetus.

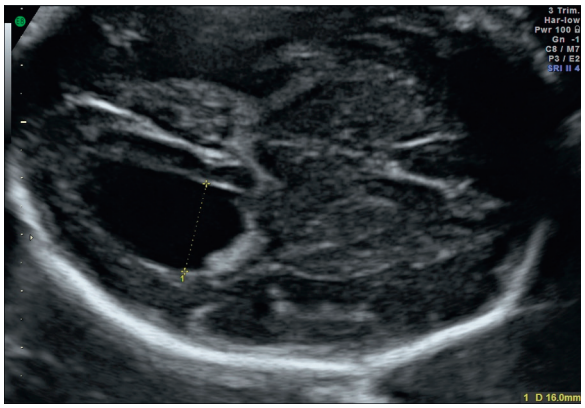

Fig. 43.3 Isolated severe VM in a 22-week gestation fetus with confirmed fetal cytomegalovirus infection.

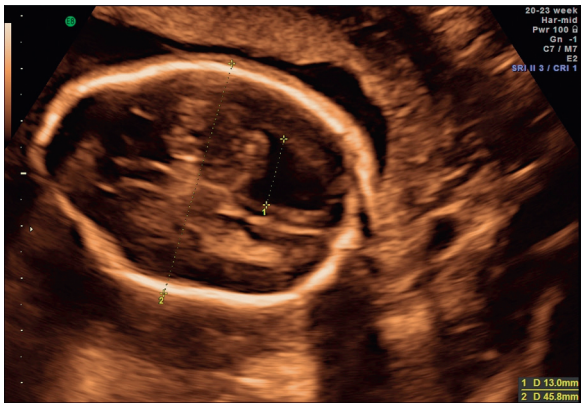

Fig. 43.4 Mild VM in a 22-week fetus with lumbosacral spina bifida.

15 mm severe VM.[6] However, definitions vary in the literature. The terms *mild, moderate,* and *severe* VM for atrial widths 10 to 12 mm, 13 to 15 mm, and greater than 15 mm are also often used (Figs. 43.1 and 43.2).[7]

PREVALENCE AND EPIDEMIOLOGY

Because the incidence of VM depends on the definition used, it has been reported to range from 1:50 to 1:1600.[8,9] The incidence of severe VM is about 1:1000 newborns.[10] Discrepancies in reported incidences are also due to differences in measuring techniques or gestational age at examination, assessment of only one hemisphere, a lack of precise correlation in the diagnosis between prenatal and neonatal life, and the possible prenatal "resolution" of the condition.[11] Male fetuses are diagnosed with VM slightly more often than female fetuses.[12]

ETIOLOGY AND PATHOPHYSIOLOGY

Many cases of VM are due to an imbalance between production and absorption of CSF caused by an obstructive event. CSF is formed mainly at the level of the choroid plexus and flows from the lateral ventricles through the foramina of Monro into the third ventricle, and then via the aqueduct of Sylvius into the fourth ventricle. At this level, it passes through the foramen of Magendie (in the roof of the fourth ventricle), or through the foramina of Luschka (at the sides of the fourth ventricle) into the subarachnoid space around the cerebral hemispheres. From there, CSF is reabsorbed by the arachnoid granulations that are mainly distributed along the superior sagittal sinus. If there is obstruction in the ventricular system, VM is defined as *noncommunicating* or *obstructive*. The obstruction can occur at different levels of the ventricular system, and different etiologies are known—either congenital, or secondary to intrinsic or extrinsic lesions.[8] Generally, the more distal the obstruction is from the foramina of Monro, the greater the degree of the involvement of the ventricular system (see Fig. 43.2).

Noncommunicating VM includes the unilateral and bilateral obstruction of foramina of Monro, congenital narrowing of the aqueduct of Sylvius, aqueductal forking, or the presence of a septum within the aqueduct. Some cases of aqueductal stenosis may be inherited as an X-linked recessive trait or, more rarely, as an autosomal recessive disease.[13]

Ventricular obstruction can also be caused by intrinsic processes such as inflammation, secondary to infections such as cytomegalovirus and toxoplasmosis (Fig. 43.3); by hemorrhage; or by other extrinsic events such as tumors, arachnoid cysts, or malformations of the CNS that impair the normal circulation of CSF between the ventricular and the extraventricular system. Open neural tube defects and posterior fossa abnormalities are also often associated with VM (Fig. 43.4).[14,15]

The term *communicating VM* describes conditions such as sagittal sinus thrombosis,[9] in which the cause is outside the ventricular system and a communication with at least part of

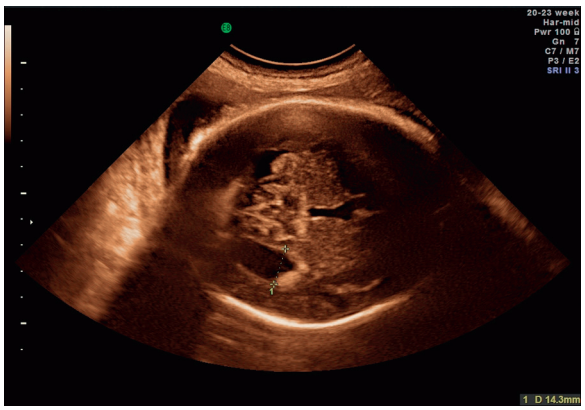

Fig. 43.5 Mild fetal VM in a 23-week fetus with complete agenesis of corpus callosum.

the subarachnoid space is possible, or conditions with increased CSF production, such as choroid plexus papilloma without an obvious obstruction.[10] VM can also develop without obstruction, in prosencephalic developmental anomalies (e.g., holoprosencephaly, agenesis of the corpus callosum [see Fig. 43.5]) and disorders of neural proliferation (e.g., microcephaly, megalencephaly) or neuronal migration (e.g., lissencephaly, schizencephaly) (Chapters 34, 36, and 39). Finally, VM can be the consequence of acquired destructive processes of the brain, resulting from vascular accidents or infections (Chapter 40).[16,17]

MANIFESTATIONS OF DISEASE

Clinical Presentation

Clinical presentation depends on the causes and the presence of intracranial and extracranial associated anomalies. VM is commonly defined as isolated only if there is no US evidence of intracranial or extracranial associated malformations or other markers of aneuploidy at the time of initial presentation (see Fig. 43.1).[2,6,12,18]

Prenatal presentation is usually at the time of the routine second-trimester US scan. Detailed expert neurosonography is indicated to search for possible causes, and further targeted investigations such as fetal brain magnetic resonance imaging (MRI), screening for congenital infection, or screening for antiplatelet antibodies may be indicated.

The most important prognostic factors in VM are

- association with other anomalies,
- the true cause of the condition, and
- the progression of ventricular dilatation.[2]

The risk of neurologic abnormality in truly isolated, mild VM that remains stable until delivery is lower compared to progressive VM.[19,20]

Mild isolated VM (Fig. 43.1) is usually asymptomatic at birth. Severe VM can manifest with signs of increased CSF pressure, including sutural diastasis, dilatations of scalp veins, bulging of the anterior fontanelle, downward deviations of the eyes, irritability, abducens nerve palsy, and, in advanced cases, bradycardia, and bradypnea.[18] Perinatal mortality is higher in cases of severe VM compared with mild VM.[6,21]

Assessing the neurodevelopmental performance of children with a prenatal diagnosis of isolated mild ventriculomegaly is challenging. Wide variation exists in the reported prevalence of neurodevelopmental delay in infants with this condition. Part of the difficulty in providing an accurate prognosis and outcome in these infants may arise from methodologic problems, as mentioned earlier. The retrospective nature of most studies, small heterogeneous samples, inconsistent imaging, and different types of follow-up have likely contributed to these variable results.[2,22] Furthermore, the term *neurodevelopmental outcome* per se can be inappropriate when dealing with subtle brain anomalies such as VM, because it includes a wide spectrum of signs that are not always easily measured, and that represent a continuous interaction between pathologic, environmental, and adaptive factors. The optimal time to assess neurodevelopmental outcome in children with isolated mild VM is also debatable. Very early assessment may not accurately predict neurodevelopmental outcomes during later life; in contrast late evaluations may be biased by the influence of socioeconomic, parenting, environmental, and educational factors, which may significantly affect developmental measures, especially when looking for subtle differences. Control populations represent another peculiar issue: defining a neurodevelopmental measure as abnormal implies knowledge of how often the measure is abnormal in the nonaffected population. However, the prevalence of neuropsychologic morbidity in the general population, defined as not being affected by brain anomalies, is extremely variable and it has been reported to be as high as 7% to 10% in some studies.

A peculiar example of how interpretation of such a subtle brain finding can change in relation to the time and type of assessment is provided by the study by Atad-Rapoport, who looked at the neurodevelopmental performance of children with isolated unilateral VM and asymmetric ventricles at school age.[22] In a previous study, the authors had found that children with unilateral mild ventriculomegaly scored significantly lower on mental development and behavioral rating scales, and that about 20% of children with asymmetric ventriculomegaly showed developmental delay when evaluated at a preschool age.[23] These findings completely changed when these children were evaluated at school age, when their neuropsychologic profile did not significantly differ from that of the general population for most of the observed outcome measures, although the study included only a part of the original cohort.[22]

Finally, the meaning of neuropsychologic impact after fetal ventriculomegaly is another fundamental issue; the large majority of the studies dealing with neurodevelopmental outcome in isolated mild VM do not discriminate between "neurodevelopmental delay" and "neurologic disability," and do not quantify the impact of an abnormal neuropsychologic outcome on daily quality of life. Mild delay may not be always associated with disabilities and may have only a minor impact on the overall quality of life; on the other hand, severe delay is commonly associated with disabilities that can significantly affect quality of life.

Bearing in mind all these limitations, the prevalence of abnormal neurodevelopmental outcome in fetuses diagnosed with isolated mild VM confirmed at birth has been reported to be about 8% in a recent systematic review.[24] Some studies have focused on the finding of unilateral or asymmetric VM, defined as a difference of width of 2 mm or more in ventricular size between the two hemispheres, to assess outcomes.[22,23]

The incidence of neurodevelopmental delay in cases of unilateral mild VM has been reported to be about 7%—not significantly different from those infants with bilateral mild VM.[25]

In severe VM, neurodevelopmental outcomes are poor in most cases, in particular if there is progressive enlargement of the ventricles in utero. However, normal or near-normal development is reported and observed.[26–28]

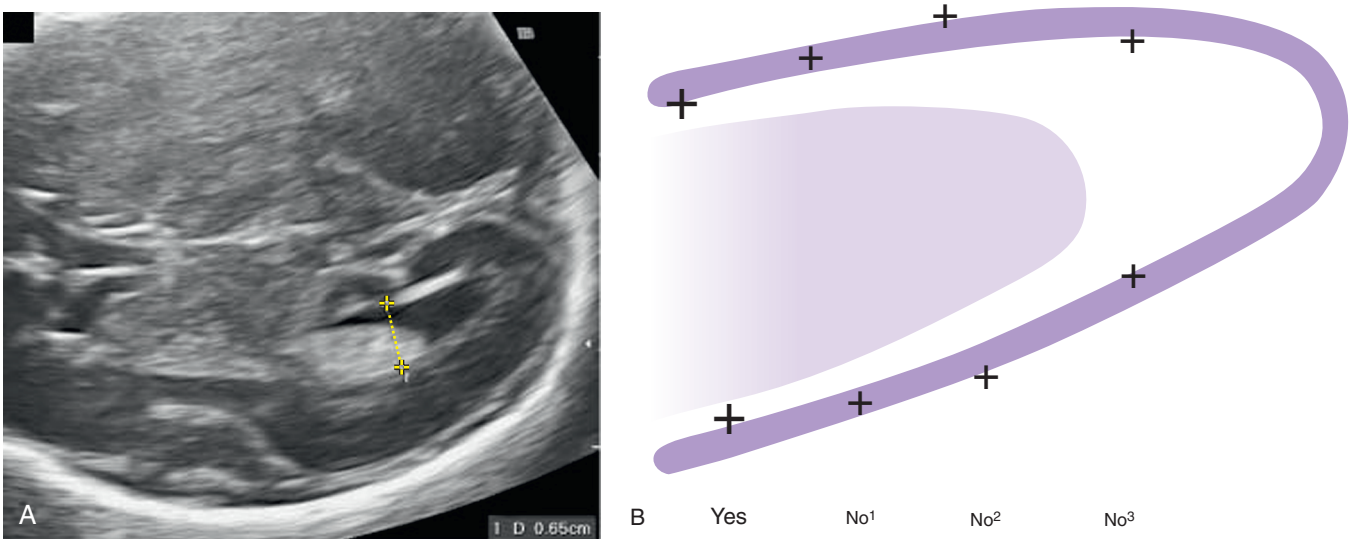

Fig. 43.6 International Society of Ultrasound in Obstetrics and Gynaecology guidelines for standard measurement of fetal ventricular width on the axial plane. *(From International Society of Ultrasound in Obstetrics and Gynaecology: Sonographic examination of the fetal central nervous system: guidelines for performing the "basic examination" and the "fetal neurosonogram."* Ultrasound Obstet Gynecol *29:109–116, 2007.)*

This underlines the urgent need for studies looking at the impact of a given neurodevelopmental delay on the overall quality of life at different time intervals, in order to estimate the actual burden of neurologic disabilities of children with VM.

Imaging Technique and Findings

Ultrasound. Measuring the width of the atria of the lateral cerebral ventricles is recommended as part of the routine anomaly scan. The lateral ventricle should be measured in the axial plane at the level of the cavum septi pellucidi, with the calipers aligned with the internal borders of the medial and lateral walls of the ventricle, and at the level of the glomus of the choroid plexus (the enlarged portion at the junction of the body of the lateral ventricle with the occipital and temporal horns of the lateral ventricles), opposite to the parietooccipital fissure (Fig. 43.6).[29,30] The diameters of both atria can often be measured on a coronal plane if shadowing of the proximal skull bones can be avoided; both choroid plexus can be seen, and measurements perpendicular to the long axis of the ventricles can be done, positioning calipers as before. This approach allows comparison of both lateral ventricles; it is also in close agreement with MRI measurements (Figs. 43.7 and 43.8).[2]

Because VM is a sign rather than a specific brain anomaly, the diagnosis of isolated VM is made by exclusion. In the case of apparently isolated VM, the entire ventricular system from supratentorial to infratentorial structures should be carefully examined in order to ascertain whether an obstructive lesion causes VM, and to recognize the level of obstruction, which may affect the extent of dilatation.[31] Pericerebral spaces should be assessed in order to rule out macrocephaly or microcephaly, which may be associated with VM and characterized by increased pericerebral fluid collection. Cortical fissures should be examined because VM may represent the first sign of an abnormal gyration patter. The main landmark of the gyration process is operculization of the Sylvian fissure, which should be systematically assessed in cases of VM.[31] However, it should be kept in mind that cortical anomalies are not commonly diagnosed at a routine second-trimester anomaly scan, and that serial follow-up scans are often needed in order to confirm this suspicion.[32] Furthermore, cortical anomalies may be difficult or impossible to detect with a standard axial view, and the use of a multiplanar approach with a high-resolution probe is required. Whether a transvaginal or transabdominal scan is performed also depends on the fetal position and the preference of the patient and the operator.[2] The ventricular wall, ventricular lumen, and periventricular areas should be also inspected in order to look for signs of ischemic-hemorrhagic lesions, commonly resulting in irregular ventricular walls and intraventricular echogenicity, and which may also involve the surrounding parenchyma, or infections, such as CMV, which are usually associated with periventricular or parenchymal calcifications, and intraventricular cystic lesions. Finally, detailed examination of the periventricular zone should be made in order to rule out early signs of periventricular heterotopia, which usually presents as nodular irregularities of the ventricular wall.

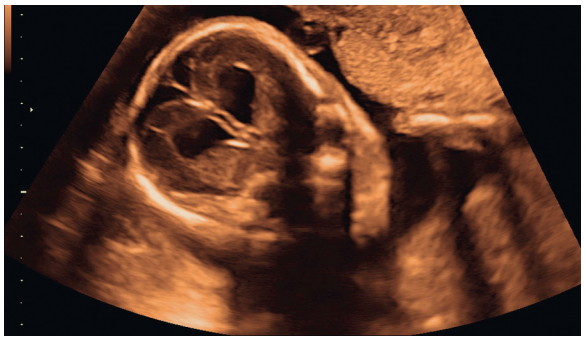

Fig. 43.7 Coronal assessment of the anterior lateral ventricles in a 23-week fetus with severe bilateral VM.

Associated major anomalies (cranial and extracranial) can be present in 50% of fetuses with VM,[2] of which the most common are agenesis of the corpus callosum (Fig. 43.5) and open spina bifida (Fig. 43.4). The rate of associated anomalies in severe VM is higher than in mild VM.[6]



Fig. 43.8 MRI in a 22-week fetus with bilateral mild VM and absent corpus callosum.

Normal brain development continues throughout pregnancy and postnatally. One can tell only that a cerebral structure appears normal for that gestational age, but not whether it will continue to develop normally later in pregnancy or after birth.[11] Because of this, prenatally detected VM can evolve, and "new" abnormalities, such as neuronal migration anomalies, may become apparent only in the third trimester or after birth.[32] The prevalence of additional brain anomalies diagnosed only after birth is 11% and 6% in bilateral and unilateral mild VM, respectively, thus underlining the need for appropriate postnatal follow-up imaging in order to rule out such anomalies.

Assessment of the ventricular system is also fundamental to stratify the prognosis of other fetal brain malformations, such as posterior fossa anomalies or spina bifida. Progressive increases in ventricular size have been associated with the need for postnatal ventriculoperitoneal shunt in fetuses with spina bifida, whereas the occurrence of VM in fetuses with posterior fossa anomalies, such as megacisterna magna and Blake's pouch cyst, increases the risk for hydrocephaly requiring postnatal decompression.[33]

Magnetic Resonance Imaging. Although US is the mainstay of the evaluation and diagnosis of fetuses with VM, MRI is particularly helpful in fetuses with CNS anomalies. MRI reportedly improves the precision and accuracy of some diagnoses. MRI has particular value in the detection of parenchymal brain disorders, migration abnormalities, infarctions, hemorrhage, and irregularity of the ventricular walls such as heterotopias.[34–36] US and MRI should be seen as complementary investigations; in expert hands, they are comparable in accuracy, although they occasionally differ in the interpretation of brain anomalies. The overall prevalence of MRI-detected additional brain abnormalities prenatally has been reported to be as high as 19% in fetuses with VM (irrespective of the degree of ventricular dilatation), and 5% in case of unilateral VM.[37]

The optimal gestational age for the fetal MRI study, whether at the time of the primary US diagnosis or later, remains unclear.

TABLE 43.1 ASSOCIATED ANOMALIES IN VENTRICULOMEGALY AND DIFFERENTIAL DIAGNOSES OF ISOLATED VENTRICULOMEGALY

Open spina bifida
Encephalocele
Posterior fossa and cerebral anomalies
Prosencephalic anomalies (holoprosencephaly, agenesis of corpus callosum, absence of cavum septi pellucidi)
Anomalies of cortical development (microcephaly, megalencephaly, lissencephaly, schizencephaly)
Fetal infections (toxoplasmosis, cytomegalovirus)
Vascular insults (porencephaly, hydranencephaly)
Aneuploidies
Choroid plexus anomalies
Intracranial tumors and cysts
Intracranial hemorrhage

Some data suggest that there is no advantage in delaying fetal MRI to improve detection rates, but this finding needs to be confirmed by further studies (Fig. 43.8).[36]

Differential Diagnosis From Imaging Findings

Isolated VM is a diagnosis of exclusion; a careful examination has to be performed to rule out conditions typically associated with VM and to determine the cause and level of the obstruction. The main associated or differential diagnoses are listed in Table 43.1.

Synopsis of Treatment Options

PRENATAL

Maternal serum cytomegalovirus, *Toxoplasma* and Parvovirus B19 studies should be considered given the possible association with fetal infections; the more guarded prognosis in cases of affected children; the potential for treatment; and the simplicity, safety, and relatively low cost of the screening test.[2] The presence of isolated VM has a likelihood ratio of 9 for the risk of aneuploidy[2,38]; the risk for aneuploidy seems to be lower in severe VM.[20] Invasive prenatal diagnosis for VM may be appropriate, depending on the prior risk.

At present, there is no evidence to support the routine search for antihuman platelet antibodies causing fetoneonatal alloimmune thrombocytopenia in isolated VM. The incidence of fetoneonatal alloimmune thrombocytopenia is low (1:1000 to 1.2:1000 in the general population), and the risk of intracranial hemorrhage among these cases is 10% to 30%. A search for maternal antihuman platelet antibodies is indicated if there is suspicion of intracranial hemorrhage on US.

There is no agreement regarding the timing and frequency of follow-up in fetuses with VM, which depends on gestational age at diagnosis. In one study, progression of VM in utero was found in 11%.[35]

The minimal time interval before performing a follow-up study should be 2 weeks after initial detailed assessment.[2]

In utero, treatment using shunts or repeated cephalocentesis was attempted for severe VM, to prevent progressive brain damage caused by increased CSF pressure. Because of the high rate of procedure-related death and lack of significantly improved outcome, in utero treatment was abandoned.[39]

The mode of delivery should be individualized. In isolated VM without significant head enlargement, the mode of delivery should not be influenced by VM. In cases of severe VM with enlargement of fetal head size, cesarean birth may be indicated.[14]

POSTNATAL

Neonates delivered after a prenatal diagnosis of isolated VM should undergo a physical examination and cerebral US. Consultation with a pediatric neurologist and neurosurgeon may be indicated. If other anomalies were detected prenatally or at birth, a consultation with a medical geneticist is warranted.

If karyotyping was not performed prenatally, it should be offered after birth. Serology for fetal infection should also be undertaken. Depending on the prenatal findings, MRI may be indicated to detect any worsening, to determine underlying causes, and to rule out associated brain anomalies.[14] Management of VM after birth is related to the presence of associated anomalies and varies considerably.

WHAT THE REFERRING PHYSICIAN NEEDS TO KNOW

- VM is not a diagnosis, but rather a nonspecific sign and is a common finding in a wide range of conditions.
- Isolated VM is a diagnosis of exclusion, but associated anomalies cannot always be ruled out at the time of the anomaly scan.
- Detailed expert US examination is warranted and may be complemented by fetal MRI. Investigations should be individualized and may include karyotyping and serologic examination for congenital infections.
- The prognosis of VM depends on the severity and cause, the presence of associated anomalies, and possible intrauterine progression.

KEY POINTS

- VM is a nonspecific term, describing dilatation of the cerebral ventricles.
- VM is the most common CNS abnormality detected with prenatal imaging techniques.
- Many cranial and extracranial anomalies also exhibit VM.
- VM can be due to an imbalance between production and absorption of CSF, abnormal midline development, cortical proliferation and migration disorders, and destructive processes such as vascular insults or infections.
- Knowledge of the possible causes of VM helps in differentiating isolated VM from the associated forms.
- US is the mainstay in the diagnosis of VM, but MRI can often add useful information.
- Prognosis depends on the severity, presence of associated anomalies, causes, and possible progression in utero.
- Neurodevelopmental delay is more common in severe VM than in mild VM.

SUGGESTED READING

Melchiorre K, Bhide A, Gika AD, et al. Counseling in isolated mild fetal ventriculomegaly. *Ultrasound Obstet Gynecol*. 2009;34:212-224.

Pagani G, Thilaganathan B, Prefumo F. Neurodevelopmental outcome in isolated mild fetal ventriculomegaly: systematic review and meta-analysis. *Ultrasound Obstet Gynecol*. 2014;44:254-260.

Santo S, D'Antonio F, Homfray T, et al. Counseling in fetal medicine: agenesis of the corpus callosum. *Ultrasound Obstet Gynecol*. 2012;40(5):513-521. doi:10.1002/uog.12315.

Scala C, Familiari A, Pinas A, et al. Perinatal and long-term outcome in fetuses diagnosed with isolated unilateral ventriculomegaly: systematic review and meta-analysis. *Ultrasound Obstet Gynecol*. 2016;doi:10.1002/uog.15943.



All references are available online at www.expertconsult.com.

REFERENCES

1. Garel C, Luton D, Oury JF, et al. Ventricular dilatations. *Childs Nerv Syst*. 2003;19:517-523.
2. Melchiorre K, Bhide A, Gika AD, et al. Counseling in isolated mild fetal ventriculomegaly. *Ultrasound Obstet Gynecol*. 2009;34:212-224.
3. Shizuo OI. Controversies in definition and classification of hydrocephalus. *Neurol Med Chir (Tokyo)*. 2010;50:859-869.
4. Gaglioti P, Oberto M, Todros T. The significance of fetal ventriculomegaly: etiology, short- and long-term outcomes. *Prenat Diagn*. 2009;29:381-388.
5. Cardoza JD, Goldstein RB, Filly RA. Exclusion of fetal ventriculomegaly with a single measurement: the width of lateral ventricular atrium. *Radiology*. 1988;169:711-714.
6. Vergani P, Locatelli A, Strobelt N, et al. Clinical outcome of mild fetal ventriculomegaly. *Am J Obstet Gynecol*. 1998;178:218-222.
7. Signorelli M, Tiberti A, Valsariati D, et al. Width of fetal lateral ventricular atrium between 10 and 12 mm: a simple variation of the norm? *Ultrasound Obstet Gynecol*. 2004;23:14-18.
8. Alagappan R, Browing PD, Laorr A, et al. Distal lateral ventricular atrium: reevaluation of normal range. *Radiology*. 1994;193:405-408.
9. Achiron R, Schimmel M, Achiron A, et al. Fetal mild idiopathic lateral ventriculomegaly: is there a correlation with fetal trisomy? *Ultrasound Obstet Gynecol*. 1993;3:89-92.
10. Nomura ML, Barini R, De Andrade C, et al. Congenital hydrocephalus: gestational age and neonatal outcomes. *Arch Gynecol Obstet*. 2010;282:607-611.
11. Levine D, Feldman H, Kazan Tannus J, et al. Frequency and cause of disagreement in diagnoses for fetuses referred for ventriculomegaly. *Radiology*. 2008;247:516-527.
12. Pilu G, Falco P, Gabrielli S, et al. The clinical significance of fetal isolated cerebral borderline ventriculomegaly: report of 31 cases and review of the literature. *Ultrasound Obstet Gynecol*. 1999;14:320-326.
13. Bianchi D, Crombleholme TM, D'Alton M, et al. *Fetology*. 2nd ed. New York: McGraw-Hill; 2010.
14. Levene D, Chevernak FA, Whittle M. *Fetal and neonatal neurology and neurosurgery*. 3rd ed. London: Churchill Livingstone; 2001.
15. D'Addario V, Pinto V, Di Cagno L, et al. Sonographic diagnosis of fetal cerebral ventriculomegaly: an update. *J Matern Fetal Neonatal Med*. 2007;20:7-14.
16. Sherer DM, Onyeije CI. Prenatal ultrasonographic diagnosis of fetal intracranial tumors: a review. *Am J Perinatol*. 1998;15:319-328.
17. Ashwal S. Congenital structural defect of the brain. In: Levene MI, Chevernak FA, Whittle M, eds. *Fetal and neonatal neurology and neurosurgery*. 3rd ed. London: Churchill Livingstone; 2001:199-236.
18. Punt J. Neurosurgical management of hydrocephalus. In: Levene MI, Chevernak FA, Whittle M, eds. *Fetal and neonatal neurology and neurosurgery*. 3rd ed. London: Churchill Livingstone; 2001:753-761.
19. Davaseelan P, Cardwell C, Bell B, et al. Prognosis of isolated mild to moderate fetal cerebral ventriculomegaly: a systematic review. *J Perinat Med*. 2010;38:401-409.
20. Weichert J, Hartge D, Krapp M, et al. Prevalence, characteristics and perinatal outcome of fetal ventriculomegaly in 29,000 pregnancies followed at a single institution. *Fetal Diagn Ther*. 2010;27:142-148.
21. Gaglioti P, Danelon D, Bontempo S, et al. Fetal cerebral ventriculomegaly: outcome in 176 cases. *Ultrasound Obstet Gynecol*. 2005;25:372-377.
22. Atad-Rapoport M, Schweiger A, Lev D, et al. Neuropsychological follow-up at school age of children with asymmetric ventricles or unilateral ventriculomegaly identified in utero. *BJOG*. 2015;122:932-938.
23. Sadan S, Malinger G, Schweiger A, et al. Neuropsychological outcome of children with asymmetric ventricles or unilateral mild ventriculomegaly identified in utero. *BJOG*. 2007;114:596-602.
24. Pagani G, Thilaganathan B, Prefumo F. Neurodevelopmental outcome in isolated mild fetal ventriculomegaly: systematic review and meta-analysis. *Ultrasound Obstet Gynecol*. 2014;44:254-260.
25. Scala C, Familiari A, Pinas A, et al. Perinatal and long-term outcome in fetuses diagnosed with isolated unilateral ventriculomegaly: systematic review and meta-analysis. *Ultrasound Obstet Gynecol*. 2016 Apr 19;doi:10.1002/uog.15943.
26. Beeghly M, Ware J, Soul J, et al. Neurodevelopmental outcome of fetuses referred for ventriculomegaly. *Ultrasound Obstet Gynecol*. 2010;35:405-416.
27. Kennelly MM, Cooley SM, McParland PJ. Natural history of apparently severe isolated fetal ventriculomegaly: perinatal survival and neurodevelopmental outcome. *Prenat Diagn*. 2009;29:1135-1140.
28. Breeze CG, Lexander MA, Murdoch EM. Obstetric and neonatal outcome in severe fetal ventriculomegaly. *Prenat Diagn*. 2009;29:124-129.
29. International Society of Ultrasound in Obstetrics and Gynaecology. Sonographic examination of the fetal central nervous system: guidelines for performing the "basic examination" and the "fetal neurosonogram.". *Ultrasound Obstet Gynecol*. 2007;29:109-116.
30. Guibaud L. Fetal cerebral ventricular measurement and ventriculomegaly: time for procedure standardization. *Ultrasound Obstet Gynecol*. 2009;3:127-130.
31. Guibaud L, Lacalm A. Etiological diagnostic tools to elucidate 'isolated' ventriculomegaly. *Ultrasound Obstet Gynecol*. 2015;46:1-11.
32. Malinger G, Lerman-Sagie T, Watemberg N, et al. A normal second trimester scan does not exclude intracranial structural pathology. *Ultrasound Obstet Gynecol*. 2002;25:51-56.
33. Khalil A, Caric V, Papageorghiou A, et al. Prenatal prediction of need for ventriculoperitoneal shunt in open spina bifida. *Ultrasound Obstet Gynecol*. 2014;43:159-164.
34. Benacerraf BR, Shipp T, Bromley B, et al. What does magnetic resonance imaging add to the prenatal diagnosis of ventriculomegaly? *J Ultrasound Med*. 2007;11:1513-1522.
35. Griffiths PD, Reeves MJ, Morris JE. A prospective study of fetuses with isolated ventriculomegaly investigated by antenatal ultrasound and in utero MR. *AJNR Am J Neuroradiol*. 2010;31:106-111.
36. Griffiths PD, Morris JE, Mason G, et al. Fetuses with ventriculomegaly diagnosed in the second trimester of pregnancy by in utero MR imaging: what happens in the third trimester? *AJNR Am J Neuroradiol*. 2011;32:474-480.
37. Rossi AC, Prefumo F. Additional value of fetal magnetic resonance imaging in the prenatal diagnosis of central nervous system anomalies: a systematic review of the literature. *Ultrasound Obstet Gynecol*. 2014;44:388-393.
38. Sethna F, Tennant PW, Rankin J, et al. Prevalence, natural history, and clinical outcome of mild to moderate ventriculomegaly. *Obstet Gynecol*. 2011;117:867-876.
39. Manning FA, Harrison MR, Rodeck C, et al. Catheter shunts for fetal hydronephrosis and hydrocephalus. *N Engl J Med*. 1986;315:336-340. doi:10.1056/nejm198607313150532.

44 Pregnancy of Unknown Location, Early Pregnancy Loss, Ectopic Pregnancy, and Cesarean Scar Pregnancy

ANNA KATERINA SFAKIANAKI | ANA MONTEAGUDO | ILAN E. TIMOR-TRITSCH

Introduction

Pregnancy is an inefficient process. A large proportion of early pregnancies end in miscarriage or early pregnancy failure. Ectopic pregnancies (EP), those located outside of the proper uterine location, cause significant maternal morbidity and mortality. It is the role of the clinician to establish that the pregnancy is properly situated within the uterus and viable. This chapter will review the utility of ultrasound (US) in early pregnancy, when its use is essential in the differentiation of normal and abnormal gestation.

Pregnancy of Unknown Location

DEFINITION

Pregnancy of unknown location (PUL) refers to a pregnancy whose location has yet to be properly identified and thus includes both pregnancies destined to be normal and those destined to be abnormal. The human chorionic gonadotropin (hCG) value is positive, but, the gestational sac has not been identified by US and there are no other US findings (e.g., echogenic free fluid; "bagel" sign) that would suggest an EP. This occurs early in gestation and represents a diagnostic dilemma for the clinician. Timely identification of a nonviable pregnancy allows prompt management, which may decrease complications and allow the woman to begin her processing of the loss. Timely identification of EP is crucial to minimize maternal morbidity and mortality and allows the broadest range of treatment options. However, overly aggressive treatment may lead to loss of a normal pregnancy.

PREVALENCE AND EPIDEMIOLOGY

In reality, all pregnancies begin as PUL. Pain and bleeding are common during early pregnancy, and patients who present with these symptoms should be evaluated promptly to define location and viability of the pregnancy. Studies looking at the prevalence of PUL have reported that 5% to 42% of patients attending a specialized first-trimester clinic are given this diagnosis.[1–5]

ETIOLOGY AND PATHOPHYSIOLOGY

Prior to 4 to 5 weeks from LMP, even high-frequency transvaginal US cannot discern the early pregnancy. Therefore, clinicians caring for women who present with pain and/or bleeding during this window are frequently faced with managing a PUL. Transvaginal US is essential in this scenario, and is guided by first-trimester developmental milestones and normal US findings, which are summarized in Table 44.1.

These generalized "landmarks" cannot be precisely correlated to human chorionic gonadotropin (hCG) values because the normal ranges of hCG levels at different gestational ages are too wide. Serial USs, rather than absolute hCG values, can be used in evaluation when EP has been excluded. After an intrauterine pregnancy (IUP) has been confirmed, serial USs can be performed if there are doubts about pregnancy viability to avoid unnecessarily interrupting a wanted IUP, while still recognizing abnormal pregnancy as early as possible.

Gestational Sac: During the first 3 to 5 weeks of gestation, the endometrium has an echogenic appearance as the hormonal mileu causes a decidual reaction. This appearance is nondiagnostic because it can be seen in late secretory phase of a nonpregnant uterus as well (Fig. 44.1A). *Gestational sac* is an US, not an anatomic term, used to describe the sonolucent round structure eccentrically located in the endometrium that represents the fluid-filled chorionic cavity (see Fig. 44.1B). The chorionic sac, the echogenic rim, is produced by the developing chorionic villi involving maternal decidual tissue and is termed a *decidual reaction;* it already contains the amnion, trilaminar embryonic disk, and yolk sac, but at this gestational age these are too small to be distinguished by US (Fig. 44.2). Depending on the US equipment employed and on the observer, the gestational sac can be measured when it is 2 to 3 mm, but it is normally seen at 5 mm in most settings, typical of 5 weeks' gestation.[6] While the thick decidual sign and a small 2 to 3 mm sac embedded on one side of the echogenic cavity line in the endometrium correlates with an intrauterine pregnancy, its absence does not necessarily imply a failed or EP.[7] Gestational age can be estimated by using the mean sac diameter (MSD), derived from averaging three orthogonal sac diameters, which can be correlated to gestational age. A simple way of estimating gestational age from the sac size

TABLE 44.1 DEVELOPMENTAL MILESTONES OF EARLY PREGNANCY, ULTRASOUND FINDINGS, AND CORRELATION TO BETA-HUMAN CHORIONIC GAONADOTROPIN LEVELS

Gestational Age After LMP	Embryonic Milestone	Transvaginal Ultrasound Findings	Level of hCG (mIU/mL)
23 days	Blastocyst implantation	Blastocyst is too small to visualize. Trilaminar normal appearance of endometrial lining	Variable
3.5–4.5 weeks	Decidual changes at implantation site	Focal echogenic thickening	Variable
4.5–5.5 weeks	Exocoelomic cavity of blastocyst	Gestational sac should be visible when it reaches 2–3 mm	1000–2000
5–5.5 weeks	Yolk sac	Thin-walled cystic structure within gestational sac should be seen when gestational sac reaches 10 mm	1000–7200
5–6 weeks	Embryo	Fetal pole is a focal echogenic area adjacent to yolk sac that should be seen when gestational sac is >10 mm	7000–10,000
5–6 weeks	Cardiac activity	Should be seen when embryo is >5 mm	

Modified from Paspulati RM, Bhatt S, Nour SG: Sonographic evaluation of first-trimester bleeding. *Radiol Clin North Am* 42:297–314, 2004; and Bree R, Edwards M, Beohm-Velez M, et al: Transvaginal sonography in the evaluation of normal early pregnancy: correlation with hCG level. *AJR Am J Roentgenol* 153:75–79, 1989.

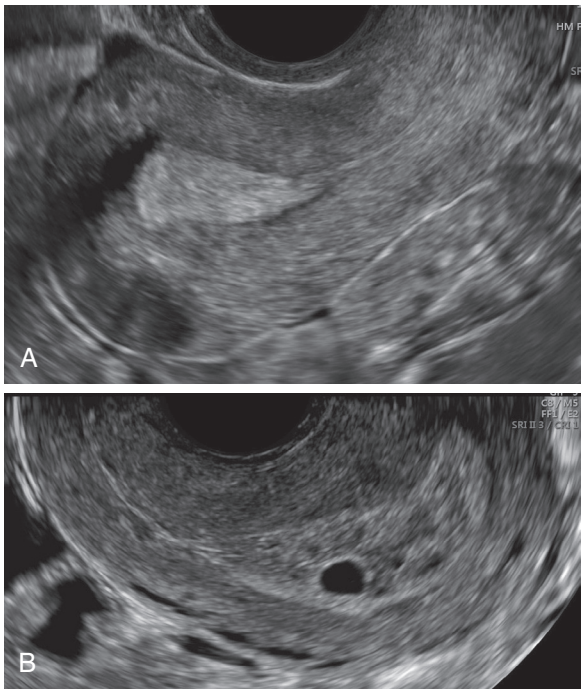

Fig. 44.1 (A) An anteverted uterus with a thick and echogenic endometrium in the late secretory phase (day 28) of the cycle is seen. (B) A retroverted uterus with a thick and echogenic endometrium in a patient with an early pregnancy; a chorionic sac is seen.

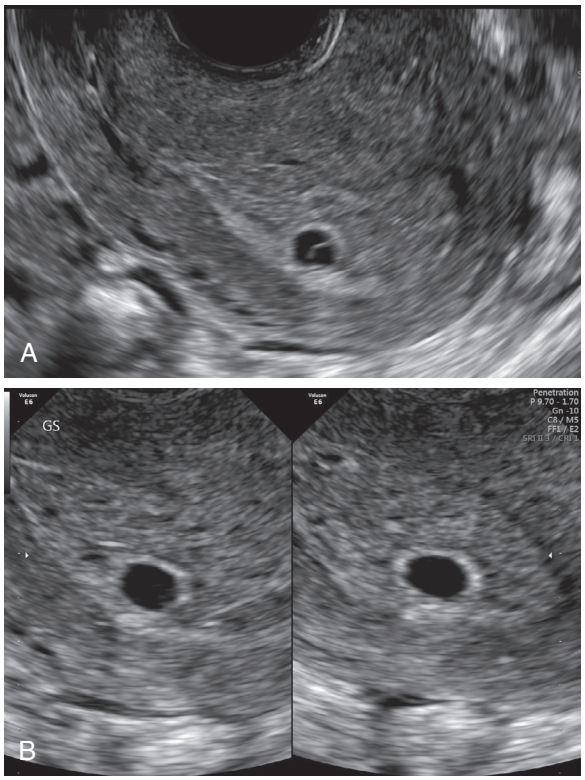

Fig. 44.2 (A) Clear chorionic sac surrounded by the bright echogenic decidual reaction is seen. (B) A magnified view of (A) demonstrates the chorionic sac; the embryonic structures (yolk sac and embryo) are not clearly imaged.

is to add 30 to the MSD in millimeters to get gestational age in days: Menstrual age (days) = MSD (mm) + 30.[8]

Once the embryo is detected, it should be used for dating. The gestational sac grows approximately 1 mm/day, so there is little utility in repeating US scans for viability check or dating purposes sooner than 4 to 7 days after the prior scan.

An actual IUP is not confirmed until a yolk sac is seen. A fluid collection (i.e., blood) in the endometrial cavity, which sometimes shifts back and forth moved by shallow uterine activity of a woman with EP, is called a *pseudosac;* it can be mistaken for an intrauterine gestational sac, especially if scanning transabdominally. Features such as location within the middle of the uterine cavity flanked by the anterior and posterior endometrial layers, elongated shape, and absence of gestational reaction all increase the level of suspicion. A presumed pseudosac, however, is not diagnostic of EP because of a high false-positive rate,[9] and some practitioners have abandoned the term.[10]

Yolk Sac: The yolk sac is a round structure with a sonolucent center and echogenic periphery, located within the gestational sac. With high-frequency US transducers it can usually be seen by the time the gestational sac reaches 5 mm and is the first definitive sign on an intrauterine gestation. Given individual variability, this sac size should not be used as a cutoff, and a follow-up US scan

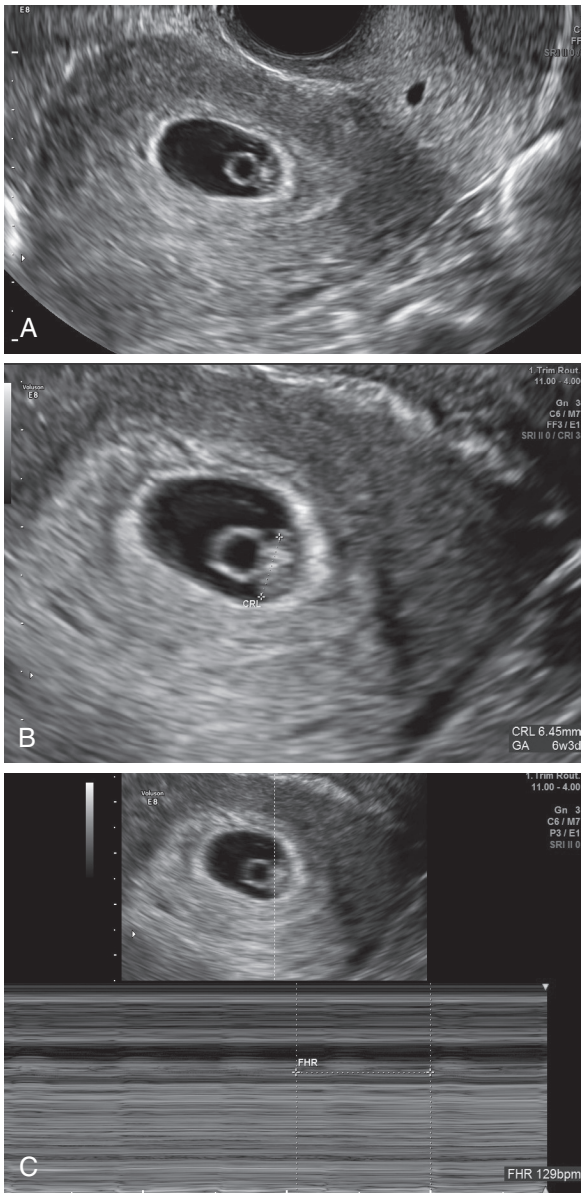

Fig. 44.3 An intrauterine pregnancy at 6 weeks 2 days is imaged. (A) The yolk sac is seen as a round echogenic ring and the embryonic pole is clearly seen in close proximity to the yolk sac. (B) The embryonic size is measured. (C) Using M-mode fetal heart of 129 bpm is imaged.

and correlation with hCG should be done. The yolk sac continues to grow up to 6 mm by 10 weeks' gestation and then migrates to the periphery of the chorionic cavity, becoming undetectable by the end of the first trimester (Fig. 44.3).[11]

Crown-rump length (CRL): the embryonic disk (also referred to as a *fetal pole,* or more correctly, *embryonic pole*) is a thickened region along the outermost part of the yolk sac (see Fig. 44.3). It becomes visible when it is 1 to 2 mm in length.[12] An embryo is usually seen by the time MSD reaches 18 mm, and lack of embryo by an MSD of 25 mm is diagnostic of early pregnancy loss.[7]

CRL is the longest linear measurement of the embryo, and the preferred dating measurement up to 14 weeks' gestation. However, before 18 mm, a true "crown" and "rump" do not exist, and measurements are taken along the long axis of the embryo (the greatest measurement should be used). As the embryo grows, the rostral neuropore closes and develops into the forebrain,

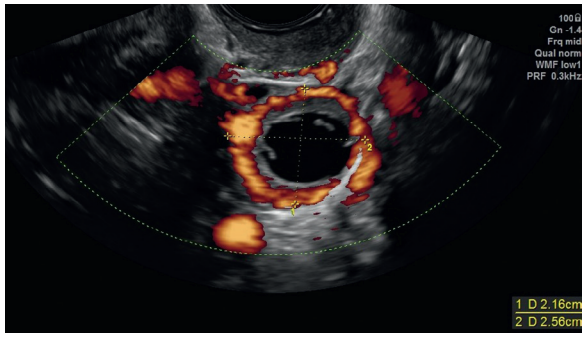

Fig. 44.4 Left ovary with a corpus luteum. Color/power Doppler demonstrates the clear "ring-of-fire" around the corpus luteum.

and the caudal neuropore elongates into a tail. The CRL generally increases 1 mm per day. This daily increase can be useful when evaluating a suspected failed pregnancy. Similar to MSD, modern US machines contain formulas to calculate gestational age from CRL.[13]

Cardiac activity: several older studies of normal pregnancies suggested that cardiac activity should be routinely seen by an embryonic size of 4 mm.[14] However, more recent literature recommends to use embryonic size of 7 mm.[7] The heart rate can be calculated via M-mode or spectral Doppler; color/power Doppler should be used for the minimal time possible time or completely avoided due to its potential bioeffects, with a concentration of energy on the embryo. The primitive heart at this early stage is very prominent and can often be detected before the embryo is seen separate from the adjacent yolk sac (see Fig. 44.3C).

MANIFESATIONS OF DISEASE

Clinical Presentation

Patients with PUL present with amenorrhea and a positive pregnancy test. They may also have pain, bleeding, or cramping. Patients with risk factors for EP (previous ectopic, tubal pathology) should be monitored closely until pregnancy location has been established.

Physical exam is usually benign. Tenderness should prompt evaluation for EP as described following.

Imaging Technique and Findings

Ultrasound. Transvaginal US was first used in 1987 to image an IUP.[15] Since then, it has become the imaging modality of choice, and is considered superior to transabdominal US because it allows for earlier and more reliable detection of pregnancy location and fetal viability. Transabdominal US (performed before a patient voids) with transducer frequency of 3.5 to 5 MHz and greater is a good starting point to get an overview of the pelvis because of its larger field of view, which is helpful when looking for the signs of hemoperitoneum and evaluating the Morrison Pouch. With an empty bladder, a transvaginal transducer with frequency of 5 to 12 MHz can be positioned closer to the pelvic organs, resulting in improved resolution while still providing adequate penetration.[16] Doppler can be used if indicated, although embryonic exposure to Doppler should be minimized to reduce the risks of bioeffects in any first-trimester US. Doppler is especially useful when examining the ovaries for the corpus luteum, which typically has a "ring of fire" appearance (Fig. 44.4); however, a tubal ectopic may also demonstrate a ring of fire.

US in PUL lacks the diagnostic findings of intrauterine pregnancy listed above. In addition, no gestation is found outside of the normal uterine location. The ovaries may demonstrate a corpus luteum, which should not be confused with an ovarian EP, a rare occurrence. Free fluid may be noted in the pelvis. If it is echogenic, it may be a sign of hemorrhage from an EP or a corpus luteum, and must be examined further.

Magnetic Resonance Imaging. MRI has a limited role in the evaluation of patients with PUL. In circumstances when rare types of EP such as abdominal or interstitial (ectopic) pregnancy are suspected, it may be useful as an adjunct to transvaginal sonography.

CLASSIC SIGNS

Classic signs of PUL are positive hCG and no sonographic evidence of an intrauterine or EP.

Differential Diagnosis From Imaging Findings

PUL must be differentiated from a normal but very early pregnancy, an early but abnormal intrauterine pregnancy, a spontaneous abortion/early pregnancy failure, and EP.

Synopsis of Treatment Options

PRENATAL

As long as the patient is stable, management is expectant until definitive diagnosis may be made of intrauterine (viable or nonviable) or EP (see the following discussion on EPF and EP on how these diagnoses are made). Patients are followed with serial hCG measurements, usually 48 hours apart.[17] The use of progesterone level(s) in the management of PUL has been proposed by many authors. In a recent publication using a two-step approach, a level of progesterone of less than or equal to 2 nmol/L was used for initial triage of patients. Those with progesterone levels greater than 2 had a serum hCG 48 hours later, and then were triaged according to the combined results. Patients with low progesterone were more likely to have failed early IUP. This protocol resulted in a more efficient classification of PUL as low-risk (those destined to have either a normal or failed IUP) and those at high risk for complications (EP).[18]

US performed with critical threshold of hCG should demonstrate intrauterine findings as listed above. Failure to confirm an IUP should lead to treatment for EP, as discussed later in the section Ectopic Pregnancy.

In an unstable patient, exploratory laparoscopy with or without uterine sampling is suggested.

Failed Pregnancy—Early Pregnancy Loss or Failure (EPF)

DEFINITION

Early pregnancy loss or early pregnancy failure refers to a nonviable pregnancy within the first 6 to 7 weeks of gestation. This term encompasses an empty gestational sac as well as an embryo with no cardiac activity.[19] *Missed abortion* was used in the past in this context, but is now an archaic term.

PREVALENCE AND EPIDEMIOLOGY

Estimates of the frequency of EPF vary depending on the patient population. Some studies look at women undergoing routine examinations, others look at patients with pregnancies from in vitro fertilization, and still others follow patients presenting to the emergency department with complaints. It also depends on whether or not loss is recognized and whether bleeding is present or not. Prevalence has a wide range; EPF has been reported in 8% to 31% of all pregnancies.[20,21]

ETIOLOGY AND PATHOPHYSIOLOGY

Vaginal bleeding in the first trimester occurs in about 25% of all pregnancies; about half of first-trimester pregnant women who bleed ultimately miscarry.[22] Multiple causes of EPF exist. The most common etiology is a chromosomal abnormality; the most frequent chromosomal abnormality is autosomal trisomy, but polyploidy, monosomy, unbalanced translocations, and structural rearrangements have been described.[23] A long list of other etiologies, including endocrine factors (uncontrolled diabetes mellitus and hypothyroidism), uterine factors (congenital uterine anomalies, fibroids, intrauterine adhesions), immunologic factors (antiphospholipid syndrome, systemic lupus erythematosus), advanced maternal age, and environmental factors (smoking, drug use, teratogens), can also contribute. In most cases, no work-up is indicated, and most future pregnancies are successful.[24] In some cases, the etiology remains unexplained. It is important to ensure that patients do not blame themselves or their level of physical activity for the miscarriage.

MANIFESATIONS OF DISEASE

Clinical Presentation

Women with EPF present with amenorrhea and a positive pregnancy test. Vaginal bleeding and pelvic pain are also present if a patient is in the process of having a spontaneous abortion. On examination, the cervix might be closed or open, and the products of conception (POC) may be seen in the vagina or the cervical orifice (os), if they have not already been passed. The finding of early pregnancy loss may also be incidental on US if the patient is asymptomatic. Table 44.2 summarizes clinical presentation in EPF.

Imaging Technique and Findings

Ultrasound. As with PUL, transvaginal US is the imaging modality of choice. An initial transabdominal US may be useful as a road map as discussed previously.

Early pregnancy loss may present on US as demise of a previously live embryo, an embryo in which cardiac activity has never been noted, or an anembryonic gestation, in which an embryo has never been identified.

Fig. 44.5 shows an anembryonic intrauterine gestation, previously termed a *blighted ovum*. A large empty sac might be a result of embryonic demise and resorption that has occurred before presentation. The gestational sac might also appear as flat and irregular in shape.

Figs. 44.5B and C show abnormal yolk sac morphology, a nonspecific sign of EPF. In abnormal pregnancies, the yolk sac may be enlarged, irregular, or sometimes described as "floating." This appearance is likely related to a hydropic change. If the gestational sac is large enough that an embryo is expected (i.e.,

TABLE 44.2 CORRELATION BETWEEN CLINICAL AND ULTRASOUND FINDINGS IN A PATIENT WITH FIRST-TRIMESTER BLEEDING AND EARLY PREGNANCY FAILURE

Type	Clinical Findings	Ultrasound Findings
Threatened abortion	Vaginal bleeding and cramping Cervix is closed	Normal-appearing IUP
Early pregnancy loss/failure	Vaginal bleeding and cramping may or may not be present Cervix is closed No expulsion of products has occurred	IUP without a heartbeat Anembryonic pregnancy
Inevitable abortion	Bleeding and pain worsens Cervix is dilated Products might be seen through the internal os, but no expulsion has occurred	Viable or nonviable IUP
Incomplete abortion	Vaginal bleeding and cramping, partial passage of POC Cervix is open or closed	Blood and trophoblastic tissue, endometrial thickness of any size, heterogeneous tissue with or without gestational sac; this tissue is referred to as POC and distinguishes complete from incomplete abortion
Retained POC	Vaginal bleeding and cramping Cervix is open or closed	Placental, fetal, or embryonic tissue or trophoblast that remains in the uterus after spontaneous pregnancy loss, termination, or delivery
Complete abortion	Vaginal bleeding and cramping, complete passage of POC Cervix is open or closed	Empty uterus with normal appearance of endometrium
Septic abortion	Abdominal pain, fever, purulent discharge, symptoms of sepsis Cervix is open or closed	POC



Fig. 44.5 (A) An empty chorionic sac. (B) The chorionic sac contains a yolk sac measuring 5.9 mm and superior; there is an empty amniotic sac. (C) A large yolk sac is seen measuring 11.34 mm as well as an amniotic sac containing a hyperechoic embryo with no cardiac activity.

25 mm MSD), and the amnion is visible but not the embryo, that is a reliable sign of EPF. *Embryonic demise* refers to a pregnancy with the death of an embryo, the diagnosis of which can be established by either its failure to grow over time or the absence of cardiac activity above the threshold sizes (see Fig. 44.5).[7] A gestational sac that grows less than 1 mm/day and a small gestational sac are associated with a poor prognosis. *First-trimester oligohydramnios*, measured as the difference between MSD and CRL, is associated with a 94% risk of EPF when the difference in sizes is less than 5 mm.[25]

Effort has been made to improve the accuracy of diagnosis of early pregnancy loss by US in order to decrease the number of false positive diagnoses that may lead to loss of a normal pregnancy. To this end, the American College of Obstetricians and Gynecologists (ACOG) has updated the diagnostic criteria for early pregnancy loss,[24] summarized in Table 44.3.

The risk of pregnancy failure after documentation of the fetal heart rate is low, so visualization of fetal cardiac activity is very reassuring to most patients. However, EPF is related to risk of aneuploidy, which is related to the maternal age. In one study of in vitro fertilization pregnancies, in women younger than 36 years old, spontaneous abortion in the presence of fetal heart motion occurred in only 4.5% of cases, whereas the rate of spontaneous abortion in the presence of fetal heart motion increased to 10% in women 36 to 39 years old and 29% in women older than 40 years.[26] A heart rate less than 70 beats/

TABLE 44.3 SOCIETY OF RADIOLOGISTS IN ULTRASOUND GUIDELINES FOR TRANSVAGINAL ULTRASONOGRAPHIC DIAGNOSIS OF EARLY PREGNANCY LOSS

Findings Diagnostic of Early Pregnancy Loss[b]	Findings Suggestive, but Not Diagnostic, of Early Pregnancy Loss[c]
Crown–rump length of 7 mm or greater and no heartbeat	Crown–rump length of less than 7 mm and no heartbeat
Mean sac diameter of 25 mm or greater and no embryo	Mean sac diameter of 16–24 mm and no embryo
Absence of embryo with heartbeat 2 weeks or more after a scan that showed a gestational sac without a yolk sac	Absence of embryo with heartbeat 7–13 days after an ultrasound scan that showed a gestational sac without a yolk sac
Absence of embryo with heartbeat 11 days or more after a scan that showed a gestational sac with a yolk sac	Absence of embryo with heartbeat 7–10 days after an ultrasound scan that showed a gestational sac with a yolk sac
	Absence of embryo for 6 weeks or longer after last menstrual period
	Empty amnion (amnion seen adjacent to yolk sac, with no visible embryo)
	Enlarged yolk sac (greater than 7 mm)
	Small gestational sac in relation to the size of the embryo (less than 5 mm difference between mean sac diameter and crown–rump length)

[a]Criteria are from the Society of Radiologists in Ultrasound Multispecialty Consensus Conference on Early First Trimester Diagnosis of Miscarriage and Exclusion of a Viable Intrauterine Pregnancy, October 2012.
[b]These are the radiologic criteria only and do not replace clinical judgment.
[c]When there are findings suspicious for early pregnancy loss, follow-up ultrasonography at 7–10 days to assess the pregnancy for viability is generally appropriate.
Reprinted from Doubilet PM, Benson CB, Bourne T, Blaivas M, Barnhart KT, Benacerraf BR, et al. Diagnostic criteria for nonviable pregnancy early in the first trimester. Society of Radiologists in Ultrasound Multispecialty Panel on Early First Trimester Diagnosis of Miscarriage and Exclusion of a Viable Intrauterine Pregnancy. *N Engl J Med* 369:1443–51, 2013.

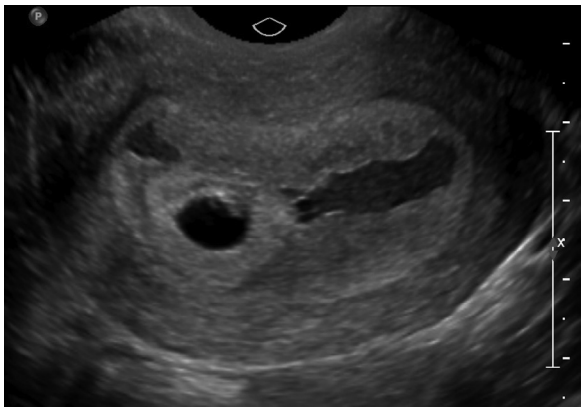

Fig. 44.6 A 6 weeks 2 days intrauterine pregnancy with a subchorionic hematoma.

min was associated with 100% mortality; however, embryonic bradycardia requires a repeat US scan because a fetal heart rate of 80 to 120 beats/min is unreliable in EFP diagnosis.[27]

Subchorionic hematoma is a crescent-shaped collection outside the gestational sac between the chorion and endometrium (Fig. 44.6). It has been looked on as a prognostic factor in EPF, but it is also a long-term risk factor for poor pregnancy outcomes. Subchorionic bleeding occurs in about 20% of threatened abortions that exhibit viability. The presence of a subchorionic hematoma in patients with positive cardiac activity reduces continuation rates to 60% to 70% from 95% to 100% in its absence.[28] Amount of blood does not seem to correlate with outcome.

Magnetic Resonance Imaging. MRI may be useful if a rare EP is suspected.

Differential Diagnosis From Imaging Findings

As discussed previously, EPF must be differentiated from a normal early pregnancy in order to avoid improper treatment.

Synopsis of Treatment Options

PRENATAL

The management of incomplete abortion and retained POC depends on clinical presentation. If a patient has been bleeding heavily or presents with clinical signs and symptoms of infection, surgical evacuation is indicated, and medical management is inappropriate. If incomplete abortion or retained POC is suspected in a stable patient, either surgical or medical management (with misoprostol) is appropriate, depending on patient preference and resources available.[29]

With EPF, if POC has not been expelled, management options consist of expectant management, surgical dilatation and curettage, or medical management. If managed expectantly, natural passage of POC usually occurs 1 to 4 weeks after a pregnancy has failed (i.e., after embryonic death). Waiting 1 to 2 weeks while excluding a normal IUP with serial US scans is unlikely to be associated with significant increase in bleeding or infection. A randomized controlled trial of EPF comparing surgical versus medical management with misoprostol found a success rate of 84% with the latter; patients treated with misoprostol experienced longer duration of bleeding and greater decrease in hematocrit, which was not clinically significant.[30] Patient preference is important in choosing surgical evacuation with local anesthesia or sedation versus spontaneous passage of POC at home. It is essential to know a patient's blood type in case Rh immune globulin is indicated and to check a patient's hematocrit to ensure that she is clinically stable.

Ectopic Pregnancy

DEFINITION

Ectopic pregnancy (EP) refers to pregnancy outside of the normal fundal uterine location. It includes a number of different diagnoses, which are summarized in Table 44.4.

Rarely, a multifetal gestation may present as heterotopic, with one normally implanted embryo and another in one of the ectopic locations listed in Table 44.4.

TABLE 44.4 ECTOPIC PREGNANCY LOCATIONS, DIAGNOSTIC FINDINGS ON ULTRASOUND

Location	Definition	Ultrasound Findings	Notes
Tubal	Located in fallopian tube, ampullary portion	Uterus without true gestational sac Tubal ring may be identified separate from the ovary, may see yolk sac or fetal pole Echogenic free fluid in the *cul-de-sac* may be a sign of rupture	Most common site
Interstitial	Gestational sac within the interstitial (myometrial) portion of the fallopian tube	Eccentric location of the gestational sac proximal to the uterine cornua Gestational sac is surrounded by thin (<5 mm) myometrium and close to the uterine serosa Interstitial line, defined as an echogenic line that extends from the most superior and lateral aspect of the endometrium to the midportion of the interstitial mass or sac	The term *cornual pregnancy* is often used interchangeably; however, cornual refers to pregnancy in a bicornuate uterus
Cervical	Gestational sac implants in the endocervical canal	Sac visualized within the endocervical canal Empty uterine cavity with clearly demonstrated endometrium Cervix may appear to be ballooning	Differentiate from abortion in process
Ovarian	Gestational sac implanted within the ovarian stroma	Difficult diagnosis Double echogenic ring within the ovary, separate from the corpus luteum Usually presents with rupture by the end of the first trimester	Rarest of the ectopic pregnancies

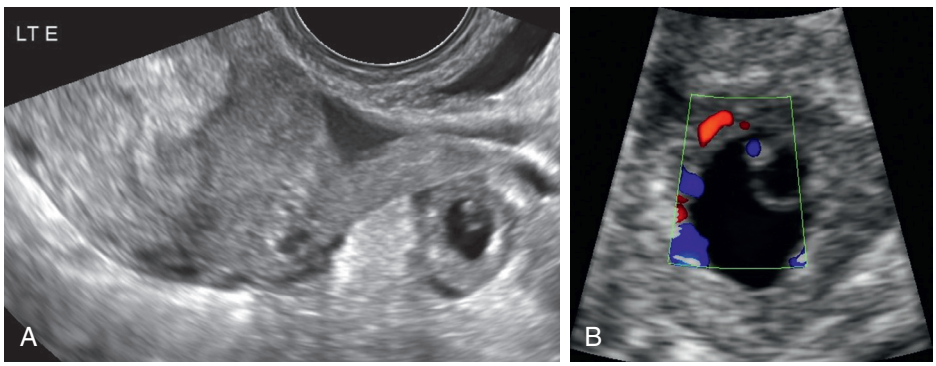

Fig. 44.7 (A) Demonstrates a tubal ectopic pregnancy. (B) Upon closer evaluation, a yolk sac and embryo with cardiac activity is seen.

PREVALENCE AND EPIDEMIOLOGY

The true prevalence of EP is difficult to ascertain. The incidence is higher in women presenting with pain or vaginal bleeding in the first trimester.

The most common site for an EP is the fallopian tubes, and abnormalities in the tubes are the most common risk factors. These include previous tubal pathology such as infections and adhesions, and previous tubal surgery. In vitro fertilization is a risk factor for EP. Ectopic pregnancies also occur more commonly in pregnancies with intrauterine devices (IUDs) in situ.

ETIOLOGY AND PATHOPHYSIOLOGY

EP occurs because of abnormal migration of the fertilized embryo. Implantation occurs outside of the fundal region of the uterus (Figs. 44.7–44.9)

Ovarian EP, similar to other EPs, is due to failure of normal embryo migration as the result of factors such as previous EP, pelvic inflammatory disease, and endometriosis, which cause damage to the epithelium of the fallopian tube.[31,32]

MANIFESTATIONS OF DISEASE

Clinical Presentation

EP most commonly presents with abdominal pain and bleeding, and presentation depends on whether or not the pregnancy has ruptured. An unruptured EP may be associated with a benign physical exam. A ruptured EP, especially if associated with significant hemoperitoneum, may lead to an acute abdomen.

Cervical EP classically presents with profuse and painless vaginal bleeding. On exam, the cervix may be boggy and enlarged, and digital exam should be avoided so as to avoid disruption of the sac (see section following on cesarean scar pregnancy).

With the increasing use of routine early US, more EPs are now being diagnosed before they become symptomatic.

Many women will also have the usual symptoms associated with early pregnancy, such as nausea, fatigue, and breast tenderness.

Imaging Technique and Findings

Ultrasound. Transvaginal US is the imaging modality of choice for the evaluation of suspected EP. US findings are summarized in Table 44.4 (see Figs. 44.7–44.9).

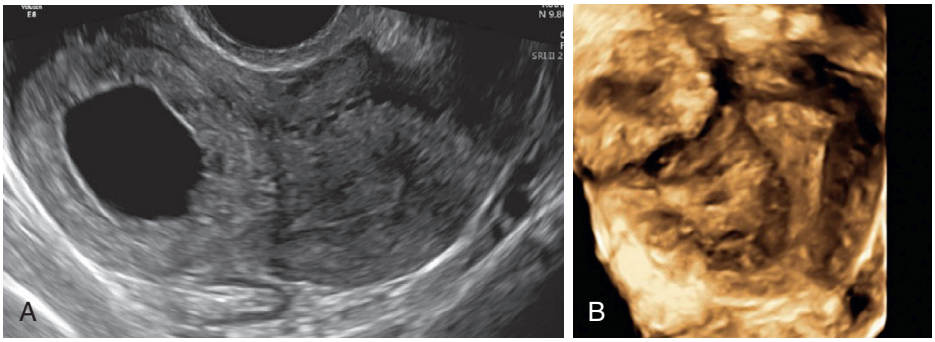

Fig. 44.8 Demonstrates an interstitial ectopic pregnancy. (A) Transverse section showing the empty uterine cavity and the pregnancy to the left side. (B) Multiplanar imaging with 3D reconstruction (lower right) demonstrating the ectopic pregnancy.

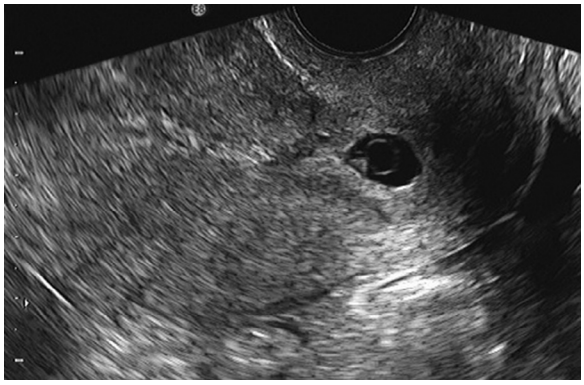

Fig. 44.9 Demonstrates a cervical ectopic pregnancy.

Magnetic Resonance Imaging. MRI may be useful for suspected abdominal pregnancies. MRI may also be useful for the evaluation of interstitial pregnancies.

CLASSIC SIGNS

The classic presentation of an EP is pain, abnormal vaginal bleeding, positive pregnancy test, and no intrauterine pregnancy seen by US.

Synopsis of Treatment Options

PRENATAL

Early tubal EP may be managed medically with methotrexate in stable patients as per published protocols.[33] Medical management has the advantage of preserving tubal anatomy, but has a number of contraindications, including active liver disease. Surgical management involves either salpingostomy or salpingectomy and is usually performed laparoscopically.

Ideally interstitial and cervical pregnancies can be managed without loss of the uterus, though the risk is higher than with other EPs. Interstitial pregnancy is frequently managed with wedge resection, which places future pregnancies at risk of uterine rupture along the suture line. Cervical pregnancies have high rates of bleeding, therefore local treatment with intrasac potassium chloride in conjunction with systemic methotrexate can be offered. Pretreatment with uterine artery embolization is considered for both interstitial and cervical pregnancies.

Unstable patients with suspected EP, regardless of location, should always be managed surgically.

WHAT THE REFERRING PHYSICIAN NEEDS TO KNOW

Transvaginal US is the imaging modality of choice in early pregnancy.

When referring a patient to an US unit, it is essential to include clinical information such as symptoms, examination findings, and relevant history and hCG levels if available. Unstable patients should not be sent to an office-based US unit for diagnosis; a quick bedside US scan, followed by referral to an emergency room as needed, is more appropriate in this setting.

Over diagnosis of early pregnancy loss (failure) may lead to loss of a normal pregnancy. Expectant management in stable patients is preferred until diagnostic criteria are met.

Cesarean Scar Pregnancy

DEFINITION

All uteri after one or more cesarean deliveries (CD) have a demonstrable scar by US. The scar, also referred as a niche, can be of variable size and shape; at times essentially no myometrium is seen at the level of the prior scar and this is referred as a dehiscence. Cesarean scar pregnancy (CSP) refers to a pregnancy that has implanted in or on the scar/niche/dehiscence of a prior cesarean delivery. This type of pregnancy is not truly an EP since the pregnancy can result in a live birth.

PREVALENCE AND EPIDEMIOLOGY

The commonly reported estimated rate of CSP ranges from 4:10,000 to 5:10,000 of patients with a history of a previous CD, although its true rate is unknown.[34] One author estimated that CSP occurs in 0.15% of all pregnancies with a history of a previous CD.[35] A more recent publication reported that in patients who had at least one CD the rates of CSP were 3:10,000 to 20:10,000.[36] However, these rates may vary due to cases missed diagnosed as cervical pregnancies or just by simply not being recognized.

ETIOLOGY AND PATHOPHYSIOLOGY

The pathophysiology of CSP is directly linked to the presence of a prior cesarean delivery (CD) scar. In the area of the prior CD scar there can be thinning or absent of the decidua basalis and Nitabuch layer.

The normal decidua basalis interacts with the trophoblast (villi) and creates a region of fibrinoid degeneration of Nitabuch layer; this layer keeps the trophoblasts from penetrating and

attaching itself to the myometrial fibers deep in the uterine wall. In a CSP, this layer is absent or deficient, allowing the placental trophoblasts to penetrate between the myometrial fibers into the uterine wall and adjacent organs, such as the bladder.

Several theories have been proposed regarding the pathophysiology of CSP; one theory suggests that low oxygen tension at the area of the scar provides a stimulus that promotes cytotrophoblast to invade the myometrium; in vitro studies using cytotrophoblast and endometrial tissues have shown a strong propensity of the cytotrophoblast for attaching to exposed extracellular matrix and then to endometrial epithelial cells.[37–39]

MANIFESTATIONS OF DISEASE

Clinical Presentation

The main clinical manifestation of a CSP is positive pregnancy test in a patient with a history of at least one prior CD. Patients are usually asymptomatic or report the usual symptoms of early pregnancy.

Imaging Technique and Findings

Ultrasound. In a patient with a prior CD and a positive pregnancy test in whom a CSP is suspected, a long-axis, sagittal view, of the uterus is obtained in which the uterine fundus, the gestational sac, and the cervix are seen. The bladder should be comfortably full in order to allow clearly visualization of the bladder-myometrial interphase (Fig. 44.10).

Using sonography, several of the following sonographic criteria may be seen; transvaginal sonography will provide images of higher diagnostic value when compared to transabdominal sonography alone (Figs. 44.11A,B):[34,40–43]

- Uterine and cervical canals devoid of a gestational sac (see Figs. 44.10 and 44.11B).
- Placenta and/or a gestational sac embedded in the anterior lower uterine segment on or in the hysterotomy scar/niche (see Figs. 44.10 and 44.11B). Caveat: the sac in pregnancies greater than 6 to 7 weeks' gestational age may have shifted, turned into the direction of, or may already be in the uterine cavity, leaving behind the firmly anchored placenta in the niche or on the scar (Fig. 44.12)
- In early gestations, a triangular gestational sac morphs to take up the shape of the niche of the scar (see Fig. 44.10).
- Thin or absent myometrium between the chorionic sac and the bladder.
- The presence of a chorionic sac, with or without embryonic/fetal pole and/or yolk sac and with or without cardiac activity.
- Color/power Doppler reveals a prominent and at times rich vascularity at or in the area of the scar. As a rule, detection of peritrophoblastic blood flow is a reliable sign of CSP (Fig. 44.13).
- The usefulness of three-dimensional (3D) US in the diagnosis is debated. In experienced hands it may contribute to the diagnosis (Fig. 44.14).

Magnetic Resonance Imaging. MRI does not add significantly to the US diagnosis and should only be performed in cases where medical or other conditions preclude US imaging.



Fig. 44.10 In this transvaginal scan of a CSP at 6 weeks 2 days, the bladder is comfortably full, creating a clear interphase and allowing visualization of the myometrium superior to the apex of the scar niche.

CLASSIC SIGNS

The classic signs of cesarean scar pregnancy are: In a patient with a history of at least one CD, an anterior or low gestational sac with an empty uterine cavity.

Differential Diagnosis From Imaging Findings

There are two main differential diagnoses. The first is a spontaneous abortion in the process of passing through the endocervical canal, and the second is a cervical pregnancy (Fig. 44.15A).

In a spontaneous abortion in the process of passing, the patient typically presents with clinical signs of a spontaneous abortion (which are pain and bleeding). The sac is elongated and *centrally* placed in the uterine cavity; using color/power Doppler, *no cardiac activity* or blood flow can be seen surrounding the sac. At times, under real-time US, the sac can be moving up-down when there is a uterine contraction. The uterine cavity may be empty or contain hyperechoic blood and blood clots.

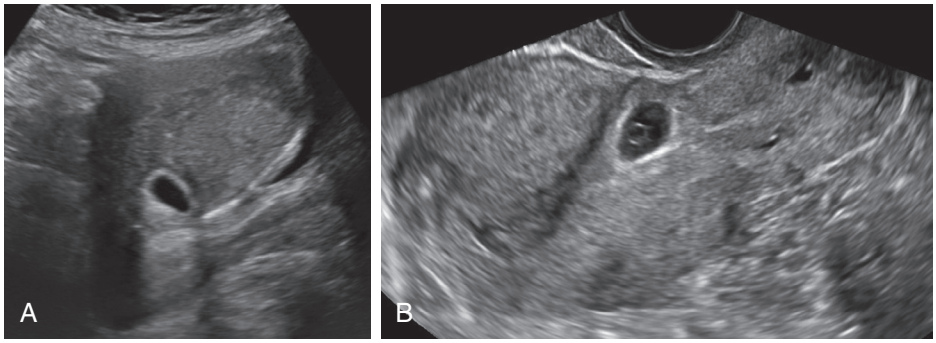

Fig. 44.11 (A) Transabdominal scan of a CSP. (B) Transvaginal scan. Both scans show the position of the pregnancy in the anterior lower uterine segment at the level of the CD scar.

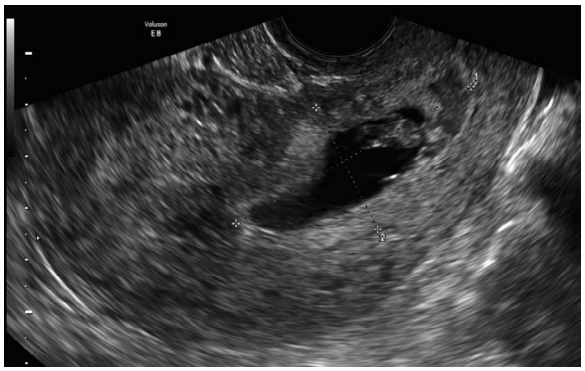

Fig. 44.12 At 8 weeks 2 days, the CSP's gestational sac appears to be "moving" up toward the uterine fundus.

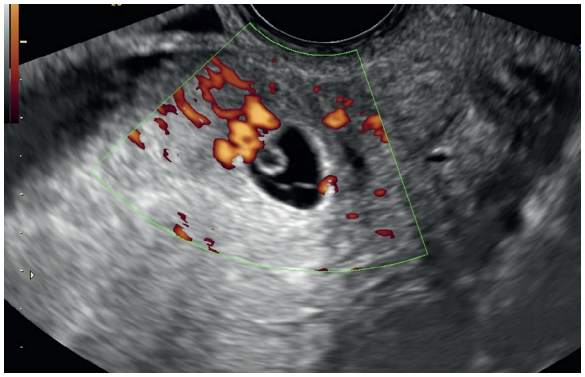

Fig. 44.13 Using color Doppler, a strong flow signal is seen in the area of the CD scar denoting the implantation site of the sac.

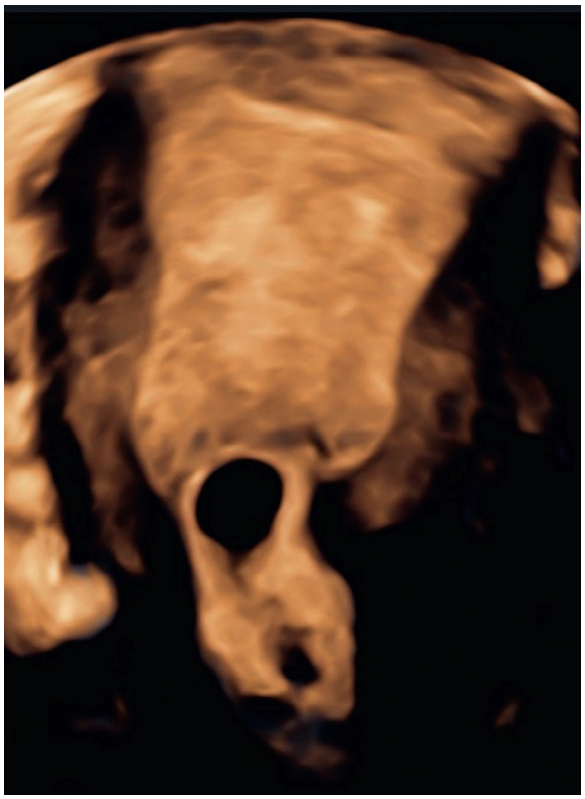

Fig. 44.14 A coronal 3D reconstruction of a CSP at 6 weeks 5 days showing a gestational sac clearly in the lower uterine segment and an empty uterine cavity.

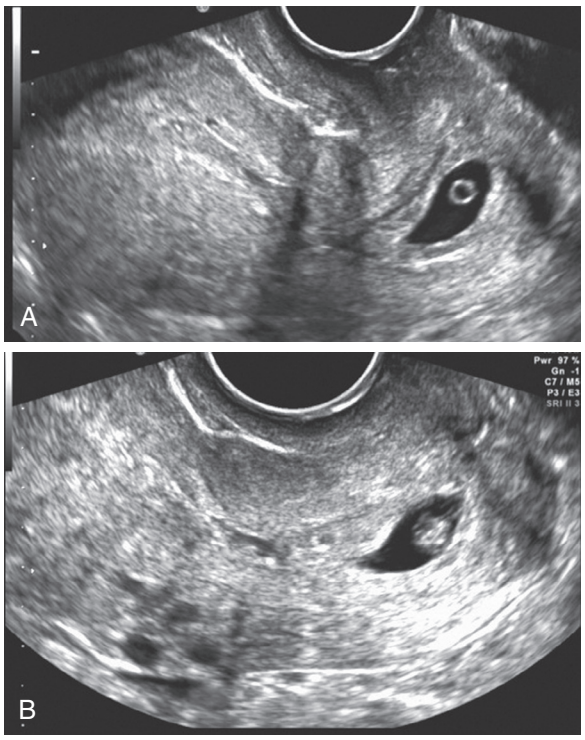

Fig. 44.15 (A) Long axis view of a centrally located cervical pregnancy at 6 weeks 6 days with the empty intrauterine cavity. (B) Is another view of the same pregnancy clearly demonstrating both internal and external os as well as the central position of the pregnancy.

In cases of cervical pregnancy, typically there is no prior history of CD and can even occur during the first pregnancy; the placenta and the entire gestational sac containing an embryo/fetus are present *centrally* within the endocervical canal below the level of the internal os. Cardiac activity can be documented using color/power Doppler. The cervical canal as well as the cervix are dilated and barrel shaped, and similarly to a CSP, the uterine cavity is empty. The internal os can be recognized by the level of the approach and insertion of the uterine arteries to the cervix on a coronal section by US using color/power Doppler.[44]

Synopsis of Treatment Options

The management of cesarean scar pregnancy is evolving and a number of different approaches have been proposed.[34,40,45] Surgical management options include hysteroscopic and transvaginal resection, laparoscopic resection, and hysterectomy. Medical management involves some combination of systemic and local, intragestational, methotrexate, and other surgical or nonsurgical therapies. The goal of the ***treatment is to immediately stop further growth and development of the pregnancy***. Uterine artery embolization is also frequently used in conjunction. Noninvasive management with a cervical ripening double-balloon catheter has recently described.[46,47]

WHAT THE REFERRING PHYSICIAN NEEDS TO KNOW

The CSP is a newly identified precursor of the morbidly adherent placenta (MAP), or accreta, in the first trimester.[48,49]

Patients need to be properly counseled about their options based on the US findings at presentation.

- CSP with yolk sac and no embryo or cardiac activity: before any treatment is instituted, the patient should be re-scanned every 2 to 3 days. If after 7 to 10 days there is no visible embryo with cardiac activity or if the embryo's CRL is measuring greater than 7 mm with no cardiac activity, the pregnancy is consistent with a failed CSP. At this point weekly US and hCG should be planned until the serum hCG is negative
- CSP with yolk sac and embryo with cardiac activity: this situation deserves a detailed counseling session, since there are two possible options with very different outcomes. The first option is for the patient to continue the pregnancy and the second is to terminate the CSP immediately before the pregnancy progresses any further. If the patient decides to continue the pregnancy, given the fact that CSP is a risk factor for abnormal placentation (accreta), it is important to follow these patients closely with US and to make the diagnosis of the degree of abnormally adherent placenta as early as possible, as this will impact the timing of the delivery and other logistics (Chapter 97).

KEY POINTS

All patients with a prior CD should be considered at risk of presenting with a CSP. The first scan should be performed as early as possible, with a comfortably full bladder and the gestational sac location clearly documented; a low anteriorly placed gestational sac with an empty cavity are key diagnostic features of a CSP. If termination is desired, this should be performed as quickly as possible. The goal of treatment is to *stop* the pregnancy from further development and growth.

SUGGESTED READING

Birch Petersen K, et al. Cesarean scar pregnancy: a systematic review of treatment studies. *Fertil Steril*. 2016;105(4):958-967.

Maymon R, Svirsky R, Smorgick N, et al. Fertility performance and obstetric outcomes among women with previous cesarean scar pregnancy. *J Ultrasound Med*. 2011;30(9):1179-1184. PubMed PMID: 21876087.

Parker VL, Srinivas M. Non-tubal ectopic pregnancy. *Arch Gynecol Obstet*. 2016;294:19-27.

Salomon LJZ, Alfirevic CM, Bilardo GE, et al. ISUOG practice guidelines: performance of first-trimester fetal ultrasound scan. *Ultrasound Obstet Gynecol*. 2013;41(1):102-113.

Seow KM, Huang LW, Lin YH, et al. Cesarean scar pregnancy: issues in management. *Ultrasound Obstet Gynecol*. 2004;23(3):247-253. PubMed PMID: 15027012.

Timor-Tritsch IE, et al. The diagnosis, treatment, and follow-up of cesarean scar pregnancy. *Am J Obstet Gynecol*. 2012;207(1):44.e1-44.e13.

Timor-Tritsch IE, Monteagudo A, Santos R, et al. The diagnosis, treatment, and follow-up of cesarean scar pregnancy. *Am J Obstet Gynecol*. 2012;207(1):44.e1-44.e13. PubMed PMID: 22607667.



All references are available online at www.expertconsult.com.

REFERENCES

1. Hahlin M, Thorburn J, Bryman I. The expectant management of early pregnancies of uncertain site. *Hum Reprod*. 1995;10(5):1223-1227.
2. Banerjee S, Aslam N, Zosmer N. The expectant management of women with early pregnancy of unknown location. *Ultrasound Obstet Gynecol*. 1999;14:231-236.
3. Banerjee S, Aslam N, Woelfer B. Expectant management of early pregnancies of unknown location: a prospective evaluation of methods to predict spontaneous resolution of pregnancy. *BJOG*. 2001;108:158-163.
4. Cacciatore B, Korhonen J, Stenman UH. Transvaginal sonography and serum hCG in monitoring of presumed ectopic pregnancies selected for expectant management. *Ultrasound Obstet Gynecol*. 1995;5:297-300.
5. Condous G, Timmerman D, Goldstein S, et al. Pregnancies of unknown location: consensus statement. *Ultrasound Obstet Gynecol*. 2006;28:121.
6. Timor-Tritsch IE, Farine D, Rosen MG. A close look at early embryonic development with the high-frequency transvaginal transducer. *Am J Obstet Gynecol*. 1988;159(3):676-681.
7. Doubilet PM, Benson CB, Bourne T, et al. Diagnostic criteria for nonviable pregnancy early in the first trimester. *N Engl J Med*. 2013;369(15):1443-1451.
8. Rossavik IK, Torjusen GO, Gibbons WE. Conceptual age and ultrasound measurements of gestational sac and crown-rump length in in vitro fertilization pregnancies. *Fertil Steril*. 1988;49(6):1012-1017.
9. Ahmed AA, Tom BD, Calabrese P. Ectopic pregnancy diagnosis and the pseudo-sac. *Fertil Steril*. 2004;81(5):1225-1228.
10. Benson CB, Doubilet PM, Peters HE, et al. Intrauterine fluid with ectopic pregnancy: a reappraisal. *J Ultrasound Med*. 2013;32(3):389-393.
11. Kucuk T, Duru NK, Yenen MC. Yolk sac size and shape as predictors of poor pregnancy outcome. *J Perinat Med*. 1995;27:316-320.
12. Goldstein SR. Embryonic death in early pregnancy: a new look at the first trimester. *Obstet Gynecol*. 1994;84(2):294-297.
13. Hadlock FP, Shah YP, Kanon DJ, et al. Fetal crown-rump length: reevaluation of relation to menstrual age (5-18 weeks) with high-resolution real-time US. *Radiology*. 1992;182(2):501-505.
14. Goldstein SR. Significance of cardiac activity on endovaginal ultrasound in very early embryos. *Obstet Gynecol*. 1992;80(4):670-672.
15. Degenhardt F. Control of early pregnancies by vaginal sonography. *Z Geburtshilfe Perinatol*. 1987;191(3):96-98.
16. American College of O, Gynecologists. ACOG Practice Bulletin No. 101: ultrasonography in pregnancy. *Obstet Gynecol*. 2009;113(2 Pt 1):451-461.
17. Kirk E, Bottomley C, Bourne T. Diagnosing ectopic pregnancy and current concepts in the management of pregnancy of unknown location. *Hum Reprod Update*. 2014;20(2):250-261.
18. Van Calster B, Bobdiwala S, Guha S, et al. Managing pregnancy of unknown location based on initial serum progesterone and serial serum hCG: development and validation of a two-step triage protocol. *Ultrasound Obstet Gynecol*. 2016.
19. *Ectopic pregnancy and miscarriage: diagnosis and initial management in early pregnancy of ectopic pregnancy and miscarriage*. London: National Institute for Health and Clinical Excellence: Guidance; 2012.
20. Wilcox AJ, Weinberg CR, O'Connor JF, et al. Incidence of early loss of pregnancy. *N Engl J Med*. 1988;319(4):189-194.
21. Wang X, Chen C, Wang L, et al. Conception, early pregnancy loss, and time to clinical pregnancy: a population-based prospective study. *Fertil Steril*. 2003;79(3):577-584.
22. Nyberg DA, Laing FC, Filly RA. Threatened abortion: sonographic distinction of normal and abnormal gestation sacs. *Radiology*. 1986;158(2):397-400.
23. Ohno M, Maeda T, Matsunobu A. A cytogenetic study of spontaneous abortions with direct analysis of chorionic villi. *Obstet Gynecol*. 1991;77(3):394-398.
24. Committee on Practice B-G. The American College of Obstetricians and Gynecologists Practice Bulletin no. 150. Early pregnancy loss. *Obstet Gynecol*. 2015;125(5):1258-1267.
25. Bromley B, Harlow BL, Laboda LA, et al. Small sac size in the first trimester: a predictor of poor fetal outcome. *Radiology*. 1991;178(2):375-377.
26. Deaton JL, Honore GM, Huffman CS, et al. Early transvaginal ultrasound following an accurately dated pregnancy: the importance of finding a yolk sac or fetal heart motion. *Hum Reprod*. 1997;12(12):2820-2823.
27. Doubilet PM, Benson CB. Embryonic heart rate in the early first trimester: what rate is normal? *J Ultrasound Med*. 1995;14(6):431-434.
28. Goldstein SR. Sonography in early pregnancy failure. *Clin Obstet Gynecol*. 1994;37(3):681-692.
29. American College of O, Gynecologists. ACOG Committee Opinion No. 427: misoprostol for postabortion care. *Obstet Gynecol*. 2009;113(2 Pt 1):465-468.
30. Zhang J, Gilles JM, Barnhart K, et al. A comparison of medical management with misoprostol and surgical management for early pregnancy failure. *N Engl J Med*. 2005;353(8):761-769.
31. Oliveira FG, Abdelmassih V, Costa AL, et al. Rare association of ovarian implantation site for patients with heterotopic and primary ectopic pregnancies after ICSI and blastocyst transfer. *Hum Reprod*. 2001;16(10):2227-2229.
32. Raziel A, Golan A, Pansky M, et al. Ovarian pregnancy: a report of twenty cases in one institution. *Am J Obstet Gynecol*. 1990;163(4 Pt 1):1182-1185.
33. American College of O, Gynecologists. ACOG Practice Bulletin No. 94: medical management of ectopic pregnancy. *Obstet Gynecol*. 2008;111(6):1479-1485.
34. Timor-Tritsch IE, Monteagudo A, Santos R, et al. The diagnosis, treatment, and follow-up of cesarean scar pregnancy. *Am J Obstet Gynecol*. 2012;207(1):44.e1-44.e13.
35. Seow KM, Huang LW, Lin YH, et al. Cesarean scar pregnancy: issues in management. *Ultrasound Obstet Gynecol*. 2004;23(3):247-253.
36. Maymon R, Svirsky R, Smorgick N, et al. Fertility performance and obstetric outcomes among women with previous cesarean scar pregnancy. *J Ultrasound Med*. 2011;30(9):1179-1184.
37. Genbacev O, Zhou Y, Ludlow JW, et al. Regulation of human placental development by oxygen tension. *Science*. 1997;277(5332):1669-1672.
38. Norwitz ER. Defective implantation and placentation: laying the blueprint for pregnancy complications. *Reprod Biomed Online*. 2006;13(4):591-599.
39. Kliman HJ, Feinberg RF, Haimowitz JE. Human trophoblast-endometrial interactions in an in vitro suspension culture system. *Placenta*. 1990;11(4):349-367.
40. Timor-Tritsch IE, Monteagudo A. Unforeseen consequences of the increasing rate of cesarean deliveries: early placenta accreta and cesarean scar pregnancy. A review. *Am J Obstet Gynecol*. 2012;207(1):14-29.
41. Godin PA, Bassil S, Donnez J. An ectopic pregnancy developing in a previous caesarian section scar. *Fertil Steril*. 1997;67(2):398-400.
42. Vial Y, Petignat P, Hohlfeld P. Pregnancy in a cesarean scar. *Ultrasound Obstet Gynecol*. 2000;16(6):592-593.
43. Seow KM, Hwang JL, Tsai YL. Ultrasound diagnosis of a pregnancy in a Cesarean section scar. *Ultrasound Obstet Gynecol*. 2001;18(5):547-549.
44. Timor-Tritsch IE, Monteagudo A, Mandeville EO, et al. Successful management of viable cervical pregnancy by local injection of methotrexate guided by transvaginal ultrasonography. *Am J Obstet Gynecol*. 1994;170(3):737-739.
45. Birch Petersen K, Hoffmann E, Rifbjerg Larsen C, et al. Cesarean scar pregnancy: a systematic review of treatment studies. *Fertil Steril*. 2016;105(4):958-967.
46. Timor-Tritsch IE, Cali G, Monteagudo A, et al. Foley balloon catheter to prevent or manage bleeding during treatment for cervical and Cesarean scar pregnancy. *Ultrasound Obstet Gynecol*. 2015;46(1):118-123.
47. Timor-Tritsch IE, Monteagudo A, Bennett TA, et al. A new minimally invasive treatment for cesarean scar pregnancy and cervical pregnancy. *Am J Obstet Gynecol*. 2016;215(3):351.e1-351.e8.
48. Timor-Tritsch IE, Monteagudo A, Cali G, et al. Cesarean scar pregnancy is a precursor of morbidly adherent placenta. *Ultrasound Obstet Gynecol*. 2014;44(3):346-353.
49. Timor-Tritsch IE, Monteagudo A, Cali G, et al. Cesarean scar pregnancy and early placenta accreta share common histology. *Ultrasound Obstet Gynecol*. 2014;43(4):383-395.

45 Nuchal Translucency

JENNIFER M. WALSH | MARY E. D'ALTON

Introduction

In 1866, Down first reported an accumulation of excessive skin in individuals with trisomy 21.[1] In the early to mid-1990s, ultrasound (US) evaluation in the first trimester revealed an accumulation of subcutaneous fluid behind the fetal neck that could explain the apparent excess skin; this finding became known as *nuchal translucency* (NT).[2] An increase in NT is now recognized to be an early presenting feature of a broad range of fetal chromosomal, genetic, and structural abnormalities. As a result, first-trimester US to assess NT has evolved from an imaging evaluation used in a research setting to a screening tool that is widely available to the general obstetric population.

Major prospective studies from the United States and Europe have confirmed that US performed for NT is a powerful prenatal marker for Down syndrome,[3–5] with detection rates ranging from 63% to 77% with a 5% false-positive rate. The First and Second Trimester Evaluation of Risk (FASTER) trial showed that screening with NT-based US is even more efficient when combined with maternal serum-free beta-human chorionic gonadotropin and pregnancy-associated plasma protein-A, increasing detection rates to 87% at a 5% false-positive rate.[6]

An increased NT measurement is not uniquely associated with trisomy 21. It is also often increased in fetuses with a variety of other genetic conditions, including trisomies 13 and 18, Turner syndrome and triploidy, as well as structural birth defects such as congenital heart defects, diaphragmatic hernia, skeletal dysplasia, fetal anemia, and neuromuscular disorders.[7,8] Identification of increased NT alerts the practitioner to the risk of aneuploidy and should prompt a thorough anatomic survey for structural abnormalities and a detailed fetal echocardiogram, even in the setting of a normal karyotype.

All women should be offered prenatal screening or diagnostic testing for aneuploidy, regardless of maternal age, but with the increasing number of prenatal screening options now available, deciding which is the most appropriate test is increasingly complex.[9] Noninvasive prenatal screening using maternal cell-free DNA (cfDNA) is rapidly transforming prenatal screening, with all tests providing a high sensitivity and specificity for trisomies 21 and 18. In high-risk obstetric populations, it is recommended that this form of testing now be offered as a first-line screening option. This population includes women 35 years or older, fetuses with ultrasonographic findings indicative of an increased risk of aneuploidy, women with a history of trisomy-affected offspring, a parent carrying a balanced Robertsonian translocation with an increased risk of trisomy 13 or trisomy 21, and women with positive first-trimester or second-trimester screening test results. Conventional screening with US for NT, however, remains the

most appropriate choice for first-line screening in the general obstetric population.[10]

It is important to note that no single test is regarded by the American College of Obstetricians and Gynecologists (ACOG) as superior to other screening tests in all characteristics, and the decision on which test to perform must be based on a number of factors, including the woman's desire for information, her prior history, cost analysis, and the local availability of reliable testing and appropriate care following an abnormal result.[9]

Disease

DEFINITION

Fetal NT refers to the normal subcutaneous fluid-filled space between the back of the neck and the overlying skin. A small but measureable amount of nuchal fluid can be identified in virtually all fetuses between the 10th and 14th week of gestation. Increased fetal NT thickness refers to the measurement of the vertical thickness in the midsagittal section of the fetus that is equal to or greater than a specific threshold.[4]

Different thresholds have been used to classify NT as abnormal or thickened. NT measurements normally increase with gestational age (crown-rump length), by approximately 15%–20% per gestational week from 10 to 13 weeks. Gestational age–specific cutoffs are required, which might include 95th or 99th percentile values, MoM values (multiples of the median NT measurement for that gestational age), or delta values (deviation of NT from the median for that gestational age). Because gestational age–specific calculations are required, the use of interpretative software programs for risk assessment is necessary. For each measured crown-rump length, the NT measurement represents a likelihood ratio, which when multiplied by the a priori maternal and gestational age–related risk produces a new risk. The larger the NT, the higher the likelihood ratio becomes and therefore the higher the new risk. In aneuploidy screening programs, NT measurements are combined with other risk data, including a range of serum markers, before a final risk estimate is provided to the patient.

PREVALENCE AND EPIDEMIOLOGY

The risk of aneuploidy increases with increasing nuchal thickness; the proportion of fetuses affected depends on the threshold used. In one large series, 12% of fetuses had chromosomal abnormalities when the 95th percentile for NT was used.[4] In another large series, the incidence of aneuploidy by nuchal thickness measurement was 7% with an NT between the 95th percentile for crown-rump length and 3.4 mm, 20% with NT between 3.5 mm and 4.4 mm, 50% with NT between 4.5 mm and 6.4 mm, and 75% with NT 8.5 mm or greater.[11] Approximately 50% of fetuses with increased NT and an abnormal karyotype had trisomy 21; the remainder had other chromosomal abnormalities, such as trisomy 13, trisomy 18, and Turner syndrome.

With respect to euploid fetuses, structural anomalies are detected in approximately 4% to 10% of fetuses with enlarged NT.[12,13] Cardiac malformations, the most common malformation associated with increased NT, have an overall risk of 3% to 5%.[14–16]

ETIOLOGY AND PATHOPHYSIOLOGY

Because of the large number of anomalies associated with increased NT thickness, it is unlikely that a single mechanism is responsible for this abnormal fluid accumulation. It is more likely that different pathophysiologic pathways lead to the endpoint of increased nuchal fluid. Cardinal proposed etiologies include abnormal dermal collagen composition in Down syndrome,[17] abnormal nuchal lymphogenesis in Turner syndrome (monosomy X),[18] and aberrant endothelial development and cardiac dysfunction in cardiac anomalies.[19–21] A number of candidate genes—mainly encoding for endothelium—are involved in both cardiac and lymphatic development. Alterations in these candidate genes may provide a genetic origin for the strong relation between increased nuchal translucency and congenital heart defects.[21] It is proposed that the association with skeletal dysplasias may be due to the presence of a narrow thorax with mediastinal compression, reduced fetal movements secondary to limb fractures, and abnormalities of the cutaneous composition linked with collagen defects.[22]

MANIFESTATIONS OF DISEASE

Imaging Technique and Findings

Ultrasound. When performing US to assess NT and obtain measurements, optimal technique is critical to ensure the greatest degree of accuracy (Fig. 45.1). The following points summarize

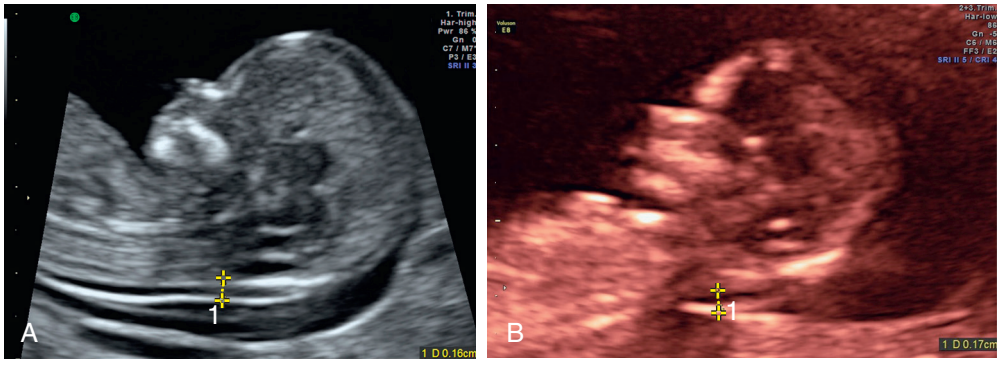

Fig. 45.1 (A) Optimizing the technique for first-trimester NT US. NT measurement in a normal fetus at 12 weeks' gestation. Components of a good US screening protocol are evident, including adequate image magnification, midsagittal plane, neutral fetal neck position, and correct caliper placement. (B) Contrasting image of NT measurement using unsatisfactory technique.

criteria derived from the Fetal Medicine Foundation (FMF) and the FASTER Research consortium:

1. NT screening should be performed only by sonographers or sonologists trained and experienced in the technique.
2. Transabdominal versus transvaginal approach should be left to the discretion of the sonographer, based on maternal body habitus, gestational age, and fetal position.
3. US and transducer settings should be optimized to ensure clarity of the image and of the borders of the nuchal space in particular.
4. Gestation should be limited to between 10 weeks and 3 days, and 13 weeks and 6 days (approximate crown-rump length of 38 to 84 mm, although the actual limits will depend on the lab performing the serum analyte testing and the software used).
5. The fetus should be examined in the midsagittal plane, which is defined by the presence of the echogenic tip of the nose and rectangular shape of the palate anteriorly, the translucent diencephalon in the center, and the nuchal membrane posteriorly.[23]
6. The fetus neck should be in a neutral position. The neck is defined as extended if the angle between the lower chin and the anterior neck is more than 90 degrees. Excessive flexion occurs when no amniotic fluid is seen between the lower chin and the anterior neck.
7. The fetus should be observed as distinct from the amnion. The amnion may be separate from the chorion until 16 weeks' gestation and may be mistakenly identified as the posterior aspect of the fetal skin. Fetal movement should be awaited to distinguish between amnion and overlying fetal skin.
8. The fetal image should occupy at least 75% of the viewable screen.
9. Calipers should be placed on the maximum echolucent space at the back of the fetal neck. The cross of the calipers should be placed on the inner borders of the nuchal fold. Only a cross-shaped caliper (+) should be used; other caliper configurations (e.g., ×, /, ÷) should not be used.
10. Calipers should be placed perpendicular to the long axis of the fetal body.
11. More than one measurement should be obtained, and the largest measurement that meets quality criteria should be used.
12. The umbilical cord may be around the fetal neck in about 5% of cases, and this finding may produce a falsely increased NT. In such cases the measurements of NT above and below the cord may differ, and in the calculation of risk it is appropriate to use the average of the two measurements.
13. At least 20 minutes should be dedicated to the NT measurement before abandoning the effort as failed.

Separate evaluation of 34 studies that were included in a meta-analysis evaluating NT screening suggested that Down syndrome detection rates vary from 29% (4% false-positive rate) to 100% (5% false-positive rate).[23] The large variation in detection is believed to be due to significant differences in US training and NT image quality. Sonographers must acquire an US measurement, accurate to a fraction of a millimeter, which is used similar to a laboratory analyte, to assign a specific patient risk for aneuploidy. Given the importance of precision in NT measurement, stringent programs have been created to train and monitor providers to perform this measurement in a standardized fashion.

The FMF in the United Kingdom and the Nuchal Translucency Quality Review (NTQR) program developed by the Maternal Fetal Medicine Foundation in the United States both advocate an initial didactic training program that outlines and discusses the theory underlying NT-based screening, and demonstrates US technique to standardize measurements. Sonographers and sonologists demonstrate their technique in the clinical setting by submitting images (five images for NTQR, three images for FMF) for approval to a central expert review team. Both groups also provide ongoing quality monitoring for their respective participants by periodically comparing the distribution and standard deviation of NT measurements against measurements obtained from a standard referent curve. Ongoing quality monitoring is essential to achieve the detection rates shown in clinical trials, with remediation for excessive deviation from established standards.[24]

Differential Diagnosis From Imaging Findings

Differentiation between septated cystic hygroma (CH) and increased NT is frequently debated in the field of first-trimester screening (Fig. 45.2). In the FASTER study, CH was defined as an enlarged hypoechoic space at the back of the fetal neck, extending along the length of the fetal back, with clearly visible septations.[25] Using this definition, 132 cases of CH were identified with a mean NT size of 6.5 mm. They were associated with abnormal fetal karyotype in 51% of fetuses and fetal structural malformation in 34% of chromosomally normal fetuses.

By contrast, simple NT tends to be confined to the occiput and upper spine, and is free of septations. Studies from the FMF did not differentiate CH from enlarged NT cases.[8] It was suggested that the presence or absence of septations in increased NT does not

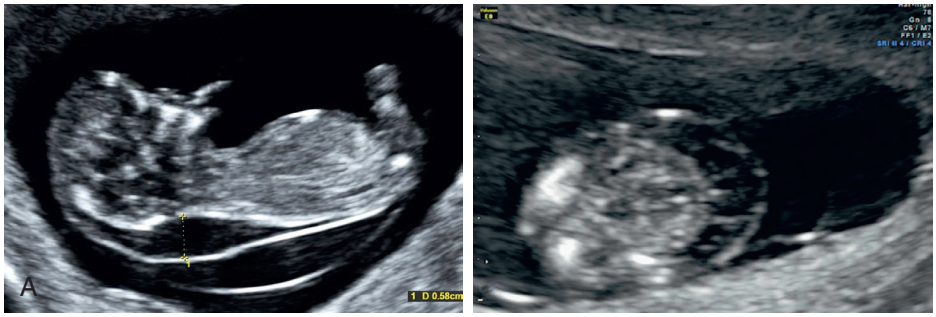

Fig. 45.2 (A) Septated CH at 12 weeks' gestation. Midsagittal US view of a fetus with septated CH, showing increased NT space extending along the entire length of the fetus. (B) Septated CH evident with transverse view through the fetal neck of the same fetus showing obvious septations.

TABLE 45.1 FETAL OUTCOMES BASED ON PRESENCE OF SEPTATED CYSTIC HYGROMA OR ENLARGED NUCHAL TRANSLUCENCY

	Abnormal Karyotype (%)	Structural Malformation (%)	Fetal Demise (%)	Normal Outcome (%)
Septated CH (FASTER, 2005)	50.8	33.8	15.2	16.7
NT 5.5–6.4 mm (FMF, 2005)	50.5	24.2	10.1	30
NT >6.5 mm (FMF, 2005)	64.5	46.2	19.0	15

change the prognosis, but that outcomes are determined primarily by NT thickness.[26] In pregnancies with NT measurements above the 99th percentile, which corresponds to 3.5 mm or greater, there was an increased rate of chromosomal abnormalities, and the prevalence of abnormalities increased as NT measurements increased. This correspondence was also evident for structural abnormalities in chromosomally normal fetuses.

Table 45.1 compares outcome data from the FASTER CH cohort with outcomes in fetuses with NT greater than 5.5 mm in the FMF cohort. The frequency of adverse pregnancy outcomes is quite similar between the groups. Given the similarity and the significantly increased risk of abnormal karyotype, structural malformation, and fetal death in both cohorts, differentiation between septated CH and NT above the 99th percentile may not be clinically important. Both groups are associated with a sufficiently high risk to prompt the immediate offer of an invasive test, without recourse to any further screening modalities. Despite the high incidence of adverse outcome in this group, however, it is important to note that the majority of fetuses that die do so by 20 weeks, generally following a gradual progression from an increased NT to overt fetal hydrops. For those cases of structurally normal fetuses that survive until mid-gestation, the risk of adverse perinatal outcome and postnatal developmental delay is not significantly increased[8]; as such, more intensive fetal monitoring is not warranted.

Other differential diagnoses to consider include neural tube defects such as posterior encephalocele or cervical meningocele, and cystic teratoma or hemangioma. Exclusion of these conditions is often aided by the use of high-resolution US to visualize an intact skull and spine and rule out the presence of a solid component. Using the transvaginal approach can also improve the level of visible detail.

Synopsis of Treatment Options

PRENATAL

Major advances have been achieved in the field of prenatal aneuploidy screening since the days when invasive testing was offered based solely on maternal age. The unifying objective of the various screening paradigms is a high detection rate for aneuploidy with a low false-positive rate. Conventional screening options involve first-trimester or second-trimester serum and US screening tools, or more complex approaches in which markers can be combined from different gestational age periods. Screening strategies that combine both first-trimester and second-trimester tests include integrated screening, stepwise-sequential screening, and contingent screening.

More recently prenatal screening has evolved dramatically, with the identification of cell-free fetal DNA in the serum of pregnant women leading to the development of noninvasive prenatal testing (NIPT). This technology offers the potential to improve and simplify prenatal screening techniques, and significantly reduce the number of patients with euploid fetuses undergoing invasive testing. Currently cfDNA screening for trisomies 13, 18, and 21 is validated; screening for microdeletion syndromes and rarer trisomies has not been validated in clinical studies, and the true sensitivity and specificity of these results remains uncertain. Routine cfDNA screening for microdeletion syndromes is not currently recommended by either the American College of Obstetricians and Gynecologists, or the Society for Maternal-Fetal Medicine.

NIPT offers superior sensitivity and specificity for trisomy 21 when compared with conventional screening methods, and is now recommended by the American College of Obstetricians and Gynecologists and the Society for Maternal-Fetal Medicine as an option for first-line screening for women at increased risk of aneuploidy.[10] There are a variety of reasons NIPT is not yet recommended as a first-line test for the low-risk general obstetric population. First, the positive predictive value is lower in this population, given the lower prevalence of aneuploidy in younger, low-risk women, and this will increase the false positive rate in the low-risk population. Additionally, trisomies 13, 18, and 21 represent a lower proportion of the chromosomal abnormalities that occur in this group than in older women. Conventional screening methods with serum analytes and NT measurements are more likely to detect other chromosomal abnormalities, as well as the risk of other adverse pregnancy outcomes. For this reason, despite ACOG's recommendation that the use of simultaneous testing with multiple screening methods is not cost-effective and should not be performed,[10] our practice is to continue to recommend that high-risk women are offered NT assessment as well as NIPT.

The main advantage of first-trimester screening is earlier provision of reassurance to patients with low-risk results or the option of definitive diagnosis with chorionic villus sampling to patients who have positive screening results. For patients who choose to terminate the pregnancy, complication rates are lower at earlier gestations, and greater privacy is afforded to patients who make this choice. Disclosure of the risk result to the patient, necessary in this setting, is the major criticism of the "integrated" screening approach (Table 45.2).

Another option is to proceed to karyotype assessment without maternal analyte screening, based solely on NT thickness. The FASTER trial found that the threshold of 3 mm or greater conferred a minimal risk of 1:6 for aneuploidy and minimal benefit in waiting for serum screening results.[27] However, the authors of the trial noted that these millimeter cutoffs apply only in cases in which the NT measurement has been obtained according to a strict protocol control. A cutoff measurement of 3.5 mm is often used because this measurement has been observed to be equivalent to the 99th percentile in high-risk pregnancies, independent of gestational age or crown-rump length.[26]

TABLE 45.2 TERMINOLOGY USED TO DESCRIBE ANEUPLOIDY SCREENING OPTIONS

Name	Components	When Results Given
First trimester combined	Maternal age Crown-rump length NT thickness Maternal serum PAPP-A, serum free or total β-hCG	First trimester after US scan and analytes measurement
Quadruple screen	Maternal age Estimated gestational age Maternal serum alpha-fetoprotein, β-hCG, unconjugated estriol, inhibin A	Second trimester
Integrated screen	Maternal age Crown-rump length NT thickness Maternal serum PAPP-A Second-trimester quadruple screen	Second trimester, only after quadruple screen results (*note:* β-hCG used only once)
Serum integrated	Maternal age Gestational age First-trimester PAPP-A Quadruple screen	Second trimester, only after quadruple screen results (*note:* β-hCG used only once)
Contingency	First-trimester combined test Quadruple screen for intermediate risk, immediate CVS if high risk, no further testing if low risk (risk levels must be programmatically determined)	Initial result in first trimester, further results in second trimester for fetuses deemed at intermediate risk (e.g., 1 : 51–1 : 999)
Stepwise sequential	First-trimester combined test Quadruple screen ± genetic US for patients desiring refined risk in second trimester, immediate CVS for patients requesting definite results in first trimester, amniocentesis for patients requesting in second trimester	First trimester for initial results, second trimester for patients requesting second blood test

β-hCG, Beta human chorionic gonadotropin; *CVS,* chorionic villus sampling; *PAPP-A,* pregnancy-associated plasma protein A.

The use of cfDNA screening as a follow-up for women with an increased NT screen can be considered for those who wish to avoid an invasive test. These women should be counseled, however, that the residual risk of aneuploidy following a normal NIPT result after an abnormal traditional screening result with US for NT is 1 in 50.[28]

The accuracy of screening for aneuploidy is limited in multiple gestations. Any method based on maternal blood, through the measurement of serum analytes or the detection of cfDNA, will be limited in the ability to distinguish a differential risk for each fetus. Measurement of fetal NT has been validated as an effective screening tool for aneuploidy in dichorionic twin pregnancies, yielding detection rates comparable to rates attained for singleton pregnancies.[29] Owing to the recognition of increased NT as an early manifestation of twin-twin transfusion in monochorionic twin gestations, this marker is less reliable for aneuploidy in this setting. It has been proposed that to calculate the risk of Down syndrome in monochorionic twin pregnancies, the NT of both fetuses should be measured, and the average of the two should be considered.[30]

When the fetus is found to be euploid in the setting of increased NT, it is important to rule out structural abnormalities. Early fetal anatomic evaluations in experienced institutions can detect major malformations in the first trimester; however, a comprehensive anatomic survey between 18 and 22 weeks' gestation is considered standard practice. Consideration may be given to more advanced genetic testing options, including microarray and sequencing for specific conditions such as Noonan syndrome.[31]

Because congenital heart disease is the most commonly associated malformation risk, which increases with increased NT thickness,[14,32] specialist fetal echocardiography is recommended. The FASTER trial showed that NT-based US in the first trimester lacked the characteristics of a good screening tool for major congenital heart disease owing to low sensitivity. However, using the 99th percentile, NT measurement cutoff for echocardiography referral would identify one major cardiac defect in every 16 patients examined.[14]

In a small proportion of cases (3%), increased nuchal translucency will persist into the second trimester and be detected at the routine anatomic scan. In these circumstances, a 10% chance of evolution to hydrops has been reported, and regular surveillance is warranted.[11]

POSTNATAL

The longer-term pediatric outcome for fetuses identified with increased NT in utero is difficult to determine. One study reported an increased prevalence (4%) of neurodevelopmental delay in children with a history of increased NT[33]; no excess risk of developmental delay in children with normal karyotype and no congenital malformations has been identified in a systematic review.[34]

WHAT THE REFERRING PHYSICIAN NEEDS TO KNOW

NT measurement in the first trimester is a powerful marker for fetal Down syndrome. Combined first-trimester screening achieves a detection rate of 87% with a 5% false-positive rate. Screening allows patients to obtain a risk assessment to determine whether invasive prenatal diagnosis should be considered. In cases of increased NT in fetuses with a normal karyotype, consideration should be given to more advanced genetic testing including microarray analysis, and structural abnormalities, particularly cardiac, should be ruled out.

The recommendation of the American College of Obstetricians and Gynecologists is that first-trimester screening using US measurement of NT should be offered only if specific training and standardized techniques are used and if ongoing quality assessment is in place. These criteria are necessary to maintain high detection rates and low screen-positive rates in clinical practice. The introduction of NIPT to clinical practice has greatly improved the accuracy of screening for the common aneuploidies, and is now recommended for those considered high risk.[10] It is not recommended as first-line screening for the general obstetric population, who should be offered US for NT with serum analyte screening in the first trimester.

KEY POINTS

- Some nuchal fluid is a normal finding in all first-trimester fetuses; however, thickened NT is associated with an increased risk of chromosomal and structural abnormalities.
- NT measurement in the first trimester is a powerful marker for fetal Down syndrome.
- The combination of NT with serum markers in the first trimester detects 87% of cases of Down syndrome for a 5% false-positive rate.
- NT screening for aneuploidy in the first trimester is feasible in multiple-gestation pregnancies but has lower sensitivity than first-trimester screening in singleton pregnancies.
- Septated cystic hygroma and NT of 3.5 mm or greater are indications for chorionic villus sampling without need to await serum marker results.
- Fetal echocardiography at 18 to 22 weeks' gestation is indicated in fetuses with NT 3.5 mm or greater or 3.0 MoM because of the increased incidence of congenital heart disease.

SUGGESTED READING

Maymon R, Weinraub Z, Herman A. Pregnancy outcome of euploid fetuses with increased nuchal translucency: how bad is the news? *J Perinat Med*. 2005;33:191.

Nicolaides KH. Screening for aneuploidies at 11 to 13 weeks. *Prenat Diagn*. 2011;31:7-15.

Rosen T, D'Alton ME. Down syndrome screening in the first and second trimesters: what do the data show? *Semin Perinatol*. 2005;29:367-375.

Said S, Malone FD. The use of nuchal translucency in contemporary obstetric practice. *Clin Obstet Gynecol*. 2008;51:37-47.

Snijders RJ, Thom EA, Zachary JM, et al. First-trimester trisomy screening: nuchal translucency measurement training and quality assurance to correct and unify technique. *Ultrasound Obstet Gynecol*. 2002;19:353.

Spencer K, Nicolaides K. Screening for trisomy 21 in twins using first trimester ultrasound and maternal serum biochemistry in a one-stop clinic: a review of three years' experience. *BJOG*. 2003;110:276-280.



All references are available online at www.expertconsult.com.

REFERENCES

1. Down LJ. Observations on an ethnic classification of idiots. *Lond Hosp Rep*. 1866;3:259-262.
2. Nicolaides KH, Azar G, Byrne D, et al. Fetal nuchal translucency: ultrasound screening for chromosomal defects in first trimester of pregnancy. *BMJ*. 1992;304:867-869.
3. Wapner R, Thom E, Simpson JL, et al. First-trimester screening for trisomies 21 and 18. First trimester maternal serum biochemistry and fetal nuchal translucency screening (BUN) study group. *N Engl J Med*. 2003;349:1405-1413.
4. Snijders RL, Noble P, Sebire N, et al. UK multicenter project on assessment of risk of trisomy 21 by maternal age and fetal nuchal-translucency thickness at 10-14 weeks of gestation. *Lancet*. 1998;352:343-346.
5. Wald N, Walter J, Rodeck C, et al. First and second trimester antenatal screening for Down syndrome: the results of the serum, urine and ultrasound screening study (SURUSS). *Int J Gynecol Obstet*. 2004;111:521-531.
6. Malone FD, Canick JA, Ball RH, et al. First- and second-trimester evaluation of risk (FASTER) research consortium: first-trimester or second-trimester screening, or both, for Down syndrome. *N Engl J Med*. 2005;353:2001-2011.
7. Souka AP, Snijders RJ, Novakov A, et al. Defects and syndromes in chromosomally normal fetuses with increased nuchal translucency thickness at 10-14 weeks of gestation. *Ultrasound Obstet Gynecol*. 1998;11:391.
8. Souka AP, Von Kaisenberg CS, Hyett JA, et al. Increased nuchal translucency with normal karyotype. *Am J Obstet Gynecol*. 2005;192:1005.
9. American College of Obstetricians and Gynecologists. Screening for fetal aneuploidy. Practice Bulletin No. 163. *Obstet Gynecol*. 2016;127:e123-e137.
10. American College of Obstetricians and Gynecologists. Committee Opinion No. 640: cell-free DNA screening for fetal aneuploidy. *Obstet Gynecol*. 2015;126(3):e31-e37.
11. Kagan KO, Avgidou K, Molina FS, et al. Relation between increased fetal nuchal translucency thickness and chromosomal defects. *Obstet Gynecol*. 2006;107:6.
12. Mangione R, Guyon F, Taine L, et al. Pregnancy outcome and prognosis in fetuses with increased first-trimester nuchal translucency. *Fetal Diagn Ther*. 2001;16:360.
13. Pandya PP, Kondylios A, Hilbert L, et al. Chromosomal defects and outcome in 1015 fetuses with increased nuchal translucency. *Ultrasound Obstet Gynecol*. 1995;5:15.
14. Simpson LL, Malone FD, Bianchi DW, et al. Nuchal translucency and the risk of congenital heart disease. *Obstet Gynecol*. 2007;109:376.
15. Lopes LM, Brizot ML, Lopes MA, et al. Structural and functional cardiac abnormalities identified prior to 16 weeks' gestation in fetuses with increased nuchal translucency. *Ultrasound Obstet Gynecol*. 2003;22:470.
16. Ghi T, Huggon IC, Zosmer N, et al. Incidence of major structural cardiac defects associated with increased nuchal translucency but normal karyotype. *Ultrasound Obstet Gynecol*. 2001;18:610.
17. Brand-Saberi B, Floel H, Christ B, et al. Alterations in the fetal extracellular matrix in the nuchal oedema of Down's syndrome. *Ann Anat*. 1994;176:539-547.
18. Von Kaisenberg CS, Nicolaides KH, Brand-Saberi B. Lymphatic vessel hypoplasia in fetuses with Turner syndrome. *Hum Reprod*. 1999;14:823-826.
19. Haak MC, Twisk JW, Bartelings MM, et al. Ductus venosus flow velocities in relation to the cardiac defects in first-trimester fetuses with enlarged nuchal translucency. *Am J Obstet Gynecol*. 2003;188:727.
20. Simpson JM, Sharland GK. Nuchal translucency and congenital heart defects: heart failure or not? *Ultrasound Obstet Gynecol*. 2000;16:30.
21. Burger NB, Bekker MN, de Groot CJ, et al. Why increased nuchal translucency is associated with congenital heart disease: a systematic review on genetic mechanisms. *Prenat Diagn*. 2015;35(6):517-528.
22. Ngo C, Viot G, Aubry C, et al. First-trimester ultrasound diagnosis of skeletal dysplasia associated with increased nuchal translucency thickness. *Ultrasound Obstet Gynecol*. 2007;30:221-226.
23. Malone FD, D'Alton ME. First trimester sonographic screening for Down syndrome. *Obstet Gynecol*. 2003;102:1066-1079.
24. D'Alton ME, Cleary-Goldman J, Lambert-Messerlian G, et al. Maintaining quality assurance for sonographic nuchal translucency measurement: lessons from the FASTER Trial. *Ultrasound Obstet Gynecol*. 2009;33:142-146.
25. Malone FD, Ball RH, Nyberg DA, et al. FASTER Trial Research Consortium: first-trimester septated cystic hygroma: prevalence, natural history, and pediatric outcome. *Obstet Gynecol*. 2005;106:288-294.
26. Nicolaides KH. First-trimester screening for chromosomal abnormalities. *Semin Perinatol*. 2005;29:190.
27. Comstock CH, Malone FD, Ball RH, et al. Is there a nuchal translucency millimeter measurement above which there is no added benefit from first trimester serum screening? *Am J Obstet Gynecol*. 2006;195:843.
28. Norton ME, Jelliffe-Pawlowski LL, Currier RJ. Chromosome abnormalities detected by current prenatal screening and noninvasive prenatal testing. *Obstet Gynecol*. 2014;124(5):979-986.
29. Sebire N, Snijders R, Hughes K, et al. Screening for trisomy 21 in twin pregnancies by maternal age and fetal nuchal translucency thickness at 10-14 weeks of gestation. *BJOG*. 1996;103:999-1003.
30. Vandecruys H, Faiola S, Auer M, et al. Screening for trisomy 21 in monochorionic twins by measurement of fetal nuchal translucency thickness. *Ultrasound Obstet Gynecol*. 2005;25:551-553.
31. Rink BD, Norton ME. Screening for fetal aneuploidy. *Semin Perinatol*. 2016;40(1):35-43.
32. Atzei A, Gajewska K, Huggon IC, et al. Relationship between nuchal translucency thickness and prevalence of major cardiac defects in fetuses with normal karyotype. *Ultrasound Obstet Gynecol*. 2005;26:154.
33. Brady A, Pandya P, Yuksel B, et al. Outcome of chromosomally normal live-births with increased fetal nuchal translucency at 10-14 weeks gestation. *J Med Genet*. 1998;35:222-224.
34. Sotiriadis A, Papatheodorou S, Makrydimas G. Neurodevelopmental outcome of fetuses with increased nuchal translucency and apparently normal prenatal and/or postnatal assessment: a systematic review. *Ultrasound Obstet Gynecol*. 2012;39(1):10-19.

PART 7

Skeletal Dysplasias: An Overview

DEBORAH KRAKOW

The skeletal dysplasias or osteochondrodysplasias are a heritable group of more than 450 disorders that affect primarily bone and cartilage, but can also have significant effects on other skeletal tissues including muscle, tendons, and ligaments.[1] By definition, skeletal dysplasias are heritable diseases that have generalized abnormalities in cartilage and bone, whereas dysostoses are genetic disorders characterized by abnormalities in a single or group of bones.[2] Over time, the distinction between these disorders has become blurred, as the field has recognized that there is radiographic, clinical, and molecular overlap. Examples include the radial ray defects that may only grossly affect a single or group of bones, but long term may be associated with generalized growth disturbances.

Recent advances in genomic technologies have identified the molecular basis of disease in 350 of the 450 well-delineated skeletal disorders. Uncovering the molecular defects have shown that differing mutations in a single gene can produce phenotypes from mild disease—for example, early onset osteoarthritis to the lethal achondrogenesis type II.

Gene discovery provided us with the opportunity to translate research findings into clinical testing, though many of these findings have not been readily translated efficiently into the prenatal period. Determining the genes that produce these disorders will allow us to provide diagnostic services for families at risk for recurrence based on mode of inheritance and confirming diagnoses in the prenatal and postnatal period.

Embryology

The skeleton develops under two distinct processes: endochondral and membranous ossification. Endochondral ossification causes the formation of most appendicular skeletal (i.e., long) bones, and involves a sequence of orchestrated developmental processes. These include embryonic limb bud initiation from lateral plate mesoderm, specification of mesenchymal cells for the future limb elements, mesenchymal condensations triggering cartilage differentiation, ossification of developing bones, and finally, proper growth and maturation in the postnatal period.[3,4] Membranous ossification is a developmental process in which condensing mesenchymal cells progress almost directly to bone cells. The bones of the skull, lateral clavicle, and pubis form via mesenchymal ossification. Postnatally, growth continues through the cartilage growth plate in which resting chondrocytes proliferate, undergo hypertrophy, and then apoptosis, becoming the growing scaffold of bone.[5] Distinct molecular mechanisms (genes) underlie skeleton formation, and perturbations to these highly orchestrated processes can lead to skeletal dysplasias.[6]

Genetics

The skeletal dysplasias are inherited in an autosomal recessive, autosomal dominant, X-linked recessive, X-linked dominant, and Y-linked manner.[1] Appreciation of the mode of inheritance is critical because it imparts information regarding future recurrences. Family history is critical for initial determination of potential modes of inheritance if a fetus has findings suspicious for a skeletal dysplasia. There are some uncommonly seen patterns of inheritance in the skeletal dysplasias, including somatic mosaicism, in which one of the parents is mildly affected and their offspring is more severely affected.[7] Evaluation of the parents should be considered if there is any question that one of the parents could have a mild skeletal disorder. Gonadal mosaicism is characterized by familial recurrence of a known dominant disorder resultant from one parent carrying heterozygosity for a mutation in one of the cell lineages in progenitor germ cells, yet the parent is clinically unaffected.[8] This is a rare occurrence, but it influences counseling of all dominant disorders, because if a newborn is diagnosed with an autosomal dominant disorder, counseling should include a less than 1% recurrence risk based on gonadal mosaicism.

Prenatal Diagnosis of Osteochondrodysplasias

Rapid advances in both imaging modalities have markedly improved our abilities to recognize osteochondrodysplasias in the prenatal period.[9,10] For those families with a parent (an autosomal dominant disorder), either molecular diagnostics via invasive techniques or ultrasound (US) imaging, or both, can aid in predicting whether the fetus will be affected. For at-risk families based on a previously affected child with an autosomal recessive disorder, the same aforementioned approach can be utilized. However, for many families, a prenatal-onset skeletal dysplasia is often the first affected individual in their respective families.

First trimester US analysis, usually used to identify aneuploidy, may also be effective in identifying severe, usually lethal, skeletal dysplasias, including osteogenesis imperfecta, thanatophoric dysplasia, and the short-rib polydactyly syndromes.[11–13] If a fetus with a skeletal disorder diagnosed later in gestation was noted to have abnormal US findings in the first trimester, including a small crown-rump length for gestational age and increased nuchal fold thickness, the likelihood is that the fetus has a severe, probably lethal, skeletal dysplasia.

Many prenatal skeletal dysplasias are diagnosed in the late second trimester by US when many pregnant women are routinely screened by US for congenital anomalies.[14] The advantage of early detection (even if an exact diagnosis is not obtained from US) is that it allows for preparation prior to delivery. This includes discussion of active resuscitation, proper assembly of consultants, collection of DNA from cord blood, and smoother transition from the prenatal to neonatal period. This is particularly critical if the neonate is predicted to have a severe but nonlethal skeletal disorder. Awareness of other potential associated morbidities, including tracheomalacia and cervical vertebral abnormalities, helps improve outcomes for these newborns.

Experience has shown that many skeletal disorders are not diagnosed in the late second trimester, particularly nonlethal, but either in the third trimester or at birth. These disorders tend to be much milder, with a less profound effect on the skeleton, and severe respiratory compromise or lethality is usually not seen. Achondroplasia, spondyloepiphyseal dysplasia congenita (SEDC), and nonlethal forms of osteogenesis imperfecta are frequently first seen in the newborn period. Many parents are then questioning if there is a suggestion of a skeletal disorder, often wondering if "something" was missed at early US. For many milder skeletal disorders, long bone measurements are frequently normal at 20 weeks, and begin to lag behind standard growth curves in the third trimester.[15]

Long-Term Follow-Up

Fetuses with skeletal disorders, and their transition to the newborn period, are best managed by a multidisciplinary approach that includes maternal fetal medicine specialists, obstetricians, pediatricians, neonatologists, medical geneticists, endocrinologists, neurosurgeons, otolaryngologists, and orthopedic surgeons based on specific needs. Quality of life is good for most children with nonlethal skeletal dysplasias. If a diagnosis is suspected, families should be encouraged, even in the prenatal period, to seek out support from organizations dedicated to the well-being of children with forms of dwarfism, such as Little People of America (http://www.lpaonline.org) and the Osteogenesis Imperfecta Foundation (http://www.oif.org).

KEY POINTS

1. Approximately 5% of children with congenital birth defects have skeletal dysplasias, many that will present in the prenatal period.
2. Lethality frequently results from small chests, with resultant pulmonary hypoplasia and respiratory compromise.
3. Prenatal diagnosis of these disorders should be suspected if a fetus presents with abnormally mineralized or bent bones, shortened bones, long bones frequently below the first percentile, and evidence for disproportion on US measurements. US diagnosis can provide a differential diagnosis confirmed by molecular diagnosis, when possible. Postnatal diagnosis is made based on clinical and radiographic findings, including molecular diagnosis when available.
4. Nonlethal skeletal dysplasias are associated with short stature, but overall, affected individuals are cognitively normal and have a good quality of life.

SUGGESTED READING

Krakow D, Lachman RS, Rimoin DL. Guidelines for the prenatal diagnosis of fetal skeletal dysplasias. *Genet Med.* 2009;11(2):127-133.

All references are available online at www.expertconsult.com.

REFERENCES

1. Warman ML, Cormier-Daire V, Hall C, et al. Nosology and classification of genetic skeletal disorders: 2010 revision. *Am J Med Genet A*. 2011;155A(5):943-968.
2. Krakow D, Rimoin DL. The skeletal dysplasias. *Genet Med*. 2010;12(6):327-341.
3. Provot S, Schipani E. Molecular mechanisms of endochondral bone development. *Biochem Biophys Res Commun*. 2005;328(3):658-665.
4. Hall BK, Miyake T. All for one and one for all: condensations and the initiation of skeletal development. *Bioessays*. 2000;22(2):138-147.
5. Ballock RT, O'Keefe RJ. The biology of the growth plate. *J Bone Joint Surg Am*. 2003;85(4):715-726.
6. Kronenberg HM. Developmental regulation of the growth plate. *Nature*. 2003;423(6937):332-336.
7. Edwards MJ, Wenstrup RJ, Byers PH, et al. Recurrence of lethal osteogenesis imperfecta due to parental mosaicism for a mutation in the COL1A2 gene of type I collagen. The mosiac parent exhibits phenotypic features of a mild form of the disease. *Hum Mutat*. 1992;1(1):47-54.
8. Cohn D, Starman B, Blumberg B, et al. Recurrence of lethal osteogenesis imperfecta due to parental mosaicism for a dominant mutation in a human type I collagen gene (COL1A1). *Am J Hum Genet*. 1990;46(3):591.
9. Krakow D, Alanay Y, Rimoin LP, et al. Evaluation of prenatal-onset osteochondrodysplasias by ultrasonography: a retrospective and prospective analysis. *Am J Med Genet A*. 2008;146A(15):1917-1924.
10. Krakow D, Lachman RS, Rimoin DL. Guidelines for the prenatal diagnosis of fetal skeletal dysplasias. *Genet Med*. 2009;11(2):127-133.
11. Parilla BV, Leeth EA, Kambich MP, et al. Antenatal detection of skeletal dysplasias. *J Ultrasound Med*. 2003;22(3):255-258.
12. Makrydimas G, Souka A, Skentou H, et al. Osteogenesis imperfecta and other skeletal dysplasias presenting with increased nuchal translucency in the first trimester. *Am J Med Genet*. 2001;98(2):117-120.
13. Dugoff L, Thieme G, Hobbins J. First trimester prenatal diagnosis of chondroectodermal dysplasia (Ellis–van Creveld syndrome) with ultrasound. *Ultrasound Obstet Gynecol*. 2001;17(1):86-88.
14. Schramm T, Gloning K, Minderer S, et al. Prenatal sonographic diagnosis of skeletal dysplasias. *Ultrasound Obstet Gynecol*. 2009;34(2):160-170.
15. Krakow D, Williams J, Poehl M, et al. Use of three-dimensional ultrasound imaging in the diagnosis of prenatal-onset skeletal dysplasias. *Ultrasound Obstet Gynecol*. 2003;21(5):467-472.

46 Atelosteogenesis Disorders

DEBORAH KRAKOW

Introduction

Atelosteogenesis (AO) refers to a group of lethal short-limb skeletal dysplasias characterized by an abnormal, characteristic facies and hypoplastic or dysplastic tubular bones.[1] Specific radiographic abnormalities, distinct histopathology, and differing inheritance patterns distinguish the three well-recognized types of AO. All three forms have abnormal facies and short limbs, but associated findings help distinguish them from each other; for example, synpolydactyly, omphalocele, and frontal encephalocele are seen in AO I, increased nuchal thickness and hitchhiker thumbs in AO II, and multiple joint dislocations and abnormal hands in AO III.[2,3]

AO is caused by defects in genes involved in skeletal development. AO I and AO III result from heterozygosity for mutations in the gene coding for filamin B (FLNB).[4] AO II, which is recessively inherited, is caused by mutations in the diastrophic dysplasia sulfate transporter (*DTDST,* also referred to as *SLC26A2*) gene.[5] Neonates with all forms of AO frequently succumb, usually in infancy, as a result of respiratory problems (pulmonary insufficiency, laryngeal hypoplasia, and recurrent infections), although some individuals with AO III survive into adulthood.

Disease

DEFINITION

AO disorders are a group of chondrodysplasias with short limbs, unique forms of brachydactyly, and underdeveloped bones. The forms can also be distinguished based on cartilage growth plate histology.[6] The diagnosis is suspected by skeletal findings, usually noted on routine prenatal ultrasound (US) and confirmed with molecular genetic testing, or postnatal radiology findings.

PREVALENCE AND EPIDEMIOLOGY

AO I and III are autosomal dominant disorders, and germ line mosaicism has been reported.[2,7,8] AO II is recessively inherited.[9] Infants with AO I or AO II usually die in the immediate neonatal period from respiratory compromise. AO III is considered semilethal, but there have been long-term survivors.

ETIOLOGY AND PATHOPHYSIOLOGY

AO I and AO III result from mutations in the gene that encodes FLNB. Because these disorders are highly lethal, these mutations are sporadic in occurrence, although germ cell mosaicism has been seen. AO II is caused by either homozygosity or a compound heterozygosity for mutations in the diastrophic dysplasia sulfate transporter *(DTDST, SLC26A2)*.

MANIFESTATIONS OF DISEASE

Clinical Presentation

AO I/III disorders manifest with flattened facies, micrognathia, and shortening of all elements in the appendicular skeleton. Fetuses and neonates with AO I have a dysmorphic facies (hypertelorism, depressed nasal bridge, cleft palate, micrognathia), shortened trunk, rhizomelia, mesomelia, and brachydactyly with a distinct paddle-shape. Dislocations are common, particularly of the hips, and equinovarus is quite common. Neonatal death is due to respiratory insufficiency, usually from pulmonary hypoplasia and laryngeal hypoplasia. There is a spectrum of variability between AO I and AO III, and AO III is distinguished by better-developed long bones.

Fetuses and neonates with AO II have relative macrocephaly, midface hypoplasia, micrognathia, cleft palate, small chest with a protuberant abdomen, equinovarus deformity, and hitchhiker thumbs and toes, with a large gap between toes 1 and 2. The limbs are severely hypoplastic or dysplastic, with poor mineralization of the spine. Neonatal death is typically due to pulmonary hypoplasia and tracheobronchomalacia.

Imaging Technique and Findings

Ultrasound. AO should be suspected in cases with very flattened facies with micrognathia and hypoplastic appendicular bones that are frequently absent or poorly formed, with hypoplastic distal ends, and polyhydramnios.[10-12] Three-dimensional or four-dimensional US is useful in the evaluation of fetuses with skeletal dysplasias, especially for imaging the face and extremities (Fig. 46.1).[13]

AO I shows poor ossification of the spine, small chest, micromelia (Figs. 46.2 and 46.3), abnormally shaped or bowing of the long bones, hypoplastic or dysplastic bones of the hands and feet (paddle shaped, Fig. 46.4), clubfeet, and severe facial dysmorphism (frontal bossing, micrognathia, and possibly cleft palate, Fig. 46.5). Distinctive features of AO II include hitchhiker thumbs and toes (see Fig. 46.1), equinovarus deformity of the feet with saddle gap deformity. The humeri and femora in AO II are severely slender at the distal ends. Phalanges are better ossified in AO II than in AO I and AO III.

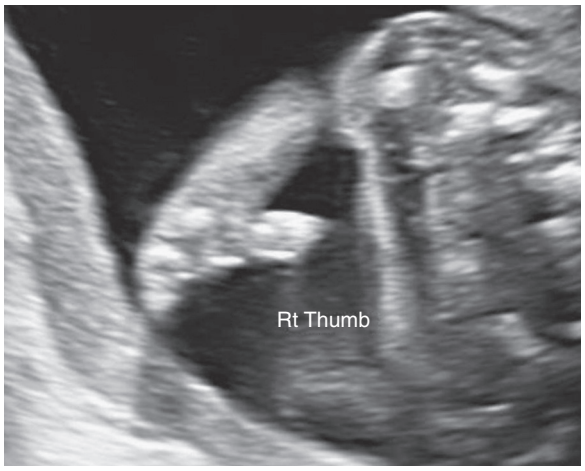

Fig. 46.1 Hitchhiker thumb in fetus with AO I *(Rt Thumb).*



Fig. 46.2 Absent ulna in fetus with AO II.



Fig. 46.3 Three-dimensional (3D) image of a fetus with AOI showing rhizomelia and mesomelia.

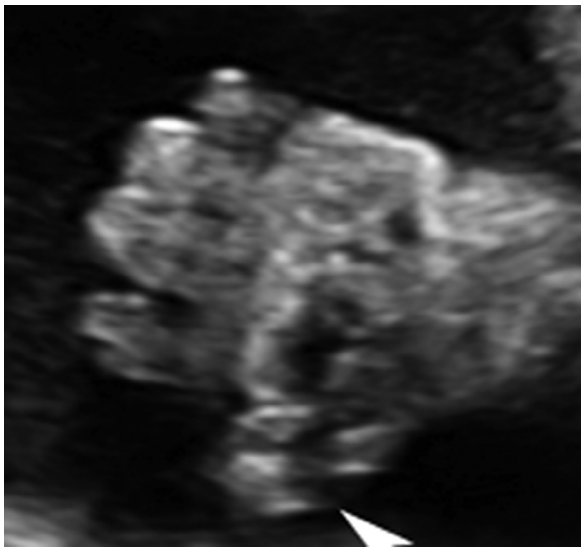

Fig. 46.4 Brachydactyly with broad digits in a fetus with AOI *(arrow).*

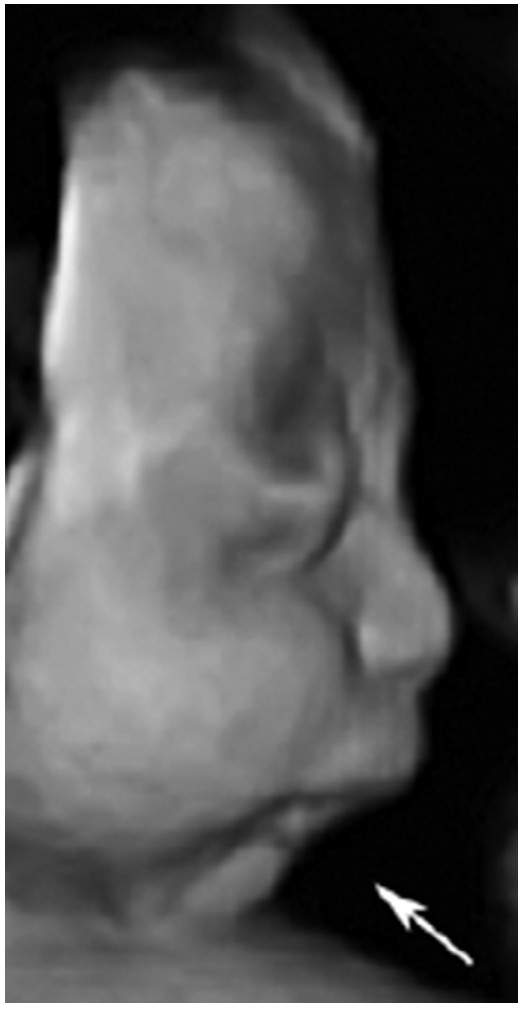

Fig. 46.5 Flattened facies in fetus with AOII *(arrow).*

Magnetic Resonance Imaging. Magnetic resonance imaging (MRI) is occasionally useful in the evaluation of fetuses with skeletal dysplasias, and has reportedly been used for evaluation of AO II.[14] However, expense, inconvenience to the patient, and lack of experience have limited the use of MRI so far.

Other Applicable Modality. Postnatal radiography distinguishes between the three types of AO:

- AO I: absent, shortened, or distally tapered humeri and femora; absent, shortened, or bowed radii; shortened, bowed tibia and ulnae; coronal clefts of the lumbar vertebrae; incomplete ossification of the spine; absent or poor ossification of the proximal and middle phalanges; marked platyspondyly; hypoplastic pelvis; and dislocated hips.
- AO II: normal-sized skull, greater ossification of the limbs and spine than in AO I, clubfeet, cervical kyphosis, hypoplastic ilia with flat acetabulum, unossified pubic bones, metaphyseal flaring of the shortened long bones, abnormal shape of the humeri (bifid, V-shaped, pointed, triangular, hypoplastic), distally rounded femora, and bowed radii and tibia.
- AO III: abnormal hands and feet with short broad metacarpals/metatarsals, multiple joint dislocations of long bones, short tubular bones that are distally tapered but well ossified, and mild vertebral hypoplasia.
- Cartilage growth plate histology findings include giant multinucleated chondrocytes in AO I and AO III. Histopathology in AO II is similar to other *DTDST* disorders, which are characterized by rings around the chondrocytes owing to undersulfated proteoglycans in the extracellular matrix.

CLASSIC SIGNS

Short and hypoplastic long bones
Abnormal flattened facies
Distinctive hands
Joint dislocations

Differential Diagnosis From Imaging Findings

1. Boomerang dysplasia resembles AO I and is allelic due to mutations in filamin B.
2. Larsen syndrome resembles AO I and AO III and is allelic due to mutations in filamin B.[15]
3. Diastrophic dysplasia resembles AO II and is allelic due to mutations in *SLC26A2.*
4. Achondrogenesis IB resembles AO II and is allelic due to mutations in *SLC26A2.*
5. Otopalatodigital dysplasia type II can resembles AO III and results from mutations in a paralogous gene, filamin A (FLNA).[16]

Synopsis of Treatment Options

PRENATAL

The US findings can help distinguish between the diagnosis and distinction between the three types, particularly the hand findings. Recurrence is more suggestive of the recessively inherited AOII. Definitive diagnosis may be offered through invasive testing for AO II *(DTDST/SLC26A2)* and for AO I and AO III (FLNB). Genetic counseling should be offered to assess the recurrence risk.

Although some patients with AO III survive, these are generally considered lethal disorders. Pregnancy termination should be discussed. In continuing pregnancies, obstetric care is routine until delivery, at which point a coordinated plan of care involving perinatal and neonatal services is recommended.

POSTNATAL

AO I and AO II are treated palliatively. Patients with AO III who survive past infancy require a multidisciplinary approach to monitor for cleft palate complications, kyphoscoliosis and dislocations, tracheomalacia, and respiratory compromise.

WHAT THE REFERRING PHYSICIAN NEEDS TO KNOW

Fetuses suspected to have a skeletal dysplasia should be referred for US and genetic counseling to a center with expertise in evaluating the fetal skeleton. Termination of pregnancy should be discussed. Radiographs and molecular genetics can help provide a definitive diagnosis. Prenatal care is routine. Postnatal care for AO I and AO II is palliative. Patients with AO III who survive past infancy require a multidisciplinary approach for the management of complications.

KEY POINTS

- AO syndromes are a group of skeletal disorders with severe micromelia and abnormal facies; associated findings distinguish between the three types and other related disorders. Other congenital anomalies are more likely to be associated with AOI.
- AO is due to mutations in genes that play critical roles in skeletal development (filamin B in the case of AO I and AO III, and diastrophic dysplasia sulfate transporter *[SLC26A2]* in the case of AO II).
- These disorders are suspected on US; definitive diagnosis depends on radiologic findings, histopathology, and molecular genetic testing.
- AO I and AO III are lethal, usually owing to respiratory insufficiency (tracheobronchomalacia and recurrent infections). AO III often results in neonatal death because of respiratory insufficiency, but there are reports of survival into adulthood.

SUGGESTED READING

Bonafe L, Mittaz-Crettol L, Ballhausen D, et al. Atelosteogenesis type 2. In: Pagon RA, Adam MP, Ardinger HH, et al, eds. *GeneReviews*. Seattle (WA): GeneReivews, 1993.
Krakow D, Lachman RS, Rimoin DL. Guidelines for the prenatal diagnosis of fetal skeletal dysplasias. *Genet Med.* 2009;11:127-133.
Krakow D, Rimoin DL. The skeletal dysplasias. *Genet Med.* 2010;12:327-341.
Robertson S. FLNB-related disorders. In: Pagon RA, Adam MP, Ardinger HH, et al, eds. *GeneReviews*. Seattle (WA): GeneReivews, 1993.



All references are available online at www.expertconsult.com.

REFERENCES

1. Sillence D, Worthington S, Dixon J, et al. Atelosteogenesis syndromes: a review, with comments on their pathogenesis. *Pediatr Radiol*. 1997;27(5):388-396.
2. Robertson S. FLNB-Related Disorders. In: Pagon RA, Adam MP, Ardinger HH, et al, eds. *GeneReviews*. Seattle (WA): GeneReivews, 1993.
3. Bonafe L, Mittaz-Crettol L, Ballhausen D, et al. Atelosteogenesis Type 2. In: Pagon RA, Adam MP, Ardinger HH, et al, eds. *GeneReviews*. Seattle (WA): GeneReivews, 1993.
4. Farrington-Rock C, Firestein MH, Bicknell LS, et al. Mutations in two regions of FLNB result in atelosteogenesis I and III. *Hum Mutat*. 2006;27(7):705-710.
5. Rossi A, Superti-Furga A. Mutations in the diastrophic dysplasia sulfate transporter (DTDST) gene (SLC26A2): 22 novel mutations, mutation review, associated skeletal phenotypes, and diagnostic relevance. *Hum Mutat*. 2001;17(3):159-171.
6. Rimoin DL, Sillence DO. Chondro-osseous morphology and biochemistry in the skeletal dysplasias. *Birth Defects Orig Artic Ser*. 1981;17(1):249-265.
7. Bicknell LS, Morgan T, Bonafe L, et al. Mutations in FLNB cause boomerang dysplasia. *J Med Genet*. 2005;42(7):e43.
8. Krakow D, Robertson SP, King LM, et al. Mutations in the gene encoding filamin B disrupt vertebral segmentation, joint formation, and skeletogenesis. *Nat Genet*. 2004;36(4):405-410.
9. Hastbacka J, Superti-Furga A, Wilcox WR, et al. Atelosteogenesis type II is caused by mutations in the diastrophic dysplasia sulfate-transporter gene (DTDST): evidence for a phenotypic series involving three chondrodysplasias. *Am J Hum Genet*. 1996;58(2):255-262.
10. Wessels MW, Den Hollander NS, De Krijger RR, et al. Prenatal diagnosis of boomerang dysplasia. *Am J Med Genet A*. 2003;122A(2):148-154.
11. Ueno K, Tanaka M, Miyakoshi K, et al. Prenatal diagnosis of atelosteogenesis type I at 21 weeks' gestation. *Prenat Diagn*. 2002;22(12):1071-1075.
12. Winer N, Kyndt F, Paumier A, et al. Prenatal diagnosis of Larsen syndrome caused by a mutation in the filamin B gene. *Prenat Diagn*. 2009;29(2):172-174.
13. Krakow D, Williams J 3rd, Poehl M, et al. Use of three-dimensional ultrasound imaging in the diagnosis of prenatal-onset skeletal dysplasias. *Ultrasound Obstet Gynecol*. 2003;21(5):467-472.
14. Miller E, Blaser S, Miller S, et al. Fetal MR imaging of atelosteogenesis type II (AO-II). *Pediatr Radiol*. 2008;38(12):1345-1349.
15. Bicknell LS, Farrington-Rock C, Shafeghati Y, et al. A molecular and clinical study of Larsen syndrome caused by mutations in FLNB. *J Med Genet*. 2007;44(2):89-98.
16. Naudion S, Moutton S, Coupry I, et al. Fetal phenotypes in otopalatodigital spectrum disorders. *Clin Genet*. 2016;89(3):371-377.

47 Campomelic Dysplasia

DEBORAH KRAKOW

Introduction

Campomelic dysplasia (CD) is a skeletal dysplasia characterized by abnormal facies, multiple congenital anomalies, a typical pattern of skeletal abnormalities, and frequent male-to-female sex reversal.[1] Newborns with CD often die as a result of respiratory insufficiency and congenital anomalies. A small subset of individuals with clinical features of CD lack characteristic long bone bowing and are classified as having acampomelic campomelic dysplasia.[2]

CD results from mutations in the gene that encodes *SOX9* gene.[3] *SOX9* is a transcription factor and is involved in testis development and in development of the skeleton. It is a master regulator of endochondral ossification.[4,5] CD is an autosomal dominant condition, and germline mosaicism has been reported.[6] Affected neonates often die in infancy because of respiratory insufficiency secondary to cervical spine instability or airway instability (laryngotracheomalacia). Despite these immediate risks, there are several reports of infants affected with CD who survived the neonatal period, although the prognosis is guarded.[7]

Disorder

DEFINITION

The term *campomelic dysplasia* is based on the Greek word *campomelic,* meaning "bent limb." CD commonly causes skeletal abnormalities, Pierre Robin sequence, and can cause XY sex reversal in 75% of cases. The diagnosis is suspected by skeletal findings often seen on routine prenatal ultrasound (US) and can be confirmed with prenatal or postnatal molecular genetic testing or radiologic findings.

PREVALENCE AND EPIDEMIOLOGY

CD is rare, and specific prevalence data are unavailable. CD does not have specific ethnicity or sex preponderance.

Infants with CD generally die shortly after birth as a result of respiratory insufficiency secondary to airway compromise or cervical spine instability. Interestingly, newborns with CD die of respiratory compromise, yet their chest size is frequently normal, suggesting underlying lung pathology.

ETIOLOGY, PATHOPHYSIOLOGY, AND EMBRYOLOGY

CD is an autosomal dominant disorder resulting from *de novo* mutations in the *SOX9* gene. Most affected individuals have an identifiable mutation. Heterozygosity for mutations involving missense mutations, nonsense mutations, deletion of the coding region, and occasionally chromosomal rearrangements that disrupt the regulatory regions of *SOX9* have been reported.[3,8-10]

If a parent has gonadal mosaicism for a mutation, the recurrence risk is increased and is higher if the parent has somatic mosaicism. There is evidence that mildly affected individuals can have children with classic features of campomelic dysplasia.[6] Unbalanced chromosomal rearrangements within the chromosomal region encoding *SOX9* inherited from a parent can also confer an increased recurrence risk.

MANIFESTATIONS OF DISEASE

Clinical Presentation

CD manifests with characteristic skeletal findings, pretibial skin dimples, dysmorphic facies, dolichocephaly, low set ears, laryngotracheomalacia, dislocated hips, and a high incidence of sex reversal in males. Skeletal abnormalities include hypoplastic scapulae (Fig. 47.1), underdeveloped pubic bones, short and often bowed long bones in the midshaft (Fig. 47.2), hip dislocations (see Fig. 47.2), cervical spine instability (Fig. 47.3) due to hypoplastic cervical vertebrae, and bell-shaped thorax with 11 pairs of ribs. Facial features commonly seen with CD include a relative macrocephaly, flattened midface, long philtrum and micrognathia (Fig. 47.4), and cleft palate.[1]

For infants who survive the neonatal period, intellect may be variable, although kyphoscoliosis, short stature, and hearing loss are commonly observed. These infants often require surgical repair of several abnormalities, including cleft palate, clubfeet, and cervical spine instability.[11]

Ultrasound. CD is often suspected based on several characteristic findings, including bent or shortened long bones, hypoplastic scapulae, clubfeet, hypoplastic, and ambiguous



Fig. 47.1 Hypoplastic scapulae in a fetus with CD.

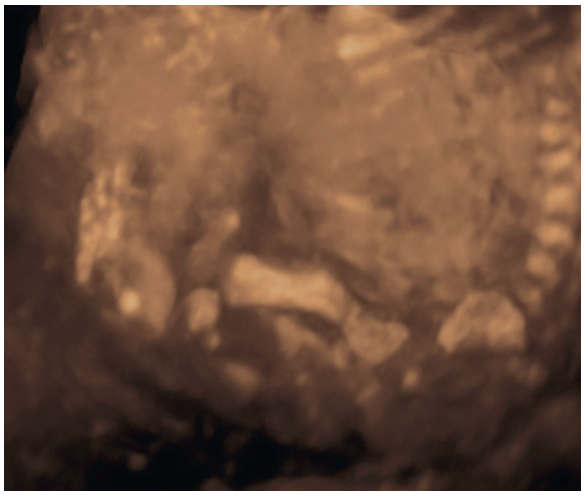

Fig. 47.2 Bent femur and joint dislocation in a fetus with CD.



Fig. 47.3 Cervical kyphosis in a fetus with CD.

genitalia or complete sex reversal in fetuses with a 46,XY karyotype.[12]

The femora and tibiae are the most frequently bent bones. Additional US findings include micrognathia and small chest size with normal head circumference. Three-dimensional or four-dimensional US is useful in the evaluation of fetuses with skeletal dysplasias, especially for imaging the face and the shape of the long bones (see Figs. 47.2–47.4). With experienced sonographers and imaging experts, many cases of CD can be predicted prenatally.

Magnetic Resonance Imaging. Magnetic resonance imaging (MRI) is occasionally useful in the evaluation of fetuses with skeletal dysplasias, particularly for clarification of vertebral abnormalities. However, expense, inconvenience to the patient, and lack of experience have limited use of MRI so far.

Other Applicable Modality. Postnatal x-rays and physical examination are mandatory to make a definitive diagnosis of



Fig. 47.4 Micrognathia in a 22-week fetus.

CD. Physical features include micrognathia, cleft palate, flattened facies, and relative macrocephaly. The radiographic constellation of findings that are highly diagnostic include bowed femora and tibiae, hypoplastic scapula, and cervical and thoracic spine abnormalities, narrow iliac bones, abnormal ischial bones, underossification of proximal tibial epiphyses, scoliosis, hip dislocations, 11 pairs of ribs, and short metacarpals and middle phalanges of the second through fifth digits.

CLASSIC SIGNS

Short or bent long bones
Joint dislocations
Hypoplastic scapulae
Underdeveloped pubic bones
Ambiguous or female genitalia in 46,XY fetuses

Differential Diagnosis From Imaging Findings

1. Osteogenesis imperfecta
2. Hypophosphatasia
3. Stuve-Wiedemann syndrome
4. Antley-Bixler syndrome
5. Cousin syndrome
6. Ischiopubic patellar syndrome

Synopsis of Treatment Options

PRENATAL

No prenatal treatment options exist for campomelic dysplasia. Although patients with CD survive in rare cases, it is generally considered a lethal disorder, and pregnancy termination should be discussed. For patients choosing to continue the pregnancy, routine obstetric care is standard until delivery, at which point a coordinated plan of care involving perinatal and neonatal services is recommended. Palliative and therapeutic treatment

options should be discussed in cases of pregnancy continuation. Definitive diagnosis is possible via molecular testing or by postnatal radiographs.

POSTNATAL

Treatment for CD after birth may either be palliative or involve supportive methods. Surgical repair of cleft palate, cervical spine instability, and kyphoscoliosis is often necessary. Additionally, orthopedic intervention is required for repair of clubfeet. In cases of 46,XY sex reversal, gonadectomy is often indicated because of the risk of gonadoblastoma.

WHAT THE REFERRING PHYSICIAN NEEDS TO KNOW

Fetuses suspected to have a skeletal dysplasia should be referred to a center with expertise in evaluating the fetal skeleton for US examination and genetic counseling. Termination of pregnancy should be discussed. Postnatal autopsy that includes radiographs and molecular genetics can lead to a definitive diagnosis. Prenatal care is routine. Postnatal care is usually palliative. Infants who survive the neonatal period require a multidisciplinary approach for management of complications.

KEY POINTS

- CD is associated with characteristic skeletal findings, including bowed or shortened long bones, hypoplastic scapulae, and dislocated hips.
- CD is due to heterozygosity for mutations in the *SOX9* gene that is involved with both *SRY* function and endochondral ossification.
- 46,XY sex reversal is seen in males.
- CD may be suspected on US, but definitive diagnosis often depends on molecular genetic testing or postnatal radiologic findings.
- CD is usually lethal, owing to respiratory insufficiency (caused by tracheobronchomalacia or cervical spine insufficiency, or both). Although most cases of CD result in neonatal death, there are reports of survival into adulthood.

SUGGESTED READING

Krakow D, Lachman RS, Rimoin DL. Guidelines for the prenatal diagnosis of fetal skeletal dysplasias. *Genet Med*. 2009;11:127-133.
Krakow D, Rimoin DL. The skeletal dysplasias. *Genet Med*. 2010;12:327-341.



All references are available online at www.expertconsult.com.

REFERENCES

1. Unger S, Scherer G, Superti-Furga A. Campomelic dysplasia. In: Pagon RA, Adam MP, Ardinger HH, et al, eds. *GeneReviews*. Seattle (WA): GeneReviews, 1993.
2. Leipoldt M, Erdel M, Bien-Willner GA, et al. Two novel translocation breakpoints upstream of SOX9 define borders of the proximal and distal breakpoint cluster region in campomelic dysplasia. *Clin Genet*. 2007;71(1):67-75.
3. McDowall S, Argentaro A, Ranganathan S, et al. Functional and structural studies of wild type SOX9 and mutations causing campomelic dysplasia. *J Biol Chem*. 1999;274(34):24023-24030.
4. Benko S, Gordon CT, Mallet D, et al. Disruption of a long distance regulatory region upstream of SOX9 in isolated disorders of sex development. *J Med Genet*. 2011;48(12):825-830.
5. Bernard P, Tang P, Liu S, et al. Dimerization of SOX9 is required for chondrogenesis, but not for sex determination. *Hum Mol Genet*. 2003;12(14):1755-1765.
6. Smyk M, Obersztyn E, Nowakowska B, et al. Recurrent SOX9 deletion campomelic dysplasia due to somatic mosaicism in the father. *Am J Med Genet A*. 2007;143A(8):866-870.
7. Mansour S, Offiah AC, McDowall S, et al. The phenotype of survivors of campomelic dysplasia. *J Med Genet*. 2002;39(8):597-602.
8. Meyer J, Sudbeck P, Held M, et al. Mutational analysis of the SOX9 gene in campomelic dysplasia and autosomal sex reversal: lack of genotype/phenotype correlations. *Hum Mol Genet*. 1997;6(1):91-98.
9. Olney PN, Kean LS, Graham D, et al. Campomelic syndrome and deletion of SOX9. *Am J Med Genet*. 1999;84(1):20-24.
10. Fukami M, Tsuchiya T, Takada S, et al. Complex genomic rearrangement in the SOX9 5' region in a patient with Pierre Robin sequence and hypoplastic left scapula. *Am J Med Genet A*. 2012;158A(7):1529-1534.
11. Thomas S, Winter RB, Lonstein JE. The treatment of progressive kyphoscoliosis in camptomelic dysplasia. *Spine*. 1997;22(12):1330-1337.
12. Schramm T, Gloning KP, Minderer S, et al. Prenatal sonographic diagnosis of skeletal dysplasias. *Ultrasound Obstet Gynecol*. 2009;34(2):160-170.

48 Chondrodysplasia Punctata

DEBORAH KRAKOW

Introduction

Chondrodysplasia punctata refers to a group of skeletal dysplasias that are characterized primarily by punctate calcifications in cartilage (calcific stippling). These disorders are characterized by short-limb dwarfism, spinal abnormalities, facial dysmorphisms, joint contractures, skin lesions, and occasionally cardiac malformations.[1] There are multiple types of chondrodysplasia punctata, and there is extensive locus and allelic heterogeneity.

Disorder

DEFINITION

The term *chondrodysplasia punctata* describes a group of osteochondrodysplasias characterized by punctate calcifications in cartilage, depending on the type and genetic alterations, and other organ system abnormalities.

PREVALENCE AND EPIDEMIOLOGY

The heterogeneous bone dysplasias comprising chondrodysplasia punctata occur with an incidence of approximately 1:100,000 live births. The exact incidence for the specific types is unknown.

ETIOLOGY, PATHOPHYSIOLOGY, AND EMBRYOLOGY

There are six main types of chondrodysplasia punctata:

- rhizomelic form types 1, 2, and 3 (autosomal recessive)
- Conradi-Hünermann syndrome 2 (X-linked dominant) (CDPX2)
- brachytelephalangic (X-linked recessive) (CDXP1)
- autosomal dominant type (autosomal dominant)

Rhizomelic chondrodysplasia punctata, usually lethal by 2 years of age, is a rare autosomal recessive disorder of peroxisome metabolism. It is characterized by rhizomelic shortening of the long bones (humeri and femora) and punctate calcifications of the cartilaginous portions of skeleton, particularly the proximal humeri and femora. Rhizomelic chondrodysplasia punctata can be subclassified into three types based on locus heterogeneity, although all are recessively inherited and result from homozygous or compound heterozygous mutations. Type 1 results from mutations in the *PEX7* gene that encodes peroxin 7.[2] Type 2 results from mutations in the acyl-CoA:dihydroxyacetonephosphate acyltransferase *(DHAPAT)* gene, and type 3 results from mutations in the alkyl-dihydroxyacetonephosphate synthase *(ADAPS)* gene.

Conradi-Hünermann syndrome is an X-linked dominant form that is due to a deficiency of delta(8)-delta(7) sterol isomerase emopamil-binding protein.[3] This form is probably

lethal in the hemizygous state in affected males. Affected females have elevated serum levels of 8(9)-cholesterol and 8-dehydrocholesterol. The brachytelephalangic type of chondrodysplasia punctata (CDXP1) results from mutations in the gene that encodes arylsulfatase E.[4,5] In the autosomal dominant type of chondrodysplasia punctata and the very similar tibia-metacarpal type, the molecular defect has not yet been defined.

MANIFESTATIONS OF DISEASE

Clinical Presentation

The clinical characteristics of rhizomelic chondrodysplasia punctata are usually severe and include microcephaly, frontal bossing, micrognathia, congenital cataracts, cleft palate, respiratory insufficiency, calcific stippling in cartilage, kyphoscoliosis, symmetric shortening of the proximal long bones (rhizomelia), joint contractures, ichthyosis, alopecia, seizures, and cortical atrophy. Affected children usually die by 2 years of age.[1]

Conradi-Hünermann syndrome (CDXP2) is an X-linked dominant type disorder characterized by failure to thrive in early infancy, mild to moderate growth deficiency, abnormal ears, deafness, cataracts, flattened midface, calcific stippling, scoliosis, hemivertebrae, asymmetric limb shortening, ichthyosis, coarse sparse hair, and occasional mental retardation. The brachytelephalangic type is an X-linked recessive disorder, and its manifestation is similar to other forms of chondrodysplasia punctata. Affected individuals have short stature, deafness, cataracts, facial dysmorphisms, calcific stippling in cartilage, distal phalangeal hypoplasia, and developmental delay. The autosomal dominant type of chondrodysplasia punctata and the similar tibia-metacarpal type are distinguished by dominant inheritance. Both manifest with short limbs; fine punctata are usually confined to the spine in the dominant form, and in the tibia-metacarpal type there is more discrete calcific stippling, particularly in the hands and vertebrae, short tibiae, and shortened second and third or third and fourth metacarpals.[6]

Imaging Technique and Findings

Ultrasound. Ultrasound (US) findings can help identify the type of chondrodysplasia punctata.[7–9] In all forms, there is evidence of cartilaginous stippling usually in the proximal humeri and femora, the distal portions of the femora, and the calcaneus. In many cases, this stippling leads to significant shortening of the rhizomelic portions of the bones. Depending on the severity, stippling may be apparent in the second trimester (Figs. 48.1 and 48.2).

In addition to the aforementioned findings, coronal clefts of the vertebrae, scoliosis, micrognathia, microcephaly, cataracts, ocular coloboma, cleft palate, flat nasal bridge (Fig. 48.3), frontal bossing, foot deformities, and polydactyly have been seen in chondrodysplasia punctata. It is crucial to obtain a detailed family history because of the recurrence risk; a high index of suspicion is needed for the recessive rhizomelic form of chondrodysplasia punctata and the X-linked recessive brachytelephalangic type. Three-dimensional or four-dimensional US is useful in the evaluation of fetuses with skeletal disorders, especially for imaging the face and extremities.

Magnetic Resonance Imaging. Magnetic resonance imaging (MRI) is occasionally useful in the evaluation of fetuses with skeletal dysplasias, particularly for clarification of vertebral abnormalities. MRI can be particularly important in these disorders because of the high risk of prenatal onset cervical stenosis, which can be seen by fetal MRI and may be a medical emergency after delivery. Microcephaly and abnormal neuronal migration may be detected in the recessive rhizomelic type of chondrodysplasia punctata, but the abnormal US findings in the skeleton may be more diagnostic.

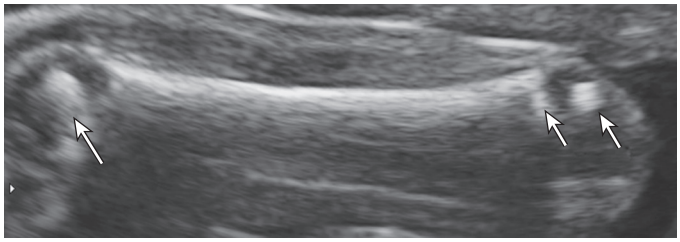

Fig. 48.1 Conradi-Hünermann syndrome at 22 weeks' gestation shows calcific stippling in the proximal and distal humerus *(arrows)*.

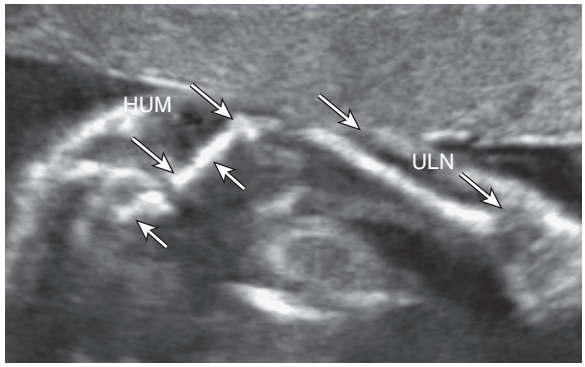

Fig. 48.2 Rhizomelic chondrodysplasia punctata at 19 weeks' gestation shows calcific stippling in the proximal humerus *(arrows)*. *Arrow* points to the foreshortened humerus *(HUM)* relative to the ulna *(ULN)*.

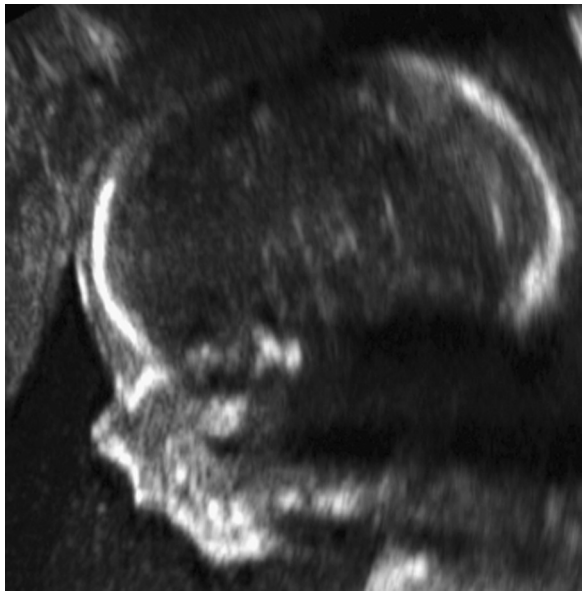

Fig. 48.3 Profile at 22 weeks' gestation of a fetus with Conradi-Hünermann syndrome shows flattened facies (absent nasal bridge) with small, upturned nares.

CLASSIC SIGNS

Punctate calcifications of epiphyseal cartilage of the long bones (calcific stippling), especially if associated with shortening in the appendicular skeleton.

Differential Diagnosis From Imaging Findings

Stippling of the calcaneus can be seen in chromosomal abnormalities and other skeletal dysplasias. Diffuse calcific stippling with significant phenotypic overlap with the types of chondrodysplasia punctata has been seen in maternal lupus erythematosus affecting the fetus and warfarin exposure.[10–12] Zellweger syndrome is an autosomal recessive systemic disorder defined by severe neurologic dysfunction, craniofacial abnormalities, and liver dysfunction. Rhizomelic chondrodysplasia punctata is considered distinct from Zellweger syndrome, although in the prenatal period the microcephaly and facial features may appear very similar and both disorders result from absence of peroxisome activity.

Synopsis of Treatment Options

PRENATAL

There are no prenatal treatment interventions at the present time for the various types of chondrodysplasia punctata. US examination suggestive of chondrodysplasia warrants referral for further detailed US evaluation and genetic counseling. Invasive testing may provide a definitive diagnosis. Termination of pregnancy should be discussed in some cases. A coordinated delivery plan involving obstetrics and neonatology teams should be developed. Prenatal and intrapartum management are generally routine. A workup for lupus should be discussed, particularly when there is no family history. Note that exposure to warfarin in early gestation can cause similar findings to this disorder.

POSTNATAL

Postnatal treatment of chondrodysplasia is largely symptomatic. Spinal deformities, choanal stenosis, cataracts, and cardiac defects may be able to be corrected surgically depending on the severity. Long-term prognosis largely depends on the underlying biochemical defect. Although the rhizomelic subtypes are almost universally fatal, the nonrhizomelic subtypes occasionally have a good prognosis with improvement of early radiologic features and normal intellect in many cases.

WHAT THE REFERRING PHYSICIAN NEEDS TO KNOW

Fetuses with a suspected skeletal dysplasia should be referred to a center with expertise in evaluating the fetal skeleton for US examination and genetic counseling. The various forms of chondrodysplasia punctata have differing modes of inheritance, different recurrence risks, and different molecular bases of disease. There are some forms that are difficult to classify. Early prenatal diagnosis of specific subtypes of chondrodysplasia punctata can be achieved through identifying the pattern of calcific stippling, which may give clues to the subtype. In some cases, termination of pregnancy should be discussed. Prenatal care is routine. A coordinated delivery plan involving obstetrics and neonatology teams should be developed. Postnatal care is supportive, depending on specific complications, and requires a multidisciplinary approach.

KEY POINTS

- Chondrodysplasia punctata is characterized by punctate calcifications of cartilage.
- There are six well-established forms with differing modes of inheritance and genetic bases of disease.

SUGGESTED READING

Krakow D, Lachman RS, Rimoin DL. Guidelines for the prenatal diagnosis of fetal skeletal dysplasias. *Genet Med*. 2009;11:127-133.
Krakow D, Rimoin DL. The skeletal dysplasias. *Genet Med*. 2010;12:327-341.



All references are available online at www.expertconsult.com.

REFERENCES

1. White AL, Modaff P, Holland-Morris F, et al. Natural history of rhizomelic chondrodysplasia punctata. *Am J Med Genet A*. 2003;118:332-342.
2. Braverman N, Steel G, Obie C, et al. Human PEX7 encodes the peroxisomal PTS2 receptor and is responsible for rhizomelic chondrodysplasia punctata. *Nat Genet*. 1997;15:369-376.
3. Braverman N, Lin P, Moebius FF, et al. Mutations in the gene encoding 3-beta-hydroxysteroid-delta(8),delta(7)-isomerase cause X-linked dominant Conradi-Hunermann syndrome. *Nat Genet*. 1999;22:291-294.
4. Franco B, Meroni G, Parenti G, et al. A cluster of sulfatase genes on Xp22.3: mutations in chondrodysplasia punctata (CDPX) and implications for warfarin embryopathy. *Cell*. 1995;81:1-20.
5. Nino M, Matos-Miranda C, Maeda M, et al. Clinical and molecular analysis of arylsulfatase E in patients with brachytelephalangic chondrodysplasia punctata. *Am J Med Genet A*. 2008;146:997-1008.
6. Savarirayam R, Boyle RJ, Masel J, et al. Long-term follow-up in chondrodysplasia punctata, tibia-metacarpal type demonstrating natural history. *Am J Med Genet A*. 2005;134:148-157.
7. Pryde PG, Bawle E, Brandt F, et al. Prenatal diagnosis of nonrhizomelic chondrodysplasia punctata (Conradi-Hünermann syndrome). *Am J Med Genet*. 1993;47:426-431.
8. Schramm T, Gloning KP, Minderer S, et al. Prenatal diagnosis of skeletal dysplasias. *Ultrasound Obstet Gynecol*. 2009;34:160-170.
9. Sherer DM, Glantz JC, Allen TA, et al. Prenatal sonographic diagnosis of non-rhizomelic chondrodysplasia punctata. *Obstet Gynecol*. 1994;83(5 Pt 2):858-860.
10. Austin-Ward E, Castillo S, Cuchacovich M, et al. Neonatal lupus syndrome: a case with chondrodysplasia punctata and other unusual manifestations. *J Med Genet*. 1998;35:695-697.
11. Elcioglu N, Hall CM. Maternal systemic lupus erythematosus and chondrodysplasia punctata in two sibs: phenocopy or coincidence? *J Med Genet*. 1998;35:690-694.
12. Kozlowski K, Basel D, Beighton P. Chondrodysplasia punctata in siblings and maternal lupus erythematosus. *Clin Genet*. 2004;66:545-549.

49 DTDST Dysplasia (Including AOII and Achondrogenesis IB)

DEBORAH KRAKOW

Introduction

Diastrophic dysplasia (DTD) is an autosomal, recessively inherited skeletal dysplasia characterized by short limbs, normal-sized skull, cleft palate in one-third of patients, characteristic swelling of the pinnae cartilage, contractures of the large joints with deformities, spinal abnormalities (scoliosis, exaggerated lumbar lordosis, cervical kyphosis), and a distinct brachydactyly associated with the characteristic "hitchhiker" thumbs.[1] Newborns with DTD have an increased risk of mortality in the neonatal period due to respiratory insufficiency (small rib cage, tracheal instability and collapsibility, and increased incidence of pneumonias), but most individuals with the condition live into adulthood and develop significant physical limitations.

DTD is caused by homozygosity or compound heterozygosity for mutations in the *SLC26A2* gene.[2] It is the only gene known

to produce this disorder with no evidence for locus heterogeneity. Recessively inherited mutations in *SLC26A2* can vary in severity from lethality to short stature associated with early onset osteoarthritis. From most to least severe, these conditions include achondrogenesis type IB, atelosteogenesis type II, and recessively inherited multiple epiphyseal dysplasia.[2] There is a known genotype-phenotype correlation with mutations in the *SLC262A* gene; those mutations associated with the least amount of sulfate uptake in the cells are associated with more severe phenotypes.

Disorder

DEFINITION

The term *diastrophic dysplasia* derives from the word diastrophism, the process of bending of the earth's crust. Thus, the term refers to the manner in which the spine and limbs appear twisted in this disorder. The diagnosis is generally suspected by skeletal findings and physical features seen after birth, but DTD should be suspected prenatally when abnormalities are seen on ultrasound (US) examination or in the presence of a positive family history, particularly consanguinity.[3] The diagnosis can be confirmed with prenatal or postnatal molecular genetic testing or postnatal radiologic findings.

PREVALENCE AND EPIDEMIOLOGY

DTD is thought to occur in approximately 1:100,000 births, although specific prevalence data are unavailable. Although DTD is seen in all ethnic backgrounds, the condition is seen more often in individuals of Finnish descent (1:30,000).[4] Individuals with DTD most often survive into adulthood and are often able to have children of their own.

ETIOLOGY, PATHOPHYSIOLOGY, AND EMBRYOLOGY

DTD is autosomal recessive in inheritance due to mutations in the *SLC26A2* gene.[2] Most of the mutations result in a loss of function of the gene. The severity of the diagnosis depends on the specific mutation present and its effects on the incorporation of sulfate into proteoglycans of the extracellular matrix of cartilage. Approximately 90% of individuals with a clinical diagnosis have an identifiable mutation; however, the most common *SLC26A2* mutations account for nearly 65% of all cases. The four most common *SLC26A2* pathogenic variants include p.Arg279Trp, c.–26+2T>C (IVS1+2T>C), p.Arg178Ter, and p.Cys653Ser and account for approximately 65% of disease alleles in diastrophic dysplasia.[1] Although chromosomal rearrangements and deletions may be possible, they have not been reported to date.

In nearly all cases of DTD, both parents are unaffected carriers and recurrence risk to their offspring is 25%. To date, no *de novo* or germline mutations have been reported in this disorder. There is evidence that heterozygous mutations in the *SLC26A2* can produce dysplastic spondylolysis, suggesting a new clinical disorder involving the lumbosacral spine.[5]

MANIFESTATIONS OF DISEASE

Clinical Presentation

Nearly all individuals (95%) with DTD display proximal, abducted thumbs, resulting in a hitchhiker thumb appearance. Skeletal abnormalities often include shortened limbs, smaller than average chest, joint contractures, cervical kyphosis, and clubfeet. Less frequently, individuals with DTD have radial dislocation, tibial and radial bowing, and a gap between the first and second toes. Cleft palate is seen in approximately one-third of affected individuals. Additionally, neonatal swelling of the ears has been seen in approximately two-thirds of individuals with DTD and may lead to deformation of the ears.[6]

For most individuals with DTD, intellect is normal; short stature, cervical spine instability, and joint contractures all are commonly observed. These individuals often require surgical repair of several abnormalities including cleft palate, clubfeet, and cervical spine instability.

Imaging Technique and Finding

Ultrasound. Lethal and life-limiting skeletal dysplasias are frequently detected on routine prenatal US, but distinguishing among the various specific skeletal dysplasias is often difficult.[7] DTD should be suspected in the case of several characteristic findings, including shortened long bones (Fig. 49.1), twisting or bending of the spine (Fig. 49.2), hitchhiker thumbs (Fig. 49.3),

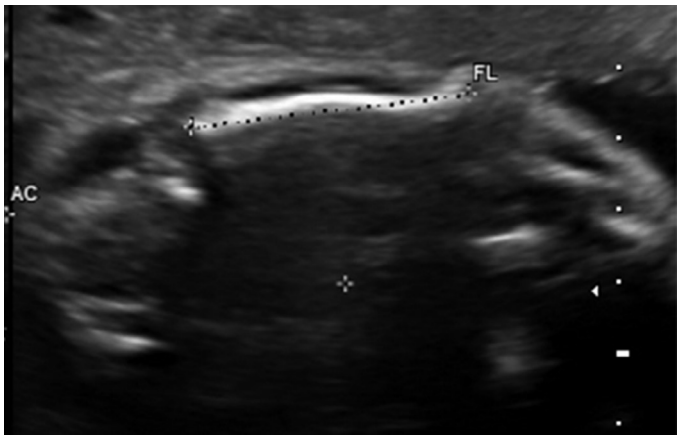

Fig. 49.1 US showing shortened bowed femur at 22 weeks.

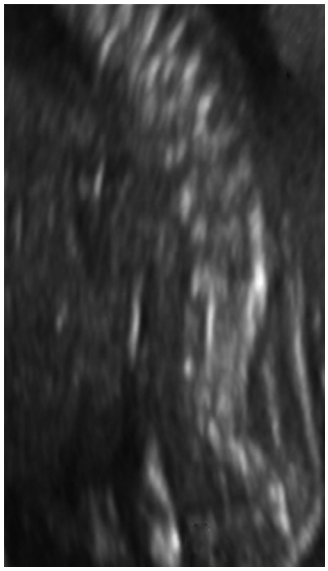

Fig. 49.2 US showing scoliosis in the spine at 22 weeks.

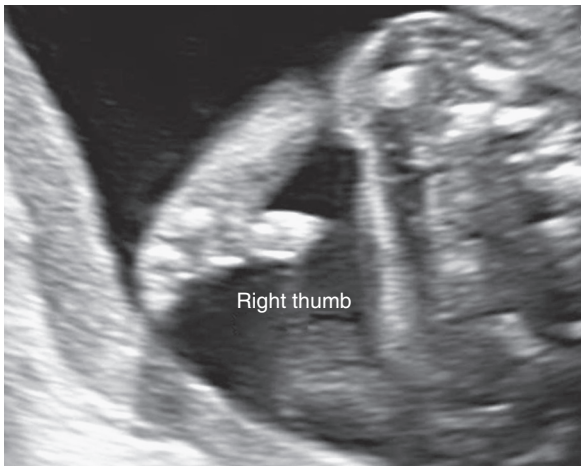

Fig. 49.3 US showing characteristic "hitcher" thumb at 22 weeks.

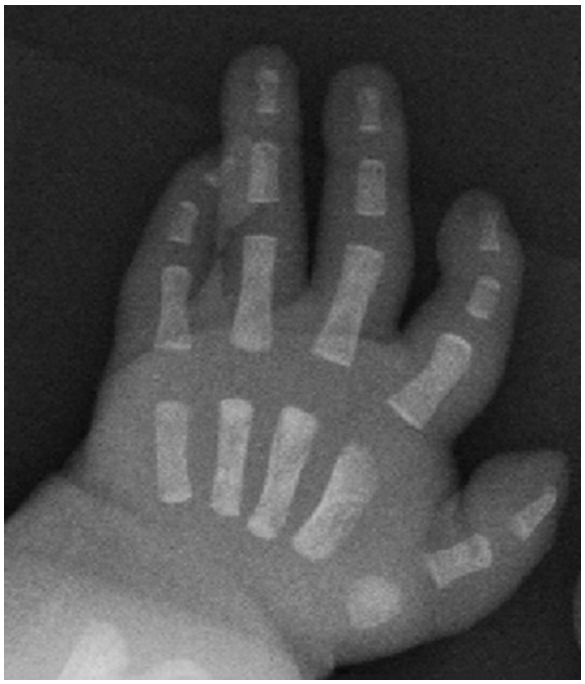

Fig. 49.4 Postnatal radiograph of the newborn showing characteristic hand abnormalities with shortened deviated thumb, brachydactyly, and advanced carpal age.

and clubfeet. Experienced sonographers and perinatologists commonly are able to diagnose cases of DTD prenatally, but cases may go undetected until after birth. Three-dimensional or four-dimensional US is useful in the evaluation of fetuses with skeletal dysplasias, especially for imaging the face and extremities.

Magnetic Resonance Imaging. Postnatal magnetic resonance imaging (MRI) may prove helpful in the evaluation and diagnosis of individuals with suspected DTD. However, it has not been reported for DTD, though MRI has been performed for the more severe allelic disorder, ateleosteogenesis II.[8]

Other Applicable Modality. Postnatal x-rays and physical examination provide a definitive diagnosis of DTD. Physical features include swelling of the ears, cleft palate, joint contractures, and short fingers. Radiologic findings are generally consistent among affected individuals, and the constellation of features often leads to a confident clinical diagnosis. Diagnostic clinical features common in individuals with DTD include features that may also be seen on US examination (i.e., shortened long bones, hitchhiker thumbs [Fig. 49.4], clubfeet [Fig. 49.5], and others that develop with age, such as hip and cervical spine abnormalities, and varying degrees of scoliosis).[9-11]

CLASSIC SIGNS

Hitchhiker thumbs
Shortened limbs
Clubfeet
Cleft palate
Cervical spine instability
Joint contractures
Scoliosis



Fig. 49.5 Postnatal radiograph of the newborn showing characteristic club foot, deviated medially placed hallux, and advanced ossification of the calcaneus and tallus.

Differential Diagnosis From Imaging Findings

1. Achondrogenesis type IB
2. Atelosteogenesis type II

Synopsis of Treatment Options

PRENATAL

No prenatal treatment options exist for DTD. Although patients with DTD may die as neonates, it is generally considered a

nonlethal disorder. Because of the associated health complications, pregnancy termination should be discussed. For continuing pregnancies, routine obstetric care is standard until delivery, at which point a coordinated plan of care involving neonatal and pediatric services is recommended.[12]

POSTNATAL

Treatment for DTD after birth involves therapeutic methods. Surgical repair of cleft palate is often indicated early in life. However, the timing of surgical repair or treatment for cervical spine instability, scoliosis, and joint abnormalities is not widely agreed on, and additional complications may arise after surgery. Additionally, orthopedic intervention is often required for the repair of clubfeet.

WHAT THE REFERRING PHYSICIAN NEEDS TO KNOW

Fetuses with a suspected skeletal dysplasia should be referred to a center with expertise in evaluating the fetal skeleton for US examination and genetic counseling. Prenatal or postnatal molecular testing, in addition to postnatal physical and x-ray examination, can provide a definitive diagnosis and, importantly, an accurate recurrence risk. Prenatal care is routine. Delivery should occur in a tertiary hospital to facilitate a multidisciplinary approach for management of complications.

KEY POINTS

- DTD is associated with various skeletal findings, including shortened limbs, joint contractures, spinal abnormalities, and hitchhiker thumbs. Cleft palate and swelling of the ears are commonly seen as well.
- DTD is due to recessive mutations in the *SLC26A2* gene, which are also associated with achondrogenesis type IB, atelosteogenesis type II, and recessively inherited multiple epiphyseal dysplasia.
- Although DTD may be suspected on US, definitive diagnosis often depends on molecular genetic testing or postnatal radiologic findings, or both.
- DTD is usually compatible with life, although stabilization of the airway may be necessary neonatally, and surgical treatments may be needed. Intelligence is generally normal.
- Because DTD is inherited in an autosomal recessive manner, couples with one affected child usually have a 25% chance of having additional children affected with the condition.

SUGGESTED READING

Bonafe L, Mittaz-Crettol L, Ballhausen D, et al. Diastrophic dysplasia. In: Pagon RA, Adam MP, Ardinger HH, et al., eds. *GeneReviews*. Seattle (WA): 1993.
Krakow D. Skeletal dysplasias. *Clin Perinatol*. 2015;42(2):301-319, viii.



All references are available online at www.expertconsult.com.

REFERENCES

1. Bonafe L, Mittaz-Crettol L, Ballhausen D, et al. Diastrophic dysplasia. In: Pagon RA, Adam MP, Ardinger HH, et al., eds. *GeneReviews*. Seattle (WA): 1993.
2. Rossi A, Superti-Furga A. Mutations in the diastrophic dysplasia sulfate transporter (DTDST) gene (SLC26A2): 22 novel mutations, mutation review, associated skeletal phenotypes, and diagnostic relevance. *Hum Mutat*. 2001;17(3):159-171.
3. Honorio JC, Bruns RF, Grundtner LF, et al. Diastrophic dysplasia: prenatal diagnosis and review of the literature. *Sao Paulo Med J*. 2013;131(2): 127-132.
4. Hastbacka J, Kerrebrock A, Mokkala K, et al. Identification of the Finnish founder mutation for diastrophic dysplasia (DTD). *Eur J Hum Genet*. 1999;7(6):664-670.
5. Cai T, Yang L, Cai W, et al. Dysplastic spondylolysis is caused by mutations in the diastrophic dysplasia sulfate transporter gene. *Proc Natl Acad Sci USA*. 2015;112(26):8064-8069.
6. Cushing SL, Swanson RL, Sie KC. Prevention of auricular deformity in children with diastrophic dysplasia. *Int J Pediatr Otorhinolaryngol*. 2011;75(5):713-715.
7. Schramm T, Gloning KP, Minderer S, et al. Prenatal sonographic diagnosis of skeletal dysplasias. *Ultrasound Obstet Gynecol*. 2009;34(2):160-170.
8. Miller E, Blaser S, Miller S, et al. Fetal MR imaging of atelosteogenesis type II (AO-II). *Pediatr Radiol*. 2008;38(12):1345-1349.
9. Al Kaissi A, Kenis V, Melchenko E, et al. Corrections of lower limb deformities in patients with diastrophic dysplasia. *Orthop Surg*. 2014;6(4):274-279.
10. Jasiewicz B, Potaczek T, Duda S, et al. Cervical spine surgery in patients with diastrophic dysplasia: case report with long-term follow-up. *J Craniovertebr Junction Spine*. 2015;6(4):216-218.
11. Jalanko T, Remes V, Peltonen J, et al. Treatment of spinal deformities in patients with diastrophic dysplasia: a long-term, population based, retrospective outcome study. *Spine*. 2009;34(20):2151-2157.
12. Krakow D. Skeletal dysplasias. *Clin Perinatol*. 2015;42(2):301-319, viii.

50 FGFR3 Disorders: Thanatophoric Dysplasia, Achondroplasia, and Hypochondroplasia

DEBORAH KRAKOW

Introduction

Fibroblast growth factor receptor 3 (*FGFR3)* disorders compromise of a spectrum of disorders that include thanatophoric dysplasia, achondroplasia, and hypochondroplasia, among other rare disorders such as severe achondroplasia with developmental delay and acanthosis nigricans (SADDAN), and craniosyntoses syndromes.[1] They are all inherited as autosomal dominant disorders due to heterozygosity for mutations in *FGFR3*.[1] Achondroplasia is the most frequent cause of nonlethal dwarfism and is characterized by relative macrocephaly, characteristic facies, shorted long bones, long trunk, and a distinct form of brachydactyly associated with a trident configuration to the hand. Because of nonassortative mating in the dwarf community, homozygosity for achondroplasia mutations are seen and frequently associated with a high degree of perinatal lethality.[2]

Disorder

DEFINITION

Thanatophoric dysplasia, achondroplasia, and hypochondroplasia were historically recognized as distinct disorders with overlapping features.[1] With the discovery of *FGFR3* as the disease gene for all three disorders, they are now considered a "bone family."[3] All three disorders are osteochondrodysplasias characterized by varying degrees of skeletal abnormalities. Thanatophoric dysplasia is lethal without very aggressive interventions.[4] Achondroplasia is nonlethal with some rare exceptions.[2] Hypochondroplasia can phenotypically mimic achondroplasia but is usually milder.[5] In hypochondroplasia, transmission is autosomal dominant, and most cases are the result of heterozygosity for *de novo* mutations in the *FGFR3* gene.[6] Thanatophoric dysplasia and achondroplasia

can be detected by prenatal ultrasound (US), and hypochondroplasia, while milder, may be detected prenatally, particularly when there is an affected parent.

PREVALENCE AND EPIDEMIOLOGY

Precise incidences of these disorders are not truly known, but they are among the more commonly seen skeletal disorders and are estimated at 1 in 20,000.[7] They result from dominantly inherited mutations, and there is no ethnic or racial predisposition. Most cases are the result of *de novo* mutations, seemingly only from the paternally derived allele.[8] The risk of FGFR3 disorders increases with advanced paternal age.[8] The chance of phenotypically normal parents having a second affected child is very low, but can occur due to germline mosaicism. Homozygous achondroplasia occurs in one-quarter of the offspring of two affected parents.[9]

ETIOLOGY, PATHOPHYSIOLOGY,[6,10,11] AND EMBRYOLOGY

Thanatophoric dysplasias, achondroplasia, and hypochondroplasia all cause gain of function mutations in the gene that encodes for FGFR3.[11] Recurrent mutations have been seen for all three disorders, allowing for targeted gene analysis. In achondroplasia, most of the patients carry the mutation p.Gly380Arg.[1]

FGFR3 disorders result from activating mutations in the receptor leading to abnormal proliferation and regulation of growth plate chondrocytes, and conasequent poor endochondral growth.[6,12] The degree of gain in *FGFR3* function correlates with phenotypic severity.[2]

To date, all *FGFR3* mutations appear to be paternally derived, due to a selective advantage to sperm that carry the mutations within the pool of sperm. This mutation increases in frequency with advancing paternal age.[8]

MANIFESTATIONS OF DISEASE

Clinical Presentation

Thanatophoric dysplasia presents with macrocephaly, a large anterior fontanel, frontal bossing, a flat facies with a depressed nasal bridge, ocular proptosis, marked shortening of the limbs (micromelia), brachydactyly with trident hands (short hands with fingers of equal length and an increased space between the third and fourth digits), redundant skin folds, narrow bell-shaped thorax with short ribs and protuberant abdomen, hypotonia, bowed femurs, and in some cases cloverleaf skull due to craniosynostosis. Radiographic features include craniosynostosis in some cases, shortening of the long bones with irregular metaphyses and platyspondyly (flat spine on lateral view).[4]

Achondroplasia presents with rhizomelic (proximal) shortening of the arms and legs with redundant skin folds, limitation of elbow extension, brachydactyly with trident hands, bowed legs, relative macrocephaly with frontal bossing, and depressed nasal bridge. Radiographic findings include short, thick tubular bones, narrowing of the interpediculate distance of the caudal spine, rounded ilia and horizontal acetabulae, narrowing of the sacrosciatic notch, proximal femoral radiolucency (fade out), and mild metaphyseal flaring. Individuals with homozygosity for achondroplasia mutations share radiographic features with thanatophoric dysplasia.[2]

Hypochondroplasia is milder than achondroplasia and frequently not immediately recognized at birth, and only recognized in the toddler period. Clinical findings then include short stature, stocky build, shortening of the proximal (rhizomelia) or middle (mesomelia) segments of the extremities, limitation of elbow extension, brachydactyly (but not typically trident), mild joint laxity, and macrocephaly with relatively normal facies. Radiographic findings are similar to achondroplasia, but are milder.[5]

Imaging Technique and Findings

Ultrasound. US findings for thanatophoric dysplasia include severe shortening of all the appendicular bones, which can be seen as early as the late first trimester, as well as an increased nuchal translucency. Significantly, by the second trimester there are very short and frequently bowed but well-mineralized bones, a narrow chest with short ribs (Fig. 50.1), relative macrocephaly with an abnormal facies (flat nasal bridge and frontal bossing) (Figs. 50.1 and 50.2), and brachydactyly with trident configuration (Fig. 50.3). Other reported US abnormalities include ventriculomegaly and other brain abnormalities, as well as frequent third trimester polyhydramnios.[13]

Achondroplasia is frequently not recognized until late second trimester or early third trimester when the proximal segments measure less than the third percentile for gestational age. This limb shortening can be severe (less than 1%) in homozygous cases. Although bones are short, ossification and shape are normal. The facial profile shows frontal bossing and a depressed nasal bridge (Fig. 50.4), and the hand is often trident-shaped (Fig. 50.5). Macrocephaly, with progressive enlargement of the biparietal diameter greater than the 95th percentile for gestational age, is also noted. Mild to moderate polyhydramnios has been reported. Three-dimensional or four-dimensional US may be useful in



Fig. 50.1 US showing lateral view of a depressed chest and relatively protuberant abdomen in thanatophoric dysplasia at 20 weeks.



Fig. 50.2 US showing a fetus with thanatophoric dysplasia at 22 weeks with depressed nasal bridge and frontal bossing

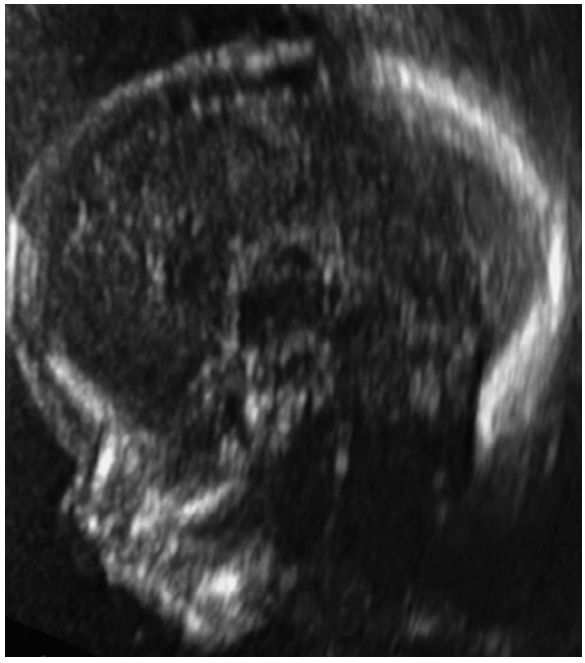

Fig. 50.4 2D US showing lateral profile of a fetus with achondroplasia at 24 weeks.

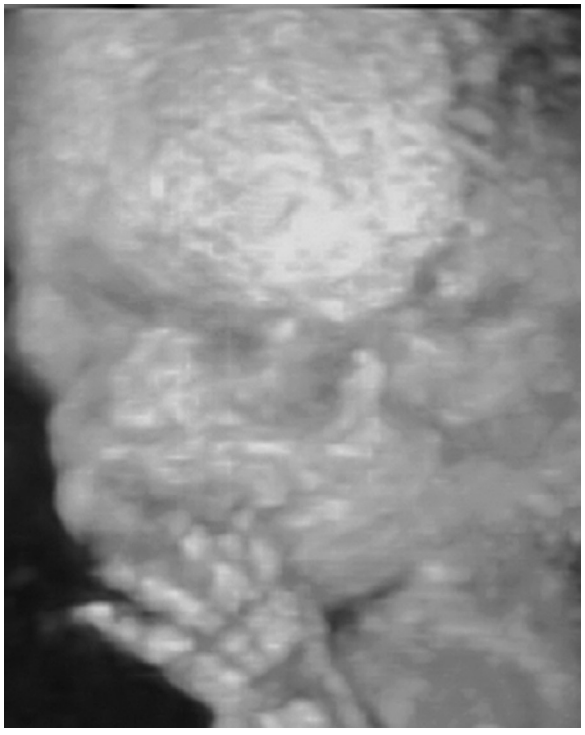

Fig. 50.3 US showing brachydactyly and trident configuration in a fetus with thanatophoric dysplasia at 18 weeks.



Fig. 50.5 US showing fetal facies and trident configuration of the hand in achondroplasia at 30 weeks.

the evaluation of fetuses with skeletal dysplasias, especially for imaging the face and extremities.[14]

Hypochondroplasia, similar to achondroplasia, can present in the fetal period with relative macrocephaly and rhizomelia, but brachydactyly with trident configuration is not seen. The facies tends to be nondysmorphic, or demonstrate very mild flattening of the nasal bridge (Fig. 50.6).

Magnetic Resonance Imaging (MRI). Computed tomography (CT) has been used for detection of thanatophoric dysplasia in the prenatal fetus and may play a complementary role to US in some centers.[15,16]

Other Applicable Modality. Analysis of cell-free DNA for *FGFR3* mutations from maternal plasma in at-risk fetuses with an unaffected mother has been reported.[17]



Fig. 50.6 US showing fetal facies in a hypochondroplasia at 28 weeks; note mild flattening of the nasal bridge.

CLASSIC SIGNS

Rhizomelic limb shortening (proximal segment—humerus and femur)
Progressive macrocephaly
Frontal bossing and depressed nasal bridge
Trident configuration of the hand

Differential Diagnosis From Imaging Findings

1. Severe achondroplasia with developmental delay and acanthosis nigricans
2. Achondrogenesis
3. Perinatal lethal osteogenesis imperfecta (type II osteogenesis imperfecta)
4. Diastrophic dysplasia
5. Short rib polydactyly syndrome

Synopsis of Treatment Options

PRENATAL

Fetuses with a suspected skeletal abnormality should be referred to a center with expertise in evaluating the fetal skeleton for US examination and genetic counseling. Termination of pregnancy should be discussed in cases of presumed lethality or based on parental wishes. Molecular genetics can provide definitive diagnosis. Prenatal care typically involves serial US scans for growth and monitoring of amniotic fluid volume. Vaginal delivery is not contraindicated, but fetuses with FGFR3 disorders often require cesarean delivery because of macrocephaly, malpresentation, or both. Although respiratory compromise or other critical care scenarios is uncommon in nonlethal cases such as achondroplasia and hypochondroplasia, consideration should be given to delivery in a tertiary center to facilitate a multidisciplinary approach to management (especially to evaluate for spinal stenosis and spinal cord compression). Infants with thanatophoric dysplasia should not undergo resuscitation.

POSTNATAL

Most infants with heterozygous achondroplasia have no serious perinatal complications, although there is an increased risk of spinal cord compression from stenosis in the first year of life. Neurosurgical and orthopedic intervention may be necessary. Recurrent otitis media, conductive hearing loss, and obesity can be chronic issues in these individuals. Hypochondroplasia is milder than achondroplasia. They can develop significant spinal stenosis later in life and they exhibit an increased incidence of developmental delays and epilepsy.

In homozygous achondroplasia and thanatophoric dysplasia, death is usually caused by respiratory compromise (pulmonary hypoplasia) or cervical cord compression.[3] Care is generally palliative.

WHAT THE REFERRING PHYSICIAN NEEDS TO KNOW

Patients at risk or patients with a fetus with a suspected skeletal disorder should be referred to a center with expertise in evaluating the fetal skeleton for US examination and genetic counseling. Heterozygous achondroplasia may not show abnormalities on US until the late second or early third trimester. Homozygous achondroplasia may manifest earlier because findings are more pronounced and severe. This disorder is rare but lethal, and pregnancy termination should be discussed. Pregnancies may be associated with mild or moderate polyhydramnios, but generally preterm labor is not an issue. Fetal macrocephaly or malpresentation may require cesarean delivery. Consideration should be given to delivery in a tertiary center for management of potential immediate complications.

KEY POINTS

- FGFR3 disorders are among the most common skeletal dysplasias. Molecular diagnosis can distinguish these disorders.
- Thanatophoric dysplasia is lethal; achondroplasia and hypochondroplasia are considered nonlethal.
- These disorders are autosomal dominant.
- Classic findings include progressive rhizomelic limb shortening, macrocephaly with frontal bossing, and brachydactyly with trident configuration of the hand.
- Homozygous achondroplasia is only seen when both parents are affected.

SUGGESTED READING

Krakow D, Lachman RS, Rimoin DL. Guidelines for the prenatal diagnosis of fetal skeletal dysplasias. *Genet Med.* 2009;11(2):127-133.
Moosa S, Wollnik B. Altered FGF signalling in congenital craniofacial and skeletal disorders. *Semin Cell Dev Biol.* 2016;53:115-125.

All references are available online at www.expertconsult.com.

REFERENCES

1. Moosa S, Wollnik B. Altered FGF signalling in congenital craniofacial and skeletal disorders. *Semin Cell Dev Biol*. 2016;53:115-125.
2. Pauli RM. Achondroplasia. In: Pagon RA, Adam MP, Ardinger HH, et al., eds. *GeneReviews(R)*. Seattle (WA); 1993.
3. Bonafe L, Cormier-Daire V, Hall C, et al. Nosology and classification of genetic skeletal disorders: 2015 revision. *Am J Med Genet A*. 2015;167A(12):2869-2892.
4. Karczeski B, Cutting GR. Thanatophoric dysplasia. In: Pagon RA, Adam MP, Ardinger HH, et al., eds. *GeneReviews(R)*. Seattle (WA); 1993.
5. Bober MB, Bellus GA, Nikkel SM, et al. Hypochondroplasia. In: Pagon RA, Adam MP, Ardinger HH, et al., eds. *GeneReviews(R)*. Seattle (WA); 1993.
6. Foldynova-Trantirkova S, Wilcox WR, Krejci P. Sixteen years and counting: the current understanding of fibroblast growth factor receptor 3 (FGFR3) signaling in skeletal dysplasias. *Hum Mutat*. 2012;33(1):29-41.
7. Barkova E, Mohan U, Chitayat D, et al. Fetal skeletal dysplasias in a tertiary care center: radiology, pathology, and molecular analysis of 112 cases. *Clin Genet*. 2015;87(4):330-337.
8. Shinde DN, Elmer DP, Calabrese P, et al. New evidence for positive selection helps explain the paternal age effect observed in achondroplasia. *Hum Mol Genet*. 2013;22(20):4117-4126.
9. Gooding HC, Boehm K, Thompson RE, et al. Issues surrounding prenatal genetic testing for achondroplasia. *Prenat Diagn*. 2002;22(10):933-940.
10. Khalil A, Pajkrt E, Chitty LS. Early prenatal diagnosis of skeletal anomalies. *Prenat Diagn*. 2011;31(1):115-124.
11. Krejci P. The paradox of FGFR3 signaling in skeletal dysplasia: why chondrocytes growth arrest while other cells over proliferate. *Mutat Res Rev Mutat Res*. 2014;759:40-48.
12. Ellman MB, Yan D, Ahmadinia K, et al. Fibroblast growth factor control of cartilage homeostasis. *J Cell Biochem*. 2013;114(4):735-742.
13. Krakow D. Skeletal dysplasias. *Clin Perinatol*. 2015;42(2):301-319, viii.
14. Krakow D, Lachman RS, Rimoin DL. Guidelines for the prenatal diagnosis of fetal skeletal dysplasias. *Genet Med*. 2009;11(2):127-133.
15. Tsutsumi S, Sawai H, Nishimura G, et al. Prenatal diagnosis of thanatophoric dysplasia by 3-D helical computed tomography and genetic analysis. *Fetal Diagn Ther*. 2008;24(4):420-424.
16. Ulla M, Aiello H, Cobos MP, et al. Prenatal diagnosis of skeletal dysplasias: contribution of three-dimensional computed tomography. *Fetal Diagn Ther*. 2011;29(3):238-247.
17. Chitty LS, Khalil A, Barrett AN, et al. Safe, accurate, prenatal diagnosis of thanatophoric dysplasia using ultrasound and free fetal DNA. *Prenat Diagn*. 2013;33(5):416-423.

51 Hypophosphatasia

DEBORAH KRAKOW

Introduction

Hypophosphatasia (HPP) is an autosomal recessive disorder that is characterized by poor mineralization of bones and teeth. There are at least six phenotypes, which are distinguished from each other by age at diagnosis, inheritance pattern, and prognosis. The primary forms are named for age at diagnosis and include perinatal (lethal), infantile, childhood, and adult HPP. In most cases that are diagnosed perinatally, infants are either stillborn or die in the immediate neonatal period from respiratory insufficiency owing to abnormal thorax and pulmonary hypoplasia, although there are cases with nonlethal outcomes. Infantile HPP manifests by 6 months of age and is associated with failure to thrive, premature craniosynostosis, respiratory complications from rickets of the chest, and seizures. Childhood HPP manifests with early loss of deciduous teeth and bone pain. The first sign of the adult form of HPP is often foot pain from stress fractures.

Other, very rare forms are odontohypophosphatasia and pseudohypophosphatasia; the former usually manifests in middle age with loss of adult teeth, and is associated with only dental and biochemical abnormalities, and the latter clinically and radiologically appears the same as the infantile form except serum alkaline phosphatase is normal. This chapter focuses on the perinatal subtype because the diagnosis can be suggested by prenatal ultrasound (US).

Disorder

DEFINITION

HPP is a disorder of bone mineralization leading to skeletal abnormalities (osteomalacia, rickets).[1] The clinical presentation ranges from perinatal lethality to a relatively benign course in which symptoms (premature loss of teeth or fractures, or both) first manifest in adulthood.

PREVALENCE AND EPIDEMIOLOGY

The incidence of lethal HPP is estimated at 1:100,000 births. In the inbred population of the Canadian Mennonites, the incidence is increased to 4:10,000 live births based on a founder effect.[2]

ETIOLOGY, PATHOPHYSIOLOGY, AND[3] EMBRYOLOGY

Severe forms (perinatal, infantile) of HPP are inherited in an autosomal recessive fashion. Inheritance of the milder forms (childhood, adult, odontohypophosphatasia) is less clear; there are reports of both autosomal dominant and autosomal recessive patterns.[2] The perinatal form of HPP is caused by a deficiency of tissue-nonspecific alkaline phosphatase *(TNSALP)* in osteoblasts and chondrocytes, resulting in reduced levels of serum alkaline phosphatase.[4] Bone mineralization is impaired, leading to osteomalacia, and perinatal death occurs as a result of pulmonary hypoplasia secondary to small chest size. Carriers can be recognized by a low level of serum alkaline phosphatase and increased urinary phosphoethanolamine levels.[5]

MANIFESTATIONS OF DISEASE

Clinical Presentation

The diagnosis of perinatal HPP is suspected on prenatal US, but molecular genetics or radiologic evaluation, or both, are required for definitive diagnosis.[3] Many affected fetuses are stillborn. Infants who survive have short limbs; poor skeletal mineralization (especially of the spine); bowed lower extremities; and bone spurs on the long bones, knees, and elbows.[6] Death is usually from respiratory failure owing to the small chest and subsequent hypoplastic lungs. Fever of unknown origin, anemia, hypercalcemia, seizures, and intracranial hemorrhage may also be seen.[5] The diagnosis is confirmed by a decrease in serum alkaline phosphatase activity, molecular genetics, serum *TNSALP* activity, and radiologic findings.

Imaging Technique and Findings

Ultrasound. Perinatal HPP should be suspected if prenatal US reveals poor mineralization of the cranium, ribs, and thoracic spine.[3,7,8] Craniosynostosis may be present, though this is rare. Lack of mineralization of the hand can be a very helpful diagnostic clue (Fig. 51.1). Poor mineralization of the calvarium (Fig. 51.2), short and thin long bones, bowed lower extremities, and cup-shaped metaphyses (lateral spikes) (Fig. 51.3) further specify the diagnosis. Bony spurs are often present but may be difficult to see by two-dimensional US; three-dimensional US may improve visualization (Fig. 51.4).[9] A thickened nuchal translucency in the first trimester may be apparent, and polyhydramnios may occur in later trimesters. Three-dimensional or four-dimensional US is useful in the evaluation of fetuses with skeletal dysplasias, especially for imaging the face and extremities.

Other Applicable Modality. Postnatal radiography shows marked variability in the degree of ossification, unossified regions of spine and cranium, abnormal vertebrae (round, flattened, or butterfly-shaped), and often a Y-shaped femur or bone spurs, or both (Fig. 51.5). The use of three-dimensional computerized

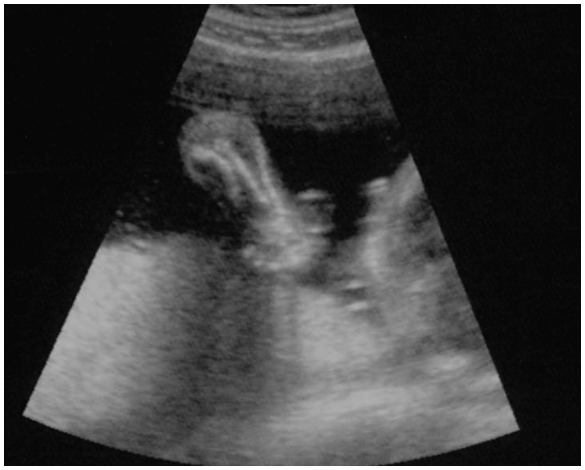

Fig. 51.1 US showing poor mineralization of the hand in HPP at 18 weeks.

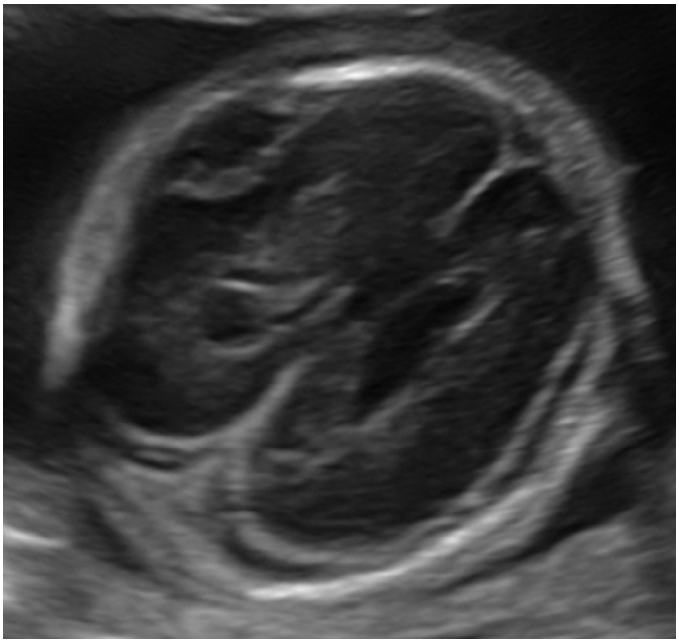

Fig. 51.2 US showing poor mineralization of the calvarium in HPP at 22 weeks.

tomography (CT) in HPP is reported with recognition of the metaphyseal changes suggestive of the disorder.[10]

CLASSIC SIGNS

Stark variability between areas of ossified and unossified bones of the cranium, ribs, and spine
Cupped metaphyses
Bony spurs on the long bones, knees, and elbows
Bowed appendicular bones
Poor mineralization of the hands

Differential Diagnosis From Imaging Findings

1. HPP
2. Perinatal lethal osteogenesis imperfecta
3. Achondrogenesis type IA

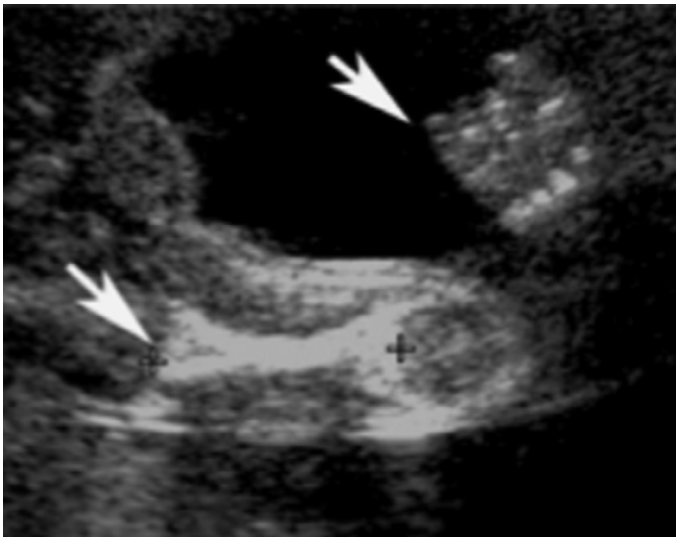

Fig. 51.3 US showing poor mineralization of the hand and a metaphyseal radiolucency that are characteristic of HPP *(arrows)* at 20 weeks.

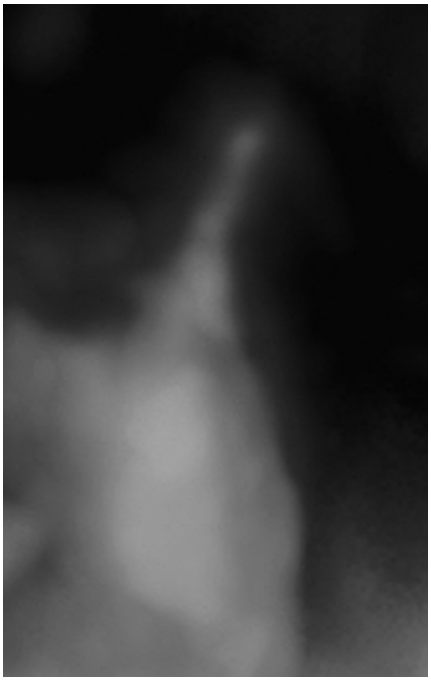

Fig. 51.4 Three-dimensional/four-dimensional US image demonstrating the Bowdler spur extending through the skin characteristic of HPP at 22 weeks.

Synopsis of Treatment Options

PRENATAL

US examination suggestive of HPP warrants referral for further detailed US examination and genetic counseling. Invasive testing may provide a definitive diagnosis. Termination of pregnancy should be discussed. A coordinated delivery plan involving obstetrics and neonatology teams should be developed, particularly if there is a possibility for treatment. Prenatal management is routine. As with most lethal disorders, cesarean section is usually reserved for maternal indications.



Fig. 51.5 Postnatal radiograph of HPP showing undermineralization of the skeleton and characteristic metaphyseal changes.

POSTNATAL

X-ray evaluation, autopsy, assessment of serum alkaline phosphatase, and genetic testing for *TNSALP* can be performed to confirm the diagnosis in live-born or stillborn neonates. Palliation is typical for infants with this disorder; if aggressive management is desired, affected neonates often require ventilation and intense support. Recently, enzyme replacement has become available for newborns, so discussions must occur between parents and treating physicians addressing whether a newborn qualifies for treatment.[1,11,12]

WHAT THE REFERRING PHYSICIAN NEEDS TO KNOW

Fetuses with a suspected skeletal dysplasia should be referred for US and genetic counseling to a center with expertise in evaluating the fetal skeleton. Termination of pregnancy should be discussed. Histopathology, x-ray and other imaging studies, and molecular genetics can provide a definitive diagnosis. Prenatal care is routine. Postnatal care is usually palliative, unless enzyme replacement is started, and this decision should best be done in a center with dedicated expertise in treatment of genetic disease. Infants who survive the neonatal period require a multidisciplinary approach for management of complications, including enzyme replacement.

KEY POINTS

- HPP is due to a mutation in *TNSALP* that leads to demineralization of bone and teeth.
- Neonates with a perinatal diagnosis of HPP may be stillborn or die in the immediate perinatal period, usually because of respiratory insufficiency owing to pulmonary hypoplasia from an abnormal chest.
- Perinatal HPP should be suspected on US in the case of varying degrees of ossification, cupped metaphysis, short limbs, bowed lower extremities, or bone spurs.
- Referral to experienced perinatal and newborn specialists is critical, particularly if enzyme replacement is a treatment option.

SUGGESTED READING

Mornet E, Nunes ME. Hypophosphatasia. In: Pagon RA, Adam MP, Ardinger HH, et al., eds. *GeneReviews(R)*. Seattle (WA): 1993.

Whyte MP. Hypophosphatasia—aetiology, nosology, pathogenesis, diagnosis, and treatment. *Nat Rev Endocrinol*. 2016;12(4):233-246.

All references are available online at www.expertconsult.com.

REFERENCES

1. Whyte MP. Hypophosphatasia—aetiology, nosology, pathogenesis, diagnosis, and treatment. *Nat Rev Endocrinol*. 2016;12(4):233-246.
2. Mornet E, Nunes ME. Hypophosphatasia. In: Pagon RA, Adam MP, Ardinger HH, et al., eds. *GeneReviews(R)*. Seattle (WA): 1993.
3. Zankl A, Mornet E, Wong S. Specific ultrasonographic features of perinatal lethal hypophosphatasia. *Am J Med Genet A*. 2008;146A(9):1200-1204.
4. Mornet E. Molecular genetics of hypophosphatasia and phenotype-genotype correlations. *Subcell Biochem*. 2015;76:25-43.
5. Coburn SP. Vitamin B-6 metabolism and interactions with TNAP. *Subcell Biochem*. 2015;76:207-238.
6. Linglart A, Biosse-Duplan M. Hypophosphatasia. *Curr Osteoporos Rep*. 2016;14(3):95-105.
7. Schramm T, Gloning KP, Minderer S, et al. Prenatal sonographic diagnosis of skeletal dysplasias. *Ultrasound Obstet Gynecol*. 2009;34(2):160-170.
8. Witters I, Moerman P, Fryns JP. Skeletal dysplasias: 38 prenatal cases. *Genet Couns*. 2008;19(3):267-275.
9. Sinico M, Levaillant JM, Vergnaud A, et al. Specific osseous spurs in a lethal form of hypophosphatasia correlated with 3D prenatal ultrasonographic images. *Prenat Diagn*. 2007;27(3):222-227.
10. Brasseur-Daudruy M, Ickowicz V, Degre S, et al. Hyperechoic metaphyses in hypophosphatasia: what does it mean? *Pediatr Radiol*. 2008;38(3):340-343.
11. Hofmann C, Jakob F, Seefried L, et al. Recombinant enzyme replacement therapy in hypophosphatasia. *Subcell Biochem*. 2015;76:323-341.
12. Scott LJ. Asfotase Alfa: a review in paediatric-onset hypophosphatasia. *Drugs*. 2016;76(2):255-262.

52 Osteogenesis Imperfecta

DEBORAH KRAKOW

Introduction

Osteogenesis imperfecta (OI), a disorder of bone characterized by hypomineralization of the skeleton, was the first disorder proposed to be due to a defect in collagen. It is characterized by life-long bone fragility and fracture predisposition. Other features, depending on the type of OI, may include blue sclerae, hearing loss, hypermobility of joints, and abnormal dentition.[1]

OI is marked by considerable clinical and genetic heterogeneity.[2] There is a continuum of severity, ranging from perinatal lethality to nearly asymptomatic disease. Historically, OI has been grouped into four major types (I–IV). However, several further subtypes have now been described. OI is discussed here as mild, severe, and perinatal, although this last classification is arbitrary because there is a broad spectrum of phenotypic variability.

Disorder

DEFINITION

OI is a heterogeneous group of chondrodysplasias characterized by increased bone fragility. Mild OI (known as *OI type I*) is the most common form of OI and usually has a mild clinical course. Individuals have normal type I collagen but only half the normal amount. Individuals are short but not to the degree of individuals

with severe deforming OI. Fractures occur, but usually in infancy and childhood rather than *in utero*. Fracture healing is normal, and the limbs do not appear deformed. Abnormal dentin (dentinogenesis imperfecta) may be present, and sclerae may be blue. Other ocular defects include scleromalacia, keratoconus, and retinal detachment. In contrast to perinatal lethal OI and, often, the more severe types of OI, diagnosis is frequently missed prenatally because fractures do not usually occur *in utero*, and the bones appear normal by ultrasound (US).

Severe deforming OI (known as *OI types III* and *IV*) encompasses a broad clinical spectrum. Approximately 90% of these cases are inherited as autosomal dominant. However, autosomal recessive inheritance accounts for the remaining 10% of cases. Individuals are very short, the limbs are severely deformed, the thorax is abnormal, and marked kyphoscoliosis is present. Pulmonary function can be affected by the abnormal spine and thorax; pulmonary insufficiency is the major cause of death. Less severely affected individuals usually show respiratory deterioration over time, resulting in restrictive lung disease and sleep apnea. They may have associated hydrocephalus, cranial nerve palsies, motor neuron lesions, and headache. Diplopia, nystagmus, cranial nerve neuralgia, decline in motor function, urinary dysfunction, and respiratory compromise are complications of basilar invagination. Individuals have significant generalized osteopenia, and fractures occur in the upper and lower extremities and vertebral bodies, especially before puberty. In contrast to mild OI, abnormal fracture healing leads to skeletal deformity. The diagnosis may be suggested *in utero* by frontal bossing, bowing of the long bones, or fractures, although the diagnosis is often missed prenatally because fractures and the accompanying skeletal deformities commonly occur later in life.

Perinatal lethal OI (known as *OI type II*), also known as *osteogenesis imperfecta congenita,* is a perinatally lethal form of OI. Most cases are the result of *de novo* mutations in one of two genes that encode type I procollagen. It is important to recognize that autosomal recessive forms can present prenatally as severe OI. *In utero* findings include fractures at various stages of healing and very short, angulated limbs; fetal hydrops is reported in the very severe forms.

PREVALENCE AND EPIDEMIOLOGY

The overall incidence of OI is approximately 0.5 : 10,000 births. OI is one of the more common prenatal onset skeletal disorders.[3]

ETIOLOGY, PATHOPHYSIOLOGY, AND EMBRYOLOGY

Most cases of OI that can be diagnosed perinatally result from a dominant mutation in one of the two genes that encode the chains of type I collagen, *COL1A1,* and *COL1A2.* The result is a marked decrease in collagen of both cortical and trabecular bone. Histologically, the normal bone structure is replaced by woven bone.[4] Abundant large osteoblasts are surrounded by little extracellular matrix. Rare recessive cases of lethal and severe OI have also been described, which are associated with mutations in genes controlling posttranslational modification and transport of collagen, including *CRTAP, P3H1, PPBI, FKBP10, HSP47, SP7, PLOD2, TMEM38B, PEDF, WNT1, P4HB, SEC24D, SPRAC, SMPD3,* and *CREB/ATF.*[2,4,5]

MANIFESTATIONS OF DISEASE

Clinical Presentation

Rare recessive forms of perinatal lethal and severe deforming OI exist, but most cases are spontaneous autosomal dominant mutations, and diagnosis usually is made at the time of routine anatomy US, when micromelia (owing to multiple fractures) is noted. Cardinal features may be visualized by the early second trimester or sooner, particularly with transvaginal US. Perinatal lethal OI may also be associated with increased nuchal translucency in euploid fetuses. Severe deforming OI may be suggested *in utero* by frontal bossing, bowing of the long bones, or fractures, although the diagnosis is often missed prenatally because fractures and the accompanying skeletal deformities commonly occur later in life.[6]

Imaging Technique and Findings

Ultrasound. The cardinal US features of perinatal lethal OI include skeletal hypomineralization, short limbs with angulation or bowing of the long bones (Fig. 52.1), and bending of the ribs (Fig. 52.2). The bones may appear "wrinkled" because of multiple fractures and subsequent callus formation.[7] The chest is small, and platyspondylisis may be apparent in the spine. Poor mineralization of the calvaria often enhances clarity of the intracranial structures (Fig. 52.3) may be compressible with the US transducer

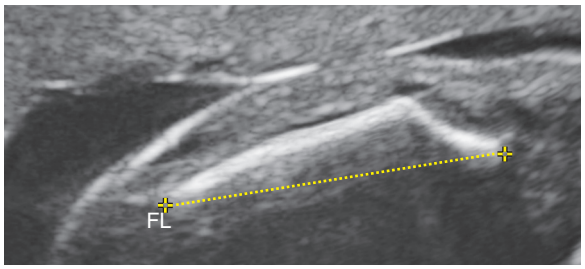

Fig. 52.1 US showing angulation or bowing of the long bones.

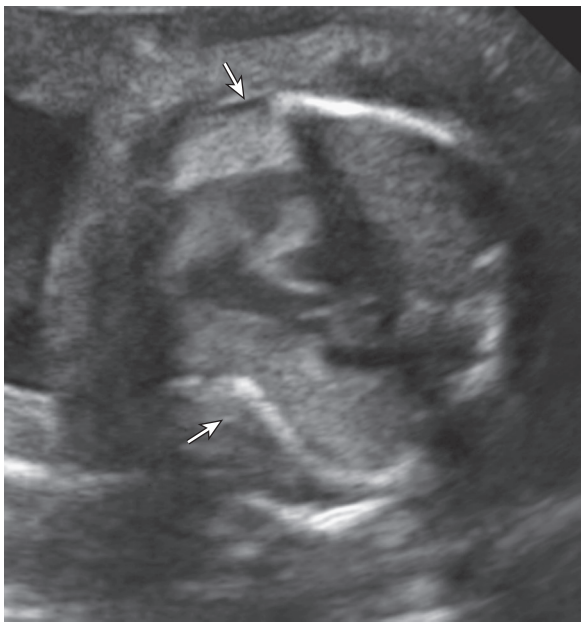

Fig. 52.2 US showing bending of the ribs *(arrows).*

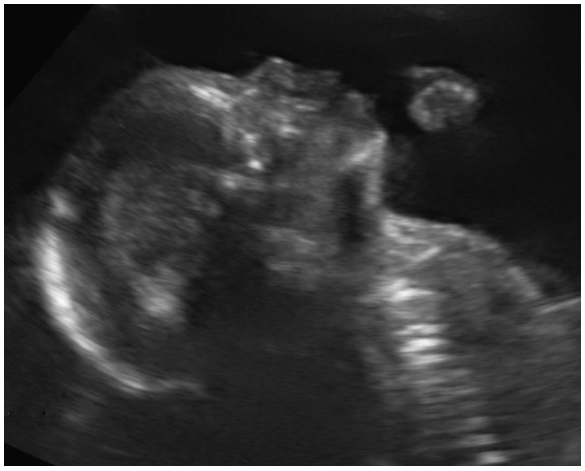

Fig. 52.3 US showing poor mineralization of the calvarium and clarity of the structures.

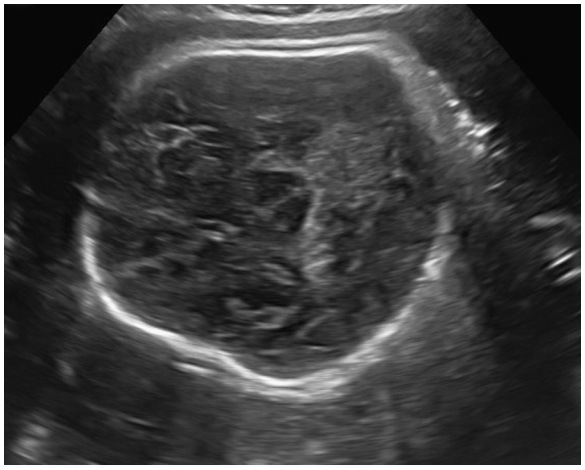

Fig. 52.4 US showing poor mineralization of the calvarium and compressibility.

(Fig. 52.4). Finally, fetal movements and limb position may be abnormal.[8–10]

Severe deforming OI is often not recognized *in utero*, but it may be suspected after the mid-second trimester when long bone length falls away from normal. Hypomineralization is less severe than in the perinatal lethal form, and there are fewer fractures. Several US examinations may be needed to recognize the evolving clinical picture. Three-dimensional (3D) or four-dimensional US is useful in the evaluation of fetuses with skeletal dysplasias, especially for imaging the face and extremities.

Magnetic Resonance Imaging (MRI). Use of 3D computed tomography (CT) has been reported as a diagnostic modality for diagnosis of OI in the third trimester, though it has not been shown to be superior to US diagnosis.[7]

Other Applicable Modality. Postnatal x-rays confirm prenatal US findings and the diagnosis (Fig. 52.5). Additional radiographic features include wormian bones (accessory skull bones completely surrounded by a suture or an irregular pattern of ossification). There are reported cases of OI seen by 3D CT in the third trimester, questioning its superiority over US.[11,12]



Fig. 52.5 Postnatal radiograph showing typical features of severe lethal OI including rib fractures and crumbled bones.

CLASSIC SIGNS

Signs of perinatal lethal OI (type II OI) include:
- Skeletal hypomineralization, particularly of the calvaria
- Micromelia
- Angulation or bowing of long bones
- "Wrinkled" bones
- Beaded S-shaped ribs
- Small chest with hypoplastic lungs
- Abnormal fetal movements and limb position

Classic signs of severe deforming OI (type III and type IV OI) include:
- Skeletal hypomineralization that is less pronounced than in type II disease
- Short long bones that first fall away from normal after 18 weeks' gestation
- Multiple fractures potentially visible later in gestation

Differential Diagnosis From Imaging Findings

1. Achondrogenesis all forms
2. Hypophosphatasia
3. Campomelic dysplasia

Synopsis of Treatment Options

PRENATAL

When OI is suspected prenatally, the patient should be referred for detailed US examination and genetic counseling. Given the lethality and long-term severity of the prenatal onset forms of OI, termination is an option. Molecular genetic testing for mutations in *COL1A1* or *COL1A2* is possible with invasive testing or on products of conception, and may be helpful in confirming

the diagnosis. Recurrence of dominant mutations owing to germline mosaicism has been documented. The recessive forms should be considered if there is a family history of multiple affected individuals or consanguinity. Molecular analysis has supplanted biochemical analysis. There is no known cure for OI; however, bisphosphonate treatment in surviving cases has decreased the number of fractures in childhood.[6,8]

POSTNATAL

Postnatal care is palliative and supportive. Almost all infants with perinatal lethal OI die as a result of respiratory failure in the first week of life. Some infants with severe deforming OI also die in the neonatal period from respiratory complications. Survivors face long-term morbidity related to multiple fractures, extremely short stature, and immobility. Management goals for survivors include minimizing fractures and disability. Infusion of bisphosphonates to improve bone quality has become the mainstay of treatment.

WHAT THE REFERRING PHYSICIAN NEEDS TO KNOW

Fetuses with a suspected skeletal dysplasia should be referred for US and genetic counseling to a center with expertise in evaluating the fetal skeleton. Termination of pregnancy should be discussed. Postmortem confirmation of the diagnosis via radiography and autopsy should be performed. Molecular testing for *COL1A1* and *COL1A2* mutations and, in appropriate cases, testing for the known recessive genes should be offered. Although perinatal lethal OI and severe deforming OI are typically spontaneous autosomal dominant conditions, rare cases of autosomal recessive inheritance and germline mosaicism may be responsible for recurrence in phenotypically normal parents. Prenatal care is routine. Postnatal care is usually palliative. Infants who survive the neonatal period require a multidisciplinary approach for management of complications.

KEY POINTS

- OI is a heterogeneous group of chondrodysplasias characterized by increased bone fragility leading to fracture predisposition.
- Perinatal lethal OI (type II OI) is a lethal form of the disease (death is usually due to respiratory insufficiency from pulmonary hypoplasia).
- Severe deforming OI (type III and type IV OI) is progressive and severely deforming, as opposed to mild OI (type I OI), which is manifested by short stature and bone fragility but shows little deformity because the bones heal normally.
- Both types of OI that can be diagnosed prenatally are usually inherited as spontaneous dominant mutations of *COL1A1* and *COL1A2,* but there are recessive forms of the disease and these should be considered candidate genes in familial recurrences and consanguinity.
- Perinatal lethal OI (type II OI) can be diagnosed prenatally, severe deforming OI (type III and IV OI) is often missed, and mild OI cannot be diagnosed prenatally.

SUGGESTED READING

Forlino A, Marini JC. Osteogenesis imperfecta. *Lancet.* 2016;387(10028):1657-1671.
Krakow D, Alanay Y, Rimoin LP, et al. Evaluation of prenatal-onset osteochondrodysplasias by ultrasonography: a retrospective and prospective analysis. *Am J Med Genet A.* 2008;146A(15):1917-1924.



All references are available online at www.expertconsult.com.

REFERENCES

1. Ben Amor M, Rauch F, Monti E, et al. Osteogenesis imperfecta. *Pediatr Endocrinol Rev*. 2013;10(suppl 2):397-405.
2. Forlino A, Marini JC. Osteogenesis imperfecta. *Lancet*. 2016;387(10028):1657-1671.
3. Marini J, Smith SM. Osteogenesis imperfecta. In: De Groot LJ, Beck-Peccoz P, Chrousos G, et al., eds. *Endotext*. South Dartmouth (MA): 2000.
4. Marini JC, Reich A, Smith SM. Osteogenesis imperfecta due to mutations in non-collagenous genes: lessons in the biology of bone formation. *Curr Opin Pediatr*. 2014;26(4):500-507.
5. Marini JC, Blissett AR. New genes in bone development: what's new in osteogenesis imperfecta. *J Clin Endocrinol Metab*. 2013;98(8):3095-3103.
6. Rauch F, Glorieux FH. Treatment of children with osteogenesis imperfecta. *Curr Osteoporos Rep*. 2006;4(4):159-164.
7. Teng SW, Guo WY, Sheu MH, et al. Initial experience using magnetic resonance imaging in prenatal diagnosis of osteogenesis imperfecta type II: a case report. *Clin Imaging*. 2003;27(1):55-58.
8. Krakow D. Skeletal dysplasias. *Clin Perinatol*. 2015;42(2):301-319, viii.
9. Krakow D, Alanay Y, Rimoin LP, et al. Evaluation of prenatal-onset osteochondrodysplasias by ultrasonography: a retrospective and prospective analysis. *Am J Med Genet A*. 2008;146A(15):1917-1924.
10. Wu Q, Wang W, Cao L, et al. Diagnosis of fetal osteogenesis imperfecta by multidisciplinary assessment: a retrospective study of 10 cases. *Fetal Pediatr Pathol*. 2015;34(1):57-64.
11. Ulla M, Aiello H, Cobos MP, et al. Prenatal diagnosis of skeletal dysplasias: contribution of three-dimensional computed tomography. *Fetal Diagn Ther*. 2011;29(3):238-247.
12. Akizawa Y, Nishimura G, Hasegawa T, et al. Prenatal diagnosis of osteogenesis imperfecta type II by three-dimensional computed tomography: the current state of fetal computed tomography. *Congenit Anom (Kyoto)*. 2012;52(4):203-206.

53 Radial Ray Deficiency

DEBORAH KRAKOW

Introduction

Ultrasound (US) evaluation of a fetus with a radial ray defect is a difficult diagnostic dilemma because the defect may be isolated, but can also result from chromosomal aneuploidy, teratogenic exposure, and more than 200 distinct genetic syndromes, including skeletal dysplasias, particularly those associated with mesomelia.[1–3] Radial aplasia or hypoplasia is a rare abnormality occurring in 2 : 10,000 liveborns,[4] but more common than isolated ulnar abnormalities. Frequently, when the radius is abnormal, the ulna is as well, as are the digits of the hands. Unilateral radial abnormalities are less likely to have an underlying genetic etiology compared to bilaterally affected limbs. Among the genetic etiologies, one of the more common disorders with radial ray anomalies is Cornelia de Lange syndrome (CDLS)[5] (Chapter 128).

Disorder

DEFINITION

Radial ray defects comprise a large spectrum of upper limb anomalies that can range from partial (radial hypoplasia) to complete (radial aplasia) deficiency of the radius with or without accompanying deficiency of the thumb and other concomitant anomalies of the upper limbs. Some authors have classified them into four types based on their radiologic severity, with type I as the mildest and type IV showing complete absence of the radius,[6] and there are other classification schemes[7] which do not necessarily help identify the underlying genetic disorder.

PREVALENCE AND EPIDEMIOLOGY

Isolated radial ray defects affect 2:10,000 newborns, though the incidence of more complicated upper limb deficiencies is approximately 5.25:10,000.[8] However, if the defect is part of a genetic syndrome whether associated with aneuploidy or genetic disorders, then the prevalence is based on the incidence of the individual disorder. It is important to note that two-thirds of infants with congenital limb deficiencies have other congenital abnormalities and increased perinatal mortality and morbidity.[9]

ETIOLOGY, PATHOPHYSIOLOGY, AND EMBRYOLOGY

The radius develops similarly to other appendicular bones through the process of endochondral ossification and develops from lateral plate mesoderm. Development of the limbs is under exquisite genetic control, and the genes that regulate the process are highly conserved through evolution. Radial ray deficiency is also seen in aneuploidies, including trisomy 18, 13, mosaic trisomy 16, and chromosomal microdeletion syndromes.[9] Teratogens, specifically valproic acid, thalidomide, and aminopterin are established to cause disruption to the development of the upper limbs. Table 53.1 lists many of the disorders associated with radial ray deficiency, frequently associated with other congenital or morphologic abnormalities. Both bilaterally affected upper limbs and/or lower limbs are more likely to be associated with an underlying genetic mechanism.

Detailed history for similarly affected children will provide diagnostic clues to recessively inherited disorders such as Fanconi anemia. Parents should be evaluated for subtle hand abnormalities, particularly their thumbs, because autosomal dominantly inherited Holt-Oram syndrome can show variable expressivity, with some affected individuals only manifesting slight thumb abnormalities and no cardiac abnormalities.[10] Thrombocytopenia–absent radius (TAR) syndrome has a complex inheritance pattern, but is inherited as a recessive disorder.[11] For CDLS, almost 60% of cases result from heterozygosity for mutations in the *NIPBL* gene that encodes for homolog of delangin. A smaller percentage of CDLS also results from heterozygosity for mutations in *SMC1A*, *SMC3*, and *RAD21*, all encoding components of the cohesin complex. There are two X-linked forms of the disease due to mutations in *SMC1A* and *HDAC8*.[5]

TABLE 53.1 DISORDERS THAT INCLUDE RADIAL RAY DEFECTS

Aase syndrome
Cornelia de Lange syndrome
Duane ray syndrome/Okihiro syndrome
Fanconi anemia
Nager syndrome
AFD, Rodriguez type
Omphalocele–radial ray complex
Rothmund-Thomson syndrome
TAR (thrombocytopenia–absent radius) syndrome
Trisomy 13
Trisomy 18
Trisomy 10 mosaicism
Trisomy 16 mosaicism
22q11 deletion
VATER/VACTERL association
Roberts SC phocomelia
Goldenhar syndrome
Treacher Collins syndrome
Baller-Gerold syndrome
Steinfeld syndrome
Gollop-Wolfgang complex
Fetal varicella syndrome
Valproic acid/thalidomide/aminopterin exposure

VATER/VACTERL, Vertebral, anal, cardiac, tracheal, esophageal, renal, and limb anomalies.

MANIFESTATIONS OF DISEASE

Clinical Presentation

Frequently, when the radius is abnormal so is the ulna. Beyond the radii and ulnae, frequently the entirety of the upper limb can be affected, including the humeri, scaphoids, trapeziums, metacarpals, and thumbs, thus the term *radial ray defects* is frequently used for an entire spectrum of abnormalities. Further preaxial and postaxial polydactyly, as well as oligodactyly, has been observed. Definitive diagnosis or etiology is predicated on other findings that include presence of amniotic bands, small for gestational age, facial dysmorphisms, intracranial, cardiac, gastrointestinal, genitourinary, or evidence of other skeletal abnormalities. One of the most common genetic disorders that present with radial ray defect is CDLS. This disorder presents with characteristic facial dysmorphism (maxillary prognathism, relative micrognathia, long philtrum, thin lips), low-set ears in association with prenatal and postnatal growth retardation, mental retardation and, in many cases, upper limb anomalies[5] (Chapter 128).

Technique and Findings

Ultrasound

US evaluation of all fetuses should include bilateral evaluation of all four limbs. Evidence of any discrepancy in the size of the radii or ulnae should prompt a more detailed evaluation of the fetus.[1] The radii may appear only shortened, but straight; bowed and displaced; abnormally shaped; severe hypoplastic; and absent. If the radius is abnormal, the thumb may also be short, hypoplastic or absent, and evaluation of the hand for the number and shape of the fingers is important. A systematic approach to evaluation of the fetus should help determine if there are any other concomitant abnormalities that would provide diagnostic clues.[12,13] Evaluation of the fetal facies for subtle defects in ears and mandible help refine the disorder.[14] Cardiac defects are common in radial ray deficiency syndromes such as Holt-Oram, Nager, and Rodriquez syndromes.

CDLS has characteristic US abnormalities that include micrognathia with an overhanging top lip and low set ears (Fig. 53.1), subjectively long philtrum with thin lips (Fig. 53.2), and varying degrees of shortened radii and oligodactyly that frequently effects upper limbs greater than lower limbs and varies from limb to limb (Fig. 53.3).[5]

Magnetic Resonance Imaging

Fetal magnetic resonance imaging (MRI) and computed tomography (CT) have been used to help evaluate at-risk fetuses with skeletal abnormalities for clues that could lead to a more precise diagnosis; the use of these modalities have not been demonstrated in radial ray defects. If the fetus has a small chest and lethality cannot be determined by US, MRI has been used to calculate fetal lung volumes to predict pulmonary insufficiency.[15]

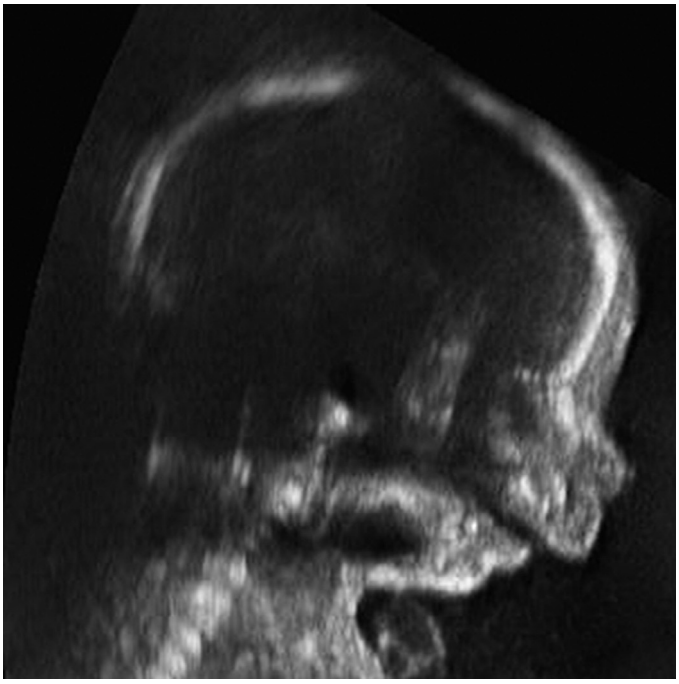

Fig. 53.1 Three-dimensional US of profile of a 24-week fetus with CDLS showing overhanging upper lip with relative micrognathia.



Fig. 53.2 Three-dimensional US of the facies of a 24-week fetus with CDLS showing a relatively long philtrum, flat nasal bridge, and thin upper lip.

Other Applicable Modality

Postnatal radiographs are mandatory in the evaluation of radial ray deficiency. Radiographs can show abnormalities of the carpal bones and phalanges, helping to differentiate disorders (Figs. 53.4 and 53.5).



Fig. 53.3 Three-dimensional US of the right arm of a 24-week fetus with CDLS showing oligodactyly and an abnormal thumb.



Fig. 53.4 Postnatal radiograph showing radial ray absence and oligodactyly in Roberts SC phocomelia.

CLASSIC SIGNS

Radial ray defect comprise a broad spectrum of upper limb anomalies that range from partial (radial hypoplasia) to a complete (radial aplasia) deficiency of the radius with or without accompanying deficiency of the thumb bones.

Differential Diagnosis From Imaging Findings

The list of disorders associated with radial ray defect comprises more than 200 disorders. While radial ray abnormalities may be

isolated, two-thirds of children have other congenital birth defects and these concomitant anomalies aid in refining the differential diagnosis.[8]

Synopsis of Treatment Options

PRENATAL

Radial ray defects are complex defects of morphogenesis highly associated with concomitant abnormalities. Fig. 53.6 outlines a schematic approach to evaluation. Because of the association with teratogens, care should be given to obtain a detailed exposure history. Aneuploidies, including microdeletions (TAR syndrome among others [see Table 53.1]), have been associated with this anomaly, and patients should be offered invasive testing for chromosomal microarray analysis. Negative noninvasive prenatal testing (NIPT) is not adequate for ruling out aneuploidy, particularly for microdeletions syndromes associated with radial ray defect.

Fetus with other congenital anomalies, in addition to radial ray defects, likely harbor an underlying genetic defect. If a pattern of abnormalities is recognized, or there is a family history of a genetic disorder, then gene-specific testing should be offered. Patients should be counseled regarding the increased incidence of multiple congenital anomalies and increased perinatal mortality in these disorders, and termination of pregnancy may be an option for some patients. If pregnancies are continued, a multispecialty team should be assembled prior to delivery to be prepared for immediate newborn issues including potential airway or cardiac issues.

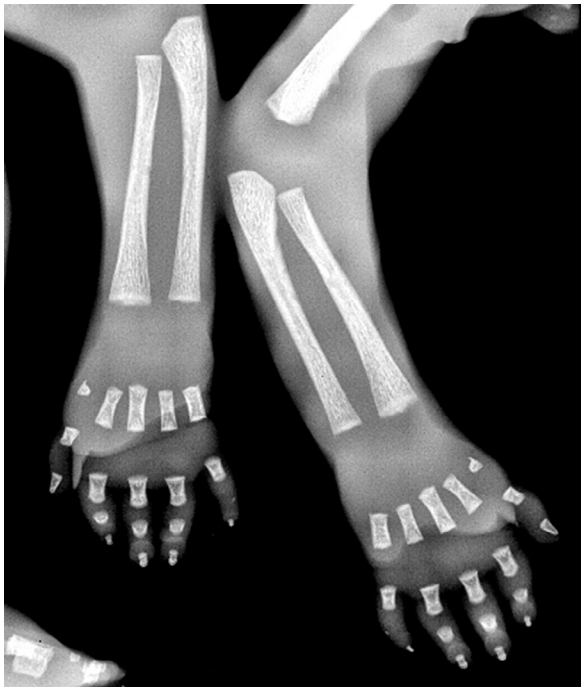

Fig. 53.5 Postnatal radiograph of hands in a fetus with CDLS showing subtle shortening of the radii and abnormal phalangeal bones, particularly the thumbs.

POSTNATAL

Postnatal management of radial ray defects is predicated first on whether there are any other congenital abnormalities. If there is a question of possible congenital heart defect or airway compromise, the newborn should be in a facility with expertise in the management of a newborn with multiple congenital anomalies. Full genetic skeletal survey will aid in determining if the radial ray defect is a manifestation of a skeletal dysplasia. A formal genetics evaluation will aid in differentiating potential genetic syndromes. If chromosomal microarray analysis was not done in the prenatal period, it should be performed in the neonatal period. Natural history and outcome will be based on the constellation of findings. Isolated radial ray defects are best managed by a team of individuals aimed at achieving optimal mobility.

WHAT THE REFERRING PHYSICIAN NEEDS TO KNOW

Outcomes for radial ray defects are based on whether the fetus has other congenital anomalies and whether it is unilateral or bilateral. Chromosomal aneuploidies and underlying genetic disorders will influence the natural history and outcome for the fetus. If there is an underlying disorder, the genetic basis should be established if possible to determine recurrence risk for the family.

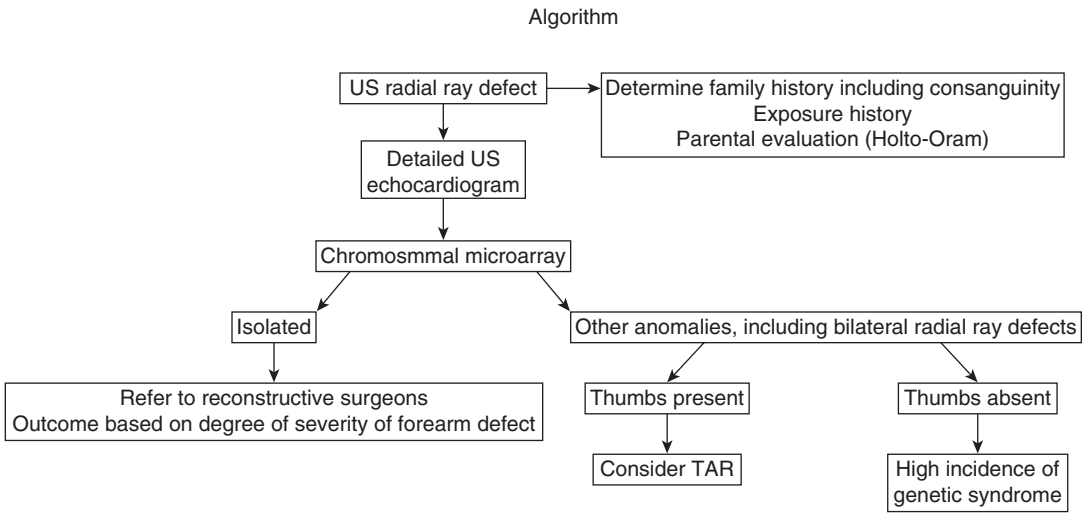

Fig. 53.6 Schematic approach to a fetus with a radial ray defect.

KEY POINTS

- Radial ray defects are associated with teratogen exposure, aneuploidy, and genetic disorders, in addition to isolated malformations.
- Evaluation for chromosomal aneuploidy should be included in the workup.
- Meticulous bilateral US evaluation of all elements of the skeleton should be performed.
- Detailed systematic US evaluation for other congenital anomalies, including echocardiogram, should be performed.
- Counseling should advise that almost two-thirds of affected infants will have other congenital anomalies and increased mortality and morbidity.

SUGGESTED READING

Koskimies E, Lindfors N, Gissler M, et al. Congenital upper limb deficiencies and associated malformations in Finland: a population-based study. *J Hand Surg Am*. 2011;36(6):1058-1065.

Pajkrt E, Cicero S, Griffin DR, et al. Fetal forearm anomalies: prenatal diagnosis, associations and management strategy. *Prenat Diagn*. 2012;32(11):1084-1093.



All references are available online at www.expertconsult.com.

REFERENCES

1. Pajkrt E, Cicero S, Griffin DR, et al. Fetal forearm anomalies: prenatal diagnosis, associations and management strategy. *Prenat Diagn*. 2012;32(11):1084-1093.
2. Binder G, Rappold GA. SHOX deficiency disorders. In: Pagon RA, Adam MP, Ardinger HH, et al, eds. *GeneReviews*. Seattle (WA); 1993.
3. Ambrosetti F, Palicelli A, Bulfamante G, et al. Langer mesomelic dysplasia in early fetuses: two cases and a literature review. *Fetal Pediatr Pathol*. 2014;33(2):71-83.
4. Stoll C, Dott B, Alembik Y, et al. Associated malformations among infants with radial ray deficiency. *Genet Couns*. 2013;24(2):223-234.
5. Deardorff MA, Noon SE, Krantz ID. Cornelia de Lange syndrome. In: Pagon RA, Adam MP, Ardinger HH, et al, eds. *GeneReviews*. Seattle (WA). 1993.
6. Bayne LG, Klug MS. Long-term review of the surgical treatment of radial deficiencies. *J Hand Surg Am*. 1987;12(2):169-179.
7. Vilkki SK. Severity grading in radial dysplasia. *J Hand Surg Eur Vol*. 2014;39(9):977-983.
8. Koskimies E, Lindfors N, Gissler M, et al. Congenital upper limb deficiencies and associated malformations in Finland: a population-based study. *J Hand Surg Am*. 2011;36(6):1058-1065.
9. Pakkasjarvi N, Koskimies E, Ritvanen A, et al. Characteristics and associated anomalies in radial ray deficiencies in Finland—a population-based study. *Am J Med Genet A*. 2013;161A(2):261-267.
10. McDermott DA, Fong JC, Basson CT. Holt-Oram syndrome. In: Pagon RA, Adam MP, Ardinger HH, et al, eds. *GeneReviews*. Seattle (WA); 1993.
11. Toriello HV. Thrombocytopenia absent radius syndrome. In: Pagon RA, Adam MP, Ardinger HH, et al, eds. *GeneReviews*. Seattle (WA); 1993.
12. Castori M, Bottillo I, D'Angelantonio D, et al. A 22-week-old fetus with Nager syndrome and congenital diaphragmatic hernia due to a novel SF3B4 mutation. *Mol Syndromol*. 2014;5(5):241-244.
13. Bottillo I, Castori M, De Bernardo C, et al. Prenatal diagnosis and post-mortem examination in a fetus with thrombocytopenia–absent radius (TAR) syndrome due to compound heterozygosity for a 1q21.1 microdeletion and a RBM8A hypomorphic allele: a case report. *BMC Res Notes*. 2013;6:376.
14. Kennelly MM, Moran P. A clinical algorithm of prenatal diagnosis of radial ray defects with two and three dimensional ultrasound. *Prenat Diagn*. 2007;27(8):730-737.
15. Vergani P. Prenatal diagnosis of pulmonary hypoplasia. *Curr Opin Obstet Gynecol*. 2012;24(2):89-94.

54 Russell-Silver Syndrome

DEBORAH KRAKOW

Introduction

Russell-Silver syndrome (RSS) or Silver-Russell syndrome is one of the growth deficiency disorders that form part of the increasing group of congenital imprinting disorders. RSS is characterized by severe intrauterine and postnatal growth restriction. Other abnormalities include relative macrocephaly, hemihypertrophy (one side of the body is larger than the other), fifth finger clinodactyly, and triangular-shaped facies. RSS is genetically heterogeneous and the phenotype can vary. This disorder illustrates the importance of recognizing genetic syndromes associated with prenatal onset intrauterine growth restriction (IUGR) and significant shortening of the long bones, but is not considered a classic skeletal dysplasia. There are more than 1000 genetic syndromes associated with prenatal growth deficiency, and differentiating them by ultrasound (US) is extremely challenging.

Disorder

DEFINITION

This syndrome was independently identified by Silver in 1953 and Russell in 1954, thus called Russell-Silver syndrome in the United States or Silver-Russell syndrome in Europe. RSS is a growth disorder characterized by growth restriction before birth that persists after birth. RSS is associated with very low birth weight and often failure to thrive. Head circumference is normal, but the head may appear unusually large when compared to the remainder of the body. RSS children are thin with poor appetites, and many develop hypoglycemia associated with poor feeding. Consistent newborn features include small triangular facies, narrow chin, smallish jaw, downturned corners of the mouth, limb asymmetry, and fifth finger clinodactyly. RSS is also associated with developmental delays, speech and language problems, and long-term learning disabilities.

PREVALENCE AND EPIDEMIOLOGY

The precise incidence of RSS remains unknown, but estimates place the frequency at between 1:100,000 and 1.3:100,000 individuals.

ETIOLOGY, PATHOPHYSIOLOGY, AND EMBRYOLOGY

RSS is a genetically heterogeneous entity and is caused by epigenetic alterations (changes in the expression, not the sequence of the gene, by biochemical modifications). Forty to sixty percent of cases result from hypomethylation of the chromosome 11p.15.5 imprinting center region 1 *(ICR1)* on the paternal chromosome 11. This is the same region that is affected in the overgrowth syndrome Beckwith-Wiedemann syndrome (Chapter 110). In about 5% of cases the etiology of RSS results from maternal uniparental disomy for chromosome 7 (UPD[7]mat) (inheriting two maternal chromosomes with no paternal contribution).[1] Other abnormally imprinted chromosomal regions[2] have been associated with RSS-like phenotypes. Autosomal dominant and recessive inheritance have been seen infrequently.

MANIFESTATIONS OF DISEASE

Clinical Presentation

RSS is characterized by IUGR accompanied by significant postnatal growth deficiency. The birth weight of affected infants is usually greater than two standard deviations below the mean. Affected individuals typically have proportionate short stature, normal head circumference, fifth finger clinodactyly, typical facial features with triangular facies, broad forehead and narrow chin, limb length asymmetry, and café au lait spots. Children with RSS are at significant risk for developmental delay (both motor and cognitive) and learning disabilities.

Imaging Technique and Findings

Ultrasound. RSS should be considered in a fetus that presents with early IUGR.[3] Very early asymmetric growth restriction is the most common prenatal US finding. The limbs are typically short and can be asymmetric, yet are morphologically normal. The head circumference may be appropriate for gestational age, but will be consistent with relative macrocephaly because of the overall small size of the infant, and dolichocephaly has been reported.[4] Postnatal facial features that may be seen with two-dimensional (2D) and three-dimensional (3D) US include a broad forehead, smaller lower facies with pointed chin (giving the appearance of a triangular shaped facies), prominent nasal bridge, and low set ears. Delay in endochondral ossification of the secondary epiphyseal centers at the calcaneus (approximately 20 weeks in normal gestations) (Figs. 54.1 and 54.2) and knee (28 weeks in normal gestations) (Fig. 54.3) has been seen. Fifth finger clinodactyly is a common finding and can be detected by US (Figs. 54.4 and 54.5). Amniotic fluid and umbilical cord Doppler have been reported as normal in earlier gestation periods, ruling out early placenta insufficiency.[3] Fifth finger clinodactyly associated with very early onset growth restriction, shortened long bones and delay in endochondral ossification, with no other etiology including chromosomal aneuploidies or infection, should alert the provider to consider RSS.

Magnetic Resonance Imaging. Prenatal magnetic resonance imaging (MRI) has been used to detect congenital anomalies, however, not for the detection of RSS. Cerebellar dysplasia has been reported postnatally in an unusual presentation and etiology of RSS.[5] The role of MRI in this disorder has not been established.

Other Applicable Modality. Postnatal clinical evaluation is the most diagnostic approach for this disorder based on the aforementioned features. Radiographic abnormalities include clinodactyly, brachydactyly, camptodactyly, syndactyly, ivory epiphyses, delayed skeletal maturation, slender long bones, elbow and hip dislocations, hypoplasia of the sacrum, and coccyx.[6]

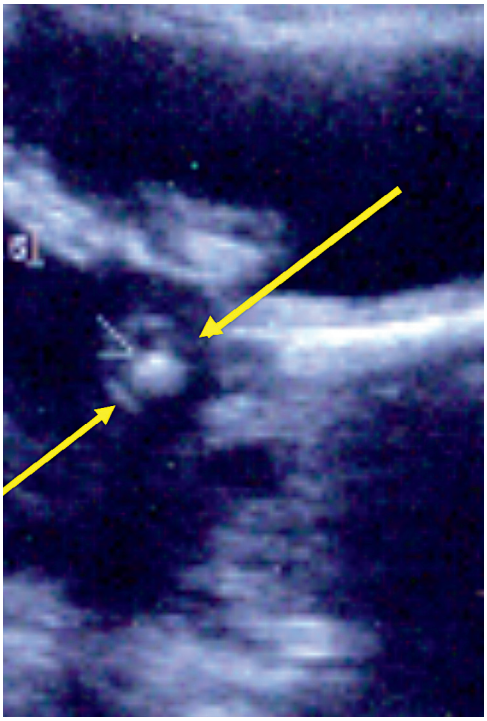

Fig. 54.1 US image of a normal appearing calcaneus at 20 weeks *(arrows).*

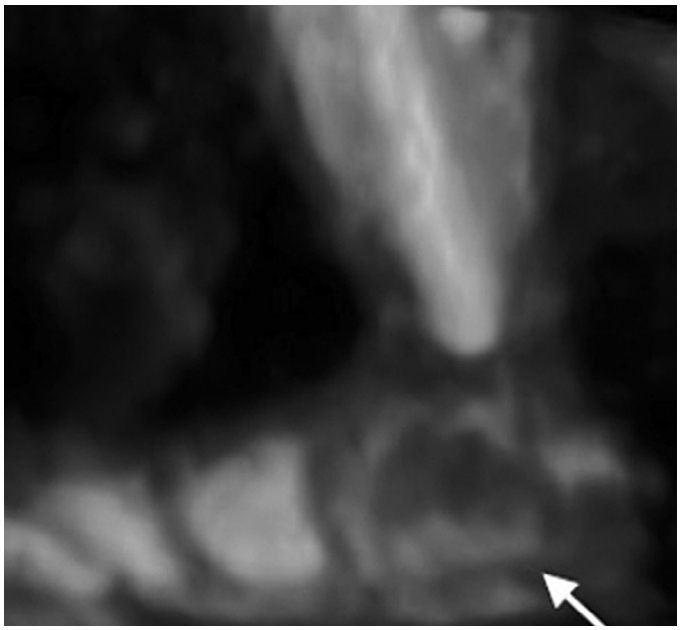

Fig. 54.2 US image of absence of the calcaneus (24 weeks) in a fetus with RSS *(arrow).*

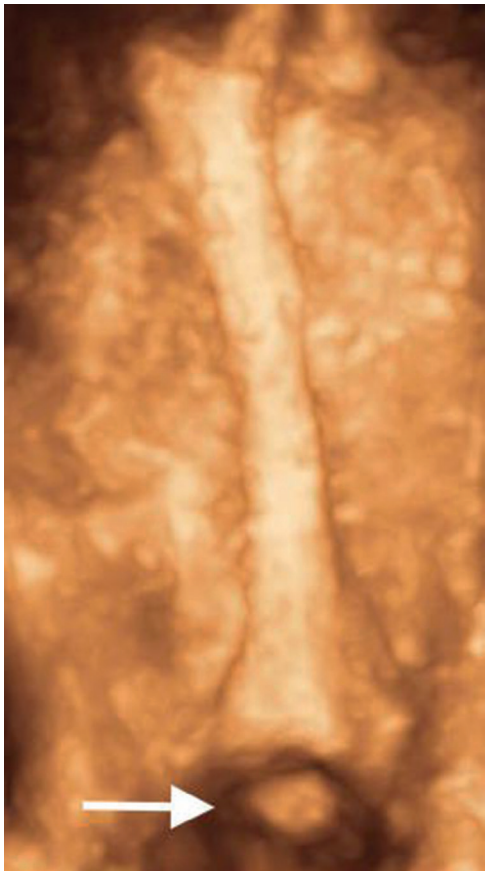

Fig. 54.3 Three-dimensional image of a normal-appearing knee epiphyses that can be seen after 28 weeks *(arrow).*



Fig. 54.4 Three-dimensional image of fifth finger clinodactyly in a fetus with Russell-Silver syndrome.



Fig. 54.5 Three-dimensional image of fifth finger clinodactyly in a fetus with Russell-Silver syndrome.

CLASSIC SIGNS

Asymmetric IUGR
Normal head circumference
Limb/body or facial asymmetry
Fifth finger clinodactyly, brachydactyly, camptodactyly
Triangular shaped facies
Frontal bossing
Café au lait or pigment changes (beyond the newborn period)

Differential Diagnosis From Imaging Findings

1. Chromosomal aneuploidies including deletion and imprinting errors
2. Mosaic Turner syndrome
3. Fanconi anemia
4. 3-M syndrome
5. IMAGe syndrome

Synopsis of Treatment Options

PRENATAL

RSS has been associated with in vitro fertility pregnancies (as have other imprinting disorders), though precise risk is unknown.[7,8] For pregnancies in which IUGR is identified by US and RSS is suspected, prenatal testing is possible for loss of paternal methylation studies on chromosome 11 *(H19-IGF2 IC1)* and for maternal uniparental disomy 7 (UPD7).

POSTNATAL

The management of children with RSS is best achieved by a multidisciplinary approach. Specific issues include poor growth, severe feeding difficulties, gastrointestinal problems, hypoglycemia and ketonuria, body asymmetry, scoliosis, motor and speech delay, and psychosocial challenges.[9] Treatment of gastrointestinal reflex and feeding difficulties can be treated with medications and fundoplication if necessary. Severe micrognathia or cleft palate (rare) is best managed by a multidisciplinary craniofacial team. There appears to be some benefit to treating these patients with growth hormone,[10] and because of premature adrenarche, treatment with gonadotropin-releasing hormone analogues has been employed.[11]

WHAT THE REFERRING PHYSICIAN NEEDS TO KNOW

RSS is a rare disorder due to imprinting defects on chromosome 11 or maternal UPD7. Pregnancies should be followed with guidelines associated with IUGR, and delivery indications should be based on maternal and fetal indications.

KEY POINTS

- RSS is associated with severe early onset IUGR.
- IVF may place pregnancy at risk for imprinting disorders.
- US findings may include short long bones, normal head circumference, delay in endochondral ossification, micrognathia, small upturned nose, and fifth clinodactyly.

SUGGESTED READING

Saal HM. Russell-Silver syndrome. In: Pagon RA, Adam MP, Ardinger HH, et al., eds. *GeneReviews*. Seattle (WA): 1993.

All references are available online at www.expertconsult.com.

REFERENCES

1. Marczak-Halupka A, Kalina MA, Tanska A, et al. Silver-Russell syndrome—part I: clinical characteristics and genetic background. *Pediatr Endocrinol Diabetes Metab*. 2015;20(3):101-106.
2. Kagami M, Mizuno S, Matsubara K, et al. Epimutations of the IG-DMR and the MEG3-DMR at the 14q32.2 imprinted region in two patients with Silver-Russell syndrome-compatible phenotype. *Eur J Hum Genet*. 2015;23(8):1062-1067.
3. Falkert A, Dittmann K, Seelbach-Gobel B. Silver-Russell syndrome as a cause for early intrauterine growth restriction. *Prenat Diagn*. 2005;25(6):497-501.
4. Wax JR, Burroughs R, Wright MS. Prenatal sonographic features of Russell-Silver syndrome. *J Ultrasound Med*. 1996;15(3):253-255.
5. Abdelhedi F, El Khattabi L, Cuisset L, et al. Neonatal Silver-Russell syndrome with maternal uniparental heterodisomy, trisomy 7 mosaicism, and dysplasia of the cerebellum. *Am J Clin Pathol*. 2014;142(2):248-253.
6. Moseley JE, Moloshok RE, Freiberger RH. The Silver syndrome: congenital asymmetry, short stature and variations in sexual development. Roentgen features. *Am J Roentgenol Radium Ther Nucl Med*. 1966;97(1):74-81.
7. Vermeiden JP, Bernardus RE. Are imprinting disorders more prevalent after human in vitro fertilization or intracytoplasmic sperm injection? *Fertil Steril*. 2013;99(3):642-651.
8. Le Bouc Y, Rossignol S, Azzi S, et al. Epigenetics, genomic imprinting and assisted reproductive technology. *Ann Endocrinol (Paris)*. 2010;71(3):237-238.
9. Saal HM. Russell-Silver syndrome. In: Pagon RA, Adam MP, Ardinger HH, et al., eds. *GeneReviews*. Seattle (WA): 1993.
10. Siklar Z, Berberoglu M. Syndromic disorders with short stature. *J Clin Res Pediatr Endocrinol*. 2014;6(1):1-8.
11. Giabicani E, Netchine I, Brioude F. New clinical and molecular insights into Silver-Russell syndrome. *Curr Opin Pediatr*. 2016;28(4):529-535.

55 Short Rib Thoracic Dysplasia With or Without Polydactyly

DEBORAH KRAKOW

Introduction

The short-rib polydactyly syndromes (SRPSs) are a genetically heterogeneous group of autosomal recessive skeletal disorders.[1] Characteristic findings in SRPS include short horizontal ribs, shortened appendicular long bones limbs, and polydactyly. Historically, four distinct SRPS types have been recognized[1]:

- SRPS I (Saldino-Noonan syndrome)
- SRPS II (Majweski syndrome)
- SRPS III (Verma-Naumoff syndrome)
- SRPS IV (Beemer-Langer syndrome)

Currently the SRPSs are classified as "*Ciliopathies with major skeletal involvement*" and this group of disorders also includes chondroectodermal dysplasia (Ellis–van Creveld syndrome or EVC), oral-facial-digital syndrome type 4 (Mohr-Majewski syndrome), and asphyxiating thoracic dystrophy (ATD or Jeune syndrome).[2] While distinct radiographic and clinical features characterize the SRPS subtypes, there is significant phenotypic overlap among them due to transitional findings. SRPSs (types I–IV) are highly associated with lethality because of pulmonary hypoplasia and respiratory compromise; live-born infants usually die shortly after birth.

Disorder

DEFINITION

SRPSs are defined by radiographic findings that include long narrow thoraces with horizontal ribs, shortened appendicular bones, often associated with hypoplastic or poorly formed bones, polydactyly, and frequently other concomitant organ system abnormalities. Similar to other Mendelian disorders that result from alterations in cilia function, multiorgan system abnormalities are common.[3]

PREVALENCE AND EPIDEMIOLOGY

Because of the rarity of this disorder, the exact incidence is unknown, though it is estimated that the frequency is 1:100,000 to 1:130,000 live births. It is well established that these disorders are autosomal recessive.[4]

ETIOLOGY

SRPS transmission is autosomal recessive. All four SRPS types and Jeune syndrome have considerable overlap. Molecular analysis has shown both allelic and locus heterogeneity; thus mutations in the same gene can produce a wide spectrum of phenotype from immediate newborn lethality to long-term survivors.[3]

The SRPS disorders share a narrow thorax, micromelia, polydactyly, and frequently visceral abnormalities. Jeune syndrome or ATD is very similar to SRPS type III; however, the clinical and radiographic findings are somewhat less severe.[5]

Advances in molecular genetics have identified numerous genes responsible for SRPS including *DYNC2H1*, *DYNC2LI1*, *NEK1*, *IFT140*, *EVC*1, *EVC2*, *KIAA0586*, *CEP120*, *WDR19*, *WDR34*, *WDR35*, *WDR60*, *TTC21B*, *IFT172*, *IFT80*, *IFT52*, *IFT81*, *ICK*, *INTU*, and *C21ORF2*.[6] These genes are thus candidate genes for at-risk families that can aid in prenatal diagnosis. However, cases remain that are not due to these genes, which can make molecular diagnosis challenging. However, mutations in *DYNC2H1* are the most common molecular cause for the SRPS and account for about 40% of the cases.[5] The term *skeletal ciliopathies* is used for these disorders because the aforementioned genes all have a profound effect on the function of the cilia.[2]

MANIFESTATIONS OF DISEASE

Clinical Presentation

The diagnosis of SRPS is suspected by ultrasound (US) findings including short, horizontal ribs with a narrow thorax; markedly short limbs (micromelia); polydactyly; and visceral anomalies. There are subtle differences between the four types, but all are lethal. Death occurs usually within a few hours after birth because of respiratory compromise secondary to pulmonary hypoplasia or asphyxia or both.

Neonates with type I SRPS are often hydropic, with long narrow thoraces, severely shortened limbs, and postaxial polydactyly (Fig. 55.1). Visceral anomalies include atrioventricular septal defects and ventral septal defects, pancreatic and renal cysts, genital anomalies, and imperforate anus. Cases with ambiguous genitalia and sex reversal have been reported.

Type II is characterized by cleft lip, low-set ears, preaxial and postaxial polydactyly, and severe tibial shortening. These infants often have ambiguous genitalia, hypoplastic glottis, malformed larynx and tracheal stenosis, glomerular and renal tubular cysts, pachygyria, and a small cerebellar vermis. Hydrops is possible, and both ventriculomegaly and narrowing of the corpus callosum have been reported.

Type III SRPS is similar to type I SRPS but with a better mineralized appendicular skeleton. Death is usually due to asphyxia instead of pulmonary hypoplasia.

Type IV is similar to type II except that often in type IV the fetus or neonate does not have polydactyly, and the tibial shortening is less severe. Hydrops, median cleft lip, narrow chest, and bowed legs were documented in the original cases by Beemer and colleagues.[7] Other clinical features are accessory



Fig. 55.1 Postdelivery radiograph of a fetus with SRPS type I. Note the micromelia, poor mineralization of the calvarium, abnormal pelvis, and spikes at the metaphyseal ends of the bones.

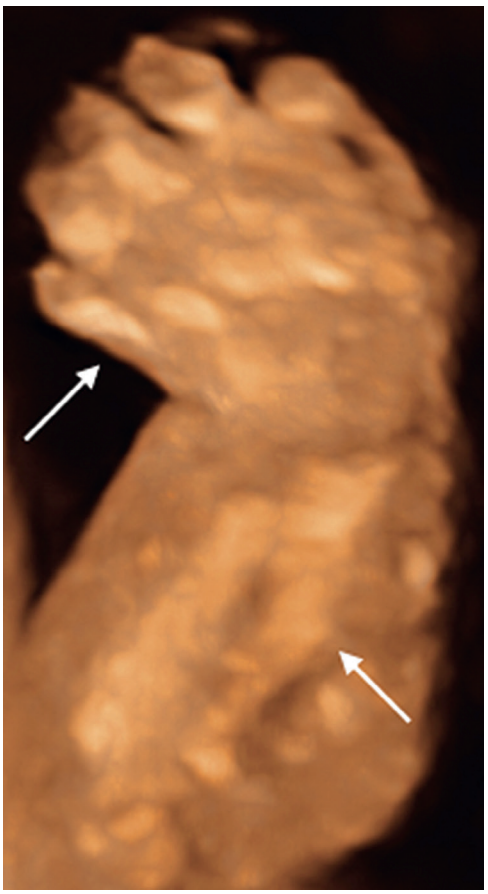

Fig. 55.2 3D US of 28-week fetus with SRPS showing micromelia and bent radius and ulna *(arrow)* and polydactyly *(arrow)*.

frenulum, anophthalmia, and transverse palmar crease. Visceral findings include renal cystic dysplasia, absent internal genitalia, pancreatic cysts, intrahepatic bile duct cysts, and periportal hepatic fibrosis.

Jeune syndrome or ATD is very similar to SRPS type III, though it is less severe, and one-third of infants survive the newborn period, with many long-term survivors reported. Long-term survivors have significant medical complications that include retinal degeneration, hepatic fibrosis, polycystic liver disease, pancreatic fibrosis, and renal failure (cystic kidneys).[8]

Imaging Technique and Findings

Ultrasound. Skeletal anomalies detectable by US include severe micromelia often with hypoplastic/bent bones (Fig. 55.2), short ribs with narrow thorax (Fig. 55.3), and polydactyly (Fig. 55.4). Visceral anomalies may also be noted (Fig. 55.5). Three-dimensional (3D) or four-dimensional (4D) US is useful in the evaluation of fetuses with skeletal dysplasias, especially for imaging the face and extremities.

Associated US-specific findings for the various types distinguish them:

- *Type I:* postaxial polydactyly, small iliac bones, and poor ossification of the calvaria, vertebrae, pelvis, and bones of the phalanges; transposition of the great vessels and ventricular septal defect; polycystic kidneys; and hydrops
- *Type II:* postaxial and preaxial polydactyly, poorly ossified vertebrae, and extremely disproportionately short tibia; cleft palate, median cleft lip, and small cerebellar vermis; ambiguous genitalia; polycystic kidneys; webbing of the toes; and hydrops
- *Type III:* similar to type I plus depressed nasal bridge, short cranial base, flat occiput, bulging forehead, and metaphyseal spikes
- *Type IV:* disproportionately short tibia (not as severe as type II), median cleft lip/palate, single umbilical artery, macrocephaly, monophthalmus (cyclopia), and possibly hydrops

Magnetic Resonance Imaging. Magnetic resonance imaging (MRI) is occasionally useful in the evaluation of fetuses with skeletal dysplasias, particularly for clarification of vertebral abnormalities, and has been used in the postmortem period as an adjunct to the diagnosis of SRPS.[9] Three-dimensional helical computed tomography has employed for the diagnosis of SRPS type III in the third trimester.[10]

Other Applicable Modality. Neonatal radiologic findings help distinguish the four types. Type I shows hypomineralization of the spine and skull, metaphyseal dysplasia, and osseous spurs on the pelvis. In type II, the radiologic appearance of the pelvis and the metaphyseal ends of tubular bones are normal. However, the tibia is disproportionately shortened, and the spine appears poorly ossified. In type III, the long bones have a distinct corticomedullary demarcation, the metaphyses are widened, and marked longitudinal spurs are present. The severity of the shortness of the tibia on x-ray separates type II from type IV because the tibial shortening is less marked in type IV.

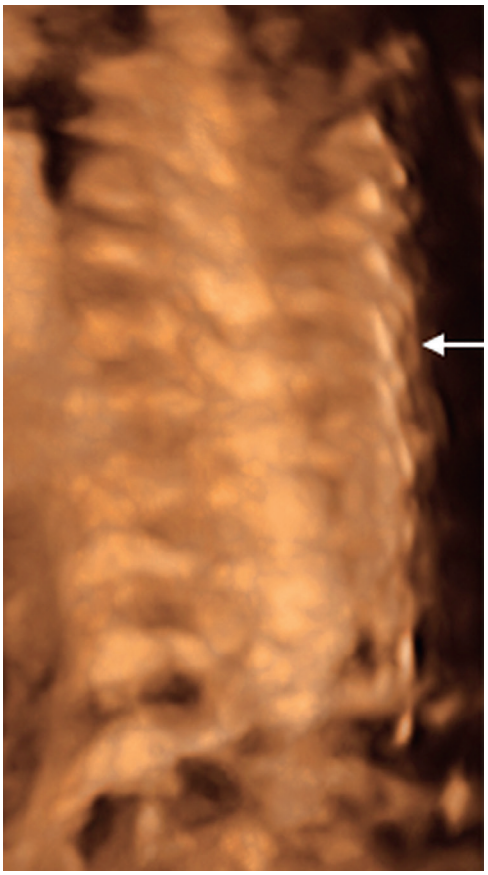

Fig. 55.3 Three-dimensional US of 28-week fetus with SRPS showing characteristic long narrow thorax *(arrow)*.



Fig. 55.4 Three-dimensional US of 28-week fetus with SRPS showing postaxial polydactyly *(arrow)*.

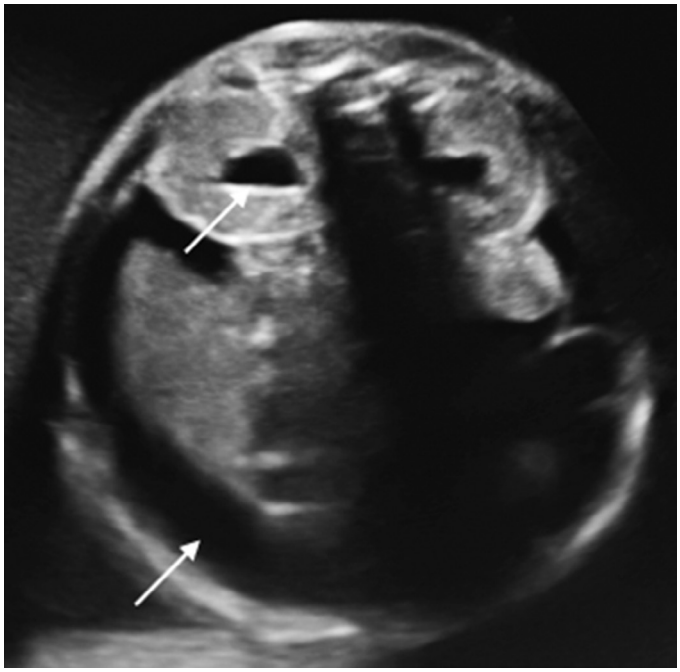

Fig. 55.5 Two-dimensional US of 32-week fetus with SRPS showing dilated renal pelvis *(arrow)* and ascites *(arrow)*.

CLASSIC SIGNS

Small thorax with short, narrow ribs
Polydactyly
Micromelia
Visceral findings

Differential Diagnosis From Imaging Findings

Ellis–van Creveld syndrome

Synopsis of Treatment Options

PRENATAL

All forms of SRPSs are lethal except the Jeune syndrome in about 30% of cases. Pregnancy termination should be discussed. Molecular testing should be offered if possible. All patients should undergo genetic counseling. Pregnancy management is routine.

POSTNATAL

Postnatal care is palliative.

WHAT THE REFERRING PHYSICIAN NEEDS TO KNOW

SRPS disorders manifest with a triad of short and narrow ribs, micromelia, and polydactyly, along with other visceral findings that can be detected on US. There are four types, all of which are lethal and show overlap with Jeune syndrome. Fetuses with a suspected

skeletal dysplasia should be referred for US and genetic counseling to a center with expertise in evaluating the fetal skeleton. Termination of pregnancy should be discussed. Histopathology, x-ray, and molecular genetics can provide definitive diagnosis. Gene discoveries can aid patients on reproductive choices. Prenatal care is routine. Postnatal care is palliative.

KEY POINTS

SRPSs have an autosomal recessive mode of inheritance.

- The classic triad includes a narrow thorax with short ribs, micromelia, and polydactyly.
- There are four subtypes, all of which are lethal.
- Jeune syndrome is similar to SRPS type III and is associated with lethality, but not uniformly.

SUGGESTED READING

Krakow D, Lachman RS, Rimoin DL. Guidelines for the prenatal diagnosis of fetal skeletal dysplasias. *Genet Med*. 2009;11(2):127-133.



All references are available online at www.expertconsult.com.

REFERENCES

1. Huber C, Cormier-Daire V. Ciliary disorder of the skeleton. *Am J Med Genet C Semin Med Genet*. 2012;160C(3):165-174.
2. Bonafe L, Cormier-Daire V, Hall C, et al. Nosology and classification of genetic skeletal disorders: 2015 revision. *Am J Med Genet A*. 2015;167A(12):2869-2892.
3. Schmidts M. Clinical genetics and pathobiology of ciliary chondrodysplasias. *J Pediatr Genet*. 2014;3(2):46-94.
4. Spranger J, Langer LO, Weller MH, et al. Short rib-polydactyly syndromes and related conditions. *Birth Defects Orig Artic Ser*. 1974;10(9):117-123.
5. Baujat G, Huber C, El Hokayem J, et al. Asphyxiating thoracic dysplasia: clinical and molecular review of 39 families. *J Med Genet*. 2013;50(2):91-98.
6. Duran I, Taylor SP, Zhang W, et al. Destabilization of the IFT-B cilia core complex due to mutations in IFT81 causes a spectrum of short-rib polydactyly syndrome. *Sci Rep*. 2016;6:34232.
7. Beemer FA, Langer LO Jr, Klep-de Pater JM, et al. A new short rib syndrome: report of two cases. *Am J Med Genet*. 1983;14(1):115-123.
8. Poyner SE, Bradshaw WT. Jeune syndrome: considerations for management of asphyxiating thoracic dystrophy. *Neonatal Netw*. 2013;32(5):342-352.
9. Taylor AM, Jones R, Offiah A, et al. Postmortem magnetic resonance imaging as an adjunct to the diagnosis of skeletal dysplasias: short-rib polydactyly syndrome. *Ultrasound Obstet Gynecol*. 2006;27(5):585-586.
10. Yamada T, Nishimura G, Nishida K, et al. Prenatal diagnosis of short-rib polydactyly syndrome type 3 (Verma-Naumoff type) by three-dimensional helical computed tomography. *J Obstet Gynaecol Res*. 2011;37(2):151-155.

SECTION TWO

Osteochondrodysplasias—Nonlethal

56 Spondyloepiphyseal Dysplasia Congenita

DEBORAH KRAKOW

Introduction

Spondyloepiphyseal dysplasias are rare, nonlethal disorders of bone growth. These disorders primarily affect the spine (spondylo-) and the ends of the long bones (epiphyseal), resulting in a short-trunk dwarfism. These disorders are clinically and genetically heterogeneous. Some spondyloepiphyseal dysplasias manifest in the prenatal period, including spondyloepiphyseal dysplasia congenita (SEDC), whereas others manifest in childhood. Other spondyloepiphyseal dysplasias are diagnosed in later life as early-onset arthropathy. This chapter focuses on the most common form that is prenatal in onset, SEDC, which results from mutations in type II collagen encoded by *COL2A1*.[1]

Disorder

DEFINITION

SEDC is a nonlethal disorder caused by mutations in the gene that encodes type II collagen, *COL2A1*.[2] Abnormal synthesis of type II collagen, a major component of cartilage, leads to short stature, kyphoscoliosis,[3] early-onset osteoarthritis, and hearing and vision problems.

PREVALENCE AND EPIDEMIOLOGY

The exact prevalence is unknown but is one of the more common nonlethal skeletal disorders.

ETIOLOGY, PATHOPHYSIOLOGY, AND EMBRYOLOGY

Autosomal dominantly inherited mutations in *COLA2A1,* the gene that encodes for the type II collagen protein, are responsible for SEDC, and therefore both sexes are equally affected. If both parents are affected because of nonassorting mating, there is a 25% chance of homozygosity, which is generally lethal in infancy.

Type II collagen is highly expressed in certain tissues, in particular in cartilage and the vitreous of the eye, and thus affected individuals have both short stature and a high incidence of eye abnormalities. Other rare forms of spondyloepiphyseal dysplasias are inherited as autosomal recessive and X-linked disorders (spondyloepiphyseal dysplasia tarda).

MANIFESTATIONS OF DISEASE

Clinical Presentation

Patients with SEDC often have odontoid hypoplasia, kyphoscoliosis, and early-onset hip and knee joint degeneration, leading to significant orthopedic complications. There is an increased incidence of cleft palate without cleft lip and micrognathia (Pierre Robin sequence) (Chapter 137).[4]

Lumbar lordosis, thoracic scoliosis, and kyphoscoliosis are usually not evident at birth but may develop in childhood. These abnormalities in spinal curvature tend to progress, and severe kyphoscoliosis can lead to difficulties in pulmonary



Fig. 56.1 Two-dimensional US showing in SEDC showing flattened vertebral bodies.



Fig. 56.3 Three-dimensional US of fetus with SEDC showing micrognathia.

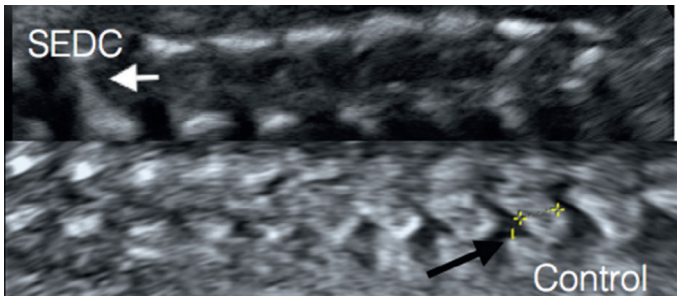

Fig. 56.2 Four-dimensional US skeletal mode in SEDC showing poorly seen vertebral bodies relative to control fetus *(arrows)*.

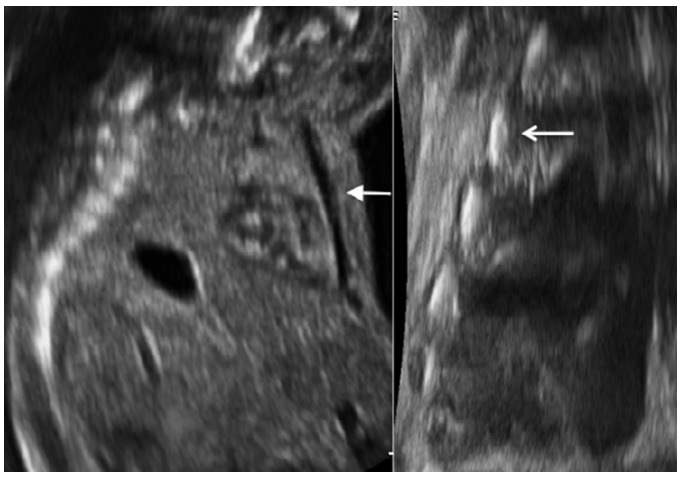

Fig. 56.4 Two-dimensional US of a fetus with SEDC and control showing lack of ossification of the sternal bodies *(arrows)*.

function, restrictive lung disease, and ultimately cor pulmonale.[5]

In SEDC, the neck is short, and atlanto-axial instability secondary to odontoid hypoplasia leads to increased risk of spinal cord compression particularly on neck flexion or extension. Other skeletal abnormalities that are often seen include flattened vertebrae (platyspondyly), pectus carinatum with barrel-shaped chest, and abnormally formed hip joints with coxa varus leading to abnormal hip articulation, frequently leading to gait abnormalities. Early-onset arthritis and decreased joint mobility are also frequently observed, particularly at the hip and the knee.

The most common ocular abnormalities are severe myopia, vitreous degeneration, and retinal detachment. About 25% of individuals have severe hearing loss or deafness.[6] Adult height ranges from 3 to 4 feet tall.[7] Intelligence is not affected.

Imaging Technique and Findings

Ultrasound. Prenatal diagnosis may also be suggested by ultrasound (US) findings of delayed ossification of the pubis and epiphysis of the femur and humerus, flattened vertebra and narrow intervertebral disk space (Figs. 56.1 and 56.2), and flattened facies with micrognathia (Fig. 56.3).[8] US findings include delayed ossification of the epiphyses of the long bones. Delayed epiphyseal endochondral ossification can also be seen, for example, in the chest with delay of ossification of the sternal centers (Fig. 56.4). The long bones of the arms and legs grow but measure below the fifth percentile.[9] Sonolucency secondary to delayed ossification of the vertebral bodies may be seen, and vertebral bodies may appear flattened or small. Bowing of the femur and humerus may also be present, though this is less common. Head size is normal. Clubfoot and cleft palate present with the previously mentioned findings are suspicious for SEDC.

Magnetic Resonance Imaging. Magnetic resonance imaging (MRI) is occasionally useful in the evaluation of fetuses with skeletal dysplasias, particularly for clarification of vertebral abnormalities. Neither prenatal MRI nor computed tomography has been reported for SEDC.

Other Applicable Modality. Postnatal radiographs and clinical appearance are important to make final diagnosis.[10]

CLASSIC SIGNS

Disproportionate dwarfism with short spine, short neck, barrel chest
Normal-sized hands and feet in most cases
Flat facies
Delayed ossification of the skeleton on US and radiographs

Differential Diagnosis From Imaging Findings

Other disorders associated with epiphyseal delay including other type II disorders.

Synopsis of Treatment Options

PRENATAL

In most cases, SEDC is nonlethal. No special precautions need to be taken for delivery. Fetal head size is normal, unlike other skeletal disorders with relative macrocephaly.

POSTNATAL

Small stature with occasional club foot and cleft palate are present at birth. These newborns can be hypotonic, and motor delay is common, but they are of normal intelligence. Respiratory complications can arise because of small thorax and decreased intrathoracic volumes. Tracheomalacia has been reported but is rare. C1–C2 instability is seen, placing the child at risk for spinal cord compression.[3] Severe myopia is common and can be associated with retinal detachment.[11] Symptomatic treatment is indicated for these complications.

WHAT THE REFERRING PHYSICIAN NEEDS TO KNOW

SEDC is a dominant, typically nonlethal disorder. Long-term complications include short stature, respiratory complications, and early-onset osteoarthritis. Delivery should be based on maternal and fetal complications and early intervention is not indicated.

KEY POINTS

- SEDC is nonlethal and autosomal dominant in inheritance caused by mutations in the gene *COL2A1* encoding for type II collagen.
- US imaging shows shortened appendicular long bones, particularly the humeri and femora.
- US imaging can demonstrate platyspondyly and delayed endochondral ossification.

SUGGESTED READING

Chitty LS, Tan AW, Nesbit DL, et al. Sonographic diagnosis of SEDC and double heterozygote of SEDC and achondroplasia—a report of six pregnancies. *Prenat Diagn*. 2006;26(9):861-865.

Terhal PA, Nievelstein RJ, Verver EJ, et al. A study of the clinical and radiological features in a cohort of 93 patients with a COL2A1 mutation causing spondyloepiphyseal dysplasia congenita or a related phenotype. *Am J Med Genet A*. 2015;167A(3):461-475.

All references are available online at www.expertconsult.com.

REFERENCES

1. Terhal PA, Nievelstein RJ, Verver EJ, et al. A study of the clinical and radiological features in a cohort of 93 patients with a COL2A1 mutation causing spondyloepiphyseal dysplasia congenita or a related phenotype. *Am J Med Genet A*. 2015;167A(3):461-475.
2. Hoornaert KP, Dewinter C, Vereecke I, et al. The phenotypic spectrum in patients with arginine to cysteine mutations in the COL2A1 gene. *J Med Genet*. 2006;43(5):406-413.
3. Morita M, Miyamoto K, Nishimoto H, et al. Thoracolumbar kyphosing scoliosis associated with spondyloepiphyseal dysplasia congenita: a case report. *Spine J*. 2005;5(2):217-220.
4. Tofield CE, Mackinnon CA. Cleft palate repair in spondyloepiphyseal dysplasia congenita: minimizing the risk of cervical cord compression. *Cleft Palate Craniofac J*. 2003;40(6):629-631.
5. Harding CO, Green CG, Perloff WH, et al. Respiratory complications in children with spondyloepiphyseal dysplasia congenita. *Pediatr Pulmonol*. 1990;9(1):49-54.
6. Tunkel D, Alade Y, Kerbavaz R, et al. Hearing loss in skeletal dysplasia patients. *Am J Med Genet A*. 2012;158A(7):1551-1555.
7. Terhal PA, van Dommelen P, Le Merrer M, et al. Mutation-based growth charts for SEDC and other COL2A1 related dysplasias. *Am J Med Genet C Semin Med Genet*. 2012;160C(3):205-216.
8. Krakow D, Lachman RS, Rimoin DL. Guidelines for the prenatal diagnosis of fetal skeletal dysplasias. *Genet Med*. 2009;11(2):127-133.
9. Chitty LS, Tan AW, Nesbit DL, et al. Sonographic diagnosis of SEDC and double heterozygote of SEDC and achondroplasia—a report of six pregnancies. *Prenat Diagn*. 2006;26(9):861-865.
10. Silveira KC, Bonadia LC, Superti-Furga A, et al. Six additional cases of SEDC due to the same and recurrent R989C mutation in the COL2A1 gene—the clinical and radiological follow-up. *Am J Med Genet A*. 2015;167A(4):894-901.
11. Ikegawa S, Iwaya T, Taniguchi K, et al. Retinal detachment in spondyloepiphyseal dysplasia congenita. *J Pediatr Orthop*. 1993;13(6):791-792.

57 Other Type II Collagen Disorders

DEBORAH KRAKOW

Introduction

Achondrogenesis II, hypochondrogenesis, platyspondylic Torrance type, spondyloepiphyseal dysplasia congenita (SEDC) (Chapter 56), Kniest dysplasia, spondyloepimetaphyseal dysplasia, Strudwick type, Legg-Calve-Perthes disease, spondyloperipheral dysplasia, spondyloepiphyseal dysplasia with metatarsal shortening (Czech type), autosomal dominant spondyloarthropathy, and Stickler syndrome form the type II collagen disorder group. This group is a continuous spectrum of disorders, some of which manifest in the prenatal period, some much later in life.

Disorder

DEFINITION

The aforementioned disorders all result from autosomal dominantly inherited disorders in the gene, *COL2A1*, the gene that encodes type II collagen. Beyond sharing a common genetic basis of disease, they share some radiographic features and clinical features such as early-onset osteoarthritis in nonlethal disorders.

PREVALENCE AND EPIDEMIOLOGY

The precise prevalence of this spectrum of disorders is not known but, as a group, type II collagen disorders are not uncommon among the skeletal disorders. For the lethal achondrogenesis II, the disorder is estimated to have a prevalence of 1:40,000 to 1:60,000.

ETIOLOGY AND PATHOPHYSIOLOGY

The aforementioned disorders all result from heterozygosity for mutations in the gene that encodes type II collagen, *COL2A1*.[1,2]

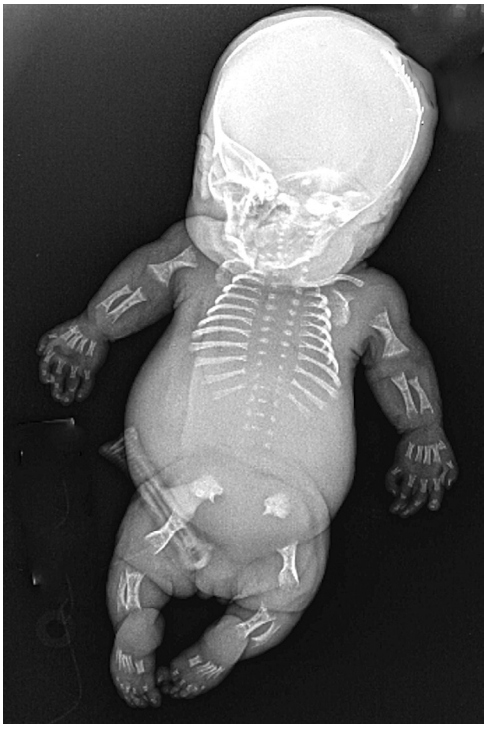

Fig. 57.1 Postnatal radiograph of achondrogenesis II; note lack of ossification of the spine and pubis.



Fig. 57.2 Postnatal radiograph of hypochondrogenesis; note poor ossification of the spine and pubis and similar-shaped bones to achondrogenesis II.

The *COL2A1* gene product is the type II collagen molecule. Somatic and germline mosaicism has been reported for type II collagen disorders.[3,4] The type II collagen molecule provides structure and strength to connective tissues, particularly cartilage. Cartilage primarily compromises the skeleton during early development and abnormalities in type II collagen can have a profound effect on the patterning and integrity of the skeleton. Type II collagen is also part of the vitreous of the eye, the inner ear, and the nucleus pulposus; thus abnormalities in type II collagen affect the eye, the spine, and hearing.

Most of the mutations that produce these disorders result from heterozygosity for missense mutations in *COL2A1*, and most of these mutations result from substitution of a glycine residue in the triple helix of the gene with a bulkier amino acid.[2] Stickler syndrome, which presents with Pierre Robin sequence, mild short stature, and significant myopia and retinal abnormalities, results from heterozygosity for nonsense mutations in *COL2A1*.[5]

MANIFESTATIONS OF DISEASE

Clinical Presentation

The following disorders can present in the prenatal period or immediate newborn period:

Achondrogenesis II. Achondrogenesis type II is also referred to as the Langer-Saldino type. This very rare disorder is characterized by extremely shortened arms and legs, a narrow chest with short ribs, hypoplastic lungs, and a lack of normal bone formation (ossification) in the spine and pelvis (Fig. 57.1). Distinctive facial features include a prominent forehead, micrognathia, and cleft palate. The abdomen is relatively enlarged, and often these fetuses present with hydrops fetalis. Newborns with achondrogenesis type II usually die before or soon after birth.

Hypochondrogenesis is very similar to achondrogenesis type II. Affected infants have short arms and legs, a small chest with short ribs, and underdeveloped lungs (Fig. 57.2). Bones in the skull develop normally, but the bones of the vertebrae and pelvis lack proper ossification. Their facies appears flat and oval-shaped, with micrognathia and cleft palate (Pierre Robin sequence) and a high incidence of hydrops fetalis. Most of these infants do not survive to term. For those who do, and survive the newborn period, they are often reclassified as spondyloepiphyseal dysplasia congenita, a relatively similar but milder disorder (see Chapter 56).

Stickler syndrome results from heterozygosity for loss of function mutations in COL2A1[5] and thus is somewhat mechanistically different. These individuals may present in the prenatal period with mild shortening of the rhizomelic segment and significant micrognathia. Long-term, most people with Stickler syndrome have skeletal abnormalities that affect the joints including scoliosis and kyphosis. As children, they may have loose joints, but as they age, their joints become less flexible. Arthritis often appears early in life causing joint pain or stiffness. Of major concern are the eye findings in Stickler syndrome that include glaucoma, cataracts, and retinal detachments, increasing the likelihood of impaired vision and in some cases blindness. Sensorineural hearing loss varies in degree of severity, but is common.

Imaging Technique and Findings

Ultrasound. Achondrogenesis II and hypochondrogenesis will present in the prenatal period. Achondrogenesis II presents in the first trimester with an increased nuchal fold and frequently a cystic hygroma.[6–8] Hypochondrogenesis will present in a similar



Fig. 57.3 Three-dimensional ultrasound of an 18-week fetus with achondrogenesis II; note very flattened facies.



Fig. 57.5 Two-dimensional ultrasound of a 16-week fetus with Stickler syndrome showing significant micrognathia.

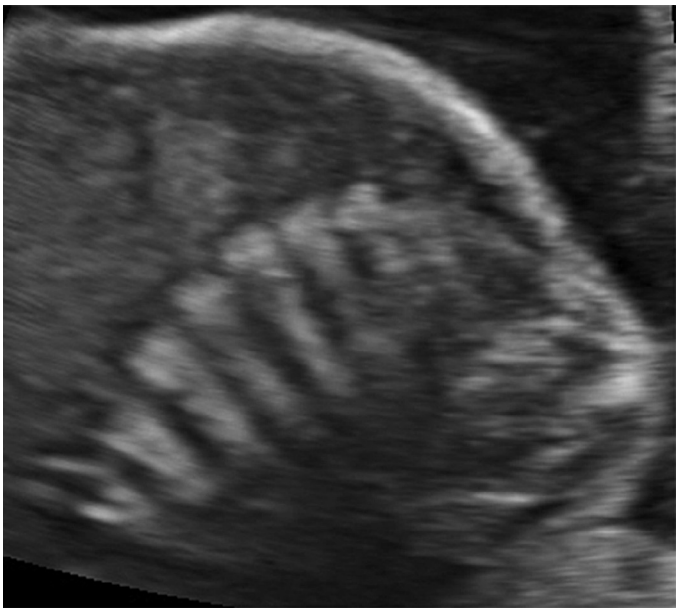

Fig. 57.4 Two-dimensional ultrasound of a 20-week fetus with achondrogenesis II showing very shortened ribs with metaphyseal cupping on sagittal view.



Fig. 57.6 Three-dimensional ultrasound of a 20-week fetus with Stickler syndrome showing significant micrognathia.

fashion. The ultrasound findings include a flattened facies (Fig. 57.3), small chest, particularly on sagittal view with short ribs with cupping at the ends (Fig. 57.4), lack of secondary ossification centers, and severe shortening of all the long bones, with relatively normal-looking hands. Ascites, hydrops fetalis, and polyhydramnios are relatively common findings.[9]

Stickler syndrome can present in the prenatal period, particularly if there is a family history. Findings in the prenatal period include micrognathia (Figs. 57.5 and 57.6) and mild rhizomelia in some cases.[10,11]

Magnetic Resonance Imaging. While prenatal magnetic resonance imaging has been useful in some circumstances, its use has not been demonstrated in this set of conditions, nor has prenatal computed tomography.

Other Applicable Modality. Postnatal clinical findings and radiographs are diagnostic for this disorder.

CLASSIC SIGNS

Achondrogenesis II/Hypochondrogenesis
Short trunk with prominent abdomen
Striking micromelia
Flat midface micrognathia, often cleft palate
Hydrops
Polyhydramnios
Stickler syndrome
Midface hypoplasia
Cleft palate
Micrognathia
Mild shortening of the rhizomelic segment

Differential Diagnosis From Imaging Findings

1. Achondrogenesis IA
2. Achondrogenesis IB
3. Spondyloepiphyseal dysplasia congenita
4. Other epiphyseal dysplasias

Synopsis of Treatment Options

PRENATAL

Achondrogenesis II and hypochondrogenesis are lethal disorders, and interruption of pregnancy should be offered to the patient. If the pregnancy is delivered near term, active resuscitation should not be undertaken and palliative care should be offered. There is no role for cesarean section unless performed for obstetric rather than fetal indications.

For Stickler syndrome, a team of individuals should be assembled to prepare for potential airway difficulties in the newborn period, including consideration for the *ex utero* intrapartum treatment (EXIT) procedure if the micrognathia is severe.

POSTNATAL

Achondrogenesis II and hypochondrogenesis are lethal. Stickler syndrome is associated with Pierre Robin sequence and should be managed by a surgical team with expertise in the area. Meticulous ongoing evaluation of the eyes should be initiated at an early age. Hearing loss and precious arthrosis are common and should be followed closely to optimize quality of life.

WHAT THE REFERRING PHYSICIAN NEEDS TO KNOW

Achondrogenesis II and hypochondrogenesis are lethal. Pregnancy interruption should be offered. Ascites, hydrops fetalis, and polyhydramnios are common complications, and delivery should be offered if indicated. Active intervention for preterm labor should not be undertaken. Mutations are dominantly inherited or sporadic in these conditions because of mutations in *COL2A1*.

KEY POINTS

- Achondrogenesis II and hypochondrogenesis are lethal conditions resulting from missense mutations in *COL2A1*.
- Stickler syndrome results from nonsense mutations in *COL2A1*.
- Severe limb shortening, poor ossification of the spine, and hydrops are common in achondrogenesis II and hypochondrogenesis.
- Stickler syndrome presents with mild rhizomelia and micrognathia (Pierre Robin sequence).

SUGGESTED READING

Krakow D, Williams J 3rd, Poehl M, et al. Use of three-dimensional ultrasound imaging in the diagnosis of prenatal-onset skeletal dysplasias. *Ultrasound Obstet Gynecol.* 2003;21(5):467-472.

Robin NH, Moran RT, Ala-Kokko L. Stickler syndrome. In: Pagon RA, Adam MP, Ardinger HH, et al., eds. *GeneReviews*. Seattle (WA): 1993.



All references are available online at www.expertconsult.com.

REFERENCES

1. Deng H, Huang X, Yuan L. Molecular genetics of the COL2A1-related disorders. *Mutat Res Rev Mutat Res*. 2016;768:1-13.
2. Barat-Houari M, Sarrabay G, Gatinois V, et al. Mutation update for COL2A1 gene variants associated with type II collagenopathies. *Hum Mutat*. 2016;37(1):7-15.
3. Nagendran S, Richards AJ, McNinch A, et al. Somatic mosaicism and the phenotypic expression of COL2A1 mutations. *Am J Med Genet A*. 2012;158A(5):1204-1207.
4. Comstock JM, Putnam AR, Sangle N, et al. Recurrence of achondrogenesis type 2 in sibs: additional evidence for germline mosaicism. *Am J Med Genet A*. 2010;152A(7):1822-1824.
5. Robin NH, Moran RT, Ala-Kokko L. Stickler syndrome. In: Pagon RA, Adam MP, Ardinger HH, et al., eds. *GeneReviews*. Seattle (WA): 1993.
6. Forzano F, Lituania M, Viassolo A, et al. A familial case of achondrogenesis type II caused by a dominant COL2A1 mutation and "patchy" expression in the mosaic father. *Am J Med Genet A*. 2007;143A(23):2815-2820.
7. Won HS, Yoo HK, Lee PR, et al. A case of achondrogenesis type II associated with huge cystic hygroma: prenatal diagnosis by ultrasonography. *Ultrasound Obstet Gynecol*. 1999;14(4):288-290.
8. Soothill PW, Vuthiwong C, Rees H. Achondrogenesis type 2 diagnosed by transvaginal ultrasound at 12 weeks' gestation. *Prenat Diagn*. 1993;13(6):523-528.
9. Krakow D, Williams J 3rd, Poehl M, et al. Use of three-dimensional ultrasound imaging in the diagnosis of prenatal-onset skeletal dysplasias. *Ultrasound Obstet Gynecol*. 2003;21(5):467-472.
10. Soulier M, Sigaudy S, Chau C, et al. Prenatal diagnosis of Pierre-Robin sequence as part of Stickler syndrome. *Prenat Diagn*. 2002;22(7):567-568.
11. Lituania M, Tonni G. Bifid uvula and familial Stickler syndrome diagnosed prenatally before the sonographic "equals sign" landmark. *Arch Gynecol Obstet*. 2013;288(3):483-487.

58 Acrofacial Dysostosis

DEBORAH KRAKOW

Introduction

Among newborns with birth defects, approximately one-third show craniofacial abnormalities, which cause significant morbidity and mortality. More than 700 distinct craniofacial syndromes have been described to date.[1] Facial dysostoses can be divided into two types: mandibulofacial dysostoses (MFDs) and acrofacial dysostoses (AFDs).[2] MFDs have typically no limb defects, while AFDs are associated with limb abnormalities. At least eight MFDs have been described, with the most common being Treacher Collins syndrome (TCS).[1] AFDs are a genetically heterogeneous group of inherited disorders unified by craniofacial and limb abnormalities. At least 18 distinct types of AFDs have been characterized based on the specific patterns of limb abnormalities. They have been further classified into those with preaxial limb abnormalities, those with postaxial defects, and a subset that cannot be classified into either group. There is significant phenotypic overlap for these disorders.

Disorder

DEFINITION

MFD disorders exhibit a profound effect on facial development and are considered facial dysostoses. AFDs show both facial and

limb abnormalities, and are part of the continuum of facial dysostoses.

PREVALENCE AND EPIDEMIOLOGY

The most common MFD is TCS, which occurs with an incidence of about 1 : 50,000 live births. TCS is inherited in an autosomal dominant manner in most cases; however, a rare recessive form has been described. Nager syndrome is the most common AFD and is extremely rare, with fewer than 100 cases reported in the literature.

ETIOLOGY, PATHOPHYSIOLOGY, AND EMBRYOLOGY

TCS results from heterozygous mutations in the gene encoding *TCOF1* in the vast majority of cases.[3] Heterozygosity for mutations in *POLR1D* can also lead to TCS, as can recessively inherited mutations in *POLR1C*. All three genes, either as binding partners or subunits of a complex, are involved in the RNA polymerase function and ribosomal biogenesis.[4]

Nager syndrome and the allelic but more severe Rodriguez syndrome are autosomal dominant disorders that both result from heterozygosity for mutations in *SF3B4*.[5] In about 50% of cases of Nager syndrome, tested mutations have been identified in *SF3B4*, suggesting that another gene is responsible for some of the cases. The *SF3B4* gene encodes a spliceosomal protein that removes introns and ligates exons during RNA splicing.[5]

MANIFESTATIONS OF DISEASE

Clinical Presentation

TCS is a congenital disorder of craniofacial development that exhibits reduced penetrance, with some very mildly affected individuals and some much more severe. Characteristic features of TCS include hypoplasia of the facial bones (particularly the maxilla, mandible, and zygoma) with orbital clefting producing a distinct facial appearance. The clefting causes downward slanting of the palpebral fissures with colobomas of the lower eyelids and absence of the medial third of the lower eyelashes. Abnormalities are commonly seen in the size, shape, and position of the ears. These external ear abnormalities are associated with atresia of the external auditory canals and anomalies of the middle ear ossicles, producing varying forms of deafness. The limbs are typically normal.[4]

Nager syndrome is an acrofacial dysostosis that encompasses malformations of the facies and the limbs. Characteristic findings include midface hypoplasia, micrognathia, choanal atresia, cleft palate, and sensorineural hearing loss. Limb defects usually affect the radial elements of the forelimbs and include hypoplasia or agenesis of the radius, or radioulnar synostosis (Fig. 58.1). In addition, hypoplasia or agenesis of the thumbs, or triphalangeal thumbs (three ossification centers) have been observed as part of the condition. Oligodactyly, phocomelia of the upper limbs, and occasionally lower-limb defects have also been reported in the more severe form of AFD, Rodriguez syndrome, which has been shown to be allelic and has even more severe limb abnormalities (Fig. 58.2).[1]

Imaging Technique and Findings

Ultrasound. Prenatal ultrasound (US) has been used to diagnose numerous MFDs and AFDs. US findings in TCS include micrognathia, transverse facial cleft, and low-set ears (Fig. 58.3), particularly if there are no other US findings and normal growth parameters.[3,6,7] Polyhydramnios has been also described in some cases.[8]

Prenatal US findings in Nager syndrome and the allelic, more severe Rodriguez syndrome show severe mandibular hypoplasia, severe retrognathia (Fig. 58.4), malformed ears, mesomelic shortening, and limb abnormalities that include radial ray defects,

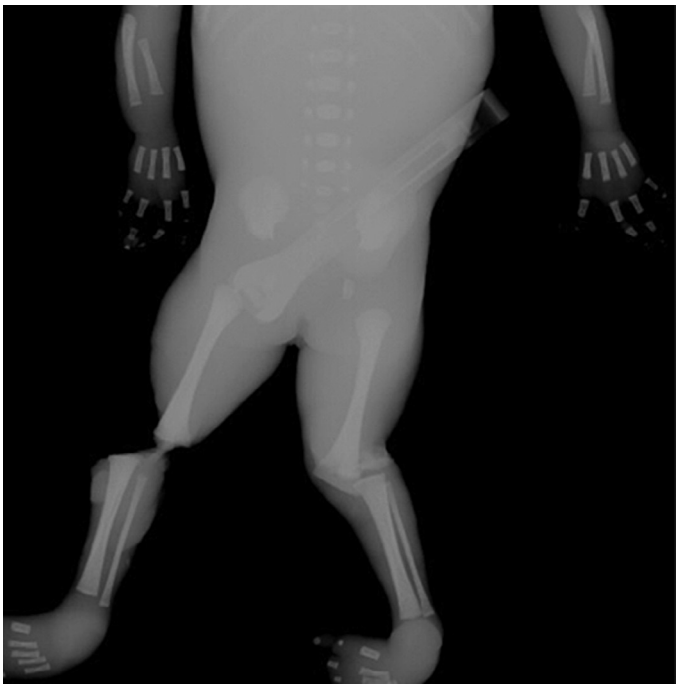

Fig. 58.1 Radiograph of a fetus with Nager syndrome. Note the bilateral shortening of the radii.

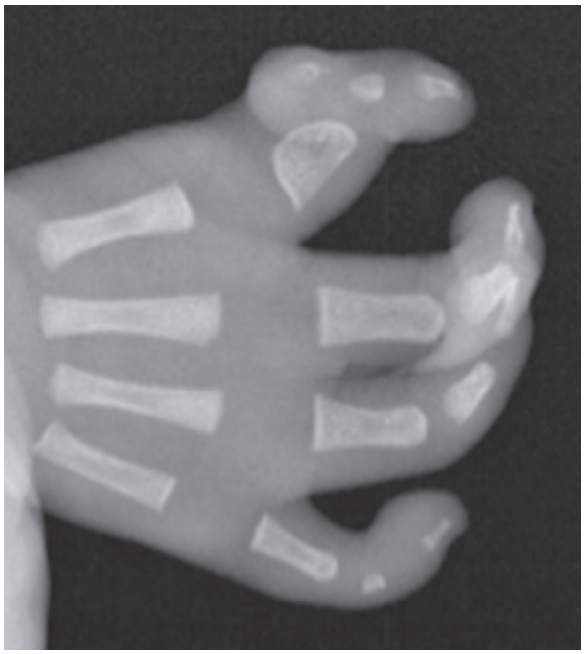

Fig. 58.2 Radiograph of a fetus with Rodriguez syndrome showing severity of the upper extremity abnormality.

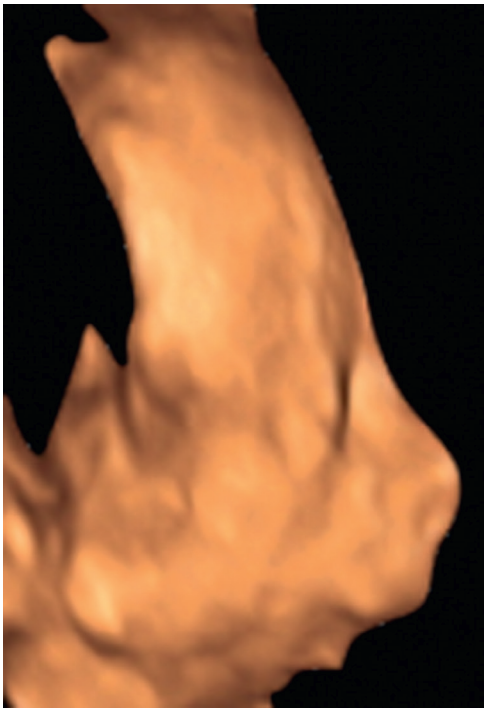

Fig. 58.3 Three-dimensional US of the facies with TCS showing significant micrognathia.



Fig. 58.4 Three-dimensional US of the facies of a fetus with Rodriguez syndrome showing micrognathia and oligodactyly.

and oligodactyly (Fig. 58.5).[9] Both the upper and lower limbs can be affected.

Magnetic Resonance Imaging. Prenatal magnetic resonance imaging (MRI) has been used to detect hemifacial microsomia and ear abnormalities.[10] MRI has also been used to visualize the middle ear cavity and was used to detect one case of TCS, thus suggesting that this modality may have a place in imaging of fetuses with MFDs and AFDs, particularly if the diagnosis of middle ear hypoplasia would influence management.[11]



Fig. 58.5 Three-dimensional US of the lower extremities in a fetus with Rodriguez syndrome showing absence of the fibulae.

Other Applicable Modality. Postnatal radiographs and clinical evaluation can be particularly helpful in differentiating AFDs.[2]

CLASSIC SIGNS

TCS

Down-slanting palpebral fissures
Malar hypoplasia
Mandibular hypoplasia
Low lid coloboma
Malformation of the ear
Cleft palate
Deafness

NAGER SYNDROME OR THE ALLELIC RODRIGUEZ SYNDROME

Malar hypoplasia
Conductive deafness
Micrognathia
Absence of the lower eyelashes
Low-set posteriorly rotated ears
Hypoplasia to aplasia of the thumbs
Oligodactyly
Short forearms
Club feet
Vertebral anomalies
Cardiac defects
Hydrocephalus
Polymicrogyria
Genitourinary abnormalities

Differential Diagnosis From Imaging Findings

Other forms of MFDs or AFDs including Miller syndrome.

Synopsis of Treatment Options

PRENATAL

The prenatal management of MFDs and AFDs is best done at a center with expertise in managing an airway, and consideration for the *ex utero* intrapartum treatment (EXIT) procedure may be applicable in some circumstances. If TCS and Nager/Rodriguez syndrome are suspected in a time frame commensurate with obtaining a molecular diagnosis, then invasive testing should be performed if it helps guide the family in decision making. Obstetric and delivery care should follow routine guidelines. Severe cases of TCS and Nager/Rodriguez syndrome may develop polyhydramnios and should be managed appropriately. Because of the severity of these conditions and life-long issues, interruptions of pregnancy should be discussed with the parents.

POSTNATAL

TCS: These patients can develop respiratory issues if there is a narrow airway and postnatal tracheostomy may be narrow. The majority of these patients have normal intelligence, but early intervention for deafness is crucial. Vision loss can result from eye abnormalities and should be followed carefully. Many of these children need multiple surgeries to improve their cosmetic appearance. Other rare abnormalities include heart defects, choanal atresia, and mental deficiency is reported in 5% of cases.

Nager syndrome and the allelic *Rodriguez syndrome:* Rodriguez syndrome is very severe and often associated with lethality in the newborn period, with a high incidence of preterm delivery. Nager syndrome is associated with multiorgan system abnormalities and perinatal mortality approaches 20%. Because of polyhydramnios, the incidence of prematurity is high. The recommendations for hearing intervention and cosmetic repair are similar to TCS. Early respiratory and feeding difficulties are common and parents should be aware of the increased need for feeding tubes and tracheostomies.

WHAT THE REFERRING PHYSICIAN NEEDS TO KNOW

Both MFDs and AFDs are severe disorders that are highly associated with polyhydramnios and preterm delivery. These are severe disorders with long-term issues for the child and family. AFDs have a higher incidence of perinatal mortality. Delivery must be coordinated with a team of physicians that can manage a complicated airway and in some cases an EXIT procedure is indicated. TCS has two dominant forms and one recessive form, and Nager syndrome and the allelic Rodriguez syndrome results from heterozygosity for mutations in *SF3B4*.

KEY POINTS

- The most common MFD is TCS which is associated with primary facial abnormalities including orofacial clefting and abnormal shaped ears
- The most common AFD is Nager syndrome associated with micrognathia, low-set ears, and upper- and sometimes lower-limb abnormalities.

SUGGESTED READING

Marques F, Tenney J, Duran I, et al. Altered mRNA splicing, chondrocyte gene expression and abnormal skeletal development due to SF3B4 mutations in Rodriguez acrofacial dysostosis. *PLoS Genet*. 2016;12(9):e1006307.

Trainor PA, Andrews BT. Facial dysostoses: etiology, pathogenesis and management. *Am J Med Genet C Semin Med Genet*. 2013;163C(4):283-294.



All references are available online at www.expertconsult.com.

REFERENCES

1. Trainor PA, Andrews BT. Facial dysostoses: etiology, pathogenesis and management. *Am J Med Genet C Semin Med Genet*. 2013;163C(4): 283-294.
2. Preis S, Raymaekers-Buntinx I, Majewski F. Acrofacial dysostosis of unknown type: nosology of the acrofacial dysostoses. *Am J Med Genet*. 1995;56(2):155-160.
3. Dixon J, Ellis I, Bottani A, et al. Identification of mutations in TCOF1: use of molecular analysis in the pre- and postnatal diagnosis of Treacher Collins syndrome. *Am J Med Genet A*. 2004;127A(3):244-248.
4. Katsanis SH, Jabs EW. Treacher Collins syndrome. In: Pagon RA, Adam MP, Ardinger HH, et al., eds. *GeneReviews*. Seattle (WA): 1993.
5. Marques F, Tenney J, Duran I, et al. Altered mRNA splicing, chondrocyte gene expression and abnormal skeletal development due to SF3B4 mutations in Rodriguez acrofacial dysostosis. *PLoS Genet*. 2016;12(9):e1006307.
6. Pereira DC, Bussamra LC, Araujo Junior E, et al. Prenatal diagnosis of Treacher-Collins syndrome using three-dimensional ultrasonography and differential diagnosis with other acrofacial dysostosis syndromes. *Case Rep Obstet Gynecol*. 2013;2013:203976.
7. Tanaka Y, Kanenishi K, Tanaka H, et al. Antenatal three-dimensional sonographic features of Treacher Collins syndrome. *Ultrasound Obstet Gynecol*. 2002;19(4):414-415.
8. Ruangvutilert P, Sutantawibul A, Sunsaneevithayakul P, et al. Ultrasonographic prenatal diagnosis of Treacher Collins syndrome: a case report. *J Med Assoc Thai*. 2003;86(5):482-488.
9. Paladini D, Tartaglione A, Lamberti A, et al. Prenatal ultrasound diagnosis of Nager syndrome. *Ultrasound Obstet Gynecol*. 2003;21(2):195-197.
10. Hattori Y, Tanaka M, Matsumoto T, et al. Prenatal diagnosis of hemifacial microsomia by magnetic resonance imaging. *J Perinat Med*. 2005;33(1):69-71.
11. Katorza E, Nahama-Allouche C, Castaigne V, et al. Prenatal evaluation of the middle ear and diagnosis of middle ear hypoplasia using MRI. *Pediatr Radiol*. 2011;41(5):652-657.

SECTION THREE

Findings—Spinal Defects

59 Caudal Regression Syndrome

CARA C. HEUSER | REBECCA S. HULINSKY | G. MARC JACKSON

Introduction

Caudal regression syndrome (CRS), also known as *caudal regression sequence, caudal dysplasia, caudal aplasia, femoral hypoplasia, phocomelic diabetic embryopathy,* or *sacral agenesis*, is a spectrum of anomalies involving the caudal end of the trunk. The pathogenesis involves abnormal differentiation of the developing spine, spinal cord, and caudal mesoderm. Although CRS is rare in the general population, maternal hyperglycemia is thought to play an important role, and the malformation is seen much more commonly in infants of diabetic mothers. Associated malformations are common, particularly those in the genitourinary tract.[1]

Disease

DEFINITION

CRS comprises various degrees of anomalous formation of the caudal trunk. The spectrum of disease can vary from isolated partial agenesis of the sacrococcygeal spine to complete absence

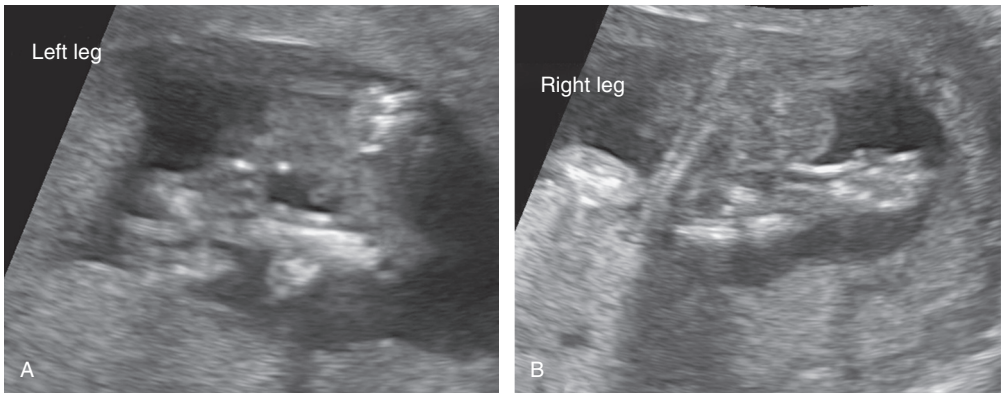

Fig. 59.1 Left leg (A) and right leg (B) shows a frog-leg position in a 16-week fetus with caudal regression.

of sacral, lumbar, or lower thoracic vertebrae. Although complete sirenomelia is considered by some authors to be part of the spectrum, many authors now consider complete sirenomelia to be a separate category.[2]

PREVALENCE AND EPIDEMIOLOGY

The frequency is estimated to be 1.3:10,000 births.[3] No gender predominance has been reported. Although CRS is not limited to infants of diabetic mothers, it occurs 200 times more frequently in these infants than in the general population.[4]

ETIOLOGY AND PATHOPHYSIOLOGY

The caudal eminence, or tailbud, is a mass of pluripotent tissue distinguished early in embryogenesis as a continuation of the primitive streak. It ultimately gives rise to all the tissues of the caudal embryo, including the primordia of the genitourinary system, the hindgut, the neural cord and crest cells, and somites. Various abnormalities that result to this structure through a combination of genetic and stochastic events, occurring before the fourth week of gestation, are thought to result in the spectrum of caudal regression.[5]

The most common teratogen implicated in this process is hyperglycemia owing to maternal diabetes; poor glycemic control is a known risk factor. Some form of CRS has been estimated to occur in 1% of infants born to diabetic mothers.[6] CRS has also been associated with more subtle levels of glucose intolerance even without overt diabetes.[7] Other proposed contributing factors include genetic predisposition, vascular anomalies altering blood flow, and drugs or other environmental exposures. Cases have been reported after exposure to minoxidil, trimethoprim-sulfamethoxazole, and tocilizumab.[8,9] CRS is likely caused by a combination of factors including genetic disposition combined with an epigenetic event. With rare exceptions, the fetal karyotype is normal.

Some investigators have described rare familial occurrences with suspected autosomal recessive inheritance. The *HLXB9* gene has been implicated in some cases of autosomal dominant form of sacral agenesis, Currarino syndrome or Currarino triad,[10,11] which is an association of partial sacral agenesis with intact first sacral vertebra (sickle-shaped sacrum), a presacral mass, and anorectal malformation, as well genitourinary abnormalities. There is variable penetrance of this disorder.

Manifestations of Disease

CLINICAL PRESENTATION

Characteristic features include short intergluteal cleft, flattened buttocks, narrow hips, distal leg atrophy, and talipes deformities. Urinary and bowel dysfunction are nearly universal. Motor function is generally more affected than sensory function and is correlated with the level of spinal aplasia. In very mild cases, such as isolated coccygeal agenesis, patients may be asymptomatic.[1]

Associated anomalies are common, often involving abnormalities of the genitourinary tract, hindgut, cardiac, and respiratory system. CRS has been associated with OEIS (*o*mphalocele, *ex*strophy, *i*mperforate anus, and *s*pinal defects)[12] and VATER (*v*ertebral defects, imperforate *a*nus, *t*racheo*e*sophageal fistula, *r*adial and *r*enal dysplasia) (Chapter 146) associations.[13] Sirenomelia is often associated with renal agenesis and pulmonary hypoplasia and thus is fatal in such cases. Prognosis largely depends on associated anomalies and the level of spinal involvement. Intelligence and mental function generally are preserved.

IMAGING TECHNIQUE AND FINDINGS

Ultrasound

Classic findings on prenatal ultrasound (US) are sudden interruption of the spine with absence of vertebrae and frog-leg position of the lower limbs (Fig. 59.1). The position of the lower limbs has also been termed *cross-legged tailor* or *Buddha* pose.

First-trimester US findings suggestive of the diagnosis include short crown-rump length, protuberance of the lower spine, and increased nuchal translucency.[14] The diagnosis has been suspected at 13 weeks' gestation but is usually not detected until the mid-second trimester because the sacrum is not fully ossified until approximately 18 weeks.[15] High-resolution vaginal US may be useful in the first trimester.

Findings described later in gestation include abrupt termination of the spine at various levels (low thoracic, lumbar, or sacral levels), short femora, and abnormal lower extremity positioning. Although CRS may be best visualized on sagittal imaging, axial or coronal views of the fetal spine also show a lack of bony ossification (Fig. 59.2). The sacrum has been described as "shield-shaped" in CRS with the iliac wings fused and decreased distance between the femoral heads (Fig. 59.3). Also, the femora may be held in a fixed V shape (Fig. 59.4) and often show

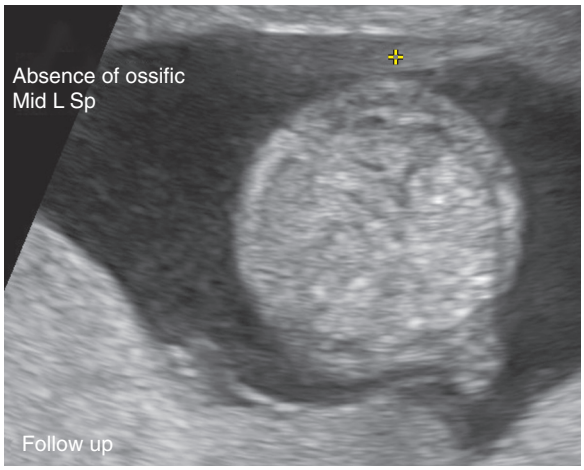

Fig. 59.2 Absent ossification of spine noted in a coronal view in a 17-week fetus with caudal regression.



Fig. 59.5 Abrupt end of spine in a sagittal view in a 17-week fetus with caudal regression.

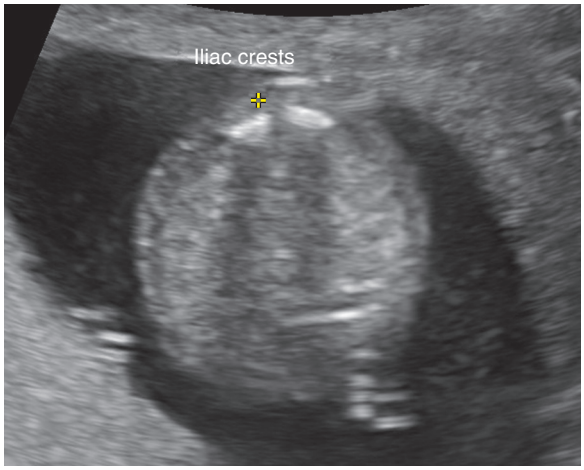

Fig. 59.3 Fused iliac wings in a 17-week fetus with caudal regression.

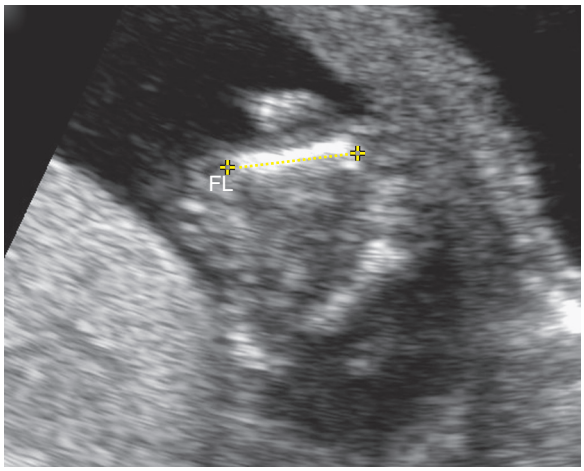

Fig. 59.4 V-shaped femora in a 14-week fetus with caudal regression (fetus did not move legs throughout examination).

TABLE 59.1 Associated Anomalies

Gastrointestinal
Rectal agenesis or imperforate anus
Duodenal atresia
Inguinal hernia
Abdominal wall defects
Malrotation
Fistulas
Genitourinary
Ambiguous genitalia
Hydronephrosis/pyelectasis
Vesicoureteral reflux
Dilated bladder
Renal agenesis (unilateral or bilateral)
Fused or horseshoe kidney
Ectopic ureter(s)
Skeletal
Kyphoscoliosis
Equinovarus or other lower leg deformities
Flexion contractures
Decreased number of ribs
Other
Facial clefts
Congenital heart disease
Neural tube defects with associated intracranial findings
Single umbilical artery

no or abnormal movement. Careful attention should be paid to the level at which the spine ends, and this may be best visualized on sagittal imaging (Fig. 59.5). In some cases, the spine can appear to "taper," and this should not be misinterpreted as a normal sacrum. On routine US, normal transverse views should show spinal ossification centers at the level of the iliac wings.

Associated anomalies are common with CRS (Table 59.1), and a detailed US examination including all fetal organ systems is imperative. A formal fetal echocardiogram should be strongly considered. Fetal growth and amniotic fluid should be serially assessed in continuing pregnancies. Assessment of fetal position before delivery is imperative because malpresentation is common. Three-dimensional or four-dimensional US is useful in evaluating the fetal spine for lack of continuity; multiplanar assessment is ideal for this.

Magnetic Resonance Imaging

Magnetic resonance imaging (MRI) may be a useful adjunct to US in certain cases of caudal regression.[6] It may help delineate the extent of the anatomic disruption or aid in further characterization of associated anomalies. It can confirm the absence or disorganization of ossification centers and may illustrate cord termination with a wedge-shaped or tapered termination of the cord. MRI may be particularly helpful in obese patients or patients with oligohydramnios when US imaging may be suboptimal.

CLASSIC SIGNS

Sudden interruption of the spine with abnormal positioning or hypoplasia of lower extremities

Differential Diagnosis From Imaging Findings

1. CRS may be associated with a pattern of anomalies such VATER or OEIS association
2. Myelomeningocele
3. Arthrogryposis-akinesia (mimics mild CRS but the spine is normal)
4. Sirenomelia

Sirenomelia involves a single fused lower extremity and is now usually considered a separate entity from CRS. It is also known as the *mermaid syndrome*. Sirenomelia is usually associated with renal agenesis and is lethal (Fig. 59.6).

Synopsis of Treatment Options

PRENATAL

No intrauterine treatment is available for CRS. Prevention should focus on identification of patients with diabetes and optimizing glycemic control. Early screening for patients at risk and aggressive glucose management, especially in the periconception and embryogenesis periods, is important in reducing the risk of anomalies associated with maternal diabetes. After diagnosis, subsequent management depends on gestational age, severity of the primary lesion, and associated anomalies. Pregnancy termination should be discussed, and patients who elect to continue the pregnancy should be referred to appropriate pediatric subspecialists before delivery. Because growth restriction and abnormal amniotic fluid volume are common, serial US examinations are appropriate. Cesarean section should be reserved for the usual obstetric indications.



Fig. 59.6 Fused lower extremity with a single femur in a 24-week fetus with sirenomelia.

POSTNATAL

Delivery should occur in a tertiary center to facilitate a multidisciplinary approach for management of complications. Individuals are usually managed primarily by pediatric, orthopedic, and urologic specialists. Surgery may be required to correct or ameliorate symptoms from associated anomalies. Treatment goals include preservation of renal function, prevention of infection, achievement of continence, and optimization of sensory and motor neurologic function, including mobility.

WHAT THE REFERRING PHYSICIAN NEEDS TO KNOW

Patients with diabetes should have glucose control optimized before conception and should be referred to an experienced center for early US after pregnancy is diagnosed. Fetuses with suspected CRS should be referred for US to a center with expertise in evaluating the fetal skeleton.

KEY POINTS

- CRS represents a spectrum of anomalies involving the caudal structures of the embryo.
- CRS is characterized by termination of the spine at various levels and is commonly accompanied by abnormalities in genitourinary and gastrointestinal system structure or function or both.
- Associated anomalies are common.
- Maternal diabetes is the primary risk factor.
- Key imaging findings are sudden interruption of the spine and abnormal lower extremity positioning.
- Prognosis depends on the level of spinal termination and associated anomalies.
- No intrauterine treatment is available.
- Patients who choose to continue the pregnancy should have consultation with the appropriate pediatric subspecialists.

SUGGESTED READING

Boulas MM. Recognition of caudal regression syndrome. *Adv Neonatal Care*. 2009;9(2):61-69, quiz 70-61.

Isik Kaygusuz E, Kurek Eken M, Sivrikoz ON, et al. Sirenomelia: a review of embryogenic theories and discussion of the differences from caudal regression syndrome. *J Matern Fetal Neonatal Med*. 2016;29(6):949-953.

All references are available online at www.expertconsult.com.

REFERENCES

1. Boulas MM. Recognition of caudal regression syndrome. *Adv Neonatal Care*. 2009;9(2):61-69, quiz 70-71.
2. Isik Kaygusuz E, Kurek Eken M, Sivrikoz ON, et al. Sirenomelia: a review of embryogenic theories and discussion of the differences from caudal regression syndrome. *J Matern Fetal Neonatal Med*. 2016;29(6):949-953.
3. Unsinn KM, Geley T, Freund MC, et al. US of the spinal cord in newborns: spectrum of normal findings, variants, congenital anomalies, and acquired diseases. *Radiographics*. 2000;20(4):923-938.
4. Negrete LM, Chung M, Carr SR, et al. In utero diagnosis of caudal regression syndrome. *Radiol Case Rep*. 2015;10(1):1049.
5. Pang D. Sacral agenesis and caudal spinal cord malformations. *Neurosurgery*. 1993;32(5):755-778, discussion 778-779.
6. Palacios-Marques A, Oliver C, Martin-Bayon T, et al. Prenatal diagnosis of caudal dysplasia sequence associated with undiagnosed type I diabetes. *BMJ Case Rep*. 2013;2013.
7. Garne E, Loane M, Dolk H, et al. Spectrum of congenital anomalies in pregnancies with pregestational diabetes. *Birth Defects Res A Clin Mol Teratol*. 2012;94(3):134-140.
8. Nakajima K, Watanabe O, Mochizuki M, et al. Pregnancy outcomes after exposure to tocilizumab: a retrospective analysis of 61 patients in Japan. *Mod Rheumatol*. 2016;26(5):667-671.
9. Rojansky N, Fasouliotis SJ, Ariel I, et al. Extreme caudal agenesis. Possible drug-related etiology? *J Reprod Med*. 2002;47(3):241-245.
10. Ross AJ, Ruiz-Perez V, Wang Y, et al. A homeobox gene, HLXB9, is the major locus for dominantly inherited sacral agenesis. *Nat Genet*. 1998;20(4):358-361.
11. Hagan DM, Ross AJ, Strachan T, et al. Mutation analysis and embryonic expression of the HLXB9 Currarino syndrome gene. *Am J Hum Genet*. 2000;66(5):1504-1515.
12. Mallmann MR, Reutter H, Muller AM, et al. Omphalocele-exstrophy-imperforate anus-spinal defects complex: associated malformations in 12 new cases. *Fetal Diagn Ther*. 2016.
13. Brosens E, Eussen H, van Bever Y, et al. VACTERL association etiology: the impact of de novo and rare copy number variations. *Mol Syndromol*. 2013;4(1-2):20-26.
14. Hartge DR, Schroer A, Weichert J. Novel insights into early embryonic demise via 3D surface rendered imaging in 107 cases. *Ultraschall Med*. 2015;36(1):47-53.
15. Yeniel AO, Ergenoglu AM, Sagol S. Prenatal diagnosis of caudal regression syndrome without maternal diabetes mellitus. *J Turk Ger Gynecol Assoc*. 2011;12(3):186-188.

60 Spinal Abnormalities and Klippel-Feil Syndrome

DEBORAH KRAKOW

Introduction

Spinal malformations associated with vertebral segmentation defects and progressive fusions are seen in numerous syndromes, particularly those associated with skeletal dysplasias.[1] Among spinal malformations, one of the best-described constellation of findings is Klippel-Feil syndrome (KFS), a triad of short neck, low posterior hairline, and limitation of head and neck movements.[2] The original case report described a patient with significant kyphosis secondary to congenital fusions of multiple level cervical vertebrae, but the term *Klippel-Feil* now applies to simple synostosis of cervical vertebrae.[3] It can be seen in isolation or with various other skeletal and visceral findings. It has been called *Klippel-Feil sequence, Klippel-Feil syndrome, Klippel-Feil abnormality, Klippel-Feil deformity,* and *Klippel-Feil phenotype,* or referred to by descriptive terms (*congenital cervicothoracic vertebrae synostosis, congenital synostosis of cervicothoracic vertebrae syndrome,* and many others). Klippel-Feil is a finding, not a diagnosis, as is true of vertebral malformations in general, which are highly associated with other issues. There are other vertebral fusion abnormality syndromes that include progressive synostoses of the vertebrae, including thoracic and lumbar segments, but most of them present beyond the newborn period.[4]

TABLE 60.1 SYNDROMES ASSOCIATED WITH KLIPPEL-FEIL ABNORMALITIES

Aicardi syndrome
Alagille syndrome
Caudal dysplasia syndrome
CHILD syndrome
Chondrodysplasia punctata
Diabetic embryopathy
Crouzon syndrome
Dubowitz syndrome
Dysspondylochondromatosis
Fanconia anemia
Fetal alcohol syndrome
Goltz syndrome
Gorlin syndrome
Holt-Oram syndrome
Ischiospinal dysostosis (diaphanospondylodysostosis)
Jarcho-Levin syndrome
Larsen syndrome
Multiple synostosis syndrome
Noonan syndrome
Robinow syndrome
Spondylocarpotarsal syndrome
VATER association
Wildervanck syndrome

Disorder

DEFINITION

KFS is denoted by various terms; it simply describes the congenital fusion of two or more cervical vertebrae.[5] KFS may be classified by the degree and location of vertebral fusion. Type I is a fusion of cervical and upper thoracic vertebrae with synostoses, type II is an isolated fusion of the cervical spine, and type III shows fusion of cervical vertebrae associated with lower thoracic or upper lumbar fusion. Significant clinical heterogeneity occurs, and KFS can occur in isolation or associated with other skeletal abnormalities; visual and hearing impairment; orofacial anomalies; or visceral anomalies including cardiac, kidney, genitourinary, and neurologic.[6–13] Some of the syndromes that are often associated with Klippel-Feil abnormalities and malsegmented or fused vertebrae are listed in Table 60.1.[14,15]

PREVALENCE AND EPIDEMIOLOGY

KFS is seen in approximately 1:40,000 births[1,16] with a female-to-male predominance of about 3:2.[17] The true incidence may be underreported because most patients with congenital abnormalities of the cervical spine appear normal and can be asymptomatic. Congenital fusions are often discovered incidentally later in life on radiographs for scoliosis, neck pain, trauma, decreased range of motion, or neurologic symptoms.

ETIOLOGY, PATHOPHYSIOLOGY, AND EMBRYOLOGY

KFS is a congenital anomaly that is caused by the failure of the spine to segment properly during embryonic development.[1,2] Congenital fusions can occur at any level of the cervical spine, although 75% occur in the region of the first three cervical vertebrae. The most prevalent fusion is between C2 and C3.

KFS can be isolated or associated with multiple disorders. Inheritance is usually sporadic or autosomal dominant. Mutations have been identified in growth differentiation factor genes (*MEOX1, GDF3, GDF6, NOTCH,* and *MYO18*). Chromosomal translocations, deletions, and duplications have also been found in association with KFS. Fetal alcohol exposure and maternal diabetes are important environmental exposures. Fusions in the cervical vertebrae occur in 50% of children with fetal alcohol syndrome.[16]

MANIFESTATIONS OF DISEASE

Clinical Presentation

KFS describes congenital cervical fusion. The classic clinical triad initially described as *Klippel-Feil syndrome* includes a shortened neck, a low posterior neckline, and limited neck mobility as demonstrated in a newborn film (Fig. 60.1). Less than half of affected individuals possess all three signs. Associated findings may provide diagnostic clues. Other disorders with progressive vertebral fusions in the postnatal period such as spondylocarpotarsal syndrome and multiple vertebral segmentation defects are illustrated in Figs. 60.2 and 60.3.

Imaging Technique and Findings

Ultrasound. Fetal cervical vertebrae should be evaluated with ultrasound (US) for cervical fusions, blocking, and hemivertebrae. More severe forms of KFS may be detected prenatally,[18] but visualization of milder forms may be complicated by incomplete vertebral ossification in the fetus, particularly in the second trimester (Fig. 60.4). Although affected individuals have cervical anomalies at birth, the finding is usually not noted until later. US is also useful for detailed evaluation of the fetus in the case of associated findings. Three-dimensional or four-dimensional US may be particularly useful for careful imaging of the spine, especially when used in skeletal mode (Fig. 60.5).

Skeletal findings seen with KFS include scoliosis, appendicular hypoplasia, rib anomalies, Sprengel deformity (upward displacement of the scapula), and carpal anomalies. Orofacial findings may include cleft palate, facial dysmorphism such as asymmetric face, microphthalmia or anophthalmia, or coloboma. Fetuses should be carefully evaluated for anomalies in the cardiovascular, genitourinary, and neurologic systems (e.g., neural tube defect).

Magnetic Resonance Imaging. Confirmation of KFS rests on subtle spinal findings, and magnetic resonance imaging (MRI) may be helpful, although its use is generally limited because of patient inconvenience and expense. Postnatally, MRI is very useful to evaluate for associated central nervous system abnormalities. MRI can also be useful to determine whether the cervical malformation is causing compression of the brain, brainstem, or spinal cord.[19]

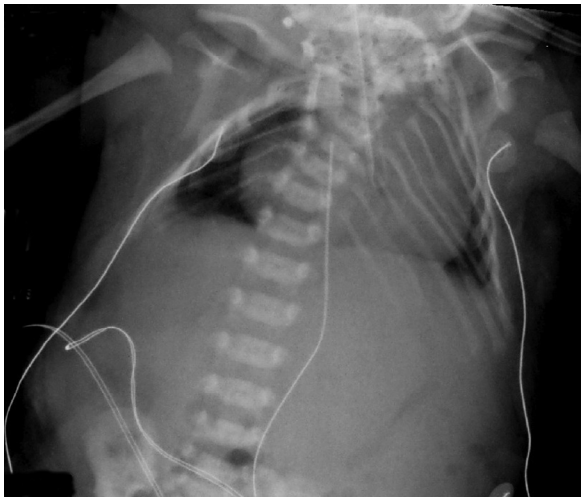

Fig. 60.1 Radiograph showing multiple fused cervical vertebrae (cervical kyphosis) in a newborn with Klippel-Feil sequence.

CLASSIC SIGNS

Fusion of the cervical vertebrae.

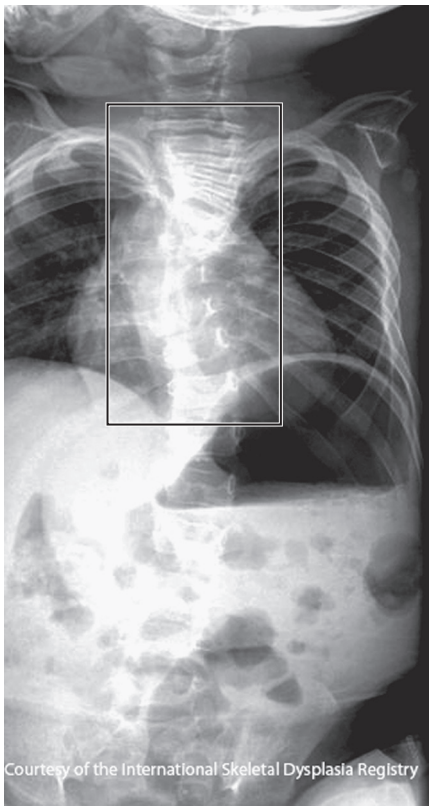

Fig. 60.2 Radiograph showing multiple vertebral fusions *(box)* in spondylocarpotarsal syndrome.



Fig. 60.3 Radiograph showing multiple vertebral fusions in a fetus with a VATER-like (vertebral defects, imperforate anus, tracheoesophageal fistula, radial and renal dysplasia) syndrome.



Fig. 60.4 Two-dimensional ultrasound image in a fetus with Klippel-Feil syndrome *(arrow)*.



Fig. 60.5 Three-dimensional ultrasound image in a fetus with Klippel-Feil syndrome *(arrow)*.

Differential Diagnosis From Imaging Findings

The short-webbed neck, cervical fusions, and possible neck extension of KFS can mimic iniencephaly. Some authors consider KFS to be the mildest form of iniencephaly. Iniencephaly differs from KFS in that there is a large foramen magnum that communicates directly with the spinal canal through a neural arch defect. Distinguishing between KFS and iniencephaly is important because the prognosis for iniencephaly is generally lethal, whereas KFS is compatible with life. VATER (*v*ertebral defects, imperforate *a*nus, *t*racheo*e*sophageal fistula, *r*adial and *r*enal dysplasia) association tends to affect the thoracic and lumbar region.

Synopsis of Treatment Options

PRENATAL

There are no known prenatal treatments. Fetuses with a suspected skeletal disorder should be referred for US to a center with expertise in evaluating the fetal skeleton. Prenatal care is routine, although cesarean section is often required owing to obstruction of labor because the fetus cannot rotate the head. Cesarean delivery should also be considered if there is concern for cervical spine instability. Delivery should occur in a tertiary center to facilitate a multidisciplinary approach for management of complications.

POSTNATAL

Treatment varies depending on the severity of the fusions and the amount of instability present and the underlying diagnosis. Isolated KFS is generally well tolerated. Initial treatment strategies include modification of activities, bracing, and traction, all of which may delay surgery and prevent neurologic compromise. Indications for surgical stabilization are symptomatic instability or neurologic compromise.[20] One of the greatest concerns for patients with KFS is the possibility of developing degenerative changes or neurologic impairments, or both. When there is cessation of movement in the joint spaces, the adjacent segments tend to compensate and become hypermobile. Hypermobility of the upper cervical vertebrae confers a greater risk of neurologic compromise. Patients with fusions in lower cervical vertebrae are more likely to exhibit more degenerative changes, such as degenerative disk disease.

WHAT THE REFERRING PHYSICIAN NEEDS TO KNOW

Fetuses with a suspected skeletal abnormality should be referred to a center with expertise in evaluating the fetal skeleton for US examination and genetic counseling. Prenatal care is routine. During labor, a fetus with cervical fusions and blocking may have difficulty turning the head without moving the shoulders, which can cause labor dystocia and possibly birth injuries.[3] Cesarean delivery should be offered if there is any concern about fetal cervical spine instability. Postnatal care is highly individualized, depending on the underlying diagnosis and prognosis. Infants require a multidisciplinary approach for management of complications. Compression of the spinal cord or nerves can lead to neurologic compromise, radiculopathy, myelopathy, quadriplegia, or sudden death. When KFS is identified, the issue of possible cervical instability needs to be addressed.

KEY POINTS

- KFS has multiple names and is often an incidental finding.
- Incomplete vertebral ossification occurs in the fetus and can make fusions difficult to appreciate prenatally.
- KFS may be considered a very mild form of iniencephaly, although the latter is considered lethal, whereas KFS is not.
- KFS is associated with multiple disorders, and the prognosis depends on the underlying etiology.

SUGGESTED READING

Samartzis D, Kalluri P, Herman J, et al. "Clinical triad" findings in pediatric Klippel-Feil patients. *Scoliosis Spinal Disord.* 2016;11:15.

All references are available online at www.expertconsult.com.

REFERENCES

1. Kaplan KM, Spivak JM, Bendo JA. Embryology of the spine and associated congenital abnormalities. *Spine J*. 2005;5(5):564-576.
2. Saker E, Loukas M, Oskouian RJ, et al. The intriguing history of vertebral fusion anomalies: the Klippel-Feil syndrome. *Childs Nerv Syst*. 2016;32(9):1599-1602.
3. Samartzis D, Kalluri P, Herman J, et al. "Clinical triad" findings in pediatric Klippel-Feil patients. *Scoliosis Spinal Disord*. 2016;11:15.
4. Krakow D, Robertson SP, King LM, et al. Mutations in the gene encoding filamin B disrupt vertebral segmentation, joint formation and skeletogenesis. *Nat Genet*. 2004;36(4):405-410.
5. Clarke RA, Catalan G, Diwan AD, et al. Heterogeneity in Klippel-Feil syndrome: a new classification. *Pediatr Radiol*. 1998;28(12):967-974.
6. Karaca E, Yuregir OO, Bozdogan ST, et al. Rare variants in the notch signaling pathway describe a novel type of autosomal recessive Klippel-Feil syndrome. *Am J Med Genet A*. 2015;167A(11):2795-2799.
7. Alazami AM, Kentab AY, Faqeih E, et al. A novel syndrome of Klippel-Feil anomaly, myopathy, and characteristic facies is linked to a null mutation in MYO18B. *J Med Genet*. 2015;52(6):400-404.
8. Giampietro PF, Armstrong L, Stoddard A, et al. Whole exome sequencing identifies a POLRID mutation segregating in a father and two daughters with findings of Klippel-Feil and Treacher Collins syndromes. *Am J Med Genet A*. 2015;167A(1):95-102.
9. Bayrakli F, Guclu B, Yakicier C, et al. Mutation in MEOX1 gene causes a recessive Klippel-Feil syndrome subtype. *BMC Genet*. 2013;14:95.
10. Markunas CA, Soldano K, Dunlap K, et al. Stratified whole genome linkage analysis of Chiari type I malformation implicates known Klippel-Feil syndrome genes as putative disease candidates. *PLoS ONE*. 2013;8(4):e61521.
11. Mohamed JY, Faqeih E, Alsiddiky A, et al. Mutations in MEOX1, encoding mesenchyme homeobox 1, cause Klippel-Feil anomaly. *Am J Hum Genet*. 2013;92(1):157-161.
12. Ye M, Berry-Wynne KM, Asai-Coakwell M, et al. Mutation of the bone morphogenetic protein GDF3 causes ocular and skeletal anomalies. *Hum Mol Genet*. 2010;19(2):287-298.
13. Tassabehji M, Fang ZM, Hilton EN, et al. Mutations in GDF6 are associated with vertebral segmentation defects in Klippel-Feil syndrome. *Hum Mutat*. 2008;29(8):1017-1027.
14. Goto M, Nishimura G, Nagai T, et al. Familial Klippel-Feil anomaly and t(5;8)(q35.1;p21.1) translocation. *Am J Med Genet A*. 2006;140(9):1013-1015.
15. Papagrigorakis MJ, Synodinos PN, Daliouris CP, et al. De novo inv(2)(p12q34) associated with Klippel-Feil anomaly and hypodontia. *Eur J Pediatr*. 2003;162(9):594-597.
16. Klimo P Jr, Rao G, Brockmeyer D. Congenital anomalies of the cervical spine. *Neurosurg Clin N Am*. 2007;18(3):463-478.
17. Tracy MR, Dormans JP, Kusumi K. Klippel-Feil syndrome: clinical features and current understanding of etiology. *Clin Orthop Relat Res*. 2004;424:183-190.
18. Prada CE, Sellars EA, Spaeth CG, et al. Severe cervical scoliosis in the fetus. *Prenat Diagn*. 2011;31(12):1198-1202.
19. Andro C, Pecquery R, De Vries P, et al. Split cervical spinal cord malformation and vertebral dysgenesis. *Orthop Traumatol Surg Res*. 2009;95(7):547-550.
20. Brokinkel B, Wiebe K, Hesselmann V, et al. Surgical treatment in a patient with Klippel-Feil syndrome and anterior cervical meningomyelocele: a case report and review of literature. *Eur Spine J*. 2013;22(suppl 3):S517-S520.

61 Abnormal Hands: Focus on the Thumbs

DEBORAH KRAKOW

Introduction

Routine second-trimester ultrasound (US) examination typically involves only a cursory evaluation of the extremities, documenting the presence or absence of the arms and legs; however, comprehensive evaluation of the fetal extremities often yields critical information.[1] Anomalies of the hands are difficult to diagnose, and malformations range from subtle deformities, such as isolated fifth-finger clinodactyly, to complete absence of extremities, as seen in phocomelia syndromes such as Roberts-SC phocomelia and Al-Awadi Raas-Rothschild syndrome.[2,3] Anomalies of the digits may be isolated or associated with other skeletal abnormalities. The differential diagnosis for abnormal fetal hands is vast and includes chromosomal abnormalities and genetic syndromes.[4,5] Correctly identifying a hand anomaly is crucial because certain hand anomalies are strongly suggestive of specific disorders and can provide valuable clues to prenatal diagnosis.

One useful way of categorizing these is to separate the anomalies into six morphologic areas:

1. alignment abnormalities (clenched hand, camptodactyly, clinodactyly, hypokinesia, clubhand, phocomelia)
2. thumb anomalies
3. abnormal size (macrodactyly, brachydactyly, trident configuration)
4. abnormal echogenicity (under or overmineralized)
5. abnormal number of digits (polydactyly, oligodactyly)
6. constriction band sequence[2]

Hand abnormalities can be grouped by findings, and similar approaches can be used to guide differential diagnosis based on prenatal US discoveries. For example, hands can be abnormal in:

1. shape (clenched, clubhand, camptodactyly, clinodactyly, phocomelia, brachydactyly, trident hand)
2. number of fingers (polydactyly, ectrodactyly, oligodactyly)
3. thumbs (aplasia, hypoplasia, hitchhiker's deformity, broad thumb, and triphalangeal thumb)

Further, with hand abnormalities, other bones of the upper limb are frequently involved. The focus of this chapter will be on the thumbs.

Disorder

DEFINITION

Hand abnormalities are associated with hundreds of different disorders. Briefly, abnormalities can affect the thumbs only and lead to hypoplasia, triphalangeal shape (three phalange bones instead of two), broadness, or abnormal angulation (hitchhiker's thumb). Any of these abnormalities can occur in isolation, or they can be associated with a multitude of aneuploidies or genetic syndromes. Some abnormalities are nearly pathognomonic for certain disorders; for instance, a prenatal finding of hitchhiker's thumb is strongly suggestive of diastrophic dysplasia (Fig. 61.1). Broad thumbs are associated with the acrocephalosyndactylies (Apert, Carpenter, or Pfeiffer syndrome) and trisomy 13.[2] Hypoplasia or aplasia of the thumb is seen in numerous disorders including Nager syndrome, radial aplasia-thrombocytopenia syndrome, Roberts-SC phocomelia syndrome, VATER (*v*ertebral defects, imperforate *a*nus, *t*racheo-*e*sophageal fistula, *r*adial and *r*enal dysplasia) association, and Townes-Brocks syndrome. Two diagnoses that should be strongly considered in the case of an absent or abnormal (hypoplastic or triphalangeal) thumb are Fanconi anemia and Holt-Oram syndrome.

PREVALENCE AND EPIDEMIOLOGY

The frequency of the hand abnormalities, particularly the thumbs, is based on the incidence of the disorder. For example, the global prevalence of Fanconi anemia is estimated to be 1:1,000,000 to 5:1,000,000, affecting males and females and all races and ethnic groups. It is an autosomal recessive disorder, and the heterozygous mutation carrier frequency is estimated to be between 0.3% and 1%. There are at least 15 genes responsible for the different forms of Fanconi syndrome.[6] The prevalence of Holt-Oram syndrome is estimated to be 1:100,000 total births. Holt-Oram syndrome is autosomal dominant, and approximately 85% of cases are attributed to new mutations in *TBX5*.[7]

ETIOLOGY, PATHOPHYSIOLOGY, AND EMBRYOLOGY

Fanconi anemia is a clinically and genetically heterogeneous disorder characterized by spontaneous chromosomal instability, visible during the DNA replication phase of the cell cycle as broken chromatids. These breakpoints can be misrepaired as chromatid interchanges, further contributing to chromosome damage. Fanconi anemia is also characterized by spontaneous arrest and delay during the G_2 stage of the cell cycle and by hypersensitivity to chromosome-breaking and antiproliferative effects of DNA cross-linking agents.[6] The relationship between the defective genetic pathway of Fanconi anemia and the associated clinical features of the disease is not well understood at this time.[4]

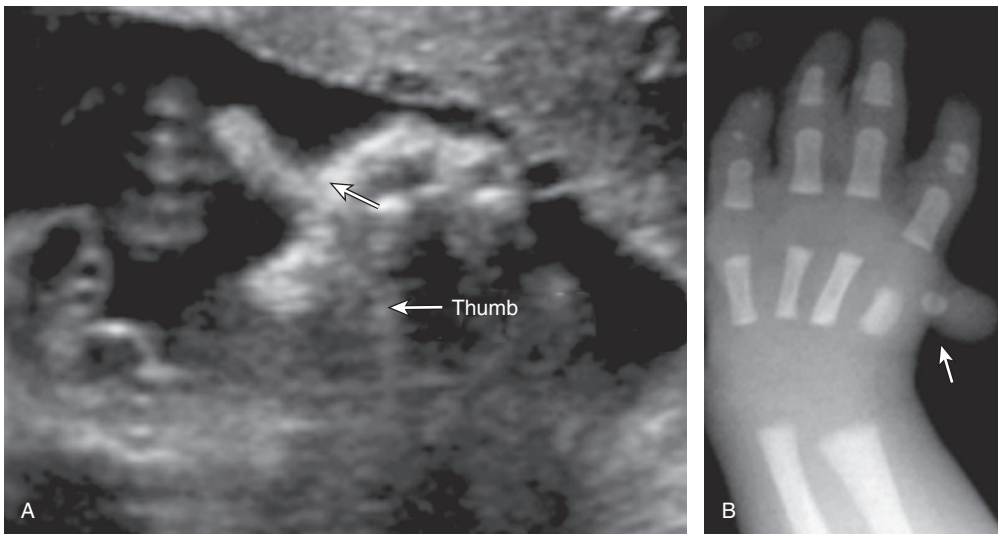

Fig. 61.1 (A) Hitchhiker thumb at 20 weeks' gestation. Arrow points to radially deviated thumb. (B) Radiograph of the hand from the same fetus, showing deviated thumb *(arrow)*.

Limited data are available regarding the pathogenic processes that account for the manifestations of Holt-Oram syndrome. The *TBX5* gene (member of the T-box family of transcription factor genes that is involved in forelimb and heart development) probably interacts with other transcription factors to produce the phenotype.[8]

MANIFESTATIONS OF DISEASE

Clinical Presentation

Fanconi anemia is characterized by numerous physical and hematologic findings, although one-fourth of individuals have no physical abnormalities. In terms of prenatal diagnosis, besides abnormal thumbs, abnormalities of the cardiac, gastrointestinal, and renal systems can be associated with Fanconi anemia. Postnatal findings include cutaneous abnormalities such as *café au lait* spots, hyperpigmentation or hypopigmentation, short stature, microcephaly with a triangular face, small ear canals, and deafness. Hypogonadism and reduced fertility are associated with Fanconi anemia. Hematologic findings typically include pancytopenia with bone marrow failure in the first 10 years of life, with 90% experiencing bone marrow failure by the fourth decade of life. There is a significant risk of developing hematologic malignancies (predominantly acute myelogenous leukemia) and other nonhematologic malignancies of the head and neck, skin, gastrointestinal tract, and genital tract.[6]

Holt-Oram syndrome is characterized by the presence of at least one upper limb preaxial radial ray malformation, including abnormal thumb (absent, hypoplastic, or triphalangeal) (Fig. 61.2). It is autosomal dominant, with nearly 100% penetrance and variable expression of the phenotype.[5] Family history of cardiac septation defects or atrioventricular conduction disease strengthens the suspicion of the diagnosis. Greater than 70% of individuals meeting the aforementioned strict diagnostic criteria have a mutation in the *TBX5* gene, and the diagnosis can be confirmed through molecular genetic testing.

Imaging Technique and Findings

Ultrasound. Fetal finger buds have been imaged with transvaginal US at 9–10 weeks' gestation, and more detailed examinations

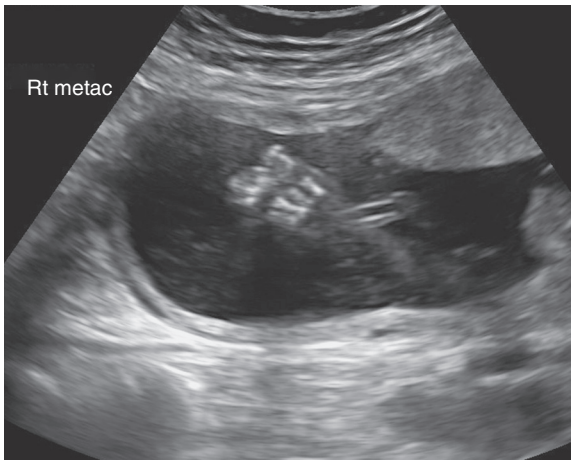

Fig. 61.2 Two-dimensional ultrasound image showing absence of the thumb as would be seen in Holt-Oram syndrome. *Rt metac,* Right metacarpals.

of the hands and feet may be performed at 12–13 weeks' gestation. However, the fetal hands are most often imaged during the routine second-trimester fetal anatomic survey, and there are limitations in the sensitivity of detecting hand or extremity abnormalities.[9,10]

The fetal hand is most commonly visualized in a relaxed, neutral position with loosely curled fingers. In this position, the thumb may not be visible in the same plane as the other four fingers, so multiple two-dimensional (2D) planes may be needed to document a normal hand. Alternatively, three-dimensional (3D) with volume acquisition and manipulation may be used to show the fetal hand anatomy, including the relationship between the thumb and other digits. Fig. 61.3 illustrates the use of 3D US to show a short broad thumb in the mitten-like hand of a fetus with Apert syndrome.

Findings in fetuses with Fanconi anemia include hypoplasia or aplasia of the thumb, radial ray defects, and growth restriction. Less commonly, supernumerary thumbs, microcephaly, microphthalmos, hypoplastic kidney, double ureter, or anomalies of the heart or ear may be present. Findings in Holt-Oram syndrome include absent, hypoplastic, triphalangeal, or bifid thumbs (see

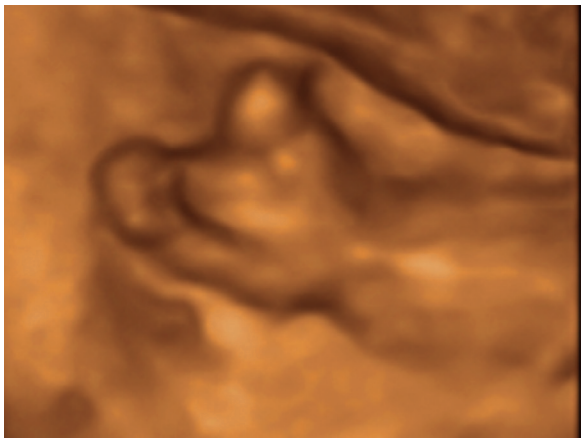

Fig. 61.3 Three-dimensional ultrasound image showing separate broad thumb and mitten hand.

Fig. 61.2); syndactyly or clinodactyly of the fingers; aplasia or hypoplasia of the radius; fusion or abnormal development of the carpal and thenar bones; and cardiac malformations, typically atrial septal defect and ventricular septal defect shows absence of the thumb in Holt-Oram syndrome with relatively normal looking metacarpals.

Magnetic Resonance Imaging. Magnetic resonance imaging (MRI) is occasionally useful in the evaluation of fetuses with skeletal disorders. However, it has not been used for evaluation of hand abnormalities, though it could provide clues if there were concomitant brain abnormalities.

CLASSIC SIGNS

Aplastic, hypoplastic, or triphalangeal thumb
Abnormal angle of thumb
Radius may also be abnormal

Differential Diagnosis From Imaging Findings

1. Deletion 13q
2. Roberts-SC phocomelia syndrome
3. Radial aplasia–thrombocytopenia syndrome
4. VACTERL (*v*ertebral, *a*nal, *c*ardiac, *t*racheal, *e*sophageal, *r*enal, and *l*imb anomalies) or VATER association
5. Nager syndrome
6. Townes-Brocks syndrome

Synopsis of Treatment Options

PRENATAL

Fetuses with suspected skeletal abnormalities should be referred to a center with expertise in evaluating the fetal skeleton for US examination and genetic counseling. In many cases, parents should also be referred to a medical geneticist for examination. Molecular diagnosis through invasive testing may be available for many disorders, and preimplantation diagnosis may be possible in cases where the mutations have been established in the family. Given the severity of the limb defects and other concomitant organ system abnormalities in some of these disorders, pregnancy termination should be discussed. Prenatal management is usually routine, although many genetic disorders associated with abnormal thumbs and other pleiotropic abnormalities can be associated with growth restriction, and serial US examinations to monitor growth may be warranted. Delivery is usually routine as well, with cesarean section reserved for the usual obstetric indications; however, fetuses with skeletal abnormalities are at increased risk of malpresentation or abnormal extremity position, or both, which may require cesarean delivery. Given the wide variations among disorders associated with abnormal hands, care should be individualized.

POSTNATAL

Isolated hand abnormalities require neonatal follow-up with pediatric, genetic, and orthopedic subspecialists, but immediate care is routine, and delivery usually does not need to occur in a tertiary center. Surgical correction is possible in many hand abnormalities, especially in cases of isolated abnormalities. However, fetuses with abnormal hands that are associated with other findings may require additional support at delivery, depending on the specific anomalies, so delivery should generally occur at a tertiary center to facilitate early consultation with experts in medical genetics and neonatal subspecialties, which may include pediatric orthopedics, hand surgery, cardiology, and cardiothoracic surgery.

WHAT THE REFERRING PHYSICIAN NEEDS TO KNOW

Hundreds of disorders are associated with abnormal hands, all of which have various outcomes and require different management strategies, ranging from physical therapy or correction of an abnormal finger to palliative care for lethal disorders. Fetuses with suspected skeletal abnormalities should be referred to a center with expertise in evaluating the fetal skeleton for US examination and genetic counseling. Termination of pregnancy should be discussed in many cases. Depending on the disorder, molecular genetics may provide definitive diagnosis. Prenatal care is usually routine, although, depending on the disorder, serial US scans may be warranted for growth monitoring. Intrapartum and postnatal care are highly individualized.

KEY POINTS

- Hundreds of disorders are associated with abnormal thumbs and hand abnormalities.
- Associated abnormalities in other organ systems provide clues to diagnosis.
- Diagnosis through molecular genetic testing is possible in many disorders.
- Fetuses discovered to have abnormal hands should be referred to a center with expertise in evaluating the fetal skeleton for US examination and genetic counseling.

SUGGESTED READING

Mehta PA, Tolar J. Fanconi anemia. In: Pagon RA, Adam MP, Ardinger HH, et al., eds. *GeneReviews*. Seattle (WA): 1993.
McDermott DA, Fong JC, Basson CT. Holt-Oram Syndrome. In: Pagon RA, Adam MP, Ardinger HH, et al., eds. *GeneReviews*. Seattle (WA): 1993.

All references are available online at www.expertconsult.com.

REFERENCES

1. Andrikopoulou M, Vahanian SA, Chavez MR, et al. Improving the ultrasound detection of isolated fetal limb abnormalities. *J Matern Fetal Neonatal Med*. 2016;1-4.
2. Schule B, Oviedo A, Johnston K, et al. Inactivating mutations in ESCO2 cause SC phocomelia and Roberts syndrome: no phenotype-genotype correlation. *Am J Hum Genet*. 2005;77(6):1117-1128.
3. Mutlu MB, Cetinkaya A, Koc N, et al. A novel missense mutation, p.(R102W) in WNT7A causes Al-Awadi Raas-Rothschild syndrome in a fetus. *Eur J Med Genet*. 2016;59:604-606.
4. Elmakky A, Stanghellini I, Landi A, et al. Role of genetic factors in the pathogenesis of radial deficiencies in humans. *Curr Genomics*. 2015;16(4):264-278.
5. Wilcox WR, Coulter CP, Schmitz ML. Congenital limb deficiency disorders. *Clin Perinatol*. 2015;42(2):281-300, viii.
6. Mehta PA, Tolar J. Fanconi anemia. In: Pagon RA, Adam MP, Ardinger HH, et al., eds. *GeneReviews(R)*. Seattle (WA): 1993.
7. McDermott DA, Fong JC, Basson CT. Holt-Oram Syndrome. In: Pagon RA, Adam MP, Ardinger HH, et al., eds. *GeneReviews*. Seattle (WA): 1993.
8. Waldron L, Steimle JD, Greco TM, et al. The Cardiac TBX5 interactome reveals a chromatin remodeling network essential for cardiac septation. *Dev Cell*. 2016;36(3):262-275.
9. Piper SL, Dicke JM, Wall LB, et al. Prenatal detection of upper limb differences with obstetric ultrasound. *J Hand Surg Am*. 2015;40(7):1310-1317 e1313.
10. Rypens F, Dubois J, Garel L, et al. Obstetric US: watch the fetal hands. *Radiographics*. 2006;26(3):811-829, discussion 830-831.

62 Craniosynostosis

DEBORAH KRAKOW

Introduction

The development of the fetal skull is a complex process involving intramembranous and endochondral ossification. The fetal cranium comprises bony plates that are joined together by areas of dense fibrous tissue termed *cranial sutures,* comprised of the sagittal, coronal, lambdoid, and metopic sutures (Fig. 62.1). The membranous sutures allow for expansion of the calvaria to accommodate rapid human brain growth prenatally and postnatally. The sutures and fontanelles, larger membranous areas where suture lines converge, are also critical to enabling the normal process of cranial molding essential to the process of vaginal birth. Although some of these sutures begin to close in the first year of life, most do not begin to close significantly before 18–24 months of life, and suture closure is not complete until adulthood.[1] Premature closure of the sutures, also termed *craniosynostosis,* results in bony deformation of the skull and may have serious implications for skull growth, which in many cases affect normal brain development.

Craniosynostosis can occur primarily or secondarily. Primary craniosynostosis can be either syndromic or nonsyndromic (isolated craniosynostosis with no evidence of a genetic syndrome). Craniosynostosis has been described as a feature of more than 150 genetic syndromes.[2] The goal of prenatal detection of craniosynostosis is to enable prenatal diagnosis of the syndromic cases and to enable awareness of the potential perinatal complications of prenatal onset craniosynostosis that includes increased incidence of malpresentation and development of secondary complications such as hydrocephalus.[3,4]

Disorder

DEFINITION

Craniosynostosis refers to the premature closure of one or more cranial sutures, which may occur during the prenatal period, early infancy, or childhood. It is a finding, not a diagnosis, and may be isolated or may be associated with genetic syndromes associated with serious sequelae.

PREVALENCE AND EPIDEMIOLOGY

The birth prevalence of craniosynostosis (primary and secondary) is estimated to be 4:10,000 live births.[5] Approximately 75% of cases of craniosynostosis are isolated, whereas additional anomalies are found in about 25% of cases, highly suggestive of a genetic syndrome.[1,6] More than 150 genetic syndromes are associated with primary craniosynostosis including the more common craniosynostoses: Crouzon, Apert, Pfeiffer, Saethre-Chotzen, and Muenke syndromes.[2] Each of these diseases are rare and usually the result of a *de novo* mutation because they are autosomal dominant or sporadic in inheritance. Exceptions occur, as seen in cases of Saethre-Chotzen syndrome, where a higher incidence of cases may be familial.[7] Other structural abnormalities are detected in 5% to 10% of primary craniosynostosis cases without

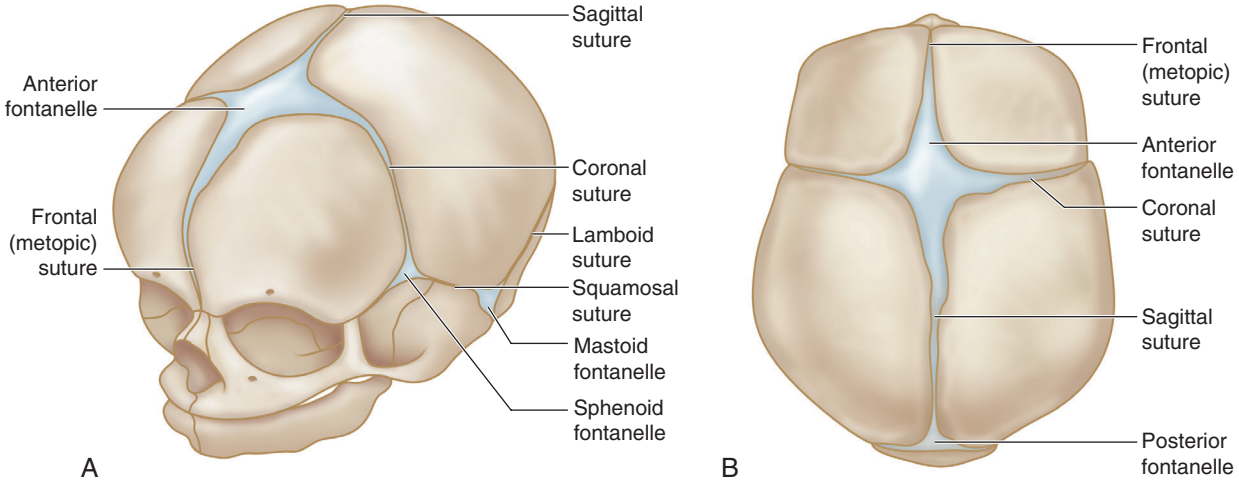

Fig. 62.1 Diagram of location of cranial sutures in a fetus.

a precise identifiable genetic syndrome, and primarily involving central nervous system, cardiovascular, or musculoskeletal anomalies.[8] Similar to other autosomal dominant disorders, advanced paternal age has been associated with *de novo* occurring mutations in fibroblast growth factor receptor 2 *(FGFR2)* that cause Apert, Crouzon, and Pfeiffer syndrome.[9]

Secondary craniosynostosis can occur, owing to deformational compressive forces,[10] maternal or neonatal metabolic derangements (such as hypophosphatasia syndrome [Chapter 51]), or teratogenic influences. Multiple gestation, hyperthyroidism, hypercalcemia, living at higher altitudes, tobacco use, and valproate therapy all have been implicated as prenatal risk factors in the development of isolated secondary craniosynostosis.

In cases of isolated, nonsyndromic craniosynostosis, the sagittal suture is most commonly involved (39%–57%), followed by unilateral or bilateral coronal sutures (17%–29%), metopic suture (10%–22%), lambdoid suture (5%–17%), and, rarely, multiple sutures (<10%) (see Fig. 62.1).[5] There is an approximate 3:1 male predominance for isolated sagittal synostosis and some studies have suggested there is also a male predominance for metopic synostosis.[11] There is a slight female predominance for isolated coronal synostosis.[12]

ETIOLOGY, PATHOPHYSIOLOGY, AND EMBRYOLOGY

The mechanisms underlying nonsyndromic premature cranial suture fusion remains poorly understood, but inroads have been made in our understanding of the molecular mechanisms. Starting with identification in 1993 of an *MSX2* mutation in a family with craniosynostosis, there have been more than 50 genes associated with craniosynostosis.[2] In cases of syndromic craniosynostosis, commonly involved genes include *FGFR1, FGFR2,* and *FGFR3*. Heterozygosity for mutations in the gene encoding *FGFR2* are the most common cause of craniosynostosis syndromes.[2,13] Heterozygosity for mutation in the gene encoding *FGFR3* produces Muenke syndrome as well as other disorders in which craniosynostosis can occur (e.g., thanatophoric dysplasia type II and Crouzon syndrome with acanthosis nigricans).[14,15] Mutations in the gene that encodes *FGFR2* produce Apert, Crouzon, and Pfeiffer syndromes. The mutations in *FGFRs* associated with craniosynostosis syndromes result in accentuated ligand binding and increased receptor activation.[16] Among craniosynostosis syndromes not related to *FGFRs* 1,2, and 3, Saethre-Chotzen syndrome results from heterozygosity for mutations in the transcription factor gene *TWIST1,* as well as *TCF12,* one of its binding partners.[2] One of the interesting findings in syndromic forms of craniosynostosis syndrome is that the genetic mutations can have variable degrees of penetrance.

MANIFESTATIONS OF DISEASE

Clinical Presentation

Craniosynostosis results in predictable skull deformation based on the sutures involved. Bony growth is greatly inhibited in the plane perpendicular to the synostotic suture and proceeds parallel to the involved suture in a compensatory, exaggerated fashion. Sagittal synostosis leads to bitemporal narrowing with frontal and occipital bossing (dolichocephaly or scaphocephaly). Bilateral coronal synostosis results in a broad, tall skull (brachycephaly). Lambdoid synostosis can result in brachycephaly similar to that seen with coronal synostosis, although lambdoidal involvement affects the posterior skull predominantly. Unilateral coronal or lambdoidal synostosis results in an asymmetric skull shape (plagiocephaly) and may be associated with facial asymmetry. When multiple sutures are affected, the skull takes on a distinctive cloverleaf appearance, also known as *kleeblattschädel*, commonly seen in thanatophoric dysplasia.[14]

Although most cases of craniosynostosis are diagnosed in infancy or early childhood, suspicious ultrasound (US) findings may lead to prenatal diagnosis, and craniosynostosis often begins in the third trimester. Fetuses with early-onset craniosynostosis may present with abnormal cranial contour in the second trimester and, in certain craniosynostosis syndromes, with characteristic malformations of the hands and feet. Identification of an abnormal cranial contour should prompt a more detailed evaluation of the fetal extremities to detect findings suggestive of the most common craniosynostosis syndromes, Apert and Pfeiffer syndromes. Fetuses with Apert syndrome have irregular craniosynostosis, causing a high, large forehead and midface hypoplasia (Figs. 62.2 and 62.3), and bony syndactyly of the hands and feet is seen in most cases, often with a characteristic mitten hand appearance resulting from bony syndactyly of the second through fourth digits (Fig. 62.4). In Pfeiffer syndrome, varying degrees of brachydactyly are seen, often in association with a characteristically broad, medially deviated thumb or hallux.[17,18] In addition, central nervous system anomalies, including agenesis of the corpus callosum and ventriculomegaly, have been seen in conjunction with both syndromes.[19]

Craniosynostosis syndromes are variably associated with cognitive impairment in affected individuals. Overall, approximately 25% of children undergoing surgery for a genetic craniosynostosis have significant cognitive delay; however, the rate is much higher for those with disorders such as Apert and Pfeiffer syndromes. Among individuals with nonsyndromic single suture craniosynostosis, there appears to be a higher prevalence of performance intelligence quotient issues and the timing of surgery

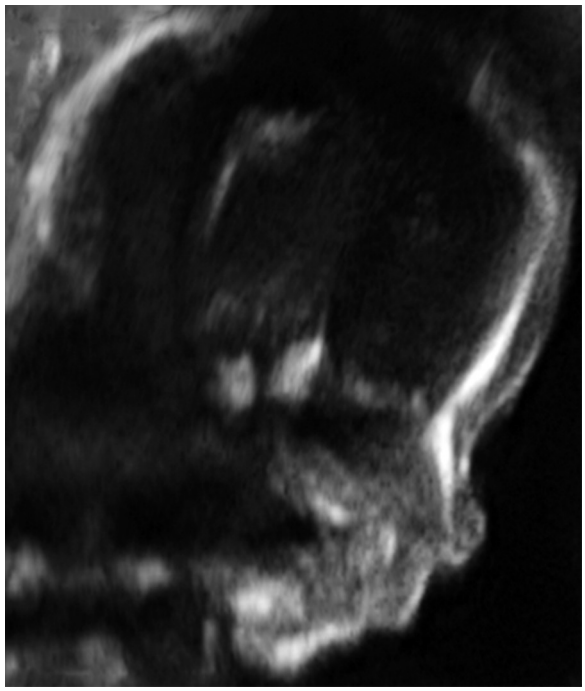

Fig. 62.2 Two-dimensional ultrasound profile of a 24-weeks fetus with Apert syndrome; note frontal bossing and midface hypoplasia.

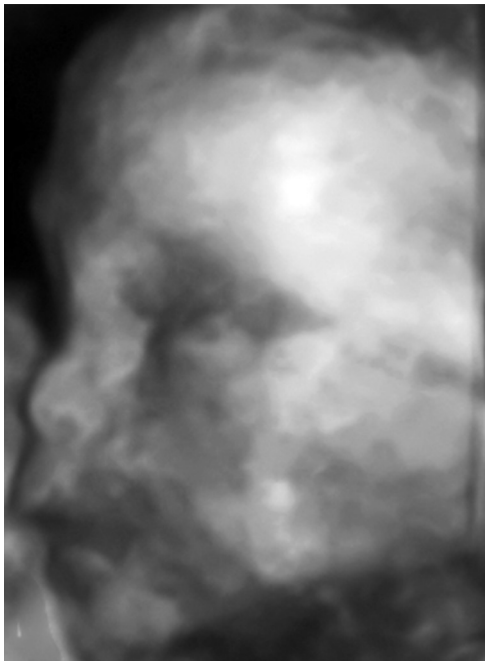

Fig. 62.3 Three-dimensional ultrasound profile of a 24-weeks fetus with Apert syndrome; note frontal bossing and rounded nose.

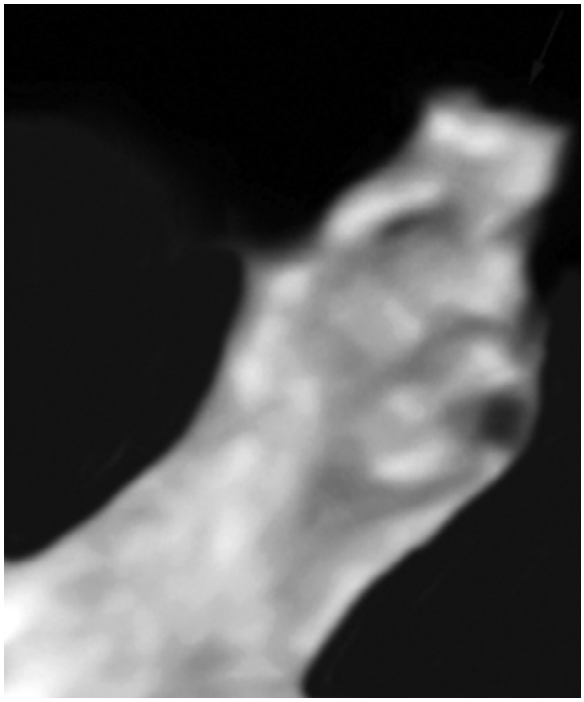

Fig. 62.4 Three-dimensional ultrasound of mitten hand in a fetus with Apert syndrome; note three syndactylous fingers.

learning disorders but not developmental delay, and the role of surgical intervention (and timing of surgery) in prevention of these complications is controversial.

Imaging Technique and Findings

Ultrasound. An axial image showing an abnormal cranial contour is usually the first sign of craniosynostosis on US (Fig. 62.5). There may be temporal indentation (coronal synostosis), dolichocephaly (sagittal synostosis), plagiocephaly (unilateral coronal

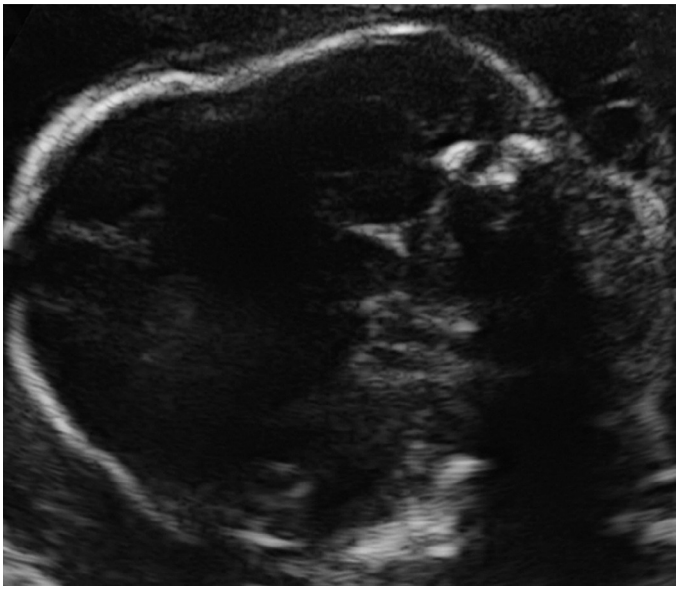

Fig. 62.5 Two-dimensional ultrasound of a calvarium in a fetus bilateral craniosynostosis syndrome.

or lambdoidal synostosis), or trigonocephaly (metopic synostosis). Findings may be subtle in the second trimester and usually progress with advancing gestational age. However, Pfeiffer syndrome type II or thanatophoric dysplasia type II may manifest with cloverleaf skull in the second trimester. Findings usually become more pronounced in the third trimester. Sagittal imaging may reveal frontal or occipital bossing and proptosis. Coronal imaging may show brachycephaly (bicoronal synostosis), proptosis, and evidence of midfacial hypoplasia with hypertelorism.[19]

A thorough skeletal survey with careful examination of the hands and feet for osseous or soft tissue syndactyly is important to evaluate for the most common craniosynostosis syndromes (Apert syndrome, see Fig. 62.2). Three-dimensional (3D) or four-dimensional (4D) US is useful in general for fetuses with craniosynostosis, especially for imaging the face and extremities. In the case of craniosynostosis, it has been useful in delineation of suture involvement since they are readily seen by 3D and 4D US (Fig. 62.6).

Magnetic Resonance Imaging. Fetal magnetic resonance imaging (MRI) may be useful for more precise characterization of suture involvement, coexistent central nervous system anomalies, and soft tissue syndactyly of the hands and feet, all of which may be challenging to evaluate with conventional US.[17,20]

Prenatal computerized tomography has also been used to delineate these disorders.[18]

CLASSIC SIGNS

Abnormal shaped skull (e.g., cloverleaf skull)

Differential Diagnosis From Imaging Findings

Isolated abnormal cranial contour without a cloverleaf skull is seen in the following conditions:

1. Primary nonsyndromic craniosynostosis
2. Primary syndromic craniosynostosis
3. Secondary (deformational) plagiocephaly

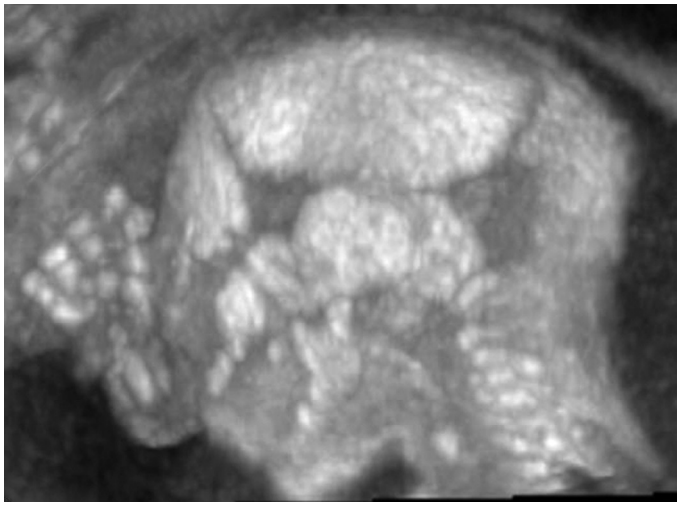

Fig. 62.6 Three-dimensional ultrasound image in skeletal mode showing normal relationship of coronal and lambdoid sutures at 20 weeks.

Synopsis of Treatment Options

PRENATAL

There is no prenatal treatment for craniosynostosis. Fetuses with a suspected skeletal disorder should be referred to a center with expertise in evaluating the fetal skeleton for US examination and genetic counseling. Detection of lethal aneuploidy, severe and lethal skeletal dysplasias (e.g., thanatophoric dysplasia), and severe genetic syndromes should be the focus of prenatal diagnosis. Invasive prenatal diagnosis should be considered if the findings suggest that aneuploidy, the constellation of findings fits a pattern such as seen in the *FGFR2* disorders, or there is family history of a disorder that places the fetus at risk. For isolated coronal craniosynostosis with no family history, consideration of testing for *FGFR3* (proline 250 arginine) should be discussed with the parents since it is one of the most common forms and can be further associated with sensorineural hearing loss and mild brachydactyly. Termination of pregnancy should be discussed in some cases, particularly if there is early onset hydrocephalus, or other anatomic brain abnormalities.

Although most cases are caused by sporadic, *de novo* mutations with a low recurrence risk, the potential exists for germline mosaicism with a recurrence risk greater than the population baseline. Prenatal genetic diagnosis is possible in cases of familial craniosynostosis when the disease-causing mutation is known within the family.

Prolonged pregnancy (>41 weeks, 6 days) is also more common among affected fetuses. There is no evidence to recommend for or against attempted external cephalic version, although extended fetal head positioning is common in craniosynostosis. Higher rates of cephalohematomas and lower umbilical arterial pH values have been observed among fetuses with craniosynostosis, and these were associated with vacuum-assisted vaginal delivery in many cases. Given the anticipated abnormal cranial contour, the avoidance of operative vaginal delivery for a prolonged second stage of labor seems prudent.[4] Cesarean section is generally reserved for maternal indications, but malpresentation is frequently seen. In addition, head size may warrant cesarean delivery in some cases.

Potential complications at delivery are increased because of other phenotypic manifestations with higher rates of admission to the newborn intensive care unit.[4] For these reasons, it is recommended that fetuses with suspected craniosynostosis be delivered in a tertiary center for a multidisciplinary approach to management of complications.

POSTNATAL

For perinatally lethal disorders, postnatal care is usually supportive. For nonlethal disorders, immediate postnatal treatment is also primarily supportive, including airway management and ocular lubrication to prevent exposure keratopathy in cases of severe proptosis. The mainstay of therapy is surgical intervention, often before 6 months of life, for cranial vault expansion, with staged procedures to allow for normal brain growth and prevention of increased intracranial pressure or hydrocephalus, or both, secondary to cranial vault constraint.[21] Other surgical interventions are also often required for other phenotypic complications.

KEY POINTS

- Abnormal contour of the calvaria should prompt a careful fetal skeletal survey, particularly of the hands and feet.
- Three-dimensional US may allow identification of involved sutures and improve detection of syndactyly.
- The rate of malpresentation and abnormal cephalic presentation is increased among fetuses with craniosynostosis.
- Craniosynostosis is best managed in a multispecialty tertiary referral unit.
- Single suture synostosis affects the sagittal suture most commonly, followed by the coronal, metopic and lambdoid sutures.
- Environmental factors (particularly intrauterine fetal head constraint) and genes (single gene mutations and chromosome abnormalities) predispose to craniosynostosis.
- Most genetically determined craniosynostosis is characterized by autosomal dominant inheritance, and around half of them result from *de novo* mutations.
- In addition to appreciating the genetic basis of the craniosynostosis, it is important to appreciate that those cases caused by a single gene defect are more likely to be associated with multiple suture synostosis and extracranial complications.
- Genes most commonly mutated in craniosynostosis are *FGFR2, FGFR3, TWIST1*, and *EFNB1*.

WHAT THE REFERRING PHYSICIAN NEEDS TO KNOW

Fetuses with a suspected skeletal disorder should be referred to a center with expertise in evaluating the fetal skeleton for US examination and genetic counseling. In cases of apparently isolated craniosynostosis, additional anomalies are found in at least 20% of cases. Associated findings may provide prognostic clues about potential lethality. Prenatal diagnosis is available in some cases. Prenatal care depends on the underlying etiology. Cesarean delivery is reserved for the usual obstetric indications, although malpresentation is common in these fetuses. Postnatal care is supportive and requires a multidisciplinary approach for management of complications.

SUGGESTED READING

Helfer TM, Peixoto AB, Tonni G, et al. Craniosynostosis: prenatal diagnosis by 2D/3D ultrasound, magnetic resonance imaging and computed tomography. *Med Ultrason*. 2016;18(3):378-385.

Twigg SR, Wilkie AO. A genetic-pathophysiological framework for craniosynostosis. *Am J Hum Genet*. 2015;97(3):359-377.

All references are available online at www.expertconsult.com.

REFERENCES

1. Aleck K. Craniosynostosis syndromes in the genomic era. *Semin Ped Neurol*. 2004;11(4):256-261.
2. Twigg SR, Wilkie AO. A genetic-pathophysiological framework for craniosynostosis. *Am J Hum Genet*. 2015;97(3):359-377.
3. Wang JC, Nagy L, Demke JC. Syndromic craniosynostosis. *Facial Plast Surg Clin North Am*. 2016;24(4):531-543.
4. Weber B, Schwabegger AH, Oberaigner W, et al. Incidence of perinatal complications in children with premature craniosynostosis. *J Perinat Med*. 2010;38(3):319-325.
5. Twigg SR, Wilkie AO. New insights into craniofacial malformations. *Hum Molec Genet*. 2015;24(R1):R50-R59.
6. Saal HM. Genetic evaluation for craniofacial conditions. *Facial Plast Surg Clin North Am*. 2016;24(4):405-425.
7. Wilkie AO, Byren JC, Hurst JA, et al. Prevalence and complications of single-gene and chromosomal disorders in craniosynostosis. *Pediatrics*. 2010;126(2):e391-e400.
8. Boulet SL, Rasmussen SA, Honein MA. A population-based study of craniosynostosis in metropolitan Atlanta, 1989-2003. *Am J Med Genet Part A*. 2008;146A(8):984-991.
9. Goriely A, Wilkie AO. Paternal age effect mutations and selfish spermatogonial selection: causes and consequences for human disease. *Am J Hum Genet*. 2012;90(2):175-200.
10. Smith DW. Recognizable patterns of human deformation. Identification and management of mechanical effects on morphogenesis. *Major Probl Clin Pediatr*. 1981;21:1-151.
11. Bennett KG, Bickham RS, Robinson AB, et al. Metopic craniosynostosis: a demographic analysis outside an urban environment. *J Craniofac Surg*. 2016;27(3):544-547.
12. Park SS, Beyer RP, Smyth MD, et al. Osteoblast differentiation profiles define sex specific gene expression patterns in craniosynostosis. *Bone*. 2015;76:169-176.
13. Johnson D, Wilkie AO. Craniosynostosis. *Eur J Hum Genet*. 2011;19(4):369-376.
14. Robin NH, Falk MJ, Haldeman-Englert CR. FGFR-related craniosynostosis syndromes. In: Pagon RA, Adam MP, Ardinger HH, et al., eds. *GeneReviews*. Seattle (WA): 1993.
15. Hamm JA, Robin NH. Newborn craniofacial malformations: orofacial clefting and craniosynostosis. *Clin Perinatol*. 2015;42(2):321-336, viii.
16. Liu C, Cui Y, Luan J, et al. The molecular and cellular basis of Apert syndrome. *Intractable Rare Dis Res*. 2013;2(4):115-122.
17. Weber B, Schwabegger AH, Vodopiutz J, et al. Prenatal diagnosis of Apert syndrome with cloverleaf skull deformity using ultrasound, fetal magnetic resonance imaging and genetic analysis. *Fetal Diagn Ther*. 2010;27(1):51-56.
18. Helfer TM, Peixoto AB, Tonni G, et al. Craniosynostosis: prenatal diagnosis by 2D/3D ultrasound, magnetic resonance imaging and computed tomography. *Med Ultrason*. 2016;18(3):378-385.
19. Ketwaroo PD, Robson CD, Estroff JA. Prenatal imaging of craniosynostosis syndromes. *Semin Ultrasound CT MR*. 2015;36(6):453-464.
20. Rubio EI, Blask A, Bulas DI. Ultrasound and MR imaging findings in prenatal diagnosis of craniosynostosis syndromes. *Pediatr Radiol*. 2016;46(5):709-718.
21. Morris LM. Nonsyndromic craniosynostosis and deformational head shape disorders. *Facial Plast Surg Clin North Am*. 2016;24(4):517-530.

63 Clubfoot (Talipes Equinovarus) and Clenched Hands

DEBORAH KRAKOW

Introduction

Congenital contractures in the newborn are actually common, ranging from 1:100 to 1:200 for some types of contractures that include clubfeet, hip dislocations, and multiple congenital contractures (MCCs).[1] Talipes equinovarus or clubfoot is an abnormality of the foot position. It may be positional, an isolated abnormality, or part of a larger constellation of abnormalities as seen in many genetic syndromes.[2] Clubfoot resulting from *in utero* positional forces, as may occur with prolonged severe oligohydramnios, multiple gestations, or breech presentations, is not a "true" clubfoot in that the deformity can usually be corrected by manual postnatal manipulation of the foot. Congenital clenched hands are part of MCC syndromes. Fetuses presenting with clubfeet or clenched hands, particularly with more than one joint involved, warrant thorough investigation even if there is a possibility of uterine constraint as an etiology, because constraint is a rare primary cause of contractures, particularly multiple contractures.[3]

Disorder

DEFINITION

Clubfoot describes a range of abnormalities in which the foot is fixed in a plantar-flexed position, and the sole is rotated inward[2] (Chapter 65). The deformity may be unilateral or bilateral and affects the bony, muscular, tendinous, and ligamentous structures. Manual manipulation of the extremity does not correct the defect. Clenched hands typically refer to abnormal posturing that can include abnormal positioning of the arms, elbows, wrists, and fingers. Similarly, bony, muscular, tendon, and ligamentous processes are affected in the upper limb.

PREVALENCE AND EPIDEMIOLOGY

Clubfoot occurs in approximately 1:1000 pregnancies and is more common in male fetuses (2:1 male-to-female ratio).[4] There is an increased incidence among first-degree relatives. Ethnic variations in frequency exist; it appears to be less common in Asians (0.5:1000) and more common in the Polynesian islands (7.5:1000 births).[4,5]

ETIOLOGY, PATHOPHYSIOLOGY, AND EMBRYOLOGY

Many cases of clubfoot, particularly unilateral, are isolated and not associated with other structural or genetic abnormalities. Clubfoot is commonly classified according to intrinsic or extrinsic causes. External forces that deform an otherwise normally developing foot are considered to be extrinsic causes of clubfoot, though controversy exists on the extent of the importance of extrinsic forces on the development of clubfeet, particularly bilateral.[3] While many clubfeet are thought to be isolated, there is compelling evidence from familial and twin studies that there is a higher prevalence of congenital clubfeet in first-degree relatives.[2] Isolated clubfeet have been shown to result from heterozygosity for mutations in the gene encoding *PITX1*, thus supporting that some isolated cases of clubfeet result from single gene mutations, though the incidence of single gene disorders among isolated club feet is small.[2] It is estimated that 20% to 25% of clubfoot cases are associated with syndromic etiologies such as MCC, congenital myopathies such as myotonic dystrophy, myelomeningocele with secondary neurologic involvement, amniotic band sequence, and chromosomal syndromes.[6] Other etiologies that increase the risk of clubfeet include maternal smoking.[2] It is critical to recognize that more than 400 genetic disorders are associated with congenital contractures, where the only manifestation of disease *in utero* may be clubfeet or clenched hands. It is important to recognize that MCC or arthrogryposis, is a highly heterogeneous group of disorders that can affect just the upper limbs, the lower limbs, or both.[6,7] The most prevalent form of MCC is amyoplasia, accounting for one-third of all cases.[7] It is a sporadic disorder that also has a specific natural history, and the underlying causes are unknown but thought to be vascular in origin.[7]

MANIFESTATIONS OF DISEASE

Clinical Presentation

Prenatal ultrasound (US) can identify 60% to 80% of cases of clubfoot.[8] In unilateral cases, the defect is more likely to be right-sided.[6] Half of cases of isolated clubfeet are bilateral. However, the precise etiologies underlying the clubfoot or clenched hands are underdiagnosed prenatally, and genetic syndromes are frequently missed.[1] Characteristic clubfeet show forefoot and midfoot abductus (Fig. 63.1), hindfoot varus, and ankle equinus. The foot presents with rigid inward turning toward the midline of the body, resembling a persistent contracted foot. Lower leg muscles are frequently hypoplastic even after correction. Muscle biopsies in cases of amyoplasia, a subset among arthrogryposis syndromes, show replacement of normal muscle tissues with fatty/fibrous tissues.[7] Clenched hands with finger flexion and wrist abnormalities rarely present as isolated anomalies. Clenched hands can be seen in chromosomal anomalies such as trisomy 18, as well as mitochondrial disorders and MCC syndromes. Individuals with clenched hands due to amyoplasia frequently

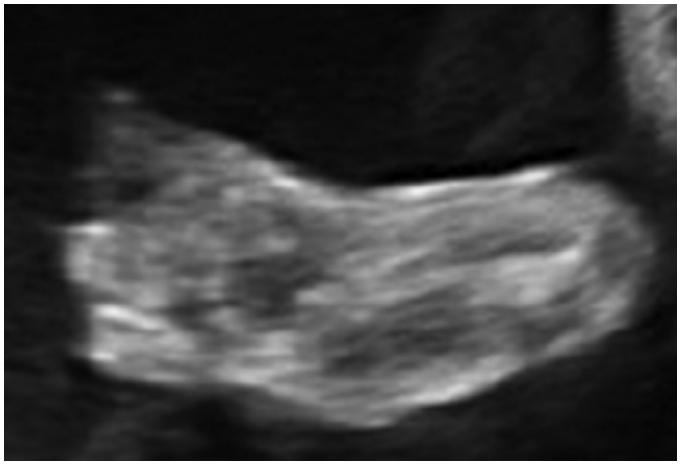

Fig. 63.1 Two-dimensional US image showing characteristic midfoot abductus seen in club foot deformity.

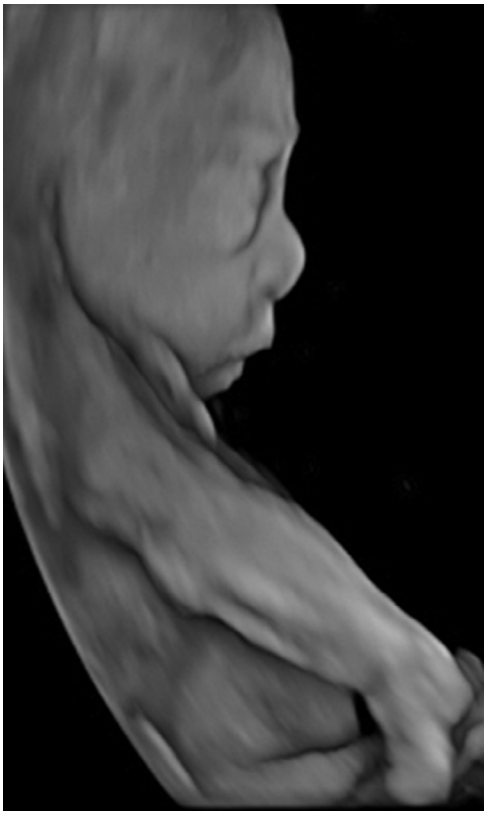

Fig. 63.2 Three-dimensional US image of a fetus with amyoplasia showing mild micrognathia, shoulder rotated inward, and bilateral flexed wrists.

have internal rotation of their shoulders, extended elbows, forearm held in pronation, and wrists rigidly flexed (Figs. 63.2 and 63.3). Similar to lower extremities and clubfeet, clenched hands are associated with decreased muscle mass, decreased flexion creases, and dimples overlying affected joints.

Imaging Technique and Findings

Ultrasound. Prenatal diagnosis is confirmed if the plantar surface of the foot is persistently visualized in the same plane as the tibia and fibula (Figs. 63.4–63.6). The foot can be seen in midfoot abductus (see Fig. 63.1).[8] For clenched hands or upper extremity arthrogryposis, particularly due to amyoplasia, the shoulders can be internally rotated, the elbows are straight, and the wrists are flexed (see Figs. 63.2 and 63.3). In cases of MCC, including amyoplasia, there are decreased *in utero* movements. Because MCC can result from abnormalities in the central nervous system, abnormalities in muscle and nerve development, connective tissue disorders, and osteochondrodysplasias, these respective systems should be thoroughly invested. Amyoplasia is a specific subtype among MCCs and is associated with an increased incidence of gastroschisis, partial absence of digits, constriction rings, and being small for gestational age. Presence of nevus flammeus ("stork bite") over the facial midline is frequently seen in amyoplasia.[7]



Fig. 63.3 Three-dimensional US image of a fetus with amyoplasia showing mild micrognathia, internally rotated shoulder, extended elbow, and flexed wrist.

Magnetic Resonance Imaging. Magnetic resonance imaging (MRI) can be useful in fetuses with talipes equinovarus or club feet, particularly if it is complex, and MRI can detect additional anomalies, particularly in the neurologic system; however, it has not been found to be helpful in cases thought to be isolated by US.[9–11]

Differential Diagnosis From Imaging Findings

The differential diagnosis includes determining if the findings of clubfeet or clenched hands are bilateral, or are associated with any other structural abnormalities. Internal rotation of the shoulders, as well as being small for gestational age, point more toward amyoplasia.[7] Microarray analysis will rule out chromosomal abnormalities, particularly if the US findings suggest a complex presentation.

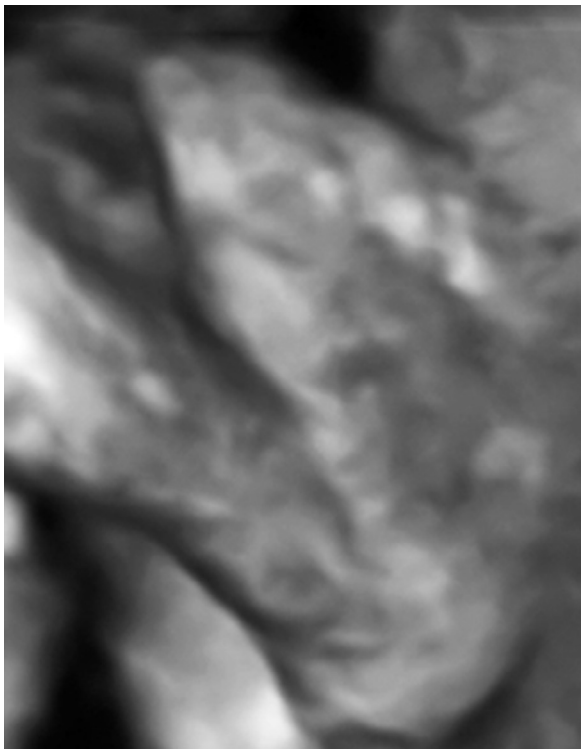

Fig. 63.4 Three-dimensional US of unilateral club foot showing internal (medial) rotation of the ankle with the hallux seen in a similar plane with the distal tibia.



Fig. 63.5 Three-dimensional US skeletal mode showing clubfoot with the hallux in the same plane with tibia.

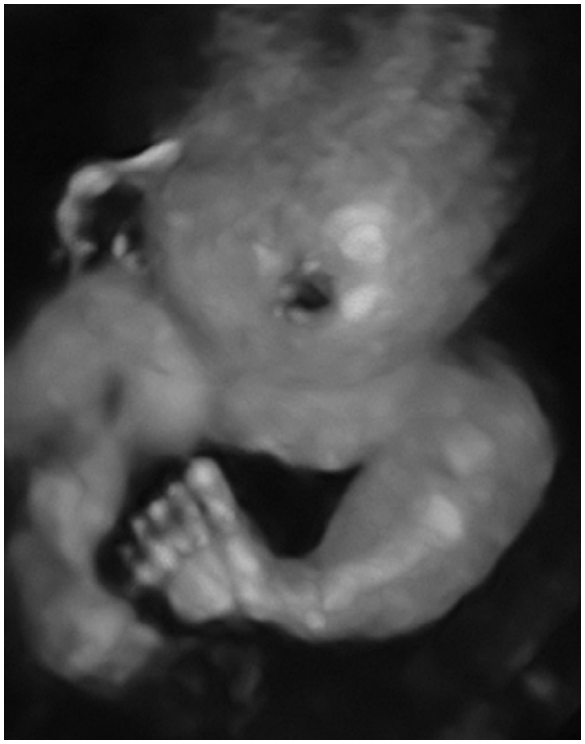

Fig. 63.6 Three-dimensional US showing bilateral fixed club feet.

Synopsis of Treatment Options

PRENATAL

Fetuses with a suspected skeletal abnormality should be referred to a center with expertise in evaluating the fetal skeleton for US examination and genetic counseling. No prenatal treatment options exist. US findings correlate poorly with the degree of severity of clubfoot and cannot be used to counsel the patient regarding the likelihood of success of various postnatal therapeutic approaches. If the clubfoot is isolated, route and timing of delivery are unchanged, and delivery does not need to occur at a tertiary center. History of isolated or bilateral clubfeet in a first-degree relative suggests that the finding may be isolated. Fetuses with complex findings in addition to clubfeet (with or without clenched hands) have a higher incidence of cesarean birth.[12]

POSTNATAL

Positional clubfoot is due to an external deforming effect and is typically managed successfully with manipulation of the foot alone. Approximately 10% of cases fit into this category.[13] Congenital clubfoot that is not associated with a syndrome, structural malformation, or neuromuscular disorder is most commonly managed by casting and bracing ("Ponseti method"). Injections of botulinum toxin, type A (Botox), may also be used in some cases as an adjunct to therapy. The need for surgical intervention varies widely and averages about 46% of cases.[14] Surgery is reserved for patients who have failed conservative therapies and is timed before the child begins ambulating. When surgical intervention is necessary, it is often a single procedure with an excellent outcome and ability to ambulate. Genetic syndromes or more complex etiologies of MCC require a dedicated team of physicians acquainted with management.

WHAT THE REFERRING PHYSICIAN NEEDS TO KNOW

Fetuses with a suspected skeletal abnormality, including clubfoot and clenched hands, should be referred to a center with expertise in evaluating the fetal skeleton for US examination and genetic counseling. The presence of bilateral clubfeet or other anomalies increases the likelihood of an underlying genetic syndrome, which should warrant prenatal diagnostic genetic testing. If the clubfoot is isolated, route and timing of delivery are unchanged, and delivery does not need to occur at a specialized center. However, identification of other structural or genetic abnormalities dictates the need for prenatal consultation with other specialists to determine whether delivery at a tertiary care center is appropriate.

KEY POINTS

- US evaluation of the fetal foot and lower leg can successfully identify clubfoot in about 60% to 80% of cases.
- If the foot is clubbed, the plantar surface of the foot is visible in the same US plane as the tibia and fibula and the foot is in a valgus position.
- Thorough US evaluation of fetal anatomy is necessary when clubfoot is identified or suspected, including bilateral evaluation of all the limbs.
- Because of the increased incidence of chromosomal abnormalities in complex clubfeet phenotypes, microarray analysis should be offered in the prenatal period.
- The presence of other anomalies increases the likelihood of an underlying genetic abnormality.
- The outcomes for fetuses with both clubfeet, abnormally positioned upper extremities, or other abnormalities are far more complex and falls under the heterogeneous category of MCC syndromes.
- The outcome for most children with isolated clubfoot who are normally grown at term is typically excellent, though determination that it is isolated is based on postnatal diagnosis.[15]

SUGGESTED READING

Bacino CA, Hecht JT. Etiopathogenesis of equinovarus foot malformations. *Eur J Med Genet*. 2014;57(8):473-479.



All references are available online at www.expertconsult.com.

REFERENCES

1. Filges I, Hall JG. Failure to identify antenatal multiple congenital contractures and fetal akinesia—proposal of guidelines to improve diagnosis. *Prenat Diagn*. 2013;33(1):61-74.
2. Bacino CA, Hecht JT. Etiopathogenesis of equinovarus foot malformations. *Eur J Med Genet*. 2014;57(8):473-479.
3. Hall JG. Uterine structural anomalies and arthrogryposis-death of an urban legend. *Am J Med Genet A*. 2013;161A(1):82-88.
4. Parker SE, Mai CT, Strickland MJ, et al. Multistate study of the epidemiology of clubfoot. *Birth Defects Res A Clin Mol Teratol*. 2009;85(11):897-904.
5. Chapman C, Stott NS, Port RV, et al. Genetics of club foot in Maori and Pacific people. *J Med Genet*. 2000;37(9):680-683.
6. Hall JG. Arthrogryposis (multiple congenital contractures): diagnostic approach to etiology, classification, genetics, and general principles. *Eur J Med Genet*. 2014;57(8):464-472.
7. Hall JG, Aldinger KA, Tanaka KI. Amyoplasia revisited. *Am J Med Genet A*. 2014;164A(3):700-730.
8. Keret D, Ezra E, Lokiec F, et al. Efficacy of prenatal ultrasonography in confirmed club foot. *J Bone Joint Surg Br*. 2002;84(7):1015-1019.
9. Nemec U, Nemec SF, Kasprian G, et al. Clubfeet and associated abnormalities on fetal magnetic resonance imaging. *Prenat Diagn*. 2012;32(9):822-828.
10. Gupta P, Sharma JB, Sharma R, et al. Antenatal ultrasound and MRI findings of Pena-Shokeir syndrome. *Arch Gynecol Obstet*. 2011;283(suppl 1):27-29.
11. Servaes S, Hernandez A, Gonzalez L, et al. Fetal MRI of clubfoot associated with myelomeningocele. *Pediatr Radiol*. 2010;40(12):1874-1879.
12. Sharma R, Stone S, Alzouebi A, et al. Perinatal outcome of prenatally diagnosed congenital talipes equinovarus. *Prenat Diagn*. 2011;31(2):142-145.
13. Lauson S, Alvarez C, Patel MS, et al. Outcome of prenatally diagnosed isolated clubfoot. *Ultrasound Obstet Gynecol*. 2010;35(6):708-714.
14. Swamy R, Reichert B, Lincoln K, et al. Foetal and congenital talipes: interventions and outcome. *Acta Paediatr*. 2009;98(5):804-806.
15. Toufaily MH, Westgate MN, Holmes LB. Congenital talipes equinovarus: frequency of associated malformations not identified by prenatal ultrasound. *Prenat Diagn*. 2015;35(3):254-257.

64 Clubfoot (Talipes Equinovarus)

STEPHANIE MARTIN

Introduction

Talipes equinovarus (clubfoot) is an abnormality of the foot position. It may be positional, congenital (isolated), or part of a syndrome. Clubfoot resulting from *in utero* positional forces, as may occur with prolonged severe oligohydramnios, multiple gestation, or breech presentation, is not a "true" clubfoot in that the deformity can usually be corrected by manual manipulation of the foot.

Disease

DEFINITION

Clubfoot is a foot malformation in which the foot is fixed in a plantar-flexed position, and the sole is rotated inward. The deformity may be unilateral or bilateral and affects the bony, muscular, and ligamentous structures. Manual manipulation of the extremity does not correct the defect.

PREVALENCE AND EPIDEMIOLOGY

Clubfoot occurs in approximately 1:1000 to 3:1000 pregnancies and is more common in males (2:1 male-to-female ratio). Frequency varies by ethnicity; it appears to be less common in Asians (0.5:1000) and more common in Polynesians and in the Maoris of New Zealand (6:1000 to 7:1000).[1–3]

ETIOLOGY AND PATHOPHYSIOLOGY

Most cases of clubfoot are isolated and idiopathic in nature and are not associated with other structural or genetic abnormalities. Clubfoot is commonly classified according to intrinsic or extrinsic causes. Intrinsic causes of clubfoot include genetic disorders, neuromuscular diseases, and other syndromes (Table 64.1). Extrinsic causes are external forces that deform an otherwise normally developing foot (Table 64.2). This chapter focuses on intrinsic causes of clubfoot.

MANIFESTATIONS OF DISEASE

Clinical Presentation

Prenatal ultrasound (US) can identify 80% of cases of clubfoot, as early as the late first trimester.[4,5] Approximately 30% to 60% of cases are bilateral. In unilateral cases, the defect is more likely to be right-sided.[6] The likelihood of an underlying chromosome abnormality is low (1.7%–3.6%) if clubfoot is isolated,[7] although reports have found that 4% to 19% of fetuses will have anomalies detected later in pregnancy or at birth.[8,9] Many karyotypic abnormalities associated with clubfoot are of the sex chromosomes (i.e., 47XXY) and are not related to maternal age.[7] Unilateral versus bilateral clubfoot does not affect the risk of chromosomal abnormality. The addition of microarray studies may increase the yield of invasive prenatal testing, although the complex inheritance patterns of clubfoot suggest that it rarely occurs due to a single gene mutation.[10]

TABLE 64.1 INTRINSIC CAUSES OF CLUBFOOT

CHROMOSOME ABNORMALITIES
Autosomal trisomy (i.e., trisomy 18)
Triploidy
Sex chromosome abnormalities (i.e., 47,XXY, 47,XXX, 47,XYY)
Microdeletion/duplication (i.e., dup[3q])
GENETIC SYNDROMES
Pena-Shokeir syndrome
Meckel-Gruber syndrome
Smith-Lemli-Opitz syndrome
Larsen syndrome
Roberts syndrome
TARP syndrome
Lambert syndrome
SKELETAL DYSPLASIA
Camptomelic dysplasia
Chondrodysplasia punctata
Diastrophic dysplasia
Ellis-van Creveld syndrome
Atelosteogenesis
Nievergelt syndrome (mesomelic dysplasia)
NEUROMUSCULAR DISORDERS
Arthrogryposis congenita
Myotonic dystrophy
Spinal muscular atrophy
NEUROLOGIC ABNORMALITIES
Neural tube defect
Holoprosencephaly
Hydranencephaly

TARP, *T*alipes equinovarus, *a*trial septal defect, *R*obin sequence, and *p*ersistent left superior vena cava.

TABLE 64.2 EXTRINSIC CAUSES OF CLUBFOOT

Oligohydramnios
Breech position
Multiple gestation
Fibroid uterus
Amniotic bands

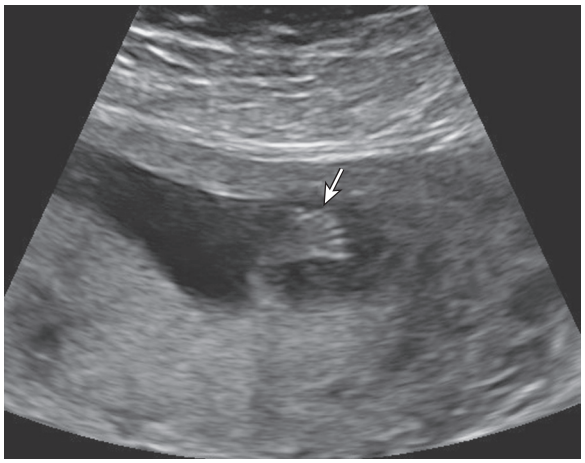

Fig. 64.1 Clubfoot *(arrow)* in a 12-week fetus.

Imaging Technique and Findings

Ultrasound. Prenatal diagnosis is confirmed if the plantar surface of the foot is persistently visualized in the same plane as the tibia and fibula. Clubfoot can be identified in the first (Fig. 64.1) or second (Fig. 64.2) trimester. Three-dimensional or four-dimensional US is useful in the evaluation of fetuses with skeletal abnormalities, especially for imaging of the extremities (Figs. 64.3 and 64.4).



Fig. 64.2 Unilateral clubfoot (isolated) in a 29-week fetus. The plantar surface of the foot and the long bones of the lower leg are visible in the same image plane.

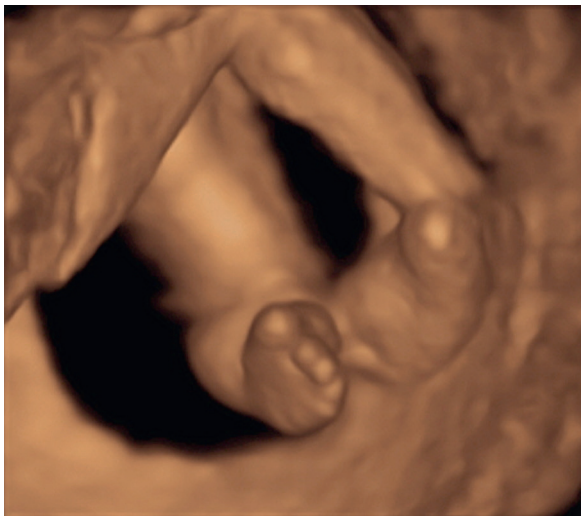

Fig. 64.3 Bilateral clubfeet seen with three-dimensional US.

Magnetic Resonance Imaging. Magnetic resonance imaging (MRI) may be useful in the evaluation of fetuses with skeletal abnormalities.[11] However, expense, inconvenience to the patient, and lack of experience limit the use of MRI.

Differential Diagnosis From Imaging Findings

The differential diagnosis includes other foot abnormalities (e.g., rocker-bottom foot).

Synopsis of Treatment Options

PRENATAL

Fetuses with a suspected skeletal abnormality should be referred to a center with expertise in evaluating the fetal skeleton and genetic counseling services. No prenatal treatment options exist.

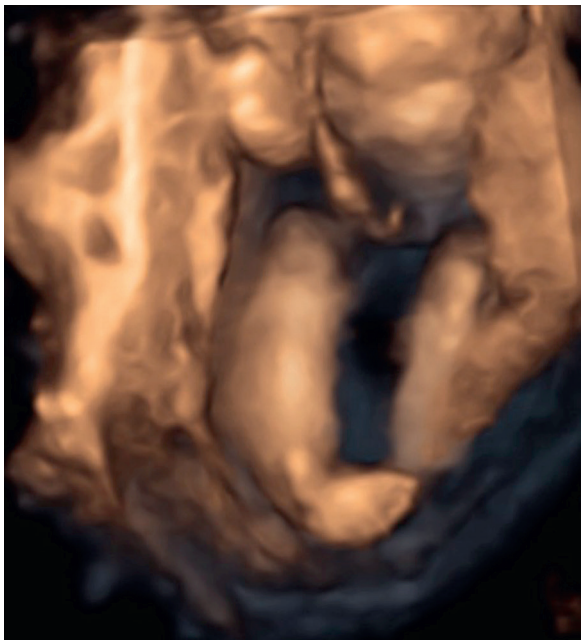

Fig. 64.4 Unilateral clubfoot seen with three-dimensional US.

US findings correlate poorly with the degree of severity of clubfoot and cannot be used to counsel the patient regarding the likelihood of success of various postnatal therapeutic approaches. If the clubfoot is isolated, route and timing of delivery are unchanged, and delivery does not need to occur at a tertiary center.

POSTNATAL

Because positional clubfoot is due to an external deforming effect, it is typically managed successfully with manipulation of the foot alone. Approximately 10% of cases fit into this category.[9] Congenital clubfoot not associated with a syndrome, structural malformation, or neuromuscular disorder is most commonly managed by casting and bracing ("Ponseti technique"). Injections of botulinum toxin, type A (Botox), may also be used in some cases as an adjunct to therapy. The need for surgical intervention varies widely and averages about 46% of cases.[9,12,13] Surgery is reserved for patients who have failed conservative therapies and is timed before the child begins ambulating. When surgical intervention is necessary, it is often a single procedure with an excellent outcome and ability to ambulate.

WHAT THE REFERRING PHYSICIAN NEEDS TO KNOW

Fetuses with a suspected skeletal abnormality should be referred for US and genetic counseling to a center with expertise in evaluating the fetal skeleton. The presence of other anomalies increases the likelihood of an underlying genetic syndrome, which should promote discussion of prenatal diagnostic genetic testing. If the clubfoot is isolated, route and timing of delivery are unchanged, and delivery does not need to occur at a specialized center. However, identification of other structural or genetic abnormalities dictates the need for prenatal consultation with other specialists to determine whether delivery at a tertiary care center is appropriate.

KEY POINTS

- US evaluation of the fetal foot and lower leg can identify clubfoot in 80% of cases.
- If the foot is clubbed, the plantar surface of the foot is visible in the same US plane as the tibia and fibula.
- Thorough US evaluation of fetal anatomy is necessary when clubfoot is identified or suspected.
- The risk of chromosomal abnormality in the case of isolated clubfoot is low, although associated anomalies are found in subsequent US or at delivery in 4% to 19% of fetuses initially suspected of isolated clubfoot.
- The presence of other anomalies increases the likelihood of an underlying genetic abnormality and warrants offering amniocentesis to these patients.
- The outcome for most children with isolated clubfoot (unilateral or bilateral) is excellent.

SUGGESTED READINGS

Canto MJ, Cano S, Palau J, et al. Prenatal diagnosis of clubfoot in low-risk population: associated anomalies and long-term outcome. *Prenat Diagn*. 2008;28:343.

Toufaily MH, Westgate MN, Holmes LB. Congenital talipes equinovarus: frequency of associated malformations not identified by prenatal ultrasound. *Prenat Diagn*. 2015;35:254.

All references are available online at www.expertconsult.com.

REFERENCES

1. Drvaric DV, Kuivila TE, Roberts JM. Congenital clubfoot: etiology, pathoanatomy, pathogenesis, and the changing spectrum of early management. *Orthop Clin North Am*. 1989;20:641.
2. Wynne-Davies R. Family studies and the cause of congenital clubfoot. *J Bone Joint Surg Am*. 1964;46:445.
3. Wynne-Davies R. Genetic and environmental factors in the etiology of talipes equinovarus. *Clin Orthop Relat Res*. 1972;84:9.
4. Offerdal K, Jebens N, Blaas HG, et al. Prenatal ultrasound detection of talipes equinovarus in a non-selected population of 49,314 deliveries in Norway. *Ultrasound Obstet Gynecol*. 2007;30:838.
5. Keret D, Ezra E, Lokiec F, et al. Efficacy of prenatal ultrasonography in confirmed club foot. *J Bone Joint Surg Br*. 2002;84:1015.
6. Kancherla V, Romitti PA, Caspers KM, et al. Epidemiology of congenital talipes equinovarus in Iowa, 1997–2005. *Am J Med Genet A*. 2010;152A:1695.
7. Lauson S, Alvarez C, Patel MS, et al. Outcome of prenatally diagnosed isolated clubfoot. *Ultrasound Obstet Gynecol*. 2010;35:708.
8. Toufaily MH, Westgate MN, Holmes LB. Congenital talipes equinovarus: frequency of associated malformations not identified by prenatal ultrasound. *Prenat Diagn*. 2015;35:254.
9. Bakalis S, Sairam S, Homfray T, et al. Outcome of antenatally diagnosed talipes equinovarus in an unselected obstetric population. *Ultrasound Obstet Gynecol*. 2002;20:226.
10. Dobbs MB, Gurnett CA. Genetics of clubfoot. *J Pediatr Orthop B*. 2012;21:7-9. doi:10.1097/BPB.0b013e328349927c.
11. Nemec U, Nemec SF, Kasprian G, et al. Clubfeet and associated abnormalities on fetal magnetic resonance imaging. *Prenat Diagn*. 2012;32:822-828. doi:10.1002/pd.3911.
12. Swamy R, Reichert B, Lincoln K, et al. Foetal and congenital talipes: interventions and outcome. *Acta Paediatr*. 2009;98:804.
13. Canto MJ, Cano S, Palau J, et al. Prenatal diagnosis of clubfoot in low-risk population: associated anomalies and long-term outcome. *Prenat Diagn*. 2008;28:343.

To access the videos in this chapter, scan this QR code or visit expertconsult.com

65 Cleft Lip and Palate

OLGA GÓMEZ | BIENVENIDO PUERTO

Introduction

Orofacial clefts, which include cleft lip (CL), cleft lip and palate (CLP), and cleft palate alone (CP), include a range of disorders affecting the lips and oral cavity, and represent the most common craniofacial malformation identified in the newborn. They can occur as a part of a syndrome involving multiple organs or as isolated malformations.

Disorder

DEFINITION

Orofacial clefts represent all those defects involving the upper lip, with or without extension to the alveolar ridge or primary palate, and to the hard or secondary palate. Defects can also be classified according to their location in unilateral, bilateral, or medial. The particular location of the defect is important in terms of evaluating the risk of associated anomalies and postnatal outcome.

PREVALENCE AND EPIDEMIOLOGY

Orofacial clefts arise in about 1:700 to 1:1000 live births, with ethnic and geographic differences; the prevalence is lowest in African Americans, intermediate in Caucasians, and highest in Native Americans and Asians. The prevalence varies for the type of orofacial cleft: 3.4:10,000 to 22.9:10,000 births for CL and CLP and 1.3:10,000 to 25.3:10,000 births for isolated CP.[1] CL and CLP are listed as a feature in more than 200 and 400 genetic syndromes, respectively. Approximately 15% to 45% are associated with other anomalies, genetic syndromes, and chromosomal abnormalities.[2–6]

ETIOLOGY, PATHOPHYSIOLOGY, AND EMBRYOLOGY

The etiology of orofacial clefts is multifactorial. Epidemiologic and experimental data suggest an influence of environmental risk factors such as maternal exposure to tobacco smoke, alcohol, poor nutrition, viral infection, medicinal drugs, and teratogens in early pregnancy. This is in line with the finding that planned pregnancies have lower risks of these defects.[1]

Because the lip and primary palate have distinct development origins from the secondary palate, orofacial clefts can be subdivided into different types (Figs. 65.1–65.5):

1. Cleft lip without cleft palate (CL): 25% of orofacial clefts. Only the lip is laterally affected and the defect can be unilateral or bilateral.
2. Cleft lip with cleft palate (CLP): 50% of cases. The lip and the primary palate are involved. This is a lateral defect that can be unilateral or bilateral.
3. Isolated cleft palate (CP): 25% of orofacial clefts. Only the secondary palate is affected. This form is very seldom diagnosed prenatally.
4. Median cleft lip and palate (MCLP): less than 1% of all orofacial clefts. It is distinguished etiologically from lateral CL and/or CLP, since it could be considered a midline defect. It is more often associated with other brain and facial midline

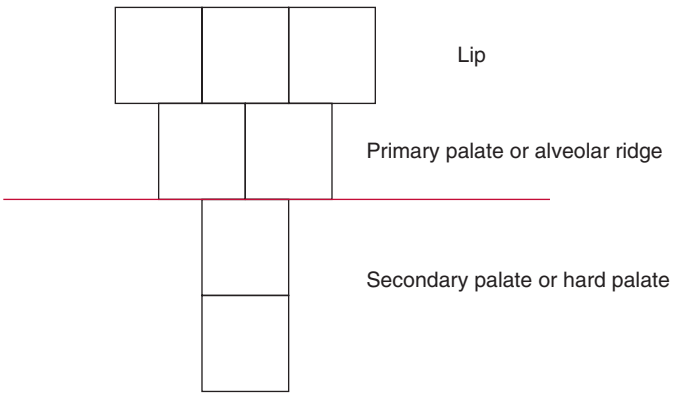

Fig. 65.1 Scheme of normal lips and palate. *(Modified from Kernohan diagram).*

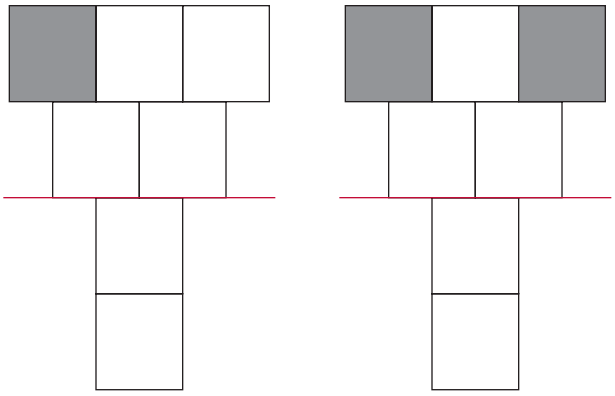

Fig. 65.2 Scheme of unilateral and bilateral cleft lip (CL). Note that the primary and secondary palates are normal.

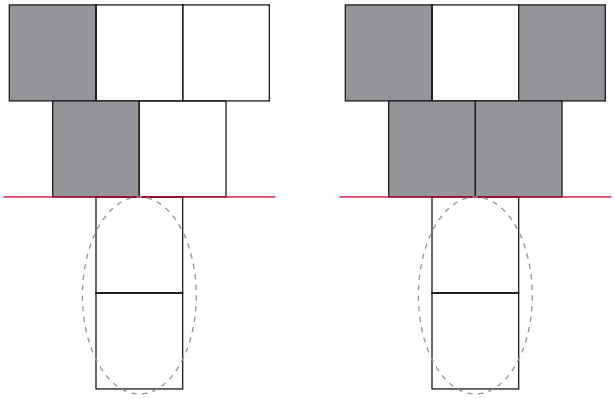

Fig. 65.3 Scheme of unilateral and bilateral cleft lip and palate (CLP). The primary palate is involved and the defect can or cannot extend to the secondary palate.

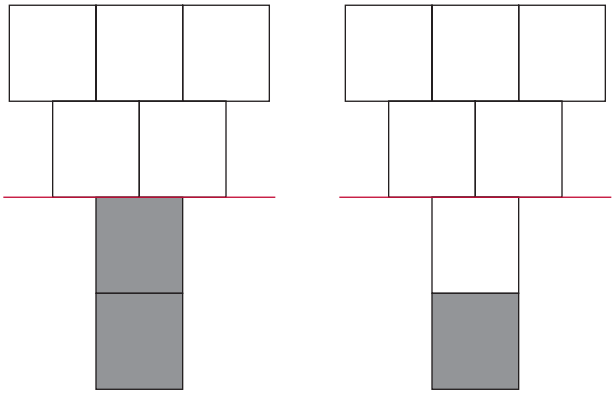

Fig. 65.4 Scheme of cleft palate (CP) alone. The lips and the primary palate are normal, and there is a defect in the hard palate that can affect only the most posterior part of it.

anomalies, and the risk of chromosomal anomalies is very high.

MANIFESTATIONS OF DISEASE

Clinical Presentation

Unilateral forms are more common than the bilateral forms (75% and 25%, respectively). The palate is affected in 75% of unilateral and 90% of bilateral cases.

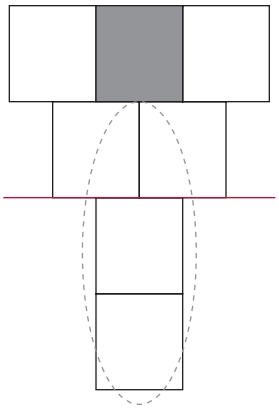

Fig. 65.5 Scheme of median cleft lip and palate (MCLP). The defect affects the central part of the upper lip and palate.

As previously mentioned, approximately 15% to 45% of orofacial clefts in the fetus are associated with other anomalies. The risk of chromosomal abnormalities is higher in bilateral forms of CLP, in isolated CP, and in those cases associated with other anomalies. Around 2% to 7% of the orofacial clefts can be associated with a genetic syndrome.[1–6]

The prognosis of orofacial clefts depends on its extension (involvement of palate) and its association with other anomalies. The effects of orofacial clefts on speech, hearing, appearance, and psychology can lead to long-lasting adverse outcomes for health and social integration. Typically, affected children need multidisciplinary care from birth to adulthood, and have increased rates of morbidity throughout life.

Imaging Technique and Findings

Ultrasound. CL and CLP can be diagnosed when the soft tissues of the fetal face are visualized sonographically, at 13–14 weeks by transabdominal ultrasound (US) and somewhat earlier by transvaginal US.[7,8] The diagnosis can be made using different views of the lower part of the face (Fig. 65.6), showing the interruption or discontinuity at the lip and/or palate. The oblique view of the mouth is essential for the diagnosis and to determine whether the defect is unilateral or bilateral. The axial view at the level of the upper maxilla will help determine the integrity or involvement of the anterior palate (Figs. 65.7 and 65.8). If CL is not associated with a palate defect, the alveolar ridge will be intact and the maxilla unremarkable. If, on the contrary, the cleft involves the bony structures, an abnormal communication between the oral and nasal cavities can be seen. It should be noted that the midline sagittal view appears normal in unilateral CL and CLP, since the defect lies in another plane. Bilateral CLP presents a characteristic appearance, with midline protuberance of soft tissue hanging from the philtrum (Fig. 65.9).[9]

Several authors have suggested the utility of color Doppler to demonstrate the passage of amniotic flow through the palate during fetal swallowing (Fig. 65.10).

Evaluation of the secondary or hard palate is highly difficult due to the acoustic shadow of the surrounding structures and the presence of the tongue. In general, isolated CP is very difficult to identify in the fetus. Three-dimensional US and magnetic resonance imaging (MRI), when available, can help evaluate the hard palate.[10–14] A novel technique to visualize the uvula and

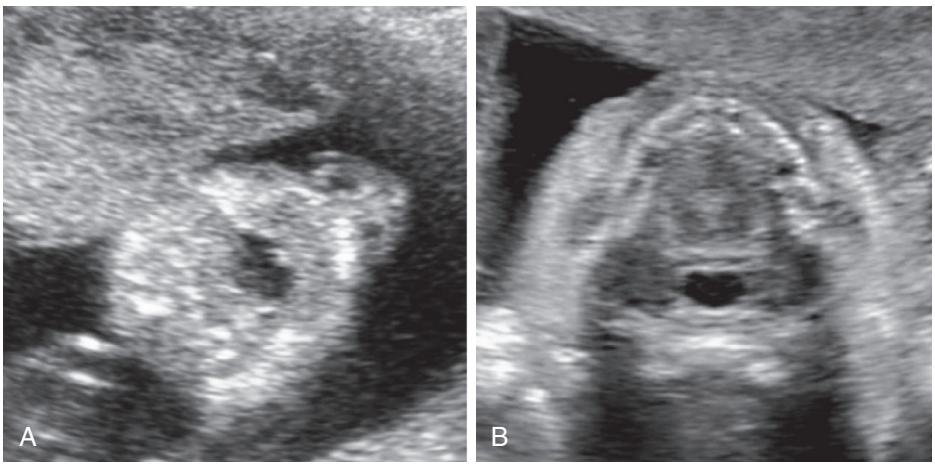

Fig. 65.6 (A) Normal oblique view of a mouth from a fetus of 21 weeks of gestation. Note the integrity of the upper lip. (B) Normal transverse view of the same fetus showing a normal alveolar ridge and posterior palate.

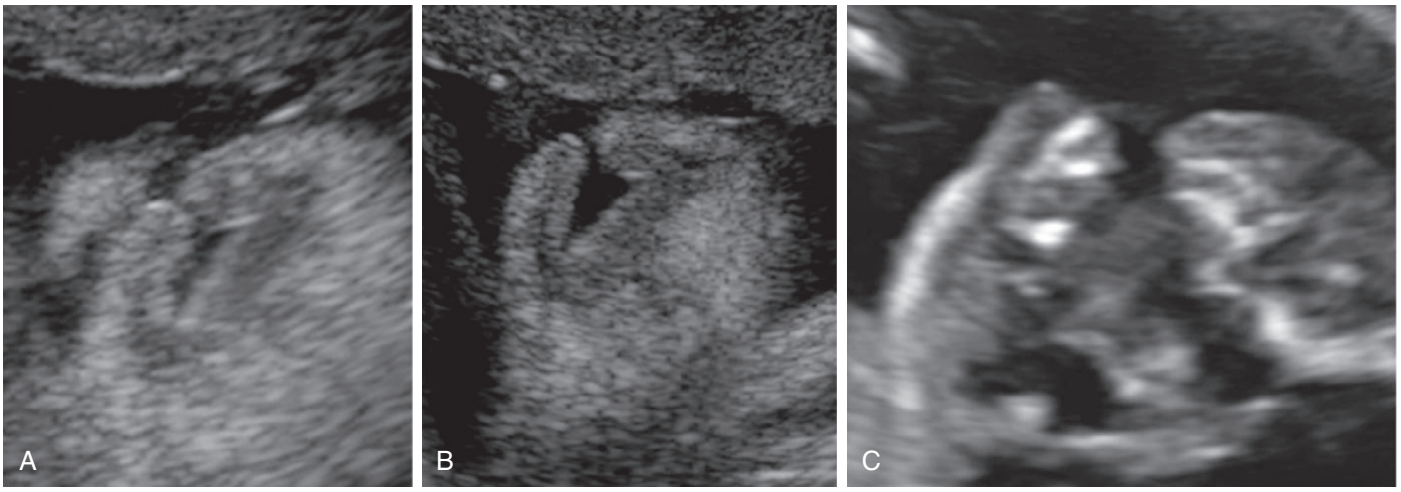

Fig. 65.7 (A, B) Oblique views of a fetus with a left cleft lip (CL). (C) Cleft palate in the view. Note the interruption of the alveolar ridge, which confirms the defect.



Fig. 65.8 (A, B) Oblique views of a fetus with a bilateral cleft lip and palate (CLP). (C) Cleft palate in the transverse view. Note the interruption of the alveolar ridge, which confirms the defect.

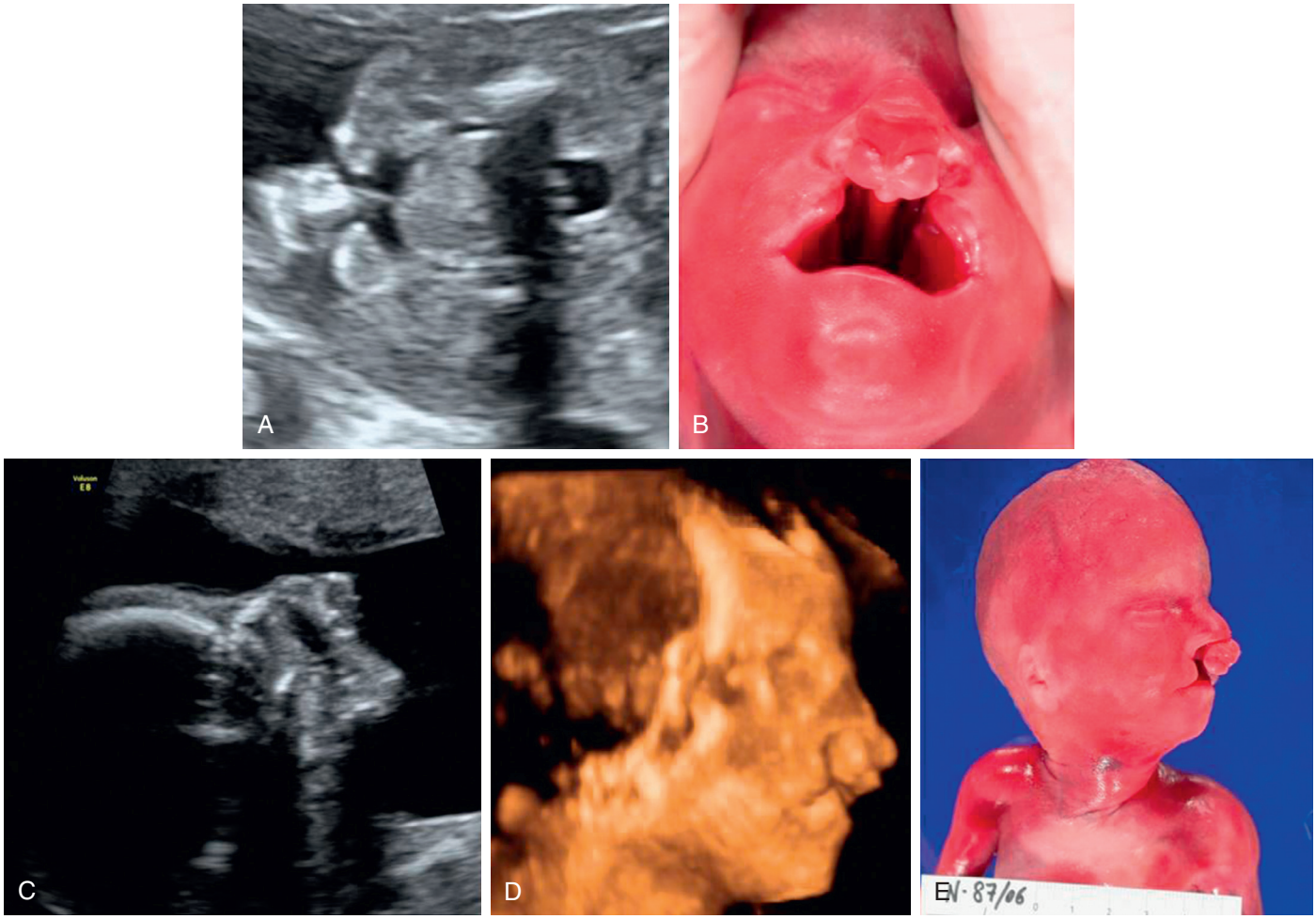

Fig. 65.9 (A, B) Oblique view of a fetus with a bilateral cleft lip (CL). (C–E) Longitudinal two-dimensional and rendered three-dimensional sagittal volume of the same fetus showing the infranasal tumor secondary to the bilateral cleft lip and palate (CLP).

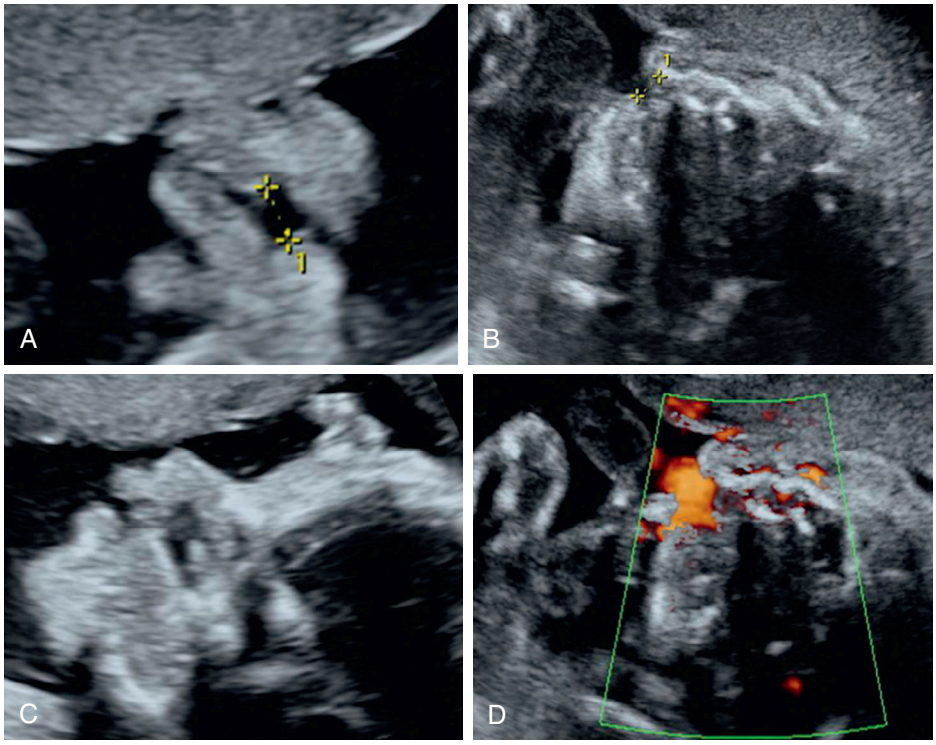

Fig. 65.10 (A–C) Different views of a fetus with a unilateral cleft lip and palate (CLP). (D) The power Doppler confirms the involvement of the primary palate since it demonstrates the entrance of amniotic flow through the defect.



Fig. 65.11 (A, B) Rendered and multiplanar three-dimensional views of a fetus with a median cleft lip and palate (MCLP). There is a central defect that affects all of the midline. Note the absence of a normal nose. (C) Postnatal image correlation.

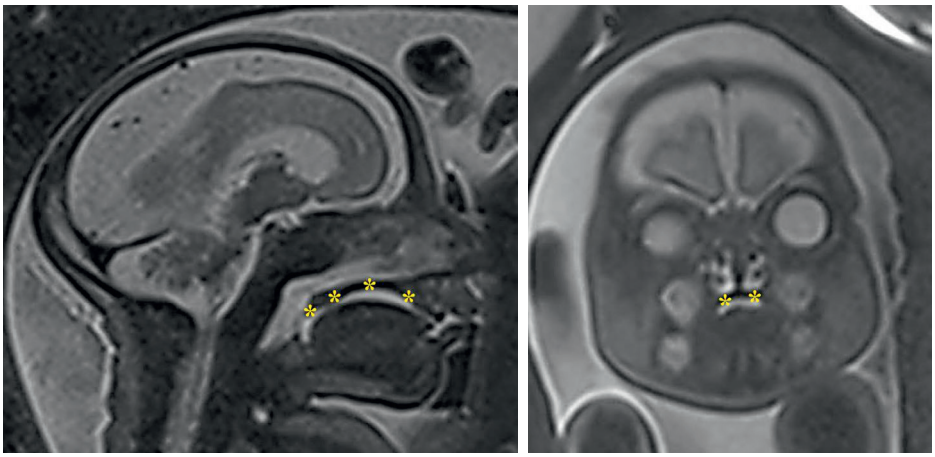

Fig. 65.12 (A, B) Sagittal and coronal T2-MRI sections showing a normal palate *(asterisks)* in a fetus at 30 weeks of gestation.

soft palate by two-dimensional imaging has also been described.[15] The visualization of the normal uvula, with a typical echo pattern ("equal sign") in a sagittal or coronal pharyngeal section, could be obtained in 91% of 667 fetuses from 20–25 weeks of gestation, thus permitting CP to be ruled out in routine examinations.

In MCLP forms the defect will be central and located at the median lip (Fig. 65.11). As mentioned, these defects are a midline anomaly almost constantly associated with other midline anomalies (different forms of holoprosencephaly, altered orbits, and nose anomalies).[9]

Magnetic Resonance Imaging. Magnetic resonance imaging is useful to assess the hard palate in the fetus (Fig. 65.12),[13] but it is more sensitive at advanced gestational ages. Therefore it can be considered a complementary tool in special cases such as those at high risk because of family or personal history.

Other Applicable Modality. Three-dimensional US offers help assessing the extent of the defect[16,17] and improves communication with parents (Figs. 65.13 and 65.14, Video 65.1).

CLASSIC SIGNS

- Unilateral, bilateral, or median interruption of the upper lip in the oblique-coronal section of the face.
- Interruption of the upper alveolar ridge in axial sections.

Differential Diagnosis From Imaging Findings

1. Amniotic band syndrome affecting the fetal face.
2. Tumors located in the orofacial region can mimic a bilateral CLP. The characteristics of the tumor and accurate assessment of the upper lip should help establish the diagnosis.

Synopsis of Treatment Options

PRENATAL

There is no prenatal treatment for orofacial clefts. *In utero* correction of orofacial clefts has been shown in animal models,

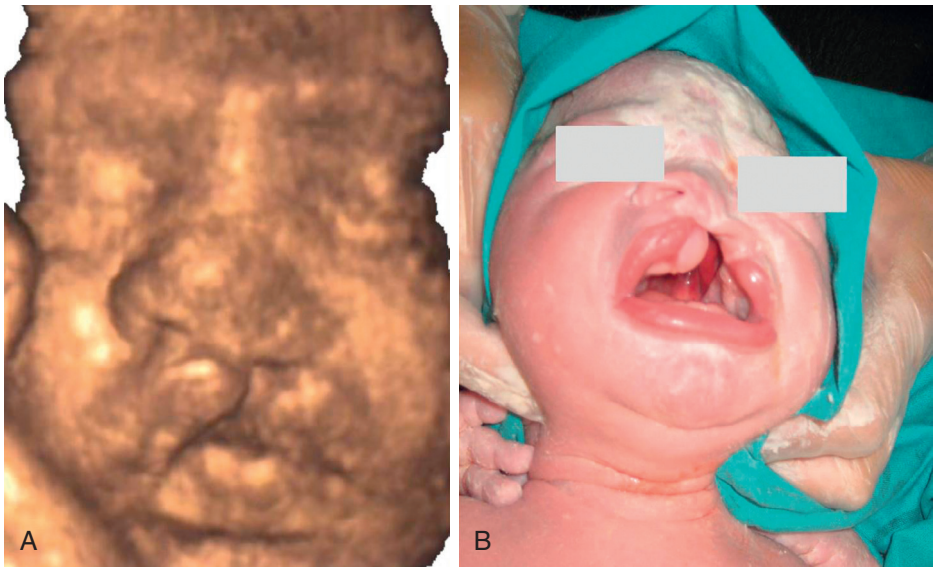

Fig. 65.13 (A) Rendered three-dimensional image of a fetus with a left cleft lip and palate (CLP) at 28 weeks of gestation. (B) Newborn after delivery.

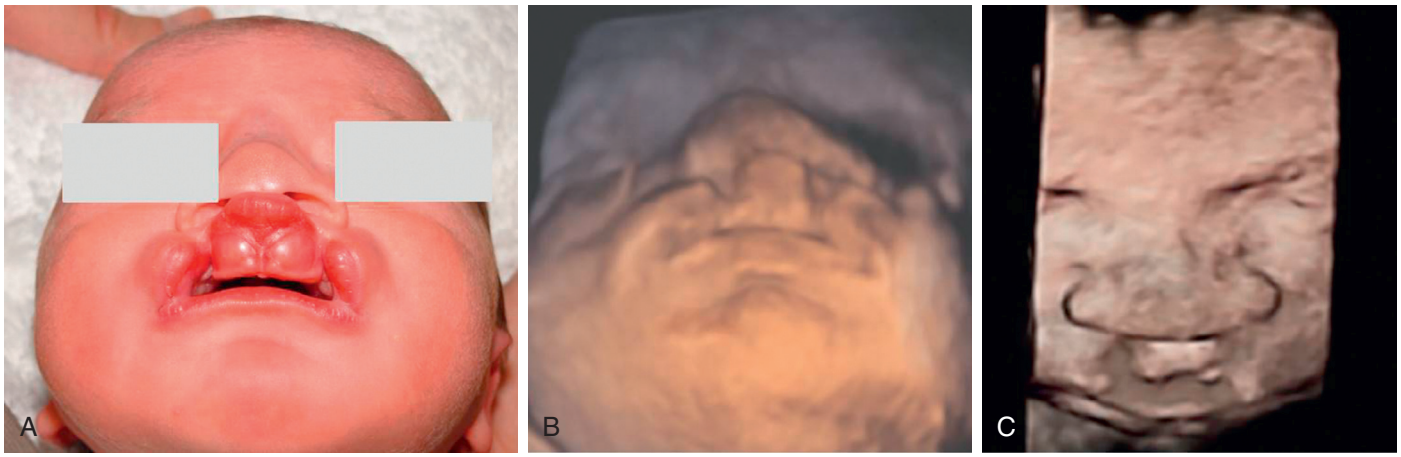

Fig. 65.14 (A) Newborn with a bilateral cleft lip and palate (CLP). (B, C) Rendered three-dimensional images of the fetus at 31 weeks of gestation.

but in human pregnancies the risks outweigh the benefits. Obstetric management should not be changed, but referral to a comprehensive management team is recommended. Special nipples to aid in feeding should be available at the site of planned birth.

POSTNATAL

Treatment protocols may differ remarkably within and between developed countries. Postnatal care entails immediate needs, such as feeding and airway problems. Primary lip repair can often be undertaken at 3 months of life, with palate repair at 6 months. Additional surgeries, as well as speech and orthodontic therapies, are often needed.

WHAT THE REFERRING PHYSICIAN NEEDS TO KNOW

- Obstetric management should not be changed in the presence of this anomaly, but it is recommended to refer the parents to a comprehensive management team.
- Amniocentesis, including array comparative genomic hybridization, should be considered, and a careful assessment for additional structural abnormalities (15%–45%) and genetic syndrome (2%–7%).
- The recurrence risk depends on the form of the defect (higher for CP), the presence of a genetic syndrome, and the existence of other cases in the family.

KEY POINTS

- Orofacial clefts are the most common craniofacial anomaly.
- High risk of associated anomalies and genetic syndromes in the fetus.
- Overall good prognosis for isolated forms.

SUGGESTED READING

Carlson DE. The ultrasound evaluation of cleft lip and palate—a clear winner for 3D. *Ultrasound Obstet Gynecol*. 2000;16(4):299-301.
Mossey PA. Cleft lip and palate. *Lancet*. 2009;374(9703):1773-1785.

All references are available online at www.expertconsult.com.

REFERENCES

1. Mossey PA, Little J, Munger RG, et al. Cleft lip and palate. *Lancet*. 2009;374(9703):1773-1785.
2. Chmait R, Pretorius D, Moore T, et al. Prenatal detection of associated anomalies in fetuses diagnosed with cleft lip with or without cleft palate in utero. *Ultrasound Obstet Gynecol*. 2006;27(2):173-176.
3. Calzolari E, Pierini A, Astolfi G, et al. Associated anomalies in multimalformed infants with cleft lip and palate: an epidemiologic study of nearly 6 million births in 23 EUROCAT registries. *Am J Med Genet A*. 2007;143(6):528-537.
4. Gillham JC, Anand S, Bullen PJ. Antenatal detection of cleft lip with or without cleft palate: incidence of associated chromosomal and structural anomalies. *Ultrasound Obstet Gynecol*. 2009;34(4):410-415.
5. Johnson CY, Honein MA, Hobbs CA, et al. Prenatal diagnosis of orofacial clefts, National Birth Defects Prevention Study, 1998–2004. *Prenat Diagn*. 2009;29(9):833-839.
6. Ensing S, Kleinrouwler CE, Maas SM, et al. Influence of the 20-week anomaly scan on prenatal diagnosis and management of facial clefts. *Ultrasound Obstet Gynecol*. 2014;44:154-159.
7. Sepulveda W, Wong AE, Martínez-Ten P, et al. Retronasal triangle: a sonographic landmark for the screening of cleft palate in the first trimester. *Ultrasound Obstet Gynecol*. 2010;35(1):7-13.
8. Ghi T, Arcangeli T, Radico D, et al. Three-dimensional sonographic imaging of fetal bilateral cleft lip and palate in the first trimester. *Ultrasound Obstet Gynecol*. 2009;34(1):119-120.
9. Gabrielli S, Piva M, Ghi T, et al. Bilateral cleft lip and palate without premaxillary protrusion is associated with lethal aneuploidies. *Ultrasound Obstet Gynecol*. 2009;34(4):416-418.
10. Campbell S, Lees C, Moscoso G, et al. Ultrasound antenatal diagnosis of cleft palate by a new technique: the 3D "reverse face" view. *Ultrasound Obstet Gynecol*. 2005;25(1):12-18.
11. Campbell S. Prenatal ultrasound examination of the secondary palate. *Ultrasound Obstet Gynecol*. 2007;29(2):124-127.
12. Faure JM, Captier G, Baumler M, et al. Sonographic assessment of normal fetal palate using three-dimensional imaging: a new technique. *Ultrasound Obstet Gynecol*. 2007;29(2):159-165.
13. Ghi T, Tani G, Savelli L, et al. Prenatal imaging of facial clefts by magnetic resonance imaging with emphasis on the posterior palate. *Prenat Diagn*. 2003;23(12):970-975.
14. Pilu G, Segata M. A novel technique for visualization of the normal cleft fetal secondary palate: angle insonation and three-dimensional ultrasound. *Ultrasound Obstet Gynecol*. 2007;29(2):166-169.
15. Wilhelm L, Borges H. The "equals sign": a novel marker in the diagnosis of fetal isolated cleft palate. *Ultrasound Obstet Gynecol*. 2010;36:439-444.
16. Carlson DE. The ultrasound evaluation of cleft lip and palate—a clear winner for 3D. *Ultrasound Obstet Gynecol*. 2000;16(4):299-301.
17. Lee W, Kirk JS, Shaheen KW, et al. Fetal cleft lip and palate detection by three-dimensional ultrasonography. *Ultrasound Obstet Gynecol*. 2000;16(4):314-320.

66 Orbital Defects: Hypertelorism and Hypotelorism

ELISENDA EIXARCH | BIENVENIDO PUERTO

Introduction

Orbits can be identified from 10 to 12 weeks of gestation by transvaginal ultrasound.[1] On ultrasound evaluation, orbits appear as echolucent circles, and inside these structures lenses can be indentified as small echogenic circular structures. In normal development, ocular structures develop laterally and migrate toward the midline to reach their final position. Orbital defects are rarely diagnosed in the fetus. However, these anomalies are highly associated with chromosomal and nonchromosomal defects.

Hypertelorism

DEFINITION

Hypertelorism is defined by an increased interocular distance (IOD) above the 95th centile.

PREVALENCE AND EPIDEMIOLOGY

This is a very rare condition.

ETIOLOGY AND PATHOPHYSIOLOGY

Three different mechanisms have been proposed to be responsible for this anomaly: (1) primary arrest of the migration process, (2) secondary arrest of migration due to the presence of a midline tumor, which mechanically limits migration, and (3) abnormal development and growth of the cranial bones.[2]

MANIFESTATIONS OF DISEASE

Clinical Presentation

Hypertelorism is rarely associated with chromosomal abnormalities, but is highly associated with nonchromosomal syndromes,[2] mainly in the face, central nervous system (CNS), or cranial bones. Some syndromes detectable *in utero* are listed in Table 66.1. Isolated hypertelorism is very rare; therefore an anatomic scan and karyotype analysis are necessary in order to detect malformations or chromosomal abnormalities. The prognosis depends on the underlying syndrome or associated anomalies.

Imaging Technique and Findings

Ultrasound. Ultrasound (US) diagnosis is made on the axial view of the orbits (lateral or ventral approach) by measuring IOD. Orbital biometry is not routinely assessed but it should be checked whenever there is suspicion of an orbital anomaly. Orbits can be assessed easily by US in an axial plane slightly caudal to the biparietal diameter plane. Ocular diameter, interocular distance, and binocular distance can be determined either in lateral or coronal planes. Additionally, a ventral view can be useful to assess the intraocular soft tissues, lenses, and posterior walls of the orbits (Fig. 66.1). Normal values for ocular measurements in early gestation,[3] midgestation, and late gestation[4] are

TABLE 66.1 NONCHROMOSOMAL SYNDROMES ASSOCIATED WITH HYPERTELORISM

Hypertelorism associated with:	Syndrome
Anterior cephalocele, median cleft lip, and bifid nose	Frontonasal dysplasia
Turricephaly, macroglossia, syndactyly, fusion of cervical vertebrae, renal anomalies, and heart anomalies	Apert syndrome
Cataract, microcephaly, agenesis of the corpus callosum, severe cerebellar hypoplasia, micrognathia, short limbs, syndactyly, joint contractures, early-onset fetal growth retardation, and polyhydramnios	Neu-Laxova syndrome

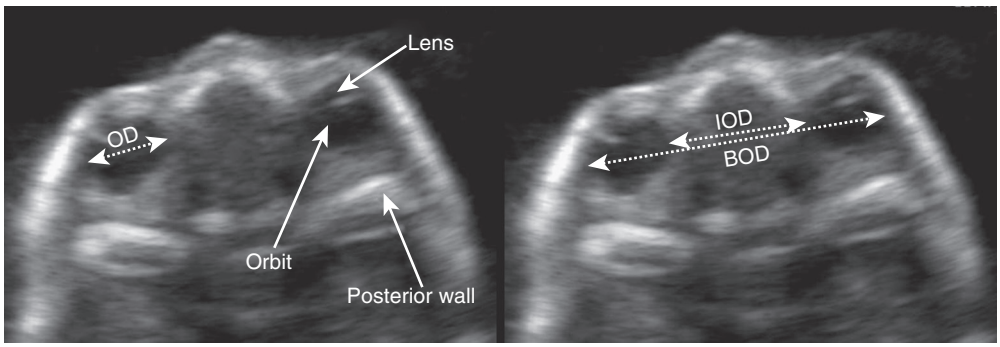

Fig. 66.1 Normal anatomy of the orbits and measurement of ocular biometry including ocular diameter *(OD)*, interocular distance *(IOD)*, and binocular distance *(BOD)*.

available. Measurements are particularly useful in moderate hypertelorism (Fig. 66.2), while in severe, very obvious cases ocular biometry may be unnecessary.

Magnetic Resonance Imaging. Orbits can be assessed by magnetic resonance imaging (MRI) and nomograms of ocular biometry are available.[5,6] Orbital measurements with MRI can provide additional information supporting normality or abnormality,[5] especially when US evaluation is inconclusive. Additionally, the use of fetal MRI could be useful to demonstrate additional associated anomalies.[7]

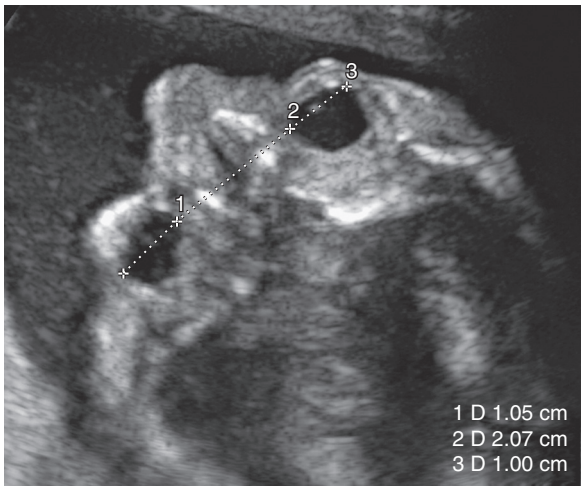

Fig. 66.2 Hypertelorism in a 21-week-old fetus with an increased interocular distance associated with turricephaly. *1 D,* right orbit diameter; *2 D,* inner orbital distance; *3 D,* left orbit diameter.

Hypotelorism

DEFINITION

Hypotelorism is defined by a decreased IOD below the fifth centile.

PREVALENCE AND EPIDEMIOLOGY

This is an uncommon condition.

ETIOLOGY AND PATHOPHYSIOLOGY

Development of midline facial structures is closely related with development of the forebrain.[8] The most common cause of hypotelorism is a defect in migration, which is frequently associated with a defect in the development of the midline embryonic forebrain producing holoprosencephaly.

MANIFESTATIONS OF DISEASE

Clinical Presentation

Isolated hypotelorism is extremely rare. In 80% of cases it is associated with holoprosencephaly.[9] Additionally, hypotelorism can be associated with microcephaly[10] and Meckel-Gruber

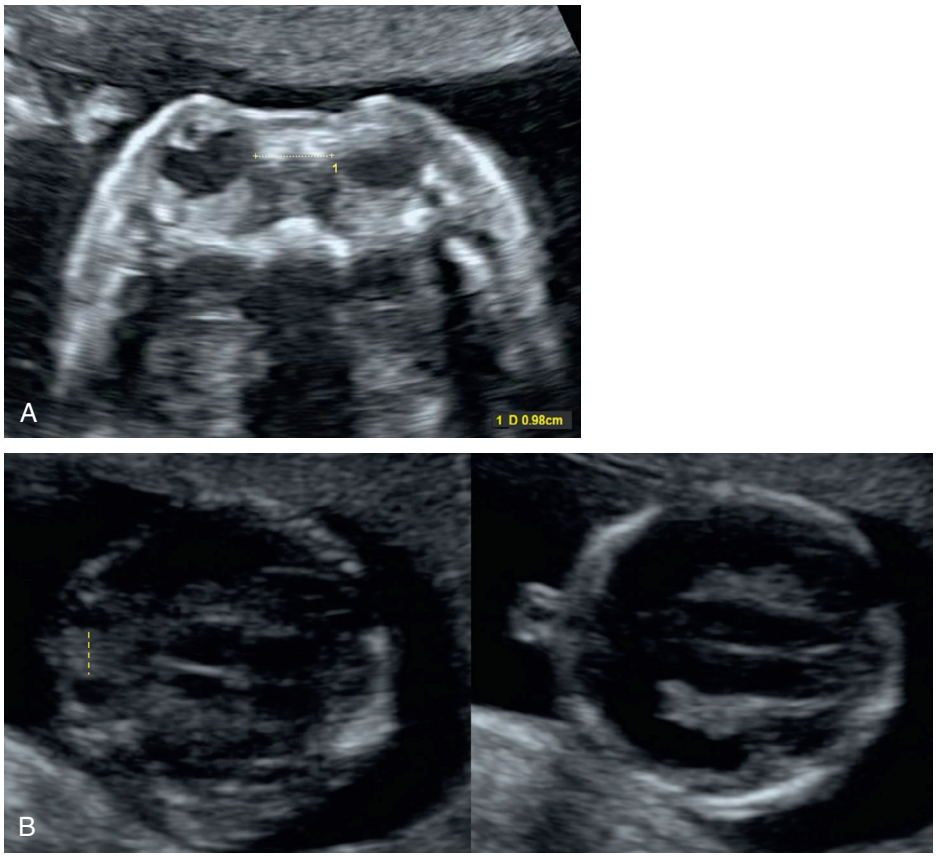

Fig. 66.3 (A) Moderate hypotelorism in a 24-week-old fetus with a decreased interocular distance, holoprosencephaly, and arhinia. (B) Severe hypotelorism in a 13-week-old fetus with alobar holoprosencephaly, microphthalmia, and proboscis. *Dashed line* depicts the measurement of IOD.

syndrome[11] (occipital cephalocele, cystic renal dysplasia, and postaxial polydactyly associated with craniofacial, CNS, and gastrointestinal anomalies). Hypotelorism is also highly associated with chromosomal abnormalities, the most common being trisomy 13,[12] thus karyotype analysis is mandatory. An anatomic scan, mainly focused on the CNS, should be performed to detect holoprosencephaly or other associated malformations. Prognosis is normally very poor due to the high mortality rate of trisomy 13 and the severe mental retardation of holoprosencephaly.

Imaging Technique and Findings

Ultrasound. US diagnosis is made on the axial view of the orbits (lateral or ventral approach) and should be based on the measurement of IOD (Fig. 66.3).

Magnetic Resonance Imaging. As in hypertelorism evaluation, orbital measurements with MRI can provide additional information,[5] especially when US evaluation is inconclusive. Due to the high association with holoprosencephaly, fetal MRI could be useful to assess intracranial structures, especially if not well seen by US.[13]

Synopsis of Treatment Options

POSTNATAL

Isolated hypertelorism results in a cosmetic problem that could be solved by means of surgical correction.[14]

WHAT THE REFERRING PHYSICIAN NEEDS TO KNOW

Orbital defects are a rare condition. However, these anomalies are frequently associated with chromosomal defects and nonchromosomal syndromes.

KEY POINTS

- IOD measurement is required to diagnose hypertelorism and hypotelorism.
- Hypertelorism is highly associated with nonchromosomal syndromes.
- Hypotelorism is highly associated with holoprosencephaly and trisomy 13.

SUGGESTED READINGS

DeMyer W. Orbital hypertelorism. In: Vinken PJ, Bruyn GW, eds. *Handbook of clinical neurology*. Amsterdam: Elsevier/North Holland Biomedical Press; 1977:235.

DeMyer W. Holoprosencephaly (cyclopia-arhinencephaly). In: Vinken PJ, Bruyn GW, eds. *Handbook of clinical neurology*. Amsterdam: Elsevier/North Holland Biomedical Press; 1977:431.

Paladini D, Volpe P. Craniofacial and neck anomalies. In: *Ultrasound of congenital fetal anomalies: differential diagnosis and prognostic indicators*. London: Informa Healthcare; 2007:63.



All references are available online at www.expertconsult.com.

REFERENCES

1. Mashiach R, Vardimon D, Kaplan B, et al. Early sonographic detection of recurrent fetal eye anomalies. *Ultrasound Obstet Gynecol*. 2004;24:640-643.
2. DeMyer W. Orbital hypertelorism. In: Vinken PJ, Bruyn GW, eds. *Handbook of clinical neurology*. Amsterdam: Elsevier/North Holland Biomedical Press; 1977:235.
3. Rosati P, Bartolozzi F, Guariglia L. Reference values of fetal orbital measurements by transvaginal scan in early pregnancy. *Prenat Diagn*. 2002;22:851-855.
4. Jeanty P, Dramaix-Wilmet M, Van Gansbeke D, et al. Fetal ocular biometry by ultrasound. *Radiology*. 1982;143:513-516.
5. Robinson AJ, Blaser S, Toi A, et al. MRI of the fetal eyes: morphologic and biometric assessment for abnormal development with ultrasonographic and clinicopathologic correlation. *Pediatr Radiol*. 2008;38:971-981.
6. Velasco-Annis C, Gholipour A, Afacan O, et al. Normative biometrics for fetal ocular growth using volumetric MRI reconstruction. *Prenat Diagn*. 2015;35:400-408.
7. Hosny IA, Elghawabi HS. Ultrafast MRI of the fetus: an increasingly important tool in prenatal diagnosis of congenital anomalies. *Magn Reson Imaging*. 2010;28(10):1431-1439.
8. Cohen MM Jr, Jirasek JE, Guzman RT, et al. Holoprosencephaly and facial dysmorphia: nosology, etiology and pathogenesis. *Birth Defects Orig Artic Ser*. 1971;7:125-135.
9. DeMyer W, Zeman W, Palmer CG. The face predicts the brain: diagnostic significance of median facial anomalies for holoprosencephaly (arhinencephaly). *Pediatrics*. 1964;34:256-263.
10. Evans DG. Dominantly inherited microcephaly, hypotelorism and normal intelligence. *Clin Genet*. 1991;39:178-180.
11. Cohen MM Jr. An update on the holoprosencephalic disorders. *J Pediatr*. 1982;101:865-869.
12. Nicolaides KH, Salvesen Dr, Snijders RJ, et al. Fetal facial defects: associated malformations and chromosomal abnormalities. *Fetal Diagn Ther*. 1993;8:1-9.
13. Dill P, Poretti A, Boltshauser E, et al. Fetal magnetic resonance imaging in midline malformations of the central nervous system and review of the literature. *J Neuroradiol*. 2009;36:138-146.
14. Richardson D, Thiruchelvam JK. Craniofacial surgery for orbital malformations. *Eye (Lond)*. 2006;20:1224-1227.

67 Choanal Atresia

FATIMA CRISPI | BIENVENIDO PUERTO

Introduction

Congenital choanal atresia is an uncommon condition resulting from a failure of the oronasal membrane to break down.[1,2] Prenatal diagnosis of choanal atresia is rarely described, and postnatal confirmation is required.[2] However, this condition can be suspected in the presence of nose anomalies, mainly if other fetal anomalies are present.

Disease

DEFINITION

Choanal atresia is a congenital obstruction of the posterior nasal apertures.[2]

PREVALENCE AND EPIDEMIOLOGY

Choanal atresia is an uncommon condition with an estimated prevalence of 0.5 : 10,000 to 3 : 10,000 live births.[1]

ETIOLOGY AND PATHOPHYSIOLOGY

Choanal atresia results from a failure of the breakdown of the wall between the nasal pits and the stomodeum in early embryogenesis.[1–3] Historically, 90% of atresias have been described as bony, whereas the remaining 10% are membranous. More recent literature suggests that mixed membranous-bony atresias are more common, occurring up to 70% of the time.[3] The condition can be unilateral or bilateral; in unilateral cases, the condition may not be detected until after the early neonatal period. Associated anomalies occur in about 50% of patients with some having recognized syndromes, including CHARGE (*c*oloboma, *h*eart disease, choanal *a*tresia, *r*etardation, *g*enital hypoplasia, and *e*ar anomalies) syndrome, 9p monosomy, Crouzon syndrome, and Marshall-Smith syndrome.[1–4] When choanal atresia is not associated with other defects, it is likely a multifactorial trait; however, a recessive or dominant transmission of the defect was described in several patients.[1,5] An association with methimazole exposure *in utero* also was reported.[6,7] Choanal atresia *per se* is of mild clinical relevance, and the prognosis depends on the underlying syndrome.



Fig. 67.1 Prenatal ultrasound in coronal section shows a single ballooned nostril. *(From: http://thefetus.net.)*

MANIFESTATIONS OF DISEASE

Clinical Presentation

The clinical presentation and diagnosis of choanal atresia is usually postnatal.[2,3] Bilateral atresias can manifest with neonatal respiratory distress because infants are obligate nose breathers. Another finding is inability to pass a nasogastric tube. Unilateral choanal atresias may manifest late in life and can be asymptomatic, or manifest with rhinorrhea.

Imaging Technique and Findings

Ultrasound. Prenatal ultrasound diagnosis is rare, and very few cases have been reported in the literature. Choanal atresia can be suspected prenatally in the presence of nose anomalies, mainly nasal septal deviation or the presence of a single nostril (Fig. 67.1).[3–6]

Magnetic Resonance Imaging. Postnatal magnetic resonance imaging and computed tomography are the gold standard imaging techniques for diagnosis of choanal atresia. The characteristic feature is a unilateral or bilateral posterior nasal narrowing with an obstruction (Fig. 67.2).[3,8]

Synopsis of Treatment Options

PRENATAL

No treatment options are available *in utero*.



Fig. 67.2 Postnatal magnetic resonance imaging confirms the diagnosis of unilateral choanal atresia. *(From: http://thefetus.net.)*

POSTNATAL

Temporary alleviation can be achieved by inserting an oral airway into the mouth. However, the only definitive treatment is surgery to correct the defect by perforating the atresia to create a nasopharyngeal airway. Multiple surgical techniques have been proposed to repair the atresia. The nasal endoscopic technique is usually the favored technique with a low long-term complication and stenosis rate (12%).[3,8]

WHAT THE REFERRING PHYSICIAN NEEDS TO KNOW

Choanal atresia is an uncommon condition consisting of congenital obstruction of the posterior nasal apertures.

KEY POINTS

- Choanal atresia is frequently associated with syndromes.
- The diagnosis is usually made postnatally.
- Choanal atresia can be suspected prenatally in the presence of nose anomalies.

SUGGESTED READING

Busa T, Legendre M, Bauge M, et al. Prenatal findings in children with early postnatal diagnosis of CHARGE syndrome. *Prenat Diagn*. 2016;36:561-567.

All references are available online at www.expertconsult.com.

REFERENCES

1. Harris J, Robert E, Kallen B. Epidemiology of choanal atresia with special reference to the CHARGE association. *Pediatrics*. 1997;99:363-367.
2. Flake CG, Ferguson CF. Congenital choanal atresia in infants and children. *Ann Otol Rhinol Laryngol*. 1961;70:1095-1110.
3. Hengerer AS, Brickman TM, Jeyakumar A. Choanal atresia: embryologic analysis and evolution of treatment, a 30-year experience. *Laryngoscope*. 2008;118:862-866.
4. Busa T, Legendre M, Bauge M, et al. Prenatal findings in children with early postnatal diagnosis of CHARGE syndrome. *Prenat Diagn*. 2016;36:561-567.
5. Qazi QH, Kanchanapoomi R, Beller E, et al. Inheritance of posterior choanal atresia. *Am J Med Genet*. 1982;13:413-416.
6. Barbero P, Ricagni C, Mercado G, et al. Choanal atresia associated with prenatal methimazole exposure: three new patients. *Am J Med Genet A*. 2004;129:83-86.
7. Kancherla V, Romitti PA, Sun L, et al. Descriptive and risk factor analysis for choanal atresia: The National Birth Defects Prevention Study, 1997–2007. *Eur J Med Genet*. 2014;57:220-229.
8. Deutsch E, Kaufman M, Eilon A. Transnasal endoscopic management of choanal atresia. *Int J Pediatr Otorhinolaryngol*. 1997;40:19-26.

To access the videos in this chapter, scan this QR code or visit expertconsult.com

68 Micrognathia and Retrognathia

MAGDALENA SANZ-CORTÉS | OLGA GÓMEZ | BIENVENIDO PUERTO

Introduction

The fetal mandible is a common site for defects caused by numerous genetic conditions and adverse environmental factors. When an anomaly in the fetal mandible is detected on ultrasound (US), the clinician should look for other anomalies in the fetal anatomy because such associations are frequent.

Disease

DEFINITION

Retrognathia refers to a facial malformation characterized by abnormal development of the mandible with an abnormal position in relation to the maxilla (Fig. 68.1).[1] *Micrognathia* refers to a facial malformation characterized by mandibular hypoplasia causing a small receding chin (Fig. 68.2).[1,2]

PREVALENCE AND EPIDEMIOLOGY

Fetal micrognathia has an incidence of 1:1000 births. It is always accompanied by retrognathia, although fetal retrognathia can be present without micrognathia.

ETIOLOGY AND PATHOPHYSIOLOGY

The etiology of mandibular hypoplasia is unclear.[3] It may be the result of a positional malformation, intrinsic growth abnormalities, or a connective tissue disorder. Attempts have been made to explain why fetal micrognathia is associated with different syndromes.[3] The harmonious development of different anatomic structures in the mandible and the overall growth of the mandible are regulated by several factors, such as the prenatal activity of the masticatory muscles, the growth of the tongue, the inferior alveolar nerve and its branches, and the development and migration of the teeth. Because normal development of the fetal mandible is a multifactorial process, the maldevelopment of the masticatory muscles or nerves may lead to a hypoplastic mandible. Also, the failure of mandibular formation displaces the tongue upward, which prevents the lateral palatine shelves from medial migration and midline fusion, and explains the high association of micrognathia with cleft palate.[3]

The normal development of the mandible can be disrupted by genetic or environmental factors (chromosomal and non-chromosomal syndromes) or environmental ones (Table 68.1). Some neuromuscular conditions in which a fixed contracture of the temporomandibular joint prevents the opening of the mouth are associated with micrognathia secondary to impaired development of the mandible.[1]

Also, micrognathia has been associated to exposure to different teratogens, such as in fetal alcohol syndrome and the use of tamoxifen and isotretinoin during pregnancy.[3] The spectrum of anomalies related to retinoic acid embryopathy includes facial

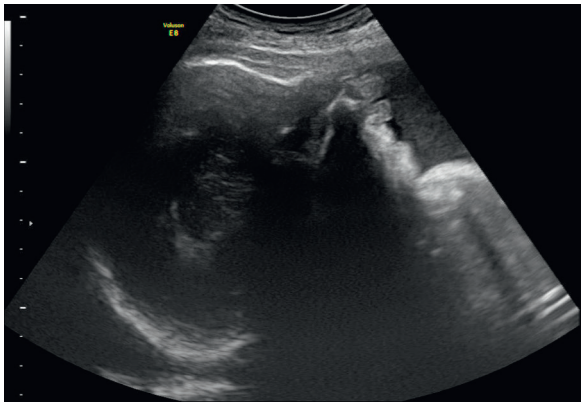

Fig. 68.1 Two-dimensional image of a fetal profile in a case of retrognathia in the third trimester. There is a receding chin with a normal size.



Fig. 68.2 Two-dimensional image of a fetal profile in a case of micrognathia. There is marked hypoplasia of the mandible that also displaces it.

TABLE 68.1 ASSOCIATED CLINICAL FINDINGS IN FETAL MICROGNATHIA

Syndrome	Predominant Features	Inheritance	Prenatal Diagnosis
Acrofacial dysostosis	Preaxial limb deficiencies, CHD, CNS anomalies	AD	Yes
Treacher-Collins	Hypoplasia of facial bones, ear anomalies, cleft palate	AD	Yes
Rodriguez type	Preaxial limb deficiencies, CHD	AR	Yes
Nager type	Microcephaly, preauricular tags, CHD, preaxial limb defects	Sporadic	Yes
Miller (Genee-Widemann) type or POADS (postaxial)	Syndactyly, thumb hypoplasia, absence of fifth digit	AR	—
Branchiooculofacial syndrome	Microcephaly, ear anomalies, hypertelorism, microphthalmia, renal anomalies, polydactyly, vermian agenesis	AD	Yes
Cerebrocostomandibular syndrome	Microthorax, CHD, small thorax, abnormal ribs, renal ectopia, polyhydramnios	AD-AR	Yes
Mandibuloacral dysplasia	Joint contractures, wide cranial sutures	AD	—
Oral-facial-digital I syndrome	Facial asymmetry, bifid tongue, polycystic kidney, syndactyly, CNS anomalies	X-linked dominant	Yes
Oral-facial-digital II syndrome or Mohr syndrome	Hypertelorism, polydactyly, porencephaly	AR	Yes
Oral-mandibular-limb hypogenesis spectrum	Acral hypoplasia, syndactyly	Sporadic	—
Otopalatodigital syndrome type II	Hypertelorism, omphalocele	X-linked dominant	—
Robin sequence	Glossoptosis, cleft palate		Yes
SKELETAL AND NEUROMUSCULAR DISEASES FREQUENTLY ASSOCIATED WITH MICROGNATHIA			
Achondrogenesis types IA and IB	Severe micromelia, short ribs	AR	Yes
Amyoplasia congenita disruptive sequence	Diffuse joint contractures, gastroschisis, polyhydramnios	Sporadic	Yes
Atelosteogenesis type I	Frontal bossing, midface hypoplasia, small thorax, 11 ribs, rhizomelia, talipes, encephalocele, polyhydramnios	Sporadic	Yes
Camptomelic dysplasia	Large anterior fontanelle, hypertelorism, CHD, small thorax, sex reversal in males, hydronephrosis, bowing of tibiae and less so of femora	AD	Yes
Cerebrooculofacioskeletal syndrome	Microcephaly, microphthalmia, CHD anomalies, contractures	AR	Yes
Chondrodysplasia punctata, X-linked dominant type	Microcephaly, rhizomelia	X-linked dominant	Yes
Diastrophic dysplasia	Hitchhiker thumbs, scoliosis, short limbs	AR	Yes
Langer mesomelic dysplasia	Mesomelia	AR	Yes
Multiple pterygium syndrome	Pterygia of neck, axillae, antecubital region, popliteal region	AR	Yes
Neu-Laxova syndrome	Microcephaly, exophthalmos, CNS anomalies, joint contractures, syndactyly, subcutaneous edema	AR	Yes
Pena-Shokeir phenotype (fetal akinesia deformation sequence)	Diffuse joint contractures, cystic hygroma, microstomia	AR	Yes
CHROMOSOMAL SYNDROMES FREQUENTLY ASSOCIATED WITH MICROGNATHIA			
Cat-eye syndrome	Preauricular tags, TAPVR, renal agenesis	AD inv dup (22)q11	Yes
Deletion 3p syndrome	Microcephaly, malformed ears, polydactyly in hands	Del 3p	—
Deletion 4p syndrome (Wolf-Hirschhorn)	Hypertelorism, preauricular tags, CHD, polydactyly, talipes, CNS anomalies	Isolated 4p16.3	Yes
Deletion 5p syndrome (cri du chat)	Microcephaly, hypertelorism, CHD	5p15.2	Yes
Deletion 9p syndrome	Trigonocephaly, abnormal ears, hypertelorism, CHD	AD, isolated	—
Deletion 11q syndrome	Trigonocephaly, microcephaly, joint contractures		—
Deletion 13q syndrome	Microcephaly, CHD, small or absent thumbs	Isolated	—
Deletion 22q 11.2 syndrome	Conotruncal CHD, thymus aplasia	AD	Yes
Monosomy X (Turner) syndrome	Left-sided CHD, cystic hygroma	Sporadic	Yes
Pallister-Killian syndrome	Thin upper lip, CDH, CHD, CNS anomalies, rhizomelia	Sporadic	Yes
Triploidy syndrome	IUGR, hypotonia, hypertelorism, syndactyly, CHD, CNS anomalies	Sporadic, 69,XYY	Yes
Trisomy 8 mosaic syndrome	Hypertelorism, joint contractures	Sporadic	Yes
Trisomy 9 mosaic syndrome	Joint contractures, CHD	Sporadic	Yes
Trisomy 13 syndrome	IUGR, microcephaly, microphthalmia, cleft palate, CNS anomalies, CHD, renal anomalies, polydactyly	Sporadic	Yes
Trisomy 18 syndrome	Clenched hands, CHD, omphalocele, renal anomalies, CHD anomalies	Sporadic	Yes

AD, Autosomal dominant; *AR,* autosomal recessive; *CDH,* congenital diaphragmatic hernia; *CHD,* congenital heart disease; *CNS,* central nervous system; *IUGR,* intrauterine growth restriction; *TAPVR,* total anomalous pulmonary venous return.
From: Palladini D. Fetal micrognathia: almost always an ominous finding. *Ultrasound Obstet Gynecol.* 2010;35:377-384.

asymmetry, microtia, micrognathia, and clefts of the secondary palate. Similar malformations have been observed in some infants exposed to tamoxifen. It is possible that these two agents could produce comparable embryotoxic effects if they function in a similar way during embryogenesis.

MANIFESTATIONS OF DISEASE

Clinical Presentation

The importance of differentiating retrognathia from micrognathia has been highlighted[1,4] because of the different prognoses and associated anomalies of each one. Fetal retrognathia is usually an isolated finding with a favorable prognosis. Although micrognathia could be a solitary finding, most affected infants have additional abnormalities, and it has been considered an ominous finding.[1,3] Vettraino et al.[5] reported a retrospective study of 54 fetuses with subjectively diagnosed micrognathia, which appeared to be isolated in 26% of cases prenatally, although almost all cases thought to be isolated before birth were found postnatally to have additional abnormalities, most frequently cleft palate. Half of the neonates in this study needed respiratory support, and one-third had feeding difficulties. More than one-third of the cases also had developmental delay.[5]

Mandibular anomalies are frequently associated with different syndromes (see Table 68.1). In these cases, the prognosis is usually dictated by the associated anomalies, as follows[3]:

1. Some syndromes and disorders typically affect the development of the fetal mandible, such as the Pierre Robin sequence, various forms of acrofacial dysostosis (Treacher-Collins or Franceschetti, Rodriguez, Nager, Miller, or Genee-Wiedemann), and oral-facial-digital syndromes. Pierre Robin sequence should be diagnosed if micrognathia is associated with glossoptosis and cleft palate.[6] It is associated with a normal life expectancy and good quality of life. Some of the other syndromes manifest with severe micrognathia that is more commonly associated with multiple anomalies, such as otocephaly or dysgnathia complex.
2. Some skeletal dysplasias and neuromuscular disorders may affect and compromise the development of the fetal mandible (see Table 68.1).
3. Some chromosomal aberrations are characteristically associated with fetal micrognathia. In some series, 66% of fetuses with micrognathia had chromosomal abnormalities.[7] Micrognathia is especially prevalent in trisomy 18 and triploidies, in which up to 80% of cases manifest with micrognathia; trisomy 13; and translocations or gene deletions.[7,8]
4. Exposure to teratogens such as alcohol, tamoxifen, retinoic acid, and mycophenolate mofetil has been associated with maldevelopment of the fetal mandible leading to micrognathia.[9]

Facial anomalies sometimes may be the most identifiable abnormality in a fetus with aneuploidy or a congenital syndrome.[3] Because of the high association of micrognathia with other anomalies and malformations in the fetus, a dedicated US evaluation should be performed to define the pathogenesis of the mandibular hypoplasia based on the associated findings, and to determine if it is part of a nonchromosomal syndrome. For this purpose, we perform the following examinations:

- Echocardiogram is performed because of the high association with congenital heart defects.
- Fetal long bones are measured for skeletal dysplasia evaluation.
- A fetal karyotype study should be offered in all cases of micrognathia because of the high association with chromosomal and genetic aberrations.
- Amniotic fluid is measured to evaluate for the presence of polyhydramnios.
- Maternal use of drugs and family history should be evaluated.
- Parental facial physiognomy should be taken into consideration because a receding chin can be a family trait.

Fetuses with mandibular anomalies are at risk of neonatal airway compromise,[4] which can lead to hypoxic-ischemic encephalopathy.[2] It was reported that 54% of newborns with micrognathia required an immediate intervention for this reason.[2] The most severe forms of micrognathia, such as isolated severe micrognathia, dysgnathia complex, isolated dysgnathia, and agnathia (Video 68.1), although rare, may have more difficult airways at birth and are often lethal secondary to airway obstruction.[2] In these cases, the tongue may obstruct the upper airway, leading to suffocation of the neonate. Prenatal recognition of these conditions allows potential treatment to be planned during the perinatal period or attendance of a neonatologist at the moment of delivery and thereafter.[4] In some cases, *ex utero* intrapartum treatment (EXIT) may be helpful, with intubation before cutting the umbilical cord.

Imaging Technique and Findings

Ultrasound. To detect both retrognathia and micrognathia prenatally, the fetal profile should be studied in the anatomic US scan. These anomalies can go undetected with the two-dimensional (2D) mentonasal coronal view that is used to assess the integrity of the lips (Fig. 68.3). The fetal mandible can be studied in a sagittal view from the 10th week of gestation virtually until term if the position of the head is favorable (Fig. 68.4).

Initially, a subjective diagnosis can be made by assessing the geometric relationship between the mandible and the rest of the profile in a midsagittal view (Fig. 68.5). When an alteration of the fetal mandible is suspected, the axial planes of the mandible and maxilla should be assessed to evaluate the mandibular bone, the alveolar ridge, the rami, and the maxilla, and the integrity of the palate.[1]

After micrognathia or retrognathia has been detected by a subjective examination, an objective diagnosis should be made. For this purpose, different indices, ratios, or facial angles have

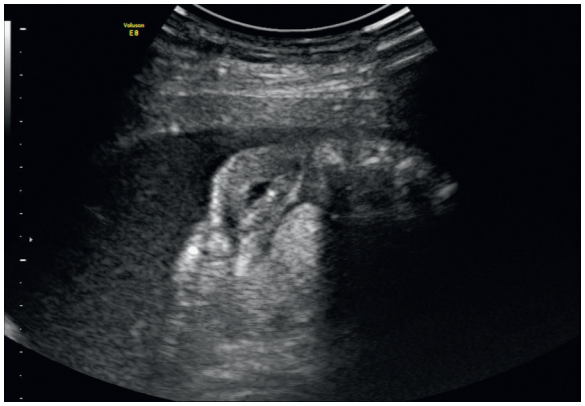

Fig. 68.3 Two-dimensional coronal view of the nose and lips. This case of micrognathia would have gone undetected in an anatomic US scan if a sagittal view had not been obtained.

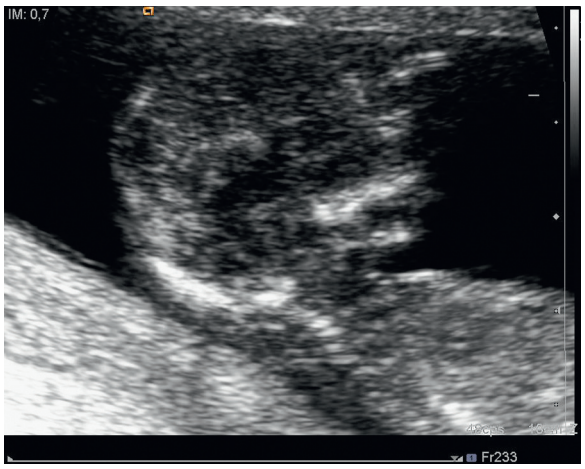

Fig. 68.4 Two-dimensional US in an early pregnancy. In this sagittal view, a retrognathic profile can be detected despite the early gestational age. Diagnosis can be made from the 10th week of pregnancy.

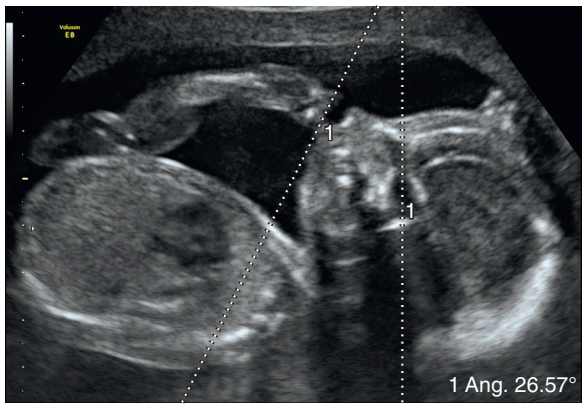

Fig. 68.6 Measurement of the IFA of the fetal profile. The upper line is orthogonal to the vertical process of the frontal bone, and the second line is traced considering the tip of the mentum and outer limit of the fetal lip. The angle that is delimited is 25 degrees, which is considered retrognathism.

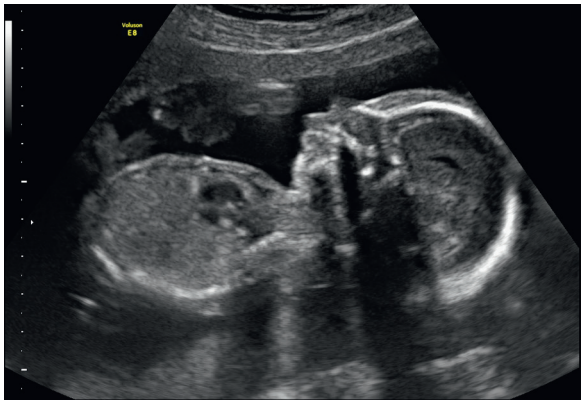

Fig. 68.5 Two-dimensional US of the fetal profile. A subjective diagnosis can be made based on the position of the mandible with respect to the maxilla.

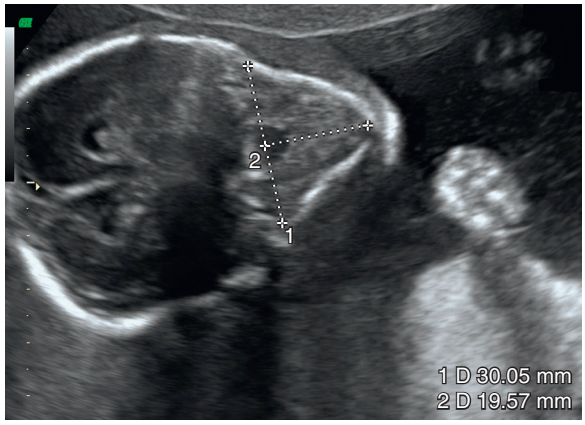

Fig. 68.7 Two-dimensional axial view of the fetal mandible. Mandibular width *(1)*; anteroposterior diameter (APD) *(2)*.

been described in the literature,[3,10–15] although not all of them are used in routine clinical practice. It is especially relevant to use measurements that are easy to obtain and ideally that are independent of gestational age. Also, because of the different prognosis of micrognathia and retrognathia, a combination of measurements should be used to discriminate both conditions and establish the severity of micrognathia. The inferior facial angle (IFA), the jaw index, the mandibular width/maxillary width ratio (MD/MX ratio), and the mandibular ratio (MR) are especially useful.

The IFA is measured in a sagittal view of the fetal face at the crossing of one line orthogonal to the vertical part of the forehead drawn at the level of the synostosis of the nasal bones and a second line traced joining the tip of the mentum and the anterior border of the more protrusive lip (Fig. 68.6).[4] Nomograms have been published of the IFA,[4] and it does not change over different gestational ages. Rotten et al.[4] reported that the average value of IFA was 65 degrees in their series from 18 to 28 weeks of gestational age. An IFA less than 49.2 degrees defined retrognathia (see Fig. 68.6). Fetuses diagnosed with a syndrome that affects primarily the development of the fetal mandible, such as Pierre Robin sequence, Treacher-Collins syndrome, or postaxial acrofacial dysostosis, had an IFA two standard deviations (2 SD) below normal values.[4]

The jaw index is measured on an axial view of the fetal mandible (Fig. 68.7). A line is drawn connecting the bases of the two rami, and the anterior-posterior diameter (APD) is measured drawing a second line from the symphysis mentis to the middle of the lateral-lateral diameter. This value is normalized to the biparietal diameter (BPD) to derive a ratio (the jaw index) and is calculated as APD/BPD × 100, which is independent of the gestational age.[13] The jaw index has been developed to predict objectively the severity of micrognathia. Using a cutoff value of less than 23 that corresponds to 2 SD below normal to define fetal micrognathia has improved the detection rate (100% sensitivity and 98% specificity) compared with subjective evaluation of the facial profile (72% sensitivity and 99% specificity).[13]

The MD and the MX are measured on an axial plane caudal to the base of the cranium, at the level of the dental arch in the maxilla (MX) and on the mandible (MD) (Fig. 68.8; see Fig. 68.7).[4] A line orthogonal to the sagittal axis is drawn 10 mm posteriorly to the anterior osseous border. Measurements are obtained from one external bone table to the other.[4] The MD/MX ratio is derived from these two measurements and is constant

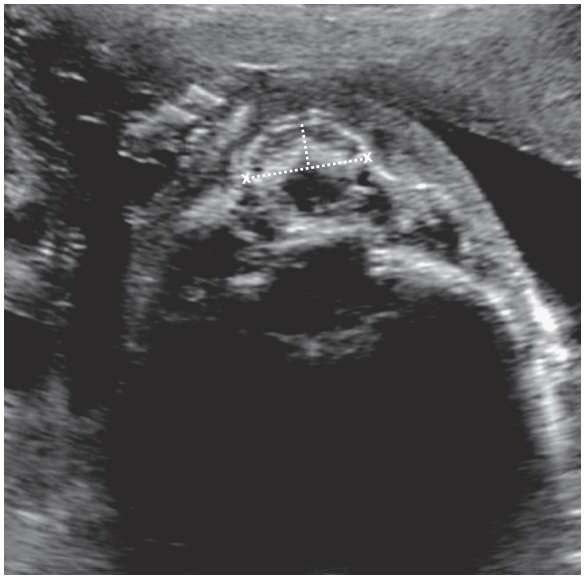

Fig. 68.8 Axial view of the fetal maxilla. On this slice, the maxillary width (MX) is traced to obtain the MD/MX ratio.

among different gestational ages. The mean value of MD/MX is 1.017 in fetuses of 18 to 28 weeks' gestation. A value less than 0.785 defines micrognathia. Cases of Treacher-Collins syndrome and postaxial acrofacial dysostosis showed MD/MX ratio values below 2 SD from the normal values. Cases with Pierre Robin sequence had moderately smaller mandibles than normal fetuses.[4]

To measure the MR, using the same view as for the jaw index, the transverse diameter and the APD are measured from inner point to inner point. The ratio between the APD and transverse diameter is the MR (see Fig. 68.7).[3] It shows a very small and nonsignificant decrease during pregnancy. Zalel et al.[3] established a constant of 1.5 for the MR for the whole period of pregnancy. To calculate the value of 2 SD to establish a diagnosis of micrognathia, the following equation is used: $MR = 1.7759 - 0.01047 \times w$, where w is the number of gestational weeks.

Each measurement has a different purpose; the IFA is to determine if there is a receding chin or retrognathia based on the angle determined by different facial structures. An advantage of the IFA is that it can be measured retrospectively with an image of the fetal profile, which is usually stored as part of anatomic US scan imaging. Alternatively, the jaw index and MD/MX ratio analyze the development of the fetal mandible independently of the gestational age and are able to determine if it is hypoplastic or not. These measurements cannot be retrospectively analyzed from a normal US examination because axial views of the mandible and maxilla are not conventional views in an anatomic scan. However, when an anomaly of the mandible is suspected, axial views may be easier to obtain. US is useful to evaluate signs of aerodigestive tract obstruction secondary to a malformed mandible, such as polyhydramnios or the absence of a stomach bubble, or to diagnose a decrease in fetal swallowing with use of color Doppler.[2]

Magnetic Resonance Imaging. Prenatal magnetic resonance imaging (MRI) has been proposed to obtain a precise study of the airway in cases in which severe micrognathia is present and the need of perinatal intubation is suspected.[2,16] The use of fetal MRI provides a more comprehensive field of view with an excellent contrast resolution from T2-weighted sequences, and multiplanar images provide more detail of the pharynx and hypopharynx, which may facilitate the diagnosis of glossoptosis.[2]

Other Applicable Modality

Three-Dimensional Ultrasound. Although views are normally obtained with 2D US, three-dimensional (3D) scanning can be more advantageous to assess mandibular anomalies for the following reasons:

1. Retrieving the right views to study suspected micrognathia and retrognathia from a stored volume is generally not time-consuming.[4] The success rate reported by some authors in obtaining acceptable measurements using 3D scanning was greater than 90%.[17]
2. It is easy to obtain perfectly symmetric views because they are computer-generated, allowing a more accurate determination of the biometry of the facial structure of interest (Fig. 68.9).[4,17]
3. A surface rendering of the face can be obtained from the stored volume, which can be useful to detect some other dysmorphic features in the fetal face that may be associated with the mandibular abnormalities (Figs. 68.10 and 68.11; Videos 68.2 and 68.3).

However, with advancing gestation, the acquisition of a good-quality 3D image may become a more difficult task because the fetus is more often in cephalic presentation with the chin on the chest, with less amniotic fluid, and the limbs and umbilical cord are more often situated in front of the chin, which may complicate the visualization of the lower face.[17]

Differential Diagnosis From Imaging Findings

In some normal fetuses, the lower lip may lie posterior to the upper lip causing a false impression of retrognathia.[7] In cases of cleft lip/palate, this protruding lip is more prevalent, leading to a false subjective impression of an associated retrognathia. However, when images of such a protruding lip were objectively analyzed using the IFA, results were normal in all cases with clefts.[4]

Synopsis of Treatment Options

PRENATAL

In severe cases of micrognathia when there is significant polyhydramnios, an amnioreduction should be considered to reduce intrauterine pressure and prolong pregnancy.

POSTNATAL

Treatment in cases of severe micrognathia should be carefully planned. To prevent an airway obstruction and a difficult intubation of the neonate at the time of delivery, EXIT should be considered before birth.[2] EXIT is designed to maintain the uteroplacental circulation and stabilize the infant while the airway is being secured.[2]

There are no standardized criteria to select cases of micrognathia that may be sufficiently severe to warrant the potential maternal and fetal risks of EXIT. Morris et al.[2] recommended using as selection criteria micrognathias with a jaw index below the fifth centile and with signs of aerodigestive tract obstruction.

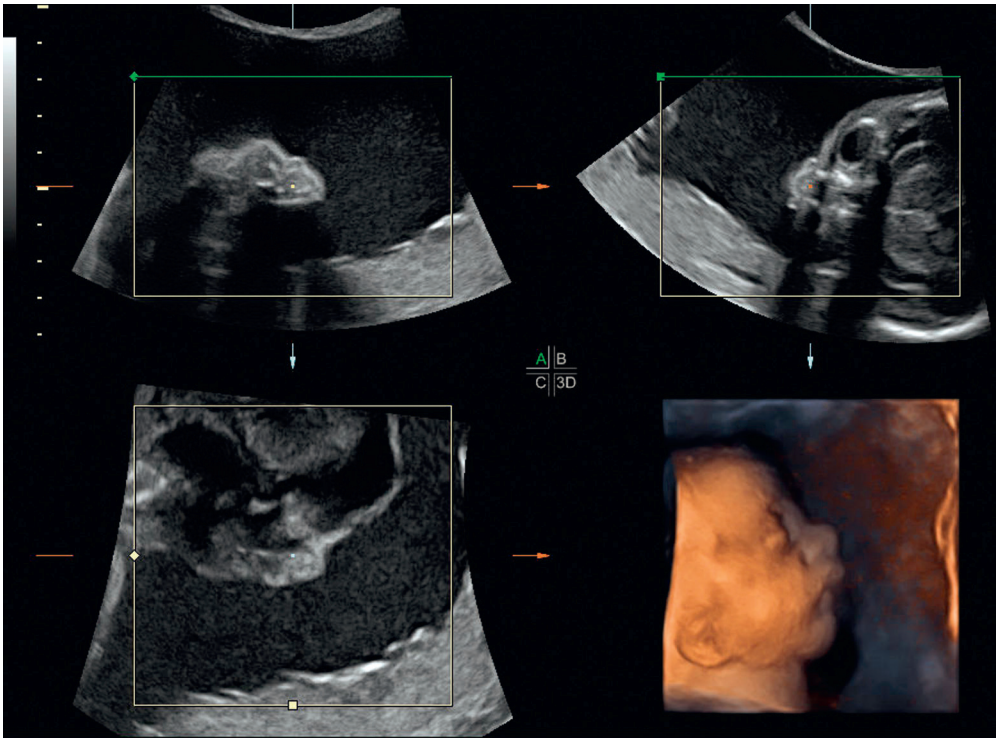

Fig. 68.9 Three-dimensional reconstruction of a micrognathia. The planes to perform measurements can be analyzed from a stored volume.



Fig. 68.10 Surface rendering of a micrognathia.



Fig. 68.11 Surface rendering of a micrognathia.

In severe cases, some authors favor proceeding directly to tracheostomy while on uteroplacental support, to ensure a safe transition from maternal oxygenation to postnatal gas exchange.

Neonates with severely hypoplastic mandibles may have severe airway obstruction, which is traditionally managed with tracheostomy. Distraction osteogenesis (DO) is considered an alternative treatment. This technique is used to induce new bone formation between bony surfaces under tension across a surgically created osteotomy. The distraction usually progresses at a rate of 0.5–1.2 mm/d. At the same time, the airway must be secured by some other means (endotracheal tube or, less frequently, tracheotomy) and intensively monitored throughout the distraction.[6] Most preliminary reports show favorable mandibular growth after DO for children with Pierre Robin sequence. DO allows the child to be successfully extubated or decannulated and typically allows the child to begin a regular oral diet.[6] This therapy option as an alternative to tracheotomy is especially important because the mortality rate from tracheotomy alone independent of the underlying diagnosis is 5%. DO avoids a tracheotomy in 90% to 95% in patients with Pierre Robin sequence.[6]

Before performing a DO, the surgeon must consider if the patient has an adequate mandibular bone stock and the level of

anoxia. If the proper criteria are not met, tracheotomy should be strongly considered.[6]

In isolated retrognathias, mandibular displacement very rarely becomes a threat for the neonatal upper airway integrity, so perinatal treatment or treatment during early childhood generally is unnecessary. Treatment of retrognathia is based on the resulting malocclusion and esthetic considerations. For this purpose, mandibular distraction is becoming a prevalent surgical treatment.[18] Many reports have shown that this technique provides great clinical benefits for mandibular deficiency and other craniofacial deformities,[18] and it can reliably remodel this craniofacial deformity.

WHAT THE REFERRING PHYSICIAN NEEDS TO KNOW

- An adequate view of the fetal profile during the anatomic US scan is very important because it is the only way to detect alterations such as retrognathia or micrognathia.
- Both anomalies in the development of the fetal jaw are different. Retrognathia implies a receding chin with a good prognosis if isolated. Micrognathia is a hypoplastic mandible, generally associated with retrognathia and mostly associated with other malformations, chromosomal abnormalities, and syndromes.
- When maldevelopment of the fetal mandible is suspected, objective measures such as IFA to determine retrognathia and the jaw index or MD/MX ratio or MR can help determine if the mandible is hypoplastic.
- When micrognathia is detected, a karyotype study should be offered to the patient, and a detailed US scan and echocardiography should be performed.
- Severe micrognathia can lead to polyhydramnios owing to a lack of swallowing. Some cases require an amnioreduction. Based on the same mechanism, severe micrognathia may cause a potentially lethal upper airway obstruction.
- Prenatal identification of severe micrognathia may improve perinatal outcome planning if EXIT and other orthopedic strategies such as DO become necessary.

KEY POINTS

- Retrognathia and micrognathia are different conditions with a different prognosis that can readily be assessed separately *in utero* using US.
- Micrognathia is frequently seen in syndromes such as Pierre Robin sequence and hemifacial microstomia and is associated with various chromosomal anomalies, such as trisomies 18 and 13, triploidy, and anomalies involving gene deletions or translocations.
- A good diagnostic strategy is to use both IFA and jaw index or MD/MX ratio to assess a fetal mandible anomaly. IFA assesses mandible position in a sagittal view. The MD/MX ratio and jaw index assess the mandible size in an axial view.
- Prenatal identification of severe forms of micrognathia implies a scheduled management of the upper airway obstruction.

SUGGESTED READING

Palladini D. Fetal micrognathia: almost always an ominous finding. *Ultrasound Obstet Gynecol.* 2010;35:377-384.

Ramos GA, Ylagan MV, Romine LE, et al. Diagnostic evaluation of the fetal face using 3-dimensional ultrasound. *Ultrasound Q.* 2008;24:215-223.



All references are available online at www.expertconsult.com.

REFERENCES

1. Paladini D. Fetal micrognathia: almost always an ominous finding. *Ultrasound Obstet Gynecol*. 2010;35:377-384.
2. Morris LM, Lim FY, Elluru RG, et al. Severe micrognathia: indications for EXIT-to-airway. *Fetal Diagn Ther*. 2009;26:162-166.
3. Zalel Y, Gindes L, Achiron R. The fetal mandible: an in utero sonographic evaluation between 11 and 31 weeks' gestation. *Prenat Diagn*. 2006;26:163-167.
4. Rotten D, Levaillant JM, Martinez H, et al. The fetal mandible: a 2D and 3D sonographic approach to the diagnosis of retrognathia and micrognathia. *Ultrasound Obstet Gynecol*. 2002;19:122-130.
5. Vettraino IM, Lee W, Bronsteen RA, et al. Clinical outcome of fetuses with sonographic diagnosis of isolated micrognathia. *Obstet Gynecol*. 2003;102:801-805.
6. Shen W, Jie C, Chen J, et al. Mandibular distraction osteogenesis to relieve Pierre Robin severe airway obstruction in neonates: indication and operation. *J Craniofac Surg*. 2009;20(suppl 2):1812-1816.
7. Nicolaides KH, Salvesen DR, Snijders RJ, et al. Fetal facial defects: associated malformations and chromosomal abnormalities. *Fetal Diagn Ther*. 1993;8:1-9.
8. Ramos GA, Ylagan MV, Romine LE, et al. Diagnostic evaluation of the fetal face using 3-dimensional ultrasound. *Ultrasound Q*. 2008;24:215-223.
9. Anderka MT, Lin AE, Abuelo DN, et al. Reviewing the evidence for mycophenolate mofetil as a new teratogen: case report and review of the literature. *Am J Med Genet A*. 2009;149:1241-1248.
10. Goldstein I, Tamir A, Weiner Z, et al. Dimensions of the fetal facial profile in normal pregnancy. *Ultrasound Obstet Gynecol*. 2010;35:191-194.
11. Goldstein I, Reiss A, Rajamim BS, et al. Nomogram of maxillary bone length in normal pregnancies. *J Ultrasound Med*. 2005;24:1229-1233.
12. Watson WJ, Katz VL. Sonographic measurement of the fetal mandible: standards for normal pregnancy. *Am J Perinatol*. 1993;10:226-228.
13. Paladini D, Morra T, Teodoro A, et al. Objective diagnosis of micrognathia in the fetus: the jaw index. *Obstet Gynecol*. 1999;93:382-386.
14. Chitty LS, Campbell S, Altman DG. Measurement of the fetal mandible—feasibility and construction of a centile chart. *Prenat Diagn*. 1993;13:749-756.
15. Otto C, Platt LD. The fetal mandible measurement: an objective determination of fetal jaw size. *Ultrasound Obstet Gynecol*. 1991;1:12-17.
16. Ryan G, Somme S, Crombleholme TM. Airway compromise in the fetus and neonate: prenatal assessment and perinatal management. *Semin Fetal Neonatal Med*. 2016;21(4):230-239.
17. Roelfsema NM, Hop WC, Wladimiroff JW. Three-dimensional sonographic determination of normal fetal mandibular and maxillary size during the second half of pregnancy. *Ultrasound Obstet Gynecol*. 2006;28:950-957.
18. Dolanmaz D, Karaman AI, Gurel HG, et al. Correction of mandibular retrognathia and laterognathia by distraction osteogenesis: follow up of five cases. *Eur J Dent*. 2009;3:335-342.

To access the videos in this chapter, scan this QR code or visit expertconsult.com

69 Facial Dysmorphism

ELISENDA EIXARCH | FRANCESC FIGUERAS | OLGA GÓMEZ | BIENVENIDO PUERTO

Introduction

Facial dysmorphism is a classical feature of many syndromes, and commonly includes one or a combination of facial features such as low-set ears, hypotelorism or hypertelorism, micrognathia or retrognathia, frontal bossing, and sloping forehead.[1] Considering some of these features are detectable prenatally,[2] facial assessment in routine ultrasound (US) could lead to the diagnosis of chromosomal anomalies or polymalformative syndromes.[3]

Disease

DEFINITION

Facial dysmorphism includes all abnormalities in facial features that are usually associated with syndromic conditions.

PREVALENCE AND EPIDEMIOLOGY

The prevalence and epidemiology of facial dysmorphism is ill defined, since under this common definition there is a wide group of conditions.

ETIOLOGY AND PATHOPHYSIOLOGY

Abnormalities associated with abnormal facial shape are listed in Table 69.1.

MANIFESTATIONS OF DISEASE

Clinical Presentation

Detection is challenging considering the large phenotypic variability in human faces. Consequently, phenotypic traits of parents could lead to misdiagnosis of abnormalities in otherwise normal fetuses manifesting a parental facial feature (Fig. 69.1). Thus isolated facial abnormalities must be evaluated, taking into account the facial characteristics of parents. Abnormalities that are detectable on the evaluation of the fetal profile can be summarized as follows:

1. Abnormalities in frontal bone:
   (a) Sloping forehead: this change in frontal bone morphology is due to a severe hypoplasia of frontal lobes that occurs in microcephaly[4] (Fig. 69.2). Once microcephaly is suspected, it is essential to carefully assess brain structures in order to exclude associated brain anomalies. Additionally, an anatomic scan and karyotype should be performed, because microcephaly is strongly associated with structural and chromosomal anomalies.
   (b) Frontal bossing: this is a prominence of frontal bone due to a premature closure of cranial sutures. This condition can be found in Apert syndrome, achondroplasia, and thanatophoric dysplasia. When frontal bossing is found in a routine US, associated anomalies should be ruled out (Table 69.2). Common syndromes with this abnormality are Apert syndrome[5] (Fig. 69.3), achondroplasia (Fig. 69.4), and thanatophoric dysplasia.[6]
2. Nose abnormalities:
   (a) Arhinia: absence of nasal bone and soft tissues.
   (b) Proboscis: soft tissue appendix that protrudes in the midline from the nasal root area.
   (c) These abnormalities are highly associated with holoprosencephaly.[6]
3. Mouth anomalies: normally included in the cleft lip spectrum (see Chapter 65).
4. Chin anomalies: see Chapter 68.
5. Hemifacial microsomia: an asymmetric hypoplasia of facial structures. It is mainly associated with the diagnosis of oculoauriculovertebral spectrum (OAVS). This is a sporadic condition with an incidence of 1:3000 to 1:5000 newborns,[7,8] but autosomal-dominant and recessive modes of inheritance have also been suggested.[6] Estimated recurrence risk is approximately 3%.[9] OAVS is characterized by a variable degree of the underdevelopment of organs originating from the first

TABLE 69.1 PATHOLOGIC CONDITIONS WITH FACIAL DYSMORPHISM

Microcephaly
Apert syndrome
Achondroplasia
Thanatophoric dysplasia
Hemifacial microsomia
Otocephaly
Proboscis
Arhinia
Bilateral facial cleft
Retro-micrognathia

TABLE 69.2 DIFFERENTIAL DIAGNOSIS OF ANOMALIES ASSOCIATED WITH FRONTAL BOSSING

Turricephaly, depressed nasal bridge, brachysyndactyly of hands and feet, craniosynostosis of the coronal suture, fusion of cervical vertebrae, renal anomalies, and heart anomalies	Apert syndrome
Rhizomelia (late-onset), low nasal bridge, macrocrania	Achondroplasia
Severe limb shortening (femurs in particular), lethal thoracic hypoplasia	Thanatophoric dysplasia

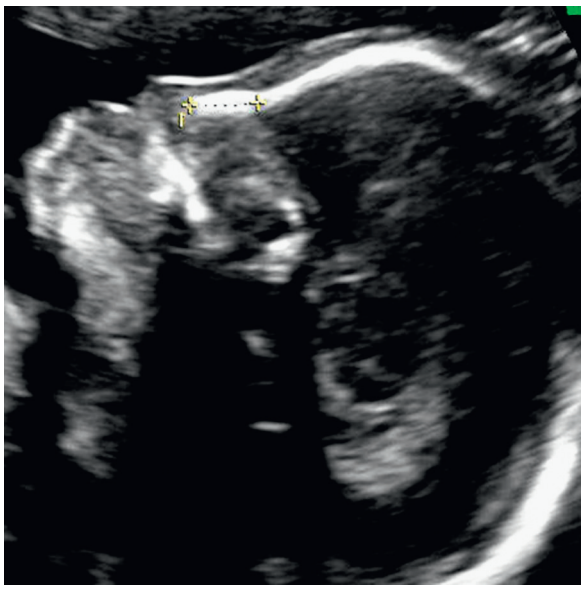

Fig. 69.1 Isolated facial dysmorphism. This fetus showed a normalization of profile on later scans.

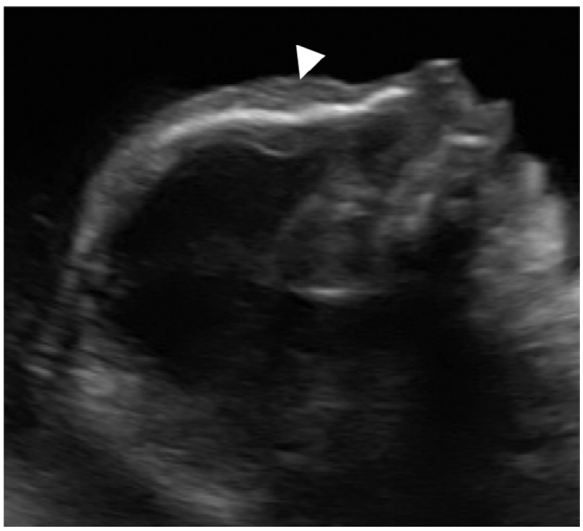

Fig. 69.2 Fetus with sloping forehead *(arrowhead)* in a case of encephalocele with microcephaly.

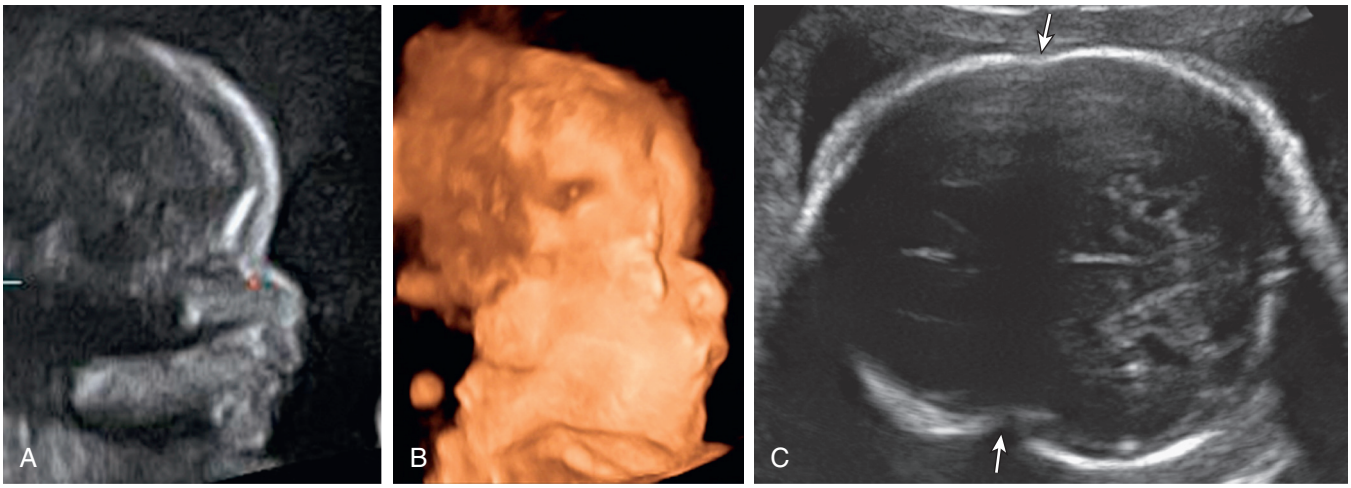

Fig. 69.3 Apert syndrome. On the midsagittal view of the facial profile, the frontal bossing and the low nasal bridge are evident in (A) 2D and (B) 3D surface-mode imaging. In 2D axial transthalamic view (C) the closure of the coronal suture *(arrows)* could be detected.

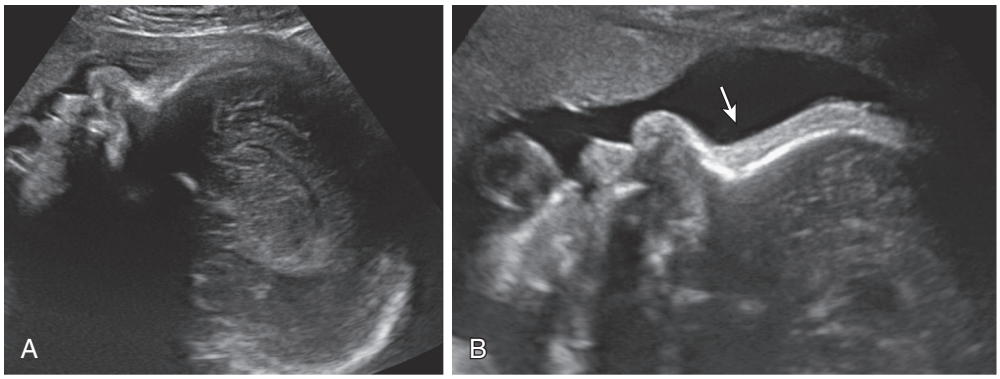

Fig. 69.4 Achondroplasia in the third trimester. (A) Midsagittal view showing tendency to macrocrania and (B) low nasal bridge *(arrow)*.

and second branchial arches. It has been speculated that it is caused by unilateral disruption of blood supply between the fourth and eighth conceptional weeks.[10] Unilateral facial anomalies include hemifacial microsomia, cleft lip/palate, microphthalmia, external ear anomalies (malformed ear, low-set ear, microtia, anotia, and preauricular tag), and vertebral anomalies. Diagnosis can be made by two-dimensional (2D) US, but three-dimensional (3D) surface-mode imaging can help in evaluating hemifacial microsomia and external ear anomalies.[6] OAVS may be associated with anomalies such as congenital heart defects (septal defects), urinary tract defects (hydroureteronephrosis and renal agenesis), central nervous system (CNS) anomalies (agenesis of the corpus callosum and cerebellar abnormalities), and lung malformations (hypoplasia or aplasia).[6,11] The term *Goldenhar syndrome* should refer to those cases of OAVS with epibulbar dermoid and vertebral anomalies.[1] Prognosis of OAVS is poor, with a birth mortality of 20%.[11] The risk of mental retardation is related to the high frequency of CNS abnormalities and microphthalmia.[11] Hearing loss may also be present due to the involvement of the external ear.[6] In survivors after birth, cosmetic surgery is indicated.

6. Otocephaly: a severe and lethal malformation with an estimated incidence of one in 70,000 infants.[12] Most cases are sporadic, but some drugs such as theophylline, beclomethasone, and salicylates are reported as associated substances.[13] It is characterized by an absence or hypoplasia of the mandible, aglossia, proximity of the temporal bones, and abnormal horizontal position of the ears.[14] Embryologically, this lethal malformation is thought to be the result of failure of mandibular development, possibly secondary to a defect in neural crest cell migration.[15] Otocephaly should be suspected when it is impossible to identify the jaw and the ears in their normal position[16] (Fig. 69.5; Video 69.1). Three-dimensional surface-mode imaging could be very useful to improve the accuracy of the diagnosis, since occasionally the anomaly is not clearly seen by 2D ultrasonography.[17] Otocephaly can be isolated, or associated with anomalies such as holoprosencephaly, neural tube defects, cephalocele, midline proboscis, tracheoesophageal fistula, cardiac anomalies, and adrenal hypoplasia.[14] No gene or chromosome aberrations are clearly associated with otocephaly.[18] The prognosis is very poor.

Imaging Technique and Findings

Ultrasound. Imaging the fetal profile is possible beyond 12 weeks of gestation.[19] The fetal face should be evaluated in the three planes since this allows a detailed study of facial anomalies[20] and

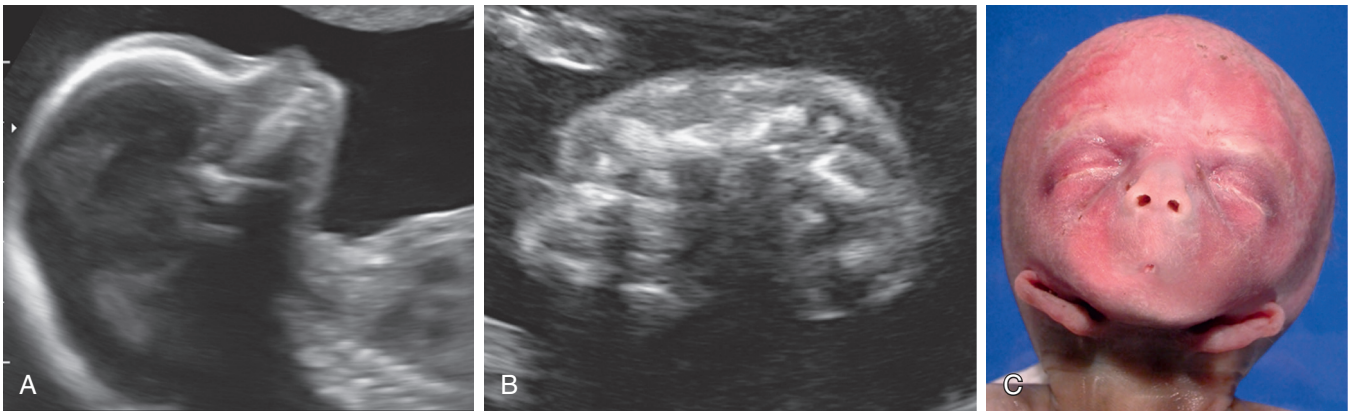

Fig. 69.5 Otocephaly. (A) Midsagittal view showing the absence of jaw. (B) Axial plane showing the impossibility to identify ears in their normal position. (C) Fetus after termination of pregnancy.

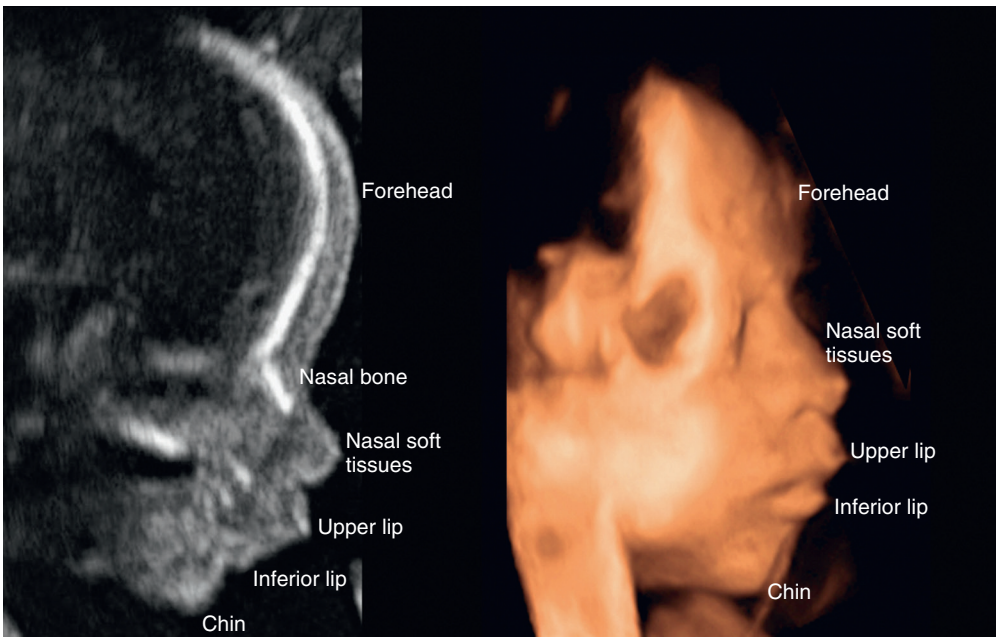

Fig. 69.6 Normal fetal profile in a midsagittal plane in 2D and 3D surface-mode imaging.

increases the detection rate.[21] Three-dimensional US facilitates diagnosis[20] and parental understanding of the abnormality.[22,23] The midsagittal plane is particularly useful, as it allows observing the three regions of the face (forehead, nose and mouth, and chin).[6,21] From top to bottom, the following landmarks should be: the echogenic curved shape of the frontal bone, with the overlying soft tissues; the nasal bone in the upper part and the soft tissue of the tip of the nose; the upper lip protruding slightly over the lower one; and the chin with the bony mandible (Fig. 69.6). Additionally, a parasagittal plane provides information about upper lip, nasal base, nares, and ears.[21] Although normal values are available,[19] diagnosis of abnormalities in the facial profile is mainly based on subjective assessment. The measurement of a fetal profile line has been suggested to detect changes in frontal bone and chin morphology.[24]

Magnetic Resonance Imaging. Magnetic resonance imaging (MRI) may be a complementary tool in selected cases.[25] There are several clinical reports of MRI assisting in the evaluation on facial dysmorphism in Apert syndrome,[26] hemifacial microsomia,[27] otocephaly,[28] and proboscis.[29]

Differential Diagnosis From Imaging Findings

See Section 1.

Synopsis of Treatment Options

POSTNATAL

Postnatal treatment entails a wide range of corrective cosmetic surgery according to the region affected and functional impairment.

WHAT THE REFERRING PHYSICIAN NEEDS TO KNOW

Anomalies in facial profile could lead to the diagnosis of chromosomal anomalies or other syndromes. Once facial dysmorphism is suspected, it is essential to perform an anatomic scan in order to diagnose associated anomalies. Obstetric management and postnatal treatment depends on the underlying condition.

KEY POINTS

- Evaluation of the fetal face should be done in the three planes.
- Midsagittal plane is particularly useful in the diagnosis of facial dysmorphism.
- Changes in frontal bone are related with severe anomalies.
- Unilateral facial malformations are associated with the diagnosis of oculoauriculovertebral spectrum.

SUGGESTED READINGS

Delahaye S, Bernard JP, Renier D, et al. Prenatal ultrasound diagnosis of fetal craniosynostosis. *Ultrasound Obstet Gynecol*. 2003;21:347.

Martinelli P, Maruotti GM, Agangi A, et al. Prenatal diagnosis of hemifacial microsomia and ipsilateral cerebellar hypoplasia in a fetus with oculoauriculovertebral spectrum. *Ultrasound Obstet Gynecol*. 2004;24:199.

Paladini D, Volpe P. Craniofacial and neck anomalies. In: *Ultrasound of congenital fetal anomalies differential diagnosis and prognostic indicators*. London: Informa Healthcare; 2007:63.

Rotten D, Levaillant JM. Two- and three-dimensional sonographic assessment of the fetal face. 1. A systematic analysis of the normal face. *Ultrasound Obstet Gynecol*. 2004;23:224.



All references are available online at www.expertconsult.com.

REFERENCES

1. Suri M. Craniofacial syndromes. *Semin Fetal Neonatal Med*. 2005;10:243-257.
2. Benacerraf B. *Ultrasound of fetal syndromes*. New York, London, Philadelphia, San Francisco: Churchill Livingstone; 1998.
3. Nicolaides KH, Salvesen DR, Snijders RJ, et al. Fetal facial defects: associated malformations and chromosomal abnormalities. *Fetal Diagn Ther*. 1993;8:1-9.
4. Pilu G, Falco P, Milano V, et al. Prenatal diagnosis of microcephaly assisted by vaginal sonography and power Doppler. *Ultrasound Obstet Gynecol*. 1998;11:357-360.
5. Delahaye S, Bernard JP, Renier D, et al. Prenatal ultrasound diagnosis of fetal craniosynostosis. *Ultrasound Obstet Gynecol*. 2003;21:347-353.
6. Paladini D, Volpe P. Craniofacial and neck anomalies. In: *Ultrasound of congenital fetal anomalies. Differential diagnosis and prognostic indicators*. London: Informa Healthcare; 2007.
7. De Catte L, Laubach M, Legein J, et al. Early prenatal diagnosis of oculo-auriculovertebral dysplasia or the Goldenhar syndrome. *Ultrasound Obstet Gynecol*. 1996;8:422-424.
8. Grabb WC. The first and second branchial arch syndrome. *Plast Reconstr Surg*. 1965;36:485-508.
9. Rollnick BR, Kaye CI. Hemifacial microsomia and variants: pedigree data. *Am J Med Genet*. 1983;15:233-253.
10. Martinelli P, Maruotti GM, Agangi A, et al. Prenatal diagnosis of hemifacial microsomia and ipsilateral cerebellar hypoplasia in a fetus with oculoauriculovertebral spectrum. *Ultrasound Obstet Gynecol*. 2004;24:199-201.
11. Castori M, Brancati F, Rinaldi R, et al. Antenatal presentation of the oculo-auriculo-vertebral spectrum (OAVS). *Am J Med Genet A*. 2006;140:1573-1579.
12. Schiffer C, Tariverdian G, Schiesser M, et al. Agnathia-otocephaly complex: report of three cases with involvement of two different Carnegie stages. *Am J Med Genet*. 2002;112:203-208.
13. Ibba RM, Zoppi MA, Floris M, et al. Otocephaly: prenatal diagnosis of a new case and etiopathogenetic considerations. *Am J Med Genet*. 2000;90:427-429.
14. O'Neill BM, Alessi AS, Petti NA. Otocephaly or agnathia-synotia-microstomia syndrome: report of a case. *J Oral Maxillofac Surg*. 2003;61:834-837.
15. Johnston MC, Sulik KK. Some abnormal patterns of development in the craniofacial region. *Birth Defects Orig Artic Ser*. 1979;15:23-42.
16. Romero R, Pilu G, Jeanty P, et al. The face. In: *Prenatal diagnosis of congenital anomalies*. East Norwalk: Appleton and Lange; 1998.
17. Tantbirojn P, Taweevisit M, Sritippayawan S, et al. Prenatal three-dimensional ultrasonography in a case of agnathia-otocephaly. *J Obstet Gynaecol Res*. 2008;34:663-665.
18. Kamnasaran D, Morin F, Gekas J. Prenatal diagnosis and molecular genetic studies on a new case of agnathia-otocephaly. *Fetal Pediatr Pathol*. 2010;29:207-211.
19. Goldstein I, Tamir A, Weiner Z, et al. Dimensions of the fetal facial profile in normal pregnancy. *Ultrasound Obstet Gynecol*. 2010;35:191-194.
20. Kurjak A, Azumendi G, Andonotopo W, et al. Three- and four-dimensional ultrasonography for the structural and functional evaluation of the fetal face. *Am J Obstet Gynecol*. 2007;196:16-28.
21. Rotten D, Levaillant JM. Two- and three-dimensional sonographic assessment of the fetal face. 1. A systematic analysis of the normal face. *Ultrasound Obstet Gynecol*. 2004;23:224-231.
22. Ghi T, Perolo A, Banzi C, et al. Two-dimensional ultrasound is accurate in the diagnosis of fetal craniofacial malformation. *Ultrasound Obstet Gynecol*. 2002;19:543-551.
23. Merz E, Weber G, Bahlmann F, et al. Application of transvaginal and abdominal three-dimensional ultrasound for the detection or exclusion of malformations of the fetal face. *Ultrasound Obstet Gynecol*. 1997;9:237-243.
24. De Jong-Pleij EA, Ribbert LS, Pistorius LR, et al. The fetal profile line: a proposal for a sonographic reference line to classify forehead and mandible anomalies in the second and third trimester. *Prenat Diagn*. 2012;32:797-802.
25. Rajeswaran R, Chandrasekharan A, Joseph S, et al. Ultrasound versus MRI in the diagnosis of fetal head and trunk anomalies. *J Matern Fetal Neonatal Med*. 2009;22:115-123.
26. Rubio EI, Blask A, Bulas DI. Ultrasound and MR imaging findings in prenatal diagnosis of craniosynostosis syndromes. *Pediatr Radiol*. 2016;46:709-718.
27. Hattori Y, Tanaka M, Matsumoto T, et al. Prenatal diagnosis of hemifacial microsomia by magnetic resonance imaging. *J Perinat Med*. 2005;33:69-71.
28. Chen CP, Wang KG, Huang JK, et al. Prenatal diagnosis of otocephaly with microphthalmia/anophthalmia using ultrasound and magnetic resonance imaging. *Ultrasound Obstet Gynecol*. 2003;22:214-215.
29. Huibers M, Papatsonis DN. Prenatal diagnosis of alobar holoprosencephaly, by use of ultrasound and magnetic resonance imaging in the second trimester. *J Matern Fetal Neonatal Med*. 2009;22:1204-1206.

SECTION TWO
Neck Anomalies

70 Cystic Hygroma

MAR BENNASAR | MARTA ARIGITA | LAURA SALAZAR | BIENVENIDO PUERTO

Introduction

Cystic hygroma (CH) is a congenital lymphatic malformation. It is the most frequently observed fetal neck pathology on prenatal ultrasound (US).

Disease

DEFINITION

CH is an abnormality of the vascular lymphatic system, characterized by the development of distended fluid-filled spaces, typically affecting the fetal neck (80% of cases). Based on the presence of septations, it can be classified into *septated* or *nonseptated CH*.

PREVALENCE AND EPIDEMIOLOGY

The true incidence of CH is unknown. It has been reported to be 1 : 6000 at birth and 1 : 750 among spontaneous abortions.[1] Data from the FASTER (First and Second Trimester Evaluation of Risk) trial showed an overall prevalence of CH at about 1 : 100, whereas septated CH affects 1 : 285 fetuses in the first trimester.[2]

ETIOLOGY AND PATHOPHYSIOLOGY

CH is frequently associated with other malformations, particularly congenital heart defects (CHD) and chromosomal abnormalities (75% of cases). Some studies suggest that septations predict an increased likelihood of aneuploidies,[3,4] but this notion has not been confirmed by others.[5,6] Turner syndrome is the most common associated chromosomal abnormality, affecting approximately 60% of cases. More recent studies suggest a higher prevalence of Down syndrome.[2] Other chromosomal abnormalities include autosomal trisomies, Klinefelter syndrome, partial trisomies, partial monosomies, translocations, and mosaicisms.[7,8] Genomic microarray analysis may lead to a decrease in the number of undiagnosed genetics disorders when compared with conventional karyotype. Microarrays enable higher resolution, with 22q11.2 microdeletion being one of the most frequently detected imbalance overlooked by conventional karyotype.[9] CH has been related to inherited disorders and malformation syndromes in euploid fetuses (Table 70.1), maternal infection, and drug intake including alcohol, aminopterin, and trimethadione.[10,11]

CH is normally caused by aberrant development of lymphatic vessels, as a consequence of an abnormal or absent connection with the venous system,[10] leading to lymphatic stasis and enlargement of the jugular sacs (Fig. 70.1). Progressive obstruction may lead to thoracic, pericardial, and abdominal

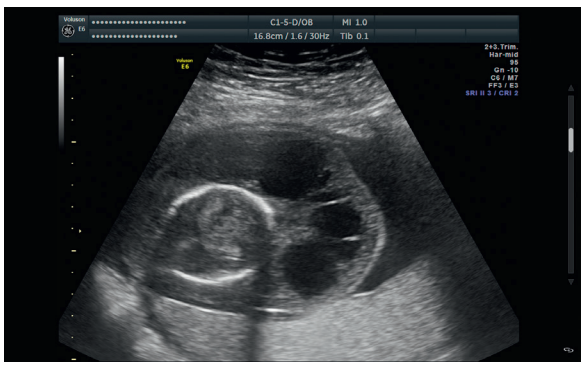

Fig. 70.1 Axial view of septated CH in second trimester. The nuchal ligament is identified.

TABLE 70.1 GENETIC AND MALFORMATION SYNDROMES ASSOCIATED WITH CYSTIC HYGROMA

Achondrogenesis type II
Achondroplasia
Beckwith-Wiedemann syndrome
Brachmann-de Lange syndrome
Campomelic dysplasia
Congenital adrenal hyperplasia
Cowchock syndrome
Cowden disease
Cumming syndrome
de Lange syndrome
Distichiasis-lymphedema syndrome
Fanconi pancytopenia syndrome
Fraser syndrome
Fryns syndrome
Hereditary lymphedema
Multiple pterygium syndrome
Noonan syndrome
Oculodentodigital syndrome
Opitz-Frias syndrome
Pena-Shokeir syndrome
Polysplenia syndrome
Proteus syndrome
Roberts syndrome
Thrombocytopenia–absent radius
VACTERL association
Williams syndrome
Zellweger syndrome

VACTERL, Vertebral, anal, cardiac, tracheal, esophageal, renal, and limb anomalies.

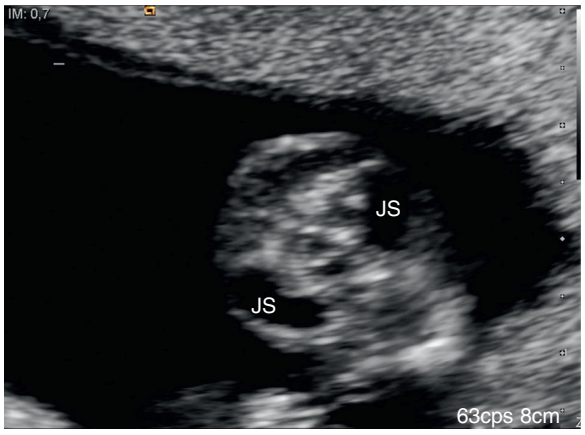

Fig. 70.2 Dilated jugular sacs *(JS)* in a case of resolved CH.

effusions. However, if an alternative route of lymphatic flow is established, the distended lymphatic sacs collapse, and the hygroma resolves either completely or showing distended jugular lymph sacs on either side of the fetal neck (Fig. 70.2).

MANIFESTATIONS OF DISEASE

Clinical Presentation

The prenatal presentation and course of CH is variable. It can resolve spontaneously or progressively affect other fetal structures separate from the neck, such as the pleura, the pericardium, or the abdomen, leading to hydrops fetalis in 75% of cases, which frequently results in fetal demise.[7] In fetuses progressing to term, a large CH may complicate obstetric and perinatal management. A cesarean section may be required to avoid birth dystocia and injury; ex utero intrapartum treatment may be helpful to prevent neonatal asphyxia secondary to difficult airway access. CH rarely regresses spontaneously after birth, and growth of the CH is generally proportional to the growth of the child. Spontaneous infection is present in one-third of cases.[11]

Imaging Technique and Findings

Ultrasound. CH develops typically late in the first trimester and is characterized by the presence of posterior or posterior-lateral, fluid-filled cavities in the fetal neck. These cavities are quite variable in size. Nuchal hygromas are frequently bilateral, separated by the nuchal ligament, resembling a complex mass with one or more septa in the center. An axial view of the fetal neck is usually required to make the diagnosis.

Oligohydramnios is present in about two-thirds of cases, thought to be the consequence of hypovolemia and renal hypoperfusion. Amniotic fluid volume can also be increased, especially in cases associated with hydrops fetalis.

CH is associated with other malformations in 60% of cases, including cardiac defects, skeletal dysplasias, genitourinary system abnormalities, congenital diaphragmatic hernia, and central nervous system abnormalities.[2]

Cystic Hygroma Versus Nuchal Translucency. There is an ongoing debate regarding the differentiation between increased nuchal translucency and CH in the first trimester. It is argued that septations can be seen in all fetuses with increased nuchal translucency, and CH should not constitute a distinct entity in the first trimester.[12]

Magnetic Resonance Imaging. In late pregnancy, magnetic resonance imaging (MRI) can be useful in prenatal evaluation of airway access and extension of the lymphatic abnormalities to plan an adequate delivery and perinatal management.

Differential Diagnosis From Imaging Findings

1. Occipital encephalocele and meningocele: The defect in the calvaria and the absence of gyral pattern (encephalocele) are clues for the diagnosis (Fig. 70.3).
2. Hemangioma: Normally irregularly shaped, low-level echoes, and color Doppler showing vascularization can establish the diagnosis.
3. Teratoma: Teratoma is usually located anteriorly, with hyperextension of the fetal neck and a solid or mixed-solid mass.
4. Goiter: A goiter appears as a bilobed mass in the anterior region.
5. Other: Other, less common anomalies that may be included in differential diagnosis of CH are metastases, sarcoma, melanoma, brachial cleft cyst, thyroglossal duct cyst, laryngocele, fibroma, and lipoma.

Synopsis of Treatment Options

PRENATAL

There are a few reports concerning intrauterine treatment of CH in selected cases without chromosomal or structural abnormalities. Experimental intralesional injection of OK-432 solution at a concentration of 1 KE/5 mL of saline and sclerotherapy have been reported.[13–15]

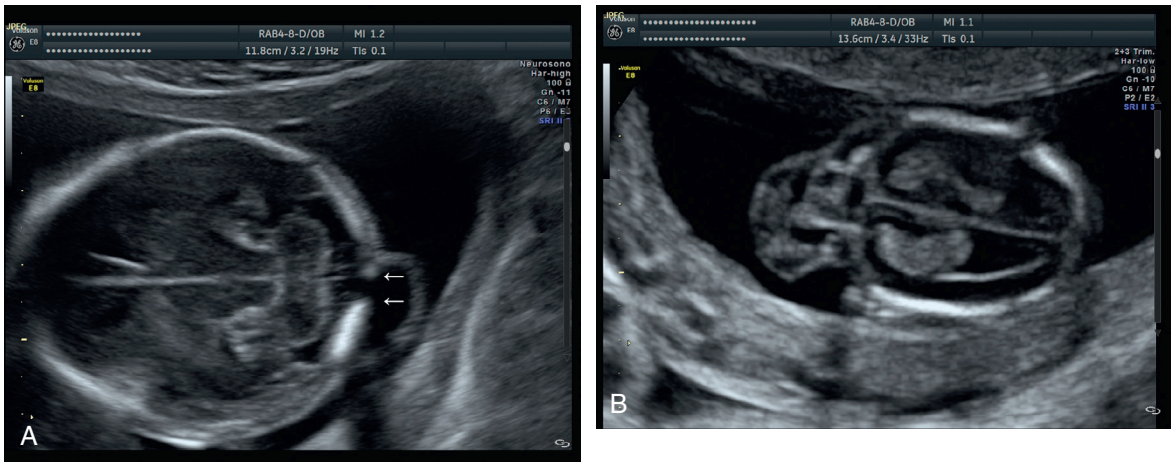

Fig. 70.3 Calvarian bone defect *(arrows)* in two cases (A,B) of encephalocele as a clue for the differential diagnosis between CH and encephalocele.

POSTNATAL

Surgical

Complete excision is the treatment of choice for CH, although it is possible in only three out of four cases. The mortality rate is extremely low, but recurrence, infection, wound seroma, and nerve damage occur in 30% of cases. Recurrence rate varies depending on the complexity of the lesion and the completeness of excision.[16]

Nonsurgical

Nonsurgical therapies are used as a treatment for recurrent or incompletely excised lesions. Injections of intralesional bleomycin (0.3 to 3 mg/kg per session)[17] and OK-432[18] are the most effective treatments. Complete regression occurs in 40% to 50% of cases.

WHAT THE REFERRING PHYSICIAN NEEDS TO KNOW

- If a CH is diagnosed prenatally, genomic microarray and a detailed US, including fetal echocardiography, should be offered. Turner syndrome is the most common disorder.
- The prognosis is uncertain, but overall mortality is high, and there is a greater than 75% association with other defects or progression to hydrops, or both.
- Size appears to be the most important determinant of outcome, irrespective of whether there are internal septations.[19]

KEY POINTS

- CH is the most frequently seen fetal neck mass on first-trimester US.
- CH is characterized by fluid-filled posterior or posterior-lateral cavities in the neck.
- Overall prognosis is poor, with a high association with chromosomal and structural anomalies, and progression to hydrops and fetal demise.
- Rare cases may resolve and show a good outcome.

SUGGESTED READINGS

Grande M, Jansen FAR, Blumenfeld J, et al. Genomic microarray in fetuses with increased nuchal translucency and normal karyotype: a systematic review and meta-analysis. *Ultrasound Obstet Gynecol*. 2015;46:650-658.

Malone FD, Ball RH, Nyberg DA, et al. FASTER Trial Research Consortium. First-trimester septated cystic hygroma: prevalence, natural history, and pediatric outcome. *Obstet Gynecol*. 2005;106:288-294.

Scholl J, Durfee SM, Russell MA, et al. First-trimester cystic hygroma: relationship of nuchal translucency thickness and outcomes. *Obstet Gynecol*. 2012;120:551-9.

All references are available online at www.expertconsult.com.

REFERENCES

1. Chen CP, Liu FF, Jan SW, et al. Cytogenetic evaluation of cystic hygroma associated with hydrops fetalis, oligohydramnios or intrauterine fetal death: the roles of amniocentesis, postmortem chorionic villus sampling and cystic hygroma paracentesis. *Acta Obstet Gynecol Scand*. 1996;75:454-458.
2. Malone FD, Ball RH, Nyberg DA, et al. FASTER Trial Research Consortium. First-trimester septated cystic hygroma: prevalence, natural history, and pediatric outcome. *Obstet Gynecol*. 2005;106:288-294.
3. Bronshtein M, Rottem S, Yoffe N, et al. First-trimester and early second-trimester diagnosis of nuchal cystic hygroma by transvaginal sonography: diverse prognosis of the septated from the nonseptated lesion. *Am J Obstet Gynecol*. 1989;161:78-82.
4. Brumfield CG, Wenstrom KD, Davis RO, et al. Second-trimester cystic hygroma: prognosis of septated and nonseptated lesions. *Obstet Gynecol*. 1996;88:979-982.
5. Shulman LP, Emerson DS, Felker RE, et al. High frequency of cytogenetic abnormalities in fetuses with cystic hygroma diagnosed in the first trimester. *Obstet Gynecol*. 1992;80:80-82.
6. Podobnik M, Singer Z, Podobnik-Sarkanji S, et al. First trimester diagnosis of cystic hygromata using transvaginal ultrasound and cytogenetic evaluation. *J Perinat Med*. 1995;23:283-291.
7. Gallagher PG, Mahoney MJ, Gosche JR. Cystic hygroma in the fetus and newborn. *Semin Perinatol*. 1999;23(4):341-356.
8. Edwards MJ, Graham JM Jr. Posterior nuchal cystic hygroma. *Clin Perinatol*. 1990;17:611-640.
9. Grande M, Jansen FAR, Blumenfeld J, et al. Genomic microarray in fetuses with increased nuchal translucency and normal karyotype: a systematic review and metaanalysis. *Ultrasound Obstet Gynecol*. 2015;46:650-658.
10. Chervenak FA, Isaacson G, Blakemore KJ, et al. Fetal cystic hygroma: cause and natural history. *N Engl J Med*. 1983;309:822-825.
11. Wiswell TE, Miller JA. Infections of congenital cervical neck masses associated with bacteremia. *J Pediatr Surg*. 1986;21:173-174.
12. Molina FS, Avgidou K, Kagan KO, et al. Cystic hygromas, nuchal edema, and nuchal translucency at 11 to 14 weeks of gestation. *Obstet Gynecol*. 2006;107:678-683.
13. Kuwabara Y, Sawa R, Otsubo Y, et al. Intrauterine therapy for the acutely enlarging fetal cystic hygroma. *Fetal Diagn Ther*. 2004;19:191-194.
14. Sasaki Y, Chiba Y. Successful intrauterine treatment of cystic hygroma colli using OK-432. A case report. *Fetal Diagn Ther*. 2003;18:391-396.
15. Ogita K, Suita S, Taguchi T, et al. Outcome of fetal cystic hygroma and experience of intrauterine treatment. *Fetal Diagn Ther*. 2001;16:105-110.
16. Hancock BJ, St-Vil D, Luks FI, et al. Complications of lymphangiomas in children. *J Pediatr Surg*. 1992;27:220-224.
17. Orford J, Barker A, Thonell S, et al. Bleomycin therapy for cystic hygroma. *J Pediatr Surg*. 1995;30:1282-1287.
18. Ogita S, Tsuto T, Tokiwa K, et al. Intracystic injection of OK-432: a new sclerosing therapy for cystic hygroma in children. *Br J Surg*. 1987;74:690-691.
19. Scholl J, Durfee SM, Russell MA, et al. First-trimester cystic hygroma: relationship of nuchal translucency thickness and outcomes. *Obstet Gynecol*. 2012;120:551-559.

To access the videos in this chapter, scan this QR code or visit expertconsult.com

71 Neck Teratoma

BIENVENIDO PUERTO | ELISENDA EIXARCH | MAGDALENA SANZ-CORTÉS

Introduction

Fetal tumors are rare; teratomas are the most common histologic type. The neck is the most common location after the sacrococcygeal area for teratomas.[1] The tissues found in fetal and infant teratomas are essentially the same regardless of the site of origin. A neck teratoma may be associated with neonatal mortality in 80% to 100% of cases if delivery is not managed properly. For large masses, adequate prenatal diagnosis allowing planned delivery with *ex utero* intrapartum treatment (EXIT) and intensive neonatal care are essential to improve the management.

Disease

DEFINITION

A normally benign tumor in the neck composed of multiple tissues derived from all three germ layers of the embryonic disk—ectoderm, mesoderm, and endoderm—with a high potential of growing in excess.[2]

PREVALENCE AND EPIDEMIOLOGY

The prevalence of fetal tumors is difficult to establish; however, it is estimated to be from 1.7:100,000 to 13.5:100,000 live births. Cervical teratomas are found in about 1:20,000 to 1:40,000 live births, accounting for 3% to 6% of all neonatal teratomas.[3]

The presentation is sporadic, without an apparent relationship to race, maternal age, parity, or fetal sex. Some cases of familial recurrence have been reported.

ETIOLOGY AND PATHOPHYSIOLOGY

The development of fetal tumors does not match the same processes as tumors observed in adults. In fetuses, tumors may result from failure of developing tissues to undergo normal cytodifferentiation and maturation.[4]

Cervical teratomas may originate from the palate, nasopharynx, or thyrocervical area. They are usually closely related to, but do not arise from, the thyroid gland. Mature or immature neuroglial tissues are the most frequent component, but cartilage, respiratory epithelium, and ependyma-lined cysts are common. Malignancy is extremely rare.[3] Immature elements present do not express the biologic behavior.

Manifestations of Disease

CLINICAL PRESENTATION

Ultrasound (US) diagnosis is usually made at routine anatomic scan. Polyhydramnios, caused by esophageal compression, is present in 30% to 40% of cases. More rarely, the diagnosis is established after an episode of preterm labor caused by polyhydramnios.

Imaging Technique and Findings

Ultrasound. Prenatal US diagnosis of a teratoma can be made as early as the first trimester,[5] but they are usually detected on routine second-trimester screening or after an initial diagnosis of polyhydramnios. The key sign is the distortion in neck contour by the presence of an asymmetric, unilateral, and well-encapsulated mass (Fig. 71.1; Video 71.1). The tumor is usually large and bulky, with mixed echostructure of cystic and solid components. Echogenic foci of calcifications, present in about half of all cases, are virtually pathognomonic of teratoma (Fig. 71.2). Located anterior to the neck, the tumor may produce a mass effect on surrounding tissues from the ear to the jaw or extend into the mediastinum (Fig. 71.3; Video 71.2). Intracranial and orbital extensions are rare.[6] Large tumors result in severe hyperextension of the fetal head (Video 71.3). Polyhydramnios indicates severity, since it reflects impaired swallowing by mouth obstruction or esophageal compression (Fig. 71.4).

Solid parts are often very vascular and with arteriovenous shunts. Color Doppler shows the intensity and characteristics of the tumor vascularization (Fig. 71.5). Three-dimensional US may provide additional detailed information on location, extension, and intracranial spread (Figs. 71.6 and 71.7).

The risk of chromosomal anomalies or malformation syndromes is low. Reported associations include trisomy 13, hypoplastic left ventricle, and central nervous system anomalies.[7–9]

Magnetic Resonance Imaging

Magnetic resonance imaging (MRI) provides additional information about tumor location, calcifications, intratumor hemorrhage, extension, facial involvement, and intracranial spread (Fig. 71.8). In addition, MRI allows evaluation of the relationship with the trachea, which may be critical for planning EXIT and postnatal surgery.[10–13]

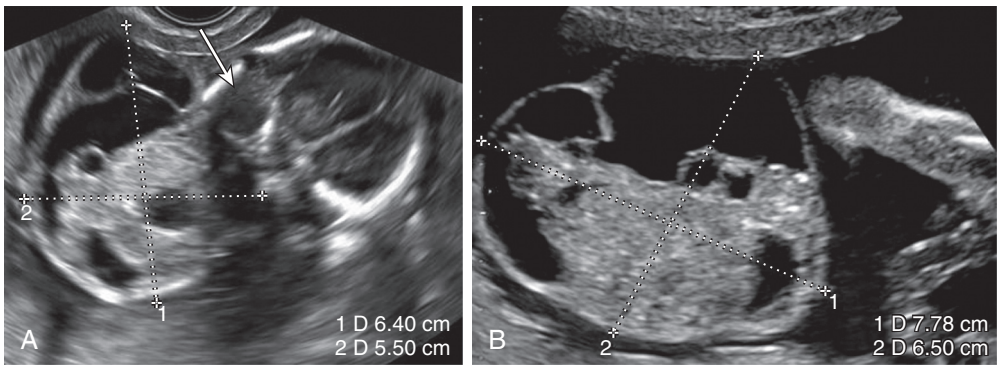

Fig. 71.1 Neck teratoma at 21 weeks' gestation. The tumor is larger than the fetal head (see three perpendicular diameters). (A) Coronal view. Note one of the orbits *(arrow)* and the mixed echostructure of the tumor. (B) Axial view.



Fig. 71.2 Sagittal view of a neck teratoma. The solid part is the most important component.



Fig. 71.3 Sagittal view of a neck teratoma shows the mass effect on the fetal face. Scattered echogenic foci are visible.

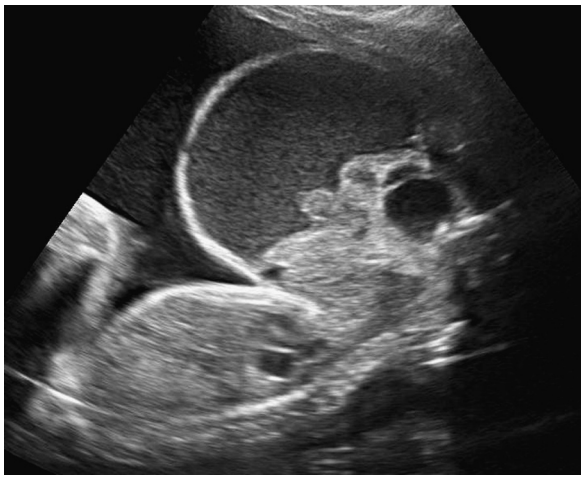

Fig. 71.4 Sagittal view of a neck teratoma and polyhydramnios.

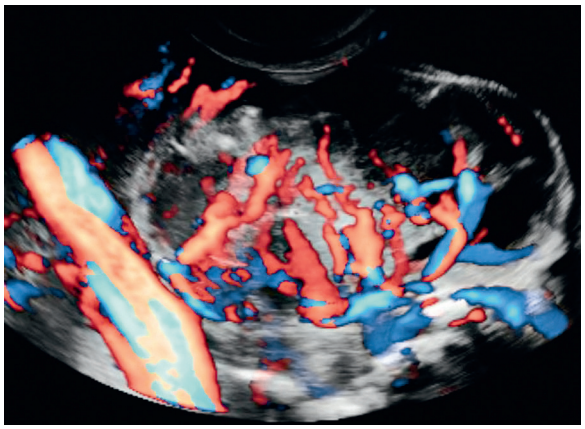

Fig. 71.5 Axial view of a neck teratoma. Color Doppler shows vascularization.

Differential Diagnosis From Imaging Findings

Cystic hygroma, lymphangioma, and hemangioma are the main differential diagnoses of a neck mass. Lymphangioma is most common in soft tissue. Neck lymphangioma is a large, unilateral, multiloculated, predominantly cystic tumor often with intrathoracic extension, and complicated by hydrops (Fig. 71.9). Cystic hygroma is posteriorly located, with septated cystic tumors (Fig. 71.10). Increased intratumor flow is demonstrated with color Doppler in hemangioma. The differential diagnosis of cervical teratoma should also include other neck masses, such as goiter, solid thyroid tumors, thyroid cyst, branchial cleft cyst, laryngocele (cystic), parotid tumor, neuroblastoma (solid tumor), hamartoma (specific Doppler study), and other soft tissues such as lipoma or fibroma (solid tumor).[14]

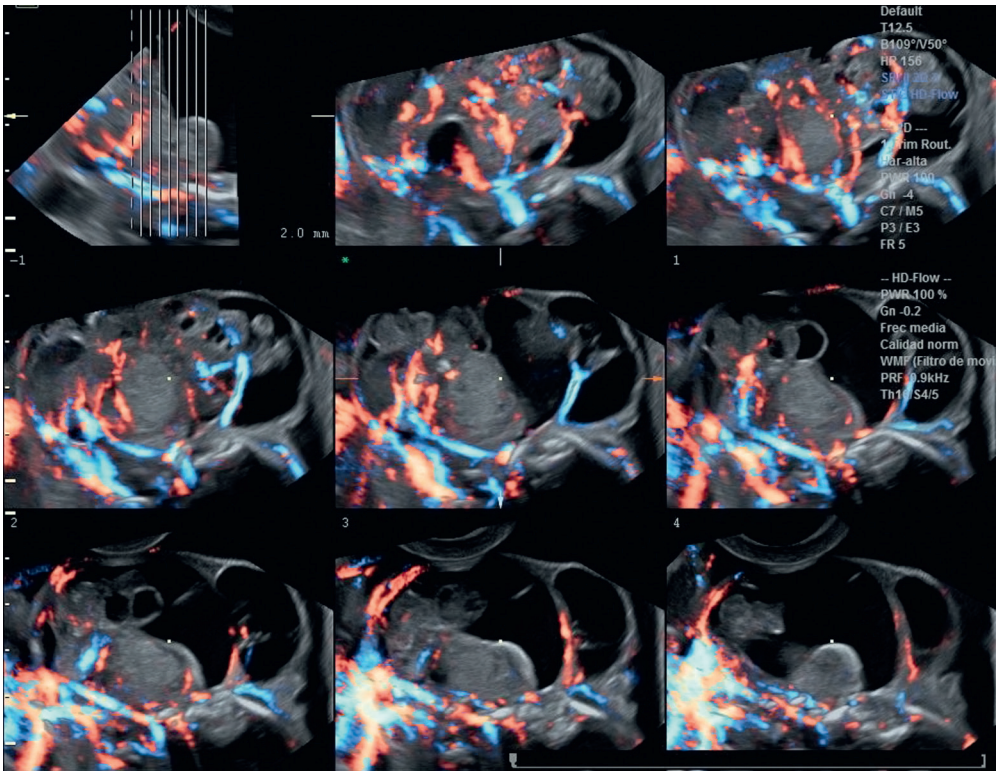

Fig. 71.6 Three-dimensional Doppler color and tomography ultrasound imaging shows vascularization characteristics of a neck teratoma and distribution.

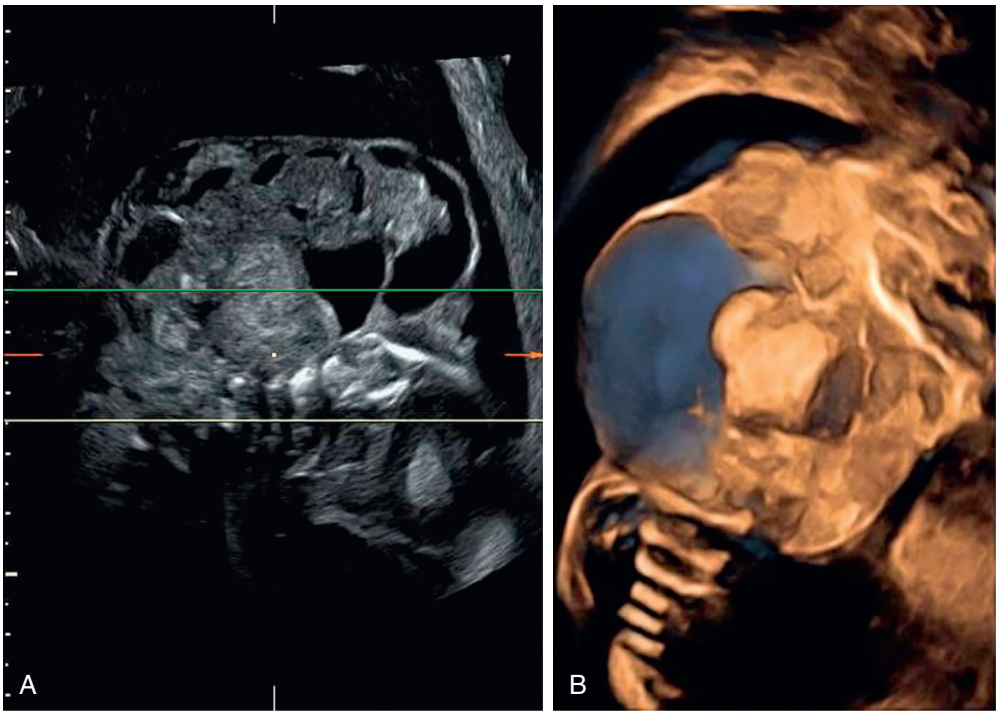

Fig. 71.7 Detailed structure of a neck teratoma on two-dimensional (A) and three-dimensional (B) ultrasound.

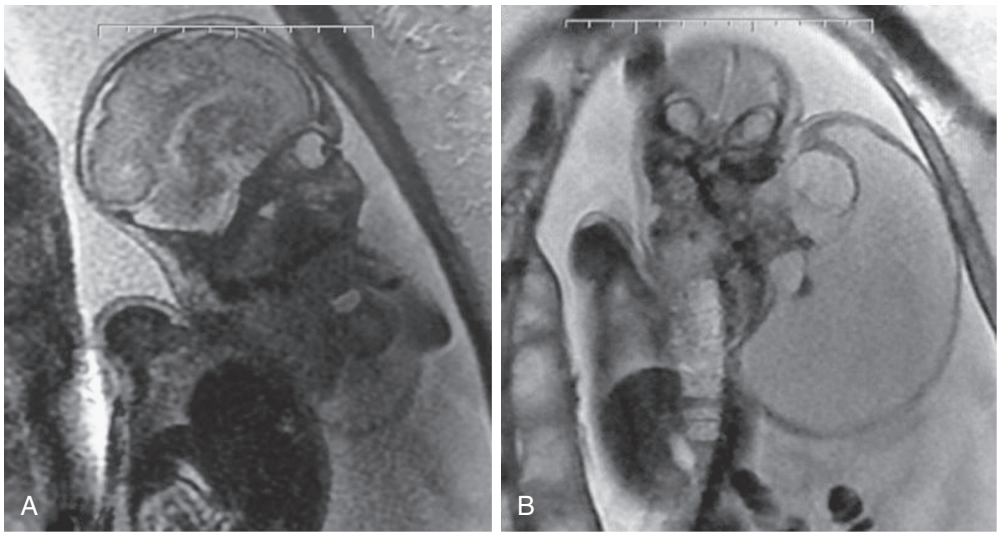

Fig. 71.8 MRI of a neck teratoma at 31 weeks' gestation (same case as shown in Fig. 71.3). (A) Sagital and (B) coronal views.

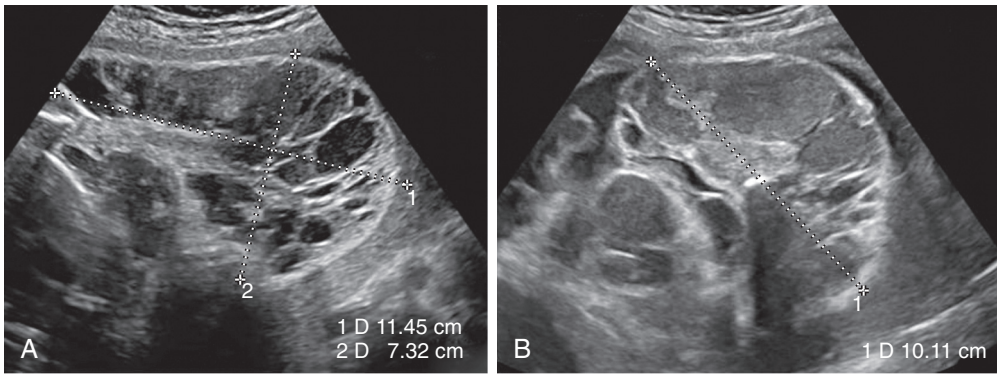

Fig. 71.9 Axillary lymphangioma, a large, multiloculated cystic tumor. (A) Axial and (B) sagital views.

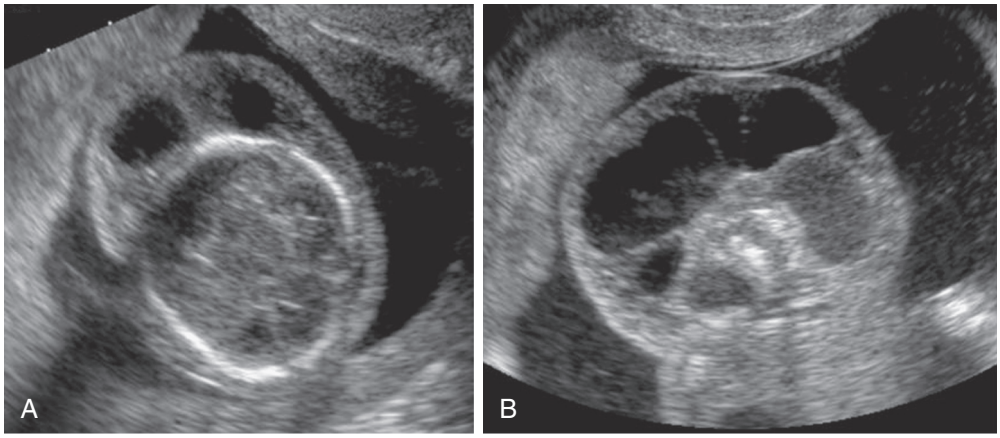

Fig. 71.10 Cystic hygroma, a posteriorly located infiltrative, septated, and cystic tumor, at 14 weeks' gestation. (A) Axial view at the level of the biparietal diameter. (B) Coronal view of the fetal neck.

Synopsis of Treatment Options

PRENATAL

There is no fetal treatment, but management often requires amnioreduction for severe polyhydramnios to reduce the risk of preterm labor (Fig. 71.11). Delivery must be planned with EXIT in a tertiary care center to reduce the risk of serious complications, which can occur even in apparently successful resuscitations,[15–18] and includes brain damage or death associated with severe pulmonary hypoplasia.[19] If laryngoscopy is unsuccessful, tracheostomy is needed. Fetal endoscopic tracheal intubation before delivery has been proposed recently, avoiding

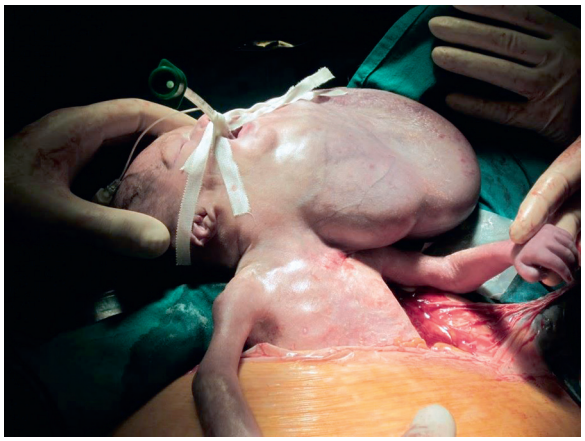

Fig. 71.11 Cesarean section with EXIT at 32 weeks' gestation of a fetus with a neck teratoma (same case as shown in Figs. 71.3 and 71.8). Photograph was taken immediately after the intubation.

the need of EXIT procedure.[20] Massive lesions may complicate delivery of the head, even at cesarean section.

POSTNATAL

Early neonatal surgical removal is the rule, since delaying surgery can result in further complications, including retention of secretions, atelectasis, and pneumonia owing to interference with swallowing.[21] In very large tumors, complete excision with acceptable functional and cosmetic results can be achieved only after several procedures. Because the thyroid and parathyroid glands may be removed or affected by tumor excision, the risk of permanent hypothyroidism and hypoparathyroidism must be considered.[22] Malignancy risk is very low.[3] There is a low but real risk of lung hypoplasia, possibly because of a combination of tracheal obstruction with nerve damage, which may result in neonatal death caused by severe respiratory insufficiency despite a successful EXIT procedure.

WHAT THE REFERRING PHYSICIAN NEEDS TO KNOW

Spontaneous mortality may be greater than 80%. Planning of delivery and EXIT are associated with survival rates in excess of 90%.

KEY POINTS

- Prenatal US diagnosis of cervical teratoma can be made as early as in the first trimester of pregnancy.
- Tracheal and esophageal obstruction can lead to polyhydramnios or to airway compromise in the newborn.
- Polyhydramnios is present in one-third of cases, and amnioreduction is often needed.
- EXIT dramatically improves neonatal survival.
- Early resection is the treatment of choice.

SUGGESTED READINGS

Dighe MK1, Peterson SE, Dubinsky TJ, et al. EXIT procedure: technique and indications with prenatal imaging parameters for assessment of airway patency. *Radiographics*. 2011;31:511-526.

Isaacs H Jr. Germ cell tumors. In: *Tumors of the fetus and infant: an atlas*. 2nd ed. Heidelberg New York Dordrecht London: Springer-Verlag; 2013:5-29.

Kadlub N, Touma J, Leboulanger N, et al. Head and neck teratoma: from diagnosis to treatment. *J Craniomaxillofac Surg*. 2014;42:1598-1603.

Laje P, Tharakan SJ, Hedrick HL. Immediate operative management of the fetus with airway anomalies resulting from congenital malformations. *Semin Fetal Neonatal Med*. 2016;21:240-245.

Peiró JL, Sbragia L, Scorletti F, et al. Management of fetal teratomas. *Pediatr Surg Int*. 2016;32-635.

Ryan G, Somme S, Crombleholme TM. Airway compromise in the fetus and neonate: prenatal assessment and perinatal management. *Semin Fetal Neonatal Med*. 2016;21:230-239.

Tonni G, De Felice C, Centini G, et al. Cervical and oral teratoma in the fetus: a systematic review of etiology, pathology, diagnosis, treatment and prognosis. *Arch Gynecol Obstet*. 2010;282:355-361.

All references are available online at www.expertconsult.com.

REFERENCES

1. Parkes SE, Muir KR, Southern L, et al. Neonatal tumours: a thirty-year population-based study. *Med Pediatr Oncol*. 1994;22:309-317.
2. Isaacs H Jr. Tumors. In: Gilbert-Barness E, ed. *Potter's pathology of the fetus and infant*. Vol 2. St Louis: Mosby; 1997:1248-1339.
3. Azizkhan RG, Haase GM, Applebaum H, et al. Diagnosis, management, and outcome of cervicofacial teratomas in neonates: a children's cancer group study. *J Pediatr Surg*. 1995;30:312-316.
4. Isaacs H Jr. Germ cell tumors. In: *Tumors of the fetus and infant: an atlas*. 2nd ed. Heidelberg New York Dordrecht London: Springer-Verlag; 2013:5-29.
5. Zielinski R, Respondek-Liberska M. Retrospective chart review of 44 fetuses with cervicofacial tumors in the sonographic assessment. *Int J Pediatr Otorhinolaryngol*. 2015;79:363-368.
6. Moreddu E, Pereira J, Vaz R, et al. Combined endonasal and neurosurgical resection of a congenital teratoma with pharyngeal, intracranial and orbital extension: case report, surgical technique and review of the literature. *Int J Pediatr Otorhinolaryngol*. 2015;79:1991-1994.
7. Kockling J, Karbasiyan M, Reis A. Spectrum of mutation and genotype phenotype analysis in Currarino syndrome. *Eur J Hum Genet*. 2001;9: 599-605.
8. Ashley DJB. Origin of teratomas. *Cancer*. 1973;2:390-394.
9. Goldstein I, Drugan A. Congenital cervical teratoma, associated with agenesis of corpus callosum and a subarachnoid cyst. *Prenat Diagn*. 2005;25: 439-441.
10. Knox EM, Muamar B, Thompson PJ, et al. The use of high resolution magnetic resonance imaging in the prenatal diagnosis of fetal nuchal tumors. *Ultrasound Obstet Gynecol*. 2005;26:672-675.
11. Figueiredo G, Pinto PS, Graham EM, et al. Congenital giant cervical teratoma: pre- and postnatal imaging. *Fetal Diagn Ther*. 2010;27: 231-232.
12. Lazar DA, Cassady CI, Olutoye OO, et al. Tracheoesophageal displacement index and predictors of airway obstruction for fetuses with neck masses. *J Pediatr Surg*. 2012;47:46-50.
13. Werner H, Lopes dos Santos JR, Fontes R, et al. Virtual bronchoscopy for evaluating cervical tumors of the fetus. *Ultrasound Obstet Gynecol*. 2013;41:90-94.
14. Woodward PJ, Sohaey R, Kennedy A, et al. From the archives of the AFIP: a comprehensive review of fetal tumors with pathologic correlation. *Radiographics*. 2005;25:215-242.
15. Sichel JY, Eliashar R, Yatsiv I, et al. A multidisciplinary team approach for management of a giant congenital cervical teratoma. *Int J Pediatr Otorhinolaryngol*. 2002;65:241-247.
16. Laje P, Johnson MP, Howell LJ, et al. Ex utero intrapartum treatment in the management of giant cervical teratomas. *J Pediatr Surg*. 2012;47:1208-1215.
17. Barthod G, Teissier N, Bellarbi N, et al. Fetal airway management on placental support: limitations and ethical considerations in seven cases. *J Obstet Gynaecol*. 2013;33:787-794.
18. Taghavi K, Berkowitz RG, Fink AM, et al. Perinatal airway management of neonatal cervical teratomas. *Int J Pediatr Otorhinolaryngol*. 2012;76:1057-1060.
19. Liechty KW, Hedrick HL, Hubbard AM, et al. Severe pulmonary hypoplasia associated with giant cervical teratomas. *J Pediatr Surg*. 2006;41:230-233.
20. Cruz-Martinez R, Moreno-Alvarez O, Garcia M. Fetal endoscopic tracheal intubation: a new fetoscopic procedure to ensure extrauterine tracheal permeability in a case with congenital cervical teratoma. *Fetal Diagn Ther*. 2015;38:154-158.
21. Azizkhan RG. Perinatal tumors. In: Carachi R, Grosfeld J, Azmy AF, eds. *The surgery of childhood tumors*. 2nd ed. Berlin: Springer-Verlag; 2008:155-156.
22. Martino F, Avila LF, Encinas JL, et al. Teratomas of the neck and mediastinum in children. *Pediatr Surg Int*. 2006;22:627-634.

72 Fetal Thyroid Masses and Fetal Goiter

MAGDALENA SANZ-CORTÉS | SUSANA FERNÁNDEZ | BIENVENIDO PUERTO

Introduction

The prenatal diagnosis of fetal goiter was first described in 1980.[1] Advances in prenatal imaging and fetal hormonal physiology have enabled the identification of some severe but treatable disorders in the fetus. The potential benefits to the fetus of any prenatal treatment regimen must be carefully weighed against the potential risks to the fetus and the mother.[2]

Disease

DEFINITION

Fetal goiter is an enlargement of the thyroid gland (Figs. 72.1 and 72.2). It is defined on ultrasound (US) as a thyroid circumference or diameter greater than the 95th centile for gestational age. It is frequently associated with maternal thyroid dysfunction, generally hypothyroidism.[2]



Fig. 72.1 Fetal goiter in an axial view. There is homogeneous enlargement of the entire gland.

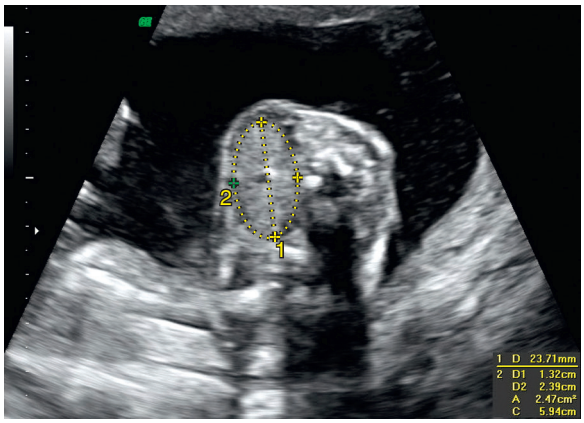

Fig. 72.2 Measurements in a fetal goiter on an axial slice. (1) Goiter diameter; (2) circumference and area. Nomograms should be used to determine if the thyroid is enlarged.

PREVALENCE AND EPIDEMIOLOGY

The prevalence of goitrous hypothyroidism is 0.2:10,000 to 0.3:10,000 live births in Europe and North America; the prevalence of the less frequent goitrous hyperthyroidism is unknown.[3,4] In areas with endemic iodine deficiency, there is a higher prevalence of congenital cretinism, which may be accompanied by a fetal goiter. Iodine deficiency is still considered a major health problem worldwide.[2]

ETIOLOGY AND PATHOPHYSIOLOGY

Congenital goiters are most commonly diagnosed in mothers with known thyroid disease, usually Graves disease.[3,5] Graves disease is a common cause of hyperthyroidism that is present in 0.2% of pregnant women.[6,7] This condition is treated with antithyroid drugs, including both propylthiouracil and methimazole because it passes less easily through the placenta.[7] Reports of aplasia cutis in the fetus after first-trimester exposure to methimazole and long-term complications in the mother from propylthiouracil, particularly hepatotoxicity, have led to recommendations of first-trimester treatment with propylthiouracil then second-trimester and third-trimester management with methimazole.[8] Fetuses of mothers with thyroid disease are especially susceptible to develop congenital hyperthyroid goiter owing to the passage of antibodies against the thyroid-stimulating hormone (TSH) receptor, also called *thyroid-stimulating immunoglobulin,* found in 1% of children born from mothers with Graves disease.[4,7] Fetuses can also develop congenital goitrous hypothyroidism because of the transplacental passage of propylthiouracil[4] or occasionally inhibitory immunoglobulins.[4–9] Different authors have reported how maternal exposure to iodine as nutritional supplements or as a contrast used for hysterosalpingography periconceptionally could be linked to the detection of fetal goiter.[10,11]

When considering all cases of congenital goitrous hypothyroidism, almost 80% are caused by thyroid dysgenesis and may be related to somatic mutations in the TSH receptor.[9] Nearly 15% of cases are caused by dyshormonogenesis or transplacental passage of TSH receptor blocking antibodies.[9] Dyshormonogenesis is the most frequent cause in the absence of maternal thyroid disease or iodine deficiency; it is frequently caused by recessively inherited biochemical defects in one or more steps in the pathway leading to the normal synthesis of thyroid hormones.[12] Less than 5% of the cases are caused by hypothalamic pituitary disorders and central hypothyroidism.[13,14] Endemic iodine deficiency, the use of goitrogens (expectorants with potassium iodine or povidone-iodine), and excess maternal iodine ingestion are considered less frequent causes of fetal goiters.[5,6,9] Congenital goitrous hyperthyroidism is most frequently caused by maternal antibodies or dyshormonogenesis.

Manifestations of Disease

CLINICAL PRESENTATION

A fetal goiter appears as an enlarged thyroid gland (see Fig. 72.1). It can be detected by a dedicated US evaluation of the fetal neck or by the complications that it may cause.

Attributable to Compression Caused by the Mass

Complications attributable to compression caused by the mass include the following:

- esophageal obstruction that can cause polyhydramnios and may lead to a preterm delivery;
- tracheal obstruction that can cause perinatal asphyxia and need for intubation; and
- neck hyperextension and consequent fetal dystocia.[14]

Related to Thyroid Dysfunction

Complications related to thyroid dysfunction involve fetal hyperthyroidism and untreated congenital hypothyroidism.

- Fetal hyperthyroidism may cause intrauterine growth restriction (IUGR) with accelerated bone maturation, intrauterine death by cardiac failure, thyrotoxicosis, or craniosynostosis with intellectual impairment.[3]
- Untreated congenital hypothyroidism is associated with impaired motor and intellectual development in the later stages of life in some affected infants.[3,6,7] The degree of neurologic impairment has been related to the severity of fetal hypothyroidism as assessed by the age at diagnosis, the lower serum thyroxine (T_4) concentrations, and the delay in postnatal treatment.[14] For this reason, an early diagnosis should be made, and subsequent treatment should be promptly started before potentially irreversible neurologic damage occurs secondary to insufficient thyroid hormone levels.[8,14,15]

When a fetal goiter is suspected, a correct study of fetal thyroid function is essential for a precise diagnosis and to plan treatment.[5]



Fig. 72.3 Coronal view of a fetal goiter. Note how it protrudes laterally.

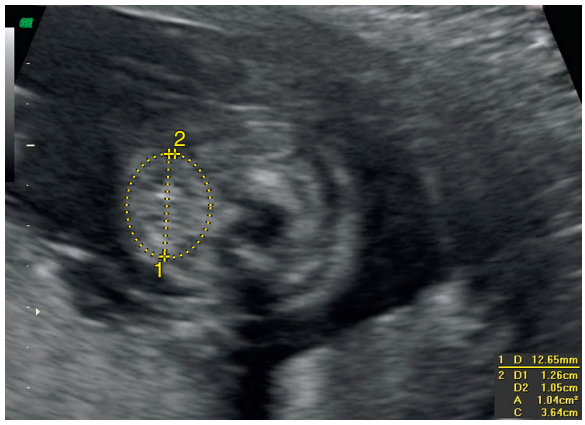

Fig. 72.4 Normal thyroid gland. Measurements are made on an axial view of the gland to determine the diameter and the circumference.

Hyperthyroid and hypothyroid goiters may manifest similar imaging findings, which are generally insufficient for a precise diagnosis.[9] Both maternal and fetal thyroid function should be assessed. Although the presence of maternal Graves disease, the intake of thyrostatic drugs, or the study of antibodies may suggest the diagnosis of the congenital thyroid alteration,[5] fetal thyroid status should be assessed in all cases of suspected fetal goiter.

The optimal way to monitor the fetal thyroid state is debated. The proposed indirect study of the fetal thyroid status, quantifying TSH and T_4 levels in amniotic fluid for diagnosis and follow-up as a less invasive technique than cordocentesis, has limitations.[16] First, the reference intervals for amniotic TSH and free T_4 are established only for the third trimester.[10,17–19] Second, there is poor correlation between amniotic and fetal serum levels of both T_4 and TSH[9,12,20,21] because of uncertain fetal and maternal contributions to amniotic fluid levels.[6,12,14]

Cordocentesis is the gold standard method of diagnosis because it enables the direct quantification of fetal thyroid hormone levels. It is the most widely used method to assess fetal thyroid status.[6,7,12,20] As a delicate invasive procedure, it is associated with an increased incidence of fetal bleeding, infections, fetal bradycardia, and premature rupture of membranes, and has a fetal loss rate of 0.5% to 9% (Chapter 112).[12,16] For this reason, some authors have relied on serial amniocentesis to determine the response to fetal treatment by amniotic fluid TSH levels and the reduction of the mass rather than with serial cordocentesis.[6,14,16] However, amniotic fluid TSH seems less reliable as an indicator of treatment efficacy because it may remain elevated in serum while being almost undetectable in amniotic fluid.[4] Several other reports have used serial cordocentesis as the best way to monitor the response to fetal treatment.[4,6,22]

Imaging Technique and Findings

Ultrasound. A fetal goiter appears on US as a homogeneous, echogenic, symmetric mass in the anterior portion of the fetal neck (Fig. 72.3; see Figs. 72.1 and 72.2).[12,22] When a fetal goiter is suspected, the transverse width and circumference of the thyroid gland should be measured (Fig. 72.4; see Fig. 72.2). The diagnosis should be made when these measurements are greater than the 95th centile based on the nomograms for gestational age.[23,24] Some US signs can be helpful in determining if the fetal goiter is associated with hypothyroidism or hyperthyroidism.

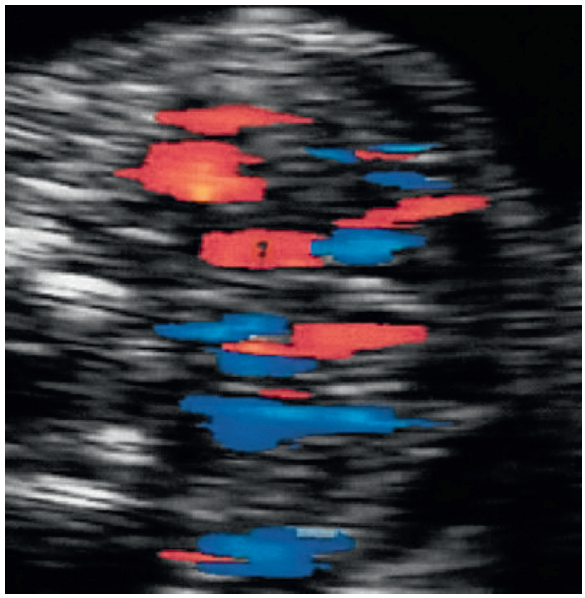

Fig. 72.5 Color Doppler assessment of a fetal goiter in an axial view. Peripheral vascularization of the goiter is associated with hypothyroidism. *(From Huel C, Guibourdenche J, Vuillard E, et al.: Use of ultrasound to distinguish between fetal hyperthyroidism and hypothyroidism on discovery of a goiter,* Ultrasound Obstet Gynecol *33:412-420, 2009.)*

Color Doppler of the thyroid may show peripheral vascularization that reflects a hypertrophic but inactive thyroid gland, more commonly present in hypothyroid goiters (Fig. 72.5). Central vascularization reveals an overactive thyroid gland, more commonly found in cases of hyperthyroid goiters (Fig. 72.6).[3] Both measurement of fetal thyroid gland and color Doppler assessment have been proposed as useful methods to monitor the response to fetal treatment. The disappearance or reduction of the mass or the Doppler signal may be associated with improvement in fetal thyroid status.[3]

Indirect signs of fetal thyroid function include the following:

- *Bone maturation.* Accelerated bone maturation is defined as *the presence of distal femoral ossification before 31 weeks' gestation* and is frequently present in hyperthyroidism. Delayed bone maturation is defined as the *absence of this center after 33 weeks' gestation* and is more frequently present in hypothyroidism.[3]

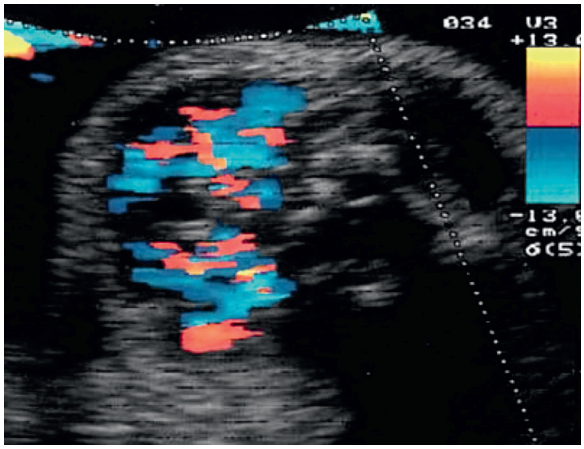

Fig. 72.6 Color Doppler assessment of a fetal goiter in an axial view. Central vascularization of the goiter is associated with hyperthyroidism. *(From Huel C, Guibourdenche J, Vuillard E, et al.: Use of ultrasound to distinguish between fetal hyperthyroidism and hypothyroidism on discovery of a goiter,* Ultrasound Obstet Gynecol *2009;33:412-420.)*

TABLE 72.1 ULTRASOUND SCORE TO DISTINGUISH BETWEEN HYPOTHYROIDISM AND HYPERTHYROIDISM

Ultrasound Finding	Weighting
Vascularization	
Peripheral or absent	0
Central	1
Fetal Heart Rate	
Normal	0
Tachycardia	1
Bone Maturation	
Delayed	–1
Normal	0
Accelerated	1
Fetal Movements	
Normal	1
Increased	0

Note. An overall score ≥2 suggests hyperthyroidism, and a score <2 indicates hypothyroidism.
(*From Huel C, Guibourdenche J, Vuillard E, et al.: Use of ultrasound to distinguish between fetal hyperthyroidism and hypothyroidism on discovery of a goiter,* Ultrasound Obstet Gynecol *33:412–420, 2009*).

- *Fetal tachycardia.* Fetal tachycardia, *defined as a continuous heart rate greater than 160 beats/min,* is an indirect sign of hyperthyroidism.
- *Fetal movements.* Huel et al.[3] described how hypothyroid fetuses in their series more frequently showed increased jerky movements, which were absent in all their cases of hyperthyroidism.

Huel et al.[3] proposed a diagnostic US score to use in cases of fetal goiter. Doppler assessment of the fetal goiter, fetal bone maturation, fetal tachycardia, and abnormal fetal movements are scored to determine if there is underlying hyperthyroidism or hypothyroidism (Table 72.1). This scoring system correctly classified 36 cases of congenital hypothyroidism or hyperthyroidism in Huel's series.[3]

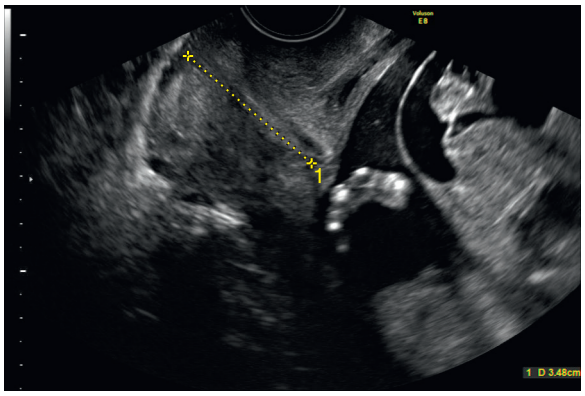

Fig. 72.7 Transvaginal measurement of cervical length in a case of polyhydramnios secondary to a cervical teratoma. Cervical length should be measured if polyhydramnios is present because it can be associated with preterm labor.

Hyperthyroidism can also be suspected when there is fetal goiter with IUGR,[3] sometimes accompanied by oligohydramnios. In advanced stages of hyperthyroidism and hypothyroidism, heart failure with or without anasarca may be seen.

Indirect signs of thyroid goiter mass: when a congenital goiter is suspected, the amniotic fluid should always be evaluated using the amniotic fluid index because of the potential compression of the fetal esophagus. Polyhydramnios is related to goiter volume rather than etiology. When polyhydramnios is present, cervical length should be measured (Fig. 72.7).

Magnetic Resonance Imaging. Magnetic resonance imaging (MRI) is considered a complementary imaging mode to study fetal thyroid masses, and its use has been reported in several cases of goitrous hypothyroidism during pregnancy.[6,25] MRI of congenital hypothyroid goiters shows a T1 and T2 signal hyperintensity. There are no published reports of assessment of MRI signal intensity in congenital hyperthyroidism, although it is possible that MRI could eventually help discriminate between hyperthyroidism and hypothyroidism.[3] Fetal MRI can be beneficial in assessing the compromise and compression of the esophagus and trachea and when neonatal intubation may seem unavoidable.[6,14]

Other Applicable Modality. Usefulness of three-dimensional (3D) US in fetal thyroid masses is limited. It may facilitate the mother's understanding of the fetal goiter, which may obtain better treatment compliance. Three-dimensional US could also be useful in assessing the reduction in size and volume of the fetal goiter after treatment (Fig. 72.8).

Differential Diagnosis From Imaging Findings

Prenatal diagnosis is normally based on the rare finding of a mass in the fetal neck. The differential diagnosis includes the following entities:

1. *Thyroid teratomas.* Cervical teratomas have an incidence of 0.5% to 3.5% of pediatric teratomas, typically in neonates. They can manifest as solid, semicystic, or multiloculated (Figs. 72.9–72.11) (see Chapter 71). Most often, teratomas derive from the embryonic thyroid anlage, even though thyroid tissue cannot always be identified in the pathologic specimen. Although fetal and pediatric thyroid teratomas are generally considered benign tumors, the size of the fetal mass and the



Fig. 72.8 Three-dimensional imaging of a fetal goiter. Surface rendering depicts the appearance of the thyroid mass. Multiplanar imaging may be helpful in the study of the relationship of the mass to its neighboring structures. *(From Corral E, Reascos M, Preiss Y, et al.: Treatment of fetal goitrous hypothyroidism: value of direct intramuscular L-thyroxine therapy,* Prenat Diagn. *2010;30:899-901.)*

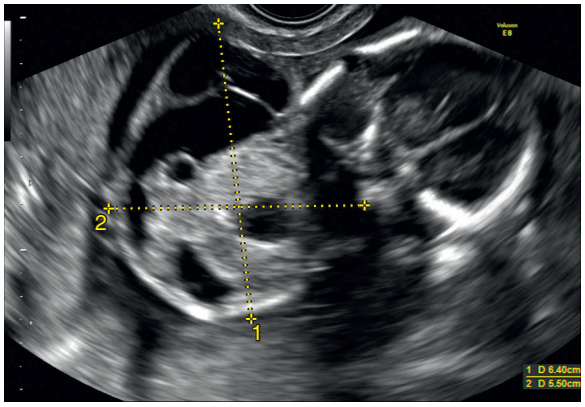

Fig. 72.9 Coronal view of a cervical teratoma. The US appearance of the mass that may aid in the diagnosis. Teratomas frequently have a semisolid appearance, as in this case.

compression over the esophagus or trachea leading to polyhydramnios may necessitate immediate neonatal intubation or EXIT at birth.

2. *Thyroglossal duct cysts.* The persistence of the thyroglossal duct, which is the hollow stalk of descent of the primitive pharynx to form the thyroid gland that usually disappears by the eighth week of gestation, and the accumulation of fluid inside of it can result in a thyroglossal duct cyst. This cyst is considered the most common congenital anomaly of thyroid development. The cyst can be located anywhere from the base of the tongue to the thyroid isthmus; it can be anechoic, hypoechoic, or complex. Excision should be performed after birth because there is an increased risk of infection of the cyst and for developing a cancer in thyroglossal duct cyst.[26]
3. *Branchial cleft cysts.* Branchial cleft cysts result from incomplete involution of the branchial apparatus, which appears by the fourth week of gestation, and is completely developed by 20 weeks' gestation. The lack of any solid elements or septations can be used to differentiate a branchial cleft cyst from a teratoma. Because of the potential upper airway compression at delivery and infection, a correct prenatal diagnosis is required, and early surgical excision is recommended. The prognosis is usually good after surgery.[27]
4. *Ectopic thymus.* Aberrant migration of the thymus causes the ectopic presence of remnants anywhere in the mediastinum, base of the skull, tracheal bifurcation, or cervical region. Ectopic thymus is rarely symptomatic because it does not invade contiguous structures, so it would very rarely cause polyhydramnios or tracheal occlusion that may necessitate perinatal intubation. When planning the excision of these remnants of the thymus, it is important to confirm the presence of the rest of the gland in its normal position because of the importance of this gland for the immune system.
5. *Other.* Other conditions that should be considered in fetal neck masses are cystic hygromas (Fig. 72.12), lymphangiomas or hemangiomas, and cervical neuroblastomas.[5,14,28]

Synopsis of Treatment Options

PRENATAL

When an early fetal goiter is detected in a mother with Graves disease who is taking antithyroid medication, the first step in treating the congenital goiter should be to decrease the dosage or discontinue the administration of medication before planning intraamniotic treatment with levothyroxine (L-T4).[2,3,6,22] However, a reduction in thyrostatic drugs is not always possible because of maternal intolerance to hyperthyroidism.[22] In most hypothyroid goiters, fetal therapy is necessary[12,14] and is able to reverse laboratory evidence of fetal hypothyroidism and reduce or resolve the neck mass. All reported cases have described a decrease in the size of the thyroid gland even when a single dose was administered.[1,29,30] The main objective for fetal treatment should be to decrease the mass size to improve associated obstetric morbidity, such as obstruction of the trachea and esophagus or dystocia caused by neck hyperextension.[a]

When fetal hypothyroidism is confirmed, replacement therapy with intraamniotic instillation of LT-4 should be considered. Intraamniotic instillation has seemed to be an ideal method for administration because of its technical simplicity.[7,14] However, Corral et al.[22] proposed that when critically impaired fetal swallowing is suspected that might prevent the intraamniotic medication from reaching the fetal circulation, intramuscular administration should be considered. LT-4 is considered the treatment of choice because its safety is based on its use in almost all the reported cases (Table 72.2) and because the passage of LT-4 to the mother is minimal.[20] The proper therapeutic dosage of LT-4 has not been standardized because of the small number of cases treated *in utero* and insufficient pharmacokinetics data of human fetal uptake and absorption of LT-4 from the amniotic fluid.[4,33] Different authors have reported a wide variety of hormone dosages and intervals of administration when treating congenital goitrous hypothyroidism (see Table 72.2). Intraamniotic doses of LT-4 ranging from 250 to 600 μg in either single or

[a]References 4, 7, 12, 14, 20, 31, and 32.

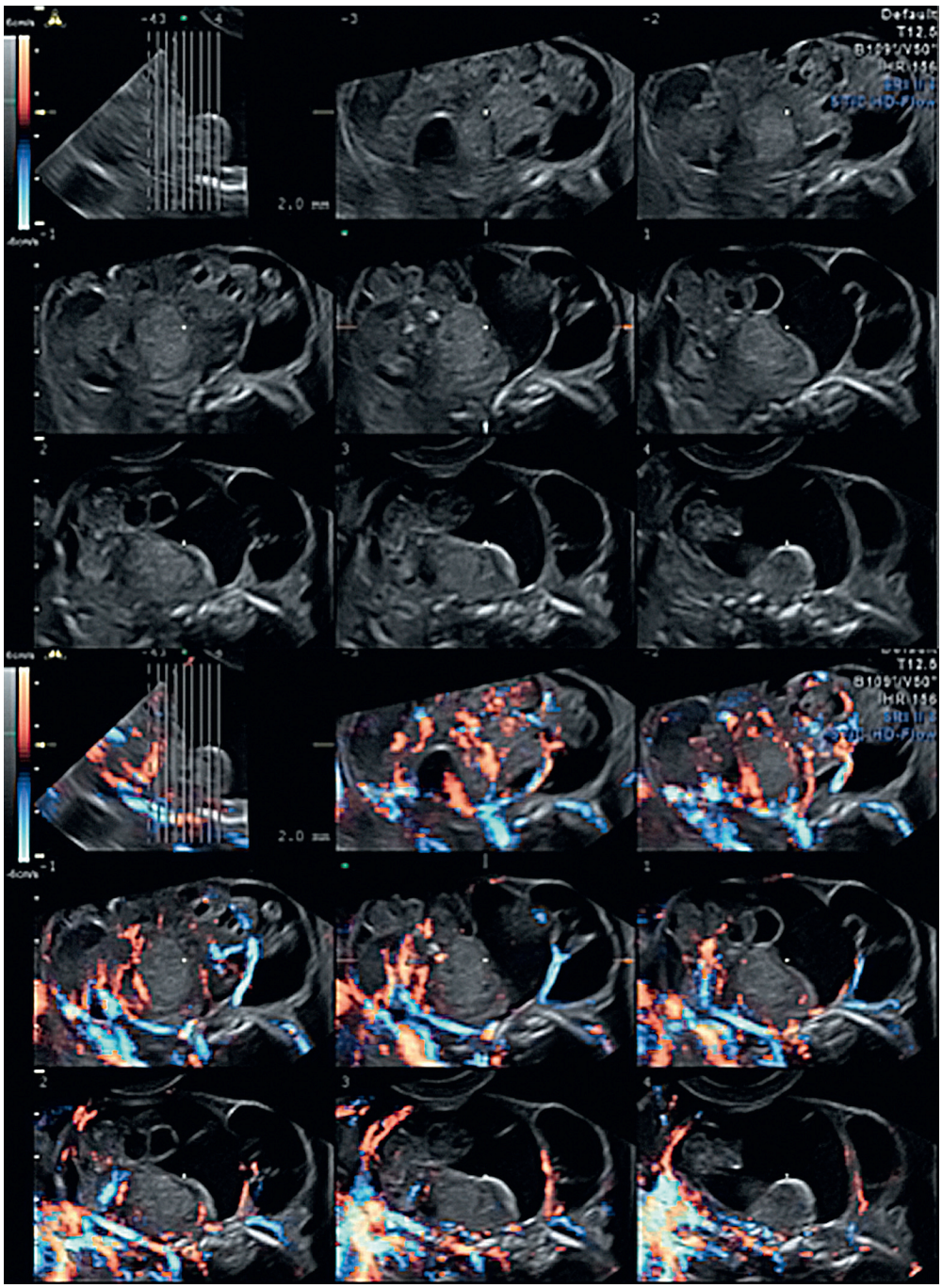

Fig. 72.10 Three-dimensional assessment of a cervical teratoma. Vascularization is increased.

repeated injections have been described.[7,12] Davidson et al.[7] first proposed using weekly doses of 250 µg of LT-4, based on their experience and the similarity with neonatal requirements. However, some authors encouraged "tailoring" the treatment, based on the response to the initial doses, and increasing the dose if necessary.[4] The best parameter to monitor the response to fetal treatment and adjust the dosage is TSH, which has the earliest response, and T_4 and triiodothyronine (T_3) in fetal serum.[4,9] In general, the effective dose of LT-4 seems to be influenced by the pathogenic basis of fetal goitrous hypothyroidism.[6] Amnioreduction should be considered as a symptomatic treatment in cases with severe polyhydramnios.

Hyperthyroidism should be treated by administering propylthiouracil or methimazole to the mother or, when already initiated, increasing the dose.[7,21,25] Occasionally, the mother may need small doses of replacement thyroid hormone.

POSTNATAL

Neonatal screening programs for congenital hypothyroidism were introduced in the 1970s and have been largely successful in facilitating diagnosis of congenital hypothyroidism shortly after birth, followed by treatment in the first weeks of life.[13] The early identification and treatment of newborns with congenital

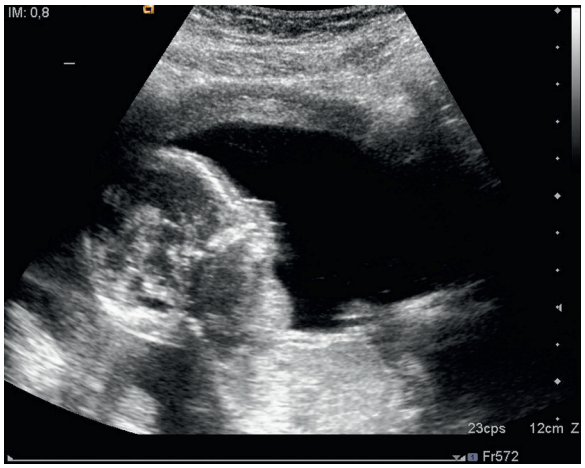

Fig. 72.11 Fetal cervical teratoma in a sagittal view. This neck mass was diagnosed at 16 weeks' gestation. The gestational age at which a neck mass is diagnosed can be helpful in the diagnosis. Typically, fetal goiters develop in the second or third trimesters. Cervical teratomas should be considered in the differential diagnosis of fetal goiters.

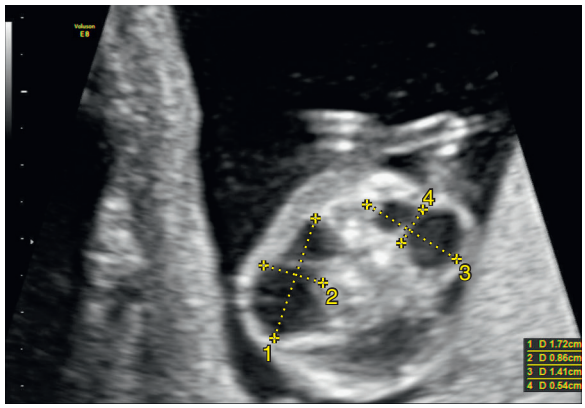

Fig. 72.12 Axial view of a cystic hygroma in the first trimester. The redundant cystic formation can also cause a compressive effect over the cervical structures. Cystic hygroma should be considered in the differential diagnosis of fetal neck masses.

TABLE 72.2 REVIEW OF TREATMENT OPTIONS FOR CONGENITAL GOITROUS HYPOTHYROIDISM

Study	Maternal Thyroid Disease	Fetal Goiter	Fetal L-T4 Treatment[a]	GA at Initiation of Therapy (Weeks)
Van Herle, 1973	Yes	NA	120 µg IM × 4	32
Lightner, 1977[34]	Yes	NA	500 µg IA × 3	33
Weiner, 1980[1]	Yes	Yes	200 µg IA × 1	33
Johnson, 1989[32]	No	Yes	500 µg IA × 2	34
Perelman, 1990[31]	No	Yes	500 µg IA × 3	34
Sagot, 1991[29]	No	Yes	300 µg IA × 1	36
Davidson, 1991[7]	Yes	Yes	250 µg IA × 3	35
Noia, 1992[30]	Yes	Yes	250 µg IA × 1	35
Abuhamad, 1995[20]	No	Yes	10 µg/kg IA weekly × 7	29
Van Loon, 1995[35]	Yes	Yes	250 µg IA weekly × 4	
Nicolini, 1996[36] (2 cases)	Yes	Yes	600 µg T_3 IA weekly × 5	22
Medeiros-Neto, 1997[13]	Yes	Yes	400 µg IA × 1	23
Bruner, 1997[37] (2 cases)	Yes	Yes	500 µg IA initially + 250 µg IA weekly × 5	29
	Yes	Yes	250 µg IA × 1	
Perrotin, 2001[16]	No	Yes	150 µg/kg IA weekly × 6	24
Gruner, 2001[4]	No	Yes	250 µg IA weekly × 5 500 µg IA weekly × 5	25
Agrawal, 2002[14]	No	Yes	450 µg IA × 2 60 µg T_3 IA × 3	29
Mirsaeid Ghazi, 2005[38]	No	Yes	500 µg IA weekly × 4	34
Miyata, 2007[6]	Yes	Yes	300 µg IA weekly × 2	37
Hanono, 2009[9]	No	Yes	250 µg IA 500 µg × 7	23
Corral, 2010[22]	Yes	Yes	500 µg IA 400 µg IA + 100 µg IM	24

[a]All doses are LT-4 unless noted as T_3 (triiodothyronine).
GA, Gestational age; *IA,* intraamniotic injection; *IM,* fetal intramuscular injection.

hypothyroidism is effective in preventing mental retardation and other long-term consequences in affected fetuses.[7,20]

In cases where a large neck mass is detected at term and a potential obstruction of the upper airway is suspected, EXIT could be used. This procedure maintains uteroplacental blood flow as the fetus is extracted from the uterine cavity, while maintaining the umbilical circulation (Fig. 72.13), until successful intubation by direct laryngoscopy. Before performing this procedure, a detailed study of the mass and its relationship to the trachea and esophagus should be carried out. Neck tumors, especially teratomas, are the most common cause for EXIT.



Fig. 72.13 EXIT. Fetal intubation is performed while the fetus is still connected to the mother.

WHAT THE REFERRING PHYSICIAN NEEDS TO KNOW

- Screening for fetal goiters should be carried out in pregnancies of mothers with thyroid disease, especially Graves disease.
- If a fetal goiter is detected, a detailed US examination should be performed looking for signs of either hyperthyroidism or hypothyroidism.
- Congenital hypothyroidism occurs most frequently and is associated with peripheral vascularization of the thyroid mass and delayed bone maturation. Congenital hyperthyroidism is associated with central vascularization of the thyroid mass, increased bone maturation, tachycardia, and IUGR.
- If the neck mass is large enough to compress the esophagus, polyhydramnios may be present, and a preterm delivery could occur. If there is tracheal occlusion, there is a risk of neonatal asphyxia, and the need for intubation should be anticipated.
- When a fetal goiter is detected, fetal thyroid function should be assessed, preferentially by cordocentesis. If there is congenital hypothyroidism, intraamniotic instillation of LT-4 is the preferred treatment option, although the dosage and the intervals of administration are not standardized.

KEY POINTS

- Fetal goiters are rare. They are associated more frequently with fetal hypothyroidism and less frequently with fetal hyperthyroidism. Prenatal euthyroid goiters can also exist.
- Graves disease in pregnant women is a risk factor for development of fetal goitrous hypothyroidism.
- Fetal goiters and some cervical masses can cause polyhydramnios, perinatal asphyxia, and fetal dystocia.
- Thyroid dysfunction can have deleterious effects on fetal development.
- The main objective of intrauterine treatment for fetal goiters is to decrease the mass size and, secondarily, to normalize thyroid function.
- Prenatal treatment of hypothyroid goiters should be with instillation of intraamniotic LT-4.

SUGGESTED READING

Abuhamad AZ, Fisher DA, Warsof SL, et al. Antenatal diagnosis and treatment of fetal goitrous hypothyroidism: case report and review of the literature. *Ultrasound Obstet Gynecol*. 1995;6:368-371.

Bruner JP, Dellinger EH. Antenatal diagnosis and treatment of fetal hypothyroidism: a report of two cases. *Fetal Diagn Ther*. 1997;12:200-204.

Gruner C, Kollert A, Wildt L, et al. Intrauterine treatment of fetal goitrous hypothyroidism controlled by determination of thyroid-stimulating hormone in fetal serum: a case report and review of the literature. *Fetal Diagn Ther*. 2001;16:47-51.

Mirsaeid Ghazi AA, Ordookhani A, Pourafkari M, et al. Intrauterine diagnosis and management of fetal goitrous hypothyroidism: a report of an Iranian family with three consecutive pregnancies complicated by fetal goiter. *Thyroid*. 2005;15:1341-1347.

Polak M, Van Vliet G. Therapeutic approach of fetal thyroid disorders. *Horm Res Paediatr*. 2010;74:1-5.

All references are available online at www.expertconsult.com.

REFERENCES

1. Weiner S, Scharf JI, Bolognese RJ, et al. Antenatal diagnosis and treatment of a fetal goiter. *J Reprod Med*. 1980;24:39-42.
2. Polak M, Van Vliet G. Therapeutic approach of fetal thyroid disorders. *Horm Res Paediatr*. 2010;74:1-5.
3. Huel C, Guibourdenche J, Vuillard E, et al. Use of ultrasound to distinguish between fetal hyperthyroidism and hypothyroidism on discovery of a goiter. *Ultrasound Obstet Gynecol*. 2009;33:412-420.
4. Gruner C, Kollert A, Wildt L, et al. Intrauterine treatment of fetal goitrous hypothyroidism controlled by determination of thyroid-stimulating hormone in fetal serum: a case report and review of the literature. *Fetal Diagn Ther*. 2001;16:47-51.
5. Jain V, Sharma R, Verma S, et al. Fetal euthyroid goiter. *Indian J Pediatr*. 2009;76:1259-1260.
6. Miyata I, Abe-Gotyo N, Tajima A, et al. Successful intrauterine therapy for fetal goitrous hypothyroidism during late gestation. *Endocr J*. 2007;54:813-817.
7. Davidson KM, Richards DS, Schatz DA, et al. Successful in utero treatment of fetal goiter and hypothyroidism. *N Engl J Med*. 1991;324:543-546.
8. American College of Obstetricians and Gynecologists. Thyroid disease in pregnancy. Practice Bulletin no. 148. *Obstet Gynecol*. 2015;125:996-1005.
9. Hanono A, Shah B, David R, et al. Antenatal treatment of fetal goiter: a therapeutic challenge. *J Matern Fetal Neonatal Med*. 2009;22:76-80.
10. Overcash RT, Marc-Aurele KL, Hull AD, et al. Maternal iodine exposure: a case of fetal goiter and neonatal hearing loss. *Pediatrics*. 2016;137(4).
11. Sasaki Y, Kikuchi A, Murai M, et al. Fetal goiter associated with preconception hysterosalpingography using an oil-soluble iodinated contrast medium. *Ultrasound Obstet Gynecol*. 2016 Mar 2.
12. Francois A, Hindryckx A, Vandecruys H, et al. Fetal treatment for early dyshormonogenetic goiter. *Prenat Diagn*. 2009;29:543-545.
13. Medeiros-Neto G, de Lacerda L, Wondisford FE. Familial congenital hypothyroidism caused by abnormal and bioinactive TSH due to mutations in the beta-subunit gene. *Trends Endocrinol Metab*. 1997;8:15-20.
14. Agrawal P, Ogilvy-Stuart A, Lees C. Intrauterine diagnosis and management of congenital goitrous hypothyroidism. *Ultrasound Obstet Gynecol*. 2002;19:501-505.
15. Goktolga U, Karasahin KE, Gezginc K, et al. Intrauterine fetal goiter: diagnosis and management. *Taiwan J Obstet Gynecol*. 2008;47:87-90.
16. Perrotin F, Sembely-Taveau C, Haddad G, et al. Prenatal diagnosis and early in utero management of fetal dyshormonogenetic goiter. *Eur J Obstet Gynecol Reprod Biol*. 2001;94:309-314.
17. Baumann NA, Gronowski AM. Establishment of reference intervals for thyroid-stimulating hormone and free thyroxine in amniotic fluid using the Bayer ADVIA Centaur. *Am J Clin Pathol*. 2007;128:158-163.
18. Hume R, Simpson J, Delahunty C, et al. Human fetal and cord serum thyroid hormones: developmental trends and interrelationships. *J Clin Endocrinol Metab*. 2004;89:4097-4103.
19. Singh PK, Parvin CA, Gronowski AM. Establishment of reference intervals for markers of fetal thyroid status in amniotic fluid. *J Clin Endocrinol Metab*. 2003;88:4175-4179.
20. Abuhamad AZ, Fisher DA, Warsof SL, et al. Antenatal diagnosis and treatment of fetal goitrous hypothyroidism: case report and review of the literature. *Ultrasound Obstet Gynecol*. 1995;6:368-371.
21. Volumenie JL, Polak M, Guibourdenche J, et al. Management of fetal thyroid goitres: a report of 11 cases in a single perinatal unit. *Prenat Diagn*. 2000;20:799-806.
22. Corral E, Reascos M, Preiss Y, et al. Treatment of fetal goitrous hypothyroidism: value of direct intramuscular L-thyroxine therapy. *Prenat Diagn*. 2010;30:899-901.
23. Achiron R, Rotstein Z, Lipitz S, et al. The development of the foetal thyroid: in utero ultrasonographic measurements. *Clin Endocrinol (Oxf)*. 1998;48:259-264.
24. Ranzini AC, Ananth CV, Smulian JC, et al. Ultrasonography of the fetal thyroid: nomograms based on biparietal diameter and gestational age. *J Ultrasound Med*. 2001;20:613-617.
25. Matsumoto T, Miyakoshi K, Kasai K, et al. Fetal goitrous hypothyroidism followed by neonatal transient hyperthyroidism: a case report. *Fetal Diagn Ther*. 2003;18:459-462.
26. Babcock DS. Thyroid disease in the pediatric patient: emphasizing imaging with sonography. *Pediatr Radiol*. 2006;36:299-308.
27. Tsai PY, Chang CH, Chang FM. Prenatal imaging of the fetal branchial cleft cyst by three-dimensional ultrasound. *Prenat Diagn*. 2003;23:605-606.
28. Vazquez E, Enriquez G, Castellote A, et al. US, CT, and MR imaging of neck lesions in children. *Radiographics*. 1995;15:105-122.
29. Sagot P, David A, Yvinec M, et al. Intrauterine treatment of thyroid goiters. *Fetal Diagn Ther*. 1991;6:28-33.
30. Noia G, De Santis M, Tocci A, et al. Early prenatal diagnosis and therapy of fetal hypothyroid goiter. *Fetal Diagn Ther*. 1992;7:138-143.
31. Perelman AH, Johnson RL, Clemons RD, et al. Intrauterine diagnosis and treatment of fetal goitrous hypothyroidism. *J Clin Endocrinol Metab*. 1990;71:618-621.
32. Johnson RL, Finberg HJ, Perelman AH, et al. Fetal goitrous hypothyroidism: a new diagnostic and therapeutic approach. *Fetal Ther*. 1989;4:141-145.
33. Morine M, Takeda T, Minekawa R, et al. Antenatal diagnosis and treatment of a case of fetal goitrous hypothyroidism associated with high-output cardiac failure. *Ultrasound Obstet Gynecol*. 2002;19:506-509.
34. Lightner ES. Congenital hypothyroidism: clues to an early clinical diagnosis. *J Fam Pract*. 1977;5:527-529.
35. Van Loon AJ, Derksen JT, Bos AF, et al. In utero diagnosis and treatment of fetal goitrous hypothyroidism, caused by maternal use of propylthiouracil. *Prenat Diagn*. 1995;15:599-604.
36. Nicolini U, Venegoni E, Acaia B, et al. Prenatal treatment of fetal hypothyroidism: is there more than one option? *Prenat Diagn*. 1996;16:443-448.
37. Bruner JP, Dellinger EH. Antenatal diagnosis and treatment of fetal hypothyroidism: a report of two cases. *Fetal Diagn Ther*. 1997;12:200-204.
38. Mirsaeid Ghazi AA, Ordookhani A, Pourafkari M, et al. Intrauterine diagnosis and management of fetal goitrous hypothyroidism: a report of an Iranian family with three consecutive pregnancies complicated by fetal goiter. *Thyroid*. 2005;15:1341-1347.

73 Congenital High Airways Obstruction Syndrome (CHAOS) and Bronchial Atresia

ROGELIO CRUZ-MARTÍNEZ | BIENVENIDO PUERTO

Introduction

Congenital high airway obstruction syndrome (CHAOS) is a rare fetal anomaly that is associated with a high mortality (80%–100%).[1] Prenatal diagnosis is clinically relevant in parental counseling and decision making regarding fetal surveillance, planning of fetal intervention, method of delivery, and postnatal management.[2,3] CHAOS can be bilateral or unilateral (bronchial atresia).

Disorder

DEFINITION

CHAOS is an extremely rare condition consisting of complete intrinsic obstruction of the fetal upper airway that can be located at the level of the larynx, trachea, or bronchi.[4] Airway obstruction results in retention of bronchial secretions, which leads to abnormal expansion of the fetal lungs, marked tracheobronchial dilatation, and pulmonary developmental impairment.

PREVALENCE AND EPIDEMIOLOGY

The incidence of CHAOS is unknown. Only a few cases have been reported in the literature.[5,6]

ETIOLOGY, PATHOPHYSIOLOGY, AND EMBRYOLOGY

CHAOS may present as an isolated anomaly with a low risk of chromosomal anomalies,[1] or in the context of a syndrome. When the obstruction is laryngeal, a significantly high proportion of cases are associated with Fraser syndrome, an autosomal recessive disease characterized by laryngeal atresia secondary to underlying fusion of the false vocal cords, cleft lip/palate, microphthalmia, syndactyly, ear anomalies, ambiguous genitalia, congenital heart disease, and severe oligohydramnios secondary to bilateral renal agenesis (Chapter 129).[7,8] In addition, other conditions can induce an extrinsic obstruction of the tracheobronchial tree, such as lymphatic congenital malformations, cervical teratoma, or vascular rings, such as double aortic arch or aberrant right subclavian artery.

The pathogenetic mechanism implicated for CHAOS includes intrinsic changes that prevented the normal development of the tracheobronchial tree during embryogenesis. The histopathologic findings of the fetal airways include the presence of webs, cysts, atresia, stenosis, or agenesis. Thus the cause of CHAOS can be a thin membrane, or web, obstructing the airway, or a more complex dysplasia and atresia of the affected portion of the airway. The obstructed flow of fetal lung fluid leads to intrapulmonary changes including alveolar hyperplasia and accumulation of fluid in the alveoli.[1]

MANIFESTATIONS OF DISEASE

Clinical Presentation

CHAOS is characterized by retention of bronchial and alveolar secretions resulting in elevated intratracheal pressure and a significant increment in the amount of fluid within the lungs and tracheobronchial tree, leading to severely increased lung volume and tracheal dilatation. The massively enlarged lung(s) result(s) in an inversion of the normal diaphragmatic convexity and, if the airway obstruction is unilateral, a mediastinal shift. These findings can be detected on ultrasound (US) in the first trimester of pregnancy.[8]

The diagnosis is usually made on examination of the fetal thorax, which is typically characterized by hyperexpanded and hyperechoic lungs (Fig. 73.1), flattened diaphragms, and

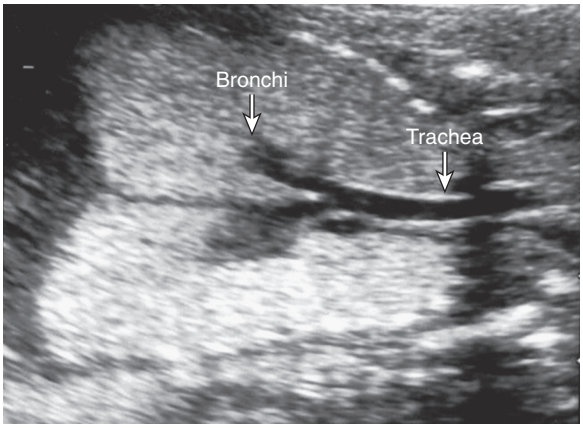

Fig. 73.1 Sagittal view of the fetal thorax shows a hyperexpanded and hyperechogenic lung with hydrothorax as an incipient sign of hydrops.

dilated airways below the level of the obstruction.[9] When the diagnosis of CHAOS is made, fetal surveillance includes weekly evaluation of lung sizes, amniotic fluid, and US signs of hydrops. Evaluation of cardiac function parameters such as Doppler of the ductus venosus and tricuspid regurgitation should also be performed to identify the early occurrence of hydrops.

CHAOS is usually a lethal abnormality, especially in the presence of Fraser syndrome. In the absence of additional congenital malformations, the prognosis depends on the lung size and the presence of hydrops. In the absence of hydrops, some cases might be salvageable with proper perinatal management.

Imaging Technique and Findings

Ultrasound. US usually shows signs related to complete airway obstruction. In a transverse view and at the level of the four-chamber view of the fetal heart, the lungs appear severely enlarged and highly hyperechoic. Secondary to the exceedingly high intrathoracic pressure and the degree of pulmonary expansion, the heart is squeezed into the middle of the fetal mediastinum between the lungs and shows a reduction of the cardiac angle. The sagittal and coronal views of the fetal thorax reveal two pathognomonic signs: flattening or inversion of the diaphragmatic convexity and markedly dilated airways, which allows observation of the entire tracheobronchial tree as a bronchogram (Fig. 73.2). The dilated trachea and bronchi are better displayed with a coronal view of the fetal chest. The diameter can be measured in a coronal or sagittal view (Fig. 73.3) and compared with normal reference ranges available in the literature.[10,11] In addition, absence of flow in the trachea during fetal breathing or swallowing can be shown using color Doppler US. Extrapulmonary signs include nonimmune hydrops fetalis and placentomegaly secondary to cardiac failure or impeded venous return, or both, and polyhydramnios secondary to esophageal compression.[5,6]

When CHAOS is unilateral (i.e., caused by bronchial atresia) it may affect the entire lung or the inferior lobes. US changes are similar in both cases. There is unilateral enlargement of the lung, which is clearly hyperechoic, inversion of the diaphragm in the same side, massive mediastinal shift that often evolves to hydrops fetalis, and a characteristic dilation of the airways in the affected lung. In rare cases, bronchial obstruction can be present in the absence of dilated bronchi on US, making the differential diagnosis between bronchial atresia and microcystic type III congenital cystic adenomatoid malformation (CCAM) very challenging.[12]

Magnetic Resonance Imaging. Magnetic resonance imaging (MRI) findings of CHAOS include confirmation of dilated airways below the level of obstruction, increased lung signal intensity, and large lung volumes with flattened or inverted hemidiaphragm(s). MRI can be very useful in the differential diagnosis between unilateral CHAOS and CCAM.[13] MRI also may help exclude additional congenital malformations and other conditions associated with extrinsic compression of the tracheobronchial tree, such as adjacent tumors.[14,15] Particularly in unilateral CHAOS, MRI may play an important role in the identification of the level of obstruction.[16,17] This information may be relevant for planning fetal surgery.

Differential Diagnosis From Imaging Findings

Differentiation between laryngeal and tracheal atresia is not feasible on US because both anomalies have the same imaging findings.

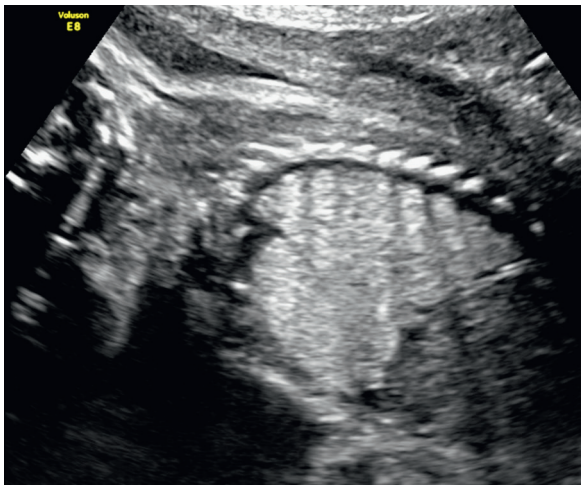

Fig. 73.2 US image obtained in a 25-week fetus with CHAOS. Coronal view of the fetal thorax shows expanded and hyperechogenic lungs with a flattened diaphragm and bifurcation of the trachea at the level of the carina in the two bronchi.

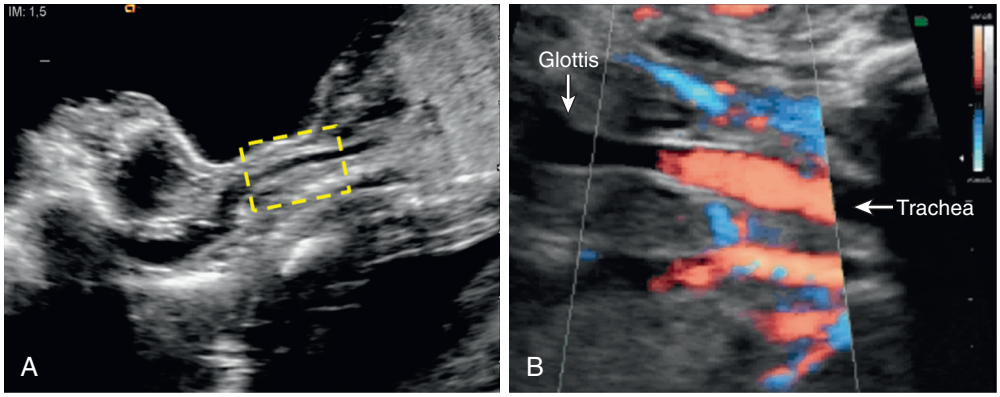

Fig. 73.3 (A) Image of a nondilated trachea obtained in a normal fetus in a sagittal view of the fetal neck. (B) Using Doppler US, the flow in the trachea is observed during fetal breathing.

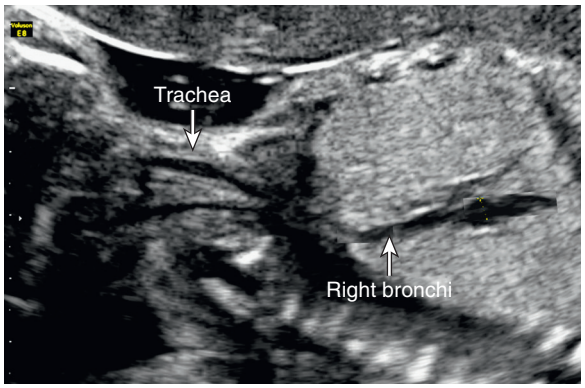

Fig. 73.4 Illustrative echographic image of a case with bronchial atresia. The affected lung appears hyperexpanded and hyperechogenic with unilateral bronchial and bronchiolar dilatation below the obstruction, appearing as a bronchogram.

Unilateral CHAOS (Fig. 73.4) must be distinguished from microcystic-solid CCAM.[18] Normally the visualization of dilated airways will make differential diagnosis easy, but in rare cases where airways are not dilated on US, MRI can be of help.

Synopsis of Treatment Options

PRENATAL

In most instances, the natural history of CHAOS includes progressive pulmonary enlargement with heart compression leading to hydrops, secondary to heart failure and subsequent perinatal death.[1]

Until recently the only available treatment option to improve survival of fetuses with CHAOS was *ex utero* intrapartum treatment (EXIT) with tracheal intubation and safe airway control.[19–21] If an endotracheal tube cannot be passed, a tracheostomy could be a reasonable option. Nonetheless, even with the combination of tracheostomy and EXIT, only a few survivors have been reported.[19–21] Survival has been reported to be associated with very high morbidity, including pulmonary dysplasia and insufficiency requiring long-term intubation, poorly functioning abdominal musculature caused by massive hydrops, and neurodevelopmental injury.

Recently, several case reports and small series have reported that selected fetuses with isolated CHAOS can benefit from *in utero* fetal therapy. When CHAOS is secondary to a single, isolated obstruction, fetal tracheoscopy can be used to break laryngeal webs, and bronchoscopy can be used to perforate the atretic bronchus and reconnect the dysplastic lung with the upper airways. These cases have resulted in a reversion of intrapulmonary expansion and hydrops, mediastinal decompression, and intact survival.[4,12,22–25]

Previous case reports have documented that spontaneous lung decompression may occur, but this does not seem to be the rule.[6]

POSTNATAL

Small case series assessing the consequences of CHAOS (not treated prenatally) have reported respiratory distress syndrome and capillary leak syndrome during the neonatal period, and tracheobronchomalacia and diaphragmatic paralysis (which may be caused by chronic diaphragmatic stretch) during the first year of life.[1,20] Although these reported complications are generally reversible, long-term mechanical ventilation, laryngeal reconstruction by a laryngotracheoplasty procedure, language skills delay, and suboptimal neurodevelopmental outcome have been described late in childhood.[1,20,23]

WHAT THE REFERRING PHYSICIAN NEEDS TO KNOW

- CHAOS is usually a lethal abnormality, especially in the presence of hydrops.
- Clinicians must rule out Fraser syndrome in fetuses with suspected CHAOS.

KEY POINTS

- The perinatal mortality of CHAOS is 100% without intervention.
- Classic US signs include hyperexpanded and hyperechoic lungs, flattened diaphragms, and dilated airways below the level of the obstruction.
- Fetuses with suspected CHAOS should be referred to a fetal medicine center with teams able to perform EXIT delivery.
- Fetal surgery may be a highly successful option in very selected isolated cases.

SUGGESTED READING

Martínez JM, Castañón M, Gómez O, et al. Evaluation of fetal vocal cords to select candidates for successful fetoscopic treatment of congenital high airway obstruction syndrome: preliminary case series. *Fetal Diagn Ther*. 2013;34:77-84.

Onderoglu L, Saygan Karamursel B, Bulun A, et al. Prenatal diagnosis of laryngeal atresia. *Prenat Diagn*. 2003;23:277-280.

Ryan G, Somme S, Crombleholme TM. Airway compromise in the fetus and neonate: prenatal assessment and perinatal management. *Semin Fetal Neonatal Med*. 2016;21:230-239.

Watson WJ, Thorp JM Jr, Miller RC, et al. Prenatal diagnosis of laryngeal atresia. *Am J Obstet Gynecol*. 1990;163:1456-1457.

All references are available online at www.expertconsult.com.

REFERENCES

1. Lim FY, Crombleholme TM, Hedrick HL, et al. Congenital high airway obstruction syndrome: natural history and management. *J Pediatr Surg*. 2003;38:940-945.
2. Watson WJ, Thorp JM Jr, Miller RC, et al. Prenatal diagnosis of laryngeal atresia. *Am J Obstet Gynecol*. 1990;163:1456-1457.
3. Richards DS, Yancey MK, Duff P, et al. The perinatal management of severe laryngeal stenosis. *Obstet Gynecol*. 1992;80:537-540.
4. Hedrick MH, Ferro MM, Filly RA, et al. Congenital high airway obstruction syndrome (CHAOS): a potential for perinatal intervention. *J Pediatr Surg*. 1994;29:271-274.
5. Gilboa Y, Achiron R, Katorza E, et al. Early sonographic diagnosis of congenital high-airway obstruction syndrome. *Ultrasound Obstet Gynecol*. 2009;33:731-733.
6. Vidaeff AC, Szmuk P, Mastrobattista JM, et al. More or less CHAOS: case report and literature review suggesting the existence of a distinct subtype of congenital high airway obstruction syndrome. *Ultrasound Obstet Gynecol*. 2007;30:114-117.
7. Schauer GM, Dunn LK, Godmilow L, et al. Prenatal diagnosis of Fraser syndrome at 18.5 weeks gestation, with autopsy findings at 19 weeks. *Am J Med Genet*. 1990;37:583-591.
8. Berg C, Geipel A, Germer U, et al. Prenatal detection of Fraser syndrome without cryptophthalmos: case report and review of the literature. *Ultrasound Obstet Gynecol*. 2001;18:76-80.
9. Onderoglu L, Saygan Karamursel B, Bulun A, et al. Prenatal diagnosis of laryngeal atresia. *Prenat Diagn*. 2003;23:277-280.
10. Kalache KD, Franz M, Chaoui R, et al. Ultrasound measurements of the diameter of the fetal trachea, larynx and pharynx throughout gestation applicability to prenatal diagnosis of obstructive anomalies of the upper respiratory-digestive tract. *Prenat Diagn*. 1999;19:211-218.
11. Richards DS, Farah LA. Sonographic visualization of the fetal upper airway. *Ultrasound Obstet Gynecol*. 1994;4:21-23.
12. Cruz-Martinez R, Mendez A, Perez-Garcilita O, et al. Fetal bronchoscopy as a useful procedure in a case with prenatal diagnosis of congenital microcystic adenomatoid malformation. *Fetal Diagn Ther*. 2015;37:75-80.
13. Kuwashima S, Kitajima K, Kaji Y, et al. MR imaging appearance of laryngeal atresia (congenital high airway obstruction syndrome): unique course in a fetus. *Pediatr Radiol*. 2008;38:344-347.
14. Coakley FV, Glenn OA, Qayyum A, et al. Fetal MRI: a developing technique for the developing patient. *AJR Am J Roentgenol*. 2004;182:243-252.
15. Courtier J, Poder L, Wang ZJ, et al. Fetal tracheolaryngeal airway obstruction: prenatal evaluation by sonography and MRI. *Pediatr Radiol*. 2010.
16. Mong A, Johnson AM, Kramer SS, et al. Congenital high airway obstruction syndrome: MR/US findings, effect on management, and outcome. *Pediatr Radiol*. 2008;38:1171-1179.
17. Guimaraes CV, Linam LE, Kline-Fath BM, et al. Prenatal MRI findings of fetuses with congenital high airway obstruction sequence. *Korean J Radiol*. 2009;10:129-134.
18. Balci S, Altinok G, Ozaltin F, et al. Laryngeal atresia presenting as fetal ascites, oligohydramnios and lung appearance mimicking cystic adenomatoid malformation in a 25-week-old fetus with Fraser syndrome. *Prenat Diagn*. 1999;19:856-858.
19. DeCou JM, Jones DC, Jacobs HD, et al. Successful ex utero intrapartum treatment (EXIT) procedure for congenital high airway obstruction syndrome (CHAOS) owing to laryngeal atresia. *J Pediatr Surg*. 1998;33:1563-1565.
20. Crombleholme TM, Sylvester K, Flake AW, et al. Salvage of a fetus with congenital high airway obstruction syndrome by ex utero intrapartum treatment (EXIT) procedure. *Fetal Diagn Ther*. 2000;15:280-282.
21. Bui TH, Grunewald C, Frenckner B, et al. Successful EXIT (ex utero intrapartum treatment) procedure in a fetus diagnosed prenatally with congenital high-airway obstruction syndrome due to laryngeal atresia. *Eur J Pediatr Surg*. 2000;10:328-333.
22. Kohl T, Van de Vondel P, Stressig R, et al. Percutaneous fetoscopic laser decompression of congenital high airway obstruction syndrome (CHAOS) from laryngeal atresia via a single trocar–current technical constraints and potential solutions for future interventions. *Fetal Diagn Ther*. 2009;25:67-71.
23. Paek BW, Callen PW, Kitterman J, et al. Successful fetal intervention for congenital high airway obstruction syndrome. *Fetal Diagn Ther*. 2002;17:272-276.
24. Martinez JM, Castanon M, Gomez O, et al. Evaluation of fetal vocal cords to select candidates for successful fetoscopic treatment of congenital high airway obstruction syndrome: preliminary case series. *Fetal Diagn Ther*. 2013;34:77-84.
25. Martinez JM, Prat J, Gomez O, et al. Decompression through tracheobronchial endoscopy of bronchial atresia presenting as massive pulmonary tumor: a new indication for fetoscopic surgery. *Fetal Diagn Ther*. 2013;33:69-74.

To access the videos in this chapter, scan this QR code or visit expertconsult.com

74 Ultrasound of Normal Fetal Heart

OLGA GÓMEZ | JOSEP M. MARTINEZ

Introduction

Congenital heart diseases (CHDs) are the most common severe congenital malformations, affecting 0.8% to 1% of newborns. Approximately half of the CHDs are severe defects. The overall mortality of a CHD diagnosed prenatally ranges from 25% to 35%, and about 15% of children born with a CHD die before they reach adolescence.

Overall, the risk of associated chromosomal aneuploidy lies between 15% and 30%, with an additional risk of other genetic anomalies, including microdeletions and microduplications, between 5% and 7%. A fetal CHD increases the risk of other extracardiac malformations 10-fold, therefore 25% to 40% of fetuses with a CHD will have an extracardiac malformation.

Most CHDs (>90% of cases) occur in fetuses with no history or known risk factor. Prenatal ultrasound (US) screening programs are essential for the detection and diagnosis of CHDs, allowing a correct evaluation of prognosis, management of pregnancy, and a delivery plan. Prenatal diagnosis is particularly relevant in those CHD where postnatal clinical evolution is dependent on the patency of the ductus arteriosus.

Normal Anatomy

GENERAL ANATOMIC DESCRIPTIONS

The heart is an organ with three connections on each side. On the left side, the pulmonary veins reach the left atrium, which communicates with the left ventricle and the aorta. On the right side, the superior vena cava and inferior vena cava drain into the right atrium, which connects with the right ventricle and the pulmonary artery. A complete cardiac US examination should visualize all these connections (including the morphology, size, and function of the different components) and the ductal and aortic arches.

Several cardiac planes or views[1–5] constitute the basic echocardiographic study at 19 to 22 weeks' gestation. The advanced echocardiographic study includes further sections and is reserved for high-risk patients.[6] The planes or views of a basic cardiac scan can be performed from the first trimester of pregnancy and include (Fig. 74.1):

1. examination of the upper abdomen
2. four-chamber view

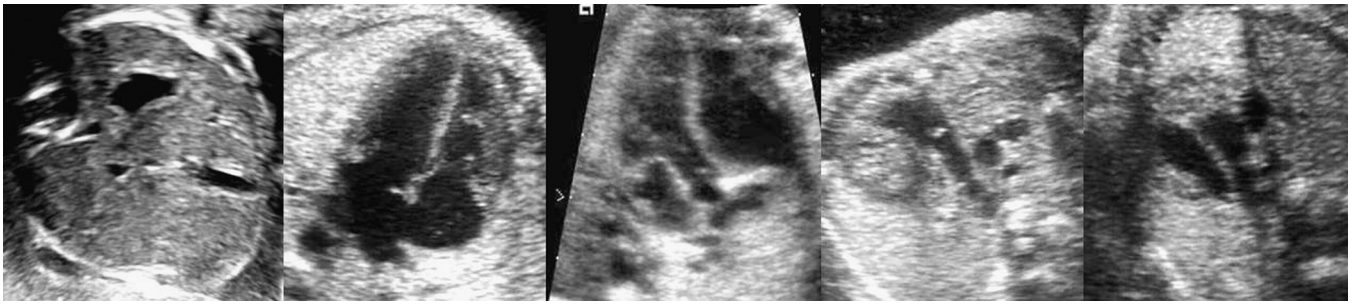

Fig. 74.1 Five short-axis views for CHD screening method during pregnancy as proposed by Yagel et al.[2]

3. five-chamber or left ventricular outflow tract view
4. short-axis or right ventricular outflow tract view
5. three-vessel and trachea view

The long-axis view of the right ventricle (Fig. 74.2) and other sagittal views, which include the cavoatrial junction view (Fig. 74.3) and the aortic arch view (Fig. 74.4), can be considered part of the advanced echocardiographic study (Table 74.1).

DETAILED DESCRIPTION OF SPECIFIC AREAS

Normal Variants

Upper Abdomen View. The upper abdomen view (Fig. 74.5) detects situs abnormalities, which are frequently associated with heart malformations. As a starting point, the fetal position and the right and left sides of the fetus should be established. In a cross-sectional plane, the stomach and the descending aorta are located on the left side of the fetus and the liver and the inferior vena cava are on the right. The umbilical vein enters the liver and continues toward the right into the portal sinus. The transducer has to be moved slightly cranially to obtain the four-chamber view. During this movement, the connection of the inferior vena cava to the right atrium can be checked.

Four-Chamber View. The four-chamber view (Fig. 74.6) can be easily obtained as a transverse view of the thorax at the level of the fourth rib (Fig. 74.6A) and permits the widest range of detection of CHD (major CHDs affecting the atria, ventricles, atrioventricular valves, and interventricular and interatrial septa can be identified in this plane). The study of the four-chamber view includes:

- Position of the heart in the thorax: in normal levocardia, two-thirds of the heart is on the left, and the heart axis is pointing to the left (see Fig. 74.6).
- Cardiac axis: compared with the sagittal axis, the cardiac axis is at 45 ± 20 degrees (see Fig. 74.6).
- Size of the heart: the normal area of the heart is less than one-third of the thoracic area, and the transverse diameter

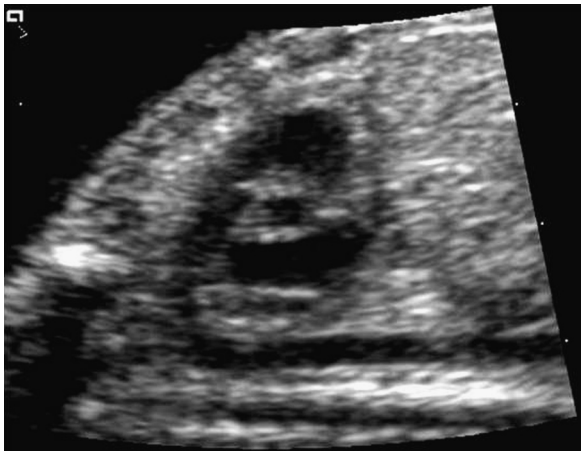

Fig. 74.2 Long-axis view of the right ventricle. The pulmonary artery arises from the right ventricle. The ductal arch has a perpendicular shape resembling a hockey stick.



Fig. 74.4 Aortic arch view. Note the presence of the three vessels to the head and the upper limbs and the right pulmonary artery, which can be recognized under the aortic arch in the cross section.

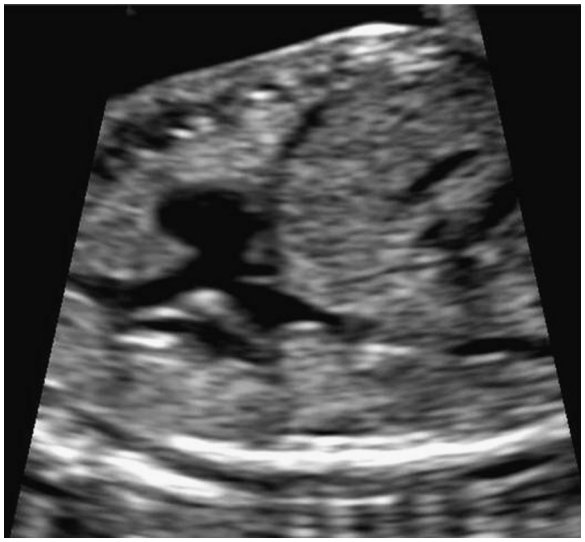

Fig. 74.3 Longitudinal view on the right side of the fetus shows the drainage of the superior vena cava and inferior vena cava to the right atrium.

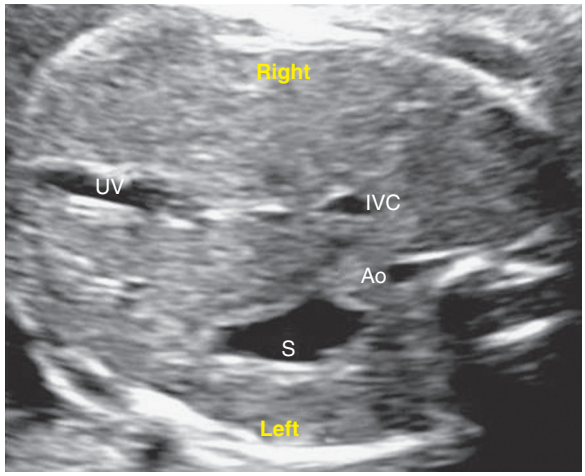

Fig. 74.5 Upper abdomen in a fetus in cephalic presentation. The stomach and descending aorta are correctly located on the left side of the fetus, and the inferior vena cava and the liver are on the right side. *Ao*, Aorta; *IVC*, inferior vena cava; *S*, stomach; *UV*, umbilical vein.

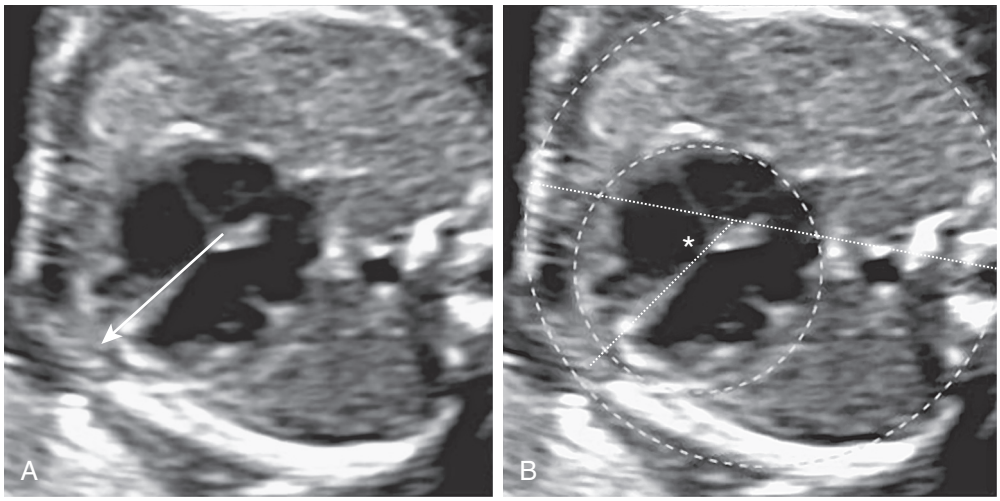

Fig. 74.6 (A) Four-chamber view of the same fetus as in Fig. 76.5 shows that two-thirds of the heart is on the left and the heart axis is pointing to the left. The transverse view of the thorax is correctly magnified and shows only one rib. (B) Normal heart axis *(asterisk)* and size are also shown.

TABLE 74.1 INDICATIONS FOR ADVANCED FETAL ECHOCARDIOGRAPHY

MATERNAL INDICATIONS
Metabolic syndrome (pregestational diabetes and phenylketonuria)
Exposure to teratogens: alcohol, high doses of ionizing radiation, drugs (anticonvulsants, lithium, warfarin, selected antidepressants and anxiolytics, retinoic acid), and maternal fever >38°C in the first trimester
Maternal CHD
Maternal connective disease (with presence of antiRo or antiLa antibodies)
High risk of aneuploidy in absence of previous invasive testing
In vitro fertilization conception
FAMILIAL INDICATIONS
Previous child with CHD
Father with CHD
Syndromes or conditions highly associated with CHD
Second-degree relative with CHD
FETAL INDICATIONS
Nuchal translucency >99th percentile between 11 and 14 weeks
Ductus venosus with absent or reversed atrial flow between 11 and 14 weeks
CHD suspected during fetal US screening
Presence of extracardiac malformation
Presence of chromosomal abnormality
Presence of fetal hydrops
Fetal infection: TORCH and coxsackievirus
Polyhydramnios, especially after an incomplete or difficult cardiac examination, or if there are other associated malformations
Intrauterine growth restriction, especially in severe and early cases
Monochorionic multiple gestations
Presence of fetal arrhythmia
Antiinflammatory treatment with risk of restriction of the ductus arteriosus (if not sporadic treatment, especially during the third trimester)

CHD, Congenital heart diseases; *TORCH,* toxoplasmosis, other [congenital syphilis and viruses], rubella, cytomegalovirus, and herpes simplex virus.

of the heart at the level of the atrioventricular valves is less than one-half of the transverse diameter of the thorax (see Fig. 74.6).

- Rhythm: a regular rate between 120 beats/min and 160 beats/min should be confirmed.

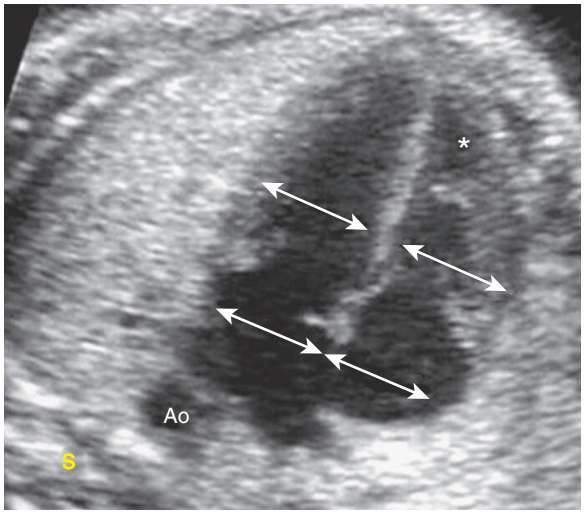

Fig. 74.7 Normal apical four-chamber view shows symmetric atria and ventricles *(asterisk).* The moderator band is correctly visible in the anterior ventricle corresponding to the right ventricle. *Ao,* Aorta; *S,* stomach.

- Contractility: the synchronous contraction of both atria and ventricles should be confirmed.
- Evaluation of the presence of pericardial effusion: pericardial effusion is physiologic if less than 2 mm and the atrioventricular level is not exceeded.
- Confirmation of the existence of four chambers and evaluation of the symmetry between the atria and the ventricles: both atria are nearly equal in size. The lumen of the left ventricle is longer than the lumen of the right ventricle and reaches the apex of the heart. The right ventricle has a short lumen mainly because of the presence of the moderator band, a septomarginal trabeculum coursing from the interventricular septum to the lower free wall of the right ventricle (Fig. 74.7).
- Assessment of the position of the left and right sides of the heart: the right ventricle appears as the most anterior cardiac structure, and the left ventricle is posterior to the right ventricle and the most left-sided cardiac structure. The right ventricle is trabeculated, and its cavity is irregular, whereas the inner shape of the left ventricle is smooth. As mentioned, the right

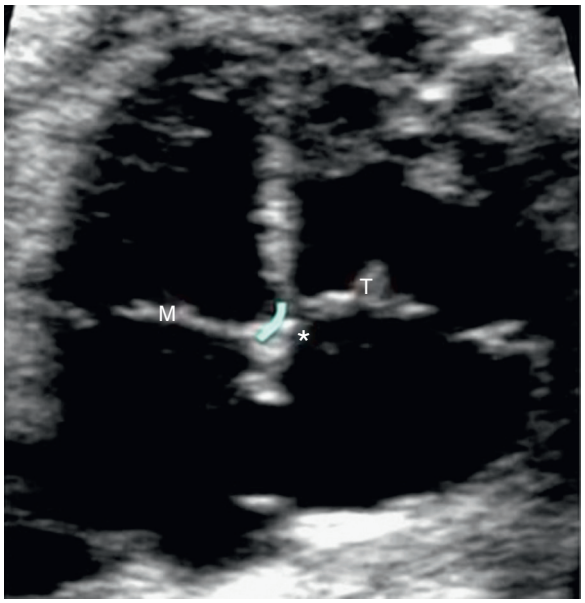

Fig. 74.8 Apical four-chamber view in which the atrioventricular septum is clearly visible between the right atrium and the left ventricle, which indicates correct implantation of the mitral and tricuspid valves. *M,* Mitral valve; *T,* tricuspid valve.

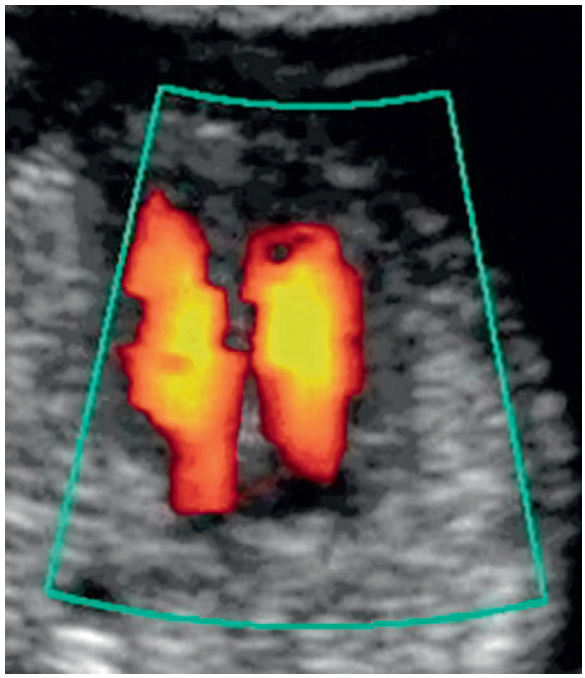

Fig. 74.9 Color Doppler confirmation of normal diastolic flow across both atrioventricular valves.

ventricle can be recognized by the presence of the moderator band. The left atrium is the most posterior cardiac chamber and is recognized by the connections of the pulmonary veins and the leaflet of foramen ovale, which bulges into it. The descending aorta is a circular pulsating structure positioned anterior-lateral to the spine and behind the left atrium (see Fig. 74.7).

- Confirmation of the pulmonary venous drainage to the left atrium: color Doppler can help identify the superior and inferior pulmonary veins (Video 74.1).
- Assessment of the correct implantation of the two atrioventricular valves*:* it is another important feature to distinguish both ventricles (Fig. 74.8). Both valves are implanted separately in the interventricular septum. The tricuspid valve is slightly more apical. This leaves a space between the insertions, the atrioventricular septum, which separates the right atrium from the left ventricle.
- Assessment of function of the atrioventricular valves: it is important to confirm that both valves open freely during diastole (the cine-loop function can be useful for this) and close correctly during systole (absence of regurgitation evaluated by color Doppler) (Fig. 74.9).
- Evaluation of the interventricular septum: the long axis four-chamber view and the application of color Doppler allow a better evaluation of the septum (Fig. 74.10).
- Assessment of the interatrial septum: the septum primum and foramen ovale (with its flap that freely moves into the left atrium) should be identified (Fig. 74.11).

Five-Chamber or Left Ventricular Outflow Tract View. The transducer should be moved slightly cranially to identify the left ventricular outflow tract. This plane is essential to identify more anterior ventricular septum defects and heart defects affecting the aortic valve and involving the great arteries, such as conotruncal defects. The aorta arises as a vessel continuing from the ventricular septum anteriorly, which also has a close connection

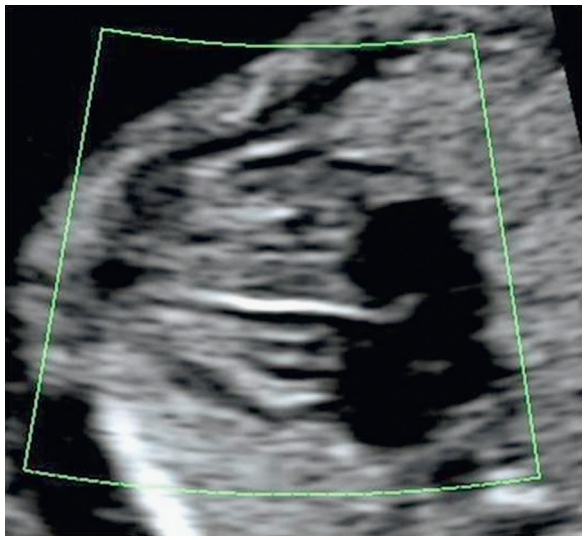

Fig. 74.10 Transverse four-chamber view shows a normal interventricular septum. Color Doppler shows the absence of flow across the interventricular septum.

with the mitral valve posteriorly. It is important to confirm also the angulation of the aorta (Fig. 74.12) and the septum (the ascending aorta points slightly to the right side), the size of the aortic root, the size of the ascending aorta, and the opening movements of the aortic valve. Color Doppler may be useful to identify normal aortic flow.

Short-Axis or Right Ventricular Outflow Tract View. The right ventricular outflow tract plane is easy to obtain by successively tilting the transducer from the four-chamber and five-chamber view to the head of the fetus. This view is an important plane to identify heart defects affecting the pulmonary artery and the great arteries. Assessment of ventriculoarterial

concordance is mandatory to identify conotruncal defects, which can have a normal four-chamber view. Thus it is important to confirm that the vessel arising from the right ventricle is the pulmonary trunk, which crosses perpendicularly over the ascending aorta and becomes the vessel on the left side (Fig. 74.13). The pulmonary artery can be differentiated from the aorta because of its straight course toward the spine of the fetus and its close trifurcation in the pulmonary arteries and ductus arteriosus (Fig. 74.14). In this view, the left pulmonary artery is not visible, whereas the right pulmonary artery can be recognized in its course under the aortic root, toward the right lung. The examiner should check for the correct connection of the right ventricle with the pulmonary artery, the crossing of the pulmonary artery with the ascending aorta, the size of the pulmonary trunk, and the correct opening movements of the pulmonary valve. The pulmonary trunk is slightly larger than the aorta. Well-designed gestational age corrected references for sizes of the aorta and pulmonary artery are available.[7] Color Doppler is also a useful tool to confirm that there is a normal pulmonary flow pattern. Finally, in this view, two other vessels can be recognized on the right side of the pulmonary trunk: the ascending aorta and the superior vena cava (see Fig. 74.14).

Three-Vessel and Trachea View. The three-vessel and trachea view is the most recently described fetal heart view; it allows simultaneous visualization of the aortic and ductus arteriosus arches, which generally are more difficult to visualize in the sagittal views. This plane is easy to obtain from the four-chamber view because the transducer has to be moved only parallel and

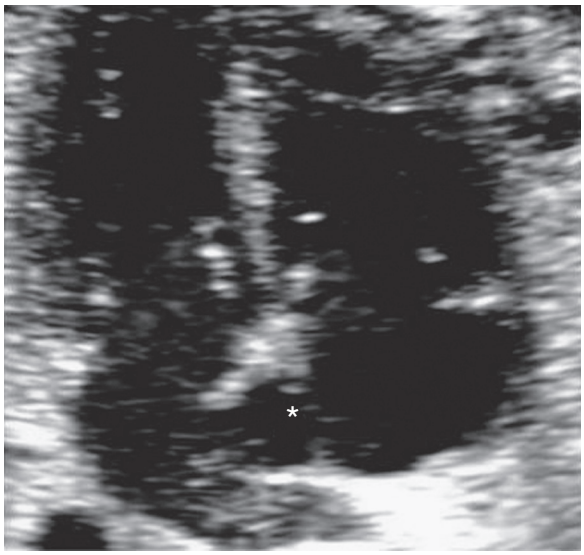

Fig. 74.11 Four-chamber view during systole. The septum primum above the atrioventricular valves can be recognized. A foramen ovale of normal size with a flap can be identified in the left atrium.



Fig. 74.12 Five-chamber view shows that the aorta arises from the left ventricle. The continuity between the aorta and the ventricular septum can be confirmed.

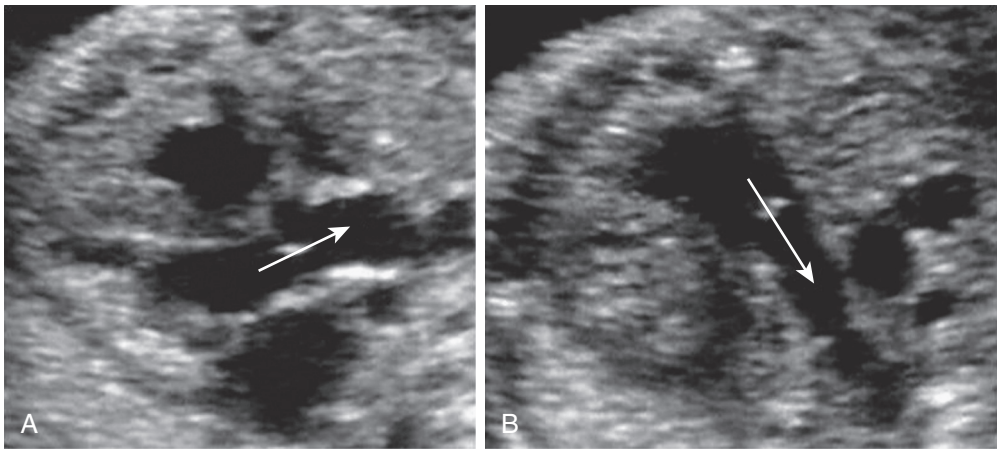

Fig. 74.13 (A) Transverse five-chamber view. The ascending aorta points to the right side. (B) Upper right outflow view. The pulmonary artery crosses perpendicularly over the ascending aorta *(arrow)*.

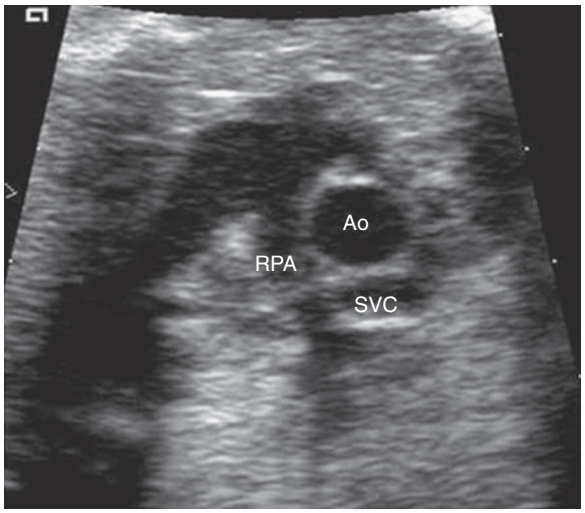

Fig. 74.14 Short-axis view of the right ventricle as described by Yoo et al.[1] The right pulmonary artery, the ascending aorta, and the superior vena cava can be distinguished. *Ao,* Aorta; *RPA,* right pulmonary artery; *SVC,* superior vena cava.

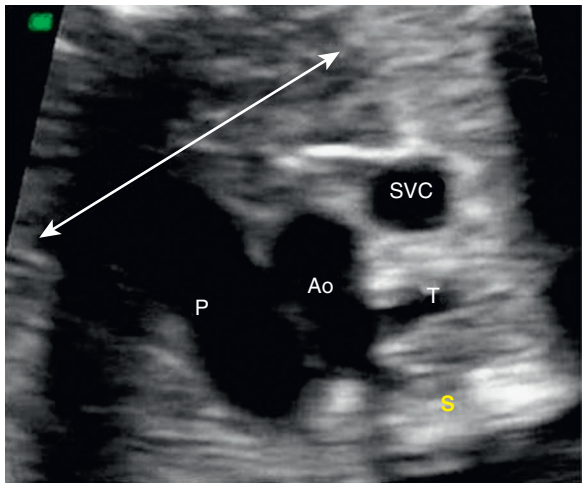

Fig. 74.15 Transverse view of the upper thorax of a fetus at 21 weeks' gestation. The ductal *(left)* and aortic *(right)* arches can be seen in a tangential cross-sectional view. The superior vena cava and the trachea can be visualized to the right of the aorta. The thymus can be identified in front of the vessels in a transverse view. *Ao,* Aorta; *P, pulmonary artery; SVC,* superior vena cava; *S,* stomach; *T,* trachea.

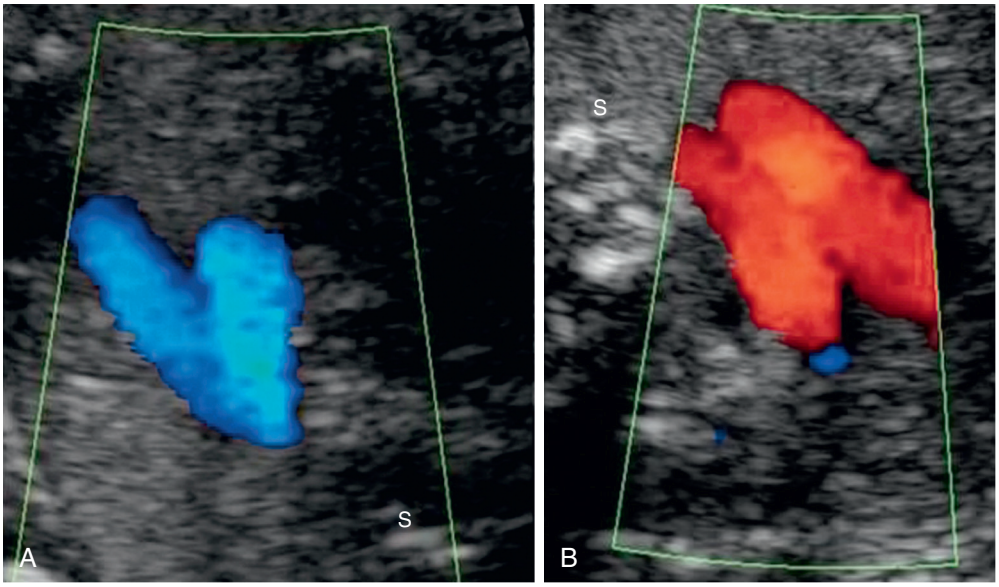

Fig. 74.16 Color Doppler shows normal flow in two different projections of three-vessel and trachea views. *S,* Stomach.

slightly to the left in the direction of the upper thorax. At this upper level of the thorax, the aortic and the ductal arches can be seen in a tangential cross section and build a "V" form, pointing to the posterior thorax on the left side of the spine (Fig. 74.15). The trachea can be recognized as a circular structure adjacent to and on the right side of the aortic isthmus. In front of the trachea and on the right side of the aortic arch, the superior vena cava can also be recognized. In this view, it is mandatory to identify the number of vessels, to confirm their correct positions (from left to right side: the ductus arteriosus arch, the aortic arch, and the superior vena cava), to compare their sizes (which normally decrease from left to right), and to identify the trachea in relation to the aortic isthmus.

Using color Doppler, the visualization of antegrade flow within both great vessels and arches under normal conditions can be easily confirmed (Fig. 74.16). In front of these three vessels, the thymus can be identified as a structure that is less echogenic than the adjacent lungs (see Fig. 74.15). The assessment of the three-vessel and trachea view is very important to identify many outflow tract and arch disorders and to assess the ductus dependency of different CHDs.

Longitudinal Views of the Fetal Heart. Sagittal views are not part of the routine cardiac scan. They permit the evaluation of the ductal arch (also called the *right ventricle long-axis view*), the aortic arch, and the cavoatrial junction. The pulmonary artery arises from the anterior right ventricle and courses straight and

slightly to the left toward the descending aorta. The ductal arch has a perpendicular shape and resembles a hockey stick (Videos 74.2 and 74.3; see Fig. 74.2). The aortic arch arises from the left ventricle below the ductal arch. The ascending aorta courses first to the right and then to the left. The aortic arch resembles a candy cane, and the three supraaortic vessels can be easily recognized (Videos 74.4 and 74.5; see Fig. 74.4). Under the aortic arch, the right pulmonary artery can be seen in a cross section. Finally, a last sagittal view situated on the right side of the fetus can show the drainage of the inferior vena cava and superior vena cava to the right atrium (Video 74.6; see Fig. 74.3). At this point, it is easy to identify the presence of the ductus venosus, which connects the umbilical vein with the inferior vena cava (Video 74.7).

These planes can only be obtained in a few fetal positions and are difficult to interpret by inexperienced examiners, especially in abnormal cases. The basic information about the main outflow tracts and the vena cava can be more reproducibly obtained in the axial planes described previously.

Early Fetal Echocardiography. Experience with US signs of aneuploidy between 11 and 14 weeks' gestation has shown that both nuchal translucency and ductus venosus Doppler have an important association with CHDs. These signs can be used during the first trimester of pregnancy to select women with a high risk of having a child with a CHD. This observation represents one of the most important advances for early prenatal detection of CHD.

Many studies have shown that echocardiography performed between 12 weeks' and 14 weeks' gestation by expert trained examiners is a technique with a high diagnostic accuracy and has clear advantages over echocardiography performed during the second trimester. The diagnosis of CHD in the first trimester permits counseling the couple about the prognosis of the defect in the early stages of pregnancy. Possible associated extracardiac malformations and chromosomal abnormalities can also be excluded. Finally, the finding of a normal echocardiographic study reduces the anxiety of the parents (Videos 74.8 and 74.9).

Differential Considerations

The main objective of fetal echocardiography is to identify the CHD to establish the prognosis and manage the pregnancy and delivery. Summaries of CHDs detectable by echocardiography during fetal life are briefly discussed here in order of frequency of prenatal recognition. The chapters that follow discuss these in more detail.

Ventricular Septal Defect. Ventricular septal defect (VSD) is the most common CHD during fetal life and at birth, accounting for 30% of CHDs. Prenatal diagnosis of VSD is difficult, in particular for small and isolated VSDs. The diagnosis is based on the identification of the defect in the septum on the four-chamber view for perimembranous, inlet, and muscular VSDs and on the five-chamber or left ventricular outflow tract view for infundibular VSDs. Prenatal detection of VSDs is very important because these defects are frequently associated with other CHDs, extracardiac malformations, and chromosomal abnormalities (especially large or perimembranous VSDs).

Hypoplastic Left Heart Syndrome. Hypoplastic left heart syndrome (HLHS) accounts for 15% to 20% of fetal CHDs. HLHS can be easily recognized on the four-chamber view (single atrioventricular inlet). The left ventricular outflow tract view and the three-vessel and trachea view also help make the diagnosis. HLHS has the worst prognosis of all CHDs, with a high perinatal morbidity and mortality, despite advances in neonatal cardiology and cardiac surgery.

Tetralogy of Fallot and Transposition of Great Arteries. Tetralogy of Fallot (TOF) and transposition of great arteries (TGA) each account for 10% of fetal CHDs. These CHDs can be identified on the ventricular outflow tract views; typically, four-chamber views are normal. An overriding aorta and an absence of crossing over between the aorta and the pulmonary arteries are the guide signs to identify TOF and TGA. It is important to identify TOF because 30% of cases are associated with chromosome abnormalities (including microdeletion 22q11). The risk of chromosomal abnormalities and the postnatal outcome depend on the degree of pulmonary obstruction. TGA is usually isolated; however, its identification prenatally significantly improves the postnatal prognosis, especially when the interventricular septum is intact.

Atrioventricular Septal Defect. Atrioventricular septal defect (AVSD) accounts for 5% to 10% of fetal CHDs. AVSD is among the most frequently diagnosed CHDs during fetal life because it always alters the four-chamber view. In this view, the normal offset aspect of the atrioventricular plane is absent because of a common atrioventricular valve. In the fetus, AVSD can be considered a complex anomaly; it is highly associated with chromosomal abnormalities (especially trisomy 21) and with cardiosplenic syndromes. Only 30% of AVSDs diagnosed during the second trimester of pregnancy are isolated.

Coarctation of Aorta. Coarctation of aorta accounts for 5% of fetal CHDs. It is difficult to diagnose during fetal life, and it is always considered a presumptive diagnosis. It can be suspected on the four-chamber view because of the presence of a marked dominance of right cavities. Prenatal detection is very important because coarctation of the aorta is associated with chromosomal abnormalities (especially Turner syndrome) in 15% of cases, and the postnatal outcome is improved if neonatal management is correctly planned.

Other Types of Congenital Heart Disease. Other CHDs account for approximately 15% of fetal CHDs. Some CHDs are more difficult to identify, especially for less experienced examiners. The incorporation of the previously described "new" echocardiographic fetal planes into the US scan at 19 to 22 weeks' gestation is now the key for the diagnosis of most fetal CHDs.

Finally, some CHDs cannot be identified or are very difficult to identify in the fetus. Ostium secundum atrial septal defects and patent ductus arteriosus may be physiologic situations in fetal life. Likewise, small VSD (<1 to 2 mm), valvular stenosis, mild forms of coarctation of aorta, and evolutionary CHD are unlikely to be diagnosed prenatally.

Pertinent Imaging Considerations

Technical factors in performing a fetal echocardiography include the following:

- The highest possible transducer frequency should be used.
- Harmonic imaging may provide improved images especially for patients with increased maternal abdominal wall thickness.
- System settings with a high-frame rate and with increased contrast resolution should be used. Low-frame persistence, a single acoustic focal zone, and a narrow image field should also be used for this purpose.
- Images should be magnified until the heart fills at least one-third to one-half of the display screen.

- If available, a cine-loop feature can be used to assist the evaluation of the heart.
- For color Doppler, the color scale should be adjusted between 40 cm/s and 70 cm/s (depending on gestational age). To study the pulmonary veins, a scale between 25 cm/s and 30 cm/s should be chosen.

KEY POINTS

- CHDs are the most common severe congenital malformations. Most occur in fetuses with no history or risk factors.
- US study of the fetal heart during the second trimester of pregnancy is the main tool for the diagnosis of fetal CHD.
- US study of the fetal heart should include the following views (Video 74.10): examination of the upper abdomen, four-chamber view, five-chamber or left ventricular outflow tract view, short-axis or right ventricular outflow tract view, and three-vessel and trachea view.
- The systematic study of the fetal heart with the aforementioned views permits the identification of most of the major CHDs.

SUGGESTED READING

Allan L, Hornberger L, Sharland G. *Textbook of fetal cardiology*. London: Greenwich Medical Media Limited; 2000.

Donofrio MT, Moon-Grady AJ, Hornberger LK, et al. Diagnosis and treatment of fetal cardiac disease. A scientific statement from the American Heart Association. *Circulation*. 2014;129:2183-2242.

Gardiner H, Chaoui R. The fetal three-vessel and trachea view revisited. *Semin Fetal Neonatal Med*. 2013;18:261-268.

ISUOG Guidelines. ISUOG Practice Guidelines (updated): sonographic screening examination of the fetal heart. *Ultrasound Obstet Gynecol*. 2013;41:348-359.

Jansen F, Blummenfeld Y, Fisher A, et al. Array comparative genomic hybridization and fetal congenital heart defects: a systematic review and meta-analysis. *Ultrasound Obstet Gynecol*. 2015;45:27-35.

Paladini D, Volpe P. *Ultrasound of congenital fetal anomalies. Differential diagnosis and prognostic indicators*. Boca Raton: CRC Press, Taylor and Francis Group; 2014.

Yagel S, Silverman NH, Gembruch U. *Fetal cardiology. Series in maternal fetal medicine*. New York: Informa Healthcare; 2009.

All references are available online at www.expertconsult.com.

REFERENCES

1. Yoo SJ, Lee YH, Kim ES, et al. Three vessel view of the upper mediastinum: an easy means of detecting abnormalities of the ventricular outflow tracts and great arteries during obstetric screening. *Ultrasound Obstet Gynecol*. 1997;9:173-182.
2. Yagel S, Cohen SM, Achiron R. Examination of the fetal heart by five short-axis views: a proposed screening method for comprehensive cardiac evaluation. *Ultrasound Obstet Gynecol*. 2001;17:367-369.
3. Yagel S. The three vessels and trachea view (3VT) in fetal cardiac scanning. *Ultrasound Obstet Gynecol*. 2002;20:340-345.
4. Chaoui R, McEwing R. Three cross-sectional planes for fetal color Doppler echocardiography. *Ultrasound Obstet Gynecol*. 2003;21:81-93.
5. Viñals F, Heredia F, Giuliano A. The role of the three vessels and trachea view (EVT) in the diagnosis of congenital heart defects. *Ultrasound Obstet Gynecol*. 2003;22:358-367.
6. Chaoui R. The four-chamber view: four reasons why it seems to fail in screening for cardiac abnormalities and suggestions to improve detection rate. *Ultrasound Obstet Gynecol*. 2003;22:3-10.
7. Schneider C, McCrindle BW, Carvalho JS, et al. Development of Z-scores for fetal cardiac dimensions from echocardiography. *Ultrasound Obstet Gynecol*. 2005;26:599-605.

SECTION TWO

Septal Defects

To access the videos in this chapter, scan this QR code or visit expertconsult.com

75 Ventricular Septal Defect

OLGA GÓMEZ | JOSEP M. MARTINEZ

Introduction

Ventricular septal defect (VSD) is the most common congenital heart disease (CHD) in children and adults. VSD is present in 25% to 30% of newborns with a CHD. VSD can frequently occur in combination with other CHDs, as part of complex heart defects, which are discussed in Chapters 76, 77, 83, and 85 to 88. This chapter addresses the prenatal features of isolated VSDs.

Disease

DEFINITION

VSDs are openings in the ventricular septum that freely communicate between the left and right ventricles. These defects are classified according to their location in the ventricular septum and may involve one or more components of the septum. The particular location of the defect has no bearing on the direction of the intracardiac shunt but has significant predictive value in terms of the frequency of involvement of the semilunar or atrioventricular valves, associated anomalies, and spontaneous closure.

PREVALENCE AND EPIDEMIOLOGY

The incidence of VSD ranges from 3:1000 to 5:1000 live births. VSD is the most common form of CHD in childhood. Although VSDs represent approximately 25% to 30% of all CHDs at birth, they are often unrecognized *in utero,* accounting for only 5% to 7% of all prenatally diagnosed CHDs.

ETIOLOGY AND PATHOPHYSIOLOGY

The etiology is multifactorial. Although only a few VSDs are associated with chromosomal abnormalities in the child, when a VSD is diagnosed in the fetus, the risk of chromosomal abnormalities is much greater (5% to 10%, especially in large or perimembranous VSD).[1–4] VSD can frequently occur in combination with, and may lead to the diagnosis of, other CHDs

and extracardiac malformations. The prenatal diagnosis of VSDs may be of great clinical relevance.

There are four types of VSD (Fig. 75.1):

1. Perimembranous VSD (70%–80%, also called *paramembranous* or *infracristal*): located in the membranous septum, which is the base of the heart between the inlet and the outlet components of the muscular septum.
2. Inlet VSD (<5%, also called *posterior* or *lower*): involving the inlet muscular septum, which is inferior-posterior to the membranous septum.
3. Muscular VSD (15%–20%): located in the trabecular muscular septum; can also be classified as *midmuscular* (superior to the moderator band) and *apical* (inferior to the moderator band).
4. Infundibular VSD (<5%, also called *outlet, supracristal, choanal, conoventricular, subpulmonary,* or *doubly committed subarterial defects*): located in the infundibular muscular septum, which is the portion of the septum separating the right and left ventricular outflow tracts.

The proportions mentioned here are the classic ones. The reported incidence of each type of VSD may change in the future because with the increasing use of color Doppler, more muscular VSDs currently are diagnosed *in utero* than perimembranous VSDs.

MANIFESTATIONS OF DISEASE

Clinical Presentation

The presence of an isolated VSD *in utero* has little effect on the normal cardiac physiology because pressures generated in each ventricle are quite similar, leading to minimal shunting of blood despite even large ventricular communications. When the infant is delivered, there is an immediate decrease in pulmonary vascular resistance and lower pressures in the right ventricle, whereas the left ventricle contracts against high systemic vascular resistance, generating higher pressures. A left-to-right shunt results, the magnitude of which is influenced by the size of the defect, the pressure in the right and left ventricles, and the pulmonary resistance. Over time, large defects may lead to Eisenmenger syndrome with pulmonary hypertension, in which elevated pulmonary artery pressure eventually leads to reversal in the direction of shunting, desaturation, cyanosis, and secondary erythrocytosis.

Imaging Technique and Findings

Ultrasound. A VSD appears on ultrasound (US) as an interruption of the septum. If the VSD is small, it can be very difficult to identify. It is often hard to define the size and course of the VSD because the muscular septum is a three-dimensional structure, and the defects may be tortuous and multiple.[5]

The best echocardiographic view for diagnosis depends on the site of the VSD. The four-chamber view can identify perimembranous (Fig. 75.2), inlet, and muscular VSDs (Fig. 75.3), and the five-chamber left ventricular outflow tract

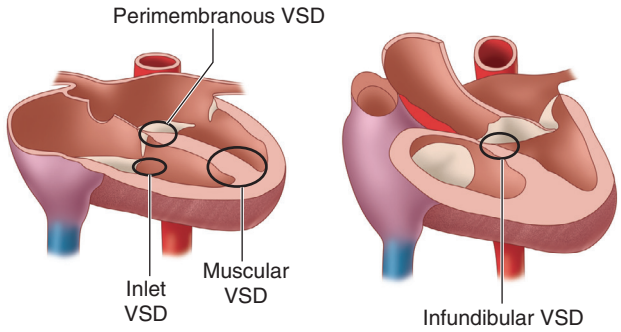

Fig. 75.1 Types of VSD in relation to location. *VSD,* Ventricular septal defect.

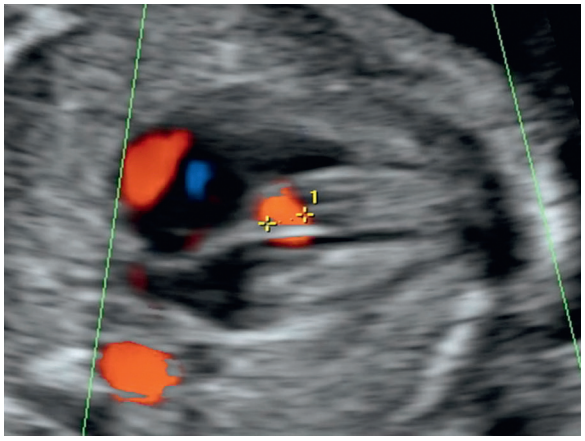

Fig. 75.2 Color Doppler shows a perimembranous VSD in the four-chamber view. The VSD is located in the upper part of the interventricular septum close to the atrioventricular valves.

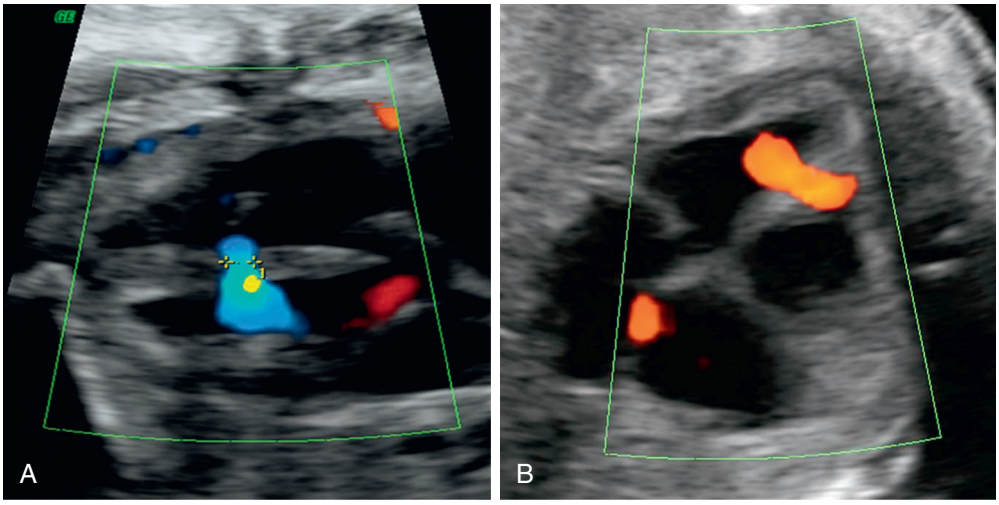

Fig. 75.3 Midmuscular (A) and apical (B) VSDs identified by color Doppler in a transverse and apical four-chamber view. The first VSD is superior to the moderator band, and the second VSD is inferior to the moderator band.

view can detect infundibular VSDs (Fig. 75.4). Infundibular VSDs can be divided into two types according to whether the remaining septum caudal to the defect and the aortic wall are aligned (simple infundibular defect) or not (malalignment VSD) (Fig. 75.5).

VSDs are best visualized with a 90-degree angle insonation, that is, in a transverse four-chamber or five-chamber view. When the VSD is large, the edges of the defect are usually bright and can be easily recognized because of the increased echogenicity (Fig. 75.6). However, small defects, especially muscular VSDs, may not be visible on grayscale US, and color Doppler is very helpful to identify the bilateral flow across the defect. Pulsed wave Doppler may be useful to confirm that the shunt across the defect is bidirectional (Fig. 75.7 and Videos 75.1 and 75.2).

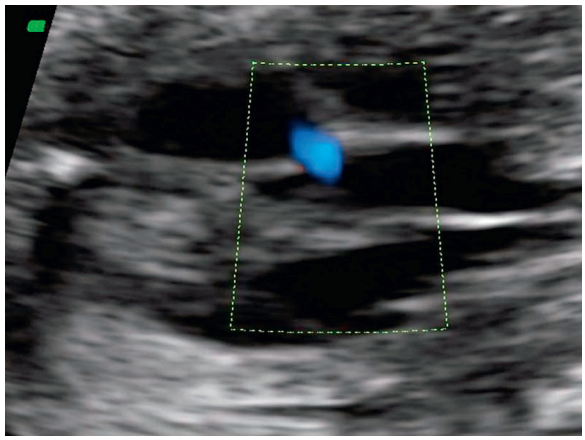

Fig. 75.4 Abnormal five-chamber view shows the presence of a little infundibular VSD. Color Doppler shows abnormal flow in the portion of the septum that separates the two outflows.

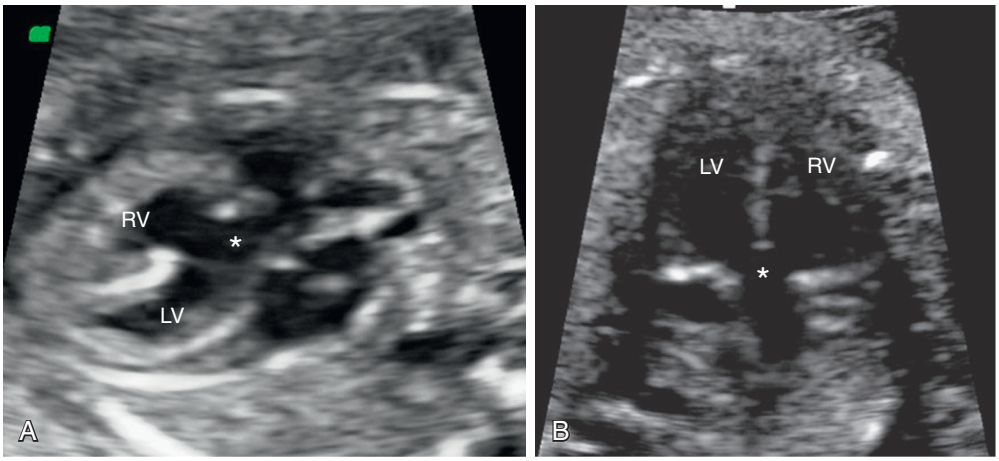

Fig. 75.5 (A) Simple infundibular VSD in a five-chamber view. The caudal part of the septum and the anterior aortic wall are correctly aligned. The aortic valve *(asterisk)* is located to the left of the septum. (B) Malalignment infundibular VSD in a five-chamber view. The infundibular septum is anteriorly displaced, and the aorta *(asterisk)* overrides the septum. *LV,* Left ventricle; *RV,* right ventricle.

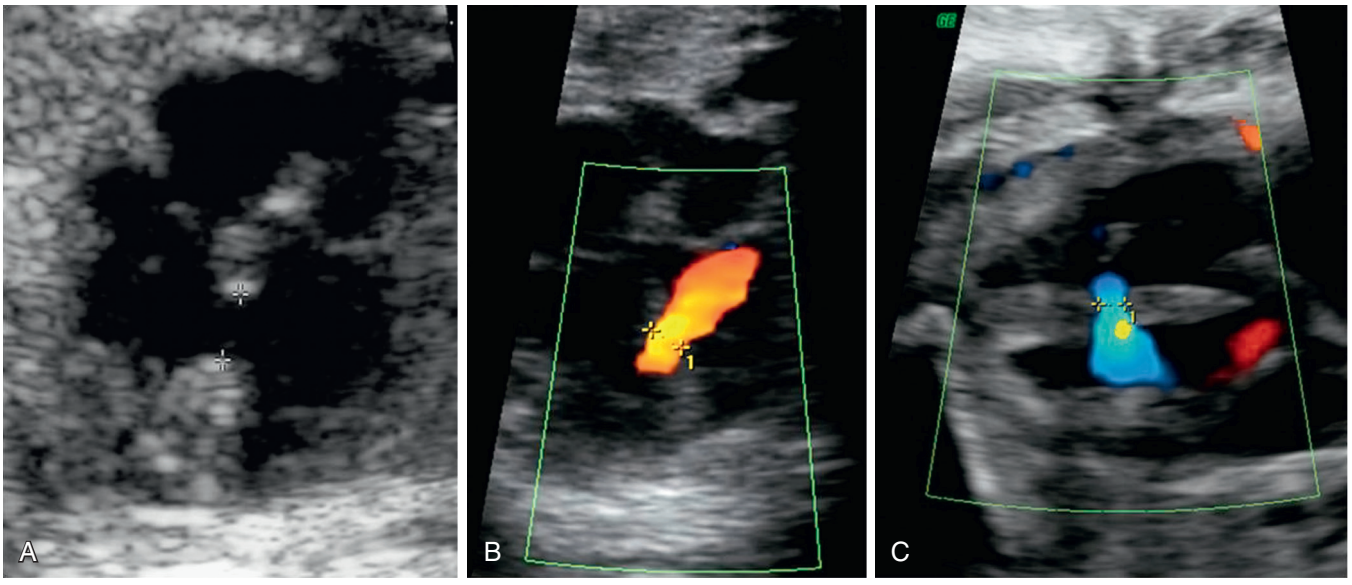

Fig. 75.6 (A) Large midmuscular VSD in a basal four-chamber view. The bright edges of the defect can help identify the VSD. (B) Color Doppler shows the presence of flow across the defect. (C) Flow is also visible in a transverse four-chamber view.

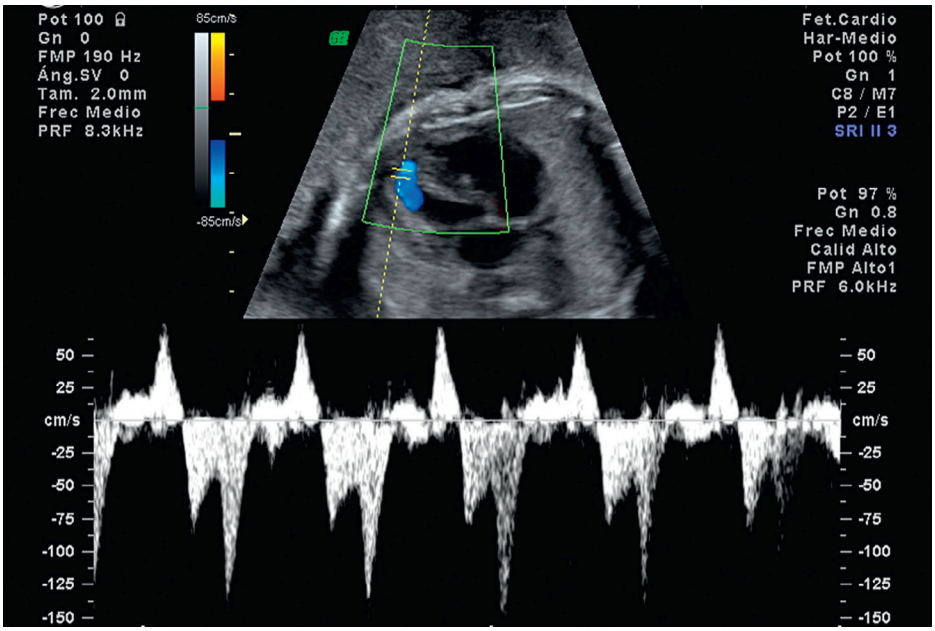

Fig. 75.7 Pulsed wave Doppler shows the bidirectional shunt across the defect. Because resistance from each ventricle is equal in the fetus, there is a minimal shunting of blood. The velocity of blood is high.

Other Applicable Modality

Four-Dimensional Echocardiography. Two-dimensional echocardiography cannot achieve comprehensive three-dimensional scanning of the ventricular septum. Spatiotemporal image correlation allows multiangle and multilayered observation of the external and internal structures of the fetal heart. Four-dimensional echocardiography can help confirm the presence of a VSD and study its size and its relationship with other cardiac structures and is considered a good supplementary tool in the diagnosis of fetal VSD.[6]

CLASSIC SIGNS

Abnormal four-chamber view: perimembranous, inlet, and muscular VSDs.
Abnormal five-chamber or left ventricular outflow tract view: infundibular VSDs.
Color and pulsed wave Doppler: bidirectional flow across the defect in isolated VSDs.

Differential Diagnosis From Imaging Findings

1. Tetralogy of Fallot: characterized by a malalignment infundibular VSD with right ventricular tract obstruction. One should consider tetralogy of Fallot whenever a malalignment VSD is detected, because pulmonary stenosis may only evolve later in pregnancy.
2. Atrioventricular septal defect: Especially between a partial atrioventricular septal defect and inlet VSD. It is important to confirm the presence of a normal septum primum, which is always absent in a partial atrioventricular septal defect, in the case of a perimembranous VSD.

Synopsis of Treatment Options

PRENATAL

Although the clinical prognosis of isolated VSD is usually good, an extensive workup is required to rule out chromosomal abnormalities, other structural abnormalities, and genetic syndromes in 25% to 35% of cases.[1–3] The association with chromosomal defects generally seems to be low, but inlet, perimembranous, malalignment, and large VSDs (>50% of the aortic lumen) are particularly associated with chromosomal abnormalities, whereas the risk is not increased for isolated muscular VSDs, especially in gestations with normal first-trimester screening tests for aneuploidies.[4]

The diagnosis of an isolated VSD does not alter the obstetric management. Echocardiographic follow-up is recommended at 4- to 6-week intervals to assess the progression in size and characteristics of the flow across the defect. Muscular VSDs can spontaneously close *in utero* (especially small perimembranous VSDs, 5%–10 % of cases).[4]

POSTNATAL

Overall, the prognosis of isolated VSD is good, with a high rate of spontaneous closure (75%–80%) within the first 2 years of life for small muscular VSDs (<5 mm or <50% aortic diameter). In contrast, inlet and infundibular VSDs rarely close spontaneously. Large defects require various degrees of medical treatment and eventual surgical closure. Advances in surgical and bypass techniques and timing of surgical repair have decreased the morbidity and mortality associated with surgery for VSD. Advances in catheter techniques and devices may allow percutaneous closure of VSDs in the future. In very rare cases, the defect may be large enough to render simple closing of the defect impossible, leading to single ventricle repair.

WHAT THE REFERRING PHYSICIAN NEEDS TO KNOW

- VSD is the most common CHD, affecting 25% to 30% of newborns and at least 10% of fetuses with CHD.
- The diagnosis of VSD can be difficult, in particular for small and isolated VSDs, and it must be actively sought on routine morphologic scans. Color and pulsed wave Doppler may be very helpful.
- The diagnosis of VSD may occur in combination with other CHDs, extracardiac anomalies, chromosomal abnormalities, and genetic syndromes, which should be actively sought.
- The obstetric management should not be changed; for muscular VSDs, patients can deliver in their local hospital. In larger VSDs, management will depend on other anomalies and the comfort of the local team in caring for the neonate.

KEY POINTS

- VSD is the most common CHD, frequently associated with more complex CHD.
- Prenatal diagnosis is difficult; four-chamber and five-chamber views in relation to the location of the defect and color Doppler can be used.
- Overall prognosis is good for isolated VSD.

SUGGESTED READING

Minette MS, Sahn DJ. Ventricular septal defects. *Circulation*. 2006;114: 2190-2197.



All references are available online at www.expertconsult.com.

REFERENCES

1. Paladini D, Palmieri S, Lamberti A, et al. Characterization and natural history of ventricular septal defects in the fetus. *Ultrasound Obstet Gynecol*. 2000;16:118-122.
2. Axt-Fliender R, Schwarze A, Smrcek J, et al. Isolated ventricular septal defects detected by color Doppler imaging: evolution during fetal and first year of postnatal life. *Ultrasound Obstet Gynecol*. 2006;27:266-273.
3. Bahtiyar MO, Dulay AT, Weeks BP, et al. Prenatal course of isolated muscular ventricular septal defects diagnosed only by color Doppler sonography: single-institution experience. *J Ultrasound Med*. 2008;27(5):715-720.
4. Gomez O, Martínez JM, Olivella A, et al. Isolated ventricular defects in the era of advanced fetal echocardiography: risk of chromosomal anomalies and spontaneous closure rate from diagnosis to 1 year. *Ultrasound Obstet Gynecol*. 2014;43:65-71.
5. Paladini D, Russo MG, Vassallo M, et al. The "in-plane" view of the interventricular septum. A new approach to the characterization of ventricular septal defects in the fetus. *Prenat Diagn*. 2003;23:1052-1055.
6. Yagel S, Valsky DV, Messing B. Detailed assessment of fetal ventricular septal defect with color Doppler ultrasound using spatiotemporal image correlation technology. *Ultrasound Obstet Gynecol*. 2005;25:97-98.

To access the videos in this chapter, scan this QR code or visit expertconsult.com

76 Atrioventricular Septal Defect

OLGA GÓMEZ | JOSEP M. MARTINEZ

Introduction

Atrioventricular septal defect (AVSD) is one of the most commonly diagnosed congenital heart diseases (CHDs) during fetal life and affects 4% to 5% of newborns with a CHD. AVSDs have a strong association with Down syndrome and frequently occur in combination with other CHDs.

Disease

DEFINITION

The term *AVSD* covers a spectrum of CHDs characterized by a common deficient separation in the atrioventricular junction. AVSD is also called *atrioventricular canal* or *endocardial cushion defect* because this CHD derives from an abnormal fusion of the endocardial cushions in the first stages of pregnancy.

PREVALENCE AND EPIDEMIOLOGY

The estimated incidence of AVSD ranges from 0.24 to 0.31 in 1000 live births. AVSD accounts for 15% to 20% of all prenatally diagnosed CHDs. In the fetus, this CHD can be considered a complex anomaly because it is frequently associated with chromosomal abnormalities and other CHDs, which may influence a high elective termination rate and help explain that the incidence of AVSD is lower in postnatal series (4% to 5% of all CHDs in newborns).[1,2]

ETIOLOGY AND PATHOPHYSIOLOGY

The etiology is multifactorial. AVSD is associated with chromosomal abnormalities in 35% to 50% of cases, of which 75% are trisomy 21.[3] It can also be associated with cardiosplenic syndromes (30% to 40% of cases). In such cases, the risk of associated complete atrioventricular block and other CHDs is also high.[1,2]

There are two forms of AVSD:

1. Complete ASVD is characterized by a common atrium, a single atrioventricular valve (usually with five leaflets), and a wide defect in the membranous portion of the interventricular septum. In most cases, the two ventricles are of normal size, and the defect is defined as a *balanced AVSD*. If one of the ventricles is hypoplastic, the AVSD is defined as *unbalanced*.
2. Ostium primum atrial septal defect (ASD) is also called *partial* or *incomplete AVSD*. There is an ASD, but part of the ventricular septum is filled, and the atrioventricular valvular orifices are divided into two distinct valves.

MANIFESTATIONS OF DISEASE

Clinical Presentation

A newborn with AVSD may present with a mild degree of central cyanosis related to the bidirectional shunting at both atrial and ventricular levels. The risk is related to the degree of elevated pulmonary vascular resistance at birth. In infants with complete AVSD and a sizable interventricular component, congestive heart failure is likely to develop within the first few months of life

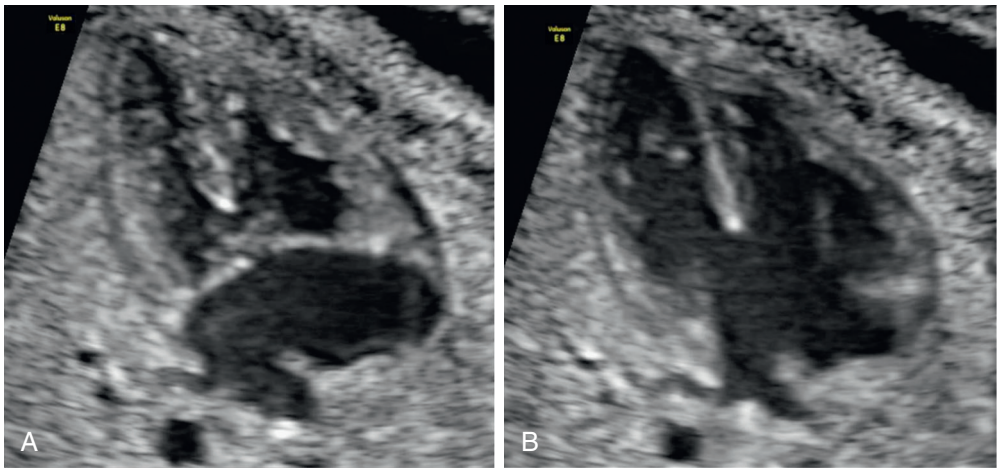

Fig. 76.1 (A) Abnormal apical four-chamber view in a complete atrioventricular septal defect *(AVSD)* during systole. The common valve appears as a line. A perimembranous ventricular septal defect *(VSD)* and a defect in the septum primum are also present. (B) During diastole, the common valve is opened, and there is a central hole in the heart.

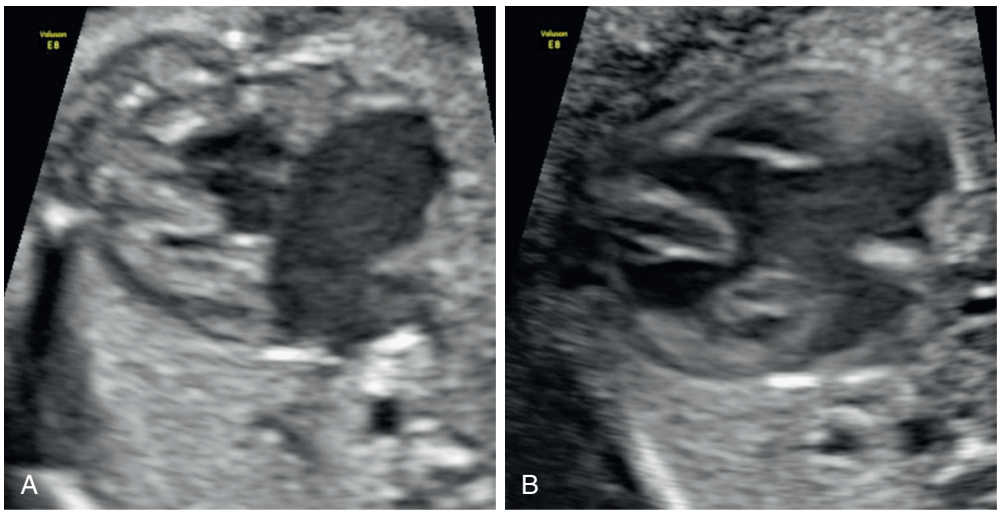

Fig. 76.2 Abnormal transverse four-chamber view in the same case shown in Fig. 76.1. (A) Complete atrioventricular septal defect *(AVSD)* during systole, showing the closed common valve that looks like a hammock. (B) During diastole, the valve is open.

as pulmonary vascular resistance declines. However, cardiac failure may occur much earlier if there is significant regurgitation of the common atrioventricular valve or ventricular imbalance. In patients with complete AVSD and a small interventricular component with minimal valve regurgitation, or in patients with a partial ASD, cardiac failure is rare, and clinical symptoms may be minimal or absent in infancy and childhood.

Imaging Technique and Findings

Ultrasound. AVSD is the CHD most frequently diagnosed in the fetus because it always alters the four-chamber view. The key diagnostic feature in complete AVSD is that the heart loses the normal aspect of the atrioventricular plane because of the presence of a common valve; the atrioventricular septum is absent, and the common atrioventricular valve appears as a single straight line during systole. There is also a typical image of a single, common atrium owing to the absence of atrial and perimembranous interventricular septa (Figs. 76.1 and 76.2). Color Doppler illustrates the common atrioventricular diastolic filling, with a characteristic H-shaped appearance (Fig. 76.3). Color Doppler may also show whether the common valve is insufficient. In such cases, the velocity of the retrograde valve flow can be measured with pulsed wave Doppler (Fig. 76.4).

In complete AVSD, it is important to assess and compare the size of the two ventricles (Videos 76.1 and 76.2). A hypoplastic ventricle indicates the presence of unbalanced complete AVSD. Color Doppler may also help define the grade of hypoplasia by evaluating the degree of diastolic ventricular filling. The ventriculoarterial connections should be checked to rule out concurrent anomalies at this level, such as tetralogy of Fallot and double-outlet right ventricle.

The prenatal diagnosis of incomplete AVSD is more difficult. The normal aspect of the atrioventricular plane is lost, but the presence of two separate atrioventricular valves with no interventricular defect renders diagnosis more challenging. The key diagnostic feature is the absence of the septum primum above the atrioventricular plane (Videos 76.3 and 76.4).

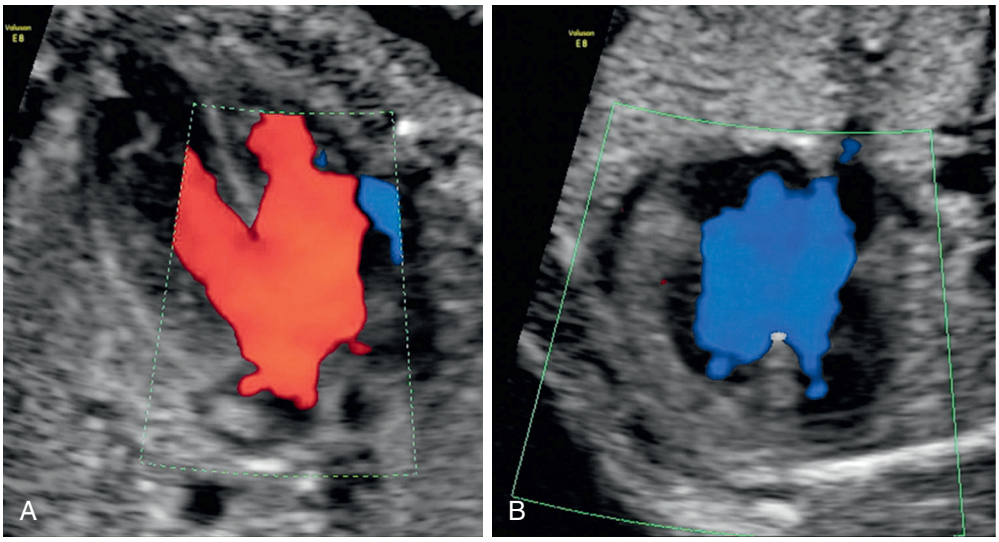

Fig. 76.3 (A) Abnormal apical four-chamber view. Color Doppler shows the H sign, corresponding to the shunt of blood from the right and left heart owing to the common valve and the septal defects. (B) Basal four-chamber view.

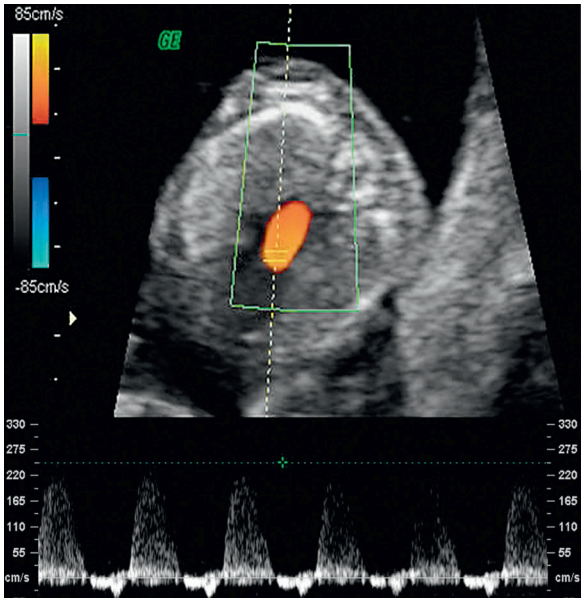

Fig. 76.4 Pulsed wave Doppler shows significant insufficiency in a case of early complete atrioventricular septal defect *(AVSD)*. The regurgitation occurs during all of systole, and the maximum velocity is greater than 200 cm/s.

Other Applicable Modality

Four-Dimensional Echocardiography. Four-dimensional echocardiography may be a useful complementary tool to assess the anatomy of the atrioventricular common valve.

CLASSIC SIGNS

Complete AVSD: absence of normal aspect of the atrioventricular plane on the four-chamber view owing to common atrioventricular valve with a common atrium and defect in the interventricular septum.

Incomplete AVSD: absence of normal aspect of the atrioventricular plane on the four-chamber view owing to a defect in the interatrial septum primum but with two separate atrioventricular valves and a normal interventricular septum.

Differential Diagnosis From Imaging Findings

1. Persistence of left superior vena cava: complete AVSD or partial ASD may be wrongly diagnosed in the presence of a dilated coronary sinus, associated with persistent left superior vena cava. The identification of the septum primum and the evaluation of the septal insertion of the atrioventricular valves and the interventricular septum in the four-chamber view should help to make the differential diagnosis (Fig. 76.5).
2. Inlet ventricular septal defect (VSD): an inlet VSD can have a similar appearance to partial ASD. The absence of the septum primum is the key sign in partial ASD, whereas this structure is always observable in perimembranous VSD.
3. Univentricular heart: the identification of the septum primum, septal insertion of the atrioventricular valves, and outflow tracts on three-vessel and trachea view may help establish the differential diagnosis between severe forms of hypoplastic heart and unbalanced AVSD.

Synopsis of Treatment Options

PRENATAL

There are no prenatal treatment options. A detailed evaluation and further workup to rule out other cardiac and extracardiac defects and chromosomal abnormalities, as discussed earlier, are warranted. A single atrioventricular valve insufficiency indicates a 25% to 30% risk of prenatal heart failure and hydrops. Identification of the two forms of complete AVSD is important. Balanced AVSDs are highly associated with chromosomal abnormalities, whereas unbalanced AVSDs have a low risk of chromosomal defects but are more frequently associated with cardiosplenic syndromes and other CHDs (Table 76.1 and Fig. 76.6).

Follow-up at 4- to 6-week intervals to assess valve insufficiency is recommended. In the absence of hydrops, obstetric management should not be changed. Delivery should occur at a cardiac center. With regard to partial AVSD,[4] a careful examination of the cardiac

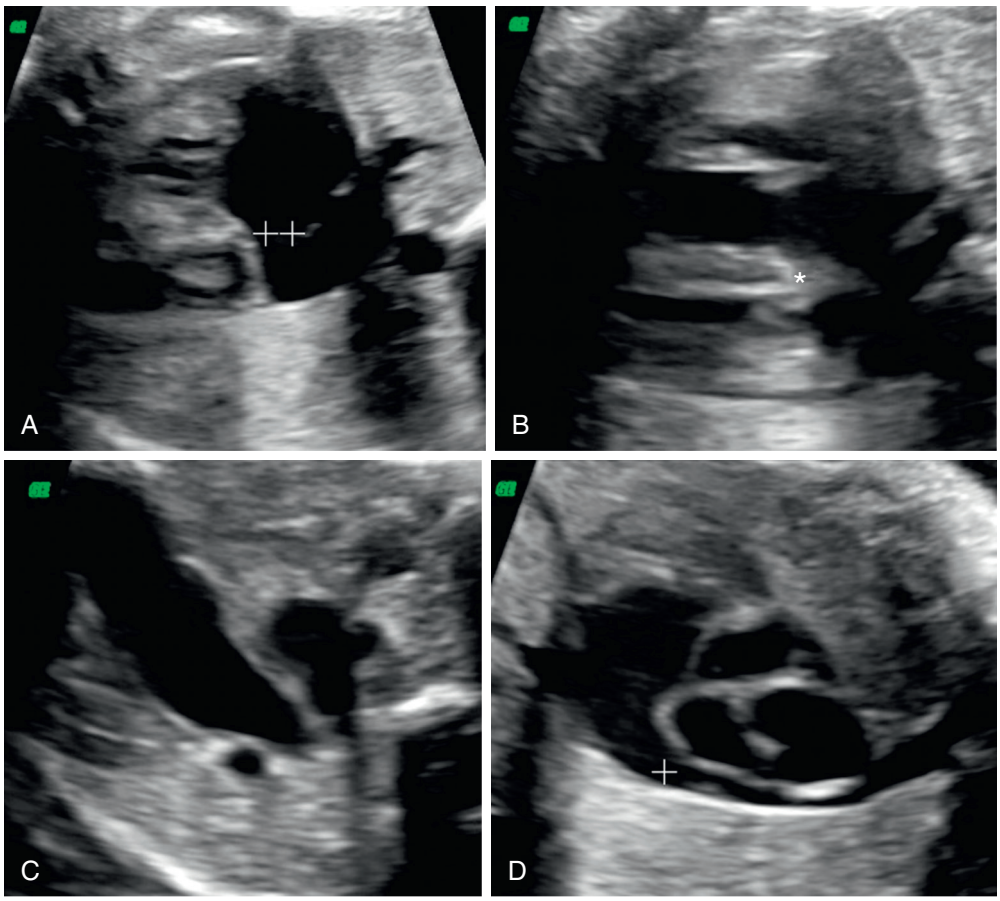

Fig. 76.5 (A) Dilated coronary sinus. (B) The septum primum can be identified in the transverse four-chamber view, which is obtained in a more cranial transverse view of the thorax. A persistent left superior vena cava can be seen in the three-vessel and trachea view (C) and in a longitudinal plane (D).

TABLE 76.1 DIFFERENCES BETWEEN BALANCED AND UNBALANCED FORMS OF COMPLETE ATRIOVENTRICULAR SEPTAL DEFECT

Balanced AVSD	Unbalanced AVSD
Chromosomal abnormalities (35%–50% of cases, 75% trisomy 21)	Cardiosplenic syndrome (15%–30% of cases)
Good prognosis in the absence of chromosomal abnormality	Complete block (15%–30% of cases)
	Associated CHD (high percentage)
	Overall bad prognosis

and extracardiac anatomy should also be carried out, and fetal karyotyping is warranted because of the strong association with Down syndrome.

POSTNATAL

The mainstay of management in complete AVSD is surgical correction of the defect, which includes closure of all septal defects and repair of the atrioventricular valve. At the present time, the aim is to provide surgical correction within the first 6 months of life to avoid the development of pulmonary vascular disease. Operative mortality is reported to be less than 10%, and some more recent series report rates of less than 5%. Associated defects may have to be corrected at the time of AVSD repair. The management of unbalanced AVSD is difficult, and single ventricle surgery is required in most cases. In patients with Down syndrome, surgical repair is normally easier because of a more favorable anatomy of the defects, but pulmonary vascular disease often appears earlier requiring prompt surgical repair. In partial ASD, the timing of surgery is less critical, and patients with few symptoms through infancy and early childhood undergo elective surgery later in life, with a very low reported operative mortality.

Survivors of AVSD repair may require further cardiac surgery owing to left atrioventricular valve regurgitation and subaortic stenosis, residual VSD, and late-onset complete heart block. Overall, 10-year survival has been reported to be 85% in different studies.

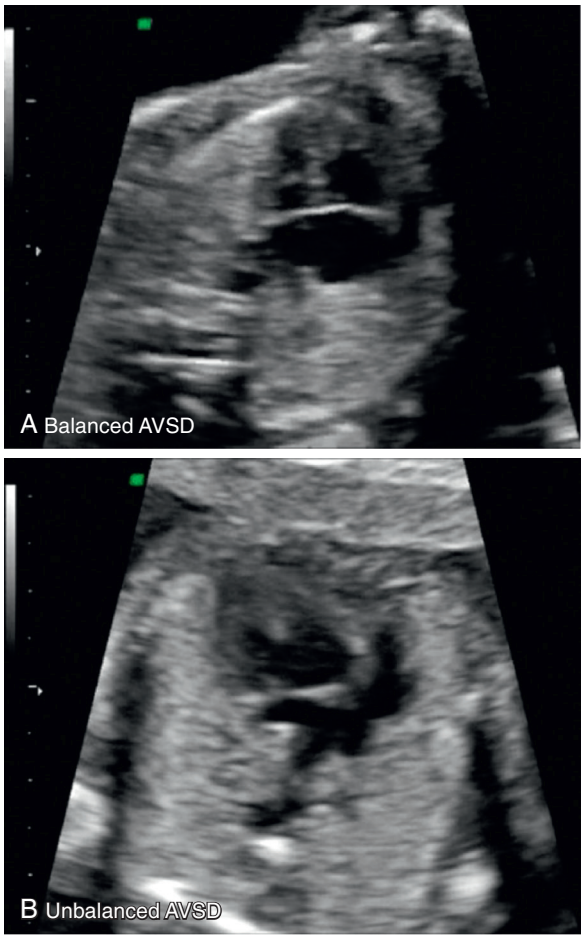

Fig. 76.6 (A) Balanced AVSD. (B) Unbalanced AVSD. *AVSD,* Atrioventricular septal defect.

WHAT THE REFERRING PHYSICIAN NEEDS TO KNOW

- AVSD is one of the most frequently diagnosed CHDs during fetal life because it always alters the four-chamber view.
- AVSD is highly associated with chromosomal abnormalities (particularly Down syndrome) and cardiosplenic syndromes.
- Follow-up every 4 to 6 weeks is recommended to rule out atrioventricular valve insufficiency, which indicates a high risk of hydrops.
- In the absence of hydrops, the obstetric management should not be changed.

KEY POINTS

- AVSD is one of the most common CHDs diagnosed in the fetus, with prognosis dependent on the many associated abnormalities that may be present.
- There is a high association with chromosomal abnormalities and complex syndromes.
- Prenatal diagnosis using the four-chamber view is easy in complete forms and more challenging in partial AVSD.
- Isolated balanced AVSDs and partial forms are associated with a good prognosis.

SUGGESTED READING

Bader RS, Punn R, Silverman NH. Evaluation of risk factors for prediction of outcome in fetal spectrum of atrioventricular septal defects. *Congenit Heart Dis.* 2014;9(4):286-293.

Craig B. Atrioventricular septal defect: from fetus to adult. *Heart.* 2006;92:1879-1885.

All references are available online at www.expertconsult.com.

REFERENCES

1. Rasiah SV, Ewer AK, Miller P, et al. Outcome following prenatal diagnosis of complete atrioventricular septal defect. *Prenat Diagn*. 2008;28:95-101.
2. Paladini D, Volpe P, Sglavo G, et al. Partial atrioventricular septal defect in the fetus: diagnostic features and associations in multicenter series of 30 cases. *Ultrasound Obstet Gynecol*. 2009;34:268-273.
3. Berg C, Kaiser C, Bender F, et al. Atrioventricular septal defect in the fetus: associated conditions and outcome in 246 cases. *Ultraschall Med*. 2009;308(1):25-32.
4. Adriaanse B, Bartelings M, Van Vugt J, et al. Differential and linear insertion of atrioventricular valves: a useful tool? *Ultrasound Obstet Gynecol*. 2014;44:568-574.

To access the videos in this chapter, scan this QR code or visit expertconsult.com

77 Tricuspid Atresia

OLGA GÓMEZ | JOSEP M. MARTINEZ

Introduction

Tricuspid atresia (TA) is a rare form of congenital heart disease (CHD) that usually involves severe hypoplasia of the right ventricle. Prenatal diagnosis of TA and associated intracardiac and extracardiac anomalies is possible with a high degree of accuracy.

Disease

DEFINITION

TA is defined by the lack of connection between the right atrium and the right ventricle. The most common form is the absence of the tricuspid valve, which is replaced by fibrous tissue. Rarely, a dysplastic imperforate tricuspid valve is present. In most cases, there is a defect in the membranous portion of the interventricular septum (ventricular septal defect [VSD]) of variable size, which establishes the degree of development of the right ventricle and pulmonary artery. In most cases of TA, there is a variable grade of right ventricle hypoplasia, and TA can be classified as a form of hypoplastic right heart syndrome.

PREVALENCE AND EPIDEMIOLOGY

TA is a rare CHD. The estimated incidence is 1:25,000 live births. In fetal series, the incidence of TA is low, ranging from 3% to 4% of all prenatally diagnosed CHDs.

ETIOLOGY AND PATHOPHYSIOLOGY

The etiology of TA is multifactorial. Associated extracardiac and chromosomal abnormalities are present in about 20% (extracardiac abnormalities) and 5% (chromosomal abnormalities) of cases. TA is associated with other cardiac malformations in approximately 30% of cases, with transposition of great arteries and pulmonary obstruction being the more commonly associated anomalies. TA is also frequently associated with fetal growth restriction.

Perimembranous VSDs are very common with TA. The size of the foramen ovale and the VSD constitute the two main prognostic factors in the fetus (Fig. 77.1).

1. If the foramen ovale is normal, a proper right-to-left shunt is maintained (right atrium–left atrium–left ventricle). In contrast, if the foramen ovale is restrictive, the risk of hydrops is high.
2. If there is a moderate to large VSD, the right ventricle and the pulmonary artery receive blood from the left ventricle (left ventricle–right ventricle–pulmonary artery). In contrast, if there is no VSD or a very small VSD, the right ventricle and pulmonary artery are hypoplastic, and the pulmonary artery receives retrograde flow from the ductus arteriosus.

MANIFESTATIONS OF DISEASE

Clinical Presentation

A newborn with TA needs immediate care in a tertiary center. Arterial oxygen content primarily depends on the respective proportion of pulmonary and systemic venous return that enters the left ventricle. If there is no VSD, the survival of these neonates depends on the patency of the ductus arteriosus as the only source of pulmonary flow. In the presence of a large VSD, pulmonary flow can be efficiently maintained through the defect,

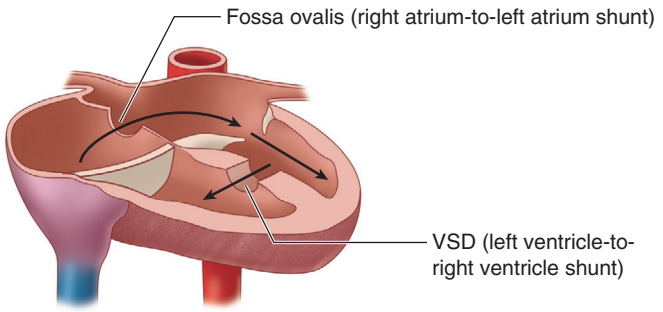

Fig. 77.1 Representation of tricuspid atresia *(TA)* showing the flow across the fossa ovalis and the ventricular septal defect *(VSD)*.

but such cases are at higher risk of cardiac failure because of high cardiac output. When TA is associated with transposition of the great arteries, the neonate may not have significant cyanosis, but there is still a risk of cardiac failure, and there is a risk of aortic coarctation or interruption.

Imaging Technique and Findings

Ultrasound. The ultrasound diagnosis of TA can be made on the four-chamber view. The key diagnostic feature is a nonpatent tricuspid valve. The valve has an abnormal aspect, with thickening, increased echogenicity, and little or no mobility (Fig. 77.2 and Video 77.1). As a consequence, there is commonly an associated small right ventricle with a dominant left ventricle. As previously mentioned, a perimembranous VSD can be identified in most cases (Video 77.2). The presence of the VSD determines the growth of the right ventricle and pulmonary artery.

Color Doppler may be highly valuable in this anomaly to:

1. Confirm the absence of right atrioventricular filling across the tricuspid valve, which is the essential diagnostic feature in TA (Fig. 77.3).
2. Evaluate the presence of flow across the VSD (left ventricle–right ventricle–pulmonary artery) (Fig. 77.4)
3. Assess the ventriculoarterial connection and the flow in the ductus arteriosus, which is important to determine if the anomaly is ductus-dependent (Video 77.3).

When there is ventriculoarterial concordance, a correct crossover of the two great arteries can be recognized on the five-chamber view. A major overload of the left-side cavities is observed with secondary dilatation of the aorta and a variable degree of diminished development of the pulmonary artery. In contrast, if there is ventriculoarterial discordance, the two arteries follow a parallel course with absence of crossover on the five-chamber view. In this case, the pulmonary artery is dilated, and the aorta and aortic arch are relatively hypoplastic.

Other Applicable Modality

Four-Dimensional Echocardiography. Four-dimensional echocardiography may be used to assess the ventriculoarterial connection.

CLASSIC SIGNS

FOUR-CHAMBER VIEW

Tricuspid valve thickening and increased echogenicity, with little or no valve motion; absence of flow across the valve, as shown with color Doppler.

Different degree of hypoplasia of the right ventricle and pulmonary artery depending on the presence of a perimembranous VSD.

FIVE-CHAMBER VIEW

Absence of normal crossover in cases associated with ventriculoarterial discordance.

THREE-VESSEL AND TRACHEA VIEW

Smaller pulmonary artery with antegrade flow across it in cases with good development of the pulmonary artery.

Smaller pulmonary artery with retrograde flow through the ductus arteriosus in cases with pulmonary atresia.

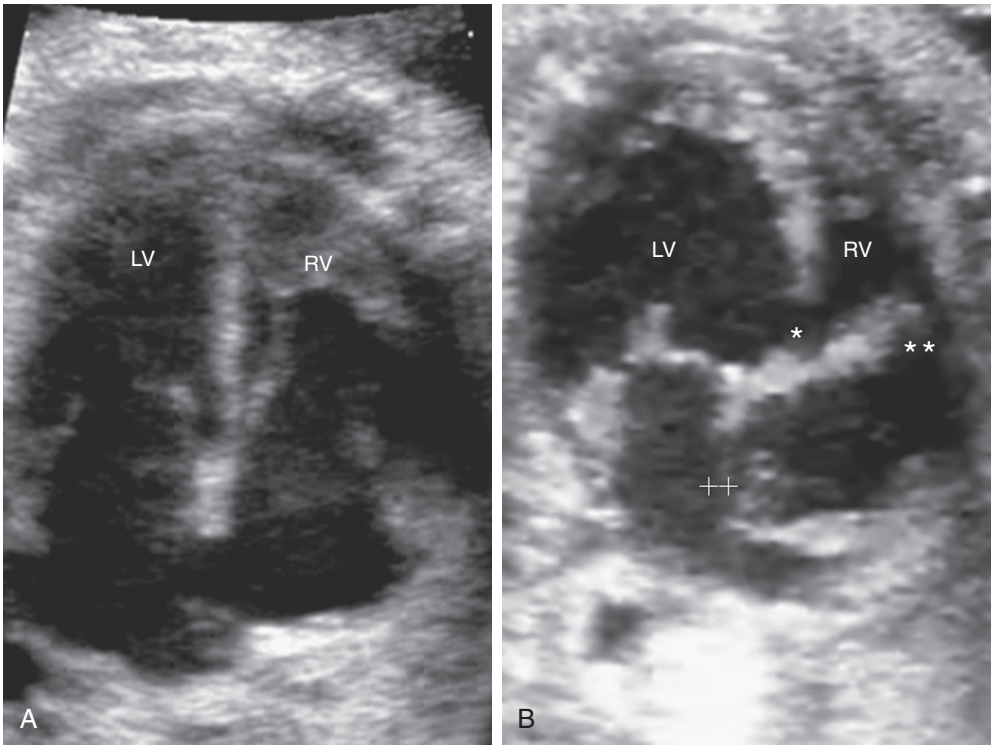

Fig. 77.2 (A) Normal apical four-chamber view during diastole shows a normal atrioventricular septum with two opened atrioventricular valves. (B) Abnormal apical four-chamber view in tricuspid atresia. The tricuspid valve *(**)* is thickened, hyperechogenic, and closed while the mitral valve is opened. The right ventricle is smaller than the left ventricle, which is clearly the dominant ventricle *(*)*. There is also a perimembranous ventricular septal defect *(++)*. The foramen ovale has a good size and is opened to the left atrium. *LV,* Left ventricle; *RV,* right ventricle.

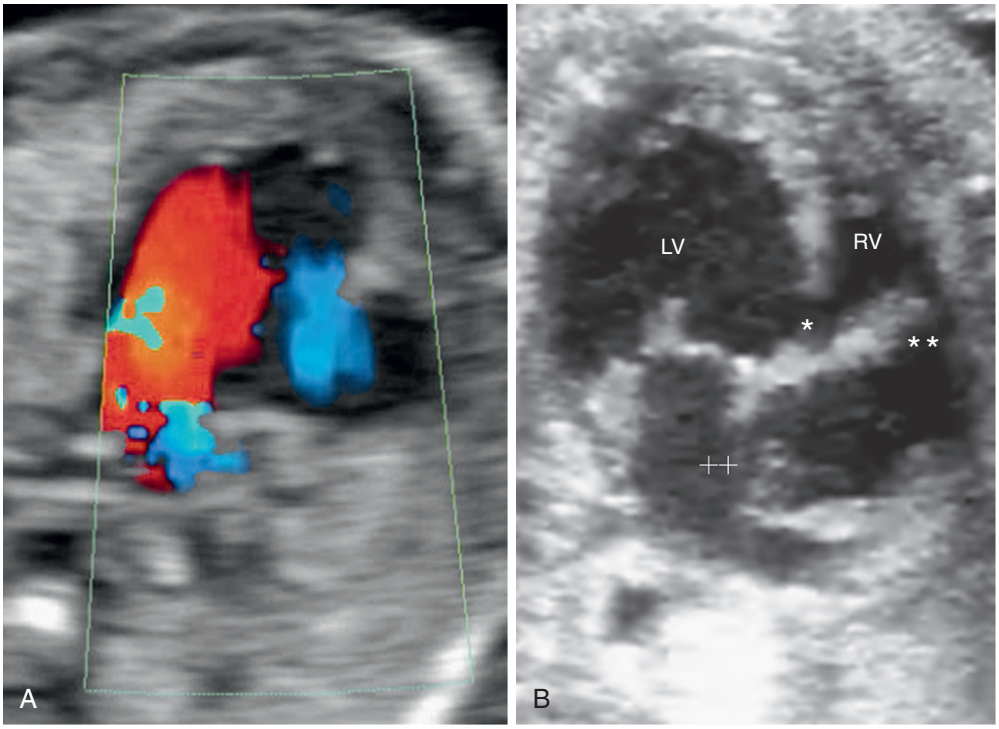

Fig. 77.3 Abnormal apical four-chamber view in the same case of tricuspid atresia (TA) shown in Fig. 77.2. Color Doppler shows the flow through the mitral valve *(red)* and the flow across the ventricular septal defect *(VSD) (blue)* to the right ventricle. There is a large VSD, and there is an absence of flow through the tricuspid valve, which is the key diagnostic sign to confirm TA. *, Dominant ventricle; **, tricuspid valve; ++, ventricular septal defect; *LV*, left ventricle; *RV*, right ventricle.

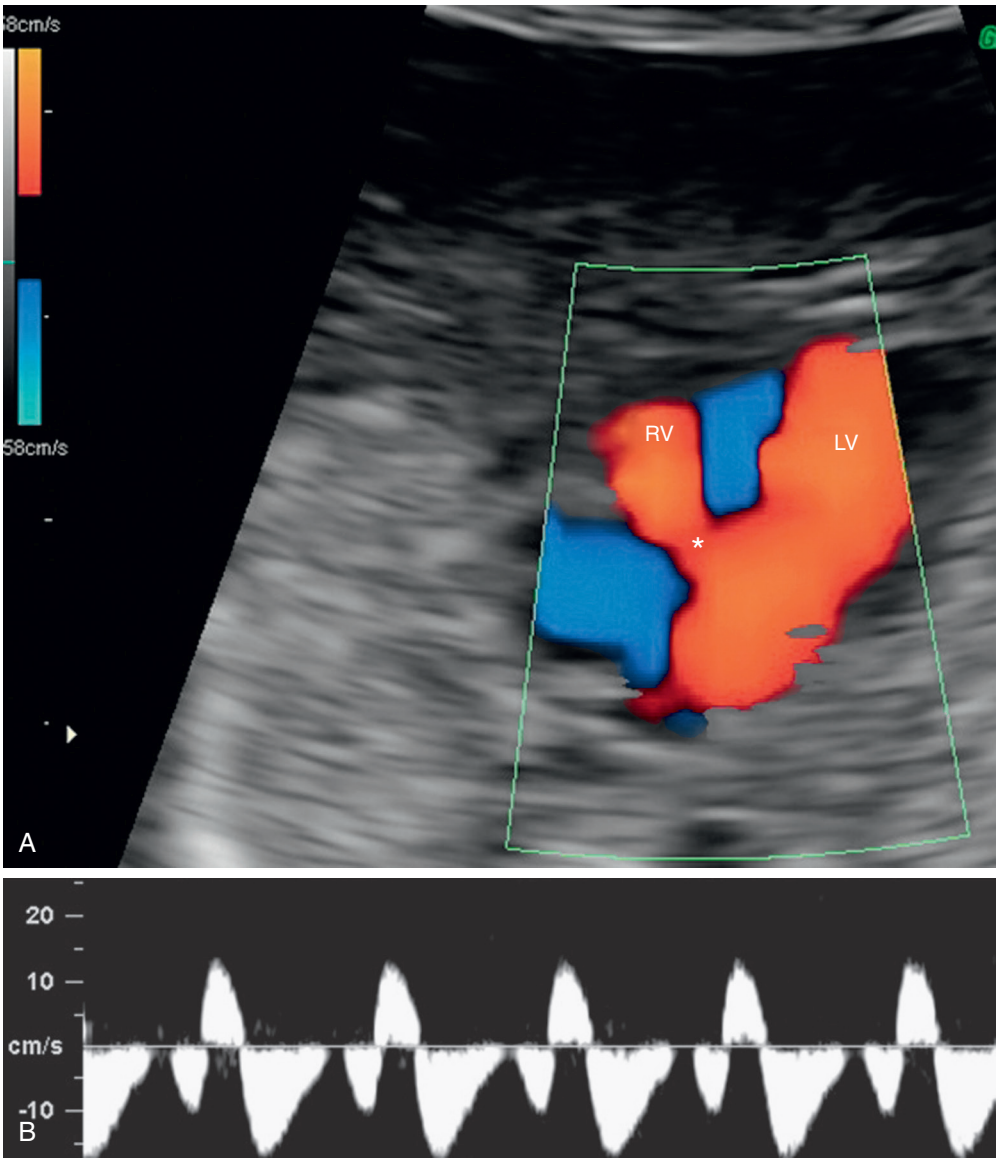

Fig. 77.4 (A) Abnormal apical four-chamber view in a 14-week fetus with tricuspid atresia. Color Doppler shows the normal flow through the mitral valve *(red)* and the flow across the ventricular septal defect *(asterisk)* to the right ventricle *(red)*. (B) Pulsed wave Doppler shows reversed flow during atrial contraction in the ductus venosus. *LV*, Left ventricle; *RV*, right ventricle.

Differential Diagnosis From Imaging Findings

1. Pulmonary atresia with intact ventricular septum: the form with an atretic tricuspid valve can be very difficult to differentiate from TA without VSD. In both conditions, the right ventricle is extremely hypoplastic. The presence of coronary sinusoids on the four-chamber view can help distinguish between the two forms because sinusoids are present in 30% of cases of pulmonary atresia with intact ventricular septum.
2. Hypoplastic left heart syndrome: It is important to identify the side of hypoplasia when evaluating a univentricular heart. In hypoplastic left heart syndrome, the left structures are hypoplastic, and the flow is reversed in the aorta on the three-vessel and trachea view.
3. Unbalanced complete atrioventricular septal defect: The recognition of a common atrioventricular valve is the essential key for the diagnosis. The frequent association with cardiosplenic syndromes can also help differentiate this anomaly from TA.

Synopsis of Treatment Options

PRENATAL

When TA is detected prenatally, a careful examination of the cardiac anatomy should be carried out.[1,2] It is essential to check the ventriculoarterial connection and to rule out other heart diseases, especially obstructed pulmonary flow and aortic coarctation, which are present in 30% of cases. It is also mandatory to rule out other extracardiac anomalies (about 20% of cases) and to reassess the risk of fetal aneuploidy (about 5% of cases).

Echocardiographic follow-up during pregnancy is recommended (at intervals of 2 to 4 weeks) to assess (1) the size and flow across the foramen ovale, which helps to determine the risk of hydrops; (2) the size of the VSD; (3) the development of the pulmonary artery and the flow in the pulmonary artery and ductus arteriosus; and (4) the size and function of the left ventricle. Right-sided cardiac lesions with obstruction of the inflow can be associated with abnormally high pulsatility in the ductus venosus and may cause a reversal of flow during atrial contraction (see Fig. 77.4). These changes do not indicate cardiac failure because they are primarily attributable to the special hemodynamics of the cardiac defect.[3,4] The overall fetal mortality rate associated with TA is 5% to 10%, which is significantly increased in the case of restrictive foramen ovale.

In the absence of hydrops, obstetric management should not be changed. Delivery must be planned in a tertiary care center, although in most cases VSD provides a wide enough shunt so that the defect is not ductus-dependent.

POSTNATAL

TA requires a stratified and palliative surgical procedure (the Fontan operation)[5] in the child with two objectives: (1) to bypass the hypoplastic right ventricle and (2) to connect the right atrium with the pulmonary trunk. The left ventricle is responsible for the pulmonary and systemic circulations.

- In the newborn, the pulmonary circulation, in the absence of VSD, depends on the ductus arteriosus. If the newborn is severely hypoxic, an atrial septostomy with a systemic-to-pulmonary shunt may be required.
- At 6 months, the pulmonary trunk is disconnected from its valve, and the two orifices are closed. The superior vena cava is cut before its entrance in the right atrium and sutured to the pulmonary artery (Glenn operation).
- At 18 to 30 months, an atrial septal defect is created, the VSD is corrected, and a synthetic conduit is created to connect the inferior vena cava to the superior vena cava so that all of the systemic return is directed to the pulmonary artery.

According to more recent fetal series, early neonatal survival after the first step of surgery is 90%. However, survival progressively decreases during early and later childhood because of reoperations, thromboembolism, arrhythmias, and congestive venous complications (survival at 1 year, 5 years, and 10 years is 80%, 70%, and 60%, respectively).

WHAT THE REFERRING PHYSICIAN NEEDS TO KNOW

- TA refers to the lack of connection between the right atrium and the right ventricle. In most cases, there is a VSD and a variable degree of diminished development of the right ventricle and pulmonary artery.
- The diagnosis is made on the four-chamber view. There is a thickened, hyperechoic tricuspid valve with little or no mobility. Absence of flow across the valve is shown with color Doppler. Hypoplasia of the right ventricle causes it to be smaller than the left ventricle.
- The association of TA with extracardiac and chromosomal abnormalities is about 20% and 5%, respectively. However, TA is frequently associated with other cardiac malformations (30% of cases, especially transposition of great arteries and pulmonary obstruction).
- Fetal karyotyping should be considered, and careful examination of the cardiac and extracardiac anatomy is mandatory. A follow-up examination every 2 to 4 weeks is recommended to assess the foramen ovale and the development of the pulmonary artery. The obstetric management should not be changed in the absence of hydrops.
- TA requires stratified and palliative surgery (the Fontan operation) in the child. Neonatal mortality is approximately 10%. Survival progressively decreases during early and later childhood.

KEY POINTS

- TA is a rare CHD. There is a low association with chromosomal abnormalities and extracardiac malformations in the fetus.
- Prenatal diagnosis is relatively easy on the four-chamber view, which shows an atretic tricuspid valve with little or no mobility and absence of flow across it.
- Overall prognosis is poor for cases with ventriculoarterial discordance.
- TA requires a stratified and palliative surgical procedure in the child. There is a progressive decline in survival.

SUGGESTED READING

Berg C, Lachmann R, Kaiser C, et al. Prenatal diagnosis of tricuspid atresia: intrauterine course and outcome. *Ultrasound Obstet Gynecol*. 2010;35:183-190.

All references are available online at www.expertconsult.com.

REFERENCES

1. Berg C, Lachmann R, Kaiser C, et al. Prenatal diagnosis of tricuspid atresia: intrauterine course and outcome. *Ultrasound Obstet Gynecol*. 2010;35:183-190.
2. Wald RM, Tham EB, McCrindle BW, et al. Outcome after prenatal diagnosis of tricuspid atresia: a multicenter experience. *Am Heart J*. 2007;153:772-778.
3. Berg C, Kremer C, Geipel A, et al. Ductus venosus blood flow alterations in fetuses with obstructive lesions of the right heart. *Ultrasound Obstet Gynecol*. 2006;28:137-142.
4. Bhawna A, Krishnan A, Donofrio MT. Clinical utility of ductus venosus flow in fetuses with right-sided congenital heart disease. *J Ultrasound Med*. 2014;33:1563-1571.
5. Yuan SM, Jing H. Palliative procedures for congenital heart defects. *Arch Cardiovasc Dis*. 2009;102:549-557.

To access the videos in this chapter, scan this QR code or visit expertconsult.com

78 Ebstein Anomaly and Tricuspid Dysplasia

OLGA GÓMEZ | JOSEP M. MARTINEZ

Introduction

Ebstein anomaly (EA) and tricuspid dysplasia (TD) are congenital heart diseases (CHDs) affecting the tricuspid valve and consequently all of the right heart.[1] Although these anomalies are two different entities from an anatomic point of view, they share many pathophysiologic features. The clinical spectrum is variable depending on the degree of disruption of the valve anatomy. Prenatal forms usually belong to the severe spectrum.

Disease

DEFINITION

EA is characterized by an inferior displacement of the proximal attachments of the septal and posterior leaflets of the tricuspid valve, from their normal insertion at the atrioventricular ring towards the apex of the heart. The anterior leaflet is properly inserted into the valve annulus, but it is usually dysplastic and hypomobile. The dysplastic leaflet causes functional valvular incompetence and determines that part of the right ventricle is functionally incorporated into the right atrium ("right ventricle atrialization").

TD affects both the leaflets and the chordae, but these are normally inserted. Thus the difference between EA and TD is essentially anatomic, because functionally, both entities lead to valvular incompetence, massive cardiomegaly, and cardiac failure. Both are frequently associated with other CHDs.

PREVALENCE AND EPIDEMIOLOGY

The estimated incidence of EA and TD is 0.5 : 100,000 and 2.5 : 100,000 live births, respectively. They account for less than 2% of all prenatally diagnosed CHDs.

ETIOLOGY AND PATHOPHYSIOLOGY

Similar to most CHDs, the etiologies of EA and TD are multifactorial. EA is thought to occur more frequently in mothers treated with lithium during the first months of pregnancy. Chromosomal abnormalities occur in less than 5% of cases in EA, whereas TD is more frequently associated with chromosomal abnormalities (trisomies 18 and 21), especially when diagnosed in the first trimester. EA and TD are frequently associated with other cardiac malformations (30% of cases; including atrial and ventricular septal defects, right ventricular outflow tract obstruction, and Wolff-Parkinson-White syndrome). Association with extracardiac abnormalities and nonchromosomal syndromes is rare.

MANIFESTATIONS OF DISEASE

Clinical Presentation

EA and TD have important clinical implications because they involve the global function of the right heart. The presentation generally has two forms: neonatal and adult.[2]

1. The neonatal form usually corresponds to more severe cases. There is a high risk of fetal demise. Newborns frequently present with a combination of cyanosis and congestive heart failure. An element of pulmonary hypoplasia resulting from cardiomegaly *in utero* may contribute to these symptoms.
2. The adult form corresponds to cases with a better prognosis; prenatal diagnosis may be more difficult. In these newborns, tricuspid regurgitation progressively decreases as pulmonary vascular resistance declines during the first months of life, and clinical symptoms may be minimal or absent in infancy and childhood.

Imaging Technique and Findings

Ultrasound

Ebstein Anomaly. The diagnosis is normally made on the four-chamber view. The finding that first draws attention is typically a markedly enlarged right atrium. The key diagnostic feature is the abnormally low insertion of the septal and posterior leaflets of the tricuspid valve (below the atrioventricular level) (Fig. 78.1). The following features can help make the diagnosis of EA:

- Apical displacement of the tricuspid valve: the distance between the mitral and the tricuspid valve leaflet attachments to the septum is at least 4–5 mm during the second trimester and 6–7 mm during the third trimester.
- Signs of TD: the valve is thickened, hyperechoic, and hypomobile.
- Tricuspid insufficiency: identified by color and pulsed wave Doppler, tricuspid insufficiency is generally holosystolic with high velocities (>200 cm/s) (Fig. 78.2).

- Cardiomegaly with severely enlarged right atrium (because of apical displacement of the tricuspid valve and tricuspid insufficiency): the degree of cardiomegaly is variable. In pronounced cases, it may induce pulmonary hypoplasia (Fig. 78.3).
- Decreased size of the right ventricle: a small right ventricle is caused by right ventricle atrialization as a consequence of apical displacement of part of the leaflets of the valve.
- Pulmonary stenosis or atresia: they may be associated with EA and should be ruled out by measuring and checking

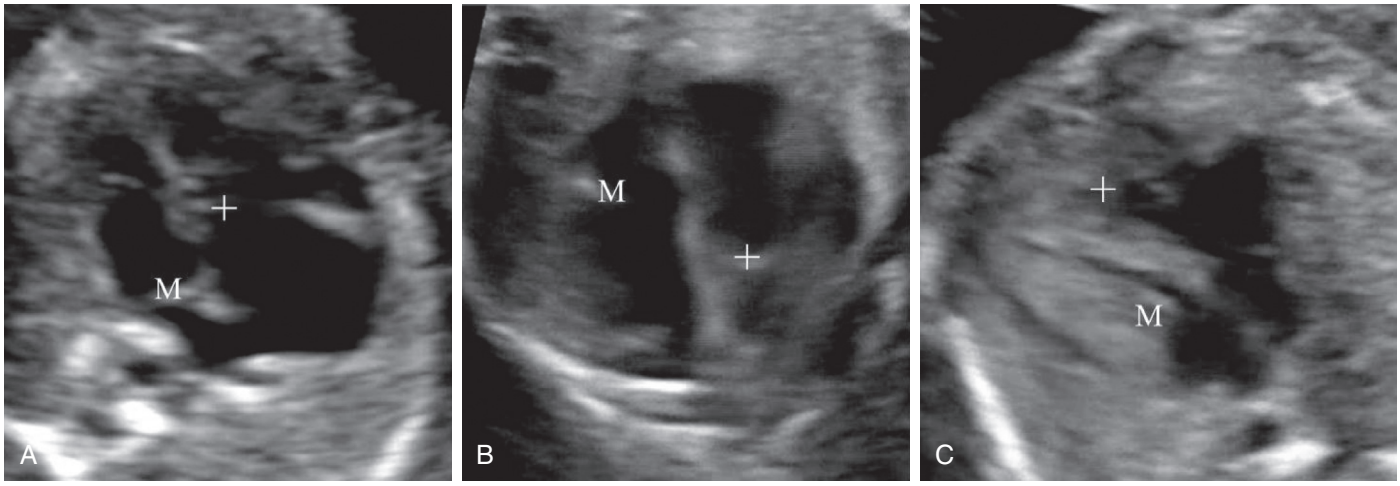

Fig. 78.1 (A) Abnormal apical, (B) basal and (C) transverse four-chamber views in different cases of EA. Note that the tricuspid valve *(+)* is significantly lower that the mitral valve *(M)* in all cases.

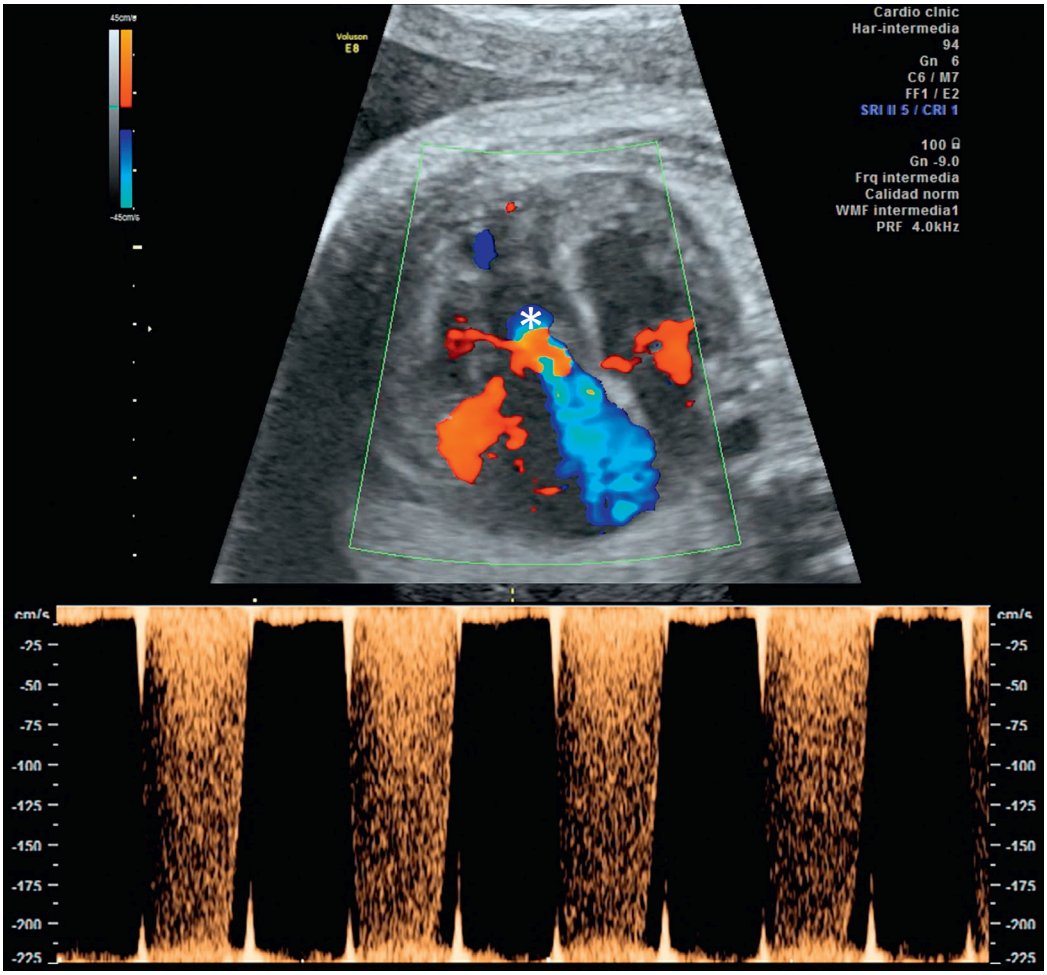

Fig. 78.2 EA with hydrops in a fetus of 21 weeks of gestation. There is pericardial effusion and bivalvular regurgitation. * Note that the blue jet corresponding to the systolic tricuspid regurgitation originates below the atrioventricular level and arrives to the top of the right atrium. Pulsed Doppler illustrating the high velocities of the TR.

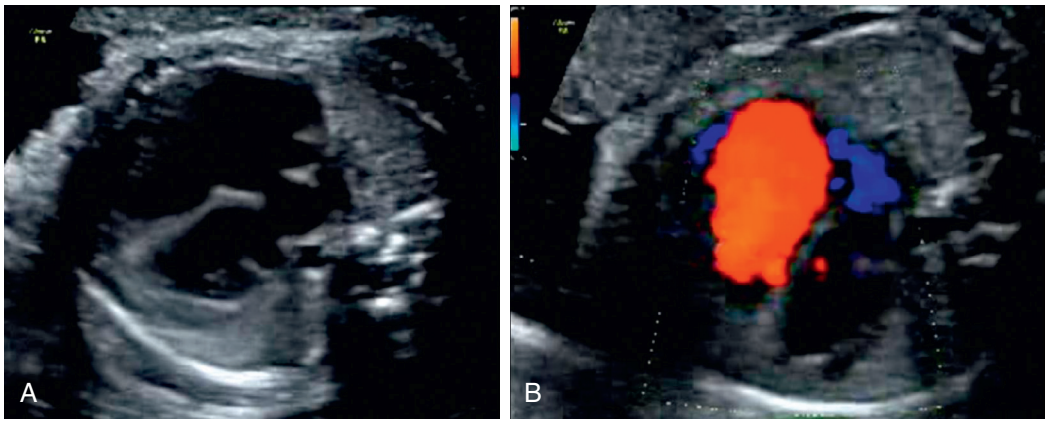

Fig. 78.3 (A) Abnormal four-chamber view: there is a cardiomegaly with an enlarged right atrium and a decreased size of the right ventricle as a consequence of the apical displacement of the tricuspid valve. (B) Color Doppler imaging illustrating the massive tricuspid regurgitation originating from the apex of the right ventricle.

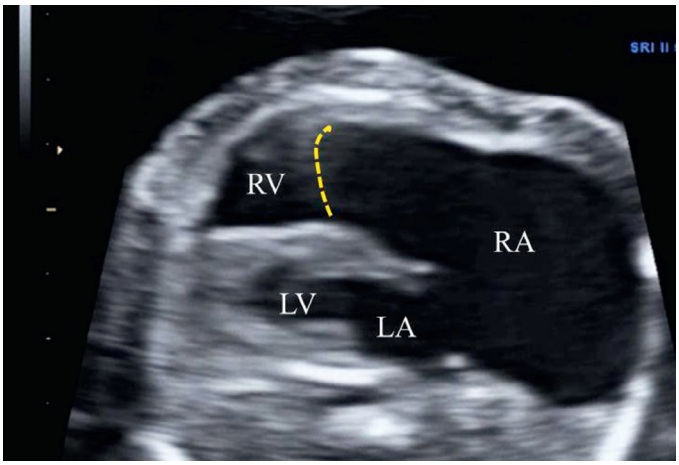

Fig. 78.4 EA with a massive enlargement of the right atrium as a consequence of the significant tricuspid regurgitation. The yellow line illustrates the insertion of the tricuspid valve. Note the reduction in the right ventricular size. *LA,* Left atrium; *LV,* left ventricle; *RA,* right atrium; *RV,* right ventricle.

Doppler in the pulmonary artery and ductus arteriosus (Video 78.1). The obstruction is usually functional because of severe tricuspid regurgitation, and in most cases, it is very difficult to distinguish it from a true anatomic defect. Identification of a mobile valve or valve insufficiency by Doppler favors a functional origin.

Tricuspid Dysplasia. The aspect of TD can be similar to EA. The main difference is the normal insertion of valve leaflets at the atrioventricular junction. However, the valve is also dysplastic (thickened, hyperechogenic, and hypomobile) and shows severe insufficiency (holosystolic or with peak velocities >200 cm/s, or both). Color Doppler may be useful to establish the differential diagnosis with EA (Fig. 78.4 and Video 78.2): in TD, the systolic regurgitant jet originates at the atrioventricular junction (Fig. 78.5), whereas in EA it originates in the ventricle, below the atrioventricular level.

TD also manifests with cardiomegaly, which if severe can cause pulmonary hypoplasia. Typically, there is an increase in size of both the right atrium and ventricle, whereas in EA, the right ventricle is small by definition. Finally, as with EA, TD can be associated with pulmonary stenosis or atresia (see previous comments).

Other Applicable Modality

Four-Dimensional Echocardiography. Four-dimensional echocardiography can help to characterize the abnormalities of the tricuspid valve.

CLASSIC SIGNS

FOUR-CHAMBER VIEW

Common Signs in EA and TD

Tricuspid valve thickened, hyperechogenic, and with little or no mobility.
Severe tricuspid insufficiency (holosystolic or with velocities >200 cm/s, or both).
Cardiomegaly (right atrium enlarged).

Different Signs Between EA and TD

Apical displacement of the tricuspid valve in EA and correct valvular insertion in TD, with differences in the origin of regurgitation by color Doppler.
Different grade of hypoplasia of the right ventricle in EA; normal or large right ventricle in TD.

RIGHT OUTFLOW TRACT VIEW AND THREE-VESSEL AND TRACHEA VIEW (IN BOTH CONDITIONS)

Smaller pulmonary artery and ductus arteriosus, with antegrade flow in cases with mild right outflow obstruction and retrograde flow in cases of severe obstruction.

Differential Diagnosis From Imaging Findings

1. Pulmonary atresia with intact ventricular septum: type II, the form with dysplastic and insufficient tricuspid valve, can be very difficult to differentiate from TD associated with severe right outflow obstruction. As previously mentioned, observation of a mobile or insufficient pulmonary valve points to TD.
2. Premature constriction or closure of the ductus arteriosus: this condition can cause severe tricuspid insufficiency with different grades of cardiomegaly, especially during the third trimester and related to the ingestion of nonsteroidal

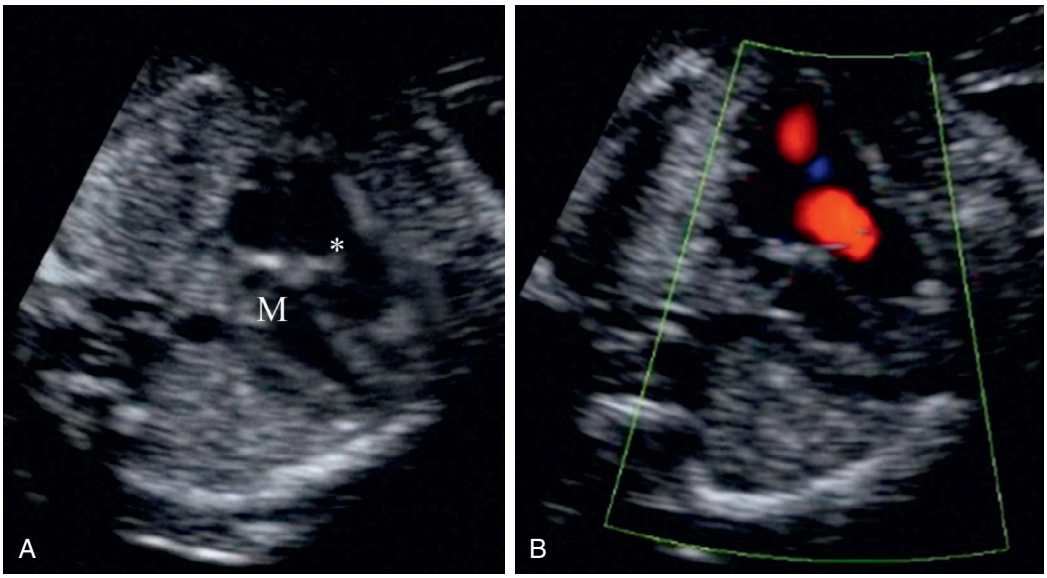

Fig. 78.5 (A) Abnormal four-chamber view in a fetus with a tricuspid dysplasia. The tricuspid valve presents a normal insertion *(asterisk)* at the same level of the mitral valve *(M)*. However, this is dysplastic and the color Doppler (B) shows a significant regurgitation, which originates at the atrioventricular level.

antiinflammatory drugs. In this anomaly, there is a typical flow in the ductus arteriosus with a low pulsatility index (<2.0 and <1.0 in severe cases), and high systolic and diastolic velocities (>140 cm/s systolic and >30 cm/s diastolic).

Synopsis of Treatment Options

PRENATAL

As in other CHDs, when these anomalies are detected in the fetus,[1–3] it is mandatory to rule out other extracardiac anomalies (very low association) and to reassess the risk of fetal aneuploidy (especially in cases of TD). It is also important to identify associated CHDs, which are present in 30% of cases (especially right outflow obstruction and septal defects).

Echocardiographic follow-up during pregnancy is recommended (2- to 4-week intervals) to assess (1) the flow across the foramen ovale and the ductus venosus, which helps to determine the risk of hydrops; (2) the development of the pulmonary artery and the flow in the pulmonary artery and ductus arteriosus; (3) the presence of arrhythmias, which can be associated with CHDs with an enlarged right atrial size; (4) the progression of cardiomegaly; and (5) the risk of lung hypoplasia.

The outcome of these CHDs when diagnosed during fetal life is bad; there is a high intrauterine mortality rate (35% to 45% of cases).[4] The presence of fetal arrhythmias and cardiac failure (30% of cases, especially in EA) worsens the prognosis. As in most CHDs, the obstetric management should not be changed unless hydrops is present. It is advisable for delivery to occur in a tertiary referral center.

POSTNATAL

Ebstein Anomaly

In severe cases, the newborn requires intensive neonatal care. Surgical treatment[5,6] is required early and is very complex, and is associated with high mortality. Most infants eventually require palliative univentricular surgery (Fontan-like repair), which briefly consists of the following:

- systemic pulmonary shunt to maintain pulmonary flow
- closure of the tricuspid valve with a patch fenestration procedure
- atrial septostomy
- resection of the redundant atrial tissue plus right ventricular reconstruction

In moderate forms, tricuspid insufficiency improves as pulmonary pressures decrease. Infants with EA can reach late adulthood with mild or no symptoms. If needed, surgery is performed in adulthood with low mortality rates in most cases.

Tricuspid Dysplasia. The postnatal course for TD is similar to EA. In mild forms, symptoms in the newborn improve with the switch from fetal to neonatal circulation. The surgical valve repair can be performed in adulthood in most cases. In contrast, perinatal mortality is high in most severe cases, especially if heart failure is already present. In these cases, surgery in the neonatal period is frequently required, with high associated mortality rates.

WHAT THE REFERRING PHYSICIAN NEEDS TO KNOW

- EA and TD are CHDs affecting the tricuspid valve with a wide spectrum of severity.
- The diagnosis is made on the four-chamber view. A remarkably enlarged right atrium with variable degrees of cardiomegaly is the most striking finding. The tricuspid valve is insufficient and dysplastic. In EA, there is apical displacement of the tricuspid valve.
- The association with extracardiac and chromosomal abnormalities is low (especially in EA). However, both anomalies are frequently associated with other cardiac malformations (30% of cases, especially right outflow obstruction and septal defects).
- Fetal karyotyping and careful examination of the cardiac and extracardiac anatomy should be considered. A follow-up examination every 2 to 4 weeks is recommended to assess the risk of hydrops and the presence of arrhythmias.

- The obstetric management should not be changed unless hydrops is present.
- The forms that appear in fetal life usually correspond to the most severe cases and are associated with high fetal mortality rates and difficult neonatal management and surgery.

KEY POINTS

- EA and TD are rare forms of CHD. There is a low association with chromosomal abnormalities (in EA) and extracardiac malformations in the fetus.
- Prenatal diagnosis is relatively easy on the four-chamber view, which shows a dysplastic tricuspid valve with apical displacement in EA.
- Overall prognosis is poor when these conditions are diagnosed in the fetus, especially the severe forms.

SUGGESTED READING

Freud LR, Escobar-Diaz MC, Kalish BT, et al. Outcomes and predictors of perinatal mortality in fetuses with Ebstein anomaly or tricuspid valve dysplasia in the current era: a multicenter study. *Circulation*. 2015;13:481-489.

Paranon S, Acar P. Ebstein's anomaly of the tricuspid valve: from fetus to adult. *Heart*. 2008;94:237-243.



All references are available online at www.expertconsult.com.

REFERENCES

1. Cherry C, Debord S, Mustapha-Nadler N. Ebstein's anomaly: a complex congenital heart defect. *AORN J*. 2009;89(6):1098-1110.
2. Zimmer EZ, Blazer S, Lorber A, et al. Fetal Ebstein's anomaly: early and late appearance. *Prenat Diagn*. 2012;32(3):228-233.
3. Flores A, Fernández L, Quero C, et al. The clinical profile of Ebstein's malformation as seen from the fetus to the adult in 52 patients. *Cardiol Young*. 2004;14:55-63.
4. Lasa JJ, Tian ZY, Guo R, et al. Perinatal course of Ebstein's anomaly and tricuspid valve dysplasia in the fetus. *Prenat Diagn*. 2012;32(3):245-251.
5. Dearani JA, Mavroudis C, Qintessenza J, et al. Surgical advances in the treatment of adults with congenital heart disease. *Curr Opin Pediatr*. 2009;21:565-572.
6. Yuan SM, Jing H. Palliative procedures for congenital heart defects. *Arch Cardiovasc Dis*. 2009;102:549-557.

To access the videos in this chapter, scan this QR code or visit expertconsult.com

79 Pulmonary Stenosis and Atresia

OLGA GÓMEZ | JOSEP M. MARTINEZ

Introduction

Pulmonary stenosis (PS) and pulmonary atresia (PA) with intact ventricular septum have a low incidence in the fetus. In PS, there is a narrowing of the right ventricular outflow tract, whereas PA is characterized by an absent ventriculoarterial connection. The conditions are anatomically related, but the prognosis may vary substantially.

Disease

DEFINITION

PS refers to a narrowing of the right ventricular outflow tract secondary to a lesion that can occur at any of three levels—valvular, subvalvular, or infundibular region of the pulmonary artery. The most common form is a dysplastic valve with partial fusion of the three pulmonary valve cusps.

PA with intact interventricular septum, also known as *hypoplastic right heart syndrome,* is characterized by complete blockage of the right ventricular outflow tract. Atresia usually occurs at the level of the valve, and less frequently the pulmonary artery is also atretic. The competence of the tricuspid valve and the presence of tricuspid anomalies determine the development of the right ventricle, but this is usually hypoplastic with a proportionally smaller tricuspid valve. Less commonly, the right ventricle is dilated or of normal size.

PREVALENCE AND EPIDEMIOLOGY

The estimated incidence of PS is approximately 9% to 10% of all congenital heart diseases (CHDs) diagnosed in neonates. PA is diagnosed in 1:22,000 live births, and it accounts for 1% to 5% of all prenatally diagnosed CHDs.

ETIOLOGY AND PATHOPHYSIOLOGY

As in most CHDs, the etiologies of PS and PA are multifactorial. The risk of chromosomal anomalies and extracardiac malformations is low; there is a 2% risk of aneuploidy. PS can appear in the context of different nonchromosomal syndromes (e.g., Williams, Alagille, and Noonan syndromes), and it is a typical finding of congenital rubella syndrome.

As with any other CHD, PS can be associated with other CHDs:

1. Isolated PS is less commonly diagnosed in fetal life because the diagnosis is more challenging, especially in less severe forms.
2. PS associated with other CHDs, typically with conotruncal anomalies, represents the most common form detected during fetal life.

In PA, the presence of a ventricular septal defect determines another important distinction: pulmonary atresia in association with a ventricular septal defect may be part of tetralogy of Fallot or other CHDs (double-outlet ventricle, transposition of great

arteries, heterotaxy syndromes; see Chapters 86–88 and 91). The characteristics of the tricuspid valve determine the size of the right ventricle in PA. Two types of PA can be distinguished in relation to the tricuspid valve:

1. PA type I (75% of cases): there is a competent or atretic tricuspid valve, and the right ventricle is hypoplastic. This form is associated with the presence of ventriculo-coronary arterial fistulas in 30% of cases.
2. PA type II (25% of cases): the tricuspid valve is incompetent or insufficient and there is a normal or, more frequently, a dilated right ventricle. This form of PA can be associated with anomalies of the tricuspid valve (e.g., Ebstein anomaly or tricuspid dysplasia; see Chapter 80).

MANIFESTATIONS OF DISEASE

Clinical Presentation

Mild forms of PS are well tolerated during fetal life, and newborns may remain initially asymptomatic. In critical PS and in PA, there is a significant risk of heart failure and cyanosis. Prostaglandin E_1 infusion in the early neonatal period is mandatory to prevent closure of the ductus arteriosus until surgery is scheduled. Neonatal management and prognosis is worse in the presence of right ventricle-dependent coronary circulation (30% of cases with PA type I) and if there is a dilated and noncontractile right ventricle (PA type II).

Imaging Technique and Findings

Ultrasound

Pulmonary Stenosis. The possibility of prenatal ultrasound diagnosis depends on the degree of obstruction of the pulmonary artery.

- Moderate obstruction (mild PS): the four-chamber view may be normal, and PS can be detectable only if the right ventricular outflow tract is evaluated, especially when applying color Doppler.
- Severe obstruction (severe or critical PS): the diagnosis can be suspected on the four-chamber view because this form is usually associated with different degrees of right ventricular hypertrophy and tricuspid insufficiency.

The following points summarize the prenatal features of PS:

- signs of dysplasia of the pulmonary valve, including increased echogenicity, thickening, and hypomobility (Fig. 79.1)
- diameter of the pulmonary valve and artery smaller than expected for gestational age (ratio pulmonary to aorta <1) (see Fig. 79.1)
- poststenotic pulmonary artery dilatation, occurring as a consequence of the systolic accelerated jet (see Fig. 79.1)
- color Doppler showing turbulent systolic flow (with aliasing) (Fig. 79.2); pulsed wave Doppler confirms the presence of this high accelerated flow, with maximum velocities during systole greater than 140–200 cm/sg (Fig. 79.3)
- hypertrophy of the right ventricle, which can progress to hypocontractility and dilatation (in more severe cases) (Fig. 79.4)
- tricuspid insufficiency, which can be severe (in more severe cases) (see Fig. 79.4)
- reverse flow in the pulmonary artery and ductus arteriosus (in critical stenosis)

Pulmonary Atresia. The four-chamber view is altered in most cases. In PA type I (hypoplastic right heart syndrome), the right ventricle is reduced, and the tricuspid valve is usually proportional to it. Right myocardial hypertrophy with a different grade of ventricular hypomotility can also be present. In more severe cases, the hypoplastic right ventricle can mimic a cardiac tumor. In 30% of cases of PA type I, there are ventriculo-coronary arterial connections which worsen the prognosis, contributing to myocardial ischemia by compromised diastolic coronary flow. The presence of these connections can be identified by the presence of tortuous vessels in the right myocardium showing bidirectional flow (Video 79.1). During fetal life, it is impossible to determine whether the coronary circulation is dependent on these connections. Initially, it was postulated that these connections were the result of the increased pressure in the right ventricle. However, the opposite has also been postulated: the primary existence of coronary fistulas diverts blood flow from the pulmonary artery to the coronary circulation causing diminished development of the pulmonary artery.

In PA type II (normal or dilated right ventricle form), the tricuspid valve is dysplastic and nonrestrictive, allowing passage of blood to the right atrium during ventricular systole. As a consequence, there is significant valvular insufficiency, which usually causes severe cardiomegaly including both the right atrium and the right ventricle (Video 79.2). This form of PA is not associated with ventriculo-coronary arterial connections.

- Right ventricular outflow tract view: the pulmonary valve may show signs of dysplasia (increased echogenicity,

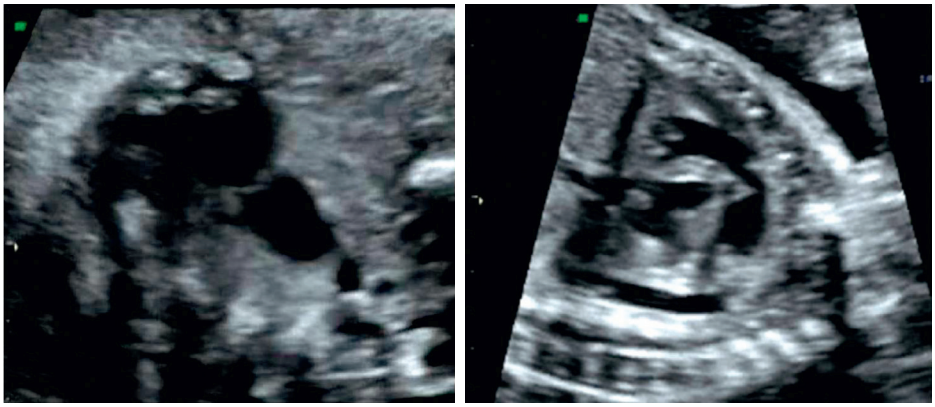

Fig. 79.1 Pulmonary stenosis in a short- and long-axis view of the right ventricle. The diameter of the pulmonary valve is decreased, the valve is thickened, and there is a poststenotic dilatation.

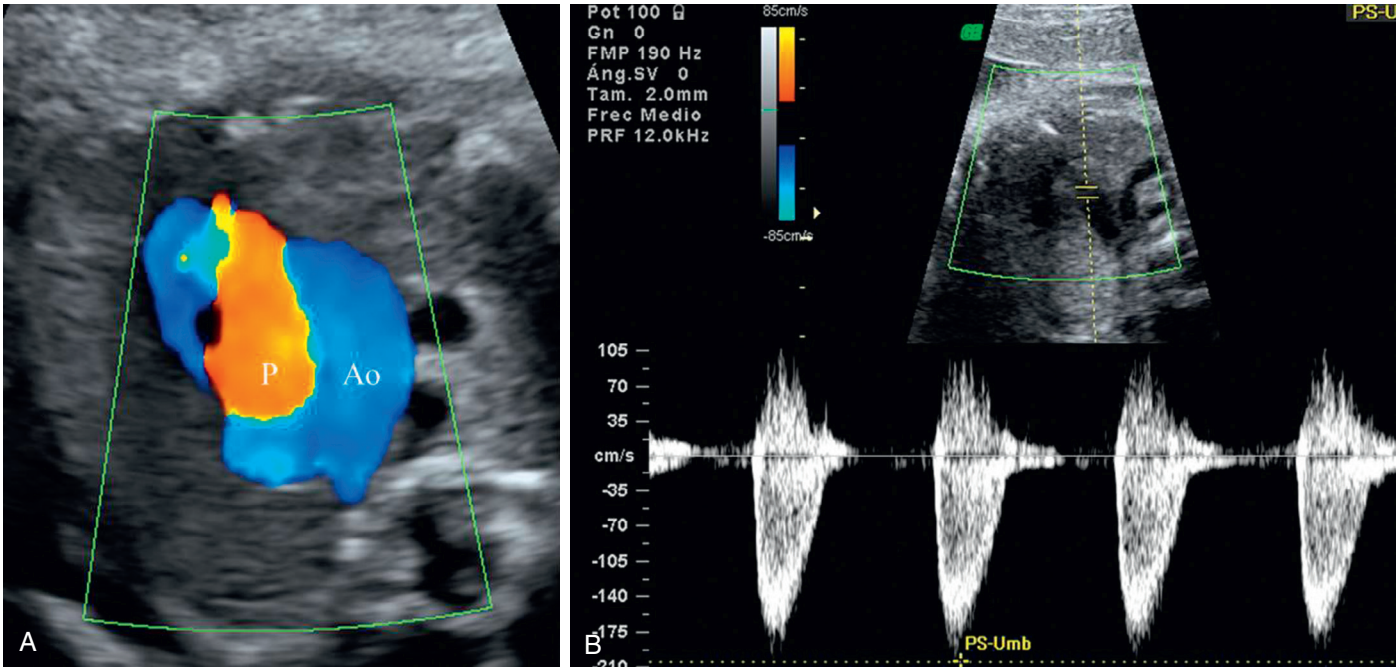

Fig. 79.2 (A) Color Doppler showing the turbulent systolic flow in a mild pulmonary stenosis. Note that there is an antegrade flow in the ductus arteriosus. (B) Pulse-wave Doppler showing the accelerated flow across the pulmonary valve (maximum velocity of 180 cm/s). *Ao*, Aorta; *P*, pulmonary artery.

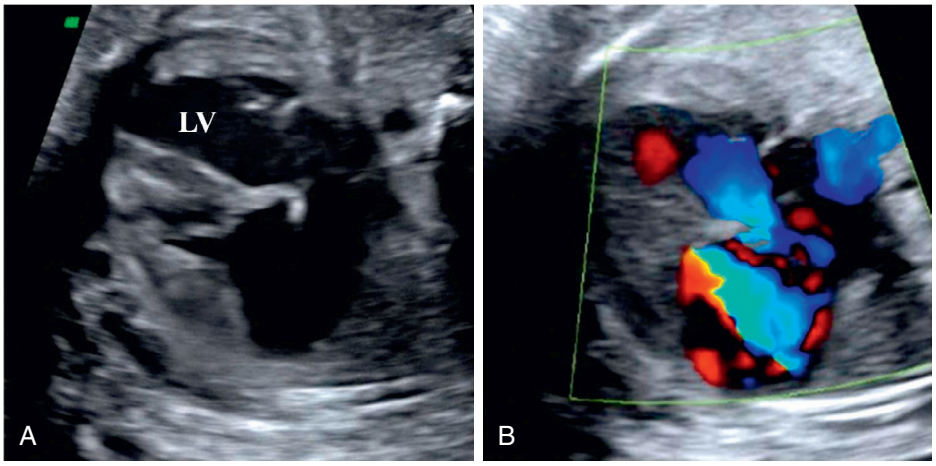

Fig. 79.3 Abnormal four-chamber view in a critical PS. There is a clear hypertrophy of the right ventricle (A) when compared with the left one and a significant tricuspid insufficiency (B), which is codified in blue during systole. *LV*, Left ventricle.

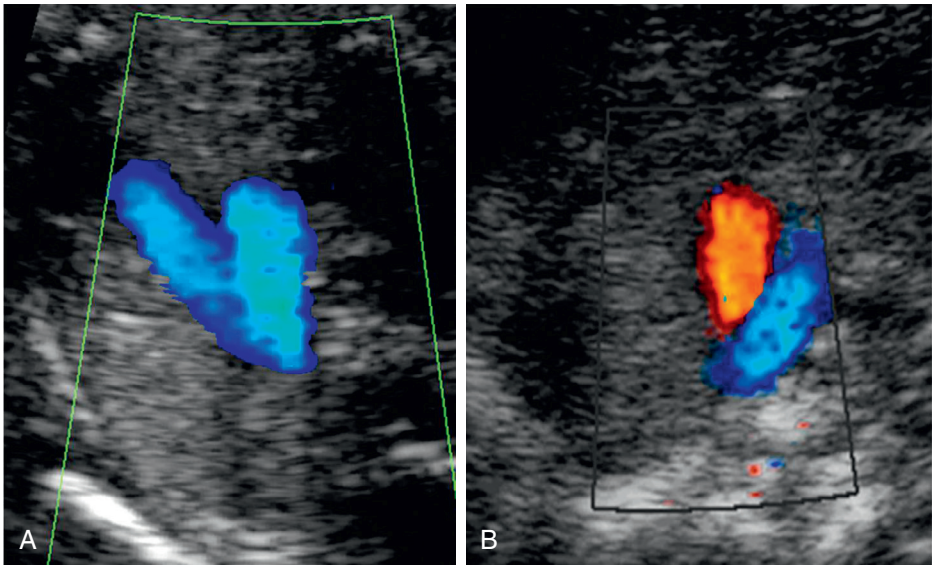

Fig. 79.4 (A) Normal three-vessel and trachea view showing an antegrade flow in the aortic isthmus and ductus arteriosus and (B) abnormal three-vessel and trachea view in a critical PS. There is a reverse flow in the pulmonary artery and ducts arteriosus.

thickening, and absence of motility during systole), and color Doppler shows the absence of flow across the valve.
- Three-vessel and trachea view: a smaller pulmonary artery with retrograde flow through the arterial duct can be identified in all cases.

PA can be very difficult to differentiate from a critical PS. However, the prognosis of both conditions is similar.

Other Applicable Modality

Four-Dimensional Echocardiography. Four-dimensional echocardiography may be used to obtain a better illustration of the abnormalities in the tricuspid and pulmonary valves but it is not critical for the diagnosis.

CLASSIC SIGNS

PULMONARY STENOSIS

Decreased pulmonary valve diameter with signs of dysplasia and presence of a turbulent and accelerated systolic flow (shown by color and pulsed wave Doppler).
Poststenotic pulmonary artery dilatation (some cases).
Hypertrophy of the right ventricle and tricuspid insufficiency (severe and critical PS).
Reverse flow in the pulmonary artery and ductus arteriosus (in critical PS).

PULMONARY ATRESIA

Four-chamber view: reduced or hypoplastic tricuspid valve and right ventricle (PA type I) or cardiomegaly with tricuspid insufficiency and normal or dilated right ventricle (PA type II); presence of ventriculo-coronary arterial connections (30% of cases of PA type I).
Right ventricular outflow tract view: pulmonary dysplastic valve with absence of flow across it.
Three-vessel and trachea view: small pulmonary artery with retrograde flow through the arterial duct.

Differential Diagnosis From Imaging Findings

1. PS or PA with ventricular septal defect: PS and PA are frequently associated with other CHDs (mainly with tetralogy of Fallot, double-outlet right ventricle, transposition of great arteries, and heterotaxia syndromes; see related Chapters 87, 88, 89, and 92). In these forms of PS and PA, evaluation of the interventricular septum at the origin of the left ventricular outflow tract view helps confirm the presence of the ventricular septal defect.
2. Tricuspid atresia without ventricular septal defect: This entity may be very difficult to differentiate from PA type I with restricted opening of the tricuspid valve. In both conditions, the right ventricle is extremely hypoplastic, and the pulmonary artery and ductus arteriosus show a reverse flow. The presence of ventriculo-coronary arterial fistulas on the four-chamber view can help distinguish between the two forms because these connections are present in 30% of cases of PA type I.
3. Ebstein anomaly or tricuspid dysplasia: PA type II can be very difficult to differentiate from a primary lesion of the tricuspid valve that causes a severe right ventricular outflow tract obstruction. The identification of a mobile pulmonary valve or the presence of pulmonary valve insufficiency points to anomalies of the tricuspid valve.
4. PS or PA associated with monochorionic twin pregnancy complications: PS and PA can be found in recipients in twin transfusion syndrome. Some cases revert after treatment. The pathophysiology is thought to be associated with massive preload increase in association with fetal hypertension affecting the right ventricle as the systemic ventricle in the fetus.

Synopsis of Treatment Options

PRENATAL

The risks of chromosomal anomalies and extracardiac malformations are low in PS and PA. A careful echocardiography examination is mandatory in all cases. The need for karyotyping should be discussed with parents. Concurrent nuchal thickening or cystic hygroma is a fetal finding that together with PS is more commonly associated with Noonan syndrome. Although extremely rare, congenital rubella syndrome should also be considered in the presence of a PS.

Echocardiographic follow-up during pregnancy is recommended (2- to 4-week intervals) mainly to monitor right ventricular development, the presence of tricuspid insufficiency, and the flow in the pulmonary valve and ductus arteriosus. Anomalies of the pulmonary valve typically can evolve *in utero.* Milder forms may appear only in the third trimester, but if anomalies are detected earlier, they may worsen significantly in some cases in late pregnancy. Close monitoring of the growth of the tricuspid valve and right ventricle is particularly important to evaluate the chances for postnatal biventricular repair.[1] In the presence of critical PS and PA (especially type II) there is an increased risk of heart failure and hydrops. The risk of fetal death depends on tricuspid function. If the degree of tricuspid insufficiency is severe, there is a 40% risk of intrauterine death, whereas if the tricuspid valve is atretic, the pulmonary defect is well tolerated *in utero,* and mortality rates are less than 10%.

In the absence of hydrops, the obstetric management should not be changed.[2] Fetuses with mild forms of PS can be delivered in a local hospital. Critical PS and PA are ductus-dependent CHDs, so it is advisable to plan delivery in a tertiary referral center.

Fetal pulmonary valvuloplasty has been carried out in an attempt to preserve the right ventricle growth in the hope that this will maximize the chances of an eventual postnatal biventricular repair. Not only are the numbers small, but there are no long-term follow-up and no clear-cut selection criteria as to which cases may benefit from prenatal intervention.[3] International clinical guidelines state that the procedure should actually only be carried out in a hospital specializing in fetal interventions and after full discussion with the parents about the risk and the uncertainties of the efficacy.

POSTNATAL

Individuals with mild forms of PS have an excellent prognosis. Newborns may remain asymptomatic during the first months of life. Typically, PS worsens over time, and a balloon valvuloplasty via interventional catheterization is eventually indicated. A surgical valvulotomy may rarely be required.

In critical PS and PA, the newborn has to be stabilized with a prostaglandin infusion to determine suitability for biventricular or univentricular repair.[4] When feasible, a biventricular repair is preferable, although long-term prognosis will be known only with follow-up into adult life.

Infants with good right ventricular function and with valve stenosis can undergo interventional catheterization and balloon dilatation. After the procedure, if the right ventricle is unable

to provide good oxygen saturation at rest, an aortopulmonary shunt is usually considered. According to fetal series, early neonatal survival is 90% in this group, with almost normal life expectancy and a low likelihood of requiring additional surgical procedures.

Cases with a hypoplastic or hypocontractile right ventricle, with right ventricle-dependent coronary circulation, or with a muscular pulmonary obstruction, may require palliative univentricular surgery consisting of a total cavopulmonary connection Fontan-like repair. In this group, the prognosis is poor with reported neonatal mortality rates of 15% to 35%. Survival decreases further during early and later childhood because of reoperations, thromboembolism, arrhythmias, and congestive venous complications. Finally, the prognosis is worst in the presence of severe coronary stenosis or of a right ventricle-dependent coronary circulation, when neonatal mortality rates exceed 70%.

WHAT THE REFERRING PHYSICIAN NEEDS TO KNOW

- PS and PA are CHDs affecting the pulmonary valve with a low incidence in the fetus.
- The diagnosis is made on the four-chamber view in most severe cases because a severe right ventricular outflow tract obstruction generally causes significant tricuspid insufficiency with variable degrees of cardiomegaly. If the tricuspid valve is also atretic, the right ventricle is hypoplastic.
- Association with extracardiac and chromosomal abnormalities is low (<2%). However, PS and PA in the presence of a ventricular septal defect are frequently associated with other cardiac malformations (especially conotruncal anomalies).
- Fetal karyotyping and careful examination of the cardiac and extracardiac anatomy should be considered. A follow-up examination every 2 to 4 weeks is recommended to assess the development of the tricuspid valve, the right ventricle, and the pulmonary artery. The obstetric management should not be changed in the absence of hydrops.
- Mild forms of PS have an excellent prognosis. In critical PS and PA, the suitability for biventricular or univentricular repair determines the prognosis.

KEY POINTS

- PS and PA are rare forms of CHD. There is a low association with chromosomal abnormalities and extracardiac malformations in the fetus.
- Prenatal diagnosis is easy on the four-chamber view in critical PS and PA. In mild forms of PS, the diagnosis is possible only in the right ventricular outflow tract view.
- Overall prognosis is good for mild forms with normal or moderate hypoplasia of the right ventricle. Prognosis is poor for cases with a severely dilated right ventricle or with right ventricle-dependent coronary circulation.

SUGGESTED READING

Shinebourne EA, Rigby ML, Carvalho J. Pulmonary atresia with intact ventricular septum: from fetus to adult. *Heart*. 2008;94:1350-1357.

Tulzer G, Arzt W. Fetal cardiac interventions: rationale, risk and benefit. *Semin Fetal Neonatal Med*. 2013;18(5):298-301.



All references are available online at www.expertconsult.com.

REFERENCES

1. Roman KS, Fouron JC, Nii M, et al. Determinants of outcome in fetal pulmonary stenosis and atresia with intact ventricular septum. *Am J Cardiol*. 2007;99:699-703.
2. Bhawna A, Krishnan A, Donofrio MT. Clinical utility of ductus venosus flow in fetuses with right-sided congenital heart disease. *J Ultrasound Med*. 2014;33:1563-1571.
3. Tworetzky W, McElhinney DB, Marx GR, et al. In utero valvuloplasty for pulmonary atresia with hypoplastic right ventricle: techniques and outcomes. *Pediatrics*. 2009;124:510-518.
4. Yuan SM, Jing H. Palliative procedures for congenital heart defects. *Arch Cardiovasc Dis*. 2009;102:549-557.

SECTION FOUR
Left Heart Defects

80 Aortic Stenosis and Aortic Atresia

MAR BENNASAR | JOSEP M. MARTINEZ

Introduction

Aortic stenosis (AS) affects 1.4:10,000 newborns. The spectrum of clinical manifestations varies widely according to the degree of valve stenosis.[1]

Disease

DEFINITION

AS and aortic atresia encompass a group of congenital heart diseases (CHDs) characterized by left ventricular outflow tract obstruction. Depending on the level of the defect, these are

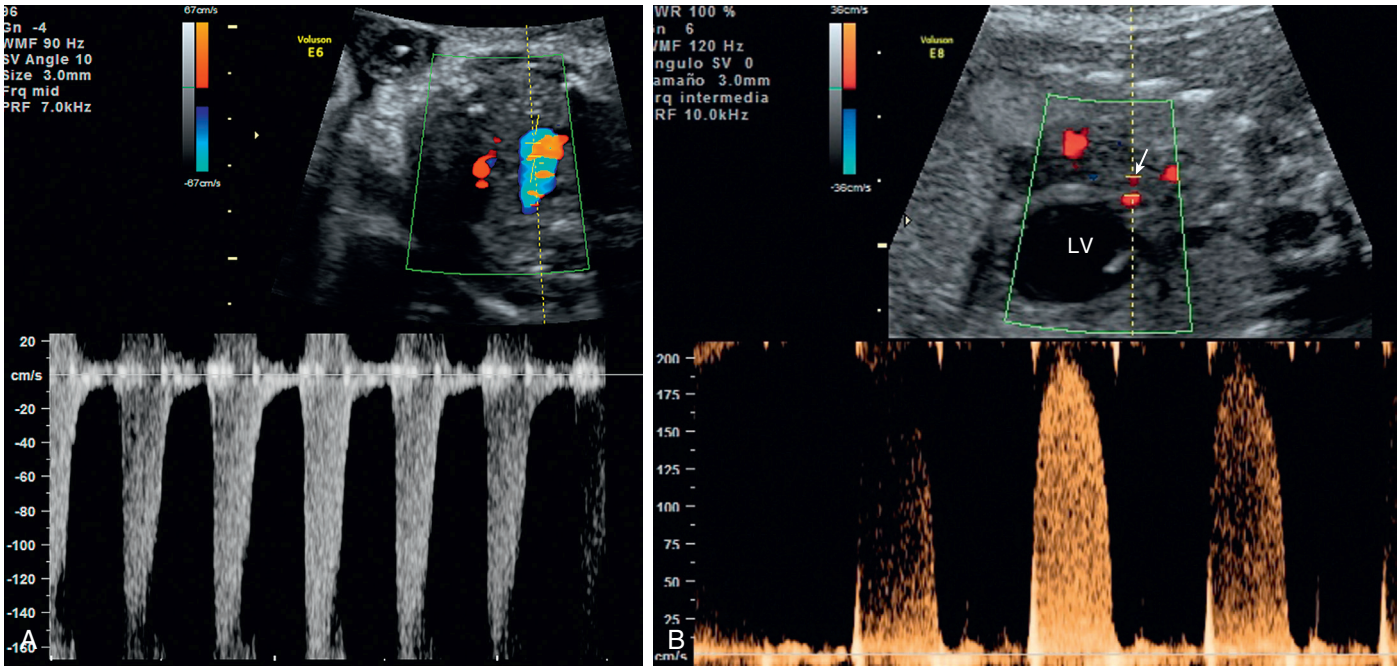

Fig. 80.1 (A) Mild aortic stenosis. Aliasing flow is identified and high postvalvular velocities confirmed by means of pulsed Doppler. (B) Color Doppler evaluation of a globular left ventricle *(LV)* outflow tract in critical aortic stenosis: aliasing *(arrow)* through the aortic valve and blood flow acceleration are identified.

classified as supravalvular, valvular, or subaortic obstruction. Valvular stenosis is the most frequently found form in the fetus.

PREVALENCE AND EPIDEMIOLOGY

AS accounts for 3% of all CHDs. There is a 15% recurrence risk, one of the highest among all forms of CHD.

ETIOLOGY AND PATHOPHYSIOLOGY

The etiology is multifactorial. Autosomal dominant and recessive inheritance forms have been reported. Subvalvular forms have been associated with hypertrophic myocardiopathy and maternal diabetes.

Aortic atresia is frequently associated with mitral atresia in the context of hypoplastic left heart syndrome (HLHS) (Chapter 81). Isolated aortic atresia is uncommon. If present, it is characterized by fused or dysplastic valve leaflets, and the aortic valve can be bicuspid, monocuspid, or quadricuspid.

Clinical and ultrasound (US) manifestations depend on the severity of the obstruction and the functionality of the mitral valve.

- Mild AS is associated with an increased pressure of the left ventricle outflow tract without ventricular dysfunction. Color Doppler evaluation is the key for diagnosing this form of AS (Fig. 80.1), showing an acceleration and aliasing of the blood flow through the aortic valve. Pulsed Doppler will identify postvalvular acceleration with high peak velocities in the outflow tract. It is frequently overlooked prenatally.
- Progressive obstruction leads to left ventricular hypertrophy to overcome the high left ventricular outflow tract pressure.
- Severe and prolonged obstruction causes myocardial ischemia and left ventricular dysfunction. Chronic myocardial stress results in proliferation of elastic and collagenous fibers, causing diffuse thickening of the endocardium and endocardial fibroelastosis (Fig. 80.2).[2]
- Chronic critical AS and aortic atresia can progress to severe hypoplasia of the left ventricle (Fig. 80.3).

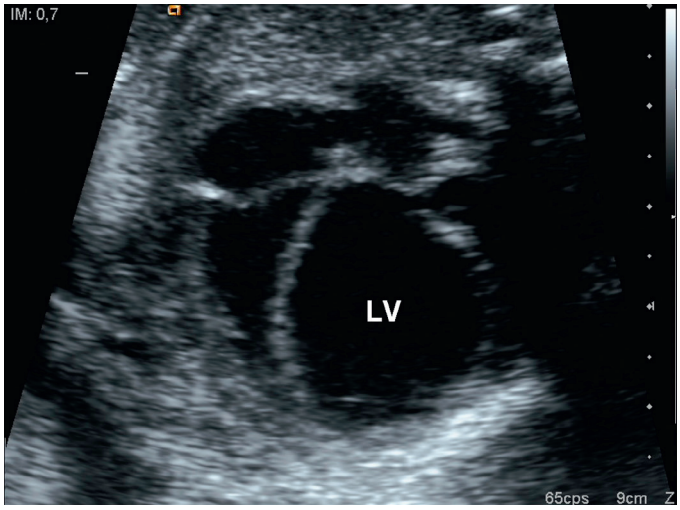

Fig. 80.2 Globular left ventricle *(LV)* occupying the cardiac apex. Echogenic left ventricle internal walls suggest endocardial fibroelastosis.

MANIFESTATIONS OF DISEASE

Clinical Presentation

Clinical manifestations depend on the severity of the obstruction and degree of ventricular dysfunction. Patients may be

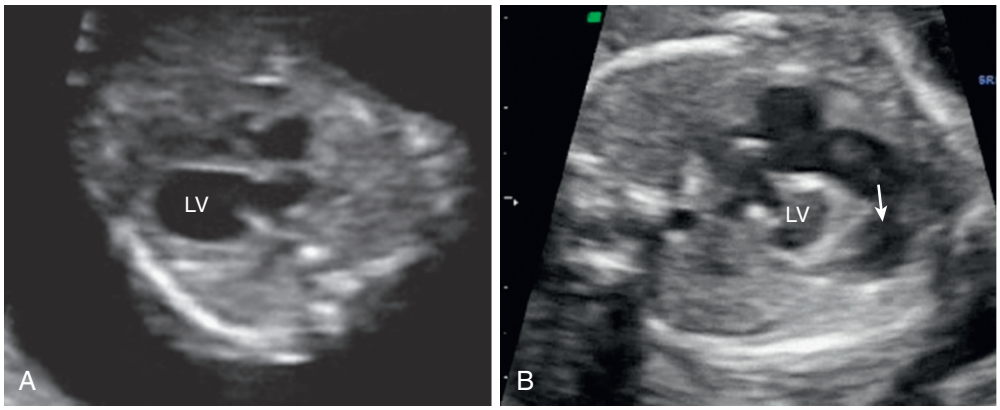

Fig. 80.3 (A) Dilated left ventricle *(LV)* in a case of severe aortic stenosis. (B) Hypertrophic, globular left ventricle in a case of aortic atresia that has progressed to hypoplastic left ventricle *(LV)*. Left ventricular cavity is reduced. The right ventricle occupies the cardiac apex of the heart *(arrow)*.

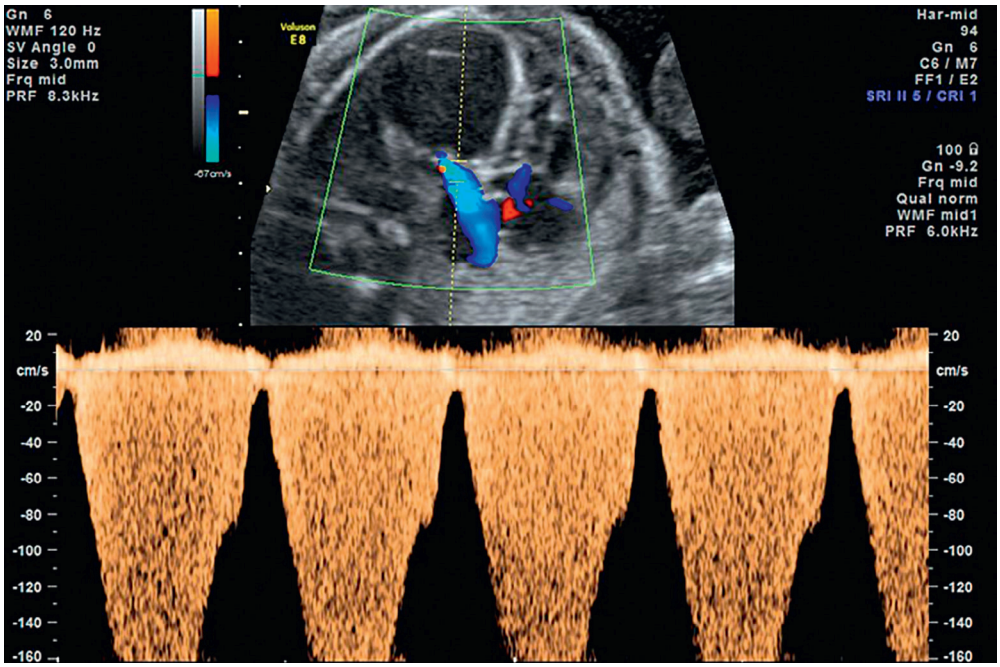

Fig. 80.4 Mitral insufficiency in severe aortic stenosis.

asymptomatic until adulthood or present with severe heart failure in the neonatal period.

Imaging Technique and Findings

Ultrasound. Mild AS is difficult to diagnose prenatally unless color Doppler is used. Progressive obstruction leads to more evident US anomalies and more frequent prenatal detection.

Although the four-chamber view and systolic function are normal in mild AS, progressive left ventricular outflow tract obstruction results in ventricular dysfunction and remodeling. The left ventricle becomes globular and occupies the cardiac apex (see Fig. 80.3). Progressive obstruction is responsible for myocardial hypertrophy and endocardial fibroelastosis, identified by marked ventricular internal wall hyperechogenicity (see Fig. 80.2). The mitral valve is frequently insufficient (Fig. 80.4).

The aortic valve is thickened and echogenic. Aortic color Doppler evaluation is the key for diagnosis of mild AS. Blood flow acceleration (aliasing) across the aortic valve may be the only finding of mild and moderate AS (see Fig. 80.1).

Systolic function is maintained, and antegrade flow in the aortic arch is preserved in mild to moderate AS, in contrast to critical AS and aortic atresia, in which systolic function is impaired, and no antegrade flow across the aortic valve is possible. Retrograde filling of the aortic arch and isthmus from the arterial duct is identified.

CLASSIC SIGNS

Globular and dilated left ventricle (see Fig. 80.3).
Aliasing through the aortic valve (see Fig. 80.1).
Retrograde aortic arch flow in critical AS and aortic atresia.

Synopsis of Treatment Options

PRENATAL

When AS is diagnosed prenatally, targeted morphologic US and fetal echocardiography should be offered. Parents should be counseled that obstructive lesions can be progressive during fetal life, so the fetus should be evaluated periodically (every 4 to 6 weeks) to rule out HLHS progression and the need for univentricular repair. Delivery should be planned in a tertiary referral center with cardiac surgery availability.

Prenatal aortic valvuloplasty has been reported as an investigational *in utero* treatment for critical AS. The aim of prenatal treatment is to avoid progression to HLHS. Prenatal valvuloplasty may increase blood flow through the left heart and improve left heart growth. The main problem is the correct selection of cases at high risk of developing left ventricular hypoplasia and determination of the necessity of postnatal univentricular palliation (Norwood procedure). These procedures are considered investigational at the present time, and the results should be interpreted with caution.[3–6]

POSTNATAL

Postnatal treatment is aimed at relieving the obstruction. Most favorable cases are treated by percutaneous valvuloplasty. More severe obstructions need valve removal. Cases with progression to HLHS require the Norwood procedure.

WHAT THE REFERRING PHYSICIAN NEEDS TO KNOW

- Identification of mild forms of AS can be challenging unless color Doppler is used. Severe forms lead to changes in the ventricular appearance, which should trigger the suspicion of AS. There is a very low risk of associated chromosomal and extracardiac anomalies.[7] However, there is a frequent association with other left heart anomalies.
- The prognosis generally depends on the severity of the stenosis and left ventricular function at birth[8] and on whether or not there is evolution to HLHS leading to univentricular heart and a much poorer long-term outcome.
- The most difficult issue after prenatal diagnosis is the prediction of the risk of progression to HLHS because even forms with a normal-sized or slightly dilated left ventricle can progress to HLHS at birth (see Fig. 80.3).
- The risk of recurrence is high, and this should be taken into account in following pregnancies.

KEY POINTS

- AS carries a high risk of recurrence.
- There is progressive evolution to HLHS.
- The left ventricle is globular and dysfunctional (see Fig. 80.3).
- Aliasing through the aortic valve is diagnostic.

SUGGESTED READING

Allan L, Hornberger L, Sharland G. *Textbook of Fetal Cardiology*. London: Greenwich Medical Media Ltd; 2000.

Paladini D, Volpe P. *Ultrasound of Congenital Fetal Anomalies: Differential Diagnosis and Prognostic Indicators*. London: Informa Health Care; 2007.

Yagel S, Silverman NH, Gembruch U. *Fetal Cardiology*. Series in maternal fetal medicine. New York: Informa Health Care; 2009.



All references are available online at www.expertconsult.com.

REFERENCES

1. Allan LD, Sharland GK, Milburn A, et al. Prospective diagnosis of 1006 consecutive cases of congenital heart disease in the fetus. *J Am Coll Cardiol*. 1994;23:1452.
2. Trastour C, Bafghi A, Delotte J, et al. Early prenatal diagnosis of endocardial fibroelastosis. *Ultrasound Obstet Gynecol*. 2005;26:303.
3. Pavlovic M, Acharya G, Huhta JC. Controversies of fetal cardiac intervention. *Early Hum Dev*. 2008;84:149.
4. Makikallio K, McElhinney DB, Levine JC, et al. Fetal aortic valve stenosis and the evolution of hypoplastic left heart syndrome: patient selection for fetal intervention. *Circulation*. 2006;113:1401.
5. Freud LR, McElhinney DB, Marshall AC, et al. Fetal aortic valvuloplasty for evolving hypoplastic left heart syndrome: postnatal outcomes of the first 100 patients. *Circulation*. 2014;130:638-645.
6. Marantz P, Grinenco S. Fetal intervention for critical aortic stenosis: advances, research and postnatal follow-up. *Curr Opin Cardiol*. 2015;30:89-94.
7. Simpson JM. Hypoplastic left heart syndrome. *Ultrasound Obstet Gynecol*. 2000;15:271.
8. D'Alton M, Russo MG, Pacileo G, et al. Left ventricular remodelling in outflow tract obstructive lesions during fetal life. *J Cardiovasc Med (Hagerstown)*. 2006;7:726.

To access the videos in this chapter, scan this QR code or visit expertconsult.com

81 Hypoplastic Left Heart Syndrome and Mitral Atresia

MAR BENNASAR | JOSEP M. MARTINEZ

Introduction

Hypoplastic left heart syndrome (HLHS) occurs in 0.1:1000 to 0.6:1000 live births and accounts for 2% to 3% of all congenital heart diseases (CHDs). HLHS is one of the most severe CHDs, with a high rate of perinatal death. Without treatment, it is responsible for 25% to 40% of all neonatal cardiac deaths.[1,2]

Disease

DEFINITION

HLHS encompasses a spectrum of congenital heart malformations characterized by underdevelopment of the left heart structures.

PREVALENCE AND EPIDEMIOLOGY

HLHS represents 2% to 3% of all CHDs. Because it is usually easily diagnosed on a four-chamber view, widespread introduction of ultrasound (US) screening significantly improved the detection rate. HLHS is associated with a poor prognosis and an intrauterine mortality rate of about 5%. Males are more frequently affected than females. There is a 2% to 4% recurrence risk. Autosomal recessive inheritance has occasionally been described.[3]

ETIOLOGY AND PATHOPHYSIOLOGY

The etiology is multifactorial. HLHS has been described as part of multiple syndromes. Mutations of *NKX2* and *NOTCH1* genes and proteins 43 and 11q23.3 have been identified. Chromosomal anomalies have been described in 5% to 12% of cases, especially in cases with other cardiac defects, mainly atrioventricular septal defects and aortic coarctation. Commonly found chromosomal anomalies include monosomy X and trisomies 18 and 13.[3] Extracardiac anomalies, mainly central nervous system defects, are present in 15% to 30% of cases.

HLHS is associated with hypoplasia and lack of function of the left heart. The right ventricle supports the systemic circulation via the ductus arteriosus. Several forms of HLHS have been reported.[4]

- The most frequent form includes mitral and aortic atresia. The lack of flow across left heart structures results in underdevelopment of the left atrium and ventricle, the mitral and aortic valves, and the aortic arch (Fig. 81.1).
- A second, relatively common form is characterized by critical aortic stenosis and aortic atresia with a hypoplastic but not atretic mitral valve. In contrast to cases with mitral atresia, the left ventricle is globular and hypertrophic and eventually evolves to left ventricular hypoplasia (Fig. 81.2, Video 81.1).
- More rarely, HLHS can be the end stage of severe forms of other cardiac defects, including the following:
  - Mitral atresia with double-outlet right ventricle, which includes mitral atresia and a perimembranous ventricular septal defect. The aortic valve is usually not atretic, and the aorta shows antegrade flow across the aortic arch. The outflow tracts can be either properly arranged or transposed (Fig. 81.3).
  - Unbalanced atrioventricular septal defects with marked asymmetry between ventricles and great arteries. When the aorta and left ventricle are hypoplastic, univentricular correction may be required.
  - Severe forms of aortic coarctation and interruption of the aortic arch.

MANIFESTATIONS OF DISEASE

Clinical Presentation

HLHS is usually asymptomatic prenatally. Infants are generally born at full term and appear healthy initially. Because HLHS is a duct-dependent anomaly, prostaglandin administration is required at birth. With closure of the ductus arteriosus, systemic perfusion becomes abruptly decreased, resulting in hypoxemia, acidosis, and cardiogenic shock.

Imaging Technique and Findings

Ultrasound. HLHS is one of the most commonly detected forms of fetal heart disease. Left heart structures are underdeveloped, which typically alters the four-chamber view:

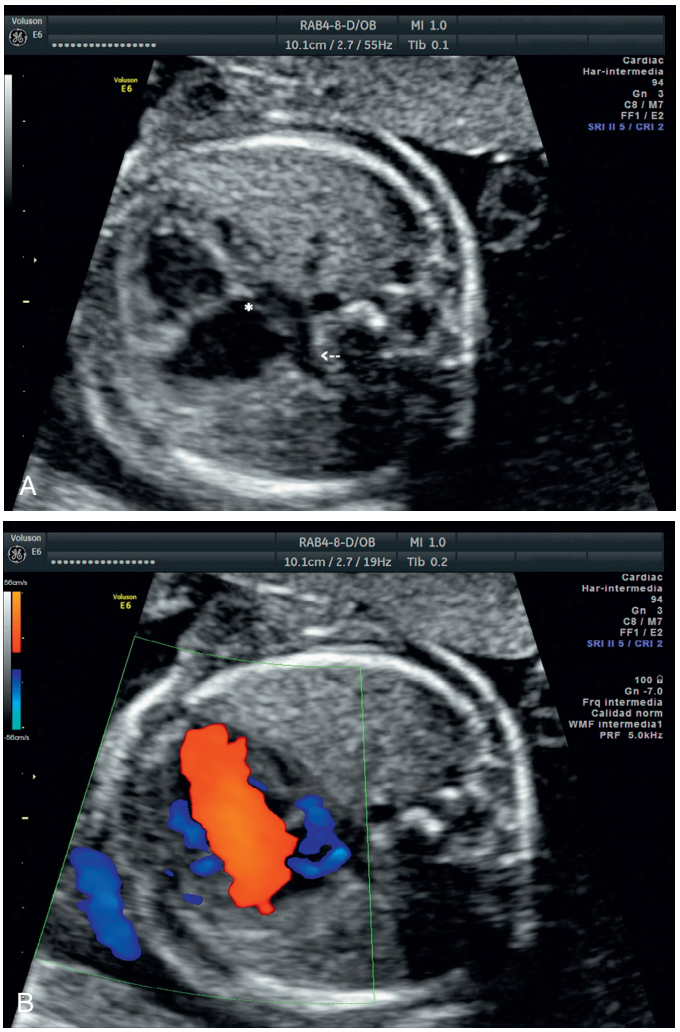

Fig. 81.1 (A) Slitlike left ventricle *(asterisk)* secondary to mitral and aortic atresia. There is no left cavity growth. The septum primum helps differentiate left from right structures *(dashed arrow)*. (B) Color Doppler evaluation shows flow across the tricuspid valve, whereas the mitral valve permits no flow across it.

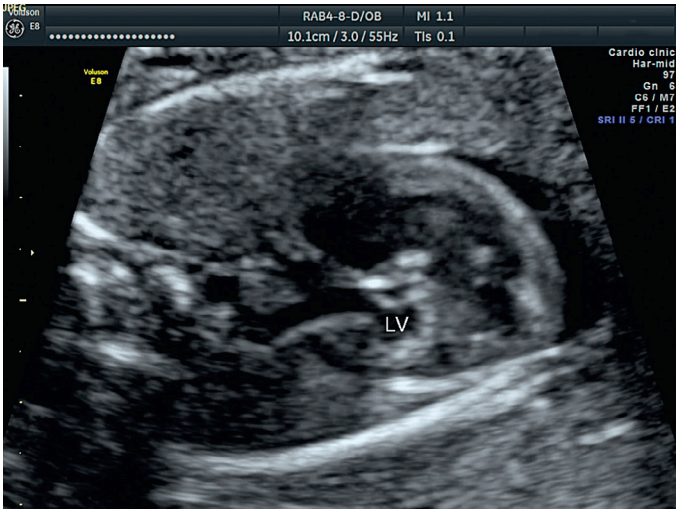

Fig. 81.2 Hypoplastic left ventricle secondary to aortic atresia. Left ventricle cavity is reduced *(LV)*; however, the left ventricle walls are hypertrophic, simulating a myocardial tumor.

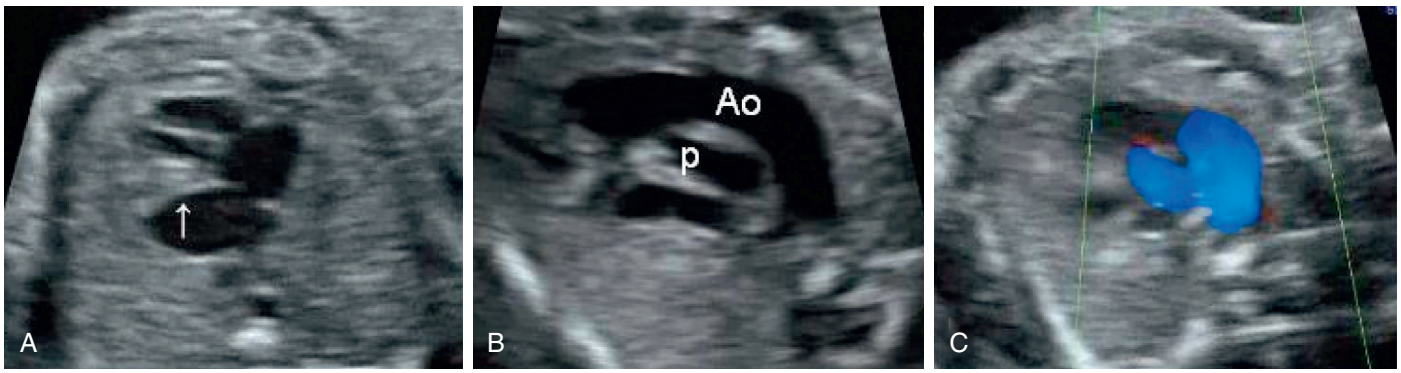

Fig. 81.3 Mitral atresia with double-outlet right ventricle, transposition of great arteries, and pulmonary stenosis. The mitral valve *(arrow)* is closed and permits no flow across it (A). There are two outflow tracts (B) with antegrade flow (C). The aorta *(Ao)* is anterior and to the right of the pulmonary artery *(p)*, which is smaller than the aorta (B).

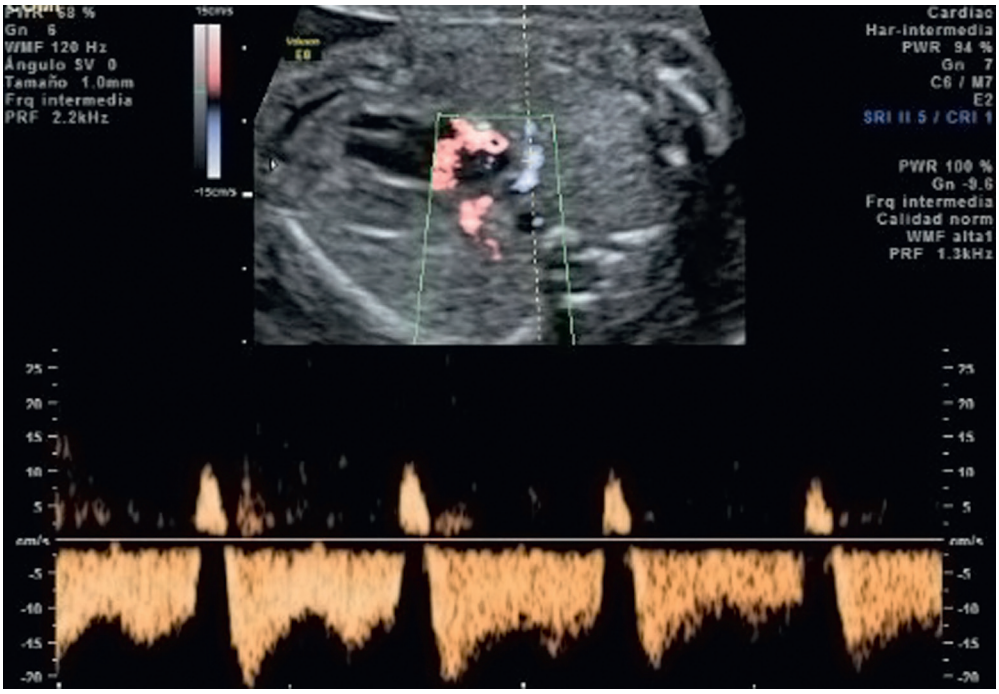

Fig. 81.4 Reversed flow through the pulmonary veins.

- The four-chamber view shows a hypoplastic left atrium and ventricle in cases with mitral and aortic atresia. There is no flow across the atrioventricular or the semilunar valve, with a resultant slitlike left ventricle. Color Doppler shows no flow across the mitral valve (see Fig. 81.1A and B). In contrast, when the mitral valve is patent and there is aortic atresia, the left ventricle is hypertrophic and echogenic with endocardial fibroelastosis. Color Doppler may show mitral regurgitation (see Fig. 81.2, Video 81.1).
- The most severe cases show reversed flow in the pulmonary veins (Fig. 81.4) secondary to pulmonary hypertension and arterialization and high left atrial pressure.
- The aorta is either not identified or hyperechoic in the five-chamber view or long-axis view, and there is no visible flow across the semilunar valve with color Doppler.
- The three-vessel and trachea view is abnormal. The aorta is extremely reduced, and sometimes it cannot be identified with gray scale. Color Doppler evaluation shows reverse aortic flow (Fig. 81.5), reflecting reverse filling through the ductus arteriosus.

CLASSIC SIGNS

- Reduced left heart structures and left ventricle hypoplasia.
- Reversed flow across the aortic arch.

Differential Diagnosis From Imaging Findings

The differential diagnosis with other cardiac defects is normally straightforward, but distinction of the original defect leading to HLHS occasionally may be challenging. Careful examination of the flow through the mitral and aortic valves, examination of the presence and patency of the aortic arch, and evaluation of the presence of the ventricular septum normally should help establish the right diagnosis. Notwithstanding this, some cases

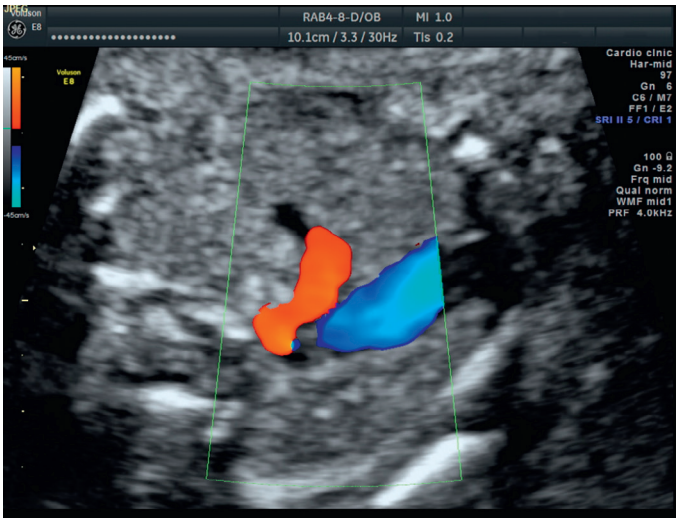

Fig. 81.5 Reversed flow *(red flow)* across the aortic arch. The pulmonary artery *(blue flow)* is larger than the aortic arch.

remain a difficult diagnosis, and only postnatal evaluation can help to clarify the correct diagnosis. Some forms of isolated critical aortic stenosis may occasionally be difficult to distinguish from severe coarctation of the aorta.

Synopsis of Treatment Options

PRENATAL

A genetic microarray and a detailed anatomic US examination to rule out chromosomic and other cardiac or extracardiac defects is mandatory.[4–7] Periodic follow-up examinations at 4- to 6-week intervals establish the evolution of each case and rule out the appearance of restrictive foramen ovale or arterialization of pulmonary veins. Delivery should be planned in a tertiary referral center with neonatal cardiac surgery availability.

There is no prenatal treatment for HLHS. Prenatal atrial septostomy by balloon has been described experimentally in cases of restrictive or closed foramen ovale to improve the poor prognosis of such cases.[7,8]

POSTNATAL

Two postnatal treatment options are:

- heart transplantation
- Norwood palliative surgery, a staged surgical palliation that was first described in 1980

The Norwood procedure is performed in stages as follows:

- The first stage is performed during the first week of life. The pulmonary artery becomes the main arterial trunk and connects with the descending aorta. A systemic–pulmonary shunt is performed to maintain pulmonary blood flow.
- In the second stage (at 6 to 12 months), the superior vena cava is connected to the pulmonary arteries.
- In the third stage (at 2 years), the inferior vena cava is redirected to pulmonary arteries. After this stage, systemic blood flow directly connects the pulmonary arteries, and the right ventricle becomes the systemic ventricle.

The overall outcome of HLHS is poor.[7–10] Prenatal series show a survival rate of 15% to 50% after Norwood stage I surgery. Postnatal series report better survival rates of 85%, which is explained by the selection bias after exclusion of intrauterine and neonatal mortality before surgery. There is significant long-term morbidity among survivors owing to the Fontan circulation. Studies assessing neurodevelopmental outcome have described reduced cognitive development, attributable both to preoperative and to operative conditions.[11,12]

WHAT THE REFERRING PHYSICIAN NEEDS TO KNOW

- HLHS is one of the most common prenatally diagnosed CHDs because it usually profoundly alters the four-chamber view.
- There is a high risk of associated chromosomal, cardiac, and extracardiac defects.[4–6]
- Established HLHS is associated with poor survival rates and quality of life in survivors.[7]

KEY POINTS

- HLHS is one of the most commonly diagnosed and severe congenital heart defects with high mortality, morbidity, and associated anomalies.
- There is reduced left ventricular lumen.
- HLHS is associated with hypoplasia of the aortic arch.
- Reversed flow occurs across the aortic arch.

SUGGESTED READING

Allan L, Hornberger L, Sharland G. *Textbook of fetal cardiology*. London: Greenwich Medical Media Ltd; 2000.

Barron DJ, Kilby MD, Davies B, et al. Hypoplastic left heart syndrome. *Lancet*. 2009;374:551.

Paladini D, Volpe P. *Ultrasound of congenital fetal anomalies: differential diagnosis and prognostic indicators*. London: Informa Health Care; 2007.

Thakur V, Munk N, Mertens L, et al. Does prenatal diagnosis of hypoplastic left heart syndrome make a difference? A systematic review. *Prenat Diagn*. 2016;36:854.

Yagel S, Silverman NH, Gembruch U. *Fetal cardiology. Series in maternal fetal medicine*. New York: Informa Health Care; 2009.

All references are available online at www.expertconsult.com.

REFERENCES

1. Barron DJ, Kilby MD, Davies B, et al. Hypoplastic left heart syndrome. *Lancet*. 2009;374:551.
2. Allan LD, Apfel HD, Printz BF. Outcome after prenatal diagnosis of the hypoplastic left heart syndrome. *Heart*. 1998;79:371.
3. Stumper O. Hypoplastic left heart syndrome. *Heart*. 2010;96:231.
4. Simpson JM. Hypoplastic left heart syndrome. *Ultrasound Obstet Gynecol*. 2000;15:271.
5. Galindo A, Nieto O, Villagra S, et al. Hypoplastic left heart syndrome diagnosed in fetal life: associated findings, pregnancy outcome and results of palliative surgery. *Ultrasound Obstet Gynecol*. 2009;33:560.
6. Tennstedt C, Chaoui R, Korner H, et al. Spectrum of congenital heart defects and extracardiac malformations associated with chromosomal abnormalities: results of a seven year necropsy study. *Heart*. 1999;82:34.
7. Feinstein JA, Benson DW, Dubin AM, et al. Hypoplastic left heart syndrome: current considerations and expectations. *J Am Coll Cardiol*. 2012;59:S1-S42.
8. Wilkins-Haug LE, Benson CB, Tworetzky W, et al. In-utero intervention for hypoplastic left heart syndrome—a perinatologist's perspective. *Ultrasound Obstet Gynecol*. 2005;26:481.
9. Munn MB. Prenatally diagnosed hypoplastic left heart syndrome. Outcome after postnatal surgery. *J Matern Fetal Med*. 1999;8:147-150.
10. Norwood WI. Physiologic repair of aortic atresia-hypoplastic left heart syndrome. *N Engl J Med*. 1983;308:23-26.
11. Miller SP, McQuillen PS, Hamrick S, et al. Abnormal brain development in newborns with congenital heart disease. *N Engl J Med*. 2007;357:1928.
12. Williams IA, Fifer WP, Andrews H. Fetal growth and neurodevelopmental outcome in congenital heart disease. *Pediatr Cardiol*. 2015;36:1135-1144.

To access the videos in this chapter, scan this QR code or visit expertconsult.com

82 Aortic Coarctation

MAR BENNASAR | JOSEP M. MARTINEZ

Introduction

Aortic coarctation (AoC) is a ductal-dependent heart anomaly characterized by a narrowing of the aorta. The presence of physiologic right-to-left shunts in the fetal circulation constitutes a challenge for prenatal diagnosis, making AoC one of the congenital heart diseases (CHDs) with the most common false-positive and false-negative diagnoses.[1,2]

Disease

DEFINITION

AoC consists of a constriction on the aortic arch that causes obstruction of the blood flow and consequently causes some degree of aortic arch hypoplasia. The constriction can affect a variable length of the vessel or consist on a shelf-like obstruction. The constriction is usually located at the level of the aortic isthmus, between the left subclavian artery and the ductus arteriosus.

PREVALENCE AND EPIDEMIOLOGY

AoC accounts for 7% of all CHDs, and affects 1:1600 newborns.[3] It is twice as common in males, and is frequently associated with other CHDs, especially ventricular septal defects and left heart obstructive lesions.[4,5]

ETIOLOGY AND PATHOPHYSIOLOGY

The etiology is unknown. AoC is usually a multifactorial disease, although familial inheritance has been described. It can be associated with chromosomal abnormalities and genetic syndromes, including Turner syndrome in 30% of cases, as well as trisomy 21 and 18, and 22q11 microdeletion.[6] Various theories have been proposed for the development of coarctation of the aorta, such as a reduced flow through the aortic arch or the presence of a ductal sling.

AoC can be classified according to its location in relation to the ductus arteriosus. Preductal AoC is the most frequent form in fetal and neonatal life. It is usually associated with other CHDs and can be suspected prenatally. Reduced blood flow leads to underdevelopment and tubular hypoplasia of the aortic arch previous to the constricted area.

Postductal AoC is typically diagnosed during childhood. It is usually an isolated CHD with a normal aortic arch, but a localized "shelflike" constriction with proximal tapering of the aorta.

MANIFESTATIONS OF DISEASE

Clinical Presentation

It depends on the severity and location of the obstruction and the presence of associated anomalies. Neonates are usually asymptomatic until postnatal closure of the ductus arteriosus. Severe cases lead to blood-flow obstruction to the left heart and eventually heart failure, shock, and even death during the first weeks of life. Less severe or postductal AoC can be misdiagnosed until childhood or adulthood.

Imaging Technique and Findings

Ultrasound. Coarctation of the aorta is the CHD with the highest rate of false-positive and false-negative diagnoses. The coarctation site itself is difficult to identify, so suspicion of AoC relies on indirect signs, mainly a size discrepancy between the left and right chambers and outflow tracts on four-chamber view, or three-vessel and tracheal views. To assess the disproportion objectively, *z* scores for right and left measurements and ratios can be calculated. Recent data suggests that gestational age-specific scoring systems combining size-based cardiac parameters may improve the accuracy of fetal echocardiography to stratify the risk of AoC.[7–9]

- Ventricular disproportion is the classic sign identified on the four-chamber view. The right ventricle appears larger than the left ventricle with a subjectively larger inflow by color Doppler (Fig. 82.1 and Video 82.1). Severe cases show inversion of the interatrial shunt (left-to-right flow). Ventricular disproportion can be present not only in AoC and other CHDs but also in extracardiac fetal conditions, such as growth restriction, maternal drug intake, and fetal anemia. In addition, the right ventricle becomes more dominant with advancing gestational age, which further challenges the accurate diagnosis of AoC.[10] For this reason, the positive predictive value is only 30%, particularly when the suspicion is established in late pregnancy.
- There is a disproportion of outflow tracts as well, with a larger pulmonary artery compared with the aorta (Fig. 82.2).

- The isthmus-to-ductal ratio is the most sensitive plane for the diagnosis of AoC.[11,12] The aortic arch is reduced on the three-vessel and trachea view. Severe cases are associated with reverse flow in the aortic arch (Figs. 82.3 and 82.4B).

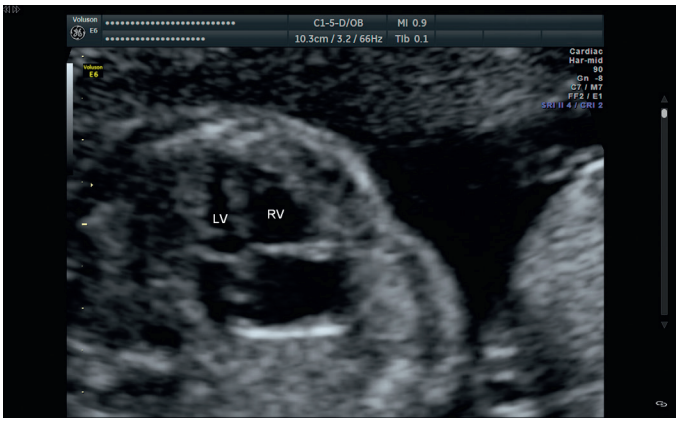

Fig. 82.1 Severe ventricular disproportion. The left ventricle *(LV)* is smaller than the right ventricle *(RV)*.

- Sagittal views can help identify the hypoplastic appearance and reversed flow at the aortic arch. The morphology of the aortic arch, and especially the angle between the left common carotid and the left subclavian artery, have been described as markers of AoC.[13]
- A persistent left superior vena cava (SVC) has been described as a potential marker for AoC (see Fig. 82.4A). However, other data regarding this association are conflicting.[14-16]
- AoC can occasionally be a progressive disease, and rarely evolution to hypoplastic left heart syndrome can be observed.

Gestational age at presentation is related to postnatal outcome. Of cases suspected before 24 weeks' gestation, 75% to 80% are confirmed postnatally, whereas false-positive diagnoses occur in 70% to 80% of cases suspected later in gestation.[2,11]

CLASSIC SIGNS

Left-to-right disproportion on the four-chamber view, outflow tracts, and transverse arches.
Left-to-right circulatory shunt inversion.
Left-to-right interatrial flow.
Reversed flow at the aortic arc.

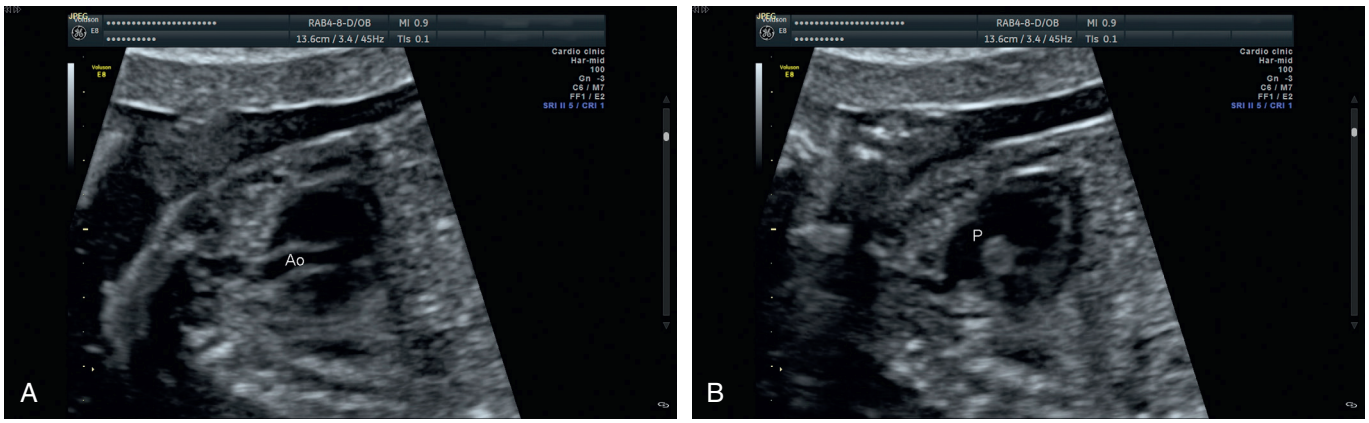

Fig. 82.2 Pulmonary *(P)* to aorta *(Ao)* disproportion (P > Ao) in a 23-week fetus with aortic coarctation.

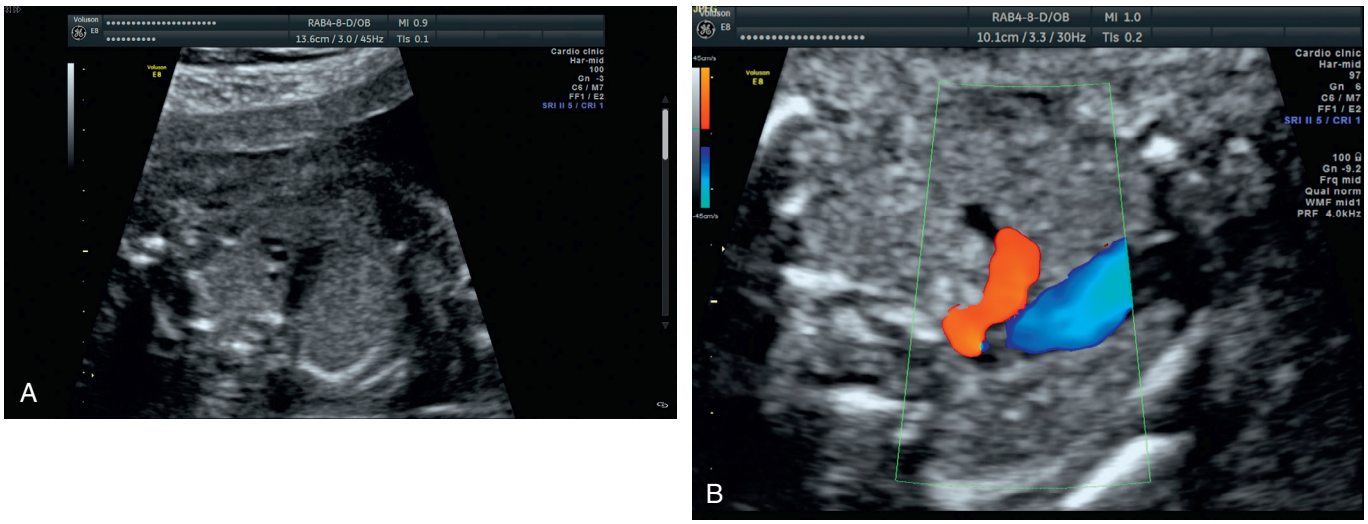

Fig. 82.3 Three-vessel and trachea view in a severe aortic arch. The aortic arch is not identified (A). Color Doppler shows reversed flow (B) in the aortic coarctation.

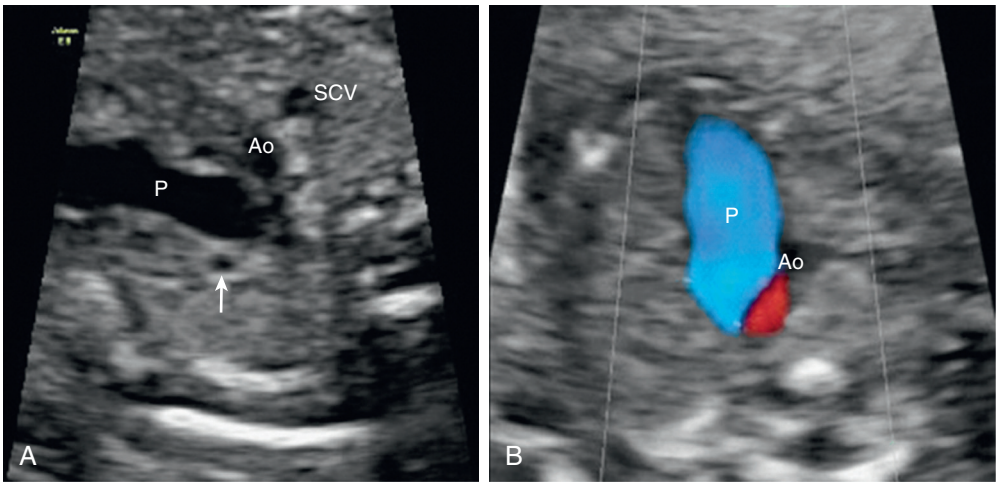

Fig. 82.4 Three-vessel and trachea view. (A) Association with left superior vena cava *(arrow)*. The aorta *(Ao)* is reduced compared with the pulmonary artery *(P)*. Superior vena cava *(SCV)* is correctly identified. (B) Reversed *(red)* flow through the aortic arch. *Ao*, Aorta; *P*, pulmonary artery.

Synopsis of Treatment Options

PRENATAL

Genomic microarray and targeted morphologic ultrasound examination should be offered. Parents should be informed that false-positive diagnoses are common, especially in the third trimester. The fetus should be evaluated periodically (every 4 to 6 weeks) to rule out evolution to hypoplastic left heart syndrome or other associated anomalies. Delivery should be planned in a tertiary referral center with cardiac surgery.

POSTNATAL

Prenatal suspicion of AoC improves the neonatal outcome.[17] AoC may be ductal-dependent and require neonatal prostaglandin administration to maintain ductal patency. The prognosis is good in isolated cases, with survival rates greater than 90% after surgical treatment. Postnatal treatment requires neonatal surgical repair. Retraction and restenosis are frequent with percutaneous dilatation techniques, so these techniques are reserved for restenosis treatment. Left thoracotomy, resection of the affected aorta, and termino-terminal or termino-lateral anastomoses are usually preferred options. Repeat coarctation requires reintervention in 15% to 20% of cases. When there are other anomalies more complex than simply the presence of a ventricular septal defect, the mortality rate increases to 20%. Eventual evolution to hypoplastic left heart syndrome requires palliative surgery, with lower survival rates.[5]

WHAT THE REFERRING PHYSICIAN NEEDS TO KNOW

- The suspicion of AoC must be raised in the presence of a discrepancy in the size of the left heart. However, the false-positive rate is high.
- There is a high risk for associated anomalies, particularly for cardiac and extracardiac abnormalities.[4]
- The overall prognosis in isolated defects is good.

KEY POINTS

- A ventricular and outflow tract (left < right) discordance
- High false-positive and false-negative diagnosis rate
- High association with other CHDs
- High association with Turner syndrome

SUGGESTED READING

Allan L, Hornberger L, Sharland G. *Textbook of Fetal Cardiology*. London: Greenwich Medical Media Ltd; 2000.

Paladini D, Volpe P. *Ultrasound of Congenital Fetal Anomalies: Differential Diagnosis and Prognostic Indicators*. London: Informa Health Care; 2007.

Yagel S, Silverman NH, Gembruch U. *Fetal Cardiology.* Series in Maternal Fetal Medicine. New York: Informa Health Care; 2009.

All references are available online at www.expertconsult.com.

REFERENCES

1. Sharland GK, Chan KY, Allan LD. Coarctation of the aorta: difficulties in prenatal diagnosis. *Br Heart J*. 1994;71:70.
2. Head CE, Jowett VC, Sharland GK, et al. Timing of presentation and postnatal outcome of infants suspected of having coarctation of the aorta during fetal life. *Heart*. 2005;91:1070.
3. Allan LD, Sharland GK, Milburn A, et al. Prospective diagnosis of 1006 consecutive cases of congenital heart disease in the fetus. *J Am Coll Cardiol*. 1994;23:1452.
4. Paladini D, Volpe P, Russo MG, et al. Aortic coarctation: prognostic indicators of survival in the fetus. *Heart*. 2004;90:1348.
5. Rosenthal E. Coarctation of the aorta from fetus to adult: curable condition or life-long disease process? *Heart*. 2005;91:1495.
6. Gill HK, Splitt M, Sharland GK, et al. Patterns of recurrence of congenital heart disease: an analysis of 6640 consecutive pregnancies evaluated by detailed fetal echocardiography. *J Am Coll Cardiol*. 2003;42:923.
7. Pasquini L, Mellander M, Seale A, et al. Z-scores of the fetal aortic isthmus and duct: an aid to assessing arch hypoplasia. *Ultrasound Obstet Gynecol*. 2007;29:628.
8. Schneider C, McCrindle BW, Carvalho JS, et al. Development of Z-scores for fetal cardiac dimensions from echocardiography. *Ultrasound Obstet Gynecol*. 2005;26:599.
9. Gómez-Montes E, Herraiz I, Gómez-Arriaga PI, et al. Gestational age-specific scoring systems for the prediction of coarctation of the aorta. *Prenat Diagn*. 2014;34:1198-1206.
10. Brown DL, Durfee SM, Hornberger LK. Ventricular discrepancy as a sonographic sign of coarctation of the fetal aorta: how reliable is it? *J Ultrasound Med*. 1997;16:95.
11. Matsui H, Mellander M, Roughton M, et al. Morphological and physiological predictors of fetal aortic coarctation. *Circulation*. 2008;118:1793.
12. Toole BJ, Schlosser B, McCracken CE, et al. Importance of relationship between ductus and isthmus in fetal diagnosis of coarctation of aorta. *Echocardiography*. 2016;33:771-777.
13. Arya B, Bhat A, Vernon M, et al. Utility of novel fetal echocardiographic morphometric measures of the aortic arch in the diagnosis of neonatal coarctation of the aorta. *Prenat Diagn*. 2016;36:127-134.
14. Galindo A, Gutierrez-Larraya F, Escribano D, et al. Clinical significance of persistent left superior vena cava diagnosed in fetal life. *Ultrasound Obstet Gynecol*. 2007;30:152.
15. Berg C, Knuppel M, Geipel A, et al. Prenatal diagnosis of persistent left superior vena cava and its associated congenital anomalies. *Ultrasound Obstet Gynecol*. 2006;27:274.
16. Gustapane S, Leombroni M, Khalil A, et al. Systematic review and metaanalysis on persistent left superior vena cava on prenatal ultrasound: associated anomalies, diagnostic accuracy and postnatal outcome. *Ultrasound Obstet Gynecol*. 2016;48(6):701-708.
17. Franklin O, Burch M, Manning N, et al. Prenatal diagnosis of coarctation of the aorta improves survival and reduces morbidity. *Heart*. 2002;87:67.

To access the videos in this chapter, scan this QR code or visit expertconsult.com

83 Interruption of the Aortic Arch

MAR BENNASAR | JOSEP M. MARTINEZ

Introduction

Interruption of the aortic arch (IAA) is an uncommon ductal-dependent congenital cardiovascular malformation. It is the most severe form of aortic coarctation (AoC).

Disease

DEFINITION

IAA is characterized by the lack of continuity between the ascending and descending aorta.

PREVALENCE AND EPIDEMIOLOGY

IAA accounts for 0.1% of all prenatally detected congenital heart diseases (CHDs) and 0.2% to 1% of postnatal CHDs, affecting 1:300,000 newborns.[1] IAA has a high prevalence of associated anomalies, including:

- Extracardiac abnormalities: central nervous system, urinary, and gastrointestinal malformations are the most frequently associated (present in 30% of cases).[2]
- Chromosomal abnormalities: type B IAA has a high association (60% to 70%) with 22q11 microdeletion.[3]
- Cardiac anomalies: associated cardiac anomalies are common, especially truncus arteriosus (10% to 20%), left ventricular outflow tract obstruction (10% to 16%), aortic valvular stenosis (10%), aortopulmonary window, double-outlet right ventricle (5%), and transposition of great arteries (4% to 6%).[4]

ETIOLOGY AND PATHOPHYSIOLOGY

IAA is due to a lack of connection between the proximal and distal portion of the aortic arch. The etiology is unknown, although it has been related to genetic and chromosomal abnormalities, especially 22q11 microdeletion.[4] Depending on the level of the interrupted site, three types of IAA have been described, as follows[5]:

1. The interruption is distal to the left subclavian artery (30% to 40%); this form is more frequent in cases with associated truncus arteriosus.
2. The interruption is between the left carotid and left subclavian artery (50% to 60%).
3. Proximal interruption, between the innominate and left carotid artery (5% to 10%).

Most patients (90%) have an associated ventricular septal defect (VSD).

MANIFESTATIONS OF DISEASE

Imaging Technique and Findings

Ultrasound. The key finding that raises suspicion of IAA is the disproportion of the left and right ventricles (Fig. 83.1).

- Ventricular disproportion can be identified on the four-chamber view, especially in IAA type A and C. The right ventricle appears larger than the left, and greater right ventricular flow is identified with color Doppler. This sign is less evident in type B IAA because there is frequently a large malaligned VSD that balances right and left flow.
- There is disproportion of the sizes of the outflow tracts. The pulmonary artery is disproportionally bigger than the aortic root.[6]

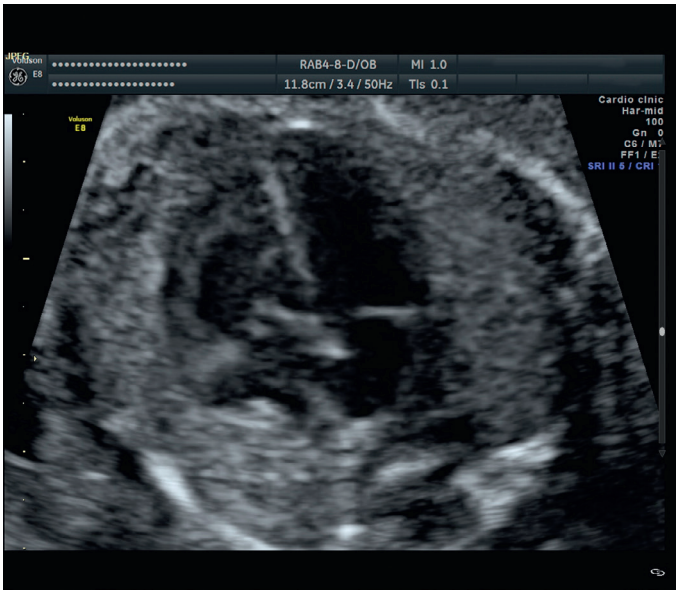

Fig. 83.1 IAA type B. Ventricular disproportion in four-chamber view. A perimembranous ventricular septal defect is identified.

- The three-vessel and trachea view shows reduced diameter or unidentifiable aorta, with pronounced asymmetry between the aortic arch and pulmonary artery (Fig. 83.2).
- The ascending aorta has the following appearances, according to IAA type:
  - Type A: W shape, corresponding to the interruption after the three head vessels.
  - Type B: ascending aorta with V shape. The interruption is between the left carotid and left subclavian artery, although with no connection between those arteries. The aortic arch fails to curve and is straight to the neck, dividing into the innominate artery and the left carotid artery (Figs. 83.3 and 83.4 and Video 83.1).

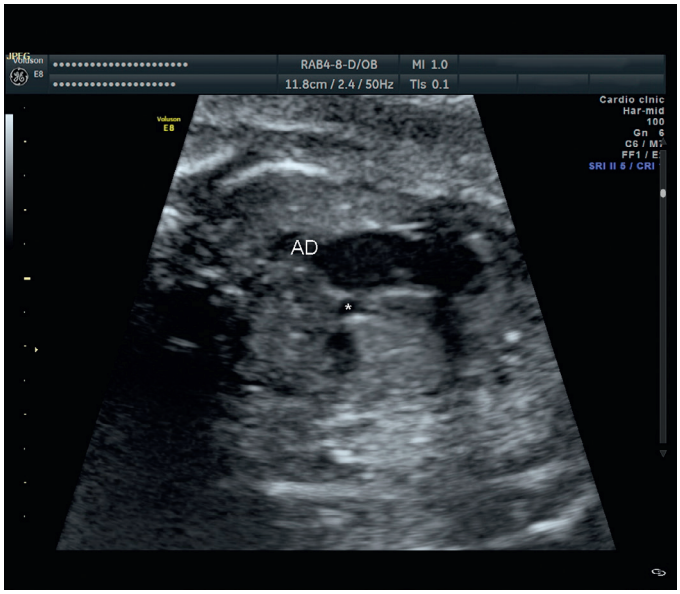

Fig. 83.2 Abnormal three-vessel and trachea view. The aortic arch *(*)* stops its course. It is not possible to identify the confluence between the arterial duct *(AD)* and the aortic isthmus.

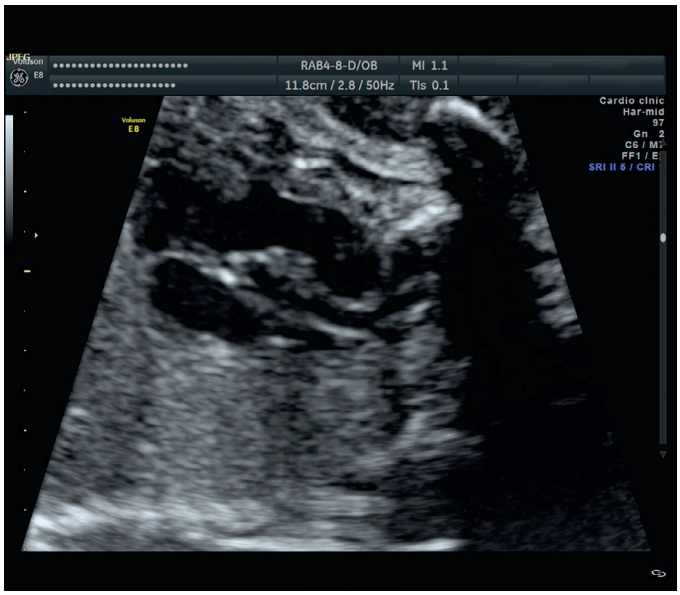

Fig. 83.3 Straight course of the ascending aorta toward the neck. The aortic arch is not identified.

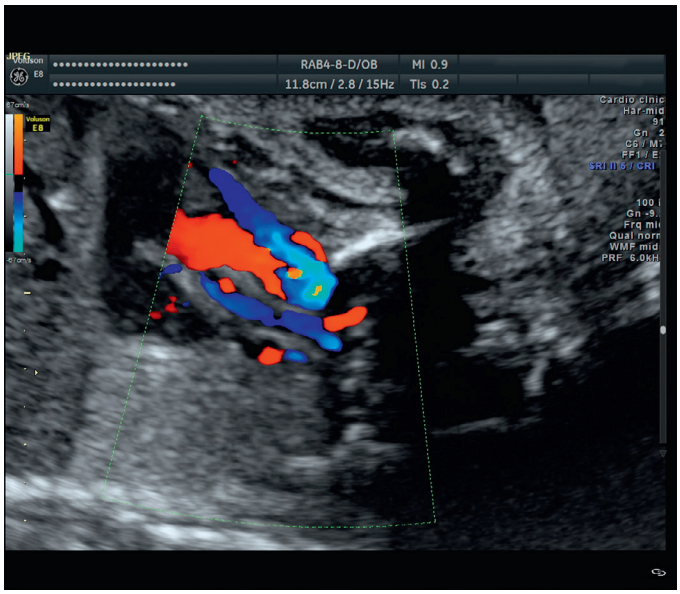

Fig. 83.4 Color Doppler showing the straight course of the ascending aorta to the neck *(red)*. The proximal portion of the aortic arch is identified in a case of type B interruption of the aortic arch.

- Type C: straight course to the neck without any aortic branching.

Other Applicable Modality

Four-Dimensional Echocardiography. It may be helpful in showing the aortic arch with B-flow and inversion-mode renderings.[7]

CLASSIC SIGNS

- Pulmonary to aortic disproportion on the three-vessel and trachea view.
- Ventricular disproportion, especially in types A and C.
- Lack of aortic curvature toward the descending aorta.

Differential Diagnosis From Imaging Findings

Coarctation of the aorta is sometimes impossible to distinguish from type A IAA. The straight course of the aorta and the W or V sign can help differentiate them.

Synopsis of Treatment Options

POSTNATAL

Surgical correction is the treatment of choice. Mortality has decreased significantly in recent years, with reported mortality rates of 19%.[8] For IAA with VSD, mortality ranges from 5% to 10%. Long-term survival rates decrease progressively to 60% at 5 years. The long-term influence on neurologic and psychomotor development is controversial.[4] Restenosis, aneurysm formation, and left ventricular outflow tract obstruction are the most significant complications.

WHAT THE REFERRING PHYSICIAN NEEDS TO KNOW

- IAA is a very rare CHD; the suspicion sign is disproportion of the left and right ventricles. It can be very difficult to distinguish from AoC.
- There is a high association with other cardiac and extracardiac anomalies.
- In isolated IAA, the prognosis is generally good, but long-term complications at the aortic repair site are possible.

KEY POINTS

- There is a lack of continuity between the ascending and descending aorta.
- There is ventricular and aortic to pulmonary disproportion.
- There is a high association with 22q11 microdeletion.
- There is usually a right heart dominance in the 4-chamber view.
- A perimembranous VSD can be frequently identified in Type B, the most commonly detected prenatally.

SUGGESTED READING

Allan L, Hornberger L, Sharland G. *Textbook of Fetal Cardiology*. London: Greenwich Medical Media Ltd; 2000.

Axt-Fliedner R, Kawecki A, Enzensberger C, et al. Fetal and neonatal diagnosis of interrupted aortic arch: associations and outcomes. *Fetal Diagn Ther*. 2011;30:299-305.

Paladini D, Volpe P. *Ultrasound of Congenital Fetal Anomalies: Differential Diagnosis and Prognostic Indicators*. London: Informa Health Care; 2007.

Yagel S, Silverman NH, Gembruch U. *Fetal Cardiology*. Series in Maternal Fetal Medicine. New York: Informa Health Care; 2009.



All references are available online at www.expertconsult.com.

REFERENCES

1. Allan LD, Sharland GK, Milburn A, et al. Prospective diagnosis of 1006 consecutive cases of congenital heart disease in the fetus. *J Am Coll Cardiol*. 1994;23:1452.
2. Paladini D, Volpe P, Russo MG, et al. Aortic coarctation: prognostic indicators of survival in the fetus. *Heart*. 2004;90:1348.
3. Volpe P, Marasini M, Caruso G, et al. Prenatal diagnosis of interruption of the aortic arch and its association with deletion of chromosome 22q11. *Ultrasound Obstet Gynecol*. 2002;20:327.
4. Mishra PK. Management strategies for interrupted aortic arch with associated anomalies. *Eur J Cardiothorac Surg*. 2009;35:569.
5. Celoria GC, Patton RB. Congenital absence of the aortic arch. *Am Heart J*. 1959;58:407.
6. Slodki M, Moszura T, Janiak K, et al. The three-vessel view in the fetal mediastinum in the diagnosis of interrupted aortic arch. *Ultrasound Med Biol*. 2011;37:1808-1813.
7. Volpe P, Tuo G, De Robertis V, et al. Fetal interrupted aortic arch: 2D-4D echocardiography, associations and outcome. *Ultrasound Obstet Gynecol*. 2010;35:302-309.
8. Brown JW, Ruzmetov M, Okada Y, et al. Outcomes in patients with interrupted aortic arch and associated anomalies: a 20-year experience. *Eur J Cardiothorac Surg*. 2006;29:666.

To access the videos in this chapter, scan this QR code or visit expertconsult.com

84 Aortic Arch Anomalies

MAR BENNASAR | JOSEP M. MARTINEZ

Introduction

Aortic arch (AA) anomalies comprise a group of congenital alterations of the aortic arch that affect the position of the aortic branching. These anomalies can occur in association with other congenital heart diseases (CHDs) or as incidental findings in asymptomatic newborns.

Disease

DEFINITION

Most frequent AA anomalies include right aortic arch (RAA) anomaly and aberrant right subclavian artery (ARSA). RAA anomaly consists of an abnormal aortic course in which the ascending aorta surrounds the trachea by its right side (instead of by the left). In ARSA, the subclavian artery arises directly from the descending aorta after the left subclavian artery branching and reaches the right arm passing behind the trachea, esophagus, and other vascular structures.

PREVALENCE AND EPIDEMIOLOGY

AA anomalies are frequent in pediatric series but prenatal reports are scarce,[1] because obtaining the required view and diagnosing requires training. The use in routine scans of the three-vessel and trachea view has improved diagnosis and understanding of normal and abnormal variants of the aortic arch.[2–4]

ARSA is the most frequent aortic arch anomaly, affecting 1% of the fetal population. RAA anomaly affects 0.1% of adult population, being the second most frequent potentially symptomatic vascular ring after double aortic arch (DAA).[1]

ETIOLOGY AND PATHOPHYSIOLOGY

The embryologic development of the aortic arch initially includes a double arch, each with a ductus arteriosus, both connecting with the descending aorta.[5,6] Branches for the common carotid and subclavian arteries arise from right and left arches. Normal development entails regression of the descending right aortic arch just after the origin of the subclavian artery branching.

Several aortic arch abnormalities may appear when this process does not occur normally:

- Mirror-image RAA is formed by the regression of the left aortic arch distal to the origin of the left subclavian artery together with persistence of the right one.
- RAA with aberrant left subclavian artery is due to left aortic arch regression between the left carotid artery and the subclavian artery. In this RAA variant, the left carotid followed by right carotid and right and left subclavian arteries arise from the RAA.
- RAA with aberrant retroesophageal left innominate artery occurs when the left aortic arch is interrupted before the left carotid artery.
- Left aortic arch with ARSA or innominate artery is formed by the regression of the RAA between the right common carotid artery and subclavian artery, or before the right common carotid artery (innominate artery).
- DAA is formed by persistence of both the right and the left arch.

MANIFESTATIONS OF DISEASE

Clinical Presentation

AA anomalies can be asymptomatic or manifest with clinical symptoms from tracheal (persistent stridor or upper airway obstruction) or esophageal (swallowing difficulties) compression secondary to vascular ring formation. DAA is the most frequent symptomatic form.

AA anomalies, especially RAA with mirror image,[7] are frequently associated with other CHDs, such as tetralogy of Fallot and ventricular septal defects. In these cases, there is a high association with chromosomal abnormalities and 22q11 microdeletion. Demonstration of a normal thymus excludes 22q11 microdeletion with 90% negative predictive value[8] (see Chapter 6). ARSA is a marker for Down syndrome, with a positive likelihood ratio of 3.94 when isolated.[9–12]

Imaging Technique and Findings

Ultrasound. Aortic arch anomalies usually are identified in the three-vessel and trachea view on ultrasound (US). The typical V shape of the pulmonary and aortic artery is lost (Fig. 84.1A).

- Mirror-image RAA: the aortic arch runs by the left side of the trachea (Fig. 84.1B and Fig. 84.2).
- RAA with aberrant left subclavian or innominate artery: the aberrant artery is identified in a retrotracheal position with its blood flow from the left ductus arteriosus to the aorta, which is located at the right of the trachea. This situation creates a typical U sign around the trachea (Video 84.1; Fig. 84.1C).
- Left aortic arch with ARSA or innominate artery: the aortic arch is properly located between the pulmonary artery and

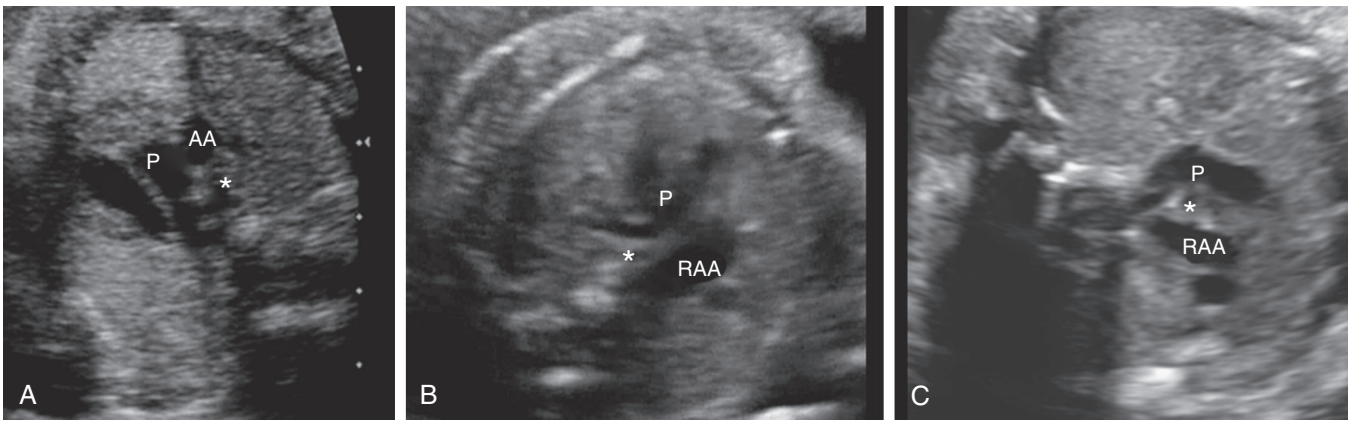

Fig. 84.1 (A) Three-vessel view in a normal fetus. (B) RAA with mirror image in a fetus with tetralogy of Fallot with pulmonary stenosis. (C) RAA with aberrant left subclavian artery. *Asterisk*, Trachea; *AA*, aortic arch; *P*, pulmonary artery; *RAA*, right aortic arch.

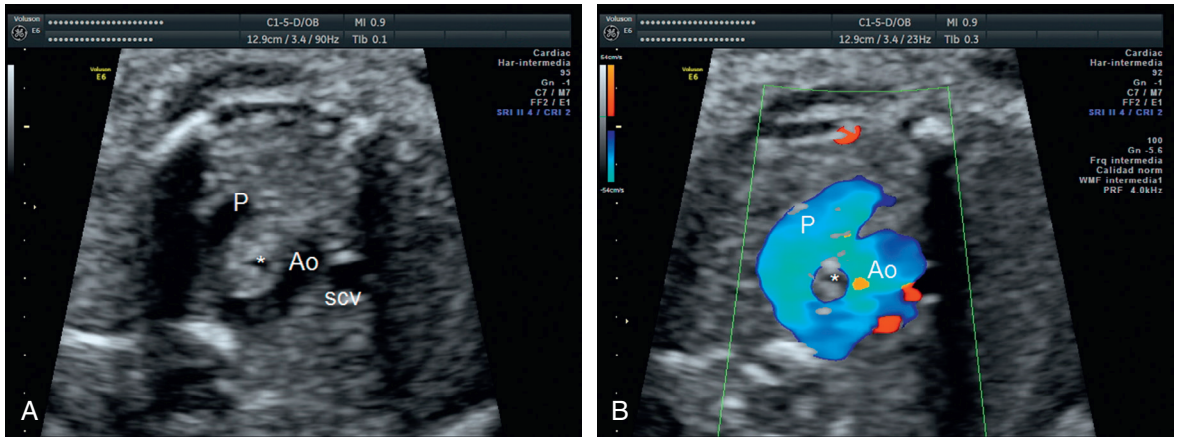

Fig. 84.2 Color Doppler in the three-vessel and trachea view in a case of right aortic arch. The aorta *(Ao)* is identified to the right of the trachea *(asterisk)*, next to the superior caval vein *(SCV)*. *P*, Pulmonary artery.

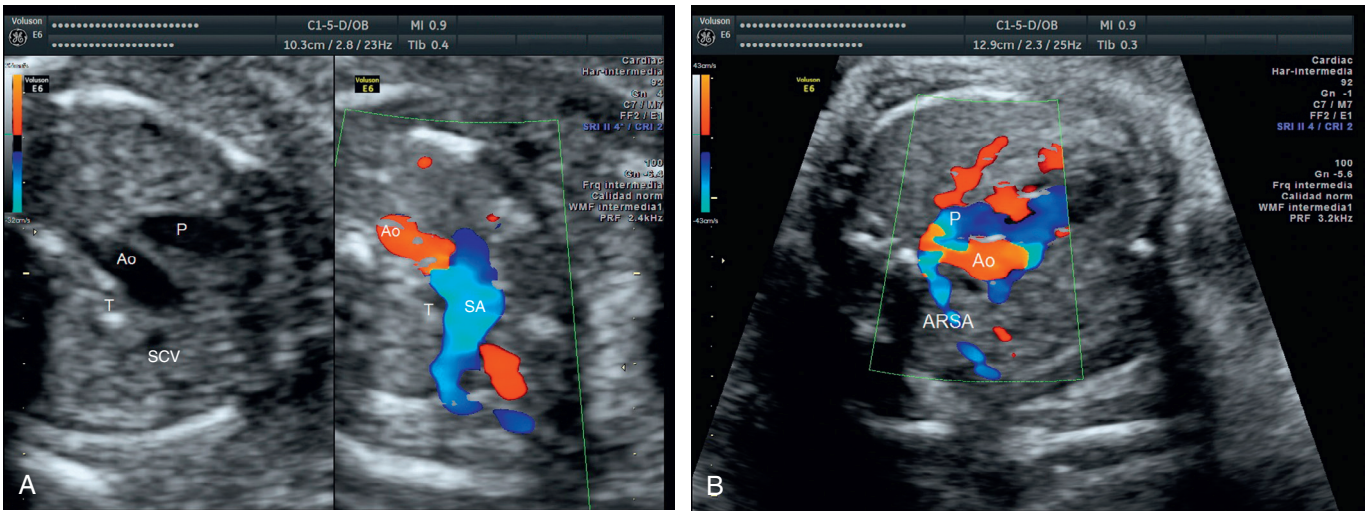

Fig. 84.3 (A) Normal subclavian artery (SA). The SA emerges from the aorta *(Ao)* and passes in front of the trachea *(T)*. (B) Aberrant right subclavian artery *(ARSA)* arising from the aorta *(Ao)*, with an abnormal course, posterior to the trachea. *P*, Pulmonary artery; *SCV*, superior caval vein.

the trachea. Color Doppler evaluation is helpful because it shows a vessel from the aorta to the right arm. Pulsed Doppler reveals arterial flow (Video 84.2; Fig. 84.3).

- DAA: there is no regression of right or left aortic arch, causing a vascular ring that encircles the trachea.

Magnetic Resonance Imaging. Magnetic resonance imaging (MRI) and spiral computed tomography (CT) are used for diagnosis of pediatric and adult aortic arch abnormalities.

Other Applicable Modality

Four-Dimensional Echocardiography. Inversion mode and B-flow can show anomalies not identifiable by two-dimensional US.

CLASSIC SIGNS

- Abnormal disposition of the vessels in the three-vessel and trachea view.
- Absence of the normal V shape of aortic and ductal arches.

Synopsis of Treatment Options

PRENATAL

Targeted morphologic US examination should be offered, including the evaluation of the fetal thymus. Genetic microarray should routinely be offered in cases with associated cardiac anomalies. The need for fetal karyotyping is controversial in isolated cases.[13]

POSTNATAL

Surgery is performed in symptomatic cases, especially in DAA, where the ring is surgically divided to release the constriction. Prognosis depends on the association with chromosomal and other anomalies and the severity of the tracheal and esophagus compression.

WHAT THE REFERRING PHYSICIAN NEEDS TO KNOW

- Aortic arch anomalies are a rare incidental finding during routine echocardiography. Active searching for these signs improves the detection rates.
- The prognosis is normally very good in isolated cases. Surgery is required only rarely.

KEY POINTS

- Abnormal three-vessel and trachea view is diagnostic.
- There is a high prevalence of associated cardiac anomalies (tetralogy of Fallot).
- There is a high risk of 22q11 microdeletion if associated with other defects or thymus hypoplasia.
- Esophageal and tracheal compression postnatally can occur.

SUGGESTED READING

Allan L, Hornberger L, Sharland G. *Textbook of fetal cardiology*. London: Greenwich Medical Media Ltd; 2000.

Li S, Luo G, Norwitz ER, et al. Prenatal diagnosis of congenital vascular rings and slings: sonographic features and perinatal outcome in 81 consecutive cases. *Prenat Diagn*. 2011;31:334.

Paladini D, Volpe P. *Ultrasound of congenital fetal anomalies: differential diagnosis and prognostic indicators*. London: Informa Health Care; 2007.

Yagel S, Silverman NH, Gembruch U. *Fetal cardiology*. Series in maternal fetal medicine. New York: Informa Health Care; 2009.

All references are available online at www.expertconsult.com.

REFERENCES

1. Achiron R, Rotstein Z, Heggesh J, et al. Anomalies of the fetal aortic arch: a novel sonographic approach to in-utero diagnosis. *Ultrasound Obstet Gynecol*. 2002;20:553.
2. Yagel S, Cohen SM, Achiron R. Examination of the fetal heart by five short-axis views: a proposed screening method for comprehensive cardiac evaluation. *Ultrasound Obstet Gynecol*. 2001;17:367.
3. Yagel S, Arbel R, Anteby EY, et al. The three vessels and trachea view (3VT) in fetal cardiac scanning. *Ultrasound Obstet Gynecol*. 2002;20:340.
4. Yoo SJ, Lee YH, Kim ES, et al. Three-vessel view of the fetal upper mediastinum: an easy means of detecting abnormalities of the ventricular outflow tracts and great arteries during obstetric screening. *Ultrasound Obstet Gynecol*. 1997;9:173.
5. Knight L, Edwards JE. Right aortic arch: types and associated cardiac anomalies. *Circulation*. 1974;50:1047.
6. Yoo SJ, Min JY, Lee YH, et al. Fetal sonographic diagnosis of aortic arch anomalies. *Ultrasound Obstet Gynecol*. 2003;22:535.
7. Chaoui R, Schneider MB, Kalache KD. Right aortic arch with vascular ring and aberrant left subclavian artery: prenatal diagnosis assisted by three-dimensional power Doppler ultrasound. *Ultrasound Obstet Gynecol*. 2003;22:661.
8. Chaoui R, Kalache KD, Heling KS, et al. Absent or hypoplastic thymus on ultrasound: a marker for deletion 22q11.2 in fetal cardiac defects. *Ultrasound Obstet Gynecol*. 2002;20:546-552.
9. Chaoui R, Heling KS, Sarioglu N, et al. Aberrant right subclavian artery as a new cardiac sign in second- and third-trimester fetuses with Down syndrome. *Am J Obstet Gynecol*. 2005;192:257.
10. Agathokleous M, Chaveeva P, Poon LC, et al. Metaanalysis of second-trimester markers for trisomy 21. *Ultrasound Obstet Gynecol*. 2013;41:247-261.
11. Momma K. Cardiovascular anomalies associated with chromosome 22q11.2 deletion syndrome. *Am J Cardiol*. 2010;105:1617-1624.
12. Gardiner HM. Mind the gap! What we don't know about right aortic arches and aberrant branches. *Ultrasound Obstet Gynecol*. 2006;28:868.
13. Pico H, Mancini J, Lafouge A, et al. Prenatal associated features in fetuses diagnosed with an aberrant right subclavian artery. *Fetal Diagn Ther*. 2016;40(3):187-194.

To access the videos in this chapter, scan this QR code or visit expertconsult.com

85 Tetralogy of Fallot

MAR BENNASAR | JOSEP M. MARTINEZ

Introduction

Tetralogy of Fallot (TOF) is one of the most common conotruncal heart anomalies. It affects 9% to 11% of newborns with congenital heart disease (CHD).[1]

Disease

DEFINITION

In TOF, there is an anterior-superior and leftward displacement of the outlet septum in relation to the trabecular interventricular septum. It is characterized by an outlet, perimembranous ventricular septal defect (VSD), an overriding aorta over the infundibular septum, and a variable degree of right ventricular outflow tract obstruction, classically in the subpulmonary (infundibular) region (Videos 85.1 and 85.2). Right ventricular hypertrophy is uncommon in fetal life because of the variable degree of right ventricular tract obstruction and the relieving effect of the physiologic right-to-left fetal circulatory shunt.

PREVALENCE AND EPIDEMIOLOGY

TOF affects 0.5:1000 to 1:1000 newborns and is the most common cyanotic CHD in childhood. It accounts for 10% of all CHDs at birth, but only 3% to 6% of prenatally diagnosed CHDs.[2,3]

ETIOLOGY AND PATHOPHYSIOLOGY

The etiology is multifactorial. TOF has been associated with untreated maternal diabetes, phenylketonuria, and intake of retinoic acid. Chromosomal anomalies occur in 30% of cases and include trisomies 21, 18, and 13 and 22q11 microdeletion, especially in pulmonary atresia and absent pulmonary valve syndrome (APVS, 40% to 50% of cases). Extracardiac anomalies, in particular abdominal and thoracic abnormalities, occur in 25% to 30% of cases. Recurrence risk is 3%.[3,4]

Prognosis depends on the type of TOF, which is classified based on the pulmonary defect:

- Pulmonary stenosis (approximately 60%) is the most frequent prenatal form of TOF.
- Pulmonary atresia (approximately 30% to 35%): the degree of pulmonary obstruction can be progressive during fetal life, occasionally evolving from stenosis to atresia.
- Absent pulmonary valve (5% to 10%): there is severe dilatation of the pulmonary trunk and branches due to the to-and-fro flow across the absent valve. It is usually associated with agenesis of the ductus arteriosus.[5]

MANIFESTATIONS OF DISEASE

Clinical Presentation

TOF is usually asymptomatic during fetal life. Postnatal manifestations depend on the severity of the right outflow tract obstruction. Forms with pulmonary stenosis are normally asymptomatic and manifest with a murmur or increasing cyanosis during the first month of life. In pulmonary atresia, there is severe cyanosis at birth, requiring a systemic-to-pulmonary shunt after birth.

Imaging Technique and Findings

Ultrasound. The four-chamber view on ultrasound (US) is typically normal (Fig. 85.1). In some cases, there is levorotation of the heart axis, which should raise suspicion of TOF (Fig. 85.2). Cases with APVS can also be associated with cardiomegaly (Fig. 85.3).[6]

The five-chamber view or long-axis view is critical for the diagnosis. The typical sign of TOF is a perimembranous subaortic VSD with an overriding aorta. Continuity of the infundibular septum with the aorta is lost, and the aorta arises from both ventricles (Fig. 85.4), which is seen with color Doppler as a typical Y sign (Fig. 85.5). Overflow through the aortic root normally causes enlargement of the ascending aorta.

In axial planes, enlargement and dilatation of the ascending aorta distort its normal trajectory. The vessel follows a steep left-to-right direction in the ascending arch and returns steeply to the left side in the descending part. In severe cases, this

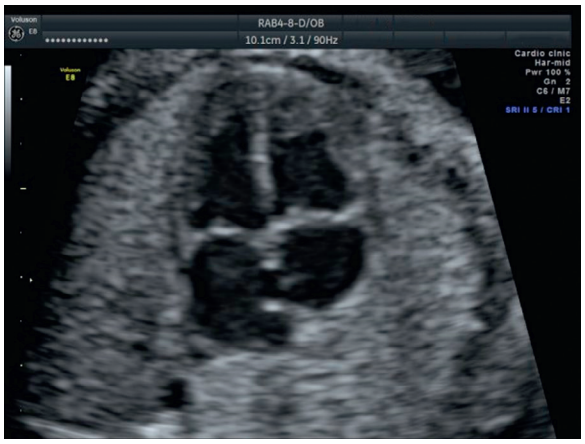

Fig. 85.1 Normal four-chamber view in a fetus with a diagnosis of tetralogy of Fallot.

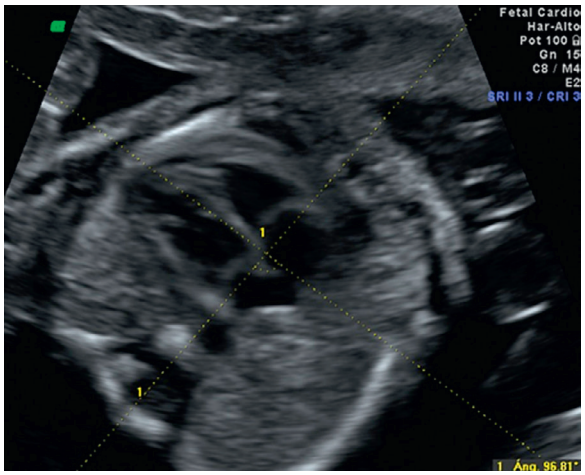

Fig. 85.2 Abnormal cardiac axis towards the left (levocardia) in a fetus with tetralogy of Fallot.

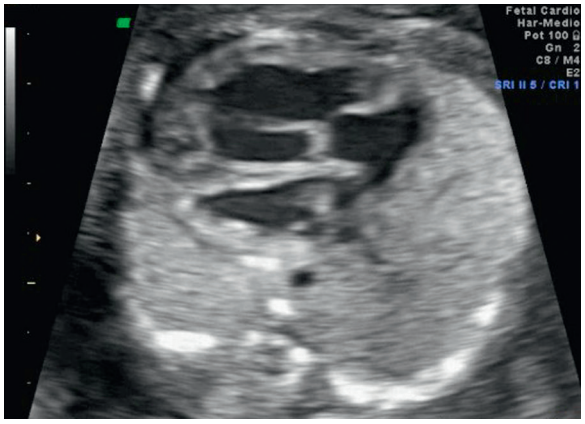

Fig. 85.3 Four-chamber view in a case of tetralogy of Fallot with absent pulmonary valve. Significant levocardia and cardiomegaly can be identified in this 22-week fetus.

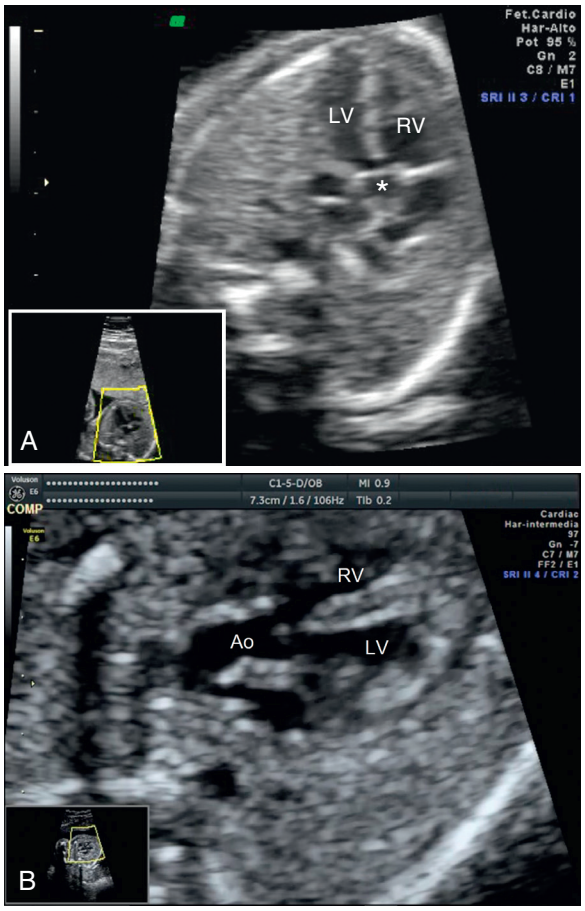

Fig. 85.4 (A) Apical five-chamber view: a perimembranous ventricular septal defect *(asterisk)* and an overriding aorta over the left ventricle *(LV)* and right ventricle *(RV)* can be identified. (B) Lateral visualization of overriding aorta *(Ao)*.

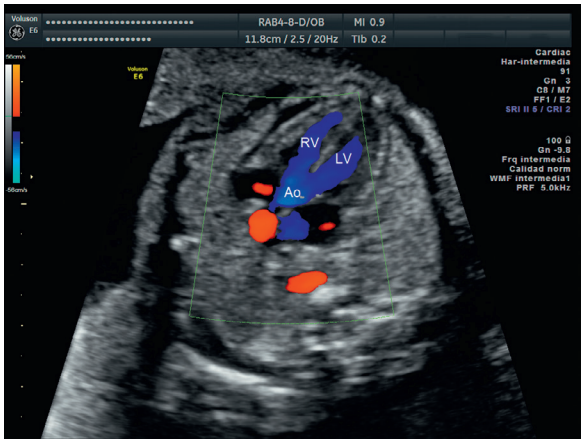

Fig. 85.5 Color Doppler shows the Y sign, corresponding to the left ventricular *(LV)* and right ventricular *(RV)* flow toward the aortic root *(Ao)*.

trajectory may create a characteristic "question mark" shape, indicating a higher risk of pulmonary atresia (55% in pulmonary stenosis versus 89% in pulmonary atresia) (Fig. 85.6). This sign has not been described in TOF with APVS or in cases with right aortic arch.[7]

The crossover of both arteries is correctly identified. There is a discrepancy in size between the aortic and pulmonary arteries that can be progressive during fetal life.

The three-vessel and trachea view is usually abnormal. In pulmonary stenosis there is a smaller pulmonary artery

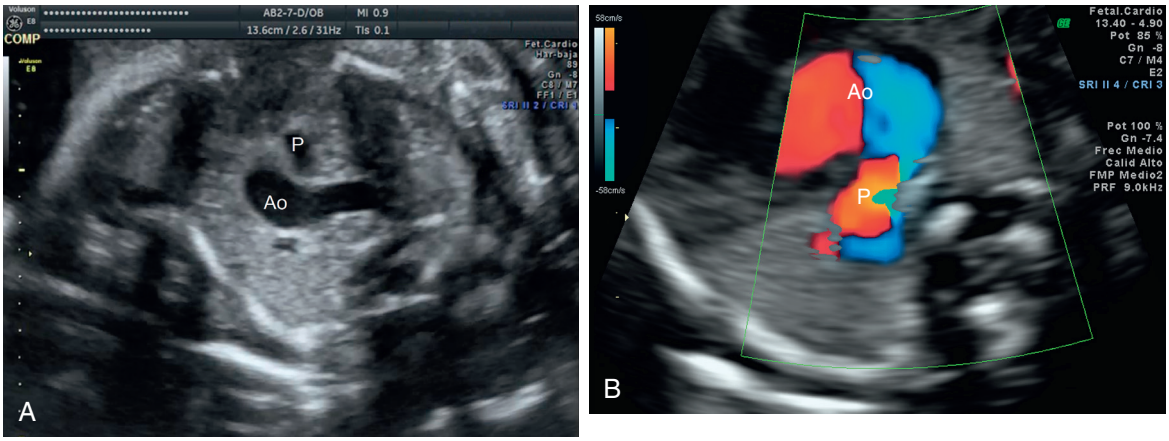

Fig. 85.6 (A) Greyscale image of a dilated aorta *(Ao)* in a case of tetralogy of Fallot (TOF) with pulmonary *(P)* atresia. (B) Enlarged ascending aorta and presence of the "question mark" sign in a case of TOF with pulmonary atresia. Color Doppler shows retrograde flow *(red)* in the whole pulmonary artery *(P)*, from the outflow tract to the ductus arteriosus, and antegrade flow (first in *red*, second in *blue*) in the whole aortic arch *(Ao)*.

with antegrade flow (Fig. 85.7A), and in pulmonary atresia, the pulmonary artery is very small with retrograde flow (Fig. 85.7B).

In about 30% of TOF there is a right aortic arch (Fig. 85.8).[8]

The uncommon form of TOF associated with APVS shows a specific, pathognomonic three-vessel and trachea view. There is a massive dilatation of the pulmonary trunk and branches secondary to pulmonary valve stenosis and insufficiency, as well as absence of ductus arteriosus. Color Doppler shows to-and-fro flow (Fig. 85.7C).

Finally, cases with severe right ventricle tract obstruction can be associated to the presence of major aortopulmonary collateral arteries (MAPCAs). They can be identified with color and pulsed Doppler as arterial vessels emerging from the descending aorta, connecting the systemic and pulmonary circulation (Fig. 85.9).

CLASSIC SIGNS

- Four-chamber view may be normal.
- Leftward deviation of the cardiac axis.
- Perimembranous subaortic VSD plus overriding aorta.
- Small pulmonary artery.

Differential Diagnosis From Imaging Findings

1. Malalignment VSD: overriding aorta without right ventricular tract obstruction. The pulmonary artery is normal, although the correct diagnosis may occasionally be very challenging because pulmonary stenosis in TOF could appear later in pregnancy.
2. Double-outlet right ventricle (DORV): the differential diagnosis can be challenging. The difference between TOF and the Fallot–DORV type is in the degree of aortic overriding. Although there is still some controversy, it is generally accepted that the diagnosis of DORV is considered when at least half of the aorta arises from the right ventricle.
3. Persistent truncus arteriosus: it must be differentiated from TOF with pulmonary atresia.[9] Truncus is usually associated with absent ductus arteriosus.

Synopsis of Treatment Options

PRENATAL

Genomic microarray and targeted morphologic US examination should be offered. In isolated TOF, a good prognosis is expected with pulmonary stenosis (greater than 90% survival after surgery), but it decreases to 70% when there is pulmonary atresia and is even poorer for APVS. The fetus should be evaluated periodically (every 4–6 weeks) to rule out progressive right ventricular tract obstruction, the presence of MAPCAs and other associated cardiac and extracardiac anomalies that could manifest later in gestation.[10]

POSTNATAL

Postnatal treatment depends on the TOF variant. In asymptomatic cases, surgical repair is usually undertaken at about 4 to 6 months of age and carries a reasonably low risk. It is a curative surgery and mainly consists of closing the VSD. Cases with severe pulmonary stenosis or pulmonary atresia are symptomatic in the neonatal period after the ductus closure. A systemic-to-pulmonary shunt is needed to avoid hypoxemia and to facilitate growth of the pulmonary branches until the definitive surgery is undertaken. The presence of MAPCAs worsens the prognosis. The presence of these vascular connections usually does not permit a corrective surgery, leading to progressive pulmonary hypertension.[11,12]

WHAT THE REFERRING PHYSICIAN NEEDS TO KNOW

- TOF is one of the most frequently occurring conotruncal anomalies.
- It is classically overlooked if the outflow tracts are not included in routine scans.
- There is a high association with chromosomal defects and extracardiac anomalies.
- Overall, TOF diagnosed prenatally has a poor prognosis due to a high association with other anomalies. In isolated TOF, the prognosis depends on the degree of pulmonary disease.

KEY POINTS

- Normal four-chamber view
- Perimembranous VSD plus overriding aorta
- Right ventricular tract obstruction

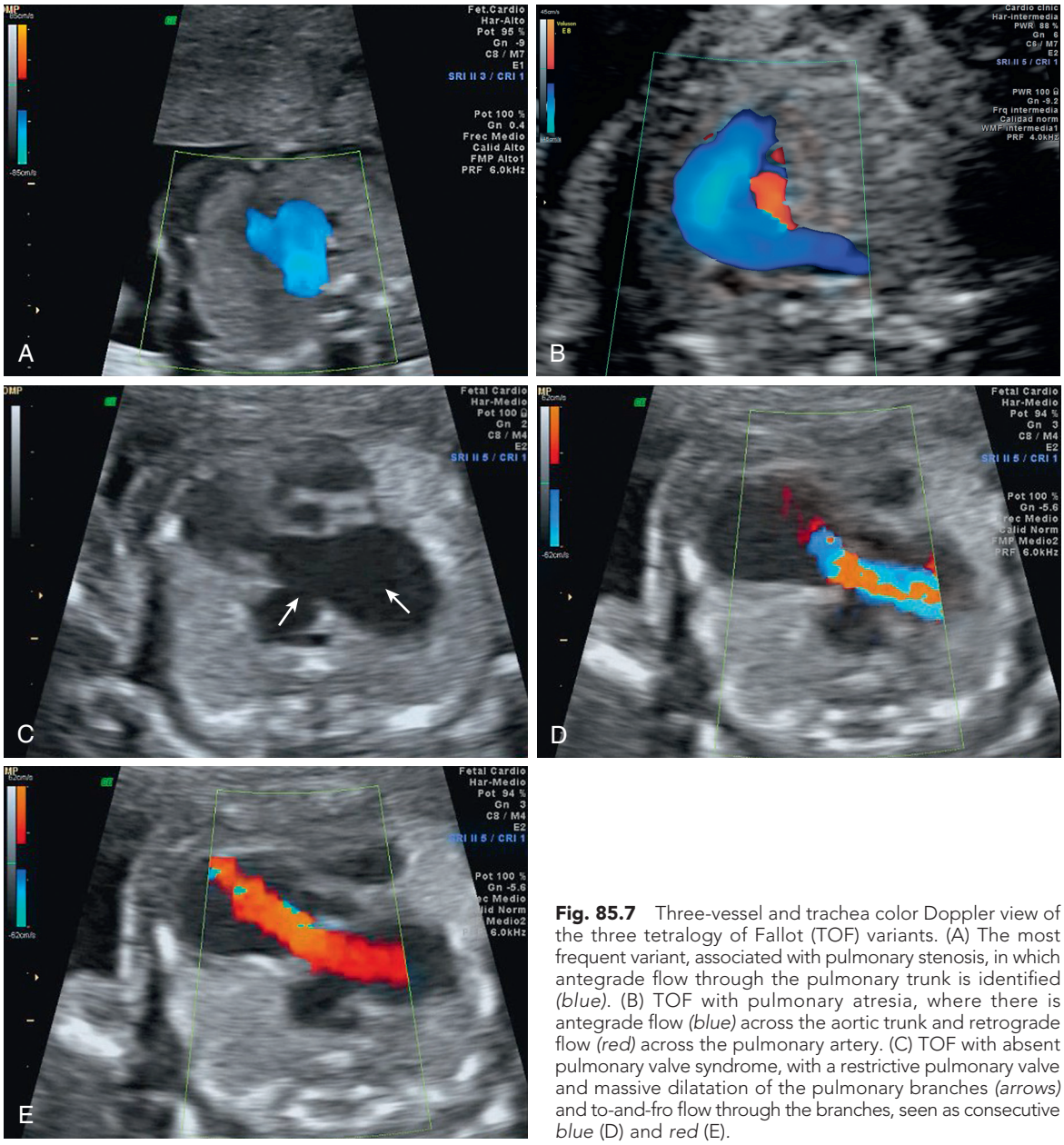

Fig. 85.7 Three-vessel and trachea color Doppler view of the three tetralogy of Fallot (TOF) variants. (A) The most frequent variant, associated with pulmonary stenosis, in which antegrade flow through the pulmonary trunk is identified *(blue)*. (B) TOF with pulmonary atresia, where there is antegrade flow *(blue)* across the aortic trunk and retrograde flow *(red)* across the pulmonary artery. (C) TOF with absent pulmonary valve syndrome, with a restrictive pulmonary valve and massive dilatation of the pulmonary branches *(arrows)* and to-and-fro flow through the branches, seen as consecutive *blue* (D) and *red* (E).

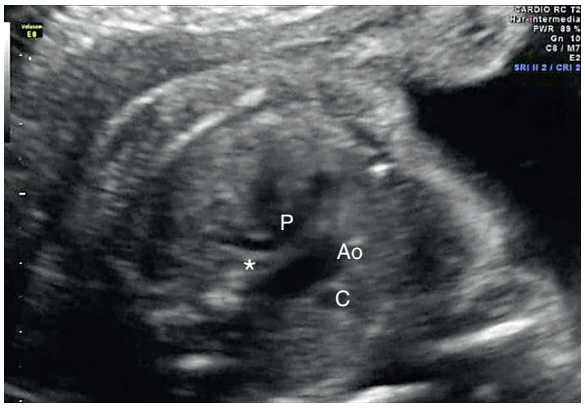

Fig. 85.8 Tetralogy of Fallot associated with a right aortic arch. The stenotic pulmonary trunk can be identified on the left *(P)*. The aortic root *(Ao)* is located to the right of the trachea *(asterisk)*, beside the vena cava *(C)*.

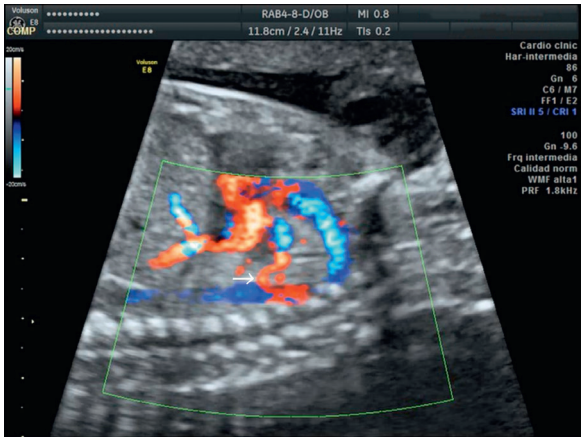

Fig. 85.9 Sagittal view of the descending aorta. Color flow shows a vessel arising from the descending aorta *(arrow)* towards the pulmonary circulation. Pulsed Doppler would reveal the arterial condition of this vessel.

SUGGESTED READING

Allan L, Hornberger L, Sharland G. *Textbook of fetal cardiology*. London: Greenwich Medical Media Ltd; 2009.

Paladini D, Volpe P. *Ultrasound of congenital fetal anomalies: differential diagnosis and prognostic indicators*. London: Informa Health Care; 2007.

Yagel S, Silverman NH, Gembruch U. *Fetal cardiology. Series in maternal fetal medicine*. New York: Informa Health Care; 2009.



All references are available online at www.expertconsult.com.

REFERENCES

1. Allan L. Prenatal diagnosis of structural cardiac defects. *Am J Med Genet C Semin Med Genet*. 2007;145C:73.
2. Chew C, Halliday JL, Riley MM, et al. Population-based study of antenatal detection of congenital heart disease by ultrasound examination. *Ultrasound Obstet Gynecol*. 2007;29:619.
3. Apitz C, Webb GD, Redington AN. Tetralogy of Fallot. *Lancet*. 2009;374:1462.
4. Poon LC, Huggon IC, Zidere V, et al. Tetralogy of Fallot in the fetus in the current era. *Ultrasound Obstet Gynecol*. 2007;29:625.
5. Galindo A, Gutierrez-Larraya F, Martinez JM, et al. Prenatal diagnosis and outcome for fetuses with congenital absence of the pulmonary valve. *Ultrasound Obstet Gynecol*. 2006;28:32.
6. Smith RS, Comstock CH, Kirk JS, et al. Ultrasonographic left cardiac axis deviation: a marker for fetal anomalies. *Obstet Gynecol*. 1995;85:187.
7. Martinez JM, Gomez O, Bennasar M, et al. The 'question mark' sign as a new ultrasound marker of tetralogy of Fallot in the fetus. *Ultrasound Obstet Gynecol*. 2010;36:556.
8. Yoo SJ, Lee YH, Kim ES, et al. Tetralogy of Fallot in the fetus: findings at targeted sonography. *Ultrasound Obstet Gynecol*. 1999;14:29.
9. Gómez O, Soveral I, Bennasar M, et al. Accuracy of fetal echocardiography in the differential diagnosis between truncus arteriosus and pulmonary atresia with ventricular septal defect. *Fetal Diagn Ther*. 2016;39(2):90-99.
10. Escribano D, Herraiz I, Granados M, et al. Tetralogy of Fallot: prediction of outcome in the midsecond trimester of pregnancy. *Prenat Diagn*. 2011;31:1126-1133.
11. Bacha EA, Scheule AM, Zurakowski D, et al. Long-term results after early primary repair of tetralogy of Fallot. *J Thorac Cardiovasc Surg*. 2001;122:154.
12. Murphy JG, Gersh BJ, Mair DD, et al. Long-term outcome in patients undergoing surgical repair of tetralogy of Fallot. *N Engl J Med*. 1993;329:593.
13. Tuo G, Volpe P, Buffi D, et al. Assessment of the ductus arteriosus in fetuses with tetralogy of Fallot and the implication for postnatal management. *Congenit Heart Dis*. 2014;9:382-390.

To access the videos in this chapter, scan this QR code or visit expertconsult.com

86 Transposition of Great Arteries

MAR BENNASAR | JOSEP M. MARTINEZ

Introduction

There are two forms of transposition of great arteries (TGA): complete and corrected.

Complete Transposition of Great Arteries

A conotruncal anomaly characterized by a discordant ventriculoarterial connection. Complete TGA affects approximately 3:10,000 newborns.

DEFINITION

Complete TGA is defined by normal atrioventricular concordance associated with an abnormal ventriculoarterial connection. The pulmonary artery arises from the morphologic left ventricle and the aorta emerges anteriorly from the morphologic right ventricle.

PREVALENCE AND EPIDEMIOLOGY

Complete TGA accounts for 6% to 8% of all CHDs at birth, but it represents only 2% to 3% of prenatally detected CHDs.[1,2] Detection rates increased to 40% to 50% when guidelines included evaluation of the outflow tracts during cardiac screening.[3] Isolated complete TGA is very rarely associated with chromosomal or extracardiac anomalies, but other CHDs are common, most typically ventricular septal defects (30%), pulmonary stenosis (15%), and aortic arch abnormalities (5%).[4]

ETIOLOGY AND PATHOPHYSIOLOGY

A multifactorial CHD, risk factors such as maternal diabetes, and exposure to drugs have been reported. Gene mutations have been described in anecdotal cases.[4] Complete TGA results from abnormal inversion and spiraling of the conus arteriosus and truncus arteriosus, which occurs in the fifth week of embryonic life.[5,6] The atria and ventricles retain their normal anatomy, a subaortic infundibulum separates the aorta from the tricuspid valve, and there is fibrous continuity between the mitral and pulmonary valves. Coronary arteries originate in the aortic sinus. The key problem is that the systemic and pulmonary circulations run in parallel, preventing normal blood oxygenation and resulting in severe hypoxemia after birth.

MANIFESTATIONS OF DISEASE

Clinical Presentation

There is severe hypoxemia, central cyanosis, and cardiac failure at birth, the severity depending on the function of right-to-left shunts of the fetal circulation. Cases with restrictive foramen ovale, or ductus arteriosus, or with intact ventricular septum, have a worse evolution.[7,8]

Imaging Technique and Findings

Ultrasound. The crossover of the great arteries while moving from the five-chamber to the three-vessel and trachea views cannot be identified.

- The four-chamber view is typically normal (Fig. 86.1), although leftward deviation of the cardiac axis is common.
- The five-chamber view or long-axis view is normal, with septopulmonary continuity. However, the vessel arising from the left ventricle, the pulmonary artery (Video 86.1) bifurcates into right and left pulmonary branches (Fig. 86.2).
- Crossover of the outflow tracts cannot be identified, because they run in parallel (Fig. 86.3).
- The three-vessel and trachea view is usually abnormal with only two vessels (Fig. 86.4), because the aorta emerges from



Fig. 86.1 Four-chamber view in complete TGA with significant perimembranous VSD.

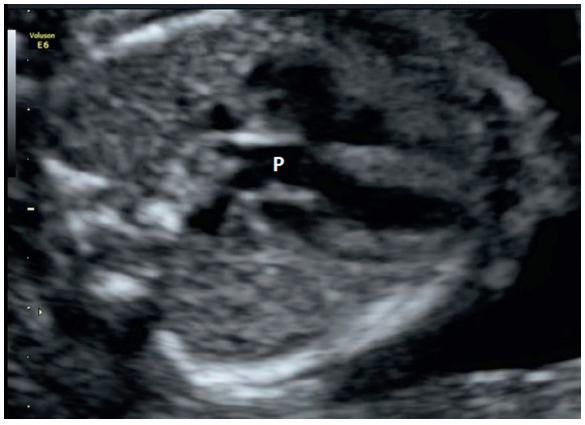

Fig. 86.2 Pulmonary artery *(P)* arising from left ventricle in complete TGA. There is early bifurcation of the left outflow tract into the right and left pulmonary branches.



Fig. 86.3 Parallel disposition of great arteries. The aorta emerges anteriorly from the right ventricle, whereas the pulmonary artery originates from the posterior ventricle.

the anterior–superior ventricle and has a hockey-stick shape, so that it runs in a superior plane with respect to the pulmonary arch.[9]

- Longitudinal views identify the supraaortic vessels in the anterior aortic arch (Fig. 86.5).



Fig. 86.4 Abnormal three-vessel and trachea view in which only the aorta *(Ao)*, the superior cava vein *(SCV)*, and the trachea can be identified *(asterisk)*.

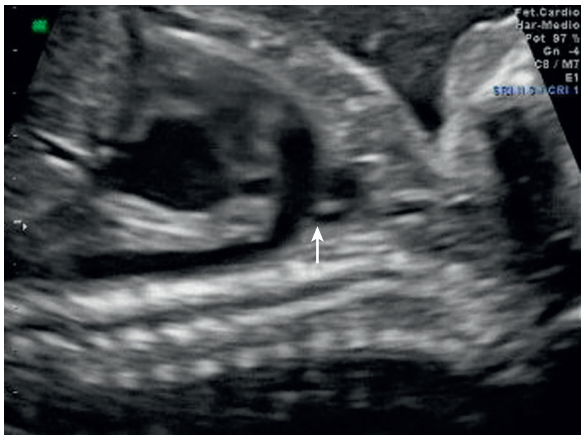

Fig. 86.5 Longitudinal view of the aortic arch emerging from the anterior ventricle. Note the hockey-stick shape and the supraaortic branching *(arrow)* far from the semilunar valve.

Other Applicable Modality

Four-Dimensional Echocardiography. Simplified approaches have been proposed to improve the detection rate of complete TGA (Fig. 86.6), but are not part of routine practice.[10,11] In addition, four-dimensional (4D) echocardiography could be helpful in identifying associated abnormal coronary arteries patterns when evaluated in the *en face* view of the atrioventricular valves.[12]

CLASSIC SIGNS

- Normal four-chamber view.
- Crossover of outflow tracts cannot be confirmed (see Video 86.1).
- Aorta arising anterior and to the right from the right ventricle with a late branching, away from the semilunar valve (see Fig. 86.5).
- Pulmonary artery connecting the left ventricle with early bifurcation into the right and left pulmonary branches (see Figs. 86.2 and 86.6).
- Two vessels in three-vessel and trachea view (see Fig. 86.4).



Fig. 86.6 Four-dimensional (4D) imaging of sagittal and transverse view of the aortic arch. Plane A shows the anterior origin of the aorta. Plane B represents the pulmonary artery emerging from the posterior ventricle *(dot)*.

Differential Diagnosis From Imaging Findings

1. Double-outlet right ventricle (DORV) can be difficult to distinguish from complete TGA with ventricular septal defects (VSDs). In DORV, the artery arising from the left ventricle overrides more than 50% of the septum.
2. Differentiation from corrected TGA is critical (see later).

Synopsis of Treatment Options

PRENATAL

The risk of prenatal complications is rare. Karyotyping is usually recommended for all cases but the risk of chromosomal anomalies is very low when the septum is intact.[4,13] Follow-up every 4 to 6 weeks will rule out associated defects that could manifest later in pregnancy. It is important to evaluate the foramen ovale and the ductus arteriosus to predict the need of an atrial septostomy immediately after birth.[8]

POSTNATAL

Prenatal diagnosis improves postnatal surveillance.[14,15] Delivery in a tertiary referral center is mandatory. Prostaglandin E_1 infusion immediately after birth avoids ductus arteriosus closure and permits normal oxygenation. Cases with severe shunt restriction need the Rashkind atrial septostomy to permit blood mixture until the definitive surgery is performed.

The treatment of choice is the arterial switch operation, usually performed during the first days of life, although it may be done later in cases with VSD depending on the size of the VSD. The outflow tracts are switched, and the (abnormally located) coronary arteries are also reconnected to the repositioned aorta. Recent data shows overall mortality of 6.5% to 8.7%, and less than 2% in simple TGA,[16] with long-term survival rates above 90%, usually with normal quality of life.[3,17] Pulmonary stenosis and coronary obstruction are the most frequent long-term complications requiring reintervention. Where a switch correction is not possible, palliative treatments for isolated (Senning or Mustard procedure) or VSD cases (Rastelli operation) are offered, with a lower survival rate (80% to 85%).

Complete TGA has been related to higher rates of neurodevelopmental problems, such as lower intelligence quotient, difficulties with language and visual skills. These problems are caused partially by neonatal and surgical complications, and, as recently shown, partially by abnormal prenatal brain development, possibly owing to suboptimal oxygen supply.[18]

WHAT THE REFERRING PHYSICIAN NEEDS TO KNOW

- Complete TGA is commonly overlooked because the four-chamber view is normal.
- It must be suspected if the crossover of outflow tracts cannot be clearly visualized.
- Prenatal diagnosis and targeted neonatal care critically improve outcomes.
- Corrective arterial switch has an overall long-term survival rate of 90%.

Corrected Transposition of Great Arteries

Corrected TGA is an infrequent conotruncal CHD.

DEFINITION

Corrected TGA is defined by the coexistence of atrioventricular and ventriculoarterial discordance. Systemic venous return enters into the right atrium, which connects to a morphologic left ventricle, which then connects to a pulmonary artery. Pulmonary venous return goes to the left atrium, which is connected to a morphologic right ventricle, which connects to the aorta. Thus,

the great vessels arise from the correct side, but with a ventricular inversion.

PREVALENCE AND EPIDEMIOLOGY

Corrected TGA represents less than 1% of all CHDs.[19] In isolated cases, chromosomal and extracardiac anomalies are rare, but other CHDs are present in more than 80% of cases,[20–22] most frequently VSD (70%), usually perimembranous and subpulmonary. Other reported CHDs are pulmonary stenosis (40%), tricuspid regurgitation (90%), and Ebstein anomaly.

ETIOLOGY AND PATHOPHYSIOLOGY

See the previous section on complete TGA. In addition, the atrioventricular node and the bundle of His have an unusual position, leading to a high rate of complete atrioventricular block.[23–25]

MANIFESTATIONS OF DISEASE

Clinical Presentation

Unless there are other associated anomalies, corrected TGA can be completely asymptomatic at birth and during childhood and adolescence. However, the systemic ventricle has a right heart anatomy, not designed to support high pressures. In the long term, there is severe cardiac remodeling with ventricular hypertrophy, and eventually dilatation and cardiac failure necessitating cardiac transplantation. Ventricular wall hypertrophy is often associated with distortion of the conduction pathways, with common arrhythmias and atrioventricular (AV) blocks.[23,24]

Imaging Technique and Findings

Ultrasound. Corrected TGA is the only conotruncal anomaly with a typical four-chamber view alteration.[25]

- The characteristic, almost pathognomonic, feature is the atrioventricular discordance on the four-chamber view (Fig. 86.7). The anterior ventricle has a "left" anatomy, whereas the posterior left ventricle is morphologically a right ventricle, with a moderator band and more apical insertion of the tricuspid valve. All venous connections are normal.
- The crossover of both arteries cannot be identified because they usually run in parallel.
- Ascending from the four-chamber view, the first vessel arises from the right heart, and connects with the ventricular valve (a mitral valve) by a fibrous tract. Morphologically, it is a pulmonary artery, with early bifurcation into right and left branches (Fig. 86.8).
- The second, superiorly located vessel is the aorta, which also has combined features: it connects with the posterior (morphologically right) ventricle through a muscular infundibulum, but, similar to a normal aortic vessel, it gives rise to a normally configured supraaortic branching far away from the semilunar valve (Video 86.2).
- As in TGA, the three-vessel and trachea view is usually abnormal (Fig. 86.4).

Other Applicable Modality

Four-Dimensional Echocardiography. Four-dimensional echocardiography can be useful to understand the abnormal vascular connections.

CLASSIC SIGNS

- Moderator band on the posterior, left-sided ventricle and apical insertion of the left atrioventricular valve on four-chamber view (see Fig. 86.7).
- Lack of outflow tracts crossover (see Video 86.2).
- Two vessels in three-vessel and trachea view.

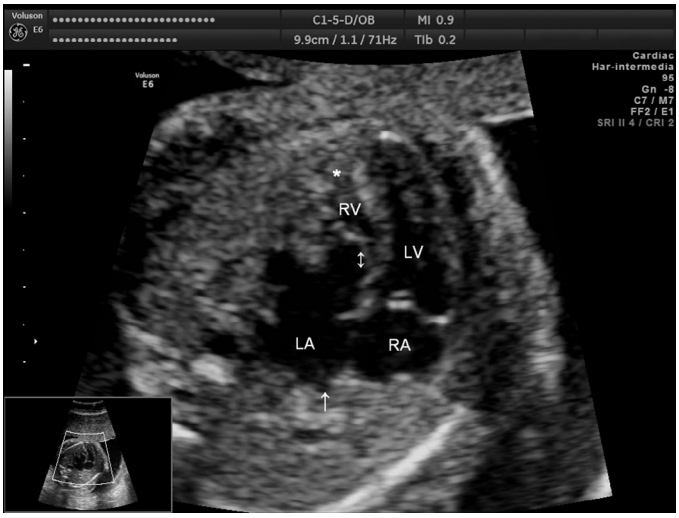

Fig. 86.7 Four-chamber view in corrected transposition of great arteries (cTGA). The anterior ventricle is the morphologic left ventricle *(LV)* connecting to the right atrium *(RA)* through a mitral valve. Pulmonary veins *(arrow)* drain into the left atrium *(LA)*, which is connected to the morphologic right ventricle *(RV)*. Note apical insertion of the tricuspid valve (↕) and the presence of a moderator band *(asterisk)* in the posterior ventricle.

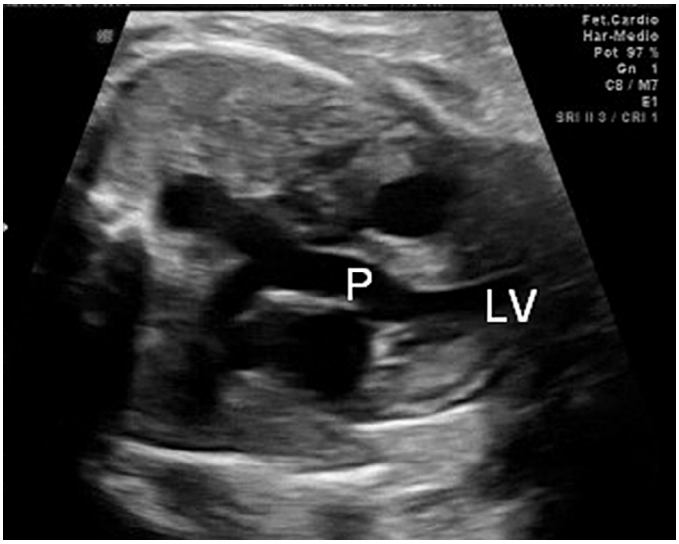

Fig. 86.8 Pulmonary artery *(P)*, with an early bifurcation into pulmonary branches, originates from the anterior morphologic left ventricle *(LV)*, showing continuity with the mitral valve.

Differential Diagnosis From Imaging Findings

Complete TGA may look similar initially, but the inversion of the normal ventricular anatomy must give the clue to differential diagnosis.

Synopsis of Treatment Options

PRENATAL

Targeted morphologic US examination and fetal echocardiography should be offered. Karyotype analysis is commonly offered, but the risk of chromosomal anomalies is low.[22] The fetus should be evaluated every 4 to 6 weeks to rule out other anomalies that could manifest later in pregnancy, such as tricuspid regurgitation.

POSTNATAL

Postnatally, patients can present with a wide spectrum of symptoms, depending on the systemic right ventricle function. Asymptomatic patients are followed to rule out ventricular dysfunction and progressive heart block. Surgical treatment is usually required in symptomatic patients and ranges from conventional physiologic repair, which consists of repairing associated anomalies, such as VSD or pulmonary stenosis, and leaving the right ventricle as the systemic ventricle, to the so-called anatomic repair or double switch operation, in which the anatomic left ventricle is connected to the systemic circulation. This surgery combines correction of atrial venous return with the arterial switch procedure. Systolic dysfunction of the left ventricle has been reported after this procedure, and long-term follow-up data are required.[26,27]

WHAT THE REFERRING PHYSICIAN NEEDS TO KNOW

- Corrected TGA is a rare cardiac defect, difficult to detect prenatally.
- Overall prognosis depends on the associated anomalies.
- Tricuspid valve dysplasia and right ventricle dysfunction are important prognostic factors.
- Initial postnatal survival is greater than 90%, which declines at 20 years to 65% to 75%.[20,25,26]
- Surgical treatment is controversial. Asymptomatic patients are usually not operated on, whereas symptomatic patients may be offered a double switch operation.

KEY POINTS

- Complete TGA
  - Normal four-chamber view
  - Lack of crossover of great arteries
  - Two vessels on three-vessel and trachea view
- Corrected TGA
  - Abnormal four-chamber view
  - Lack of crossover of great arteries
  - Two vessels on three-vessel and trachea view

SUGGESTED READING

Allan L, Hornberger L, Sharland G. *Textbook of fetal cardiology*. London: Greenwich Medical Media Ltd; 2000.

Paladini D, Volpe P. *Ultrasound of congenital fetal anomalies: differential diagnosis and prognostic indicators*. London: Informa Health Care; 2007.

Yagel S, Silverman NH, Gembruch U. *Fetal cardiology.* Series in maternal fetal medicine. New York: Informa Health Care; 2009.



All references are available online at www.expertconsult.com.

REFERENCES

1. Garne E, Stoll C, Clementi M. Evaluation of prenatal diagnosis of congenital heart diseases by ultrasound: experience from 20 European registries. *Ultrasound Obstet Gynecol*. 2011;17:386-391.
2. Shih JC, Shyu MK, Su YN, et al. 'Big-eyed frog' sign on spatiotemporal image correlation (STIC) in the antenatal diagnosis of transposition of the great arteries. *Ultrasound Obstet Gynecol*. 2008;32:762-768.
3. Escobar MC, Freud LR, Bueno A, et al. Prenatal diagnosis of transposition of great arteries over a 20-year period: improved but imperfect. *Ultrasound Obstet Gynecol*. 2015;45:678-682.
4. Martins P, Castela E. Transposition of the great arteries. *Orphanet J Rare Dis*. 2008;3:27.
5. Goor DA, Edwards JE. The spectrum of transposition of the great arteries: with specific reference to developmental anatomy of the conus. *Circulation*. 1973;48:406-415.
6. Lomonico MP, Bostrom MP, Moore GW, et al. Arrested rotation of the outflow tract may explain tetralogy of Fallot and transposition of the great arteries. *Pediatr Pathol*. 1988;8:267-281.
7. Maeno YV, Kamenir SA, Sinclair B, et al. Prenatal features of ductus arteriosus constriction and restrictive foramen ovale in d-transposition of the great arteries. *Circulation*. 1999;99:1209-1214.
8. Jouannic JM, Gavard L, Fermont L, et al. Sensitivity and specificity of prenatal features of physiological shunts to predict neonatal clinical status in transposition of the great arteries. *Circulation*. 2004;110:1743-1746.
9. Gardiner H, Chaoui R. The fetal three-vessel and tracheal view revisited. *Semin Fetal Neonatal Med*. 2013;18:261-268.
10. Goncalves LF, Espinoza J, Romero R, et al. A systematic approach to prenatal diagnosis of transposition of the great arteries using 4-dimensional ultrasonography with spatiotemporal image correlation. *J Ultrasound Med*. 2004;23:1225-1231.
11. DeVore GR, Polanco B, Sklansky MS, et al. The "spin" technique: a new method for examination of the fetal outflow tracts using three-dimensional ultrasound. *Ultrasound Obstet Gynecol*. 2004;24:72-82.
12. Paladini D, Volpe P, Sglavo G, et al. Transposition of the great arteries in the fetus: assessment of the spatial relationships of the arterial trunks by four-dimensional echocardiography. *Ultrasound Obstet Gynecol*. 2008;31:271-276.
13. Galindo A, Mendoza A, Arbues J, et al. Conotruncal anomalies in fetal life: accuracy of diagnosis, associated defects and outcome. *Eur J Obstet Gynecol Reprod Biol*. 2009;146:55-60.
14. Bonnet D, Coltri A, Butera G, et al. Detection of transposition of the great arteries in fetuses reduces neonatal morbidity and mortality. *Circulation*. 1999;99:916-918.
15. Bartlett JM, Wypij D, Bellinger DC, et al. Effect of prenatal diagnosis on outcomes in D-transposition of the great arteries. *Pediatrics*. 2004;113:e335-e340.
16. Domínguez-Manzano P, Mendoza A, Herraiz I, et al. Transposition of the great arteries in fetal life: accuracy of diagnosis and short-term outcome. *Fetal Diagn Ther*. 2016;40:268-276.
17. Villafañe J, Lantin-Hermoso MR, Bhatt AB, et al. D-transposition of the great arteries: the current era of the arterial switch operation. *J Am Coll Cardiol*. 2014;64:498-511.
18. Miller SP, McQuillen PS, Hamrick S, et al. Abnormal brain development in newborns with congenital heart disease. *N Engl J Med*. 2007;357:1928-1938.
19. Connelly MS, Liu PP, Williams WG, et al. Congenitally corrected transposition of the great arteries in the adult: functional status and complications. *J Am Coll Cardiol*. 1996;27:1238-1243.
20. Galindo A, Mendoza A, Arbues J, et al. Conotruncal anomalies in fetal life: accuracy of diagnosis, associated defects and outcome. *Eur J Obstet Gynecol Reprod Biol*. 2009;146:55-60.
21. Hraska V, Duncan BW, Mayer JE Jr, et al. Long-term outcome of surgically treated patients with corrected transposition of the great arteries. *J Thorac Cardiovasc Surg*. 2005;129:182-191.
22. Paladini D, Volpe P, Marasini M, et al. Diagnosis, characterization, and outcome of congenitally corrected transposition of the great arteries in the fetus: a multicenter series of 30 cases. *Ultrasound Obstet Gynecol*. 2006;27:281-285.
23. Hornung TS, Calder L. Congenitally corrected transposition of the great arteries. *Heart*. 2010;96:1154-1161.
24. Chiappa E1, Micheletti A, Sciarrone A, et al. The prenatal diagnosis of, and short-term outcome for, patients with congenitally corrected transposition. *Cardiol Young*. 2004;14:265-276.
25. McEwing RL, Chaoui R. Congenitally corrected transposition of the great arteries: clues for prenatal diagnosis. *Ultrasound Obstet Gynecol*. 2004;23:68-72.
26. Ly M, Belli E, Leobon B, et al. Results of the double switch operation for congenitally corrected transposition of the great arteries. *Eur J Cardiothorac Surg*. 2009;35:879-883.
27. Warnes CA. Transposition of the great arteries. *Circulation*. 2006;114:2699-2709.

To access the videos in this chapter, scan this QR code or visit expertconsult.com

87 Double-Outlet Right Ventricle

MAR BENNASAR | JOSEP M. MARTINEZ

Introduction

Double-outlet right ventricle (DORV) refers to a group of complex heart anomalies in which both great arteries arise entirely, or to a great extent, from the right ventricle.

Disease

DEFINITION

DORV encompasses a spectrum of lesions in which both outflow tracts connect to the right ventricle entirely or predominantly.

PREVALENCE AND EPIDEMIOLOGY

DORV accounts for 4% to 8% of prenatal congenital heart diseases (CHDs). The high association of DORV with cardiac, extracardiac, and chromosomal anomalies is responsible for its lower postnatal incidence (1% to 3%).[1]

Associated anomalies are frequent in fetuses with DORV. Chromosomal abnormalities are found in 10% to 20% of cases; trisomies 18 and 13 are the most frequent, and trisomy 21 and 22q11 microdeletion are also found in DORV.[2] Other commonly associated cardiac anomalies are atrioventricular septal defect, cardiosplenic syndromes, aortic coarctation, mitral atresia, and straddling or overriding of the atrioventricular valves with consequent hypoplasia of the underlying ventricle.[2] Finally, extracardiac anomalies are present in two-thirds of cases,[2,3] especially gastrointestinal and central nervous system anomalies.

ETIOLOGY AND PATHOPHYSIOLOGY

The etiology is multifactorial. DORV consists of a large ventricular septal defect (VSD). The VSD may have a variable disposition, including a subaortic or subpulmonary isolated defect; a doubly committed defect, immediately below the valves and spanning both outflow tracts; and a noncommitted defect, low in the septum and far from the semilunar outflow valves.[4]

Isolated subaortic and subpulmonary VSDs are the most frequent types found in prenatal and surgical series, respectively.[5] Subaortic VSD is usually associated with a normal orientation of the great arteries, with some degree of pulmonary obstruction. This form resembles tetralogy of Fallot (TOF) from a pathophysiologic point of view. In cases with subpulmonary VSD, the great arteries are usually malpositioned, and the defect resembles transposition of the great arteries (TGA) with VSD.

A doubly committed VSD is characterized by complete absence of the muscular outlet septum, is perimembranous, and is considered noncommitted because it opens into the right ventricle beneath the septal leaflet of the tricuspid valve, or because the tension apparatus of the atrioventricular valves is interposed between the margins of the defect and the subarterial outflow tracts.

MANIFESTATIONS OF DISEASE

Clinical Presentation

The clinical presentation depends on the location of the VSD, the relationship of great arteries, and the degree of outflow tract obstruction, resembling TOF, VSD, or TGA.

Imaging Technique and Findings

Ultrasound. Prenatal diagnosis with ultrasound (US) is challenging. The four-chamber view appears normal, unless there is a left axis deviation or a large VSD that extends posteriorly, which is then visible on the four-chamber view.

- The four-chamber view is typically normal, unless other anomalies are associated. Levocardia can also be present in this conotruncal anomaly.
- On the five-chamber view or long-axis view, there is usually a perimembranous VSD with an overriding vessel. To be considered as DORV, the semilunar valve should override the VSD by at least 50% (Fig. 87.1).
- There is a normal relationship of great vessels in cases with subaortic VSD and parallel outflow tracts in cases with subpulmonary VSD (Video 87.1). It is important to identify the left and right outflow tracts correctly to classify DORV. As previously described, the pulmonary artery bifurcates early into pulmonary branches, and the aorta gives origin to supraaortic vessels far from the semilunar valve.

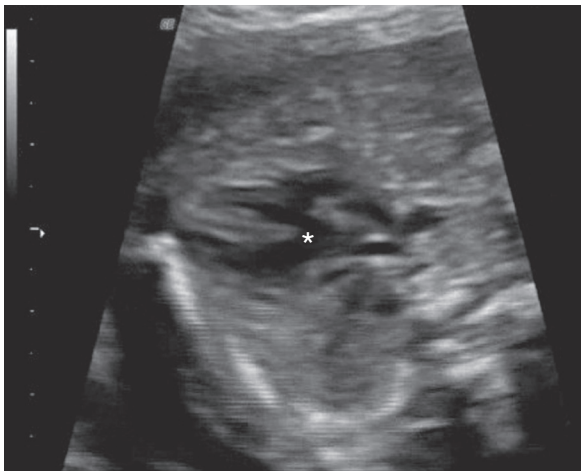

Fig. 87.1 Perimembranous VSD *(asterisk)* with pulmonary artery overriding in a DORV. There is parallel disposition of both great arteries.

CLASSIC SIGNS

- Normal four-chamber view
- Large VSD
- Overriding outflow tract: more than 50% of the semilunar valve

Differential Diagnosis From Imaging Findings

1. TOF and malalignment VSD: the difference between these anomalies is controversial and depends on the degree of overriding of the aorta. Most authors consider DORV when the semilunar valve overrides more than 50% from the right ventricle.[6] It can be extremely difficult to differentiate between them, even postnatally.
2. TGA with VSD: differential diagnosis is based on the degree of overriding of the pulmonary artery.

Synopsis of Treatment Options

PRENATAL

Genetic microarray and targeted morphologic US examination should be offered. In cases of isolated DORV, the prognosis depends on the DORV subtype (TOF or TGA). The fetus should be evaluated periodically (every 4 to 6 weeks) to rule out progressive outflow tract obstruction and other associated cardiac and extracardiac anomalies that could manifest later in pregnancy. Delivery should be planned in a tertiary referral center with cardiac surgery capabilities.

POSTNATAL

Treatment depends on the VSD disposition and the severity of the outflow tract obstruction. Cases with subaortic VSD are managed as TOF. Although arterial switch operation would be

the preferred treatment of TGA-like DORV, performance of this procedure is frequently difficult because of the large degree of overriding of the pulmonary artery. Other options, such as redirecting the pulmonary artery to the right ventricle through an extracardiac conduit and the aorta to the left ventricle through the VSD, may be considered.

Prognosis generally varies depending on other anomalies, which also influence the pregnancy termination rate. Overall survival rate of prenatally diagnosed DORV ranges from 30% to 50%.[2] Postnatal surgery and prognosis of isolated DORV depend on the location of the VSD and arrangement of the great arteries. If postnatal series are considered, the overall surgical mortality rate for biventricular repair is low; a 10-year survival rate greater than 80% is reported.

WHAT THE REFERRING PHYSICIAN NEEDS TO KNOW

- Diagnosis on routine US examination is challenging because the four-chamber view is usually normal.
- A key finding is a large VSD on the five-chamber view with both outflow tracts apparently arising from the right ventricle.
- High association to chromosomal, extracardiac, and cardiac anomalies. Prognosis is generally poor.

KEY POINTS

- Normal four-chamber view
- Perimembranous VSD
- Overriding aorta in DORV resembling TOF
- Overriding pulmonary artery in DORV resembling TGA

SUGGESTED READING

Allan L, Hornberger L, Sharland G. *Textbook of fetal cardiology*. London: Greenwich Medical Media Ltd; 2000.

Paladini D, Volpe P. *Ultrasound of congenital fetal anomalies: differential diagnosis and prognostic indicators*. London: Informa Health Care; 2007.

Yagel S, Silverman NH, Gembruch U. *Fetal cardiology.* Series in maternal fetal medicine. New York: Informa Health Care; 2009.



All references are available online at www.expertconsult.com.

REFERENCES

1. Hoffman JI, Kaplan S. The incidence of congenital heart disease. *J Am Coll Cardiol*. 2002;39:1890.
2. Kim N, Friedberg MK, Silverman NH. Diagnosis and prognosis of fetuses with double outlet right ventricle. *Prenat Diagn*. 2006;26:740.
3. Boldt T, Andersson S, Eronen M. Outcome of structural heart disease diagnosed in utero. *Scand Cardiovasc J*. 2002;36:73.
4. Walters HL 3rd, Mavroudis C, Tchervenkov CI, et al. Congenital heart surgery nomenclature and database project: double outlet right ventricle. *Ann Thorac Surg*. 2000;69:S249.
5. Kleinert S, Sano T, Weintraub RG, et al. Anatomic features and surgical strategies in double-outlet right ventricle. *Circulation*. 1997;96:1233.
6. Lev M, Bharati S, Meng CC, et al. A concept of double-outlet right ventricle. *J Thorac Cardiovasc Surg*. 1972;64:271.

To access the videos in this chapter, scan this QR code or visit expertconsult.com

88 Common Arterial Trunk

MAR BENNASAR | JOSEP M. MARTINEZ

Introduction

Common arterial trunk (CAT), also called *truncus arteriosus,* is an infrequent conotruncal anomaly in which there is a single outflow tract for both ventricles.

Disease

DEFINITION

CAT is characterized by a single great artery connecting both ventricles, which is responsible for the pulmonary, systemic, and coronary circulation (Video 88.1).

PREVALENCE AND EPIDEMIOLOGY

CAT accounts for 1% of all congenital heart diseases (CHDs),[1] and it is frequently associated with other anomalies,[2,3] especially 22q11 microdeletion (30%), and other cardiac (35% and 50%) and extracardiac (35%) anomalies. The most frequently associated CHDs are aortic arch abnormalities and absence of the ductus arteriosus, although tricuspid atresia and double-inlet ventricle have also been described.

ETIOLOGY AND PATHOPHYSIOLOGY

Embryologically, CAT is the consequence of a failure of septation of the truncal artery, whereby the aortopulmonary septum and subpulmonary infundibulum are missing. The truncal valve annulus is usually dysplastic and is formed by two, three, or four cusps. It may be stenotic, incompetent, or both. The common truncal artery supplies the pulmonary, aortic, and coronary circulations. Coronary artery patterns are abnormal in many patients; the most frequent variations are an intramural course and a single coronary artery.[4] Classifications for CAT by Collett and Edwards[5] and R. Van Praagh and S. Van Praagh[6] are shown in Tables 88.1 and 88.2.

TABLE 88.1 COLLETT AND EDWARDS CLASSIFICATION FOR COMMON ARTERIAL TRUNK

Type	Anatomic Features
I	Main pulmonary trunk originates from common trunk.
II	Absence of pulmonary trunk. Pulmonary arteries originate separately but with proximate origins from common trunk.
III	Absence of pulmonary trunk. Pulmonary arteries arise laterally from the arterial trunk.
IV	Pulmonary branches arise from the aorta (now accepted as pulmonary atresia with VSD).

From: Collett RW, Edwards JE. Persistent truncus arteriosus: a classification according to anatomic types. *Surg Clin North Am* 1949;29:1245.

TABLE 88.2 VAN PRAAGH R. AND VAN PRAAGH S. CLASSIFICATION FOR COMMON ARTERIAL TRUNK

Type	Anatomic Features
A1	Origin of partially separate main pulmonary trunk from common trunk. Corresponds to Collett and Edwards type I.
A2	Pulmonary arteries originate separately from common trunk.
A3	Absence of one pulmonary artery. The other originates from the ductus arteriosus or directly from the descending aorta (hemitruncus).
A4	Defined by coexistence of interrupted aortic arch or aortic hypoplasia.

From: Van Praagh R, Van Praagh S. The anatomy of common aorticopulmonary trunk (truncus arteriosus communis) and its embryologic implications: a study of 57 necropsy cases. *Am J Cardiol* 1965;16:406.

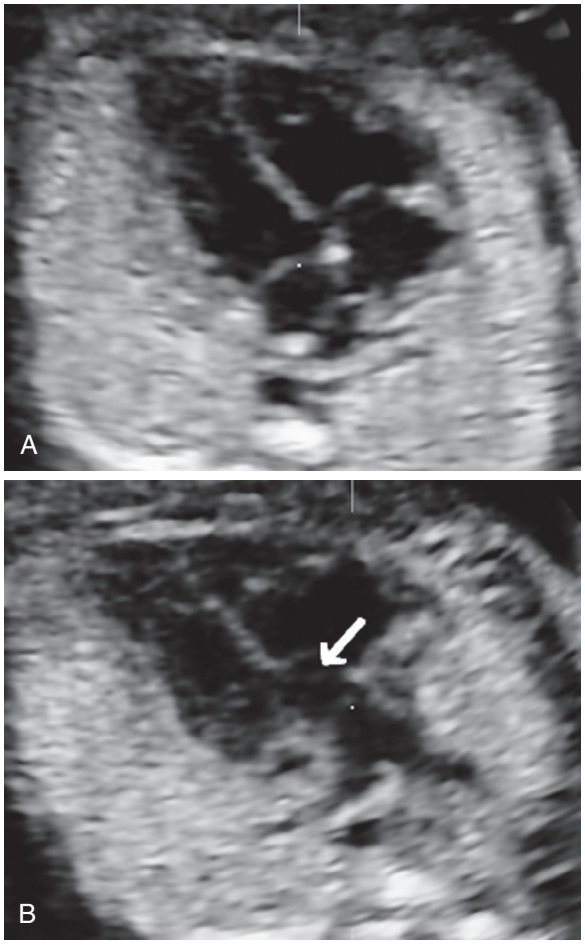

Fig. 88.1 Normal 4-chamber view in CAT (A). Perimembranous VSD *(arrow)* with CAT overriding left ventricle and right ventricle (B) showing pulmonary branching. CAT, Common arterial trunk; VSD, ventricular septal defect.

MANIFESTATIONS OF DISEASE

Clinical Presentation

Although CAT can be asymptomatic *in utero,* the truncal valve is frequently dysplastic and can be associated with moderate to severe valve regurgitation. The latter may lead to cardiac failure and hydrops. Postnatal manifestations appear during the first days of life and are a consequence of saturated and desaturated blood flow mixing and a nonrestrictive left-to-right shunt, resulting in a variable degree of cyanosis and pulmonary vascular disease.

Imaging Technique and Findings

Ultrasound

- The four-chamber view on ultrasound (US) is typically normal, unless other anomalies are associated. Levocardia is a common finding (Fig. 88.1A).
- On the five-chamber view or long-axis view, there is usually a large perimembranous VSD with an overriding vessel. The arterial trunk arises from the middle of the heart (Fig. 88.1B). The truncal valve annulus is usually dysplastic, leading to valve regurgitation, which can be evaluated with color Doppler (Fig. 88.2).
- The common trunk supplies the systemic, pulmonary, and coronary circulations. The identification of both supraaortic and pulmonary vessels from the common trunk is pathognomonic (see Fig. 88.1 and Fig. 88.3). Pulmonary branches are often not easy to identify, especially in truncus type IV.

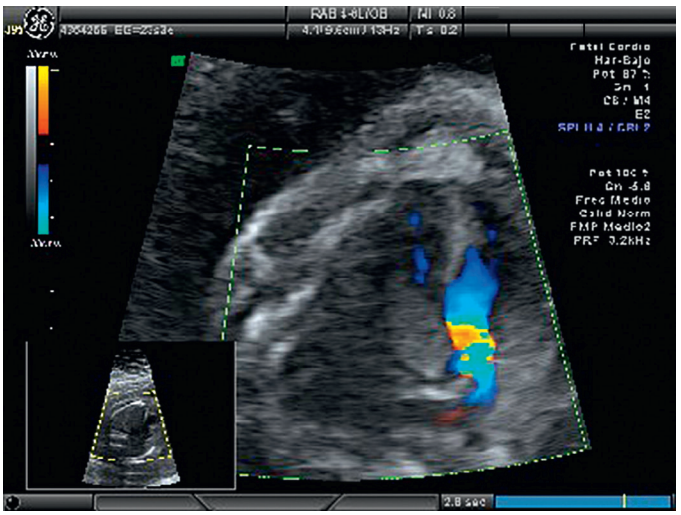

Fig. 88.2 Type I CAT by means of color Doppler. Arterial trunk supplies the systemic and pulmonary circulations. Supraaortic and pulmonary trunk and branches originate from CAT with anterograde flow.



Fig. 88.3 Type I CAT. Arterial trunk supplying systemic and pulmonary circulation. Supraaortic vessels *(arrow)* and pulmonary trunk *(asterisk)* and branches originate from the common arterial trunk.

- There is one big vessel in the three-vessel and trachea view. Also, the ductus arteriosus is often absent.

Other Applicable Modality

Four-Dimensional (4D) Echocardiography. Four-dimensional echocardiography is useful to understand the anatomy better and to identify the pulmonary branches (Fig. 88.4), especially in pulmonary atresia with VSD (truncus type IV).[2]

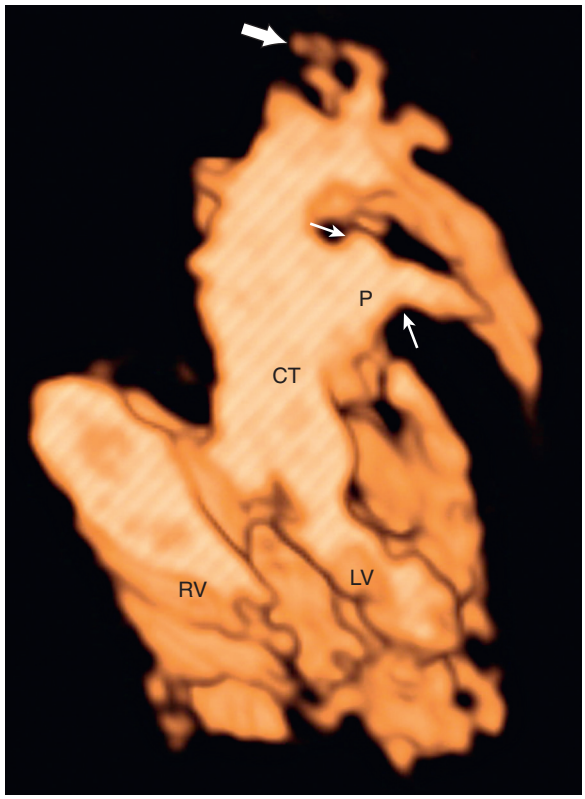

Fig. 88.4 Spatiotemporal image correlation (STIC) inversion mode of type I CAT. A common trunk *(CT)* overrides the right ventricle *(RV)* and left ventricle *(LV)*. The pulmonary trunk *(P)* and branches *(arrows)*, and supraaortic vessels *(thick arrow)* are identified arising from the common trunk.

CLASSIC SIGNS

- Normal four-chamber view, often with left deviation of the cardiac axis
- Large VSD
- Unique arterial trunk emerging from the center of the heart (see Fig. 88.1)
- Pulmonary and systemic circulations arising from the common trunk (see Fig. 88.2)

Differential Diagnosis From Imaging Findings

It is usually very difficult to differentiate pulmonary atresia with VSD and tetralogy of Fallot (TOF) from CAT prenatally. In TOF there is retrograde flow through the ductus arteriosus, whereas CAT is frequently associated with absence of the ductus arteriosus. The identification of the pulmonary branches from a central arterial trunk indicates the presence of CAT.[1,7–9]

Synopsis of Treatment Options

PRENATAL

Genomic microarray and targeted morphologic US examination should be offered. It is important to look for 22q11 deletion as it is associated in 30% of cases. The fetus should be evaluated periodically (every 4 weeks) to rule out progressive valve dysfunction and other associated cardiac and extracardiac anomalies that could manifest later in pregnancy. Delivery should be planned in a tertiary referral center with cardiac surgery capabilities.

The outcome in CAT detected prenatally is poor if there are chromosomal and structural defects, or hydrops, leading to a relatively high rate of termination of pregnancy.[2,3,7]

POSTNATAL

Patients with persistent CAT are normally operated on during the first 3 months of life, preferably after pulmonary vascular resistance decreases, which may occur during the second or third week of life, or earlier if there is congestive heart failure or aortic arch interruption. Surgery consists of connecting pulmonary branches to the right ventricle with an extracardiac conduit, reconstruction of the aorta, and VSD closure.

Overall, the survival rate of prenatally diagnosed CAT ranges from 29% to 40%, but this takes into consideration terminations of pregnancy and hydrops. For those delivered at term, 15-year survival rate has been reported at 65% to 80%.[10-11] Survival progressively decreases because of the need for additional surgery to replace the pulmonary conduit (68%, 37%, and 26% freedom from homograft reoperation after 10 years, 20 years, and 30 years, respectively) and the truncal valve (19% need for repair at 30 years). The appearance of pulmonary vascular disease and systemic valve failure worsens the prognosis.

WHAT THE REFERRING PHYSICIAN NEEDS TO KNOW

- CAT is a very rare anomaly. The four-chamber view can be normal, but routine outflow tract examination shows a typical appearance.
- CAT can resemble TOF. The differentiation is critical for counseling because the prognosis differs substantially.
- Overall, CAT is associated with a poor prognosis.

KEY POINTS

- Normal four-chamber view
- Large perimembranous VSD
- Overriding arterial trunk
- Systemic, pulmonary, and coronary circulations arising from the unique arterial trunk

SUGGESTED READING

Allan L, Hornberger L, Sharland G. *Textbook of fetal cardiology*. London: Greenwich Medical Media Ltd; 2000.

Cifarelli A, Ballerini L. Truncus Arteriosus. In: *Orphanet encyclopedia*. 2003.

Paladini D, Volpe P. *Ultrasound of congenital fetal anomalies: differential diagnosis and prognostic indicators*. London: Informa Health Care; 2007.

Yagel S, Silverman NH, Gembruch U. *Fetal cardiology.* Series in maternal fetal medicine. New York: Informa Health Care; 2009.



All references are available online at www.expertconsult.com.

REFERENCES

1. Allan LD, Sharland GK, Milburn A, et al. Prospective diagnosis of 1006 consecutive cases of congenital heart disease in the fetus. *J Am Coll Cardiol*. 1994;23:1452.
2. Volpe P, Campobasso G, Stanziano A, et al. Novel application of 4D sonography with B-flow imaging and spatio-temporal image correlation in the assessment of the anatomy of pulmonary arteries in fetuses with pulmonary atresia and ventricular septal defect. *Ultrasound Obstet Gynecol*. 2006;28:40.
3. Swanson TM, Selamet Tierney ES, Tworetzky W, et al. Truncus arteriosus: diagnostic accuracy, outcomes, and impact of prenatal diagnosis. *Pediatr Cardiol*. 2009;30:256.
4. Volpe P, Paladini D, Marasini M, et al. Common arterial trunk in the fetus: characteristics, associations, and outcome in a multicentre series of 23 cases. *Heart*. 2003;89:1437.
5. Collett RW, Edwards JE. Persistent truncus arteriosus: a classification according to anatomic types. *Surg Clin North Am*. 1949;29:1245.
6. Van Praagh R, Van Praagh S. The anatomy of common aorticopulmonary trunk (truncus arteriosus communis) and its embryologic implications: a study of 57 necropsy cases. *Am J Cardiol*. 1965;16:406.
7. Galindo A, Mendoza A, Arbues J, et al. Conotruncal anomalies in fetal life: accuracy of diagnosis, associated defects and outcome. *Eur J Obstet Gynecol Reprod Biol*. 2009;146:55.
8. Tometzki AJ, Suda K, Kohl T, et al. Accuracy of prenatal echocardiographic diagnosis and prognosis of fetuses with conotruncal anomalies. *J Am Coll Cardiol*. 1999;33:1696.
9. Gómez O, Soveral I, Bennasar M, et al. Accuracy of fetal echocardiography in the differential diagnosis between truncus arteriosus and pulmonary atresia with ventricular septal defect. *Fetal Diagn Ther*. 2015 Jun 25.
10. Duke C, Sharland GK, Jones AM, et al. Echocardiographic features and outcome of truncus arteriosus diagnosed during fetal life. *Am J Cardiol*. 2001;88:1379.
11. Vohra HA, Whistance RN, Chia AX, et al. Long-term follow-up after primary complete repair of common arterial trunk with homograft: a 40-year experience. *J Thorac Cardiovasc Surg*. 2010;140:325-329.

SECTION SIX
Other Anomalies

To access the videos in this chapter, scan this QR code or visit expertconsult.com

89 Double-Inlet Single Ventricle

FATIMA CRISPI | JOSEP M. MARTINEZ

Introduction

Double-inlet single ventricle is a rare anomaly, accounting for 2% to 3% of all congenital heart diseases (CHDs). Double-inlet single ventricle comprises a heterogeneous group of cardiac anomalies characterized by the presence of two atria with a single ventricle. Cardiac and extracardiac anomalies are commonly associated. The prognosis is usually very poor, and univentricular repair is required.

Disease

DEFINITION

Double-inlet single ventricle comprises a heterogeneous group of cardiac anomalies characterized by two atria and a single ventricle with one or two atrioventricular valves. Although a rudimentary accessory ventricle may also exist, only one ventricle is functional, receiving the flow from both atria. This entity does not include cases with a single functional ventricle secondary to mitral or tricuspid atresia.

PREVALENCE AND EPIDEMIOLOGY

Double-inlet single ventricle is a rare anomaly. It occurs in approximately 0.5:10,000 to 1.0:10,000 live births and accounts for 2% to 3% of all CHDs.

ETIOLOGY AND PATHOPHYSIOLOGY

The morphologic spectrum of double-inlet single ventricle is broad, with a variety of segmental patterns and anatomic variables, including differences in anatomic pattern of the single ventricle (left, right, or indeterminate); the sizes of the atrioventricular valves or atresia of one atrioventricular valve; variable ventricular looping and ventriculoarterial relationship; and obstruction to systemic or pulmonary outflow (or both systemic and pulmonary outflow). The most common form is a single left ventricle with a rudimentary right ventricle, two atrioventricular valves, and aorta disposed anteriorly and to the left of the pulmonary artery.

Other cardiac (valvular atresia or stenosis or coarctation of aorta) or noncardiac (heterotaxia, cystic hygroma, congenital diaphragmatic hernia) anomalies are frequently associated.

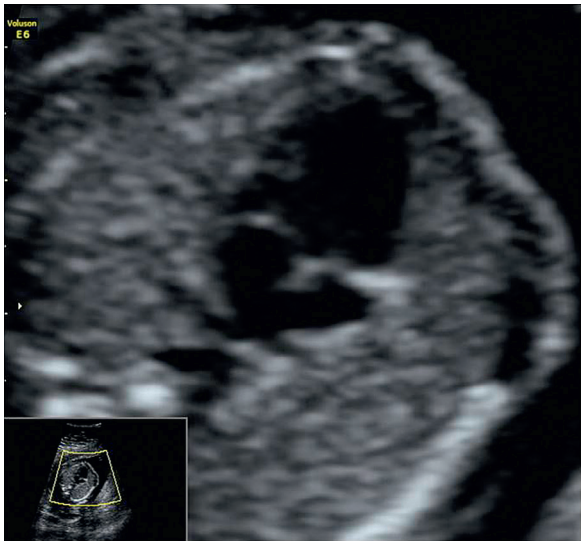

Fig. 89.1 One single ventricle receiving flow from both atria. In this case, two atrioventricular valves are present.

Chromosomal anomalies may be also associated (trisomy 18, Klinefelter syndrome, DiGeorge syndrome, or Goldenhar syndrome).

MANIFESTATIONS OF DISEASE

Clinical Presentation

Double-inlet single ventricle typically appears as a single ventricle on the anatomic ultrasound (US).[1,2]

Imaging Technique and Findings

Ultrasound. The diagnosis is suspected on the four-chamber view with one single ventricle receiving flow from both atria (Figs. 89.1 and 89.2, and Video 89.1). A rudimentary ventricle not receiving flow may also be present.

The connection between both atria and one ventricle may be through one or two atrioventricular valves.[1,2] Although prenatal distinction of the ventricular pattern is almost impossible, right (with moderator band), left (less trabeculation), or indeterminate features may be present. Outflows from the great arteries are usually anomalous, with typically an anterior and left aortic disposition.

CLASSIC SIGNS

- Two atria with a single ventricle

Differential Diagnosis From Imaging Findings

The main entity in the differential diagnosis is single functional ventricle secondary to mitral or tricuspid atresia.[2]

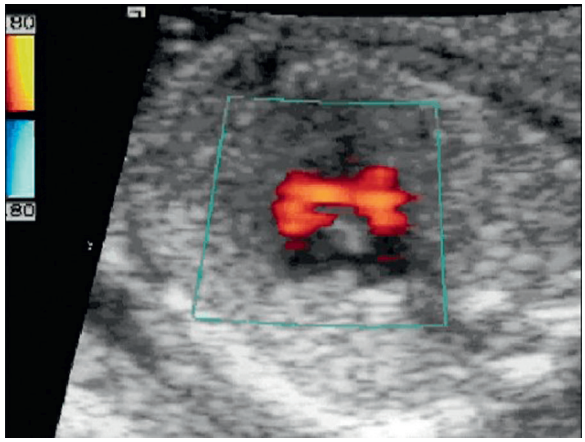

Fig. 89.2 Color Doppler shows flow to the single ventricle through both atrioventricular valves.

Synopsis of Treatment Options

POSTNATAL

The main problem is the univentricular circulation.[3–5] One ventricle has to support the systemic and pulmonary circulations. Most cases require a modified Fontan surgical approach; the single ventricle is destined to support the systemic circulation, and anastomoses between the superior vena cava and inferior vena cava and the pulmonary arteries are created to pass systemic venous drainage directly to the lungs.[3-5] The rate of overall mortality or heart transplantation is greater than 30%. Additionally, associated noncardiac anomalies may affect the outcome.

WHAT THE REFERRING PHYSICIAN NEEDS TO KNOW

- The diagnosis should be straightforward if the routine US is performed carefully. The typical four-chamber view cannot be identified.
- Double-inlet single ventricle is a very rare condition with a poor prognosis.

KEY POINTS

- Abnormal four-chamber view with a single ventricle
- Cardiac and extracardiac anomalies are commonly associated
- Very poor prognosis owing to univentricular circulation

SUGGESTED READING

Allan L, Hornberger L, Sharland G. *Textbook of fetal cardiology*. London: Greenwich Medical Media Ltd; 2000.

Paladini D, Volpe P. *Ultrasound of congenital fetal anomalies: differential diagnosis and prognostic indicators*. London: Informa Health Care; 2007.

Yagel S, Silverman NH, Gembruch U. *Fetal cardiology*. Series in maternal fetal medicine. New York: Informa Health Care; 2009.

All references are available online at www.expertconsult.com.

REFERENCES

1. Munoz-Castellanos L, Espinola-Zavalete N, Keirns C. Anatomoechocardiographic correlation double inlet left ventricle. *J Am Soc Echocardiogr*. 2005;18:237-243.
2. Saleeb SF, Juraszek A, Geva T. Anatomic, imaging, and clinical characteristics of double-inlet, double-outlet right ventricle. *Am J Cardiol*. 2010;105:542-549.
3. Clarke AJ, Kasahara S, Andrews DR, et al. Mid-term results for double inlet left ventricle and similar morphologies: timing of Damus-Kaye-Stansel. *Ann Thorac Surg*. 2004;78:650-657.
4. Tham EB, Wald R, McElhinney DB, et al. Outcome of fetuses and infants with double inlet single left ventricle. *Am J Cardiol*. 2008;101:1652-1656.
5. Beroukhim RS, Gauvreau K, Benavidez OJ, et al. Perinatal outcome after prenatal diagnosis of single-ventricle cardiac defects. *Ultrasound Obstet Gynecol*. 2015;45:657-663.

To access the videos in this chapter, scan this QR code or visit expertconsult.com

90 Atrial Isomerism

FATIMA CRISPI | JOSEP M. MARTINEZ

Introduction

Heterotaxy (or *situs ambiguus*) is defined as the abnormal arrangement of thoracic or abdominal organs, or both, across the left-right axis (Video 90.1); it is different from complete situs inversus, which involves all organs.[1,2] The term *isomerism* refers to the symmetric development of normally asymmetric organs or organ systems; this is the main feature of heterotaxy syndromes.[1,2] These syndromes comprise a combination of cardiac, vascular, and visceral abnormalities. The terms *heterotaxy syndrome, cardiosplenic syndrome, right and left isomerism,* and *situs ambiguus* are often used to describe these defects.[1,2]

Atrial isomerism manifests as a varied spectrum of corporeal and cardiac malformations. It is associated with a very poor prognosis owing to high *in utero* and neonatal mortality.[1]

Disease

DEFINITION

Isomerism is defined as symmetric development of normally asymmetric organs or organ systems.[1,2] The combination of situs ambiguus and congenital heart disease is the main clue for the diagnosis.[3]

PREVALENCE AND EPIDEMIOLOGY

Atrial isomerism is very rare, accounting for 4% of congenital heart anomalies.[1-4]

ETIOLOGY AND PATHOPHYSIOLOGY

Atrial isomerism manifests with a varied spectrum of cardiac malformations with viscerocardiac heterotaxy occurring in most cases.[1–4] Although there is wide variation in the range of anomalies that may be present, isomerism is classified as follows.[2,3,5,6]

- Right isomerism: paired right-side viscera; left-sided structures may be absent. Typical features include asplenia, bilateral trilobed lungs, intestinal malrotation, abnormal drainage of the pulmonary veins, persistence of the left superior vena cava, aorta and inferior vena cava located on the same abdominal side, atrioventricular septal defect, and ductus-dependent pulmonary flow.
- Left isomerism: paired left-side viscera; right-sided structures may be absent. Fetal anomalies include bilateral morphologic left atrial appendages, bilobed lungs, multiple splenules, and malrotation of the intestines. Interruption of the inferior vena cava with azygos continuation is an almost universal echocardiographic finding (Figs. 90.1 and 90.2). Heart block, atrioventricular septal defect, double-outlet right ventricle, right or left ventricular outflow tract obstruction, total anomalous pulmonary vein drainage, persistence of left superior vena cava, and aorta and inferior vena cava located on the same abdominal side may also be present.



Fig. 90.1 Dilated azygos vein parallel to the thoracic aorta, secondary to interruption of the inferior vena cava.

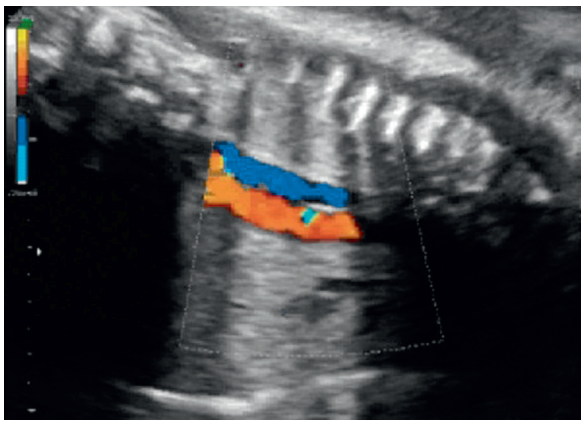

Fig. 90.2 Color Doppler in the same case as shown in Fig. 90.1 clearly shows the opposite direction of the flow.

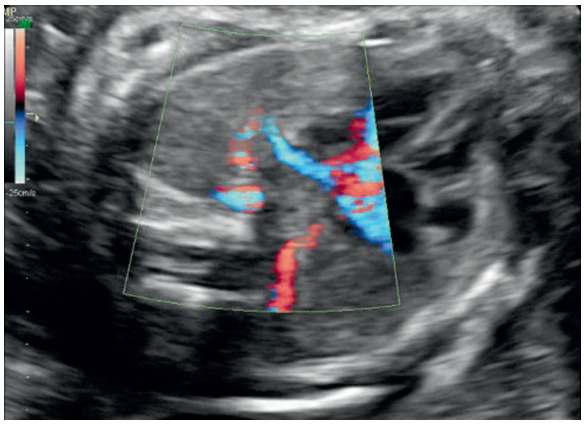

Fig. 90.3 Abnormal drainage of two pulmonary veins to the right atria.

In most cases, fetal karyotype is normal. However, associations with chromosome 22q11 deletion (DiGeorge syndrome), trisomy 18, trisomy 13, and other chromosomal deletions or inversions have been described.[5,6]

The prognosis depends on the cardiac defect. Complete heart block, complex cardiac abnormalities, and fetal hydrops are poor prognostic features.[5,6] In addition, cases with only minor cardiac malformations are at risk postnatally for biliary atresia, bowel obstruction owing to malrotation, and immune dysfunction. Right isomerism is associated with a worse prognosis with a very high mortality rate, over 90% in the first year after birth.[1,5–7] Left isomerism has a better outcome but still has an 80% mortality at 5 years of age.[1,5–7]

MANIFESTATIONS OF DISEASE

Clinical Presentation

Typically, the routine anatomic ultrasound (US) scan shows a complex combination of structural cardiac malformations or viscerocardiac heterotaxy.[4–6] Even in routine scans, it is important to identify that the stomach and heart are on the left side of the body. Atrial isomerism also can be diagnosed in the first trimester as increased nuchal translucency, cardiac rhythm disturbance, or hydrops.[6–8]

Imaging Technique and Findings

Ultrasound. A wide spectrum of possible cardiac and extracardiac anomalies may be present.[3,5–9] Typical US signs are situs ambiguus (see Video 90.1), cardiac axis malposition, heart block, atrioventricular septal defect, and abnormal venous drainage (Fig. 90.3). A proper situs abdominal exploration is essential to detect typical anomalies such as stomach dextroposition, intestinal obstruction, and inferior vena cava malposition (Video 90.2). Other typical anomalies, such as asplenia or pulmonary lobulation, may require postnatal imaging or necropsy.

Other Applicable Modality. Other typical anomalies such as asplenia or pulmonary lobulation require postnatal abdominal US, or computed tomography (CT), or an autopsy by a specialized pathologist.[3,5–9]

CLASSIC SIGNS

- Complex combinations of structural cardiac malformations and viscerocardiac heterotaxy

Synopsis of Treatment Options

POSTNATAL

The prognosis of isomerism is usually very poor, with high intrauterine and neonatal mortality.[1,5,8] In postnatal survivors, morbidity and mortality in the neonatal period are determined mainly by cardiac defects. With the improvement in long-term outlook for these patients as a result of modern cardiac surgery, intraabdominal anomalies have become increasingly relevant because they may affect long-term outcome.[1,5–9]

WHAT THE REFERRING PHYSICIAN NEEDS TO KNOW

- The presence of situs ambiguus and congenital heart disease is almost pathognomonic for atrial isomerism.
- Atrial isomerism manifests with a varied spectrum of cardiac malformations and viscerocardiac heterotaxy.

KEY POINTS

- Varied spectrum of cardiac and extracardiac malformations
- Typically associated with visceral heterotaxy
- Very poor outcome in most cases

SUGGESTED READING

Allan L, Hornberger L, Sharland G. *Textbook of Fetal Cardiology*. London: Greenwich Medical Media Ltd; 2000.

Jacobs JP, Anderson RH, Weinberg PM, et al. The nomenclature, definition and classification of cardiac structures in the setting of heterotaxy. *Cardiol Young*. 2007;17(suppl 2):1-28.

Paladini D, Volpe P. *Ultrasound of Congenital Fetal Anomalies: Differential Diagnosis and Prognostic Indicators*. London: Informa Health Care; 2007.

Pepes S, Zidere V, Allan LD. Prenatal diagnosis of left atrial isomerism. *Heart*. 2009;9524:1974-1977.

Yagel S, Silverman NH, Gembruch U. *Fetal Cardiology*. Series in Maternal Fetal Medicine. New York: Informa Health Care; 2009.

All references are available online at www.expertconsult.com.

REFERENCES

1. Lim JS, McCrindle BW, Smallhorn JF, et al. Clinical features, management and outcome of children with fetal and postnatal diagnoses of isomerism syndromes. *Circulation*. 2005;112:2454-2461.
2. Gottschalk I, Stressig R, Ritgen J, et al. Extracardiac anomalies in prenatally diagnosed heterotaxy syndrome. *Ultrasound Obstet Gynecol*. 2016;47:443-449.
3. Escobar-Diaz MC, Friedman K, Salem Y, et al. Perinatal and infant outcomes of prenatal diagnosis of heterotaxy syndrome (asplenia and polysplenia). *Am J Cardiol*. 2014;114(4):612-617.
4. Huggon IC, Cook AC, Smeeton NC, et al. Atrioventricular septal defects diagnosed in fetal life: associated cardiac and extra-cardiac abnormalities and outcome. *J Am Coll Cardiol*. 2000;36:593-601.
5. Berg C, Geipel A, Kamil D, et al. The syndrome of left isomerism: sonographic findings and outcome in prenatally diagnosed cases. *J Ultrasound Med*. 2005;24:921-931.
6. Berg C, Geipel A, Smrcek J, et al. Prenatal diagnosis of cardiosplenic syndromes: a 10-year experience. *Ultrasound Obstet Gynecol*. 2003;22:451-459.
7. Eronen MP, Aittomäki KA, Kajantie EO, et al. The outcome of patients with right atrial isomerism is poor. *Pediatr Cardiol*. 2013;34:302-307.
8. Atkinson DE, Drant S. Diagnosis of heterotaxy syndrome by fetal echocardiography. *Am J Cardiol*. 1998;82:1147-1149.
9. Taketazu M, Lougheed J, Yoo SJ, et al. Spectrum of cardiovascular disease: accuracy of diagnosis and outcome in fetal heterotaxy syndrome. *Am J Cardiol*. 2006;97:720-724.

To access the videos in this chapter, scan this QR code or visit expertconsult.com

91 Anomalies of Pulmonary Venous Return

FATIMA CRISPI | JOSEP M. MARTINEZ

Introduction

Anomalous pulmonary venous return (APVR) is an uncommon congenital heart anomaly with abnormal drainage of pulmonary venous blood into the systemic venous system. Despite its very low incidence, it is a pediatric cardiology emergency.[1]

Disease

DEFINITION

APVR is defined as abnormal drainage of pulmonary venous blood into the systemic venous system. Total APVR is characterized by the anomalous drainage of all the pulmonary veins, whereas partial APVR is characterized by the anomalous drainage of one, two, or three of the four pulmonary veins.[1–3]

PREVALENCE AND EPIDEMIOLOGY

The incidence of APVR has been reported to be 1:10,000 live births, with an incidence of approximately 2.2% of patients with congenital heart disease (CHD).[1–4]

ETIOLOGY AND PATHOPHYSIOLOGY

The main consequence of APVR is interruption of the normal circulation of blood that enters the left atrium after closure of the foramen ovale.[1] In total APVR, there is virtually no oxygenated blood return to the left atrium, left ventricle, and aorta. Immediate and increasing hypoxemia and acidosis are the rule, which can be reversed only by emergency postnatal cardiac surgery.

APVR can be classified by the location of the abnormal drainage and further designated as being with or without obstruction, as follows[1–5]:

- Type I: supracardiac (50%). The four pulmonary veins drain into a venous collector located behind the left atrium, from which a vertical vein runs up to reach the innominate vein, and this terminates in the right superior vena cava and right atrium. It has been reported that the vertical vein may be obstructed, but this is rarely severe in the perinatal period.
- Type II: cardiac (25%). The pulmonary veins drain through the coronary sinus or directly into the right atrium. Usually, there is no obstruction.
- Type III: infracardiac or infradiaphragmatic (20%). The pulmonary veins converge into a descending vertical vein that reaches the abdomen through the diaphragm. It usually drains into the portal vein or, more rarely, into the ductus venosus or the inferior vena cava. Almost always, the vertical vein is significantly obstructed.
- Type IV: mixed (5%). The pulmonary veins drain separately to different sites.

APVR can be an isolated lesion or occur in combination with other cardiac defects, such as single ventricle, hypoplastic left heart syndrome, truncus arteriosus, transposition of the great arteries, and heterotaxies.[1,2] Associated chromosomal anomalies are rare, but some cases are described (unbalanced translocations).[1–4]

MANIFESTATIONS OF DISEASE

Clinical Presentation

If APVR is isolated, the prenatal course is uneventful. Postnatal clinical signs are variable and depend on any associated cardiac anomaly, but total APVR commonly represents a neonatal emergency.[1–3] In contrast, partial APVR usually has a very good prognosis and often remains asymptomatic with no need of surgery.[1–3]

Imaging Technique and Findings

Ultrasound. Prenatal diagnosis generally is quite challenging, and the condition is often missed *in utero*. Total APVR can be diagnosed in the fetus by indirect indicators on an echocardiogram, such as the following[3–9]:

- Lack of a visible connection of the pulmonary veins to the atrium.
- The presence of a chamber or collector of the pulmonary venous confluence behind the left atrium (Figs. 91.1 and 91.2, Video 91.1).
- The presence of additional vertical venous channels on three-vessel or axial abdominal views: a dilated superior vena cava, an ascending or descending common pulmonary vein or vertical vein.
- Right-to-left discrepancy in heart chambers and great arteries.
- Increased distance between the left atrium and the descending aorta (ratio of the left atrium–descending aorta distance to the diameter of the descending aorta greater than 1.27).

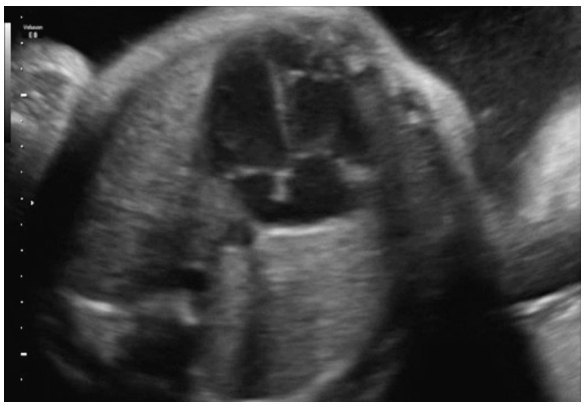

Fig. 91.1 Vein collector of the pulmonary venous confluence behind the left atrium.

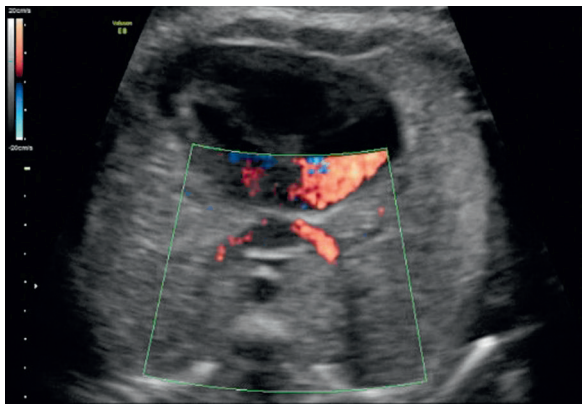

Fig. 91.2 Color Doppler shows the connection of right and left pulmonary veins to the collector.

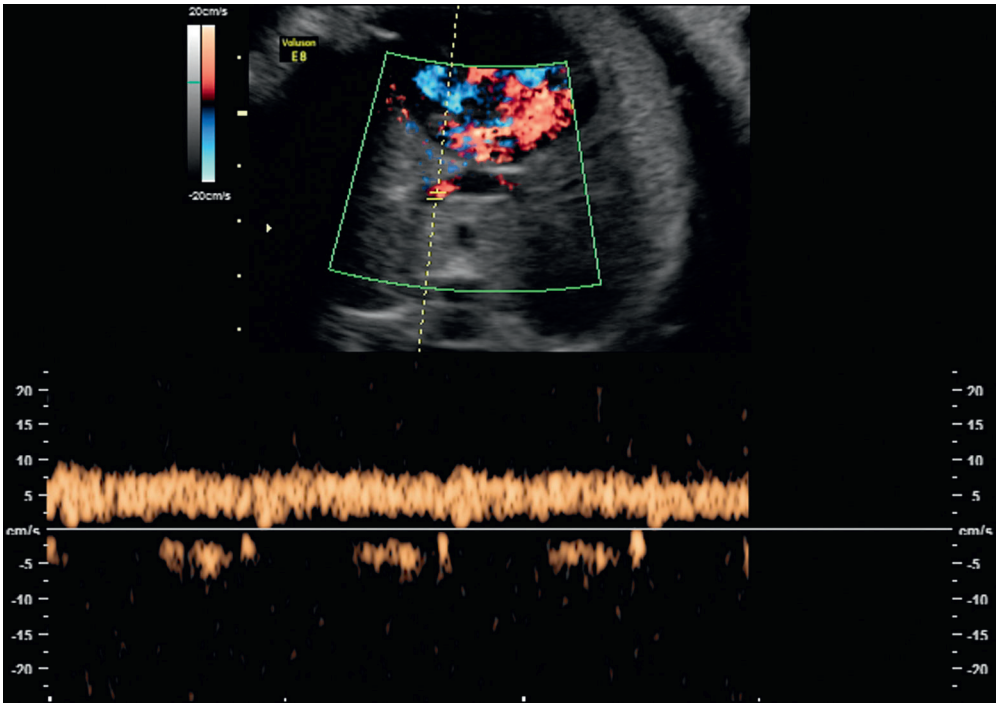

Fig. 91.3 Pulsed Doppler shows atypical nonpulsatile flow in the veins.

When suspicion of APVR is established, typical signs supporting the diagnosis are as follows:

- Pulsed Doppler evaluation of the abnormal veins lose the characteristic triphasic waveform (Fig. 91.3, see Video 91.1).
- In some cases, direct connection of the pulmonary veins to the right atrium can be observed (Fig. 91.4).

These diagnostic features are mainly indirect indicators and may not all be present. The common association with complex CHD complicates the diagnosis further. For instance, coexistence of a heterotaxy may make diagnosis very difficult because of the variable number of pulmonary veins.

Other Applicable Modality. B-flow imaging using spatiotemporal image correlation may be helpful in refining the diagnosis of anomalous pulmonary venous return.[10,11] A starfish-like appearance of confluent pulmonary veins has been described as a typical sign of the supracardiac form of total APVR.[10,11]

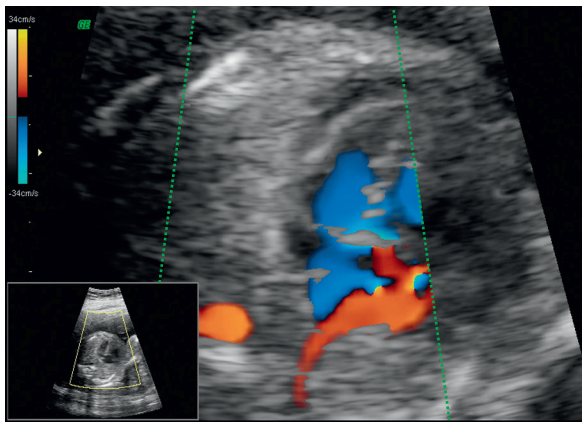

Fig. 91.4 Direct connection of one of the right pulmonary veins to the right atrium.

CLASSIC SIGNS

- Absence of pulmonary venous blood flow into the left atrium—evident by color or pulsed Doppler

Differential Diagnosis From Imaging Findings

Diagnostic features of APVR are mainly indirect indicators, and the differential diagnosis includes other complex CHDs.[3–8]

Synopsis of Treatment Options

PRENATAL

If total APVR is diagnosed prenatally, transfer to a tertiary referral center where cardiac surgery can be performed. If severe obstruction is suspected, it may be necessary to intervene in the first few hours of life.[1–4]

POSTNATAL

Despite its low incidence, total APVR is commonly a severe emergency. Infants with isolated total APVR often show severe decompensation and require urgent surgical repair.[1–4] If surgical repair can be accomplished safely, the outlook is usually good, with a reported mortality of less than 10%. If there is an obstructive total APVR or association with heterotaxia syndromes, the outcome is highly unfavorable, with short-term mortality rates greater than 50%. Prenatally diagnosed nonobstructed total APVR and partial APVR, regardless of prenatal detection, are usually asymptomatic at birth, and conservative management can be safely scheduled. Reported survival rates are 95% to 98%.[1–4]

WHAT THE REFERRING PHYSICIAN NEEDS TO KNOW

- APVR is a rare and often missed cardiac defect.
- Total APVR may manifest as a serious pediatric emergency. In contrast, partial anomalies have a more benign course.
- Prenatal diagnosis in fetal life can be reliably excluded only by direct examination of pulmonary venous blood flow entering the left atrium on color or pulsed flow mapping.

KEY POINTS

- Pulmonary venous anatomy should be checked during prenatal examination.
- Prenatal suspicion of APVR improves surgical and long-term outcome.
- A venous structure behind the left atrium should raise the suspicion of APVR.

SUGGESTED READING

Allan L, Hornberger L, Sharland G. *Textbook of Fetal Cardiology*. London: Greenwich Medical Media Ltd; 2000.

Ganesan S, Brook MM, Silverman NH, et al. Prenatal findings in total anomalous pulmonary venous return: a diagnostic road map starts with obstetric screening views. *J Ultrasound Med*. 2014;33:1193-1207.

Paladini D, Volpe P. *Ultrasound of Congenital Fetal Anomalies: Differential Diagnosis and Prognostic indicators*. London: Informa Health Care; 2007.

Yagel S, Silverman NH, Gembruch U. *Fetal Cardiology*. Series in Maternal Fetal Medicine. New York: Informa Health Care; 2009.



All references are available online at www.expertconsult.com.

REFERENCES

1. Allan LD, Sharland GK, Milburn A, et al. Prospective diagnosis of 1006 consecutive cases of congenital heart disease in the fetus. *J Am Coll Cardiol*. 1994;23:1452-1458.
2. Cormier CM, Kramer LA, Gupta-Malhotra M. Prenatal diagnosis of a mixed type of total anomalous pulmonary venous return. *Fetal Diagn Ther*. 2010;27:118-120.
3. Valsangiacomo ER, Hornberger LK, Barrea C, et al. Partial and total anomalous pulmonary venous connection in the fetus: two-dimensional and Doppler echocardiographic findings. *Ultrasound Obstet Gynecol*. 2003;22:257-263.
4. Chen YY, Hsu CY. Prenatal diagnosis and antenatal history of total anomalous pulmonary venous return. *Taiwan J Obstet Gynecol*. 2006;45:283-285.
5. Allan LD, Sharland GK. The echocardiographic diagnosis of totally anomalous pulmonary venous connection in the fetus. *Heart*. 2001;85:433-437.
6. Papa M, Camesasca C, Santoro F, et al. Fetal echocardiography in detecting anomalous pulmonary venous connection: four false positive cases. *Br Heart J*. 1995;73:355-358.
7. Ganesan S, Brook MM, Silverman NH, et al. Prenatal findings in total anomalous pulmonary venous return: a diagnostic road map starts with obstetric screening views. *J Ultrasound Med*. 2014;33:1193-1207.
8. Kawazu Y, Inamura N, Shiono N, et al. Post-LA space index' as a potential novel marker for the prenatal diagnosis of isolated total anomalous pulmonary venous connection. *Ultrasound Obstet Gynecol*. 2014;44:682-687.
9. Olsen R, Doyle Z, Levy D, et al. Anomalous pulmonary venous return: Insights into prenatal detection. *J Ultrasound Med*. 2016;35:1193-1206.
10. Volpe P, Campobasso G, De Robertis V, et al. Two- and four-dimensional echocardiography with B-flow imaging and spatiotemporal image correlation in prenatal diagnosis of isolated total anomalous pulmonary venous connection. *Ultrasound Obstet Gynecol*. 2007;30:830-837.
11. Lee W, Espinoza J, Cutler N, et al. The 'starfish' sign: a novel sonographic finding with B-flow imaging and spatiotemporal image correlation in a fetus with total anomalous pulmonary venous return. *Ultrasound Obstet Gynecol*. 2010;35:124-125.

To access the videos in this chapter, scan this QR code or visit expertconsult.com

92 Anomalies of Systemic Venous Return

FATIMA CRISPI | JOSEP M. MARTINEZ

Introduction

Congenital anomalies of systemic venous drainage represent a heterogeneous group of malformations. The most frequently reported anomalies are persistent left superior vena cava (PLSVC),[1,2] absence of inferior vena cava (IVC),[3] and agenesis of the ductus venosus.[4,5] More rarely, right absent superior vena cava,[6] persistent right umbilical vein, and total anomalous systemic venous return toward the coronary sinus have also been reported prenatally.

Abnormal systemic venous drainage may be isolated or associated with complex heart diseases, mainly heterotaxy syndromes (Chapter 91), and chromosomal defects. Prognosis depends mainly on the association with other anomalies.

Disease

DEFINITION

Anomalies of systemic venous return include abnormalities of the umbilical, portal, hepatic, and caval venous systems.

PREVALENCE AND EPIDEMIOLOGY

Anomalous systemic venous return is rarely seen prenatally. The estimated prevalence is 0.3% to 0.5%.

ETIOLOGY AND PATHOPHYSIOLOGY

Although knowledge of the normal anatomy of the fetal venous system has increased enormously, little information is available on the mechanisms leading to abnormal *in utero* development. Anomalies of systemic venous drainage represent a heterogeneous group of malformations including abnormalities in cardinal, umbilical, and vitelline veins. The most common anomalies are described next.

Persistent Left Superior Vena Cava

PLSVC is the most common congenital anomaly of the thoracic venous system; it occurs in 0.3% to 0.5% of the general adult population and accounts for 10% of cases of congenital heart disease (CHD).[1,2] PLSVC results when the left superior cardinal vein caudal to the innominate vein fails to regress.[1,2] In most cases, there is a normal right superior vena cava. However, in rare cases, the right superior vena cava is absent, and the left superior vena cava becomes the only systemic vein draining blood from the upper part of the body back to the heart. PLSVC drains into the coronary sinus, the right atrium, or both atria, via an unroofed coronary sinus leading to a dilated coronary sinus (Fig. 92.1).

PLSVC is located to the left of the ductal arch and creates a "four-vessel" instead of three-vessel view in the high axial sections[1,2] (Fig. 92.2). A parasagittal section shows a typical "pipe" sign[1,2] (Fig. 92.3). PLSVC is most commonly observed as an isolated finding, but it can also be associated with other cardiovascular abnormalities, including atrial septal defect, bicuspid aortic valve, coarctation of the aorta, coronary sinus ostial atresia, and cor triatriatum.[1,2] In the absence of other congenital abnormalities, PLSVC draining into the coronary sinus is an asymptomatic condition with no hemodynamic significance.[1,2]



Fig. 92.1 Four-chamber view shows persistent left superior vena cava draining to a dilated coronary sinus.

Inferior Vena Cava Interruption

IVC interruption with azygos or hemiazygos vein continuation is considered to be a rare congenital anomaly. The estimated prevalence is 0.6% to 2% in the presence of congenital heart disease (CHD) and less than 0.3% in otherwise normal fetuses.[3] This malformation results from a connection failure between the right subcardinal vein and the right vitelline vein. Consequently, the venous blood from the caudal part of the body reaches the heart via the azygos or hemiazygos vein through the superior vena cava.[3] Systemic venous flow beyond this point is compensated by the dilated azygos and hemiazygos arch[5] (see Figs. 90.1–90.3). Interrupted IVC is usually associated with visceral heterotaxy and cardiac anomalies.[5] Most of the published literature addresses interrupted IVC as a marker of left atrial isomerism, and both entities are associated in most publications.[5] However, there are some reports of isolated cases with good prognosis.[3]



Fig. 92.2 Three-vessel and trachea view shows a fourth vessel to the left of the ductus arteriosus, which corresponds to persistent left superior vena cava.

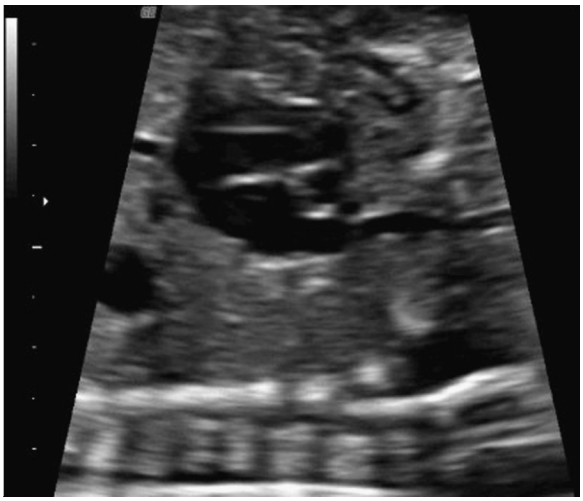

Fig. 92.3 Parasagittal view shows persistent left superior vena cava draining to the coronary sinus, forming the pipe sign.

Agenesis of the Ductus Venosus

Agenesis of the ductus venosus is a rare condition[4,5] resulting from failure of the embryonic anastomosis between the primitive portal and systemic venous systems. Outcome is related to the associated anomalies and may be affected by agenesis or underdevelopment of the fetal portal system.[4,5] The presence of associated congenital anomalies and premature delivery are associated with poor prognosis in fetuses with ADV. In most cases, the umbilical vein has intrahepatic drainage with a good prognosis.[4,5] Less frequently, the umbilical vein drainage is extrahepatic (portosystemic shunt), leading to a higher risk of heart failure and hydrops. These cases usually manifest with cardiomegaly in the third trimester (Fig. 92.4, Video 92.1) and should be monitored once or twice a month to detect early signs of heart failure.[4,5] The postnatal outcome depends mainly on the association with other anomalies. If the anomaly is isolated, the prognosis is generally excellent.[4,5]

MANIFESTATIONS OF DISEASE

Clinical Presentation

The prenatal course is mostly uneventful[1–6] except for very rare cases of absent ductus venosus leading to right heart overload and failure, which might evolve to hydrops.[4,5]

Imaging Technique and Findings

Ultrasound. The key signs on ultrasound (US) examination depend on the type of anomaly and include a four-vessel view with dilated coronary sinus for PLSVC,[1,2] a dilated azygos or hemiazygos vein for interruption of IVC,[3] and absence of ductus venosus.[4,5] If PLSVC is present, it is located to the left of the ductal arch, and four instead of three vessels are seen.[1,2] Suspicion for interrupted IVC is high in the presence of a dilated azygos vein, and the diagnosis can be confirmed with color Doppler of the cava system[3] (see Figs. 91.1–91.3). Agenesis of ductus venosus is diagnosed by showing the abnormal connection of the umbilical vein to either the IVC or the iliac vein, or connection directly to the right atrium[4,5] (Fig. 92.5). Applying color Doppler on the final part of the umbilical vein is useful to confirm the absence of the ductus venosus and the abnormal drainage of the umbilical vein (Fig. 92.6).

Other Applicable Modality. B-flow by spatiotemporal image correlation may be helpful to better understand complex venous return anomalies.

CLASSIC SIGNS

- Four-vessel view with dilated coronary sinus for PLSVC
- Dilated azygos or hemiazygos vein for interruption of IVC
- Absence of ductus venosus

Synopsis of Treatment Options

POSTNATAL

The prognosis of systemic venous return anomalies depends mainly on the association with heterotaxia or other anomalies. If the anomaly is isolated, the prognosis is generally good. PLSVC and agenesis of ductus venosus do not require postnatal treatment and have an excellent outcome.[1–5] Postnatal treatment of IVC interruption depends on the complexity of the drainage.[3]

WHAT THE REFERRING PHYSICIAN NEEDS TO KNOW

- Systemic venous return anomalies may be difficult to detect, but routine examination should allow diagnosis in most instances.
- Prenatal evolution is normally uneventful.
- There is a high association with heterotaxia or other structural or chromosomal anomalies.
- Isolated cases often have a good prognosis.



Fig. 92.5 Umbilical vein drains directly to the right atrium in the same case as shown in Fig. 92.4.



Fig. 92.4 Agenesis of ductus venosus with extrahepatic drainage in the third trimester. Four-chamber view shows severe cardiomegaly.

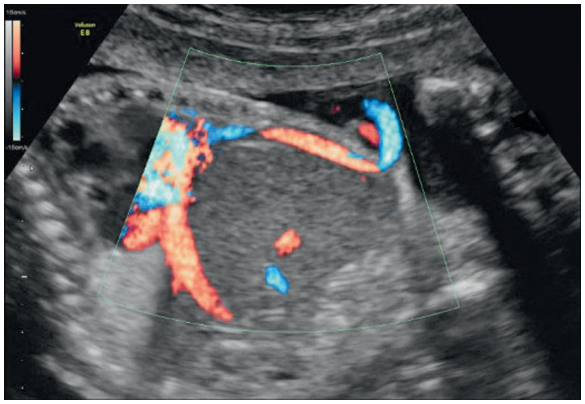

Fig. 92.6 Color Doppler better depicts the abnormal drainage of the umbilical vein to the right atrium.

KEY POINTS

- Systemic venous return anomalies are usually associated with heterotaxia or other anomalies.
- In the presence of dilatation of the coronary sinus or azygos vein, an anomalous systemic venous return may be suspected.
- If the anomaly is isolated, the prognosis is usually favorable.

SUGGESTED READING

Allan L, Hornberger L, Sharland G. *Textbook of Fetal Cardiology*. London: Greenwich Medical Media Ltd; 2000.

Paladini D, Volpe P. *Ultrasound of Congenital Fetal Anomalies: Differential Diagnosis and Prognostic Indicators*. London: Informa Health Care; 2007.

Yagel S, Kivilevitch Z, Cohen SM, et al. The fetal venous system, part I: normal embryology, anatomy, hemodynamics, ultrasound evaluation, and Doppler investigation. *Ultrasound Obstet Gynecol*. 2010;35:741-750.

Yagel S, Kivilevitch Z, Cohen SM, et al. The fetal venous system, part II: ultrasound evaluation of the fetus with congenital venous system malformation or developing circulatory compromise. *Ultrasound Obstet Gynecol*. 2010;36:93-111.

Yagel S, Silverman NH, Gembruch U. *Fetal Cardiology*. *Series in maternal fetal medicine*. New York: Informa Health Care; 2009.



All references are available online at www.expertconsult.com.

REFERENCES

1. Biffi M, Boriani G, Frabetti L, et al. Left superior vena cava persistence in patients undergoing pacemaker or cardioverter-defibrillator implantation: a 10-year experience. *Chest*. 2001;120:139-144.
2. Gustapane S, Leombroni M, Khalil A, et al. Systematic review and metaanalysis on persistent left superior vena cava on prenatal ultrasound: associated anomalies, diagnostic accuracy, and postnatal outcome. *Ultrasound Obstet Gynecol*. 2016;48:701-708.
3. Bronshtein M, Khatib N, Blumenfeld Z. Prenatal diagnosis and outcome of isolated interrupted inferior vena cava. *Am J Obstet Gynecol*. 2010;202:398.e1-398.e4.
4. Moaddab A, Tonni G, Grisolia G, et al. Predicting outcome in 259 fetuses with agenesis of ductus venosus–a multicenter experience and systematic review of the literature. *J Matern Fetal Neonatal Med*. 2016;3:1-9.
5. Shen O, Valsky DV, Messing B, et al. Shunt diameter in agenesis of ductus venosus with extrahepatic portosystemic shunt impacts prognosis. *Ultrasound Obstet Gynecol*. 2011;37:184-190.
6. Choi JY, Anderson RH, Macartney FJ. Absent right superior caval vein (vena cava) with normal atrial arrangement. *Br Heart J*. 1987;57:474-478.

To access the videos in this chapter, scan this QR code or visit expertconsult.com

93 Cardiomyopathy

FATIMA CRISPI | JOSEP M. MARTINEZ

Introduction

Cardiomyopathy is a very rare disease in the fetus. It is almost invariably associated with a poor outcome.[1–5] Only isolated case reports and small case series have been published.[1–5] There is a great variability in presentation, etiology, and hemodynamic consequences, which hampers diagnosis and parental counseling.

Disease

DEFINITION

Cardiomyopathy is defined as a primary cardiac muscle anomaly with no association with structural heart or pericardial disease.

PREVALENCE AND EPIDEMIOLOGY

Only isolated case reports and small case series have been published. In series including neonates and infants, cardiomyopathies represent about 2% to 7% of all cardiac defects. The prevalence is thought to be higher during fetal life, probably around 6% to 11%. The difference is explained by intrauterine loss, which may occur in one-third of affected fetuses.[1–5]

ETIOLOGY AND PATHOPHYSIOLOGY

Fetal cardiomyopathy may manifest in several forms, as follows:

- Dilated or congestive cardiomyopathy is the most frequent cardiomyopathy during fetal life; it is characterized by cardiomegaly owing to dilatation of either or both ventricles and impaired ventricular function (Fig. 93.1). There may be great variability in the presentation of dilated cardiomyopathy in the fetus. Aside from primary forms, which are very rare, several conditions, including infectious (cytomegalovirus, parvovirus, coxsackievirus), hemodynamic (monochorionic twins),[3–4] cardiac (arrhythmias), genetic, and metabolic diseases, may be associated with cardiac dilatation. Dilation of valvular rings can lead to valvular insufficiency (Fig. 93.2, Video 93.1), which in combination with primary cardiac failure, explains a high association with fetal hydrops.[2]

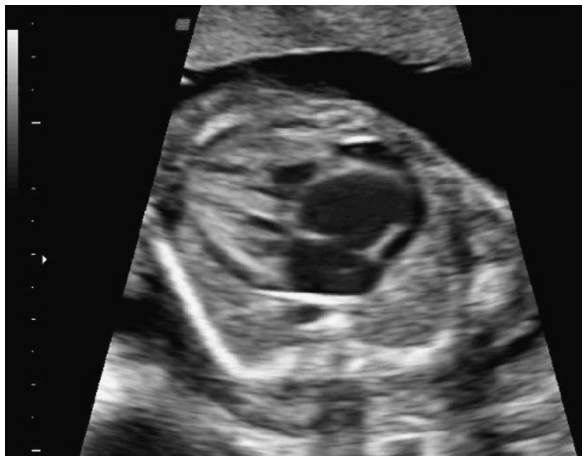

Fig. 93.1 Mixed cardiomyopathy with cardiomegaly, hypertrophic myocardium, and dilatation of both atria.

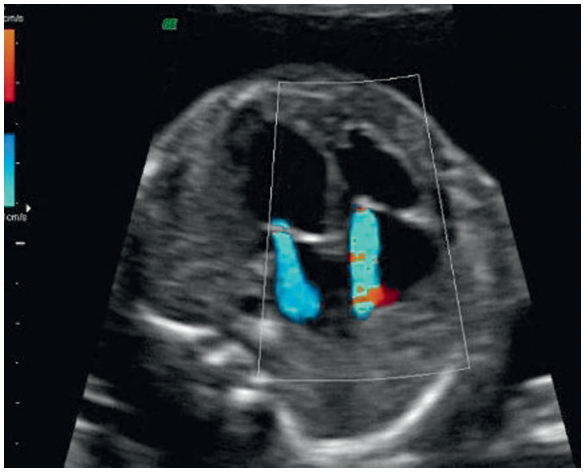

Fig. 93.2 Severe tricuspid and mitral insufficiency secondary to dilatation of valvular rings.

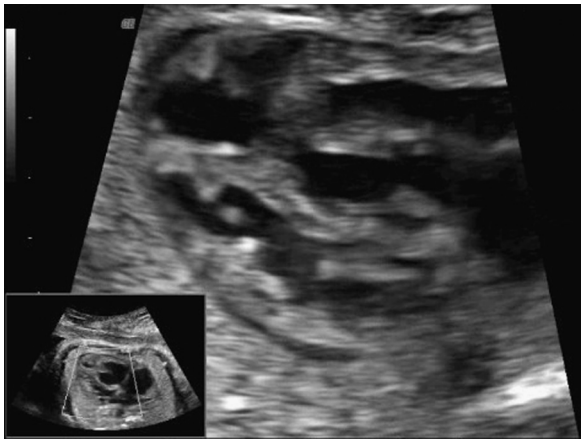

Fig. 93.4 Ventricular noncompacted cardiomyopathy with prominent trabeculations with deep myocardial recesses clearly shown.



Fig. 93.3 Hypertrophic cardiomyopathy with increased thickness of the septum and the ventricular walls in a fetus from a diabetic mother.

- Hypertrophic cardiomyopathy is defined as an enlarged heart with hypertrophic myocardial walls[1,3–5] (Fig. 93.3). Fetal hypertrophic cardiomyopathy is a heterogeneous condition that can be primary or secondary to extrinsic factors.[1,3–5] Wall thickening in cardiac hypertrophy can be concentric or asymmetric. Fetuses from diabetic mothers (30% to 50%) typically present with asymmetric septal hypertrophy with increased septal wall thickness (>6 mm), which in severe cases can lead to subvalvar aortic stenosis. In general, the prognosis of infants with hypertrophy associated with maternal diabetes or twin transfusion syndrome is reasonably good, whereas progression after birth is often the rule in primary forms of hypertrophic cardiomyopathy.[5]
- Restrictive cardiomyopathy is very rare and characterized by primary subendocardial fibroelastosis leading to hyperechogenic endocardium.
- Ventricular noncompaction is a more recently described cardiomyopathy characterized by numerous prominent trabeculations with deep myocardial recesses caused by disturbance of the myocardial compaction process during fetal endomyocardial morphogenesis[6–8] (Fig. 93.4, Video 93.2). Fetal noncompaction most often involves the left ventricle, but can involve the right ventricle or both ventricles. It is rarely described in fetal and neonatal patients with variable manifestations, including fetal hydrops, left ventricular enlargement, increased wall thickness, and decreased ejection fraction.[6–8]

All forms of cardiomyopathy are characterized by a stiffer myocardium, with a reduced contractility and compliance, eventually leading to cardiac dysfunction and decreased cardiac output.[1–6] Ventricular dysfunction may be progressive *in utero* and after birth, but anecdotal cases of improvement or normalization of left ventricular function have been reported for all forms of cardiomyopathy.[1–6] The outcome is poorer in the presence of fetal hydrops, severe cardiomegaly, significant atrioventricular valve regurgitation, reversed atrial flow in ductus venosus, earlier gestational age at diagnosis, and signs of diastolic dysfunction.[9]

MANIFESTATIONS OF DISEASE

Clinical Presentation

The clinical presentation includes cardiomegaly, valvular insufficiency, myocardial hypertrophy or hyperechogenicity, heart failure, and fetal hydrops.[1–6]

Imaging Technique and Findings

Ultrasound. Ultrasound signs include cardiomegaly (see Fig. 93.1), hypertrophic or hyperechoic myocardium, cardiac dilatation, tricuspid and mitral insufficiency (see Fig. 93.2), pericardial effusion, fetal hydrops, and different degrees of systolic and diastolic dysfunction.[1–6] Specifically, fetuses from diabetic mothers should be evaluated for septal asymmetric hypertrophy by measuring septal thickness in a transverse view, using M-mode measurement taken just below the atrioventricular valves at end diastole, and aortic peak velocity.[1]

Magnetic Resonance Imaging. Magnetic resonance imaging may be helpful to provide prognostic information for prenatal counseling, although prenatal data for comparison are limited.[10]

CLASSIC SIGNS

Cardiomegaly.
Myocardial hypertrophy or hyperechogenicity.
Fetal hydrops.

Synopsis of Treatment Options

PRENATAL

A poor outcome is observed in most cases.[1–6] Only a few therapeutic options are available in cases with a known etiology (e.g., tachycardia,[2] anemia, twin transfusion syndrome[3]). The prognosis mainly depends on the underlying cause, with fetal hydrops and reversed atrial flow in ductus venosus as signs of poor prognosis.

Asymmetric septal hypertrophy in fetuses from diabetic mothers usually regresses spontaneously by the first year of age, and few cases require treatment.[1] However, there is concern about the long-term outcome of these children. Improved maternal glycemic control can help reduce severe hypertrophy prenatally.[1]

POSTNATAL

Postnatal treatment depends on the underlying cause and the degree of ventricular dysfunction. If no treatable cause is present, management focuses on ameliorating symptoms. Heart transplantation is the only long-term option in many cases.[5] Genetic evaluation for metabolic diseases may help identify the etiology.

WHAT THE REFERRING PHYSICIAN NEEDS TO KNOW

The presence of cardiomegaly or fetal hydrops warrants comprehensive echocardiography to rule out cardiomyopathies.

KEY POINTS

- Cardiomyopathy exhibits a great variability of forms.
- Most cases have a very poor outcome.
- Fetuses from poorly-controlled diabetic mothers can develop septal asymmetric hypertrophy.

SUGGESTED READING

Allan L, Hornberger L, Sharland G. *Textbook of fetal cardiology*. London: Greenwich Medical Media Ltd; 2000.

Mongiovì M, Fesslova V, Fazio G, et al. Diagnosis and prognosis of fetal cardiomyopathies: a review. *Curr Pharm Des*. 2010;16:2929-2934.

Pedra SR, Smallhorn JF, Ryan G, et al. Fetal cardiomyopathies: pathogenic mechanisms, hemodynamic findings, and clinical outcome. *Circulation*. 2002;106:585-591.

Yagel S, Silverman NH, Gembruch U. *Fetal cardiology. Series in Maternal Fetal Medicine*. New York: Informa Health Care; 2009.



All references are available online at www.expertconsult.com.

REFERENCES

1. Russell NE, Foley M, Kinsley BT, et al. Effect of pregestational diabetes mellitus on fetal cardiac function and structure. *Am J Obstet Gynecol*. 2008;199:312.e1-312.e7.
2. Cornette J, ten Harkel AD, Steegers EA. Fetal dilated cardiomyopathy caused by persistent junctional reciprocating tachycardia. *Ultrasound Obstet Gynecol*. 2009;33:595-598.
3. Michelfelder E, Gottliebson W, Border W, et al. Early manifestations and spectrum of recipient twin cardiomyopathy in twin-twin transfusion syndrome: relation to Quintero stage. *Ultrasound Obstet Gynecol*. 2007;30:965-971.
4. Muñoz-Abellana B, Hernandez-Andrade E, Figueroa-Diesel H, et al. Hypertrophic cardiomyopathy-like changes in monochorionic twin pregnancies with selective intrauterine growth restriction and intermittent absent/reversed end-diastolic flow in the umbilical artery. *Ultrasound Obstet Gynecol*. 2007;30:977-982.
5. Prandstraller D, Leone O, Biagini E, et al. Prenatal echographic recognition of hypertrophic cardiomyopathy leading to heart transplantation in the newborn. *Eur Heart J*. 2008;29:845.
6. Cook AL, Cnota JF. Fetal echocardiographic imaging of ventricular noncompaction. *Cardiol Young*. 2008;18:351-352.
7. Tian L, Zhou Q, Zhou J, et al. Ventricular non-compaction cardiomyopathy: prenatal diagnosis and pathology. *Prenat Diagn*. 2015;35:221-227.
8. Stöllberger C, Wegner C, Benatar A, et al. Postnatal outcome of fetal left ventricular hypertrabeculation/noncompaction. *Pediatr Cardiol*. 2016;37:919-924.
9. Weber R, Kantor P, Chitayat D, et al. Spectrum and outcome of primary cardiomyopathies diagnosed during fetal life. *JACC Heart Fail*. 2014;2:403-411.
10. Whitham JK, Hasan BS, Schamberger MS, et al. Use of cardiac magnetic resonance imaging to determine myocardial viability in an infant with in utero septal myocardial infarction and ventricular noncompaction. *Pediatr Cardiol*. 2008;29:950-953.

To access the videos in this chapter, scan this QR code or visit expertconsult.com

94 Cardiac Tumors

FATIMA CRISPI | JOSEP M. MARTINEZ

Introduction

Cardiac tumors are rare and usually benign with few cardiac complications; most are asymptomatic and eventually involute.[1–3] Cardiac complications include arrhythmias, obstruction of the ventricular outflow tracts, and secondary cardiogenic shock leading to fetal hydrops and death.[1–3] Prenatal diagnosis is helpful to monitor these cases and, if necessary, to schedule delivery or perform *in utero* treatment to improve secondary heart failure.[1–3]

Disease

DEFINITION

Cardiac tumors are benign (95%) or malignant (5%) neoplasms arising primarily in the inner lining, muscle layer, or the surrounding pericardium of the heart.[3]

PREVALENCE AND EPIDEMIOLOGY

Cardiac tumors are uncommon, with an estimated incidence during fetal life of approximately 1.4 : 1000. The estimated prevalence from pediatric autopsy series is 0.017 : 1000 to 0.28 : 1000.[1–3]

ETIOLOGY AND PATHOPHYSIOLOGY

Most cardiac tumors are benign (95%). Rhabdomyoma is the most common cardiac tumor during fetal life and childhood[1,3–4] (Fig. 94.1). It is followed in frequency by teratoma, fibroma, myxoma, and hemangioma.

Cardiac tumors are usually isolated, with no association with chromosomal anomalies or other structural malformations.[1–3] The only exception is rhabdomyomas, which show a very high association (75% to 90%) with tuberous sclerosis[4] (Fig. 94.2). Detection of multiple cardiac tumors should raise a strong



Fig. 94.1 Single rhabdomyoma. Hyperechoic tumor is in the apex of the ventricular wall.

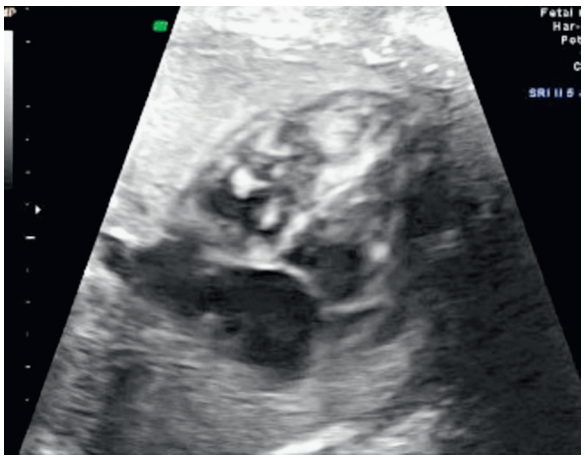

Fig. 94.2 Multiple rhabdomyomas. Hyperechoic tumors spread by the myocardium, ventricular walls, and septum.

suspicion of rhabdomyoma and tuberous sclerosis. A detailed family history should be obtained in such patients, and genetic counseling should be offered. Tuberous sclerosis is a rare multisystemic neuroectodermal disease characterized by multiple cardiac, intracranial, renal, pulmonary, and skin tumors. Rhabdomyomas generally regress after birth, although the associated neurodevelopmental complications (four-fifths of patients have epilepsy, and two-thirds have delayed neurodevelopment) dominate the clinical picture and should be an important part of the prenatal counseling of parents.[1,4]

Prenatally, cardiac tumors are usually detected in the third trimester. Most keep on growing during pregnancy without hemodynamic consequences. However, depending on the size, number, and location, complications such as arrhythmias, coronary flow reduction, or outflow tract or foramen ovale obstruction can occur, triggering heart failure, fetal hydrops, or eventually perinatal death.[1–3] It is mandatory to perform complete structural and functional echocardiography and to arrange regular follow-up.

MANIFESTATIONS OF DISEASE

Clinical Presentation

The clinical presentation includes a cardiac mass and occasionally fetal hydrops.



Fig. 94.3 Giant extracardiac teratoma with severe pericardial effusion.

Imaging Technique and Findings

Ultrasound. The tumor characteristics on ultrasound depend on the histologic content:

- Rhabdomyomas (65% to 70%): these are typically multiple homogeneous and hyperechogenic masses within the myocardium or chordae tendineae cordis[1] (see Fig. 94.2, Video 94.1).
- Teratomas (20% to 25%): these are isolated heterogeneous and encapsulated cystic masses located adjacent to the pericardium. Most cases manifest with accumulation of fluid in the pericardial space, which can trigger fetal hydrops and stillbirth[2] (Fig. 94.3, Video 94.2).
- Fibromas (10% to 15%): these are usually solid, homogeneous, isolated, and located within the ventricular myocardium.
- Myxoma: this is a pediculated tumor in the atria lumen.
- Hemangiomas: these are solid tumors.

Other US findings relate to the mass effect of the tumor: heart failure, hydrops, pericardial effusion, and arrhythmia[1–3] (see Video 94.1). A strict functional echocardiographic follow-up is mandatory.

Other Applicable Modality. Echocardiography, computed tomography, and magnetic resonance imaging of the heart are the main noninvasive diagnostic tools.[1–3] However, postnatal tumor biopsy or surgical resection with histologic assessment remains the gold standard for confirmation of the diagnosis.

Synopsis of Treatment Options

PRENATAL

Expectant management is the recommended approach.[1–3] Prenatal therapy is proposed only in the presence of severe fetal hemodynamic deterioration, hydrops, or uncontrollable arrhythmias.[1–5] In the presence of hydrops, treatment depends on gestational age. Neonatal management is always preferred when lung maturity is very likely or assured. Earlier in gestation, *in utero* pericardiocentesis, pericardioamniotic shunting, and anticancer drugs[6] have anecdotally been described with good results in terms of reversing hydrops and prolonging pregnancy to allow a live newborn. Notwithstanding the anecdotal reports, teratomas leading to hydrops generally are associated with very challenging postnatal management and have an overall poor prognosis.[2]

POSTNATAL

Rhabdomyomas generally regress after birth.[1] Surgical resection of cardiac tumors depends on histologic suspicion and localization or association with symptoms, or mechanical obstruction to blood flow.[3]

WHAT THE REFERRING PHYSICIAN NEEDS TO KNOW

Most prenatally detected cardiac tumors are rhabdomyomas, which usually are benign. However, if multiple tumors are observed, the possibility of tuberous sclerosis has to be considered. Strict monitoring of heart function to rule out impending cardiac failure or hydrops is recommended.

KEY POINTS

- The most frequent cardiac tumors are rhabdomyomas.
- The presence of multiple cardiac tumors suggests tuberous sclerosis.
- Strict follow-up is warranted. Outflow tract obstruction, arrhythmia, and hydrops may develop.
- In the presence of fetal hydrops, particularly in the case of pericardial effusion secondary to teratoma, *in utero* treatment may be an option.

SUGGESTED READING

Degueldre S, Chockalingam P, Mivelaz Y, et al. Considerations for prenatal counselling of patients with cardiac rhabdomyomas based on their cardiac and neurologic outcomes. *Cardiol Young*. 2010;20:18-24.

Holley DG, Martin GR, Brenner JI. Diagnosis and management of fetal cardiac tumors: a multicenter experience and review of published reports. *J Am Coll Cardiol*. 1995;26:516-520.



All references are available online at www.expertconsult.com.

REFERENCES

1. Paladini D, Palmieri S, Russo MG, et al. Cardiac multiple rhabdomyomatosis: prenatal diagnosis and natural history. *Ultrasound Obstet Gynecol*. 1996;7:84-85.
2. Devlieger R, Hindryckx A, Van Mieghem T, et al. Therapy for foetal pericardial tumors: survival following in utero shunting, and literature review. *Fetal Diagn Ther*. 2009;25:407-412.
3. Uzun O, Wilson DG, Vujanic GM, et al. Cardiac tumors in children. *Orphanet J Rare Dis*. 2007;2:11.
4. Isaacs H. Perinatal (fetal and neonatal) tuberous sclerosis: a review. *Am J Perinatol*. 2009;26:755-760.
5. Wacker-Gussmann A, Strasburger JF, Cuneo BF, et al. Fetal arrhythmias associated with cardiac rhabdomyomas. *Heart Rhythm*. 2014;11:677-683.
6. Mlczoch E, Hanslik A, Luckner D, et al. Prenatal diagnosis of giant cardiac rhabdomyoma in tuberous sclerosis complex: a new therapeutic option with everolimus. *Ultrasound Obstet Gynecol*. 2015;45:618-621.

SECTION SEVEN
Arrhythmias

To access the videos in this chapter, scan this QR code or visit expertconsult.com

95 Arrhythmias

FATIMA CRISPI | JOSEP M. MARTINEZ

Introduction

Arrhythmia is defined as any abnormality in normal heart rhythm. Fetal arrhythmias include regular heart rates less than 100 beats/min or greater than 180 beats/min, or any irregularity in fetal heart rate in the absence of uterine contractions.[1,2] Fetal arrhythmias occur in 2% of pregnancies, and most are benign, with no requirement for *in utero* treatment.[1,2] At least 90% of arrhythmias are caused by irregular rhythms (ectopic beats); 8% by tachyarrhythmias (heart rate >180 beats/min); and 2% by bradyarrhythmias (heart rate <100 beats/min). Tachyarrhythmia most commonly relates to supraventricular reentrant tachycardia, atrial flutter, and sinus tachycardia. Enduring bradycardia may result from sinus node dysfunction, complete heart block or nonconducted atrial bigeminy. In this chapter, the most common arrhythmias during intrauterine life are reviewed: (1) atrial ectopic beats, (2) supraventricular tachycardia, and (3) complete atrioventricular block.

Atrial Ectopic Beats

DEFINITION

Atrial ectopic beats refer to an irregular rhythm also known as extrasystoles.[1]

PREVALENCE AND EPIDEMIOLOGY

Atrial ectopic beats (extrasystoles) typically appear in the third trimester and account for 85% to 90% of fetal arrhythmias, affecting 1% to 2% of all pregnancies.[1]

ETIOLOGY AND PATHOPHYSIOLOGY

Although their etiology is unknown, it is hypothesized that atrial ectopic beats appear after a spontaneous atrial depolarization owing to immaturity or instability of the fetal conduction

system. Most cases are isolated; however, 1% to 2% of cases can be caused by an underlying structural heart disease or cardiac tumor.[1] A complete echocardiographic assessment is warranted.

The prognosis is benign, and most cases are self-limited without treatment. Usually, atrial ectopic beats are well tolerated by the fetus, and the fetus remains stable hemodynamically.[1] However, 2% to 5% can progress to tachycardia or bradycardia. For this reason, follow-up of patients with heart rate auscultation every 1 to 2 weeks is recommended to exclude any runs of tachycardia (>200 beats/min).

MANIFESTATIONS OF DISEASE

Clinical Presentation

Atrial ectopic beats are found by auscultation of a fetal irregular rhythm or observation during an ultrasound (US) scan performed for other reasons.

Imaging Technique and Findings

Ultrasound. The diagnosis is usually easily made with US because of the typical irregularity of the rhythm. Premature atrial wall movements by M-mode or atrial beats by pulsed Doppler are observed.[1] The space between the ectopic beat and the previous one is shorter than the space between two previous beats. The ectopic beat may be followed by a ventricular beat, and typically the next atrial beat is delayed because of a compensatory pause (Fig. 95.1). Ectopic beats can be coupled to sinus beats leading to bigeminy (1 sinus beat for 1 ectopic beat), trigeminy (2 sinus beats for 1 ectopic beat), and so on (Fig. 95.2).[1,2]

CLASSIC SIGNS

Irregular rhythm with premature atrial beat followed by a compensating pause

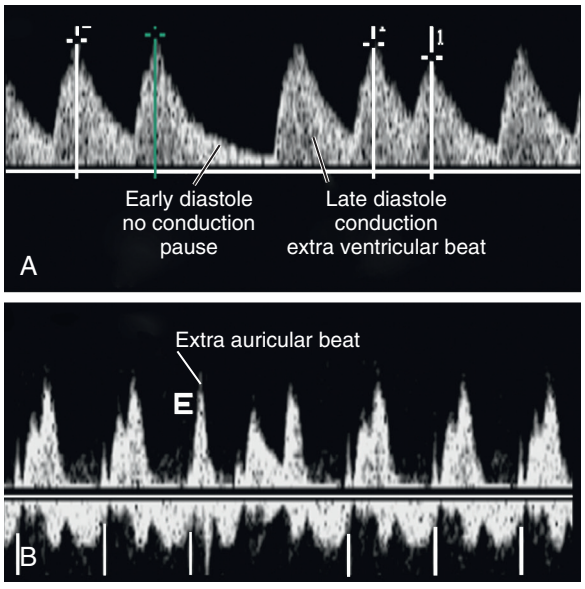

Fig. 95.1 Atrial ectopic beats detected by pulsed Doppler in the umbilical artery (A) and intracardiac flow (recording simultaneously left ventricular inflow and aortic outflow) (B).

Synopsis of Treatment Options

PRENATAL

No treatment is required because most cases are well tolerated and self-limited. However, reduced caffeine intake and smoking withdrawal is empirically recommended by some groups. Perinatal management does not need to be changed, and a vaginal delivery in a nontertiary center can be offered.

POSTNATAL

Usually, no treatment is required.

WHAT THE REFERRING PHYSICIAN NEEDS TO KNOW

Most cases are benign and self-limited; however, a complete echocardiographic assessment and follow-up are required. Follow-up may be through auscultation at routine prenatal visits for any evidence of tachycardia.

Supraventricular Tachycardia

DEFINITION

Supraventricular tachycardia is atrial tachycardia (usually 220 to 260 beats/min) with 1:1 atrioventricular conduction.

PREVALENCE AND EPIDEMIOLOGY

Supraventricular tachycardia accounts for 1% to 5% of fetal arrhythmias. Despite being the most common fetal tachyarrhythmia, it is infrequent, affecting 1 in 10,000 pregnancies.[1,2]

ETIOLOGY AND PATHOPHYSIOLOGY

The mechanism is an atrioventricular reentry, usually based on retrograde atrial activation across a fast-conducting accessory pathway, although antegrade conduction can also occur.[2] Structural heart disease or tumors underlie 5% to 10% of cases. Some cases are secondary to frequent atrial ectopic beats explaining

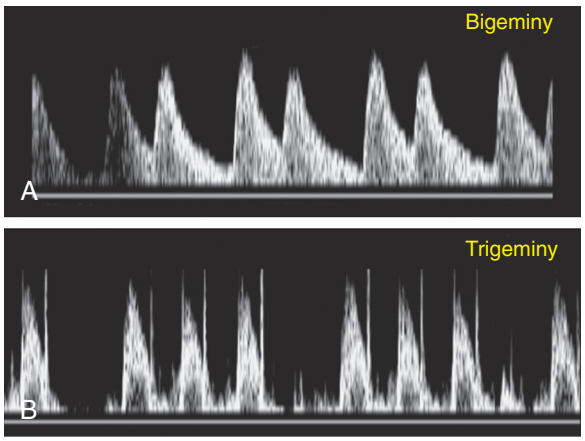

Fig. 95.2 Bigeminy (A) and trigeminy (B) as shown in umbilical artery flow.

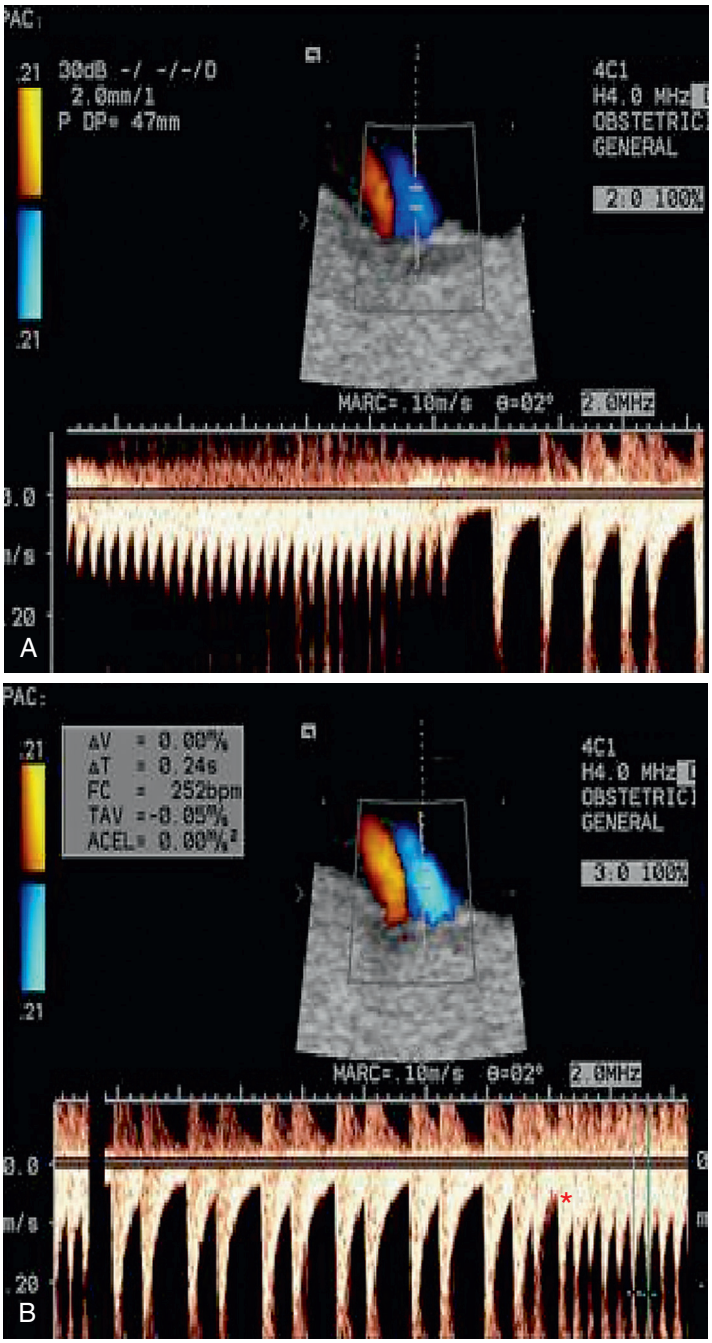

Fig. 95.3 (A) Paroxysmal supraventricular tachycardia (259 beats/min), which suddenly stops falling in a bigeminal pattern. (B) After 1 minute, tachycardia is suddenly triggered by an ectopic premature beat *(asterisk)*.

an intermittent pattern of tachycardia, with tachycardia beginning and ending suddenly[2] (Fig. 95.3).

Hydrops can occur in 30% to 50% of cases, typically associated with heart rates greater than 210 to 220 beats/min.[2] A maintained tachycardia can lead to dilated myocardiopathy with valvular insufficiency, decrease of ventricular filling time and cardiac output, congestive heart failure, and finally hydrops.[2] The presence of hydrops is a marker of worse prognosis owing to increased mortality (>30%) or later neurologic impairment.

MANIFESTATIONS OF DISEASE

Clinical Presentation

Clinical presentation consists of auscultation of maintained fetal heart rate at 220 to 260 beats/min, with or without fetal hydrops.[2]

Imaging Technique and Findings

Ultrasound. Supraventricular tachycardia is characterized by a fetal heart rate greater than 180 beats/min (usually 220 to 260 beats/min) with 1 : 1 atrioventricular conduction. Atrial rhythm

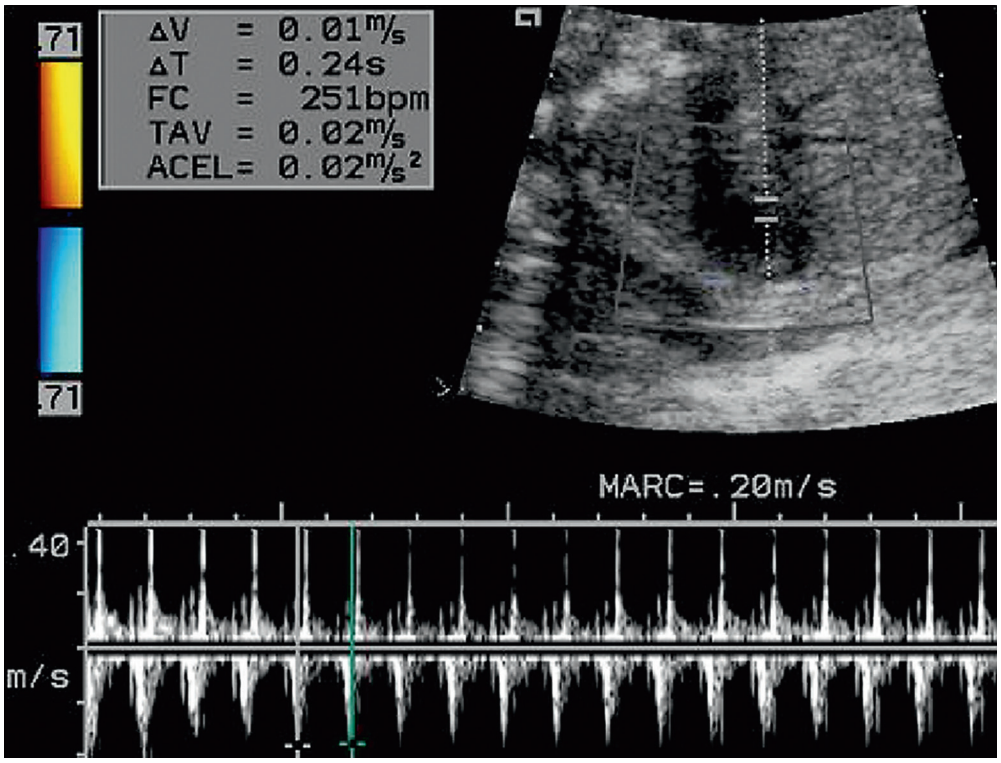

Fig. 95.4 Supraventricular tachycardia evaluated by intracardiac Doppler (251 beats/min).

and ventricular rhythm should be almost equal (Videos 95.1 and 95.2).[2] Atrial and ventricular rates can be evaluated simultaneously by pulsed Doppler or M-mode (Figs. 95.4 and 95.5).

CLASSIC SIGNS

In most cases the tachycardia is incidentally noted during routine prenatal care, whereas in 30% to 50% of cases, hydrops fetalis is the first diagnostic sign.

Differential Diagnosis From Imaging Findings

The differential diagnosis includes atrial flutter characterized by much higher atrial rates (>300 to 400 beats/min). The ventricular rate is often much slower (180 to 200 beats/min) because of varying degrees of atrioventricular block, leading to 3:1 to 4:1 conduction[1] (Video 95.3).

Synopsis of Treatment Options

PRENATAL

The decision to treat depends on gestational age, heart rate, intermission, and presence of hydrops.[1,2] In most cases, an intrauterine cardioversion can be tried, with drugs administered to the mother. Only in selected cases (short periods of tachycardia without hydrops near term) is the treatment postponed postnatally. The aim of treatment is cardioversion to sinus rhythm or at least to decrease the heart rate to less than 210 to 220 beats/min.[1]

Supraventricular Tachycardia Without Hydrops

Maternal administration of digoxin (0.25 mg every 8 hours orally) or flecainide (150 mg every 8 hours orally) is considered the best option because of high efficacy, safety, and low cost.[1–3] Maternal administration of flecainide can be added to digoxin if tachycardia persists after therapeutic maternal digitalis levels are reached. Cardioversion can be achieved in 80% to 95% of cases.

Supraventricular Tachycardia and Hydrops

Maternal flecainide is the first option because hydrops reduces the transplacental transfer of digoxin.[1–3] Efficacy of the treatment is reduced in such cases, and cardioversion is achieved in 65% to 75% of cases. In refractory cases, other drugs such as sotolol can be used. After cardioversion is achieved, fetal hydrops may remain for 2 to 3 weeks.

POSTNATAL

Postnatal treatment during the first year of life is usually required. Afterward, more than 80% of cases resolve spontaneously owing to progressive atrophy (anatomic or functional) of the accessory pathway. However, recurrence or persistence in childhood requiring ablation of the accessory pathway has also been described.[1,2]

WHAT THE REFERRING PHYSICIAN NEEDS TO KNOW

Prenatal treatment of fetal tachycardia can reduce the risk of hydrops and improve prognosis.

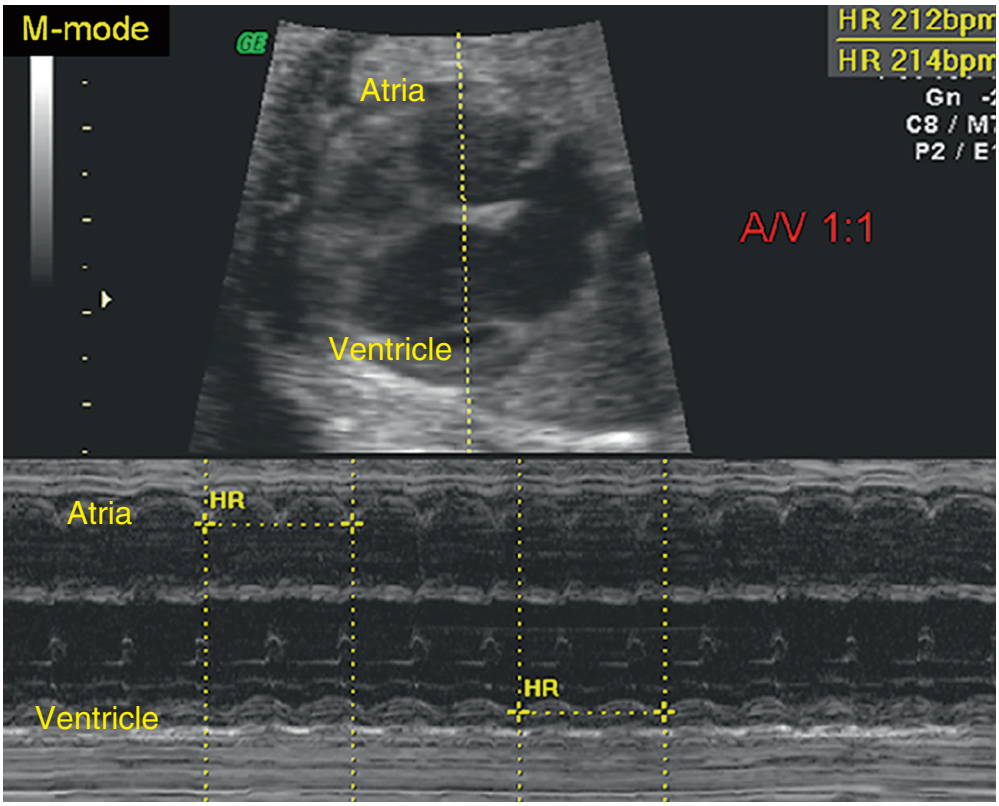

Fig. 95.5 Supraventricular tachycardia evaluated by M-mode, showing 1:1 atrioventricular *(A/V)* conduction. Atrial rate is 212 beats/min, and ventricular rate is 214 beats/min. *HR,* Heart rate.

Complete Atrioventricular Block

DEFINITION

Complete atrioventricular block refers to fetal bradycardia characterized by complete dissociation between atrial (normal) and ventricular (<100 beats/min) heart rates.[1,4]

PREVALENCE AND EPIDEMIOLOGY

Atrioventricular block is rare, affecting 1 in 20,000 pregnancies.[1]

ETIOLOGY AND PATHOPHYSIOLOGY

Atrioventricular block is mainly associated with the following two conditions:

1. Structural heart anomaly (45% to 50%) affecting atrioventricular conduction tissue. The most common heart diseases are atrioventricular septal defect and great vessel anomalies, often in the context of complex cardiac disease with atrial isomerism. It can also be associated with corrected transposition of great vessels (atrioventricular discordance with ventriculoatrial discordance).[1,4]
2. Autoimmune disease (45% to 55%), with inflammation leading to irreversible fibrosis of the conduction tissue secondary to maternal anti-Ro (SS-A) or anti-La (SS-B) antibodies, or both.[1,4,5] The probability of atrioventricular block developing secondary to autoimmune disease is 8% to 10% in patients with Sjögren syndrome, 3% to 5% in patients with systemic lupus erythematosus, 0.5% to 1% in asymptomatic patients with anti-Ro or anti-La antibodies, and 15% to 20% in patients with a previously affected child. In these cases, frequent echocardiographic follow-up is recommended from 16 to 18 weeks' gestation until delivery (the major risk is from 18 to 26 weeks' gestation).[1,4,5]

Regardless of the exact etiology, the prognosis of atrioventricular block is poor, owing to a high association with hydrops (40% to 60%) and *in utero* mortality (45% to 50%). The main factors related to poor prognosis are association with structural heart disease, heart rate less than 55 beats/min, and the presence of fetal hydrops.[1,4]

MANIFESTATIONS OF DISEASE

Clinical Presentation

Atrioventricular block is discovered by auscultation of maintained fetal heart rate at less than 100 beats/min during a routine obstetric visit or US diagnosis of fetal hydrops.

Imaging Technique and Findings

Ultrasound. Atrioventricular block is characterized by the dissociation of atrial and ventricular rates (Video 95.4), which are best shown by Doppler (Fig. 95.6) or M-mode (Fig. 95.7).[1] Typically, the atrial rate is normal (120 to 160 beats/min), and the ventricular rate is less than 100 beats/min.

Other Applicable Modality. Detailed echocardiography is mandatory to rule out structural anomalies.[2] The disease is often associated with cardiomegaly, myocardial hypertrophy,

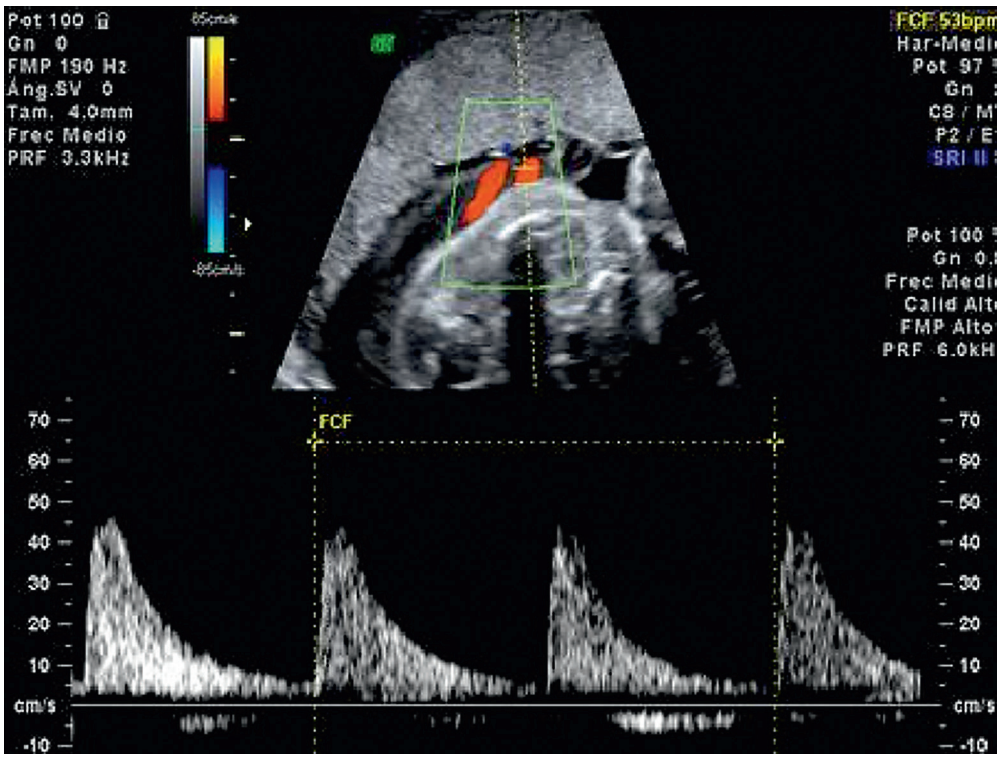

Fig. 95.6 Complete atrioventricular block. Ventricular rate is measured in the umbilical artery (53 beats/min). *FCF*, Fetal heart rate.

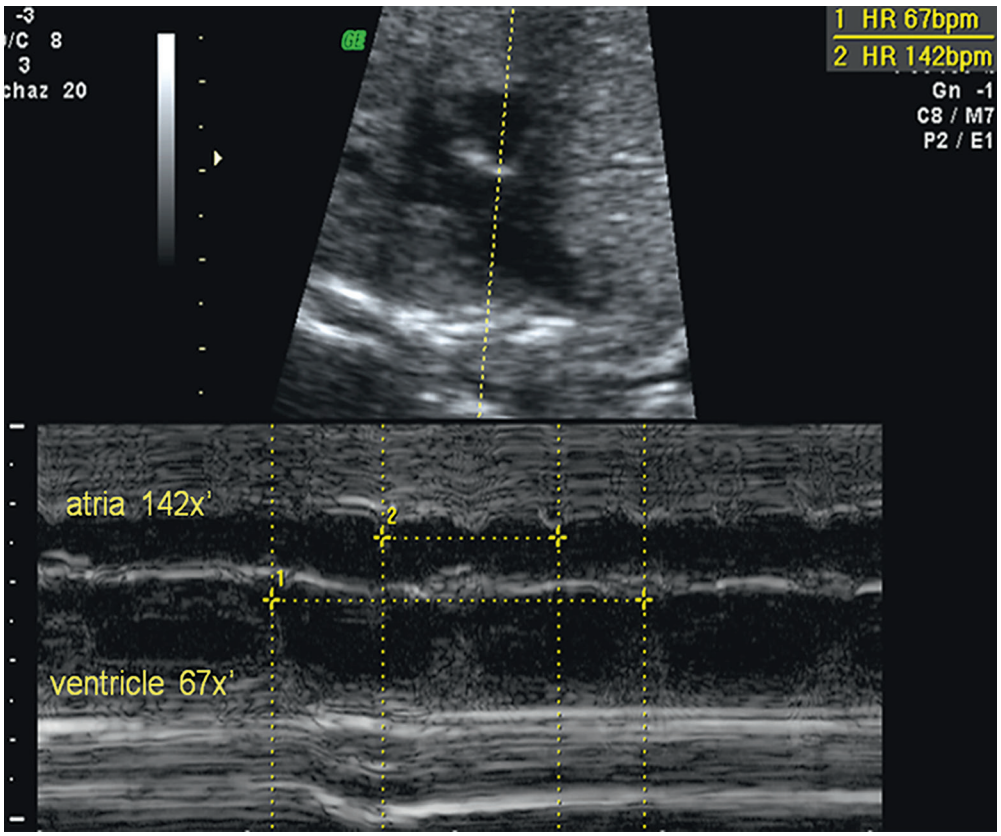

Fig. 95.7 Complete atrioventricular block evaluated by M-mode showing the characteristic atrioventricular rate dissociation. Atrial rate is 142 beats/min, and ventricular rate is 67 beats/min.

atrioventricular valve insufficiency, and reversed atrial flow in the ductus venosus. Evaluation of anti-Ro (SS-A) and anti-La (SS-B)[1,4,5] antibodies in maternal blood is required to rule out autoimmune disease.

CLASSIC SIGNS

Severe bradycardia with complete dissociation of atrial and ventricular rates

Differential Diagnosis From Imaging Findings

Second-degree (incomplete) heart block is a differential diagnostic consideration. In second-degree heart block, the most common finding is a 2:1 (or 3:1) atrioventricular rate, secondary to a fixed ratio of block (Fig. 95.8).[1,4] Progressive prolongation of the P–R interval until an atrial beat is nonconducted (Wenckebach) may also be found.[1,4]

Synopsis of Treatment Options

PRENATAL

The only effective treatment for complete atrioventricular block is neonatal pacing, and so the main goal *in utero* is to maintain fetal well-being until delivery.[1,4–6] Although maternal administration of beta-sympathomimetics (ritodrine, salbutamol, terbutaline) or digoxin has been used to increase heart rate slightly in hopes of reducing the probability of heart failure and hydrops, there are no clear data on the safety and benefits of these treatments.[1,4–6] However, if signs of fetal deterioration appear, the only option is elective delivery (ideally cesarean section in a referral center) and neonatal pacing.[1,4–6]

In the presence of demonstrated autoimmune disease, corticosteroids have not shown any benefit in patients with established complete heart block.[1,4–6] The use of corticosteroids as preventive therapy in patients with a previous affected child or in the presence of incomplete atrioventricular block is also controversial.[1,4–6] Some groups have proposed that corticosteroids reduce inflammation and progression to complete heart block,

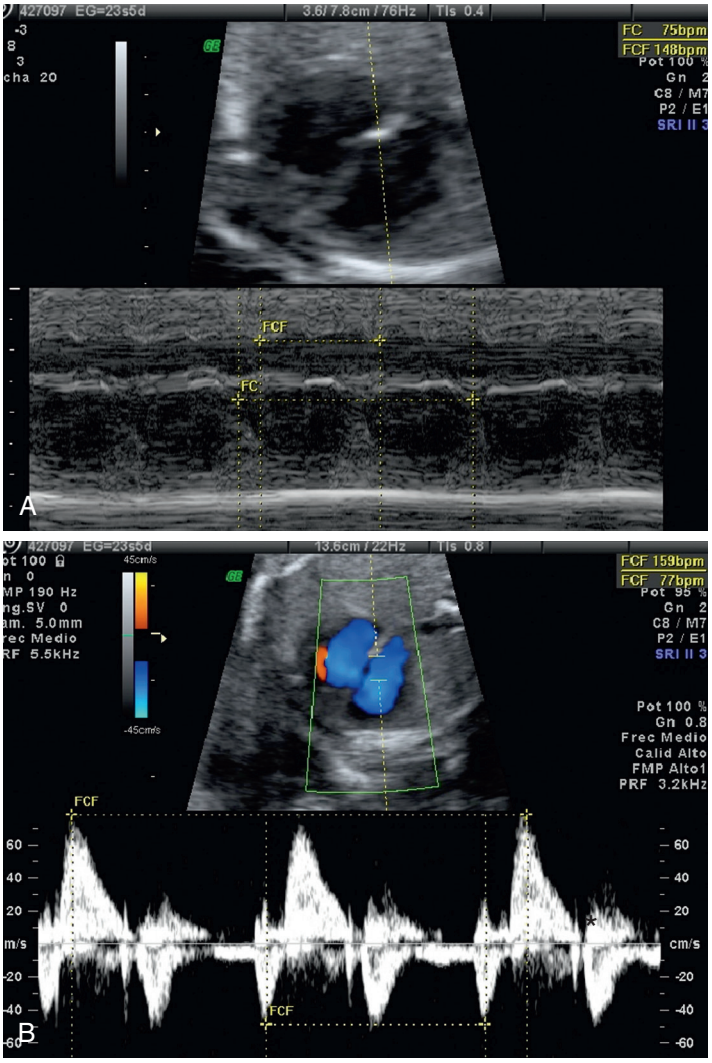

Fig. 95.8 Second-degree (incomplete) atrioventricular block evaluated by M-mode (A) and pulsed Doppler (B), showing the characteristic 2:1 atrioventricular rate relationship. There are two atrial beats (rate 148 to 155 beats/min) for each ventricular beat (rate 75 to 77 beats/min). *FCF,* Fetal heart rate.

but results from recent observational studies are still controversial.[1,4–7]

POSTNATAL

Postnatal pacing is required in more than 50% to 70% of fetuses with atrioventricular block.

WHAT THE REFERRING PHYSICIAN NEEDS TO KNOW

- Ectopic beats are very common and usually associate an excellent prognosis.
- Both Doppler or M-mode are useful for defining the relation of atrial and ventricular rhythm and the type of arrhythmia.
- Prenatal treatment of supraventricular tachycardia can prevent evolution to hydrops.

KEY POINTS

ATRIAL ECTOPIC BEATS

- Ectopic beats are the most frequent fetal arrhythmia.
- The prognosis is excellent and no prenatal treatment is needed.

SUPRAVENTRICULAR TACHYCARDIA

- Supraventricular tachycardia may lead to development of hydrops in 50% of cases.
- Intrauterine cardioversion by transplacental transfer of medication is virtually always indicated.

COMPLETE ATRIOVENTRICULAR BLOCK

- Complete atrioventricular block must be suspected in the presence of sustained bradycardia.
- It is characterized by dissociation between a normal atrial rate and a bradycardic ventricular rate, and it is optimally shown using Doppler or M-mode.
- Complete atrioventricular block associated with structural heart disease or hydrops is almost always a lethal condition.
- In cases not associated with structural heart disease or hydrops, the prognosis is better, especially if ventricular rate is greater than 50 beats/min. However, postnatal pacing is needed in most cases.

SUGGESTED READING

Api O, Carvalho JS. Fetal dysrhythmias. *Best Pract Res Clin Obstet Gynaecol*. 2008;22:31-48.

Fouron JC. Fetal arrhythmias: the Saint-Justine hospital experience. *Prenat Diagn*. 2004;24:1068-1080.

Jaeggi E, Öhman A. Fetal and neonatal arrhythmias. *Clin Perinatol*. 2016;43:99-112.

Simpson JM. Fetal arrhythmias. *Ultrasound Obstet Gynecol*. 2006;27:599-606.



All references are available online at www.expertconsult.com.

REFERENCES

1. Jaeggi E, Öhman A. Fetal and neonatal arrhythmias. *Clin Perinatol*. 2016;43:99-112.
2. Simpson JM, Sharland GK. Fetal tachycardias: management and outcome of 127 consecutive cases. *Heart*. 1998;79:576.
3. Strizek B, Berg C, Gottschalk I, et al. High-dose flecainide is the most effective treatment of fetal supraventricular tachycardia. *Heart Rhythm*. 2016;13:1283-1288.
4. Kuleva M, Le Bidois J, Decaudin A, et al. Clinical course and outcome of antenatally detected atrioventricular block: experience of a single tertiary centre and review of the literature. *Prenat Diagn*. 2015;35:354-361.
5. Mevorach D, Elchalal U, Rein AJ. Prevention of complete heart block in children of mothers with anti-SSA/Ro and anti-SSB/La autoantibodies: detection and treatment of first-degree atrioventricular block. *Curr Opin Rheumatol*. 2009;21:478-482.
6. DeNoble AE, Kuller JA, Rhee EJ. Controversies in the management of isolated congenital atrioventricular block. *Obstet Gynecol Surv*. 2015;70:518-523.
7. Izmirly PM, Saxena A, Sahl SK, et al. Assessment of fluorinated steroids to avert progression and mortality in anti-SSA/Ro-associated cardiac injury limited to the fetal conduction system. *Ann Rheum Dis*. 2016;75:1161-1165.

96 Placental Abruption

AUDREY MERRIAM | MARY E. D'ALTON

Introduction

Placental abruption complicates a small fraction of pregnancies but has the potential to carry major maternal and fetal morbidity. As this entity is diagnosed clinically, imaging plays a limited role in diagnosis and management, which varies based on gestational age and the severity of the abruption at the time of presentation.

Disease

DEFINITION

Placental abruption is defined as the premature separation of a normally implanted placenta after 20 weeks' gestation and before birth.[1] The separation can be complete, where the entire placenta separates, typically resulting in fetal death, or partial, where only a portion of the placenta separates from the uterus. Abruptions can be "revealed" or "concealed." A revealed abruption presents with vaginal bleeding as the blood tracks between the decidua and the membranes to the cervix and then to the vagina. A concealed abruption does not present with vaginal bleeding as the bleeding that occurs because of placental separation accumulates behind the placenta without tracking anywhere.[1]

PREVALENCE AND EPIDEMIOLOGY

Placental abruption is a clinical diagnosis that complicates approximately 1.2% of pregnancies in the United States.[2] On pathologic examination of placentas, rates have been found to be as high as 2.1%–3.8%, however, as cases diagnosed solely on pathologic examination do not have clinical consequence, some have suggested that the term should apply to clinical diagnoses only.[1]

The incidence in the United States has slowly increased over the past 30 years in contrast to European countries.[2] The incidence of abruption in Canada was also increasing until the early 2000s when it began to decrease.[2] Over half of cases of abruption occur before 37 weeks' gestation, with the highest incidence occurring between 24 and 26 weeks' gestation and decreasing with advancing gestational age.[1,3]

Many risk factors for placental abruption have been identified, some of which can be adjusted by patient behavior. A history of abruption in a prior pregnancy is the most important nonmodifiable risk factor and increases the risk up to 15- to 20-fold.[4] Additional modifiable and nonmodifiable risk factors are listed in Table 96.1. Thrombophilia, amniocentesis, chorionic villus sampling, and genetic factors have been implicated; but results from multiple studies are inconsistent, and they are generally not considered to be major risk factors for abruption.[5–7]

ETIOLOGY AND PATHOPHYSIOLOGY

The physiology behind placental abruption is unknown in many cases, but a few of the risk factors have identifiable pathophysiologic mechanisms. In some cases there are shearing forces that cause the placenta to separate from the wall of the uterus and lead to bleeding, such as in cases of trauma or rapid decompression of the uterus, as seen in delivery of the first infant in a multifetal pregnancy or after rupture of membranes with polyhydramnios.[8] Vasospasm and vasoconstriction of the small arterioles at the decidual-placental interface may lead to areas of hypoxia and necrosis in the decidua. This necrosis leads to venous hemorrhage and causes more of the placenta to separate from the uterine wall, causing more bleeding. This is thought to be the cause in cases where cocaine, shock/sepsis, or hypertensive urgency are the etiology of the abruption.[1]

The majority of cases seem to suggest a long-standing process starting at the time of trophoblastic invasion in the first trimester. This inadequate invasion leads to the lack of adequate remodeling of the uterine arterioles, similar to what is seen in pregnancies complicated by preeclampsia.[9] This correlates with the abnormal serum analytes seen in cases of placental abruption, particularly low pregnancy-associated plasma protein A and increased alpha-fetoprotein that are associated with abnormally formed or damaged villi.[10] This theory is further supported by the association between preeclampsia and growth restriction in pregnancies complicated by abruption.[1] In addition, there is an association between a history of abruption and an increased risk of hypertensive disorders in a subsequent pregnancy.[11] Regardless of the initial cause, the end of the pathophysiologic pathway involves separation between the placenta and the decidua because of retroplacental bleeding, which decreases the functional surface area of the placenta and can lead to further separation and bleeding.

MANIFESTATIONS OF DISEASE

Clinical Presentation

The classic presentation of placental abruption is abdominal pain and bleeding, but the presence or absence of symptoms is not necessarily indicative of the severity of the abruption. In cases of concealed abruption, there will be no bleeding in

TABLE 96.1 RISK FACTORS FOR PLACENTAL ABRUPTION

Nonmodifiable Risk Factors	Modifiable Risk Factors
• Advanced maternal age • Prior cesarean delivery • Uterine anomaly/fibroids • Multiparity • Multifetal gestations • First-trimester bleeding • Preterm premature rupture of membranes • Preeclampsia • Short umbilical cord • Velamentous cord insertion • History of miscarriage or stillbirth • Oligohydramnios • Polyhydramnios • Male fetus • Low PAPP-A on first-trimester screening • High levels of maternal serum AFP or beta-HCG on second trimester screening	• Chronic hypertension • Anemia during pregnancy • Gestational diabetes • Smoking during pregnancy • Cocaine use • Short interval between pregnancies • Trauma • Shock/sepsis

AFP, Alpha-fetoprotein; *beta-HCG*, beta human chorionic gonadotropin; *PAPP-A*, pregnancy-associated plasma protein A.
Data from references 1, 3, 10, and 27–30.

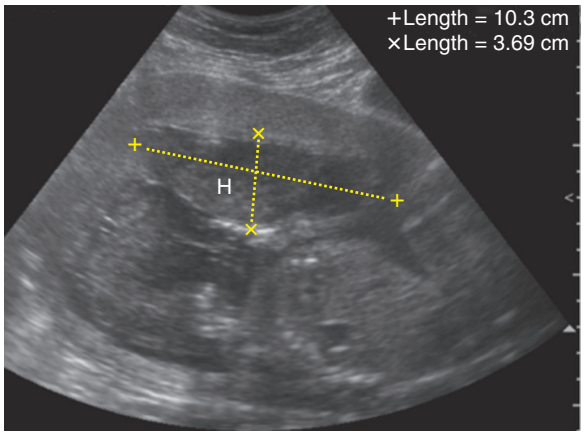

Fig. 96.1 Subchorionic hematoma. Hemorrhage *(H)* is located between the chorion and the uterine wall. This is the most common location of hemorrhage.

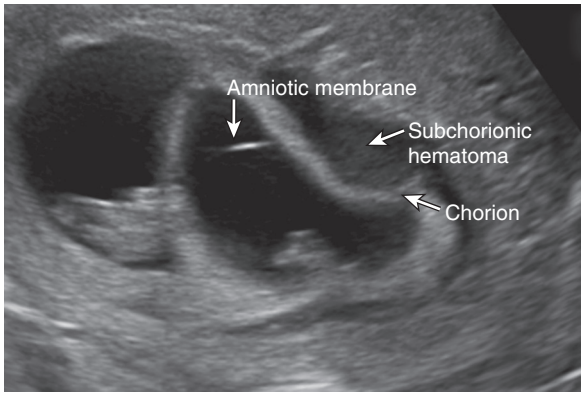

Fig. 96.2 First-trimester subchorionic hematoma. A dichorionic-diamniotic twin pregnancy complicated by subchorionic hematoma at 9 weeks' gestation. The hypoechoic appearance suggests a nonacute resolving hematoma.

approximately 10% of cases. Back pain can also be the presenting symptom if there is a posterior placenta. Physical examination findings range from a benign exam to findings of a firm, tender uterus or uterine tenderness and evidence of preterm labor. Tocography may show uterine contractions, which may be seen as high-frequency, low-amplitude contractions. When more than 50% of the placenta has separated, the fetal heart rate may show minimal to absent variability and/or recurrent variable and late decelerations.[1]

Maternal complications associated with abruption are related to hypovolemia and blood loss. In cases of mild abruptions there may be no maternal sequelae. With more significant abruptions and increased blood loss, maternal complications can include hypotension, shock, disseminated intravascular coagulopathy, and associated end-organ damage. The retroplacental bleeding can cause uterine irritation and contractions leading to preterm labor. Bleeding into the uterus can cause uterine atony and can give the uterus a bluish hue, known as a *Couvelaire* uterus.[12] This atony can increase the risk of blood loss caused by atony and associated complications. In rare cases, large amounts of bleeding can lead to maternal death.

Fetal complications are secondary to decreased functional capacity of the placenta. Decreased functional surface area of the placenta can lead to fetal hypoxia and morbidity related to preterm delivery. In cases where greater than 50% of the placenta is separated from the wall of the uterus, intrauterine fetal demise can occur.[1] Perinatal mortality can approach 20% to 30%, and persists after accounting for mortality related to preterm delivery.[13–15] Pregnancies complicated by chronic abruption may be complicated by preterm labor, preterm premature rupture of membranes, oligohydramnios, and fetal growth restriction.[16]

Imaging Technique and Findings

Ultrasound. Placental abruption is a clinical diagnosis, and the main role of imaging in abruption is to rule out placenta previa or other abnormal placentation as a cause of vaginal bleeding.

The hematoma formed from an abruption is most commonly visualized in the subchorionic area (Fig. 96.1). This hematoma is believed to be secondary to abruption at the placental margin and correlates with the fact that first-trimester bleeding and subchorionic hematomas increase the risk for placental abruption (Fig. 96.2). A retroplacental location for bleeding and clot formation is more common after 20 weeks' gestation (Fig. 96.3). A preplacental hematoma is the least common, occurring only in about 1% of cases (Fig. 96.4).[17] The echotexture of the blood varies with time compared to the initial abruption. Blood initially appears hyperechoic to isoechoic when compared to the placenta and may be interpreted as a thick placenta. By 1 week from the initial event, the blood becomes hypoechoic (Fig. 96.5), and by 2 weeks it is usually sonolucent.[17]

Ultrasound (US) only allows for the visualization of blood or clot in 50% of cases of suspected placental abruption, so a negative US does not rule out placental abruption.[18] Sensitivity of US for diagnosis of abruption is around 25% in most studies; however, the positive predictive value is high, with a range of 82%–100%.[1,19] Some studies have found a positive correlation between location of clot (retroplacental), percentage of placental detachment (>50%), and fetal outcomes.[16]

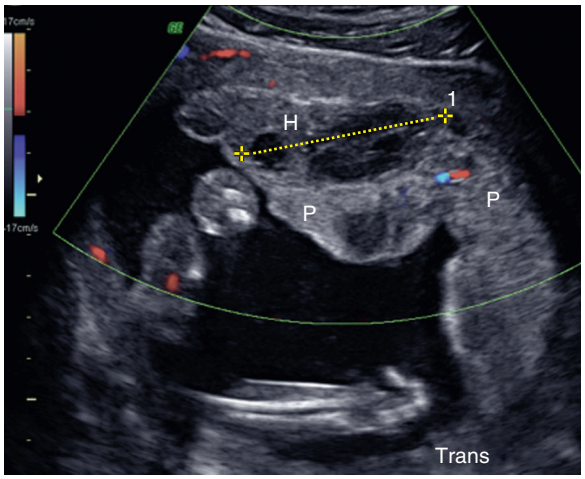

Fig. 96.3 Uterus in transverse view *(Trans)* showing a retroplacental hematoma. Retroplacental hematoma. Hemorrhage *(H)* with a heterogeneous appearance is located behind the placenta *(P)*, with a small subchorionic component. Caliper *(1)* show measurement of the retroplacental hematoma.

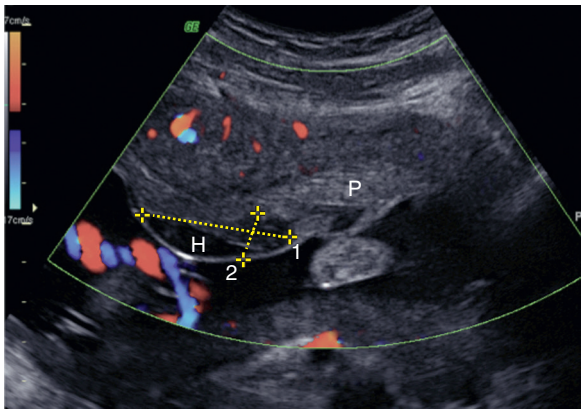

Fig. 96.4 Preplacental hematoma. Hemorrhage *(H)* is between the placenta *(P)* and the amniotic membrane but does not leak into the amniotic fluid cavity, which would cause a "snowstorm" appearance in the amniotic fluid. Calipers (*1* and *2*) depict the dimensions of the hematoma.

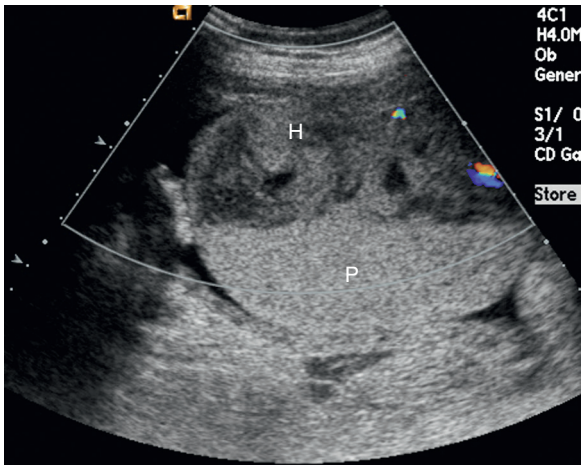

Fig. 96.5 Retroplacental hematoma with hypoechoic features. This hematoma *(H)* appears hypoechoic compared with the placenta *(P)*, suggestive of a resolving hematoma.

US should also be used to assess for fetal anomalies as the risk of congenital anomalies is increased twofold in pregnancies complicated by abruptions.[20]

Magnetic Resonance Imaging. Magnetic resonance imaging (MRI) has been studied as a potential adjunctive imaging modality for placental abruption. One study found a 100% positive detection rate with diffusion and T1-weighted MRI in 19 patients who were suspected of having an abruption, and in whom this was later confirmed on placental pathology.[21] At this time, MRI could be considered as an investigational imaging method after US, but in cases where abruption is suspected clinically, a negative MRI should not rule out abruption. MRI may also be useful in identifying some cases of abnormal placentation, such as placenta accrete, and may help to distinguish this entity from a placental abruption (see Chapter 98).

Other Applicable Modality. Computed tomography (CT) is not commonly used for the diagnosis of abruption, but in pregnant patients already undergoing a CT as part of a trauma evaluation, they have been shown to be effective in identifying abruptions. One study about the use of CT for evaluation of placental abruption in trauma patients showed a sensitivity of 43% to 100%.[22] Given the radiation dose associated with an abdominal/pelvis CT, this imaging modality should only be used in selective cases and not as a primary method of assessing for placental abruption, even in the case of a negative US.

CLASSIC SIGNS

A "jello" sign has been described in evaluating for abruption. This occurs when the placenta or intrauterine clot is seen to "jiggle" when sudden pressure is applied by the US transducer.[1]

Differential Diagnosis From Imaging Findings

1. Placenta previa should be ruled out in all cases of midgestation bleeding.
2. Placenta accreta/increta/percreta may also need to be ruled out, especially in patients with prior cesarean deliveries or intrauterine instrumentation.
3. US evidence of abruption should be differentiated from succenturiate lobe, uterine fibroids, chorioangioma, placentomegaly, and molar pregnancy. Resolution of the area of concern on subsequent examinations may help to establish the diagnosis of abruption.[17]

Synopsis of Treatment Options

PRENATAL

Management of placental abruption is individualized, with decision-making based on gestational age, severity of abruption, and maternal and fetal well-being after the abruption occurs. There are no large trials that evaluate interventions for pregnancies affected by placental abruption.[23]

The primary concern when a patient presents with antepartum bleeding is the evaluation of maternal and fetal well-being. Evidence of maternal hemodynamic compromise, as evidenced by hypotension, tachycardia, and altered mental status, necessitates immediate stabilization, including volume replacement and blood product replacement as needed. In these cases, delivery should be expedited regardless of gestational age. If there is evidence of coagulopathy,

delivery should also be expedited and necessary blood products given as needed. Fetal compromise requires immediate delivery at viable gestational ages; however, at periviable gestations when the mother is hemodynamically stable, discussion should occur about mode of delivery and intervention on fetal behalf.

In the absence of maternal or fetal compromise, gestational age is the primary guide for management. Abruptions that occur at/or beyond the late preterm period, 34 weeks' gestation and later, should be managed by delivery. In the late preterm period, consideration can be given to delay for corticosteroid administration.[24] In the extreme premature period, approximately 24–28 weeks' gestation, when risks of prematurity outweigh risks of prolonging the pregnancy, conservative management may be attempted.[25] In these cases, patients should be admitted to the hospital for close monitoring of maternal and fetal status. Corticosteroids should be given for fetal lung maturity, serial assessment of fetal growth and well-being through fetal monitoring and US, and assessment for maternal anemia or coagulopathy via laboratory assessment should be performed. Tocolysis can be considered in select cases, although its role in cases of placental abruption is controversial.[18,25,26] Vaginal delivery can be attempted in all cases where fetal and maternal status allows.[1]

POSTNATAL

In the postpartum period, pregnancies complicated by placental abruption are at increased risk for hemorrhage because of the increased risk of uterine atony.[12]

Women who have had placental abruption are more likely to have a placental abruption in a subsequent pregnancy, with a potential 20-fold increased risk.[1,4] In subsequent pregnancies, one of the goals of care should be to reduce modifiable risk factors of abruption, such as smoking and substance abuse cessation, treating chronic hypertension, and diet modification to reduce the risk of gestational diabetes. Patients should be counseled to wait at least 2 years between pregnancies, as short-interval pregnancies can increase the risk of a repeat abruption.[1]

Routine testing for inherited thrombophilias after an abruption is not recommended because of the lack of evidence that prenatal anticoagulation prophylaxis prevents recurrence; however, in patients with known thrombophilias and a history of abruption, prophylactic anticoagulation in a subsequent pregnancy should be considered.[1] Growth scans in future pregnancies can be considered as the risk for growth restriction, and hypertensive disorders of pregnancy have been found to be increased in pregnancies following those complicated by placental abruptions.[1,11]

WHAT THE REFERRING PHYSICIAN NEEDS TO KNOW

- There is a low threshold for diagnosis of placental abruption with antepartum hemorrhage, as the clinical presentation is varied, and negative US does not rule out the diagnosis.
- US should be used to rule out the presence of placenta previa and accrete.
- Expedited delivery is required when maternal or fetal compromise exists in the presence of abruption; in the absence of maternal and fetal compromise, management is individualized based primarily on gestational age.
- History of placental abruption is the main risk factor for recurrence, and reducing modifiable risk factors is key in future pregnancies.
- Close surveillance is required in future pregnancies.

KEY POINTS

- Placental abruption complicates approximately 1% of pregnancies but can cause major maternal and fetal morbidity.
- Placental abruption is a clinical diagnosis.
- US is not sensitive for diagnosis of an abruption, and a negative US should not rule out abruption as a diagnosis.
- US should be used to rule out placenta previa or abnormal placentation in cases of bleeding 20 weeks' gestation.
- Management is individualized and based on bleeding severity, clinical signs, and gestational age.

SUGGESTED READING

Boisrame T, Sananes N, Fritz G, et al. Placental abruption: risk factors, management and maternal-fetal prognosis. Cohort study over 10 years. *Eur J Obstet Gynecol Reprod Biol*. 2014;179:100-104.

Oyelese Y, Ananth CV. Placental abruption. *Obstet Gynecol*. 2006;108:1005-1016.

Tikkanen M. Placental abruption: epidemiology, risk factors and consequences. *Acta Obstet Gynecol Scand*. 2011;90:140-149.



All references are available online at www.expertconsult.com.

REFERENCES

1. Oyelese Y, Ananth C. Placental abruption. *Obstet Gynecol*. 2006;108: 1005-1016.
2. Ananth C, Keyes K, Hamilton A, et al. An international contrast of rates of placental abruption: an age-period-cohort analysis. *PLoS ONE*. 2015;10.
3. Tikkanen M. Placental abruption: epidemiology, risk factors and consequences. *Acta Obstet Gynecol Scand*. 2011;90:140-149.
4. Ananth C, Savitz D, Williams M. Placental abruption and its association with hypertension and prolonged rupture of membranes: a methodologic review and meta-analysis. *Obstet Gynecol*. 1996;88:309-318.
5. Stella C, Sibai B. Thrombophilia and adverse maternal-perinatal outcome. *Clin Obstet Gynecol*. 2006;49:850-860.
6. Zdoukopoulos N, Zintzaras E. Genetic risk factors for placental abruption: a HuGE review and meta-analysis. *Epidemiology*. 2006;19:309-323.
7. Denis M, Enquobahrie D, Tadesse M, et al. Candidate gene association study of placental abruption. *PLoS ONE*. 2014;9.
8. Brown H. Trauma in pregnancy. *Obstet Gynecol*. 2009;114:147-160.
9. Dommisse J, Tiltman A. Placental bed biopsies in placental abruption. *Br J Obstet Gynaecol*. 1992;99:651-654.
10. Blumenfeld Y, Baer R, Druzin M, et al. Association between maternal characteristics, abnormal serum aneuploidy analytes, and placental abruption. *Am J Obstet Gynecol*. 2014;211:144.e1-144.e9.
11. Parker S, Werler M, Gissler M, et al. Placental abruption and subsequent risk of pre-eclampsia: a population-based case–control study. *Paediatr Perinat Epidemiol*. 2015;29:211-219.
12. Rai S, Singh R. Couvelaire uterus with coagulopathy—a rare case report. *Int J Sci Appl Res*. 2014;3:364-365.
13. Hurd W, Miodovnik M, Hertzberg V, et al. Selective management of abruptio placentae: a prospective study. *Obstet Gynecol*. 1983;61:467-473.
14. Ananth C, VanderWeele T. Placental abruption and perinatal mortality with preterm delivery as a mediator: disentangling direct and indirect effects. *Am J Epidemiol*. 2011;174:99-108.
15. Karegard M, Gennser G. Incidence and recurrence rate of abruptio placentae in Sweden. *Obstet Gynecol*. 1986;67:523-528.
16. Nyberg D, Mack L, Benedetti T, et al. Placental abruption and placental hemorrhage: correlation of sonographic findings with fetal outcome. *Radiology*. 1987;164:357-361.
17. Nyberg D, Cyr D, Mack L, et al. Sonographic spectrum of placental abruption. *AJR Am J Roentgenol*. 1987;148:161-164.
18. Scholl J. Abruptio Placentae: Clinical management in nonacute cases. *Am J Obstet Gynecol*. 1987;156:40-51.
19. Glantz C, Purnell L. Clinical utility of sonography in the diagnosis and treatment of placental abruption. *J Ultrasound Med*. 2002;21:837-840.
20. Riihimaki O, Metsaranta M, Ritvanen A, et al. Anomalies in births with placental abruption. *Obstet Gynecol*. 2014;122:268-274.
21. Masselli G, Brunelli R, DiTola M, et al. MR imaging in the evaluation of placental abruption: correlation with sonographic findings. *Radiology*. 2011;259:222-230.
22. Wei S, Helmy M, Cohen A. CT evaluation of placental abruption in pregnant trauma patients. *Emerg Radiol*. 2009;16:365-373.
23. Neilson J. Interventions for treating placental abruption. *Cochrane Database Syst Rev*. 2003;(1).
24. Gyamfi-Bannerman C, Thom E, Blackwell S, et al. Antenatal betamethasone for women at risk for late preterm delivery. *N Engl J Med*. 2016;374:1311-1320.
25. Bond A, Edersheim T, Curry L, et al. Expectant management of abruptio placentae before 35 weeks' gestation. *Am J Perinatol*. 1989;6:121-123.
26. Towers C, Pircon P, Heppard M. Is tocolysis safe in the management of third-trimester bleeding? *Am J Obstet Gynecol*. 1999;180:1572-1578.
27. Hladky K, Yankowitz J, Hansen W. Placental abruption. *Obstet Gynecol Surv*. 2002;57:299-305.
28. Ananth C, Oyelese Y, Yeo L, et al. Placental abruption in the United States, 1979 through 2001: temporal trends and potential determinants. *Am J Obstet Gynecol*. 2005;192:191-198.
29. Ruiter L, Ravellia A, de Graaf I, et al. Incidence and recurrence rate of placental abruption: a longitudinal linked national cohort study in the Netherlands. *Am J Obstet Gynecol*. 2015;213:573.e1-573.e8.
30. Boisrame T, Sananes N, Fritz G, et al. Placental abruption: risk factors, management and maternal-fetal prognosis. Cohort study over 10 years. *Eur J Obstet Gynecol Reprod Biol*. 2014;179:100-104.

97 Placenta Accreta

LESLIE MOROZ | MARY E. D'ALTON

Introduction

The rising rates of cesarean delivery in recent years have led to an increase in the diagnosis of placenta accreta, increta, and percreta. Also referred to as morbidly adherent placenta or abnormally invasive placentation, this spectrum of conditions refers to excessive invasion of the placenta into the uterus. Placenta accreta is associated with significant maternal morbidity and a mortality rate of up to 7%.[1,2] However, delivery in a tertiary referral center by a multidisciplinary team, consistent with the proposed criteria for an accreta "center of excellence," has been shown to attenuate these risks.[3,4] A high index of suspicion and prenatal imaging are critical for identifying patients at risk and planning for delivery.

Disease

DEFINITION

Placenta accreta specifically indicates trophoblastic invasion beyond the Nitabuch fibrinoid layer but not into the myometrium. Placenta increta describes invasion into the myometrium. Placenta percreta indicates invasion beyond the uterine serosa, which may involve adjacent organs such as the bladder or vessels. This chapter uses the term *placenta accreta* to describe all three conditions.

While placenta accreta may be suspected prenatally, the clinical diagnosis is made when either part or the entire placenta fails to separate from the uterus at the time of delivery, often resulting in massive hemorrhage requiring hysterectomy. Fig. 97.1 shows a hysterectomy specimen with placental tissue adherent to the myometrium after attempted removal of the placenta in a case where diagnosis was not suspected prenatally. Pathologic examination of the surgical specimen is the gold standard to confirm the diagnosis by histologic demonstration of abnormal trophoblastic invasion.

PREVALENCE AND EPIDEMIOLOGY

Placenta accreta is reported to complicate 1:533 to 1:2500 deliveries; this represents a 10-fold increase over the last 50 years.[5] The major risk factors are prior cesarean deliveries and the presence of placenta previa in the current pregnancy.[5,6] In the presence of placenta previa, the risk of invasive placentation increases with the number of previous cesarean deliveries, reaching 50% to 67% with four or more previous cesarean deliveries.[5,7,8] Additional risk factors include advanced maternal age, smoking, multiparity, previous curettage or myomectomy, Asherman syndrome, prior endometrial ablation, a history of pelvic radiation, and submucosal fibroids.[5–10] Among cases of invasive placentation, the majority (75%) are consistent with a histologic diagnosis of accreta, whereas diagnoses of increta (18%) or percreta (7%) are less common.[6]

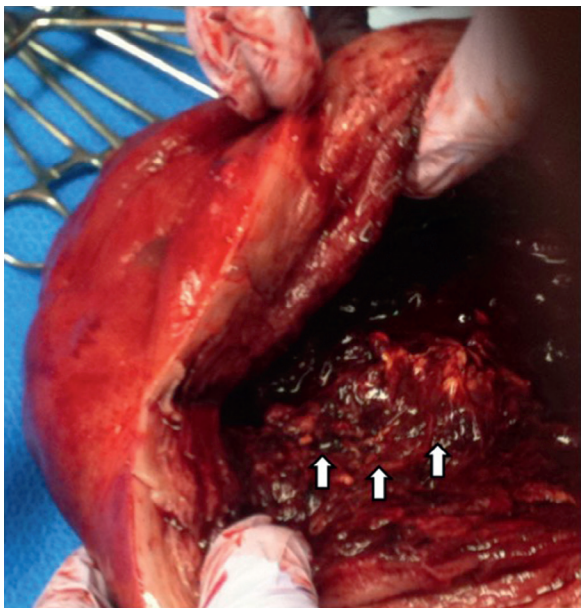

Fig. 97.1 Hysterectomy specimen with placental tissue adherent to the myometrium (*arrows*) after attempted delivery of the placenta in a case of posterior accreta not suspected on prenatal imaging. Final pathology demonstrated placenta increta.

ETIOLOGY AND PATHOPHYSIOLOGY

Defects of the decidua basalis and excessive trophoblast invasion secondary to failed reconstitution of the endometrium after prior injury are considered to be underlying predisposing factors for invasive placental implantation.[11] Histologic confirmation of placenta accreta usually involves demonstration of trophoblasts in direct contact with the myometrium, invading the myometrium, or extending into or beyond the uterine serosa.

MANIFESTATIONS OF DISEASE

Clinical Presentation

The most important step in diagnosis is to have a high index of suspicion for a diagnosis of placenta accreta in patients with risk factors. A history of cesarean delivery or prior uterine surgery, particularly in women who also have a diagnosis of placenta previa or low-lying placenta in the current pregnancy, should prompt a thorough evaluation for evidence of placenta accreta. Patients may remain asymptomatic during the prenatal period, or, if there is placenta previa or low-lying placenta, they may present with bleeding. There have been a few reports of spontaneous uterine rupture and subsequent intraabdominal hemorrhage in the second half of pregnancy[12] and cases of placenta accreta manifesting with excessive hemorrhage at the time of dilatation and evacuation in the second trimester.[13] There are no prenatal symptoms that are specific to the diagnosis of invasive placentation.

Abnormal placental invasion may be apparent at the time of laparotomy for cesarean delivery: the placental mass may be seen distorting the lower uterine segment, sometimes with engorged and abnormal-appearing vasculature, and can extend into the bladder or toward the pelvic sidewalls. However, in some cases, placenta accreta may not be suspected until difficulties are encountered when separating the placenta in the third stage of labor or when heavy bleeding occurs from the implantation site (see Fig. 97.1).[8] Women with placenta accreta experience higher estimated blood loss, with an average loss of 3000 to 5000 mL, and require more transfusions than women with previa who do not have accreta.[8–10,12] Massive bleeding may require hysterectomy or may result in surgical injury to adjacent organs, acute respiratory distress syndrome, renal failure, disseminated intravascular coagulation, or death.[12]

Imaging Technique and Findings

Ultrasound. All women with a prior cesarean delivery, placenta previa or a low-lying placenta, prior uterine surgery or a history of Asherman syndrome, prior endometrial ablation, or pelvic radiation should be assessed for possible placenta accreta in the midtrimester.[3] Ordering clinicians should communicate these risks to imagers to ensure that a thorough assessment is performed. Transabdominal and transvaginal ultrasound (US) can be further enhanced by use of Doppler imaging and potentially three-dimensional (3D) imaging.[14,15] Between careful imaging and evaluation of risk factors, obstetricians can identify patients who will benefit from referral to an accreta center of excellence that is equipped to provide preoperative planning and the necessary intraoperative services.

In the first trimester, US may demonstrate a gestational sac located in the lower uterine segment. A retrospective cohort study of 94,230 patients, 20 of whom were ultimately diagnosed with placenta accreta at the time of delivery, identified seven

patients with first-trimester imaging at 10 weeks' gestation or before. The gestational sac was located in the lower uterine segment in six of seven patients, as opposed to the fundal location in which it is expected to be found before 11 weeks' gestation.[16] Cesarean scar ectopic pregnancy refers to implantation of the gestational sac at the location of a prior hysterotomy and differs from placenta accreta in that the gestational sac is completely surrounded by myometrium and/or scar tissue, separate from the endometrial cavity. However, growth of trophoblastic tissue may occur in the direction of the cervix and uterine cavity, or toward the bladder and abdominal cavity, eventually resulting in either placenta accreta or abdominal pregnancy.[6,7] Timor-Tritsch et al.[17] described 60 patients with cesarean scar pregnancies, nine of whom elected expectant management and had outcomes available. Eight patients eventually required hysterectomy: three following cesarean delivery of live-born offspring and five after second-trimester complications including uterine rupture (three), uterine dehiscence (one), and bulging membranes (one).[17] One patient underwent cesarean delivery at 36 weeks and was subsequently lost to follow-up. Sonographically, cesarean scar ectopic pregnancy is differentiated from an incomplete abortion by demonstration of an empty uterine cavity and cervical canal, a gestational sac in the anterior aspect of the uterine isthmus, a defect in the myometrial tissue posterior to the bladder, and circumferential vascular flow around the gestational sac on Doppler imaging.[18]

US findings suggestive of placenta accreta in the second and third trimesters include: (1) loss of the retroplacental "clear space," the hypoechoic border between the placenta and myometrium (Fig. 97.2), (2) bulging of the placenta into the posterior aspect of the bladder because of increased vascularity at the interface with the bladder (Figs. 97.3 and 97.4), and (3) multiple vascular lacunae within the placenta, which appear as irregular anechoic spaces with a "moth-eaten" or "Swiss cheese" appearance and may demonstrate turbulent Doppler flow (see Figs. 97.3 and 97.4). Several series have reported on the test characteristics of individual sonographic markers as presented in Table 97.1. Lacunae are reported to be the single most predictive sonographic marker, with a sensitivity of 79% at 15 to 20 weeks' gestation and 93% at 15 to 40 weeks' gestation.[15,19,20] Some have reported that the higher the number of lacunae, the higher the risk of placenta accreta.[18] Loss of the retroplacental hypoechoic space has been reported to be responsible for the most false-positive

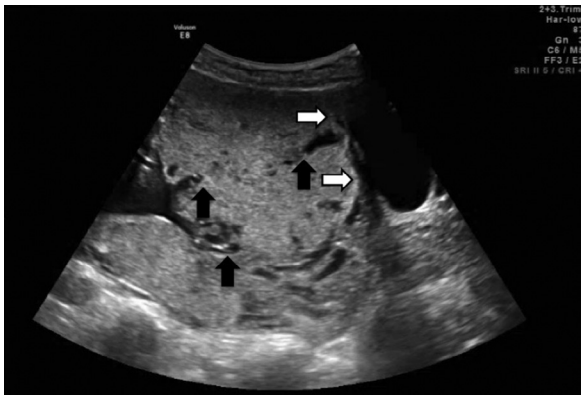

Fig. 97.3 Placenta accreta in the early third trimester. The echogenic border between the uterus and the bladder is absent, the placenta appears to bulge into the bladder (*white arrows*), and multiple anechoic lacunae are seen (*black arrows*).

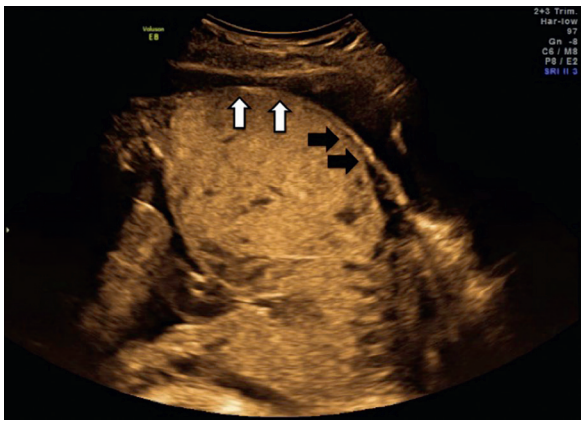

Fig. 97.2 Placenta accreta in the early third trimester. The hypoechoic space between the placenta and the myometrium (*black arrows*) is disrupted superiorly (*white arrows*).

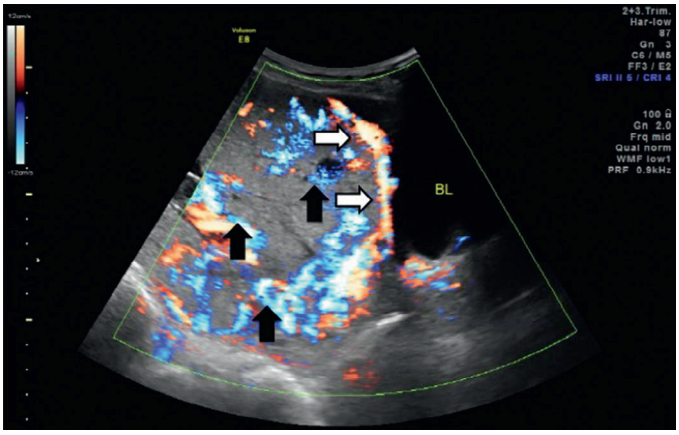

Fig. 97.4 Power Doppler demonstrates increased vascularity between the placenta and the bladder (*white arrows*) and turbulent flow within the lacunae (*black arrows*).

TABLE 97.1 RANGE OF TEST CHARACTERISTICS FOR SONOGRAPHIC MARKERS OF INVASIVE PLACENTATION REPORTED IN THE LITERATURE

	Sensitivity %	Specificity %	PPV %	NPV %
Loss of retroplacental clear space	73–100	35–81	14–57	97–100
Loss of boundary between bladder and placenta	11–70	99–100	75–100	88–92
Lacunae	73–100	28–97	21–94	88–100
Turbulent blood flow on color Doppler	89–100	94–100	80–100	97–100

NPV, Negative predictive value; *PPV*, positive predictive value.

diagnoses.[15,20] Color flow Doppler US may provide another means of visualizing abnormal vasculature suggestive of invasive placentation. Sensitivity of 82% to 100% and specificity of 72% to 100%[14,19] have been reported in some series, although these retrospective studies may be limited by case selection bias and single technicians with particular experience with this technique. A technique for estimating the largest confluent area of 3D power Doppler signal at the uteroplacental interface has also been described. The calculated area of confluence (cm^2) was reported to provide a quantitative means for the diagnosis of placenta accreta and for determining the severity of invasion.[21] While promising, such calculations should be subject to further validation before being introduced into routine clinical practice.

Overall, the reported sensitivity of US for diagnosing placenta accreta, defined by histologic confirmation of invasive placentation, using the features previously described, ranges from 53% to 100%, with estimates of specificity ranging from 37% to 96%.[12,19,22–29] As previously mentioned, many studies are subject to criticism that knowledge of clinical circumstances, interpretation of imaging by a single or few experts, and selection cases may bias the reporting of test characteristics. In a recent case-control study of images from patients with placenta previa with and without accreta that were reviewed by six investigators with similar levels of training and experience, who were blinded to clinical circumstances, the reported sensitivity was only 53.5% with a specificity of 88%.[28] Furthermore, the authors reported that there was a wide range in interobserver variability in the diagnoses given by the interpreting provider ($\kappa = 0.32$ to 0.73).[29] The use of a Placenta Accreta Index, derived from predictive sonographic features and a history of at least two prior cesarean deliveries, has been proposed to standardize sonographic assessment and aid in risk assessment.[30] Additional studies are still needed to validate this scoring system. While US is an essential tool for characterizing placentation, these studies highlight that it is not a perfect test, and clinicians should maintain an index of suspicion for the diagnosis even in at-risk patients in whom imaging is not suggestive of accreta. When imaging is planned for high-risk patients, the ordering physician should clearly indicate that an assessment for evidence of invasive placentation is requested.

Magnetic Resonance Imaging. Magnetic resonance imaging (MRI) is more expensive and less accessible than US; however, some have questioned whether MRI might provide superior diagnostic accuracy. The sensitivity of MRI for placenta accreta is reported to range from 75% to 100%, with a specificity of 84% to 100%, ranges of test characteristics that are similar to those of US.[23–25,31,32] While MRI has not been demonstrated to be superior to US, it may serve as a useful adjunct in some cases. MRI is especially recommended for cases of posterior placenta or in attempts to better diagnose the extent of invasion into adjacent structures.[23,31,32] MRI findings most predictive of placenta accreta include T2-dark intraplacental bands, heterogeneity of the placenta, bulging of the uterus, and interruption of the uteroplacental interface.[31,32]

Other Applicable Modality. A few studies evaluating the diagnostic role of maternal second-trimester serum markers have shown that elevated alpha-fetoprotein and β-human chorionic gonadotropin are associated with placenta accreta.[33,34] One possible explanation is that an abnormal placental-uterine interface allows leakage into the maternal circulation. Similarly, the hypothesis has been posited that an abnormally vascularized placenta may lead to altered levels of angiogenic and antiangiogenic substances. However, an investigation of serum markers of angiogenesis demonstrated that levels observed in pregnancies with and without evidence of placenta accreta were similar.[35]

Differential Diagnosis From Imaging Findings

A false-positive diagnosis of placenta accreta is possible using any of the imaging modalities described earlier. Uterine scar windows, aberrant blood vessels around the cervix, or bladder varices, for example, may be falsely interpreted as evidence of placenta accreta. However, when placenta previa is diagnosed, even with a false-positive diagnosis of accreta, patients remain at risk for obstetric hemorrhage, and careful delivery planning is warranted.

Synopsis of Treatment Options

PRENATAL

Suspecting a possible diagnosis of placenta accreta before delivery is critical because it permits appropriate delivery planning to minimize the potentially significant morbidity or mortality associated with this diagnosis. Placenta accreta has been associated with impaired fetal growth, so serial growth scans should be performed.[36] When accreta is suspected, referral to a high-volume center with a multidisciplinary team experienced in cesarean hysterectomy, intensive care facilities, and blood services—the features of an accreta center of excellence—is recommended.[3] Maternal-fetal medicine, gynecologic oncology, obstetric anesthesia, blood bank, and perfusion therapy specialists may be involved in coordinating care. Interventional radiology, urology, vascular surgery, and intensive care specialists may also be required.[3] Studies have shown decreased morbidity if cesarean hysterectomy is required in a setting where access to these resources is available.[3,37] Patients diagnosed with placenta accreta should be counseled about the likelihood of hysterectomy and blood transfusion, as well as the possibility of involvement of adjacent structures requiring more extensive surgery.[38]

The mode of delivery in cases of suspected placenta accreta is by cesarean, and the timing is generally between 34 weeks 0 days and 35 weeks 6 days in the absence of other complications of pregnancy.[39] Knowledge of placental location is a key component of preoperative planning, and use of a portable US for mapping placental boundaries before surgical incision may be helpful. A fundal hysterotomy is often performed to avoid disruption of the placenta (Fig. 97.5). If the suspicion of accreta is confirmed at the time of delivery, the surgeon clamps the umbilical cord after delivery, leaves the placenta *in situ,* and completes the hysterectomy after closing the uterine incision with a whipstitch (Fig. 97.6). Additional interventions before delivery may include preoperative cystoscopy and placement of ureteric stents to prevent urinary tract injury.[3] Placement of prophylactic pelvic artery balloon catheters is controversial; although the procedure has the potential to decrease blood loss, risks include vascular injury, thrombosis, and infection.[40–42] Preoperative placement of balloon catheters was shown not to decrease the number of units of packed red blood cells transfused in a randomized controlled trial of women with a preoperative diagnosis of placenta accreta.[42]

Neonatal outcomes in cases of placenta accreta are reported to be similar to outcome in cases of previa without accreta.[8]

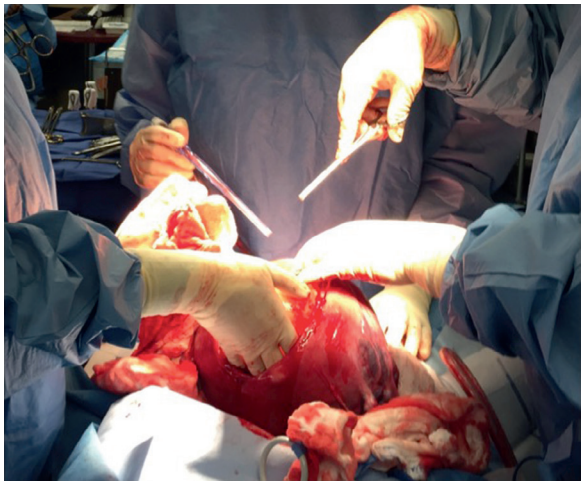

Fig. 97.5 A fundal hysterotomy is performed to avoid disruption of the placenta at the time of delivery.

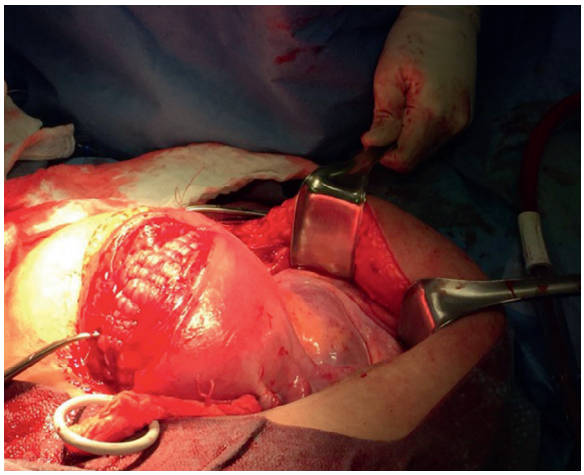

Fig. 97.6 Fundal hysterotomy closed with a whipstitch before completion of hysterectomy.

POSTNATAL

Because placenta accreta may cause massive intrapartum hemorrhage,[8] it is one of the leading causes of cesarean hysterectomy.[1] The condition has been associated with an increase in postoperative morbidity, including infection, ureteral and bladder damage, fistula formation, intensive care unit admission, and reoperation.[2,9] Interval hysterectomy following postdelivery selective embolization of the uterus and placental bed has been proposed to minimize surgical morbidity, and conservative management with the goal of uterine conservation has also been described.[43–46] The efficacy of these procedures has not been proven, and the risk of severe morbidity is significant, including hemorrhage, sepsis, and the need for emergent surgery.[46] In the absence of conclusive supporting data, uterine preservation should be considered only when a patient has a strong desire to preserve fertility. In these cases, both the physician and the patient need to understand the risk of potential complications in the postpartum period and develop a plan for surveillance. Furthermore, counseling about the risk for recurrent placenta accreta in subsequent pregnancies is appropriate.[47,48]

WHAT THE REFERRING PHYSICIAN NEEDS TO KNOW

- A history of cesarean delivery and placenta previa in the current pregnancy are the main risk factors for development of placenta accreta.
- Patient counseling regarding risks in pregnancy after any cesarean delivery should include risks of abnormal placentation and associated morbidities.
- US is the preferred technique for prenatal diagnosis of placenta accreta; MRI may be used adjunctively in certain conditions. Physicians who order imaging studies should clearly indicate that an evaluation for invasive placentation should be performed for patients with risk factors.
- When accreta is suspected, the patient should be counseled about potential morbidity and the possibility of hysterectomy.
- Delivery by a multidisciplinary team at a high-volume center or accreta center of excellence is recommended.

KEY POINTS

- The incidence of placenta accreta has increased dramatically in recent decades.
- A diagnosis of placenta accreta should be considered in all women with any of the following: prior cesarean delivery, placenta previa or low-lying placenta and a history of prior uterine surgery, Asherman syndrome, endometrial ablation, or pelvic radiation.
- Placenta accreta may be associated with significant morbidity, and optimal management requires a multidisciplinary team approach.

SUGGESTED READING

Hull AD, Resnik R. Placenta previa, placenta accreta, abruptio placentae and vasa previa. In: Creasy RK, Resnik R, Iams JD, et al., eds. *Creasy and Resnik's Maternal Fetal Medicine: Principles and Practice*. 7th ed. Philadelphia.: Saunders; 2014:732-742.

Silver RM, Fox KA, Barton JR, et al. Center of excellence for placenta accreta. *Am J Obstet Gynecol*. 2015;212:561-568.

All references are available online at www.expertconsult.com.

REFERENCES

1. Shellhaas CS, Gilbert S, Landon MB, et al. The frequency and complication rates of hysterectomy accompanying cesarean delivery. *Obstet Gynecol*. 2009;114:224-229.
2. ACOG committee opinion. Placenta accreta. *Obstet Gynecol*. 2002;99: 169-170.
3. Silver RM, Fox KA, Barton JR, et al. Center of excellence for placenta accreta. *Am J Obstet Gynecol*. 2015;212:561-568.
4. Eller AG, Bennet MA, Sharshiner M, et al. Maternal morbidity in cases of placenta accreta managed by a multidisciplinary care team compared with standard obstetric care. *Obstet Gynecol*. 2011;117:331-337.
5. Wu S, Kocherginsky M, Hibbard JU. Abnormal placentation: twenty-year analysis. *Am J Obstet Gynecol*. 2005;192:1458-1461.
6. Miller DA, Chollet JA, Goodwin MT. Clinical risk factors for placenta previa–placenta accreta. *Am J Obstet Gynecol*. 1997;177:210-214.
7. Clark SL, Koonings PP, Phelan JP. Placenta previa/accreta and prior cesarean section. *Obstet Gynecol*. 1985;66:89-92.
8. Usta IM, Hobeika EM, Abu Musa AA, et al. Placenta previa-accreta: risk factors and complications. *Am J Obstet Gynecol*. 2005;193:1045-1049.
9. Silver RM, Landon MB, Rouse DJ, et al. Maternal morbidity associated with multiple repeat cesarean deliveries. *Obstet Gynecol*. 2006;107: 1226-1232.
10. Zaki ZMS, Bahar AM, Ali ME, et al. Risk factors and morbidity in patients with placenta previa accreta compared to placenta previa non accreta. *Acta Obstet Gynecol Scand*. 1998;77:391-394.
11. Tantbirojn P, Crum CP, Parast MM. Pathophysiology of placenta creta: the role of deciduas and extravillous trophoblast. *Placenta*. 2008;29:639-645.
12. Oyelese Y, Smulian JC. Placenta previa, placenta accreta and vasa previa. *Obstet Gynecol*. 2006;107:927-941.
13. Rashbaum WK, Gates EJ, Jones J, et al. Placenta accreta encountered during dilation and evacuation in the second trimester. *Obstet Gynecol*. 1995;85:701-703.
14. Lerner JP, Deane S, Timor-Tritsch IE. Characterization of placenta accreta using transvaginal sonography and color Doppler imaging. *Ultrasound Obstet Gynecol*. 1995;5:198-201.
15. Comstock CH. Antenatal diagnosis of placenta accreta: a review. *Ultrasound Obstet Gynecol*. 2005;26:89-96.
16. Comstock CH, Bronsteen RA. The antenatal diagnosis of placenta accreta. *BJOG*. 2014;121:171-181.
17. Timor-Tritsch IE, Khatib N, Monteagudo A, et al. Cesarean scar pregnancies: experience of 60 cases. *J Ultrasound Med*. 2015;34:601-610.
18. Ash A, Smith A, Maxwell D. Caesarean scar pregnancy. *BJOG*. 2007;114:253-263.
19. Finberg HJ, Williams JW. Placenta accreta: prospective sonographic diagnosis in patients with placenta previa and prior cesarean section. *J Ultrasound Med*. 1992;11:333-343.
20. Cali G, Giambanco L, Puccio G, et al. Morbidly adherent placenta: evaluation of ultrasound diagnostic criteria and differentiation of placenta accreta from percreta. *Ultrasound Obstet Gynecol*. 2013;41:406-412.
21. Collins SL, Stevenson GN, Al-Khan A, et al. Three-dimensional power Doppler ultrasonography for diagnosing abnormally invasive placenta and quantifying the risk. *Obstet Gynecol*. 2015;126:645-653.
22. Chou MM, Tseng JJ, Ho ESC. Usefulness of gray-scale ultrasound and complementary color Doppler ultrasound in the prenatal diagnosis of placenta previa accreta. *Am J Obstet Gynecol*. 2004;190:1135-1140.
23. Warshak CR, Eskander R, Hull AD, et al. Accuracy of ultrasonography and magnetic resonance imaging in the diagnosis of placenta accreta. *Obstet Gynecol*. 2006;108:573-581.
24. Riteau AS, Tassin M, Chambon G, et al. Accuracy of ultrasonography and magnetic resonance imaging in the diagnosis of placenta accreta. *PLoS ONE*. 2014;9:e94866.
25. Meng X, Xie L, Song W. Comparing the diagnostic value of ultrasound and magnetic resonance imaging for placenta accreta: a systematic review and meta-analysis. *Ultrasound Med Biol*. 2013;39:1958-1965.
26. Esakoff TF, Sparks TN, Kaimal AJ, et al. Diagnosis and morbidity of placenta accreta. *Ultrasound Obstet Gynecol*. 2011;37:324-327.
27. Chalubinski KM, Pils S, Klein K, et al. Prenatal sonography can predict degree of placental invasion. *Ultrasound Obstet Gynecol*. 2013;42: 518-524.
28. Bowman ZS, Eller AG, Kennedy AM, et al. Interobserver variability of sonography for prediction of placenta accreta. *J Ultrasound Med*. 2014;33:2153-2158.
29. Bowman ZS, Eller AG, Kennedy AM, et al. Accuracy of ultrasound for the prediction of placenta accreta. *Am J Obstet Gynecol*. 2014;211:177.e1-177.e7.
30. Rac MWF, Dashe JS, Wells CE, et al. Ultrasound predictors of placental invasion: the Placenta Accreta Index. *Am J Obstet Gynecol*. 2015;212: 343.e1-343.e7.
31. D'Antonio F, Iacovella C, Palacios-Jaraquemada J, et al. Prenatal identification of invasive placentation using magnetic resonance imaging: systematic review and meta-analysis. *Ultrasound Obstet Gynecol*. 2014;44:8-16.
32. Rahaim NSA, Whitby EH. The MRI features of placental adhesion disorder and their diagnostic significance: a systematic review. *Clin Radiol*. 2015;70:917-925.
33. Kupferminc MJ, Tamura RK, Wigton TR, et al. Placenta accreta is associated with elevated maternal serum alpha fetoprotein. *Obstet Gynecol*. 1993;82:266-269.
34. Dreux S, Salomon LJ, Muller F, et al. Second-trimester maternal serum markers and placenta accreta. *Prenat Diagn*. 2012;32:1010-1012.
35. Biberoglu E, Kirbas A, Daglar K, et al. Serum angiogenic profile in abnormal placentation. *J Matern Fetal Neonatal Med*. 2016;Early online 1-5.
36. Gielchinsky Y, Mankuta D, Rojansky N, et al. Perinatal outcome of pregnancies complicated by placenta accreta. *Obstet Gynecol*. 2004;104:527-530.
37. Wright JD, Herzog TJ, Shah M, et al. Regionalization of care for obstetric hemorrhage and its effect on maternal mortality. *Obstet Gynecol*. 2010;115:1194-1200.
38. Manyonda IT, Varma TR. Massive obstetric hemorrhage due to placenta previa/accrete with prior cesarean section. *Int J Gynecol Obstet*. 1990;34:183-186.
39. Medically indicated late-preterm and early-term deliveries. Committee Opinion No. 560. American College of Obstetricians and Gynecologists. *Obstet Gynecol*. 2013;121:908-910.
40. Kayem G, Sentilhes L, Deneux-Tharaux C. Management of placenta accreta. *BJOG*. 2009;116:1536-1537.
41. Shrivastava V, Nageotte M, Major C, et al. Case-control comparison of cesarean hysterectomy with and without prophylactic placement of intravascular balloon catheters for placenta accreta. *Am J Obstet Gynecol*. 2007;197:402.e1-402.e5.
42. Salim R, Chulski A, Romano S, et al. Precesarean prophylactic balloon catheters for suspected placenta accreta: a randomized controlled trial. *Obstet Gynecol*. 2015;126:1022-1028.
43. Angstmann T, Gard G, Harrington T, et al. Surgical management of placenta accreta: a cohort series and suggested approach. *Am J Obstet Gynecol*. 2010;202:38.e1-38.e9.
44. Timmermans S, van Hof AC, Duvekot JJ. Conservative management of abnormally invasive placentation. *Obstet Gynecol Surv*. 2007;62: 529-539.
45. Bretelle F, Courbiere B, Mazouni C, et al. Management of placenta accreta: morbidity and outcome. *Eur J Obstet Gynaecol*. 2007;133:34-39.
46. Fox KA, Shamshirsaz AA, Carusi D, et al. Conservative management of morbidly adherent placenta: expert review. *Am J Obstet Gynecol*. 2015;213:755-760.
47. Provansal M, Courbiere B, Agostini A, et al. Fertility and obstetric outcome after conservative management of placenta accreta. *Int J Gynecol Obstet*. 2010;109:147-150.
48. Kayem G, Clement D, Goffinet F. Recurrence following conservative management of placenta accreta. *Int J Gynaecol Obstet*. 2007;99:142-143.
49. Wong HS, Cheung YK, Zucollo J, et al. Evaluation of sonographic diagnostic criteria for placenta accreta. *J Clin Ultrasound*. 2008;36:551-559.
50. Yang JI, Lim YK, Kim HS, et al. Sonographic findings of placental lacunae and the prediction of adherent placenta in women with placenta previa totalis and prior Cesarean section. *Ultrasound Obstet Gynecol*. 2006;28:178-182.

98 Amniotic Band Sequence

JOSES A. JAIN | KARIN M. FUCHS

Introduction

Amniotic band sequence (ABS) refers to a broad group of highly variable congenital anomalies involving multiple fetal structures. Embryologically normal fetal structures become entangled in amniotic bands, leading to constriction, disruption, and malformation defects.[1–3] The term *sequence* describes this condition as a heterogeneous pattern of malformations, which cannot be traced back to a single factor.[4]

Disorder

DEFINITION

ABS is a set of congenital malformations caused by amniotic bands that adhere, entangle, and disrupt developing fetal parts. The distribution of involvement is variable and can range from minor constriction rings and lymphedema of the digits to multiple, unusually complex anomalies of craniofacial, thoracic, abdominal, and extremity structures.[3,4]

PREVALENCE AND EPIDEMIOLOGY

The estimated incidence of ABS ranges from 1:1200 to 1:15,000 live births.[2–6] ABS affects both genders equally. African Americans are affected 1.76 times more frequently than Caucasians.[5]

ETIOLOGY, PATHOPHYSIOLOGY, AND EMBRYOLOGY

Although the etiology of ABS is unclear, several theories have been proposed to explain the occurrence of the associated anomalies. Two major theories have been suggested: the intrinsic theory, proposed by Streeter[7] in 1930, and the extrinsic theory, proposed by Torpin[8] in 1965.

1. The intrinsic theory proposes that during embryogenesis, at the time of germ disk and amniotic cavity formation, a disruption initiates a series of events leading to multiple anomalies. Streeter proposed that amniotic bands are the result, not the cause, of the pathologic process.[7] The precise cause of a germline defect leading to ABS is unknown and could be multifactorial. Various causative factors have been proposed, including teratogens and a vascular insult during early development. The intrinsic theory is often used to explain the major anomalies seen in ABS, such as craniofacial defects, body wall abnormalities, and internal organ malformations.
2. The extrinsic theory is the most widely accepted explanation for ABS. Torpin studied the placenta and fetal membranes in affected cases and surmised that primary rupture of the amnion early in gestation caused the disorder, allowing the fetus to pass from the amniotic cavity to the extraembryonic coelom through the defect.[2,8] The subsequent contact of the fetus with loose "sticky" mesoderm on the chorionic surface of the amnion would lead to entanglement of fetal parts, causing mechanical disruption, vascular disruption, or both. Swallowing the bands could cause asymmetric clefts on the face.

The actual cause of amnion rupture is variable. It has been observed following maternal abdominal trauma, after amniocentesis, and in fetuses with hereditary collagen defects (i.e., Ehlers-Danlos syndrome and osteogenesis imperfecta).[1] ABS has also been associated with maternal fever, in addition to maternal consumption of lysergic acid diethylamide, methadone, and misoprostol.

Since the early work of Streeter[7] and Torpin,[8] other authors have attempted to determine the etiology of ABS. In 1992 Moerman et al.[1] published their study of fetopathologic evaluation of 18 cases of ABS. The authors concluded that the malformations observed were caused by three distinct lesions: (1) constrictive tissue bands, (2) amniotic adhesions, and (3) complex anomaly patterns (limb–body wall complex). In the series by Moerman et al.,[1] four cases had constrictive bands involving the fetal limbs, resulting in annular deformations. No internal malformations or complex anomalies were noted in this group with constrictive bands. In contrast, cases involving broad amniotic adhesions resulted in more disfiguring malformations. The investigators concluded that constrictive bands were morphologically and pathogenetically different from adhesive amniotic bands, which are associated with more severe craniofacial defects such as encephalocele and facial clefts.[1]

MANIFESTATIONS OF DISEASE

Clinical Presentation

The clinical spectrum of ABS is highly variable. Amniotic bands most commonly affect the fetal extremities, with a greater affinity for the distal segments. Approximately 80% of ABS cases involve the fetal hands and feet, with the second, third, and fourth fingers most commonly affected.[2,3] Constriction rings and digital and limb amputations are common. Defects can range in severity from mild constriction to complete intrauterine limb amputation and fetal demise.

In general, the anomalies observed in ABS can be described as disruptions, deformations, and malformations. Disruptions refer to breakdown or alteration of otherwise normally developed tissue. The classic disruptive features in ABS include constriction bands, amputations, and acrosyndactyly. Deformation is the end result of abnormal forces acting on the developing fetus. For example, oligohydramnios can lead to scoliosis, talipes equinovarus, and joint contractures by limiting fetal movement and exerting direct pressure on developing structures. An insult during organogenesis leads to abnormal development or malformation.

Classic malformations seen in ABS include limb–body wall complex, internal organ abnormalities, and craniofacial lesions such as encephalocele.[5]

Imaging Technique and Findings

Ultrasound. ABS is associated with various features on prenatal ultrasound (US). Constriction rings of the fingers and toes are the most common findings.[9] ABS should be suspected in cases with limb amputations and in the presence of unusual, asymmetric body wall, thoracic, or craniofacial defects. In some instances, the amniotic band may be seen entangling the fetus, restricting movement within the amniotic cavity. Amniotic bands can be extremely difficult to visualize on routine US examination; in most cases, they are never seen. Inubashiri et al.[6] reported that three-dimensional and four-dimensional US can help to visualize more clearly the relationship of amniotic bands on the fetus (Figs. 98.1–98.3).[6]

The diagnosis of ABS is based on defects observed on US, with confirmation on postnatal physical examination and histopathologic evaluation of the placenta and membranes. Anomalies that can be identified on US are outlined in Table 98.1.

Magnetic Resonance Imaging. Magnetic resonance imaging (MRI) has been shown to be a useful adjunct to US examination in providing a more comprehensive view of congenital anomalies.[10] In a review by Neuman et al.,[11] prenatal MRI was shown to be able to visualize amniotic bands and their secondary manifestations, suggesting a complementary role for the imaging modality.

Differential Diagnosis From Imaging Findings. Because of the highly variable involvement of multiple fetal structures in ABS, the differential diagnosis is dependent on the specific defects noted on US. In the case of isolated constrictive amniotic bands, possible etiologies include lymphatic and vascular malformations.

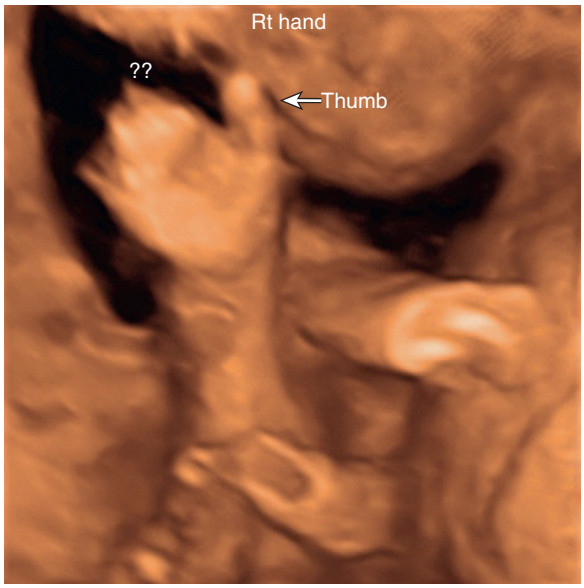

Fig. 98.1 Three-dimensional rendering showing amputation of distal phalanges. *??*, Fingers with absent distal phalanges; *Rt*, right.



Fig. 98.3 Two-dimensional image showing swelling of the fetal foot because of constriction by an amniotic band.

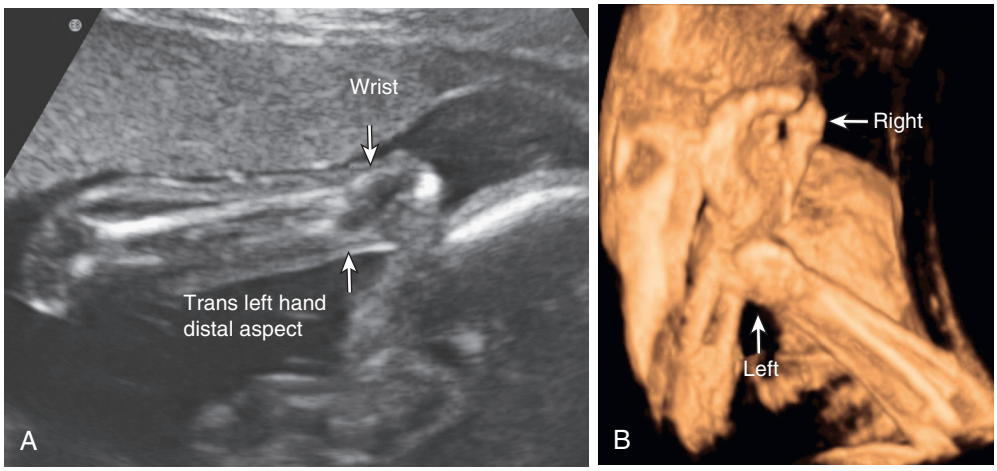

Fig. 98.2 (A) Two-dimensional grayscale image of the left fetal forearm showing amputation distal to the wrist. (B) Three-dimensional rendering confirming the absence of the left fetal hand with a normal distal right upper extremity.

TABLE 98.1 ULTRASOUND FINDINGS IN AMNIOTIC BAND SEQUENCE

LIMBS	
	Constriction rings of limbs or digits
	Amputation of limbs or digits
	Lymphedema
	Pseudosyndactyly
	Clubfoot
CRANIOFACIAL	
	Encephalocele (asymmetric)
	Anencephaly
	Acrania
	Cleft lip/palate and face (asymmetric)
	Nasal deformities
	Asymmetric microphthalmia
THORAX AND ABDOMEN	
	Slash-like defect with evisceration
	Gastroschisis
	Omphalocele
	Bladder exstrophy
PERINEUM	
	Ambiguous genitalia
	Imperforate anus

Color Doppler interrogation should show blood flow to the region in question if a vascular malformation is present.[2] If the upper extremity is affected, VACTERL (*v*ertebral anomalies, *a*nal atresia, *c*ardiac defects, *t*racheoesophageal fistula and/or *e*sophageal atresia, *r*enal and *r*adial anomalies, *l*imb defects) association and Fanconi anemia should be considered. Benign processes such as intrauterine synechiae and chorion-amnion separation can also mimic ABS without the associated fetal anomalies.[2,3]

Synopsis of Treatment Options

PRENATAL

Although most experts agree that extremity ABS is not an indication for fetoscopic surgery, some advocate *in utero* therapy to avoid the devastating deformation and limb amputation that results from the progressive constriction.[12–16] Because umbilical cord constriction can be fatal, there is widespread agreement that prenatal intervention should be considered after careful assessment of the maternal risks and procedure-related complications. Complications of surgery may include preterm delivery, premature rupture of membranes, and infection.[2] Fetuses with more severe defects of the craniofacial region or with limb–body wall complex should not be considered candidates for *in utero* surgical intervention, owing to poor prognosis.

POSTNATAL

Fetuses with a prenatal diagnosis of ABS should be delivered in a tertiary care center where multispecialty care is available. Postnatal care requires a team of neonatology, pediatric surgery, and pediatric plastic and orthopedic surgery specialists. Depending on the severity of the deformity at delivery, intervention may involve minor surgery to release a constrictive band or a more extensive procedure for débridement, reconstruction, and, in some cases, amputation.[3] Cases of limb–body wall complex are universally fatal, and surgical intervention is not indicated.

WHAT THE REFERRING PHYSICIAN NEEDS TO KNOW

ABS refers to a highly variable set of malformations involving early amnion disruption. There can be amputations or constrictions of limbs, or various asymmetric abnormalities.

KEY POINTS

- ABS refers to a group of highly variable congenital malformations associated with amniotic bands.
- Defects can range from constriction bands encircling digits or a limb, to more complex and unusual patterns involving the thoracic, abdominal, and craniofacial regions.
- Amniotic bands are difficult to visualize on routine US evaluation. Diagnosis is made on the basis of the observed defects.
- *In utero* therapy is experimental and should be considered on a case-by-case basis.
- Prognosis depends on the severity of the anomalies; extensive craniofacial lesions and limb–body wall complex carry a worse prognosis.

SUGGESTED READING

Bodamer O. Amniotic band sequence. In: Basow DS, ed. *UpToDate*. Waltham, MA: 2010.

Lockwood C, Ghidini A, Romero R, et al. Amniotic band syndrome: reevaluation of its pathogenesis. *Am J Obstet Gynecol*. 1989;160:1030.

Purandare S, Zackai E. Amniotic band sequence. *Neoreviews*. 2005;6(12): e567-e571.



All references are available online at www.expertconsult.com.

REFERENCES

1. Moerman P, Fryns JP, Vandenberghe K, et al. Constrictive amniotic bands, amniotic adhesions, and limb-body wall complex: discrete disruption sequence with pathogenic overlap. *Am J Med Genet*. 1992;42:470.
2. Bianchi D, Crombleholme T, D'Alton M, et al. *Fetology: Diagnosis and Management of the Fetal Patient*. 2nd ed. New York: McGraw-Hill; 2010.
3. Moran S, Jensen M, Bravo C. Amniotic band syndrome of the upper extremity: diagnosis and management. *J Am Acad Orthop Surg*. 2007;15:397.
4. Online Mendelian Inheritance in Man, OMIM. Johns Hopkins University, Baltimore, MD. MIM Number: 217100: 9/27/2011: Available from: http://omim.org/.
5. Goldfarb C, Sathienkijkanchai A, Robin N. Amniotic constriction band: a multidisciplinary assessment of etiology and clinical presentation. *J Bone Joint Surg Am*. 2009;91(suppl 4):68.
6. Inubashiri E, Hanaoka U, Kanenishi K, et al. 3D and 4D sonographic imaging of amniotic band syndrome in early pregnancy. *J Clin Ultrasound*. 2008;36:573.
7. Streeter G. Focal deficiencies in fetal tissue and their relation to intrauterine amputations. *Contrib Embryol*. 1930;22:1.
8. Torpin R. Amniochorionic mesoblastic fibrous strings and amniotic bands: associated constricting fetal malformations or fetal death. *Am J Obstet Gynecol*. 1965;91:65.
9. Fiedler J, Phelan J. The amniotic band syndrome in monozygotic twins. *Am J Obstet Gynecol*. 1983;14:863-864.
10. Rohrbach M, Chitayat D, Drake J, et al. Prenatal diagnosis of fetal exencephaly associated with amniotic band sequence at 17 weeks of gestation by fetal magnetic resonance imaging. *Fetal Diagn Ther*. 2007;22:112.
11. Neuman J, Calvo-Garcia M, Kline-Fath B, et al. Prenatal imaging of amniotic band sequence: utility and role of fetal MRI as an adjunct to prenatal US. *Pediatr Radiol*. 2012;42(5):544-551.
12. Soldado F, Aguirre M, Peiró J, et al. Fetoscopic release of extremity amniotic bands with risk of amputation. *J Pediatr Orthop*. 2009;29:290.
13. Quintero RA, Morales WJ, Phillips J, et al. In utero lysis of amniotic bands. *Ultrasound Obstet Gynecol*. 1997;10:316.
14. Keswani S, Johnson M, Adzick N, et al. In utero limb salvage: fetoscopic release of amniotic bands for threatened limb amputation. *J Pediatr Surg*. 2003;38:848.
15. Javadian P, Hamshirsaz AA, Haeri S, et al. Perinatal outcome after fetoscopic release of amniotic bands: a single-center experience and review of the literature. *Ultrasound Obstet Gynecol*. 2013;42:449-455.
16. Belfort MA, Whitehead WE, Ball R, et al. Fetoscopic amniotic band release in a case of chorioamniotic separation: an innovative new technique. *AJP Rep*. 2016;6:e222-e225.

99 Chorioangioma

JACLYN M. COLETTA | MARY E. D'ALTON

Introduction

Chorioangiomas are the most common histologic type of placental tumor. They are usually well circumscribed, vascular, and predominantly hypoechoic, ranging from microscopic to several centimeters in diameter.[1]

Disease

PREVALENCE AND EPIDEMIOLOGY

Chorioangiomas are found in 0.5% to 1% of placentas examined at delivery.[2] Microangiomas are the most common but are less likely to cause any fetal or maternal complications and will often go undetected. Masses greater than 5 cm, also known as larger or giant chorioangiomas, however, are found in 1 : 10,000 to 3 : 10,000 pregnancies.[1]

ETIOLOGY AND PATHOPHYSIOLOGY

Histologically, there are two main types of chorioangiomas: angiomatous (formed from numerous blood vessels), and cellular (formed by loose mesenchymal tissue).[3] Large tumors often contain degenerative changes such as necrosis, calcification, and myxoid changes.[3] They are formed by excessive proliferation of blood vessels in chorionic villi and are perfused by the fetal circulation.[1] The size, therefore, determines the amount of fetal blood that is sequestered within the tumor and increases the risk for fetal complications.

MANIFESTATIONS OF DISEASE

Clinical Presentation

Chorioangiomas over 4–5 cm in maximum diameter, or multiple smaller chorioangiomas, have been associated with adverse perinatal outcomes, including intrauterine growth restriction, polyhydramnios leading to preterm labor and preterm delivery, and placental abruption.[4] Fetal complications include high-output failure, thrombocytopenia due to platelet sequestration, feto-maternal hemorrhage, disseminated intravascular coagulopathy, and potentially, fetal or neonatal demise.[4]

Imaging Techniques and Findings

Ultrasound. Most chorioangiomas are small, intraplacental, singular tumors, and are often not identified on ultrasound (US) as they do not cause any complications. In addition, it is difficult to differentiate these tumors from other placental lesions.[3] They generally can appear as well-circumscribed, hypoechoic lesions compared to the surrounding placental tissue[3] (Fig. 99.1). Large tumors can be of variable shapes and can contain fibrous septae.[4] The use of Doppler is helpful in the evaluation since this is a vascular lesion with prominent blood flow[5] (Fig. 99.2). It can also estimate the degree of vascularity as increased vascularity would increase the risk for fetal complications. This may help in differentiating it from a hematoma or fibrin collection that would not have any significant blood flow.[5] Prapas et al. retrospectively reviewed cases of a suspected chorioangioma over a 9-year period.[5] As the grayscale appearance of a chorioangioma is indistinguishable from placental hemorrhage, they confirmed the utility of color flow mapping and pulsed Doppler for diagnosis.[5] In addition, color Doppler imaging can also confirm vascular channels that are continuous with the fetal circulation, ruling out other diagnoses such as degenerated myoma, placental teratoma, or incomplete hydatidiform mole.[5] Previous research has shown the benefit of color Doppler for identifying a discrete

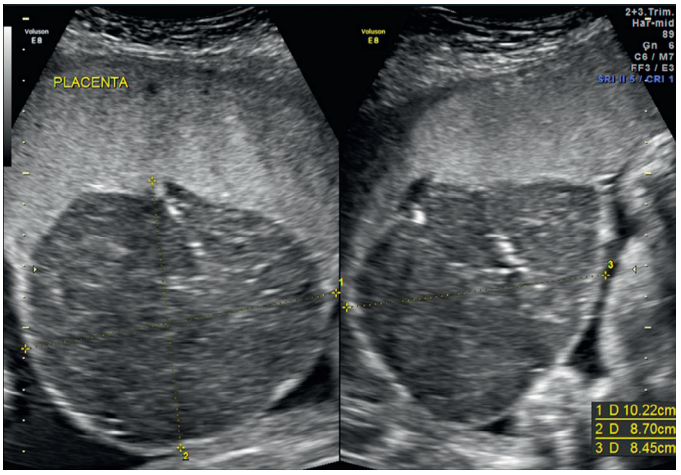

Fig. 99.1 Two-dimensional image demonstrating the homogeneous placenta with a well-circumscribed, hypoechoic mass along the anterior surface.

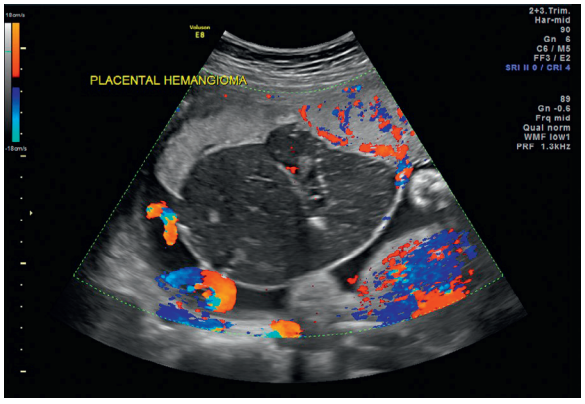

Fig. 99.2 Color Doppler demonstrating blood flow along the surface of the mass.

"feeding vessel," especially in cases when prenatal therapy is being considered.

Magnetic Resonance Imaging. Placental magnetic resonance imaging has been reported as being used as an adjunct to US placental imaging, though it is not necessary for diagnosis.[6]

Differential Diagnosis From Imaging Findings

The differential diagnosis of solid placental masses includes placental hemorrhage, placental teratoma, partial hydatidiform mole, degenerated myoma, and maternal tumor metastatic to the placenta.[7] As chorioangiomas are vascularized tumors, the use of color and pulsed Doppler can aid in the differentiation.[5]

Synopsis of Treatment Options

PRENATAL

Antenatal management depends on the size of the tumor and the presence of fetal compromise. Once the diagnosis is suspected, US surveillance is initially recommended every 2 to 3 weeks, followed by surveillance on a weekly basis beginning at 32 weeks. As the hemodynamic changes have been reported to progress rapidly, Doppler evaluation of the fetal circulation, as well as fetal echocardiography, is recommended.[1,2] Asymptomatic cases can be managed conservatively, and if fetal growth is normal and there are no signs of fetal compromise, spontaneous delivery at term is reasonable. The management of symptomatic or complicated chorioangiomas is primarily dependent on fetal symptoms and gestational age.[1] Previous cases have been treated with indomethacin and digoxin given to the mother.[8] These treatments were successful in cases with maternal mirror hydrops and cardiac failure. In 1996, Quintero et al. attempted direct treatment of a large chorioangioma by endoscopic-guided ligation and bipolar electrocautery of the feeding vessel.[9] Although the procedure itself was considered successful, the fetus died 3 days later.[9] Nicolini et al. performed a less invasive procedure of percutaneous sonographic-guided chemosclerosis using absolute alcohol.[10] These initial cases resulted in a good outcome; however, several other authors have employed the same technique without success. Embolization of the chorioangioma using microcoils and enbucrilate have also been reported but have resulted in fetal demise.[11,12] Finally, endoscopic-assisted laser coagulation of feeding vessels has been attempted in few cases with mixed results. Improvement of current techniques and more research is necessary to determine the risks and benefits of intervention.[13,14]

POSTNATAL

Given the risk for significant neonatal anemia and thrombocytopenia in cases of a large chorioangioma, delivery at a tertiary center with access to immediate neonatology evaluation is recommended.

KEY POINTS

- Chorioangiomas are the most common benign tumor of the placenta.
- They are usually well circumscribed, vascular, and predominantly hypoechoic, ranging from microscopic to several centimeters in diameter.
- Chorioangiomas over 4–5 cm in maximum diameter have been associated with adverse perinatal outcomes including intrauterine growth restriction, polyhydramnios, fetomaternal hemorrhage, fetal anemia, disseminated intravascular coagulopathy, platelet sequestration, and neonatal hypoalbuminemia.
- After diagnosis, US surveillance every 2 to 3 weeks is recommended, followed by surveillance on a weekly basis after 32 weeks to monitor for complications.
- Multiple medical and surgical interventions have been employed with unclear benefits.

SUGGESTED READINGS

Amer HZ, Heller DS. Chorioangioma and related vascular lesions of the placenta—a review. *Fetal Pediatr Pathol*. 2010;29(4):199-206.

Fan M, Skupski D. Placental chorioangioma: literature review. *J Perin Med*. 2013;42(3):273-279.

Sepulveda W, Alcalde JL, Schnapp C, et al. Perinatal outcome after prenatal diagnosis of placental chorioangioma. *Obstet Gynecol*. 2003;102:1028.

Wattar B, Hillman S, Marton T, et al. Placenta chorioangioma: a rare case and systematic review of literature. *J Matern Fetal Neonatal Med*. 2014;27(10):1055-1063.

Zalel Y, Weisz B, Gamzu R, et al. Chorioangiomas of the placenta. *J Ultrasound Med*. 2002;21:909-913.

Zanardini C, Papageorghiou A, Bhide A, et al. Giant placental chorioangioma: natural history and pregnancy outcome. *Ultrasound Obstet Gynecol*. 2010;35:332-336.



All references are available online at www.expertconsult.com.

REFERENCES

1. Wattar B, Hillman S, Marton T, et al. Placenta chorioangioma: a rare case and systematic review of literature. *J Matern Fetal Neonatal Med*. 2014;27(10):1055-1063.
2. Fan M, Skupski D. Placental chorioangioma: literature review. *J Perin Med*. 2013;42(3):273-279.
3. Amer HZ, Heller DS. Chorioangioma and related vascular lesions of the placenta—a review. *Fetal Pediatr Pathol*. 2010;29(4):199-206.
4. Zanardini C, Papageorghiou A, Bhide A, et al. Giant placental chorioangioma: natural history and pregnancy outcome. *Ultrasound Obstet Gynecol*. 2010;35:332-336.
5. Prapas N, Liang RI, Hunter D, et al. Color Doppler imaging of placental masses: differential diagnosis and fetal outcome. *Ultrasound Obstet Gynecol*. 2000;16:559-563.
6. Zaidi SF, Moshiri M, Osman S, et al. Comprehensive imaging review of abnormalities of the placenta. *Ultrasound Q*. 2016;32:25-42.
7. Benirschke K, Kaufman P. *Pathology of the Human Placenta: Benign Tumors*. New York: Springer-Verlag; 1995:pp709-pp718.
8. Kriplani A, Abbi M, Bannerjee N, et al. Indomethacin therapy in the treatment of polyhydramnios due to placental chorioangioma. *J Obstet Gynaecol Res*. 2001;27:245-248.
9. Quintero RA, Reich H, Romero R, et al. In utero endoscopic devascularization of a large chorioangioma. *Ultrasound Obstet Gynecol*. 1996;8:48.
10. Nicolini U, Zuliani G, Caravelli E, et al. Alcohol injection: a new method of treating placental chorioangiomas. *Lancet*. 1999;353:1674-1675.
11. Sepulveda W, Alcalde JL, Schnapp C, et al. Perinatal outcome after prenatal diagnosis of placental chorioangioma. *Obstet Gynecol*. 2003;102:1028.
12. Zalel Y, Weisz B, Gamzu R, et al. Chorioangiomas of the placenta. *J Ultrasound Med*. 2002;21:909-913.
13. Lau TK, Leung TY, Yu SC, et al. Prenatal treatment of chorioangioma by microcoil embolisation. *BJOG*. 2003;110:70-73.
14. Lau TK, Yu SC, Leung TY, et al. Prenatal embolisation of a large chorioangioma using enbucrilate. *BJOG*. 2005;112:1002-1004.

100 Choriocarcinoma

JACLYN M. COLETTA | JUNE Y. HOU | MARY E. D'ALTON

Introduction

Malignant gestational trophoblastic disease (GTD) occurs when there is clinical, radiologic, pathologic, or hormonal evidence of persistent trophoblastic tissue, or abnormal growth of trophoblastic tissue. This is most commonly diagnosed after a molar pregnancy, but it can occur after any type of pregnancy.[1]

Disease

DEFINITION

Choriocarcinoma is a form of malignant GTD. It arises from cytotrophoblast as well as syncytiotrophoblasts without villi, and produces human chorionic gonadotropin (hCG).[2]

PREVALENCE AND EPIDEMIOLOGY

Choriocarcinoma develops in approximately 0.6:10,000 normal gestations, 0.7:10,000 abortions, and 250:10,000 complete molar pregnancies.[1,2] It is the most aggressive form of gestational trophoblastic neoplasia (GTN), most commonly characterized by early vascular invasion and widespread metastases to the lungs, followed in frequency by the vagina, liver, and brain.[2] The two factors consistently associated with increased risk of GTN are maternal age and history of hydatidiform mole.

ETIOLOGY AND PATHOPHYSIOLOGY

Gestational choriocarcinoma is comprised of both neoplastic syncytiotrophoblast and cytotrophoblast elements without chorionic villi.[3] Choriocarcinoma is the most aggressive type of GTN, and often metastasizes hematogenously. Most choriocarcinomas have an aneuploidy karyotype, and approximately three-quarters contain a Y chromosome. Half of choriocarcinomas follow a molar pregnancy, and approximately one-fourth of choriocarcinomas are preceded by a full-term pregnancy.

MANIFESTATIONS OF DISEASE

Clinical Presentation

Following evacuation of a complete or partial molar pregnancy, the diagnosis of malignant trophoblastic disease, including choriocarcinoma, is usually made clinically based on a rising or stable serum beta hCG. However, women who develop malignant GTD after a nonmolar pregnancy usually undergo evaluation with ultrasound (US) and serum beta hCG only after they present with symptoms such as late postpartum bleeding.[2]

According to the International Federation of Gynecology and Obstetrics (FIGO), the diagnosis can be made based on clinical or histopathologic criteria including:

1. an hCG plateau for at least four values over 3 weeks
2. an hCG increase of 10% or greater for at least three values over 2 weeks
3. hCG persistence 6 months or more after molar pregnancy evacuation
4. histopathologic diagnosis of choriocarcinoma
5. presence of metastatic disease[4]

Choriocarcinoma can metastasize due to its propensity for early vascular invasion. As the most common metastatic sites are lung (80%), vagina (30%), brain (10%), and liver (10%), disease can present with respiratory symptoms such as cough, chest pain, or hemoptysis or with gastrointestinal, urologic, or intracerebral bleeding.[5]

Imaging Technique and Findings

Ultrasound. Patients with suspected malignant GTD must undergo a thorough evaluation prior to institution of therapy. Patients should have pelvic ultrasonography with Doppler to look for retained trophoblastic tissue, measure the uterine size and volume, and evaluate the pelvis for local disease spread and disease vascularity.[6] Choriocarcinomas appear as heterogeneous, echogenic uterine masses with areas of necrosis and hemorrhage. They are markedly hypervascular on Doppler interrogation.[6]

Magnetic Resonance Imaging. As pulmonary metastases are most common, chest imaging via chest radiograph or computed tomography (CT) are required to evaluate for lung metastases.[7] If lesions are noted within the chest, whole body imaging with CT or 18-fluorodeoxyglucose positron emission tomography (18-FDG-PET) scan can be used to evaluate for more widespread disease. Brain magnetic resonance imaging (MRI), and in cases of equivocal findings, a lumbar puncture may be indicated to evaluate occult cerebral or meningeal disease.[7] Choriocarcinomas typically present on MRI as heterogeneous endometrial or myometrial masses with necrosis, hemorrhage, and solid enhancing components. T2-weighted images are usually hyperintense, and MRI may also help to discern extrauterine invasion. Biopsies should not be performed because these lesions are highly vascular and may bleed heavily.

Synopsis of Treatment Options

PRENATAL

Treatment recommendations will depend on a staging system that includes the International FIGO classification of disease stage,[8] as well as the World Health Organization (WHO), which published a prognostic scoring system that assigned a weighted value to different individual clinical variables.[2] Choriocarcinoma is staged similar to malignant GTN. The total prognostic index score used was a sum of the individual component scores to

generate three risk categories. This scoring system was incorporated into the revised FIGO staging system (Tables 100.1 and 100.2).[8]

Most patients with hydatidiform mole who develop neoplasia have low-risk disease. These patients (score 0 to 6 or FIGO stage I) should be treated with single-agent methotrexate or actinomycin-D chemotherapy.[9,10] The traditional treatment consists of methotrexate given intramuscularly or intravenously for 5 to 8 days every 2 weeks.[9] In one study of 253 patients initially treated with this regimen, 89.3% achieved primary remission with methotrexate, 8.7% achieved primary remission with actinomycin-D, and only 2% required multiagent chemotherapy or hysterectomy for cure.[9] When resistance to single-agent chemotherapy develops, multiagent regimens, as for high-risk disease, should be given. Cure rates for low-risk metastatic GTN approach 100% when appropriate classification is made and proper treatment is administered.[11]

Patients with high-risk metastatic GTN (FIGO stage IV or WHO score of 7 or greater) should be treated initially with multiagent chemotherapy with or without adjuvant surgery or radiation therapy.[12,13] EMACO (*e*toposide, high-dose *m*ethotrexate with folinic acid, *a*ctinomycin D, *c*yclophosphamide, and vincristine) has been extensively studied for the past 20 years and its efficacy has been confirmed with complete response rates from 67% to 78% and long-term survival rates of 85% to 94%.[13] This protocol is currently the initial treatment of choice for high-risk metastatic GTN because of low toxicity, adherence to treatment schedules, high complete response rates, and overall high survival.[13] When central nervous system metastases are present, whole brain irradiation or surgical excision is employed along with chemotherapy.[14]

TABLE 100.1 FIGO STAGING OF GESTATIONAL TROPHOBLASTIC NEOPLASIA

Stage I	Disease confined to uterus
Stage II	Disease extending outside of uterus, but limited to genital structures
Stage III	Disease spread to lungs, with or without genital tract involvement
Stage IV	All other metastatic sites

TABLE 100.2 REVISED FIGO SCORING SYSTEM

FIGO Score	0	1	2	4
Age (years)	<40	>40	–	–
Prior pregnancy	Molar	Abortion	Term pregnancy	–
Months from prior	<4	4–6	7–12	>12
Pretreatment hCG	<1000	1000–10,000	>10,000–100,000	>100,000
Largest tumor (cm)	<3	3–4	5 or larger	–
Site of metastases	Lung, vagina	Spleen, kidney	GI tract	Brain, liver
Number of metastases	0	1–4	5–8	>8
Failed chemotherapy	–	–	Single drug	2 or more

FIGO, International Federation of Gynecology and Obstetrics; *hCg,* human chorionic gonadotropin.

POSTNATAL

After hCG remission has been achieved, patients with malignant trophoblastic disease should undergo serial determinations of hCG levels at 2-week intervals for the first 3 months of remission and then at 1-month intervals until monitoring has shown 1 year of normal hCG levels.[15,16] The risk of recurrence after 1 year of remission is less than 1%.[16] Patients must be counseled on the importance of contraception during the first year of remission. As there is a 1% to 2% risk for recurrence in a subsequent pregnancy, early US and clinical examination is recommended.[16]

KEY POINTS

- Malignant GTD occurs when there is clinical, radiologic, pathologic, or hormonal evidence of persistent trophoblastic tissue.
- Abnormal bleeding should be evaluated with beta hCG.
- Patients with suspected GTD should undergo pelvic US, chest radiography, and possible CT/MRI/PET scan for metastatic assessment.
- Biopsy of any suspicious lesion is not recommended.
- Women with low-risk disease can be treated with single-agent chemotherapy.
- Women with high-risk disease should be treated with multiagent chemotherapy.
- Post treatment, patients should be monitored with serial hCG levels for 1 year to observe for recurrence. Contraception should be used.

SUGGESTED READINGS

ACOG Practice Bulletin #53: diagnosis and treatment of gestational trophoblastic disease. *Obstet Gynecol.* 2004;103:1365.
Altieri A, Franceschi S, Ferlay J, et al. Epidemiology and aetiology of gestational trophoblastic diseases. *Lancet Oncol.* 2003;4:670.
Berkowitz R, Goldstein D. Molar Pregnancy. *N Engl J Med.* 2009;360:1639-1644.
Berkowitz R, Goldstein D. Current management of gestational trophoblastic diseases. *Gynecol Oncol.* 2009;112:654-662.
Morgan JM, Lurain JR. Gestational trophoblastic neoplasia: an update. *Curr Oncol Rep.* 2008;10:497-504.
Seckl MJ, Sebire NJ, Berkowitz R. Gestational trophoblastic disease. *Lancet.* 2010;376:717-729.
Soper JT. Gestational trophoblastic disease. *Obstet Gynecol.* 2006;108:176.



All references are available online at www.expertconsult.com.

REFERENCES

1. Berkowitz RS, Goldstein DP. Gestational trophoblastic diseases. In: Hoskins WJ, Perez CA, Young RC, eds. *Principals and Practice of Gynecologic Oncology*. 3rd ed. Philadelphia (PA): Lippincott Williams & Wilkins; 2000: 1117-1137.
2. Seckl MJ, Sebire NJ, Berkowitz R. Gestational trophoblastic disease. *Lancet*. 2010;376:717-729.
3. Morgan JM, Lurain JR. Gestational trophoblastic neoplasia: an update. *Curr Oncol Rep*. 2008;10:497-504.
4. Kohorn EI. The new FIGO 2000 staging and risk factor scoring system for gestational trophoblastic disease: description and clinical assessment. *Int J Gynecol Cancer*. 2001;11:73-77.
5. Berkowitz RS, Goldstein DP. Molar pregnancy. *N Engl J Med*. 2009;360:1639-1645.
6. Allen SD, Lim AK, Seckl MJ, et al. Radiology of gestational trophoblastic neoplasia. *Clin Radiol*. 2006;61:301-313.
7. Berkowitz RS, Goldstein DP. Molar pregnancy. *N Engl J Med*. 2009;360:1639-1645.
8. FIGO Oncology Committee. FIGO staging for gestational trophoblastic neoplasia 2000. FIGO Oncology Committee. *Int J Gynaecol Obstet*. 2002;77:285.
9. Soper JT, Clarke-Pearson DL, Berchuck A, et al. 5-day methotrexate for women with metastatic gestational trophoblastic disease. *Gynecol Oncol*. 1994;54:76-79.
10. Seckl MJ, Fisher RA, Salerno GA, et al. Choriocarcinoma and partial hydatidiform moles. *Lancet*. 2000;356:36-39.
11. Alazzam M, Tidy J, Hancock BW, et al. First line chemotherapy in low-risk gestational trophoblastic neoplasia. *Cochrane Database Syst Rev*. 2009;(1):CD007102.
12. Deng L, Yan X, Zhang J, et al. Combination chemotherapy for high-risk gestational trophoblastic tumour. *Cochrane Database Syst Rev*. 2009;(3):CD005196.
13. Turan T, Karacay O, Tulunay G, et al. Results with EMA/CO chemotherapy in gestational trophoblastic neoplasia. *Int J Gynecol Cancer*. 2006;16:1432-1438.
14. Newlands ES, Holden L, Seckl MJ, et al. Management of brain metastases in patients with high-risk gestational trophoblastic tumors. *J Reprod Med*. 2002;47:465-471.
15. Hancock BW, Tidy JA. Current management of molar pregnancy. *J Reprod Med*. 2002;47:347-354.
16. Committee on Practice Bulletins-Gynecology. American College of Obstetricians and Gynecologists. ACOG Practice Bulletin #53: diagnosis and treatment of gestational trophoblastic disease. *Obstet Gynecol*. 2004;103:1365.

101 Placenta Circumvallata

AUDREY MERRIAM | MARY E. D'ALTON

Introduction

Circumvallate placenta is a placental anomaly in which the membranous chorion transitions to a villous chorion, not at the placental edge, but at an area inward from the placental margins, closer to the insertion of the umbilical cord. This entity was first described in the 18th century.[1] Although previously thought not to affect the course of pregnancy, it may in fact be associated with several adverse pregnancy outcomes.[2]

Disorder

DEFINITION

Circumvallate placenta is a placental anomaly in which the transition from membranous to villous chorion occurs away from the placental edge, resulting in a central depression surrounded by a thickened, raised, and plicated gray-white ring on the fetal surface of the placenta and a chorionic plate that is smaller than the placental basal plate. The gray-white ring of tissue is composed of a double fold of chorion and amnion, with degenerated decidua and fibrin in between. The ring may be at varying distances from the periphery and may be found around the entire circumference of the placenta or just a portion of it, which is known as a *marginal circumvallate placenta.* The portion of the placental disk that is not covered by chorion is called the *extrachorialis*.[3]

Circummarginate placenta refers to a condition similar to circumvallate placenta, but the prominent fold and central depression is lacking. The insertion of the amnion and chorion into the placental disk occurs with a smooth transition and lacks the folding seen in the circumvallate placenta.[1,4] Again, this area of abnormal insertion of the membranes may be complete or limited to a portion of the placenta. Some placentas may show combined elements of circummarginate placenta and circumvallate placenta.

PREVALENCE AND EPIDEMIOLOGY

The reported prevalence of circumvallate placenta ranges from 0.5% to 21%.[5,6] The wide variation in prevalence is caused by multiple factors. There are no uniform inclusion criteria, so cases included may be complete and/or partial circumvallate. Population and temporal variation also accounts for some of the wide variation. More recent studies have placed the prevalence of circumvallate placenta between 1% to 7% of deliveries.[3,7]

Definite risk factors have not been identified. A few reports suggest a higher risk in a multigravida and a risk of recurrence in future pregnancies.[2,4]

ETIOLOGY, PATHOPHYSIOLOGY, AND EMBRYOLOGY

The cause of circumvallate placenta is unclear, and many theories have been proposed. One theory suggests that the extrachorialis develops as the result of bleeding at the edge of the placenta early in pregnancy.[5] Other theories attribute this condition to abnormal implantation. Older explanations theorized that the development of circumvallate placenta is caused by shallow placental implantation into the decidual layer of the endometrium.[5,8] The most widely held belief currently suggests that this condition results from excessive implantation of the blastocyst into the endometrium.[2,3,8] According to this deep implantation theory, an early placenta covers more than half of the fetal sac as a result of the deep implantation, and as the amniotic sac expands, the peripheral excess placental tissue is withdrawn from the uterine wall. The detached area of placenta slowly atrophies, leaving a double fold of chorion and amnion, with degenerated decidua and fibrin in between. This fold then settles away from the edge of the placenta, giving the characteristic rim of tissue seen on visual inspection. The ring itself may extend through the whole circumference of the placenta, or just a portion of it. The fetal surface within the ring appears normal except that large vessels terminate abruptly at the ring edge. The final result is an area, either all or partway around the placenta, where some of the placental tissue is not covered by the chorionic plate.

MANIFESTATIONS OF DISEASE

Clinical Presentation

The uncovered, extrachorialis layer has been implicated in facilitating chorioamnionitis through the spread of ascending infection and antepartum bleeding caused by lack of amnion-chorion membrane coverage. Both of these potential complications can increase the risk of preterm labor and preterm delivery.[4,5,7,9]

A circumvallate placenta has been associated with various adverse pregnancy outcomes. The range of complications varies between studies as inclusion criteria are not consistent, as discussed earlier. There are studies with no reported differences between patients with and without circumvallate placenta.[2,10] The majority of pregnancies have no symptoms that suggest the presence of circumvallate placenta.[2,4] Antepartum hemorrhage is the most common sign and usually the initial complication. Bleeding has been reported in 25%–50% of these pregnancies, thought to be arising from the uncovered, extrachorialis layer being more prone to bleeding caused by the lack of amnion-chorion membrane coverage.[4] A higher risk of placental abruption has also been reported in pregnancies with circumvallate placenta,

occurring in approximately 5% of patients with a circumvallate placenta.[4,7] Bleeding may occur at any gestational age, is usually intermittent, and is variable in amount.[5,7,11] The bleeding complications associated with circumvallate placenta can continue after delivery, as it has been associated with postpartum hemorrhage and retained placenta, requiring manual removal of the placenta.[2,5] Circummarginate placenta has also been associated with bleeding complications in the antepartum period.[4]

A watery vaginal discharge, termed *hydrorrhea gravidarum,* has been reported in 10% of pregnancies complicated by placenta circumvallate and must be differentiated from rupture of the amniotic membranes.[2] Preterm delivery can occur in 40% of circumvallate pregnancies.[5,10] Circumvallate placenta may also be responsible for early miscarriages.[2]

Reported neonatal outcomes include intrauterine growth restriction, low birth weight, and oligohydramnios. These complications could potentially be the result of the reported smaller amniotic cavity seen with circumvallate placentas.[3,6,9] Other neonatal complications associated with this placental anomaly include low Apgar scores, intrauterine fetal demise, and a higher rate of congenital malformations.[5,7,11] Perinatal mortality has been reported in 11% to 33% of pregnancies.[3,8,9] Circummarginate placenta has not been associated with increased rates of perinatal death or congenital malformations, but may be associated with an increased rate of preterm delivery.[10]

Imaging Technique and Findings

Ultrasound. Although the diagnosis of circumvallate placenta is a clinical one, there are a few reports on ultrasound (US) characteristics of this placental anomaly. US findings may include infolding of the fetal membrane on the fetal surface of the placenta during the middle of the second trimester and a bright border at the periphery of the placenta in the third trimester as a result of fibrin deposits.[3,12] A shelf of tissue, continuous with the edge of the placenta and protruding into the uterine cavity at the margin of the placenta, has also been described.[13] The extrachorialis may appear to have anechoic subamniotic cystic areas.[3] US may also reveal a detached amniotic membrane, secondary to amnion rupture (Figs. 101.1 and 101.2).[14]

Recently, three-dimensional (3D) US has been described in the use of diagnosing circumvallate placenta. The two-dimensional (2D) imaging of the placenta in this case was unremarkable, but 3D imaging revealed a central depression with a thick peripheral ring on the chorion plate. The authors described this appearance as a "tire mounted on a wheel" (Fig. 101.3). Circumvallate placenta was then confirmed after delivery.[9]

This anomaly is classically difficult to diagnose on US, regardless of 2D or 3D imaging. In a study of 139 reported cases, none were detected prenatally.[7] Another study aiming to determine the accuracy of prenatal diagnosis of circumvallate placenta found high false-positive and false-negative rates in utilizing targeted US.[14] Even if a suggestive feature is seen on US, such as a placental shelf, it may not be diagnostic of circumvallate placenta and can result in grossly normal placental pathology. The US findings can also resolve on subsequent examinations, which further decreases the chance of a circumvallate placenta.[13]

In pregnancies where circumvallate placenta is seen, a detailed fetal anatomic survey should be performed as the incidence of congenital malformations has been reported to be increased in these pregnancies.[10] In pregnancies complicated by antepartum bleeding without evidence of abruption, placenta accreta/increta/percreta or placenta previa, the diagnosis of circumvallate placenta should be considered, and detailed US of the placenta should be performed.[11]

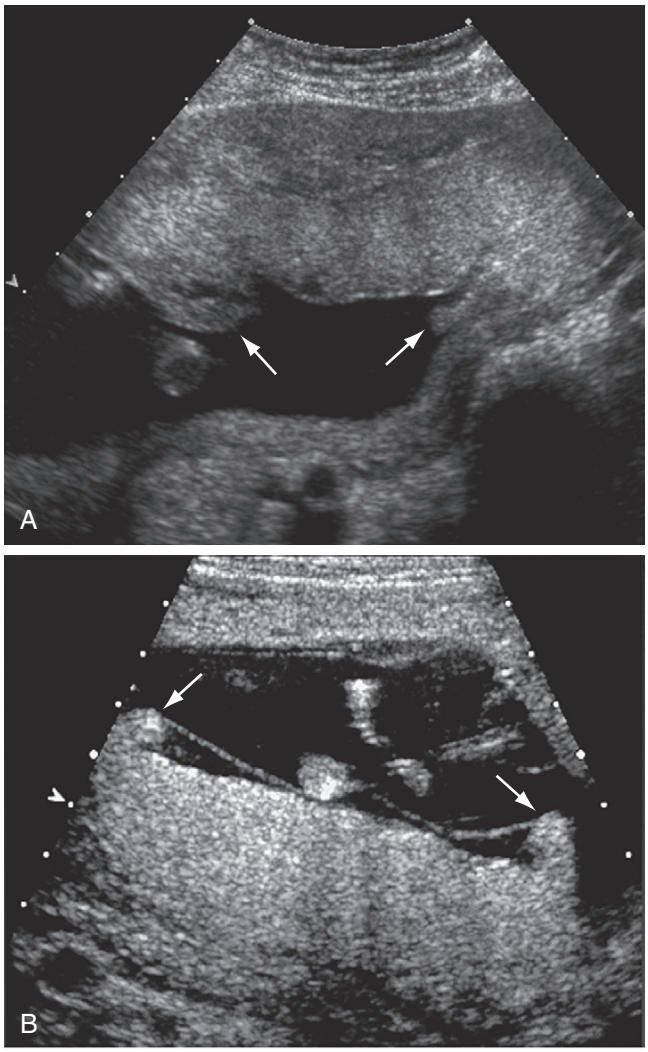

Fig. 101.1 Characteristic appearance on US of circumvallate placenta. (A) Curled peripheral edges *(arrows)* are seen in this anterior placenta. (B) Curled peripheral edges *(arrows)* are seen in this pregnancy at 15 weeks' gestation. At this stage, the amnion is not yet apposed to the chorion. *(From Callen PW:* Ultrasonography in obstetrics and gynecology, *ed 5, Philadelphia, 2008, Saunders, pp 725.)*

Magnetic Resonance Imaging. The role of magnetic resonance imaging (MRI) in the diagnosis of circumvallate placenta has not been studied, and the use of MRI is not recommended.

Differential Diagnosis From Imaging Findings

1. The diagnosis of circumvallate placenta should be considered in any case of prenatal bleeding after placenta previa, placenta accreta/increta/percreta, and placental abruption have been ruled out.
2. The differential diagnosis when circumvallate placenta is suspected on US includes subchorionic thrombosis or fibrin deposition, which may be found in 20% of normal placentas.
3. Chorioangioma, which may appear as a well-circumscribed and lobulated, dense mass.[3]
4. Amniotic bands, uterine synechiae, and septate uterus should be considered in the differential diagnosis when a protrusion into the amniotic cavity from the placenta is noted.[13]

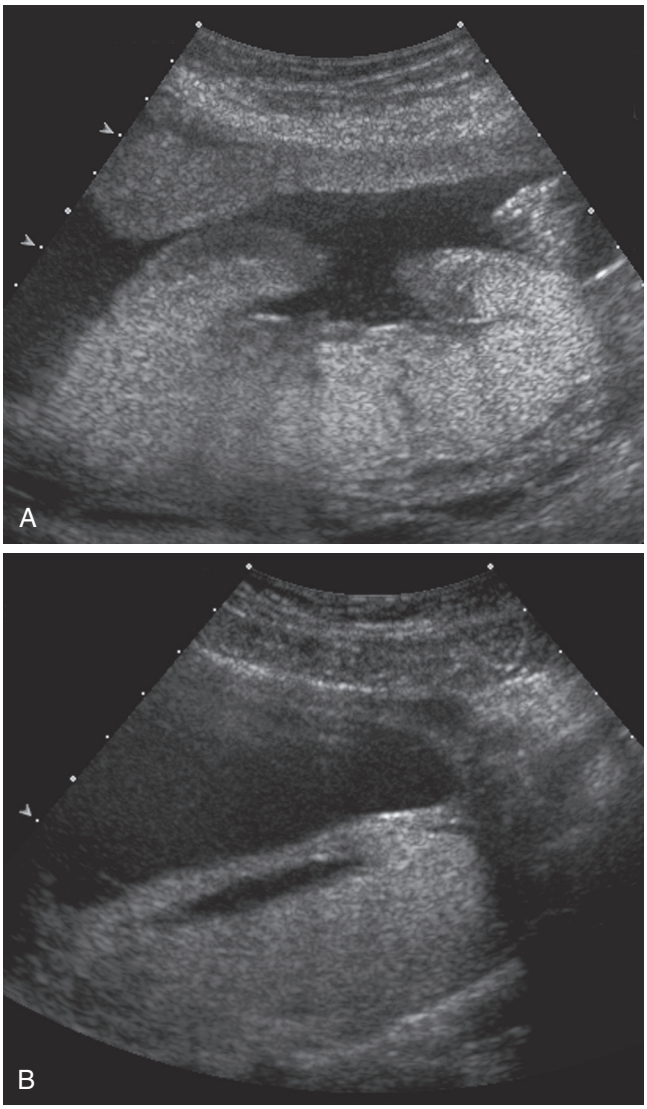

Fig. 101.2 (A) View of a complete circumvallate placenta in the second trimester with a thick, curled peripheral ridge. This appearance should not be confused with uterine synechiae (B). *(From Callen PW:* Ultrasonography in obstetrics and gynecology, *ed 5, Philadelphia, 2008, Saunders, pp 725.)*

Synopsis of Treatment Options

PRENATAL

In cases where circumvallate placenta is diagnosed prenatally, intervention is not usually required other than serial assessment of fetal growth and routine prenatal care. In cases complicated by antepartum bleeding or preterm rupture of membranes, other supportive measures should be taken in an attempt to prolong the pregnancy to term.[2,4]

POSTNATAL

Careful inspection and pathology evaluation of prenatally diagnosed cases should be pursued. Inspection of all placentas after delivery would potentially improve the detection rate of placenta circumvallate. If circumvallate placenta is diagnosed, close attention should be taken to monitor for third-stage complications, such as postpartum hemorrhage and retained placenta, which are increased in these cases.[3]

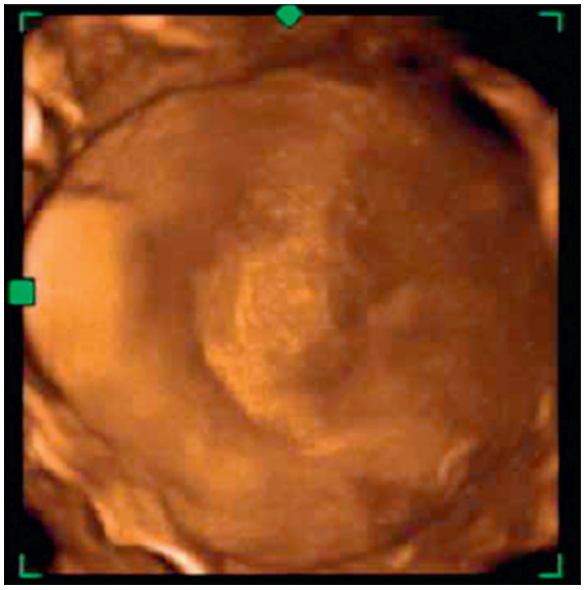

Fig. 101.3 A three-dimensional surface rendering of a circumvallate placenta by ultrasound, showing a thickened peripheral ring of tissue with a central depression described as a "tire mounted on a wheel." This diagnosis was confirmed after delivery of the placenta. *(From Arlicot C, Herve P, Simon E, Perrotin F: Three-dimensional surface rendering of the chorionic placental plate: the "tire" sign for the diagnosis of a circumvallate placenta.* J Ultrasound Med *31:340–341, 2012.)*

WHAT THE REFERRING PHYSICIAN NEEDS TO KNOW

- Circumvallate placenta should be considered in any case of antepartum bleeding with a normally located placenta.
- Circumvallate placenta is associated with adverse pregnancy outcomes.
- Circumvallate placenta is associated with third-stage complications such as postpartum hemorrhage and retained placenta.
- Careful inspection of the delivered placenta is recommended as this condition is clinically diagnosed.

KEY POINTS

- Circumvallate placenta should be suspected when prenatal hemorrhage occurs in the presence of a normally located placenta.
- The prenatal detection rate of circumvallate placenta by US is low.
- Circumvallate placenta is associated with increased risk of prenatal bleeding, preterm delivery, low birth weight, oligohydramnios, congenital malformations, and perinatal mortality.
- A definitive diagnosis of circumvallate placenta requires inspection of the delivered placenta.
- When circumvallate placenta is identified postpartum, complete removal of the placenta should be confirmed.

SUGGESTED READING

Sistrom CL, Ferguson JE. Abnormal membranes in obstetrical ultrasound: incidence and significance of amniotic sheets and circumvallate placenta. *Ultrasound Obstet Gynecol.* 1993;3:249-255.

All references are available online at www.expertconsult.com.

REFERENCES

1. Torpin R. Placenta circumvallata and placenta marginata. *Obstet Gynecol*. 1955;6:277-278.
2. Wilson D, Paalman RJ. Clinical significance of circumvallate placenta. *Obstet Gynecol*. 1967;29:774-778.
3. Jauniaux E, Avni F, Donner C, et al. Ultrasonographic diagnosis and morphological study of placenta circumcallate. *J Clin Ultrasound*. 1989;17:126-131.
4. Benson RC, Fujikura T. Circumvallate and circummarginate placental: unimportant clinical entities. *Obstet Gynecol*. 1969;34:799-804.
5. Ziel HA. Circumvallate placenta, a cause of antepartum bleeding, premature delivery, and perinatal mortality. *Obstet Gynecol*. 1963;22:798-802.
6. Harris RD, Wells WA, Black WC, et al. Accuracy of prenatal sonography for detecting circumvallate placenta. *AJR Am J Roentgenol*. 1997;168: 1603-1608.
7. Suzuki S. Clinical significance of pregnancies with circumvallate placenta. *J Obstet Gynaecol Res*. 2008;34:51-54.
8. Torpin R. Evolution of a placenta circumvallata. *Obstet Gynecol*. 1966;27:98-101.
9. Arlicot C, Herve P, Simon E, et al. Three-dimensional surface rendering of the chorionic placental plate: the "tire" sign for the diagnosis of a circumvallate placenta. *J Ultrasound Med*. 2012;31:336-337.
10. Lademacher D, Vermeulen R, Harten J, et al. Circumvallate placenta and congenital malformation. *Lancet*. 1981;1:732.
11. Maqueo-Topete M, Chavez-Azuela J, Valenzuela-Lopez S, et al. Placenta accreta and circumvallate (extrachorialis). *Obstet Gynecol*. 1968; 32:397-401.
12. McCarthy J, Thurmond AS, Jones MK, et al. Circumvallate placental: sonographic diagnosis. *J Ultrasound Med*. 2008;14:21-26.
13. Shen O, Golomb E, Lavie O, et al. Placental shelf-a common, typically transient and benign finding on early second-trimester sonography. *Ultrasound Obstet Gynecol*. 2007;29:192-194.
14. Sherer D, Smith S, Metlay L, et al. Sonographic and pathologic features of a circumvallate placenta associated with early amnion rupture. *J Clin Ultrasound*. 1991;19:241-243.

102 Cord Cyst

JOSES A. JAIN | KARIN M. FUCHS

Introduction

The widespread use of high-resolution ultrasound (US) in routine obstetric care has led to greater detection of placental and umbilical cord abnormalities.[1,2] Cysts of the umbilical cord have been reported in all trimesters. The clinical significance and prognosis of cord cysts vary depending on the gestational age at diagnosis, persistence of the cyst, and associated structural or chromosomal abnormalities.[2–5]

Disorder

DEFINITION

A cord cyst is defined as an echolucent area within the umbilical cord.[5]

PREVALENCE AND EPIDEMIOLOGY

First-trimester umbilical cord cysts have been reported to occur in approximately 0.4% to 3.4% of pregnancies.[5] Most cysts (approximately 80%) that are diagnosed in early pregnancy resolve by 12 to 14 weeks' gestation and are not associated with an adverse pregnancy outcome.[5] Umbilical cord cysts that persist into the second and third trimester of pregnancy, however, are associated with an increased risk of fetal aneuploidy or fetal structural defects.[5,6]

ETIOLOGY, PATHOPHYSIOLOGY, AND EMBRYOLOGY

Most cord cysts detected in the first trimester are transient and disappear by 14 weeks' gestation. These transient cysts are not associated with an additional risk to the pregnancy.[3,6–8] Umbilical cord cysts are classified as either true cysts or pseudocysts.[4,5] True cysts develop from remnants of the allantois or omphalomesonephric duct.[9] Histologically, they are lined by either columnar, mucin-secreting cells (omphalomesonephric), cuboidal cells resembling transitional epithelium (allantoic), or amniotic epithelium (amniotic).[4] Umbilical cord cysts are located more frequently at the fetal abdominal cord insertion site and range in size from 4–60 mm.[5,9] Pseudocysts are encountered more frequently than true cysts and are generally located near the fetal end of the umbilical cord as well. They contain no epithelial lining and represent mucinous degeneration or localized edema of Wharton jelly.[4] Differentiation between a true cyst and a pseudocyst on US is challenging because both manifest as anechoic structures primarily located toward the fetal cord insertion site.[4]

Regardless of the histologic diagnosis, both true cysts and pseudocysts that persist in the second and third trimesters are associated with congenital anomalies and aneuploidy.

The association between adverse fetal outcomes and umbilical cord cysts seen in the second and third trimester has been demonstrated in several studies. However, the overall prevalence of associated abnormalities is unclear, with reports ranging from 20% to 100%.[2,4–6,10] Associated anomalies include patent urachus, multiple vascular anomalies, congenital heart disease, and umbilical hernia, as well as intrauterine growth restriction and aneuploidy. An "hourglass" appearance from the bladder to an umbilical cord cyst can indicate significant disease ranging from patent urachus to bladder exstrophy, and the need for birth at a tertiary center with pediatric urologic consultation readily available.[11]

MANIFESTATIONS OF DISEASE

Clinical Presentation

Cord cysts are diagnosed during US examination at any time in pregnancy.

Imaging Technique and Findings

Ultrasound. Cord cysts are anechoic structures located within the fetal umbilical cord. They can occur as a solitary lesion or as multiple lesions and range in size from 4–60 mm. Although these cysts are usually located near the fetal end of the umbilical cord, they can be located anywhere along the length of the cord. Cord cysts can be axial, within the center of the umbilical cord and displacing the umbilical vessels, or paraxial, on the periphery of the cord. Use of color Doppler demonstrates no flow (Fig. 102.1).

Differential Diagnosis From Imaging Findings. The differential diagnosis for cystic masses of the umbilical cord includes the following[9]:

1. true cyst
2. pseudocyst
3. allantoic cyst
4. hematoma

Synopsis of Treatment Options

PRENATAL

There are currently no prenatal or postnatal treatment options for fetuses with umbilical cord cysts. The presence of an umbilical cord cyst should prompt a thorough search for other structural malformations.[9] A cord cyst detected in the first trimester should be reassessed with US examination in the second trimester. If the cyst persists into the second trimester, or if any associated structural defects are diagnosed, amniocentesis should be recommended for genetic testing. The prognosis for fetuses without additional US or chromosomal abnormalities is excellent.[12]

POSTNATAL

At the time of birth, physical examination of the neonate, umbilical cord, and placenta is indicated.

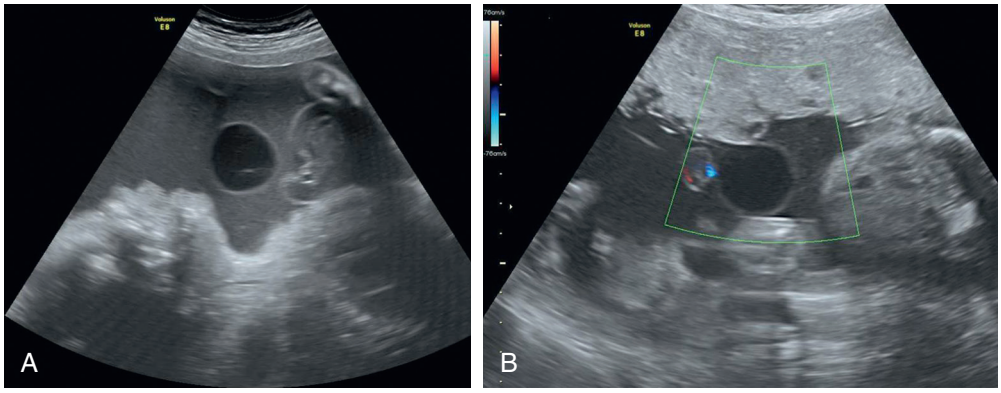

Fig. 102.1 Umbilical cord cysts. Umblical cord cyst, characterized by a well-circumscribed sonolucent area adjacent to the umbilical cord, as seen in A. Note the lack of flow in the cyst when interrogated with color Doppler in B.

WHAT THE REFERRING PHYSICIAN NEEDS TO KNOW

Cord cysts may be found in any trimester, and their presence should prompt a detailed fetal US evaluation for structural anomalies. Genetic amniocentesis should be recommended if the cyst persists into the second trimester or if other structural anomalies are present. If genetic studies are negative in the setting of a persistent cyst, the prognosis is generally favorable.

KEY POINTS

- A cord cyst manifests as an anechoic structure within the umbilical cord.
- Most cord cysts seen in the first trimester resolve by 12 to 14 weeks' gestation.
- If a cord cyst is seen in the second or third trimester, or if additional fetal abnormalities are noted on US examination, fetal genetic testing analysis should be considered.

SUGGESTED READING

Marino T. Ultrasound abnormalities of the amniotic fluid, membranes, umbilical cord, and placenta. *Obstet Gynecol Clin North Am*. 2004;31:177-200.

Moshiri M, Zaidi S, Robinson T, et al. Comprehensive imaging review of abnormalities of the umbilical cord. *Radiographics*. 2014;34:179-196.

Sepulveda W. Opinion: beware of the umbilical cord "cyst." *Ultrasound Obstet Gynecol*. 2003;21:213-214.

All references are available online at www.expertconsult.com.

REFERENCES

1. Sepulveda W, Gutierrez J, Sanchez J, et al. Pseudocyst of the umbilical cord: prenatal sonographic appearance and clinical significance. *Obstet Gynecol*. 1999;93:377.
2. Zangen R, Boldes R, Yaffe H, et al. Umbilical cord cysts in the second and third trimesters–the significance and prenatal approach. *Ultrasound Obstet Gynecol*. 2010;36:296.
3. Skibo L, Lyons E, Levi C. First-trimester umbilical cord cysts. *Radiology*. 1992;182:719.
4. Smith G, Walker M, Johnston S, et al. The sonographic finding of persistent umbilical cord cystic masses is associated with lethal aneuploidy and/or congenital anomalies. *Prenat Diagn*. 1996;16:1141.
5. Ross J, Jurkovic D, Zosmer N, et al. Umbilical cord cysts in early pregnancy. *Obstet Gynecol*. 1997;89:442.
6. Marino T. Ultrasound abnormalities of the amniotic fluid, membranes, umbilical cord, and placenta. *Obstet Gynecol Clin North Am*. 2004;31: 177-200.
7. Sepulveda W, Leible S, Ulloa A, et al. Clinical significance of first trimester umbilical cord cysts. *J Ultrasound Med*. 1999;18:95.
8. Hannaford H, Reeves S, Wegner E. Umbilical cord cysts in the first trimester: are they associated with pregnancy complications? *J Ultrasound Med*. 2013;32(5):801-806.
9. Bianchi D, Crombleholme T, D'Alton M, et al. *Fetology: Diagnosis and Management of the Fetal Patient*. 2nd ed. New York: McGraw-Hill; 2010.
10. Shipp T, Bromley B, Benacerraf B. Sonographically detected abnormalities of the umbilical cord. *Int J Gynaecol Obstet*. 1995;48:179-185.
11. Riddell JV, Houle AM, Franc-Guimond J, et al. Prenatal vesico-allantoic cyst outcome–a spectrum from patent urachus to bladder exstrophy. *Prenat Diagn*. 2015;35:1342-1346.
12. Weissman A, Drugan A. Sonographic findings of the umbilical cord: implications for the risk of fetal chromosomal anomalies. *Ultrasound Obstet Gynecol*. 2001;17:536.

To access the videos in this chapter, scan this QR code or visit expertconsult.com

103 Cord Varix

JOSES A. JAIN | KARIN M. FUCHS

Introduction

Although umbilical vascular anomalies are congenital malformations seen commonly, venous abnormalities of the umbilical vein, such as an umbilical cord varix, are rare.[1,2] The widespread use of routine sonography has facilitated the prenatal diagnosis of umbilical vein varix (UVV), the clinical significance of which remains unclear.[2–4]

Disorder

DEFINITION

UVV is a rare, idiopathic, focal dilatation of the umbilical vein, either within the intraamniotic portion of the umbilical cord or within the fetal abdomen.[5]

PREVALENCE AND EPIDEMIOLOGY

UVV is a rare entity, representing approximately 4% of umbilical cord malformations.[6] In a retrospective review, Byers et al.[7] reported an incidence of 1.1:1000 pregnancies. These lesions have been reported more commonly in the umbilical cord than in the fetus. In cases of intraabdominal UVVs, extrahepatic varices are more common than intrahepatic varices.[8,9]

ETIOLOGY, PATHOPHYSIOLOGY, AND EMBRYOLOGY

The etiology of UVV is unknown. It has been speculated that any condition that increases venous pressure could potentially lead to dilatation of the extrahepatic portion of the umbilical vein because this anatomic region is the weakest area of umbilical circulation.[7] Another proposed etiology is an intrinsic weakness of the umbilical vein wall, which subsequently leads to venous dilatation and the development of the varix.[2]

UVV is associated with a high rate of fetal anomalies and intrauterine fetal demise, but published series report large differences in fetal outcome. Sepulveda et al.[10] reported 10 cases of UVV and found 30% were associated with additional ultrasound (US) malformations, 20% with aneuploidy, and 40% with intrauterine fetal demise.[10] In a review of published literature, Zalel et al.[3] concluded that UVV was associated with a fetal mortality rate of 22.7%, aneuploidy in 11.4% of cases, and hydrops fetalis in 9% of cases.[3] Rahemtullah et al.[9] published a retrospective review of 25 cases of UVV; 35% of these fetuses had associated structural malformations, and 4% had chromosomal abnormalities. Fung et al.[4] published a case series of 13 fetuses and included 80 additional cases previously reported in the literature. They reported a 31.9% rate of associated structural malformations, a 9.9% rate of aneuploidy, and a 13% perinatal loss rate. Normal outcomes were observed in 59.3% of cases. Intrauterine demise occurred between 29 weeks' and 38 weeks' gestation in 8.1% of fetuses with isolated UVV.[4]

In the largest case series to date, Byers et al.[7] identified 52 cases of UVV and recorded their outcomes. The authors found chromosomal abnormalities in 5.8% of fetuses; 28.8% had additional US abnormalities. No cases of intrauterine pregnancy loss were reported.[7]

MANIFESTATIONS OF DISEASE

Clinical Presentation

UVV can be diagnosed during US examination at any time in pregnancy.

Imaging Technique and Findings

Ultrasound. On US, UVV appears as a round or fusiform, anechoic structure, located either within the umbilical cord or within the fetal abdomen, inferior to the fetal liver and close to the anterior abdominal wall.[5,9] Color flow, power Doppler, and pulsed wave Doppler US are useful to confirm the vascular nature of this lesion by showing venous flow in its lumen (Figs. 103.1 and 103.2, Videos 103.1 and 103.2).[3,11,12]

Although the average diameter of the umbilical vein ranges between 2–4 mm at 15 weeks' gestation and 7–8 mm at term, UVV diameters vary between 8 and 30 mm.[13–15] There is no single set of criteria for the *in utero* diagnosis of UVV. Some suggest an umbilical vein diameter of >9 mm or an index portion of the umbilical vein that is at least 50% wider than the nondilated portion. Others have defined UVV as a measurement that is more than two standard deviations above the mean for the corresponding gestational age.[13–15]

Differential Diagnosis From Imaging Findings. The differential diagnosis for UVV includes the following[7]:

1. normal structures such as the gallbladder or stomach
2. pathologic cystic lesions such as urachal cysts, duplication cysts, or mesenteric cysts
3. other cystic masses originating from the cord such as true cysts or pseudocysts

Synopsis of Treatment Options

PRENATAL

There are currently no prenatal or postnatal treatment options for fetuses with UVV. The presence of UVV should prompt a thorough search for other structural malformations and should prompt obstetricians to suspect aneuploidy.[7] If additional screening reveals structural abnormalities, fetal karyotype analysis is recommended because aneuploidy rates of 27.6% have been reported.[4]

The reported risks of intrauterine fetal demise in cases of UVV are disparate. Mortality ranges from 0% to 44%.[16] Because of the increased risk of fetal death, even in cases with isolated UVV, serial growth measurements and prenatal surveillance are recommended. There is currently no consensus regarding recommendations for management strategies. Weissman-Brenner et al.[5] proposed the most intensive management plan to date, recommending frequent prenatal US scans with Doppler assessment of the UVV and fetal cardiac monitoring, from the time of diagnosis until delivery at 36 to 37 weeks' gestation.[5,16] However, Maayan et al.[2] found no basis to recommend induction of labor before term in their study group of fetuses with cord varix. There were no cases of fetal demise in their study, which also demonstrated significantly increased risks of cesarean section and neonatal intensive care unit admission among fetuses delivered preterm or near-term (35–37 weeks) compared to those delivered after 37 weeks.

WHAT THE REFERRING PHYSICIAN NEEDS TO KNOW

If seen on prenatal US, a UVV should prompt a complete, detailed fetal anatomic evaluation for other structural abnormalities. Genetic amniocentesis should be recommended if other anomalies are detected. As UVV is associated with intrauterine fetal demise, fetal surveillance is recommended in the third trimester, and term delivery should be considered.

KEY POINTS

- UVV is a rare abnormality of the cord associated with structural malformations, aneuploidy, and intrauterine fetal demise.
- A detailed anatomic survey is recommended, and amniocentesis may be considered.
- Prenatal testing and elective delivery at term are recommended.

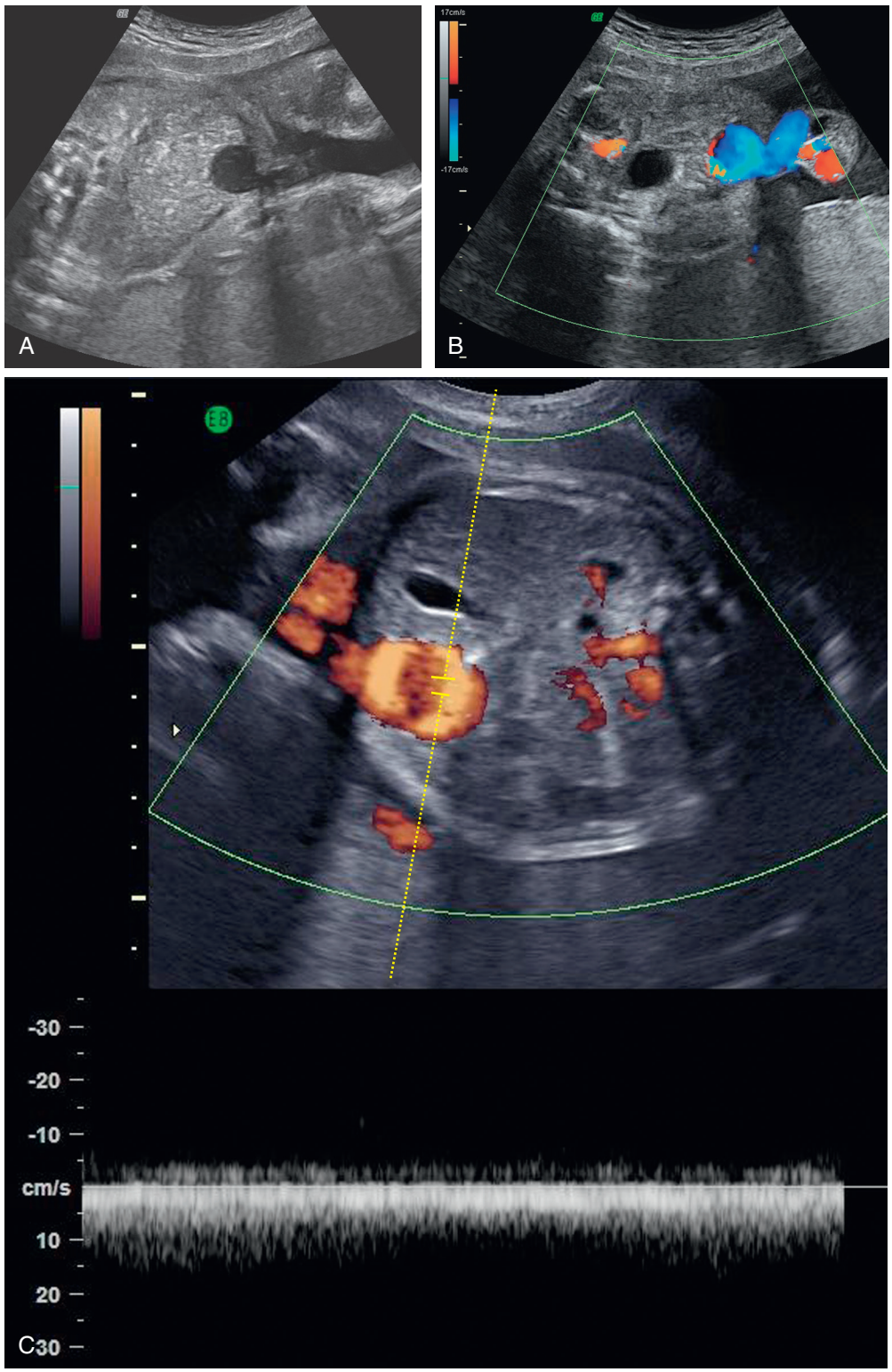

Fig.103.1 (A) Axial image of the fetal abdomen shows intraabdominal cystic dilatation of the umbilical vessel. (B) Color Doppler image confirms vascular flow within intraabdominal cystic dilatation of the umbilical vessel. (C) Pulsed Doppler image confirms venous flow within the intraabdominal UVV. *UVV,* Umbilical vein varix.

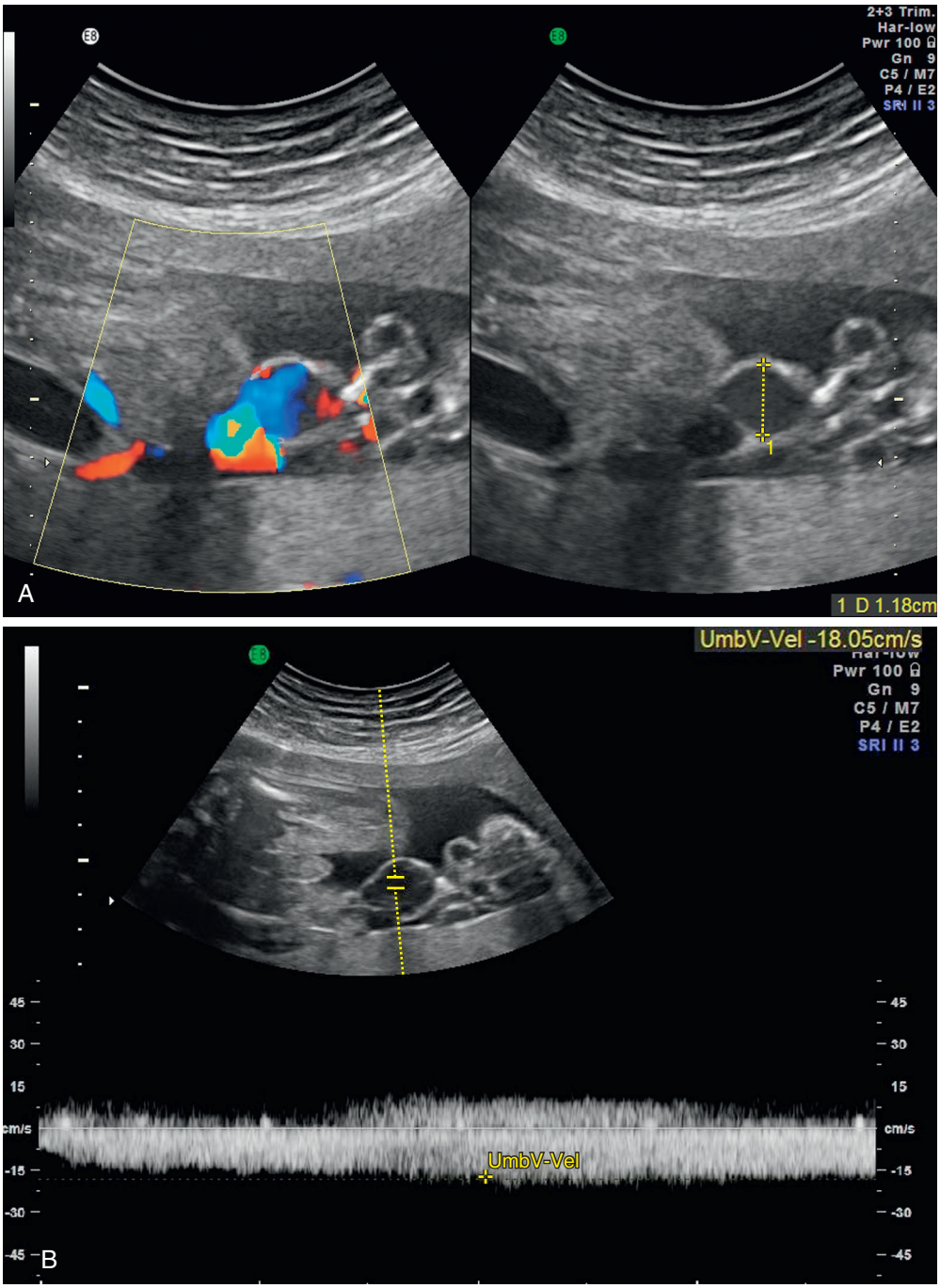

Fig. 103.2 (A) Color Doppler and gray-scale and images show extraabdominal cystic dilatation of the umbilical vessel. (B) Pulsed Doppler image confirms venous flow within the extraabdominal UVV. *UVV,* Umbilical vein varix.

SUGGESTED READING

Byers BD, Goharkhay N, Mateus J, et al. Pregnancy outcome after ultrasound diagnosis of fetal intra-abdominal umbilical vein varix. *Ultrasound Obstet Gynecol*. 2009;33:282-286.

Fung TY, Leung TN, Leung TY, et al. Fetal intra-abdominal umbilical vein varix: what is the clinical significance? *Ultrasound Obstet Gynecol*. 2005;25:149-154.

Mankuta D, Nadjari M, Pomp G. Isolated fetal intra-abdominal umbilical vein varix: clinical importance and recommendations. *J Ultrasound Med*. 2011;30:273-276.

Weissmann-Brenner A, Simchen MJ, Moran O, et al. Isolated fetal umbilical vein varix—prenatal sonographic diagnosis and suggested management. *Prenat Diagn*. 2009;29:229-233.

All references are available online at www.expertconsult.com.

REFERENCES

1. Achiron R, Orvieto R. Assessment of fetal cardiovascular function: ultrasound study of the fetal circulatory compartments. *Curr Opin Obstet Gynecol*. 1999;11(2):119-123.
2. Maayan B, Rabinowitz R, Samueloff A, et al. The prenatal diagnosis of isolated fetal varix of the intra-abdominal umbilical vein is associated with favorable neonatal outcome at term: a case series. *Arch Gynecol Obstet*. 2013;288(1):33-39.
3. Zalel Y, Lehavi O, Heifetz S, et al. Varix of the fetal intra-abdominal umbilical vein: prenatal sonographic diagnosis and suggested in utero management. *Ultrasound Obstet Gynecol*. 2000;16:476.
4. Fung TY, Leung TN, Leung TY, et al. Fetal intra-abdominal umbilical vein varix: what is the clinical significance? *Ultrasound Obstet Gynecol*. 2005;25:149.
5. Weissman-Brenner A, Simchen M, Moran O, et al. Isolated fetal umbilical vein varix—prenatal sonographic diagnosis and suspected management. *Prenat Diagn*. 2009;29:229.
6. Konstantinova B. Malformations of the umbilical cord. *Acta Genet Med Gemellol*. 1977;26:259.
7. Byers BD, Goharkhay N, Mateus J, et al. Pregnancy outcome after ultrasound diagnosis of fetal intra-abdominal vein varix. *Ultrasound Obstet Gynecol*. 2009;33:282.
8. Jeanty P. Fetal and funicular vascular anomalies: identification with prenatal US. *Radiology*. 1989;173:367.
9. Rahemtullah A, Lieberman E, Benson C, et al. Outcome of pregnancy after prenatal diagnosis of umbilical vein varix. *J Ultrasound Med*. 2001;20:135.
10. Sepulveda W, Mackenna A, Sanchez J, et al. Fetal prognosis in varix of the intrafetal umbilical vein. *J Ultrasound Med*. 1998;17:171.
11. Viora E, Sciarrone A, Bastonero S, et al. Thrombosis of the umbilical vein varix. *Ultrasound Obstet Gynecol*. 2002;19:212.
12. Ipek A, Kurt A, Tosun O, et al. Prenatal diagnosis of fetal intra-abdominal umbilical vein varix: report of 2 cases. *J Clin Ultrasound*. 2008;36:48.
13. Mahony BS, McGahan JP, Nyberg DA. Varix of the fetal intraabdominal umbilical vein: comparison with normal. *J Ultrasound Med*. 1992;11:73-76.
14. Weissman A, Jakobi P, Goldstein I. Sonographic measurements of the umbilical cord and vessels during normal pregnancies. *J Ultrasound Med*. 1994;13:11-14.
15. Melcer Y, Ben-Ami I, Wiener Y. Long-term outcomes of children with umbilical vein varix diagnosed prenatally. *Prenat Diagn*. 2013;33(5):492-496.
16. Valsky DV, Rosenak D, Hochner-Celnikier D, et al. Adverse outcome of isolated fetal intra-abdominal umbilical vein varix despite close monitoring. *Prenat Diagn*. 2004;24:451.

104 Gestational Trophoblastic Disease

JACLYN M. COLETTA | JUNE Y. HOU | MARY E. D'ALTON

Introduction

Gestational trophoblastic disease (GTD) is a spectrum of disorders arising from abnormal proliferation of the trophoblastic epithelium of the placenta.[1] There are several histologically distinct types of GTD that range from premalignant, complete, and partial hydatidiform moles (HMs), to malignant diseases, also known as *gestational trophoblastic neoplasia* (GTN), which includes persistent/invasive GTN, placental site trophoblastic tumors, epithelioid trophoblastic tumor (ETT), and choriocarcinoma.[1] Choriocarcinoma is discussed separately (Chapter 100).

Disease

PREVALENCE AND EPIDEMIOLOGY

The incidence of GTD varies in different regions of the world.[2,3] Within North America, Australia, and Europe, the incidence of HM is between 5.7:10,000 and 11:10,000 pregnancies.[2] In contrast, in Southeast Asia and Japan, incidence is as high as 20:10,000 pregnancies. The two main risk factors include maternal age with an increased risk in women over age 35 and under 20, as well as a history of previous GTD.[4] The risk of recurrence is 1%–2% following the first molar pregnancy, about 10–20 times the risk for the general population. There is also an increased risk for both a complete and partial mole in women with a history of prior spontaneous abortion and infertility. Inverse relationships between beta-carotene and a high animal-fat, diet with molar pregnancy are the only consistent environmental associations observed.[5,6]

There are cases reported of a complete or partial mole arising with a coexistent fetus, although this is rarely occurring in 0.1:10,000 to 0.5:10,000 pregnancies.[7] The majority of cases resulted in spontaneous or elective termination of pregnancy because of severe maternal complications including preeclampsia, thyrotoxicosis, or hemorrhage.[8]

Placental site trophoblastic tumor (PSTT) is a rare form of GTN. It constitutes about 1%–2% of trophoblastic disease.[2]

ETIOLOGY AND PATHOPHYSIOLOGY

GTD occurs after abnormal growth and fertilization with a proliferation of trophoblastic tissue.[9] Complete moles have no identifiable embryonic or fetal tissue. Histologically, the chorionic villi have diffuse trophoblastic hyperplasia with marked atypia and generalized swelling.[10] About 90% of complete moles are euploid and homozygous, arising from an anuclear ovum that has been fertilized by a haploid (23X) sperm, which then replicates its own chromosomes resulting in the most common karyotype 46XX, or by fertilization by two sperm (46XY or 46XX).[9]

A partial mole is the result of fertilization of a haploid ovum by two sperm or duplication of one sperm, resulting in a triploid karyotype: 69XXY (most common), 69 XXX, or 69 XYY.[11] It is characterized by chorionic villi that vary in size and have focal swelling with trophoblastic hyperplasia and mild atypia at the implantation site, and identifiable fetal or embryonic tissue.[11] This can result in misdiagnosis of an incomplete or missed abortion, with the correct diagnosis made only after pathology review of the specimen.

Malignant GTD is diagnosed when there is clinical, radiologic, pathologic, or hormonal evidence of persistent or invasive trophoblastic tissue. Malignant forms include invasive GTN, choriocarcinoma, and PSTTs. The diagnosis is most commonly made following a molar pregnancy but can occur after any type of gestation. Any of the malignant forms of GTD can metastasize, most commonly to the lungs and/or vagina.[7]

Locally invasive GTN develops in 15%–20% of patients following evacuation of a complete mole and less frequently after other gestations (<5% after partial mole).[12] These may perforate through the myometrium or invade the uterine vessels, causing intraperitoneal or vaginal hemorrhage.[7]

PSTTs are extremely rare, and can occur months or years after a term gestation, spontaneous abortion, or a molar pregnancy.[13,14] Most cases of PSTT are diploid with an XX genomic composition in 90%; however, a few cases of tetraploidy have also been reported.[14] PSTTs are tumors of the intermediate trophoblasts—a transitional form between cytotrophoblasts and syncytiotrophoblasts—with a gross appearance of a gray/yellow circumscribed mass, often containing areas of hemorrhage.[15] The intermediate trophoblasts form sheets or nests of cells that invade the uterus and divide individual myometrial fibers.[15] They can also extensively invade both blood vessels and lymphatic channels.[15]

ETT is a rarer variant of PSTT, and appears to arise from malignant transformation of intermediate trophoblasts. Most ETTs are diagnosed many years after full-term delivery.[16]

MANIFESTATIONS OF DISEASE

Clinical Presentation

In the past, complete moles were typically diagnosed in the second trimester, most commonly with signs/symptoms of excessive uterine size for the gestational age, vaginal bleeding, and hyperemesis.[17] However, with the availability of accurate and sensitive tests for human chorionic gonadotropin (hCG) and the use of early ultrasound (US), the diagnosis is now made in the first trimester, before the classic signs or symptoms.[14] Previous symptoms at presentation of a partial mole included vaginal bleeding and a uterine size that is small or appropriate for the gestational age, worrisome for incomplete or missed abortion.[1]

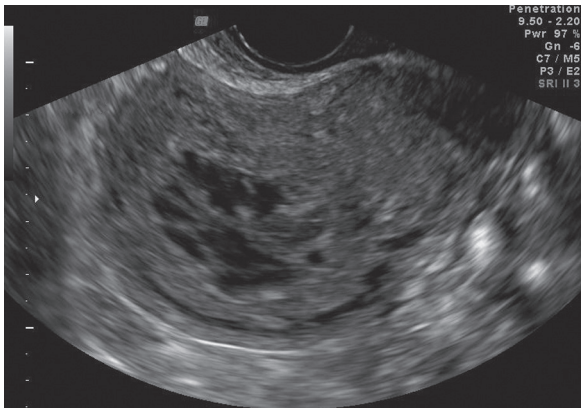

Fig. 104.1 Transvaginal ultrasound shows a distended endometrial cavity with multiple anechoic areas typical of a complete mole.

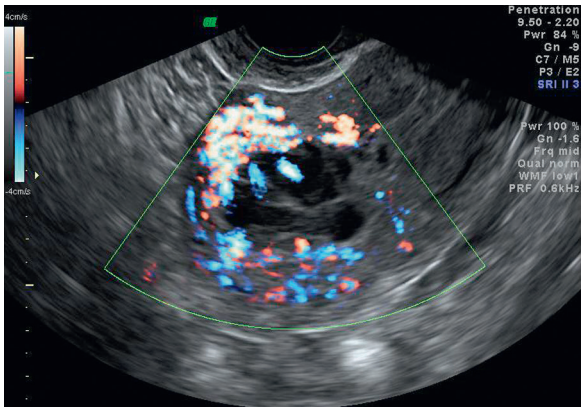

Fig. 104.2 Transvaginal ultrasound with color Doppler depicts the marked vascularity seen with a complete mole.

Partial or complete moles with a coexistent fetus can be diagnosed by US findings of a complex, cystic placental component distinct from the fetoplacental unit or can present with vaginal bleeding or uterine size larger than the gestational age.[7] Compared with singleton HMs, twin pregnancies with a fetus and a mole carry an increased risk for postmolar GTD, with a higher proportion of patients having metastatic disease and requiring multiagent chemotherapy.[18] Many patients that continue such pregnancies develop early complications leading to termination of the pregnancy before fetal viability.

The majority of PSTT and ETT remain confined to the uterus at the time of diagnosis with only 10%–15% being clinically malignant.[19] Symptoms can present weeks to years after the preceding pregnancy and most commonly occur as vaginal bleeding and enlargement of the uterus.[19] Metastases are most commonly in the lung but have also been reported in the brain, stomach, liver, spleen, bowel, pancreas, kidney, and adjacent pelvic organs.[20] The International Federation of Gynecology and Obstetrics (FIGO) staging determines prognosis.[19] Patients with disease confined to the genital tract (stage I and II) have over 90% survival, whereas stage III and IV have only 33% survival.[20] Disease localized to the uterus and diagnosis less than 2 years from the antecedent pregnancy are associated with a better outcome.[21] Vascular space involvement, endomyometrial invasion, and brain metastases are poor prognostic factors.[21]

Imaging Technique and Findings

Ultrasound. Ultrasonographic findings of a complete mole include absence of an embryo or fetus, absence of amniotic fluid, and a central heterogeneous mass containing multiple anechoic spaces, previously described as a "snowstorm" appearance (Figs. 104.1 and 104.2). The smaller cystic areas correspond to the hydropic villi. Prior studies have demonstrated a 70%–90% sensitivity of pelvic US for the diagnosis of complete mole, with improved detection rates as gestational age increases. A partial mole often demonstrates either enlarged cystic spaces, and/or increased echogenicity within the placenta with a coexistent embryo or fetus[22] (Figs. 104.3 and 104.4). If the fetus is viable, it is often growth restricted, and the amniotic fluid volume is often reduced. It is therefore diagnosed as a missed or incomplete abortion in 15%–60% of cases.

Theca lutein cysts are often also present with a concurrent complete mole and are a form of ovarian hyperstimulation

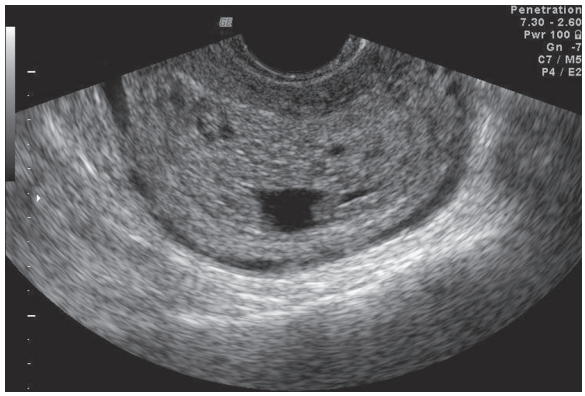

Fig. 104.3 Transvaginal ultrasound of a partial mole shows the focal cystic changes with a coexistent embryo.



Fig. 104.4 Transabdominal US of a partial mole with a coexistent fetus contrasts the interface between the normal placental appearance on the right side of the image and the hypoechoic areas replacing the placental tissue on the left side of the image.

resulting from high circulating levels of hCG. Sonographically, the ovaries are enlarged with bilateral, multiloculated cysts.

Ultrasonography in PSTT shows an echogenic mass containing both solid and cystic components that can involve both the endometrium and myometrium.[20] They can be either hyper or

hypovascular, which can be differentiated by the use of Doppler.[20] Computed tomography (CT) or magnetic resonance imaging (MRI) can aid in determining the size and location of the tumor.

Magnetic Resonance Imaging. A CT scan of the chest, abdomen, and pelvis is usually performed for detection of metastasis. MRI is not usually indicated for diagnosis of molar pregnancy; however, MRI is typically preferred over CT and US for assessing the degree of uterine myometrial invasion.[21] The endometrial cavity is usually expanded with heterogeneously high T2 signal intensity, with multiple cystic spaces representing hydropic villi. These correlate with the classic "cluster of grapes" finding on ultrasonography. Noninvasive HM demonstrates a normal hypointense myometrial layer surrounding these cystic changes. Invasive moles disrupt the junctional zone as they penetrate the myometrium.[23]

Differential Diagnosis From Imaging Findings. Diagnosis is ultimately made histologically. The differential diagnosis includes an incomplete abortion, choriocarcinoma, placental site nodule, and nontrophoblastic malignancies such as germ cell tumors.[17] During a spontaneous abortion, the chorionic villi may degenerate and develop hydropic changes, appearing molar. Immunohistochemistry can be used in differentiating the disease entities. For example, in PSTT, mean Ki 67 staining is 14% of total specimen area, when compared to 69% in choriocarcinoma.[13] In addition, beta hCG is much higher in choriocarcinoma than in PSTT. Placental site nodules are usually focal, superficial, well-circumscribed nodules with a lack of cells in the center, surrounded by intermediate trophoblasts in the periphery.[15]

Synopsis of Treatment Options

PRENATAL

Management of a molar pregnancy includes evaluation for potential medical complications including anemia, hypertension, and hyperthyroidism.[24] All patients should have a complete physical examination and laboratory testing with evaluation of blood type including Rh status, hematocrit, thyroid function tests, hepatic and renal function tests, and chest x-ray.[25] Suction curettage with or without US guidance is the optimal method of evacuation.[25]

After evacuation, serial hCG levels should be monitored weekly until levels are undetectable for 3 weeks.[25] Following this, monthly testing should continue until levels remain undetectable for 12 months. Persistent GTN may develop in a complete or partial molar pregnancy and may be noninvasive or metastatic depending on whether the molar tissue invades beyond the myometrium.[22] This is suspected when hCG levels do not become negative after evacuation, or if choriocarcinoma is found on pathologic examination. Clinical risk factors that predict the occurrence of persistent disease include marked trophoblastic proliferation on histology, an initial hCG level >100,000, a uterine size that was excessively larger than appropriate for the gestational age, and theca lutein cysts larger than 6 cm in diameter.[25] Patients with one or more of these signs have about a 40% incidence of postmolar GTN compared to an overall risk of 4% without them.[22] Data from multiple centers indicate that once the level of hCG becomes undetectable, recurrent elevation occurs in less than 1% of patients.[25]

As the occurrence of a new pregnancy would interfere with follow-up testing of hCG levels, reliable contraception is strongly advised immediately following evacuation. Subsequent pregnancies carry a 1% risk of another molar pregnancy, so early US is recommended.[13]

For patients with a suspected coexisting HM and fetus on US, there are no clear guidelines for management. This occurs once in every 22,000 to 100,000 pregnancies, and should be discerned from a partial mole. If the diagnosis is suspected and continuation of the pregnancy is desired, fetal karyotype should be obtained, a chest x-ray performed to screen for metastases, and serial serum hCG values monitored.[11] These patients are at an increased risk for medical complications of pregnancy requiring evacuation, including bleeding, preterm labor, and pregnancy-induced hypertension.[11] They should be counseled about these risks and the increased risk of postmolar trophoblastic disease after evacuation or delivery. If the fetal karyotype is normal, major fetal malformations are excluded by US examination, and there is no evidence of metastatic disease, it is reasonable to allow the pregnancy to continue unless pregnancy-related complications force delivery.[9] After delivery, the placenta should be histologically evaluated and the patient followed closely with serial hCG values.[11]

Hysterectomy remains the primary treatment for both early and locally advanced PSTT, with dilation and curettage or local resection recommended only in cases of fertility preservation.[15] Chemotherapy should be used in patients with advanced disease or in FIGO stage I disease with >2 years since the antecedent pregnancy.[26] PSTT is resistant to the chemotherapeutic agents most commonly used in GTD such as methotrexate and actinomycin D; however, combination chemotherapy using EMACO (*e*toposide, *c*isplatin, *m*ethotrexate, *a*ctinomycin D, *c*yclophosphamide, and *v*incristine) is more effective, with a 28% response rate in metastatic disease.[13] Adjuvant radiation is useful in the setting of localized and isolated recurrences, or for palliative therapy.[27]

KEY POINTS

- GTD arises from the trophoblastic epithelium of the placenta and results in aberrant proliferation.
- GTD should be suspected when beta hCG levels persist following delivery or termination.
- The types include HM, PSTT, ETT, and choriocarcinoma.
- Complete moles are homozygous, without any identifiable fetal or embryonic tissue; and have marked swelling of the chorionic villi, appearing as cystic areas on US.
- A partial mole demonstrates focal cystic changes in the placenta on US with a coexistent embryo.
- PSTTs are rare and appear as an echogenic mass containing both cystic and solid components that can invade the myometrium.

SUGGESTED READINGS

ACOG Practice Bulletin 53. Diagnosis and treatment of gestational trophoblastic disease. *Obstet Gynecol*. 2004;103:1365.

Allen SD, Lim AK, Seckl MJ, et al. Radiology of gestational trophoblastic neoplasia. *Clin Radiol*. 2006;61:301-313.

Altieri A, Franceschi S, Ferlay J, et al. Epidemiology and aetiology of gestational trophoblastic diseases. *Lancet Oncol*. 2003;4:670.

Berkowitz R, Goldstein D. Current management of gestational trophoblastic diseases. *Gynecol Oncol*. 2009;112:654-662.

Berkowitz R, Goldstein D. Molar pregnancy. *N Engl J Med*. 2009;360:1639-1644.

Feltmate CM, Genest DR, Wise L, et al. Placental site trophoblastic tumor, a 17-year experience at the New England Trophoblastic Disease Center. *Gynecol Oncol*. 2001;82:415-419.

FIGO staging for gestational trophoblastic neoplasia 2000. FIGO Oncology Committee. *Int J Gynaecol Obstet*. 2002;77:285.
Hassadia A, Gillespie A, Tidy J, et al. Placental site trophoblastic tumour: clinical features and management. *Gynecol Oncol*. 2005;99:603.
Morgan JM, Lurain JR. Gestational trophoblastic neoplasia: an update. *Curr Oncol Rep*. 2008;10:497-504.
Shih L. Gestational trophoblastic neoplasia—pathogenesis and potential therapeutic targets. *Lancet Oncol*. 2007;8:642-650.
Soper JT. Gestational trophoblastic disease. *Obstet Gynecol*. 2006;108:176.
Wee L, Jauniaux E. Prenatal diagnosis and management of twin pregnancies complicated by a co-existing molar pregnancy. *Prenat Diagn*. 2005;25:772-776.



All references are available online at www.expertconsult.com.

REFERENCES

1. Altieri A, Franceschi S, Ferlay J, et al. Epidemiology and aetiology of gestational trophoblastic diseases. *Lancet Oncol*. 2003;4:670.
2. Smith HO. Gestational trophoblastic disease epidemiology and trends. *Clin Obstet Gynecol*. 2003;46:541.
3. Di Cintio E, Parazzini F, Rosa C, et al. The epidemiology of gestational trophoblastic disease. *Gen Diagn Pathol*. 1997;143:103.
4. Altman AD, Bentley B, Murray S, et al. Maternal age-related rates of gestational trophoblastic disease. *Obstet Gynecol*. 2008;112:244.
5. Lurain JR. Gestational trophoblastic disease I: epidemiology, pathology, clinical presentation and diagnosis of gestational trophoblastic disease, and management of hydatidiform mole. *Am J Obstet Gynecol*. 2010;203(6): 531-539.
6. Parazzini F, LaVecchia C, Mangill G, et al. Dietary factors and risk of trophoblastic disease. *Am J Obstet Gynecol*. 1988;158:93-99.
7. Lee SW, Kim MY, Chung JH, et al. Clinical findings of multiple pregnancy with a complete hydatidiform mole and coexisting fetus. *J Ultrasound Med*. 2010;29:271-280.
8. Vasibuch E, Ben-Arie A, Dgani R, et al. Twin pregnancy consisting of a complete hydatidiform mole and co-existent fetus: report of two cases and review of literature. *Gynecol Oncol*. 2005;98:19-23.
9. Soper JT. Gestational trophoblastic disease. *Obstet Gynecol*. 2006;108:176.
10. Mosher R, Goldstein D, Berkowitz R, et al. Complete hydatidiform mole comparison of clinicopathologic features, current and past. *J Reprod Med*. 1998;43:21.
11. Berkowitz RS, Goldstein DP. Chorionic tumors. *N Engl J Med*. 1996;335: 1740.
12. Ayhan A, Tuncer ZS, Halilzade H, et al. Predictors of persistent disease in women with complete hydatidiform mole. *J Reprod Med*. 1996;41:591.
13. Hassadia A, Gillespie A, Tidy J, et al. Placental site trophoblastic tumour: clinical features and management. *Gynecol Oncol*. 2005;99:603.
14. Zhao J, Xiang Y, Wan XR, et al. Clinical and pathologic characteristics and prognosis of placental site trophoblastic tumor. *J Reprod Med*. 2006;51:939.
15. Behtash N, Zarchi M. Placental site trophoblastic tumor. *J Cancer Res Clin Oncol*. 2008;134:1-6.
16. Allison KH, Love JE, Garcia RL, et al. Epithelioid trophoblastic tumor review of a rare neoplasm of the chorionic-type intermediate trophoblast. *Arch Pathol Lab Med*. 2006;130:1875-1877.
17. Soto-Wright V, Bernstein M, Goldstein DP, et al. The changing clinical presentation of complete molar pregnancy. *Obstet Gynecol*. 1995;86:775.
18. Wee L, Jauniaux E. Prenatal diagnosis and management of twin pregnancies complicated by a co-existing molar pregnancy. *Prenat Diagn*. 2005;25:772-776.
19. Disaia PJ, Creasman WT. Gestational trophoblastic disease. In: Disaia PJ, Creasman WT, eds. *Clinical Gynecology Oncology*. 6th ed. St. Louis: Mosby yearbook; 2002:185-206.
20. Guvendag Guven ES, Guven S, Esinter I, et al. Placental site trophoblastic tumor in a patient with brain and lung metastases. *Int J Gynecol Cancer*. 2004;14:558.
21. Montclair T, Abeler VM, Kaern J, et al. PSTT in mother and child, first report of PSTT in infancy. *Med Pediatr Oncol*. 2002;38:187-191.
22. Berkowitz R, Goldstein D. Current management of gestational trophoblastic diseases. *Gynecol Oncol*. 2009;112:654-662.
23. Shanbhogue AKP, Lalwani N, Menias C. Gestational trophoblastic disease. *Radio Clin N Am*. 2013;52:1023-1034.
24. Sumi Y, Ozaki Y, Shindoh N, et al. Placental site trophoblastic tumor: imaging findings. *Radiat Med*. 1999;17:427.
25. Berkowitz R, Goldstein D. Molar pregnancy. *N Engl J Med*. 2009;360:1639-1644.
26. Hoesketra AV, Keh P, Lurain JR. PSTT, a review of 7 cases and their implications for prognosis and treatment. *J Reprod Med*. 2004;49:447-452.
27. Armes J. Placental site trophoblastic tumor, report of three cases and review of the literature. *Int J Gynecol Cancer*. 1995;5:241-249.

105 Limb–Body Wall Complex

JOSES A. JAIN | KARIN M. FUCHS

Introduction

Limb–body wall complex (LBWC) refers to a combination of multiple malformations involving the craniofacial structures, thoracoabdominal wall, extremities, and spine.[1] LBWC is almost uniformly lethal and associated with a very poor outcome because of, among other factors, pulmonary hypoplasia.[2–5] The associated anomalies can be significantly disfiguring, often involving extensive lesions of the thoracoabdominal region with visceral herniation, a short or absent umbilical cord, and exteriorization of the fetal heart and bladder.[6] Although what is described as LBWC in the literature includes a highly variable phenotype, clues suggestive of the diagnosis include an asymmetric and/or anteriorly placed cranioschisis (especially if associated with facial cleft); an extensive abdominal wall defect not typical of an omphalocele or gastroschisis; or any concurrence of cranioschisis, limb defect, or thoracoabdominoschisis.[7]

Disorder

DEFINITION

The characteristic defects seen in affected fetuses with LBWC are exencephaly or encephalocele with facial cleft, lateral body wall defect with evisceration, and limb defects.[6]

PREVALENCE AND EPIDEMIOLOGY

LBWC is a rare, sporadic disorder, with an incidence ranging from approximately 0.2 : 10,000 to 1.3 : 10,000 pregnancies.[2,3,8–12]

ETIOLOGY, PATHOPHYSIOLOGY, AND EMBRYOLOGY

In early gestation, the developing embryo changes from a flat, three-layered disk into a cylindric structure through circumferential folding. This process results in closing of the embryonic body, formation of the body stalk, and separation of the intraembryonic coelom (peritoneal cavity) from the extraembryonic coelom (chorionic cavity). Completion of this process forms the umbilical cord.[13] Any disturbance during this folding stage can disrupt the separation process that creates the internal environment of the embryo, distinct from the chorionic cavity.

The pattern of malformations associated with LBWC varies according to the degree of aberrant development of the cephalic, caudal, and lateral folds in early gestation.[1,13] Defects in the cephalic fold can result in anterior diaphragmatic hernia, ectopia cordis, sternal cleft, and cardiac defects. Incomplete lateral fold closure can produce an omphalocele or massive evisceration of intraabdominal organs, depending on the extent of the abdominal wall defect. Caudal fold defects can lead to cloacal exstrophy, imperforate anus, and intestinal atresia or agenesis.[1,13]

Various mechanisms have been proposed to explain the pathogenesis of LBWC. The three main theories are (1) early amnion rupture causing mechanical injury, (2) vascular disruption during embryogenesis, and (3) defective development in the germinal disk.[1,7] Early amnion rupture, which was at one time the most widely accepted theory, accounts for the craniofacial and limb deformities seen in LBWC. According to this theory, the neural tube defects and facial clefts were considered to be a direct consequence of secondary disruption by bands and/or compression, whereas the ventral wall defect was considered a primary malformation.[7] Limb defects were considered to be caused by an amniotic band interfering with limb budding.[7,13] The theory was supported by case reports documenting the presence of amniotic bands adjacent to major congenital defects. However, this theory does not adequately explain cases showing an intact amniotic membrane or the high prevalence of internal structural defects noted in cases of LBWC.[7] There is also a lack of evidence to support the resorption of amniotic fluid by the chorion, or that the nature of the chorionic surface is such that it would abrade fetal skin. It is also unclear how rupture of the amnion closer to the stages of neural tube and facial closure would have time to develop bands of adequate consequence to become tangled, or otherwise interfere with the planes of closure.[7] Streeter[14] and Hartwig et al.,[15] among others, have demonstrated cases of LBWC in the absence of amniotic bands, and with an intact amnion at delivery.[7]

Van Allen et al.[16] proposed a vascular etiology for LBWC and postulated that a disruption of embryonal vessels during the fourth through sixth weeks of gestation led to a systemic impairment of blood flow. This in turn led to tissue ischemia and

necrosis, resulting in the associated internal anomalies such as renal and gallbladder agenesis.[7,17,18] The cranial anomalies were thought to be a secondary disruption that occurred shortly after closure. The primary concern with this theory is that the ventral wall anomaly and cranial malformations are thought to occur very early in development, at a time when limb buds are early in their appearance; some limb anomalies seen in LBWC, such as terminal limb syndactyly and constriction rings, would appear to relate to an inciting event significantly later in gestation.[7]

Another theory proposed by Hunter et al.[7] suggests that an ectodermal defect of the embryonic disk during embryogenesis leads to the malformations seen in LBWC. The findings of exencephaly/encephalocele are thought to be secondary to a deficient response and growth of ectodermal cells that typically form the forebrain. A deficiency in ectodermal growth can result in the ectodermal-amnion border coming into contact with the malformed forebrain and would explain the frequent attachment of the cranial defect to the amnion, in addition to the often-distorted brain tissue. The same ectodermal deficiency could lead to an associated neural crest deficiency affecting the frontonasal process, leading to facial clefts. An early step in the formation of the lateral abdominal wall is the ventral folding of the lateral margin of the embryonic disk, which is preceded by an increase in ectodermal cell division.[7,19] An initial ectodermal cell deficiency could result in a delay or disruption of initial folding, resulting in the abdominoschisis and thoracoabdominoschisis anomalies seen in LBWC. The limb anomalies and internal malformations are thought to be the result of secondary vascular compromise.[7]

More recently, evidence has emerged to support the notion of a genetic etiology to LBWC. Using whole exome sequencing, Kruszka et al.[20] were able to identify a *de novo* heterozygous mutation in the gene *IQCK*: c.667C>G; p.Q223E in a patient with the phenotypic characteristics of LBWC, which was then confirmed by Sanger sequencing. The p.Q223E mutation affects glutamine, a very conserved amino acid of the IQ domain. In functional studies using morpholino knockdown, the authors were able to reproduce abnormal phenotypes in zebrafish using p.Q223E human IQCK messenger RNA. More cases are needed to confirm *IQCK* as a causative gene in LBWC, and further investigation involving whole exome sequencing is likely to reveal the involvement of more genes that may or may not be involved in the same cellular pathway.

MANIFESTATIONS OF DISEASE

Clinical Presentation

The classic clinical triad of LBWC includes a craniofacial defect, limb deformity, and body wall malformation. Some authors have proposed that at least two of the aforementioned defects must be present to meet criteria for LBWC.[7,16,21] LBWC shares similarities with amniotic band sequence, where defects are variable, and no two affected cases have the same phenotype.

Several authors have attempted to classify these cases based on the phenotype and the specific fetoplacental relationship. Two distinct phenotypic categories have resulted: (1) cranioplacental and (2) abdominoplacental. The cranioplacental phenotype usually includes cases with craniofacial defects, with facial clefts and upper limb defects, in the presence of amniotic bands. This phenotype favors the more typical amniotic band sequence with broad amniotic adhesions producing disruptive lesions. The placenta may be abnormally attached to the malformed cranial structures. Thoracic, abdominal, and cloacal disruptions are not features of the cranioplacental type of LBWC.[1,22]

In contrast, fetuses with the abdominoplacental phenotype have body wall defects, with varying degrees of thoracoabdominal evisceration, urogenital anomalies, imperforate anus, meningocele, and severe spinal deformities, with tight attachment of the fetus to the placenta.[16,18,23] There is also persistence of the extraembryonic coelom-associated short umbilical cord. Craniofacial defects and amniotic bands are not described in this group. This subset of LBWC can be more clearly explained by a disturbance during the embryonic folding process in early gestation (Figs. 105.1 and 105.2).[22]

Imaging Technique and Findings

Ultrasound. The main features of LBWC can be identified by routine obstetric ultrasound (US). Because of the increase in the number of first-trimester US scans being performed for aneuploidy screening, cases of LBWC are being detected earlier in pregnancy. Diagnosis during the second trimester can be more challenging, however, owing to associated oligohydramnios.[24] The abdominal wall defect in LBWC is recognized as a mass, often consisting of fetal liver and bowel, seen anteriorly to the abdomen or thorax.[23] Massive evisceration of organs, including the fetal heart, lungs, spleen, liver, bowel, kidneys, and bladder, can be seen in the most severe form of thoracoabdominoschisis (see Fig. 105.2).[24] The body wall defect is typically large and lateral in location, with the herniated amnioperitoneal sac attached to the placenta, and persistence of the extraembryonic coelom.[22,23] Severe kyphoscoliosis is a postural deformity caused by abnormal tight fixation of the fetus to the placenta, with a short umbilical cord, often containing a single umbilical artery.[13,21,24] The limb defects in LBWC can be similar to defects found in cases with isolated amniotic band syndrome and can include constriction rings, pseudosyndactyly, and digital or limb amputations.[25] Craniofacial defects including encephalocele and exencephaly and midfacial clefts can be seen. These deformities are likely caused by broad, adherent amniotic bands because pathologic evaluation of affected fetuses has shown the amnion to be continuous with the skin defect at the base of the skull and the skin margins on the face.[18]



Fig. 105.1 Two-dimensional image shows abdominoplacental LBWC with adhesion of omphalocele to the placenta. *(Courtesy Lawrence Platt, MD.)*

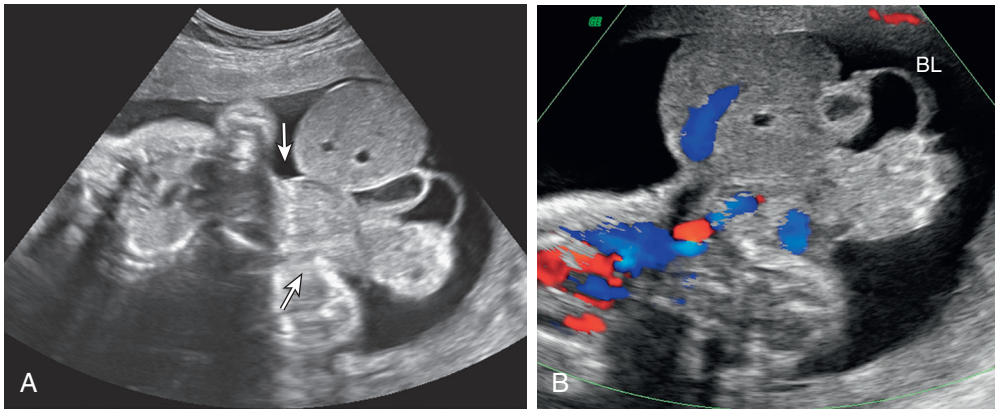

Fig. 105.2 (A) Two-dimensional image shows massive thoracoabdominal evisceration *(arrows)* with the extracorporeal fetal liver adherent to the placenta. (B) Color Doppler image shows massive thoracoabdominal evisceration of the bowel, bladder *(BL)*, and extracorporeal fetal liver adherent to the placenta.

Magnetic Resonance Imaging. Magnetic resonance imaging (MRI) has been reported to be a useful adjunct to US because it provides more comprehensive images of congenital anomalies.[26] In a case series by Aguirre-Pascual et al.,[2] MRI was able to detect and characterize all body parts affected and the associated abnormalities in fetuses diagnosed with LBWC on US.

CLASSIC SIGNS

The classic clinical triad of LBWC includes a craniofacial defect, limb deformity, and body wall malformation.

Differential Diagnosis From Imaging Findings. The differential diagnosis for LBWC includes amniotic band sequence, isolated omphalocele, isolated gastroschisis, and short umbilical cord syndrome.[13] Body stalk anomaly is also high on the list of differential diagnoses because it shares many phenotypic characteristics with LBWC; this condition is characterized by a large abdominal wall defect, short umbilical cord, and severe spinal angulation, but is not associated with craniofacial or limb defects.

Synopsis of Treatment Options

PRENATAL

There are currently no prenatal or postnatal treatment options for fetuses with LBWC. Termination of pregnancy should be offered because this abnormality is almost uniformly lethal.[13,24]

WHAT THE REFERRING PHYSICIAN NEEDS TO KNOW

Limb–body wall malformations are rare abnormalities that include severe deformation of the abdominal and thoracic walls, probably secondary to defective formation of the early body stalk. They can often be diagnosed via US in the first trimester and classically involve a craniofacial defect, limb deformity, and body wall malformation. The complex is almost uniformly fatal, and pregnancy termination should be offered if the diagnosis is made.

KEY POINTS

- LBWC is a sporadic disorder that leads to severe deformations of the craniofacial structures, abdominal wall, and limbs.
- The patterns of malformation vary depending on the degree of abnormal development during embryogenesis.
- Cases of LBWC are almost uniformly lethal.

SUGGESTED READING

Chen C, Lin C, Chang T, et al. Second-trimester diagnosis of limb–body wall complex with literature review of pathogenesis. *Genet Couns*. 2007;18:105.

Hunter A, Seaver L, Stevenson R. Limb–body wall defect. Is there a defensible hypothesis and can it explain all the associated anomalies? *Am J Med Genet A*. 2011;155:2045-2059.

Keppler-Noreuil K, Gorton S, Foo F, et al. Prenatal ascertainment of OEIS complex/cloacal exstrophy—15 new cases and literature review. *Am J Med Genet A*. 2007;143:2122-2128.

Mastroiacovo P, Lisi A, Castilla EE, et al. Gastroschisis and associated defects: an international study. *Am J Med Genet A*. 2007;143:660-671.

Sahinoglu Z, Uludogan M, Arik H, et al. Prenatal ultrasonographical features of limb body wall complex: a review of etiopathogenesis and a new classification. *Fetal Pediatr Pathol*. 2007;26:135-151.

All references are available online at www.expertconsult.com.

REFERENCES

1. Sahinoglu Z, Uludogan M, Arik H, et al. Prenatal ultrasonographical features of limb body wall complex: a review of etiopathogenesis and a new classification. *Fetal Pediatr Pathol*. 2007;26:135-151.
2. Aguirre-Pascual E, Epelman M, Johnson A. Prenatal MRI evaluation of limb–body wall complex. *Pediatr Radiol*. 2014;44:1412-1420.
3. Mann L, Ferguson-Smith MA, Desai M, et al. Prenatal assessment of anterior abdominal wall defects and their prognosis. *Prenat Diagn*. 1984;4: 427-435.
4. De Silva M, Senanayake H, Siriwardana K. Body stalk anomaly. *Ceylon Med J*. 2001;46:68.
5. Kanamori Y, Hashizume K, Sugiyama M, et al. Long-term survival of a baby with body stalk anomaly: report of a case. *Surg Today*. 2007;37: 30-33.
6. Van Allen M, Curry C, Walden C, et al. Limb body wall complex: II. limb and spine defects. *Am J Med Genet*. 1987;28:549-565.
7. Hunter A, Seaver L, Stevenson R. Limb–body wall defect. Is there a defensible hypothesis and can it explain all the associated anomalies? *Am J Med Genet A*. 2011;155:2045-2059.
8. Smrcek J, Germer U, Krokowski M, et al. Prenatal ultrasound diagnosis and management of body stalk anomaly: analysis of nine singletons and two multiple pregnancies. *Ultrasound Obstet Gynecol*. 2003;21(4): 322-328.
9. Costa M, Couto E, Furlan E, et al. Body stalk anomaly: adverse maternal outcomes in a series of 21 cases. *Prenat Diagn*. 2012;32:264-267.
10. Morrow R, Whittle M, McNay M, et al. Prenatal diagnosis and management of anterior abdominal wall defects in the west of Scotland. *Prenat Diagn*. 1993;13:111-115.
11. Forrester M, Merz R. Epidemiology of abdominal wall defects, Hawaii, 1986–1997. *Teratology*. 1999;60:117-123.
12. Daskalakis G, Sebire N, Jurkovic D, et al. Body stalk anomaly at 10–14 weeks of gestation. *Ultrasound Obstet Gynecol*. 1997;10:416-418.
13. Bianchi DW, Crombleholme TM, D'Alton ME, et al. *Fetology: Diagnosis and Management of the Fetal Patient*. 2nd ed. New York: McGraw-Hill; 2010.
14. Streeter G. Focal deficiencies in fetal tissues and their relation to intra-uterine amputation. *Contrib Embryol*. 1930;22:3-44.
15. Hartwig N, Vermeij-Keers C, De Vries H, et al. Limb body wall malformation complex: an embryologic etiology? *Hum Pathol*. 1989;20:1071-1077.
16. Van Allen M, Curry C, Walden C, et al. Limb body wall complex: II. limb and spine defects. *Am J Med Genet*. 1987;28:549.
17. Van Allen M, Hoyme H, Jones K. Vascular pathogenesis of limb defects. I. Radial artery anatomy in radial aplasia. *J Pediatr*. 1982;101:832-838.
18. Van Allen M, Curry C, Gallagher L. Limb body wall complex: I. pathogenesis. *Am J Med Genet*. 1987;28:529-548.
19. Miller S. Differential proliferation in morphogenesis of lateral body folds. *J Exp Zool*. 1982;221:205-211.
20. Kruszka P, Uwineza A, Mutesa L, et al. Limb body wall complex, amniotic band sequence, or new syndrome caused by mutation in IQ Motif containing K (IQCK)? *Mol Genet Genomic Med*. 2015;3(5):424-432.
21. Moerman P, Fryns J, Vandenberghe K, et al. Constrictive amniotic bands, amniotic adhesions, and limb–body wall complex: discrete disruption sequence with pathogenic overlap. *Am J Med Genet*. 1992;42:470.
22. Russo R, D'Armiento M, Angrisani P, et al. Limb body wall complex: a critical review and a nosological proposal. *Am J Med Genet*. 1993;47:893.
23. Pumberger W, Schaller A, Bernaschek G. Limb–body wall complex: a compound anomaly pattern in body-wall defects. *Pediatr Surg Int*. 2001;17:486.
24. Stephenson C, Lockwood J, MacKenzie A. Obstetrical and neonatal management of body stalk anomalies and cloacal exstrophy. In: Basow DS, ed. *UpToDate*. Waltham, MA: UpToDate; 2010.
25. Martinez-Frias M, Bermejo E, Rodriguez-Pinilla E. Body stalk defects, body wall defects, amniotic bands with and without body wall defects and gastroschisis: comparative epidemiology. *Am J Med Genet*. 2000;92:13.
26. Chen CP, Cheng SJ, Lin YH, et al. Prenatal imaging of limb-body wall complex by magnetic resonance imaging. *Prenat Diagn*. 2005;25:516.

106 Placenta Previa

AUDREY MERRIAM | MARY E. D'ALTON

Introduction

Placenta previa is a leading cause of antepartum bleeding. Diagnosis of this condition prenatally by ultrasound (US) is key in preventing the significant maternal and fetal morbidity that can occur as a result of this condition.

Disease

DEFINITION

Placenta previa refers to a placenta located either fully or partially in the lower uterine segment and covering the internal cervical os. Historically, terms such as *complete, marginal,* and *partial* were used to describe how much of the placenta was covering the internal os. Transvaginal ultrasonography has improved sonographic description of the precise location of the placenta, and these terms have been abandoned.[1–3] Any placenta overlying the internal os is now referred to as a *placenta previa*, negating the need for the complete or partial previa designation. Placentas that are near but not overlying the os are now designated as "low-lying."[1]

PREVALENCE AND EPIDEMIOLOGY

Placenta previa is estimated to occur in approximately 5:1000 pregnancies.[1,4] Worldwide, the incidence has been found to vary, with a higher incidence noted in Asian studies (12.2:1000 pregnancies) and lower incidences in European, North American, and African studies (2.7:1000–3.6:1000 pregnancies).[5] The incidence of placenta previa is much higher before the third trimester and may exceed 5%; however, upward of 90% of cases resolve as the pregnancy progresses through a process called trophotropism, where the placenta remodels and grows toward the area in the uterus with the best blood supply.[1,6,7]

One of the primary risk factors for placenta previa is prior cesarean delivery, and the risk increases with increasing numbers of cesarean deliveries. In these cases, the risk for placenta accreta is also increased, and careful attention should be taken to assess for this condition (Chapter 98).[8] Additional risk factors include a history of placenta previa in a prior pregnancy, advanced maternal age, multiparity, multiple pregnancy, smoking, cocaine use, and previous uterine surgery (i.e., curettage, abortion).[1,8–11]

ETIOLOGY AND PATHOPHYSIOLOGY

The exact etiology is unknown, but prior endometrial damage and uterine scarring seem to be associated with development of placenta previa.[1] The presence of a lower uterine scar from a prior cesarean has been suggested to prevent development and growth of the lower uterine segment leading to delayed migration of the placenta away from the internal os.[12,13] An association with hypoxia has also been suggested. It is known that placentas from women who smoke during pregnancy have a larger surface area to facilitate effective gas exchange and therefore may be more likely to cover the os.[14,15]

MANIFESTATIONS OF DISEASE

Clinical Presentation

Classically, placenta previa has been associated with painless vaginal bleeding, although bleeding from a placenta previa can be associated with contractions and abdominal pain. Antepartum bleeding is the most common finding with placenta previa, with 50%–60% of women with placenta previa reporting bleeding during pregnancy.[10,16,17] Some women will remain asymptomatic and may only be diagnosed on US or at the onset of labor. Any woman presenting with vaginal bleeding in the second half of pregnancy, especially if painless, should undergo a US, including a transvaginal approach if necessary, to assess for placenta previa before any digital vaginal examination. Measurement of the cervical length via transvaginal US may help predict if women are at increased risk for massive hemorrhage and preterm delivery with placenta previa. One study demonstrated that a cervical length less than 30 mm was significantly associated with increased risk of antepartum hemorrhage necessitating emergency cesarean delivery before 34 weeks' gestation.[18]

Neonatal complications associated with placenta previa are primarily related to prematurity and include risks such as death, intraventricular hemorrhage, low Apgar scores, anemia, and respiratory distress syndrome. A population-based cohort study from the United States found that approximately 55% of women with a previa deliver before 37 weeks' gestation, with 17% delivering less than 34 weeks' gestation.[10] Even controlling for gestational age, at delivery, neonatal risk for respiratory distress syndrome and anemia is increased with placenta previa.[19]

Imaging Technique and Findings

Ultrasound. US is the gold standard for diagnosing placenta previa. The vast majority of women in high-income countries undergo routine US screening. Transabdominal US can be used in most cases as a reliable screening exam (Fig. 106.1). One study that found a cutoff of 4.2 cm between the placenta edge and the internal os measured on transabdominal US had a negative predictive value of 99.8%, specificity of 76.7%, and a sensitivity of 93.3% in evaluating placenta previa.[20] Transabdominal US cannot be reliably used in all cases because of uterine contractions, fibroids, overdistended urinary bladder, and fetal positioning, all of which can obscure the placental edge and make measurements inaccurate.[21] Low-lying placentas may be missed on transabdominal US (Fig. 106.2). A false-positive rate of up to 8%–9% has been reported in screening for previa with

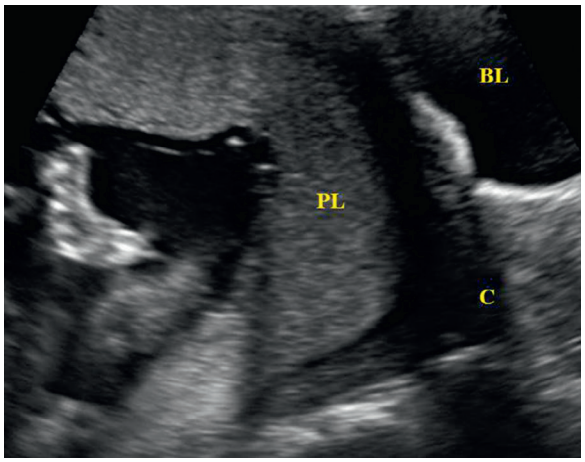

Fig. 106.1 Transabdominal view of placenta previa. *BL*, Maternal bladder; *C*, cervix; *PL*, placenta previa.

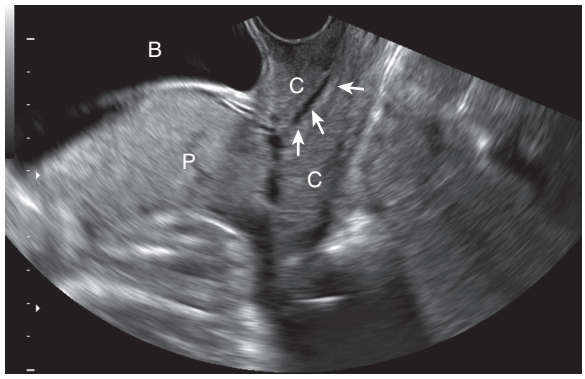

Fig. 106.3 Posterior complete placenta previa. Transvaginal ultrasound showing the placenta completely covering the internal os and extending posteriorly. *Arrows* indicate cervical canal. *B*, Maternal bladder; *C*, cervix; *P*, placenta.

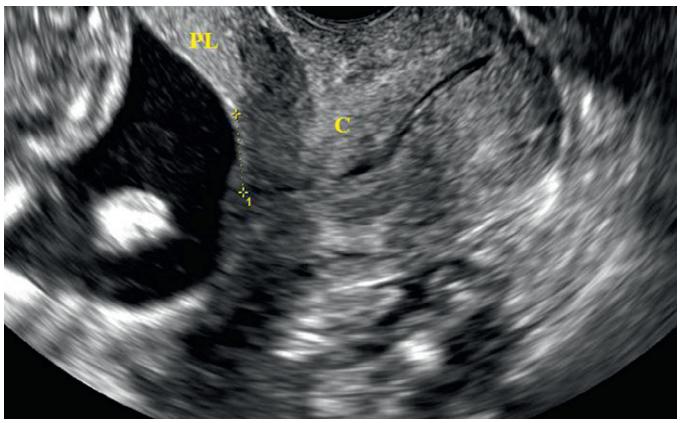

Fig. 106.2 Low-lying placenta. Transvaginal ultrasound of an anterior low-lying placenta that was measured 1.6 cm from the internal os. *C*, Cervix; *PL*, placenta.

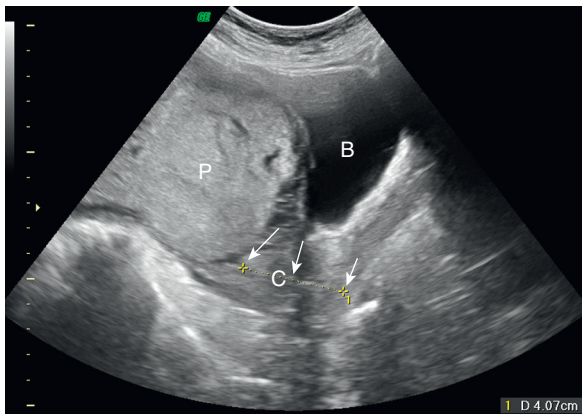

Fig. 106.4 Anterior complete placenta previa. Transvaginal US showing the placenta completely covering the internal os and extending anteriorly. *Arrows* indicate cervical canal. *B*, Maternal bladder; *C*, cervix; *P*, placenta.

transabdominal US.[20,21] Transperineal US has also been used to accurately screen for placenta previa and remains an alternative if patients are resistant to transvaginal US.[22]

Transvaginal US is the most accurate way to diagnose placenta previa and the true distance from the placental edge to the internal os, especially in cases that are concerning via transabdominal US (Figs. 106.3 and 106.4).[3] This screening method can be used during routine screening of asymptomatic women and must be used before digital examination of women with vaginal bleeding in the second half of pregnancy. The vaginal probe should be inserted while watching the on-screen image to avoid placental manipulation in the case of cervical dilation. The probe should be positioned 2–3 cm away from the cervix so the operator can clearly show the relationship of the placenta to the cervix and internal os. Where there is no placenta previa, the distance between the placental edge and the internal os should be measured.[21]

Because of the timing of most anatomic and screening USs in pregnancy, the diagnosis of placenta previa is most commonly made before the third trimester. Repeat US examinations are required in the third trimester in these cases because around 90% of placenta previas diagnosed in the second trimester resolve before delivery.[1] The degree of placenta overlap of the internal os at midgestation has been shown to correlate with the risk of persistence at term. One study found that an overlap of at least 25 mm at 20–23 weeks' gestation indicated persistence of placenta previa in 100% of cases at term.[23] If a placenta previa has been found to "resolve," other entities, such as a succenturiate lobe and vasa previa, should also be ruled out using color mapping over the internal os. In patients with a history of cesarean delivery and diagnosis of placenta previa, one must also assess for the presence of placenta accreta, as this will greatly alter maternal and fetal risk, delivery timing, and possibly delivery method (Fig. 106.5).

Efforts have been made to determine whether predisposing factors for massive hemorrhage during cesarean delivery for cases of placenta previa can be identified. A few studies have suggested that a sponge-like appearance of the cervical wall and an anterior placenta were associated with massive intraoperative hemorrhage.[24,25] Regardless of findings on US, providers should be prepared for potential hemorrhage at the time of delivery. In addition, a detailed fetal anatomic survey should occur in all cases of placenta previa as the risk for congenital anomalies is higher in these cases.[19]

Magnetic Resonance Imaging. Magnetic resonance imaging (MRI) is not required in the diagnosis of placenta previa. In

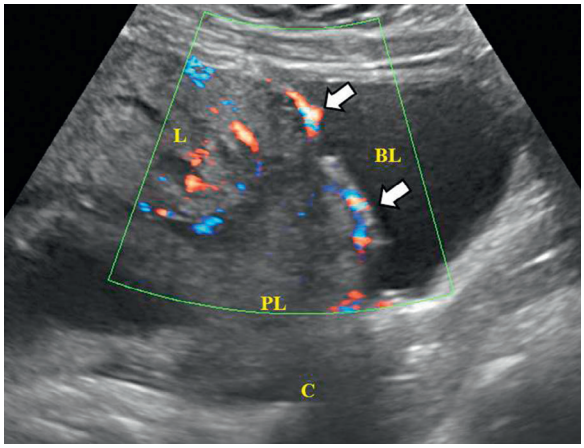

Fig. 106.5 Placenta previa. Transabdominal ultrasound image showing a placenta previa with characteristics suggestive of placenta accreta, including lacunae *(L)*, increased vascularity *(arrows)* at the posterior border of the bladder *(BL)*, and the lack of a clear zone behind the anterior portion of the placenta. *C*, Cervix; *PL*, placenta.

cases of a placenta previa with a history of prior cesarean delivery, MRI may be useful to assist in evaluation for placenta accreta, especially in the presence of other concerning findings (i.e., lack of retroplacental clear space and placental lacunae).[1]

CLASSIC SIGNS

Placenta is seen covering the internal os.

Differential Diagnosis From Imaging Findings. The differential diagnosis of placenta previa before US examination includes other etiologies for third-trimester vaginal bleeding, as this is the most common presenting symptom. Conditions such as placental abruption, vasa previa, and placenta accreta/increta/percreta can also be evaluated with US. Preterm labor and lesions of the lower genital tract (i.e., lacerations and cervical polyps) can be evaluated on physical exam after US. A blood clot caused by a placental abruption that is on top of the internal os can be mistaken for a previa, especially if the placental edge abuts the clot. Color Doppler should be used in attempts to rule out this etiology.

Synopsis of Treatment Options

PRENATAL

Patients diagnosed with placenta previa on screening US at midgestation should be informed of this condition and scheduled for follow-up US examination. Pelvic rest is typically recommended in all patients with placenta previa, but activity restriction is not necessary in the absence of other complications.

Any patient presenting with vaginal bleeding in the second half of pregnancy should undergo evaluation of placental location via US before digital vaginal examination. Visual examination of the cervix and lower genital tract via speculum before US is acceptable and will not cause further disruption of the placenta. Initial management of a bleeding previa includes assessment of maternal vital signs and hemodynamic state, assessment of fetal well-being and laboratory work-up. Significant hemorrhage can result in maternal and fetal compromise and can require resuscitation with intravenous fluids and blood products. In cases of maternal and/or fetal compromise, providers should proceed with delivery via cesarean section regardless of the gestational age. In centers where trained providers are available, dilation and evacuation may be used before 24 weeks' gestation, but hemorrhage to the degree that delivery is indicated is rare at this point in gestation.

In women with antepartum bleeding that is not significant enough to cause maternal or fetal compromise before 36 weeks' gestation, conservative management is appropriate.[1] Management should include admission to a hospital with an appropriate level neonatal intensive care unit, administration of glucocorticoids before 37 weeks' gestation, tocolysis in selected cases, Rh immune globulin, and blood product transfusion if needed.[26,27] With a first episode of bleeding, the admission can be for an observation period only, but patients with repeated bleeding episodes should be considered for longer admissions.[28] Repeat US assessment for the persistence of placenta previa is recommended in the third trimester.[23] Patients with placenta previa should be delivered between 36 and 37 weeks' gestation via cesarean section.[29]

Cesarean delivery is generally recommended in cases where the placental edge is within 1 cm of the internal cervical os. Patients with the placental edge 2 cm or greater from the internal os can safely undergo a trial of labor with monitoring for vaginal bleeding.[1] In patients where the edge of the placenta is 1.1–2.0 cm from the internal os, the mode of delivery should be individualized as small studies have found that between 70%–90% of patients will have a successful vaginal delivery without increased risk of hemorrhage.[1,3,30]

POSTNATAL

Even in the absence of antepartum hemorrhage, placenta previa carries a risk for postpartum hemorrhage, primarily caused by uterine atony, as the lower uterine segment does not have the same contractile ability as the fundus after delivery.[16] Anticipation of this potential complication is key, and the availability of uterotonics and intrauterine balloon tamponade should be confirmed in addition to planning for potential surgical maneuvers such as B-Lynch sutures or hysterectomy. Consideration should be given to preparation of blood products before delivery, as the hemorrhage can be brisk, leading to maternal hemodynamic instability.

KEY POINTS

- Early diagnosis of placenta previa in midgestation requires repeat evaluation in the third trimester because more than 90% of cases resolve.
- Evaluation of vaginal bleeding in the second half of pregnancy should always include US evaluation of placental location before a digital vaginal examination.
- Placenta previa is a risk factor for the development of placenta accreta, especially in the presence of prior cesarean deliveries, and close attention should be paid to screening for an accreta in these patients.
- Pregnancies with placenta previa or placental edge within 1 cm of the internal os should be delivered by cesarean delivery between 36 and 37 weeks' gestation or earlier, if clinically indicated. Patients with the placental edge ≥2 cm from the internal os can safely undergo a trial of labor, whereas patients with the placental edge between 11 and 20 mm should have tailored delivery planning.

SUGGESTED READING

Cresswell J, Ronsmans C, Calvert C, et al. Prevalence of placenta previa by world region: a systemic review and meta-analysis. *Trop Med Int Health*. 2013;18:712-714.

Silver R. Abnormal placentation: placenta previa, vasa previa, and placenta accreta. *Obstet Gynecol*. 2015;126:654-668.



All references are available online at www.expertconsult.com.

REFERENCES

1. Silver R. Abnormal placentation: placenta previa, vasa previa, and placenta accreta. *Obstet Gynecol*. 2015;126:654-668.
2. Oppenheimer L, Farine D. A new classification of placenta previa: measuring progress in obstetrics. *Am J Obstet Gynecol*. 2009;227-229.
3. Vergani P, Ornaghi S, Pozzi I, et al. Placenta previa: distance to internal os and mode of delivery. *Am J Obstet Gynecol*. 2009;201:e1-e5.
4. Oyelese Y, Smulian J. Placenta previa, placenta accreta, and vasa previa. *Obstet Gynecol*. 2006;107:927-941.
5. Cresswell J, Ronsmans C, Calvert C, et al. Prevalence of placenta previa by world region: a systemic review and meta-analysis. *Trop Med Int Health*. 2013;18:712-714.
6. Wexler P, Gottesfeld K. Early diagnosis of placenta previa. *Obstet Gynecol*. 1979;54:231-234.
7. Newton E, Barss V, Cetrulo C. The epidemiology and clinical history of asymptomatic midtrimester placenta previa. *Am J Obstet Gynecol*. 1984;148:743-748.
8. Ananth C, Smulian J, Vintzileos A. The association of placenta previa with history of cesarean delivery and abortion: a metaanalysis. *Am J Obstet Gynecol*. 1997;177:1071-1077.
9. Jolly M, Sebire N, Harris J, et al. The risks associated with pregnancy in woman aged 35 years or older. *Hum Reprod*. 2000;15:2433-2437.
10. Ananth C, Demissie K, Smulian J, et al. Placenta previa in singleton and twin births in the United States, 1989 through 1998: a comparison of risk factor profiles and associated conditions. *Am J Obstet Gynecol*. 2003;188:275-281.
11. Macones G, Sehdev H, Parry S, et al. The association between maternal cocaine use and placenta previa. *Am J Obstet Gynecol*. 1997;177:1097-1100.
12. Clark S, Koonings P, Phelan J. Placenta previa/accreta and prior cesarean section. *Obstet Gynecol*. 1985;68:89-92.
13. Taylor V, Kramer M, Vaughn T, et al. Placenta previa and prior cesarean delivery: how strong is the association. *Obstet Gynecol*. 1994;84:55-57.
14. Ananth C, Savitz D, Luther E. Maternal cigarette smoking as a risk factor for placental abruption, placenta previa, and uterine bleeding in pregnancy. *Am J Epidemiol*. 1996;144:881-889.
15. Monica G, Lilja C. Placenta previa, maternal smoking and recurrence risk. *Acta Obstet Gynecol Scand*. 1995;74:341-345.
16. Crane JMGVDHM, Doods L, Armson A, et al. Maternal complications with placenta previa. *Am J Perinatol*. 2000;17:101-105.
17. Bhide A, Prefumo F, Moore J, et al. Placental edge to internal os distance in the late third trimester and mode of delivery in placenta previa. *BJOG*. 2003;110:860-864.
18. Ghi T, Contro E, Martina T, et al. Cervical length and risk of antepartum bleeding in women with complete placenta previa. *Ultrasound Obstet Gynecol*. 2009;33:209-212.
19. Crane L, Hof MVD, Doods L, et al. Neonatal outcomes with placenta previa. *Obstet Gynecol*. 1999;93:541-544.
20. Quant H, Friedman A, Wang E, et al. Transabdominal ultrasonography as a screening test for second-trimester placenta previa. *Obstet Gynecol*. 2014;123:628-633.
21. Smith R, Lauria M, Comstock C, et al. Transvaginal ultrasonography for all placentas that appear to be low-lying or over the internal cervical os. *Ultrasound Obstet Gynecol*. 1997;9:22-24.
22. Hertzberg B, Bowie J, Carroll B, et al. Diagnosis of placenta previa during the third trimester: role of transperineal sonography. *AJR*. 1992;159:83-87.
23. Becker R, Vonk R, Mende B, et al. The relevance of placental location at 20-23 gestational weeks for prediction of placenta previa at delivery: evaluation of 8650 cases. *Ultrasound Obstet Gynecol*. 2001;17:496-501.
24. Hasegawa J, Matsuoka R, Ichizuka K, et al. Predisposing factors of massive hemorrhage during cesarean section in patients with placenta previa. *Ultrasound Obstet Gynecol*. 2009;34:80-84.
25. Saitoh M, Ishihara K, Sekiya T, et al. Anticipation of uterine bleeding in placenta previa based on vaginal sonographic evaluation. *Gynecol Obstet Invest*. 2001;54:37-42.
26. Sharma A, Suri V, Gupta I. Tocolytic therapy in conservative management of symptomatic placenta previa. *Int J Gynaecol Obstet*. 2004;84:109-113.
27. Gyamfi-Bannerman C, Thom E, Blackwell S, et al. Antenatal betamethasone for women at risk for late preterm delivery. *N Engl J Med*. 2016;374:1311-1320.
28. Wing D, Paul R, Millar L. Management of the symptomatic placenta previa: a randomized, controlled trial of inpatient versus outpatient expectant management. *Am J Obstet Gynecol*. 1996;175:806-811.
29. Spong C, Mercer B, D'Alton M, et al. Timing of indicated late-preterm and early-term birth. *Obstet Gynecol*. 2011;118:323-333.
30. AlWadi K, Schneider C, Burym C, et al. Evaluating the safety of labor in women with a placental edge 11 to 20 mm from the internal cervical os. *J Obstet Gynaecol Can*. 2014;36:674-677.

107 Vasa Previa

JACLYN M. COLETTA | MARY E. D'ALTON

Introduction

Vasa previa is a condition in which the umbilical vessels course through the membranes within the lower uterine segment and traverse over, or near, the endocervical os.[1] These vessels can rupture spontaneously without rupture of the membranes, and result in fetal exsanguination and demise.[1] In addition, since the vessels are not protected by the umbilical cord, they are at increased risk of cord compression.

Disease

DEFINITION

Vasa previa occurs when the fetal vessels located over the internal cervical os are surrounded only by membranes without Wharton's jelly.

PREVALENCE AND EPIDEMIOLOGY

The prevalence of vasa previa ranges from 2:10,000 to 4:10,000 deliveries.[1] Risk factors include a velamentous cord insertion, a low-lying placenta or placenta previa, multiple gestations, as well as bilobed or succenturiate lobe placentas.[2] Vasa previa has been reported in as many as 50:10,000 pregnancies following *in vitro* fertilization.[3] One systematic review reported that 83% of cases had one or more known risk factors.[4]

ETIOLOGY AND PATHOPHYSIOLOGY

The proposed etiology of vasa previa is that there is initial central implantation of the umbilical cord vessels but with trophoblastic growth of one pole of the placenta toward the well-vascularized uterine fundus; the cord insertion becomes progressively more peripheral and eccentric until the vessels are surrounded only by fetal membranes.[5] When these vessels traverse between the cervix and the presenting part of the fetus, it is a vasa previa.

MANIFESTATIONS OF DISEASE

Clinical Presentation

Before the wide use of transvaginal ultrasound (US), the classic presentation of vasa previa included either spontaneous vessel rupture or rupture at amniotomy with vaginal bleeding causing fetal shock or death.[6] If a vasa previa has not been diagnosed or suspected prenatally, it should be considered when vaginal bleeding occurs after membrane rupture and results in fetal heart rate abnormalities, particularly a sinusoidal pattern.[7]

With the common use of transvaginal US, it is more often diagnosed during the middle of the second trimester. These cases may resolve over time, allowing for vaginal delivery at term.

Imaging Technique and Findings

Ultrasound. During an anatomic survey of the fetus, a detailed assessment of the placenta and placental cord insertion should be performed. A velamentous cord insertion is characterized by splaying of the vessels at the periphery of the placenta.[8] Once a velamentous cord insertion or an accessory placental lobe is visualized, transvaginal sonography with color Doppler should be performed to look specifically for vasa previa[8] (Fig. 107.1). Diagnosis is based on the identification of membranous fetal vessels passing across, or within 2 cm, of the internal os (Figs. 107.2 and 107.3). Pulsed Doppler can be used to differentiate from maternal vessels by demonstrating a rate consistent with the fetal heart.[9] In addition, a vasa previa can be distinguished from a funic presentation by changing the mother's position or placing her in the Trendelenburg position, as the umbilical cord should move in the setting of a funic presentation. In a prospective trial by Sepulveda et al., velamentous cord insertion was detected

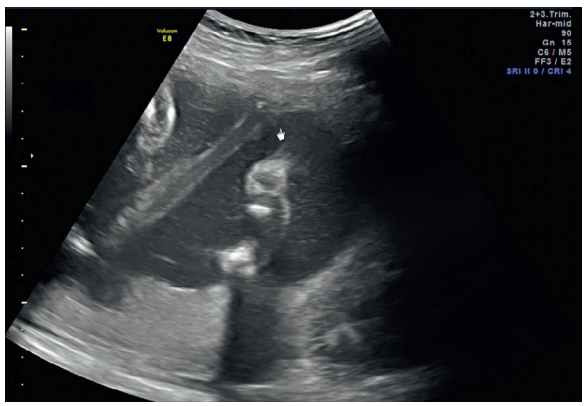

Fig. 107.1 Transabdominal image of a velamentous cord insertion.

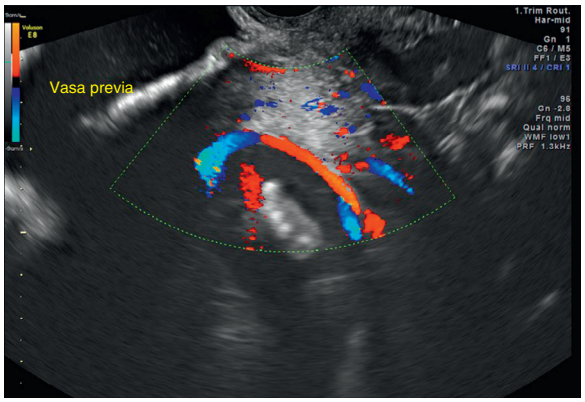

Fig. 107.2 Transvaginal image using color demonstrating fetal vessels running superior to the internal cervical os.

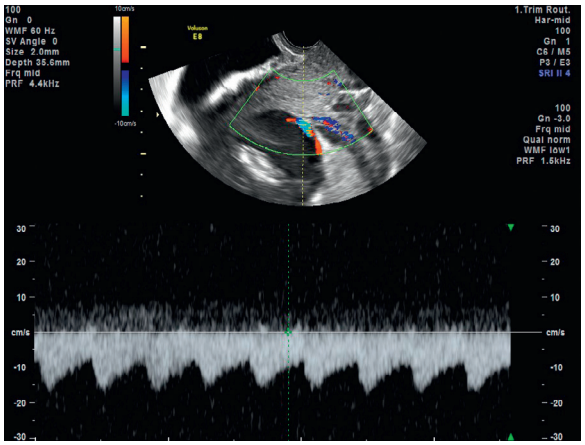

Fig. 107.3 Transvaginal image using color and pulsed Doppler demonstrating an arterial vessel with a rate consistent with the fetal heart rate.

using color Doppler with a sensitivity of 100%, specificity of 99.8%, positive predictive value of 83%, and negative predictive value of 100%.[10] After suspicion of a velamentous umbilical cord, 78% of vasa previas were diagnosed in asymptomatic women prenatally.[3] Prenatal diagnosis of vasa previa is crucial as it has been found to significantly decrease perinatal morbidity and mortality.[11] Undiagnosed cases of vasa previa have resulted in significantly lower 5-minute Apgar scores, and increased frequencies of neonatal acidemia and demise.[11] Surviving infants require more blood transfusions.[11]

Magnetic Resonance Imaging. Magnetic resonance imaging (MRI) has had an increasing role in obstetrics and is especially useful in the diagnosis and exclusion of placental abnormalities such as placenta previa and accreta. One study examined the use of MRI in a case of known vasa previa and demonstrated that the exact number of vessels running over the cervix as well as their course and orientation could be determined.[12] In addition, the number of placental lobes and their location were further delineated.[12] However, given the increased expense and relative inaccessibility of MRI, US with color and pulsed Doppler are adequate in most cases.

Differential Diagnosis From Imaging Findings. The differential diagnosis of a suspected vasa previa includes maternal cervical vessels, chorioamniotic separation, or a funic presentation. These can be differentiated with the use of color and pulsed Doppler imaging.

Synopsis of Treatment Options

PRENATAL

Women with placenta previa or low-lying placenta on midtrimester US should undergo transvaginal US with color and pulsed Doppler at 28–32 weeks' gestation to screen for vasa previa. There are no data from large or controlled studies to help determine the optimal management of prenatally diagnosed vasa previa. Hospitalization should be considered at 30–32 weeks for possible steroid administration, more frequent fetal heart rate monitoring, and to facilitate an emergency cesarean delivery if premature rupture of membranes or labor occurs. Delivery should be considered if repetitive variable decelerations are evident on fetal heart rate tracing. If the patient remains stable, delivery via cesarean section is recommended between 34 and 36 weeks' gestation.[13]

KEY POINTS

- A velamentous cord refers to umbilical vessels surrounded only by fetal membranes.
- Vasa previa occurs when the umbilical vessels are located in advance of the fetal-presenting part.
- Transvaginal US examination using color Doppler is recommended in women with risk factors for vasa previa as prenatal diagnosis markedly improves neonatal survival.
- Twice-weekly testing is recommended starting at 28 weeks' gestation, followed by hospital admission and fetal heart rate monitoring at 32 weeks' gestation.
- Cesarean delivery is recommended between 34 and 36 weeks' gestation, before premature rupture of membranes or labor.

SUGGESTED READINGS

Baulies S, Maiz N, Munoz A, et al. Prenatal ultrasound diagnosis of vasa previa and analysis of risk factors. *Prenat Diagn*. 2007;27:595.

Bronsteen R, Whitten A, Balasubramanian M, et al. Vasa previa: clinical presentations, outcomes, and implications for management. *Obstet Gynecol*. 2013;122:352.

Catanzarite V, Maida C, Thomas W, et al. Prenatal sonographic diagnosis of vasa previa: ultrasound findings and obstetric outcome in ten cases. *Ultrasound Obstet Gynecol*. 2001;18:109.

Esakoff TF, Cheng YW, Snowden JM, et al. Velamentous cord insertion: is it associated with adverse perinatal outcomes? *J Matern Fetal Neonatal Med*. 2015;28:409.

Gagnon R, Morin L, Bly S, et al. Guidelines for the management of vasa previa. *J Obstet Gynaecol Can*. 2009;31:748.

Hubinont C, Lewi L, Bernard P, et al. Anomalies of the placenta and umbilical cord in twin gestations. *Am J Obstet Gynecol*. 2015;S91-S102.

Lee W, Lee VL, Kirk JS, et al. Vasa Previa: prenatal diagnosis, natural evolution, and clinical outcome. *Obstet Gynecol*. 2000;95:572.

Oyelese Y, Smulian JC. Placenta previa, placenta accreta and vasa previa. *Obstet Gynecol*. 2006;107:927-941.

Schacter M, Tovbin Y, Arieli S, et al. In vitro fertilization is a risk factor for vasa previa. *Fertil Steril*. 2002;78:642.

Silver RM. Abnormal placentation: placenta previa, vasa previa, and placenta accreta. *Obstet Gynecol*. 2015;126:654-668.

Vintzeleos AM, Ananth CV, Smulian JC. Using ultrasound in the clinical management of placental implantation abnormalities. *Am J Obstet Gynecol*. 2015;S70-S77.

All references are available online at www.expertconsult.com.

REFERENCES

1. Silver RM. Abnormal placentation: placenta previa, vasa previa, and placenta accreta. *Obstet Gynecol*. 2015;126:654-668.
2. Vintzeleos AM, Ananth CV, Smulian JC. Using ultrasound in the clinical management of placental implantation abnormalities. *Am J Obstet Gynecol*. 2015;S70-S77.
3. Schacter M, Tovbin Y, Arieli S, et al. In vitro fertilization is a risk factor for vasa previa. *Fertil Steril*. 2002;78:642.
4. Baulies S, Maiz N, Munoz A, et al. Prenatal ultrasound diagnosis of vasa previa and analysis of risk factors. *Prenat Diagn*. 2007;27:595.
5. Lee W, Lee VL, Kirk JS, et al. Vasa Previa: prenatal diagnosis, natural evolution, and clinical outcome. *Obstet Gynecol*. 2000;95:572.
6. Oyelese KO, Turner MJ, Lees CC, et al. Vasa previa: an avoidable obstetric tragedy. *Obstet Gynecol Surv*. 1999;54:138-145.
7. Oyelese Y, Catanzarite V, Prefumo F, et al. Vasa previa: the impact of prenatal diagnosis on outcomes. *Obstet Gynecol*. 2004;103:937.
8. Kouyoumdjian A. Velamentous insertion of the umbilical cord. *Obstet Gynecol*. 1980;56:737.
9. Nomiyama M, Toyota Y, Kawano H. Antenatal diagnosis of velamentous umbilical cord insertion and vasa previa with color Doppler imaging. *Ultrasound Obstet Gynecol*. 1998;12:426.
10. Sepulveda W, Rojas I, Robert JA, et al. Prenatal detection of velamentous insertion of the umbilical cord: a prospective color Doppler ultrasound study. *Ultrasound Obstet Gynecol*. 2003;21:564.
11. Oyelese Y, Smulian JC. Placenta previa, placenta accreta and vasa previa. *Obstet Gynecol*. 2006;107:927-941.
12. Oyelese Y, Jha R, Moxley M, et al. Magnetic resonance imaging of vasa praevia. *BJOG*. 2003;110:1127-1128.
13. Gagnon R, Morin L, Bly S, et al. Guidelines for the management of vasa previa. *J Obstet Gynaecol Can*. 2009;31:748.

108 Fetal Macrosomia

MICHELLE SILASI

Introduction

The term *macrosomia* is used to describe a fetus or neonate with excessive growth. However, during pregnancy, as the fetus cannot be weighed directly, the term *fetal macrosomia* is intended to convey a suspicion of excessive fetal growth beyond a specified threshold, based on indirect assessment such as physical examination or ultrasound (US) assessment. Because of the increased risk of labor dystocia, birth trauma, and permanent injury to the fetus with increasing birth weight, being able to determine an accurate estimated fetal weight may affect the mode of delivery. The finding of fetal macrosomia may require additional screening and counseling before delivery.

Disorder

DEFINITION

While the terms *large for gestational age* (LGA) and *fetal macrosomia* are both meant to convey a concern for excessive growth, the two terms differ slightly in their specific definitions. LGA refers to neonatal birth weight larger than the 90th percentile for a given gestational age. In contrast to LGA, fetal macrosomia is defined as an absolute birth weight above a specified threshold regardless of gestational age. Varying thresholds have been used, including 4000 g and 4500 g, and both thresholds have been associated with adverse pregnancy outcomes. The American College of Obstetricians and Gynecologists suggests a threshold of 4500 g for considering changes in management, secondary to estimated fetal weight for women with diabetes, and a threshold of 5000 g for women without diabetes.[1]

PREVALENCE AND EPIDEMIOLOGY

The prevalence of macrosomia depends on the definition used and the population studied. In the United States in 2014, 6.9% of neonates weighed more than 4000 g, 1% weighed more than 4500 g, and about 0.1% of neonates weighed more than 5000 g.[2]

ETIOLOGY, PATHOPHYSIOLOGY, AND EMBRYOLOGY

Fetal macrosomia is a description of excessive fetal size. In many cases, it represents a consequence of a multitude of differing environmental and genetic factors that ultimately result in the macrosomic state. Multiple risk factors contribute to fetal macrosomia, some of which are discussed subsequently.[3] Risk factors include:

1. Maternal obesity, defined as a prepregnancy body mass index greater than 30, and excessive gestational weight gain are two important risk factors for macrosomia given the high prevalence of both in the United States.[3–5]
2. Maternal diabetes and gestational diabetes are well-recognized risk factors for macrosomia because chronic and intermittent maternal hyperglycemia has been strongly associated with accelerated fetal growth and fat deposition.[6,7] Abnormal glucose tolerance without the diagnosis of gestational diabetes has even been suggested to increase the risk of macrosomia.[8] Management of gestational diabetes with glucose monitoring, nutritional consultation, and hypoglycemic agents, when indicated, significantly mitigates this risk.[9,10]
3. Postterm pregnancy is a risk factor. In the United States, after 42 weeks' gestation, 25.3% of fetuses weigh more than 4000 g, and 5.2% weigh more than 4500 g.[2]
4. Genetic syndromes are rare in fetuses with macrosomia without other findings but must be considered, especially when other congenital abnormalities are identified (see Differential Diagnosis From Imaging Findings).
5. Other important risk factors are multiparity, prior macrosomic infants, male sex, ethnicity, maternal birth weight greater than 4000 g, and advanced maternal age.[11]

In some infants, the pathophysiology is clear, such as postterm pregnancy or poorly controlled diabetes. However, the etiology of macrosomia is unclear in many cases. More recently, it has become clear that increases in maternal glycemia, even at levels thought to rule out diabetes, are associated with increasing fetal size and LGA.[12] Many of the aforementioned listed risk factors may ultimately be related to subclinical maternal glucose intolerance, including diabetes, obesity, excessive gestational weight gain, maternal birth weight, and advancing age.

MANIFESTATIONS OF DISEASE

Clinical Presentation

Fetal macrosomia may be present without any maternal clinical manifestations and is commonly identified on physical examination or screening US. Both fundal height measurements and Leopold maneuvers are commonly used to estimate fetal size, but both methods have poor sensitivity and specificity for macrosomia. Fetal macrosomia may be identified on routine screening US during pregnancies with risk factors or as an adjunct to a concerning physical examination. However, some data suggest

similar accuracy between US and Leopold maneuvers for predicting macrosomia.[13] Nevertheless, identifying macrosomic fetuses is important given the implications on fetal and maternal pregnancy outcomes.

Fetus and Neonate. Perinatal outcomes for macrosomic fetuses differ from smaller fetuses, with an increased risk of perinatal death and birth trauma.[11,14,15] This is a global phenomenon.[16–18]

Shoulder dystocia and subsequent birth injuries are a consequence of increasing fetal weight.[15,17,19] In fetuses weighing more than 4500 g, the risk for shoulder dystocia is 9% to 24% among nondiabetic mothers, and 19% to 50% in diabetic mothers.[1] Both clavicular fractures and brachial plexus injuries are more commonly identified in macrosomic neonates after a vaginal delivery.[11,14] Additional neonatal risks include many conditions that are common to infants of diabetic mothers, including hypoglycemia, polycythemia, and metabolic and electrolyte abnormalities.

Mother. There are significant maternal implications that are strongly associated with macrosomic fetuses, including postpartum hemorrhage and subsequent transfusion, perineal trauma, especially third-degree and fourth-degree lacerations after a vaginal birth, infection, and cesarean birth.[17,20,21]

Imaging Technique and Findings

Ultrasound. Two-dimensional (2D) US coupled with physical examination is the current standard for estimating fetal weight and identifying fetal macrosomia. Fetal weight cannot be directly measured. There are multiple formulas to predict fetal weight based on several biometric measurements, such as femur length, abdominal circumference, and head circumference/biparietal diameter (Fig. 108.1). For diagnosing fetal macrosomia, performing US as near to delivery as possible appears to be more accurate for diagnosis.[22]

Of the multiple formulas for estimating fetal weight, no single one is universally used.[23] A review of different US experiences showed a concerning wide range of sensitivity (12% to 75%), specificity (68% to 99%), and posttest probability (17% to 79%) for identifying macrosomia, highlighting the limitations of US for identifying macrosomia. The value of US may be in its ability to rule out macrosomia rather than confirmation. More recently, greater attention has been directed toward using three-dimensional (3D) US techniques to better predict fetal weight (Fig. 108.2). Although some investigators have found greater accuracy with 3D techniques,[24,25] at present, there is no evidence to abandon 2D US evaluations.[26,27]

Magnetic Resonance Imaging. Magnetic resonance imaging (MRI) can also be used to estimate fetal weight, and some studies showed greater accuracy for estimating birth weight than with US alone.[28] However, no studies have yet shown the accuracy of MRI for identifying fetal macrosomia. Because of issues of both cost and availability, MRI is not a standard for estimating fetal weight and identifying macrosomia.

Differential Diagnosis From Imaging Findings

The differential diagnosis is broad because macrosomia is not specific to any disease process and may be physiologic. Although most cases are caused by obesity and diabetes, the possibility of genetic syndromes should be considered, especially in the setting of a fetal abnormality. Some genetic syndromes, such as Pallister-Killian, Beckwith-Wiedemann (Chapter 109), Sotos, Perlman, and Simpson-Golabi-Behmel, may be tested with the aid of a clinical geneticist.[29]

Synopsis of Treatment Options

PRENATAL

Prevention of macrosomia is typically focused on women with significant risk factors such as gestational weight gain and diabetes. Intensive dietary and lifestyle counseling reduces both maternal weight gain and neonatal birth weight. For women with diabetes, careful glycemic control may prevent macrosomia.[9,10]

When fetal macrosomia is suspected, the risks of macrosomia on both neonatal and maternal outcomes and the mode of delivery should be discussed.[1] A targeted anatomic survey to identify other associated anomalies should be performed if one was not done previously. However, an anatomic survey may be limited in scope because of the late gestational age at which fetal macrosomia



Fig. 108.1 Example of abdominal circumference at 36 weeks' gestation. At birth, the neonate weighed more than 5000 g.



Fig. 108.2 Example of a three-dimensional image of the fetal face at 36 weeks' gestation. At birth, the neonate weighed more than 5000 g.

is typically identified. The risks of genetic syndromes may be discussed with a genetic counselor if there are concurrent fetal abnormalities and a genetic syndrome is being considered.

Offering an elective cesarean section for fetal macrosomia is controversial. Elective cesarean delivery is intended to reduce complications from cesarean deliveries performed in labor and neonatal birth injury. However, outcomes from this approach have not been proven in randomized trials. One decision analysis estimated that elective cesarean section would not be cost-effective because 3695 elective cesarean sections would be performed at a cost of $8.7 million to prevent one case of permanent brachial plexus injury if a policy of routine elective cesarean section for macrosomia were adopted.[30] The American Congress of Obstetricians and Gynecologists stated that elective cesarean delivery may be offered to a diabetic woman with a fetus estimated to weigh more than 4500 g and a nondiabetic woman with a fetus estimated to weigh more than 5000 g with the understanding of the accuracy limitations of US when estimating fetal weight (level C evidence).[1]

Induction of labor for both macrosomia and suspected or "impending macrosomia" is perhaps more controversial than cesarean delivery, and certainly remains an open area of study. One recent study showed a benefit for early-term induction of labor versus expectant management for fetuses with estimated fetal weights >95th percentile. The authors found lower birth weights and rates of shoulder dystocia in patients who were induced compared to the expectant management group. This study supports a possible management strategy for fetuses with excessive fetal weight. However, the authors contend that the benefits found in their study should be weighed against the effects of early term delivery.[31] Current evidence suggests that the benefits of lower birth weight and decreased shoulder dystocia need to be weighed against the risks of early-term births and maternal perineal injury.[30] Certainly, the current mainstay of management involves an informed discussion between the obstetric provider, neonatal providers, and the patient.

POSTNATAL

Postnatal management should be based on the findings at birth.

WHAT THE REFERRING PHYSICIAN NEEDS TO KNOW

- There is no universal definition for fetal macrosomia, but most would agree that the fetal weight threshold should be approximately 4000 g to 4500 g.
- Important risk factors include maternal obesity, excessive gestational weight gain, maternal diabetes, postterm pregnancy, multiparity, prior macrosomic infants, male infant, and advanced maternal age.
- Macrosomic fetuses are at increased risk for perinatal death, birth trauma, metabolic abnormalities, and neonatal intensive care unit admission.
- Mothers of macrosomic fetuses are at risk for hemorrhage, significant perineal lacerations, infection, and cesarean section.

KEY POINTS

- Fetal macrosomia is a description of excessive fetal size.
- Genetic disorders should be considered when macrosomia and congenital birth defects are identified.
- A detailed anatomic survey should be performed if it was not done previously.
- Although physical examination and US are commonly used to diagnose fetal macrosomia, both techniques are limited by low sensitivity and specificity for fetal macrosomia.
- Three-dimensional US and MRI are promising but are not the standard for identifying fetal macrosomia.
- Elective cesarean delivery for macrosomia is controversial and has not been shown to significantly reduce the risk of fetal birth injury.

SUGGESTED READING

ACOG Practice Bulletin, Number 22. Fetal macrosomia. *Am Coll Obstet Gynecol.* 2000.

Boulvain M, et al. Induction of labour at or near term for suspected fetal macrosomia. *Cochrane Database Syst Rev*. 2016;(5);CD000938.



All references are available online at www.expertconsult.com.

REFERENCES

1. ACOG Practice Bulletin No. 22. Fetal macrosomia. *Am Coll Obstet Gynecol*. 2000.
2. Hamilton BE, et al. Births: final data for 2014. *Natl Vital Stat Rep*. 2015;64(12):1-64.
3. Heude B, et al. Pre-pregnancy body mass index and weight gain during pregnancy: relations with gestational diabetes and hypertension, and birth outcomes. *Matern Child Health J*. 2012;16(2):355-363.
4. Shin D, Song WO. Prepregnancy body mass index is an independent risk factor for gestational hypertension, gestational diabetes, preterm labor, and small- and large-for-gestational-age infants. *J Matern Fetal Neonatal Med*. 2015;28(14):1679-1686.
5. Tian C, et al. Excessive weight gain during pregnancy and risk of macrosomia: a meta-analysis. *Arch Gynecol Obstet*. 2016;293(1):29-35.
6. Alberico S, et al. The role of gestational diabetes, pre-pregnancy body mass index and gestational weight gain on the risk of newborn macrosomia: results from a prospective multicentre study. *BMC Pregnancy Childbirth*. 2014;14:23.
7. He XJ, et al. Is gestational diabetes mellitus an independent risk factor for macrosomia: a meta-analysis? *Arch Gynecol Obstet*. 2015;291(4):729-735.
8. Roeckner JT, et al. Single abnormal value on 3-hour oral glucose tolerance test during pregnancy is associated with adverse maternal and neonatal outcomes: a systematic review and metaanalysis. *Am J Obstet Gynecol*. 2016;215(3):287-297.
9. Falavigna M, et al. Effectiveness of gestational diabetes treatment: a systematic review with quality of evidence assessment. *Diabetes Res Clin Pract*. 2012;98(3):396-405.
10. Niromanesh S, et al. Metformin compared with insulin in the management of gestational diabetes mellitus: a randomized clinical trial. *Diabetes Res Clin Pract*. 2012;98(3):422-429.
11. Boulet SL, et al. Macrosomic births in the United States: determinants, outcomes, and proposed grades of risk. *Am J Obstet Gynecol*. 2003;188(5):1372-1378.
12. The HAPO Study Cooperative Research Group. Hyperglycemia and adverse pregnancy outcomes. *N Engl J Med*. 2008;358(19):1991-2002.
13. O'Reilly-Green C, Divon M. Sonographic and clinical methods in the diagnosis of macrosomia. *Clin Obstet Gynecol*. 2000;43(2):309-320.
14. Cordero L, et al. Neonatal outcomes of macrosomic infants of diabetic and non-diabetic mothers. *J Neonatal Perinatal Med*. 2015;8(2):105-112.
15. Gyurkovits Z, et al. Neonatal outcome of macrosomic infants: an analysis of a two-year period. *Eur J Obstet Gynecol Reprod Biol*. 2011;159(2):289-292.
16. Cung TG, et al. Stillbirths at a hospital in Nablus, 2010: a cohort study. *Glob Health Action*. 2014;7:25222.
17. Nkwabong E. Maternal and neonatal complications of macrosomia. *Trop Doct*. 2014;44(4):201-204.
18. Zhang X, et al. How big is too big? The perinatal consequences of fetal macrosomia. *Am J Obstet Gynec*. 2008;198(5):517 e1-517 e6.
19. Mehta SH, Sokol RJ. Shoulder dystocia: risk factors, predictability, and preventability. *Semin Perinat*. 2014;38(4):189-193.
20. Fuchs F, et al. Adverse maternal outcomes associated with fetal macrosomia: what are the risk factors beyond birthweight? *BMC Pregnancy Childbirth*. 2013;13:90.
21. Jin R, Guo Y, Chen Y. Risk factors associated with emergency peripartum hysterectomy. *Chin Med J*. 2014;127(5):900-904.
22. Souka AP, et al. Performance of the ultrasound examination in the early and late third trimester for the prediction of birth weight deviations. *Prenat Diagn*. 2013;33(10):915-920.
23. Esinler D, et al. Finding the best formula to predict the fetal weight: comparison of 18 formulas. *Gynecol Obstet Invest*. 2015;80(2):78-84.
24. Lima JC, et al. Biometry and fetal weight estimation by two-dimensional and three-dimensional ultrasonography: an intraobserver and interobserver reliability and agreement study. *Ultrasound Obstet Gynecol*. 2012;40(2):186-193.
25. Lindell G, Kallen K, Marsal K. Ultrasound weight estimation of large fetuses. *Acta Obstet Gynecol Scand*. 2012;91(10):1218-1225.
26. Lindell G, Marsal K. Sonographic fetal weight estimation in prolonged pregnancy: comparative study of two- and three-dimensional methods. *Ultrasound Obstet Gynecol*. 2009;33(3):295-300.
27. Tuuli MG, et al. Three- versus two-dimensional sonographic biometry for predicting birth weight and macrosomia in diabetic pregnancies. *J Ultrasound Med*. 2016;35(9):1925-1930.
28. Malin GL, et al. Antenatal magnetic resonance imaging versus ultrasound for predicting neonatal macrosomia: a systematic review and meta-analysis. *BJOG*. 2016;123(1):77-88.
29. Vora N, Bianchi DW. Genetic considerations in the prenatal diagnosis of overgrowth syndromes. *Prenat Diagn*. 2009;29(10):923-929.
30. Boulvain M, et al. Induction of labor at or near term for suspected fetal macrosomia. *Cochrane Database Syst Rev*. 2016;(5):CD000938.
31. Boulvain M, et al. Induction of labour versus expectant management for large-for-date fetuses: a randomized controlled trial. *Lancet*. 2015;385(9987):2600-2605.

109 Beckwith-Wiedemann Syndrome

FRANCE GALERNEAU

Introduction

Beckwith-Wiedemann syndrome (BWS) was first described in 1963 and 1964 by Beckwith,[1,2] an American pediatric pathologist, and Wiedemann,[3] a German geneticist. Since the first descriptions, more than 500 cases have been reported.[4] Prenatal diagnosis of BWS was first reported in 1980.[5] With the increased knowledge of the clinical features and possible causes of BWS, the diagnosis is now often suspected prenatally, allowing for genetic testing, counseling, and preparation for adequate neonatal care of affected infants. Close to 40 cases of BWS diagnosed prenatally have now been reported.

Disorder

DEFINITION

BWS is a congenital somatic overgrowth disorder characterized by a constellation of abnormalities or physical findings that may include macrosomia, macroglossia, visceromegaly, and omphalocele or other umbilical cord anomalies. It was originally called *EMG syndrome* based on the presence of exomphalos, macroglossia, and gigantism in many cases.[6,7]

PREVALENCE AND EPIDEMIOLOGY

The exact prevalence of BWS is unclear and thought to be underestimated because of the variability of presentations and modes of inheritance of the syndrome, sometimes resulting in milder cases. Prevalence rates of 1:10,000 to 7:10,000[8,9] births have been reported in the general population, and as high as 2.5:10,000 in pregnancies conceived by in vitro fertilization (IVF).[10] BWS has been described in various ethnic groups[11] and has a male-to-female ratio of 1:1.

ETIOLOGY, PATHOPHYSIOLOGY, AND EMBRYOLOGY

The genetic mechanisms underlying BWS are complex but are known to involve perturbations of the balance of genes located at chromosome 11p15.5.[6,7,12] Most cases of BWS are sporadic (85%). In 10% to 15% of cases, the mode of inheritance is autosomal dominant with incomplete penetrance and preferential maternal transmission.[6,7] Less than 1% of affected individuals have a chromosomal abnormality such as a translocation, duplication, or inversion of chromosome 11p15.[7] The genes for BWS at 11p15 are a highly imprinted region of the genome. Genomic imprinting is an epigenetic process by which genes from only one parental allele are expressed. In the case of band 11p15 of chromosome 11, the paternal allele is normally expressed, and the maternal allele is inactivated. Abnormal transcription and regulation of the genes may occur by various mechanisms, including the following[6,7,12]:

- loss of methylation on maternal chromosome at IC2 (50%–60%)
- paternal uniparental disomy for chromosome 11p15 (10%–20%)
- gain of methylation on the maternal chromosome at IC1 (5%)
- deoxyribonucleic acid mutations of an imprinted gene (5%–10% of sporadic cases, 40% of autosomal dominant families)
- deletion or duplication of regions of the chromosome with imprinting genes (1%–2%)

The imprinted genes that have been identified at the BWS location so far include the insulin-like growth factor-II *(IGF2)* and *H19* in the telomeric domain 1 and *CDKN1C, KCNQ1,* and *KCNQ1OT1* in the centromeric domain 2.[12,13] Regardless of the mechanism involved, imprinting anomalies leading to an increased expression of *IGF2* gene result in fetal somatic overgrowth and have been identified in multiple tumors including Wilms tumor, as often seen in BWS.[12,14,15]

Anomalies of the imprinting process are thought to occur during the preimplantation phase of embryonic development, in the early part of meiosis I and II. Assisted reproductive technologies (ARTs) have been linked to imprinting disorders including BWS.[10] In most of these cases, isolated hypomethylation at the maternal *KVDMR1/LIT1* locus at 11p15.5 is demonstrated, in contrast to BWS cases not conceived by IVF in which this molecular mechanism is less common. This suggests that infertility and/or ARTs disturb methylation in the oocyte or early embryo.[10]

Molecular genetic testing is available for 70% of the known mechanisms for BWS, including karyotyping and fluorescence *in situ* hybridization, uniparental disomy studies, methylation studies, and mutation scanning.[7,12] Testing may be done prenatally or postnatally on the affected individual. Although the diagnosis of BWS is mostly clinical, genetic studies are important because they allow for genetic counseling of the family and determination of the risk to siblings and offspring of a person with BWS. Shuman et al.[7] provide an in-depth discussion of genetic counseling in affected families. BWS has been reported numerous times in monozygotic twins, mostly female pairs discordant for the condition.[7,16]

MANIFESTATIONS OF DISEASE

Clinical Presentation

Although there are no specific diagnostic criteria, BWS is characterized by various clinical features. Some authors suggested that the presence of a combination of one to three major features and one to three minor features be required to make the diagnosis of BWS.[7,16,17] However, there does not seem to be agreement on what features should be considered major or minor. Clinical features of BWS and their frequency are listed in Table 109.1, and divided into categories as follows:

1. Clinical features include prenatal and postnatal macrosomia-gigantism (estimated fetal weight and/or abdominal circumference >90th percentile and height and weight >97th percentile), macroglossia (hyperplasia of muscle fibers, normal histology[22]), visceromegaly (liver, kidneys, adrenal glands, pancreas, and spleen), ear pits or creases, facial dysmorphology (midfacial hypoplasia, mandibular hypoplasia), and hemihyperplasia (abnormality of cell proliferation resulting in asymmetric overgrowth). Overgrowth is usually present at birth in affected individuals[16] and worsens over time. The increase in size continues through early childhood and decreases with increasing age, so that adults with BWS are of normal size.[23]
2. Histopathology includes diffuse adrenal cytomegaly, pancreatic beta islet cell hyperplasia, and nephroblastomatosis and placental mesenchymal dysplasia.[9,13,24]

TABLE 109.1 Clinical Features of Beckwith-Wiedemann Syndrome

Clinical Features	Frequency (%)
Macrosomia	88
Macroglossia	82–99
Abdominal wall defects	50–60
Visceromegaly (≥1 intraabdominal organs)	59
Hemihyperplasia	24
Renal anomalies (nephromegaly, structural anomalies, nephrocalcinosis)	62
Hypoglycemia/hyperinsulinism	50–75
Facial nevus flammeus	62
Embryonal tumors in childhood	4–10
Polyhydramnios	50–60

Data from references 4, 6, 7, 9, 11, 16, 18–21.

3. Structural fetal anomalies include omphalocele or other umbilical abnormalities (60%), renal anomalies (medullary dysplasia, cystic changes, diverticula, and nephromegaly), and rarely cardiac anomalies and cleft palate. Agenesis of the cerebellar vermis has been reported.[21]
4. Neonatal metabolic issues are hypoglycemia and hyperinsulinism that occasionally persists for a few months, nephrocalcinosis and hypercalciuria, polycythemia, and less commonly, hypothyroidism.
5. Neoplasia is increased (5%–10%). Children with BWS are at increased risk for embryonal tumors, particularly Wilms tumor and hepatoblastoma but also neuroblastoma, adrenocortical carcinoma, and rhabdomyosarcoma. Tumors rarely develop after 10 years of age. Of tumors, 40% are associated with hemihypertrophy.
6. Normal intellectual and social development occurs unless there is an underlying chromosomal anomaly[23] or untreated severe hypoglycemia.
7. Perinatal mortality of 10% to 20% is related to prematurity (30%–50%) and fetal anomalies.

Imaging Technique and Findings

Ultrasound. Since the first case of prenatal diagnosis of BWS was reported in 1980,[5] about 40 cases have been reported.[17,21] In most of them, macrosomia in the second or third trimester, macroglossia, enlarged kidneys, and polyhydramnios are the suggestive findings. When omphalocele is present (50%–80% of cases), the diagnosis can be suspected at 12 weeks' gestation. However, less than 3% of omphaloceles are caused by BWS[16] (5%–20% if isolated and of normal karyotype). Macroglossia in children is defined as protrusion of a resting tongue beyond the teeth or alveolar ridge.[25] The diagnosis of macroglossia prenatally is subjective,[22] although nomograms of the tongue size in the first and second trimester have been published.[26,27]

The fetal tongue can be seen on ultrasound (US) in an inferior coronal view of the fetal face and in the sagittal profile view (Figs. 109.1 and 109.2). A persistently protruding tongue in the absence of a discrete mass is consistent with macroglossia (Fig. 109.3). Placentomegaly with cysts within the placenta is a common feature (Fig. 109.4). Normal placental thickness in millimeters is usually equal to the number of weeks ± 10 mm.[28] Large multicystic maternal ovaries may also be seen in association with elevated human chorionic gonadotropin levels.[21]

Fetal kidney enlargement (renal length >90th percentile) is present in 65% of cases[16] with increased echogenicity of the kidneys (Fig. 109.5). Renal anomalies are seen in 50% of these cases. The fetal kidneys are considered echogenic if the reflectivity of the parenchyma is greater than that of the liver. Polyhydramnios is found in 50% to 60% of cases,[9,11,17,21] likely as a result of impaired fetal swallowing by the enlarged tongue. Prenatal diagnosis of intraabdominal tumors is limited to a few case reports including

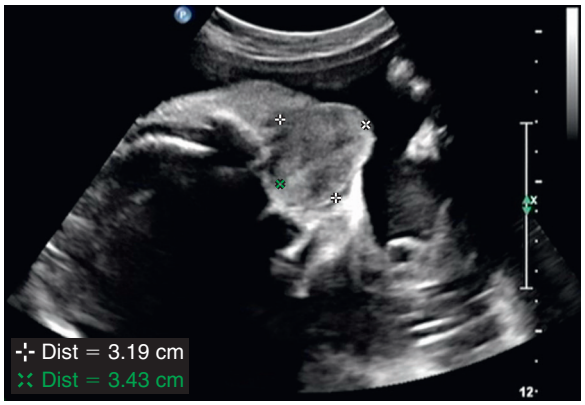

Fig. 109.1 Inferior coronal view of macroglossia in a fetus with macrosomia and enlarged kidneys at 30 weeks' gestation. Initial referral was for elevated maternal alpha-fetoprotein. Prenatal suspicion of Beckwith-Wiedemann syndrome was confirmed postnatally.



Fig. 109.2 Sagittal profile view of the same fetus shown in Fig. 109.1 with protruding tongue.



Fig. 109.3 Three-dimensional image of the same fetus shown in Fig. 109.1 with macroglossia.

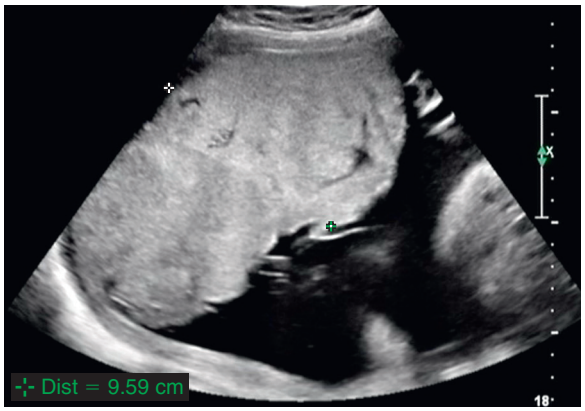

Fig. 109.4 Placentomegaly in the same fetus shown in Fig. 109.1.

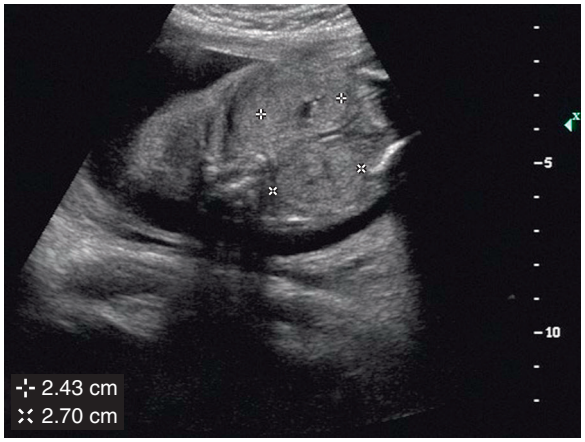

Fig. 109.5 Enlarged echogenic kidneys in the same fetus shown in Fig. 109.1.

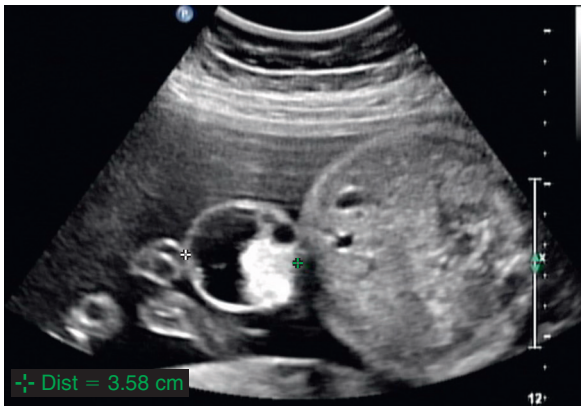

Fig. 109.6 Omphalocele.

a pancreatoblastoma and bilateral adrenal carcinoma.[29,30] One case of intracardiac rhabdomyoma has been reported.

Magnetic Resonance Imaging. Magnetic resonance imaging may be useful to characterize renal, adrenal, or pancreatic tumors if they are suspected.

Other Applicable Modality. Increased nuchal translucency with omphalocele (Fig. 109.6) was reported in one fetus with BWS.[31] Alpha-fetoprotein may be elevated in BWS with or without omphalocele.[32]

CLASSIC SIGNS

Macrosomia
Macroglossia
Visceromegaly (kidneys in particular)
Polyhydramnios
Enlarged cystic placenta
Omphalocele

Differential Diagnosis From Imaging Findings

1. Macrosomia: wrong dates; diabetes; and other overgrowth disorders[7,12] such as Simpson-Golabi-Behmel syndrome (X-linked recessive condition), Perlman syndrome (rare autosomal recessive condition), Costello syndrome (unknown etiology, sporadic), and Sotos syndrome (autosomal dominant) need to be considered.
2. Macroglossia[22,33]: the overall incidence of fetal macroglossia is estimated to be 0.9:10,000 to 0.04:10,000.[22] Macroglossia can be seen in trisomy 21 (other stigmata of Down syndrome should be sought); congenital hypothyroidism (goiter should be present); mucopolysaccharidoses; vascular or lymphatic malformations; and tumors such as rhabdomyoma, dermoid cysts, hemangioma, and lymphangioma.
3. Placentomegaly: placentomegaly is also associated with fetal hydrops, maternal diabetes with fetal macrosomia, triploidy, and molar pregnancy. When mesenchymal dysplasia is present, the cystic placental appearance is similar to that seen with triploidy and molar pregnancy.[24]
4. Omphalocele: omphalocele is often associated with other anomalies and a 30% incidence of aneuploidy. Aneuploidy is more common when there is no liver herniation. It is also seen in other syndromes such as pentalogy of Cantrell, cloacal exstrophy, and Meckel-Gruber syndrome.
5. Nephromegaly: nephromegaly is also seen in polycystic kidneys and Meckel-Gruber syndrome. Echogenic kidneys can be seen with renal dysplasia and cytomegalovirus infection, but in these cases the kidneys are normal in size.

Synopsis of Treatment Options

PRENATAL

There are no treatment options for BWS prenatally. When BWS is suspected, investigations should include fetal echocardiography and amniocentesis for karyotype, an array comparative genomic hybridization, and methylation studies in consultation with medical genetics. A consultation with a pediatric surgeon is indicated if there is an omphalocele. Macroglossia may result in airway obstruction at birth, and consultation with a pediatric otolaryngologist is advisable. In certain cases, ex utero intrapartum treatment procedure may be considered for airway management at birth. A neonatologist should be consulted to discuss special neonatal management considerations with the family.

Serial prenatal US scans are done to monitor fetal growth and amniotic fluid level. Pregnancies with BWS are at increased risk of premature labor and delivery, with or without polyhydramnios. Cervical length measurement and decompression amniocentesis may be helpful in some cases. Delivery should occur in a tertiary center with the neonatal team present and a

pediatric otolaryngologist readily available to help manage airway obstruction and intubation difficulties. Tracheostomy is sometimes required.

POSTNATAL

The immediate concern after delivery of a neonate with BWS is assessment of airway sufficiency. Other possible problems requiring evaluation and treatment include hyperinsulinism and hypoglycemia, other metabolic problems (polycythemia, nephrocalcinosis, hypothyroidism), and feeding difficulties. Surgical repair of omphalocele and imaging of intraabdominal organs to rule out organomegaly, malformations, or tumors may be required. Long-term follow-up requires a multidisciplinary approach including a craniofacial team, endocrinology, orthopedic surgery (if hemihyperplasia and limb asymmetry are present), medical genetics, and urology.[19] Screening for embryonal tumors with abdominal US is performed on a regular schedule until 8 years of age. Alpha-fetoprotein is measured in the first few years of life to screen for hepatoblastoma.

WHAT THE REFERRING PHYSICIAN NEEDS TO KNOW

Pregnancies complicated by BWS are at increased risk for premature labor. Delivery by cesarean is common owing to fetal macrosomia. Overdistention of the uterus leads to an increased risk of placental abruption and postpartum hemorrhage. The perinatal mortality rate of 20% is attributable to complications of prematurity, associated anomalies, and possibly unrecognized hypoglycemia. Newborns with BWS often need immediate attention to establish the airway and treat hypoglycemia and other metabolic problems. Early prenatal diagnosis of BWS allows for prompt referral to tertiary centers where a multidisciplinary team will give the necessary care to the mother and baby. When fetal macrosomia is diagnosed on US, the possibility of an overgrowth syndrome should be considered after dating errors and diabetes have been ruled out.

KEY POINTS

- BWS is a congenital overgrowth syndrome affecting 0.1:10,000 births.
- The genetic inheritance of BWS is complex and involves imprinting anomalies of genes at chromosome 11p15.5.
- An abnormal karyotype is uncommon (<1%).
- An association between ART and BWS and other imprinting disorders has been reported.
- The most common features of BWS seen prenatally include macrosomia, macroglossia, omphalocele, nephromegaly, polyhydramnios, and placentomegaly.
- Delivery in a tertiary care center is indicated so that the newborn may receive adequate care to prevent complications from macroglossia and hypoglycemia and undergo surgical repair of omphalocele, if present.
- Children with BWS are at risk of developing embryonic tumors until 8 years of age.
- Children with BWS are developmentally normal, and their stature is normal by the time they reach adulthood.

SUGGESTED READING

Cohen MM Jr. Beckwith-Wiedemann syndrome: historical, clinicopathological and etiopathogenetic perspectives. *Pediatr Dev Pathol*. 2005;8:287-304.

National Organization for Rare Disorders (NORD). http://rarediseases.org/rare-diseases/beckwith-wiedemann-syndrome/. Contains information for families and health care providers, as well as numerous useful resources.

Shuman C, Beckwith JB, Smith AC, et al. Beckwith-Wiedemann Syndrome. In: Pagon RA, Adam MP, Ardinger HH, et al, eds. *GeneReviews* [Internet]. Seattle (WA: University of Washington; 2000:1993-2016.

Vora N, Bianchi DW. Genetic considerations in the prenatal diagnosis of overgrowth syndromes. *Prenat Diagn*. 2009;29:923-929.



All references are available online at www.expertconsult.com.

REFERENCES

1. Beckwith JB Extreme cytomegaly of the adrenal fetal cortex, omphalocele, hyperplasia of the kidneys and pancreas, and Leydig cell hyperplasia—another syndrome? Presented at the Annual Meeting of Western Society for Pediatric Research, Los Angeles, November 11, 1963.
2. Beckwith JB. Macroglossia, omphalocele, adrenal cytomegaly, gigantism and hyperplastic visceromegaly. *Birth Defects*. 1969;5:188.
3. Wiedemann HR. Complexe malformatif familial avec hernie ombilicale et macroglossie—un "syndrome nouveau"? *J Genet Hum*. 1964;13:223.
4. Harker CP, Winter T III, Mack L. Prenatal diagnosis of Beckwith-Wiedemann syndrome. *AJR Am J Roentgenol*. 1997;168:520-522.
5. Weinstein L, Anderson C. In utero diagnosis of Beckwith-Wiedemann syndrome by ultrasound. *Radiology*. 1980;134:474.
6. Jones KL. *Smith's recognizable patterns of human malformations*. 7th ed. Philadelphia: Saunders; 2013.
7. Shuman C, Beckwith JB, Smith AC, et al. Beckwith-Wiedemann Syndrome. In: Pagon RA, Adam MP, Ardinger HH, et al, eds. *GeneReviews* [Internet]. Seattle (WA: University of Washington; 2000:1993-2016.
8. Mussa A, Russo S, De Crescenzo A, et al. Prevalence of Beckwith-Wiedemann Syndrome in the North West of Italy. *Am J Med Genet A*. 2013;161A: 2481-2486.
9. Engstrom W, Lindham S, Schofield P. The Wiedemann-Beckwith syndrome. *Eur J Pediatr*. 1988;147:450-457.
10. Halliday J, Oke K, Breheny S, et al. Beckwith-Wiedemann syndrome and IVF: a case-control study. *Am J Hum Genet*. 2004;75:526-528.
11. Pettenati MJ, Haines JL, Higgins RR, et al. Wiedemann-Beckwith syndrome: presentation of clinical and cytogenetic data on 22 new cases and review of the literature. *Hum Genet*. 1986;74:143-154.
12. Vora N, Bianchi DW. Genetic considerations in the prenatal diagnosis of overgrowth syndromes. *Prenat Diagn*. 2009;29:923-929.
13. Cohen MM Jr. Beckwith-Wiedemann syndrome: historical, clinicopathological and etiopathogenetic perspectives. *Pediatr Dev Pathol*. 2005;8:287-304.
14. Sun FL, Dean WL, Kelsey G, et al. Transactivation of Igf2 in a mouse model of Beckwith-Wiedemann syndrome. *Nature*. 1997;389:809-815.
15. D'Ercole AJ. Mechanism of in-utero overgrowth. *Acta Paediatr Suppl*. 1999;88:31-36.
16. Elliott M, Maher ER. Beckwith-Wiedemann syndrome. *J Med Genet*. 1994;31:560-564.
17. Williams DH, Gauthier DW, Maizels M. Prenatal diagnosis of Beckwith-Wiedemann syndrome. *Prenat Diagn*. 2005;25:879-884.
18. Wiedemann HR. Tumors and hemihypertrophy associated with Wiedemann-Beckwith syndrome (letter). *Eur J Pediatr*. 1983;141:129.
19. Wong CA, Cuda S, Kirsh A. A review of the urologic manifestations of Beckwith-Wiedemann syndrome. *J Pediatr Urol*. 2011;7:140-144.
20. Elliott M, Bayly R, Cole T, et al. Clinical features and natural history of Beckwith-Wiedemann syndrome: presentation of 74 new cases. *Clin Genet*. 1994;46:168-174.
21. Kagan OK, Berg C, Dufke A, et al. Novel fetal and maternal sonographic findings in confirmed cases of Beckwith-Wiedemann syndrome. *Prenat Diagn*. 2015;35:394-399.
22. Bianchi DW, Crombleholme TM, D'Alton ME, eds. Macroglossia. In: *Fetology—Diagnosis and management of the fetal patient*. New York: McGraw-Hill; 2000:537-540.
23. Wong CA. Longitudinal observations on 15 children with Beckwith-Wiedemann syndrome. *Am J Med Genet*. 1995;55:366.
24. Nayeri UA, West AB, Grossetta Nardini HK, et al. Systematic review of sonographic findings of mesenchymal dysplasia and subsequent pregnancy outcome. *Ultrasound Obstet Gynecol*. 2013;41:366-374.
25. Weiss LS, White JA. Macroglossia: a review. *J la State Med Soc*. 1990;142:13-16.
26. Achiron R, Ben Arie A, Gabbay U, et al. Development of the fetal tongue between 14 and 26 weeks of gestation: in utero ultrasonographic measurements. *Ultrasound Obstet Gynecol*. 1997;9:39-41.
27. Bronshtein M, Zimmer EZ, Tzidony D, et al. Transvaginal sonographic measurement of fetal lingual width in early pregnancy. *Prenat Diagn*. 1998;18:577-580.
28. O'Connor BA, Levine D. Case 49: Beckwith-Wiedemann syndrome. *Radiology*. 2002;224:375-378.
29. Pelizzo G, Conoscenti G, Kalache KD, et al. Antenatal manifestation of congenital pancreatoblastoma in a fetus with Beckwith-Wiedemann syndrome. *Prenat Diagn*. 2003;23:771.
30. Izbizky G, Elias D, Gallo A, et al. Prenatal diagnosis of fetal bilateral adrenal carcinoma. *Ultrasound Obstet Gynecol*. 2005;26:669-671.
31. Souka AP, Snijders RJ, Novakov A, et al. Defects and syndromes in chromosomally normal fetuses with increased nuchal translucency thickness at 10-14 weeks of gestation. *Ultrasound Obstet Gynecol*. 1998;11:391-400.
32. Aagaard-Tillery KM, Buchbinder A, Boente MP, et al. Beckwith-Wiedemann syndrome presenting with an elevated triple screen in the second trimester of pregnancy. *Fetal Diagn Ther*. 2007;22:18-22.
33. Rimell FL, Shapiro AM, Shoemaker DL, et al. Head and neck manifestations of Beckwith-Wiedemann syndrome. *Otolaryngol Head Neck Surg*. 1995;113:262-265.

110 Intrauterine Growth Restriction

URANIA MAGRIPLES

Introduction

Intrauterine growth restriction (IUGR) is a significant pregnancy complication that has both short-term and long-term implications for the fetus and the neonate. A growth-restricted fetus is at increased risk of perinatal morbidity and mortality, and the risks are carried into adulthood with an increased risk of cardiovascular disease, hypertension, obesity, diabetes, and osteoporosis, regardless of the gestational age at delivery.[1–3]

Disease

DEFINITION

IUGR is generally defined as an estimated fetal weight at or below the 10th percentile. There is a direct relationship between fetal growth and adverse outcomes with the greatest risk of perinatal mortality and morbidity at weights below the third percentile.[4,5] Correctly diagnosing IUGR is essential in managing pregnancy and hinges on the establishment of accurate dating criteria as early as possible.

PREVALENCE AND EPIDEMIOLOGY

The prevalence of IUGR is 10% by definition, although the population studied, geographic location, altitude, and growth curves that are used all affect rates. Controversy exists because many fetuses classified as growth restricted are constitutionally small and healthy and are not at risk for adverse outcomes, whereas others who may be above the 10th percentile but are not achieving their growth potential, are at higher risk for complications. It is important to use growth curves specific for the population being followed. Higher rates are seen in developing countries because of the underlying disease burden and malnutrition.

Genetic factors, including gender, significantly contribute to the variation seen in birth weights. Maternal genes influence birth weight more than the paternal genome. Maternal birth weight and a history of a prior growth-restricted infant or poor pregnancy outcome increase the risk of subsequent pregnancies having growth restriction.[6] Higher rates are seen with advancing maternal age and with chronic medical diseases.

Approximately 25% of multiple gestations are growth restricted, with the highest rates seen in monochorionic gestations. Growth restriction is observed in 20% to 25% of fetuses with congenital anomalies and in 20% of stillborns. Fetal mortality is increased because of the underlying etiology and associated preterm deliveries. Perinatal mortality rates are four to eight times higher for growth-restricted infants, and morbidity is present in 50% of surviving infants. Male fetuses with IUGR have a higher overall mortality than female fetuses.[5]

ETIOLOGY AND PATHOPHYSIOLOGY

There are multiple etiologies associated with IUGR, which can be intrinsic or extrinsic to the fetus (Table 110.1). Any disease that affects the vascular endothelium and the uteroplacental circulation has the potential to affect nutrient delivery.

The uterine blood supply derives mainly from the uterine arteries, which give rise to the arcuate arteries that run circumferentially around the uterus. The radial arteries arise from arcuate vessels and penetrate at right angles into the outer third of the myometrium, giving rise to the basal and spiral arteries, which supply the myometrium, decidua, and intervillous space. The first-trimester placenta is an organ with high impedance to blood flow. Physiologic modification of the spiral arteries is necessary to allow the 10-fold increase in uterine circulation necessary for fetal growth. This increase occurs in the second wave of trophoblastic invasion when the spiral arteries are invaded by cytotrophoblast cells and are converted into uteroplacental arteries. Normal uteroplacental arteries have dilated and tortuous lumina, a noncontinuous endothelial lining, and complete absence of muscular and elastic tissue, which converts the placenta into a low-resistance organ. Fewer spiral arteries, less branching, and occlusion of the lumina characterize the growth-restricted placenta, with additional wall thickening and fewer gas-exchanging terminal villi, which are poorly branched. The failure of normal development of maternal placental arteries leads to reduced oxygen and nutrient delivery into the intervillous space, whereas reduction in the number of placental terminal capillaries leads to poor transfer of oxygen and nutrients to the fetus.[7,8]

If the physiologic conversion to low resistance develops appropriately, there is high-velocity diastolic blood flow in the uterine arteries in the latter part of the second trimester and the early diastolic notching of the uterine artery Doppler signal, which is present in the nonpregnant state and early pregnancy, disappears (Figs. 110.1 and 110.2). If the physiologic conversion has not occurred, uterine artery blood flow and Doppler patterns present in the first trimester persist into the second and third trimesters, with high systolic-to-diastolic (S/D) ratios, notching, and reversal of flow (Fig. 110.3). The occurrence of the physiologic change has been used as a screening tool for IUGR and pregnancy complications in high- and low-risk pregnancies. Abnormalities in flow in the uterine arteries are associated with higher incidence of IUGR, oligohydramnios, preeclampsia, emergency cesarean delivery, abruption, shorter duration of pregnancy, and poorer neonatal outcome. Elevated uterine artery Doppler indices at 10 to 14 weeks' gestation also have been shown to be predictive of IUGR and pregnancy complications, whether used alone or in combination with maternal history.[9–12]

Fetal growth aberrations have been classified into symmetric and asymmetric (or head sparing). Normally, abdominal

TABLE 110.1 RISK FACTORS FOR GROWTH RESTRICTION

MATERNAL
Advanced maternal age
Chronic medical disease (25%–30%)
Hypertension
Cardiovascular disease
Diabetes of advanced classes
Renal disease
Thyroid
Hemoglobinopathies
Collagen vascular disease
Thrombophilia
Preeclampsia
Severe lung disease or asthma
Inadequate nutrition, malabsorption, and poor weight gain
Medications
Phenytoin (Dilantin)
Trimethadione
Warfarin (Coumadin)
Chemotherapeutic agents
Drug abuse
Alcohol
Cocaine
Methamphetamines
Heroin
Smoking
High altitude
FETAL
Multiple gestations (5% of IUGR)
Infection (5%–10% of IUGR)
Rubella
Cytomegalovirus
Herpes
Toxoplasmosis
Malaria
Syphilis
Chagas disease
Anomalies (1%–2% of IUGR)
Chromosomal and genetic (5%–20% of IUGR)
PLACENTA
Single umbilical artery
Abnormal cord insertions (velamentous, marginal)
Bilobed or circumvallate placenta
Small placenta
Confined placental mosaicism

IUGR, Intrauterine growth restriction.

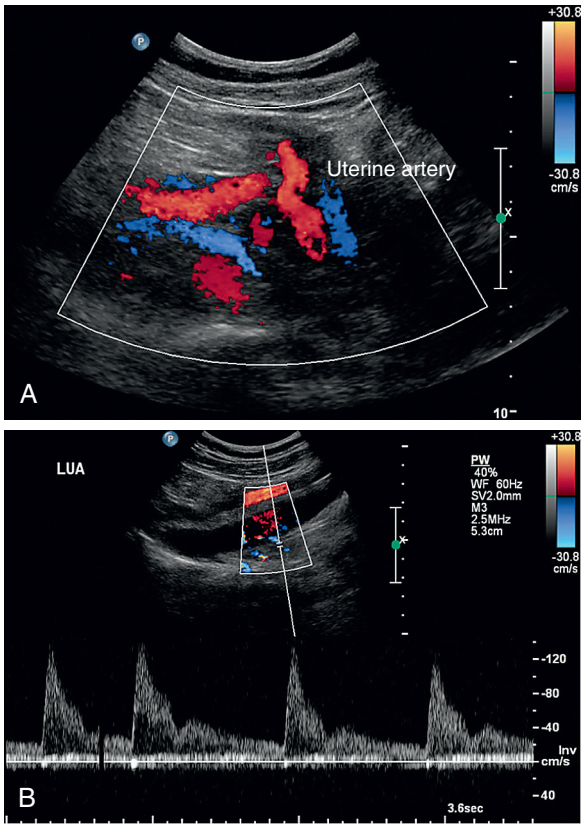

Fig. 110.1 Normal first-trimester uterine artery blood flow. (A) Color flow mapping. (B) Duplex Doppler signal. *LUA,* Left uterine artery.

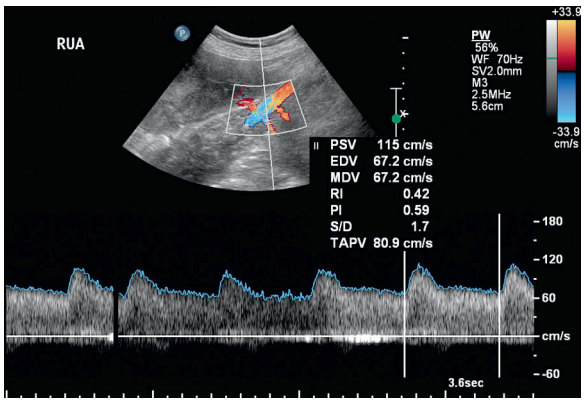

Fig. 110.2 Normal second-trimester and third-trimester uterine artery blood flow.

circumference increases in the third trimester because of increasing adiposity and an increase in liver glycogen stores and size. Symmetric growth restriction, which accounts for 20% to 30% of growth-restricted fetuses, refers to a growth pattern in which all fetal organs and growth parameters are decreased proportionally, secondary to impairment of early fetal cell growth. Etiologies include genetic or chromosomal causes, early infections, drug or alcohol exposure, and severe early placental insufficiency. Asymmetric growth restriction is characterized by a decrease in abdominal circumference relative to the head circumference. This pattern results from the fetus using nutritional stores in the liver and adapting blood flow to compensate for inadequate

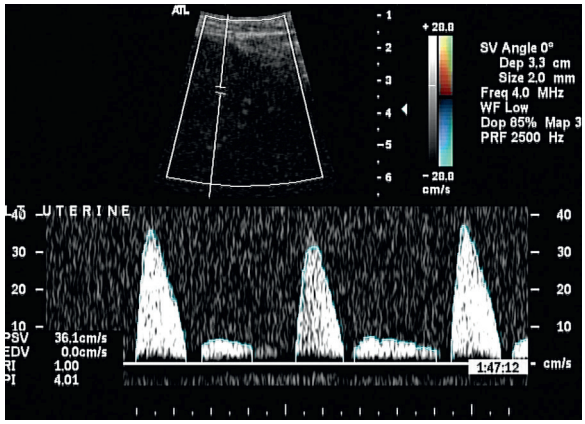

Fig. 110.3 Abnormal third-trimester uterine artery notching.

placental perfusion. The redistribution of blood flow to more vital organs (brain, heart, and adrenals) at the expense of less vital organs (intestines, muscle, kidneys, and lungs) leads to oligohydramnios from decreased renal perfusion and urine output. The decreased tissue perfusion contributes to fetal acidemia and causes direct damage to the deprived tissues. Blood flow alterations as assessed by Doppler velocimetry and oligohydramnios precede changes in fetal heart rate reactivity and variability.

These ultrasound (US) findings strengthen the diagnosis of IUGR and indicate an increased likelihood of perinatal mortality and morbidity. Progressive compensation by the fetus leads to decreased diastolic flow and eventually absent or reversed end-diastolic flow in the umbilical artery. Both signs are highly predictive of perinatal mortality. Progressive hypoxemia and acidemia lead to cardiac dysfunction and myocardial ischemia. Tricuspid regurgitation and right-sided heart failure can be detected as venous backflow by sampling the inferior vena cava, ductus venosus, and umbilical vein. Venous Doppler changes occur in more than half of cases before an abnormal biophysical profile or nonstress test. Umbilical vein pulsations should be considered a near-terminal event.[13,14]

MANIFESTATIONS OF DISEASE

Clinical Presentation

The most important tool in the diagnosis of fetal growth restriction is a thorough assessment of underlying risk factors. In the absence of baseline risk factors, fundal height measurements, weight gain or loss, and the development of pregnancy-related complications are followed during the course of routine prenatal care to determine the need for further assessment by US. Routine screening of uterine and umbilical artery Doppler has not been shown to reduce maternal or perinatal morbidity and mortality in a low-risk population.[15] Patients with underlying risk factors should be followed by serial assessments of growth and amniotic fluid volume.

Imaging Technique and Findings

Ultrasound. US is the main diagnostic modality for both screening and determination of IUGR. The presence of a fetal or placental abnormality at any gestational age warrants follow-up assessment of growth and amniotic fluid (Figs. 110.4 and 110.5). The discovery of growth restriction by US at any gestational age

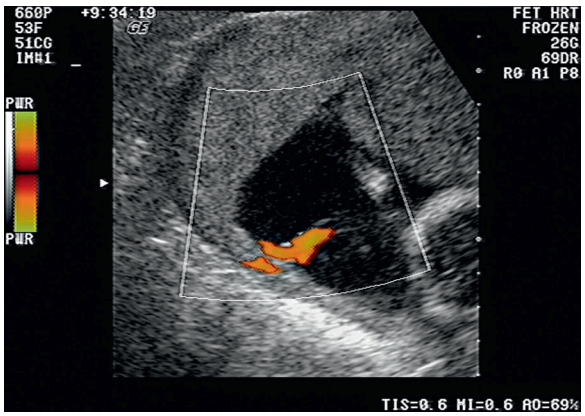

Fig. 110.4 Velamentous cord insertion.

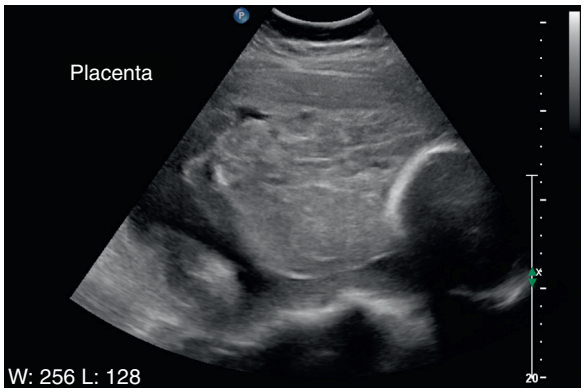

Fig. 110.5 Retroplacental hematoma. *L*, Length; *W*, width.

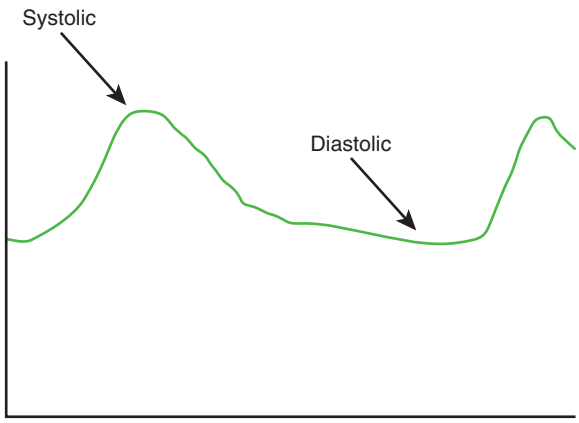

$$\text{PI} = \frac{\text{Systolic} - \text{Diastolic}}{\text{Mean velocity}}$$

$$\text{RI} = \frac{\text{Systolic} - \text{Diastolic}}{\text{Systolic}}$$

$$\text{S/D ratio} = \frac{\text{Systolic}}{\text{Diastolic}}$$

Fig. 110.6 Normal umbilical artery waveform. *PI*, Pulsatility index; *RI*, resistance index; *S/D*, systolic-to-diastolic.

requires a detailed anatomic survey for underlying fetal etiologies and a detailed maternal history. Genetic counseling and amniocentesis for the diagnosis of aneuploidy or infection can be offered to the patient, especially if there are associated fetal structural abnormalities.

Accurate assessment of gestational age is crucial to the diagnosis of growth aberrations. Estimating gestational age beyond the first trimester produces highly variable results owing to the wider distribution of normal biometry. In the second and third trimesters, gestational age estimations can vary by up to 2 to 3 weeks. In the absence of reliable dating, US parameters of growth should be followed at 2-week intervals. Over any interval, the abdominal circumference is expected to increase by 1 cm/week. Assessments of growth at intervals less than 2 weeks are not useful given the inherent margin of error of US estimates of fetal weight. Serial assessments of growth should be followed using the estimated fetal weight and abdominal circumference measurements, which are the most sensitive in the determination of aberrations. An abdominal circumference below the 2.5 percentile has a sensitivity of greater than 95% for growth restriction. Other growth parameters such as transcerebellar diameter, foot length, and determinations of soft tissue density have been proposed but are not standard in the determination of growth restriction.

Doppler. Doppler velocimetry is a noninvasive technique frequently used to determine maternal and fetal hemodynamic status. The Doppler effect or Doppler shift occurs because the frequency of reflected energy varies in relation to the velocity of a moving object. In US, the frequency of the US beam is changed when encountering blood flow. Indices and nomograms by gestational age are well established.[16,17] The S/D ratio is easiest to use clinically and to conceptualize, whereas the pulsatility index and resistive index are more commonly used in research studies. Pulsatility index is more resistant to fetal heart rate variation and is the only normally (i.e., Gaussian) distributed index. The resistive index and S/D ratio are non-Gaussian and require nonparametric statistics for any research studies (Fig. 110.6).

Uterine artery blood flow increases in pregnancy with the increase in maternal cardiac output. Doppler signals reflect this increase with a continuous forward flow and progressive increase in diastolic flow after 18 weeks' gestation. The presence of high resistance (S/D ratio >2.7) or notching, or both, in the uterine arteries in the late second and third trimesters is abnormal and has been used as a screening tool for pregnancy complications. Abnormalities in uterine artery blood flow generally precede abnormal umbilical blood flow.

Umbilical Artery. Doppler of the umbilical artery is not useful as a screening tool for IUGR in normal pregnancies.[15] Its primary utility is in the evaluation and management of a growth-restricted fetus. Normal umbilical artery flow mirrors uterine artery flow and shows progressive increases in diastolic flow after 18 weeks' gestation, leading to a decreasing S/D ratio over the course of the pregnancy. The S/D ratio is normally less than 3.5 in preterm fetuses and less than 2.5 at term (Fig. 110.7). Worsening blood flow is reflected by increasing S/D ratio, with eventual absent end-diastolic flow and reversal of diastolic flow (Figs. 110.8–110.10).

Middle Cerebral Artery. The middle cerebral artery is normally a high-impedance bed with low-end diastolic flow (i.e.,

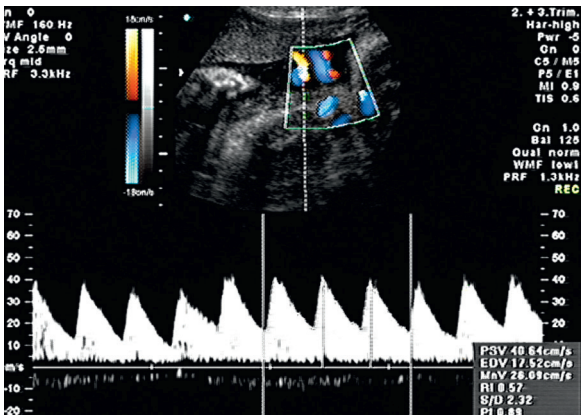

Fig. 110.7 Normal umbilical artery pattern.

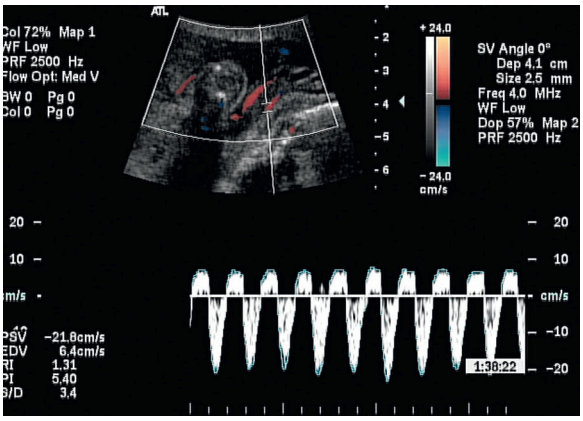

Fig. 110.10 Umbilical artery: reverse end-diastolic flow.

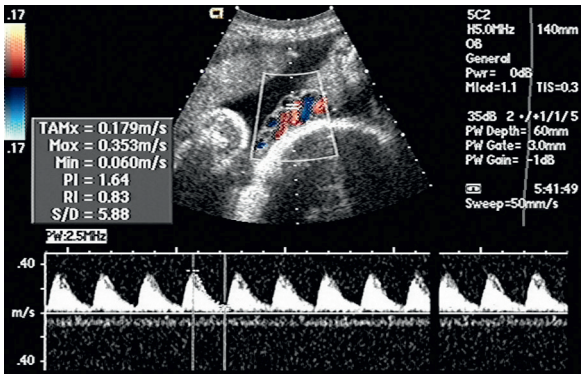

Fig. 110.8 Worsening umbilical artery pattern: elevated S/D ratio.

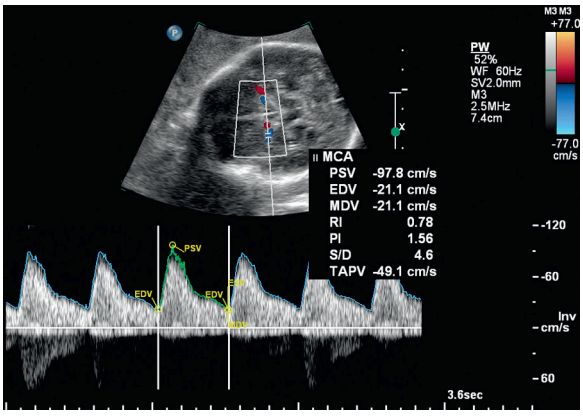

Fig. 110.11 Middle cerebral artery anatomy.

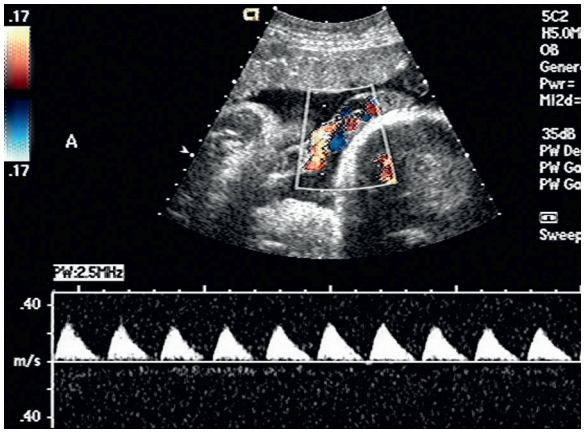

Fig. 110.9 Umbilical artery: absent end-diastolic flow.

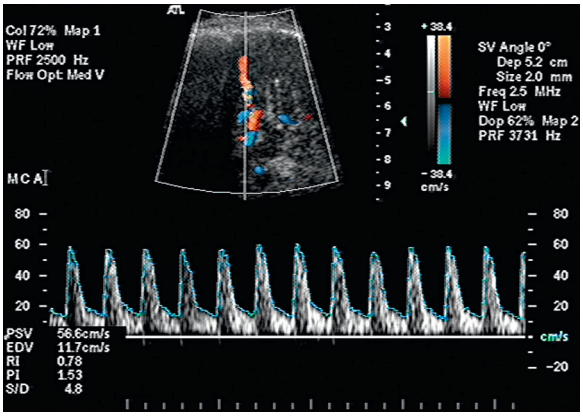

Fig. 110.12 Normal middle cerebral artery waveform.

the opposite of the umbilical artery) (Figs. 110.11 and 110.12). The increase in diastolic blood flow, secondary to redistribution of blood flow to the brain with fetal hypoxemia, leads to asymmetric growth of the head circumference relative to the abdominal circumference (Fig. 110.13). Gestational age-dependent nomograms are widely available. The cerebral-to-umbilical ratio provides a quick assessment of blood flow without nomograms.[18] The resistance of the cerebral circulation should always be higher than the umbilical resistance (ratio >1). Ratios less than 1 signify brain sparing.

Venous Doppler. Venous backflow during atrial contraction (tricuspid regurgitation) is most predictive of metabolic acidemia and signifies myocardial dysfunction and progressive fetal decompensation.[19] Reversal of flow can be detected in the inferior vena cava and ductus venosus and progresses to umbilical vein pulsations (Fig. 110.14). Venous Doppler changes occur in more

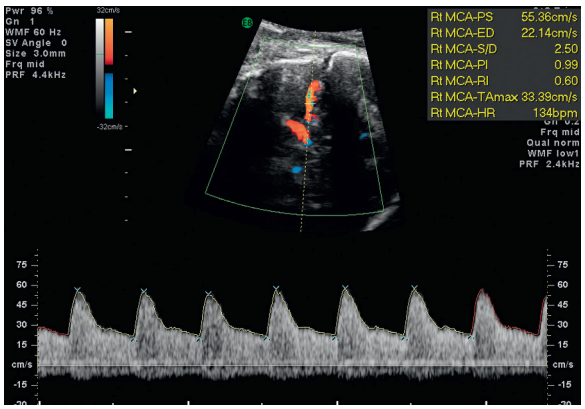

Fig. 110.13 Brain sparing with increase in diastolic flow of the middle cerebral artery.

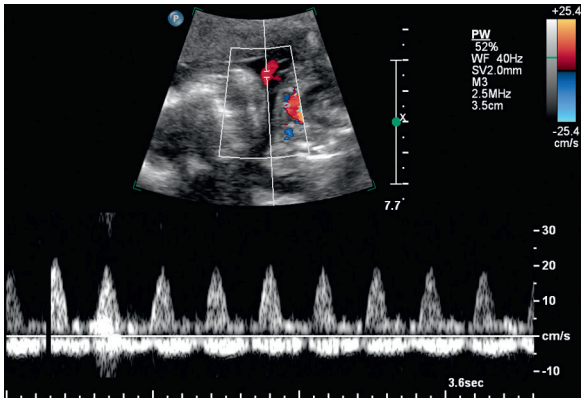

Fig. 110.14 Umbilical vein pulsations, seen in the signal below the baseline.

than 50% of cases before an abnormal biophysical profile and nonstress test. The addition of venous Doppler studies to the fetal examination improves the prediction of fetal acidemia and stillbirth and may improve long-term neurologic outcomes.[20]

CLASSIC SIGNS

Presence of lagging abdominal circumference.
Oligohydramnios in the setting of intact membranes and normal fetal kidneys.

Differential Diagnosis From Imaging Studies

The distinction between a normally grown fetus with inaccurate dating and a compromised fetus can be difficult, especially in the late second trimester and third trimester. The presence of fetal anomalies warrants further evaluation for aneuploidy and infection, and a fetal echocardiogram to exclude cardiac abnormalities. The presence of oligohydramnios should be investigated further by a sterile speculum examination and amniocentesis with dye injection if appropriate. In the absence of ruptured membranes or fetal renal abnormalities, oligohydramnios is highly associated with growth restriction, and perinatal mortality and morbidity.

The presence of Doppler abnormalities of the umbilical or middle cerebral artery strengthens the diagnosis of IUGR, but the absence of Doppler abnormalities does not preclude the diagnosis because there is a continuum seen. Follow-up growth evaluations or Doppler studies are often necessary to confirm the diagnosis. After the diagnosis is made, follow-up US scans are necessary for surveillance and management. Close follow-up of the mother is also necessary because the abnormal fetal growth pattern may be an early manifestation of preeclampsia. The presence of hypertension or preeclampsia has a shorter latency to delivery as well as worse perinatal outcomes.[21]

Synopsis of Treatment

PRENATAL

Growth restriction from etiologies intrinsic to the fetus cannot be treated or reversed. Severe IUGR secondary to placental dysfunction is generally progressive, and there is no definitive treatment to reverse or halt the process. Smoking cessation before the third trimester has been associated with increase in birth weight.[22,23] Controversy exists regarding whether low-dose aspirin in midpregnancy can reverse the process after abnormal uterine artery Doppler signals have been identified,[24] although aspirin may reduce the incidence of fetal growth restriction in some high-risk populations.[25]

The mainstay of treatment is timing of delivery, which is the balance of prematurity versus a continued intrauterine course and potential risk of intrauterine death. Steroids are indicated before 34 weeks' gestation in anticipation of delivery. Doppler studies have been shown to decrease the risk of intrauterine fetal demise and neonatal morbidity, and should be used in conjunction with nonstress tests and biophysical profiles.[19,26,27]

POSTNATAL

Postnatal morbidity and mortality are directly related to fetal weight, gestational age, and the underlying etiology. In general, the smaller the fetus, the higher the risk of complications. The compensatory changes and redistribution of blood flow to vital organs in response to hypoxia and nutrient deficiency contribute to prenatal and postnatal morbidity. Prenatal oligohydramnios correlates with postnatal oliguria and renal dysfunction. The decrease in blood flow to the large and small bowel increases the risk of necrotizing enterocolitis. The changes in cerebral perfusion increase the risk of intraventricular hemorrhage, periventricular leukomalacia, and cerebral infarction. The worsening cardiac decompensation from acidemia and hypoxia, which lead to prenatal venous Doppler changes, contribute to postnatal myocardial ischemia, cardiac dysfunction, and right-sided heart failure. The increased perfusion of the liver through the ductus venosus leads to postnatal liver dysfunction and transaminitis.

The neonate is also at increased risk of hypoxia-induced polycythemia through diminished blood flow to the bone marrow, which may also cause thrombocytopenia and leukopenia, leading to an increased risk of infection. Neuroendocrine changes also occur and contribute to the elevated risk of insulin resistance, central adiposity, and type 2 diabetes, especially in the setting of rapid postnatal catch-up growth.[3] The lifelong risks of impaired

fetal growth, particularly of cardiovascular disease, have led to the theory of fetal origin of adult-onset disease (Barker hypothesis) and have strengthened the need for further research and potential interventions to improve fetal growth.[1,2]

WHAT THE REFERRING PHYSICIAN NEEDS TO KNOW

- The earliest US scan available should be used to establish dates if the last menstrual period is unreliable. After dates are established, they should not be changed because later US scans are more a reflection of growth and not of gestational age.
- A targeted US scan is recommended to evaluate the fetus for anomalies if growth restriction is suspected.
- The presence of lagging abdominal circumference and oligohydramnios in the setting of intact membranes and normal fetal kidneys is highly suspicious of growth restriction.
- Doppler studies are useful in the management of growth restriction and have been shown to decrease the risk of fetal demise.
- Absent or reverse end-diastolic flow in the umbilical artery is an indication for steroids in the preterm fetus and delivery in the term fetus.
- Abnormal ductus venosus flow has a poor prognosis.
- Pulsations in the umbilical vein are a premorbid condition.

KEY POINTS

- There are multiple etiologies for IUGR, and a thorough patient history and physical examination are important to identify risk factors.
- There are both short-term and long-term risks of IUGR.
- US, Doppler velocimetry, and prenatal testing are useful in determining the appropriate timing of delivery.

SUGGESTED READING

Baschat AA. Fetal growth restriction—from observation to intervention. *J Perinat Med*. 2010;38:239-246.

Copel JA, Bahtiyar MO. A practical approach to fetal growth restriction. *Obstet Gynecol*. 2014;123(5):1057-1069.

Mari G. Doppler ultrasonography in obstetrics: from the diagnosis of fetal anemia to the treatment of intrauterine growth-restricted fetuses. *Am J Obstet Gynecol*. 2009;200:589-596.



All references available online at
www.expertconsult.com

REFERENCES

1. Barker DJ. Early growth and cardiovascular disease. *Arch Dis Child*. 1999;80:305-307.
2. Barker DJ. Fetal origins of coronary heart disease. *BMJ*. 1995;311:171-174.
3. Phillips DI, Barker DJ, Hales CN, et al. Thinness at birth and insulin resistance in adult life. *Diabetologia*. 1994;37:150-154.
4. McIntire DD, Bloom SL, Casey BM, et al. Birth weight in relation to morbidity and mortality among newborn infants. *N Engl J Med*. 1999;340:1234-1238.
5. Bernstein IM, Horbar JD, Badger GJ, et al. Morbidity and mortality among very-low-birth-weight neonates with intrauterine growth restriction. The Vermont Oxford Network. *Am J Obstet Gynecol*. 2000;182:198-206.
6. Selling KE, Carstensen J, Finnstrom O, et al. Intergenerational effects of preterm birth and reduced intrauterine growth: a population-based study of Swedish mother-offspring pairs. *BJOG*. 2006;113:430-440.
7. Salafia CM. Placental pathology of fetal growth restriction. *Clin Obstet Gynecol*. 1997;40:740-749.
8. Scifres CM, Nelson DM. Intrauterine growth restriction, human placental development and trophoblast cell death. *J Physiol*. 2009;587:3453-3458.
9. Dugoff L, Lynch AM, Cioffi-Ragan D, et al, FASTER Trial Research Consortium. First trimester uterine artery Doppler abnormalities predict subsequent intrauterine growth restriction. *Am J Obstet Gynecol*. 2005;193:1208-1212.
10. Gomez O, Maritinez JM, Figueras F, et al. Uterine artery Doppler at 11-14 weeks of gestation to screen for hypertensive disorders and associated complications in an unselected population. *Ultrasound Obstet Gynecol*. 2005;26:490-494.
11. Papageorghiou AT, Yu CK, Erasmus IE, et al. Assessment of risk for the development of pre-eclampsia by maternal characteristics and uterine artery Doppler. *BJOG*. 2005;111:703-709.
12. Cnossen J, Morris R, Riet G, et al. Use of uterine artery Doppler ultrasonography to predict preeclampsia and intrauterine growth restriction: a systematic review and bivariable meta-analysis. *CMAJ*. 2008;178:701-711.
13. Baschat AA. Doppler application in the delivery timing of the preterm growth-restricted fetus: another step in the right direction. *Ultrasound Obstet Gynecol*. 2004;23:111-118.
14. Alfirevic Z, Stampalija T, Gyte GM. Fetal and umbilical Doppler ultrasound in high-risk pregnancies. *Cochrane Database Syst Rev*. 2010;(1):CD007529.
15. Alfirevic Z, Stampalija T, Gyte GM. Fetal and umbilical Doppler ultrasound in normal pregnancy. *Cochrane Database Syst Rev*. 2010;(8):CD001450.
16. Mari G, Deter RL. Middle cerebral artery flow velocity waveforms in normal and small-for-gestational-age fetuses. *Am J Obstet Gynecol*. 1992;166:1262-1270.
17. Thompson RS, Trudinger BJ, Cook CM. Doppler ultrasound waveform indices: AB ratio, pulsatility index and Pourcelot ratio. *Br J Obstet Gynaecol*. 1988;95:589-591.
18. Bahado-Singh RO, Kovanci E, Jeffres A, et al. The Doppler cerebroplacental ratio and perinatal outcome in intrauterine growth restriction. *Am J Obstet Gynecol*. 1999;180:750-756.
19. Seravalli V, Miller JL, Block-Abraham D, et al. Ductus venosus Doppler in the assessment of fetal cardiovascular health: an updated practical approach. *Acta Obstet Gynecol Scand*. 2016;95:635-644.
20. Lees CC, Marlow N, Van Wassenaer-Leemhuis A, et al. Two year neurodevelopmental and intermediate perinatal outcomes in infants with very preterm fetal growth restriction (TRUFFLE): a randomized trial. *Lancet*. 2015;385:2162-2172.
21. Lees CC, Marlow N, Arabin B, et al. Perinatal morbidity and mortality in early-onset fetal growth restriction: cohort outcomes of the trial of randomized umbilical and fetal flow in Europe (TRUFFLE). *Ultrasound Obstet Gynecol*. 2013;42(4):400-408.
22. Vardavas CI, Chatzi L, Patelarou E, et al. Smoking and smoking cessation during early pregnancy and its effect on adverse pregnancy outcomes and fetal growth. *Eur J Pediatr*. 2010;169:741-748.
23. Polakowski LL, Akinbami LJ, Mendola P. Prenatal smoking cessation and the risk of delivering preterm and small-for-gestational-age newborns. *Obstet Gynecol*. 2009;114:318-325.
24. Bujold E, Morency AM, Roberge S, et al. Acetylsalicylic acid for the prevention of preeclampsia and intra-uterine growth restriction in women with abnormal uterine artery Doppler: a systematic review and meta-analysis. *J Obstet Gynaecol Can*. 2009;31:818-826.
25. Bujold E, Roberge S, Nicolaides KH. Low-dose aspirin for prevention of adverse outcomes related to abnormal placentation. *Prenat Diagn*. 2014;34:642-648.
26. Arduini D, Rizzo G, Romanini C. Changes of pulsatility index from fetal vessels preceding the onset of late decelerations in growth-retarded fetuses. *Obstet Gynecol*. 1992;79:605-610.
27. Baschat AA, Gembruch U, Weiner CP, et al. Qualitative venous Doppler waveform analysis improves prediction of critical perinatal outcomes in premature growth-restricted fetuses. *Ultrasound Obstet Gynecol*. 2003;22:240-245.

111 Amniocentesis

JOY VINK | MELISSA QUINN

Introduction

Amniocentesis is a procedure in which a transabdominally placed needle is used to withdraw amniotic fluid from the amniotic sac. "Early amniocentesis" (<15 weeks' gestation) should be avoided because of increased complications, including a higher fetal loss rate and an increased risk of talipes equinovarus.[1,2]

Procedure

DESCRIPTION, TECHNIQUE, AND EQUIPMENT

Amniocentesis should be performed by a physician who has experience with the procedure and ultrasound (US). Before amniocentesis, the patient should be counseled regarding the purpose, risks, and alternatives to the procedure, and informed consent should be obtained. US examination should be performed initially to establish fetal position, fetal heart rate, placental location, and placental umbilical cord insertion site. The presence of an amnion-chorion separation, which may be noted up to 17 weeks' gestation, should be documented. If the location of the amnion-chorion separation cannot be avoided during amniocentesis, one may consider postponing the procedure to a gestational age when the amnion and chorion are fused.

An optimal needle insertion site should be selected. The maternal bowel and bladder should be identified and avoided because traversing the maternal bowel can introduce bowel flora into the amniotic cavity, leading to chorioamnionitis and subsequent pregnancy loss. Although some studies suggested complications were increased after transplacental amniocentesis,[3–7] other studies refuted this suggestion.[8–14] When possible, most operators avoid traversing the placenta. If it cannot be avoided, the needle is usually directed through the thinnest portion of the placenta. Color Doppler may be useful in avoiding the umbilical cord insertion site and large chorionic vessels. When an optimal site is located, the distance from the US transducer to the target in the fluid pocket can be measured to determine the length of the spinal needle that should be used for the procedure.

After the aforementioned steps are accomplished, the operator should ensure that the supplies needed for the procedure are available, including antiseptic solution, a pack of 4-inch × 4-inch gauze pads, a sterile drape, a sterile US probe cover, sterile US gel, a 20-gauge or 22-gauge spinal needle, sterile syringes, and specimen tubes (Fig. 111.1). The maternal abdomen is prepared and draped. A large area should be prepared because the fetus may move, changing the optimal fluid pocket site. The sterile cover is placed over the US probe, and the sterile US gel is used to relocate the optimal fluid pocket to confirm the fetus has not moved. Local anesthesia can be administered before inserting the spinal needle; however, most patients tolerate the procedure with minimal discomfort. Local anesthesia does not alleviate the discomfort or cramping that usually occurs when the needle is inserted into the myometrium.

When the operator locates the optimal fluid pocket, he or she inserts the spinal needle at a 45-degree angle to the US transducer. The "freehand technique" allows adjustment of the needle direction and is the method that most experienced operators prefer. A needle-guiding device that is attached to the transducer is also available, which may assist in reaching the designated fluid pocket. The procedure should be performed under continuous US guidance. Operators should be familiar with the appearance of the spinal needle on the US screen (Fig. 111.2), and the needle should not be advanced if the position of the needle tip cannot be clearly visualized. Most operators prefer to insert the spinal needle while holding the US transducer. When the needle tip is in the targeted fluid pocket, the assistant holds the transducer and maintains visualization of the needle tip while the operator withdraws the amniotic fluid.

With the needle tip in the targeted fluid pocket, the operator removes the needle stylet and attaches the sterile syringe to the needle. If amniotic fluid cannot be easily withdrawn, the fetal membranes are likely tented over the needle tip. A quick, smooth, small thrust of the needle usually pierces the membranes. If this thrust does not pierce the membranes, the operator may need to reposition the needle.

The initial drop of amniotic fluid may contain maternal cells collected as the needle passed through the maternal tissues. Most operators discard this initial drop because it may introduce low-level mosaicism with maternal cells in cytogenetic studies. The amount of amniotic fluid withdrawn should be based on the gestational age and the type of test being performed on the fluid. Karyotype analysis may take from 15 mL to 40 mL depending on the laboratory, and microarray testing may require a larger sample; a fetal lung maturity test requires 5 mL to 10 mL



Fig. 111.1 Supplies needed for amniocentesis: antiseptic solution, pack of 4-inch × 4-inch gauze pads, sterile drape, sterile ultrasound probe cover, sterile US gel, 20-gauge or 22-gauge spinal needle, sterile syringes, and specimen tubes.

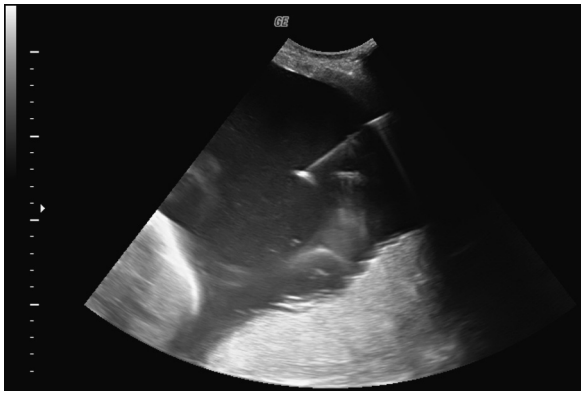

Fig. 111.2 Ultrasound image of a spinal needle in an amniotic fluid pocket during amniocentesis.

of fluid. After the appropriate amount of amniotic fluid is withdrawn, the operator detaches the syringe, replaces the stylet, and quickly removes the spinal needle. Amniotic fluid is transferred from the syringes to the specimen tubes for laboratory testing.

After removing the spinal needle, the operator should assess the fetal heart rate on US. If the fetus is past fetal viability (≥24 weeks' gestation), a nonstress test and tocometry should be performed to document reassuring fetal status and to verify that the mother is not regularly contracting before discharge. The patient should be counseled that mild intermittent cramping is common but that she should call her physician or midwife if she has regular, painful contractions, leakage of fluid from the vagina, vaginal bleeding, or a fever. Patients should be advised to maintain pelvic rest and decreased activity for 24 hours after the procedure. Unsensitized Rh_0(D)-negative women should be given Rh_0(D) immune globulin after an amniocentesis to prevent Rh sensitization.

INDICATIONS

Amniocentesis is most commonly indicated for prenatal diagnosis and for fetal lung maturity. Other indications include amnioreduction, diagnosis of an intraamniotic infection, confirmation of preterm premature rupture of membranes, evaluation of hemolytic anemia in the fetus, diagnosis of hemoglobinopathy, and diagnosis of neural tube defects. Indigo carmine has been used in the "amnio dye test" to confirm ruptured membranes in the past; however, widespread shortages in the availability of this agent and the absence of a suitable substitute have made this test impractical. The guidance is similar to that used during cordocentesis to evaluate for fetal platelet count, anemia, and blood type.

Genetic amniocentesis is usually performed between 15 weeks' and 17 weeks' gestation. This window generally ensures enough time to obtain the results if the patient should choose to terminate the pregnancy based on an abnormal karyotype. Genetic amniocentesis can also be performed later in pregnancy to assist in deciding the mode or timing of delivery and plans for the extent of fetal or neonatal intervention if a lethal karyotype is discovered. Cytogenetic results usually take about 1 week. Interphase fluorescence in situ hybridization, which detects aneuploidy (i.e., only an incorrect number of chromosomes and will not detect structural or other karyotype abnormalities), yields results within 24 to 48 hours. Although fluorescence in situ hybridization results are accurate, rare cases of false-positive and false-negative results have been reported. The American College of Medical Genetics recommends that clinical decisions, such as termination, be based on traditional metaphase chromosome analysis or additional clinical findings such as an abnormal US scan.[15]

Amniocentesis to determine fetal lung maturity is usually done after 32 weeks' gestation because pulmonary maturity is unlikely before this gestational age. The amniotic fluid can be evaluated for a lecithin-to-sphingomyelin (L/S) ratio and the presence or absence of phosphatidylglycerol. The risk of respiratory distress is exceedingly low when the L/S ratio is greater than 2 in nondiabetics and phosphatidylglycerol is present. Some laboratories use other cutoffs, and physicians should be familiar with local standards. Other available studies include assessment of the lamellar body count, fluorescence polarization, and the foam stability index.

CONTRAINDICATIONS

The possibility of vertical transmission of human immunodeficiency virus (HIV) was eloquently shown by the Pediatric AIDS Clinical Trials Group in 1999.[16] This study reported an increase in HIV-affected infants in HIV-positive women who had amniocentesis (five infants among 14 HIV-infected women [36%]) compared with HIV-positive women who did not undergo the procedure (54 infected infants among 379 HIV-infected women [14%]). Some studies also showed that the HIV vertical transmission rate is lower, but not eliminated, in women who are treated for HIV compared with women who are not treated.[16–18]

Vertical transmission of infectious diseases such as hepatitis C, toxoplasmosis, and cytomegalovirus after amniocentesis was shown in case reports.[19,20] The rate of vertical transmission of hepatitis B virus was not increased after amniocentesis in several small studies.[21–23] Although vertical transmission is biologically plausible for infectious agents, epidemiologic data are still limited. Until substantial evidence exists regarding the safety of amniocentesis in women with the aforementioned infections, women should be counseled regarding the plausible risk of vertical transmission and alternative options, including first-trimester and second-trimester screening for aneuploidy.

Outcomes and Complications

Many large studies have confirmed the safety of genetic amniocentesis and the cytogenetic diagnostic accuracy of the procedure.[24] The most commonly discussed complication is the procedure-related loss rate. In more recent studies, the procedure-related loss rate was reported to be 0.1% (1:900) to 0.3% (1:370), and the rate may be even lower depending on the experience of the operator.[1,25,26] However, the exact procedure-related loss rate has been elusive owing to several factors, including varying definitions of pregnancy loss, the underestimation of fetal loss because of elective pregnancy termination owing to abnormal karyotype in the amniocentesis group, and the natural loss rate secondary to maternal age and other maternal factors (abnormal serum screening results, past history of miscarriage, vaginal bleeding). Risk factors that have been associated with increased pregnancy loss after amniocentesis include vaginal bleeding, higher maternal body mass index, and a history of recurrent abortions.[27–29]

Other infrequent complications include amniotic fluid leakage (which occurs in about 1%–2% of all cases), vaginal bleeding, chorioamnionitis (which occurs in <1%), needle injuries to the fetus, and amniotic fluid cell culture failure.[1] Among patients who experienced amniotic fluid leakage after a genetic amniocentesis, the perinatal survival rate was reported to be greater than 90%.[30] Rare cases of needle injuries to the fetus have been reported, but such injuries are unlikely when continuous US guidance is used. Amniotic fluid cell culture failure occurs in 0.1% of samples, and mosaicism occurs in 0.25% of cultures from amniocentesis.[1] Several studies reported that the procedure-related complication rate is related to operator experience and the use of continuous US guidance.[31,32]

KEY POINTS

- Amniocentesis can technically be performed at any gestational age after 11 weeks; however, early amniocentesis (<15 weeks' gestation) should be avoided because of increased complications including a higher fetal loss rate.
- Amniocentesis is most commonly indicated for prenatal diagnosis and fetal lung maturity.
- Amniocentesis should be performed by a physician who has experience with the procedure.
- The procedure should be done under continuous US guidance.
- The procedure-related loss rate is approximately 0.1% to 0.3% and may be lower or higher depending on the experience of the operator.
- Until further studies are available, women who have HIV, hepatitis B or C, cytomegalovirus, or toxoplasmosis should be counseled regarding the plausible risk of vertical transmission and alternative options, which include first-trimester and second-trimester screening for aneuploidy.

SUGGESTED READING

Alfirevic Z, Sundberg K, Brigham S. Amniocentesis and chorionic villus sampling for prenatal diagnosis. *Cochrane Database Syst Rev*. 2003;(3):CD003252.

Mujezinovic F, Alfirevic Z. Procedure-related complications of amniocentesis and chorionic villous sampling: a systematic review. *Obstet Gynecol*. 2007;110:687-694.

Tabor A, Alfirevic Z. Update on procedure-related risks for prenatal diagnosis techniques. *Fetal Diagn Ther*. 2010;27:1-7.



All references are available online at www.expertconsult.com.

REFERENCES

1. Practice Bulletin No. 162 Summary: prenatal diagnostic testing for genetic disorders. *Obstet Gynecol*. 2016;127(5):976-978.
2. The Canadian Early and Mid-trimester Amniocentesis Trial (CEMAT) Group. Randomised trial to assess safety and fetal outcome of early and midtrimester amniocentesis. *Lancet*. 1998;351:242-247.
3. Tabor A, Philip J, Madsen M, et al. Randomised controlled trial of genetic amniocentesis in 4606 low-risk women. *Lancet*. 1986;1:1287-1293.
4. Kappel B, Nielsen J, Brogaard Hansen K, et al. Spontaneous abortion following mid-trimester amniocentesis: clinical significance of placental perforation and blood-stained amniotic fluid. *Br J Obstet Gynaecol*. 1987;94:50-54.
5. Andreasen E, Kristoffersen K. Incidence of spontaneous abortion after amniocentesis: influence of placental localization and past obstetric and gynecologic history. *Am J Perinatol*. 1989;6:268-273.
6. Bombard AT, Powers JF, Carter S, et al. Procedure-related fetal losses in transplacental versus nontransplacental genetic amniocentesis. *Am J Obstet Gynecol*. 1995;172:868-872.
7. Reid KP, Gurrin LC, Dickinson JE, et al. Pregnancy loss rates following second trimester genetic amniocentesis. *Aust N Z J Obstet Gynaecol*. 1999;39:281-285.
8. Crane JP, Kopta MM. Genetic amniocentesis: impact of placental position upon the risk of pregnancy loss. *Am J Obstet Gynecol*. 1984;150:813-816.
9. Hanson FW, Tennant FR, Zorn EM, et al. Analysis of 2136 genetic amniocenteses: experience of a single physician. *Am J Obstet Gynecol*. 1985;152:436-443.
10. Giorlandino C, Mobili L, Bilancioni E, et al. Transplacental amniocentesis: is it really a higher-risk procedure? *Prenat Diagn*. 1994;14:803-806.
11. Marthin T, Liedgren S, Hammar M. Transplacental needle passage and other risk-factors associated with second trimester amniocentesis. *Acta Obstet Gynaecol Scand*. 1997;76:728-732.
12. Saltvedt S, Almström H. Fetal loss rate after second trimester amniocentesis at different gestational age. *Acta Obstet Gynaecol Scand*. 1999;78:10-14.
13. Kong CW, Leung TN, Leung TY, et al. Risk factors for procedure-related fetal losses after mid-trimester genetic amniocentesis. *Prenat Diagn*. 2006;26:925-930.
14. Müngen E, Tütüncü L, Muhcu M, et al. Pregnancy outcome following second-trimester amniocentesis: a case-control study. *Am J Perinatol*. 2006;23:25-30.
15. Test and Technology Transfer Committee, American College of Medical Genetics. Technical and clinical assessment of fluorescence in situ hybridization: an ACMG/ASHG position statement. I. Technical considerations. Test and Technology Transfer Committee. *Genet Med*. 2000;2:356-361.
16. Shapiro DE, Sperling RS, Mandelbrot L, et al. Risk factors for perinatal human immunodeficiency virus transmission in patients receiving zidovudine prophylaxis. Pediatric AIDS Clinical Trials Group protocol 076 Study Group. *Obstet Gynecol*. 1999;94:897-908.
17. Somigliana E, Bucceri AM, Tibaldi C, et al. Italian Collaborative Study on HIV Infection in Pregnancy. Early invasive diagnostic techniques in pregnant women who are infected with the HIV: a multicenter case series. *Am J Obstet Gynecol*. 2005;193:437-442.
18. Mandelbrot L, Jasseron C, Ekoukou D, et al. ANRS French Perinatal Cohort (EPF). Amniocentesis and mother-to-child human immunodeficiency virus transmission in the Agence Nationale de Recherches sur le SIDA et les Hépatites Virales French Perinatal Cohort. *Am J Obstet Gynecol*. 2009;200:160.e1-160.e9.
19. Giorlandino C, Bilancioni E, D'Alessio P, et al. Risk of iatrogenic fetal infection at prenatal diagnosis. *Lancet*. 1994;343:922-923.
20. Minola E, Maccabruni A, Pacati I, et al. Amniocentesis as a possible risk factor for mother-to-infant transmission of hepatitis C virus. *Hepatology*. 2001;33:1341-1342.
21. Ko TM, Tseng LH, Chang MH, et al. Amniocentesis in mothers who are hepatitis B virus carriers does not expose the infant to an increased risk of hepatitis B virus infection. *Arch Gynecol Obstet*. 1994;225:25.
22. Alexander JM, Ramus R, Jackson G, et al. Risk of hepatitis B transmission after amniocentesis in chronic hepatitis B carriers. *Infect Dis Obstet Gynecol*. 1999;7:283.
23. Towers CV, Asrat T, Rumney P. The presence of hepatitis B surface antigen and deoxyribonucleic acid in amniotic fluid and cord blood. *Am J Obstet Gynecol*. 2001;184:1514.
24. Jackson LG, Zachary JM, Fowler SE, et al. A randomized comparison of transcervical and transabdominal chorionic-villus sampling. The U.S. National Institute of Child Health and Human Development Chorionic-Villus Sampling and Amniocentesis Study Group. *N Engl J Med*. 1992;327:594-598.
25. Akolekar R, Beta J, Picciarelli G, et al. Procedure-related risk of miscarriage following amniocentesis and chorionic villus sampling: a systematic review and meta-analysis. *Ultrasound Obstet Gynecol*. 2015;45(1):16-26.
26. Eddleman KA, Malone FD, Sullivan L, et al. Pregnancy loss rates after midtrimester amniocentesis. *Obstet Gynecol*. 2006;108(5):1067.
27. Antsaklis A, Papantoniou N, Xygakis A, et al. Genetic amniocentesis in women 20-34 years old: associated risks. *Prenat Diagn*. 2000;20(3):247.
28. Harper LM, Cahill AG, Smith K, et al. Effect of maternal obesity on the risk of fetal loss after amniocentesis and chorionic villus sampling. *Obstet Gynecol*. 2012;119(4):745-751.
29. Odibo AO, Gray DL, Dicke JM, et al. Revisiting the fetal loss rate after second-trimester genetic amniocentesis: a single center's 16-year experience. *Obstet Gynecol*. 2008;111(3):589.
30. Borgida AF, Mills AA, Feldman DM, et al. Outcome of pregnancies complicated by ruptured membranes after genetic amniocentesis. *Am J Obstet Gynecol*. 2000;183:937-939.
31. Romero R, Jeanty P, Reece EA, et al. Sonographically monitored amniocentesis to decrease intraoperative complications. *Obstet Gynecol*. 1985;65:426-430.
32. Leschot NJ, Verjaal M, Treffers PE. Risks of midtrimester amniocentesis: assessment in 3,000 pregnancies. *Br J Obstet Gynaecol*. 1985;92:804-807.

112 Cordocentesis and Fetal Transfusion

GLORIA TOO | RICHARD L. BERKOWITZ

Introduction

Cordocentesis is a procedure that has both diagnostic and therapeutic value in fetal medicine, and is used for fetal blood sampling (FBS) and administration of fetal transfusions. Sir William Liley described the first successful intraperitoneal transfusion in 1963 with x-ray assistance.[1] Almost 20 years later, Rodeck et al. reported using a fetoscopic approach to gain direct fetal vascular access.[2] Ultrasound (US) guided percutaneous umbilical sampling (PUBS) was then described by Daffos et al. in 1983 and was subsequently used for testing karyotype, genetic disorders, blood/antigen typing, infectious testing, and to give direct intravascular fetal therapy.[3] However, the development of less invasive diagnostic techniques has led to a decreased need for FBS. In a single center in Italy, the reported use of cordocentesis for prenatal diagnosis of karyotype analysis decreased from 26.4% (372 of 1408) during 1982–1985 to 2.2% (213 of 9341) during 2000–2004.[4]

Procedure

SETTING

Early cordocentesis is performed in a US unit because emergent cesarean delivery is not indicated for the previable fetus if there is evidence of fetal distress during or following the procedure. Once the fetus is viable, the procedure should be performed in a setting where an urgent cesarean delivery can take place if a complication occurs. It is useful to have the patient evaluated by the anesthesia team and prepared for a possible emergent delivery in that setting. Before the procedure, consideration should be given to administering prenatal steroids for fetal lung maturity.

COUNSELING

All cordocentesis procedures should be preceded by an extensive counseling session in which the indication, risks, benefits, and alternatives to the procedure are discussed.

INDICATIONS

Currently, the most common indication for FBS and cordocentesis is diagnosis and management of isoimmunization (56%) and nonimmune hydrops (18%).[5] Cordocentesis is occasionally performed for other diagnostic purposes or therapeutic indications, which may include fetal drug administration for fetal thyrotoxicosis or fetal arrhythmia unresponsive to maternal therapy.

Fetal Anemia

Fetal anemia is defined as hemoglobin levels less than two standard deviations below the mean and can lead to high-output cardiac failure, hydrops fetalis, and fetal demise.[6] This condition used to be common, with most cases resulting from Rhesus-D sensitization. This, however, has become much less prevalent with the development and widespread use of anti-D immune globulin. Nevertheless, alloimmune fetal anemia may still occur if there is inadequate anti-D immune globulin administration or if sensitization develops to other red blood cell antigens (e.g., Kell, c, C, e, Duffy, etc.). As alloimmune anemia and subsequent hydrops has decreased, nonimmune hydrops now accounts for 90% to 99% of hydrops fetalis cases.[6,7] Nonimmune causes of fetal anemia include infection, fetal-maternal hemorrhage, and hematologic disorders, such as thalassemia. Parvovirus is the most common infectious cause of anemia. In one case series, hydrops fetalis occurred in 4% of patients with acute parvovirus infection.[8]

Doppler velocimetry measuring the peak systolic velocity (PSV) of the middle cerebral artery (MCA) is used to screen pregnancies at risk for fetal anemia. When the PSV is >1.5 multiples of the median (MoM) or there is evidence of hydrops fetalis, severe anemia is suspected and IUT or delivery is indicated. FBS remains the gold standard for definitive diagnosis of severe anemia and should be performed immediately before any IUT.

Serial transfusions may be necessary to prolong the gestation, especially if anemia is diagnosed early in pregnancy. However, after transfusion, MCA Dopplers may not be as predictive of severe anemia since the introduction of the smaller, less rigid adult red blood cells may alter fetal blood flow. One study reported that MCA Doppler >1.5 MoM was a good predictor of severe anemia before the first transfusion, but was associated with a false-positive rate of 37% after the first, and 90% after the second transfusion.[9] The false-positive rate decreased and negative predictive value increased when a higher MoM threshold for severe anemia was used. Another approach to predicting anemia following transfusion is to use the expected daily decline of hemoglobin to determine the interval to the next transfusion. The reported daily decline in hemoglobin was 0.45 g/dL after the first transfusion, 0.35 g/dL after the second, and 0.32 g/dL after the third. This study also reported the median time to subsequent transfusion was 13, 25, and 27 days after the first, second, and third transfusion, respectively.[10] After the first transfusion, the Society of Maternal Fetal Medicine recommends the use of 1.69 MoM as the threshold for further cordocentesis/IUT to decrease the frequency of unnecessary procedures.[11,12]

Neonatal Alloimmune Thrombocytopenia

Neonatal alloimmune thrombocytopenia (NAIT) is fetal thrombocytopenia that occurs in 1:1000 to 2:1000 live births in the United States and is caused by maternal sensitization to fetal platelet antigens that are discordant from her own.[13,14] This process is similar to fetal anemia caused by erythrocyte alloimmunization, and has a high recurrence rate and likelihood for earlier and more severe disease with future pregnancies. Unlike fetal anemia from alloimmunization, significant fetal thrombocytopenia may occur in the first pregnancy. NAIT can cause a spectrum of outcomes ranging from mild, asymptomatic thrombocytopenia to severe thrombocytopenia and may lead to intracranial hemorrhage (ICH) in 20% to 30% of affected cases.[13] This condition should be suspected if there is ICH in the current pregnancy or there is a personal or family history suggestive of NAIT in prior pregnancies (unexplained neonatal thrombocytopenia, intracranial hemorrhage). While maternal antibody evaluation and fetal antigen typing can be done with serum testing and amniocentesis, definitive diagnosis requires FBS to confirm fetal thrombocytopenia. To date, no noninvasive biomarker is available for assessment of fetal platelet count or genotype. The goal of NAIT management is to prevent intracranial bleeding by preventing the development of severe thrombocytopenia *in utero*. The role of cordocentesis in the management of this disorder has evolved over time and is now used judiciously under specific circumstances.

During the early investigations on NAIT, cordocentesis was used frequently to determine the baseline platelet count, evaluate the effectiveness of therapies *in utero,* and to determine if the platelet count was high enough for a safe vaginal delivery. As the number of indications for performing cordocentesis in general decreased, there was a concomitant reduction in the number of individuals with substantial experience performing the procedure. As a consequence, the number of patients with procedure-related complications increased, including emergent cesarean delivery and fetal loss. Enormous progress has been made toward reducing the need for cordocentesis in this disorder over the past 3 decades, and it is now possible to avoid dangerously low platelet counts in most affected fetuses with prophylactic maternal management with intravenous immunoglobulin and prednisone.[15] Cordocentesis, previously done to assess the fetal response to maternal therapy at fixed intervals, has been eliminated in favor of empiric increases in therapies based on the risk of developing severe fetal thrombocytopenia. Early-term delivery by cesarean section is recommended. FBS should currently only be performed close to delivery to verify that the fetal platelet count is high enough to permit a safe vaginal delivery in women who would like to avoid abdominal surgery.

CONTRAINDICATIONS

While there are no absolute contraindications to cordocentesis, certain maternal viral infections and early gestational age are considered relative contraindications. There is a theoretic risk of vertical transmission of blood-borne diseases, such as human immunodeficiency virus and hepatitis. The risk is likely elevated with a higher viral load, but there is little data on the rates of transmission with this procedure. Early gestational age is associated with increased complication rates and technical difficulty. In one study, the procedure-related fetal loss rate was 5.6% when FBS was performed at less than 20 weeks' gestation, and 0.8% to 2.2% when performed at greater than 20 weeks' gestation.[16] A recent single-center study reported that, in their institution, cordocentesis was rarely performed before 18 weeks (accounting for only 3.5% of their cordocentesis cases), but was not associated with an increased risk of fetal loss when compared to FBS performed after 18 weeks' gestation (2.9% versus 1.8%, $P = .40$).

The overall fetal loss rate in this study was 1.9%.[17] Therefore early gestational age may be considered a relative contraindication for FBS, as there is conflicting data on whether this is associated with a higher rate of fetal loss. However, FBS should be considered if no alternative exists to prevent an imminent demise *in utero*.[18,19]

RISKS

The risks for this procedure include: infection, preterm premature rupture of membranes, placental abruption, preterm labor, maternal-fetal hemorrhage, alloimmunization, fetal bradycardia, and loss of the pregnancy. Fetal bradycardia occurs during or immediately after the procedure in 5% of patients with decreasing prevalence as gestational age increased.[20] This can occur with vasospasm of the umbilical artery because of contraction of the muscularis, so umbilical vein entry is recommended. Streaming from the needle insertion site into the fetal vessel occurs in 20% to 30% of cases and is often transient, but rarely may cause fetal exsanguination. This occurs less frequently with an intrahepatic vein approach (9%) compared with needle insertion into a cord vessel (26%).[21] Iatrogenic umbilical cord hematoma may cause cord compression and fetal bradycardia (Fig. 112.1). This is often asymptomatic or transient, but may require delivery if there is persistent evidence of nonreassuring fetal status, such as prolonged fetal bleeding or bradycardia. One series reported an emergency cesarean delivery incidence of 2.4%, which was associated with birth asphyxia in 73% and neonatal demise in 33%. In another series, emergent cesarean delivery was performed in 5% of patients with alloimmune thrombocytopenia (NAIT) who underwent diagnostic cordocentesis.[22] Others report the fetal loss rate is 1.4% to 1.9% after cordocentesis.[17,23]



Fig. 112.1 Hematoma in umbilical cord after cordocentesis indicated by calipers.

TECHNIQUE

A detailed US examination, including Doppler color evaluation flow, is performed to identify the fetal position and placental cord insertion site (Fig. 112.2). This procedure can be performed by introducing a needle into a fetal vessel at the placental cord insertion site, within the liver, within a free loop of cord, or at the fetal abdominal cord insertion site. If the placenta is anterior, it should be traversed to reach the cord insertion, as this is the safest entry site. When the placenta is posterior, the cord insertion site can be reached only by traversing the amniotic cavity, where fetal activity could disrupt the needle during the procedure. In these cases, medical paralysis of the fetus can be considered, especially if a transfusion is to be performed. If the procedure is being performed for suspected anemia, the operator should be set up to provide transfusion.

The patient's abdomen should be prepped with an antiseptic solution and draped in a sterile manner. There is insufficient evidence to recommend prophylactic antibiotics. After covering the transducer with a sterile sheath, the vascular target should be identified again. Before needle insertion, a subcutaneous local anesthetic agent is administered. In most diagnostic cases, a 22-gauge needle can be used, but blood transfusions should be performed through a 20-gauge needle. The needle length is determined by the measured distance from the skin to the target vessel (ranging from 9–16 cm in most cases). The needle is advanced under direct visualization with US guidance. As the needle approaches the vessel, the US image should be magnified and the umbilical vein identified using Doppler. The needle tip is positioned against the vessel wall and then sharply thrust into the umbilical vein (Fig. 112.3).

When the needle tip is seated within the vessel, the stylus is removed, a heparin flush is attached to the needle, and a fetal blood sample is aspirated. The sample should be analyzed

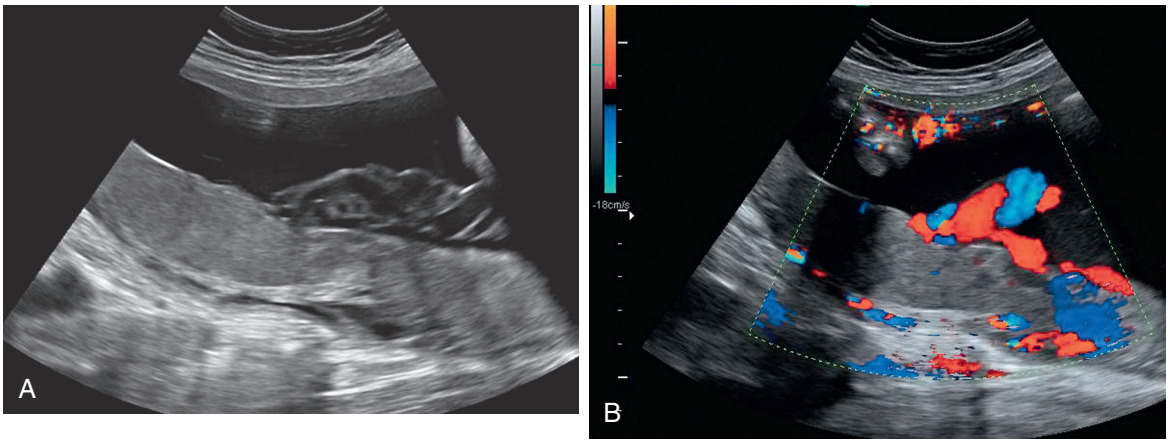

Fig. 112.2 Gray scale (A) and color Doppler (B) visualization of cord insertion into a posterior placenta.

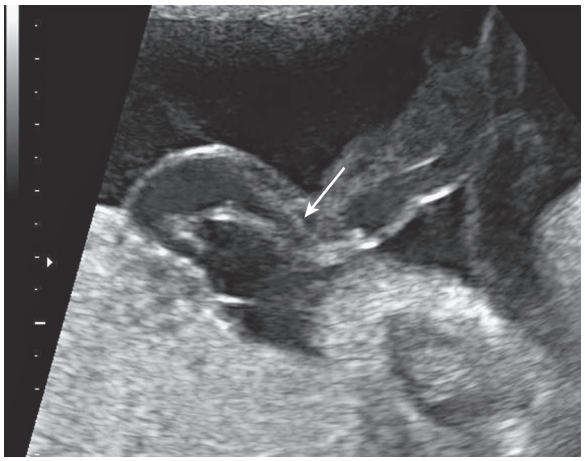

Fig. 112.3 Needle *(arrow)* inserted into umbilical vein near placental cord insertion.

immediately. This can be accomplished with a bedside point-of-care test (Coulter counter) or via the stat lab. The mean corpuscular volume can be used to document that the blood is fetal in origin. If fetal paralysis is needed, we recommend using vecuronium bromide at a dose of 0.1 mg/kg estimated fetal weight, injected directly into the umbilical vein. In cases where a transfusion is indicated, T-connector tubing is attached to the needle so that transfusion and further sampling does not cause inadvertent movement of the needle tip. The blood transfused should be cytomegalovirus-negative, irradiated, filtered, O-negative packed red blood cells. The blood volume to be transfused depends on several factors, including: donor hematocrit, estimated fetal weight, initial fetal hematocrit, and target hematocrit.

After the predetermined quantity of blood has been administered, a repeat sample is taken to ensure that the desired final hemoglobin level was achieved, and the needle is withdrawn. The puncture site is visually assessed for streaming and observed until its cessation. During and after the procedure, fetal well-being is assessed by intermittent visualization of cardiac activity. Fetal heart rate and uterine activity in viable pregnancies should be monitored for at least 2 hours after the procedure.

Outcomes

The success rate of FBS is high (97%–98.5%) in experienced hands.[20,24] A study comparing the success rate of blood sampling reported a 94.9% success rate with cordocentesis versus 82.5% when using intrahepatic vein entry.[21] A study comparing the rate of preterm premature rupture of membranes, chorioamnionitis, placental abruption, and gestational hypertension found no statistically increased risk in women who underwent FBS versus those who did not undergo cordocentesis.[24]

Survival rates after IUT for red blood cell alloimmunization range from 80% to 95%, depending on the gestational age at first transfusion and presence and severity of hydrops fetalis.[20,25–27] There is a higher rate of perinatal loss if severe anemia develops before 20 weeks' gestation.[27]

There is limited information on long-term, neurodevelopmental outcomes of hydrops fetalis after IUT. Smaller studies are reassuring, reporting no known short-term or long-term effect of hydrops and its treatment on subsequent neurodevelopment.[28,29] The LOTUS (Long-Term follow-up after intra-Uterine transfusionS) study followed the neurodevelopmental outcomes of 291 children who were treated with IUT for alloimmunization, of which 26% had developed hydrops fetalis. The composite neurodevelopmental outcome (cerebral palsy, severe development delay, bilateral deafness, or blindness) was observed in 4.8% of children. They reported an incidence of severe neurodevelopmental delay in 1.7%, cerebral palsy in 0.7%, and deafness in 1.0%. Severe hydrops was independently associated with neurodevelopmental impairment (odds ratio, 11.2; 95% confidence interval, 1.7–92.7).[30] The prognosis of the infant depends on the underlying indication for intervention; however, poor postnatal outcomes are infrequent, and even more rare if hydrops is absent.

KEY POINTS

1. Cordocentesis may be performed for diagnostic and therapeutic purposes. Currently, it is used most commonly to verify and treat fetal anemia.
2. Common sites for FBS or fetal transfusion are the placental cord insertion and the intrahepatic umbilical vein. The choice of site depends on the fetal position, placental location, and physician preference.
3. The risk of a fatal complication after cordocentesis or IUT ranges from 1.4% to 2.0% in experienced hands.
4. Fetal anemia most commonly results from red blood cell alloimmunization and can lead to fetal anemia, fetal hydrops, and death *in utero*. Noninvasive US assessment of fetal cerebral blood flow by measuring the PSV of blood flow in the MCA has become the method of choice to identify fetuses at high risk of severe anemia. When significant fetal anemia is detected, FBS and IUT are indicated in fetuses who are felt to be too premature to deliver. Survival rates in fetuses that require transfusions *in utero* vary from 80% to 95%, depending on the gestational age at first transfusion and/or the presence and severity of hydrops fetalis.
5. Patients at risk for AIT should be treated with intravenous immunoglobulin and prednisone according to protocols based on their risk assessment for carrying a fetus who might develop severe thrombocytopenia. FBS should be limited to patients who want to avoid a cesarean section and are willing to undergo the procedure to verify that the fetal platelet count is high enough to safely proceed with a vaginal delivery.

SUGGESTED READING

Society for Maternal-Fetal Medicine (SMFM), Berry SM, Stone J, et al. Fetal blood sampling. *Am J Obstet Gynecol*. 2013;209(3):170-180.

All references available online at www.expertconsult.com

REFERENCES

1. Liley AW. Intrauterine transfusion of foetus in haemolytic disease. *Br Med J*. 1963;2:1107-1109.
2. Rodeck CH, Kemp JR, Holman CA, et al. Direct intravascular fetal blood transfusion by fetoscopy in severe Rhesus isoimmunisation. *Lancet*. 1981;1(8221):625-627.
3. Daffos F, Caplla-Pavlovski M, Forestier F. A new procedure for fetal blood sampling innutero: preliminary results of fifty-three cases. *Am J Obstet Gynecol*. 1983;146:985-987.
4. Monni G, Zoppi MA, Axiana C, et al. Changes in the approach for invasive prenatal diagnosis in 35,127 cases at a single center from 1977 to 2004. *Fetal Diagn Ther*. 2006;21:348-354.
5. Bigelow CA, Cinelli CM, Little SE, et al. Percutaneous umbilical blood sampling: current trends and outcomes. *Eur J Obstet Gynecol Reprod Biol*. 2016;200:98-101.
6. Hartge DR, Weichert J, Gembicki M, et al. Confirmation of etiology in fetal hydrops by sonographic evaluation of fluid allocation patterns. *Eur J Obstet Gynecol Reprod Biol*. 2015;195:128-132.
7. Sohan K, Carroll SG, De La Fuente S, et al. Analysis of outcome in hydrops fetalis in relation to gestational age at diagnosis, cause and treatment. *Acta Obstet Gynecol Scand*. 2001;80(8):726-730.
8. Enders M, Weidner A, Zoellner I, et al. Fetal morbidity and mortality after acute human parvovirus B19 infection in pregnancy: prospective evaluation of 1018 cases. *Prenat Diagn*. 2004;24(7):513-518.
9. Scheier M, Hernandez-Andrade E, Fonseca EB, et al. Prediction of severe fetal anemia in red blood cell alloimmunization after previous intrauterine transfusions. *Am J Obstet Gynecol*. 2006;195:1550-1556.
10. Friszer S, Maisonneuve E, Macé G, et al. Determination of optimal timing of serial in-utero transfusions in red-cell alloimmunization. *Ultrasound Obstet Gynecol*. 2015;46(5):600-605.
11. Mari G, Norton ME, Stone J, et al. Society for Maternal-Fetal Medicine (SMFM) Clinical Guideline #8: the fetus at risk for anemia–diagnosis and management. *Am J Obstet Gynecol*. 2015;212(6):697-710.
12. Detti L, Oz U, Guney I, et al. Doppler ultrasound velocimetry for timing the second intrauterine transfusion in fetuses with anemia from red cell alloimmunization. *Am J Obstet Gynecol*. 2001;185(5):1048-1051.
13. Kjeldsen-Kragh J, Killie MK, Tomter G, et al. A screening and intervention program aimed to reduce mortality and serious morbidity associated with severe neonatal alloimmune thrombocytopenia. *Blood*. 2007;110:833-839.
14. Spencer JA, Burrows RF. Fetomaternal alloimmune thrombocytopenia: a literature review and statistical analysis. *Aust N Z J Obstet Gynaecol*. 2001;41:45-55.
15. Bussel J. Diagnosis and management of the fetus and neonate with alloimmune thrombocytopenia. *J Thromb Haemost*. 2009;7(suppl 1):253-257.
16. Van Kamp IL, Klumper FJ, Oepkes D, et al. Complications of intrauterine intravascular transfusion for fetal anemia due to maternal red-cell alloimmunization. *Am J Obstet Gynecol*. 2005;192:171-177.
17. Tongsong T, Wanapirak C, Piyamongkol W, et al. Second-trimester cordocentesis and the risk of small for gestational age and preterm birth. *Obstet Gynecol*. 2014;124(5):919-925.
18. Voto LS, Mathet ER, Zapaterio JL, et al. High-dose gammaglobulin (IVIG) followed by intrauterine transfusions (IUTs): a new alternative for the treatment of severe fetal hemolytic disease. *J Perinat Med*. 1997;25:85-88.
19. Ruma MS, Moise KJ Jr, Kim E, et al. Combined plasmapheresis and intravenous immune globulin for the treatment of severe maternal red cell alloimmunization. *Am J Obstet Gynecol*. 2007;196:138.e1-138.e6.
20. Liao C, Wei J, Li Q, et al. Efficacy and safety of cordocentesis for prenatal diagnosis. *Int J Gynaecol Obstet*. 2006;93:13-17.
21. Aina-Mumuney AJ, Holcroft CJ, Blakemore KJ, et al. Intrahepatic vein for fetal blood sampling: one center's experience. *Am J Obstet Gynecol*. 2008;198:387.e1-387.e6.
22. Berkowitz RL, Kolb EA, McFarland JG, et al. Parallel randomized trials of risk-based therapy for fetal alloimmune thrombocytopenia. *Obstet Gynecol*. 2006;107:91-96.
23. Ghidini A, Sepulveda W, Lockwood CJ, et al. Complications of fetal blood sampling. *Am J Obstet Gynecol*. 1993;168:1339-1344.
24. Tongsong T, Wanapirak C, Kunavikatikul C, et al. Fetal loss rate associated with cordocentesis at midgestation. *Am J Obstet Gynecol*. 2001;184:719-723.
25. Yinon Y, Visser J, Kelly EN, et al. Early intra-uterine transfusions in severe red blood cell alloimmunization. *Obstet Gynecol*. 2010;36:601-606.
26. Schumacher B, Moise KJ Jr. Fetal transfusion for red blood cell alloimmunization in pregnancy. *Obstet Gynecol*. 1996;88:137-150.
27. Lindenburg IT, van Kamp IL, van Zwet EW, et al. Increased perinatal loss after intrauterine transfusion for alloimmune anaemia before 20 weeks of gestation. *BJOG*. 2013;120(7):847-852.
28. Weisz B, Rosenbaum O, Chayen B, et al. Outcome of severely anaemic fetuses treated by intrauterine transfusions. *Arch Dis Child Fetal Neonatal Ed*. 2009;94:F201-F204.
29. Hudon L, Moise KJ Jr, Hegemier SE, et al. Long-term neurodevelopmental outcome after intrauterine transfusion for the treatment of fetal hemolytic disease. *Am J Obstet Gynecol*. 1998;179:858-863.
30. Verduin EP, Lindenburg IT, Smits-Wintjens VE, et al. Long-term follow up after intra-uterine transfusions; the LOTUS study. *BMC Pregnancy Childbirth*. 2010;10:77.

113 Chorionic Villus Sampling

JOY VINK | MELISSA QUINN

Introduction

Chorionic villus sampling (CVS) is a procedure in which small samples of placental tissue are obtained for prenatal diagnosis of aneuploidy or for DNA analysis. CVS is an outpatient procedure usually performed between 10 and 14 weeks' gestation. The main advantage of CVS compared with amniocentesis is that the results are available earlier in pregnancy, allowing for earlier and safer methods of pregnancy termination if abnormal results are detected.

Procedure

DESCRIPTION, TECHNIQUE, AND EQUIPMENT

Before CVS, the patient should be counseled regarding the purpose, risks, and alternatives to the procedure, and informed consent should be obtained. Transvaginal ultrasound (US) should be performed to determine the number of embryos, chorionicity, fetal viability, and any early US evidence of fetal anomalies.

CVS can be performed transabdominally or transcervically (Figs. 113.1 and 113.2). No differences in fetal loss rates were noted by Jackson et al.[1] after transcervical versus transabdominal CVS. The procedure should be performed with US by a physician who is experienced in performing the latter. A sonographer who is trained to recognize the US appearance of a transabdominal needle and a transcervical catheter (Fig. 113.3) is crucial for a successful procedure.

Transcervical Chorionic Villus Sampling

Before transcervical CVS, obtaining cervicovaginal cultures is recommended and pathogens should be appropriately treated. The supplies needed for the procedure include antiseptic solution, 4-inch × 4-inch gauze pads, a sterile speculum, a single-toothed tenaculum or ring forceps (optional), a 26-cm-long polyethylene cannula with an outer diameter of 1.5 mm and a soft stainless steel blunt stylet (alternatively, biopsy forceps may be used[2]), a 20-mL syringe containing nutrient medium, a tissue culture dish or specimen tube, sterile US gel, and US probe cover (Fig. 113.4).

The patient is placed in the lithotomy position, and the speculum is inserted into the vagina. When the cervix can be seen, the vagina and cervix are prepared with antiseptic solution. Some operators use either a single-toothed tenaculum or ring forceps to grasp the anterior lip of the cervix to manipulate the cervix and uterine position gently; others perform the procedure without these instruments. A full bladder may facilitate the ideal angle between the anterior uterine wall and the endocervical canal. The transcervical catheter can be bent to mimic the curve of the endocervical canal noted on the US scan (a uterine sound can be placed in the cervical canal to help with visualization before catheter placement).

While the sonographer provides direct transabdominal US guidance, the physician can carefully insert the transcervical catheter through the endocervical canal and into the placenta. The stylet is removed, and the 20-mL syringe containing several

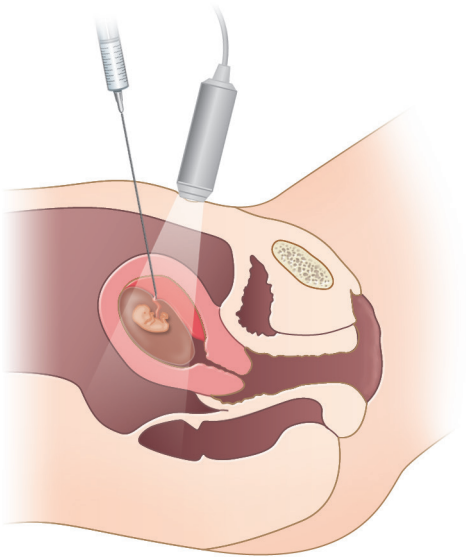

Fig. 113.1 Transabdominal chorionic villus sampling. *(Adapted from Gabbe SG, Niebyl JR, Simpson JL, et al.* Obstetrics: normal and problem pregnancies. *4th ed. Churchill-Livingstone; 2001:202).*

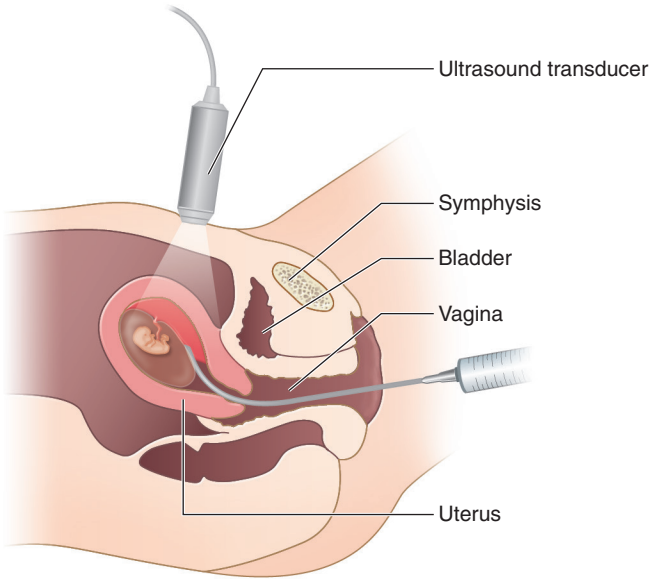

Fig. 113.2 Transcervical chorionic villus sampling. *(Adapted from Gabbe SG, Niebyl JR, Simpson JL, et al.* Obstetrics: normal and problem pregnancies. *4th ed. Churchill-Livingstone; 2001:201).*

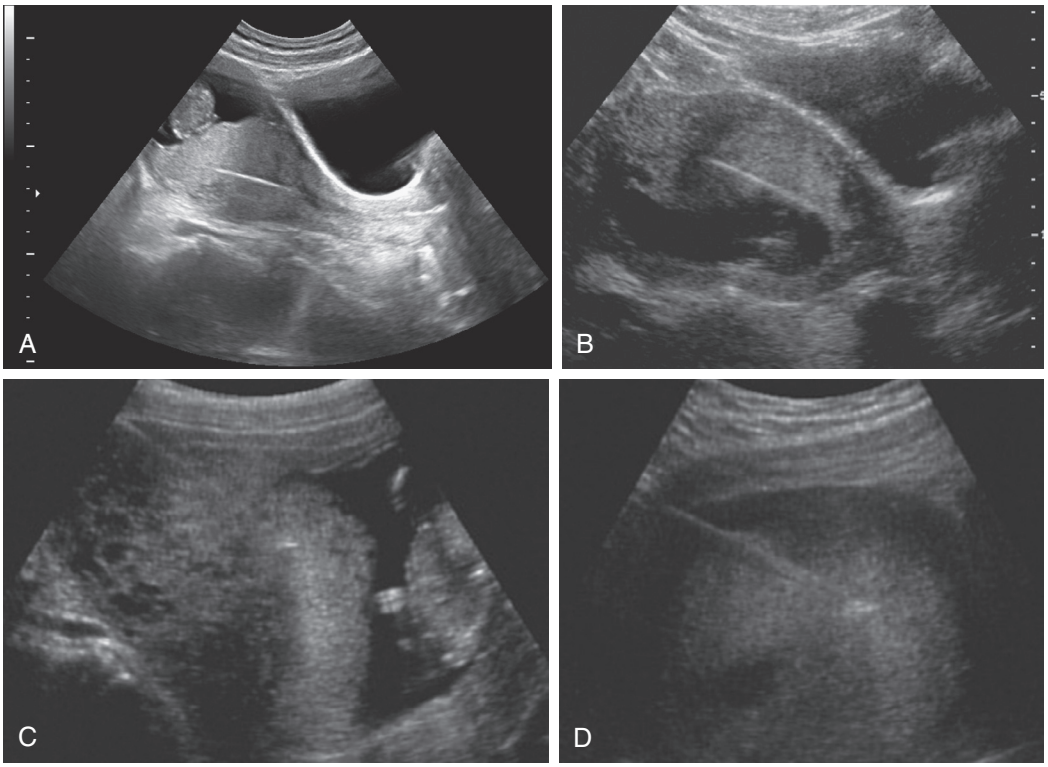

Fig. 113.3 (A) Transcervical catheter located in a posterior placenta during transcervical chorionic villus sampling (CVS). (B) Transcervical catheter located in an anterior placenta during transcervical CVS. (C) Sampling needle located in a posterior placenta during transabdominal CVS. (D) Sampling needle located in an anterior placenta during transabdominal CVS.



Fig. 113.4 Supplies needed in transcervical chorionic villus sampling: antiseptic solution, 4-inch × 4-inch gauze pads, sterile speculum, single-toothed tenaculum or ring forceps, 26-cm-long polyethylene cannula with outer diameter of 1.5 mm and a soft steel blunt stylet, 20-mL syringe, nutrient medium, tissue culture dish or sterile specimen tubes, sterile US gel, and US probe cover.



Fig. 113.5 Supplies needed in transabdominal chorionic villus sampling: antiseptic solution, 4-inch × 4-inch gauze pads, sterile drape, 20-mL syringe, nutrient medium, sterile US gel, US probe cover, 9-cm-long or 12-cm-long 20-gauge spinal needle with stylet, holder to mount the syringe, and specimen tubes or tissue culture dish.

milliliters of nutrient medium is attached to the transcervical catheter. Using negative pressure, the catheter is gently moved back and forth within the placenta to aspirate placental villi. While the syringe is under negative pressure, the catheter is removed, and the sample is placed into a plastic tissue culture dish or specimen tube. The physician examines the sample under direct light or a microscope to ensure that adequate placental villi were obtained.

Transabdominal Chorionic Villus Sampling

Supplies needed for the procedure include antiseptic solution, 4-inch × 4-inch gauze pads, a sterile drape, nutrient medium, tissue culture dish or specimen tube, sterile US gel, US probe cover, a 9-cm-long or 12-cm-long 20-gauge spinal needle with stylet, and a 20-mL syringe and holder to mount the syringe (Fig. 113.5).

The patient is placed in the supine position to confirm placental location. The lower abdomen is prepared, and the patient's thighs are covered with a sterile drape. The sterile cover is placed over

the US probe, and sterile US gel is placed on the patient's abdomen. The needle is inserted under continuous US guidance at an angle that penetrates the long axis of the placenta. When the needle is in the desired location, the stylet is removed, and the syringe is attached to the needle. With the syringe under negative pressure, the needle is moved gently back and forth, staying within the placenta. After placental tissue is aspirated within the syringe, the needle is removed while maintaining negative pressure in the syringe. The physician places the sample in a tissue culture dish or a specimen tube and examines the specimen under direct light or a microscope to ensure adequate placental villi were obtained. Because fetomaternal hemorrhage has been documented after CVS, unsensitized Rh_0(D)-negative women should be given Rh_0(D) immune globulin after CVS to prevent Rh sensitization.

INDICATIONS

The most common indication for CVS is for prenatal diagnosis of conditions in which DNA analysis or diagnostic cytogenetic analysis is possible.

CONTRAINDICATIONS

Relative contraindications to CVS include the presence of an intrauterine device and the desire to screen for neural tube defects using alpha-fetoprotein levels (alpha-fetoprotein levels cannot be determined on CVS samples). Maternal isoimmunization is also a relative contraindication because Moise and Carpenter[3] reported that women who are sensitized and undergo CVS appear to be at increased risk for fetal erythroblastosis. These authors suggested that this risk may be caused by an enhanced maternal antibody response after the procedure.

Contraindications to transcervical CVS include an inability to insert the catheter through the endocervical canal (i.e., cervical stenosis, cervical myoma), cervical or vaginal infections, inability to access the placenta because of uterine myomas or severe anteflexion or retroflexion of the uterus, and patient intolerance of the procedure (i.e., vaginismus). A contraindication to transabdominal CVS is the inability to reach the placenta because of uterine or fetal position. The transabdominal approach is also preferred when uterine anomalies are present.

Outcomes and Complications

The most frequently discussed complications are procedure-related pregnancy loss and fetal damage, in particular, limb-reduction defects and oromandibular hypogenesis.

FETAL LOSS

The true pregnancy loss rate is challenging to quantify because few randomized trials have studied the fetal loss rate after CVS compared with the spontaneous fetal loss rate in women who did not undergo CVS. In addition, studies assessing loss used various definitions of procedure-related loss. However, when CVS was compared with second-trimester genetic amniocentesis, most studies reported loss rates that were slightly higher in the CVS group, mainly with the transcervical approach.[4–10] A Cochrane review concluded that the overall pregnancy loss rate of transabdominal CVS was similar to the pregnancy loss rate of second-trimester amniocentesis (odds ratio 0.90, 95% confidence interval [CI], 0.66–1.23) and transcervical CVS was associated with a significantly higher risk of pregnancy loss (14.5% versus 11%; relative risk 1.40, 95% CI, 1.09–1.81) and spontaneous miscarriage (12.9% versus 9.4%; relative risk 1.50, 95% CI, 1.07–2.11).[11] Risk factors for increased fetal loss after CVS were studied and included a small-for-gestational-age fetus,[12] an inexperienced operator,[13] and introduction of the sampling device more than three times.[14]

LIMB-REDUCTION DEFECTS AND OROMANDIBULAR HYPOGENESIS

Although CVS has been associated with limb-reduction defects and oromandibular hypogenesis, the evidence is conflicting. Initial reports documented an increase in limb malformations when CVS was performed at less than 9 completed weeks of gestation.[15–21] However, a report by the World Health Organization reviewed more than 216,381 CVS procedures and could not confirm the association of limb-reduction defects after CVS, especially after 10 weeks' gestation. The study concluded that limb defects after CVS performed before 10 weeks' gestation were limited.[22] At Columbia University Medical Center, performance of CVS before 10 weeks' gestation is avoided. Other complications after CVS include vaginal spotting (occurs in approximately one-third of patients) and excessive vaginal bleeding (rare but more common after transcervical CVS). Sample or culture failure, infection, and amniotic fluid leakage occur in less than 0.5% of cases.[23]

KEY POINTS

- CVS is an outpatient procedure performed between 10 weeks' and 14 weeks' gestation to obtain placental villi for prenatal diagnosis of aneuploidy or for DNA analysis.
- The main advantage of CVS compared with amniocentesis is that the results are available earlier in pregnancy, allowing for earlier and safer methods of pregnancy termination if abnormal results are detected.
- CVS can be performed transabdominally or transcervically.
- The procedure should be performed under continuous US guidance by an experienced physician and a sonographer trained in recognizing the US appearance of a transabdominal needle and a transcervical catheter.
- Unsensitized Rh_0(D)-negative women should be given Rh_0(D) immune globulin after CVS to prevent Rh sensitization.
- CVS should not be performed at less than 10 weeks' gestation because of the possibility of limb-reduction defects and oromandibular hypogenesis.

SUGGESTED READING

Alfirevic Z, Sundberg K, Brigham S. Amniocentesis and chorionic villus sampling for prenatal diagnosis. *Cochrane Database Syst Rev*. 2003;(3):CD003252.
Alfirevic Z, von Dadelszen P. Instruments for chorionic villus sampling for prenatal diagnosis. *Cochrane Database Syst Rev*. 2003;(1):CD000114.
Brambati B, Tului L. Chorionic villus sampling and amniocentesis. *Curr Opin Obstet Gynecol*. 2005;17:197-201.
Evaluation of chorionic villus sampling safety: WHO/PAHO consultation on CVS. *Prenat Diagn*. 1999;19:97-99.
Jenkins TM, Wapner RJ. First trimester prenatal diagnosis: chorionic villus sampling. *Semin Perinatol*. 1999;23:403-413.
Stone JL, Lockwood CJ. Amniocentesis and chorionic villus sampling. *Curr Opin Obstet Gynecol*. 1993;5:211-217.
Tabor A, Alfirevic Z. Update on procedure-related risks for prenatal diagnosis techniques. *Fetal Diagn Ther*. 2010;27:1-7.

All references available online at www.expertconsult.com

REFERENCES

1. Jackson LG, Zachary JM, Fowler SE, et al. A randomized comparison of transcervical and transabdominal chorionic-villus sampling. The U.S. National Institute of Child Health and Human Development Chorionic-Villus Sampling and Amniocentesis Study Group. *N Engl J Med*. 1992;327: 594-598.
2. Alfirevic Z, von Dadelszen P. Instruments for chorionic villus sampling for prenatal diagnosis. *Cochrane Database Syst Rev*. 2003;(1):CD000114.
3. Moise KJ Jr, Carpenter RJ Jr. Increased severity of fetal hemolytic disease with known rhesus alloimmunization after first-trimester transcervical chorionic villus biopsy. *Fetal Diagn Ther*. 1990;5:76-78.
4. Mujezinovic F, Alfirevic Z. Procedure-related complications of amniocentesis and chorionic villous sampling: a systematic review. *Obstet Gynecol*. 2007;110:687-694.
5. Multicentre randomized clinical trial of chorion villus sampling and amniocentesis. First report. Canadian Collaborative CVS-Amniocentesis Clinical Trial Group. *Lancet*. 1989;1:1-6.
6. Rhoads GG, Jackson LG, Schlesselman SE, et al. The safety and efficacy of chorionic villus sampling for early prenatal diagnosis of cytogenetic abnormalities. *N Engl J Med*. 1989;320:609-617.
7. Caughey AB, Hopkins LM, Norton ME. Chorionic villus sampling compared with amniocentesis and the difference in the rate of pregnancy loss. *Obstet Gynecol*. 2006;108:612-616.
8. Tabor A, Vestergaard CH, Lidegaard Ø. Fetal loss rate after chorionic villus sampling and amniocentesis: an 11-year national registry study. *Ultrasound Obstet Gynecol*. 2009;34:19-24.
9. MRC Working Party in the Evaluation of Chorion Villus Sampling: Medical Research Council European Trial of chorion villus sampling. *Lancet*. 1991;337:1491-1499.
10. Smidt-Jensen S, Permin M, Philip J, et al. Randomised comparison of amniocentesis and transabdominal and transcervical chorionic villus sampling. *Lancet*. 1992;340:1237-1244.
11. Alfirevic Z, Mujezinovic F, Sundberg K, et al. Amniocentesis and chorionic villus sampling for prenatal diagnosis. *Cochrane Database Syst Rev*. 2003;(3):CD003252.
12. Wilson RD, Gibson W, Bebbington M, et al. First trimester fetal heart rate: response to chorionic villus sampling in the chromosomally normal fetus. *Fetal Diagn Ther*. 1997;12:236-240.
13. Silver RK, MacGregor SN, Sholl JS, et al. An evaluation of the chorionic villus sampling learning curve. *Am J Obstet Gynecol*. 1990;163:917-922.
14. Williams J 3rd, Wang BB, Rubin CH, et al. Chorionic villus sampling: experience with 3016 cases performed by a single operator. *Obstet Gynecol*. 1992;80:1023-1029.
15. Firth HV, Boyd PA, Chamberlain PF, et al. Analysis of limb reduction defects in babies exposed to chorionic villus sampling. *Lancet*. 1994;343: 1069-1071.
16. Firth HV, Boyd PA, Chamberlain P. Severe limb abnormalities after chorion villus sampling at 56-66 days of gestation. *Lancet*. 1991;337:762-763.
17. Olney RS, Khoury MJ, Alo CJ, et al. Increased risk for transverse digital deficiency after chorionic villus sampling: results of the United States Multistate Case-Control Study, 1988-1992. *Teratology*. 1995;51:20-29.
18. Mastroiacovo P, Botto LD, Cavalcanti DP, et al. Limb anomalies following chorionic villus sampling: a registry based case-control study. *Am J Med Genet*. 1992;44:856-864.
19. Dolk H, Bertrand F, Lechat MF. Chorionic villus sampling and limb abnormalities. The EUROCAT Working Group. *Lancet*. 1992;339: 876-877.
20. Holmes LB. Report of National Institute of Child Health and Human Development Workshop on Chorionic Villus Sampling and Limb and Other Defects, October 20, 1992. *Teratology*. 1993;48:7-13.
21. Froster UG, Jackson L. Limb defects and chorionic villus sampling: results from an international registry, 1992-1994. *Lancet*. 1996;347:489-494.
22. Evaluation of chorionic villus sampling safety: WHO/PAHO consultation on CVS. *Prenat Diagn*. 1999;19:97-99.
23. American College of Obstetricians and Gynecologists. ACOG Practice Bulletin No. 88, December 2007. Invasive prenatal testing for aneuploidy. *Obstet Gynecol*. 2007;110:1459-1467.

114 Radiofrequency Ablation

RUSSELL S. MILLER | CLAUDIA MOSQUERA | LYNN L. SIMPSON

Introduction

The use of radiofrequency energy to create focal thermal tissue injury was first studied in the liver in the early 1990s.[1] In 1996 the first radiofrequency ablation (RFA) procedure was performed on a patient with a liver tumor at Massachusetts General Hospital.[2] RFA has since been used for various indications including unresectable tumors and cardiac arrhythmias.[3] This technology has also been successfully applied to selective fetal reduction in cases of complex monochorionic gestations discordant for growth or congenital anomalies, twin-twin transfusion syndrome (TTTS), or twin reversed arterial perfusion (TRAP) sequence.

As a result of vascular anastomoses that link twin circulations within a shared placenta, cardiovascular disturbances affecting one twin in a monochorionic pair can present substantial risk of morbidity and mortality to the co-twin. On spontaneous demise of a monochorionic twin, transient hemodynamic changes occur that place the co-twin at risk for hypoxic-ischemic injury resulting in death (12%) or, if the fetus survives, profound neurologic injury (18%).[4]

Because of the presence of a shared placental circulation, usual methods for selective fetal reduction in the setting of dichorionic twins are inappropriate in the setting of monochorionicity. In particular, intracardiac potassium chloride instillation, for selective termination, is contraindicated because this may trigger hemodynamic instability that affects the nontargeted twin. There is also the theoretic risk of injury to the nontargeted fetus as a result of bolus potassium chloride transfer between fetuses.[5]

Techniques for selective fetal reduction within a monochorionic twin or higher-order multiple gestation are intended to achieve simultaneous occlusion of all umbilical vessels within the target fetus, minimizing the risk of periprocedural co-twin insult. An RFA-based, ultrasound (US)-guided percutaneous approach to achieve cord occlusion has become a popular therapeutic option because of its apparent safety and efficacy. The most robust published documentation of RFA involves its application for reduction of an acardiac twin with a TRAP presentation.[6–10] By interrupting blood flow to the acardiac fetus, the "pump" co-twin is relieved of excess cardiovascular burden, preventing progression to high-output heart failure (Chapter 164).

The literature documenting experience with RFA application for other discordant abnormalities with monochorionic twins is limited.[11–14] Case reports reveal a range of procedural outcomes, but data regarding short-term and long-term outcomes or procedural risks are limited. In particular, data for long-term neurologic outcomes in survivors of technically successful RFA procedures are scarce.

Procedure

DESCRIPTION, TECHNIQUE, AND EQUIPMENT

RFA selective fetal reduction uses a minimally invasive, US-guided percutaneous technique for targeted umbilical cord occlusion. High-frequency sinusoidal current (400 to 500 kHz) creates thermal energy at a focused target tissue site.[15] To disperse this energy, the generator is connected to the patient through grounding pads applied bilaterally to the anterior and posterior aspects of the thighs. Current is conducted through the patient to a specialized probe and then back to the generator, completing the circuit.[9] RFA probes contain an insulated shaft and a non-insulated distal tip. Some probes contain deployable tines, which enable the user to secure the probe within a target tissue site and allow adjustment of the diameter for tissue ablation. The energy released at the exposed tip produces ionic agitation and frictional heat, which at the appropriate temperatures leads to cell death and coagulation necrosis.[3]

At Columbia University Medical Center, RFA for complicated monochorionic twin and higher-order multiple gestations is generally restricted to pregnancies between gestational age 16 weeks, 0 days and 23 weeks, 6 days; US evidence of amnion-chorion fusion is a further prerequisite. We perform most RFA procedures in an outpatient setting under local anesthesia after having the patient take oral opioid analgesia; however, selected cases with concern for extreme technical difficulty or patient pain intolerance are performed under regional anesthesia in an operating room. We use the RF 3000 Generator (Boston Scientific, Natick, MA; Fig. 114.1) and the LeVeen SuperSlim Needle Electrode RFA probe (Boston Scientific; Fig. 114.2). Table 114.1 lists all equipment needed for the procedure. The LeVeen SuperSlim Needle Electrode is preferred because of its narrow gauge and deployable tines. A needle without tines can also be used in certain circumstances, including cases with oligohydramnios where movement of the target site tends to be limited. However, displacement of needles



Fig. 114.1 RF 3000 Generator (Boston Scientific, Natick, MA).

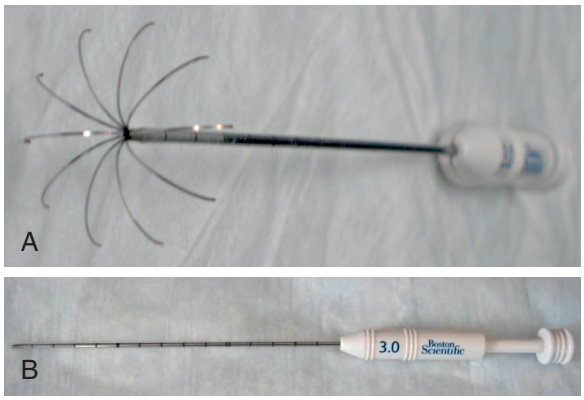

Fig. 114.2 LeVeen Needle Electrode (Boston Scientific, Natick, MA). With radial tines (A) deployed and (B) retracted.

TABLE 114.1 EQUIPMENT FOR RADIOFREQUENCY ABLATION PROCEDURE

RFA machine
RFA grounding pads
US machine
Cesarean delivery table
Laparotomy tray
Prophylactic antibiotic
Povidone-iodine preparation
Sterile drapes
Sterile sleeve for US probe
Blue towels
Sponges
Gowns
Gloves
RFA needle/probe, 14-gauge
Marking pen
No. 11 blade scalpel
Hemostat
Spinal needle, 22-gauge[a]
Sterile tubing[a]
Vacuum bottles[a]

[a]Needed only if amnioreduction is being considered.
RFA, Radiofrequency ablation; *US*, ultrasound.

without tines can occur with fetal movements in cases with normal or increased amniotic fluid.

We routinely administer intravenous cefazolin as preoperative antibiotic prophylaxis, although not all centers use antibiotics. After placing the patient in the supine position with a slight leftward tilt, grounding pads are applied. After adequate anesthesia has been administered, US is used to locate both fetuses, the shared placental mass, and the dividing membrane. Discordant US findings are visualized, and designation of the appropriate target fetus is confirmed a second time. An intrafetal target site is identified near the umbilical cord insertion into the abdominal wall of the target fetus. A No. 11 blade scalpel is used to create a 5-mm skin incision on the maternal abdomen at the corresponding location along the intended entry approach. A needle electrode is advanced through this incision to the fetal target site under continuous US guidance, taking care to avoid traversing the dividing membrane (Fig. 114.3). Whenever possible, a transplacental approach is avoided.

After confirmation of an appropriate target, using both two-dimensional and color Doppler imaging (Fig. 114.4), the radial tines of the probe are deployed to a predetermined diameter (Fig. 114.5). Energy is gradually increased until complete tissue



Fig. 114.3 Three-dimensional rendering of radiofrequency ablation needle being inserted into the abdominal wall of the target fetus near the umbilical cord insertion site.



Fig. 114.4 Oblique view of the target fetus with the radiofrequency ablation probe inserted within the abdominal wall with tines deployed.



Fig. 114.5 Oblique view of the target fetus with the radiofrequency ablation probe inserted within the abdominal wall. The radial tines are deployed, and thermal energy is being released.

impedance has been achieved, usually over a period of roughly 1 to 2 minutes. Doppler is then used to confirm cessation of blood flow within all target fetus umbilical vessels. Persistent fetal bradycardia within the targeted fetus usually indicates technical success, although cardiac activity can persist for hours within the targeted fetus after the umbilical vessels have been successfully coagulated. After a sustained absence of blood flow is confirmed within the target cord, the tines are fully retracted within the needle sheath, and the RFA probe is removed.

Determining whether flow exists within the targeted cord after ablation is a potential technical challenge of RFA. Formation of gas bubbles during coagulation can create artefactual color Doppler signals, giving the appearance of vascular flow. Thus it can be difficult to determine the absence of flow within the umbilical cord. Waiting a few minutes for the effects of coagulation to subside can be helpful.[6] A blood flow convective cooling effect has also been described as one of the limitations of RFA.[10] In cases of high blood flow in the targeted fetus, such as cases of severe TTTS, the cooling effect may predispose the procedure to failure.[8]

If uterine irritability or contractions are suspected after therapy, a limited course (48 to 72 hours) of indomethacin tocolysis may be considered. Interval US evaluation is usually performed before patient discharge to confirm target fetus demise and procedural success. In some instances, a sustained target fetal bradycardia can persist for a protracted period of time after successful therapy. Should this occur in the setting of absent flow within the target fetus umbilical cord, then target fetus asystole can be confidently anticipated. Patients are usually discharged with instructions to complete 5 days of oral cephalexin antibiotic prophylaxis.

Usual surveillance after the procedure includes serial US follow-up and a cervical length assessment 1 week after the procedure. Doppler velocimetry abnormalities or polyhydramnios of the nontargeted fetus that occurred as the result of a complicated monochorionic twin presentation, often is observed to normalize over several weeks after the procedure. We recommend that patients undergo fetal magnetic resonance imaging approximately 3 to 4 weeks after the procedure to assess the fetal neuroanatomy. Although no robust observational data exist to support this clinical practice, normal neuroanatomic findings without evidence of changes suggestive of hypoxic-ischemic or other injury may provide some objective reassurance to patients as they continue with a pregnancy after RFA.

INDICATIONS

RFA for selective fetal reduction is indicated in the management of TRAP sequence, monochorionic twin gestations discordant for severe fetal malformation, severe early fetal growth restriction, chromosomal or severe genetic abnormality, or monochorionic-diamniotic twin gestations with early-onset severe TTTS when laser therapy is not an option because of technical limitations or patient refusal.

CONTRAINDICATIONS

Absolute contraindications to RFA include active labor, preterm labor, and maternal bleeding predisposition that precludes minimally invasive intervention. Relative contraindications include rupture of membranes, short cervix, higher-order multiple gestations, and maternal infections such as human immunodeficiency virus and hepatitis C.

Benefits of RFA include termination of an anomalous fetus (and a theoretically decreased risk of neurologic injury) or death of the nontargeted fetus. Procedure-related risks to the pregnancy include preterm premature rupture of membranes (PPROM), which is arbitrarily defined in some studies as a procedure-related event if it occurred within 4 weeks of the procedure[16]; preterm labor; preterm delivery; chorioamniotic membrane separation; placental abruption; intrauterine infection or chorioamnionitis; and amniotic band formation.[17] However, the risk of PPROM with RFA seems to be reduced compared with other techniques that require the introduction of relatively larger instruments and ports (up to 5 mm in diameter), such as bipolar forceps, laser coagulation, and cord ligation under fetoscopic guidance.[15] Potential risks to the nontargeted fetus include thermal injury and intrauterine death. Maternal risks include thermal burns from grounding pad injuries, bleeding, and injury to internal organs. The use of four grounding pads on newer models rather than two pads has substantially reduced the risk of maternal thermal injuries.[6]

A notable disadvantage to the use of RFA is cost. A disposable RFA needle and maternal grounding pads cost approximately $1900. A radiofrequency generator can cost approximately $37,000.[14]

Outcomes and Complications

TWIN REVERSED ARTERIAL PERFUSION SEQUENCE

In a retrospective review of pregnancies treated with RFA of an acardiac twin, in the setting of TRAP sequence at a single center from 1998–2005, 29 cases were reported: 26 with monochorionic-diamniotic pregnancies, two with monochorionic-monoamniotic pairs, and one with a triplet pregnancy containing a monochorionic-diamniotic pair. Of 29 pump twins, 25 (86%) survived and delivered at a mean gestational age of 34 weeks, 6 days. When analysis was restricted to monochorionic-diamniotic pregnancies, survival was 92% with a mean gestational age at delivery of 35 weeks, 6 days.[6]

Another single-center retrospective series reported outcomes of 13 consecutive cases of monochorionic twin gestations that underwent selective reduction for a TRAP diagnosis. Of 13 pump fetuses, 12 survived and were neurodevelopmentally normal based on neonatal assessments.[7] Long-term outcome data were unavailable.

More recently, another retrospective, single-center experience described a series of 17 pregnancies complicated by TRAP sequence that were treated with RFA, revealing similarly favorable results. Pregnancies were managed with RFA if the pump fetus was hydropic, the pump fetus had an increased combined ventricular output, or there was an acardiac-to-pump weight ratio greater than 50%. Four pump twins survived the immediate postoperative recovery but remained undelivered at the time the report was published. Of the remaining 13 fetuses, 12 (94%) survived, with an average gestational age at delivery of 37 weeks. One postoperative death was reported for a pump twin, who was hydropic before therapy. There were no neonatal losses in the first 30 days of life.[9]

Available data suggest that RFA and other intrafetal cord ablation techniques result in superior outcomes compared with cord occlusion modalities for selective fetal reduction of an acardiac fetus within a TRAP sequence pair. In a retrospective review of the literature designed to determine pregnancy outcomes

after minimally invasive techniques for occlusion of the vascular supply to the acardiac twin in TRAP sequence, 71 cases were identified. Cord occlusion, which included embolization, cord ligation by fetoscopy or minihysterotomy, laser coagulation, bipolar diathermy, and monopolar diathermy, was used to treat 40 cases. There were 31 cases treated with intrafetal ablation techniques, which included alcohol ($n = 5$), monopolar diathermy ($n = 9$), interstitial laser ($n = 4$), and RFA ($n = 13$). Intrafetal ablation was associated with a lower technical failure rate; also, the pump twin survival rate was higher with treatment with intrafetal ablation than with treatment with cord occlusion, although this was not statistically different.[8]

The largest study to date investigating RFA for the treatment of TRAP was a retrospective review of the North American Fetal Therapy Network registry.[18] Among 98 patients undergoing therapy, over a roughly 10-year period, there was an 80% overall pump twin survival. Mean gestational age at delivery was 33.4 weeks, and 36 weeks among survivors. There were no maternal deaths or cases of severe hemorrhage requiring transfusion.

OTHER COMPLICATED MONOCHORIONIC OR DIAMNIOTIC PREGNANCIES

Although the published TRAP sequence experience has been extrapolated to support RFA as a safe and effective modality for selective fetal reduction in the setting of other complicated monochorionic twin presentations, data specifically investigating this application of RFA are limited. A systematic review analyzed selective termination procedures performed over an 8-year period for complex monochorionic twin presentations.[16] Selective reduction was performed in 345 complicated monochorionic pregnancies, including 35 by RFA. One of the 35 RFA procedures failed because of the presence of an accessory vessel that was not successfully coagulated. The rate of PPROM was 17% in the RFA group compared with 21% in the bipolar cord occlusion group. Survival rate trended highest among pregnancies treated with RFA (86%) compared with bipolar cord coagulation (82%), laser cord coagulation (72%), and cord ligation (70%). RFA was also associated with the lowest rate of intrauterine demise of the nontargeted fetus (6%). With respect to gestational age at the time of intervention, the lowest survival rate was achieved when selective termination by any technique was performed at 16 weeks' gestation, whereas the highest survival rates were observed when surgery was performed after 18 weeks' gestation.[16]

RFA seems to represent an optimal contemporary approach to selective fetal reduction in the setting of abnormal monochorionic twin pregnancies. Studies showed high success rates and a low incidence of complications when applied to TRAP sequence presentations, with more limited data supporting superiority of RFA for other complex monochorionic twin indications. Further investigation is needed to determine long-term neurologic outcomes.

KEY POINTS

- RFA selective fetal reduction involves a minimally invasive, US-guided percutaneous technique for targeted umbilical cord occlusion using high-frequency sinusoidal current to create thermal energy at a focused target tissue site.
- RFA is indicated in the management of TRAP sequence, monochorionic twin gestations discordant for severe fetal malformation, severe early fetal growth restriction, chromosomal or severe genetic abnormality, or monochorionic-diamniotic twin gestations with early-onset severe TTTS.
- Absolute contraindications include active labor, preterm labor, and maternal bleeding predisposition that precludes minimally invasive intervention.
- Procedure-related risks include PPROM, preterm labor, preterm delivery, chorioamniotic membrane separation, placental abruption, intrauterine infection or chorioamnionitis, and amniotic band formation.
- Potential direct risks to the nontargeted fetus include thermal injury and intrauterine death.
- Maternal risks include thermal burns from grounding-pad injuries, bleeding, and injury to internal organs.

SUGGESTED READING

Rossi AC, D'Addario V. Umbilical cord occlusion for selective feticide in complicated monochorionic twins: a systematic review of literature. *Am J Obstet Gynecol*. 2009;200:123-129.



All references available online at www.expertconsult.com

REFERENCES

1. McGahan JP, Dodd G. Perspective. Radiofrequency ablation of the liver: current status. *AJR Am J Roentgenol*. 2001;176:3-16.
2. Tanabe KK, Curley SA, Dodd GD, et al. Radiofrequency ablation: the experts weigh in. *Cancer*. 2004;100(3):641-650.
3. National Institutes of Health Clinical Center. Radiology and imaging sciences: radiofrequency ablation (RFA). Overview for physicians. http://www.cc.nih.gov/drd/rfa/pdf/physicians.pdf.
4. Ong S, Zamora J, Khan K, et al. Prognosis for the co-twin following single-twin death: a systematic review. *BJOG*. 2006;113:992-998.
5. Olivennes F, Doumerc S, Senat MV, et al. Evidence of early placental vascular anastomosis during selective embryo reduction in monozygotic twins. *Fertil Steril*. 2002;77:183-184.
6. Lee H, Wagner A, Sy E, et al. Efficacy of radiofrequency ablation for twin-reversed arterial perfusion sequence. *Am J Obstet Gynecol*. 2007;196:459.e1-459.e4.
7. Tsao K, Feldstein VA, Albanese CT, et al. Selective reduction of acardiac twin by radiofrequency ablation. *Am J Obstet Gynecol*. 2002;187:635-640.
8. Tan TYT, Sepulveda W. Acardiac twin: a systematic review of minimally invasive treatment modalities. *Ultrasound Obstet Gynecol*. 2003;22:409-419.
9. Livingston JC, Lim FY, Polzin W, et al. Intrafetal radiofrequency ablation for twin reversed arterial perfusion (TRAP): a single-center experience. *Am J Obstet Gynecol*. 2007;197:399.e1-399.e3.
10. Morel O, Malartic C, Barranger E. Radiofrequency ablation for twin-reversed arterial perfusion sequence: the unknown cord occlusion delay calls for long term neonatal follow-up of the surviving twins. *Am J Obstet Gynecol*. 2007;197:557-558, author reply 558.
11. Sydorak RM, Feldstein V, Machin G, et al. Fetoscopic treatment for discordant twins. *J Pediatr Surg*. 2002;37:1736-1739.
12. Shevell T, Malone FD, Weintraub J, et al. Radiofrequency ablation in a monochorionic twin discordant for fetal anomalies. *Am J Obstet Gynecol*. 2004;190:575-576.
13. Smok D, Simpson LL, Shevell T, et al. Selective fetal reduction in monochorionic twin pregnancies with radiofrequency cord ablation. *Am J Obstet Gynecol*. 2004;191:S147.
14. Moise KJ, Johnson A, Moise KY, et al. Radiofrequency ablation for selective reduction in the complicated monochorionic gestation. *Am J Obstet Gynecol*. 2008;198:198e1-198e5.
15. Morel O, Tran N, Marchal F, et al. Ultrasound-guided radiofrequency-driven umbilical cord occlusion: an in-vitro study. *Ultrasound Obstet Gynecol*. 2006;28:187-192.
16. Rossi AC, D'Addario V. Umbilical cord occlusion for selective feticide in complicated monochorionic twins: a systematic review of literature. *Am J Obstet Gynecol*. 2009;200:123-129.
17. Spadola AC, Simpson LL. Selective termination procedures in monochorionic pregnancies. *Semin Perinatol*. 2005;29:330-337.
18. Lee H, Bebbington M, Crumbleholme TM, et al. The North American Fetal Therapy Network registry data on outcomes of radiofrequency ablation for twin-reversed arterial perfusion sequence. *Fetal Diagn Ther*. 2013;33:224-229.

To access the videos in this chapter, scan this QR code or visit expertconsult.com

115 Selective Laser Photocoagulation

RUSSELL S. MILLER | AMBER SAMUEL | LYNN L. SIMPSON

Introduction

Monochorionic twin gestations are at increased risk of perinatal morbidity and mortality related to a shared placental circulation. They are uniquely susceptible to the development of twin-twin transfusion syndrome (TTTS), with an incidence of approximately 10% to 15%.[1] TTTS involves unbalanced shunting of blood between twins across vascular anastomoses within the placental bed.[2] Without intervention, early-onset TTTS has a mortality rate that can approach 95%; among survivors, there is a substantial risk for profound neurologic handicap.[3,4]

Fetoscopic selective laser photocoagulation (SLP) of anastomotic vessels has emerged as the most efficacious therapy to treat TTTS. SLP refers to intentional, laser-induced interruption of pathologic vascular communications linking donor and recipient circulations across a shared placental surface. By interrupting flow through these aberrant channels, the procedure directly disrupts a key component of the underlying disease process. In contrast, amnioreduction is an alternative therapy for TTTS that temporizes the condition indirectly by removing excess recipient twin amniotic fluid. Because amnioreduction addresses a consequence (polyhydramnios) of the disease state, but does not disrupt the underlying disease pathway itself, serial interventions are often required to support an affected pregnancy to an advanced gestational age.

SLP for treatment of TTTS involving laparotomy and direct uterine entry was first described by De Lia et al. in 1990.[5] Advances in technique and technology since that first description permit minimally invasive percutaneous approaches. The procedure introduces custom-designed fetoscopic equipment with articulating eyepieces and fiber optic video displays under continuous ultrasound (US) guidance through percutaneous uterine access. Previously, the procedure involved nonselective photocoagulation of any vessels that crossed the division created by the insertion of the amniotic membrane onto the chorionic plate; however, at the present time, careful evaluation of the vascular equator between the twins targets photocoagulation of identified pathologic anastomoses. Available outcomes data suggest SLP is superior to amnioreduction with respect to survival, and survival free of severe neurologic injury, validating SLP as the optimal therapy for early-onset, severe TTTS (Chapter 169).

Procedure

DESCRIPTION, TECHNIQUE, AND EQUIPMENT

In our institution, after providing informed consent, the patient undergoes SLP in a sterile operating room, following administration of preoperative antibiotic prophylaxis. Essential personnel include the operator and assistants, anesthesiologist, surgical technician, circulating nurse, and an assistant to record location and number of placental anastomoses. Evidence suggests that a learning curve exists for achieving SLP proficiency and that the physician performing the procedure should have prior pedagogic and simulation training, with initial procedures supervised by an experienced surgeon.[6]

Although SLP can be performed under anesthesia ranging from local to general, in most centers in the United States, including ours, regional anesthesia is preferred. The anesthetized patient is positioned on the operating table in dorsal position with a slight leftward tilt. After the patient's abdomen has been prepared and draped, transabdominal US confirms placental location, donor and recipient position, course of the dividing membrane, and placental cord insertion sites for each twin. The axis of the vascular equator is estimated, and an appropriate entry site into the polyhydramniotic recipient sac is determined relative to this estimate. A 5-mm skin incision is made on the maternal abdomen overlying the path of intended uterine entry.

Under continuous US guidance, a 10-F (for 0-degree fetoscope) or 12-F (for 30-degree fetoscope) flexible plastic cannula (Cook Medical, Inc., Bloomington, IN) (Fig. 115.1) loaded with a sharp



Fig. 115.1 A 10-F flexible cannula loaded with a sharp trocar for insertion.



Fig. 115.2 A 0-degree, 2-0 mm fetoscope (detached eyepiece).



Fig. 115.3 Straight double-lumen sheath.

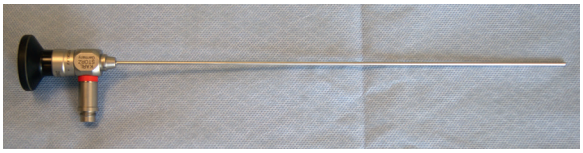

Fig. 115.4 A 30-degree, 2-0 mm fetoscope (standard eyepiece).



Fig. 115.5 Video source.

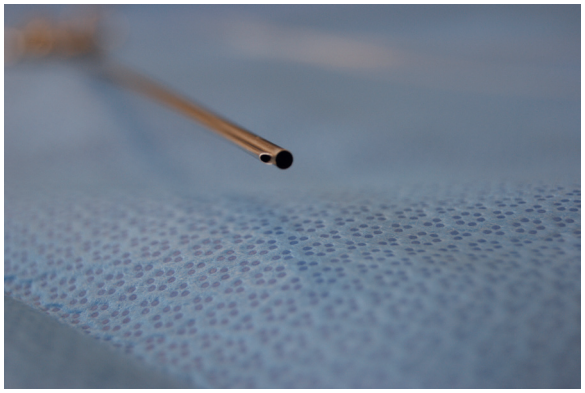

Fig. 115.6 Tip of double-lumen sheath.

trocar, is introduced into the recipient sac. The trocar is removed from the cannula, and an amniotic fluid sample is obtained for karyotype analysis (if not previously performed) and other analyses as indicated. At this time, a fetoscope (Fig. 115.2) housed within a paired double-lumen operative sheath (Fig. 115.3), is introduced through the cannula into the polyhydramniotic space. Although fetoscope technical specifications vary, it is important to consider the viewing angle when selecting the proper fetoscope for a given procedure.[7] Although 0-degree fetoscopes are generally used for cases with a straightforward posterior placental approach, in cases with anterior placentation or otherwise challenging access, 30-degree fetoscopy may facilitate adequate visualization (Fig. 115.4). Fetoscopes are attached to light and video output sources (Fig. 115.5), and the use of an articulating eyepiece with the 0-degree fetoscope allows the operator enhanced maneuverability.

The operative sheath has a large central lumen that accommodates the fetoscope and irrigation through an accessory side port (Fig. 115.6). It also contains a second lumen through which a laser fiber (outer diameter ≤1 mm) can be advanced (Fig. 115.7). Laser sources for SLP include diode, neodymium:yttrium-aluminum-garnet, and potassium-titanyl-phosphate, all selected because their energy absorption profiles fall within the spectrum of hemoglobin. At our center, we use a Medilas D Multibeam (Dornier MedTech, Kennesaw, GA) diode laser device for SLP set between 40 and 60 W.

Under fetoscopic visualization, both twins are identified, and their umbilical cords are traced to their respective placental insertion sites using both fetoscopy and intraoperative US (Videos 115.2 and 115.3). The fetoscope allows the team to trace vessels along the chorionic plate, map the vascular equator, and identify pathologic anastomoses. The operator advances the laser fiber for selective photocoagulation of all identified anastomoses, taking care to avoid inadvertent microseptostomy, which can result from photocoagulation through the dividing membrane. Although all visible anastomoses are ultimately targeted, the order in which they are photocoagulated may also be important (Video 115.1). Quintero et al.[8] suggested that sequential selective treatment, beginning with photocoagulation of arteriovenous connections (first donor-to-recipient communications, then recipient-to-donor) before arterioarterial and venovenous communications, may provide significant benefit. Further research is needed to determine whether sequential selective photocoagulation strategies correlate with improved procedural outcomes. After all anastomoses have been photocoagulated, a final sweep is conducted to confirm that no vessels have been missed or indicate residual flow.



Fig. 115.7 Laser fiber.

Fetoscopic SLP of the vascular equator (the Solomon technique) before completion of laser therapy has been recommended to address small anastomoses that might be unaddressed with selective photocoagulation alone. A recent open-label randomized controlled trial has demonstrated that the Solomon technique can reduce complications of recurrent TTTS and twin anemia polycythemia sequence (TAPS), with reduced rates of residual placental anastomoses.[9,10] When technically possible, the Solomon technique is therefore a reasonable adjunct to SLP.

After photocoagulation, an amnioreduction is performed under continuous US guidance, using the access port of the flexible cannula, to achieve a maximum vertical pocket of 6 cm or less within the recipient sac. The cannula is removed under US guidance. Observation after the procedure includes several hours of continuous external tocometry monitoring. A limited course of perioperative tocolysis may be considered.

INDICATIONS

SLP is generally considered for early-onset severe TTTS manifesting between 16 weeks' and 26 weeks' gestation. Although international practices vary, in the United States, candidates referred to a fetal care center with trained operators are offered SLP on confirmation of Quintero stage II through IV disease. In some centers, echocardiographic evidence of recipient twin-acquired cardiac dysfunction is considered sufficient to "upstage" TTTS using modified scoring systems, potentially indicating SLP for selected cases with stage I disease.[11]

SLP for stage I TTTS is a controversial practice. Stage I disease has an overall favorable prognosis. In one study by Quintero et al.,[12] there was 100% survival of at least one twin without laser therapy in cases of stage I TTTS. High rates of nonprogression or resolution with stage I disease must also be weighed against the risks of any invasive therapy. Retrospective data do not clearly indicate differences in outcomes between SLP and amnioreduction for treatment of stage I disease.[13] However, the available data on stage I outcomes after therapy are limited, conflicting, and potentially biased because these cases are underrepresented in treatment trials.

In an uncontrolled retrospective study reported by Quintero et al.[12] assessing stage-based treatment, an inverse relationship was observed between survival and stage in the group undergoing serial amnioreduction. This same trend was not seen in the SLP group, where outcomes were relatively uniform across all stages. When modalities were compared, benefit of SLP was apparent only with advanced stage disease. Based on these data, the authors recommended offering serial amnioreduction for stage I disease, offering either amnioreduction or SLP for stage II disease based on a consideration of gestational age, and reserving SLP for stage III and IV disease. In contrast, Huber et al.[14] reported overall improved, stage-based outcomes within a prospective cohort undergoing SLP, despite a trend toward worsening outcomes with advancing stage. Although this series lacked an amnioreduction comparison group, based on the favorable outcomes, the authors concluded that SLP should be offered across all TTTS disease stages but that amnioreduction may be considered with stage I disease manifesting at an advanced gestational age.

To date, there are no results from a well-designed prospective trial designed to compare outcomes for stage I disease with SLP compared with amnioreduction or expectancy with close observation for progression of disease. Until such time, SLP for stage I disease remains a matter for debate. In most U.S. fetal therapy centers, contemporary practice includes expectant observation after a diagnosis of early-onset stage I TTTS. Although it might be tempting to proceed with amnioreduction in such a case, a complication such as preterm premature rupture of membranes (PPROM), bleeding, or amnion-chorion separation may preclude treatment with SLP should the disease progress to a more advanced stage.

CONTRAINDICATIONS

Absolute contraindications to SLP include PPROM, preterm labor, chorioamnionitis, active abruption, and a maternal bleeding disorder or medical condition that would preclude percutaneous uterine access. Relative contraindications include major fetal anomalies, aneuploidy, short cervix, amnion-chorion separation, and maternal human immunodeficiency virus or hepatitis C infection.

Outcomes and Complications

After single-center observational series suggested a likely benefit of SLP over amnioreduction,[12,15] the Eurofetus trial was published by Senat and colleagues.[16] This was a prospective, randomized, controlled trial of laser treatment (72 subjects) compared with serial amnioreduction (70 subjects). The trial convincingly showed a significantly higher survival of at least one twin in cases treated with SLP compared with amnioreduction (76% versus 56%; $P = .001$). Survival of one twin for 6 or more months after birth (76% versus 51%; $P = .002$) was also significantly improved within the laser arm. The study was stopped at a planned interim analysis because of significant procedural benefit within the laser treatment group. In addition, a decrease in neurologic complications was observed in surviving infants at 6 months of age, from

TABLE 115.1 NEUROLOGIC ABNORMALITY IN SURVIVORS OF SELECTIVE LASER PHOTOCOAGULATION FOR TWIN-TWIN TRANSFUSION SYNDROME: SELECTED TRIALS

Study	Median Follow-Up (Months)	Type of Neurologic Testing	Number of Laser Subjects	Minor Abnormality (%)	Major Abnormality (%)
Sutcliffe et al., 2001[18]	24	ICD-9 and GMDS	67	—	9
Banek et al., 2003[19]	21, 34[a]	GMDS, SONVIT	89	11	11
Graef et al., 2006[20]	38	GMDS, SONVIT	167	7.2	6
Lopriore et al., 2007[21]	24	BSID	115	—	17
Lenclen et al., 2009[23]	N/A[b]	ASQ, standardized neurologic assessment	88	6.8	4.6
Gray et al., 2011[22]	27.5	GMDS, BSID	113	4.4	12.4

[a]21 months if GMDS used; 34 months if SONVIT used.
[b]Mean follow-up investigation 23.5 ± 1.0 months corrected for prematurity.
ASQ, Ages and Stages; *BSID,* Bayley Scales of Infant Development; *GMDS,* Griffiths Mental Development Scale; *ICD-9,* International Classification of Diseases, 9th Edition; *N/A,* not applicable; *SONVIT,* Snijeders-Oomen Non-Verbal Intelligence Test.

52% in the amnioreduction group to 31% in the laser group ($P = .003$).

With regard to evidence supporting use of the Solomon technique, a recent randomized trial by Slaghekke and colleagues demonstrated reduced rates of a composite primary outcome (including TAPS, recurrent TTTS, perinatal mortality, and severe neonatal morbidity) in subjects undergoing the Solomon technique at time of SLP (139 subjects) when compared to a standard SLP treatment group (135 subjects).[9] Specifically, the Solomon group was associated with significantly reduced rates of TAPS (3% versus 16%) and recurrent TTTS (1% versus 7%). A follow-up study evaluating neurodevelopmental outcomes at 2 years among survivors from this trial demonstrated no difference in survival free of neurodevelopmental impairment between groups.[17]

When counseling candidates for SLP, a particular concern involves long-term neurologic outcomes among survivors of therapy. Although outcomes seem to be improved when SLP is compared with serial amnioreduction, there is still substantial risk for major neurologic abnormality among SLP survivors.[18–23] These outcomes have been reported in several large single-center cohorts (Table 115.1). All studies used validated neurocognitive testing methodologies including the Griffiths Mental Development Scale, Snijeders-Oomen Non-verbal Intelligence Test, and Bayley Scales of Infant Development and International Classification of Diseases (9th Edition) coding. SLP survivors were assessed at postnatal follow-up examinations no earlier than 14 months of life. Major neurologic problems in these series included cerebral palsy, gross motor dysfunction, neurocognitive delay, psychomotor delay, developmental delay, blindness, and deafness. Overall, risk for major neurologic deficits ranged from 4.6% to 17% across the reported cohorts.

Cardiac function after SLP is also an important consideration. Before or without treatment, recipient twins may develop cardiomegaly, biventricular hypertrophy, and mitral and tricuspid regurgitation as a result of acquired hypervolemic overload. Right ventricular outflow tract obstruction and pulmonary stenosis have also been noted with increased frequency in recipient fetuses.[24,25] After SLP, numerous neonates show normalization of previously aberrant cardiac function and evidence of structural remodeling. In one series, abnormal echocardiographic findings decreased from 54.9% among recipient twins before SLP to 13.7% on postnatal evaluation.[26]

The risks of the procedure include PPROM, preterm labor, preterm delivery or pregnancy loss, amniotic fluid leakage into the maternal peritoneal cavity, abruption, and intrauterine infection. The risk of PPROM has been reported to range from less than 10% to 28%.[16,27] There is also a risk of trocar-related maternal hemorrhage or internal injury as well as fetal injury or death; however, these are rare complications.

KEY POINTS

- SLP is considered optimal contemporary therapy for early-onset, advanced stage TTTS.
- SLP increases perinatal survival over serial amnioreduction and seems to be associated with improved neurologic outcomes.
- Although SLP reduces risk of long-term neurologic injury, risks after technically successful therapy remain significant.
- The most common risk of SLP is PPROM.

SUGGESTED READING

Hecher K, Plath H, Bregenzer T, et al. Endoscopic laser surgery versus serial amniocentesis in the treatment of severe twin-twin transfusion syndrome. *Am J Obstet Gynecol.* 1999;180:717-724.

Klaritsch P, Albert K, Mieghem TV, et al. Instrumental requirements for minimal invasive fetal surgery. *BJOG.* 2009;16:188-197.

Quintero RA, Dickinson JE, Morales WJ, et al. Stage-based treatment of twin-twin transfusion syndrome. *Am J Obstet Gynecol.* 2003;188:1333-1340.

Senat MV, Deprest J, Boulvain M, et al. Endoscopic laser surgery versus serial amnioreduction for severe twin-twin transfusion syndrome. *N Engl J Med.* 2004;351:136-144.

Slaghekke F, Lopriore E, Lewi L, et al. Fetoscopic laser coagulation of the vascular equator versus selective coagulation for twin-to-twin transfusion syndrome: an open-label randomized controlled trial. *Lancet.* 2014;383:2144-2151.

All references available online at www.expertconsult.com

REFERENCES

1. Van Gemert MJ, Umur A, Tijssen JG, et al. Twin-twin transfusion syndromes: etiology, severity and rational management. *Curr Opin Obstet Gynecol*. 2001;13:193-206.
2. Quintero R, Quintero L, Bornick P, et al. The donor-recipient (D-R) score: in vivo endoscopic evidence to support the hypothesis of a net transfer of blood from donor to recipient in twin-twin transfusion syndrome. *Prenat Neonatal Med*. 2000;5:84-91.
3. Saunders NJ, Snijders RJ, Nicolaides KH. Therapeutic amniocentesis in twin-twin transfusion syndrome appearing in the second trimester of pregnancy. *Am J Obstet Gynecol*. 1992;166:820-824.
4. Reisner DP, Mahony BS, Petty CN, et al. Stuck twin syndrome: outcome in thirty-seven consecutive cases. *Am J Obstet Gynecol*. 1993;169:991-995.
5. De Lia JE, Cruikshank DP, Keye WRJ. Fetoscopic neodymium: YAG laser occlusion of placental vessels in severe twin-twin transfusion syndrome. *Obstet Gynecol*. 1990;75:1046-1053.
6. Peeters S, Oepkes D, Lopriore E, et al. Fetoscopic laser coagulation in twin-twin transfusion syndrome: the learning curve. *Am J Obstet Gynecol*. 2007;197:S162.
7. Klaritsch P, Albert K, Mieghem TV, et al. Instrumental requirements for minimal invasive fetal surgery. *BJOG*. 2009;16:188-197.
8. Quintero RA, Ishii K, Chmait RH, et al. Sequential selective laser photocoagulation of communicating vessels in twin-twin transfusion syndrome. *J Matern Fetal Neonatal Med*. 2007;20:763-768.
9. Slaghekke F, Lopriore E, Lewi L, et al. Fetoscopic laser coagulation of the vascular equator versus selective coagulation for twin-to-twin transfusion syndrome: an open-label randomized controlled trial. *Lancet*. 2014;383:2144-2151.
10. Slaghekke F, Lewi L, Middeldorp JM, et al. Residual anatomoses in twin-twin transfusion syndrome after laser: the Solomon randomized trial. *Am J Obstet Gynecol*. 2014;211:285.e1-285.e7.
11. Harkness UF, Crombleholme TM. Twin-twin transfusion syndrome—where do we go from here? *Semin Perinatol*. 2005;29:296-304.
12. Quintero RA, Dickinson JE, Morales WJ, et al. Stage-based treatment of twin-twin transfusion syndrome. *Am J Obstet Gynecol*. 2003;188:1333-1340.
13. O'Donoghue K, Cartwright E, Galea P, et al. Stage I twin-twin transfusion syndrome: rates of progression and regression in relation to outcomes. *Ultrasound Obstet Gynecol*. 2007;30:958-964.
14. Huber A, Diehl W, Bregenzer E, et al. Stage-related outcome in twin-twin transfusion syndrome treated by fetoscopic laser coagulation. *Obstet Gynecol*. 2006;108:333-337.
15. Hecher K, Plath H, Bregenzer T, et al. Endoscopic laser surgery versus serial amniocentesis in the treatment of severe twin-twin transfusion syndrome. *Am J Obstet Gynecol*. 1999;180:717-724.
16. Senat MV, Deprest J, Boulvain M, et al. Endoscopic laser surgery versus serial amnioreduction for severe twin-twin transfusion syndrome. *N Engl J Med*. 2004;351:136-144.
17. van Klink JMM, Slaghekke F, Balestriero MA, et al. Neurodevelopmental outcome at 2 years in twin-twin transfusion syndrome survivors randomized for the Solomon trial. *Am J Obstet Gynecol*. 2016;214:113.e1-113.e7.
18. Sutcliffe AG, Sebire NJ, Pigott AJ, et al. Outcome for children born after in utero laser ablation therapy for severe twin-twin transfusion syndrome. *BJOG*. 2001;108:1246-1250.
19. Banek CS, Hecher K, Hackeloer BJ, et al. Long-term neurodevelopmental outcome after intrauterine treatment for severe twin-twin transfusion syndrome. *Am J Obstet Gynecol*. 2003;188:876-880.
20. Graef C, Ellenrieder B, Hecher K, et al. Long-term neurodevelopmental outcomes of 167 children after intrauterine laser treatment for severe twin-twin transfusion syndrome. *Am J Obstet Gynecol*. 2006;194:303-308.
21. Lopriore E, Middledorp JM, Sueters M, et al. Long-term neurodevelopmental outcome in twin-to-twin transfusion syndrome treated with fetoscopic laser surgery. *Am J Obstet Gynecol*. 2007;196:231-234.
22. Gray PH, Poulsen L, Gilshenan K, et al. Neurodevelopmental outcome and risk factors for disability for twin-twin transfusion syndrome treated with laser surgery. *Am J Obstet Gynecol*. 2011;204:159e.1-159e.6.
23. Lenclen R, Ciarlo G, Paupe A, et al. Neurodevelopmental outcome at 2 years in children born preterm treated by amnioreduction or fetoscopic laser surgery for twin-to-twin transfusion syndrome: comparison with dichorionic twins. *Am J Obstet Gynecol*. 2009;201:291.e1-291.e5.
24. Fesslova V, Villa L, Nava S, et al. Fetal and neonatal echocardiographic findings in twin-twin transfusion syndrome. *Am J Obstet Gynecol*. 1998;179:1056-1062.
25. Simpson LL, Marx GR, Elkadry EA, et al. Cardiac dysfunction in twin-twin transfusion syndrome: a prospective, longitudinal study. *Obstet Gynecol*. 1998;92:557-562.
26. Herberg U, Gross W, Bartmann P, et al. Long-term cardiac follow-up of severe twin to twin transfusion syndrome after intrauterine laser coagulation. *Heart*. 2006;92:95-100.
27. Yamamoto M, El Murr L, Robyr R, et al. Incidence and impact of perioperative complications in 175 fetoscopy-guided laser coagulations of chorionic plate anastomoses in fetofetal transfusion syndrome before 26 weeks of gestation. *Am J Obstet Gynecol*. 2005;193(3 Pt 2):1110-1116.

116 Fetal Shunts

RUSSELL S. MILLER | LYNN L. SIMPSON

Introduction

Intrauterine fetal shunts provide continuous drainage of fluid accumulations that are associated with a high risk of death or profound morbidity without decompression. The shunts are flexible plastic catheters that are percutaneously guided to a fetal location *in utero* under continuous ultrasound (US) guidance. Although shunt placement is considered to be minimally invasive, procedural risks and uncertain long-term prognosis despite technical success limit this therapy to motivated, well-informed patients.

Vesicoamniotic shunts for fetal bladder outlet obstruction and thoracoamniotic shunts for fetal hydrothorax are the two most commonly placed shunt types. Shunt placement may be considered for congenital cystic adenomatoid malformations (CCAM) of the thorax with a large cystic component causing fetal compromise.[1] Case reports also exist of shunt placement for massive fetal pericardial effusion,[2] although the benefit of this intervention is unproven. Historically, shunt placement was also considered for severe fetal hydrocephalus,[3,4] but this is no longer a standard management option.

Fetal lower urinary tract obstructive uropathy, which causes an overdistended urinary bladder and a highly pressurized collecting system, places the fetus at substantial risk for renal insufficiency or failure in addition to ureteral and bladder dysfunction. Long-standing severe oligohydramnios or anhydramnios is usually associated with obstructive uropathy, which subjects the fetus to pulmonary hypoplasia that can severely limit or preclude survival after birth. A vesicoamniotic shunt performed sufficiently early decompresses the bladder and reconstitutes the amniotic space, allowing pulmonary development. Theoretically, it may also prevent further renal, bladder, and ureteral damage because of high pressure within the genitourinary system, although there are insufficient published data to validate this claim.

Because of a variable natural course after the diagnosis of fetal hydrothorax, thoracoamniotic shunt placement is generally reserved for severe prenatal presentations involving hydrops, polyhydramnios, evidence of fetal cardiovascular compromise, or rapid fluid reaccumulation following thoracocentesis.[5,6] Although perinatal mortality for conservatively managed isolated fetal hydrothorax is approximately 37%, the aforementioned factors diminish survival prognosis.[7] Some interventionists consider significant mediastinal shift without hydrops or polyhydramnios as an indication for intervention. In candidates for therapy, shunt placement decompresses the pleural space, allowing for pulmonary expansion within the thoracic cavity, which may promote pulmonary development. By reducing intrathoracic pressure, shunt-facilitated continuous drainage may also increase venous return to the fetal heart and improve overall hemodynamic performance.

Vesicoamniotic Shunt

DESCRIPTION, TECHNIQUE, AND EQUIPMENT

Fetal shunts are designed with a double-pigtail shape to prevent dislodgment after placement.[8] Although several options exist, the two most common types are the Rocket (Rocket KCH Fetal Bladder Drain; Rocket Medical, Hingham, MA) and Harrison (Harrison Fetal Bladder Stent Set; Cook Medical Inc., Bloomington, IN) shunts. The Harrison shunt (Fig. 116.1) is smaller than the Rocket (1.7-mm diameter versus 2.1-mm diameter) allowing introduction through a narrower, 13-gauge needle (2.4-mm diameter) than the cannula used for Rocket shunt placement (3.0-mm diameter). Although narrower shunts are intuitively associated with decreased risk of premature rupture of membranes and perhaps iatrogenic fetal injury, these shunts may be more prone to obstruction, migration, and dislodgment, which increase the likelihood of needing a repeat shunt. No robust data exist showing superiority of one particular type over another, and shunt selection remains a matter of physician discretion.

Before shunt placement, a diagnosis of fetal bladder outlet obstruction must be confirmed. Outlet obstruction is usually accompanied by severe oligohydramnios. US scanning reveals a markedly distended fetal bladder. A "keyhole" appearance indicates a dilated proximal urethra suggestive of posterior urethral valves as the cause of obstructive uropathy (Figs. 116.2 and 116.3). Bladder wall thickening may suggest long-standing obstruction.

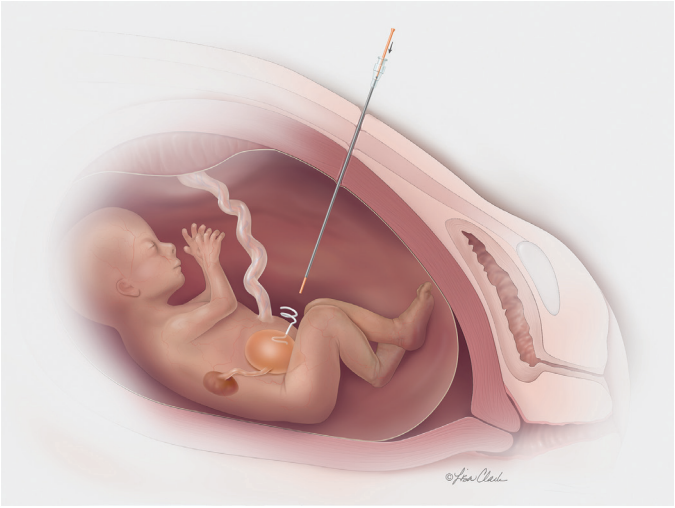

Fig. 116.1 Components included in the Harrison Fetal Bladder Stent set. *(Courtesy Cook Medical Inc., Bloomington, IN).*

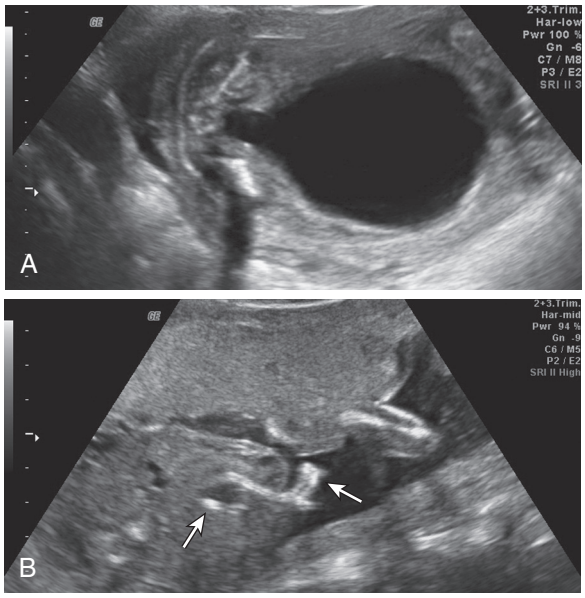

Fig. 116.2 (A) Axial image shows a dilated fetal bladder with a keyhole sign in a 20-week fetus with oligohydramnios. (B) The same fetus with a decompressed bladder after successful vesicoamniotic shunt placement. *Arrows* indicate a double-pigtail shunt.

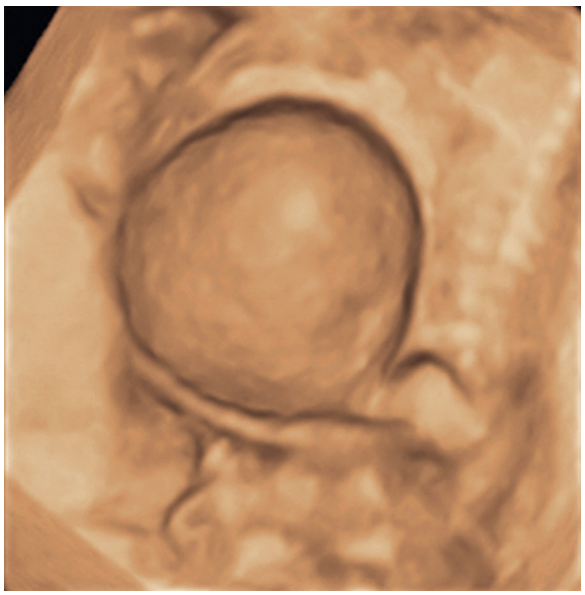

Fig. 116.3 Sagittal three-dimensional rendering of a dilated fetal bladder with keyhole sign.

Bilateral hydronephrosis and enlarged kidneys with an irregular and echogenic echotexture are additional diagnostic indications. Bilateral hydroureters may also be apparent (Chapter 14). The US examination should include visualization of the external genitalia because lower urinary tract obstruction is usually, but not always, associated with male gender.

Following diagnosis, the patient should be counseled regarding the natural history of obstructive uropathy and an extremely poor fetal prognosis without intervention. In addition to options of expectant care and pregnancy termination, if within legal gestational limits, the possibility of vesicoamniotic shunt therapy should be introduced with a discussion of procedure-related risks and potential benefits. Alternative approaches involving open fetal surgery for vesicostomy, fetal cystoscopy, and fetoscopic transurethral catheterization may also be offered at selected quaternary care fetal therapy centers; however, there are no data indicating that these approaches offer benefits outweighing any additional maternal and fetal risks when compared with percutaneous vesicoamniotic shunt placement.

Informed consent for vesicoamniotic shunt placement requires the interventionist to explain to patients that this therapy does not reverse preexisting renal damage or pulmonary compromise; however, it may prevent further injury. Counseling must stress that even with technically successful shunt placement, a significant chance remains of delivering a surviving child with severe long-term genitourinary and pulmonary compromise.

Urinalysis by vesicocentesis is recommended when considering a fetal candidate for shunt therapy because of an inconsistent correlation between US appearance of the fetal kidneys and degree of renal dysplasia and dysfunction. The rationale for fetal urinalysis derives from an understanding of fetal urinary production. Owing to resorption at the level of the proximal tubules, fetal urine is a hypotonic ultrafiltrate of fetal serum that becomes progressively more hypotonic with advancing gestational age until the middle of the third trimester (see Chapter 14).[9,10] However, in the setting of progressive uropathic injury, the proximal tubules can be damaged, resulting in urine that is relatively hypertonic for gestational age.

Two or three vesicocenteses are required to determine if the resultant urinary analyte profile is favorable. Because of concern that the initial vesicocentesis may not be reflective of current renal function, a series of up to three vesicocenteses (spaced approximately 48 hours between samplings) should be performed before offering vesicoamniotic shunt placement.[11,12] Serial vesicocenteses are believed to give a better representation of current renal function because the urine sampled in an initial vesicocentesis sample has been pooled over weeks. Vesicocenteses are performed with a 20- or 22-gauge needle under continuous US guidance, using standard aseptic technique. Karyotype determination should be performed at the same time.

Although no single urinary analyte predicts long-term renal function with great accuracy, a urinary profile pattern that suggests preserved renal function should be obtained before shunt placement. Initial studies established urinary electrolyte (sodium <100 mg/dL, calcium <8 mg/dL, chloride <90 mg/dL), osmolality (<200 mOsm/L), and protein (beta-2-microglobulin <4 mg/L, total protein <40 mg/dL) concentrations as test cutoffs. Numerous subsequent series showed that these thresholds possess moderate ability to successfully differentiate fetuses that might benefit from shunt therapy from fetuses with irreversible damage.[13–15] A systematic review of the literature suggested that using sodium concentration greater than the 95th percentile for gestational age may be more accurate than using absolute thresholds.[16]

Cases presenting before 20 weeks' gestation pose a particular challenge. Early second-trimester fetal urine is nearly isotonic with fetal plasma, presumably owing to immature tubular function. Nomograms for these earlier gestational ages are lacking. Screening before 20 weeks' gestation must consider that nomograms, normally consulted for risk assessment, are lacking for these earlier evaluations.

Other proposed forms of renal evaluation before shunt placement include fetal blood sampling (to measure beta-2-microglobulin concentration) and renal biopsy.[17,18] Because of

invasiveness and unproven benefit over urine sampling, these techniques have not been widely adopted.

Vesicoamniotic shunt placement is performed under continuous US guidance, usually after administering lidocaine along the entry approach. A target site over the distended fetal bladder is identified, ideally at a level between the umbilical cord insertion and the symphysis pubis when technically possible. This more caudal placement is recommended because as the fetal bladder is decompressed within the fetal pelvis, a lower shunt stands a reduced risk of becoming kinked or dislodged. Placement should also target the fetal midline, or immediately lateral to it, to decrease risk of iatrogenic vascular or intestinal injury. Color Doppler can assist in identifying the course of the umbilical arteries along the distended bladder before placement. After placement, the fetal bladder should rapidly decompress, and amniotic fluid volume should gradually reaccumulate.

Perioperative antibiotics (cephalosporins are used at our center) are recommended, administered intravenously before the procedure or injected into the amniotic sac after the procedure. Intraamniotic antibiotics may also be used, and are recommended with placement of the Rocket shunt. Some interventionists administer universal tocolysis; others reserve therapy for cases with evidence of contractions after the procedure.

Bladder outlet obstruction with severe oligohydramnios or anhydramnios may first require amnioinfusion to facilitate vesicoamniotic shunt placement. Amnioinfusion may also allow for a more detailed fetal anatomic survey. When performed, 300–500 mL of lactated Ringer solution may be infused via a 20- or 22-gauge spinal needle to reconstitute the amniotic space along the fetal abdominal wall. Some groups routinely warm the saline using a blood transfusion warmer; others do not. Care must be taken during this step because improper needle location may result in creation of an amnion-chorion separation that can preclude shunt placement. Care after the procedure includes weekly US observation to ensure that the shunt remains in situ and functions properly.

INDICATIONS

As noted earlier, shunt placement is considered for a fetus with US evidence of obstructive uropathy, including oligohydramnios. Before vesicoamniotic shunt placement, a favorable fetal urinary analyte profile should be obtained. Informed consent is necessary before shunt placement.

CONTRAINDICATIONS

Absolute contraindications include early gestational age (<16 weeks) because this may increase risk of membrane rupture, preterm premature rupture of membranes (PPROM), preterm labor, and active placental abruption. Other contraindications include a patient's decision for termination or nonintervention. Relative contraindications include fetal aneuploidy, associated major fetal anomalies, and maternal infectious diseases (i.e., human immunodeficiency virus, hepatitis C); in these cases, the risks of vertical transmission must be considered against the potential benefits of shunt placement.

The management of bladder outlet obstruction with US preserved amniotic fluid volume is controversial because the natural history with this presentation is unclear. There are no data to indicate a benefit to shunt placement; however, this presentation has not been well studied. Vigilant US surveillance may be considered in this setting, with a plan for shunt placement if evidence of oligohydramnios develops.

Another controversy involves vesicoamniotic shunt placement for fetuses with urinary analyte profiles suggestive of poor renal function. In these cases, nonintervention is routinely recommended, with a plan for pregnancy termination or postnatal comfort care.

OUTCOMES AND COMPLICATIONS

Outcomes data are largely relegated to case series describing single-institution experiences with vesicoamniotic shunt placement. Recently, results of the sole completed and randomized trial attempting to prospectively assess vesicoamniotic shunt efficacy among fetal lower urinary tract obstruction presentations was published.[19] The study was prematurely stopped because of poor recruitment, with only 16 shunt cases and 15 controls, which was far short of a target recruitment of 150 subjects. Although intention-to-treat analysis did not demonstrate a survival benefit to shunting, there was a significant survival benefit when subjects were compared by treatment received. Long-term renal morbidity was substantial in both groups, suggesting little renal-protective benefit to shunt therapy. Notably, there was a high rate of procedural complications, with over half of all shunt placements complicated by PPROM, dislodgement, or occlusion. Overall, these data suggest that while vesicoamniotic shunt placement may confer a survival benefit, renal morbidity is expected to be substantial among survivors regardless of fetal therapy received.

Beyond the results of the PLUTO (percutaneous shunting in lower urinary tract obstruction) randomized trial, an uncontrolled comparison with the natural disease course is further suggestive of a survival benefit to the shunt procedure. In a retrospective analysis by Crombleholme et al.,[20] untreated oligohydramnios was associated with a 100% mortality rate, whereas normal or restored amniotic fluid volume was associated with 94% survival.

Short-term periprocedural complications of vesicoamniotic shunt placement include PPROM, preterm labor, premature delivery, chorioamnionitis, bleeding, and abruption. Shunts may be misplaced or migrate into the fetal abdominal cavity over time, resulting in urinary ascites requiring surgical removal after birth. Shunts may also dislodge or become occluded, potentially requiring repeat shunt placement. Shunts may be placed entirely within the fetal bladder or may migrate there, necessitating repeat shunt placement and postnatal removal. There is risk of fetal injury, including injury to vascular, intestinal, and genitourinary structures. The fetal bladder may rupture at the time of shunt placement. There is a small risk of fetal vascular injury leading to death and risk of fetal bowel evisceration through a trocar entry site.[3] Theoretic risk for maternal small bowel or uterine injury exists, although the former is highly unlikely because the procedure is performed under continuous US guidance. Maternal ascites as a result of amniotic fluid leakage through a uterine trocar wound has been described.

Although short-term data support a survival benefit with vesicoamniotic shunt placement, long-term series suggest that survivors are at risk for potentially severe morbidities involving the genitourinary and pulmonary systems.[21–23] Renal, bladder, and other genitourinary complications are likely related to degree of obstruction and type of underlying obstructive uropathy, with pulmonary morbidities attributable to duration and severity of

oligohydramnios. Even among survivors with favorable urinary analyte profiles before shunt placement, there is significant risk for long-term renal insufficiency, end-stage renal failure, dialysis requirement, and ultimate renal transplantation. In small series, risk of long-term renal failure seems to be at least 33% among shunt survivors. Long-term bladder dysfunction is also reported, with survivors at risk for recurrent urinary tract infections or self-catheterization requirements. In addition, these children commonly have musculoskeletal and growth disturbances and potential developmental delays. When oligohydramnios is severe and prolonged, limb positioning abnormalities and Potter facies can be observed.

Thoracoamniotic Shunts

DESCRIPTION, TECHNIQUE, AND EQUIPMENT

For a patient to be considered for thoracoamniotic shunt placement for primary fetal hydrothorax, fetal compromise must be evident. Comprehensive evaluation includes an assessment of effusion size and whether it is unilateral or bilateral; visualization of associated hydrops, polyhydramnios, or mediastinal shift; a study of cardiac function; and a survey for other associated fetal anomalies. After diagnosis, the patient should be counseled regarding the natural history of severe fetal hydrothorax and clinical suspicion for a poor fetal prognosis without intervention. In addition to options of expectant care and pregnancy termination (if <24 weeks' gestation), the possibility of thoracoamniotic shunt therapy should be introduced with a discussion of procedure-related risks and potential benefits. Informed consent also requires that the interventionist explains limitations of therapy, including incomplete medical knowledge and data of outcomes derived from limited case series.

Before shunt placement for severe fetal hydrothorax, one or two fetal thoracocenteses are generally recommended. Thoracocentesis allows for cell count and culture studies to determine if an effusion is chylous (>80% lymphocytes on differential) in nature. The procedure also temporarily decompresses the fetal chest, which allows for a comprehensive evaluation of the fetal heart. Thoracocentesis is performed with a 22-gauge needle under continuous US guidance using standard aseptic technique. After fetal chest decompression, a sample of amniotic fluid should be obtained for karyotype and genetic (i.e., microarray, Noonan syndrome) analyses.[24] Although thoracocentesis is primarily a diagnostic procedure, effusions occasionally show spontaneous regression, so it may be reasonable to perform up to two additional thoracocenteses to temporize and observe for fluid reaccumulation and rate of return. In the setting of a hydrothorax that recurs after two thoracocenteses, or a severe presentation with rapid reaccumulation after a single decompression, thoracoamniotic shunt placement may be considered.

Shunt placement may also be considered for severe fetal CCAM presentations involving hydrops, severe polyhydramnios, or prolonged and severe mediastinal shift and fetal lung compression (Fig. 116.4). When there is a significant macrocystic component, therapy is designed to drain the largest cysts.[25] Usually one or two thoracocenteses are performed before considering a thoracoamniotic shunt procedure.

Options for thoracoamniotic shunt placement are the same as the options discussed for vesicoamniotic shunt placement; again, the Harrison shunt is favored at our institution (see Fig. 116.1). Shunt placement is performed under continuous US

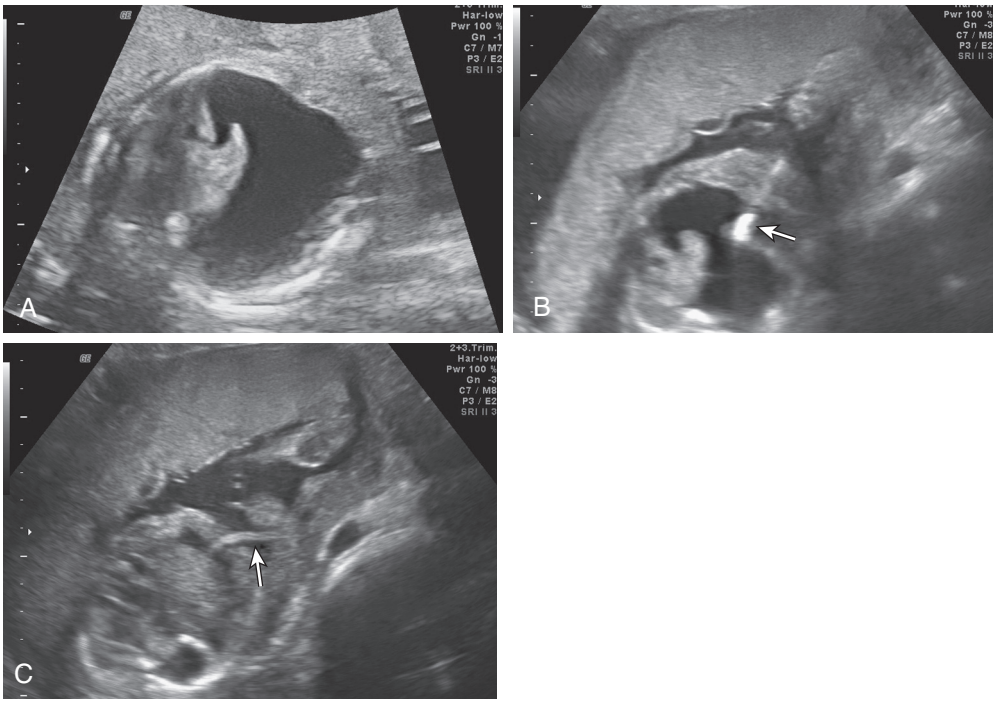

Fig. 116.4 (A) Axial image of a 19-week fetus with a large right-sided pleural effusion causing mediastinal shift. The effusion had rapidly reaccumulated after thoracocentesis. (B) The same fetus undergoing thoracoamniotic shunt placement. In this image, the Harrison shunt trocar can be visualized within the pleural space immediately before shunt placement. *Arrow* indicates the echogenic trocar tip. (C) The same fetus with a decompressed pleural effusion after thoracoamniotic shunt placement. *Arrow* indicates a portion of the shunt traversing the fetal thoracic wall.

guidance, after administering maternal lidocaine along the entry site. A target site on the fetal chest wall overlying the target lesion is identified; sometimes, bilateral shunt placement is indicated. Shunt placement proceeds as described for vesicoamniotic shunt placement. Although a single reported case exists of a fatal laceration of a fetal intercostal artery at the time of shunt placement,[26] fetal chest wall vasculature is not something that can be practically observed using Doppler. Perioperative tocolysis, antibiotics, and US follow-up recommendations are the same as described for vesicoamniotic shunt placement.

INDICATIONS

Indications for thoracoamniotic shunt placement are not clearly defined but include cases of bilateral severe hydrothorax, severe and rapidly progressive hydrothorax, and hydrothorax causing fetal hydrops or other evidence of fetal compromise (polyhydramnios). Some interventionists consider fetal mediastinal shift in the absence of hydrops or polyhydramnios sufficient indication for therapy. For CCAM, a macrocystic lesion associated with early-onset hydrops, severe polyhydramnios, or substantial mediastinal shift or fetal lung compression should be observed before therapy. For all indications, failure to respond to initial thoracocentesis is recommended before shunt placement. There is no consensus regarding appropriate indications for intervention, and there is limited evidence supporting therapy.

CONTRAINDICATIONS

Contraindications are the same as for vesicoamniotic shunt placement.

OUTCOMES AND COMPLICATIONS

Short-term complications of thoracoamniotic shunt placement are similar to complications associated with vesicoamniotic shunt placement and include PPROM, preterm labor, premature delivery, chorioamnionitis, bleeding, and abruption. Shunts may be misplaced or migrate into the fetal thoracic cavity over time, requiring repeat shunt placement and surgical removal after birth. There is a report of a shunt migration into the maternal peritoneal cavity and a case involving maternal ascites after shunt placement.[27,28] Shunts may also dislodge or become occluded, which would potentially indicate repeat shunt placement. Rates of migration or obstruction are estimated to be approximately 20%.[29] There is a small risk of fetal vascular injury or death. A case report exists of a fetal intercostal artery laceration at the time of thoracoamniotic shunt placement. A fatal, shunt-related umbilical cord torsion was also reported.[30] Theoretic risk of injury to maternal bowel, bladder, or vascular structure exists, although these injuries are unlikely.

Although the procedure was first described in 1986,[31] data regarding outcomes after thoracoamniotic shunt placement for fetal hydrothorax are limited to retrospective series.[6,32] Outcomes are believed to depend on the duration, severity, and nature of effusions; gestational age at diagnosis; the presence of cardiac dysfunction or hydrops; the underlying etiology for effusions (including syndromic and aneuploidy causes); and the presence of associated anomalies. In successfully treated cases, reversal of hydrops and a decreased incidence of respiratory morbidity are reported. Although these anecdotal cases suggest therapeutic benefit, there are insufficient data to show a clear survival benefit after thoracoamniotic shunt placement.

In a systematic literature review of primary fetal hydrothorax,[33] 80 shunt cases were described; 79 were pleuroamniotic, and one was pleurocutaneous. Deterioration to fetal or infant death occurred in 26% of cases. Among the remaining 59 cases, disease regression was observed in 81%, and 10% of cases required repeated shunt placement. Among cases with available procedural information, most (56%) received bilateral shunts.

Limited data exist regarding thoracoamniotic shunt placement for CCAM. In one study of fetuses with pleural effusion or macrocystic CCAM who underwent shunt placement, subgroup data were presented for the CCAM cases.[26] Ten thoracoamniotic shunt procedures were performed for CCAM with hydrops or concern for pulmonary hypoplasia at an average gestational age of 23 weeks, 1 day. Three (30%) deaths were observed. With all three deaths, short intervals from shunt placement to delivery (mean 11 days) were noted, all owing to obstetric complications.

KEY POINTS

- Intrauterine fetal shunts provide continuous drainage of fluid accumulations that are associated with a high risk of death or profound morbidity without decompression.
- Harrison and Rocket shunts are the two most commonly used shunt types.
- By decompressing the fetal bladder and restoring the amniotic fluid volume, vesicoamniotic shunt placement offers a survival advantage when fetal bladder outlet obstruction with oligohydramnios is present.
- Child survivors of fetal vesicoamniotic shunt placement are at substantial risk for long-term health complications.
- Thoracoamniotic shunt placement is currently reserved for severe cases of fetal hydrothorax, usually involving hydrops, polyhydramnios, or other evidence of cardiac compromise.
- There are no robust data showing a clear survival benefit after thoracoamniotic shunt placement.

SUGGESTED READING

Freedman AL, Johnson MP, Smith CA, et al. Long-term outcome in children after antenatal intervention for obstructive uropathies. *Lancet*. 1999;354:374-377.

Klaritsch P, Albert K, Van Mieghem T, et al. Instrumental requirements for minimal invasive fetal surgery. *BJOG*. 2009;116:188-197.

Morris RK, Malin GL, Quinlan-Jones E, Middleton LJ, et al. Percutaneous vesicoamniotic shunting versus conservative management for fetal lower urinary tract obstruction (PLUTO): a randomised trial. *Lancet*. 2013;382(9903):1496-1506.

Morris RK, Quinlan-Jones E, Kilby MD, et al. Systematic review of accuracy of fetal urine analysis to predict poor postnatal renal function in cases of congenital urinary tract obstruction. *Prenat Diagn*. 2007;27:900-911.

Rustico MA, Lanna M, Coviello D, et al. Fetal pleural effusion. *Prenat Diagn*. 2007;27:793-799.

Wilson RD, Baxter JK, Johnson MP, et al. Thoracoamniotic shunts: fetal treatment of pleural effusions and congenital cystic adenomatoid malformations. *Fetal Diagn Ther*. 2004;19:413-420.



All references available online at www.expertconsult.com

REFERENCES

1. Wilson RD, Hedrick HL, Liechty KW, et al. Cystic adenomatoid malformation of the lung: review of genetics, prenatal diagnosis, and in utero treatment. *Am J Med Genet*. 2006;140:151-155.
2. Steffensen TS, Quintero RA, Kontopoulos EV, et al. Massive pericardial effusion treated with in utero pericardioamniotic shunt in a fetus with intrapericardial teratoma. *Fetal Pediatr Pathol*. 2009;28:216-231.
3. Manning FA, Harrison MR, Rodeck C. Catheter shunts for fetal hydronephrosis and hydrocephalus: report of the International Fetal Surgery Registry. *N Engl J Med*. 1986;315:336-340.
4. Vintzileos AM, Campbell WA, Weinbaum PJ, et al. Perinatal management and outcome of fetal ventriculomegaly. *Obstet Gynecol*. 1987;69:5-11.
5. Klam S, Bigras J-L, Hudon L. Predicting outcome in primary fetal hydrothorax. *Fetal Diagn Ther*. 2005;20:366-370.
6. Rustico MA, Lanna M, Coviello D, et al. Fetal pleural effusion. *Prenat Diagn*. 2007;27:793-799.
7. Hagay Z, Reece A, Roberts A, et al. Isolated fetal pleural effusion: a prenatal management dilemma. *Obstet Gynecol*. 1993;81:147-152.
8. Klaritsch P, Albert K, Van Mieghem T, et al. Instrumental requirements for minimal invasive fetal surgery. *BJOG*. 2009;116:188-197.
9. Nicolini U, Fisk VM, Rodeck CH, et al. Fetal urine biochemistry: an index of renal maturation and dysfunction. *Br J Obstet Gynaecol*. 1992;99:46-50.
10. Nicolini U. Spelzini F. Invasive assessment of fetal renal abnormalities: urinalysis, fetal blood sampling and biopsy. *Prenat Diagn*. 2001;21: 964-969.
11. Nicolini U, Tanniarandorn Y, Vaughan J, et al. Further predictors of renal dysplasia in fetal obstructive uropathy: bladder pressure and biochemistry of "fresh" urine. *Prenat Diagn*. 1991;11:159-166.
12. Johnson MP, Corsi P, Bradfield W, et al. Sequential urinalysis improves evaluation of fetal renal function in obstructive uropathy. *Am J Obstet Gynecol*. 1995;173:59-65.
13. Glick PL, Harrison MR, Golbus MS, et al. Management of the fetus with congenital hydronephrosis, II: prognostic criteria and selection for treatment. *J Pediatr Surg*. 1985;20:376-387.
14. Grannum PA, Ghidini A, Scioscia A, et al. Assessment of fetal renal reserve in low level obstructive uropathy. *Lancet*. 1989;333:281-282.
15. Johnson MP, Bukowski TP, Reitleman C, et al. In utero surgical treatment of fetal obstructive uropathy: a new comprehensive approach to identify appropriate candidates for fetal vesicoamniotic shunt therapy. *Am J Obstet Gynecol*. 1994;170:1770-1779.
16. Morris RK, Quinlan-Jones E, Kilby MD, et al. Systematic review of accuracy of fetal urine analysis to predict poor postnatal renal function in cases of congenital urinary tract obstruction. *Prenat Diagn*. 2007;27:900-911.
17. Berry SM, Lecolier B, Smith RS, et al. Predictive value of fetal beta2-microglobulin for neonatal renal function. *Lancet*. 1995;345:1277-1278.
18. Budunki V, Saldanha LB, Sadek L, et al. Fetal renal biopsies in obstructive uropathy: feasibility and clinical correlations—preliminary results. *Prenat Diagn*. 1998;18:101-109.
19. Morris RK, Malin GL, Quinlan-Jones E, et al. Percutaneous vesicoamniotic shunting in Lower Urinary Tract Obstruction (PLUTO) Collaborative Group. Percutaneous vesicoamniotic shunting versus conservative management for fetal lower urinary tract obstruction (PLUTO): a randomised trial. *Lancet*. 2013;382(9903):1496-1506.
20. Crombleholme TM, Harrison MR, Golbus MS, et al. Fetal intervention in obstructive uropathy: prognostic indicators and efficacy of intervention. *Am J Obstet Gynecol*. 1991;162:1239-1244.
21. Freedman AL, Johnson MP, Smith CA, et al. Long-term outcome in children after antenatal intervention for obstructive uropathies. *Lancet*. 1999;354:374-377.
22. McLorie G, Farhat W, Khoury A, et al. Outcome analysis of vesicoamniotic shunting in a comprehensive population. *J Urol*. 2001;166:1036-1040.
23. Biard J-M, Johnson MP, Carr MC, et al. Long-term outcomes in children treated by prenatal vesicoamniotic shunting for lower urinary tract obstruction. *Obstet Gynecol*. 2005;106:503-508.
24. Waller K, Chaithongwongwatthana S, Yamasmit W, et al. Chromosomal abnormalities among 246 fetuses with pleural effusions detected on prenatal ultrasound examination: factors associated with an increased risk of aneuploidy. *Genet Med*. 2005;7:417-421.
25. Laberge JM, Flageole H, Pugash D, et al. Outcome of the prenatally-diagnosed congenital adenomatoid lung malformation: a Canadian experience. *Fetal Diagn Ther*. 2001;16:178-186.
26. Wilson RD, Baxter JK, Johnson MP, et al. Thoracoamniotic shunts: fetal treatment of pleural effusions and congenital cystic adenomatoid malformations. *Fetal Diagn Ther*. 2004;19:413-420.
27. Nicolaides KH, Azar GB. Thoracoamniotic shunting. *Fetal Diagn Ther*. 1990;5:153-164.
28. Ronderos-Dumit D, Nicolini U, Vaughan J, et al. Uterine-peritoneal amniotic fluid leakage: an unusual complication of intrauterine shunting. *Obstet Gynecol*. 1991;78:913-915.
29. Sepulveda W, Galindo A, Sosa A, et al. Intrathoracic dislodgement of pleuro-amniotic shunt. *Fetal Diagn Ther*. 2005;20:102-105.
30. Longaker MT, Laberge J-M, Dansereau J, et al. Primary fetal hydrothorax: natural history and management. *J Pediatr Surg*. 1989;24:573-576.
31. Seeds JW, Bowes WA. Results of treatment of severe fetal hydrothorax with bilateral pleuroamniotic catheters. *Obstet Gynecol*. 1986;68:577-580.
32. Rodeck CH, Fisk NM, Fraser DI, et al. Long-term in utero drainage of fetal hydrothorax. *N Engl J Med*. 1988;319:1135-1138.
33. Aubard Y, Derouineau I, Aubard V, et al. Primary fetal hydrothorax: a literature review and proposed antenatal clinical strategy. *Fetal Diagn Ther*. 1998;13:325-333.

117 Multifetal Pregnancy Reduction

GLORIA TOO | RICHARD L. BERKOWITZ

Introduction

Multiple gestations are at risk for perinatal morbidity and mortality that increase with higher-order pregnancies, primarily caused by complications of prematurity.[1] The risk of preterm delivery increases as the number of fetuses increases. In 2014, preterm delivery <32 weeks occurred in 1% of singletons, 11% of twins, 39% of triplets, and 72% of quadruplets.[2] Infant mortality increases fourfold in twins, 12-fold in triplets, and 26-fold in quadruplet births.[3]

In addition to perinatal concerns, maternal risk is also significantly increased in higher-order pregnancies. Compared with twins, triplet pregnancies were at higher risk for pregnancy-associated hypertension (odds ratio [OR], 1.22; 95% confidence interval [CI], 1.15–1.30), eclampsia (OR, 1.69; 95% CI, 1.46–19.4), cesarean delivery (OR, 6.55; 95% CI, 6.15–6.97), and excessive bleeding in labor and delivery (OR, 1.41; 95% CI, 1.25–1.56).[4]

The incidence of multifetal pregnancies has increased significantly over the past 3 decades, primarily because of the success of assisted reproductive technologies. The twin birth rate increased by 76% from 1980 to 2009, and accounted for 3.39% of live births in 2014. Triplet or higher-order pregnancies increased by 400% between 1980 and 1998. However, the rate of higher-order pregnancies had declined by 40% by 2009 as a result of primary prevention such as guidelines advocating the transfer of fewer embryos and secondary prevention with multifetal pregnancy reduction (MFPR).[2]

In the 1980s several authors reported on MFPR as a method to improve maternal and fetal outcomes in high-order multiple pregnancies.[6,7] This procedure involves the termination of one or more presumably normal fetuses to increase the overall likelihood of survival, and to decrease the long-term morbidity of the remaining fetus or fetuses. MFPR increases the rate of live birth, while decreasing the risk of pregnancy loss, preterm delivery, neonatal/infant demise, preeclampsia, and gestational diabetes.[8]

Procedure

SETTING

MFPR is performed as an outpatient procedure in an ultrasound (US) unit in the late first or early second trimester.

COUNSELING

The American College of Obstetrics and Gynecology recommends nondirective counseling when reviewing the details of a patient's multifetal pregnancy (maternal health issues/risks, number of fetuses, and potential outcomes of pregnancy continuation versus reduction). The psychologic, economic, social, and health risks should be addressed before the procedure. The risks of the procedure should be reviewed, as well as the expected prognosis.[8]

US should be performed before counseling to determine fetal number, chorionicity, and screen for possible genetic, growth, or anatomic abnormalities. The chorionicity of the pregnancy should be identified as early as possible, as this will affect the counseling relating to fetal selection for termination. Monochorionic twins are fraught with potential concerns, such as twin-twin transfusion syndrome and unequal placental sharing. Potassium chloride (KCl) termination of one fetus is contraindicated in a monochorionic twin gestation, as the anastomoses in the shared placenta may cause an inadvertent termination of the co-twin. Radiofrequency cord ablation can be used to selectively terminate one fetus in monochorionic twins, but this is associated with a higher risk of preterm labor, delivery in the periviable period, and loss of the pregnancy. Consideration should be given to reducing both monochorionic twins when present in a higher-order multiple pregnancy.

Risks of the procedure are similar to the risks of amniocentesis, including amniotic fluid leakage from the sac of a viable fetus, placental abruption, infection (chorioamnionitis), and pregnancy loss.

GENETIC TESTING

Multifetal pregnancies are more common with increasing maternal age. Advanced maternal age and assisted reproductive technology are known to increase the risk of fetal malformations and, therefore chromosomal analysis should be considered. As a consequence, patients should be counseled on the risks and benefits of prenatal screening and testing before fetal reduction, as the findings may lead to selective termination of an anomalous fetus. Screening for aneuploidy with nuchal translucency alone in twin pregnancies has a detection rate of approximately 70% for trisomy 21 with a 5% false-positive rate.[9] When nuchal translucency was combined with first-trimester serum screening and nasal bone in a retrospective analysis of 4188 twin fetuses, the detection rates were 79% for nuchal translucency combined with serum analysis and 89% if the nasal bone was also included.[10] For triplet pregnancies, screening options are limited. Serum screening, including cell-free fetal DNA and biomarker testing, has not been validated for triplets and higher-order multiples. The use of nuchal translucency has not been established, as the limited studies on this subject are conflicting.[11,12]

Invasive prenatal diagnosis with chorionic villus sampling (CVS) has the advantage of reassuring the parents by confirming that the remaining fetuses are chromosomally normal; this is especially important in cases where the pregnancy is reduced to a singleton. At our institution, we offer karyotyping, microarray, and targeted diagnostic testing based on pregnancy risk factors.

In recent years, several studies have shown the accuracy and safety of performing CVS in multifetal pregnancies before MFPR. One study documented successful performance of the procedure in 98.8% (85 of 86) of patients, with detection of an abnormal karyotype in 1.8% (3 of 165 fetuses) and an error rate of 1.2% (2 of 165).[13] A larger study comparing patients who had CVS before MFPR ($n = 437$) with those who did not ($n = 321$) reported that women who underwent CVS had the reduction performed on average 1 week later (12.6 weeks) than those who did not (11.6 weeks). There was no difference in the overall loss rate, reported at 4% (17 of 437) in the CVS group versus 7% (21 of 321) in the non-CVS group ($P = .098$). In that series, CVS was associated with a reduction in the pregnancy loss rate by 76% in women who reduced to a singleton; the loss rate was 2% (4 of 192) in the CVS group versus 9% (6 of 90) in the non-CVS group.[14] These authors concluded that CVS before MFPR does not increase the risk for pregnancy loss and possibly may reduce the risk for adverse outcomes before reduction to a singleton. On the basis of recent series that indicate a growing rate of MFPR procedures to a singleton, first-trimester screening and CVS should be offered to all women who are considering undergoing MFPR..

TECHNIQUE

At our institution, MFPR procedures are ideally performed between 11 and 13 weeks' gestation. At this gestational age range, most spontaneous losses will already have occurred, the procedure is technically easier to perform, and US screening/invasive testing can be performed. The procedure is most commonly performed transabdominally because transvaginal and transcervical approaches have been reported to be associated with higher pregnancy loss (13.3% versus 3.5%, $P = .04$)[15] (Fig. 117.1).

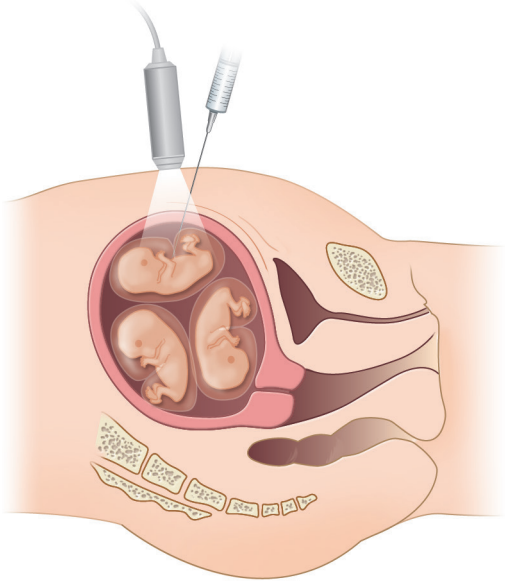

Fig. 117.1 Diagram showing the transabdominal approach to multifetal pregnancy reduction under direct real-time US guidance. *(Adapted from Hankins GDV. Operative obstetrics, 5th ed. New York, 1995, McGraw-Hill/Appleton & Lange, p 643).*

Before performing an MFPR, a US exam should be performed to identify the position and chorionicity of the pregnancy. The decision of which fetus or fetuses to reduce should take into consideration the outcomes of available screening/testing results or other US evidence of early intrauterine growth restriction or detection of a major fetal anomaly. If all prenatal diagnostic tests are normal, the most easily accessible fetuses are targeted for reduction, and the fetus overlying the internal cervical os is spared (Fig. 117.2) because of the theoretic risk of infection or preterm delivery if that fetus were reduced. This should be differentiated from selective termination, in which a fetus is reduced based on genetic or structural abnormality regardless of its position.

Before the insertion of the needle, the patient's abdomen is prepared with an antiseptic solution and draped in a sterile manner. Using a sterile cover for the US transducer, the thorax of the targeted fetus is identified. Either a 20-gauge or a 22-gauge needle can be used. The needle is inserted into the fetal thorax under direct real-time US guidance (Fig. 117.3). When the needle tip is in the thorax, it is advanced to the fetal heart, and the

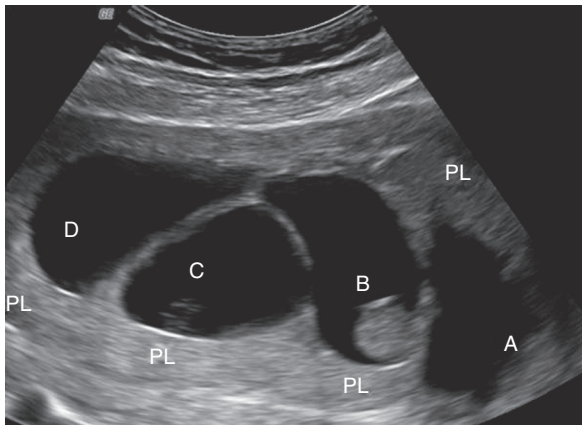

Fig. 117.2 Sagittal ultrasound view through a uterus containing a quintuplet pregnancy in a 23-year-old woman resulting from ovulation induction treatments shows the locations of sacs *A* to *D* before multifetal pregnancy reduction to assist in planning the reduction. The most accessible sacs are targeted for reduction, and the sac overlying the cervix is spared. *PL*, Placenta.

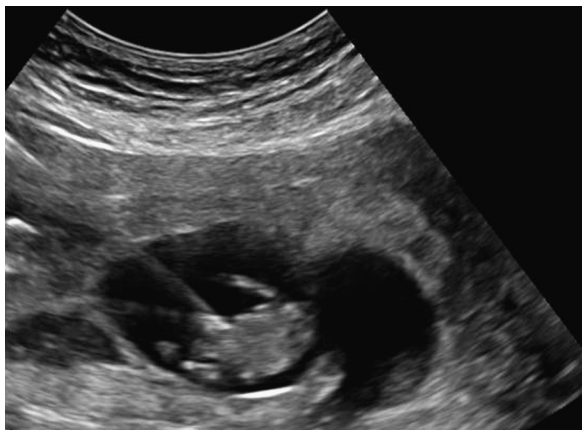

Fig. 117.3 Sagittal ultrasound view during multifetal pregnancy reduction shows a 22-gauge needle while it is advanced to the chest of fetus *D* in a 10-weeks' quintuplet pregnancy reduced to a twin pregnancy.

stylus is removed. A syringe containing 1 to 5 mL of KCl (2 mEq/mL) is attached to the needle and the KCl is then injected. If necessary, this procedure can be repeated several times to reduce more than one fetus. Fetuses targeted for reduction should be assessed for sustained fetal asystole for at least 2 minutes before removal of the needle, and the remaining fetuses should be monitored for viability. All fetuses should be reassessed 15 to 30 minutes after the procedure (Fig. 117.4). If reactivation of the fetal heart rate activity is appreciated in the targeted fetus, the procedure should be repeated. Like amniocentesis or CVS, there is no indication for antibiotic prophylaxis. For Rhesus D-negative patients, prophylactic Rh immune globulin should be administered after the procedure.

Outcomes

FETAL/NEONATAL

Most of the literature published regarding MFPR is derived from tertiary care centers with a limited number of experienced operators performing the procedure. It has been shown that as operators' experience with the procedure increased, pregnancy loss rate before 24 weeks' gestation decreased from 13.2% (1986–1990) to 9.4% (1991–1994) and then further to 6.4% (1995–1998).[16] A single-center study showed a similar trend among the most recent 1000 MFPR cases performed at that institution. The overall pregnancy loss rate was 4.7%, with a mean gestational age at delivery of 36.2 weeks. The gestational age at delivery was related to the number of remaining fetuses (38.0 weeks for a singleton, 35.2 weeks for twins, and 30.0 weeks for triplets).[17]

It is evident that fetal outcome following MFPR relies on both starting and finishing fetal numbers. A series of 3513 MFPR procedures from 11 centers in five countries showed a correlation between pregnancy loss rates and starting fetal numbers (15.4%, 11.4%, 7.3%, 4.5%, and 6.2% for more than six, five, four, three, and two fetuses). In addition, there was a correlation between overall loss rates and finishing number of fetuses (triplet 18.4%, twin 6%, and singleton 6.7%).[16]

Triplet to Twin Pregnancy

Few studies have directly compared the outcomes of reduced versus nonreduced multifetal pregnancies in the same cohort stratified by the number of starting fetuses. One study described pregnancy loss rates and mean gestational age at delivery in 140 women with triplets who did ($n = 34$) and did not ($n = 106$) undergo reduction to twins.[18] Total pregnancy loss rates were 20.7% in triplets managed expectantly compared with 8.7% in those reduced to twins. In addition, the mean gestational age at delivery was significantly lower in the nonreduced group compared with the reduced group (33.5 weeks versus 36.7 weeks). Similar results were found in another study of 127 triplet pregnancies with the same study design. Total pregnancy loss rates were 9.8% in the pregnancies that were managed expectantly compared with 3.2% in the reduced group, and the mean gestational age at delivery was significantly lower in the nonreduced group (31.1 weeks versus 35.6 weeks).[19] These studies suggest that the benefit of fetal reduction of triplets to twins exceeds the risk involved in the procedure, and the outcomes of the reduced pregnancies are improved compared to those who did not undergo the procedure.

One study compared trichorionic triplet pregnancies that were reduced to twins ($n = 57$) versus triplet pregnancies that were expectantly managed ($n = 58$). Reduction was associated with decreased preterm delivery less than 28 weeks (2% versus 14%, $P = .001$), perinatal mortality (6% versus 17.6%, $P = .007$), decreased neonatal intensive care unit admission rate (28% versus 63%, $P < .001$) and a higher live birth rate (94% versus 82.4%, $P = .007$).[20]

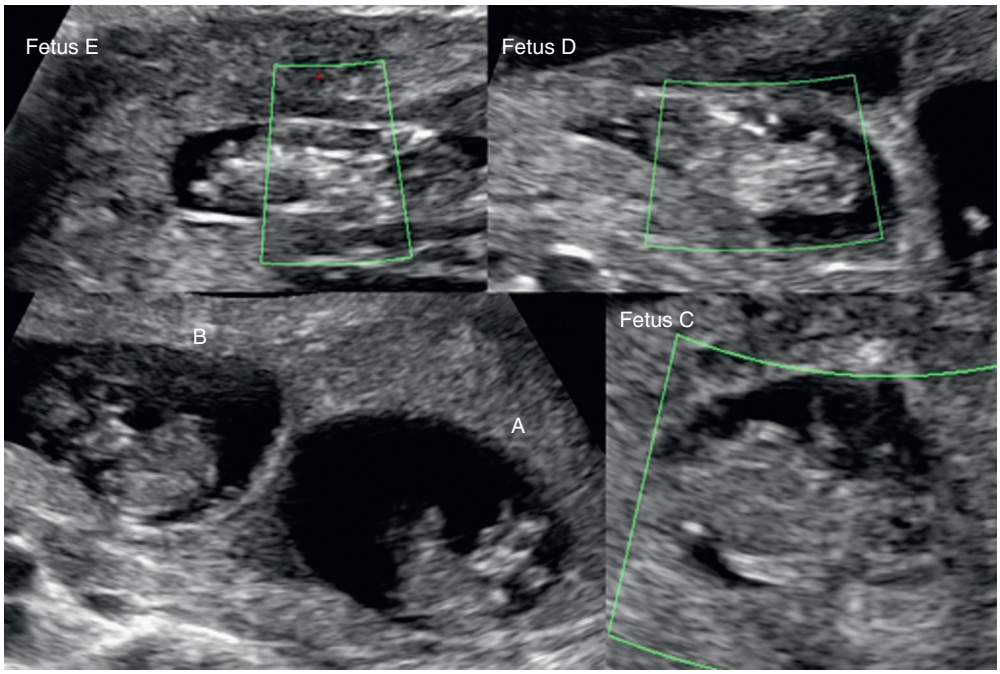

Fig. 117.4 Twin pregnancy resulting from reduction of a quintuplet pregnancy. Color flow Doppler sectors in fetuses *C, D,* and *E* show no cardiac activity immediately after multifetal pregnancy reduction.

Triplet to Singleton

Few studies have reported outcomes of triplet reduction to twin versus a singleton. One cohort study of trichorionic triplets reported higher delivery rates at >37 weeks for those who reduced to a singleton pregnancy (72.5% versus 46.9%), but no difference in the rate of bringing a live baby home, preterm delivery <32 weeks, <28 weeks, or pregnancy loss <24 weeks.[21]

Twin to Singleton

The literature on reducing dichorionic twins to a singleton is sparse. One study that compared outcomes of patients reduced to twin (n = 255) and singleton (n = 169) pregnancies with spontaneously conceived twin (n = 147) and singleton pregnancies (n = 885) reported similar rates of severe prematurity (<33 weeks' gestation), low birth weight, or neonatal death between the two groups.[22] However, two recent retrospective cohort studies comparing dichorionic twins reduced to a singleton versus nonreduced twins had conflicting results. Van de Mheen et al. (2015) reported higher rates of pregnancy loss <24 weeks (risk ratio [RR], 3.1; 95% CI, 2.0–4.9), preterm delivery <32 weeks (RR, 1.6; 95% CI, 1.1–2.5), and women without a surviving child in the reduction group.[23] Gupta et al. (2015), however, reported that the twin reduction group had significantly fewer preterm deliveries (10% versus 43%; $P < .001$) and birth weight <10% (49% versus 23%, $P < .001$), but no difference in fetal demise at >24 weeks.[24] Although there appears to be a benefit to reducing high-order multiples to twins, the evidence that reduction to a singleton further improves long-term outcome is less compelling.

MATERNAL

Maternal morbidity and mortality in multifetal pregnancy are directly correlated with the number of fetuses being carried. It was theorized that with a smaller fetal number and less placental mass, there would be a reduction in the rate of associated medical problems such as hypertensive disorders of pregnancy and gestational diabetes mellitus. In one series, preeclampsia occurred in 4.8% of singleton pregnancies, 8.3% of twin pregnancies, and 11% of triplet pregnancies; prenatal hospitalization occurred in 12.2% of singleton pregnancies, 30.5% of twin pregnancies, and 56.9% of triplet pregnancies; and premature rupture of membranes occurred in 3.1% of singleton pregnancies, 7.9% of twin pregnancies, and 13.1% of triplet pregnancies.[25]

Only two studies directly compared the mode of delivery in a cohort of reduced and nonreduced multifetal pregnancies. Both studies contained populations of similar size and showed a reduction in cesarean delivery rates from approximately 90% to 50% in reduced triplet pregnancies versus nonreduced triplets.[26,27] Gestational diabetes occurred in 22.3% (23 of 103) of the nonreduced triplet pregnancies versus 5.8% (5 of 85) of the reduced cohort (P = .003), and preeclampsia occurred in 13.5% (14 of 103) of the nonreduced triplet pregnancies versus 10.6% (9 of 85) of the reduced triplets (P = .688).[27] In a triplet cohort, reduction to a singleton pregnancy did not significantly change the rate of severe preeclampsia/HELLP (*h*emolysis, *e*levated *l*iver enzyme, *l*ow *p*latelet count) syndrome.[21]

KEY POINTS

1. The incidence of multifetal pregnancy has substantially increased over the past several decades. This condition is associated with increased risks for the fetuses and their mothers compared to singleton pregnancies.
2. MFPR is a procedure performed in the late first and early second trimester of a multifetal pregnancy, which decreases the number of fetuses that had been conceived, to reduce the risk of perinatal morbidity and mortality related to premature delivery.
3. The only absolute contraindication for the intrathoracic injection of KCl into a targeted fetus when performing MFPR is monochorionic placentation associated with that pregnancy.
4. Extensive counseling is required before performing MFPR.
5. CVS is safe and recommended before performing the procedure.
6. There are benefits for reduction of high-order multiples to twin gestation; however, the evidence that reduction to a singleton improves long-term outcome is less compelling.

SUGGESTED READING

American College of Obstetricians and Gynecologists. ACOG Committee opinion no. 553: multifetal pregnancy reduction. *Obstet Gynecol.* 2013;121(2 Pt 1):405-410.

Stone J, Ferrara L, Kamrath J, et al. Contemporary outcomes with the latest 1000 cases of multifetal pregnancy reduction (MPR). *Am J Obstet Gynecol.* 2008;199:406.e1-406.e4.



All references are available online at ***www.expertconsult.com.***

REFERENCES

1. American College of Obstetricians and Gynecologists; Society for Maternal-Fetal Medicine. ACOG Practice Bulletin No. 144: multifetal gestations: twin, triplet, and higher-order multifetal pregnancies. *Obstet Gynecol*. 2014;123(5):1118-1132.
2. Hamilton BE, Martin JA, Osterman MJ, et al. Births: final data for 2014. *Natl Vital Stat Rep*. 2015;64(12):1-64.
3. Matthews TJ, MacDorman MF, Thoma ME. Infant mortality statistics from the 2013 period linked birth/infant death data set. *Natl Vital Stat Rep*. 2015;64(9):1-30.
4. Luke B, Brown MB. Maternal morbidity and infant death in twin vs triplet and quadruplet pregnancies. *Am J Obstet Gynecol*. 2008;198(4):401.e1-401.e10.
5. Reference deleted in review.
6. Berkowitz RL, Lynch L, Chitkara U, et al. Selective reduction of multifetal pregnancies in the first trimester. *N Engl J Med*. 1988;318(16):1043-1047.
7. Shalev J, Frenkel Y, Goldenberg M, et al. Selective reduction in multiple gestations: pregnancy outcome after transvaginal and transabdominal needle-guided procedures. *Fertil Steril*. 1989;52(3):416-420.
8. American College of Obstetricians and Gynecologists. ACOG Committee opinion no. 553: multifetal pregnancy reduction. *Obstet Gynecol*. 2013;121(2 Pt 1):405-410.
9. Cleary-Goldman J, Berkowitz RL. First trimester screening for Down syndrome in multiple pregnancy. *Semin Perinatol*. 2005;29:395-400.
10. Cleary-Goldman J, Rebarber A, Krantz D, et al. First-trimester screening with nasal bone in twins. *Am J Obstet Gynecol*. 2008;199:283.e1-283.e3.
11. Cuckle H, Moskovitch M, Vaknin Z, et al. Nuchal translucency screening in triplets: down syndrome risk calculation taking account of between-fetus correlations. *Prenat Diagn*. 2012;32(3):214-219.
12. Sepulveda W, Wong AE, Casasbuenas A. Nuchal translucency and nasal bone in first-trimester ultrasound screening for aneuploidy in multiple pregnancies. *Ultrasound Obstet Gynecol*. 2009;33(2):152-156.
13. Eddleman KA, Stone JL, Lynch L, et al. Chorionic villus sampling before multifetal pregnancy reduction. *Am J Obstet Gynecol*. 2000;183:1078-1081.
14. Ferrara L, Gandhi M, Litton C, et al. Chorionic villus sampling and the risk of adverse outcome in patients undergoing multifetal pregnancy reduction. *Am J Obstet Gynecol*. 2008;199:408.e1-408.e4.
15. Timor-Tritsch IE, Bashiri A, Monteagudo A, et al. Two hundred ninety consecutive cases of multifetal pregnancy reduction: comparison of the transabdominal versus the transvaginal approach. *Am J Obstet Gynecol*. 2004;191(6):2085-2089.
16. Evans MI, Berkowitz RL, Wapner RJ, et al. Improvement in outcomes of multifetal pregnancy reduction with increased experience. *Am J Obstet Gynecol*. 2001;184:97-103.
17. Stone J, Ferrara L, Kamrath J, et al. Contemporary outcomes with the latest 1000 cases of multifetal pregnancy reduction (MPR). *Am J Obstet Gynecol*. 2008;199:406.e1-406.e4.
18. Lipitz S, Reichman B, Uval J, et al. A prospective comparison of the outcome of triplet pregnancies managed expectantly or by multifetal reduction to twins. *Am J Obstet Gynecol*. 1994;170:874-879.
19. Geipel A, Berg C, Katalinic A, et al. Targeted first-trimester prenatal diagnosis before fetal reduction in triplet gestations and subsequent outcome. *Ultrasound Obstet Gynecol*. 2004;24:724-729.
20. Shiva M, Mohammadi Yeganeh L, Mirzaagha E, et al. Comparison of the outcomes between reduced and nonreduced triplet pregnancies achieved by Assisted Reproductive Technology. *Aust N Z J Obstet Gynaecol*. 2014;54(5):424-427.
21. Kuhn-Beck F, Moutel G, Weingertner AS, et al. Fetal reduction of triplet pregnancy: one or two? *Prenat Diagn*. 2012;32(2):122-126.
22. Brambati B, Tului L, Camurri L, et al. First-trimester fetal reduction to a singleton infant or twins: outcome in relation to the final number and karyotyping before reduction by transabdominal chorionic villus sampling. *Am J Obstet Gynecol*. 2004;191:2035-2040.
23. van de Mheen L, Everwijn SM, Knapen MF, et al. Pregnancy outcome after fetal reduction in women with a dichorionic twin pregnancy. *Hum Reprod*. 2015;30(8):1807-1812.
24. Gupta S, Fox NS, Feinberg J, et al. Outcomes in twin pregnancies reduced to singleton pregnancies compared with ongoing twin pregnancies. *Am J Obstet Gynecol*. 2015;213(4):580.
25. ESHRE Capri Workshop Group. Multiple gestation pregnancy. The ESHRE Capri Workshop Group. *Hum Reprod*. 2000;15:1856-1864.
26. Boulot P, Vignal J, Vergnes C, et al. Multifetal reduction of triplets to twins: a prospective comparison of pregnancy outcome. *Hum Reprod*. 2000;15:1619-1623.
27. Sivan E, Maman E, Homko CJ, et al. Impact of fetal reduction on the incidence of gestational diabetes. *Obstet Gynecol*. 2002;99:91-94.

To access the videos in this chapter, scan this QR code or visit expertconsult.com

118 Open Fetal Surgery

AHMED I. MARWAN | DEBNATH CHATTERJEE | LISA W. HOWLEY | TIMOTHY M. CROMBLEHOLME

Introduction

Development of fetal surgery would not have been possible without advances in prenatal imaging, understanding the natural history of diseases, experimental animal models, and above all, the vision, innovation, and discipline of a dedicated group of surgeons, maternal-fetal medicine specialists, and anesthesiologists. The first human open fetal intervention was performed in 1982, with bilateral ureterostomies to manage a lower urinary tract obstruction (LUTO).[1,2] Fetal surgery poses a unique challenge as it involves two patients: the mother and her fetus, a scenario similar to transplantation from a living donor. Because of the risk to the mother who derives no direct benefit from fetal surgery, open fetal surgery was only performed in lethal conditions. In the intervening decades, however, the indications have been expanded to include non–life threatening conditions such as myelomeningocele (MMC). Before human implementation, surgical, tocolytic, and anesthetic techniques were developed and refined in sheep and nonhuman primate models with extensive translational research. Innovative techniques for opening and closing the gravid uterus had to be developed to minimize risks to the mother's health and future reproductive potential,[3] including the development of an absorbable uterine stapler to minimize myometrial bleeding.[4,5]

Every fetal intervention requires a rigorous process entailing understanding the natural history of the disease, demonstrating its pathophysiology, and providing proof of concept in an applicable animal model before any human surgery[6] (Table 118.1).

In this chapter, we will focus on the techniques of open fetal surgery, anesthetic management, and intraoperative monitoring as applied for MMC with a brief synopsis on the other indications (Table 118.2).

TABLE 118.1 CRITERIA FOR FETAL SURGERY

1. Accurate diagnosis and staging possible, no other associated anomalies.
2. Documented natural history of the disease with clear prognosis.
3. Absence of current successful postnatal therapy.
4. *In utero* surgery proven feasible in animal models with reversal of the condition.
5. Interventions performed in specialized multidisciplinary fetal treatment centers with strict protocols, approval of the Ethics Committee, oversight, and informed consent.

Adapted from Harrison MR, Naakayama DK, Noall RA, et al.: Correction of congenital hydronephrosis in utero. II. Decompression reverses effects of obstruction on the fetal lung and urinary tract. *J Pediatr Surg* 17:965–974, 1982.

TABLE 118.2 INCLUSION AND EXCLUSION CRITERIA FOR PRENATAL REPAIR OF MMC

Inclusion Criteria	Exclusion Criteria
• Lesion T1–S1 with hindbrain herniation, level of MMC confirmed by US and hindbrain herniation confirmed by MRI • Maternal age greater than or equal to 18 years • Gestational age $19^{0/7}$ weeks to $26^{0/7}$ at the time of prenatal surgery • Normal karyotype or FISH • Normal fetal echocardiogram • Singleton pregnancy	• Other significant anomaly • Kyphosis >30 degrees • History of incompetent cervix • BMI >35 • Infectious disease • Uterine anomaly • Maternal medical issues • Previous hysterotomy in active segment of the uterus

BMI, Body mass index; *FISH*, fluorescent in situ hybridization; *MMC*, myelomeningocele; *MRI*, magnetic resonance imaging; *US*, ultrasound.

Current Indications for Open Fetal Surgery

MYELOMENINGOCELE

Neural tube defects (NTDs) are the leading cause of central nervous system malformation in humans and a devastating birth defect resulting in destruction of the exposed developing spinal cord (Chapter 41) (Fig. 118.1). The sequelae of NTDs include anatomic effects secondary to the primary defect, as well as functional, emotional, and psychologic morbidities including bladder and bowel incontinence, paralysis, musculoskeletal deformity, shunt malfunctions, and infections.[7–9] The associated morbidity and mortality is thought to be a result of prolonged



Fig. 118.1 Operative image of an myelomeningocele during an open fetal repair.



Fig. 118.2 An ultrasound image demonstrating a lumbosacral myelomeningocele measuring 2.93 cm.

mechanical trauma to neural elements, as well as chemical irritation and inflammation associated with exposure to toxic molecules in the amniotic fluid[10] (Fig. 118.2). Ultimately, the compound nature of this malformation results in an immense financial burden on the afflicted families and our health care system amounting to $1,400,000 per child affected by MMC, over a 20-year life span.[7] The incidence has plateaued around 1 in 1000 births following an initial decrease from widespread prenatal folic acid supplementation.[8,9] With a global population of 7 billion and a yearly birth rate of 20 per 1000 individuals, there are about 140,000 NTD cases per year worldwide[7] (Fig. 118.3).

In animal models, prenatal coverage of NTDs preserves neurologic function and improves hindbrain herniation.[10,11] In addition, naturally occurring skin-covered NTDs are usually neurologically intact without the complications of open NTDs, and ultrasound (US) and autopsy studies have demonstrated that injury to the exposed neural tissues is a progressive process. Prenatal repair of open spina bifida is performed at 23–24 weeks and is associated with a 50% reduction in the need for postnatal ventriculoperitoneal (VP) shunting as well as a higher likelihood

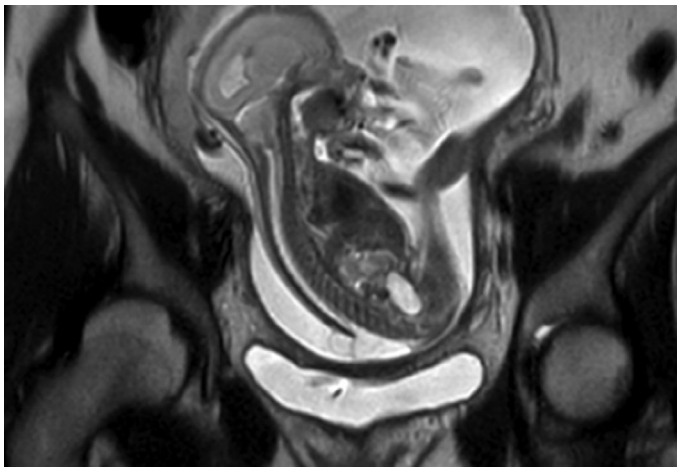

Fig. 118.3 A fetal MRI sagittal image demonstrating a lumbosacral myelomeningocele with evidence of hindbrain herniation.

of ambulation. The Management of Myelomeningocele Study (MOMS) trial hinges on achieving skin closure of the defect to prevent further neural damage and cerebrospinal fluid leak.[12] Table 118.2 summarizes the inclusion and exclusion criteria for offering prenatal repair of MMC according to the MOMS trial.

Our group has extended the inclusion criteria for offering prenatal repair of MMC to include maternal body mass index >35. More recent follow-up results from the MOMS trial show that the size of the fetal lateral ventricles at the time of prenatal MMC repair determines the likelihood that VP shunting can be avoided. In addition, even though repair with dilated lateral ventricles (≥15 mm) may not prevent the need for VP shunting, prenatal repair may improve the neurologic function of lower extremities and decrease the need for chronic intermittent bladder catheterization.[13,14]

FETAL RESECTION FOR LARGE CONGENITAL PULMONARY AIRWAY MALFORMATION LESIONS

Congenital cystic adenomatoid malformation (CCAM) also recently known as *congenital pulmonary airway malformation* (CPAM) is a benign congenital cystic lung lesion of pulmonary tissue with proliferation of bronchial structures (Chapter 2). It was originally described as an adenomatoid proliferation of the terminal bronchial tree resulting in cystic lesions coated in bronchial epithelium (Figs. 118.4 and 118.5).

Fetuses found to have a fetal chest mass on a screening US should undergo a comprehensive evaluation at a tertiary care center including ultrasonography, ultrafast magnetic resonance imaging (MRI), and fetal echocardiography. The differential diagnosis of a fetal chest mass includes CCAM, bronchopulmonary sequestration (BPS), bronchogenic cyst, and congenital diaphragmatic hernia. CPAMs occur at the fifth or sixth week of gestation during the pseudoglandular stage of lung development but do not tend to grow rapidly until 20 weeks' gestation. Their classification has been modified by Adzick et al. depending on their natural history and effects to include either microcystic or macrocystic lesions.[15] The natural history of prenatally diagnosed lung lesions is variable and depends on their size and resulting physiologic derangements. Almost 20% of fetal CCAMs demonstrate a decrease in size, and two-thirds of BPS lesions

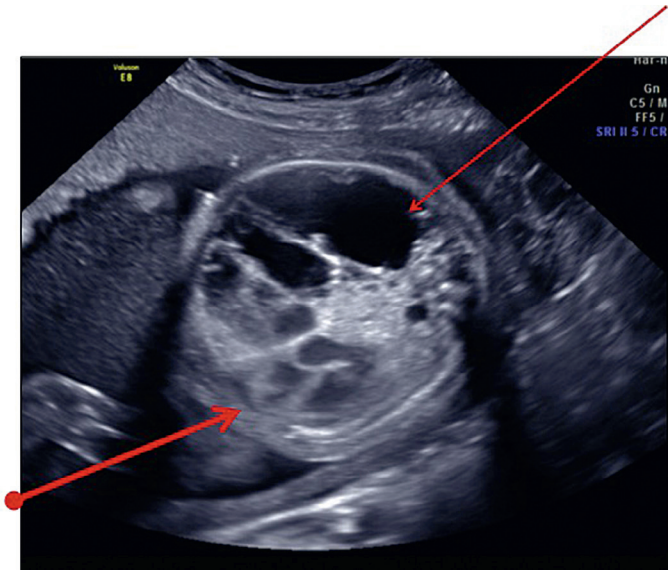

Fig. 118.4 An ultrasound image demonstrating a large multicystic congenital pulmonary airway malformation lesion *(thin arrow)* with a displaced heart *(thick arrow)*.

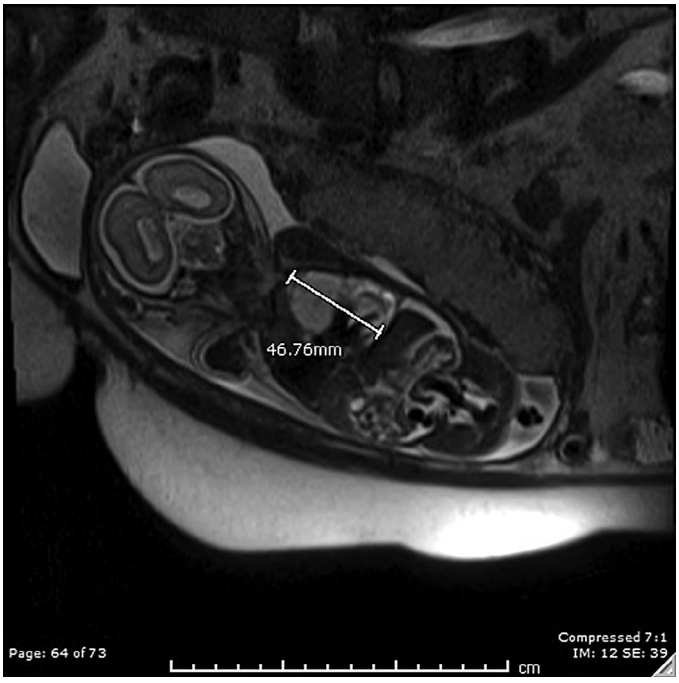

Fig. 118.5 A fetal MRI demonstrating a coronal image of a large congenital pulmonary airway malformation.

shrink dramatically before birth.[16] Because of this unpredictable growth, we recommend biweekly US evaluations until growth plateau is achieved. To better understand the natural history and prognosticate CPAM lesions, we developed the CPAM-Volume-Ratio (CVR).[17] A CPAM volume is determined using the formula for a prolate ellipse (length × height × width × 0.52). The CVR is obtained by dividing the CPAM volume by head circumference to correct for differences in fetal size. A CVR >1.6 at the initial presentation is predictive of an 80% risk of developing hydrops. The development of fetal hydrops

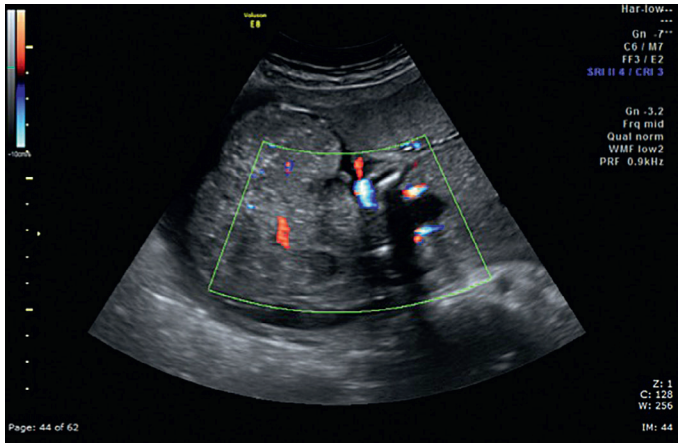

Fig. 118.6 An ultrasound image of a large type II sacrococcygeal teratoma.

unresponsive to maternal steroid administration is the only indication for fetal intervention in fetal lung lesions, as it may be an indicator of impending fetal demise. Maternal betamethasone was empirically observed to arrest the growth of CCAMs and allow the fetus to grow around the CPAM and cause hydrops to resolve.[18]

Open fetal surgery should be considered in predominantly solid large lung lesions associated with fetal hydrops and mediastinal shift, presenting before 32 weeks' gestation that have not responded to at least one or two courses of maternal betamethasone.

FETAL DEBULKING FOR LARGE SACROCOCCYGEAL TERATOMAS

Sacrococcygeal teratoma (SCT) is a congenital germ cell tumor. It is a mass located at the base of the coccyx and occurs in an average of 1:40,000 births. Most newborns diagnosed with SCT have a very favorable outcome, with a very small risk of associated malignancy. In contrast, prenatally diagnosed SCT has a poor prognosis and is fatal 30% to 50% of the time.[19] These tumors have a variable consistency, can undergo an unpredictable rate of growth, and demonstrate significant hemodynamic changes. While US is the primary modality to diagnose SCT (Fig. 118.6), MRI is crucial to delineate the intrapelvic extent of the SCT[20] (Fig. 118.7). The high mortality associated with prenatally diagnosed SCTs may be caused by premature birth secondary to polyhydramnios, dystocia secondary to large tumors resulting in traumatic tumor rupture and hemorrhage, and high output cardiac failure as a result of a large blood vessel supplying the tumor, or hemorrhage into the tumor.[21] A large tumor may result in a vascular steal from the placenta that can be documented by Doppler US and echocardiography. Some of the associated manifestations include reversal of diastolic flow in the umbilical arteries, abnormalities of placental thickness, diameter of the suprahepatic inferior vena cava, combined ventricular output, and descending aortic flow velocity.[22] The end result of this is placentomegaly, fetal hydrops, and ultimately a maternal "mirror syndrome," which can be life threatening for both mother and fetus. Very similar to cases of CCAM with hydrops, fetal intervention in these cases is indicated before the development of maternal mirror syndrome,[23] at which point the only option is delivery.



Fig. 118.7 A fetal MRI demonstrating a coronal image with a large type II sacrococcygeal teratoma.

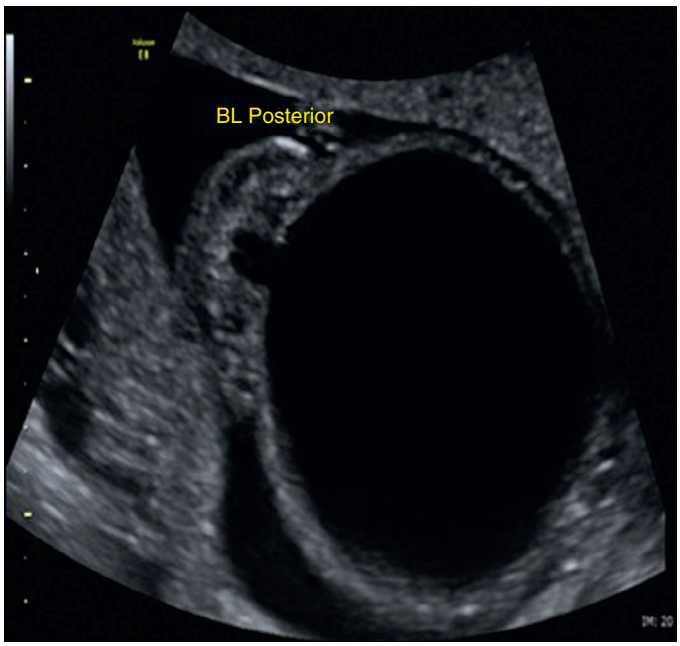

Fig. 118.8 An ultrasound image demonstrating the characteristic keyhole sign seen in cases of bladder *(BL)* outlet obstruction.

FETAL VESICOSTOMY FOR BLADDER OUTLET OBSTRUCTION

Fetal urinary tract obstruction has an incidence of approximately 1:500 pregnancies. Obstruction may be at any point along the genitourinary (GU) tract including the ureteropelvic junction, ureterovesical junction, bladder outlet obstruction (BOO) (Figs. 118.8 and 118.9), or anterior urethra. Differential diagnosis of LUTO is shown in Table 118.3.

BOO is a congenital obstruction of the GU tract estimated to occur between 0.4:10,000 and 2.0:10,000 live births. It is usually a sporadic finding without a known genetic cause and constitutes 10% of prenatal uropathies. The magnitude of the problem is highlighted by the associated 33% incidence of end-stage kidney disease in children <4 years of age.

Fetal surgery for BOO has had limited success. Despite 33 years of intervention, fetal therapy for BOO is suboptimal, and we are still treating a pulmonary problem with a GU indication.[24] The goal of fetal surgery is to allow pulmonary survival. However, we have not really addressed the primary underlying cause and prevented fetal renal failure or reversed its sequelae. Objective prediction of expected postnatal renal outcomes remains challenging, as not all fetuses with BOO are good candidates for intervention.[25] Some fetuses will clearly not benefit from intervention. Some are too healthy, so the risk of intervention outweighs any possible benefits (normal amniotic fluid index, nonobstructive dilatation, or unilateral involvement) or they are too sick, so intervention has minimal possibility of benefit and might harm the mother (cases of renal cystic dysplasia, abnormal urinary



Fig. 118.9 A fetal MRI image demonstrating a thickened bladder wall *(black arrow)* with a keyhole sign *(white arrow)* in a case of bladder outlet obstruction.

TABLE 118.3 DIFFERENTIAL DIAGNOSIS OF LOWER URINARY TRACT OBSTRUCTION

Transient Normal Variation in Bladder Size
Neurogenic bladder • Myelomeningocele • Caudal regression • Prune belly syndrome
Myopathic-Megacystis-Microcolon-Intestinal Hypoperistalsis Syndrome
Obstruction • Posterior urethral valves • Urethral atresia • Cloacal abnormalities

parameters, abnormal karyotype, or multiple associated anomalies). Patients who may benefit from fetal intervention include those with high-grade BOO associated with reversible renal injury and reversible lung impairment.

Glick et al. introduced fetal urinary electrolyte criteria in 1985 to develop predictive parameters for fetal intervention.[26] Renal damage from fetal urinary tract obstruction is associated with salt wasting. Crombleholme et al. reported that a good prognosis was associated with urinary sodium of <100 mEq/L, a chloride of <90 mEq/L and an osmolality of <220 mOsm/L.[27] Data has been defined by sampling after 20 weeks, although normative values before 20 weeks have not been well defined.

The first successful surgical *in utero* decompression for hydronephrosis was achieved in 1982 when bilateral cutaneous ureterostomy was performed in a 21-week fetus; however, the neonate died from pulmonary hypoplasia.[1] A series of eight fetal vesicostomies had 50% survival. There have been no new case reports of open fetal surgery for obstructive uropathy since 2006, presumably because overall results are not better than with percutaneous shunting and the potential morbidity of fetal surgery is significantly higher.[28]

Procedure

The detailed technical aspects of open fetal intervention depend on the disease process being treated; however, approaches to entering the gravid uterus, fetal exposure, fetal and maternal monitoring, and anesthetic and tocolytic management are largely the same and will be discussed later (Fig. 118.10, Video 118.1).

EXPOSURE

The maternal abdomen is entered through a low transverse abdominal incision after marking the skin to determine symmetry. A midline fascial incision usually suffices to gain access to the peritoneal cavity (see Fig. 118.10). In cases of an anterior placenta, the rectus muscles may need to be incised to allow tilting of the uterus forward outside the abdominal cavity, providing access for a fundal or posterior hysterotomy. A large Alexis-O retractor (Applied Medical, CA, USA) is then placed deep to the fascia for improved exposure (see Fig. 118.10). It is important at this point to evaluate the degree of pressure on the uterine vessels when releasing the peritoneum and/or making a releasing incision in the fascia if needed. Depending on the need for uterine reposition, warm saline-soaked laparotomy pads are placed in the abdomen to retract the bowel and support the uterus. At this point, intraoperative US is used to map the fetal position and placental location. Occasionally, some fetal repositioning is required to allow for a direct access to the required fetal part. This is performed by external version, sometimes aided by removal of the abdominal packs. The edge of the placenta is then identified and marked on the surface of the uterus using electrocautery.

HEMOSTATIC HYSTEROTOMY

The position and orientation of the hysterotomy is planned to stay parallel to, and 3–4 cm from, the closest edge of the placenta (see Fig. 118.10). Before initiation of the hysterotomy, communication with the anesthesia team is crucial to time-transition to a tocolytic anesthetic regimen, as outlined subsequently. A "box stitch" is then created using polydioxanone sutures (PDS) placed transmurally under US guidance to anchor the membranes to the uterine wall and allow for retraction of the uterine wall away from the fetal parts (see Fig. 118.10). A 1-cm cruciate uterine incision is then made through the myometrium and amnion using electrocautery. Once the amnion is exposed and entered, we confirm clarity of the amniotic fluid, then compress the myometrium with Bainbridge clamps (Aesculap, Tuttlingen, Germany) to allow for successful firing of the uterine stapling device (see Fig. 118.10). At this point, an amniotic fluid sample is obtained for analysis. The uterine incision is then extended along the compressed tissues using a specially developed absorbable

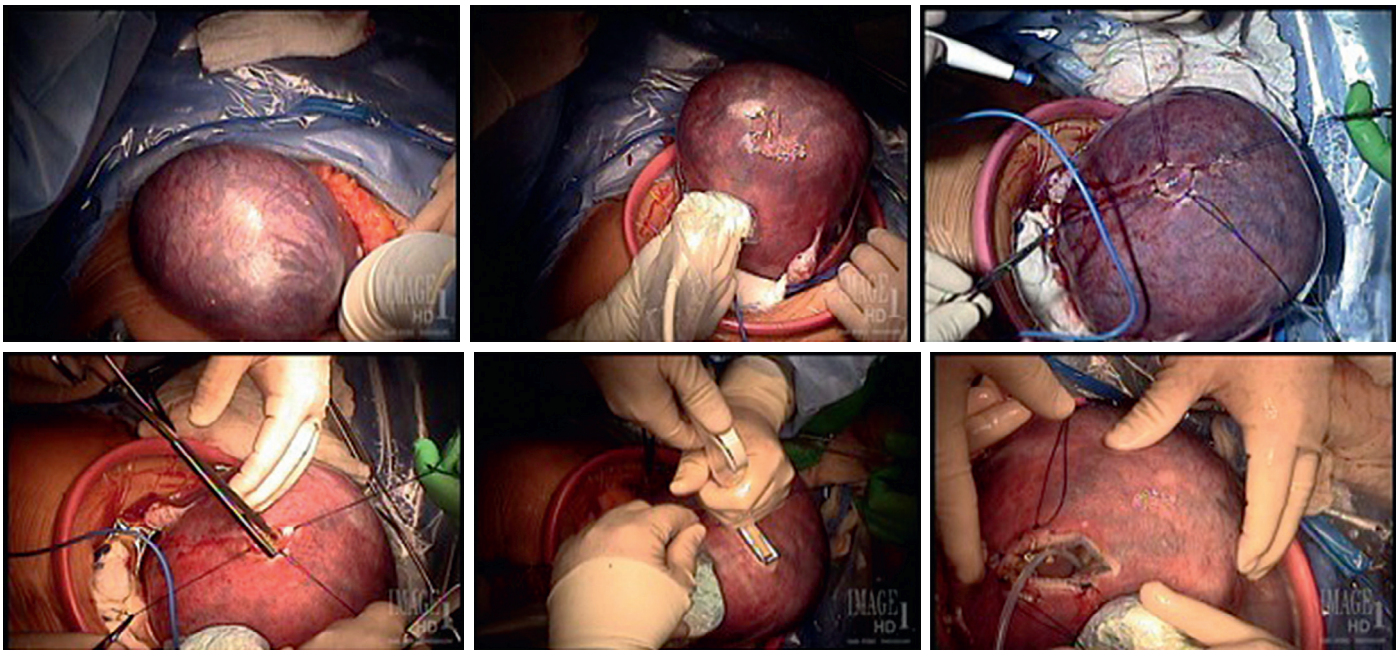

Fig. 118.10 A composite image demonstrating the steps of an open fetal repair of a myelomeningocele.

uterine stapler (Medtronic, Minneapolis, USA) that is fast, hemostatic, and seals the membranes to the myometrium.[4,5]

Once the hysterotomy is performed, a silicone catheter attached to a Level I (CO City USA) rapid-volume infusion device is placed into the uterine cavity followed by steady stream infusion of lactated Ringer's solution warmed to 37°C. This infusion is important to avoid cord compression and to maintain uterine volume. The appropriate fetal part is then brought into the field, leaving the rest of the fetus entirely within the womb.

ECHOCARDIOGRAPHIC MONITORING

Intraoperative fetal hemodynamic monitoring is a critical component of open fetal surgery, as fetal cardiovascular compromise has been reported in up to 60% of MMC repairs.[29,30] Before maternal anesthesia exposure, a fetal echocardiogram is performed the morning of surgery, to establish baseline fetal cardiovascular status. Continuous intraoperative fetal cardiac imaging begins after maternal abdominal incision and uterine exposure and extends through repositioning of the uterus within the maternal abdomen. Using a US probe in a sterile sheath, a pediatric cardiologist performs continuous fetal echocardiography on the exposed uterine wall to monitor fetal heart rate, ventricular filling, myocardial contractility, ductus arteriosus flow, and atrioventricular valve competence. Complete hemodynamic data is collected approximately every 15 minutes throughout the surgery, increasing to every 2 minutes during the period of open hysterotomy.

Acute fetal cardiovascular compromise, including fetal bradycardia, myocardial depression, valvular dysfunction, and ductus arteriosus constriction has been commonly reported.[30–32] Fetal bradycardia is most frequently a result of mechanical compression or kinking of the umbilical cord that can be seen at the time of fetal positioning for the repair. While the precise mechanism of fetal ventricular and valvular dysfunction remains unclear, the myocardial depressant effects of inhalational anesthesia may play a central role. Correlation between the duration and dosage of inhalational agents and fetal myocardial depression has been previously demonstrated,[33] leading to modifications in anesthetic management that is discussed later. Finally, progressive constriction of the ductus arteriosus during open fetal MMC repair can occur and is speculated to result from the combined effects of preoperative indomethacin, supplemental oxygen, and concurrent inhalational anesthesia.[31]

With careful echocardiographic monitoring during open fetal surgery, early recognition of fetal hemodynamic instability is possible. The real-time information provided from the fetal echocardiographic data can optimize intraoperative decision-making and guide therapy.

ANESTHETIC TECHNIQUE AND TOCOLYSIS

Open fetal surgical procedures are performed under general anesthesia. Preoperatively, a lumbar epidural catheter is inserted for postoperative analgesia. The patient is placed supine on the operating table with a wedge to maintain at least 15 degrees of left uterine displacement. After adequate preoxygenation, a rapid sequence induction is performed to facilitate endotracheal intubation. In addition to standard American Society of Anesthesiologists monitors, a radial arterial catheter is inserted for close hemodynamic monitoring, and a second intravenous access is obtained. General anesthesia is maintained with either inhalational agents or intravenous anesthetic agents such as propofol and remifentanil infusions. Maintaining adequate uteroplacental blood flow is vital during open fetal surgery, and maternal hypotension is treated with vasopressors such as phenylephrine and ephedrine.

Achieving controlled uterine hypotonia is one of the central tenets of open fetal surgery and traditionally high doses (2–3 times minimum alveolar concentration [MAC]) of inhalational agents have been used to ensure adequate uterine relaxation. Unfortunately, significant fetal cardiac dysfunction has been reported with the prolonged fetal exposure to high doses of inhalational agents.[29] Alternatively, using intravenous anesthetic agents (propofol and remifentanil infusions) for maintenance of maternal general anesthesia and starting inhalational agents just before hysterotomy, has enabled lowering the dose and duration of inhalational agents (1.5 MAC) for adequate uterine relaxation and minimized fetal cardiac dysfunction.[30] In addition, a 6-g load of intravenous magnesium sulfate followed by 2 g per hour infusion is started before hysterotomy. To minimize the risk of maternal pulmonary edema, intraoperative intravenous fluids are commonly limited to <1 L for the entire case.

Upon fetal exposure, a fetal intramuscular cocktail of fentanyl, muscle relaxant (pancuronium, vecuronium, or rocuronium), and atropine is administered to ensure fetal anesthesia and immobilization. Estimated fetal weight–based resuscitation doses of epinephrine and atropine are available on the surgical field. Close communication between the surgical and anesthesia teams is critical throughout the open fetal surgical procedure.

HYSTEROTOMY CLOSURE

Upon the successful completion of the procedure, the fetal part is returned to the uterine cavity followed by uterine closure. The absorbable uterine staples, made of polyglycolic acid, are left in place to avoid bleeding from the edge of the hysterotomy. Full-thickness No. 1 polydioxanone stay sutures are placed along the length of the hysterotomy. A running 0 PDS is used to complete the first layer. Before tying the running PDS, a deep vertical pocket (DVP) of amniotic fluid is measured followed by infusion of 400–500 mL of warm lactated Ringer's solution to reach a DVP of 3–5 cm. Ringer's infusion is then followed by instillation of 2 g of Nafcillin. The second layer follows by tying the stay sutures, and then a third layer of serosa-to-serosa sutures is placed to imbricate the hysterotomy. An omental flap is then placed over the hysterotomy and tacked in place using 4-0 Vicryl. After hysterotomy closure, the maternal laparotomy incision is closed in layers with tacking of the subcutaneous tissue to the fascia to limit postoperative seroma. A subcuticular maternal skin closure is then performed, reinforced by Dermabond (Ethicon, Somerville, NJ) to allow postoperative US surveillance.

POSTOPERATIVE MANAGEMENT

After closure of the laparotomy, a transvaginal US is performed to document cervical length. The patient is extubated at the end of the surgical procedure after bolusing the epidural catheter and reversing muscle paralysis. Adequate analgesia is an integral part of the postoperative management, as pain increases uterine irritability. We use continuous epidural fentanyl and local anesthetic (bupivacaine or ropivacaine), with patient-controlled rescue doses, and additional analgesics such as acetaminophen and ketorolac.

One of the most formidable consequences of open fetal surgery is preterm labor and premature rupture of membranes, secondary to the large uterine incision needed to safely perform these procedures. To minimize that risk, we use an aggressive tocolytic management strategy, including a combination of indomethacin, magnesium sulfate, and calcium channel blockers with transition to oral agents once stable. Despite such an aggressive approach, preterm labor is still a major risk in open fetal surgery, with the MOMS trial reporting a 38% risk of spontaneous labor and 50% of incidents of preterm premature rupture of membranes.[12]

Complications

Prenatal repair of MMC has expanded the indications of open fetal surgery, for the first time, to include nonlethal conditions.

Despite the benefits of such an approach, a 50% reduction in the need for postnatal ventriculoperitoneal shunting and reversal of hindbrain herniation, there are no direct benefits to the mother. In fact the mother has to assume the risks of fetal surgery including risks of anesthesia, surgery, hysterotomy, and postoperative tocolysis in addition to the obligatory need for future cesarean section delivery. In the 33-year history of open fetal surgery, there have been no maternal deaths, but the potential for maternal morbidity is significant. Maternal morbidity following open fetal surgery includes risk of chorioamniotic membrane separation, premature rupture of membranes (50%), chorioamnionitis, placental abruption, uterine dehiscence, pulmonary edema from aggressive tocolysis, subsequent uterine rupture, and the need for future cesarean section delivery.

Significant progress has been made in safely performing open fetal surgery, and the indications for fetal surgery have expanded. It is now well established that fetal surgery can improve fetal outcomes. Our current goal is to develop a less invasive surgical approach in order to reduce risk to the maternal-fetal dyad without altering our surgical goals. We have observed a progressive shift toward minimally invasive procedures, such as fetal tracheal occlusion for congenital diaphragmatic hernia, and anticipate that this trend will continue for prenatal MMC repair.

SUGGESTED READINGS

Adzick NS, Thom EA, Spong CY, et al. A randomized trial of prenatal versus postnatal repair of myelomeningocele. *N Engl J Med*. 2011;364:993-1004.

Deprest JA, Flake AW, Gratacos E, et al. The making of fetal surgery. *Prenat Diagn*. 2010;30:653-667.

Rychik J, Tian Z, Cohen MS, et al. Acute cardiovascular effects of fetal surgery in the human. *Circulation*. 2004;110:1549-1556.



All references available online at www.expertconsult.com

REFERENCES

1. Harrison MR, Ross N, Noall R, et al. Correction of congenital hydronephrosis in utero. I. The model: fetal urethral obstruction produces hydronephrosis and pulmonary hypoplasia in fetal lambs. *J Pediatr Surg*. 1983;118: 247-256.
2. Harrison MR, Naakayama DK, Noall RA, et al. Correction of congenital hydronephrosis in utero. II. Decompression reverses effects of obstruction on the fetal lung and urinary tract. *J Pediatr Surg*. 1982;17:965-974.
3. Harrison MR. Fetal surgery. *West J Med*. 1993;159:341-349.
4. Adzick NS, Harrison MR, Glick PL, et al. Automatic uterine stapling devices in fetal operation: Experience in a primate model. *Surg Forum*. 1985;36:479-480.
5. Bond SJ, Harrison MR, Slotnick RN, et al. Cesarean delivery and hysterotomy using an absorbable stapling device. *Obstet Gynecol*. 1989;74:25-28.
6. Deprest JA, Flake AW, Gratacos E, et al. The making of fetal surgery. *Prenat Diagn*. 2010;30:653-667.
7. Copp AJ, Adzick NS, Chitty LS, et al. Spina bifida. *Nat Rev*. 2015;1:1-18.
8. Detrait ER, George TM, Etchevers HC, et al. Human neural tube defects: developmental biology, epidemiology, and genetics. *Neurotoxicol Teratol*. 2005;27(3):515-524.
9. Greene ND, Copp AJ. Neural tube defects. *Annu Rev Neurosci*. 2014;37:221-242.
10. Meuli M, Meuli-Simmen C, Yingling CD, et al. In utero repair of experimental myelomeningocele saves neurological function at birth. *J Pediatr Surg*. 1996;31(3):397-402.
11. Adzick NS. Fetal surgery for myelomeningocele: trials and tribulations. *J Pediatr Surg*. 2010;47(2):273-281.
12. Adzick NS, Thom EA, Spong CY, et al. A randomized trial of prenatal versus postnatal repair of myelomeningocele. *N Engl J Med*. 2011;364:993-1004.
13. Tulipan N, Wellons JC, Thom EA, et al. Prenatal surgery for myelomeningocele and the need for cerebrospinal fluid shunt placement. *J Neurosurg Pediatr*. 2015;16:613-620.
14. Brock JW, Carr MC, Adzick NS, et al. Bladder function after fetal surgery for myelomeningocele. *Pediatrics*. 2015;136(4):e906-e913.
15. Adzick NS, Harrison MR, Glick PL, et al. Fetal cystic adenomatoid malformation: prenatal diagnosis and natural history. *J Pediatr Surg*. 1984;19: 649-657.
16. Adzick NS, Harrison MR, Crombleholme TM, et al. Fetal lung lesions: management and outcome. *Am J Obstet Gynecol*. 1998;179:884-889.
17. Crombleholme TM, Coleman BG, Howell LJ, et al. Cystic adenomatoid malformation volume ratio (CVR) predicts outcome in prenatal diagnosis of cystic adenomatoid malformation of the lung. *J Pediatr Surg*. 2002;37(3):331-338.
18. Morris LM, Lim FY, Livingston JC, et al. High-risk fetal congenital pulmonary airway malformations have a variable response to steroids. *J Pediatr Surg*. 2009;44:60-65.
19. Holterman AX, Filiatrault D, Lallier M, et al. The natural history of sacrococcygeal teratomas diagnosed through routine obstetric sonogram: a single institution experience. *J Pediatr Surg*. 1998;33:899-903.
20. Kirkinen PK, Partanen J, Merikanto J, et al. Ultrasonic and magnetic resonance imaging of fetal-sacrococcygeal teratoma. *Acta Obstet Gynecol Scand*. 1997;76:917-922.
21. Langer JC, Harrison MR, Schmidt KG, et al. Fetal hydrops and death from sacrococcygeal teratoma: rational for fetal surgery. *Am J Obstet Gynecol*. 1989;160:1145-1150.
22. Schmidt KG, Silverman NH, Harrison MR, et al. High output cardiac failure in fetuses with large sacrococcygeal teratoma: diagnosis by echocardiography and Doppler ultrasound. *J Pediatr*. 1989;114:1023-1028.
23. Adzick NS, Crombleholme TM, Morgan MA, et al. A rapidly growing fetal teratoma. *Lancet*. 1997;349:538.
24. Crombleholme TM, Harrison MR, Golbus MS, et al. Fetal intervention in obstructive uropathy: prognostic indicators and efficacy of intervention. *Am J Obstet Gynecol*. 1991;162:1239-1244.
25. Peters CA, Reid LM, Docimo S, et al. The role of kidney in lung growth and maturation in the setting of obstructive uropathy and oligohydramnios. *J Urol*. 1991;146:597-600.
26. Glick PL, Harrison MR, Golbus MS, et al. Management of the fetus with congenital hydronephrosis II. Prognostic criteria and selection for treatment. *J Pediatr Surg*. 1985;20:376-381.
27. Crombleholme TM, et al. Fetal intervention in obstructive uropathy: prognostic indicators and efficacy of intervention. *Am J Obstet Gynecol*. 1990;162(5):1239-1244.
28. Crombleholme TM, Harrison MR, Langer JC, et al. Congenital hydronephrosis: early experience with open fetal surgery. *J Pediatr Surg*. 1998;23:1114-1121.
29. Rychik J, Cohen D, Tran KM, et al. The role of echocardiography in the intraoperative management of the fetus undergoing myelomeningocele repair. *Fetal Diagn Ther*. 2015;37(3):172-178.
30. Rychik J, Tian Z, Cohen MS, et al. Acute cardiovascular effects of fetal surgery in the human. *Circulation*. 2004;110:1549-1556.
31. Howley L, Wood C, Patel S, et al. Flow patterns in the ductus arteriosus during open fetal myelomeningeocele repair. *Prenat Diagn*. 2015;35(6): 564-570.
32. Keswani S, Crombleholme T, Rychik J, et al. Impact of continuous intraoperative monitoring on outcomes in open fetal surgery. *Fetal Diagn Ther*. 2005;20:316-320.
33. Boat A, Mahmoud M, Michelfelder EC, et al. Supplementing desflurane with intravenous anesthesia reduces fetal cardiac dysfunction during open fetal surgery. *Paediatr Anaesth*. 2010;20:748-756.

119 Polyhydramnios

DOTUN OGUNYEMI | PERRY FRIEDMAN

Introduction

Polyhydramnios (also called *hydramnios*) is defined as an excessive amount of amniotic fluid. Although idiopathic in more than 50% of cases, it may be associated with maternal and fetal disorders. Polyhydramnios should prompt a detailed fetal anatomic ultrasound (US) scan and maternal evaluation.

Disease

DEFINITION

An amniotic fluid volume greater than 2000 mL constitutes polyhydramnios,[1] but accurate measurement requires invasive study and is difficult to assess clinically. In practice, ultrasonography methods used for diagnosing polyhydramnios include subjective assessment,[2,3] single deepest pocket (SDP),[3,4] or amniotic fluid index (AFI).[3,5] Polyhydramnios is defined by an absolute value or a gestational age–specific value. Some clinicians prefer the latter because the amniotic fluid volume changes throughout pregnancy, increasing linearly until the early third trimester and then remaining constant until term.[6,7] A recent study of 482 AFI and 468 SDP pregnancies with dye-determined amniotic fluid volumes between 15 and 41 weeks, demonstrated that both AFI and SDP correlated with actual amniotic fluid volume.[8]

Definitions of polyhydramnios vary and include AFI of ≥18 cm,[5] ≥20 cm,[9] ≥24 cm,[10] ≥25 cm[11] or SDP of ≥8 cm.[12–15] Polyhydramnios has been further classified as mild (AFI 24–30 cm, SDP 8–11.9 cm), moderate (AFI 30.1–35 cm, SDP 12–15.9 cm), and severe (AFI > 35 cm, SDP 16 cm).[3,16,17]

In gestational age–specific percentile charts, polyhydramnios is usually considered as ≥95th percentile or ≥97.5th percentile.[5,6]

PREVALENCE AND EPIDEMIOLOGY

Polyhydramnios affects approximately 1% of pregnancies (range 0.2%–3.9%) and has no apparent ethnic or geographic distribution.[1,3,11,18] Prevalence is affected by diagnostic criteria, but it is seen more frequently with certain conditions including diabetes, multiple gestations, fetal aneuploidy, and congenital defects such as fetal neurologic or musculoskeletal disorders, fetal anemia, and some genetic syndromes.

ETIOLOGY AND PATHOPHYSIOLOGY

Excessive production or decreased uptake of amniotic fluid can cause polyhydramnios. The former may result from increased urination by the fetus or increased transudation of fluid from exposed fetal surfaces.[1,6] Fetal diuresis in cases of high cardiac output or borderline cardiac failure may be caused by elevated atrial natriuretic peptide or brain natriuretic peptide.[1,6] Decreased uptake may occur from decreased swallowing of amniotic fluid by the fetus, usually secondary to neurologic dysfunction, esophageal compression, or atresia or other gastrointestinal obstructions (Table 119.1).[1,6]

Common causes of polyhydramnios include congenital anomalies or aneuploidy or genetic disorders (6%–45%), maternal diabetes (5%–25%), multiple gestations (7%–10%), and fetal anemia (1%–11%).[15,18,19] In one review of 672 pregnancies complicated by polyhydramnios, maternal diabetes accounted for 7% of cases; aneuploidy, 2%; and congenital anomalies, 11%.[18] In addition, the rate of anomalies was associated with the degree of polyhydramnios; 31% of fetuses with severe polyhydramnios (≥30 cm) had anomalies compared with 12% of fetuses with moderate polyhydramnios (25–29.9 cm), and 8% with mild polyhydramnios (20–24.9 cm).

Idiopathic polyhydramnios is defined as polyhydramnios, or excess amniotic fluid volume, which is not associated with congenital fetal anomalies, maternal diabetes, isoimmunization, fetal infection, placental tumors, or multiple gestations. Approximately 50%–60% of all cases of polyhydramnios are classified as idiopathic in etiology.[3,17] A review of literature on idiopathic polyhydramnios from 1950 to 2007 revealed an increase in the risk of adverse pregnancy outcomes, and a two- to fivefold increase in the risk of perinatal mortality when compared to pregnancies without polyhydramnios.[19]

MANIFESTATIONS OF DISEASE

Clinical Presentation

Polyhydramnios should be suspected when uterine size is larger than expected dates. It is usually gradual and chronic and associated with mild maternal discomfort. However, acute polyhydramnios is a potentially critical situation in which a sudden severe increase in amniotic fluid results in rapid increase of maternal abdominal size, often causing dyspnea, abdominal discomfort, uterine tenderness, and contractions.

TABLE 119.1 ETIOLOGY OF POLYHYDRAMNIOS BASED ON EXCESSIVE PRODUCTION OR DECREASED UPTAKE OF AMNIOTIC FLUID

Pathophysiology	Etiology
EXCESSIVE PRODUCTION OF AMNIOTIC FLUID	
Increased fetal cardiac output and/or polyuria	Uncontrolled maternal diabetes
	Twin transfusion syndrome
	Macrosomia
	Fetal hydrops
	Congenital infections
	Fetal anemia (e.g., isoimmunization, parvovirus infection)
	Fetal tumors (e.g., sacrococcygeal tumors)
	Placental tumors (e.g., chorioangioma)
	Congenital cardiac defects
	Fetal Bartter syndrome
	Anencephaly (lack of antidiuretic hormone)
Fetal diarrhea	Congenital chloride diarrhea
	Congenital sodium diarrhea
Increased transudation from exposed fetal surfaces	Anencephaly
	Spina bifida
DECREASED UPTAKE OF AMNIOTIC FLUID	
Neurologic dysfunction most likely causing decreased swallowing	Encephalopathy (white matter atrophy)
	Anencephaly (lack of swallowing reflex)
	Fetal akinesia deformation sequence
	Chromosomal anomalies (trisomies 21, 13, and 18)
Craniofacial dysfunction or obstruction	Pharyngeal teratoma (epignathus)
	Cleft lip
	Choanal atresia
	Fetal goiter
Gastrointestinal obstruction	Tracheoesophageal fistula
	Esophageal atresia
	Duodenal atresia
	Other intestinal atresia
	Midgut volvulus
	Gastroschisis
	Omphalocele
	Mesenteric cysts
	Imperforate anus
External gastrointestinal compression	Congenital diaphragmatic hernia
	Cystic adenomatoid malformation
	Skeletal dysplasia
	Unilateral massive multidysplastic kidney

The prognosis for untreated acute polyhydramnios is worse than for chronic polyhydramnios, with marked risks of premature delivery, neonatal morbidity, and mortality.[19] Amnioreduction (serial large-volume amniocentesis) is indicated if clinical symptoms would be improved by removing amniotic fluid (see later) or for disorders such as twin transfusion syndrome (Chapter 162).

Imaging Technique and Findings

Ultrasound. Amniotic fluid volume is evaluated via AFI or SDP. AFI is a sum of the deepest vertical pocket in each quadrant of the uterus excluding umbilical cord loops or fetal parts (Fig. 119.1).[14] SDP is a measure of the SDP of fluid (Fig. 119.2). In multiple pregnancies, SDP for each fetus is typically reported (Fig. 119.3).

Anomalies are noted in about 20% of cases of polyhydramnios,[20] especially if fetal swallowing is impaired. Fetal micrognathia or cleft lip/palate may obstruct swallowing. These anomalies are associated with multiple genetic syndromes and aneuploidies. Abnormal brain function may also compromise swallowing, and the fetus should be evaluated for central nervous system findings including neural tube defects, dilated ventricles, intracerebral cysts, or evidence of fusion or migration disorders.

In the chest, a mediastinal shift may suggest an intrathoracic mass that is causing esophageal compression, such as congenital diaphragmatic hernia (Fig. 119.4) or a cystic adenomatoid malformation of the lung. The fetal abdomen may show an abnormally small or absent stomach in cases of polyhydramnios, suggesting tracheoesophageal fistula or esophageal atresia (Fig. 119.5). Duodenal atresia, imperforate anus, choanal atresia, and other gastrointestinal obstructions may manifest with polyhydramnios, along with dilated loops of bowel or the "double bubble" sign in the abdomen, particularly after the second trimester.[18] A narrow thorax, especially in conjunction with shortened limbs, may suggest a skeletal dysplasia. Limb contractures may be seen with fetal akinesia syndrome, which is associated with reduced fetal swallowing.

Fetal hydrops (skin edema, ascites, pleural or pericardial effusion) with polyhydramnios should raise suspicion of aneuploidy or infection, in particular, if there are other findings (intraabdominal or intracranial calcifications, growth restriction, and thickened placenta). In the absence of other findings, fetal anemia should be suspected, and Doppler studies should be done for assessment. The placenta may reveal other pathology, such as chorioangioma, which may be associated with polyhydramnios because of increased fetal cardiac output.

In the absence of obvious anomalies, a fetal neurologic or musculoskeletal disorder must be considered. Two-dimensional and three-dimensional (3D) or four-dimensional (4D) US may elucidate the fetal swallowing mechanism; if this appears abnormal, suspicion of neuromuscular disorder is increased. Dynamic imaging with 4D US may identify movement disorders such as akinesia syndromes.

Polyhydramnios in the setting of a monochorionic multiple gestation raises concern for twin transfusion syndrome, especially if the other fetus has oligohydramnios (Fig. 119.6) (Chapter 162).

Doppler US should be considered in evaluation of a fetus with polyhydramnios. Middle cerebral artery Doppler is indicated in cases of suspected anemia (Chapters 123 and 124), and twin transfusion syndrome (see Chapter 162). Even if there is a low suspicion of these conditions, Doppler evaluation may provide information about fetal well-being; an inverse relationship between decreasing middle cerebral artery Doppler pulsatility index and increasing AFI exists, suggesting redistribution of blood flow to the brain.[21,22] An increased SDP and amniotic fluid pressure have been correlated with decreased fetal cord pH.[23,24]

Finally, 3D US imaging may be useful for evaluation of the fetal face, including the mandible in cases of micrognathia. As noted earlier, 4D US imaging allows observation

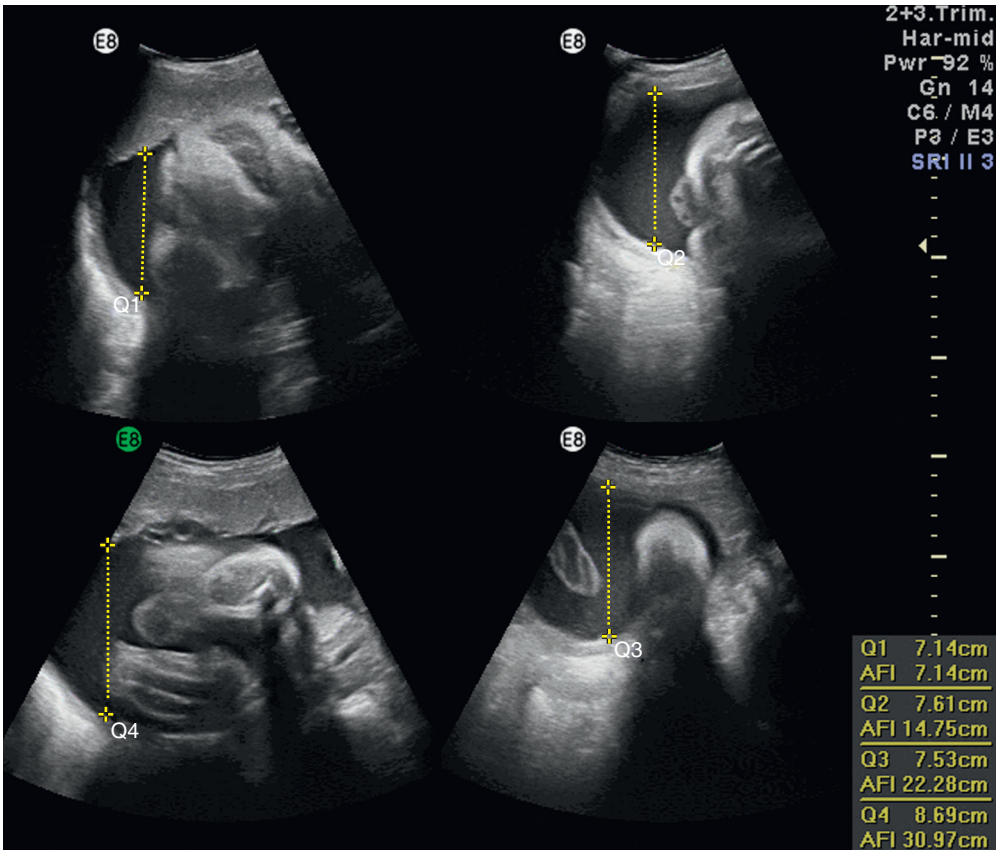

Fig. 119.1 Polyhydramnios measurement via sum of four quadrants.

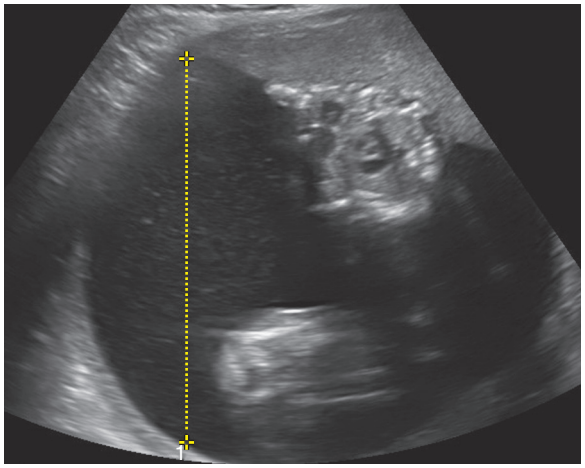

Fig. 119.2 Polyhydramnios measurement via the single deepest pocket in a twin pregnancy.

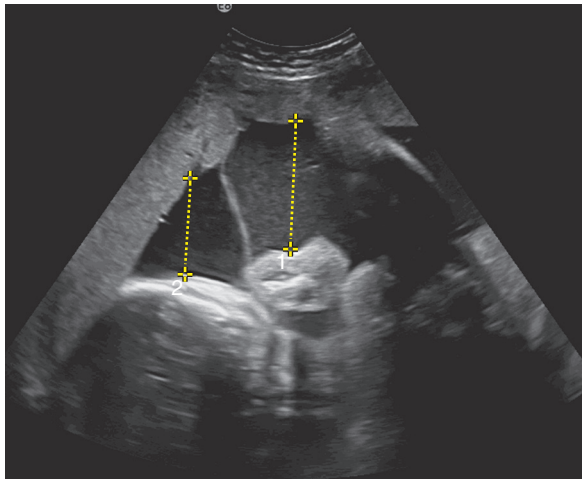

Fig. 119.3 Single deepest pocket measured on both sides of the dividing membrane in a patient with diamniotic dichorionic twin pregnancy.

of fetal swallowing, which may suggest a neuromuscular disorder.

Magnetic Resonance Imaging. Magnetic resonance imaging (MRI) may be a useful adjunct to US in cases of polyhydramnios[25] in which no anomalies are seen on US or to clarify or confirm CNS findings.[26] In addition, MRI should be considered for examination of fetuses with dilated bowels because it can be instrumental in making a prenatal diagnosis of congenital chloride or sodium diarrhea.[27]

CLASSIC SIGNS

Increased maternal abdominal girth and discomfort, possibly shortness of breath and a sensation of tightness.

In cases of monochorionic twins, rapid onset should raise suspicion of twin transfusion syndrome.

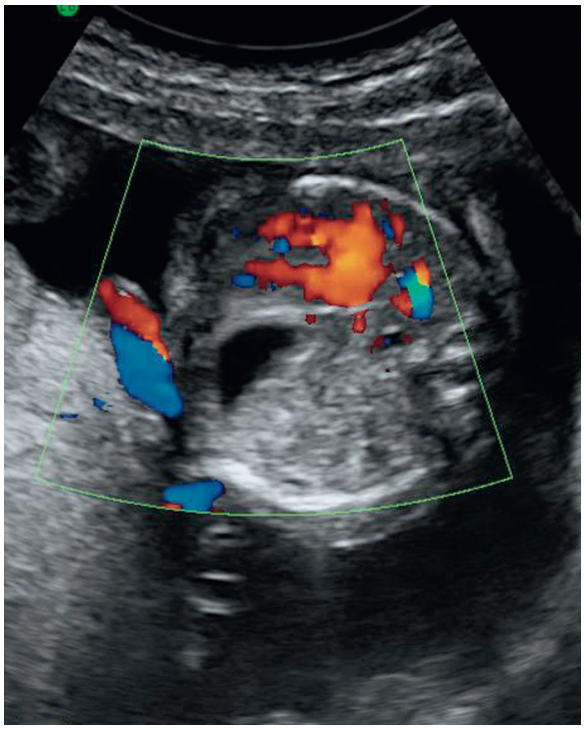

Fig. 119.4 Polyhydramnios in a fetus with congenital diaphragmatic hernia.



Fig. 119.5 Polyhydramnios in a fetus with esophageal atresia (note absence of stomach bubble).

Differential Diagnosis From Imaging Findings

The differential diagnosis of polyhydramnios is vast and is based on different etiologic factors (see Table 119.1).

Synopsis of Treatment Options

PRENATAL

Because polyhydramnios has multiple etiologies, there are several reasonable approaches to management and treatment.

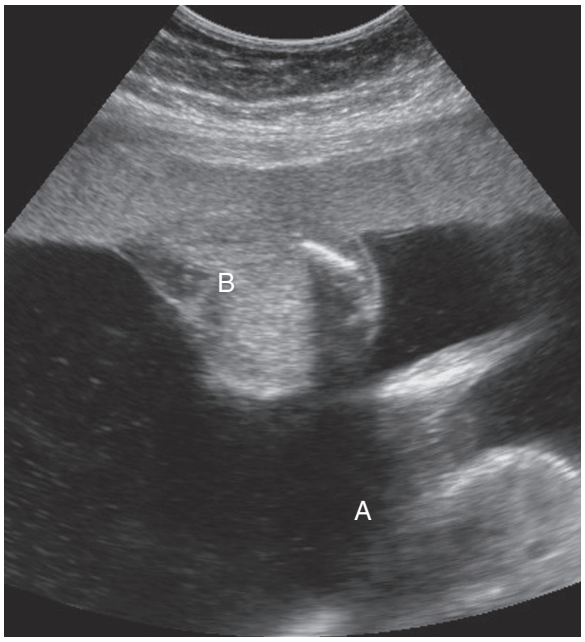

Fig. 119.6 Polyhydramnios of twin *A* and oligohydramnios of "stuck" twin *B* in fetuses with twin-twin transfusion syndrome.

Maternal diabetes is the cause in up to one-fourth of cases of polyhydramnios,[15] therefore all women presenting with this finding should be evaluated for diabetes with glucose screening. If routine glucose screening was previously normal, a repeat screen should be considered, especially if fetal biometry suggests macrosomia.

Amniocentesis for definitive genetic diagnosis should be offered, especially if there is high suspicion of aneuploidy, such as when polyhydramnios is accompanied by anomalies, minor markers of aneuploidy, advanced maternal age, abnormal maternal serum screen, or symmetric fetal growth restriction. Management of congenital anomalies and aneuploidies depends on the specific diagnosis. *In utero* therapy may be available for certain abnormalities (e.g., neural tube defects, diaphragmatic hernia, and certain heart lesions).

Congenital infection or alloimmunization should be in the differential diagnosis, especially if polyhydramnios is accompanied by fetal hydrops. Other evidence of infection includes intra-abdominal or intracranial calcifications, intrauterine growth restriction, or thickened placenta. Management approaches to congenital infections vary (Chapters 165 to 169), but for diagnosis, maternal serology should be offered, and polymerase chain reaction can be performed on amniotic fluid. A thickened placenta and other signs of fetal hydrops also raise suspicion of alloimmunization and should prompt maternal evaluation of red blood cell antibodies.

Amnioreduction is a therapeutic intervention aimed at reducing pain, dyspnea, and possibly preterm labor in cases with acute or symptomatic polyhydramnios. Amnioreduction has not been studied in randomized controlled trials. Comparisons of rapid versus slow decompression and single large-volume reduction versus serial small reductions have shown no difference in outcome.[15] A recent study of 135 cases of severe polyhydramnios in which 44 (32.6%) required amnioreduction showed no significant increase of complications with having the procedure.[28] Management of these cases will depend on gestational age, severity

of polyhydramnios, underlying cause, maternal symptoms, and the risk/benefit analysis.

Indomethacin reduces fetal urine production by reducing renal blood flow,[29] and its use has been reported in some cases of polyhydramnios.[15] Although indomethacin also has tocolytic effects, as with amnioreduction, there are no randomized controlled trials, and premature closure of the fetal ductus arteriosus is known to occur even with short-term use of indomethacin, especially after 32 weeks. Because of the potential for ductal closure, as well as longer-term fetal/neonatal renal side effects, this agent should be used cautiously, if at all, for the shortest possible duration and with the lowest possible dose, while under close surveillance, with fetal echocardiograms to assess flow through the fetal ductus arteriosus as indicated.[30]

With polyhydramnios secondary to anemia, intrauterine blood transfusion may be required. Laser ablation of placental vascular anastomoses may resolve fluid discrepancies in twin transfusion syndrome (see Chapter 162).[31]

Regardless of whether or not invasive intervention is pursued, close fetal monitoring is necessary because of associated increased fetal morbidity and mortality.[32,33] Monitoring may include fetal growth monitoring, biophysical profile, nonstress testing or both, and Doppler surveillance. Decreased adverse perinatal outcomes have been shown in pregnancies in which polyhydramnios spontaneously resolved.[34]

Finally, other consequences of polyhydramnios that may require specific antepartum and intrapartum pregnancy management include macrosomia, malpresentation, preterm labor, placental abruption, cord prolapse, cesarean delivery, postpartum hemorrhage secondary to uterine atony, neonatal intensive care unit admission, and perinatal mortality.[15,31,35,36]

POSTNATAL

Immediate neonatal assessment is warranted even in the absence of prenatally diagnosed anomalies. Further management is individualized and based on diagnosis. Neonates with a normal newborn examination typically do well. One prospective study examined 2597 pregnancies in which 73 had polyhydramnios. These pregnancies were more likely to be complicated by fetal macrosomia, abnormal fetal heart tracing, cesarean delivery for intolerance of labor, and neonatal intensive care unit admission.[32] A retrospective review of 24 children with unexplained polyhydramnios who were followed for 5 years after birth showed 19 (79%) had a normal outcome. West syndrome, polyuria, and pulmonary stenosis were diagnosed in three children during follow-up, while there were two perinatal deaths. It was suggested that pediatric follow-up of children born out of pregnancies complicated by unexplained polyhydramnios should be carried out systematically.[36]

KEY POINTS

- The definition of polyhydramnios varies; absolute AFI (e.g., ≥24 cm) or SDP (e.g., ≥8 cm) cutoffs or gestational age-specific tables may be used.[3]
- More than 50% of cases are idiopathic; if persistent, may be associated with increased risks of preterm delivery and macrosomia.[3]
- Significant etiologies include congenital anomalies, aneuploidy, genetic disorders, fetal infection, fetal anemia, and maternal diabetes.
- Prenatal care involves referral for a detailed US examination and consultation and close fetal monitoring.
- Polyhydramnios increases the risk of maternal dyspnea, preterm delivery, fetal macrosomia, malpresentation, umbilical cord prolapse, cesarean delivery, perinatal mortality, abruption, and postpartum hemorrhage.
- Treatment must be highly individualized and may include amnioreduction.

WHAT THE REFERRING PHYSICIAN NEEDS TO KNOW

More than half of cases of polyhydramnios are idiopathic and have an excellent prognosis. However, polyhydramnios may be associated with serious fetal or maternal disorders and warrants thorough fetal and maternal evaluation. This evaluation typically includes referral for detailed fetal anatomic US and possibly genetic counseling. Maternal evaluation should include a diabetic screen and possibly antibody titer and viral studies in appropriate cases. Close prenatal monitoring is indicated, even in cases of unexplained polyhydramnios, because of increased rates of perinatal morbidity and mortality.[17] Peripartum, the risk of cord prolapse, and postpartum hemorrhage are increased.

SUGGESTED READINGS

Harman CR. Amniotic fluid abnormalities. *Semin Perinatol*. 2008;32:288-294.

Magann EF, Chauhan SP, Doherty DA, et al. A review of idiopathic hydramnios and pregnancy outcomes. *Obstet Gynecol Surv*. 2007;62:795-802.

Magann EF, Doherty DA, Lutgendorf MA, et al. Peripartum outcomes of high-risk pregnancies complicated by oligo- and polyhydramnios: a prospective longitudinal study. *J Obstet Gynaecol Res*. 2010;36:268-277.

Marino T. Ultrasound abnormalities of the amniotic fluid, membranes, umbilical cord, and placenta. *Obstet Gynecol Clin North Am*. 2004;31:177-200.

Odibo IN, Newville TM, Ounpraseuth ST, et al. Idiopathic polyhydramnios: persistence across gestation and impact on pregnancy outcomes. *Eur J Obstet Gynecol Reprod Biol*. 2016;199:175-178.

Sandlin AT, Chauhan SP, Magann EF. Clinical relevance of sonographically estimated amniotic fluid volume: polyhydramnios. *J Ultrasound Med*. 2013;32(5):851-863.



All references available online at www.expertconsult.com

REFERENCES

1. Nobile de Santis MS, Radaelli T, Taricco E, et al. Excess of amniotic fluid: pathophysiology, correlated diseases and clinical management. *Acta Biomed*. 2004;75(suppl 1):53-55.
2. Magann EF, Perry KG Jr, Chauhan SP, et al. The accuracy of ultrasound evaluation of amniotic fluid volume in singleton pregnancies: the effect of operator experience and ultrasound interpretative technique. *J Clin Ultrasound*. 1997;25:249-253.
3. Odibo IN, Newville TM, Ounpraseuth ST, et al. Idiopathic polyhydramnios: persistence across gestation and impact on pregnancy outcomes. *Eur J Obstet Gynecol Reprod Biol*. 2016;199:175-178.
4. Manning FA, Platt LD, Sipos L. Antepartum fetal evaluation: development of a fetal biophysical profile. *Am J Obstet Gynecol*. 1980;136:787-795.
5. Phelan JP, Smith CV, Broussard P, et al. Amniotic fluid volume assessment with the four-quadrant technique at 36-42 weeks' gestation. *J Reprod Med*. 1987;32:540-542.
6. Brace RA, Wolf EJ. Normal amniotic fluid volume changes throughout pregnancy. *Am J Obstet Gynecol*. 1989;161:382-388.
7. Magann EF, Doherty DA, Chauhan SP, et al. How well do the amniotic fluid index and single deepest pocket indices (below the 3rd and 5th and above the 95th and 97th percentiles) predict oligohydramnios and hydramnios? *Am J Obstet Gynecol*. 2004;190:164-169.
8. Magann EF, Ounpraseuth S, Chauhan SP, et al. Correlation of ultrasound estimated with dye-determined or directly measured amniotic fluid volume revisited. *Gynecol Obstet Invest*. 2015;79:46-49.
9. Harlev A, Sheiner E, Friger M, et al. Polyhydramnios and adverse perinatal outcome—what is the actual cutoff? *J Matern Fetal Neonatal Med*. 2014;27(12):1199-1203.
10. Carlson DE, Platt LD, Medearis AL, et al. Quantifiable polyhydramnios: diagnosis and management. *Obstet Gynecol*. 1990;75:989-993.
11. Pri-Paz S, Khalek N, Fuchs KM, et al. Maximal amniotic fluid index as a prognostic factor in pregnancies complicated by polyhydramnios. *Ultrasound Obstet Gynecol*. 2012;39:648-653.
12. Magann EF, Sanderson M, Martin JN, et al. The amniotic fluid index, single deepest pocket, and two-diameter pocket in normal human pregnancy. *Am J Obstet Gynecol*. 2000;182:1581-1588.
13. Moore TR. Superiority of the four-quadrant sum over the single-deepest-pocket technique in ultrasonographic identification of abnormal amniotic fluid volumes. *Am J Obstet Gynecol*. 1990;163:762-767.
14. Marino T. Ultrasound abnormalities of the amniotic fluid, membranes, umbilical cord, and placenta. *Obstet Gynecol Clin North Am*. 2004;31:177-200.
15. Harman CR. Amniotic fluid abnormalities. *Semin Perinatol*. 2008;32:288-294.
16. Hill LM, Breckle R, Thomas ML, et al. Polyhydramnios: ultrasonically detected prevalence and neonatal outcome. *Obstet Gynecol*. 1987;69:21-25.
17. Moore TR, Cayle JE. The amniotic fluid index in normal human pregnancy. *Am J Obstet Gynecol*. 1990;162:1168-1173.
18. Dashe JS, McIntire DD, Ramus RM, et al. Hydramnios: anomaly prevalence and sonographic detection. *Obstet Gynecol*. 2002;100:134-139.
19. Magann EF, Chauhan SP, Doherty DA, et al. A review of idiopathic hydramnios and pregnancy outcomes. *Obstet Gynecol Surv*. 2007;62:795-802.
20. Ben-Chetrit A, Hochner-Celnikier D, Ron M, et al. Hydramnios in the third trimester of pregnancy: a change in the distribution of accompanying fetal anomalies as a result of early ultrasonographic prenatal diagnosis. *Am J Obstet Gynecol*. 1990;162:1344-1345.
21. Hershkovitz R, Furman B, Bashiri A, et al. Evidence for abnormal middle cerebral artery values in patients with idiopathic hydramnios. *J Matern Fetal Med*. 2001;10:404-408.
22. Hershkovitz R, Sheiner E, Furman B, et al. Uterine artery Doppler velocimetry in patients with idiopathic hydramnios. *Fetal Diagn Ther*. 2002;17:48-51.
23. Fisk NM, Tannirandorn Y, Nicolini U, et al. Amniotic pressure in disorders of amniotic fluid volume. *Obstet Gynecol*. 1990;76:210-214.
24. Fisk NM, Vaughan J, Talbert D. Impaired fetal blood gas status in polyhydramnios and its relation to raised amniotic pressure. *Fetal Diagn Ther*. 1994;9:7-13.
25. Laifer-Narin S, Budorick NE, Simpson LL, et al. Fetal magnetic resonance imaging: a review. *Curr Opin Obstet Gynecol*. 2007;19:151-156.
26. Rutherford MA. Magnetic resonance imaging of the fetal brain. *Curr Opin Obstet Gynecol*. 2009;21:180-186.
27. Colombani M, Ferry M, Toga C, et al. Magnetic resonance imaging in the prenatal diagnosis of congenital diarrhea. *Ultrasound Obstet Gynecol*. 2010;35:560-565.
28. Kleine RT, Bernardes LS, Carvalho MA, et al. Pregnancy outcomes in severe polyhydramnios: no increase in risk in patients needing amnioreduction for maternal pain or respiratory distress. *J Matern Fetal Neonatal Med*. 2016;29:1-4.
29. Norton ME. Teratogen update: fetal effects of indomethacin administration during pregnancy. *Teratology*. 1997;56:282-292.
30. Abou-Ghannam G, Usta IM, Nassar AH. Indomethacin in pregnancy: applications and safety. *Am J Perinatol*. 2012;29:175-186.
31. Chmait R, Kontopoulos E, Quintero R. Fetoscopic management of complicated monochorionic twins. *Clin Obstet Gynecol*. 2009;52:647-653.
32. Magann EF, Doherty DA, Lutgendorf MA, et al. Peripartum outcomes of high-risk pregnancies complicated by oligo- and polyhydramnios: a prospective longitudinal study. *J Obstet Gynaecol Res*. 2010;36:268-277.
33. Wiegand SL, Beamon CJ, Chescheir NC, et al. Idiopathic polyhydramnios: severity and perinatal morbidity. *Am J Perinatol*. 2016;33:658-664.
34. Glantz JC, Abramowicz JS, Sherer DM. Significance of idiopathic midtrimester polyhydramnios. *Am J Perinatol*. 1994;11:305-308.
35. Ott WJ. Reevaluation of the relationship between amniotic fluid volume and perinatal outcome. *Am J Obstet Gynecol*. 2005;192:1803-1809, discussion 9.
36. Touboul C, Boileau P, Picone O, et al. Outcome of children born out of pregnancies complicated by unexplained polyhydramnios. *BJOG*. 2007;114:489-492.

120 Oligohydramnios

PERRY FRIEDMAN | DOTUN OGUNYEMI

Introduction

Oligohydramnios, a reduced amount of amniotic fluid, is associated with increased perinatal morbidity and mortality. Its presence should prompt fetal and maternal evaluation.

Disease

DEFINITION

The definition of oligohydramnios varies. It may be described subjectively, but accuracy is dependent on operator experience and gestational age; precise objective measurement requires invasive study and is difficult to assess clinically.[1,2] In practice, the amniotic fluid volume is usually approximated by semiquantitative sonographic measures: amniotic fluid index (AFI), single deepest vertical fluid pocket (SDP), or assessment of a single pocket (e.g., 2 × 2 cm).[1–6] Techniques are described later.

Amniotic fluid volume changes throughout pregnancy, increasingly linearly until the early third trimester and then remaining constant until term. Oligohydramnios is most often defined as AFI ≤ 5 cm or SDP ≤ 2 cm,[3,7] but has been defined in gestational age–specific percentile charts as less than or equal to third percentile or less than or equal to fifth percentile.[2,8] In a study of almost 300 women with dye-determined amniotic fluid volumes, there was no difference in oligohydramnios detection using absolute cutoffs of AFI or SDP versus gestational age–specific values.[2] Comparison of the sensitivities and specificities of AFI versus SDP in 11 studies suggested that the SDP may be the better descriptor of oligohydramnios; the predictive accuracy of SDP was identical to AFI and SDP correlated better with tests such as biophysical profile and Doppler assessment.[4,9,10] A metaanalysis of four randomized clinical trials (n = 3125) comparing perinatal outcomes of pregnancies with oligohydramnios based on AFI versus SDP found no difference in the primary outcome (neonatal intensive care unit admission), or in Apgar scores or umbilical artery pH less than 7.1, although use of AFI resulted in more frequent induction of labor and cesarean delivery for fetal distress. A recent multicenter randomized controlled trial including 1052 women with term singleton pregnancies also showed that use of the AFI method increased the rate of diagnosis of oligohydramnios and labor induction for oligohydramnios without improving perinatal outcome.[11] These findings suggest that SDP may be the preferable method, especially in a low-risk population.[12,13]

PREVALENCE AND EPIDEMIOLOGY

Oligohydramnios complicates 0.5% to 8% of pregnancies, and management and prognosis depend on gestational age and associated obstetric complications.[14,15] Outcomes are worse with earlier or more severe oligohydramnios (e.g., anhydramnios) (Fig. 120.1).[15–17] Etiologies include preterm premature rupture of membranes (PPROM) (Fig. 120.2), fetal abnormalities (especially of the genitourinary tract), and placental insufficiency (Fig. 120.3). In a retrospective review of 128 second-trimester (13–24 weeks, n = 128) and 122 third-trimester (25–42 weeks, n = 122) fetuses with oligohydramnios, the former were more likely to be anomalous and less likely to have unexplained oligohydramnios, whereas the reverse was true of third-trimester fetuses.[17] Specifically, among second-trimester fetuses, 50.7% were complicated by anomalies, 33.6% by PPROM, 7% by

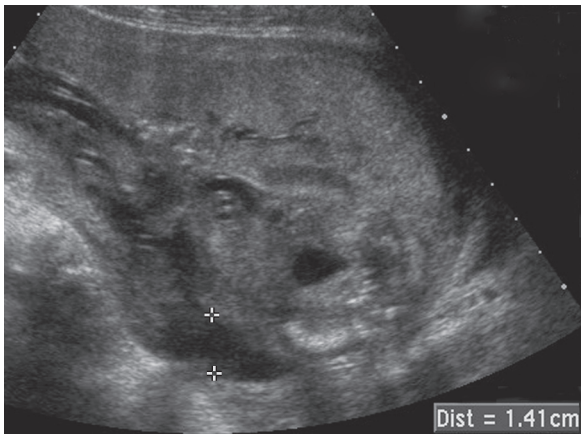

Fig. 120.1 Severe oligohydramnios in a 21-week fetus.

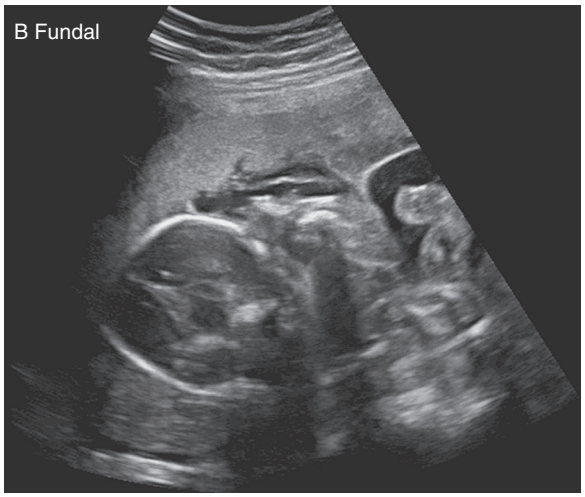

Fig. 120.2 Preterm premature rupture of membranes in a dichorionic diamniotic twin gestation.

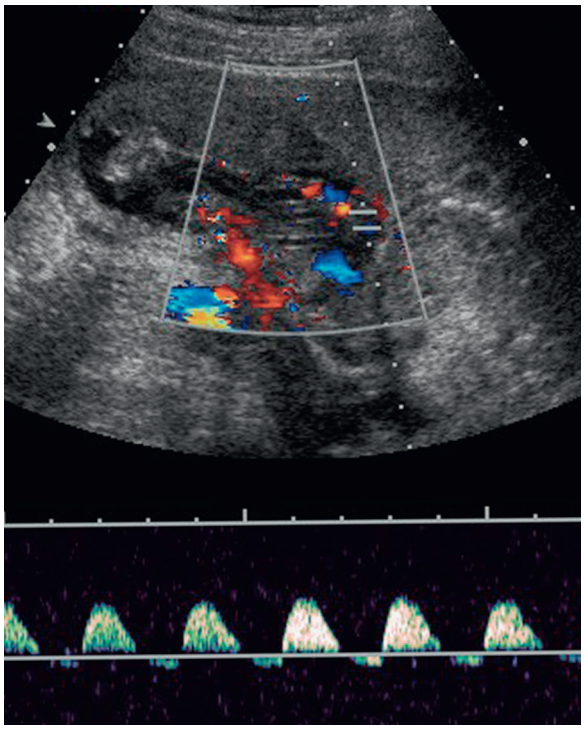

Fig. 120.3 Reversed end-diastolic flow and oligohydramnios in a 23-week fetus with growth restriction; the mother subsequently developed severe preeclampsia.

abruption, 5% by growth restriction, and only 4% were unexplained. In contrast, third-trimester fetuses were most likely to have unexplained oligohydramnios (52.5%), with anomalies noted in 22.1%, growth restriction in 20.5%, PPROM in 3.3%, and placental abruption in 1.6%. Accordingly, only 10.2% of second-trimester fetuses survived compared with 85.3% of third-trimester fetuses.

Pulmonary hypoplasia is the primary cause of mortality in pregnancies complicated by second-trimester oligohydramnios. Because amniotic fluid is required for the normal development and expansion of the pulmonary system, lack of adequate fluid at critical stages of lung development is associated with poor outcome. Pulmonary hypoplasia is more likely with oligohydramnios during or before 16–24 weeks' gestation, the canalicular phase of lung development, when the terminal sacs are developing, compared with later in gestation, when the terminal sacs are developed, and the primary changes to prepare for eventual gas exchange have occured.[18,19]

The association between outcome and severity of oligohydramnios was shown in a review of almost 29,000 fetuses at 24 to 34 weeks.[15] Of these, 166 had oligohydramnios (AFI ≤ 5 cm), 204 had "borderline" fluid (5.1–8 cm), and the remainder were normal (8.1–24 cm). Major malformations were present in 25% of fetuses with oligohydramnios compared to 10% with borderline, and 2% with normal fluid. Compared to fetuses with normal fluid, growth restriction was nine times more likely in fetuses with oligohydramnios, and five times more likely in those with borderline fluid. Risks of preterm birth and cesarean section were higher with oligohydramnios and borderline fluid, but morbidity and mortality were not significantly different with borderline fluid if fetal growth was appropriate. The authors concluded that close surveillance or delivery for oligohydramnios is warranted, but recommendations are not clear for borderline fluid.[15]

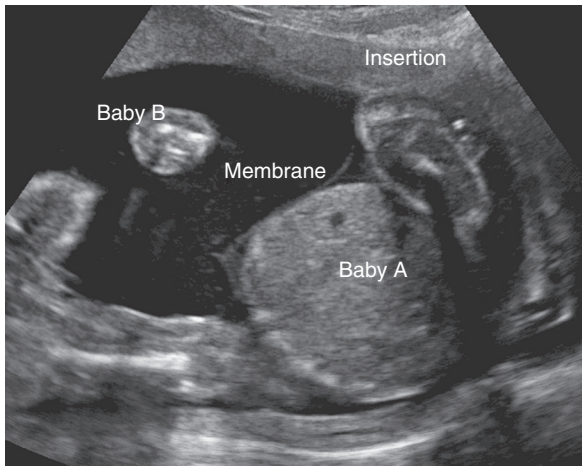

Fig. 120.4 Oligohydramnios in a fetus *(Baby A)* affected by tiwn-twin transfusion syndrome. *Baby B* has polyhydramnios.

ETIOLOGY AND PATHOPHYSIOLOGY

Amniotic fluid is necessary for normal development of the fetal respiratory, gastrointestinal, urinary, and musculoskeletal systems.[20] In the early fetal period, transudation across fetal skin and placental surfaces is the main contributor to amniotic fluid. After the skin is keratinized (22–23 weeks' gestation), the fluid is predominantly produced by fetal urine, with smaller contributions from oral, nasal, tracheal, and pulmonary fluids.[21] Removal of fluid occurs primarily through fetal swallowing.[20]

Reduced fetal urinary excretion from decreased production or genitourinary obstruction can cause oligohydramnios. These conditions can be characterized as prerenal, renal, or postrenal. Prerenal causes include fetal growth restriction (Chapter 112), twin-twin transfusion syndrome (Chapter 162) (Fig. 120.4), and maternal drug ingestion (including the tocolytic indomethacin and other nonsteroidal antiinflammatories). Briefly, placental insufficiency leads to chronic hypoxemia and growth restriction, and the fetus adapts by redistributing blood flow to vital organs such as the brain, heart, and adrenal glands, and away from peripheral organs, such as the kidney. Decreased renal perfusion leads to decreased urine output and oligohydramnios.[22] Maternal ingestion of drugs that affect fetal renal function can cause oligohydramnios. Angiotensin-converting enzyme inhibitors may affect renal development and function when taken in the second and third trimesters because they directly affect the fetal renin-angiotensin system. Other drugs that affect renal function include nonsteroidal antiinflammatory drugs (especially indomethacin) and cocaine.[23]

Renal causes of oligohydramnios include renal agenesis, multicystic dysplastic kidney, and polycystic kidney disease (Chapters 10, 11, 15, and 16).[23] Bilateral renal agenesis is lethal because of anhydramnios and subsequent pulmonary hypoplasia.

Postrenal causes of oligohydramnios result from obstructive uropathy, which affects 2.2:10,000 births.[24] Most cases are benign, but perinatal mortality is 90% in fetuses with severe oligohydramnios (anhydramnios) manifesting in the second trimester. Causes include posterior urethral valves, ureteropelvic junction

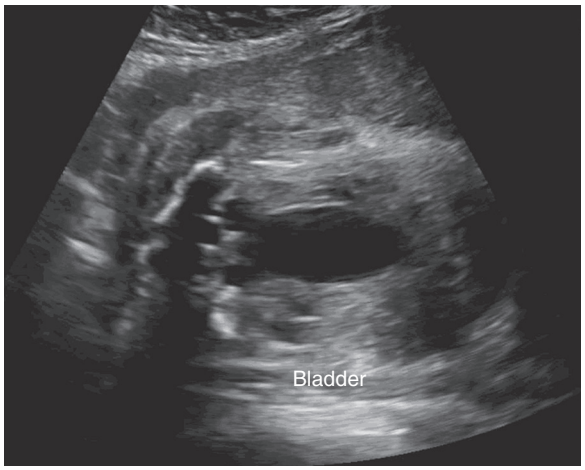

Fig. 120.5 Oligohydramnios in a fetus with obstructive uropathy. Note keyhole sign.

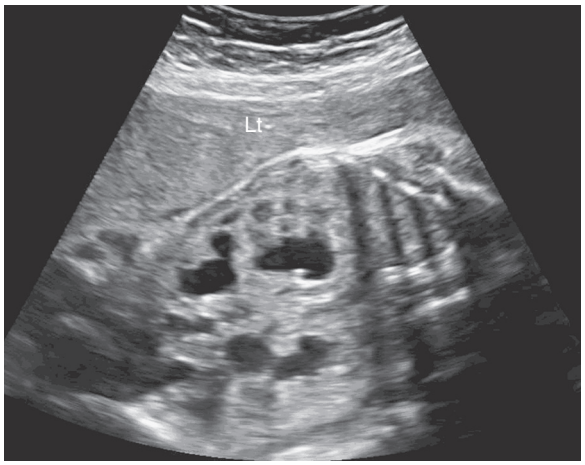

Fig. 120.6 Oligohydramnios in a fetus with ureteropelvic junction obstruction. *Lt,* Left side.

obstruction, urethral atresia, and urethral stenosis (Figs. 120.5 and 120.6). Male fetuses are more commonly affected, but affected female fetuses may have more complex pathologies, such as cloacal anomalies.[24] The prognosis depends on renal function and underlying etiology.

PPROM is a major cause of oligohydramnios and can be spontaneous or iatrogenic from invasive fetal diagnostic or therapeutic procedures. Overall, PPROM occurs in 3% of pregnancies and accounts for one-third of all preterm births. Umbilical cord compression secondary to oligohydramnios can increase perinatal morbidity and mortality. The latency period between PPROM and delivery is associated with severity of oligohydramnios (e.g., anhydramnios is associated with shorter latency).[25] In addition, there is an inverse relationship between degree of oligohydramnios and risk of chorioamnionitis and neonatal sepsis in patients with PPROM.[25]

MANIFESTATIONS OF DISEASE

Clinical Presentation

Oligohydramnios is typically an incidental finding on routine ultrasound (US) examination. It should be suspected clinically when the fundal height is less than expected for dates, or if the patient complains of vaginal leaking of fluid. Common tests for rupture of membranes include sterile speculum examination (for fluid that is nitrazine positive and shows ferning) or tests that detect a protein marker of amniotic fluid in the vagina. If tests are equivocal, rupture of membranes can be diagnosed via US-guided amnioinfusion of indigo carmine dye followed by observation of leakage of blue fluid through the cervix.[26] Indigo carmine has been used in the "amnio-dye test" to confirm ruptured membranes in the past; however, widespread shortages in the availability of this agent and the absence of a suitable substitute have made this test impractical.

Imaging Technique and Findings

Ultrasound. US has been used for semiquantitative measures of amniotic fluid using tools such as AFI, SDP, or assessment of a single pocket (e.g., 2 × 2 cm).[2–6] The patient lies supine, and the transducer is kept in the maternal sagittal plane, perpendicular to the maternal coronal plane. AFI is the sum of the deepest vertical pocket of fluid, excluding fetal parts and umbilical cord, in four quadrants between the maternal midline vertically and a transverse line halfway between the pubic symphysis and uterine fundus.[14,27] SDP is a measure of the single deepest pocket of fluid.

A careful fetal structural survey is warranted in the case of oligohydramnios, even with a previous normal anatomic survey, because of the possibility of a previously unrecognized anomaly, especially renal. One pitfall in bilateral renal agenesis is that the adrenal glands may assume a discoid shape and move laterally and inferiorly, mimicking kidneys. One distinguishing feature of renal agenesis is absence of a bladder.[28] Color or power Doppler US can be used to identify the renal arteries, distinguishing kidneys from adrenal glands (see Chapter 11). Multicystic dysplastic kidney disease, a congenital renal condition with severely disorganized tubules, glomeruli, and ducts with cystic lesions in the collecting tubules, on US shows multiple noncommunicating cysts of varied sizes starting at the periphery of the affected kidneys with echogenic renal parenchyma between the cysts. Amniotic fluid may be normal in unilateral cases[23] (see Chapter 15).

Prenatal renal impairment may result from polycystic kidney disease, in which cysts form in normally developing kidneys, making them appear cystic and echogenic upon US. There are two forms: autosomal dominant and autosomal recessive. The latter manifests as large hyperechogenic kidneys and oligohydramnios, and can be lethal[23] (see Chapter 16). In contrast, autosomal dominant polycystic kidney disease manifests later in life and typically is not found on prenatal US, although cyst formation begins *in utero.*

Oligohydramnios may result from various forms of renal obstruction, and US detects fetal obstructive uropathy with a sensitivity of 95% and specificity of 80%.[24] Findings suggestive of obstruction are dilation of the renal pelvis and calyces, increased renal echogenicity, and bladder distention. When obstructive uropathy is suspected, detailed assessment should include evaluation of dilation (hydronephrosis, hydroureter), renal parenchyma (echogenicity), renal size, and bladder size. In the case of bilateral hydronephrosis, a small or absent bladder suggests ureteropelvic obstruction, whereas a large bladder suggests bladder outlet obstruction. Posterior urethral valves should be suspected if the "keyhole" sign is present (enlarged bladder with dilatation of proximal urethra) (Chapters 12 and 14).

Severe oligohydramnios may result in deformation syndromes such as craniofacial deformities and limb defects, although detection is often because inadequate fluid results in a poor acoustic window. The fetus may have Potter facies, a "silk stocking effect," with flattened nose and low-set, flattened, enlarged external auricles.[18] There may be positional deformation of the hands and feet with flexion contractures of the elbows, knees, and feet. Transvaginal US scan may assist in evaluating extremities.

In the fetus with suspected placental insufficiency-related oligohydramnios, especially if growth restriction is also present, Doppler evaluation is indicated (Chapter 110).

Magnetic Resonance Imaging. If oligohydramnios makes US visualization suboptimal, magnetic resonance imaging (MRI) may be helpful.[29] This may be a useful complementary tool in fetal urinary tract anomalies diagnosed on US (see Fig. 120.6).[30]

CLASSIC SIGNS

Fundal height less than expected dates.
Leaking of fluid per vagina.

Differential Diagnosis From Imaging Findings

Conditions associated with oligohydramnios are listed in Table 120.1.

TABLE 120.1 CONDITIONS ASSOCIATED WITH OLIGOHYDRAMNIOS

MATERNAL
Uteroplacental insufficiency
Hypertension
Preeclampsia
Diabetes
Medications
- Angiotensin-converting enzyme inhibitors
- Nonsteroidal antiinflammatory drugs
- Cocaine abuse

FETAL
Premature rupture of membranes
Fetal growth restriction
Postterm pregnancy
Congenital anomalies
- Fetal renal defects
- Bilateral renal agenesis
- Infantile polycystic kidney disease
- Multicystic dysplastic kidney disease
- Fetal postrenal defects
- Posterior urethral valves
- Urethral atresia
- Urethral stenosis
- Megacystitis microcolon syndrome
- Ureterocele

Chromosomal abnormalities
Fetal demise

PLACENTAL
Twin transfusion syndrome
Placental abruption

Synopsis of Treatment Options

PRENATAL

Management of oligohydramnios depends on the underlying etiology and gestational age. Pregnancy termination should be discussed in the case of certain lethal conditions that can be found in early pregnancy, such as bilateral renal agenesis and autosomal recessive polycystic kidney disease. If the cause of oligohydramnios is obstructive uropathy, US-guided percutaneous vesicoamniotic shunt placement may partially relieve the obstruction, improving renal function, increasing amniotic fluid volume, and reducing the risk of pulmonary hypoplasia. Although shunt placement may improve overall perinatal survival, long-term renal morbidity occurs among survivors.[24]

Serial assessment of fetal growth in patients with second-trimester unexplained oligohydramnios is warranted because of the concern for uteroplacental insufficiency. Antepartum testing that includes assessment of fluid (biophysical profile or modified biophysical profile) is also indicated because of the association between oligohydramnios and increased perinatal morbidity and mortality. In suspected cases of uteroplacental insufficiency, the addition of Doppler evaluation increases the sensitivity for detecting poor perinatal outcomes.[31] Frequency of testing should be dictated by the clinical scenario.

If the cause of oligohydramnios is PPROM, delivery should be accomplished if the pregnancy is beyond 34 weeks.[32] Before 34 weeks, management that includes steroids to accelerate fetal lung maturity, latency antibiotics, and possibly magnesium sulfate neuroprophylaxis is directed at prolonging the pregnancy while monitoring closely for chorioamnionitis, preterm labor, placental abruption, or evidence of umbilical cord compression that would indicate delivery.[26,33]

A study of 987 pregnancies complicated by isolated oligohydramnios at term compared to 22,280 low-risk pregnancies with normal AFI revealed an association with increased labor inductions, cesarean section rates and short-term neonatal morbidities including neonatal intensive care unit admission.[34] However, after adjusting for confounding variables, isolated oligohydramnios was not found to be independently associated with increased risk for composite adverse outcome; this finding has been confirmed by other studies.[35,36]

Intrapartum, oligohydramnios may be associated with recurrent variable decelerations. Transcervical amnioinfusion has been shown to reduce decelerations and the risk of cesarean section in cases of category 2 fetal heart rate tracings. Experimental studies have evaluated transabdominal amnioinfusion for improvement of perinatal outcome after second-trimester spontaneous or iatrogenic PPROM (after amniocentesis or fetal surgery), but currently this is not standard practice.[37]

Postnatal management depends on the etiology of oligohydramnios.

WHAT THE REFERRING PHYSICIAN NEEDS TO KNOW

When oligohydramnios is detected, referral to a center with expertise in fetal evaluation for US and possibly genetic counseling is indicated. The prognosis and prenatal and postnatal care depend on the source of the oligohydramnios.

KEY POINTS

- Oligohydramnios is defined as SDP≤ 2 cm, AFI ≤ 5 cm, or AFI at the ≤ fifth percentile or ≤ third percentile for gestational age.
- The most common cause of oligohydramnios is ruptured membranes.
- Targeted US should be performed to evaluate fetal anatomy, with specific attention to fetal renal pathology or obstructive uropathy.
- Fetal growth should be assessed serially.
- Second-trimester oligohydramnios or anhydramnios is associated with lethal pulmonary hypoplasia.
- Third-trimester unexplained oligohydramnios is typically associated with a good outcome.

SUGGESTED READINGS

Morris RK, et al. Association and prediction of amniotic fluid measurements for adverse pregnancy outcome: systematic review and meta-analysis. *BJOG*. 2014;121(6):686-699.

Petrozella LN, Dashi JS, McIntire DD, et al. Clinical significance of borderline amniotic fluid index and oligohydramnios in preterm pregnancy. *Obstet Gynecol*. 2011;117:338-342.



All references are available online at www.expertconsult.com.

REFERENCES

1. Goldstein RB, Filly RA. Sonographic estimation of amniotic fluid volume. Subjective assessment versus pocket measurements. *J Ultrasound Med*. 1988;7:363-369.
2. Magann EF, Doherty DA, Chauhan SP, et al. How well do the amniotic fluid index and single deepest pocket indices (below the 3rd and 5th and above the 95th and 97th percentiles) predict oligohydramnios and hydramnios? *Am J Obstet Gynecol*. 2004;190:164-169.
3. Magann EF, Sanderson M, Martin JN, et al. The amniotic fluid index, single deepest pocket, and two-diameter pocket in normal human pregnancy. *Am J Obstet Gynecol*. 2000;182:1581-1588.
4. Magann EF, Chauhan SP, Doherty DA, et al. The evidence for abandoning the amniotic fluid index in favor of the single deepest pocket. *Am J Perinatol*. 2007;24:549-555.
5. Manning FA, Harman CR, Morrison I, et al. Fetal assessment based on fetal biophysical profile scoring IV. An analysis of perinatal morbidity and mortality. *Am J Obstet Gynecol*. 1990;162:703-709.
6. Manning FA, Hill LM, Platt LD. Qualitative amniotic fluid volume determination by ultrasound: antepartum detection of intrauterine growth retardation. *Am J Obstet Gynecol*. 1981;139:254-258.
7. Phelan JP, Smith CV, Broussard P, et al. Amniotic fluid volume assessment with the four-quadrant technique at 36-42 weeks' gestation. *J Reprod Med*. 1987;32:540-542.
8. Brace RA, Wolf EJ. Normal amniotic fluid volume changes throughout pregnancy. *Am J Obstet Gynecol*. 1989;161:382-388.
9. Harman CR. Amniotic fluid abnormalities. *Semin Perinatol*. 2008;32:288-294.
10. Magann EF, Morton ML, Nolan TE, et al. Comparative efficacy of two sonographic measurements for the detection of aberrations in the amniotic fluid volume and the effect of amniotic fluid volume on pregnancy outcome. *Obstet Gynecol*. 1994;83:959-962.
11. Kehl S, Schelkle A, Thomas A, et al. Single deepest vertical pocket or amniotic fluid index as evaluation test for predicting adverse pregnancy outcome (SAFE trial): a multicenter, open-label, randomized controlled trial. *Ultrasound Obstet Gynecol*. 2016;47:674-679.
12. Nabhan AF, Abdelmoula YA. Amniotic fluid index versus single deepest vertical pocket as a screening test for preventing adverse pregnancy outcome. *Cochrane Database Syst Rev*. 2008;(3):CD006593.
13. Nabhan AF, Abdelmoula YA. Amniotic fluid index versus single deepest vertical pocket: a meta-analysis of randomized controlled trials. *Int J Gynaecol Obstet*. 2009;104:184-188.
14. Marino T. Ultrasound abnormalities of the amniotic fluid, membranes, umbilical cord, and placenta. *Obstet Gynecol Clin North Am*. 2004;31:177-200.
15. Petrozella LN, Dashe JS, McIntire DD, et al. Clinical significance of borderline amniotic fluid index and oligohydramnios in preterm pregnancy. *Obstet Gynecol*. 2011;117:338-342.
16. Moore TR, Longo J, Leopold GR, et al. The reliability and predictive value of an amniotic fluid scoring system in severe second-trimester oligohydramnios. *Obstet Gynecol*. 1989;73:739-742.
17. Shipp TD, Bromley B, Pauker S, et al. Outcome of singleton pregnancies with severe oligohydramnios in the second and third trimesters. *Ultrasound Obstet Gynecol*. 1996;7:108-113.
18. Graham JM. *Smith's Recognizable Patterns of Human Deformation*. 3rd ed. Philadelphia: Saunders; 2007.
19. Spong CY. Preterm premature rupture of the fetal membranes complicated by oligohydramnios. *Clin Perinatol*. 2001;28:753-759, vi.
20. Sherer DM. A review of amniotic fluid dynamics and the enigma of isolated oligohydramnios. *Am J Perinatol*. 2002;19:253-266.
21. Underwood MA, Gilbert WM, Sherman MP. Amniotic fluid: not just fetal urine anymore. *J Perinatol*. 2005;25:341-348.
22. Turan S, Miller J, Baschat AA. Integrated testing and management in fetal growth restriction. *Semin Perinatol*. 2008;32:194-200.
23. Vanderheyden T, Kumar S, Fisk NM. Fetal renal impairment. *Semin Neonatol*. 2003;8:279-289.
24. Lissauer D, Morris RK, Kilby MD. Fetal lower urinary tract obstruction. *Semin Fetal Neonatal Med*. 2007;12:464-470.
25. Vintzileos AM, Campbell WA, Nochimson DJ, et al. Degree of oligohydramnios and pregnancy outcome in patients with premature rupture of the membranes. *Obstet Gynecol*. 1985;66:162-167.
26. Mercer BM. Preterm premature rupture of the membranes. *Obstet Gynecol*. 2003;101:178-193.
27. Moore TR. Clinical assessment of amniotic fluid. *Clin Obstet Gynecol*. 1997;40:303-313.
28. Hubert KC, Palmer JS. Current diagnosis and management of fetal genitourinary abnormalities. *Urol Clin North Am*. 2007;34:89-101.
29. Hormann M, Brugger PC, Balassy C, et al. Fetal MRI of the urinary system. *Eur J Radiol*. 2006;57:303-311.
30. Barseghyan K, Jackson HA, Chmait R, et al. Complementary roles of sonography and magnetic resonance imaging in the assessment of fetal urinary tract anomalies. *J Ultrasound Med*. 2008;27:1563-1569.
31. Bardakci M, Balci O, Acar A, et al. Comparison of modified biophysical profile and doppler ultrasound in predicting the perinatal outcome at or over 36 weeks of gestation. *Gynecol Obstet Invest*. 2010;69:245-250.
32. Bulletins-Obstetrics ACoP. ACOG Practice Bulletin No. 80: premature rupture of membranes. Clinical management guidelines for obstetrician-gynecologists. *Obstet Gynecol*. 2007;109:1007-1019.
33. NIH Consensus Development Panel on the Effect of Corticosteroids for Fetal Maturation on Perinatal Outcomes. Effect of corticosteroids for fetal maturation on perinatal outcomes. *JAMA*. 1995;273:413-418.
34. Ashwal E, Hiersch L, Melamed N, et al. The association between isolated oligohydramnios at term and pregnancy outcome. *Arch Gynecol Obstet*. 2014;290:875-881.
35. Shrem G, Nagawkar SS, Hallak M, et al. Isolated oligohydramnios at term as an indication for labor induction: a systematic review and meta-analysis. *Fetal Diagn Ther*. 2016;40:161-173.
36. Rossi AC, Prefumo F. Perinatal outcomes of isolated oligohydramnios at term and post-term pregnancy: a systematic review of literature with meta-analysis. *Eur J Obstet Gynecol Reprod Biol*. 2013;169:149-154.
37. Ogunyemi D, Thompson W. A case controlled study of serial transabdominal amnioinfusions in the management of second trimester oligohydramnios due to premature rupture of membranes. *Eur J Obstet Gynecol Reprod Biol*. 2002;102:167-172.

SECTION TWO
Fetal Fluid Abnormalities

121 Lymphedema and Lymphatic Malformations

ANGELA BURGESS | ROBERT SILVER

Background

Dysregulation of the lymphatic system is a key factor in a variety of disorders, and may be associated with aneuploidy (especially monosomy X), autosomal, or X-linked genetic disorders, and/or multiple other conditions. Lymphatic disorders can be classified as primary or secondary. Primary or congenital lymphedema is most commonly associated with cystic hygroma (CH), and often leads to hydrops fetalis and fetal demise. Secondary lymphedema is typically the result of trauma, infection, or radiation treatment for cancer.[1] This chapter will focus on primary (congenital) lymphedema, especially the most common form of lymphatic malformation, CH.

Definition and Associated Conditions

Lymphedema, an accumulation of fluid in interstitial spaces, is characterized by an anatomic or functional defect that causes an imbalance between the rate of lymph production in tissues and removal via the lymphatic system. This results in an array of clinical outcomes ranging from mild cosmetic problems to serious genetic conditions. CH, the most common form of lymphatic abnormality, can lead to nonimmune hydrops and pregnancy loss. It is also discussed in Chapter 71.

Cystic Hygroma: is caused by a defect in communication between the lymphatic and venous systems leading to localized fluid accumulation within the posterior and posterolateral aspect of the neck, which can eventually progress to fetal hydrops.

Nonimmune Hydrops: are characterized by the presence of fluid in two or more fetal soft tissues and serous cavities. The prevalence ranges from 3 : 10,000–6 : 10,000 births. These include ascites, pleural effusions, pericardial effusions, and generalized skin edema[2] (Chapter 123).

There are many other causes of lymphedema that can have prenatal findings.

- Milroy disease (VEGFR-3): is usually inherited in an autosomal dominant fashion, may also be autosomal recessive and has multiple presentations, including unilateral or bilateral swelling of lower limbs or face with irreversible fibrotic changes, prominent veins, "ski-jump" toenails, and papillomatosis.[3]
- Noonan syndrome: can be autosomal dominant inheritance or *de novo,* with a prevalence of 1 : 10,000–4 : 10,000; is characterized by CH, short limbs, and cardiac defects in addition to lymphedema and pulmonary lymphangiectasia (Chapter 136).
- Neurofibromatosis: is an autosomal dominant disorder, with a prevalence of 2.5 : 10,000–3 : 10,000; characterized by a mutation in *NF1,* presents prenatally with macrocephaly, megalencephaly, *café-au lait* spots, pseudarthrosis, lisch nodules, and neurofibromas.
- Adams-Oliver syndrome: can be transmitted in an autosomal dominant or recessive manner, characterized by congenital cutis aplasia, scalp and skull defects, limb abnormalities, and occasional congenital heart defects.[4]
- Hennekam syndrome: is a rare autosomal recessive disorder with only 50 cases reported worldwide; characterized by lymphangiectasia, bilateral pleural effusion, hydrops,

facial anomalies, and mental retardation in addition to lymphedema.[5]

- Prader-Willi syndrome: is an autosomal recessive disorder that can be caused by a deletion in genes within the paternal arm of chromosome 15, or inheritance of two copies of chromosome 15 of maternal origin, termed *uniparental disomy,* and rarely translocation. There is a prevalence of 0.3:10,000–1:10,000 people worldwide. It is characterized by facial anomalies, hypogonadism, small hands and feet, and mental retardation.
- Angelman syndrome: is caused by a deletion of maternal arm of chromosome 15 with a prevalence of 0.5:10,000–0.8:10,000; characterized by microcephaly, neurologic delays with delayed development, severe intellectual disability, and ataxia.
- Aagenaes syndrome: an autosomal recessive disorder characterized as childhood growth delay, cholestatic liver disease, and generalized lymphedema.
- Lymphedema-distichiasis: is characterized by pubertal onset of peripheral lymphedema and is associated with the presence of a supplemental row of eyelashes (distichiasis) that arise from Meibomian glands.[3]
- Hypotrichosis-lymphedema-telangiectasia: has hair and cardiovascular anomalies along with lymphedema (severity associated with hydrops and stillbirth), linked to an abnormal *SOX18* gene.[6]
- Primary pulmonary lymphangiectasia: is associated with polyhydramnios, bilateral pleural effusions, severe thickening of the small bowel, and ascites. It can occur as a primary disease or as part of other lymphedema syndromes and may be transmitted in an autosomal dominant, recessive, or X-linked manner.[7]

Differential Diagnosis

The differential diagnosis of prenatally detected lymphedema includes teratoma (germ cell tumor with aggressive growth located on the anterior aspect of the neck), occipital encephalocele and meningocele (neural tube defect characterized by protrusions of the membranes of the brain, often associated with craniofacial abnormalities), hemangioma (benign vascular tumor involving the endovascular vessels that usually occurs on face or back, often self-resolving), and goiter (*in utero* enlargement of the thyroid).

Diagnosis

A CH, the most common lymphatic abnormality, is a congenital abnormality of the lymphatic system characterized by the presence of fluid-filled spaces (edema) at the sites of lymphatic-venous connection within the posterior neck and back of a fetus.[8] The diagnosis is made by ultrasound (US) findings of an enlarged hypoechoic space at the back of the fetal neck extending along the length of the fetal back. It can also be classified according to the presence or absence of septations; that is, septated versus nonseptated CH.[9] When CH appears septated, the prognosis may be worse than the nonseptated form (Fig. 121.1).[10,11] However, some studies have shown no difference in outcome between nonseptated and septated forms. Increasing size of the hygroma is associated with relatively worse outcome, regardless of septation. Therefore all fetuses with CHs, regardless of size and septation, require serial evaluation and assessment for associated anomalies.[12]

Prevalence

The incidence of prenatally diagnosed CH ranges from 1:200 spontaneous abortions,[13] but it is only 1:600 to 1:700[14] in low-risk pregnancies later in pregnancy. Data from the First and Second-Trimester Evaluation of Risk Trial showed a prevalence of 1:285 in first-trimester pregnancies.[9]

Primary lymphedema is relatively rare, affecting approximately 1:10,000 to 1.3:10,000 live births.[15] There is a slight female predominance with most of the associated syndromes, with female to male ratios estimated to be between 2.5:1 and 10:1.

Etiology

Lymphatic malformations are benign vascular lesions that arise from abnormalities in the embryologic development of the lymphatic system. Lymphatic malformations can be seen in any anatomic region but are more common in lymphatic-rich areas such as the head, neck, axilla and mediastinum, abdomen, and retroperitoneum. Cystic lymphatic lesions can be classified as macrocytic, microcytic, or combined.[16] The cause of CH is thought to be a defect in communication between lymphatic vessels, jugular lymph sacs, and jugular veins.[17] This is attributed to an expansion of either irregular embryonic lymphatic tissue or from

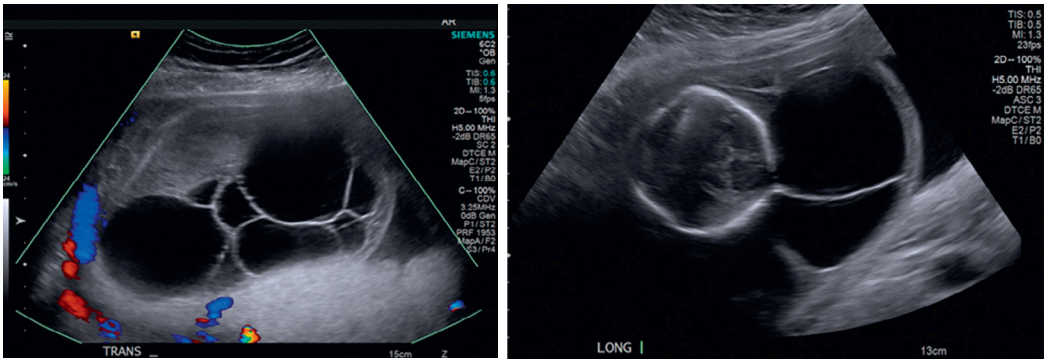

Fig. 121.1 Cystic hygroma in a 22-week fetus with multiple septations and oligohydramnios. *(Courtesy University of Utah Maternal-Fetal Diagnostic Center, Salt Lake City, Utah).*

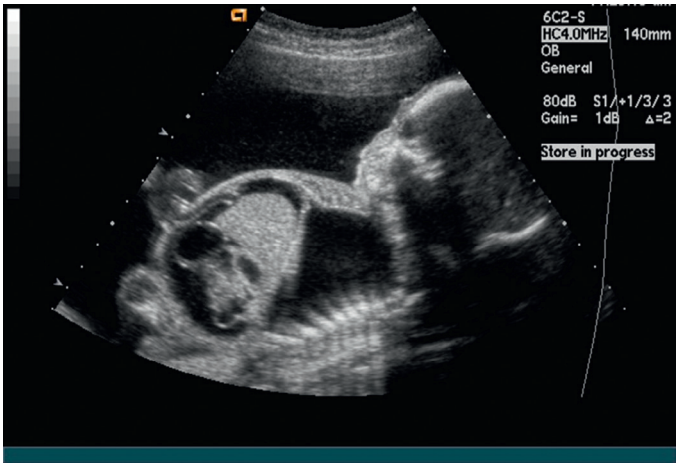

Fig. 121.2 Sagittal view of fetus with chylothorax. *(Courtesy of University of Utah Maternal-Fetal Diagnostic Center Salt Lake City, Utah).*

TABLE 121.1 Associated Malformations With Cystic Hygroma

Complications of Cystic Hygroma With Normal Karyotype	Defect Types
Cardiac anomaly	Hypoplastic left heart defect, VSD, aortic coarctation, tetralogy of Fallot
Genitourinary	Hydronephrosis, bladder malformations, hypoplastic or multicystic dysplastic kidney
CNS	Dandy-Walker malformation
Body wall defects	Gastroschisis, omphalocele, limb–body. wall complications

CNS, Central nervous system; *VSD,* ventricular septal defect.
Modified from Scholl J, Durfee S, Russell M, et al. First-trimester cystic hygroma: relationship of nuchal translucency thickness and outcomes. Obstet Gynecol 2012;120(3):551-9.

abnormal growth of lymphatic endothelium between 6 and 9 weeks' gestation, resulting in deficits within lymphatic vessels. Failure of the jugular lymphatic sacs to attach and drain into the jugular veins leads to lymphatic fluid stasis and progresses to a single or numerous fluid-filled lesions in various locations.[18] This leads to lymph fluid accumulation in the tissue, and in some cases, results in hydrops fetalis.

Primary lymphedema can also manifest as lymphangiectasia of internal organs. As described earlier, pulmonary lymphangiectasia is characterized by pulmonary, subpleural, interlobar, perivascular, and peribronchial lymphatic dilatation, and may be complicated by a chylous pleural effusion.[19] Lymphangiectasia can also occur in the intestines, leading to poor nutritional absorption and severe protein loss with resultant growth restriction.[5]

Nonimmune hydrops fetalis is associated with several congenital disorders, including those with lymphatic dysplasia.[2] One of the most common etiologies of hydrops is an imbalance in the regulation of fluid movement between vascular and interstitial spaces, with an increase in interstitial fluid production or a decrease in venous return.[2] The most common etiology of an isolated effusion leading to hydrops is chylothorax (Fig. 121.2) (Chapter 4), which is caused by lymphatic obstruction. The diagnosis is confirmed by the finding of a fetal pleural cell count with 80% lymphocytes in the absence of infection. Nonimmune hydrops is reviewed in more detail in Chapter 123.

There is a strong association between CH or other lymphedemas and genetic abnormalities, major congenital anomalies, perinatal loss, and other adverse outcomes. These abnormalities include genetic syndromes such as Angelman syndrome, Noonan syndrome, skeletal dysplasia, cystic fibrosis, neurofibromatosis, and cerebromandibular syndrome.[12,20] Turner syndrome is the most common associated chromosomal abnormality, affecting approximately 60% of aneuploidies. In addition, more recent studies have shown a considerable risk for Down syndrome, accounting for about 30% of aneuploidies.[9] Even fetuses with normal karyotype are at risk for major congenital anomalies; the majority are cardiac anomalies, and urinary, central nervous system, and body wall anomalies (Table 121.1).[9]

Manifestations of Disease

The prenatal presentation of CH varies. Primary lymphedema in the first trimester is suggested by increased nuchal translucency (NT), CH, regional lymphedema, or in some cases, generalized lymphedema.[1] In the second trimester, CH, fetal hydrops, and regional edema are more common (see Classic Signs box). CHs can resolve spontaneously or progressively affect other fetal structures separate from the neck including the pleura, pericardium, or the abdomen, leading to hydrops fetalis.[2,21]

Abnormalities associated with CH are increasingly common with increasing nuchal thickness. For example, some reports note that for every 1-mm increase in NT thickness, the odds of an abnormal karyotype increase by 42%.[22,23] Especially poor outcomes are associated with an abnormal karyotype and nuchal thickness of >6 mm.[9] The clinical presentation is highly variable, and includes multiple phenotypes because of the sheer number of genetic syndromes and structural malformations associated with lymphedema and lymphatic malformations.

Genetic Testing

Owing to the high rate of aneuploidy associated with CH, women should be offered genetic testing. Karyotype is usually the primary screening test for genetic abnormalities in cases of CH. Cells for analysis can be obtained via chorionic villus sampling or amniocentesis, depending upon gestational age and patient and provider preference. Fluorescence *in situ* hybridization (FISH) analysis may provide more rapid results for the most common aneuploidies associated with CH. Cell-free fetal deoxyribonucleic acid (cfDNA) screening is suboptimal and is not recommended in women with CH. If the test is performed, the family should be counseled regarding its limitations.

In fetuses with an increased NT (including CH) and normal karyotype, chromosomal microarray yields additional clinical valuable information beyond that obtained from karyotype in as many as 5% of cases.[24] Advantages over traditional karyotype include an ability to assess DNA extracted from cells (even nonviable ones), avoiding the need to culture amniocytes, as well as the identification of smaller chromosomal additions and deletions, termed *copy number changes*, than can be identified by cytogenetic testing. Disadvantages include cost

TABLE 121.2 Associated Genetic Abnormalities With Cystic Hygroma

ANEUPLOIDY
45, X (Turner syndrome)
Trisomy 21 (Down syndrome)
Trisomy 18 (Edward syndrome)
Trisomy 13 (Patau syndrome)
Trisomy 22
Triploidy
Ring chromosome 13
MALFORMATION SYNDROMES
Achondrogenesis II
Achondroplasia
Angelman syndrome
Cerebromandibular syndrome
Noonan syndrome
Beckwith-Wiedermann syndrome
Multiple pterygium syndrome
Short-Rib-polydactyl syndrome
Fryn syndrome
Fetal alcohol syndrome
Cowchock syndrome
Cowden syndrome
de Lange syndrome
Distichiasis-lymphedema
Fraser syndrome
Neurofibromatosis
Oculodentodigital syndrome
Opitz-Frias syndrome
Pena-Shokeir syndrome
Polysplenia syndrome
Proteus syndrome
Robert syndrome
Thrombocytopenia-absent radius
Williams syndrome
Zellweger syndrome

and the identification of copy number changes of uncertain clinical relevance. Accordingly, microarray can be performed as a primary screening tool in cases with CH, or alternatively, as a secondary test after most common aneuploidies have been excluded with normal FISH, polymerase chain reaction (PCR), or karyotype.[24–26]

Additional testing may be appropriate if there is suspicion of specific genetic syndromes or single gene disorders. This may involve PCR to assess known mutations, assessment of uniparental disomy, or unbalanced translocations. Genetic counseling is advised to facilitate testing for genetic conditions, including those that are not identified by karyotype on routine chromosomal microarray (Table 121.2).

Imaging

ULTRASOUND FINDINGS

CH is usually identified in the first trimester and is characterized by the presence of an enlarged hypoechoic space located posterior or posterolateral within the neck of the fetus with and without visible septations.[8,27,28]

Nuchal hygromas are frequently bilateral, separated by the nuchal ligament resembling a complex mass with one or more septa in the center. Oligohydramnios may also be present. Alternatively, there may be increased amniotic fluid volume, especially in cases with hydrops.

NT is measured in the midsagittal position. NT is considered increased when it is above the 99th percentile for gestational age. Increased NT is associated with increasing rates of abnormal karyotype, major congenital anomaly, perinatal loss, and abnormal outcome.[12] Increased NT is reviewed in detail in Chapter 46.

Serial US examinations are recommended and are useful to evaluate lesion size and progression. This can be helpful in guiding clinical decision-making and patient counseling regarding mode and timing of delivery.[7] In addition, worsening of prognosis can be determined by progression of hydrops or new onset of oligo- or polyhydramnios.[21] A fetal echocardiogram should be offered at 20–22 weeks' gestation caused by the increased risk for fetal cardiac abnormalities even in chromosomally normal fetuses.

MAGNETIC RESONANCE IMAGING

In select cases, magnetic resonance imaging may be useful in prenatal evaluation of airway access in cases of concern for airway compression and severe pleural effusions. Planning delivery with a multidisciplinary team including neonatal surgeons may be lifesaving in rare instances.

CLASSIC SIGNS

FIRST TRIMESTER	SECOND TRIMESTER
Increased nuchal translucency	Cystic hygroma
Cystic hygroma	Fetal hydrops
Generalized edema	Regional edema (face or extremities)
Regional edema (face or extremities)	Pleural or pericardial effusion

Synopsis of Treatment Options

PRENATAL

Fetuses with suspected lymphedema or lymphatic malformations should undergo targeted US and genetic counseling. Molecular genetic testing including microarray analysis may be warranted. Patients should be referred to a center with expertise in detailed examination of the fetus. Patients should also undergo serial USs for progression of disease. Termination of pregnancy may be offered, as appropriate. In rare cases, preparations for an ex utero intrapartum treatment (EXIT) procedure at a tertiary center with expertise in management in neonatal airway, and depending on the diagnosis, associated complications may be warranted.[7]

DEFINITIVE TREATMENT

Surgical

(1) *In utero* treatment: *in utero* treatment has been reported, although efficacy is uncertain. It is considered experimental and should be reserved for cases with normal karyotype

and an otherwise dismal prognosis. *In utero* sclerotherapy has been used for treatment of large intrathoracic macrocytic lymphatic formations. A palliative option is to drain pleural fluid, which may decrease the risk of pulmonary hypoplasia.[29] Options include thoracentesis, thoracoamniotic shunting, and pleurodesis. Good perinatal outcomes have been reported following these fetal interventions,[29] although the procedures should be reserved for severe cases of bilateral pleural effusion with an otherwise good prognosis. Reasonable candidates include those without (a) chromosomal abnormalities; (b) structural anomalies, or (c) severe hydrops.[17,30]

(2) Postnatal surgical excision: postnatal resection is the treatment of choice for CH and isolated lymphatic lesions. Although lesions are usually resectable, they may also involve the airway or other essential structures. Complications of surgical resection may include infection, recurrence, wound seroma, and nerve damage in 30% of cases.[31]

Nonsurgical

(3) OK-432 or Bleomycin injection: OK-432 (Chugai Pharmaceutical, Tokyo) is a biologic response modifier with an antitumor effect that has been used *in utero* and postnatally to treat CH. It has been established that intralesional injection of OK-432 is a safe and effective therapy for CH. Complete regression occurs in 40% to 50% of cases.[32] Bleomycin is an inhibitor of DNA biosynthesis and has a local sclerosing effect on endothelial cells.

With the advent of genetic testing and microarray analysis, basic investigations of lymphatic circulation have led to identification of key molecular processes that promote normal vascular and lymphatic development and differentiation. In turn, genetic and molecular abnormalities of several primary inheritable lymphatic disorders including *VEGFR-3* for Milroy disease, *FOXC2* for lymphedema-distichiasis syndrome, *SOX18* for lymphedema hypertrichosis, and a number of aneuploidies and chromosomal abnormalities associated with the development of lymphatic malformations and hydrops have been identified.[33] Theoretically, identification of these genetic associations and the possibilities for discovery of epigenetic modifications may hold the key for future studies in gene therapy.

KEY POINTS[7]

- Invasive testing for molecular diagnosis should be offered.
- Serial US examinations every 3–4 weeks to monitor progression and observe for fetal hydrops are recommended.
- Fetal echocardiogram is recommended.
- Fetuses with lymphedema should be immediately referred to a specialized center for detailed US and genetic counseling.
- Delivery should occur in a tertiary center with ability to perform EXIT procedure if airway or lung capacity is compromised.

WHAT THE REFERRING PHYSICIAN NEEDS TO KNOW

- Fetuses with suspected lymphedema or lymphatic malformations should undergo detailed US and genetic counseling.
- These patients should be referred to a center with expertise in detailed examination of the fetus.
- Molecular genetic testing including microarray analysis may be warranted.
- Patients should also undergo serial USs for progression of disease as well as fetal echocardiogram.
- Termination of pregnancy may be discussed, depending on the findings and prognosis.

SUGGESTED READINGS

American College of Obstetrics and Gynecology. Practice Bulletin No.162: prenatal diagnostic testing for genetic disorders. *Obstet Gynecol*. 2016;127(5):976-978.

American College of Obstetrics and Gynecology. Practice Bulletin No.163: screening for aneuploidy. *Obstet Gynecol*. 2016;127(5):e123-e137.

Grande M, Jansen F, Blumfield Y, et al. Genomic microarray in fetuses with increased nuchal translucency and normal karyotype: a systematic review and metaanalysis. *Ultrasound Obstet Gynecol*. 2015;46:650-658.

Laje P, Tharakan S, Hedrick H. Immediate operative management of the fetus with airway anomalies resulting from congenital malformations. *Semin Fetal Neonatal Med*. 2016;21:240-245.

Norton M, Chauhan S, Dashi J. Nonimmune hydrops fetalis. *Am J Obstet Gynecol*. 2015;127-138.

Ogita K, Suita S, Taguchi T, et al. Outcome of fetal cystic hygroma and experience of intrauterine treatment. *Fetal Diagn Ther*. 2001;16:105-110.

Rockson SG, Rivera KK. Estimating the population burden of lymphedema. *Ann N Y Acad Sci*. 2008;1131:147-154.



All references are available online at www.expertconsult.com.

REFERENCES

1. Rockson SG, Rivera KK. Estimating the population burden of lymphedema. *Ann N Y Acad Sci*. 2008;1131:147-154.
2. Norton M, Chauhan S, Dashi J. Nonimmune hydrops fetalis. *Am J Obstet Gynecol*. 2015;127-138.
3. Connell F, Brice G, Mortimer P. Phenotypic characterization of primary lymphedema. *Ann N Y Acad Sci*. 2008;1131:1-40.
4. Becker R, Kunze J, Horn D, et al. Autosomal recessive type of Adams-Oliver syndrome. *Ultrasound Obstet Gynecol*. 2002;20:506-510.
5. Bellini C, Mazella M, Aroni C, et al. Hennekam syndrome presenting as nonimmune hydrops fetalis, congenital chylothorax, and congenital pulmonary lymphangiectasia. *Am J Med Genet*. 2003;26:1058-1061.
6. Irrthum A, Devriendt K, Chitayat D, et al. Mutations in the transcription factor gene SOX18 underlie recessive and dominant forms of hypotrichosis-lymphedema-telangiectasia. *Am J Hum Genet*. 2003;72:1470-1478.
7. Helvey M, Feltovich H, Copel J, et al. *Lymphedema and lymphatic malformations. Obstetric Imaging*. Philadelphia, PA.: Elsevier; 2012:562-566.
8. Graesslin O, Derniaux E, Alanio E, et al. Characteristics and outcome of fetal cystic hygroma diagnosed in the first trimester. *Acta Obstet Gynecol Scand*. 2007;86:1442-1446.
9. Malone F, Ball R, Nyberg D, et al. First trimester septated cystic hygroma: prevalence, natural history, and pediatric outcome. *Obstet Gynecol*. 2005;106:288-294.
10. Bronstein M, Bar-hava I, Blumenfeld I, et al. The difference between septated and nonseptated nuchal cystic hygroma in the early second trimester. *Obstet Gynecol*. 1993;81:683-687.
11. Bernstein HS, Filly RA, Goldberg JD, et al. Prognosis of fetuses with a cystic hygroma. *Prenat Diagn*. 1991;11(6):349-355.
12. Scholl J, Durfee S, Russell M, et al. First-trimester cystic hygroma: relationship of nuchal translucency thickness and outcomes. *Obstet Gynecol*. 2012;120(3):551-559.
13. Azar G, Snijders RJM, Gosden CM, et al. Fetal nuchal cystic hygromata: associated malformations and chromosomal defects. *Fetal Diagn Ther*. 1991;6:46-57.
14. Marchese C, Savin E, Dragine E, et al. Cystic hygroma: prenatal diagnosis and genetic counseling. *Prenat Diagn*. 1985;221-227.
15. Rockson S. Primary lymphedema. In: Ernst C, Stanley J, eds. *Current Therapy in Vascular Surgery*. 4th ed. Philadelphia, PA: Mosby; 2000:915-918.
16. Elluri R, Balakrishnan K, Padur H. Lymphatic malformations: diagnosis and management. *Semin Pediatr Surg*. 2014;23(4):178-185.
17. Ogita K, Suita S, Taguchi T, et al. Outcome of fetal cystic hygroma and experience of intrauterine treatment. *Fetal Diagn Ther*. 2001;16(2):105-110.
18. Gedikbasi A, Oztarhan K, Aslan G, et al. Multidisciplinary approach in cystic hygroma: prenatal diagnosis, outcome, and postnatal follow-up. *Pediatr Int*. 2009;51:670-677.
19. Bellini C, Boccardo F, Campisi C. Congenital pulmonary lymphangiectasia. *Orphanet J Rare Dis*. 2006;1:43.
20. Howarth E, Draper E, Budd J, et al. Population-based study of the outcome following prenatal diagnosis of cystic hygroma. *Prenat Diagn*. 2005;25:286-291.
21. Ogita K, Suita S, Taguchi T, et al. Outcome of fetal cystic hygroma and experience of intrauterine treatment. *Fetal Diagn Ther*. 2001;16:105-110.
22. Shulman L, Emerson D, Felker R, et al. High frequency of cytogenetic abnormalities in fetuses with cystic hygroma diagnosed in first trimester. *Obstet Gynecol*. 1992;80:80-82.
23. Molina F, Avgidou K, Kagan K, et al. Cystic hygromas, nuchal edema, and nuchal translucency at 11-14 weeks of gestation. *Obstet Gynecol*. 2006;107:678-683.
24. Grande M, Jansen F, Blumfield Y, et al. Genomic microarray in fetuses with increased nuchal translucency and normal karyotype: a systematic review and metanalysis. *Ultrasound Obstet Gynecol*. 2015;46:650-658.
25. American College of Obstetrics and Gynecology. Practice Bulletin No.162: prenatal diagnostic testing for genetic disorders. *Obstet Gynecol*. 2016;127(5):976-978.
26. American College of Obstetrics and Gynecology. Practice Bulletin No.163: screening for aneuploidy. *Obstet Gynecol*. 2016;127(5):e123-e137.
27. Zalen-Sprock RM, Van Vugt JM, Van Geijn HP. First trimester diagnosis of cystic hygroma course and outcome. *Am J Obstet Gynecol*. 1992;167:94-98.
28. Pandeya PP, Santiago C, Snijders RJ, et al. First trimester fetal nuchal translucency. *Curr Opin Obstet Gynecol*. 1995;7:95-102.
29. Jeong B, Won H, Lee M, et al. Perinatal outcomes of fetal pleural effusion following thoracoamniotic shunting. *Prenat Diagn*. 2015;35:1365-1370.
30. Chen M, Chen CP, Shih JC, et al. Antenatal treatment of chylothorax and cystic hygroma with OK-432 in non-immune hydrops fetalis. *Fetal Diagn Ther*. 2005;20:309-315.
31. Raveh E, de Jong AL, Taylor GP, et al. Prognostic factors in treatment of lymphatic malformations. *Arch Otolaryngol Head Neck Surg*. 1997;123(10):1061-1065.
32. Kuwabara Y, Sawa R, Otsubo Y, et al. Intrauterine therapy for the acutely enlarging fetal cystic hygroma. *Fetal Diagn Ther*. 2004;191-194.
33. Lee BB, Villavicencio JL. Primary lymphedema and lymphatic malformation: are they the two sides of the same coin? *Eur J Vasc Endovasc Surg*. 2010;39:646-653.

122 Nonimmune Hydrops Fetalis

SAUL SNOWISE | ANTHONY JOHNSON

Introduction

Nonimmune hydrops fetalis (NIHF) was first explained by Potter,[1] who described fetal hydrops in the nonanemic fetuses of Rh-positive women. With the advent of anti-D immunoglobulin and the decreased incidence of immune-mediated hydrops, NIHF now comprises 90% of all fetal hydrops cases.[1a] NIHF presents a diagnostic dilemma for the treating physician secondary to the myriad etiologies that result in NIHF. Although overall fetal mortality remains high, the prognosis for fetuses affected by NIHF differs markedly depending on the underlying etiology. It is essential to attempt to identify the etiology to appropriately

counsel the patient about the prognosis, to plan possible corrective intervention, and to arrange for delivery in an appropriately-resourced center to maximize postnatal outcomes.[2]

DEFINITION

NIHF is defined as the presence of fetal hydrops in the absence of a maternal immunologic response to a paternally derived red blood cell antigen in the fetus.[3] Fetal hydrops is traditionally defined as the accumulation of fluid in at least two of the following fetal serous compartments; abdomen, pleural cavity, pericardium, and skin. Polyhydramnios and placental thickening are commonly included in the diagnostic criteria.

PREVALENCE AND EPIDEMIOLOGY

The prevalence of NIHF is estimated to be about 3:10,000–6:10,000 live births,[1a] but is higher in early gestation because of the hidden mortality associated with fetal demises and pregnancy terminations. This is evidenced by the reported incidence of NIHF ranging from 13:10,000–60:10,000 pregnancies in centers specializing in ultrasound (US) diagnosis.[4,5] There is a wide range of pathologies resulting in NIHF listed in Table 122.1 and discussed in depth subsequently.

The reported mortality from NIHF varies widely, ranging from 50%–98%[6–8] and most dependent on the underlying etiology, the gestational age at onset, the gestational age at the time of delivery, and the presence of pleural effusions. In general, the earlier the diagnosis of NIHF is made, the worse the prognosis. Euploid fetuses without major structural abnormalities have a better prognosis.

ETIOLOGY AND PATHOPHYSIOLOGY

Although numerous disparate etiologies result in fetal hydrops, the underlying pathophysiology in all NIHF cases is the altered

TABLE 122.1 ETIOLOGIES OF NONIMMUNE HYDROPS FETALIS

Cardiovascular	Structural • Hypoplastic left heart syndrome, atrioventricular septal defect, tricuspid atresia, pulmonary atresia, tetralogy of Fallot, premature closure of the ductus arteriosus or foramen ovale, rhabdomyoma, teratoma Arrhythmia • Tachyarrhythmia; supraventricular tachycardia, atrial fibrillation, Wolf-Parkinson-White syndrome, ventricular tachycardia maternal Graves' disease • Bradyarrhythmia; systemic lupus erythematous, Sjögren syndrome Functional • Parvovirus, cytomegalovirus • Cardiomyopathy
Chromosomal	Turner syndrome (45X), trisomy 21, trisomy 13, trisomy 18, triploidy
Hematologic	Hemorrhage • Chronic, acute fetomaternal hemorrhage • Fetal hemorrhage (intracranial, adrenal) Abnormal hemoglobin production • Alpha thalassemia Decreased red blood cell production • Congenital leukemia • Parvovirus, cytomegalovirus • Red call aplasia Increased hemolysis • Glucose-6-phosphate dehydrogenase deficiency, glucose phosphate isomerase deficiency, pyruvate kinase deficiency
Infectious	Parvovirus, syphilis, cytomegalovirus, toxoplasmosis, adenovirus, varicella, coxsackie virus, herpes simplex virus, respiratory syncytial virus, rubella, trypanosomiasis
Thoracic	Congenital pulmonary malformation, bronchopulmonary sequestration, congenital diaphragmatic hernia, hamartoma, teratoma, hydrothorax
Tumors	Teratoma (sacral, mediastinal, pharyngeal), hemangioma, lymphangioma, rhabdomyoma, neuroblastoma
Twins	Twin transfusion syndrome Twin reversed arterial perfusion sequence Heterokaryotic twins
Gastrointestinal	Midgut volvulus, malrotation, duplication, obstruction, meconium peritonitis, atresia (intestinal or biliary), hepatic (cirrhosis, necrosis or fibrosis), tumor, cholestasis
Genitourinary	Congenital nephrosis
Placenta, Cord	Chorioangioma, umbilical artery aneurysm, umbilical vein thrombosis
Skeletal Dysplasia	Thanatophoric dysplasia, osteogenesis imperfecta, achondrogenesis, short-rib polydactyly, thoracic dysplasia
Metabolic	Lysosomal Storage Disease • Gaucher disease • Generalized (GM1) gangliosidosis • Sialidosis • Mucopolysaccharidosis types IV and V • Tay-Sachs

movement of fluid between fetal vascular and interstitial spaces caused by one of several mechanisms:

- disruption of lymphatic drainage,
- increased venous pressures,
- increased capillary permeability,
- decreased osmotic pressure.

Bellini et al.[9] recently performed a systematic review evaluating the etiology of NIHF reported in the literature from 2007–2013, including 1338 cases. The categories most frequently associated with NIHF were, in descending order, cardiovascular (20.1%), lymphatic (15.0%), hematologic (9.3%), chromosomal (9.0%), infectious (7.0%), syndromic (5.5%), twin transfusion syndrome (TTS); placental (4.1%), thoracic (2.3%), inborn errors of metabolism (1.3%), gastrointestinal (1.3%), urinary tract (0.9%), and extrathoracic tumors (0.7%). The authors found that in 19.8% of cases, no cause of NIHF could be identified. Their work highlights some of the issues that exist when trying to classify the primary causes of NIHF. For example, there is a strong correlation between congenital heart disease and aneuploidy, as such, recording a cardiac malformation as the underlying etiology of fetal hydrops when the fetal karyotype is also abnormal, will lead to a decrease in the reported prevalence of aneuploidy in NIHF.

Cardiac abnormalities are the most common cause of NIHF, accounting for 20% of cases. They can be subdivided into disorders of structure, rhythm, or function. Structural CHD affects 8–9/1000 live births and the presence of a significant lesion in the presence of hydrops is almost universally lethal. The most common structural lesions associated with NIHF are hypoplastic left heart and atrioventricular septal defects,[9] but tricuspid and pulmonary atresia, tetralogy of Fallot, premature closure of the ductus arteriosus or foramen ovale, and cardiac tumors such as rhabdomyomas and teratomas have all been associated with NIHF. Structural cardiac defects result in hydrops either by increasing right atrial pressure or causing volume overload, with the end result of right-sided heart congestion. CHD has a strong correlation with aneuploidy, with over 15% of cases found to be affected.[10]

Cardiac arrhythmias are also associated with NIHF and can be divided in tachyarrhythmias and bradyarrhythmias. The most common tachyarrhythmias are supraventricular tachycardia, atrial flutter, Wolf-Parkinson-White, and ventricular tachycardia. Tachyarrhythmias lead to increased right atrial pressures and hydrops by decreasing ventricular filling times and causing venous congestion. Digoxin has been used successfully for cardioversion in the nonhydropic tachycardic fetus, but the presence of hydrops decreases placental transfer of this medication. Although it has increased maternal side effects, flecainide reaches therapeutic levels in the fetal compartment in the presence of hydrops and is the preferred medication for fetal tachycardia in this setting. Fetal arrhythmias can also result from maternal autoimmune disorders. Tachyarrhythmias with NIHF secondary to maternal Graves' disease can be treated with propylthiouracil or methimazole. Bradyarrhythmias are commonly associated with structural abnormalities that disrupt the normal cardiac conduction pathways. Similarly, circulating maternal antibodies associated with systemic lupus erythematous and Sjögren syndrome, specifically anti-Ro/SSA and anti-La/SSB antibodies can cross the placenta and damage the Purkinje fibers in the fetal heart leading to complete heart block. Fetuses can tolerate the ventricular escape heart rate that is normally between 70–75 beats/minute, but when the fetal heart rate drops below 50–55 beats/minute congestive heart failure and resulting hydrops are a risk. The development of hydrops before 32 weeks is associated with a poor prognosis as external cardiac pacing is unlikely to be successful in these preterm neonates. Treatment with steroids to prevent the progression of first or second degree heart block to complete heart block and treatment with B-agonists to increase fetal heart rates have not been shown to be effective and should only be undertaken in a research setting.[1a] Vascular tumors of the fetus and placenta can also result in cardiac decompensation and NIHF. Large, vascular lesions such as sacrococcygeal tumors and chorioangiomas can compromise cardiac output via the vascular steal phenomenon. The sequestration of fetal blood in these tumors when they are large and vascular may lead to high output cardiac failure and eventually hydrops.

Chromosomal abnormalities affect 7%–45% of NIHF cases and are more prevalent the earlier the hydrops is identified or in the presence of a structural abnormality.[8] The most common abnormalities are Turner syndrome (45X) and trisomy 21, but trisomy 13, trisomy 18, and triploidy have all been associated.[11] The underlying mechanism causing hydrops varies with each chromosomal abnormality. Turner syndrome is classically associated with cystic hygromas and lymphatic malformations, but is also strongly associated with coarctation of the aorta and hypoplastic left heart syndrome. Trisomy 21 is also strongly correlated with cardiac defects, in particular, atrioventricular septal defects. In addition, trisomy 21 affected fetuses also have an increased incidence of lymphatic malformations and congenital leukemia, both of which are associated with an increased risk of developing NIHF even with normal cardiac anatomy.[12] Fetal karyotype is indicated in all cases of NIHF. If not ordered at the time of initial testing, microarray should be requested if the fetal karyotype is normal, as molecular testing will detect an additional 7% of chromosomal abnormalities in NIHF missed by traditional tissue culture analysis.[13]

Hematologic abnormalities will be found in 7%–55% of NIHF cases[2,9] and include problems with abnormal hemoglobin production, decreased red blood cell production, increased hemolysis, and fetomaternal hemorrhage (acute or chronic), all of which can result in high output cardiac failure and NIHF. There are differences in the prevalence of certain hematologic abnormalities, determined by the ethnic population studied. The most common inherited hemoglobinopathy is alpha thalassemia, which accounts for over 50% of NIHF in patients of Southeast Asian ancestry and approximately 10% in other ethnic groups. Parents can be suspected as carriers of alpha thalassemia when there is a microcytic (mean corpuscular volume <80 fL), hypochromic anemia with normal iron studies. The most severe fetal form of alpha thalassemia is Bart's hemoglobinopathy in which the fetus lacks all four copies of the genes responsible for alpha globin chain formation. Other causes of NIHF caused by increased red blood cell destruction and fetal anemia include glucose-6-phosphate dehydrogenase deficiency (X-linked), glucose phosphate isomerase deficiency, and pyruvate kinase deficiency.[14] If fetomaternal hemorrhage is suspected, a Kleihauer-Betke test or flow cytometry should be ordered to detect the presence of fetal cells in the maternal circulation. In these cases, when severe enough, fetal blood sampling and intrauterine transfusion can maintain an adequate fetal hemoglobin concentration and prolong the gestation.[15] Regardless of the cause of the suspected anemia, interrogation of the middle cerebral artery peak systolic velocity (MCA-PSV) is predictive of fetal anemia when it exceeds 1.5 multiples of the median with a sensitivity of nearly 100% and

a specificity of 88%.[16] An MCA-PSV is therefore indicated in the evaluation of all hydropic fetuses.

Infections cause 4%–15% of NIHF.[2] Parvovirus is the most commonly encountered infection,[17] but syphilis, cytomegalovirus, and toxoplasmosis have all been reported to cause NIHF. Less frequent infectious causes include varicella, coxsackie virus, herpes simplex virus, and respiratory syncytial virus.[1a] Infections may result in hydrops via suppression of erythroid precursors, causing myocardial dysfunction, or hepatitis with a resultant hypoproteinemia. The infectious insult from parvovirus is usually transient, but if the anemia and myocarditis is severe enough, fetal transfusion may be needed to bridge the fetus until normal erythropoiesis is reinitiated (Chapter 167).

Complications from monochorionic (MC) twins make up a small percentage of NIHF, but are one of the causes most amenable to prenatal therapy (Chapters 159, 160, and 162). TTS results from the unequal distribution of volume across placental vascular anastomoses that exist between the twins all MC gestations. The end result is the net loss of volume in one fetus ("donor"), and volume overload in the other fetus ("recipient"). This volume overload in the recipient can potentiate congestive heart failure and hydrops as seen in Stage IV TTS. Fetoscopic laser ablation of the anastomotic vessels separates the circulation of the twins and leads to the eventual resolution of the hydrops in the recipient. Dual survival rates of approximately 70% in Stage IV TTS can be expected after laser surgery when performed in experienced centers[18] (http://childrens.memorialhermann.org/fetal/ttts/outcomes/). Twin reversed arterial perfusion (TRAP) sequence is another complication of MC twinning (Chapter 163). An arterioarterial anastomosis between the normal ("pump") twin and its acardiac sibling keeps the acardiac twin supplied with blood via retrograde flow through the umbilical artery. If the acardiac mass continues to grow, it may cause high output cardiac failure in the pump twin. Thermal occlusion of the acardiac twin's umbilical vessels by radiofrequency ablation (RFA) or bipolar cautery can reverse the process. Survival rates >80% have been reported for the pump twin after therapy.[19]

Compromise of the fetal thoracic cavity can also cause NIHF. Thoracic masses, fluid collections, or herniation of fetal tissues into the thoracic cavity can all lead to NIHF by increasing thoracic pressure and decreasing venous return and lymphatic flow. The most common thoracic mass is congenital cystic adenomatous malformation (CCAM) (Chapter 2). Congenital diaphragmatic hernias, bronchogenic cysts, and hamartomas are other rare thoracic causes of NIHF. CCAMs can be micro- or macrocystic. Lesions with rapidly enlarging cystic components may be amenable to thoracocentesis or shunting if hydrops develops and solid lesions have been shown to respond to corticosteroid administration.[20] For the rare, nonresponding, rapidly growing microcystic lesion, sclerosing therapy has been reported as a possible treatment option, but with mixed results.[21] Open maternal-fetal surgery with resection of the mass in potentially viable pregnancies remote from delivery is a last resort as outcomes have been suboptimal with survival rates of approximately 50%[22] (Chapter 118). Hydrothorax is the unilateral or bilateral accumulation of fluid in the pleural space (Chapter 4). This may be an isolated primary process or secondary to another underlying disorder. Prenatal primary hydrothorax corresponds to congenital chylothorax that is caused by lymphatic leakage from a malformation in the development of the thoracic duct. Regardless of whether the hydrothorax is a primary or secondary process, rapid accumulation of fluid in the pleural space can precipitate NIHF in a similar mechanism to solid thoracic masses. Mortality rates when NIHF is associated with hydrothorax can approach 100% if left untreated, however, with *in utero* therapy, specifically pleuroamniotic shunting, survival rates in primary hydrothorax can be expected to be <70%.[23]

Single gene disorders are a heterogeneous group of disorders that also contribute to NIHF. They include, but are not limited to, inborn errors of metabolism, skeletal dysplasias, neurodevelopment disorders, cardiomyopathies, congenital nephrosis, and mitochondrial mutations.[24] Lysosomal storage diseases are the most common inborn errors of metabolism and include mucopolysaccharidoses, Gaucher disease, and Niemann-Pick disease. They lead to hydrops through the development of visceromegaly and the obstruction of venous return, decreased red blood cell production, and the development of hypoproteinemia. Although they constitute a small percentage of total NIHF cases, a recent review of 678 affected gestations demonstrated that lysosomal storage diseases constitute almost 30% of cases previously classified as idiopathic.[25] Skeletal dysplasias causing NIHF include thanatophoric dysplasia, osteogenesis imperfecta, achondrogenesis short-rib polydactyly syndrome, and thoracic dysplasia. The mechanism of how these disorders cause NIHF is unclear, but may be secondary to hepatic enlargement from increased erythropoiesis in an attempt to compensate for the relatively small bone marrow volume.[1a] Many of the skeletal dysplasias associated with NIHF result from mutations in the *FGFR3* gene. The importance in identifying any of the aforementioned conditions as the causative agent is that they are usually inherited in an autosomal recessive fashion and thus have a 25% recurrence risk. Part of the investigation of NIHF should include storage of fetal amniotic fluid for further evaluation of these rare diseases.

Clinical Presentation

Most pregnant women in the developed world have a midtrimester US for the evaluation of fetal anomalies and this is when the majority of NIHF cases are identified. With improvements in the quality of US equipment, one could argue that NIHF should never be missed during a routine scan. Patients who do not, however, have access to medical care or fetuses with late-presenting pathologies, may present with maternal symptoms suggestive of NIHF. Polyhydramnios can lead to a uterine size greater than dates, preterm contractions, and preterm labor. Mothers of hydropic infants are also at risk of developing Mirror syndrome, also known as *Ballantyne syndrome.* This is characterized by a preeclampsia-like picture with generalized maternal edema, hypertension, proteinuria, and often pulmonary edema.[26] It differs from preeclampsia in that the hematocrit is low, as opposed to the hemoconcentration seen in preeclampsia, and it is reversible if the NIHF can be treated and resolves. In cases where the fetal condition is not treatable, delivery is recommended.

Imaging Techniques and Findings

Ultrasound. The diagnosis of NIHF is dependent on identifying any two of the following:

- Abdominal ascites: is initially seen as a rim of echolucent fluid on the periphery of the abdominal cavity and as it progresses, the bowel and liver will become more echolucent secondary to the surrounding fluid (Figs. 122.1 and 122.2). Ascites should not be confused with pseudoascites, which is the hypoechoic rim normally seen around the anterior abdominal wall caused by the abdominal muscles. Care must



Fig. 122.1 Ascites: hypoechoic fluid is noted within the abdominal cavity outlining the liver. Edema of the abdominal skin is also seen.

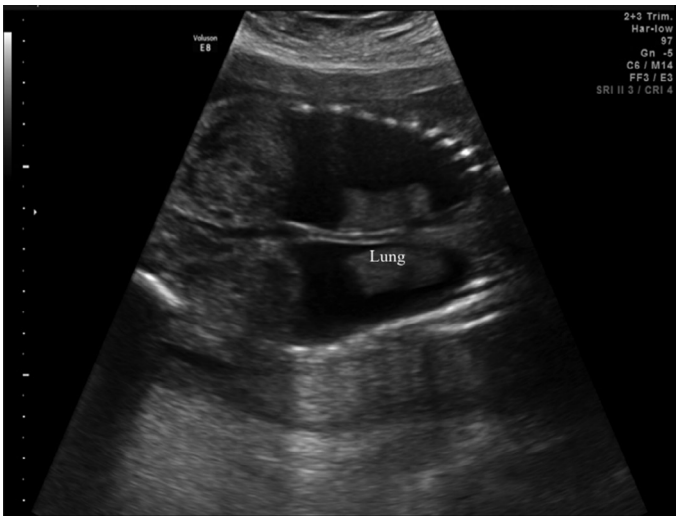

Fig. 122.3 Pleural effusions: hypoechoic fluid is noted within the thoracic cavity compressing the lung tissue bilaterally.

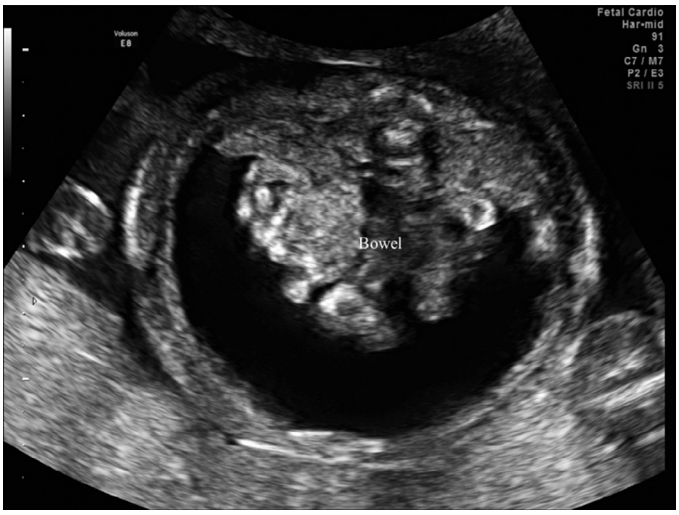

Fig. 122.2 Ascites: hypoechoic fluid is noted within the abdominal cavity outlining the bowel.

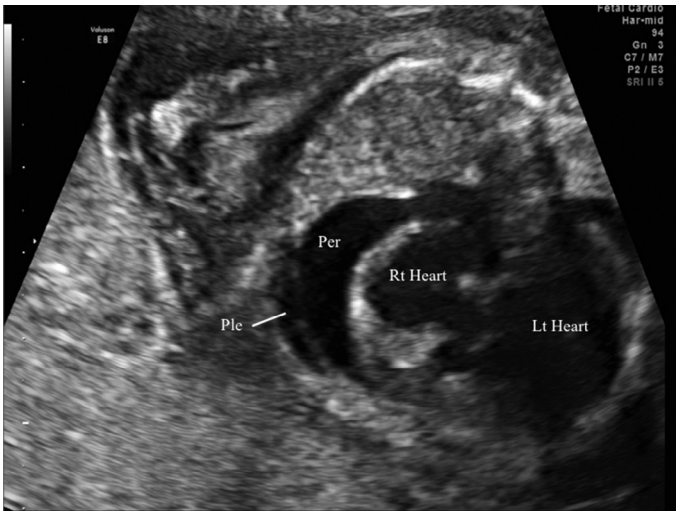

Fig. 122.4 Pericardial effusion: the enlarged left *(Lt Heart)* and right *(Rt Heart)* sides of the heart can be seen with the enlarged pericardial space *(Per)* seen. This fetus also has pleural effusions *(Ple)*.

also be taken to differentiate isolated urinary ascites, as seen with a cloacal abnormality or a decompressed lower urinary tract obstruction, from early NIHF.

- Pleural effusions: similar to ascites, present as a rim of echolucent fluid, but within the thoracic cavity surrounding the lungs (Fig. 122.3). The effusions may be unilateral or bilateral, and if persistent and severe may result in pulmonary hypoplasia.
- Pericardial effusions: may initially present as a rim of echolucent fluid surrounding the heart (Fig. 122.4). Up to 2 mm of fluid around the heart is considered normal,[27] and care must be taken to measure the fluid during cardiac diastole to avoid artificially increasing the thickness of the pericardial space. True pericardial effusions generally extend all the way around the heart, extending above the atrioventricular groove, and do not move with adjacent cardiac activity.
- Skin edema: is defined as skin thickness greater than 5 mm and must be differentiated from underlying subcutaneous fat (Figs. 122.5–122.7).
- Polyhydramnios: is present in 75% of NIHF cases and is defined most accurately as a maximum vertical pocket of fluid greater than 8 cm.
- Placental thickening: associated with NIHF is associated with an increased maternal risk. Nomograms have been reported for abnormal placental thickness at varying gestational ages,[28] however, as a general rule, placental thickness greater than 4 cm in the second trimester and 6 cm in the third trimester should be considered abnormal.[29]

US examination of a fetus suspected to have NIHF should include a systematic comprehensive evaluation of the fetus, umbilical cord, and placenta for any of the potentially detectable etiologies of NIHF listed in Table 122.1. An MCA-PSV should be obtained

TABLE 122.2 EVALUATION OF NONIMMUNE HYDROPS FETALIS

Ultrasound
- Anatomical survey
  - Fetus
  - Placenta
  - Cord
- Doppler velocimetry study of the middle cerebral artery, peak systolic velocity
- Fetal echocardiography

History
- Ethnicity
- Consanguinity
- Family history
  - Neonatal death
  - Developmental delay
  - Syndromes
  - Inherited disorders
- Infectious exposure/travel
  - Medications

Labs
- Indirect Coombs
- Hemoglobin electrophoresis
- Complete blood count
- Kleihauer-Betke
- RPR/VDRL
- Parvovirus IgM/IgG
- TORCH titers
- Amniocentesis
  - Karyotype
  - Microarray
  - Additional fluid for further studies

Ig, Immunoglobulin; *RPR/VDRL*, rapid plasma reagin/venereal disease research laboratory; *TORCH*, toxoplasmosis, other infections, rubella, cytomegalovirus, and herpes simplex virus.

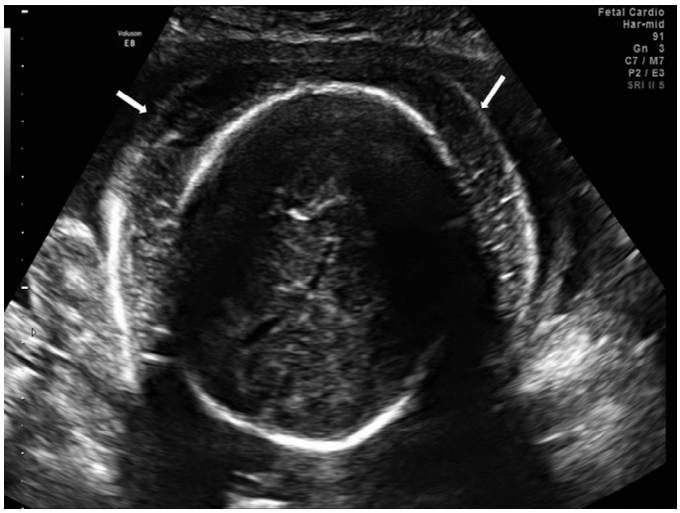

Fig. 122.5 Skin edema: thickening of the skin around the scalp is seen as a surrounding halo *(arrows)*.



Fig. 122.7 Skin edema: the skin is thickened surrounding the tibia and fibula.

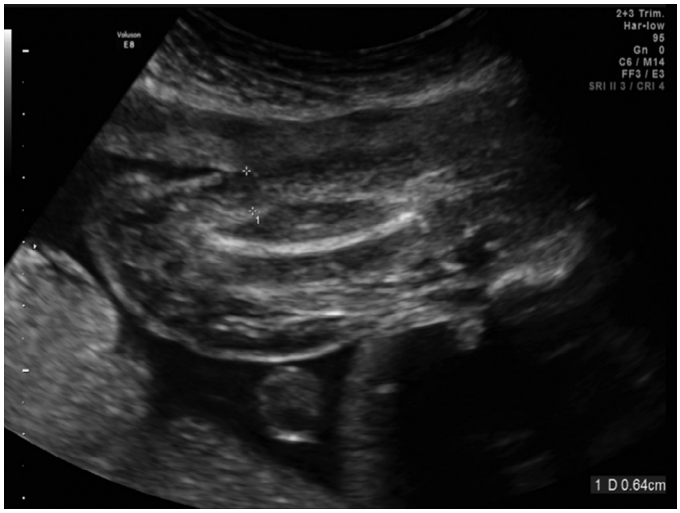

Fig. 122.6 Skin edema: the skin is thickened surrounding the humerus.

to evaluate for anemia, and because of the high incidence of cardiac anomalies, a fetal echocardiogram should also be performed to evaluate cardiac structure, rhythm, and function.

Magnetic Resonance Imaging. US is usually sufficient for the evaluation and diagnosis of masses responsible for causing NIHF, but magnetic resonance imaging can be used to further assist in the evaluation of sacrococcygeal teratomas (Chapter 31) and help differentiate lung masses.

Differential Diagnosis From Imaging Findings

Once the diagnosis of hydrops is made by US, effort must be made to identify the underlying etiology (Table 122.2). A complete maternal history should be taken. The patient's ethnicity and any history of consanguinity should be identified. A three-generational family pedigree should be performed with specific notation of any neonatal deaths, fetal losses, developmental delays, syndromes, or inherited disorders. Any recent travel history or infectious exposures should be documented, as well as any recent or current medication use. Evaluation of maternal blood pressure, proteinuria, and preeclampsia labs should be done periodically to evaluate for Mirror syndrome if the pregnancy is continuing. Maternal blood work should include an indirect Coombs test to rule out an immune cause of anemia if present, a hemoglobin electrophoresis, complete blood count, Kleihauer-Betke or flow cytometry, and a serologic test for syphilis. TORCH (*t*oxoplasmosis, *o*ther infections, *r*ubella, *c*ytomegalovirus, and *h*erpes simplex virus) titers can be difficult to interpret, as immunoglobulin M

levels for both toxoplasmosis and cytomegalovirus may remain positive for 9–12 months after infection. Avidity studies can help differentiate early from late infectious exposure, but it may be more prudent to directly examine the amniotic fluid by polymerase chain reaction for any suspected infections. A fetal karyotype, including microarray, is an integral part of the evaluation of the hydropic fetus. Sufficient sample should be obtained at the time of amniocentesis for an infectious screen and to be kept for further evaluation of single gene mutations if no other etiologies of NIHF are elucidated.

Synopsis of Treatment Options

PRENATAL

Survival through the prenatal period is dependent on the onset and etiology of NIHF. McCoy et al. reported less than a 5% survival for fetuses with the onset of hydrops before 24 weeks and survival of 20% for infants with the onset after 24 weeks.[7] In addition, once chromosomal abnormalities are excluded, the NIHF survival rate ranges from 31%–48%.[2]

Prenatal fetal therapy has been shown to improve survival in selected cases of NIHF.[29] Table 122.3 lists the prenatal interventions and the disorders that may be amenable to treatment. Intrauterine transfusion, single or serial, can treat anemia from either infectious or genetic etiology. Serial thoracocentesis or placement of a pleuroamniotic shunt can alleviate thoracic compression from primary hydrothorax, macrocystic CCAM lesions, and any other cystic chest masses causing hydrops. Fetoscopic laser surgery is the standard treatment for TTS. Thermal vascular occlusion of umbilical cord vessels by RFA, or bipolar coagulation, can effectively treat TRAP sequence and NIHF associated with heterokaryotic twins. Medical management of congenital pulmonary airway malformations, fetal arrhythmias and maternal Graves' disease has been undertaken with success. Thermal occlusion by laser ablation, RFA or bipolar coagulation of the vascular supply to bronchopulmonary sequestrations or chorioangiomas has been shown to be effective in reversing NIHF associated with these malformations. Ex utero intrapartum treatment (EXIT) can also be used to facilitate the stabilization of the fetal airway before surgery for fetal thoracic masses, and EXIT to resection has also been used in selected cases where a fetal lesion needs immediate postnatal surgery. Open fetal surgery in the midtrimester is still an option in very select cases, but only after the previously mentioned options have been exhausted.

POSTNATAL

Fetuses that survive until delivery with NIHF still experience high rates of morbidity and mortality. Abrams et al. reported on 597 neonates with NIHF of which 215 (36%) died before discharge. The highest mortality rate of 58% was noted in neonates with congenital anomalies and the lowest mortality rate of 5.5% was noted in isolated chylothorax. The authors noted an increased mortality rate with decreasing gestational age, low 5-minute Apgar scores, and the need for high levels of support postnatally.[30] Huang et al. reported similar findings in 28 live born neonates with NIHF with an overall survival rate of 50%, but an 83% survival rate with isolated lymphatic malformations. They also noted that delivery before 34 weeks conveyed a poor prognosis.[31]

TABLE 122.3 PRENATAL INTERVENTIONS FOR NONIMMUNE HYDROPS FETALIS CAUSED BY SELECTIVE DISORDERS

Treatment	Disorder
Medical Management • Steroids • Antiarrhythmic medications • PTU, methimazole	Congenital pulmonary adenomatoid malformation Arrhythmia Tachyarrhythmia secondary to Graves' disease
Intrauterine transfusion	Anemia of any cause • Hemorrhage: fetal or fetomaternal • Alpha thalassemia • Parvovirus, cytomegalovirus
Thoracocentesis, pleuroamniotic shunt placement	Cystic chest masses • Macrocystic congenital pulmonary adenomatoid malformations • Bronchogenic cyst Hydrothorax
Amnioreduction	Symptomatic polyhydramnios
Laser photocoagulation	Twin transfusion syndrome
Interstitial laser, radiofrequency ablation	Bronchopulmonary sequestration Chorioangioma Sacrococcygeal teratoma
Cord occlusion • Radiofrequency ablation • Bipolar cautery	Complicated monochorionic twins • Twin transfusion syndrome (selective reduction) • Twin reversed arterial perfusion syndrome • Heterokaryotic twins
Open fetal surgery	Large solid chest masses Sacrococcygeal teratoma
EXIT	Tracheal compromise from any cause

EXIT, Ex utero intrapartum treatment; *PTU*,propylthiouracyl.

WHAT THE REFERRING PHYSICIAN NEEDS TO KNOW

NIHF is the most common type of hydrops fetalis and has a wide range of etiologies, including fetal, placental, and maternal causes. Mortality rates remain extremely high, and early detection, investigation, diagnosis, and treatment lead to increased rates of survival. Narrowing the range of possible etiologies is crucial; comprehensive US evaluation, including fetal echocardiography, should be performed when fetal hydrops is encountered.

KEY POINTS

- Hydrops is diagnosed by fluid accumulation in two or more fetal serous cavities.
- Accumulations of fluid may result in subcutaneous edema, abdominal ascites, pleural effusion, pericardial effusion, placentomegaly, and/or polyhydramnios.
- NIHF is the result of nonred blood cell antigen-related disorders.
- Cardiac anomalies are the most common causes of NIHF.
- Comprehensive US evaluation is central to the assessment of NIHF, providing diagnostic information and treatment options.

SUGGESTED READINGS

Bellini C, Hennekam RCM, Fulcheri E, et al. Etiology of nonimmune hydrops fetalis: a systematic review. *Am J Med Genet Part A*. 2008;149A:844-851

Bellini C, Donarini G, Paladini D, et al. Etiology of non-immune hydrops fetalis: an update. *Am J Med Genet Part A* 2015;167A:1082-8

Society for Maternal-Fetal Medicine. Society for maternal-fetal medicine (SMFM) clinical guideline #7: nonimmune hydrops fetalis. *Am J Obstet Gynecol*. 2015;212:127-39

Society of Obstetricians and Gynaecologists of Canada. Investigation and management of non-immune fetal hydrops. *J Obstet Gynaecol*. 2013;35:923-38



All references are available online at www.expertconsult.com.

REFERENCES

1. Potter EL. Universal edema of the fetus in association with erythroblastosis. *Am J Obstet Gynecol*. 1943;46:130-134.

1a. Society for Maternal-Fetal Medicine clinical guideline #7: nonimmune hydrops fetalis. *Am J Obstet Gynecol*. 2015;212:127-139.

2. Society of Obstetrics and Gynaecologists of Canada. Investigation and management of non-immune fetal hydrops. *J Obstet Gynaecol*. 2013;35:923-938.

3. Fung Kee Fung K, Eason E, Crane J, et al. Prevention of Rh alloimmunization. *J Obstet Gynaecol*. 2003;25:765-773.

4. Rose CH, Bofill JA, Le M, et al. Non-immune hydrops fetalis: prenatal diagnosis and perinatal outcomes. *J Miss State Med Assoc*. 2005;46:99-102.

5. Anandakumar C, Biswas A, Wong YC, et al. Management of non-immune hydrops: 8 years' experience. *Ultrasound Obstet Gynecol*. 1996;8:196-200.

6. Santo S, Mansour S, Thilaganathan B, et al. Prenatal diagnosis of non-immune hydrops fetalis: what do we tell the parents? *Prenat Diagn*. 2011;31:186-195.

7. McCoy MC, Katz VL, Gould N, et al. Non-immune hydrops after 20 weeks' gestation: review of 10 years' experience with suggestions for management. *Obstet Gynecol*. 1995;85:578-582.

8. Ismail KM, Martin WL, Ghosh S, et al. Etiology and outcome of hydrops fetalis. *J Matern Fetal Med*. 2001;10:175-181.

9. Bellini C, Donarini G, Paladini D, et al. Etiology of non-immune hydrops fetalis: an update. *Am J Med Genet Part A*. 2015;167A:1082-1088.

10. McBrien A, Sands A, Craig B, et al. Major congenital heart disease: antenatal detection, patient characteristics and outcomes. *J Matern Fetal Neonatal Med*. 2009;22:101-105.

11. Machin GA. Hydrops revisited: literature review of 1,414 cases published in the 1980s. *Am J Med Genet*. 1989;34:366-390.

12. Malin GL, Kilby MD, Velangi M. Transient abnormal myelopoiesis associated with Down syndrome presenting as severe hydrops fetalis: a case report. *Fetal Diagn Ther*. 2010;27:171-173.

13. Wapner RJ, Driscoll DA, Simpson JL. Integration of microarray technology into prenatal diagnosis: counselling issues generated during the NICHD clinical trial. *Prenat Diagn*. 2012;32:396-400.

14. Matthay KK, Mentzer WC. Erythrocyte enzymopathies in the newborn. *Clin Haematol*. 1981;10:31-55.

15. Rubod C, Houfflin V, Belot F, et al. Successful in utero treatment of chronic and massive fetomaternal hemorrhage with fetal hydrops. *Fetal Diagn Ther*. 2006;21:410-413.

16. Mari G, Deter RL, Carpenter RL, et al. Noninvasive diagnosis by Doppler ultrasonography of fetal anemia due to maternal red-cell alloimmunization. Collaborative Group for Doppler Assessment of the Blood Velocity in Anemic Fetuses. *N Engl J Med*. 2000;342:9-14.

17. de Jong EP, Walther FJ, Kroes AC, et al. Parvovirus B19 infection in pregnancy: new insights and management. *Prenat Diagn*. 2011;31:419-425.

18. Chmait RH, Kontopoulos EV, Korst LM, et al. Stage-based outcomes of 682 consecutive cases of twin-twin transfusion syndrome treated with laser surgery: the US fetus experience. *Am J Obstet Gynecol*. 2011;204:393 e1-393 e6.

19. Sugibayashi R, Ozawa K, Sumie M, et al. Forty cases of twin reversed arterial perfusion sequence treated with radio frequency ablation using the multistep coagulation method: a single-center experience. *Prenat Diagn*. 2016;36:437-443.

20. Derderian SC, Coleman AM, Jeanty C, et al. Favorable outcomes in high-risk congenital pulmonary airway malformations treated with multiple courses of maternal betamethasone. *J Pediatr Surg*. 2015;50:515-518.

21. Lee FL, Said N, Grikscheit TC, et al. Treatment of congenital pulmonary airway malformation induced hydrops fetalis via percutaneous sclerotherapy. *Fetal Diagn Ther*. 2012;31:264-268.

22. Adzick NS, Harrison MR, Crombleholme TM, et al. Fetal lung lesions: management and outcome. *Am J Obstet Gynecol*. 1998;179:884-889.

23. Walsh J, Mahony R, Higgins S, et al. Thoraco-amniotic shunting for fetal pleural effusion–a case series. *Ir Med J*. 2011;104:205-208.

24. Bellini C, Hennekam RC. Non-immune hydrops fetalis: a short review of etiology and pathophysiology. *Am J Med Genet Part A*. 2012;158A:597-605.

25. Gimovsky AC, Luzi P, Berghella V. Lysosomal storage disease as an etiology of nonimmune hydrops. *Am J Obstet Gynecol*. 2015;212:281-290.

26. Braun T, Brauer M, Fuchs I, et al. Mirror syndrome: a systematic review of fetal associated conditions, maternal presentation and perinatal outcome. *Fetal Diagn Ther*. 2010;27:191-203.

27. Dizon-Townson DS, Dildy GA, Clark SL. A prospective evaluation of fetal pericardial fluid in 506 second-trimester low-risk pregnancies. *Obstet Gynecol*. 1997;90:958-961.

28. Elchalal U, Ezra Y, Levi Y, et al. Sonographically thick placenta: a marker for increased perinatal risk–a prospective cross-sectional study. *Placenta*. 2000;21:268-272.

29. Ayida GA, Soothill PW, Rodeck CH. Survival in non-immune hydrops fetalis without malformation or chromosomal abnormalities after invasive treatment. *Fetal Diagn Ther*. 1995;10:101-105.

30. Abrams ME, Meredith KS, Kinnard P, et al. Hydrops fetalis: a retrospective review of cases reported to a large national database and identification of risk factors associated with death. *Pediatrics*. 2007;120:84-89.

31. Huang HR, Tsay PK, Chiang MC, et al. Prognostic factors and clinical features in liveborn neonates with hydrops fetalis. *Am J Perinatol*. 2007;24:33-38.

123 Immune Hydrops Fetalis

SAUL SNOWISE | ANTHONY JOHNSON

Introduction

The fetal-maternal interface in pregnancy does not act as a barrier to the passage of fetal cells into the maternal circulation, and the passage of fetal deoxyribonucleic acid into the maternal compartment is one proposed mechanism for preventing immunologic rejection of the fetus with its paternally derived foreign antigen. The transfer of fetal red blood cells into the maternal circulation, however, has the ability to initiate a maternal immunologic response that can be deleterious to the health of the fetus. If red blood cell antigens foreign to the maternal immune system cross into the maternal compartment, a process may be initiated leading to the immune destruction of fetal red blood cells. This can lead to severe fetal anemia, and if untreated, eventually to immune-mediated hydrops fetalis. This process can affect both the fetus and the neonate, and is thus known as *hemolytic disease of the fetus and newborn* (HDFN).

HDFN is an example of modern medicine both treating and preventing a disease process with significant morbidity and mortality. In the 1950s, 15% of all "isoimmunized" (the currently accepted term is the more appropriate *"alloimmunization"*) gestations ended in stillbirth.[1] Today, survival in severely affected neonates is well over 90%.[2] Advancements in ultrasound and intrauterine transfusion technique have certainly played a role in the improved outcome, but the prevention of rhesus (Rh) alloimmunization by the introduction of rhesus immunoglobulin (RhIG) has significantly decreased the disease burden of Rh(D) disease in particular. As stated in the Benjamin Franklin axiom, "an ounce of prevention is worth a pound of cure."

Disease

DEFINITION

Immune hydrops is defined as the diagnosis of fetal hydrops in the presence of a maternal immunologic response to a paternally derived red blood cell antigen in the fetus. Fetal hydrops is further defined as the accumulation of fluid in at least two of the following fetal serous compartments: abdomen, pleural cavity, pericardium, and skin. Polyhydramnios and placental thickening are also commonly included in the diagnostic criteria.

PREVALENCE AND EPIDEMIOLOGY

The incidence of Rh alloimmunization in the United States is reported to be 6.8:1000 live births.[2] The adoption of prenatal and postpartum RhIG has resulted in a marked reduction in the incidence of disease caused by the presence of the paternal Rh(D) antigen, however, 1%–3% of Rh(D)-negative women will still become alloimmunized despite proper prophylaxis.[3] There has been a corresponding increase in the incidence of other Rh antigens and non-Rh antigens that can cause HDFN, with a reported incidence for these antigens of 0.2% of pregnancies.[3] A recent Canadian study identified 559 cases of alloimmunization among 155,153 pregnancies for an incidence of 0.36%. Only 34 (0.06%) of the affected pregnancies had adverse outcomes defined by the need for prenatal therapy (maternal plasmapheresis or intrauterine transfusions), an intrauterine death attributed to alloimmunization, preterm delivery secondary to HDFN, or neonatal treatment (intravenous immunoglobulin [IVIg] administration, transfusion, or exchange transfusion).[4] A prospective analysis of over 300,000 women in The Netherlands showed that the antibodies most commonly associated with HDFN were anti-E, followed in decreasing frequency by anti-D, anti-Kell, and anti-c antibodies.[5] The decreasing prevalence of anti-D antibodies was also shown in the aforementioned Canadian study with anti-E (43%), anti-c (13%), anti-Jk^a (9%), and anti-C (5%) antibodies making up a majority of affected women, with anti-D accounting for only 0.4% of women with a single antibody identified.[4] Currently in the United States, HDFN causes approximately 200 perinatal deaths yearly, most from alloimmunization to the Rh(D), Rh(c), and Kell antigens.[2]

ETIOLOGY AND PATHOGENESIS

Fetal red blood cells express antigens by 30 days of gestation, half of which are paternally derived. The transfer of fetal antigens across the fetal-maternal interface occurs in almost all gestations with increasing frequency and volume as the pregnancy progresses.[6] Fetomaternal hemorrhage before or during birth is thought to be the primary factor in maternal alloimmunization. A list of potential spontaneous and iatrogenic events associated, with maternal sensitization are listed in Table 123.1.

TABLE 123.1 CAUSES OF SENSITIZATION TO RED BLOOD CELLS

Unprovoked	Provoked
Idiopathic-spontaneous	Termination of pregnancy
Delivery	Amniocentesis
Spontaneous abortion	Chorionic villus sampling
Ectopic pregnancy	Cordocentesis
Abruption	External cephalic version
Antepartum hemorrhage	Fetal intervention: fetoscopy, shunt, drainage
	Trauma
	Manual removal of placenta

The maternal response to foreign antigen is well documented. Cells of the innate immune system identify and destroy foreign cells and present the antigens to the humoral immune system, where specialized B lymphocytes can recognize the antigen in future encounters and respond rapidly with immunoglobulin (Ig) G antibodies. The initial development of IgG antibodies is a slow process taking 5–15 weeks for a human antiglobulin titer to be detected after a sensitizing event. With few exceptions, the maternal response to the paternal antigen is not sufficient to affect the sensitizing pregnancy. Exposure to a subsequent gestation with the precipitating antigen present will trigger the rapid production of IgG antibodies. These IgG antibodies freely cross the placenta and bind to fetal red blood cells with the offending antigen. These marked cells are then sequestered by the fetal spleen and destroyed by macrophages resulting in fetal anemia if the response is significant enough.

The maternal response to paternal antigens on fetal red blood cells that cross the fetomaternal barrier is variable. Studies in Rh(D)-negative men have demonstrated that some individuals can be sensitized by as little as 0.1 mL of Rh(D)-positive blood, whereas 30% of individuals are still not sensitized after subsequent exposure to 10 mL of Rh(D)-positive blood.[7,8] Other factors thought to play a role in sensitization are the frequency of the exposure, the ABO compatibility between the fetus and the mother, the antibody class, placental transport of the antibody, the maturity of the fetal red blood cell antigen, and the status of the maternal immune system as immunodeficiency may prevent alloimmunization.

Hydrops occurs when the fetal hemoglobin is greater than 7 g/dL below the mean for the estimated gestational age. This is consistent with a fetal hematocrit and hemoglobin of less than 15% and 5 g/dL, respectively.[9] Erythropoiesis is elevated in the fetus with the exception of alloimmunization caused by anti-Kell antibodies that destroy erythroid precursor cells and result in an earlier onset and more severe anemia than that found with other alloantibodies.

The exact mechanism for the development of hydrops is not understood. Lower serum albumin has been hypothesized to lead to decreased colloid osmotic pressure, the third-spacing of fetal fluid, and finally the development of hydrops. This theory, however, is not supported by animal models or in human fetuses with hypoproteinemia.[10,11] Other proposed theories for hydrops are: (1) iron overload from hemolyzed red blood cells leading to increased free radical formation and endothelial cell dysfunction, (2) tissue hypoxia from anemia leading to increased capillary permeability, and (3) elevated central venous pressure resulting in lymphatic blockage. The development of hydrops is also gestational-age dependent. Hydrops under 22 weeks' gestation is rare despite the presence of severe anemia.[12]

Clinical Presentation

The American College of Obstetrics and Gynecology recommends the screening of all women for red blood cell antibodies at their first prenatal visit.[13] A positive maternal antibody screen should identify all women at risk for HDFN, and this should prompt a referral to a maternal-fetal medicine unit with expertise in handling alloimmunization and the appropriate monitoring of the pregnancy. Patients who do not, however, have access to medical care or fetuses with late-presenting developing antibodies may first present with maternal symptoms suggestive of hydrops fetalis. Polyhydramnios can lead to size greater than dates, preterm contractions, and preterm labor. Mothers of hydropic fetuses are at risk of developing Mirror syndrome. This is characterized by a preeclampsia-like picture with generalized edema, hypertension, proteinuria, and often pulmonary edema.[14] It differs from preeclampsia in that the hematocrit is low, as opposed to the hemoconcentration seen in preeclampsia, and it is reversible if the cause of the fetal hydrops, in this case anemia, can be treated and resolves.

Imaging Techniques and Findings

Ultrasound. The diagnosis of hydrops is dependent on identifying any two of the following:

- Abdominal ascites: is initially seen as a rim of echolucent fluid on the periphery of the abdominal cavity, and as it progresses the bowel and liver will become more prominent secondary to the surrounding fluid (Fig. 123.1). Ascites must not be confused with pseudoascites, which is the hypoechoic rim normally seen around the anterior abdominal wall caused by the abdominal muscles. Care must also be taken to differentiate isolated urinary ascites, as seen with a cloacal abnormality or a decompressed lower urinary tract obstruction, from early HDFN.
- Pleural effusion: similar to ascites, presents as a rim of echolucent fluid, but within the thoracic cavity surrounding the lungs (Fig. 123.2). The effusions may be unilateral or bilateral and if persistent and severe, may result in pulmonary hypoplasia.
- Pericardial effusion: presents as a rim of echolucent fluid surrounding the heart (Fig. 123.3). Up to 2 mm of fluid around the heart is considered normal,[15] and care must be taken to measure the fluid during cardiac diastole to avoid artificially increasing the thickness of the pericardial space. True pericardial effusions generally extend all the way around the heart, extending above the atrioventricular groove, and do not move with adjacent cardiac activity.
- Skin edema: is defined as skin thickness greater than 5 mm and must be differentiated from underlying subcutaneous fat (Fig. 123.4).
- Polyhydramnios: is defined as a maximum vertical pocket or amniotic fluid index greater than 8 cm or 25 cm, respectively.
- Placental thickening: has been defined as a measurement greater than 4 cm in the second and 6 cm in the third trimesters. Nomograms allowing more accurate identification of abnormal placental thickness at varying gestational ages are available[16,17] (Fig. 123.5).

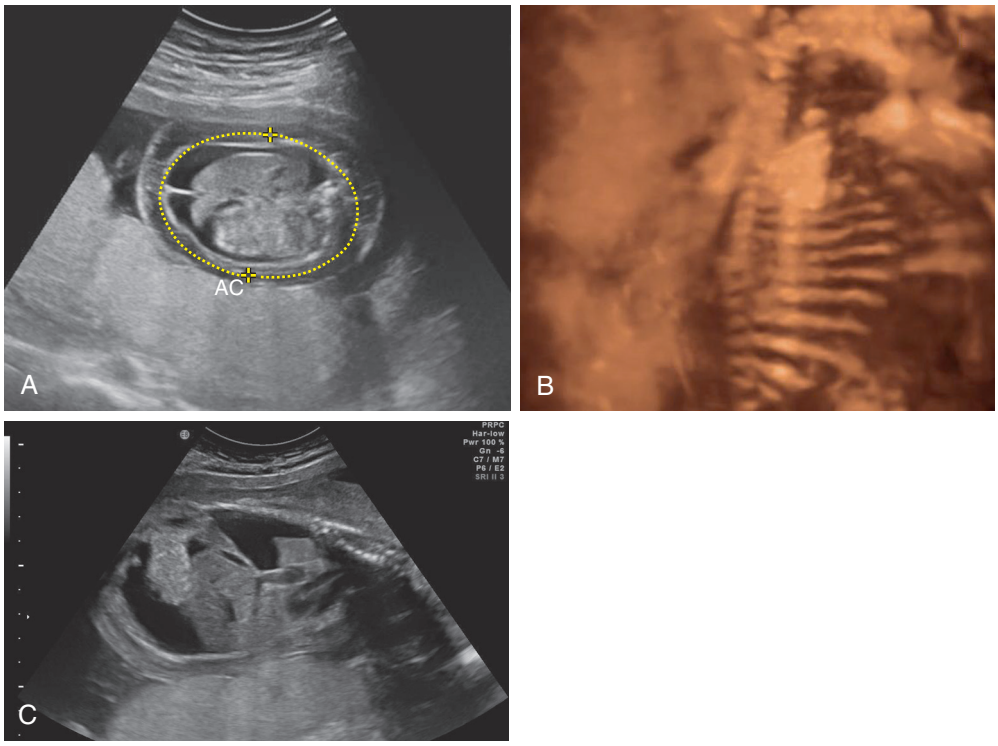

Fig. 123.1 (A) Fetal ascites and body wall edema. (B) Three-dimensional image of fetal abdominal ascites. (C) Sagittal view of pleural effusion and ascites. *AC,* Abdominal circumference.



Fig. 123.2 Pleural effusion shown with the lung and fetal heart (there is also body wall edema).

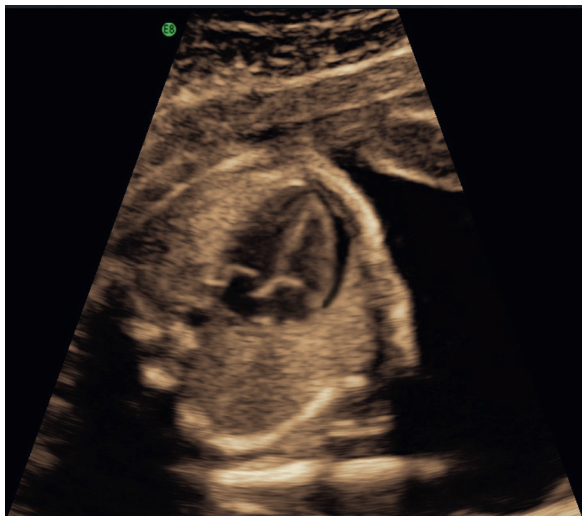

Fig. 123.3 Pericardial effusion at the level of the fetal four-chamber view.

Ultrasound evaluation of a fetus suspected to have HDFN should include a systematic, comprehensive evaluation of the fetus, umbilical cord, and placenta, also evaluating for any other cause of the findings.

Doppler interrogation of the middle cerebral artery peak systolic velocity (MCA-PSV) has become the mainstay for the evaluation of fetal anemia from any etiology.[18] The principle of using the MCA-PSV Doppler is that the anemic fetus preserves the brain by increasing cerebral blood flow. The low viscosity blood, combined with the increased flow, results in an increased PSV. In a review comparing MCA-PSV to hemoglobin levels obtained via fetal blood sampling Mari et al. demonstrated that an MCA level >1.5 multiples of median (MoM) predicted moderate or severe anemia with a sensitivity of 100% (95% confidence interval [CI], 86–100), with or without hydrops, with a false positive rate of 12%.[19]

Proper technique for obtaining the MCA-PSV is critical to the accuracy of the testing (Fig. 123.6). The Doppler angle of interrogation should be as close to zero degrees as possible, although angle correction can be used up to 30 degrees with good correlation with the true velocity.[20] In addition, the Doppler cursor should be as close to the origin of the vessel as possible, and the fetus should be in a quiescent state as activity can falsely elevate the result.[21] Values that remain below 1.5 MoM are

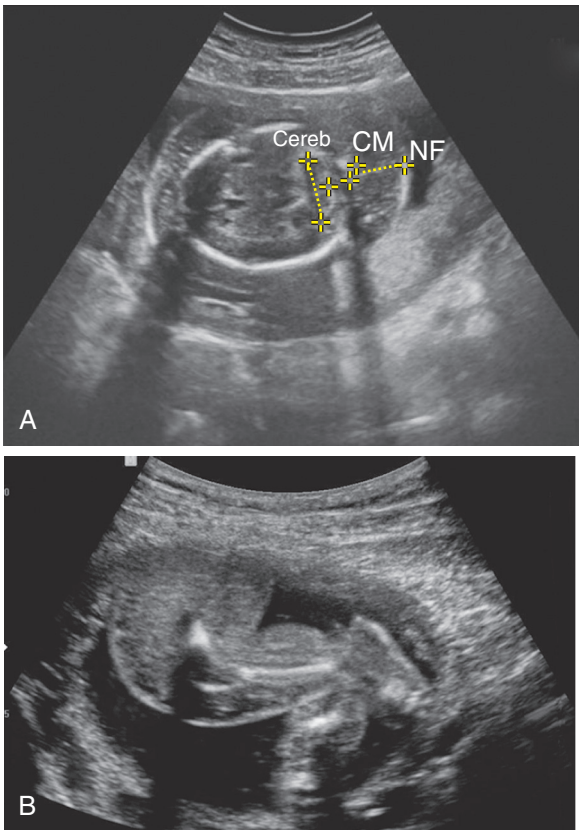

Fig. 123.4 (A) Subcutaneous edema in the fetal scalp. (B) Subcutaneous edema in the fetal lower extremity. *Cereb,* Cerebellum; *CM,* cisterna magna; *NF,* nuchal fold.

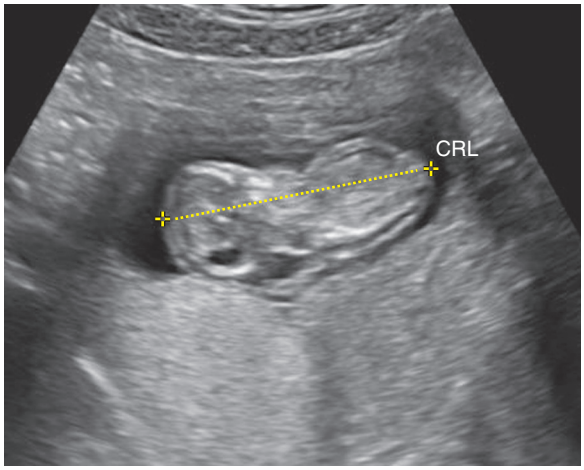

Fig. 123.5 Placental edema in first-trimester pregnancy. *CRL,* Crown rump length.

consistent with the absence of moderate to severe fetal anemia, and intervention is not necessary.

Magnetic Resonance Imaging. There is no role for magnetic resonance imaging in cases of immune hydrops.

Other Applicable Modality. Amniocentesis for delta optical density (OD) 450 has been used in the past to evaluate for possible anemia, but MCA Doppler is more sensitive for the detection of anemia without the risks associated with an invasive procedure. As such, there is no longer a clinical indication for the use of delta OD 450 in the care of patients with alloimmunization.[22]

CLASSIC SIGNS

Ascites.
Pleural or pericardial effusion.
Skin or scalp edema.
Polyhydramnios.
Placental edema.
Cardiomegaly.
MCA peak systolic velocity >1.5 MoM.

Differential Diagnosis From Imaging Findings

Nonimmune hydrops fetalis.

Synopsis of Treatment Options

PRENATAL

Maternal antibody screening is recommended in all pregnancies. It is routine to evaluate for maternal antibodies at the first prenatal visit, and if initially negative, to retest at 28 weeks and then after delivery. Although late-onset alloimmunization is rare, the physician will miss the opportunity for intervention if no antibody screening is done between the initial visit and the postpartum period. Identification of maternal antibodies is accomplished by performing the indirect Coombs test. The level of antibody response is reported as the reciprocal of the last dilutional tube that demonstrated evidence of agglutination. For example, a titer of 32 is equivalent to the loss of the presence of agglutination after the sixth dilution, or 1:32. It is clinically important to note that interlaboratory differences in titer levels exist, and because of the somewhat subjective determination of "agglutination," intralaboratory variations also occur. This intralaboratory variation should always be within one dilution, and the treating physician should be aware that a titer increase from 16 to 32 might not be indicative of an increased maternal immune response.

As it takes time for the humoral immune system to perfect its antibody response, first affected alloimmunized pregnancies differ from subsequent ones in the fact that they usually have lower antibody titers and severe fetal anemia may not develop or develop only late in gestation. After identifying the presence of a maternal antibody, it is imperative to assess if the fetus is at risk. If the father is homozygous for the antigen, the fetus is at risk for HDFN, but if the father is heterozygous, there is a 50% chance that the fetus will not be at any risk, and further maternal and fetal testing and monitoring can be eliminated. Correct ascertainment of paternity is important, as nonpaternity is estimated from 2%–5%.[23]

If paternal zygosity testing demonstrates that the fetus is at risk of carrying the offending antigen, then fetal blood genotyping needs to be performed. The development of cell-free DNA (cfDNA) testing has changed this approach for Rh(D)-negative women. Fetal cfDNA can be detected as early as 38 days and increases with advancing gestation, disappearing after delivery. The fetal Rh(D) status can be determined by evaluation of the fetal cfDNA sequences in the maternal plasma using reverse transcriptase polymerase chain reaction (PCR) and has a 99.1% sensitivity for detection of the fetal Rh(D) status in the first and second trimester. Testing should be performed after 10 weeks'

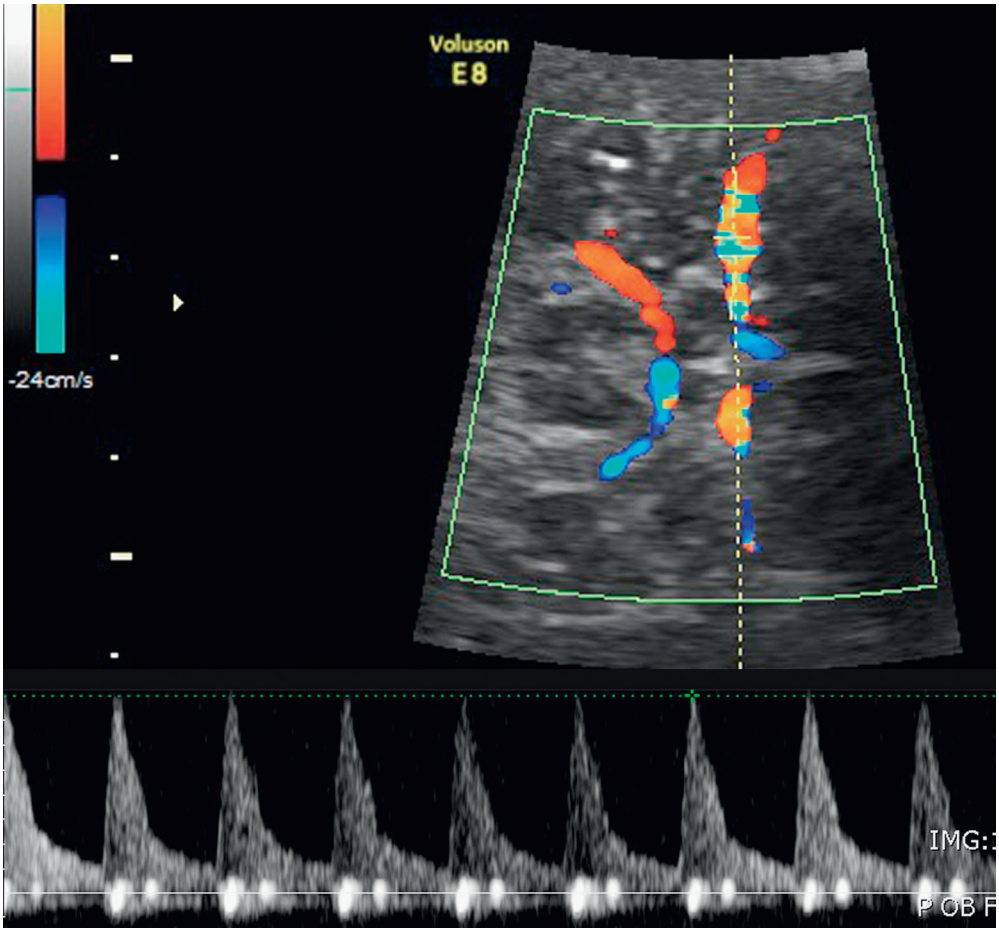

Fig. 123.6 Normal Doppler waveform of the middle cerebral artery *(MCA)*.

gestation to ensure an adequate fetal fraction of cfDNA, and combinations of assays for the detection of exons 4, 5, 7, and 10 on the *Rh(D)* gene are recommended.[24] If these exons are not present, then the fetus is determined to be Rh(D)-negative, and no further testing is recommended as long as it can be determined that it is fetal cfDNA that has been tested. This can be done by identification of the Y chromosome gene sequence denoting the presence of a male fetus, or additionally, single nucleotide polymorphisms can be used to determine that the sample is from a fetal source.[25] Assays for Kell, Rh(E), Rh(C), and Rh(c) fetal blood typing exist, but are not yet available in the United States.

In the absence of cfDNA testing, the fetal blood type can be determined by PCR of uncultured amniocytes obtained from an amniocentesis performed after 15 weeks' gestation. All efforts should be made to avoid a transplacental approach to the amniocentesis as this has the potential to heighten the maternal immune response and increase the severity of alloimmunization.[26] Similarly, chorionic villus sampling for prenatal diagnosis is contraindicated in pregnancies at risk for HDFN because of increased risk of maternal fetal hemorrhage associated with the procedure.

Once it has been determined that the fetus is at risk of HDFN, monthly repeat indirect Coombs tests are recommended. The same laboratory should be used to ensure consistent results, and titers that are below a critical threshold, but rising, should be repeated at shorter intervals.

The "critical titer" is defined as the titer at which the fetus is at risk of developing severe anemia and hydrops, and denotes when MCA-PSV exams should be initiated. A critical titer of either 16 or 32 is used for all but Kell alloimmunization. Because of the erythroid precursor suppression present with Kell alloimmunization, a critical titer of 8 should prompt the initiation MCA-PSV evaluation.[27] Initiation of MCA-PSV evaluation should start at 20 weeks in a first affected gestation, and at 18 weeks in anti-Kell affected gestations. The MCA-PSV increases throughout gestation, and calculators to determine the MoM are available at http://www.perinatology.com. The optimal interval for exams has not been determined, but expert opinion is that exams should be every 1–2 weeks and can be guided by both the previous MCA-PSV level and the antibody titer.[19] Although there are no studies on the validity, type, or frequency, prenatal testing is recommended to start at 32 weeks in these patients in conjunction with MCA-PSV measurements.[28] These patients should also have a scheduled delivery between 37 and 38 weeks, as per the Society for Maternal Fetal Medicine guidelines.[29] MCA-PSV measurements above 1.5 MoM before 35 weeks should be investigated with fetal blood sampling with the intention to transfuse if fetal anemia is confirmed. After 35 weeks, delivery is recommended, as the risks of prematurity are lower risks than fetal blood sampling at this gestational age.

As the innate immune system becomes more efficient, alloimmunized mothers have the potential for increasingly severe hemolytic disease with each subsequent gestation. In susceptible

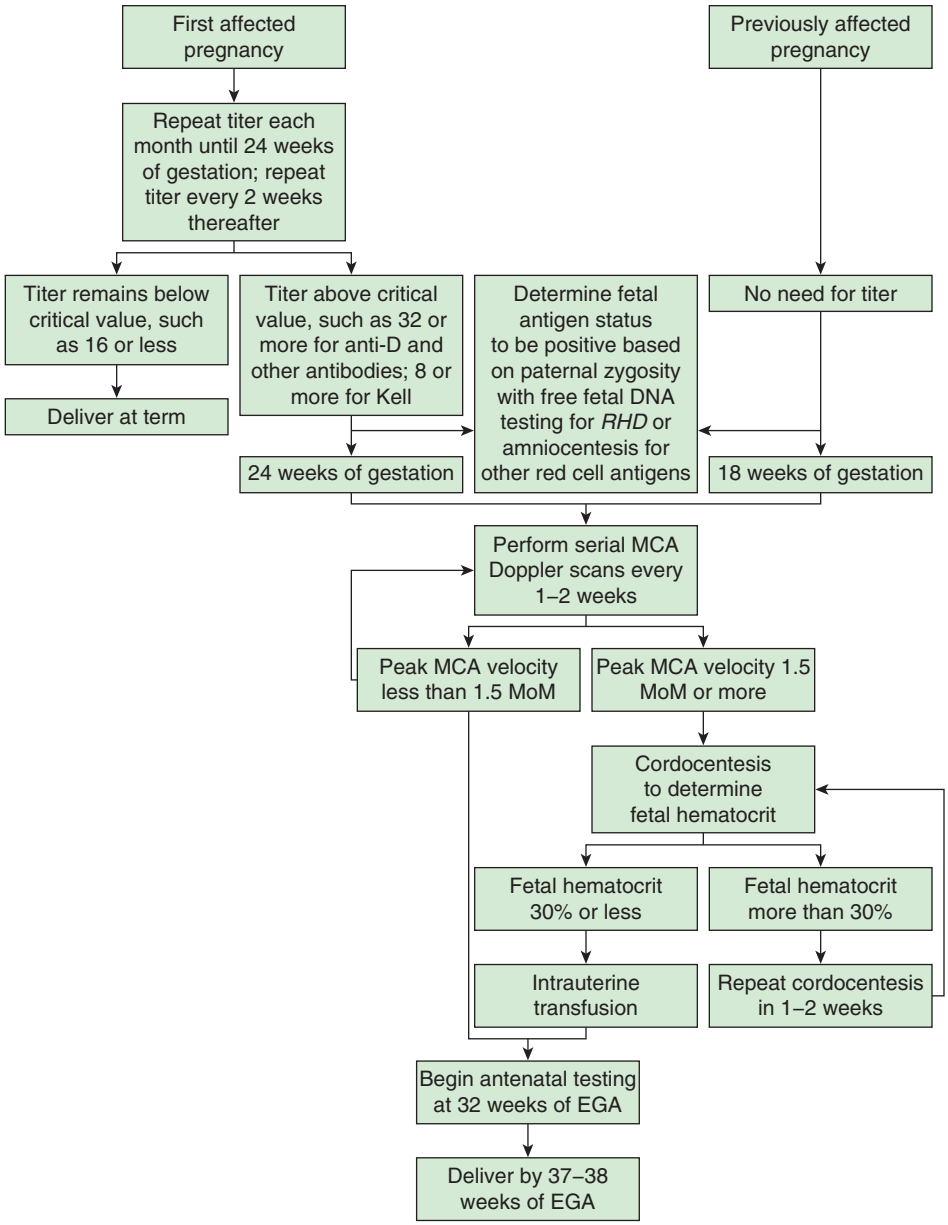

Fig. 123.7 Algorithm for management of at risk gestation. *EGA,* Estimated gestational age; *MCA,* middle cerebral artery. *(From Moise Jr KJ, Argoti PS. Management and prevention of red cell alloimmunization in pregnancy: a systematic review,* Obstet Gynecol *120:1132–1139, 2012).*

fetuses, the anemia will occur earlier than in prior gestations, with case reports demonstrating the onset of severe anemia as early as 15 weeks.[30] If not already done, paternal zygosity testing needs to be performed with fetal testing as previously described, as necessary. The algorithm for the management of alloimmunization is presented in Fig. 123.7.

In pregnancies with a previous need for intrauterine transfusion (IUT), postnatal exchange transfusion, or who had a perinatal loss secondary to HDFN, early evaluation in an experienced, qualified center with the initiation of weekly MCA-PSV Dopplers from as early as 16 weeks is recommended. Data on early MCA-PSV measurements are available to guide management in early cases with severe disease.[31] The remaining management is identical to that of first affected gestations, with the exception that it will be rare to not perform an IUT in these cases.

Patients with a history of severe HDFN with early second trimester losses have been successfully treated with immunomodulation consisting of plasmapheresis followed by weekly IVIg. This has delayed the gestational age at which IUT needs to be initiated and has also improved fetal survival.[32] In cases where severe anemia is suspected before 18 weeks, intraperitoneal transfusions (IPT) with or without immunomodulation may allow for stabilization of the fetus until fetal blood sampling and intravenous transfusion can be undertaken at 18–20 weeks' gestation.[33] The main limitation to the efficacy of IPT in the setting of fetal anemia, is the presence of hydrops that prevents the efficient absorption of red blood cells secondary to the disruption to the lymphatic system associated with hydrops.

Once the MCA-PSV demonstrates evidence of severe fetal anemia, fetal blood sampling, with the intention to transfuse if

fetal anemia is confirmed, should be undertaken. In high-volume centers, neonatal survival rates after performing intravascular transfusions are excellent. Overall survival rates of 94% for nonhydropic fetuses and 74% for hydropic fetuses have been reported.[34] As stated earlier, we do not recommend performing IUTs after 35 weeks, as the aforementioned risks outweigh the associated risks of preterm delivery.

POSTNATAL

Successful serial IUTs will lead to suppression of fetal erythropoiesis, and these neonates are born with suppressed reticulocytosis. As the donated red blood cells age and are removed from the circulation, a slowly developing anemia may occur. This is exacerbated by the persistence of maternal antibodies in the infant's circulation for weeks after delivery that will continue the hemolysis of newly produced red blood cells. So-called top-up transfusions may be needed in the first 2–3 months after delivery. It is imperative that there is serial monitoring during this period to prevent a severe and potentially fatal anemia from developing. In our institution, we recommend that all discharged infants have weekly hematocrit and reticulocyte counts until the hematocrit is stable and the reticulocyte count is rising for 2 consecutive weeks.

WHAT THE REFERRING PHYSICIAN NEEDS TO KNOW

Patients with a positive antibody screen may be at risk for anemia and immune-mediated fetal hydrops. Evaluation of the father and the fetus will determine if further monitoring is necessary in the gestation. Fetal testing can be via cfDNA or amniocentesis. At-risk gestations should be followed with serial maternal antibody titers until a critical titer is reached, and then MCA-PSV screening for fetal anemia should be initiated. MCA-PSV >1.5 MoM should prompt referral to a center with expertise in fetal blood sampling and IUT.

KEY POINTS

- Fetal hydrops is defined as the accumulation of fluid in two fetal compartments (abdominal ascites, pleural or pericardial effusion, skin or scalp edema). It may also be associated with polyhydramnios and placental edema.
- Immune hydrops is the result of alloimmunization to red blood cell antigens.
- RhIG has decreased the relative frequency of Rh(D) disease.
- Kell alloimmunization is associated with the least predictable and most severe fetal anemia.
- Doppler measurement of fetal MCA-PSV has transformed the diagnosis and treatment of fetal anemia and greatly reduced the use of invasive procedures.
- Fetal blood transfusions in cases of severe anemia and hydrops have dramatically improved the outcome of these pregnancies.

SUGGESTED READINGS

de Haas M, Thurik FF, Koelewijn JM, et al. Haemolytic disease of the fetus and newborn. *Vox Sang*. 2015;109:99-113.

Moise KJ Jr, Argoti PS. Management and prevention of red cell alloimmunization in pregnancy: a systematic review. *Obstet Gynecol*. 2012;120:1132-1139.

Moise KJ. Management of rhesus alloimmunization in pregnancy. *Obstet Gynecol*. 2008;112:164-176.

Zwingerman R, Jain V, Hannon J, et al. Alloimmune red blood cell antibodies: prevalence and pathogenicity in a Canadian prenatal population. *J Obstet Gynaecol*. 2015;37:784-790.



All references are available online at www.expertconsult.com.

REFERENCES

1. Fairweather DV, Tacchi D, Coxon A, et al. Intrauterine transfusion in Rh-isoimmunization. *Br Med J*. 1967;4:189-194.
2. Moise KJ. Management of rhesus alloimmunization in pregnancy. *Obstet Gynecol*. 2008;112:164-176.
3. de Haas M, Thurik FF, Koelewijn JM, et al. Haemolytic disease of the fetus and newborn. *Vox Sang*. 2015;109:99-113.
4. Zwingerman R, Jain V, Hannon J, et al. Alloimmune Red Blood Cell Antibodies: Prevalence and Pathogenicity in a Canadian Prenatal Population. *J Obstet Gynaecol*. 2015;37:784-790.
5. Koelewijn JM, Vrijkotte TG, van der Schoot CE, et al. Effect of screening for red cell antibodies, other than anti-D, to detect hemolytic disease of the fetus and newborn: a population study in the Netherlands. *Transfusion*. 2008;48:941-952.
6. Medearis AL, Hensleigh PA, Parks DR, et al. Detection of fetal erythrocytes in maternal blood post partum with the fluorescence-activated cell sorter. *Am J Obstet Gynecol*. 1984;148:290-295.
7. Pollack W, Ascari WQ, Kochesky RJ, et al. Studies on Rh prophylaxis. 1. Relationship between doses of anti-Rh and size of antigenic stimulus. *Transfusion*. 1971;11:333-339.
8. Zipursky A, Israels LG. The pathogenesis and prevention of Rh immunization. *Can Med Assoc J*. 1967;97:1245-1257.
9. Green GH, Liley AW, Liggins GC. The place of foetal transfusion in haemolytic disease. A report of 22 transfusions in 16 patients. *Aust N Z J Obstet Gynaecol*. 1965;5:53-59.
10. Cormode EJ, Lyster DM, Israels S. An albuminemia in a neonate. *J Pediatr*. 1975;86:862-867.
11. Moïse AA, Gest AL, Weickmann PH, et al. Reduction in plasma protein does not affect body water content in fetal sheep. *Pediatr Res*. 1991;29:623-626.
12. Yinon Y, Visser J, Kelly EN, et al. Early intrauterine transfusion in severe red blood cell alloimmunization. *Ultrasound Obstet Gynecol*. 2010;36:601-606.
13. American College of Obstetricians and Gynecologists. ACOG Practice Bulletin No. 75: Management of alloimmunization during pregnancy. *Obstet Gynecol*. 2006;108:457-464.
14. Braun T, Brauer M, Fuchs I, et al. Mirror syndrome: a systematic review of fetal associated conditions, maternal presentation and perinatal outcome. *Fetal Diagn Ther*. 2010;27:191-203.
15. Dizon-Townson DS, Dildy GA, Clark SL. A prospective evaluation of fetal pericardial fluid in 506 second-trimester low-risk pregnancies. *Obstet Gynecol*. 1997;90:958-961.
16. Arcasoy MO, Gallagher PG. Hematologic disorders and nonimmune hydrops fetalis. *Semin Perinatol*. 1995;19:502-515.
17. Elchalal U, Ezra Y, Levi Y, et al. Sonographically thick placenta: a marker for increased perinatal risk—a prospective cross-sectional study. *Placenta*. 2000;21:268-272.
18. Moise KJ Jr. The usefulness of middle cerebral artery Doppler assessment in the treatment of the fetus at risk for anemia. *Am J Obstet Gynecol*. 2008;198:161.e1-161.e4.
19. Mari G, Deter RL, Carpenter RL, et al. Noninvasive diagnosis by Doppler ultrasonography of fetal anemia due to maternal red-cell alloimmunization. Collaborative Group for Doppler Assessment of the Blood Velocity in Anemic Fetuses. *N Engl J Med*. 2000;342:9-14.
20. Ruma MS, Swartz AE, Kim E, et al. Angle correction can be used to measure peak systolic velocity in the fetal middle cerebral artery. *Am J Obstet Gynecol*. 2009;200:397.e1-397.e3.
21. Sallout BI, Fung KF, Wen SW, et al. The effect of fetal behavioral states on middle cerebral artery peak systolic velocity. *Am J Obstet Gynecol*. 2004;191:1283-1287.
22. Moise KJ Jr, Argoti PS. Management and prevention of red cell alloimmunization in pregnancy: a systematic review. *Obstet Gynecol*. 2012;120:1132-1139.
23. Le Roux MG, Pascal O, Andre MT, et al. Non-paternity and genetic counselling. *Lancet*. 1992;340:607.
24. Wikman AT, Tiblad E, Karlsson A, et al. Noninvasive single-exon fetal RHD determination in a routine screening program in early pregnancy. *Obstet Gynecol*. 2012;120:227-234.
25. Finning KM, Martin PG, Soothill PW, et al. Prediction of fetal D status from maternal plasma: introduction of a new noninvasive fetal RHD genotyping service. *Transfusion*. 2002;42:1079-1085.
26. Moise KJ Jr, Carpenter RJ Jr. Increased severity of fetal hemolytic disease with known rhesus alloimmunization after first-trimester transcervical chorionic villus biopsy. *Fetal Diagn Ther*. 1990;5:76-78.
27. van Wamelen DJ, Klumper FJ, de Haas M, et al. Obstetric history and antibody titer in estimating severity of Kell alloimmunization in pregnancy. *Obstet Gynecol*. 2007;109:1093-1098.
28. ACOG practice bulletin. Antepartum fetal surveillance. Number 9, October 1999 (replaces Technical Bulletin Number 188, January 1994). Clinical management guidelines for obstetrician-gynecologists. *Int J Gynaecol Obstet*. 2000;68:175-185.
29. Society for Maternal-Fetal Medicine, Mari G, Norton ME, et al. Society for Maternal-Fetal Medicine (SMFM) Clinical Guideline #8: the fetus at risk for anemia—diagnosis and management. *Am J Obstet Gynecol*. 2015;212:697-710.
30. MacKenzie IZ, MacLean DA, Fry A, et al. Midtrimester intrauterine exchange transfusion of the fetus. *Am J Obstet Gynecol*. 1982;143:555-559.
31. Tongsong T, Wanapirak C, Sirichotiyakul S, et al. Middle cerebral artery peak systolic velocity of healthy fetuses in the first half of pregnancy. *J Ultrasound Med*. 2007;26:1013-1017.
32. Papantoniou N, Sifakis S, Antsaklis A. Therapeutic management of fetal anemia: review of standard practice and alternative treatment options. *J Perinat Med*. 2013;41:71-82.
33. Fox C, Martin W, Somerset DA, et al. Early intraperitoneal transfusion and adjuvant maternal immunoglobulin therapy in the treatment of severe red cell alloimmunization prior to fetal intravascular transfusion. *Fetal Diagn Ther*. 2008;23:159-163.
34. Schumacher B, Moise KJ. Fetal transfusion for red blood cell alloimmunization in pregnancy. *Obstet Gynecol*. 1996;88:137-150.

SECTION THREE
Preterm Labor

124 Cervical Length and Spontaneous Preterm Birth

MICHAEL HOUSE | HELEN FELTOVICH

Introduction

Preterm birth (PTB) touches communities everywhere. Around the world, one in 10 babies is born too early. The toll is more than 15,000,000 babies per year. The deep impact of this problem has fostered widespread efforts to use the best available medical practices to address it. Accordingly, the U.S. PTB rate fell from 10.44% to 9.57% from 2007–2014, although, unfortunately, preliminary 2015 birth data shows an increase (to 9.62%).[1] Risk of PTB is inversely associated with cervical length (CL), and midtrimester CL is currently the strongest clinical risk factor for PTB.[2,3] This chapter addresses the (1) clinical significance of a short cervix, (2) pathophysiology of cervical shortening, (3) ultrasound (US) technique for cervical measurement, and (4) management options for the short cervix.

Disease

DEFINITION

The cervix is a cylindric anatomic structure with a central canal that forms the lower part of the uterus. It has a dual role: first, it must remain closed throughout pregnancy to allow fetal growth and development during pregnancy, and then open completely at term to allow fetal passage. The responsible molecular and biomechanic mechanisms are incompletely elucidated.

The inverse relationship between CL and PTB risk was identified 20 years ago; specifically, the shorter the cervix, the greater the risk.[4] The definition of a short cervix depends on gestational age and fetal number, but the cutoff is usually 20–30 mm. The most common definition is less than 25 mm, but significance varies with gestational age; 25 mm corresponds to the first percentile at 18 weeks, the third percentile at 22 weeks, the fifth percentile at 24 weeks, and the 10th percentile at 28 weeks of gestation.[5] The definition of 25 mm is also widely applied to twin gestation, and short cervix is more common in multiples; in the National Institute of Child Health and Human Development Maternal Fetal Medicine Unit (NICHD MFMU) network's Preterm Prediction Study, 18% of women with twins had a short cervix in the midtrimester, compared to 9% in singletons.[6] Another definition of a short cervix is 10–20 mm; this definition was used in a randomized, double-blinded, placebo-controlled trial of vaginal progesterone for PTB prevention.[7] Another common definition is less than 15 mm because the risk of PTB increases exponentially below that value.[8,9]

PREVALENCE AND EPIDEMIOLOGY

The predictive accuracy of a short cervix for spontaneous PTB depends on the length of the cervix, gestational age at testing, fetal number, and risk factors for PTB (Table 124.1).

TABLE 124.1 RISK OF SPONTANEOUS PRETERM BIRTH BEFORE 35 WEEKS' GESTATION

Incidence Spb <35 Weeks' Gestation	Risk	Characteristics
>50%	Highest risk	Singleton, candidate for a physical examination–indicated cerclage; or cervix <15 mm, history of SPB, no cerclage; twin, cervix <15 mm
20%–50%	High risk	Singleton, cervix <15 mm, no history of SPB, no therapy; or cervix 15–25 mm, history of SPB, no therapy; or cervix <25 mm + progesterone ± cerclage; Twin, cervix 15–25 mm
10%–20%	Medium risk	Singleton, cervix >25 mm, history of SPB or other risk factor; or cervix 15–25 mm, no history of SPB; Twin, cervix >25 mm
<10%	Low risk	Singleton; no history of SPB or other risk factor

SPB, Spontaneous preterm birth.

Length of Cervix

As noted earlier, the risk of PTB increases as the cervix shortens. In an NICHD MFMU network trial, transvaginal CL was measured in asymptomatic women at 24 weeks of gestation to predict PTB before 35 weeks.[2] The relative risk (RR) increased steadily as CL shortened, and reached its highest (RR = 14) when the cervix was less than or equal to 13 mm. A systematic review of 17 studies of asymptomatic singletons reported a significantly increased risk of PTB with CL <25 mm before 34 weeks of gestation; the likelihood ratio was 6.29 (95% confidence interval [CI], 3.29–12.02).[10]

Gestational Age at Testing

A short cervix before 20 weeks of gestation has a worse prognosis than a short cervix later in pregnancy. In a systematic review of 17 pooled studies of asymptomatic singletons, the likelihood ratio for PTB was increased if the gestational age at testing was less than 20 weeks compared with 20 to 24 weeks.[10] This finding is not surprising; 25 mm corresponds to the first percentile at 18 weeks but the 10th percentile at 28 weeks,[5] so a 25-mm cervix at 18 weeks is more concerning.

Risk Factors for Preterm Birth

The sensitivity of CL for predicting PTB depends on the patient population. For instance, multiple gestation increases the PTB risk, but a short cervix increases it further. In the Preterm Prediction study, the risk of PTB in twins with CL 25 mm or less was similar to that for singletons with CL 15 mm or less.[6] A systematic review of 11 pooled studies of asymptomatic twins found an 18.5% baseline risk of PTB before 34 weeks' gestation compared with 29%–48% when the cervix was less than 25 mm.[10] In singleton pregnancy, women with a history of spontaneous PTB and a short cervix are at highest risk;[11] in an unselected, low-risk patient population, the sensitivity of a CL less than 25 mm for predicting PTB before 35 weeks of gestation was 37.3%,[2] but in a population of women at high risk based on a prior history of PTB, the sensitivity increased to 69%.[3]

ETIOLOGY AND PATHOPHYSIOLOGY

Although a short cervix is clearly associated with PTB, the question of whether a short cervix is a "cause" of PTB (i.e., cervical insufficiency or "weakness") or a "consequence" of a pathophysiology unrelated to cervical "weakness" is unclear.[12]

Infection/Inflammation

In a study of 52 women with cervical dilation at least 1.5 cm, without active labor (contractions or bleeding), 80% had evidence of infection/inflammation.[13] Positive amniotic fluid culture was present in half of cases and, even when this was negative, evidence of inflammation (higher intraamniotic interleukin-6 levels) was often present.

Similarly, infection/inflammation is common in the setting of a short cervix (less than 25 mm), particularly with a very short cervix. In a study of 401 patients admitted for preterm labor at 22 to 35 weeks of gestation, microbial invasion was more prevalent when the cervix was less than 15 mm (26.3%) compared with 15 to 25 mm (3.8%).[14] In another study in which a panel of inflammatory cytokines was studied as a function of CL, most inflammatory cytokines became elevated at a CL less than or equal to 5 mm.[15]

These studies confirm that intraamniotic infection and inflammation are common when the cervix is short.

Uterine Contractility

Although it seems intuitive that uterine contractility would cause a short cervix, this association is weak at best. In a secondary analysis of a NICHD MFMU study in which subjects had both home uterine activity monitoring and CL measurement, there was no association between CL (less than 25 mm versus greater than or equal to 25 mm) and frequency of uterine contractions.[16]

Uterine Overdistention

Uterine overdistention from multiple gestation or polyhydramnios is associated with PTB and cervical shortening. Although the risk of PTB increases rapidly when CL is less than 15 mm in a singleton gestation, in a twin gestation, a similar increase in risk is seen at a higher threshold, with a CL of less than 25 mm.[6] The pathophysiology of PTB is clearly different for multiple versus singleton gestations.

Cervical "Insufficiency" or "Incompetence"

Cervical tissue gets its "strength" from its collagen-rich connective tissue, and abnormalities of cervical tissue have been associated with adverse outcomes.[17,18] However, the definition of cervical "insufficiency" or "incompetence" has recently come under scrutiny.[12,19] The term has traditionally been applied to pre- or periviable midtrimester pregnancy loss, and presumed to be caused by "weak" tissue. However, studies that have tried to identify signs of acquired "weakness" (cone biopsy, obstetric laceration) or inherent "weakness" (uterine anomalies, genetic disorders involving collagen) have been inconclusive.[12,20] A significant limitation of studies linking "weak" cervical tissue with cervical shortening is the lack of a clinically acceptable method to measure tissue properties quantitatively and objectively. Noninvasive quantitative US methods such as shear wave elasticity imaging are under active investigation[21] (Chapter 170).

Summary

It is likely that cervical shortening is associated with several different pathophysiologic pathways. Research aimed at clarifying the role of a short cervix in PTB will aid efforts to tailor suitable preventive therapies.

MANIFESTATIONS OF DISEASE

Clinical Presentation and Screening

Most pregnant women with a short cervix are asymptomatic, regardless of whether the discovery is incidental or the result of screening. The 2016 Society of Maternal Fetal Medicine (SMFM) recommendations for CL screening,[11] which closely approximate those of the American College of Obstetricians and Gynecologists,[22] and the International Society of Ultrasound in Obstetrics and Gynecology,[23] support routine screening in high-risk women (i.e., those with a history of spontaneous PTB) and are noncommittal on screening in low-risk women. Specifically, the latter practice is considered reasonable but not mandatory. Serial transvaginal CL screening of high-risk women should occur at least every 2 weeks between 16 and 24 weeks (grade 1A evidence).[11] If the cervix is 25–29 mm, it is reasonable to perform measurements weekly.[24] Further, SMFM guidelines state that appropriate training should be undertaken in centers that perform CL evaluation because of the potential for over- and underdiagnoses and treatment with erroneous measurements.[11]

Imaging Technique and Findings

Ultrasound. The gold standard for CL measurement is transvaginal US, via a technique well described by the NICHD MFMU network trials.[11] This approach is more reproducible and sensitive than transabdominal assessment, and is also unaffected by maternal obesity or shadowing from fetal parts. However, the practicality of transabdominal US may make it useful as an initial screening step.[25]

Transvaginal Technique. For transvaginal measurement of CL,[2,3,11] the bladder is emptied, and the patient positioned in the dorsal lithotomy position. The transducer is introduced into the vagina and gently applied to the cervix in the anterior fornix. Pressure is applied until a satisfactory image is seen and then withdrawn slightly until the image starts to degrade. The anterior and posterior width of the cervix should be equal; excessive pressure from the transducer may falsely lengthen the cervix, and too little pressure may result in poor image quality.[2] CL is determined by measuring the linear distance between the internal and external cervical os (Fig. 124.1A). If the cervix is curved, a linear distance may underestimate the CL, making it best to measure with two or three sequential lines (Fig. 124.1B). Out of three images, the shortest, best measurement should be recorded.

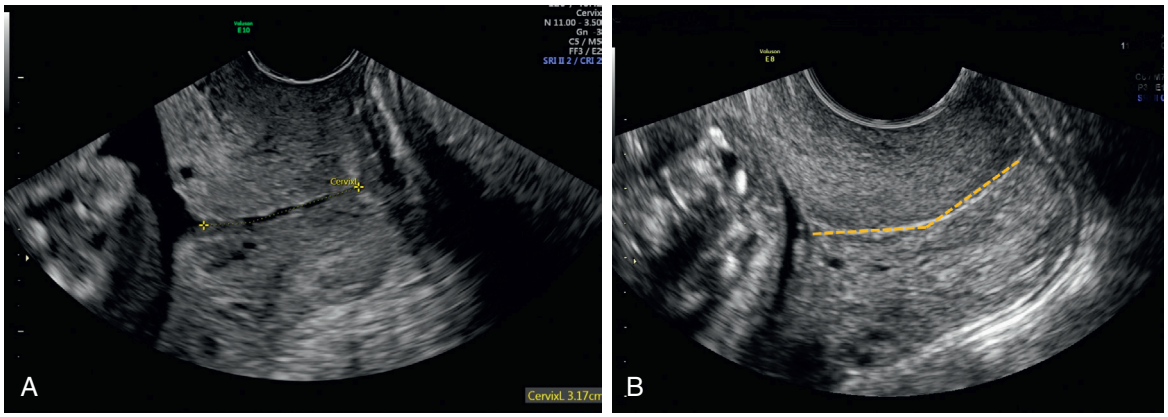

Fig. 124.1 (A and B) Transvaginal cervical length measurement.

Transabdominal Technique. Although the gold standard for CL measurement is transvaginal US, a transabdominal approach can also be used. For transabdominal measurement, with the patient in the dorsal supine position and with the examining table as flat as possible, the cervix is imaged with the transducer in the sagittal plane, using moderate downward pressure to visualize the desired landmarks.[25] These landmarks are (1) the cervical/vaginal interface (marked by a border of increased echogenicity), (2) internal cervical os, (3) external cervical os, (4) full length of the cervical canal, and (5) outline of the cervix corpus. Imaging is considered adequate if at least three components are visualized, and an optimal image is one in which four or more components are visualized (Fig. 124.2).

TYVU Progression, Funneling, and Dynamic Cervix. Early studies of cervical changes during pregnancy showed that the cervix shortens in a characteristic pattern, termed *TYVU progression*.[26] Under normal circumstances, the fetal membranes are well applied to the lower uterine segment and form a right angle to the endocervical canal ("T"). As the cervix shortens, the fetal membranes increasingly protrude into the cervical canal, forming an enlarging funnel ("Y → V"; Fig. 124.3A). As the funnel enlarges and CL approaches zero, the protruding membranes widen to form a "U" (Fig. 124.3B).

Funneling is a prominent feature of a short cervix. The most common definition of a funnel is 5 mm of dilated internal os, and several studies suggest that the presence of a funnel confers increased risk of PTB, regardless of whether or not the cervix is short.[2] However, other studies found a funnel was not an independent risk factor when the analysis was controlled for CL.[27] One drawback of funneling is marked interobserver variability compared with CL measurement.[2] In addition, trials of progesterone and cerclage have used CL rather than funneling to target treatment.

Fundal pressure should be applied to evaluate for a "dynamic" cervix. Dynamic changes can occur spontaneously or can be elicited by a provocative maneuver such as fundal pressure. In the NICHD MFMU network trials, fundal pressure was applied for 15 seconds, and the cervix was observed for approximately 5 minutes, after which the "functional" CL was measured (the residual CL after dynamic changes have occurred).[3,25]

Amniotic Fluid Debris or Sludge. Amniotic fluid debris, or "sludge," is described as particulate matter in the amniotic fluid next to the internal os. Amniotic fluid sludge is found in 20% to 30% of women at high risk for PTB.[28] The composition of amniotic fluid sludge is unknown but likely related to hemorrhage, meconium, or intraamniotic infection. In addition, among women at high risk for PTB, amniotic fluid sludge is an independent risk factor for intrauterine infection and PTB.[28]

Magnetic Resonance Imaging. Although it is possible to evaluate the cervix with magnetic resonance imaging (MRI), the lack of proven superiority and the cost of MRI preclude its routine use.

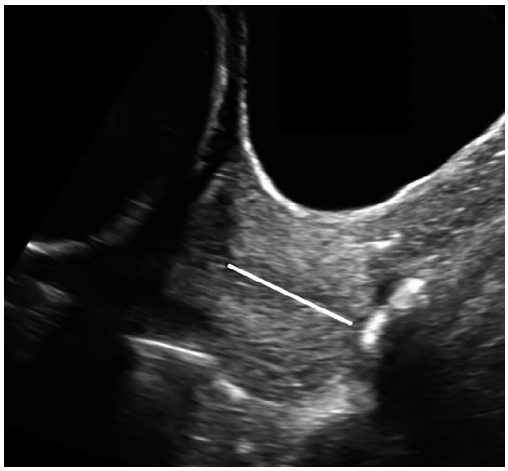

Fig. 124.2 Transabdominal cervical length measurement.

CLASSIC SIGNS

Short cervix on transvaginal US.

Synopsis of Treatment Options

PRENATAL

At this time there are three interventions for the short cervix: vaginal progesterone, cerclage (stitch around the cervix), and pessary (silicone ring). These are not new; cerclage was introduced in 1902, pessary in 1959, and the concept of progesterone supplementation for PTB prevention in 1964. However, the 1990s recognition of the inverse relationship between PTB risk and CL inspired new clinical trials of cervix-focused treatments.

Vaginal Progesterone

In a 2007 Fetal Medicine Foundation trial, more than 24,000 unselected (high- and low-risk) women were screened with

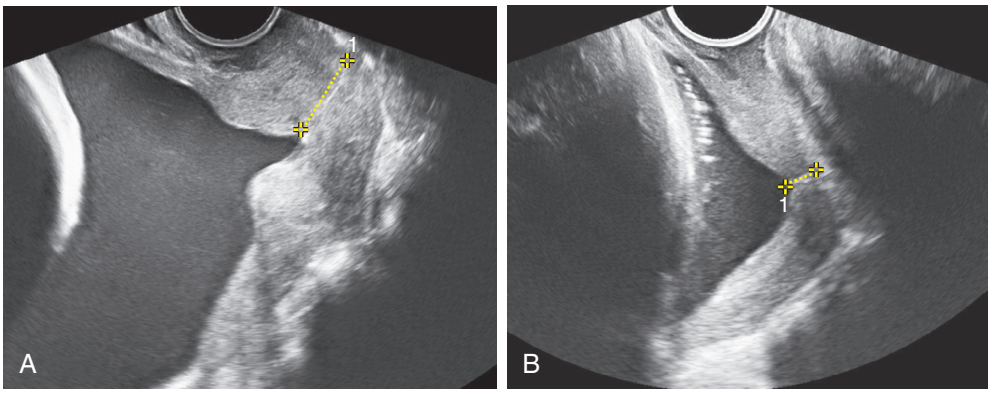

Fig. 124.3 (A and B) Cervical funneling.

transvaginal US at 20 to 25 weeks of gestation.[8] When CL was less than 15 mm (incidence 1.7%), women were randomly assigned to either placebo or 200 mg progesterone nightly until 33 weeks, 6 days. The primary outcome was PTB before 34 weeks of gestation. Progesterone significantly reduced this risk; PTB occurred in 19.2% of the progesterone arm compared to 34.4% of the placebo arm (RR, 0.56; 95% CI, 0.36–0.86). Progesterone was also associated with decreased incidence of treatment for neonatal sepsis (RR, 0.28; 95% CI, 0.08–0.97). Similar results were found in an international randomized, double-blinded, placebo-controlled trial of another form of vaginal progesterone (90 mg gel).[7] Women with a short cervix 10 mm–20 mm (n = 465 out of 32,091 screened, incidence 2.3%) were randomized at 19 to 23 weeks, 6 days' gestation. The primary outcome was PTB at less than 33 weeks. A significant difference was seen between groups; PTB occurred in 8.9% of the progesterone group versus 16.1% in the placebo group (RR, 0.54; 95% CI, 0.33–0.89; p = .01). In addition, a significant reduction was seen in adverse neonatal outcomes (respiratory distress syndrome and birth weight <1500 g).

The largest and most recent randomized trial of vaginal progesterone for PTB prevention, OPPTIMUM, failed to show benefit.[29] In this multicenter, placebo-controlled trial, 1228 women at high risk of PTB (because of CL 25 mm or less, history of PTB 34 weeks' gestation or less, or a positive fetal fibronectin in combination with other clinical risk factors) were randomized to placebo or 200 mg vaginal progesterone daily from 22–24 weeks to 34 weeks of pregnancy. Progesterone had no significant effect on obstetric outcome (delivery or death at less than 34 weeks), neonatal outcome (composite of death, bronchopulmonary dysplasia, and brain injury), or childhood outcome at age 2 years (Bayley III cognitive composite score). The odds ratio (OR) for the primary obstetric outcome (adjusted for multiple comparisons) was 0.86 (95% CI, 0.61–1.22).

Vaginal progesterone significantly decreased the risk of PTB at less than or equal to 34 weeks of gestation or fetal death in a metaanalysis of 974 women from five trials including OPPTIMUM. In the progesterone group, 18.1% delivered preterm compared to 27.5% of controls (RR 0.66; 95% CI, 0.52–0.83; p = .0005). The authors recommended universal CL screening at 18–24 weeks of pregnancy, and vaginal progesterone for the cervix less than or equal to 25 mm.[30]

Cerclage

In 2005, a metaanalysis of four trials of US-indicated cerclage revealed a possible benefit of cerclage in singleton pregnancies, especially when the obstetric history was complicated by a history of PTB or second-trimester loss or both.[31] Subsequently, in an NICHD MFMU network trial of cerclage, women at high risk (history of spontaneous PTB at less than 34 weeks of gestation) were screened with transvaginal US from 16 weeks, 0 days to 22 weeks, 6 days.[9] When CL was <25 mm, women were randomly assigned to McDonald cerclage or expectant management. The primary outcome variable of PTB before 35 weeks was seen in 32% of the cerclage group and 42% of the expectant management group (OR, 0.67; 95% CI, 0.42–1.07; p = .09). When the analysis was stratified by CL, cerclage benefit was significant only when CL at randomization was <15 mm (p = .006), with no benefit when CL was 15 to 24 mm (p = .52). Secondary perinatal outcomes revealed cerclage was associated with decreased previable birth (p = .03) and perinatal mortality (p = .046). A recent Cochrane Database review concluded that while cerclage may reduce the risk of PTB, this is not associated with improved neonatal outcome.[32]

Pessary

The first randomized controlled trial of pessary for the prevention of PTB, PECEP (cervical pessary in pregnant women with a short cervix), was published in 2012.[32] Women from five hospitals were offered transvaginal CL screening at the time of routine second-trimester fetal survey. Of 385 with short cervix (25 mm or less), 192 were randomized to pessary, and 193 to expectant management. Pessary significantly reduced PTB before 34 weeks; this occurred in 12 (6%) women assigned to pessary compared to 51 (27%) controls (OR, 0.18; 95% CI, 0.08–0.37; p < .0001).

A more recent and larger multicenter, multinational, randomized controlled trial failed to show benefit of pessary.[33] From an unselected population with singleton pregnancy and CL ≤25 mm at 20–24 weeks, 6 days' gestation, 932 of 1829 eligible women were randomized (n = 465 to pessary and n = 467 to control). Women in both groups with CL 15 mm or less received vaginal progesterone. The primary outcome of PTB <34 weeks of gestation occurred in 12% of the pessary group and 10.8% of controls (OR, 1.12; 95% CI, 0.75–1.69; p<= .57). Research on pessary for prevention of PTB continues, particularly in twin gestation.

Twins

At least half of twins are born preterm; the mean gestational age at delivery is 35–36 weeks.[34] Cerclage, progesterone, and pessary have been studied for prevention of PTB in twins with short cervix. An individual patient data metaanalysis of randomized trials of twin pregnancies showed no benefit of cerclage for women with short cervix less than 25 mm before 24 weeks of gestation.[35] Three trials, involving 49 twin pregnancies, were included. There was no difference in the primary outcome of PTB before 34 weeks' gestation among women with a CL less than 25 mm before 24 weeks (adjusted OR, 1.17; 95% CI, 0.23–0.79). In fact, neonatal outcome (primarily respiratory distress) appeared worsened by cerclage.

An individual patient data metaanalysis of progesterone to prevent PTB in twins showed no benefit of 17-alpha-hydroxyprogesterone caproate (17P) or vaginal progesterone on the primary outcome of a composite of adverse perinatal outcome (perinatal death, respiratory distress, intraventricular hemorrhage, etc.).[36] The analysis included 3768 women from 13 trials. For 17P, the RR was 1.1 (95% CI, 0.97–1.4), and for vaginal progesterone the RR was 0.97 (95% CI, 0.77–1.2). Stratified subgroup analyses for adverse perinatal outcome based on CL less than 25 mm at randomization and before 24 weeks of gestation showed benefit of vaginal progesterone. The RR for the former was 0.57 (95% CI, 0.47–0.70), and for the latter, 0.56 (95% CI, 0.42–0.75).

Pessary has also been studied in twins. In one study of 40 women with twins and a CL of <25 mm from 21–31 weeks of gestation, compared to controls matched for gestational age and CL, pessary reduced the incidence of PTB before 36 and before 34 weeks of gestation (p < .05), but not before 32 weeks.[37] A subsequent trial of 137 women with twin gestation and CL ≤25 mm (out of 2287 screened) showed a significant decrease in the primary outcome of PTB less than 34 weeks.[38] PTB was lower in women who received pessary (11/68, 16.2%) than controls (26/66, 39.4%), with a RR of 0.41 (95% CI, 0.22–0.76).

These two interventions (vaginal progesterone and pessary) are currently being studied in the NICHD MFMU network's Randomized Trial of Pessary and Progesterone for Preterm

Prevention in Twin Gestation. Women with twins who are less than 24 weeks of gestation and with a CL of 30 mm or less (n = 630) will be randomized to pessary or vaginal progesterone. Those randomized to the latter group will be further randomized to progesterone (200 mg nightly) or placebo (ClinicalTrials.gov identifier NCT02518495).

Currently, because cerclage is ineffective (and possibly harmful), vaginal progesterone does not appear effective, and trials of pessary are inconclusive/ongoing, CL screening for the purpose of preventing PTB is not recommended in multiple gestation outside of the confines of a clinical trial.[11]

KEY POINTS

- Grade 1A evidence supports CL screening in high-risk patients with singleton pregnancy.
- Universal US screening of CL is not presently standard of care in either singleton or multiple gestation.
- Treatments for a short cervix in singleton pregnancy include vaginal progesterone, cerclage, or pessary.
- Pessary and vaginal progesterone for a short cervix in twin pregnancy are under active study.
- Transvaginal US is the gold standard for CL measurement, and performing practitioners should have adequate training.

WHAT THE REFERRING PHYSICIAN NEEDS TO KNOW

Currently, there is grade 1A evidence for transvaginal CL screening in high-risk women (history of PTB) every 1 to 2 weeks from 16 to 20 weeks until 22 weeks, 6 days. Although studies conflict about their efficacy, and research is ongoing at this time, interventions for a short cervix in singletons include cerclage, vaginal progesterone, or pessary. Screening in low-risk women is considered reasonable, but not yet universally mandated by the societies. In twin pregnancy, CL screening is not recommended outside of the confines of a clinical trial because of the lack of effective interventions. Progesterone and pessary for prevention of PTB in twins are currently under active investigation. CL screening should only be done by practitioners with appropriate training (certification programs are offered by the Perinatal Quality Foundation and the Fetal Medicine Foundation) and expertise in counseling about treatment options.

SUGGESTED READINGS

Committee on Practice Bulletins—Obstetrics. American College of Obstetricians and Gynecologists Practice Bulletin no. 130: prediction and prevention of preterm birth. *Obstet Gynecol.* 2012;120:964-973.

Nicolaides KH, Syngelaki A, Poon LC, et al. A randomized trial of a cervical pessary to prevent preterm singleton birth. *N Engl J Med.* 2016;374(11):1044-1052.

SMFM, McIntosh J, Feltovich H, et al, Society for Maternal Fetal Medicine Consult Series #40. The role of routine cervical length screening in selected high- and low-risk women for preterm birth prevention. *Am J Obstet Gynecol.* 2016;215:B2-B7.

Vink J, Feltovich H. Cervical etiology of spontaneous preterm birth. *Semin Fetal Neonatal Med.* 2016;21:106-112.



All references available online at www.expertconsult.com

REFERENCES

1. Hamilton BE, Martin JA, Osterman MJ. Births: preliminary data for 2015. *Natl Vital Stat Rep*. 2016;65(3).
2. Iams JD, Goldenberg RL, Meis PJ, et al. The length of the cervix and the risk of spontaneous premature delivery. *N Engl J Med*. 1996;334:567-572.
3. To MS, Skentou CA, Royston P, et al. Prediction of patient-specific risk of early preterm delivery using maternal history and sonographic measurement of cervical length: a population-based prospective study. *Ultrasound Obstet Gynecol*. 2006;27:362-367.
4. Iams JD, Johnson FF, Sonek J, et al. Cervical competence as a continuum: a study of ultrasonographic cervical length and obstetric performance. *Am J Obstet Gynecol*. 1995;172:1097-1103.
5. Salomon LJ, Diaz-Garcia C, Bernard JP, et al. Reference range for cervical length throughout pregnancy: non-parametric LMS-based model applied to a large sample. *Ultrasound Obstet Gynecol*. 2009;33:459-464.
6. Goldenberg RL, Iams JD, Miodovnik M, et al. The preterm prediction study: risk factors in twin gestations. National Institute of Child Health and Human Development Maternal-Fetal Medicine Units Network. *Am J Obstet Gynecol*. 1996;175:1047-1053.
7. Hassan SS, Romerto R, Vidyadhari D, et al, PREGNANT Trial. Vaginal progesterone reduces the rate of preterm birth in women with a sonographic short cervix: a multicenter, randomized, double-blind, placebo-controlled trial. *Ultrasound Obstet Gynecol*. 2011;38:18-31.
8. Fonseca EB, Celik E, Parra M, et al. Progesterone and the risk of preterm birth among women with a short cervix. *N Engl J Med*. 2007;357:462-469.
9. Owen J, Hankins G, Iams JD, et al. Multicenter randomized trial of cerclage for preterm birth prevention in high-risk women with shortened midtrimester cervical length. *Am J Obstet Gynecol*. 2009;201:375.e371-375.e378.
10. Honest H, Bachmann LM, Coomarasamy A, et al. Accuracy of cervical transvaginal sonography in predicting preterm birth: a systematic review. *Ultrasound Obstet Gynecol*. 2003;22:305-322.
11. SMFM, McIntosh J, Feltovich H, et al, Society for Maternal Fetal Medicine Consult Series #40. The role of routine cervical length screening in selected high- and low-risk women for preterm birth prevention. *Am J Obstet Gynecol*. 2016;215:B2-B7.
12. Vink J, Feltovich H. Cervical etiology of spontaneous preterm birth. *Semin Fetal Neonatal Med*. 2016;21:106-112.
13. Lee SE, Romero R, Park CW, et al. The frequency and significance of intraamniotic inflammation in patients with cervical insufficiency. *Am J Obstet Gynecol*. 2008;198:633.e631-633.e638.
14. Gomez R, Romero R, Nien JK, et al. A short cervix in women with preterm labor and intact membranes: a risk factor for microbial invasion of the amniotic cavity. *Am J Obstet Gynecol*. 2005;192:678-689.
15. Kiefer DG, Keeler SM, Rust OA, et al. Is midtrimester short cervix a sign of intraamniotic inflammation? *Am J Obstet Gynecol*. 2009;200:374.e371-374.e375.
16. Berghella V, Iams JD, Newman RB, et al. Frequency of uterine contractions in asymptomatic pregnant women with or without a short cervix on transvaginal ultrasound scan. *Am J Obstet Gynecol*. 2004;191:1253-1256.
17. House M, Kaplan DL, Socrate S. Relationships between mechanical properties and extracellular matrix constituents of the cervical stroma during pregnancy. *Semin Perinatol*. 2009;33:300-307.
18. Vink J, Qin S, Brock CO, et al. A new paradigm for the role of smooth muscle cells in the human cervix. *Am J Obstet Gynecol*. 2016;215:418.e1-418.e11.
19. Iams JD, Cebrik D, Lynch C, et al. The rate of cervical change and the phenotype of spontaneous preterm birth. *Am J Obstet Gynecol*. 2011;205:130.e1-130.e6.
20. Committee on Practice Bulletins—Obstetrics. American College of Obstetricians and Gynecologists Practice Bulletin no. 142: cerclage for the management of cervical insufficiency. *Obstet Gynecol*. 2014;123(2 Pt 1):372-379.
21. Carlson LC, Romero ST, Palmeri MT, et al. Changes in shear wave speed pre and post induction of labor: a feasibility study. *Ultrasound Obstet Gynecol*. 2015;46:93-98.
22. Committee on Practice Bulletins—Obstetrics. American College of Obstetricians and Gynecologists Practice Bulletin no. 130: prediction and prevention of preterm birth. *Obstet Gynecol*. 2012;120:964-973.
23. Salomon LJ, Alfirevic Z, Berghella V, et al, ISUOG Clinical Standards Committee. Practice guidelines for performance of the routine mid-trimester fetal ultrasound scan. *Ultrasound Obstet Gynecol*. 2011;37:116-126.
24. Owen J, Hankins G, Iams JD, et al. Multicenter randomized trial of cerclage for preterm birth prevention in high-risk women with shortened midtrimester cervical length. *Am J Obstet Gynecol*. 2009;201:375.e371-375.e378.
25. Saul LL, Kurtzman JT, Hagemann C, et al. Is transabdominal sonography of the cervix after voiding a reliable method of cervical length assessment? *J Ultrasound Med*. 2008;27:1305-1311.
26. Zilianti M, Azuaga A, Calderon F, et al. Monitoring the effacement of the uterine cervix by transperineal sonography: a new perspective. *J Ultrasound Med*. 1995;14:719-724.
27. Berghella V, Owen J, MacPherson C, et al. Natural history of cervical funneling in women at high risk for spontaneous preterm birth. *Obstet Gynecol*. 2007;109:863-869.
28. Kusanovic JP, Espinoza J, Romero R, et al. Clinical significance of the presence of amniotic fluid "sludge" in asymptomatic patients at high risk for spontaneous preterm delivery. *Ultrasound Obstet Gynecol*. 2007;30:706-714.
29. Norman JE, Marlow M, Messow C-M, et al. Vaginal progesterone prophylaxis for preterm birth (the OPPTIMUM study): a multicentre, randomised, double-blind trial. *Lancet*. 2016;387(10033):2016-2116.
30. Romero R, Nicolaides K, Conde-Agudelo A, et al. Vaginal progesterone decreases preterm birth ≤34 weeks of gestation in women with a singleton pregnancy and a short cervix: an updated meta-analysis including data from the OPPTIMUM study. *Ultrasound Obstet Gynecol*. 2016;48:308-310.
31. Berghella V, Odibo AO, To MS, et al. Cerclage for short cervix on ultrasonography: meta-analysis of trials using individual patient-level data. *Obstet Gynecol*. 2005;106:181-189.
32. Alfirevic Z, Stampalija T, Robert D, et al. Cervical stitch for preventing preterm births in singleton pregnancies. *Cochrane Database Syst Rev*. 2012;(4):CD008991.
33. Goya M, Pratcorona L, Merced C, et al. Cervical pessary in pregnant women with a short cervix (PECEP): an open-label randomized controlled trial. *Lancet*. 2012;379:1800-1806.
34. Gordon MC, McKenna DS, Stewart TL, et al. Transvaginal cervical length scans to prevent prematurity in twins: a randomized controlled trial. *Am J Obstet Gynecol*. 2016;214:277.e1-277.e7.
35. Saccone G, Rust O, Althuisius S, et al. Cerclage for short cervix in twin pregnancies: systematic review and meta-analysis of randomized trials using individual patient-level data. *Acta Obstet Gynecol Scand*. 2015;94:352-358.
36. Schuit E, Stock S, Rode L, et al, Global Obstetrics Network (GOnet) collaboration. Effectiveness of progestogens to improve perinatal outcome in twin pregnancies: an individual participant data meta-analysis. *BJOG*. 2015;122:27-37.
37. DiTommaso M, Seravilli V, Arduino S, et al. Arabin cervical pessary to prevent preterm birth in twin pregnancies with short cervix. *J Obstet Gynaecol*. 2016;36:715-718.
38. Goya M, de la Calle M, Pratcorona L, et al. Cervical pessary to prevent preterm birth in women with twin gestation and sonographic short cervix: a multicenter randomized controlled trial (PECEP-Twins). *Am J Obstet Gynecol*. 2016;214(2):145-152.

SECTION FOUR
Other

To access the videos in this chapter, scan this QR code or visit expertconsult.com

125 Fetal Biophysical Profile

CHRISTINA S. HAN | LAWRENCE D. PLATT

Introduction

The biophysical profile (BPP) was first described in 1980 as a method to quantify and standardize antepartum fetal evaluation.[1] The full BPP test is performed using a combination of real-time ultrasound (US) and cardiotocography, also known as a *nonstress test* (NST). The US component combines the assessment of four activities: fetal movement, fetal breathing, and tone over a 30-minute period, along with amniotic fluid assessment. The NST component continuously monitors the fetal heart rate and

TABLE 125.1 INDICATIONS FOR ANTEPARTUM FETAL TESTING

Maternal Conditions	Pregnancy-Related Conditions
• Pregestational diabetes mellitus • Hypertension • Systemic lupus erythematosus • Chronic renal disease • Antiphospholipid syndrome • Hyperthyroidism (poorly controlled) • Hemoglobinopathies (sickle cell, sickle cell–hemoglobin C, or sickle cell–thalassemia disease) • Cyanotic heart disease	• Gestational hypertension • Preeclampsia • Decreased fetal movement • Gestational diabetes mellitus (poorly controlled or medically treated) • Oligohydramnios • Fetal growth restriction • Late-term or postterm pregnancy • Isoimmunization • Previous fetal demise (unexplained or recurrent risk) • Monochorionic multiple gestation (with significant growth discrepancy)

*These indications are considered relative, because antepartum fetal surveillance results have not been definitively demonstrated to improve perinatal outcome.

TABLE 125.2 BIOPHYSICAL PROFILE SCORING SYSTEM

Parameter	Description	Score
Breathing	≥1 episode of ≥30 seconds in 30 minutes. Hiccups are considered breathing activity.	2
Movement	At least three body or limb movements in 30 minutes.	2
Tone	At least one episode of active extension/flexion in 30 minutes.	2
Amniotic fluid	A single 2 cm × 2 cm pocket.	2
Nonstress test	Two accelerations >15 beats per minute of at least 15 seconds duration.	2

uterine activity over 20+ minutes. Relative indications for antepartum fetal surveillance, including BPP, are listed in Table 125.1. The BPP is usually initiated only after 32 weeks for patients at risk of stillbirth.[2,3] In patients with multiple or severe comorbidities, BPP testing may begin at even earlier gestational ages if delivery would be considered for fetal benefit.[4]

Five variables—breathing, movement, tone, amniotic fluid volume, and NST—are included in the test. Table 125.2 describes the specific parameters required to obtain a score of 2 in each category. A reassuring BPP score is 8 or 10 out of 10, whereas a score of 6 is equivocal, and 4 or less is abnormal.[4] These parameters are indicators of a functional fetal central nervous system and absence of hypoxemia (Fig. 125.1).[5,6]

The composite score is better at differentiating normal from compromised fetuses than any single parameter. In a study evaluating patients undergoing elective prelabor cesarean delivery, predelivery BPP yielded 90% sensitivity, 96% specificity, and 82% positive and 98% negative predictive value in predicting fetal acidosis, defined by an umbilical cord arterial pH <7.20.[7] The efficacy of composite BPP to indicate fetal acidosis was found to be superior to the 1- and 5-minute Apgar scores in sensitivity and positive predictive value. A modified BPP, using

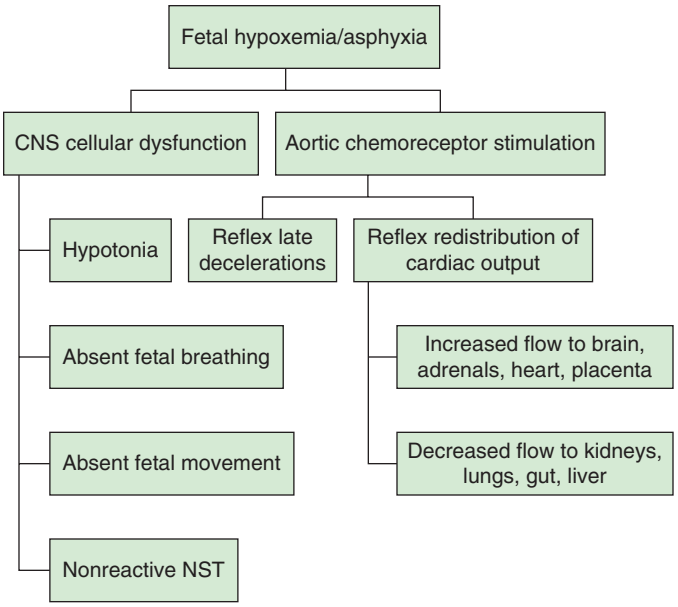

Fig. 125.1 Fetal functional responses to hypoxemia. *CNS,* Central nervous system; *NST,* nonstress test.

only NST and amniotic fluid assessment, has also been found to have good predictive value, and is commonly used.

A normal BPP is considered highly reassuring, as reflected in the low false-negative rate of antepartum fetal surveillance, defined as the incidence of stillbirth occurring within 1 week of a normal test result.[4] The negative predictive value is 99.8% for the NST and is greater than 99.9% for the contraction stress test, BPP, and modified BPP.

Disorder

Decreased fetal breathing.

DEFINITION

Decreased fetal breathing is defined by the absence of at least one 30-second segment of continuous fetal breathing over a 30-minute real-time examination. Some experts accept fetal hiccups as equivalent to breathing, although no data are available on the reliability of this sign.

PREVALENCE AND EPIDEMIOLOGY

Fetal breathing occurs intermittently and usually develops around 20 weeks' gestation,[8] fluctuating throughout the day. In a study continuously evaluating fetal breathing behavior in 11 healthy women at 34–35 weeks of gestation, breathing frequency changes were seen with meals (increase 2–3 hours following consumption) and during the night (between 1 and 7 a.m.).[9] Fetal gross movements and breathing movements are present for periods of 20–60 minutes out of every 1–1.5 hours of observation time, likely reflecting biologic changes of sleep state in the fetus.

ETIOLOGY AND PATHOPHYSIOLOGY

Factors implicated in altered fetal breathing are noted in Table 125.3. When a fetus is acidotic, the first fetal behavior changes

TABLE 125.3 FACTORS AFFECTING FETAL BREATHING

Increased Breathing	Decreased Breathing	No Change
• Meal consumption • Maternal glucose level rise • Increased gestational age	• Magnesium sulfate • Alcohol • Nicotine • Narcotics • Benzodiazepines labor • Premature rupture of membranes • Intraamniotic infection	• Caffeine

are a nonreactive NST and loss of fetal breathing motion.[7] In animal models, fetal breathing movements cease abruptly when the tissue PO_2 falls by about 8 to 10 torr.[10]

MANIFESTATIONS OF DISEASE

Clinical Presentation

Absence of rhythmic movement of the chest, diaphragm, and abdominal wall, occurring at a frequency of 1/sec (Video 125.1).

Imaging Technique and Findings

Ultrasound. US real-time imaging is used to visualize fetal chest and abdominal walls, and diaphragmatic motion. The image can be obtained in the coronal, sagittal, or less ideally, transverse plane. M-mode can also be used to document wall motion. A clip or video of the fetal breathing motion should be recorded when technology permits (see Video 125.1). It is important to ensure that the movement noted is not from maternal breathing motions or fetal cardiac activity moving the diaphragm.

Differential Diagnosis From Imaging Findings

Fetal sleep cycle or other external factors decreasing movement. (See Table 125.3)

Synopsis of Treatment Options

PRENATAL

Decision on expectant management, repeat surveillance or delivery should be based made on the composite BPP score, factoring in gestational age and other relevant clinical parameters.

POSTNATAL

Neonatal resuscitation may be required in fetuses delivered for abnormal BPP. Delivery plans should be coordinated with a pediatric resuscitation team.

WHAT THE REFERRING PHYSICIAN NEEDS TO KNOW

The examination should continue until completion of 30 minutes if the fetus does not meet criteria, to allow for completion of a sleep cycle.

Disorder

Decreased fetal movement and tone.

DEFINITION

Decreased fetal movement is defined by less than three body or limb movements in a 30-minute period. Decreased tone is defined by absence of an active extension/flexion motion in limbs or hands in a 30-minute period.

PREVALENCE AND EPIDEMIOLOGY

Fetal movement and tone are also intermittent in normal fetuses, developing around 7.5 and 9 weeks, respectively.[11] The centers regulating fetal movement and tone have a higher threshold for hypoxemia than those for fetal breathing or heart rate accelerations. Therefore loss of fetal breathing and heart rate accelerations predictably occur earlier in a hypoxemic event, when pH is less than 7.2, followed by loss of tone and movement when pH is less than 7.1.[7]

ETIOLOGY AND PATHOPHYSIOLOGY

The most common cause of decreased fetal movement and tone is a period of fetal sleep. In fetuses between 36 and 42 weeks the mean duration of fetal sleep is 20 minutes, and episodes can extend up to 40 minutes.[12] Other common causes of decreased fetal movement are steroid administration, labor, and smoking.

MANIFESTATIONS OF DISEASE

Clinical Presentation

Patients may subjectively describe decreased fetal movement. In those performing fetal kick counts, they may note an increase in time to achieve 10 kicks, which should always prompt some other testing for fetal well-being.

Imaging Technique and Findings

Ultrasound. US real-time imaging is used to visualize fetal tone and movement, as described previously.

Differential Diagnosis From Imaging Findings

Fetal sleep should be considered. The same factors that cause decreased fetal breathing may also affect fetal movement.

Synopsis of Treatment Options

PRENATAL

Decision on expectant management, repeat surveillance, or delivery should be based made on the composite BPP score, factoring in gestational age and other relevant clinical parameters.

POSTNATAL

Neonatal resuscitation may be required in fetuses delivered for abnormal BPP. Delivery plans should be coordinated with a pediatric resuscitation team.

WHAT THE REFERRING PHYSICIAN NEEDS TO KNOW

The examination should continue until completion of 30 minutes if the fetus does not meet criteria, to allow for completion of a sleep cycle.

TABLE 125.4 PERINATAL MORTALITY AND BIOPHYSICAL PROFILE[13]

BPP Score	Perinatal Mortality per 1000
8–10	1.86
6	9.76
4	26.3
2	94.0
0	285.7

BPP, Biophysical profile.

Disorder

Abnormal BPP result.

DEFINITION

A BPP score of 6/10 is most commonly caused by deductions from fetal breathing movement and nonreactive fetal heart tracing. However, oligohydramnios may replace one of the other deductions. A BPP of 6/10 without oligohydramnios is considered an equivocal test. A BPP of 6/10 with oligohydramnios is a pathologic result, with increased risk of fetal asphyxia within one week of test result.[13] A BPP score of 0, 2 or 4/10 is considered abnormal, and delivery is usually indicated, although management decisions at early gestational age may be individualized because of the risks of extreme prematurity.[4]

PREVALENCE AND EPIDEMIOLOGY

Perinatal mortality associated with each BPP result is listed in Table 125.4.

ETIOLOGY AND PATHOPHYSIOLOGY

Loss of fetal breathing, movement, or tone are described earlier. Etiology of oligohydramnios is described in Chapter 120.

MANIFESTATIONS OF DISEASE

Clinical Presentation

Diagnosis is made during routine testing for high-risk indications, or upon patient complaint of decreased fetal movement.

Imaging Technique and Findings

Ultrasound. US real-time imaging is used to visualize fetal BPP parameters, as described previously.

Synopsis of Treatment Options

PRENATAL

A BPP of 6/10 without oligohydramnios can be repeated in 24 hours. A BPP of 6/10 with oligohydramnios requires evaluation of gestational age, maternal comorbidities, obstetric factors, and maternal-fetal risks to continuation of pregnancy. Clinical judgment following a score of 6/10 should be based on the risk-benefit trade-off between expectant management and immediate delivery. A BPP of 0 to 4/10 usually requires immediate delivery. Route of delivery will depend on whether cervix is favorable, parity, duration of impending labor and delivery, and fetal ability to tolerate labor.

POSTNATAL

Neonatal resuscitation may be required in fetuses delivered for abnormal BPP. Delivery plans should be coordinated with a pediatric resuscitation team.

WHAT THE REFERRING PHYSICIAN NEEDS TO KNOW

The examination should continue until completion of 30 minutes if the fetus does not meet criteria, to allow for completion of a sleep cycle.

KEY POINTS

- Multiple indications exist for use of BPP in antepartum surveillance.
- The examination should continue until completion of 30 minutes if the fetus does not meet criteria, to allow for completion of a sleep cycle.
- External factors, including medications, exposures, and gestational age, may affect BPP scores.
- Perinatal mortality and morbidity is inversely proportional to BPP score.

SUGGESTED READINGS

ACOG Practice Bulletin Number 145: antepartum fetal surveillance. *Obstet Gynecol*. 2014;124:182-192.

Manning FA. Fetal biophysical profile: a critical appraisal. *Clin Obstet Gynecol*. 2002;45(4):975-985.



All references available online at www.expertconsult.com

REFERENCES

1. Manning FA, Platt LD, Sipos L. Antepartum fetal evaluation: development of a fetal biophysical profile. *Am J Obstet Gynecol*. 1980;136(6):787-795.
2. Pircon RA, et al. Antepartum testing in the hypertensive patient: when to begin. *Am J Obstet Gynecol*. 1991;164(6 Pt 1):1563-1569, discussion 1569-1570.
3. Rouse DJ, et al. Determinants of the optimal time in gestation to initiate antenatal fetal testing: a decision-analytic approach. *Am J Obstet Gynecol*. 1995;173(5):1357-1363.
4. ACOG. Practice bulletin no. 145: antepartum fetal surveillance. *Obstet Gynecol*. 2014;124(1):182-192.
5. Humphrey T. Function of the nervous system during prenatal life. In: Uwe Stave, ed. *Perinatal Physiology*. Springer US; 1978:651-652.
6. Manning FA. Fetal biophysical profile: a critical appraisal. *Clin Obstet Gynecol*. 2002;45(4):975-985.
7. Vintzileos AM, et al. The relationships among the fetal biophysical profile, umbilical cord pH, and Apgar scores. *Am J Obstet Gynecol*. 1987;157(3):627-631.
8. Fox HE, Hohler CW. Fetal evaluation by real-time imaging. *Clin Obstet Gynecol*. 1977;20(2):339-349.
9. Patrick J, Natale R, Richardson B. Patterns of human fetal breathing activity at 34 to 35 weeks' gestational age. *Am J Obstet Gynecol*. 1978;132(5):507-513.
10. Boddy K, et al. Foetal respiratory movements, electrocortical and cardiovascular responses to hypoxaemia and hypercapnia in sheep. *J Physiol*. 1974;243(3):599-618.
11. Fitzgerald JE, Windle WF. Some observations on early human fetal movements. *J Comp Neurol*. 1942;76:159-167.
12. Pillai M, James D. Behavioural states in normal mature human fetuses. *Arch Dis Child*. 1990;65(1 Spec No):39-43.
13. Chamberlain PF, et al. Ultrasound evaluation of amniotic fluid volume. I. The relationship of marginal and decreased amniotic fluid volumes to perinatal outcomes. *Am J Obstet Gynecol*. 1984;150(3):245-249.
14. Manning FA. *Fetal Assessment: Principles and Practices*. Norwalk, CT: Appleton and Lange; 1995.

126 CHARGE Syndrome

RYAN E. LONGMAN

Introduction

CHARGE (*c*oloboma, *h*eart disease, choanal *a*tresia, *r*etardation, *g*enital hypoplasia, and *e*ar anomalies) syndrome is an autosomal dominant disorder that was first described as a recognizable pattern of congenital malformations by Hall in 1979.[1] He described 17 children with multiple congenital anomalies in which choanal atresia was the primary feature. Also in 1979, Hittner et al.[2] described 10 children with similar findings. The pattern of congenital malformations was further refined 2 years later by Pagon et al.,[3] and the acronym CHARGE was created. Formal criteria for the diagnosis of CHARGE syndrome were outlined in 1998 by Blake et al.[4]; Verloes[5] suggested updating of the criteria 6 years later. Chromodomain-helicase-deoxyribonucleic acid-binding protein (CHD)-7 is the only known genetic etiology in CHARGE syndrome.[6] Children with CHARGE syndrome are frequently born with grave medical conditions. For children who survive the neonatal period, the long-term prognosis and outcome are variable, and ultimately depend on associated anomalies.

Disease

DEFINITION

The diagnosis of CHARGE syndrome is based on clinical criteria, which are listed in Table 126.1 (also refer to Figs. 126.1 and 126.2). A definitive diagnosis of CHARGE syndrome is made when all four major characteristics or three major and three minor characteristics are identified in an individual. A diagnosis of CHARGE syndrome should be considered if one or two major and several minor characteristics are identified in an individual.[4]

PREVALENCE AND EPIDEMIOLOGY

CHARGE syndrome occurs in approximately 1 : 10,000 births.[4,7,8]

ETIOLOGY AND PATHOPHYSIOLOGY

CHARGE syndrome is an autosomal dominant disorder with CHD-7 as the only known genetic etiology. The link between CHD-7 and CHARGE syndrome was first made by Vissers et al.[6] and confirmed by Johnson et al.[9] CHD-7 maps to chromosome 8q12.1. It consists of 38 exons that stretch 188 kb.[6] CHD-7 is part of a family of proteins referred to as *chromodomain-helicase-DNA-binding proteins*. CHD proteins contain a combination of chromatin organization modifiers, SNF2-related helicase/ATPase, and DNA-binding domains. The exact function of the CHD-7 protein is unknown, but the CHD family of proteins is involved in chromatin remodeling.[9–14] *CHD-7* gene alterations account for approximately 58% to 65% of cases of CHARGE syndrome, with most consisting of nonsense and frameshift mutations.[6,14–17] Deletions involving the *CHD-7* gene have also been reported in individuals with CHARGE syndrome.[15,18]

Most individuals diagnosed with CHARGE syndrome represent a *de novo* mutation in the family. Rarely, CHARGE syndrome can be inherited from a parent with mild symptoms.[19] If a parent of an affected child exhibits mild features of the syndrome, molecular testing is indicated. If the parent is found to be affected or has a CHD-7 mutation, the future risk for another child with CHARGE syndrome is 50%. If neither parent exhibits features of the syndrome and both have negative CHD-7 molecular testing, the risk of having another child with CHARGE syndrome is 3% owing to the risk of germline mosaicism.[20] CHARGE syndrome also has variable expressivity and does not exhibit genotype-phenotype correlation.[14,15,17,19]

MANIFESTATIONS OF DISEASE

Clinical Presentation

- ocular anomalies
  - coloboma
  - microphthalmia
  - nystagmus
  - others—hypoplasia of optic nerve, anophthalmia, amblyopia, squint, and refractive error
- cardiac defects
  - conotruncal
  - ventricular septal defect
  - patent ductus arteriosus
  - outflow anomalies (pulmonic stenosis)
  - aortic arch
- vesicular anomalies
  - semicircular canal hypoplasia
  - mondini malformation
- external ear malformations (see Fig. 126.1)
- hearing loss
- choanal atresia
- cranial nerve defects
  - I: olfactory
  - V: mastication and sensory region of the face

TABLE 126.1 DIAGNOSTIC CHARACTERISTICS OF CHARGE SYNDROME

Major

Coloboma
Choanal atresia
Ear abnormalities
- External ear
  - Truncation of lobe/helix (see Fig. 126.1)
- Middle ear
  - Ossicular malformations
  - Cochlear defects

Cranial nerve defects: I, VII, VIII, IX, X

Minor

Genital hypoplasia
Developmental delay
Cardiac defects
Growth deficiency
Orofacial cleft (see Fig. 126.2)
Tracheoesophageal fistula
Distinctive facies
- Broad forehead
- Full nasal tip
- Facial asymmetry



Fig. 126.1 Orofacial clefting in a fetus with CHARGE syndrome.

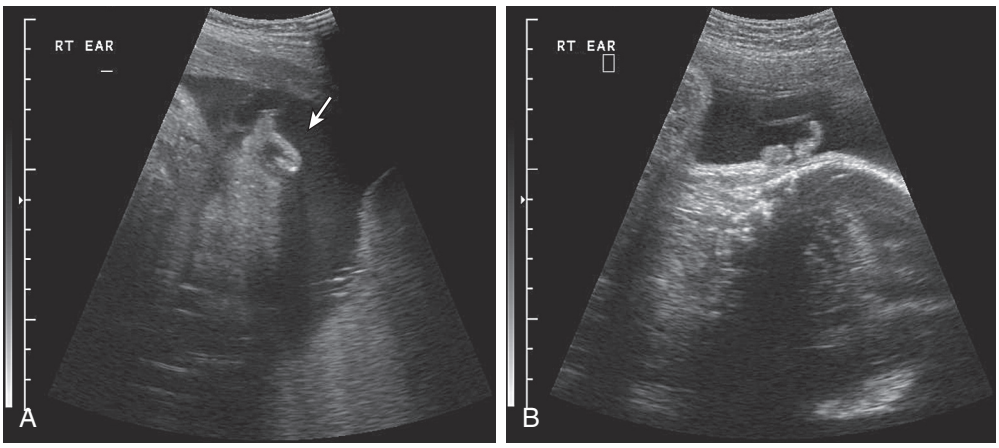

Fig. 126.2 The truncated helix of the external ear in a fetus with CHARGE syndrome.

  - VII: facial expression and salivary lacrimal glands
  - VIII: sensory hearing
  - IX and X: swallowing
- genitourinary
  - micropenis
  - cryptorchidism
  - hypospadias
  - chordee
  - bifid scrotum
  - hypoplasia of labia majora, labia minora, and clitoris
  - absent uterus, vagina, and ovaries
- immunodeficiency
  - mild to severe t-cell deficiency
- limb anomalies: no consistent pattern
- central nervous system anomalies
  - agenesis of corpus callosum
  - arrhinencephaly
  - cephalogenesis
  - meningoencephalocele
  - posterior fossa abnormality
  - intracranial asymmetry
  - cerebral atrophy
- cognitive impairment
- growth abnormalities
  - intrauterine growth restriction
  - postnatal failure to thrive
- overall increased morbidity and mortality

Imaging Technique and Findings

Ultrasound. Fetuses with CHARGE syndrome are noted to have abnormal prenatal ultrasound (US) scans in almost 38% of cases. The most common abnormal findings are polyhydramnios (25%), intrauterine growth restriction (17.5%), and dilated lateral ventricles (10%).[21] Other findings noted on prenatal US are cardiac defects, central nervous system abnormalities, and cystic hygromas.[22–25]

Magnetic Resonance Imaging. Fetal magnetic resonance imaging (MRI) has been found to be a useful adjunct testing

modality in suspected cases of CHARGE syndrome. In addition to adding to the characterization of anomalies identified on prenatal US, MRI has been used to diagnose fetal inner ear abnormalities and ocular colobomas.[26,27]

Differential Diagnosis From Imaging Findings

1. Trisomies 13 and 18
2. 22q11.2 deletion syndrome
3. VACTERL (*v*ertebral, *a*nal, *c*ardiac, *t*racheal, *e*sophageal, *r*enal, and *l*imb anomalies) association
4. Kallmann syndrome
5. Cat-eye syndrome

Synopsis of Treatment Options

PRENATAL

Prenatal genetic diagnosis is available for CHARGE syndrome. Patients with fetal prenatal findings suggestive of the syndrome should be offered the option of amniocentesis with a karyotype to exclude chromosomal abnormalities. If the karyotype results are normal, CHD-7 molecular testing should be offered.

POSTNATAL

Postnatal management should consist of a multidisciplinary team approach to correct structural defects and assess and treat developmental and cognitive impairments.

WHAT THE REFERRING PHYSICIAN NEEDS TO KNOW

CHARGE syndrome is a complex genetic disorder associated with multiple congenital anomalies. The diagnosis is based on clinical findings. The only known causative genetic etiology is CHD-7. Children with CHARGE syndrome have an increased morbidity and mortality, especially in the neonatal period, with long-term outcomes dictated by associated anomalies and variable cognitive impairment.

KEY POINTS

- CHARGE syndrome is a complex genetic disorder associated with multiple congenital anomalies.
- Diagnosis is based on clinical findings.
- CHD-7 is the only known causative genetic etiology associated with CHARGE syndrome.
- The syndrome is associated with increased morbidity and mortality in the neonatal period and a variable long-term prognosis.

SUGGESTED READINGS

Blake KD, Prasad C. CHARGE syndrome. *Orphanet J Rare Dis*. 2006;1:1-8.

Busa T, Legendre M, Bauge M, et al. Prenatal findings in children with early postnatal diagnosis of CHARGE syndrome. *Prenat Diagn*. 2016;26:561-567.

Lalani SR, Hefner MA, Belmont JW, et al. CHARGE syndrome. In: Pagon RA, Adam MP, Hardinger HH, eds. *GeneReviews [Internet]*, Seattle (WA). University of Washington Seattle. 2006:1993-2007.

OMIM Entry #214800: CHARGE syndrome. www.ncbi.nlm.nih.gov/omim/214800.

Sanlaville D, Verloes A. CHARGE syndrome: an update. *Eur J Hum Genet*. 2007;15:389-399.

All references available online at www.expertconsult.com

REFERENCES

1. Hall BD. Choanal atresia and associated multiple anomalies. *J Pediatr*. 1979;95:395-398.
2. Hittner HM, Hirsch NJ, Kreh GM, et al. Colobomatous microphthalmia, heart disease, hearing loss, and mental retardation—a syndrome. *J Pediatr Ophthalmol Strabismus*. 1979;16:122-128.
3. Pagon RA, Graham JM, Zonana J, et al. Coloboma, congenital heart disease, and choanal atresia with multiple anomalies: CHARGE association. *J Pediatr*. 1981;99:223-227.
4. Blake KD, Davenport SL, Hall BD, et al. CHARGE association: an update and review for the primary pediatrician. *Clin Pediatr (Phila)*. 1998;37:159-174.
5. Verloes A. Updated diagnostic criteria for CHARGE syndrome. *Am J Med Genet A*. 2005;133A:306-308.
6. Vissers LE, van Ravenenswaaij CM, Admiraal R, et al. Mutations in a new member of the chromodomain gene family cause CHARGE syndrome. *Nat Genet*. 2004;36:955-957.
7. Issekutz KA, Graham JM, Prasad C, et al. An epidemiological analysis of CHARGE syndrome: preliminary results from a Canadian study. *Am J Med Genet A*. 2005;133A:309-317.
8. Harris J, Robert E, Kallen B. Epidemiology of choanal atresia with special reference to the CHARGE association. *Pediatrics*. 1997;99:363-367.
9. Johnson D, Morrison N, Grant L, et al. Confirmation of CHD7 as a cause of CHARGE association identified by mapping a balanced chromosome translocation in affected monozygotic twins. *J Med Genet*. 2006;43:280-284.
10. Sanlaville D, Verloes A. CHARGE syndrome: an update. *Eur J Hum Genet*. 2007;15:389-399.
11. Brehm A, Tufteland KR, Aasland R, et al. The many colours of chromodomains. *Bioessays*. 2004;26:133-140.
12. Woodage T, Basrai MA, Baxevanis AD, et al. Characterization of the CHD family of proteins. *Proc Natl Acad Sci USA*. 1997;94:11472-11477.
13. Dirscheri SS, Krebs JE. Functional diversity of ISWI complexes. *Biochem Cell Biol*. 2004;82:482-489.
14. Lalani SR, Safiullah AM, Fernbach SD, et al. Spectrum of CHD7 mutations in 110 individuals with CHARGE syndrome and genotype-phenotype correlation. *Am J Hum Genet*. 2006;78:303-314.
15. Wincent J, Holmberg E, Stromland K, et al. CHD7 mutation spectrum in 28 Swedish patients diagnosed with CHARGE syndrome. *Clin Genet*. 2008;74:31-38.
16. Jongmans MCJ, Admiraal RJ, van der Donk KP, et al. CHARGE syndrome: the phenotypic spectrum of mutations in the CHD7 gene. *J Med Genet*. 2006;43:306-314.
17. Armamaki M, Udaka T, Kosaki R, et al. Phenotypic spectrum of CHARGE syndrome with CHD7 mutations. *J Pediatr*. 2006;148:410-414.
18. Bergman JEH, de Wijs I, Jongmans MCJ, et al. Exon copy number alterations of the CHD7 gene are not a major cause of CHARGE and CHARGE-like syndrome. *Eur J Med Genet*. 2008;51:417-425.
19. Jongmans MCJ, Hoefsloot LH, van der Donk KP, et al. Familial CHARGE syndrome and the CHD7 gene: a recurrent missense mutation, intrafamilial recurrence and variability. *Am J Med Genet A*. 2008;146:43-50.
20. Pauli S, Pieper L, Haberle J, et al. Proven germline mosaicism in a father of two children with CHARGE syndrome. *Clin Genet*. 2009;75:473-479.
21. Tellier AL, Cormier-Daire V, Abadie V, et al. CHARGE syndrome: report of 47 cases and review. *Am J Med Genet*. 1998;76:402-409.
22. Sanlaville D, Etchevers HC, Gonzales M, et al. Phenotypic spectrum of CHARGE syndrome in fetuses with CHD7 truncating mutations correlates with expression during human development. *J Med Genet*. 2006;43:211-217.
23. Kharrat R, Yamamoto M, Roume J, et al. Karyotype and outcome of fetuses diagnosed with cystic hygroma in the first trimester in relation to nuchal translucency thickness. *Prenat Diagn*. 2006;26:369-372.
24. Becker R, Stiemer B, Neumann L, et al. Mild ventriculomegaly, mild cerebellar hypoplasia and dysplastic choroid plexus as early prenatal signs of CHARGE association. *Fetal Diagn Ther*. 2001;16:280-283.
25. Hertxber BS, Kliewer MA, Lile RL. Antenatal ultrasonographic findings in the CHARGE association. *J Ultrasound Med*. 1994;13:238-242.
26. Tilea B, Garel C, Menex F, et al. Contribution of fetal MRI to the diagnosis of inner ear abnormalities: report of two cases. *Pediatr Radiol*. 2006;36:149-153.
27. Righini A, Avagliano L, Doneda C, et al. Prenatal magnetic resonance imaging of optic nerve head coloboma. *Prenat Diagn*. 2008;28:242-246.

127 Cornelia de Lange Syndrome

RACHEL G. SINKEY | ANTHONY O. ODIBO

Introduction

Cornelia de Lange syndrome (CdLS), also known as Brachmann-de Lange or de Lange syndrome, is a condition characterized by mental retardation, craniofacial dysmorphism, prenatal and postnatal growth failure, hirsutism, and upper limb abnormalities. Other defects occasionally associated with CdLS include congenital cardiac defects and genital anomalies. There are three subtypes of CdLS. CdLS1, the classic form, is caused by autosomal dominant mutations in the *NIPBL* gene; 99% are *de novo*, whereas 1% are attributed to parental germline mosaicism.[1,2] CdLS2 is caused by mutations in the X-linked *SMC1A* gene.[3] CdLS3, a mild variant of the disorder, is caused by mutations in the *SMC3* gene.[4] In individuals with CdLS3, the facial dysmorphisms, anatomic anomalies, and learning deficits can be minor or completely absent. The number of individuals with mild CdLS or CdLS3 is thought to be underreported.[4]

Disease

DEFINITION

The diagnosis of CdLS is clinical; gene testing is available to support the clinical diagnosis, but not all individuals with CdLS will have a known genetic mutation. Individuals affected with classic CdLS have distinct craniofacial abnormalities including high arched palate, microbrachycephaly, and micrognathia.[5–7] In addition, hirsutism, including synophrys, hirsute ears, and long, coarse eyelashes are noted in most individuals. Prenatal growth failure continuing throughout life is identified in greater than 95% of affected individuals, as are severe to profound mental retardation and upper limb abnormalities. Genetic testing can be helpful in determining which subtype of CdLS the individual has, the cause of the syndrome, and the risk to other family members.

PREVALENCE AND EPIDEMIOLOGY

The incidence of classic CdLS is 1:100,000 to 1:10,000.[8] It is thought that a large proportion of individuals with mild CdLS are not diagnosed, and the prevalence may be much higher than these estimates suggest.[4] CdLS affects all ethnic groups and can be found equally in males and females.

ETIOLOGY AND PATHOPHYSIOLOGY

Several genes have been associated with CdLS. Approximately 60% of individuals with this condition have been found to have heterozygous alterations in the *NIPBL* gene, another 5% of individuals with CdLS have been found to have mutations in the *SMC1A* gene, 4% have mutations within the *HDAC8* gene, 1%–2% have mutations in the *SMC3* gene, and <1% have alterations within the *RAD21* gene.[1–4,8] No genetic abnormalities are identified in approximately 30% of affected individuals. For "mutation-negative" patients with CdLS, deeper sequencing from multiple tissues may lend a genetic diagnosis.[9]

NIPBL mutations are associated with the CdLS1subtype.[1,2] Although the exact function of the NIPBL protein, delangin, is unknown, it is thought that it is important in proper sister chromatid cohesion.[10] Individuals with CdLS1 may display the classic signs of this syndrome or may display milder manifestations, although most individuals with more severe manifestations of CdLS have mutations in the *NIPBL* gene.[11,12] In most cases, these *NIPBL* gene alterations are *de novo*, although autosomal dominant transmission has been reported in several families.[13]

Mutations in the *SMC1A* and *SMC3* genes have been identified in only a few affected individuals, and genotype-phenotype associations are not well established, although individuals with mutations in these genes appear to have milder manifestations of the syndrome than individuals with *NIPBL* mutations.[3,4] The limb and other structural defects seen in individuals with CdLS are rarely found in individuals with mutations in these genes. The SMC1A and SMC3 proteins are components of the cohesin complex. Similar to the NIPBL protein, they are thought to be important in cohesion of sister chromatids.[4] For this reason, CdLS is thought to be a cohesinopathy. *SMC1A* mutations can cause CdLS in males or females.[3] CdLS2 is thought to be X-linked dominant. *SMC3* mutations are associated with the CdLS3 subtype and are typically *de novo* but can be associated with autosomal dominant transmission.[4]

MANIFESTATIONS OF DISEASE

Clinical Presentation

All three subtypes and CdLS resulting from unknown genetic cause can manifest similarly; however, manifestations are often milder in individuals with no mutation or with *SMC1A* or *SMC3* mutations than in individuals with *NIPBL* mutations. Limb and other structural defects are typically absent in individuals with *SMC1A* or *SMC3* mutations. Common manifestations of this condition include the following:

- prenatal and postnatal growth restriction
- intellectual disability with mean intellectual quotient of 53[8]
- autistic features[14]
- craniofacial abnormalities
  - microbrachycephaly
  - synophrys
  - high arched palate
  - micrognathia
  - flat, broad nasal bridge with anteverted nares
- limb anomalies
  - limited elbow extension
  - upper limb reduction defects
  - radial hypoplasia
  - proximally placed thumbs
  - fifth finger clinodactyly
  - oligodactyly (Fig. 127.1)
  - syndactyly
- hirsutism
- sensorineural or conductive hearing loss
- myopia
- late-erupting, widely spaced teeth
- short neck
- congenital heart defects in 30% of patients[15]
- other structural birth defects (cleft lip/palate, congenital diaphragmatic hernia [Fig. 127.2])
- genitourinary abnormalities (hypoplastic male genitalia, renal tract anomalies)
- immunodeficiency[16]
- very low or absent first-trimester or second-trimester maternal serum pregnancy-associated plasma protein a[17,18]
- increased first-trimester nuchal translucency[19]

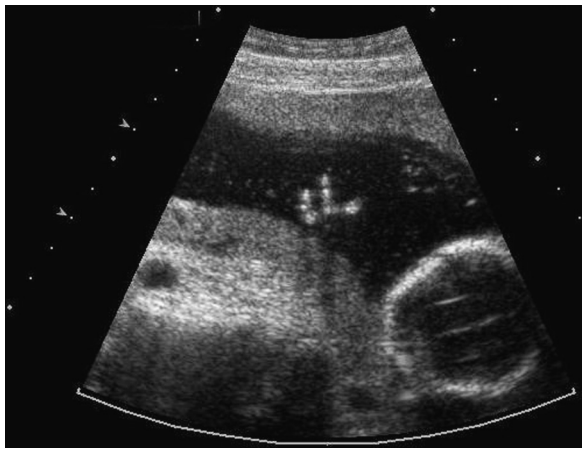

Fig. 127.1 Oligodactyly.



Fig. 127.2 Congenital diaphragmatic hernia.

Imaging Technique and Findings

Ultrasound. There is no ultrasound feature that is specific to CdLS. The following findings may be found in pregnancies



Fig. 127.3 Ultrasound findings from select cases with postnatal correlation. (A to F) Facial profiles in CdLS pregnancies: (A) Facial features at 21 weeks and subsequent 3D ultrasound. (B) Facial features at 28 weeks and postnatal facial features at 28 2/7 weeks. (C) Facial profile, ultrasound at 19 weeks, postnatal profile at 1 year. (D) Prenatal ultrasound profile at 23 weeks and immediate postnatal profile. (E) Prenatal ultrasound of full face at 19 weeks and postnatal full face at 1 year. (F) Prenatal ultrasound profile at 18 weeks and postnatal profile at 16 months. (G and H) Limb findings in CdLS pregnancies: (G) Prenatal ultrasound at 19 weeks showing oligodactyly of upper limbs and 20 week autopsy images. (H) Prenatal ultrasound at 23 weeks of right limb showing severe oligodactyly with postnatal confirmation. *(From Clark DM, Sherer I, Deardorff MA, et al. Prenatal profile of Cornelia de Lange syndrome (CdLS): a review of 53 pregnancies. Am J Med Genet A 2012; 158A:1848–1856.)*

complicated by CdLS: increased nuchal translucency, growth restriction, micrognathia, flat and broad nasal bridge, cleft lip/palate, eyelashes, upper limb reduction defects, fifth finger clinodactyly, oligodactyly or syndactyly, congenital heart defect, congenital diaphragmatic hernia, and renal tract anomalies (Fig. 127.3).[20–25]

Magnetic Resonance Imaging. Magnetic resonance imaging (MRI) findings are complementary to the previously mentioned ultrasound findings and are nonspecific.

CLASSIC SIGNS

Increased first-trimester nuchal translucency
Intrauterine growth restriction
Short or absent upper limbs
Absent digits
Fifth finger clinodactyly
Syndactyly
Radial hypoplasia
Microcephaly
Micrognathia
Congenital heart defect

Differential Diagnosis From Imaging Findings

1. Chromosome abnormalities such as partial duplication of 3q or deletions of 2q31
2. Fetal alcohol syndrome
3. Fryns syndrome
4. CHOPS (*c*ognitive impairment, *c*oarse facial features, *h*eart defects, *o*besity, lung [*p*ulmonary] involvement, *s*hort stature and *s*keletal abnormalities) syndrome
5. TAF1 and TAF6

Synopsis of Treatment Options

PRENATAL

No prenatal treatment is available. Serial ultrasound scans for growth monitoring are recommended.

POSTNATAL

Postnatal treatment considerations include the following:
1. surgical correction of any congenital defects,
2. dietary supplementation for failure to thrive,
3. treatment for hearing or vision problems,
4. physical, occupational, and speech therapies.

A *Drosophilia melanogaster* model is currently under study to investigate CdLS and to develop novel therapeutics.[26]

Acknowledgement

The authors would like to acknowledge the contributions of Rachael Bradshaw to the first edition of this chapter.

WHAT THE REFERRING PHYSICIAN NEEDS TO KNOW

CdLS should be considered in any fetus with growth restriction in addition to limb or craniofacial abnormalities, with or without a congenital heart defect. However, unless there is a previous family history of CdLS, prenatal diagnosis is unlikely to be possible, and the diagnosis will have to be made after postnatal examination. In families with a history of CdLS where a mutation has been identified, prenatal diagnosis by chorionic villus sampling or amniocentesis is likely to be available. Normal first-trimester nuchal translucency, normal first-trimester or second-trimester maternal serum pregnancy-associated plasma protein A, or a normal second-trimester ultrasound examination in a fetus with a family history of CdLS would be largely reassuring but could not entirely rule out recurrence (Fig. 127.4 for

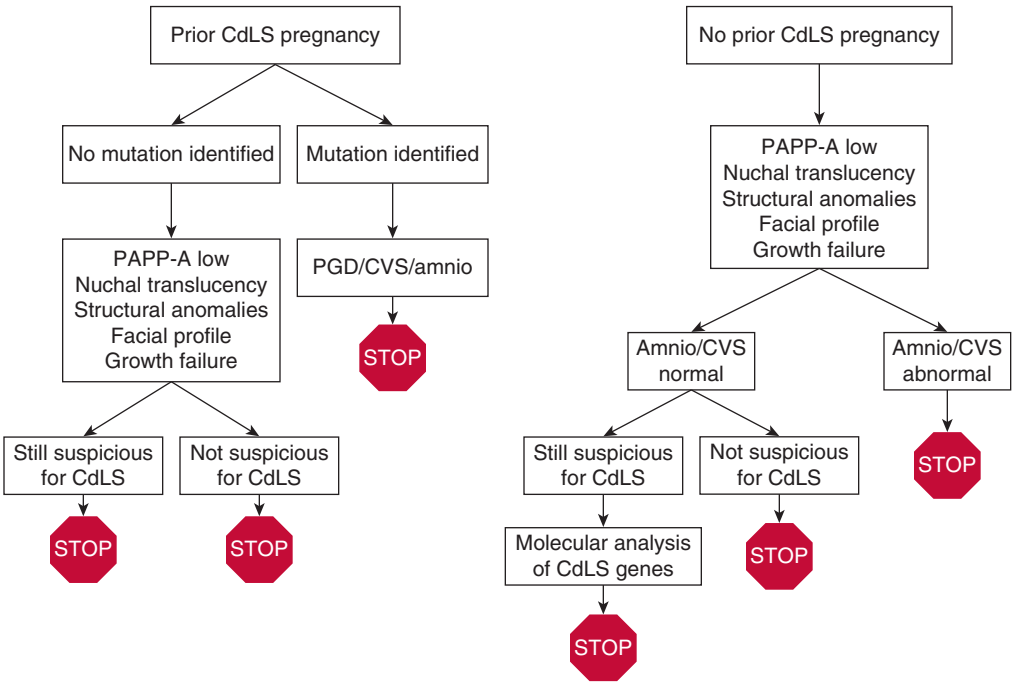

Fig. 127.4 Prenatal diagnostic workup for cases of Cornelia de Lange syndrome (CdLS). License number 3855030645373. *CVS*, Chorionic villus sampling; *PAPP-A*, pregnancy-associated plasma protein A; *PGD*, preimplantation genetic diagnosis.

proposed prenatal workup). Because most cases of CdLS are *de novo*, couples who do not have CdLS but have a previously affected child have a 1.5% risk of recurrence.[6] If a parent of the affected child has CdLS, there is a 50% chance of a recurrence for each pregnancy.

KEY POINTS

- Individuals with classic CdLS have distinct craniofacial abnormalities.
- First- and second-trimester serum screening in conjunction with a detailed sonographic examination can be useful for prenatal screening of CdLS.
- Molecular diagnostics may be available to provide a prenatal diagnosis.

SUGGESTED READINGS

Boyle MI, Jespersgaard C, Brondum-Nielsen K, et al. Cornelia de Lange syndrome. *Clin Genet*. 2015;88(1):1-12.

Deardorff MA, Noon SE, Krantz ID. Cornelia de Lange Syndrome. In: Pagon RA, Adam MP, Ardinger HH, et al, eds. *GeneReviews*. Seattle (WA): University of Washington, Seattle; 2005:1993-2016.

Liu J, Krantz ID. Cornelia de Lange syndrome, cohesin, and beyond. *Clin Genet*. 2009;76:303-314.



All references available online at www.expertconsult.com

REFERENCES

1. Krantz ID, McCallum J, DeScipio C, et al. Cornelia de Lange syndrome is caused by mutations in NIPBL, the human homolog of Drosophila melanogaster Nipped-B. *Nat Genet*. 2004;36(6):631-635.
2. Tonkin ET, Wang TJ, Lisgo S, et al. NIPBL, encoding a homolog of fungal Scc2-type sister chromatid cohesion proteins and fly Nipped-B, is mutated in Cornelia de Lange syndrome. *Nat Genet*. 2004;36(6):636-641.
3. Musio A, Selicorni A, Focarelli ML, et al. X-linked Cornelia de Lange syndrome owing to SMC1L1 mutations. *Nat Genet*. 2006;38(5):528-530.
4. Deardorff MA, Kaur M, Yaeger D, et al. Mutations in cohesin complex members SMC3 and SMC1A cause a mild variant of cornelia de Lange syndrome with predominant mental retardation. *Am J Hum Genet*. 2007;80(3):485-494.
5. Ireland M, Donnai D, Burn J. Brachmann-de Lange syndrome. Delineation of the clinical phenotype. *Am J Hum Genet*. 1993;47(7):959-964.
6. Jackson L, Kline AD, Barr MA, et al. de Lange syndrome: a clinical review of 310 individuals. *Am J Med Genet*. 1993;47(7):940-946.
7. Preus M, Rex AP. Definition and diagnosis of the Brachmann-De Lange syndrome. *Am J Med Genet*. 1983;16(3):301-312.
8. Deardorff MA, Noon SE, Krantz ID. Cornelia de Lange Syndrome. In: Pagon RA, Adam MP, Ardinger HH, et al, eds. *GeneReviews [Internet]*. Seattle (WA): University of Washington, Seattle University of Washington, Seattle; 2005:1993-2016.
9. Ansari M, Poke G, Ferry Q, et al. Genetic heterogeneity in Cornelia de Lange syndrome (CdLS) and CdLS-like phenotypes with observed and predicted levels of mosaicism. *J Med Genet*. 2014;51(10):659-668.
10. Kaur M, DeScipio C, McCallum J, et al. Precocious sister chromatid separation (PSCS) in Cornelia de Lange syndrome. *Am J Med Genet A*. 2005;138(1):27-31.
11. Bhuiyan ZA, Klein M, Hammond P, et al. Genotype-phenotype correlations of 39 patients with Cornelia De Lange syndrome: the Dutch experience. *J Med Genet*. 2006;43(7):568-575.
12. Borck G, Redon R, Sanlaville D, et al. NIPBL mutations and genetic heterogeneity in Cornelia de Lange syndrome. *J Med Genet*. 2004;41(12):e128.
13. Feingold M, Lin AE. Familial Brachmann-de Lange syndrome: further evidence for autosomal dominant inheritance and review of the literature. *Am J Med Genet*. 1993;47(7):1064-1067.
14. Nakanishi M, Deardorff MA, Clark D, et al. Investigation of autistic features among individuals with mild to moderate Cornelia de Lange syndrome. *Am J Med Genet A*. 2012;158a(8):1841-1847.
15. Chatfield KC, Schrier SA, Li J, et al. Congenital heart disease in Cornelia de Lange syndrome: phenotype and genotype analysis. *Am J Med Genet A*. 2012;158a(10):2499-2505.
16. Jyonouchi S, Orange J, Sullivan KE, et al. Immunologic features of Cornelia de Lange syndrome. *Pediatrics*. 2013;132(2):e484-e489.
17. Aitken DA, Ireland M, Berry E, et al. Second-trimester pregnancy associated plasma protein-A levels are reduced in Cornelia de Lange syndrome pregnancies. *Prenat Diagn*. 1999;19(8):706-710.
18. Arbuzova S, Nikolenko M, Krantz D, et al. Low first-trimester pregnancy-associated plasma protein-A and Cornelia de Lange syndrome. *Prenat Diagn*. 2003;23(10):864.
19. Huang WH, Porto M. Abnormal first-trimester fetal nuchal translucency and Cornelia De Lange syndrome. *Obstet Gynecol*. 2002;99(5 Pt 2):956-958.
20. Sekimoto H, Osada H, Kimura H, et al. Prenatal findings in Brachmann-de Lange syndrome. *Arch Gynecol Obstet*. 2000;263(4):182-184.
21. Clark DM, Sherer I, Deardorff MA, et al. Identification of a prenatal profile of Cornelia de Lange syndrome (CdLS): a review of 53 CdLS pregnancies. *Am J Med Genet A*. 2012;158a(8):1848-1856.
22. Boog G, Sagot F, Winer N, et al. Brachmann-de Lange syndrome: a cause of early symmetric fetal growth delay. *Eur J Obstet Gynecol Reprod Biol*. 1999;85(2):173-177.
23. Thellier E, Levaillant JM, Roume J, et al. Cornelia de Lange syndrome: specific features for a prenatal diagnosis. *Ultrasound Obstet Gynecol*. 2015;[Epub ahead of print].
24. Dempsey MA, Knight Johnson AE, et al. Molecular confirmation of nine cases of Cornelia de Lange syndrome diagnosed prenatally. *Prenat Diagn*. 2014;34(2):163-167.
25. Spaggiari E, Vuillard E, Khung-Savatovsky S, et al. Ultrasound detection of eyelashes: a clue for prenatal diagnosis of Cornelia de Lange syndrome. *Ultrasound Obstet Gynecol*. 2013;41(3):341-342.
26. Dorsett D. The Drosophila melanogaster model for Cornelia de Lange syndrome: implications for etiology and therapeutics. *Am J Med Genet C Semin Med Genet*. 2016;172:129-137.

128 Fraser Syndrome

METHODIUS G. TUULI | ANTHONY O. ODIBO

Introduction

Fraser syndrome is a rare congenital malformation syndrome characterized by cryptophthalmos, syndactyly, and urogenital defects.[1]

Disease

DEFINITION

Thomas et al.[2] formulated the diagnostic criteria for Fraser syndrome including four major (cryptophthalmos, syndactyly, abnormal genitalia, and affected sibling) and eight minor criteria (congenital malformations of nose, ears, and larynx; cleft lip with or without cleft palate; skeletal symptoms; umbilical hernia; renal agenesis; mental retardation). These authors suggested that the diagnosis be assigned if two major and one minor criteria or one major and four minor criteria are present in a patient. In practice, prenatal diagnosis often relies on detection of some of the more easily detectable minor criteria, such as renal agenesis (Figs. 128.1 and 128.2) and laryngeal atresia, together with a family history. Cryptophthalmos is the most important diagnostic feature of Fraser syndrome and has been described in 90% of affected patients (Fig. 128.3).[3] It consists of a continuous skin covering from the forehead to the cheek with absent palpebral fissures.

PREVALENCE AND EPIDEMIOLOGY

The incidence of Fraser syndrome is 0.43:100,000 live births and 11.06:100,000 stillbirths.[4] The inheritance pattern is autosomal recessive, with an unusual proportion of infants born to consanguineous parents.

ETIOLOGY AND PATHOPHYSIOLOGY

Mutations in the *FRAS1* and *FREM2* genes have been implicated in the etiology of Fraser syndrome.[5,6] An underlying defect of apoptosis is suggested because several of the anomalies such as fused eyelids, digits, larynx, and vagina result from failure of programmed cell death.

MANIFESTATIONS OF DISEASE

Clinical Presentation

Clinical features of Fraser syndrome are heterogeneous. Predominant malformations are cryptophthalmos, syndactyly, bilateral renal agenesis, and laryngeal stenosis or atresia. Stillbirth is common, especially in cases associated with renal agenesis. Eye abnormalities result in significant visual impairment among survivors.

Imaging Technique and Findings

Ultrasound. Prenatal diagnosis of Fraser syndrome has been rarely reported and mostly occurs in families with a prior history. Definitive diagnosis is difficult in families without a prior affected child. Ultrasound (US) diagnosis is based on documenting renal agenesis with oligohydramnios, tracheal atresia with huge hyperechoic lungs, syndactyly, and cryptophthalmos. Fetal ascites and hydrops may also be seen. Three-dimensional ultrasound is particularly useful for the detection of abnormalities of the ears and the nose.

Magnetic Resonance Imaging. Magnetic resonance imaging may be used to show many of the malformations seen in Fraser syndrome.

Differential Diagnosis From Imaging Findings

The Fraser syndrome phenotype is complex and significantly overlaps with other malformation syndromes. Differential diagnosis includes the following:

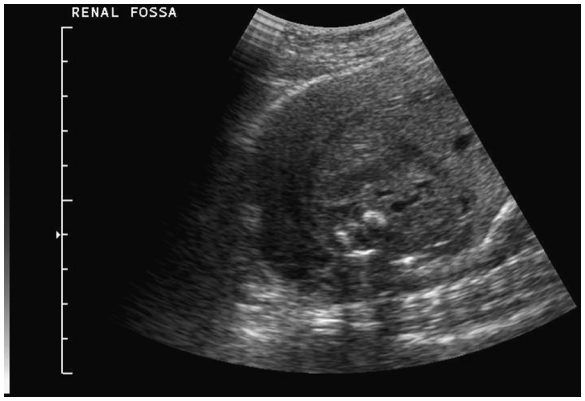

Fig. 128.1 Bilateral renal agenesis manifesting as absence of kidneys in the renal fossae bilaterally on grayscale imaging. Associated anhydramnios is also present.

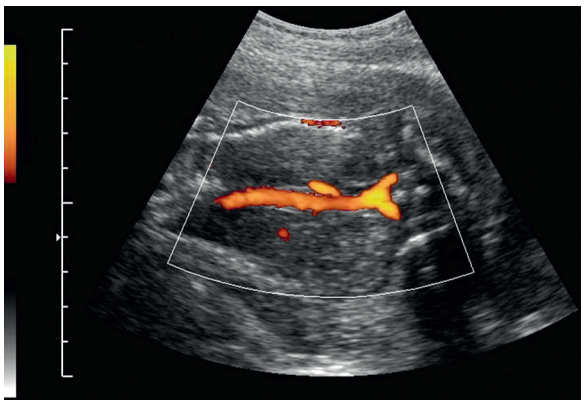

Fig. 128.2 Bilateral renal agenesis manifesting as absence of renal vessels bilaterally on ultrasound with color Doppler.

1. Other syndromes: Walker-Warburg syndrome, Peters plus syndrome, MURCS (*mü*llerian, *r*enal, *c*ervicothoracic, somite abnormalities) association, and Bardet-Biedl syndrome.[7]
2. Echogenic lungs: congenital diaphragmatic hernia, cystic adenomatoid malformation type III, sequestered lung, tracheal and bronchial atresia.
3. Cryptophthalmos: alobar holoprosencephaly or hydrocephalus.

Synopsis of Treatment Options

PRENATAL

The prognosis of Fraser syndrome is poor and depends on the predominant anomalies. Termination of pregnancy may be recommended when diagnosis is made early, especially in the setting of renal agenesis or laryngeal atresia.

POSTNATAL

There is no specific treatment for Fraser syndrome. Reconstructive and cosmetic surgery has been attempted with the goal of optimizing visual potential of patients.[8] In cases of fetal and neonatal death, the diagnosis should be confirmed by postmortem examination. Genetic counseling should be offered in confirmed cases.

WHAT THE REFERRING PHYSICIAN NEEDS TO KNOW

Fraser syndrome is a rare congenital malformation syndrome characterized by cryptophthalmos, syndactyly, and urogenital defects. Although the diagnosis may be suspected from prenatal US findings, definitive diagnosis should be made with caution.

KEY POINTS

- Fraser syndrome is a rare congenital malformation syndrome characterized by cryptophthalmos, syndactyly, and urogenital defects.

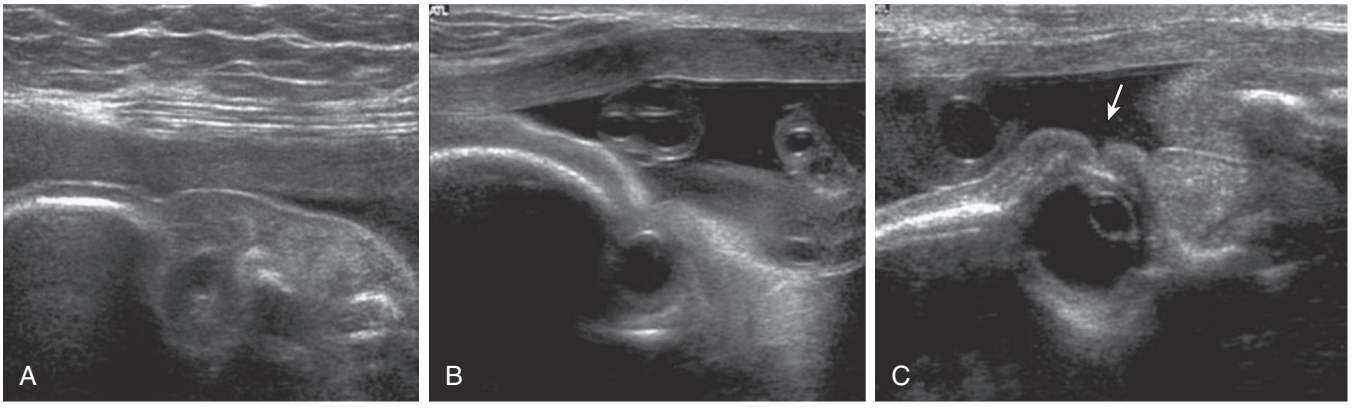

Fig. 128.3 (A and B) Sagittal US scan of right (A) and left (B) orbits shows bilateral cryptophthalmos, microphthalmos on the right side, and absent anterior chamber differentiation of the eyeball on both sides. (C) Similar section of the orbit of a normal fetus of the same gestational age shows the palpebral fissure (*arrow*) and the normal appearance of the eyeball with echoes from the lens and ciliary body dividing the cavity of the eyeball. *(From Vijayaraghavan SB, Suma N, Lata S, et al. Prenatal sonographic appearance of cryptophthalmos in Fraser syndrome.* Ultrasound Obstet Gynecol *2005;25:629-630.)*

- Two major and one minor criteria or one major and four minor criteria are required to establish the diagnosis, but prenatal diagnosis often relies on detection of some of the more easily detectable minor criteria, such as renal agenesis and laryngeal atresia, and a family history.
- Mutations in the *FRAS1* and *FREM2* genes have been implicated in the etiology of Fraser syndrome, and an underlying defect of apoptosis is thought to be the key mechanism.
- The prognosis is generally poor and depends on the predominant anomalies.

SUGGESTED READINGS

Eskander BS, Shehata BM. Fraser syndrome: a new case report with review of the literature. *Fetal Pediatr Pathol.* 2008;27(2):99-104.

Thomas IT, Frias JL, Felix V, et al. Isolated and syndromic cryptophthalmos. *Am J Med Genet.* 1986;25:85-98.

van Haelst MM, Scambler PJ, Hennekam RC. Fraser syndrome: a clinical study of 59 cases and evaluation of diagnostic criteria. *Am J Med Genet A.* 2007;143A:3194-3203.



All references available online at www.expertconsult.com

REFERENCES

1. Fraser GR. Our genetic load: a review of some aspects of genetical variation. *Ann Hum Genet*. 1962;25:387-415.
2. Thomas IT, Frias JL, Felix V, et al. Isolated and syndromic cryptophthalmos. *Am J Med Genet*. 1986;25:85-98.
3. Vijayaraghavan SB, Suma N, Lata S, et al. Prenatal sonographic appearance of cryptophthalmos in Fraser syndrome. *Ultrasound Obstet Gynecol*. 2005;25:629-630.
4. Martinez-Frias ML, Bermejo Sanchez E, Felix V, et al. Fraser syndrome: frequency in our environment and clinical-epidemiological aspects of a consecutive series of cases. *An Esp Pediatr*. 1998;48:634-638.
5. Jadeja S, Smyth I, Pitera JE, et al. Identification of a new gene mutated in Fraser syndrome and mouse myelencephalic blebs. *Nat Genet*. 2005;37:520-525.
6. McGregor L, Makela V, Darling SM, et al. Fraser syndrome and mouse blebbed phenotype caused by mutations in FRAS1/Fras1 encoding a putative extracellular matrix protein. *Nat Genet*. 2003;34:203-208.
7. Slavotinek AM, Tifft CJ. Fraser syndrome and cryptophthalmos: review of the diagnostic criteria and evidence for phenotypic modules in complex malformation syndromes. *J Med Genet*. 2002;39:623-633.
8. Saleh GM, Hussain B, Verity DH, et al. A surgical strategy for the correction of Fraser syndrome cryptophthalmos. *Ophthalmology*. 2009;116:1707.e1-1712.e1.

129 Fryns Syndrome

SARA SHELLEY | KATHERINE R. GOETZINGER

Introduction

First described in 1979, Fryns syndrome is a rare autosomal recessive disorder characterized by diaphragmatic defects, dysmorphic facial features, distal limb hypoplasia, pulmonary hypoplasia, and associated anomalies of other major organ systems.[1–3] To date the diagnosis is made solely by clinical criteria, as only one candidate gene has been identified through whole exome sequencing.[4–6] Although Fryns syndrome was initially thought to be uniformly lethal, there are now multiple reports of survivors exhibiting varying phenotypes.[7,8] While prenatal ultrasound (US) may identify features suggestive of Fryns syndrome, postnatal confirmation is required for diagnosis.[9]

Disorder

DEFINITION

Diagnostic guidelines have most recently been reviewed and revised by Lin et al. in 2005 and include six major clinical features[5]:

1. diaphragmatic defect (hernia, eventration, hypoplasia, agenesis)
2. distal digital hypoplasia (nails and/or phalanges)
3. significant pulmonary hypoplasia[4]
4. characteristic facial appearance (coarse face, hypertelorism, broad and flat nasal bridge, long philtrum, low-set and poorly formed ears, tented upper lip with macrostomia, micrognathia)
5. associated anomalies (polyhydramnios, cloudy cornea or microphthalmia, orofacial cleft, brain malformation, cardiovascular malformation, renal dysplasia, gastrointestinal malformation, genitourinary malformation)
6. sibling affected with Fryns syndrome

Patients are then further categorized into one of the following three subtypes based on the aforementioned clinical criteria:

1. Narrowly defined: four of six clinical features.
2. Broadly defined: three of six clinical features.
3. Atypical.

PREVALENCE AND EPIDEMIOLOGY

Over 110 cases of Fryns syndrome have been reported since its initial description in 1979, with an estimated prevalence of 7:100,000 live births.[5,10] It is the most common syndrome associated with congenital diaphragmatic hernia, with a risk association ranging from 1%–10%.[11,12]

ETIOLOGY AND PATHOPHYSIOLOGY

Fryns syndrome is inherited in an autosomal recessive pattern and should be considered in any patient with a congenital diaphragmatic hernia and a prior affected family member.[3] Although the molecular mechanism has yet to be elucidated, multiple chromosome aberrations, such as microdeletions on chromosomes 1, 8, and 15; partial trisomy 22; and mosaic tetrasomy 12p, have been associated with a similar phenotype. It is recommended that these chromosome abnormalities be excluded by karyotype or chromosome microarray before assigning the diagnosis of Fryns syndrome.[13–16]

The pathogenesis of Fryns syndrome is not well understood; however, abnormal neural crest cell migration may play a role.[17] In addition, with the clinical implementation of whole exome sequencing, novel deleterious mutations in the *PIGN* gene have been reported in multiple individuals with a clinical diagnosis of Fryns syndrome. *PIGN* is one of a number of genes that codes for the production of glycosylphosphatidylinositol (GPI), which functions by attaching various proteins to the lipid layer of cell membranes. GPIs are involved in many cellular processes, some

of which function in developmental pathway signaling. Mutations in this gene have also been reported in other individuals with multiple congenital anomalies. Additional research is needed to delineate the association between *PIGN* and Fryns syndrome as well as to determine other genes that may be implicated in this condition.[6]

MANIFESTATIONS OF DISEASE

Clinical Presentation

The clinical presentation of Fryns syndrome is largely dependent on the particular anomalies present and the organ systems affected by these anomalies. As congenital diaphragmatic hernia is a common finding, respiratory distress and/or failure secondary to pulmonary hypoplasia, is often present in early neonatal life. The mortality rate for *in utero* death combined with early neonatal death has been quoted to be as high as 86%.[18] Surviving patients have exhibited a range of clinical manifestations including seizures, developmental delay, and mild to severe intellectual disability.[8] Both postnatal exam as well as pathologic exam at the time of autopsy may reveal clinical features such as facial dysmorphism, hypoplastic thorax with widely spaced nipples, cloudy cornea, nail hypoplasia, brachytelephalangy, webbed neck, gastroesophageal reflux, Hirschsprung disease, and hydronephrosis with vesicoureteral reflux.[4,7,8,19] The most common cardiac malformations observed in Fryns syndrome include conotruncal and aortic arch defects, and both atrial and ventricular septal defects.[5]

Imaging Technique and Findings

Ultrasound. Although not required for diagnosis, diaphragmatic hernia in the presence of another major anomaly should prompt concern for Fryns syndrome (Figs. 129.1 and 129.2). Diaphragmatic hernias observed in Fryns syndrome tend to be posterolateral defects associated with significant lung hypoplasia.[1,9] Other prenatal sonographic findings may include the following:[5,7,9,20,21]

- ventriculomegaly
- Dandy-Walker malformation
- agenesis of the corpus callosum
- hypoplasia of the distal phalanges
- renal malformations (bilateral renal enlargement and/or cystic kidneys)
- intestinal malrotation
- micrognathia
- cleft lip/palate
- cardiovascular malformations (most commonly conotruncal defects, aortic arch defects, and atrial/ventricular septal defects).

Elevated nuchal translucency and cystic hygroma have also been reported as sonographic findings in Fryns syndrome and correlate to the autopsy finding of webbed neck in many affected infants.[6,19,22] Given that diaphragmatic hernias are not typically diagnosed until after 16 weeks, increased nuchal translucency measurements and/or cystic hygroma may serve as first-trimester markers for Fryns syndrome, especially in families with a previously affected child. Fetal growth is either normal or excessive, and polyhydramnios is a common finding.[9,17] The use of three-dimensional US may aid in delineating facial dysmorphisms associated with Fryns syndrome. However, considering the subtleties of the facial and digital abnormalities present in Fryns syndrome, these features are likely to go undetected until postnatal examination.[21]

Magnetic Resonance Imaging. Although not required for diagnosis, fetal magnetic resonance imaging (MRI) may be a useful adjunct to prenatal US in characterizing neurologic anomalies as well as predicting fetal lung volume in cases of congenital diaphragmatic hernia. Recent studies suggest that lung volumes assessed by fetal MRI may be predictive of extracorporeal membrane oxygenation (ECMO) requirements and overall neonatal survival in fetuses with congenital diaphragmatic hernia (Chapter 27).[23,24]

Other Applicable Modality. Given the overall increased risk of cardiovascular malformations in fetuses with congenital diaphragmatic hernia, fetal echocardiography is warranted. This risk association has been estimated to be as high as 50% in patients diagnosed with Fryns syndrome.[5]

Differential Diagnosis From Imaging Findings

Other major cytogenetic abnormalities produce a phenotype similar to that observed in Fryns syndrome and should therefore be excluded before making the diagnosis. The most common are trisomy 22, Pallister-Killian syndrome (tetrasomy 12p), trisomy 18, Cornelia de Lange syndrome (Chapter 127), and

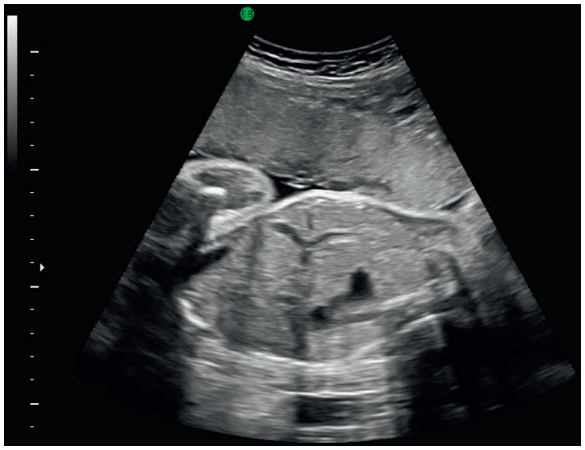

Fig. 129.1 Sagittal view of a fetus with a congenital diaphragmatic hernia diagnosed on prenatal ultrasound.

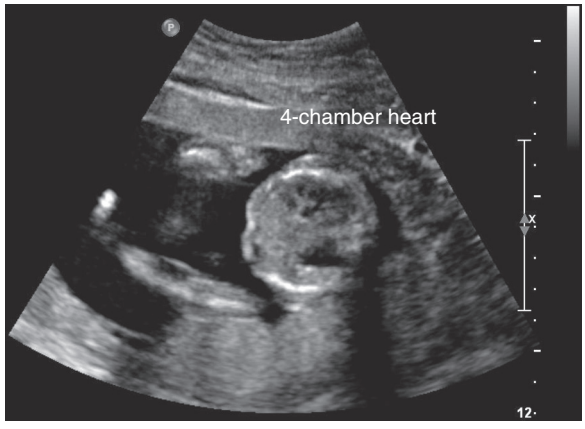

Fig. 129.2 Axial view of a fetus with congenital diaphragmatic hernia diagnosed on prenatal ultrasound. Note that both the heart and stomach are visualized in the same axial plane.

Simpson-Golabi-Behmel syndrome.[15,16] Intrauterine growth restriction is typically observed in trisomy 18, trisomy 22, and Cornelia de Lange syndrome as opposed to the normal or excessive growth observed in Fryns syndrome. Cornelia de Lange syndrome can also be differentiated based on distinctive facial features and upper limb abnormalities.[17] Simpson-Golabi-Behmel syndrome is inherited in an X-linked manner and has a higher incidence of fetal overgrowth and tumor formation than Fryns syndrome. Pallister-Killian syndrome shares many common features with Fryns syndrome including similar coarse facial features and diaphragmatic hernia. Internal malformations are less common in Pallister-Killian syndrome, and syndactyly, rather than distal limb hypoplasia, is more characteristic of Pallister-Killian syndrome. The prognosis for Pallister-Killian syndrome is more favorable, with a recurrence risk in subsequent pregnancies estimated to be that of the general population given that the genetic origin is thought to be a sporadic event resulting in tetrasomy. Therefore correct diagnosis of Fryns syndrome, and in particular the distinction from Pallister-Killian, is necessary to provide an accurate recurrence risk for patient counseling.[15,17]

Synopsis of Treatment Options

PRENATAL

There are currently no prenatal treatment options for fetuses suspected of having Fryns syndrome, and *in utero* mortality is high.[18] Exclusion of other chromosome abnormalities by chorionic villus sampling or amniocentesis is a viable option, as the diagnosis of Fryns syndrome most often cannot be definitively made until after birth or at the time of autopsy.[9,13–15,21]

POSTNATAL

For survivors, the treatment of Fryns syndrome is dependent on the constellation of particular anomalies. For neonates with congenital diaphragmatic hernia, stabilization is typically achieved through the use of high-frequency oscillatory ventilation or ECMO, followed by attempted surgical correction when and if the infant is deemed medically stable. Surgical correction of other anomalies or supportive care can also be undertaken. For those patients who survive into childhood, cognitive and developmental skills must be closely evaluated as developmental delay and/or intellectual disability is expected.[8]

WHAT THE REFERRING PHYSICIAN NEEDS TO KNOW

Fryns syndrome should be on the differential diagnosis for any fetus with congenital diaphragmatic hernia plus another major anomaly detected on US. The index of suspicion should be raised in pregnant women with a previous child with a congenital diaphragmatic hernia. While the molecular defect(s) for this syndrome are currently under investigation, exclusion of other chromosomal abnormalities that result in a similar phenotype should be performed. Careful consideration to the diagnosis of this syndrome should be paid, given its poor prognosis and increased recurrence risk for subsequent pregnancies.

KEY POINTS

- Fryns syndrome is a rare autosomal recessive disorder characterized by diaphragmatic defects, distal limb hypoplasia, facial dysmorphism, and associated major anomalies.
- While genetic loci for this disorder are currently under investigation, structural chromosome abnormalities, may produce a similar phenotype but with a different prognosis, should be excluded before making a clinical diagnosis of Fryns syndrome.
- While US findings can be extremely variable, common findings in cases of Fryns syndrome include diaphragmatic hernia, cardiovascular malformations, cystic hygroma, and polyhydramnios.
- A wide range of clinical manifestations with varying degrees of severity have been observed in the small number of patients who have survived into childhood.

SUGGESTED READINGS

Enns GM, Cox VA, Goldstein RB, et al. Congenital diaphragmatic defects and associated syndromes, malformations, and chromosome anomalies: a retrospective study of 60 patients and literature review. *Am J Med Genet*. 1998;79:215-225.

Lin AE, Pober BR, Mullen MP, et al. Cardiovascular malformations in Fryns syndrome: is there a pathogenic role for neural crest cells? *Am J Med Genet*. 2005;139A:186-193.

Sheffield JS, Twickler DM, Timmons C, et al. Fryns syndrome: prenatal diagnosis and pathologic correlation. *J Ultrasound Med*. 1998;17:585-589.

Slavotinek AM. Fryns syndrome: a review of the phenotype and diagnostic guidelines. *Am J Med Genet*. 2004;124A:427-433.

Slavotinek AM. The genetics of common disorders-congenital diaphragmatic hernia. *Eur J Med Genet*. 2014;57:418-423.

Vasudevan PC, Stewart H. A case of Fryns syndrome without diaphragmatic hernia and review of the literature. *Clin Dysmorphol*. 2004;13:179-182.



All references available online at
www.expertconsult.com

REFERENCES

1. Fryns JP, Moerman F, Goddeeris P, et al. A new lethal syndrome with cloudy cornea, diaphragmatic defects and distal limb deformities. *Hum Genet*. 1979;50:65-70.
2. Fryns JP. Fryns syndrome: a variable MCA syndrome with diaphragmatic defects, coarse face and distal limb hypoplasia. *J Med Genet*. 1987;24: 271-274.
3. Samueloff A, Navot D, Birkenfeld A, et al. Fryns syndrome—a predictable, lethal pattern of multiple congenital anomalies. *Am J Obstet Gynecol*. 1987;156:86-88.
4. Slavotinek AM. Fryns syndrome: a review of the phenotype and diagnostic guidelines. *Am J Med Genet*. 2004;124A:427-433.
5. Lin AE, Pober BR, Mullen MP, et al. Cardiovascular malformations in Fryns syndrome: is there a pathogenic role for neural crest cells? *Am J Med Genet*. 2005;139A:186-193.
6. McInerney-Leo AM, Harris J, Gattas M, et al. Fryns syndrome associated with recessive mutations in *PIGN* in two separate families. *Hum Mutat*. 2016;37:695-702.
7. Gadow EC, Lippold S, Serafin E, et al. Prenatal diagnosis and long survival of Fryns syndrome. *Prenat Diagn*. 1994;14:673-676.
8. Dentici ML, Brancati F, Mingarelli F, et al. A 6-year-old child with Fryns syndrome: further delineation of the natural history of the condition in survivors. *Eur J Med Genet*. 2009;52:421-425.
9. Sheffield JS, Twickler DM, Timmons C, et al. Fryns syndrome: prenatal diagnosis and pathologic correlation. *J Ultrasound Med*. 1998;17: 585-589.
10. Ayme S, Julian C, Gambarelli D, et al. Fryns syndrome: report on 8 new cases. *Clin Genet*. 1989;5:191-201.
11. Philip N, Gambarelli D, Guys JM, et al. Epidemiological study of congenital diaphragmatic defects with special reference to aetiology. *Eur J Pediatr*. 1991;150:726-729.
12. Neville HL, Jaksic T, Wilson JM, et al. Fryns syndrome in children with congential diaphragmatic hernia. *J Pediatr Surg*. 2002;37:1685-1687.
13. Slavotinek S, Lee SS, Davis R, et al. Fryns syndrome phenotype caused by chromosome microdeletions at 15q26.2 and 8p23.1. *J Med Genet*. 2005;42:730-736.
14. Enns GM, Cox VA, Goldstein RB, et al. Congenital diaphragmatic defects and associated syndromes, malformations, and chromosome anomalies: a retrospective study of 60 patients and literature review. *Am J Med Genet*. 1998;79:215-225.
15. McPherson EW, Ketterer DM, Salsburey DJ. Pallister-Killian and Fryns syndromes: nosology. *Am J Med Genet*. 1993;47:241-245.
16. Alessandri JL, Cuillier F, Malan V, et al. Fryns syndrome without diaphragmatic hernia, DOOR syndrome or Fryns-like syndrome? Report on patients from Indian ocean islands. *Am J Med Genet Part A*. 2014;164A:648-654.
17. Vasudevan PC, Stewart H. A case of Fryns syndrome without diaphragmatic hernia and review of the literature. *Clin Dysmorphol*. 2004;13:179-182.
18. Davis C, Samarakkody U. Fryns syndrome: a surviving case with associated Hirschsprung's disease and hemi diaphragmatic agenesis. *J Paediatr Child Health*. 2002;38:318-320.
19. Bulas DI, Saal HM, Allen JF, et al. Cystic hygroma and congenital diaphragmatic hernia: early prenatal sonographic evaluation of Fryns syndrome. *Prenat Diagn*. 1992;12:867-875.
20. Pellissier MC, Philip N, Potier A, et al. Prenatal diagnosis of Fryns syndrome. *Prenat Diagn*. 1992;12:299-303.
21. Peron A, Bedeschi MA, Fabietti I, et al. Prenatal and postnatal findings in five cases of Fryns syndrome. *Prenat Diagn*. 2014;34:1227-1230.
22. Hosli M, Tercantli S, Rehder H, et al. Cystic hygroma as an early first-trimester ultrasound marker for recurrent Fryns syndrome. *Ultrasound Obstet Gynecol*. 1997;10:422-424.
23. Kilian AK, Busing KA, Scheutz EM, et al. Fetal MR lung volumetry in congenital diaphragmatic hernia (CDH): prediction of clinical outcome and the need for extracorporeal membrane oxygenation (ECMO). *Klin Padiatr*. 2009;221:295-301.
24. Busing KA, Kilian AK, Schaible T, et al. MR lung volume in fetal congenital diaphragmatic hernia: logistic regression analysis—mortality and extracorporeal membrane oxygenation. *Radiology*. 2008;248:233-239.

130 Goldenhar Syndrome

FALLON R. BREWER | LORIE M. HARPER

Introduction

In 1952, Dr. Maurice Goldenhar described a variant of hemifacial microsomia.[1] Although Goldenhar syndrome is frequently listed as synonymous with hemifacial microsomia, it is distinct.[2–4] Also known as *ocular-auriculo-vertebral syndrome,* Goldenhar syndrome is a defect in the development of the first and second branchial arches.[3,5] Characterized by epibulbar dermoids, mandibular asymmetry, and cervical vertebrae anomalies, the syndrome exhibits extreme heterogeneity.

Disorder

DEFINITION

The heterogeneous nature of the syndrome is reflected in the fact that the syndrome has never been precisely defined. The primary feature, definitive of hemifacial microsomia, is asymmetry of the face and ears.[3,4] Classically, this includes microtia and asymmetric hypoplasia of the mandible. The original report described 30 patients with epibulbar dermoids, lipodermoids, preauricular skin tags, and dysostosis of the mandible and face.[2] In addition, vertebral anomalies such as cervical spine hemivertebrae and scoliosis are reported and, according to some authors, are a requirement.[2,6,7] Several cases of radial defects have been noted in association with this syndrome,[6,8] as well as complex cardiac defects.[6,9,10]

PREVALENCE AND EPIDEMIOLOGY

The reported incidence of Goldenhar syndrome ranges from 1:3500 to 1:26,550, but the most accepted estimation is 1:5600.[2,5] In the largest case series reported (294 patients), the male-to-female ratio was nearly 2:1.[11] The majority of cases were Caucasian (78%), although no data regarding the overall makeup of the population were reported, leaving it unclear if this finding was reflective of a variation in incidence of the syndrome by ethnicity, or attributable to the overall population studied.[11]

ETIOLOGY AND PATHOPHYSIOLOGY

The pathologic findings of Goldenhar syndrome appear to originate as a defect in the development of the first and second branchial arches.[3,4] Animal models have suggested that disruption of the facial circulatory system or interruption of chondrogenesis may be responsible for facial features of the syndrome.[5,7] In addition, almost half of patients with Goldenhar have an imbalanced fibroblast expression of the protein BAPX1, suggesting that dysregulation of this protein plays a role in the syndrome.[12] Mutations in the coding region of *HOXA2,* which specifies branchial arch 2 identity, have also been found in patients with microtia phenotypes, further supporting disruption of branchial arch 2 and the association with abnormal craniofacial features.[13]

The majority of reports consider Goldenhar to be a sporadic syndrome. It has been associated with teratogenic exposures such as thalidomide, retinoic acid, and primidone as well as with maternal diabetes.[5,7] Other associated exposures include tamoxifen and cocaine.[14]

Attempts have been made to identify a genetic locus for Goldenhar. Although traditionally the syndrome is considered sporadic, examination of 97 probands demonstrated that 45% had a family history of relatives, mostly first-degree relatives, affected by ear malformations, mandibular defects, or early-onset hearing loss.[15] This suggests that perhaps this syndrome is characterized by a genetic origin with variable penetrance as opposed to a sporadic occurrence. In addition, at least two families with an apparent autosomal dominant inheritance pattern of the syndrome have been reported.[16,17] In addition to autosomal dominant inheritance, autosomal recessive and multifactorial inheritance patterns have been observed with Goldenhar.[18] An empiric sibling recurrence risk of 2%–3% is given in the case of a proband with "oculo-auriculo-vertebral spectrum" (OAVS), with normal chromosomes and no family history.

Several cases of 22q11.2 deletions in children with Goldenhar syndrome have been reported.[18] This locus is characterized by low copy repeats and subject to variations in repeat number, suggesting that haploinsufficiency for one or more genes may be responsible for the phenotype. In addition, deletions in this region are associated with DiGeorge syndrome, possibly explaining the frequency of heart defects seen in Goldenhar syndrome.

Others have suggested that Goldenhar syndrome is a 5p15 deletion syndrome.[19–22] The association of Cri-du-Chat syndrome with deletions on the short arm of chromosome 5 also implicates this region in the development of the branchial arches.

More recently, deletions of the 12p13.33 region involving the *WNT5B* gene were observed in several patients with OAVS features as well as partially overlapping microduplications on 14q23.1. Other candidate single-gene loci for OAVS have been reported including 14q32 (containing the *GSC* gene), and potential linkage was suggested at 15q26.2-q26.3.[18]

MANIFESTATIONS OF DISEASE

Clinical Presentation

Findings may be unilateral or bilateral. In patients with bilateral findings, one side is typically more affected than the other (Table 130.1).[2,11] Some reports state that mental retardation is rare, and others state that it is common.[11,23] This variation may be resulting from differences in diagnosis. In addition, Goldenhar syndrome

TABLE 130.1 CLINICAL PRESENTATION OF GOLDENHAR SYNDROME

Ocular Findings
Coloboma
Epibulbar dermoids
Lipodermoids
Microophthalmia
Auditory Findings
Microtia
Anotia
Periauricular tags/preauricular tags
Craniofacial Findings
Microsomia
Macrostomia
Cleft lip/palate
Mandibular hypoplasia
Vertebral Anomalies
Cervical spine hemivertebrae
Cervical spine fusion
Scoliosis
Spina bifida
Complex Cardiac Defects
Radial Anomalies
Hypoplasia of the thumb
Agenesis of the thumb
Polydactyly
Functional Deficits
Impaired vision
Sensorineural hearing loss
Conductive hearing loss
Dysphagia

may be associated with other nonrandom associations of malformations, such as CHARGE (*c*oloboma, *h*eart defect, *a*tresia choanae, *r*etarded growth and development, *g*enital abnormality and *e*ar abnormality), and VATER (*v*ertebral defects, *a*nal atresia, *t*racheo-esophageal fistula, and *r*enal anomalies).[24]

Imaging Technique and Findings

Ultrasound. One of the clues to this diagnosis on ultrasound (US) is severe unilateral craniofacial anomalies. Ear abnormalities (microtia, malformed ear, preauricular skin tags) have been diagnosed on US, as well as microophthalmia and anophthalmia (Figs. 130.1 and 130.2).[16,25–29] Witters et al. also reported a case of nose hemiatrophy associated with Goldenhar diagnosed on US.[30] Additional findings associated with the syndrome that may be diagnosed on US include cleft lip/palate, vertebral anomalies, skeletal (radial) abnormalities, and cardiac defects.

Three-dimensional imaging may supplement routine US in the diagnosis and further characterization of hemifacial microsomia and preauricular skin tags.[27]

Magnetic Resonance Imaging. Hattori et al. reported a case of using magnetic resonance imaging (MRI) to image fetal facial findings when ultrasonography revealed findings suspicious for Goldenhar but was limited by bony artifacts. The MRI confirmed right orbital hypoplasia (Fig. 130.3) and right ear hypoplasia.[31]

CLASSIC SIGNS

Asymmetric mandibular hypoplasia with microtia, microphthalmia, and preauricular skin tags in association with vertebral findings. In addition, cardiac defects and skeletal anomalies may be present.



Fig. 130.1 Frontal view demonstrating unilateral microphthalmia. *(From Martinelli P, Maruotti GM, Agangi A, et al. Prenatal diagnosis of hemifacial microsomia and ipsilateral cerebellar hypoplasia in a fetus with oculo-auriculovertebral spectrum.* Ultrasound Obstet Gynecol *2004;24[2]: 199-201).*



Fig. 130.2 Three-dimensional image demonstrating unilateral microphthalmia and ipsilateral cleft lip. *(From Volpe P, Gentile M. Three-dimensional diagnosis of Goldenhar syndrome.* Ultrasound Obstet Gynecol *2004;24[7]:798-800).*



Fig. 130.3 Fetal MRI demonstrating unilateral microphthalmia in a transverse view. *(From Hattori Y, Tanaka M, Matsumoto T, et al. Prenatal diagnosis of hemifacial microsomia by magnetic resonance imaging.* J Perinat Med *2005;33[1]:69-71).*

Differential Diagnosis From Imaging Findings

1. Branchio-oculo-facial syndrome
2. Branchio-oto-renal syndrome
3. Fraser syndrome
4. Fryns syndrome
5. Klippel-Feil sequence
6. Meier-Gorlin syndrome
7. Opitz
8. Stickler
9. Shprintzen syndrome
10. Treacher Collins
11. Walker-Warburg syndrome

Synopsis of Treatment Options

PRENATAL

Currently, no prenatal treatment options exist.

POSTNATAL

Postnatal treatment often includes cosmetic surgery, as well as correction of other associated defects.

WHAT THE REFERRING PHYSICIAN NEEDS TO KNOW

Goldenhar syndrome is an extremely heterogeneous disease, and prenatal prediction of functional outcomes (i.e., deafness, mental retardation) is not possible in the absence of other major anomalies. US detection of mandibular asymmetry and microtia could indicate Goldenhar syndrome, and consideration of referral for consultation is warranted.

KEY POINTS

- May be unilateral (majority) or bilateral, with a more severely affected side.
- Sporadic inheritance initially presumed, but several genetic loci have been proposed and may represent a disease with variable penetrance.

SUGGESTED READINGS

Hartsfield JK. Review of the etiologic heterogeneity of the oculo-auriculo-vertebral spectrum (Hemifacial Microsomia). *Orthod Craniofac Res*. 2007;10:121.

Heike CL, Luquetti DV, Hing AV. Craniofacial Microsomia Overview. In: Pagon RA, Adam MP, Ardinger HH, et al, eds. *GeneReviews* [Internet]. Seattle (WA): University of Washington, Seattle; 2009:1993-2016.

All references available online at www.expertconsult.com

REFERENCES

1. Goldenhar M. Association malformatives de l'oeil et de l'oreille. *J Genet Hum*. 1952;1:243.
2. Stromland K, Miller M, Sjogreen L, et al. Oculo-auriculo-vertebral spectrum: associated anomalies, functional deficits and possible developmental risk factors. *Am J Med Genet A*. 2007;143A(12):1317-1325.
3. Benacerraf BR. *Ultrasound of fetal syndromes*. 2nd ed. Philadelphia: Churchill Livingstone, Elsevier; 2008.
4. Heike CL, Luquetti DV, Hing AV. Craniofacial Microsomia Overview. In: Pagon RA, Adam MP, Ardinger HH, et al, eds. *GeneReviews* [Internet]. Seattle (WA): University of Washington, Seattle; 2009:1993-2016.
5. Hartsfield JK. Review of the etiologic heterogeneity of the oculo-auriculo-vertebral spectrum (Hemifacial Microsomia). *Orthod Craniofac Res*. 2007;10(3):121-128.
6. Zelante L, Gasparini P, Castriota Scanderbeg A, et al. Goldenhar complex: a further case with uncommon associated anomalies. *Am J Med Genet*. 1997;69(4):418-421.
7. Rollnick BR. Oculoauriculovertebral anomaly: variability and causal heterogeneity. *Am J Med Genet Suppl*. 1988;4:41-53.
8. Vendramini S, Richieri-Costa A, Guion-Almeida ML. Oculoauriculovertebral spectrum with radial defects: a new syndrome or an extension of the oculoauriculovertebral spectrum? Report of fourteen Brazilian cases and review of the literature. *Eur J Hum Genet*. 2007;15(4):411-421.
9. Digilio MC, Calzolari F, Capolino R, et al. Congenital heart defects in patients with oculo-auriculo-vertebral spectrum (Goldenhar syndrome). *Am J Med Genet A*. 2008;146A(14):1815-1819.
10. Lin HJ, Owens TR, Sinow RM, et al. Anomalous inferior and superior venae cavae with oculoauriculovertebral defect: review of Goldenhar complex and malformations of left-right asymmetry. *Am J Med Genet*. 1998;75(1):88-94.
11. Rollnick BR, Kaye CI, Nagatoshi K, et al. Oculoauriculovertebral dysplasia and variants: phenotypic characteristics of 294 patients. *Am J Med Genet*. 1987;26(2):361-375.
12. Alasti F, Van Camp G. Genetics of microtia and associated syndromes. *J Med Genet*. 2009;46(6):361-369.
13. Cox TC, Camci ED, Vora S, et al. The genetics of auricular development and malformation: new findings in model systems driving future directions for microtia research. *Eur J Med Genet*. 2014;57(8):394-401.
14. Ashokan CS, Sreenivasan A, Saraswathy GK. Goldenhar syndrome—review with case series. *J Clin Diagn Res*. 2014;8(4):ZD17-ZD19.
15. Rollnick BR, Kaye CI. Hemifacial microsomia and variants: pedigree data. *Am J Med Genet*. 1983;15(2):233-253.
16. Stoll C, Viville B, Treisser A, et al. A family with dominant oculoauriculo-vertebral spectrum. *Am J Med Genet*. 1998;78(4):345-349.
17. Tasse C, Majewski F, Bohringer S, et al. A family with autosomal dominant oculo-auriculo-vertebral spectrum. *Clin Dysmorphol*. 2007;16(1):1-7.
18. Beleza-Meireles A, Clayton-Smith J, Saraiva JM, et al. Oculo-auriculo-vertebral spectrum: a review of the literature and genetic update. *J Med Genet*. 2014;51(10):635-645.
19. Ala-Mello S, Siggberg L, Knuutila S, et al. Further evidence for a relationship between the 5p15 chromosome region and the oculoauriculovertebral anomaly. *Am J Med Genet A*. 2008;146A(19):2490-2494.
20. Josifova DJ, Patton MA, Marks K. Oculoauriculovertebral spectrum phenotype caused by an unbalanced t(5;8)(p15.31;p23.1) rearrangement. *Clin Dysmorphol*. 2004;13(3):151-153.
21. Descartes M. Oculoauriculovertebral spectrum with 5p15.33-pter deletion. *Clin Dysmorphol*. 2006;15(3):153-154.
22. Choong YF, Watts P, Little E, et al. Goldenhar and cri-du-chat syndromes: a contiguous gene deletion syndrome? *J AAPOS*. 2003;7(3):226-227.
23. Schrander-Stumpel CT, de Die-Smulders CE, Hennekam RC, et al. Oculoauriculovertebral spectrum and cerebral anomalies. *J Med Genet*. 1992;29(5):326-331.
24. Kallen K, Robert E, Castilla EE, et al. Relation between oculo-auriculo-vertebral (OAV) dysplasia and three other non-random associations of malformations (VATER, CHARGE, and OEIS). *Am J Med Genet A*. 2004;127A(1):26-34.
25. Martinelli P, Maruotti GM, Agangi A, et al. Prenatal diagnosis of hemifacial microsomia and ipsilateral cerebellar hypoplasia in a fetus with oculoauriculovertebral spectrum. *Ultrasound Obstet Gynecol*. 2004;24(2):199-201.
26. Castori M, Brancati F, Rinaldi R, et al. Antenatal presentation of the oculo-auriculo-vertebral spectrum (OAVS). *Am J Med Genet A*. 2006;140(14):1573-1579.
27. Volpe P, Gentile M. Three-dimensional diagnosis of Goldenhar syndrome. *Ultrasound Obstet Gynecol*. 2004;24(7):798-800.
28. Maymon R, Schneider D, Hegesh J, et al. Antenatal sonographic findings of right pulmonary agenesis with ipsilateral microtia: a possible new laterality association. *Prenat Diagn*. 2001;21(2):125-128.
29. De Catte L, Laubach M, Legein J, et al. Early prenatal diagnosis of oculo-auriculovertebral dysplasia or the Goldenhar syndrome. *Ultrasound Obstet Gynecol*. 1996;8(6):422-424.
30. Witters I, Schreurs J, Van Wing J, et al. Prenatal diagnosis of facial clefting as part of the oculo-auriculo-vertebral spectrum. *Prenat Diagn*. 2001;21(1):62-64.
31. Hattori Y, Tanaka M, Matsumoto T, et al. Prenatal diagnosis of hemifacial microsomia by magnetic resonance imaging. *J Perinat Med*. 2005;33(1):69-71.

131 Klippel-Trénaunay-Weber Syndrome

RYAN E. LONGMAN

Introduction

Klippel-Trénaunay-Weber syndrome (KTWS) is characterized by a triad of cutaneous hemangiomas, hemihypertrophy, and vascular abnormalities. This triad of anomalies was first described by Klippel and Trénaunay in 1900. Parkes-Weber described an additional case 18 years later that had the triad of findings described by Klippel and Trénaunay and an arteriovenous malformation.[1] The exact pathophysiology and genetic etiology of the disorder are unknown. Treatment consists of symptomatic management.

Disease

DEFINITION

The diagnosis of KTWS is based on clinical findings. The major clinical findings are cutaneous hemangiomas, vascular

abnormalities, and hemihypertrophy. To assign a diagnosis of KTWS, two of the three major findings must be present.[2–4]

PREVALENCE AND EPIDEMIOLOGY

The prevalence of KTWS is 1:100,000.[5] It occurs equally in males and females and has no racial predilection.[1]

ETIOLOGY AND PATHOPHYSIOLOGY

The pathophysiology and genetic etiology are unknown. Although a few familial cases and individuals with *de novo* balanced translocations have been reported, KTWS is generally accepted to be a sporadic disorder with no clear hereditary pattern.[2,6–8]

MANIFESTATIONS OF DISEASE

Clinical Presentation

Cutaneous Hemangioma. Hemangiomas are usually of the nevus flammeus type but can also occur as cavernous hemangiomas or lymphangiomas. Hemangioma depth is variable and can be limited to the skin or extend deeper into the visceral organs. If significantly large, hemangiomas can lead to platelet sequestering and possible Kasabach-Merritt syndrome (thrombocytopenia and microangiopathic hemolytic anemia in small children with hemangiomas).[1,6,9,10]

Vascular Abnormalities. The most common vascular abnormality seen is varicose veins. Varicose veins may manifest as superficial or deep and can remain stable or expand in size. Both lymphedema and pain have been associated with the varicosities.[1,6,9] Arteriovenous malformations are less common vascular abnormalities in this syndrome.[10]

Hemihypertrophy. Hemihypertrophy usually occurs in extremities. Limb hypertrophy can manifest as bony or soft tissue involvement (Figs. 131.1–131.3).[1,6]

Occasional Findings. Occasional findings include developmental delay, lymphatic obstruction, neural tube defect, hypospadias, polydactyly, syndactyly, oligodactyly, hyperhidrosis, hypotrichosis, ulceration, thrombophlebitis, angiosarcoma, pulmonary embolism, congestive cardiac failure, gangrene of the affected limb, and cellulitis.[1–3,6,9,11,12]

Imaging Technique and Findings

Ultrasound. Prenatal ultrasound (US) diagnosis of KTWS has been reported at 15 weeks' gestation.[13] Diagnosis is based on limb hypertrophy with the association of subcutaneous cystic lesions (see Fig. 131.1). Doppler interrogation of these

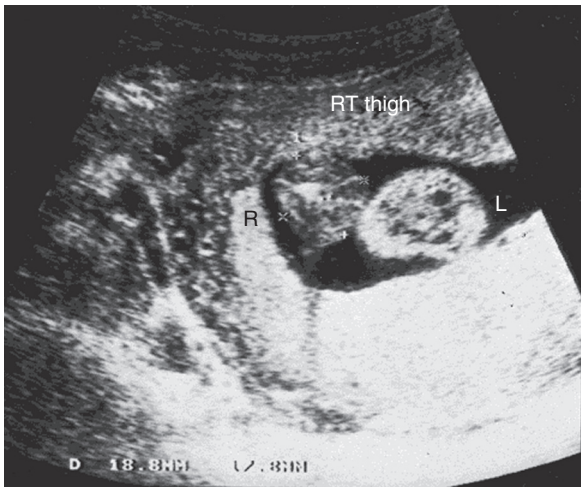

Fig. 131.2 Cross-section of the thighs in a fetus with KTWS shows hypertrophy of the left leg. *L*, Left; *R*, right; *RT*, right thigh. *(From Shih JC, Shyu MK, Chang CY, et al. Application of the surface rendering technique of three-dimensional ultrasound in prenatal diagnosis and counseling of Klippel-Trenaunay-Weber syndrome.* Prenat Diagn *1998;18:298–302.)*

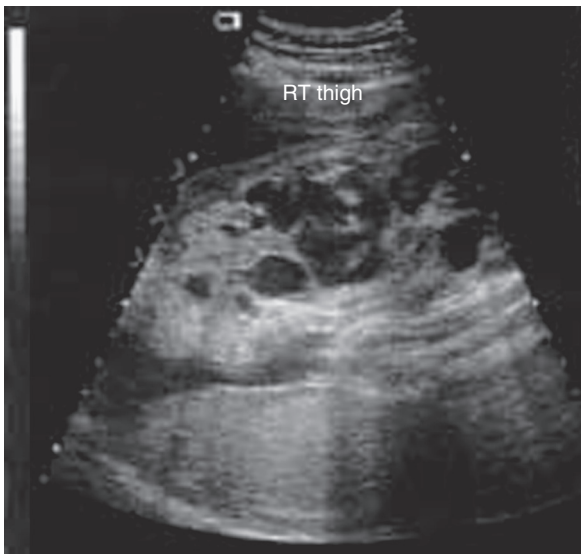

Fig. 131.1 Longitudinal ultrasound image of the right thigh *(RT thigh)* in a fetus with KTWS shows limb hypertrophy with subcutaneous cystic lesions. *(From Goncalves LF, Munoz Rojas MV, Vitorello D, et al. Klippel-Trenaunay-Weber syndrome presenting as massive lymphangiohemangioma of the thigh: prenatal diagnosis.* Ultrasound Obstet Gynecol *2000;15:537–541.)*

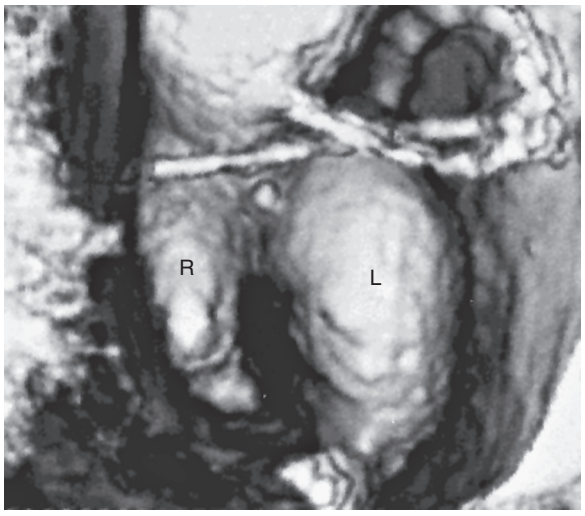

Fig. 131.3 Three-dimensional ultrasound image of a fetus with KTWS shows significant left leg hypertrophy compared with the right. *L*, Left; *R*, right. *(From Shih JC, Shyu MK, Chang CY, et al. Application of the surface rendering technique of three-dimensional ultrasound in prenatal diagnosis and counseling of Klippel-Trenaunay-Weber syndrome.* Prenat Diagn *1998;18:298–302.)*

subcutaneous cystic lesions failed to exhibit internal arterial or venous blood flow suggesting that either the vascular flow rates were too low for detection or lymphangiomas constituted most of the cystic mass.[14,15] Other features noted on prenatal US consist of cardiac failure, polyhydramnios, Kasabach-Merritt syndrome, and fetal hydrops.[13,14,16–28] Three-dimensional US has been used for additional assessment of leg width difference (see Fig. 131.3).[13]

Magnetic Resonance Imaging. Fetal magnetic resonance imaging (MRI) has been reported to be a useful adjunct testing modality in suspected cases. MRI aids in the characterization of soft tissue lesions and vascular abnormalities seen in KTWS.[16]

CLASSIC SIGNS

Cutaneous hemangiomas.
Vascular abnormalities.
Hemihypertrophy.

Differential Diagnosis From Imaging Findings

1. Beckwith-Wiedemann syndrome
2. Proteus syndrome
3. Russell-Silver syndrome
4. Maffucci syndrome
5. CHILD (*c*ongenital *h*emidysplasia with *i*chthyosiform erythroderma and *l*imb *d*efects) syndrome
6. Neurofibromatosis 1
7. Triploidy
8. *PIK3CA*-Related Overgrowth Spectrum

Synopsis of Treatment Options

PRENATAL

Patients with a fetal diagnosis of KTWS should be followed with serial US scans to exclude fetal hydrops and cardiac failure. Patients should also be offered an amniocentesis for fetal karyotype and chromosomal microarray to exclude the possibility of chromosomal abnormalities or microdeletion/duplication syndromes. There is no prenatal diagnostic genetic testing for KTWS.

POSTNATAL

Postnatal management consists of symptomatic treatment (Fig. 131.4).



Fig. 131.4 Postnatal image of a newborn with KTWS. *(From Goncalves LF, Munoz Rojas MV, Vitorello D, et al. Klippel-Trenaunay-Weber syndrome presenting as massive lymphangiohemangioma of the thigh: prenatal diagnosis.* Ultrasound Obstet Gynecol *2000;15:537–541.)*

WHAT THE REFERRING PHYSICIAN NEEDS TO KNOW

- KTWS is characterized by cutaneous hemangiomas, vascular abnormalities, and limb hypertrophy.
- The pathophysiology and genetic etiology are unknown.
- Prenatal diagnosis is possible; US shows hemihypertrophy and subcutaneous cystic lesions.
- Patients with a fetal diagnosis of KTWS should be followed with serial US scans to exclude fetal hydrops and cardiac failure.
- Postnatal treatment consists of symptomatic management.

KEY POINTS

- KTWS is characterized by cutaneous hemangiomas, vascular abnormalities, and limb hypertrophy.
- The pathophysiology and genetic etiology are unknown.
- Prenatal diagnosis is possible using US.
- If a fetal diagnosis of KTWS is made, serial US scans to exclude fetal hydrops and cardiac failure should be performed.
- Postnatal treatment consists of symptomatic management.

SUGGESTED READINGS

Goncalves LF, Munoz Rojas MV, Vitorello D, et al. Klippel-Trenaunay-Weber syndrome presenting as massive lymphangiohemangioma of the thigh: prenatal diagnosis. *Ultrasound Obstet Gynecol.* 2000;15:537-541.

Meine JG, Schwartz RA, Janniger CK. Klippel-Trenaunay-Weber syndrome. *Cutis.* 1997;60:127-132.

OMIM Entry %149000: Klippel-Trenaunay syndrome. www.ncbi.nlm.nih.gov/omim/149000.

All references available online at www.expertconsult.com

REFERENCES

1. Kihiczak GC, Meine JG, Schwartz RA, et al. Klippel-Trenaunay syndrome: a multisystem disorder possibly resulting from a pathogenic gene for vascular and tissue overgrowth. *Int J Dermatol*. 2006;45:883-890.
2. Wang Q, Timur AA, Szafranski P, et al. Identification and molecular characterization of de novo translocation (8;14)(q22.3;q13) overgrowth syndrome. *Cytogenet Cell Genet*. 2001;95:183-188.
3. Sethi S. Shubha BS. Klippel-Trenaunay syndrome. *Indian J Pediatr*. 2001;68:787-789.
4. Jacob AG, Driscoll DJ, Shaughnessy WJ, et al. Klippel-Trenaunay syndrome: spectrum and management. *Mayo Clin Proc*. 1998;73:28-36.
5. Lorda-Sanches I, Prieto L, Rodrigues-Pinilla E, et al. Increased parental age and number of pregnancies in Klippel-Trenaunay-Weber syndrome. *Ann Hum Genet*. 1998;62:235-239.
6. Aelvoet GE, Jorens PG, Roelen LM. Genetic aspects of the Klippel-Trenaunay syndrome. *Br J Dermatol*. 1992;126:603-607.
7. Ceballos-Quintal JM, Pinto-Escalante D, Castillio-Zapata I. A new case of Klippel-Trenaunay-Weber (KTW) syndrome: evidence of autosomal dominant inheritance. *Am J Med Genet*. 1996;63:426-427.
8. Whelan AJ, Watson MS, Porter FD, et al. Klippel-Trenaunay-Weber syndrome associated with a 5:11 balanced translocation. *Am J Med Genet*. 1995;59:492-494.
9. Viljoen D, Saxe N, Pearn J, et al. The cutaneous manifestation of the Klippel-Trenaunay-Weber syndrome. *Clin Exp Dermatol*. 1987;12:12-17.
10. Berry SA, Peterson C, Mize W, et al. Klippel-Trenaunay syndrome. *Am J Med Genet*. 1998;79:319-326.
11. Samuel M, Spitz L. Klippel-Trenaunay syndrome: clinical features, complications and management in children. *Br J Surg*. 1995;82:757-761.
12. Muluk SC, Ginns LC, Semigran MJ, et al. Klippel-Trenaunay syndrome with multiple pulmonary emboli—an unusual cause of progressive pulmonary dysfunction. *J Vasc Surg*. 1995;5:686-690.
13. Shih JC, Shyu MK, Chang CY, et al. Application of the surface rendering technique of three-dimensional ultrasound in prenatal diagnosis and counseling of Klippel-Trenaunay-Weber syndrome. *Prenat Diagn*. 1998;18:298-302.
14. Roberts RV, Dickinson JE, Hugo PJ, et al. Prenatal sonographic appearances of Klippel-Trenaunay-Weber syndrome. *Prenat Diagn*. 1999;19:369-371.
15. Yang JI, Kim HS, Ryu HS. Prenatal sonographic diagnosis of Klippel-Trenaunay-Weber syndrome. *J Reprod Med*. 2005;50:291-294.
16. Martin WL, Ismail KMK, Brace V, et al. Klippel-Trenaunay-Weber (KTW) syndrome: the use of in utero magnetic resonance imaging (MRI) in a prospective diagnosis. *Prenat Diagn*. 2001;21:311-313.
17. Peng HH, Wang TH, Chao AS, et al. Klippel-Trenaunay-Weber syndrome involving fetal thigh: prenatal presentations and outcomes. *Prenat Diagn*. 2006;26:825-830.
18. Paladini D, Lamberti A, Teodoro A, et al. Prenatal diagnosis and hemodynamic evaluation of Klippel-Trenaunay-Weber syndrome. *Ultrasound Obstet Gynecol*. 1998;12:215-217.
19. Chen CP, Lin SP, Chang TY, et al. Prenatal sonographic findings of Klippel-Trenaunay-Weber syndrome. *J Clin Ultrasound*. 2007;35:409-412.
20. Assimakopoulos E, Zafrakas M, Athanasiades A, et al. Klippel-Trenaunay-Weber syndrome with abdominal hemangiomata appearing on ultrasound examination as intestinal obstruction. *Ultrasound Obstet Gynecol*. 2003;22:547-551.
21. Goncalves LF, Munoz Rojas MV, Vitorello D, et al. Klippel-Trenaunay-Weber syndrome presenting as massive lymphangiohemangioma of the thigh: prenatal diagnosis. *Ultrasound Obstet Gynecol*. 2000;15:537-541.
22. Zoppi MA, Ibba RM, Floris M, et al. Prenatal sonographic diagnosis of Klippel-Trenaunay-Weber syndrome with cardiac failure. *J Clin Ultrasound*. 2001;29:422-426.
23. Sahinoglu Z. Uludogan M, Delikara NM. Prenatal diagnosis of Klippel-Trenaunay-Weber syndrome associated with umbilical cord hemangioma. *Am J Perinatol*. 2003;20:1-5.
24. Yankowitz J, Slagel DD, Williamson R. Prenatal diagnosis of the Klippel-Trenaunay-Weber syndrome by ultrasound. *Prenat Diagn*. 1994;14:745-749.
25. Jorgenson RJ, Darby B, Patterson R, et al. Prenatal diagnosis of the Klippel-Trenaunay-Weber syndrome. *Prenat Diagn*. 1994;14:989-992.
26. Christenson I, Yankowitz J, Robinson R. Prenatal diagnosis of the Klippel-Trenaunay-Weber syndrome as a cause for in utero heart failure and severe postnatal sequelae. *Prenat Diagn*. 1997;17:1176-1180.
27. Tanaka K, Miyazaki N, Matsushima M, et al. Prenatal diagnosis of Klippel-Trenaunay-Weber syndrome with Kasabach-Merritt syndrome in utero. *J Med Ultrasonics*. 2015;42:109-112.
28. Cakiroglu Y, Doger E, Kopuk SY, et al. Sonographic identification of Klippel-Trenaunay-Weber syndrome. *Case Rep Obstet Gynecol*. 2013;Article ID 595476.

132 Holt-Oram Syndrome

SARAH OBIČAN | LINDSAY MAGGIO

Introduction

Holt-Oram, also known as *hand-heart syndrome I,* was first described in 1960 by Mary Clayton Holt and Samuel Oram as a constellation of malformations that they observed in four generations of one family.[1] The original description included atrial septal defects and a thumb anomaly that lay in the same plane as the finger. Individuals affected by this disorder have the classically described upper limb anomaly and heart defects (mostly atrial septal defects), but may additionally present with pectus excavatum or carinatum and vertebral anomalies.[2] Holt-Oram is now known to occur because of a mutation in the *TBX5*[3] gene located on 12q24.1 and is a rare autosomal dominant syndrome characterized by high penetrance and variable expression.

Disorder

DEFINITION

Hallmark features of Holt-Oram syndrome include cardiovascular defects, most of which are atrial septal defects (up to 60%),[4] and radial arm malformation affecting the thumb. Other possible cardiac anomalies include arrhythmias and complex cardiac malformations, most commonly atrioventricular canal defects and tetralogy of Fallot.[5] Other potential syndromic features include variable upper limb anomalies and skeletal anomalies. This syndrome has been associated with over 70 unique mutations in the transcription factor *TBX5* located on 12q24.1.[6]

PREVALENCE AND EPIDEMIOLOGY

Holt-Oram syndrome has a mean prevalence of 0.7 : 100,000[7] and is typically diagnosed prenatally or in the early years of life. There is high regional variation; in Ireland, the prevalence is 0.2 : 100,000 and in Belgium, 1.4 : 100,000. There appears to be a significant lower prevalence rate in more modern reports (post-2001) compared to earlier epidemiologic studies; however, this finding has no obvious explanation.[7,8] The male-to-female ratio is close to 1 : 1.[7]

ETIOLOGY, PATHOPHYSIOLOGY, AND EMBRYOLOGY

Holt-Oram presentation may be sporadic, but more commonly it follows autosomal dominant transmission with nearly 100% penetrance but variable expressivity. Individual carriers of *TBX5* allelic variants have a high variability of clinical presentation even within families.[7] Two groups, Li et al. and Basson et al. determined that Holt-Oram syndrome is caused by a mutation in *TBX5*.[9,10] *TBX5* mutations have been noted in 30%–75% of patients clinically suspected to have Holt-Oram syndrome.[11,12] Pathogenic mutations in this gene are typically inactivating, such as deletions, nonsense, and truncations, though missense mutations in functional domains have also been described.[6,10,13] *TBX5* is located on the long arm of chromosome 12, locus 12q24.1. *TBX5* is a member of the T-box family of transcription factors, and has been found to be critically important in cardiac and limb development. Pathogenic mutations typically affect the ability of the subsequent protein to dimerize with other proteins, with the end result being dysregulation of function.[6,10]

MANIFESTATIONS OF DISEASE

Clinical Presentation

Cardiac disease when present may include dysrhythmias and/or malformations.[14] The prevalence of congenital heart disease (CHD) in individuals affected with Holt-Oram syndrome is reportedly between 75% and 95%.[7,11] The most common cardiac malformations are septal defects (54.2%)[7] (atrial septal defect > ventricular septal defect), whereas 25% are considered complex CHD.[7] Individuals should be followed with pediatric cardiology to time surgical intervention as there is a risk of development of pulmonary hypertension in uncorrected septal defects. In addition, affected individuals should be assessed for possible arrhythmias such as bradycardias and atrioventricular conduction abnormalities that may require placement of a pacemaker.[11]

Skeletal abnormalities, particularly in the upper extremities, are the other main class of defect in Holt-Oram syndrome (Fig. 132.1). The most commonly observed defects are agenesis or hypoplasia of the radius, aplasia or hypoplasia of the ulna, and phocomelia.[7] Defects involving the thumb are exceptionally common (Fig. 132.2). The defect can present as a missing thumb, or a thumb that appears as a finger. Skeletal abnormalities are usually bilateral in 84% of cases[6] and can be similar in phenotype, but in cases where they differ, the left side is typically more severely affected than the right.[15] Chest anomalies, such as pectus excavatum, narrow sloping shoulders, and vertebral anomalies have also been described but are less common.[2] Importantly for the genetic counseling of families, there is no known intellectual impairment associated with Holt-Oram syndrome.[7] While the classic constellation of malformations in conjunction with an autosomal dominant distribution in a family is sufficient for clinical diagnosis, often there is a lengthy differential diagnosis and genetic studies may be needed for confirmation.

Imaging Technique and Findings

Ultrasound. Prenatal diagnosis of Holt-Oram syndrome is frequently accomplished when there is a family history and a strong suspicion for the disorder.[16] It is important to image both upper extremities with measurements of the long bones of the upper extremities, and attention to the radius–ulna–hand complex.[17,18] Given the high prevalence of congenital heart defects in those with this suspected disorder, a fetal echocardiogram should be performed with particular attention to septal wall

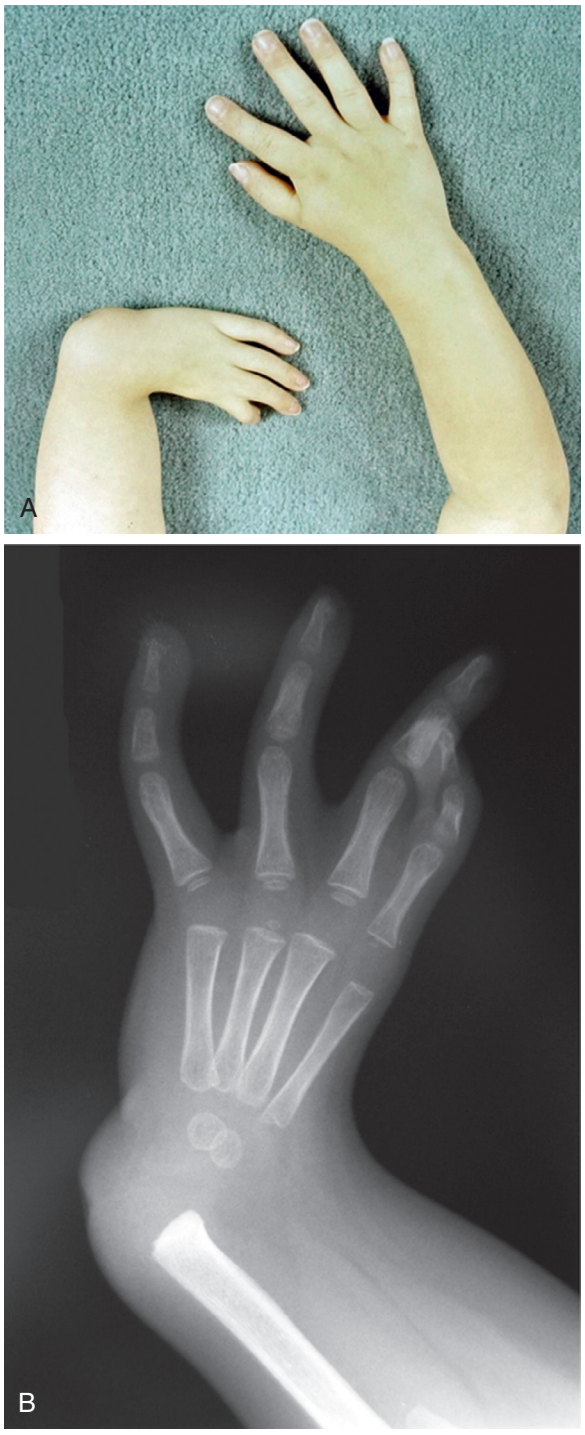

Fig. 132.1 (A) Left radial longitudinal deficiency. (B) Radiograph of same left hand, hypoplastic index ray. *(Reprinted from Chryssostomidisa G, et al. Diversity of congenital cardiac defects and skeletal deformities associated with the Holt–Oram syndrome.* Int J Surg Case Rep *2014;5:389-92.)*

defects. Unfortunately, the diagnostic utility of ultrasound (US) in diagnosing upper extremity abnormalities is limited, with detection rates around 30%.[19] There may be a limited role in three-dimensional real-time ultrasonography in improving the detection rate of these constellation of findings, most specifically, the upper extremity defects.[20]

CLASSIC SIGNS

- Upper limb abnormality often involving the thumb.
- Congenital heart defects.
  - Atrial septal defects.
  - Ventricular septal defects.
  - Conduction abnormalities.

Differential Diagnosis From Imaging Findings

- Radial longitudinal deficiency
- Duane-radial ray syndrome (*SALL* gene family)
- Hand-heart syndrome II (Tabatznik)
- Hand-heart syndrome III (Spanish type)
- Ulnar-mammary syndrome
- Townes-Brocks syndrome
- Kaufmann McKusick
- Roberts syndrome
- Fanconi anemia
- Thrombocytopenia-absent radius syndrome
- 22q11.2 deletion syndrome
- VACTERL (*v*ertebral defects, *a*nal atresia, *c*ardiac defects, *t*racheo*e*sophageal fistula, *r*enal anomalies, and *l*imb abnormalities)
- Teratogen exposure (i.e., thalidomide, valproate)

Synopsis of Treatment Options

PRENATAL

With a family history of Holt-Oram syndrome and ultrasonographic findings consistent with this syndrome, the diagnosis can be made. There are no treatments or prenatal interventions for this syndrome; however, with a high degree of suspicion, consultation with a geneticist, hand surgeon, and a pediatric cardiologist should be obtained in the prenatal period.

POSTNATAL

Treatment of Holt-Oram syndrome involves a multidisciplinary team including a geneticist, pediatric cardiologist, and cardiac surgeon, and a specialist in hand surgery (orthopedics or plastics). The cardiology team will assess the extent of the cardiac defects and determine if any surgical intervention is necessary. The hand surgeon will be able to determine if an individual is a candidate for surgery to improve function of the affected upper extremities. Some limb defects may not be amenable to surgical correction and would benefit from a prosthesis.

WHAT THE REFERRING PHYSICIAN NEEDS TO KNOW

If any upper extremity or cardiac abnormalities are suspected on routine prenatal imaging, a simple family history and pedigree can help determine if the family is affected by Holt-Oram syndrome. Prompt referral to maternal-fetal medicine for further prenatal imaging and diagnosis, as well as coordination with a multidisciplinary team, is paramount to the care of these individuals. In the absence of a family history or classic constellation of malformations, the differential diagnosis is broad and may require genetic testing to confirm the diagnosis.

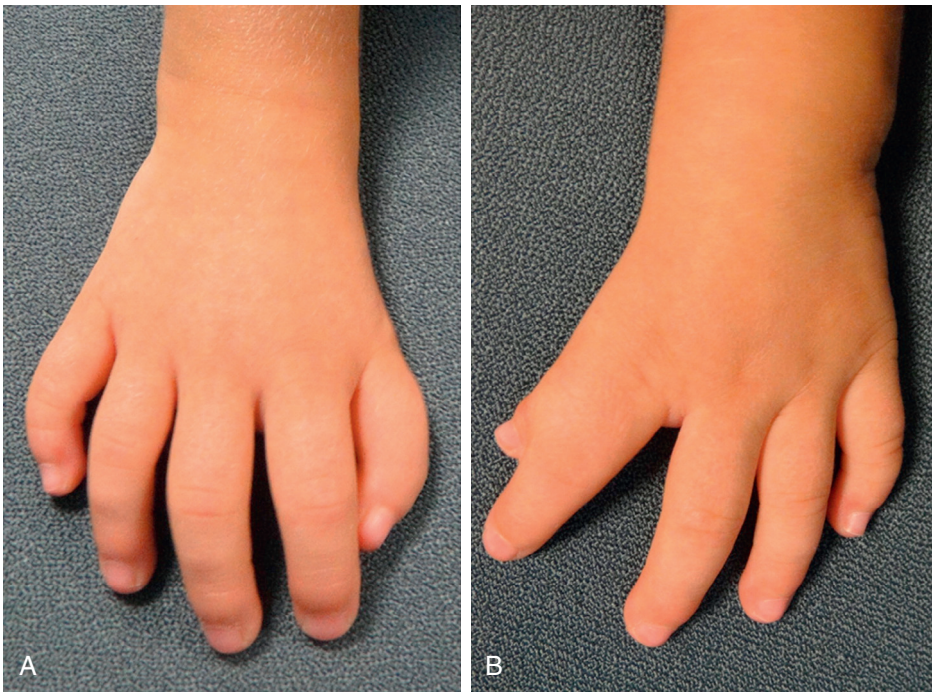

Fig. 132.2 (A) Malformation of the right thumb. (B) Left-sided thumb and index finger syndactyly. *(Reprinted from Chryssostomidisa G, et al. Diversity of congenital cardiac defects and skeletal deformities associated with the Holt–Oram syndrome.* Int J Surg Case Rep *2014;5:389-92.)*

KEY POINTS

- Characterized by skeletal abnormalities of the upper limb, namely thumb abnormalities and cardiac anomalies.
- Holt-Oram syndrome is an autosomal dominant disorder. Most cases are caused by a mutation on the transcription factor gene *TBX5* located on 12q24.1.
- There is a 100% penetrance and variable expressivity.
- Seventy-five percent of individuals with Holt-Oram syndrome have congenital heart disease, which can be life threatening. Most of the cardiac anomalies are septal defects.

SUGGESTED READINGS

Barisic I, Boban L, Greenlees R, et al. Holt Oram syndrome: a registry-based study in Europe. *Orphanet J Rare Dis*. 2014;9:156.

McDermott DA, Fong JC, Basson CT. Holt-Oram Syndrome. In: Pagon RA, Adam MP, Ardinger HH, et al, eds. *GeneReviews*. Seattle (WA): University of Washington, Seattle; 1993.

OMIM Clinical Synopsis - #142900–Holt-Oram Syndrome; Hos. http://www.omim.org/clinicalSynopsis/142900. Accessed 22 June 2016.

Wall LB, Piper SL, Habenicht R, et al. Defining Features of the Upper Extremity in Holt-Oram Syndrome. *J Hand Surg Am*. 2015;40(9):1764-1768.

All references available online at www.expertconsult.com

REFERENCES

1. Holt M, Oram S. Familial heart disease with skeletal malformations. *Br Heart J*. 1960;22:236-242.
2. OMIM Clinical Synopsis - #142900–Holt-Oram Syndrome; Hos. http://www.omim.org/clinicalSynopsis/142900.
3. Virdis G, Dessole M, Dessole S, et al. Holt Oram syndrome: a case report and review of the literature. *Clin Exp Obstet Gynecol*. 2016;43(1):137-139.
4. Tidake A, Gangurde P, Shaikh Z, et al. Tetralogy of Fallot with Holt-Oram syndrome: case report and review. *Clin Res Cardiol*. 2015;104(9):790-793.
5. Baban A, Postma AV, Marini M, et al. Identification of TBX5 mutations in a series of 94 patients with Tetralogy of Fallot. *Am J Med Genet A*. 2014;164A(12):3100-3107.
6. Wall LB, Piper SL, Habenicht R, et al. Defining features of the upper extremity in Holt-Oram syndrome. *J Hand Surg*. 2015;40(9):1764-1768.
7. Barisic I, Boban L, Greenlees R, et al. Holt Oram syndrome: a registry-based study in Europe. *Orphanet J Rare Dis*. 2014;9:156.
8. Elek C, Vitéz M, Czeizel E. Holt-Oram syndrome. *Orv Hetil*. 1991;132(2):73-74, 77-78.
9. Li QY, Newbury-Ecob RA, Terrett JA, et al. Holt-Oram syndrome is caused by mutations in TBX5, a member of the Brachyury (T) gene family. *Nat Genet*. 1997;15(1):21-29.
10. Basson CT, Bachinsky DR, Lin RC, et al. Mutations in human TBX5 cause limb and cardiac malformation in Holt-Oram syndrome. *Nat Genet*. 1997;15(1):30-35.
11. Jhang WK, Lee BH, Kim G-H, et al. Clinical and molecular characterisation of Holt-Oram syndrome focusing on cardiac manifestations. *Cardiol Young*. 2015;25(6):1093-1098.
12. McDermott DA, Bressan MC, He J, et al. TBX5 genetic testing validates strict clinical criteria for Holt-Oram syndrome. *Pediatr Res*. 2005;58(5):981-986.
13. Gruenauer-Kloevekorn C, Froster UG. Holt-Oram syndrome: a new mutation in the TBX5 gene in two unrelated families. *Ann Genet*. 2003;46(1):19-23.
14. Basson CT, Cowley GS, Solomon SD, et al. The clinical and genetic spectrum of the Holt-Oram syndrome (heart-hand syndrome). *N Engl J Med*. 1994;330(13):885-891.
15. Holt-Oram syndrome–Genetics Home Reference. https://ghr.nlm.nih.gov/condition/holt-oram-syndrome#diagnosis. Accessed 22 June 2016.
16. Gray BL, Calfee RP, Dicke JM, et al. The utility of prenatal ultrasound as a screening tool for upper extremity congenital anomalies. *J Hand Surg*. 2013;38(11):2106-2111.
17. Tongsong T, Chanprapaph P. Prenatal sonographic diagnosis of Holt-Oram syndrome. *J Clin Ultrasound*. 2000;28(2):98-100.
18. Brons JT, van Geijn HP, Wladimiroff JW, et al. Prenatal ultrasound diagnosis of the Holt-Oram syndrome. *Prenat Diagn*. 1988;8(3):175-181.
19. Gray BL, Calfee RP, Dicke JM, et al. The utility of prenatal ultrasound as a screening tool for upper extremity congenital anomalies. *J Hand Surg*. 2013;38(11):2106-2111.
20. Sunagawa S, Kikuchi A, Sano Y, et al. Prenatal diagnosis of Holt-Oram syndrome: role of 3-D ultrasonography. *Congenit Anom (Kyoto)*. 2009;49(1):38-41.

133 Meckel-Gruber Syndrome

ADETOLA F. LOUIS-JACQUES | ANTHONY O. ODIBO

Introduction

Meckel-Gruber syndrome, also known as *Meckel syndrome* or *Gruber syndrome,* is a severe ciliopathy. This developmental disorder was first described by Meckel in 1822 and later by Gruber in 1934.[1] The minimum diagnostic criteria are controversial because the clinical manifestations of the syndrome are highly variable.[2–4] The classic triad consists of a central nervous system malformation, typically occipital encephalocele; cystic kidneys; and polydactyly, most commonly postaxial. Fraser et al. reviewed affected siblings of probands, and proposed broadening the diagnostic criteria to include cystic kidney disease plus two or more frequently seen anomalies.[5] Salonen et al. suggested including hepatic abnormalities in the triad instead of polydactyly.[6]

Most affected individuals die *in utero*, or mothers elect for termination of pregnancy.[7] The postnatal mortality is 100% for

individuals who survive to birth,[7,8] with the longest survivor dying at 28 months.[8,9] The major causes of death are pulmonary hypoplasia from oligohydramnios and liver disease.[7]

Twelve genetic mutations are associated with Meckel-Gruber syndrome (designated *MKS1* through *MKS12*).[10,11] There is variable expressivity of the condition within families.[6,12,13] Genotype-phenotype interactions have been noted; for example, polydactyly and encephalocele are commonly identified in individuals with *MKS1* mutations but are rarer in individuals with *MKS3* mutations.[14] In all cases, this disorder has shown autosomal recessive inheritance.

Disorder

DEFINITION

Meckel-Gruber syndrome is considered in an individual with a normal karyotype who has at least two of the three classic features: occipital encephalocele (Figs. 133.1 and 133.2); large, polycystic kidneys (Fig. 133.3); and postaxial polydactyly (Fig. 133.4).[1]

PREVALENCE AND EPIDEMIOLOGY

The prevalence of this disorder is not well established because of its early fatality and similarity to other diseases. The worldwide incidence ranges from 1:1300 in Gujarati Indians[15] to 1:140,000 in England.[16] Although the disease occurs in all ethnic groups, there appear to be certain ethnicities in which this disorder is more common. Barisic et al. in a recent population-based study reported an incidence of 1:38,615 births in Europe.[7] The incidence in Finnish populations is approximately 1:9000.[17] Meckel-Gruber syndrome also is more common in individuals of Belgian, Pakistan, Kuwait, and Israeli-Jewish descent.[18] A higher prevalence has been reported when consanguinity is present.[7] There is no predilection for gender because the male-to-female ratio is equivalent.

ETIOLOGY AND PATHOPHYSIOLOGY

Several genetic loci have been identified in individuals with Meckel-Gruber syndrome.[10] The disorder is caused by dysfunction of primary cilia during embryogenesis.[10] It is believed that heterozygous mutations in the associated genes cause disruption in mediation of ciliary development and epithelial morphogenesis, leading to the multitude of malformations identified in affected individuals.[19,20]

MANIFESTATIONS OF DISEASE

Clinical Presentation

There are various malformations in Meckel-Gruber syndrome. At least two of the following three abnormalities must be identified: occipital encephalocele; large, polycystic kidneys; and postaxial polydactyly. Polycystic kidneys are present in almost all cases (95%–100%). Occipital encephalocele is present in 60%–80% and postaxial polydactyly in 55%–75% of patients.[3,5–7] Hepatic malformations such as portal fibrosis and ductal proliferation are present in 38.5%–100% of cases.[5–7] In addition, many other anomalies have been noted in affected individuals, including the following[3,6,7,10,21]:

- other renal, bladder, and urinary tract malformations
- gastrointestinal disorders
- other central nervous system malformations
  - Dandy-Walker malformation
  - absent corpus callosum
  - anencephaly
- craniofacial defects
  - oral clefts
  - micrognathia



Fig. 133.1 Large occipital encephalocele indicated by calipers.



Fig. 133.2 Large occipital encephalocele.

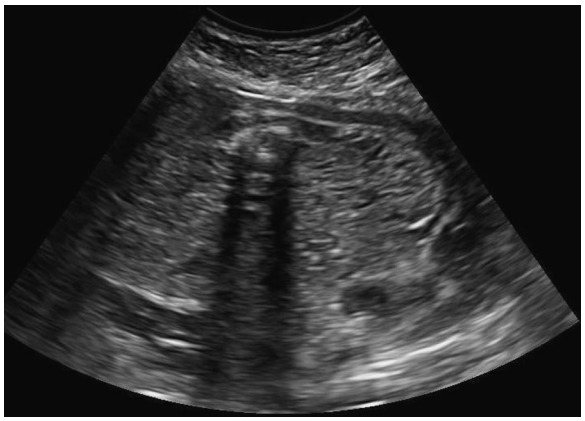

Fig. 133.3 Large, polycystic kidneys.

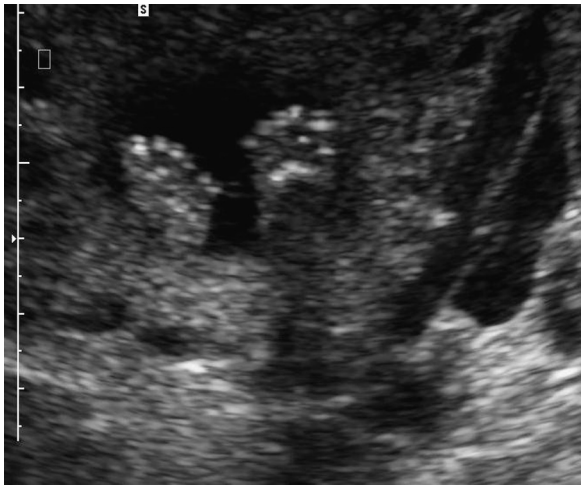

Fig. 133.4 Postaxial polydactyly.

- microcephaly
- sloping forehead

- ophthalmologic abnormalities
  - hypotelorism or hypertelorism
  - iris coloboma
- endocrine defects
  - absent pituitary
  - hypoplastic thyroid
  - absent or small adrenals
- cardiovascular defects
- spleen abnormalities
- abnormal genitalia or gonads
- bowed long bones
- oligohydramnios

Imaging Technique and Findings

Ultrasound. The diagnosis of Meckel-Gruber syndrome is typically made by prenatal ultrasound examination in the first or second trimester.[7,22–26] In particular, occipital encephalocele may be identified at the end of the first trimester.[24] Oligohydramnios is a common finding, especially in fetuses with polycystic kidneys, making visualization of fetal anatomy difficult.

Magnetic Resonance Imaging. Magnetic resonance imaging may be complementary to ultrasound, especially when oligohydramnios limits the scanning resolution.

CLASSIC SIGNS

Occipital encephalocele.
Large, polycystic kidneys.
Postaxial polydactyly.

Differential Diagnosis From Imaging Findings

1. Trisomy 13
2. Bardet-Biedl syndrome
3. Smith-Lemli-Opitz syndrome
4. Joubert syndrome
5. Larsen syndrome
6. Hydrolethalus syndrome
7. Carbohydrate-deficient glycoprotein syndrome
8. Autosomal recessive polycystic kidney disease

Synopsis of Treatment Options

PRENATAL

There is no prenatal treatment available. The presence of anhydramnios or encephalocele requires a discussion about elective pregnancy termination.

POSTNATAL

Palliative care is offered postnatally. Surgical intervention is rare.[8]

WHAT THE REFERRING PHYSICIAN NEEDS TO KNOW

Meckel-Gruber syndrome is a rare, lethal condition and should be suspected in any fetus with two of the following three abnormalities: occipital encephalocele; large, polycystic kidneys; and postaxial polydactyly. Additional anomalies may be noted. Because of the strong similarity to trisomy 13, which is much more common, it is essential that a karyotype be obtained. Chorionic villus sampling or amniocentesis can be performed in the prenatal period. Karyotyping is especially important because the recurrence risk for trisomy 13 is very low, whereas the recurrence risk for Meckel-Gruber syndrome is 25%. In families with a previous child with Meckel-Gruber syndrome, prenatal diagnosis by chorionic villus sampling or amniocentesis is possible if the genetic defect in the previously affected individual has been identified or if typical ultrasound findings are present.

KEY POINTS

1. Meckel-Gruber syndrome is typically characterized by occipital encephalocele; large, polycystic kidneys; and postaxial polydactyly.
2. Twelve genetic mutations are associated with Meckel-Gruber syndrome.
3. In all cases, this disorder has shown autosomal recessive inheritance.
4. Typical second-trimester ultrasound findings include encephalocele, oligohydramnios or anhydramnios, and polycystic kidneys. Diagnosis can be made in the late first trimester.

Acknowledgment

The authors are grateful for the contributions of Rachael Bradshaw in the prior edition.

SUGGESTED READINGS

Alexiev BA, Lin X, Sun CC, et al. Meckel-Gruber syndrome: pathologic manifestations, minimal diagnostic criteria, and differential diagnosis. *Arch Pathol Lab Med*. 2006;130:1236-1238.

Salonen R, Paavola P. Meckel syndrome. *J Med Genet*. 1998;35:497-501.



All references available online at
www.expertconsult.com

REFERENCES

1. Opitz JM, Howe JJ. The Meckel syndrome (dysencephalia splanchnocystica, the Gruber syndrome). *Birth Defects*. 1969;5:167.
2. Wright C, Healicon R, English C, et al. Meckel syndrome: what are the minimum diagnostic criteria? *J Med Genet*. 1994;31:482-485.
3. Hsia YE, Bratu M, Herbordt A. Genetics of the Meckel syndrome (dysencephalia splanchnocystica). *Pediatrics*. 1971;48:237-247.
4. Mecke S, Passarge E. Encephalocele, polycystic kidneys, and polydactyly as an autosomal recessive trait simulating certain other disorders: the Meckel syndrome. *Ann Genet*. 1971;14.
5. Fraser FC, Lytwyn A, Opitz JM. Spectrum of anomalies in the Meckel syndrome, or: "maybe there is a malformation syndrome with at least one constant anomaly". *Am J Med Genet*. 1981;9:67-73.
6. Salonen R, Opitz JM, Reynolds JF. The Meckel syndrome: clinicopathological findings in 67 patients. *Am J Med Genet*. 1984;18:671-689.
7. Barisic I, Boban L, Loane M, et al. Meckel–Gruber Syndrome: a population-based study on prevalence, prenatal diagnosis, clinical features, and survival in Europe. *Eur J Hum Genet*. 2015;23:746-752.
8. Parelkar SV, Kapadnis SP, Sanghvi BV, et al. Meckel-Gruber syndrome: a rare and lethal anomaly with review of literature. *J Pediatr Neurosci*. 2013;8:154.
9. Ramadani HM, Nasrat HA. Prenatal diagnosis of recurrent Meckel syndrome. *Int J Gynaecol Obstet*. 1992;39:327-332.
10. Omim. Meckel syndrome, type 1; MKS1 (vol 2016). http://omim.org/entry/249000.
11. Szymanska K, Hartill VL, Johnson CA. Unraveling the genetics of Joubert and Meckel-Gruber syndromes. *J Pediatr Genet*. 2014;3:65-78.
12. Farag T, Usha R, Uma R, et al. Phenotypic variability in Meckel–Gruber syndrome. *Clin Genet*. 1990;38:176-179.
13. Alexiev BA, Lin X, Sun C-C, et al. Meckel-Gruber syndrome: pathologic manifestations, minimal diagnostic criteria, and differential diagnosis. *Arch Pathol Lab Med*. 2006;130:1236-1238.
14. Consugar MB, Kubly VJ, Lager DJ, et al. Molecular diagnostics of Meckel–Gruber syndrome highlights phenotypic differences between MKS1 and MKS3. *Hum Genet*. 2007;121:591-599.
15. Young ID, Rickett AB, Clarke M. High incidence of Meckel's syndrome in Gujarati Indians. *J Med Genet*. 1985;22:301-304.
16. Seller MJ. Meckel syndrome and the prenatal diagnosis of neural tube defects. *J Med Genet*. 1978;15:462-465.
17. Salonen R, Norio R, Opitz JM, et al. The Meckel syndrome in Finland: epidemiologic and genetic aspects. *Am J Med Genet*. 1984;18:691-698.
18. Lurie IW, Prytkov AN, Meldere LV, et al. Meckel syndrome in different populations. *Am J Med Genet*. 1984;18:661-669.
19. Dawe HR, Smith UM, Cullinane AR, et al. The Meckel–Gruber syndrome proteins MKS1 and meckelin interact and are required for primary cilium formation. *Hum Mol Genet*. 2007;16:173-186.
20. Kyttälä M, Tallila J, Salonen R, et al. MKS1, encoding a component of the flagellar apparatus basal body proteome, is mutated in Meckel syndrome. *Nat Genet*. 2006;38:155-157.
21. Rapola J, Salonen R. Visceral anomalies in the Meckel syndrome. *Teratology*. 1985;31:193-201.
22. Fryns J-P, Vandenberghe K, Van Assche FA, et al. Prenatal diagnosis of Meckel syndrome. *J Genet Hum*. 1980;28:89-94.
23. Ickowicz V, Eurin D, Maugey-Laulom B, et al. Meckel–Grüber syndrome: sonography and pathology. *Ultrasound Obstet Gynecol*. 2006;27:296-300.
24. Pachi A, Giancotti A, Torcia F, et al. Meckel–Gruber syndrome: ultrasonographic diagnosis at 13 weeks' gestational age in an at-risk case. *Prenat Diagn*. 1989;9:187-190.
25. Roy J, Pal M. Meckel Gruber syndrome. *J Clin Diagn Res*. 2013;7:2102.
26. Salonen R, Paavola P. Meckel syndrome. *J Med Genet*. 1998;35:497-501.

134 Neu-Laxova Syndrome

RYAN E. LONGMAN

Introduction

Neu-Laxova syndrome (NLS) is an autosomal recessive, lethal disorder. The syndrome was first described in 1971 by Neu et al.[1] who reported three siblings who were either stillborn or died shortly after birth with microcephaly and multiple congenital anomalies. In 1972 Laxova et al.[2] reported three siblings born to consanguineous parents with similar findings. In 1979 Lazjuk et al.[3] described another case with similar findings and named the disorder. The prognosis for fetuses with NLS is poor because they either are delivered stillborn or die shortly after birth.

Disease

DEFINITION

There are no formal diagnostic criteria for NLS. The diagnosis is based on clinical findings. The most commonly described characteristics are intrauterine growth restriction (IUGR), microcephaly, dysmorphic facies, central nervous system (CNS) malformations, ichthyosis, and limb deformities.[4–14]

PREVALENCE AND EPIDEMIOLOGY

NLS is a rare disorder with less than 100 reported cases.[4,5] There does not appear to be a predilection for the syndrome in certain ethnic backgrounds.[4]

ETIOLOGY AND PATHOPHYSIOLOGY

Until recently, the underlying pathogenesis and genetic etiology of NLS were unknown. Studies have now suggested that the syndrome represents the severe end of the spectrum for serine deficiency disorders. The serine biosynthesis pathway involves three enzymes: phosphoglycerate dehydrogenase, phosphoserine aminotransferase, and phosphoserine phosphatase. These three enzymes work together to convert 3-phospho-D-glycerate to L-serine.[15] Individuals with defects in this pathway have been shown to have varying degrees of microcephaly, psychomotor retardation, severe spastic tetraplegia, nystagmus, intractable seizures, growth restriction, ichthyosis, cortical and subcortical hypotrophy, and abnormal myelination. Multiple studies have now reported cases of NLS with homozygous mutations in the genes responsible for the enzymes of the serine biosynthesis pathway; *PHGDH* (phosphoglycerate dehydrogenase), *PSAT1* (phosphoserine aminotransferase), and *PSPH* (phosphoserine phosphatase).[15–17] Although several NLS cases have been found to have a homozygous mutation in one of these three genes, there are still some cases in which no mutation has been found, suggesting the possible involvement of at least a fourth gene in the syndrome.[15]

MANIFESTATIONS OF DISEASE

Clinical Presentation

The clinical presentation includes craniofacial and other abnormalities (Table 134.1).

Imaging Technique and Findings

Ultrasound. Prenatal ultrasound (US) diagnosis of NLS has been reported at 19 weeks' gestation.[18] The characteristic findings are severe IUGR, polyhydramnios, microcephaly with sloping forehead (Fig. 134.1), exophthalmos, syndactyly,



Fig. 134.1 Ultrasound image of the face of a fetus with NLS, which has a canine appearance. *(From Shivarajan MA, Suresh S, Jagadeesh S, et al. Second trimester diagnosis of Neu-Laxova syndrome.* Prenat Diagn *2003;23:21–24.)*

TABLE 134.1 CLINICAL PRESENTATION OF NEU-LAXOVA SYNDROME

CRANIOFACIAL
Slanted forehead
Hypertelorism
Exophthalmos
Malformed low-set ears
Micrognathia
Wide nasal bridge
Flat nose
Cleft lip/palate
Short neck
Absent eyelids
Hypodontia
Cataract
Prominent occiput (see Fig. 134.1)
CENTRAL NERVOUS SYSTEM
Microcephaly
Lissencephaly
Agenesis of corpus callosum
Hypoplastic cerebellum
Decreased gyri
Neural tube defect
LIMBS
Digit deformities (see Fig. 134.2)
Limb deformities
Flexion contractures
Syndactyly of fingers and toes
Prominence of the calcaneus
OTHER
Intrauterine growth restriction
Short umbilical cord
Polyhydramnios
Subcutaneous edema
Ichthyosis
Pulmonary hypoplasia
Abnormal genitalia
Congenital heart defect

flexion deformities of the limbs, edema of hands and feet (Fig. 134.2), and CNS abnormalities. Cataracts, cystic hygroma, clubbing of the feet, and hypodontia have also been reported.[4,5,12–14,18–26]

Differential Diagnosis From Imaging Findings

1. Chromosomal abnormalities
2. Cornelia de Lange syndrome
3. Freeman-Sheldon syndrome
4. Miller-Dieker syndrome
5. Seckel syndrome
6. Smith-Lemli-Opitz syndrome
7. Lethal multiple pterygium
8. Cerebrooculofacioskeletal syndrome
9. Restrictive dermopathy
10. Harlequin ichthyosis
11. Walker-Warburg syndrome
12. Pena-Shokeir phenotype
13. Cerebroarthrodigital syndrome
14. Roberts syndrome

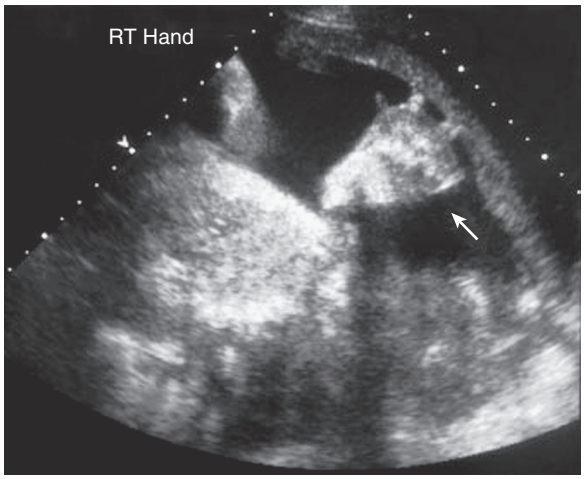

Fig. 134.2 Ultrasound image of the hand of a fetus with NLS. *(From Manning MA, Cunniff CM, Colby CE, et al. Neu-Laxova syndrome: detailed prenatal diagnostic and post-mortem findings and literature review.* Am J Med Genet *2004;125A:240–249.)*

Synopsis of Treatment Options

PRENATAL

Parents that have had a prior child or fetus diagnosed with NLS should be offered carrier testing for the syndrome. If the causative genetic mutation in the prior fetus or child has been identified, each parent should be tested to confirm that they are a carrier. When genetic testing was not performed on the prior affected child or fetus, the parents should be sequenced for all three known genes (*PHGDH*, *PSAT1*, and *PSPH*) responsible for the syndrome to see if they are carriers. If parental carrier status is identified, they should be offered the option of preimplantation genetic diagnosis (PGD) or prenatal genetic diagnosis with chorionic villus sampling or amniocentesis.

Parents at risk of having a fetus with NLS that do not want PGD or prenatal diagnosis should be followed closely with prenatal US scans. The first US scan should be performed at 6 to 8 weeks' gestation for accurate dating, followed by a scan at 12 to 16 weeks' to assess for fetal movement, and then a scan at 16 to 20 weeks' for a detailed fetal anatomic survey. If a fetus at risk for NLS is found to have US findings consistent with the disorder, the patient should be offered the option of fetal diagnostic genetic testing again. When testing is performed, the sample should be sent not only for NLS gene testing, but also for karyotype and chromosomal microarray (CMA) to exclude the possibility of a chromosomal abnormality or microdeletion/duplication syndrome as the possible etiology for the US findings.

If a fetus is noted to have US findings consistent with NLS in the absence of a family history, prenatal diagnostic genetic testing should be offered. In addition to NLS gene testing, karyotype and CMA should also be performed as previously mentioned.

When a diagnosis of NLS is made, the option for termination of pregnancy should be presented to the patient. If the pregnancy is continued, expectant management should be discussed with the parents to avoid unnecessary interventions, such as a cesarean section. Delivery usually occurs near term.[4,13,19,20]



Fig. 134.3 Term fetus with NLS. *(From Manning MA, Cunniff CM, Colby CE, et al. Neu-Laxova syndrome: detailed prenatal diagnostic and post-mortem findings and literature review.* Am J Med Genet *2004;125A:240–249.)*

POSTNATAL

NLS is universally lethal. In most reported cases, the fetus either was stillborn or died shortly after delivery (Fig. 134.3). One infant was reported to live for 134 days.[4]

WHAT THE REFERRING PHYSICIAN NEEDS TO KNOW

NLS is an autosomal recessive lethal disorder characterized by multiple congenital anomalies. Recurrence risk is 25%. Couples that are known carriers should be offered PGD or prenatal genetic diagnosis. Those at-risk couples that are not interested in genetic diagnosis should be followed with serial US scans in the late first trimester and early second trimester to identify affected fetuses.

Patients with fetuses that have findings consistent with NLS should be offered fetal diagnostic genetic testing. If testing is performed, karyotype and CMA should also be sent to exclude chromosomal abnormalities and deletion duplication syndromes.

When a diagnosis of NLS is made, the option for termination of pregnancy should be discussed with the patient. If the patient continues with the pregnancy, the remainder of gestation can be expected to be uneventful, with a term or near-term delivery. Most pregnancies result in stillbirth or neonatal death soon after delivery.

KEY POINTS

- NLS is an autosomal recessive lethal disorder with multiple congenital anomalies. Couples at risk should be offered PGD or prenatal genetic diagnosis. Couples not interested in prenatal genetic diagnosis should be followed with serial US scans in the late first trimester and early second trimester to identify affected fetuses.
- If findings suggestive of NLS are detected on a prenatal US scan in a low-risk fetus, amniocentesis should be offered for diagnostic genetic testing. In addition to NLS gene testing, karyotype and CMA should also be performed.
- Pregnancies with the diagnosis of NLS that are continued usually result in stillbirth or neonatal death soon after delivery.

SUGGESTED READINGS

King JA, Gardner V, Chen H, et al. Neu-Laxova syndrome: pathological evaluation of a fetus and review of the literature. *Pediatr Pathol Lab Med*. 1995;15:57-79.

Manning MA, Cunniff CM, Colby CE, et al. Neu-Laxova syndrome: detailed prenatal diagnostic and post-mortem findings and literature review. *Am J Med Genet*. 2004;125A:240-249.

OMIM Entry %256520: Neu-Laxova syndrome; NLS. www.ncbi.nlm.nih.gov/omim/256520.

Rode ME, Mennuti MT, Giardine RM, et al. Early ultrasound diagnosis of Neu-Laxova syndrome. *Prenat Diagn*. 2001;21:575-580.

All references available online at www.expertconsult.com

REFERENCES

1. Neu RL, Kajii T, Gardner LI, et al. A lethal syndrome of microcephaly with multiple congenital anomalies in three siblings. *Pediatrics*. 1971;47:610-612.
2. Laxova R, Ohara PT, Timothy JA. A further example of a lethal autosomal recessive condition in sibs. *J Ment Defic Res*. 1972;16:139-143.
3. Lazjuk GI, Lurie LW, Ostrowskaja TI, et al. Brief clinical observations: the Neu-Laxova syndrome—a distinct entity. *Am J Med Genet*. 1979;3:261-267.
4. Manning MA, Cunniff CM, Colby CE, et al. Neu-Laxova syndrome: detailed prenatal diagnostic and post-mortem findings and literature review. *Am J Med Genet*. 2004;125A:240-249.
5. Kahyaoglu S, Turgay I, Ertas IE, et al. Neu-Laxova syndrome, grossly appearing normal on 20 weeks ultrasonographic scan that manifested late in pregnancy: a case report. *Arch Gynecol Obstet*. 2007;276:367-370.
6. Opitz JM. Comments on the Neu-Laxova syndrome and CAD complex. *Am J Med Genet*. 1981;9:165-175.
7. Fitch N, Resch L, Rochon L. The Neu-Laxova syndrome: comments on syndrome identification. *Am J Med Genet*. 1982;13:445-452.
8. Curry CJ. Further comments on the Neu-Laxova syndrome. *Am J Med Genet*. 1982;13:441-444.
9. Karimi-Nejad MH, Khajavi H, Gharavi MJ, et al. Neu-Laxova syndrome: report of a case and comments. *Am J Med Genet*. 1987;28:17-23.
10. Ostorovskaya TI, Lazjuk GI. Cerebral abnormalities in the Neu-Laxova syndrome. *Am J Med Genet*. 1988;30:747-756.
11. Manjunath N, Sreenivas V. New manifestations of Neu-Laxova syndrome. *Am J Med Genet*. 1990;35:55-59.
12. Shapiro I, Borochowitz Z, Degani S, et al. Neu-Laxova syndrome: prenatal ultrasonographic diagnosis, clinical and pathological studies, and new manifestations. *Am J Med Genet*. 1992;43:602-605.
13. Sabih D, Khan AN, Sabih Z. Prenatal sonographic diagnosis of Neu-Laxova syndrome. *J Clin Ultrasound*. 2001;29:531-534.
14. Shivarajan MA, Suresh S, Jagadeesh S, et al. Second trimester diagnosis of Neu-Laxova syndrome. *Prenat Diagn*. 2003;23:21-24.
15. Acuna-Hidalgo R, Schanze D, Kariminejad A, et al. Neu-Laxova syndrome is a heterogeneous metabolic disorder caused by defects in enzymes of the L-serine biosynthesis pathway. *Am J Hum Genet*. 2014;95:285-293.
16. Shaheen R, Rahbeeni Z, Alhashem A, et al. Neu-Laxova syndrome, an inborn error of serine metabolism, is caused by mutations in *PHGDH*. *Am J Hum Genet*. 2014;94:898-904.
17. Mattos EP, da Silva AA, Magalhaes JAA, et al. Identification of a premature stop codon mutation in the PHGDH gene in severe Neu-Laxova syndrome-evidence for phenotypic variability. *Am J Med Genet A*. 2015;167A:1323-1329.
18. Driggers RW, Isbister S, McShane SI, et al. Early second trimester prenatal diagnosis of Neu-Laxova syndrome. *Prenat Diagn*. 2002;22:118-120.
19. Muller LM, de Jong G, Mouton SCE, et al. A case of the Neu-Laxova syndrome: prenatal ultrasonographic monitoring in the third trimester and the histopathological findings. *Am J Med Genet*. 1987;26:421-429.
20. Aslan H, Gul A, Polat I, et al. Prenatal diagnosis of Neu-Laxova syndrome: a case report. *BMC Pregnancy Childbirth*. 2002;2:1-4.
21. Mihci E, Simsek M, Mendilcioglu I, et al. Evaluation of a fetus with Neu-Laxova syndrome through prenatal, clinical, and pathological findings. *Fetal Diagn Ther*. 2005;20:167-170.
22. Rode ME, Mennuti MT, Giardine RM, et al. Early ultrasound diagnosis of Neu-Laxova syndrome. *Prenat Diagn*. 2001;21:575-580.
23. Kainer F, Prechtl HFR, Dudenhausen JW, et al. Qualitative analysis of fetal movement patterns in the Neu-Laxova syndrome. *Prenat Diagn*. 1996;16:667-669.
24. Russo R, D'Armiento M, Martinelli P, et al. Neu-Laxova syndrome: pathological, radiological, and prenatal findings in a stillborn female. *Am J Med Genet*. 1989;32:136-139.
25. Gulmezoglu AM, Ekici E. Sonographic diagnosis of Neu-Laxova syndrome. *J Clin Ultrasound*. 1994;22:48-51.
26. Bronshtein M, Blumenfeld I, Cohen I, et al. Fetal ultrasound detection of hypodontia in the Neu-Laxova syndrome. *J Clin Ultrasound*. 1993;21:648-650.

135 Noonan Syndrome

RACHEL G. SINKEY | ANTHONY O. ODIBO

Introduction

Noonan syndrome (NS), first described by Dr. Jacqueline Noonan in 1968,[1] is a disorder characterized by facial dysmorphisms, cardiovascular defects primarily consisting of pulmonary stenosis, short stature, and variable developmental delay. In addition, affected individuals often display pectus excavatum or carinatum, webbed neck, coagulopathies, and ocular anomalies. There is a great deal of variability in disease expression. NS is genetically heterogeneous; in almost all cases, it is autosomal dominant in nature, typically owing to a mutation in one of the known associated genes (*PTPN11, KRAS, SOS1, RAF1, BRAF, SHOC2,*

and *NRAS)*. A rare form of NS is NS 2, which appears to be autosomal recessive in nature.[2]

Disease

DEFINITION

Hallmark features of NS include typical dysmorphisms (hypertelorism, downslanting palpebral fissures, and webbed neck), cardiovascular defects (in 80%), short stature, and pectus excavatum or carinatum. Other features include cognitive delay (30%), coagulopathies (50%), and other anatomic anomalies in varying degrees. In 61% of patients with NS, a mutation in an associated gene can be identified (*PTPN11* in 41% of cases, *KRAS* in 1.4%, *SOS1* in 11.1%, *RAF1* in 5%, *BRAF* in 1%, *SHOC2* in 2%, and *NRAS* in 0.2% of cases).[3]

PREVALENCE AND EPIDEMIOLOGY

NS is estimated to be present in 1:1000 to 1:2500 individuals in the general population.[4] The disorder affects all ethnic groups and occurs equally in males and females.

ETIOLOGY AND PATHOPHYSIOLOGY

Several genes have been identified as causes of NS; nevertheless, the pathophysiology of this condition is not well delineated. Each gene (*PTPN11, KRAS, SOS1, RAF1, BRAF*, *SHOC2*, and *NRAS*) is part of the RAS/RAF/MEK/ERK signal transduction pathway, which is important in cell growth regulation.[5] Somatic mutations of several of these genes have been identified in tumor cells; however, it remains unclear how germline mutations in these genes lead to the wide array of anomalies found in individuals with NS.

MANIFESTATIONS OF DISEASE

Clinical Presentation

NS shares many features with Turner syndrome, and it is important that normal karyotyping be confirmed first in a female in whom the diagnosis of NS is suspected. In addition, the NS phenotype overlaps with many other disorders, including LEOPARD syndrome (which is allelic to NS caused by either *PTPN11* or *RAF1* mutations), cardiofaciocutaneous syndrome (which can also rarely be caused by *KRAS* mutations), neurofibromatosis–NS, and Costello syndrome. Molecular testing may help delineate which of these diagnoses is correct in an individual with features consistent with more than one of these syndromes. There are no set diagnostic criteria for NS; however, the diagnosis can be made in an individual in whom several of the following cardinal features are noted including, but not limited to[6–10]:

- postnatal growth failure
- mild cognitive delay
- cardiovascular defects
  - pulmonary stenosis
  - coarctation of aorta (Fig. 135.1)
  - hypertrophic obstructive cardiomyopathy (Fig. 135.2)[11]
  - abnormal electrocardiogram
- skeletal
  - pectus excavatum or carinatum and/or cubitus valgus
  - fifth finger clinodactyly and/or brachydactyly
  - scoliosis

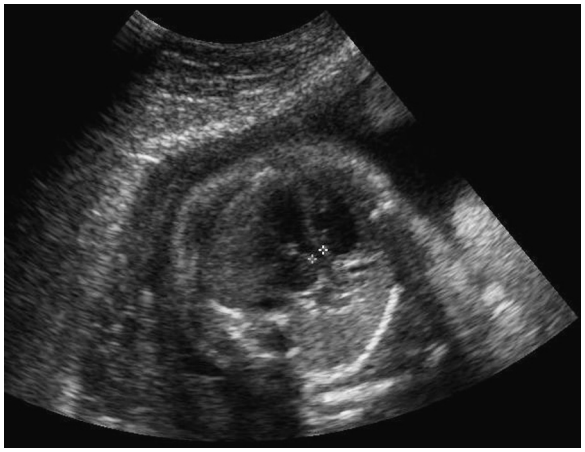

Fig. 135.1 Long-axis view of the left ventricle in a fetus with coarctation of the aorta shows a narrowed aortic root.

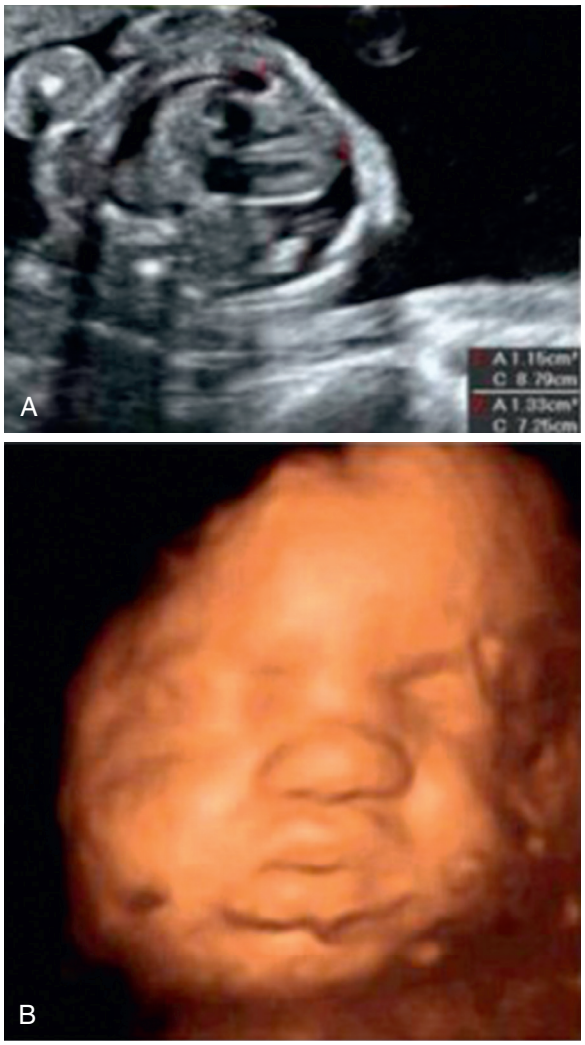

Fig. 135.2 (A) pleural effusion and (B) facial dysmorphism in a fetus with postnatal confirmation of NS. License Number: 3854930403226.

- facial dysmorphisms (see Fig. 135.2)
  - hypertelorism and ptosis with downslanting palpebral fissures
  - epicanthal folds
  - triangular facies
  - low, posteriorly rotated, fleshy ears
  - deeply grooved philtrum, upper lip vermilion border with high peaks
  - micrognathia and other oral manifestations
- neck abnormalities including: webbed neck or cystic hygroma (see Fig. 135.2), broad neck with low posterior hairline
- widely spaced nipples
- prenatal and postnatal lymphedema
- genitourinary (renal anomalies, cryptorchidism in males, and incontinence)
- ocular findings (myopia, blue-green irides)
- ear–nose–throat involvement
  - eustachian tube dysfunction including potential hearing loss
  - speech delay
- woolly hair
- keratoses
- coagulopathies
- myeloproliferative disorder
- malignant schwannoma
- chronic pain
- psychiatric disease

Imaging Technique and Findings

Ultrasound. First-trimester ultrasound (US) performed between 10 weeks and 14 weeks may show evidence of cystic hygroma (Fig. 135.3) or increased nuchal translucency in the presence of normal fetal karyotype.[12] Later in gestation, US may reveal a thickened nuchal fold, polyhydramnios, ascites, pleural effusion (see Fig. 135.2), macrocephaly, shortened long bones, cardiac and/or renal malformations.[13,14] A recent review found 75% of infants with NS had one US abnormality, whereas 25% had two or more abnormal sonographic findings.[15] However, the sonographic findings are often nonspecific and do not predict postnatal phenotype of NS.[16]

Other Applicable Modality. Fetal echocardiography may show right-sided cardiac anomalies such as pulmonary stenosis. Aortic coarctation may also be seen. While hypertrophic cardiomyopathy (HCM) is the second most common cardiac finding in NS, prenatal diagnosis of HCM is infrequent in NS.[17]

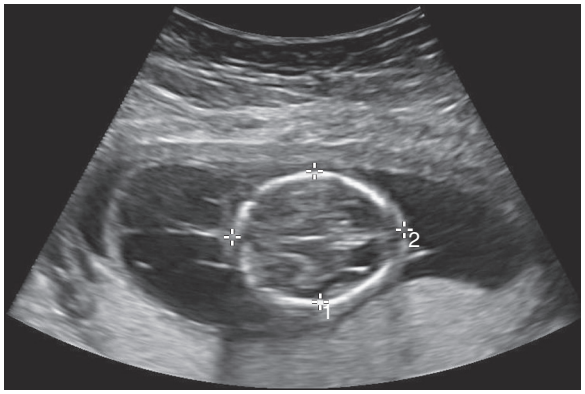

Fig. 135.3 Cystic hygroma. *1*, Right lateral aspect of fetal head; *2*, anterior fetal head.

CLASSIC SIGNS

Cystic hygroma
Pulmonary stenosis

Differential Diagnosis From Imaging Findings

1. Turner syndrome
2. LEOPARD syndrome
3. Cardiofaciocutaneous syndrome
4. Neurofibromatosis type 1
5. Costello syndrome

Synopsis of Treatment Options

PRENATAL

Fetal echocardiography, serial fetal growth assessment, and surveillance for hydrops should be performed. If an affected family member has NS with a known genetic diagnosis, prenatal testing may be offered.

POSTNATAL

Treatment of defects in individuals with NS is typically the same as treatments of those defects in the general population. Traditional surgical intervention for cardiac defects (most commonly pulmonary stenosis [66%] and hypertrophic cardiomyopathy [14%]) is available.[17] Individuals should be monitored for coagulopathies and should generally avoid aspirin.[3] If there is a suspicion of developmental and/or speech delay, an early intervention program should be offered. Growth hormone therapy may be used to increase adult height.[18]

WHAT THE REFERRING PHYSICIAN NEEDS TO KNOW

NS should be suspected prenatally in any fetus with cystic hygroma and normal karyotype, especially if a congenital heart defect is noted (particularly pulmonary stenosis). Because of the overlap between features of NS and other genetic disorders, postnatal physical examination in addition to molecular testing may be necessary for proper diagnosis. In addition, in any individual with suspected NS, the parents should be closely examined for stigmata of this condition, because its presentation is mild enough in some cases to escape detection. Life expectancy among patients with NS and minor cardiac anomalies is normal.[19]

KEY POINTS

- NS is a disorder characterized by specific facial dysmorphisms, cardiovascular defects, short stature, and variable developmental delay.
- NS is genetically heterogeneous; it is mostly inherited in an autosomal dominant manner with complete penetrance and variable expressivity.
- Prenatal sonographic findings do not predict postnatal phenotype of NS.

Acknowledgement

The authors would like to acknowledge the contributions of Rachael Bradshaw to the first edition of this chapter.

SUGGESTED READINGS

Allanson JE, Roberts AE. Noonan syndrome. In: Pagon RA, Adam MP, Ardinger HH, et al, eds. *GeneReviews*. Seattle (WA): University of Washington, Seattle University of Washington, Seattle; 1993.

Roberts AE, Allanson JE, Tartaglia M, et al. Noonan syndrome. *Lancet*. 2013;381(9863):333-342.

Romano AA, Allanson JE, Dahlgren J, et al. Noonan syndrome: clinical features, diagnosis, and management guidelines. *Pediatrics*. 2010;126(4):746-759.



All references available online at www.expertconsult.com

REFERENCES

1. Noonan JA. Hypertelorism with Turner phenotype. A new syndrome with associated congenital heart disease. *Am J Dis Child*. 1968;116(4):373-380.
2. van Der Burgt I, Brunner H. Genetic heterogeneity in Noonan syndrome: evidence for an autosomal recessive form. *Am J Med Genet*. 2000;94(1):46-51.
3. Romano AA, Allanson JE, Dahlgren J, et al. Noonan syndrome: clinical features, diagnosis, and management guidelines. *Pediatrics*. 2010;126(4):746-759.
4. Tartaglia M, Mehler EL, Goldberg R, et al. Mutations in PTPN11, encoding the protein tyrosine phosphatase SHP-2, cause Noonan syndrome. *Nat Genet*. 2001;29(4):465-468.
5. Allanson JE, Roberts AE. Noonan syndrome. In: Pagon RA, Adam MP, Ardinger HH, et al, eds. *GeneReviews*. Seattle (WA: University of Washington, Seattle University of Washington, Seattle; 1993.
6. Roberts AE, Allanson JE, Tartaglia M, et al. Noonan syndrome. *Lancet*. 2013;381(9863):333-342.
7. Mallineni SK, Yung Yiu CK, King NM. Oral manifestations of Noonan syndrome: review of the literature and a report of four cases. *Rom J Morphol Embryol*. 2014;55(4):1503-1509.
8. Niemczyk J, Equit M, Borggrefe-Moussavian S, et al. Incontinence in persons with Noonan Syndrome. *J Pediatr Urol*. 2015;11(4):201.e201-201.e205.
9. Vegunta S, Cotugno R, Williamson A, et al. Chronic pain in Noonan Syndrome: a previously unreported but common symptom. *Am J Med Genet A*. 2015;167(12):2998-3005.
10. Graf H, Brummer D, Abler B. Noonan-syndrome: a considerably prevalent but neglected psychiatric differential diagnosis. *J Neuropsychiatry Clin Neurosci*. 2014;26(3):E30.
11. Gaudineau A, Doray B, Schaefer E, et al. Postnatal phenotype according to prenatal ultrasound features of Noonan syndrome: a retrospective study of 28 cases. *Prenat Diagn*. 2013;33(3):238-241.
12. Gandhi SV, Howarth ES, Krarup KC, et al. Noonan syndrome presenting with transient cystic hygroma. *J Obstet Gynaecol*. 2004;24(2):183-184.
13. Croonen EA, Nillesen WM, Stuurman KE, et al. Prenatal diagnostic testing of the Noonan syndrome genes in fetuses with abnormal ultrasound findings. *Eur J Hum Genet*. 2013;21(9):936-942.
14. Myers A, Bernstein JA, Brennan ML, et al. Perinatal features of the RASopathies: Noonan syndrome, cardiofaciocutaneous syndrome and Costello syndrome. *Am J Med Genet A*. 2014;164a(11):2814-2821.
15. Hakami F, Dillon MW, Lebo M, et al. Retrospective study of prenatal ultrasound findings in newborns with a Noonan spectrum disorder. *Prenat Diagn*. 2016;36:418-423.
16. Baldassarre G, Mussa A, Dotta A, et al. Prenatal features of Noonan syndrome: prevalence and prognostic value. *Prenat Diagn*. 2011;31(10):949-954.
17. Colquitt JL, Noonan JA. Cardiac findings in Noonan syndrome on long-term follow-up. *Congenit Heart Dis*. 2014;9(2):144-150.
18. Noonan JA, Kappelgaard AM. The efficacy and safety of growth hormone therapy in children with noonan syndrome: a review of the evidence. *Horm Res Paediatr*. 2015;83(3):157-166.
19. Araz C, Kaval E, Torgay A, et al. Fatal outcome after renal transplant in a pediatric patient with Noonan syndrome. *Exp Clin Transplant*. 2015;13(suppl 1):273-275.

136 Pentalogy of Cantrell

KATHERINE R. GOETZINGER

Introduction

First described in 1958, pentalogy of Cantrell is a rare syndrome consisting of five anomalies including: (1) a midline supraumbilical abdominal wall defect, (2) a defect in the diaphragmatic pericardium, (3) a defect in the lower sternum, (4) a defect in the anterior diaphragm, and (5) various intracardiac anomalies.[1] In the most severe cases, the heart herniates through the diaphragmatic defect, resulting in ectopia cordis. The association of an omphalocele with ectopia cordis is the hallmark of this syndrome.[2] Multiple variants have been reported, and only a few patients display the complete spectrum of disease. The mortality rate is high; however, survival and prognosis ultimately depend on the type and complexity of the associated defects.[3,4]

Disorder

DEFINITION

The full pentad of the syndrome of pentalogy of Cantrell is rare and consists of the following five defects:

1. deficiency of the anterior diaphragm,
2. defect of the lower sternum,
3. midline supraumbilical abdominal wall defect,
4. defect in the diaphragmatic pericardium,
5. congenital intracardiac abnormality.

In 1972 Toyama suggested an alternative classification system to describe the more common variants of this syndrome[3]:

Class 1: definite diagnosis (all five defects present).

Class 2: probable diagnosis (four defects present, including ventral wall abnormalities and cardiac defects).

Class 3: incomplete expression (various combinations of defects present, including a sternal abnormality).

Skeletal and dermatologic manifestations have also been described in relation to this disorder, leading some to suggest that the term be replaced with hexalogy or heptalogy of Cantrell.[5,6]

PREVALENCE AND EPIDEMIOLOGY

The prevalence of pentalogy of Cantrell has been reported to range from 1:65,000 to 5.5:1 million live births.[7,8] This wide range is secondary to the variation in classification of the syndrome and whether estimates are made using the strictest criteria (class 1) versus more liberal criteria (class 3). A 2:1 male predominance has been reported in some series.[5]

ETIOLOGY, PATHOPHYSIOLOGY, AND EMBRYOLOGY

The etiology and pathogenesis for this syndrome is not well understood and is thought to be of a heterogeneous origin. On an embryologic basis, Cantrell et al.[1] proposed that the association of defects is mesodermal in origin, occurring in the third week of embryonic life. Abnormal migration of splanchnic and somatic mesoderm with premature breakage of the vitelline sac results in a midline defect. Abnormal formation of the transverse septum of the diaphragm occurs because of abnormal migration of myoblasts; premature atrophy of the cardinal vein leads to associated pericardial defects.[1,4,5]

Most reported cases of pentalogy of Cantrell are thought to be sporadic in occurrence; however, mutations in genes located on the X chromosome have been associated with ventral midline disruptions. An X-linked dominant inheritance pattern has been observed in some families.[9,10] In such cases, the ventral midline is viewed as a developmental field, and embryologic disruptions in single genes involved in the development of this field are responsible for the wide range of midline defects.[7,11,12] It is unclear whether pentalogy of Cantrell represents a separate entity as opposed to an extreme end of the spectrum of ventral midline disorders.

A responsible gene for this disorder has not yet been identified; however, a recent case report demonstrated a novel maternally-in herited microduplication of chromosome 15q21.3 on postnatal chromosomal microarray of a newborn with a prenatal diagnosis of pentalogy. This region includes the gene *ALDH1A2*, which encodes for retinaldehyde dehydrogenase type 2, an enzyme with a critical role in normal cardiac and diaphragm development, thereby demonstrating a biologically plausible association with this disorder.[13]

MANIFESTATIONS OF DISEASE

Clinical Presentation

There is tremendous variability in the number and type of defects observed in pentalogy of Cantrell. Common findings include[1,4,14–16]:

- abdominal wall defects (giant omphalocele, diastasis of the rectus muscles),

- anterior diaphragmatic hernia,
- anterior sternal defect with the heart protruding outside of the thoracic cavity,
- displacement of the heart through a diaphragmatic defect (thoracoabdominal ectopia cordis),
- cardiac malformations (ventricular septal defect, atrial septal defect, tetralogy of Fallot, ventricular diverticula, ventricular aneurysm).

Other associated midline defects may include[4,7,17–21]:

- central nervous system malformations (neural tube defects, encephalocele, hydrocephalus),
- craniofacial defects (cleft lip and/or palate, craniorachischisis, exencephaly),
- limb defects (club foot, absence of tibia or radius, hypodactyly),
- abdominal organ defects (intestinal malrotation, polysplenia, gallbladder agenesis).

Reported associated skeletal and dermatologic manifestations include scoliosis, lordosis, and hemivertebrae.[5,6] A strong association with abnormal umbilical cord formation, including short cord with atypical coiling patterns, has also been reported.[22]

Imaging Technique and Findings

Ultrasound. Sonographic diagnosis of pentalogy of Cantrell has been reported as early as 10–12 weeks' gestation.[23,24] Identification of an omphalocele and an ectopia cordis should raise suspicion for the diagnosis of pentalogy of Cantrell (Figs. 136.1–136.3). The sonographic appearance of ectopia cordis is variable but, in its most severe form, can be identified as the fetal heart protruding through a wide sternal cleft outside of the thoracic cavity.[14] In cases where ectopia cordis is not easily identifiable on ultrasound (US), the presence of a transient pericardial or pleural effusion in the setting of an omphalocele may be a marker for a coexisting diaphragmatic or pericardial defect.[1,3,14,15] Increased nuchal translucency and cystic hygroma have also been associated with this syndrome and may serve as additional first-trimester markers.[14,25]

Three-dimensional US can also be used as an adjunct to traditional two-dimensional US to determine the volume and content of the omphalocele, quantify fetal lung volumes, and further evaluate associated craniofacial and skeletal anomalies[5,6,26] (see Fig. 136.2).

Magnetic Resonance Imaging. While prenatal diagnosis of pentalogy of Cantrell primarily relies on the use of ultrasonography, fetal magnetic resonance imaging may provide better delineation of the extent of herniation of thoracic and abdominal organs and may also aid in determining the exact borders of the sternal, diaphragmatic, and abdominal wall defects.[27]

Other Applicable Modality. Fetal echocardiography is essential for evaluation of cardiac malformations associated with the syndrome, such as septal defects, tetralogy of Fallot, and ventricular diverticula/aneurysms.[4,16,27]



Fig. 136.2 Three-dimensional ultrasound image of a fetus with an omphalocele.



Fig. 136.1 Axial view of omphalocele diagnosed on prenatal ultrasound.



Fig. 136.3 Classic constellation of both omphalocele and ectopia cordis in pentalogy of Cantrell.

CLASSIC SIGNS

Omphalocele.
Ectopia cordis.

Differential Diagnosis From Imaging Findings

Differential diagnosis based on sonographic findings may include[14,18]:

- isolated omphalocele
- physiologic midgut herniation
- isolated thoracic ectopia cordis
- amniotic band syndrome
- limb-body stalk abnormality
- thoracoabdominal syndrome
- Beckwith-Wiedemann syndrome

Considering midline defects are often common findings in cases of aneuploidy, chromosomal studies including karyotype and microarray are recommended.[7]

Synopsis of Treatment Options

PRENATAL

Currently, there are no fetal interventions available that can alter the course of the disease or prognosis, and no genetic testing is available to provide definitive prenatal diagnosis. In cases associated with ventricular aneurysm/diverticulum complicated by pericardial effusion, fetal pericardiocentesis has been reported to be a successful *in utero* intervention, although this has only been reported in a small number of cases.[28]

POSTNATAL

Prognosis and survival in patients with pentalogy of Cantrell depends on the extent of the sternal and thoracic defect as well as the severity of the other associated anomalies, particularly intracardiac defects. Prenatal loss is common, and few patients survive the first few days of life.[29] The overall survival rate is estimated at approximately 40%, with even lower rates observed in those patients with the complete pentad of findings.[5,8] For survivors, either a staged or single surgical approach can be undertaken to attempt to repair the cardiovascular, diaphragmatic, and ventral abdominal wall defects. Surgical mortality rates have been reported to be as high as 40%–50%, with early surgical intervention being a risk factor for mortality.[5,29] Conservative intensive care management through the neonatal period with later surgical intervention has become the favored approach when possible.[29]

WHAT THE REFERRING PHYSICIAN NEEDS TO KNOW

Pentalogy of Cantrell is a rare syndrome consisting of ventral midline defects and is likely sporadic in occurrence. Identification of an omphalocele and ectopia cordis on US should prompt a more thorough evaluation for other associated anomalies. Prognosis and survival depends largely on the type, number, and extent of abnormalities. A multidisciplinary team approach is essential for accurate diagnosis as well as prenatal and postnatal care.

KEY POINTS

- Pentalogy of Cantrell is a rare syndrome of ventral midline defects including supraumbilical abdominal wall defects, defects in the diaphragmatic pericardium, defects in the lower sternum, defects in the anterior diaphragm, and various congenital intracardiac anomalies.
- The etiology for this syndrome is not well understood but is thought to occur as a result of early embryologic developmental failure of a segment of the lateral mesoderm.
- Sonographic diagnosis of pentalogy of Cantrell can be made as early as the first trimester, with the hallmark being the identification of an omphalocele in addition to an ectopia cordis.
- A spectrum of cardiac malformations as well as other midline defects can also be associated with this syndrome.
- Overall survival rate is poor and is directly correlated to the type and complexity of the thoracoabdominal defects and any associated intracardiac abnormalities.

SUGGESTED READINGS

Carmi R, Boughman JA. Pentalogy of Cantrell and associated midline anomalies: a possible ventral midline developmental field. *Am J Med Genet*. 1992;42:90-95.
Desselle C, Herve P, Toutain A, et al. Pentalogy of Cantrell: sonographic assessment. *J Clin Ultrasound*. 2007;35:216-220.
Mallula KK, Sosnowski C, Awad S. Spectrum of Cantrell's pentalogy: case series from a single tertiary care center and review of the literature. *Pediatr Cardiol*. 2013;34:1703-1710.
Van Hoorn JHL, Moonen RMJ, Huysentruyt CJR, et al. Pentalogy of Cantrell: two patients and a review to determine prognostic factors for optimal approach. *Eur J Pediatr*. 2008;167:29-35.



All references available online at www.expertconsult.com

REFERENCES

1. Cantrell JR, Haller JA, Ravitch MM. A syndrome of congenital defects involving the abdominal wall, sternum, diaphragm, pericardium, and heart. *Surg Gynecol Obstet*. 1958;107:602-614.
2. Angtuaco TL. Fetal anterior abdominal wall defect. In: Callen PW, ed. *Ultrasonography in Obstetrics and Gynecology*. 5th ed. Philadelphia: WB Sanders; 2008.
3. Toyama WM. Combined congenital defects of the anterior abdominal wall, sternum, diaphragm, pericardium, and heart: a case report and review of the syndrome. *Pediatrics*. 1972;50:778-792.
4. Van Hoorn JHL, Moonen RMJ, Huysentruyt CJR, et al. Pentalogy of Cantrell: two patients and a review to determine prognostic factors for optimal approach. *Eur J Pediatr*. 2008;167:29-35.
5. Mallula KK, Sosnowski C, Awad S. Spectrum of Cantrell's Pentalogy case series from a single tertiary care center and review of the literature. *Pediatr Cardiol*. 2013;34:1703-1710.
6. Gun I, Kurdoglu M, Mungen E, et al. Prenatal diagnosis of vertebral deformities associated with pentalogy of Cantrell: the role of three-dimensional sonography? *J Clin Ultrasound*. 2010;38:446-449.
7. Carmi R, Boughman JA. Pentalogy of Cantrell and associated midline anomalies: a possible ventral midline developmental field. *Am J Med Genet*. 1992;42:90-95.
8. Vazquez-Jiminez JR, Eberhard GM, Daebritz S, et al. Cantrell's syndrome: a challenge to the surgeon. *Ann Thorac Surg*. 1998;65:1178-1185.
9. Carmi R, Barbash A, Mares AJ. The thoracoabdominal syndrome (TAS): a new X-linked dominant disorder. *Am J Med Genet*. 1990;36:109-114.
10. Parvari R, Carmi R, Weissnbach J, et al. Refined genetic mapping of X linked thoracoabdominal syndrome. *Am J Med Genet*. 1996;61:401-402.
11. Optiz JM, Gilbert EF. CNS anomalies and the midline as a "developmental field." *Am J Med Genet*. 1982;12:443-455.
12. Martin RA, Cunniff C, Erickson L, et al. Pentalogy of Cantrell and ectopia cordis, a familial developmental field complex. *Am J Med Genet*. 1992;42:839-841.
13. Steiner MB, Vengoechea J, Collins RT. Duplication of the ALDH1A2 gene in association with pentalogy of Cantrell: a case report. *J Med Case Rep*. 2013;7:287.
14. Desselle C, Herve P, Toutain A, et al. Pentalogy of Cantrell: sonographic assessment. *J Clin Ultrasound*. 2007;35:216-220.
15. Siles C, Boyd PA, Manning N, et al. Omphalocele and pericardial effusion: possible sonographic markers for the pentalogy of Cantrell or variants. *Obstet Gynecol*. 1996;87:840-842.
16. Grethel EJ, Hornberger LK, Farmer DL. Prenatal and postnatal management of a patient with pentalogy of Cantrell and left ventricular aneurysm. *Fetal Diagn Ther*. 2007;22:269-273.
17. Morales JM, Patel SG, Duff JA, et al. Ectopia cordis and other midline defects. *Ann Thorac Surg*. 2000;71:111-114.
18. Polat I, Gul A, Aslan H, et al. Prenatal diagnosis of pentalogy of Cantrell in three cases, two with craniorachischisis. *J Clin Ultrasound*. 2005;33:308-311.
19. Bittmann S, Ulus H, Springer A. Combined pentalogy of Cantrell with tetralogy of Fallot, gallbladder agenesis, and polysplenia: a case report. *J Pediatr Surg*. 2004;39:107-109.
20. Uygur D, Kis S, Sener E. An infant with pentalogy of Cantrell and limb defects diagnosed prenatally. *Clin Dysmorphol*. 2004;13:57-58.
21. Kousseff BG, Jervis GL, Gilbert-Barness E, et al. Pentalogy of Cantrell: detection through fetal board registry and fetal pathology. *Birth Defects*. 1996;30:189-202.
22. Brochut AC, Baumann MU, Kuhn A, et al. Pentalogy of hexalogy of Cantrell? *Pediatr Dev Pathol*. 2011;14:396-401.
23. Liang RI, Huang SE, Chang FM. Prenatal diagnosis of ectopia cordis at 10 weeks of gestation using two-dimensional and three-dimensional ultrasonography. *Ultrasound Obstet Gynecol*. 1997;10:137-139.
24. Sarkar P, Bastin J, Katoch D, et al. Pentalogy of Cantrell: diagnosis in the first trimester. *J Obstet Gynaecol*. 2005;25:812-813.
25. Hsieh YY, Lee CC, Chang CC, et al. Prenatal diagnosis of Cantrell's pentalogy with cystic hygroma in the first trimester. *J Clin Ultrasound*. 1998;26:409-412.
26. Araujo Junior E, Zanforlin Filho SM, Guimaraes Filho HA, et al. Diagnosis of pentalogy of Cantrell by three-dimensional ultrasound in third trimester of pregnancy: a case report. *Fetal Diagn Ther*. 2006;21:544-547.
27. McMahon CJ, Taylor MD, Cassady CI, et al. Diagnosis of pentalogy of Cantrell in the fetus using magnetic resonance imaging and ultrasound. *Pediatr Cardiol*. 2007;28:172-175.
28. McAuliffe FM, Hornberger LK, Johnson J, et al. Cardiac diverticulum with pericardial effusion: report of two new cases treated by in-utero pericardiocentesis and a review of the literature. *Ultrasound Obstet Gynecol*. 2005;25:401-404.
29. Zhang X, Xing Q, Sun J, et al. Surgical treatment and outcomes of pentalogy of Cantrell in eight patients. *J Pediatr Surg*. 2014;49:1335-1340.

137 Pierre Robin Sequence

FALLON R. BREWER | LORIE M. HARPER

Introduction

Pierre Robin sequence (PRS) is a result of hypoplasia of the mandible leading to retrognathia or micrognathia, cleft palate, and posterior displacement of the tongue (glossoptosis).[1,2] The classic cleft palate in PRS is a U-shape.[3,4] Retrognathia and glossoptosis lead to airway obstruction of varying severity, occasionally requiring intubation or tracheostomy for airway management. The PRS may occur in isolation or as part of a syndrome.[5]

Disorder

DEFINITION

PRS is typically defined as a *clinical triad composed of retrognathia (or micrognathia), glossoptosis and cleft palate;* however, cleft palate may be absent in up to 50% of cases.[1,6] Although PRS may occur as part of a syndrome, it is isolated in about 40%–65% of cases.[5,6] The syndromes most commonly associated with PRS are velocardiofacial syndrome and Stickler syndrome.

PREVALENCE AND EPIDEMIOLOGY

The most cited estimated prevalence of PRS is 1:8500, although ranges from 1:2000 to 1:30,000 have been reported.[6] In one case series, the diagnosis was suspected prenatally in only 7% of patients.[7]

ETIOLOGY AND PATHOPHYSIOLOGY

Hypoplasia of the mandible allows the tongue to be posteriorly displaced, thereby interrupting closure of the palate.[4,8] Hypoplasia of the mandible may be caused by mechanical forces such as oligohydramnios,[9] uterine anomalies or, rarely, amniotic bands.[6] Several genetic syndromes have been associated with PRS; the three most common (accounting for 65% of syndromic cases) are Stickler (the most frequent), velocardiofacial, and Treacher Collins.[10]

PRS is more commonly isolated. Much work has been done in the area of identifying the genetic defect(s) associated with PRS. Several chromosomal aberrations have been found in patients with PRS, including 2q duplication,[11] 2q deletion,[12] 4q deletion, 11q deletion,17q deletion, and 18q deletion.[13,14] Genes of interest include *SOX9*, implicated in cartilage differentiation, and collagen *XI* genes.[15,16] However, the precise roll of genetics in development of PRS is unknown currently, and therefore definitive molecular testing for PRS is not available. Teratogenic exposures such as alcohol, methotrexate, valproic acid, and tamoxifen have also been reported in association with PRS.[2,6,17]

MANIFESTATIONS OF DISEASE

Clinical Presentation

The anomalies associated with PRS lead to airway obstruction and feeding difficulties caused by airway obstruction of varying severity.[18,19] Abnormalities of the hyoid bone have been documented and may be associated with more severe feeding abnormalities, even in the absence of severe upper airway obstruction.[20] In nonsyndromic PRS, major cognitive developmental delay has not been demonstrated, although minor developmental delays may be present.[21]

Imaging Technique and Findings

Ultrasound

Micrognathia: has been reported in first trimester[22]; three-dimensional imaging may be useful[23] (Fig. 137.1).

Polyhydramnios: may be seen in as many as 65% of cases.[24]

Cleft palate: although observed in 50% of patients with PRS, may only be diagnosed prenatally in 25%[24] (Figs. 137.2 and 137.3).

Glossoptosis: the tongue is an echogenic structure that should reach the anterior mandibular ridge. In a case report, the tongue could be demonstrated to reach only half way to the anterior mandibular alveolar ridge in the midtrimester[25] (Figs. 137.4 and 137.5).

CLASSIC SIGNS

Micrognathia.
Polyhydramnios.

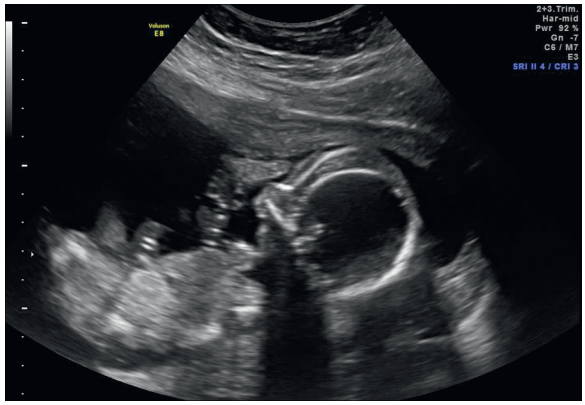

Fig. 137.1 Micrognathia seen on a sagittal view of the fetal face.



Fig. 137.2 Coronal view of fetal face demonstrating a cleft lip.



Fig. 137.3 Three-dimensional image demonstrating a cleft lip.

Differential Diagnosis From Imaging Findings

Amniotic band syndrome
Campomelic dysplasia
Cerebrocostomandibular syndrome
Cerebrooculofacioskeletal syndrome
Cornelia de Lange syndrome
Crouzon syndrome
Ectrodactyly–ectodermal dysplasia–clefting syndrome
Goldenhar syndrome
Marshall syndrome
Meckel-Gruber syndrome
Opitz syndrome
Oral-facial-digital syndrome
Shprintzen syndrome
Smith-Lemli-Opitz syndrome
Stickler syndrome
Treacher Collins syndrome
Van der Woude syndrome
Velocardiofacial syndrome

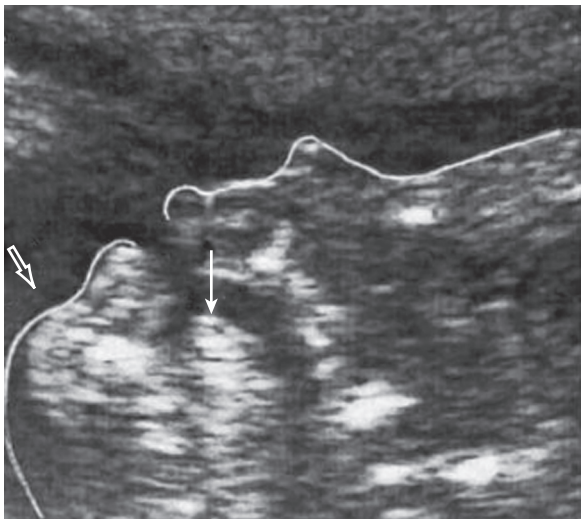

Fig. 137.4 The normal appearance of the fetal tongue. The *open arrow* marks a normal fetal chin, and the *closed arrow* denotes a normal fetal tongue reaching the anterior mandibular alveolar ridge. *(From Bronshtein M, Blazer S, Zalel, et al. Ultrasonographic diagnosis of glossoptosis in fetuses with Pierre Robin sequence in early and mid pregnancy.* Am J Obstet Gynecol *2005;193:1561–4.)*

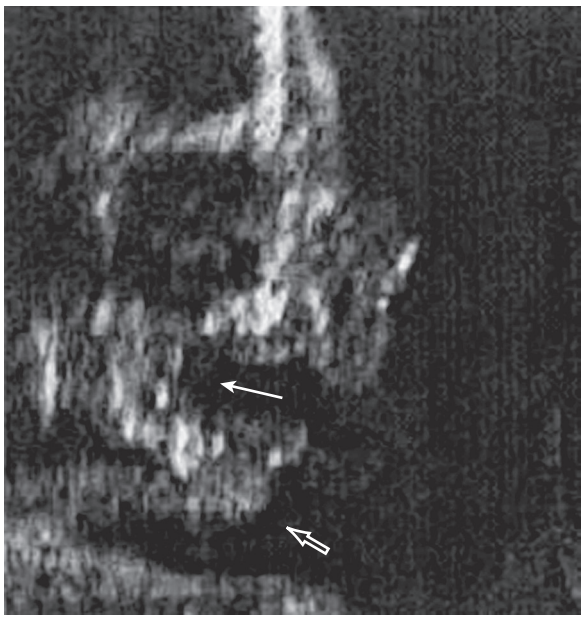

Fig. 137.5 Sagittal view demonstrating micrognathia *(open arrow)* and glossoptosis *(closed arrow). (From Bronshtein M, Blazer S, Zalel, et al. Ultrasonographic diagnosis of glossoptosis in fetuses with Pierre Robin sequence in early and midpregnancy.* Am J Obstet Gynecol *2005;193:1561–4.)*

Synopsis of Treatment Options

PRENATAL

Currently, no prenatal treatment options exist.

POSTNATAL

The core principles of treating PRS depend on airway management and feeding. Mild cases of PRS can be treated with prone

positioning.[18,19] Airway management with intubation or oral and nasopharyngeal airway stenting may be attempted. More refractory cases have been treated with tongue-lip adhesion and tracheostomy.[18,19] Distraction osteogenesis of the mandible has been applied to PRS with good success, obviating the need for tracheostomy in these patients.[26]

Feeding may be accomplished with conservative techniques such as an upright feeding position and nipple modifications. Some infants may require orogastric or nasogastric feeding tubes or gastrostomy tubes.[18]

WHAT THE REFERRING PHYSICIAN NEEDS TO KNOW

While many cases of PRS are not diagnosed prenatally, consideration of the diagnosis on differential is reasonable in the setting of cleft palate and/or micrognathia and polyhydramnios.

Micrognathia/retrognathia and glossoptosis can lead to significant airway obstruction. At delivery, if the diagnosis of PRS is known or strongly suspected, a pediatric or otherwise specialized team should be available for airway management.

KEY POINTS

- Micrognathia and polyhydramnios are frequent findings on ultrasound.
- Cleft palate may be diagnosed prenatally in only 25% of cases.
- The delivery team should be ready for possible significant airway obstruction.
- PRS may occur in isolation or as part of a syndrome; prenatal and postnatal diagnosis should focus on excluding commonly associated syndromes.

SUGGESTED READINGS

Hunt JA, Hobar PC. Common craniofacial anomalies: the facial dysostoses. *Plast Reconstr Surg*. 2002;110(7):1714-1725.

Taylor MR. Consultation with the specialist: the Pierre Robin sequence: a concise review for the practicing pediatrician. *Pediatr Rev*. 2001;22(4):125-130.



All references available online at www.expertconsult.com

REFERENCES

1. Hunt JA, Hobar PC. Common craniofacial anomalies: the facial dysostoses. *Plast Reconstr Surg*. 2002;110(7):1714-1725.
2. Benacerraf BR. *Ultrasound of Fetal Syndromes*. 2nd ed. Philadelphia: Churchill Livingstone, Elsevier; 2008.
3. Printzlau A, Andersen M. Pierre Robin sequence in Denmark: a retrospective population-based epidemiological study. *Cleft Palate Craniofac J*. 2004;41(1):47-52.
4. Schubert J, Jahn H, Berginski M. Experimental aspects of the pathogenesis of Robin sequence. *Cleft Palate Craniofac J*. 2005;42(4):372-376.
5. van den Elzen AP, Semmekrot BA, Bongers EM, et al. Diagnosis and treatment of the Pierre Robin sequence: results of a retrospective clinical study and review of the literature. *Eur J Pediatr*. 2001;160(1):47-53.
6. Taylor MR. Consultation with the specialist: the Pierre Robin sequence: a concise review for the practicing pediatrician. *Pediatr Rev*. 2001;22(4):125-130.
7. Holder-Espinasse M, Abadie V, Cormier-Daire V, et al. Pierre Robin sequence: a series of 117 consecutive cases. *J Pediatr*. 2001;139(4):588-590.
8. Graham JM, Smith DW. *Smith's Recognizable Patterns of Human Deformation*. 3rd ed. Philadelphia: Saunders/Elsevier; 2007.
9. Aggarwal S, Kumar A. Fetal hydrocolpos leading to Pierre Robin sequence: an unreported effect of oligohydramnios sequence. *J Perinatol*. 2003;23(1):76-78.
10. Cote A, Fanous A, Almajed A, et al. Pierre Robin sequence: review of diagnostic and treatment challenges. *Int J Pediatr Otorhinolaryngol*. 2015;79(4):451-464.
11. Ounap K, Ilus T, Laidre P, et al. A new case of 2q duplication supports either a locus for orofacial clefting between markers D2S1897 and D2S2023 or a locus for cleft palate only on chromosome 2q13-q21. *Am J Med Genet A*. 2005;137A(3):323-327.
12. Houdayer C, Portnoi MF, Vialard F, et al. Pierre Robin sequence and interstitial deletion 2q32.3-q33.2. *Am J Med Genet*. 2001;102(3):219-226.
13. Benko S, Fantes JA, Amiel J, et al. Highly conserved non-coding elements on either side of SOX9 associated with Pierre Robin sequence. *Nat Genet*. 2009;41(3):359-364.
14. Gomez-Ospina N, Bernstein JA. Clinical, cytogenetic, and molecular outcomes in a series of 66 patients with Pierre Robin sequence and literature review: 22q11.2 deletion is less common than other chromosomal anomalies. *Am J Med Genet A*. 2016;170(4):870-880.
15. Gordon CT, Tan TY, Benko S, et al. Long-range regulation at the SOX9 locus in development and disease. *J Med Genet*. 2009;46(10):649-656.
16. Melkoniemi M, Koillinen H, Mannikko M, et al. Collagen XI sequence variations in nonsyndromic cleft palate, Robin sequence, and micrognathia. *Eur J Hum Genet*. 2003;11(3):265-270.
17. Berger JC, Clericuzio CL. Pierre Robin sequence associated with first trimester fetal tamoxifen exposure. *Am J Med Genet A*. 2008;146A(16):2141-2144.
18. Evans AK, Rahbar R, Rogers GF, et al. Robin sequence: a retrospective review of 115 patients. *Int J Pediatr Otorhinolaryngol*. 2006;70(6):973-980.
19. Caouette-Laberge L, Bayet B, Larocque Y. The Pierre Robin sequence: review of 125 cases and evolution of treatment modalities. *Plast Reconstr Surg*. 1994;93(5):934-942.
20. El Amm CA, Denny A. Hyoid bone abnormalities in Pierre Robin patients. *J Craniofac Surg*. 2008;19(1):259-263.
21. Drescher FD, Jotzo M, Goelz R, et al. Cognitive and psychosocial development of children with Pierre Robin sequence. *Acta Paediatr*. 2008;97(5):653-656.
22. Teoh M, Meagher S. First-trimester diagnosis of micrognathia as a presentation of Pierre Robin syndrome. *Ultrasound Obstet Gynecol*. 2003;21(6):616-618.
23. Lee W, McNie B, Chaiworapongsa T, et al. Three-dimensional ultrasonographic presentation of micrognathia. *J Ultrasound Med*. 2002;21(7):775-781.
24. Hsieh YY, Chang CC, Tsai HD, et al. The prenatal diagnosis of Pierre-Robin sequence. *Prenat Diagn*. 1999;19(6):567-569.
25. Bronshtein M, Blazer S, Zalel Y, et al. Ultrasonographic diagnosis of glossoptosis in fetuses with Pierre Robin sequence in early and mid pregnancy. *Am J Obstet Gynecol*. 2005;193(4):1561-1564.
26. Fritz MA, Sidman JD. Distraction osteogenesis of the mandible. *Curr Opin Otolaryngol Head Neck Surg*. 2004;12(6):513-518.

138 Poland Sequence

RYAN E. LONGMAN

Introduction

Poland sequence refers to congenital unilateral absence of the sternal costal portion of the pectoralis major muscle and ipsilateral upper limb anomalies.[1] There is no known genetic etiology for Poland sequence. The pathogenesis of this disorder is suggested to be caused by a vascular disruptive sequence. Postpartum management usually consists of surgical correction and rehabilitation therapy for musculoskeletal defects.

Disease

DEFINITION

There are no formal diagnostic criteria for Poland sequence. The diagnosis is based on clinical findings of unilateral absence or hypoplasia of the pectoralis muscle with ipsilateral upper limb anomalies.

PREVALENCE AND EPIDEMIOLOGY

The incidence of Poland sequence is 1:30,000 to 1:90,000.[2–5] The disorder is two to three times more common in males than in females.[5]

ETIOLOGY AND PATHOPHYSIOLOGY

The anomalies seen in Poland sequence are suspected to be caused by a vascular disruptive sequence. Early embryonic disruption of blood supply to the subclavian artery, distal to the origin of the vertebral artery and proximal to the internal thoracic artery, are thought to lead to absence of the pectoralis major muscle and terminal transverse limb defects.[6–9]

There is no known genetic etiology for this disorder. The disorder is generally thought to be sporadic, but familial cases have been described suggesting a possibility of an autosomal dominant inheritance pattern.[10–14] Without a family history of Poland sequence, the recurrence risk has been suggested to be considerably less than 1%.[14]

MANIFESTATIONS OF DISEASE

Clinical Presentation

Poland sequence manifests with unilateral absence or hypoplasia of the pectoralis muscle with ipsilateral upper limb anomalies (Fig. 138.1). The right side of the body is affected in 75% of cases. The upper limb anomalies consist of varying degrees of syndactyly, brachydactyly, and oligodactyly. Occasionally, more significant reduction deficiencies of the long bones of the arm can be present. Other abnormalities that have been seen in Poland sequence are dextrocardia; absence of the pectoralis minor muscle; hypoplasia of the ipsilateral nipple, areola, and breast; hemivertebrae; Sprengel deformity (upward displacement of the scapula); and renal abnormalities.[7,11,15–17] Poland sequence has also been associated with oculo-auriculo-vertebral spectrum and Möbius syndrome.[18,19]

Imaging Technique and Findings

Ultrasound. There is one reported case of a prenatal ultrasound (US) diagnosis of Poland sequence in the literature. US findings were left-sided hypomelia, specifically the clavicle, humerus, ulna,

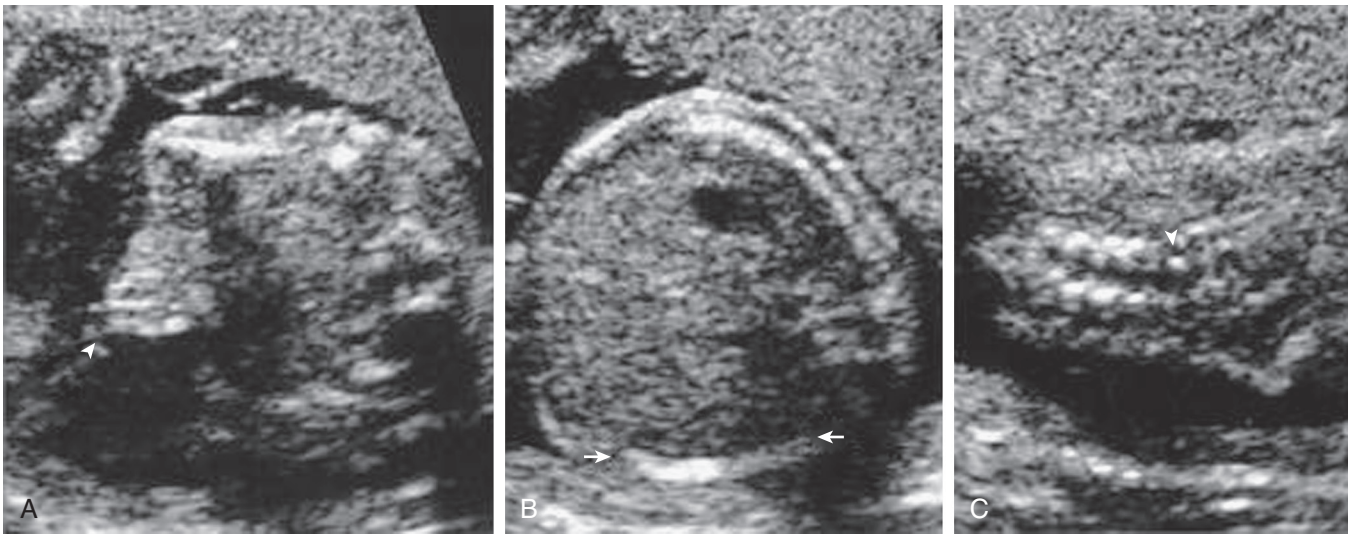

Fig. 138.1 (A) Oblique scan of the chest shows the arm flexed *(arrowhead)* at the elbow without evidence of radial or ulnar ossification. The individual digits cannot be distinguished. (B) Cross-section of the fetal chest shows rib hypoplasia on the right side *(arrows)*. (C) Coronal view shows hemivertebrae *(arrowhead)* of the thoracic spine. *(From Paladini D, D'Armiento MR, Matinelli P. Prenatal ultrasound diagnosis of Poland syndrome.* Obstet Gynecol *2004;104:1156–1159.)*



Fig. 138.2 Three-dimensional ultrasound image shows radial and ulnar dysplasia of the right forearm with absence of the right hand *(arrow). (From Berdel AL, Henrich W. Antenatal sonographic features of Poland syndrome on 2- and 3-dimensional sonography.* J Ultrasound Med *2010;29:679–680.)*

and metacarpals, with absence of the radius. Asymmetry of the rib cage was also noted. The patient elected for termination of pregnancy, and fetal autopsy confirmed the diagnosis.[20]

When prenatal US findings reveal unilateral limb abnormalities and chest asymmetry, a diagnosis of Poland sequence should be considered. Given the suspected pathogenesis of Poland sequence as a vascular disruption, an attempt should be made to assess the ipsilateral subclavian artery with Doppler interrogation. Three-dimensional US should also be used to aid in the characterization of the limb anomaly (Figs. 138.2 and 138.3).[21]

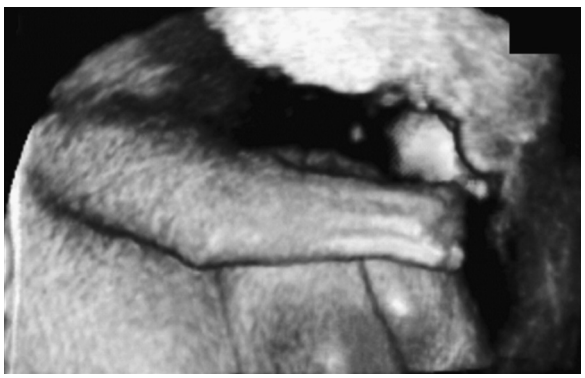

Fig. 138.3 Three-dimensional ultrasound image shows the right upper limb with absence of the right hand. *(From Berdel AL, Henrich W. Antenatal sonographic features of Poland syndrome on 2- and 3-dimensional sonography.* J Ultrasound Med *2010;29:679–680.)*

Differential Diagnosis From Imaging Findings

1. Chromosomal abnormalities
2. CHILD (*c*ongenital *h*emidysplasia with *i*chthyosiform erythroderma and *l*imb *d*efects) syndrome
3. Craniofacial microsomia
4. Ulnar-mammary syndrome
5. Holt-Oram syndrome
6. Levy-Hollister syndrome
7. Fanconi syndrome
8. Aase syndrome

Synopsis of Treatment Options

PRENATAL

Fetuses with suspected Poland sequence should have a detailed fetal anatomic survey to exclude additional anomalies. Patients

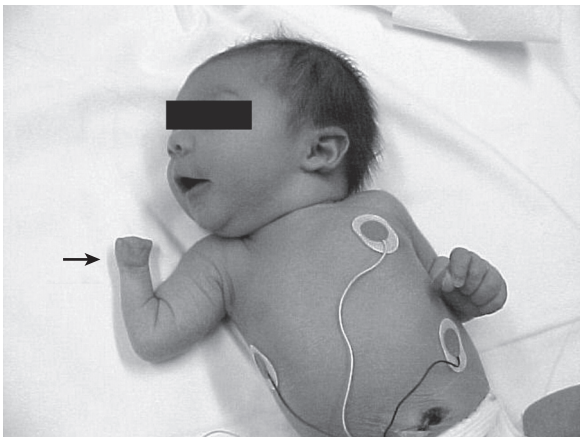

Fig. 138.4 Newborn with Poland sequence shows a right arm deformity *(arrow). (From Berdel AL, Henrich W. Antenatal sonographic features of Poland syndrome on 2- and 3-dimensional sonography.* J Ultrasound Med *2010;29:679–680.)*

should be offered the option of amniocentesis for karyotype and chromosomal microarray (CMA) to exclude chromosomal abnormalities and deletion duplication syndromes. Prenatal genetic diagnosis for Poland sequence is unavailable.

POSTNATAL

The infant should be evaluated by a multidisciplinary team to explore surgical correction and rehabilitation therapy for musculoskeletal defects (Fig. 138.4).

WHAT THE REFERRING PHYSICIAN NEEDS TO KNOW

Poland sequence is characterized by unilateral pectoralis major muscle absence or hypoplasia with ipsilateral upper limb abnormalities. The severity of upper limb involvement can vary. The diagnosis can be suspected based on prenatal US findings but must be confirmed on postnatal examination. Prenatal management consists of a detailed fetal US anatomic survey and the option for amniocentesis with karyotype and CMA analysis to exclude chromosomal abnormalities and deletion duplication syndromes. Postnatal management consists of surgical correction and rehabilitation therapy for musculoskeletal defects.

KEY POINTS

- Poland sequence is characterized by unilateral pectoralis major muscle absence or hypoplasia with ipsilateral upper limb abnormalities.
- The diagnosis can be suspected on prenatal US but must be confirmed on postnatal examination.
- Prenatal management consists of a detailed fetal US anatomic survey with the option of amniocentesis for karyotype and CMA.
- Postnatal management consists of surgical correction and rehabilitation therapy for musculoskeletal defects.

SUGGESTED READINGS

Fraser FC, Teebi AS, Walsh S, et al. Poland sequence with dextrocardia: which comes first? *Am J Med Genet*. 1997;73:194-196.

OMIM Entry %173800: Poland syndrome. www.ncbi.nlm.nih.gov/omim/173800.

All references available online at www.expertconsult.com

REFERENCES

1. Suzuki T, Takazawa H, Koshino T. Computed tomography of the pectoralis muscles in Poland's syndrome. *Hand*. 1983;15:35-41.
2. Freire-Maia N, Chautard EA, Opitz JM, et al. The Poland syndrome—clinical and genealogical data dermatoglyphic analysis and incidence. *Hum Hered*. 1973;23:97-104.
3. Czeizel A, Vitez M, Lenz W. Birth prevalence of Poland sequence and proportion of its familial cases. *Am J Med Genet*. 1990;36:524.
4. McGillivray BC, Lowry RB. Poland syndrome in British Columbia: incidence and reproductive experience of affected persons. *Am J Med Genet*. 1977;1:65-74.
5. Castilla EE, Paz JE, Oriole LM. Pectoralis major muscle defect and Poland complex. *Am J Med Genet*. 1979;4:263-269.
6. Bouwes Bavinck JN, Weaver DD. Subclavian artery supply disruption sequence: hypothesis of a vascular etiology for Poland, Klippel-Feil, and Möbius anomalies. *Am J Med Genet*. 1986;23:903-918.
7. Fraser FC, Teebi AS, Walsh S, et al. Poland sequence with dextrocardia: which comes first? *Am J Med Genet*. 1997;73:194-196.
8. Issaivanan M, Virdi VS, Parmar VR. Subclavian artery supply disruption sequence—Klippel-Feil and Möbius anomalies. *Indian J Pediatr*. 2002;69:441-442.
9. Bouvet JP, Leveque D, Bernetieres F. Vascular origin of Poland syndrome. *Eur J Pediatr*. 1978;128:17-26.
10. Sujansky E, Riccardi VM, Matthew AL. The familial occurrence of Poland syndrome. *Birth Defects Orig Art Ser*. 1977;13:117-121.
11. Cobben JM, Robinson PH, van Essen AJ, et al. Poland anomaly in mother and daughter. *Am J Med Genet*. 1989;33:519-521.
12. Fraser FC, Ronen GM, O'Leary E. Pectoralis major defect and Poland sequence in second cousins: extension of the Poland sequence spectrum. *Am J Med Genet*. 1989;33:468-470.
13. David TJ, Winter RM. Familial absence of the pectoralis major, serratus anterior, and latissimus dorsi muscles. *J Med Genet*. 1985;22:390-392.
14. David TJ. Familial Poland anomaly. *J Med Genet*. 1982;19:293-296.
15. Hegde HR, Shokeir MHK. Posterior shoulder girdle abnormalities with absence of pectoralis major muscle. *Am J Med Genet*. 1982;13:285-293.
16. Der Kaloustian VM, Hoyme HE, Hogg H, et al. Possible common pathogenic mechanisms for Poland sequence and Adams-Oliver syndrome. *Am J Med Genet*. 1991;38:69-73.
17. Jones KL. *Smith's Recognizable Patterns of Human Malformations*. 6th ed. Philadelphia: Saunders; 2006.
18. Chopan M, Sayadi L, Laub D. Mobius syndrome and Poland syndrome presenting together in a single patient. *Eplasty*. 2015;15:ic12.
19. Al-Mazrou KA, Al-Ghonaim YA, Al-Fayez AI. Poland-Mobius syndrome in an infant girl. *Ann Saudi Med*. 2009;6:482-484.
20. Paladini D, D'Armiento MR, Matinelli P. Prenatal ultrasound diagnosis of Poland syndrome. *Obstet Gynecol*. 2004;104:1156-1159.
21. Berdel AL, Henrich W. Antenatal sonographic features of Poland syndrome on 2- and 3-dimensional sonography. *J Ultrasound Med*. 2010;29:679-680.

139 Prune-Belly Syndrome

FALLON R. BREWER | LORIE M. HARPER

Introduction

Prune-belly syndrome (PBS), also known as *Eagle-Barrett syndrome,* is a triad of anomalies composed of abdominal wall flaccidity, urologic abnormalities, and bilateral cryptorchidism.[1–4] The typical urologic findings are distended bladder, hydronephrosis, and renal dysplasia. A patent urachus is a common finding. In some infants, urinary obstruction may lead to oligohydramnios or anhydramnios with a resulting Potter sequence (pulmonary hypoplasia, dysmorphic facies). Concomitant cardiac, orthopedic, and gastrointestinal anomalies are frequent and are reported in approximately 75% of PBS cases.[1,5]

Disorder

DEFINITION

PBS is characterized by urologic abnormalities, dysplasia, or flaccidity of the abdominal wall musculature, and bilateral cryptorchidism (in males). The poorly developed abdominal wall results in a wrinkled appearance of the infant's abdomen, giving the syndrome its name.

PREVALENCE AND EPIDEMIOLOGY

The reported incidence ranges from 1:29,000 to 1:50,000 live births with a significant male preponderance; 95% of cases occur in males.[1,3,6,7] The syndrome is twice as common in blacks compared to whites.[8] Also the incidence in twins has been reported to be four times higher than in singletons.[8] An apparent increase in incidence of PBS in children of younger mothers has also been observed.[9]

ETIOLOGY AND PATHOPHYSIOLOGY

Two theories exist as to the etiology of PBS. The first suggests that the sequence is initiated by an obstructive uropathy. This theory posits that a primary urinary tract obstruction leads to

distention of the bladder, prohibiting formation of the anterior abdominal wall muscles and descent of the testis.[1,6] The resulting oligohydramnios then results in a Potter sequence, leading to contractures and pulmonary hypoplasia. However, this theory does not fully explain the associated cardiac and gastrointestinal defects associated with PBS; furthermore, it does not explain why some urinary tract obstructions, such as posterior urethral valves, do not lead to the spectrum of findings found in PBS. Last, most infants born with PBS do not actually have a urinary tract obstruction.

The second theory focuses on embryogenesis; an aberration of mesenchymal development between the sixth and 10th weeks of gestation could lead to the spectrum of findings in PBS.[1,10] A mesenchymal defect in the sixth to seventh week could explain not only the typical triad of findings, but also the commonly found orthopedic and gastrointestinal findings.[1,11–13]

The male preponderance has suggested an X-linked recessive or perhaps a sex-influenced autosomal recessive mode of inheritance.[14] A few case reports exist of PBS in association with a trisomy or a chromosomal deletion, but the loci of the abnormality is inconsistent across these reports.[15–17] At this time, no chromosomal abnormality has been linked definitively to PBS. However, an abnormality of hepatocyte nuclear factor 1β (HNF1β), which is expressed on chromosome 17, has been demonstrated in patients with sporadic PBS.[17,18] This transcription factor is found on numerous tissues in the body including mesonephric duct derivatives, renal tubules of the metanephros, and the developing prostate. Other potential genetic factors have been suggested including hypomethylation on chromosome 6q24 and 11p15[18] and *ACTG2* mutations, which encodes for enteric actin.[19]

The risk of recurrence of PBS is considered low[5]; however, considering the genetic factors/influences of PBS are not well understood, this may change as technology/genetic testing options improve.

MANIFESTATIONS OF DISEASE

Clinical Presentation

Abdominal Wall. The defect in the development of the abdominal wall musculature gives the infant's abdomen a wrinkled, prune-like appearance. In severe defects, the muscle may be completely absent ventral to the midaxillary line.[3]

Urogenital System. Distention of the bladder leads to thickening of the bladder wall, displacement of the ureteral orifices laterally, and vesicoureteric reflux. Urinary obstruction is present in approximately 25% of infants, and most infants demonstrate urinary retention, in part caused by defects in the abdominal wall musculature.[3] Imaging of the upper urinary tract is necessary: hydronephrosis is a common finding, and polycystic kidneys, renal atrophy, and renal agenesis have all been documented.[10,15]

A patent urachus is present in 20%–50% of cases.[10] This can be diagnosed on physical exam by noting the presence of a clear discharge from the umbilical cord; specific gravity can be done on the liquid to confirm that it is urine.[1] The significance of this finding is unclear; some have suggested that a patent urachus is associated with an increased mortality rate, whereas others have suggested that a patent urachus may allow urinary drainage *in utero*, thereby preventing oligohydramnios and pulmonary hypoplasia.[10,20]

Bilateral cryptorchidism is present in affected males, possibly caused by interruption of testicular descent by a distended bladder. In most cases both testes are present intraabdominally and viable.[3] Affected females are rare, but may present as pseudohermaphrodites with an abnormally located urethral meatus, fused labia, and clitoral hypertrophy.[1]

Pulmonary System. Oligohydramnios *in utero* frequently leads to pulmonary hypoplasia. The degree of pulmonary hypoplasia varies and typically determines outcomes in these infants. In addition, recurrent pulmonary infections occur, likely caused by impaired ventilation as a result of abdominal wall laxity.[13]

Cardiovascular System. The incidence of cardiovascular anomalies has been estimated at 10%.[10] Anomalies described include patent foramen ovale, atrial and ventricular septal defects, and tetralogy of Fallot.[3]

Gastrointestinal System. Anomalies in the gastrointestinal system seem to affect approximately 30% of infants with PBS.[13] Commonly reported findings include malrotation, mesenteric anomalies, atresia (particularly colonic atresia), fistula, imperforate anus, and diverticula.[13]

Musculoskeletal System. Abnormalities of the musculoskeletal system have been reported in up to 63% of patients.[11] This may be a consequence of a mesenchymal insult during embryogenesis or a result of oligohydramnios, as in Potter sequence.[1,11,12] Common findings include congenital hip dysplasia, scoliosis, club foot, torticollis, and contractures.

Prognosis. PBS can be classified into three prognostic groups.[7,10] The first group comprises 20% of cases; these infants are typically stillborn or die shortly after birth because of significant pulmonary hypoplasia and renal dysplasia. Infants in group 2, representing 40% of cases, have adequate renal function at birth but require intervention; without intervention, one-third of these patients will die from renal failure or sepsis. Patients in group 3, making up the remaining 40% of cases, have mild urinary tract abnormalities and most will survive.

Imaging Technique and Findings

Ultrasound. The earliest time of diagnosis of PBS reported in the literature was made in the 12th week of gestation.[20] The most frequent ultrasound finding in cases of PBS is a distended bladder (Figs. 139.1 and 139.2). This may be accompanied by hydronephrosis, dysplastic kidneys, or unilateral renal

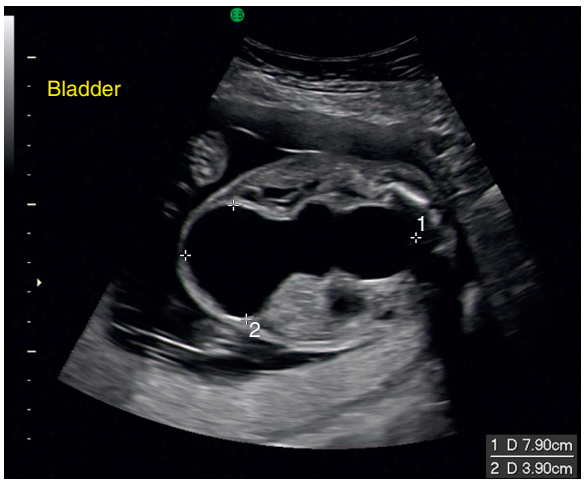

Fig. 139.1 Transverse view of the abdomen demonstrates an enlarged bladder.

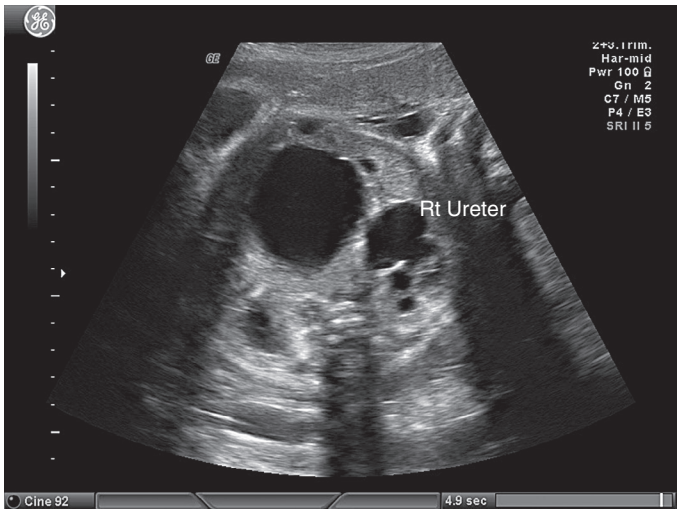

Fig. 139.2 Hydronephrosis and hydroureter may be seen in association with enlarged bladder. *Rt,* Right.

agenesis.[6,15,20,21] Oligohydramnios is a frequent finding. Cryptorchidism can be detected prenatally; however, this diagnosis should not occur before 25 weeks as testicular descent is not observed until after 25 weeks; 97% of normal males will have bilateral testicular descent at 32 weeks.[22] Cardiac and musculoskeletal anomalies may be seen, but oligohydramnios may limit the examination of these and other structures.

Differential Diagnosis From Imaging Findings

Megacystis
Megacystis-microcolon-intestinal hypoperistalsis syndrome
Neurogenic bladder
Posterior urethral valves

Synopsis of Treatment Options

PRENATAL

The mainstay of prenatal treatment is a vesicoamniotic shunt in cases of lower urinary tract obstruction, which alleviates the urinary distention and oligohydramnios, interrupting sequence of renal dysplasia, and pulmonary hypoplasia.[1,23] Candidates for intervention are those with distended urinary bladder and oligohydramnios. Serial vesicocenteses to determine renal function based on urinary electrolytes are performed to ensure good fetal candidates are selected for shunt procedures (Chapters 111 and 116). A double pigtail catheter is positioned in the bladder to drain into the amniotic space. In a study of 18 women and their fetuses who underwent the procedure (including all obstructive uropathies), the one-year survival rate was 91%.[23] Approximately one-half of infants had normal pulmonary, renal, and musculoskeletal function.

POSTNATAL

Postnatal management first must focus on the respiratory status of the infant with possible pulmonary hypoplasia. Urinary drainage, assessment of renal function, and management of fluid and electrolytes is necessary. Surgical interventions occur at a mean of 23 months and focus on urinary tract reconstructive surgery and abdominoplasty.[7] Orchiopexy should be performed. Associated cardiac, gastrointestinal, and orthopedic anomalies should be evaluated and corrected in the usual fashion.

Long term, 25%–30% of patients experience chronic and end-stage renal failure, requiring dialysis or renal transplantation.[1,3]

WHAT THE REFERRING PHYSICIAN NEEDS TO KNOW

In patients with a prenatal diagnosis of distended bladder and oligohydramnios, prenatal interventions may exist and the opportunity to perform them is time-sensitive. Referral should be made promptly for prenatal evaluation of renal function and possible vesicoamniotic shunt placement.

KEY POINTS

- PBS is a triad of dysplastic abdominal wall musculature, urologic abnormalities, and bilateral cryptorchidism.
- Male infants are affected in 95% of cases.
- Prenatal interventions (vesicoamniotic shunt) exist and may improve postnatal survival and function.
- Inheritance pattern has not been determined.

SUGGESTED READINGS

Grimsby GM, Harrison SM, Granberg CF, et al. Impact and frequency of extra-genitourinary manifestations of prune belly syndrome. *J Pediatr Urol.* 2015;11(5):280.e1-280.e6.

Hassett S, Smith GH, Holland AJ. Prune belly syndrome. *Pediatr Surg Int.* 2012;28(3):219-228.

Lopes RI, Tavares A, Srougi M, et al. 27 years of experience with the comprehensive surgical treatment of prune belly syndrome. *J Pediatr Urol.* 2015;11(5):276.e1-276.e7.

Woods AG, Brandon DH. Prune belly syndrome. A focused physical assessment. *Adv Neonatal Care.* 2007;7(3):132-143, quiz 144-135.

All references available online at www.expertconsult.com

REFERENCES

1. Woods AG, Brandon DH. Prune belly syndrome. A focused physical assessment. *Adv Neonatal Care*. 2007;7(3):132-143, quiz 144-135.
2. Yiee J, Wilcox D. Abnormalities of the fetal bladder. *Semin Fetal Neonat Med*. 2008;13(3):164-170.
3. Strand WR. Initial management of complex pediatric disorders: prune belly syndrome, posterior urethral valves. *Urol Clin North Am*. 2004;31(3):399-415.
4. Campbell MF, Wein AJ, Kavoussi LR. *Campbell-Walsh urology*. 9th ed. Philadelphia: W.B. Saunders; 2007.
5. Papantoniou N, Papoutsis D, Daskalakis G, et al. Prenatal diagnosis of prune-belly syndrome at 13 weeks of gestation: case report and review of literature. *J Matern Fetal Neonatal Med*. 2010;23(10):1263-1267.
6. Herman TE, Siegel MJ. Prune belly syndrome. *J Perinatol*. 2009;29(1):69-71.
7. Denes FT, Arap MA, Giron AM, et al. Comprehensive surgical treatment of prune belly syndrome: 17 years' experience with 32 patients. *Urology*. 2004;64(4):789-793, discussion 793-784.
8. Balaji KC, Patil A, Townes PL, et al. Concordant prune belly syndrome in monozygotic twins. *Urology*. 2000;55(6):949.
9. Druschel CM. A descriptive study of prune belly in New York State, 1983 to 1989. *Arch Pediatr Adolesc Med*. 1995;149(1):70-76.
10. Adebonojo FO. Dysplasia of the anterior abdominal musculature with multiple congenital anomalies. Prune belly or triad syndrome. *J Natl Med Assoc*. 1973;65(4):327-333.
11. Loder RT, Guiboux JP, Bloom DA, et al. Musculoskeletal aspects of prune-belly syndrome. Description and pathogenesis. *Am J Dis Child*. 1992;146(10):1224-1229.
12. Brinker MR, Palutsis RS, Sarwark JF. The orthopaedic manifestations of prune-belly (Eagle-Barrett) syndrome. *J Bone Joint Surg*. 1995;77(2):251-257.
13. Wright JR Jr, Barth RF, Neff JC, et al. Gastrointestinal malformations associated with prune belly syndrome: three cases and a review of the literature. *Pediatr Pathol*. 1986;5(3-4):421-448.
14. Ramasamy R, Haviland M, Woodard JR, et al. Patterns of inheritance in familial prune belly syndrome. *Urology*. 2005;65(6):1227.
15. Chen L, Cai A, Wang X, et al. Two- and three-dimensional prenatal sonographic diagnosis of prune-belly syndrome. *J Clin Ultrasound*. 2010;38(5):279-282.
16. Fryns JP, Vandenberghe K, Van den Berghe H. Prune-belly anomaly and large interstitial deletion of the long arm of chromosome 6. *Ann Genet*. 1991;34(2):127.
17. Hassett S, Smith GH, Holland AJ. Prune belly syndrome. *Pediatr Surg Int*. 2012;28(3):219-228.
18. Tonni G, Ida V, Alessandro V, et al. Prune-belly syndrome: case series and review of the literature regarding early prenatal diagnosis, epidemiology, genetic factors, treatment, and prognosis. *Fetal Pediatr Pathol*. 2013;31(1):13-24.
19. Wangler MF, Gonzaga-Jauregui C, Gambin T, et al. Heterozygous de novo and inherited mutations in the smooth muscle actin (ACTG2) gene underlie megacystis-microcolon-intestinal hypoperistalsis syndrome. *PLoS Genet*. 2014;10(3):e1004258.
20. Hoshino T, Ihara Y, Shirane H, et al. Prenatal diagnosis of prune belly syndrome at 12 weeks of pregnancy: case report and review of the literature. *Ultrasound Obstet Gynecol*. 1998;12(5):362-366.
21. Benacerraf BR. *Ultrasound of fetal syndromes*. 2nd ed. Philadelphia: Churchill Livingstone/Elsevier; 2008.
22. Maymon R, Schneider D, Hegesh J, et al. Antenatal sonographic findings of right pulmonary agenesis with ipsilateral microtia: a possible new laterality association. *Prenat Diagn*. 2001;21(2):125-128.
23. Biard JM, Johnson MP, Carr MC, et al. Long-term outcomes in children treated by prenatal vesicoamniotic shunting for lower urinary tract obstruction. *Obstet Gynecol*. 2005;106(3):503-508.

140 Roberts Syndrome

METHODIUS G. TUULI | ANTHONY O. ODIBO

Introduction

Roberts syndrome, also known as *Roberts-SC phocomelia syndrome* or *pseudothalidomide syndrome,* is a rare genetic disorder characterized by prenatal growth restriction, limb reductions, and craniofacial abnormalities.[1] The upper extremities are more severely affected than the lower extremities, with common limb abnormalities including bilateral symmetric tetraphocomelia or hypomelia. Other limb malformations, such as oligodactyly, syndactyly (Fig. 140.1), clinodactyly, and elbow and knee flexion contractures, may also be seen. Craniofacial abnormalities include cleft lip/palate, premaxillary protrusion, micrognathia, malar hypoplasia, slanting palpebral fissures, ocular hypertelorism, exophthalmos, corneal clouding, nasal alae hypoplasia, beaked nose, and ear malformations.[2]

Definition

Based on a cohort of 49 patients with confirmed diagnosis by genetic analysis, Vega et al.[3] established the clinical criteria for the diagnosis of Roberts syndrome as growth restriction, symmetric mesomelic shortening of the limbs with upper limbs more commonly and severely affected than lower limbs, and characteristic facies with microcephaly.



Fig. 140.1 Soft tissue syndactyly. Ultrasound image of a fetus at 18 weeks' gestation shows soft tissue syndactyly of the fourth and fifth fingers, which remained linked throughout the ultrasound examination, whereas the other fingers moved independently. *(From Rypens F, Dubois J, Garel L, et al. Obstetric US: watch the fetal hands.* Radiographics *2006;26:811–829.)*

PREVALENCE AND EPIDEMIOLOGY

Roberts syndrome is a rare disorder with no accurate estimates of prevalence. Fewer than 200 individuals of diverse racial and ethnic backgrounds have been reported in the literature.[2] Parental consanguinity is common in affected cases.

ETIOLOGY AND PATHOPHYSIOLOGY

Roberts syndrome is caused by mutations in the *e*stablishment of the *co*hesion 1 homologue 2 *(ESCO2)* gene located on chromosome 8.[4] *ESCO2* is the only known gene with mutations associated with Roberts syndrome, and all individuals with cytogenetically diagnosed Roberts syndrome have had mutations in this gene.[4] This gene encodes a protein belonging to the Eco1 family of acetyltransferases that is involved in sister chromatid cohesion during the S phase and postreplicative sister chromatid cohesion. Mutations in the gene result in loss of *ESCO2* acetyltransferase activity.[5,6] This loss of function manifests as premature centromere separation or separation of the heterochromatic regions in most metaphase chromosomes.[7] This separation is seen in standard cytogenetic preparations stained with Giemsa or C-banding techniques (Fig. 140.2). As a result, cell division is slow, and daughter cells are typically aneuploid, leading to the malformations associated with Roberts syndrome.[8] It is transmitted in an autosomal recessive pattern.

MANIFESTATIONS OF DISEASE

Clinical Presentation

Roberts syndrome is suspected prenatally in fetuses with growth restriction, limb malformations, and craniofacial abnormalities. Diagnosis is made from cytogenetic testing of individuals with suggestive clinical findings. The presence of premature centromere separation establishes the diagnosis. However, one negative cytogenetic analysis does not exclude Roberts syndrome; a second analysis using a different type of fetal tissue is required. There is a wide clinical variability among affected individuals, and prognosis generally depends on the malformations present. Mortality rates are high among severely affected fetuses and newborns.

Imaging Technique and Findings

Ultrasound. Ultrasound examination is used to estimate growth and evaluate the limbs, heart, palate, and other organs or structures affected in Roberts syndrome discussed earlier.[9]

Other Applicable Modality. Fetal echocardiography may be needed to assess for structural heart defects. Postnatal



Fig. 140.2 C-banding of metaphase chromosomes. *Arrows* show selected chromosomes with premature centromere separation. *Closed arrowhead* points to "splitting" of the Y chromosome heterochromatic region. *Open arrowheads* show selected chromosomes with normal C-banded regions. *(From Vega H, Waisfisz Q, Gordillo M, et al. Roberts syndrome is caused by mutations in ESCO2, a human homolog of yeast ECO1 that is essential for the establishment of sister chromatid cohesion.* Nat Genet *2005;37:468–470.)*

x-rays of affected individuals reveal the characteristic skeletal anomalies.

Differential Diagnosis From Imaging Findings

The differential diagnosis of Roberts syndrome depends on the severity of the manifestations, and includes[2]:

1. mild malformations: Baller-Gerold syndrome, Fanconi anemia;
2. severe malformations: thrombocytopenia–absent radius syndrome, tetra-amelia (X-linked or autosomal recessive), splenogonadal fusion with limb defects and micrognathia, DK phocomelia syndrome, Holt-Oram syndrome, thalidomide embryopathy;
3. cytogenetic findings of Roberts syndrome: Cornelia de Lange syndrome, mosaic variegated aneuploidy syndrome.

Synopsis of Treatment Options

PRENATAL

Genetic counseling should be offered to patients carrying fetuses with suspected Roberts syndrome. Prenatal diagnosis for pregnancies at increased risk is possible by analysis of deoxyribonucleic acid extracted from fetal cells obtained by chorionic villus sampling or amniocentesis. Termination of pregnancy may be offered when the diagnosis is made before viability. Standard obstetric management is provided for continuing pregnancies.

POSTNATAL

Postnatal treatment is tailored to the affected individual's specific needs.[10] Treatment options include surgical reconstructive procedures for cleft lip/palate and limb abnormalities, prostheses, speech therapy, and standard treatment for specific cardiac defects.

WHAT THE REFERRING PHYSICIAN NEEDS TO KNOW

Roberts syndrome is a rare genetic disorder characterized by prenatal growth restriction and limb malformations. Upper limbs are more severely affected than lower limbs. The diagnosis is made from cytogenetic testing of individuals with suggestive clinical findings. There is wide variability in the phenotype among affected individuals, and prognosis depends on the malformations present.

KEY POINTS

- Roberts syndrome is a rare genetic disorder caused by mutations in the *ESCO2* gene.
- Clinical diagnostic criteria include growth restriction, symmetric mesomelic shortening of the limbs, and characteristic facies with microcephaly. Upper limbs are more commonly and severely affected than lower limbs.
- Diagnosis is made from cytogenetic testing of individuals with suggestive clinical findings.
- There is a wide clinical variability among affected individuals, and prognosis generally depends on the malformations present.

SUGGESTED READINGS

Gordillo M, Vega H, Jabs EW. In: Pagon RA, Bird TC, Dolan CR, eds. *GeneReviews*. Seattle: University of Washington; 1993-2006.

Petrikovsky BM, Gross B, Bailer M, et al. Prenatal diagnosis of pseudothalidomide syndrome in consecutive pregnancies of a consanguineous couple. *Ultrasound Obstet Gynecol*. 1997;10:425-428.

Vega H, Trainer AH, Gordillo M, et al. Phenotypic variability in 49 cases of ESCO2 mutations, including novel missense and codon deletion in the acetyltransferase domain, correlates with ESCO2 expression and establishes the clinical criteria for Roberts syndrome. *J Med Genet*. 2010;47:30-37.

All references available online at www.expertconsult.com

REFERENCES

1. Roberts JB. Salvage of the hand by timely reparative surgery. *Ann Surg*. 1919;70:627-632.
2. Gordillo M, Vega H, Jabs EW. In: Pagon RA, Bird TC, Dolan CR, eds. *GeneReviews*. Seattle: University of Washington; 1993–2006.
3. Vega H, Trainer AH, Gordillo M, et al. Phenotypic variability in 49 cases of ESCO2 mutations, including novel missense and codon deletion in the acetyltransferase domain, correlates with ESCO2 expression and establishes the clinical criteria for Roberts syndrome. *J Med Genet*. 2010;47:30-37.
4. Vega H, Waisfisz Q, Gordillo M, et al. Roberts syndrome is caused by mutations in ESCO2, a human homolog of yeast ECO1 that is essential for the establishment of sister chromatid cohesion. *Nat Genet*. 2005;37: 468-470.
5. Ivanov D, Schleiffer A, Eisenhaber F, et al. Eco1 is a novel acetyltransferase that can acetylate proteins involved in cohesion. *Curr Biol*. 2002;12: 323-328.
6. Tanaka K, Watanabe Y. Chromatid cohesion: acetylation joins the sisters. *Curr Biol*. 2008;18:R917-R919.
7. Stanley WS, Pai GS, Horger EO 3rd, et al. Incidental detection of premature centromere separation in amniocytes associated with a mild form of Roberts syndrome. *Prenat Diagn*. 1988;8:565-569.
8. Gordillo M, Vega H, Trainer AH, et al. The molecular mechanism underlying Roberts syndrome involves loss of ESCO2 acetyltransferase activity. *Hum Mol Genet*. 2008;17:2172-2180.
9. Kennelly MM, Moran P. A clinical algorithm of prenatal diagnosis of radial ray defects with two and three-dimensional ultrasound. *Prenat Diagn*. 2007;27:730-737.
10. Karabulut AB, Aydin H, Erer M, et al. Roberts syndrome from the plastic surgeon's viewpoint. *Plast Reconstr Surg*. 2001;108:1443-1445.

141 Cystic Fibrosis

KATHERINE R. GOETZINGER

Introduction

Cystic fibrosis (CF) is a single-gene autosomal recessive disorder characterized by chronic airway infection, pancreatic insufficiency, gastrointestinal dysfunction, and male infertility. Symptoms typically manifest during childhood, leading to early mortality in the third and fourth decades of life.[1] Greater than 1000 different mutations in the CF transmembrane conductance regulator *(CFTR)* gene have been identified with an expansive ethnic and racial distribution as well as varying phenotype and penetrance. With advances in medical care, there are a growing number of CF patients who are advancing into childbearing years, thereby heightening awareness of strategies for prenatal carrier screening and diagnosis.

Disorder

DEFINITION

CF is caused by a mutation in the CFTR protein, which is a cyclic adenosine monophosphate regulated chloride channel located on the apical membrane of epithelial cells. Mutations in the responsible gene, located on chromosome 7, lead to an absent, nonfunctional, or partially functional protein, with resultant abnormal fluid and electrolyte transport across cells. Direct consequences of this defect include dehydrated secretions, decreased mucous clearance in the lung, deficient secretion of pancreatic enzymes, gut dysmotility, and increased sodium chloride levels in sweat.[1,2] These result in the clinical manifestations of CF, which can range from severe pulmonary and pancreatic insufficiency to an otherwise normal phenotype with only male infertility or chronic sinusitis.[1]

PREVALENCE AND EPIDEMIOLOGY

Approximately 30,000 individuals in the United States (70,000 worldwide) are currently affected with CF, and approximately 1000 new cases are diagnosed each year. CF is one of the most common single-gene disorders in the Caucasian population, with an incidence between 1:3000 and 1:3300 individuals.[3] Both the Ashkenazi Jewish and the Hispanic population also have a relatively high incidence of the disease, whereas African American and Asian populations have a much lower disease incidence. Prenatal carrier testing for this disorder poses a challenge, as there is an expansive ethnic/racial distribution of the greater than 1000 detectable mutations. The current detection rate of CF carriers in the general population using a standard 23 mutation panel ranges from 30%–97% depending on ethnic/racial origin.[3–7] Parental carrier screening is typically performed in a stepwise manner using a standardized panethnic mutation panel.[8] Expanded mutation panels as well as complete *CFTR* gene sequencing are available for patients with a personal or family history of CF.

ETIOLOGY AND PATHOPHYSIOLOGY

CF is inherited in an autosomal recessive manner. The most common mutation in the *CFTR* gene is ΔF508, a frameshift mutation caused by a three base-pair deletion at codon 508 in exon 10 of *CFTR*, resulting in the absence of a phenylalanine residue. This mutation causes a protein misfold that inhibits migration of the CFTR protein from the endoplasmic reticulum to the cell membrane. Other mutations result in a spectrum of protein dysfunction ranging from the production of unstable ribonucleic acid to CFTR cell surface instability.[1,2] These mutations in the CFTR protein lead to abnormal fluid and electrolyte transfer across epithelial cell membranes, causing dehydrated and viscous secretions in major end organ systems. In the lung, these secretions interfere with mucociliary clearance, obstruct airflow, and provide a growth medium for pathogenic bacteria. In the pancreas, exocrine enzymes are retained, causing progressive damage and, ultimately, fibrosis of the pancreas. The function of CFTR has been most extensively studied in the sweat gland, in which dysfunction of CFTR leads to failure of chloride resorption. This leads to a change in the normal electrochemical gradient of the cell, which typically drives sodium across the cell membrane. The resulting increase in sodium and chloride concentration in sweat is the basis for the diagnostic "sweat test" often used in children with clinical manifestations suspicious for CF.[1,2,9]

MANIFESTATIONS OF DISEASE

Clinical Presentation

Greater than 90% of CF patients manifest symptoms in early childhood. Of them, 15%–20% present at birth with meconium ileus.[1,9] Both the constellation and severity of symptoms are highly variable and somewhat dependent on the responsible mutation.[10–14] While pulmonary complaints are the hallmark of this disease, they are not necessary for diagnosis. Common clinical manifestations by organ system are listed subsequently.[1,2,9]

Respiratory tract
- Chronic sinusitis
- Chronic airway infection (*h. Influenza, s. Aureus, p. Aeruginosa, b. Cepacia*)
- Bronchiectasis
- Cor pulmonale
- Respiratory failure

Gastrointestinal tract
- Meconium ileus (failure to pass stool, abdominal distention, emesis)
- Exocrine pancreatic insufficiency (malabsorption of protein, fat, and fat-soluble vitamins)

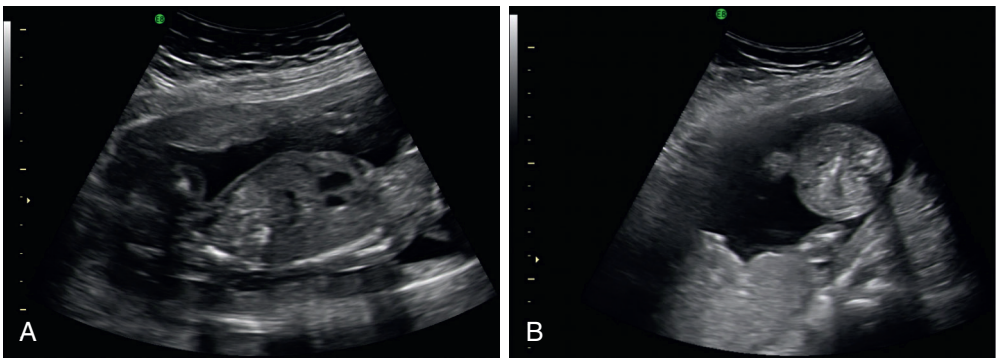

Fig. 141.1 Echogenic bowel detected during prenatal exam. (A) Sagittal view. (B) Axial view.

- Focal biliary cirrhosis
- Failure to thrive

Endocrine system
- Insulin resistance/diabetes mellitus (destruction of pancreatic islet cells)
- Osteoporosis (vitamin D deficiency)

Reproductive tract
- Delayed onset puberty
- Azoospermia (congenital bilateral absence of the vas deferens)

Imaging Technique and Findings

Ultrasound. Ultrasonographic markers have been linked to the prenatal diagnosis of CF, although none are diagnostic. Echogenic bowel, defined as bowel with a sonographic density equal to or greater than that of bone, is the most well studied of these markers and is observed in 0.1%–1.8% second-trimester ultrasounds[15] (Fig. 141.1). The magnitude of risk association between echogenic bowel and CF is reported to range from 0%–33%.[15–19] Other sonographic findings associated with CF include mildly dilated loops of bowel, nonvisualization of the fetal gallbladder, and complete bowel obstruction with severely dilated loops of bowel and polyhydramnios.[17,20] Some studies have also suggested that meconium ileus may be detected on routine prenatal ultrasonography, with the characteristic appearance of echogenic bowel ± dilated intestinal loops. This appearance is thought to be secondary to the dehydration of intestinal secretions, which then leads to increased bowel viscosity and subsequent obstruction.

The risk association of these sonographic findings and CF has been variably reported within the literature. One study reported a 2.5% incidence of CF in fetuses with isolated echogenic bowel and a 2.9% incidence of CF in fetuses with isolated bowel dilation. These two findings together increased the risk of CF to 17%.[17] When evaluating patients with a high *a priori* risk (i.e., known CF mutation carriers), this risk association has been quoted to be as high as 25%–60%.[21]

Magnetic Resonance Imaging. To date, there is only one study in the literature evaluating fetal magnetic resonance imaging (MRI) to further establish the underlying diagnosis in cases of sonographically detected echogenic bowel. This study revealed no complementary value of fetal MRI in cases of isolated echogenic bowel diagnosed on prenatal ultrasound. In cases of echogenic bowel and associated gastrointestinal abnormalities such as dilated bowel and/or ascites, fetal MRI did aid in providing additional information leading to the diagnosis of bowel obstruction and bowel duplication in many cases.[22] Further research is needed before recommending routine MRI in cases of echogenic bowel detected on prenatal ultrasound for the purposes of establishing a diagnosis of CF.

Differential Diagnosis From Imaging Findings

The differential diagnosis for sonographically detected echogenic bowel includes:
- normal variant
- congenital infection (i.e., cytomegalovirus infection)
- aneuploidy
- fetal bowel obstruction
- early-onset intrauterine growth restriction
- recent history of intraamniotic bleeding

Recommended evaluation of fetuses with echogenic bowel includes detailed anatomic survey to assess for other structural defects and growth restriction, aneuploidy screening, maternal studies for congenital infection, and parental CF carrier screening (Chapter 22).[15,23]

Synopsis of Treatment Options

PRENATAL

At present, there are no known fetal therapies or interventions that alter disease course or progression. Invasive fetal diagnostic testing for CF can be performed via chorionic villus sampling or amniocentesis. Invasive testing is recommended in cases of two known parental mutations, family history of CF, and echogenic bowel diagnosed on ultrasound.[4,24] Preimplantation genetic diagnosis is an option for known CF carrier couples.[25,26]

POSTNATAL

As of 2010, all 50 states have mandated CF screening to be part of their standard newborn screening panel. In areas that do not mandate newborn screening, infants and children who exhibit disease manifestations undergo sweat testing to make a definitive diagnosis.[27] Deoxyribonucleic acid analysis to evaluate for specific mutations is also becoming increasingly more available.[9]

Treatment of CF broadly consists of adequate maintenance of nutrition, supplementation of vitamins and pancreatic enzymes, chest physiotherapy to clear secretions, and early and aggressive treatment of pulmonary infections. Lung transplantation is the only definitive therapy for respiratory failure in CF.[1,2,9] Research is currently under way on the use of gene therapy and biologic mutation-specific therapies as potential treatment modalities for CF.

WHAT THE REFERRING PHYSICIAN NEEDS TO KNOW

Carrier screening for CF should be made available to all couples in the preconception or early prenatal period regardless of race and ethnicity, recognizing the inherent limitations and implications of testing. While ultrasound findings have been linked to CF, none are diagnostic. Obstetricians should be familiar with the current prenatal screening guidelines and reproductive options available to carrier couples.

KEY POINTS

- CF is a monogenic, autosomal recessive disorder characterized by altered fluid and electrolyte transport across epithelial cells.
- Common manifestations of CF include pancreatic insufficiency, chronic airway infection, bronchiectasis, gastrointestinal dysfunction, and male infertility.
- Prenatal carrier screening should be made available to all patients, although carrier frequency and detection rates widely vary based on ethnicity.
- Ultrasound markers such as echogenic bowel and dilated bowel are suggestive of, but not diagnostic of, CF.

SUGGESTED READING

American College of Obstetricians and Gynecologists. *Update on Carrier Screening for Cystic Fibrosis. ACOG Committee Opinion #486*. Washington DC.: ACOG; 2011.

Brennan ML, Schrijver I. Cystic fibrosis: a review of associated phenotypes, use of molecular diagnostic approaches, genetic characteristics, progress, and dilemmas. *J Mol Diagn*. 2016;18:3-14.

Moskowitz SM, Chmiel JF, Sternen DL, et al. Clinical practice and genetic counseling for cystic fibrosis and CFTR-related disorders. *Genet Med*. 2008;10:851-868.

Nishida K, Smith Z, Rana D, et al. Cystic fibrosis: a look into the future of prenatal screening and therapy. *Birth Defects Res C Embryo Today*. 2015;105:73-80.

O'Sullivan BP, Freedman SD. Cystic fibrosis. *Lancet*. 2009;373:1891-1904.

Rosenfeld M, Sontag MK, Ren CL. Cystic fibrosis diagnosis and newborn screening. *Pediatr Clin N Am*. 2016;63:599-615.

Watson MS, Cutting GR, Desnick RJ, et al. Cystic fibrosis population carrier screening: 2004 revision of American College of Medical Genetics mutation panel. *Genet Med*. 2004;6:387-391.



All references available online at www.expertconsult.com

REFERENCES

1. Boucher RC. Cystic fibrosis. In: Harrison TR, Kasper DL, eds. *Harrison's Principles of Internal Medicine*. 16th ed. New York: McGraw-Hill; 2005:1543-1546.
2. Nussbaum RL, McInnes RR, Willard HL. The molecular, biochemical, and cellular basis of genetic disease. In: *Thompson & Thompson: Genetics in Medicine*. 7th ed. Philadelphia: Saunders Elsevier; 2007:364-367.
3. Wapner RJ, Jenkins TM, Khalek M. Prenatal diagnosis of congenital disorders. In: Creasy KK, Resnik R, Iams JD, eds. *Maternal-Fetal Medicine. Principles and Practice*. 6th ed. Philadelphia: Saunders Elsevier; 2009:221-274.
4. American College of Obstetricians and Gynecologists. *Update on Carrier Screening for Cystic Fibrosis. ACOG Committee Opinion #486*. Washington DC.: ACOG; 2011.
5. Cutting GR. Genetic epidemiology and genotype/phenotype correlations. NIH Consensus Development Conference on Genetic Testing for Cystic Fibrosis, 1997.
6. Grody WW, Cutting GR, Klinger KW, et al. Laboratory standards and guidelines for population-based cystic fibrosis carrier screening. *Genet Med*. 2001;3:149-154.
7. Watson MS, Cutting GR, Desnick RJ, et al. Cystic fibrosis population carrier screening: 2004 revision of American College of Medical Genetics mutation panel. *Genet Med*. 2004;6:387-391.
8. Miedzybrodzka ZH, Hall MH, Mollison J, et al. Antenatal screening for carriers of cystic fibrosis. *BMJ*. 1995;310:353-357.
9. O'Sullivan BP, Freedman SD. Cystic fibrosis. *Lancet*. 2009;373:1891-1904.
10. The Cystic Fibrosis Genotype-Phenotype Consortium. Correlation between genotype and phenotype in patients with cystic fibrosis. *N Engl J Med*. 1993;329:1308-1313.
11. Osborne L, Santis G, Schwarz M, et al. Incidence and expression of the N1303K mutation of the cystic fibrosis (CFTR) gene. *Hum Genet*. 1992;89:653-658.
12. Gasparini P, Borgo G, Mastella G, et al. Nine cystic fibrosis patients homozygous for the CFTR nonsense mutation R1162X have mild or moderate lung disease. *J Med Genet*. 1992;29:558-562.
13. Chillon M, Casals T, Mercier B, et al. Mutations in the cystic fibrosis gene in patients with congenital absence of the vas deferens. *N Engl J Med*. 1995;332:1475-1480.
14. Kiesewetter S, Macek M, Davis C, et al. A mutation in CFTR produces different phenotypes depending on chromosomal background. *Nat Genet*. 1993;5:274-277.
15. Norton MF. Genetics and prenatal diagnosis. In: Callen PW, ed. *Ultrasonography in Obstetrics and Gynecology*. 5th ed. Philadelphia: Saunders Elsevier; 2008:26-59.
16. Sepulveda W, Leung KY, Robertson ME, et al. Prevalence of cystic fibrosis mutations in pregnancies with fetal echogenic bowel. *Obstet Gynecol*. 1996;87:103-106.
17. Muller F, Simon-Bouy B, Girodon E, et al. Predicting the risk of cystic fibrosis with abnormal ultrasound signs of fetal bowel: results of a French Molecular Collaborative study based on 641 prospective cases. *Am J Med Genet*. 2002;110:109-115.
18. Nyberg DA, Dubinsky T, Resta RG, et al. Echogenic fetal bowel during the second trimester: clinical importance. *Radiology*. 1993;188:527-531.
19. Dicke JM, Crane JP. Sonographically detected hyperechoic fetal bowel: significance and implications for pregnancy management. *Obstet Gynecol*. 1992;80:778-782.
20. Corteville JE, Gray DL, Langer JC. Bowel abnormalities in the fetus—Correlation of prenatal ultrasonographic findings with outcome. *Am J Obstet Gynecol*. 1996;175:724-729.
21. Boue A, Muller F, Nezelop C, et al. Prenatal diagnosis in 200 pregnancies with a 1 in 4 risk of cystic fibrosis. *Hum Genet*. 1986;74:288-297.
22. Carcopino X, Chaumoitre K, Shojai R, et al. Foetal magnetic resonance imaging and echogenic bowel. *Prenat Diagn*. 2007;27:272-278.
23. Penna L, Bower S. Hyperechogenic bowel in the second trimester fetus: a review. *Prenat Diagn*. 2000;20:909-913.
24. Richards CS, Bradley LA, Amos J, et al. Standards and guidelines for CFTR mutation testing. *Genet Med*. 2002;4:379-391.
25. Ao A, Ray P, Harper J, et al. Clinical experience with preimplantation genetic diagnosis of cystic fibrosis (ΔF508). *Prenat Diagn*. 1996;16:137-142.
26. Gutierrez-Mateo C, Sanchez-Garcia JF, Fischer J, et al. Preimplanatation genetic diagnosis of single gene disorders: experience with more than 200 cycles conducted by a reference laboratory in the United States. *Fertil Steril*. 2009;92:1544-1556.
27. Rosenfeld M, Sontag MK, Ren CL. Cystic fibrosis diagnosis and newborn screening. *Pediatr Clin North Am*. 2016;63:599-615.

142 Pontocerebellar Disorders

RACHEL G. SINKEY | ANTHONY O. ODIBO

Introduction

Autosomal recessive pontocerebellar hypoplasias (PCHs) are a group of severe neurodegenerative disorders affecting the cerebellum and pons. This disease appears in fetal or neonatal life with subsequent pontocerebellar degeneration, progressive microcephaly, and atrophy of the cerebral cortex.[1] Most affected individuals have profound motor and cognitive deficits. Life expectancy generally lasts into infancy or childhood, though there are reports of some individuals with PCH who live into adulthood. At the time of this publication, Online Mendelian Inheritance in Man cites 10 known PCH subtypes *(PCH1-10)*.

Disorder

DEFINITION

Individuals affected by PCH are typically diagnosed in the neonatal period because of profound motor and cognitive delay. The phenotype and life expectancy vary based on PCH subtype. However, most individuals with PCH share common clinical manifestations including profound motor and cognitive delay, movement disorders, epilepsy, hypotonia, feeding difficulties requiring gastrostomy, and respiratory distress.

PREVALENCE AND EPIDEMIOLOGY

Autosomal recessive PCH is rare and the prevalence is unknown. Several genetically isolated communities with founder mutations are reported in the literature.[2,3] One such founders' community in the Netherlands has a carrier frequency of PCH2 of 14.3%.[3]

ETIOLOGY AND PATHOPHYSIOLOGY

PCH is inherited in an autosomal recessive manner. Several gene mutations have been isolated among individuals affected by PCH including *TSEN54*, *RARS2*, *EXOSC3*, and *PCLO*.[1] PCH2 is the most common PCH subtype and is caused by a mutation in *TSEN54*; other *TSEN*-related PCH disorders include PCH4 and 5.[4] Of note, *TSEN54*, *TSEN2*, and *TSEN34* encode the transfer ribonucleic acid (tRNA) splicing endonuclease complex subunits whereas *RARS2* mutation, which is implicated in PCH6, encodes mitochondrial arginyl tRNA synthetase. However, it is unclear why the cerebellum and pons are most severely affected, unlike other structures that also rely heavily on protein synthesis.[5]

MANIFESTATIONS OF DISEASE

Clinical Presentation

Severe motor delay in an infant with abnormal neuroradiologic imaging increases the suspicion for PCH. The clinical presentation

depends on the subtype of PCH, but most forms share several common clinical manifestations including the following:

- seizures
- suck-and-swallow impairment, which can result in breastfeeding challenges and often require gastrostomy placement
- profound motor and cognitive delay
- loss of developmental milestones if they were once achieved
- progressive microcephaly
- hypotonia
- chorea
- irritability
- visual impairment
- increased risk of malignant hyperthermia associated with febrile illness but not with general anesthesia
- elevated creatinine kinase
- arthrogryposis
- respiratory distress and/or obstructive sleep apnea

Imaging Technique and Findings

Ultrasound. Prenatal ultrasound (US) of affected fetuses is usually normal. Posterior fossa structures appear normal at midgestation as cerebellar development lags typically in third trimester.[4,6] In the third trimester, nomograms for posterior fossa structures could be used in pregnancies for families with an affected child. However, even among families with a known affected child, detailed prenatal sonographic surveillance may fail to diagnose PCH.[7]

There are certain findings among families with an affected child that raise suspicion: polyhydramnios or arthrogryposis may be visualized in 1%–2% of cases with PCH.[4,8] Microcephaly may be detected between 32 and 35 weeks. For some affected fetuses with PCH5, chorea and/or seizures first manifest *in utero* and may be perceived by the mother and visualized on US.[9] In addition, hydrops may be associated with PCH.[10] However, thus far, the role of US in prenatal diagnosis is limited.

Magnetic Resonance Imaging. Fetal magnetic resonance imaging (MRI) in the third trimester may demonstrate lagging cerebellar growth. Fig. 142.1 demonstrates MRI findings in affected neonates from 2 weeks to 9 months of life. In addition, MRI tractography may show absence of pontine crossing fibers in affected fetuses (Fig. 142.2).[6] Rarely, cerebellar cysts may be visualized.

Other Applicable Modality. Hypertrophic cardiomyopathy and tetralogy of the Fallot have been reported in individuals with PCH.[10–12] Therefore fetal echocardiography may aid in prenatal diagnosis of complex cardiac malformations.

CLASSIC SIGNS

- Progressive microcephaly
- Severe motor and cognitive delay
- Seizures
- Impaired suck-and-swallow reflex
- Hypotonia
- Chorea

Differential Diagnosis From Imaging Findings[13]

1. Lissencephaly
2. Glycosylation disorders
3. Genetic disorders such as *CASK* mutations and cerebellar agenesis
4. Congenital muscular dystrophies such as Walker-Warburg syndrome
5. Microcephaly with pontine and cerebellar hypoplasia[14]
6. Pontine tegmental cap dysplasia
7. Other forms of PCH such as extreme prematurity

Synopsis of Treatment Options

PRENATAL

No prenatal treatment is available. In families with a known mutation, preimplantation genetic diagnosis may be offered in the preconception setting and genetic testing via chorionic villus sampling or amniocentesis can be offered for a current pregnancy.[4,8]

POSTNATAL

Postnatal treatment focuses on symptom management and requires a multidisciplinary approach. Thorough neurologic and ophthalmologic evaluations are indicated. Respiratory support may be warranted. Dietitians are vital to ensuring the caloric needs of these children are met, as many affected individuals have swallowing difficulties and a gastrostomy tube is often required. Orthopedic consultation and physical therapy can help contractures.[4] Levodopa may help patients with PCH complicated by movement disorders.[13]

Patients with PCH who develop febrile illnesses require additional attention as dehydration can lead to malignant hyperthermia. It is important to note that an increased risk of malignant hyperthermia has not been associated with general anesthesia.[15]

Genetic counseling should be offered to all families with an affected member. Psychosocial support should also be provided for all affected families, as caregiving for PCH is extensive; the infant or child may need to be placed in a skilled nursing facility to meet his or her needs.

WHAT THE REFERRING PHYSICIAN NEEDS TO KNOW

Autosomal recessive PCH is a group of devastating neurodegenerative disorders that leads to severe motor and cognitive impairment. Life expectancy varies based on subtype and is unpredictable; few patients live into adulthood. [5] Prenatal diagnosis is challenging as midtrimester imaging is usually normal. Families with a known mutation should be offered genetic counseling to discuss deoxyribonucleic acid (DNA) banking of affected individuals, preimplantation, and prenatal testing options.[4,8]

KEY POINTS

- Autosomal recessive PCH comprises a spectrum of degenerative neurologic disorders characterized by profound motor and cognitive deficits.
- Life expectancy is short; few affected individuals survive into adulthood.
- Prenatal diagnosis is challenging as imaging in the second trimester is normal.
- DNA banking and molecular testing options should be discussed with families who have an affected member.

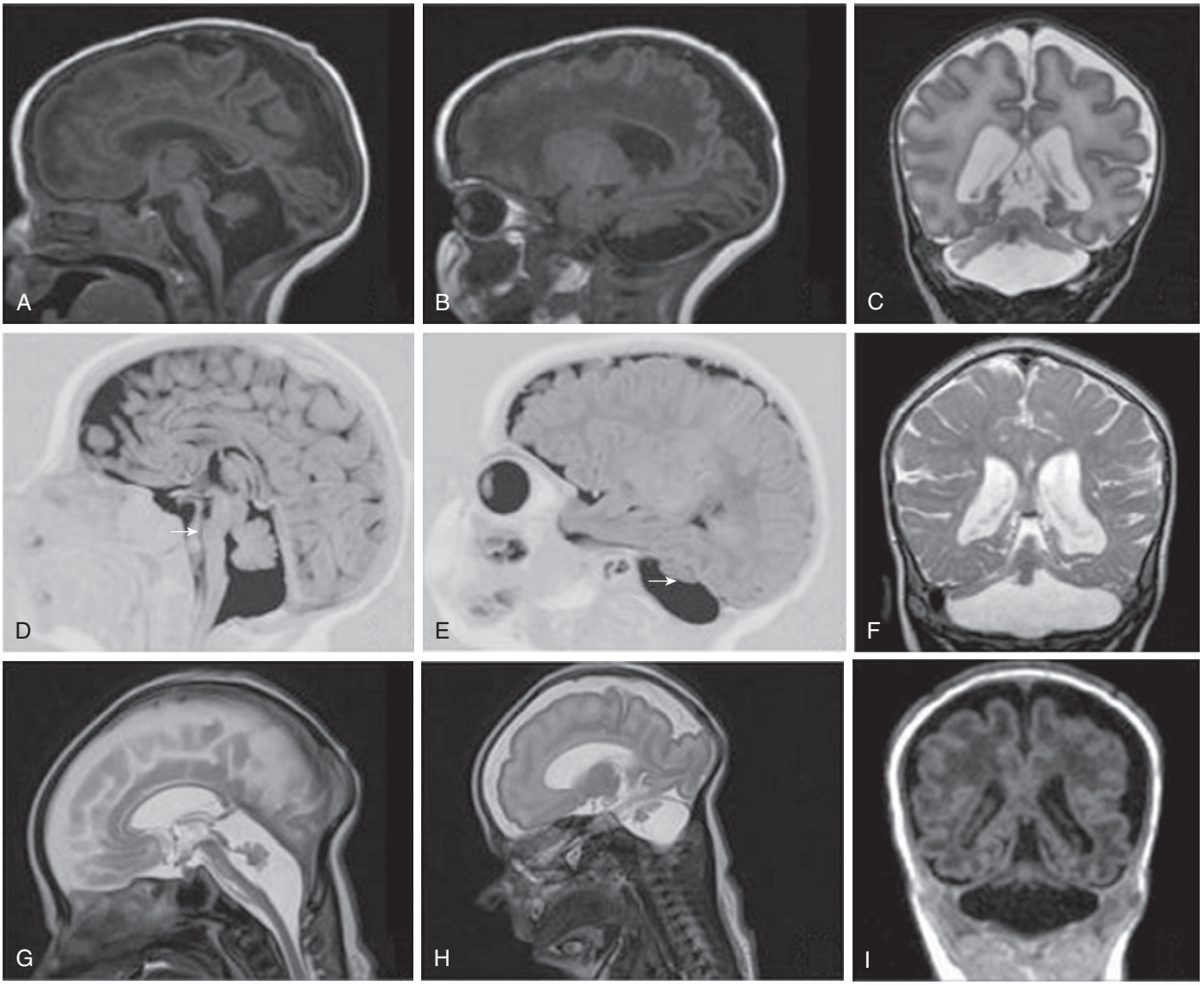

Fig. 142.1 MRI sections of cases with PCH type 1, type 2 and type 4. (A–C) Images of a 2-week-old neonate with PCH1. (A) Midsagittal section (T1) shows vermal hypoplasia and marked cerebellar hypoplasia. (B) Lateral sagittal section (T1) shows severe hypoplasia of the cerebellar hemispheres. (C) Coronal section (T2) shows flattened cerebellar hemispheres, which also display some atrophy. The vermis is relatively spared. (D–E) Images of a 2-month-old baby with PCH2. (D) Midsagittal section (T1IR) shows a flat ventral pons *(arrow)* and vermal hypoplasia. (E) Lateral sagittal section (T1IR) shows severely hypoplastic cerebellar hemispheres *(arrow)* leaving most of the posterior fossa empty. (F) Coronal section (T2) of a 9-month-old infant with PCH2 shows flat cerebellar hemispheres and mild vermal hypoplasia (dragonfly configuration). Cerebral cortical atrophy is also present. (G–I) Images of a 31+5 weeks neonate with PCH4. (G) Midsagittal section (T2) shows severe vermal hypoplasia and ventral pontine flattening. (H) Lateral sagittal section (T2) shows severe hypoplasia of the cerebellar hemispheres. Above the tentorium there is an increased distance between the cortical surface and the skull visible, which is probably because of diminished brain growth *in utero*. (I) Coronal section (T1) shows extremely small and flattened cerebellar hemispheres and severe vermal hypoplasia. Immaturity of cerebral cortex and enlarged ventricles are also visible. *(Reproduced, according to the Creative Commons Attribution License, from Namavar Y, Barth PG, Poll-The BT, Baas F. Classification, diagnosis and potential mechanisms in pontocerebellar hypoplasia.* Orphanet J Rare Dis *2011;6:50. The images of the PCH1 case were kindly provided by Professor Darin, The Queen Silvia Children's Hospital, Gothenburg University, Sweden.)*

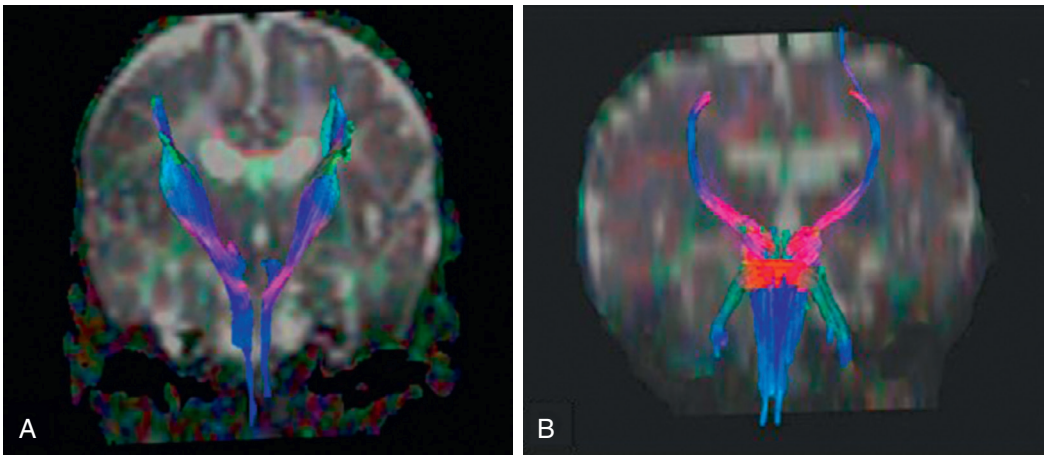

Fig. 142.2 Coronal MRI tractography of a patient with PCH showing absent transverse pontine fibers as compared to a healthy, age-matched control in (B). *(From Graham JM, Jr., Spencer AH, Grinberg I, et al. Molecular and neuroimaging findings in pontocerebellar hypoplasia type 2 (PCH2): is prenatal diagnosis possible?* Am J Med Genet A *2010;152a:2268–respec76.)*

SUGGESTED READING

Eggens VRC, Barth PG, Baas F. EXOSC3-Related Pontocerebellar Hypoplasia. In: Pagon RA, Adam MP, Ardinger HH, et al, eds. *GeneReviews*. Seattle (WA): University of Washington, Seattle University of Washington, Seattle; 1993.

Namavar Y, Barth PG, Poll-The BW, et al. Classification, diagnosis and potential mechanism in pontocerebellar hypoplasia. *Orphanet J Rare Dis*. 2011;6:50.

Namavar Y, Eggens VR, Barth PG, et al. TSEN54-Related Pontocerebellar Hypoplasia. In: Pagon RA, Adam MP, Ardinger HH, et al, eds. *GeneReviews*. Seattle (WA): University of Washington, Seattle University of Washington, Seattle; 1993.

Poretti A, Boltshauser E, Doherty D. Cerebellar hypoplasia: differential diagnosis and diagnostic approach. *Am J Med Genet C*. 2014;166C(2):211-226.

All references available online at www.expertconsult.com

REFERENCES

1. Ahmed MY, Chioza BA, Rajab A, et al. Loss of PCLO function underlies pontocerebellar hypoplasia type III. *Neurology*. 2015;84:1745-1750.
2. Schwabova J, Brozkova DS, Petrak B, et al. Homozygous EXOSC3 mutation c.92G–>C, p.G31A is a founder mutation causing severe pontocerebellar hypoplasia type 1 among the Czech Roma. *J Neurogenet*. 2013;27: 163-169.
3. Mathijssen IB, Henneman L, van Eeten-Nijman JM, et al. Targeted carrier screening for four recessive disorders: high detection rate within a founder population. *Eur J Med Genet*. 2015;58:123-128.
4. Namavar Y, Eggens VRC, Barth PG, et al. TSEN54-Related Pontocerebellar Hypoplasia. In: Pagon RA, Adam MP, Ardinger HH, et al, eds. *GeneReviews*. Seattle (WA): University of Washington, Seattle University of Washington, Seattle; 1993.
5. Namavar Y, Barth PG, Poll-The BT, et al. Classification, diagnosis and potential mechanisms in pontocerebellar hypoplasia. *Orphanet J Rare Dis*. 2011;6:50.
6. Graham JM Jr, Spencer AH, Grinberg I, et al. Molecular and neuroimaging findings in pontocerebellar hypoplasia type 2 (PCH2): is prenatal diagnosis possible? *Am J Med Genet A*. 2010;152a:2268-2276.
7. Ajibola AJ, Netzloff M, Samaraweera R, et al. Two cases of pontocerebellar hypoplasia: ethical and prenatal diagnostic dilemma. *Am J Perinatol*. 2010;27:181-187.
8. Eggens VRC, Barth PG, Baas F. EXOSC3-Related Pontocerebellar Hypoplasia. In: Pagon RA, Adam MP, Ardinger HH, et al, eds. *GeneReviews*. Seattle (WA): University of Washington, Seattle University of Washington, Seattle; 1993.
9. Sanchez-Albisua I, Frolich S, Barth PG, et al. Natural course of pontocerebellar hypoplasia type 2A. *Orphanet J Rare Dis*. 2014;9:70.
10. Lax NZ, Alston CL, Schon K, et al. Neuropathologic characterization of pontocerebellar hypoplasia type 6 associated with cardiomyopathy and hydrops fetalis and severe multisystem respiratory chain deficiency due to novel RARS2 mutations. *J Neuropathol Exp Neurol*. 2015;74:688-703.
11. Nakamura K, Nishiyama K, Kodera H, et al. A de novo CASK mutation in pontocerebellar hypoplasia type 3 with early myoclonic epilepsy and tetralogy of Fallot. *Brain Dev*. 2014;36:272-273.
12. Jinnou H, Okanishi T, Enoki H, et al. Pontocerebellar hypoplasia type 3 with tetralogy of Fallot. *Brain Dev*. 2012;34:392-395.
13. Grosso S, Mostadini R, Cioni M, et al. Pontocerebellar hypoplasia type 2: further clinical characterization and evidence of positive response of dyskinesia to levodopa. *J Neurol*. 2002;249:596-600.
14. Moog U, Uyanik G, Kutsche K. CASK-Related Disorders. In: Pagon RA, Adam MP, Ardinger HH, et al, eds. *GeneReviews*. Seattle (WA): University of Washington, Seattle University of Washington, Seattle; 1993.
15. Balbi KE, Taicher BM, Litman RS. Pontocerebellar hypoplasia, malignant hyperthermia, and inappropriate use of secondary references. *Paediatr Anaesth*. 2016;26:857-858.

To access the videos in this chapter, scan this QR code or visit expertconsult.com

143 Tuberous Sclerosis

SARA SHELLEY | KATHERINE R. GOETZINGER

Introduction

Tuberous sclerosis, also known as the *tuberous sclerosis complex (TSC),* is a disorder of cellular differentiation, proliferation, and migration in early development that variably affects multiple organ systems. First described in 1862 by Friedrich von Recklinghausen, TSC is characterized by the formation of benign, hamartomatous lesions in virtually any organ system, most commonly the central nervous system (CNS), skin, heart, lungs, kidneys, bones, and blood vessels.[1–4] The inheritance pattern of TSC is autosomal dominant, although sporadic mutations are found in over two-thirds of affected patients. Despite complete penetrance, the phenotypic variability is quite high, leading to a wide spectrum of clinical manifestations as well as heterogeneity in symptom onset and severity.[5]

Disorder

DEFINITION

Diagnostic criteria for tuberous sclerosis require either: (1) genetic testing identifying a known pathogenic mutation/disruption in

either *TSC1* or *TSC2* or (2) a clinical diagnosis based on established major and minor criteria (Table 143.1). A "definite" diagnosis of tuberous sclerosis is considered in the presence of two major features or one major feature with two or more minor features. A "possible" diagnosis is defined as having either one major feature or two or more minor features.[6]

PREVALENCE AND EPIDEMIOLOGY

TSC is the second most common neurocutaneous syndrome after neurofibromatosis type 1. The prevalence is approximately 1:6000 live births, with over 1.5 million people affected worldwide. There is no gender or race-specific bias.[5,7]

ETIOLOGY AND PATHOPHYSIOLOGY

Two responsible genes have been identified in the pathogenesis of tuberous sclerosis, *TSC1* (9q34) and *TSC2* (16p13.3).[8,9] These genes encode the proteins hamartin and tuberin, which together form an intracellular complex which functions as a tumor suppressor of the mTOR (mammalian target of rapamycin) kinase cascade. The mTOR cascade plays a crucial role in regulating cell growth and proliferation and is thought to play an important role in neural stem cell production and migration. Dysfunctional gene products from mutations in either *TSC1* or *TSC2* lead to upregulation of the mTOR kinase cascade and subsequent disorganized cellular growth and differentiation.[10–12] A mutation in each allele at either the *TSC1* or *TSC2* loci is necessary for the expression of TSC (i.e., "two-hit" hypothesis) with the first being a germline mutation followed by a somatic mutation of the remaining allele.[11,13]

There is no definitive correlation between genotype and phenotype, although mutations or deletions in *TSC2* tend to have more severe clinical manifestations. Mutations in *TSC2* are more common and more often tend to be sporadic. Deletions also tend to be the more common type of mutation in *TSC2* and may involve neighboring gene *PKD1* (responsible for polycystic kidney disease). Individuals with this contiguous gene deletion will often present with renal cysts in early childhood and have a more severe renal phenotype than the renal disease observed in patients with TSC.[14] In contrast, mutations in *TSC1* tend to be familial. No identifiable mutation is found in 10%–15% of TSC patients; therefore diagnosis is made based on clinical features alone. These patients tend to have milder clinical manifestations of disease.[15–17] It is thought that mosaicism or mutations in the regulatory and intronic components of *TSC1* and *TSC2*, as opposed to a potential third candidate gene, account for the percentage of cases that have no identifiable mutation.[14]

TABLE 143.1 MAJOR AND MINOR FEATURES OF TUBEROUS SCLEROSIS

Major Features	Minor Features
Hypomelanotic macules (≥3, at least 5-mm diameter)	"Confetti" skin lesions
Angiofibromas (≥3) or fibrous cephalic plaque	Dental enamel pits (>3)
Ungual fibromas (≥2)	Intraoral fibromas (≥2)
Shagreen patch	Retinal achromic patch
Multiple retinal hamartomas	Multiple renal cysts
Cortical dysplasias (including tubers and white matter radial migration lines)	Nonrenal hamartomas
Subependymal nodules	
Subependymal giant cell astrocytoma	
Cardiac rhabdomyoma	
Lymphangioleiomyomatosis (LAM)*	
Angiomyolipomas (≥2)*	

*Combination of these two major features without other features does not meet criteria for a definite diagnosis

MANIFESTATIONS OF DISEASE

Clinical Presentation

The classically described triad of epilepsy, mental retardation, and facial angiofibromas is only observed in 30%–40% of patients with TSC. Greater than 85% of affected patients will have some CNS manifestation of disease and more than 90% will have cutaneous findings. CNS lesions and renal complications are the leading causes of morbidity and mortality in TSC.[2,3] The majority of patients are diagnosed during childhood, but given the extreme phenotypic variability of disease, a proportion of patients are diagnosed only when genetic testing is used secondary to diagnosis in another family member. Significant clinical manifestations and findings are listed in Table 143.2, categorized by organ system.[1–4,14,16]

Imaging Technique and Findings

Ultrasound. Prenatal sonographic findings of TSC are generally limited to the heart, brain, and kidney. Cardiac rhabdomyomas are the most common prenatal finding, appearing as round, echogenic, homogeneous masses located in the ventricular walls

TABLE 143.2 CLINICAL MANIFESTATIONS AND FINDINGS (BY ORGAN SYSTEM)

Central nervous system	Seizures, developmental delay, intellectual disability, autism, neuropsychiatric disorders, retinal achromic patch, cortical and subcortical tubers/dysplasias, subependymal nodules, subependymal giant cell astrocytomas, retinal hamartomas
Dermatologic system	Hypomelanotic macules (ash leaf spots), angiofibromas, adenoma sebaceum, fibrous cephalic plaques, raised connective tissue nevi (shagreen patches), ungual fibromas, confetti skin lesions, *café au lait* spots, dental pits
Renal system	Renal cysts, angiomyolipomas (with associated risk of life-threatening hemorrhage and renal failure or hypertension owing to mass effect), increased lifetime risk of renal cell carcinoma
Cardiopulmonary system	Lymphangioleiomyomatosis (proliferation of atypical smooth muscle cells in the lymphatics of the lungs leading to interstitial lung disease and cystic lung destruction), cardiac rhabdomyomas, cardiac angiolipomas
Skeletal system	Localized areas of sclerosis
Vascular system	Vascular dysplasia, aneurysms (intracranial, thoracic, abdominal)

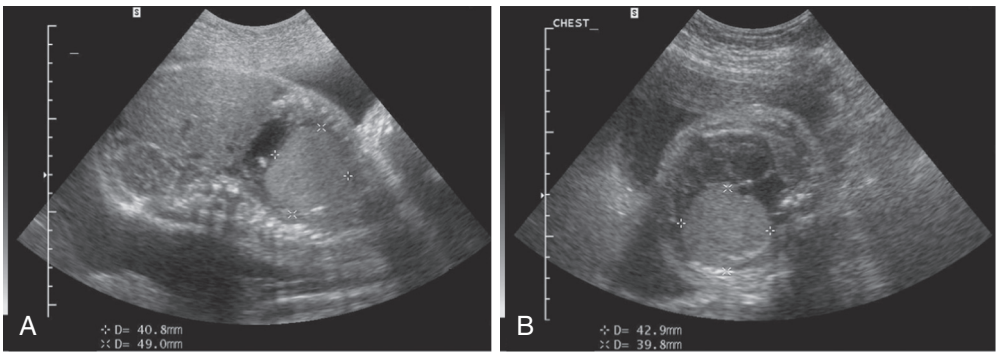

Fig. 143.1 Large cardiac rhabdomyoma detected on prenatal ultrasound in a fetus ultimately diagnosed with TSC (A) sagittal view, (B) axial view.

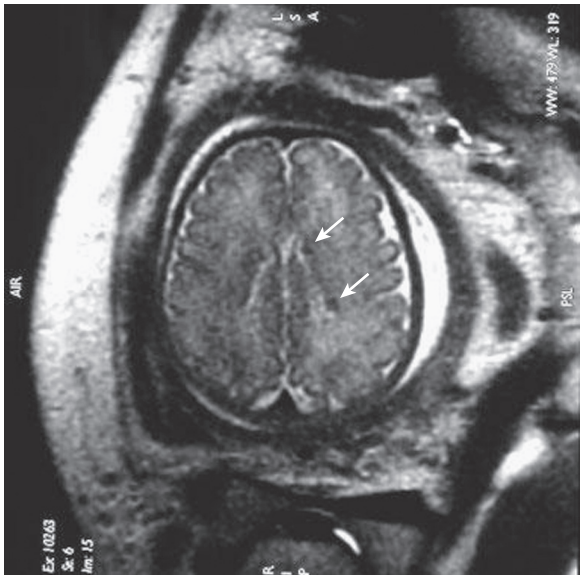

Fig. 143.2 Fetal MRI performed at 36 weeks' gestation. T2-weighted cerebral image reveals subependymal tubers *(arrows)*.

and often protruding into the cardiac chambers[18] (Fig. 143.1, Video 143.1). The incidence of TSC in fetuses diagnosed with cardiac rhabdomyoma ranges from 39%–82% in the literature.[19] These tumors tend to increase in size and number as pregnancy progresses and can lead to fetal arrhythmia and hydrops fetalis. Although the presence of multiple tumor foci has a well-established association with TSC, cases with solitary cardiac rhabdomyomas have been reported.[19–21] CNS sonographic findings of TSC are not well delineated, although asymmetric dilation of the lateral ventricles and areas of increased echogenicity within the basal ganglia and periventricular region have been reported.[22,24] Sonographically detected renal cysts have also been reported in fetuses who subsequently were diagnosed with TSC.[20]

Magnetic Resonance Imaging. Fetal magnetic resonance imaging (MRI) can be a valuable adjunct to prenatal ultrasound (US) to evaluate for intracerebral signs of TSC (Fig. 143.2). These lesions appear as hyperintense nodules on T1-weighted images corresponding to periventricular and subcortical tubers.[24] Prior studies have demonstrated a correlation between fetal MRI findings and both pathomorphologic as well as clinical neurologic manifestations, although these studies are limited by small numbers because of the overall rarity of the disorder.[25,26]

Other Applicable Modality. Given the risk of arrhythmia and heart failure with cardiac rhabdomyoma, fetal echocardiography can be useful in further delineating cardiac functional impairment by evaluating inflow and outflow tract obstruction, conduction abnormalities, and atrioventricular valve dysfunction. Cardiac rhabdomyomas have been reported as early as 15 weeks' gestation, although they are most commonly observed in the third trimester. Serial fetal echocardiography may be warranted in cases diagnosed at the time of midtrimester anatomic survey.[20,22,24]

Differential Diagnosis From Imaging Findings

While rhabdomyomas are the most common fetal intracardiac tumors, other differential diagnoses in the setting of this finding include teratomas, hemangiomas, myxomas, and fibromas.[22] Renal cysts associated with TSC may also have a similar US appearance to polycystic kidney disease, although renal cystic disease is a rare prenatal finding in cases of TSC.[20]

Synopsis of Treatment Options

PRENATAL

Cardiac rhabdomyomas diagnosed in the fetus tend to regress in early childhood, whereas cerebral lesions tend to progressively increase in size and number over time.[20] There are no known fetal therapies that alter progression of the disease. In families with a known TSC mutation, the identification of cardiac rhabdomyomas on US should prompt further imaging and prenatal genetic testing, keeping in mind that 70%–80% of TSC mutations are sporadic.[3] Prenatal diagnostic testing is available by gene sequencing for a suspected diagnosis of TSC or is available if a known mutation has been identified in the proband. Perinatal morality is significantly increased in cases complicated by fetal dysrhythmia and hydrops fetalis.[27]

POSTNATAL

The mainstay of treatment for tuberous sclerosis is symptomatic management and close surveillance. Cranial MRI, ophthalmic exams, electroencephalogram, echocardiography, renal ultrasonography, and neurodevelopmental testing should be performed at the time of diagnosis and as clinically indicated. Drug therapy targeting the mTOR pathway by using rapamycin and its analogs

is currently under investigation and has demonstrated promise in the treatment of angiomyolipomas, subependymal giant cell astrocytomas, and seizure frequency.[3,28]

WHAT THE REFERRING PHYSICIAN NEEDS TO KNOW

Patients with a personal and/or family history of TSC should be referred for genetic counseling during pregnancy and should undergo thorough assessment of the fetal cardiac and intracranial anatomy. Fetal MRI as well as echocardiography may be useful adjuncts to routine prenatal US. In patients with no known history but with prenatal findings suspicious for TSC, genetic testing should also be considered given the large proportion of sporadic disease-causing mutations. Diagnosis in the fetus may also be the first sign of a mildly affected parent given the wide phenotypic variation in TSC mutations. Alternatively, fetal diagnosis may reveal an unaffected parent with gonadal mosaicism, and consequent transmission risk to future children.

KEY POINTS

- Tuberous sclerosis is a disorder of cellular differentiation and migration affecting multiple organ systems with a wide spectrum of clinical manifestations.
- While tuberous sclerosis is inherited in an autosomal dominant pattern, there is a high rate of sporadic mutation as well as wide variation in phenotype, even among affected family members.
- Cardiac rhabdomyomas are the most common prenatal US finding, typically multifocal in nature and observed in the second half of pregnancy.
- Fetal MRI and echocardiography may be useful adjuncts to prenatal US in further characterizing intracerebral pathology and degree of cardiac involvement.

SUGGESTED READING

Baskin HJ. The pathogenesis and imaging of the tuberous sclerosis complex. *Pediatr Radiol*. 2008;38:936-952.

Curatolo PC, Bombardieri R, Jozwiak S. Tuberous sclerosis. *Lancet*. 2008;372:657-668.

Franz DN. Diagnosis and management of tuberous sclerosis complex. *Semin Pediatr Neurol*. 1998;5:253-268.

Isaacs H. Perinatal (fetal and neonatal) tuberous sclerosis: a review. *Am J Perinatol*. 2009;26:755-760.

Northrup H, Krueger DA. Tuberous sclerosis complex diagnostic criteria update: recommendations of the 2012 international tuberous sclerosis complex consensus conference. *Pediatr Neurol*. 2013;49:243-254.

Roach SE, Sparagana SP. Diagnosis of tuberous sclerosis complex. *J Child Neurol*. 2004;19:643-649.



All references available online at
www.expertconsult.com

REFERENCES

1. Gomez MR, Sampson JR, Whittemore VH. *Tuberous Sclerosis Complex*. 3rd ed. New York: Oxford University Press; 1999.
2. Baskin HJ. The pathogenesis and imaging of the tuberous sclerosis complex. *Pediatr Radiol*. 2008;38:936-952.
3. Curatolo PC, Bombardieri R, Jozwiak S. Tuberous sclerosis. *Lancet*. 2008;372:657-668.
4. Franz DN. Diagnosis and management of tuberous sclerosis complex. *Semin Pediatr Neurol*. 1998;5:253-268.
5. Sybert VP, Hall JG. Inheritance of tuberous sclerosis. *Lancet*. 1979;1:783.
6. Northrup H, Krueger DA. Tuberous sclerosis complex diagnostic criteria update: recommendations of the 2012 international tuberous sclerosis complex consensus conference. *Pediatr Neurol*. 2013;49:243-254.
7. Osborne JP, Fryer AE, Webb DW. Epidemiology of tuberous sclerosis. *Ann N Y Acad Sci*. 1991;615:125-127.
8. Van Slegtenhorst M, de Hoogt R, Hermans C, et al. Identification of the tuberous sclerosis gene TSC1 on chromosome 9q34. *Science*. 1997;277:805-808.
9. European Chromosome 16 Tuberous Sclerosis Consortium. Identification and characterization of the tuberous sclerosis gene on chromosome 16. *Cell*. 1993;75:1305-1315.
10. Ess KC. The neurobiology of tuberous sclerosis complex. *Semin Pediatr Neurol*. 2006;13:37-42.
11. Chan JA, Zhang H, Roberts PS, et al. Pathogenesis of tuberous sclerosis subependymal giant cell astrocytomas: biallelic inactivation of TSC1 or TSC2 leads to mTOR activation. *J Neuropathol Exp Neurol*. 2004;63:1236-1242.
12. Tee AR, Sampson JR, Pal DK, et al. The role of mTOR signaling in neurogenesis, insights from tuberous sclerosis complex. *Semin Cell Dev Biol*. 2016;52:12-20.
13. Sepp T, Yates JR, Green AJ. Loss of heterozygosity in tuberous sclerosis hamartomas. *J Med Genet*. 1996;33:962-964.
14. Curatolo P, Moavero R, Roberto D, et al. Genotype/phenotype correlations in tuberous sclerosis complex. *Semin Pediatr Neurol*. 2015;22:259-273.
15. Dabora SL, Jozwiak S, Franz DN, et al. Mutation analysis in a cohort of 224 tuberous sclerosis patients indicates increased severity of TSC2, compared with TSC1, disease in multiple organs. *Am J Hum Genet*. 2001;68:64-80.
16. Roach SE, Sparagana SP. Diagnosis of tuberous sclerosis complex. *J Child Neurol*. 2004;19:643-649.
17. Sancak O, Nellist M, Goedbloed M, et al. Mutational analysis of the TSC1 and TSC2 genes in a diagnostic setting: genotype-phenotype correlations and comparison of diagnostic DNA techniques in tuberous sclerosis complex. *Eur J Hum Genet*. 2005;13:731-741.
18. Groves MM, Fagg NLK, Cook AC, et al. Cardiac tumors in intrauterine life. *Arch Dis Child*. 1992;67:1189-1192.
19. Jozwiak S, Kotulska K. Are all prenatally diagnosed multiple cardiac rhabdomyomas a sign of tuberous sclerosis? *Prenat Diagn*. 2006;26:867-868.
20. Isaacs H. Perinatal (fetal and neonatal) tuberous sclerosis: a review. *Am J Perinatol*. 2006;26:755-760.
21. Gamzu R, Achiron R, Hegesh J, et al. Evaluating the risk of tuberous sclerosis in cases with prenatal diagnosis of cardiac rhabdomyoma. *Prenat Diagn*. 2002;22:1044-1047.
22. Axt-Fliedner R, Qush H, Hendrik HJ, et al. Prenatal diagnosis of cerebral lesions and multiple intracardiac rhabdomyomas in a fetus with tuberous sclerosis. *J Ultrasound Med*. 2001;20:63-67.
23. Tworetzky W, McElhinney DB, Margossian R, et al. Association between cardiac tumors and tuberous sclerosis in the fetus and neonate. *Am J Cardiol*. 2003;92:487-489.
24. Brackley KJ, Farndon PA, Weaver JB, et al. Prenatal diagnosis of tuberous sclerosis with intracerebral signs at 14 weeks' gestation. *Prenat Diagn*. 1999;19:575-579.
25. Muhler MR, Rake A, Schwabe M, et al. Value of fetal cerebral MRI in sonographically proven cardiac rhabdomyoma. *Pediatr Radiol*. 2007;37:467-474.
26. Sonigo P, Elmaleh A, Fermont L, et al. Prenatal MRI diagnosis of fetal cerebral tuberous sclerosis. *Pediatr Radiol*. 1996;26:1-4.
27. King JA, Stamilio DM. Maternal and fetal tuberous sclerosis complicating pregnancy: a case report and overview of the literature. *Am J Perinatol*. 2005;22:103-108.
28. Julich K, Sahin M. Mechanism-based treatment in tuberous sclerosis complex. *Pediatr Neurol*. 2014;50:290-296.

144 Sirenomelia

FALLON R. BREWER | LORIE M. HARPER

Introduction

Sirenomelia is a rare congenital disorder that was previously considered a severe form of caudal regression, although it is currently considered a completely different entity.[1] Also known as the *mermaid syndrome*, it is characterized by a variable degree of atrophy of the lower limbs, with the resultant appearance of a mermaid tail or fin (Fig. 144.1). Because of the associated anomalies (particularly bilateral renal agenesis), the syndrome is typically considered lethal; however, several case reports now exist of survival to several years of life.[2–4]

Disorder

DEFINITION

Sirenomelia is characterized by three common findings: a single lower limb, bilateral renal agenesis, and a single umbilical artery contiguous with the aorta.[5–7] Multiple other severe anomalies may present. Reported associated findings include ambiguous or absent external genitalia, absent internal genitalia, absent bladder, absence of the anus and rectum, and sacral agenesis.[5–9]

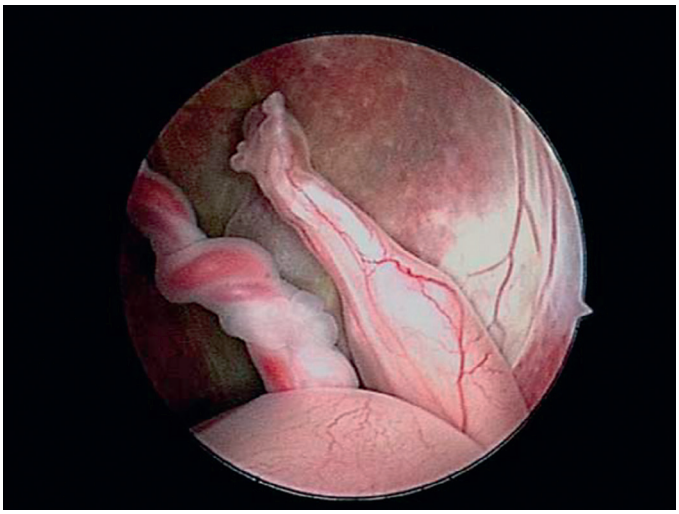

Fig. 144.1 Embryoscopic image of an embryo with sirenomelia. The lower limbs are fused, and the umbilical cord demonstrates a single large umbilical artery. *(From Clemente CM, Farino M, Cianci A. Sareri MI. Sirenomelia with oligodactylia: early ultrasonographic and hysteroscopic embryoscopic diagnosis during the first trimester of gestation.* Fetal Diagn Ther *2010;28:43–45.)*

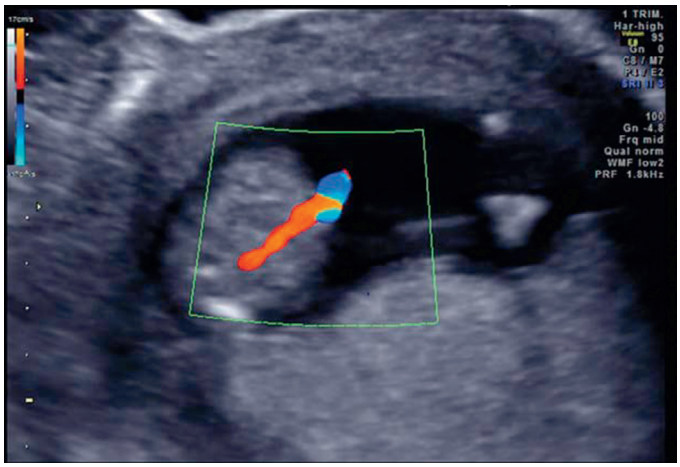

Fig. 144.2 Color Doppler demonstrates a single umbilical artery that appears to arise from the aorta. *(From Singh C, Lodha P, Arora D, Sharam AP, Kaul A. Diagnosis of sirenomelia in the first trimester.* J Clin Ultrasound *2014;41:355–359.)*

Two methods of classifying sirenomelia have been proposed. The first categorizes cases into three groups based on the number of feet present: symelia apus, symelia unipus, and symelia dipus.[6,7] Symelia apus is the most common and is characterized by a single lower extremity and absent or rudimentary feet. Symelia unipus shows a single foot with two femurs, tibiae, and fibulae. With symelia dipus both feet are present but are malrotated, thus resembling fins.

The second classification system is based on the presence or absence of bones in the lower limb.[7] Type I sirenomelia has all the bones of the limb present (two femurs, two tibiae, two fibulae). Type II has two femurs and two tibiae but fused fibulae, and in type III the fibulae are completely absent. Types IV and V are both characterized by partially fused femurs and are distinguished by the presence of fused fibulae in type IV and absent fibulae in type V. In type VI, a fused femur and fused tibia are present, and type VII has a fused femur and no tibia.

A key feature to distinguish sirenomelia from caudal regression syndrome is the anatomy of the umbilical artery.[5] In sirenomelia, a large artery arises from the aorta and functions as a single umbilical artery (Fig. 144.2).[5,10] This artery is likely a remnant of the vitelline artery complex and is almost always associated with sirenomelia.[5] In contrast, cases of caudal regression may be distinguished by the presence of two umbilical arteries, nonlethal renal anomalies, and two hypoplastic lower limbs.[11]

PREVALENCE AND EPIDEMIOLOGY

Sirenomelia is a rare disorder, occurring in 1.5:100,000–4.2:100,000 births.[6,8,9] It is 100–150 times more common in monozygotic twins than singletons.[12] The sirenomelia spectrum of defects includes external and internal genital defects. Because of the absence of external genital and infrequent information on gonadal or chromosomal sex, data on sex distribution are very scarce; however, the limited information that is available indicates male sex preference or does not indicate any substantial sex preference.[13]

Sirenomelia is also strongly associated with maternal pregestational diabetes; 2% of reported cases are in diabetic mothers.[12,14] A recent epidemiologic study by Orioli et al. observed a higher prevalence (2.36:100,000) of sirenomelia in the Mexican registry (one of 19 birth defect surveillance systems analyzed worldwide)[13] with an increased prevalence with maternal age less than 20 years. Considering twinning and maternal diabetes are both associated with sirenomelia, and both conditions are more common in older gravidae, the higher prevalence of sirenomelia found in younger mothers in this study was unexpected.

ETIOLOGY, PATHOPHYSIOLOGY, AND EMBRYOLOGY

Although this has been described as "fused lower limbs," it more likely represents failure of blastogenesis of the lower limb buds.[10,15] Two theories exist as to the etiology. The first is the vascular steal theory developed by Stevenson et al.[10] This theory posits that blood flow is diverted from the embryo, caudal to the origin of the aberrant vitelline remnant. As a result, tissues distal to this site are either malformed or not formed because of lack of oxygen and nutrients. As the vitelline remnant normally arises superior to the inferior mesenteric and renal arteries, the affected tissues typically include the kidneys, lower intestine, sacrum, and lower extremities. For this theory to be accurate, the vascular steal must occur before day 23 of development, which is before the cleavage of the lower limb bud.

More attention is now being focused on an alternative theory; the concept of primary development field defects.[15,16] During blastogenesis, the caudal eminence gives rise to the lower limb buds as well as the perineum, somites, and vertebrae. An insult at the caudal neuropore could give rise to the spectrum of anomalies seen in sirenomelia.

Mutations in the superfamily of *CYP* genes have been noted in animal models (mice) with sirenomelia.[17,18] Specifically, *CYP26A1* is the receptor of retinoic acid, and lower vertebral column malformations have been reported in pregnancies after exposure to high doses of retinoic acid at different gestational ages, linking sirenomelia and retinoic acid intoxication.[19,20] Another observation is the link between bone morphogenic protein 7 (BMP7) and twisted gastrulation (Tsg); loss of BMP7 combined with a complete loss or half-dose of Tsg in mice models is associated with sirenomelia.[21,22] These studies have not been replicated in humans.

Sirenomelia is considered to be a sporadic event.[15] Affected fetuses typically have a normal karyotype, and the recurrence risk is not thought to be greater than that of the general population. No instances of familial recurrence of sirenomelia have been reported; however, under the pathogenetic concept of sirenomelia as part of caudal regression syndrome, familial cases are known.[13] Teratogenic exposures may play a role. Animal models demonstrate associations between sirenomelia and exposure to retinoic acid, cadmium, lithium, diethylpropion, lead, hyperthermia, and radiation.[5,12] In addition, there are case reports of sirenomelia after cocaine use.[23]

MANIFESTATIONS OF DISEASE

Clinical Presentation

Sirenomelia is characterized by the presence of a single lower limb. Inspection of the umbilical cord will reveal a single umbilical artery, which is connected directly to the aorta. Renal agenesis leads to anhydramnios *in utero* and a subsequent Potter sequence, resulting in dysmorphic facies and pulmonary hypoplasia. Other



Fig. 144.3 A 13-week ultrasound demonstrating a fused lower extremity. All bones are visible, as in type 1. *(From Schiesser M, Holzgreve W, Lapaire O, et al. Sirenomelia, the mermaid syndrome–detection in the first trimester.* Prenat Diagn *2003;23(6):493–495.)*

severe anomalies are likely to be present. In the lower half of the fetus: ambiguous or absent external genitalia, absent internal genitalia, absent bladder, absence of the anus and rectum, neural tube defect, and sacral agenesis.[5–9] In addition, upper body/limb malformations have been reported, albeit rarely, and include cardiovascular abnormalities, cleft palate, pulmonary hypoplasia, abdominal wall defects, scoliosis, and other skeletal deformities.[1,7,24]

Imaging Technique and Findings

Ultrasound. Uniquely, sirenomelia may be best diagnosed on a first-trimester ultrasound (US) rather than the second trimester. In the second trimester, amniotic fluid production is reliant on functional kidneys and a normal urinary outflow tract. Renal agenesis is typical with sirenomelia, and the subsequent oligohydramnios or anhydramnios in the second trimester makes a detailed anatomic survey difficult. Consequently, a first-trimester US usually provides more detail in cases where renal agenesis is present.

Several authors report cases of sirenomelia diagnosed in the first trimester, as early as 9 weeks' gestation.[8,12,14] Findings at this time include a thickened nuchal translucency, fused lower extremities (Fig. 144.3), a single umbilical artery contiguous with the aorta (see Fig. 144.2), and absent fetal bladder.

Findings reported on second-trimester US have been less specific. Fetal size and anhydramnios make delineation of a single lower extremity difficult; one clue may be that the femurs move in the same direction for the entire US. It may be possible to demonstrate that only one femur is present in cases of symelia apus.

Bilateral renal agenesis can be documented by absence of renal tissue and by absence of renal arteries on Doppler. Use of Doppler US may aid in differentiating isolated renal agenesis from sirenomelia by demonstrating the absence of iliac arteries in cases of sirenomelia.[25,26] The presence of two umbilical arteries on either side of the bladder virtually excludes the diagnosis of sirenomelia.[12]

Magnetic Resonance Imaging. Magnetic resonance imaging (MRI) may enable better visualization and characterization of sacral and lower extremity anomalies, particularly in cases where anhydramnios limits visualization (Fig. 144.4).[12] However, this may be of limited clinical utility as the presence of anhydramnios and the resulting pulmonary hypoplasia is typically lethal, even in the absence of sirenomelia.



Fig. 144.4 Fetal MRI demonstrating fused lower limbs. *(From Van Keirsbilck J, Cannie M, Robrechts C, et al. First-trimester diagnosis of sirenomelia.* Prenat Diagn *2006;26(8):684–688.)*

Differential Diagnosis From Imaging Findings

1. Amniotic band
2. Bilateral renal agenesis
3. Caudal regression syndrome

Synopsis of Treatment Options

PRENATAL

No prenatal treatments exist at this time.

POSTNATAL

Sirenomelia was previously universally fatal, although over the last two decades a handful of case reports of survival to the first several years of life exist.[2–4] Little has been reported about long-term outcomes. In case reports of survivors, renal tissue was present and amniotic fluid was present in sufficient quantity to allow pulmonary development. Multidisciplinary surgical approaches have been used to correct associated anomalies. Necessary procedures have included urinary and intestinal drainage procedures. Soft tissue expanders and skin flaps have been used to separate the lower extremities. At least one patient required dialysis and renal transplant for renal failure.

WHAT THE REFERRING PHYSICIAN NEEDS TO KNOW

While sirenomelia is rare, inability to visualize distinct lower limbs in the setting of oligo- or anhydramnios should raise the consideration for the diagnosis and warrants referral.

KEY POINTS

- Sirenomelia is characterized by a single lower limb, a single umbilical artery arising at the aorta, and bilateral renal agenesis.
- Sirenomelia can be distinguished sonographically from bilateral renal agenesis by the absence of iliac arteries.
- Survival has been reported when normal renal tissue is present.

SUGGESTED READING

Boulas MM. Recognition of caudal regression syndrome. *Adv Neonatal Care*. 2009;9(2):61-69, quiz 70-61.

Garrido-Allepuz C, Haro E, Gonzalez-Lamuno D, et al. A clinical and experimental overview of sirenomelai: insight into the mechanisms of congenital limb malformations. *Dis Model Mech*. 2011;4:289-299.



All references available online at
www.expertconsult.com

REFERENCES

1. Tonni G, Grisolia G. Sirenomelia: a review on embryogenic environmental theories, novel three-dimensional ultrasound imaging and first trimester diagnosis in a case of mosaic 69,XXX/46,XX fetus. *Arch Gynecol Obstet*. 2013;288(1):3-11.
2. Messineo A, Innocenti M, Gelli R, et al. Multidisciplinary surgical approach to a surviving infant with sirenomelia. *Pediatrics*. 2006;118(1):e220-e223.
3. Pinette MG, Hand M, Hunt RC, et al. Surviving sirenomelia. *J Ultrasound Med*. 2005;24(11):1555-1559.
4. Stanton MP, Penington EC, Hutson JM. A surviving infant with sirenomelia (Mermaid syndrome) associated with absent bladder. *J Pediatr Surg*. 2003;38(8):1266-1268.
5. Das BB, Rajegowda BK, Bainbridge R, et al. Caudal regression syndrome versus sirenomelia: a case report. *J Perinatol*. 2002;22(2):168-170.
6. Horikoshi T, Kikuchi A, Tatematsu M, et al. Two cases of a fetus with sirenomelia sequence. *Congenit Anom*. 2005;45(3):93-95.
7. van Zalen-Sprock MM, van Vugt JM, van der Harten JJ, et al. Early second-trimester diagnosis of sirenomelia. *Prenat Diagn*. 1995;15(2):171-177.
8. Monteagudo A, Mayberry P, Rebarber A, et al. Sirenomelia sequence: first-trimester diagnosis with both two- and three-dimensional sonography. *J Ultrasound Med*. 2002;21(8):915-920.
9. Banerjee A, Faridi MM, Banerjee TK, et al. Sirenomelia. *Indian J Pediatr*. 2003;70(7):589-591.
10. Stevenson RE, Jones KL, Phelan MC, et al. Vascular steal: the pathogenetic mechanism producing sirenomelia and associated defects of the viscera and soft tissues. *Pediatrics*. 1986;78(3):451-457.
11. Boulas MM. Recognition of caudal regression syndrome. *Adv Neonatal Care*. 2009;9(2):61-69, quiz 70-61.
12. Van Keirsbilck J, Cannie M, Robrechts C, et al. First trimester diagnosis of sirenomelia. *Prenat Diagn*. 2006;26(8):684-688.
13. Orioli IM, Amar E, Arteaga-Vazquez J, et al. Sirenomelia: an epidemiologic study in a large dataset from the International Clearinghouse of Birth Defects Surveillance and Research, and literature review. *Am J Med Genet C*. 2011;157C(4):358-373.
14. Schiesser M, Holzgreve W, Lapaire O, et al. Sirenomelia, the mermaid syndrome–detection in the first trimester. *Prenat Diagn*. 2003;23(6):493-495.
15. Opitz JM, Zanni G, Reynolds JF Jr, et al. Defects of blastogenesis. *Am J Med Genet*. 2002;115(4):269-286.
16. Rougemont AL, Bouron-Dal Soglio D, Desilets V, et al. Caudal dysgenesis, sirenomelia, and situs inversus totalis: a primitive defect in blastogenesis. *Am J Med Genet A*. 2008;146A(11):1470-1476.
17. Isik Kaygusuz E, Kurek Eken M, Sivrikoz ON, et al. Sirenomelia: a review of embryogenic theories and discussion of the differences from caudal regression syndrome. *J Matern Fetal Neonat Med*. 2016;29(6):949-953.
18. Garrido-Allepuz C, Haro E, Gonzalez-Lamuno D, et al. A clinical and experimental overview of sirenomelia: insight into the mechanisms of congenital limb malformations. *Dis Model Mech*. 2011;4(3):289-299.
19. Abu-Abed S, Dolle P, Metzger D, et al. The retinoic acid-metabolizing enzyme, CYP26A1, is essential for normal hindbrain patterning, vertebral identity, and development of posterior structures. *Gene Dev*. 2001;15(2):226-240.
20. Young T, Rowland JE, van de Ven C, et al. Cdx and Hox genes differentially regulate posterior axial growth in mammalian embryos. *Dev Cell*. 2009;17(4):516-526.
21. Zakin L, Reversade B, Kuroda H, et al. Sirenomelia in Bmp7 and Tsg compound mutant mice: requirement for Bmp signaling in the development of ventral posterior mesoderm. *Development*. 2005;132(10):2489-2499.
22. Larrain J, Oelgeschlager M, Ketpura NI, et al. Proteolytic cleavage of Chordin as a switch for the dual activities of twisted gastrulation in BMP signaling. *Development*. 2001;128(22):4439-4447.
23. Sarpong S, Headings V. Sirenomelia accompanying exposure of the embryo to cocaine. *South Med J*. 1992;85(5):545-547.
24. Su D, Yao Q. Sirenomelia with upper limb malformation: a case report and review of the literature. *Clin Exp Obstet Gynecol*. 2015;42(4):537-539.
25. Sepulveda W, Corral E, Sanchez J, et al. Sirenomelia sequence versus renal agenesis: prenatal differentiation with power Doppler ultrasound. *Ultrasound Obstet Gynecol*. 1998;11(6):445-449.
26. Patel S, Suchet I. The role of color and power Doppler ultrasound in the prenatal diagnosis of sirenomelia. *Ultrasound Obstet Gynecol*. 2004;24(6):684-691.

145 Smith-Lemli-Opitz Syndrome

ADETOLA F. LOUIS-JACQUES | ANTHONY O. ODIBO

Introduction

Smith-Lemli-Opitz syndrome (SLOS) is an autosomal recessive disorder caused by abnormal cholesterol synthesis. SLOS was originally named *RSH syndrome,* derived from the surnames of the first three families identified with this disorder.[1] SLOS is characterized by growth failure, cognitive delay, behavioral disturbances, dysmorphic faces, and congenital malformations.[2] There is marked variability in presentation of this condition among affected individuals.[3]

Although SLOS was historically divided into two subtypes, with type I being milder and type II being more severe, there is now thought to be a clinical and biochemical continuum.[4] SLOS is caused by mutations in the gene encoding the 7-dehydrocholesterol reductase *(DHCR7* gene).[5–7] These mutations results in elevation of the cholesterol precursor 7-dehydrocholesterol (7-DHC) and typically decreased cholesterol synthesis.[8,9] Genotype-phenotype correlations have been noted, wherein mutations that lead to lower or absent gene function are found in the most severely affected individuals and mutations that lead to more residual function are found in less severely affected individuals.[3,4,10]

Disorder

DEFINITION

SLOS is an autosomal recessive syndrome that is biochemically defined. Although there are abnormalities commonly associated with SLOS, diagnosis is made based on elevated 7-DHC because of the variable presentation in affected individuals.[8,9,11] Decreased serum cholesterol is also noted in most affected individuals; however, 10% have normal serum cholesterol. Therefore the cholesterol level alone is inadequate to confirm the diagnosis.[4]

PREVALENCE AND EPIDEMIOLOGY

The estimated incidence of SLOS is 1:39,000 conceptions, with a carrier rate of approximately 1%.[12] Although SLOS is panethnic, higher carrier prevalence is reported in individuals of European or North American heritage (1%–2%). Older studies identified a greater than 2:1 ratio for males to females affected with SLOS; however, this is likely caused by ascertainment bias. Males are often identified owing to abnormal external genitalia, a finding lacking in affected females. Recent studies demonstrate an equivalent male-to-female ratio.

ETIOLOGY AND PATHOPHYSIOLOGY

SLOS is an inborn error of metabolism syndrome caused by homozygous mutations in the *DHCR7* gene,[5–7] which codes for the enzyme 7-DHC reductase. These mutations lead to decreased or absent function of this enzyme. Seven-DHC reductase is responsible for catalyzing the final step in cholesterol synthesis, wherein 7-DHC is converted to cholesterol. Increased levels of 7-DHC are seen in affected individuals.[8,9] The clinical sequelae of SLOS may be secondary to one or all of these factors: low levels of cholesterol, deficient total sterols, and toxic effects of markedly elevated concentrations of 7-DHC.[13,14]

The severity of the condition is likely related to the percent of remaining 7-DHC activity in the individual.[3,4,10] Cholesterol has many functions in the body and is essential for fetal development.[15] It is a required precursor to many important molecules, such as androgens. Low or absent cholesterol explains the incidence of abnormal or feminized external genitalia in XY individuals with SLOS. The other abnormalities noted in SLOS are likely caused by the fact that cholesterol interacts with "hedgehog" proteins, which encode inductive signals during embryogenesis.[16] If an individual has deficient cholesterol levels, it may be caused by downregulation of hedgehog proteins. The spectrum of anomalies noted in SLOS is consistent with anomalies in individuals with mutations in these hedgehog proteins.

In contrast to many other metabolites, minimal cholesterol is supplied to the developing fetus by the mother.[15] Signs of SLOS are often noted prenatally because cholesterol is an essential building block during fetal development. For this reason, SLOS may be suspected if maternal estriol levels are low during second-trimester maternal serum screening, particularly when characteristic congenital anomalies are also noted on ultrasound (US).[17,18] Data suggest that fetuses with SLOS are likely to have low maternal serum estriol levels, low beta-human chorionic gonadotropin levels, and low alpha-fetoprotein levels. The detection rate for fetuses affected with SLOS by this screening method has not been established. Nonetheless, evaluation

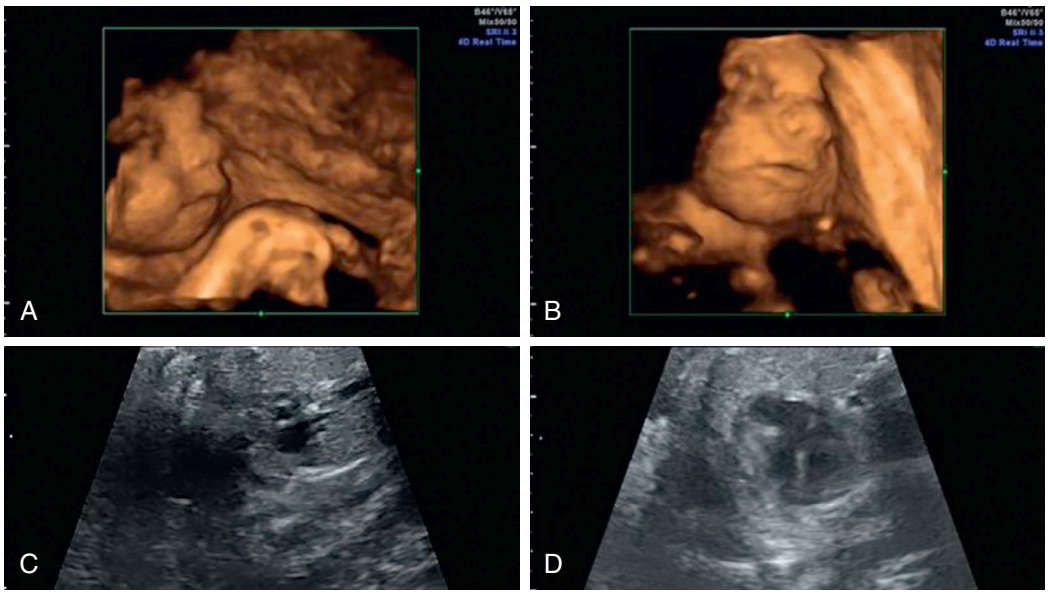

Fig. 145.1 Ultrasound images obtained at 31 weeks' gestation. (A) Dysmorphic profile with micrognathia and anteverted nares; (B) frontal imaging shows a narrow forehead, micrognathia, and anteverted nares; (C) three-vessels view showing the superior vena cava, aorta, and the pulmonary artery. The aorta is significantly smaller than the pulmonary artery and the aorta is narrow, suggesting coarctation of the aorta; (D) four-chamber view reveals atrioventricular septal defect. *(From Szpera Goździewicz A, MaRioLa R, Rzymski P, et al. Smith-Lemli-Opitz Syndrome—a challenging prenatal diagnosis.* Ginekol Pol *2016;87:76–78.)*

for SLOS is commonly discussed if the maternal serum estriol level is lower than 0.3 multiples of the median adjusted for gestational age.

MANIFESTATIONS OF DISEASE

Clinical Presentation

SLOS presentation can range from such mild effects that an individual remains undiagnosed to serious congenital anomalies, cognitive delay, and fetal or neonatal death.[2] Findings commonly associated with SLOS are listed subsequently[2–4,13,14,19–21]:

- general
  - cognitive delays
  - developmental delays
  - prenatal and postnatal growth restriction
- behavioral disturbances
  - autism spectrum disorder
  - self-injury
- central nervous system malformations
  - holoprosencephaly
  - agenesis or partial agenesis of corpus callosum
- craniofacial
  - microcephaly
  - cleft palate/arched palate/bifid uvula
  - dysmorphic facial features (anteverted nares, micrognathia, blepharoptosis)
  - cataracts
- extremities
  - syndactyly of toes two and three
  - polydactyly
- cardiac defects (septal defects)
- renal hypoplasia
- hypoplastic or unilobar lungs
- visceral anomalies



Fig. 145.2 Holoprosencephaly.

- abnormal external genitalia or cryptorchidism in XY individuals
- photosensitivity

Imaging Technique and Findings

Ultrasound. The following findings on US in association with low maternal serum estriol are highly suggestive of SLOS (Figs. 145.1–145.4)[18,21]:

- syndactyly/polydactyly
- growth restriction
- microcephaly
- micrognathia
- cleft palate
- cardiac defects



Fig. 145.3 Ambiguous genitalia.



Fig. 145.4 Polysyndactyly.

In addition, increased nuchal translucency has been reported in the first trimester.[21,22] Other malformations on prenatal US include agenesis of the corpus callosum, microcephaly, holoprosencephaly, sexual ambiguity with male karyotype, and agenesis of the kidneys leading to oligohydramnios/anhydramnios.[21]

Magnetic Resonance Imaging. Magnetic resonance imaging may complement the aforementioned US findings.

CLASSIC SIGNS

- Polydactyly/syndactyly.
- Growth restriction.
- Microcephaly.
- Cleft palate.
- Low second-trimester maternal serum estriol.

Differential Diagnosis From Imaging Findings

Fetuses with trisomy 18 and trisomy 13 often display similar abnormalities to fetuses with SLOS, including low maternal serum estriol levels. A normal karyotype should be established before initiating SLOS testing. Other syndromes with similar presentation include:

1. Dubowitz syndrome
2. Russell-Silver syndrome
3. Pseudo–trisomy 13 syndrome
4. Pallister-Hall syndrome
5. Lethal acrodysgenital dwarfism

Synopsis of Treatment Options

PRENATAL

SLOS is typically undiagnosed until the second trimester, at which point many of the associated anomalies are already present, and reversal is impossible. Nevertheless, *in utero* fetal cholesterol supplementation via intravenous and intraperitoneal transfusions of fresh frozen plasma has been reported. An improvement in fetal plasma cholesterol levels, fetal mean corpuscular volume, and maternal estriol levels were noted.[23]

POSTNATAL

The most common postnatal therapy for SLOS is dietary cholesterol supplementation. Case reviews have demonstrated an improvement in growth, behavioral problems, gastrointestinal symptoms, photosensitivity, and ability to walk and speak once cholesterol deficiency was treated.[11,24–26] Other used therapies include bile acid, fresh frozen plasma, stress steroid dosing, simvastatin, and antioxidants.[14] However, no large, well-controlled clinical trials to date have displayed clear clinical utility of these interventions.[14] In individuals with SLOS and certain congenital defects, the typical course of treatment includes dietary cholesterol supplementation and surgical intervention for the given defect or defects, as appropriate.

WHAT THE REFERRING PHYSICIAN NEEDS TO KNOW

SLOS is one of the most common genetic disorders in which prenatal diagnosis is likely and possible. SLOS should be considered in fetal cases with polydactyly/syndactyly, growth restriction, low maternal serum estriol, and other defects, especially if there is a normal karyotype. SLOS should also be considered in an XY fetus with ambiguous genitalia. Prenatal testing is available in at-risk pregnancies. In couples who are known carriers for SLOS, molecular testing can be performed through chorionic villus sampling or amniocentesis if the familial mutations are known. In pregnancies suspected to be at risk for SLOS based on maternal serum analyte levels and or abnormal US examinations, prenatal diagnosis is possible by measuring cholesterol and 7-DHC concentrations in either chorionic villi or amniotic fluid.[27,28] In addition, steroid measurements in maternal urine has been identified as an effective tool for diagnosing SLOS during pregnancy.[29]

KEY POINTS

- SLOS is a disorder of cholesterol synthesis.
- Clinical presentation is highly variable, necessitating biochemical diagnosis.
- Prenatal diagnosis is possible.

Acknowledgment

The authors are grateful for the contributions of Rachael Bradshaw in the prior edition.

SUGGESTED READING

Bianconi SE, Cross JL, Wassif CA, et al. Pathogenesis, epidemiology, diagnosis, and clinical aspects of Smith-Lemli-Opitz syndrome. *Expert Opin Orphan Drugs*. 2015;3(3):267-280.

Porter FD. Smith-Lemli-Opitz syndrome: pathogenesis, diagnosis, and management. *Eur J Hum Genet*. 2008;16:535-541.

Shinawi M, Szabo S, Popek E, et al. Recognition of Smith-Lemli-Opitz syndrome (RSH) in the fetus: utility of ultrasonography and biochemical analysis in pregnancies with low maternal serum estriol. *Am J Med Genet A*. 2005;138:56-60.

SzpeRaY Goździewicz A, MaRioLa R, Rzymski P, et al. Smith-Lemli-Opitz syndrome—a challenging prenatal diagnosis. *Ginekol Pol*. 2016;87:76-78.



All references available online at www.expertconsult.com

REFERENCES

1. Smith DW, Lemli L, Opitz JM. A newly recognized syndrome of multiple congenital anomalies. *J Pediatr*. 1964;64:210-217.
2. OMIM. Smith-lemli-Opitz Syndrome; SLOS (vol 2016).
3. Ryan A, Bartlett K, Clayton P, et al. Smith-Lemli-Opitz syndrome: a variable clinical and biochemical phenotype. *J Med Genet*. 1998;35:558-565.
4. Cunniff C, Kratz LE, Moser A, et al. Clinical and biochemical spectrum of patients with RSH/Smith-Lemli-Opitz syndrome and abnormal cholesterol metabolism. *Am J Med Genet*. 1997;68:263-269.
5. Waterham HR, Wijburg FA, Hennekam RC, et al. Smith-Lemli-Opitz syndrome is caused by mutations in the 7-dehydrocholesterol reductase gene. *Am J Hum Genet*. 1998;63:329-338.
6. Wassif CA, Maslen C, Kachilele-Linjewile S, et al. Mutations in the human sterol Δ 7-reductase gene at 11q12-13 cause Smith-Lemli-Opitz syndrome. *Am J Hum Genet*. 1998;63:55-62.
7. Fitzky BU, Witsch-Baumgartner M, Erdel M, et al. Mutations in the Δ7-sterol reductase gene in patients with the Smith–Lemli–Opitz syndrome. *Proc Natl Acad Sci U S A*. 1998;95:8181-8186.
8. Tint GS, Irons M, Elias ER, et al. Defective cholesterol biosynthesis associated with the Smith-Lemli-Opitz syndrome. *N Engl J Med*. 1994;330:107-113.
9. Irons M, Elias ER, Salen G, et al. Defective cholesterol biosynthesis in Smith-Lemli-Opitz syndrome. *Lancet*. 1993;341:1414.
10. Tint G, Salen G, Batta AK, et al. Correlation of severity and outcome with plasma sterol levels in variants of the Smith-Lemli-Opitz syndrome. *J Pediatr*. 1995;127:82-87.
11. Irons M, Elias ER, Tint G, et al. Abnormal cholesterol metabolism in the Smith-Lemli-Opitz syndrome: report of clinical and biochemical findings in four patients and treatment in one patient. *Am J Med Genet*. 1994;50:347-352.
12. Cross J, Iben J, Simpson C, et al. Determination of the allelic frequency in Smith–Lemli–Opitz syndrome by analysis of massively parallel sequencing data sets. *Clin Genet*. 2015;87:570-575.
13. Porter FD. Smith-Lemli-Opitz syndrome: pathogenesis, diagnosis, and management. *Eur J Hum Genet*. 2008;16:535-541.
14. Bianconi SE, Cross JL, Wassif CA, et al. Pathogenesis, epidemiology, diagnosis, and clinical aspects of Smith-Lemli-Opitz syndrome. *Expert Opin Orphan Drugs*. 2015;3:267-280.
15. Woollett LA. Maternal cholesterol in fetal development: transport of cholesterol from the maternal to the fetal circulation. *Am J Clin Nutr*. 2005;82:1155-1161.
16. Porter JA, Young KE, Beachy PA. Cholesterol modification of hedgehog signaling proteins in animal development. *Science*. 1996;274:255-259.
17. Craig WY, Haddow JE, Palomaki GE, et al. Identifying Smith–Lemli–Opitz syndrome in conjunction with prenatal screening for Down syndrome. *Prenat Diagn*. 2006;26:842-849.
18. Goldenberg A, Wolf C, Chevy F, et al. Antenatal manifestations of Smith-Lemli-Opitz (RSH) syndrome: a retrospective survey of 30 cases. *Am J Med Genet A*. 2004;124:423-426.
19. Tierney E, Nwokoro NA, Porter FD, et al. Behavior phenotype in the RSH/Smith-Lemli-Opitz syndrome. *Am J Med Genet*. 2001;98:191-200.
20. Thurm A, Tierney E, Farmer C, et al. Development, behavior, and biomarker characterization of Smith-Lemli-Opitz syndrome: an update. *J Neurodev Disord*. 2016;8:12.
21. Quelin C, Loget P, Verloes A, et al. Phenotypic spectrum of fetal Smith-Lemli-Opitz syndrome. *Eur J Med Genet*. 2012;55:81-90.
22. Hyett JA, Clayton PT, Moscoso G, et al. Increased first trimester nuchal translucency as a prenatal manifestation of Smith-Lemli-Opitz syndrome. *Am J Med Genet*. 1995;58:374-376.
23. Irons MB, Nores J, Stewart TL, et al. Antenatal therapy of Smith-Lemli-Opitz syndrome. *Fetal Diagn Ther*. 1999;14:133-137.
24. Kelley RI. RSH/Smith-Lemli-Opitz syndrome: mutations and metabolic morphogenesis. *Am J Hum Genet*. 1998;63:322.
25. Irons M, Elias ER, Abuelo D, et al. Treatment of Smith-Lemli-Opitz syndrome: results of a multicenter trial. *Am J Med Genet*. 1997;68:311-314.
26. Nwokoro NA, Mulvihill JJ. Cholesterol and bile acid replacement therapy in children and adults with Smith-Lemli-Opitz (SLO/RSH) syndrome. *Am J Med Genet*. 1997;68:315-321.
27. Kelley RI. Diagnosis of Smith-Lemli-Opitz syndrome by gas chromatography/mass spectrometry of 7-dehydrocholesterol in plasma, amniotic fluid, and cultured skin fibroblasts. *Clin Chim Acta*. 1995;236:45-58.
28. Dallaire L, Mitchell G, Giguere R, et al. Prenatal diagnosis of smith–lemli–opitz syndrome is possible by measurement of 7-dehydrocholesterol in amniotic fluid. *Prenat Diagn*. 1995;15:855-858.
29. Shackleton CH, Marcos J, Palomaki GE, et al. Dehydrosteroid measurements in maternal urine or serum for the prenatal diagnosis of Smith–Lemli–Opitz syndrome (SLOS). *Am J Med Genet A*. 2007;143:2129-2136.

146 VATER Association

FALLON R. BREWER | LORIE M. HARPER

Introduction

The VATER association is a nonrandom association of congenital malformations that include *v*ertebral anomalies, *a*nal atresia, *t*racheo*e*sophageal fistula, and *r*enal and *r*adial limb anomalies.[1] This definition has been expanded to include vascular defects as well, and some have renamed this association VACTERL, so that congenital *c*ardiovascular defects and *l*imb anomalies are represented in the name.[2,3]

VATER is not a syndrome; rather, it likely represents a common defect in development leading to several types of anomalies.[4,5] The prognosis will vary depending on the nature, number, and severity of anomalies. In one study on long-term outcomes, 18 of 20 individuals identified and located survived past the age of 10.[6] In patients that did survive and were only affected by VATER, intelligence was normal.

Disorder

DEFINITION

Although the majority of reports define VATER as requiring three anomalies in the association, some studies include subjects with two of the anomalies.[6,7] Furthermore, studies disagree as to whether or not cardiac defects are associated with VATER, and no single cardiac defect has been specifically associated with VATER.[6,7] One study noted that anomalies tended to group in "upper" and "lower" malformations, where upper malformations included upper preaxial limb reduction defects, esophageal atresia, and costovertebral malformations, whereas lower malformations included costovertebral malformations with anal atresia.[6] This same study noted that cardiac defects tended to occur in the upper group, whereas kidney anomalies occurred in the lower group. VATER/VACTERL association is considered a clinical diagnosis.[8]

PREVALENCE AND EPIDEMIOLOGY

The reported prevalence of the VATER association ranges from 1.43 : 10,000 to 13.06 : 10,000.[7,9] The variance in reported prevalence is likely caused by discrepancies in the number of anomalies required for diagnosis in VATER, the inclusion or exclusion of subjects with other syndromes, and the type of radial limb anomalies included in the definition.

ETIOLOGY AND PATHOPHYSIOLOGY

The proposed etiology of VATER is a defect in mesodermal development.[1] The mesoderm contributes to the development of the vertebrae (paraxial mesoderm developing in a craniocaudal direction), limb buds, renal structures (intermediate mesoderm), the urorectal septum (intermediate mesoderm), and the heart (lateral plate mesoderm).[4] This defect in mesodermal development may be termed a *primary developmental field defect* and may represent an insult to the embryo at the blastocyst stage.[3]

Animal models have been proposed to study VATER. In rats and chicks, exposure to adriamycin, a cytotoxic agent, creates anomalies consistent with VATER.[10] These animal models demonstrate abnormal development of the notochord, which leads to the vertebral, tracheoesophageal, and anal anomalies associated with VATER.

VATER/VACTERL association has typically been considered a diagnosis of exclusion.[11] VATER seems to be a sporadic event in the majority of cases (90%).[12] Copy number variations (CNVs) may play a role in this association.[11] A region affecting chromosome band 17q23 containing two candidate genes (*TBX2* and *TBX4*) has been observed. Another possible locus is chromosome 8q24.3. This locus includes several genes including *GLI4*. The exact function of this gene is not well understood; however, similar zinc-finger protein gene mutations have been observed in mice with a VACTERL phenotype. Other CNVs of interest include chromosome 10q25.3 (duplication), 22q11.2 (duplication), and CNVs involving a gain in *SHOX*, which plays an important role in limb development. Deletions in other regions (5q11.2, 6q, 7q35-qter, distal 13q, 19p13.3, and 20q13.33) and duplications on 1q41 and 2q37.3 have also been reported.[11–13] Another case report exists of VATER associated with a supernumerary ring chromosome derived from chromosome 12.[14] Two case series of patients with VATER and hydrocephalus suggest that this may be a separate syndrome with autosomal recessive inheritance or X-linked inheritance, and one case report

suggests a *PTEN* gene mutation could be responsible for this syndrome.[15–17] It is difficult to provide accurate recurrence risk in general, although it is likely low, as long as similar conditions with inherited forms are ruled out.[12] It is also necessary to obtain a detailed family history to adjust recurrence risk appropriately.

Reported environmental factors associated with VATER include maternal diabetes, uterine vascular pathology, and infertility treatment.[18]

MANIFESTATIONS OF DISEASE

Clinical Presentation

The following lists commonly seen defects for each anomaly type.[1,7,19]

Vertebral anomalies
- Hemivertebrae
- Butterfly vertebrae
- Scoliosis
- Spina bifida
- Lordosis
- Spinal dysraphism
- Rib anomalies may accompany vertebral anomalies (i.e., a missing rib in hemivertebrae)

Anal atresia
- Imperforate anus

Tracheoesophageal (T-E) fistula
- Esophageal atresia (may accompany T-E fistula)
- Duodenal atresia (may accompany T-E fistula)

Renal anomalies
- Hydronephrosis
- Cystic kidneys or renal dysplasia
- Renal agenesis
- Urethral atresia

Radial limb anomalies
- Polydactyly
- Syndactyly
- Hypoplastic/aplastic radial ray

Cardiac defects
- Ventricular septal defect (most common)
- Truncus arteriosus
- Transposition of the great vessels
- Tetralogy of Fallot
- Atrial septal defect
- Anomalous valves
- Dextrocardia
- Hypoplastic left heart
- Coarctation of the aorta
- Pulmonary stenosis
- Patent ductus arteriosus

Imaging Technique and Findings

Ultrasound. Case reports of prenatally diagnosed VATER association exist.[20–23] In the majority of cases, the prenatal findings included vertebral anomalies, renal anomalies, and radial limb anomalies; tracheoesophageal fistula and anal atresia were rarely documented prenatally. Ultrasound (US) findings vary based on the defects present, but the following is a listing and description of possible findings.

Vertebral
- Hemivertebrae (Fig. 146.1)
- Butterfly vertebrae
- Spina bifida (Fig. 146.2)
- Rib anomalies

Anal Atresia (Fig. 146.3)

In one case series, only 15.9% were diagnosed prenatally.[24] In all cases that were diagnosed prenatally, dilation of the rectum or colon was noted. Abnormally dilated bowel may be present as early as 12 weeks' gestation.[25,26] Intraluminal calcifications may be present.[19,24]

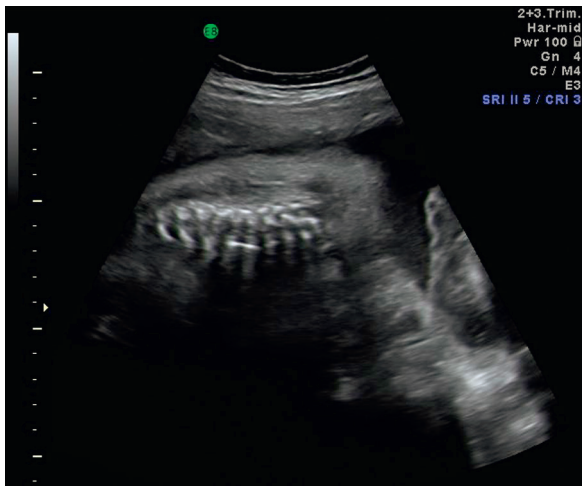

Fig. 146.1 A coronal view of the spine demonstrating hemivertebrae.

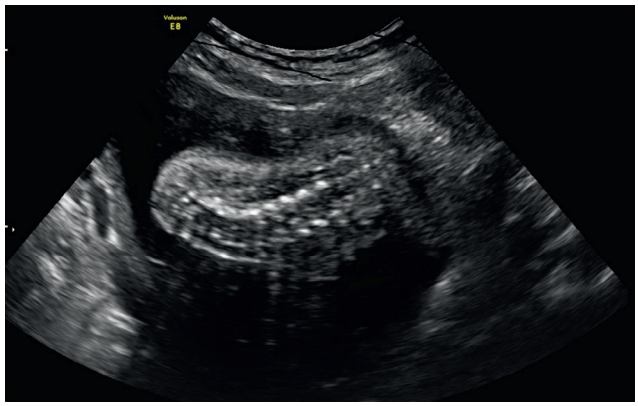

Fig. 146.2 A coronal view of the spine demonstrating scoliosis.



Fig. 146.3 A cross-section of the abdomen demonstrates dilation of bowel and intraluminal calcifications seen in association with anal atresia.

Tracheoesophageal Fistula (Fig. 146.4)
Tracheoesophageal fistula may be diagnosed prenatally by a small or absent stomach bubble.[27,28] Polyhydramnios may also be seen. The positive predictive value of these findings has been reported as 44%–56%.[28] An upper pouch sign may be visualized in the neck region, typically described in the third trimester.
Renal anomalies
- Renal agenesis may be documented by absent renal arteries, either unilateral or bilateral.
- Hydronephrosis
- Cystic or dysplastic kidneys (Fig. 146.5)

Radial anomalies
- Agenesis/hypoplasia of radius
- Agenesis/hypoplasia of thumb
- Polydactyly
- Syndactyly

Three-dimensional imaging of the hand may enable more complete assessment of the hand.[29]

Magnetic Resonance Imaging. Magnetic resonance imaging may be a useful adjunct to US in cases of suspected tracheoesophageal fistula, although the esophagus may not be visualized in as many as 64% of cases, leading to a high false-positive rate.[28,30]



Fig. 146.4 A cross-section of the abdomen at the level of the portal vessels demonstrates no stomach bubble. Persistently absent stomach in this view can be suggestive of tracheoesophageal fistula or esophageal atresia, particularly when associated with polyhydramnios.

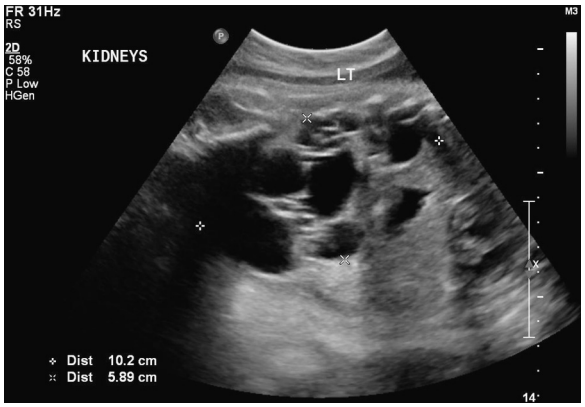

Fig. 146.5 Coronal view of the abdomen demonstrating bilateral multicystic, dysplastic kidneys.

Differential Diagnosis From Imaging Findings

13q-deletion
Alagille syndrome
Baller-Gerold syndrome
CHARGE syndrome
Caudal regression
Fanconi anemia
Fryns syndrome
Holt-Oram syndrome
Jarcho-Levin
Meckel syndrome
MURCS
Nager
Roberts
Sirenomelia
Townes-Brocks syndrome
Trisomy 13
Trisomy 18
Thrombocytopenia-absent radius syndrome

Synopsis of Treatment Options

PRENATAL

No prenatal interventions exist at this time.

POSTNATAL

The management of VATER depends on the exact anomalies present. Corrective surgery may be required for vertebral defects. Anal atresia may require urgent decompressive surgery and can be managed in the long term through reconstructive surgery.[24] Tracheoesophageal fistula and esophageal fistula may be primarily surgically repaired in the majority of cases.[30] Renal and cardiac defects should be managed according to standards of care for the particular defect present.

WHAT THE REFERRING PHYSICIAN NEEDS TO KNOW

Findings of one anomaly in the VATER association should prompt a thorough evaluation for other anomalies. Findings of two or more of the associated malformations of the VATER association should raise suspicion and prompt referral. Presence of tracheoesophageal fistula can complicate management of the airway; delivery at a center equipped for the management of difficult airways is indicated.

KEY POINTS

- VATER is most often a sporadic event.
- Three associated anomalies are required to make the diagnosis of VATER.
- VATER association is likely a result of a defect in mesodermal development.

SUGGESTED READING

Benacerraf BR. *Ultrasound of Fetal Syndromes*. 2nd ed. Philadelphia: Churchill Livingstone/Elsevier; 2008.
Solomon BD. VACTERL/VATER Association. *Orphanet J Rare Dis*. 2011;6:56.

All references available online at www.expertconsult.com

REFERENCES

1. Quan L, Smith DW. The VATER association. Vertebral defects, anal atresia, T-E fistula with esophageal atresia, radial and renal dysplasia: a spectrum of associated defects. *J Pediatr*. 1973;82(1):104-107.
2. Nora AH, Nora JJ. A syndrome of multiple congenital anomalies associated with teratogenic exposure. *Arch Environ Health*. 1975;30(1):17-21.
3. Martinez-Frias ML, Frias JL, Opitz JM. Errors of morphogenesis and developmental field theory. *Am J Med Genet*. 1998;76(4):291-296.
4. Russell LJ, Weaver DD, Bull MJ. The axial mesodermal dysplasia spectrum. *Pediatrics*. 1981;67(2):176-182.
5. Wheeler PG, Weaver DD. Adults with VATER association: long-term prognosis. *Am J Med Genet A*. 2005;138A(3):212-217.
6. Kallen K, Mastroiacovo P, Castilla EE, et al. VATER non-random association of congenital malformations: study based on data from four malformation registers. *Am J Med Genet*. 2001;101(1):26-32.
7. Rittler M, Paz JE, Castilla EE. VACTERL association, epidemiologic definition, and delineation. *Am J Med Genet*. 1996;63(4):529-536.
8. Hilger A, Schramm C, Draaken M, et al. Familial occurrence of the VATER/VACTERL association. *Pediatr Surg Int*. 2012;28(7):725-729.
9. Khoury MJ, Cordero JF, Greenberg F, et al. A population study of the VACTERL association: evidence for its etiologic heterogeneity. *Pediatrics*. 1983;71(5):815-820.
10. Beasley SW, Diez Pardo J, Qi BQ, et al. The contribution of the adriamycin-induced rat model of the VATER association to our understanding of congenital abnormalities and their embryogenesis. *Pediatr Surg Int*. 2000;16(7):465-472.
11. Brosens E, Eussen H, van Bever Y, et al. VACTERL Association Etiology: the impact of de novo and rare copy number variations. *Mol Syndromol*. 2013;4(1-2):20-26.
12. Solomon BD. VACTERL/VATER Association. *Orphanet J Rare Dis*. 2011;6:56.
13. Reutter H, Hilger AC, Hildebrandt F, et al. Underlying genetic factors of the VATER/VACTERL association with special emphasis on the "Renal" phenotype. *Pediatr Nephrol*. 2016;31:2025-2033.
14. Cinti R, Priolo M, Lerone M, et al. Molecular characterization of a supernumerary ring chromosome in a patient with VATER association. *J Med Genet*. 2001;38(2):E6.
15. Evans JA, Stranc LC, Kaplan P, et al. VACTERL with hydrocephalus: further delineation of the syndrome(s). *Am J Med Genet*. 1989;34(2):177-182.
16. Reardon W, Zhou XP, Eng C. A novel germline mutation of the PTEN gene in a patient with macrocephaly, ventricular dilatation, and features of VATER association. *J Med Genet*. 2001;38(12):820-823.
17. Lomas FE, Dahlstrom JE, Ford JH. VACTERL with hydrocephalus: family with X-linked VACTERL-H. *Am J Med Genet*. 1998;76(1):74-78.
18. Agochukwu NB, Pineda-Alvarez DE, Keaton AA, et al. Analysis of FOXF1 and the FOX gene cluster in patients with VACTERL association. *Eur J Med Genet*. 2011;54(3):323-328.
19. Benacerraf BR. *Ultrasound of Fetal Syndromes*. 2nd ed. Philadelphia: Churchill Livingstone/Elsevier; 2008.
20. Tongsong T, Wanapirak C, Piyamongkol W, et al. Prenatal sonographic diagnosis of VATER association. *J Clin Ultrasound*. 1999;27(7):378-384.
21. Miller OF, Kolon TF. Prenatal diagnosis of VACTERL association. *J Urol*. 2001;166(6):2389-2391.
22. Krapp M, Geipel A, Germer U, et al. First-trimester sonographic diagnosis of distal urethral atresia with megalourethra in VACTERL association. *Prenat Diagn*. 2002;22(5):422-424.
23. Mori M, Matsubara K, Abe E, et al. Prenatal diagnosis of persistent cloaca associated with VATER (vertebral defects, anal atresia, tracheo-esophageal fistula, and renal dysplasia). *Tohoku J Exp Med*. 2007;213(4):291-295.
24. Brantberg A, Blaas HG, Haugen SE, et al. Imperforate anus: a relatively common anomaly rarely diagnosed prenatally. *Ultrasound Obstet Gynecol*. 2006;28(7):904-910.
25. Lam YH, Shek T, Tang MH. Sonographic features of anal atresia at 12 weeks. *Ultrasound Obstet Gynecol*. 2002;19(5):523-524.
26. Taipale P, Rovamo L, Hiilesmaa V. First-trimester diagnosis of imperforate anus. *Ultrasound Obstet Gynecol*. 2005;25(2):187-188.
27. Choudhry M, Boyd PA, Chamberlain PF, et al. Prenatal diagnosis of tracheo-oesophageal fistula and oesophageal atresia. *Prenat Diagn*. 2007;27(7):608-610.
28. Houben CH, Curry JI. Current status of prenatal diagnosis, operative management, and outcome of esophageal atresia/tracheo-esophageal fistula. *Prenat Diagn*. 2008;28(7):667-675.
29. Kennelly MM, Moran P. A clinical algorithm of prenatal diagnosis of radial ray defects with two and three-dimensional ultrasound. *Prenat Diagn*. 2007;27(8):730-737.
30. Holland AJ, Fitzgerald DA. Oesophageal atresia and tracheo-oesophageal fistula: current management strategies and complications. *Paediatr Respir Rev*. 2010;11(2):100-106, quiz 106-107.

147 Introduction to Aneuploidy

HINDI E. STOHL | LAWRENCE D. PLATT

Introduction

Aneuploidy is a chromosomal anomaly in which the number of one or more chromosomes is abnormal. Normal human somatic cells (i.e., nonegg or sperm cells) carry 46 chromosomes: two copies of each of the 22 autosomal chromosomes and two sex chromosomes, either XX for female or XY for male. Monosomy and trisomy conditions result from the subtraction or addition of chromosomal material, respectively.

Aneuploid conditions are often suspected by prenatal ultrasound (US) when multiple, and sometimes severe, structural anomalies are seen. Different aneuploid conditions are typically associated with specific constellations of US findings. US on its own, however, is an insufficient screening tool for aneuploidy. Other methods, including serum biomarkers and noninvasive prenatal screening, should also be a part of a comprehensive prenatal screening program.

Disorder

DEFINITION

Aneuploidy refers to an abnormal copy number of one or more chromosomes. Aneuploid conditions have a subtraction (monosomy) or an addition (trisomy) of chromosomal material in one or more of the chromosome pairs.

Polyploidy refers to an abnormal copy number of all of the chromosomes. The normal human cell is diploid, meaning it contains two copies of genetic material, with one copy coming from each parent. A triploid cell has 69 chromosomes (69, XXX, 69 XXY, 69, XYY) and thus three copies of genetic material. Triploidy is most commonly the result of ovum fertilization by two spermatozoa. It is not compatible with life and usually ends in pregnancy loss in the first trimester. The rare fetuses born alive usually die shortly after birth.

PREVALENCE AND EPIDEMIOLOGY

Aneuploidy is the most common genetic abnormality detected by prenatal diagnosis. Maternal age is directly related to the incidence of aneuploidy. For example, as maternal age increases, the combined risk of delivering a child affected by any of the three most common trisomies (trisomy 13, 18, or 21) increases from about 1:1065 at age 25 to 1:300 at age 35 and 1:28 at age 45.

Prenatal screening approaches use one or a combination of tests, including maternal serum biomarkers, cell-free fetal deoxyribonucleic acid, nuchal translucency, and detailed anatomic US. Each of these tests is associated with their own detection rates for the various aneuploid conditions, but none of them are considered diagnostic modalities. Chorionic villus sampling (CVS) and amniocentesis remain the mainstays for definitive prenatal diagnosis of aneuploidy. While percutaneous umbilical blood sampling can also be used, it is not commonly performed for aneuploidy detection in the absence of another indication for the procedure (e.g., planned fetal transfusion).

Fetal chromosomal abnormalities are more common in the first and second trimesters than in live births caused, in large part, by the high rate of spontaneous fetal loss in affected pregnancies. In one United Kingdom study, miscarriage or stillbirth occurred between 12 weeks and term in 49% of pregnancies diagnosed with trisomy 13, and in 72% of pregnancies diagnosed with trisomy 18.[1] Similarly, for pregnancies affected by trisomy 21, the average fetal loss rate between the time of CVS and term was 32%, and between the time of amniocentesis and term was 25%.[2] The midtrimester incidence of trisomies 13, 18, and 21 in a 35-year-old-woman is 1:2975, 1:1230 and 1:260, respectively.

The finding of a fetal structural anomaly on prenatal US increases the likelihood of an underlying chromosomal abnormality, and the magnitude of the increase depends on the specific anomaly. A finding, for example, of a shortened humerus is associated with a likelihood ratio for trisomy 21 of 4.8, whereas a thickening of the nuchal fold has a likelihood ratio of 23.[3] The total number of anomalies detected as well as the specific combination of anomalies identified impacts the frequency of aneuploidy.[4] While an isolated fetal anomaly is associated with fetal chromosomal abnormalities in 2%–18% of cases, aneuploidy was detected in up to 29% of fetuses with multiple anomalies.[5,6]

ETIOLOGY AND PATHOPHYSIOLOGY

Aneuploidy results from aberrations in cell division, most commonly through nondisjunction of paired chromosomes in meiosis or of chromatids in mitosis. Aneuploidy can also occur as a result of anaphase lag during either meiosis or mitosis.

Meiosis is a specialized form of cell division that occurs in egg and sperm cells whereby the number of chromosomes is reduced in half. The cell first undergoes DNA replication, which results in

two identical copies of each of the 46 chromosomes. The identical copies are called *sister chromatids*. Replication is followed by two rounds of cell division, ultimately producing four daughter cells, or gametes, each with half of the genetic information of the original parent cell. In the first division, called *meiosis I*, homologous chromosomes pair up along the equatorial line of the cell, where they engage in genetic recombination through a process called *crossovers*. The homologous chromosomes then separate from each other, producing two cells with only 23 chromosomes in each. Meiosis II, the second division, proceeds like a standard mitotic division. The 23 chromosomes line up in one line along the equatorial plate, and the sister chromatids of each chromosome separate and segregate to the opposite poles of the cell.

Disjunction is the term typically used to describe the normal separation of the homologous chromosomes or the sister chromatids to opposite poles during nuclear division. Nondisjunction is a failure of this segregation, where two chromosomes in meiosis I or two chromatids in meiosis II go together to one pole. The result is an increased number of chromosomes in one gamete and a decreased number of chromosomes in the other. Fertilization of the gamete with the missing chromosome results in a monosomic zygote, and fertilization of the gamete with the extra chromosome yields a trisomy.

Alternatively, aneuploidy may result from nondisjunction in postzygotic mitotic division. Like in meiosis II, failure of separation of the sister chromatids during mitosis results in excess genetic material in one daughter cell and decreased genetic material in the other.

In general, aneuploidy is predominantly the result of meiosis I errors. However, chromosome-specific patterns exist. Meiosis I errors predominate for the acrocentric chromosomes 15 and 21, while meiosis II errors predominate for trisomy 18. Trisomy 16 results almost exclusively from maternal meiosis I nondisjunction. Postzygotic mitotic nondisjunction accounts for up to 15% of trisomies 15, 18, and 21, and for the majority of trisomy 8.[7]

The origin and mechanism of nondisjunction is not fully elucidated, but it appears to be the result of spindle microtubular dysfunction. Nondisjunction is also thought to be a spontaneous process, but some familial patterns have been found.[8] The only well-documented and consistent risk factor for meiotic nondisjunction is advanced maternal age. The incidence, for example, of trisomy 21 in a 25-year-old woman is 1:1339 at term. In contrast, the incidence at term for a 40-year-old woman is 1:85.[9]

MANIFESTATIONS OF DISEASE

Clinical Presentation

Autosomal monosomies are not viable unless they occur in the setting of mosaicism, a condition in which there is a mixture of monosomic and karyotypically normal cell types. Pregnancies with an autosomal monosomy usually end in embryonic death. Monosomy of the X chromosome is the only nonlethal monosomy. Also known as *Turner syndrome*, monosomy X occurs in 4:10,000 female births and is associated with short stature, webbed neck, and gonadal dysfunction (Chapter 152).

Unlike autosomal monosomies, not all autosomal trisomies are lethal in the prenatal period. The most common autosomal trisomies that can result in live births are trisomies of chromosomes 13, 18, or 21. Trisomy 13, also known as *Patau syndrome*, occurs in 0.5:10,000–2:10,000 births, while the incidence of trisomy 18, or Edwards syndrome, is 2:10,000 live births. Fetuses with either of these trisomies may survive to term, but most affected children do not live past 1 year, although substantially longer survival, especially with surgical intervention for correctable anomalies, has been reported.[10,11] One study reported median survivals of 2.5 days and 6.0 days for trisomy 13 and trisomy 18, respectively.[12]

Trisomy 21, or Down syndrome, occurs in 1.4:10,000 live births and is the most common chromosome abnormality in live born infants.[13] Individuals with trisomy 21 can live into adulthood. Trisomy 21 is characterized by intellectual disability, dysmorphic features, and short stature and is often associated with cardiac, gastrointestinal, or renal malformations. Approximately 74% of cases of trisomy 21 are detected prenatally using traditional screening methods such as serum screening and US surveillance.[14]

Several sex-linked trisomies are also associated with survival through adulthood. Klinefelter syndrome (47, XXY) occurs in approximately 10:10,000–20:10,000 male births. The syndrome is characterized by tall stature and hypogonadism that often results in infertility in the absence of specialized assisted reproductive technologies.[15] Affected males may also have cognitive or behavioral problems. Triple X syndrome (47, XXX) and the presence of an extra Y chromosome (47, XYY) are both associated with increased growth velocity but otherwise have few defining clinical characteristics.

Imaging Technique and Findings

Ultrasound. Antepartum detection of aneuploidy is one of the major objectives of prenatal screening programs. Aneuploid fetuses often have anatomic changes or abnormalities, many of which can be detected on detailed US examination of the fetus. US, however, remains a screening test. A CVS or amniocentesis are required for definitive diagnosis.

US findings vary for the different aneuploidy syndromes:

Sonographic findings in fetuses with trisomy 21 include thickening of the nuchal fold, cardiac abnormalities, duodenal atresia, shortened femur, shortened humerus, renal pyelectasis, absence of the nasal bone, echogenic bowel, choroid plexus cyst, and an echogenic intracardiac focus.[16] None of these markers, however, are specific for the condition, and each of them are associated with significant false-positive rates. In the absence of serum screening, detection of trisomy 21 by US and age-related risk alone may be as low as 43%[17] and as high as 69%.[18]

Trisomy 18 is associated with abnormal hand positioning (a "clenched hand" appearance with the index finger overlapping the third finger and the fifth finger overlapping the fourth), micrognathia, horseshoe kidney, choroid plexus cysts, omphalocele, polyhydramnios, and intrauterine growth restriction. Congenital heart disease also occurs in over 50% of affected fetuses, with ventricular septal defects among the most common forms.[19]

Although trisomy 13 is rarer than trisomies 18 or 21, trisomy 13 is sonographically detectable in over 90% of cases because of the multiple, and often severe, structural anomalies associated with the condition. An early defect in the development of the prechordal mesoderm, which is the origin of the midface, eye, and forebrain, causes many of the classic findings associated with trisomy 13, including alobar holoprosencephaly, cyclopia, midline facial clefts, or hypoplastic nose. Other common sonographic anomalies include posterior fossa anomalies, agenesis of the corpus callosum, ventriculomegaly, neural tube defects, cardiac malformations, horseshoe or polycystic kidneys, and omphalocele.[20]

Turner syndrome is often characterized by an increased nuchal translucency, cystic hygroma, fetal hydrops, and cardiac defects. Among the cardiac defects, coarctation of the aorta is the most common (44% of all cardiac defects).[21] Coarctation, however, is often very difficult to diagnose in early pregnancy.

Magnetic Resonance Imaging. Magnetic resonance imaging (MRI) is not used routinely for the detection of aneuploidy. MRI would only be indicated when the suspected anomaly is one in which MRI has independently been shown to be useful. The mainstays for prenatal screening remain ultrasonography and serum testing, whether with measurements of serum analytes or assessment of cell-free DNA. For prenatal diagnosis, CVS and amniocentesis remain the diagnostic modalities of choice.

KEY POINTS

- Aneuploidy refers to an abnormal number of one or more chromosomes.
- Aneuploidy most commonly results from meiosis I nondisjunction.
- Monosomy X is the only nonlethal monosomy.
- Trisomies 13, 18, and 21 are the most common autosomal trisomies and are typically associated with structural abnormalities.
- US alone is insufficient as a screening tool for aneuploidy detection.

SUGGESTED READING

Benacerraf BR. The role of the second trimester genetic sonogram in screening for fetal Down syndrome. *Semin Perinatol*. 2005;29(6):386-394.

Kuliev A, Verlinsky Y. Meiotic and mitotic nondisjunction: lessons from preimplantation genetic diagnosis. *Hum Reprod Update*. 2004;10(5):401-407.

Nicolaidis P, Petersen MB. Origin and mechanisms of non-disjunction in human autosomal trisomies. *Hum Reprod*. 1998;13(2):313-319.

Norton ME. Follow-up of sonographically detected soft markers for fetal aneuploidy. *Semin Perinatol*. 2013;37(5):365-369.

Rao R, Platt LD. Ultrasound screening: status of markers and efficacy of screening for structural abnormalities. *Semin Perinatol*. 2016;40(1):67-78.

Reddy UM, Abuhamad AZ, Levine D, et al. Fetal imaging: executive summary of a Joint Eunice Kennedy Shriver National Institute of Child Health and Human Development, Society for Maternal-Fetal Medicine, American Institute of Ultrasound in Medicine, American College of Obstetricians and Gynecologists, American College of Radiology, Society for Pediatric Radiology, and Society of Radiologists in Ultrasound Fetal Imaging Workshop. *Am J Obstet Gynecol*. 2014;210(5):387-397.

Rink BD, Norton ME. Screening for fetal aneuploidy. *Semin Perinatol*. 2016;40(1):35-43.

Stefanovic V. Soft markers for aneuploidy following reassuring first trimester screening: what should be done? *Curr Opin Obstet Gynecol*. 2015;27(2):151-158.



All references available online at ***www.expertconsult.com***

REFERENCES

1. Morris JK, Savva GM. The risk of fetal loss following a prenatal diagnosis of trisomy 13 or trisomy 18. *Am J Med Genet A*. 2008;146A(7):827-832.
2. Savva GM, et al. Maternal age-specific fetal loss rates in Down syndrome pregnancies. *Prenat Diagn*. 2006;26(6):499-504.
3. Agathokleous M, Chaveeva P, Poon LC, et al. Meta-analysis of second-trimester markers for trisomy 21. *Ultrasound Obstet Gynecol*. 2013;41(3):247-261. [Epub 2013 Jan 24].
4. Staebler M, Donner C, Van Regemorter N, et al. Should determination of the karyotype be systematic for all malformations detected by obstetrical ultrasound? *Prenat Diagn*. 2005;25(7):567.
5. Halliday J, Lumley J, Bankier A. Karyotype abnormalities in fetuses diagnosed as abnormal on ultrasound before 20 weeks' gestational age. *Prenat Diagn*. 1994;14(8):689-697.
6. Nicolaides KH, Snijders RJ, Gosden CM, et al. Ultrasonographically detectable markers of fetal chromosomal abnormalities. *Lancet*. 1992;340(8821):704.
7. Nicolaidis P, Petersen MB. Origin and mechanisms of non-disjunction in human autosomal trisomies. *Hum Reprod*. 1998;13(2):313-319.
8. Hassold T, Sherman S. Down syndrome: genetic recombination and the origin of the extra chromosome 21. *Clin Genet*. 2000;57(2):95-100.
9. Morris JK, Mutton DE, Alberman E. Revised estimates of the maternal age specific live birth prevalence of Down's syndrome. *J Med Screen*. 2002;9:2.
10. Nelson KE, Hexem KR, Feudtner C. Inpatient hospital care of children with trisomy 13 and trisomy 18 in the United States. *Pediatrics*. 2012;129(5):869-876.
11. Xa. Nelson KE, Rosella LC, Mahant S, et al. Survival and surgical interventions for children with trisomy 13 and 18. *JAMA*. 2016;316(4):420-428.
12. Goldstein H, Nielsen KG. Rates and survival of individuals with trisomy 13 and 18. Data from a 10-year period in Denmark. *Clin Genet*. 1988;34(6):366-372.
13. Chandra N, Cyril C, Lakshminarayana P, et al. Cytogenetic evaluation of Down syndrome: a review of 1020 referral cases. *Int J Hum Genet*. 2010;10(1-3):87.
14. Morris JK, Alberman E, Mutton D. The proportions of Down's syndrome pregnancies detected prenatally in England and Wales from 1989 to 2004. *J Med Screen*. 2006;13(4):163-165.
15. Wikström AM, Dunkel L. Klinefelter syndrome. *Best Pract Res Clin Endocrinol Metab*. 2011;25(2):239-250.
16. Benacerraf BR. The role of the second trimester genetic sonogram in screening for fetal Down syndrome. *Semin Perinatol*. 2005;29(6):386-394.
17. Offerdal K, Blaas HG, Eik-Nes SH. Prenatal detection of trisomy 21 by second-trimester ultrasound examination and maternal age in a non-selected population of 49 314 births in Norway. *Ultrasound Obstet Gynecol*. 2008;32(4):493-500.
18. Aagaard-Tillery KM, Malone FD, Nyberg DA, et al. Role of second-trimester genetic sonography after Down syndrome screening. *Obstet Gynecol*. 2009;114:1189-1196.
19. Viora E, et al. Trisomy 18: fetal ultrasound findings at different gestational ages. *Am J Med Genet A*. 2007;143A(6):553-557.
20. Watson WJ, Miller RC, Wax JR, et al. Sonographic detection of trisomy 13 in the first and second trimesters of pregnancy. *J Ultrasound Med*. 2007;26(9):1209.
21. Papp C, et al. Prenatal diagnosis of Turner syndrome: report on 69 cases. *J Ultrasound Med*. 2006;25(6):711-717.

148 Triploidy

JULIE A. GAINER

Introduction

Chromosome abnormalities are often the cause of early pregnancy loss, fetal malformations, and stillbirth. Triploidy is a lethal chromosome abnormality caused by the presence of a complete extra set of chromosomes (Fig. 148.1); it can lead to spontaneous miscarriage, congenital anomalies, abnormal placental appearance, and severe intrauterine growth restriction (IUGR). A triploid karyotype is also found in most cases of partial hydatidiform mole (Chapter 104). Most infants with triploidy are stillborn, and those who are born alive usually die shortly after birth. The phenotype of these fetuses depends on paternal origin of the extra set of chromosomes. There is no treatment or cure for triploidy.

Disease

DEFINITION

Nuclei of most human cells contain two sets of haploid chromosomes, one inherited from each parent, which join to create 23 pairs of chromosomes. Each normal diploid cell has a 2*n* constitution: 46 chromosomes (22 pairs of autosomes and one pair of sex chromosomes). This normal state is termed *euploidy*. The presence of additional haploid sets of chromosomes is referred to as *polyploidy*. For instance, *triploidy* describes the presence of a complete extra haploid set of chromosomes (the cell complement is 3*n*, i.e., 69 chromosomes), and *tetraploidy* describes two extra haploid sets of chromosomes (4*n*, i.e., 92 chromosomes).

PREVALENCE AND EPIDEMIOLOGY

Triploidy, which is lethal, occurs in 1% to 3% of all clinically recognized conceptions.[1] Polyploid conceptions, which account for about one-quarter of spontaneous abortions, typically demise early in development.[2,3] Triploidy is the third most common cytogenetic abnormality identified at spontaneous abortion (15%), preceded by monosomy X (20%) and trisomies (60%).[4] Its prevalence at 16 to 20 weeks is 20:10,000,[5] and it is rarely reported in live births (1:10,000).[1] There are no reported survivors beyond 10 months, although sporadic reports describe mosaic individuals living into their 20s. Triploidy is sporadic, and its rate, in contrast to trisomy, does not increase with advancing maternal age.

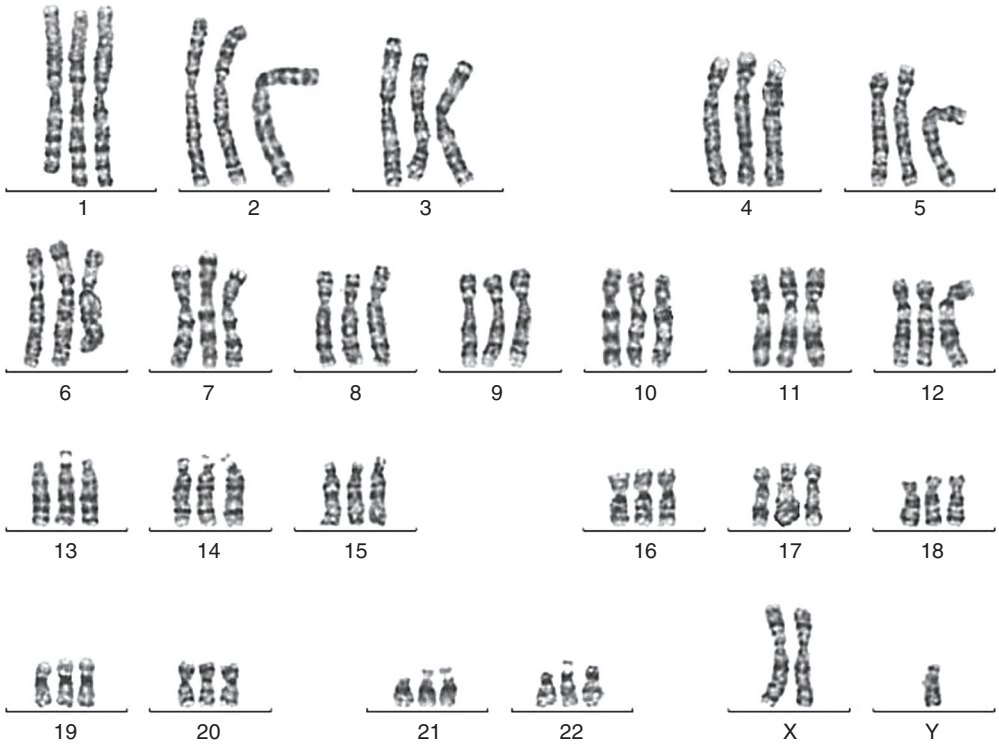

Fig. 148.1 Fetal karyotype showing triploidy.

ETIOLOGY AND PATHOPHYSIOLOGY

The joining of one haploid spermatozoon and one haploid oocyte produces a normal diploid cell count of 46 chromosomes. Proper meiosis (gamete formation) ensures that gametes are haploid in number before fusion. If there is an error in meiosis I or meiosis II, the gamete may remain in the diploid state. Triploidy can arise from (1) the fertilization of one egg by two spermatozoa, a condition referred to as *dispermy;* (2) fertilization of one oocyte by a diploid sperm, referred to as *diandry;* or (3) fertilization of a diploid oocyte by one sperm, referred to as *digyny*. When a normal haploid oocyte is fertilized by two haploid sperm or a diploid sperm, the karyotype result can be XXX, XXY, or XYY. This is type I triploidy and is paternally derived (two sets of the haploid chromosomes are paternal in origin). Type II triploidy is maternally derived and results from the fertilization of a diploid oocyte by a haploid sperm, and the karyotype result can be XXX or XXY (two sets of the haploid chromosomes are maternal in origin). The distribution of karyotypes seen in triploid conceptuses is 69,XXY (60%), 69,XXX (37%), and 69,XYY (3%).[6]

The origin of human triploidy is controversial. Initial studies of parental origin of triploidy showed that most cases of triploid conceptuses were of paternal origin, with dispermy being the most common cause.[6,7] Redline et al.[8] examined 1054 karyotyped spontaneous abortions before 20 weeks' gestation. Triploidy was detected in 64 of 832 successfully karyotyped specimens. Polymerase chain reaction analysis for parent of origin of the extra haploid chromosomal set was successful in 59 of 64 triploids analyzed. Paternal origin was confirmed in 39 cases (66%). However, later studies reported that most cases of triploidy were of maternal origin.[9,10] The difference between these studies might be explained by the gestational age included in the analysis. Early studies of triploid conceptuses included specimens from a wide range of gestational ages, usually without correlation with developmental stage of the embryo or fetus. When analysis is divided into embryonic diagnosis (<10 weeks' gestation) versus fetal diagnosis (>10 weeks' gestation), maternal origin appears to be more common in pregnancies that persist beyond the embryonic period.

MANIFESTATIONS OF DISEASE

Clinical Presentation

Most studies agree that the phenotype of a triploid fetus depends on the parental origin of the extra chromosome set. Two distinct phenotypes of triploidy have been described.[11] The type I phenotype describes a relatively well-grown fetus that has a normal head size or microcephaly and a large, cystic placenta. The type II phenotype is a growth-restricted fetus with a disproportionately large head and a normal-appearing but small placenta. Characteristically, triploidy of paternal origin results in the type I phenotype, including partial mole, whereas triploidy of maternal origin often results in the type II phenotype, which is nonmolar. Multiple similar anomalies are found in fetuses of either type of parental origin.

Most triploidies abort spontaneously during the first trimester. Paternal origin triploidies are associated with a higher miscarriage rate than triploidies of maternal origin, probably because the excess of paternal contribution to the zygote has a more deleterious effect on the placental implantation and development.[12] Hyperemesis gravidarum is often seen, especially in the case of type I (partial mole). Maternal beta-hCG levels are also higher in these pregnancies compared with type II (nonmolar).

If the pregnancy does not abort, triploidy typically manifests with a structurally abnormal fetus or an abnormal-appearing placenta, or both, and other pregnancy complications. In a study of 70 cases of triploidy over a 10-year period, prenatal complications were observed in 37 cases (53%).[13] These complications included vaginal bleeding in the first or second trimester (n =

33); bilateral multicystic ovaries with chronic pelvic pain (n = 6); severe hyperemesis gravidarum requiring intravenous fluids (n = 4); and early onset of preeclampsia (n = 3) at 18, 20, and 24 weeks' gestation.

It is crucial to differentiate pure triploidy from partial hydatidiform mole (gestational trophoblastic disease) because clinical recommendations after evacuation of the uterus are different. An increasing number of conditions manifesting with placental villous hydropic changes and a coexisting fetus are recognized, making the differential diagnosis of a partial mole complex at any stage of gestation and even after delivery.[12] While partial moles are usually triploid (some are tetraploid), triploidy does not always result in a partial mole. The incidence of triploidy is 1% to 3% of all recognized conceptions, whereas the estimated incidence of a partial mole is 1:700 pregnancies.[14] A partial molar pregnancy is diagnosed in the setting of identifiable embryonic or fetal tissue plus placental pathology consistent with a partial molar pregnancy. Pathologic placental findings include circumferential trophoblast hyperplasia, dimorphic villus population without intermediate forms, hydropic or molar degeneration with maximum villus diameter greater than 0.5 mm, and irregular villus contour with or without trophoblast inclusions.[15,16] Villus hydrops alone is not pathognomonic of molar pregnancies or gestational trophoblastic disease and can be found without trophoblastic anomalies. Partial molar pregnancy is more likely to occur with paternally derived triploidy. In an analysis of 1054 karyotyped spontaneous abortions before 20 weeks' gestation, 20 of the 39 diandric specimens met all the criteria for diagnosis of a partial mole. None of the digynic triploids fulfilled all criteria for partial mole, and they infrequently showed any of the typical features.[8]

Imaging Technique and Findings

Ultrasound. Ultrasound (US) is the primary modality for prenatal identification of triploidy. Before its widespread use, if analysis was not performed on aborted tissue, the diagnosis would usually go undetected. Triploidy should be suspected in any pregnancy with IUGR and fetal anomalies. The placenta usually demonstrates cystic changes in the type I phenotype (Fig. 148.2), and is more commonly small and noncystic in the type II phenotype.

The diagnosis may be suspected in the first trimester by small crown-rump length, increased nuchal translucency, increased head-to-body ratio, oligohydramnios, and/or placental abnormalities. One study found increased nuchal translucency in type I, and increased head-to-body ratio in type II[17] triploidy. From 2008–2014, one group identified 25 cases of triploidy (2:10,000 pregnancies) with transvaginal US at 12–16 weeks.[18] Four of these manifested molar placental changes. Of the other 21, all were IUGR, and most (n = 20) had oligohydramnios and intracranial abnormalities (abnormal posterior fossa or enlargement of the fourth ventricle). Furthermore, 81% demonstrated absent gallbladder, 70% cardiac anomalies, and >50% renal anomalies and/or clenched hands.

In the second and third trimesters, major fetal malformations can more readily be seen (Fig. 148.3). IUGR (most commonly with abdominal circumference lag) and oligohydramnios are present in most fetuses. US investigation of anomalies is often difficult because of oligohydramnios. Reported fetal anomalies are listed in Table 148.1.[18–21]

Magnetic Resonance Imaging. Magnetic resonance imaging (MRI) may be used in combination with US to evaluate fetal anomalies. MRI may be helpful in the setting of severe oligohydramnios, which makes US diagnosis of structural abnormalities more difficult. However, the common findings associated with triploidy can often be observed with US alone.

Other Applicable Modality. Combined maternal serum screening and US at 10 to 14 weeks' gestation has been used to identify fetuses with triploidy. Spencer et al.[17] examined the effectiveness of screening for triploidy by a combination of fetal nuchal translucency and maternal serum free beta-hCG and pregnancy-associated plasma protein A (PAPP-A) at 10 to 14 weeks. In triploidy pregnancies compared with controls, the median fetal nuchal translucency (1.89 multiples of median gestational age [MoM]), maternal serum free beta-hCG (4.59 MoM), and total hCG (3.13 MoM) were significantly increased ($P < .0001$), whereas PAPP-A (0.12 MoM) was decreased ($P < .0001$). When divided into type I phenotype versus type II phenotype, the type I phenotype, associated with a partial molar placenta and relatively well-grown fetus, had increased fetal nuchal translucency, serum total hCG, free beta-hCG and alpha-fetoprotein with mildly decreased PAPP-A. In comparison, the type II phenotype, characterized by a small normal-looking placenta and severe IUGR, was associated with normal fetal nuchal translucency, and markedly decreased maternal serum total hCG, free beta-hCG, and PAPP-A.

Syngelaki et al. compared combined screening to cell-free DNA (cfDNA) testing in approximately 1800 chromosomally abnormal pregnancies.[22] The cfDNA performed well for trisomies but not triploidy; it missed two-thirds of triploidies in this cohort.

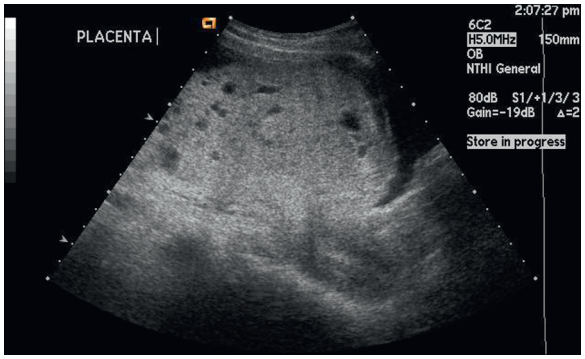

Fig. 148.2 Fetus with confirmed triploidy and placental echolucencies.

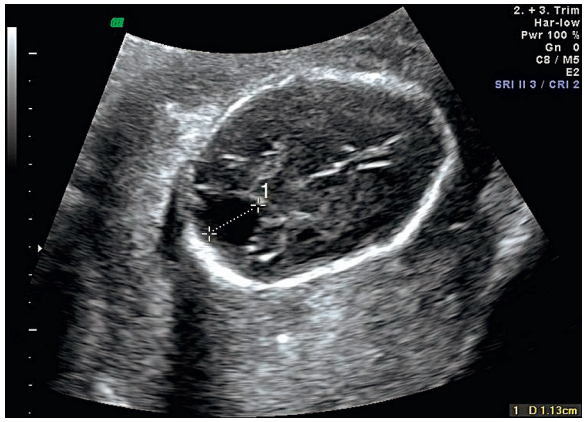

Fig. 148.3 Fetus with confirmed triploidy and posterior fossa abnormality (Dandy-Walker malformation).

TABLE 148.1 ULTRASOUND FINDINGS WITH TRIPLOIDY

HEAD	
	Ventriculomegaly
	Agenesis of corpus callosum
	Holoprosencephaly
	Dandy-Walker malformation or variant
	Posterior fossa abnormalities
	Dilation of fourth ventricle
SPINE	
	Myelomeningocele
FACE AND NECK	
	Hypertelorism
	Microphthalmia
	Micrognathia
	Cleft lip/palate
	Increased nuchal thickening
	Cystic hygroma
CARDIAC	
	Ventricular and atrial septal defects
ABDOMEN	
	Omphalocele
	Hydronephrosis
	Renal dysplasia
GENITALIA	
	Ambiguous genitalia
	Hypospadias
	Cryptorchidism
EXTREMITIES	
	Syndactyly of third and fourth digits
	Clubbed feet
PLACENTA	
	Molar changes
	Enlarged placenta with echolucencies
	Premature calcification
GENERAL	
	Intrauterine growth restriction (skeleton more than head)

In a small study of eight triploid pregnancies (four diandric, four digynic), cfDNA identified multiple paternal haplotypes in the diandric cases (this indicates either diandric triploidy or dizygotic twins), and the fetal fraction was <0.5 percentile in the digynic cases.[23] The authors concluded that cfDNA can detect diandric triploidy and raise suspicion for digynic triploidy. 69,XXX triploidy is not distinguishable from 46,XX by array comparative genomic hybridization (CGH) because it corrects for DNA concentration. However, single-nucleotide polymorphism (SNP)-based microarray performs better for triploidy detection because of the allelic information.[24] Further, patients should be carefully counseled about the uncertainty after cfDNA that suggests triploidy (or other rare conditions) because the posttest risk calculation is significantly influenced by prevalence.[24]

CLASSIC SIGNS

IUGR and oligohydramnios are seen in most fetuses with triploidy as early as the first trimester.
The most common structural anomalies include syndactyly of the third and fourth digits, ventriculomegaly, and cardiac defects.
An enlarged cystic placenta should raise concern for triploidy and partial molar pregnancy.

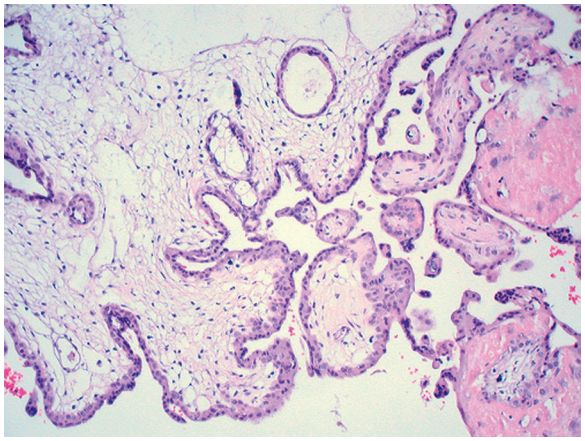

Fig. 148.4 Histology showing partial molar pregnancy.

Differential Diagnosis From Imaging Findings

The differential diagnosis for triploidy includes the following:

1. maternal infections
2. trisomy 18
3. trisomy 9
4. fetal demise with hydropic degeneration of the placenta
5. twin gestation with a complete mole and coexisting fetus
6. early complete molar pregnancy
7. Wolf-Hirschhorn syndrome
8. Neu-Laxova syndrome
9. Russell-Silver syndrome
10. Seckel syndrome

All of the aforementioned syndromes are associated with early-onset IUGR and fetal anomalies.

Synopsis of Treatment Options

PRENATAL

If triploidy is suspected, invasive testing should be discussed, including chorionic villus sampling or placental biopsy, or amniocentesis. One should consider a short interval of follow-up to detect IUGR and anomalies that may be visible by 12 weeks' gestation. If triploidy is confirmed by invasive testing or suggested by US findings, the poor prognosis and maternal risks should be discussed. Termination of pregnancy should be offered if triploidy is confirmed. If termination of pregnancy is declined, the patient should be carefully monitored for the development of gestational hypertension, which is more prevalent in partial molar pregnancies.

POSTNATAL

Histopathologic evaluation of both fetal and placental tissue should be performed to evaluate for a partial hydatidiform mole (Fig. 148.4). If molar pathology is confirmed, patients should be monitored with weekly determinations of beta-hCG levels until these levels are normal for 3 consecutive weeks, followed by monthly determinations until the levels are normal for 6 consecutive months.[25] Patients should be encouraged to use effective contraception during the entire interval of beta-hCG follow-up. If patients have persistently elevated serum beta-hCG levels, they should be

referred to a specialist for evaluation for possible persistent gestational trophoblastic disease. If a molar pregnancy is not confirmed, routine follow-up after delivery is appropriate.

WHAT THE REFERRING PHYSICIAN NEEDS TO KNOW

If routine US evaluation reveals evidence of increased head-to-body ratio, early-onset IUGR, oligohydramnios, fetal structural abnormalities, or placental echolucencies, the patient should be referred for a more detailed US evaluation and consultation.

KEY POINTS

- Triploidy occurs in 1% to 3% of all clinically recognized conceptions, and spontaneous abortion is the most common outcome.
- Dispermy is the most common cause of triploidy.
- Triploidy can be associated with a partial hydatidiform mole.
- Most triploid pregnancies that do not spontaneously abort can be detected by abnormal US findings.
- The findings of increased head-to-body ratio, early-onset IUGR, oligohydramnios, fetal anomalies, and abnormal placental appearance suggest triploidy.
- No anomaly is specific to triploidy, and most organ systems can be affected. However, ventriculomegaly and syndactyly of the third and fourth digits are common.

SUGGESTED READING

Jauniaux E, Brown R, Rodeck C, et al. Prenatal diagnosis of triploidy during the second trimester of pregnancy. *Obstet Gynecol*. 1996;88:983-989.

McFadden DE, Kalousek DK. Two different phenotypes of fetuses with chromosomal triploidy: correlation with parental origin of the extra haploid set. *Am J Med Genet*. 1991;38:535-538.

Philipp T, Grillenberger K, Separovic ER, et al. Effects of triploidy on early human development. *Prenat Diagn*. 2004;24:276-281.

Spencer K, Liao AWJ, Skentou H, et al. Screening for triploidy by fetal nuchal translucency and maternal serum free β-hCG and PAPP-A at 10–14 weeks of gestation. *Prenat Diagn*. 2000;20:495-499.

Toufaily MH, Roberts DJ, Westgate MN, et al. Triploidy: Variation of Phenotype. *Am J Clin Pathol*. 2016;145:86-95.

Zaragoza MV, Surti U, Redline RW, et al. Parental origin and phenotype of triploidy in spontaneous abortions: predominance of diandry and association with the partial hydatidiform mole. *Am J Hum Genet*. 2000;66:1807.



All references available online at
www.expertconsult.com

REFERENCES

1. McWeeney DT, Munne S, Miller RC, et al. Pregnancy complicated by triploidy: a comparison of the three karyotypes. *Am J Perinatol*. 2009;26:641.
2. Hassold T, Chen N, Funkhouser J, et al. A cytogenetic study of 1000 spontaneous abortions. *Ann Hum Genet*. 1980;44:151-164.
3. Hsu LYF. Prenatal diagnosis of chromosomal abnormalities through amniocentesis. In: Milunsky A, ed. *Genetic Disorders and the Fetus*. 4th ed. Baltimore: The Johns Hopkins University Press; 1998:179.
4. McKinlay Gardner RJ, Sutherland GR. Gametogenesis and conception, pregnancy loss and infertility. In: Motulsky AG, Bobrow M, Harper PS, et al, eds. *Chromosome Abnormalities and Genetic Counseling*. 3rd ed. New York: Oxford University Press; 2004:344.
5. Fergusson-Smith MA, Yates JRW. Maternal age specific rates for chromosomal aberrations and factors influencing them: report of a collaborative European Study on 52,965 amniocenteses. *Prenat Diagn*. 1984;4:5-44.
6. Jacobs PA, Szulman AE, Funkhouser J, et al. Human triploidy: relationship between parental origin of the additional haploid complement and the development of partial hydatidiform mole. *Ann Hum Genet*. 1982;46: 223-231.
7. Uchida IA, Freeman VC. Triploidy and chromosomes. *Am J Obstet Gynecol*. 1985;151:65-69.
8. Redline RW, Hassold T, Zaragoza M. Prevalence of the partial molar phenotype in triploidy of maternal and paternal origin. *Hum Pathol*. 1998;29:505-511.
9. McFadden DE, Kwong LC, Yam IYL, et al. Parental origin of triploidy in human fetuses: evidence for genomic imprinting. *Hum Genet*. 1993;92: 465-469.
10. McFadden DE, Langlois S. Parental and meiotic origin of triploidy in the embryonic and fetal periods. *Clin Genet*. 2000;58:192-200.
11. McFadden DE, Kalousek DK. Two different phenotypes of fetuses with chromosomal triploidy: correlation with parental origin of the extra haploid set. *Am J Med Genet*. 1991;38:535-538.
12. Jauniaux E. Partial moles: from postnatal to prenatal diagnosis. *Placenta*. 1999;20:379-388.
13. Jauniaux E, Brown R, Rodeck C, et al. Prenatal diagnosis of triploidy during the second trimester of pregnancy. *Obstet Gynecol*. 1996;88:983-989.
14. Jeffers MD, O'Dwyer P, Curran B, et al. Partial hydatidiform mole: a common but under diagnosed condition. *Int J Gynecol Pathol*. 1993;12:315-323.
15. Szulman AE, Surti U. The syndromes of hydatidiform mole. II. Morphologic evolution of the complete and partial mole. *Am J Obstet Gynecol*. 1978;132:20-27.
16. Mostoufi-Zadeh M, Berkowitz RS, Driscoll SG. Persistence of partial mole. *Am J Clin Pathol*. 1987;87:377-380.
17. Spencer K, Liao AWJ, Skentou H, et al. Screening for triploidy by fetal nuchal translucency and maternal serum free β-hCG and PAPP-A at 10-14 weeks of gestation. *Prenat Diagn*. 2000;20:495-499.
18. Zalel Y, Shapiro I, Weissmann-Brenner A, et al. Prenatal sonographic findings of triploidy at 12-16 weeks. *Prenat Diagn*. 2016;36(7):650-655.
19. Benacerraf BR. *Ultrasound of Fetal Syndromes*. 2nd ed. Philadelphia: Churchill Livingstone; 2008.
20. Nyberg DA, McGahan JP, Pretorius DH, et al. *Diagnostic Imaging of Fetal Anomalies*. Philadelphia: Lippincott Williams & Wilkins; 2003:196-200.
21. Woodward PJ. Triploidy. In: Woodward PJ, Kennedy A, Sohaey R, et al, eds. *Diagnostic Imaging Obstetrics*. Salt Lake City: Amirsys, Inc; 2008. 14/19–14/21.
22. Syngelaki A, Pergament E, Homfray T, et al. Replacing the combined test by cell-free DNA testing in screening for trisomies 21, 18 and 13: impact on the diagnosis of other chromosomal abnormalities. *Fetal Diagn Ther*. 2014;35(3):174-184.
23. Nicolaides KH, Syngelaki A, del Mar Gil M, et al. Prenatal detection of fetal triploidy from cell-free DNA testing in maternal blood. *Fetal Diagn Ther*. 2014;35(3):212-217.
24. Breman A, Pursley AN, Hixson P, et al. Prenatal chromosomal microarray analysis in a diagnostic laboratory: experience with >1000 cases and review of the literature. *Prenat Diagn*. 2012;32:351.
25. Benn P. Posttest risk calculation following noninvasive prenatal screening using cell-free DNA in maternal plasma. *Am J Obstet Gynecol*. 2016;214(6): 676.e1-676.e7.

149 Trisomy 13

STEPHANIE L. GAW | LAWRENCE D. PLATT

Introduction

Trisomy 13, also known as *Patau syndrome,* is one of the three most common trisomy syndromes. It is often diagnosed prenatally by the identification of one or more congenital abnormalities seen on ultrasound (US). Trisomy 13 is associated with severe physical and mental disabilities in addition to poor long-term survival rates in live-born infants.

Disorder

DEFINITION

First genetically described by Patau et al.[1] in 1960, trisomy 13 comprises a group of congenital abnormalities resulting from an extra chromosome number 13. The syndrome can also result from a translocation of chromosome 13.

PREVALENCE AND EPIDEMIOLOGY

Trisomy 13 is estimated to occur in approximately 0.5–1.0:10,000 live births.[2] The prevalence of trisomy 13 does not differ among races, and it occurs equally in both genders. However, a larger proportion of female fetuses survive to birth.[3] Of live-born trisomy 13 cases, 5% are mosaic.[2]

ETIOLOGY AND PATHOPHYSIOLOGY

Trisomy 13 results from an extra chromosome 13 secondary to nondisjunction or translocation. Approximately 75% of cases of trisomy 13 are due to nondisjunction.[3] Abnormal ventral induction by the prechordal mesoderm of the prosencephalon is thought to be embryologic disturbance resulting in the brain and midfacial findings in trisomy 13.[4] The mechanism by which the presence of an extra chromosome 13 leads to multiple anomalies is unknown.

MANIFESTATIONS OF DISEASE

Clinical Presentation

Because of routine prenatal US and screening in developed countries, most cases of trisomy 13 are identified in the prenatal period. Approximately half of pregnancies with trisomy 13 result in miscarriage or stillbirth between 12 weeks' gestation and term.[5]

Physical findings in live-born infants with trisomy 13 include holoprosencephaly, microphthalmia, cleft lip/palate, microcephaly, scalp defects, polydactyly, capillary hemangiomas, colobomas of the iris, and umbilical hernias.[6] Most infants born with trisomy 13 die during the perinatal period. Severe mental and physical disability is seen in these infants. Isolated cases of survival into

adulthood have been reported.[7,8] One case series from Canada showed that surgical intervention can prolong survival, with approximately 70% surviving for 1 year after the first surgery, although these patients were likely to have been carefully selected due to the controversies surrounding surgical intervention in these cases.[9]

Imaging Technique and Findings

Ultrasound. US is the primary imaging modality for suspected cases of trisomy 13. One study showed that 95% of fetuses with trisomy 13 were detected on first-trimester or second-trimester US.[10] Another study showed that all fetuses with trisomy 13 had one or more abnormalities or abnormal growth on US.[11] In another study of 33 fetuses with trisomy 13, greater than 90% of affected fetuses had US findings suggestive of trisomy 13.[12]

In the last decade, first-trimester combined screening and cell-free fetal DNA screening have emerged as the leading methods of diagnosis of trisomies, including trisomy 13.[13] US findings include increased nuchal translucency above the 95th percentile for crown-rump length (Fig. 149.1), decreased crown-rump length, congenital heart defects, holoprosencephaly, and omphalocele.[14]

In the second trimester, the most common major abnormalities are congenital heart defects and central nervous system lesions (e.g., holoprosencephaly).[10] Cardiac abnormalities are present in more than 50% of fetuses and include ventricular septal defects, hypoplastic left ventricle, and double-outlet right ventricle.[15] Other findings include cleft lip/palate (Fig. 149.2), hypotelorism, facial abnormalities, and postaxial polydactyly (Fig. 149.3).[12] Echogenic or polycystic kidneys and omphalocele (Fig. 149.4) may also be seen. The finding of omphalocele increases the risk of trisomy 13 or trisomy 18 by 340-fold.[16] Fetal growth restriction (less than the fifth percentile) in the second trimester is found in at least one-half of fetuses with trisomy 13.[10]

Magnetic Resonance Imaging. Fetal magnetic resonance imaging (MRI) has been used more recently as a second-line imaging modality to characterize further anomalies found on US, especially brain abnormalities. MRI has been used in suspected cases of alobar holoprosencephaly to confirm neural and craniofacial abnormalities.[17] MRI can be considered in suspected cases of trisomy 13 to differentiate the type of holoprosencephaly.

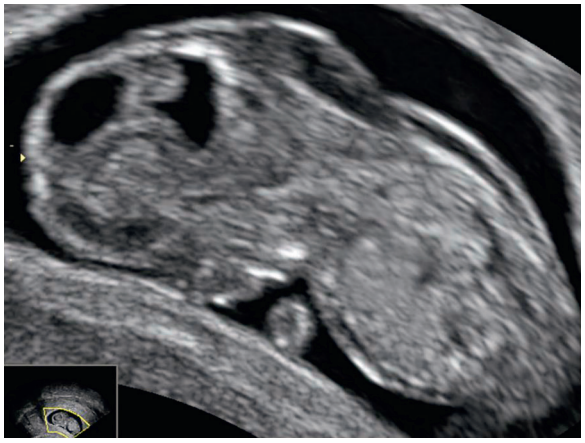

Fig. 149.1 Enlarged nuchal translucency.



Fig. 149.2 Cleft lip.



Fig. 149.3 Postaxial polydactyly.



Fig. 149.4 Omphalocele.

Differential Diagnosis From Imaging Findings

(1) Isolated holoprosencephaly: holoprosencephaly (HPE) can be isolated or also be caused by other chromosomal abnormalities, commonly trisomy 18 and triploidy.
(2) Pseudo–trisomy 13: this has been described as a syndrome that encompasses normal chromosomes with a combination of holoprosencephaly, midface hypoplasia, premaxillary agenesis, or polydactyly.[18] It is thought to have an autosomal recessive inheritance pattern with a 25% recurrence risk. The criteria for diagnosis include a normal karyotype with holoprosencephaly and postaxial polydactyly with or without other abnormalities; holoprosencephaly with other characteristics but without polydactyly; or a combination of postaxial polydactyly, brain defects (microcephaly, hydrocephaly, agenesis of corpus callosum), and other characteristics.[19]
(3) Mosaic–trisomy 13: this is a rare condition in which a percentage of cells are trisomic for an entire chromosome 13, whereas the remaining cells are typically euploid. The phenotype varies widely, and prognosis depends upon the percentage and distribution of trisomic cells in affected tissues, and the associated anomalies. Common features include hemangiomas and cleft lip/palate.[20]
(4) Smith-Lemli-Opitz syndrome: this (Chapter 145) is an autosomal recessive disease caused by an inborn error of cholesterol metabolism. Common clinical findings include microcephaly, small upturned nose, ptosis, micrognathia, cleft palate, genital abnormalities, short thumbs, postaxial polydactyly, and syndactyly of the second and third toes. This diagnosis is often first considered based on biochemical screening in the first trimester. The manifestations of Smith-Lemli-Opitz syndrome are broad, ranging from mild disease with behavioral and learning disabilities to a lethal disease caused by the accumulation of toxic metabolites of cholesterol synthesis.[21]
(5) Meckel-Gruber syndrome: this (Chapter 133) is another disease in the differential diagnosis for trisomy 13. The classic findings in Meckel-Gruber syndrome include cystic renal dysplasia, occipital encephalocele or other abnormality of the central nervous system, and postaxial polydactyly. Similar to Smith-Lemli-Opitz syndrome, Meckel-Gruber syndrome is autosomal recessive. It is also considered a lethal syndrome with mortality rate of 100%.[22]

Synopsis of Treatment Options

PRENATAL

Patients with findings on US that are consistent with trisomy 13 should be offered a karyotype for definitive diagnosis. A genetic consultation may be offered. There are no prenatal treatments or fetal interventions for trisomy 13. Termination of pregnancy may be offered because this is usually considered a lethal condition. In patients who opt to continue the pregnancy, routine prenatal care should be continued. During labor, interventions on behalf of the fetus (e.g., cesarean section for fetal distress) should be carefully considered and discussed with the patient, given the severity of trisomy 13.

POSTNATAL

When a karyotype has confirmed the diagnosis, usually only comfort measures are pursued because the prognosis is so poor. Length of survival is related to the severity of the anomalies. Individuals who survive have severe mental and physical disabilities. Most infants do not survive beyond the neonatal period.[2] Infants who survive the immediate neonatal period have complicated courses, including feeding difficulties, failure to thrive, apnea, seizures, hypertension, and scoliosis, among other problems.[14] Although surgical treatment in select patients may improve long-term survival, there is currently no intervention to improve the prognosis of the severe neurocognitive deficits.[9,23] These issues should be thoroughly discussed with the patient.

WHAT THE REFERRING PHYSICIAN NEEDS TO KNOW

Trisomy 13 is a chromosomal disorder resulting from an extra chromosome number 13. It leads to multiple congenital abnormalities that are most commonly diagnosed on first-trimester or second-trimester US. Prenatal consultation with maternal-fetal medicine specialists and a genetics consultation should be considered; chorionic villus sampling or amniocentesis for definitive diagnosis should be offered. The outcome for fetuses with trisomy 13 is poor; most infants do not survive the perinatal period, and individuals who do survive have severe physical and mental disabilities.

KEY POINTS

- Trisomy 13 results from an extra chromosome 13 secondary to nondisjunction or translocation.
- US is the primary imaging modality for suspected trisomy 13. More than 95% of fetuses with trisomy 13 exhibit US findings.
- Common US findings in trisomy 13 include cardiac defects, holoprosencephaly, cleft lip/palate, microphthalmia, and polydactyly.

SUGGESTED READING

Hodes ME, Cole J, Palmer CG, et al. Clinical experience with trisomy 18 and 13. *J Med Genet*. 1978;15:48-60.
Watson WJ, Miller RC, Wax JR, et al. Sonographic detection of trisomy 13 in the first and second trimesters of pregnancy. *J Ultrasound Med*. 2007;26:1209-1214.
Witters G, Van Robays J, Willekes C, et al. Trisomy 13, 18, 21, Triploidy and Turner syndrome: the 5T's. Look at the hands. Facts, views & vision. *Facts Views Vis Obgyn*. 2011;3(1):15-21.
Wyllie JP, Wright MJ, Burn J, et al. Natural history of trisomy 13. *Arch Dis Child*. 1994;71:343-345.

All references available online at www.expertconsult.com

REFERENCES

1. Patau K, Smith DW, Therman E, et al. Multiple congenital anomaly caused by an extra chromosome. *Lancet*. 1960;1:790-793.
2. Jinawath N, Zambrano R, Wohler E, et al. Mosaic trisomy 13: understanding origin using SNP array. *J Med Genet*. 2011;48:323-326.
3. Jacobs PA, Hassold TJ, Henry A, et al. Trisomy 13 ascertained in a survey of spontaneous abortions. *J Med Genet*. 1987;24:721-724.
4. Witters G, Van Robays J, Willekes C, et al. Trisomy 13, 18, 21, Triploidy and Turner syndrome: the 5T's. Look at the hands. Facts, views & vision. *Facts Views Vis Obgyn*. 2011;3(1):15-21.
5. Morris JK, Savva GM. The risk of fetal loss following a prenatal diagnosis of trisomy 13 or 18. *Am J Med Genet A*. 2008;146:827-832.
6. Hodes ME, Cole J, Palmer CG, et al. Clinical experience with trisomy 18 and 13. *J Med Genet*. 1978;15:48-60.
7. Singh KST. Trisomy 13 (Patau's syndrome): a rare case of survival into adulthood. *J Ment Defic Res*. 1990;34:91-93.
8. Nanjiani A, Hossain A, Mahgoub N. Patau syndrome. *J Neuropsychiatry Clin Neurosci*. 2007;19:201-202.
9. Nelson KE, Rosella LC, Mahant S, et al. Survival and surgical interventions for children with trisomy 13 and 18. *JAMA*. 2016;316(4):420-428.
10. Watson WJ, Miller RC, Wax JR, et al. Sonographic detection of trisomy 13 in the first and second trimesters of pregnancy. *J Ultrasound Med*. 2007;26:1209-1214.
11. Seoud MA, Alley DC, Smith DL, et al. Prenatal sonographic findings in trisomy 13, 18, 21, and 22: a review of 46 cases. *J Reprod Med*. 1994;39:781-787.
12. Lehman CD, Nyberg DA, Winter TC, et al. Trisomy 13 syndrome: prenatal US findings in a review of 33 cases. *Radiology*. 1995;194:217-222.
13. Screening for fetal aneuploidy. Practice Bulletin No. 163. American College of Obstetricians and Gynecologists. *Obstet Gynecol*. 2016;127:e123-e137.
14. Snijders RJM, Sebire NJ, Nayar R, et al. Increased nuchal translucency in trisomy 13 fetuses at 10-14 weeks of gestation. *Am J Med Genet*. 1999;86:205-207.
15. Bianchi DW, Crombleholme TM, D'Alton ME. *Fetology—diagnosis and management of the fetal patient*. New York: McGraw Hill; 2000:989-996.
16. Snidjers RJ, Brizot ML, Faria M, et al. Fetal exomphalos at 11 to 14 weeks of gestation. *J Ultrasound Med*. 1995;14:569-574.
17. Huibers M, Papatsonis DN. Prenatal diagnosis of alobar holoprosencephaly by use of ultrasound and magnetic resonance imaging in the second trimester. *J Matern Fetal Neonatal Med*. 2009;22:1204-1206.
18. Seller MJ, Chitty LS, Dunbar H. Pseudotrisomy 13 and autosomal recessive holoprosencephaly. *J Med Genet*. 1993;30:970-971.
19. Lurie IW, Wulfsberg EA, eds. Holoprosencephaly-polydactyly (pseudotrisomy 13) syndrome: expansion of the phenotypic spectrum. *Am J Med Genet*. 1993;47:405-409.
20. Pachajoa H, Meza Escobar LE. Mosaic trisomy 13 and a sacral appendage. *BMJ Case Rep*. 2013;2013:bcr2012008150.
21. Porter FD. Smith-Lemli-Opitz syndrome: pathogenesis, diagnosis and management. *Eur J Hum Genet*. 2008;16:535-541.
22. Alexiev BA, Lin X, Sun C, et al. Meckel-Gruber syndrome: pathologic manifestations, minimal diagnostic criteria, and differential diagnosis. *Arch Pathol Lab Med*. 1980;130:1236-1238.
23. Lantos JD. Trisomy 13 and 18—treatment decisions in a stable gray zone. *JAMA*. 2016;316(4):396-398.

150 Trisomy 18

STEPHANIE L. GAW | LAWRENCE D. PLATT

Introduction

Trisomy 18 is the second most common autosomal trisomy (after trisomy 21).

Disorder

DEFINITION

Trisomy 18, also called *Edwards syndrome,* results from the presence of an extra copy of chromosome 18.

PREVALENCE AND EPIDEMIOLOGY

Trisomy 18 is the second most common autosomal trisomy among live-born fetuses after Down syndrome.[1] The incidence of trisomy 18, 0.6–2.5 : 10,000, is considerably lower than that for Down syndrome.[2] It is associated with multiple congenital anomalies, profound neurologic damage, and severe developmental delays in surviving neonates.

ETIOLOGY AND PATHOPHYSIOLOGY

The incidence of trisomy 18 is increased in women with advanced maternal age. Most cases of trisomy 18 are the result of maternal meiotic nondisjunction (more than 90%). Paternal meiotic nondisjunction may also occur (5%). Occasionally, trisomy 18 is the result of chromosomal translocation.[1]

MANIFESTATIONS OF DISEASE

Clinical Presentation

Trisomy 18 is almost always lethal. Most studies show that approximately 50% of affected infants die within the first week of life, and only 3% to 10% survive the first year of life.[2] Surgical interventions may improve overall survival in select patients, with approximately 70% of patients surviving after the first surgery in one case series; however, surviving infants have severe mental and physical deficits.[3,4] The phenotypic features are variable. This disorder is more commonly seen in female fetuses. Hsiao et al.[2] reported clinical features in 31 cases of trisomy 18, which are listed in Table 150.1.

TABLE 150.1 COMMON CLINICAL FEATURES INTRISOMY 18

Common Clinical Features	Frequency (%)
Cardiovascular system	77
Gastrointestinal system	75
FACE	
• Low-set malformed ears	71
• Small mouth	61
• Microcephaly	52
• Micrognathia	58
• Prominent occiput	55
• Short palpebral fissure	22
• Narrow palatal arch	22
• Corneal opacification	16
MUSCULOSKELETAL	
• Short sternum	32
• Hypotonia or hyprtonia	52
• Smal pelvis	26
EXTREMITIES	
• Flexed fingers with overriding index fingers or third fingers	58
• Hypoplastic or absent thumb	29
• Rocker-bottom feet	52
• Syndactyly of toes or fingers	26
• Short hallux	22
• Radial or ulnar deviation of hands	13
OTHER	
• Inrauterine growth restriction*	90
• Thrombocytopenia	26
• Single umbilical artery	10

*Seen in about 90% of fetuses.
Data from Hsiao C, Tsao L, Chen H, et al. Changing clinical presentations and survival pattern in trisomy 18. *Pediatr Neonatol* 2009;50:147–151.

Imaging Technique and Findings

Ultrasound. Fetuses with trisomy 18 have a very high rate of structural abnormalities (birth defects), many of which are detectable on prenatal ultrasound (US). The detection rate of trisomy 18 by US ranges from 53%[5] to 100%.[6] With high-resolution US and attention to detail by experienced sonographers or sonologists, achieving a sensitivity of 100% is possible. A 2009 systematic review and metaanalysis concluded that the accuracy of a genetic US scan for detection of trisomy 18 was 86%.[7] The authors reported that a normal genetic US scan reduces a patient's risk by almost 90%. This information also helps patients make decisions regarding invasive testing. These findings illustrate the importance of completing the anatomic survey as recommended by the American Institute of Ultrasound in Medicine, American Congress of Obstetrics and Gynecology, and International Society of Ultrasound in Obstetrics and Gynecology.[8-10]

The gestational age range at which the genetic US scan is performed plays a role in its sensitivity. Bronsteen et al.[11] performed a retrospective chart review of 49 fetuses with trisomy

18 and found that anomaly detection increased from 67% at 15 to 16 weeks' gestation to 100% at 19 to 24 weeks' gestation. The number of anomalies found in trisomy 18 also increased from an average of 2.8 at 15 to 16 weeks' gestation to 4 with advancing gestational age. Early menstrual age, fetal position at the time of US scanning, and maternal body habitus may also affect the accuracy of a genetic US scan.

Abnormalities can be classified into major structural anomalies and minor anomalies including soft markers. Major structural anomalies associated with trisomy 18 include cardiac, central nervous system (CNS), gastrointestinal, genitourinary, hydrops, and cystic hygroma. Minor anomalies can be divided into limb and facial anomalies, clenched hands (Fig. 150.1), nuchal fold thickness greater than 6 mm, short limbs (less than the 10th percentile), pyelectasis, echogenic bowel, echogenic intracardiac focus, choroid plexus cyst, and single umbilical artery. Different studies report varying incidence of these anomalies in fetuses with trisomy 18.

Most fetuses with trisomy 18 have at least three to four anomalies.[6,11-12] Bronsteen et al.[11] examined 49 fetuses with trisomy 18 and found that 81% had a cardiac defect. Papp et al.[13] reported a 47% rate of cardiac anomalies. Both studies found that the most common finding is an atrioventricular septal defect or a ventricular septal defect (Fig. 150.2). Other heart abnormalities include hypoplastic left heart and coarctation of the aorta.

CNS abnormalities can be seen in about 80% of fetuses.[6,11] These most commonly include ventriculomegaly, strawberry-shaped or lemon-shaped head, posterior fossa abnormalities, Dandy-Walker malformations (Fig. 150.3), and agenesis of corpus callosum. Absent cavum septi pellucidi and holoprosencephaly have also been reported. Neural tube defects can be seen in about 30% of cases.[14]

Musculoskeletal abnormalities associated with trisomy 18 include clenched hands (see Fig. 150.1), overlapping digits, contractures, radial dysplasia, polydactyly, and foot abnormalities such as clubfoot or rocker-bottom foot. When trisomy 18 is suspected, the hands and feet need to be specifically examined.[14] Facial anomalies such as micrognathia, cleft lip/palate, hypotelorism, low-set ears, and short ears have been noted. Yeo et al.[6] reported short ear length and clenched hands with overlapping digits as some of the most sensitive markers in detection of trisomy 18.

Gastrointestinal anomalies, which are seen in about 20% of cases, include omphalocele (Fig. 150.4), diaphragmatic hernia, tracheoesophageal fistula, duodenal or anorectal atresia, and ventral wall defects. Genitourinary abnormalities such as pyelectasis; echogenic, absent, or malpositioned kidneys; and hypoplastic genitalia have also been noted.

Minor abnormalities or soft markers (i.e., nuchal fold thickness greater than 6 mm, pyelectasis, choroid plexus cysts, single umbilical artery, polyhydramnios, and growth restriction) are listed in Table 150.2.[13] The importance of screening for these minor anomalies is underlined by the fact that not all fetuses with trisomy 18 have major anomalies, but minor anomalies may be seen in about 80% of cases.[13] Growth restriction, often early in pregnancy, may be noted in about 50% of cases.[14] Of the minor markers, choroid plexus cysts are a common finding, present in 50% to 70% of cases of trisomy 18 (Fig. 150.5).[6,11-12]

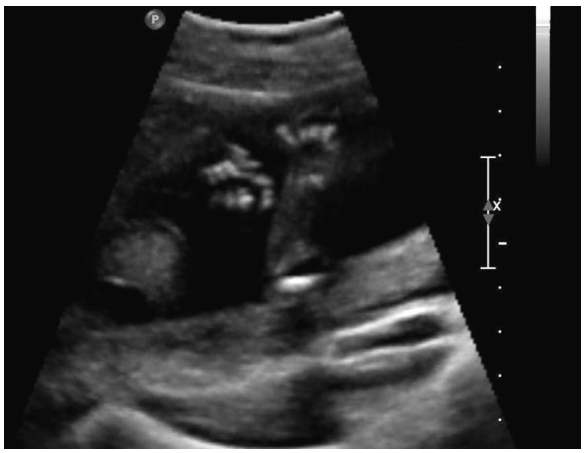

Fig. 150.1 Clenched hands.



Fig. 150.2 Ventricular septal defect.

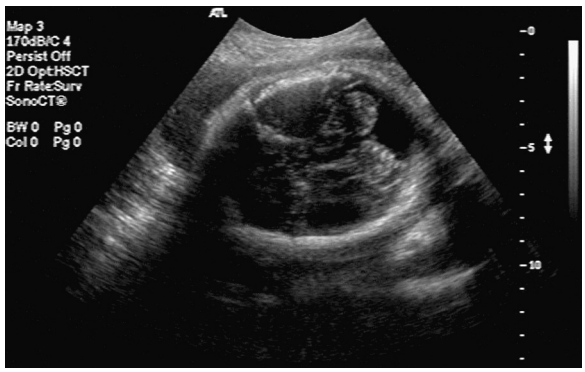

Fig. 150.3 Dandy-Walker malformation.



Fig. 150.4 Omphalocele.

TABLE 150.2 MOST COMMON MINOR ABNORMALITIES FOUND IN FETUSES WIIH TRISOMY 18

Choroid plexus cyst	27 (38.6%)
Nuchal fold thickness >6 mm	12 (17.1%)
Pyelectasis	8 (11.4%)
Echogenic bowel	5 (7.1%)
Short femur and humerus (<10th percentile)	4 (5.7%)
Echogenic intracardiac focus	0 (0.0%)
Intrauterine growth restriction	8 (11.4%)
Polyhydramnios	8 (11.4%)
Single umbilical artery	1 (1.4%)

From Papp C, Ban Z, Szigeti Z, et al. Role of second trimester sonography in detecting trisomy 18: a review of 70 cases. *J Clin Ultrasound* 2007;35:68–72.



Fig. 150.5 Choroid plexus cysts.

Bronsteen et al.[11] also reported a direct relationship between cyst size and genetic risk for trisomy 18. They described a choroid plexus cyst as a large anechoic cyst with a thin remnant of surrounding echogenic choroid, which was noted in 14 of 27 fetuses with trisomy 18. However, no fetus in their series had a choroid plexus cyst exclusively. Nyberg et al.[15] noted an isolated choroid plexus cyst in 17% of fetuses. Snijders et al.[16] observed that with an isolated choroid plexus cyst, the risk of trisomy 18 was only marginally increased. However, if one additional abnormality was found, the maternal age-related risk increased 20 times, and if two or more abnormalities were found, the risk increased almost 1000 times.

Zheng et al.[17] looked at 26 fetuses with trisomy 18 and compared the findings of two-dimensional US with three-dimensional or four-dimensional US and concluded that three-dimensional or four-dimensional US offered a diagnostic advantage for many anomalies, especially anomalies of the face and extremities. These investigators suggested this modality to be a powerful adjunct in anatomic evaluation of fetuses with trisomy 18.

Magnetic Resonance Imaging. Magnetic resonance imaging (MRI) may be used as an adjunct to US in evaluations of brain lesions and other structural anomalies.

Differential Diagnosis From Imaging Findings

1. Trisomy 13: trisomies 13 and 18 may share phenotypic features, including ventriculomegaly, enlarged cistern magna, cleft lip/palate, cystic hygroma, and cardiac abnormalities. Various kidney, heart, and limb abnormalities similar to trisomy 18 may be noted with trisomy 13. Features such as holoprosencephaly, polydactyly, and facial clefts are more commonly seen in trisomy 13.
2. Trisomy 21: trisomy 18 may share common features with trisomy 21. US findings including pyelectasis, heart defects, growth restriction, echogenic bowel, and increased nuchal translucency may also be found in fetuses with trisomy 18. Choroid plexus cysts are not seen with increased frequency in trisomy 21. The only definitive way to confirm the diagnosis prenatally is chromosome analysis. This confirmation is important because the outcome for trisomy 21 is better, and the prenatal management would be different.
3. Pena-Shokeir I syndrome: this syndrome, also known as fetal *akinesia/hypokinesia sequence,* is an autosomal recessive syndrome, and its features include arthrogryposis, intrauterine growth restriction, low-set malformed ears, small mouth, micrognathia, rocker-bottom feet, pulmonary hypoplasia, and cryptorchidism. Features that distinguish this syndrome from trisomy 18 include scalp edema, lung hypoplasia, and family history. Additional features commonly found in trisomy 18 but not Pena-Shokeir I are cardiac arrhythmias, omphalocele, and prominent occiput.[18]
4. Pseudo–trisomy 18: this is a diagnosis of exclusion. The features closely resemble trisomy 18, but the fetus has a normal karyotype. It is an autosomal recessive lethal condition. Cardiac abnormalities are not seen in this condition.

Synopsis of Treatment Options

PRENATAL

Maternal serum screening and/or cell-free DNA screening affords the opportunity for early diagnosis and reassurance.[19] It also allows earlier termination of pregnancy if desired, which may be associated with less clinical morbidity and emotional difficulty. If a woman has a screening test or US findings suggestive of trisomy 18, karyotype analysis by chorionic villus sampling or amniocentesis should be offered. Genetic consultation is also recommended. There are no prenatal treatments or fetal interventions for trisomy 18. Termination of pregnancy may be offered because this is considered a lethal condition. In patients who opt to continue the pregnancy, routine prenatal care should be continued. During labor, interventions on behalf of the fetus (e.g., cesarean section for fetal distress) should be carefully considered and discussed with the patient given the severity of trisomy 18.

POSTNATAL

Patients choosing to continue the pregnancy must make decisions regarding delivery and postpartum treatment of the infant. Consultations with neonatal intensive care unit clinicians help with difficult decision making. Care plans should be developed with as much patient input as possible, balancing safety, resource use, and patient preference. Postnatal management usually focuses on comfort care. Closure of ventricular septal defects in patients with trisomy 18 is associated with extended survival.[3,20]

WHAT THE REFERRING PHYSICIAN NEEDS TO KNOW

Trisomy 18 is a generally lethal condition associated with a wide range of fetal anomalies and fetal growth restrictions. Abnormal serum screening, cell-free fetal DNA screening, or the presence of fetal anomalies may suggest the presence of trisomy 18, and confirmatory testing with chorionic villus sampling or amniocentesis is needed in these cases. Genetic counseling and karyotype testing should be offered to all patients with suspected trisomy 18.

KEY POINTS

- Trisomy 18 is usually a lethal condition, with death *in utero* or soon after birth in most fetuses.
- The phenotypic features vary from fetus to fetus and may involve many organ systems, and multiple anomalies involving most organ systems are seen.
- US sensitivity is approximately 86%.
- Clenched hands with overlapping digits and cardiac, CNS, and musculoskeletal defects are most commonly noted.
- Choroid plexus cyst is the minor marker most often associated with trisomy 18.
- Growth restriction is commonly noted in the first trimester.
- Amniocentesis and chorionic villus sampling help confirm the diagnosis.
- Comfort care is usually provided to the newborn.

SUGGESTED READING

Bronsteen R, Lee W, Vettraino IM, et al. Second-trimester sonography and trisomy 18. *J Ultrasound Med*. 2004;23:233-240.

Oyelese Y, Vintzileos AM. Is second-trimester genetic amniocentesis for trisomy 18 ever indicated in the presence of a normal genetic sonogram? *Ultrasound Obstet Gynecol*. 2005;26:691-694.

Papp C, Ban Z, Szigeti Z, et al. Role of second trimester sonography in detecting trisomy 18: a review of 70 cases. *J Clin Ultrasound*. 2007;35:68-72.

Yeo L, Guzman ER, Day-Salvatore D, et al. Prenatal detection of fetal trisomy 18 through abnormal sonographic features. *J Ultrasound Med*. 2003;22:581-590.



All references available online at
www.expertconsult.com

REFERENCES

1. Jones KL. *Smith's Recognizable Patterns of Human Malformation*. Philadelphia: Saunders; 1997.
2. Hsiao C, Tsao L, Chen H, et al. Changing clinical presentations and survival pattern in trisomy 18. *Pediatr Neonatol*. 2009;50:147-151.
3. Nelson KE, Rosella LC, Mahant S, et al. Survival and surgical interventions for Children with Trisomy 13 and 18. *JAMA*. 2016;316(4):420-428.
4. Lantos JD. Trisomy 13 and 18—treatment decisions in a stable gray zone. *JAMA*. 2016;316(4):396-398.
5. Gupta JK, Khan KS, Thornton JG, et al. Management of fetal choroid plexus cysts. *Br J Obstet Gynaecol*. 1997;104:881-886.
6. Yeo L, Guzman ER, Day-Salvatore D, et al. Prenatal detection of fetal trisomy 18 through abnormal sonographic features. *J Ultrasound Med*. 2003;22:581-590.
7. Cho RC, Chu P, Smith-Bindman R, et al. Second trimester prenatal ultrasound for the detection of pregnancies at increased risk of trisomy 18 based on serum screening. *Prenat Diagn*. 2009;29:129-139.
8. American Institute of Ultrasound in Medicine. AIUM practice guideline for the performance of obstetric ultrasound examinations. *J Ultrasound Med*. 2013;32:1083-1101.
9. Ultrasonography in Pregnancy. Practice Bulletin No 101. American College of Obstetricians and Gynecologists. *Obstet Gynecol*. 2009;113:451-461.
10. Salomon LJ, Alfirevic Z, Berghella V, et al. Practice Guidelines for performance of the routine mid-trimester fetal ultrasound scan. *Ultrasound Obstet Gynecol*. 2001;37:116-126.
11. Bronsteen R, Lee W, Vettraino IM, et al. Second-trimester sonography and trisomy 18. *J Ultrasound Med*. 2004;23:233-240.
12. Witters G, Van Robays J, Willekes C, et al. Trisomy 13, 18, 21, Triploidy and Turner syndrome: the 5T's. Look at the hands. Facts, views & vision. *Obgyn*. 2011;3(1):15-21.
13. Papp C, Ban Z, Szigeti Z, et al. Role of second trimester sonography in detecting trisomy 18: a review of 70 cases. *J Clin Ultrasound*. 2007;35:68-72.
14. Watson WJ, Miller RC, Wax JR, et al. Sonographic findings of trisomy 18 in the second trimester of pregnancy. *J Ultrasound Med*. 2008;27:1033-1038.
15. Nyberg DA, Kramer D, Resta RG, et al. Prenatal sonographic findings of trisomy 18: review of 47 cases. *J Ultrasound Med*. 1993;12:103-113.
16. Snijders RJ, Shawa L, Nicolaides KH. Fetal choroid plexus cysts and trisomy 18: assessment of risk based on ultrasound findings and maternal age. *Prenat Diagn*. 1994;14:1119-1127.
17. Zheng Y, Zhou XD, Zhu YL, et al. Three- and four-dimensional ultrasonography in the prenatal evaluation of fetal anomalies associated with trisomy 18. *J Ultrasound Med*. 2008;27:1041-1051.
18. Muller LM, de Jong G. Prenatal ultrasonographic features of the Pena-Shokeir I syndrome and the trisomy 18 syndrome. *Am J Med Genet*. 1986;25:119-129.
19. Screening for fetal aneuploidy. Practice Bulletin No. 163. American College of Obstetricians and Gynecologists. *Obstet Gynecol*. 2016;127:e123-e137.
20. Kobayashi J, Kaneko Y, Yamamoto Y, et al. Radical surgery for a ventricular septal defect associated with trisomy 18. *Gen Thorac Cardiovasc Surg*. 2010;58:223-227.

151 Trisomy 21

STEPHANIE L. GAW | LAWRENCE D. PLATT

Introduction

Trisomy 21 (Down syndrome) is the most common trisomy in live-born infants and in spontaneous abortions. British physician John Langdon Down first described the syndrome in 1866. The chromosomal abnormality was discovered in 1959 by French geneticist Jerome Lejeune, and in 1961, the name Down syndrome was proposed by the editors of *The Lancet*.

Disorder

DEFINITION

Trisomy 21, also called *Down syndrome,* results from three copies of chromosome 21, either the entire chromosome or the critical region. The syndrome has a distinctive phenotype.

PREVALENCE AND EPIDEMIOLOGY

Trisomy 21 is the most common inherited cause of intellectual disability. About 0.45% of human conceptuses have trisomy 21.[1] The incidence of Down syndrome in live births is between 1:319 and 1:1000, depending on the population.[2] The risk of trisomy 21 increases with increasing maternal age and decreases with advancing gestation (because of pregnancy loss). Controversy exists about whether the incidence increases with advancing paternal age. Table 151.1 presents maternal and gestational age risks, demonstrating these changes.[3]

ETIOLOGY AND PATHOPHYSIOLOGY

Most cases of trisomy 21 are due to meiotic nondisjunction (95%), usually in the ovum. In the remaining 5% of cases, unbalanced translocation accounts for 3% to 4%, and mosaicism accounts for 1%. The additional copy of chromosome 21 presumably causes increased expression of many genes on the chromosome, and the imbalance in expression is thought to cause the various phenotypic expressions of the disorder.[2]

MANIFESTATIONS OF DISEASE

Clinical Presentation

Clinical presentation of trisomy 21 may vary, but most cases have distinct ultrasound (US) features including major structural anomalies and minor ("soft") markers of aneuploidy. Nearly half of fetuses with trisomy 21 have a cardiac defect (for example, ventricular septal defects, atrioventricular septal defects, and tetralogy of Fallot).[4] Other major anomalies include duodenal atresia and tracheoesophageal fistula/esophageal atresia. Findings may include increased nuchal fold, cerebral ventriculomegaly, echogenic intracardiac focus, pyelectasis, echogenic bowel, enlarged cisterna magna, pericardial effusion, liver calcification, and digit anomalies (polydactyly, clinodactyly, sandal gap, and clubfoot). Hepatosplenomegaly and fetal hydrops may occur secondary to a leukemoid reaction.[5]

Imaging Technique and Findings

Ultrasound. US screening is one component of currently available screening strategies for trisomy 21, which also includes serum

TABLE 151.1 PREVALENCE OF TRISOMY 21 BY MATERNAL AGE AND GESTATIONAL AGE

Maternal Age (y)	GESTATIONAL AGE (WK)					
	10	12	14	16	20	40
20	1:983	1:1068	1:1140	1:1200	1:1295	1:1527
25	1:870	1:946	1:1009	1:1062	1:1147	1:1342
30	1:576	1:626	1:668	1:703	1:759	1:895
31	1:500	1:543	1:580	1:610	1:658	1:776
32	1:424	1:461	1:492	1:518	1:559	1:659
33	1:352	1:383	1:409	1:430	1:464	1:547
34	1:287	1:312	1:333	1:350	1:378	1:446
35	1:229	1:249	1:266	1:280	1:302	1:356
36	1:180	1:196	1:209	1:220	1:238	1:280
37	1:140	1:152	1:163	1:171	1:185	1:218
38	1:108	1:117	1:125	1:131	1:142	1:167
39	1:82	1:89	1:95	1:100	1:108	1:128
40	1:62	1:68	1:72	1:76	1:82	1:97
41	1:47	1:51	1:54	1:57	1:62	1:73
42	1:35	1:38	1:41	1:43	1:46	1:55
43	1:26	1:29	1:30	1:32	1:35	1:41
44	1:20	1:21	1:23	1:24	1:26	1 :30
45	1:15	1:16	1:17	1:18	1:19	1:23

From Snijders RJM, Sundberg K, Holzgreve W, et al. Maternal age- and gestation-specific risk for trisomy 21. *Ultrasound Obstet Gynecol* 13:167–170, 1999.

biochemistry screening and cell-free DNA screening (cfDNA). Definitive diagnosis depends on direct fetal testing, typically by chorionic villus sampling or amniocentesis.[1]

The multicenter Biochemistry, Ultrasound, Nuchal translucency (BUN) trial demonstrated that the combination of maternal age, first-trimester serum biochemistry, and nuchal translucency combined had a trisomy 21 detection rate of 85% at a 5% false-positive rate.[6] A study that was part of the *F*irst- *a*nd *s*econd-*t*rimester *e*valuation of *r*isk (FASTER) trial showed that at a 5% false-positive rate, detection of Down syndrome was 95% with stepwise sequential screening and 96% with fully integrated screening (nuchal translucency measurement performed at 11 to 14 weeks' gestation, with greater detection earlier). Using both measurement of nuchal translucency and serum markers in the first trimester was more effective for trisomy 21 screening than using either screening modality alone.[7]

Another FASTER trial study confirmed that genetic US evaluation to assess for both major and minor markers of aneuploidy increases detection rates of trisomy 21 after first-trimester screening and second-trimester biochemistry screening. At a 5% false-positive rate, genetic US evaluation increases the detection rate from 81% to 90% after combined or quadruple marker screening. Detection was improved, albeit to a lesser degree, after integrated (from 93%–98%), stepwise (from 97%–98%), or contingent (from 95%–97%) screening.[5]

The absence of any marker on a second-trimester US scan conveys a 60% to 80% reduction in Down syndrome risk based on advanced maternal age or serum screen. In other words, the likelihood ratio (LR) of trisomy 21 after a normal genetic US scan is 0.2 to 0.4 times the prior risk.[8]

Introduced into clinical practice in 2011, cfDNA screening has high sensitivity and specificity, and low negative predictive values for the detection of trisomy 21. In the general obstetric population, the positive predictive value cfDNA screening for trisomy 21 has been reported to be 45.5%, compared with 4.2% for standard serum biochemistry screening,[9] although the true positive predictive value will depend on the baseline risk in the patient population and may be different in clinical practice.[10]

In the FASTER trial, major structural malformations were seen in 8.5% of second-trimester fetuses with trisomy 21 in an unselected population. Older studies (from the 1990s) showed a higher prevalence of major malformation (17%), although these data were collected before first-trimester screening, which presumably detects many cases earlier than the second trimester, so some of the fetuses were terminated before the second-trimester US scan to detect anomalies.[11]

The two most common major malformations associated with trisomy 21 are cardiac defects and duodenal atresia. Nearly half of fetuses with Down syndrome have heart defects; most common are atrioventricular septal defects (atrioventricular canal), ventricular septal defects, and atrial septal defects.[4] Tetralogy of Fallot, although less common, is also associated with trisomy 21. Atrioventricular septal defects are very strongly associated with Down syndrome. In a large population-based study of congenital heart defects in Down syndrome, 45% of infants with Down syndrome had atrioventricular septal defects, and 35% had ventricular septal defects.[12]

Duodenal atresia (Chapter 26) is the most common gastrointestinal anomaly, seen in 30% of fetuses with Down syndrome, making it a strong and classic marker. It is seen on US as a double bubble sign comprising the fluid-filled stomach and the proximal duodenum on either side of the fetal abdomen. Even with normal biochemical markers and in the absence of other US markers, the presence of isolated duodenal atresia confers an LR of 30 for Down syndrome.

Minor markers are seen more commonly than major malformations in an unselected population (Table 151.2). One of the FASTER trial studies found increased nuchal fold to be the

TABLE 151.2 ULTRASOUND FEATURES OF TRISOMY 21

STRUCTURAL DEFECTS
Cardiac defects
Ventriculomegaly
Duodenal atresia
Esophageal atresia/tracheoesophageal fistula
ANEUPLOIDY MARKERS
Clinodactyly
Absent nasal bone
Echogenic intracardiac focus
Echogenic bowel
Nuchal fold
Pyelectasis
Sandal gap
Short long bones
Widened iliac angle
Short ear length

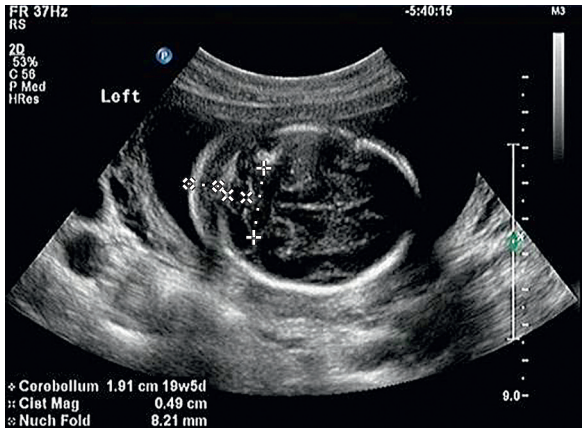

Fig. 151.1 Increased nuchal fold.



Fig. 151.2 Normal nasal bone.

most statistically significant minor marker (LR 49). Other statistically significant findings were short femur, short humerus, echogenic intracardiac focus, pyelectasis, echogenic bowel, and ventriculomegaly.[5] The risk of trisomy 21 is higher with an increasing number of US markers.[8] US identification of a minor marker should prompt a referral for perinatal and genetics counseling. Specific markers are described subsequently. For the presence of minor markers in the setting of a negative cfDNA screen, some experts advocate that additional diagnostic testing may not be necessary due to the high negative predictive value of these screening tests, although patients should be counseled that the detection rate of cfDNA is significantly lower than standard karyotype or microarray analysis.[13,14] However, some patients may find this to be an acceptable alternative to invasive testing modalities.[14]

Nuchal Translucency and Cystic Hygroma. Abnormal nuchal translucency in the first trimester should raise suspicion for trisomy 21. Nuchal translucency is the normal subcutaneous fluid-filled space between the back of the fetal neck and the overlying skin. In a large study by the Fetal Medicine Foundation, nuchal translucency had a trisomy 21 detection rate of 77% with a 5% false-positive rate.[15] The BUN and FASTER trials also validated the role of nuchal translucency measurement. In these trials, the detection rate of Down syndrome with nuchal translucency measurement alone was 70% with a 5% false-positive rate.[7,16]

Cystic hygroma refers to a fluid-filled collection behind the fetal neck that often extends down the fetal body with septations. There is controversy about whether it is a separate entity or on the severe end of the spectrum of nuchal translucency. Cystic hygroma carries an aneuploidy risk of 50% and should raise suspicion of trisomy 21.[17]

Nuchal Fold. A thickened nuchal fold is the most sensitive and specific marker for the detection of Down syndrome in the second trimester and was the first US marker described.[18] The nuchal fold is measured by first obtaining the transverse plane of the fetal head used to measure the biparietal diameter, then angling caudad to include the cerebellum and occiput, while the cavum septi pellucidi remains visible anteriorly. The soft tissue thickness posterior to the occiput, measured from the outer edge of the bone to the outer edge of the skin, is the nuchal fold. A measurement of 6 mm or greater is considered abnormal (Fig. 151.1).[19] The nuchal fold measurement should be used only from 15 to 20 weeks, when the skin thickness remains relatively constant and is less affected by changes in head position than later in pregnancy.[19]

The sensitivity of nuchal fold thickness for detection of Down syndrome has been reported to be 42% to 43% with false-positive rates of 0.1% to 1.3%.[20-21] Even when isolated, an abnormal nuchal fold is associated with an LR of 11–49 for Down syndrome.[5,8,22] In the absence of aneuploidy, increased nuchal fold remains a marker for Noonan syndrome and congenital heart defects.

Absent or Hypoplastic Nasal Bone. Absent ossification, hypoplasia, and agenesis of the nasal bone have been described in radiographs of fetuses with Down syndrome.[23] Cicero et al.[24] first described absent or hypoplastic nasal bone as a US marker of Down syndrome. In their study, absent nasal bone was seen in 73% of fetuses with Down syndrome, with a 0.5% false-positive rate (Figs. 151.2 and 151.3). A review of studies evaluating first-trimester nasal bone identification found that this is a sensitive and specific marker in high-risk pregnancies when performed in specialized centers with appropriately trained personnel.[25]

The nasal bone should be viewed in the midsagittal plane of the profile, visualized as a linear echogenic structure. The angle of insonation should be kept close to 45 degrees or 135 degrees. With angles less than 45 degrees or more than 135 degrees, the nasal bone may appear artificially absent. If the angle is close to



Fig. 151.3 Absent nasal bone.



Fig. 151.5 Echogenic intracardiac focus.

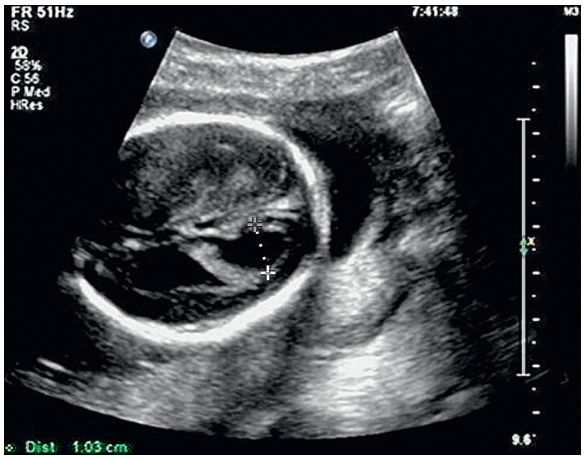

Fig. 151.4 Ventriculomegaly.

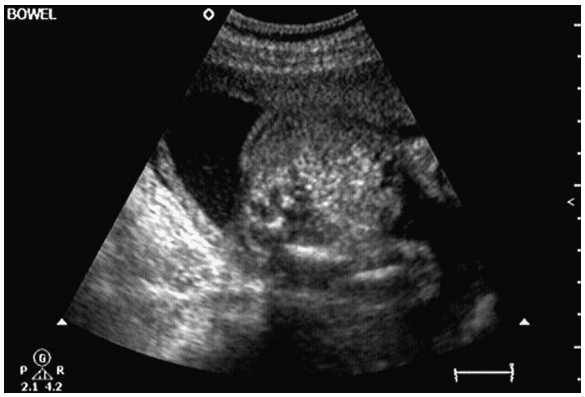

Fig. 151.6 Echogenic bowel.

90 degrees, the nasal bone measurement appears larger. In the first trimester, a midsagittal view of the fetal profile should be obtained, with the fetus occupying greater than 50% of the image. The tip of the nose should be seen, and the angle between the transducer and a line passing from the fetal forehead to the chin should be 45 degrees. When the nasal bone is present, three echogenic lines should be visible (tip of nose, skin overlying nasal bone, and nasal bone itself).

Many studies have examined the sensitivities of nasal bone measurements for detection of Down syndrome. Sensitivities ranged from 28% to 66% with false-positive rates of 0% to 20%. The sensitivity of a genetic US evaluation for detection of Down syndrome is increased from 87% to 92.8% after inclusion of an absent nasal bone as an aneuploidy marker.[26] One study found that an absent nasal bone confers a LR of 83 for Down syndrome.[27] Hypoplastic nasal bone (less than 2.5 multiples of median for gestational age) is also associated with an increased risk for Down syndrome, although the length of the fetal nasal bone varies with gestational age and has racial and ethnic differences.

Ventriculomegaly. Ventriculomegaly is defined as a width of 10 mm or greater of the lateral ventricles at the level of the atria (Fig. 151.4). It is associated with an increased risk of aneuploidy, including Down syndrome. In a large series of 2743 cases, 3.8% of fetuses had aneuploidy, and 2% of all cases had Down syndrome.[28] In euploid fetuses, aneuploid fetuses, and fetuses with Down syndrome, mild ventriculomegaly was seen in 0.5%, 6.8%, and 5.5% of cases, respectively.[27] The LR for Down syndrome with mild ventriculomegaly in the FASTER trial was 25.[5]

Echogenic Intracardiac Focus. An echogenic intracardiac focus (EIF) is a bright echogenicity in a cardiac ventricle, typically in a papillary muscle (Fig. 151.5). It is best seen in the four-chamber apical view of the heart. It may be seen in either ventricle, although it is more common in the left ventricle. This echogenicity is caused by reflection from the papillary muscles and chordae tendineae, and histopathology has shown it to be due to papillary muscle mineralization.[28] An EIF may also represent coarse intramyocardial calcification.[27] This is a subjective finding and can be seen in 3% to 4% of normal fetuses.[28] It is not associated with heart defects or poor long-term outcome. The echogenicity should be as bright as surrounding bone, and seen both in apical and lateral views to be considered present.

The LR of an EIF for Down syndrome is estimated to be between 1.8 and 6.2.[5,29-30] One group found that, in high-risk populations, the presence of an EIF in the right ventricle or bilaterally confers a two times increased risk of aneuploidy compared with an EIF in the left ventricle.[31] In the FASTER trial, there was no difference in risk between an EIF on the right ventricle and an EIF on the left.[5] In low-risk populations and in absence of any other US marker, the EIF may be considered a normal variant, especially in families of Asian origin, in whom EIF is quite common.[31]

Echogenic Bowel. Bowel is considered echogenic when it appears as bright as bone (Fig. 151.6). The FASTER trial used

two categories of echogenic bowel (marked, which is as bright as bone, and moderate). This is a subjective finding, and it may be overdiagnosed with high gain settings on the US machine or with high-frequency transducers, which can increase the echogenicity of bowel. Harmonics should not be used when evaluating for echogenicity. Echogenic bowel is present in 0.5% of normal fetuses, but it is seen with increased frequency in aneuploid fetuses, particularly fetuses with trisomy 21.[8,32-33] The LR for trisomy 21 in the presence of marked echogenicity is 6 to 24.[5,8] The differential diagnosis for echogenic bowel includes aneuploidy, fetal infections (cytomegalovirus, herpes, and parvovirus), cystic fibrosis, meconium ileus, bowel obstructions or malformations, and fetal swallowing of blood. It may also be idiopathic; in the absence of an identifiable cause, the prognosis is favorable.

Pyelectasis. Renal pelvis dilatation is measured in the anterior-posterior dimension of the fluid-filled renal pelvis (Fig. 151.7). It is commonly defined as a renal pelvis diameter 4 mm or greater at 15 to 20 weeks' gestation,[34,35] although the FASTER trial definition was greater than 3 mm. It is seen in 2% to 2.8% of euploid fetuses but occurs more commonly in fetuses with trisomy 21 (10%–25%).[34,35] The LR for Down syndrome of pyelectasis is 1.6 to 5.5.[5,36] Pyelectasis may also indicate genitourinary obstruction or be a normal variant. It is also more common in males than females.

Short Long Bones. Individuals with trisomy 21 have short stature, which may manifest in second-trimester fetuses as a shortened femur or humerus. In one study, 68% of fetuses with Down syndrome had observed-to-expected femur lengths of less than 0.91.[21] The same authors found that an observed-to-expected humerus length of less than 0.9 detected 50% of fetuses with Down syndrome with a 6.25% false-positive rate.[37] Combining the two measurements decreased the false-positive rate. If both the femur and humerus are shortened, the likelihood that the fetus has Down syndrome increases 11-fold over the age-based risk.

Other markers detected on US, such as clinodactyly, sandal gap toe, short fifth digit, widened iliac angle, aberrant subclavian artery, and shortened ear length, have been described as minor markers. These are frequently seen in normal fetuses and should not be used in isolation to detect fetuses with trisomy 21.

Magnetic Resonance Imaging. Magnetic resonance imaging (MRI) is not used in the prenatal diagnosis of fetuses with Down syndrome. MRI may be useful in the presence of ventriculomegaly to rule out structural abnormalities.

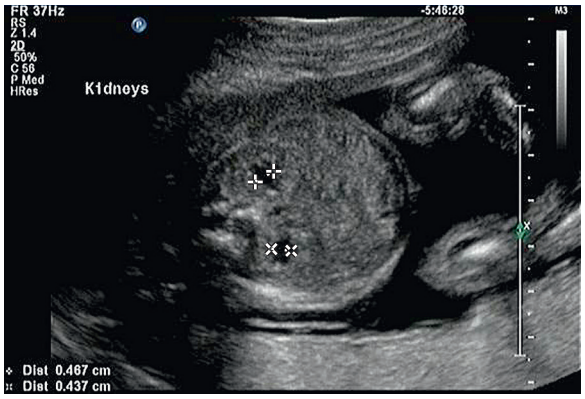

Fig. 151.7 Pyelectasis.

Differential Diagnosis From Imaging Findings

There are many markers of Down syndrome that share commonality with other diagnoses, including normal variants. Pyelectasis may be due to structural defects of the genitourinary system or be a normal part of the renal filling cycle. Ventriculomegaly may be due to other structural abnormalities, such as aqueductal stenosis or absence of the corpus callosum, or it may be acquired after perinatal infections. Echogenic bowel may be caused by fetal cystic fibrosis, viral infections, or swallowing of blood. Heart defects are common in all aneuploidies and are common isolated defects as well.

Synopsis of Treatment Options

PRENATAL

Numerous strategies for Down syndrome screening have been developed. Before current sophisticated US technology and techniques, maternal age greater than 35 years was considered a great enough aneuploidy risk to warrant invasive diagnostic testing by amniocentesis or chorionic villus sampling. Biochemical markers are commonly used for aneuploidy screening in the first and second trimesters, often in combination with US. In 2011, cell-free fetal DNA was clinically introduced as a screening test for trisomy 21, and its use is increasing due to its higher sensitivity and specificity for trisomy 21 compared to serum biochemistry.[38] Each different combination or method has unique detection rates, sensitivities, and false-positive rates.

The identification of markers on a second-trimester US scan warrants revision of the *a priori* risk of a patient carrying a fetus with trisomy 21. Invasive diagnostic testing with amniocentesis or chorionic villus sampling may be offered to all patients, in particular, patients with a major or minor marker for Down syndrome, after a thorough discussion of the risks and benefits of the procedure compared with the chance that the fetus has the syndrome.

Patients with a confirmed diagnosis of fetal trisomy 21 should be offered genetic counseling, including discussion of the wide range of variability in manifestations and prognosis of children with Down syndrome. Termination of pregnancy is an option. If pregnancy is continued, a fetal echocardiogram at around 20 to 22 weeks' gestation for detection of cardiac anomalies is warranted. Information on early intervention, support groups, and Down syndrome advocacy groups may be offered.

POSTNATAL

Children born with Down syndrome require ongoing evaluation to monitor growth and development. These patients have increased risks of leukemia, hypertension, and Alzheimer disease. The American Academy of Pediatrics has recommendation guidelines for clinicians taking care of children with Down syndrome.[39]

WHAT THE REFERRING PHYSICIAN NEEDS TO KNOW

- All pregnant women should be offered screening for aneuploidy and invasive testing for definitive diagnosis after a thorough discussion of the risks and benefits of the procedure versus the chance that the fetus has a genetic abnormality.

- The identification of any US marker should prompt referral to a specialized center for US evaluation, discussion of invasive procedures for definitive diagnosis, and genetic counseling.
- Cell-free DNA screening has very high negative predictive value for trisomy 21.

KEY POINTS

- The major structural malformations in trisomy 21 are cardiac anomalies and duodenal atresia.
- As an isolated US finding, an increased nuchal fold carries the highest risk of Down syndrome.
- Other markers for trisomy 21 include absent nasal bone, bilateral pyelectasis, echogenic intracardiac focus, echogenic bowel, and shortened long bones.
- The presence of US markers, either isolated or in combination, increase the baseline risk of Down syndrome, and patients should be referred to a specialized center for counseling and diagnostic options.
- A normal anatomy scan decreases the risk of Down syndrome by 60% to 80%. The scan may be used to decrease the maternal *a priori* risk.

SUGGESTED READING

Cell-free DNA screening for fetal aneuploidy. Committee Opinion No. 640. American College of Obstetricians and Gynecologists. *Obstet Gynecol*. 2015;126:e31-e37.

Conner SN, Longman RE, Cahill AG. The role of ultrasound in the diagnosis of fetal genetic syndromes. *Best Pract Res Clin Obstet Gynaecol*. 2014;28(3):417-428.

Screening for fetal aneuploidy. Practice Bulletin No. 163. American College of Obstetricians and Gynecologists. *Obstet Gynecol*. 2016;127:e123-e137.



All references available online at www.expertconsult.com

REFERENCES

1. Screening for fetal aneuploidy. Practice Bulletin No. 163. American College of Obstetricians and Gynecologists. *Obstet Gynecol*. 2016;127:e123-e137.
2. Wiseman FK, Alford KA, Tybulewicz VLJ, et al. Down syndrome—recent progress and future prospects. *Hum Mol Genet*. 2009;18:R75-R83.
3. Snijders RJM, Sundberg K, Holzgreve W, et al. Maternal age- and gestation-specific risk for trisomy 21. *Ultrasound Obstet Gynecol*. 1999;13:167-170.
4. Freeman SB, Bean LH, Allen EG, et al. Ethnicity, sex, and the incidence of congenital heart defects: a report from the national Down syndrome project. *Genet Med*. 2008;10:173-180.
5. Aagard-Tillery KM, Malone FD, Nyberg DA, et al. FASTER Research Consortium. Role of second-trimester genetic sonography after Down syndrome screening. *J Obstet Gynecol*. 2009;114:1189-1996.
6. Wapner R, Thom E, Simpson JL, et al. First-Trimester Screening for Trisomies 21 and 18. *N Engl J Med*. 2003;349:1405-1413.
7. Malone F, Canick JA, Ball RH, et al. First and Second Trimester Evaluation of Risk (FASTER) Research Consortium. *N Engl J Med*. 2005;353: 2001-2011.
8. Nyberg DA, Souter VL, El-Bastawissi A, et al. Isolated sonographic markers for detection of fetal Down syndrome in the second trimester of pregnancy. *J Ultrasound Med*. 2001;10:1053.
9. Bianchi DW, Parker HL, Wentworth J, et al. DNA sequencing versus standard prenatal aneuploidy screening. *N Engl J Med*. 2014;370:799-808.
10. Valderramos SG, Rao RR, Scibetta EW, et al. Cell-free DNA screening in clinical practice: abnormal autosomal aneuploidy and microdeletion results. *Am J Obstet Gynecol*. 2016;215(5):626.e1-626.e10.
11. Nyberg DA, Resta R, Luthy DA. Prenatal sonographic findings of Down syndrome: a review of 94 cases. *Obstet Gynecol*. 1990;76:370.
12. Freeman SB, Taft LF, Dooley KJ, et al. Population based study of congenital heart defects in Down syndrome. *Am J Med Genet*. 1998;80:213-217.
13. Stefanovic V. Soft markers for aneuploidy following reassuring first trimester screening: what should be done? *Curr Opin Obstet Gynecol*. 2015;27: 151-158.
14. Beulen L, Faas BHW, Feenstra I, et al. The clinical utility of non-invasive prenatal testing in pregnancies with ultrasound anomalies. *Ultrasound Obstet Gynecol*. 2016;doi:10.1002/uog.17228.
15. Snijders RJ, Noble P, Sebire N, et al. UK Multicenter project on assessment of risk of trisomy 21 by maternal age and nuchal translucency thickness at 10 to 14 weeks of gestation. *Lancet*. 1998;351:343.
16. Wapner RJ. First trimester aneuploid screening: results of the NICHD multicenter study. *Am J Obstet Gynecol*. 2001;185:S70.
17. Malone FD, Canick JA, Ball RH, et al. First trimester septated cystic hygromas: prevalence, natural history and pediatric outcome. *Obstet Gynecol*. 2005;106:288.
18. Benacerraf BR, Barss VA, Laboda LA. A sonographic sign for the detection in the second trimester of the fetus with Down syndrome. *Am J Obstet Gynecol*. 1985;151:1078.
19. Benacerraf BR, Frigoletto FD Jr, Cramer DW. Down syndrome: sonographic sign for diagnosis in the second-trimester fetus. *Radiology*. 1987;163: 811-813.
20. Crane JP, Gray DL. Sonographically measured nuchal skinfold thickness as a screening tool for Down syndrome: results of a prospective clinical trial. *Obstet Gynecol*. 1991;77:53.
21. Benacerraf BR, Gelman R, Frigoletto FD. Sonographic identification of second trimester fetuses with Down's syndrome. *N Engl J Med*. 1987;317:1371.
22. Bromley B, Lieberman E, Shipp TD, et al. The genetic sonogram: a method of risk assessment for Down syndrome in the second trimester. *J Ultrasound Med*. 2002;21:1087.
23. Keeling JW, Hansen BF, Kjaer I. Pattern of malformation in the axial skeleton in human trisomy 21 fetuses. *Am J Med Genet*. 1997;68:466.
24. Cicero S, Curcio P, Papageorghiou A, et al. Absence of nasal bone in fetuses with trisomy 21 at 11 to 14 weeks of gestation: an observational study. *Lancet*. 2001;358:1665.
25. Rosen T, D'Alton ME, Platt LD, et al. Maternal Fetal Medicine Foundation Nuchal Translucency Oversight Committee. First-trimester ultrasound assessment of the nasal bone to screen for aneuploidy. *Obstet Gynecol*. 2007;110:339-404.
26. Yeo L, Ananth CV, Kontopoulos E, et al. The addition of absent nasal bone increases the sensitivity of the genetic sonogram. *Am J Obstet Gynecol*. 2005;191:525.
27. Bromley B, Lieberman E, Shipp TD, et al. Fetal nasal bone length: a marker for fetal Down syndrome in the second trimester. *J Ultrasound Med*. 2002;21:1387.
28. Sohl BD, Sciosa AL, Budorick NE, et al. Utility of minor sonographic markers in the prediction of abnormal fetal karyotype at a prenatal diagnostic center. *Am J Obstet Gynecol*. 1999;181:898.
29. Bromley B, Lieberman E, Shipp TD. Significance of an echogenic focus in fetuses at high and low risk for aneuploidy. *J Ultrasound Med*. 1998;17:127.
30. Sepulveda W, Cullen S, Nicolaides P. Echogenic foci in the heart: a marker for chromosomal abnormality. *Br J Obstet Gynaecol*. 1995;102:490.
31. Levy DW, Mintz MC. The left ventricular echogenic focus: a normal finding. *AJR Am J Roentgenol*. 1988;150:85.
32. Bromley B, Doubilet P, Frigoletto FD Jr. Is fetal hyperechogenic bowel in the second trimester an indication for amniocentesis? *Obstet Gynecol*. 1994;83:647.
33. Al-Kouatly HB, Chasen ST, Strelzoff J. The clinical significance of echogenic bowel. *Am J Obstet Gynecol*. 2001;185:1035.
34. Benacerraf BR, Mandel J, Estroff JA. Fetal pyelectasis: a possible association with Down syndrome. *Obstet Gynecol*. 1990;76:58.
35. Corteville JE, Dicke JM, Crane JP. Fetal pyelectasis and Down syndrome: is genetic amniocentesis warranted? *Obstet Gynecol*. 1992;79:770.
36. Snijders RJ, Sebire NJ, Faria M. Fetal mild hydronephrosis and chromosomal defects: relation to maternal age and gestation. *Fetal Diagn Ther*. 1995;10:349.
37. Benacerraf BR, Neuberg D, Frigoletto FD. Humeral shortening in second trimester fetuses with Down syndrome. *Obstet Gynecol*. 1991;77:223.
38. Cell-free DNA screening for fetal aneuploidy. Committee Opinion No. 640. American College of Obstetricians and Gynecologists. *Obstet Gynecol*. 2015;126:e31-e37.
39. American Academy of Pediatrics. Health supervision for children with Down syndrome. *Pediatrics*. 2001;107:442.

152 Turner Syndrome (Monosomy X)

YALDA AFSHAR | LAWRENCE D. PLATT

Introduction

Turner syndrome (monosomy X) is characterized by complete or partial loss of the second X chromosome in the female, with or without cell line mosaicism. There are three distinct phenotypes: (1) first trimester abortus (98%), (2) second trimester hydrops fetalis (often resulting in fetal demise), and least commonly (3) neonate with a cystic hygroma (thin-walled cyst containing lymphatic fluid). Turner syndrome is the only monosomy that is compatible with life and has wide phenotypic variability.

Disorder

Turner Syndrome

DEFINITION

The phenotypic pattern of Turner syndrome was described in 1938[1] and defined cytogenetically in 1959 as an absent or abnormal second sex chromosome.[2] Individuals with Turner syndrome always have short stature, typically have a webbed neck, and often have lymphedema, cardiac malformations, renal malformations, gonadal dysgenesis, and/or endocrinopathies. Many of these findings can be identified prenatally with ultrasound (US).

PREVALENCE AND EPIDEMIOLOGY

Turner syndrome is the most common sex chromosome abnormality, and the second most common chromosomal abnormality associated with spontaneous abortion.[3] Its true prevalence is difficult to ascertain because mild phenotypes may go undiagnosed. Best estimates are that it occurs in 4–5 : 10,000 live-born females.[3,4] Turner syndrome is not associated with advanced maternal or paternal age, and has no known ethnic or racial influences.

More than 90% of conceptions with Turner syndrome spontaneously abort. Karyotypic analysis of products of conception from spontaneous pregnancy losses demonstrates an approximate 10% prevalence of 45,X.[5] Prenatal prevalence, estimated through evaluation of cytogenetic registries, is about 40 : 10,000 in the late first trimester by chorionic villus sampling, and 17.5 : 10,000 in the second trimester by amniocentesis.[6,7]

ETIOLOGY AND PATHOPHYSIOLOGY

Distinct etiologies are responsible for the various Turner syndrome karyotypes. Complete monosomy (45,X), the most common etiology of Turner syndrome, is due to absence of one sex chromosome, usually the paternal (80%).[8]

More than 50% of individuals with Turner syndrome have a mosaic chromosomal complement, such as 45,X/46,XX.[9,10] In the case of cell line mosaicism, the loss of genetic material occurs after fertilization. Mosaicism can also result from a cell division error, resulting in one cell line that exhibits a 45,X karyotype and a second line containing a 46,XX, 46,XY, or 47,XXX karyotype. Less commonly, there may be a structurally altered second X chromosome, or some cells carry a Y chromosome, resulting in a virilized adolescent.[11] Individuals who are mosaics for sex chromosomes and/or have structurally abnormal karyotypes appear female and usually have fewer anomalies than the 45,X phenotype.

Postnatal karyotype of 200 patients with phenotypic Turner syndrome demonstrated 46% were 45,X, 41% had a second structurally abnormal X chromosome, 7% were 45,X/46,XX or 45,X/46,XX/47,XXX mosaics, and 6% had a structurally abnormal

TABLE 152.1 KARYOTYPES OF ULTRASOUND DETECTED CASES OF TURNER SYNDROME

Karyotype	Number of Cases	%
45,X	76	90.4
45,X/46,XX	5	5.9
45,X/47,XXX	1	1.2
45,X/46,XY	1	1.2
45,X/46,XX/47,XXX	1	1.2
Total	84	100

From Baena N, De Vigan C, Cariati E, et al. Turner syndrome: evaluation of prenatal diagnosis in 19 European registries. *Am J Med Genet A.* 129A(1):16–20, 2004.

TABLE 152.2 45,X PHENOTYPE: FEATURES AND THEIR INCIDENCE

Feature	Incidence (%)
Small stature	100
Ovarian dysgenesis	90+
Transient congenital lymphedema	80+
Shield chest and widely spaced nipples	80+
Prominent auricles	80+
Low posterior hairline	80+
Webbing of posterior neck	50
Anomalies of the elbow, including cubitus valgus	70
Hypoplastic or hyperconvex nails	70
Renal anomalies	60+
Short metacarpal and/or metatarsal	50
Hearing loss	50
Cardiac anomalies	20+

Data from Gravholt CH. *Nat Clin Pract Endocrinolo Metab* 1:41–52, 2005; Kesler SR. *Child Adolesc Psychiatr Clin N Am* 16:709–22, 2007; Tassone F, et al. *J Mol Diagn* 10:43–9, 2008; Tuohy VK, et al. *Curr Opin Obstet Gynecol* 19:366–9, 2007.

Y chromosome.[12] In contrast, in 90% of prenatally diagnosed Turner syndrome, the karyotype is 45,X[13] (Table 152.1).

Clinical manifestations appear to result from a reduced complement of genes normally expressed on the randomly inactivated X chromosome and therefore karyotype alone cannot predict phenotype. Short stature is the only clinical finding invariably associated with 45,X individuals although, while this has been associated with a pseudoautosomal deletion encompassing a homeobox gene (short stature homeobox-containing gene on the X chromosome, *SHOX*),[14,15] this deletion is also present in 2% to 15% of cases of idiopathic short stature.[16,17]

Common clinical manifestations, such as webbing of the neck, shield chest, renal anomalies, and cardiac defects may be a consequence of lymphedema interfering with organ development. For instance, it has been proposed that lymphatic obstruction at the level of the ascending aorta may directly cause flow-related cardiac defects such as bicuspid aortic valve and/or aortic coarctation as well as neck webbing.[18]

MANIFESTATIONS OF DISEASE

Clinical Presentation

Characteristics of the 45,X phenotype are listed in Table 152.2. The most consistent feature is short stature. Ovarian dysgenesis and renal anomalies, such as horseshoe kidney, ureteral duplication, and unilateral renal agenesis, are also relatively common. Cardiovascular abnormalities, which are seen more in 45,X individuals than in mosaics,[19] were present in 44% of 173 patients with Turner syndrome in one series.[20] Of these, 34% involved the aortic valve, 19% the aortic arch, 8% the systemic venous system, 5% the ventricular septum, and 4% the pulmonary venous system. Mental retardation is not normally seen unless a small ring X chromosome is present.



Fig. 152.1 Cystic hygroma in a first-trimester fetus, with thickening around the head that extends down the back. *(Courtesy of Dr. Lawrence Platt.)*

Two-thirds of cases are suspected from US findings.[21] Classic US findings in the first trimester include increased NT, cystic hygroma, and hydrops fetalis (Figs. 152.1, 152.3, 152.5). Although these findings increase risk for many aneuploidies, persistence of cystic hygroma[13] is highly correlated with Turner syndrome.[21]

Imaging Technique and Findings

Serum Analytes. Serum analytes are not consistently abnormal, nor is there an indicative pathognomonic pattern when they are abnormal. However, the presence of a cystic hygroma or hydrops increases the sensitivity of serum analytes; second-trimester multiple marker screening is abnormal in 60% of cases with a cystic hygroma versus 11% of Turner cases without a cystic hygroma.[22] Furthermore, fetuses with, but not those without, hydrops demonstrate elevated levels of inhibin A and beta-human chorionic gonadotropin.[23]

Ultrasound. The Turner phenotype refers to neonates, but many findings can be suspected and/or detected prenatally with US. Congenital anomalies are detected in about two-thirds of prenatally diagnosed Turner syndrome, and the classic finding is cystic hygroma (Figs. 152.1 and 152.2; Table 152.3).[13,24] Central lymphatic obstruction in the form of a thickened NT, cystic hygroma, or subcutaneous edema is often apparent (see Figs. 152.1 and 152.2). Hydrops fetalis also commonly develops secondary to an absent connection between the lymphatic and venous system, resulting in effusion in potential spaces (thoracic, pericardial, and abdominal) (Figs. 152.3 and 152.4). The hygroma may resolve if a connection is later established restoring lymphatic flow, but this leaves a webbed neck and prominent nuchal skin folds.[24]

During the first trimester, a nuchal translucency (NT) greater than 2.5 mm confers a nine times increased risk of Turner syndrome, with a detection rate of approximately 75%.[25] The FASTER trial showed that NT in Turner fetuses is generally much

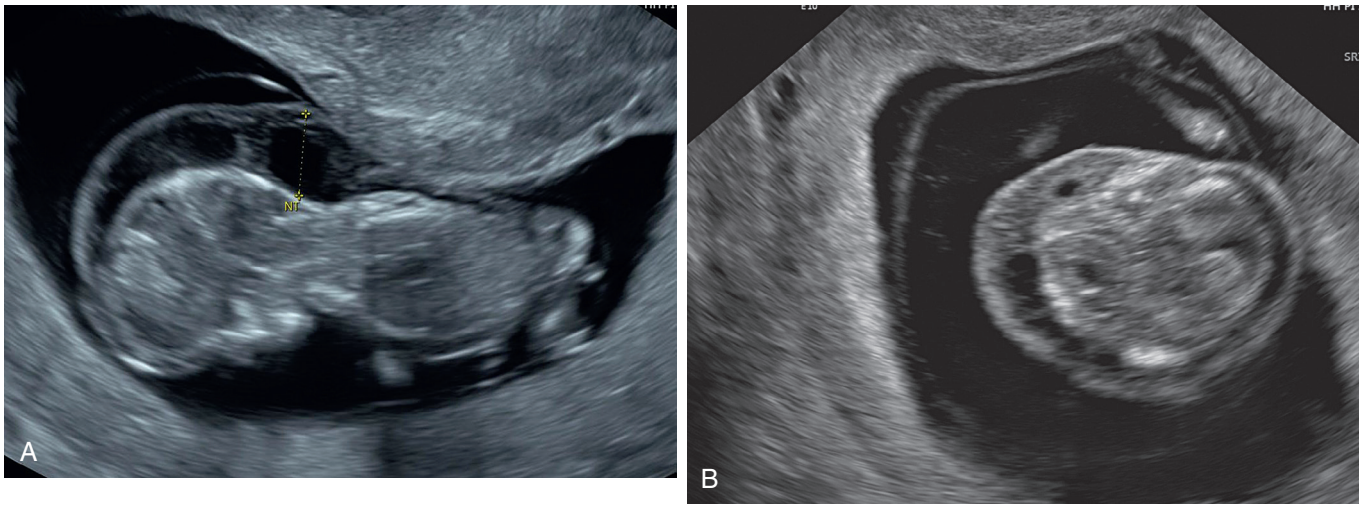

Fig. 152.2 (A) Cystic hygroma with a large posterior neck fluid collection, with septations and edema along the entire trunk. (B) Several fluid collections are visible in axial view of the neck and a large central septation. *(Courtesy of Dr. Lawrence Platt.)*

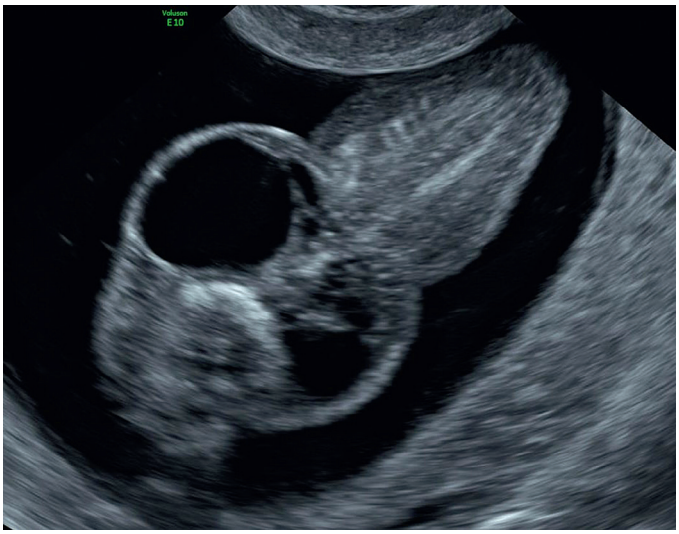

Fig. 152.3 Coronal view of the fetus with hydrops fetalis with severe skin edema and a pleural effusion. *(Courtesy of Dr. Lawrence Platt.)*

TABLE 152.3 FETAL CONGENITAL ANOMALIES IN CASES OF TURNER SYNDROME

	ULTRASOUND DETECTED CASES (%)	
Congenital Anomaly	**Baena N, et al. 2004 (N = 125)[13]**	**Papp C, et al. 2006 (N = 69)[22]**
Cystic hygroma	59.5	26.1
Hydrops fetalis	19	11.6
Congenital heart defect	7.8	13
Nuchal thickening	3.5	13
Pulmonary defect	3.5	–
Renal defect	2.6	11.6
Central nervous system defect	1.7	–
Short femur	1.7	10.1
Abdominal wall defect	0.9	2.9
Ventriculomegaly	–	4.3
Coarctation of aorta	–	5.8
Choroid plexus cyst	–	8.7
Dilated right ventricle	–	1.4
Ventricular septal defects	–	2.9
Tetralogy of Fallot	–	2.9
Echogenic intracardiac focus	–	1.4

Data from Baena N, et al. *Am J Med Genet A.* 129:16–20, 2004; Papp C, et al. *J Ultrasound Med.* 25:711–717, 2006.

larger, averaging 11.8 mm.[26] In this trial, Turner syndrome was diagnosed in 28% of 132 cases of septated cystic hygroma, most of which (95%) were electively or spontaneously aborted. Sixteen percent of the remaining cases resulted in live birth. The presence of a second-trimester cystic hygroma, particularly with hydrops, portended a poor prognosis.

The prevalence of cardiac malformations is estimated to be 23% to 56% of surviving individuals with Turner syndrome.[27–29] Of the various defects found with Turner syndrome, coarctation of the aorta and hypoplastic left heart syndrome are most commonly diagnosed prenatally,[13,21,28] whereas partial anomalous pulmonary venous return has the highest relative risk (RR) compared with the general population (RR = 3.5).[27–29]

Turner syndrome fetuses may also show intrauterine growth restriction (IUGR). The incidence of IUGR was 39.2% in one review.[30]

Besides the aforementioned abnormal neck, and cardiovascular and renal anomalies, neonates may have congenital lymphedema of the hands and/or feet (which usually resolves), as well as other dysmorphic features: webbed neck, shield chest, low posterior hairline, abnormal nails, dysmorphic facies and high-arched palate, and skeletal abnormalities of the hands, feet, and elbows. Hearing loss, hypothyroidism, liver function abnormalities, and autoimmune diseases can occur as patients age.[13,31,21]

Although Turner syndrome may be suspected from US findings, prenatal diagnosis requires invasive testing (chorionic villus sampling or amniocentesis) for karyotype.

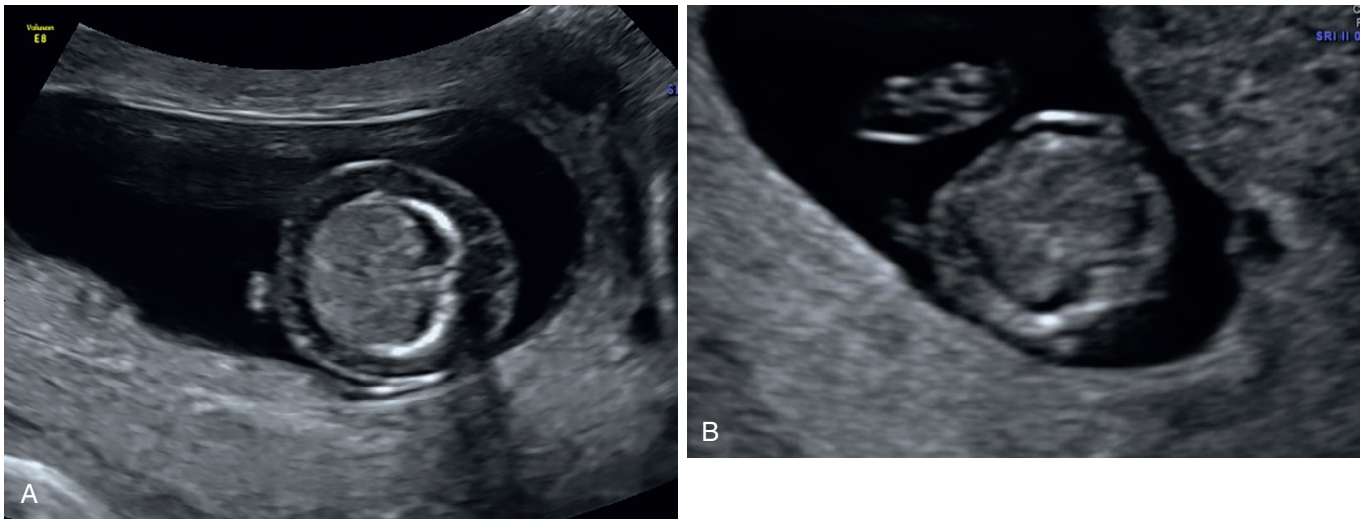

Fig. 152.4 (A) Severe scalp edema with a large cystic hygroma. (B) Axial image around the chest demonstrating bilateral pleural effusions. *(Courtesy of Dr. Lawrence Platt.)*



Fig. 152.5 Severe edema of head extending to upper thorax with separate fluid collection visible in neck. *(Courtesy of Dr. Lawrence Platt.)*

Magnetic Resonance Imaging. Currently, there is little role for magnetic resonance imaging (MRI) to evaluate the fetus with Turner syndrome, although it has been used postnatally to evaluate the aorta.[32]

Other Applicable Modality. Fetal echocardiography is recommended because of the increased incidence of cardiovascular abnormalities in fetuses with suspected or confirmed Turner syndrome.

CLASSIC SIGNS

- Cystic hygroma.
- Hydrops fetalis.

Differential Diagnosis From Imaging Findings

The differential diagnoses of increased NT/cystic hygroma includes other chromosomal aneuploidies (particularly trisomy 21, or 18, or 13), cervical lymphangioma or teratoma, rarer genetic syndromes such as Noonan syndrome, or nonaneuploidy-related cardiac defects (in the case of increased NT).

Synopsis of Treatment Options

PRENATAL

There are no prenatal treatment options. If Turner syndrome is suspected, patients should be offered genetic counseling and prenatal diagnosis via chorionic villus sampling or amniocentesis. Genetic counseling should emphasize the variable phenotypes of Turner syndrome, even when karyotype is known. Depending upon karyotype and/or US findings, patients should be counseled about the high rate of spontaneous loss, and the option of pregnancy termination. For continuing pregnancies, a second-trimester detailed US and fetal echocardiogram should be offered. Follow-up will depend upon the specific scenario, but growth monitoring is reasonable because of the increased risk of fetal growth restriction. Despite a higher rate of intrauterine fetal demise, there is no clear role for antenatal testing in these fetuses. Delivery should be planned at a tertiary center if there is concern for airway management, hydrops, or heart defect.

POSTNATAL

Turner syndrome is often apparent at birth due to classic anatomic abnormalities such as lymphedema. Neonates with suspected or confirmed Turner syndrome should have an echocardiogram, and abdominal/renal US.[33] Lymphedema in the extremities is typically treated symptomatically, and cystic hygromas usually recede to become neck webbing.

In milder phenotypes, the major presenting feature may be short stature, incomplete pubarche, or secondary amenorrhea in adolescence. If diagnosis is made early enough, height and external sexual development can be managed by an endocrinologist. Unfortunately, many girls with short stature are not diagnosed until after 10 years of age, and therefore do not receive early treatment with growth hormone. Even when it is too late to

address height, the issues of gonadal dysgenesis, pubertal development, and infertility should be addressed. Virilized girls should be evaluated for Y chromosome mosaicism because prophylactic removal of the gonads is indicated due to the increased risk of gonadoblastoma. Patients are also at risk for endocrine/autoimmune disorders such as diabetes[34] and hypothyroidism, which is present in about 10% of children and 50% of adults with Turner syndrome.

While most individuals with Turner syndrome are of normal intelligence, there is an association with nonverbal learning disorder[35] and therefore evaluation with an expert in developmental pediatrics is warranted.

WHAT THE REFERRING PHYSICIAN NEEDS TO KNOW

US evidence of a thickened NT, cystic hygroma, or hydrops fetalis significantly increases the risk of Turner syndrome and other fetal aneuploidies (see Figs. 152.1 to 152.5), and consultation with geneticists and maternal-fetal medicine is recommended.

KEY POINTS

- Turner syndrome is the most common sex chromosome abnormality.
- Common prenatal US findings are increased NT, cystic hygroma, hydrops fetalis, cardiac or renal anomalies, and fetal growth restriction.
- Phenotype varies, and is related to the underlying karyotypic abnormality; complete monosomy X (45,X) is more severe than cell line mosaicism.
- Spontaneous abortion occurs in greater than 90% of conceptuses with Turner syndrome.
- The incidence of complete monosomy (45,X) is much higher in prenatally, as compared to postnatally diagnosed Turner syndrome.
- The incidence of Turner syndrome is 1:2000–2500 live-born females.
- Turner syndrome is not associated with an increased recurrence risk.
- Patients with Turner syndrome are at risk of endocrine, autoimmune, cardiovascular, renal, and multiple other complications, and care should be coordinated with appropriate experts.

SUGGESTED READING

Bondy CA. Turner syndrome 2008. *Horm Res*. 2009;71(S1):52-56.

Cohen M, Schwartz S, Scwartz M, et al. Antenatal detection of cystic hygroma. *Obstet Gynecol Surv*. 1989;44(6):481-490.

Granger A, Zurada A, Zurada-Zielińska A, et al. Anatomy of turner syndrome. *Clin Anat*. 2016;29(5):638-642.

Legro RS. Turner syndrome: new insights into an old disorder. *Fertil Steril*. 2012;98(4):773-774.

Levitsky LL, Luria AH, Hayes FJ, et al. Turner syndrome: update on biology and management across the life span. *Curr Opin Endocrinol Diabetes Obes*. 2015;22(1):65-72.

Nicolaides KH. Nuchal translucency and other first-trimester sonographic markers of chromosomal abnormalities. *Am J Obstet Gynecol*. 2004;191:45-67.

Saenger P, Albertsson Wikland K, Conway GS, et al. Recommendations for the diagnosis and management of Turner syndrome. *J Clin Endocrinol Metab*. 2001;86:3061-3069.

Said S, Malone F. The use of nuchal translucency in contemporary obstetric practice. *Clin Obstet Gynecol*. 2008;51:37-47.

Tartaglia NR, Howell S, Sutherland A, et al. A review of trisomy X (47,XXX). *Orphanet J Rare Dis*. 2010;5:8.



All references available online at
www.expertconsult.com

REFERENCES

1. Classic pages in obstetrics and gynecology by Henry H. Turner. A syndrome of infantilism, congenital webbed neck, and cubitus valgus. *Endocrinology*. 23;566–574, 1938. *Am J Obstet Gynecol*. 1972;113(2):279.
2. Ford CE, Jones KW, Polani PE, et al. A sex-chromosome anomaly in a case of gonadal dysgenesis (Turner's syndrome). *Lancet*. 1959;1(7075): 711-713.
3. Stochholm K, Juul S, Juel K, et al. Prevalence, incidence, diagnostic delay, and mortality in Turner syndrome. *J Clin Endocrinol Metab*. 2006;91(10): 3897-3902.
4. Hook EB, Warburton D. The distribution of chromosomal genotypes associated with Turner's syndrome: livebirth prevalence rates and evidence for diminished fetal mortality and severity in genotypes associated with structural X abnormalities or mosaicism. *Hum Genet*. 1983;64(1):24-27.
5. Menasha J, Levy B, Hirschhorn K, et al. Incidence and spectrum of chromosome abnormalities in spontaneous abortions: new insights from a 12-year study. *Genet Med*. 2005;7(4):251-263.
6. Gravholt CH, Juul S, Naeraa RW, et al. Prenatal and postnatal prevalence of Turner's syndrome: a registry study. *BMJ*. 1996;312(7022):16-21.
7. Han SH, An JW, Jeong GY, et al. Clinical and cytogenetic findings on 31,615 mid-trimester amniocenteses. *Korean J Lab Med*. 2008;28(5):378-385.
8. Cockwell A, MacKenzie M, Youings S, et al. A cytogenetic and molecular study of a series of 45,X fetuses and their parents. *J Med Genet*. 1991;28(3):151-155.
9. Gunther DF, Eugster E, Zagar AJ, et al. Ascertainment bias in Turner syndrome: new insights from girls who were diagnosed incidentally in prenatal life. *Pediatrics*. 2004;114(3):640-644.
10. Nielsen J, Wohlert M. Chromosome abnormalities found among 34,910 newborn children: results from a 13-year incidence study in Arhus, Denmark. *Hum Genet*. 1991;87(1):81-83.
11. Hassold T, Pettay D, Robinson A, et al. Molecular studies of parental origin and mosaicism in 45,X conceptuses. *Hum Genet*. 1992;89(6):647-652.
12. Jacobs P, Dalton P, James R, et al. Turner syndrome: a cytogenetic and molecular study. *Ann Hum Genet*. 1997;61(Pt 6):471-483.
13. Baena N, De Vigan C, Cariati E, et al. Turner syndrome: evaluation of prenatal diagnosis in 19 European registries. *Am J Med Genet A*. 2004;129A(1):16-20.
14. Fukami M, Seki A, Ogata T. SHOX Haploinsufficiency as a cause of syndromic and Nonsyndromic Short Stature. *Mol Syndromol*. 2016;7(1):3-11.
15. Rao E, Weiss B, Fukami M, et al. Pseudoautosomal deletions encompassing a novel homeobox gene cause growth failure in idiopathic short stature and Turner syndrome. *Nat Genet*. 1997;16(1):54-63.
16. Levy B, Sigurjonsson S, Pettersen B, et al. Genomic imbalance in products of conception: single-nucleotide polymorphism chromosomal microarray analysis. *Obstet Gynecol*. 2014;124(2 Pt 1):202-209.
17. Romero ST, Geiersbach KB, Paxton CN, et al. Differentiation of genetic abnormalities in early pregnancy loss. *Ultrasound Obstet Gynecol*. 2015;45(1):89-94.
18. Loscalzo ML, Van PL, Ho VB, et al. Association between fetal lymphedema and congenital cardiovascular defects in Turner syndrome. *Pediatrics*. 2005;115(3):732-735.
19. Tokita MJ, Sybert VP. Postnatal outcomes of prenatally diagnosed 45,X/46,XX. *Am J Med Genet A*. 2016;170(5):1196-1201.
20. Cramer JW, Bartz PJ, Simpson PM, et al. The spectrum of congenital heart disease and outcomes after surgical repair among children with Turner syndrome: a single-center review. *Pediatr Cardiol*. 2014;35(2):253-260.
21. De Groote K, Cools M, De Schepper J, et al. Cardiovascular pathology in males and females with 45,X/46,XY mosaicism. *PLoS ONE*. 2013;8(2):e54977.
22. Papp C, Beke A, Mezei G, et al. Prenatal diagnosis of Turner syndrome: report on 69 cases. *J Ultrasound Med*. 2006;25(6):711-717, quiz 8-20.
23. Wenstrom KD, Boots LR, Cosper PC. Multiple marker screening test: identification of fetal cystic hygroma, hydrops, and sex chromosome aneuploidy. *J Matern Fetal Med*. 1996;5(1):31-35.
24. Lambert-Messerlian GM, Saller DN Jr, Tumber MB, et al. Second-trimester maternal serum inhibin A levels in fetal trisomy 18 and Turner syndrome with and without hydrops. *Prenat Diagn*. 1998;18(10):1061-1067.
25. Gedikbasi A, Gul A, Sargin A, et al. Cystic hygroma and lymphangioma: associated findings, perinatal outcome and prognostic factors in live-born infants. *Arch Gynecol Obstet*. 2007;276(5):491-498.
26. Alexioy E, Alexioy E, Trakakis E, et al. Predictive value of increased nuchal translucency as a screening test for the detection of fetal chromosomal abnormalities. *J Matern Fetal Neonatal Med*. 2009;22(10):857-862.
27. Malone FD, Ball RH, Nyberg DA, et al. First-trimester septated cystic hygroma: prevalence, natural history, and pediatric outcome. *Obstet Gynecol*. 2005;106(2):288-294.
28. Yaegashi N, Uehara S, Ogawa H, et al. Association of intrauterine growth retardation with monosomy of the terminal segment of the short arm of the X chromosome in patients with Turner's syndrome. *Gynecol Obstet Invest*. 2000;50(4):237-241.
29. Mazzanti L, Cacciari E. Congenital heart disease in patients with Turner's syndrome. Italian Study Group for Turner Syndrome (ISGTS). *J Pediatr*. 1998;133(5):688-692.
30. Surerus E, Huggon IC, Allan LD. Turner's syndrome in fetal life. *Ultrasound Obstet Gynecol*. 2003;22(3):264-267.
31. Sybert VP. Cardiovascular malformations and complications in Turner syndrome. *Pediatrics*. 1998;101(1):E11.
32. Matura LA, Ho VB, Rosing DR, et al. Aortic dilatation and dissection in Turner syndrome. *Circulation*. 2007;116(15):1663-1670.
33. Lippe B, Geffner ME, Dietrich RB, et al. Renal malformations in patients with Turner syndrome: imaging in 141 patients. *Pediatrics*. 1988;82(6): 852-856.
34. Jorgensen KT, Rostgaard K, Bache I, et al. Autoimmune diseases in women with Turner's syndrome. *Arthritis Rheum*. 2010;62(3):658-666.
35. Ross J, Roeltgen D, Zinn A. Cognition and the sex chromosomes: studies in Turner syndrome. *Horm Res*. 2006;65(1):47-56.

153 Mosaic Trisomies 8, 9, and 16

ABIGAIL A. ARMSTRONG | STEPHANIE L. GAW | LAWRENCE D. PLATT

Introduction

Trisomies can occur with any chromosome, but most often result in spontaneous abortion. For example, trisomy 16 is the most common trisomy in human pregnancies, and the majority of the time results in miscarriage. These severe trisomies are more likely to survive past the first trimester and possibly to birth if they are mosaics, in which the condition of trisomy only affects a portion of the cells in the body. Here, we discuss mosaic trisomies 8, 9, and 16.

Disorder

Trisomy 8

DEFINITION

Trisomy 8 mosaicism is a genetic abnormality that results from a cell line with an extra chromosome number 8 in addition to a genetically normal cell line. Trisomy 8 mosaicism is also

called *Warkany syndrome 2*.[1] Unlike some other trisomies, trisomy 8 mosaicism can be compatible with life. These individuals vary in phenotype and can be recognized by mental retardation, abnormal facies, absent or dysplastic patellas, joint contractures, plantar/palmar furrows, distinctively abnormal toe posture, vertebral anomalies, narrow pelvis, and urorenal anomalies.[2]

PREVALENCE AND EPIDEMIOLOGY

Mosaic trisomy 8 is estimated in 2–4:100,000 births. Eight of 10 spontaneous abortions is due to complete trisomy 8, which is lethal in a conceptus.[1] There is a 3:1 male-to-female sex ratio in the mosaic cases.[3] A review of PubMed's database shows that only 120 cases have been reported.[4]

ETIOLOGY AND PATHOPHYSIOLOGY

According to Fineman et al., chromosome 8 is the "largest autosome thus far found to be trisomic among live-born infants."[5] Most cases of trisomy 8 mosaicism result from mitotic nondisjunction.[1]

MANIFESTATIONS OF DISEASE

Clinical Presentation

Mosaic trisomy 8 has a wide range of clinical phenotypes depending on the cell lines present. Individuals can be normal or have severe malformations.[1] Twenty-five per cent of patients may have congenital cardiac malformations. Other physical findings of live-born infants with trisomy 8 mosaicism include mild-to-moderate mental retardation due to corpus callosum agenesis, strabismus, osseous and soft tissue abnormalities, broad bulbous nose, palate deformity, hydronephrosis, cryptorchidism, reduced joint mobility, various vertebral and costal anomalies, eye anomalies, camptodactyly, and deep plantar and palmar creases. Deep plantar creases are very characteristic of this disease.[1,5]

Imaging Technique and Findings

Ultrasound. Ultrasound (US) can identify cases of suspected trisomy 8 mosaicism. US findings include agenesis of the corpus callosum, hydrocephalus, abnormal facies, cardiac malformations, ventriculomegaly, and joint contractures.[6]

Magnetic Resonance Imaging. There are few cases that address magnetic resonance imaging (MRI) in trisomy 8 mosaicism. However, MRI can further characterize brain abnormalities, including enlarged lateral ventricles and corpus callosum agenesis, which exist in trisomy 8 mosaicism. One case report describes a 33-year-old man treated for Marfan syndrome during childhood who presented with "lumbar spine herniated nucleus propulsus" on MRI.[7]

Differential Diagnosis From Imaging Findings

1. Other trisomies
2. Syndromes with Arthrogryposis

Other trisomies should be on the differential diagnosis for trisomy 8 mosaicism. Syndromes with arthrogryposis should be differentiated from trisomy 8 mosaicism. Both diagnoses include joint contractures. Arthrogryposis syndromes are multifactorial and it is often hard to find a cause.[7]

Synopsis of Treatment Options

PRENATAL

Most patients with mosaic trisomy 8 will be detected with chorionic villus sampling; however, the results are not specific. This is due to the fact that trisomy 8 mosaic found in the sample may be due to confined placental mosaicism. Like other chromosomal abnormalities, maternal serum alpha-fetoprotein (MSAFP) may be in trisomy 8 mosaicism. Amniocentesis can confirm the diagnosis.[1]

POSTNATAL

Postnatal diagnosis of trisomy 8 mosaicism may be delayed because of the wide spectrum of phenotypes that exist.[2] Some individuals with trisomy 8 mosaicism may not be diagnosed until after birth when a child presents with progressive neurodevelopmental delay and dysmorphic facial features. Life expectancy may be normal. These children can be diagnosed with karyotyping on serum blood cells. Mosaic trisomy 8 individuals may have an increased risk of leukemia and myelodysplastic syndrome. This is a result of progenitor cell proliferation due to abnormal stromal cells.[1]

Disorder

Trisomy 9

DEFINITION

Trisomy 9 mosaicism is a genetic abnormality that results from a cell line that has an extra chromosome number 9 in addition to a genetically normal cell line.

PREVALENCE AND EPIDEMIOLOGY

The earliest report of trisomy 9 mosaicism was in 1973.[8] Trisomy 9 is extremely rare in live births. Only 0.1% of trisomy 9 conceptions will result in live birth with poor prognosis, with survival times ranging from mere minutes to 9 months after birth.[9] Live-born fetuses will have a mosaic phenotype. Trisomy 9 affects both genders equally.

ETIOLOGY AND PATHOPHYSIOLOGY

Trisomy 9 mosaicism is a result of meiotic error with trisomy rescue. Similar to trisomy 16, trisomy 9 mosaicism increases with maternal age because the genetic error occurs in meiosis.[10]

MANIFESTATIONS OF DISEASE

Clinical Presentation

Mosaic trisomy 9 has a similar phenotype to those individuals with pure trisomy 9. Individuals with the disease will most likely die within 1 year of age. Typical characteristics of this disease are "failure to thrive, severe intellectual and motor deficiency, cryptorchidism in males, and renal cysts." Other physical findings

of live-born infants with trisomy 9 mosaicism include bulbous nose and dislocated limbs.[11]

Imaging Technique and Findings

Ultrasound. US can identify cases of suspected trisomy 9 mosaicism. Characteristic findings have been noted in up to 60% of these individuals, including microcephaly, deep-set eyes, fleshy nose, receding lower lip, subluxation of hips, and cardiac disease.[12] US findings are nonspecific for trisomy 9 mosaicism. The most common findings are intrauterine growth restriction and amniotic fluid disorders, followed by craniofacial, cardiac, skeletal, and urinary findings. In a review of 13 mosaic trisomy 9 fetuses, 7.7% had one single umbilical artery and 15.4% had gastrointestinal findings on US.[13]

Magnetic Resonance Imaging. There are few cases that address magnetic resonance imaging (MRI) in trisomy 9 mosaicism. Of note, most trisomy 9 mosaic individuals do not have CNS structural anomalies, and so MRI is unlikely to be of great clinical value.[14]

Differential Diagnosis From Imaging Findings

Trisomy 18 in particular has similar sonographic findings as trisomy 9 mosaicism, as both contain facial and cardiac abnormalities. Trisomy 18 is the second most common autosomal trisomy occurring in 1 in 5500 live births.[15] Similar to other chromosomal abnormalities, the disease can involve any organ. The phenotypic characteristics of trisomy 18 are intrauterine growth restriction, hypertonia, prominent occiput, small mouth, micrognathia, pointy ears, short sternum, horseshoe kidney, and flexed fingers, with the index finger overlapping the third finger and the fifth finger overlapping the fourth.[16,17]

Synopsis of Treatment Options

PRENATAL

Many of the trisomy 9 mosaicism anomalies can be discovered with prenatal ultrasound. Most patients with trisomy 9 mosaicism will be diagnosed by amniocentesis or a peripheral blood sample.[18] Abnormal maternal serum screens will include elevated MSAFP and low free beta-human chorionic gonadotrophin (beta-hCG).[19]

POSTNATAL

Individuals with trisomy 9 mosaicism will be treated according to their spectrum of disease. Multidisciplinary specialists will be needed to tailor specific treatment.

Disorder

Trisomy 16

DEFINITION

Trisomy 16 is a genetic abnormality that results from an extra copy of chromosome 16. The diagnosis of a trisomy 16 conceptus will most likely result in a fetal loss in the first trimester. If mosaic trisomy 16 is present, the fetus may survive with near-normal developmental outcomes depending on the presence and degree of malformations.[20]

PREVALENCE AND EPIDEMIOLOGY

Trisomy 16 is estimated in 1.5% of pregnancies that are clinically recognized.[21] The prevalence of trisomy 16 varies among genders. The trisomy 16 diagnosis has been more commonly identified in the male gender. In mosaic trisomy 16, however, a larger proportion of female fetuses exist.[20] Trisomy 16 accounts for 16% of first-trimester spontaneous abortions.[20]

ETIOLOGY AND PATHOPHYSIOLOGY

Most cases of trisomy 16 result from nondisjunction in maternal meiosis I, which usually results in a first-trimester loss. If a trisomy 16 fetus is diagnosed on chorionic villus sampling or amniocentesis, then it is due to mosaicism in which one of the trisomic chromosomes is lost in mitotic cell division.[22] According to Hassold,[23] in over 60 studied cases of trisomy 16, all were due to maternal division errors because paternal nondisjunction is less likely to occur in shorter chromosomes like chromosome 16. The incidence of trisomy 16 increases with maternal age because the genetic error occurs in meiosis I. Complete trisomy 16 is incompatible with life. Cases that survive are mosaic for trisomy 16, or cases of confined placental mosaicism.[20,22]

MANIFESTATIONS OF DISEASE

Clinical Presentation

Live-born infants with mosaic trisomy 16 have an average gestational age of 35.7 weeks with a birth weight near 2 SD below the average, and 93% live beyond the neonatal period.[22] Physical findings in live-born infants with trisomy 16 include cardiac malformations, hypospadias, two vessel cords, clinodactyly and pulmonary hypoplasia. Cardiac defects account for the majority of malformations with VSD being the most prevalent. Pulmonary hypoplasia is more likely caused by another malformation such as diaphragmatic hernia, renal anomalies, premature rupture of membranes, severe scoliosis, and omphalocele with kyphoscoliosis.[22]

Imaging Technique and Findings

Ultrasound. US can identify cases of suspected mosaic trisomy 16. US findings include single organ malformations including ventricular septal defect, hypospadias, imperforate anus, inguinal hernia, and clubfoot.[20] Findings for fetuses with mosaic trisomy 16 include intrauterine growth restriction and altered placental.[24] One case report showed placentomegaly with multiple cysts, polyhydramnios, a single umbilical artery, and a small ventricular septal defect.[25]

Magnetic Resonance Imaging. There are few cases that address MRI in trisomy 16 mosaicism. However, MRI can further characterize brain abnormalities if applicable.

Differential Diagnosis From Imaging Findings

1. Trisomy 18
2. Trisomy 9

Other trisomies should be on the differential diagnosis for trisomy 16. Trisomy 18 is a syndrome that has the ability to affect every organ, with findings similar to trisomy 16. Trisomy 18 is also complicated by intrauterine growth restriction.

Trisomy 9 is also in the differential diagnosis for trisomy 16. The classic findings in trisomy 9 are genitourinary anomalies, congenital heart defects, dysmorphic face, bilateral cleft lip, hypoplastic corpus callosum, and Dandy-Walker malformation. It is considered a lethal disease unless mosaicism is present.[9]

Synopsis of Treatment Options

PRENATAL

Most patients with trisomy 16 fetuses will be originally diagnosed by chorionic villus sampling.[5] In a study with 28 fetuses with trisomy 16, most cases were discovered at either chorionic villus sampling or with amniocentesis. Most were found to have decreased maternal levels of pregnancy-associated plasma protein A and increased human chorionic gonadotrophin and alpha-fetoprotein levels.[26,27] There are no prenatal treatments for trisomy 16, and patients can be counseled on the option for termination. In mosaic cases of trisomy 16, outcome can be fair, with intrauterine growth restriction being cited as the most prevalent issue.[24] Multidisciplinary prenatal consultations should be offered to all patients.

POSTNATAL

Mosaic trisomy 16 individuals who survive beyond the neonatal period may have complicated prognoses depending on their degree of congenital heart disease, intrauterine growth restriction, pulmonary hypoplasia, and other organ abnormalities. The postnatal course is tailored to the individual.

WHAT THE REFERRING PHYSICIAN NEEDS TO KNOW

Trisomy 8 mosaicism is a chromosomal disorder from postzygotic mitotic error.[3] Individuals have many congenital malformations that can be diagnosed on imaging such as US. Prenatal consultation with geneticists is difficult due to the large phenotypic diversity. Prognosis and treatment depend on the individual's physical malformations and mental abnormalities. Patients should be conscious of the possible increased risk of malignancy.

Trisomy 9 mosaicism is a chromosomal disorder as a result of meiosis. Individuals have many congenital malformations that can be diagnosed by US or other imaging. Prognoses and treatment depend on the individual's physical malformations and mental abnormalities.

Trisomy 16 is a chromosomal disorder from nondisjunction in maternal meiosis I. Fetuses have many congenital malformations that can be diagnosed on imaging such as US. Prenatal consultation with maternal-fetal medicine specialists and geneticists is recommended. The outcome for fetuses with trisomy 16 depends largely on the degree of mosaicism, which can be ascertained from the fetal and placenta tissue.

KEY POINTS

- Trisomy 8 mosaicism results from a postzygotic mitotic error. Diagnosis can be missed in the prenatal period.
- Common US findings in trisomy 8 mosaicism include agenesis of the corpus callosum and ventriculomegaly.
- Life expectancy can be normal in trisomy 8 mosaic individuals.
- Trisomy 9 mosaicism results from a meiotic error.
- Common US findings in trisomy 9 mosaicism include IUGR and amniotic fluid abnormalities, craniofacial, cardiac, skeletal, and urinary findings.
- Individuals with mosaic trisomy 9 can live into childhood only if they have a low percentage of trisomic cells.
- Trisomy 16 results from an extra chromosome 16 secondary to nondisjunction.
- Common US findings in trisomy 16 include IUGR, cardiac malformations, genital anomalies, imperforate anus, and gut malrotation.
- If a trisomy 16 conceptus survives the first trimester, then it is most likely mosaic and can have a good outcome depending on the amount of cells with trisomy.

SUGGESTED READING

Benn P. Trisomy 16 and trisomy 16 mosaicism: a review. *Am J Med Genet*. 1998;79:121-133.

Fineman RM, Ablow RC, Howard RO, et al. Trisomy 8 mosaicism syndrome. *Pediatrics*. 1975;56(5):762-767.

Hsu LY, Yu MT, Neu RL, et al. Rare trisomy mosaicism diagnosed in amniocytes, involving an autosome other than chromosomes 13, 18, 20, and 21: karyotype/phenotype correlations. *Prenat Diagn*. 1997;17(3):201-242.

Lin Hsiang-Yu, Lin Shuan-Pei, Chen Yen-Jiun, et al. Clinical characteristics and survival of trisomy 18 in a medical center in Taipei, 1988-2004. *Am J Med Genet A*. 2006;140(9):945-951.

Mosaicism in trisomy 8: phenotype differences according to tissular repartition of normal and trisomic clones. *Ann Genet*. 1997;40(3):181-184.

Yong PJ, Barrett IJ, Kalousek DK, et al. Clinical aspects, prenatal diagnosis, and pathogenesis of trisomy 16 mosaicism. *J Med Genet*. 2003;40(3):175-182.



All references available online at
www.expertconsult.com

REFERENCES

1. Agrawal A, Agrawal R. Warkany syndrome: a rare case report. *Case Rep Pediatr*. 2011;2011:437101.
2. Riccardi VM. Trisomy 8: an international study of 70 patients. *Birth Defects Orig Artic Ser*. 1977;13(3C):171-184.
3. Karadima G, Bugge M, Nicolaidis P, et al. Origin of nondisjunction in trisomy 8 and trisomy 8 mosaicism. *Eur J Hum Genet*. 1998;6(5): 432-438.
4. Hale NE. Piecing together a picture of trisomy 8 mosaicism syndrome. *J Am Osteopath Assoc*. 2010;110(1):21-23.
5. Fineman RM, Ablow RC, Howard RO, et al. Trisomy 8 Mosaicism Syndrome. *Pediatrics*. 1975;56(5):762-767.
6. Miller K, Arslan-Kirchner A, Schulze B, et al. Mosaicism in trisomy 8: phenotype differences according to tissular repartition of normal and trisomic clones. *Ann Genet*. 1997;40(3):181-184.
7. Bevan WP, Hall JG, Bamshad M, et al. Arthrogryposis multiplex congenita (amyoplasia): an orthopaedic perspective. *J Pediatr Orthop*. 2007;27(5):594-600.
8. Schwendemann WD, Contag SA, Wax JR, et al. Sonographic Findings in Trisomy 9. *J Ultrasound Med*. 2009;28(1):39-42.
9. Machin GA, Crolla JA. Chromosome constitution of 500 infants dying during the perinatal period. With an appendix concerning other genetic disorders among these infants. *Humangenetik*. 1974;23(3):183-198.
10. Slater HR, Ralph A, Daniel A, et al. A case of maternal uniparental disomy of chromosome 9 diagnosed prenatally and the related problem of residual trisomy. *Prenat Diagn*. 2000;20(11):930-932.
11. Arnold GL, Kirby RS, Stern TP, et al. Trisomy 9: review and report of two new cases. *Am J Med Genet*. 1995;56(3):252-257.
12. Benacerraf BR, Pauker S, Quade BJ, et al. Prenatal sonography in trisomy 9. *Prenat Diagn*. 1992;12(3):175-181.
13. Stipoljev F, Kos M, Miskovi B, et al. Antenatal detection of mosaic trisomy 9 by ultrasound: a case report and literature review. *J Matern Fetal Neonatal Med*. 2003;14(1):65-69.
14. Miryounesi M, Dianatpour M, Shadmani Z, et al. Report of a Case with Trisomy 9 Mosaicism. *Iran J Med Sci*. 2016;41(3):249-252.
15. Kosho T, Nakamura T, Kawame H, et al. Neonatal management of trisomy 18: clinical details of 24 patients receiving intensive treatment. *Am J Med Genet A*. 2006;140(9):937-944.
16. Jones KL. *Smith's Recognizable Patterns of Human Malformation*. 6th ed. Philadelphia: Elsevier Saunders; 2006.
17. Lin HY, Lin SP, Chen YJ, et al. Clinical characteristics and survival of trisomy 18 in a medical center in Taipei, 1988-2004. *Am J Med Genet A*. 2006; 140(9):945-951.
18. Hsu LY, Yu MT, Neu RL, et al. Rare trisomy mosaicism diagnosed in amniocytes, involving an autosome other than chromosomes 13, 18, 20, and 21: karyotype/phenotype correlations. *Prenat Diagn*. 1997;17(3): 201-242.
19. Chen CP, Chern SR, Cheng SJ, et al. Second-trimester diagnosis of complete trisomy 9 associated with abnormal maternal serum screen results, open sacral spina bifida and congenital diaphragmatic hernia, and review of the literature. *Prenat Diagn*. 2004;24(6):455-462.
20. Benn P. Trisomy 16 and trisomy 16 mosaicism: a review. *Am J Med Genet*. 1998;79(2):121-133.
21. Wolstenholme J. An audit of trisomy 16 in man. *Prenat Diagn*. 1995;15(2):109-121.
22. Yong PJ, Barrett IJ, Kalousek DK, et al. Clinical aspects, prenatal diagnosis, and pathogenesis of trisomy 16 mosaicism. *J Med Genet*. 2003;40(3): 175-182.
23. Hassold T, Hunt PA, Sherman S, et al. Trisomy in humans: incidence, origin and etiology. *Curr Opin Genet Dev*. 1993;3(3):398-403.
24. Hsu WT, Shchepin DA, Mao R, et al. Mosaic trisomy 16 ascertained through amniocentesis: evaluation of 11 new cases. *Am J Med Genet*. 1998;80(5): 473-480.
25. Astner A, Schwinger E, Caliebe A, et al. Sonographically detected fetal and placental abnormalities associated with trisomy 16 confined to the placenta. A case report and review of the literature. *Prenat Diag*. 1998;18(12): 1308-1315.
26. Spencer K, Pertile MD, Bonacquisto L, et al. First trimester detection of trisomy 16 using combined biochemical and ultrasound screening. *Prenat Diagn*. 2014;34(3):291-295.
27 Neiswanger K, Hohler PM, Hively-Thomas LB, et al. Variable outcomes in mosaic trisomy 16: five case reports and literature analysis. *Prenat Diagn*. 2006;26(5):454-461.

154 22q11.2 Deletion Syndrome

WESLEY LEE | IGNATIA B. VAN DEN VEYVER

Introduction

The 22q11.2 deletion syndrome is the most common human chromosomal microdeletion syndrome and one of the most common syndromes associated with prenatally detected congenital heart defects (CHDs). It has a variable phenotype, with a wide range of associated clinical findings.[1] *DiGeorge syndrome,* first described in 1965, is its most severe presentation, with primary symptoms of thymus and parathyroid aplasia and severe immunologic abnormalities; CHDs were a later added feature.[2] Other names, based on presence of predominant features, have been given to the syndrome and include *Shprintzen* or *velocardiofacial syndrome,*[3] *autosomal dominant Opitz G/BBB syndrome, Caylor cardiofacial syndrome,* and *CATCH 22* (*c*ardiac abnormality, *a*bnormal facies, *t*hymic hypoplasia, *c*left palate, *h*ypocalcemia from deletion in chromosome 22).[1,2] Considering the recognition that most affected individuals with these conditions have a deletion in 22q11.2, the recommended name is now *22q11.2 deletion syndrome* (22q11.2DS).[1] Fluorescence *in situ* hybridization (FISH) and the more recently preferred chromosomal microarray analysis (CMA) reliably detect the most common 1.5 to 3 Mb deletions in children with features of 22q11.2DS, and prenatally in the fetus through amniocentesis or chorionic villus sampling (CVS).[4–7] More recently, noninvasive prenatal screening for microdeletion syndromes from cell-free fetal DNA (cffDNA) in maternal plasma has been introduced in the clinic with variable false positive and false negative rates[8,9] and is changing prenatal diagnosis of 22q11.2DS from a specific targeted test offered because of specific identified fetal anomalies, such as CHDs, to a broader screen for apparently unaffected pregnancies, and occasionally for fetuses with other abnormalities. Considering the variability and severity of the clinical features of 22q11.2DS, it is important that practitioners know its prenatally detectable findings, health issues, and complications of the syndrome that are not prenatally observable, and implications for prenatal management and counseling when it is diagnosed in a pregnancy.

Disorder

DEFINITION

The 22q11.2DS is a pleiotropic genomic disorder with a widely variable clinical presentation, caused by heterozygous deletions of 0.7 Mb to 3 Mb in the q11.2 region of chromosome 22.[1,2] It can present with varying combinations of features listed in order of decreasing frequency in Table 154.1. Currently, 22q11.2DS has replaced other nomenclature, and the term *DiGeorge syndrome* is reserved for the more severe form associated with thymic hypoplasia or aplasia and hypocalcemia. Velocardiofacial syndrome, which points to the typical combination of velopharyngeal incompetence leading to hypernasal speech, cardiac abnormality, and distinct facial features seen in many individuals with 22q11.2DS, is now less commonly used to describe this microdeletion syndrome.[1,10]

TABLE 154.1 CLINICAL MANIFESTATIONS OF THE 22Q11.2 DELETION SYNDROME

Feature	Likelihood in Affected Individuals (%)
Characteristic facial features	>80
Congenital cardiac defects	75
Immune deficiency, including thymic hypoplasia	77
Palatal abnormalities	69
Feeding, swallowing, and gastrointestinal problems	30
Learning difficulties	70–90
Hypotonic limbs and hyperextensible joints	60
Hypocalcemia and hypoparathyroidism	50
Microcephaly	50
Hearing loss	40
Genitourinary anomalies	31
Neuropsychiatric disease	25

PREVALENCE AND EPIDEMIOLOGY

It is estimated that 22q11.2DS affects 1:3000 to 1:6000 individuals, making it the most prevalent microdeletion syndrome.[1,2,11] Although there is no known predisposition based on ethnicity or gender, data from the United States Centers for Disease Control and Prevention suggest that Hispanics have a higher prevalence of 22q11.2DS than non-Hispanic Americans (1:3800 versus 1:6000).[12] It is the most common cause of syndromic abnormality of the palate and the second most common cause of CHDs with developmental disability.[2] Although there is increased early death, with modern treatments, 90% to 95% of individuals survive beyond infancy. Some recent reports of more widely performed prenatal testing and screening suggest that the incidence is higher (approx. 1:350 to approx. 1:1000) in prenatally tested pregnancies, and close to 1:100 in fetuses with CHDs and other major structural anomalies.[1,2,6,13] This may imply that some prenatally detected affected fetuses could either demise prior to delivery or postnatally before a genetic diagnosis is made. Alternatively, milder or asymptomatic cases may be more common but until

now were undetected. Considering the wide clinical variability and the fact that subtle cardiac defects may remain undiagnosed for prolonged periods, it is possible that the true prevalence of 22q11.2DS is underestimated. This is consistent with reported higher incidence data of 1:1000 from noninvasive cell-free DNA screening[8] and the clinical observation that mildly affected individuals can be unrecognized until they have a more severely affected child.

ETIOLOGY, PATHOPHYSIOLOGY, AND EMBRYOLOGY

The developmental abnormalities in 22q11.2DS involve primarily craniofacial structures, thymus, hypoparathyroid, and cardiac outflow structures, and can be explained by abnormal development of mesoderm, endoderm, and neural crest derivatives of the branchial arches.[2] The most typical cardiac defects are a type B interrupted aortic arch, which results from aplasia of the left fourth pharyngeal artery,[14] and tetralogy of Fallot, caused by defective development of the pulmonary infundibulum.[2]

The 22q11.2DS is a heterozygous contiguous deletion syndrome that is usually sporadic and *de novo* (90%–95%) but may be inherited in an autosomal dominant fashion in approximately 10% of cases. There is a 50% risk to transmit the deletion from an affected parent, but clinical severity in the offspring is variable.[5] *De novo* deletions occur more commonly on the maternally inherited chromosome 22.[5] Because of potential gonadal mosaicism for the deletion, there is approximately 1% risk for recurrence, even in apparent *de novo* cases. The genomic locus contains many low-copy-number repeat (LCR) sequences of DNA that predispose to the formation of duplications and deletions in this region during meiosis. The most common deletion (in 85% of cases) is 3 Mb, but up to 10% have a smaller 1.5 Mb deletion in the proximal half of the region, followed by smaller and also more distal deletions of 0.7 Mb to 1.5 Mb.[15,16] There are 90 genes in the 3 Mb deletion, including protein-coding genes, microRNAs and long noncoding RNAs, not all of which cause disease when one copy is missing.[2]

Human studies and mouse models have identified that *TBX1* is a critical gene for many of the features, in particular the heart defects,[17,18] but other genes, such as *CRKL,* may be involved in smaller deletions that do not include *TBX1.* Among the genes that have been linked to the cognitive deficits and neuropsychiatric symptoms are *COMT, PRODH,* and *DGCR8.*[1,2] Although most individuals with the syndrome have 22q11.2 deletions, some have point mutations in *TBX1,* or have no clearly identified genetic cause. Other chromosomal defects have been described, mostly deletions of 10p responsible for DiGeorge syndrome/velocardiofacial syndrome complex 2.

MANIFESTATIONS OF DISEASE

Clinical Presentation

Most prenatally diagnosed cases of 22q11.2DS syndrome are identified because of abnormal cardiac anatomy during routine screening prenatal ultrasound (US), but more recently they may be ascertained through genetic testing by CMA or noninvasive cffDNA screening.[6,8,13] Of the approximate 10% of affected fetuses with an inherited 3 Mb deletion, the affected parent can be asymptomatic or have conditions, such as neuropsychiatric disease, not previously recognized to be caused by the deletion. This number may be slightly higher for smaller atypical deletions. This variability underscores the importance of a thorough prenatal US exam at 18 to 20 weeks' gestation, including imaging of the four-chamber heart, three vessels, and cardiac outflow tracts crossing and long-axis views, for optimal detection of CHDs and identification of at-risk fetuses.

When a CHD, in particular a conotruncal defect, is detected prenatally, 22q11.2DS should always be considered. Postnatally, in addition to (or sometimes in absence of) a CHD, velopharyngeal incompetence with palatal abnormalities (bifid uvula and palatal submucosal clefts) with feeding and speech difficulty, learning disability and psychopathology, hypocalcemia secondary to hypoparathyroidism, T-cell immune defects secondary to thymic hypoplasia, typical facial features (square nasal root, bulbous nose with hypoplastic alae nasi, small palpebral fissures, elongated face, smooth philtrum, simple protruding and low-set ears, and tapered fingers), and hearing loss all can be found with variable frequency.

Structural abnormalities of other organs (genitourinary, central nervous system [CNS], skeletal, gastrointestinal, laryngotracheal) are less commonly described, but can certainly be present and be diagnosed prenatally.[1,2,4,5]

Imaging Technique and Findings

Ultrasound. With the increased screening and testing, often before the first anatomical survey US is performed; accurate recognition of potentially visible clinical features and knowledge of their frequency in 22q11.2DS is critical. About 75% of affected fetuses and infants have CHDs, typically conotruncal anomalies, but other defects can be present together with those or in isolation. The most common are tetralogy of Fallot (20%) (Fig. 154.1), interrupted aortic arch (seen in 13%; in patients with type B interrupted aortic arch, 52% have 22q11.2DS) (Fig. 154.2) or hypoplastic aortic arch (Fig. 154.3), ventricular septal defect (14%) with or without pulmonary atresia, truncus arteriosus (6%) (Fig. 154.4), vascular ring (5.5%) as well other defects (10%) such as hypoplastic left heart (Fig. 154.5), endocardial cushion defect (Fig. 154.6), or atrial septum defects.[19,20]

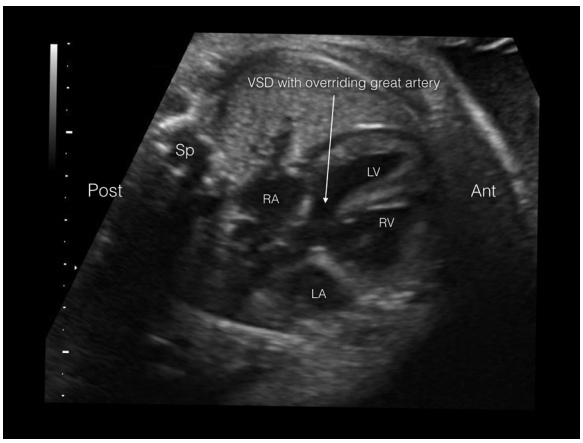

Fig. 154.1 Tetralogy of Fallot. Transverse view of the fetal chest with abnormal four-chamber view with a large VSD and overriding great vessel. The typical small right ventricular outflow tract is not seen at this scanning plane. *Ant,* Anterior; *LA,* left atrium; *LV,* left ventricle; *Post,* posterior; *RA,* right atrium; *RV,* right ventricle; *Sp,* fetal spine; *VSD,* ventricular septal defect.

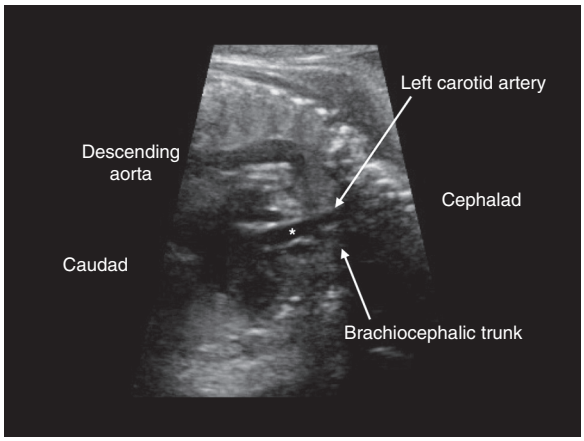

Fig. 154.2 Interrupted aortic arch type B. An interrupted aortic arch is seen between the left carotid artery and the left subclavian artery. In this case, the brachiocephalic trunk and left carotid artery *(arrows)* arise from the ascending aorta *(asterisk)*, but the left subclavian artery originates from the descending aorta (not shown).

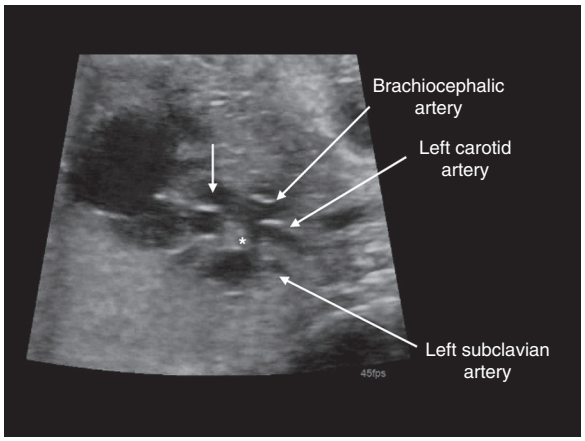

Fig. 154.3 Hypoplastic aortic arch. The transverse aortic arch is narrowed *(asterisk)* between the left carotid artery and left subclavian artery. *Asc Ao,* ascending aorta.

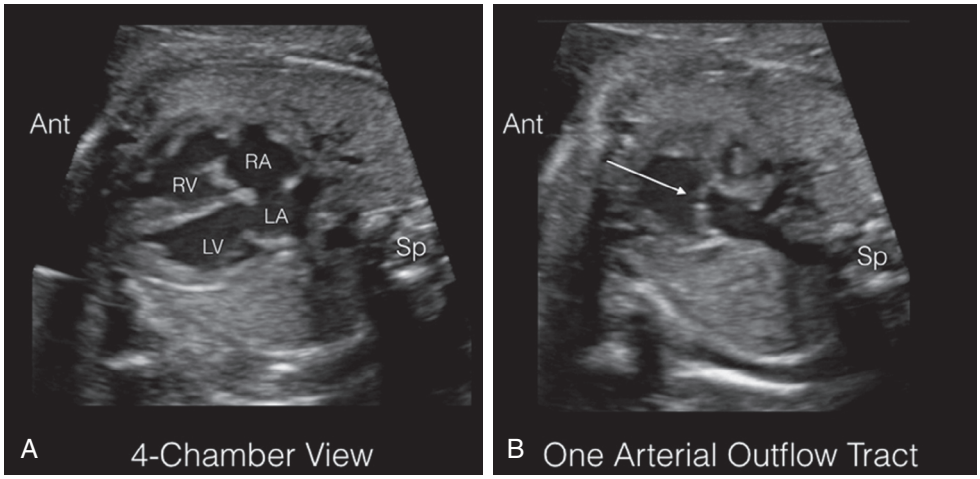

Fig. 154.4 Truncus arteriosus. (A) Transverse view of the fetal chest demonstrates a normal appearing four-chamber view of the heart. (B) As one scans cephalad toward the fetal head, only a single arterial outflow tract can be visualized with thickened valve leaflets *(arrow)*. A second arterial outflow tract could not be found. *Ant,* anterior; *LA,* left atrium; *LV,* left ventricle; *RA,* right atrium; *RV,* right ventricle; *Sp,* fetal spine.

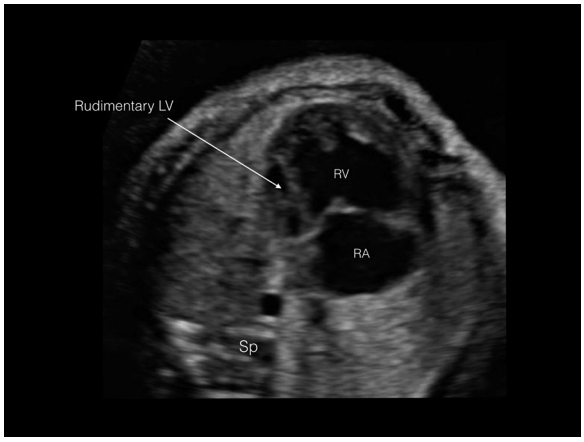

Fig. 154.5 Hypoplastic left heart. A rudimentary left ventricle *(LV)* is present with a dominant right ventricle *(RV)*. Hypoplastic left heart syndrome (HLHS) is typically associated with severe aortic stenosis or atresia. *LV,* left ventricle; *RV,* right ventricle; *RA,* right atrium; *Sp,* spine.

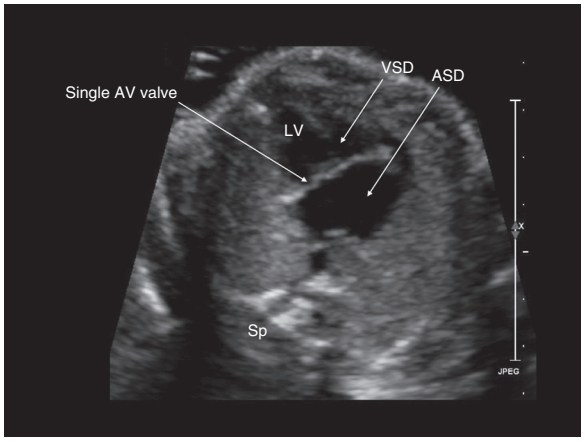

Fig. 154.6 Atrioventricular septal defect (endocardial cushion defect). The four-chamber view demonstrates a ventricular septal defect *(VSD)*, atrial ventricular defect *(ASD)*, and a single atrioventricular *(AV)* valve. There is loss of normal offsetting between the mitral and tricuspid valves. This abnormality is associated with a high incidence of trisomy 21. *LV,* left ventricle; *Sp,* spine.

Palatal abnormalities are present in 69% of cases, but the more common velopharyngeal incompetence (present in 27%) as well as bifid uvula are not detectable by US, and submucosal palatal cleft (16%) is difficult to detect. Visible cleft lip and palate are present in 2% of cases. Additional and less common prenatal US findings include polyhydramnios, which can indicate swallowing difficulties (Fig. 154.7),[21] thymic aplasia or hypoplasia[22] (Chapter 6), laryngotracheoesophageal anomalies, renal anomalies (horseshoe kidney [Fig. 154.8], unilateral renal agenesis, double collecting system, or multicystic dysplastic kidney [Fig. 154.9]),[23–25] mild microcephaly, rarer CNS abnormalities, increased nuchal translucency[26] or nuchal fold thickness, and poor growth.[27] Other rarer findings can include congenital diaphragmatic hernia (1%), skeletal abnormalities (vertebral abnormalities, scoliosis, clubfeet, and polydactyly), CNS abnormalities (polymicrogyria and cerebellar abnormalities), intestinal malrotation, and intrauterine growth restriction.[2]

Magnetic Resonance Imaging. There is usually no immediate indication for fetal magnetic resonance imaging (MRI) in the evaluation of fetuses with suspected or confirmed typical 22q11.2 deletion syndrome. Nevertheless, MRI may be beneficial in the evaluation of more complex presentations with multiple anomalies, such as those with defects involving the larynx and trachea, particularly to evaluate the fetal airway if difficult intubation is anticipated at birth, or with suspected intracranial, pulmonary, or urogenital and other intraabdominal pathology.

Other Applicable Modality. Three-dimensional (3D) US may be helpful in evaluation of the palate in suspected cases. Surface rendering may reveal characteristic facial features (long face with bulbous nose and small cupped ears with overfolded helices), although these usually remain undetected prenatally. Fetal echocardiography is important to characterize the cardiac defects identified by a prenatal US exam. Although no specific guidelines on this exist, it is prudent to offer a targeted US exam to search for fetal CHDs to the increased numbers of pregnant women who may be found to be at high risk for 22q11.2DS in the fetus after noninvasive chromosomal microdeletion screening on cffDNA.

A formal fetal echocardiogram is recommended for those found to have a fetus with a 22q11.2 deletion through CMA

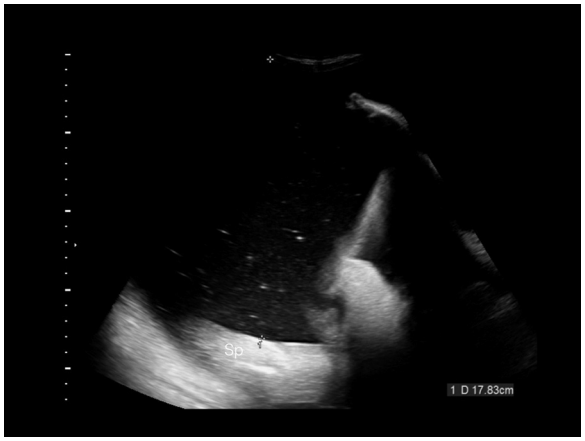

Fig. 154.7 Polyhydramnios.

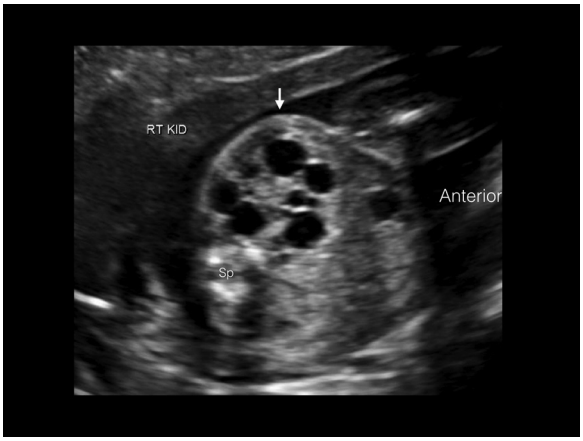

Fig. 154.9 Multicystic dysplastic kidney. Prenatal ultrasound findings for multicystic dysplastic kidney (MCDK) indicate the presence of a multicystic mass in the right renal fossa *(arrow)*. Variably sized cysts are usually anechoic and are sometimes associated with hyperechoic renal parenchyma due to fibrosis. *RT KID,* right kidney; *Sp,* spine.

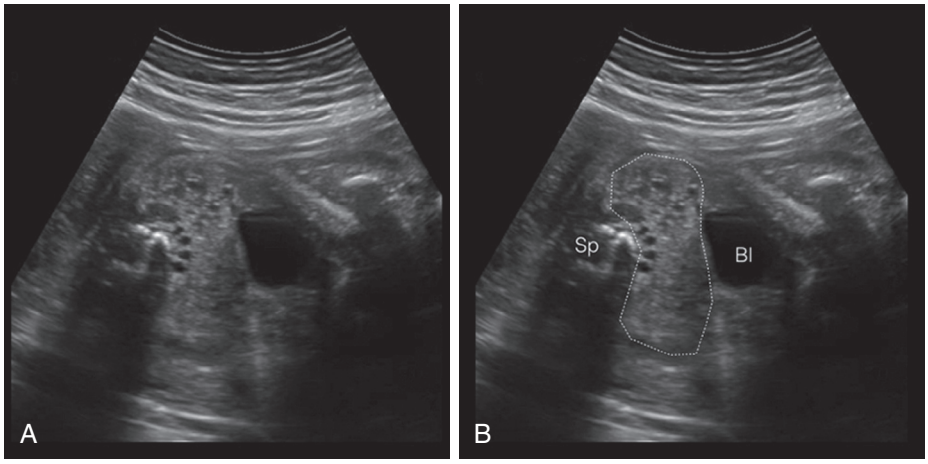

Fig. 154.8 Horseshoe kidney. Horseshoe kidneys are the most common fusion defect of the kidney that are typically associated with abnormalities of position, rotation, and vascular supply. In this example, a single renal mass (outlined in image B) appears to connect both kidneys just anterior to the fetal spine *(Sp)* and posterior to the bladder *(Bl)*.

performed on amniotic fluid or CVS samples for unrelated reasons, or as confirmation of a positive cffDNA screen. Echocardiography will help characterize the clinical phenotype and will aid with formulating a comprehensive perinatal management plan for those fetuses with CHD to optimize smooth perinatal transition and neonatal outcome. This may include assessment of the need for prostaglandin in ductal-dependent lesions, recommendation for location and time of delivery, preparation of neonatal and pediatric cardiac care, and potential plans for surgery.

CLASSIC SIGNS

- Congenital heart defect in 75%.[a]
- Characteristic facial features are present in many cases (prominent nose with bulbous root and narrow alar base, smooth philtrum, short palpebral fissures, elongated face, high-arched palate, deficient malar area, and micrognathia).[b]
- Palatal abnormality in 69% (velopharyngeal insufficiency with overt[a] or submucosal cleft palate, resulting in dysphagia and hypernasal speech).
- Thymic hypoplasia with severe immunodeficiency or milder immune dysfunction.
- Neonatal hypocalcemia because of hypoparathyroidism in 17% to 60%.
- Variable learning difficulties in 70% to 90% to neurodevelopmental delay, intellectual disability, neurobehavioral disability.
- Renal anomalies in 31%.[a]
- Neuropsychiatric disease in 25% of adults.

[a]Only the congenital heart defects, renal anomalies, and thymic hypoplasia may be detectable by prenatal US.
[b]Facial features may be visualized using 3D US.

Differential Diagnosis From Imaging Findings

The differential diagnosis should include fetal syndromes with overlapping features, such as the following:

1. aneuploidies, including trisomies 18, 13, and 21, and 45,X (Turner syndrome)
2. Smith-Lemli-Opitz syndrome
3. Goldenhar syndrome (oculoauriculovertebral dysplasia)
4. CHARGE (*c*oloboma, *h*eart disease, choanal *a*tresia, *r*etardation, *g*enital hypoplasia, and *e*ar anomalies) syndrome
5. Wolf-Hirschhorn syndrome
6. Alagille syndrome
7. Holt-Oram syndrome
7. Cornelia de Lange syndrome
8. cri du chat syndrome
9. VACTERL (*v*ertebral defects, imperforate *a*nus, *c*ardiac anomaly, *t*racheo*e*sophageal fistula, *r*enal dysplasia and *l*imb anomaly) association

It is important to consider 22q11.2 deletion syndrome whenever fetal cardiac defects are detected.

Synopsis of Treatment Options

PRENATAL

No specific prenatal treatments exist for 22q11.2 deletion syndrome, except for supportive treatments for associated complications, such as drainage of symptomatic polyhydramnios. Parental testing with appropriate genetic counseling is indicated when a fetus is diagnosed with 22q11.2DS.[5] Because 22q11.2DS is transmitted as an autosomal dominant trait, when a 22q11.2 deletion is identified in a parent, at-risk couples should be offered genetic counseling to discuss future reproductive options, which can include *in vitro* fertilization with preimplantation genetic diagnosis to avoid future affected children, or timely diagnostic testing through CVS or amniocentesis.

Noninvasive screening for the microdeletion in low-risk women is not yet considered standard of care and comes with inherent false-positive and false-negative rates leading to a low positive predictive value for positive tests; it should also not replace diagnostic testing for high-risk pregnancies.[28] When a genetic diagnosis of 22q11.2DS in the fetus is confirmed at a gestational age when termination of pregnancy is legally permissible, this option can be discussed in the context of the (cardiac) US findings and the variable clinical severity of the syndrome. In the third trimester, perinatal management planning of affected pregnancies should be based on input from a multidisciplinary team, to optimize perinatal survival and coordinate the birth plan and optimal location (e.g., tertiary referral center with good pediatric cardiac surgery access) with neonatal services (including pediatric surgery, intensive care, cardiology, endocrinology, otorhinolaryngology, genetics, and immunology).

POSTNATAL

The outcome is variable, but individuals with severe congenital heart disease that cannot be surgically corrected may die within 1 to 6 months after birth.[1,2] Delivery at a tertiary care center is recommended and often required. Neonatal management depends on the particular cardiac pathology and other features of the syndrome, such as hypocalcemia, immunodeficiency, feeding difficulties, laryngomalacia, and renal anomalies. It has recently been suggested that prenatal detection may improve neurologic outcomes because of improved ability to rapidly identify and control hypocalcemia and secondary seizures.[29] This has been used as a supportive argument by those advocating for universal noninvasive prenatal screening for 22q11.2DS. Children with 22q11.2DS should be followed for learning and speech delays, as well as for neurobehavioral disabilities including anxiety and depression, and appropriate interventions should be offered. It is also estimated that 25% of individuals with 22q11.2DS will develop neuropsychiatric disease, such as schizophrenia.[30,31]

Support groups such as the following can help families cope with affected infants.

International 22q11.2 Deletion Syndrome Foundation, Inc.
Address: 4 State Road #201, Media, PA 19063, USA
Telephone: +1-877-739-1849 (toll-free)
E-mail: info@22q.org
Website: http://www.22q.org

WHAT THE REFERRING PHYSICIAN NEEDS TO KNOW

- When a fetal cardiac defect is detected, 22q11.2DS should always be considered. Conversely, when genetic screening and testing identifies a 22q11.2 deletion, fetal US should be targeted to identify cardiac defects and other associated anomalies for which referral to an experienced center may be needed.
- This syndrome is an increasingly recognized condition with variable clinical expression. When an affected fetus is identified, parents should be offered genetic counseling and invasive testing for definitive diagnosis.

- If a parent is newly identified to have the same deletion, the counseling should address that other relatives can also be at risk and must address the difficult issue of the increased risk for neuropsychiatric disease.
- Modern tools of genetic testing (primarily CMA) allow for accurate diagnosis. Delivery of affected fetuses should preferentially occur at a tertiary care center and be planned in a multidisciplinary approach.
- Although most deletions are sporadic, familial cases with a 50% recurrence risk are possible. In apparent *de novo* cases, potential gonadal mosaicism could also increase the recurrence risk. A detailed US evaluation and genetic testing should be offered in subsequent pregnancies.

KEY POINTS

- Resulting from one of the most common microdeletions in humans, 22q11.2DS is an increasingly detected genetic disorder that was formerly known as *DiGeorge syndrome* or *velocardiofacial syndrome*.
- When a fetal cardiac defect is detected, 22q11.2DS should be considered.
- When genetic testing and screening identifies a 22q11.2 deletion, targeted US and echocardiography to search for cardiac defects and other associated anomalies is indicated.
- Prenatal US features that further suggest this syndrome include thymic hypoplasia, polyhydramnios, renal anomalies, and poor growth.
- 10% of cases have an affected parent, and 90% have *de novo* deletions.
- There is a 50% risk for offspring to have the deletion when a parent is affected.
- Pregnancy termination may be discussed before viability; perinatal care should be coordinated in a multidisciplinary approach for optimal outcome in the third trimester.
- Delivery occurs best at a tertiary care center.

SUGGESTED READING

McDonald-McGinn DM, Emanuel BS, Zackai EH. 22q11.2 Deletion Syndrome. In: Pagon RA, Adam MP, Ardinger HH, et al, eds. *GeneReviews*. Seattle, WA: 1993.

McDonald-McGinn DM, Sullivan KE, Marino B, et al. 22q11.2 deletion syndrome. *Nat Rev Dis Primers*. 2015;1:15071.



All references available online at www.expertconsult.com

REFERENCES

1. McDonald-McGinn DM, Emanuel BS, Zackai EH. 22q11.2 Deletion Syndrome. In: Pagon RA, Adam MP, Ardinger HH, et al, eds. *GeneReviews*. Seattle WA: 1993.
2. McDonald-McGinn DM, Sullivan KE, Marino B, et al. 22q11.2 deletion syndrome. *Nat Rev Dis Primers*. 2015;1:15071.
3. Shprintzen RJ, Goldberg RB, Lewin ML, et al. A new syndrome involving cleft palate, cardiac anomalies, typical facies, and learning disabilities: velo-cardio-facial syndrome. *Cleft Palate J*. 1978;15:56-62.
4. Driscoll DA. Prenatal diagnosis of the 22q11.2 deletion syndrome. *Genet Med*. 2001;3:14-18.
5. McDonald-McGinn DM, Tonnesen MK, Laufer-Cahana A, et al. Phenotype of the 22q11.2 deletion in individuals identified through an affected relative: cast a wide FISHing net! *Genet Med*. 2001;3:23-29.
6. Wapner RJ, Martin CL, Levy B, et al. Chromosomal microarray versus karyotyping for prenatal diagnosis. *N Engl J Med*. 2012;367:2175-2184.
7. Zhu X, Li J, Ru T, et al. Identification of copy number variations associated with congenital heart disease by chromosomal microarray analysis and next-generation sequencing. *Prenat Diagn*. 2016;36:321-327.
8. Gross SJ, Stosic M, McDonald-McGinn DM, et al. Clinical experience with single-nucleotide polymorphism-based non-invasive prenatal screening for 22q11.2 deletion syndrome. *Ultrasound Obstet Gynecol*. 2016;47:177-183.
9. Hui L. Cell-free DNA testing for 22q11.2 deletion syndrome: appraising the viability, effectiveness and appropriateness of screening. *Ultrasound Obstet Gynecol*. 2016;47:137-141.
10. Driscoll DA, Salvin J, Sellinger B, et al. Prevalence of 22q11 microdeletions in DiGeorge and velocardiofacial syndromes: implications for genetic counselling and prenatal diagnosis. *J Med Genet*. 1993;30:813-817.
11. Devriendt K, Fryns JP, Mortier G, et al. The annual incidence of DiGeorge/velocardiofacial syndrome. *J Med Genet*. 1998;35:789-790.
12. Botto LD, May K, Fernhoff PM, et al. A population-based study of the 22q11.2 deletion: phenotype, incidence, and contribution to major birth defects in the population. *Pediatrics*. 2003;112:101-107.
13. Grati FR, Molina Gomes D, Ferreira JC, et al. Prevalence of recurrent pathogenic microdeletions and microduplications in over 9500 pregnancies. *Prenat Diagn*. 2015;35:801-809.
14. Lewin MB, Lindsay EA, Jurecic V, et al. A genetic etiology for interruption of the aortic arch type B. *Am J Cardiol*. 1997;80:493-497.
15. Morrow B, Goldberg R, Carlson C, et al. Molecular definition of the 22q11 deletions in velo-cardio-facial syndrome. *Am J Hum Genet*. 1995;56:1391-1403.
16. Carlson C, Sirotkin H, Pandita R, et al. Molecular definition of 22q11 deletions in 151 velo-cardio-facial syndrome patients. *Am J Hum Genet*. 1997;61:620-629.
17. Lindsay EA, Vitelli F, Su H, et al. Tbx1 haploinsufficieny in the DiGeorge syndrome region causes aortic arch defects in mice. *Nature*. 2001;410:97-101.
18. Merscher S, Funke B, Epstein JA, et al. TBX1 is responsible for cardiovascular defects in velo-cardio-facial/DiGeorge syndrome. *Cell*. 2001;104:619-629.
19. Volpe P, Marasini M, Caruso G, et al. 22q11 deletions in fetuses with malformations of the outflow tracts or interruption of the aortic arch: impact of additional ultrasound signs. *Prenat Diagn*. 2003;23:752-757.
20. Volpe P, Marasini M, Caruso G, et al. Prenatal diagnosis of interruption of the aortic arch and its association with deletion of chromosome 22q11. *Ultrasound Obstet Gynecol*. 2002;20:327-331.
21. Devriendt K, Van Schoubroeck D, Eyskens B, et al. Polyhydramnios as a prenatal symptom of the digeorge/velo-cardio-facial syndrome. *Prenat Diagn*. 1998;18:68-72.
22. Chaoui R, Kalache KD, Heling KS, et al. Absent or hypoplastic thymus on ultrasound: a marker for deletion 22q11.2 in fetal cardiac defects. *Ultrasound Obstet Gynecol*. 2002;20:546-552.
23. Ryan AK, Goodship JA, Wilson DI, et al. Spectrum of clinical features associated with interstitial chromosome 22q11 deletions: a European collaborative study. *J Med Genet*. 1997;34:798-804.
24. Goodship J, Robson SC, Sturgiss S, et al. Renal abnormalities on obstetric ultrasound as a presentation of DiGeorge syndrome. *Prenat Diagn*. 1997;17:867-870.
25. Devriendt K, Swillen A, Fryns JP, et al. Renal and urological tract malformations caused by a 22q11 deletion. *J Med Genet*. 1996;33:349.
26. Lazanakis MS, Rodgers K, Economides DL. Increased nuchal translucency and CATCH 22. *Prenat Diagn*. 1998;18:507-510.
27. Chen M, Hwu WL, Kuo SJ, et al. Subtelomeric rearrangements and 22q11.2 deletion syndrome in anomalous growth-restricted fetuses with normal or balanced G-banded karyotype. *Ultrasound Obstet Gynecol*. 2006;28:939-943.
28. Practice Bulletin No. 163 Summary: screening for fetal aneuploidy. *Obstet Gynecol*. 2016;127:979-981.
29. Cheung EN, George SR, Andrade DM, et al. Neonatal hypocalcemia, neonatal seizures, and intellectual disability in 22q11.2 deletion syndrome. *Genet Med*. 2014;16:40-44.
30. Bassett AS, Chow EW, Husted J, et al. Clinical features of 78 adults with 22q11 deletion syndrome. *Am J Med Genet A*. 2005;138:307-313.
31. Bassett AS, McDonald-McGinn DM, Devriendt K, et al. Practical guidelines for managing patients with 22q11.2 deletion syndrome. *J Pediatr*. 2011;159:332-339 e331.

155 Chromosome 4p Deletion Syndrome (Wolf-Hirschhorn Syndrome)

WESLEY LEE | IGNATIA B. VAN DEN VEYVER

Introduction

First clinically described in 1961 by Hirschhorn and subsequently in 1965 by Wolf, the 4p deletion syndrome, or Wolf-Hirschhorn Syndrome (WHS), is the first example of a classic human chromosomal deletion syndrome.[1,2] This rare condition, characterized by severe prenatal findings and confirmatory genetic testing, is more limited and consists of isolated case reports and small case series.[3–13] Although more than 50% of deletions are visible by standard karyotyping, use of fluorescence *in situ* hybridization (FISH) and the now recommended array-based copy-number analysis or chromosomal microarray analysis (CMA) have improved the diagnosis of chromosome 4p deletions that cause WHS.[2,14,15] Recently, noninvasive prenatal screening for microdeletion syndromes on cell-free fetal DNA (cffDNA) in maternal plasma have been developed and are being introduced into practice.[16–19] This has widened the prenatal ascertainment for 4p deletion syndrome to a broader screen for potentially affected fetuses even in the absence of sonographic findings. Hence practitioners should be familiar with WHS syndrome features that are detectable by prenatal imaging and those that are not prenatally observable, its prognosis, and the implications for perinatal management and counseling when a 4p deletion is detected prenatally.

Disorder

DEFINITION

The 4p deletion syndrome is a heterozygous deletion syndrome of variable size of the short arm of chromosome 4 with a core phenotype of severe prenatal and postnatal growth restriction, distinctive craniofacial features of prominent glabella, wide nasal bridge with beaked nose, high forehead, hypertelorism, down-turned corners of the mouth and short philtrum (referred to as "Greek warrior helmet" face), together with moderate to profound developmental delay, intellectual disability, and severe seizures.[2,14] The 4p deletion syndrome is also variably associated with congenital abnormalities detectable by prenatal ultrasound (US), of which many are thought to result from midline fusion defects. Postnatally, low muscle mass, hypotonia, and feeding difficulties are common. Other features include immunoglobulin abnormalities, eye and ear abnormalities, and hearing loss. Developmental prognosis is poor, and there is increased risk for early childhood death.[2,20]

PREVALENCE AND EPIDEMIOLOGY

The 4p deletion syndrome is rare, with an estimated prevalence of 0.2–0.5:10,000 and a 2:1 female-to-male ratio.[2,14,21] The 4p

deletion can be *de novo* in about 50% to 60% with low recurrence risk, or can be the result of an unbalanced translocation in 40% to 50%, which is associated with partial trisomy of another region.[22] Parents who carry balanced translocations involving 4p16.3 have an increased risk of affected offspring with an inherited unbalanced translocation.

ETIOLOGY AND PATHOPHYSIOLOGY

The 4p deletion syndrome is caused by monosomy of part of the short arm of chromosome 4, encompassing the 4p16.3 critical region. About 50% to 60% of individuals have a simple deletion, and 40% to 50% have an unbalanced translocation with duplication of another region. In a recent survey on 109 cases, 32% were caused by an unbalanced translation; 75% of deletions encompassed the entire critical region, of which 43% were associated with duplication of other regions and 8% of adjacent regions.[15] The Wolf-Hirschhorn syndrome critical region (WHSCR) has been narrowed down to two regions within 4p16.3, containing multiple genes, several of which, such as *WHSCR1, LETM1,* have been investigated for their role in the different clinical features.[2,14,15,22] Prenatal genetic diagnosis by G-banded karyotyping detects the 50% to 60% of deletions that are larger than 5 Mb, and FISH with WHSCR-specific probes can detect 90% of suspected cases. However, CMA, the recommended analysis for pregnancies with major anomalies,[23] is the most effective for detecting 4p deletions,[15] particularly in cases with low clinical suspicion or with small deletions that do not include the region targeted by the FISH probes. Although noninvasive screening for microdeletion syndromes, including 4p deletion, has recently become available, it does not replace diagnostic testing for pregnancies with fetal abnormalities.[17,18] All patients with positive results from such screening should be offered diagnostic testing by amniocentesis or CVS, with CMA as the genetic test of choice.

MANIFESTATIONS OF DISEASE

Clinical Presentation

The 4p deletion syndrome has a complex and variable phenotype.[2,14] Most prenatally diagnosed cases are associated with severe early-onset growth restriction and microcephaly that persist postnatally. Other more variable findings (many of which have been reported prenatally) include craniofacial asymmetry, dolichocephaly, hypertelorism, wide nasal bridge, cystic hygroma or increased nuchal fold thickness, thin corpus callosum, ventriculomegaly, and hypotonia, micrognathia, cleft lip/palate, abnormally positioned ears, midline scalp defects, cardiac defects, diaphragmatic hernia, variable intestinal defects, renal and urinary tract anomalies (horseshoe kidney, vesicoureteral reflux, renal agenesis, cystic dysplasia, bladder exstrophy), hypospadias, single umbilical artery, and skeletal abnormalities (talipes, scoliosis, split hand).[4-13] The cardiac defects are usually not complex and include ventricular or atrial septum defects, but others, like hypoplastic left heart[24] and tetralogy of Fallot, have been reported. Postnatal complications include severe early-onset seizures, hypotonia, reduced muscle mass, severe feeding and swallowing difficulties, poor growth, and moderate to profound intellectual disability. Affected children also have hearing loss, eye abnormalities, immunoglobulin deficiencies, and a predisposition to hematopoietic dysfunction and hepatic adenomas. There is increased risk for early death, and one-third of affected individuals die by 2 years of age, but with supportive treatments, survival into adulthood is possible.[20]

Imaging Technique and Findings

Ultrasound. The prenatal US findings of 4p deletion syndrome are listed in Table 155.1. The most common findings are early-onset severe intrauterine growth restriction (IUGR) that persists postnatally, and microcephaly. The IUGR is symmetrical and can be associated with abnormal umbilical artery Doppler indices, decreased fetal movements, and oligohydramnios.[5,6] Most 4p deletions occur *de novo,* thus affected individuals are usually born to low-risk parents. With the increasingly common practice of noninvasive screening of pregnancies for microdeletions,[16,18,19] recognition of associated US features will benefit interpretation of positive screens within the clinical context. Features reported in the literature include cerebellar hypoplasia, cystic hygroma (Fig. 155.1), microcephaly (Fig. 155.2), cleft lip and palate (Fig. 155.3), micrognathia (Fig. 155.4), hypertelorism (Fig. 155.5), absent nasal bone (Fig. 155.6), tetralogy of Fallot (Fig. 155.7), echogenic bowel (Fig. 155.8), pyelectasis and other renal anomalies, clubfeet (Fig. 155.9), ambiguous genitalia (Fig. 155.10), and single umbilical artery (Fig. 155.11).

TABLE 155.1 PRENATAL ULTRASOUND FEATURES OF 4P DELETION SYNDROME (WOLF-HIRSCHHORN SYNDROME)

Severe, early-onset growth restriction in almost all prenatal cases
Microcephaly in >75%
Hypertelorism, prominent glabella (Greek warrior helmet facies) in >75%[a]
Micrognathia in >75%
Abnormal ears in >75%
Skeletal defects (Talipes, vertebral defects, split hand, craniofacial asymmetry) in 50%–75%
Cardiac defects (mostly VSD, ASD) in 25%–50%
Cleft lip/palate in 25%–50%
Genitourinary tract defects and hypospadias in 25%–50%
Structural brain abnormalities (thin corpus callosum, cerebellar hypoplasia) in 25%–50%
Single umbilical artery in <25%
Diaphragmatic hernia in <25%
Other organ abnormalities in <25%

Notes: Frequencies based on combined prenatal and postnatal data.
[a]Difficult to diagnose prenatally.
VSD, ventricular septal defect; *ASD,* atrial septal defect.

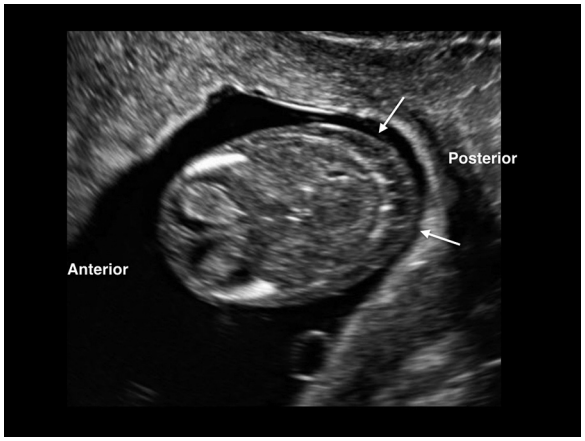

Fig. 155.1 Cystic hygroma. Transverse view of the fetal neck. A posterior nuchal cystic hygroma *(arrows)* with linear septations is visualized.

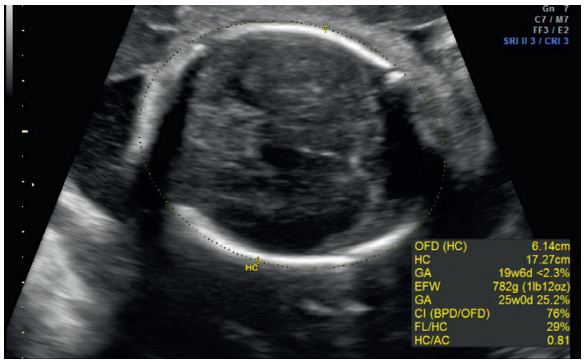

Fig. 155.2 Microcephaly. Ultrasound image shows small head circumference.



Fig. 155.4 Micrognathia. A small mandible is present *(arrow)* on this 3D surface rendering of the fetal face.

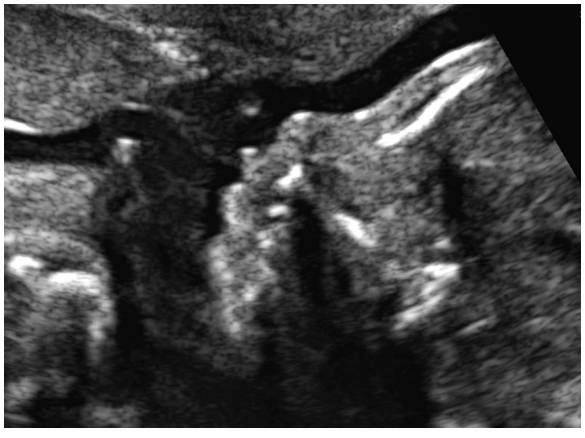

Fig. 155.6 Absent nasal bone. The fetal nasal bone is evaluated from a median sagittal view of the face.



Fig. 155.3 Cleft lip. Three-dimensional surface rendering image showing cleft lip in a case of 4p deletion syndrome.

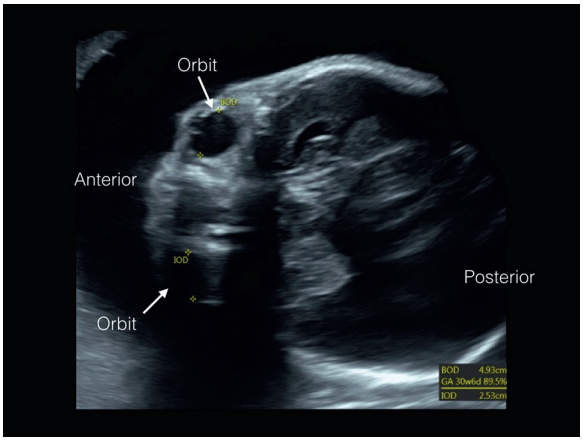

Fig. 155.5 Hypertelorism. Axial views of the fetal head indicates widely spaced orbits.

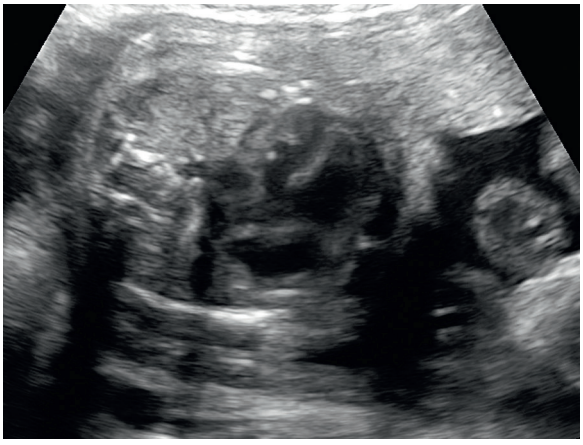

Fig. 155.7 Tetralogy of Fallot. Transverse view showing abnormal five-chamber view of the heart with ventricular septal defect and overriding aorta.

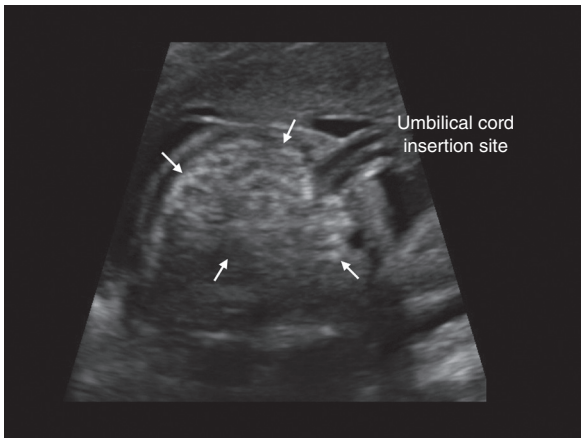

Fig. 155.8 Echogenic bowel. Hyperechoic bowel at level of cord insertion *(arrows)*.



Fig. 155.9 Clubbed foot. Lower extremity with abnormal relationship between the internally rotated foot *(arrow)* and lower leg indicating clubfoot.

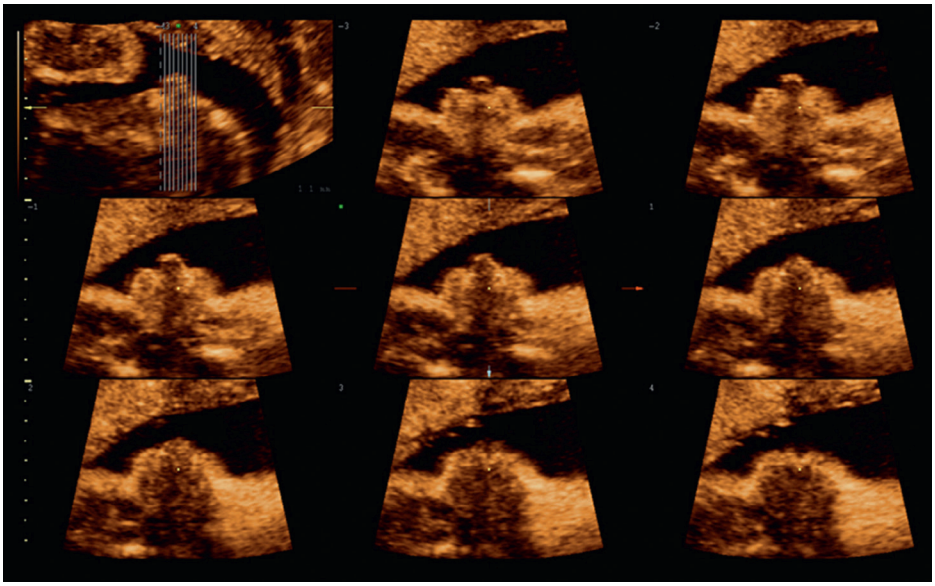

Fig. 155.10 Ambiguous Genitalia (Hypospadias). Three-dimensional ultrasound serial images of abnormal male external genitalia.

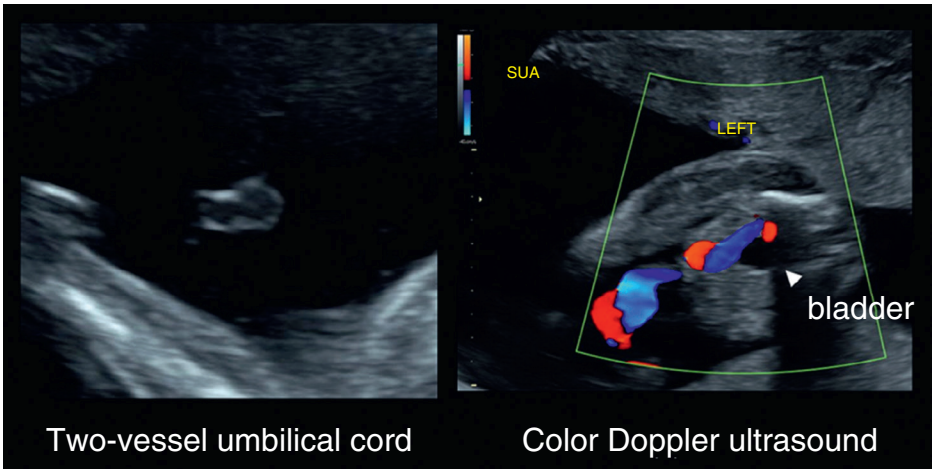

Fig. 155.11 Single umbilical artery. Two-vessel umbilical cord with one umbilical artery and vein *(left)*, and image of only one umbilical vessel around the fetal bladder *(arrow head)* by color Doppler ultrasound *(right)*.

Magnetic Resonance Imaging. Magnetic Resonance Imaging (MRI) can be useful for detecting subtle neuronal migration anomalies that may accompany microcephaly, or to find additional pathology such as corpus callosum anomalies or isolated cleft palate. It can also improve delineation of other variable abnormalities when present, but it should be considered on an individual basis, guided by US findings.

Other Applicable Modality. Three-dimensional US with surface rendering may be helpful in showing the characteristic facial features[7] (see Figs. 155.3, 155.4, and 155.10).

CLASSIC SIGNS

Detectable by prenatal US:
- Severe growth restriction.
- Microcephaly.
- Variable other congenital anomalies.
- Characteristic (Greek warrior helmet) facies, with the broad nasal bridge continuing to a supraorbital ridge and prominent glabella.

Other features:
- Seizures
- Intellectual disability and developmental delay.
- Hypotonia and reduced muscle mass.
- Feeding difficulties.
- Eye, ear, and skin changes.
- Immunoglobulin deficiencies.

Differential Diagnosis From Imaging Findings

The differential diagnosis depends on the features of each individual case and includes other fetal syndromes such as:
1. triploidy
2. trisomy 18 (Edwards syndrome)
3. 11q deletion syndrome (Jacobsen syndrome)
4. Fryns syndrome (especially when diaphragmatic hernia is present)
5. Seckel syndrome
6. VACTERL (*v*ertebral defects, *a*nal, *c*ardiac, *t*racheal, *e*sophageal, *r*enal and *l*imb anomalies) association
7. CHARGE syndrome (*c*oloboma, *h*eart defect, choanal *a*tresia, *r*etardation, *g*enital hypoplasia, and *e*ar abnormalities)
8. Smith-Lemli-Opitz syndrome

Synopsis of Treatment Options

PRENATAL

There is no prenatal treatment for 4p deletion syndrome. When the diagnosis is confirmed at a gestational age when termination of pregnancy is an option, it should be discussed in view of the poor prognosis for neurodevelopmental outcome. For patients who continue the pregnancy, prenatal and perinatal management, including intervention for nonreassuring fetal status, should be addressed.

POSTNATAL

Supportive care for associated anomalies (rehabilitation, speech therapy or sign language, gastrostomy, repair of heart defects) and medical treatment of seizures are the mainstay of management. Early intervention programs and individualized programs for developmental support may improve the acquisition of skills and socialization. Individuals with antibody deficiencies may require antibiotic suppression or immunoglobulin therapy.[2,14] Regular surveillance for hematopoietic abnormalities and hepatic adenomas may be indicated. Families of affected individuals may benefit from support groups.

4P-Support Group Inc,
Address: 2159 128th Street, New Richmond, WI 54017
Telephone: 715-248-3937
Website: http://www.4p-supportgroup.org

WHAT THE REFERRING PHYSICIAN NEEDS TO KNOW

The 4p deletion syndrome, although rare, is a possible cause of severe early-onset IUGR. When 4p deletion syndrome is confirmed in a fetus or newborn, referral to a tertiary center for targeted imaging, genetic counseling, and perinatal management planning should be offered. Parental chromosome analysis by karyotyping is indicated to determine if one of the parents carries a balanced translocation, which would increase recurrence risk. Carrier parents should be offered genetic testing for future pregnancies, including the option of *in vitro* fertilization with preimplantation genetic diagnosis or prenatal testing. They should also be notified that other family members can be carriers for the same translocation and are at risk of having children with 4p deletion syndrome.

KEY POINTS

- The 4p deletion syndrome is a rare deletion syndrome with a poor neurodevelopmental outcome, seizures, and distinct facial features.
- The diagnosis should be considered when early-onset IUGR is associated with signs consistent with the characteristic facial features.
- Other anomalies, in particular midline defects, are variably present.
- CMA is the most sensitive tool for prenatal genetic diagnosis. Fetal karyotype and FISH are less sensitive.
- Pregnancy termination can be offered if before viability.
- Perinatal management should be addressed on a case-by-case basis.

SUGGESTED READING

Battaglia A, Carey JC, South ST. Wolf-Hirschhorn syndrome: a review and update. *Am J Med Genet C Semin Med Genet*. 2015;169:216-223.

Battaglia A, Carey JC, South ST. Wolf-Hirschhorn Syndrome. In: Pagon RA, Adam MP, Ardinger HH, et al, eds. *GeneReviews [Internet]*. Seattle, WA: University of Washington, Seattle; 2002:1993-2016.

Debost-Legrand A, Goumy C, Laurichesse-Delmas H, et al. Prenatal ultrasound findings observed in the Wolf-Hirschhorn syndrome: data from the registry of congenital malformations in Auvergne. *Birth Defects Res A Clin Mol Teratol*. 2013;97:806-811.

Sifakis S, Manolakos E, Vetro A, et al. Prenatal diagnosis of Wolf-Hirschhorn syndrome confirmed by comparative genomic hybridization array: report of two cases and review of the literature. *Mol Cytogenet*. 2012;5:12.

All references available online at www.expertconsult.com

REFERENCES

1. Wolf U, Reinwein H, Porsch R, et al. Deficiency on the short arms of a chromosome no. 4. *Humangenetik*. 1965;1:397-413.
2. Battaglia A, Carey JC, South ST. Wolf-Hirschhorn syndrome: a review and update. *Am J Med Genet C Semin Med Genet*. 2015;169:216-223.
3. Malvestiti F, Benedicenti F, De Toffol S, et al. Recombinant chromosome 4 from a familial pericentric inversion: prenatal and adulthood Wolf-Hirschhorn phenotypes. *Case Rep Genet*. 2013;2013:306098.
4. Ikonomou T, Antsaklis P, Daskalakis G, et al. Prenatal diagnosis of Wolf-Hirschhorn syndrome: ultrasonography and genetics. *J Matern Fetal Neonatal Med*. 2013;26:941-942.
5. Debost-Legrand A, Goumy C, Laurichesse-Delmas H, et al. Prenatal ultrasound findings observed in the Wolf-Hirschhorn syndrome: data from the registry of congenital malformations in Auvergne. *Birth Defects Res A Clin Mol Teratol*. 2013;97:806-811.
6. Sifakis S, Manolakos E, Vetro A, et al. Prenatal diagnosis of Wolf-Hirschhorn syndrome confirmed by comparative genomic hybridization array: report of two cases and review of the literature. *Mol Cytogenet*. 2012;5:12.
7. Sepulveda W. Prenatal 3-dimensional sonographic depiction of the Wolf-Hirschhorn phenotype: the "Greek warrior helmet" and "tulip" signs. *J Ultrasound Med*. 2007;26:407-410.
8. Sase M, Hasegawa K, Honda R, et al. Ultrasonographic findings of facial dysmorphism in Wolf-Hirschhorn syndrome. *Am J Perinatol*. 2005;22: 99-102.
9. Beaujard MP, Jouannic JM, Bessieres B, et al. Prenatal detection of a de novo terminal inverted duplication 4p in a fetus with the Wolf-Hirschhorn syndrome phenotype. *Prenat Diagn*. 2005;25:451-455.
10. Boog G, Le Vaillant C, Collet M, et al. Prenatal sonographic patterns in six cases of Wolf-Hirschhorn (4p-) syndrome. *Fetal Diagn Ther*. 2004;19: 421-430.
11. De Keersmaecker B, Albert M, Hillion Y, et al. Prenatal diagnosis of brain abnormalities in Wolf-Hirschhorn (4p-) syndrome. *Prenat Diagn*. 2002;22:366-370.
12. Vinals F, Sepulveda W, Selman E. Prenatal detection of congenital hypospadias in the Wolf-Hirschhorn (4p-) syndrome. *Prenat Diagn*. 1994;14:1166-1169.
13. Verloes A, Schaaps JP, Herens C, et al. Prenatal diagnosis of cystic hygroma and chorioangioma in the Wolf-Hirschhorn syndrome. *Prenat Diagn*. 1991;11:129-132.
14. Battaglia A, Carey JC, South ST. Wolf-Hirschhorn Syndrome. In: Pagon RA, Adam MP, Ardinger HH, et al, eds. *GeneReviews*. Seattle, WA: 1993.
15. Bi W, Cheung SW, Breman AM, et al. 4p16.3 microdeletions and microduplications detected by chromosomal microarray analysis: new insights into mechanisms and critical regions. *Am J Med Genet A*. 2016;Part A 170A:2540-2550.
16. Wapner RJ, Babiarz JE, Levy B, et al. Expanding the scope of noninvasive prenatal testing: detection of fetal microdeletion syndromes. *Am J Obstet Gynecol*. 2015;212(332):e331-e339.
17. Yaron Y, Jani J, Schmid M, et al. Current status of testing for microdeletion syndromes and rare autosomal trisomies using cell-free DNA technology. *Obstet Gynecol*. 2015;126:1095-1099.
18. Vora NL, O'Brien BM. Noninvasive prenatal testing for microdeletion syndromes and expanded trisomies: proceed with caution. *Obstet Gynecol*. 2014;123:1097-1099.
19. Lefkowitz RB, Tynan JA, Liu T, et al. Clinical validation of a noninvasive prenatal test for genomewide detection of fetal copy number variants. *Am J Obstet Gynecol*. 2016;215(2):227.e1-227.e16.
20. Searle CJ, Shearing E, Quarrell OW. Wolf-Hirschhorn syndrome: a historical note and comment on an older adult. *Clin Dysmorphol*. 2013;22:149-151.
21. Maas NM, Van Buggenhout G, Hannes F, et al. Genotype-phenotype correlation in 21 patients with Wolf-Hirschhorn syndrome using high resolution array comparative genome hybridisation (CGH). *J Med Genet*. 2008;45: 71-80.
22. South ST, Whitby H, Battaglia A, et al. Comprehensive analysis of Wolf-Hirschhorn syndrome using array CGH indicates a high prevalence of translocations. *Eur J Hum Genet*. 2008;16:45-52.
23. American College of O, Gynecologists Committee on G. Committee Opinion No. 581: the use of chromosomal microarray analysis in prenatal diagnosis. *Obstet Gynecol*. 2013;122:1374-1377.
24. von Elten K, Sawyer T, Lentz-Kapua S, et al. A case of Wolf-Hirschhorn syndrome and hypoplastic left heart syndrome. *Pediatr Cardiol*. 2013;34:1244-1246.

156 Chromosome 5p Deletion Syndrome (Cri du Chat Syndrome)

WESLEY LEE | IGNATIA B. VAN DEN VEYVER

Introduction

Monosomy for the distal portion of the short arm of chromosome 5 causes 5p deletion syndrome, which is also known by the currently less favored term *"cri du chat" syndrome,* from the French description of the monotonous high-pitched "cat-like" cry of affected infants.[1] Initially described in 1963 by Lejeune et al.,[2] this syndrome is readily detectable by karyotype or with molecular cytogenetic methods, such as chromosomal microarray analysis (CMA).[3–5] The prenatal diagnosis of this rare deletion syndrome is relatively uncommon; however, recent introduction of noninvasive prenatal screening for microdeletion syndromes using (cffDNA) in maternal plasma[6–9] has widened the prenatal ascertainment of 5p deletion syndrome to screening for potentially affected fetuses in low-risk pregnancies. Thus practitioners should be familiar with the clinical presentation and prognosis of 5p deletion syndrome, including features that can be seen by prenatal imaging and those that are not prenatally detectable, as well as with the implications for perinatal management and counseling when a 5p deletion is diagnosed prenatally.

Disorder

DEFINITION

The 5p deletion syndrome is characterized by poor prenatal and postnatal growth, hypotonia, microcephaly, and a distinct round face with hypertelorism, micrognathia, epicanthal folds, and low-set ears. Affected children often have a high-pitched monotonous cry in infancy and have variable, but sometimes severe, psychomotor delay and intellectual disability.[4]

PREVALENCE AND EPIDEMIOLOGY

The 5p deletion syndrome is a rare genetic syndrome, affecting 0.2–0.6 : 10,000 individuals[3,4] and is found in 0.3% to 1% of individuals with severe intellectual disability.[3]

ETIOLOGY AND PATHOPHYSIOLOGY

The 5p deletion syndrome is caused by heterozygous partial deletions of the short arm of chromosome 5, which can be between 5 and 40 Mb. Most cases are the result of *de novo* terminal deletions (77%) or interstitial deletions (9%). For reasons incompletely understood, 80% of *de novo* deletions occur on the paternally inherited chromosome 5.[10] The remainder are caused by unbalanced translocations, of which 5% are *de novo* and the remainder are familial, inherited from a parent carrying a balanced translocation (4%) or rarely an inversion (1%).[1,3] Rare familial smaller deletions with significant variability in the phenotype within a family have been described,[11] including one where a parent was ascertained after prenatal diagnosis of an affected fetus.[12] Thus the degree of intellectual disability can be difficult to predict when an early diagnosis is made.[1,11] A critical region from proximal 5p15.3 to distal 5p15.2 has been associated with the typical cry, and one in 5p15.2 is thought to be responsible for the dysmorphism, microcephaly, and intellectual disability. Genetic diagnosis can be achieved by standard G-banded karyotyping in many cases, and if the condition is clinically suspected, fluorescence *in situ* hybridization (FISH) with 5p15.2-specific probes can be performed. More recently, array-based copy-number analysis, or chromosomal microarray analysis (CMA) has become the method of choice for detection of microdeletions, including for prenatal diagnosis on amniotic fluid samples of pregnancies complicated by sonographically detected fetal anomalies.[13,14] CMA has higher resolution and can achieve diagnosis for typical as well as for atypical presentations with smaller deletions and can differentiate simple deletions from unbalanced translocations or more complex genomic rearrangements.[15] Noninvasive screening for microdeletion syndromes has recently become available but does not replace diagnostic testing in pregnancies complicated by fetal anomalies.[7,8] Any positive results from such screening should be followed up by an offer for diagnostic testing by amniocentesis or CVS with CMA as the genetic testing strategy of choice. Finally, cases with mosaic deletions of 5p have been described, complicating genetic counseling.[16]

MANIFESTATIONS OF DISEASE

Clinical Presentation

The typical clinical presentation of 5p deletion syndrome in infants includes low birth weight, microcephaly, a distinctive face, and the typical high-pitched cry, which is transient and related to delayed development of the larynx and hypotonia.[1,3] Typical facial features include a round face with hypertelorism with a broad flat nasal bridge, epicanthal folds, down-slanting palpebral fissures, short philtrum, and micrognathia, most of which cannot easily be seen on prenatal imaging. Additional findings that occur less frequently include cardiac defects (present in up to 30% of cases), brain abnormalities (cerebellar hypoplasia, ventriculomegaly, and encephalocele),[5,17] cystic hygroma, single umbilical artery, and hydrops.[18,19] Several reports have shown that, although there is no specific predictive pattern, 5p deletion syndrome can be associated with high or low beta-human chorionic gonadotropin in several instances, as well as low

maternal serum pregnancy associated plasma protein A (PAPP-a) or high alpha-fetoprotein on maternal serum analyte screening.[20–22] Early in life it can be complicated by hypotonia, cyanotic crises, and feeding difficulties. Variable but often severe psychomotor delay becomes evident later.[3] Affected individuals can survive into adulthood but have intellectual disability and often other neurobehavioral phenotypes (autistic features, and attention deficit hyperactivity disorder).[1]

Imaging Technique and Findings

Ultrasound. Table 156.1 lists the main prenatal sonographic findings of 5p deletion syndrome.[18] The common US features of 5p deletion syndrome are fairly nonspecific and include microcephaly (Fig. 156.1), growth restriction (both of which can have later onset after the second trimester), micrognathia (Fig. 156.2), and hypertelorism (Fig. 156.3). Some affected fetuses have been ascertained because of the presence of soft marker(s)

TABLE 156.1 PRENATAL ULTRASOUND FEATURES OF 5P SYNDROME (CRI DU CHAT SYNDROME) IN ORDER OF DECREASING FREQUENCY

Fetal (and postnatal) growth restriction
Microcephaly
Micrognathia
Hypertelorism
Nasal bone hypoplasia
Increased nuchal fold thickness or cystic hygroma
Brain anomalies (ventriculomegaly, agenesis of corpus callosum, cerebellar hypoplasia, and Dandy-Walker malformation)
Cardiac defects
Cleft lip/palate

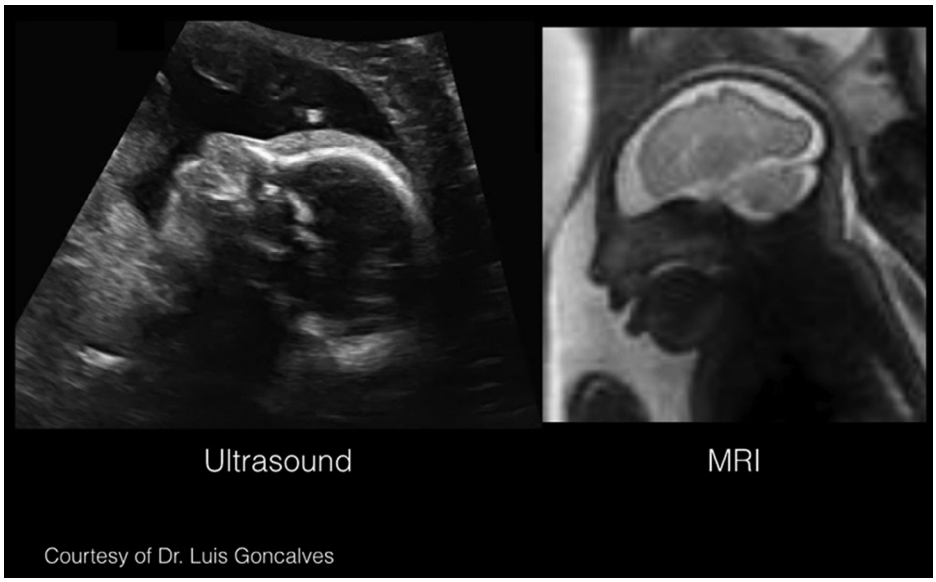

Fig. 156.1 Microcephaly**.** Abnormal median facial profiles are evident from ultrasound and MR images of the fetal head. *(Courtesy of Dr. L. Goncalves).*

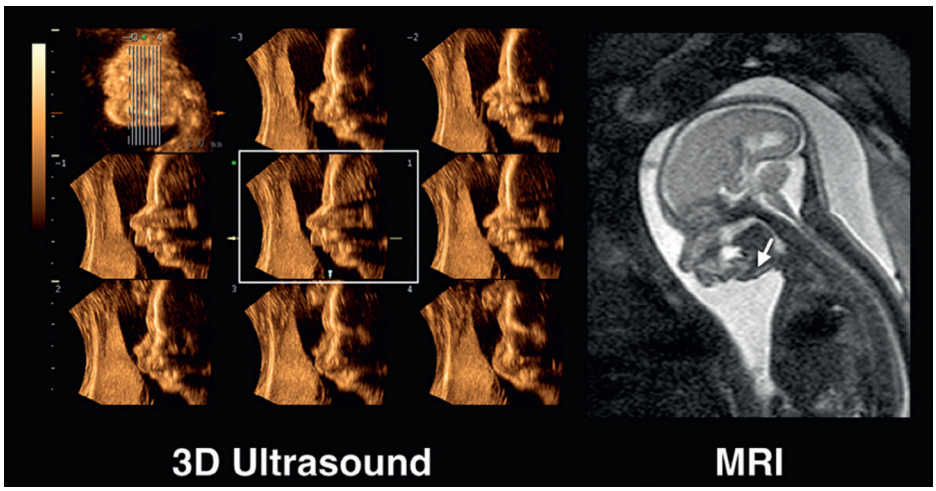

Fig. 156.2 Micrognathia. Three-dimensional ultrasound serial sagittal images of median facial profile with micrognathia *(left).* Corresponding MRI views of small mandible *(right; arrow).*



Fig. 156.3 Hypertelorism. Widely spaced orbits indicating hypertelorism.



Fig. 156.4 Absent nasal bone. Median sagittal view of face with absent nasal bone.

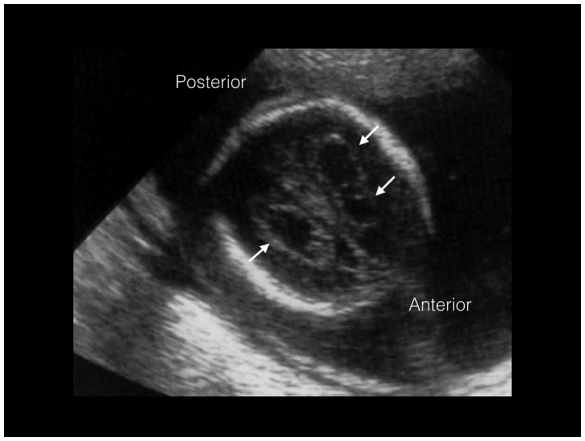

Fig. 156.5 Choroid plexus cyst. Axial view of fetal head with bilateral choroid plexus cysts *(arrows)*.

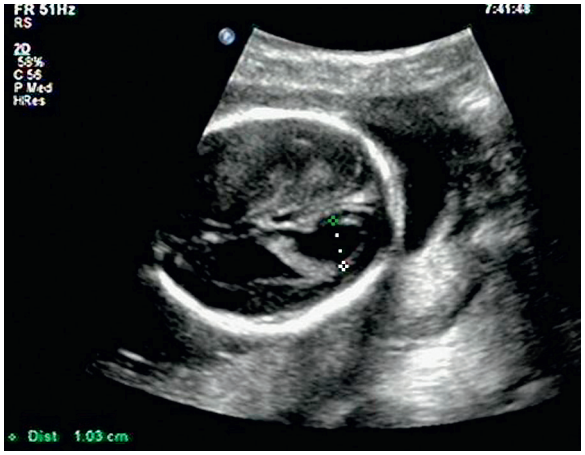

Fig. 156.6 Mild bilateral ventriculomegaly.

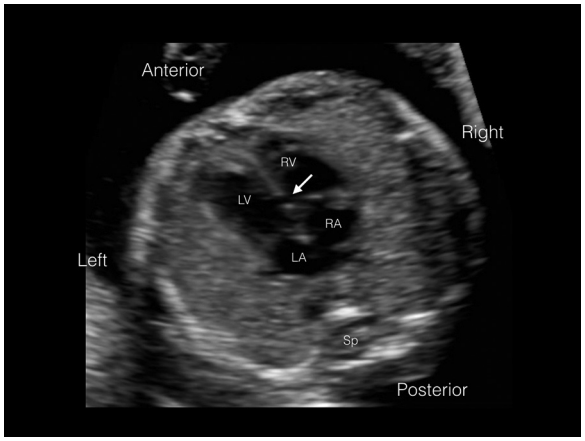

Fig. 156.7 Ventricular septal defect (VSD**).** Four-chamber view of the fetal heart with small ventricular septal defect *(arrow). RA,* Right atrium; *LA,* left atrium; *LV,* left ventricle; *RA,* right atrium; *RV,* right ventricle; *Sp,* fetal spine.



Fig. 156.8 Encephalocele**.** Axial view of the fetal head demonstrates extrusion of fetal brain tissue through a posterior defect of the calvarium.

for aneuploidy, including hypoplastic nasal bone (Fig. 156.4), choroid plexus cysts[22] (Fig. 156.5), single umbilical artery, mild to moderate ventriculomegaly (Fig. 156.6),[19] thick nuchal fold, or cystic hygroma. Cardiac defects can be present in up to 30%.[1] The most common are ventricular or atrial septal defects (Fig. 156.7), patent ductus arteriosus (which cannot be diagnosed prenatally), followed by tetralogy of Fallot, pulmonary valve stenosis, or double-outlet right ventricle.[23] While these cardiac defects are relatively rare in 5p deletion syndrome, they are overrepresented compared to the general population with congenital heart defects.[23] Other rarer findings include encephalocele (Fig. 156.8), facial clefting (Fig. 156.9), cerebellar hypoplasia and Dandy-Walker malformation (Fig. 156.10),[17] hemivertebrae

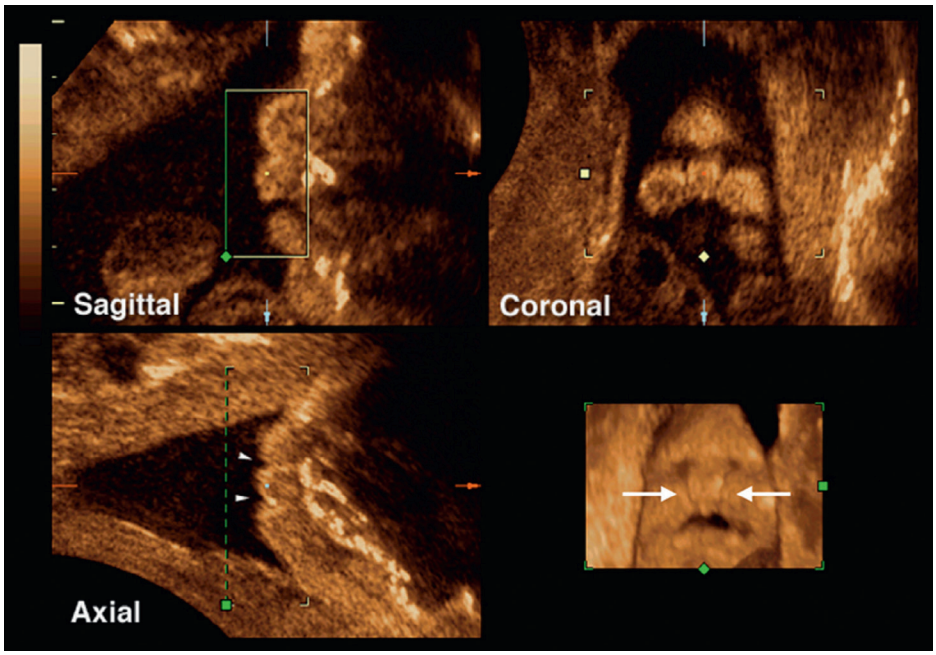

Fig. 156.9 Bilateral cleft lip. Three-dimensional multiplanar images show orthogonal scanning planes of a fetus with bilateral cleft lip. A green rendering box *(top left)* indicates region of interest used to display surface rendering of cleft lip *(bottom right, arrows)*.

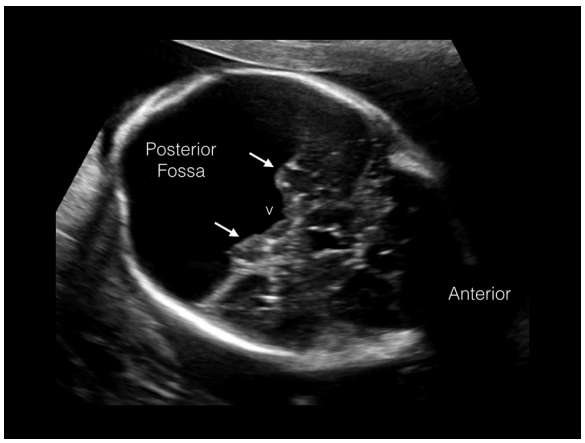

Fig. 156.10 Dandy-Walker malformation. Enlarged posterior fossa with small widely splayed cerebellar hemispheres *(arrows)* and absence of midline vermis *(v)*.

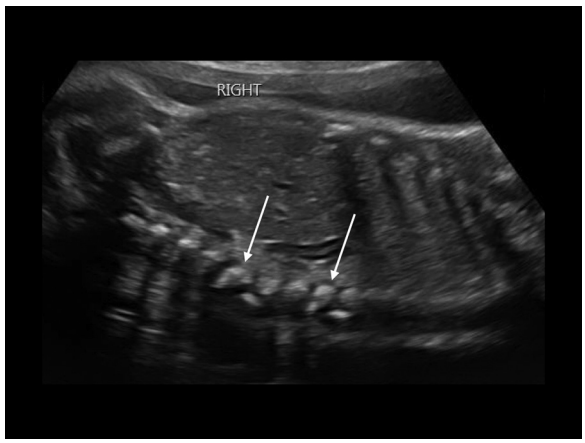

Fig. 156.11 Hemivertebrae. Presence of wedge-shaped vertebral bodies *(arrows)*, indicating hemivertebrae.

(Fig. 156.11), and clinodactyly (Fig. 156.12). All these findings are nonspecific, but when they occur, 5p deletion syndrome should be considered in the differential diagnosis. Conversely, if a 5p deletion is suspected by noninvasive cffDNA screening, ultrasound can be targeted to search for these features.

Magnetic Resonance Imaging. Magnetic resonance imaging is helpful to search for associated neuronal migration defects when there is microcephaly, cerebellar hypoplasia, or ventriculomegaly. It may also help better characterize certain other abnormalities, depending on the type of defect that is observed (see Figs. 156.1, 156.2).

Other Applicable Modality. Three-dimensional prenatal US may be useful in depicting the characteristic facies and better delineate other abnormalities in suspected cases (see Figs. 156.2, 156.10).

CLASSIC SIGNS

Growth restriction or low birth weight (>80%).[a]
Microcephaly (>80%).[a]
Hypertelorism (>80%).[a]
Micrognathia (>95%).[a]
Typical high-pitched monotonous cry in infancy (>95%).
Psychomotor delay and intellectual disability (variable degrees, >90%).
Characteristic facial features
- Round face (>80%).
- Epicanthal folds (>90%).
- Broad and flat nasal bridge (>85%).
- Downward-slanting palpebral fissures (>55%).
- Low-set ears with preauricular tags (70%).[a]

Transverse palmar flexion creases (>90%).
Cardiac defects (in 30%).[a]

[a]These features, when present, can be detected by prenatal US.

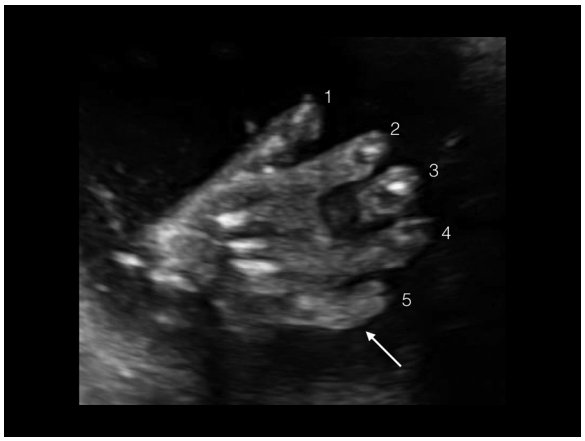

Fig. 156.12 Clinodactyly. Inward curvature of the fifth digit of the hand *(arrow)*.

Differential Diagnosis From Imaging Findings

Depending on the sonographic findings in each case, the differential diagnosis is broad and should include the following conditions:

1. aneuploidies (e.g., trisomies 9, 18, and 21 and monosomy X)
2. triploidy
3. Pierre Robin sequence
4. Stickler syndrome

Synopsis of Treatment Options

PRENATAL

There is no prenatal treatment for 5p deletion syndrome. Molecular genetic testing by CMA, followed by expert genetic counseling, is important, especially for cases with smaller interstitial deletions. When the diagnosis is confirmed at a gestational age when termination of pregnancy is legally permissible, this option can be discussed in view of the guarded prognosis for neurodevelopment and any associated congenital anomalies. It is recommended that for patients who continue the pregnancy or are diagnosed at a later gestational age, intrapartum and neonatal management is considered by multidisciplinary teams in discussions with the parents.

POSTNATAL

Supportive care for associated congenital anomalies should be offered, including, but not limited to, rehabilitation or corrective surgery for scoliosis and surgical repair of heart defects or open neural tube defects. Early interventions with speech therapy or sign language is important, and special education in home-reared children with 5p deletion syndrome can improve functional level compared with institutionalized historical controls.[24] Families of affected individuals may benefit from psychologic support and interaction with support groups. Mortality in 5p deletion syndrome is increased (5%–9%), particularly in the first year, but there is high survival after the first years, and many individuals reach adulthood.[1,3,4] Inheritance from an affected parent has been documented,[12] and fertility should be addressed when counseling families.

WHAT THE REFERRING PHYSICIAN NEEDS TO KNOW

The 5p deletion syndrome, although very rare, is a differential diagnosis when fetal growth restriction with microcephaly and micrognathia, with or without other anomalies, is detected. It can occasionally be detected in low-risk patients via maternal serum screening and more recently through use of cffDNA screening that includes microdeletion syndromes. When a genetic diagnosis of 5p deletion syndrome is confirmed in a fetus or newborn, referral to a tertiary center for targeted imaging, genetic counseling, and perinatal management planning should be offered. When a new diagnosis of 5p deletion syndrome is made, parental chromosome analysis is indicated to determine if one of the parents carries a balanced translocation (found in 10%–15% of cases). When a parental balanced translocation or inversion is found, the recurrence risk is increased, and preimplantation genetic diagnosis prior to a future pregnancy or genetic testing during future pregnancies should be offered. Parents should be notified that other family members can be carriers for the detected balanced abnormality and may be at risk for having children with 5p deletion syndrome and will benefit from genetic counseling and diagnosis.

KEY POINTS

- The 5p deletion syndrome is rare but has a poor neurodevelopmental outcome.
- The diagnosis should be considered when growth restriction, microcephaly, micrognathia, and hypertelorism are associated with characteristic facies.
- The 5p deletion syndrome is a rare differential diagnosis when sonographic markers of aneuploidy, such as ventriculomegaly, nasal bone hypoplasia, and increased nuchal fold thickness are present.
- Chromosomal microarray analysis is the most sensitive tool for prenatal genetic diagnosis, but larger deletions are detectable by fetal karyotype or targeted FISH.
- Atypical and mosaic deletions with more variable phenotypes are possible.
- Pregnancy termination before viability can be discussed.
- Perinatal management should be addressed on a case-by-case basis.
- The typical high-pitched cry of infancy is a transient finding.
- Early and sustained developmental support and interventions can improve life skills and functioning of affected individuals.

SUGGESTED READING

Cerruti Mainardi P. Cri du Chat syndrome. *Orphanet J Rare Dis*. 2006;1:33.
Nguyen JM, Qualmann KJ, Okashah R, et al. 5p deletions: current knowledge and future directions. *Am J Med Genet C Semin Med Genet*. 2015;169:224-238.
OMIM Entry #123450: Cri-du-chat syndrome. www.ncbi.nlm.nih.gov/omim/123450.

All references available online at ***www.expertconsult.com***

REFERENCES

1. Cerruti Mainardi P. Cri du Chat syndrome. *Orphanet J Rare Dis*. 2006;1:33.
2. Lejeune J, Lafourcade J, Berger R, et al. Three cases of partial deletion of the short arm of a 5 chromosome. *C R Hebd Seances Acad Sci*. 1963;257:3098-3102.
3. Niebuhr E. The Cri du Chat syndrome: epidemiology, cytogenetics, and clinical features. *Hum Genet*. 1978;44:227-275.
4. Nguyen JM, Qualmann KJ, Okashah R, et al. 5p deletions: current knowledge and future directions. *Am J Med Genet C Semin Med Genet*. 2015;169:224-238.
5. Chen CP, Huang MC, Chen YY, et al. Cri-du-chat (5p-) syndrome presenting with cerebellar hypoplasia and hypospadias: prenatal diagnosis and aCGH characterization using uncultured amniocytes. *Gene*. 2013;524:407-411.
6. Wapner RJ, Babiarz JE, Levy B, et al. Expanding the scope of noninvasive prenatal testing: detection of fetal microdeletion syndromes. *Am J Obstet Gynecol*. 2015;212(332):e331-e339.
7. Yaron Y, Jani J, Schmid M, et al. Current status of testing for microdeletion syndromes and rare autosomal trisomies using cell-free DNA Technology. *Obstet Gynecol*. 2015;126:1095-1099.
8. Vora NL, O'Brien BM. Noninvasive prenatal testing for microdeletion syndromes and expanded trisomies: proceed with caution. *Obstet Gynecol*. 2014;123:1097-1099.
9. Lefkowitz RB, Tynan JA, Liu T, et al. Clinical validation of a noninvasive prenatal test for genomewide detection of fetal copy number variants. *Am J Obstet Gynecol*. 2016;215:227.e1-227.e16.
10. Overhauser J, McMahon J, Oberlender S, et al. Parental origin of chromosome 5 deletions in the cri-du-chat syndrome. *Am J Med Genet*. 1990;37:83-86.
11. Zhang B, Willing M, Grange DK, et al. Multigenerational autosomal dominant inheritance of 5p chromosomal deletions. *Am J Med Genet A*. 2016;170:583-593.
12. Macayran Nguyen J, Gamble C, Smith JL, et al. Prenatal diagnosis of 5p deletion syndrome in a female fetus leading to identification of the same diagnosis in her mother. *Prenat Diagn*. 2014;34:1115-1118.
13. American College of O, Gynecologists Committee on G. Committee Opinion No. 581: the use of chromosomal microarray analysis in prenatal diagnosis. *Obstet Gynecol*. 2013;122:1374-1377.
14. Wapner RJ, Martin CL, Levy B, et al. Chromosomal microarray versus karyotyping for prenatal diagnosis. *N Engl J Med*. 2012;367:2175-2184.
15. Wang JC, Coe BP, Lomax B, et al. Inverted duplication with terminal deletion of 5p and no cat-like cry. *Am J Med Genet A*. 2008;146A:1173-1179.
16. Chen CP, Lee CC, Chang TY, et al. Prenatal diagnosis of mosaic distal 5p deletion and review of the literature. *Prenat Diagn*. 2004;24:50-57.
17. Vialard F, Robyr R, Hillion Y, et al. Dandy-Walker syndrome and corpus callosum agenesis in 5p deletion. *Prenat Diagn*. 2005;25:311-313.
18. Aoki S, Hata T, Hata K, et al. Antenatal sonographic features of cri-du-chat syndrome. *Ultrasound Obstet Gynecol*. 1999;13:216-217.
19. Stefanou EG, Hanna G, Foakes A, et al. Prenatal diagnosis of cri du chat (5p-) syndrome in association with isolated moderate bilateral ventriculomegaly. *Prenat Diagn*. 2002;22:64-66.
20. Torun D, Bahce M, Alanbay I, et al. Prenatal diagnosis of Cri-du chat syndrome following high maternal serum human chorionic gonadotrophin and choroid plexus cysts. *Prenat Diagn*. 2009;29:536-537.
21. Li DZ. Prenatal diagnosis of Cri-du chat syndrome following high maternal serum human chorionic gonadotrophin and ventricular septal defect. *Prenat Diagn*. 2009;29:914.
22. Teoh XH, Tan TY, Chow KK, et al. Prenatal diagnosis of cri-du-chat syndrome: importance of ultrasonographical markers. *Singapore Med J*. 2009;50:e181-e184.
23. Hills C, Moller JH, Finkelstein M, et al. Cri du chat syndrome and congenital heart disease: a review of previously reported cases and presentation of an additional 21 cases from the Pediatric Cardiac Care Consortium. *Pediatrics*. 2006;117:e924-e927.
24. Wilkins LE, Brown JA, Wolf B. Psychomotor development in 65 home-reared children with cri-du-chat syndrome. *J Pediatr*. 1980;97:401-405.

157 Miller-Dieker Syndrome (17p13.3 Deletion Syndrome)

KATHERINE R. GOETZINGER | ALISON G. CAHILL

Introduction

Miller-Dieker syndrome (MDS) is a rare, contiguous gene deletion syndrome characterized by type I lissencephaly, facial dysmorphism, seizures, and severe mental retardation.[1–3] Other associated defects including cardiac malformations, neural tube defects, omphalocele, gastrointestinal anomalies, genitourinary anomalies, and intrauterine growth restriction have also been described in relationship to this syndrome.[3–6] MDS is caused by a deletion at the chromosome 17p13.3 locus and is thought to represent the severe end of the spectrum of classical lissencephaly.[7,8] The prognosis for affected patients is poor, with mortality typically occurring within the first 1 to 2 years of life.[3,9]

Disorder

DEFINITION

Lissencephaly is a defect in neuronal migration characterized by a smooth cerebral surface, either with agyria (absent gyri) or pachygyria (abnormally broad brain folds), a thickened cerebral cortex, and an increased ratio of gray to white matter. Mutation in the causative *LIS1* gene leads to a spectrum of disorders encompassing isolated lissencephaly, subcortical band heterotopia, and MDS.[10] Patients with MDS tend to have larger deletions, resulting in more severe lissencephaly in combination with craniofacial dysmorphisms, as well as other associated anomalies.[3,11,12]

PREVALENCE AND EPIDEMIOLOGY

Due to the rarity of disease, the prevalence of MDS is unknown. At least 29 cases of MDS with the 17p13.3 deletion and prenatal findings have been reported in the literature.[13] Classical lissencephaly is reported to occur in 11.7–40:1 million births.[14]

ETIOLOGY, PATHOPHYSIOLOGY, AND EMBRYOLOGY

Impaired neuronal migration between 6 and 15 weeks' gestation is the underlying etiologic mechanism for lissencephaly. Postmitotic neurons are unable to migrate to their final destination and therefore do not correctly populate the cortical plate of the cerebral cortex. This leads to the absence of sulci and gyri on the surface of the brain, as well as abnormal cortical thickness.

Heterozygous deletions in the region of chromosome 17p13.3 result in the MDS phenotype. Located within this region is the responsible lissencephaly gene *(LIS1* or *PAFAH1B1),* which has been highly conserved throughout evolution. This gene encodes the β subunit of the platelet-activating factor acetylhydrolase brain isoform, which inactivates platelet-activating factor, a neuroregulatory molecule.[7,15] While deletions in *LIS1* are observed in both isolated lissencephaly and MDS, it is thought that the more severe phenotype observed in MDS is caused by a combined genetic effect from deletions in both *LIS1* as well as the *YWHAE* gene, located about 40 kb telomeric to *LIS1* within a region known as the "*MDS telomeric critical region.*"[7,10,16,17] Loss of the *YWHAE* gene, not including *LIS1*, results in facial dysmorphism, intrauterine growth restriction (IUGR), and neuroradiologic changes.[18] Large deletions that extend farther toward the 17p telomere, including the *YWHAE* gene, result in the more severe phenotype as observed in MDS.[12,17,19] Approximately 80% of patients with MDS have a *de novo* deletion in the 17p13.3 region, and the remaining 20% are thought to inherit the deletion from a parent who carries a balanced chromosomal translocation.[20]

MANIFESTATIONS OF DISEASE

Clinical Presentation

The clinical features of MDS include profound neurodevelopmental delay, seizure activity, failure to thrive, and feeding difficulties. Infants are typically hypotonic at birth and subsequently develop spasticity. The classic facial dysmorphisms include a prominent forehead, low-set ears, widely spaced eyes, a thickened upper lip with a thin vermillion border, an elongated philtrum, a short, upturned nose, bitemporal narrowing, and micrognathia.[3,21] Other variable findings include microcephaly, clubfoot, polydactyly, cleft lip/palate, omphalocele, duodenal atresia, hepatosplenomegaly, sacral dimples, joint contractures, hypoplastic genitalia in affected males, and renal and cardiac malformations.[3,6,22]

Imaging Technique and Findings

Ultrasound. The sonographic evaluation for lissencephaly at the time of the midtrimester anatomic survey poses a diagnostic challenge given that brain development and maturation, including formation of normal cerebral gyration, continues throughout gestation. Suspicious sonographic findings include an absent parietooccipital and calcarine fissure as well as a smooth, shallow sylvian fissure, which can be detected in the standard plane used to measure biparietal diameter (Fig. 157.1). These findings have been reported on prenatal ultrasound (US) as early as 23 weeks' gestation. It is important to note that prior to 20 weeks' gestation, it is normal for the sylvian fissure to appear as a smooth, shallow depression.[23] Other central nervous system (CNS) findings such as ventriculomegaly and agenesis of the corpus callosum (ACC) can be markers for lissencephaly. IUGR and polyhydramnios (secondary to impaired fetal swallowing) are common

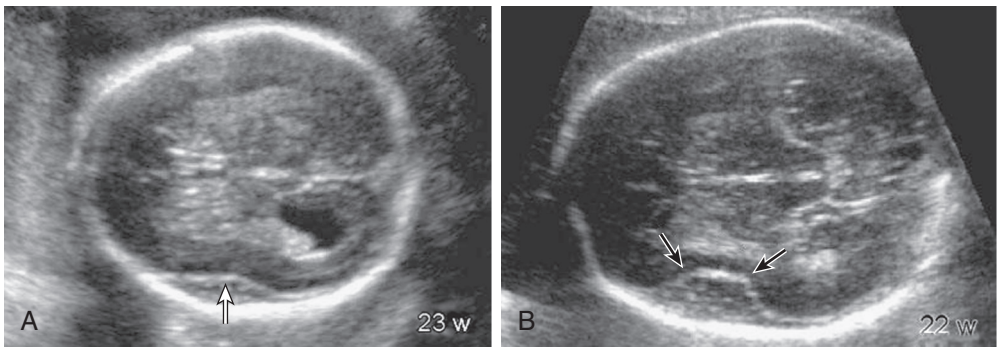

Fig. 157.1 (A) Axial ultrasound image at 23 weeks' gestation demonstrating a shallow/flat sylvian fissure *(arrow)* in a fetus with Miller-Dieker syndrome. (B) Normal "square" appearance of the sylvian fissure *(arrows)*.

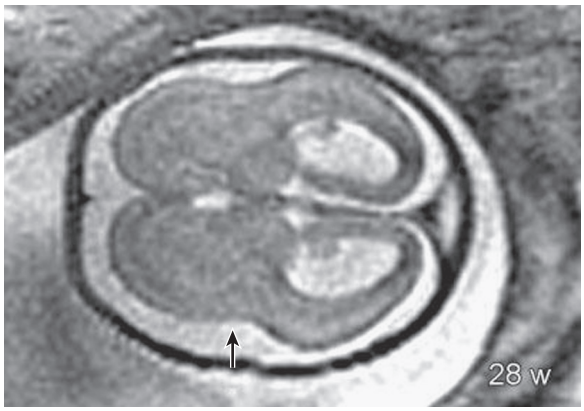

Fig. 157.2 Axial T2-weighted image from fetal MRI performed at 28 weeks' gestation demonstrating the classic hourglass appearance of the brain with agyria and a shallow sylvian fissure *(arrow)*.

findings.[6,23,24] In the 29 documented cases of MDS with prenatal findings, polyhydramnios, IUGR, and ventriculomegaly were the most common associated sonographic findings, each seen in approximately 2 out of 3 of cases.[13] With the exception of micrognathia, the characteristic facial dysmorphisms are difficult to detect with sonographic imaging.[24]

Magnetic Resonance Imaging. If abnormal cerebral sulci development is suspected on US, especially in the presence of ventriculomegaly or ACC, fetal magnetic resonance imaging (MRI) can be useful in obtaining a more definitive diagnosis. The appearance of lissencephaly on MRI includes a smooth brain surface with an abnormally shallow sylvian fissure, giving the brain an hourglass or figure-of-eight appearance (Fig. 157.2). These findings are more reliably seen on MRI after 24 weeks' gestation.[3,21,23] MRI may also be more useful in detecting pachygyria as opposed to routine sonography, on which even agyria can be difficult to diagnose.[23] Finally, MRI may also aid in detecting and further delineating other associated intra- and extra-cranial malformations.

Differential Diagnosis From Imaging Findings

The differential diagnosis of lissencephaly includes the following:

- isolated lissencephaly
- Norman-Roberts syndrome
- Neu-Laxova syndrome
- Walker-Warburg syndrome (type 2)
- Fukuyama congenital muscular dystrophy (type 2)
- Baraitser-Winter syndrome

Other syndromes associated with facial dysmorphisms, seizures, microcephaly, and hypotonia include Cornelia de Lange, Wolf-Hirschorn, Smith-Lemli-Opitz, and Zellweger syndrome, although none of these syndromes have lissencephaly as a feature.[23,25]

Synopsis of Treatment Options

PRENATAL

MDS is an incurable syndrome with no known prenatal interventions or treatment options. In cases of a previously affected child or suspicious imaging findings, prenatal diagnosis is available through chorionic villus sampling or amniocentesis. High-resolution chromosomal microarray or fluorescent *in situ* hybridization (FISH) studies with a *LIS1*-specific probe can be performed to evaluate for 17p13.3 deletion. Given the uniformly fatal nature of this syndrome, pregnancy termination may be considered.

POSTNATAL

Currently, there are no gene-specific treatments for lissencephaly. Postnatal management of MDS patients consists mainly of antiepileptics for seizure control and supportive care. Feeding difficulties are common and can be managed with either nasogastric or gastrostomy tubes. Aspiration pneumonia occurs frequently. Affected individuals rarely survive through the second year of life.[3,9,26]

WHAT THE REFERRING PHYSICIAN NEEDS TO KNOW

Suspicion for MDS should be raised in patients with a family history and/or imaging findings concerning lissencephaly. These should prompt both fetal MRI and genetic studies to evaluate for deletions in the 17p13.3 chromosomal region. While routine evaluation of the cerebral sulci is not part of the midtrimester anatomical survey, the presence of ventriculomegaly or other intracranial abnormalities may prompt follow-up imaging at a later gestational age, at which time the sonographic features of lissencephaly may be more prominent.[23,25] While the majority of 17p13.3 deletions are *de novo*, 20% of offspring with MDS inherit the deletion from a parent who carries a balanced chromosomal rearrangement. This warrants parental chromosomal analysis when a diagnosis is made in a child. If neither parent carries the translocation, the risk to subsequent offspring is no greater than that for the background population.[27]

KEY POINTS

- Miller-Dieker syndrome is a rare contiguous gene deletion syndrome characterized by type 1 lissencephaly, facial dysmorphism, seizures, and profound mental retardation.
- Miller-Dieker syndrome is a disorder of impaired neuronal migration and is caused by a deletion at the chromosome 17p13.3 locus.
- Characteristic imaging findings on both prenatal US and MRI include a smooth brain surface with an abnormally shallow sylvian fissure, creating an hourglass or figure-of-eight appearance.
- Parental chromosomal analysis is indicated at the time of diagnosis, as 20% of deletions are inherited from a parent with a balanced chromosomal rearrangement.

SUGGESTED READING

Chen C, Chang T, Guo W, et al. Chromosome 17p13.3 deletion syndrome: aCGH characterization, prenatal findings and diagnosis, and literature review. *Gene*. 2013;152-159.

Fry AE, Cushion TD, Pilz DT. The genetics of lissencephaly. *Am J Med Genet C Semin Med Genet*. 2014;166C:198-210.

Ghai S, Fong FW, Toi A, et al. Prenatal US and MRI imaging findings of lissencephaly: review of fetal and cerebral sulcal development. *Radiographics*. 2006;26:389-405.

Saltzmann DH, Krauss CM, Goldman JM, et al. Prenatal diagnosis of lissencephaly. *Prenat Diagn*. 1991;11:139-143.

Wynshaw-Boris A. Lissencephaly and *LIS1*: insights into the molecular mechanisms of neuronal migration and development. *Clin Genet*. 2007;72:296-304.



All references available online at
www.expertconsult.com

REFERENCES

1. Miller JQ. Lissencephaly in two siblings. *Neurology*. 1963;13:841-850.
2. Dieker H, Edwards RH, ZuRhein G, et al. The lissencephaly syndrome. *Birth Defects Orig Artic Ser*. 1969;5:53-64.
3. Dobyns WB, Curry CJR, Hoyme HE, et al. Clinical and molecular diagnosis of Miller-Dieker syndrome. *Am J Med Genet*. 1991;48:584-594.
4. Chitayat D, Toi A, Babul R, et al. Omphalocele in Miller-Dieker syndrome: expanding the phenotype. *Am J Med Genet*. 1997;69:293-298.
5. Chen CP. Syndromes, disorders, and maternal risk factors associated with neural tube defects (V). *Taiwan J Obstet Gyencol*. 2008;47:259-266.
6. Saltzmann DH, Krauss CM, Goldman JM, et al. Prenatal diagnosis of lissencephaly. *Prenat Diagn*. 1991;11:139-143.
7. Reiner O, Carrozzo R, Shen Y, et al. Isolation of a *Miller-Dieker lissencephaly* gene containing G protein beta-subunit-like repeats. *Nature*. 1993;364:717-721.
8. Dobyns WB, Reiner O, Carrozzo R, et al. Lissencephaly. A human brain malformation associated with deletion of the *LIS1* gene located at chromosome 17p13. *JAMA*. 1993;270:2838-2842.
9. El Ayoubi M, de Bethmann O. Monset-Couchard M. Lenticulostriate echogenic vessels: clinical and sonographic study of 70 neonatal cases. *Pediatr Radiol*. 2003;33:697-703.
10. Wynshaw-Boris A. Lissencephaly and *LIS1*: insights into the molecular mechanisms of neuronal migration and development. *Clin Genet*. 2007;72:296-304.
11. Dobyns WB, Stratton RF, Greenburg F. Syndromes with lissencephaly 1: Miller-Dieker and Norman-Robert syndromes and isolated lissencephaly. *Am J Med Genet*. 1984;18:509-524.
12. Dobyns WB, Truwit CL, Ross ME, et al. Differences in the gyral pattern distinguish chromosome 17-linked and X-linked lissencephaly. *Neurology*. 1999;53:270-277.
13. Chen C, Chang T, Guo W, et al. Chromosome 17p13.3 deletion syndrome: aCGH characterization, prenatal findings and diagnosis, and literature review. *Gene*. 2013;152-159.
14. Leite JM, Granese R, Jeanty P, et al. Fetal syndromes. In: Callen PW, ed. *Ultrasonography in Obstetrics and Gynecology*. 5th ed. Philadelphia: Saunders; 2008:151-152.
15. Tokuoka SM, Ishii S, Kawamura N, et al. Involvement of platelet-activating factor and *LIS1* in neuronal migration. *Eur J Neurosci*. 2003;18:563-570.
16. Cardoso C, Leventer RJ, Ward HL, et al. Refinement of a 400-kb critical region allows genotypical differentiation between isolated lissencephaly, Miller-Dieker syndrome, and other phenotypes secondary to deletions of 17p13.3. *Am J Hum Genet*. 2003;72:918-920.
17. Kato M, Dobyns WB. Lissencephaly and the molecular basis of neuronal migration. *Hum Mol Genet*. 2003;12:R89-R96.
18. Fry AE, Cushion TD, Pilz DT. The genetics of lissencephaly. *Am J Med Genet C Semin Med Genet*. 2014;166C:198-210.
19. Cardoso C, Leventer RJ, Dowling JJ, et al. Clinical and molecular basis of classical lissencephaly: Mutations in the *LIS1* gene (PAFAH1B1). *Hum Mutat*. 2002;19:4-15.
20. Thomas MA, Duncan AMV, Bardin C, et al. Lissencephaly with der(17)t(17;20)(p13.3;p12.2)mat. *Am J Med Genet*. 2004;124A:292-295.
21. Herman TE, Siegel MJ. Miller-Dieker syndrome, type 1 lissencephaly. *J Perinatol*. 2008;28:313-315.
22. Pilz DT, Quarrell OW. Syndromes with lissencephaly. *J Med Genet*. 1996;33:319-323.
23. Fong KW, Ghai S, Toi A, et al. Prenatal ultrasound findings of lissencephaly associated with Miller-Dieker syndrome and comparison with pre- and postnatal magnetic resonance imaging. *Ultrasound Obstet Gynecol*. 2004;24:716-723.
24. McGahan JP, Grix A, Gerscovich EO. Prenatal diagnosis of lissencephaly. *J Clin Ultrasound*. 1994;22:560-563.
25. Ghai S, Fong FW, Toi A, et al. Prenatal US and MRI imaging findings of lissencephaly: review of fetal and cerebral sulcal development. *Radiographics*. 2006;26:389-405.
26. Matarese CA, Renaud DL. Classical (type 1) lissencephaly and Miller-Dieker syndrome. *Pediatr Neurol*. 2009;40:324-325.
27. Hamosh A. Miller-Dieker syndrome. In: Nussbaum RL, McInnes RR, Willard HF, eds. *Thompson & Thompson Genetics in Medicine*. 7th ed. Philadelphia: Saunders; 2007:288-289.

158 Chorionicity of Multiple Gestations

KARIN M. FUCHS | MARY E. D'ALTON

Introduction

In 2014, the twin birth rate in the United States rose to an all-time high of 33.9 per 1000 live births.[1] Multiple gestations result from either the fertilization of multiple ova or the division of a single fertilized ovum into more than one fetus. The terms *monozygotic* and *dizygotic* refer to the number of ova leading to a multifetal gestation. A monozygotic pregnancy results from a single fertilized ovum that divides into more than one fetus. In contrast, dizygotic pregnancies originate from the fertilization of two separate ova and are genetically dissimilar.

In contrast to zygosity, which refers to the genetic constitution of a twin pregnancy, the terms *chorionicity* and *amnionicity* describe the placentation and membrane composition of a pregnancy. More so than zygosity, the determination of chorionicity and amnionicity is essential in the clinical management of multiple gestations because monochorionic multiples, whether diamniotic or monoamniotic, are at increased risk of adverse outcomes.

Normal Anatomy

GENERAL ANATOMIC DESCRIPTIONS

Chorionicity refers to the number of placentas in a multiple gestation; *amnionicity* refers to the number of amniotic cavities. The term *dichorionic* refers to a multiple gestation with two distinct placental disks (or two chorions), whereas the term *monochorionic* refers to a pregnancy with a single placental disk (or one chorion). Similarly, a pregnancy with two distinct amniotic cavities is described as *diamniotic,* and a pregnancy with a single amniotic cavity is *monoamniotic*. Depending on the number of chorions and amnions, twin pregnancies can be described as *dichorionic diamniotic, monochorionic diamniotic,* or *monochorionic monoamniotic*.

DETAILED DESCRIPTION OF SPECIFIC AREAS

Normal Variants

Monochorionic twins occur spontaneously in 0.4% of the general population. Studies have reported that the frequency of monozygotic twinning may be more than 10 times higher in pregnancies after fertility treatment.[2,3]

In contrast, the frequency of dizygotic twins varies by maternal age, parity, family history, maternal weight, nutritional state, and race.[4] Some of these risk factors lead to an increased frequency of dizygotic twinning through increases in serum concentrations of follicle-stimulating hormone and luteinizing hormone, which increase the likelihood of multiple ovulations in a single menstrual cycle. Because gonadotropin levels are increased with advancing maternal age and use of infertility medications, both delayed childbearing and assisted reproductive technologies are associated with an increased frequency of dizygotic twinning. In addition, the incidence of spontaneous dizygotic twins varies by race, with highest rates among certain populations in Africa and relatively lower rates in whites and Asians. Other factors associated with an increased likelihood of dizygotic twinning include maternal family history of twin gestations and increasing maternal height and weight.[5]

Dizygotic pregnancies are almost always dichorionic diamniotic, with each fetus having its own placenta and amniotic cavity. In contrast, chorionicity of monozygotic gestations is determined by the time at which division of the fertilized ovum occurs, and monozygotic gestations can be dichorionic diamniotic, monochorionic diamniotic, or monochorionic monoamniotic. If twinning occurs during the first 2 to 3 days, it precedes the separation of cells that eventually become the chorion and results in a monozygotic dichorionic diamniotic pregnancy. After approximately 3 days, twinning cannot split the chorionic cavity, and from that time forward, a monochorionic placenta results. If the split occurs between the third and eighth days, a monochorionic diamniotic pregnancy develops. Between the eighth and twelfth days, the amnion has already formed, and the pregnancy is monochorionic monoamniotic if twinning occurs. Embryonic cleavage between the 13th and 15th days results in conjoined twins within a single amnion and chorion; beyond that point, twinning does not occur. Among monozygotic twin gestations, approximately one-third are dichorionic diamniotic, whereas almost two-thirds are monochorionic diamniotic, and less than 1% are monochorionic monoamniotic.[6]

By definition, essentially all monochorionic twins are monozygotic. In contrast, among spontaneously conceived same-sex dichorionic twins, approximately 18% are monozygotic.[7] There have been several case reports of twin pregnancies conceived using assisted reproductive technology that resulted in dizygotic monochorionic gestations[8–10]; the mechanism of this phenomenon is not yet understood.

Differential Considerations

Compared with singletons, multiples face an increased risk of preterm delivery, growth disorders, and maternal complications. In addition to these general risks, multiples also face increased

TABLE 158.1 ULTRASOUND CHARACTERISTICS OF CHORIONICITY AND AMNIONICITY

	EARLY FIRST TRIMESTER			LATER GESTATION				
	Gestational Sacs	Intertwin Membrane	Yolk Sacs	Gender	Placentas	Intertwin Membrane	Membrane Insertion	Membrane Layers
Dichorionic-diamniotic	2	Thick	2	Discordant or concordant	2	Thick	Twin peak or lambda sign	4
Monochorionic-diamniotic	1	Thin	2	Concordant	1	Thin	T sign	2
Monochorionic-monoamniotic	1	None	1	Concordant	1	None	NA	NA

NA, Not applicable.

risk depending on the zygosity, chorionicity, and amnionicity of the pregnancy.

Monochorionic twins have a worse prognosis than dichorionic twins because of numerous complications unique to the twinning process and to monochorionic placentation. Monozygotic twins, whether monochorionic or dichorionic, have a significantly higher incidence of congenital anomalies than singletons or dizygotic twins.[11–14] A primary concern in twin gestations with monochorionic placentation is twin transfusion syndrome, characterized by an unequal distribution of the blood flow across the shared placenta of two fetuses. Although all monochorionic twins share a portion of their vasculature, only approximately 15% to 20% develop this condition.[15,16] Untreated, twin transfusion syndrome is associated with a 60% to 100% mortality rate for both twins.

There is an increased risk of fetal loss with monochorionic twins across all gestational ages and an increased risk of complications secondary to fetal demise. Specifically, owing to vascular anastomoses within the monochorionic placenta, hemodynamic changes associated with the death of one fetus result in an approximately 20% risk of multicystic encephalomalacia in the surviving twin, and an increased risk of preterm delivery.[17] The literature has suggested that the risk of intrauterine death of one or both twins is higher in monochorionic than dichorionic pregnancies. In a study of 1000 consecutive twin pairs, monochorionic diamniotic twins had a higher risk of stillbirth compared with dichorionic diamniotic twins overall and at each gestational age after 24 weeks[18]; this increased risk of fetal loss persisted in "apparently normal" monochorionic diamniotic twins unaffected by growth abnormalities, congenital anomalies, or twin transfusion syndrome.

Other unique but rare problems that occur in monochorionic pregnancies include cord entanglement in monoamniotic twins, conjoined twins, and twin reversed arterial perfusion sequence, also known as *acardiac twinning* (Chapter 163). Monoamniotic gestations are associated with increased perinatal mortality secondary to cord entanglement. Previous studies reported a fetal mortality rate of greater than 50%, but more recent studies indicate a perinatal mortality rate ranging from 10% to 21%.[19]

Pertinent Imaging Considerations

Given the impact that chorionicity and amnionicity have on pregnancy outcome, determination of placentation and membrane composition is vital to guide prenatal care of a twin pregnancy. Although chorionicity and amnionicity can be definitively determined postnatally by gross and histologic evaluation of the placenta and fetal membranes, prenatal diagnosis is preferable to allow appropriate prenatal evaluation and intervention. Prenatal determination of chorionicity and amnionicity is possible using ultrasound (US) (Table 158.1).

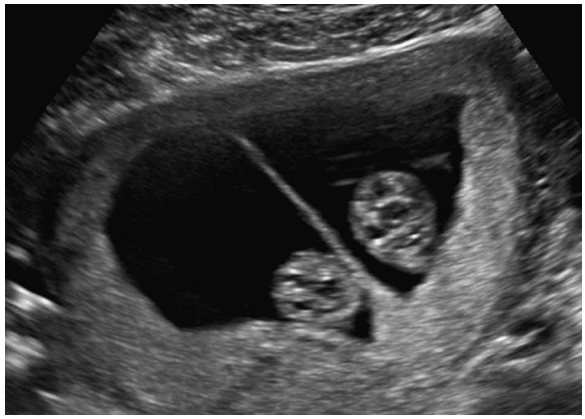

Fig. 158.1 First-trimester dichorionic twin pregnancy with twin peak (lambda) sign.

Chorionicity is best determined in the first trimester. From 6 to 10 weeks' gestation, counting the number of gestational sacs with evaluation of the thickness of the dividing membrane is the optimal method of assessing chorionicity. Two separate gestational sacs separated by a thick dividing membrane suggest a dichorionic diamniotic pregnancy, whereas one gestational sac with a thin membrane dividing the sac into two separate cavities, each with a separate fetus, suggests a monochorionic diamniotic pregnancy.[20] Similarly, the finding of a single gestational sac with no dividing membrane and two fetuses is diagnostic of a monochorionic monoamniotic twin pregnancy. Because the intertwin membrane of monochorionic gestations can be difficult to visualize, the number of yolk sacs can also be used as an indirect method of determining amnionicity early in gestation.[21] The presence of two yolk sacs is diagnostic of a diamniotic twin pregnancy, whereas the finding of a single yolk sac suggests a monoamniotic twin pregnancy.

If chorionicity and amnionicity are not determined early in the first trimester, systematic evaluation of numerous characteristics can be used to determine chorionicity and amnionicity later in gestation. Specifically, US examination of the insertion of the intertwin membrane into the placenta can reliably distinguish between dichorionic and monochorionic pregnancies in the late first trimester and early second trimester.[22–25] In dichorionic pregnancies, the intertwin membrane remains thick, with a triangular projection of placenta visible between the layers of the dividing membrane at their attachment to the placenta (Fig. 158.1); this finding, known as the *twin peak* or *lambda sign,*

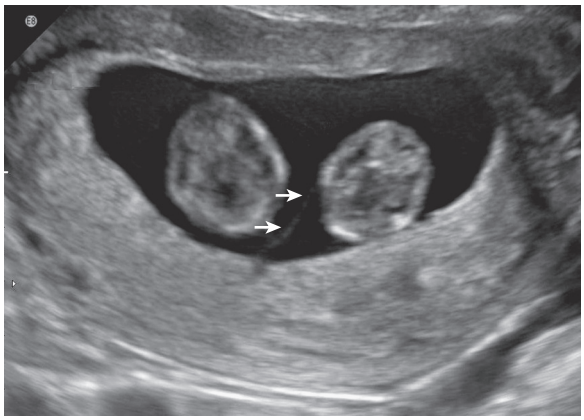

Fig. 158.2 First-trimester monochorionic diamniotic twin pregnancy shows thin intertwin membrane *(arrows)* and "T" sign.

has a sensitivity greater than 97% and specificity of 100% in predicting dichorionicity.[26] In monochorionic pregnancies, the intertwin membranes become progressively thinner after 9 weeks, and the intertwin membrane appears to insert directly into the placenta at a 90-degree angle. This finding, known as the *"T" sign* (Fig. 158.2), has 100% sensitivity and greater than 98% specificity for detecting monochorionic diamniotic gestations.[26] In a study of more than 400 twin pregnancies undergoing US at less than 24 weeks' gestation at a single tertiary care center, evaluation of placental locations, membrane insertion (including twin peak and "T" signs), or fetal genders resulted in accurate prenatal diagnosis of chorionicity in greater than 95% of cases.[27]

Later in pregnancy, determination of chorionicity and amnionicity by assessing the membrane insertion becomes less accurate because of loss of the twin peak sign and crowding of the uterine cavity. US assessment of chorionicity and amnionicity can still be attempted by determining the number of placentas and the sex of each fetus. If two separate placental disks are seen, the pregnancy is most likely dichorionic. Likewise, if the twins are different genders, the pregnancy is almost certainly dichorionic. Although the finding of concordant fetal gender and an apparent single placental mass may support a diagnosis of monochorionic placentation, these findings are nonspecific and may be present in dizygotic and dichorionic twin pregnancies.

Careful US examination of the dividing membrane may also be used to aid in the diagnosis of chorionicity in midgestation. Specifically, the thickness and number of layers of the intertwin membrane can be assessed in a highly magnified image obtained with the membrane perpendicular to the US beam. If the membrane is thick (greater than 2 mm) or has three to four visible layers, the pregnancy is dichorionic; in contrast, the intertwin membrane of monochorionic twin pregnancies is thinner, consisting of only two layers.[28] Determination of the number of membrane layers has been reported to have greater than 98% accuracy in prenatal determination of chorionicity.[28]

When attempting to determine amnionicity of a monochorionic gestation, it is important to remember that the thin dividing membranes of some monochorionic diamniotic pregnancies may not be visualized on US because severe oligohydramnios causes them to be closely opposed to the fetus in that sac. This results in a "stuck twin" appearance: the trapped fetus remains firmly held against the uterine wall despite changes in maternal position. Diagnosis of this condition confirms the presence of a diamniotic gestation, which should be distinguished from a monoamniotic gestation with an absent dividing membrane. In the latter situation, free movement of both twins and entanglement of their umbilical cords can be identified.[29]

KEY POINTS

- Prenatal determination of chorionicity and amnionicity is essential in the clinical management of multiple gestations.
- Chorionicity refers to the number of placentas in a multiple gestation; amnionicity refers to the number of amniotic cavities.
- In the first trimester, chorionicity can be determined by counting the number of gestational sacs, and the number of yolk sacs can be used to predict amnionicity.
- In the late first trimester and early second trimester, systematic evaluation of placental number, fetal gender, and insertion of the intertwin membrane into the placenta allows accurate prenatal diagnosis of chorionicity.
- In dichorionic pregnancies, the intertwin membrane remains thick with a triangular projection of placenta—the twin peak, or lambda sign—visible between the layers of the dividing membrane.
- In monochorionic pregnancies, the intertwin membrane inserts directly into the placenta, forming a characteristic "T" sign.

SUGGESTED READING

American College of Obstetricians and Gynecologists; Society for Maternal-Fetal Medicine. ACOG Practice Bulletin No. 144: multifetal gestations: twin, triplet, and higher-order multifetal pregnancies. *Obstet Gynecol*. 2014;123(5):1118-1132.

Bajoria R, Kingdom J. The case for routine determination of chorionicity and zygosity in multiple pregnancy. *Prenat Diagn*. 1997;17:1207-1225.

Egan JFX, Borgida AF. Multiple gestations: the importance of ultrasound. *Obstet Gynecol Clin North Am*. 2004;31:141-158.

Machin GA. Why is it important to diagnose chorionicity and how do we do it? *Best Pract Res Clin Obstet Gynaecol*. 2004;18:515-530.

Monteagudo A, Roman AS. Ultrasound in multiple gestations: twins and other multifetal pregnancies. *Clin Perinatol*. 2005;32:329-354.

Shetty A, Smith AP. The sonographic diagnosis of chorionicity. *Prenat Diagn*. 2005;25:735-739.

Simpson LL. Ultrasound in twins: dichorionic and monochorionic. *Semin Perinatol*. 2013;37(5):348-358.

Sperling L, Tabor A. Twin pregnancy: the role of ultrasound in management. *Acta Obstet Gynecol Scand*. 2001;80:287-299.

All references available online at
www.expertconsult.com

REFERENCES

1. Hamilton BE, Martin JA, Osterman MJK, et al. Births: final data for 2014. National Vital Statistics Reports, Volume 64 Number 12. http://www.cdc.gov/nchs/data/nvsr/nvsr64/nvsr64_12.pdf.
2. Blickstein I, Verhoeven HC, Keith LG. Zygotic splitting after assisted reproduction. *N Engl J Med*. 1999;340:738-739.
3. Blickstein I. Estimation of iatrogenic monozygotic twinning rate following assisted reproduction: pitfalls and caveats. *Am J Obstet Gynecol*. 2005;192:365-368.
4. Hankins GV, Saade GR. Factors influencing twins and zygosity. *Paediatr Perinat Epidemiol*. 2005;19(suppl 1):8-9.
5. Reddy UM, Branum AM, Klebanoff MA. Relationship of maternal body mass index and height to twinning. *Obstet Gynecol*. 2005;105:593.
6. Lee KA, Oh KJ, Lee SM, et al. The frequency and clinical significance of twin gestations according to zygosity and chorionicity. *Twin Res Hum Genet*. 2010;13:609-619.
7. Cameron AH. The Birmingham twin survey. *Proc R Soc Med*. 1968;61:229.
8. Souter VL, Kapur RP, Nyholt DR, et al. A report of dizygous monochorionic twins. *N Engl J Med*. 2003;349:154.
9. Yoon G, Beischel LS, Johnson JP, et al. Dizygotic twin pregnancy conceived with assisted reproductive technology associated with chromosomal anomaly, imprinting disorder, and monochorionic placentation. *J Pediatr*. 2005;146:565.
10. Miura K, Niikawa N. Do monochorionic dizygotic twins increase after pregnancy by assisted reproductive technology? *J Hum Genet*. 2005;50:1.
11. Hendricks CH. Twinning in relation to birth weight, mortality, and congenital anomalies. *Obstet Gynecol*. 1966;27:47-53.
12. Onyskowova A, Dolezal A, Jedlicka V. The frequency and the character of malformations in multiple birth (a preliminary report). *Teratology*. 1971;4:496.
13. Rogue H, Gillen-Goldstein J, Funai E, et al. Perinatal outcomes in monoamniotic gestations. *J Matern Fetal Neonatal Med*. 2003;13:414-421.
14. Bahtiyar MO, Dulay AT, Weeks BP, et al. Prevalence of congenital heart defects in monochorionic/diamniotic twin gestations: a systematic literature review. *J Ultrasound Med*. 2007;26:1491-1498.
15. D'Alton ME, Simpson LL. Syndromes in twins. *Semin Perinatol*. 1995;19:375-386.
16. Jain V, Fisk NM. The twin-twin transfusion syndrome. *Clin Obstet Gynecol*. 2004;47:181-202.
17. Petersen IR, Nyholm J. Multiple pregnancies with single intrauterine demise. *Acta Obstet Gynecol Scand*. 1999;78:202.
18. Lee YM, Wylie BJ, Simpson LL, et al. Twin chorionicity and the risk of stillbirth. *Obstet Gynecol*. 2008;111:301-308.
19. Allen VM, Windrim R, Barrett J, et al. Management of monoamniotic twin pregnancies: a case series and systematic review of the literature. *Br J Obstet Gynaecol*. 2001;108:931-936.
20. Barth RA, Crowe HC. Ultrasound evaluation of multifetal gestations. In: Callen PW, ed. *Ultrasonography in obstetrics and gynecology*. 4th ed. Philadelphia: Saunders; 2000:171.
21. Bromley B, Benacerraf B. Using the number of yolk sacs to determine amnionicity in early first trimester monochorionic twins. *J Ultrasound Med*. 1995;14:415-419.
22. Finberg HJ. The "twin peak" sign: reliable evidence of dichorionic twinning. *J Ultrasound Med*. 1992;11:571-577.
23. Monteagudo A, Timor-Tritsch IE, Sharma S. Early and simple determination of chorionic and amniotic type in multifetal gestations in the first 14 weeks by high-frequency transvaginal ultrasonography. *Am J Obstet Gynecol*. 1994;170:824-829.
24. Sepulveda W, Seibre NJ, Hughes K, et al. The lambda sign at 10 to 14 weeks of gestation as a predictor of chorionicity in twin pregnancies. *Ultrasound Obstet Gynecol*. 1996;7:421-423.
25. Egan JFX, Borgida AF. Multiple gestations: the importance of ultrasound. *Obstet Gynecol Clin North Am*. 2004;31:141-158.
26. Carroll SG, Soothill PW, Abdel-Fattah SA, et al. Prediction of chorionicity in twin pregnancies at 10 to 14 weeks of gestation. *Br J Obstet Gynaecol*. 2002;109:182-186.
27. Lee YM, Cleary-Goldman J, Thaker HM, et al. Antenatal sonographic prediction of twin chorionicity. *Am J Obstet Gynecol*. 2006;195:863.
28. D'Alton ME, Dudley DK. The ultrasonographic prediction of chorionicity in twin gestation. *Am J Obstet Gynecol*. 1989;160:557.
29. Nyberg DA, Filly RA, Golbus MS, et al. Entangled umbilical cords: a sign of monoamniotic twins. *J Ultrasound Med*. 1984;3:29-32.

159 Monochorionic Monoamniotic Twin Gestations

KARIN M. FUCHS | MARY E. D'ALTON

Introduction

In addition to the general risks associated with twin pregnancies and with specific risks of monochorionic gestations, monoamniotic twin gestations face the unique risk of cord entanglement and are at increased risk of fetal demise. Ultrasound (US) plays a vital role in prenatal determination of chorionicity and amnionicity and in the prenatal management of monochorionic monoamniotic twin pregnancies.

Disease

DEFINITION

The term *monochorionic* refers to a multiple gestation with one placental disk (or chorion), whereas the term *monoamniotic* describes the presence of a single amniotic cavity. A monochorionic monoamniotic twin pregnancy is one in which there is one shared placenta and a single amniotic sac containing two fetuses. By definition, monochorionic monoamniotic twin pregnancies are monozygotic.

PREVALENCE AND EPIDEMIOLOGY

Although twin gestations accounted for almost 3.4% of live births in the United States in 2014,[1] the estimated incidence of monoamniotic twins is only 1:10,000 pregnancies. The frequency of monozygotic twins is constant worldwide at 4:1000 births. More than two-thirds of monozygotic twin gestations have monochorionic placentation; however, monoamnionicity affects less than 5% of monozygotic twin gestations.[2] The literature shows that monoamniotic gestations are more common following assisted reproductive technologies such as intracytoplasmic sperm injection.[3]

ETIOLOGY AND PATHOPHYSIOLOGY

Monozygotic twinning results from the division of a single fertilized ovum into two distinct fetuses. Chorionicity and amnionicity of monozygotic gestations are determined by the time at which division of the fertilized ovum occurs. If twinning occurs during the first 2 to 3 days, it precedes the separation of cells that eventually become the chorion and results in a dichorionic diamniotic pregnancy. After approximately 3 days, twinning cannot split the chorionic cavity, and division of an ovum results in monochorionic placentation. If the split occurs between the third and eighth days, a monochorionic diamniotic pregnancy develops; monochorionic monoamniotic pregnancies result from divisions that occur between the eighth and twelfth days. Embryonic cleavage between the 13th and 15th days results in conjoined twins; splitting does not occur beyond the 15th day of gestation.

MANIFESTATIONS OF DISEASE

Clinical Presentation

Multifetal gestations should be suspected if the uterine size is greater than expected. Similarly, the possibility of a multiple gestation should be considered if elevated concentrations of maternal serum analytes, such as beta-human chorionic gonadotropin, alpha-fetoprotein, and other serum aneuploidy markers, are noted in the first or second trimester. When a multiple gestation is suspected clinically, US should be performed to assess plurality, and if a multiple gestation is confirmed, to determine chorionicity and amnionicity. There are no non-US clinical findings that can differentiate monoamniotic multiple gestations from diamniotic multiples.

Imaging Technique and Findings

Ultrasound. In the first trimester, monochorionic twin pregnancies can be easily detected on US. Between 6 and 10 weeks' gestation, a monochorionic twin pregnancy can be identified by the presence of a single gestational sac containing two fetuses. The presence or absence of an intertwin membrane may be difficult to determine in the middle of the first trimester (Fig. 159.1); however, the number of yolk sacs can also be used as an indirect method of determining amnionicity early in gestation.[4] The presence of a single yolk sac suggests a monoamniotic twin pregnancy (Fig. 159.2), whereas the finding of two yolk sacs is diagnostic of a diamniotic twin pregnancy.

Later in gestation, monochorionic monoamniotic pregnancies can be differentiated from other types of twin pregnancies through a systematic evaluation of the placental number, fetal gender, and intertwin membrane.[5-9] Specifically, monochorionic monoamniotic pregnancies are characterized by the presence of two fetuses of the same gender with a single placenta, single amniotic sac, and no intertwin membrane.

When attempting to determine amnionicity of a monochorionic gestation, lack of visualization of an intertwin membrane in a monochorionic pregnancy has relatively low positive predictive value for the diagnosis of a monoamniotic gestation.[10] This low positive predictive value is likely explained by the fact that the thin intertwin membrane of monochorionic gestations may be difficult to visualize on US. It is significantly more difficult to visualize the intertwin membrane of monochorionic pregnancies complicated by oligohydramnios because the intertwin



Fig. 159.1 Image of a monochorionic diamniotic twin gestation at 10 weeks shows two fetuses within a single amniotic sac.

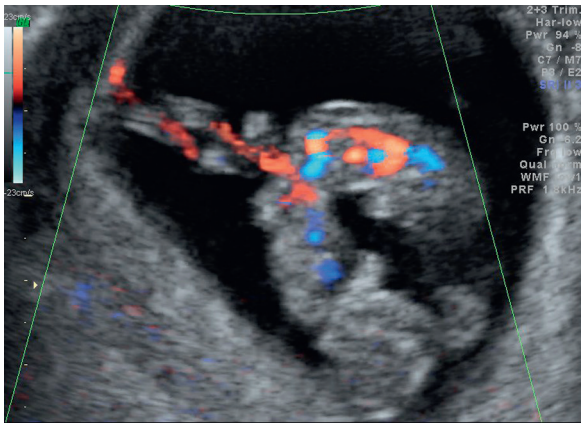

Fig. 159.2 First-trimester image of a monochorionic monoamniotic twin gestation shows a single yolk sac and early evidence of cord entanglement.

membrane may become so closely apposed to the fetus in that sac that it becomes undetectable on US. A "stuck twin" appearance results, with the trapped fetus remaining firmly held against the uterine wall despite changes in maternal position. Diagnosis of this condition confirms the presence of a diamniotic gestation, which should be distinguished from a monoamniotic gestation with an absent dividing membrane.

In addition, visualization of cord entanglement is diagnostic of a monochorionic monoamniotic twin gestation (Fig. 159.3; see Fig. 159.2).[11] The placental cord insertions of monochorionic twins may be within close proximity of each other (Fig. 159.4).

Differential Diagnosis From Imaging Findings

The differential diagnosis of monochorionic monoamniotic twin gestations includes twin gestations with alternative placentation and membrane composition. Specifically, monochorionic monoamniotic pregnancies can be differentiated from monochorionic diamniotic twin gestations by assessing the presence of an intertwin membrane. Monochorionic pregnancies can be differentiated from dichorionic pregnancies by assessing placental number, fetal gender, and characteristics of the intertwin membrane and umbilical cords.

Synopsis of Treatment Options

PRENATAL

Twin pregnancies are known to be at increased risk of many complications including preterm delivery, growth disorders, and malpresentation. In addition to these risks associated with twin pregnancies in general and the risks specifically associated with monochorionic gestations, monoamniotic twin gestations have additional complications related to the twinning process and monoamnionicity. Throughout gestation, US plays a vital role in the prenatal management of monochorionic monoamniotic twin pregnancies.

As in all twin pregnancies, transvaginal assessment of cervical length between 20 and 24 weeks' gestation can be used to identify women with cervical length of 25 mm or less, which is associated with an increased risk of preterm delivery.[12] Women with cervical

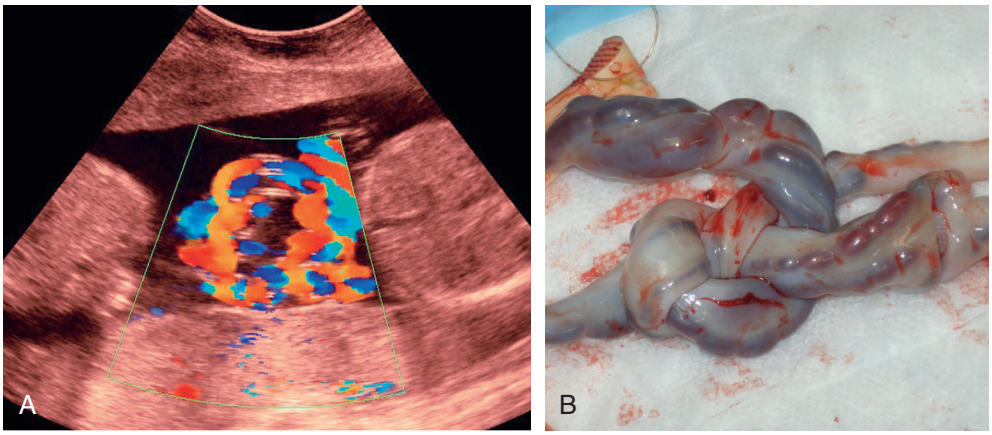

Fig. 159.3 (A) Second-trimester US image shows cord entanglement in a monochorionic monoamniotic twin gestation. (B) Postnatal image of the same cord entanglement shown in (A).

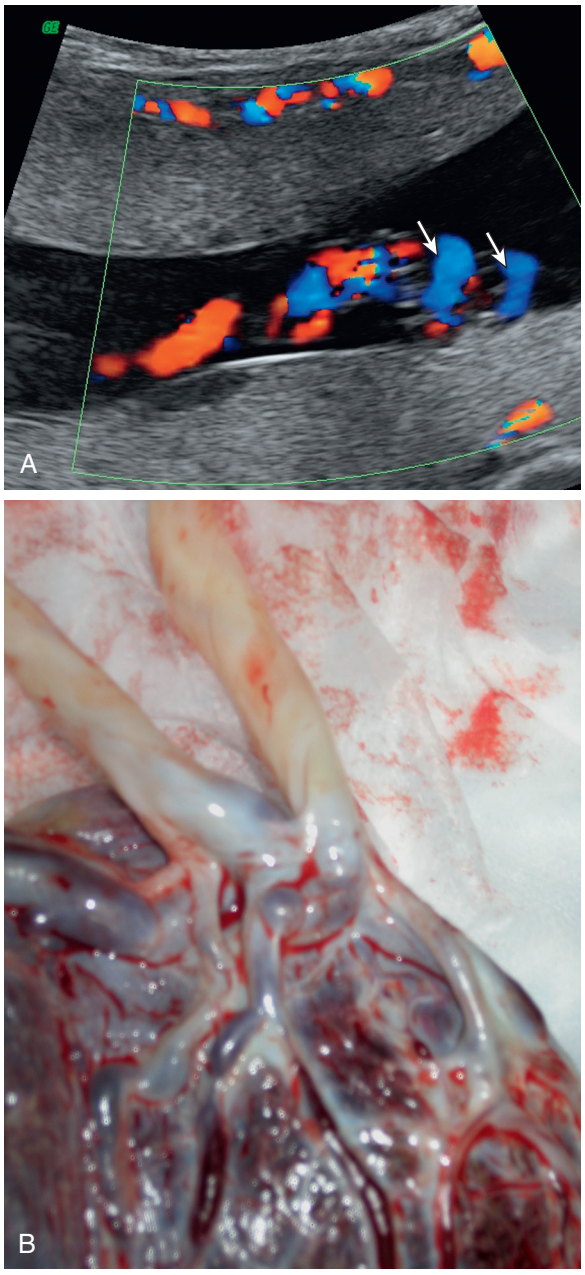

Fig. 159.4 (A) Second-trimester US image shows adjacent placental cord insertions in a monochorionic monoamniotic twin gestation. (B) Postnatal image of the same placental cord insertions shown in (A).

shortening or other risk factors for preterm birth may benefit from serial US assessment of cervical length.

In some studies, more than 25% of monoamniotic twins have been noted to have congenital anomalies. Although some of this increased risk is related to monozygosity, monoamniotic monozygotic twins have an increased likelihood of structural anomalies compared with diamniotic monozygotic twins.[13,14] Although a primary concern in twin gestations with monochorionic placentation is twin transfusion syndrome, this syndrome is less common in monoamniotic gestations than in monochorionic diamniotic gestations, occurring in only 5% of cases.[15]

Previous studies reported a fetal mortality rate of greater than 50% in monoamniotic twin pregnancies, but more recent studies indicate a perinatal mortality rate ranging from 10% to 21%.[14,16–22] Although some of this increased risk is related to the increased risk of anomalies, the risk is largely related to cord entanglement of monoamniotic twin gestations, which has been shown to be present in most, if not all, monoamniotic gestations.[18] Although perinatal mortality related to cord entanglement cannot be entirely prevented, outcomes seem to be improved in the setting of heightened prenatal surveillance and elective preterm delivery after administration of prenatal corticosteroids.[14,19–22] The nonstress test is generally the preferred method of testing over the biophysical profile because cord compression may be indicated by variable decelerations not detected on US.

Doppler evaluation of the umbilical vessels may also be useful in the prenatal evaluation of monoamniotic twin gestations. Specifically, cord entanglement may be suggested by absent end-diastolic flow, notching in the umbilical artery waveform, or increased velocity in the umbilical vein.[23–25] Given the likelihood of cord entanglement, cesarean delivery is generally recommended for monoamniotic twins.[26]

POSTNATAL

Neonatal care is generally determined by the gestational age at delivery, birth weight, and presence of any anomalies or fetal complications. In the absence of additional complications, postnatal management of monoamniotic twins does not differ from management of matched singletons.

WHAT THE REFERRING PHYSICIAN NEEDS TO KNOW

As with all twin gestations, monoamniotic twin gestations have an increased risk for complications such as preterm delivery, malpresentation, and growth disorders. Monoamniotic twin gestations are at risk for several additional complications, including twin transfusion syndrome owing to monochorionic placentation and increased risk for structural anomalies and cord entanglement. Because of increased perinatal mortality risk related to cord entanglement, monoamniotic twins warrant consideration of inpatient prenatal surveillance and iatrogenic preterm delivery. Prenatal US evaluation is essential to determine chorionicity and amnionicity and to allow evaluation of fetal anatomy and serial assessment of fetal growth, cervical length, and fetal well-being throughout pregnancy.

KEY POINTS

- The term *monochorionic* refers to a multiple gestation with one placental disk (or chorion), whereas *monoamniotic* describes the presence of only one amniotic cavity.
- By definition, monoamniotic twin pregnancies are monozygotic.
- In the early first trimester, monochorionic monoamniotic twin pregnancies can be identified by the presence of one gestational sac and one amniotic sac containing two fetuses.
- Monochorionic monoamniotic pregnancies are characterized by the presence of two fetuses of the same gender, a single placenta, and the absence of an intertwin membrane.
- US detection of cord entanglement is diagnostic of a monoamniotic gestation.
- In addition to risk of preterm delivery and growth disorders present in all twin gestations, monochorionic monoamniotic pregnancies are at risk of congenital anomalies, twin transfusion syndrome, and an increased risk of perinatal mortality related to cord entanglement.
- Serial prenatal US scans and heightened prenatal surveillance are essential in the management of monoamniotic twin pregnancies.

SUGGESTED READING

American College of Obstetricians and Gynecologists; Society for Maternal-Fetal Medicine. ACOG Practice Bulletin No. 144: multifetal gestations: twin, triplet, and higher-order multifetal pregnancies. *Obstet Gynecol*. 2014;123(5):1118-1132.

Chauhan SP, Scardo JA, Hayes E, et al. Twins: prevalence, problems, and preterm births. *Am J Obstet Gynecol*. 2010;203:305-315.

Dias T, Mahsud-Dornan S, Bhide A, et al. Cord entanglement and perinatal outcome in monoamniotic twin pregnancies. *Ultrasound Obstet Gynecol*. 2010;35:201-204.

Emery SP, Bahtiyar MO, Moise KJ, et al. The North American Fetal Therapy Network consensus statement: management of complicated monochorionic gestations. *Obstet Gynecol*. 2015;126(3):575-584.

Hack KE, Derks JB, Schaap AH, et al. Perinatal outcome of monoamniotic twin pregnancies. *Obstet Gynecol*. 2009;113:353.

Ishii K. Prenatal diagnosis and management of monoamniotic twins. *Curr Opin Obstet Gynecol*. 2015;27(2):159-164.

Lim KI, Dy C, Pugash D, et al. Monoamniotic twins discordant for anencephaly managed conservatively with good outcomes: two case reports and a review of the literature. *Ultrasound Obstet Gynecol*. 2005;26:188-193.

Post A, Heyborne K. Managing monoamniotic twin pregnancies. *Clin Obstet Gynecol*. 2015;58(3):643-653.

Shetty A, Smith AP. The sonographic diagnosis of chorionicity. *Prenat Diagn*. 2005;25:735-739.

Simpson LL. Ultrasound in twins: dichorionic and monochorionic. *Semin Perinatol*. 2013;37(5):348-358.

Simpson LL. What you need to know when managing twins: 10 key facts. *Obstet Gynecol Clin North Am*. 2015;42(2):225-239.

Strohbehn K, Dattel BJ. Pitfalls in the diagnosis of nonconjoined monoamniotic twins. *J Perinatol*. 1995;15:484.

Vink J, Wapner R, D'Alton ME. Prenatal diagnosis in twin gestations. *Semin Perinatol*. 2012;36(3):169-174.



All references available online at
www.expertconsult.com

REFERENCES

1. Hamilton BE, Martin JA, Osterman MJK, et al. Births: final data for 2014. National Vital Statistics Reports, Volume 64 Number 12. http://www.cdc.gov/nchs/data/nvsr/nvsr64/nvsr64_12.pdf.
2. D'Alton ME, Simpson LL. Syndromes in twins. *Semin Perinatol*. 1995;19:375-386.
3. Slotnick RN, Ortega JE. Monoamniotic twinning and zona manipulation: a survey of U.S. IVF centers correlating zona manipulation procedures and high-risk twinning frequency. *J Assist Reprod Genet*. 1996;13:381.
4. Bromley B, Benacerraf B. Using the number of yolk sacs to determine amnionicity in early first trimester monochorionic twins. *J Ultrasound Med*. 1995;14:415-419.
5. Finberg HJ. The "twin peak" sign: reliable evidence of dichorionic twinning. *J Ultrasound Med*. 1992;11:571-577.
6. Monteagudo A, Timor-Tritsch IE, Sharma S. Early and simple determination of chorionic and amniotic type in multifetal gestations in the first 14 weeks by high-frequency transvaginal ultrasonography. *Am J Obstet Gynecol*. 1994;170:824-829.
7. Sepulveda W, Seibre NJ, Hughes K, et al. The lambda sign at 10 to 14 weeks of gestation as a predictor of chorionicity in twin pregnancies. *Ultrasound Obstet Gynecol*. 1996;7:421-423.
8. Egan JFX, Borgida AF. Multiple gestations: the importance of ultrasound. *Obstet Gynecol Clin North Am*. 2004;31:141-158.
9. Shetty A, Smith AP. The sonographic diagnosis of chorionicity. *Prenat Diagn*. 2005;25:735-739.
10. Strohbehn K, Dattel BJ. Pitfalls in the diagnosis of nonconjoined monoamniotic twins. *J Perinatol*. 1995;15:484.
11. Nyberg DA, Filly RA, Golbus MS, et al. Entangled umbilical cords: a sign of monoamniotic twins. *J Ultrasound Med*. 1984;3:29.
12. Conde-Agudelo A, Romero R, Hassan SS, et al. Transvaginal sonographic cervical length for the prediction of spontaneous preterm birth in twin pregnancies: a systematic review and metaanalysis. *Am J Obstet Gynecol*. 2010;203:128.e1-128.e12.
13. Hack KE, Derks JB, Schaap AH, et al. Perinatal outcome of monoamniotic twin pregnancies. *Obstet Gynecol*. 2009;113:353.
14. Allen VM, Windrim R, Barrett J, et al. Management of monoamniotic twin pregnancies: a case series and systematic review of the literature. *BJOG*. 2001;108:931.
15. Hack KE, van Gemert MJ, Lopriore E, et al. Placental characteristics of monoamniotic twin pregnancies in relation to perinatal outcome. *Placenta*. 2009;30:62.
16. Carr SR, Aronson MP, Coustan DR. Survival rates of monoamniotic twins do not decrease after 30 weeks' gestation. *Am J Obstet Gynecol*. 1990;163:719-722.
17. Rodis JF, McIlveen PF, Egan JF, et al. Monoamniotic twins: improved perinatal survival with accurate prenatal diagnosis and antenatal fetal surveillance. *Am J Obstet Gynecol*. 1997;177:1046-1049.
18. Dias T, Mahsud-Dornan S, Bhide A, et al. Cord entanglement and perinatal outcome in monoamniotic twin pregnancies. *Ultrasound Obstet Gynecol*. 2010;35:201-204.
19. Beasley E, Megerian G, Gerson A, et al. Monoamniotic twins: case series and proposal for antenatal management. *Obstet Gynecol*. 1999;93:130.
20. Ezra Y, Shveiky D, Ophir E, et al. Intensive management and early delivery reduce antenatal mortality in monoamniotic twin pregnancies. *Acta Obstet Gynecol Scand*. 2005;84:432.
21. Heyborne KD, Porreco RP, Garite TJ, et al. Improved perinatal survival of monoamniotic twins with intensive inpatient monitoring. *Am J Obstet Gynecol*. 2005;192:96.
22. DeFalco LM, Sciscione AC, Megerian G, et al. Inpatient versus outpatient management of monoamniotic twins and outcomes. *Am J Perinatol*. 2006;23:205.
23. Abuhamad AZ, Mari G, Copel JA, et al. Umbilical artery flow velocity waveforms in monoamniotic twins with cord entanglement. *Obstet Gynecol*. 1995;86:674.
24. Gembruch U, Baschat AA. True knot of the umbilical cord: transient constrictive effect to umbilical venous blood flow demonstrated by Doppler sonography. *Ultrasound Obstet Gynecol*. 1996;8:53.
25. Rosemond RL, Hinds NE. Persistent abnormal umbilical cord Doppler velocimetry in a monoamniotic twin with cord entanglement. *J Ultrasound Med*. 1998;17:337.
26. Graham GM 3rd, Gaddipati S. Diagnosis and management of obstetrical complications unique to multiple gestations. *Semin Perinatol*. 2005;29:282-295.

160 Monochorionic Diamniotic Twin Gestations

KARIN M. FUCHS | MARY E. D'ALTON

Introduction

Compared with dichorionic twin gestations, monochorionic twin gestations, whether diamniotic or monoamniotic, have an increased risk of adverse pregnancy outcomes. Ultrasound (US) plays a vital role in prenatal determination of chorionicity and in the management of monochorionic diamniotic twin pregnancies.

Disease

DEFINITION

The term *monochorionic* refers to a multiple gestation with one placental disk (or chorion), and the term *diamniotic* describes the presence of two distinct amniotic cavities. In a monochorionic diamniotic twin pregnancy, there is one shared placenta, and each fetus has its own amniotic sac. By definition, monochorionic twin pregnancies are monozygotic.

PREVALENCE AND EPIDEMIOLOGY

Twin gestations accounted for almost 3.4% of live births in the United States in 2014.[1] The frequency of monozygotic twins is constant worldwide at 4:1000 births. Approximately two-thirds of monozygotic twin gestations have monochorionic placentation and diamniotic membrane composition.[2] Dizygotic monochorionic diamniotic twin gestations resulting from assisted reproductive technology have been described in case reports.[3,4]

ETIOLOGY AND PATHOPHYSIOLOGY

Monozygotic twinning results from the division of a single fertilized ovum into two distinct fetuses. Chorionicity and amnionicity of monozygotic gestations are determined by the time at which division of the fertilized ovum occurs. If twinning occurs during the first 2 to 3 days, it precedes the separation of cells that eventually become the chorion and results in a dichorionic diamniotic pregnancy. After approximately 3 days, twinning cannot split the chorionic cavity, and division of an ovum results in monochorionic placentation. If the split occurs between the third and eighth days, a monochorionic diamniotic pregnancy develops, whereas divisions that occur between the eighth and thirteenth days result in a monochorionic monoamniotic pregnancy.

MANIFESTATIONS OF DISEASE

Clinical Presentation

Multifetal gestations should be suspected if uterine size is greater than expected. Similarly, the possibility of a multiple gestation should be considered if elevated concentrations of maternal serum analytes, such as beta-human chorionic gonadotropin, alpha-fetoprotein, and other serum aneuploidy markers, are noted in the first or second trimester. When a multiple gestation is suspected clinically, US should be performed to assess plurality and, if a multiple gestation is confirmed, to determine chorionicity and amnionicity. There are no non-US clinical findings that can differentiate monochorionic from dichorionic twin gestations.

Imaging Technique and Findings

Ultrasound. In the first trimester, monochorionic twin pregnancies can be easily detected on US. Between 6 and 10 weeks' gestation, a monochorionic twin pregnancy can be identified by the presence of a single gestational sac containing two fetuses. The presence or absence of an intertwin membrane may be difficult to determine in the middle of the first trimester; however, the number of yolk sacs can also be used as an indirect method of determining amnionicity early in gestation.[5] The presence of two yolk sacs is diagnostic of a diamniotic twin pregnancy, whereas a single yolk sac suggests a monoamniotic twin pregnancy.

Later in gestation, monochorionic diamniotic pregnancies can be differentiated from dichorionic diamniotic and monochorionic monoamniotic twin pregnancies through a systematic evaluation of the placental number, fetal gender, and intertwin membrane.[6–10] In monochorionic pregnancies, there is a single placenta and a thin intertwin membrane that inserts directly into the placenta; this finding, known as the *"T" sign* (Figs. 160.1 and 160.2), has 100% sensitivity and greater than 98% specificity for detecting monochorionic diamniotic gestations.[11] In contrast, the intertwin membrane of dichorionic gestations has a characteristic twin peak or "lambda" sign, and monoamniotic gestations lack an intertwin membrane altogether.

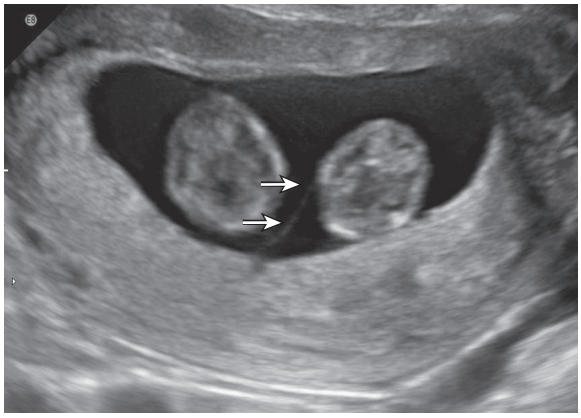

Fig. 160.1 Image of a late first-trimester monochorionic diamniotic twin pregnancy shows a single gestational sac with thin intertwin membrane and "T" sign *(arrows)*.



Fig. 160.2 Image of a second-trimester monochorionic diamniotic twin pregnancy shows a single placental mass with "T" sign.

Although the findings of concordant fetal gender and a single placental mass support the diagnosis of monochorionic placentation, these findings are nonspecific and may also be detected in dizygotic and dichorionic twin pregnancies. In a study of more than 400 twin pregnancies undergoing US at less than 24 weeks' gestation at a single tertiary care center, evaluation of a combination of features including placental number and location, membrane insertion (including twin peak and "T" signs), and fetal gender resulted in accurate prenatal diagnosis of chorionicity in greater than 95% of cases.[12]

Careful US examination of the dividing membrane may also be used to aid in the diagnosis of chorionicity in midgestation. Specifically, the thickness and number of layers of the intertwin membrane can be assessed in a highly magnified image obtained with the membrane perpendicular to the US beam. If the membrane is thin and has only two layers, the pregnancy is monochorionic; in contrast, the intertwin membrane of monochorionic twin pregnancies is thicker (greater than 2 mm) or has three to four visible layers.[13] Determination of the number of membrane layers has been reported to have greater than 98% accuracy in prenatal determination of chorionicity.[13]

When attempting to determine amnionicity of a monochorionic gestation, the thin dividing membranes of some monochorionic diamniotic pregnancies may not be visualized on US because severe oligohydramnios causes them to be closely apposed to the fetus in that sac. A "stuck twin" appearance results, with the trapped fetus remaining firmly held against the uterine wall despite changes in maternal position. Diagnosis of this condition confirms the presence of a diamniotic gestation, which should be distinguished from a monoamniotic gestation with an absent dividing membrane. In the latter situation, free movement of both twins and entanglement of their umbilical cords can be identified.[14]

Differential Diagnosis From Imaging Findings

The differential diagnosis of monochorionic diamniotic twin gestations includes twin gestations with alternative placentation and membrane composition. Specifically, monochorionic diamniotic pregnancies can be differentiated from dichorionic diamniotic pregnancies by assessing fetal gender, placental number, and characteristics of the intertwin membrane as described earlier. By definition, twins of a monochorionic pregnancy are of the same gender and share a single placenta (see Figs. 160.1 and 160.2). The intertwin membrane of monochorionic diamniotic pregnancies is composed of only two layers and appears thinner than the dividing membrane of dichorionic pregnancies. The placental insertion of a monochorionic membrane has the characteristic appearance of a "T" sign (see Figs. 160.1 and 160.2). In contrast, fetuses of a dichorionic twin pregnancy each have a separate placental mass, may be of different gender, and are separated by a thick four-layer membrane with a characteristic twin peak or lambda sign at its placental insertion.

Synopsis of Treatment Options

PRENATAL

Twin pregnancies are known to be at increased risk of many complications, including preterm delivery, growth disorders, and malpresentation. In addition, monochorionic twins also have

numerous complications unique to the twinning process and monochorionic placentation. Throughout gestation, US plays a vital role in the prenatal management of monochorionic twin pregnancies.

A primary concern in twin gestations with monochorionic placentation is twin transfusion syndrome (TTS), which is characterized by an unequal distribution of the blood flow across the shared placenta of two fetuses. Although all monochorionic twins share a portion of their vasculature, only approximately 15% to 20% develop TTS.[15,16] Untreated, TTS is associated with a 60% to 100% mortality rate for both twins. Another unique but rare complication that occurs in monochorionic diamniotic pregnancies is twin reversed arterial perfusion sequence, also known as *acardiac twinning* (Chapter 163).

In monochorionic gestations, nuchal translucency can be measured as part of a first-trimester combined aneuploidy screening program. In monochorionic twin gestations, an increased nuchal translucency measurement is associated with an increased risk of TTS, as is discordant nuchal translucency measurements between fetuses of a monochorionic pair.[17,18] Similarly, discordant measurements of crown-rump length between fetuses of a monochorionic pair were associated with an increased risk of TTS.[19] Given the increased risk of fetal structural anomalies in monozygotic twin pregnancies, a comprehensive US survey of the fetal anatomy is warranted in the early second trimester; fetal echocardiography is also recommended in monochorionic twin pregnancies, given the increased risk of congenital heart disease.[20,21]

As in all twin pregnancies, transvaginal assessment of cervical length at 20 to 24 weeks' gestation can be used to identify women with cervical length of 25 mm or less, which is associated with an increased risk of preterm delivery.[22] Women with cervical shortening or other risk factors for preterm birth may benefit from serial US assessment of cervical length.

Even in the absence of TTS, monochorionic twin pregnancies can be complicated by discordant fetal growth (usually defined as a difference in the estimated fetal weights that exceeds 20% of the weight of the larger twin) or intrauterine growth restriction of one or both fetuses. In monochorionic twin gestations, velamentous cord insertion of one or both fetuses and unequal placental sharing are additional risk factors for birth-weight discordance.[23] Monochorionic pregnancies also have an increased risk of intrauterine death of one or both twins compared with dichorionic pregnancies. In a study of 1000 consecutive twin pairs, monochorionic diamniotic twins had a higher risk of stillbirth compared with dichorionic diamniotic twins overall and at each gestational age after 24 weeks[24]; this increased risk of fetal loss persisted in "apparently normal" monochorionic diamniotic twins unaffected by growth abnormalities, congenital anomalies, or TTS.

Given the increased risk of sonographically diagnosed complications in monochorionic gestations, experts recommend serial sonographic surveillance of monochorionic gestations at least every 2 weeks beginning at 16 weeks.[25] At a minimum, these serial scans should include assessment of amniotic fluid volume and presence of fluid within the fetal bladders with assessment of fetal growth at least monthly. More intensive prenatal testing with Doppler velocimetry is recommended in monochorionic gestations complicated by TTS, intrauterine growth restriction, discordant growth, abnormal amniotic fluid volumes, fetal anomalies, single fetal demise, and other medical or obstetric complications.[26]

Before delivery, US is essential to determine the position of the presenting twin. If vaginal delivery of a twin gestation is attempted, intrapartum US should be available for evaluation of the position of the second twin after delivery of the first twin.

POSTNATAL

Neonatal care is generally determined by gestational age at delivery, birth weight, and presence of any anomalies or fetal complications. In the absence of additional complications, postnatal management of monochorionic twins does not differ from management of matched singletons.

WHAT THE REFERRING PHYSICIAN NEEDS TO KNOW

As with all twin gestations, monochorionic twin gestations have an increased risk of complications such as preterm delivery, malpresentation, and growth disorders. In addition, monochorionic diamniotic twin gestations have many complications unique to the twinning process and monochorionic placentation, including an increased risk of structural anomalies, TTS, and twin reversed arterial perfusion sequence. Prenatal US is essential to determine chorionicity and to allow evaluation of fetal anatomy and serial assessment of fetal growth, cervical length, and fetal well-being throughout pregnancy.

KEY POINTS

- The term *monochorionic* refers to a multiple gestation with one placental disk (or chorion), and the term *diamniotic* describes the presence of two distinct amniotic cavities.
- By definition, monochorionic twin pregnancies are monozygotic.
- In the early first trimester, monochorionic diamniotic twin pregnancies can be identified by the presence of one gestational sac containing two fetuses.
- Monochorionic diamniotic pregnancies are characterized by the presence of two fetuses of the same gender, a single placenta, a thin two-layered intertwin membrane, and a characteristic T-shaped insertion of the intertwin membrane at the placental surface.
- In addition to risk of preterm delivery and growth disorders present in all twin gestations, monochorionic diamniotic pregnancies have many complications unique to the twinning process and monochorionic placentation, including an increased risk of structural anomalies, TTS, and twin reversed arterial perfusion sequence.
- Serial prenatal US evaluations are essential in the management of monochorionic twin pregnancies.

SUGGESTED READING

American College of Obstetricians and Gynecologists, Society for Maternal-Fetal Medicine. ACOG Practice Bulletin No. 144: multifetal gestations: twin, triplet, and higher-order multifetal pregnancies. *Obstet Gynecol*. 2014;123(5):1118-1132.

Bahtiyar MO, Dulay AT, Weeks BP, et al. Prevalence of congenital heart defects in monochorionic/diamniotic twin gestations: a systematic literature review. *J Ultrasound Med*. 2007;26:1491-1498.

Chauhan SP, Scardo JA, Hayes E, et al. Twins: prevalence, problems, and preterm births. *Am J Obstet Gynecol*. 2010;203:305-315.

Emery SP, Bahtiyar MO, Dashe JS, et al. The North American fetal therapy network consensus statement: prenatal management of uncomplicated monochorionic gestations. *Obstet Gynecol*. 2015;125(5):1236-1243.

Emery SP, Bahtiyar MO, Moise KJ, et al. The North American fetal therapy network consensus statement: management of complicated monochorionic gestations. *Obstet Gynecol*. 2015;126(3):575-584.

Johnson A. Diagnosis and management of twin-twin transfusion syndrome. *Clin Obstet Gynecol*. 2015;58(3):611-631.

Shetty A, Smith AP. The sonographic diagnosis of chorionicity. *Prenat Diagn*. 2005;25:735-739.
Simpson LL. Ultrasound in twins: dichorionic and monochorionic. *Semin Perinatol*. 2013;37(5):348-358.
Simpson LL. What you need to know when managing twins: 10 key facts. *Obstet Gynecol Clin North Am*. 2015;42(2):225-239.
Vink J, Wapner R, D'Alton ME. Prenatal diagnosis in twin gestations. *Semin Perinatol*. 2012;36(3):169-174.



All references available online at
www.expertconsult.com

REFERENCES

1. Martin JA, Hamilton BE, Sutton PD, et al. Births: final data for 2007. *Natl Vital Stat Rep*. 2010;http://www.cdc.gov/nchs/data/nvsr/nvsr58/nvsr58_24.pdf.
2. Lee KA, Oh KJ, Lee SM, et al. The frequency and clinical significance of twin gestations according to zygosity and chorionicity. *Twin Res Hum Genet*. 2010;13:609-619.
3. Souter VL, Kapur RP, Nyholt DR, et al. A report of dizygous monochorionic twins. *N Engl J Med*. 2003;349:154.
4. Yoon G, Beischel LS, Johnson JP, et al. Dizygotic twin pregnancy conceived with assisted reproductive technology associated with chromosomal anomaly, imprinting disorder, and monochorionic placentation. *J Pediatr*. 2005;146:565.
5. Bromley B, Benacerraf B. Using the number of yolk sacs to determine amnionicity in early first-trimester monochorionic twins. *J Ultrasound Med*. 1995;14:415-419.
6. Finberg HJ. The "twin peak" sign: reliable evidence of dichorionic twinning. *J Ultrasound Med*. 1992;11:571-577.
7. Monteagudo A, Timor-Tritsch IE, Sharma S. Early and simple determination of chorionic and amniotic type in multifetal gestations in the first fourteen weeks by high-frequency transvaginal ultrasonography. *Am J Obstet Gynecol*. 1994;170:824-829.
8. Sepulveda W, Seibre NJ, Hughes K, et al. The lambda sign at 10 to 14 weeks of gestation as a predictor of chorionicity in twin pregnancies. *Ultrasound Obstet Gynecol*. 1996;7:421-423.
9. Egan JFX, Borgida AF. Multiple gestations: the importance of ultrasound. *Obstet Gynecol Clin North Am*. 2004;31:141-158.
10. Shetty A, Smith AP. The sonographic diagnosis of chorionicity. *Prenat Diagn*. 2005;25:735-739.
11. Carroll SGM, Soothill PW, Sherif AA, et al. Prediction of chorionicity in twin pregnancies at 10-14 weeks of gestation. *Br J Obstet Gynaecol*. 2002;109:182-186.
12. Lee YM, Cleary-Goldman J, Thaker HM, et al. Antenatal sonographic prediction of twin chorionicity. *Am J Obstet Gynecol*. 2006;195:863.
13. D'Alton ME, Dudley DK. The ultrasonographic prediction of chorionicity in twin gestation. *Am J Obstet Gynecol*. 1989;160:557.
14. Nyberg DA, Filly RA, Golbus MS, et al. Entangled umbilical cords: a sign of monoamniotic twins. *J Ultrasound Med*. 1984;3:29-32.
15. D'Alton ME, Simpson LL. Syndromes in twins. *Semin Perinatol*. 1995;19:375-386.
16. Jain V, Fisk NM. The twin-twin transfusion syndrome. *Clin Obstet Gynecol*. 2004;47:181-202.
17. Sebire NJ, D'Ercole C, Hughes K, et al. Increased nuchal translucency thickness at 10 to 14 weeks of gestation as a predictor of severe twin-to-twin transfusion syndrome. *Ultrasound Obstet Gynecol*. 1997;10:86-89.
18. Kagan KO, Gazzoni A, Sepulveda-Gonzalez G, et al. Discordance in nuchal translucency thickness in the prediction of severe twin-to-twin transfusion syndrome. *Ultrasound Obstet Gynecol*. 2007;29:527-532.
19. Fratelli N, Prefumo F, Fichera A, et al. Nuchal translucency thickness and crown rump length discordance for the prediction of outcome in monochorionic diamniotic pregnancies. *Early Hum Dev*. 2011;87:27-30.
20. Bahtiyar MO, Dulay AT, Weeks BP, et al. Prevalence of congenital heart defects in monochorionic/diamniotic twin gestations: a systematic literature review. *J Ultrasound Med*. 2007;26:1491-1498.
21. American Institute of Ultrasound in Medicine. AIUM practice guideline for the performance of fetal echocardiography. *J Ultrasound Med*. 2013;32:1067-1082.
22. Conde-Agudelo A, Romero R, Hassan SS, et al. Transvaginal sonographic cervical length for the prediction of spontaneous preterm birth in twin pregnancies: a systematic review and metaanalysis. *Am J Obstet Gynecol*. 2010;203:128.e1-128.e12.
23. De Paepe ME, Shapiro S, Young L, et al. Placental characteristics of selective birth weight discordance in diamniotic-monochorionic twin gestations. *Placenta*. 2010;31:380-386.
24. Lee YM, Wylie BJ, Simpson LL, et al. Twin chorionicity and the risk of stillbirth. *Obstet Gynecol*. 2008;111:301-308.
25. Emery SP, Bahtiyar MO, Dashe JS, et al. The North American fetal therapy network consensus statement: prenatal management of uncomplicated monochorionic gestations. *Obstet Gynecol*. 2015;125(5):1236-1243.
26. Emery SP, Bahtiyar MO, Moise KJ. North American fetal therapy network. The North American fetal therapy network consensus statement: management of complicated monochorionic gestations. *Obstet Gynecol*. 2015;126(3):575-584.

161 Dichorionic Diamniotic Twin Gestations

KARIN M. FUCHS | MARY E. D'ALTON

Introduction

Twin pregnancies account for more than 3% of live births in the United States.[1] Determination of chorionicity and amnionicity is essential in the clinical management of multiple gestations. Although dichorionic twin gestations are not associated with as many fetal complications as monochorionic gestations, all twin pregnancies, whether dichorionic or monochorionic, have an increased risk of adverse pregnancy outcomes compared with singletons. Ultrasound (US) plays a vital role in prenatal determination of chorionicity and in the management of dichorionic diamniotic twin pregnancies.

Disease

DEFINITION

The term *dichorionic* refers to multiple gestations with two distinct placental disks (or two chorions), and the term *diamniotic* describes a pregnancy with two distinct amniotic cavities. A dichorionic diamniotic twin pregnancy is a twin pregnancy in which each fetus has its own placenta and amniotic sac.

PREVALENCE AND EPIDEMIOLOGY

Twin gestations accounted for more than 3% of live births in the United States in 2007.[1] Dichorionic diamniotic twin gestations comprise most twin births.

ETIOLOGY AND PATHOPHYSIOLOGY

Twinning can occur from either the fertilization of multiple ova or the division of a single fertilized ovum into more than one fetus. The terms *monozygotic* and *dizygotic* refer to the number of ova responsible for a twin gestation. A monozygotic pregnancy results from a single fertilized ovum that divides into two distinct fetuses. In contrast, dizygotic pregnancies originate from the fertilization of two separate ova and are genetically dissimilar. The frequency of monozygotic twins is constant worldwide at 4:1000 births. In contrast, the frequency of dizygotic twins varies by maternal age, parity, family history, maternal weight, nutritional state, and race.[2]

Either monozygotic or dizygotic twinning can result in a dichorionic diamniotic twin gestation. Dizygotic pregnancies are almost always dichorionic diamniotic, with each fetus having its own placenta and amniotic cavity.[3] In contrast, chorionicity of monozygotic gestations is determined by the time at which division of the fertilized ovum occurs. If twinning occurs during the first 2 to 3 days, it precedes the separation of cells that eventually become the chorion and results in a monozygotic dichorionic diamniotic pregnancy. After approximately 3 days, twinning cannot split the chorionic cavity, and division of an ovum results in monochorionic placentation. Among spontaneously conceived same-sex dichorionic twins, approximately 18% are monozygotic.[4]

MANIFESTATIONS OF DISEASE

Clinical Presentation

Multifetal gestations should be suspected if the uterine size is greater than expected. Similarly, the possibility of a multiple gestation should be considered if elevated concentrations of maternal serum analytes, such as beta-human chorionic gonadotropin, alpha-fetoprotein, and other serum aneuploidy markers, are noted in the first or second trimester. When a multiple gestation is suspected clinically US should be performed to assess plurality, and if a multiple gestation is confirmed, to determine chorionicity and amnionicity. There are no non-US clinical findings that can differentiate dichorionic from monochorionic twin gestations prenatally.

Imaging Technique and Findings

Ultrasound. In the first trimester, dichorionic diamniotic twin pregnancies can be easily detected on US. Between 6 and 10 weeks' gestation, a dichorionic diamniotic twin pregnancy can be identified by the presence of two distinct gestational sacs separated by a thick dividing membrane, each containing a separate fetal pole, yolk sac, and amniotic sac (Fig. 161.1).

Later in the first trimester and in the second trimester, dichorionic pregnancies can be differentiated from monochorionic

pregnancies through a systematic evaluation of the placental number, fetal gender, and insertion of the intertwin membrane into the placenta.[5–9] When examining the insertion of the intertwin membrane into the placenta, dichorionic pregnancies show a thick triangular projection of placenta between the layers of the dividing membrane. This finding, known as the *twin peak* or *lambda sign*, has a sensitivity greater than 97% and specificity of 100% in predicting dichorionicity (Fig. 161.2).[10] In addition, the finding of two distinct placental masses (Fig. 161.3) each with a cord insertion or the finding of discordant fetal gender is almost always diagnostic of a dichorionic twin gestation. In a study of more than 400 twin pregnancies undergoing US at less than 24 weeks' gestation at a single tertiary care center, evaluation of placental location, membrane insertion, or fetal gender resulted in accurate prenatal diagnosis of chorionicity in greater than 95% of cases.[11]



Fig. 161.1 Early first-trimester image of a dichorionic diamniotic twin pregnancy shows two gestational sacs, each containing a fetus and yolk sac.

Determination of chorionicity becomes more difficult beyond 20 weeks' gestation because of fusion of dichorionic placental masses and loss of the twin peak sign characteristic of dichorionic twin pregnancies. Nevertheless, careful US examination of the dividing membrane has been shown to diagnose dichorionicity in midgestation with greater than 98% accuracy.[12] Using a highly magnified image with the intertwin membrane perpendicular to the US probe, the membrane of a dichorionic pregnancy appears thick (>2 mm) and comprises three to four visible layers; in contrast, the intertwin membrane of a monochorionic-diamniotic twin gestation is thin and comprises two layers.

Differential Diagnosis From Imaging Findings

The differential diagnosis of dichorionic diamniotic twin gestations includes twin gestations with alternative placentation and

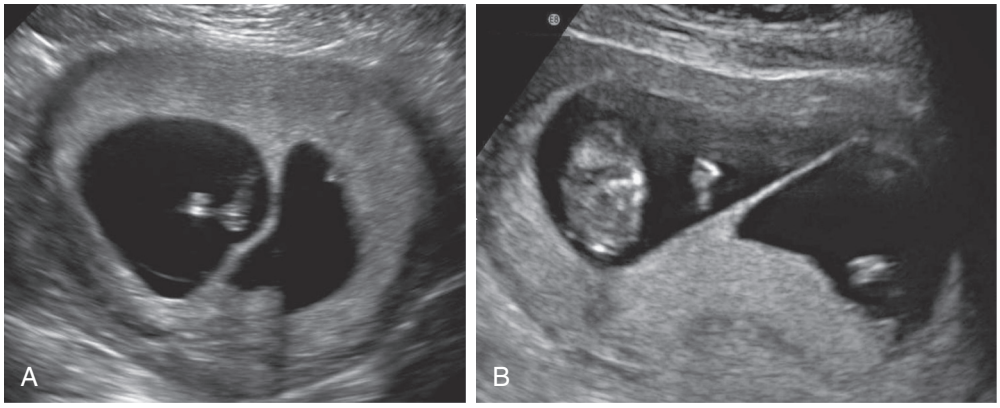

Fig. 161.2 (A) Image of first-trimester dichorionic twin pregnancy shows a twin peak (or lambda) sign and thick intertwin membrane. (B) Image of first-trimester dichorionic twin pregnancy shows twin peak (or lambda) sign and thick intertwin membrane.

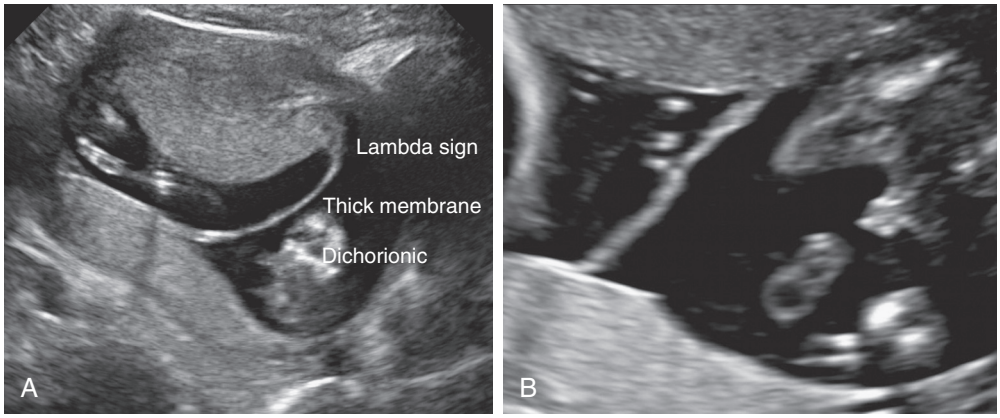

Fig. 161.3 (A) Late first-trimester image of a dichorionic twin pregnancy shows two placental masses with a thick intertwin membrane. (B) Second-trimester image of a dichorionic twin pregnancy shows two placental masses with a thick intertwin membrane.

membrane composition. Specifically, dichorionic diamniotic pregnancies can be differentiated from monochorionic diamniotic pregnancies by assessing fetal gender, placental number, and characteristics of the intertwin membrane (i.e., thickness, placental insertion, number of layers). Twins of a dichorionic pregnancy may be either of the same or different genders and have separate placental masses (see Fig. 161.3) (albeit possibly fused) and a thick, four-layer intertwin membrane that has a characteristic twin peak sign at its placental insertion (see Fig. 161.2). In contrast, fetuses of a monochorionic twin pregnancy are by definition of the same gender, share one placental mass, and are separated by a thin two-layer membrane that inserts directly into the placenta forming a characteristic "T" sign.

Synopsis of Treatment Options

PRENATAL

Twin pregnancies are known to be at increased risk of many complications, including preterm delivery, growth disorders, and malpresentation. US plays a vital role in the prenatal management of twin gestations.

In the first trimester, measurement of nuchal translucency on US, which assesses each fetus independently, can be performed as part of a combined aneuploidy screening program. Because the distribution of nuchal translucency does not differ significantly in singletons compared with twins, the Down syndrome detection rate in multiples using nuchal translucency measurement together with maternal age[13] and biochemistry studies is similar to the rate in singleton pregnancies.[14]

Given the increased risk of fetal structural malformations in monozygotic twin pregnancies, a comprehensive US survey of the fetal anatomy is warranted in the early second trimester. Also given the increased risk of preterm delivery in twin gestations, assessment of cervical length in the second trimester may be helpful in identifying women at increased risk of preterm delivery. The literature suggests that a transvaginal cervical length of 25 mm or less with or without funneling at 20 to 24 weeks' gestation predicts a high risk for preterm labor and delivery in asymptomatic women carrying twins.[15] Women with cervical shortening or other risk factors for preterm may benefit from serial US assessment of cervical length.

Twin gestations are associated with an increased risk of fetal growth disorders, which may include discordant fetal growth (usually defined as a difference in the estimated fetal weights that are greater than 20% of the weight of the larger twin) or intrauterine growth restriction (IUGR) of one or both fetuses. Because of the increased risk of fetal growth disorders in twin gestations, serial US assessment of fetal growth is recommended.

Prenatal testing is suggested in all patients with dichorionic twins complicated by IUGR, discordant growth, abnormal amniotic fluid volumes, fetal anomalies, single fetal demise, and other medical or obstetric complications.[16] Routine Doppler studies have not been found to be helpful in the management of women with uncomplicated dichorionic twins,[17,18] but Doppler velocimetry of the umbilical artery and ductus venosus may serve as a useful adjunct in the management of dichorionic twins with IUGR, discordant growth, or amniotic fluid volume abnormalities.

Before delivery, US is essential to determine the position of the presenting twin. If vaginal delivery of a twin gestation is attempted, intrapartum US should be available for evaluation of the position of the second twin after delivery of the first twin.

POSTNATAL

Postnatal management of dichorionic twins does not differ from management of singletons and is generally determined by gestational age at delivery, birth weight, and presence of any anomalies or other fetal complications.

WHAT THE REFERRING PHYSICIAN NEEDS TO KNOW

Dichorionic twin gestations have an increased risk of maternal and fetal complications. Careful prenatal management is recommended. Prenatal US is essential to allow determination of chorionicity, detailed evaluation of fetal anatomy, and serial US assessment of cervical length and fetal growth.

KEY POINTS

- The term *dichorionic* refers to a multiple gestation with two distinct placental disks (or two chorions); the term *diamniotic* describes a pregnancy with two distinct amniotic cavities.
- Either monozygotic or dizygotic twinning can result in a dichorionic diamniotic twin gestation.
- In the early first trimester, dichorionic diamniotic twin pregnancies can be identified by the presence of two distinct gestational sacs separated by a thick dividing membrane, each containing a separate fetal pole, yolk sac, and amniotic sac.
- Dichorionic pregnancies have a thick intertwin membrane and a characteristic thick triangular projection of placenta between the layers of the dividing membrane known as the *twin peak,* or *lambda sign*.
- The finding of two distinct placental masses each with a cord insertion or the finding of discordant fetal gender is almost always diagnostic of a dichorionic twin gestation.
- Prenatal US is essential in the management of dichorionic twin pregnancies to allow determination of chorionicity, evaluation of fetal anatomy, and serial US assessment of cervical length and fetal growth.

SUGGESTED READINGS

American College of Obstetricians and Gynecologists; Society for Maternal-Fetal Medicine. ACOG Practice Bulletin No. 144: Multifetal gestations: twin, triplet, and higher-order multifetal pregnancies. *Obstet Gynecol.* 2014;123(5):1118–1132.

Chauhan SP, Scardo JA, Hayes E, et al. Twins: prevalence, problems, and preterm births. *Am J Obstet Gynecol.* 2010;203:305-315.

Cleary-Goldman J, D'Alton ME. Growth abnormalities and multiple gestations. *Semin Perinatol.* 2008;32:206-212.

Conde-Agudelo A, Romero R, Hassan SS, et al. Transvaginal sonographic cervical length for the prediction of spontaneous preterm birth in twin pregnancies: a systematic review and metaanalysis. *Am J Obstet Gynecol.* 2010;203:128.e1-128.e12.

Devoe LD. Antenatal fetal assessment: multifetal gestation—an overview. *Semin Perinatol.* 2008;32:281-287.

Shetty A, Smith AP. The sonographic diagnosis of chorionicity. *Prenat Diagn.* 2005;25:735-739.

Simpson LL. Ultrasound in twins: dichorionic and monochorionic. *Semin Perinatol.* 2013;37(5):348-358.

Simpson LL. What you need to know when managing twins: 10 key facts. *Obstet Gynecol Clin North Am.* 2015;42(2):225-239.

Vink J, Wapner R, D'Alton ME. Prenatal diagnosis in twin gestations. *Semin Perinatol.* 2012;36(3):169-174.

Winn HN, Cimino J, Powers J, et al. Intrapartum management of nonvertex second-born twins: a critical analysis. *Am J Obstet Gynecol.* 2001;185:1204.



All references available online at
www.expertconsult.com

REFERENCES

1. Hamilton BE, Martin JA, Osterman MJK, et al. Births: final data for 2014. *Natl Vital Stat Rep*. 2015;64(12):http://www.cdc.gov/nchs/data/nvsr/nvsr64/nvsr64_12.pdf.
2. Hankins GV, Saade GR. Factors influencing twins and zygosity. *Paediatr Perinat Epidemiol*. 2005;19(suppl 1):8-9.
3. Souter VL, Kapur RP, Nyholt DR, et al. A report of dizygous monochorionic twins. *N Engl J Med*. 2003;349:154.
4. Cameron AH. The Birmingham twin survey. *Proc R Soc Med*. 1968;61:229.
5. Finberg HJ. The "twin peak" sign: reliable evidence of dichorionic twinning. *J Ultrasound Med*. 1992;11:571-577.
6. Monteagudo A, Timor-Tritsch IE, Sharma S. Early and simple determination of chorionic and amniotic type in multifetal gestations in the first fourteen weeks by high-frequency transvaginal ultrasonography. *Am J Obstet Gynecol*. 1994;170:824-829.
7. Sepulveda W, Seibre NJ, Hughes K, et al. The lambda sign at 10–14 weeks of gestation as a predictor of chorionicity in twin pregnancies. *Ultrasound Obstet Gynecol*. 1996;7:421-423.
8. Egan JFX, Borgida AF. Multiple gestations: the importance of ultrasound. *Obstet Gynecol Clin North Am*. 2004;31:141-158.
9. Shetty A, Smith AP. The sonographic diagnosis of chorionicity. *Prenat Diagn*. 2005;25:735-739.
10. Carroll SGM, Soothill PW, Sherif AA, et al. Prediction of chorionicity in twin pregnancies at 10–14 weeks of gestation. *Br J Obstet Gynaecol*. 2002;109:182-186.
11. Lee YM, Cleary-Goldman J, Thaker HM, et al. Antenatal sonographic prediction of twin chorionicity. *Am J Obstet Gynecol*. 2006;195:863.
12. D'Alton ME, Dudley DK. The ultrasonographic prediction of chorionicity in twin gestation. *Am J Obstet Gynecol*. 1989;160:557.
13. Odibo AO, Lawrence-Cleary K, Macones GA. Screening for aneuploidy in twins and higher-order multiples: is first-trimester nuchal translucency the solution? *Obstet Gynecol Surv*. 2003;58:609-614.
14. Spencer K, Nicolaides KH. Screening for trisomy 21 in twins using first trimester ultrasound and maternal serum biochemistry in a one stop clinic: a review of three years' experience. *Br J Obstet Gynaecol*. 2003;110:276-280.
15. Conde-Agudelo A, Romero R, Hassan SS, et al. Transvaginal sonographic cervical length for the prediction of spontaneous preterm birth in twin pregnancies: a systematic review and metaanalysis. *Am J Obstet Gynecol*. 2010;203:128.e1-128.e12.
16. Devoe LD. Antenatal fetal assessment: multifetal gestation—an overview. *Semin Perinatol*. 2008;32:281-287.
17. Geipel A, Berg C, Germer U, et al. Doppler assessment in the uterine circulation in the second trimester in twin pregnancies: prediction of pre-eclampsia, fetal growth restriction and birth weight discordance. *Ultrasound Obstet Gynecol*. 2002;20:541-545.
18. Giles W, Bisits A, O'Callaghan S, et al; DAMP Study Group. The Doppler assessment in multiple pregnancy randomized controlled trial of ultrasound biometry versus umbilical artery Doppler ultrasound and biometry in twin pregnancy. *Br J Obstet Gynaecol*. 2003;110:593-597.

162 Twin-Twin Transfusion Syndrome

LYNN L. SIMPSON | RUSSELL S. MILLER

Introduction

Twin-twin transfusion syndrome (TTTS) is a serious condition that can complicate twin pregnancies with monochorionic diamniotic (MCDA) placentation. MCDA twin pregnancies should be monitored for TTTS with serial ultrasound (US) scans beginning in the second trimester. Early-stage TTTS can be managed conservatively, but because of the unpredictable risks of disease progression and intrauterine fetal demise, prenatal testing and delivery before term should be considered. Limited data from randomized trials and retrospective experience suggest that fetoscopic laser photocoagulation may be the best available treatment for advanced TTTS diagnosed in the second trimester. Despite the availability of laser treatment, a significant risk of twin demise and neurologic handicap remains among survivors. Early detection, intervention for advanced disease, serial surveillance, and timed delivery can improve the prognosis for TTTS.

Disease

DEFINITION

TTTS is diagnosed prenatally by US and staged based on various US findings.[1] The initial staging of TTTS, as described by Quintero et al.,[2] was judged to have prognostic significance and thought to provide a method to compare outcome data between different therapeutic interventions. Although the staging system may not correlate perfectly with perinatal survival, it improves communication between patients and providers and identifies a subset of cases that may benefit from treatment. TTTS has five stages ranging from mild disease with isolated discordant amniotic fluid volume to severe disease involving demise of one or both twins (Table 162.1).

PREVALENCE AND EPIDEMIOLOGY

In general, only twin gestations with MCDA placentation are at significant risk for TTTS. The number of TTTS cases is increasing secondary to the increase in monozygotic twinning associated with in vitro fertilization. Overall, about two-thirds of monozygotic twins are MCDA, and 8% to 15% of these pregnancies develop TTTS.[1,3] TTTS is rare in monozygotic twins with dichorionic or monoamniotic placentation.

The presentation of TTTS is highly variable, and TTTS does not always progress in a predictable manner. The natural history of advanced TTTS is bleak, with reported perinatal loss rates of 70% to 100%, particularly when disease manifests early in gestation.[4] It is estimated that TTTS accounts for 15% to 20% of the total perinatal mortality in twins and for about half of all perinatal deaths in MCDA twins. Although TTTS may manifest at any point in pregnancy, most cases are diagnosed in the second trimester. Without treatment, the loss of at least one fetus is very common with significant risk of co-twin demise or neurologic handicap in cases of co-twin survival.[5] Overall, single twin survival rates in TTTS vary widely between 15% and 70%, depending on gestational age at diagnosis and the severity of disease. However, two-thirds of early-stage TTTS remains stable or regresses without invasive interventions.[6] The lack of predictability of TTTS poses a significant challenge to clinicians caring for MCDA twins.

ETIOLOGY AND PATHOPHYSIOLOGY

Although the pathophysiology of TTTS is not completely understood, intertwin vascular connections within the placenta are critical for its development. Virtually all MCDA placentas have anastomoses that link the circulations of the twins, yet not all MCDA twins develop TTTS. There are three main types of anastomoses in monochorionic placentas: venovenous anastomoses (VVA), arterioarterial anastomoses (AAA), and arteriovenous anastomoses (AVA). AVA are found in 90% to 95% of MCDA placentas, AAA are found in 85% to 90%, and VVA are found in 15% to 20%.[7]

Both AAA and VVA are superficial connections on the surface of the placenta with the potential for bidirectional flow (Fig. 162.1). AVA are deep within the placenta and can result in

TABLE 162.1 STAGING OF TWIN-TWIN TRANSFUSION SYNDROME

	Ultrasound Parameter	Staging Criteria
Stage I	MVP of amniotic fluid	MVP <2 cm in donor sac; MVP >8 cm in recipient sac
Stage II	Fetal bladder	Nonvisualization of fetal bladder in donor twin over 60 min of observation
Stage III	Umbilical artery, ductus venosus, and umbilical vein Doppler waveforms	Absent or reversed umbilical artery diastolic flow, reversed ductus venosus a-wave flow, pulsatile umbilical vein flow
Stage IV	Fetal hydrops	Hydrops in one or both twins
Stage V	Absent fetal cardiac activity	Fetal demise of one or both twins

MVP, Maximal vertical pocket.
From Quintero RA, Morales WJ, Allen MH, et al. Staging of twin-twin transfusion syndrome. *J Perinatol* 19:550-555, 1999.

unidirectional flow from one twin to the other and, if uncompensated, may lead to an imbalance of volume flow between the twins. In contrast to AAA and VVA, which are direct vessel-to-vessel connections, AVA are linked through large capillary beds deep within a cotyledon. AVA are believed to be essential, but not sufficient alone, for the development of TTTS, which explains why they have been found in more than 90% of MCDA placentas with TTTS and in more than 90% without TTTS.[7] These deep AVA are usually multiple and overall balanced by AVA coursing in the opposite direction so that TTTS does not occur. Although the number of AVA from donor to recipient may be important, their size and placental resistance likely influence the volume of intertwin transfusion that occurs. Placentas in cases of TTTS are also more likely to have VVA but less likely to have AAA.[7] It is thought that AAA may compensate for the unidirectional flow through AVA, preventing the development of TTTS or decreasing its severity when it does occur. Mortality is highest in the absence of AAA and lowest when these anastomoses are present. However, the presence of AAA is not completely protective because 25% to 30% of TTTS cases also have these anastomoses. Although chronic TTTS seems to be the result of deep AVA, acute TTTS may occur when there is rapid intertwin transfusion through superficial anastomoses. This uncommon complication, referred to as twin anemia-polycythemia sequence, is most often observed at the time of delivery and is rarely detected prenatally.

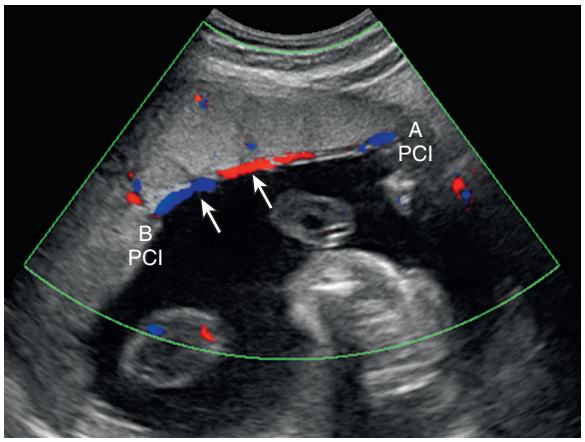

Fig. 162.1 Superficial anastomosis *(arrows)* observed using color flow imaging of the placental equator between the placental cord insertion *(PCI)* of the two twins *A* and *B*.

Although the primary problem lies with the placenta, additional factors beyond placental morphology appear to be involved in the development of TTTS. The simple imbalance of blood flow through placental anastomoses may lead to a more complex interplay between fetal adaptations and altered vascular reactivity. Donor twins exhibit evidence on US of volume depletion with oliguria and oligohydramnios, whereas recipient twins exhibit fluid overload with polyuria, polyhydramnios, and acquired cardiac dysfunction (Fig. 162.2). Hypovolemia in donor twins leads to upregulation of the renin-angiotensin system (RAS) with increased renal renin production and angiotensin synthesis with subsequent vasoconstriction and hypertension.[8] In contrast, hypervolemia in recipient twins results in downregulation of the RAS with decreased renin production and suppression of antidiuretic hormone to increase diuresis and reduce blood pressure.[8] This discordance in the RAS in MCDA twins may occur by 13 to 14 weeks' gestation. Vasoactive hormones produced by the donor may affect placental resistance resulting in changes in the umbilical artery waveforms. These vasoactive hormones can also reach the recipient through placental anastomoses resulting in worsening hypertension and cardiac dysfunction. Discordant endothelin levels have also been reported, and elevated levels in recipient twins may contribute to the development of systemic hypertension and diastolic dysfunction.[9] Although renin levels are higher in both donor and recipient twins compared with controls, recipient twins are exposed to the highest levels of renin-angiotensin effectors, suggesting that regional RAS upregulation in the placenta may also contribute to the elevated RAS effectors found in recipient twins.[10] Discordant activation of the RAS in MCDA twins and in the placenta may play an important role in the development of TTTS.

MANIFESTATIONS OF DISEASE

Clinical Presentation

Although monthly US scans were previously considered standard surveillance for twin pregnancies regardless of chorionicity, more recent studies suggest that this frequency is insufficient for the prompt detection of acute complications in twins with MCDA

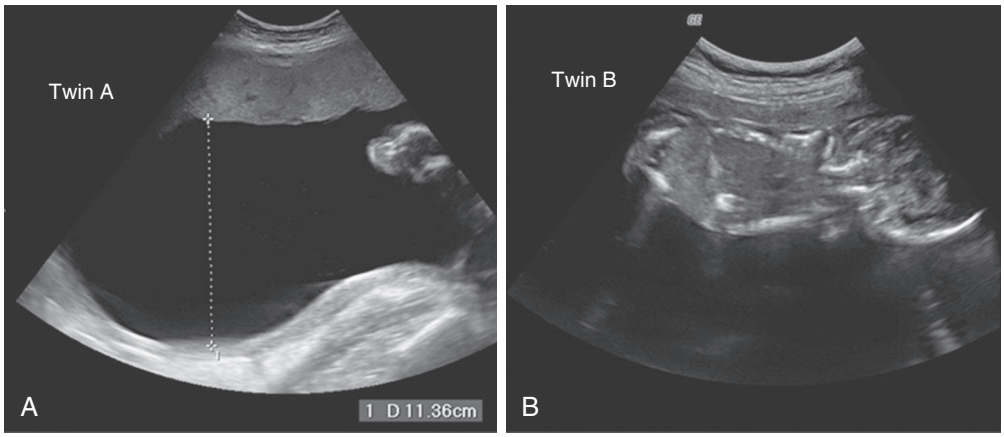

Fig. 162.2 Image of monochorionic diamniotic twins with TTTS shows polyhydramnios in the recipient's sac (A), whereas the donor (B) was stuck to the anterior uterine wall owing to marked oligohydramnios.

placentation.[11] TTTS is a dynamic condition that can remain unchanged throughout gestation, progress slowly over numerous weeks, or develop quickly within days with rapid deterioration in fetal well-being. US surveillance every 2 weeks and patient education about the signs and symptoms of polyhydramnios have been shown to increase the early detection of TTTS.[11] Although early-stage TTTS resolved in 41% of cases and remained stable in 28%, cases that progress to advanced TTTS usually do so within 2 weeks.[12] Given that TTTS usually manifests in the second trimester and that a subset of pregnancies rapidly deteriorates to advanced disease, serial US scans every 2 weeks beginning at 14 to 16 weeks' gestation is reasonable until better risk stratification is established.

Some first-trimester and second-trimester findings may warrant increased surveillance of MCDA gestations. Intertwin discrepancies in amniotic fluid volume, crown-rump length, nuchal translucency thickness, placental cord insertion (PCI), and abdominal circumference each independently increases the risk of TTTS. Nuchal translucency measurements greater than the 95th percentile and discordant nuchal translucency measurements of 20% or more between MCDA twins have been associated with TTTS.[13,14] Reversed a-wave in the ductus venosus waveform in MCDA twin pregnancies at 11 to 13 weeks' gestation is another risk factor for TTTS, with the condition developing in about one-third of cases.[15] The detection of membrane folding in the second trimester is a sign of developing fluid discordance between the two sacs, and about half of all MCDA twins with membrane folding develop TTTS (Fig. 162.3).[16] Changes in middle cerebral peak systolic flow may also indicate discordance in fetal hemoglobin between the twins. Abnormal PCI and, in particular, velamentous insertion may also increase the likelihood of TTTS. Velamentous PCI is found in one-third of TTTS placentas compared with an incidence of 10% in placentas without TTTS (Fig. 162.4).[7] In addition, donor twins are more likely to have velamentous PCI compared with recipients when TTTS is diagnosed. In contrast, marginal PCI is found at a similar rate in placentas with TTTS and without TTTS.[7]

It has been reported that AAA can be identified by US, and if AAA are detected in MCDA gestations, the risk of TTTS is decreased.[17] If TTTS develops, the finding of AAA may confer a more favorable prognosis.[17] However, US is best at detecting these anastomoses late in gestation, limiting the clinical usefulness of this assessment.

Intertwin transfusion appears to be a fragile equilibrium that can result in a spectrum of TTTS severity; TTTS can regress, remain stable, progress slowly, or deteriorate rapidly. Although several markers may help identify a subset of MCDA twins at increased risk, no marker performs well enough to change current surveillance or clinical care of MCDA gestations. Although uterine distention secondary to polyhydramnios, preterm contractions, and pelvic pressure may be recognized clinically, many patients are asymptomatic at the time of presentation. A high level of suspicion and serial US evaluations are necessary for timely diagnosis and management of TTTS.

Imaging Technique and Findings

Ultrasound. A necessary finding for the US diagnosis of TTTS is the presence of the polyhydramnios-oligohydramnios sequence, or significant amniotic fluid volume discordance. Defined as a maximal vertical fluid pocket of less than 2 cm in the donor sac and greater than 8 cm in the recipient sac, these findings represent less than the fifth percentile (<2 cm) and greater than the 95th percentile (>8 cm) for amniotic fluid measurements, and are used to define stage I TTTS.[2] In the setting of otherwise discordant amniotic fluid volume that fails to meet staging criteria,

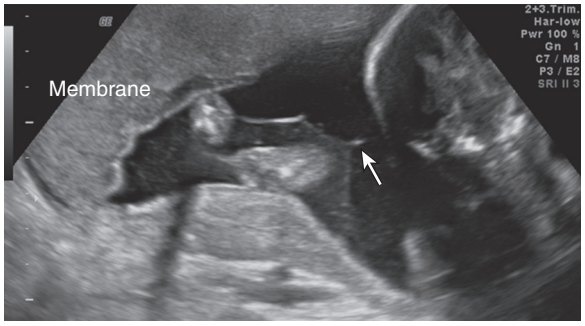

Fig. 162.3 Membrane folding *(arrow)* suggestive of discordant amniotic fluid volume in monochorionic diamniotic twin gestation.

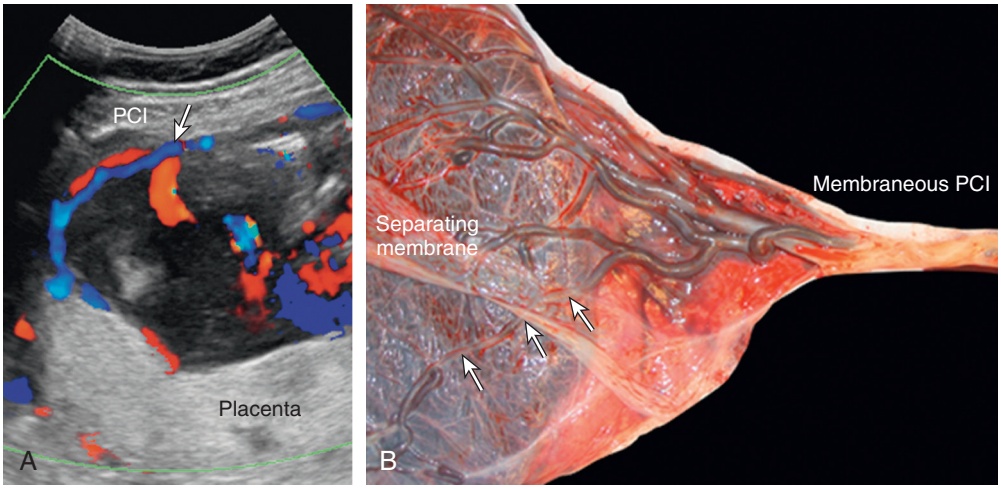

Fig. 162.4 (A) Velamentous or membranous placental cord insertion *(PCI) (arrow)* of monochorionic diamniotic twin detected by color Doppler. (B) Velamentous placental cord insertion *(PCI)* was confirmed on examination of the placenta with identification of an anastomosis *(arrows)* passing beneath the separating membrane and joining the circulations of the twins.

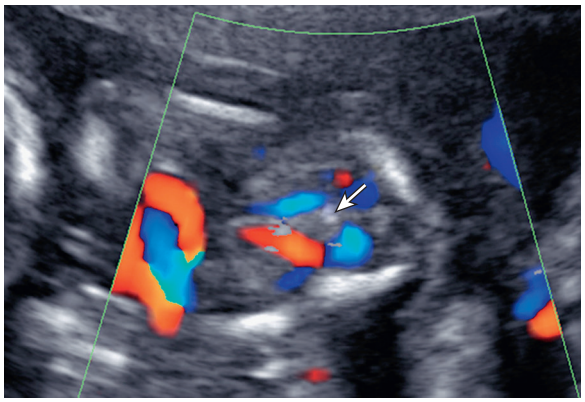

Fig. 162.5 Nonvisualization of the fetal bladder *(arrow)* between the umbilical arteries in a donor twin.

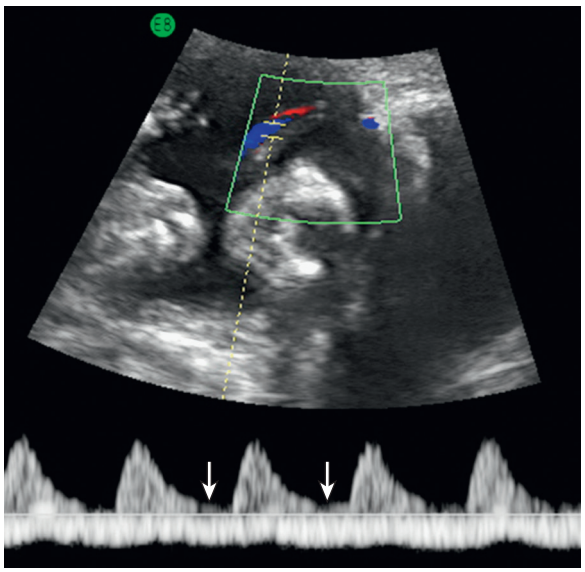

Fig. 162.6 Absent end-diastolic flow *(arrows)* in the umbilical artery of a donor twin.

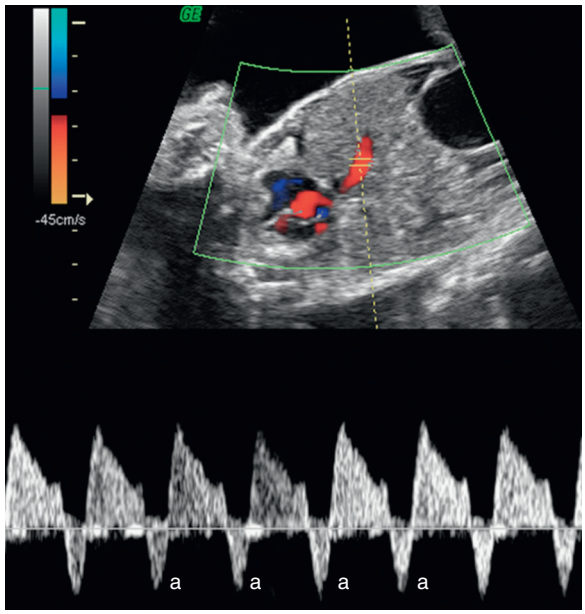

Fig. 162.7 Reversed a-wave *(a)* in the ductus venosus waveform of a recipient twin.

progression to TTTS occurs in less than 15% of cases.[18] In cases of TTTS, polyhydramnios-oligohydramnios sequence is usually followed by marked oliguric oligohydramnios in the donor twin represented by nonvisualization of the urinary bladder (stage II) (Fig. 162.5). Absent or reversed end-diastolic flow in the umbilical artery of the donor and absent or reversed a-wave in the ductus venosus of the recipient can subsequently develop (stage III) followed by hydrops (stage IV) (Figs. 162.6 and 162.7). Although growth discordance and intrauterine fetal growth restriction (IUGR) may complicate TTTS, growth disorders are no longer used to establish the diagnosis or to stage disease. Despite the debate over the merit of TTTS staging, it appears to be useful in diagnosing the condition, monitoring progression, and providing a common framework for research.

Magnetic Resonance Imaging. Although fetal magnetic resonance imaging (MRI) is not commonly used in the initial evaluation of TTTS, fetal MRI has been shown to be superior to obstetric US in the identification of cerebral ischemia and intraventricular hemorrhage in TTTS.[19] Fetal MRI may also show evidence of altered hemodynamics as suggested by enlargement of the cerebral venous sinuses in donor and recipient twins and dilatation of the renal collecting system in recipient twins.[19] Given that the risk for adverse neurologic outcome is significant in TTTS, MRI may prove useful in the evaluation of the fetal brain, but further studies are needed to define its role in the workup of TTTS. Despite a lack of compelling data, fetal MRI is often performed after invasive therapy for TTTS or after death of one twin to document an absence of resultant central nervous system ischemic or hemorrhagic injury.

Other Applicable Modality. Screening for congenital heart disease is warranted in all monochorionic twins because the risk of cardiac anomalies is increased ninefold in MCDA twins and 14-fold in cases of TTTS.[20] Overall, the incidence of congenital heart disease in TTTS has been reported to be about 5%. It is theorized that the abnormal placentation that occurs in monochorionic twins, particularly in cases in which TTTS develops, contributes to abnormal fetal heart formation.[20]

In addition to congenital heart defects, structural cardiac abnormalities can also be acquired in TTTS; this phenomenon is virtually exclusive to recipient twins. The discordant cardiovascular physiology in MCDA twins appears to be related both to unbalanced flow through AVA and to changes in the RAS. The initial hypervolemia in the recipient results in endocrine dysregulation, systemic hypertension, and cardiac dysfunction. Volume overload causes increased pulmonary and aortic velocities, cardiomegaly, and atrioventricular valve regurgitation (Fig. 162.8). Over time, recipient twins can develop progressive biventricular hypertrophy and diastolic dysfunction and poor right ventricular systolic function that can lead to functional right ventricular outflow tract obstruction and pulmonic stenosis (Figs. 162.9 and 162.10).[20] The development of right ventricular outflow obstruction, observed in almost 10% of all recipient twins, is likely multifactorial, a consequence of increased preload; afterload; and circulating factors such as renin, angiotensin, endothelin, and atrial and brain natriuretic peptides.[21] The cardiovascular response to TTTS contributes to the poor outcome of recipient twins, whereas recipients with normal cardiac function have improved survival.

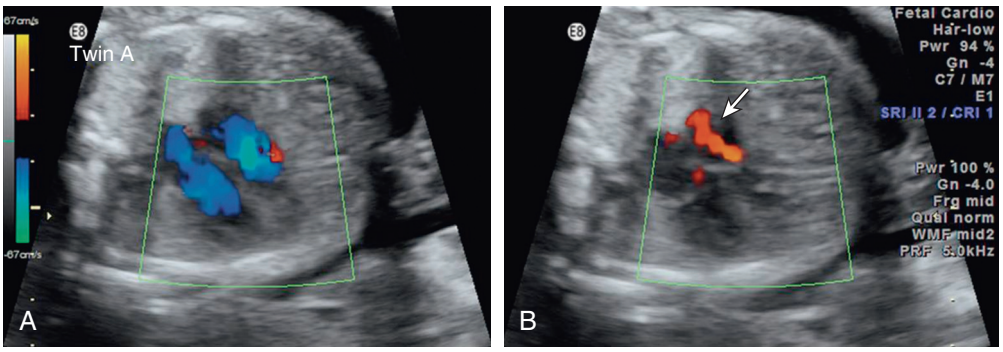

Fig. 162.8 Color flow imaging shows forward flow across the atrioventricular valves in diastole and (B) severe tricuspid regurgitation *(arrow)* during systole in a recipient twin.

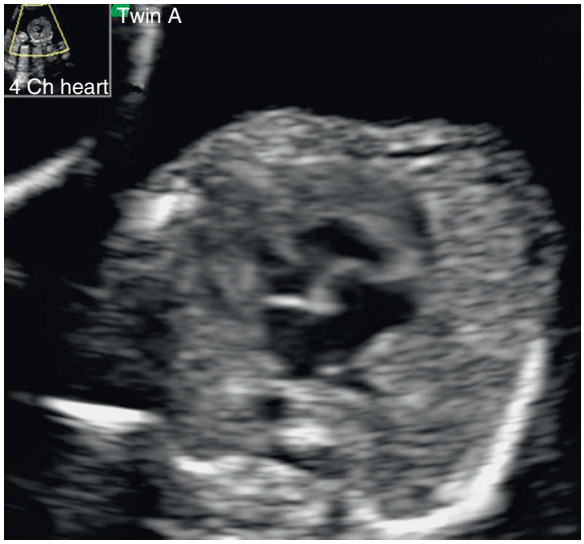

Fig. 162.9 Four-chamber view shows biventricular hypertrophy in a recipient twin.

A functional assessment of the fetal heart may be useful in identifying cases that would benefit from therapy and evaluating the response to treatment. The myocardial performance index, or Tei index, an index of global ventricular performance by Doppler velocimetry, is a measure of both systolic and diastolic function. Donor twins tend to have normal cardiac function, in contrast to recipient twins, which may develop ventricular hypertrophy (61%), atrioventricular valve regurgitation (21%), or abnormal right ventricular (50%) or left ventricular (58%) function.[21,22] Overall, two-thirds of recipient twins exhibit diastolic dysfunction, as indicated by a prolonged ventricular isovolumetric relaxation time, which is associated with an increased risk of fetal death.[21]

Despite the fact that fetal cardiac findings are not officially part of the TTTS staging system, many centers routinely perform fetal echocardiography in cases of TTTS and have observed worsening cardiac function in advanced stages.[22,23] However, cardiac dysfunction can be detected in 10% of early-stage TTTS.[22,23] The early diagnosis of recipient twin cardiomyopathy may identify MCDA gestations that would benefit from early intervention. Scoring systems of cardiac dysfunction have been developed, but their usefulness to predict outcome in TTTS is controversial.[23,24] Further evaluation of fetal echocardiography as a tool for decision making about intervention and management in TTTS is needed.

CLASSIC SIGNS

US signs of TTTS are used to establish the diagnosis and stage disease (see Table 162.1). Although many MCDA twins are referred to quaternary care centers for suspected TTTS, US findings on intake assessment are often inconsistent with the diagnosis. Although TTTS cases may manifest with varied findings, the polyhydramnios-oligohydramnios sequence should be considered the *sine qua non* when establishing a prenatal diagnosis of TTTS.[1,2]

Differential Diagnosis From Imaging Findings

Unequal placental sharing with or without discordant twin growth, discordant fetal anomalies resulting in oligohydramnios or polyhydramnios in one sac, or preterm premature rupture of membranes (PPROM) affecting one twin making it appear "stuck" should be considered when US findings suggest TTTS. Unequal placental sharing occurs in 20% of MCDA gestations and can coexist with TTTS, complicating the diagnosis and management of affected pregnancies. Abnormal umbilical artery waveforms in MCDA twins may represent placental insufficiency but may also be secondary to the presence of intertwin anastomoses and changes in vascular reactivity.

Synopsis of Treatment Options

PRENATAL

Various therapeutic interventions have been tried in TTTS, including intentional septostomy of the intervening membrane to equalize the fluid in both sacs, amnioreduction to remove excess fluid from the recipient sac, and laser photocoagulation of placental anastomoses. The three major randomized trials designed to evaluate the different treatment modalities for TTTS were all terminated before recruitment of the planned subject number.[25–27] A randomized trial of amnioreduction versus septostomy ended after an interim analysis found the rate of survival of at least one twin was similar between the two groups.[26] The Eurofetus trial, which randomly assigned patients to receive either laser photocoagulation or serial amnioreduction as first-line treatment for TTTS, was stopped after an interim analysis showed laser to be superior to amnioreduction with improved perinatal survival and fewer short-term neurologic abnormalities (Table 162.2).[25] A trial of amnioreduction versus fetoscopic laser photocoagulation for severe TTTS funded by the National Institute

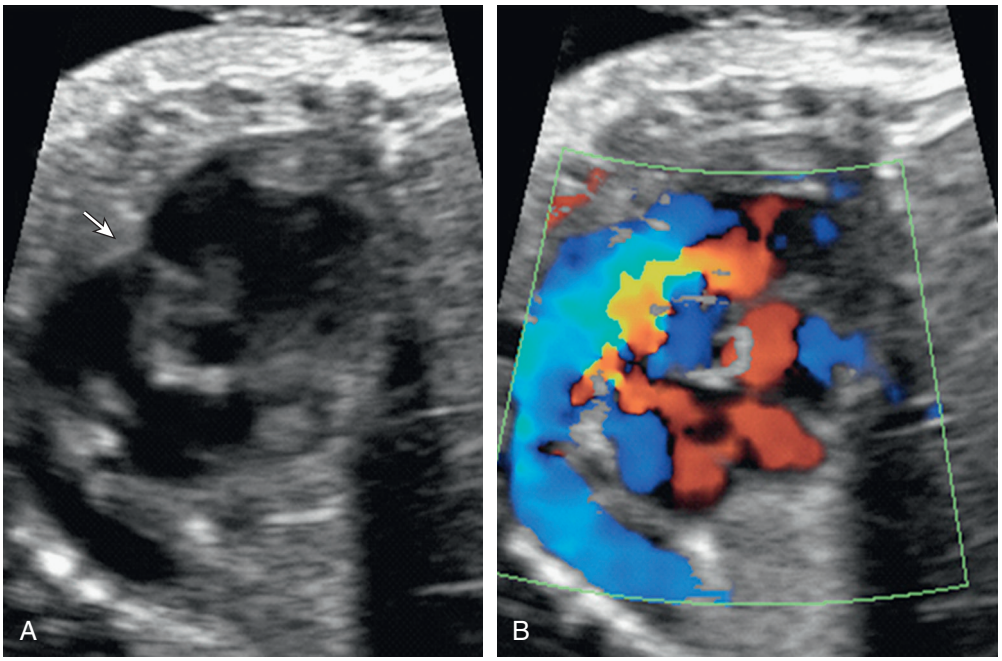

Fig. 162.10 (A) Short-axis view shows abnormal narrowing at the level of the pulmonic valve *(arrow)*. (B) Color flow Doppler shows bidirectional turbulent flow across this valve, suggestive of both pulmonic stenosis and regurgitation, which was confirmed after birth in this recipient twin.

TABLE 162.2 RANDOMIZED TRIAL OF LASER PHOTOCOAGULATION VERSUS AMNIOREDUCTION

	Laser (n = 72)	Amnioreduction (n = 70)	P Value
Gestational age at delivery (weeks)	33	29	.004
Survival of at least one twin to 28 days of age (%)	76	56	.009
Cystic periventricular leukomalacia at 6 months (%)	6	14	.02
Free of neurologic complications at 6 months (%)	52	31	.003
Normal neurologic development at 6 years (%)	82	70	.12

Data from Senat MV, Deprest J, Boulvain M, et al. Endoscopic laser surgery versus serial amnioreduction for severe twin-to-twin transfusion syndrome. *N Engl J Med* 351:136–144, 2004 and Chalouhi GE, Stirnemann JJ, Salomon L, et al. Specific complications of monochorionic twin pregnancies: twin-twin transfusion syndrome and twin reversed arterial perfusion sequence. *Semin Fetal Neonat Med* 15:349–356, 2010.

of Child Health and Development was also terminated early because of poor recruitment and a trend of increased neonatal mortality of recipient twins treated with laser.[27] Despite the limitations and early termination of these clinical trials, they represent the best data on which to judge the various treatments for TTTS. At the present time, fetoscopic laser photocoagulation of placental anastomoses is considered the best available approach for advanced disease in ongoing pregnancies.

The primary advantage of laser coagulation is that by destroying the aberrant placental anastomoses critical to TTTS pathophysiology, it directly interrupts the disease process. Selective coagulation of both deep AVA and superficial AAA and VVA is preferred over nonselective coagulation of all vessels crossing the separating membrane because it appears to lead to fewer procedure-related fetal losses. The goal of laser photocoagulation is to separate functionally the placenta into two regions, each supplying one of the twins. This unlinking of the circulations of the twins is often referred to as *dichorionization* of the monochorionic placenta. However, similar to all invasive procedures, laser has been associated with complications, which include PPROM, amniotic fluid leakage into the maternal peritoneal cavity, vaginal bleeding or abruption, and chorioamnionitis. Fetoscopy equipment is of larger gauge than the spinal needles used for amnioreduction or septostomy, and as expected, the risks of complications are threefold higher.[25] In the Eurofetus trial, the overall risk for most complications was about 3% except for PPROM, which occurred in 25% of patients undergoing laser compared with 18% in the amnioreduction group.[25] Despite these risks, fetoscopic laser photocoagulation appears to be the optimal treatment for stage III and IV TTTS.

Intentional septostomy has been abandoned as a treatment for TTTS because it offers no significant therapeutic advantage over other treatment modalities and could lead to disruption of the membrane and a functional monoamniotic situation, which increases perinatal risk.[26] Amnioreduction generally tends to be reserved for patients who decline laser coagulation, cannot travel to a center that performs the procedure, or are beyond the accepted treatment window of 26 weeks' gestation. However, amnioreduction may be the preferred approach after 26 weeks' gestation, particularly in cases with maternal respiratory distress or preterm contractions from polyhydramnios, when a delay in delivery is desired to administer prenatal steroids. Amnioreduction is also used as an adjunct to laser to reduce excess fluid in the recipient's sac at the completion of laser photocoagulation. In

cases complicated by severe unequal placental sharing with marked discordant growth and IUGR, major malformations affecting one twin, or evidence of brain injury either before or after laser, selective reduction by cord occlusion or termination of the entire pregnancy may be reasonable management choices for the patient and her partner before 24 weeks' gestation.

Although there is general consensus that laser is best for advanced stages of TTTS, the management of early-stage TTTS is controversial. Patients with stage I TTTS are usually managed expectantly because approximately three-fourths of cases remain stable or regress spontaneously.[6] Amnioreduction is reported to have fewer procedure-related complications than laser, and early TTTS may regress after this treatment in 20% to 30% of cases. However, serial amnioreduction may be necessary in TTTS, and repeated procedures increase the likelihood of complications such as PPROM, preterm labor, abruption, infection, and fetal death.[28] In addition, any invasive procedure before fetoscopy may decrease the success of laser owing to bleeding, chorioamnion separation, inadvertent septostomy, or membrane rupture. Adequate visualization of the vascular equator that separates the cotyledons of one twin from the other is critical for laser photocoagulation. In experienced hands, laser may be the treatment of choice for all stages of TTTS because stage I TTTS progresses to more advanced TTTS in 10% to 30% of cases and laser can be curative, usually after a single procedure.[6] In a metaanalysis of stage I TTTS treated with laser photocoagulation, survival of both twins occurred in 45 of 60 twin pairs (75%), which is similar to other management strategies.[29] Further studies are ongoing to determine the optimal management of early-stage TTTS, including an international stage I TTTS randomized trial.

POSTNATAL

MCDA pregnancies are at increased risk of fetal demise and related cerebral injury, which warrants close prenatal surveillance and consideration of early delivery.[30] Many experts recommend delivery of MCDA twins without recognized complications at 34 to 36 weeks' gestation with earlier delivery in the setting of TTTS based on the results of prenatal surveillance and response to interventions.[30,31] Although delaying delivery until 34 to 36 weeks' gestation may be reasonable after successful laser coagulation, prenatal testing is recommended because it is well documented that not all anastomoses are ablated at the time of laser. Residual anastomoses, either missed or revascularized after laser, have been observed in one-third of cases. Placental casting has also shown the presence of deep, atypical AVA beneath the chorionic plate that would not be visible by fetoscopy.[32] Failure to coagulate all AVA can lead to persistent, recurrent, or reversed TTTS.

Persistent or recurrent TTTS has been reported in 14% of cases after laser, and reversed TTTS, with the recipient becoming anemic and the donor polycythemic, has been reported in 13% of cases.[33,34] Although twin anemia-polycythemia sequence (TAPS) can occur spontaneously in MCDA gestations, it is a known iatrogenic complication of laser and is recognized by discordant peak systolic velocities of the middle cerebral arteries. The potential for TAPS and recurrent TTTS form the therapeutic basis for photocoagulation along the vascular equator (the Solomon technique) before the completion of laser therapy, with a recent randomized trial demonstrating efficacy of this technique.[35] Weekly surveillance for these complications after laser photocoagulation is recommended. In cases of persistent, recurrent, or reversed TTTS, repeat laser, amnioreduction, fetal transfusion, selective reduction, or early delivery may be indicated based on gestational age and condition of the twins. A consensus can be difficult to reach; however, the median gestational age at delivery in the major trials and case series of laser-treated TTTS was 33 to 34 weeks' gestation.[24,26,34,36–38] Because of the potential for complications, routine early delivery is recommended for most cases of TTS after the administration of prenatal steroids.

Although the risk of membrane rupture may be only 10% in experienced centers, there is 10% to 30% procedure-associated fetal loss with laser.[24,36,39] Both double and single fetal deaths are common complications in advanced stages of TTTS treated with laser (Table 162.3). In a multicenter observational study, fetal demise occurred in 23.8% of donors and in 16.5% of recipients after laser.[43] Survival of one or two fetuses after laser may depend on coexisting unequal placental sharing that may not be visible before or even at the time of fetoscopy. Preoperative IUGR with absent or reversed end-diastolic flow in the umbilical artery has a 20% to 40% risk of postoperative donor death.[43] Recipient twin demise after laser is more common when the recipient has IUGR, reversed a-wave in the ductus venosus, or hydrops.[43]

After successful laser photocoagulation, the amniotic fluid volume of recipient twins tends to normalize in about 4 weeks. Pulmonic valve abnormalities, affecting about 20% of recipient twins with advanced TTTS, have also been observed to improve after laser, with less than one-third of surviving twins having persistent pulmonic valve defects requiring treatment after birth. Overall, 87% of recipient twins who survived after laser were reported to have normal echocardiograms at a median age slightly younger than 2 years.[44] A 10-year follow-up study showed that both donor and recipient twins had normal cardiac structure and function.[45]

Quality data to determine stage-specific survival rates or well-defined neurologic outcome for TTTS after laser are limited. The Eurofetus trial reported an 86% survival rate of at least one fetus for combined stage I and II disease treated with laser, decreasing to 66% for combined stage III and IV.[25] In general, survival rates of 50% to 70% can be expected after fetoscopic laser for the treatment of TTTS.[28] Two metaanalyses supported improved perinatal survival (odds ratio, 2.04; 95% confidence interval [CI], 1.52–2.76) and decreased short-term neurologic morbidity (odds ratio 0.20; 95% CI, 0.12–0.33) with laser compared with amnioreduction.[28,46] However, twin death or neurologic handicap was reported as the outcome in two-thirds of laser-treated TTTS.[47] Although procedure-related fetal loss is a recognized complication of fetoscopic laser photocoagulation, survival with neurologic handicap may be the most serious long-term sequelae of TTTS with or without treatment. A review estimated that only half of TTTS cases treated with laser result in two neurologically intact survivors.[47]

Although gestational age at delivery is a significant risk factor for adverse neurologic outcome, initial studies implied the outlook may be better for cases managed with laser photocoagulation.[48] Infants in the laser group of the Eurofetus trial had a lower incidence of cystic periventricular leukomalacia and were more likely to be free of neurologic complications at 6 months of age compared with infants treated with amnioreduction (see Table 162.2).[49] However, a 6-year follow-up evaluation of 120 children from this trial found no significant difference in major neurologic handicap in TTTS survivors treated with laser versus amnioreduction.[49] Another more recent study reported no difference in neurodevelopmental outcome between donors and recipients

TABLE 162.3 PERINATAL OUTCOMES OF TWIN-TWIN TRANSFUSION SYNDROME PREGNANCIES TREATED WITH FETOSCOPIC LASER PHOTOCOAGULATION

	Ville et al., 1998[40]	Hecher et al., 2000[36]	Yamamoto et al., 2005[41]	Huber et al., 2006[37]	Quintero et al., 2007[38]	Morris et al., 2010[42]	Totals
No. (*N*)	132	200	175	200	137	164	1008
Stage I, % (*n*/*N*)	0	0	9.7% (17/175)	14.5% (29/200)	16.1% (22/137)	0	6.7% (68/1008)
Stage II, % (*n*/*N*)	78.0% (103/132)	100%[a] (200/200)	48% (84/175)	40.5% (81/200)	28.5% (39/137)	4.8% (8/164)	51.1% (515/1008)
Stage III, % (*n*/*N*)	12.1% (16/132)	Doppler not reported	37.5% (66/175)	40% (80/200)	43.8% (60/137)	78.7% (129/164)	34.8% (351/1008)
Stage IV, % (*n*/*N*)	9.9% (13/132)	Hydrops not reported	4% (8/175)	5% (10/200)	11.7% (16/137)	16.5% (27/164)	7.3% (74/1008)
Median GA at Delivery (weeks)	Not reported	34.4	Not reported	34.3	33.7	33.2	
Pregnancies with Two Survivors, % (*n*/*N*)	36% (47/132)	50% (100/200)	35% (61/175)	59% (119/200)	73.7% (101/137)	38% (63/164)	48.7% (491/1008)
Pregnancies with One Survivor, % (*n*/*N*)	38% (50/132)	30% (61/200)	38% (67/175)	24% (48/200)	16.8% (23/137)	46% (76/164)	32.2% (352/1008)
Pregnancies with Zero Survivors, % (*n*/*N*)	27% (35/132)	20% (39/200)	27% (47/175)	17% (33/200)	9.5% (13/137)	15% (25/164)	19.1% (192/1008)
Neonatal Death, % (*n*/*N*)	4.5% (12/264)	3.8% (15/400)	5.4% (19/350)	4.8% (19/400)	11.3% (31/274)	6.4% (21/328)	5.8% (117/2016)
Overall Perinatal Survival, % (*n*/*N*)	54.5% (144/264)	65.3% (261/400)	54% (189/350)	71.5% (286/400)	82.5% (224/275)	61.6% (202/328)	64.8% (1306/2016)

GA, Gestational age.
[a]All cases met criteria for stage II and classified as such because Doppler results and hydrops not reported.

treated with laser or amnioreduction, although the investigators observed a trend of increased major neurologic impairment in survivors after amnioreduction compared with survivors treated with laser (9.5% versus 4.6%).[50]

The abnormal neurologic outcome in some survivors of TTTS may be related more to demise of a co-twin than the actual modality used to treat the condition.[51] It is well recognized that death of one twin of a monochorionic pair can result in periventricular leukomalacia, intraventricular hemorrhage, hydrocephaly, and porencephaly in the surviving twin. Severe brain lesions, including cystic periventricular leukomalacia or grade 3 and 4 intraventricular hemorrhage, affect 10% of MCDA twins with TTTS compared with 2% of MCDA twins without TTTS.[52] Other risk factors for neurodevelopmental impairment in TTTS survivors are advanced gestational age at laser surgery, low birth weight, and severe TTTS.[48]

Both US and MRI are used to evaluate abnormalities of the fetal brain. In general, fetal MRI is optimal in the third trimester to evaluate cortical development and exclude ischemic injury. After a single twin demise in MCDA gestation, neurologic injury may be detected by US in 1 to 2 weeks, whereas ischemic injury can be detected 1 to 2 days after demise of one twin using MRI.[53,54] Routine neuroimaging is recommended in TTTS before and after therapeutic interventions or in cases complicated by single twin demise.[39] Overall, rates of long-term neurologic sequelae in early-stage TTTS are reported to be low (≤3% with rates of about 10% to 20% in survivors of advanced TTTS treated with laser coagulation) (Chapter 116, Table 116.1).[48,55] The risk of abnormal neurodevelopment seems to be similar in donor and recipient survivors and not drastically different between survivors treated with laser or amnioreduction. Follow-up of all survivors of TTTS is critical to determine accurate long-term outcomes and stage-specific rates of neurologic handicap of these complicated MCDA pregnancies.

WHAT THE REFERRING PHYSICIAN NEEDS TO KNOW

Twins with MCDA placentation are at risk for TTTS and should be monitored with serial US examinations beginning early in the second trimester and continuing until delivery. Screening for TTTS every 2 weeks is recommended with early referral to a center that performs laser photocoagulation when TTTS is suspected or diagnosed. Although there are many US markers that may increase the likelihood of TTTS, oligohydramnios-polyhydramnios is required to establish the diagnosis. Ideally, referral should occur before any invasive procedure is performed because amniocentesis or amnioreduction may compromise subsequent fetoscopy and laser therapy. Even after successful laser photocoagulation, close surveillance of twin growth and well-being is required because these pregnancies remain at risk for adverse outcomes. The exact timing of delivery depends on numerous factors, but in most cases, we recommend delivery at 34 weeks' gestation after the administration of prenatal steroids.

KEY POINTS

- All MCDA twin pregnancies should be monitored for TTTS, with serial US examinations every other week beginning in the second trimester.
- Oligohydramnios-polyhydramnios is essential to establish the diagnosis of TTTS.
- Screening for congenital heart disease is warranted because TTTS is a risk factor for both structural and functional heart abnormalities.
- Stage I TTTS can be managed conservatively, but consultation or referral to a center that performs laser photocoagulation should be considered whenever possible before other invasive interventions are performed.
- Before 26 weeks' gestation, laser photocoagulation is the optimal treatment for advanced stages of TTTS with expected outcome of two surviving twins in about 50% of cases, one surviving twin in 30% of cases, and no survivors in 20% of cases.

- Neuroimaging should be considered in TTTS owing to the 10% to 20% risk of neurologic handicap in survivors regardless of the treatment approach.
- We recommend delivery at 34 weeks' gestation for TTTS after the administration of prenatal steroids.

SUGGESTED READINGS

Chalouhi GE, Stirnemann JJ, Salomon L, et al. Specific complications of monochorionic twin pregnancies: twin-twin transfusion syndrome and twin reversed arterial perfusion sequence. *Semin Fetal Neonat Med*. 2010;15:349-356.

Fisk NM, Duncombe GJ, Sullivan MH. The basic and clinical science of twin-twin transfusion syndrome. *Placenta*. 2009;30:379-390.

Graef C, Ellenrieder B, Hecher K, et al. Long-term neurodevelopment outcome of 167 children after intrauterine laser treatment for severe twin-twin transfusion syndrome. *Am J Obstet Gynecol*. 2006;194:303-308.

Jain V, Fisk N. The twin-twin transfusion syndrome. *Clin Obstet Gynecol*. 2004;47:181-202.

Lewi L, Gucciardo L, Van Mieghem T, et al. Monochorionic diamniotic twin pregnancies: natural history and risk stratification. *Fetal Diagn Ther*. 2010;27:121-133.

Slaghekke F, Lopriore E, Lewi L, et al. Fetoscopic laser coagulation of the vascular equator versus selective coagulation for twin-to-twin transfusion syndrome: an open-label randomized controlled trial. *Lancet*. 2014;383:2144-2151.

Society for Maternal-Fetal Medicine, Simpson LL. Twin-twin transfusion syndrome. *Am J Obstet Gynecol*. 2013;208(1):3-18.

Sutcliffe AG, Sebire NJ, Pigott AJ, et al. Outcome for children born after in utero laser ablation therapy for severe twin-to-twin transfusion syndrome. *BJOG*. 2001;108:1246-1250.



All references available online at
www.expertconsult.com

REFERENCES

1. Society for Maternal-Fetal Medicine, Simpson LL. Twin-twin transfusion syndrome. *Am J Obstet Gynecol*. 2013;208(1):3-18.
2. Quintero RA, Morales WJ, Allen MH, et al. Staging of twin-twin transfusion syndrome. *J Perinatol*. 1999;19:550-555.
3. Bajoria R, Wigglesworth J, Fisk NM. Angioarchitecture of monochorionic placentas in relation to the twin-twin transfusion syndrome. *Am J Obstet Gynecol*. 1995;172:856-863.
4. Berghella V, Kaufmann M. Natural history of twin-twin transfusion syndrome. *J Reprod Med*. 2001;46:480-484.
5. Ong SS, Zamora J, Khan KS, et al. Prognosis for the co-twin following single-twin death: a systematic review. *BJOG*. 2006;113:992-998.
6. O'Donoghue K, Cartwright E, Galea P, et al. Stage I twin-twin transfusion syndrome: rates of progression and regression in relation to outcome. *Ultrasound Obstet Gynecol*. 2007;30:958-964.
7. De Paepe ME, Shapiro S, Greco D, et al. Placental markers of twin-to-twin transfusion syndrome in diamniotic-monochorionic twins: a morphometric analysis of deep artery-to-vein anastomoses. *Placenta*. 2010;31:269-276.
8. Mahieu-Caputo D, Dommergues M, Delezoide AL, et al. Twin-to-twin transfusion syndrome: role of the fetal renin-angiotensin system. *Am J Pathol*. 2000;156:629-636.
9. Fisk NM, Duncombe GJ, Sullivan MH. The basic and clinical science of twin-twin transfusion syndrome. *Placenta*. 2009;30:379-390.
10. Galea P, Barigye O, Wee L, et al. The placenta contributes to activation of the renin-angiotensin system in twin-twin transfusion syndrome. *Placenta*. 2008;29:734-742.
11. Sueters M, Middeldorp JM, Lopriore E, et al. Timely diagnosis of twin-to-twin transfusion syndrome in monochorionic twin pregnancies by biweekly sonography combined with patient instruction to report onset of symptoms. *Ultrasound Obstet Gynecol*. 2006;28:659-664.
12. O'Donoghue K, Cartwright E, Galea P, et al. Stage I twin-twin transfusion syndrome: rates of progression and regression in relation to outcome. *Ultrasound Obstet Gynecol*. 2007;30:958-964.
13. Kagan KO, Gazzoni A, Sepulveda-Gonzalez G, et al. Discordance in nuchal translucency thickness in the prediction of severe twin-to-twin transfusion syndrome. *Ultrasound Obstet Gynecol*. 2007;29:527-532.
14. Sebire NJ, D'Ercole C, Hughes K, et al. Increased nuchal translucency thickness at 10-14 weeks of gestation as a predictor of severe twin-to-twin transfusion syndrome. *Ultrasound Obstet Gynecol*. 1997;10:86-89.
15. Maiz N, Staboulidou I, Leal AM, et al. Ductus venosus Doppler at 11 to 13 weeks of gestation in the prediction of outcome in twin pregnancies. *Obstet Gynecol*. 2009;113:860-865.
16. Sebire NJ, Souka A, Skentou H, et al. Early prediction of severe twin-to-twin transfusion syndrome. *Hum Reprod*. 2000;15:2008-2010.
17. Taylor MJ, Denbow ML, Tanawattanacharoen S, et al. Doppler detection of arterio-arterial anastomoses in monochorionic twins: feasibility and clinical application. *Hum Reprod*. 2000;15:1632-1636.
18. Huber A, Diehl W, Zikulnig L, et al. Perinatal outcome in monochorionic twin pregnancies complicated by amniotic fluid discordance without severe twin-twin transfusion syndrome. *Ultrasound Obstet Gynecol*. 2006;27:48-52.
19. Kline-Fath BM, Calvo-Garcia MA, O'Hara SM, et al. Twin-twin transfusion syndrome: cerebral ischemia is not the only fetal MR imaging finding. *Pediatr Radiol*. 2007;37:47-56.
20. Bahtiyar MO, Dulay AT, Weeks BP, et al. Prevalence of congenital heart defects in monochorionic/diamniotic twin gestations: a systemic literature review. *J Ultrasound Med*. 2007;26:1491-1498.
21. Barrea C, Alkazaleh F, Ryan G, et al. Prenatal cardiovascular manifestations in the twin-to-twin transfusion syndrome recipients and the impact of therapeutic amnioreduction. *Am J Obstet*. 2005;192:892-902.
22. Michelfelder E, Gottliebson W, Border W, et al. Early manifestations and spectrum of recipient twin cardiomyopathy in twin-twin transfusion syndrome: relation to Quintero stage. *Ultrasound Obstet Gynecol*. 2007;30:965-971.
23. Rychik J, Tian Z, Bebbington M, et al. The twin-twin transfusion syndrome: spectrum of cardiovascular abnormality and development of a cardiovascular score to assess severity of disease. *Am J Obstet Gynecol*. 2007;197:392.e1-392.e8.
24. Stirnemann JJ, Nasr B, Proulx F, et al. Evaluation of the CHOP cardiovascular score as a prognostic predictor of outcome in twin-twin transfusion syndrome after laser coagulation of placental vessels in a prospective cohort. *Ultrasound Obstet Gynecol*. 2010;36:52-57.
25. Senat MV, Deprest J, Boulvain M, et al. Endoscopic laser surgery versus serial amnioreduction for severe twin-to-twin transfusion syndrome. *N Engl J Med*. 2004;351:136-144.
26. Moise KJ, Dorman K, Lamvu G, et al. A randomized trial of amnioreduction versus septostomy in the treatment of twin-twin transfusion syndrome. *Am J Obstet Gynecol*. 2005;193:701-707.
27. Crombleholme TM, Shera D, Lee H, et al. A prospective, randomized, multicenter trial of amnioreduction vs selective fetoscopic laser photocoagulation for the treatment of severe twin-twin transfusion syndrome. *Am J Obstet Gynecol*. 2007;197:396.e1-396.e9.
28. Roberts D, Gates S, Kilby M, et al. Interventions for the treatment of twin-twin transfusion syndrome: a Cochrane review. *Ultrasound Obstet Gynecol*. 2008;31:701-711.
29. Rossi AC, D'Addario V. The efficacy of Quintero staging system to assess severity of twin-twin transfusion syndrome treated with laser therapy: a systematic review with meta-analysis. *Am J Perinatol*. 2009;26:537-544.
30. Lee YM, Wylie BJ, Simpson LL, et al. Twin chorionicity and the risk of stillbirth. *Obstet Gynecol*. 2008;111:301-308.
31. Cleary-Goldman J, D'Alton ME. Uncomplicated monochorionic diamniotic twins and the timing of delivery. *PLoS Med*. 2005;2:e180.
32. Wee LY, Taylor M, Watkins N, et al. Characterization of deep arterio-venous anastomoses within monochorionic placentae by vascular casting. *Placenta*. 2005;26:19-24.
33. Robyr R, Lewi L, Salomon LJ, et al. Prevalence and management of late fetal complications following successful selective laser coagulation of chorionic plate anastomoses in twin-to-twin transfusion syndrome. *Am J Obstet Gynecol*. 2006;194:796-803.
34. Yamamoto M, Ville Y. Recent findings on laser treatment of twin to twin transfusion syndrome. *Curr Opin Obstet Gynecol*. 2006;18:89-92.
35. Slaghekke F, Lopriore E, Lewi L, et al. Fetoscopic laser coagulation of the vascular equator versus selective coagulation for twin-to-twin transfusion syndrome: an open-label randomized controlled trial. *Lancet*. 2014;383:2144-2151.
36. Hecher K, Diehl W, Zikulnig L, et al. Endoscopic laser coagulation of placental anastomoses in 200 pregnancies with severe midtrimester twin-to-twin transfusion syndrome. *Eur J Obstet Gynecol Reprod Biol*. 2000;92:135-139.
37. Huber A, Diehl W, Bregenzer T, et al. Stage-related outcome in twin-twin transfusion syndrome treated by fetoscopic laser coagulation. *Obstet Gynecol*. 2006;108:333-337.
38. Quintero RA, Ishii K, Chmait RH, et al. Sequential selective laser photocoagulation of communicating vessels in twin-twin transfusion syndrome. *J Matern Fetal Neonatal Med*. 2007;20:763-768.
39. Cavicchioni O, Yamamoto M, Robyr R, et al. Intrauterine fetal demise following laser treatment in twin-to-twin transfusion syndrome. *BJOG*. 2006;113:590-594.
40. Ville Y, Hecher K, Gagnon A, et al. Endoscopic laser coagulation in the management of severe twin-to-twin transfusion syndrome. *BJOG*. 1998;105:446-453.
41. Yamamoto M, Murr L, Robyr R, et al. Incidence and impact of perioperative complications in 175 fetoscopy-guided laser coagulations of chorionic plate anastomoses in feto-fetal transfusion syndrome before 26 weeks gestation. *Obstet Gynecol*. 2005;193:796-803.
42. Morris RK, Selman TJ, Harbidge A, et al. Fetoscopic laser coagulation for severe twin-to-twin transfusion syndrome: factors influencing perinatal outcome, learning curve of the procedure and lessons for new centres. *BJOG*. 2010;117:1350-1357.
43. Skupski DW, Luks FI, Walker M, North American Fetal Therapy Network (NAFTNet), et al. Preoperative predictors of death in twin-to-twin transfusion syndrome treated with laser ablation of placental anastomoses. *Am J Obstet Gynecol*. 2010;203:388.e1-388.e11.
44. Herberg U, Gross W, Bartmann P, et al. Long-term cardiac follow-up of severe twin to twin transfusion syndrome after intrauterine laser coagulation. *Heart*. 2006;92:95-100.
45. Halvorsen CP, Bilock SL, Pilo C, et al. Childhood cardiac function after twin-to-twin transfusion syndrome—a 10-year follow-up. *Acta Paediatr*. 2009;98:1468-1474.
46. Rossi AC, D'Addario V. Laser therapy and serial amnioreduction as treatment for twin-twin transfusion syndrome: a metaanalysis and review of literature. *Am J Obstet Gynecol*. 2008;198:147-152.
47. Fisk NM, Galea P. Twin-twin transfusion syndrome—as good as it gets? *N Engl J Med*. 2004;351:182-184.
48. Lopriore E, Ortibus E, Acosta-Rojas R, et al. Risk factors for neurodevelopmental impairment in twin-twin transfusion syndrome treated with fetoscopic laser surgery. *Obstet Gynecol*. 2009;113:361-366.
49. Chalouhi GE, Stirnemann JJ, Salomon L, et al. Specific complications of monochorionic twin pregnancies: twin-twin transfusion syndrome and twin reversed arterial perfusion sequence. *Semin Fetal Neonat Med*. 2010;15:349-356.

50. Lenclen R, Ciarlo G, Paupe A, et al. Neurodevelopmental outcome at 2 years in children born preterm treated by amnioreduction or fetoscopic laser surgery for twin-to-twin transfusion syndrome: comparison with dichorionic twins. *Am J Obstet Gynecol*. 2009;291.e1-291.e5.
51. Banek CS, Hecher K, Hackeloer BJ, et al. Long-term neurodevelopmental outcome after intrauterine laser treatment for severe twin-twin transfusion syndrome. *Am J Obstet Gynecol*. 2003;188:876-880.
52. Lopriore E, van Wezel-Meijler G, Middeldorp JM, et al. Incidence, origin, and character of cerebral injury in twin-to-twin transfusion syndrome treated with fetoscopic laser surgery. *Am J Obstet Gynecol*. 2006;194: 1215-1220.
53. Simonazzi G, Segata M, Ghi T, et al. Accurate neurosonographic prediction of brain injury in the surviving fetus after the death of a monochorionic cotwin. *Ultrasound Obstet Gynecol*. 2006;27:517-521.
54. Righini A, Kustermann A, Parazzini C, et al. Diffusion-weighted magnetic resonance imaging of acute hypoxic-ischemic cerebral lesions in the survivor of a monochorionic twin pregnancy: case report. *Ultrasound Obstet Gynecol*. 2007;29:453-456.
55. Stamilio DM, Fraser WD, Moore TR. Twin-twin transfusion syndrome: an ethics-based and evidence-based argument for clinical research. *Am J Obstet Gynecol*. 2010;203:3-16.

To access the videos in this chapter, scan this QR code or visit expertconsult.com

163 Twin Reversed Arterial Perfusion Sequence

KOBINA GHARTEY | RUSSELL S. MILLER | LYNN L. SIMPSON

Introduction

Twin reversed arterial perfusion (TRAP) sequence is a rare complication specific to monochorionic twin pregnancies. As a result of early vascular disruption occurring during embryogenesis, a dysmorphic acardiac twin receives circulatory support from a pump twin via aberrant placental arterioarterial anastomoses. Because the acardiac twin is entirely dependent on perfusion from the pump twin, the pump twin is at risk of hemodynamic compromise.

Originally described as *acardia,* the condition was classified further according to the overall appearance of the acardiac fetus on postmortem and radiographic evaluation.[1] The most common presentation, acardius acephalus, consists of a well-formed fetal pelvis and lower limbs without a head or skull and usually without thoracic organs and arms (Fig. 163.1). However, this classification system has been supplanted by the broader, albeit less descriptive, TRAP acronym.[1]

Disease

PREVALENCE AND EPIDEMIOLOGY

The estimated occurrence of TRAP sequence is approximately 1:35,000 pregnancies, including 1:100 monozygotic twins and 1:30 monozygotic triplets.[2] Most (74%) TRAP presentations occur within monochorionic diamniotic pregnancies, with the remaining cases monoamniotic.[3] Although it is generally accepted that acardia is unique to monochorionic pregnancies, there are two reported cases within dichorionic twin pregnancies.[4,5]

ETIOLOGY AND PATHOPHYSIOLOGY

Theories exist to explain disease pathogenesis; however, the precise etiology of TRAP is unknown. The most widely accepted theory is that the condition is the result of abnormal arterioarterial anastomoses established early in embryogenesis between twin fetuses sharing a single placenta.[1] The acardiac mass lacks direct placental perfusion and is dependent on a retrograde arterial supply of relatively deoxygenated blood from the pump twin. Asymmetric circulation favoring caudal aspects of the acardiac fetus and tissue hypoxia are believed to contribute to resultant fetal dysmorphology. Excess circulatory workload can prove detrimental to the recipient twin, which is at increased risk of high-output cardiac failure. An alternative, although less widely supported, hypothesis for disease pathogenesis involves a primary defect in cardiac embryogenesis, which secondarily permits retrograde blood flow within the acardiac twin.[6]

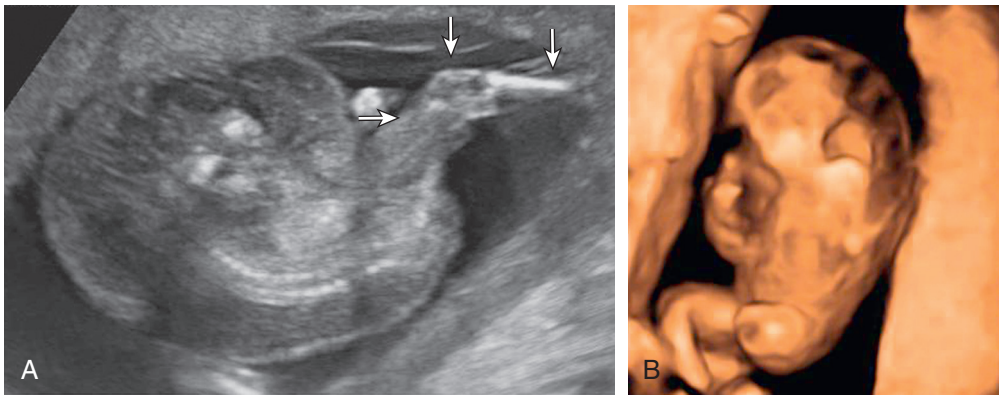

Fig. 163.1 (A) A 16-week, 2-day, acardiac twin within a monochorionic-diamniotic twin reversed arterial perfusion (TRAP) pair. *Arrows* demonstrate a lower extremity. (B) Three-dimensional view of a 15-week, 1-day acardiac twin within a monochorionic-monoamniotic TRAP pair.

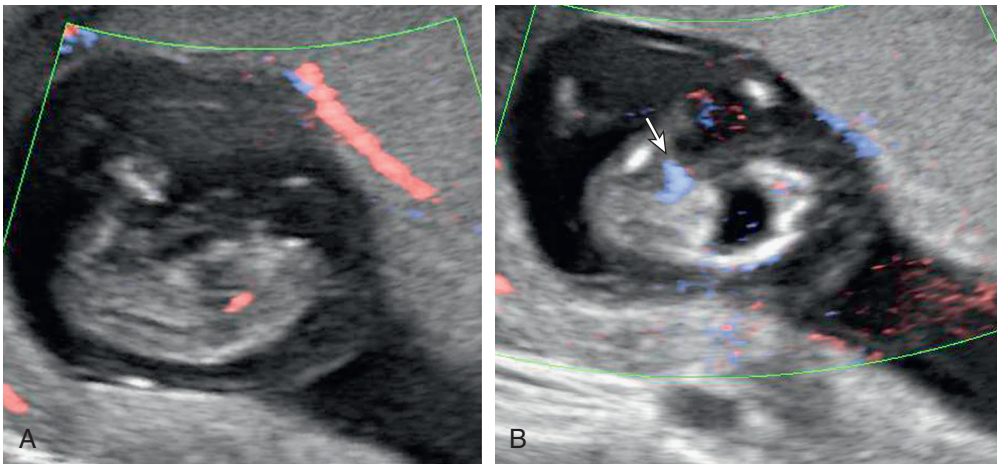

Fig. 163.2 A 12-week acardiac twin within a twin reversed aterial perfusion (TRAP) sequence presentation, with (A) color Doppler demonstrating a rudimentary cardiac structure and (B) *arrow* demonstrating retrograde arterial perfusion of the acardiac mass upon color Doppler study.

MANIFESTATIONS OF DISEASE

Clinical Presentation

TRAP presentation includes a normal-appearing (pump) fetus and a grossly abnormal (acardiac) fetus in the setting of a monochorionic pregnancy. Although the acardiac fetus may possess some discernible features, it either lacks a heart or possesses a rudimentary cardiac structure. In some cases, the acardiac twin may appear only as an amorphous tissue mass. There is a predisposition toward acardiac twin deformities of the head, trunk, and upper extremities. Other common findings within the acardiac mass include subcutaneous edema, cystic inclusions within the trunk, and general hydropic changes (Videos 163.1 and 163.2).

Imaging Technique and Findings

Ultrasound. Although ultrasound (US) diagnosis of a TRAP sequence usually involves showing absent cardiac activity within an acardiac fetal mass that possesses reversed umbilical artery blood flow on Doppler study, the identification of acardiac fetal cardiac activity does not altogether preclude this diagnosis. Cardiac activity in the recipient is infrequently observed, and may be the result of rudimentary heart function or transmitted arterial pulsations from the pump twin (Fig. 163.2).

Because of excess circulatory demands on the pump twin, it is prone to the development of high-output cardiac failure. Given that there is no chance of *ex utero* survival for the acardiac fetus, this potential complication is of paramount importance when managing TRAP presentations. US evidence of cardiovascular deterioration or frank cardiac failure in the pump twin includes the detection of polyhydramnios, cardiomegaly or cardiac dysfunction, abnormal fetal fluid collections, hydrops, and abnormalities of the ductus venosus Doppler waveform.

In addition to changes reflective of circulatory failure, the pump twin is at increased risk for major anatomic malformations and aneuploidy. Review of case reports with known karyotype information of pump and acardiac fetuses revealed the following abnormalities: monosomy, trisomy, deletions, mosaicism, and polyploidy, with almost 9% of pump fetuses being karyotypically abnormal.[3] In addition to comprehensive fetal anatomic surveys, invasive genetic testing for karyotype determination is recommended. Fetal echocardiography is also recommended in the evaluation of TRAP pregnancies, owing to the potential for pump twin cardiac dysfunction but also because of a known increase in risk of cardiovascular malformation in monochorionic twins.

Abnormalities of the umbilical cord may be present in both twins. A single umbilical artery is detected in approximately

two-thirds of cases.[3] Reports exist of TRAP pregnancies involving a conjoined cord, such that the umbilical cord of the acardiac twin directly anastomoses with the pump twin umbilical cord without any interface along the placental surface.[7]

As a result of gross deformity, conventional biometric parameters are not applicable when assessing acardiac fetuses. Alternative formulas have been devised to estimate weight of the acardiac fetus; however, because of the protean morphologies of acardiac twins, the accuracy and generalizability of these formulas are unproven. An example of a commonly used formula is: weight (g) = 1.2 × length^2 (cm) − 1.66 × length (cm), where the length used is the longest linear measurement (Fig. 163.3).[8]

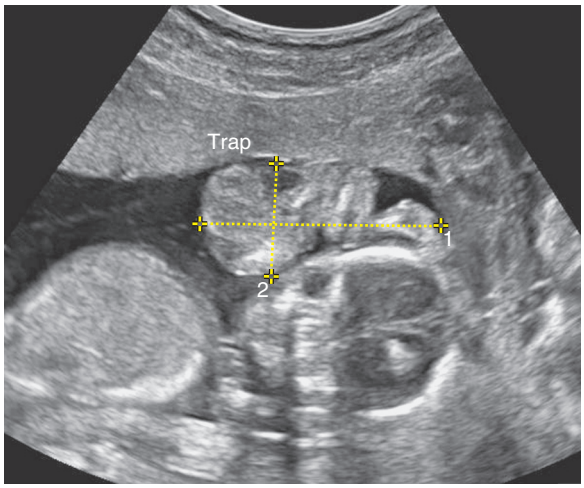

Fig. 163.3 A 15-week, 5-day triplet gestation with monochorionic-monoamniotic twin reversed arterial perfusion pair.

Assessment of acardiac twin size is an important consideration when evaluating pregnancies with TRAP sequence because elevations in acardiac-to-pump twin weight ratio appear to parallel increases in cardiovascular workload imposed on the pump twin as it supports a co-twin mass in addition to itself. Analyzing a series of 49 TRAP cases, investigators revealed a significant association between acardiac-to-pump twin weight ratios and perinatal outcomes.[8] Applying an acardiac-to-pump twin ratio cutoff of greater than 0.7, a positive finding was associated with significantly greater rates of preterm delivery (90% versus 75%), polyhydramnios (40% versus 30%), and pump twin congestive heart failure (30% versus 10%).[8]

Doppler velocimetry study also plays a role in the comprehensive evaluation of TRAP sequence. Small series suggested that the difference in the umbilical artery Doppler resistive index value between the pump twin and acardiac twin may correspond to pregnancy outcome. Findings of a decreased resistive index within the acardiac twin compared with the pump twin portended a poor outcome.[7] Ductus venosus Doppler waveforms may also be abnormal in the pump twin with evolving or frank heart failure.

CLASSIC SIGNS

Color Doppler demonstration of seemingly paradoxical arterial blood flow toward, rather than away from, the acardiac twin; this reversal of arterial blood flow is widely accepted as a pathognomonic finding (Fig. 163.4).

Differential Diagnosis From Imaging Findings

1. An acardiac twin can be mistaken for an intrauterine fetal demise in the setting of a twin gestation.[2] Although the absence

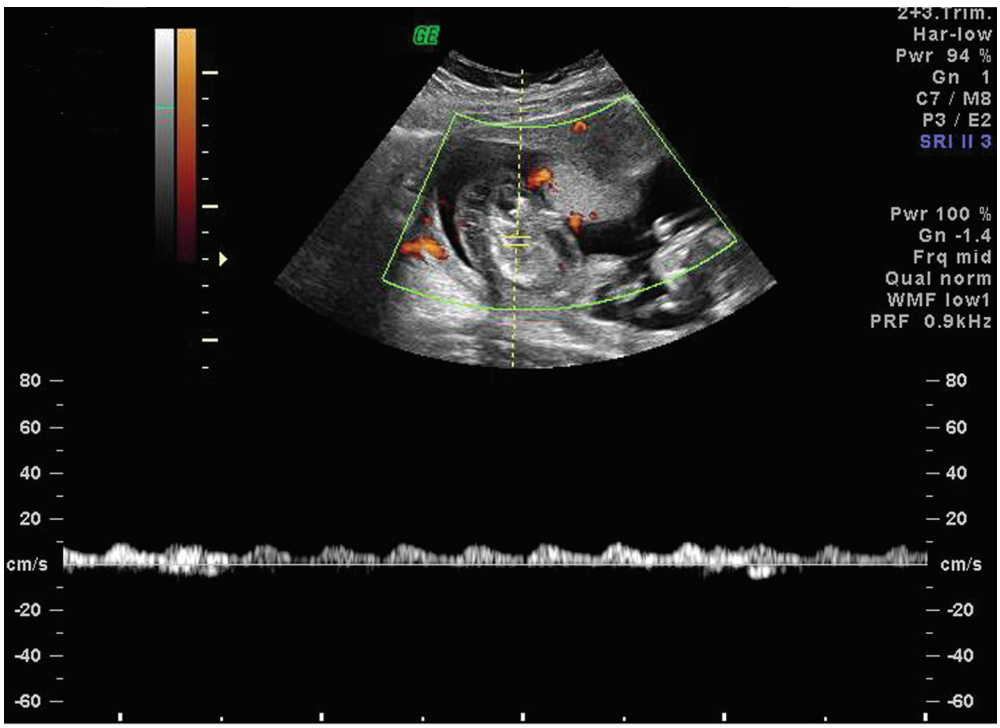

Fig. 163.4 A 15-week, 1-day acardiac twin within a monochorionic-monoamniotic twin reversed arterial perfusion pair with Doppler showing acardiac arterial blood flow.

of cardiac activity is compatible with either diagnosis, continued growth of a grossly dysmorphic fetal mass over interval evaluations helps to distinguish between the two diagnoses; color Doppler study is confirmatory.

2. With a presentation of an acardiac amorphous mass lacking any discernible fetal structures, the alternative diagnosis of a placental teratoma must be considered. Presence of an umbilical cord facilitates a TRAP diagnosis in this setting.[7]

Synopsis of Treatment Options

PRENATAL

Indication for Treatment

The goal of management in cases of TRAP sequence is to maximize gestational age at delivery without cardiovascular compromise for the pump twin. When pump twin compromise is suspected or diagnosed at a previable gestational age, invasive cord occlusion therapy is recommended to sever the pump-to-acardiac vascular circuit, relieving the pump twin of its hemodynamic burden. Owing to a lack of robust data, there are no clear guidelines available at the present time to guide practitioners with regard to the necessity or timing of this intervention. Although some physicians recommend prophylactic cord occlusion therapy for all ongoing TRAP presentations, this strategy subjects all TRAP pregnancies to the risks of invasive therapy even though overt pump twin cardiac failure develops in only a few cases.

In some TRAP cases, spontaneous cessation of acardiac twin blood flow occurs, which would obviate the need for therapy. A common practice involves reserving therapy for the following findings: a high acardiac-to-pump twin weight ratio, rapid acardiac mass growth, pump twin cardiac dysfunction or heart failure, polyhydramnios, and hydrops. With respect to acardiac-to-pump twin weight ratio, the particular cutoff that might indicate therapy has not been rigorously studied. In our center, a ratio of greater than 0.5 is considered an indication for therapy.

Therapy Options. Selective reduction of the acardiac fetus in TRAP pregnancies is usually performed via cord occlusion procedures. The intent of cord occlusion is to interrupt blood flow to the acardiac fetus instantaneously while minimizing hemodynamic disturbance that might adversely affect the pump twin. Cord occlusion methods include fetoscopic ligation, bipolar coagulation, harmonic scalpel coagulation, thermocoagulation, and radiofrequency ablation (RFA). These strategies vary in invasiveness, occlusion modality, and whether they target the cord at a free loop or an intrafetal site. A commonly practiced contemporary management strategy involves US-guided percutaneous application of RFA to occlude the intrafetal cord insertion within the acardiac twin (Chapter 114).

RFA causes umbilical cord coagulation by inducing temperature changes through the application of high-frequency alternating current to a target tissue site. It is a minimally invasive procedure that can be performed with a relatively small gauge needle, which helps to reduce the risk of preterm delivery of the pump twin. The small-gauge needle also aids in minimizing maternal discomfort, allowing the procedure to be performed under local anesthesia.[9] Table 163.1 summarizes published experiences with RFA for TRAP sequence. The largest series examining the use of RFA for TRAP presentations collected the NAFTNet (North American Fetal Therapy Network) retrospective multicenter experience with this technique.[10] The authors demonstrated an overall 80% survival rate among nontargeted pump twins and a mean gestational age delivery of 33.4 weeks. Reported and theoretic risks of RFA include preterm labor, preterm premature rupture of membranes, intrafetal hemorrhage, maternal bleeding, and thermal injuries.

Outcomes in the Literature

Based on case series and case reports, the historically reported perinatal mortality rate in TRAP pregnancies with nonintervention is 35% to 55%.[3,8] In a review of 184 case reports published in the literature from 1960 to 1991, the four most common complications were preterm labor (79%), polyhydramnios (51%), congestive heart failure in the pump fetus (28%), and intrauterine demise (25%). More recent series evaluating TRAP outcomes have had the benefit of incorporating cases involving invasive therapy (see Table 163.1).[10–12]

POSTNATAL

Published literature describing long-term outcomes of survivors of TRAP sequence is limited, consisting entirely of case reports. Among these reports, there is wide variation in (1) time of TRAP diagnosis, (2) pregnancy management, and (3) neonatal outcomes. Given this variability, limited conclusions can be formed regarding long-term outcomes. Parents should be counseled to monitor

TABLE 163.1 TWIN REVERSED ARTERIAL PERFUSION OUTCOMES

Study	No.	Treatment	Pregnancy Outcome	Acardiac Twin Weight: Pump Twin Weight (g)
Livingston et al.,[12] 2007	21	17 (81%) RFA; 4 (19%) conservative management	94% survival overall: 12 pump twin survivors; 4 pump twins survived immediate postoperative period, postnatal information was unavailable; 1 pump twin demise, fetus noted to be hydropic at presentation	Average 0.7 (range 0.4–1.1); 12 patients had ratio >0.5
Lee et al.,[14] 2007	29	29 (100%) RFA	86% survival	All cases were ≥0.5
Jelin et al.,[11] 2010	21	7 (39%) RFA; 14 (67%) conservative management[a]	100% survival after RFA; 91% survival of conservative management cases[b]	All cases were ≤0.5
Lee et al.,[10] 2013	98	98 (100%) RFA	80% survival	All cases were >50%

RFA, Radiofrequency ablation.

[a]Two cases were excluded from analysis because of clear syndromic abnormalities, and one case was excluded because of lack of follow-up information.

[b]88% survival of conservative management cases when three cases with no documented blood flow to the acardiac twin are included (not statistically significant).

an affected child's mental and motor developmental milestones carefully.[13]

WHAT THE REFERRING PHYSICIAN NEEDS TO KNOW

TRAP sequence is a rare abnormality, and most cases occur in monochorionic diamniotic twin gestations. In the setting of a monochorionic twin pregnancy involving a grossly dysmorphic fetus devoid of cardiac activity, a TRAP sequence diagnosis must always be considered. Color Doppler imaging showing reversal of arterial blood flow to the acardiac fetus confirms the diagnosis. After diagnosis, prompt referral to a tertiary care center for further evaluation is recommended. In selected cases with evolving or overt pump twin cardiac failure, cord occlusion therapy using RFA decreases pump twin morbidity, resulting in improved perinatal outcomes.

KEY POINTS

- TRAP sequence is a rare complication specific to monochorionic twin pregnancies.
- The estimated occurrence of TRAP sequence is approximately 1:35,000 pregnancies.
- TRAP sequence is thought to develop as a result of abnormal arterioarterial anastomoses established early in embryogenesis between twin fetuses sharing a single placenta.
- The diagnosis is secured by US; necessary findings include a normal-appearing (pump) fetus and a grossly abnormal (acardiac) fetus in the setting of a monochorionic pregnancy.
- Because pump fetuses possess a 9% risk of aneuploidy, invasive genetic testing for karyotype determination is recommended.
- Therapy with invasive cord occlusion to sever the pump-to-acardiac vascular circuit should be considered when pump twin compromise is suspected or diagnosed at a previable gestational age.

SUGGESTED READINGS

Brassard M, Fouron JC, Leduc I, et al. Prognostic markers in twin pregnancies with an acardiac fetus. *Obstet Gynecol*. 1999;94:409-414.

Cavoretto P, Serafini A, Valsecchim L, et al. Early diagnosis, follow-up, and prenatal treatment of a case of TRAP sequence occurring in a dichorionic triamniotic triplet pregnancy. *J Clin Ultrasound*. 2009;37:350-353.

Chen CC, Hsu YH, Chan TF. Poor long-term outcome in a survivor presenting with the TRAP sequence in utero: a case report. *Kaohsiung J Med Sci*. 2003;19:526-530.

Roethlisberger M, Strizek B, Gottschalk I, et al. First trimester intervention in twin reversed arterial perfusion (TRAP) sequence—does size matter? *Ultrasound Obstet Gynecol*. 2016;8. [Epub ahead of print].

Rossi A, D'Addario V. Umbilical cord occlusion for selective feticide in complicated monochorionic twins: a systematic review of literature. *Am J Obstet Gynecol*. 2009;200:123-129.

Tan TY, Sepulveda W. Acardiac twin: a systematic review of minimally invasive treatment modalities. *Ultrasound Obstet Gynecol*. 2003;22:409-419.



All references available online at www.expertconsult.com

REFERENCES

1. Van Allen MI, Smith SW, Shepard TH. Twin reversed arterial perfusion (TRAP) sequence: a study of 14 twin pregnancies with acardius. *Semin Perinatol*. 1983;7:285-293.
2. D'Alton ME, Simpson LL. Syndromes in twins. *Semin Perinatol*. 1995;19:375-386.
3. Healey MG. Acardia: predictive risk factors for the co-twin's survival. *Teratology*. 1994;50:205-213.
4. Gewolb IH, Freedman RM, Kleinman CS, et al. Prenatal diagnosis of a human pseudocardiac anomaly. *Obstet Gynecol*. 1983;61:657-662.
5. Schinzel AA, Smith DW, Miller JR. Monozygotic twinning and structural defects. *J Pediatr*. 1979;95:921-930.
6. Wong EA, Sepulveda W. Acardiac anomaly: current issues in prenatal assessment and treatment. *Prenat Diagn*. 2005;25:796-806.
7. Dashe JS, Fernandez CO, Twickler DM. Utility of Doppler velocimetry in predicting outcome in twin reversed arterial perfusion sequence. *Am J Obstet Gynecol*. 2001;185:135-139.
8. Moore TR, Gale S, Benirschke K. Perinatal outcome of forty-nine twin pregnancies complicated by acardiac twinning. *Am J Obstet Gynecol*. 1990;163:907.
9. Paramasivam G, Wimalasundera R, Wiechec M, et al. Radiofrequency ablation for selective reduction in complex monochorionic pregnancies. *BJOG*. 2010;117:1294-1298.
10. Lee H, Bebbington M, Crumbleholme TM, et al. The North American Fetal Therapy Network registry data on outcomes of radiofrequency ablation for twin-reversed arterial perfusion sequence. *Fetal Diagn Ther*. 2013;33:224-229.
11. Jelin E, Hirose S, Rand L, et al. Perinatal outcome of conservative management versus fetal intervention for twin reversed arterial perfusion sequence with a small acardiac twin. *Fetal Diagn Ther*. 2010;27:138-141.
12. Livingston JC, Lim FY, Polzin W, et al. Intrafetal radiofrequency ablation for twin reversed arterial perfusion (TRAP): a single-center experience. *Am J Obstet Gynecol*. 2007;197:399.e1-339.e3.
13. Simpson PC, Trudinger BJ, Walker A, et al. The intrauterine treatment of fetal cardiac failure in a twin pregnancy with an acardiac, acephalic monster. *Am J Obstet Gynecol*. 1983;147:842-844.
14. Lee H, Wagner AJ, Sy E, et al. Efficacy of radiofrequency ablation for twin-reversed arterial perfusion sequence. *Am J Obstet Gynecol*. 2007;196:451-458.

164 Diagnostic Procedures in Multiples

JOY VINK

Introduction

The number of multiple pregnancies has exponentially increased in the last several decades mainly as a result of women delaying childbearing until they are of advanced maternal age and the expanded use of assisted reproductive techniques. The risk of chromosomal abnormalities increases with advancing maternal age; however, it has also been reported that there is an increased risk of structural and genetic abnormalities in twins compared with singleton gestations.[1] This chapter focuses on procedures for invasive karyotype analysis: chorionic villus sampling (CVS) and amniocentesis (Chapters 111 and 113).

Procedure

DESCRIPTION, TECHNIQUE, AND EQUIPMENT

CVS and amniocentesis should be performed by a physician experienced with the procedures and ultrasound (US). Similar to singleton pregnancies, unsensitized Rh(D)-negative women should be given Rh_0(D) immune globulin after CVS and amniocentesis to prevent Rh sensitization.

When performing invasive prenatal karyotype analysis on monochorionic twin gestations, the question remains whether one or both fetuses should be sampled. Although monochorionic twins theoretically should have identical karyotypes, case reports exist showing monochorionic twins discordant for chromosomal abnormalities.[2–4] Although this is a rare event, because of this reported risk of discordant karyotypes, we recommend sampling both sacs if the patient is undergoing invasive prenatal genetic testing.

CHORIONIC VILLUS SAMPLING IN MULTIPLE GESTATIONS

Before a CVS procedure, a transvaginal US scan should be done to evaluate the number of embryos, chorionicity, fetal viability, and any early US evidence of fetal anomalies. CVS in multiple gestations is performed in the same way as for singletons (see Chapter 113). The procedure can be done using the transabdominal or the transcervical method, or both. If there are two separate placentas, both methods may be used to avoid twin-twin contamination. If the placentas are fused or the chorionicity is unclear, the transcervical catheter or the transabdominal spinal

needle should be directed to the placental margin farthest from the fusion site or the area closest to the umbilical cord insertion site. This approach helps avoid sampling the same fetus twice. To eliminate contamination of the samples, the aspiration device should not pass through one placenta to reach the second placenta. Although deoxyribonucleic acid (DNA) polymorphism and cytogenetic results can assist in ensuring accuracy of the results, an amniocentesis may be needed later in the pregnancy if the CVS results are unclear.

AMNIOCENTESIS IN MULTIPLE GESTATIONS

Before an amniocentesis, US should be performed to evaluate the number of fetuses, chorionicity, fetal positions, fetal heart rates, placental location, and placental umbilical cord insertion sites.

Multiple-Needle Technique

First, an optimal needle insertion site is selected for each sac. The optimal insertion site avoids the maternal bowel and bladder and, if possible, the placenta. Using color Doppler may help to avoid the umbilical cord insertion site and large chorionic vessels.

Next, one should ensure that the required equipment is available (supplies are listed in Chapter 111). The maternal abdomen is prepared and draped. The sterile cover is placed over the US probe, and sterile US gel is used to relocate the optimal fluid pocket. The spinal needle is inserted under continuous US guidance. When the needle is ideally located in the fluid pocket, the needle stylet is removed, and the sterile syringe is attached to the needle. An appropriate amount of amniotic fluid is withdrawn, and the syringe is removed. When available, indigo carmine dye (2–3 mL) can be injected into the sac before withdrawing the needle.

After withdrawing the first needle, the operator turns to the second sac and performs amniocentesis with a fresh needle. The amniotic fluid in the subsequent sac should be clear, which confirms that the first sac has not been sampled twice. In higher-order multiple gestations, indigo carmine (if available) is injected into each subsequent sac to ensure a new sac is sampled each time. Methylene blue dye should not be used for this purpose because it has been associated with fetal skin staining, fetal small bowel atresia, and methemoglobinemia in newborns. Also, the mother should be alerted to potential greenish discoloration of her own urine over several hours or days as the dye is eliminated from the circulation.

In the absence of indigo carmine, care should be taken to ensure that each needle is inserted as far as possible from the other twin's sac, and patients counseled about the potential for sampling the same sac twice.

Single-Needle Insertion Technique

The single-needle insertion technique has two benefits: (1) it reduces maternal discomfort because only one needle is inserted to withdraw amniotic fluid from both amniotic sacs, and (2) it does not require injecting indigo carmine dye to confirm separate sacs are sampled. The supplies needed are otherwise identical to the supplies required for the multiple-needle procedure.

First, the operator localizes an area where both amniotic sacs and the dividing membrane are clearly seen. The operator inserts the spinal needle into the more anterior sac and aspirates the appropriate amount of amniotic fluid. After attaching a new syringe to the spinal needle, the operator advances the needle through the dividing membrane into the second sac and aspirates the amniotic fluid. The disadvantages of this technique include the potential for contamination of the second sample by the first and the risk of membrane tearing.

INDICATIONS

The most common indication for CVS is to diagnose conditions in which DNA analysis or diagnostic cytogenetic analysis is possible early in pregnancy. The most common indications for amniocentesis include prenatal diagnosis of abnormal conditions and fetal lung maturity. Other indications include amnioreduction, diagnosing an intraamniotic infection, and confirming preterm premature rupture of membranes with an amnio dye test.

CONTRAINDICATIONS

The contraindications for CVS are listed in Chapter 113, and the contraindications for amniocentesis are listed in Chapter 111.

OUTCOMES AND COMPLICATIONS

CVS and amniocentesis appear to be safe for multiple gestations when performed by experienced clinicians. The complications are similar to CVS and amniocentesis in singleton gestations. However, the exact procedure-related loss rate after CVS or amniocentesis in multiple gestations, especially monochorionic twins, is unclear because of varying definitions of pregnancy loss, the natural loss rate secondary to maternal age, and the natural increased loss rate in twins compared with singletons.

Chorionic Villus Sampling

Although miscarriage rates of 4.5% have been reported,[5] studies by Wapner et al.[1] and Antsaklis et al.[5] showed that CVS in multiple gestations has postprocedural loss rates comparable to amniocentesis performed in the second trimester. The advantage of CVS versus amniocentesis is that it can be performed earlier in pregnancy and allows patients to undergo an early selective termination if abnormal results are discovered.

Amniocentesis

Several studies evaluated pregnancy loss rates after amniocentesis in twin gestations. The range of loss rates reported included loss at less than 20 weeks (0%–6.3%), at less than 24 weeks (1.1%–10.6%), and at less than 28 weeks (1.1%–12.7%).[5–26] A systematic review of articles published between 1970 and 2010 found that there was significant heterogeneity in the definition of "pregnancy loss" after amniocentesis in twins. The pooled procedure-related loss rate at less than 24 weeks was 3.5% (95% confidence interval [CI], 2.6–4.7). The pooled loss rates at less than 28 weeks and to term could not be calculated, as the studies exhibited unacceptable heterogeneity of data. Seven of the included studies had a control (no amniocentesis) group. The reported pooled odds ratio in these studies for total pregnancy loss among cases was 1.8 (95% CI, 1.2–2.7).[27]

Monochorionic Twins

At the present time, studies evaluating CVS in twins are limited, and studies specifically evaluating the loss rates in monochorionic twins are lacking. Only two studies reported loss rates after amniocentesis in monochorionic twins. Millaire et al. reported

no losses at less than 24 weeks' gestation in 45 patients with monochorionic twin pregnancies who underwent amniocentesis.[17] Cahill et al. reported a significant difference in loss rates before 24 weeks' gestation in patients with monochorionic twins who had an amniocentesis compared with patients who did not have an amniocentesis (7.7% versus 1.4%; $P = .02$).[7]

KEY POINTS

- CVS and amniocentesis should be performed by a physician experienced with the procedures and US.
- CVS in multiple gestations can be done using the transabdominal or the transcervical method, or both.
- Amniocentesis in multiple gestations can be performed using the multiple-insertion technique or the single-insertion technique.
- When performing an amniocentesis using the multiple-insertion technique, methylene blue dye should not be used because it has been associated with staining of the fetal skin, fetal small bowel atresia, and methemoglobinemia in newborns.
- Unsensitized Rh(D)-negative women should be given Rh_0(D) immune globulin after CVS or amniocentesis to prevent Rh sensitization.

SUGGESTED READINGS

Appelman Z, Furman B. Invasive genetic diagnosis in multiple pregnancies. *Obstet Gynecol Clin North Am*. 2005;32:97-103.
Appelman Z, Vinkler C, Caspi B. Chorionic villus sampling in multiple pregnancies. *Eur J Obstet Gynecol Reprod Biol*. 1999;85:97-99.
Cleary-Goldman J, D'Alton ME, Berkowitz RL. Prenatal diagnosis and multiple pregnancy. *Semin Perinatol*. 2005;29:312-320.
Dommergues M. Prenatal diagnosis for multiple pregnancies. *Curr Opin Obstet Gynecol*. 2002;14:169-175.
Jenkins TM, Wapner RJ. The challenge of prenatal diagnosis in twin pregnancies. *Curr Opin Obstet Gynecol*. 2000;12:87-92.
Rochon M, Stone J. Invasive procedures in multiple gestations. *Curr Opin Obstet Gynecol*. 2003;15:167-175.
Wapner RJ. Genetic diagnosis in multiple pregnancies. *Semin Perinatol*. 1995;19:351-362.
Weisz B, Rodeck CH. Invasive diagnostic procedures in twin pregnancies. *Prenat Diagn*. 2005;25:751-758.



All references available online at
www.expertconsult.com

REFERENCES

1. Wapner R, Johnson A, Davis G. Prenatal diagnosis in twin gestations: a comparison between second trimester amniocentesis and first trimester chorionic villus sampling. *Obstet Gynecol*. 1993;82:49-56.
2. Rogers JG, Voullaire L, Gold H. Monozygotic twins discordant for trisomy 21. *Am J Med Genet*. 1982;11:143-146.
3. Dallapiccola B, Stomeo C, Ferranti B, et al. Discordant sex in one of three monozygotic triplets. *J Med Genet*. 1985;22:6-11.
4. Perlman E, Stetten G, Tuck-Muller C, et al. Sexual discordance in monozygotic twins. *Am J Obstet Gynecol*. 1990;37:551-557.
5. Antsaklis A, Souka A, Daskalakis G, et al. Second-trimester amniocentesis vs. chorionic villus sampling for prenatal diagnosis in multiple gestations. *Ultrasound Obstet Gynecol*. 2002;20:476-481.
6. Bovicelli L, Michelacci L, Rizzo N, et al. Genetic amniocentesis in twin pregnancy. *Prenat Diagn*. 1983;3:101-106.
7. Cahill A, Macones G, Stamilio D, et al. Pregnancy loss rate after mid-trimester amniocentesis in twin pregnancies. *Am J Obstet Gynecol*. 2009;200: 257.e1-257.e6.
8. Daskalakis G, Anastasakis E, Papantoniou N, et al. Second trimester amniocentesis in assisted conception versus spontaneously conceived twins. *Fertil Steril*. 2009;91:2572-2577.
9. Elias S, Gerbie A, Simpson L, et al. Genetic amniocentesis in twin gestations. *Am J Obstet Gynecol*. 1980;138:169-174.
10. Filkins K, Russo J, Brown T, et al. Genetic amniocentesis in multiple gestations. *Prenat Diagn*. 1984;4:223-226.
11. Ghidini A, Lynch L, Hicks C, et al. The risk of second-trimester amniocentesis in twin gestation: a case control study. *Am J Obstet Gynecol*. 1993;169: 1013-1016.
12. Goldstein AI, Stills SM. Midtrimester amniocentesis in twin pregnancies. *Obstet Gynecol*. 1983;62:659-661.
13. Hanprasertpong T, Kor-anantakul O, Prasartwanakit V, et al. Outcome of second trimester amniocentesis in twin pregnancies at Songklanagarind hospital. *J Med Assoc Thai*. 2008;91:1639-1643.
14. Kidd S, Lancaster P, Anderson J, et al. A cohort study of pregnancy outcome after amniocentesis in twin pregnancy. *Paediatr Perinat Epidemiol*. 1997;11:200-213.
15. Ko T, Tseng L, Hwa H. Second-trimester genetic amniocentesis in twin pregnancy. *Int J Gynaecol Obstet*. 1998;61:285-287.
16. Librach L, Doran T, Benzie R, et al. Genetic amniocentesis in seventy twin pregnancies. *Am J Obstet Gynecol*. 1984;148:585-591.
17. Millaire M, Bujold E, Morency AM, et al. Mid-trimester genetic amniocentesis in twin pregnancy and the risk of fetal loss. *J Obstet Gynaecol Can*. 2006;28:512-518.
18. Palle C, Andersen J, Tabor A, et al. Increased risk of abortion after genetic amniocentesis in twin pregnancies. *Prenat Diagn*. 1983;3:83-89.
19. Pruggmayer M, Joahoda M, Van der Pol J, et al. Genetic amniocentesis in twin pregnancies: results of a multicenter study of 529 cases. *Ultrasound Obstet Gynecol*. 1992;2:6-10.
20. Redwine F, Cruikshank D, Brown J. Antenatal genetic studies in twin pregnancies. *Acta Genet Med Gemellol (Roma)*. 1984;33:39-41.
21. Reid K, Gurrin L, Dickinson J, et al. Pregnancy loss rates following second trimester genetic amniocentesis. *Aust N Z J Obstet Gynaecol*. 1999;39(3): 281-285.
22. Simonazzi G, Curti A, Farina A, et al. Amniocentesis and chorionic villus sampling in twin gestations: which is the best sampling technique? *Am J Obstet Gynecol*. 2010;202:365.e1-365.e5.
23. Supadilokluck S, Tongprasert F, Tongsong T, et al. Amniocentesis in twin pregnancies. *Arch Gynecol Obstet*. 2009;280:207-209.
24. Tabsch K, Crandell B, Labherz T, et al. Genetic amniocentesis in twin pregnancy. *Obstet Gynecol*. 1985;65:843-845.
25. Toth-Pal E, Papp C, Beke A, et al. Genetic amniocentesis in multiple pregnancy. *Fetal Diagn Ther*. 2004;19:138-144.
26. Yukobowich E, Anteby E, Cohen S, et al. Risk of fetal loss in twin pregnancies undergoing second trimester amniocentesis. *Obstet Gynecol*. 2001;98: 213-234.
27. Vink J, Fuchs K, D'Alton ME. Amniocentesis in twin pregnancies: a systematic review of the literature. *Prenat Diagn*. 2012;32(5):409-416.

165 Cytomegalovirus, Rubella, Toxoplasmosis, Herpes Simplex Virus, and Varicella

SONYA S. ABDEL-RAZEQ | SARAH N. CROSS | HEATHER S. LIPKIND | JOSHUA A. COPEL

Cytomegalovirus

SONYA S. ABDEL-RAZEQ

Introduction

The acronym *TORCH* refers to a group of organisms associated with congenital infections: *t*oxoplasmosis, *o*ther (congenital syphilis and viruses), *r*ubella, *c*ytomegalovirus (CMV), and *h*erpes simplex virus (HSV). The approximate number of cases per year in the United States of these infections is listed in Table 165.1. In the United States, CMV is the most common fetal infection.

In the United States, CMV, a deoxyribonucleic acid (DNA) herpesvirus, is the most common viral infection of the fetus, affecting nearly 40,000 infants annually. This ubiquitous virus causes a wide variety of clinical manifestations.

Disease

PREVALENCE AND EPIDEMIOLOGY

CMV is the most common cause of *in utero* infection, with a birth prevalence of 0.5% to 2.5%.[1,2] Seroprevalence for CMV varies with geographic region, income, and ethnicity and ranges from 40%–83%.[3–5] Previous exposure to CMV is greater in women of lower socioeconomic status and in developing countries.

Humans are the only known reservoir for human CMV, which is excreted in most bodily fluids of an infected individual. Saliva, urine, cervical secretions, semen, and breast milk are all potential sources for infection.

The fetus may be infected by either a primary or a secondary maternal infection. Vertical transmission is 30% to 50% after primary infection (Fig. 165.1) and less than 1% after secondary infection (Fig. 165.2).[6] Maternal antibodies to CMV do not prevent reactivation of latent disease or reinfection with CMV strains different from that acquired during primary infection.

TABLE 165.1 CONGENITAL INFECTIONS

Infection	Cases/Year in the United States
CMV[34]	40,000
Toxoplasmosis[35]	400–4000
Herpes simplex[36]	100
Varicella[37]	70
Rubella[38]	11

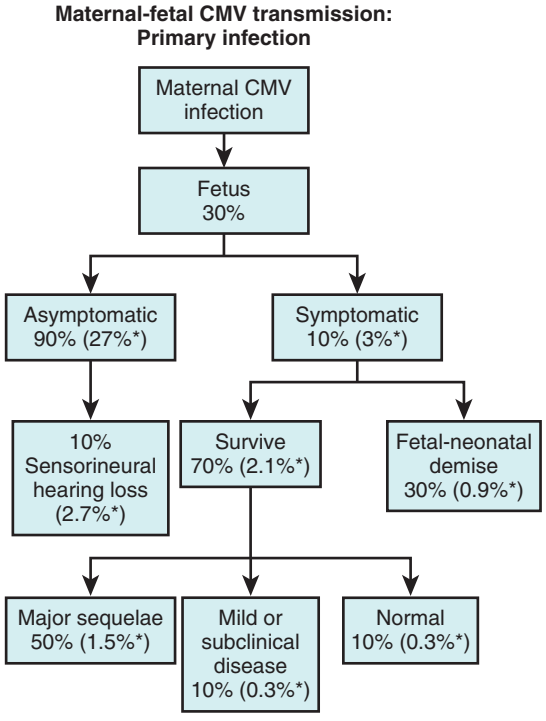

Fig. 165.1 Maternal-fetal CMV transmission: primary infection. *CMV*, Cytomegalovirus. *(Adapted from Benoist G, Ville Y.* Fetal Matern Med Rev *18:181–199, 2007.)*

Although maternal immunity reduces maternal-fetal transmission, the severity of congenital CMV may be the same for recurrent or reactivated maternal CMV as for primary infection (see Fig. 165.2).[7]

The likelihood of fetal infection increases, and the prevalence of severe congenital infection decreases with advancing gestation.

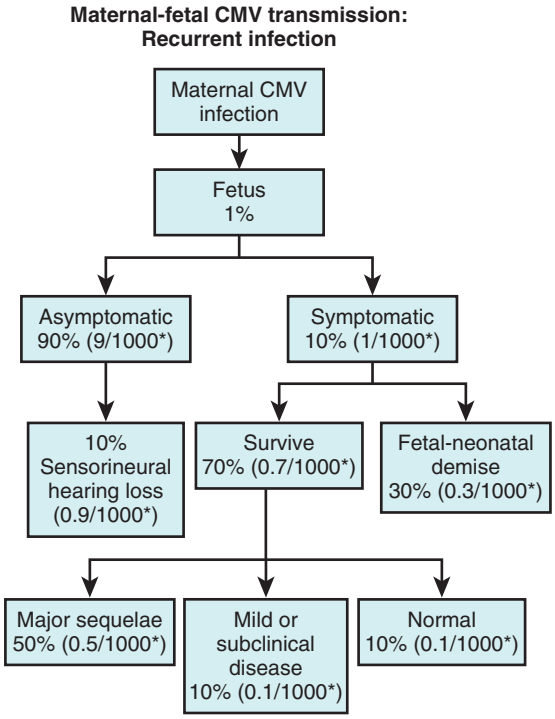

*Number of fetal infections from original recurrent cases of maternal CMV.

Fig. 165.2 Maternal-fetal CMV transmission: recurrent infection. *CMV*, Cytomegalovirus. *(Adapted from Benoist G, Ville Y.* Fetal Matern Med Rev *18:181–199, 2007.)*

In general, 10% of infected newborns are symptomatic at birth, and an additional 10%–15% of asymptomatic infected newborns have late neurologic sequelae during the first 2 years of life.[7] In the latter group, injury is usually limited to sensorineural hearing loss (see Figs. 165.1 and 165.2) but may also include cognitive deficit, seizures, and death. Auditory damage is caused by viral replication in sensory neuroepithelium and a subsequent host immune response. The prognosis among symptomatic infants is poor; survivors generally have serious permanent abnormalities. The severe neurologic complications of CMV are correlated with the presence of hematologic signs, specifically hepatosplenomegaly. Approximately 3% to 5% of neonates acquire CMV in the peripartum period from infected cervical secretions or infected breast milk.[8]

ETIOLOGY AND PATHOPHYSIOLOGY

CMV is a member of the herpesvirus family, and thus demonstrates periods of latency and reactivation with viral shedding. The incubation period after infection is 3 to 12 weeks. The virus is excreted for months to years after infection and may remain latent with excretion recurring if immunosuppression of the host occurs. CMV replicates in the placenta, impairing placental development and resulting in placental insufficiency (Figs. 165.3 and 165.4). The placenta can serve as a reservoir for viral replication before embryo or fetal infection. CMV may result in a first-trimester miscarriage without infecting the fetus.[9]

MANIFESTATIONS OF DISEASE

Clinical Presentation

In immunocompetent adults, CMV is generally mild—with nonspecific symptoms of fatigue, myalgia, headache, rhinitis, pharyngitis—and self-limited, and may even be clinically asymptomatic in approximately 90% of cases. Conversely, active infection may present as an illness similar in appearance to

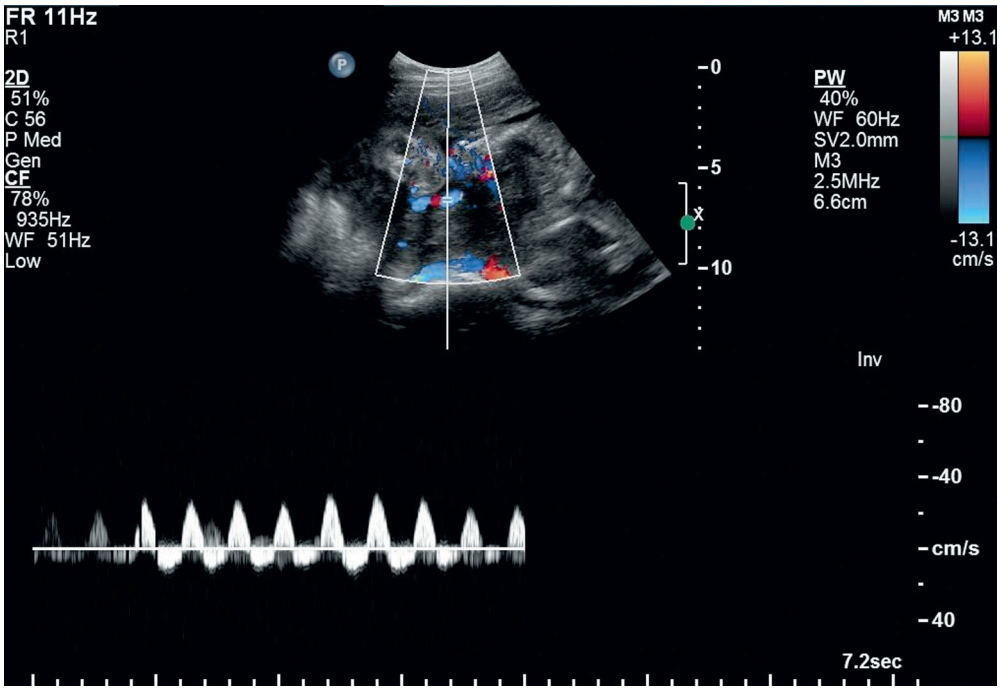

Fig. 165.3 Reversed diastolic flow in the umbilical artery indicating increased placental resistance.

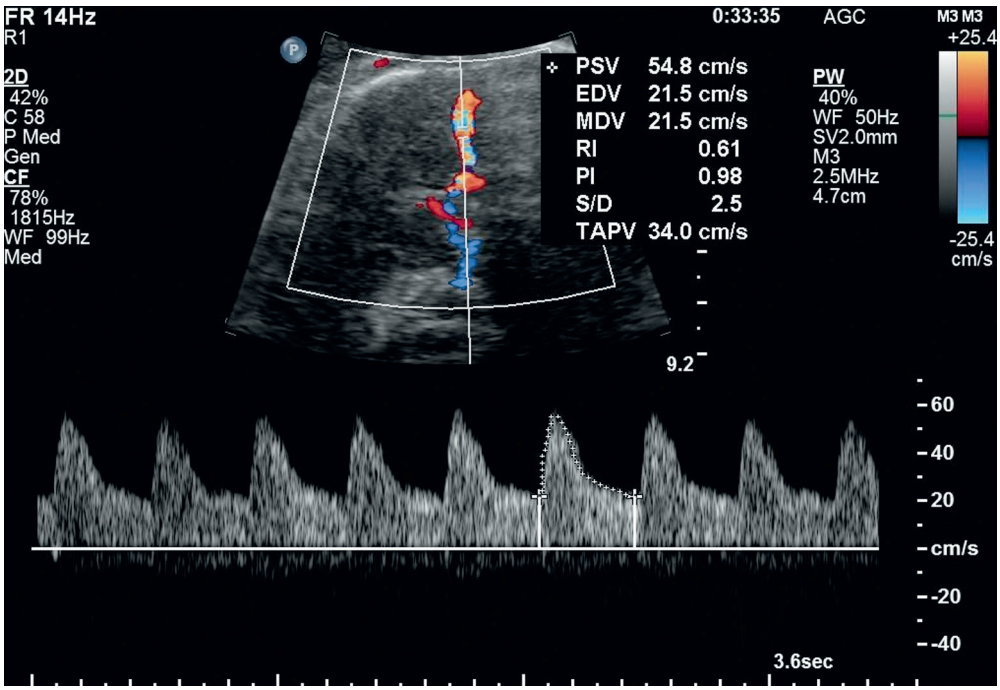

Fig. 165.4 Doppler assessment of middle cerebral artery. There is increased diastolic flow indicating decreased resistance owing to hypoxia.

mononucleosis with symptoms of fever, myalgias, bronchitis, and a flu-like syndrome. In more severe cases, pneumonia and hemolytic anemia may occur. In immunodeficient individuals, CMV may cause pneumonia as well as hepatitis and gastrointestinal symptoms.

Congenital CMV has a similar range from mild disease to severe generalized infection with multiorgan disease and nonimmune hydrops. With severe disease, *in utero* demise may occur. Most newborns of women with either primary or secondary infection are asymptomatic at birth; however, 10%–15% of these ultimately develop neurodevelopmental damage within the first 3 years of life.[10] The sequelae in neonatal survivors of severe systemic CMV may also include microcephaly, hearing loss, and motor disabilities. The available data suggest that the range of severity of clinical abnormalities in congenitally infected newborns is the same whether the mother has a primary or nonprimary infection.[11] The severity of fetal disease is determined by the timing of infection and the affinity for nervous tissue of various CMV strains. It has not been determined why the fetal brain is more susceptible to CMV than the adult brain.

In multiple gestation, CMV infection may affect one or both twins, regardless of placentation. When both twins are infected, the severity of disease may vary.[12]

Diagnosis. The diagnosis of clinically suspected maternal CMV infection is based on serology. The new appearance of CMV-specific immunoglobulin (Ig)G is diagnostic of new acute infection. IgM is not a reliable marker for acute infection or timing exposure for several reasons:

- IgM may remain positive for over 1 year following acute infection.
- IgM may revert to positive from negative in women with reactivation or reinfection with a new viral strain.
- It is present in 75%–90% of those with acute infection, and there exists a high false-positive rate for IgM assays performed in commercial, nonreference laboratories.

In the absence of documented IgG seroconversion, the IgG avidity assay may be used to more accurately determine the acuity of infection and thus vertical transmission risk.[13–15] Antibodies produced at the time of primary infection have lower antigen avidity than those produced during a nonprimary response. Low avidity IgG (<0.3) indicates a recent infection. With time and antibody maturation, the antigen avidity will increase and reach even higher avidity levels (≥0.65), indicative of past infection.[16]

Despite the availability of avidity testing, the diagnosis of acute infection may remain elusive as intermediate results are difficult to interpret and the appropriate cutoff for low avidity is not universally defined. In the setting of maternal infection and/or findings on ultrasound (US) suggestive of fetal infection (echogenic fetal bowel, cerebral periventricular echogenicities, hepatic calcifications, microcephaly, fetal growth restriction), amniocentesis should be considered to perform polymerase chain reaction (PCR) for CMV DNA in amniotic fluid. Timing of this procedure is critical as test sensitivity is highest after 21 weeks' gestation and greater than 6 weeks between maternal infection and procedure.[17,18] This 6-week lag time allows for placental viral replication, transmission to fetus, viral replication in the fetal kidney, and excretion into amniotic fluid. If amniocentesis is performed earlier in gestation or soon after diagnosis of maternal infection, it is reliable evidence of fetal infection if positive, but should be repeated later in gestation if negative.

PCR is the preferred test, as sensitivities of viral isolation from amniotic fluid vary from 45%–80%.[17] The prognostic value of DNA quantification of CMV in amniotic fluid is controversial. Lazzarotto et al.[18] reported that with viral loads less than 10^3 copies/mL, there is a low risk of symptomatic neonatal infection. Benoist et al.[19] did not find a correlation between viral load and the likelihood of symptomatic neonatal CMV.

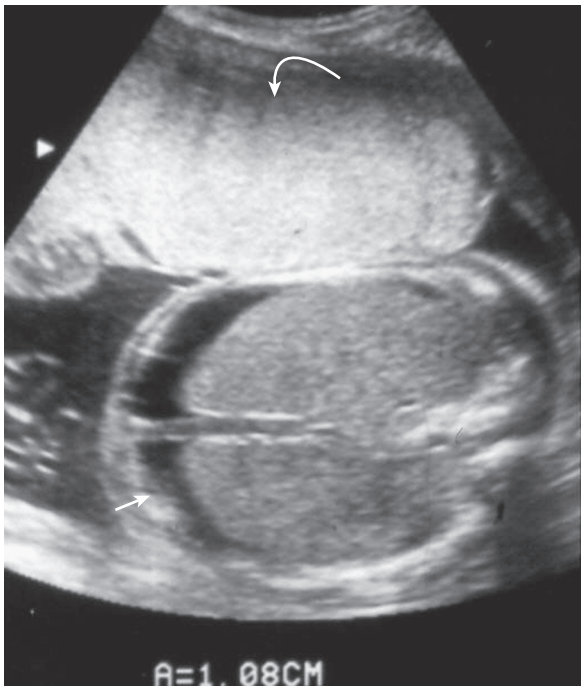

Fig. 165.5 Placentomegaly *(curved arrow)* and ascites *(straight arrow)*.



Fig. 165.6 Chronic placentitis with microcalcifications *(arrow)*.

TABLE 165.2 ULTRASOUND FINDINGS ASSOCIATED WITH CONGENITAL CYTOMEGALOVIRUS

Central nervous system
Microcephaly
Porencephaly
Lissencephaly
Cerebellum
Hemorrhage
Calcifications
Atrophy
Incomplete formation
Lateral ventricles
Ventriculomegaly
Intraventricular hemorrhage
Adhesions
Periventricular echogenicities
Periventricular halo
Subependymal cysts
Periventricular leukomalacia
Large subarachnoid space
Lenticulostriate vasculitis
Microphthalmia
Anemia
Nonimmune hydrops
Ascites
Pleural effusion
Cardiomegaly
Patchy cardiac echogenicity
Pericardial calcifications
Hepatomegaly
Echogenic liver foci
Splenomegaly
Echogenic bowel
Echogenic nephromegaly
IUGR
Oligohydramnios or polyhydramnios
Placentomegaly

IUGR, Intrauterine growth restriction.

Imaging Technique and Findings

Ultrasound. Between 16 and 36 weeks' gestation, women with primary CMV infection and newborns with symptomatic CMV have significantly thicker placentas than control women without CMV. At 20 weeks' gestation, placental thickness in control pregnancies without CMV was 20 mm compared with 40 mm (Fig. 165.5) in CMV-infected pregnancies.[20] Some of the US findings associated with CMV (e.g., intrauterine growth restriction [IUGR]) may be caused by placental dysfunction (Fig. 165.6) rather than from direct viral infection. This placental dysfunction may partly explain why CMV DNA load in amniotic fluid does not correlate with the severity of abnormalities associated with congenital CMV infection visualized on US.

Of congenital infections, CMV is the major cause of destructive cerebral lesions (Table 165.2 and Fig. 165.7). Brain damage is caused by a direct cytopathic effect and an immune inflammatory response to CMV. Because the fetal brain is a focus of all congenital infectious evaluations, transvaginal US should always be attempted when the vertex is in a suitable position to detect subtle abnormalities.

Neurons form between 8 and 20 weeks' gestation; migration of neuronal cells to the cerebral cortex continues until 24 to 26 weeks' gestation. Both neuronal loss and a disturbance in neuronal migration may play a role in the development of microcephaly associated with CMV infection.[21]

A periventricular halo (see Fig. 165.7E) is indicative of white matter injury and is detected before brain calcifications. The periventricular halo is initially noncontinuous and may be appreciated only with transvaginal US. As white matter damage progresses, the halo coalesces and is detectable with transabdominal US. The duration and severity of the cerebral infection determine whether ventriculomegaly is present at the time of the periventricular halo.[22] Focal symmetric periventricular cysts generally cannot be detected until the third trimester.

Cerebral calcifications associated with CMV are generally periventricular in location. Calcifications associated with toxoplasmosis are scattered throughout the brain.

Lenticulostriate vasculitis results in the deposit of amorphous material in the walls of the vessels within the basal ganglia and thalamus. Although the vessels are echogenic, they are not occluded. Resolution of the lesions may occur. However, with severe infections, the vessel walls eventually may become calcified. These linear echogenicities have also been found with other infections (rubella, syphilis), chromosomal abnormalities (trisomies 21 and 18), and prematurity.[22]

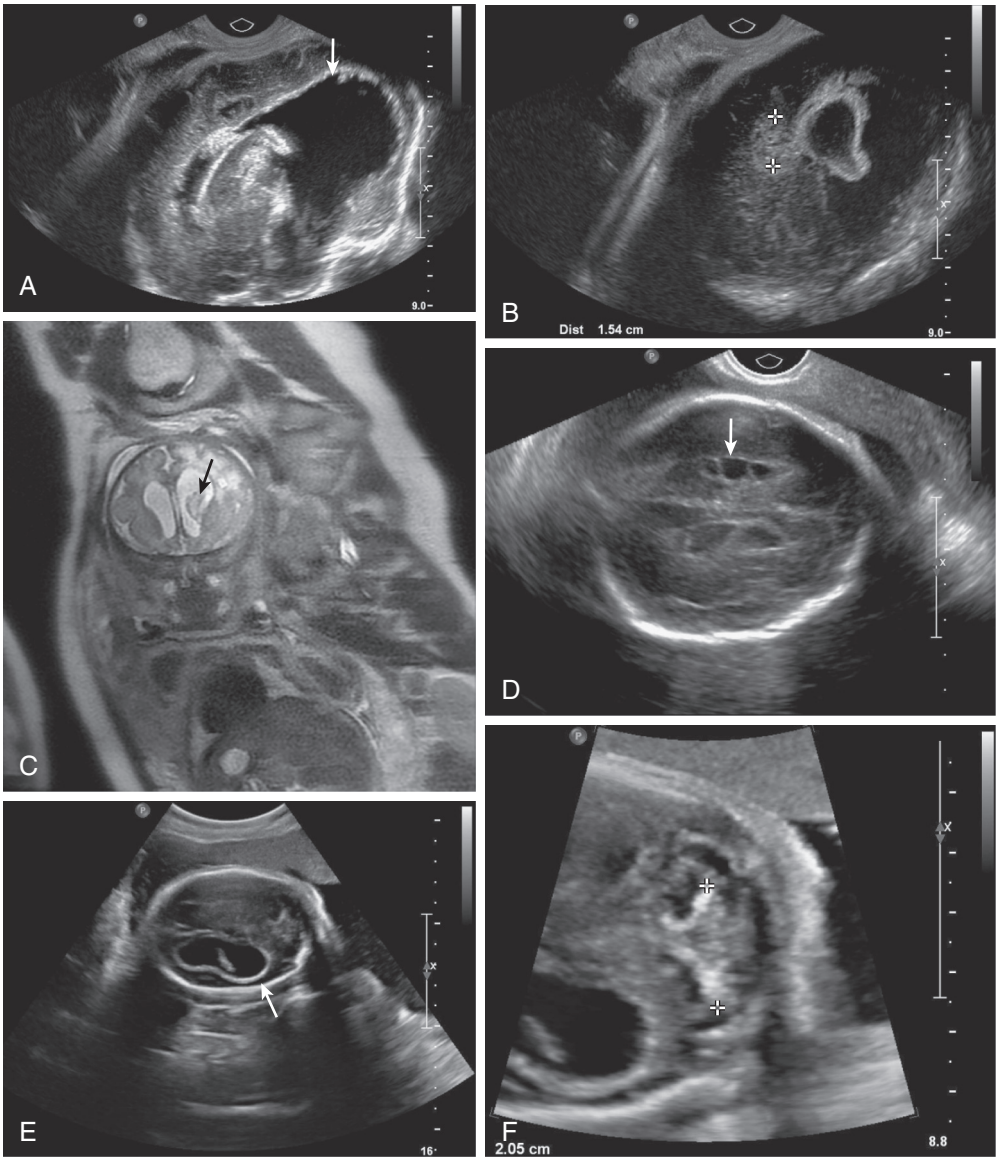

Fig. 165.7 CNS manifestations. (A) Ventriculomegaly *(arrow)*. (B) Periventricular leukomalacia *(between graticules)*. (C) MRI of intraventricular hemorrhage *(arrow)*. (D) Ventricular adhesions *(arrow)*. (E) Periventricular halo *(arrow)*. (F) Cerebellar calcifications and hypoplasia *(between graticules)*.

Anomalies of the cerebellum (i.e., vermian hypoplasia) suggest that the CMV infection occurred before 18 weeks' gestation, when cerebellar formation is complete.[23] Lissencephaly is a disturbance of neuronal migration between 3 and 5 months' gestation. US diagnosis of lissencephaly can be made at around 28 weeks' gestation. The presence of cerebellar hypoplasia (see Fig. 165.7F) in association with lissencephaly should suggest a diagnosis of congenital CMV infection.

In one series of 73 *in utero* CMV infections, 34 of 73 (52%) had US findings; 27 of 34 (79%) infections involved the central nervous system (CNS). There were isolated extracerebral US abnormalities in 11 (32.4%) infections.[7] Simon-Bouy et al.[24] prospectively evaluated 682 cases of fetal echogenic bowel (Fig. 165.8). CMV was found in 15 (2.2%) fetuses. In 11 of 15 fetuses with CMV, echogenic bowel was the only US abnormality detected. Echogenic bowel or bowel dilatation is caused by viral enterocolitis.

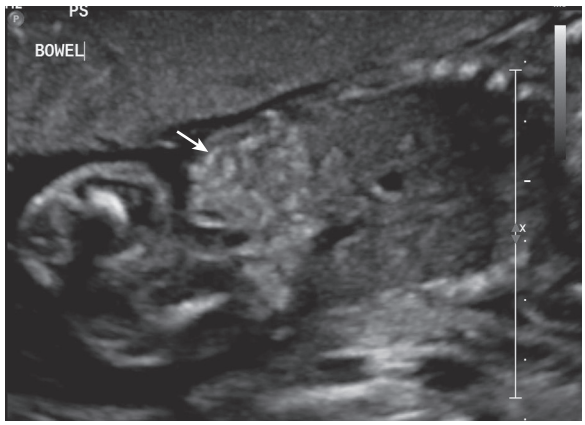

Fig. 165.8 Second-trimester echogenic fetal small bowel *(arrow)*.

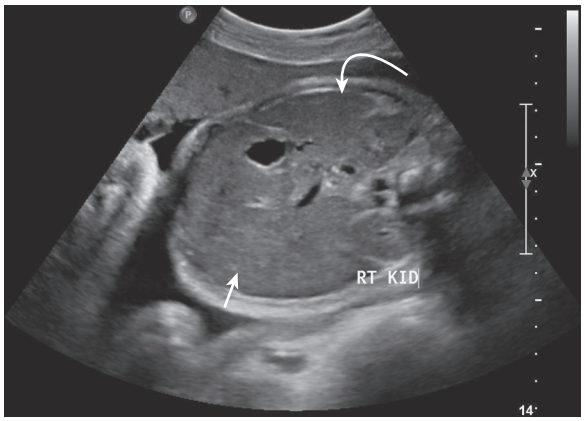

Fig. 165.9 Hepatomegaly *(straight arrow)*; splenomegaly *(curved arrow)*. *RT KID;* Right kidney.

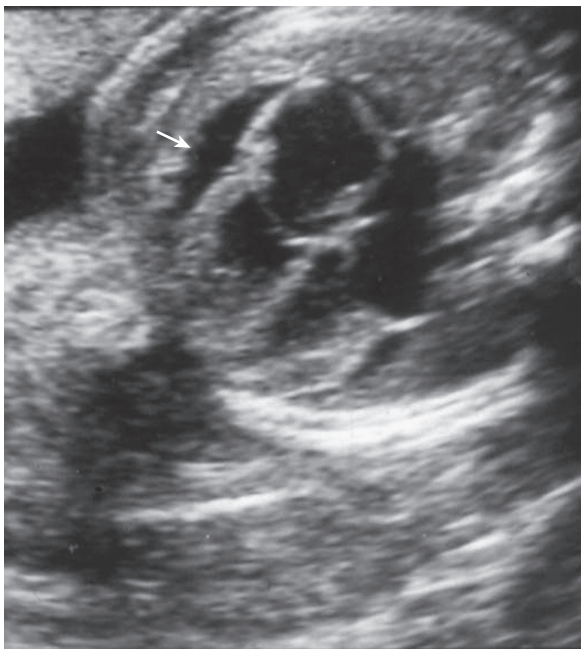

Fig. 165.10 Nonimmune hydrops, cardiomegaly, and pericardial effusion *(arrow)*.

Isolated hepatic echogenic foci are infrequently associated with infection and are usually caused by a vascular accident. Multiple hepatic calcifications secondary to hepatitis are more likely associated with congenital infection.[25] Hepatosplenomegaly is common with severe symptomatic congenital CMV (Fig. 165.9).

Occasionally, hydrops (Fig. 165.10; see Fig. 165.5) secondary to CMV infection is detectable by 16 weeks' gestation. This early manifestation of hydrops is secondary to hepatic dysfunction, liver congestion, and subsequent anemia.[26] Myocarditis can also play a role in the development of hydrops. Isolated fetal ascites is caused by hepatic dysfunction. When the liver recovers, the ascites resolves. IUGR is present in 50% of symptomatic infants infected with CMV; the prematurity rate is 34% in this subgroup.[27] Renal involvement may result in temporary or persistent oligohydramnios and, occasionally, polyhydramnios. Calcifications of the retina secondary to chorioretinitis have been detected on third-trimester US examinations of fetuses with CMV.[28]

The reported US markers associated with congenital CMV are outlined in Table 165.2. These findings may be transient or become manifest only late in pregnancy, requiring serial US examinations to be detected.[29] Although the possible US markers are numerous, they are not specific.

TABLE 165.3 FACTORS AFFECTING ULTRASOUND DETECTION OF CONGENITAL CYTOMEGALOVIRUS

Small sample size
Gestational age at exposure
Severity of congenital infection
Duration from exposure to ultrasound
Gestational age at scan
Single versus serial scans

The US detection rate of congenital CMV is difficult to assess because of the variables listed in Table 165.3. Crino[30] combined data from three studies to obtain a 30% sensitivity, 98% specificity, 90% positive predictive value, and 70% negative predictive value for the detection of congenital CMV with US. In one study, 23 of 154 congenitally infected fetuses (14.9%) had identifiable US findings. The positive predictive value of US in detecting congenital infections was 35.3% for all fetuses of mothers with primary CMV and 78.3% for fetuses with documented infection.[29] In two series of 62 infected fetuses with US abnormalities, approximately half of abnormalities were detected between 18 and 22 weeks' gestation. The remaining 50% of the detectable anomalies associated with congenital CMV were identified after a gestational age of 22 weeks. A normal second-trimester US examination does not exclude an abnormal US examination at a later gestational age or the birth of an infant with significant CMV sequelae.[29]

Prognosis is based mainly on the presence of fetal brain abnormalities. However, all detectable brain lesions do not have the same prognostic significance. Even ventriculomegaly, considered one of the most ominous US findings, does not invariably result in long-term sequelae.[31] When US abnormalities are detected, neonates may still escape significant morbidity. Nonspecific isolated US findings (i.e., echogenic bowel) are not associated with a poor outcome.[26]

Magnetic Resonance Imaging. MRI may provide additional information in the assessment of a fetus suspected to have congenital CMV. Even with a normal fetal anatomic survey, MRI has detected subtle brain abnormalities, increasing the positive predictive value of prenatal assessment. Although brain anomalies associated with CMV infection may be detected on MRI before 24 weeks' gestation, the results can be misleading. Repeat MRI in the third trimester is required to better elucidate the prognostic reliability of the earlier MRI examination or to monitor previously diagnosed brain abnormalities.[27]

The type of brain abnormalities detected on MRI helps to approximate the time of fetal infection. Lissencephaly suggests a brain injury before 16 to 18 weeks' gestation, whereas polymicrogyria is associated with an injury between 18 and 24 weeks' gestation. The development of a normal gyral pattern indicates the fetus was not infected until the third trimester.[27] Despite the possibility of detecting abnormalities, MRI use remains controversial as normal brain imaging does not necessarily predict normal neurodevelopmental outcomes.

CLASSIC SIGNS

Intracranial and intrahepatic calcifications.

Differential Diagnosis From Imaging Findings

Although there are numerous US signs associated with CMV, none are specific. With documented maternal CMV, the US findings listed in Table 165.2 are strongly associated with congenital CMV. The differential diagnosis depends on the specific US findings associated with a particular case of congenital CMV. In general, the US findings listed in Table 165.2 can be found with other congenital infections.

1. Echogenic bowel as an isolated finding may be a physiologic variation of normal or be caused by cystic fibrosis, aneuploidy, bowel obstruction, or congenital CMV.
2. CMV is only one of a long list of etiologies for nonimmune hydrops. A detailed maternal history, an extended fetal anatomic survey, maternal blood work, and amniocentesis help to narrow the differential diagnosis.

Synopsis of Treatment Options

PRENATAL

The use of antiviral medications may be indicated for treatment of maternal end-organ CMV disease, but have not been shown to decrease vertical transmission. However, the use of antivirals in symptomatic neonates may potentially decrease neonatal morbidity and mortality. Hyperimmunoglobulin (HIG) therapy has been reported to cause regression of cranial and abdominal US sequelae associated with CMV.[32,33] The first randomized trial to address the use of CMV HIG (the CHIP study) was recently completed in Italy and did not show a significant reduction in congenital infection.[33] This study randomly assigned 124 women with primary CMV infection to either CMV HIG or placebo. There was no difference in the viral characteristics of the infected neonates and similar viral loads in amniotic fluid and neonatal urine were detected among the groups. Interestingly, the HIG arm was notable for increased risk of adverse outcome, specifically preterm delivery, preeclampsia, fetal growth restriction. The risk was not statistically significant. There is currently one trial in progress addressing HIG use.

POSTNATAL

Treatment is generally not necessary or recommended for healthy children and adults. Newborns are treated if they are symptomatic. Antiviral medications (ganciclovir, cidofovir, and foscarnet) are used to prevent viral division. However, these drugs are not curative. Two CMV vaccines have been evaluated, but a reliable vaccine is not yet available.[8]

KEY POINTS

- CMV is the most common cause of *in utero* infection.
- US signs associated with CMV are multiple and nonspecific.
- As the number of US findings increases, the likelihood of CMV as the cause also increases.
- The sensitivity of US examination in detecting fetal CMV is 30%; only half of the US signs are detected before 22 weeks' gestation.
- A normal second-trimester US examination does not exclude a severely affected fetus.
- A diagnostic amniocentesis should not be performed until 6 weeks after maternal exposure and after 21 weeks' gestation.
- An abnormal prenatal US examination, a low neonatal platelet count, and microcephaly have been identified as the most predictive markers of adverse outcome after an *in utero* CMV infection.

Acknowledgment

The authors are indebted to Lyndon M. Hill, MD, for his work on this chapter in the first edition, and for generously contributing the images.

SUGGESTED READINGS

Bailao LA, Osborne NG, Rizzi MC, et al. Ultrasound markers of fetal infection. Part I. Viral infections. *Ultrasound Q*. 2005;21:295-308.

Crino UP. Ultrasound and fetal diagnosis of perinatal infection. *Clin Obstet Gynecol*. 1999;42:71-80.

Johnson J, Anderson B. Screening, prevention, and treatment of congenital cytomegalovirus. *Obstet Gynecol Clin North Am*. 2014;41:593-599.

Kenneson A, Cannon MJ. Review and meta-analysis of the epidemiology of congenital cytomegalovirus (CMV) infection. *Rev Med Virol*. 2007;17(4):253.

Nigro G. Maternal-fetal cytomegalovirus infection: from diagnosis to therapy. *J Matern Fetal Neonatal Med*. 2009;22:69-74.

Revello MG, Lazzarotto T, Guerra B, et al. CHIP Study Group. A randomized trial of hyperimmune globulin to prevent congenital cytomegalovirus. *N Engl J Med*. 2014;370:1316-1326.

Stagno S, Britt W. Cytomegalovirus infections. In: Remington JS, Kelin JO, Wilson CB, et al, eds. *Infectious diseases of the fetus and newborn infant*. 6th ed. Philadelphia: Saunders; 2006:739-781.

Rubella

SARAH N. CROSS

Introduction

Rubella, which is also called *German measles*, was first described in the 1750s. In the 1940s an association between congenital cataracts and maternal rubella was noted[39] during an epidemic in Australia. Subsequently, congenital rubella syndrome (CRS) was identified.[40] There was a worldwide rubella pandemic between 1962 and 1965; in the United States between 1964 and 1965 there were an estimated 12.5 million cases of rubella, 11,250 fetal deaths, 2100 neonatal deaths, and 20,000 infants born with CRS.[41] In 1969 a vaccine was introduced in the United States that substantially decreased the incidence of rubella infection.[42,43]

Disorder

DEFINITION

Congenital rubella infection (CRI) refers to all pregnancy outcomes associated with intrauterine rubella infection including miscarriage, fetal demise, congenital malformations, as well as asymptomatic infection.[43] *CRS* refers to a variable constellation of birth defects such as hearing impairment, congenital heart defects, cataracts/glaucoma, and retinopathy.[43] To meet criteria for CRS, there has to be more than one identifiable birth defect.[43]

PREVALENCE AND EPIDEMIOLOGY

Once rubella became a nationally notifiable disease in 1966, accurate estimates of the number of cases in the United States

was possible.[42] In 1969 just before the introduction of the vaccine, the reported incidence of rubella was 57,686 cases.[42] By 1983 fewer than 0.5 cases per 100,000 people were reported.[44]

In 2004 rubella was officially declared eliminated from the United States, and in 2015 rubella was officially declared eliminated from the Americas.[45] However, cases have been seen in the United States, potentially because of a drop-off in vaccination; in 2013 there were nine cases of rubella and one case of CRS reported in the United States.[44]

Worldwide, the incidence of rubella correlates with economic development. By 2002 rubella immunization existed in 100% of industrialized nations, 71% of countries with transitioning economies, and 48% of developing countries.[46] Rubella vaccine was introduced nationwide in 140 countries by the end of 2014, up from 85 countries in 1996.[47]

ETIOLOGY AND PATHOPHYSIOLOGY

Rubella virus is a single stranded ribonucleic acid virus that belongs to the *Rubivirus* genus and the *Togavirus* family. Humans are the only known natural host.[48] The virus replicates primarily in the nasopharynx, and primary infection occurs by respiratory transmission. Viremia begins 5 to 7 days postinfection. Rubella infection persists for an average of 14 days (range 12–23 days) with a prodrome of low-grade fever and lymphadenopathy in the second week, followed by macropapular rash 14–17 days postexposure.[48] Infectivity is possible from 1–2 weeks before the onset of symptoms to 14 days after the rash has resolved. Infection usually confers immunity; however, reinfection can occur.

During maternal viremia, maternal-fetal transmission can occur via hematogenous spread. After infecting the placenta, the virus spreads through the fetal vascular system. Rubella virus is thought to exert its teratogenic effects via vasculitis or apoptosis.[48,49]

MANIFESTATIONS OF DISEASE

Clinical Presentation

CRS refers to a variable constellation of birth defects often including hearing impairment, congenital heart defects, cataracts/glaucoma, and retinopathy,[42] as well as fetal growth restriction, hypotonia, developmental delay, and seizures.[50] Miller et al. followed 1016 cases with confirmed maternal rubella infection.[51] The frequency of congenital infection varied with gestational age; it occurred in more than 80% of women infected in the first trimester, and 54% infected between 13 and 14 weeks, decreasing to 25% by the end of the second trimester.[51] Improved fetal immune response and transfer of maternal antibodies across the placenta after 16 weeks are thought to make congenital damage less severe after 16 weeks.[40]

Imaging Technique and Findings

Ultrasound. The most common US findings associated with rubella infection include cardiac defects (atrial and ventricular septal defects, pulmonary artery hypoplasia, and after birth, patent ductus arteriosus), ocular anomalies (cataracts and microphthalmia), microcephaly, hepatomegaly, splenomegaly, and growth restriction.[50] Less common anomalies include peripheral pulmonic stenosis, glaucoma, meningocele, renal disorders, hypospadias,[52] meconium peritonitis,[53] and hyperechoic bowel as well as intracranial calcifications[54] and subependymal pseudocysts.[55]

In pregnancies suspected to be complicated by rubella infection, a detailed fetal US should be performed, with special attention to intracranial, ophthalmic, and cardiac structures. If necessary, transvaginal US should be performed for optimal intracranial imaging. A fetal echocardiogram should also be performed.

CLASSIC SIGNS

- Cardiac defects (atrial and ventricular septal defects, pulmonary stenosis).
- Ocular anomalies (cataracts and microphthalmia).
- Microcephaly.
- Hepatomegaly.
- Splenomegaly.
- Growth restriction.

Magnetic Resonance Imaging. The CNS findings make MRI an ideal modality to assess the fetus in the late second or third trimester. MRI may be more sensitive than US for minor atrophic changes and white matter lesions.[56]

Differential Diagnosis From Imaging Findings

Several congenital infections have overlapping findings, such as cataracts and hepatosplenomegaly. Therefore all the TORCH infections (e.g., *t*oxoplasmosis, *o*ther [syphilis, varicella], *r*ubella, *c*ytomegalovirus, and *h*erpes) should be considered in the differential diagnosis. In addition, several syndromes have similar findings, such as Smith-Lemli-Opitz syndrome, an autosomal recessive condition caused by 7-dehydrocholesterol reductase deficiency that includes growth restriction and congenital heart disease.[57] With an estimated incidence of 1 in 20,000, Smith-Lemli-Opitz syndrome is more common than congenital rubella.

Evaluation of maternal rubella immunization status, evaluation for other TORCH infections as well as carrier testing for Smith-Lemli-Opitz syndrome can be performed to help determine the correct diagnosis.

Synopsis of Treatment Options

PRENATAL

The most important management strategy for CRS is prevention, as there is no effective treatment. Females of childbearing age should be immunized against rubella if nonimmune. Women planning pregnancy should have their immunization status checked preconception and vaccinated as necessary. Pregnant women should also have their immunization status checked. Nonimmune women should be counseled on avoidance of individuals with suspected rubella and then be vaccinated postpartum. Importantly, the vaccine is not administered during pregnancy, as the live attenuated vaccine can be transmitted to the placenta,[58] although there is no evidence of CRS occurring after immunization.

Women suspected of having a pregnancy affected by rubella infection should be referred to a physician with expertise in the area. Prenatal consultations depending on organ system involvement are recommended. Delivery at a tertiary care center is recommended.

POSTNATAL

Postnatal management involves vaccination for prevention in unaffected infants. The Centers for Disease Control recommends two doses of the measles-mumps-rubella vaccine; the first dose at 12–15 months and the second dose at 4–6 years of age.[45]

Affected infants require multidisciplinary individualized supportive therapies depending on disease status and organ system involvement.

WHAT THE REFERRING PHYSICIAN NEEDS TO KNOW

Women who are nonimmune to rubella should be counseled on avoidance of exposure to infection during pregnancy. Nonimmune women with suspected exposure should be referred to a physician with expertise, such as maternal-fetal medicine. Women with US findings suspicious for congenital rubella should also be referred to imaging experts, and should be delivered at a tertiary care center.

KEY POINTS

- CRS occurs in 80% of women infected with rubella in the first trimester.
- Fetal damage from rubella is rare after 16 weeks' gestation.
- Common US findings include congenital heart disease and ocular abnormalities.
- Women of childbearing age should be vaccinated against rubella if nonimmune.

SUGGESTED READINGS

Degani S. Sonographic findings in fetal viral infections: a systematic review. *Obstet Gynecol Surv*. 2006;61(5):329-336.

Toxoplasmosis

SARAH N. CROSS

Introduction

Toxoplasmosis is caused by an intracellular parasite, *Toxoplasma gondii,* that can infect most animals. Although common in France, Central America, and Africa, toxoplasmosis is uncommon in the United States.[59] In patients with a suspected fetal toxoplasmosis infection, associated US findings can assist in counseling as infection during pregnancy poses significant threat to the fetus/newborn.

Disorder

PREVALENCE AND EPIDEMIOLOGY

Serologic confirmation of prior *T. gondii* infection is as high as 84% in Paris.[60] Congenital toxoplasmosis is estimated to occur in 1:1000–1:10,000 live births[61] in the United States, causing 400–4000 cases per year.[62] The fetal infection rate in France is 10 times the infection rate in the United States.[59]

ETIOLOGY AND PATHOPHYSIOLOGY

T. gondii is an obligate intracellular protozoan parasite that reproduces in cats, the only known hosts.[63] The organisms burrow into the small intestines; oocytes are passed through the feces.

TABLE 165.4 FETAL INFECTION AFTER MATERNAL TOXOPLASMOSIS INFECTION

Gestational Age (Week)	Infection Rate (%)
<6	1
6–16	4–6
17–28	20–40
>36	60–80

From Antsaklis A, Daskalakis G, Papantoniou N, Mentis A, Michalas S. Prenatal diagnosis of congenital toxoplasmosis. *Prenat Diagn* 22:1107–1111, 2002.

Infection occurs by consuming undercooked meat containing oocytes, consumption of insect-containing foods, by contact with oocytes in the feces of infected cats, or contact with infected insects in soil.[64]

Maternal risk factors, such as exposure to cat litter or eating raw meat, and a detectable illness have been recognized by less than half of women with infected neonates.[65] Fetal infection rates increase by gestational age (Table 165.4); however, infection within 2 weeks of the last menstrual period has not been associated with fetal disease.[66] Vertical transmission increases with gestation but severity of disease decreases.[64] During parasitemia the parasite crosses the placenta and infects the fetus.[64]

MANIFESTATIONS OF DISEASE

Clinical Presentation

Most people who are infected with toxoplasmosis are asymptomatic. When symptoms occur, they are nonspecific such as headache, fever, fatigue, and muscle aches and are usually present after 5–18 days.[64,67] When an adult is infected, the parasite spreads throughout the body, forming cysts. A pregnant woman with reactivated *T. gondii* can transmit the organism to her fetus.

Most children with congenital toxoplasmosis are normal, but they can have significant long-term sequelae, including visual impairment and neurologic damage.[68] Up to 85% of newborns with congenital toxoplasmosis are asymptomatic at birth, but they may go on to develop symptoms if left untreated.[69]

Serologic tests are used to diagnose acute toxoplasmosis in pregnant women; however, they are limited by the fact that IgM can persist for several months to 1 year.[67] Because false-positive results can occur, a serologic diagnosis should be confirmed by an acknowledged reference laboratory for avidity testing.[64]

Fetal diagnosis relies on amniocentesis. Second-trimester amniocentesis PCR DNA amplification is the test of choice to diagnose fetal toxoplasmosis.[66] Because the fetal immune system may not produce IgM antibodies until after 22 weeks' gestation, second-trimester fetal blood sampling lacks sufficient sensitivity to establish or refute a diagnosis of fetal infection.[63]

Imaging Technique and Findings

Ultrasound. US findings associated with toxoplasmosis are outlined in Table 165.5. Many findings are nonspecific. Ventriculomegaly (Fig. 165.11), secondary to white matter necrosis, is one of the most frequent findings.[70] Cerebral dilation is usually bilateral and symmetric.

Multifocal diffuse parenchymal necrosis of the cerebrum, cerebellum, brain stem, and spinal cord can be seen.[71] Other findings include intracranial calcifications, microcephaly, ascites, and hepatosplenomegaly.[72,73]

TABLE 165.5 ULTRASOUND FINDINGS WITH CONGENITAL TOXOPLASMOSIS

- Central nervous system
  - Ventriculomegaly
  - Intracerebral calcifications
  - Periventricular calcifications
  - Lenticulostriate vasculitis
  - Microcephaly
  - Microphthalmia
  - Cataracts
  - Retinal calcifications
- Anemia
- Nonimmune hydrops
- Ascites
- Pleural effusion
- Pericardial effusion
- Myocardial calcifications
- Hepatomegaly
- Hepatic calcifications
- Placentomegaly

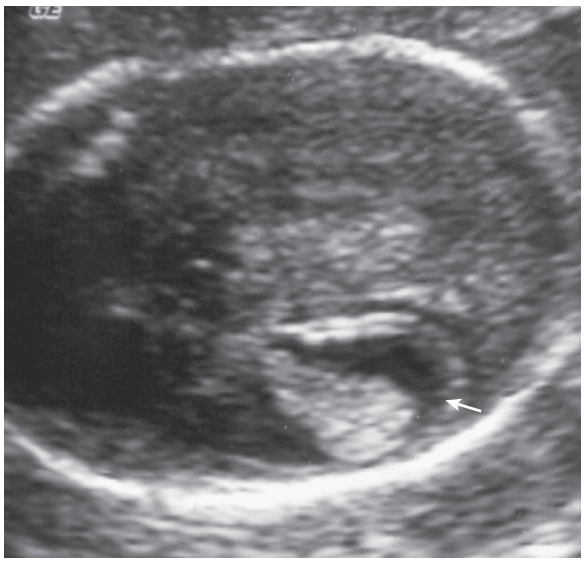

Fig. 165.11 White matter necrosis and secondary ventriculomegaly *(arrow)*.

Magnetic Resonance Imaging. As with other congenital infections, MRI can be used as an adjunct to US in the evaluation of fetuses with toxoplasmosis infection. MRI can be used to monitor severity of neurologic disease, but imaging can be normal in infected fetuses.[74]

CLASSIC SIGNS

Ventriculomegaly.
Intracranial calcifications.

Differential Diagnosis From Imaging Findings

Many of the congenital infections have significant overlap in US abnormalities; therefore other congenital infections must be considered. Other infections to consider include CMV (ventriculomegaly, intracranial calcifications, hepatosplenomegaly, and ascites) and parvovirus (ascites) among others. When hydrops is present, the differential diagnosis extends far beyond congenital infections. A systematic workup is required, including maternal history and blood work and a detailed US scan. Amniotic fluid sampling and MRI, when appropriate, may also be performed.

TABLE 165.6 FETAL INFECTION AFTER MATERNAL TOXOPLASMOSIS INFECTION

Trimester	Treated (%)	Untreated (%)
1st	4.5	10.0
2nd	17.3	30.0
3rd	29.0	60.0

From Wong SY, Remington JS. Toxoplasmosis in pregnancy. *Clin Infect Dis* 18:853–61, 1994.

Synopsis of Treatment Options

PRENATAL

There is insufficient evidence to conclude whether treatment prevents maternal-fetal transmission, according to a Cochrane review.[75]

However, spiramycin should be used in the setting of acute maternal infection (with no fetal infection by amniotic fluid PCR) as there is some evidence that it may reduce transplacental transmission (Table 165.6). Importantly, spiramycin does not cross the placenta and cannot be used to treat fetal disease.[76]

When there is evidence of fetal infection, pyrimethamine, sulfadiazine, and folinic acid are administered.[76]

POSTNATAL

Infants with congenital toxoplasmosis are treated with pyrimethamine and sulfadiazine for approximately 1 year.

WHAT THE REFERRING PHYSICIAN NEEDS TO KNOW

Signs of toxoplasmosis on US can be nonspecific.
Pregnant women and women planning pregnancy should be counseled on prevention.
Women suspected of having toxoplasmosis by history, symptoms, or because of abnormal US findings should be referred to Maternal-Fetal Medicine.

KEY POINTS

Serologic testing can have false results and requires confirmation in a reference laboratory.
Diagnosis of fetal infection can be made by amniocentesis.
Treatment should be offered for both maternal and fetal infection.

SUGGESTED READINGS

ACOG. Practice bulletin no. 151: Cytomegalovirus, Parvovirus B19, Varicella Zoster, and Toxoplasmosis in pregnancy. *Obstet Gynecol*. 2015;125(6):1510-1525.

Peyron F, Wallon M, Liou C, et al. Treatments for toxoplasmosis in pregnancy. *Cochrane Database Syst Rev*. 2000;(2):CD001684.

Herpes Simplex Virus

HEATHER S. LIPKIND

Introduction

Perinatal herpes simplex virus is primarily acquired as the fetus descends through the birth canal. Prospective data suggests that the incidence of neonatal HSV disease is 1:10,000–3:10,000 deliveries.[77,78] Congenital infection is rare—approximately 5% of reported cases with the balance acquired during birth (acquired). US assessment of the fetus has a limited role in assisting in the management of congenital HSV.

Disease

PREVALENCE AND EPIDEMIOLOGY

There are 1500 to 2000 cases of neonatal herpes reported in the United States each year[79]; 5% are acquired *in utero*.[80,81] Neonatal herpes may be caused by either type 1 or type 2 HSV infection. Congenital infection is caused by type 2 HSV in 90% of cases; however, HSV-1 has been associated with an increasing proportion of cases, especially among young women.

Infection with either HSV-1 or HSV-2 has been categorized into either:

1. primary, or first episode, which is when a patient has a first occurrence of a genital HSV lesion and no preexisting HSV type 1 or 2,
2. nonprimary first episode, when there is a new infection with one virus type, but antibodies to the other virus type are present, owing to a prior infection (either HSV-1 or HSV-2),
3. recurrent infection after reactivation of a dormant virus.[82]

ETIOLOGY AND PATHOPHYSIOLOGY

The herpesvirus has a double-stranded DNA genome. Fetal infection may occur through maternal blood or ascend through the cervix.[80] *In utero*, HSV may be caused by either primary or recurrent maternal infection, although the majority occurs with primary infection.[83] One-third of women have clinical symptoms associated with HSV infection, which typically present as painful genital ulcers, pruritus, dysuria, fever, tender inguinal lymphadenopathy, and headache. However, most patients have only mild symptoms or remain asymptomatic.[84] Neonatal herpes can be divided into three categories: localized skin, eye, mouth infection (45%), CNS disease (30%), and disseminated herpes, a sepsis-like presentation involving multiple organs (25%).[85]

HSV-1 or HSV-2 becomes latent by hiding in nerves. With reactivation, the virus is transported via the nerve to the skin. The virus may be reactivated by illness, injury, or emotional stress. Viral replication and shedding occurs from pustules on the skin. HSV-1 and HSV-2 are spread through close contact with an individual who is shedding the virus. HSV-2 is primarily spread through sexual contact, whereas HSV-1 is usually acquired orally. HSV cannot be eradicated from the body. Antiviral medication interferes with viral replication, reducing the severity of outbreaks. The use of acyclovir can reduce HSV-2 viral shedding by 60% to 80% and transmission by 50%. Attempts at developing a vaccine have been unsuccessful to date.[86]

MANIFESTATIONS OF DISEASE

Clinical Presentation

During a primary maternal infection, there are higher titers of virus, and the virus is excreted for a longer period. As a result, transplacental infection occurs, more commonly with a primary rather than a recurrent infection.[87] Infection may also be ascending, resulting in chorioamnionitis. This can occur after prolonged rupture of membranes or rupture of membranes near term in someone with an active HSV infection. With an ascending infection, the infant might be born with only skin and mucous membrane lesions. This has also been noted to occur at the time of a cesarean in cases with intact membranes and active herpes.[88] Both primary and recurrent maternal infections can result in intrauterine transmission of HSV to the fetus.

An association with elevated maternal serum alpha-fetoprotein is because of fetal hepatic damage. Amniotic fluid acetylcholinesterase may be abnormally elevated owing to the severity of HSV skin lesions.[89] Cutaneous, brain, and eye (chorioretinitis) abnormalities occur in 94%, 79%, and 54% of *in utero* infections, respectively.[90] The cytotoxic effects of HSV on the CNS can result in microcephaly or hydranencephaly. Severe brain damage may develop within 1 week of infection.[91]

Diagnosis. The diagnosis of HSV-1 or HSV-2 can be confirmed with amniotic fluid culture and herpes DNA PCR.

Imaging Technique and Findings

Ultrasound. US findings associated with congenital herpes simplex are outlined in Table 165.7 and shown in Figs. 165.12–165.17. The predominance of CNS findings is consistent with the prevalence of CNS-associated infection. Focal cystic necrosis may result in intracerebral hemorrhage (see Fig. 165.13). Irregular echogenicities along the skin and esophagus are caused by erosive skin and mucosal lesions.[92] Dystrophic calcification of the myocardium indicates severe myocardial injury and has been reported with both CMV and HSV *in utero* infections.[93] Early HSV infection may prevent normal placental attachment, resulting in miscarriage. Placental villitis has been described with HSV infection and is associated with a risk of intrauterine

TABLE 165.7 ULTRASOUND FINDINGS WITH IN UTERO HERPES SIMPLEX VIRUS

1. Central Nervous System
   - Ventriculomegaly
   - Intracranial calcifications
   - Microcephaly
   - Hydranencephaly
   - Porencephaly
   - Cerebellar hypoplasia
   - Microphthalmia
   - Cataracts
2. Nonimmune hydrops
3. Pleural effusion
4. Pericardial effusion
5. Myocarditis and dystrophic calcification
6. Hepatosplenomegaly
7. Esophageal echogenicity
8. Echogenic bowel
9. Absent fetal movements
10. Flexion deformities
11. IUGR
12. Polyhydramnios

IUGR, Intrauterine growth restriction.

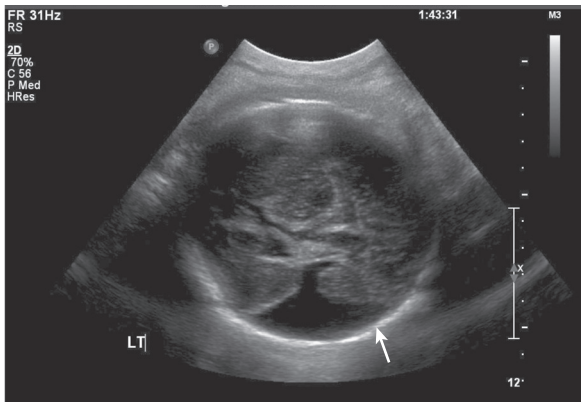

Fig. 165.12 Porencephalic cyst *(arrow)*. *LT,* Left.

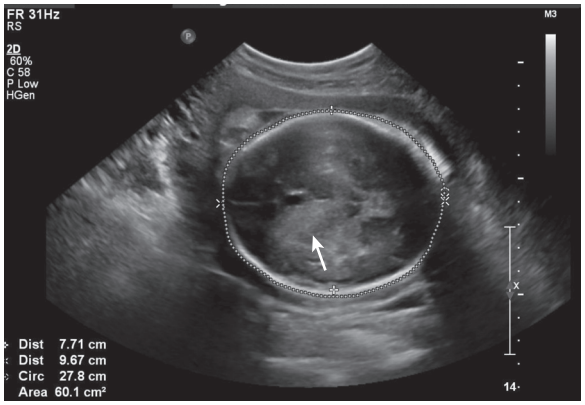

Fig. 165.13 Intracerebral clot *(arrow)*.

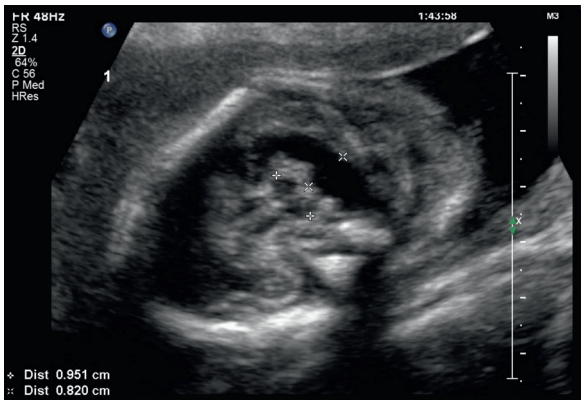

Fig. 165.14 Cerebellar hypoplasia *(between +…+)*.

growth restriction (IUGR) and fetal demise.[94] Nonimmune fetal hydrops (see Figs. 165.16 and 165.17) is only rarely reported with maternal-fetal transmission of herpes. Myocarditis has been proposed as the possible etiology of nonimmune hydrops.[95]

Magnetic Resonance Imaging. The role of MRI in congenital herpes infection is to assess the severity of CNS malformations in the late second or early third trimester.[80]

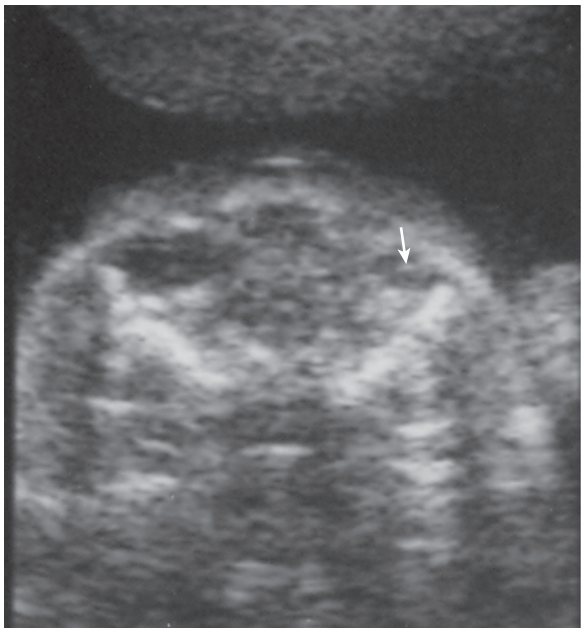

Fig. 165.15 Unilateral *(arrow)* microphthalmia.

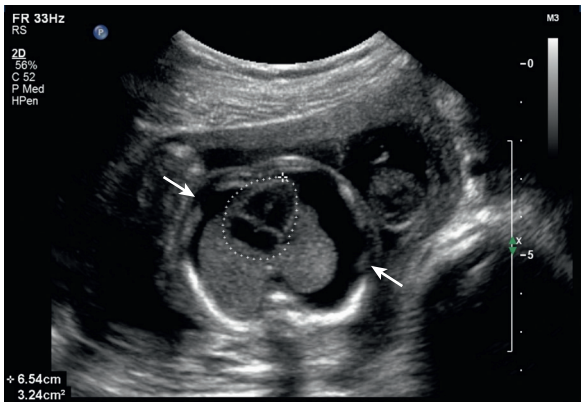

Fig. 165.16 Bilateral pleural effusions *(arrows)*. The heart circumference *(graticules)* is normal for a 22-week intrauterine pregnancy.

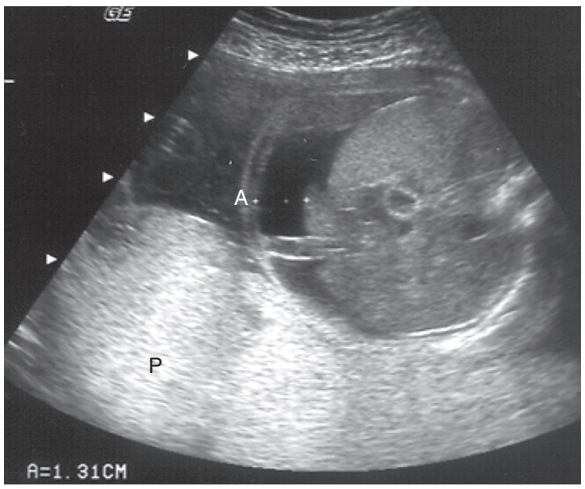

Fig. 165.17 Ascites *(A)* and placentomegaly *(P)* associated with nonimmune hydrops.

Differential Diagnosis From Imaging Findings

Limb hypoplasia has been described with both congenital varicella and congenital HSV. Other US findings associated with *in utero* HSV infection may also be caused by other *in utero* infections. IUGR has numerous etiologies. Placental villitis associated with congenital herpes must be distinguished from other etiologies of IUGR.

Synopsis of Treatment Options

PRENATAL

The observed rate of congenital anomalies after first-trimester acyclovir exposure is the same as in the general population.[96] The use of acyclovir to prevent fetal infection or to try to improve fetal prognosis is controversial.

POSTNATAL

Untreated neonatal HSV has a 40% survival rate. Antiviral therapy with intravenous acyclovir reduces the mortality from CNS disease to 6% and to 30% in infants with disseminated disease.[92] However, neonates with CNS herpes who are appropriately treated still have high rates of developmental problems, and 50% have neurologic abnormalities.[97]

KEY POINTS

- Only 5% of neonatal herpes is acquired *in utero*.
- HSV cannot be eradicated from the body.
- Transplacental infection is more common with primary rather than recurrent infection.
- A newborn with a vesicular rash should be evaluated for HSV.
- Because of herpes predilection for the CNS, any neonate with a CNS infection should be evaluated for HSV.

SUGGESTED READINGS

Brown ZA, Selke S, Zeh J, et al. The acquisition of herpes simplex virus during pregnancy. *N Engl J Med*. 1997;337(8):509.

Core L, Wald A. Maternal and neonatal HSV infections. *N Engl J Med*. 2009;361:1376-1385.

Sauerbrei A, Wutzler P. Herpes simplex and varicella-zoster virus infections during pregnancy: current concepts of prevention, diagnosis and therapy. Part I. Herpes simplex virus infections. *Med Microbiol Immunol*. 2007;196: 89-94.

Varicella

HEATHER S. LIPKIND

Introduction

Although the Varicella infection has decreased over the past decade because of the introduction of the vaccine in 1995,[98] varicella remains a highly contagious viral infection. Fetal varicella syndrome (FVS) can occur because of transplacental infection by the Varicella zoster virus (VZV) following maternal disease. When infection occurs before 20 weeks' gestation the incidence of FVS is about 1%–2% and can affect the fetal skin, limbs, nervous system, eyes, and can cause growth restriction and mortality. US, MRI, and amniocentesis can be used to help diagnosis of viral transmission.[99]

Disease

PREVALENCE AND EPIDEMIOLOGY

VZV can manifest as two distinct forms of disease, either varicella (chicken pox) or herpes zoster (shingles). The incidence of varicella infection during pregnancy in the United States is estimated to be one to five cases per 10,000 pregnancies.[100] The decreased incidence is caused by the increased uptake of the varicella vaccine in temperate climates, as 90% to 95% of adult women are immunized to VZV, having had either chicken pox or a vaccination in childhood.[101] This proportion is lower in tropical latitudes. Varicella has a seasonal variation, with the highest rates of infection occurring in winter and early spring.[102] Transmission requires direct contact with vesicular fluid or droplets from respiratory secretions. Maternal consequences of disease in pregnancy can be as high as 10% to 20%, with reported cases of severe pneumonia, and the illness can be more severe than in nonpregnant adults.[101] Herpes zoster (shingles) is caused by the reactivation of latent varicella virus.[103] The risk of fetal damage related to maternal zoster during pregnancy appears to be lower than with maternal varicella.[99]

ETIOLOGY AND PATHOPHYSIOLOGY

VZV is a DNA virus of the herpes family. It has properties of latency and reactivation. After the primary illness (varicella), the virus remains dormant in sensory nerve ganglia. When the virus is reactivated at a later date, shingles (herpes zoster) results. The overall risk of congenital varicella is very low. The miscarriage rate for pregnant women infected with varicella in the first 20 weeks of pregnancy is not higher than among uninfected pregnant controls, although there may be an increase in the risk for preterm delivery.[104] When a pregnant woman of any gestational age is infected with varicella, the risk of embryopathy is generally less than 1%.[105] The fetus can be infected transplacentally, and the fetal consequences depend on the period of gestation in which the infection occurs. The risk of congenital varicella syndrome (CVS) is greatest with infection during weeks 13 to 20 of pregnancy (1%–2%),[104] and some cases have been reported between 20 and 25 weeks. A syndrome of congenital anomalies associated with early pregnancy varicella infection has been known since 1947 and consists of limb hypoplasia, cortical atrophy, skin scarring, tissue calcifications, and eye defects.[106] Since this description, several other cases have been reported. Maternal varicella diagnosed shortly before delivery is associated with a high incidence of neonatal varicella because of the lack of protective IgG antibodies crossing the placenta from the mother.[107] Transmission can occur *in utero* or postnatally through respiratory droplets, or by direct contact with someone with varicella.

There have been only isolated case reports of congenital abnormalities after maternal herpes zoster.[108] No infants with varicella embryopathy were observed in the large prospective series of Enders et al., which included 119 pregnancies in women who had zoster in gestational weeks 0–12, 117 pregnancies in women who had zoster in weeks 13–24, and 130 pregnancies in women who had zoster after the 24th week.[104]

MANIFESTATIONS OF DISEASE

Clinical Presentation

The primary symptoms of varicella include fever, headache, sore throat, and an absence of appetite. A pruritic vesicular rash involving the scalp and face and often the trunk develops 1 to 2 days after the onset of symptoms. If the physician is not certain of the diagnosis, fluid or scrapings from the lesions can be tested for the presence of VZV. Treatment is symptomatic to reduce the fever and itching associated with the rash. Possible complications from chicken pox include a secondary bacterial skin infection, dizziness, and tremors secondary to cerebellar ataxia, pneumonia, and encephalitis.

The first symptom of herpes zoster is a burning pain along the dermatome supplied by a specific sensory nerve. The pain resolves over 3 to 5 weeks. *Postherpetic neuralgia* refers to pain in the affected area that may last for months to years.

Diagnosis. Prenatal diagnosis is based mainly on US and amniocentesis. Women should not be seen in a practice setting in proximity to other pregnant women until 2 weeks after all active lesions have disappeared to avoid infecting other pregnant women. Fetal varicella can be diagnosed by amniotic fluid VZV DNA PCR. PCR is more sensitive than a cell culture of amniotic fluid for detecting VZV. False-positive and false-negative reactions may occur with PCR.[109] Demonstration of VZV DNA in amniotic fluid with PCR is not inevitably associated with CVS.[109,110]

Imaging Technique and Findings

Ultrasound. Fetal malformations associated with VZV (Table 165.8) have been reported after infection in all three trimesters.[111] Limb involvement is a hallmark of CVS and may be manifested by hypoplasia, flexed limbs, or clubbed feet (Figs. 165.18–165.21). Skin lesions are the most common manifestation of CVS, and occasionally the only manifestation, and may not be accessible to US. A pericranial halo suggests the presence of scalp lesions.

TABLE 165.8 ULTRASOUND FINDINGS WITH CONGENITAL VARICELLA

Central Nervous System or eye abnormalities
Ventriculomegaly
Cerebral calcifications
Microcephaly
Cerebral hypoplasia
Microphthalmia
Cataracts
Musculoskeletal
Contractures
Clubbed foot
Limb atrophy/hypoplasia
Decreased limb movement
Rudimentary digits
Hypoplastic scapula
Hypoplastic clavicle
Nonimmune hydrops
Transient ascites
Lung calcifications
Hepatic calcifications
Myocardial calcifications
Pericranial echogenicities suggesting scalp lesions
Intrauterine growth restriction
Polyhydramnios or oligohydramnios
Defects of other organs

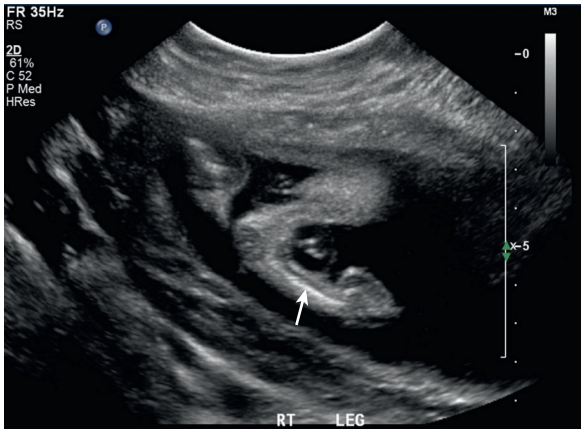

Fig. 165.18 Right leg atrophy *(arrow)* and clubbed foot.

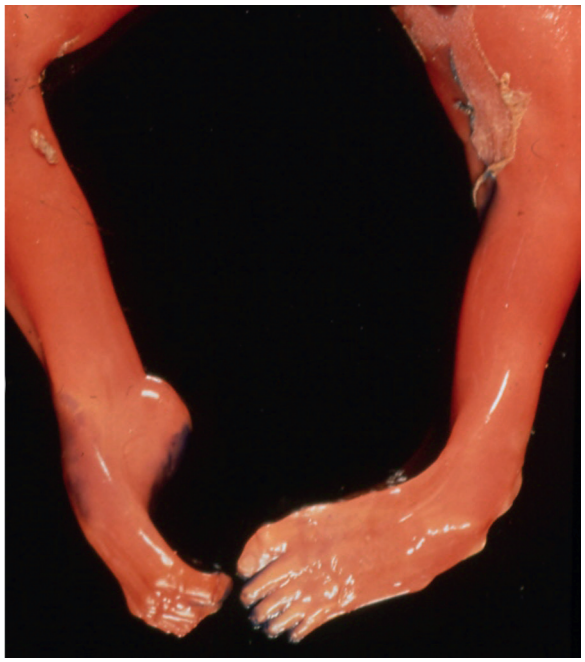

Fig. 165.19 Lower limb clubbing and atrophy. This is a pathologic specimen from the case shown in Fig. 165.18.



Fig. 165.20 Right arm atrophy and contracture.

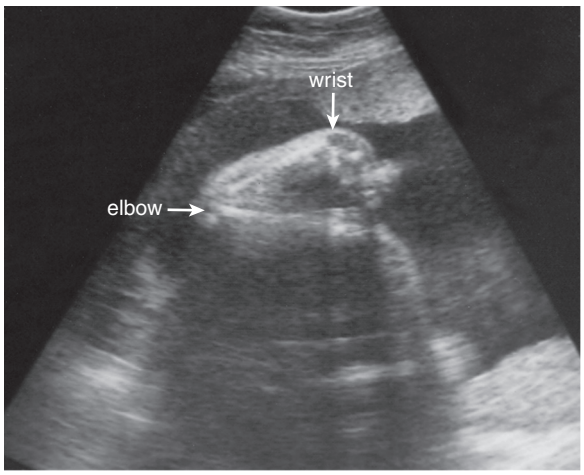

Fig. 165.21 Contracture of the arm.

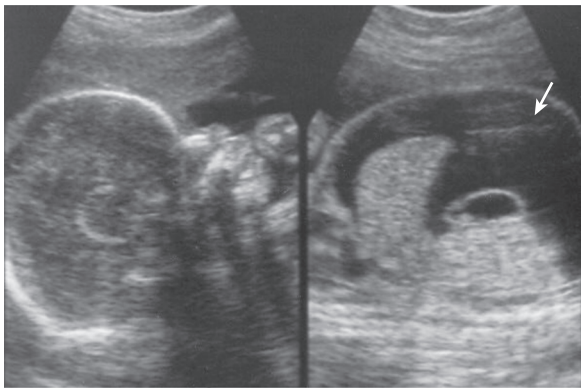

Fig. 165.22 Ascites *(arrow)* associated with hydrops.

Varicella frequently affects the CNS, resulting in necrotizing encephalitis.[112] Of fetuses with varicella and a hypoplastic limb, 39% have brain damage or die in infancy.[110] The punctate calcifications that may occur with CVS in the lungs, heart, and liver are spread diffusely throughout the organ.[106,110] Nonimmune hydrops (Fig. 165.22) has been detected within 5 weeks of maternal exposure to varicella. The rapid onset of hydrops suggests that it may be secondary to myocarditis.[111]

Pretorius et al.[111] evaluated 37 cases of maternal varicella infection from seven institutions; 28 cases involved exposure in the first trimester, and nine cases involved exposure in the second trimester. Varicella embryopathy was diagnosed on prenatal US in five cases. However, defects may not be evident on US until late in pregnancy, either because maternal infection occurs later in gestation or because of the variable time frame from primary infection to reactivation of the virus.[112] A normal detailed second-trimester US examination cannot exclude fetal damage. Reassuringly, however, a study has shown that as a group, children born to women infected with VZV during pregnancy who did not have structural characteristics of fetal varicella syndrome were not neurologically different from controls.[113]

Invasive Testing. When maternal infection has been confirmed, two approaches should be discussed with the patient, as there is no treatment for *in utero* varicella, and it has such a variable prognosis. The first is to offer invasive diagnosis in the case of maternal varicella before 20 weeks; the other is to perform serial US examinations to look for anomalies. Invasive testing can be reassuring, as the majority will test negative.[99] Amniocentesis should not be performed until all skin lesions have resolved to avoid seeding the amniotic fluid with virus, and it may be advisable to wait 4 weeks or more to avoid false-negative results.[99] With positive testing and a normal US, poor neurologic outcome is possible even if nothing is seen. The collection of cases from multiple centers serves to indicate that detailed US can detect cases with physical stigmata. As with other congenital infections, a time interval of at least 5 weeks is required between fetal infection and the manifestations of the abnormalities that may be detectable with US.[111] The data on CVS for prenatal diagnosis of fetal varicella is scarce. False-positive results may occur because of maternal contamination.[114]

The severity of the effects on the fetus depends on gestational age at exposure, the dermatomes involved by herpes zoster, and the severity of herpes zoster. The resulting effects on the fetus may vary from lesions limited to a single organ such as the skin to multiple organs, including the CNS, eyes, urogenital tract, and other organs.[115] Although US can document potential effects from fetal herpes zoster syndrome, the US findings do not predict postnatal outcome. Lecuru et al.[114] reported a case of fetal herpes zoster syndrome with ascites, pericardial effusion, and hepatomegaly detected at 27 weeks' gestation. The ascites and pericardial effusion resolved by 32 weeks' gestation. The infant was clinically normal at delivery; there were no ophthalmic abnormalities.

Magnetic Resonance Imaging. Because varicella frequently infects the CNS, MRI may be a valuable adjunct to US in evaluating the fetus in the third trimester. In addition to severe CNS abnormalities, MRI can detect neuronal migration disorders and other subtle CNS malformations.[112]

Differential Diagnosis From Imaging Findings

There is a significant overlap in US findings associated with congenital infections secondary to varicella, herpes, toxoplasmosis, and cytomegalovirus. If the characteristic limb contractures are the only US findings, amniotic bands must also be considered in the differential diagnosis.

Synopsis of Treatment Options

PRENATAL

Nonimmune pregnant women who are exposed to varicella should be given varicella zoster Ig antibodies intramuscularly within 72 hours of exposure. Although there is no evidence that this treatment prevents fetal viremia or CVS, it lessens the severity of maternal chicken pox.[116]

POSTNATAL

Acyclovir is used to treat disseminated maternal infection and pneumonia. There are no controlled studies evaluating acyclovir in preventing CVS.[114] Ideally, seronegative women should be immunized before pregnancy.

KEY POINTS

- The risk for CVS (1%–2%) is greatest between 13 and 20 weeks' gestation.
- CVS is caused be reactivation of VZV.
- Limb involvement is a hallmark of CVS.
- Varicella frequently affects the CNS.
- The congenital abnormalities associated with VZV may not be evident until late in gestation.
- Biologic effects of VZV infection detected on US do not predict postnatal outcome.

SUGGESTED READINGS

Mandelbrot L. Fetal varicella—diagnosis, management, and outcome. *Prenat Diagn*. 2012;32:511-518.



All references available online at www.expertconsult.com

REFERENCES

Cytomegalovirus

1. Kenneson A, Cannon MJ. Review and meta-analysis of the epidemiology of congenital cytomegalovirus (CMV) infection. *Rev Med Virol*. 2007;17(4):253.
2. Ornoy A, Diav-Citrin O. Fetal effects of primary and secondary cytomegalovirus infection in pregnancy. *Reprod Toxicol*. 2006;21(4):399.
3. Stagno S, Pass RF, Cloud G, et al. Primary cytomegalovirus infection in pregnancy. Incidence, transmission to fetus, and clinical outcome. *JAMA*. 1986;256:1904-1908.
4. Johnson J, Anderson B. Screening, prevention, and treatment of congenital cytomegalovirus. *Obstet Gynecol Clin North Am*. 2014;41:593-599.
5. Staras SA, Dollard SC, Radford KW, et al. Seroprevalence of cytomegalovirus infection in the United States, 1988-1994. *Clin Infect Dis*. 2006;43(9):1143.
6. Zalel Y, Gilboa Y, Berkenshtat M, et al. Secondary cytomegalovirus infection can cause severe fetal sequelae despite maternal preconceptional immunity. *Ultrasound Obstet Gynecol*. 2008;31:417-420.
7. Benoist G, Salomon LJ, Mohlo M, et al. Cytomegalovirus in related fetal brain lesions: comparison between targeted ultrasound examination and magnetic resonance imaging. *Ultrasound Obstet Gynecol*. 2008;32:900-905.
8. Chandler SH, Alexander ER, Holmes HR. Epidemiology of cytomegalovirus infection in a heterogeneous population of pregnant women. *J Infect Dis*. 1985;152:249-256.
9. Adler SP, Nigro G, Pereira L. Recent advances in the prevention and treatment of congenital cytomegalovirus. *Semin Perinatol*. 2007;31:10-18.
10. Fowler KB, McCollister FP, Dahle AJ, et al. Progressive and fluctuating sensorineural hearing loss in children with asymptomatic congenital cytomegalovirus infection. *J Pediatr*. 1997;130(4):624.
11. Boppana SB, Fowler KB, Britt WJ, et al. Symptomatic congenital cytomegalovirus infection in infants born to mothers with preexisting immunity to cytomegalovirus. *Pediatrics*. 1999;104(1 Pt 1):55.
12. Lazzarotto T, Gabrielli L, Fuschini MP, et al. Congenital cytomegalovirus in twin pregnancies: viral load in amniotic fluid and pregnancy outcome. *Pediatrics*. 2003;112:e.153-e.157.
13. Lazzarotto T, Ripalti A, Bergamini G, et al. Development of a new cytomegalovirus (CMV) immunoglobulin M (IgM) immunoblot for detection of CMV-specific IgM. *J Clin Microbiol*. 1998;36(11):3337.
14. Leruez-Ville M, Sellier Y, Salomon LJ, et al. Prediction of fetal infection in cases with cytomegalovirus immunoglobulin M in the first trimester of pregnancy: a retrospective cohort. *Clin Infect Dis*. 2013;56(10):1428.
15. Kanengisser-Pines B, Hazan Y, Pines G, et al. High cytomegalovirus IgG avidity is a reliable indicator of past infection in patients with positive IgM detected during the first trimester of pregnancy. *J Perinat Med*. 2009;37(1):15.
16. Azam AZ, Vial Y, Fawer CL, et al. Prenatal diagnosis of congenital cytomegalovirus infection. *Obstet Gynecol*. 2001;97(3):443.
17. Liesnard C, Donner C, Brancart F, et al. Prenatal diagnosis of congenital cytomegalovirus infection: prospective study of 237 pregnancies at risk. *Obstet Gynecol*. 2000;95(6 Pt 1):881.
18. Lazzarotto T, Guerra B, Lanari M, et al. New advances in the diagnosis of congenital cytomegalovirus infection. *J Clin Virol*. 2008;41:192-197.
19. Benoist G, Salomon LJ, Jacquemard F, et al. The prognostic value of ultrasound abnormalities and biological parameters in blood of fetuses infected with cytomegalovirus. *Br J Obstet Gynaecol*. 2008;115:823-829.
20. LaTorre R, Nigro G, Manuela M, et al. Placental enlargement in women with a primary maternal cytomegalovirus infection is associated with fetal and neonatal disease. *Clin Infect Dis*. 2006;43:994-1000.
21. Shinmura Y, Kosugi I, Aiba-Masago S, et al. Disordered migration and loss of virus infected neuronal cells in developing mouse brains infected with murine cytomegalovirus. *Acta Neuropathol*. 1997;53:551-557.
22. Mittendorf R, Kuban K, Pryde PG, et al. Antenatal risk factors associated with the development of lenticulostriate vasculopathy (LSV) in neonates. *J Perinatol*. 2005;25:101-107.
23. Malingen G, Lev D, Zahalka N, et al. Fetal cytomegalovirus infection of the brain: the spectrum of sonographic findings. *AJNR Am J Neuroradiol*. 2003;24:28-32.
24. Simon-Bouy B, Satre V, Feree C, et al; French Collaborative Group. Hyperechogenic fetal bowel: a large French collaborative study of 682 cases. *Am J Med Genet A*. 2003;121:209-213.
25. Stein B, Bromley B, Michewitz H, et al. Fetal liver calcifications: sonographic appearance and postnatal outcome. *Radiology*. 1995;197:489-492.
26. Tongsong T, Sukpan K, Wanapirak C, et al. Fetal cytomegalovirus infection associated with cerebral hemorrhage, hydrops fetalis, and echogenic bowel: case report. *Fetal Diagn Ther*. 2008;23:169-172.
27. Benoist G, Ville Y. Features of the congenital CMV infection in the unborn and 23 newborn infant. *Fetal Matern Med Rev*. 2007;18:181-199.
28. Bailao LA, Osborne NG, Rizzi MC, et al. Ultrasound markers of fetal infection. Part 1. Viral infections. *Ultrasound Q*. 2005;21:295-308.
29. Guerra B, Simonazzi G, Puccetti C, et al. Ultrasound prediction of symptomatic congenital cytomegalovirus infection. *Am J Obstet Gynecol*. 2008;198:380.e1-380.e7.
30. Crino JP. Ultrasound and fetal diagnosis of perinatal infection. *Clin Obstet Gynecol*. 1999;42:71-80.
31. Enders G, Baden U, Lindemann L, et al. Prenatal diagnosis of congenital cytomegalovirus infection in 189 pregnancies with known outcome. *Prenat Diagn*. 2001;21:362-377.
32. Nigro T, LaTorre R, Pentinalli H, et al. Regression of fetal cerebral abnormalities by primary cytomegalovirus infection following hyperimmunoglobulin therapy. *Prenat Diagn*. 2008;28:512-517.
33. Revello MG, Lazzarotto T, Guerra B, et al. CHIP Study Group. A randomized trial of hyperimmune globulin to prevent congenital cytomegalovirus. *N Engl J Med*. 2014;370:1316-1326.
34. Harrison GJ. Cytomegalovirus. In: Cherry JD, Harrison GJ, Kaplan SL, et al, eds. *Feigin and Cherry's. Textbook of Pediatric Infectious Diseases*. 7th ed. Philadelphia: Elsevier Saunders; 2014:1969.
35. Lopez A, Dietz VJ, Wilson M, et al. Preventing congenital toxoplasmosis. *MMWR Recomm Rep*. 2000;49:57-75.
36. Sauerbrei A, Wutzler P. Herpes simplex and varicella-zoster virus infections during pregnancy: current concepts of prevention, diagnosis and therapy. Part I. Herpes simplex virus infections. *Med Microbiol Immunol*. 2007;196:89-94.
37. Hartung J, Enders G, Chaoui R, et al. Prenatal diagnosis of congenital varicella syndrome and detection of varicella-zoster in the fetus: a case report. *Prenat Diagn*. 1999;19:163-166.
38. Centers for Disease Control and Prevention. Summary of notifiable diseases, United States 1992. *MMWR Morb Mortal Wkly Rep*. 1993;41:50-73.

Rubella

39. Gregg NM. Congenital cataract following German measles in the mother. 1941. *Epidemiol Infect*. 1991;107(1):iii-xiv, discussion xiii-xiv.
40. Webster WS. Teratogen update: congenital rubella. *Teratology*. 1998;58(1):13-23.
41. Centers for Disease Control. Achievements in public health: elimination of rubella and congenital rubella syndrome—United States, 1969–2004. *MMWR Morb Mortal Wkly Rep*. 2005;54(11):279-282.
42. Orenstein WA, Bart KJ, Hinman AR, et al. The opportunity and obligation to eliminate rubella from the United States. *JAMA*. 1984;251(15):1988-1994.
43. Reef SE, Plotkin S, Cordero JF, et al. Preparing for elimination of congenital rubella syndrome (CRS): summary of a workshop on CRS elimination in the United States. *Clin Infect Dis*. 2000;31(1):85-95.
44. Adams D, Fullerton K, Jajosky R, et al. Summary of notifiable infectious diseases and conditions—United States, 2013. *MMWR Morb Mortal Wkly Rep*. 2015;62(53):1-122.
45. Center for Disease Control. Rubella, 2015. http://www.cdc.gov/rubella/.
46. Robertson SE, Featherstone DA, Gacic-Dobo M, et al. Rubella and congenital rubella syndrome: global update. *Rev Panam Salud Publica*. 2003;14(5):306-315.
47. World Health Organization. http://www.who.int/immunization/monitoring_surveillance/Global_Immunization_Data.pdf?ua=1.
48. Atreya CD, Mohan KV, Kulkarni S. Rubella virus and birth defects: molecular insights into the viral teratogenesis at the cellular level. *Birth Defects Res A Clin Mol Teratol*. 2004;70(7):431-437.
49. Wilson CB, Nizet V, Maldonado Y, et al. *Remington and Klein's infectious diseases of the fetus and newborn*. 8th ed. Philadelphia: Elsevier; 2016. In Print.
50. Degani S. Sonographic findings in fetal viral infections: a systematic review. *Obstet Gynecol Surv*. 2006;61(5):329-336.
51. Miller E, Cradock-Watson JE, Pollock TM. Consequences of confirmed maternal rubella at successive stages of pregnancy. *Lancet*. 1982;2(8302):781-784.
52. Benaceraf BR. *Ultrasound of fetal syndromes*. 2nd ed. Philadelphia: Elsevier; 2008.
53. Radner M, Vergesslich KA, Weninger M, et al. Meconium peritonitis: a new finding in rubella syndrome. *J Clin Ultrasound*. 1993;21(5):346-349.

54. Fakhry J, Khoury A. Fetal intracranial calcifications. The importance of periventricular hyperechoic foci without shadowing. *J Ultrasound Med*. 1991;10(1):51-54.
55. Makhoul IR, Zmora O, Tamir A, et al. Congenital subependymal pseudocysts: own data and meta-analysis of the literature. *Isr Med Assoc J*. 2001;3(3):178-183.
56. Yamashita Y, Matsuishi T, Murakami Y, et al. Neuroimaging findings (ultrasonography, CT, MRI) in 3 infants with congenital rubella syndrome. *Pediatr Radiol*. 1991;21(8):547-549.
57. Irons MB, Tint GS. Prenatal diagnosis of Smith-Lemli-Opitz syndrome. *Prenat Diagn*. 1998;18(4):369-372.
58. Yamauchi T, Wilson C, Geme JW Jr. Transmission of live, attenuated mumps virus to the human placenta. *NEJM*. 1974;290(13):710-712.

Toxoplasmosis

59. Antsaklis A, Daskalakis G, Papantoniou N, et al. Prenatal diagnosis of congenital toxoplasmosis. *Prenat Diagn*. 2002;22:1107-1111.
60. Desmonts G, Couvreur J. Congenital toxoplasmosis. A prospective study of 378 pregnancies. *N Engl J Med*. 1974;290:1110-1116.
61. Guerina NG, Hsu HW, Meissner HC, et al. Neonatal serologic screening and early treatment for congenital *Toxoplasma gondii* infection. The New England Regional Toxoplasma Working Group. *N Engl J Med*. 1994;330:1858-1863.
62. Lopez A, Dietz VJ, Wilson M, et al. Preventing congenital toxoplasmosis. *MMWR Recomm Rep*. 2000;49:59-68.
63. Elmore SA, Jones JL, Conrad PA, et al. *Toxoplasma gondii*: epidemiology, feline clinical aspects, and prevention. *Trends Parasitol*. 2010;26:190-196.
64. ACOG. Practice bulletin no. 151: Cytomegalovirus, Parvovirus B19, Varicella Zoster, and Toxoplasmosis in pregnancy. *Obstet Gynecol*. 2015;125(6):1510-1525.
65. Boyer KM, Holfels E, Roizen N, et al. Risk factors for *Toxoplasma gondii* infection in mothers of infants with congenital toxoplasmosis: implications for prenatal management and screening. *Am J Obstet Gynecol*. 2005;192:564-571.
66. Hohlfeld P, Daffos F, Costa JM, et al. Prenatal diagnosis of congenital toxoplasmosis with a polymerase-chain-reaction test on amniotic fluid. *N Engl J Med*. 1994;331:695-699.
67. Dhakal R, Gajurel K, Pomares C, et al. Significance of a positive toxoplasma immunoglobulin m test result in the United States. *J Clin Microbiol*. 2015;53:3601-3605.
68. SYROCOT (Systematic Review on Congenital Toxoplasmosis) study group, Thiébaut R, Leproust S, et al. Effectiveness of prenatal treatment for congenital toxoplasmosis: a meta-analysis of individual patients' data. *Lancet*. 2007;369:115-122.
69. Montoya JG, Liesenfeld O. Toxoplasmosis. *Lancet*. 2004;363:1965-1976.
70. Hohlfeld P, MacAleese J, Capella-Pavlovski M, et al. Fetal toxoplasmosis: ultrasonographic signs. *Ultrasound Obstet Gynecol*. 1991;1:241-244.
71. Lago EG, Baldisserotto M, Hoefel Filho JR, et al. Agreement between ultrasonography and computed tomography in detecting intracranial calcifications in congenital toxoplasmosis. *Clin Radiol*. 2007;62:1004-1011.
72. Friedman S, Ford-Jones LE, Toi A, et al. Congenital toxoplasmosis: prenatal diagnosis, treatment and postnatal outcome. *Prenat Diagn*. 1999;19:330-333.
73. Malinger G, Werner H, Rodriguez Leonel JC, et al. Prenatal brain imaging in congenital toxoplasmosis. *Prenat Diagn*. 2011;31:881-886.
74. Barkovich AJ, Girard N. Fetal brain infections. *Childs Nerv Syst*. 2003;19:501-507.
75. Peyron F, Wallon M, Liou C, et al. Treatments for toxoplasmosis in pregnancy. *Cochrane Database Syst Rev*. 2000;(2):CD001684.
76. Montoya JG, Remington JS. Management of *Toxoplasma gondii* infection during pregnancy. *Clin Infect Dis*. 2008;47:554-566.

Herpes Simplex Virus

77. Marquez L, Levy ML, Munoz F. A report of three cases and review of intrauterine herpes simplex virus infection. *Pediatr Infect Dis J*. 2012;31(11):1144-1147.
78. Flagg EW, Weinstock H. Incidence of neonatal herpes simplex virus infections in the United States, 2006. *Pediatrics*. 2011;127(1):e1.
79. Overall JC Jr. Herpes simplex virus infection of the fetus and newborn. *Pediatr Ann*. 1994;23:131-136.
80. Duin LK, Willekes C, Baldewijns MML, et al. Major brain lesions by intrauterine herpes simplex virus infection: MRI contribution. *Prenat Diagn*. 2007;27:81-84.
81. Mahnert N, Roberts SW, Laibl VR, et al. The incidence of neonatal herpes infection. *Am J Obstet Gynecol*. 2007;196:e55-e56.
82. Xu F, Schillinger JA, Sternberg MR, et al. Seroprevalence and co-infection with herpes simplex virus type I and type 2 in the United States, 1988-1994. *J Infect Dis*. 2002;185:1019-1024.
83. Hutto C, Arvin A, Jacobs R, et al. Intrauterine herpes simplex virus infections. *J Pediatr*. 1987;110:97-101.
84. Brown ZA, Selke S, Zeh J, et al. The acquisition of herpes simplex virus during pregnancy. *N Engl J Med*. 1997;337(8):509.
85. Kimberlin DW. Herpes simplex virus infections of the newborn. *Semin Perinatol*. 2007;31(1):19-25.
86. Koelle DM, Corey L. Herpes simplex insights on pathogenesis and possible vaccines. *Annu Rev Med*. 2008;59:381-395.
87. Barefoot KH, Little GA, Ornvold KT. Fetal demise due to herpes simplex virus: an illustrated case report. *J Perinatol*. 2002;22:86-88.
88. Hyde SR, Giacoia GP. Congenital herpes infection: placental and umbilical cord findings. *Obstet Gynecol*. 1993;81(Pt 2):852.
89. Lanouette JM, Duquette DA, Jacques SM, et al. Prenatal diagnosis of fetal herpes simplex infection. *Fetal Diagn Ther*. 1996;11:414-416.
90. Johansson A-B, Rassart A, Blum D, et al. Lower-limb hypoplasia due to intrauterine infection with herpes simplex virus type 2: possible confusion with intrauterine varicella-zoster syndrome. *Clin Infect Dis*. 2004;38:e57-e62.
91. Vasileiadis GT, Roukema HW, Romano W, et al. Intrauterine herpes simplex infection. *Am J Perinatol*. 2003;20:55-58.
92. Diguet A, Patrier S, Eurin D, et al. Prenatal diagnosis of an exceptional intrauterine herpes simplex type I infection. *Prenat Diagn*. 2006;26:154-157.
93. Mitra A, O'Malley DP, Banks PM, et al. Myocardial calcification in a fetus: a distinctive presentation of in-utero herpes simplex virus type II infection. *J Ultrasound Med*. 2004;23:1385-1390.
94. Avgil M, Ornoy A. Herpes simplex virus and Epstein-Barr virus infections in pregnancy: consequences of neonatal or intrauterine infection. *Reprod Toxicol*. 2006;21:436-445.
95. Dubois-Lebbe C, Houfflin-Debarge V, Dewidle A, et al. Non-immune hydrops fetalis due to herpes simplex virus type 1. *Prenat Diagn*. 2007;27:188-189.
96. Stone KM, Reitt-Eldridge R, White AD, et al. Pregnancy outcome following systemic prenatal acyclovir exposure: conclusions from the International Acyclovir Pregnancy Registry, 1984-1999. *Birth Defects Res Part A Clin Mol Teratol*. 2004;70:201-207.
97. Corey L, Wald A. Maternal and neonatal HSV infections. *N Engl J Med*. 2009;361:376-385.

Varicella

98. Mirlesse V, Lebon P. Chickenpox during pregnancy. *Arch Pediatr*. 2003;10(12):1113-1118.
99. Mandelbrot L. Fetal varicella—diagnosis, management, and outcome. *Prenat Diagn*. 2012;32:511-518.
100. Zhang HJ, Patenaude V, Abenhaim HAJ. Maternal outcomes in pregnancies affected by varicella zoster virus infections: population-based study on 7.7 million pregnancy admissions. *J Obstet Gynaecol Res*. 2015;41(1):62.
101. Aumarin M, Güris D, Chaves SS, et al; Advisory Committee on Immunization Practices, Centers for Disease Control and Prevention (CDC). Prevention of varicella: recommendations of the Advisory Committee on Immunization Practices (ACIP). *MMWR Recomm Rep*. 2007;56(RR-4):1.
102. U.S. Department of Health and Human Services. Public Health Services, Centers for Disease Control and Prevention, National Center for Prevention Services. Varicella, 1992.
103. Well TH. Varicella-herpes zoster virus. In: Evans AS, Kaslow RA, eds. *Viral infections of humans: epidemiology and control*. New York: Plenum Press; 1977:865-892.
104. Enders G, Miller E, Cradock-Watson J, et al. Consequences of varicella and herpes zoster in pregnancy: prospective study of 1739 cases. *Lancet*. 1994;343:1548-1551.
105. Petignat P, Vial Y, Laurini R, et al. Fetal varicella-herpes zoster syndrome in early pregnancy: ultrasonographic and morphological correlation. *Prenat Diagn*. 2001;21:121-124.
106. Laforet EG, Lynch CL Jr. Multiple congenital defects following maternal varicella; report of a case. *N Engl J Med*. 1947;236(15):534-537.

107. Miller E, Cradock-Watson JE, Ridehalgh MK. Outcome in newborn babies given anti-varicella-zoster immunoglobulin after perinatal maternal infection with varicella-zoster virus. *Lancet*. 1989;2(8659):371-373.
108. Webster MH, Smith CS. Congenital abnormalities and maternal herpes zoster. *BMJ*. 1997;2:1193.
109. Mouly F, Mirlesse V, Meritet JF, et al. Prenatal diagnosis of fetal varicella-zoster virus infection with polymerase chain reaction of amniotic fluid in 107 cases. *Am J Obstet Gynecol*. 1997;177:894-898.
110. Meyberg-Solomayer GC. Prenatal ultrasound diagnosis, follow-up, and outcome of congenital varicella syndrome. *Fetal Diagn Ther*. 2006;21: 296-301.
111. Pretorius DH, Hayward I, Jones KL, et al. Sonographic evaluation of pregnancies with maternal varicella infection. *J Ultrasound Med*. 1992;11:459-463.
112. Verstraelen H, Varzieleghem B, Defoorte P, et al. Prenatal ultrasound and magnetic resonance imaging in fetal varicella syndrome: correlation with pathology findings. *Prenat Diagn*. 2003;23:705-709.
113. Mattson SN. Neurodevelopmental follow-up of children of women infected with varicella during pregnancy: a prospective study. *Pediatr Infect Dis J*. 2003;22:819-823.
114. Lecuru F, Taurelle R, Bernard JP, et al. Varicella zoster virus infection during pregnancy: the limits of prenatal diagnosis. *Eur J Obstet Gynecol Reprod Biol*. 1994;56(1):67-68.
115. Nikkels AF, Delbecque K, Pierard G, et al. Distribution of varicella-zoster virus DNA and gene products in tissues of a first-trimester varicella-infected fetus. *J Infect Dis*. 2005;191:540-545.
116. Sauerbrei A, Wutzk P. Herpes simplex and varicella-zoster virus infections during pregnancy: current concepts of prevention, diagnosis, and therapy. Part II. Varicella-zoster virus infections. *Med Microbiol Immunol*. 2007;196:95-102.

166 Congenital Zika Virus Syndrome

GUSTAVO MALINGER | ILAN E. TIMOR-TRITSCH | MAURICIO HERRERA

Introduction

Every few years the threat of a "new" infectious disease becomes the center of world attention, producing waves of fear and even mass panic. Until now, at least in the beginning, these diseases affected only adult populations. Although, since the Yap island epidemic in 2007,[1] Zika virus (ZIKAV) was known to be able to produce epidemics, it remained unknown for the general population at large as well as for most of the medical profession. The situation changed in October and November of 2015 when it appeared in Brazil in the form of the "neonatal microcephaly epidemic." The disproportionally large number and the severity of the cases affecting newborns brought the epidemic to the center of world attention, with countless articles in the press and in social/electronic media. By August 2016 the current epidemic has extended to immunologically naive populations in 67 countries.

Quite rapidly it became apparent that the easily diagnosed microcephaly was only a first sign of severe brain involvement and imaging descriptions of the different brain pathologies associated with congenital Zika virus syndrome (CZVS) started to be reported.[2,3] By the time of this writing in 2016, 20 countries have reported CZVS cases. In four of these countries, the cases resulted from travel-related infections.

Questions regarding the different ways of transmission arose:

- What is the possibility of transmission by other *Aedes* species, especially the more prevalent and longer-lived *Aedes albopictus* (Asian tiger mosquito)?
- If currently only the most severe cases are being diagnosed, what is the full extent of fetal brain damage?
- Are there available treatment options?

Disorder

DEFINITION

CZVS is defined as an intrauterine insult affecting mainly, but not only, the brain, and characterized by arrest of development and even destruction of different portions of the cerebrum and cerebellum. ZIKAV is a ribonucleic acid mosquito-borne virus of the *Flavivirus* genus closely related to yellow fever, dengue, tick-borne encephalitis virus, chikungunya, and West Nile viruses. In adults and children, it may be either asymptomatic or cause a mild disease with fever, erythema, and arthralgia, or in its severe form cause Guillain-Barré syndrome.[4]

PREVALENCE AND EPIDEMIOLOGY

Data regarding the prevalence and epidemiology of ZIKAV shows that once the disease starts to spread in a particular region, almost 80% of the population is infected but only around 20% have clinical disease.[1] Using a theoretic model based on more of 30,000 cases in French Polynesia, Kucharski et al. found that an estimated 94% (95% confidence interval, 91–97%) of the total population of the six archipelagos were infected during the outbreak.[5] The outbreak ended after 5–6 months, and since then there were no newly reported cases. The authors concluded that based on the demography of French Polynesia, the results imply that if ZIKAV infection provides complete protection against future infection, it would take 12–20 years before there are a sufficient number of susceptible individuals for ZIKAV to reemerge. This interesting point is also apparently applicable to the Yap epidemic, but still needs to be proved in noninsular countries.

In Brazil, until May 2016 there were 174,003 reported cases for an incidence of 85.1 : 100,000 inhabitants. By August 20, 2016, the total number of children suspected to be infected and have CZVS was 9091[6]; with 2968 of them being still investigated. Out of 6123 fully investigated cases, the diagnosis was confirmed in 1854 (30%) children including 129 (7%) cases of fetal or neonatal death. In only 51 cases was the diagnosis made using specific criteria (either serology or polymerase chain reaction [PCR]). According to these reports the number of declared and confirmed cases has decreased in the last months (Fig. 166.1).

From Brazil, the ZIKAV traveled north, affecting fetuses and children and reaching the continental United States of America

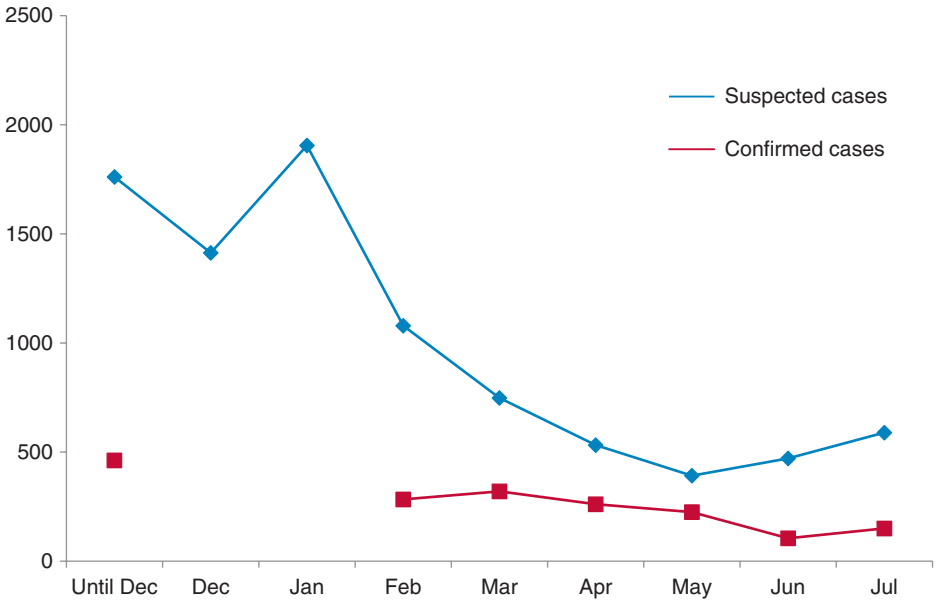

Fig. 166.1 Monthly report of new cases with suspected and confirmed congenital Zika virus syndrome as notified to the Brazil Ministry of Health.

through Miami, where there were 29 cases of autochthonous infections reported by August 24, 2016.

ETIOLOGY AND PATHOPHYSIOLOGY

ZIKAV is transmitted by the bite of mosquitos of the *Aedes* species, mainly by *Aedes Aegypti;* in addition, there are reports of transmission through sexual intercourse and probably also through blood products. It can also be transmitted vertically from pregnant women to their fetuses.

As with other intrauterine infections (IUI), the virus enters the fetus after infecting the placenta. The central nervous system (CNS) infection is facilitated by the fact that the blood-brain barrier is not yet functional. Tang et al.[7] showed that ZIKAV infects human embryonic cortical neural progenitor cells, multiplying in these cells and causing their death. Adult neurons and astrocytes can also be infected.[8]

Although until now most of the reported cases involved severely affected fetuses and newborns, it will not be surprising if cases with less severe pathologic features are diagnosed in the near future, as with cytomegalovirus (CMV) and toxoplasmosis.

MANIFESTATIONS OF DISEASE

Clinical Presentation

A history of a febrile disease accompanied by arthralgia, rash, and conjunctivitis may be obtained in some patients, but many cases remain asymptomatic. The risk to develop severe complications is estimated to be low.

Most of the cases diagnosed postpartum are recognized by the presence of microcephaly, usually severe with small fontanels, narrow sutures, and an abnormal head shape. In the absence of microcephaly, the diagnosis is more difficult and may be suspected by the presence of various degrees of ventriculomegaly, abnormal eyes, and limb abnormalities such as arthrogryposis.

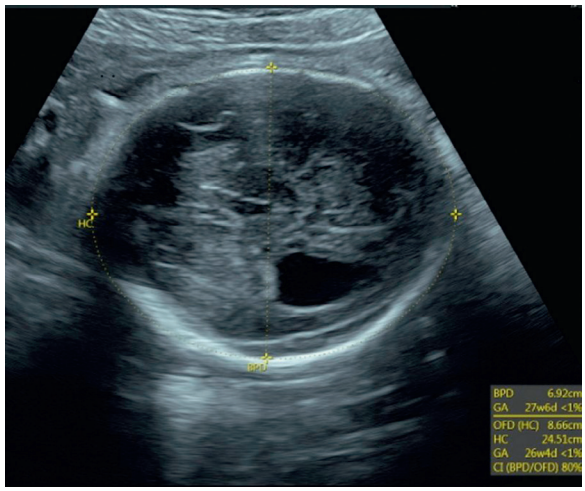

Fig. 166.2 Congenital Zika virus syndrome at 31.6 weeks' gestation. The head circumference is 24.5 cm, –3.5 SD below the norm for the gestational age. The lateral ventricle measurement is 13 mm.

Asymptomatic or mild involvement following transmission to the fetus have not yet been reported.

Maternal serologic diagnosis is predominantly based on PCR or immunoglobulin M testing, based on timing since exposure or symptoms. As those clinical pathways are rapidly changing in response to new data, clinicians should consult local public health departments or the World Health Organization, Centers for Disease Control, or other authoritative web resources for current information.

Imaging Technique and Findings

Ultrasound. CNS findings include the following[2,9,10]:

- microcephaly (Fig. 166.2)
- ventriculomegaly, sometimes asymmetric (see Figs. 166.2 and 166.3)



Fig. 166.3 Congenital Zika virus syndrome at 24.4 weeks' gestation. Transvaginal coronal ultrasound at the level of the thalami shows bilateral ventriculomegaly with parietal porencephalic cysts *(arrows)*. Note the slightly increased amount of cerebrospinal fluid between the hemispheres. *LV*, Lateral ventricles.

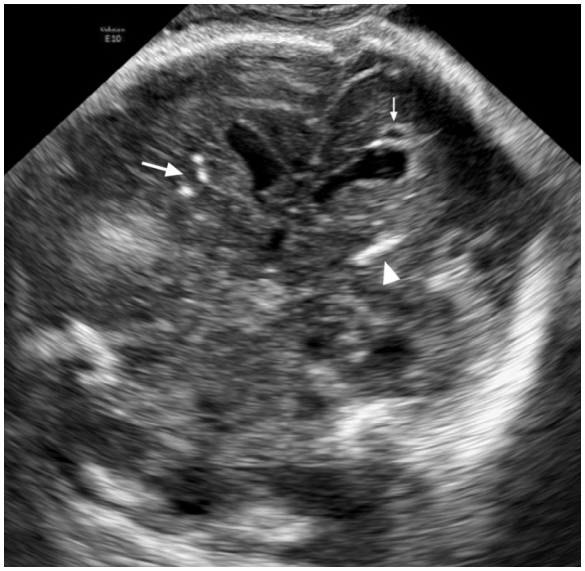

Fig. 166.4 Same fetus as in Fig. 166.1. Transvaginal coronal ultrasound at the level of the caudate nuclei shows a group of three punctuate calcifications at the border of the caudate *(large arrow)* and a calcified plaque in the contralateral side *(arrowhead)*. A small porencephalic cyst is also present on this side *(small arrow)*.

- widespread calcifications (cortical, parenchymatic, periventricular) punctuate or *en plaque* (Fig. 166.4)
- periventricular echogenicity with or without cysts (Fig. 166.5)
- porencephalic cysts, predominantly occipital (see Figs. 166.3–166.5)
- cerebellar hypoplasia
- brain-stem hypoplasia
- callosal hypoplasia
- malformations of cortical development (see Fig. 166.5)
- intraventricular hemorrhage

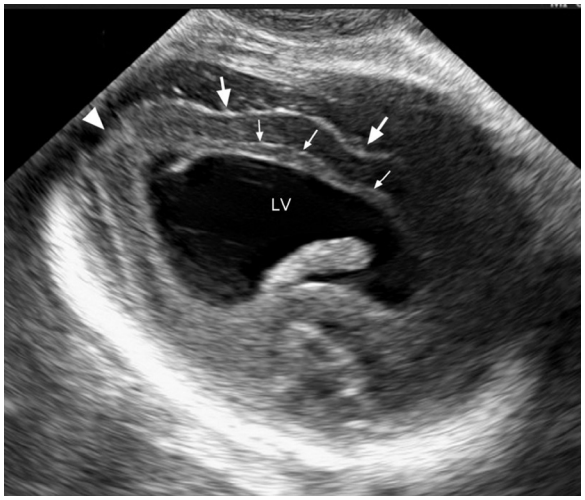

Fig. 166.5 Same fetus as in Fig. 166.1. Transvaginal parasagittal ultrasound shows hyperechogenic periventricular white matter *(small arrows)*; delayed development of sulci and gyri *(large arrows)* and cortical destruction *(arrowhead)*. *LV*, lateral ventricles.



Fig. 166.6 Same fetus as in Fig. 166.2. Microphthalmia. The orbits are small in relationship to the lenses.

Extracerebral findings include the following[2,10]:

- microphthalmia, cataracts (Fig. 166.6)
- arthrogryposis

Interestingly, most cases of CZVS reported represent the severe spectrum of the disease; early prenatal detection of affected fetuses will need to focus on the presence of subtler single findings such as mild ventriculomegaly, focal calcification, periventricular cysts, smaller-than-expected transverse cerebellar diameter or corpus callosum length, or mega cisterna magna. In these cases, close follow-up at 1–2 weeks will be required.

Magnetic Resonance Imaging. Magnetic resonance imaging (MRI) findings are the same as those demonstrated by ultrasound (US).[10] In some cases, particularly during the last stage of pregnancy, MRI may produce a better depiction of the brain,

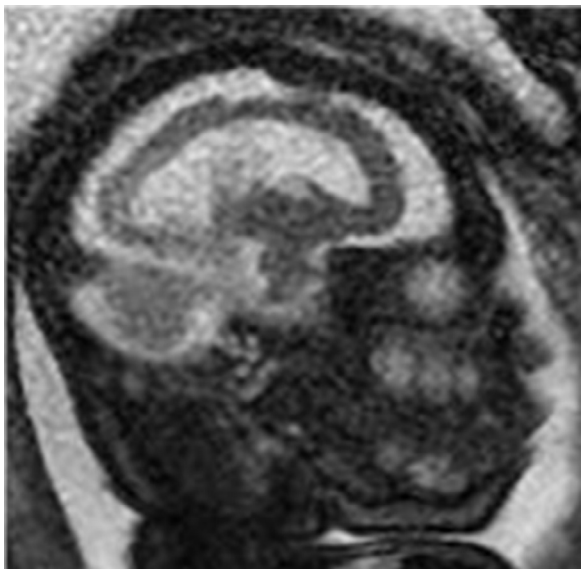

Fig. 166.7 Congenital Zika virus syndrome at 32 weeks' gestation. T2 weighted parasagittal magnetic resonance imaging shows very thin parenchyma without sulci and gyri, ventriculomegaly, and large subarachnoid space as a sign of brain atrophy/destruction.

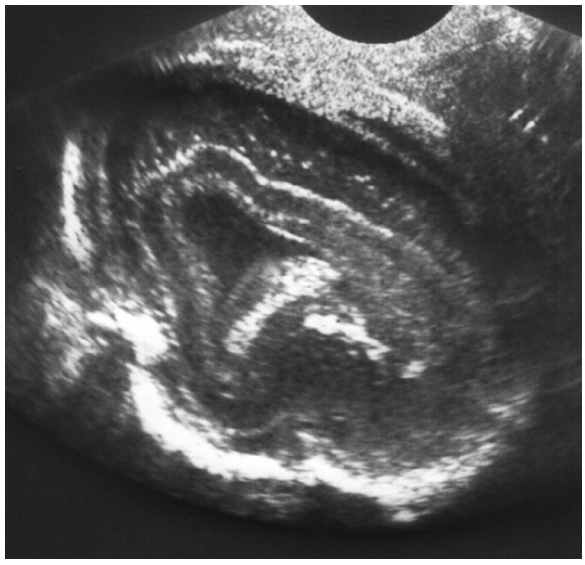

Fig. 166.8 Severe congenital cytomegalovirus infection at 32 weeks. Note the similarities with the congenital Zika virus syndrome case in Fig. 166.4.

particularly when the fetus is in breach presentation and in cases of severe microcephaly when small or closed fontanels and sutures can be difficult for US wave penetration (Fig. 166.7).

CLASSIC SIGNS

The triad of fetal microcephaly, dense calcifications spread at different brain locations, and ventriculomegaly during a ZIKAV epidemic is highly suggestive of CZVS.

Differential Diagnosis From Imaging Findings

In contrary to current understanding,[11] we believe that other TORCH (*t*oxoplasmosis, *o*ther [congenital syphilis and viruses], *r*ubella, *c*ytomegalovirus, and *h*erpes simplex virus) IUIs, particularly CMV, can produce, in severe cases, brain insults similar and even identical to these produced by congenital zoster virus[12] (Fig. 166.8).

Two well-documented publications described similar findings apparently unrelated to IUIs.[13,14]

Synopsis of Treatment Options

PRENATAL

No treatment has been reported until now. If available, the option for termination of pregnancy can be offered.

POSTNATAL

Symptomatic treatment followed by rehabilitation and support for the families of affected children is by now the only therapeutic alternative. In children with mild signs of the disease, antiviral treatments may be considered in experimental clinical trials.

WHAT THE REFERRING PHYSICIAN NEEDS TO KNOW

Primary providers need to be up to par with the ongoing and updated information provided by medical organizations and governmental bodies.[15–17] They have to take a detailed medical history of the patients as well as their spouses' travel history. Early referral for testing and imaging is of paramount importance.

In seropositive patients and following clinical disease, pregnant patients should be examined by US every 3–4 weeks until delivery to look for subtle findings of CNS infection. Severely affected cases are usually easier to diagnose.

KEY POINTS

- ZIKAV infection may cause serious fetal and neonatal consequences.
- Transmission is by mosquito bites, sexual intercourse, blood product transfusion, and vertically from mother to fetus.
- Although serologic tests are available for the diagnosis, their specificity and sensitivity are still limited.
- CZVS causes infection of the brain, detectable by US and MRI.

SUGGESTED READINGS

Knowledge of congenital Zika virus infection changes rapidly with new publications on a frequent basis. In lieu of Suggested Readings, we refer the reader to the following websites, which are regularly updated:

https://www.cdc.gov/zika/.
http://www.ama-assn.org/ama/pub/physician-resources/public-health/zika-resource-center.page.
http://www.nejm.org/page/zika-virus.
http://www.acog.org/About-ACOG/ACOG-Departments/Zika-Virus.
http://www.who.int/emergencies/zika-virus/en/ (also available in Portuguese).

All references available online at www.expertconsult.com

REFERENCES

1. Duffy MR, Chen TH, Hancock WT, et al. Zika virus outbreak on Yap Island, Federated States of Micronesia. *N Engl J Med*. 2009;360:2536-2543.
2. Oliveira Melo AS, Malinger G, Ximenes R, et al. Zika virus intrauterine infection causes fetal brain abnormality and microcephaly: tip of the iceberg? *Ultrasound Obstet Gynecol*. 2016;47:6-7.
3. Mlakar J, Korva M, Tul N, et al. Zika virus associated with microcephaly. *N Engl J Med*. 2016;374:951-958.
4. Lessler J, Chaisson LH, Kucirka LM, et al. Assessing the global threat from Zika virus. *Science*. 2016;353:aaf8160.
5. Kucharski AJ, Funk S, Eggo RM, et al. Transmission dynamics of Zika virus in island populations: a modelling analysis of the 2013–14 French Polynesia outbreak. *PLoS Negl Trop Dis*. 2016;10:e0004726.
6. Brazil Ministry of Health. http://www.combateaedes.saude.gov.br/images/sala-de-situacao/informe_microcefalia_epidemiologico40.pdf. 2016.
7. Tang H, Hammack C, Ogden SC, et al. Zika virus infects human cortical neural progenitors and attenuates their growth. *Cell Stem Cell*. 2016;18:587-590.
8. Cugola FR, Fernandes IR, Russo FB, et al. The Brazilian Zika virus strain causes birth defects in experimental models. *Nature*. 2016;534:267-271.
9. Brasil P, Pereira JP Jr, Raja Gabaglia C, et al. Zika virus infection in pregnant women in Rio de Janeiro—preliminary report. *N Engl J Med*. 2016;375:2321-2334.
10. Soares de Oliveira-Szejnfeld P, Levine D, Melo AS, et al. Congenital brain abnormalities and Zika virus: what the radiologist can expect to see prenatally and postnatally. *Radiology*. 2016;161584.
11. Klase ZA, Khakhina S, Schneider Ade B, et al. Zika fetal neuropathogenesis: etiology of a viral syndrome. *PLoS Negl Trop Dis*. 2016;10:e0004877.
12. Malinger G, Lev D, Lerman-Sagie T. Imaging of fetal cytomegalovirus infection. *Fetal Diagn Ther*. 2011;29:117-126.
13. Nakamura K, Kato M, Sasaki A, et al. Congenital dysplastic microcephaly and hypoplasia of the brainstem and cerebellum with diffuse intracranial calcification. *J Child Neurol*. 2012;27:218-221.
14. Abdel-Salam GM, Abdel-Hamid MS, El-Khayat HA, et al. Fetal brain disruption sequence versus fetal brain arrest: a distinct autosomal recessive developmental brain malformation phenotype. *Am J Med Genet A*. 2015;167A:1089-1099.
15. World Health Organization. Pregnancy management in the context of Zika virus. 2016. http://www.who.int/csr/resources/publications/zika/pregnancy-management/en/.
16. Papageorghiou AT, Thilaganathan B, Bilardo CM, et al. ISUOG interim guidance on ultrasound for Zika virus infection in pregnancy: information for healthcare professionals. *Ultrasound Obstet Gynecol*. 2016;47:530-532.
17. Oduyebo T, Igbinosa I, Petersen EE, et al. Update: interim guidance for health care providers caring for pregnant women with possible Zika virus exposure—United States, July 2016. *MMWR Morb Mortal Wkly Rep*. 2016;65:739-744.

167 Parvovirus B19 Infection During Pregnancy

UNZILA A. NAYERI | MERT OZAN BAHTIYAR

Introduction

Parvovirus B19 infection during pregnancy is rare, but potentially dangerous. In susceptible mothers, transplacental transmission of parvovirus B19 is possible. If acquired *in utero*, parvovirus B19 infection can lead to severe fetal anemia and myocarditis. In some instances, the infection may result in fetal death in the second or third trimester. Although *in utero* fetal infection is usually self-limited, severe cases are treated with intrauterine fetal blood transfusion to maintain fetal red blood cell levels until the fetus recovers from the infection.

Disorder

PREVALENCE AND EPIDEMIOLOGY

Parvovirus B19, a single-stranded deoxyribonucleic acid (DNA) virus, is most commonly associated with erythema infectiosum (also referred to as *fifth disease*). Although one-third of infections are asymptomatic, the virus may also cause maternal arthritis, aplastic crisis, and hydrops fetalis.

Parvovirus B19 is primarily transmitted by respiratory droplets and infected blood products. The patient is considered infectious 5 to 10 days after exposure and before the onset of a rash or other symptoms. When a rash erupts, the patient is no longer infectious. Approximately 50% to 60% of women of reproductive age have evidence of prior infection. The secondary attack rate for the household is approximately 50%. Susceptible individuals exposed in a classroom setting have a 20% to 30% chance of acquiring the disease. Of pregnant women, 40% to 50% are immune to parvovirus B19. The incidence of this acute infection in pregnancy ranges from 3%–4%.[1,2] The risk of fetal transmission, which does not change with gestational age, is approximately 33%.[1,2] The rate of fetal loss ranges from 2%–9% among women with serologically proven parvovirus B19 infection.[2,3] However, fetal loss rate appears to be significantly higher if the disease is acquired before 20 weeks' gestation (11% versus <1%).[4] Although immunity is lifelong, there have been reports of reinfection.[5]

ETIOLOGY AND PATHOPHYSIOLOGY

The incubation period for parvovirus is 10 to 20 days. Manifestations of erythema infectiosum include low-grade fever, malaise, myalgias, arthralgias, and a "slapped cheek" facial rash. An erythematous, lacelike rash may extend onto the torso and upper extremities. In children, parvovirus infection can cause a transient aplastic crisis. An aplastic crisis may also occur in adults with an underlying hemoglobinopathy.

When maternal parvovirus infection occurs during pregnancy, the virus can cross the placenta and infect red blood cell progenitors in the fetal bone marrow. The virus attaches to the P antigen on red blood cell stem cells and suppresses erythropoiesis,[6] resulting in severe anemia and high-output congestive heart failure. This same antigen is also present on fetal myocardial cells, and in some fetuses, the viral infection causes a cardiomyopathy that contributes further to heart failure.[7] As long as fetal anemia is treated, spontaneous recovery is expected. Fetal complications are unlikely to occur more than 8 to 10 weeks after the initial exposure to the virus. Epidemiologic studies have failed to establish any association between parvovirus B19 infection and congenital malformations.

MANIFESTATIONS OF DISEASE

Clinical Presentation

Hydrops fetalis is the most obvious and serious manifestation of an intrauterine parvovirus B19 infection, which is seen in approximately 4% of all affected pregnancies (Fig. 167.1).[4] The

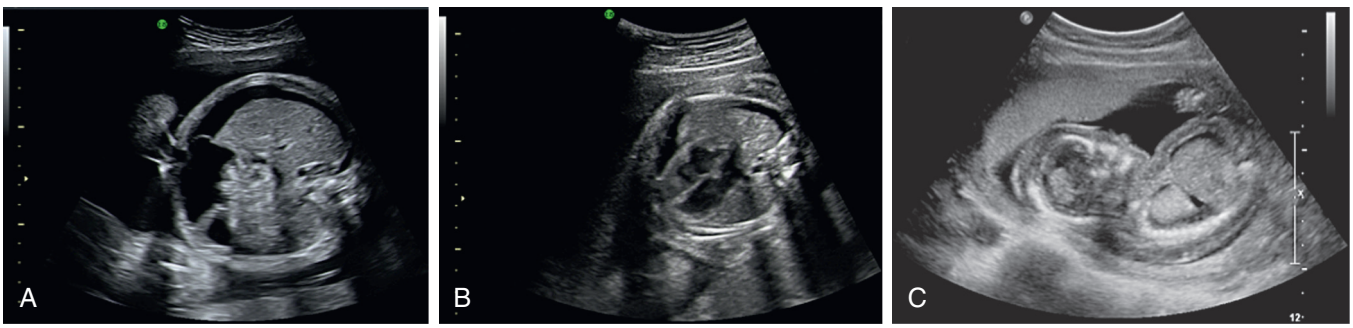

Fig. 167.1 Fetal hydrops. Ascites (A), pleural effusion (B), and skin edema (C) in a fetus infected with parvovirus B19.

risk of hydrops depends on the gestational age at which maternal infection occurs. If infection develops during the first 12 weeks of gestation, the risk of hydrops ranges from 5%–10%. If infection occurs during weeks 13 through 20, the risk decreases to 5% or less. Infection after the 20th week of gestation is associated with a fetal hydrops risk of 1% or less.[1] In addition to fetal anemia, parvovirus B19 has been linked to late second-trimester and third-trimester intrauterine fetal death. Most of these fetuses are not hydropic.[8]

Serologic testing is used to confirm the diagnosis of maternal parvovirus infection. Enzyme-linked immunosorbent assay, radioimmunoassay, or Western blot can be used to determine maternal serologies. The sensitivity of the serologic immunoglobulin (Ig)G and IgM testing is approximately 80%. IgM results should be evaluated cautiously because false-positive results can occur. IgM may be present in the maternal circulation for 3 months or longer. Possible serologic test results are presented in Table 167.1.

TABLE 167.1 INTERPRETATION OF MATERNAL SEROLOGIC FINDINGS

IgM	IgG	Interpretation
Negative	Negative	Susceptible
Negative	Positive	Immune
Positive	Negative	Acute infection (within previous 7 days)
Positive	Positive	Subacute infection[a]

Ig, Immunoglobulin.
[a]Caution: Occasionally low levels of IgM antibodies may persist for >12 months after infection. Possible exposure time should be determined before further surveillance is planned.

Fetal infection can be diagnosed by detection of parvovirus-specific IgM in fetal blood by enzyme immunoassay, immunofluorescence test, or radioimmunoassay and by detection of viral DNA in fetal blood or amniotic fluid by the polymerase chain reaction technique. When maternal infection is confirmed, the fetus should be evaluated for evidence of anemia. Assessment of the middle cerebral artery (MCA) peak systolic velocity via Doppler velocimetry is considered the optimal method for detection of fetal anemia (Fig. 163.2).[9] Serial ultrasound (US) examinations should be performed every 1 to 2 weeks for 8 to 12 weeks after exposure.

The most obvious US manifestation of fetal anemia is hydrops (see Fig. 167.1). By the time US evidence of hydrops is present, the fetal hematocrit is likely to be less than 20%.[10]

Imaging Technique and Findings

Ultrasound

Grayscale Ultrasound. The fetus should be evaluated for the presence of hydrops. A complete anatomic survey of the fetus should be performed to rule out any defect that may account for hydrops, including vascular lesions, which may lead to high-output cardiac failure, structural heart defects, and cardiac arrhythmias.

Middle Cerebral Artery Doppler Ultrasound. Historically, measurement of amniotic fluid bilirubin levels with spectral analysis at 450 nm (ΔOD_{450}) was used to assess the severity of erythroblastosis *in utero*.[11] However, because the anemia in parvovirus B19 infection is caused by bone marrow suppression, this approach is unreliable in assessing the status of the fetal anemia.

Doppler velocimetry in the fetal MCA is a precise, noninvasive way to detect fetal anemia (see Fig. 167.2).[9] With this approach,

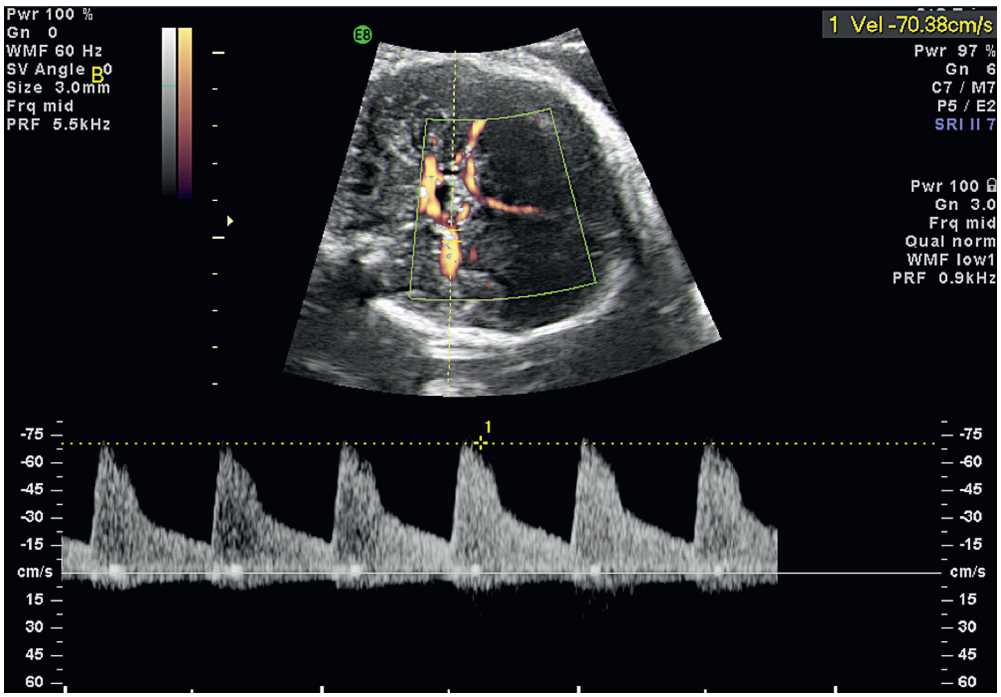

Fig. 167.2 Middle cerebral artery (MCA) Doppler assessment. MCA peak systolic velocity is determined at its origin at the level of the circle of Willis. Either the proximal or the distal vessel can be used reliably. Angle insonation should be kept as close as possible to 0 degrees.

TABLE 167.2 MIDDLE CEREBRAL ARTERY PEAK SYSTOLIC VELOCITIES

Gestational Age (week)	MULTIPLES OF MEDIAN			
	1.00	1.29	1.50	1.55
18	23.2	29.9	34.8	36.0
20	25.5	32.8	38.2	39.5
22	27.9	36.0	41.9	43.3
24	30.7	39.5	46.0	47.5
26	33.6	43.3	50.4	52.1
28	36.9	47.6	55.4	57.2
30	40.5	52.2	60.7	62.8
32	44.4	57.3	66.6	68.9
34	48.7	62.9	73.1	75.6
36	53.5	69.0	80.2	82.9
38	58.7	75.7	88.0	91.0
40	64.4	83.0	96.6	99.8

Adapted from Mari G. Noninvasive diagnosis by Doppler ultrasonography of fetal anemia due to maternal red-cell alloimmunization. *N Engl J Med* 342:9–14, 2000.

moderate or severe anemia is predicted by values of peak systolic velocity in the fetal MCA above 1.5 times the multiples of median for gestational age (Table 167.2), with a sensitivity of 100% and a false-positive rate of 12% in fetuses with red blood cell alloimmunization. Increased MCA peak systolic velocity can also reliably predict anemia in fetuses with parvovirus B19 infection.[12] If velocimetry indicates fetal anemia, cordocentesis should be performed to determine the fetal hematocrit, unless the fetus is mature enough for delivery. An intrauterine blood transfusion should be performed when anemia has been confirmed. It has been shown that MCA peak systolic velocity can be reliably used even in fetuses with prior transfusions.[13]

Correct technique is critical in determining the MCA peak systolic velocity. An axial section of the brain, including the thalami and cavum septi pellucidi, should be obtained. Color Doppler or power Doppler is used to visualize the circle of Willis. MCA of one side is examined with the pulsed Doppler sample volume placed as close as possible to the origin of the vessel. For standardization and reliability purposes, the point of measurement is very important. It has been shown that peak systolic velocity decreases as the distance from the circle of Willis increases. The angle between the US beam and the direction of blood flow should be kept as close as possible to 0 degrees. The highest point of the waveform is measured.[9,14]

CLASSIC SIGNS

Hydrops fetalis (see Fig. 167.1)—the presence of two or more of the following abnormal fetal fluid collections:
Ascites.
Pleural effusion.
Pericardial effusion.
Skin edema.
Polyhydramnios.

Differential Diagnosis From Imaging Findings

1. Immune hydrops: immune hydrops is caused by alloimmunization against Rh and non-Rh erythrocyte antigens. Maternal blood typing and indirect Coombs testing should be included in the initial evaluation of a hydropic fetus.
2. Other causes for nonimmune hydrops: other possible etiologies for nonimmune hydrops should be considered, including fetal anemia, congenital anomalies, metabolic syndromes, infections, and genetic abnormalities.

Synopsis of Treatment Options

PRENATAL

Intrauterine transfusion is lifesaving in the setting of congenital parvovirus infection and subsequent hydrops fetalis.[15,16] MCA Doppler velocimetry can be used to assess fetal status. When fetal anemia is diagnosed, transfusion with O, Rh-negative, cytomegalovirus-negative, and irradiated packed red blood cells should be considered.

POSTNATAL

Overall, infants who survive intrauterine infection with parvovirus B19 have a good long-term prognosis.[15] However, one-third of fetuses with hydrops requiring intrauterine transfusion may exhibit delayed psychomotor development.[17]

WHAT THE REFERRING PHYSICIAN NEEDS TO KNOW

- Maternal blood type and indirect Coombs testing: if the fetus is hydropic, maternal blood type and indirect Coombs testing should be performed because fetal red blood cell alloimmunization is one of the most common causes of fetal hydrops.
- Parvovirus B19 immunity status of the mother: if the maternal serology indicates previous exposure, no further intervention is needed, and normal prenatal care should follow (see Table 167.1).
- Determination of the time of exposure to the parvovirus B19 virus: if the fetus is affected, parvovirus B19 infection is usually self-limited. It is rare for fetal infection to occur more than 10 weeks after the initial exposure.
- Gestational age at the time of exposure: if infection develops during the first 12 weeks of gestation, the risk of hydrops varies from less than 5% to approximately 10%. If infection occurs between 13 and 20 weeks' gestation, the risk of hydrops decreases to 5% or less. After 20 weeks' gestation, the risk of fetal hydrops is 1% or less.

KEY POINTS

- Parvovirus B19 is a single-stranded DNA virus and has been associated with fetal death, anemia, and fetal hydrops.
- Assessment of MCA peak systolic velocity via Doppler velocimetry can detect fetal anemia.
- Serial ultrasounds to assess for signs of anemia and hydrops fetalis should be performed every 1 to 2 weeks for 8 to 12 weeks after exposure.
- If fetal anemia is suspected, cordocentesis should be performed to confirm the diagnosis.
- Severely anemic fetuses should be treated with an intrauterine blood transfusion, or delivered if close to term.

SUGGESTED READINGS

American College of Obstetricians and Gynecologists. Cytomegalovirus, parvovirus B19, varicella zoster, and toxoplasmosis in pregnancy. *ACOG Practice Bulletin*. 2015;20.

Mari G, Deter R, Carpenter R, et al. Noninvasive diagnosis by Doppler ultrasonography of fetal anemia due to maternal red-cell alloimmunization. Collaborative Group for Doppler assessment of the blood velocity in anemic fetuses. *N Engl J Med*. 2000;342:9-14.



All references available online at www.expertconsult.com

REFERENCES

1. Public Health Laboratory Service Working Party on Fifth Disease. Prospective study of human parvovirus (B19) infection in pregnancy. *BMJ*. 1990;300:1166-1170.
2. Gratacos E, Torres P, Vidal J, et al. The incidence of human parvovirus B19 infection during pregnancy and its impact on perinatal outcome. *J Infect Dis*. 1995;171:1360-1363.
3. Rodis J, Quinn D, Gary GJ, et al. Management and outcomes of pregnancies complicated by human B19 parvovirus infection: a prospective study. *Am J Obstet Gynecol*. 1990;163(4 Pt 1):1168-1171.
4. Enders M, Weidner A, Zoellner I, et al. Fetal morbidity and mortality after acute human parvovirus B19 infection in pregnancy: prospective evaluation of 1018 cases. *Prenat Diagn*. 2004;24:513-518.
5. Anderson M, Higgins P, Davis L, et al. Experimental parvoviral infection in humans. *J Infect Dis*. 1985;152:257-265.
6. Brown K, Anderson S, Young N. Erythrocyte P antigen: cellular receptor for B19 parvovirus. *Science*. 1993;262:114-117.
7. Markenson G, Yancey M. Parvovirus B19 infections in pregnancy. *Semin Perinatol*. 1998;22:309-317.
8. Tolfvenstam T, Papadogiannakis N, Norbeck O, et al. Frequency of human parvovirus B19 infection in intrauterine fetal death. *Lancet*. 2001;357:1494-1497.
9. Mari G, Deter R, Carpenter R, et al. Noninvasive diagnosis by Doppler ultrasonography of fetal anemia due to maternal red-cell alloimmunization. Collaborative Group for Doppler assessment of the blood velocity in anemic fetuses. *N Engl J Med*. 2000;342:9-14.
10. Schild R, Bald R, Plath H, et al. Intrauterine management of fetal parvovirus B19 infection. *Ultrasound Obstet Gynecol*. 1999;13:161-166.
11. Liley A. Liquor amnii analysis in the management of the pregnancy complicated by rhesus sensitization. *Am J Obstet Gynecol*. 1961;82:1359-1370.
12. Cosmi E, Mari G, Delle Chiaie L, et al. Noninvasive diagnosis by Doppler ultrasonography of fetal anemia resulting from parvovirus infection. *Am J Obstet Gynecol*. 2002;187:1290-1293.
13. Mari G, Zimmermann R, Moise KJ, et al. Correlation between middle cerebral artery peak systolic velocity and fetal hemoglobin after 2 previous intrauterine transfusions. *Am J Obstet Gynecol*. 2005;193(3 Pt 2):1117-1120.
14. Mari G, Abuhamad A, Cosmi E, et al. Middle cerebral artery peak systolic velocity: technique and variability. *J Ultrasound Med*. 2005;24:425-430.
15. Rodis J, Rodner C, Hansen A, et al. Long-term outcome of children following maternal human parvovirus B19 infection. *Obstet Gynecol*. 1998;91:125-128.
16. Fairley C, Smoleniec J, Caul O, et al. Observational study of effect of intrauterine transfusions on outcome of fetal hydrops after parvovirus B19 infection. *Lancet*. 1995;346:1335-1337.
17. Nagel H, de Haan T, Vandenbussche F, et al. Long-term outcome after fetal transfusion for hydrops associated with parvovirus B19 infection. *Obstet Gynecol*. 2007;109:42-47.

168 Congenital Syphilis

CLARK T. JOHNSON | JEANNE S. SHEFFIELD

Introduction

A number of maternal perinatal infections result in congenital malformations. Traditionally these diseases were delineated by the acronym TORCH (*t*oxoplasmosis, *o*ther, *r*ubella, *c*ytomegalovirus, and *h*erpes simplex virus). Syphilis has dominated the "other" category, although several other infections have increased over time, including coxsackievirus, human immunodeficiency virus (HIV), parvovirus B19, and varicella zoster virus. Syphilis is the quintessential bacterial infection that may cause observable pathology in the fetus and neonate following maternal infection; importantly, this pathology often resolves with adequate treatment of the mother. The use of ultrasound (US) for the identification of congenital syphilis *in utero* has come to the forefront in recent years with the introduction of US equipment with high resolution. This modality has helped to better define the pathophysiology of congenital syphilis and the fetal response to treatment. With the recent resurgence of primary and secondary syphilis in women in the United States and the resultant increase in congenital syphilis, the need for maternal syphilis screening and prenatal identification of congenital disease is paramount for appropriate management of both the mother and the fetus.

Disease

DEFINITION

Syphilis is an infection caused by *Treponema pallidum* subsp. *pallidum,* a spirochete transmitted via either direct oral-genital or genital-genital contact through mucosal surfaces or by transplacental passage to a fetus. Congenital infection may occur as early as 9 to 10 weeks of gestation, though most of the clinical manifestations identifiable on US occur after 18 to 20 weeks' gestation when the fetus starts to become immunocompetent.[1] Maternal primary and secondary syphilis are associated with congenital syphilis transmission rates of up to 23% and 60%, respectively.

PREVALENCE AND EPIDEMIOLOGY

According to the Centers for Disease Control and Prevention, there was a 28% increase in congenital syphilis in the United States from 2013 to 2014 (11.6 cases per 100,000 live births).[2,3] This correlated with a 23% increase in the rate of primary and secondary infection during the same period. Twenty-two percent of infants diagnosed with congenital syphilis were born to mothers with no prenatal care. More worrisome is the fact that 59% of women who had prenatal care and yet delivered an infant with congenital syphilis were either not tested or did not receive appropriate treatment.[2,3]

The highest rate of syphilis in women is in the reproductive age groups, 15 to 44 years of age. The greatest risk factors for syphilis in pregnancy include African American race, Hispanic ethnicity, young age, substance abuse, limited access to health care, poverty, prostitution, and inadequate prenatal care.

ETIOLOGY AND PATHOPHYSIOLOGY

Treponema pallidum subsp. *pallidum* is a macroaerophilic gram-negative motile spirochete 5–15 μm long and 0.1–0.15 μm in diameter. There are over 55 subtypes, only a few causing clinical disease in humans. Syphilis is able to avoid systemic immune detection and eradication by encoding multiple antigenic variants of its TprK outer membrane protein. This effectively evades humoral and cell-mediated responses. Eradication may occur when T cells activate $CD68^+$ macrophages that phagocytose the antibody-coated treponemes.[4]

Sexual transmission occurs when the spirochetes gain access through a break in a mucosal surface through genital-genital or oral-genital contact with an infected partner. The spirochete replicates locally in the primary stage (chancre) and then disseminates causing secondary infection. Transmission may also occur transplacentally or at the time of delivery to infect a fetus/neonate, causing congenital or neonatal syphilis infection.

MANIFESTATIONS OF DISEASE

Clinical Presentation

Although congenital syphilis may be detected prenatally, the findings are often nonspecific and may be seen with other TORCH infections. Postnatal examination and testing of the neonate and the placenta/umbilical cord is critical for accurate diagnosis.

Prenatal. The consequences of congenital syphilis include premature delivery, low birth weight, nonimmune hydrops fetalis,

and intrauterine demise. Suggestive US findings are discussed in the subsequent section on imaging.

Neonatal. Two-thirds of live-born infants with congenital syphilis are asymptomatic; however, two-thirds of all untreated neonates exhibit symptoms by 3 to 8 weeks of life.[5] Clinical manifestations may occur either within the first 2 years of life, with signs and symptoms similar to the inflammatory-driven manifestations of adult secondary syphilis or up to the first two decades of life, similar to gumma formation in bone, cardiac, and the central nervous system consistent with the chronic granulomatous inflammation typical of tertiary syphilis.[4]

Early-stage congenital syphilis manifestations include hepatomegaly (51%–71%), maculopapular rash (41%–68%), fever (42%), neurosyphilis or cerebrospinal fluid abnormalities (23%–28%), pneumonitis (17%), rhinitis and snuffles (14%–23%), lymphadenopathy (14%–32%), and ascites (9%). Leukocytosis (72%), hemolytic anemia (34%–58%), thrombocytopenia (40%), jaundice (30%), pseudoparalysis (28%), renal disease (16%), and periostitis or osteochondritis (78%) may also be found.[4–6] Skeletal findings are usually symmetric and multifocal and resolve spontaneously in the first 6 months of life. Hepatitis or pancreatitis may develop, with other possible gastrointestinal abnormalities such as ileitis or malabsorptive intestinal fibrosis. Skin may manifest pemphigus, with vesiculobullous lesions or condyloma lata. Mucous ulcers or fissures may also be seen. Neurosyphilis may develop later with acute leptomeningitis in the first few months or chronic meningosyphilis, causing progressive hydrocephalus, seizures, and neurodevelopmental regression later in neonatal life. Glomerulonephritis may result in nephrotic syndrome. Ophthalmologic findings may include chorioretinitis, glaucoma, or uveitis. Myocarditis, testicular masses, alopecia, and nail exfoliation are also seen.

Late-stage congenital syphilis occurs in 40% of untreated or incompletely treated survivors. These manifestations include saddle-nose deformity from rhinitis-related cartilage destruction (10%–30%); bowing and thickening of the brow, clavicle, midtibia, and/or scapula from prolonged periostitis (30%–95%); perforation of the hard palate (76%); peg-shaped, notched central incisors, and multicuspid first molars from vasculitis injury to tooth buds (55%); corneal scarring and glaucoma; interstitial keratitis (20%–50%); eighth cranial nerve deafness with high-frequency hearing loss between ages 8 and 10 years (3%–4%); and Clutton joints (hydrarthrosis of knees and elbows) (1%–5%). Asymptomatic neurosyphilis affects 25% to 33% of survivors of untreated congenital syphilis older than 2 years of age. Tabes dorsalis and cerebrovascular lesions develop in 1%–5% of children or adolescents.[4,6]

Imaging Technique and Findings

Ultrasound. Although congenital syphilis can occur at any gestational age, US findings, if present, are noted after 18–20 weeks' gestation. This is secondary to the required fetal inflammatory response necessary for the development of the characteristic abnormalities. Advancing maternal stage correlates with the US abnormalities seen. US findings of congenital syphilis most commonly include hepatomegaly (Figs. 168.1 and 168.2) and placental thickening (Figs. 168.3 and 168.4).[1] Other findings such as ascites, skin edema, and polyhydramnios occur less frequently (Figs. 168.5 and 168.6). Unusual findings include small bowel dilatation or hyperechogenicity. Long bones may be lagging in growth, irregularly shaped, bowed in multiple locations, or thickened (Figs. 168.7 and 168.8). Doppler evaluation of the middle cerebral artery has been used to assess fetal anemia, a finding known to occur later in the progression of congenital syphilis. Elevated middle cerebral artery (MCA) peak systolic velocity (PSV) was found in almost one-third of infants with congenital syphilis.

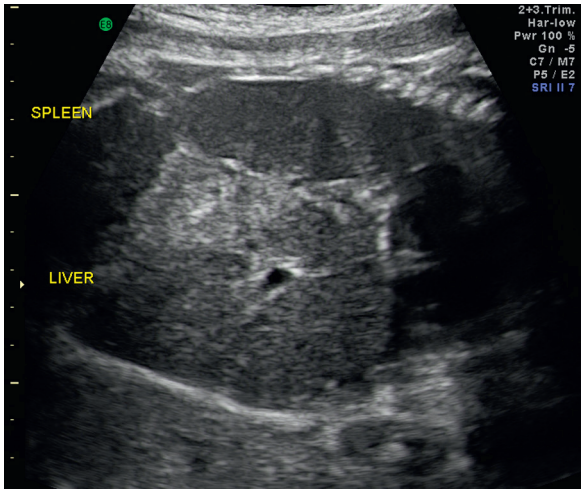

Fig. 168.1 Ultrasound showing hepatomegaly in the coronal plane.

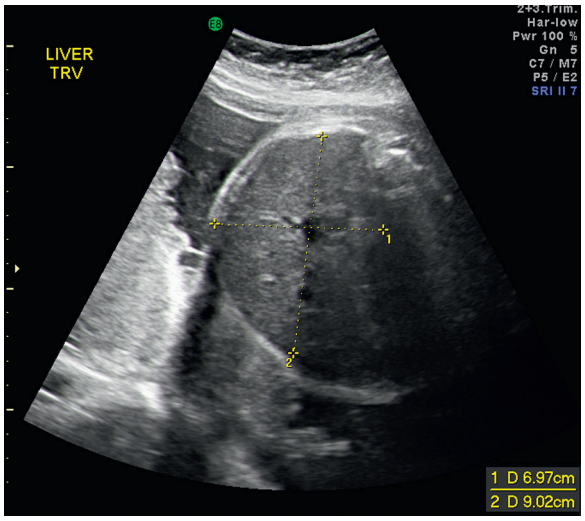

Fig. 168.2 Ultrasound of hepatomegaly in the transverse plane.



Fig. 168.3 Placental thickening shown on prenatal ultrasound.

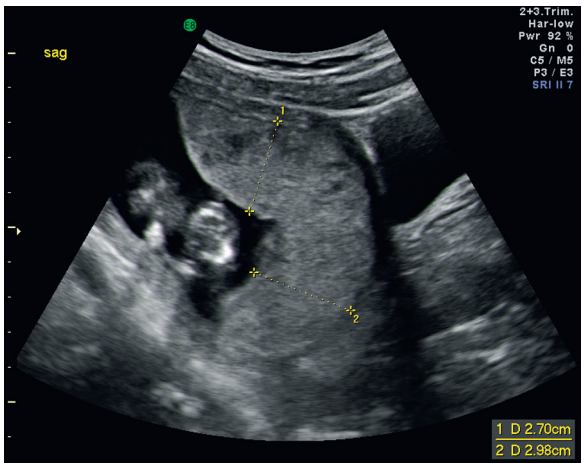

Fig. 168.4 Placental thickening shown on prenatal ultrasound.



Fig. 168.7 Bowing of fetal long bones visible on prenatal ultrasound.



Fig. 168.5 Fetal nonimmune hydrops, as evidenced by the presence of ascites, skin edema, and pleural effusion in the sagittal plane on ultrasound.

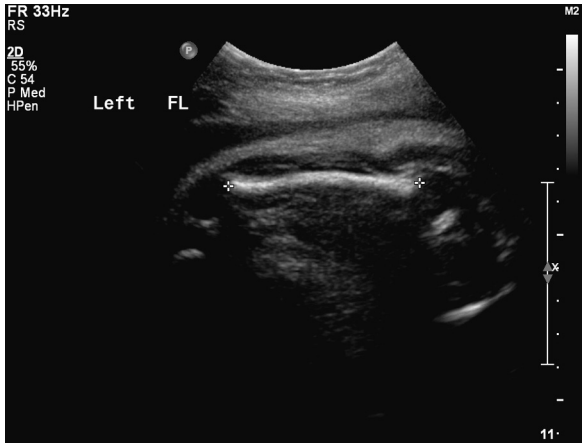

Fig. 168.8 Bowing of fetal long bones *(FL)* visible on prenatal ultrasound.



Fig. 168.6 Fetal nonimmune hydrops noted in the transverse plane with evidence of fetal ascites and skin edema.

The largest report of US findings in infants with congenital syphilis was published by Rac and colleagues.[1] Hepatomegaly, elevated MCA PSV, and placentomegaly were the most common findings (79%, 33% and 27%, respectively) followed by polyhydramnios (12%) and ascites (10%). This mirrored what had previously been hypothesized regarding the pathophysiology of congenital syphilis infection. Hepatic dysfunction and placental infection are noted early, followed by amniotic fluid infection and hematologic abnormalities.[7] Importantly, the authors showed that adequate maternal treatment led to the resolution of abnormal US findings. Late fetal manifestations resolved first, and findings that occur early in congenital syphilis infection, such as hepatomegaly and placentomegaly, resolved last.

CLASSIC SIGNS

The classic US findings of congenital syphilis are described in the previous section. Hepatomegaly may result from the development of acute fetal hepatitis, hepatic congestion secondary to heart failure from syphilitic myocarditis or fetal anemia, or increased extramedullary hematopoiesis.[8] Hepatomegaly is the most common finding in the congenital syphilis neonate, regardless of adequate maternal treatment. The persistence may also be secondary to the hepatitis reported to occur after maternal syphilis treatment with penicillin.[9] The elevated MCA PSV associated with fetal anemia reflects the hematologic dysfunction, with resulting anemia previously reported in fetuses infected with congenital syphilis. The placentomegaly is evidence of villous enlargement and acute villitis, with edema reported on histopathology studies of congenital syphilis.[10] Importantly, a normal US does not rule out a congenitally infected infant. In one study, 12% of neonates with clinical evidence of congenital syphilis at delivery had a normal antepartum US.[1]

Differential Diagnosis From Imaging Findings

The differential diagnosis of the most commonly described US findings is broad and often overlap with many of the other TORCH infections. The differential diagnoses of three of the most common findings—hepatomegaly, placental thickening, and fetal nonimmune hydrops—are discussed here.

1. Hepatomegaly (see Figs. 168.1 and 168.2) is the most common sonographic manifestation of congenital syphilis, although it may be present in other congenital infections, most commonly cytomegalovirus and toxoplasmosis. Other potential infectious etiologies include congenital hepatitis and *Listeria monocytogenes* infection. In developing countries, malarial diseases, tuberculosis, and schistosomiasis should also be considered. Hydrops fetalis, regardless of etiology, may manifest with hepatomegaly. Nonimmune hydrops and hepatomegaly may be found in cases of chromosomal abnormalities, particularly trisomy 21. Genetic conditions such as Beckwith-Wiedemann syndrome (Chapter 109), chronic granulomatous disease of childhood, or polycystic kidney disease should also be considered. Metabolic storage disorders may also manifest with an enlarged liver, as will hemangiomas and hepatoblastomas.[11]
2. Placental thickening (see Figs. 168.3 and 168.4) is classically defined as *a placenta measuring greater than 4 to 6 cm*, but varies substantially with gestational age. Placentomegaly be seen with any of the immune or nonimmune causes of fetal hydrops, including infectious, genetic, and metabolic causes. Etiologies specifically related to the placenta include placental separation or hemorrhage, partial molar pregnancy, and placental hemangiomas.[11]
3. Fetal hydrops fetalis (see Figs. 168.5 and 168.6) is defined as *evidence of fluid or edema in at least two potential cavities.* Classic compartments include the skin, the abdominal compartment (ascites), the pericardium, the pleura, the amnion (polyhydramnios), and the placenta (placentomegaly). The etiology of fetal hydrops is typically divided into "immune" and "nonimmune" etiologies (Chapters 122 and 123). Immune hydrops may be caused by Rhesus or other blood group incompatibilities. Nonimmune hydrops has an extensive differential diagnosis, including infection (most commonly parvovirus B19 or syphilis), aneuploidy, fetal cardiovascular disease, metabolic disease, monochorionic multiple gestation, obstructive neoplasms, and others.[11]

Synopsis of Treatment Options

PRENATAL

Abnormal US findings consistent with congenital syphilis are more likely to be associated with treatment failure and obstetric complications from the treatment itself, e.g., preterm delivery.[7,12] Women with pretreatment US findings consistent with congenital syphilis are three times more likely to have an infant requiring treatment for congenital syphilis.[1] Benzathine penicillin G remains the definitive treatment for syphilis in pregnancy.[13] Maternal treatment depends on the stage of disease. Benzathine penicillin G, 2.4 million units administered intramuscularly, may be given as a single dose or two doses, 1 week apart for primary, secondary, or early latent syphilis. Late latent, tertiary syphilis, or syphilis of unknown duration stages are treated with a series of three doses at weekly intervals. Treatment regimens are not affected by fetal manifestations on US, though treatment in labor and delivery is warranted if the fetus is at a gestational age that intervention would be performed if a fetal Jarisch-Herxheimer reaction were to occur. This is believed to be more common in those fetuses with evidence of congenital syphilis on US.[12,14]

Nonpenicillin regimens have a higher failure rate in pregnancy. Thus in penicillin-allergic pregnant women, desensitization to penicillin is recommended over other treatment strategies.[11] Adequate maternal treatment results in a 95% to 100% success rate based on maternal stage of syphilis and gestational age.[15]

POSTNATAL

Neonatal treatment depends on examination, prenatal maternal treatment, and maternal and fetal nontreponemal titers.[13,16] A fourfold change in titer, equivalent to an increase of two dilutions (e.g., from 1:2 to 1:8) is the threshold used to define a clinically significant difference between two nontreponemal test results that were obtained using the same serologic test. If an infant has (1) a normal examination with an adequately treated mother, (2) the infant's titers are the same as or fourfold less than the maternal titers, and (3) the maternal titers are low and stable, then the infant does not require treatment or evaluation. If the mother was treated less than 4 weeks before delivery with no evidence of reinfection and the neonate has a normal examination, the infant is treated with a single injection of benzathine penicillin and a complete workup is performed, including complete blood count (CBC) with platelet count, lumbar puncture for a cerebrospinal fluid (CSF) venereal disease research laboratory test, and long bone radiographs to evaluate for neonatal manifestations of disease.[8] If these tests are abnormal or if neonatal serology increases with serial evaluations, the neonate should receive a 10-day course of aqueous crystalline penicillin G or procaine penicillin G. The Jarisch-Herxheimer reaction is rare in newborns.[13]

Infants with findings of congenital syphilis should have a CBC with platelet count, CSF, and long bone evaluation performed as well as liver function tests, cranial US, ophthalmologic examination, and auditory brain-stem response to thoroughly evaluate for potential congenital syphilis sequelae. Infants should be treated with the 10-day regimen described previously. If more than 1 day of therapy is missed, the entire course should be reinitiated.[13]

Infants should be reexamined and syphilis serology followed every 2 to 3 months until the titers have decreased by a fourfold margin (e.g., 1:16 to 1:4). Maternal antibodies may persist in the fetal circulation for 15 months; reactivity beyond 18 months indicates congenital infection. Infants with congenital neurosyphilis should undergo CSF evaluations every 6 months until indices are within normal limits. Finally, all infants with congenital syphilis are recommended to be evaluated for concurrent HIV infection.[13]

WHAT THE REFERRING PHYSICIAN NEEDS TO KNOW

Congenital syphilis in the United States has been increasing, with concurrent increases of disease prevalence in the population. All women should be screened for syphilis during the course of their pregnancy—at their first prenatal visit and again near delivery, particularly in high prevalence areas.[17] Most cases of congenital syphilis occur in women with late or no prenatal care. Other attributable factors include mothers with inadequate treatment or mothers

who did not have an adequate serologic response to therapy. Antibody titers should be followed in all affected women, even after appropriate treatment. Although universal screening may be associated with false-positive results and exposure to possible allergic reactions to treatment, the U.S. Preventive Services Task Force reaffirmed the benefit of continued universal screening.[17]

KEY POINTS

- Incidence of congenital syphilis has been increasing in the United States and worldwide after a long period of decline. Universal prenatal maternal syphilis screening remains an important component of prenatal care.
- Prenatal US findings are nonspecific and not always observed with congenital syphilis, but can include hepatomegaly, placental thickening, and nonimmune hydrops fetalis. Other manifestations include bowel dilatation and long bone abnormalities.
- A normal US does not rule out a congenitally infected infant.
- US abnormalities consistent with congenital syphilis often resolve with adequate maternal treatment.
- The most common prenatal outcomes of untreated congenital syphilis are fetal nonimmune hydrops, prematurity, low birth weight, and intrauterine death.
- Neonatal manifestations occur in virtually every organ system and may be avoided with adequate maternal treatment.
- Penicillin-based therapy is the mainstay of treatment, and desensitization of allergic mothers followed by treatment is preferred over treatment regimens with other antibacterial agents to optimize outcomes.

SUGGESTED READINGS

Centers for Disease Control and Prevention. Congenital syphilis—United States, 2003–2008. *MMWR Morb Mortal Wkly Rep*. 2010;59:413-417.

Chakraborty R, Luck S. Syphilis is on the increase: the implications for child health. *Arch Dis Child*. 2008;93:105-109.

Walker GJA, Walker DG. Congenital syphilis: a continuing but neglected problem. *Semin Fetal Neonatal Med*. 2007;12:198-206.

Wolff T, Shelton E, Sessions C, et al. Screening for syphilis infection in pregnant women: evidence for the U.S. Preventive Services Task Force reaffirmation recommendation statement. *Ann Intern Med*. 2009;150:710-716.

Woods CR. Congenital syphilis—persisting pestilence. *Pediatr Infect Dis J*. 2009;28:536-537.



All references available online at
www.expertconsult.com

REFERENCES

1. Rac MWF, Bryant SN, McIntire DD, et al. Progression of ultrasound findings of congenital syphilis after maternal treatment. *Am J Obstet Gynecol*. 2014;211:426.e1-426.e6.
2. Centers for Disease Control and Prevention. *Sexually Transmitted Disease Surveillance 2014*. Atlanta: U.S. Department of Health and Human Services; 2015. http://www.cdc.gov/std/stats.
3. Bowen V, Su J, Torrone E, et al. Increase in incidence of congenital syphilis—United States, 2012-2014. *MMWR Morb Mortal Wkly Rep*. 2015;64(44):1241-1245.
4. Woods CR. Congenital syphilis—persisting pestilence. *Pediatr Infect Dis J*. 2009;28:536-537.
5. Su JR, Brooks LC, Davis DW, et al. Congenital syphilis: trends in mortality and morbidity in the United States, 1999 through 2013. *Am J Obstet Gynecol*. 2016;214(3):381.e1-381.e9.
6. Chakraborty R, Luck S. Syphilis is on the increase: the implications for child health. *Arch Dis Child*. 2008;93:105-109.
7. Hollier LM, Harstad TW, Sanchez PJ, et al. Fetal syphilis: clinical and laboratory characteristics. *Obstet Gynecol*. 2001;97:947-953.
8. Hira SK, Bhat GJ, Patel JB, et al. Early congenital syphilis: clinic-radiologic features in 202 patients. *Sex Transm Dis*. 1985;12:177-183.
9. Long WA, Ulshen MH, Lawson EE. Clinical manifestations of congenital syphilis hepatitis: implications for pathogenesis. *J Pediatr Gastroenterol Nutr*. 1984;3:551-555.
10. Sheffield JS, Sanchez PJ, Wendel GD, et al. Placental histopathology of congenital syphilis. *Obstet Gynecol*. 2002;100(1):126-133.
11. Creasy RK, Resnik R, Iams JD, et al, eds. *Creasy and Resnik's maternal-fetal medicine: principles and practice*. 7th ed. Philadelphia: Saunders; 2014.
12. Wendel GD, Sheffield JS, Hollier LM, et al. Treatment of syphilis in pregnancy and prevention of congenital syphilis. *Clin Infect Dis*. 2002;35(suppl 2):S200-S209.
13. Centers for Disease Control and Prevention. Sexually transmitted diseases treatment guidelines 2015. *MMWR Morb Mortal Wkly Rep*. 2015;64:1-138.
14. Klein VR, Cox SM, Mitchell MD, et al. The Jarisch-Herxheimer reaction complicating syphilotherapy in pregnancy. *Obstet Gynecol*. 1990;75:375-380.
15. Alexander JM, Sheffield JS, Sanchez PJ, et al. Efficacy of treatment for syphilis in pregnancy. *Obstet Gynecol*. 1999;93:5-8.
16. Kwak J, Lamprecht C. A review of the guidelines for the evaluation and treatment of congenital syphilis. *Pediatr Ann*. 2015;44(5):e108-e114.
17. Wolff T, Shelton E, Sessions C, et al. Screening for syphilis infection in pregnant women: evidence for the U.S. Preventive Services Task Force reaffirmation recommendation statement. *Ann Intern Med*. 2009;150:710-716.

169 Ultrasound Physics for the Clinician

IVAN M. ROSADO-MENDEZ

Introduction

Since its introduction to the medical community in the 1950s,[1] ultrasound (US) has become a widespread imaging modality because of its portability, nonionizing energy,[2] and relatively low cost. This chapter reviews basic physics concepts behind the formation of an US image, emphasizing conventional B-mode imaging. Other approaches, including US-based elasticity assessment, Doppler, and three-dimensional imaging, as well as magnetic resonance imaging, are discussed in other chapters.

Components of an Imaging System

In an imaging system, a source produces a stimulus that interacts with the object to be imaged. That interaction produces a response within the object, which is sensed by a detector, and transformed into a signal that an image generator uses to produce the image.

THE STIMULUS

In a clinical US system, the stimulus is a US pulse. This is a short disturbance (about one-millionth of a second) that progressively moves from the source (the US transducer, described subsequently) through the object (the human body).[3,4] This disturbance consists of a sound wave, which is a series of pressure increments and reductions that cause small volumes (approx. 0.1 mm^3) of tissue to sequentially shrink (compression) and expand (decompression, also called *rarefaction*).[5] One compression followed by one rarefaction is called a *cycle,* and a typical US pulse might contain between one and four cycles.[5,6]

The amplitude of the wave can be described by the maximum compression achieved by the pulse.[7,8] The frequency is the number of compression and decompression cycles that a small volume experiences per second.[8] The unit "one cycle per second" is called a *Hertz* (Hz).[3,7] Humans are able to hear sound waves with frequencies between about 20 Hz and 20 kHz.[5] The prefix *ultra-* refers to sound waves with frequency beyond the audible range, i.e., higher than 20 kHz. Frequencies in diagnostic obstetric US span roughly 1 to 10 MHz.

The volume occupied by the US pulse (pulse size) is about 0.25 mm^3 and is defined in three dimensions: the axial length, the lateral width, and the elevational width (crosshairs in Fig. 169.1). The axial dimension is parallel to the propagation direction of the pulse and is called the *pulse length,* i.e., the extent occupied by adjacent compression/decompression zones within the pulse (about 0.5 mm). The lateral and elevational dimensions are perpendicular to the propagation direction—one within and one outside of the image plane, respectively. These dimensions are on the order of 1 mm and vary with the distance of the US pulse from the source, with the US beam geometry having an hourglass shape[5] (see dashed blue lines in Fig. 169.1) determined by the size of the source (see red area in the transducer in Fig. 169.1).[6] The depth at which the lateral and elevational dimensions are the smallest is the focus (see green mark in Fig. 169.1).[4]

THE OBJECT

The object with which the US pulse interacts is the human body. The pulse travels within the object along a well-defined path from the source, the propagation axis, represented by the red line in Fig. 169.1. To the pulse, the body is a collection of materials with different acoustic impedances. The acoustic impedance is a measure of the resistance of a material to compress and decompress under the action of the US pulse (how much the material impedes the propagation of the wave). Because acoustic impedance is related to a tissue's density and stiffness, it informs the speed at which the pulse travels.[3,6–8] Specifically, a pulse will move faster in tissues with larger impedance (tendon, about 1750 m/s) than in those with lower impedance (fat, about 1400 m/s).[3] The average sound speed in soft tissue is 1540 m/s.[4]

THE RESPONSE

The tissue response from which US signals and images are created is called an *echo*. An echo is created when the pulse reaches an interface between two materials of different acoustic impedance.[6] The amplitude of the echo depends on three main factors: the properties of the impedance interface, the amplitude of the ultrasonic pulse when it reaches the interface, and the energy lost by the echo on its way back to the detector. The larger the amplitude of an echo, the brighter it appears in the image.

The main property of the impedance interface that defines the echo's amplitude is its physical dimensions compared to the size of the US pulse. If the size of the impedance interface is significantly larger than that of the pulse, the interface acts as a (partially reflective) mirror that reflects the pulse. The stronger the difference in acoustic impedance at either side of the interface, the larger the fraction of the incident pulse amplitude in the echo.[8] Echoes from large interfaces provide the anatomic landmarks of conventional US images. For clinical imaging, gels or oils are used to couple the surface of the US transducer to the

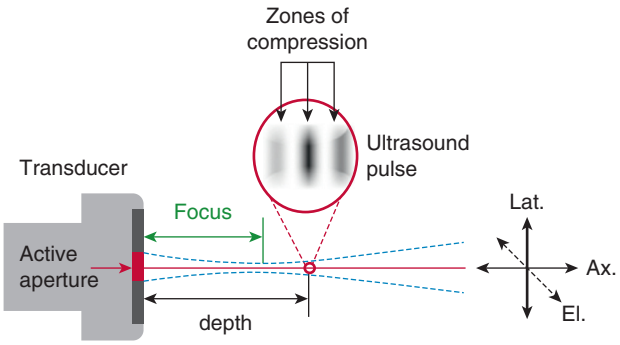

Fig. 169.1 Propagation of the ultrasound pulse from the active aperture of the ultrasound transducer. The crosshair indicates the axial, lateral, and elevational directions. *Ax*, Axial; *el*, elevational; *lat*, lateral.

patient's skin to avoid a large impedance difference between air and tissue.[3] This coupling creates an acoustic "window" into the body.

Once in the tissue, the pulse encounters *scatterers*, which are microstructural elements such as collagen bundles or cells that create a set of minute changes in acoustic impedance on a physically small size compared to the pulse. Each of these redirects the pulse with smaller amplitude.[6] All the scattered pulses within the volume occupied by the US pulse interact with each other to generate a total echo. The amplitude of the total echo depends on the number of scatterers and their spatial distribution within the US pulse, as well as their impedance difference relative to the surrounding tissue.[4] Most of the US appearance of tissue parenchyma is produced by scatterers that are poorly organized, e.g., collagen bundles.[8,10] As a result, the amplitude of the total echo varies from location to location, creating a ubiquitous "noise" known as *speckle*.[5] The term *echogenicity* refers to the overall brightness of speckle from tissue parenchyma. The terms *hypoechoic*, *isoechoic* or *hyperechoic* describe a region of the image that looks less, equal, or more echogenic than its surroundings, respectively.[4]

Other properties that define the amplitude of the echo signal are the amplitude of the pulse that reaches a particular location within tissue. This is affected by tissue attenuation. Attenuation is the exponential loss of energy that the US pulse experiences as it travels through tissue.[3,8] This loss is caused by reflection and scattering as well as absorption (the conversion of acoustic energy to heat).[5,10] Attenuation is usually quantified in the amount of energy lost by the pulse as it traverses 1 cm of tissue, expressed in decibels, which is defined as 10 times the logarithm of the energy loss.[5] For instance, an energy loss of 50% corresponds to $10 \times \log(0.5) = 3$ dB.[4] Higher frequencies attenuate more than lower frequencies, and most tissues have attenuation between 0.5 and 1 dB/cm/MHz.[4,7] The attenuation-related loss of US signal with depth can be partially compensated by amplifying echoes coming from deeper locations through adjusting control knobs (time-gain compensation) on the imaging system.[3]

Finally, the amplitude of the echo itself has both a geometric and a physical component. The geometric component is related to the sensitivity of the detector to the spatial location at which each echo is generated. The spatial pattern of sensitivity is similar to the focused beam geometry that determines the size of the US pulse. The physical component is also caused by attenuation.

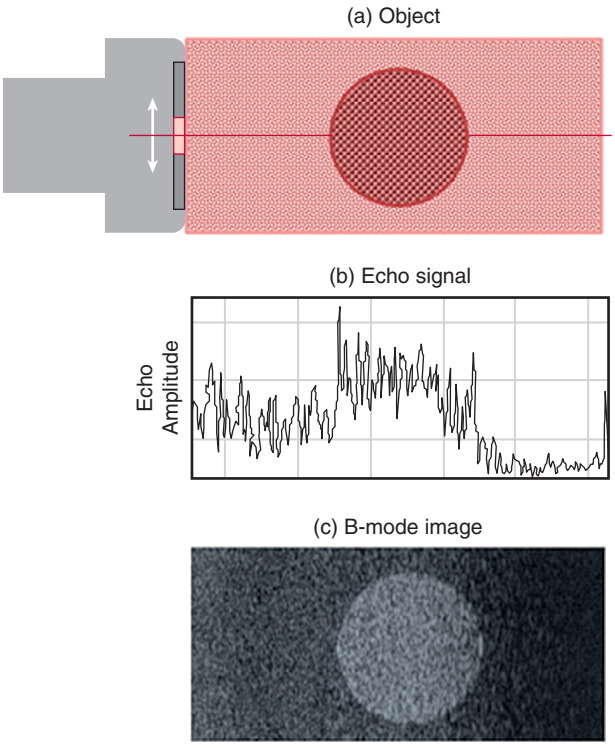

Fig. 169.2 Formation of a B-mode image.

Image Formation

ULTRASOUND TRANSDUCER

US imaging systems operate in a scanned, pulse-echo mode, in which a handheld wand "transduces" electric energy into acoustic energy, thus the term *transducer*.[4] The transducer acts both as the source of the stimulus (like a speaker on a radio sending waves) and the detector of the echoes (like a microphone detecting waves).[1] Most transducers are composed of an array,[5] a series of 100 to 300 piezoelectric elements arranged sequentially one next to the other. Each piezoelectric element is able to vibrate at a particular frequency, and thereby generate a sound wave, when subjected to an electric pulse. Conversely, they can generate an electric response when hit by an echo sound.[7] The thickness of the elements defines the frequency at which they can respond, and the clinician's choice of transducer depends on the desired frequency range.

The aperture (where the transducer elements are) is the part of the transducer that is placed in contact with the patient's skin. To emit a pulse, part of the aperture is activated (red area in Fig. 169.2A). Immediately after the pulse is emitted, the same (part of, or more of the) aperture is used to "listen" to echoes generated at tissue interfaces along the pulse trajectory.[4] The transducer transforms the echo information into an electric echo signal (see Fig. 169.2B). This signal is composed of a series of spikes that correspond to echoes from within the tissue being examined. The amplitude of the spike is defined by the amplitude of the corresponding echo. The time at which a spike (or echo) is detected corresponds to the time needed for the US pulse to travel a distance *(D)* to the impedance interface, plus the time needed for the echo to travel the same distance *D* back to the transducer.[3,5] By assuming a specific sound speed in tissue (e.g., 1540 m/s), the *D* is implied from the time the echo is detected.[1]

The pulse-echo detection is repeated as the active aperture is swept across the transducer's aperture stepwise (see white arrow in Fig. 169.2A), obtaining one echo signal at each step. After scanning the active aperture across the entire aperture, the final brightness mode (B-mode) US image (see Fig. 169.2C) is formed from the set of adjacent echo signals, each one containing the information of the echoes generated at various depths within tissue.[4]

There are two basic image geometries: rectangular and trapezoid (sector) images. Rectangular images are produced by linear arrays in which the elements are arranged in a flat surface. Trapezoid images are generated when the echo signals spread away from the transducer. This fan geometry can be produced by curvilinear arrays or phased arrays. Curvilinear arrays are similar to flat linear arrays but with the elements laying on a curved surface. Phased arrays are linear arrays that change time delays in the transmitted and received pulse to produce steered scan lines in addition to the electronic delays used during transmit and receive focusing.[4] Transducer choice depends upon the tissue to be evaluated, as described later.

IMAGE OPTIMIZATION

The clinician's ultimate goal is to obtain the best quality image to detect or diagnose a disease process. Image quality is determined by many properties, the three primary of which are spatial resolution, temporal resolution, and contrast resolution. Spatial resolution, the minimum separation that must exist between two features of the object for them to be displayed individually, is determined by the volume occupied by the US pulse.[5] If two features are contained within this volume, a single signal will be generated by both features, so they will not be resolved. As described previously, the volume of the US pulse is defined by the extent of the cycles of compression and decompression of the pulse in the axial direction, as well as by the beam geometry in the lateral and axial direction. Increasing the US frequency improves spatial resolution in the axial direction by shrinking the span of the compression and decompression cycles.[3] It also narrows the beam geometry, thus improving the resolution in the lateral and elevational directions.[4,5,8] However, considering attenuation increases with frequency, higher frequency pulses do not penetrate as deep as lower frequency pulses. Given that different transducers have different frequency ranges, the choice of the transducer involves a compromise between spatial resolution and penetration.[3,4,11] For instance, high-frequency, linear array transducers are optimal for superficial scanning whereas low-frequency, curvilinear, and phased arrays are typically used for transabdominal scanning.[2]

Temporal resolution refers to the minimum time interval that must exist between two events occurring within the object for them to be observed individually.[5] To achieve this, an image must be created for each of the events.[6] Thus temporal resolution is determined by the speed at which images are formed within the system. To appear "real-time," images must be refreshed at a rate of about 15 per second.[5] Contrast resolution refers to the minimum difference in echogenicity between two regions of the object for them to be distinguished as different features.[6] For this to occur, the echogenicity difference must be larger than the background noise.[6] Noise can be reduced by many imaging processing strategies, such as creating multiple images and averaging them. Again, there is a trade-off; averaging reduces the time required to create the averaged image, thus limiting the temporal resolution.

WHAT THE REFERRING PHYSICIAN NEEDS TO KNOW

Optimal imaging always involves compromise. The best images are obtained by increasing the frequency as well as the number of averaging images to reduce noise. Because of attenuation, however, this can result in significant absorption of sound energy into tissue, causing tissue heating and other potentially harmful bioeffects. Although the risk of diagnostic US appears very low,[12] it is never zero and therefore the ALARA (As Low As Reasonably Achievable) principle must always be respected. This principle states that an US system should be used only to obtain valuable diagnostic information with the least exposure to US energy.[13]

KEY POINTS

- US is a widespread imaging modality because of its portability, nonionizing energy, and low cost.
- The user's choice of transducer involves a compromise between spatial resolution and penetration; high-frequency, linear array transducers are optimal for superficial scanning whereas low-frequency, curvilinear, and phased arrays are typically used for transabdominal scanning.
- The ALARA principle should always be respected.

SUGGESTED READINGS

American Institute of Ultrasound in Medicine. AIUM practice guideline for the performance of obstetric ultrasound examinations. *J Ultrasound Med*. 2013;32(6):1083-1101.

Fowlkes JB, Bioeffects Committee of the American Institute of Ultrasound in Medicine. American Institute of Ultrasound in Medicine Consensus Report on potential bioeffects of diagnostic ultrasound: executive summary. *J Diagn Med*. 2008;27(4):503-515.

McDicken WN, Anderson T. Basic physics of medical ultrasound. In: Allan PL, Baxter GM, Weston MJ, eds. *Clinical Ultrasound*. 3rd ed. Edinburgh: Churchill Livingstone; 2011:3-15.



All references available online at www.expertconsult.com

REFERENCES

1. Shung KK. Diagnostic ultrasound: past, present, and future. *J Med Biol Eng*. 2011;31(6):371-374.
2. Colquhoun K, Alam A, Wilson D. Basic science: ultrasound, in mini-symposium: radiology for the FRCS (orth). *Curr Orthop*. 2005;19(1): 27-33.
3. Williams D. The physics of ultrasound. *Anaest Intens Care Med*. 2012; 13(6):264-268.
4. Zagzebski JA. *Essentials of ultrasound physics*. St. Louis: Mosby-Year Book; 1996.
5. Lieu D. Ultrasound physics and instrumentation for the pathologists. *Arch Pathol Lab Med*. 2010;134(10):1541-1556.
6. McDicken WN, Anderson T. Basic physics of medical ultrasound. In: Allan PL, Baxter GM, Weston MJ, eds. *Clinical Ultrasound*. 3rd ed. Edinburgh: Churchill Livingstone; 2011:3-15.
7. Aldrich JE. Basic physics of ultrasound imaging. *Crit Care Med*. 2007;35(5):S131-S137.
8. Ziskin MC. Fundamental physics of ultrasound and its propagation in tissue. *Radiographics*. 1993;13(3):705-709.
9. Zagzebski JA, Lu F, Yao LX. Quantitative ultrasound imaging: in vivo results in normal liver. *Ultrason Imaging*. 1993;15(4):335-351.
10. Hershkovitz R, Sheiner E, Mazor M. Ultrasound in obstetrics: a review of safety. *Eur J Obstet Gynecol Reprod Biol*. 2002;101(1):15-18.
11. American Institute of Ultrasound in Medicine. AIUM practice guideline for the performance of obstetric ultrasound examinations. *J Ultrasound Med*. 2013;32(6):1083-1101.
12. Abramowicz JS, Fowlkes JB, Skelly AC, et al. Conclusions regarding epidemiology for obstetric ultrasound. *J Ultrasound Med*. 2008;27:637-644.
13. Fowlkes JB, Bioeffects Committee of the American Institute of Ultrasound in Medicine. American Institute of Ultrasound in Medicine consensus report on potential bioeffects of diagnostic ultrasound: executive summary. *J Ultrasound Med*. 2008;27(4):503-515.

To access the videos in this chapter, scan this QR code or visit expertconsult.com

170 Elasticity Imaging in Obstetrics

LINDSEY DREHFAL

Introduction

Palpation, the technique by which clinicians evaluate a patient by touch, has been fundamental to medical practice for thousands of years. Information about tissue stiffness can provide diagnostic information about the presence or status of disease, or about structural or microstructural changes in tissue because of physiologic and pathologic processes.[1] Quantification of this type of information, however, did not emerge until the past two decades, with the advent of elasticity imaging (EI). EI is a medical imaging modality that maps elastic properties of soft tissue.[1–3] Although B-mode ultrasound (US) imaging remains the standard modality in obstetrics (brightness mode, Chapter 169), EI is gradually being introduced. While it has not yet found a place in obstetric clinical practice, it may ultimately complement conventional imaging, if only to improve image contrast in soft tissues because the range of tissue stiffness is much wider than the range of tissue echogenicity that creates B-mode images.[4]

Some EI applications, such as breast and liver, are commonplace in clinical practice.[5,6] Therefore most high-end clinical systems have some variant of an elasticity/stiffness software package. Obstetric EI is still in its infancy, with research focused primarily on the cervix, somewhat on the uterus and placenta and to a lesser extent, on the fetus. This chapter describes basic concepts and terminology of EI and briefly reviews potential applications in obstetrics.

Elasticity Imaging

Elasticity describes the restoring forces of an object or material to resume its original shape after being subjected to a deforming force (stretching or compressing). It can be quantified if the applied stress (force per unit area) and strain (relative change in shape) are both known. Typical moduli to describe elastic quantities are Young's modulus *(E)* and Shear modulus *(G)*. However, imaging modalities must rely on metrics that are related to elastic properties, because the stress distribution in the body is complex and usually unknown, and soft tissues have complicated boundary conditions that require derivation of precise equations specific to type of applied force and tissue type.[1,7] Therefore understanding the principles of EI is essential to applying this technique to clinical practice. There are three basic approaches to EI: strain (static) elastography (SE), dynamic elastography, and transient elastography. These vary with respect to the type of force applied and the quantity of measure, as described subsequently and in Table 170.1.

STRAIN ELASTOGRAPHY

SE was developed in the 1970s. For SE, force is applied to the tissue surface through mechanical or manual compression of the US transducer, or by taking advantage of normal physiologic movement, such as arterial pulsations. Comparison of US frames before and after compression allows tracking of tissue displacement and subsequent conversion to strain, typically displayed as an image (elastogram). This image is qualitative rather than quantitative, because strain is a relative measurement of stiffness and its value changes based on amount of pressure applied. Images (and thus interpretation) can be enhanced by performing multiple compression cycles and calculating incremental strain (persistence) because accumulation of multiple frames reduces noise in elastogram images. Displays can show B-mode images side-by-side with a grayscale strain image for direct comparison or overlay a color map on top of the B-mode. A good strain image starts with a good B-mode image and requires adjustments in palpation

TABLE 170.1 SUMMARY AND DESCRIPTIONS OF ELASTICITY METHODS

Method	Description
Strain (static) elastography	Qualitative image of relative strain. Compress at skin surface with probe or with physiologic movement and compare before and after compression frames to compute strain.
Dynamic elastography: acoustic radiation force imaging	Qualitative image of relative displacement. Produce local displacement using focused US pulse and track displacement.
Dynamic elastography: shear-wave elasticity imaging	Quantitative point measure (left) or image (right) of SWS. Shear-wave is produced by ARF pulse and peak displacement is tracked to calculate speed.
Transient elastography	Quantitative point measure of SWS. Shear-wave is produced by a mechanical "punch." Speed is converted to Young's modulus (currently only applicable to liver.)

ARF, Acoustic radiation force; *SWS*, shear-wave speed.

speed and pressure to display the detail of interest. Many systems have a "quality" metric on the US system screen to inform the operator of necessary adjustments for optimal strain imaging. Such metrics are often mistakenly interpreted as a measure of force applied by the operator with the transducer.

It is unfortunate that the US system cannot provide such information, because it is critical; a small or inconsistent (i.e., nonuniform) stress applied to the target tissue will produce strain with limited penetration and poor homogeneity in stress. Another factor that complicates interpretation of elastograms is that the amount of strain is dependent on depth from the transducer. Further, softer tissue strains more when adjacent to stiffer tissue, and areas of high strain may be seen at boundaries because of the slipping of tissue, which creates artefact.

Attempts to make SE more quantitative include comparing strain between the target tissue and a reference material using strain ratios or quantifying strain heterogeneity. For this approach, it is critically important that the reference tissue be evaluated under the same stress conditions as the target tissue. This technique works well for evaluating tissues such as the breast, where assessing relative strain is useful because tumors typically have different stiffness properties than surrounding normal tissue.[1] The approach does not work as well for the cervix, because the goal is to evaluate overall tissue stiffness.

Strain Elastography in the Cervix

To date, the most developed clinical application of SE in obstetrics is evaluation of the pregnant cervix to determine risk of preterm birth or success of labor induction.[8–14] Studies first appeared in 2006 but failed to show significant changes in cervical elasticity during pregnancy.[8] Swiatkowska and Preis reported that strain imaging could predict successful induction of labor, but noted that the inability to standardize measurements limited meaningful comparisons between women.[10] Molina et al., in an attempt to reproduce prior results, suggested that SE values may be merely a reflection of the force applied, not a measure of underlying tissue stiffness[11] (Fig. 170.1).

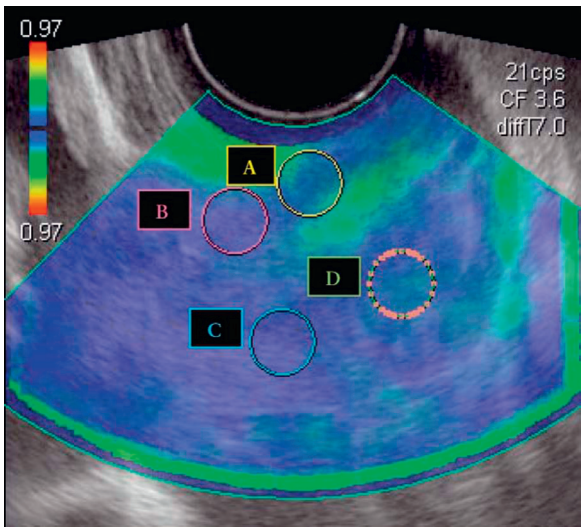

Fig. 170.1 Cervical elastographic image showing regions of interest selected for quantification. Region *A:* external and superior cervical lip. Region *B:* internal and superior cervical lip. Region *C:* internal and inferior cervical lip. Region *D:* external and inferior cervical lip. *(From Molina FS, Gomez LF, Florido J, et al. Quantification of cervical elastography: a reproducibility study.* Ultrasound Obstet Gynecol *39:685–689, 2012.)*

Since then, attempts have been made to quantify the force applied to the cervix. For instance, Hernandez-Andrade et al. studied the ability of SE at 16–24 weeks to predict subsequent preterm birth in a study of 189 women.[14] The sonographer manually applied continuous oscillatory pressure to the cervix with the transducer. Quantification was accomplished by analyzing three cervical projections (cross-sectional at the internal os, cross-sectional at the external os, and sagittal in the midcervix at the level of the cervical length measurement). Strain values represented the percentage of tissue displacement averaged among consecutive frames. Women whose percentage displacement was ≤25th percentile (i.e., less deformation, meaning stiffer tissue) had a lower risk of delivering preterm. Specifically, 20 of 135 (15%) women with strain values >25th percentile delivered preterm compared to one of 51 (2%) women with strain values ≤25th percentile.

There have been several other studies of cervical SE, and a common problem addressed by all of their investigators is that of quantification of force.[15]

Strain Elastography in the Placenta

A handful of studies have used SE to evaluate the placenta. For instance, Cimsit et al. used SE to evaluate the placenta in 119 patients (28 with preeclampsia, 15 with history of preeclampsia, and 101 healthy) and found that those with early onset preeclampsia had significantly higher strain ratios.[16] One issue with SE in the placenta is that it has arguably even greater complexity of boundary conditions than the cervix. Nevertheless, if transducer force could be standardized, SE could have significant promise.

DYNAMIC ELASTOGRAPHY

Acoustic Radiation Force Imaging

Dynamic elastography requires displacing tissue with some type of US pulse. One of these approaches, acoustic radiation force impulse (ARFI) imaging, uses focused, long-duration, high-intensity US pulses that produce tissue displacement up to 10 microns.[17] The degree of displacement is related to tissue stiffness; softer tissues will displace more than stiffer tissues. This method is much less user-dependent than SE, although it must be noted that pressure by the transducer (i.e., prestress, or preload) may itself cause tissue stiffening. Also when evaluating highly attenuating (i.e., US-wave absorbing) tissues, limited penetration is possible because of absorption of the pushing pulse, as well as potential reduction of frame rate caused by limitations on thermal and mechanical indices required to produce high-power pulses, either of which could yield poor results.[2,3]

Shear-Wave Elasticity Imaging

Shear-wave elasticity imaging (SWEI), another form of dynamic elastography, is very similar to ARFI because it uses the same excitation pulse to displace the tissue but instead quantifies the speed of the shear wave produced by the excitation. The displacement produced by the moving wave at several positions radiating from the push can be tracked and used to estimate shear-wave speed (SWS).[17,18] Shear waves travel faster in stiffer tissue and slower in softer tissues and under simple conditions E and G can be directly calculated. Systems either display a point measure (estimate the speed in a small box, approx. 5×5 mm) or at multiple locations to produce an image (sweep push pulses at multiple locations). SWS point measures have higher precision and accuracy because the wave is tracked over longer distances but

do not show spatial variations in speeds/stiffness. SWS images have higher variance at any given location as compared to point measures because the displacement is tracked over shorter distances to show spatial variations. When making SWS measurements, it is important to choose a locally homogeneous region in the tissue away from boundaries and structures that may disrupt wave propagation (e.g., blood vessels). Generating SWSs near boundaries or in thin tissues may introduce bias and variance in results because wave generation is unpredictable near boundaries (including the boundary of the tissue which is in contact with the transducer). It should be noted that, because SWEI techniques are still under active development (more accurate estimation algorithms of SWS), there is not yet a reliable metric to objectively confirm data quality.

Shear-Wave Elasticity Imaging in the Cervix. SWEI has been applied to the pregnant cervix.[19–23] Unfortunately, producing adequate shear waves in the cervix is a complex challenge. As discussed earlier, thin, heterogeneous tissues violate many assumptions needed to quantify elastic moduli. In addition, cervical tissue is highly attenuating (wave energy is rapidly lost) because of its microstructural complexity. These characteristics, particularly its thinness (radius 12–15 mm) cause difficulties. For this reason, a transvaginal transducer may not be ideal because its large acoustic elements limit how close to the transducer reliable shear waves can be produced.

In a cross-sectional study of women at 24–35 weeks' gestation, Muller et al. found a "slight" decrease in SWS in a group hospitalized for preterm labor ($n = 81$, of which 12% delivered preterm) compared to a control group ($n = 27$, of which 4.3% delivered preterm).[19] Interestingly, they did not find a significant difference in cervical stiffness between the first and second trimesters, unlike several other investigators who used other (some nonelastography based) methods of cervical stiffness evaluation. The authors mention the high variance in their first-trimester estimates, noting this could explain the nonsignificance of their results. It is imaginable that variability was so high because of the use of a standard transvaginal transducer, as described earlier. Fig. 170.2 shows how close the transducer (tissue boundary) is to the region of interest (white circle). They did find a statistically significant difference between the first and third trimesters.

Another possible reason that their results did not agree with the findings of other investigators is their assessment location in the cervix (external os). In fact, Hernandez-Andrade et al. evaluated SWS in multiple areas of the cervix (including the internal and external os), and found SWS decreased with increasing gestational age, but only at the internal os[20] (Fig. 170.3).

These studies highlight the complexity of evaluating cervical stiffness. To minimize sources of experimental variance and study potential sources of biologic variability inherent in cervical tissue, we scanned the *ex vivo* cervix ($n = 22$) over its entire length and circumference with a linear transabdominal transducer.[21,22] The smaller elements in a linear transducer allow adequate shear waves production closer to aperture than is possible with a curvilinear (transvaginal) transducer with its larger elements as described previously. Fig. 170.4 shows relatively planar shear-wave fronts overlaid on a microscopy image (obtained after that cervix was scanned) (Video 170.1). We found SWS increased from the external to the internal os, suggesting both that the cervix is stiffer at the internal os and that measurement location is important. We also found the ripened cervix ($n = 13$) to be significantly softer than the unripened ($n = 9$).[21,22] It is interesting that although we studied the *ex vivo*, nonpregnant cervix, our findings were similar to those of Hernandez-Andrade et al. in the pregnant *in vivo* cervix.[20] An *in vivo* feasibility study using the same approach with a prototype (linear) transducer in 20 women demonstrated significant differences in SWS before and after cervical ripening at induction of labor.[23]

Shear-Wave Elasticity Imaging in Other Pregnancy Tissues. Dynamic elastography techniques have also been applied to the uterus and placenta. Gennisson et al. studied six pregnant women with uterine contractions, and found the myometrium to be significantly stiffer during contraction than at rest.[24] Kılıç et al. used SWS techniques to evaluate the placenta of 50 women ($n = 23$ with preeclampsia, $n = 27$ control) and found SWS to

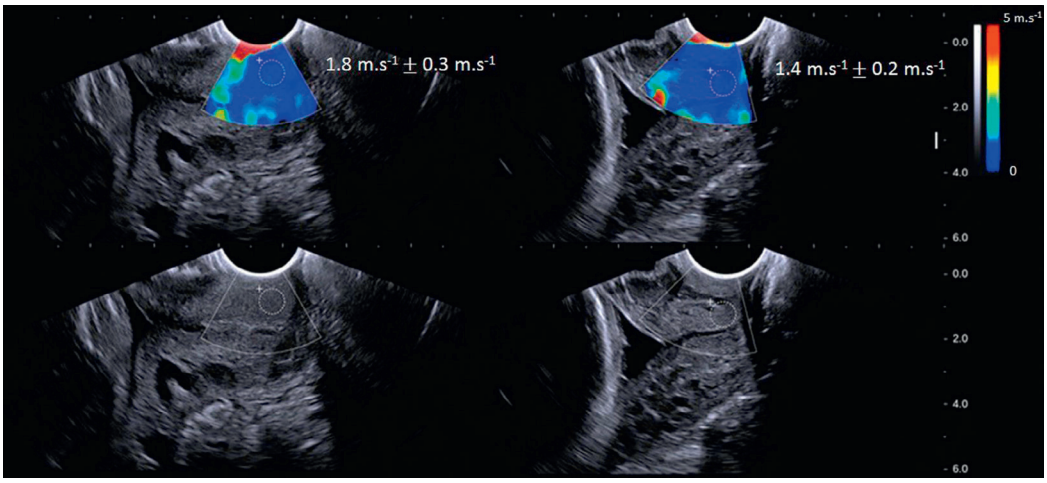

Fig. 170.2 Elastography and B-mode images of the cervix in pregnant women. Left: normal patient (32.6-week gestational age). Stiffness: 1.8 ± 0.3 m/s. Right: Preterm uterine activity (PUA) patient (32.7-week gestational age). Stiffness: 1.4 ± 0.22 m/s. The regions of interest are represented by the *white circles. (From Muller M, Aït-Belkacem D, Hessabi M, et al. Assessment of the cervix in pregnant women using shear-wave elastography: a feasibility study.* Ultrasound Med Biol *41;2789–2797, 2015.)*

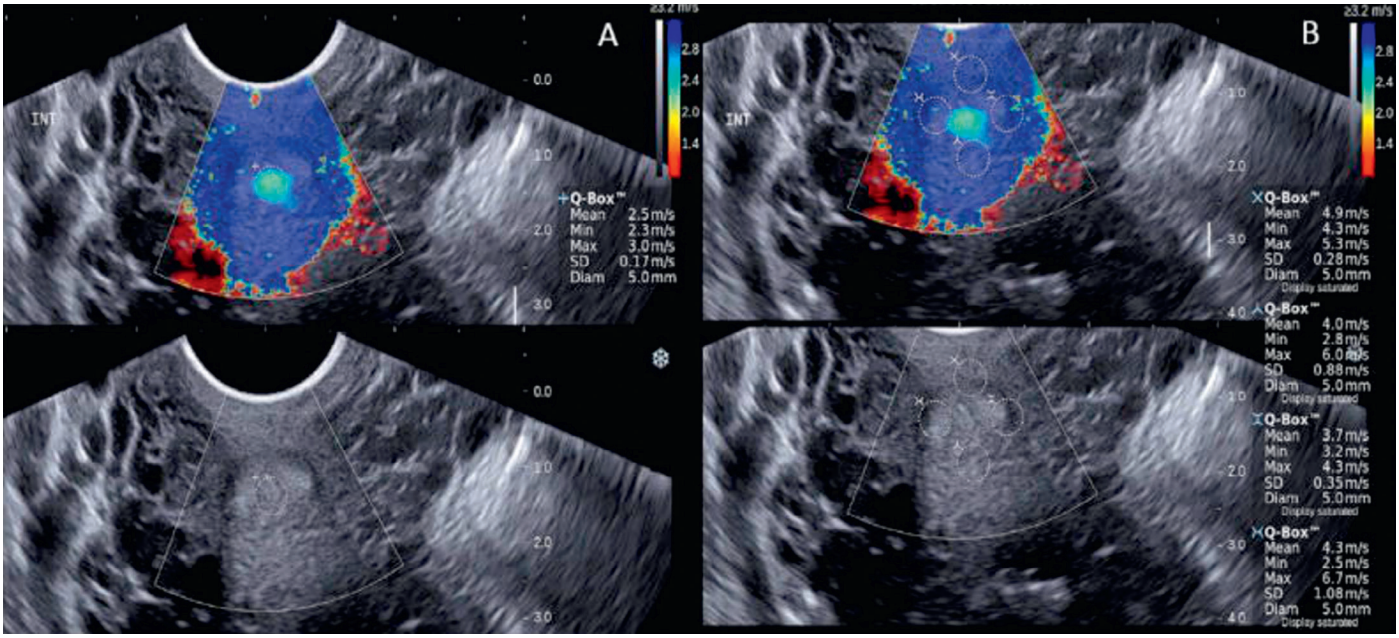

Fig. 170.3 Shear-wave elastography of the cross-sectional view of the internal os: (A) endocervix, (B) anterior, posterior, and lateral regions. Upper panels show the color elastogram overimposed to the fundamental US image. The color bar shows the shear-wave speed in relation to the color code. Fast shear-wave propagation is represented in blue, and can be related to denser tissue. The regions of interest *(Q-box)* have similar size and are located equidistant from the midline. The system allows only four simultaneous measurements, the endocervix is evaluated separately. Propagation of the shear wave is expressed in meters per second. *(From Hernandez-Andrade E, Aurioles-Garibay A, Garcia M, et al. Effect of depth on shear wave elastography estimated in the internal and external cervical os during pregnancy.* J Perinatal Med *42:549–557, 2014).*



Fig. 170.4 Shear-wave displacements 3 ms after the acoustic radiation force impulse excitation overlaid on a microscopy image of a sagittal anterior cervix slice (obtained after cervix was scanned). The color bar indicates the displacement in micrometers and the shear-wave fronts are shown in white.

be increased in the placenta of preeclamptic women.[25] Surely, as SWEI develops further, more obstetric applications will be realized.

TRANSIENT ELASTOGRAPHY

Transient elastography, included here only for the sake of completeness, involves generating a shear wave from an external source (a piston that produces a "thump" on the skin surface) and tracking it with US.[26] Currently, this approach has been applied to liver alone, and is unlikely to be useful for pregnancy tissues.

WHAT THE REFERRING CLINICIAN NEEDS TO KNOW

SE shows promise for evaluating stiffness of pregnancy tissues if transducer force can be reliably standardized. Dynamic elastography techniques are appealing because they are less user-dependent, but an objective measure of data quality will be required for the technique to be widely useful. A clinically meaningful tool will require partnership between clinicians, basic scientists, and industry to comprehensively understand sources of variance (system and biologic).

KEY POINTS

- Although palpation has been critical in diagnosing disease for thousands of years, it is only recently that measurements have been objectively quantifiable.
- SE may not be suitable to evaluation of the pregnant cervix because of difficulties with standardizing force applied by the US transducer.
- Dynamic elastography holds promise for evaluation of pregnancy tissues, but is in a relatively early stage of development with respect to obstetric applications.
- Advanced development of elastography techniques will require partnership between clinicians, basic scientists, and industry.

SUGGESTED READINGS

Bamber J, Cosgrove C, Dietrich C, et al. EFSUMB guidelines and recommendations on the clinical use of ultrasound elastography. Part 1: basic principles and technology. *Ultraschall Med*. 2013;34(2):169-184.

Feltovich H, Hall TJ. Quantitative imaging the cervix: setting the bar. *Ultrasound Obstet Gynecol.* 2013;41(2):121-128.
Shiina T, Nightingale KR, Palmeri ML, et al. WFUMB guidelines and recommendations for clinical use of ultrasound elastography: Part 1: basic principles and terminology. *Ultrasound Med Biol.* 2015;41(5):1126-1147.



All references available online at
www.expertconsult.com

REFERENCES

1. Sarvazyan A, Hall TJ, Urban MW, et al. An overview of elastography—an emerging branch of medical imaging. *Curr Med Imaging Rev*. 2011;7(4):255-282.
2. Bamber J, Cosgrove C, Dietrich C, et al. EFSUMB guidelines and recommendations on the clinical use of ultrasound elastography. Part 1: basic principles and technology. *Ultraschall Med*. 2013;34(2):169-184.
3. Shiina T, Nightingale KR, Palmeri ML, et al. WFUMB guidelines and recommendations for clinical use of ultrasound elastography: Part 1: basic principles and terminology. *Ultrasound Med Biol*. 2015;41(5):1126-1147.
4. Sarvazyan A, Hill C. Physical chemistry of the ultrasound-tissue interaction. In:Hill C, Bamber JC, ter Haar GR, eds. *Physical Principles of Medical Ultrasonics*. 2nd ed. Chichester: John Wiley; 2004:223-235.
5. Barr RG, Nakashima K, Amy D, et al. WFUMB guidelines and recommendations for clinical use of ultrasound elastography: Part 2: breast. *Ultrasound Med Biol*. 2015;41(5):1148-1160.
6. Ferraioli G, Filice C, Castera L, et al. WFUMB guidelines and recommendations for clinical use of ultrasound elastography: Part 3: liver. *Ultrasound Med Biol*. 2015;41(5):1161-1179.
7. Wells PN, Liang HD. Medical ultrasound: imaging of soft tissue strain and elasticity. *J R Soc Interface*. 2011;8(64):1521-1549.
8. Thomas A. Imaging of the cervix using sonoelastography. *Ultrasound Obstet Gynecol*. 2006;28(2):356-357.
9. Parra-Saavedra M, Gomez L, Barrero A, et al. Prediction of preterm birth using the cervical consistency index. *Ultrasound Obstet Gynecol*. 2011;38(1):44-51.
10. Swiatkowska M, Preis K. Elastography of the uterine cervix: implications for success of induction of labor. *Ultrasound Obstet Gynecol*. 2011;38(1):52-56.
11. Molina FS, Gomez LF, Florido J, et al. Quantification of cervical elastography: a reproducibility study. *Ultrasound Obstet Gynecol*. 2012;39(6):685-689.
12. Hernandez-Andrade E, Hassan SS, Ahn H, et al. Evaluation of cervical stiffness during pregnancy using semiquantitative ultrasound elastography. *Ultrasound Obstet Gynecol*. 2013;42(2):152-161.
13. Fruscalzo A, Schmitz R. Quantitative cervical elastography in pregnancy. *Ultrasound Obstet Gynecol*. 2012;40(5):612.
14. Hernandez-Andrade E, Romero R, Korzeniewski SJ, et al. Cervical strain determined by elastography and its association with spontaneous preterm delivery. *J Perinat Med*. 2014;43(6):159-169.
15. Feltovich H, Hall TJ. Quantitative imaging the cervix: setting the bar. *Ultrasound Obstet Gynecol*. 2013;41(2):121-128.
16. Cimsit C, Yoldemir T, Akpinar I. Strain elastography in placental dysfunction: placental elasticity differences in normal and preeclamptic pregnancies in the second trimester. *Arch Gynecol Obstet*. 2015;291(4):811-817.
17. Sarvazyan AP, Rudenko OV, Swanson SD, et al. Shear wave elasticity imaging: a new ultrasonic technology of medical diagnostics. *Ultrasound Med Biol*. 1998;24(9):1419-1435.
18. Nightingale K, Palmeri ML, Trahey G. Analysis of contrast in images generated with transient acoustic radiation force. *Ultrasound Med Biol*. 2006;32(1):61-72.
19. Muller M, Ait-Belkacem D, Hessabi M, et al. Assessment of the cervix in pregnant women using shear wave elastography: a feasibility study. *Ultrasound Med Biol*. 2015;41(11):2789-2797.
20. Hernandez-Andrade E, Aurioles-Garibay A, Garcia M, et al. Effect of depth on shear-wave elastography estimated in the internal and external cervical os during pregnancy. *J Perinat Med*. 2014;42(5):549-557.
21. Carlson LC, Feltovich H, Palmeri ML, et al. Estimation of shear wave speed in the human uterine cervix. *Ultrasound Obstet Gynecol*. 2014;43(4):452-458.
22. Carlson LC, Feltovich H, Palmeri ML, et al. Statistical analysis of shear wave speed in the uterine cervix. *IEEE Trans Ultrason Ferroelectr Freq Control*. 2014;61(10):1651-1660.
23. Carlson LC, Romero ST, Palmeri ML, et al. Changes in shear wave speed pre- and post-induction of labor: a feasibility study. *Ultrasound Obstet Gynecol*. 2015;46(1):93-98.
24. Gennisson J, Muller M, Gabor P, et al. Quantification of elasticity changes in the myometrium during labor using supersonic shear imaging: a feasibility study. *Ultrasonics*. 2015;56(1):183-188.
25. Kılıç F, Kayadibi Y, Yüksel MA, et al. Shear wave elastography of placenta: in vivo quantitation of placental elasticity in preeclampsia. *Diagn Interv Radiol*. 2015;21(3):202-207.
26. Sandrin L, Tanter M, Gennisson JL, et al. Shear elasticity probe for soft tissue with 1-D transient elastography. *IEEE Trans Ultrason Ferroelectr Freq Control*. 2002;49(4):436-446.

171 Doppler Ultrasound Evaluation of the Fetus and Placenta

JENA MILLER | HELEN FELTOVICH | AHMET BASCHAT

Introduction

Doppler ultrasound (US) can be used to assess waveform patterns of blood flow in various vascular beds in the maternal, fetal, and placental circulation. The information gained from the analysis of waveforms in combination with clinical factors provides insight into maternal adaptation to pregnancy, placental resistance, and fetal cardiovascular status, and thus can guide pregnancy management in many conditions. Doppler evaluation can be roughly divided into arterial, venous, or cardiac Doppler. Doppler evaluation of the uterine artery, umbilical artery (UA), middle cerebral artery (MCA), descending aorta, ductus venosus (DV), inferior vena cava, umbilical vein, and the hepatic veins provides valuable information on placental and fetal circulations in pregnancy. However, in clinical practice placental (uterine and UA Doppler), MCA, and DV Doppler are the most frequently used. Cardiac Doppler, which is used primarily for evaluation of diastolic function, global myocardial performance, and cardiac ejection force or systolic performance, is reviewed in Chapters 74–94. This chapter will discuss technique and applications for the vessels most commonly examined in pregnancy: uterine, umbilical, and middle cerebral arteries, as well as the DV.

Fundamentals of Doppler Imaging

ARTERIAL DOPPLER

A simple way of thinking about the arterial flow waveform (in all vascular beds except the coronary) is that it depends on the forward ejection of blood from the fetal heart, the elastic properties of the vessel, and the viscosity of ejected blood.[1] The most relevant measures are the peak systolic velocity (PSV) and the end diastolic velocity (EDV). During systole, the velocity of the blood ejected after the semilunar valve opens increases to a maximum (the PSV), evidenced as the highest point in the waveform. During diastole, when the cardiac contraction can no longer maintain forward flow against the elastic properties of the downstream vascular bed and the viscosity of the blood, flow decelerates to its nadir (the EDV), the lowest point on the arterial waveform. The EDV is primarily dependent on downstream vascular impedance, the combined result of resistance and vascular response, and to a lesser degree input pressure. Fig. 171.1 illustrates a normal arterial waveform.

Optimal measurement of flow velocity is obtained when the US beam at a zero-degree angle to the blood flow through the vessel. Under these circumstances the intensity of the reflected beam is highest, producing a high signal to noise ratio and the measured blood flow velocity corresponds to the actual velocity of red cells in the measured vessel. The Doppler equation describes how the frequency shift relates to the actual flow velocity, which is reduced by the cosine of the angle between the vessel and the US image beam. This can lead to overestimation of flow velocities unless the angle correction on the US machine is used as the incident angle increases.[2] However, minimizing the need for angle correction is ideal, because once the angle exceeds about 20 degrees, the cosine drops rapidly with small angle changes, leading to larger error in measurements. In contrast to the semiquantitative Doppler indices, absolute blood flow quantification also requires accurate measurement of blood vessel diameter. Since consistent zero-degree incident angle insonation and accurate measurement of vessel diameter are challenging, semiquantitative, angle-independent Doppler indices are typically used in clinical practice. These indices, which are related to downstream vascular impedance, depend on the relationship between PSV and EDV (as opposed to their absolute values). They include the UA systolic/diastolic (S/D) ratio (PSV/EDV), the pulsatility index (PI) (PSV-EDV/Tmax) and the resistive index (RI) (PSV-EDV/PSV). The PI provides the least variation and margin of error, and is thus most reproducible.[3] All of these indices decrease gradually with increasing gestational age.

The placental circulation can be evaluated with uterine artery Doppler (maternal compartment) and UA Doppler (fetal compartment of the placenta). Uterine artery Doppler targets the spiral and arcuate arteries. In very early pregnancy, the uterine arteries have high resistance and recoil, which limits blood flow into the uterus. As pregnancy progresses and the vascular tree undergoes trophoblastic transformation, the walls of these vessels become less muscular creating a low-resistance, high-capacitance system.[4] As a result, first-trimester uterine artery waveforms demonstrate a high pulsatility index and an early diastolic notch. As normal placental development and vascular relaxation occurs, the pulsatility index decreases, and the diastolic notch disappears in the second trimester. Failure of this normal progression, as evidenced by persistent elevated uterine artery resistance and notching, suggests abnormal placental development. This is associated with an increased risk of maternal hypertension and/or placental

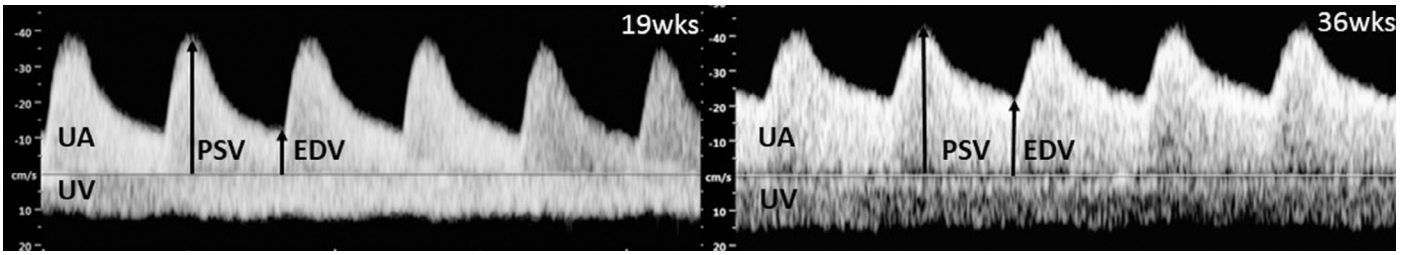

Fig. 171.1 Normal arterial waveform. Each waveform of the umbilical artery *(UA)* Doppler represents one cardiac cycle with the highest velocity designated as the peak systolic velocity *(PSV)* and the lowest velocity designated as the end diastolic velocity *(EDV)*. The umbilical vein is nonpulsatile and flows in the opposite direction. UA Doppler indices decrease during gestation primarily because of an increase in EDV.

dysfunction, as well as preeclampsia and fetal growth restriction.[5]

UA Doppler is used to measure impedance in the fetal villous vascular tree, which is related to vascular surface area and vessel elasticity. In singleton gestation, impedance increases if there is decreased villous sprouting, villous atrophy, or placental thrombus.[6] In monochorionic twin pregnancies, pressure from direct arterial anastomoses can create characteristic waveform patterns that are related to opposing fetal pulse pressures.[1]

UA Doppler indices normally decline (indicating decreased impedance) as pregnancy progresses. Because of the large surface area of the villous circulation, Doppler indices do not show increased impedance until at least 30% of the villous vasculature is abnormal. Absent or reversed UA end diastolic flow is not observed until 60%–70% of the placenta is affected.[7,8] It is important to recognize that the mechanisms that lead to abnormal elevation of umbilical (and uterine artery) Doppler index are the histologic properties of the placental vascular bed resulting in decreased perfusion. Risk of fetal growth restriction, nutrient deficiency, acid-base imbalance and stillbirth are related to the degree of Doppler abnormality.[9] Identifying absent or reversed UA EDV is an important first step in the assessment of fetal status in the setting of placental dysfunction. Combination of the UA with multivessel Doppler and biophysical parameters is required to determine the optimal frequency of monitoring and identifying delivery triggers to maximize gestational age and neurodevelopment, while minimizing the risk of fetal or neonatal death.[10,11]

Fig. 171.2A is an example of a normal UA waveform. Figs. 171.2B–D show increased resistance, absent EDV and reversed EDV, respectively.

The fetal cerebral circulation can be evaluated with MCA Doppler. Interpretation of the MCA Doppler must be done in the context of the clinical situation, because the waveform can be altered by several factors that may impact flow indices or blood flow speed, measured as the PSV. In response to fetal hypoxia, the cerebral vessels dilate to allow preferential shunting of oxygenated blood to the brain, resulting in an increase in EDV and a decline in the Doppler indices. In growth-restricted fetuses, this is known as *brain sparing*.[12] Early changes in fetal autoregulation and redistribution of cardiac output can be apparent by examination of the cerebroplacental ratio (MCA PI/UA PI) before qualitative changes in the UA waveform are apparent.[13] Of note, placental pathology that predominantly results in immature thick-walled villi may result in a significant decrease in oxygen and carbon dioxide diffusion but little change in villous perfusion. This makes the MCA Doppler important in the evaluation of placental function, because isolated brain sparing may be the only hint of placental dysfunction when umbilical perfusion is normal. This is of particular importance in late-onset fetal growth restriction, where redistribution of cardiac output toward the brain may be the only apparent sign of fetal compensation before overt fetal compromise, and may also predict adverse neonatal outcome in normally grown fetuses.[14] Other factors such as fetal hypertension may also manifest as decreased cerebral flow indices.[15] Alteration in blood viscosity impacts the MCA PSV. Acceleration of blood flow (increased PSV) is seen with fetal anemia, and conversely decreased PSV with polycythemia.[16] Under physiologic conditions fetal partial pressure of carbon dioxide ($paCO_2$) is the primary regulator of the MCA PSV; an increase in PSV may also be seen with placental dysfunction when fetal $paCO_2$ is increased.[17]

VENOUS DOPPLER

The typical venous waveform, which depends on volume pressure changes in the atria throughout the cardiac cycle, is characterized by four phases: *S-wave* (height of systole), *V-trough* (ventricular relaxation after the height of contraction), *D-wave* (early diastole), and *a-wave* (atrial systole).[18] The first peak (S-wave) is seen after blood flow increases throughout systole to its maximum. The V-trough (end systole) follows as the ventricles relax and forward flow decreases. This marks the point at which the atrioventricular valves open as atrial pressure exceeds ventricular pressure. The D-wave (diastolic forward peak) describes the increase of forward flow during the early diastolic (passive) filling of the ventricles. This is followed by a trough corresponding to atrial systole (a-wave) when an acute rise in atrial pressure creates increased resistance to forward flow as part of active diastole (atrial contraction). Fig. 171.3 shows a normal venous waveform. All central venous vessels demonstrate this waveform and exhibit higher pulsatility the closer to the heart they are sampled. The umbilical vein is an exception because it has a constant waveform after 8 to 12 weeks of gestation because the DV attenuates retrograde atrial pressure changes to the vein.[19]

Venous waveforms can be analyzed quantitatively or semiquantitatively by applying the same principles as arterial Doppler, although novel venous Doppler indexes have also been described.[2,16,18] The most commonly examined venous vessel, the DV, demonstrates antegrade flow throughout the entire cardiac cycle, which allows for qualitative waveform analysis because quick visual analysis easily identifies an absent or reversed a-wave. Increased central venous pressure (increased preload) and decreasing forward cardiac function from increased afterload,

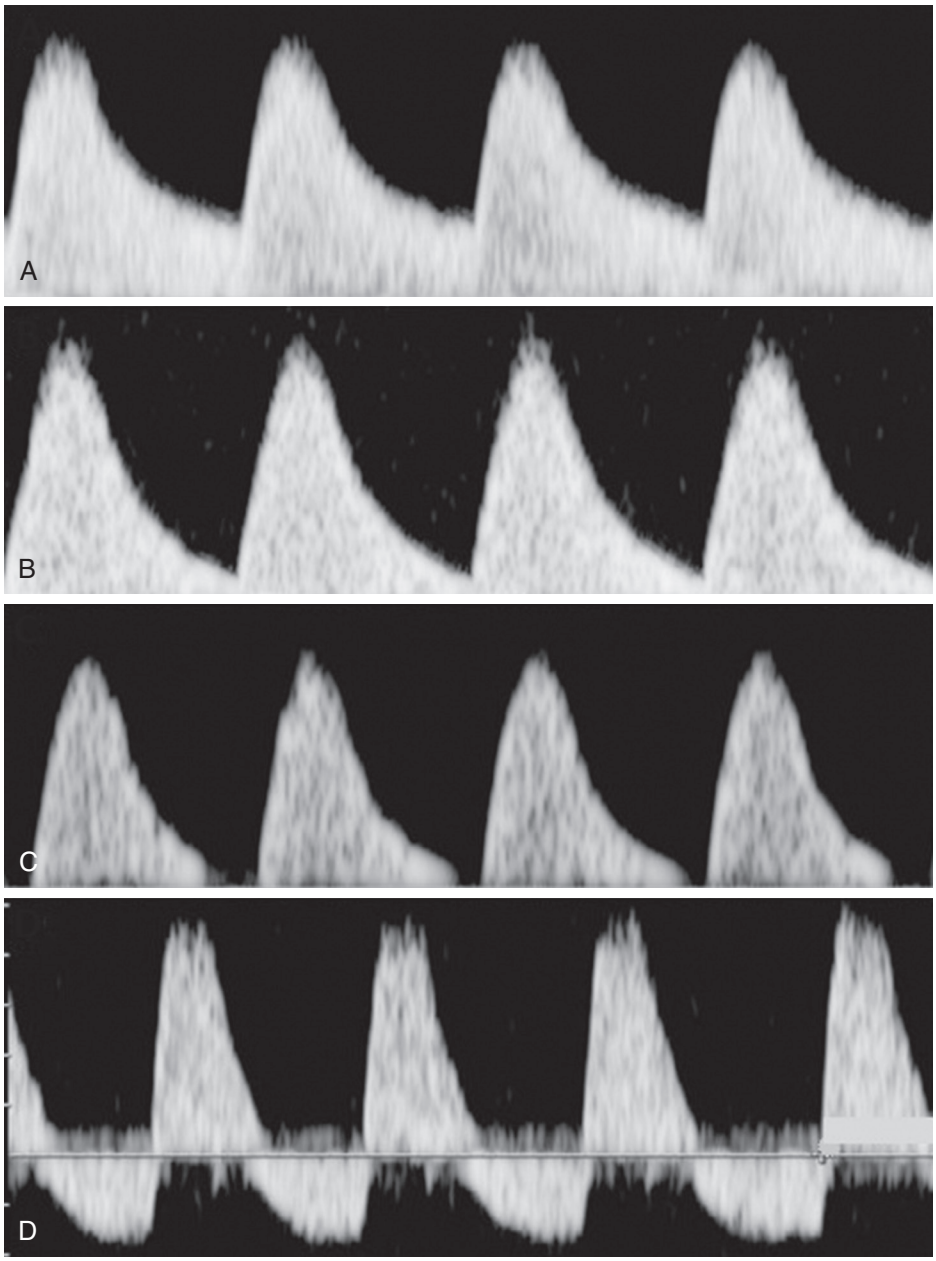

Fig. 171.2 The normal umbilical artery waveform has continuous forward flow through the entire cardiac cycle (A). Increased resistance is manifested by a decrease in the EDV (B). Absent (C) or reversed (D) EDV is observed when at least 60%–70% of the villous vasculature is abnormal. *EDV,* end diastolic velocity.

increased vessel diameter, myocardial dysfunction, or their combination will result in increased venous Doppler indexes.[18,20–22] Fig. 171.4A shows an absent a-wave, and Fig. 171.4B a reversed a-wave. As opposed to arterial Doppler indexes, which are velocity ratios that describe relative forward flow during individual phases of the cardiac cycle, some venous Doppler indexes incorporate multiple velocities[18,21,23–27] (Table 171.1). Of these, the pulsatility index for veins (PIV) is used most often clinically.

The DV has a central role in the distribution of highly oxygenated umbilical venous blood from the placenta to the fetal heart. It is useful for monitoring conditions that may affect forward cardiac function; its waveform is related to the pressure-volume changes in the cardiac atria. Factors that influence forward cardiac function include preload, afterload, and myocardial performance.[28] A decreased a-wave is most sensitive and reliable for identifying aberrant forward flow during atrial systole because of abnormal preload or afterload. Myocardial performance is better assessed through evaluation of the v-wave (end-systolic relaxation) because of its relationship with decreased forward velocities.

Technique

The basic technique for assessing maternal and fetal Doppler applies regardless of the vessel being studied, and measurements should ideally be obtained in the absence of fetal activity or breathing. In general, the vessel of interest is identified and the image narrowed and magnified to optimize visualization. The

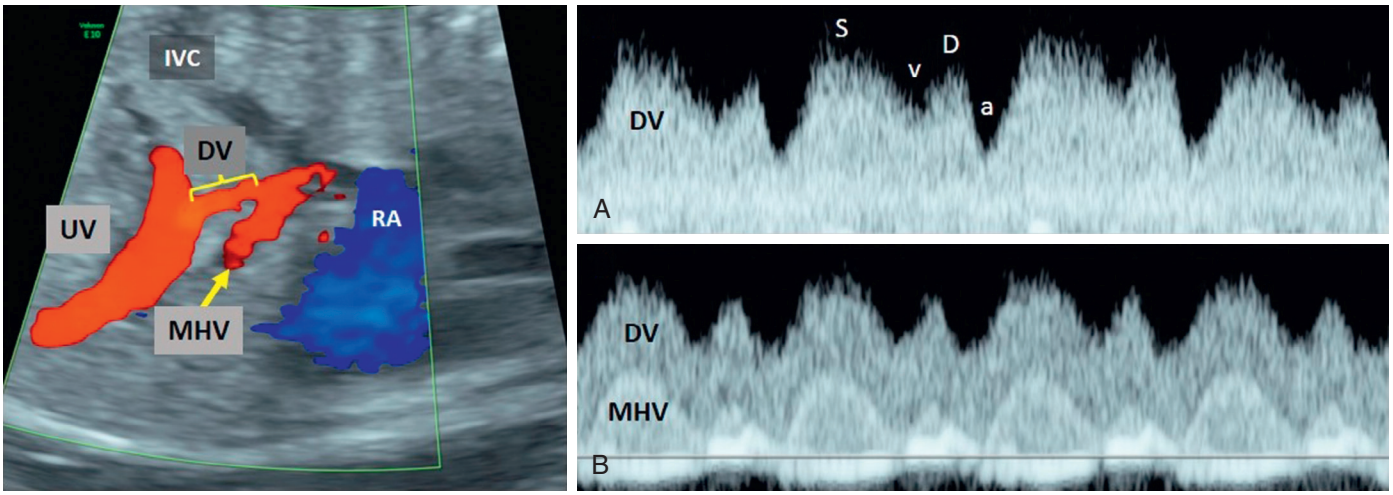

Fig. 171.3 (A) The normal ductus venous *(DV)* waveform is continually antegrade under normal circumstances and has four phases: maximum systole *(S)*, ventricular trough *(v)*, early diastole *(D)*, and atrial systole *(a)*. It is sampled at the isthmus where aliasing is observed on real-time color Doppler. If the Doppler gate is misplaced or too wide, adjacent vessels can be sampled inadvertently or simultaneously as shown in (B). *IVC*, Inferior vena cava; *MHV*, middle hepatic vein; *RA*, right atrium; *UV*, umbilical vein.

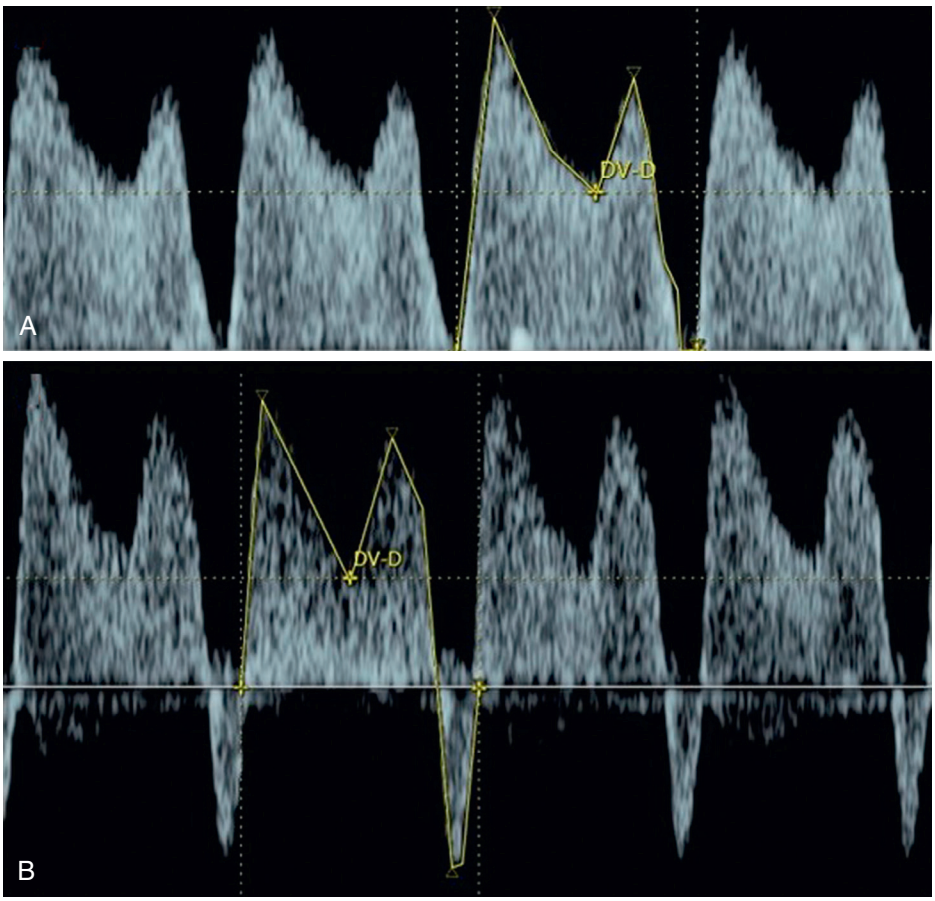

Fig. 171.4 Increased preload, progressive cardiac dysfunction, impaired forward cardiac function, or increased afterload can result in absent (A) forward or reversed (B) flow in the a-wave.

TABLE 171.1 DUCTUS VENOSUS DOPPLER INDICES

DV preload index	$\frac{\text{Systolic} - \text{Diastolic peak velocity}}{\text{Systolic peak velocity}}$
DV pulsatility index for veins	$\frac{\text{Systolic} - \text{End-diastolic velocity (a)}}{\text{Time average maximum velocity}}$
DV peak velocity index for veins	$\frac{\text{Systolic} - \text{End-diastolic velocity (a)}}{\text{Diastolic peak velocity}}$
Percentage reverse flow	$\frac{\text{Systolic time averaged velocity}}{\text{Diastolic time averaged velocity}} \times 100$
VELOCITY RATIOS	
S/v ratio	Forward flow into the atria during ventricular relaxation
v/D ratio	Early diastolic filling
D/a ratio	Forward flow during passive and active diastolic filling
S/D ratio	Ventricular systolic to early passive diastolic filling
S/a ratio	Ventricular systolic to active diastolic filling
v/a ratio	Late-systolic to late-diastolic filling

DV, Ductus venous; *S*, maximum systole; *v*, ventricular trough; *D*, early diastole; *a*, atrial systole.

From Seravalli V, Miller J, et al. Ductus venosus Doppler in the assessment of fetal cardiovascular health: an updated practical approach. *Acta Obstet Gynecol Scand* 95:635–644, 2016.

focal zone is adjusted to the area of the vessel being interrogated. Color Doppler is applied as indicated and limited to the region of interest. Gain and pulse repetition frequency are adjusted based on the flow conditions. These steps will maximize the frame rate for Doppler interrogation. Pulse wave Doppler is activated and the gate placed on the vessel, ideally at a zero-angle to flow through the vessel. Sweep speed is ideally set to visualize four to six waveforms, and the Doppler waveforms should take up about 75% of the height of Doppler screen. Angle correction can be applied if required to best estimate flow velocity.[29]

UA Doppler indices vary depending upon whether measurement is made at the fetal end, placental end, or in a free loop of cord. Impedance is highest at the fetal end. UA Doppler is best measured in a free loop, but that makes it difficult to standardize measurement for accurate comparison of exams. Therefore choice of sampling location is based on the clinical scenario.

The uterine artery is most easily evaluated after it crosses the external iliac artery near the internal cervical os, before it branches into the arcuate arteries. This can be achieved using either a transabdominal or transvaginal approach. The measurement should be repeated on both sides and the presence or absence of notching noted. PSV in the uterine artery is typically greater than 50 cm/s, which can be used to help distinguish it from arcuate arteries.

The MCA is imaged well through the parietotemporal bone window along the ala of the sphenoid bone. Unlike the UA, the MCA is usually close to parallel with respect to the US waves, which means it is readily interrogated at zero-degree insonation. MCA PSV should be measured in the proximal third as it exits the circle of Willis because the PSV decreases along the course of the vessel. For evaluation of the pulsatility index and cerebroplacental ratio, reference ranges are established on the distal straight portion of the vessel.[30]

The DV can be examined in a longitudinal or transverse view of the upper abdomen. Its isthmus is the smallest part of this trumpet-shaped vessel and can be identified easily by the high forward velocity and aliasing on color Doppler. A pulsed wave Doppler gate is placed on the isthmus with an angle as close to 0 degrees as possible.[31] The gate should be 2 mm or less to avoid inadvertent sampling of nearby vessels. Using a high velocity color Doppler scale over 48 cm/s helps to discriminate the DV from adjacent venous vessels with slower flow.[32] A normal waveform will show a PSV of 48–71 cm/s and PDV of 31–58 cm/s, depending on gestational age.[32,33] A good quality waveform can be assessed qualitatively (absent or reversed a-wave), or semiquantitatively using angle-independent Doppler indices.

Clinical Applications of Doppler Ultrasound

Doppler US can be used to evaluate various vascular beds within the fetal-maternal circulation. It is therefore used clinically to diagnose and manage multiple conditions including fetal growth restriction (Chapter 110), twin transfusion syndrome (Chapter 162), fetal hydrops (Chapters 122 and 123), and fetal arrhythmias (Chapter 95). Serial assessments are often required to monitor fetal compensation, progression of disease, fetal decompensation, and response to fetal intervention or treatments.

WHAT THE REFERRING CLINICIAN NEEDS TO KNOW

Doppler evaluation of the maternal and fetal circulations is useful for understanding maternal adaptation to pregnancy, placental dysfunction, and fetal cardiovascular status, and is therefore useful for managing certain pregnancy complications. Multivessel, qualitative and semiquantitative, angle-independent Doppler indices can be assessed to generate a more complete clinical picture than using only one vessel alone. Integration of maternal and fetal Doppler parameters with other tools to evaluate fetal well-being are required to determine the clinical management and frequency of testing.

KEY POINTS

- The most relevant measures in arterial Doppler US are the PSV and the EDV.
- Semiquantitative, angle-independent Doppler indexes used to describe blood flow include the UA S/D ratio (PSV/EDV), the PI (PSV-EDV/Tmax), and the RI (PSV-EDV/PSV).
- UA Doppler is most useful identifying placental dysfunction in fetal growth restriction.
- MCA Doppler is the primary noninvasive tool to screen for fetal anemia.
- The DV waveform, which reflects pressure-volume changes in the fetal heart, is correlated with cardiac forward function and can be used to manage the fetus at risk of cardiovascular compromise/deterioration.
- Integration of multivessel Doppler of the maternal and fetal circulations is required to generate a more complete clinical assessment of multiple fetal conditions.

All references available online at www.expertconsult.com

REFERENCES

1. Baschat AA. Examination of the fetal cardiovascular system. *Semin Fetal Neonatal Med*. 2011;16:2-12.
2. Gosling RG, King DH. Ultrasound angiology. In: Marcus AW, Adamson L, eds. *Arteries and Veins*. Edinburgh: Churchill Livingstone; 1975:61-98.
3. Thompson RS, Trudinger BJ, Cook CM. Doppler ultrasound waveform indices: A/B ratio, pulsatility index and Pourcelot ratio. *Br J Obstet Gynaecol*. 1988;95:581-588.
4. Pijnenborg R, Bland JM, Robertson WB, et al. Uteroplacental arterial changes related to interstitial trophoblast migration in early human pregnancy. *Placenta*. 1983;4:397-413.
5. Bower S, Schuchter K, Campbell S. Doppler ultrasound screening as part of routine antenatal scanning: prediction of pre-eclampsia and intrauterine growth retardation. *Br J Obstet Gynaecol*. 1993;100:989-994.
6. Macara L, Kingdom JC, Kohnen G, et al. Elaboration of stem villous vessels in growth restricted pregnancies with abnormal umbilical artery Doppler waveforms. *Br J Obstet Gynaecol*. 1995;102:807-812.
7. Giles WB, Trudinger BJ, Baird PJ. Fetal umbilical artery flow velocity waveforms and placental resistance: pathological correlation. *Br J Obstet Gynaecol*. 1985;92:31-38.
8. Morrow RJ, Adamson SL, Bull SB, et al. Effect of placental embolization on the umbilical artery velocity waveform in fetal sheep. *Am J Obstet Gynecol*. 1989;161:1055-1060.
9. Bilardo C, Nicolaides KH, Campbell S. Doppler measurements of fetal and uteroplacental circulations: relationship with umbilical venous blood gases measured at cordocentesis. *Am J Obstet Gynecol*. 1990;162:115-120.
10. Lees CC, Marlow N, van Wassenaer-Leemhuis A, et al. 2-year neurodevelopmental and intermediate perinatal outcomes in infants with very preterm fetal growth restriction (TRUFFLE): a randomized trial. *Lancet*. 2015;38:2162-2172.
11. Turan S, Miller J, Baschat A. Integrated testing and management in fetal growth restriction. *Semin Perinatol*. 2008;32:194-200.
12. Wladimiroff JW, Tonge HM, Stewart PA. Doppler ultrasound assessment of cerebral blood flow in the human fetus. *Br J Obstet Gynaecol*. 1986;93:471-475.
13. Bahado-Singh RO, Kovanci E, Jeffers A, et al. The Doppler cerebroplacental ratio and perinatal outcome in intrauterine growth restriction. *Am J Obstet Gynecol*. 1999;180:750-756.
14. DeVore GR. The importance of the cerebroplacental ratio in the evaluation of fetal well-being in SGA and AGA fetuses. *Am J Obstet Gynecol*. 2015;213:5-15.
15. Galan HL, Anthony RV, Rigano S, et al. Fetal hypertension and abnormal Doppler velocimetry in an ovine model of intrauterine growth restriction. *Am J Obstet Gynecol*. 2005;192:272-279.
16. Mari G, Deter RL, Carpenter RL, et al. Noninvasive diagnosis by Doppler ultra-sonography of fetal anemia due to maternal red-cell alloimmunization. Collaborative group for Doppler Assessment of the blood velocity in anemic fetuses. *N Engl J Med*. 2000;342:9-14.
17. Picklesimer AH, Oepkes D, Moise KJ Jr, et al. Determinants of the middle cerebral artery peak systolic velocity in the human fetus. *Am J Obstet Gynecol*. 2007;197:526.
18. Hecher K, Campbell S, Snijders R, et al. Reference ranges for fetal venous and atrioventricular blood flow parameters. *Ultrasound Obstet Gynecol*. 1994;4:381-390.
19. Rizzo G, Arduini D, Romanini C. Umbilical vein pulsations: a physiologic finding in early gestation. *Am J Obstet Gynecol*. 1992;167:675-677.
20. Baschat AA, Güclü S, Kush ML, et al. Venous Doppler in the prediction of acid-base status of growth-restricted fetuses with elevated placental blood flow resistance. *Am J Obstet Gynecol*. 2004;191:277-284.
21. Baschat AA, Harman CR. Venous Doppler in the assessment of fetal cardiovascular status. *Curr Opin Obstet Gynecol*. 2006;18:156-163.
22. Bellotti M, Pennati G, De Gasperi C, et al. Simultaneous measurements of umbilical venous, fetal hepatic, and ductus venosus blood flow in growth-restricted human fetuses. *Am J Obstet Gynecol*. 2004;190:1347-1358.
23. Bahlmann F, Wellek S, Reinhardt I, et al. Reference values of ductus venosus flow velocities and calculated waveform indices. *Prenat Diagn*. 2000;20:623-634.
24. DeVore GR, Horenstein J. Ductus venosus index: a method for evaluating right ventricular preload in the second-trimester fetus. *Ultrasound Obstet Gynecol*. 1993;3:338-342.
25. Rizzo G, Capponi A, Talone PE, et al. Doppler indices from inferior vena cava and ductus venosus in predicting pH and oxygen tension in umbilical blood at cordocentesis in growth-retarded fetuses. *Ultrasound Obstet Gynecol*. 1996;7:401-410.
26. Ferrazzi E, Bozzo M, Rigano S, et al. Temporal sequence of abnormal Doppler changes in the peripheral and central circulatory systems of the severely growth-restricted fetus. *Ultrasound Obstet Gynecol*. 2002;19:140-146.
27. Nakagawa K, Tachibana D, Nobeyama H, et al. Reference ranges for time-related analysis of ductus venosus flow velocity waveforms in singleton pregnancies. *Prenat Diagn*. 2012;32:803-809.
28. Seravalli V, Miller JL, Block-Abraham D, et al. Ductus venosus Doppler in the assessment of fetal cardiovascular health: an updated practical approach. *Acta Obstet Gynecol Scand*. 2016;95:635-644.
29. Bhide A, Acharya G, Bilardo CM, et al. ISUOG practice guidelines: use of Doppler ultrasonography in obstetrics. *Ultrasound Obstet Gynecol*. 2013;41:233-239.
30. Baschat AA, Gembruch U. The cerebroplacental Doppler ratio revisited. *Ultrasound Obstet Gynecol*. 2003;21:124-127.
31. Huisman TW, Stewart PA, Wladimiroff JW. Ductus venosus blood flow velocity waveforms in the human fetus—a Doppler study. *Ultrasound Med Biol*. 1992;18:33-37.
32. Bahlmann F, Wellek S, Reinhardt I, et al. Reference values of ductus venosus flow velocities and calculated waveform indices. *Prenat Diagn*. 2000;20:623-634.
33. Kessler J, Rasmussen S, Hanson M, et al. Longitudinal reference ranges for ductus venosus flow velocities and waveform indices. *Ultrasound Obstet Gynecol*. 2006;28:890-898.

172 Magnetic Resonance Imaging in Obstetrics

ANNE-ELODIE MILLISCHER | PASCALE SONIGO | LAURENT J. SALOMON

Introduction

Assessment of fetal development and screening for congenital anomalies are essential elements of prenatal care. Ultrasound (US) imaging remains the first-line modality because of its convenience, low cost, and wide availability, but it can be limited by several factors, sometimes making US incompatible with women's expectations, or subject to misdiagnosis-related legal issues.[1–5] Compared to US, magnetic resonance imaging (MRI) is less limited by fetal lie, oligohydramnios, multiple pregnancy, or obesity. It offers high-contrast images that can be acquired in true anatomic planes. Over the past decade, in part because of shorter acquisition times that eliminate the need for fetal sedation, MRI has grown from a tool for highly targeted examination in select fetuses (primarily those who require brain evaluation)[6–10] to a feasible and reproducible modality for a number of fetal applications.[11,12]

MRI is not yet a standard screening tool, however, and should be used only to answer specific questions raised by targeted US, or help refine prognosis in certain high-risk situations. For instance, MRI may identify subtle signs of recurrence of an anomaly noted in a previous pregnancy, or when suspected fetal infection or ischemia may have caused fetal brain injury.[13,14] MRI can also provide functional information, which may become a common tool for assessment of fetal cerebral or placental physiology.[15,16] Importantly, the clinician performing and interpreting the MRI should have a clear understanding of previous US findings, and of the relevant fetal anatomy and pathophysiology.[17]

Technique

Smith et al. reported the first use of MRI during pregnancy in 1983.[18] Since then, techniques have evolved dramatically. Most fetal MRIs are performed at 1.5 tesla (T). Some recent studies have pointed out the potential benefits of stronger magnetic fields (3 T), but the advantages of additional signal intensity and resolution[19,20] may be offset by increased artifacts because of fetal movement and by greater radiofrequency power deposition.

Developments in ultrafast acquisition have reduced fetal motion-based artifacts and, thus the need for fetal sedation. Fast (typically 20–30 s) T2-weighted acquisitions, as in single-shot fast spin echo (SSFSE) or *h*alf-Fourier *a*cquisition *s*ingle-shot *t*urbo-spin *e*cho- imaging (HASTE) (Siemens, Erlangen, Germany) and *r*apid *a*cquisition with *r*elaxation *e*nhancement (RARE; Brucker, Ettlingen, Germany), are the mainstay of fetal MRI. These sequences provide good resolution and perform well for surface delineation (because of the hypersignal of water in amniotic and cerebrospinal fluid [CSF]) and gyration analysis. Echo planar imaging with gradient-echo T2-weighted images (T2*) allows detection of chronic hemorrhagic lesions and calcifications, as hemosiderin deposits and calcifications lead to a loss of signal on sequences with a long echo time (TE).[21]

T1-weighted sequences have lower spatial resolution and little inherent contrast, owing to the large water content. However, they may complement T2-weighed sequences by detecting lesions that the latter may overlook, such as laminar necrosis and calcified leukomalacia.[22] In general, T1-weighted sequences are performed using gradient echo sequences and are useful for evaluating hemorrhage, the pituitary axis, and the thyroid, and the presence of meconium in the large bowel. They can also help to locate the liver in cases of diaphragmatic hernia.

Diffusion-weighted imaging (DWI) sequences, which can detect ischemic lesions at an early stage, may prove useful in high-risk settings.[23] DWI is also useful for locating the kidneys, as functioning renal parenchyma gives a bright DWI signal.[24] More generally, functional imaging sequences, especially for central nervous system indications, include diffusion tensor imaging with tractography, single-voxel spectroscopy for brain metabolism, and blood-oxygen-level dependent (BOLD) imaging.[25–29] Functional imaging is also emerging for *in vivo* assessment of the placenta.[15]

Timing of Examination

There are no contradictions to MRI in any trimester of pregnancy,[30] although it is typically performed from 20–22 weeks' gestation until birth because small fetal size and motion artifacts tend to compromise the exam before 18 weeks. Its intended role in guiding pregnancy management is key; if the purpose is to confirm ominous fetal findings, local laws regarding pregnancy termination may dictate timing. However, questions such as adequate cortical development or information about airway impingement at delivery can only be addressed late in pregnancy.

Fetal Anatomic Evaluation

BRAIN

Thanks to its superior soft-tissue contrast resolution, MRI is able to distinguish fetal brain structures such as cortical sulcation/gyration, posterior fossa structures, and CSF spaces. However, because brain development is a dynamic process, it is important to recognize the normal MRI aspect of the brain at different gestational ages to avoid false-positive or false-negative diagnoses. For instance, during the second trimester, cerebral malformations

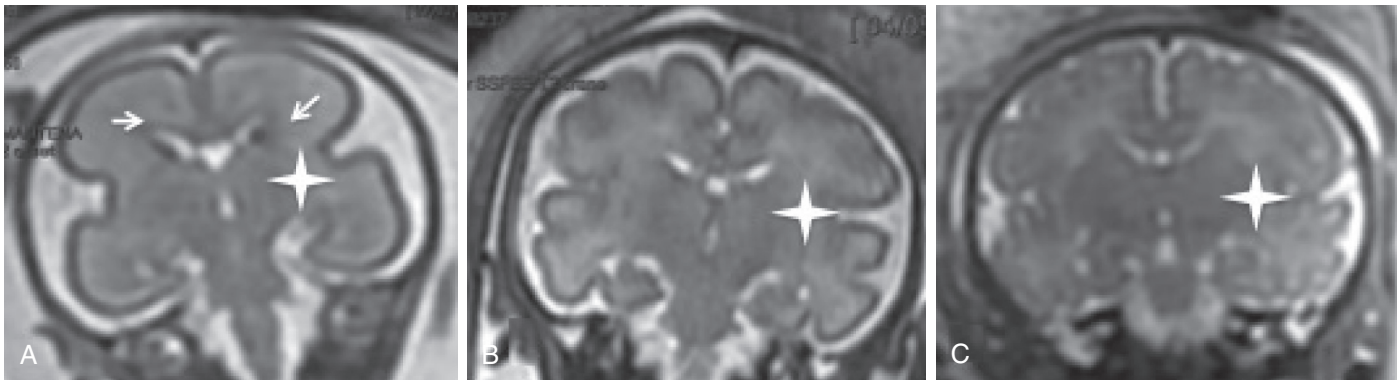

Fig. 172.1 Single-shot fast spin echo T2-weighted images of a normal fetal brain, illustrating the dynamic brain maturation process on coronal planes. (A) 26 weeks of gestation: the germinal matrix *(white arrows)* is present as hyposignal T2 bands, underlying the wall of the ventricles. (B) 31 weeks of gestation; (C) 36 weeks of gestation: note the development of sulcation. The Sylvian fissure *(stars)* is a major landmark for the assessment of sulcation (*white star* on the left Sylvian fissure).

may result in morphologic features that differ from those seen in a more mature brain.[31–34] Thus the sulcation pattern should always be analyzed (Fig. 172.1) and measurements should be compared with published reference ranges.[35] Importantly, MRI allows not only the skull but also the developing brain to be measured, thus avoiding errors caused by abnormal pericerebral spaces.

MRI can delineate fetal brain structures because it produces different signals for different structures. For instance, the high neuron density in the germinal matrix (a cell-dense layer immediately adjacent to the ventricular walls) produces a low signal on T2 and a higher signal on T1-weighted images. Fetal white matter, however, has the opposite signal characteristics (high T2 and lower T1) because of its higher water content and lack of myelination. Neurons from the germinal matrix migrate from the ventricular wall to the surface of the brain during the second trimester, producing a five-layered appearance of migrating cells between 20 and 28 weeks of gestation (see Fig. 172.1). Myelination mainly occurs after birth, but can be detected in the fetus by high signal intensity on T1-weighted images in certain structures.[35]

Common indications for fetal brain MRI include (1) ventriculomegaly, (2) midline defects, such as agenesis of the corpus callosum, (3) posterior fossa anomalies, (4) cerebral cortical malformations, and (5) screening in a family with history of brain abnormalities such as tuberous sclerosis, corpus callosal dysgenesis, or lissencephaly.[17,36-38] Although most of these pathologies are amenable to US diagnosis, MRI appears to have consistently higher reproducibility and sensitivity, and can often improve US diagnosis.

Cortex

MRI of the normal fetal cerebrum is characterized initially by a smooth surface that matures into cortical sulcations. The degree of sulcation on fetal MRI is an indicator of gestational-age–related cortical development. The main landmark is the Sylvian sulcus, which is typically developed by 28–30 weeks, and therefore exclusion of cortical malformations cannot be excluded until after this point in gestation.[22,39,40] Disorders of cortical development should be suspected in the case of abnormal gyration mimicking the preterm appearance of the gyri. Cortical lesions can be defined by pathophysiologic processes, broadly subdivided into undermigration, overmigration, and organizational disorders.[41,42] Undermigration leads to lissencephaly type 1 (pachygyri and shallow sulci) and gray-matter heterotopia (T2 hyposignal foci, underlying the ventricle wall). Heterotopias must be distinguished from subependymal nodules of tuberous sclerosis. Tubers appear hypointense on T2-weighted images and hyperintense on T1-weighted images. Subependymal giant astrocytoma is rare, typically occurring in the wall of the lateral ventricle near the foramen of Monro (Fig. 172.2). Overmigration leads to lissencephaly type 2 (Walker-Warburg syndrome) with a typical Z-shaped brain stem.[43–45] Polymicrogyria is caused by abnormal organization of neuronal cells, with excessive folding of the cerebral cortical surface, and numerous small and shallow gyri. Associated causes such as infection (commonly cytomegalovirus), genetic abnormalities, and ischemia should be suspected.[13,14] The most commonly affected area is around the Sylvian fissure.

Ventricles

Like the cortex, the fetal ventricles change during gestation.[46,47] Early, they appear prominent because of the relative paucity of brain parenchyma. Physiologically disproportionate enlargement of the occipital horns in relation to the frontal horns is apparent on fetal MRI until 23 weeks, after which the occipital horns gradually diminish. In the absence of ventriculomegaly, the atrial diameter of normal lateral ventricles remains constant (≤10 mm) from 15 to 35 weeks and the lateral borders are concave.[48,49]

Ventriculomegaly on US is one of the main indications for fetal MRI, which is used to look for associated cerebral lesions.[10,49–53] The shape of the ventricles can provide important clues: colpocephaly is associated with corpus callosum agenesis and pointed posterior horns with Chiari II malformation. Aqueductal stenosis is associated with widened posterior horns and third ventricle, and reduced extracerebral fluid. A potential cause of aqueduct obliteration is hemorrhagic intraventricular material, which can be detected with MRI (T1 hypersignal). Ventriculomegaly arising from ischemic or infectious events that cause cerebral atrophy can be associated with porencephaly, which may be seen with MRI.

Midline Structures

The septum pellucidum is a thin vertical membrane walled off by the corpus callosum above and the fornix below, separating

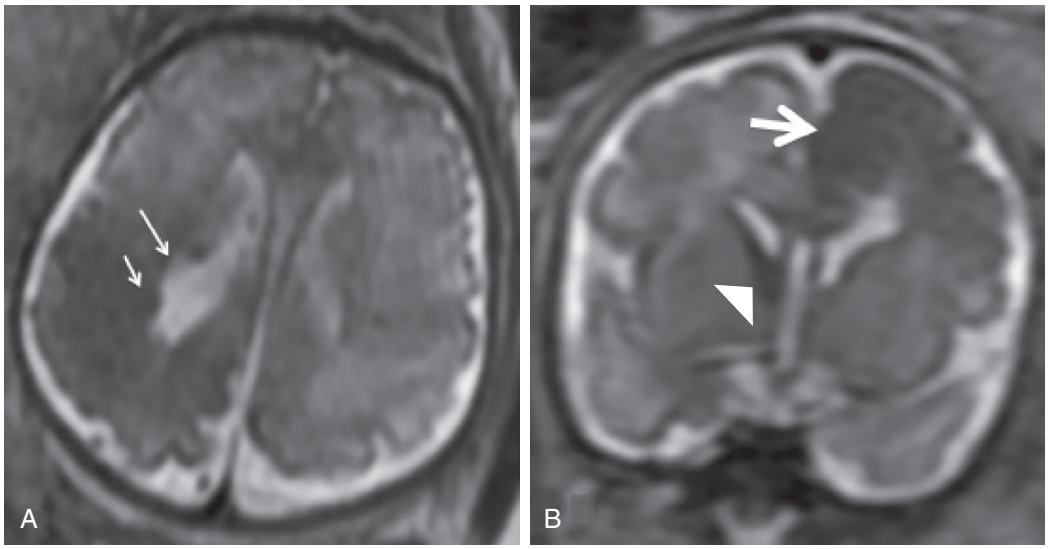

Fig. 172.2 Tuberous sclerosis in a 33-week fetus. (A) Axial single-shot fast spin echo T2-weighted image: subependymal nodules located on the wall of the ventricles in hyposignal T2 (thin white arrow). (B) Coronal single-shot fast spin echo T2-weighted image: subependymal giant astrocytoma located typically in the wall of the lateral ventricle, in hyposignal T2, near the foramen of Monro *(white arrowhead)*, accompanied by cortical dysplasia *(thick white arrow)*.

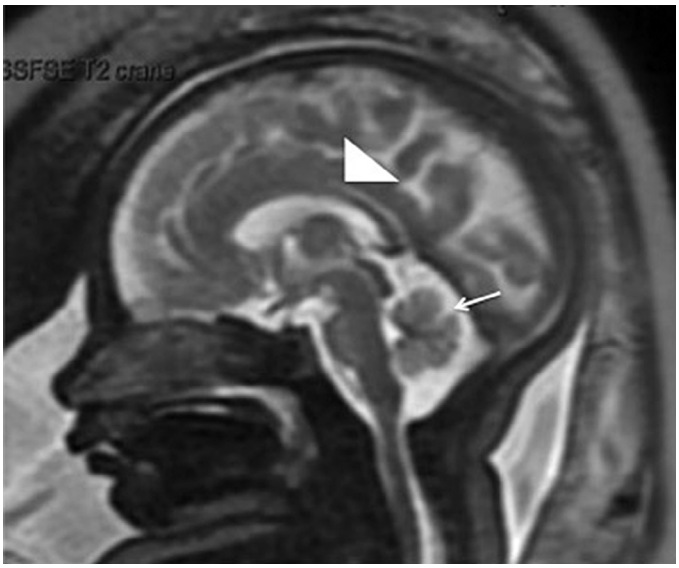

Fig. 172.3 Midsagittal plane single-shot fast spin echo T2-weighted images of a normal fetal brain at 31 weeks. The corpus callosum is complete in hyposignal T2 *(white arrowhead)*. Note the posterior fossa, with a normal vermis and the primary fissure *(white arrow)*.

the frontal horns of the lateral ventricles (Fig. 172.3). The septum pellucidum is in close developmental association with the corpus callosum. During fetal development, the septum pellucidum is filled with CSF and is referred to as the *cavum septi pellucidi*.[31,54] The corpus callosum appears on midline sagittal T2-weighted images as a C-shaped hypointense structure at the upper margin of the cavum septi pellucidi. It increases in length, width, and thickness with gestational age.[55,56]

Agenesis/hypogenesis of the corpus callosum (Fig. 172.4) (Chapter 34) is one of the most common congenital brain malformations suspected upon prenatal US by the presence of a colpocephalic configuration of the occipital horns with parallel orientation of the lateral ventricles, and absence of the septum pellucidum. MRI should be used to rule out associated intracranial or extracranial anomalies, such as cortical malformations, parenchymal lesions, and brain-stem or cerebellar abnormalities. Lesions such as interhemispheric lipoma and interhemispheric cyst can coexist.[55,57,58]

Posterior Fossa

The pontine flexure develops at the same time as the cerebellar hemispheres, and the midsagittal plane is essential to assess the primary flexure after 25 weeks. The transverse cerebellar diameter increases throughout gestation and can be measured on axial and coronal MRI. The vermis can be detected on midsagittal and axial plane MRI after 20 weeks of gestation. The dorsal part of the midbrain and pons has low signal intensity on T2-weighted images and high signal intensity on T1-weighted images after 24 weeks of gestation, because of myelination.[31,59–61]

A common reason for MRI referral is an enlarged retrocerebellar fluid space (>10 mm) (Chapter 37). MRI is better than US for the evaluation and multidimensional analysis of the cerebellum, cerebellar parenchyma, vermis, and brain stem. For instance, a significant reduction in the transverse cerebellar diameter is seen with cerebellar agenesis or hypoplasia, the cerebellum can be compressed in the case of an arachnoid cyst and the position of the tentorium cerebelli and the shape of the fourth ventricle can determine diagnosis of Dandy-Walker malformation (Fig. 172.5). Other causes of enlarged CSF-filled spaces include Blake's pouch cyst, defined as failure of regression of the rudimentary fourth ventricle. The retrocerebellar fluid space may be reduced in the case of Arnold-Chiari malformation, which should raise suspicions of myelomeningocele and prompt further MRI evaluation.[62]

Acquired Brain Lesions

Causes of acquired fetal brain lesions include ischemic infarction, hemorrhage, tumor, or infection. The main intracranial signs of prenatal infection are ventriculomegaly, periventricular

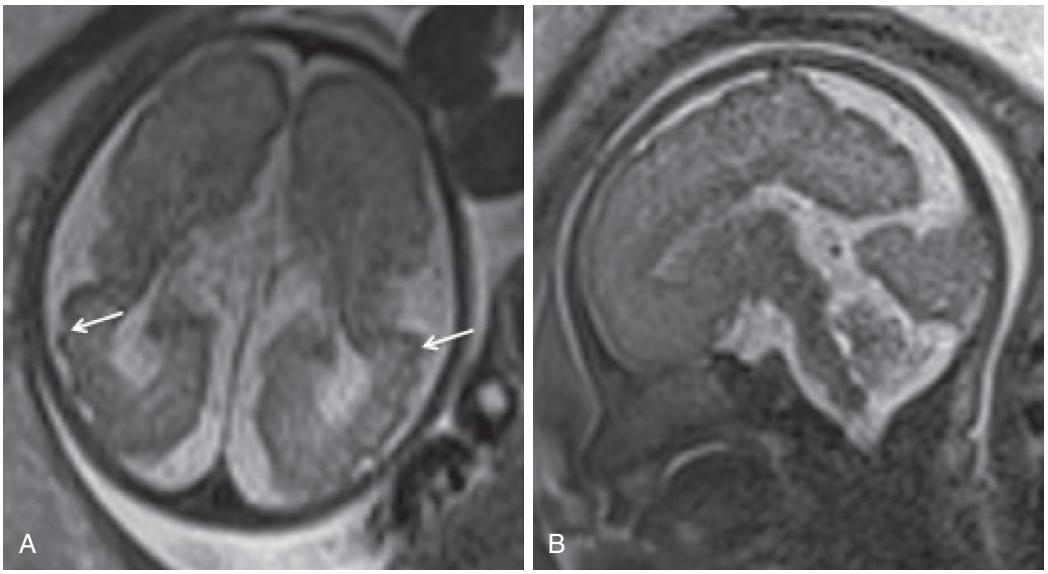

Fig. 172.4 Nonisolated complete agenesis of the corpus callosum in a 31-week fetus. (A) Axial plane single-shot fast spin echo T2-weighted image: bilateral polymicrogyria *(white arrows).* (B) Midsagittal plane single-shot fast spin echo T2-weighted image: no corpus callosum.

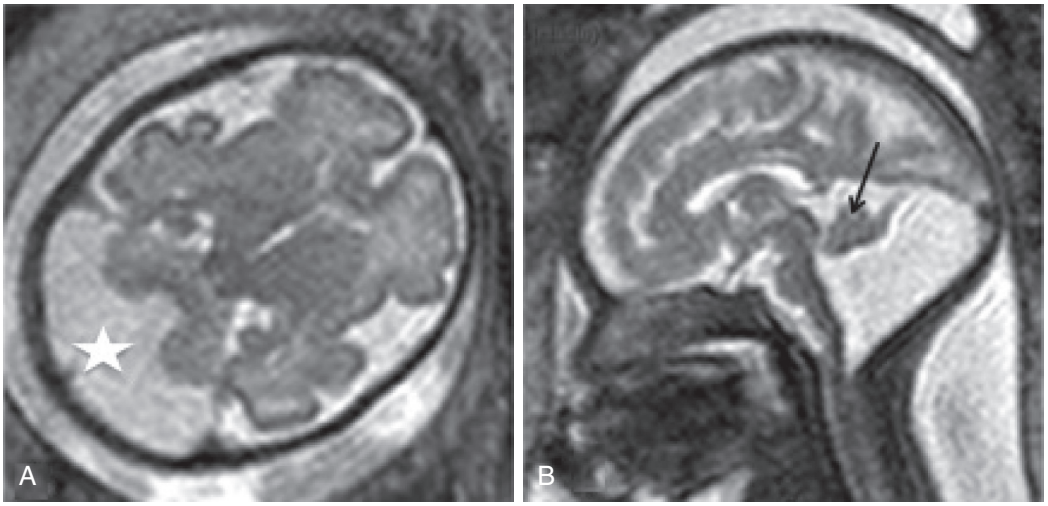

Fig. 172.5 Dandy-Walker malformation in a 31-week fetus. (A) Axial single-shot fast spin echo T2-weighted image: enlargement of the posterior cisterna *(white star)* and absent vermis. (B) Sagittal single-shot fast spin echo T2-weighted image: elevation of the tent of the cerebellum, with the vermis located high and compressed *(black arrow).* The size and aspect of the vermis will determine the prognosis.

calcifications, microcephaly, polymicrogyria, and cerebellar hypoplasia. MRI can detect cortical lesions and hypersignal in the white matter, specifically the temporal lobe,[63] and should be performed systematically in cases of proven fetal infection. Ischemic lesions can lead to a reduction in brain tissue, with porencephaly or schizencephaly.[64] MRI can diagnose brain injury, including after laser therapy for twin-twin transfusion syndrome.[13]

Hemorrhagic lesions can be detected by T1-weighted and echoplanar sequences.[65] Hemorrhagic and parenchymal atrophy may be seen with the most common vascular lesion, vein of Galen malformation[66] (Chapter 42).

THORAX AND LUNGS

The most common lung lesions in the fetus are congenital diaphragmatic hernia (CDH), bronchopulmonary sequestration, congenital cystic adenomatoid malformation, bronchogenic cyst, congenital high airway obstruction syndrome, and bronchial plug. Because normal fetal lungs and airways are mainly filled with amniotic fluid, they have a relative hypersignal on T2-weighted sequences, allowing easy evaluation of lung volume and anatomy[67] (Fig. 172.6). MRI can distinguish cystic spaces from cysts and sequestration in the fetal lung, as well as identify vascular communication with the bronchial tree. The cystic spaces can be distinguished from cysts and sequestration as they

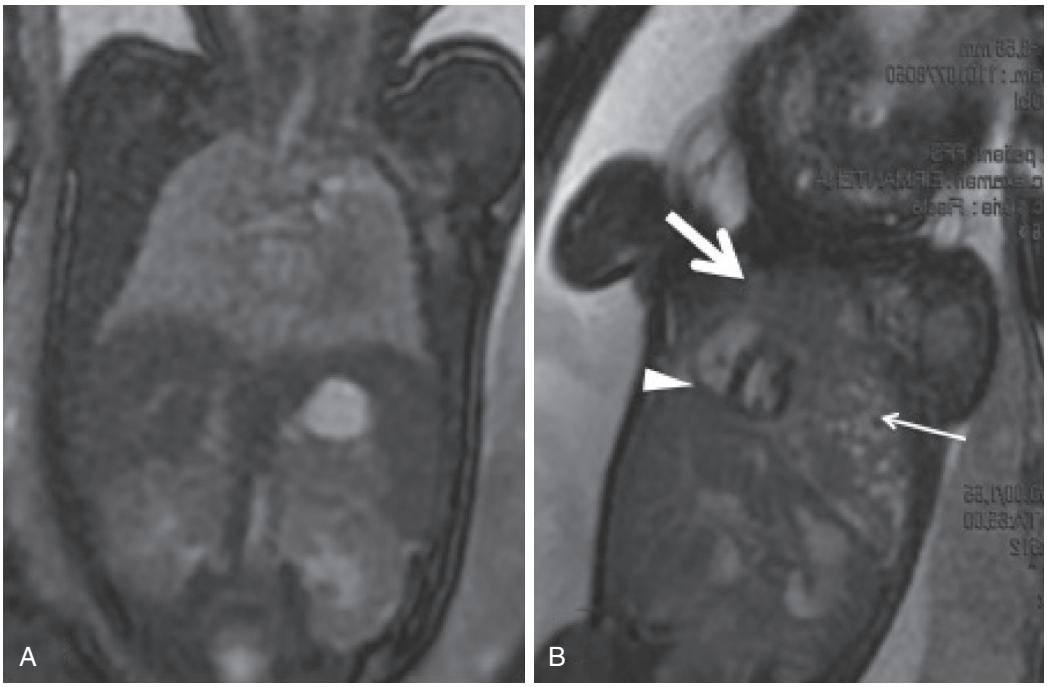

Fig. 172.6 Fetal lung at 28 weeks. (A) Coronal single-shot fast spin echo T2: normal fetal lung in hypersignal T2 at 28 weeks. (B) Coronal plane: left isolated congenital diaphragmatic hernia in a 28-week fetus: note the herniation of bowel loops *(white arrow),* and the undetectable left lung. The heart is displaced to the right *(white arrowhead),* and the right lung is slightly compressed *(thick white arrow).*

communicate with the bronchial tree and are fed and drained by arteries and veins derived from the pulmonary circulation (in contrast with sequestration). Depending on the subtype, with variable-size cysts, their exact appearance can be better described with MRI. In the case of bronchial atresia or plug, segmental or subsegmental occlusion will lead to a dilated T2 hyperintense tubular structure that can be easily seen on MRI. MRI can evaluate pulmonary sequestration, which arises as an accessory pulmonary bud, composed of nonfunctioning lung tissue with no normal communication with the airways and an abnormal systemic arterial supply.

MRI has several advantages over US alone in the workup of fetal lung lesions: it can help to confirm a diagnosis, evaluate tracheal anatomy and lung lesion size, detect subtle accompanying anomalies, and improve the detection of chest anomalies.[34,68,69] The biggest contribution of MRI is probably in CDH (see Fig. 172.6). Indeed, MRI can help to determine the position of the liver, assess the herniated content, detect commonly associated abnormalities, and evaluate the volume of the normal lung. Indeed, pulmonary volumes reflect the degree of lung hypoplasia and correlate directly with postnatal outcome. Pulmonary volume measurements must be standardized by gestational age, using the lung to head ratio and/or volumes reported to expected measurements.[70–72] MRI may also reveal the presence of a sac around herniated organs, a finding associated with better outcome.[73] Finally, MRI may prove useful in the evaluation of lung maturity, based on diffusion-weighted imaging and spectroscopy[74,75]

NECK AND FACE

Neck masses are rare, and MRI is particularly helpful for detecting associated brain abnormalities, as well as assessing the extent of lesion to assist in delivery planning (e.g., need for *ex utero* intrapartum treatment).[76]

GASTROINTESTINAL AND GENITOURINARY TRACTS

MRI can improve prenatal diagnosis of esophageal atresia by demonstrating the pouch sign on dynamic sequences. It is also useful for detecting associated malformations, including tracheoesophageal fistula.[77–79] Because of its large field of view and better tissue contrast than US, and because of the T1 hypersignal of meconium, MRI can assist in the evaluation of dilated bowel loops, and differentiation of proximal from distal obstruction (Figs. 172.7 and 172.8).

In cases of abdominal wall defects such as gastroschisis (Chapter 20) or omphalocele (Chapter 21) the extracorporeal structures may be difficult to visualize by US alone. MRI can assess the size of the wall defect and calculate lung volume. Critically, MRI can be used to screen for omphalocele-associated anomalies that may be overlooked by US.[80–82]

Another application of fetal MRI is to characterize abdominal cystic masses[83] such as ovarian cysts in cystic lymphatic malformations. MRI can also help identify compression of adjacent structures in cystic lymphatic malformations, and identify the location of a choledochal cyst, intestinal duplication cyst, or renal/suprarenal cystic lesion.[83]

The most common fetal anomalies involve the kidney and bladder. US is the primary imaging modality, but may be compromised by oligohydramnios, which does not significantly affect MRI. In fact, thanks to multiplanar acquisitions, MRI can be used to analyze the renal parenchyma, the degree and extent of pyelectasis, ureteral dilatation, ureterocele, the posterior urethra in the male fetus, and the digestive tract (Fig. 172.9).[84,85]

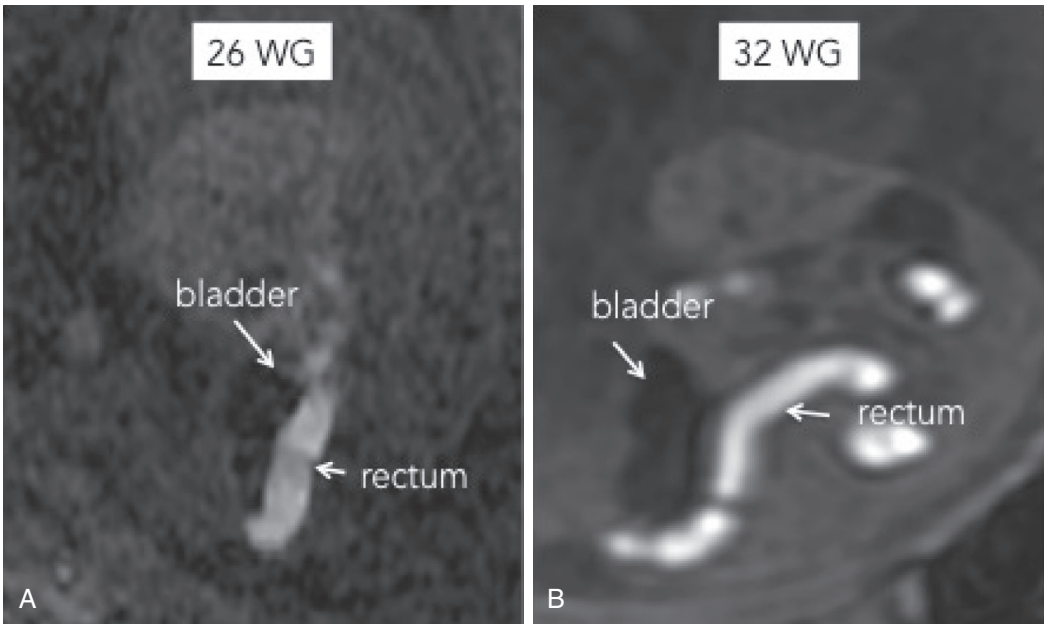

Fig. 172.7 Normal bowel: sagittal T1-weighted gradient-echo image. (A) 26-week fetus. (B) 32-week fetus. The colon and rectum can be characterized early in gestation (magnetic resonance imaging colonography), based on the high signal arising from meconium (a proteinaceous fluid) within the bowel on T1-weighted sequences after 20 weeks of gestation (WG).

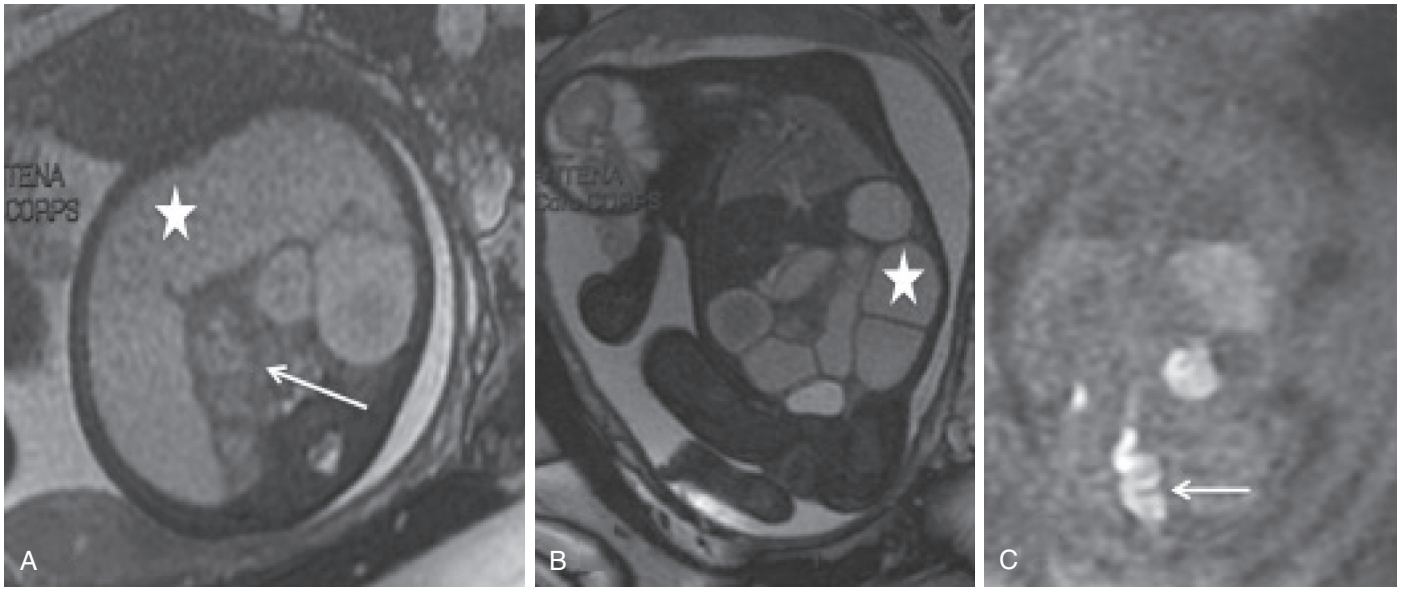

Fig. 172.8 Distal bowel atresia in a 29-week fetus. (A) Axial single-shot fast spin echo (SSFSE) T2 image: dilated bowel in hypersignal T2 *(white star)* adjacent to normal bowel *(white arrow).* (B) Coronal SSFSE T2 image: dilated bowel *(white star).* (C) Coronal T1 gradient-echo image: microcolon and microrectum in hypersignal T1 *(white arrow).*

Finally, urogenital anomalies are complex because they often share similar clinical presentations despite markedly different prognoses. MRI can be helpful in evaluating these anomalies when US is unable to differentiate between persistent cloaca, urogenital sinus, and simple genital obstruction, and for abnormalities such as teratoma or anterior myelomeningocele.[86] Specifically, MRI can differentiate a cloaca from urogenital sinus by validating the presence of the rectum (on hypersignal T1), hydrocolpos, uterus, and bladder.[87]

HEART

Congenital heart defects are among the most common congenital anomalies and are often associated with extracardiac anomalies.[88] Fetal echocardiography remains the gold standard for evaluation, but MRI may detect extracardiac lesions and/or anomalies of brain development.[89,90] MRI of the fetal heart requires further technical developments to overcome problems such as the need for gating, fast fetal heart movements, and fetal movements.[88]

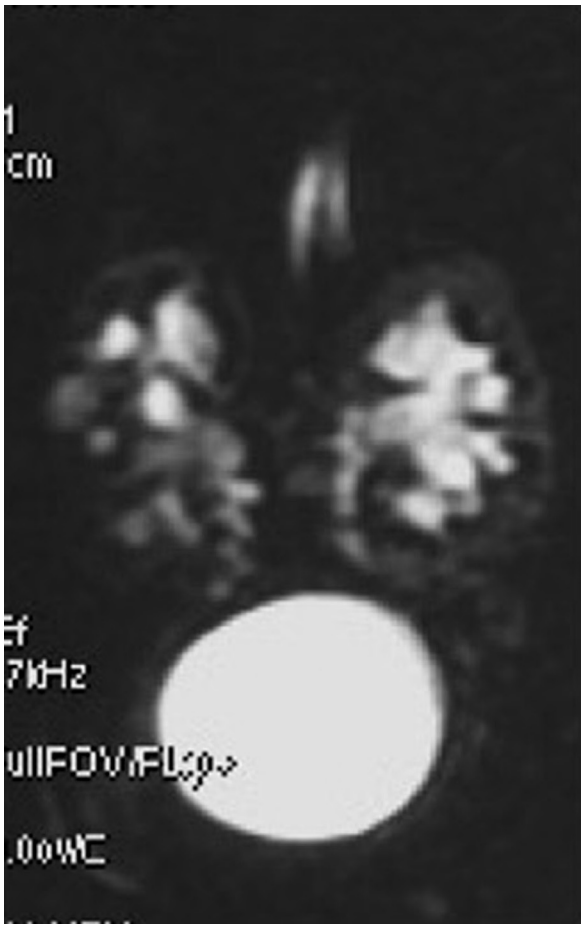

Fig. 172.9 Uro magnetic resonance imaging in a 33-week fetus: coronal plane. A specific T2 sequence (HASTE sequence) allows the whole dilated tract to be visualized.

SKELETON

Bones are usually better evaluated by US, but MRI may be useful in the evaluation of skeletal dysplasia when evaluation of cartilage and muscle is desired.[9]

Other Applications

PLACENTA

Because of its wide field of view and high contrast resolution, MRI is mainly useful for analyzing an abnormally invasive placenta, placental tumors, or hematomas. The normal placenta has a low signal on T1-weighted images and a relatively high signal on T2-weighted images. Heterogeneous areas that develop in late pregnancy may correspond to regions of infarction, necrosis, or fibrosis.[91] Subchorionic hemorrhage can be seen as an increased signal on T1-weighted images. The last few years have seen increasing interest in the use of MRI for the diagnosis of abnormal invasive placenta. Functional MRI has also been used to study vascular particularities of the placenta.

The morbidly adherent placenta, including previa, accreta, and percreta (Fig. 172.10) is defined by a spectrum of abnormal presence of placental tissue throughout the myometrium (Chapter 97). Prenatal detection can reduce maternal morbidity by allowing delivery planning.[92] The following features should be sought to document accreta: heterogeneous intraplacental signal intensity on T2-weighted images, focal interruption of the myometrial borders with exophytic placental tissue throughout the myometrium, dark placental bands on T2-weighted sequences, abnormal uterine bulging, visibility of the entire hypointense T2-weighted interface between the myometrium and the placenta, and placental invasion of adjacent organs (suspected in cases of bladder wall irregularity or tenting).[93,94] Recently, contrast injection was shown to improve the accuracy of diagnosis, especially by inexperienced radiologists, but should be reserved for cases beyond 30 weeks in which the diagnosis cannot be confirmed or ruled out by anatomic sequences alone.[30]

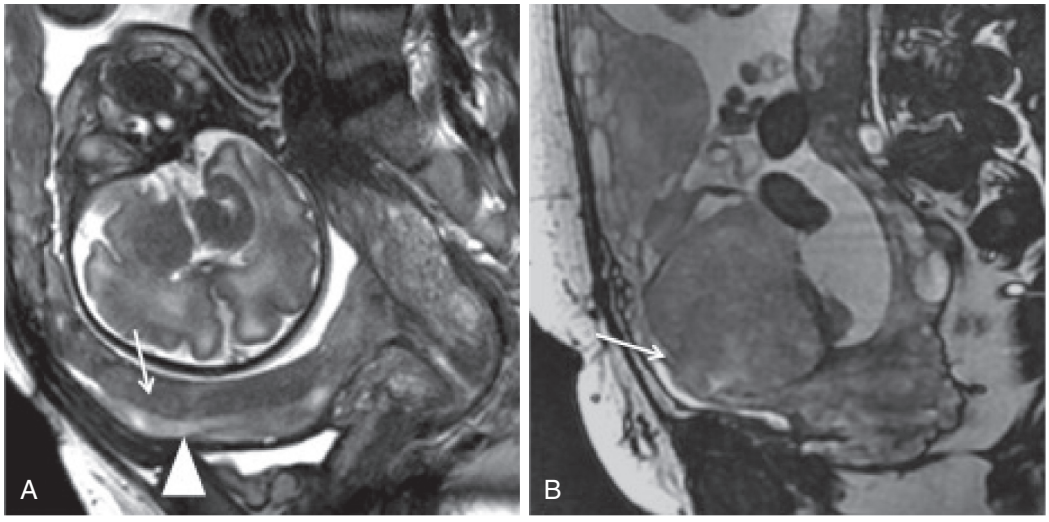

Fig. 172.10 Magnetic resonance imaging of placenta previa. (A) Sagittal plane steady state free precession: placenta previa without accreta. Myometrium is present *(white arrowhead)*, with a distinct placenta *(thin white arrow)*. (B) Sagittal plane steady state free precession: placenta percreta, with a heterogeneous and bulging placenta; note the lack of a clear demarcation between the myometrium and adjacent placenta.

Recent developments in MRI offer new perspectives for placental imaging, based on functional MRI (fMRI) tools to explore vascularization, oxygenation, and metabolism.[15] DWI and intravoxel incoherent motion MRI studies of the movement of water molecules within tissues provide information on tissue vascularization and structure. The apparent diffusion coefficient and the perfusion fraction *(f)* are significantly decreased in intrauterine growth restriction (IUGR) when compared to normal pregnancy. BOLD and oxygen-enhanced MRI uses hemoglobin as an endogenous contrast agent. Changes in T2* signal intensity can be seen when the oxygenation status of the organ of interest is modified. BOLD MRI could be used as a noninvasive diagnostic tool to detect placental insufficiency and to distinguish healthy fetuses from those with IUGR. Arterial spin labeling MRI relies on magnetically labeled water to quantify blood flow and was the first functional MRI technique used to study the human placenta, in 1998.[95] Last, dynamic contrast-enhanced MRI can quantify placental perfusion, permeability, and blood volume fractions but requires a gadolinium-based contrast agent, the use of which should be limited to situations where the benefits outweigh the risks. Functional MRI of the placenta is still evolving, but shows promise for detection and management of placental insufficiency.[15]

VIRTOPSY

MRI may offer an acceptable alternative to conventional autopsy. Minimally invasive autopsy combines computed tomography/MRI with targeted biopsy and has similar accuracy to conventional autopsy for determining the cause of death and detecting major abnormalities. MRI could therefore help to increase autopsy rates for stillbirths and terminations with anomalies.[96]

LABOR AND DELIVERY

MRI has been used to image a normal delivery[97] and can be used to measure fetal volumes and weight[98] and maternal pelvic dimensions,[99] potentially making it useful for monitoring birth,[100] although current cost, convenience, and access issues make that impractical presently.

Safety Issues

MRI does not expose the fetus to ionizing radiation, but the magnetic fields and gradients used to build the images are potentially harmful. The American College of Radiology guidelines state that "*present data have not conclusively documented any deleterious effects of MR imaging exposure of the developing fetus,*" but the number of cases is insufficient for definitive conclusions, especially when higher-strength (greater than 1.5 T) magnets are used.[19,101,102] The Guidelines for Diagnostic Imaging During Pregnancy and Lactation advise against gadolinium contrast enhancement unless benefits clearly outweigh risks.[103] Also the specific absorption rate (the potential for heating of a tissue related to the radiofrequency energy necessary to produce the MR signal) should be closely monitored because system limits are not always programmed for pregnancy. The advantages and safety of fetal MRI, including its impact on long-term outcomes, should be evaluated in large studies.

WHAT THE REFERRING PHYSICIAN NEEDS TO KNOW

MRI has become an increasingly routine prenatal imaging procedure. It may be useful when US suggests, but cannot confirm, an anomaly, and as a tool to provide functional information. The development of open or semiopen magnets, as well as tables capable of handling patients weighing up to 250 kg, will likely broaden obstetric indications. A team approach to the development and interpretation of a fetal MRI program is essential, and in addition, to the obstetric care provider, should involve experts in US imaging, MRI, high-risk pregnancy, and pediatric imaging.

KEY POINTS

- Fetal MRI is not yet standard, and should be used only to answer specific questions raised by targeted US, or in certain high-risk situations (such as determining extent of fetal neck mass for delivery planning).
- Indications for fetal MRI have grown recently, and are likely to broaden further in the near future.
- Conducting and interpreting an MRI study requires a clear understanding of the US findings leading to the referral, as well as relevant fetal anatomy and pathophysiology.
- The advantages and safety of fetal MRI for perinatal care and its impact on long-term outcomes should be evaluated in large studies.

SUGGESTED READINGS

Adamsbaum C, Moutard ML, Andre C, et al. MRI of the fetal posterior fossa. *Pediatr Radiol*. 2005;35(2):124-140.

Amini H, Wikström J, Ahlström H, et al. Second trimester fetal magnetic resonance imaging improves diagnosis of non-central nervous system anomalies. *Acta Obstet Gynecol Scand*. 2011;90(4):380-389.

Boddaert N, Klein O, Ferguson N, et al. Intellectual prognosis of the Dandy-Walker malformation in children: the importance of vermian lobulation. *Neuroradiology*. 2003;45(5):320-324.

Brugger PC, Prayer D. Fetal abdominal magnetic resonance imaging. *Eur J Radiol*. 2006;57(2):278-293.

Garel C, Fallet-Bianco C, Guibaud L. The fetal cerebellum: development and common malformations. *J Child Neurol*. 2011;26(12):1483-1492.

Guibaud L. Practical approach to prenatal posterior fossa abnormalities using MRI. *Pediatr Radiol*. 2004;34(9):700-711.

Kandula T, Fahey M, Chalmers R, et al. Isolated ventriculomegaly on prenatal ultrasound: what does fetal MRI add? *J Med Imaging Radiat Oncol*. 2015;59(2):154-162.

Lyons K, Cassady C, Mehollin-Ray A, et al. Current role of fetal magnetic resonance imaging in body anomalies. *Semin Ultrasound CT MRI*. 2015;36(4):310-323.

Lyons K, Cassady C, Jones J, et al. Current role of fetal magnetic resonance imaging in neurologic anomalies. *Semin Ultrasound CT MRI*. 2015;36(4):298-309.

Nemec U, Nemec SF, Bettelheim D, et al. Ovarian cysts on prenatal MRI. *Eur J Radiol*. 2012;81(8):1937-1944.

Rubesova E. Fetal bowel anomalies–US and MR assessment. *Pediatr Radiol*. 2012;42(suppl 1):S101-S106.

Saguintaah M, Couture A, Veyrac C, et al. MRI of the fetal gastrointestinal tract. *Pediatr Radiol*. 2002;32(6):395-404.

Stagno S, Pass RF, Cloud G, et al. Primary cytomegalovirus infection in pregnancy. Incidence, transmission to fetus, and clinical outcome. *JAMA*. 1986;256(14):1904-1908.

Widjaja E, Geibprasert S, Mahmoodabadi SZ, et al. Corroboration of normal and abnormal fetal cerebral lamination on postmortem MR imaging with postmortem examination. *AJNR Am J Neuroradiol*. 2010;31(10):1987-1993.



All references available online at
www.expertconsult.com

REFERENCES

1. Maxwell C, Glanc P. Imaging and obesity: a perspective during pregnancy. *AJR Am J Roentgenol*. 2011;196(2):311-319.
2. Frates MC, Kumar AJ, Benson CB, et al. Fetal anomalies: comparison of MR imaging and US for diagnosis. *Radiology*. 2004;232(2):398-404.
3. Paladini D. Sonography in obese and overweight pregnant women: clinical, medicolegal, and technical issues. *Ultrasound Obstet Gynecol*. 2009;33(6):720-729.
4. Racusin D, Stevens B, Campbell G, et al. Obesity and the risk and detection of fetal malformations. *Semin Perinatol*. 2012;36(3):213-221.
5. Fuchs F, Houllier M, Voulgaropoulos A, et al. Factors affecting feasibility and quality of second-trimester ultrasound scans in obese pregnant women. *Ultrasound Obstet Gynecol*. 2013;41(1):40-46.
6. Brugger PC, Prayer D. Actual imaging time in fetal MRI. *Eur J Radiol*. 2012;81:e194-e196.
7. Peruzzi P, Corbitt RJ, Raffel C. Magnetic resonance imaging versus ultrasonography for the in utero evaluation of central nervous system anomalies. *J Neurosurg Pediatr*. 2010;6(4):340-345.
8. Pugash D, Brugger PC, Bettelheim D, et al. Prenatal ultrasound and fetal MRI: the comparative value of each modality in prenatal diagnosis. *Eur J Radiol*. 2008;68(2):214-226.
9. Lyons K, Cassady C, Mehollin-Ray A, et al. Current role of fetal magnetic resonance imaging in body anomalies. *Semin Ultrasound CT MRI*. 2015;36(4):310-323.
10. Lyons K, Cassady C, Jones J, et al. Current role of fetal magnetic resonance imaging in neurologic anomalies. *Semin Ultrasound CT MRI*. 2015;36(4):298-309.
11. Amini H, Wikström J, Ahlström H, et al. Second trimester fetal magnetic resonance imaging improves diagnosis of non-central nervous system anomalies. *Acta Obstet Gynecol Scand*. 2011;90(4):380-389.
12. Millischer A, Sonigo P, Ville Y, et al. Standardized anatomical examination of the fetus at MRI. A feasibility study. *Ultrasound Obstet Gynecol*. 2013;42:553-559.
13. Stirnemann J, Chalouhi G, Essaoui M, et al. Fetal brain imaging following laser surgery in twin-to-twin surgery. *BJOG Int J Obstet Gynaecol*. 2016;[Ahead of Print].
14. Benoist G, Salomon LJ, Mohlo M, et al. Cytomegalovirus-related fetal brain lesions: comparison between targeted ultrasound examination and magnetic resonance imaging. *Ultrasound Obstet Gynecol*. 2008;32(7):900-905.
15. Siauve N, Chalouhi GE, Deloison B, et al. Functional imaging of the human placenta with magnetic resonance. *Am J Obstet Gynecol*. 2015;213(4 suppl):S103-S114.
16. Jakab A, Pogledic I, Schwartz E, et al. Fetal cerebral magnetic resonance imaging beyond morphology. *Semin Ultrasound CT MR*. 2015;36(6):465-475.
17. Reddy UM, Abuhamad AZ, Levine D, et al. Fetal imaging: executive summary of a joint Eunice Kennedy Shriver National Institute of Child Health and Human Development, Society for Maternal-Fetal Medicine, American Institute of Ultrasound in Medicine, American College of Obstetricians and Gynecologists, American College of Radiology, Society for Pediatric Radiology, and Society of Radiologists in ultrasound fetal imaging workshop. *Am J Obstet Gynecol*. 2014;210(5):387-397.
18. Smith FW, Adam AH, Phillips WD. NMR imaging in pregnancy. *Lancet*. 1983;1(8314-5):61-62.
19. Victoria T, Johnson AM, Edgar JC, et al. Comparison between 1.5-T and 3-T MRI for fetal imaging: is there an advantage to imaging with a higher field strength? *Am J Roentgenol*. 2016;206(1):195-201.
20. Victoria T, Jaramillo D, Roberts TPL, et al. Fetal magnetic resonance imaging: jumping from 1.5 to 3 tesla (preliminary experience). *Pediatr Radiol*. 2014;44(4):376-386.
21. Salomon LJ, Garel C. Magnetic resonance imaging examination of the fetal brain. *Ultrasound Obstet Gynecol*. 2007;30(7):1019-1032.
22. Salomon LJ, Garel C. How we do it? MRI of the fetal brain. *Ultrasound Obstet Gynecol*. 2007;30(7):1019-1032.
23. Weisz B, Hoffmann C, Ben-Baruch S, et al. Early detection by diffusion-weighted sequence magnetic resonance imaging of severe brain lesions after fetoscopic laser coagulation for twin-twin transfusion syndrome. *Ultrasound Obstet Gynecol*. 2014;44(1):44-49.
24. Savelli S, Di Maurizio M, Perrone A, et al. MRI with diffusion-weighted imaging (DWI) and apparent diffusion coefficient (ADC) assessment in the evaluation of normal and abnormal fetal kidneys: preliminary experience. *Prenat Diagn*. 2007;27(12):1104-1111.
25. Wedegartner U, Tchirikov M, Schafer S, et al. Functional MR imaging: comparison of BOLD signal intensity changes in fetal organs with fetal and maternal oxyhemoglobin saturation during hypoxia in sheep. *Radiology*. 2006;238:872-880.
26. Girard N, Chaumoitre K, Confort-Gouny S, et al. Magnetic resonance imaging and the detection of fetal brain anomalies, injury, and physiologic adaptations. *Curr Opin Obstet Gynecol*. 2006;18(2):164-176.
27. Girard N, Fogliarini C, Viola A, et al. MRS of normal and impaired fetal brain development. *Eur J Radiol*. 2006;57:217-225.
28. Schöpf V, Kasprian G, Brugger PC, et al. Watching the fetal brain at "rest." *Int J Dev Neurosci*. 2011;30:11-17.
29. Kasprian G, Brugger PC, Weber M, et al. In utero tractography of fetal white matter development. *Neuroimage*. 2008;43(2):213-224.
30. Millischer AE, Salomon LJ, Porcher R, et al. Magnetic resonance imaging for abnormally invasive placenta: the added value of intravenous gadolinium injection. *BJOG*. 2016;124:88-95.
31. Saleem SN. Fetal magnetic resonance imaging (MRI): a tool for a better understanding of normal and abnormal brain development. *J Child Neurol*. 2013;28(7):890-908.
32. Behairy NH, Talaat S, Saleem SN, et al. Magnetic resonance imaging in fetal anomalies: what does it add to 3D and 4D US? *Eur J Radiol*. 2010;74(1):250-255.
33. Prayer D, Kasprian G, Krampl E, et al. MRI of normal fetal brain development. *Eur J Radiol*. 2006;57(2):199-216.
34. Kul S, Korkmaz HAA, Cansu A, et al. Contribution of MRI to ultrasound in the diagnosis of fetal anomalies. *J Magn Reson Imaging*. 2011;35:882-890.
35. Tilea B, Alberti C, Adamsbaum C, et al. Cerebral biometry in fetal magnetic resonance imaging: new reference data. *Ultrasound Obstet Gynecol*. 2009;33(2):173-181.
36. Chung HW, Chen CY, Zimmerman RA, et al. T2-Weighted fast MR imaging with true FISP versus HASTE: comparative efficacy in the evaluation of normal fetal brain maturation. *AJR Am J Roentgenol*. 2000;175(5):1375-1380.
37. Levine D, Barnes PD, Madsen JR, et al. Fetal central nervous system anomalies: MR imaging augments sonographic diagnosis. *Radiology*. 1997;204(3):635-642.
38. Whitby E, Paley MN, Davies N, et al. Ultrafast magnetic resonance imaging of central nervous system abnormalities in utero in the second and third trimester of pregnancy: comparison with ultrasound. *BJOG Int J Obstet Gynaecol*. 2001;108(5):519-526.
39. Glenn OA, Barkovich AJ. Magnetic resonance imaging of the fetal brain and spine: an increasingly important tool in prenatal diagnosis, part 1. *AJNR Am J Neuroradiol*. 2006;27(8):1604-1611.
40. Brisse H, Fallet C, Sebag G, et al. Supratentorial parenchyma in the developing fetal brain: in vitro MR study with histologic comparison. *AJNR Am J Neuroradiol*. 1997;18(8):1491-1497.
41. Striedter GF, Srinivasan S, Monuki ES. Cortical folding: when, where, how, and why? *Annu Rev Neurosci*. 2015;38(1):291-307.
42. Barkovich AJ, Guerrini R, Kuzniecky RI, et al. A developmental and genetic classification for malformations of cortical development: update 2012. *Brain J Neurol*. 2012;135(Pt 5):1348-1369.
43. Ghai S, Fong KW, Toi A, et al. Prenatal US and MR imaging findings of lissencephaly: review of fetal cerebral sulcal development. *Radiogr Rev*. 2006;26(2):389-405.
44. Fogliarini C, Chaumoitre K, Chapon F, et al. Assessment of cortical maturation with prenatal MRI: part II: abnormalities of cortical maturation. *Eur Radiol*. 2005;15(9):1781-1789.
45. Righini A, Parazzini C, Doneda C, et al. Early formative stage of human focal cortical gyration anomalies: fetal MRI. *AJR Am J Roentgenol*. 2012;198(2):439-447.
46. Salomon LJ, Chalouhi GE, Stirnemann JJ, et al. Cerebral ventricle width measurements vary in relation to gestational age, fetal gender, and cephalometry. *Ultrasound Obstet Gynecol*. 2011;37(3):370-371.
47. Salomon LJ, Bernard JP, Ville Y. Reference ranges for fetal ventricular width: a non-normal approach. *Ultrasound Obstet Gynecol*. 2007;30(1):61-66.
48. Guibaud L. Fetal cerebral ventricular measurement and ventriculomegaly: time for procedure standardization. *Ultrasound Obstet Gynecol*. 2009;34(2):127-130.
49. Guibaud L, Lacalm A. Etiological diagnostic tools to elucidate "isolated" ventriculomegaly. *Ultrasound Obstet Gynecol*. 2015;46(1):1-11.
50. Salomon L, Ouahba J, Delezoide AL, et al. Third-trimester fetal MRI in isolated 10- to 12-mm ventriculomegaly: is it worth it? *BJOG*. 2006;113(8):942-947.
51. Parazzini C, Righini A, Doneda C, et al. Is fetal magnetic resonance imaging indicated when ultrasound isolated mild ventriculomegaly is present in pregnancies with no risk factors? *Prenat Diagn*. 2012;1–6.

52. Blondiaux E, Garel C. Fetal cerebral imaging—ultrasound vs. MRI: an update. *Acta Radiol*. 2013;54(9):1046-1054.
53. Manganaro L, Savelli S, Francioso A, et al. Role of fetal MRI in the diagnosis of cerebral ventriculomegaly assessed by ultrasonography. *Radiol Med (Torino)*. 2009;114(7):1013-1023.
54. Cagneaux M, Guibaud L. From cavum septi pellucidi to anterior complex: how to improve detection of midline cerebral abnormalities. *Ultrasound Obstet Gynecol*. 2013;42(4):485-486.
55. Raybaud C. The corpus callosum, the other great forebrain commissures, and the septum pellucidum: anatomy, development, and malformation. *Neuroradiology*. 2010;52(6):447-477.
56. Harreld JH, Bhore R, Chason DP, et al. Corpus callosum length by gestational age as evaluated by fetal MR imaging. *AJNR Am J Neuroradiol*. 2011;32(3):490-494.
57. Rossi AC, Prefumo F. Additional value of fetal magnetic resonance imaging in the prenatal diagnosis of central nervous system anomalies: a systematic review of the literature. *Ultrasound Obstet Gynecol*. 2014;44(4):388-393.
58. Glenn OA, Goldstein RB, Li KC, et al. Fetal magnetic resonance imaging in the evaluation of fetuses referred for sonographically suspected abnormalities of the corpus callosum. *J Ultrasound Med*. 2005;24(6):791-804.
59. Chapman T, Mahalingam S, Ishak GE, et al. Diagnostic imaging of posterior fossa anomalies in the fetus and neonate: part 2, posterior fossa disorders. *Clin Imaging*. 2015;39(2):167-175.
60. Chapman T, Mahalingam S, Ishak GE, et al. Diagnostic imaging of posterior fossa anomalies in the fetus and neonate: part 1, normal anatomy and classification of anomalies. *Clin Imaging*. 2015;39(1):1-8.
61. Ber R, Bar-Yosef O, Hoffmann C, et al. Normal fetal posterior fossa in MR imaging: new biometric data and possible clinical significance. *AJNR Am J Neuroradiol*. 2015;36(4):795-802.
62. Sudhakaran N, Sothinathan U, Patel S. Best practice guidelines: fetal surgery. *Early Hum Dev*. 2012;88(1):15-19.
63. Picone O, Simon I, Benachi A, et al. Comparison between ultrasound and magnetic resonance imaging in assessment of fetal cytomegalovirus infection. *Prenat Diagn*. 2008;28(8):753-758.
64. Garel C, Delezoide AL, Elmaleh-Berges M, et al. Contribution of fetal MR imaging in the evaluation of cerebral ischemic lesions. *AJNR Am J Neuroradiol*. 2004;25(9):1563-1568.
65. Zizka J, Elias P, Hodik K, et al. Liver, meconium, haemorrhage: the value of T1-weighted images in fetal MRI. *Pediatr Radiol*. 2006;36(8):792-801.
66. Deloison B, Chalouhi GE, Sonigo P, et al. Hidden mortality of prenatally diagnosed vein of Galen aneurysmal malformation: retrospective study and review of the literature. *Ultrasound Obstet Gynecol*. 2012;40(6):652-658.
67. Recio Rodríguez M, Martínez de Vega V, Cano Alonso R, et al. MR imaging of thoracic abnormalities in the fetus. *Radiogr Rev Publ Radiol Soc N Am Inc*. 2012;32(7):E305-E321.
68. Levine D, Barnewolt CE, Mehta TS, et al. Fetal thoracic abnormalities: MR imaging. *Radiology*. 2003;228(2):379-388.
69. Bulas D, Egloff AM. Fetal chest ultrasound and magnetic resonance imaging: recent advances and current clinical applications. *Radiol Clin North Am*. 2011;49(5):805-823.
70. Gajewska-Knapik K, Impey L. Congenital lung lesions: prenatal diagnosis and intervention. *Semin Pediatr Surg*. 2015;24(4):156-159.
71. Victoria T, Danzer E, Scott Adzick N. Use of ultrasound and MRI for evaluation of lung volumes in fetuses with isolated left congenital diaphragmatic hernia. *Semin Pediatr Surg*. 2013;22(1):30-36.
72. Jani J, Cannie M, Sonigo P, et al. Value of prenatal magnetic resonance imaging in the prediction of postnatal outcome in fetuses with diaphragmatic hernia. *Ultrasound Obstet Gynecol*. 2008;32(6):793-799.
73. Zamora IJ, Mehollin-Ray AR, Sheikh F, et al. Predictive value of MRI findings for the identification of a hernia sac in fetuses with congenital diaphragmatic hernia. *Am J Roentgenol*. 2015;205(5):1121-1125.
74. Joe BN, Vahidi K, Zektzer A, et al. (1)H HR-MAS spectroscopy for quantitative measurement of choline concentration in amniotic fluid as a marker of fetal lung maturity: inter- and intraobserver reproducibility study. *J Magn Reson Imaging*. 2008;28(6):1540-1545.
75. Cannie M, Jani J, De Keyzer F, et al. Diffusion-weighted MRI in lungs of normal fetuses and those with congenital diaphragmatic hernia. *Ultrasound Obstet Gynecol*. 2009;34(6):678-686.
76. Mirsky DM, Shekdar KV, Bilaniuk LT. Fetal MRI: head and neck. *Magn Reson Imaging Clin N Am*. 2012;20(3):605-618.
77. Spaggiari E, Faure G, Rousseau V, et al. Performance of prenatal diagnosis in esophageal atresia. *Prenat Diagn*. 2015;35(9):888-893.
78. Salomon LJ, Sonigo P, Ou P, et al. Real-time fetal magnetic resonance imaging for the dynamic visualization of the pouch in esophageal atresia. *Ultrasound Obstet Gynecol*. 2009;34(4):471-474.
79. Hochart V, Verpillat P, Langlois C, et al. The contribution of fetal MR imaging to the assessment of oesophageal atresia. *Eur Radiol*. 2015;25(2):306-314.
80. Brugger PC, Prayer D. Development of gastroschisis as seen by magnetic resonance imaging. *Ultrasound Obstet Gynecol*. 2011;37(4):463-470.
81. Danzer E, Victoria T, Bebbington MW, et al. Fetal MRI-calculated total lung volumes in the prediction of short-term outcome in giant omphalocele: preliminary findings. *Fetal Diagn Ther*. 2012;31(4):248-253.
82. Nakagawa M, Hara M, Shibamoto Y. MRI findings in fetuses with an abdominal wall defect: gastroschisis, omphalocele, and cloacal exstrophy. *Jpn J Radiol*. 2013;31(3):153-159.
83. Gupta P, Sharma R, Kumar S, et al. Role of MRI in fetal abdominal cystic masses detected on prenatal sonography. *Arch Gynecol Obstet*. 2010;281(3):519-526.
84. Pico H, Dabadie A, Bourliere-Najean B, et al. Contribution of the foetal uro-MRI in the prenatal diagnosis of uronephropathies. *Diagn Interv Imaging*. 2014;95(6):573-578.
85. Alamo L, Laswad T, Schnyder P, et al. Fetal MRI as complement to US in the diagnosis and characterization of anomalies of the genito-urinary tract. *Eur J Radiol*. 2010;76(2):258-264.
86. Capito C, Belarbi N, Paye Jaouen A, et al. Prenatal pelvic MRI: additional clues for assessment of urogenital obstructive anomalies. *J Pediatr Urol*. 2014;10(1):162-166.
87. Calvo-Garcia MA, Kline-Fath BM, Levitt MA, et al. Fetal MRI clues to diagnose cloacal malformations. *Pediatr Radiol*. 2011;41(9):1117-1128.
88. Wielandner A, Mlczoch E, Prayer D, et al. Potential of magnetic resonance for imaging the fetal heart. *Semin Fetal Neonatal Med*. 2013;18(5):286-297.
89. Khalil A, Bennet S, Thilaganathan B, et al. Prevalence of prenatal brain abnormalities in fetuses with congenital heart disease: systematic review. *Ultrasound Obstet Gynecol*. 2016;48:296-307.
90. Jansen FAR, Everwijn SMP, Scheepjens R, et al. Fetal brain imaging in isolated congenital heart defects—a systematic review and meta-analysis. *Prenat Diagn*. 2016;36(7):601-613.
91. Messerschmidt A, Baschat A, Linduska N, et al. Magnetic resonance imaging of the placenta identifies placental vascular abnormalities independently of Doppler ultrasound. *Ultrasound Obstet Gynecol*. 2011;37(6):717-722.
92. Sentilhes L, Goffinet F, Kayem G. Management of placenta accreta. *Acta Obstet Gynecol Scand*. 2013;92(10):1125-1134.
93. Lax A, Prince MR, Mennitt KW, et al. The value of specific MRI features in the evaluation of suspected placental invasion. *Magn Reson Imaging*. 2007;25(1):87-93.
94. D'Antonio F, Iacovella C, Palacios-Jaraquemada J, et al. Prenatal identification of invasive placentation using Magnetic Resonance Imaging (MRI): a systematic review and meta-analysis. *Ultrasound Obstet Gynecol*. 2014;44(1):8-16.
95. Gowland PA, Francis ST, Duncan KR, et al. In vivo perfusion measurements in the human placenta using echo planar imaging at 0.5 T. *Magn Reson Med*. 1998;40(3):467-473.
96. Thayyil S, Sebire NJ, Chitty LS, et al. Post-mortem MRI versus conventional autopsy in fetuses and children: a prospective validation study. *Lancet Lond Engl*. 2013;382(9888):223-233.
97. Bamberg C, Rademacher G, Güttler F, et al. Human birth observed in real-time open magnetic resonance imaging. *Am J Obstet Gynecol*. 2012;206(6):505.e1-505.e6.
98. Kacem Y, Cannie MM, Kadji C, et al. Fetal weight estimation: comparison of two-dimensional US and MR imaging assessments. *Radiology*. 2013;267(3):902-910.
99. Zaretsky MV, Alexander JM, McIntire DD, et al. Magnetic resonance imaging pelvimetry and the prediction of labor dystocia. *Obstet Gynecol*. 2005;106(5 Pt 1):919-926.
100. Bamberg C, Deprest J, Sindhwani N, et al. Evaluating fetal head dimension changes during labor using open magnetic resonance imaging. *J Perinat Med*. 2016;[Ahead of Print].
101. Strizek B, Jani JC, Mucyo E, et al. Safety of MR imaging at 1.5 T in fetuses: a retrospective case-control study of birth weights and the effects of acoustic noise. *Radiology*. 2015;275(2):530-537.
102. Expert Panel on MR Safety, Kanal E, Barkovich AJ, et al. ACR guidance document on MR safe practices: 2013. *J Magn Reson Imaging*. 2013;37(3):501-530.
103. Guidelines for diagnostic imaging during pregnancy and lactation. Committee Opinion No. 656. American College of Obstetricians and Gynecologists. *Obstet Gynecol*. 2016;127:e75-e80.

To access the videos in this chapter, scan this QR code or visit expertconsult.com

173 Three-Dimensional Ultrasound: Techniques and Clinical Applications

BORIS TUTSCHEK

Introduction

Fetal anatomy is three-dimensional (3D). Cross-sections obtained during real-time ultrasound (US) examination are an artificial reduction of anatomy to produce one still image, created to capture a standard view or the essence of a particular pathology. Acquisition of a good US volume is not trivial, but a comprehensive volume may enable examination at a greater level of detail than is possible from a single cross-section; this is similar to a video in that multiple different neighboring sections are displayed.

Volume Displays

Three-dimensional US volumes can be analyzed visually in two principal ways: by viewing cross-sections or surface-rendered views. Cross-sections (planes placed anywhere in the volume) are viewed in either one single plane or two/three (typically orthogonal) planes. The latter is usually called *multiplanar display* (Fig. 173.1).

Before examining the anatomy, the multiplanar display should be used to align the volume according to standard planes (Fig. 173.2 [face acquire, align]). A curved section can also be placed to follow anatomic structures that do not lie in a straight plane, such as the fetal palate (Fig. 173.3). A display of a number of parallel cross-sections is usually called *tomographic display* (Fig. 173.4). Surface-rendered views are formatted to display tissue interfaces, either of soft tissue (e.g., the facial skin surface, seen from the amniotic fluid cavity) or bone (e.g., the skull bones, seen from the outside or inside), or a mixture of both (Fig. 173.5).

Technique

It is a misunderstanding and oversimplification to assume that any volume containing the structures of interest will enable extraction of diagnostic images. Three main aspects, each of which requires physical knowledge and careful execution, determine the diagnostic quality of successful 3D US: volume

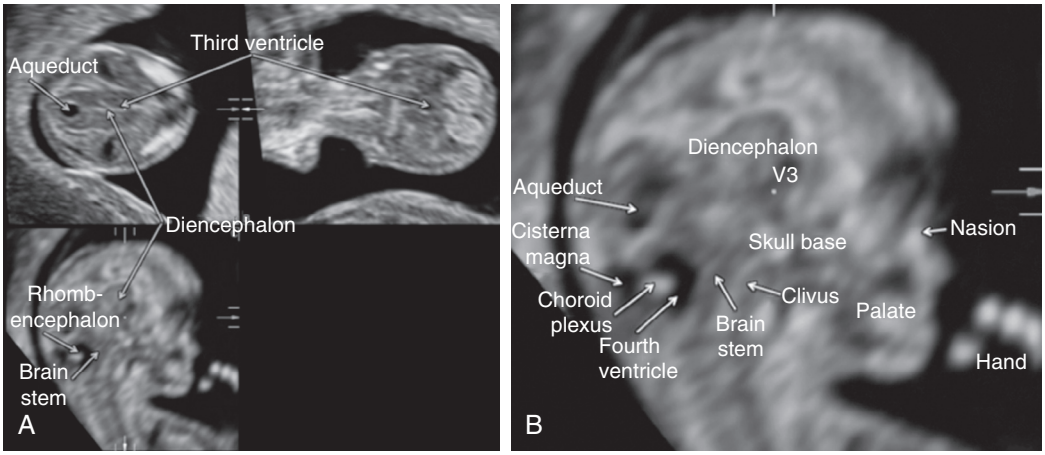

Fig. 173.1 Multiplanar display of the head of a normal fetus at 44 mm crown-rump length (corresponding to 11 postmenstrual weeks). The volume was acquired transvaginally with a median section and aligned anatomically. The reference dot is positioned in the third ventricle, and volume contrast enhancement (1 mm slice thickness) was used. (A) Multiplanar display of axial, coronal, and sagittal sections. (B) Sagittal section, reformatted from the same volume (selected anatomic structures labeled).

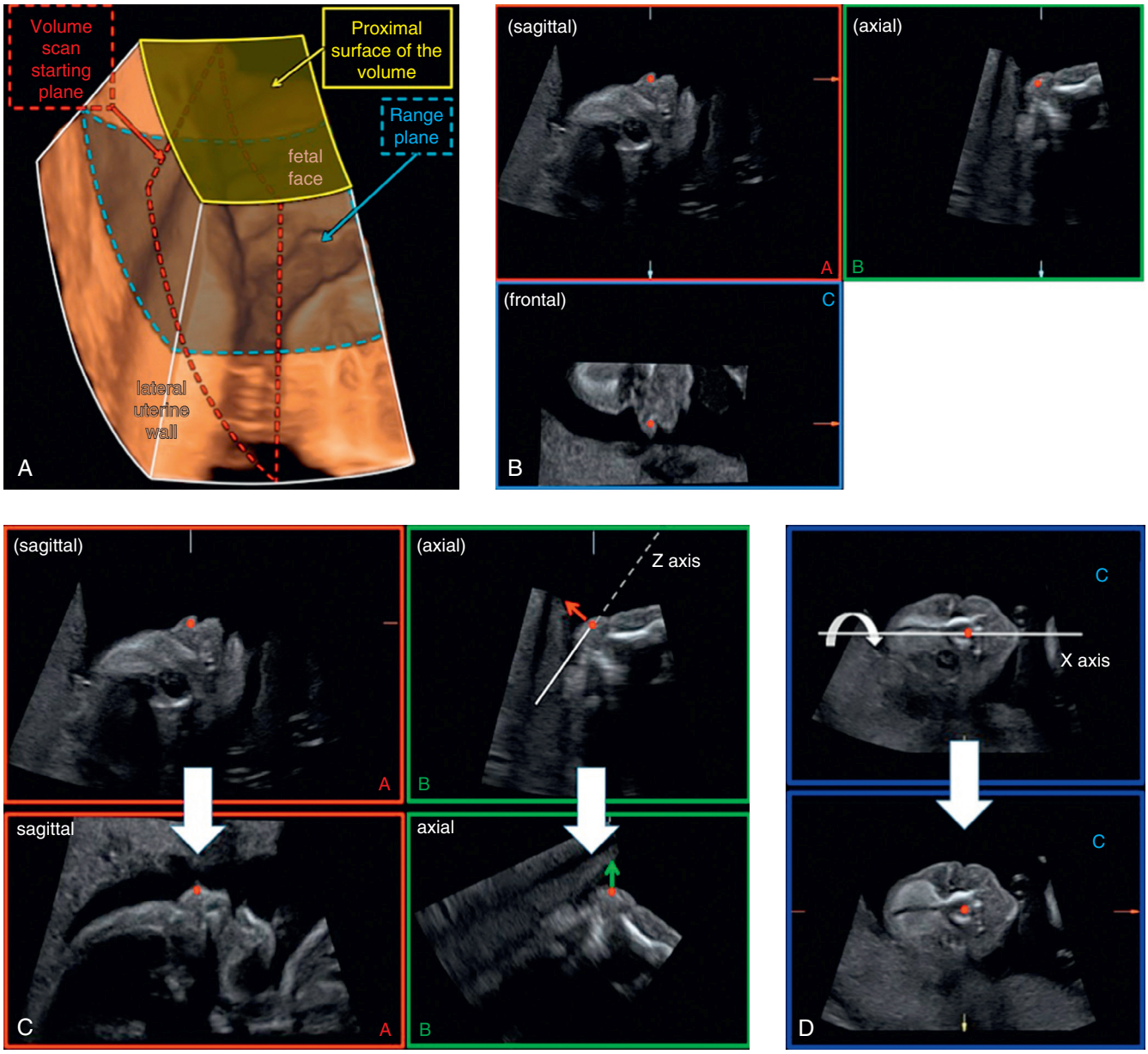

Fig. 173.2 Systematic approach to volume acquisition and stepwise alignment and rotation to extract the exact median section of a normal fetal face at 21 weeks' gestation (3). This volume was obtained from a fetus whose profile could not be obtained using real-time scanning because the fetus was facing to the side. First, the closest possible section to the profile was selected as the starting scan. Panels B to E show the stepwise extraction and eventually, analysis of the profile. (A) After volume acquisition a data block is stored, but usually not displayed. To understand the alignment better the entire volume block is shown, and the volume scan starting plane *(red)* and the range plane *(blue)* are indicated. (B) The reference dot is the intersection of the three orthogonal planes (highlighted as a *red dot* in near-sagittal, axial, and frontal sections in panels A, B, and C). In the multiplanar display the reference dot is placed on an easily recognizable structure, e.g., the tip of the nose. (C) Using the volume rotation in panel B, the direction of the nose is turned upright *(red and green arrows)*, using rotation around the Z-axis (so-called *in-plane rotation)*. (D) Then, the apparent nonalignment in panel C is adjusted to show the frontal view, using rotation around the X-axis in plane C. (E) Finally, the perfectly aligned, exactly median profile is rotated upright and studied, using the maxilla-nasion-mandible angle *(blue lines)* and the facial profile line *(yellow line)*.

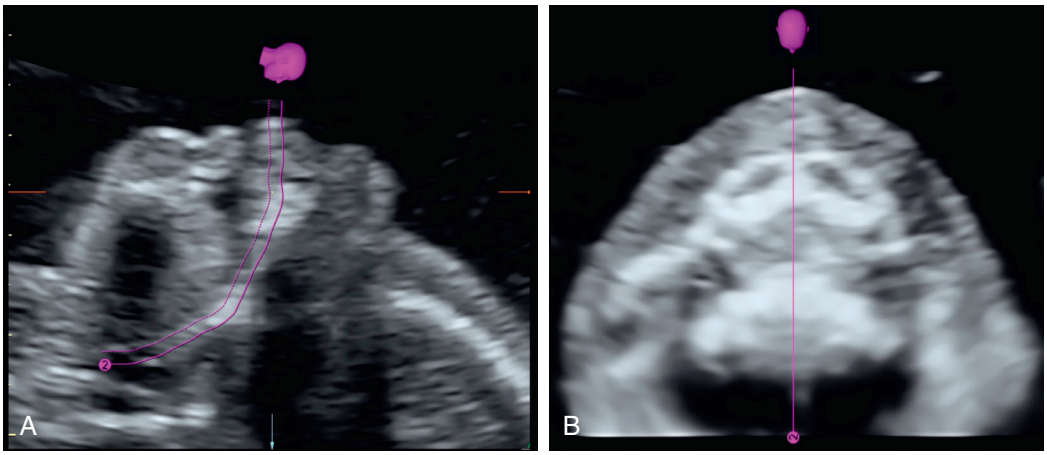

Fig. 173.3 Reconstruction of the normal fetal palate, using a curved plane. A frontal insonation of the fetal profile with transducer parallel to the frontal edges of the maxilla and the mandible was used to acquire the volume. The curved reconstruction plane (placement shown by the purple line in the sagittal section [A]) displays the entire hard and the soft palate down to the uvula in (B). *(From Tutschek B, Blaas HG, Abramowicz J, Baba K, Deng J, Lee W, et al. Three-dimensional ultrasound imaging of the fetal skull and face.* Ultrasound Obstet Gynecol *[Epub ahead of print], 2017.)*

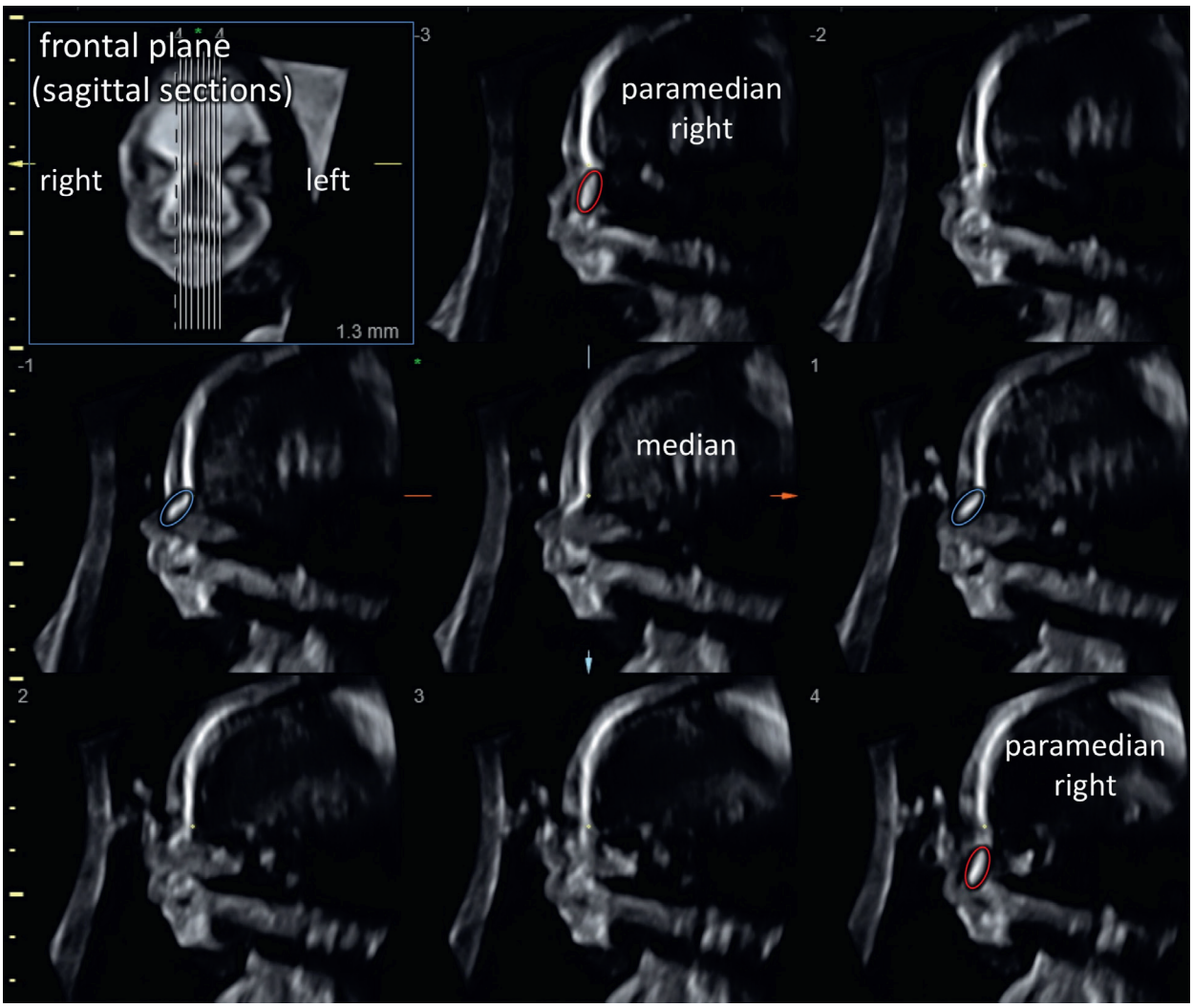

Fig.173.4 Tomographic imaging of a normal fetal profile. Narrow spacing of the adjacent sections permits differentiation between the nasal bones *(blue circles,* images –1 and 1) and the maxillary processes *(red circles,* images –3 and 4) on both sides. *(From Tutschek B, Blaas HG, Abramowicz J, Baba K, Deng J, Lee W, et al. Three-dimensional ultrasound imaging of the fetal skull and face.* Ultrasound Obstet Gynecol *[Epub ahead of print], 2017.)*

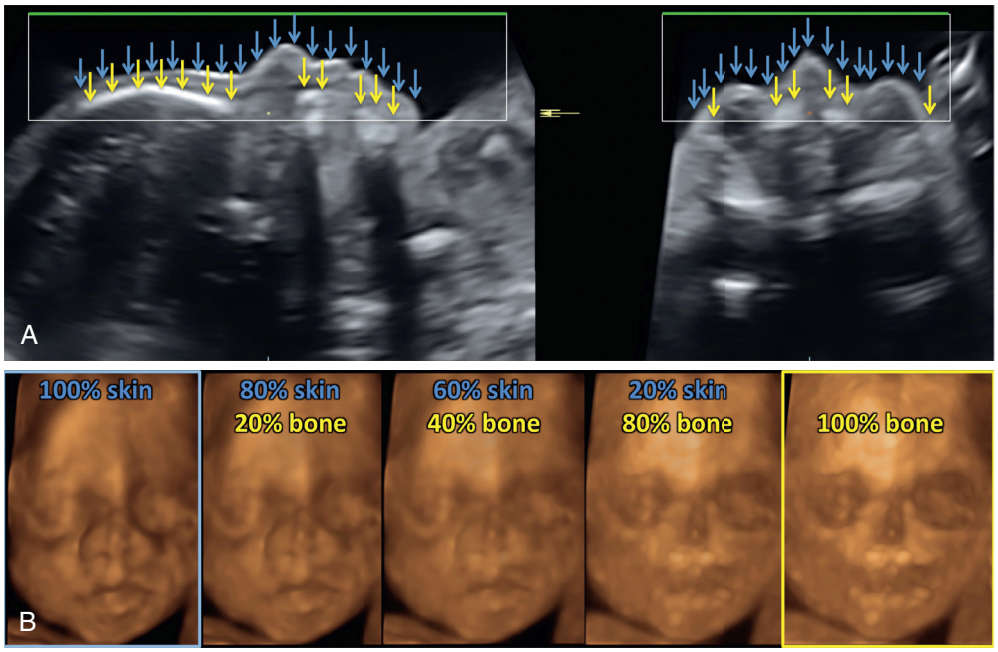

Fig. 173.5 Three-dimensional US surface rendering of the fetal face. All images in this figure were reformatted from the same volume that had been acquired using frontal insonation. For such a volume, ideally at least a small amount of amniotic fluid should be present between the face and other echogenic structures beneath the transducer. (A) Sagittal and axial sections: the adjustable render box *(white lines)* determines what the algorithm will display in 3D. The *green line* defines the direction of rendering (not necessarily, but in this example also the direction from which the object is viewed), in this example from the front. The *blue arrows* define the soft tissues seen in the display in (B), the *yellow arrows* define the bones. (B) The same volume can be "rendered" (surface-reconstructed) for either the skin surface ("100% skin," far left) or the bone surface ("100% bone," far right), or a mix of both. Note the absent ossification of both nasal bones apparent in the far-right image of (B) in this fetus with trisomy 21. *(From Tutschek B, Blaas HG, Abramowicz J, Baba K, Deng J, Lee W, et al. Three-dimensional ultrasound imaging of the fetal skull and face.* Ultrasound Obstet Gynecol *[Epub ahead of print], 2017.)*

acquisition and alignment; volume contrast enhancement; and possibly, surface rendering.

ACQUIRING AND ALIGNING A VOLUME

Successful 3D US first requires optimization of the two-dimensional (2D) image. The correct starting insonation angle with regard to the structure(s) of interest is of paramount importance. Not all sections that can be reformatted (extracted) from a 3D volume have the same resolution. In diagnostic US, the axial resolution (in the axis directed perpendicular away from the transducer) is better than the lateral resolution. Therefore the resolution in the acquisition plane (also called *azimuth plane)* is best; this plane is typically displayed in panel A directly after volume acquisition. The so-called *range plane* (blue plane in Fig. 173.2A), which cannot be obtained in real-time scanning by simply rotating the transducer, offers the lowest resolution, yet it often contains valuable information that cannot be obtained by maneuvering the transducer on the maternal abdomen, or in case of transvaginal scanning, in the vagina.

The starting plane for a volume acquisition should be placed to show the structures of interest as well as possible. Then the volume is acquired and initially displayed in the multiplanar mode (showing three orthogonal planes: A, B, and C; Fig. 173.6). Each of these planes can be aligned, using rotation around the X, Y, and Z axes, respectively, to achieve the intended orientation, typically in standard anatomic sectional planes. A clinical example of this workflow for the fetal face is shown in Fig. 173.2.

VOLUME CONTRAST ENHANCEMENT

US volume contrast enhancement is an excellent tool to differentiate tissues better than simple real-time 2D imaging. Its principle is to compare information for closely adjacent parallel sections ("slices") in the volume to identify true signals and "noise." Then only signals present in several sections are displayed, resulting in a markedly improved contrast. The "slice thickness" for volume contrast enhancement can be adjusted according to the age of the embryo or fetus (usually 1 mm during early gestation; see Fig. 173.1) or 2–5 mm or more (from the second trimester onward) and that of the targeted anatomic region, e.g., brain, trunk (Fig. 173.7), or extremities (Fig. 173.8).

Volume contrast enhancement works on static volumes as well as during live scanning. Static volumes analyzed with contrast enhancements are particularly useful for examination of early pregnancies (with transabdominal and transvaginal scanning) and for the fetal brain. Dynamic volume contrast enhancement is useful for regions with relevant anatomic structures in adjacent but different planes, such as the small bones in the hands and feet or the vessel near the fetal heart (Video 173.1).

SURFACE RENDERING

Rendered views display outer or inner surfaces using 3D US data. A *render box* defines the exclusive volume in which structures will be considered for spatial reconstruction (see Fig. 173.5). It also determines the direction of view toward the reconstructed

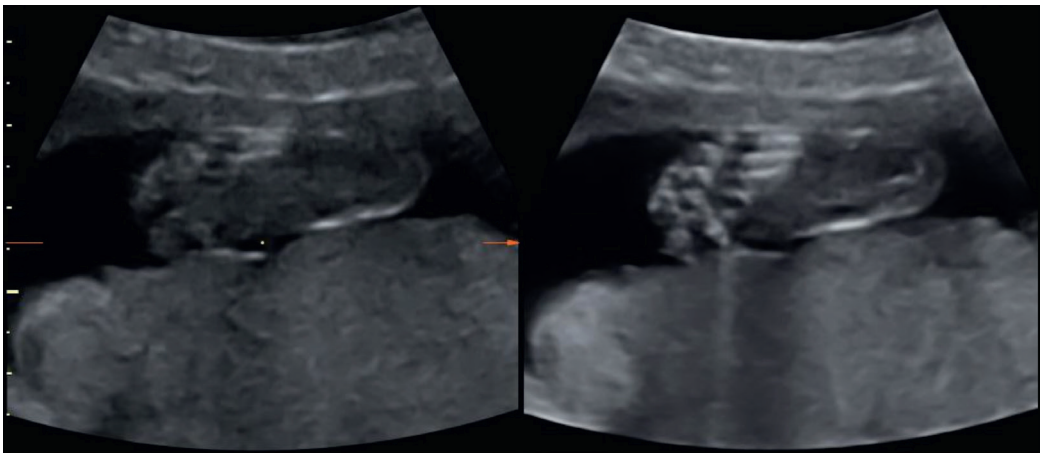

Fig. 173.6 Still image from a real-time scan to examine the foot of a normal 20-week fetus using volume contract enhancement. The regular cross-sectional image is shown on the left, and the three-dimensional ultrasound image with volume contrast enhancement on the right. In the left panel, the foot can be seen, and a few of the small bones are apparent. Real-time volume contrast enhancement (right panel) visualizes both the soft tissue as well as all mineralized bones from all toes and the middle foot that lie in different, but neighboring, sections. The slice thickness used for this example was 5 mm.



Fig. 173.7 Median section of a normal fetal trunk, 3D display using volume contrast enhancement. This still image was extracted from Video 173.1 acquired as a live sequence with a slice thickness of 5 mm. *Desc. Ao*, Descending aorta; *DV*, ductus venosus; *IVC*, inferior vena cava; *RV*, right ventricle; *UV*, umbilical vein.

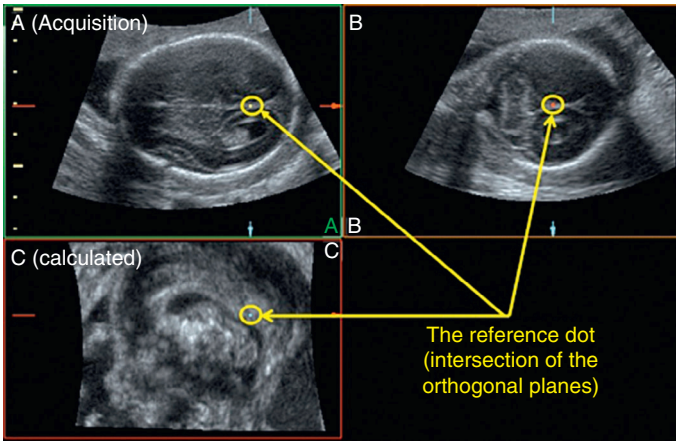

Fig.173.8 Multiplanar display of a normal fetal head, reformatted from the volume acquired using lateral insonation with the ear facing the transducer. Panel (A) initially represents the section corresponding to the starting section of the volume sweep, in this case an axial view of the transventricular plane. Panel (B) could also be obtained in real-time cross-sectional scanning by rotating the transducer around its cable axis. (C) is the most heavily "calculated" plane, in this case a sagittal section of the head that in this fetal lie could not be obtained using transabdominal scanning.

structure. The render box can be adapted to encompass the entire anatomic structure of interest. The "skeletal mode" is used to display skeletal structures such as the fetal skull or other segments of the fetal skeleton.[1,2] Changing the postprocessing allows display of surface views for the skin and/or the bones from the same volume (see Fig. 173.5).

Fetal Anatomic Evaluation

BRAIN

Even in the first trimester, embryonic and fetal brain structures can be resolved using transvaginal and transabdominal probes, often with amazing detail (see Fig. 173.1).

Beyond the first trimester, a typical starting insonation for standard axial section is a lateral view with the ear facing the transducer (see Fig. 173.6). The resulting multiplanar display is then used to align the volume anatomically in three planes, analogous to the description for the fetal face (see Fig. 173.2) using the reference dot (the intersection of the three orthogonal planes) to navigate, and by rotating and scrolling each plane.

The posterior fossa and its contents benefit from a slightly more dorsal starting view, exploiting the mastoid fontanel and the lambdoid suture (Fig. 173.9). This insonation, possibly combined with volume contrast enhancement, permits detailed analysis of the cerebellar vermis. The ideal starting insonation to obtain a volume optimized for the cerebellar vermis is a median section. Although a median section is often more difficult to obtain, the fontanels can be used as acoustic windows (Fig. 173.10). The midline structures and the posterior fossa are better resolved in median sections, both in 2D and 3D.[3] If the fetus is not in cephalic lie, a median section can usually be acquired by exploiting the sagittal suture and the anterior and posterior fontanels (see Fig. 173.10), or using the transvaginal approach, if the fetus is in cephalic lie.[4]

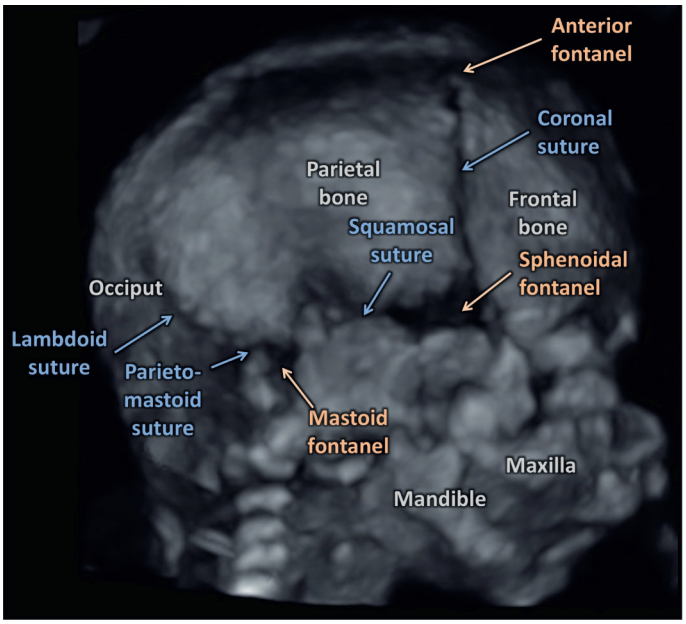

Fig. 173.9 A normal skull of a 19-week fetus, analyzed using three-dimensional ultrasound. This volume had been acquired transabdominally, with a starting scan in axial orientation and the fetal ear facing the transducer, and rendered for bone surfaces. *(From Tutschek B, Blaas HG, Abramowicz J, Baba K, Deng J, Lee W, et al. Three-dimensional ultrasound imaging of the fetal skull and face.* Ultrasound Obstet Gynecol *[Epub ahead of print], 2017.)*

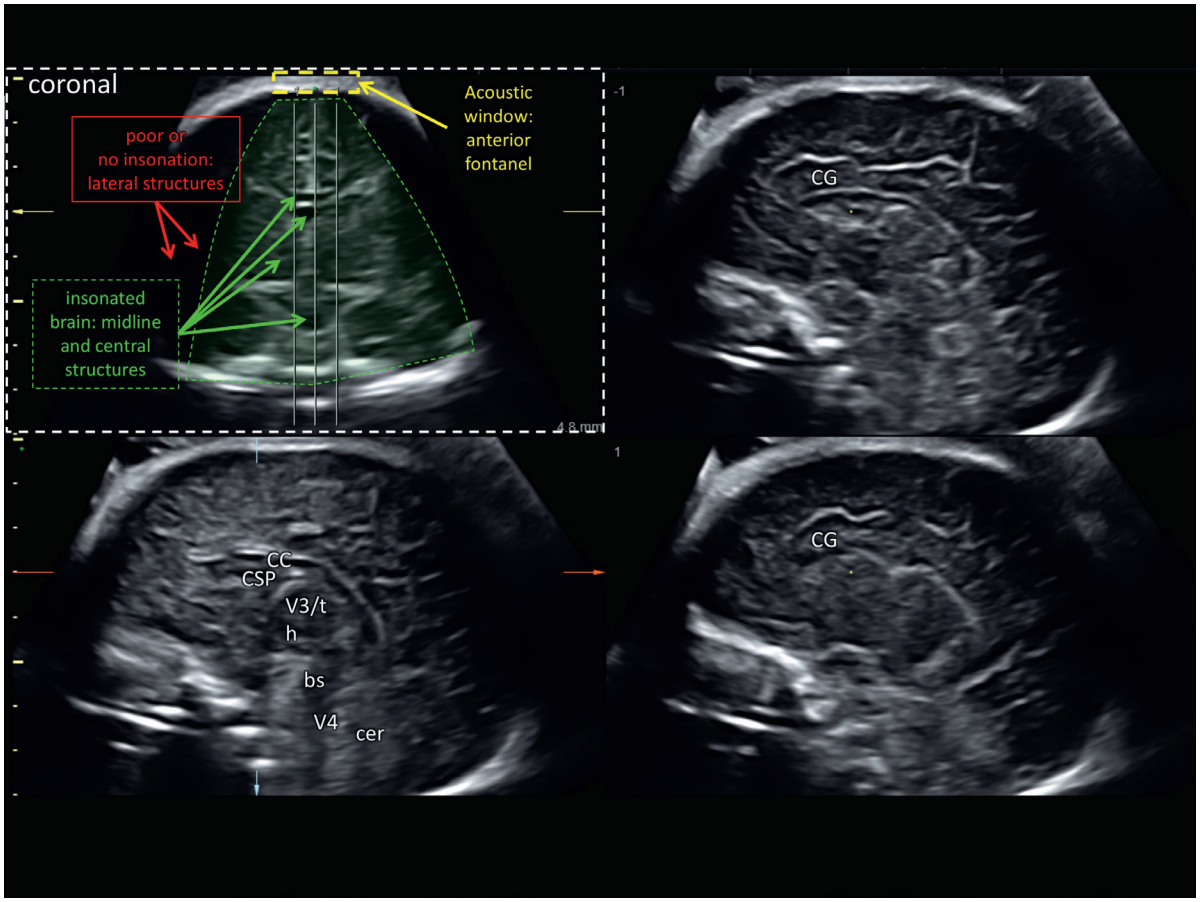

Fig. 173.10 Detailed brain analysis in a 33-week fetus, using transabdominal three-dimensional ultrasound and transfontanel insonation. This image shows a volume contrast-enhanced multiplanar view of a fetal brain, acquired through the large fontanel and sagittal suture with the 3D transducer placed above the vertex. Three-dimensional US provided excellent resolution of the fissures and gyri on the medial brain surface. *bs*, Brain stem; *CC*, corpus callosum; *cer*, cerebellar vermis; *CG*, cingulate gyrus; *CSP*, cavum of the septum pellucidum; *V3/th*, third ventricle and thalamus; *V4*, fourth ventricle.

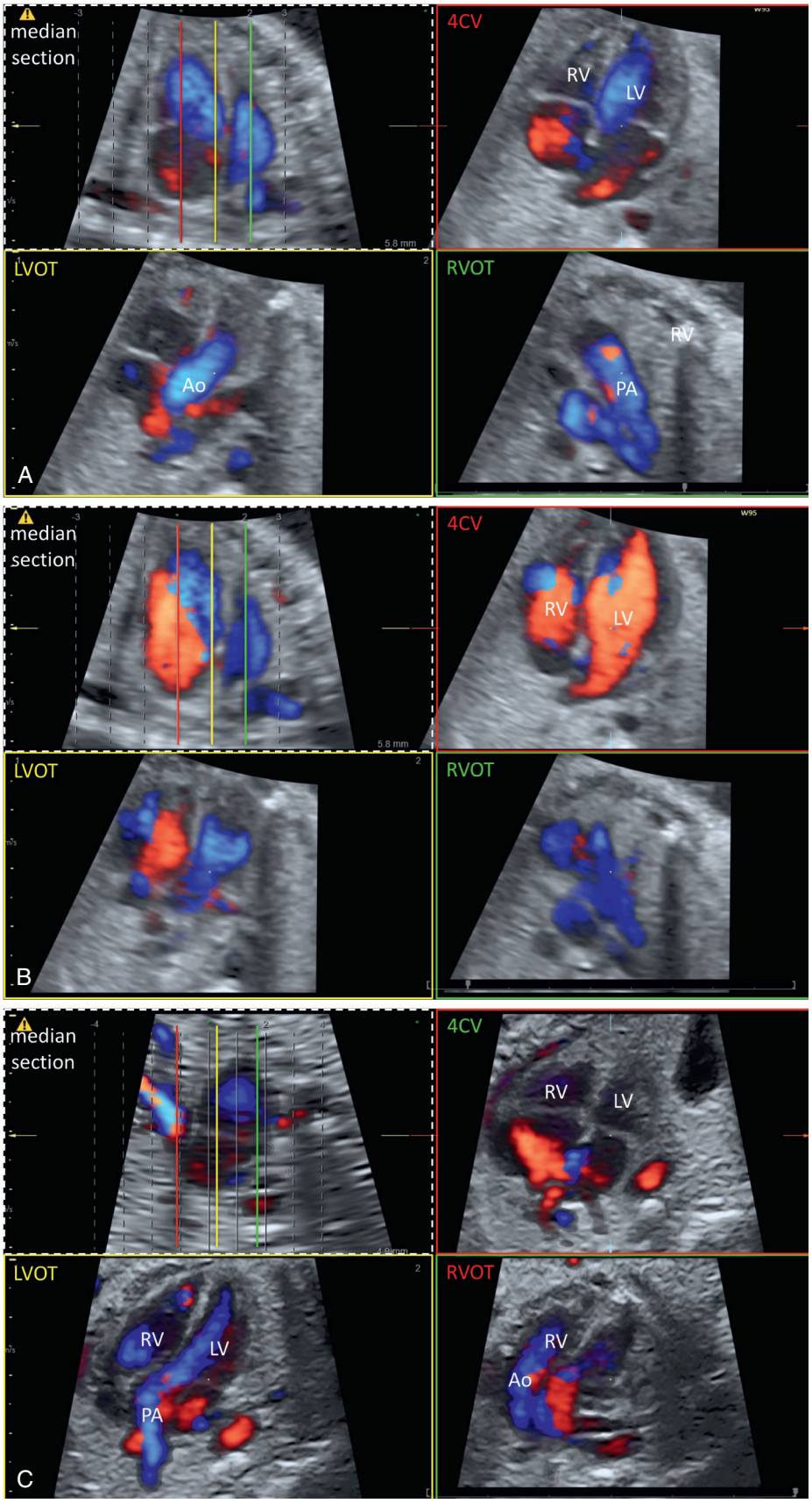

Fig. 173.11 Normal and abnormal midtrimester fetal hearts, displayed using color Doppler and tomographic imaging. (A) A fetal heart at 23 weeks in systole, showing tomographic imaging of the four-chamber view *(4CV)* and the left and right outflow tracts *(LVOT/Ao, RVOT/PA)* in systole. Note that at 23 weeks in a normal heart the *4CV, LVOT*, and outflow tracts are almost in parallel planes and that these planes are at an equal distance of about 5 mm apart from each other. (B) The same heart in diastole. For a video of this display, see Video 173.2. (C) The same display used for a fetal heart with d-transposition of the great arteries *(d-TGA)* at 23 weeks. The vessel arising from the left ventricle branches after a short course; it is the transposed pulmonary artery. The second vessel, arising from the right ventricle, is the aorta, which travels parallel to the pulmonary artery and does not cross the pulmonary artery. For a video of this display, see Video 173.3. *Ao*, Aorta; *LV*, left ventricle; *LVOT*, left ventricular outflow tract; *PA*, pulmonary artery; *RV*, right ventricle; *RVOT*, right outflow tract.

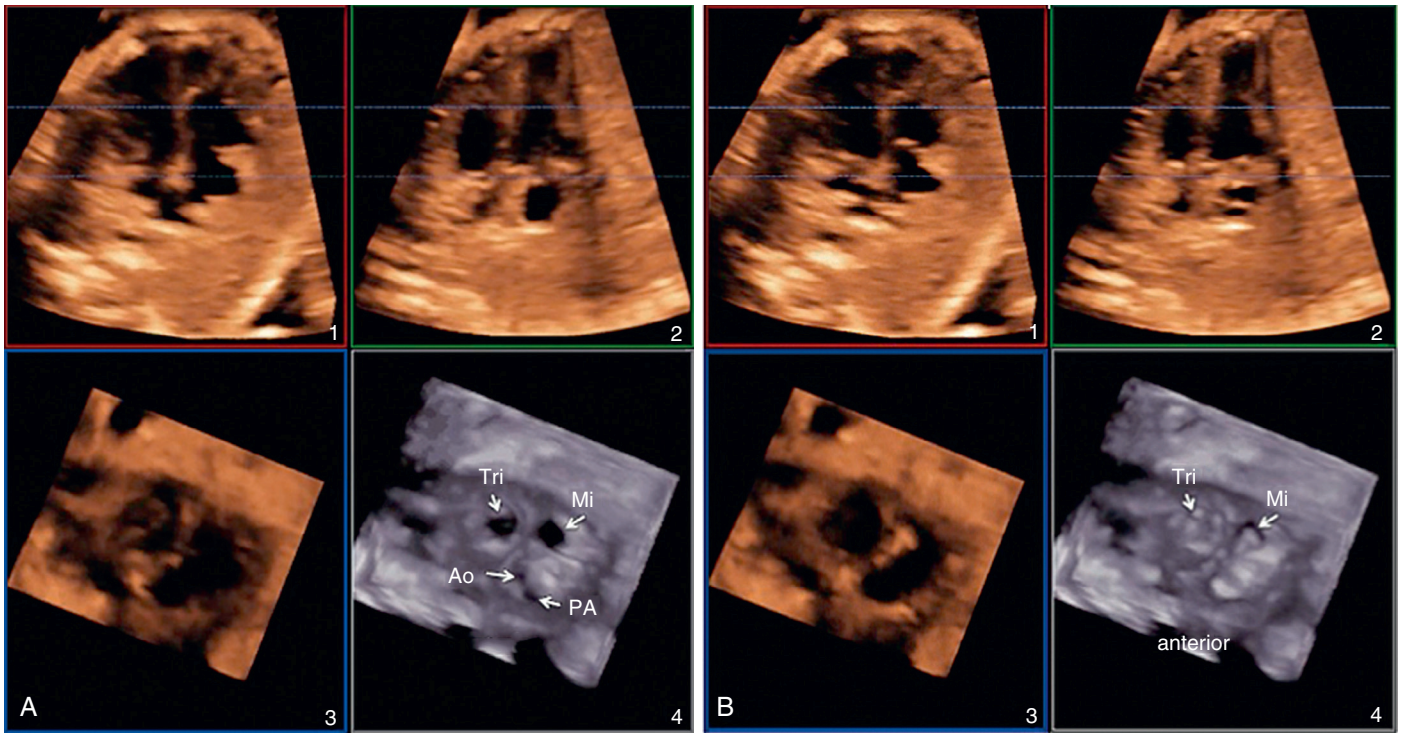

Fig. 173.12 Multiplanar display plus surface rendering of a normal midtrimester heart. The sepia-colored panels show three orthogonal planes with the four-chamber view in the top left. The gray image is a rendered *en-face* view of the atrioventricular *(AV)* valve plane. (A) shows the AV-valves open, (B) closed (Video 173.4). *Ao,* Aortic valve; *Mi,* mitral valve; *PA,* pulmonary artery; *Tri,* tricuspid valve.

In the third trimester, there is increasing shadowing because of progressive ossification of the skull. Using the sutures and fontanels as acoustic windows into the brain (see Figs. 173.9 and 173.10) can help to partially overcome this limitation. Fig. 173.10 shows a volume contrast-enhanced multiplanar view of a fetal brain, acquired from a normal 33-week fetus in transverse position through the large fontanel and sagittal suture. In this fetal lie, positioning of the 3D transducer above the vertex is possible. Appropriate use of 3D US provides excellent resolution, superior to 2D US, to study the fissures and gyri on the medial brain surface.

Detailed descriptions of the 3D US analysis of the fetal brain have been proposed.[4-7] Operators with specific technical expertise have demonstrated that remote review of 3D US volumes of the fetal brain can provide accurate and reliable diagnoses of fetal brain anomalies.[8]

3D US is also ideally suited for teaching, self-study, and to provide reference material or atlases of normal and abnormal anatomy. Normal brain section in anatomic standard orientations and an interactive atlas of fetal brain pathologies can be seen at http://pb.fetal.ch.[9]

HEART

Capturing images of the fetal heart adds another level of complexity, a "fourth" dimension: motion. Today's diagnostic systems cannot yet acquire volume sequences at a rate that would allow detailed assessment of the fetal heart with sufficient temporal resolution during a cardiac cycle. Reconstructed echocardiography is the current standard: during an automated sweep of the probe across the fetal heart over a few seconds, a series of adjacent cross-sectional images is acquired. Then reconstruction into one virtual heartbeat as a volume sequence is achieved by automatic spatial and temporal rearrangement of several hundred sections (spatial-temporal image correlation [STIC]).[10] Clinical systems commercially available today mostly use STIC for grayscale and color Doppler[11-13] (for review, see Tutschek et al.[14]).

Cardiac volumes or volume sequences can be used to extract a single diagnostic plane, to produce multiplanar or tomographic displays, or to reconstruct (inner) surfaces including the space occupied by blood flow, detectable with color Doppler. Fig. 173.11 shows a normal and abnormal fetal midtrimester heart, analyzed identically using tomographic imaging. Reconstructions of inner surfaces are useful to assess atrioventricular valve anatomy or relationship of valve orifices—for example, from a reconstructed plane resembling the view of the cardiac surgeon from the atria onto the atrioventricular valve plane (Fig. 173.12).

Blood flow can be visualized together with the surrounding tissues, which can be useful to characterize small vessels or shunts (Fig. 173.13). The blood pool during individual segments of the cardiac cycle can be rendered as an "internal surface," which is possible also with added blood flow information from color Doppler (Fig. 173.14).

WHAT THE REFERRING PHYSICIAN NEEDS TO KNOW

Diagnosticians should of course understand anatomy in its three dimensions. Currently, 2D US is the standard for the fetal screening exam, but there should be a low threshold for using 3D US because of its potential for enhanced visualization of fetal structures.

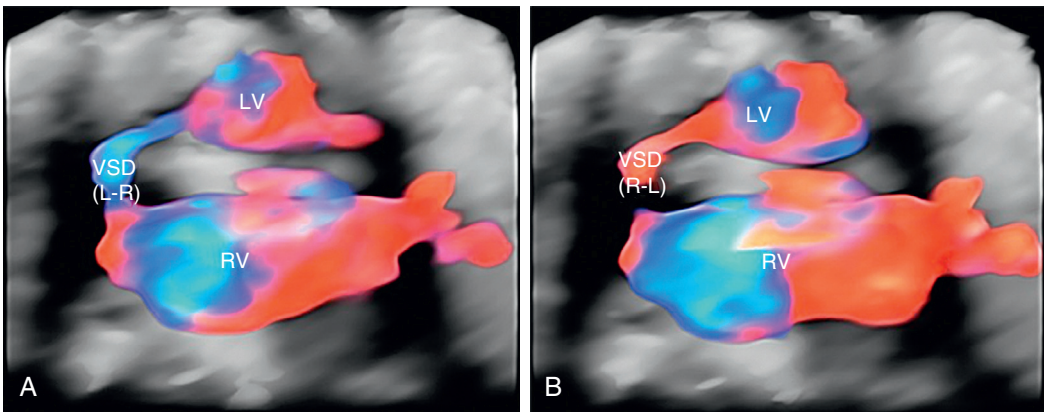

Fig. 173.13 Fetal muscular ventricular septal defect *(VSD)* at 27 weeks, shown in three-dimensional imaging with color Doppler, rendered to display only the ventricles and the VSD. This VSD was not apparent on the central four-chamber view because it crossed the septum close to the diaphragmatic surface. Note the bidirectional flow; (A) left to right, *shown in blue;* (B) right to left, *shown in red,* apparent in different segments of the cardiac cycle. See Videos 173.5 and 173.6. *LV,* Left ventricle; *RV,* right ventricle; *VSD (L-R),* ventricular septal defect, left-to-right shunt; *VSD (R-L),* ventricular septal defect, right-to-left shunt.

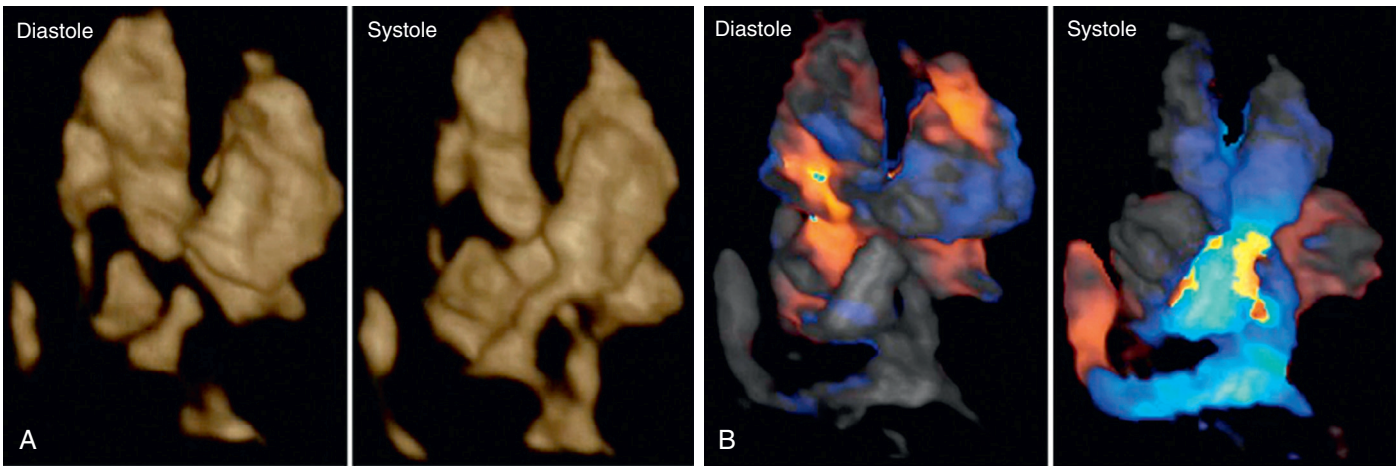

Fig. 173.14 Reconstruction of blood flow and blood pool as "internal surface" of a normal fetal heart at 29 weeks' gestation, full volume rendering seen from cranially. (A) Blood pool, surface rendered. (B) Blood pool plus color Doppler signal from moving blood, surface-rendered. *(From Tutschek B, Sahn DJ. Three-dimensional echocardiography for studies of the fetal heart: present status and future perspectives.* Cardiol Clin *25(2):341–55, 2007.)*

KEY POINTS

- Obtaining 3D volumes, while not trivial, is certainly possible and easily learned.
- 3D US can add significant value to the fetal anatomic examination, especially for certain structures such as central nervous system, face, and heart.
- 3D US should be considered an integral part of the general obstetric US.

All references available online at
www.expertconsult.com

REFERENCES

1. Benoit B. The value of three-dimensional ultrasonography in the screening of the fetal skeleton. *Childs Nerv Syst*. 2003;19(7-8):403-409.
2. Tutschek B, Blaas HG, Abramowicz J, et al. Three-dimensional ultrasound imaging of the fetal skull and face. *Ultrasound Obstet Gynecol*. 2017;[Epub ahead of print].
3. Pilu G, Segata M, Ghi T, et al. Diagnosis of midline anomalies of the fetal brain with the three-dimensional median view. *Ultrasound Obstet Gynecol*. 2006;27(5):522-529.
4. Monteagudo A, Timor-Tritsch IE, Mayberry P. Three-dimensional transvaginal neurosonography of the fetal brain: "navigating" in the volume scan. *Ultrasound Obstet Gynecol*. 2000;16(4):307-313.
5. Blaas HG, Eik-Nes SH, Kiserud T, et al. Three-dimensional imaging of the brain cavities in human embryos. *Ultrasound Obstet Gynecol*. 1995;5(4):228-232.
6. Pilu G, Ghi T, Carletti A, et al. Three-dimensional ultrasound examination of the fetal central nervous system. *Ultrasound Obstet Gynecol*. 2007;30(2):233-245.
7. Pooh RK. Normal anatomy by three-dimensional ultrasound in the second and third trimesters. *Semin Fetal Neonatal Med*. 2012;17(5):269-277.
8. Rizzo G, Abuhamad AZ, Benacerraf BR, et al. Collaborative study on 3-dimensional sonography for the prenatal diagnosis of central nervous system defects. *J Ultrasound Med*. 2011;30(7):1003-1008.
9. Tutschek B, Pilu G. Pocket Brain, an interactive, web-based ultrasound atlas of normal and abnormal fetal brain development. *Ultrasound Obstet Gynecol*. 2016;[Epub ahead of print].
10. Nelson TR, Pretorius DH, Sklansky M, et al. Three-dimensional echocardiographic evaluation of fetal heart anatomy and function: acquisition, analysis, and display. *J Ultrasound Med*. 1996;15(1):1-9 quiz 11-2.
11. DeVore GR, Falkensammer P, Sklansky MS, et al. Spatio-temporal image correlation (STIC): new technology for evaluation of the fetal heart. *Ultrasound Obstet Gynecol*. 2003;22(4):380-387.
12. Goncalves LF, Lee W, Chaiworapongsa T, et al. Four-dimensional ultrasonography of the fetal heart with spatiotemporal image correlation. *Am J Obstet Gynecol*. 2003;189(6):1792-1802.
13. Chaoui R, Hoffmann J, Heling KS. Three-dimensional (3D) and 4D color Doppler fetal echocardiography using spatio-temporal image correlation (STIC). *Ultrasound Obstet Gynecol*. 2004;23(6):535-545.
14. Tutschek B, Sahn DJ. Three-dimensional echocardiography for studies of the fetal heart: present status and future perspectives. *Cardiol Clin*. 2007;25(2):341-355.