Mc Graw Hill Education

COLOR ATLAS OF FAMILY MEDICINE

SECOND EDITION

RICHARD P. USATINE

Mindy Ann Smith E.J. Mayeaux, Jr. Heidi Chumley

THE COLOR ATLAS OF FAMILY MEDICINE

NOTICE

Medicine is an ever-changing science. As new research and clinical experience broaden our knowledge, changes in treatment and drug therapy are required. The authors and the publisher of this work have checked with sources believed to be reliable in their efforts to provide information that is complete and generally in accord with the standards accepted at the time of publication. However, in view of the possibility of human error or changes in medical sciences, neither the authors nor the publisher nor any other party who has been involved in the preparation or publication of this work warrants that the information contained herein is in every respect accurate or complete, and they disclaim all responsibility for any errors or omissions or for the results obtained from use of the information contained in this work. Readers are encouraged to confirm the information contained herein with other sources. For example and in particular, readers are advised to check the product information sheet included in the package of each drug they plan to administer to be certain that the information contained in this work is accurate and that changes have not been made in the recommended dose or in the contraindications for administration. This recommendation is of particular importance in connection with new or infrequently used drugs.

THE COLOR ATLAS OF FAMILY MEDICINE

Second Edition

EDITORS

Richard P. Usatine, MD

Professor of Family and Community Medicine
Professor of Dermatology and Cutaneous Surgery
Assistant Director, Medical Humanities Education
University of Texas Health Science Center at San Antonio
Medical Director, Skin Clinic, University Health System
San Antonio, Texas

Mindy A. Smith, MD

Clinical Professor, Department of Family Medicine
Michigan State University
East Lansing, MI
Deputy Editor, Essential Evidence Plus
Associate Medical Editor, *FP Essentials*

E.J. Mayeaux, Jr., MD

Professor of Family Medicine
Professor of Obstetrics and Gynecology
Family Medicine Residency Program Director and Vice-Chair
Louisiana State University Health Sciences Center
Shreveport, Louisiana

Heidi S. Chumley, MD

Associate Professor, Family Medicine
University of Kansas School of Medicine
Associate Vice Chancellor, Educational Resources and Interprofessional Education
University of Kansas Medical Center
Kansas City, Kansas

Mc Graw Hill Education Medical

New York Chicago San Francisco Lisbon London Madrid Mexico City
Milan New Delhi San Juan Seoul Singapore Sydney Toronto

Copyright © 2013 by McGraw-Hill Education, LLC. All rights reserved. Except as permitted under the United States Copyright Act of 1976, no part of this publication may be reproduced or distributed in any form or by any means, or stored in a database or retrieval system, without the prior written permission of the publisher.

ISBN: 978-0-07-176965-5

MHID: 0-07-176965-X

The material in this eBook also appears in the print version of this title: ISBN: 978-0-07-176964-8,
MHID: 0-07-176964-1.

All trademarks are trademarks of their respective owners. Rather than put a trademark symbol after every occurrence of a trademarked name, we use names in an editorial fashion only, and to the benefit of the trademark owner, with no intention of infringement of the trademark. Where such designations appear in this book, they have been printed with initial caps.

McGraw-Hill Education eBooks are available at special quantity discounts to use as premiums and sales promotions, or for use in corporate training programs. To contact a representative please e-mail us at bulksales@mcgraw-hill.com.

TERMS OF USE

This is a copyrighted work and McGraw-Hill Education, LLC. and its licensors reserve all rights in and to the work. Use of this work is subject to these terms. Except as permitted under the Copyright Act of 1976 and the right to store and retrieve one copy of the work, you may not decompile, disassemble, reverse engineer, reproduce, modify, create derivative works based upon, transmit, distribute, disseminate, sell, publish or sublicense the work or any part of it without McGraw-Hill Education's prior consent. You may use the work for your own noncommercial and personal use; any other use of the work is strictly prohibited. Your right to use the work may be terminated if you fail to comply with these terms.

THE WORK IS PROVIDED "AS IS." McGRAW-HILL EDUCATION AND ITS LICENSORS MAKE NO GUARANTEES OR WARRANTIES AS TO THE ACCURACY, ADEQUACY OR COMPLETENESS OF OR RESULTS TO BE OBTAINED FROM USING THE WORK, INCLUDING ANY INFORMATION THAT CAN BE ACCESSED THROUGH THE WORK VIA HYPERLINK OR OTHERWISE, AND EXPRESSLY DISCLAIM ANY WARRANTY, EXPRESS OR IMPLIED, INCLUDING BUT NOT LIMITED TO IMPLIED WARRANTIES OF MERCHANTABILITY OR FITNESS FOR A PARTICULAR PURPOSE. McGraw-Hill Education and its licensors do not warrant or guarantee that the functions contained in the work will meet your requirements or that its operation will be uninterrupted or error free. Neither McGraw-Hill Education nor its licensors shall be liable to you or anyone else for any inaccuracy, error or omission, regardless of cause, in the work or for any damages resulting therefrom. McGraw-Hill Education has no responsibility for the content of any information accessed through the work. Under no circumstances shall McGraw-Hill Education and/or its licensors be liable for any indirect, incidental, special, punitive, consequential or similar damages that result from the use of or inability to use the work, even if any of them has been advised of the possibility of such damages. This limitation of liability shall apply to any claim or cause whatsoever whether such claim or cause arises in contract, tort or otherwise.

DEDICATION

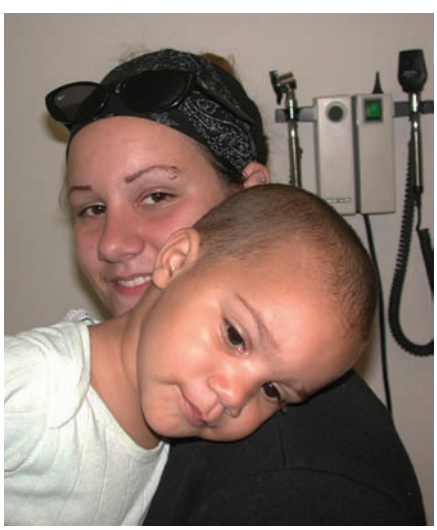

To our patients who unselfishly agreed to let us display their diseases and afflictions to the world to enhance the study and practice of medicine. We are honored by this trust. We have learned much from our patients as they continue to help us teach the next generation of health care providers.

Sincerely,

Richard P. Usatine, MD

Mindy Ann Smith, MD

E.J. Mayeaux, MD

Heidi Chumley, MD

This page intentionally left blank

CONTENTS

Contributors . . . xi
Preface . . . xv
Acknowledgments . . . xvii

PART 1
LEARNING WITH IMAGES AND DIGITAL PHOTOGRAPHY
1 An Atlas to Enhance Patient Care, Learning, and Teaching . . . 2

PART 2
THE ESSENCE OF FAMILY MEDICINE
2 Doctor—Patient Relationship . . . 8
3 Family Planning . . . 12
4 Pregnancy and Birth . . . 17
5 End of Life . . . 25
6 Social Justice . . . 37
7 Global Health . . . 53

PART 3
PHYSICAL AND SEXUAL ABUSE
8 Child Physical Abuse . . . 82
9 Child Sexual Abuse . . . 89
10 Intimate Partner Violence . . . 95
11 Adult Sexual Assault . . . 102

PART 4
OPHTHALMOLOGY
12 Pterygium . . . 110
13 Hordeolum and Chalazion . . . 114
14 Scleral and Conjunctival Pigmentation . . . 118
15 Corneal Foreign Body and Corneal Abrasion . . . 122
16 Conjunctivitis . . . 126
17 Scleritis and Episcleritis . . . 131
18 Uveitis and Iritis . . . 135
19 Glaucoma . . . 139
20 Diabetic Retinopathy . . . 143
21 Hypertensive Retinopathy . . . 147
22 Papilledema . . . 151
23 Age-Related Macular Degeneration . . . 155
24 Eye Trauma—Hyphema . . . 159
25 Differential Diagnosis of the Red Eye . . . 163

PART 5
EAR, NOSE, AND THROAT
Section 1: Ear
26 Otitis Media: Acute Otitis and Otitis Media with Effusion . . . 170
27 Otitis Externa . . . 180
28 Ear: Foreign Body . . . 185
29 Chondrodermatitis Nodularis Helicis and Preauricular Tags . . . 189
Section 2: Nose and Sinus
30 Nasal Polyps . . . 193
31 Sinusitis . . . 197
Section 3: Mouth and Throat
32 Angular Cheilitis . . . 203
33 Torus Palatinus . . . 206
34 Scarlet Fever and Strawberry Tongue . . . 208
35 Pharyngitis . . . 213
36 The Larynx (Hoarseness) . . . 220

PART 6
ORAL HEALTH
37 Black Hairy Tongue . . . 228
38 Geographic Tongue . . . 232
39 Gingivitis and Periodontal Disease . . . 236
40 Gingival Overgrowth . . . 240
41 Aphthous Ulcer . . . 244
42 Leukoplakia . . . 249
43 Oropharyngeal Cancer . . . 253
44 Early Childhood Caries . . . 257
45 Adult Dental Caries . . . 262

PART 7
THE HEART AND CIRCULATION
Section 1: Central
46 Coronary Artery Disease . . . 268
47 Hypertension . . . 272
48 Heart Failure . . . 277
49 Pericardial Effusion . . . 281
50 Bacterial Endocarditis . . . 287
Section 2: Peripheral
51 Clubbing . . . 292
52 Venous Insufficiency . . . 295

PART 8
THE LUNGS
53 Pneumonia . . . 300
54 Tuberculosis . . . 310
55 Asthma . . . 320
56 Chronic Obstructive Pulmonary Disease . . . 334
57 Pulmonary Embolus . . . 345
58 Lung Cancer . . . 355

CONTENTS

PART 9

GASTROINTESTINAL

59 Peptic Ulcer Disease 366
60 Gastric Cancer 371
61 Liver Disease 377
62 Gallstones 386
63 Colon Polyps 393
64 Colon Cancer 399
65 Inflammatory Bowel Disease 405
66 Hemorrhoids 414

PART 10

GENITOURINARY

67 Urinary Sediment 420
68 Kidney Stones 425
69 Hydronephrosis 430
70 Polycystic Kidneys 436
71 Renal Cell Carcinoma 441
72 Bladder Cancer 448
73 Prostate Cancer 453

PART 11

WOMEN'S HEALTH

Section 1: Pregnancy

74 Skin Findings in Pregnancy 462
75 Pruritic Urticarial Papules and Plaques of Pregnancy 467
76 Pemphigoid Gestationis 471
77 First Trimester Obstetrical Ultrasound 475
78 Second Trimester Obstetrical Ultrasound 478
79 Third Trimester Obstetric Ultrasound 482

Section 2: Vaginitis and Cervicitis

80 Overview of Vaginitis 485
81 Atrophic Vaginitis 489
82 Bacterial Vaginosis 494
83 Candida Vulvovaginitis 499
84 Trichomonas Vaginitis 504
85 Chlamydia Cervicitis 509

Section 3: Vulva

86 Paget Disease of the External Genitalia 514
87 Vulvar Intraepithelial Neoplasia 519

Section 4: Colposcopy

88 Colposcopy—Normal and Noncancerous Findings 525
89 Colposcopy of Low-Grade Lesions 530
90 Colposcopy of High-Grade Lesions 535
91 Colposcopy of Cervical Cancer 541

Section 5: Breast

92 Breast Abscess and Mastitis 546
93 Breast Cancer 551
94 Paget Disease of the Breast 557

PART 12

MUSCULOSKELETAL PROBLEMS

95 Arthritis Overview 562
96 Osteoarthritis 569
97 Rheumatoid Arthritis 575
98 Ankylosing Spondylitis 580
99 Back Pain 585
100 Gout 590
101 Olecranon Bursitis 596
102 Clavicular Fracture 601
103 Distal Radius Fracture 605
104 Metatarsal Fracture 611
105 Hip Fracture 615
106 The Knee 619
107 Dupuytren Disease 625

PART 13

DERMATOLOGY

Section 1: Childhood Dermatology

108 Normal Skin Changes 630
109 Childhood Hemangiomas and Vascular Malformations 636
110 Pustular Diseases of Childhood 642
111 Diaper Rash and Perianal Dermatitis 646

Section 2: Acneiform Disorders

112 Acne Vulgaris 651
113 Rosacea 659
114 Pseudofolliculitis and Acne Keloidalis Nuchae 665
115 Hidradenitis Suppurativa 671

Section 3: Bacterial

116 Impetigo 676
117 Folliculitis 680
118 Pitted Keratolysis 686
119 Erythrasma 689
120 Cellulitis 693
121 Abscess 698
122 Necrotizing Fasciitis 702

Section 4: Viral

123 Chickenpox 707
124 Zoster 712
125 Zoster Ophthalmicus 718
126 Measles 723
127 Fifth Disease 728

128 Hand, Foot, and Mouth Disease . . . 732
129 Herpes Simplex . . . 735
130 Molluscum Contagiosum . . . 743
131 Common Warts . . . 749
132 Flat Warts . . . 755
133 Genital Warts . . . 759
134 Plantar Warts . . . 766

Section 5: Fungal

135 Fungal Overview . . . 771
136 Candidiasis . . . 777
137 Tinea Capitis . . . 782
138 Tinea Corporis . . . 788
139 Tinea Cruris . . . 795
140 Tinea Pedis . . . 799
141 Tinea Versicolor . . . 805

Section 6: Infestations

142 Lice . . . 809
143 Scabies . . . 815
144 Cutaneous Larva Migrans . . . 823

Section 7: Dermatitis/Allergic

145 Atopic Dermatitis . . . 826
146 Contact Dermatitis . . . 834
147 Hand Eczema . . . 843
148 Nummular Eczema . . . 851
149 Self-Inflicted Dermatoses . . . 856
150 Urticaria and Angioedema . . . 863

Section 8: Papulosquamous Conditions

151 Seborrheic Dermatitis . . . 871
152 Psoriasis . . . 878
153 Pityriasis Rosea . . . 896
154 Lichen Planus . . . 901
155 Reactive Arthritis . . . 910
156 Erythroderma . . . 915

Section 9: Benign Neoplasms

157 Skin Tag . . . 922
158 Seborrheic Keratosis . . . 926
159 Sebaceous Hyperplasia . . . 931
160 Dermatofibroma . . . 935
161 Pyogenic Granuloma . . . 940

Section 10: Nevi

162 Benign Nevi . . . 945
163 Congenital Nevi . . . 953
164 Epidermal Nevus and Nevus Sebaceous . . . 958
165 Dysplastic Nevus . . . 963

Section 11: Pre Cancer/Early Cancer

166 Actinic Keratosis and Bowen Disease . . . 969
167 Keratoacanthoma . . . 977
168 Lentigo Maligna . . . 981
169 Cutaneous Horn . . . 985

Section 12: Skin Cancer

170 Basal Cell Carcinoma . . . 989
171 Squamous Cell Carcinoma . . . 999
172 Melanoma . . . 1008

Section 13: Infiltrative Immunologic

173 Granuloma Annulare . . . 1022
174 Pyoderma Gangrenosum . . . 1028
175 Sarcoidosis . . . 1035
176 Cutaneous T-Cell Lymphoma . . . 1042

Section 14: Hypersensitivity Syndromes

177 Erythema Multiforme, Stevens-Johnson Syndrome, and Toxic Epidermal Necrolysis . . . 1049
178 Erythema Nodosum . . . 1056
179 Vasculitis . . . 1062

Section 15: Connective Tissue Disease

180 Lupus: Systemic and Cutaneous . . . 1070
181 Dermatomyositis . . . 1079
182 Scleroderma and Morphea . . . 1089

Section 16: Bullous Disease

183 Overview of Bullous Diseases . . . 1097
184 Bullous Pemphigoid . . . 1104
185 Pemphigus . . . 1109
186 Other Bullous Diseases . . . 1119

Section 17: Hair and Nail Conditions

187 Alopecia Areata . . . 1128
188 Traction Alopecia and Trichotillomania . . . 1133
189 Scarring Alopecia . . . 1138
190 Normal Nail Variants . . . 1145
191 Pigmented Nail Disorders . . . 1151
192 Ingrown Toenail . . . 1156
193 Onychomycosis . . . 1160
194 Paronychia . . . 1166
195 Psoriatic Nails . . . 1170
196 Subungual Hematoma . . . 1175

Section 18: Pigmentary and Light-Related Conditions

197 Melasma . . . 1179
198 Vitiligo and Hypopigmentation . . . 1184
199 Photosensitivity . . . 1191
200 Erythema Ab Igne . . . 1198

Section 19: Vascular

201 Acquired Vascular Skin Lesions . . . 1203
202 Hereditary and Congenital Vascular Lesions . . . 1207

Section 20: Other Skin Disorders

203 Cutaneous Drug Reactions . . . 1211
204 Keloids . . . 1224
205 Genodermatoses . . . 1229
206 Erythema Annulare Centrifugum . . . 1236

CONTENTS

PART 14

PODIATRY

207 Corn and Callus 1241
208 Bunion Deformity 1247
209 Hammer Toe 1251
210 Ischemic Ulcer 1255
211 Neuropathic Ulcer 1258
212 Charcot Arthropathy 1261
213 Dry Gangrene 1265

PART 15

INFECTIOUS DISEASES

214 Intestinal Worms and Parasites 1270
215 Urethritis in Men 1275
216 Syphilis 1278
217 AIDS and Kaposi's Sarcoma 1285
218 Lyme Disease 1289

PART 16

ENDOCRINE

219 Diabetes Overview 1300
220 Acanthosis Nigricans 1310
221 Diabetic Dermopathy 1314
222 Necrobiosis Lipoidica 1317
223 Hyperlipidemia and Xanthomas 1322
224 Obesity 1329
225 Osteoporosis and Osteopenia 1338
226 Goitrous Hypothyroidism 1346
227 Graves' Disease and Goiter 1353
228 Acromegaly 1360

PART 17

NEUROLOGY

229 Headache 1366
230 Cerebral Vascular Accident 1371
231 Subdural Hematoma 1376
232 Normal Pressure Hydrocephalus 1380
233 Bell's Palsy 1383
234 Neurofibromatosis 1387

PART 18

SUBSTANCE ABUSE

235 Substance Abuse Disorder 1391
236 Tobacco Addiction 1398
237 Alcoholism (Alcohol Use Disorder) 1411
238 Methamphetamine 1424
239 Cocaine 1431
240 Injection-Drug Use 1439

APPENDIX

A Interpreting Evidence-Based Medicine 1448
B Guide for the Use of Topical and Intralesional Corticosteroids 1451
C Dermoscopy 1455

Subject Index 1473
Morphology Index for Diagnosis 1544
Regional Index for Diagnosis 1557

Jim Anderst, MD, MSCI
Associate Professor of Pediatrics
Division of Child Abuse and Neglect
Children's Mercy Hospital
University of Missouri Kansas City School of Medicine
Kansas City, Missouri

Michael J. Babcock, MD
Colorado Springs Dermatology Clinic
Colorado Springs, Colorado

Yoon-Soo Cindy Bae-Harboe, MD
Boston University Hospital
Medical Center Department of Dermatology
Boston, Massachusetts

James C. Barrow, MD, FACOG
Assistant Professor of OB/GYN
Louisiana State University
Shreveport, Louisiana

Luke M. Baudoin, MD
Associate Professor of Family Medicine
Louisiana State University Health
Shreveport, Louisiana

Ruth E. Berggren, MD
Professor of Medicine
Director, Center for Medical Humanities & Ethics
Division of Infectious Diseases
University of Texas Health Science Center
San Antonio, Texas

Margaret L. Burks, BA
Student Affiliate, School of Medicine
University of Texas Health Science Center at San Antonio
San Antonio, Texas

Kevin J. Carter, MD
Assistant Professor
Department of Family Medicine
Louisiana State University Health Center
Shreveport, Louisiana

Gina Chacon, MD
Michigan State University
East Lansing, Michigan

Beth Choby, MD
Associate Professor
Department of Family Medicine
University of Tennessee Health Sciences Center
Memphis, Tennessee

Danielle B. Cooper, MD
Assistant Professor
Department of Obstetrics and Gynecology
Louisiana State University Health
Shreveport, Louisiana

John E. Delzell, Jr., MD, MSPH
Associate Professor
Associate Chair for Medical Student Education
Department of Family Medicine
University of Kansas
Kansas City, Kansas

Rowena A. DeSouza, MD
Assistant Professor
Division of Urology
University of Texas Medical School at Houston
Houston, Texas

Lucia Diaz, MD
Chief Resident
Dermatology Department
University of Tesxas Medical School at Houston
MD Anderson Cancer Center
Houston, Texas

Cristina Fernandez, MD
Associate Professor of Pediatrics
Creighton University/Children's Physicians
Medical Director, HEROES Program
Associate Program Director
UNMC/Creighton University/Children's Hospital and Medical Center
Omaha, Nebraska

Lindsey B. Finklea, MD
Dermatology Resident
University of Texas Health Science Center
San Antonio, Texas

Linda French, MD
Professor and Chair
Department of Family Medicine
University of Toledo College of Medicine and Life Sciences
Toledo, Ohio

Bridget C. Godwin, MD
Department of Pediatrics
New York Presbyterian, Weill Cornell
New York, New York

Radha Raman Murthy Gokula, MD, CMD
Geriatrician & Palliative Medicine Consultant
University of Toledo Medical Center
Assistant Professor
Department of Family Medicine
University of Toledo
Toledo, Ohio

Mary Kelly Green, MD
Ophthalmology, Private Practice
Marble Falls, Texas
Clinical Assistant Professor
Department of Ophthalmology
University of Texas Health Science Center
San Antonio, Texas

Alfonso Guzman, Jr., BSN, MD
Resident Physician
Department of Family and Community Medicine
Texas Tech University
Paul L. Foster School of Medicine
El Paso, Texas

Meredith M. Hancock, MD
Preliminary Resident
Internal Medicine
Loyola University Medical Center
Maywood, Illinois

Jimmy H. Hara, MD, FAAFP
Professor of Clinical Family Medicine
David Geffen School of Medicine at UCLA
Los Angeles, California

David Henderson, MD
Associate Professor, Department of Family Medicine
Associate Dean, Medical Student Affairs
University of Connecticut School of Medicine
Farmington, Connecticut

Nathan Hitzeman, MD
Faculty, Sutter Health Family Medicine Residency Program
Sacramento, California

Michaell A. Huber, DDS
Associate Professor
Oral Medicine Subject Expert
Department of Comprehensive Dentistry
University of Texas at San Antonio Health Science
Center Dental School
San Antonio, Texas

Karen A. Hughes, MD, FAAFP
Associate Director
North Mississippi Center Family Medicine Residency Program
Tupelo, Mississippi

Carlos Roberto Jaén, MD, PhD, MS
Professor of Family & Community Medicine
Epidemiology and Biostatistics
University of Texas Health Science Center at San Antonio
Adjunct Professor of Public Health
University of Texas School of Public Health
San Antonio Campus
San Antonio, Texas

Natalia Jaimes, MD
Assistant Professor
Department of Dermatology
Universidad Pontificia Bolivariana
Attending Physician
Aurora Skin Cancer Center
Medellin, Colombia

Anne E. Johnson, MD
Psychiatry Resident
University of Texas Southwestern
Dallas, Texas

Jonathan B. Karnes, MD
Faculty, MDFMR Dermatology Services
Maine Dartmouth Family Medicine Residency
Augusta, Maine

Jennifer A. Keehbauch, MD, FAAFP
Director of Research, Graduate Medical Education
Florida Hospital
Assistant Director, Family Medicine, Residency, Florida Hospital
Director, Women's Medicine Fellowship, Florida Hospital, Florida

Nancy D. Kellogg, MD
Professor, Division Chief of Child Abuse
Department of Pediatrics
Univesity of Texas Health Science Center at San Antonio
San Antonio, Texas

Melanie Ketchandji, MD
Urology Resident
University of Texas Health Science Center
Houston, Texas

Amor Khachemoune, MD, FAAD, FACMS
Attending Physician
Dermatologist, Mohs Surgeon and Dermatopathologist
Veterans Affairs Medical Center Brooklyn, New York

Robert L. Kraft, MD
Clinical Assistant Professor
Department of Family and Community Medicine
University of Kansas School of Medicine
Wichita, Kansas

Javier LaFontaine, DPM, MS, FACFAS
Associate Professor
Department of Plastic Surgery
University of Texas Southwestern Medical Center
Dallas, Texas

Juanita Lozano-Pineda, DDS, MPH
Assistant Professor
Department of Comprehensive Dentistry
University of Texas at San Antonio Health Science
Center Dental School
San Antonio, Texas

Ashfaq A. Marghoob, MD
Associate Professor
Director, Skin Cancer Clinic, Hauppauge, Long Island
Memorial Sloan-Kettering Cancer Center
New York, New York

Laura Matrka, MD
Assistant Professor
Department of Otolaryngology – Head and Neck Surgery
The Ohio State University Wexner Medical Center
Columbus, Ohio

Kevin Christopher McMains, MD
Clinical Associate Professor
University of Texas Health Science Center at San Antonio
San Antonio, Texas

Carolyn Milana, MD
Assistant Professor of Pediatrics
Stony Brook Long Island Children's Hospital
Stony Brook, New York

Asad K. Mohmand, MD, FACP
VCU Pauley Heart Center
Medical College of Virginia
Virginia Commonwealth University
Richmond, Virginia

Melissa A. Muszynski, MD
Resident, Department of Dermatology
Georgetown University Hospital
Washington Hospital Center
Washington, DC

Brian Z. Rayala, MD
Assistant Professor
Department of Family Medicine
University of North Carolina School of Medicine
Chapel Hill, North Carolina

Catherine Reppa, MD
Resident, University of Pittsburgh
Pittsburgh, Pennsylvania

Mark Jason Sanders, MD
Assistant Professor
Division of Community and General Pediatrics
Department of Pediatrics
UT Health Medical School at Houston
Houston, Texas

Khashayar Sarabi, MD
Internal & Integrative Medicine
Irvine, California

Shehnaz Zaman Sarmast, MD
Dermatologist, Skin Specialist
Allen/Addison, Texas

Andrew D. Schechtman, MD, FAAFP
Adjunct Clinical Assistant Professor
Stanford University School of Medicine
Division of General Medical Disciplines
Faculty, San Jose – O'Connor Hospital Family Medicine Residency Program, San Jose, California

Adriana Segura, DDS, MS
Professor
Associate Dean of Student Affairs
Department of Comprehensive Dentistry
University of Texas Health Science Center San Antonio Dental School
San Antonio, Texas

Maureen K. Sheehan, MD, MHA
Associate Professor, Division of Vascular Surgery
University of Texas Health Science Center San Antonio, San Antonio, Texas

Naohiro Shibuya, DPM, MS, FACFAS
Associate Professor of Surgery
Texas A&M Health and Science Center
College of Medicine
Bryan, Texas

Leslie A. Shimp, PharmD, MS
Professor, College of Pharmacy
University of Michigan
Ann Arbor, Michigan

Julie Scott Taylor, MD, MSc
Associate Professor of Family Medicine
Director of Clinical Curriculum
Alpert Medical School of Brown University
Providence, Rhode Island

Ernest E. Valdez, DDS
Assistant Professor
Department of Oral and Maxillofacial Surgery
The University of Texas Health Science Center at San Antonio
San Antonio, Texas

Yu Wah, MD
Assistant Professor
Department of Family and Community Medicine
University of Texas Health Science Center at Houston
Houston, Texas

Christopher J. Wenner, MD
Associate Director
University of Minnesota/St. Cloud Hospital Family Medicine Residency Program
St. Cloud, Minnesota
Assistant Professor of Family Medicine
University of Minnesota
Minneapolis, Minnesota

Mark L. Willenbring, MD
Founder and CEO, ALLTYR
Saint Paul, Minnesota

Congjun Yao, MD, PhD
Resident, Department of Family and Community Medicine
University of Texas Health Science Center
San Antonio, Texas

Jana K. Zaudke, MD
Assistant Professor
Department of Family Medicine
The University of Kansas School of Medicine
Kansas City, Kansas

This page intentionally left blank

Family physicians probably see a wider variety of rashes, eye conditions, foot disorders, lumps and bumps, and undifferentiated problems than any other specialty. In speaking with healthcare providers and medical students over the years, it became clear that a comprehensive atlas that aided in diagnosis using visible signs and internal imaging would be of tremendous value. We have assembled more than 2000 outstanding clinical images for this very purpose, and are proud to present the second edition of the first modern comprehensive atlas of family medicine ever produced. Some photographs will amaze you; all will inform you about the various conditions that befall our patients.

We were gratified by the great response to the first edition. The iPad and smartphone versions were also very well received and are again available for the second edition. Readers sent in a number of suggestions for additions and we have taken those to heart, with extensive new coverage of fundamental conditions.

New in the second edition are:

- New chapters that expand the scope of the book, including chapters on Global Health, Nummular Eczema, Alcoholism, and Tobacco Addiction. Most importantly, we have added chapters on topics that are found in the core curriculum for a Family Medicine Clerkship or a Family Medicine Residency:
  - Hypertension, diabetes, asthma, prostate cancer, arthritis overview, osteoarthritis, back pain, obesity, osteoporosis, and headache.
- The chapter template has been expanded to include more on prevention, prognosis, and risk factors for disease in many of the chapters.

It took a number of people many years to create the first edition of ***The Color Atlas of Family Medicine***. For me it was a life work that started with little notebooks I kept in my white coat pocket to take notes during my residency. It then took on color and images as I kept a camera at work and took photographs with my patient's permission of any interesting clinical finding that I might use to teach medical students and residents the art and science of medicine. I was inspired by many great family physicians, including Dr. Jimmy Hara, who had the most amazing 35-mm slide collection of clinical images. His knowledge of medicine is encyclopedic and I thought that his taking photographs might have something to do with that. Also, I realized that these photographs would greatly enhance my teaching of others. As I began to expand my practice to see more dermatology cases, my photograph collection skyrocketed. Digital photography made it more affordable and practical to take and catalogue many new images.

The Color Atlas of Family Medicine is written for family physicians and all healthcare providers involved in primary care. It can also be invaluable to medical students, residents, internists, pediatricians, and dermatologists. This second edition is coming out just prior to the release of two new *Color Atlas*'s in our new series:

- ***The Color Atlas of Internal Medicine***
- ***The Color Atlas of Pediatrics***

The first edition of *The Color Atlas of Family Medicine* is available electronically for iPad, iPhone, iPod touch, all Android devices, Kindle, and on the web through Access Medicine. These electronic versions have allowed healthcare providers to access the images and content rapidly at the point-of-care.

> *One doctor wrote, "As a teacher and learner in Family Medicine and Dermatology, this atlas is an invaluable resource. Excellent quality pictures look great on the iPad. My patients appreciate seeing pictures of other people with the same medical conditions as theirs. Concise and evidence-based recommendations are just what we need in the busy setting of primary care. It is one of my most frequently referenced books/apps. A must-have for every teacher, learner or practitioner of Family Medicine or primary care."*

The second edition will also have all the same electronic versions with increased functionality.

The second edition of ***The Color Atlas of Family Medicine*** is for anyone who loves to look at clinical photographs for learning, teaching, and practicing medicine. The first chapter begins with an introduction to learning with images and digital photography. The core of the book focuses on medical conditions organized by anatomic and physiologic systems. Both adult and childhood conditions are included as this book covers healthcare from birth to death. There are special sections devoted to the essence of family medicine, physical/sexual abuse, women's health, and substance abuse.

The collection of clinical images is supported by evidence-based information that will help the healthcare provider diagnose and manage common medical problems. The text is concisely presented with many easy to access bullets as a quick point of care reference. Each chapter begins with a patient story that ties the photographs to the real life stories of our patients. The photographic legends are also designed to connect the images to the people and their human conditions. Strength of recommendation ratings are cited throughout so that the science of medicine can be blended with the art of medicine for optimal patient care.

We have created 3 special indexes to help you find information and diagnoses quickly and efficiently. The topic index printed on the front inside cover allows for quick access to major topic areas. The regional index for diagnosis can be used when you have an unknown condition and want to search for possible diagnoses by region of the body. Finally, the morphology index is to aid in the diagnosis of conditions which you can describe morphologically but for which the actual diagnosis remains uncertain.

Because knowledge continues to advance after any book is written, use the online resources presented in many of the chapters to keep up with the newest changes in medicine. Care deeply about your patients and enjoy your practice, as it is a privilege to be a healthcare provider and healer.

Strength of Recommendation (SOR)	Definition
A	Recommendation based on consistent and good-quality patient-oriented evidence.*
B	Recommendation based on inconsistent or limited-quality patient-oriented evidence.*
C	Recommendation based on consensus, usual practice, opinion, disease-oriented evidence, or case series for studies of diagnosis, treatment, prevention, or screening.*

*See Appendix A on pages 1447–1450 for further information.

This page intentionally left blank

This book could not have been completed without the contributions of many talented physicians, healthcare professionals, and photographers. We received photographs from people who live and work across the globe. Each photograph is labeled and acknowledges the photographer and contributor. Some photographs were previously published in the Photo Rounds column of the *Journal of Family Practice*. For these we thank Frontline Medical Communications, for generously sharing these photographs with our readers. Being the founding editor of this column has given me the opportunity to see a great collection of clinical photographs over the years.

In the year 2000, I began giving every medical student a digital camera as they rotated through the family medicine clerkship at UCLA. We have continued this process at University of Texas Health Sciences Center at San Antonio (UTHSCSA) except now most students have their own digital cameras or smartphones with cameras. Some of their best photographs are incorporated into our book. What could be better than to have our medical students record the clinical images that they see while rotating on family medicine? Not only do the students teach each other using these photographs, but they now will help educate our readers on the vast breadth and scope of family medicine.

There are some people who contributed so many photographs it is appropriate to acknowledge them upfront in the book. Paul Comeau was the professional ophthalmology photographer at UTHSCSA. His beautiful photographs of the external and internal eye make the ophthalmology section of this book so rich and valuable. The dermatology division at UTHSCSA contributed much of their expertise in photography, writing, and reviewing the extensive dermatology section. During the last few years, I was fortunate to work closely with the dermatology faculty and residents and they contributed generously to our book. Dr. Eric Kraus, the program director, gave us many wonderful photographs, especially for the section on bullous diseases. He also gave us open access to the 35-mm slides collected by the Division of Dermatology. Dr. Jeff Meffert also contributed photographs to many chapters. Many dermatology residents wrote chapters and contributed photographs. Dr. Jack Resneck, Sr., from Louisiana, scanned his slides from more than 40 years of practice and gave them to Dr. E.J. Mayeaux, Jr., for use. Dr. Resneck's vast dermatologic experiences add to our atlas.

The UTHSCSA Head and Neck Department contributed many photographs for this book. We especially thank Dr. Frank Miller and Dr. Blake Simpson for their contributions. UTHSCSA pediatrics faculty contributed to our chapters on child abuse and otitis media. We are fortunate to have Dr. Nancy Kellogg contribute her photographs and expertise in caring for abused children to the book. Dr. Dan Stulberg, a family physician from New Mexico, with a passion for photography and dermatology, contributed many photographs throughout our book. Dr. Ellen Eisenberg, an oral pathologist was generous in sharing her vast collection of images with us.

We thank our learners, many of whom coauthored chapters with us. UTHSCSA medical students and residents and fellows from Michigan State University's Primary Care Faculty Development Fellowship program coauthored chapters and contributed photographs with great enthusiasm to the creation of this work. It was a pleasure to mentor these young writers and experience with them the rewards of authorship. This second edition is special because I (Dr. Usatine) had the privilege of mentoring 2 wonderful physicians in my new "Underserved Dermatology Fellowship" for family physicians. Both of my recent fellows have contributed significantly to this edition. Dr. Jonathan Karnes updated all our skin cancer chapters and contributed his own photos. Dr. Yu Wah wrote our new nummular eczema chapter, contributed photos, and her eye for quality images was indispensable when I was choosing between many possible photos for our book. Working closely with such brilliant and caring doctors in our Skin Clinic and free outreach clinics allowed me to learn from them while doing my best to advance their academic and humanistic careers.

We want to thank Dr. Kelly Green for reviewing and improving the ophthalmology section. She not only went over each chapter word by word, but she also made sure that our photographs were properly described and labeled. Dr. Green was a former student of mine and I am proud to see the wonderful ophthalmologist that she has become.

Of course, we would have no book without the talented writing and editing of my coeditors, Drs. Mindy A. Smith, E.J. Mayeaux, and Heidi Chumley. They each bring years of clinical and educational experience to the writing of the *Atlas*. Dr. Mayeaux contributed many of his own photographs, especially in women's healthcare, to our *Atlas*. I value their friendship along with what they contributed to this new edition.

Most of all we need to thank our patients who generously gave their permission for their photographs to be taken and published in this book. While some photos are not recognizable, we have many photos of the full face that are very recognizable and were generously given to us by our patients with full written permission to be published as is. For photographs that were taken decades ago in which written consents were no longer available, we have used bars across the eyes to make the photos less recognizable—verbal consent was always obtained for these images.

The last section of this book is dedicated to understanding substance abuse (chemical dependency) and its treatment. This could not have been done without the generous contributions of the dedicated staff and the women residents at Alpha Home, a nonprofit alcohol and drug treatment program in San Antonio. The medical students and faculty (including Dr. Usatine every Monday evening) from UTHSCSA spend 2 to 3 evenings a week providing free healthcare to these women who are bravely facing their addictions and fighting to stay sober 1 day at a time. Their pictures have been generously added to our book with their permission.

I (Dr. Richard Usatine) thank my family for giving me the support to see this book through. It has taken much time from my family life and my family has supported me through the long nights and weekends it takes to write a book while continuing to practice and teach medicine. I am fortunate to have a loving wife and 2 beautiful children and one very cute grandson who add meaning to my life and allowed me to work hard on the creation of this *Color Atlas*.

Dr. Mindy Smith adds, "I thank my husband, Gary, and daughter, Jenny, for their support and willingness to listen when I struggle with phrasing and wording in my writing and editing. I also thank several colleagues who have helped me to establish myself as an editor and supported my continued growth in this field—Drs. Barry Weiss, Mark Ebell, Richard Usatine, Suzanne Sorkin, and Leslie Shimp."

Dr. E.J. Mayeaux adds, "I would like to thank my wife and son for understanding the many hours of work and computer time in my meager efforts to leave the world a better place. I would also thank my family for teaching me to see the world as a beautiful, joyous,

photogenic, beckoning, fascinating place. I hope this book helps each reader see the world this way."

Dr. Heidi Chumley adds, "I want to thank my husband, John Delzell, who has brought love and peace to my often chaotic life, and my children, Cullen, Sierra, David, Selene, and Jack, who give me joy and provide the incentive to stay on task. Each one, in turn, has cheerfully pitched in to help a grumpy and tired mom who stayed up most of the night working on one of many chapters. I have been very blessed."

Finally, we all thank James Shanahan and Karen Edmonson from McGraw-Hill for believing in this project and never giving up as our book grew larger and more comprehensive over time. Jim Shanahan's wisdom and support have been particularly valuable as our first edition became an early iPhone app and is developing into two new color atlases for pediatricians and internists. Jim not only helped us keep our eye on the puck but helped us to keep our eye on where the puck was going.

PART 1

LEARNING WITH IMAGES AND DIGITAL PHOTOGRAPHY

Strength of Recommendation (SOR)	Definition
A	Recommendation based on consistent and good-quality patient-oriented evidence.*
B	Recommendation based on inconsistent or limited-quality patient-oriented evidence.*
C	Recommendation based on consensus, usual practice, opinion, disease-oriented evidence, or case series for studies of diagnosis, treatment, prevention, or screening.*

*See Appendix A on pages 1447–1450 for further information.

1 AN ATLAS TO ENHANCE PATIENT CARE, LEARNING, AND TEACHING

Richard P. Usatine, MD

People only see what they are prepared to see.

—Ralph Waldo Emerson

Whether you are viewing **Figure 1-1** in a book, in an aquarium, or in the sea, you immediately recognize the image as a fish. Those of you who are more schooled in the classification of fish might recognize that this is an angelfish with the tail resembling the head of the angel and the posterior fins representing the wings. If you are truly prepared to see this fish in all its splendor, you would see the blue circle above its eye as the crown of the queen angelfish.

Making a diagnosis in medicine often involves the kind of pattern recognition needed to identify a queen angelfish. This is much the same as recognizing a beautiful bird or the painting of a favorite artist. If you are prepared to look for the clues that lead to the identification (diagnosis), you will see what needs to be seen. How can we be best prepared to see these clues? There is nothing more valuable than seeing an image or a patient who has the condition in question at least once before you encounter it on your own. The memory of a powerful visual image can become hard wired into your brain for ready recall.

In medicine it also helps to know where and how to look to find the clues you may need when the diagnosis cannot be made at a single glance. For example, a patient with inverse psoriasis may present with a rash under the breast that has been repeatedly and unsuccessfully treated with antifungal agents for candidiasis or tinea (**Figures 1-2** and **1-3**). The prepared clinician knows that not all erythematous plaques under the breast are fungal and looks for clues such as nail changes (**Figures 1-2** and **1-4**) or scaling erythematous plaques around the elbows, knees, or umbilicus (**Figure 1-3**). Knowing where to look and what to look for is how an experienced clinician makes the diagnosis of psoriasis.

FIGURE 1-1 Queen angelfish (*Holacanthus ciliaris*). (*Courtesy of Sam Thekkethil. http://www.flickr.com/photos/natureloving.*)

USING OUR SENSES

As physicians we collect clinical data through sight, sound, touch, and smell. Although physicians in the past used taste to collect data, such as tasting the sweet urine of a patient with diabetes, this sense is rarely, if ever, used in modern medicine. We listen to heart sounds, lung sounds, bruits, and percussion notes to collect information for diagnoses. We touch our patients to feel lumps, bumps, thrills, and masses. We occasionally use smell for diagnosis. Unfortunately, the smells of disease are rarely pleasant. Even the fruity odors of *Pseudomonas* are not like the sweet fruits of a farmers' market. Of course, we also use the patient's history, laboratory data, and more advanced imaging techniques to diagnose and manage patients' illnesses.

FIGURE 1-2 Inverse psoriasis under the breast that might appear to be a fungal infection to the untrained eye. Note the splinter hemorrhages in the nail of the third digit that provide a clue that the patient has psoriasis. (*Courtesy of Richard P. Usatine, MD.*)

OUR NEW EDITION DELIVERS MORE IMAGES AND INFORMATION

It was our belief in the value of visual imagery that led to the development of the first edition of *The Color Atlas of Family Medicine*. We delivered more than 1500 images to doctors around the world, first as a large color textbook and then as an interactive electronic application for easy use on the iPhone, iPod touch, iPad, and all Android devices. Our images were so valuable for learning and practicing medicine that they were requested for use and then incorporated into other primary care and specialty textbooks, websites, CME presentations, and test-preparation services. Now it is our pleasure to bring you our second edition of *The Color Atlas of Family Medicine* with more than 2000 clinical images.

We also have added many new chapters on such important topics as diabetes, hypertension, headache, osteoporosis, alcoholism, tobacco addiction, and global health. Although these topics were covered to some extent in the first edition, we decided to create these new chapters so that the text and images would become a comprehensive resource for the full range of family medicine. Electronic applications for the new color atlas will be available in all major platforms at the same time that the new book will be released.

EXPANDING OUR INTERNAL IMAGE BANKS

The larger our saved image bank in our brain, the better clinicians and diagnosticians we can become. The expert clinician has a large image bank stored in memory to call on for rapid pattern recognition. Our image banks begin to develop in medical school when we view pictures in lectures and textbooks. We then begin to develop our own clinical image bank by our clinical experiences. Our references are printed color atlases and those color atlases available on the Internet and electronically.

Studying and learning the patterns from any atlas can enhance your expertise by enlarging the image bank stored in your memory. An atlas takes the clinical experiences of clinicians over decades and gives it to you as a single reference. We offer you, for the first time in the United States, a modern comprehensive family medicine color atlas, which includes areas such as oral health, dermatology, podiatry, and the eye.

USING IMAGES TO MAKE A DIAGNOSIS

We all see visible clinical findings on patients that we do not recognize. When this happens, open this book and look for a close match. Use the Appendix, Index, or Table of Contents to direct you to the section with the highest yield photos. If you find a direct match, you may have found the diagnosis. Read the text and see if the history and physical examination match your patient. Perform or order tests to confirm the diagnosis, if needed.

If you cannot find the image in our book try the Internet and the Google search engine. Try a Google image search and follow the leads. Of course this is easiest to do if you have a good differential diagnosis and want to confirm your impression. If you don't have a

FIGURE 1-3 The patient in **Figure 1-2** with inverse psoriasis had a typical psoriatic plaque in the umbilicus. This was the only other area involved besides the breasts and the nails but easily could have been missed without the knowledge of where to look for the clues needed to make the diagnosis. (*Courtesy of Richard P. Usatine, MD.*)

FIGURE 1-4 When the diagnosis of psoriasis is being considered, look at the nails for pitting or other nail changes such as splinter hemorrhages, onycholysis, or oil spots. This is a good example of nail pitting in a patient with psoriasis. (*Courtesy of Richard P. Usatine, MD.*)

TABLE 1-1 Excellent Clinical Image Collections on the Internet

Derm Atlas	www.dermatlas.org/	Johns Hopkins University
DermIS	www.dermis.net	Derm Information Systems from Germany
Dermnet	www.dermnet.com/	Skin Disease Image Atlas
Interactive Derm Atlas	www.dermatlas.net/	From Richard P. Usatine, MD
ENT	www.entusa.com	From an ENT physician
Eye	www.eyerounds.org	From University of Iowa
Images of all types	http://commons.wikimedia.org/	Wikimedia Commons
Infectious Diseases	www.phil.cdc.gov/	CDC Public Health Image Library
Radiology	http://rad.usuhs.edu/medpix/index.	MedPix
Skinsight	http://www.skinsight.com/html	Logical Images

diagnosis in mind, you may try putting in descriptive words and look for an image that matches what you are seeing. If the Google image search does not work, try a Web search and look at the links for other clues.

Finally, there are dedicated atlases on the Internet for organ systems that can help you find the needed image. Most of these atlases have their own search engines, which can help direct you to the right diagnosis.

Table 1-1 lists some of the best resources currently available online.

USING IMAGES TO BUILD TRUST IN THE PATIENT–PHYSICIAN RELATIONSHIP

If you are seeing a patient with a mysterious illness that remains undiagnosed and you figure out the diagnosis, you can often bridge the issues of mistrust and anxiety by showing the patient the picture of another person with the diagnosis. Use our atlas for that purpose and supplement it with the Internet. This is especially important for a patient who has gone undiagnosed or misdiagnosed for some time. "Seeing is believing" for many patients. Ask first if they would want to see some pictures of other persons with a similar condition; most will be very interested. The patient can see the similarities between their condition and the other images and feel reassured that your diagnosis is correct. Write down the name of the diagnosis for your patient and use your patient education skills.

Do be careful when searching for images on the Web in front of patients. Sometimes what pops up is not "pretty" (or, for that matter, G or PG rated). I turn the screen away from the patients before initiating the search and then censor what I will show them.

If you teach, model this behavior in front of your students. Show them how reference books and the Internet at the point of care can help with the care of patients.

TAKING YOUR OWN PHOTOGRAPHS

Images taken by you with your own camera of your own patients complete with their own stories are more likely to be retained and retrievable in your memory because they have a context and a story to go with them. We encourage our readers to use a digital camera (within a smartphone or a stand-alone camera) and consider taking your own photos. Of course, always ask permission before taking any photograph of a patient. Explain how the photographs can be used to teach other doctors and to create a record of the patient's condition at this point in time. If the photograph will be identifiable, ask for written consent; for patients younger than age 18 years, ask the parent to sign. Store the photos in a manner that avoids any Health Insurance Portability and Accountability Act (HIPAA) privacy violations, such as on a secure server or on your own computer with password protection and data encryption. These photographs can directly benefit the patient when, for example, following nevi for changes.

Digital photography is a wonderful method for practicing, teaching, and learning medicine. You can show patients pictures of conditions on parts of their bodies that they could not see without multiple mirrors and some unusual body contortions. You can also use the zoom view feature on the camera or smartphone to view or show a segment of the image in greater detail. Children generally love to have their photos taken and will be delighted to see themselves on the screen of your camera.

The advent of digital photography makes the recording of photographic images less expensive, easier to do, and easier to maintain. Digital photography also gives you immediate feedback and a sense of immediate gratification. No longer do you have to wait for a roll of film to be completed and processed before finding out the results of your photography. Not only does this give you immediate gratification to see your image displayed instantaneously in the camera, but also alerts you to poor-quality photographs that can be retaken while the patient is still in the office. This speeds up the learning curve of the beginning photographer in a way that could not happen with film photography.

OUR GOALS

Many of the images in this atlas are from my collected works over the past 27 years of my practice in family medicine. My patients

have generously allowed me to photograph them so that their photographs would help the physicians and patients of the future. To these photos, we have added images that represent decades of experiences by other family physicians and specialists. Family physicians who have submitted their images to Photo Rounds in the *Journal of Family Practice* are also sharing their photos with you. Finally, 12 years of providing students with cameras during their Family Medicine clerkships at the University of California at Los Angeles (UCLA) and the University of Texas Health Sciences Center at San Antonio (UTHSCSA) have allowed our students to add their experiences to our atlas.

It is the goal of this atlas to provide you with a wide range of images of common and uncommon conditions and provide you with the knowledge you need to make the diagnosis and initiate treatment. We want to help you be the best diagnostician you can be. We may aspire to be a clinician like Sir William Osler and have the detective acumen of Sherlock Holmes. The images collected for this atlas can help move you in that direction by making you prepared to see what you need to see.

This page intentionally left blank

PART 2

THE ESSENCE OF FAMILY MEDICINE

Strength of Recommendation (SOR)	Definition
A	Recommendation based on consistent and good-quality patient-oriented evidence.*
B	Recommendation based on inconsistent or limited-quality patient-oriented evidence.*
C	Recommendation based on consensus, usual practice, opinion, disease-oriented evidence, or case series for studies of diagnosis, treatment, prevention, or screening.*

*See Appendix A on pages 1447–1450 for further information.

2 DOCTOR—PATIENT RELATIONSHIP

Mindy A. Smith, MD, MS

Humor is one way through which patients and physicians relate to each other on a human level. Even politics is not off-limits in the doctor–patient relationship.

PATIENT STORY

Patient stories, particularly if we listen attentively and nonjudgmentally, provide us with a window into their lives and experiences. These stories help us to know our patients in powerful ways, and that knowledge about the patient, as someone special, provides the context, meaning, and clues about their symptoms and illnesses that can lead to healing. At our best, we serve as witness to their struggles and triumphs, supporter of their efforts to change and grow, and guide through the medical maze of diagnostic and therapeutic options. Sometimes, their stories become our own stories—those patients who we will never forget because their stories have changed our lives and the way we practice medicine (**Figure 2-1**).

FIGURE 2-1 Dr. Jim Legler caring for a young girl in a free clinic within a transitional housing village for homeless families. He is a family physician who volunteers every week to care for the 40 families working their way out of homelessness. He had been caring for Kimberly and her family for many months at the time this photograph was taken. Dr. Legler serves as a role model for students interested in primary care of the underserved. He is known for his kindness and compassion to all his patients.

WHAT PATIENTS WANT FROM THEIR PHYSICIAN

As part of the future of family medicine (FFM) initiative, telephone interviews of the general public (N = 1031) were conducted in 2002.[1] Most patients strongly agreed that they wanted to take an active role in their healthcare (82% and 91%, patients with family physicians and patients with general internists, respectively), they wanted their physicians to treat a wide variety of medical problems but refer to a specialist when necessary (88% and 84%), and they wanted a physician who looks at the whole person—emotional, psychological, and physical (73% and 74%). In addition, of 39 possible attributes of physicians, most patients (68% to 97% stated extremely or very important) viewed the following as the most important attributes/services that drive overall satisfaction with their physician:

- Does not judge; understands and supports.
- Always honest, direct.
- Acts as partner in maintaining health.
- Treats both serious and nonserious conditions.
- Attends to emotional and physical health.
- Listens to me.
- Encourages healthier lifestyle.
- Tries to get to know me.
- Can help with any problem.
- Someone I can stay with as I get older.

WHAT PHYSICIANS WANT FROM AND FOR PATIENTS

Although the types and intensity of relationships with patients differ, our positive and negative experiences with patients shape us as clinicians, influence us in our personal relationships, and shape the character of our practices. Arthur Kleinman, in his prologue to *Patients and Doctors: Life-Changing Stories from Primary Care*, wrote, "We all seem to want (or demand) experiences that matter, but maybe what is foremost is that we want experiences in which *we* matter." There is perhaps no greater satisfaction than the beliefs that what we do and who we are matters to those we care for in both our personal and professional lives.[2] A positive relationship with a patient is one of mutual growth. This concept of doctor–patient reciprocity is not new and can be found in the writings of Erasmus, more than 500 years ago, arising from a classical conception of friendship.[3]

As clinicians we want patients to be healthier and improved in some meaningful way after our encounter with them. Meaningful elements common to healing practices across cultures include:[4]

- Providing a meaningful explanation for the sickness.
- Expressing care and concern.
- Offering the possibility of mastery and control over the illness or its symptoms.

Family physicians (N = 300) who were interviewed as part of the FFM initiative stated that the following things completely captured the essence of what they found as most satisfying about being a family physician:[1]

- The deep relationships developed with patients over the years (54%).
- The variety—no day is ever the same (54%).
- Offers me a strong sense of purpose because I can make a real difference in people's lives (48%).
- Don't spend their days taking care of illness, but take care of the whole patient (**Figure 2-2**) (46%).

LEARNING FROM PATIENTS

To learn from patients, clinicians must do the following:

- Move outside of their worldview and accept the patient's point of view and belief system.
- Let go of stereotypes, biases, and dogma.
- Use active empathic listening, see the patient in context, and adopt reflective and reflexive practices.[5]
- Emphasize patient dignity and control within a supportive team, which may include family, friends, aides, and community resources.
- Graciously accept differences of opinion or patient refusal without abandoning the patient.
- Look at each patient encounter as a cross-cultural event.[4] Western medical training acculturates clinicians into a world seen in large part as one of problems and solutions; this is often at odds with patients' need to find meaning in the illness episode, be heard and acknowledged, and learn to live a quality life with chronic illness.

FIGURE 2-2 Dr. Alan Blum is a family physician who has been doing sketches of his patients for decades now. When he presents his drawings of his patients, he reads his poetic stories that go with the drawings. Some of his drawings have been published in *JAMA*. Here is the poem that goes with this man's story:

"Gov'ment gave me a chance
to get a hearin' aid for free.
But when I went to th' doctor,
he say,
'Well, cap'n,
there gonna be a lot o' things
you don't want to hear!'"

BENEFITS OF A GOOD DOCTOR–PATIENT RELATIONSHIP

Beyond the benefit of enhancing the medical experience for both clinicians and patients, data that support developing a good doctor–patient relationship include the following:

- Patients who are satisfied with their physicians are three times more likely to follow a prescribed medical regimen.[6]
- Patients with diabetes cared for by physicians with high empathy scores (based on the physician's self-administered Jefferson Scale of Empathy) were significantly more likely to have good control based on hemoglobin A_{1C} than were patients of physicians with low empathy scores (56% and 40%, respectively).[7]
- Patients who reported an established relationship with a primary care provider (PCP) were less likely to currently smoke than those who lacked a PCP relationship (26.5% and 62.3%, respectively).[8]
- There is a direct link between patient satisfaction and the amount of information that physicians provide.[9,10]
- There is also a strong positive correlation between patient satisfaction, recall, and understanding and physician's partnership building (e.g., enlisting patient input).[10]
- Provision of health information to patients influences patient decision making in important ways.

ESSENTIALS OF GOOD DOCTOR–PATIENT RELATIONSHIP

Although the doctor–patient relationship may be viewed as a contract for providing services, Dr. Candib argues that this view does not fit well with developing a healing relationship that must be based on "unconditional positive regard," beneficence, caring, and a moral basis of conduct.[11] Furthermore, contracts fail to deal with the unpredictable and fail to acknowledge the power inequality between physicians and patients. To counter this power imbalance, Candib emphasizes the need for clinicians to use that power to empower the patient. Following are the requirements of empowerment of patients:[12]

- Recognition of oppression—Acknowledging the patient's contextual problems (e.g., poverty, race, religion, sexual preference) and the sources of inequality and oppression that contribute to their health status for the purpose of naming and supporting the patient's reality.
- Expressing empathy—A characteristic of being with the patient that leads to empowerment by confirming the worthiness of the other.
- Respecting the patient as a person (particularly those who are cognitively or otherwise impaired).
- Responding to the changing abilities of the patient—Using flexibility, timing, and a shifting of skills to advance the movement of the patient in a positive stronger direction.
- Using language that increases patient's power—Solicit and legitimize the patient's explanations and experience. This may include using questions about what patients want from the encounter, what they think about their problem, what they think the clinician should do about the problem, and what they have tried that has worked for them in the past.
- Taking the patient seriously—This includes respecting the patients' fears, not trivializing their concerns, and allowing the truth to unfold over time to prevent patient harm or embarrassment.
- Supporting choice and control—Accepting patient priorities, even if health is not the top one, and allowing patients to choose, even if their choice is to relinquish control.
- Eliciting the patient's story, often over time, to be able to put the illness experience into historical and social context.
- Providing patient education in a context in which the clinician asks what the patient already knows, what they want and need to know, and whether they have any questions. Health educators should discuss risks and benefits of a proposed diagnostic or treatment plan that are meaningful to the patient and provide patients with the tools and information to make their own decisions.

Some patients prefer to delegate authority to the physician to make medical decisions; the challenge then is for the physician to find out the patient's preferences and values.

Caring is also an essential feature of a good doctor–patient relationship. Caring, as connectedness with a patient, evolves from the relationship. Within the context of this relationship, the clinician makes the patient feel known, pays attention to the meaning that a symptom or illness has in the patient's life, expresses real feeling (separate from reflecting back the patient's feelings), and practices devotion (e.g., a willingness at times to do something extra for the patient).[13] To provide caring to patients, clinicians must take care of themselves.

SKILLS FOR BUILDING GOOD DOCTOR–PATIENT RELATIONSHIPS

- One strategy for improving communication with patients is using the patient-centered interview.[14] This technique focuses on eliciting the patient's agenda in order to address their concerns more promptly.
- Incorporating the BATHE (Background, Affect, Trouble and Handling of their current situation, and Empathy) method into the standard patient interview was found to increase 8 of 11 measures of patient satisfaction.[15]
- Using self-disclosure for the purposes of role modeling and guiding, showing empathy, building trust, and developing a stronger relationship in the context of shared assumptions about the relationship. Self-disclosure, however, must be balanced with the obligation not to take advantage of patients by using such disclosure as an appeal for help or intimacy.[16] In addition, it may be prudent to avoid disclosure of unresolved issues and to avoid repetitiousness (as when disclosure predominates over inquiry).

MAXIMIZING THE EFFECTIVENESS OF PATIENT EDUCATION

Steps for maximizing patient education for behavior change include the following:[17]

- Understanding the power of the clinician's expertise as a motivator toward behavior change.
- Being patient centered and patient responsive (e.g., assess readiness to change, patient wishes for autonomy or assistance in decision making).
- Encouraging the patient to choose one or at most two behavior goals at a time.
- Being specific in the advice given.
- Obtaining commitment from the patient for change.
- Using multiple educational strategies, often over time and from a team of providers.
- Using social support when possible.
- Assuring appropriate follow-up.

Some guidance can be found in the literature for discussing clinical evidence with patients in the process of making medical decisions. Despite lack of clinical outcomes from this research, authors of a systematic review found the following:[18]

- Methods for communicating clinical evidence to patients include nonquantitative general terms, numerical translation of clinical evidence, graphical representations, and decision-making aids.
- Focus-group data suggested that clinicians present options and/or equipoise before asking patients about preferred decision-making roles or formats for information.
- Absolute risk reduction is preferred.
- The order of information presented and time frame of outcomes can bias patient understanding.
- Limited evidence supports use of human stick figure graphics or faces for single probabilities and vertical bar graphs for comparative information.
- Less-educated and older patients preferred proportions to percentages and did not appreciate confidence intervals.

REFERENCES

1. American Academy of Family Physicians. *Future of Family Medicine Project*. http://www.aafp.org/online/en/home/membership/initiatives/futurefamilymed.html. Accessed March 2012.
2. Kleinman A. Prologue. In: Borkan J, Reis S, Steinmetz D, Medalie JH, eds. *Patients and Doctors: Life-Changing Stories from Primary Care*. Madison, WI: University of Wisconsin Press; 1999:ix.
3. Albury WR, Weisz GM. The medical ethics of Erasmus and the physician-patient relationship. *Med Humanit*. 2001;27(1):35-41.
4. Brody H. Family and community—reflections. In: Borkan J, Reis S, Steinmetz D, Medalie JH, eds. *Patients and Doctors: Life-Changing Stories from Primary Care*. Madison, WI: University of Wisconsin Press; 1999:67-72.
5. Medalie JH. Learning from patients—reflections. In: Borkan J, Reis S, Steinmetz D, Medalie JH, eds. *Patients and Doctors: Life-changing Stories from Primary Care*. Madison, WI: University of Wisconsin Press; 1999:50.
6. Rosenberg EE, Lussier MT, Beaudoin C. Lessons for clinicians from physician-patient communication literature. *Arch Fam Med*. 1997;6:279-283.
7. Hojat M, Louis DZ, Markham FW, et al. Physicians' empathy and clinical outcomes for diabetic patients. *Acad Med*. 2011;86(3):359-364.
8. DePew Z, Gossman W, Morrow LE. Association of primary care physician relationship and insurance status with reduced rates of tobacco smoking. *Chest*. 2010;138(5):1278-1279.
9. Blanchard CG, Labrecque MS, Ruckdeschel JC, Blanchard EB. Physician behaviors, patient perceptions, and patient characteristics as predictors of satisfaction of hospitalized adult cancer patients. *Cancer*. 1991;65:186-192.
10. Hall JA, Roter KL, Katz NR. Meta-analysis of correlates of provider behavior in medical encounters. *Med Care*. 1988;26:657-675.
11. Candib LM. *Medicine and the Family—A Feminist Perspective*. New York: Basic Books; 1995:119-145.
12. Candib LM. *Medicine and the Family—A Feminist Perspective*. New York: Basic Books; 1995:246-273.
13. Candib LM. *Medicine and the Family—A Feminist Perspective*. New York, NY: Basic Books; 1995:206-239.
14. Brown J, Stewart M, McCracken E, et al. The patient-centered clinical method. 2. Definition and application. *Fam Pract*. 1986;3:75-79.
15. Leiblum SR, Schnall E, Seehuus M, DeMaria A. To BATHE or not to BATHE: patient satisfaction with visits to their family physician. *Fam Med*. 2008;40(6):407-411.
16. Candib LM. *Medicine and the Family—A Feminist Perspective*. New York: Basic Books; 1995:181-205.
17. Jaques LB, Curtis P, Goldstein AO. Helping your patients stay healthy. In: Sloane PD, Slatt LM, Ebell MH, Jacques LB, eds. *Essentials of Family Medicine*. Baltimore, MD: Lippincott Williams & Wilkins; 2002:117-125.
18. Epstein RM, Alper BS, Quill TE. Communicating evidence for participatory decision making. *JAMA*. 2004;291(19):2359-2366.

3 FAMILY PLANNING

E.J. Mayeaux Jr., MD
James C. Barrow, MD, FACOG

PATIENT STORY

Your patient is a 25-year-old married woman who wants to postpone having children for another 2 years while she finishes graduate school. She and her husband are currently using condoms, but would like to change to something different. She is in good health and does not smoke. It is now your opportunity to discuss with her all the methods available to prevent pregnancy. First, you determine what she knows about the methods and if she has any preferences. She tells you that she is specifically interested in either the *hormonal vaginal ring* (NuvaRing) (**Figure 3-1**) or the newest *intrauterine device* that releases a hormone (**Figure 3-2**). Then you participate in shared decision making as she comes up with the method that best fits her lifestyle and health issues.

FIGURE 3-1 NuvaRing is a combined hormonal intravaginal contraceptive ring. The flexible material of the ring allows for easy insertion and removal. Note the size in comparison to a quarter. (*Courtesy of Richard P. Usatine, MD.*)

INTRODUCTION

Contraception is like many other treatments in medicine. Each method has its risks and benefits. Each method has its barriers to use, such as compliance, cost, and social stigmas. By educating patients appropriately and letting them know beforehand of potential side effects, we can greatly increase compliance and satisfaction.

EPIDEMIOLOGY

- Approximately one-half of pregnancies in the United States are unintended.[1] Approximately one-half of these occurred in women using reversible contraception.[2]
- The most commonly used contraceptive methods in the United States are oral contraceptive pills (OCPs), male condoms, and female sterilization.[3]
- Long-acting reversible forms of contraception are increasingly popular. Encouraging these methods may help lower the unintended pregnancy rate. Gaps or discontinuation of use of short-acting methods lead to unintended pregnancy.[4]
- Newer contraceptives often have improved side-effect profiles or have more convenient delivery systems that may not require daily patient adherence. Having a wide range of contraceptive options helps patients find a method that will work best for them.
- This chapter focuses on contraceptive methods available in the United States and the considerations one must address when counseling patients on their choice of method.

FIGURE 3-2 Mirena (levonorgestrel-releasing intrauterine system) provides effective contraception for at least 5 years. (*Printed with permission from Bayer HealthCare Pharmaceuticals Inc.*)

CONSIDERATIONS

- No contraception method is perfect. Each individual or couple must balance the advantages and disadvantages of each method and decide which offers the best choice. As the physician, one must help

TABLE 3-1 Contraceptive Options Available in the United States in 2012

Method	Unintended Pregnancies with 1 Year of Use (%)		Noncontraceptive Benefits	Use with Breastfeeding
	Typical Use	Theoretical		
None	85	85	—	—
Spermicide	29	18	None	Yes
Withdrawal	27	4	None	Yes
Periodic abstinence (fertility awareness)	25	3–5	None	Yes
Diaphragm with spermicide	16	6	None	Yes
Female condom	21	5	Prevents STDs	Yes
Male condom	15	2	Prevents STDs	Yes
OCPs–combined and progestin-only	8	0.3	Regulation of menstrual cycle and dysmenorrhea, possible decrease in ovarian and endometrial cancer risk, decrease acne	No
Contraceptive patch	8	0.3	Same as OCPs	No
Vaginal ring	8	0.3	Same as OCPs	No
Depo-Provera	3	0.3	Same as OCPs	Yes
Copper-containing IUD	0.8	0.6	None	Yes
Levonorgestrel IUD	0.2	0.2	Regulation of menstrual cycles and dysmenorrhea	Yes
Female sterilization	0.5	0.5	None	Yes
Male sterilization	0.15	0.10	None	Yes
Etonogestrel implant	0.05	0.05	Same as OCPs	Safety conditional

OCP, oral contraceptive pill; IUD, intrauterine device; STD, sexually transmitted disease.
Data from Trussell J. Contraceptive efficacy. In Hatcher RA, Trussell J, Nelson AL, Cates W, Stewart FH, Kowal D, Policar M, eds. *Contraceptive Technology,* 20th rev ed. New York: Ardent Media; 2011:827–1010; Herndon EJ, Zieman M. New contraceptive options. *Am Fam Physician.* 2004;69:853–860; Herndon EJ, Zieman M. *Improving Access to Quality Care in Family Planning: Medical Eligibility Criteria for Contraceptive Use*, 2nd ed. Geneva, Switzerland: Reproductive Health and Research, World Health Organization, 2000. Available at: http://whqlibdoc.who.int/publications/2004/9241562668.pdf (accessed July 4, 2006); Speroff L, Fritz MA. *Clinical Gynecologic Endocrinology and Infertility,* 7th ed. Philadelphia: Lippincott Williams & Wilkins, 2005.

the patient make the appropriate decision based on many factors that are unrelated to their medical history or to the side-effect profile of the method, such as the likelihood of compliance and access to follow up.

- Some important considerations in choosing a contraceptive method are its potential side effects, failure rates, and noncontraceptive benefits. See **Table 3-1**.
- Smoking increases the risks of the most dangerous side effects of estrogen-containing contraceptives. This is an important issue in helping a patient choose the safest and the best method. Encouraging smoking cessation is always a good intervention, but one might avoid prescribing an estrogen-containing contraceptive until the patient can truly quit smoking.

- Avoid estrogen-containing contraceptives in women with hypertension or migraine with aura. In both cases, the theoretical or proven risk of stroke outweighs the advantages.

NEWER CONTRACEPTIVE CHOICES

- In addition to the traditional 20 to 35 mcg ethinyl estradiol (EE) OCPs, 30 and 20 mcg EE in combination with the new progestogen *drospirenone* (Yasmin, YAZ) are available. Drospirenone has some antimineralocorticoid activity and has been shown to decrease the water retention, negative effect, and appetite changes that are commonly associated with menstrual cycle changes.[4] Serum potassium levels should be monitored when women are at a risk for hyperkalemia. The progesterone in these pills often helps in decreasing the severity of acne. Beyaz is a newer formulation of the above with the addition of folate. If a patient becomes pregnant while taking this pill, her folate levels would be adequate to prevent neural tube defects.
- *Extended OCP* regimens with 84 days of levonorgestrel-EE pills and 7 days of nonhormonal pills (Seasonale) are available. Seasonique has the same pills for the first 84 days but uses 10 mcg EE pills for the last 7 days to make up the 91-day cycle. They have similar advantages to other OCPs except that the patient has only four periods a year. Another extended OCP regimen combining levonorgestrel and ethinyl estradiol has been released in which there are no nonhormonal pills at all (Lybrel).
- The *hormonal vaginal ring* (NuvaRing) has similar active ingredients of OCPs, but does not require daily attention (see **Figure 3-1**). It is placed in the vagina for 3 weeks at a time (with 1 week off) and releases EE and etonogestrel. Withdrawal bleeding occurs during the ring-free week. The vaginal ring is associated with a lower incidence of breakthrough bleeding than standard OCPs.
- There is a newer form of Depo-Provera given every 3 months, but given SQ instead of IM. The SQ version provides 30% less hormone, 104 versus 150 mg per injection. It works at least as well as Depo-Provera IM does as a contraceptive, and also works as well as Lupron Depot for endometriosis pain with fewer hot flashes and less bone loss. If long-term use is considered, it may be prudent to select another contraceptive, discuss the risk of possible bone loss, or consider monitoring bone density in women using either version of Depo-Provera for more than 2 years. These medications can increase the incidence of acne and weight gain in some women as a result of the androgenic effects of the progesterone.
- The Mirena *intrauterine device* (IUD) releases levonorgestrel and provides effective contraception for at least 5 years (see **Figure 3-2**). Pregnancy rates are comparable with those occurring with surgical sterilization. Copper-containing IUDs are another long-term option lasting up to 10 years; however, it may be associated with dysmenorrhea and irregular vaginal bleeding some of the time. Twenty percent of women have amenorrhea after 1 year of use with Mirena, and as with the copper-containing IUDs, there is a risk of expulsion. The absolute risk of ectopic pregnancy with IUD use is extremely low because of the high effectiveness of IUDs. However, if a woman becomes pregnant during

FIGURE 3-3 Nexplanon implantable subcutaneous contraceptive system. The insertion device is a sharp trochar and the implant is made of a soft silastic tube. (*Courtesy of E.J. Mayeaux Jr., MD.*)

FIGURE 3-4 Essure tubal occlusion device for permanent sterilization. It is placed within the fallopian tubes using a vaginal approach and a hysteroscope. (*Courtesy of Jay Berman, MD.*)

IUD use, the relative likelihood of ectopic pregnancy is greatly increased.[5]

- Nexplanon (etonogestrel implant) is an *etonogestrel-containing single rod implant* for subdermal use (**Figure 3-3**). It is a long-acting (up to 3 years), reversible, contraceptive method. It must be removed or replaced by the end of the third year. The implant is 4 cm in length with a diameter of 2 mm and contains 68 mg of the synthetic progestin etonogestrel (ENG). It does not contain estrogen or latex and is not radiopaque. The contraceptive effect of the ENG implant involves suppression of ovulation, increased viscosity of the cervical mucus, and alterations in the endometrium. In the first year of use, it had the lowest failure rate of any form of contraception, including tubal ligation.[7] The effectiveness of Nexplanon in women who weigh more than 130% of their ideal body weight has not been studied. Problems with Nexplanon are similar to other progestin-only contraceptives (acne and gaining weight).
- Sterilization by tubal ligation is a common and very effective form of contraception that should be considered permanent.
- Hysteroscopic tubal occlusion (Essure) is a newer technique (**Figures 3-4** to **3-6**). The device is a flexible microcoil designed to promote tissue growth in the fallopian tubes. It does not require any incisions and can be performed without general anesthesia, typically in less than 30 minutes. There is a 3-month waiting period after the device is placed when an alternative birth control must be used. At the 3-month follow-up visit, a hysterosalpingogram is performed to document that the tubes have been blocked.
- The *combination contraceptive patch* (Ortho Evra) releases EE and norelgestromin and has the same mechanism of action as OCPs (**Figure 3-7**). It is applied weekly for 3 weeks, followed by a patch-free week during which menses occur. Recommended application sites include the upper arm, buttocks, and torso (excluding the back and breasts). It has similar efficacy to OCPs but may be less effective in women weighing more than 90 kg (198 lb). In a rare instance of patch detachment, it must be replaced. The progesterone in the patch may decrease the severity of acne.

PATIENT EDUCATION

For some contraceptive methods to be effective, the patient must be willing to use them consistently and correctly. Other methods do not require any action on the part of the patient. Patients will need to understand the benefits and risks of the method they choose and how to be best assured that the method is working for them. If patients are aware of the possible side effects, they can address any such effect with their physician if an adverse effect occurs.

FOLLOW-UP

Monitor for side effects, level of usage, and tolerability. The contraceptive choice should be periodically reexamined as the patient may want to switch to a different method of contraception as needs and circumstances change.

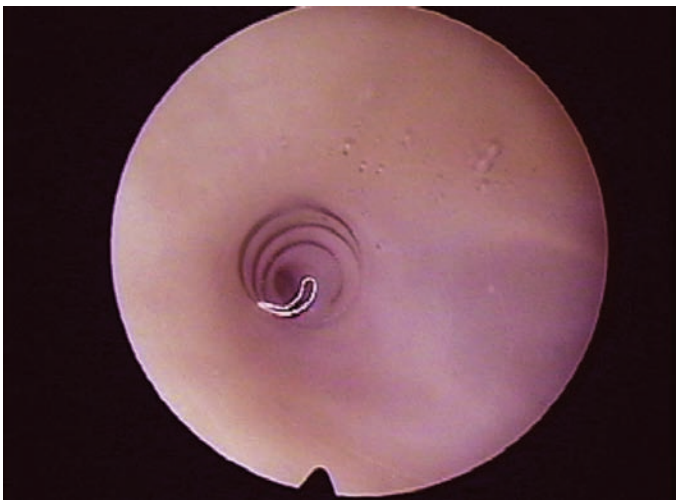

FIGURE 3-5 Hysteroscopic view showing the coiled Essure device within a fallopian tube immediately after it was implanted. (*Courtesy of Jay Berman, MD.*)

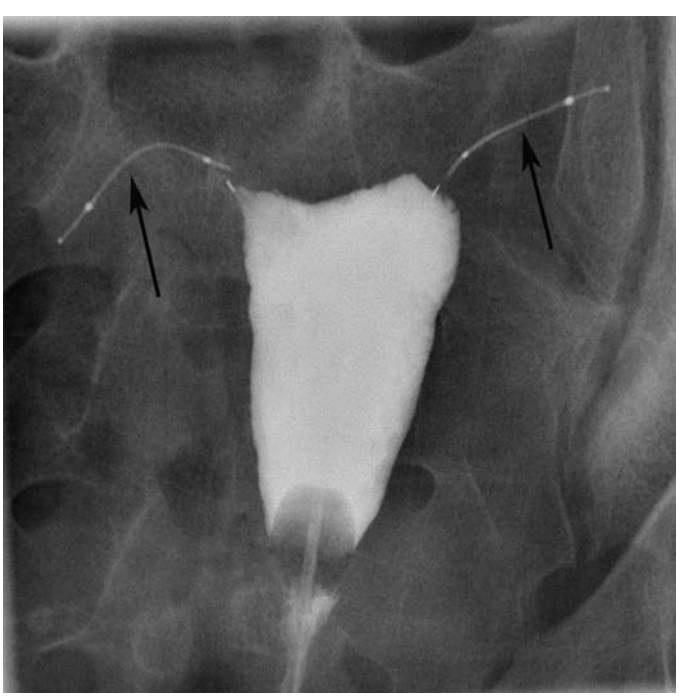

FIGURE 3-6 Hysterosalpingogram (HSG) with bilateral Essure devices within the fallopian tubes (*arrows*). Contrast material distends the uterine cavity but does not enter the cornua, fallopian tubes or peritoneal cavity, indicating successful occlusion. The black/gray bubble in the white-appearing uterus is the HSG catheter balloon. (*Courtesy of E.J. Mayeaux Jr., MD.*)

PATIENT RESOURCES

- Managing Contraception Web site has a choices section that is good for patients, **http://managingcontraception.com/.**
- NuvaRing Web site, **http://www.nuvaring.com/.**
- Mirena Web site, **http://www.mirena-us.com/.**
- Essure Web site, **http://www.essure.com/.**
- Nexplanon Web site, **http://www.nexplanon-usa.com/**

CDC Web site, **http://www.cdc.gov/reproductivehealth/UnintendedPregnancy/Contraception.htm.**

ACOG Web site, **http://www.acog.org/publications/patient_education/ab020.cfm.**

PROVIDER RESOURCES

- Contraceptive Technology Table of Contraceptive Efficacy, **http://www.contraceptivetechnology.org/table.html.**
- American Family Physician. "New Contraceptive Options," **http://www.aafp.org/afp/20040215/853.html.**
- World Health Organization. *Medical Eligibility Criteria for Contraceptive Use*, Fourth edition, 2009. **http://www.who.int/reproductivehealth/topics/en/.**

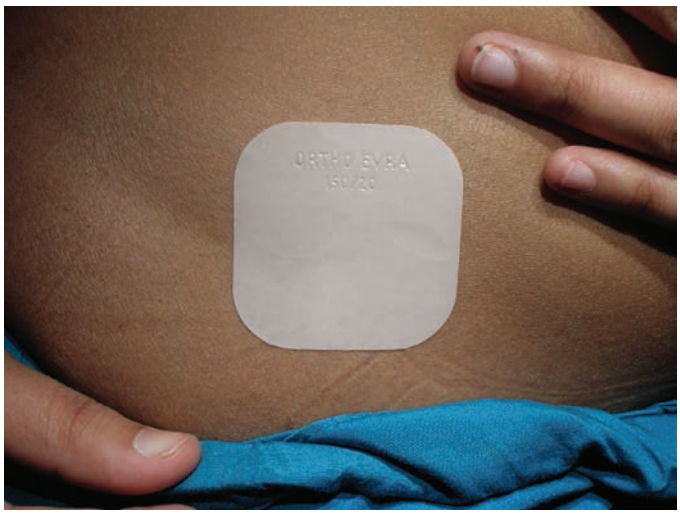

FIGURE 3-7 The Ortho Evra combined hormonal contraceptive patch. The patch is changed weekly for 3 weeks then left off for 1 week per cycle. (*Courtesy of E.J. Mayeaux, Jr., MD.*)

REFERENCES

1. Henshaw SK. Unintended pregnancy in the United States. *Fam Plann Perspect*. 1998;30:24-29, 46.
2. Kost K, Singh S, Vaughan B, et al. Estimates of contraceptive failure from the 2002 National Survey of Family Growth. *Contraception*. 2008;77:10.
3. Piccinino LJ, Mosher WD. Trends in contraceptive use in the United States: 1982-1995. *Fam Plann Perspect*. 1998;30:4-10, 46.
4. Raine TR, Foster-Rosales A, Upadhyay UD, et al. One-year contraceptive continuation and pregnancy in adolescent girls and women initiating hormonal contraceptives. *Obstet Gynecol*. 2011; 117(2 Pt 1):363-371.
5. Herndon EJ, Zieman M. New contraceptive options. *Am Fam Physician*. 2004;69:853-860.
6. World Health Organization. *Medical Eligibility Criteria for Contraceptive Use,* Fourth edition, 2009. http://www.who.int/reproductivehealth/topics/en/. Accessed May 21, 2012.
7. Trussell J. Contraceptive failure in the United States. *Contraception*. 2011;83(5);397-404.

4 PREGNANCY AND BIRTH

Beth Choby, MD
Mindy A. Smith, MD, MS
Leslie A. Shimp, PharmD, MS

PATIENT STORY

As a longtime pregnancy care provider, it was difficult to choose a single story as representative of pregnancy and birth. Most of the stories are meaningful because of the context of the relationship with the woman and the family—a few are tragic and yet filled with grace and the amazing strength displayed by even the very young, some are truly epic tales, and all are learning opportunities. Pregnancy experiences are filled with consternation at the myriad of changes, discomforts, and worries. They are filled with laughter as women's bodies alter in amazing ways; we waddle, unconsciously rest plates on our bellies, and lose sight of our feet (**Figure 4-1**). Our partners and/or supportive others alternate between reassurance and befuddlement. And then a child appears, miraculously from a space that seems far too small to accommodate, and (regardless of the outcome) a new journey begins.

FIGURE 4-1 Dr. Mindy A. Smith and her husband, Gary, touching bellies during Mindy's pregnancy with Jenny.

EPIDEMIOLOGY

- Planned pregnancy—Approximately 85% of sexually active women not using a contraceptive method will become pregnant over the course of a year. The probability of conception is 15% to 33% per cycle, depending upon the frequency of sexual intercourse.[1]
- Unplanned pregnancy—Half of all pregnancies in the United States are unintended, and approximately half of these unintended pregnancies end in abortion.[2]
  - Unintended pregnancy (defined as a pregnancy mistimed or not wanted at the time conception occurred) is the result of lack of use of a contraceptive or failure of the contraceptive.
  - Unintended pregnancy occurs among women of all ages, socioeconomic status, and marital status. Although unintended pregnancies are often associated with teens, 41% of pregnancies among women 35 to 39 years of age and 51% of those among women older than 40 years are unintended.[3]
  - Some unintended pregnancies end in abortions. A total of 827,609 legally induced abortions occurred in the United States in 2007 (16 per 1000 women aged 15 to 44 years).[4]

    The highest percentages of reported abortions were for women who were unmarried (82%), white (55%), and aged <25 years (51%).

    Of all abortions for which gestational age was reported, 62.3% were performed at ≤8 weeks' gestation.[4]
- Maternal mortality has declined dramatically in the United States over the past century. Rates declined from 607.9 maternal deaths per 100,000 livebirths in 1915 to 12.7 per 100,000 livebirths in 2007. Still, maternal mortality over the past 25 years has not improved.[5] The leading causes of pregnancy-related death are

embolism (20%), hemorrhage (17%), and pregnancy-induced hypertension (16%).[6] Major racial disparities continue to exist.
  - Maternal mortality (2007) in non-Hispanic black women was 34 per 100,000 live births compared with 10.4 per 100,000 live births in non-Hispanic whites and 9.6 per 100,000 live births in Hispanics. African-American women have 2.7 times the risk of pregnancy-related death compared with whites.
- Care delivery by family physicians (**Figure 4-2**)—Eighteen percent of family physicians perform deliveries as a regular part of their practice; 19.6% perform vacuum extraction; 6.9% do forceps deliveries; 6.3% offer trial of labor after cesarean delivery; and 7.3% perform cesarean deliveries.[7]
- Care outcomes by family physicians—Several studies compare outcomes between family physicians and obstetricians, primarily for comparable patients at low maternal risk (although proportions of high-risk patients are frequently similar across disciplines). One study examining management of vaginal delivery found that obstetricians are more likely to perform episiotomies than family physicians; no difference between groups was noted for instrument use (vacuum or forceps) or neonatal outcomes.[8] Another study comparing rates of trial of labor attempts and vaginal birth after cesarean (VBAC) rates found a trial of labor attempt rate of 81.1% for family physicians and 50.6% for obstetricians. Success rates were 76.1% for family physicians and 64.3% for obstetricians ($P = 0.002$), although there was a statistically nonsignificant higher uterine rupture/dehiscence rate in the family physician group.[9]

FIGURE 4-2 Family physicians Drs. Scott Fields and Katherine Schlessman have just delivered Jennifer Kam's baby. Dr. Fields has known Jennifer (Dr. John Saultz's daughter—Oregon's Chair of Family Medicine) since she was 6 years old. This is a happy event for all.

ETIOLOGY AND PATHOPHYSIOLOGY

- The most fertile period for women is the several days prior to ovulation and ends 24 hours after ovulation.[10] The ovum is able to be fertilized for only 12 to 24 hours after ovulation.[10]
- Sperm usually remain viable for 3 days after intercourse.
- Once the egg is fertilized, it is transported to the uterine cavity in approximately 2 to 3 days. Implantation occurs approximately 6 to 7 days after fertilization following cell division that forms a blastocyst.[10]
- Pregnancy is defined by the National Institutes of Health, the American College of Obstetricians and Gynecologists, and the Food and Drug Administration as implantation of the blastocyst in the endometrium.[11]
- The precise cause of labor is not known but the physiologic changes prior to labor onset include decreased placental progesterone secretion and stimulation of prostaglandin production (E_2 and $F_{2\alpha}$) from the decidua, uterine endometrium, and fetal membranes.
- Labor is defined as progressive dilation of the cervix with uterine contractions. Bloody show (blood-tinged mucus from the vagina), indicating extrusion of the mucus plug, is helpful in predicting impending labor onset.

DIAGNOSIS

A detailed menstrual history should be obtained with the goal of accurately determining the first day of the most recent menstrual cycle. This date is traditionally used to calculate the estimated date of

delivery (EDD) by using Naegele's rule (EDD = [first day of last menstrual period minus 3 months] plus 7 days). The rule is most useful in women who have regular 28-day cycles followed by an abrupt cessation of menses.

CLINICAL FEATURES

- Common early symptoms include amenorrhea, nausea, fatigue, and breast tenderness.
- Signs of pregnancy include the following:
  - Alterations in the skin (e.g., a hyperpigmented streak appearing below the umbilicus [linea nigra] and a reddish hyperpigmentation over the bridge of the nose and cheeks [chloasma]) (**Figure 4-3**).
  - Alterations in the vulva, vagina, and cervix (i.e., bluish discoloration [Chadwick sign] caused by vascular engorgement of the pelvic organs and softening of the cervix [Hegar sign]).

LABORATORY

- Pregnancy tests are an accurate marker for pregnancy and use urine (qualitative) or serum (quantitative) to check for β-human chorionic gonadotropin (HCG).
  - Urine tests are generally positive around the time of the first missed period. β-HCG concentrations in the range of 25 to 50 mIU/mL are detectable in qualitative urine samples.
  - Home pregnancy test kits detect β-HCG in the urine. β-HCG is detectable within 1 to 2 weeks after fertilization, but a pregnancy cannot be detected prior to implantation. The highest sensitivity (97%) of home pregnancy tests is at 1 week after the first day of the missed period.
  - Serum pregnancy tests detect β-HCG at levels as low as 10 to 15 mIU/mL and mean levels closely correspond with gestational age during the first trimester. In healthy gestations, β-HCG levels double every 1.4 to 2 days, increasing exponentially until the fetus is 8 to 10 weeks old. Levels then decline somewhat and remain steady throughout the pregnancy. A minimum increase of 66% is expected every 48 hours. An appropriate rise in β-HCG levels on two quantitative (serum) pregnancy tests drawn 48 hours apart is reassuring for normal pregnancy development.

IMAGING

- Transvaginal ultrasound may be used to confirm and date a pregnancy. Sonographic landmarks like the gestational sac and fetal pole correlate highly with β-HCG levels.
  - The gestational sac is generally seen when the pregnancy is 4.5 to 5 weeks along and the β-HCG level is greater than 1000 mIU/mL.
  - The double decidual sign is a thick, hyperechoic (white) ring that surrounds the gestational sac. The yolk sac is the early nourishment for the embryo, seen at 6 weeks when β-HCG levels are greater than 2500 mIU/mL.
  - The fetal pole is seen at 7 weeks gestation with β-HCG levels more than 5000 mIU/mL.
  - Ultrasound measurements of the gestational sac and the crown to rump length (**Figure 4-4**) of the fetus are a very accurate means of establishing the EDD. First trimester transvaginal ultrasound confirms gestational age within ± 7 days.

FIGURE 4-3 Chloasma (melasma) in a young woman after having children. This hyperpigmentation over the cheeks and nose is sometimes called the mask of pregnancy. (*Courtesy of Richard P. Usatine, MD.*)

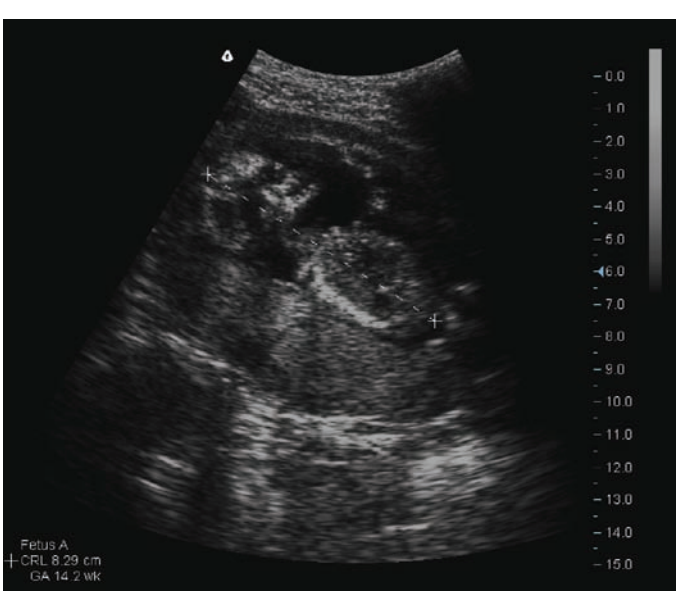

FIGURE 4-4 First trimester ultrasound showing crown to rump length. (*Courtesy of Richard P. Usatine, MD.*)

DIFFERENTIAL DIAGNOSIS

The differential diagnosis of pregnancy includes several gynecologic and nongynecologic conditions. Conditions presenting with an enlarged uterus or abdominal mass include the following:

- Uterine leiomyomas—benign tumors arising from uterine smooth muscle cells. Although most women with symptomatic leiomyomas are in the age range of 30 to 40 years, tumors are occasionally found in adolescents. Myomas occur as single or multiple tumors and range in size from microscopic to large masses. A 20-cm myoma often mimics pregnancy with increased abdominal girth and fullness, but can be distinguished on ultrasound.
- Large adnexal masses and tuboovarian abscesses (TOAs)—The bimanual examination often distinguishes between an adnexal mass and an enlarged uterus. TOA is associated with cervical motion tenderness and abdominal pain. Both conditions can be further evaluated by transvaginal ultrasonography.

Conditions that can present with amenorrhea include the following:

- Hyperthyroidism—Reproductive symptoms can include hypomenorrhea, irregular menses, infertility, and decreased libido. Graves disease is the most common cause among younger patients and common symptoms are nervousness, fatigue, heat intolerance, and tachycardia. Hyperthyroidism is confirmed by a subnormal or undetectable thyroid-stimulating hormone (TSH) and elevated thyroxine (T_4).
- Sheehan syndrome is a form of acquired hypopituitarism; pituitary apoplexy (sudden neurologic impairment resulting from cerebrovascular disorder) can occur in the postpartum period and may result in severe hypoglycemia and hypotension. Acute symptoms include severe headache and bilateral visual changes; long-term symptoms depend on which hormones are deficient (i.e., TSH, follicle-stimulating hormone [FSH], and luteinizing hormone [LH]; prolactin; adrenocorticotropin hormone [ACTH]; and growth hormone [GH]) and the extent of the hormone deficiency. Diagnosis is made with low levels of trophic hormones in conjunction with low levels of target hormones.
- Premature menopause—Menopause, defined as permanent amenorrhea in a previously cycling woman, is considered premature when it occurs before the age of 40 years; approximately 10% of women are menopausal by the age of 46 years. Vasomotor symptoms (e.g., hot flashes) and menstrual irregularity usually precede cessation of menses, the latter by approximately 4 years. An FSH level greater than 40 mIU/mL helps to confirm, but may drop again if ovulatory cycles return.

Conditions that can present with symptoms of pregnancy include the following:

- Ectopic pregnancy is an important diagnosis to exclude in women with a positive pregnancy test, abdominal pain, or vaginal bleeding. Transvaginal ultrasound in combination with serial β-HCG measurements is useful to delineate between intrauterine and ectopic gestation. Heterotopic pregnancies (i.e., concomitant intrauterine and ectopic pregnancies) are seen in 1 in 30,000 gestations.
- Pseudopregnancy is a psychiatric condition in which a woman thinks she is pregnant when she is actually not. She may have symptoms and behaviors consistent with a diagnosis of pregnancy, including weight gain, abdominal pain, and sensations of fetal movement. Confirmatory lab work is negative, although the woman often cannot be convinced of these results.

MANAGEMENT

- Decision making—Many women and their partners find themselves facing an unplanned pregnancy. Options include continuing the pregnancy and caring for the infant, continuing the pregnancy and placing the infant with an adoptive family, or ending the pregnancy via medical or surgical abortion. Couples need support and information to assist them with this decision.
- Methods to prevent or terminate an unwanted pregnancy include the following:
  - Emergency contraceptives (ECs)—These oral methods can be used after unprotected intercourse or contraceptive failure to prevent pregnancy. These agents are not abortifacients and prevent pregnancy before implantation occurs. They do not disrupt an already established pregnancy and there are no evidence-based medical contraindications to their use. However, ECs, like other hormonal contraceptives, have the potential to inhibit implantation of a fertilized egg.[11] The agents are most effective when the first dose is taken within 12 hours of unprotected intercourse; each 12-hour delay in beginning use reduces efficacy by 50%.
    a. The levonorgestrel product Plan B One-Step reduces the likelihood of pregnancy by 84%. Side effects include heavier menstrual bleeding (31%) and nausea (14%). The standard dosing regimen is one 1.5-mg tablet as soon as possible within 72 hours of unprotected intercourse. Clinical trials demonstrate reasonable efficacy rates up to 120 hours postcoitus. Next Choice is a generic version of the original Plan B and contains two 0.75-mg levonorgestrel doses which may be taken at once or 12 hours apart. Levonorgestrel is available to women age 17 years and older as a nonprescription product. The mechanism of action is delay/inhibition of ovulation; it does not prevent fertilization or interfere with blastocyst implantation. It does not affect an existing pregnancy and will not harm a fetus.[12]
    b. Ulipristal acetate (ella) is a selective progesterone receptor modulator that is also FDA approved as an emergency contraceptive for use for up to 5 days after unprotected intercourse or contraceptive failure. It is given as a single 30-mg dose; ella is only available by prescription. Use is not approved for patients younger than 18 years of age. Pregnancy should be excluded prior to prescribing ella. It is not known if ella will harm a developing fetus. Side effects include headache (18%), nausea (12%), fatigue (6%), dizziness (5%), and abdominal pain (12%).[13] The mechanism of action is prevention/delay of the LH surge and follicular rupture—delay of ovulation; it may interfere with implantation of a blastocyst but the 30-mg dose may not prevent implantation (Planned Parenthood, 2010). Ella is more effective than levonorgestrel 72 to 120 hours after unprotected intercourse.[14] Ella may make hormonal contraceptives less effective so a barrier method of birth control (e.g., condom) should be used in addition to hormonal contraceptives for the remainder of that same menstrual cycle.

c. Use of oral contraceptives containing ethinyl estradiol, plus either levonorgestrel or norgestrel, reduces the likelihood of pregnancy by 75%.[11] Approximately 50% of users experience nausea and 20% experience vomiting. Use of oral contraceptives as ECs requires a regimen that includes 2 doses—1 dose taken as soon as possible within 72 hours of unprotected intercourse and the second dose taken 12 hours later. Each dose must include at least 100 mcg of ethinyl estradiol and either 1 mg of norgestrel or 0.5 mg of levonorgestrel.

- Medical abortion (i.e., use of medications to induce an abortion)—Medical abortions account for 12% of the abortions performed in the United States.[4] Medical abortion is an option for women who wish to terminate a pregnancy up to 63 days' gestation (calculated from the first day of the last menstrual period). The efficacy of the various regimens ranges from 88% to 99%. Regimens including 200 mg of oral mifepristone followed by 800 mcg of misoprostol vaginally from 6 to 8 hours to 72 hours afterwards been shown to be most effective with fewer side effects and lower cost.[15,16] SOR A Side effects of medical abortion using mifepristone and misoprostol include nausea (20% to 52%), thermoregulatory dysfunction (i.e., warmth, fever, chills, hot flashes; 9% to 56%), dizziness (12% to 37%), headache (10% to 37%), vomiting (5% to 30%), and diarrhea (1% to 27%).[15]
- Surgical (aspiration) abortion—This method can be performed in the office up to 13 weeks' gestation and has a rate of major complications of less than 1 in 200 cases.[4] A Cochrane review found no data showing that any one procedure (manual or electrical vacuum aspiration or dilation and curettage) is superior.[17]

• Pregnancy care—Despite the widespread use of prenatal care, evidence of its effectiveness is limited. Prenatal care offered by family physicians likely benefits both maternal and infant health by encouraging long-term health maintenance within a continuity relationship and increasing the likelihood that those infants receive timely care. Future research must explore whether enhanced prenatal care benefits certain groups of women, that is, the young, the uninsured, and women in high-risk ethnic groups. Routine visits provide opportunities for screening, management of complications, anticipatory guidance, and educational activities.[18]

- First trimester care includes a detailed history to identify medical, health habit, and prior pregnancy problems requiring management (e.g., use of safer medications for pregnancy, smoking cessation, prior gestational diabetes).

  An initial pelvic examination is appropriate to detect anatomic defects of the reproductive tract and to screen for gonorrhea and chlamydia.

  Screening laboratory tests include blood type (D [Rh] factor), hepatitis B surface antigen, Venereal Disease Research Laboratory (VDRL) (syphilis), urine culture, and HIV for high-risk women. SOR A

  Blood pressure and weight are monitored.

  Folic acid fortified multivitamin supplements once daily are recommended. SOR A In a recent metaanalysis, use of multivitamin supplements provided consistent protection against neural tube defects, cardiovascular defects, and limb defects in multiple types of studies, including randomized controlled trials.[19] Folic acid (400 to 800 mcg/day) ideally should be started in the preconception period and continued during pregnancy.

  Iron supplementation of at least 30 mg of elemental iron is recommended orally daily (may start in the second trimester). SOR C Although demonstrated to increase hemoglobin levels in maternal blood in both the antenatal and postnatal periods, there is limited information related to clinical maternal and infant outcomes.[20]

  Common chronic medical conditions that may require treatment modification or more intense monitoring include asthma (e.g., lowest dose of steroids and stress–dose coverage in labor), hypertension (e.g., safer medication such as α-methyldopa and consideration of discontinuing diuretics [metabolic abnormalities] and angiotensin-converting enzyme inhibitors [adverse fetal effects]), thyroid disease (e.g., increased thyroid hormone dose is usually needed), and seizure disorders (e.g., possible teratogenesis of phenytoin; 50% have worsening seizures).

- Second trimester care includes continued monitoring, support, and education. Women should be queried about new symptoms and fears, including direct questions about intimate partner violence (present in up to 20% of pregnant women).

  Routine measurement of maternal weight, blood pressure, fundal height, and fetal heart tones are conducted. SOR C

  Second trimester screening can include maternal serum tests (e.g., quadruple test combines serum markers of maternal serum α-fetoprotein, estriol, β-HCG, and inhibin A, and detects 86% of infants with Down syndrome [trisomy 21], with a false positive rate of 8.2%), amniocentesis, 1-hour Glucola (gestational diabetes), and an antibody screen for Rh-negative women.

  Ultrasound at 18 to 20 weeks' gestation is the standard of care in many regions; however, current evidence fails to correlate routine ultrasound screening in pregnancy with improved fetal outcomes.[21]

  Counseling to encourage a healthful diet and moderate exercise.

- Third trimester care includes preparation for birth and newborn care, monitoring, and support.

  Evidence-based recommendations include repeat screening for hepatitis B, syphilis, gonorrhea, and chlamydia in high-risk populations (i.e., women younger than age 25 years with two or more sexual contacts, women who are sex workers, and women with prior history of syphilis or gonorrhea) and screening for group B streptococcus (GBS) at 35 to 37 weeks' gestation.

  Breastfeeding for 6 months should be encouraged and birth preferences discussed (**Figure 4-5**).

  Childbirth classes are often recommended, but evidence supporting their benefit is lacking.

- Labor and birthing:

  Labor—Labor is defined as regular uterine contractions with progressive cervical dilation. Effacement, the process of thinning of the cervix, occurs before and during labor. Traditionally, labor has been defined as occurring in three stages:

  a. First stage is divided into latent (1 to 20 hours) characterized by milder and less frequent contractions and active (averaging 5 hours in multiparas and 8 hours in primiparas), where the cervix dilates from 4 cm to complete (10 cm) characterized by stronger, regular contractions lasting 60 seconds or more.

b. Second stage begins when dilation is complete and ends with the birth of the baby and averaging 20 minutes in multiparas and 50 minutes in primiparas.
c. Third stage is from the delivery of the baby to delivery of the placenta (up to 30 minutes is considered normal).

Birthing requires flexibility and patience. Traditional labor interventions such as withholding food and drink, giving enemas, and perineal shaving have no evidence to support their routine use. Many options are available to increase comfort and ease the process of labor and birth. For example:

a. Ambulation and frequent changes in position (e.g., side, upright) during labor.
b. The presence of a supportive labor companion (e.g., partner, doula).
c. Pain control options include supportive others, physical contact, massage, warm showers, inhaled nitrous oxide, narcotic pain control, and regional analgesia (e.g., blocks and epidurals). Epidural anesthesia is not believed to interfere with the process or outcome of labor, although earlier research suggested an increase in operative delivery rates (e.g. forceps or vacuum).[22]

There is no evidence to support routine electronic fetal monitoring,[23] episiotomy,[24] or supine birth positions.[25]

Women who are culture positive for GBS should receive antibiotic prophylaxis when in labor (e.g., intravenous penicillin G [PCN G] in nonallergic women).

FIGURE 4-5 We are privileged to observe this newborn baby breastfeeding for the first time immediately after the delivery performed by Dr. Richard P. Usatine. (*Courtesy of Richard P. Usatine, MD.*)

PATIENT EDUCATION

- Pregnancy detection with home pregnancy test kits—The first morning urine is the best specimen for testing. The most accurate results are obtained by waiting at least 1 week after the date of the expected period to test. The urine collection container in the kit should be used and the urine tested immediately after collection. If the urine is refrigerated, it should be allowed to come to room temperature (20 to 30 minutes) prior to testing. Common reasons for a test to be read as negative when a woman is actually pregnant include testing too early (i.e., on or before the first day of a missed period), using a waxed cup for urine collection, soap residue in the container used to collect urine, or testing refrigerated urine.
- Pregnancy prevention—Use of contraceptives dramatically reduces the likelihood of unplanned pregnancy (only 8% of women per year using oral contraceptives become pregnant and of women whose partners are using a condom only 15% become pregnant).[1] Many pregnancies occur when a woman discontinues a contraceptive method and does not begin use of another method prior to intercourse; women should be encouraged to have a backup method they can use if the chosen method proves unsatisfactory (see Chapter 3, Family Planning) and should be educated about the availability of the emergency contraception.
- Abortion choices—Since the FDA approval of mifepristone for elective first trimester termination, medical abortion is increasingly common. In 2007, approximately 12% of abortions were performed using combinations of mifepristone and/or misoprostol.[4]
- Pregnancy planning begins with preconception care, ideally occurring 3 to 6 months prior to the conception to discuss health promotion, risk assessment, and medical intervention.

- Environmental exposures that adversely affect the fetus should be minimized (e.g., pesticides, paint thinner/strippers, fertilizers, and heavy metals). Women who work in hospital settings should avoid exposure to ionizing radiation, chemotherapeutic agents, and misoprostol.
- Intake of 400 mcg/day of folic acid prior to and during the early part of pregnancy reduces the risk of neural tube defects. SOR A
- Certain heritable genetic diseases can be diagnosed in individuals prior to becoming pregnant (e.g., sickle cell disease, cystic fibrosis).
- Treatment of chronic medical conditions (e.g., diabetes, epilepsy, hypertension) can be optimized to reduce fetal loss and adverse effects, including possible change to medications safer in pregnancy.
- Smoking cessation and eliminating alcohol consumption should be encouraged.
- Immunizations (e.g., rubella, varicella) can be provided.
- Patients should be encouraged to discuss their birthing preferences and their practitioner's practice style with respect to the routine use of technology.

PATIENT RESOURCES

- **http://womenshealth.gov/pregnancy/**
- **http://www.childbirth.org/** (includes birth planning forms)
- **http://ec.princeton.edu/questions/dose.html**

PROVIDER RESOURCES

- **http://www.nlm.nih.gov/medlineplus/pregnancy.html**
- **http://www.cdc.gov/ncbddd/pregnancy_gateway/index.html**

REFERENCES

1. Smith MA, Shimp LA. Family planning. In: Smith MA, Shimp LA, eds. *20 Common Problems in Women's Health Care*. New York: McGraw-Hill; 2000:21-64.
2. Stulberg DB. Abortion provision among practicing obstetrician-gynecologists. *Obstet Gynecol*. 2011;118:609-614.
3. Seibert C, Barbouche E, Fagan J, et al. Prescribing oral contraceptives for women older than 35 years of age. *Ann Intern Med*. 2003;138:54-64.
4. Pazol K, Zane S, Parker WY, et al. Abortion services—United States, 2007. *MMWR Surveill Summ*. 2011;60(1):1-42.
5. Singh GK. *Maternal Mortality in the United States, 1935-2007: Substantial Racial/Ethnic, Socioeconomic, and Geographic Disparities Persist. A 75th Anniversary Publication*. Rockville, MD: US Department of Health and Human Services; 2010.
6. Xu JQ, Kochanek KD, Murphy SL, Tejada-Vera B. Deaths: final data for 2007. *Natl Vital Stat Rep*. 2010;58(19). Available at http://www.cdc.gov/nchs/data/nvsr/nvsr58/nvsr58_19.pdf. Accessed September 2011.
7. American Academy of Family Physicians. *Facts About Family Medicine. 2008*. Leawood, KS: American Academy of Family Physicians, 2008.

8. Abenhaim HA, Welt M, Sabbah R, Audibert F. Obstetrician or family physician: are vaginal deliveries managed differently? *J Obstet Gynaecol Can*. 2007;29(10):801-805.
9. Russillo B, Sewitch MJ, Cardinal L, Brassard N. Comparing rates of trial of labour attempts, VBAC success, and fetal and maternal complications among family physicians and obstetricians. *J Obstet Gynaecol Can*. 2008;30(2):123-128.
10. Hatcher RA, Namnoun AB. The menstrual cycle. In: Hatcher RA, Trussell J, Stewart FH, et al, eds. *Contraceptive Technology*, 18th ed. New York: Ardent Media; 2004:63-72.
11. Stewart FH, Trussell J, Van Look PFA. Emergency contraception. In: Hatcher RA, Trussell J, Stewart FH, et al, eds. *Contraceptive Technology*, 18th ed. New York: Ardent Media; 2004:279-303.
12. Gemzell-Danielsson K. Mechanism of action of emergency contraception. *Contraception*. 2010;82(5):404-409.
13. Kim A, Bridgeman MB. Ulipristal acetate (ella) A selective progesterone receptor modulator for emergency contraception. *P T*. 2011;36(6):325-331.
14. McKeage K, Croxtall JD. Ulipristal acetate: a review of its use in emergency contraception. *Drugs*. 2011;71(7):935-945.
15. ACOG practice bulletin. Clinical management guidelines of obstetrician-gynecologists. Number 67, October 2005. Medical management of abortion. *Obstet Gynecol*. 2005;106(4):871-882.
16. Kulier R, Kapp N, Gülmezoglu AM, Hofmeyr GJ, Cheng L, Campana A. Medical methods for first trimester abortion. *Cochrane Database Syst Rev*. 2010(8):CD002855.
17. Kulier R, Cheng L, Fekih A, Hofmeyr GJ, Campana A. Surgical methods for first trimester termination of pregnancy. *Cochrane Database Syst Rev*. 2009;(3):CD002900.
18. Choby B. Prenatal Care. In: Sloane PD, Slatt LM, Ebell MH, Smith MA (eds). *Essentials of Family Medicine*. 6th edition. Baltimore, MD: Lippincott William & Wilkins;2011.
19. Goh YI, Bollano E, Einason TR, Koren G. Prenatal multivitamin supplementation and rates of congenital anomalies: a meta-analysis. *J Obstet Gynaecol Can*. 2006;28(8):680-689.
20. Pena-Rosas JP, Viteri FE. Effects of routine oral iron supplementation with or without folic acid for women during pregnancy. *Cochrane Database Syst Rev*. 2006;3:CD004736.
21. Ewigman BG, Crane JP, Frigoletto FD, et al. Effect of prenatal ultrasound screening on perinatal outcome. RADIUS Study Group. *N Engl J Med*. 1993;329:821-827.
22. Halpern SH, Abdallah FW. Effect of labor analgesia on labor outcomes. *Current Opin Anaesthesiol*. 2010;23(3):317-322.
23. Graham EM, Patersen SM, Christo DK, Fox HE. Intrapartum electronic fetal heart rate monitoring and the prevention of perinatal brain injury. *Obstet Gynecol*. 2006;108(3 Pt 1): 656-666.
24. Carroli G, Mignini L. Episiotomy for vaginal birth. *Cochrane Database Syst Rev*. 2009;(1):CD000081.
25. Zwelling E. Overcoming the challenges- maternal movement and positioning to facilitate labor progress. *MCN Am J Matern Child Nurs*. 2010;35(2):72-78.

5 END OF LIFE

Mindy A. Smith, MD, MS
Radha Raman Murthy Gokula, MD, CMD

PATIENT STORY

An 89-year-old frail woman presents with Alzheimer dementia, hypothyroidism, depression, congestive heart failure, and macular degeneration. Her functional status was gradually declining. It was difficult for her family to provide 24-hour care and she was admitted to a nursing facility. Her dementia worsened over a period of 2 years in the nursing facility and she became incontinent of urine and feces while developing limitations in speech and ambulation. She could not sit up without assistance and lost her ability to smile and hold her head up independently. The facility was very supportive and a hospice consult was initiated. **Figure 5-1** shows Dr. Gokula along with the hospice nurse visiting the patient for admission to hospice care.

FIGURE 5-1 Family physician Dr. Murthy Gokula and hospice nurse Chris Emch are comforting and examining a terminally ill patient nearing the end-of-life in Heartland Hospice.

INTRODUCTION

End-of-life care is care that is delivered to patients of all ages who have a very short life expectancy. This care is focused on meeting the patient's emotional and physical needs for symptom relief and general comfort care, and offering patient and family support.

The five basic principles of palliative care are:[1]

- Respect the goals, preferences, and choices of the person.
- Look after the medical, emotional, social, and spiritual needs.
- Support the needs of family members.
- Help patients and their families access needed healthcare providers and appropriate care settings.
- Provide excellence in care at the end of life (see **Figure 5-1**).

The quality-of-care domains for a person at the end of life are:[2]

- Physical and emotional symptom management.
- Support of function, autonomy, personal dignity, and self-respect.
- Advanced care planning.
- Aggressive symptom control near death.
- Patient and family satisfaction.
- Patient's assessment of overall quality of life and well-being.
- Family burden—emotional and financial.
- Survival time.
- Provider continuity and skill.
- Bereavement services.

EPIDEMIOLOGY

- Approximately 25,000 children per year in the United States are born with or develop a serious or life-threatening disease such as cancer, cystic fibrosis, cerebral palsy, or muscular dystrophy.[3]
- According to National Health Center statistics, there were approximately 2.46 million deaths in the United States in 2010; most were attributed to cardiovascular disease and cancer.[4]
  - Among patients ages 1 to 24 years, leading causes of death were external causes (i.e., accidents, homicide, and suicide), followed by cancer and heart disease. As age increases, there is a trend toward chronic conditions being responsible for deaths.
  - The major causes of death in the population ages 25 to 44 years were accidents, cancer, heart disease, suicide, homicide, and other causes.
  - For those ages 45 to 64 years, leading causes of death were cancer, heart disease, accidents, chronic respiratory diseases, and liver disease.

  The common causes of death in persons older than age 65 years are heart disease, cancer, chronic lower respiratory disease, stroke, and Alzheimer disease.
- In 2009, heart disease, cancer, chronic lower respiratory diseases, stroke, and accidents accounted for almost 64% of all deaths in the United States.[5]
- Thirty-two percent of all deaths in the United States in 2007 were inpatient hospital deaths.[6] Average hospital costs for a stay ending in death were $23,000, approximately 2.7 times higher than for a patient discharged alive.

Hospice services were involved for approximately 20% of dying patients.[7] More than 70% of hospice patients had cancer and 90% of hospice patients died outside the hospital. The use of hospice and other end-of-life services varies among different racial groups in the United States:[8]

- Whites are more aware of advanced directives when compared to the nonwhite racial or ethnic groups.
- The use of life-sustaining treatments is more common among African Americans when compared to other racial groups.
- Cultural differences are also seen for disclosure of information about a terminal illness. Korean, Mexican, Japanese, and Native American populations are more likely to discourage discussion of terminal illness and patient prognosis and prefer families to be informed.
- The involvement of family in the decision-making process with end-of-life care was seen among all racial groups, but Asian and Hispanic Americans prefer family-centered decision making when compared to other racial and ethnic groups.

ETIOLOGY AND PATHOPHYSIOLOGY

Causes of death are multifactorial. Following are the major modifiable contributors:

- Tobacco use—Of all the adults in the United States, 20.6% smoke cigarettes; the highest rates are among men (23.5%) and American Indians/Alaska Natives (23.2%).[9] It is estimated that nearly 1 of every 5 deaths each year in the United States is attributable to smoking.[10] Smoking increases the risk of developing emphysema (10- to 13-fold), heart and cardiovascular disease (2- to 4-fold), and many cancers (1.4- to 3-fold).
- Poor diet—Diets that are high in fat (>40% of calories consumed) are associated with increased risk of breast, colon, endometrial, and prostate cancer. Diet is important in controlling diabetes, heart disease, obesity, and chronic renal disease.
- Physical inactivity—Those who exercise regularly live longer and are healthier; exercise reduces the risk of cardiovascular disease and hypertension and improves function in those with depression, osteoarthritis, and fibromyalgia. Unfortunately less than 20% of adults met the 2008 federal guidelines for aerobic activity and muscle-strengthening.[11]
- Alcohol consumption—Alcohol is consumed by 80% of the population, and 10% to 15% of men and 5% to 8% of women are alcohol dependent. Excess alcohol consumption (>3 drinks per day) is associated with mood disorders (10% to 40%), cirrhosis (15% to 20%), and neuropathy (5% to 15%); it increases the risk of pancreatitis (3-fold) as well as cancers of the breast (1.4-fold), esophagus (3-fold), and rectum (1.5-fold).[12] In addition, based on data from 2009, an estimated 30.2 million people (12%) ages 12 years or older reported driving under the influence of alcohol at least once in the past year.[13]
- Injury—In 2004, 167,184 people died as a result of injury, accounting for 7% of all deaths.[14] The majority of injury-related deaths are unintentional. Falls are the leading mechanism of injury-related death for elderly people, while for adults 35 to 53 years of age, poisoning is the leading mechanism of injury-related death. Motor vehicles in traffic are the leading mechanism of injury-related death for all other age groups, except for children younger than age 2 years. Many of these deaths are preventable.
- Sexual behaviors—Sexually transmitted infections (STIs) are among the most common infectious diseases and affect approximately 13 million people in the United States each year; most of these people are younger than age 25 years. Sexually transmitted diseases (STDs) are associated with increased risk of HIV/AIDS; in 2007, there were approximately 455,636 persons living with AIDS in the United States.[15] Causes of death from AIDS include infections (especially pulmonary and central nervous system), cancer (especially Kaposi sarcoma and non-Hodgkin lymphoma), cardiomyopathy, and nephropathy.
- Illicit use of drugs—Drug addiction remains a major problem in the United States. According to data from the National Institute on Drug Abuse Monitoring the Future Survey of more than 46,000 eighth to 12th grade students, increases were seen in daily marijuana use (21.4% of high school seniors in the past 30 days) and lifetime ecstasy use in eighth graders (from 2.2% in 2009 to 3.3% in 2010), while decreases were noted in methamphetamine use (from 6.5% in 1999 to 2.2% in 2010) and current cocaine use (from 2.3 million in 2003 to 1.6 million in 2009).[12] Cocaine is associated with death from respiratory depression, cardiac arrhythmias, and convulsions; methamphetamine use is associated with life-threatening hypertension, cardiac arrhythmia, subarachnoid and intracerebral hemorrhage, ischemic stroke, convulsions, and coma.

- Microbial agents—Microbial agents remain a major cause of death and disability with continued discovery of new agents and increasing drug resistance. Although it is difficult to ascertain whether an infectious agent caused death or was incidental to death, the expert panel of investigators in New Mexico, on the basis of autopsy data, found that 85% (106 of 125) of the deaths (late 1994 to mid-1996) were identified as infectious disease related.[16]
- Toxic agents—Toxic agents include poisons and environmental toxins. In the United States in 2008, there were 36,500 poisoning deaths; the vast majority were unintentional.[17] Opioid pain medications were involved in more than 40%. Poisoning was the third-leading method of suicide from 2005 to 2007, with 75% a result of alcohol and/or drug overdose. The most commonly used drugs identified in drug-related suicides were prescription drugs in the opioid, benzodiazepine, and antidepressant classes.[18]

DIAGNOSIS

It is estimated that approximately 70% of all deaths are preceded by a disease/condition such that it is reasonable to plan for dying in the near future.[6] These diseases/conditions are as follows:

- Cancer that is widespread, aggressive, or metastatic and for patients who no longer seek curative care. Other clues include a decline in performance status and/or significant unintentional weight loss.
- Dementia with an inability to ambulate, bathe, or dress without assistance; associated urinary or fecal incontinence; inability to meaningfully communicate; or associated with life-threatening infections, multiple stage 3 or 4 skin ulcers, inability to maintain sufficient fluid and calorie intake, or failure to thrive (including a temporal decline in functional status).
- Patients confined to bed or who require assistance with all the basic activities of daily living.
- Patients with a body mass index less than 22 and/or those who refuse or do not respond to enteral or parenteral nutritional support.
- Heart disease that is poorly responsive to optimal medical treatment, New York Heart Association (NYHA) class IV, or congestive heart failure with poor ejection fraction (≤20%). Based on data from multiple studies including SUPPORT, Framingham, and IMPROVEMENT, 1-year mortality estimates are as follows: NYHA Class II (mild symptoms), 5% to 10%; Class III (moderate symptoms), 10% to 15%; Class IV (severe symptoms), 30% to 40%. Independent predictors of poor prognosis in patients with heart failure include recent cardiac hospitalization, renal insufficiency (creatinine ≥1.4 mg/dL), systolic blood pressure less than 100 mm Hg and/or pulse greater than 100 beats/min, treatment-resistant ventricular dysrhythmias, treatment resistant-anemia, hyponatremia, cachexia, reduced functional capacity, and comorbidities (e.g., diabetes).[19]
- HIV/AIDS with CD4 count less than 25 or persistent viral load greater than 100,000 copies/mL plus at least one of the following: wasting (loss of 33% of lean body mass); major AIDS-defining refractory infection (e.g., *Cryptosporidium* infection) or malignancy (e.g., central nervous system or systemic lymphoma); progressive multifocal leukoencephalopathy; renal failure; Karnofsky Performance Status (KPS) less than 50%; advanced AIDS dementia complex; or significant functional decline in the activities of daily living.
- Neurologic disease (e.g., Parkinson disease, amyotrophic lateral sclerosis, multiple sclerosis, muscular dystrophy, and myasthenia gravis) that is associated with rapid progression and/or critical nutritional state, life-threatening infections in the preceding 12 months, stage 3 or 4 skin ulcers, critically impaired breathing capacity and declined ventilator support, or life-threatening complications (e.g., recurrent aspiration, sepsis).
- Pulmonary disease, including disabling dyspnea at rest or with minimal exertion, increased emergency department visits and/or hospitalizations, hypoxemia on room air (oxygen saturation <88%), cor pulmonale, unintentional progressive weight loss, or resting tachycardia greater than 100 beats/min.
- End-stage renal disease with progressive decline in those not seeking dialysis (or not a candidate), with a calculated creatinine clearance less than 10 (<15 for patients with diabetes) or serum creatinine greater than 8 mg/dL (>6 mg/dL for patients with diabetes).
- End-stage liver disease with progressive decline in those with refractory ascites, spontaneous bacterial peritonitis, hepatorenal syndrome, hepatic encephalopathy, or recurrent variceal bleeding despite treatment.
- Stroke associated with coma in the acute phase; coma with abnormal brainstem response, absent verbal response, absent withdrawal response to pain, or serum creatinine greater than 1.5 mg/dL at day 3; dysphagia and insufficient intake of fluids and calories; poor functional status; or poststroke dementia.
- Nonspecific terminal illness characterized by a rapid decline, disease progression, or progressive weight loss; dysphasia with aspiration; increase in emergency department visits and/or hospitalizations; worsening pressure ulcers despite optimum care; or a decline in systolic blood pressure below 90 mm Hg.

Unfortunately, physicians are often reluctant to make this determination, resulting in palliative and hospice care not being offered until very late in the course of the illness. In addition, physicians often believe that they must be able to predict a life expectancy of less than 6 months with certainty to institute hospice care.

The National Hospice and Palliative Care Organization has evidence-based guidelines on determining prognosis for a number of noncancer conditions.[20] This information can assist clinicians in working with patients who are at the end of life on their advanced care decisions and planning.

Two validated instruments that may help clinicians estimate prognosis are the Palliative Performance Scale (PPS) and the KPS.

- The PPS (http://meds.queensu.ca/palliativecare/assets/pps_scale_tool.pdf) rates information on ambulation, activity and evidence of disease, self-care, intake, and consciousness level. In a retrospective cohort study, the PPS was found to be a strong predictor of survival when applied at admission to patients in palliative care.[21] In this study, median survival time at PPS of 10% was 1 day, survival with PPS of 20% was 2 days, at PPS of 30% survival was 9 days, while at PPS of 60% median survival was 40 days.
- The KPS (http://www.hospicepatients.org/karnofsky.html) is often used to follow the course of illness and is based on performance status ranging from normal (100%) to dead (0%).

CLINICAL FEATURES

Common physical symptoms reported by dying patients:[6]

- Constipation (90%).
- Fatigue and weakness (90%).
- Dyspnea (75%) and other cardiopulmonary symptoms such as cough.
- Pain (36% to 90%).
- Insomnia.
- Other GI symptoms, including dry mouth, anorexia, nausea, vomiting, constipation, diarrhea, and dysphagia.
- Fecal and urinary incontinence.
- Dizziness.
- Swelling and numbness of the extremities.

Common mental and psychological symptoms reported by dying patients:[6]

- Depression (75% symptomatic; <25% with major depression) and feelings of hopelessness, anxiety, and/or irritability.
- Confusion and delirium (up to 85% at the end stage).

A population-based survey of family members, friends, and care givers in six U.S. communities found that:[22]

- Seventy-one percent of terminally ill patients had shortness of breath.
- Fifty percent had moderate to severe pain.
- Thirty-six percent were incontinent of urine or feces.
- Eighteen percent were fatigued enough to spend more than 50% of their waking hours in bed.

MANAGEMENT

Management often begins with communicating bad news to patients and families about likely or imminent death. This task can be extremely difficult. In cases where the patient is not deemed legally competent, make sure that the legal decision maker is present. In addition, if the patient is a non-English speaker, consider obtaining a skilled medical interpreter rather than relying on a family member. Providers may find the following P-SPIKES approach useful:[23]

- Preparation—Review information to be presented and practice.
- Setting—Arrange time and place, ensure privacy, and include important support persons.
- Perception of patient—Inquire about the patient's and the family's understanding of the illness.
- Information needs—Find out about what the patient and family need to be told and in how much detail.
- Knowledge of the condition—Provide bad news sensitively and slowly, warning them any bad news is imminent and checking to see whether there is understanding.
- Empathy and exploration—Acknowledge the feelings expressed, give the patient and family time to react, and remind them that you are not abandoning them.

- Summary/strategic planning—Discuss next steps or schedule follow-ups to do this if more time is needed.

Roles for the primary care provider include consultation, providing anticipatory guidance, providing support and comfort, and assisting with identifying and managing symptoms (including pain control) (**Figure 5-2**).

In assisting dying patients and their families/caregivers with making decisions about their care, clinicians should be prepared to discuss the following:

- Realistic treatment options for cure or palliation of the primary disease process.
- Advance directives and withholding of life-sustaining treatment.
- Cultural beliefs and preferences (e.g., truth-telling vs. protecting the patient, religious beliefs).
- Preferences for place of care for those dying, involvement of others, and symptom management.

A number of factors are important in providing optimal care to the dying. In a study of factors considered important to seriously ill patients, recently bereaved family members, and physicians involved in end-of-life care, investigators found the following:[24]

- There was a general agreement on the items relating to having preferences in writing, symptom control, being kept clean, experiencing physical touch, good communication and knowing what to expect, getting one's affairs in order and achieving a sense of completion, and maintaining dignity and a sense of humor.
- Patients reported wanting to remain mentally aware, not be a burden, and noted the importance of prayer and being at peace with God. They were not as concerned about dying at home.
- Family members reported wanting to use all the treatment options and to help patients avoid pain, shortness of breath, and suffering.

ADVANCE DIRECTIVES

Advance directives and advance care planning continue to be poorly utilized. Clinicians should consider outpatient and inpatient opportunities to introduce these concepts with the goals of empowering the patient and understanding the patient's preferences if they are too sick to speak for themselves. Possible scenarios can be discussed such as recovery from an acute event (specifying acceptable interventions) and persistent vegetative state (preferences for life-sustaining interventions).

- The national POL ST (physician orders for life-sustaining treatment) Paradigm task force is a new program designed to improve the quality of end-of-life care based on effective communication of patient wishes, documentation of medical orders, and a commitment by healthcare professionals to honor these wishes. Information can be found at **http://closure.org** and includes web-based resources for patients and health providers.
- Advance directive documents are of two broad types: instructional directives and proxy designations.
  - Instructional directives, such as living wills, describe decisions about care and healthcare. These can be general or specific. Although 80% of Americans endorse completing living wills, only 20% (and fewer than one-third of healthcare providers)

FIGURE 5-2 Photograph of Marjorie Clarke taken by her grandson. She suffered from Alzheimer disease that left her depressed and frustrated. In this picture, taken in 1996, Marjorie listens to her nurse describe the scene and explain that they are on the front porch of her home. She died in January, 1997. (*Courtesy of Marshall Clarke.*)

have completed them.[6] Specific forms do not have to be used and oral directives may be enforceable.[25]

- Proxy designations—Appointing an individual or individuals to make medical decisions (i.e., durable power of attorney for healthcare).

Legal aspects—The United States Supreme Court has ruled that patients have a right to decide about refusing or terminating medical interventions. Many states have their own statutory forms for living wills.

- The American College of Physicians and the American Society of Internal Medicine End-of-Life Care Consensus Panel note that life-sustaining treatment may be withheld for patients unable to speak for themselves if it is believed to be the patient's wish, the surrogate decision maker states that it is the patient's wish, and/or it is in the patient's best interests to do so.[25]
- The prescription of high-dose opioids to relieve pain in terminally ill patients that result in death will not lead to criminal prosecution provided it was the physician's intent to relieve suffering.[25]

HOSPICE CARE AND SERVICES

Hospice care refers to care when curative interventions have been judged to be no longer beneficial. This type of care can be delivered in many settings, including home, hospital, and special residential facilities.

- The types of hospice services include physician and nursing care, home health aides, pastoral care, counseling, respite care, and bereavement programs (**Figure 5-3**).
- Hospice eligibility general guidelines include fulfilling the criteria for end-stage disease as outlined above and documenting both the patient's and family's decision on palliative care rather than curative care and rapid disease progression. In addition, documentation of significant functional decline is important using validated instruments like FAST (Functional Assessment Staging), PPS, BADLs (Basic Activities of Daily Living), and/or NYHA Class IV heart disease. Other criteria include weight loss of 7.5% or 10% in the preceding 3 to 6 months, respectively, or serum albumin less than 2.5 g/dL.

Physicians should be aware of the Medicare Hospice Benefit (MHB) covered under Medicare Part A (physician services are billed under Medicare Part B).[26] In the United States, the MHB pays for 80% of all hospice care including medical, nursing, counseling, and bereavement services to terminally ill patients and their families. Medicare beneficiaries who choose hospice care receive noncurative medical and support services for their terminal illness. Home care may be provided along with inpatient care if needed and a variety of other services that are not covered by Medicare. Eligibility criteria are:

- Patient eligible for Medicare Part A or Medicaid.
- Patient is terminally ill, that is, patient's physician and the medical director of hospice certify that the patient is terminally ill and has a life expectancy of 6 months or less if the disease runs its normal course. If the medical director is the patient's physician, only one signature is required.
- Patient chooses hospice care and signs a Medicare hospice benefits form. This process is reversible and patients may at a future time elect to return to Medicare Part A.

FIGURE 5-3 Dr. Alan Blum is a family physician who has been doing sketches of his patients for decades now. When he presents his drawings of his patients, he reads his poetic stories that go with the drawings. Some of his drawings have been published in *JAMA*.

- Hospice care is provided by a Medicare-certified hospice program.
- Under Medicare, do not resuscitate (DNR) status cannot be used as a requirement for admission.

Length of benefits:

- Entitled to receive hospice care as long as he or she meets the eligibility criteria.
- Hospice benefit consists of two 90-day benefit periods, followed by an unlimited number of 60-day benefit periods.
- Benefit periods may be used consecutively or at intervals.
- Patient needs to be certified terminally ill at the beginning of each period.
- No lifetime limit to hospice care for Medicare beneficiaries.
- If patient experiences remission of the disease and is discharged from hospice, the patient can be eligible for hospice care in the future without any regard to the previous use of hospice services.
- The same rules apply for Medicaid patients.

Services covered include physician, nurse, dietician, medical social services, medical supplies and equipment, outpatient drugs for symptom management and pain relief, and home care (e.g., aids, physical, occupational, and speech therapy). Other included services are as follows:

- Short-term general inpatient care for problems that cannot be managed at home—Most commonly intractable pain or delirium.
- Short-term respite care—Up to 5 days to permit family caregivers to take a break (can incur a 5% copayment).
- Counseling in home for patient and family.
- Bereavement, pastoral, and spiritual support for patient and family.
- Payment of consulting physician fees at 100% of Medicare allowance.
- Physician, nurse, social worker, and counselor on-call availability 24 hours a day, 7 days a week.

Services not covered include active treatment of terminal illness (except for symptom management and pain control of the terminal illness), care provided by a physician or facility that has not contracted with the patient's hospice agency, and continuous nursing assistant or nursing home room-and-board charges.

PALLIATIVE CARE

Palliative care is care focused on preventing, relieving, reducing, or soothing symptoms of disease without effecting a cure.[27] As such, it is not restricted to patients who are dying, but can be used along with a curative therapy. Many hospitals now have inpatient palliative care services to assist patients, families, and primary care providers in delivering this type of care.

General approach to palliative care focuses on 4 broad domains: managing physical symptoms, managing psychological symptoms, addressing social needs. and understanding spiritual needs.

- Needs assessment—Clinicians should focus on the four domains and try to understand the degree of difficulty and how much the identified problem interferes with the patient's life.
- Setting goals and continuous reassessment—Goals for care include improving symptoms, delaying disability, finding peace, and

providing for the loved ones. Plan times to review these goals as the course of the illness changes or progresses.

- Pain management—There is no reason that patients need to suffer, particularly at the end of life. Barriers to managing pain successfully include limited ability of providers to assess pain severity, fear of sanction/prosecution, and lack of knowledge (including awareness of guidelines).
  - Assessment of pain—Important aspects include periodicity (e.g., continuous), location, intensity, modifying factors, effects of treatments, and impact on the patient.
  - Intervention—This includes nonpharmacologic treatment (e.g., massage, positioning, transcutaneous electrical nerve stimulation [TENS], physical therapy), pain medications, and other palliative procedures (e.g., nerve blocks, radiotherapy, acupuncture).
  - Pain medications may be approached in a stepwise fashion from nonopioids (e.g., acetaminophen [4 g/day], ibuprofen [1600 mg/day]), to mild opioids (e.g., codeine [30 mg every 4 hours] or hydrocodone [5 mg every 4 hours]) to stronger opioids (e.g., morphine 5 to 10 mg every 4 hours).[28] Doses should be titrated as needed. Side effects (e.g., constipation, nausea, and drowsiness) should be anticipated and prevented (e.g., laxatives and antiemetic) or treated. Patients may become tolerant to these side effects after approximately 1 week. Specific pain syndromes may require additional consideration. These include:
    - Continuous pain, which requires round-the-clock dosing, rescue medication, and regular assessment and readjustment. If rescue medication has been needed, increase the daily opioid dose by the total dose of rescue medication the next day. For longer duration of action, transdermal fentanyl may be considered (100 mcg/h is equianalgesic to morphine 4 mg/h and has a duration of 48 to 72 hours).
    - Neuropathic pain (arising from disordered, ectopic nerve signals), which is typically shock-like or burning. Medications to consider in addition to opioids are gabapentin (100 to 300 mg daily or up to 3 times daily), 5% lidocaine patch (3 patches daily for a maximum of 12 hours), tramadol (50 to 100 mg 1 to 3 times daily), and tricyclic antidepressants (10 to 25 mg at bedtime titrated to 75 to 150 mg).[29]
  - Adjunctive analgesic medications are those that potentiate the effects of opioids. These include the above treatments for neuropathic pain, glucocorticoids (e.g., dexamethasone once daily), clonidine, and baclofen.
  - Legal concerns—Physicians may be unwilling or uncomfortable providing high-dose opioids out of fear that they would be hastening the patient's death. However, the assumption that opioids appropriately titrated to control pain hasten death is not supported by medical evidence. In addition, as noted above, the physician's intent to relieve suffering, despite the risk of death, is ethical and unlikely to result in prosecution.

Control of common symptoms:[6]

- Constipation—Secondary to medications, inactivity, poor nutritional/hydration, limited fiber intake, confusion, and intestinal obstruction; comorbidities such as diabetes mellitus, hypothyroidism, and hypercalcemia. The goal of treatment should be one bowel movement every 1 to 2 days. Constipation prophylaxis should be started for all patients taking regular opiate regimens. Options include increasing fiber, stool softeners (e.g., sodium docusate [Colace] 300 to 600 mg/day orally), stimulant laxatives (e.g., prune juice ½ to 1 glass/day, senna [Senokot] 2 to 4 tablets/day, bisacodyl 5 to 15 mg/day orally or per rectum), and osmotic laxatives (e.g., lactulose 15 to 30 mL every 4 to 8 hours, magnesium hydroxide [milk of magnesia] 15 to 30 mL/day).
- Dyspnea—When possible, treat reversible causes (e.g., infection, hypoxia). Options include opioids (e.g., codeine 30 mg every 4 hours, morphine 5 to 10 mg every 4 hours) and anxiolytics (e.g., lorazepam 0.5 to 2 mg oral/sublingual/IV, diazepam 5 to 10 mg oral/IV). A parenteral infusion or long-acting opiate can also be tried, with bolus dosing for breakthrough pain; nebulized opiates are ineffective for dyspnea.[30] For patients with a history of respiratory disease, consider bronchodilators and/or glucocorticoids. For those with excessive secretions, scopolamine may be considered, starting with a low dose every 2 hours, or with worsening dyspnea, as needed. Oxygen is commonly prescribed, although data do not support effectiveness in improving the sensation of breathlessness;[30] one crossover trial found ambient air delivered by nasal cannula was as effective as oxygen for dyspnea.[31] The inexpensive and simple practice of blowing ambient air on the patient's face may help relieve dyspnea.
- Fatigue—Secondary to disease factors (e.g., heart failure, tumor necrosis factor), cachexia, dehydration, anemia, hypothyroidism, and medications. Options include decreasing activity, increasing exercise as tolerated, changing medications, glucocorticoids (e.g., dexamethasone once daily), or stimulants (e.g., dextroamphetamine 5 to 10 mg orally). Modafinil, an analeptic drug, may also be considered (initial dose: 200 mg).
- Depression—Because many of the somatic symptoms used to diagnose depression in healthy individuals are present in patients who are dying, psychological criteria become more important in making treatment decisions. Options include counseling, exercise, and medications (e.g., selective serotonin reuptake inhibitors); low doses should be used initially (e.g., fluoxetine 10 mg/day) and increased as needed. Psychostimulants (e.g., dextroamphetamine or methylphenidate 2.5 to 5 mg twice daily) may be considered if rapid onset of action is needed; these may be used in conjunction with traditional antidepressants.
- Delirium—Secondary to metabolic abnormalities (liver failure, electrolyte disturbance, vitamin B12 deficiency), infection, brain tumors, medications, and multiple other causes. Options include treating reversible causes and medications including neuroleptics (e.g., haloperidol 0.5 to 5 mg orally/subcutaneous/IM/IV every 1 to 4 hours, risperidone 1 to 3 mg every 12 hours), anxiolytics (e.g., lorazepam 0.5 to 2 mg oral/IM/IV), and anesthetics (propofol 0.3 to 2 mg/h continuous infusion).

ADDRESSING SOCIAL NEEDS

Considerations include economic burden and caregivers.

- The U.S. health insurance system is neither universal nor comprehensive and many patients and their families find themselves under tremendous financial strain.
- Twenty percent of terminally ill patients spend more than 10% of the family income on healthcare costs beyond insurance premiums.[6]

- Ten percent to 30% of families need to secure additional monies by means such as selling assets or taking out a second mortgage to cover healthcare costs.[6]
- Twenty percent of caregivers stop work to provide care for a terminally ill family member.[6]
- Families/caregivers often need outside help, such as providing personal care for the patient (such as bathing), psychological or spiritual counseling, respite care, or making arrangements for the body after death.
- Primary care providers can facilitate encounters with family and friends by offering their presence and suggestions about easing the visits (e.g., reading to the patient, sharing music, or creating a videotape, audiotape, or scrapbook).
- Hospice and social workers can offer great assistance to patients and families in addressing these needs.

Understanding spiritual needs:

- Approximately 70% of dying patients become more religious or spiritual at the end of life.
- As noted by Steinhauser et al., patients noted the importance of prayer and being at peace with God.[24]
- Physicians should ask about and support patient and family expressions of spirituality and consider encouraging pastoral care, as desired.

PATIENT AND FAMILY EDUCATION

It is very important to involve patients and their families in discussion at an early stage as most want to know their diagnosis and prognosis.

- The role of the primary care physician should be discussed, particularly if other providers are involved in the care of the patient. Possible roles include consultation about care needs, anticipatory guidance on prognosis and expected symptoms, provision of support and comfort, and assistance with managing symptoms.
- Families usually suffer emotionally, spiritually, and financially as they care for the patient.[21] Family members often experience a sense of hopelessness, anger, guilt, and powerlessness when they cannot relieve the suffering of their terminally ill family member.
- Families who need to provide care for a terminally ill patient should be made aware of community resources and the provisions in the Family Medical Leave Act.[32]
- It is not unusual to see hidden family conflicts resurface in the face of a terminal illness, and any emotional tension that exists between the caregivers and patient can impede care. Physicians should be sensitive to the conflicts and cultural influences and closely observe how patients and their families are communicating so that they can better support them, allowing them to express their emotions and concerns and referring them to appropriate counselors or support groups when needed.[33,34]
- Children should not be excluded from this process and the physician, with permission, can help in determining what children already know about the illness and in providing accurate information about the diagnosis, prognosis, and treatment expectations for the dying family member. Also advise caregivers to try to maintain the children's daily schedule and routines of the family as much as possible, monitor for problems at school, encourage questions, and plan activities (e.g., reading a story) when visiting ill family members. It may be helpful to inform teachers and counselors at school about the family situation and request that the teachers let the parent know if the child is having any difficulty or talks about worries.
- Consider counseling for the child if the child requests help or displays symptoms of depression or anxiety that interfere with school, home, or peers; risk-taking behavior; or significant discord with others.

The following are processes that many dying persons go through:

- Social withdrawal—Initial withdrawal is from the surroundings and then worldly interests decline and finally withdrawal from family, ultimately leading to loss of communication.
- Decreasing nutritional requirements—There is a decreased need for fluids and solids; fluids are usually preferred and should follow what the patient wants rather than force-feeding.
- Disorientation—There is increased confusion with time, place, and person. Usually patients talk about seeing people who have already died or state that their death is nearing. Redirecting the patient is necessary only if asked for or if the patient is distressed.
- Decreased senses—Hearing and vision decrease. Using soft lights helps with decreasing visual hallucinations. Speak softly and gently as patients hear even at the end of life. Hearing is the last of the five senses to be lost.
- Restlessness—Also called "terminal restlessness" is caused by the change in the body's metabolism. Reassurance is important, and appropriate symptom management with medications may be helpful.
- Sleep—There is increased time spent in sleep that may be as a result of changes in the body's metabolism or natural to the underlying disease process. Spending time at the bedside can help capture the time when the patient is most alert.
- Incontinence of urine and bowel movements is often not a problem until death is very near. Absorbent pads can be placed under the patient for greater comfort and cleanliness or a urinary catheter may be used for comfort care. The amount of urine will decrease and becomes darker at the end of life.

Physical changes to be expected include the following:

- Skin color changes including flushing, bluish hue to the skin, and cold sensation of the skin. Skin may have a jaundiced look when the patient is approaching death. The arms and legs of the body may become cool to the touch. The hands and feet become purplish. The knees, ankles, and elbows are blotchy. These symptoms are a result of decreased circulation.
- Blood pressure decreases; the pulse may increase or decrease.
- Body temperature can fluctuate; fever is common.
- Increased perspiration along with clamminess.
- Respirations may increase, decrease, or become irregular; there may be periods of cessation of breathing (apnea).
- Congestion can present as a rattling sound in the lungs and/or upper throat. This occurs because the patient is too weak to clear the throat or cough. The congestion can be affected by positioning,

may be very loud, and sometimes just comes and goes. Elevating the head of the bed and swabbing the mouth with oral swabs may be helpful.

- The patient may enter a coma before death and not respond to verbal or tactile stimuli.

FOLLOW-UP

Withdrawal of life-sustaining treatment:

- Evidence-based criteria for guiding physicians through this process is lacking; however, general consensus exists based on ethical and clinical principles in the care of these patients.[35,36]
  - Withdrawal of life-sustaining treatment can be considered when curative care is not possible and supportive or other treatment is no longer desired and does not provide comfort to the patient.
  - Withholding life-sustaining treatment is morally, ethically, and legally equivalent to withdrawing life support. Any kind of treatment that is given to the patient can be withdrawn or withheld. In conducting these discussions with patients and their families, the physician needs to consider a patient's information-sharing preferences (e.g., a preference for limited information), minimum acceptable quality of life and functional status, whether the patient is able to understand the consequences of life-sustaining treatment, whether procedures offered conflict with the patient's values, and the patient's need for advice and guidance.[37]
  - Treat withdrawal of life-sustaining treatment equivalent to a medical procedure and all formalities (e.g., informed consent) should be fulfilled prior to the procedure.
  - If withdrawal of one life-sustaining treatment is indicated, then consider withdrawing all existing treatments for the patient.
- A general consensus should be reached with the healthcare team and family members that is in the best interest of the patient. Following are the steps that should be taken for withdrawal of life support:[36]
  - Informed consent.
  - Appropriate setting and monitoring.
  - Sedation and analgesia.
  - Having a plan for withdrawal (information about the protocol can be found in fast facts at www.eperc.mcw.edu).
  - Pastoral, nursing, and emotional support.
  - Documentation.
  - Interventions to improve care during withdrawal of life-sustaining treatment that can be considered are consultation with an ethics committee, palliative care team, family conferences, and a standardized order form for withdrawing life-sustaining therapies.[38]

Grief and bereavement follow-up:

- Manifestations of grief consist of both psychological symptoms (e.g., sadness, anxiety, emotional lability, apathy, impaired concentration) and physical symptoms (anorexia, change in weight, trouble initiating or maintaining sleep, fatigue, headache). In the first month following a death, it is important to reassure surviving family members and friends that these manifestations of grief are normal and to offer support, suggestions for symptom management, and coping resources.
- Subsequent follow-up visits should be used to assess the progress of mourning and to identify depression; if the latter is identified, consider pharmacotherapy and counseling.
- Usually, the primary physician is notified of the death and may be required to make the pronouncement (based on lack of vital signs and lack of response to noxious stimulus) and complete the death certificate (noting cause of death and contributing medical conditions).
- Following the death of the patient, personal expressions of condolence from the primary care provider(s) and staff should be encouraged and range from cards to attending visitation and the funeral; based on personal experience, the latter can assist with grieving and closure for the physician.

PATIENT RESOURCES

- Caring Connections—**http://www.caringinfo.org.**
- Get Palliative Care—**www.getpalliativecare.org.**
- National Family Caregivers Association—**http://www.nfcacares.org/.**
- National Hospice and Palliative Care Organization—**http://www.nhpco.org.**

Online Living Will Completion for Texans—**https://www.texaslivingwill.org/.**

PROVIDER RESOURCES

- American Academy of Hospice and Palliative Medicine—**http://www.aahpm.org/.**
- National Hospice and Palliative Care Organization—**http://www.nhpco.org.**
- American Pain Society—**http://www.ampainsoc.org.**
- American Society for Bioethics and Humanities—**http://www.asbh.org.**
- American Society of Law, Medicine and Ethics—**http://www.aslme.org.**
- End-of-Life Care Consensus Panel—American College of Physicians-American Society of Internal Medicine—**http://www.acponline.org/running_practice/ethics/.**
- The EPEC Project (Education resource online)—**www.epec.net.**
- Palliative Care Matters—**http://www.pallcare.info.**

SUGGESTED READINGS

- Baugher R, Calija M. *A Guide to the Bereaved Survivor*. Newcastle, WA; 1998. [ISBN:0-9635975-0-7.]
- Brown LK, Brown M. *When Dinosaurs Die: A Guide to Understanding Death*. Little Brown & Company;1996. [ISBN:0-316-11955-5.]
- Callanan M, Kely, P. *Final Gifts: Understanding the Special Awareness, Needs and Communications of the Dying*. Bantam Books; 1992. [ISBN: 0-553-37876-7.]
- Hanson W. *The Next Place*. Waldman House Press; 1997. [ISBN: 0-931674-32-8.]

- Heegaard M. *When Someone Special Dies: Children Can Learn to Cope with Grief*. Woodland Press; 1988. [ISBN:0-9620502-0-2.]
- Lattanzi-Licht M, Mahoney JJ, Miller GW. *The National Hospice Organization Guide to Hospice Care: The Hospice Choice: In Pursuit of A Peaceful Death*. Simon & Schuster;1998. [ISBN:0-684-82269-5.]
- Ray MC. *I Am Here to Help: A Hospice Workers Guide to Communicating with Dying People and Their Loved Ones.* Hospice Handouts, McRay Company;1992. [ISBN:0-963611-0-1.]
- Sameul-Traisman E. *Fire in My Heart, Ice in My Veins: A Journey for Teenagers Experiencing a Loss*. Centering Corporation;1992. [ISBN:1-56123-056-1.]

REFERENCES

1. Von Gunten CF. Interventions to manage symptoms at the end of life. *J Palliat Med.* 2005;8 (Suppl 1):S88-S94.
2. Lynn J. Measuring quality of care at the end of life: a statement of principles. *J Am Geriatr Soc*. 1997;45:526-527.
3. Friebert SE. *NHPCO Facts and Figures: Pediatric Palliative and Hospice Care in America*. Alexandria, VA: National Hospice and Palliative Care Organization; 2009.
4. Murphy SL, Xu J, Kochanek KD. Deaths: preliminary data for 2010. *Natl Vital Stat Rep*. 2012;60(4):1-69.
5. Kochanek KD, Xu JQ, Murphy SL, et al. *Deaths: Preliminary data for 2009*. *National Vital Statistics Reports*; Vol. 59 No. 4. Hyattsville, MD: National Center for Health Statistics. 2011.
6. Zhao Y, Encinosa W. *The cost of end-of-life hospitalizations, 2007: Statistical Brief #81*. Rockville, MD: Agency for Healthcare Research and Quality; November 2009, revised April 2010. Available at http://www.hcup-us.ahrq.gov/reports/statbriefs/sb81.pdf. Accessed March 2012.
7. Emanuel EJ, Emanuel LL. Palliative and end-of-life care. In: Kasper DL, Braunwald E, Fauci AS, Hauser SL, Longo DL, Jameson JL, eds. *Harrison's Principles of Internal Medicine,* 16th ed. New York: McGraw-Hill; 2005:53-66.
8. Kwak J, Healy WE. Current research findings on end-of-life decision making among racially or ethnically diverse groups. *Gerontologist*. 2005;45(5):634-641.
9. Centers for Disease Control and Prevention. Vital signs: current cigarette smoking among adults aged ≥18 years—United States, 2009. *MMWR Morb Mortal Wkly Rep*. 2010;59(35):1135-1140.
10. Centers for Disease Control and Prevention. State-specific smoking-attributable mortality and years of potential life lost—United States, 2000-2004. *MMWR Morb Mortal Wkly Rep*. 2009;58(2):29-33.
11. National Center for Health Statistics. *Health, United States, 2010: In Brief*. Hyattsville, MD: National Center for Health Statistics; 2011.
12. Schuckit MA. Alcohol and alcoholism. In: Kasper DL, Braunwald E, Fauci AS, Hauser SL, Longo DL, Jameson JL, eds. *Harrison's Principles of Internal Medicine*, 16th ed. New York: McGraw-Hill; 2005:2562-2566.
13. National Institute on Drug Abuse. *InfoFacts: Nationwide Trends*. http://www.drugabuse.gov/publications/infofacts/nationwide-trends. Accessed March 2012.
14. United States Department of Health and Human Services. *Injury in the United States: 2007 Chartbook*. http://www.cdc.gov/nchs/data/misc/injury2007.pdf. Accessed March 2012.
15. Centers for Disease Control and Prevention. *AIDS in the United States by Geographic Distribution*. http://www.cdc.gov/hiv/resources/factsheets/geographic.htm. Accessed March 2012.
16. Wolfe MI, Nolte KB, Yoon SS. *Fatal Infectious Disease Surveillance in a Medical Examiner Database*. http://www.cdc.gov/ncidod/eid/vol10no1/02-0764.htm. Accessed March 2012.
17. Centers for Disease Control and Prevention. *Drug Poisoning Deaths in the United States, 1980-2008*. http://www.cdc.gov/nchs/data/databriefs/db81.htm. Accessed March 2012.
18. Centers for Disease Control and Prevention. *Suicides Due to Alcohol and/or Drug Overdose*. http://www.cdc.gov/ViolencePrevention/pdf/NVDRS_Data_Brief-a.pdf. Accessed March 2012.
19. Reisfield GM, Wilson GR. *Prognostication in Heart Failure. Fast Facts and Concepts #143*. http://www.eperc.mcw.edu/fastfact/ff_143.htm. Accessed March 2012.
20. National Hospice and Palliative Care Organization. www.nhpco.org (for members). Accessed March 2012.
21. Lau F, Downing GM, Lesperance M, et al. Use of Palliative Performance Scale in end-of-life prognostication. *J Palliative Med*. 2006;9(5):1066-1075.
22. Emanuel EJ, Fairclough DL, Slutsman J, et al. Assistance from family members, friends, paid care givers, and volunteers in the care of terminally ill patients. *N Engl J Med*. 1999;341(13):956-963.
23. Buckman R. *How to Break Bad News: A Guide for Health Care Professionals*. Baltimore, MD: Johns Hopkins University Press; 1992.
24. Steinhauser KE, Christakis NA, Clipp EC, et al. Factors considered important at the end of life by patients, family physicians, and other care providers. *JAMA*. 2000;284(19):1476-1482.
25. Meisel A, Snyder L, Quill T; American College of Physicians—American Society of Internal Medicine End-of-Life Care Consensus Panel. Seven legal barriers to end-of-life care: myths, realities and grains of truth. *JAMA*. 2000;284(19):2495-2501.
26. Turner R. *Fast Facts and Concepts No. 82 and 83. Medicare Hospice Benefit Part 1*. January 2003. End-of-Life Physician Education Resource Center. www.eperc.mcw.edu. Accessed March 2012.
27. Field MJ, Cassel CK, eds. *Approaching Death: Improving Care at the End of Life*. Washington, DC: National Academy Press; 1997.
28. World Health Organization. *Pain Ladder*. www.who.int/entity/cancer/palliative/painladder/en/. Accessed March 1, 2007.
29. Dworkin RH, Backonja M, Rowbotham MC, et al. Advances in neuropathic pain: diagnosis, mechanisms, and treatment recommendations. *Arch Neurol*. 2003;60:1524-1534.
30. Clemens KE, Quednau I, Klaschik E. Use of oxygen and opioids in the palliation of dyspnoea in hypoxic and non-hypoxic palliative care patients: a prospective study. *Support Care Cancer*. 2009;17:367-377.
31. Philip J, Gold M, Milner A, et al. A randomized, double-blind, crossover trial of the effect of oxygen on dyspnea in patients with advanced cancer. *J Pain Symptom Manage*. 2006;32:541-550.

32. Department of Labor, Wage and Hour Division. *Family and Medical Leave Act*. http://www.dol.gov/whd/fmla/. Accessed March 2012.

33. Larson DG, Tobin DR. End of life conversations: evolving practice and theory. *JAMA*. 2000;284:1573-1578.

34. Della Santina C, Bernstein RH. Whole patient assessment, goal planning, and inflection points: their role in achieving quality end-of life care. *Clin Geriatr Med*. 2004;20:595-620.

35. Jonsen AR, Seigler M, Winslade WJ. *Clinical Ethics: A Practical Approach to Ethical Decisions in Clinical Medicine*, 4th ed. New York: McGraw-Hill; 1998.

36. Gordon DR. Principles and practice of withdrawing life-sustaining treatments. *Crit Care Clin*. 2004;20:435-451.

37. Billings JA, Krakauer EL. On patient autonomy and physician responsibility in end-of-life care. *Arch Intern Med*. 2011;171(9): 849-853.

38. Curtis JR. Interventions to improve care during withdrawal of life-sustaining treatments. *J Palliat Med*. 2005;8(Suppl 1): S116-S131.

6 SOCIAL JUSTICE

Mindy A. Smith, MD, MS
Richard P. Usatine, MD

Of all the forms of inequality, injustice in health care is the most shocking and inhumane.

—Martin Luther King, Jr.

The first question which the priest and the Levite asked was "If I stop to help this man, what will happen to me?" But … the Good Samaritan reversed the question: "If I do not stop to help this man, what will happen to him?"

—Martin Luther King, Jr.

PATIENT STORIES

At only 5.5 pounds (10 pounds less than the fifth percentile for weight on the World Health Organization's growth chart), an 8-month-old boy suffered from severe malnutrition. In the summer of 2003, amidst the height of Liberia's civil war, his aunt brought him to the Médecins sans Frontières/Doctors without Borders hospital for treatment. Because of the war, his family had been forced to flee from their home, leaving behind their usual methods of getting food. Dr. Andrew Schechtman was there to help the day the child was brought to the clinic in Liberia (**Figure 6-1**). Despite the best available treatment for the malnutrition and concurrent pneumonia, the boy died on his third hospital day.

FIGURE 6-1 Dr. Andrew Schechtman was there to help the day a severely malnourished child was brought to the clinic in war-torn Liberia. Despite the best available treatment that could be provided in the Doctors Without Borders hospital, the child died of complications of malnutrition and pneumonia—a casualty of war and poverty. (*Courtesy of Andrew Schechtman, MD.*)

OUR STORIES AS CARING CLINICIANS

Those of us who become family physicians or other healthcare providers do so for many reasons. One reason is because of a desire to help someone else. Along the way, we sometimes lose ourselves in the day-to-day struggles, the disappointments, the obligations, the fatigue, and the profound helplessness that descends upon us after a particularly bad day. But we are still here and, if we listen with our hearts, we are still capable of great and small things.

We are privileged in so many ways and we must recognize our power over ourselves and over the communities that we serve. It is easy to become overwhelmed by the problems that we face as clinicians and as fellow human beings. Our healthcare system is in shambles, our natural world is being poisoned, our nations are continually at war, and yet, as this chapter highlights, there is so much that we can do—we can listen, we can observe, we can witness, we can bring aid, we can touch, we can love, and we can lead.

The text that follows highlights just a few examples of the ways in which our colleagues are challenging themselves to find creative solutions to the many problems faced by those who are underserved, displaced, or suffering.

DOCTORS WITHOUT BORDERS (ANDREW SCHECHTMAN, MD)

EPIDEMIOLOGY

The United Nations (UN) High Commissioner for Refugees reported that in 2011 there were 10.9 million refugees (those displaced across an international border) and 27.5 million internally displaced persons (IDPs, those displaced within their own country).[1] At the end of 2010, the UN refugee agency was caring for an estimated 14.7 million of these IDPs. During times of a complex humanitarian emergency (defined as a humanitarian crisis in a country, region, or society where there is a breakdown of authority resulting from internal or external conflict and which requires an international response that goes beyond the mandate or capacity of any single agency and/or the ongoing UN country program), the following usually occur:[2]

- Civilian casualties.
- Populations besieged or displaced.
- Serious political or conflict-related impediments to delivery of assistance.
- Inability of people to pursue normal social, political, or economic activities.
- High security risks for relief workers.

ETIOLOGY

People can be displaced from their homes by manmade (war, persecution) or natural disasters (tsunami, earthquake, or hurricane). War is responsible for most of the displacement. Some of the source countries accounting for the most refugees are Afghanistan, Sudan, Somalia, the Palestinian territories, and Iraq.

- Communicable diseases usually cause the most illness and deaths in humanitarian emergencies in less-developed countries. Children younger than 5 years of age are the most vulnerable.[2] Other priority areas include provision of adequate, safe water, food, shelter, and protection from violence.
- In addition to the usual causes of illness and death in emergency-affected populations in less-developed countries (measles, malaria, pneumonia, and diarrhea), crowded settlements may be prone to outbreaks of cholera, meningitis, and other diseases, which can be rapidly spread. Such outbreaks may be explosive and cause many deaths in a relatively short period of time.

PROBLEM IDENTIFIED

In times of stability, writes Dr. Andrew Schechtman, many of the poorest people in the world succeed in their struggle to meet basic needs for shelter, food, and water. When displaced from their homes by manmade or natural disaster, communities and extended families are disrupted, access to food and water are lost, and

marginal circumstances become desperate. Displaced people are often dependent on the support of the international aid community to meet their basic needs.

BEING PART OF THE SOLUTION

When infrastructure collapses as a result of manmade or natural disasters, access to healthcare can be limited or nonexistent. Serving as a volunteer physician with Medecins sans Frontieres (Doctors Without Borders) allowed Dr. Schechtman to provide medical care to people in desperate circumstances who had nowhere else to turn for assistance. Bearing witness to tragedies such as the case described in **Figure 6-1** gave him another means to help, that is, the authority to speak out on behalf of victims like this child, focus public attention on the situation, and encourage political pressure to bring the fighting to an end.

ACCESS AND ADVOCACY: PROSTHETIC PARITY (JEFF CAIN, MD)

EPIDEMIOLOGY

Health insurance reform is on the minds of many, as the US citizens debate the pros and cons of President Obama's healthcare bill. In the midst of this debate, many people find themselves without health insurance. The 2010 U.S. Census Bureau reported that the percentage of people without health insurance (16.3%) although not statistically different from the rate in 2009, resulted in an increase in the number of uninsured people from 49.0 million to 49.9 million; this percentage of uninsured is 4% higher (representing 5.1 million more people) than at the first writing of this book in 2005.[3]

- Lack of insurance disproportionately affects Hispanics (30.7% are uninsured), followed by blacks (20.8%), Asians (18.1%), and non-Hispanic whites (11.7%).[4] (**Figures 6-2** and **6-3**)
- According to the American College of Physicians 2000 report, uninsured Americans may be up to three times as likely as privately insured individuals to experience adverse health outcomes and up to four times as likely as insured patients to require both avoidable hospitalizations and emergency hospital care.[5]
- Uninsured adults have a 25% greater mortality risk than adults with coverage; approximately 18,000 excess deaths among people younger than age 65 years are attributed to lack of coverage every year.[6]
- In 2007, 62% of personal bankruptcies were caused by medical bills, a rise of almost 50% since 2001.[7] Importantly, of those bankruptcies, three quarters were actually insured at the time of their illness.

One area where insurance coverage may be limited is for prosthetics, where coverage may consist of a single lifetime prosthesis or be placed under restrictive arbitrary caps that cover less than a third of the cost. Unfortunately, limb loss is fairly common and risk is greatest among vulnerable populations:

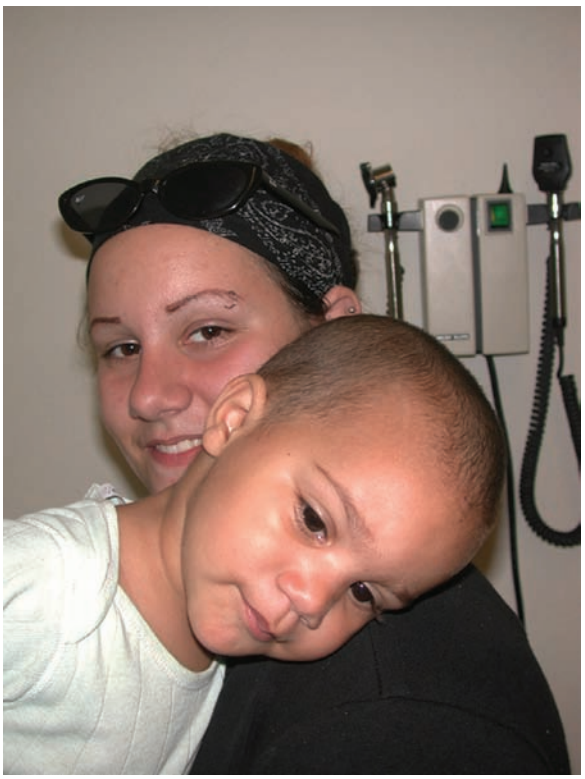

FIGURE 6-2 This mother and child are being cared for in the University of California at Los Angeles (UCLA)/Salvation Army free clinic run by medical students for homeless families in a transitional housing village. The boy had a bacterial infection on his leg and required antibiotics. The computer system in a pharmacy rejected his name and number, but, fortunately, the family doctor advocated for this child and the medicine was obtained. (*Courtesy of Richard P. Usatine, MD.*)

FIGURE 6-3 This 18-year-old mother has had type I diabetes since age 13 years. As a single mom she qualified for one of the living units within the Salvation Army transitional housing village. The week before this photo was taken, she presented to the student-run free clinic with diabetic ketoacidosis secondary to running out of her insulin. She knew that she needed her insulin but the pharmacy would not fill it because her insurance appeared to have lapsed in the computer system. After many calls to many pharmacies with no luck, her needed insulin was obtained from another free clinic in town. She survived without hospitalization and was feeling much better at the time of this photograph. (*Courtesy of Richard P. Usatine, MD.*)

- In 2005, 1.6 million people (approximately 1 in 190) in the United States were living with limb loss.[8]
- In 1997, 131,218 hospital discharges had a lower extremity amputation (LEA) discharge diagnosis code.[9] Regardless of comorbidity, these rates were higher for men than women and higher for non-Hispanic blacks than for Hispanics or non-Hispanic whites.[9] According to the *Disparities in Health and Health Care among Medicare Beneficiaries*, the rate of amputation is four times greater in blacks than in whites.[10]

ETIOLOGY

- Most cases of limb loss are as a consequence of vascular disease (54%), trauma (45%), and cancer (<2%).[7]
- Of the 1997 hospital discharges noted above, 67% were related to diabetes.[9] The age-adjusted LEA rate for persons with diabetes (5.5 per 1000 persons) was 28 times that of persons without diabetes (0.2 per 1000 persons).
- Nearly half of the individuals who have an amputation as a consequence of vascular disease will die within 5 years.[11] This is higher than the 5-year mortality rates for breast cancer, colon cancer, and prostate cancer.
- Of persons with diabetes who have a LEA, up to 55% will require amputation of the second leg within 2 to 3 years.[12]

PROBLEM IDENTIFIED

As a practicing family physician in Denver, Colorado, Jeff Cain had already been a leader for health advocacy in cocreating a tobacco-free education program for children called Tar-Wars. This program has grown from a local Denver activity into an international campaign reaching more than 8.5 million children in all 50 states and in 14 countries.

Dr. Cain became acutely aware of insurance disparity for patients with disabilities when a 1996 airplane accident resulted in a LEA and he was surprised to find his hospital residency's insurance policy provided only $1000 for a year's prosthetic benefits, far short of the needed cost. Although he was fortunate to be able to afford the much larger copay for his prosthetics himself, most Americans could not. Indeed, he found that most insurance companies did not provide enough coverage for most amputees to afford the necessary prosthetics to fully live their lives.

BEING PART OF THE SOLUTION

To change the situation, Dr. Cain (**Figure 6-4**) founded and led the Colorado Coalition of Working Amputees, a grassroots organization whose work led to Colorado becoming the first state to pass "prosthetic parity" insurance legislation in 2001. This legislation required insurance companies to pay for artificial arms and legs.

Following this success, Dr. Cain joined the board of directors of the Amputee Coalition of America where he provided vision and leadership establishing the Coalition's Action Plan for People with Limb Loss. The Amputee Coalition created a tool kit modeled on materials

FIGURE 6-4 Dr. Jeff Cain in his advocacy role at the Capitol in Washington, DC in 2010. Dr. Cain's highly rated speaking presentations have focused on youth tobacco prevention, healthcare reform, and adaptive devices. (*Courtesy of Jeffrey Cain, MD.*)

FIGURE 6-5 Dr. Cain at Jackson Hole on a Ski-bike in 2004. His participation in sports continues to encourage and inspire many adaptive athletes. (*Courtesy of Jeffrey Cain, MD.*)

developed by the Colorado Coalition of Working Amputees, which has been used by grassroots organizations across the country to advocate for changes in insurance laws on the state level. This work has led to 20 states passing insurance mandate legislation with 16 introducing legislation and 8 states organizing for introduction of legislation in 2012. Dr. Cain participated in Hill Visit days in 2010 and 2011, resulting in the introduction of the 2012 federal Fair Insurance Access for Amputee bill, and was instrumental in President Obama's signing of a proclamation for April 2012 as Limb Loss Awareness Month.

Dr. Cain encourages others to advocate for justice using personal stories that help us connect with each other and with the larger community. He states, "A story has superpowers for persuading people of the importance of your cause. If you can combine your story with the facts and economic reality, people will line up with your position."

As current president of the American Academy of Family Physicians, Dr. Cain continues his leadership and advocacy work. In addition, as a sports enthusiast and gold medal winner in adaptive slalom snowboarding (**Figure 6-5**), Dr. Cain works to develop and share ways to adapt sports equipment for use by people with limb loss (**Figures 6-6** and **6-7**), improving quality of life and health through exercise.

FIGURE 6-6 Dr. Cain "hanging zero" on two prosthetic legs. (*Courtesy of Jeffrey Cain, MD.*)

REFUGEES AND ASYLUM SEEKERS (LUCY CANDIB, MD)

EPIDEMIOLOGY

A refugee is a person who is outside his or her country of nationality or habitual residence; has a well-founded fear of persecution because of his or her race, religion, nationality, membership in a particular social group, or political opinion; and is unable or unwilling to avail himself or herself of the protection of that country, or to return there, for fear of persecution. Worldwide, in 2010, there were approximately 15.6 million refugees and approximately 27.5 million persons displaced within their own countries.[13]

An asylum seeker is an individual who has sought international protection and whose claim for refugee status has not been determined yet. As part of its obligation to protect refugees within its territory, the country of asylum is normally responsible for determining whether an asylum seeker is a refugee or not. As of January 2011, there were 264,574 officially settled refugees residing in the United States and 6285 asylum seekers.[14]

An "asylee" is someone who has been granted asylum. They are the same as a "refugee" at that point. The only difference is their process of becoming a refugee. Asylees receive protection through seeking asylum from within the United States, whereas refugees seek safety from their location abroad. Those who get to the United States are chosen for resettlement to the United States after being granted protection. Each year the United States agrees with the United Nations High Commissioner for Refugees to take a specified number of refugees from designated countries. Within those countries, many other refugees are declared refugees but are not resettled. The United Nations or other refugee agency may choose to keep them in a camp, integrate them locally in the country they fled to, or send them to another country that accepts refugees.

FIGURE 6-7 Dr. Cain in a 2010 bike race despite two prosthetic legs. (*Courtesy of Jeffrey Cain, MD.*)

Within the United States, legally resettled refugees are able to work and can obtain medical care through routine systems of care. Asylum seekers, who must place their application for asylum within 1 year of entry into the United States, are unable to work or receive any government benefits, and have no coverage for any preventive or curative healthcare.

Many asylum seekers have been victims of violence in their country of origin and have experienced a very high rate of torture (defined as an act committed by a person acting under the color of law specifically intended to inflict severe physical or mental pain or suffering [other than pain or suffering incidental to lawful sanctions] upon another person within his custody or physical control) (**Figures 6-8** and **6-9**).[15]

- For example, from more than 2000 applications for asylum from Turkish nationals (primarily Kurds) to the United Kingdom in 2003, investigators interviewed and examined 97 individuals requiring medical evaluation for evidence of torture.[16] A wide variety of injuries and psychological disorders were documented, including posttraumatic stress disorder (PTSD) and major depression.
- In the United States, at a mental health center in California serving survivors of torture and refugee trauma, a chart review of 134 consecutive asylum seekers (two-thirds women) showed that 82% were diagnosed with PTSD and 96% with a depressive disorder. Some reports had a high risk of a history of torture, rape (odds ratio [OR] = 4.23), political persecution (OR = 9.28), and symptoms of PTSD (OR = 4.93).[17]
- However, unless specifically being questioned about their past experiences of trauma and torture, refugees are unlikely to disclose their history. In a 2003 study from three community clinics in Los Angeles, only 3% of torture victims told their physicians about their experience.[18]

ETIOLOGY

- In a study of 89 asylum seekers from 30 countries, commonly reported reasons for abuse were political activity (59%), ethnicity (42%), and religion (32%).[19] Types of abuse in this population included punching/kicking (79%), genital electrical shock (8%), and rape (7%). Persistent psychological symptoms were common; 40% had PTSD.
- Increasingly, gay and lesbian asylum seekers are surfacing within the United States because of persecution of homosexuals in their countries of origin, including torture, death threats, and murder of publically identified gay and lesbian figures.
- For an asylum seeker, proving "persecution" to an immigration officer or a judge within the United States may be very difficult if he or she escaped with few or no documents from his or her country. The asylum seeker may be unable to communicate with family out of fear of disclosure of their location. The asylum seeker's family members may also still be at risk of detention and torture by officials trying to extract information about the location of the asylum seeker. The legal application process can include a medical and psychological evaluation to support the history of persecution the person experienced, including ongoing harassment of the asylum seeker's family and friends.

PROBLEM IDENTIFIED

Dr. Lucy Candib is a family physician working at a community health center in Worcester, MA, a city of 168,000 people that has been a home to immigrants for hundreds of years. She has always been committed to cross-cultural medicine and has cared for patients and families from all over the world since her early training. She has a long-standing commitment to work with women survivors of physical and sexual violence, but had never been involved in a formal way in working with immigrants seeking political asylum. She writes, "I started about 10 years ago with an evaluation of a woman from Kenya fleeing severe physical violence from her husband. Her story was emblematic of everything I had ever learned about battered women, including marital rape, the abduction of the children, and threats and harm against the woman's own parents."

FIGURE 6-8 This African man suffered a depressed skill fracture when he was detained for his political activity. His captors struck him with a hoe. He heard his own skull crack open and fell to the ground bleeding. His captors left him for dead, but he was able to struggle to a roadside where he was brought to safety by a passerby.

BEING PART OF THE SOLUTION

Dr. Candib attended a 1-day training for medical professionals offered by Physicians for Human Rights and recently attended their advanced training program. She works regularly with the local refugee and immigrant settlement organizations to conduct physical examinations and provide medical documentation for their clients who were seeking political asylum in the United States. She also involves her residents in working with these patients. She describes the process as follows:

- The asylum lawyer contacts me to schedule an evaluation and sends me the materials relevant to his/her client's case and to the country of origin about once every 1 to 2 months.
- I meet with the man or woman, often from a country in West Africa. I usually start with situating the person in their family and their region, and then move slowly into eliciting a history of the events that unfolded in their experiences of persecution, imprisonment, torture, and flight. I include a full medical history and review of their current symptoms. This detailed process may take 1 to 3 sessions, depending on the person's ability to tell his/her story and tolerate the feelings that always emerge when recounting it.
- Afterwards, I do a physical examination, carefully documenting scars by measurement and photographs and describing any physical injuries resulting in pain or limitation of movement. I include an assessment of their mental and emotional condition. I do these assessments at the health center on my days off, as these long sessions do not fit in the short medical appointments in my regular schedule.
- Drawing on my notes, I then provide a narrative history and examination in a formal document for the asylum hearing and attach any relevant photographs. Some pictures leave no room for doubt: the symmetrical scars on both sides of the scalp of a man who had been clubbed by police wielding truncheons, or the ridged scalp and skull of a man struck by a hoe across the top of his head by his captors (**Figures 6-8** and **6-9**). Often I do some research on the Internet to understand how my clients' experiences fit into the overall political history of their country. This documentation work takes anywhere from 5 to 10 hours for each individual. The lawyers tell me that my assessments weigh heavily in their clients' favor at the hearings. Most recently, I have been involving second- and third-year family

FIGURE 6-9 A skull radiograph showing the depressed skull fracture in the patient in **Figure 6-8**.

medicine residents in this work. They, too, are stunned and then gratified by the intensity and immediacy of the work.

Dr. Candib concludes saying, "This work has changed me as a human being. After 35 years of clinical practice with low-income families, moments come when I feel that my work has been slow and incremental. But this work—engaged in advocacy that directly affects a person's future—reaffirms that I *can* make a clear and immediate difference, 1 person at a time. This is also humbling work. These individuals teach me not only about what unspeakable pain humans inflict on each other, but also what amazing strengths each person carries inside. These patients teach me about myself and how much I don't understand or know about any given person in front of me in the examination room, and, at the same time, teach me about the world. Without leaving Worcester, I become a doctor without a border, acting on behalf of others while growing myself."

CARING FOR THOSE WITH DISABILITIES (LAURIE WOODARD, MD)

EPIDEMIOLOGY

Approximately 54 million Americans currently live with at least 1 disability and the vast majority (52 million) live in their communities (**Figure 6-10**).[20]

- According to data from 1999, the prevalence rate of disability was 24% among women and 20% among men.[21] Approximately 32 million adults had difficulty with 1 or more functional activities, and approximately 16.7 million adults had a limitation in the ability to work around the house. Two million adults used a wheelchair and 7 million used a cane, crutches, or a walker.
- Of children ages 3 to 17 years, 4.9 million were told that they have some type of learning disability and 12.8% (9.4 million) have special healthcare needs.[20]
- Racial and ethnic minorities have higher rates of disabilities than whites or Asian Americans; 7.3 million individuals (ages 15 to 65 years) with disabilities are of racial or ethnic minorities.
- In 2005, the surgeon general issued a Call to Action to improve the health and wellness of persons with disabilities underscoring the need in this population.[20]

ETIOLOGY

Challenges to a person's health can happen at any age and at any time. Disabilities are not illnesses, rather they are limitations related to a medical condition that have an influence on essential life functions such as walking, seeing, or working.[20] Furthermore, disabilities do not affect all people in the same way.

- Of all the adults with disabilities, 41.2 million (93.4%) reported that their disability was associated with a health condition including arthritis and rheumatism (17.5%), back or spine problems (16.5%), heart trouble/hardening of the arteries (7.8%), lung or

FIGURE 6-10 Dr. Laurie Woodard and her daughter Anika share a good laugh following breakfast while on vacation in New Mexico. Although Anika is dependent for all her activities of daily living and is nonverbal because of spastic quadriparetic cerebral palsy, she loves to travel and has a wonderful sense of humor.

respiratory problems (4.7%), deafness or hearing problems (4.2%), mental or emotional problems (3.7%), blindness or visual problems (3.4%), and intellectual disability (2%).[21]

- Rates of disability are increasing in part because of the aging population, better survival of catastrophic illnesses and trauma, and advances in preventing infant and child mortality.

PROBLEM IDENTIFIED

As a mother of a child with profound disabilities, Dr. Laurie Woodard found that her medical training did little to prepare her for caring for her child or finding help (**Figure 6-10**). She became acutely aware that people with disabilities had great difficulty finding physicians and those who provided care often seemed afraid of them. She said, "I couldn't imagine someone not wanting to care for her because she had a disability." Physicians tend to focus on the medical condition and not the whole person and their families; when confronted with the patient's healthcare needs and functional issues, the feeling of acting more like a social worker than a physician caused them to fall back into medical model framework. In addition, societal support for those with disabilities, particularly disabilities acquired as an adult, are fragmented and the primary care physician needs to become the link.

BEING PART OF THE SOLUTION

Dr. Woodard began to care for increasing numbers of patients with disabilities, training herself through reading, experience, and asking patients what worked. As she worked with individual students she planned for a time when she could break into the medical student curriculum to provide this training. Eight years ago, when the curriculum for third-year students underwent major reform, she saw her opportunity. Within the primary care 12-week experience, a curriculum on special populations was planned and Laurie made sure that it included teaching about persons with disabilities. Her curriculum, implemented in 2005 with goals ranging from sensitivity training to understanding both the capabilities and needs of individuals with disabilities, contains the following components:

- Clinic-like experience with 8 to 10 patients with physical disabilities (e.g., cerebral palsy, communication issues, wheelchair users) where pairs of students complete brief interview and physical examination under video monitoring. The session ends with a debriefing circle wrap up with students and patients.
- Panel discussion with patients with varying abilities who usually represent an advocacy agency or organization. Special emphasis is placed on community services and opportunities including the arts and sports.
- Home visits where student pairs (2 medical students or a medical student and physical therapy student) receive a preparation sheet and checklist and learn how disability affects individuals and their family. Following the visit, students prepare reflection plus research reports that are posted on blackboard; part of the assignment is to read and comment on all the papers.
- Service learning project where students give presentations on health topics (e.g., first aid, influenza) selected by staff at an adult

daycare facility for individuals with intellectual disabilities or the high school group noted above, or assist in the recreational activities for individuals with disabilities (e.g., free physicals for riders in therapeutic horseback riding program).

- An objective structured clinical examination (OSCE) case involving a manual wheelchair user with shoulder pain; the standardized patients are individuals who are wheelchair users.
- Sensitivity training session, run by Parks and Recreation where students are randomly assigned a disability (e.g., using a wheelchair or other assistive device or blindfold) and complete tasks followed by watching the movie *Murderball* (an informative and proactive documentary about the Paralympics sport, quadriplegic rugby, and its players). A speech pathologist also provides a hands-on assistive/augment communication device tutorial.

"The students learn to see the patient first," she says, "that caring for these individuals requires recognizing the patient's expertise about their disability and problem solving together. For most students, even the most jaded, this is simply an eye opening experience as the patients are usually quite physically impaired but lead full and active lives" (**Figure 6-11**).

Dr. Woodard has expanded this program and is co-teaching with faculty from the School of Physical Therapy (PT) so that medical and PT students interview and examine patients together. In addition, she will begin providing training within the courses Doctoring 1 and Doctoring 2 to first- and second-year medical students (the home visit and panel discussion will be moved to the first year) allowing more complex and challenging issues to be addressed during the clerkship. Finally, she is also involved with Alliance for Disability in Health Education, a group mainly out of the Northeast whose mission is to get the American Association of Medical Colleges (AAMC) to require the topic of disability in the curriculum.

Since the initial publication of this chapter, Dr. Woodard's daughter graduated from high school in June 2011. The family is working on helping her structure her day and move beyond the interminable wait list for services to which she is entitled. She is happy and healthy and the family members consider themselves lucky to have good, affordable caregivers and companions to assist her.

FIGURE 6-11 Dr. Woodard, daughter Anika, and dog Nikki are part of a team of University of South Florida (USF) medical students, faculty, and family who participated in a "wheel-a-thon" to raise money for Tampa's first fully accessible playground. Teaching medicals students the therapeutic value of sports and recreation for people with disabilities is an important aspect of the USF curriculum.

CARING FOR THE HOMELESS (RICHARD P. USATINE, MD)

EPIDEMIOLOGY

At least 643,000 persons were homeless on any given night in 2009 and 1 in every 200 Americans (approximately 1.56 million people) spent at least 1 night in a shelter during that year.[22] Of those who were homeless in one study, 3% reported having HIV/AIDS and 26% reported other acute health problems, including tuberculosis and other sexually transmitted infections.[23]

Causes of death were investigated in one study of 40 homeless people for more than a 1-year period (1985 to 1986) conducted by the Fulton County Medical Examiner in Georgia. It was thought at that time that between 4000 and 7000 individuals were homeless, so the crude death rate for that year was estimated at 5.7 to 10 per 1000.[24]

- Black males accounted for 19 (48%) of the 40 deaths, white males for 18 (45%), and black females for 3 (8%). The median age for 36 individuals whose age was known was 44 years (range = 21 to 70 years).
- Twenty-two individuals (55%) died or were found dead outdoors. Of the 18 persons who died indoors, 7 were found in vacant buildings and 5 died at shelters.
- Cause of death, based on the medical history, investigation scene information, circumstances of death, and autopsy and toxicologic studies (when performed) was classified as natural (16), accidental (19), or homicide (4) or suicide (1). Natural deaths included alcohol related (9 including 3 with seizures likely from alcohol withdrawal), heart disease (4), and lung disease (3). Accidental deaths were primarily a result of acute alcohol toxicity (7), fire (6), hypothermia (2), and pedestrian–motor vehicle incidents (2). No deaths were attributed to drugs other than alcohol.

ETIOLOGY

Homeless persons are often extremely poor and socially isolated, the latter is considered a significant contributor to being homeless. Many medical conditions are caused by or exacerbated by the adverse living conditions and lack of healthcare experienced by the homeless. These include:

- Psychiatric illnesses (as many as 40% of homeless persons).
- Physical health problems, including injuries from trauma, respiratory disease (e.g., tuberculosis), scabies and pediculosis infestations, and chronic illnesses such as diabetes.

PROBLEM IDENTIFIED

Dr. Usatine has worked with homeless individuals and families for 28 years. Their stories and lives have touched his heart and soul in profound ways. He writes, "the homeless in America are at the bottom of our society in dire poverty and lacking a stable living environment. Losing a job and a home and suffering with mental illness and addictions make the homeless one of the most vulnerable populations in our wealthy country."

BEING PART OF THE SOLUTION

In 1984, Dr. Usatine began to provide healthcare to homeless people at the Venice Family Clinic, a free clinic in Venice, CA. Along with Mary Smith, NP, a seasoned nurse practitioner who had years of experience working with the homeless, he delivered healthcare to the homeless of Los Angeles both in the free clinic and in the surrounding shelters. Dr. Usatine was also the medical director of a nurse-practitioner-run full-time free clinic in the largest homeless shelter on skid row of Los Angeles. Working with Aaron Strehlow, NP, PhD, they made care accessible to the approximately 1000 homeless persons staying in that shelter on a daily basis.

He first established 2 student-run clinics for homeless families and individuals with the medical students of UCLA. He states that the

"passion and motivation of the students to serve this vulnerable population has been a tremendous inspiration to him throughout his career." After moving to San Antonio, Texas, Dr. Usatine worked with medical students to establish 2 more student-run clinics: one for homeless families and another for women in a residential drug and alcohol treatment home (**Figures 6-12** and **6-13**).

The students and faculty of University of Texas Health Sciences Center at San Antonio (UTHSCSA) have created a whole a program called FOCUS (Free Outreach Clinics for the Underserved in San Antonio). Three new clinics have been created, including 1 interdisciplinary clinic for refugees, 1 for free dermatology care, and 1 working with Haven for Hope. Haven for Hope is a transformational village for homeless individuals and families in San Antonio. It is a large collaborative effort by many people and agencies and shows students what can be done when good people work together for the benefit of their community.

- Dr. Usatine has made it easier for medical students to volunteer their time in the student-run clinics by creating approved courses that give students credit for their work with the homeless. Currently he is running a "Humanism Fellowship" in which fourth-year medical students work throughout their fourth year to take leadership roles in managing and directing the student-run clinics under faculty supervision. The elective supports and nourishes the inherent altruism of the students. A second elective "Homelessness and Addiction" is available to first and second year students who want to work in the clinics and learn more about the populations they serve. Both courses are prime examples of Community Service Learning (CSL) and exist under the umbrella of the Center for Medical Humanities and Ethics.
- As part of these experiences, students are asked to reflect on their work with the homeless. This comment from one student perhaps best expresses what many students have written about providing care to this vulnerable population, "Seeing how difficult it is to get back on your feet has greatly impacted how I treat those who are struggling. It has taught me that I am blessed with such a gift of providing healthcare that I should give back without any expectations of reimbursements or praise. I realize what a difference I can make in the lives of those who are homeless by providing them not only with healthcare but encouragement. It has taught me to be blind to those with and without insurance and to treat everyone equally regardless of their social background. It has made me more appreciative of the comforts that I take for granted and how easily we can be living in a bubble."

Dr. Usatine strongly believes that these students will be better physicians for the experiences in these student-run clinics. He states, "It is wonderful to be part of the solution to help people who have slipped through the cracks of the healthcare system get the healthcare they need. It is especially rewarding to see medical students put their hearts and souls into caring for this population." Students learn compassion and are inspired by the efforts being made by their patients to get their lives back together. They are always amazed by the tragic stories of abuse, violence, poverty, and deprivation that many of their patients have lived through.

Dr. Usatine also takes medical students on medical mission trips to Ethiopia, Haiti, Dominican Republic, Guatemala, and Panama, and codirects a Global Health Elective in his medical school. Working

FIGURE 6-12 In an effort to help women recovering from substance abuse, the students and faculty of University of Texas Health Sciences Center San Antonio partnered with Alpha Home to open a free clinic on site. Alpha home is a residential treatment unit with a 40-year track record of helping women become clean and sober. Prior to the opening of this clinic within the home in which the women reside, most of these uninsured women would go to the crowded university emergency department for healthcare. Many went without healthcare for fear that a 36-hour wait would drive them back to drugs and alcohol. The photograph shows (from left to right) Melanie Lane, the head counselor; Amy Cantor, the student founder; Julie Wisdom-Wild, the CEO; and Richard P. Usatine, the faculty founder and advisor.

FIGURE 6-13 Amy Cantor as a fourth-year medical student in the Humanism Fellowship caring for a family at the second student-run clinic established in San Antonio. The mom and her 4 children have been reunited at the San Antonio Metropolitan Ministries Transitional Living and Learning Center. We saw this family almost weekly in our clinic and helped them make the transition from homelessness to independence. (*Courtesy of Richard P. Usatine, MD.*)

with impoverished populations abroad is a natural extension of the work being done at home. Dr. Usatine states, "We partner with other humanitarian organizations abroad so that our work has a longer lasting impact on the people we try to help. We try to bring equipment and provide training to people in these countries so that we are not just popping in and leaving the people with not much but a few medications. These experiences transform the lives and world views of our medical students and we hope they will continue to be inspired to give to people in global and local communities throughout their careers." (**Figures 6-14** and **6-15**).

FIGURE 6-14 Dr. Richard P. Usatine with a young HIV-positive girl in rural Ethiopia during a mission trip with eight medical students. The year before we helped her get diagnosed and treated for tuberculosis, HIV, and tinea capitis. Her mom died of HIV and now she lives with her grandmother and goes to school at Common River (an NGO that helps many families in Aleta Wondo). Now 1 year later she is healthier and happier. (*Courtesy of Tsegaye Bekele, Common River.*)

DISPARITY IN CAREERS IN MEDICINE (CRYSTAL CASH, MD)

EPIDEMIOLOGY

According to data from the AAMC, about one-quarter of U.S medical school graduates practicing medicine in 2008 were of minority race; blacks comprised only 6.3%, 5.5% were Hispanic or Latino, 12.8% were Asian, and 0.5% were Native American/Alaskan Native.[25] Of black physicians, the vast majority (70.4%) were in office-based practice and 9.2% were in hospital-based practice (with an additional 20.3% who were residents and fellows); the percentages are similar for physicians of other races.

- With respect to specialty, higher proportions of Native American/Alaskan Native (23.6%), Hispanic or Latino (14.0%), and black (13.6%) physicians were in family medicine or general practice compared to 12.7% of whites and 7.1% of Asians.[25]
- In the report on *Minorities in Medical Education* (2005), only 1% of black physicians were in medical teaching (compared with 0.9% of Hispanics, 0.4% of Asians, and 0.4% of Native Americans). This lack of diversity is problematic for many reasons including workforce distribution; minority physicians are more likely to provide care for minority and indigent patients and to practice in underserved areas (51% of black, 41% of Native American, and 34% of Hispanic graduates in 2004 intended to practice in underserved areas compared with 18.4% of whites).[26]
- In 2011, 59.7% of students enrolled in U.S. medical schools were white and 7% were black.
- Over the past 3 decades, the percentage of white male physicians graduating from U.S. allopathic medical schools has decreased from a peak of 10,323 in 1982 to 5,346 in 2008.[25] The number of white women has steadily increased from 1714 in 1978 to 4728 in 2008. Over the same period, similar trends were seen among black physician graduates; black men are poorly represented with 429 graduates in 2008 (down from 474 in 1978) whereas increases were seen for black women (763 in 2008 up from 250 in 1978). Following initial increases for both Hispanic (or Latino) men and women, in 2008 the graduation numbers for men had fallen so that slightly more women than men graduated (460 vs. 459).

FIGURE 6-15 Matt and Annie (two UTHSCSA medical students) spotted a young boy lying still in the tall grass just inside the metal gates of the government health clinic in rural Ethiopia. He was alone, not moving, and his skin was burning hot. Matt (with EMT experience) leapt into action and scooped the boy up from the grass running with him into our makeshift clinic. Matt yelled for Dr. Usatine as he placed the boy on the only examination table. The boy was barely conscious but was able to cooperate with an oral thermometer which read a surprising 41.5°C (106.7°F). After treatment with IV fluids and antibiotics for a presumed meningitis, Abraham woke up. Unfortunately, at 10 years old he had already been living on the streets by himself for 4 years. The following morning the medical students gathered food from their breakfast to take it to Abraham. Abraham was awake and his fever was gone. The students were delighted to see Abraham sitting on the side of his bed looking well. He gave them a big smile in greeting. The students gathered around Abraham as he devoured the food, barely taking a moment to breathe between bites. Two years later, Abraham lives and attends school at Common River. He is a great student and a very kind and helpful person. (*Courtesy of Richard P. Usatine, MD.*)

- Of 114,087 medical school faculty in 2005, 71.9% were white, 12.6% were Asian, 4.0% were Hispanic, and 3.1% were blacks.[26] Minority faculty were primarily at the rank of assistant professor, with 9% to 19% at full professor, compared to whites, where nearly 30% were at the rank of full professor.

ETIOLOGY

- Lack of representation of minorities in medicine is likely multifactorial and includes lack of educational opportunity and encouragement, prejudice, and lack of mentoring.
- Problems in the pipeline from kindergarten to grade 12 play an essential role in hindering the numbers of ethnic and racial minorities from applying to medical school.[26]
- Blacks and Hispanics have lower rates of graduating from high school than whites.
- Only 39.9% of blacks and 34% of Hispanic high-school graduates enrolled in college from 2000 to 2002, compared to 45.5% of whites.

PROBLEM IDENTIFIED

In an attempt to improve test scores in a failing Chicago public school, the school was divided into three institutes, one of which is the Daniel Hale Williams Prep School for Medicine. Dr. Cash was one of the several physicians from Provident Hospital (also founded by Dr. Daniel Hale Williams) who were invited to an open house called "Doctor's Day." The idea for a mentoring program sprang from the days' activities to provide access for kids to practicing physicians.

BEING PART OF THE SOLUTION

- The Future Doctors of America Club (**Figure 6-16**) proposes that through leadership training and skills development, the students themselves can become resources and will mentor other students.
- The program is based on principles similar to the school's mission—to have the students become physicians through improved resources and hands-on activities.
- Mentors were assigned one to three mentees and mentor–student experiences included shadowing, tutoring, advising, volunteer activities, and social interaction.
- "In our first year," writes Dr. Cash, "we inducted 27 students into the club, and by 2006 we added another 54 students. We developed guidelines for mentors, students, and for parent participation. The students developed their organizational structure, vision, and mission statements as well as a schedule of desired activities. Activities, including a medical boot camp, were associated with service learning hours and skills development."

Since the first edition of this book, the program is no longer affiliated with Dr. Cash's institution. However, of the 72 students who participated in this program as junior high school students, all graduated high school and 58 are now attending 4-year colleges. Most students received scholarships to offset some of the tuition costs. Dr. Cash remains in touch with some of her former students and is hopeful that many will ultimately seek careers in medicine.

FIGURE 6-16 Dr. Crystal Cash working with inner-city students in The Future Doctors of America Club. This peer education session was held at a Chicago Public School (Daniel Hale Williams Preparatory School for Medicine).

PROVIDER RESOURCES

Refugee and Asylum seekers information

- United Nations High Commissioner for Refugees, www. unhcr. ch; the U.S. Committee on Refugees, **www.refugees.org;** and Relief Web, **www.reliefweb.org.**
- Doctors Without Borders, **www.doctorswithoutborders.org.**

Access and Advocacy

- Institute of Medicine, **http://www.iom.edu/.**
- Physicians for a National Health Plan, **www.pnhp.org.**
- American Academy of Family Physicians, **http://www.aafp.org/online/en/home/policy.html.**
- Kaiser Family Foundation, **http://www.kff.org/uninsured/index.cfm.**
- Amputee Coalition of America, **http://www.amputee-coalition.org/.**

Disabled Persons

- U.S. Department of Justice, **www.usdoj.gov/crt/ada/cguide.htm.**
- Social Security Administration, **www.ssa.gov/disability/** (information on benefits).
- Information on sports events for the disabled, **www.dsusa.org.**
- **www.disabilityinfo.gov.**

Homeless

- National Coalition for the Homeless, **http://www.nationalhomeless.org/.**
- National Alliance to End Homelessness, **http://www.naeh.org/.**
- U.S. Department of Housing and Urban Development, **http://www.hud.gov/homeless/index.cfm.**
- Veterans Affairs, **http://www1.va.gov/homeless/.**
- Student-run Free Clinics in San Antonio, **http://www.studentrunclinics.org/**.
- The Society of Student-run Free Clinics, **http://www.studentrunfreeclinics.org/**.
- Haven for Hope, **http://www.havenforhope.org/**.

Underrepresented Minorities in Healthcare

- Association of American Medical Colleges, **www.aamc.org/students/minorities/.**
- American Medical Student Association, **http://www.amsa.org/AMSA/Homepage/About/Priorities/Diversity.aspx**.

REFERENCES

1. United Nations High Commissioner for Refugees (UNHCR), http://www.unhcr.org/pages/49c3646c11.html, accessed April 26, 2012.

2. Center for Disease Control (CDC), http://www.cdc.gov/globalhealth/gdder/ierh/FAQ.htm#What health issues are most important early in an emergency?, accessed April 26, 2012.
3. United States Census. *Highlights 2010*, http://www.census.gov/hhes/www/hlthins/data/incpovhlth/2010/highlights.html, accessed April 2012.
4. DeNavas-Walt C, Proctor BD, Smith JC. *U.S. Census Bureau, Current Population Reports, P60–239, Income, Poverty, and Health Insurance Coverage in the United States: 2010*. Washington, DC: U.S. Government Printing Office; 2011.
5. *Statement of the American College of Physicians to the Ways and Means Committee, Subcommittee on Health* (March 9, 2004), http://www.acponline.org/advocacy/where_we_stand/access/way_means04.pdf, accessed May 1, 2012.
6. Institute of Medicine: Fact Sheet 5. *Uninsurance Facts and Figures*, http://www.iom.edu/~/media/Files/Report%20Files/2004/Insuring-Americas-Health-Principles-and-Recommendations/Factsheet5Quality.pdf , accessed May 1, 2012.
7. Himmelstein DU, Thorne D, Warren E, Woolhandler S. Medical bankruptcy in the United States, 2007: results of a national study. *Am J Med*. 2009;122(8):741-746.
8. Ziegler-Graham K, MacKenzie EJ, Ephraim PL, et al. Estimating the prevalence of limb loss in the United States: 2005 to 2050. *Arch Phys Med Rehabil*. 2008;89(3):422-429.
9. Centers for Disease Control and Prevention. Hospital discharge rates for nontraumatic lower extremity amputation by diabetes status—United States, 1997. *MMWR Morb Mortal Wkly Rep*. 2001;50(43):954-958.
10. *Disparities in Health and Health Care Among Medicare Beneficiaries*, http://www.rwjf.org/pr/product.jsp?id =31251, accessed April 2012.
11. Robbins JM, Strauss G, Aron D, et al. Mortality rates and diabetic foot ulcers. *J Am Podiatr Med Assoc*. 2008;98(6):489-493.
12. Hanzlick R. Office of the Fulton County Medical Examiner. Surveillance and Programs Br, Div of Environmental Hazards and Health Effects, Center for Environmental Health, CDC. *MMWR Morb Mortal Wkly Rep*. 1987;36(19):297-299.
13. *UNHCR 2011 Refugee Statistics: Full Data*, http://www.guardian.co.uk/news/datablog/2011/jun/20/refugee-statistics-unhcr-data, accessed May 2012.
14. United Nations High Commissioner for Refugees. *2012 Regional Operations Profile – North America and the Caribbean*, http://www.unhcr.org/cgi-bin/texis/vtx/page?page=49e492086&submit=GO, accessed April 2012.
15. *Torture Victims Relief Act of 1998*, 18 USC 2340.
16. Bradley L, Tawfig N. The physical and psychological effects of torture in Kurds seeking asylum in the United Kingdom. *Torture* 2006;16(1):41-47.
17. Piwowarczyk L. Asylum seekers seeking mental health services in the United States: clinical and legal implications. *J Nerv Ment Dis.* 2007;195(9):715-722.
18. Eisenman DP, Gelberg L, Liu H, et al. Mental health and health-related quality of life among adult Latino primary care patients living in the United States with previous exposure to political violence. *JAMA.* 2003;290(5):627-634.
19. Asgary RG, Metalios EE, Smith CL, et al. Evaluating asylum seekers/torture survivors in urban primary care: A collaborative approach at the Bronx Human Rights Clinic. *Health Hum Rights* 2006;9(2):164-179.
20. Department of Health and Human Services. *The Surgeon General's Call to Action to Improve the Health and Wellness of Persons with Disabilities*. Rockville, MD: Public Health Service; 2005, http://www.surgeongeneral.gov/library/disabilities/calltoaction/calltoaction.pdf, accessed April 25, 2007.
21. Prevalence of disabilities and associated health conditions among adults—United States, 1999. *MMWR Morb Mortal Wkly Rep*. 2001;50(07):120-125.
22. Centers for Disease Control and Prevention. *National Prevention Information Network*, http://www.cdcnpin.org/scripts/population/homeless.asp, accessed May 1, 2012.
23. National Resource Center on Homelessness and Mental Illness. *Who Is Homeless?* Newton, MA: U.S. Department of Health and Human Services, Substance Abuse & Mental Health Services Administration; 2003, http://homeless.samhsa.gov/Resource/View.aspx?id=32511.
24. Centers for Disease Control and Prevention. Enumerating deaths among homeless persons: comparison of medical examiner data and shelter-based reports—Fulton County, Georgia, 1991. *MMWR Morb Mortal Wkly Rep.* 1993;42(37):719, 725-726.
25. *Diversity in the Physician Workforce: Facts & Figures 2010*, https://members.aamc.org/eweb/upload/Diversity%20in%20the%20Physician%20Workforce%20Facts%20and%20Figures%202010.pdf, accessed May 1, 2012.
26. *Minorities in Medical Education: Facts & Figures 2005*, https://members.aamc.org/eweb/upload/Minorities%20in%20Medical%20Education%20Facts%20and%20Figures%202005.pdf, accessed May 1, 2012.

7 GLOBAL HEALTH

Ruth E. Berggren, MD
Richard P. Usatine, MD

COMMUNITY STORY

Common River is a U.S.-based nongovernmental organization (NGO) implementing a community development program in Aleta Wondo, Ethiopia. This NGO is founded on the principle of positive deviance, in which local best practices are identified and replicated to maximize agricultural production (organically grown coffee is produced in this region), as well as to improve the nutritional status, health, and education of orphaned and vulnerable children. Since 2009, a group from the University of Texas School of Medicine has travelled annually to Aleta Wondo to provide school health screening and free healthcare, including treatment of endemic helminth infections, trachoma, and skin diseases, while collaborating with and supporting the local government-sponsored health clinic (**Figures 7-1A** and **B**). In **Figure 7-1C**, the schoolchildren of Common River are looking at the new group of American medical students that have just arrived in Africa. In the coming week, these children will receive oral albendazole to treat intestinal parasites and have complete physical exams to detect and treat other common conditions, such as head lice, tinea capitis, trachoma, and foot infections. Note that many of the children are barefoot. In **Figure 7-1D**, a group of women has just completed their woman's literacy class for the day. Improving women's literacy can improve the health of the entire community.

FIGURE 7-1 **A.** Many people still live in extreme poverty with no running water and electricity. This is a typical hut in Ethiopia. This one is inhabited by a grandmother, her grandchild and a cow. The photograph was taken after a home visit to provide IM ceftriaxone to the child after her release from the local hospital where she was treated for a neck abscess and cellulitis. The medical team was staying at Common River and originated from the University of Texas. (*Courtesy of Richard P. Usatine, MD.*) **B.** A University of Texas medical student helps an elderly man to a chair where he will be seen by the medical team working in Aleta Wondo. One of the local nursing students is observing the clinical activity. (*Courtesy of Lester Rosebrock.*) (*continued*)

WHAT IS GLOBAL HEALTH?

For years, the term *international health* has described health work in resource-limited settings with an emphasis on tropical diseases, communicable diseases, and illness caused by poor nutrition and inadequate access to water, sanitation, and maternal care.[1] More recently, *global health* is commonly used to emphasize mutual sharing of experience and knowledge, in a bilateral exchange between industrialized nations and resource-limited countries, and the emphasis is expanding to include noncommunicable diseases and chronic illness.[2] One definition of global health, proposed by the Consortium of Universities for Global Health Executive Board, is "an area for study, research, and practice that places a priority on improving health and achieving equity in health for all people worldwide."[1] This chapter focuses on a few conditions commonly encountered in developing nations, emphasizing communicable diseases and malnutrition.

Ethical dilemmas abound when professionals from resource-rich settings leave their familiar environment and apply their practices in a severely resource limited setting. Consiuder, for example, breastfeeding guidelines in the setting of maternal-to-child HIV prevention. National protocols differ depending on resource availability. In some settings, telling an HIV-positive mother not to breastfeed (because breast-milk can transmit HIV) may sentence her infant to near-certain death from diarrhea. If a program overturns local teaching about exclusive breastfeeding, it must ensure a safe and sustainable alternative

FIGURE 7-1 (*Continued*) **C.** The schoolchildren of Common River in rural Ethiopia greet the new group of American medical students that have just arrived in Africa. **D.** Smiling women that have just completed their woman's literacy class for the day. Improving woman's literacy is a great way to raise the health status of the community. (*Courtesy of Richard P. Usatine, MD.*)

form of infant feeding. Imposing the standards of industrialized nations in a community that cannot afford to continue to provide these standards can undo years of program development. Care must be taken not to undermine the trust a community has placed in local health providers, as this can ultimately increase morbidity rather than relieve suffering. Working with local health providers is essential so that a short trip can result in extended benefits to the community (**Figure 7-2**).

This chapter briefly introduces some of the relevant subject areas with which global health providers should familiarize themselves when preparing for international work. Statistics that aid in understanding the state of a nation's health relative to other countries are the mortality rate of children younger than age of 5 years old and adult life expectancy. Least-developed countries report that as many as 112 of 1000 children die before age 5 years, compared to 8 per 1000 in developed countries,[3] and adult life expectancy ranges from 48 or 49 years at birth (Chad, Swaziland) to 88 or 89 years (Japan, Monaco).[3] Another important parameter by which to compare the health status of countries is that of maternal mortality, defined as the number of maternal deaths per 100,000 livebirths. These figures, together with basic epidemiology of disease provide important insights into public health priorities for populations.

What statistics do not provide, however, is the level of importance ascribed to a particular health issue by a community. It is necessary to acknowledge and address the needs expressed by communities themselves, in order of their own priorities, so as to achieve sustained improvements in health outcomes. All health improvements ultimately rely on long-term behavioral changes, whether dietary, pill taking, physical activity, or hygiene related. Group behavioral change requires buy-in from the population with approbation and influence of local leadership.

A useful method of creating a positive impact is to make use of ongoing peer-to-peer adult education techniques through the introduction of community health clubs. This can be effective for empowering resource-limited communities to develop their priorities, and to advocate for their community health and development needs.[4] It is best to learn about and collaborate with the local and governmental community health activities before launching any intervention, be it clinical, infrastructural, or preventive.

FIGURE 7-2 The physician in the front of this picture is pleased to receive medications that are unavailable to her hospital in rural Panama. Before shipping or bringing medications abroad, it is essential to learn what practicing physicians need. Bringing redundant or nearly expired meds or short-term supplies of expensive brand medications causes more harm than good. Donated medications should be locally relevant generics that are not expired. The WHO list of essential medications may be helpful in planning (**http://www.who.int/medicines/publications/essentialmedicines/en/index.html**). (*Courtesy of Richard P. Usatine, MD.*)

WATER AND SANITATION

Many diseases in resource-poor settings are traceable to deficits in clean water supply and storage, lack of soap for bathing, and lack of functioning infrastructure to manage human waste (garbage collection, latrines) (**Figure 7-3**). Some of the most important ones include typhoid fever, cholera, and intestinal parasites.

Lack of governmental and public health infrastructure in the developing world leads to large populations living without clean running water. World Health Organization (WHO) and UNICEF estimate that 780 million persons are without access to improved water sources and 2.5 billion (37% of the world's population) people are without access to improved sanitation sources.[6]

Water and sanitation deficiencies are responsible for most of the global burden of diarrheal disease. The most common diarrheal disease of returning travelers is caused by enterotoxigenic *Escherichia coli*. All over the world, young and malnourished children die of preventable diarrhea caused by rotavirus, *E. coli*, *Salmonella*, *Shigella*, and *Campylobacter*.

FIGURE 7-3 **A.** A covered pit latrine serving the needs of an Ethiopian family. The latrine is located on the edge of the garden near their home, and presents a fall hazard for young children. (*Courtesy of Richard P. Usatine, MD.*) (*continued*)

Diseases that are particularly deadly as a result of lack of access to clean water include typhoid fever and cholera. Intestinal parasites, while usually not deadly, do lead to chronic problems with malnutrition and anemia, which themselves contribute to cyclical poverty and disease because they lead to impaired learning, reduced productivity, and vulnerability to other infectious diseases.

TYPHOID FEVER

Typhoid fever, also known as enteric fever, is an acute systemic illness caused by the invasive bacterial pathogen, *Salmonella typhi*. *Salmonella* is ingested in contaminated water or food, invades the mucosal surface of the small intestine, and causes bacteremia, with seeding of the liver, spleen and lymph nodes.

EPIDEMIOLOGY

Typhoid fever is mainly found in countries with poor sanitary conditions. Because most such countries do not routinely confirm the diagnosis with blood cultures, the disease is highly underreported. Outbreaks of typhoid are often seen in the rainy season, and in areas where human fecal material washes into sources of drinking water. Shallow water tables and improperly placed latrines are environmental risk factors for typhoid. Globally there are 16 to 33 million cases annually, with up to a half a million deaths every year.[7]

CLINICAL PRESENTATION

Patients develop an acute systemic illness with prolonged fever, malaise, and abdominal pain after ingesting contaminated food or water. This truly nonspecific syndrome may include headache, mild cough, and constipation, with nausea and vomiting. Diarrhea may be present but it is not the rule. After a 10- to 20-day incubation period, there is a stepwise progression of fever over a period of 3 weeks, and the patient may display a transient rash described as rose spots (2- to 4-mm pink macules on the torso, which fade on pressure). Temperature pulse dissociation with relative bradycardia despite high fever may be noted in fewer than 25% of patients. In the second week, the patient becomes more toxic and may develop hepatosplenomegaly. Untreated, typhoid can progress to include delirium, neurologic complications and intestinal perforation caused by a proliferation of *Salmonella* in the Peyer patches (lymphoid tissue) of the intestinal mucosa. Although the mortality rate for untreated typhoid is 20%, early antibiotic therapy can decrease mortality. Approximately 1% to 4% of those who recover from acute typhoid fever become carriers of the disease who continue to shed *Salmonella* in their stool despite not being ill.[7]

DIAGNOSIS

Culture of blood, stool, rectal swab, or bone marrow.[8]

DIFFERENTIAL DIAGNOSIS[9]

- Malaria (often clinically indistinguishable from typhoid; empiric therapy for both malaria and typhoid may be warranted if diagnostic testing is unavailable).
- Enteroinvasive *E. coli*
- *Campylobacter*

FIGURE 7-3 (*Continued*) **B.** An Ethiopian pit latrine, which offers no mitigation for flies and is situated in proximity to the water table below. Heavy rains will lead to contamination of the water supply with fecal pathogens. (*Courtesy of Richard P. Usatine, MD.*) **C.** An elevated, ventilated improved pit latrine can protect the water table and reduce flies. Air circulates down the squat hole, into the pit and up through the pipe. To ensure unhindered flow of air, the top of the vent pipe must be 0.5 meters above the top of the shelter. The latrine interior is kept dark so the main light source in the pit comes from the vent pipe. Flies are attracted to the light, but the pipe has a fly-proof screen at the top, so they cannot escape and eventually die.[5] Many countries consider the ventilated improved pit latrine to be the minimum standard for improved sanitation. (*Courtesy of Jason Rosenfeld, MPH.*)

- Paratyphoid fever (*Salmonella para typhi*, other less virulent *Salmonellae*)
- Dengue fever (mosquito borne arbovirus infection spread by *Aedes aegypti*)
- Rickettsial diseases (typhus, spotted fever, Q fever)
- Brucellosis
- Leptospirosis
- Heat stroke

MANAGEMENT

Prompt diagnosis and initiation of antibiotic therapy is essential and life-saving. Oral rehydration therapy should be initiated first, followed by IV fluids if vomiting cannot be controlled and for patients with altered mental status or hypovolemic shock. Antibiotic resistance patterns differ with geographic location.

For Africa and resource-limited settings in the Americas, the first choice is chloramphenicol 1 g PO daily for 10 to 14 days, or ciprofloxacin. Historically, trimethoprim-sulfamethoxazole 960 mg PO twice daily for 10 to 14 days has been used,[8] but there has been increasing drug resistance to sulfa in these areas. In Asia, where multidrug resistant *S. typhi* strains are well described, ciprofloxacin (500 to 750 mg twice daily), ceftriaxone (60 mg/kg IV daily) or azithromycin (500 mg daily) may be used for 7 to 14 days.[8–10] Azithromycin should only be used in mild disease. Some guidelines advocate the use of dexamethasone, 3 mg/kg IV followed by 1 mg/kg every 6 hours for 2 days in the setting of shock or altered mental status.[8] See vaccine information at the end of this chapter.

CHOLERA

Cholera is an acute, diarrheal disease caused by *Vibrio cholerae*. It is usually transmitted by contaminated water or food, and is associated with pandemics in countries that lack public health infrastructure and resources for sanitation. Although the infection is often mild or asymptomatic, in 5% to 10% of patients it can be severe and life-threatening.[14]

EPIDEMIOLOGY

V. cholerae reservoirs occur in brackish and salt water, as well as estuaries. Although the organism occurs in association with copepods and zooplankton, its largest reservoir is in humans. Cholera pandemics have been reported in south Asia, Africa, and Latin America. Characteristically, cholera outbreaks occur in countries that have suffered destruction of public health infrastructure (collapse of water supplies, sanitation, and garbage collection systems). The 2010 outbreak in postearthquake Haiti has been traced to UN Peace-keeping soldiers, whose waste contaminated a major Haitian river used for bathing, irrigation, and drinking water. In just 10 months, 300,000 cases were reported, of whom 4500 died, and the outbreak has continued to wax and wane with the rainy seasons for years.[11] A large infective dose is necessary for infection, and although only approximately 10% of those infected fall ill, the infection can be fatal for young children, elderly, and malnourished individuals.

PATHOPHYSIOLOGY

V. cholerae is a motile, gram-negative rod. After ingestion via contaminated water or food, it must survive the acid environment of the

stomach before colonizing the mucosal surface of the small intestine. The organism is noninvasive, and not associated with bloody diarrhea. Rather, it makes a potent toxin causing massive secretion of electrolyte-rich fluid into the gut lumen. Human to human contact spread virtually never occurs. Transmission through contaminated food or water is the rule.[12]

Clinical presentation ranges from mild watery diarrhea to acute, fulminant watery diarrhea which looks like rice water. After an incubation period of 18 to 40 hours, patients may lose up to 30 L of fluid daily, with resulting metabolic acidosis and electrolyte disturbances. Severe dehydration can lead to death in a matter of hours. Vomiting, when present, starts after the onset of diarrhea. Profoundly dehydrated patients present with decreased skin turgor, sunken eyes, and lethargy. Children, but not adults, may have mild fever. Cramping caused by loss of calcium and potassium is common.[12]

DIFFERENTIAL DIAGNOSIS AND LABORATORY TESTS

Early presentation may resemble enterotoxigenic *E. coli*; however, the syndrome is quickly distinguishable because of the extreme volume of "rice water" secretory diarrhea that is the result of cholera toxin. *V. cholerae* may be confirmed by stool culture, polymerase chain reaction (PCR) for toxin genes, or dark-field microscopy with specific antisera, which will immobilize the *V. cholerae*.[13] The Centers for Disease Control and Prevention (CDC) recommends confirmation of cholera by stool specimen culture or rectal swab. For transport, Cary Blair media is used, and for identification, thiosulfate-citrate-bile-salts (TCBS) agar is recommended.[14]

MANAGEMENT

Water, sanitation, and hygiene education is essential, as is education about recognizing the symptoms and immediately seeking medical attention while initiating oral rehydration. Optimally, rehydration should commence with reconstitution of WHO-distributed oral rehydration salts (ORS), which is available in all but the most remote areas of the world. Hydration is the mainstay of therapy, and replacement of fluids should be calibrated to match losses. ORS should be prepared with previously boiled water and consumed within 24 hours of reconstitution. IV or intraosseous hydration with Ringer lactate solution should be initiated if the patient is vomiting or in danger of hypovolemic shock. The volume needed to rehydrate a cholera patient is often underestimated; for this reason, collection and measurement of the watery stool in a bucket placed under the cholera cot is recommended.

Antibiotics are recommended for severe cases of cholera; options include[15]:

1. Doxycycline 300 mg orally as single dose (contraindicated in pregnancy)
2. Azithromycin 1 g orally as single dose (more effective than either erythromycin or ciprofloxacin; appropriate first-line therapy for children and in pregnancy)
3. Ciprofloxacin
4. Furazolidone 100 mg orally

In pregnancy, erythromycin 250 mg PO daily for 3 days may also be used.

PREVENTION OF DISEASES SECONDARY TO CONTAMINATED WATER

Drinking purified or treated water, good handwashing practices, and avoidance of contaminated food are essential. Travellers should be reminded not to brush their teeth with tap water and to avoid having potentially contaminated ice added to their beverages. Carbonated beverages are safe as the carbonation process is bactericidal. Community education about handwashing and treatment of water is essential. In communities lacking running water (**Figure 7-4**), home storage of drinking water should be in containers with protective lids. Local guidelines regarding addition of chlorine to home stored water containers should be followed.

FIGURE 7-4 In this Ethiopian community without running water, water is collected in Jerry cans. Thousands of women carry these heavy, filled cans for miles after filling them up from this single pipe. The local town has provided one single pipe as the water source for the community. Although there is muddy water below, the water coming from the pipe appears clear, although it is likely to harbor bacteria and parasites. (*Courtesy of Richard P. Usatine, MD.*)

INTESTINAL PARASITES

EPIDEMIOLOGY AND GEOGRAPHIC DISTRIBUTION

One-third of the world's population is infected with intestinal parasites, and although many parasitic infections are asymptomatic, some have serious health consequences. Especially affected are pregnant women and children, for whom hookworm-associated anemia results in maternal mortality, low-birth-weight babies, growth stunting, and impaired learning. The CDC recommends predeparture albendazole treatment as a single 600-mg dose for all refugees from sub-Saharan Africa and South Asia. While this treatment will eradicate most of the nematodes, it is insufficient for *Strongyloides stercoralis* and schistosomiasis.[16]

CLINICAL PRESENTATION

Abdominal pain, cramps, bloating, anorexia, anemia, fatigue, growth stunting of children, hepatomegaly (schistosomiasis).

DIAGNOSIS

Stool for ova and parasite studies (**Figure 7-5**). Note that these will not reliably detect *Strongyloides* or schistosomiasis; serologic testing is available for the latter. Eosinophilia is an important diagnostic clue for the presence of parasites; the finding of persistent eosinophilia warrants a careful diagnostic evaluation for parasitic infection.

TREATMENT

▶ Adults

Albendazole 400 mg orally as single dose will eradicate hookworm, and *Ascaris*, but not *Trichuris* in most people.[17] Eradication of *Trichuris trichiura* requires 3 daily doses of albendazole or adding ivermectin to mebendazole.[18]

▶ Children 12 months to 2 years

Albendazole 200 mg orally as a single dose.[19] *S. stercoralis* requires 7 days of albendazole at 400 mg twice daily. For schistosomiasis, praziquantel is effective against all species of schistosomes. Give 2 doses of 20 mg/kg PO 4 to 6 hours apart (3 doses 4 hours apart for *Schistosoma japonicum*).[20]

PREVENTION

Preventative measures include proper management of human waste, handwashing after defecation and before cooking, and wearing shoes

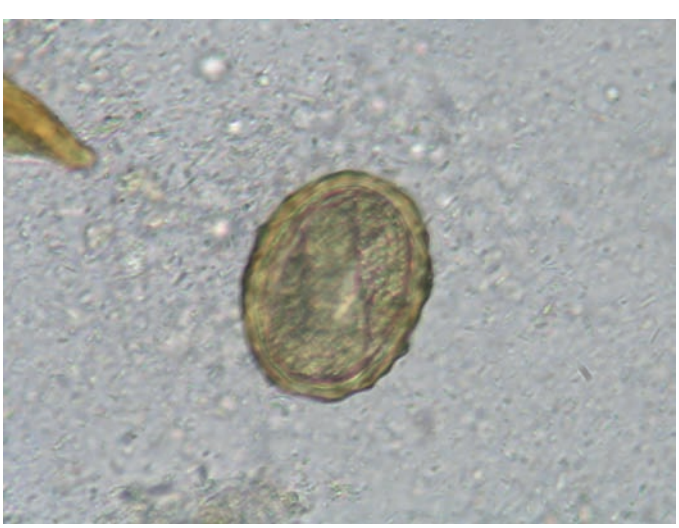

FIGURE 7-5 *Ascaris* egg found in the stool of a child with intestinal parasites. In most developing countries *Ascaris* is treated empirically with albendazole; stool studies are not always available or may not be cost effective. (*Courtesy of Richard P. Usatine, MD.*)

(prevents hookworm and *Strongyloides*). WHO guidelines recommend mass treatment of school children in endemic areas with single-dose albendazole therapy once every 6 months.

MALNUTRITION

Types of malnutrition include:

- Kwashiorkor
- Marasmus
- Micronutrient deficiencies

A global shift is underway, from diseases of undernutrition to overnutrition in tandem with industrialization and advances in transportation and technology. In spite of this global shift, about a quarter of the world's preschool children demonstrate growth stunting caused by nutritional deficiencies. In resource-poor countries, adult obesity and childhood undernutrition may coexist within the same families. The causes of this seeming paradox include many factors associated with poverty: the vulnerability of preschool children to infection when sanitation is inadequate, lack of nutrition education, decreased physical activity with increasing availability of technology and transportation, and mass marketing of inexpensive, calorie-rich foods.

Two classic presentations of malnutrition in children are important to recognize because they signal a patient who is immunocompromised and vulnerable not only to infection but also to preventable developmental delay. The accompanying photographs show an emaciated child with marasmus (severe, nonedematous malnutrition caused by calorie deprivation; **Figure 7-6**), and a puffy child with kwashiorkor (severe, edematous protein energy malnutrition; **Figure 7-7**). Marasmic kwashiorkor is another descriptor, illustrating the high level of overlap in the etiology and presentation of these extreme forms of malnutrition.[21] Whenever possible, one should avoid hospitalizing these children for nutritional rehabilitation as hospitalization will expose them to many infectious pathogens that could be lethal during their vulnerable period of "nutritional AIDS."[22]

DIAGNOSIS

Growth chart monitoring is important for earliest detection of weight loss, growth stunting, or failure to gain height and weight over time. In most resource-poor countries, growth monitoring is implemented by trained community health workers, who refer mothers for nutrition and education programs upon detecting faltering growth in children younger than the age of 5 years. Children often fail to gain weight normally after an episode of infectious diarrhea or malaria; this should be followed by a period of rapid catchup growth. If a child becomes reinfected before catchup growth is complete, the child will fall further behind on the growth curve.

Depending on the relative protein content of the diet, patients develop marasmus (calorie deprivation), characterized by emaciation and listlessness (**Figure 7-6**), or kwashiorkor, "the disease of weaning"—protein-energy malnutrition. Kwashiorkor is characterized by red discoloration of the hair (**Figure 7-8**), which is also brittle, puffy eyes, bloated bellies and pitting edema of the extremities (**Figure 7-7**). These children feel miserable and are lethargic

FIGURE 7-6 This 12 month-old Bolivian child with marasmus presented to medical attention with pneumonia. She has severe growth stunting, atrophied limbs, and looks miserable. Her presentation highlights the association between malnutrition and infection. (*Courtesy of Carolina Clark.*)

FIGURE 7-7 This 2-year-old child presented with classic signs and symptoms of kwashiorkor, a severe form of protein-energy malnutrition. The word *kwashiorkor*, from a Ghanaian language, refers to the sickness a child develops when it is weaned from breastfeeding. In countries with limited protein sources, newly weaned children are especially vulnerable to this disease. They present with depigmentation, red discoloration of the hair, distended abdomens, and peripheral edema. (*Courtesy of Ruth Berggren, MD.*)

and uninterested in food. The differential diagnosis of kwashiorkor includes nephrotic syndrome, renal failure, or right-side congestive heart failure.

PATHOPHYSIOLOGY

Childhood malnutrition, and especially kwashiorkor, may begin when a breastfeeding mother weans her child from the breast. Deprived of protective maternal antibodies and protein source, weaning infants begin sampling their contaminated environments and ingesting pathogens. Production of cytokines such as tumor necrosis factor (TNF)-α during infectious episodes suppresses appetite and impedes nutritional recovery.[22]

Micronutrient deficiencies coexist,[21] and deficiencies of vitamin A and zinc, in particular, predispose children to increased morbidity from subsequent infections. When parents are unable to replace protein requirements of weaning infants, children eat whatever locally available calorie sources (grains, cereals, bread, fruit) they can find. The poor in many developing countries lack protein sources and toddlers are frequently not prioritized when meat, milk, or eggs become available.

As a result of severe protein deficiency, hypoalbuminemia and decreased intravascular oncotic pressure lead to edema, and the classic puffy appearance of the child with kwashiorkor. For years it was believed that children with kwashiorkor are disproportionately deprived of protein, whereas children with marasmus are deprived of both protein and carbohydrate calories proportionally; it now appears there is a great deal of overlap between these two presentations of severe malnutrition.[21]

FIGURE 7-8 Child with kwashiorkor, protein-calorie malnutrition and red hair. The red hair is a result of the kwashiorkor. (*Courtesy of Richard P. Usatine, MD.*)

MANAGEMENT

The endless cycle of infection leading to poor appetite and weight loss leading to malnutrition and further risk of infection[22] can be difficult to break unless mothers of malnourished children are taught to introduce calorie-dense weaning food supplements and snacks. Many countries have locally produced ready-to-use therapeutic foods (RUTF),[21] offering products like Plumpy'nut, or Haiti's Nourimanba, made from peanut butter, milk powder, vegetable oil, sugar, and a vitamin mix.[23]

These therapeutic foods are a useful adjunct to breaking the cycle of infection, anorexia, weight loss and malnutrition, but they are not a substitute for educating mothers about how to rehabilitate their malnourished child using locally available and affordable foods. Nonmeat protein substitutes, such as red beans, and locally available green leafy vegetables are easier for mothers to obtain than meat, cow's milk, or expensive imported food supplements.

MICRONUTRIENT DEFICIENCIES

VITAMIN A DEFICIENCY

In contrast to marasmus and kwashiorkor, growth stunting is a more subtle syndrome affecting 200 million children who are younger than the age of 5 years. A variety of micronutrient deficiencies are believed to contribute to stunting syndrome and to accompany developmental delays, reduced cognitive function, impaired immunity, and future risk of obesity and hypertension.[24] There are 4 micronutrient

deficiencies of global importance, each with associated clinical syndromes that should be recognized. All can be associated with growth stunting in children, who may present with abnormally short stature but relatively normal weight for height.

Vitamin A is a critical regulator of immune function, which is required for maintaining the integrity of mucosal surfaces. Vitamin A supplementation in countries with malnutrition reduces blindness (from xerophthalmia) as well as the morbidity of infectious diseases (especially measles, diarrhea, and respiratory infections). **Figure 7-9** shows a photograph of blindness caused by vitamin A deficiency. In 2009, the WHO estimated that clinical vitamin A deficiency (night blindness) and biochemical vitamin A deficiency (serum retinol concentration <0.70 μmol/L) affected 5.2 and 190 million preschool-age children, respectively.[26] About 250,000 children develop blindness caused by vitamin A deficiency every year, and half of these die within 12 months of losing sight.[27]

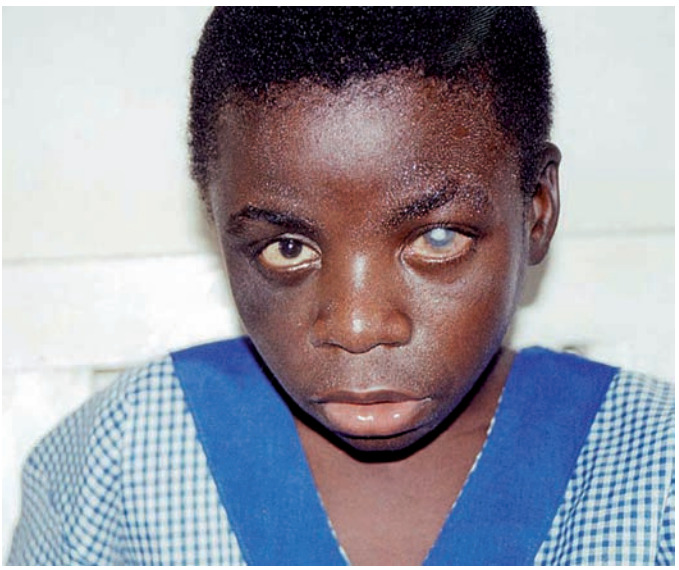

FIGURE 7-9 Child with severe xerophthalmia of the left eye secondary to vitamin A deficiency.[25] (*Used with permission from SIGHT AND LIFE www.sightandlife.org.*)

▶ Clinical presentation

The earliest presentation of vitamin A deficiency is poor night vision, which may progress to night blindness, xerophthalmia, ulceration, and scarring of the cornea, with ultimate blindness. Vitamin A deficiency is also associated with anemia, and is particularly dangerous in patients with measles, for whom mortality rates are high.

▶ Management

A metaanalysis of 43 trials involving 216,000 children younger than the age of 5 years who were given vitamin A supplements revealed striking reductions in mortality and morbidity. Seventeen of these trials reported a 24% reduction in mortality, and 7 trials reported a 28% reduction in mortality associated with diarrhea. Vitamin A reduced diarrhea and measles incidence. Vitamin A significantly reduces morbidity, mortality, and eye disease. Vitamin A supplements are recommended to all children who are at risk in low- and middle-income countries.[28] Most countries implement WHO guidelines for vitamin A supplementation synchronized with childhood vaccine schedules.

ZINC DEFICIENCY

Zinc plays a central role in cellular growth, differentiation, and metabolism. It is necessary for physical growth, GI and immune function. Many zinc studies show improved growth of children and decreased infections when supplements are given to vulnerable populations. Studies suggest that the global prevalence of zinc deficiency approaches 31%, especially in Africa, the eastern Mediterranean, and South Asia.[29]

▶ Clinical presentation

The most common presentation of zinc deficiency is nonspecific and may include growth stunting, delayed sexual maturation, dermatitis, and defective immunity. Zinc deficiency is associated with decreased macrophage chemotaxis, decreased neutrophil activity, and decreased T-cell responses.[22] It is widely acknowledged that zinc deficiency contributes significantly to child mortality from pneumonia, diarrhea and malaria. A rare but characteristic presentation of profound zinc deficiency is acrodermatitis enteropathica (**Figure 7-10**).

Diagnosis

Because there is no good biomarker for zinc deficiency, diagnosis must rest on clinical suspicion and documentation of therapeutic response to supplementation.

Management

WHO guidelines for diarrhea recommend use of low concentration ORS together with routine zinc supplementation for 10 to 14 days. Children older than age 6 months should get 20 mg daily; infants younger than age 6 months should get 10 mg daily.[30] Zinc supplementation decreases the duration and volume of diarrheal stools by 25% and 30%, respectively. More importantly, 14 days of zinc supplementation for a diarrheal episode reduces the incidence of diarrhea and pneumonia in the subsequent 2 to 3 months, reduces hospital admissions for diarrhea, and brings approximately a 50% reduction in noninjury deaths in the year following the treatment.[31] Unfortunately, zinc supplementation benefits are still not widely known by healthcare workers in developing countries.[32]

IRON

Iron deficiency is the most common micronutrient deficiency in the world, and 2 billion people (nearly one-third of the global population) are anemic. In resource-limited countries, iron-deficiency anemia is either caused or aggravated by malaria, intestinal parasites such as hookworm, and other chronic infections such as HIV, tuberculosis, or schistosomiasis. Iron deficiency causes enormous morbidity and contributes 20% of global maternal mortality. Because the consequences include impaired cognition and physical development, increased risk of illness in children and reduced work productivity, iron deficiency is a real barrier to economic development in resource-poor countries.[33] As with zinc and vitamin A, Iron deficiency can be detrimental to host immunity, causing decreased neutrophil chemotaxis.[22]

Interventions

The WHO has developed a 3-pronged strategy for addressing global iron deficiency: increasing iron uptake through dietary diversification and supplementation, improvement of nutritional status, and controlling infections, especially worms. In countries with significant iron-deficiency anemia, malaria, and helminth infections, these interventions can restore individual health as well as raise national productivity levels, thereby interrupting the cycle of poverty and disease.[33]

IODINE

Insufficient dietary iodine can significantly lower the IQ of whole populations and is the leading preventable cause of brain damage. Although iodine deficiency is easily solved through food fortification costing 2 cents per person annually, prevalences of 60% to 90% iodine deficiency among school-age children are observed in multiple African, Asian, and eastern Mediterranean countries. There is tremendous variance of iodine deficiency within individual countries and deficiency is not linked to poor or disadvantaged districts.[34] Iodine deficiency occurs where the soil has low iodine content because of past glaciation or repeated leaching effects of precipitation. Food crops grown in iodine-deficient soil provide inadequate dietary iodine.[35]

FIGURE 7-10 Acrodermatitis enteropathica caused by a zinc deficiency. Zinc supplementation is a standard recommendation from WHO in treatment of childhood diarrhea. Even children who do not have skin findings of zinc deficiency benefit with reduced duration of diarrhea and reduced mortality from all infectious causes in the ensuing months after receiving supplementation. Note the typical lesions around the **(A)** mouth and **(B)** buttocks. (*Courtesy of Richard P. Usatine, MD.*)

Clinical presentation

Because iodine is required for thyroid hormone synthesis, iodine deficiency results in hypothyroidism and goiter (**Figure 7-11**). Congenital iodine deficiency results in a form of profound cognitive impairment known as *cretinism*. Other consequences include stillbirths, deaf mutism, subclinical hyper- or hypothyroidism, impaired mental function, and retarded physical development.[35]

Interventions

Iodine may be supplied in tablets or liquid form and taken daily; in adults, 150 μg/day is sufficient for thyroid function and an adult multivitamin typically contains 150 μg of iodine per tablet, but this is impractical. Population-based interventions should include iodization of salt, and in some developing countries, eradication of iodine deficiency has been accomplished by adding iodine drops to well water.

FIGURE 7-11 Massive goiter caused by iodine deficiency. This woman is from a country in Africa where iodine is not routinely supplemented in the diet and goiter is endemic. (*Courtesy of Richard P. Usatine, MD.*)

VECTOR BORNE DISEASES

MALARIA

Malaria is a protozoan infection spread by the *Anopheles* mosquito vector in endemic areas. Of the four species of malaria (*Plasmodium falciparum*, *Plasmodium ovale*, *Plasmodium malariae*, and *Plasmodium vivax*), *P. falciparum* is the most important to address, because if unrecognized and untreated, it can be rapidly fatal. Only *P. falciparum* exhibits high levels of parasitemia in blood, and it is the only type of malaria that causes sequestration of parasitized erythrocytes in microvasculature. This unique feature of *P. falciparum* is responsible for the severe end-organ damage, including renal failure, acute respiratory distress syndrome, and coma that is seen with untreated disease.[36]

Epidemiology and geographic distribution

There are more than 200 million cases of malaria in the world every year. According to the WHO, up to 1 million people worldwide die annually from malaria, with 89% of these deaths occurring in Africa. Most of the deaths caused by malaria occur in children younger than age 5 years. *P. falciparum*, *P. vivax, P. malariae*, and *P. ovale* are globally distributed in the tropics. *P. vivax* is more common in Asia, South America, Oceania, and India. *P. ovale* is found mainly in West Africa, and *P. malariae* is much less common than *P. vivax* or *P. falciparum*.

The risk for malaria varies greatly within a given country, and depends on altitude (higher altitudes have lower risk), season (greatest risk in rainy season), and urbanization (rural areas have greater risk than urban areas). Thus, travelers should be aware of these differences and plan for prophylaxis accordingly.

The CDC publication, *Health Information for International Travel*, is available online at http://www.cdc.gov/travel/ and should be consulted for updates about regional patterns of malaria risk, as well as drug resistance and guidelines, which are subject to frequent changes.[37]

Clinical presentation

After a 1- to 3-week incubation period following the bite of an infected female mosquito, patients develop a nonspecific syndrome of

high fever, headache, myalgia, and shaking chills. This syndrome is frequently accompanied by nausea, vomiting, and back pain, and occasional diarrhea. Splenomegaly and anemia (related to hemolysis) are common in all 4 types of malaria.

As untreated *P. falciparum* progresses, there is a risk of cerebral malaria, which is caused by parasitized erythrocytes sequestered in the capillaries of the brain, with secondary metabolic consequences. Cerebral malaria is characterized by severe headache and altered consciousness. These patients may also develop acute respiratory distress syndrome (ARDS), hypoglycemia, acidosis, and shock in the setting of hyperparasitemia. Untreated patients with cerebral malaria ultimately progress to coma, respiratory failure, and death.[38]

Differential diagnosis

The initial presentation of malaria is so nonspecific that it mimics influenza (without the respiratory symptoms), enteric fever (see section on typhoid), dengue fever, rickettsial infections, brucellosis, and leishmaniasis. If hemolysis has been extensive, the patient may present with jaundice, and viral hepatitis or leptospirosis may also be on the differential diagnosis.[36]

Laboratory diagnosis

Malaria is usually diagnosed by light microscopy of peripheral blood smears prepared with a Giemsa, Field, or modified Wright stain (**Figures 7-12** and **7-13**). A thick-and-thin smear should be obtained whenever possible in every febrile patient in whom malaria is suspected, especially from febrile travelers returning from malaria endemic areas. Thin smears allow relative quantification and speciation of parasites when the parasitemia is high; thick smears are useful to rule in malaria, especially when parasitemia is low. Because a single negative smear does not rule out malaria, the test must be repeated on at least 3 occasions at 12- to 24-hour intervals.[39] Patients with high levels of parasitemia (>5%) have a worse prognosis, and should be considered for inpatient care.

Other diagnostic modalities include the fluorochrome acridine orange stain for fluorescence microscopy and PCR (not yet widely available but helpful for very low levels of parasitemia). Rapid antigen assays using fingerstick blood samples on cards impregnated with specific antibodies are alternative methods for laboratory diagnosis of malaria. In the United States, the U.S. Food and Drug Administration has approved the BinaxNOW Malaria test, which, although costly, is convenient for rapid field use. Unfortunately, this and other immunochromatographic strip assays are not able to determine parasite load.[37]

Treatment

Many cases of malaria can be treated effectively with oral medication, and parenteral therapy is reserved for severe disease or for patients who are vomiting. Before prescribing therapy, determine which species is most likely involved based on microscopy or rapid diagnostic test; consider the geographic area and local drug resistance patterns.

After the patient has been given the first dose of medication, the patient should be observed for an hour. Vomiting can be managed with metoclopramide, 10 mg orally, and if the vomiting occurs within 30 minutes, the full initial dose can be repeated. The WHO

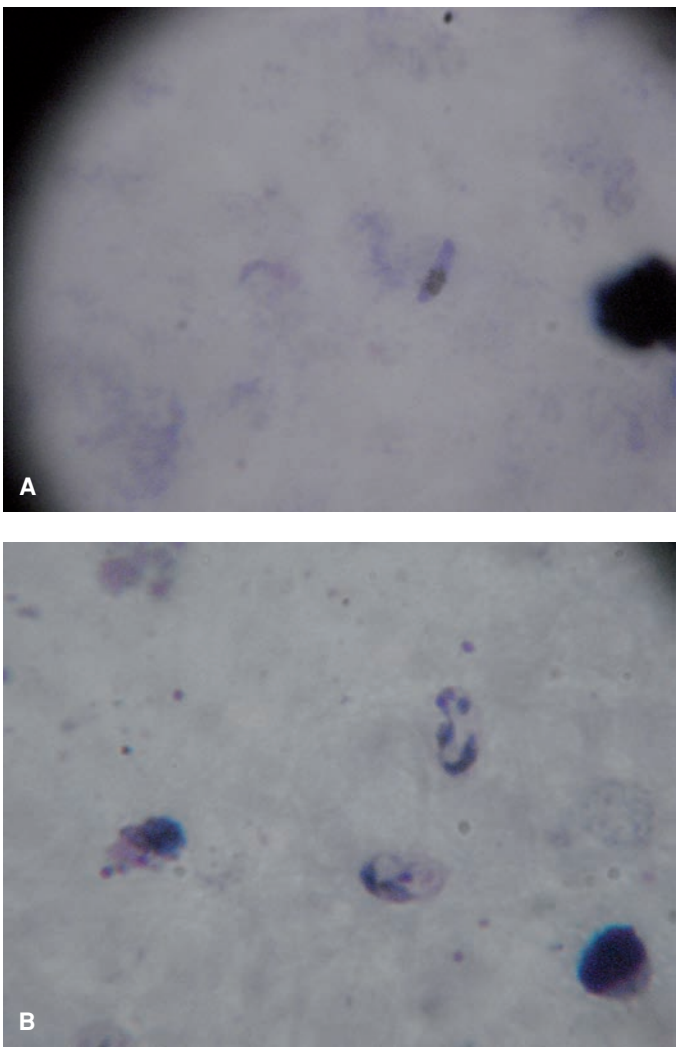

FIGURE 7-12 **A.** *Plasmodium falciparum* with a banana-shaped gametocyte. Of all the species of malaria, *P. falciparum* is the most likely to cause severe morbidity and mortality. **B.** *Plasmodium falciparum* with chromatin in rings. (*Courtesy of Richard P. Usatine, MD.*)

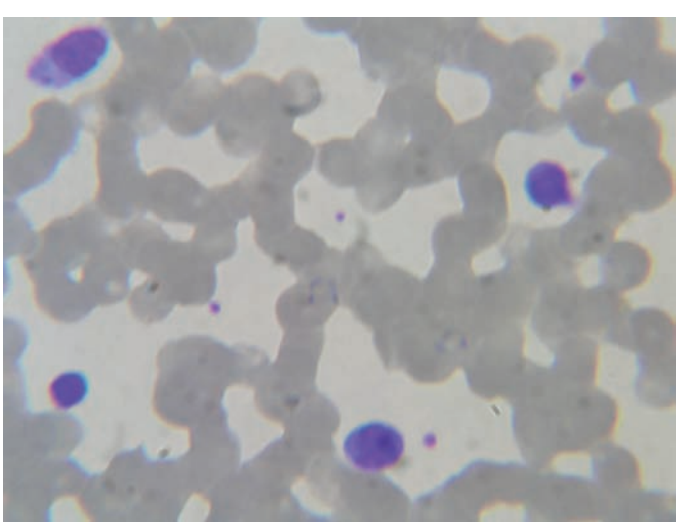

FIGURE 7-13 Blood smear for malaria diagnosis showing *Plasmodium vivax*. Rapid field tests are now available but still more expensive than microscopy. (*Courtesy of Richard P. Usatine, MD.*)

recommends artemisinin-based combination treatments as first-line for uncomplicated *P. falciparum*: artemether-lumefantrine 1 dose at hours 1, 8, 24, 36, 48, and 60 based on body weight: 5 to 14 kg: 1 tablet per dose; 15 to 24 kg: 2 tablets per dose; 25 to 34 kg: 3 tablets per dose; >34 kg: 4 tablets per dose.

Other artemisinin combinations can be used as follows: artesunate plus amodiaquine, artesunate plus mefloquine, and artesunate plus sulfadoxine-pyrimethamine. The combination of choice depends on the level of resistance of the partner medication in a given region. Artemisinin and derivatives should not be given as monotherapy.

For United States-returning travelers:

- Quinine + doxycycline: quinine 10 mg/kg 3 times daily for 7 days and doxycycline twice daily for 7 days
  or
- Atovaquone-proguanil: atovaquone 20 mg/kg per day, proguanil 8 mg/kg per day for 3 days.

Treatment of severe P. falciparum

All cases of severe malaria should be managed as medical emergencies. Give IV or IM artesunate, artemether, or quinine dihydrochloride (not available in the United States).

In the United States. give quinidine gluconate, 10 mg base/kg (up to 600 mg) in 0.9% saline by rate-controlled IV infusion over 1 to 2 hours, followed by a maintenance dose of 0.02 mg base/kg per minute with electrocardiogram (ECG) monitoring until patient can take oral drugs. Quinine and quinidine must never be given by IV bolus because of the potential for fatal hypotension.

Patients with cerebral malaria should undergo lumbar puncture to rule out bacterial meningitis (**Figure 7-14**) and their blood glucose should be checked every 4 hours because of the significant risk of hypoglycemia in severe malaria. Careful hemodynamic monitoring and management of seizures (with intravenous benzodiazepines) are essential.

FIGURE 7-14 Meningitis in a child with a very rigid neck. Cerebral malaria should be in the differential diagnosis for this child. Most bacterial meningitis in children can now be prevented by vaccines frequently still not available in developing countries. (*Courtesy of Richard P. Usatine, MD.*)

▶ Prevention

Prevention measures are a public health priority and should include mosquito control, elimination of standing water in households and gardens, insect repellant containing at least 10% to 50% diethyltoluamide (DEET; 30% DEET provides 6 to 8 hours of protection), and permethrin-impregnated bed nets. Since 2000, prevention and control measures have reduced malaria mortality by more than 25% globally and by 33% in Africa.[40]

Prevention for travelers

Choice of chemoprophylaxis depends on drug resistance patterns for *P. falciparum* in the country being visited. Generally, prophylaxis should start 1 week before arrival and should continue through 4 weeks after leaving the endemic area. In the case of atovaquone-proguanil, prophylaxis may start the day before arrival and end 7 days after departure. Drugs commonly used in prophylaxis include atovaquone-proguanil (Malarone, which is expensive in the United States), mefloquine (may cause central nervous system side effects), and doxycycline (causes photosensitivity). Chloroquine can be used only in a few areas; chloroquine-susceptible malaria is restricted to the Caribbean, Central America, and parts of the Middle East.

RESOURCES

- Centers for Disease Control and Prevention. *Malaria*—**http://www.cdc.gov/malaria.**
- World Health Organization. **http://www.who.int/malaria/en/.**

LEISHMANIASIS

Leishmaniasis is a vector-borne disease transmitted by the sandfly. It can be divided into 2 major forms, a cutaneous form, which is the most common, and the visceral form. There is also a more rare mucocutaneous form that can cause significant facial disfigurement around the nose and mouth.

▶ Synonyms

Kala-azar is another name for visceral leishmaniasis.

▶ Epidemiology

- New World leishmaniasis is found in Mexico, Central America, and South America. Old World leishmaniasis is found in India, Africa, the Middle East, southern Europe, and parts of Asia.
- Most leishmaniasis diagnosed in the United States occurs in travelers returning from endemic areas including military personnel who served in Iraq or Afghanistan.
- Some cutaneous leishmaniasis cases acquired in the United States have been reported in Texas and Oklahoma.[41]
- Ninety percent of cutaneous leishmaniasis occurs in Afghanistan, Algeria, Iran, Saudi Arabia, Syria, Brazil, Colombia, Peru, and Bolivia.[41]
- Ninety percent of visceral leishmaniasis cases occur in parts of India, Bangladesh, Nepal, Sudan, Ethiopia, and Brazil.[41]

▶ Etiology and pathophysiology

- Leishmaniasis is caused by more than 20 species of the protozoan genus *Leishmania*.
- Leishmaniasis is transmitted to people through the bite of the sandfly.
- The intracellular amastigotes of *Leishmania* replicate within macrophages.
- The disease can also be transmitted like any bloodborne infection, but human-to-human transmission is rare.

▶ Risk factors

- Living in and traveling to endemic countries.
- Rural areas have a higher prevalence of disease in the endemic countries.
- Not protecting the skin from sandfly bites during the time from dusk to dawn.
- Blood transfusions, needle sharing in injection-drug users, needlestick injuries, and congenital transmission also are all reported risk factors for visceral leishmaniasis.[42]

▶ Diagnosis

Clinical features

- Six weeks after a sandfly bite, the cutaneous form may be localized to a single ulcer or nodule (**Figure 7-15**) or may be disseminated widely (**Figure 7-16**).

FIGURE 7-15 Examples of leishmaniasis on the face. Lesions emerge in the site of the sandfly bite; the nose is commonly affected as seen in the women in figures **A** and **B** from Africa. (*Courtesy of Richard P. Usatine, MD.*)

- After a 2- to 6-month incubation period, the visceral form can involve the liver, spleen, and bone marrow and causes systemic illness. The patient may present with fever, anemia, night sweats, weight loss and an enlarged abdomen because of hepatosplenomegaly.[43]
- Mucocutaneous leishmaniasis affects the nose and mouth and may affect the nasal septum and palate (**Figure 7-17**). This form may occur months to years after what appears to be healing of cutaneous leishmaniasis.

Distribution

- A cutaneous form of leishmaniasis has a predilection for the nose and face (**Figure 7-15**).
- Cutaneous leishmaniasis is also commonly seen on the extremities. Note that the sandfly would generally have more access to bite the face and extremities where clothing is less likely to be a protective barrier.
- Disseminated cutaneous leishmaniasis can be seen from the head to the toes (**Figure 7-16**).

Laboratory testing

- Cutaneous leishmaniasis may be diagnosed by clinical appearance and a biopsy or a scraping of the ulcer. A Giemsa stain will demonstrate parasites in the skin smears taken from the edge of an active ulcer.[43] In some centers, PCR is available and is considered the method of choice.[44]
- Visceral leishmaniasis is diagnosed from a blood sample or a bone marrow biopsy. Several serologic agglutination tests (direct agglutination test [DAT] or fluorescent allergosorbent test [FAST]) are highly sensitive for detection of leishmania antibodies. Culture of a bone marrow aspirate or PCR improve diagnostic yield.[43]

▶ Differential diagnosis

- The differential diagnosis of cutaneous leishmaniasis includes leprosy, sarcoidosis, pyoderma gangrenosum, primary syphilis, and venous stasis ulcers.
- The differential diagnosis of visceral leishmaniasis includes malaria, typhoid fever, and lymphoma.

▶ Management

Nonpharmacologic

- Wound care for ulcers.

Medications

- The main drugs used to treat leishmaniasis include sodium stibogluconate (available from the CDC) and meglumine antimonate.[45,46] Other medications used include miltefosine (the only oral drug for leishmaniasis) fluconazole and liposomal amphotericin b (this is the only drug with FDA approval for visceral leishmaniasis in the United States).[45,46] Amphotericin b is the standard of care in India because of antimonial resistance.[44]

FIGURE 7-16 Diffuse leishmaniasis in an African man with involvement from the face to the toes. The multiple nodules look like lepromatous leprosy but by skin snip testing, the diagnosis of leishmaniasis was confirmed. Figures **A** and **B** show different views of the same patient. (*Courtesy of Richard P. Usatine, MD.*)

Surgery

- Plastic surgery may be used to treat the disfigurement of mucocutaneous or cutaneous leishmaniasis.

PREVENTION OF VECTOR-BORNE DISEASES

Prevention is a public health priority that must include vector (mosquito and sandfly) control, elimination of standing water in households and gardens, insect repellant containing 20% to 30% DEET, and permethrin-coated bednets. Sandflies and *Anopheles* mosquitoes bite from dusk to dawn, but the *Aedes aegypti* vector of dengue fever bites any time during the day, making daytime use of mosquito repellant especially important in dengue-endemic areas.

PROGNOSIS

- Cutaneous leishmaniasis does resolve spontaneously in some cases and in other cases it may persist and resist treatments. The prognosis is related to the severity of the case and the community of the host. Even in those cases that resolve scarring is frequent.
- Visceral leishmaniasis is fatal if not diagnosed and treated.

FIGURE 7-17 Severe mucocutaneous leishmaniasis causing destruction of the nose. (*Courtesy of Richard P. Usatine, MD.*)

RESOURCES

- PubMed Health. *Leishmaniasis*—**http://www.ncbi.nlm.nih.gov/pubmedhealth/PMH0002362/.**
- Centers for Disease Control and Prevention. *Parasites–Leishmaniasis*—**http://www.cdc.gov/parasites/leishmaniasis/.**

EYES—TRACHOMA

EPIDEMIOLOGY AND GEOGRAPHIC DISTRIBUTION

Chlamydia trachomatis is the leading infectious cause of blindness, accounting for 3% of the world's blindness. Globally, 21.4 million people have trachoma, and of these, 1.2 million are blind.[47] Trachoma is associated with poor sanitation, inadequate water supply, and lack of personal hygiene. It is transmitted from person to person via unwashed fingers, flies, and close family contact (sharing of face towels and bedclothes). Trachoma is endemic in Africa (especially in the driest regions) India, South Asia, Australia, and parts of South America.

CLINICAL PRESENTATION

Patients experience inflammation of the eye with watery discharge, itching, burning, and blurry vision. Examination of the tarsal conjunctiva reveals follicles (round swellings that are paler than the surrounding conjunctiva, at least 0.5 mm in diameter). With progression, intense trachomatous inflammation develops, producing inflammatory thickening of the tarsal conjunctiva, which appears red and thickened with numerous follicles (**Figure 7-18**).

Eventually, trachoma causes scarring, with white lines or bands in the tarsal conjunctiva as well as trichiasis, in which eyelashes turn inward and begin to rub against the cornea, and entropion, or inward

FIGURE 7-18 Trachoma causing prominent follicles on the upper eyelid in a person infected with *C. trachomatis*. Note how flipping the eyelid is needed to see the follicles under the upper eyelid. (*Courtesy of Richard P. Usatine, MD.*)

turning of the eyelid itself. With time, this chronic rubbing causes corneal opacity and blindness (**Figure 7-19**).

DIAGNOSIS

Although laboratory diagnostic testing is available for staining *C. trachomatis* in scrapings from the tarsal plate, most settings where trachoma is endemic do not offer this resource, and visual inspection of the everted upper eyelid must suffice. Each eye should be examined for trichiasis and corneal opacities. The upper eyelid is everted by asking the patient to look down, holding eyelashes between thumb and finger, and everting the lid using a cotton-tipped applicator. The everted lid is then checked for follicles, inflammation, and scarring. The differential diagnosis of trachoma includes allergic conjunctivitis (which can also produce follicles of the tarsal plate), and bacterial or viral conjunctivitis.

MANAGEMENT

- Azithromycin, 1 g single oral dose for adults and 20 mg/kg for children in a single dose.
- In pregnancy: erythromycin 500 mg twice daily for 7 days.
- Less effective: topical erythromycin and tetracycline.[10]
- In some settings, surgery is available to correct entropion and trichiasis.

PREVENTION

Preventive measures include community hygiene education, use of soap and water for washing hands and faces, and control of flies through use of ventilated improved pit (VIP) latrines. The WHO has developed the acronym "SAFE" for the global elimination of trachoma:

S Surgery for entropion and trichiasis

A Antibiotics for infectious trachoma

F Facial cleanliness to reduce transmission

E Environmental improvements such as control of disease-spreading flies and access to clean water[48]

SKIN

INFECTIOUS SKIN DISEASES

Many of the skin diseases encountered in resource-limited countries are secondary to crowded living conditions and lack of clean water and soap. Scabies mites and human lice are endemic in many populations that are unable to wash frequently. If clean water is scarce it is more likely to be used for drinking and cooking than bathing. In developed countries, we take clean running water (hot and cold), soap, and shampoo for granted. In developing countries, even if water is available, it may not be accessible as warm running water for showers or baths.

When an intervention as simple as mass distribution of free soap for personal hygiene draws enormous crowds to a mobile clinic, the vastness of inequality in access to basic health measures around the world becomes painfully obvious. So although people recognize

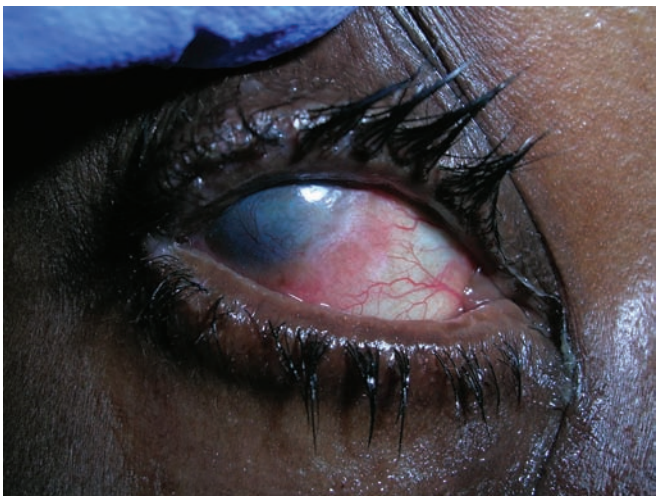

FIGURE 7-19 Blindness caused by untreated trachoma. Although this is one of the most common causes of blindness worldwide, trachoma is easily treatable with a single dose of oral azithromycin. Prevention is achieved through better access to water and soap, together with education about the three "Fs": flies, fingers, facial hygiene. (*Courtesy of Richard P. Usatine, MD.*)

FIGURE 7-20 An American medical student is washing the feet of Ethiopian schoolchildren to treat skin infections and to educate them on preventive hygiene measures. (*Courtesy of Richard P. Usatine, MD.*)

FIGURE 7-21 Badly superinfected scabies with pustules and crusting sores on this young child's leg. (*Courtesy of Richard P. Usatine, MD.*)

the importance of access to soap and clean water, the absence of this luxury results in skin infections and infestations that are highly prevalent and spread from person-to-person (**Figure 7-20**).

We can divide the skin diseases into infestations, bacterial, viral, and fungal infections. All of these skin infections are covered in the dermatology section of this book. Here we highlight some cases seen in developing countries.

Scabies (see Chapter 143, Scabies) is caused by a human mite that burrows under the skin causing itching and leading to scratching. The itching and scratching may keep the person awake at night and may lead to bacterial superinfections (**Figure 7-21**). Scabies is spread by direct skin contact (**Figures 7-22** and **7-23**), shared bedding and clothing, and occasionally by fomites.

Human lice (see Chapter 142, Lice) exist as 3 separate species that are known as head lice, body lice, and pubic lice. Schoolchildren are particularly at risk for head lice, and in areas with limited head washing, the majority of kids may be infested. Body lice live on clothing and feed on the blood of their host. Body lice are more prevalent on adults that bathe rarely and wear the same unwashed clothing day after day. Pubic lice are transmitted through sexual contact and are not known to be more prevalent in developing countries. Water and hygiene issues do predispose to increased head and body lice in developing countries.

Bacterial infections of the skin (see Chapter 116, Impetigo) are ubiquitous throughout the world. Impetigo is a superficial bacterial infection that presents with honey crusts (**Figure 7-24**) or bullae. Good hygiene can prevent impetigo and therefore is not surprising that many cases of impetigo will be seen in countries that lack access to soap and clean water. Impetigo is often secondary to other skin diseases such as scabies or fungal infections that create breaks in the skin barrier function. Cases of secondarily infected scabies and tinea are seen commonly in developing countries.

Viral infections of the skin (see Chapters 123, Chickenpox; 124, Zoster; 125, Zoster Ophthalmicus; 126, Measles; 127, Fifth Disease; 128, Hand, Foot, and Mouth Disease; 129, Herpes Simplex; 130, Molluscum Contagiosum; 131, Common Warts; 132, Flat Warts; 133, Genital Warts; and 134, Plantar Warts) include herpes simplex, varicella zoster, molluscum contagiosum, and human papilloma virus infections. These infections are seen commonly in HIV-infected persons who are not receiving optimal antiretroviral therapy. In countries with a high prevalence of HIV-infected persons, a severe case of molluscum, warts, or shingles in a young person should prompt a clinician to consider HIV testing, if possible. Molluscum infections and warts are so ubiquitous throughout the world that it is important to realize that healthy people with healthy immune systems can get these infections too. Viral exanthems caused by such diseases as varicella and measles may be more prevalent in countries where vaccinations are less available.

Fungal infections of the skin (see Chapters 135, Fungal Overview; 136, Candidiasis; 137, Tinea Capitis; 138, Tinea Corporis; 139, Tinea Cruris; 140, Tinea Pedis; and 141, Tinea Versicolor) can occur from the head down to the toes. Heat, humidity, and lack of bathing are predisposing factors to fungal skin infections. Therefore tropical developing countries provide good environments for tinea capitis (**Figure 7-25**), tinea corporis, and tinea pedis.

FIGURE 7-22 A malnourished baby with marasmus is infested with scabies seen on the hands and arms. Lack of adequate nutrition also is a risk factor for many infections and diseases. The scabies infestation is a marker for scarcity of clean water; the consequences of both may be contributing to the child's irritability and poor feeding. (*Courtesy of Richard P. Usatine, MD.*)

FIGURE 7-23 Scabies infestation covering the mother's breast and her baby's hand. With poor access to healthcare, this infestation would likely remain untreated, and could lead to bacterial superinfection and impetigo on the baby's skin. (*Courtesy of Richard P. Usatine, MD.*)

MYCOBACTERIUM (LEPROSY AND TUBERCULOSIS-HIV COINFECTION)

LEPROSY

Patient story

A young boy presents with significant changes to his face (**Figure 7-26**). The boy and his father are from rural Africa and it is obvious to the physician that the boy has lepromatous leprosy. The father is also examined and he has more subtle signs of leprosy present (several patches of hypopigmented anesthetic skin). A slit skin exam is performed on the ear lobe of the boy and many acid-fast bacilli, characteristic of *Mycobacterium leprae*, are found. The boy is started on the WHO-standard multidrug therapy using rifampin, clofazimine, and dapsone. The father is also examined and treated.

Introduction

Leprosy (Hansen disease) is caused by *M. leprae* and is still endemic in many parts of the developing world where there is poverty and poor access to clean water. At one time, persons with leprosy were called "lepers" and isolated to leper colonies because the disease was disfiguring and the communities were afraid that it was highly contagious. Current science and epidemiology tell us that leprosy is transmitted via droplets from the nose and mouth during close and frequent contact over a period of years, and not by casual contact. Thus doctors working with patients who have leprosy are at no real risk of becoming infected. Issues related to stigma and discrimination still do exist.

Epidemiology

- There were 219,075 new cases reported in the world by 105 countries in 2011.[49]
- The United States reported 173 new cases reported in 2011.[49]
- Since 1990, more than 14 million leprosy patients have been cured, about 4 million from 2000 to 2010.[50]

Etiology and pathophysiology

- The clinical manifestations of leprosy depend upon the immunologic reaction to the infection. The 2 opposite ends of the spectrum consist of:
  - Lepromatous leprosy in which there is a strong antibody response and a poor cell-mediated community resulting in larger amounts of *M. leprae* in the tissues (**Figure 7-26**).
  - Tuberculoid leprosy in which there is a strong cell-mediated immunity and a poor antibody response resulting in less *M. leprae* in the tissues. This tends to present with hypopigmented anesthetic patches (**Figure 7-27**).
- There is also borderline leprosy in which there is a mixed cell-mediated immunity and antibody response showing features of both lepromatous leprosy and tuberculoid leprosy.
- Treatment regimens differ depending on whether the patient has paucibacillary (fewer organisms) or multibacillary leprosy. Lepromatous leprosy and borderline lepromatous leprosy are most likely to be multibacillary.

FIGURE 7-24 Impetigo caused by a bacterial infection on the buttocks of this child in Haiti. Impetigo is more prevalent when there is inadequate hygiene and lack of access to healthcare. (*Courtesy of Richard P. Usatine, MD.*)

FIGURE 7-25 Tinea capitis in this young boy living in a developing country. Many children live with untreated tinea capitis in developing countries because of limited hygiene resources and poor access to healthcare. (*Courtesy of Richard P. Usatine, MD.*)

Risk factors

- Poverty and living in an endemic area
- Inadequate access to clean water and poor hygiene
- Living in the household of an infected person
- Eating or handling armadillos as these animals are natural hosts for *M. leprae*

Diagnosis

Clinical features

- Facial features include leonine facies, madarosis (loss of eyebrows as seen in **Figure 7-26**), elongated and dysmorphic earlobes, and saddle-nose deformities from destruction of the nasal cartilage and bone.
- Visible skin changes include nodules in lepromatous leprosy, hypopigmented patches in tuberculoid (**Figure 7-27**) and borderline leprosy, and annular saucer-like lesions in borderline leprosy.
- Nerve involvement can cause a clawhand (flexion contractures of the fingers as seen in **Figure 7-28**), wristdrop, footdrop, Bell palsy, hammertoes, and sensory neuropathy leading to neurotropic ulcers and traumatic blisters.
- Eye involvement can cause corneal anesthesia, keratitis, episcleritis, lagophthalmos (the inability to close the eyelid completely) and blindness.
- Advanced untreated leprosy can lead to shortening and/or loss of fingers as a result of bone resorption in hands that have become anesthetic and not protected from repeated trauma (**Figure 7-29**).

Distribution

The nodules of lepromatous leprosy are mostly seen on the face and ears but can be seen in other areas. Hypopigmented patches can be seen anywhere on the body including the face.

Laboratory testing

- In obvious cases of leprosy, the slit skin exam done on the ear lobe for bacillary index is the most important test to determine if the patient has multibacillary or paucibacillary leprosy.
- In cases that are suspicious for leprosy (especially outside of endemic areas), a skin punch biopsy of a suspicious lesion is useful for finding *M. leprae* in the tissues.

Differential diagnosis

Superficial mycoses, vitiligo, and cutaneous filariasis all cause changes in pigmentation similar to leprosy. Infiltrated lesions that resemble leprosy include those of leishmaniasis, psoriasis, and sarcoidosis.[52]

Management

Early diagnosis and multidrug therapy are essential to reducing the disease burden of leprosy worldwide. The WHO has supplied multidrug therapy free of cost to leprosy patients in all endemic countries.[51]

- Leprosy is curable and treatment in an early stage can prevent disability.
- Multidrug therapy is a combination of rifampin, dapsone, and clofazimine for multibacillary leprosy patients, and rifampin and dapsone for paucibacillary patients.

FIGURE 7-26 Lepromatous leprosy with leonine facies in a young boy. **A.** Note the loss of eyebrows called madarosis. **B.** Also note the prominent ear involvement. (*Courtesy of Richard P. Usatine, MD.*)

- Duration of multidrug therapy is 12 to 24 months for multibacillary and 6 months for paucibacillary patients.[52]
- Treatment with a single antileprosy drug will always result in development of drug resistance to that drug and is therefore an unethical practice.
- Strategies to increase early access to care and provide easy-to-obtain free multidrug treatment are essential to eliminating leprosy in the world. Research on a preventive vaccine continues in tandem with *Mycobacterium tuberculosis* vaccine research.[53]
- Comprehensive treatment of advanced cases with neuropathy should include foot and hand care to prevent further damage to these insensitive limbs.[52]
- Surgical management for some leprosy-associated problems, such as tendon transfer to correct the clawhand, may be available in some centers.[54]

TUBERCULOSIS AND HIV

▶ Epidemiology

Tuberculosis (TB) is a very common HIV-associated infection, and causes at least 13% of HIV-associated deaths worldwide.[55] In 2010 alone, the WHO estimated there were 1.1 million HIV-associated new cases of TB, the majority of who live in sub-Saharan Africa (**Figure 7-30**). Globally, about one-third of HIV-infected people are coinfected with TB (at least 11 million people) (**Figure 7-31**).[56]

▶ Pathogenesis

TB is transmitted by aerosolized respiratory droplet nuclei (see Chapter 54, Tuberculosis). Weakened cell-mediated immunity in HIV-infected individuals allows more rapid disease progression and causes higher mortality rates from TB. At the same time, untreated TB infection accelerates immunologic decline in HIV infection. Because these 2 diseases preferentially afflict populations with reduced access to medications and supportive care, the emergence of multidrug resistant TB has become an increasing threat.

▶ Clinical presentation

The clinical presentation of TB in an HIV-infected person with a relatively preserved immune system (CD4+ T-cell count greater than 350 cells/μL), is identical to that seen in HIV-negative patients. With increasing immunodeficiency, however, TB often presents atypically. Chest radiographs may not demonstrate classic findings of upper lobe fibronodular or cavitary disease, and extrapulmonary presentations (lymphadenitis, pleuritis, pericarditis, meningitis) are seen. Tuberculous lymphadenitis and cutaneous TB (designated scrofula when it affects the neck) are illustrated in **Figures 7-32, 7-33** and **7-34**.

▶ Diagnosis

HIV screening should be performed in all patients diagnosed with TB, and HIV-infected patients should be screened annually for *M. tuberculosis* with purified protein derivative (PPD) skin testing, chest x-ray, and/or blood test for interferon-γ release assay (IGRA) depending on availability. Patients with low CD4 cell counts (below 200 cells/μL) commonly have poorly reactive skin tests for TB, and thus need a careful history of exposures, review of symptoms, and monitoring of the chest x-ray for evidence of active disease, with repeat TB screening when the CD4 cell count rises above 200 cells/μL.

FIGURE 7-27 Multibacillary leprosy with hypopigmented patches. These patches are commonly numb due to cutaneous nerve damage from mycobacterial infection. (*Courtesy of Richard P. Usatine, MD.*)

FIGURE 7-28 Clawhand caused by the neurological damage of leprosy. This condition may be amenable to surgical intervention involving tendon transfer. (*Courtesy of Richard P. Usatine, MD.*)



FIGURE 7-29 Leprosy has caused this older man to lose his fingers but he continues to lead a productive life weaving rugs for sale at a leprosy hospital. (*Courtesy of Richard P. Usatine, MD.*)

▶ Management

Latent TB infection

HIV-positive patients with latent tuberculosis infection (LTBI) should have a chest x-ray and 3 sputum smears for acid-fast bacilli to rule out active disease. Once active TB is ruled out, isoniazid prophylaxis should be initiated regardless of age for any HIV-positive person with the following characteristics: (a) a positive diagnostic test for LTBI, or (b) a negative LTBI test but with evidence of old or poorly healed fibrotic lesions on chest x-ray, or (c) negative LTBI diagnostic test in a close contact of a person with infectious pulmonary TB.

Duration of LTBI prophylaxis: Isoniazid 300 mg daily or twice weekly for 9 months given with vitamin B_6 (pyridoxine 25 mg daily). An alternative regimen of 12 doses of once weekly isoniazid-rifapentine has recently been validated. Pyridoxine prevents isoniazid-associated peripheral neuropathy.[57]

Active M. tuberculosis *disease*

Any HIV-positive patient with cough and pulmonary infiltrates should be placed in respiratory isolation until TB is ruled out by 3 separately obtained sputum smears (Ziehl-Neelsen) with cultures sent for acid-fast bacilli. This rule applies even when the chest radiograph does not demonstrate cavitary or upper lobe infiltrates. Smear-negative, culture-positive *M. tuberculosis* is not uncommon.

Treatment regimens for HIV-TB coinfected patients are largely identical to those of TB mono-infected patients. It is important not to start antiretroviral therapy (ART) and TB therapy simultaneously, to avoid confusion about drug allergies and side effects. In addition, there is a risk of immune reconstitution syndrome (IRIS [immune reconstitution inflammatory reaction]: inflammatory response that worsens manifestations of any opportunistic infection) when ART is started too soon after initiating TB medication.

Guidelines for ART in TB coinfection are specific. If the CD4 cell count is less than 50, ART should start within 2 weeks of TB therapy. If the CD4 count is greater than 50, ART should start within 8 to 12 weeks of TB therapy. If IRIS does occur, both ART and TB treatment should be continued while managing the IRIS.[58]

Directly observed therapy (DOT) for TB is strongly recommended for HIV-TB coinfected patients.

FIGURE 7-30 Young girl who acquired HIV at birth and now has papular pruritic eruption. One in 3 children born to HIV-infected mothers may be infected; mother-to-child transmission is preventable with simple and affordable antiviral regimens. Fortunately this girl had no signs or symptoms of tuberculosis. (*Courtesy of Richard P. Usatine, MD.*)

PROVIDER AND PATIENT RESOURCES

- Traveler's Health from the Centers for Disease Control and Prevention is a comprehensive site that includes information on more than 200 international destinations, travel vaccinations, diseases related to travel, illness and injury abroad, finding travel health specialists, insect protection, safe food and water, and a survival guide—**http://wwwnc.cdc.gov/travel/.**
- The Yellow Book 2012 is available online as a reference for those who advised international travelers about health risks—**http://wwwnc.cdc.gov/travel/page/yellowbook-2012-home.htm.**
- Detailed vaccine information for travel can be obtained at the CDC website on vaccinations. This includes information on yellow fever vaccine, typhoid vaccine and routine vaccines—**http://wwwnc.cdc.gov/travel/page/vaccinations.htm.**

FIGURE 7-31 Young Ethiopian girl with HIV since birth who has neck swelling secondary to tuberculosis. She also has tinea capitis. HIV is a highly stigmatizing disease in most cultures, and clinicians can play an important role in mitigating community stigma by modeling compassionate care. (*Courtesy of Richard P. Usatine, MD.*)

- Vaccine information can be looked up by specific destination on the traveler's health website—**http://wwwnc.cdc.gov/travel/.**
- U.S. Department of State International Travel Site, including country specific information, travel alert and travel warnings—**http://travel.state.gov/travel/travel_1744.html.**

CONCLUSION

Medical students and health professionals are increasingly drawn to global health for reasons ranging from the desire for enhanced cultural understanding, to the mission to work for global health equity, to alleviate suffering, or to broaden medical experience beyond geographic boundaries. Whatever one's personal motivation, such experiences should never be undertaken without disciplined preparation. Medical professionals should learn in advance of their travels about the culture, language, and expressed needs and priorities of the local government and health providers and their service populations. In addition, they need to learn about the diagnoses and locally appropriate management of prevalent diseases in the population they plan to serve. Equally important, they should take appropriate preventive measures (vaccines, malaria prophylaxis) to protect their own health. Lack of personal and professional preparation can easily turn the tide from net benefit to major burdens for host country organizations. Ultimately, well-prepared medical educators and clinicians, wherever they may come from, are uniquely positioned to share knowledge that saves lives and leads to a more equitable world.

REFERENCES

1. Kaplan JP, Bond TC, Merson MH, et al. Towards a common definition of global health. *Lancet* 2009;373:1993-1995.
2. Brown TM, Cueto M, Fee E. The World Health Organization and the transition from "international" to global" public health. *Am J Public Health* 2006;96:62-72.
3. Central Intelligence Agency. *The World Factbook*. www.cia.gov/library/publications/the-world-factbood/geos/cy.html, accessed September 20, 2012.
4. Waterkeyn J, Carincross S. Creating demand for sanitation and hygiene through community health clubs: a cost-effective intervention in two districts in Zimbabwe. *Soc Sci Med* 2005;61(9): 1958-1970.
5. World Health Organization. *VIP and ROEC latrines*. www.who.int/water_sanitation_health/hygiene/emergencies/fs3_5.pdf, accessed September 21, 2012.
6. UNICEF and WHO. *Progress on Drinking Water and Sanitation 2012 Update*. www.wssinfo.org/fileadmin/user_upload/resources/JMP-report-2012-en.pdf, accessed September 21, 2012.
7. Epstein J, Hoffman S. Typhoid fever. In: Guerrant, RL, Walker DH, Weller PF, eds. *Tropical Infectious Diseases; Principles, Pathogens & Practice*. 2nd ed. Philadelphia, PA: Elsevier; 2006:220-240.

FIGURE 7-32 Scrofula in the inguinal area caused by *M. tuberculosis*. The patient appears systemically ill with weight loss. (*Courtesy of Richard P. Usatine, MD.*)

FIGURE 7-33 Scrofula of the neck caused by *M. tuberculosis* in a child. Chronic drainage and fistulous tract formation are commonly associated with this entity, and therapy is the same as for pulmonary tuberculosis. (*Courtesy of Richard P. Usatine, MD.*)

FIGURE 7-34 Scrofula of the neck caused by *M. tuberculosis* in an adult who did not complete his tuberculosis treatment. The long duration of therapy leads to challenges for adherence, and drug-resistant tuberculosis commonly results. (*Courtesy of Richard P. Usatine, MD.*)

8. Araujo-Jorge T, Callan M, Chappuis F, et al. Multisystem diseases and infections. In: Eddleston M, Davidson R, Brent A, Wilkinson R, eds. *Oxford Handbook of Tropical Medicine*. 3rd ed. New York, NY: Oxford University Press; 2008:665-739.
9. Boggild AK, Van Voorhis WC, Liles WC. Travel-acquired illnesses associated with fever. In: Jong E, Sanford E, eds. *Travel and Tropical Medicine Manual*. 4th ed. Philadelphia, PA: Saunders Elsevier; 2008.
10. Gilbert D, Moellering R, Eliopoulos G, Chambers H, Saag M. *The Sanford Guide to Antimicrobial Therapy*. 41st Ed. Sperryville, VA: Antimicrobial Therapy; 2011.
11. Cravioto A, Lanata CF, Lantagne DS, Nair GB. *Final Report of the Independent Panel of Experts on the Cholera Outbreak in Haiti 2011*. http://www.un.org/News/dh/infocus/haiti/UN-cholera-report-final.pdf, accessed September 21, 2012.
12. Levine MM, Gotuzzo E, and Sow SO. Cholera Infections. In: Guerrant RL, Walker DH, Weller, PF. eds. Tropical Infectious Diseases; Principles, Pathogens & Practice, 2nd Ed Philadelphia, PA: Elsevier; 2006:273-282.
13. Penny ME. Diarrhoeal Diseases. In: Eddleston M, Davidson R, Brent A, Wilkinson R. eds. Oxford Handbook of Tropical Medicine 3rd Ed. New York, NY: Oxford University Press; 2008:213-267.
14. Centers for Disease Control and Prevention. *Cholera Diagnosis and Testing*. http://www.cdc.gov/cholera/diagnosis.html, accessed September 21, 2012.
15. Centers for Disease Control and Prevention. *Recommendations for the Use of Antibiotics for the Treatment of Cholera*. http://www.cdc.gov/cholera/treatment/antibiotic-treatment.html, accessed September 21, 2012.
16. Centers for Disease Control and Prevention. *Domestic Intestinal Parasite Guidelines*. http://www.cdc.gov/immigrantrefugeehealth/guidelines/domestic/intestinal-parasites-domestic.html, accessed September 21, 2012.
17. Keiser J, Utzinger J. Efficacy of current drugs against soil-transmitted helminth infections: systematic review and meta-analysis. *JAMA* 2008;299(16):1937-1948.
18. Knopp S, Mohammed K, Speich B, et al. Mebendazole administered alone or in combination with ivermectin against *Trichuris trichiura*: a randomized controlled trial. *Clin Infect Dis* 2010; 51(12):1420-1428.
19. World Health Organization. *Model Formulary for Children, 2010*. http://www.who.int/selection_medicines/list/WMFc_2010.pdf, accessed September 21, 2012.
20. Mendelson M. Gastroenterology. In: Eddleston M, Davidson R, Brent A, Wilkinson R, eds. *Oxford Handbook of Tropical Medicine*. 3rd ed. New York, NY: Oxford University Press; 2008: 269-327.
21. Alderman H, Shekar M. Nutrition, food security and health. In: Kliegman RM, Behrman RE, Jenson HB, Bonita, Stanton, eds. *Nelson Textbook of Pediatrics*. 19th ed. St. Louis, MO: Saunders; 2011.
22. Kosek M, Black R, Keusch G. Nutrition and micronutrients in tropical infectious diseases. In: Guerrant, RL, Walker DH,

Weller PF, eds. *Tropical Infectious Diseases; Principles, Pathogens & Practice*. 2nd ed. Philadelphia, PA: Elsevier; 2006:36-52.

23. Diop el HI, Dossou NI, Ndour MM, Briend A, Wade S. Comparison of the efficacy of a solid ready-to-use food and a liquid, milk-based diet for the rehabilitation of severely malnourished children: a randomized trial. *Am J Clin Nutr* 2003; 78:302-307.
24. Branca F, Ferrari M. Impact of micronutrient deficiencies on growth: the stunting syndrome. *Ann Nutr Metab* 2002;46 Suppl 1: 8-17.
25. Burgess A. Mother and child undernutrition—vitamin A deficiency. *So Sudan Med J* 2008;1:13. http://www.southsudanmedicaljournal.com/assets/images/Articles/feb08/image2.jpg, accessed September 21, 2012.
26. World Health Organization. *Global Prevalence of Vitamin A Deficiency in Populations at Risk 1995-2005.* In: WHO Global Database on Vitamin A Deficiency. http://whqlibdoc.who.int/publications/2009/9789241598019_eng.pdf, accessed Sept 21, 2012.
27. World Health Organization. *Micronutrient Deficiencies: Vitamin A Deficiency*. http://www.who.int/nutrition/topics/vad/en/index.html, accessed Sept 21, 2012.
28. Mayo-Wilson E, Imdad A, Herzer K, Yakoob MY, Bhutta ZA. Vitamin A supplements for preventing mortality, illness, and blindness in children aged under 5: systematic review and meta-analysis. *BMJ* 2011;343:d5094.
29. Brown K, Wuehler S, Peerson J. The importance of zinc in human nutrition and estimation of the global prevalence of zinc deficiency. *Food Nutr Bull* 2001;22:113-169.
30. World Health Organization. *Implementing the New Recommendations of the Clinical Management of Diarrhea. Guidelines for Policy Makers and Programme Managers*. Geneva, Switzerland: World Health Organization; 2006. http://whqlibdoc.who.int/publications/2006/9241594217_eng.pdf, accessed September 21, 2012.
31. Baqui AH, Black RE, Shams EA, et al. Effect of zinc supplementation started during diarrhoea on morbidity and mortality in Bangladeshi children: community randomised trial. *BMJ* 2002; 325:1059.
32. Brown K, Wuehler S, Peerson J. The importance of zinc in human nutrition and estimation of the global prevalence of zinc deficiency. *Food Nutr Bull* 2001. http://archive.unu.edu/unupress/food/fnb22-2.pdf, accessed September 21, 2012.
33. World Health Organization. *Micronutrient Deficiencies. Iron Deficiency Anaemia.* http://www.who.int/nutrition/topics/ida/en/index.html, accessed September 21, 2012.
34. Horton S, Miloff, A. Iodine status and availability of iodized salt: an across-country analysis. *Food Nutr Bull* 2010;31: 214-220.
35. World Health Organization. *Iodine Status Worldwide*. http://whqlibdoc.who.int.publications/2004/9241592001.pdf, accessed September 21, 2012.
36. Day N. Malaria. In: Eddleston M, Davidson R, Brent A, Wilkinson R, eds. *Oxford Handbook of Tropical Medicine*. 3rd ed. New York, NY: Oxford University Press; 2008:31-65.
37. Ashley E, White N. Malaria diagnosis and treatment. In: Jong E, Sanford E, eds *Travel and Tropical Medicine Manual.* 4th ed. Philadelphia, PA: Saunders Elsevier; 2008:303-321.
38. Hoffman S, Campbell C, White N. Malaria. In: Guerrant, RL, Walker DH, Weller PF, eds. *Tropical Infectious Diseases; Principles, Pathogens & Practice.* 2nd ed. Philadelphia, PA: Elsevier; 2006:1024-1062.
39. Centers for Disease Control. *Treatment of Malaria (Guidelines for Clinicians)*. April 2011. http://www.cdc.gov/malaria/resources/pdf/clinicalguidance.pdf, accessed September 21, 2012.
40. World Health Organization. *10 Facts on Malaria*. http://www.who.int/features/factfiles/malaria/en/index.html, accessed September 21, 2012.
41. Centers for Disease Control and Prevention. *Parasites—Leishmaniasis*. http://www.cdc.gov/parasites/leishmaniasis/, accessed September 15, 2012.
42. Singh S. New developments in diagnosis of leishmaniasis. *Indian J Med Res* 2006;123:311-330.
43. Ryan T. Dermatology. In: Eddleston M, Davidson R, Brent A, Wilkinson R, eds. *Oxford Handbook of Tropical Medicine.* 3rd ed. New York, NY: Oxford University Press; 2008:566.
44. Schwartz E. Leishmaniasis. In: Jong E, Sanford E, eds. *Travel and Tropical Medicine Manual.* 4th ed. Philadelphia, PA: Saunders Elsevier; 2008:532-542.
45. Pub Med Health. *Leishmaniasis*. http://www.ncbi.nlm.nih.gov/pubmedhealth/PMH0002362/, accessed September 15, 2012.
46. Pearson R, Weller P, Guerrant R. Chemotherapy of parasitic diseases. In: Guerrant, RL, Walker DH, Weller PF, eds. *Tropical Infectious Diseases; Principles, Pathogens & Practice*. 2nd ed. Philadelphia, PA: Elsevier; 2006:142-168.
47. World Health Organization. *Prevention of Blindness and Visual Impairment, Priority Eye Diseases: Trachoma*. http://www.who.int/blindness/causes/priority/en/index2.html, accessed September 21, 2012.
48. Yorston D. Ophthalmology. In: Eddleston M, Davidson R, Brent A, Wilkinson R, eds. *Oxford Handbook of Tropical Medicine.* 3rd ed. New York, NY: Oxford University Press; 2008:523.
49. Global Leprosy Situation, 2012. *Wkly Epidemiol Rec* 2012;87(34): 317-328.
50. World Health Organization. *Leprosy; Fact Sheet No.101.* http://www.who.int/mediacentre/factsheets/fs101/en/index.html, accessed August 26, 2012.
51. World Health Organization. *Leprosy Elimination. WHO Multidrug Therapy.* http://www.who.int/lep/mdt/en/index.html, accessed August 26, 2012.
52. Meyers W. Leprosy. In: Guerrant, RL, Walker DH, Weller PF, eds. *Tropical Infectious Diseases; Principles, Pathogens & Practice*. 2nd ed. Philadelphia, PA: Elsevier; 2006:436.
53. Gormus BJ, Meyers WM. Under-explored experimental topics related to integral mycobacterial vaccines for leprosy. *Expert Rev Vaccines* 2003;2(6):791-804.

54. Sapienza A, Green S. Correction of the claw hand. *Hand Clin* 2012;28(1):53-66.

55. National Institutes of Health Clinical Guidelines Portal. *Federally Approved HIV/AIDS Medical Practice Guidelines*. http://www.aidsinfo.nih.gov/contentfiles/lvguidelines/adult_oi_041009.pdf, accessed September 21, 2012.

56. World Health Organization. *TB/HIV FACTS 2011-2012*. http://www.who.int/tb/publications/TBHIV_Facts_for_2011.pdf, accessed September 21, 2012.

57. Johnson J, Ellner J. Tuberculosis and atypical mycobacterial infections. In: Guerrant, RL, Walker DH, Weller PF, eds. T*ropical Infectious Diseases; Principles, Pathogens & Practice*. 2nd ed. Philadelphia, PA: Elsevier; 2006:411.

58. National Institutes of Health Clinical Guidelines Portal. *Considerations for Antiretroviral Use in Patients with Coinfections; Mycobacterium Tuberculosis Disease with HIV Coinfection*. http://www.aidsinfo.nih.gov/guidelines/html/1/adult-and-adolescent-treatment-guidelines/27/, accessed September 21, 2012.

This page intentionally left blank

PART 3

PHYSICAL AND SEXUAL ABUSE

Strength of Recommendation (SOR)	Definition
A	Recommendation based on consistent and good-quality patient-oriented evidence.*
B	Recommendation based on inconsistent or limited-quality patient-oriented evidence.*
C	Recommendation based on consensus, usual practice, opinion, disease-oriented evidence, or case series for studies of diagnosis, treatment, prevention, or screening.*

*See Appendix A on pages 1447–1450 for further information.

8 CHILD PHYSICAL ABUSE

Jim Anderst, MD, MSCI
Ashley D. Hopkins, MD

PATIENT STORIES

CASE 1

A 1-month-old child was seen in the emergency room for bruising. Physical examination revealed bruises to the buttocks, chest, and eye. The parents reported that the child received the buttock bruise (**Figure 8-1**) after being dropped by the father, that the chest bruise was from the child's seat belt, and the eye bruise from accidentally hitting the child with an elbow while cosleeping. The social worker was consulted in the emergency room, and found no concerning "red flags" in the family. The emergency room physician felt the findings were because of inexperienced parents. The child was sent home with the parents, and the emergency room later reported the case to Children's Protective Services (CPS) in hopes of providing the family with support services. A child abuse pediatrician (CAP) was consulted by CPS to review the case the next day. The CAP requested that the child be brought back to the hospital emergently for further evaluation. A skeletal survey, including oblique views of the ribs, at that time showed a healing fracture of the eighth posterior rib (**Figure 8-2**). A head CT and liver function tests were performed to screen for occult trauma, and laboratory tests were done to evaluate for a bleeding diathesis. All were negative. Law enforcement was contacted and coinvestigated with CPS. The child was placed in the home of a relative. Two weeks later, a repeat skeletal survey showed new bone formation over the right femur, indicating a healing fracture.

FIGURE 8-1 Bruising to the left buttock noted in a 1-month-old child. Any bruising on an immobile child is highly concerning for child physical abuse. Bleeding disorders must be considered in the differential diagnosis. (*Courtesy of James Anderst, MD, MS.*)

CASE 2

A 15-month-old child is brought to the emergency department by the police after a relative called 911. The child and his mother attended a family gathering where concerned relatives viewed the mother's story that the child "falls a lot" with suspicion. On examination there were many signs of physical abuse (**Figures 8-3** to **8-5**). His face was covered with bruises, especially around the right eye and cheek (**Figure 8-3**). His axilla showed signs of being gouged with fingernails (**Figure 8-4**). Although an initial skeletal survey did not show any fractures, a repeat skeletal survey and oblique views of the ribs were done 2 weeks later. The second skeletal series showed eight healing rib fractures. Repeat skeletal surveys are recommended in children younger than 4 years of age, who are confirmed or suspected victims of abuse (**Figure 8-5**). The child was admitted to the hospital and the police, hospital social workers, and CPS were notified. In the emergency department, the child was evaluated by a forensic nurse examiner trained in child-abuse photo documentation. The child was then referred to a CAP who assessed mechanisms of injuries, reexamined the child, and interpreted the initial and follow-up skeletal surveys.

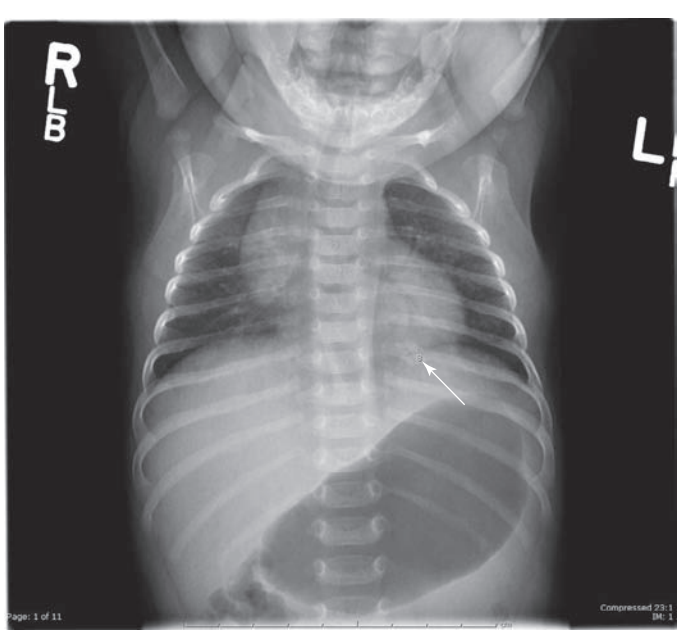

FIGURE 8-2 Healing eighth posterior rib fracture in the same child from **Figure 8-1**. A skeletal survey is indicated in any child younger than 2 years of age where suspicions of physical abuse exist. (*Courtesy of James Anderst, MD, MS.*)

INTRODUCTION

The appropriate identification of child physical abuse is critical. Misdiagnoses in either direction (missed abuse or inappropriate diagnosis of abuse) are extremely harmful to the child and family. A careful evaluation of each case, coupled with an application of the existing scientific data on child physical abuse, may result in improved outcomes for the child and family.

EPIDEMIOLOGY

- Occurs in 9.2 per 1000 children, with highest rate of victimization in the birth to 1 year age group (20.6 per 1000).
- The Department of Health and Human Services compilation of State CPS Child Maltreatment 2010 had 3.3 million CPS reports filed in 2010, with 695,000 confirmed child victims.[1] Of these:
  - Seventy-eight percent were neglected.
  - Eighteen percent were physically abused.
  - Nine percent were sexually abused.
  - Eight percent were psychologically abused.
- Nearly 81% of victims were abused by a parent acting alone or with another person.
- Medical personnel made only 8.2% of the referrals to CPS.

RISK FACTORS

Caregiver factors associated with child abuse include the following:[2–4]

- Inappropriate parental expectations of the child.
- Lack of empathy toward the child's needs.
- The parent's belief in physical punishment.
- Parental role reversal.
- Caregiver's personal history:
  - Was abused during childhood.
  - Parents' rearing practices modeled.
  - Mental illness or substance abuse.

Factors specific to the child that are associated with abuse:[2]

- Prematurity.
- Disabilities.
- Difficult temperament.

Environmental factors associated with abuse:

- Domestic violence.
- Financial, family, or work stressors.
- Housing issues.

DIAGNOSIS

CONCERNING HISTORY[5]

- History inconsistent with child's developmental stage.
- Injuries inconsistent with history given.

FIGURE 8-3 A 15-month-old boy who has been physically abused by his mother's boyfriend for several weeks. There is bruising under both eyes, with the greatest degree of bruising seen under the right eye and on the right cheek. The boy is in the emergency department after concerned relatives called the police. (*Courtesy of James Anderst, MD, MS.*)

FIGURE 8-4 Same 15-month-old boy from **Figure 8-3** with multiple fingernail gouges in his right axilla. Some are fresh and one appears to be older and somewhat crusted. Injuries in different stages of healing may indicate chronicity of abuse. (*Courtesy of James Anderst, MD, MS.*)

- History changes over time.
- History differs among witnesses.
- Delay in seeking medical care (must consider family's access to care and availability of transportation).
- Sibling blamed.
- Magical injury—No one knows how it happened.

CLINICAL FEATURES

- Bruising:[6]
  - In children who are not independently mobile.
  - Seen away from boney prominences.
  - To the face, hands, ears, buttocks, back, abdomen, and arms.
  - In the shape of an imprint of an object or hand, or a ligature (**Figure 8-6**).
  - Multiple bruises in clusters.
- Burns:[7]
  - Inconsistent with history (**Figure 8-7**).
  - Stocking/glove distribution.
  - Well-demarcated edges.
  - Symmetrical burns.
  - No splash marks.
- Fractures:[8]
  - Rib fractures.
  - Fractures in immobile children that are not attributable to birth injury.
  - Multiple fractures and/or multiple fractures of different ages.
  - Fractures in the absence of a history of trauma.
  - Any fracture that is inconsistent with the reported mechanism.
- Intracranial injury:
  - Highly variable clinical presentation, however presence of apnea, retinal hemorrhages, and/or rib fractures is more strongly associated with inflicted (versus noninflicted) intracranial injury.[9,10]
  - Mild abusive head injury may present with isolated vomiting or fussiness.[11]
- Oral lesions—Torn frenula, palatal petechiae, contusions, or lacerations (typically from a bottle, finger, or other object forced into the child's mouth).[12]

Failure to thrive and signs of malnutrition as a result of intentional withholding of food and/or liquids.

LABORATORY STUDIES AND IMAGING

- Concerning bruising that is not obviously abusive—Prothrombin time/partial thromboplastin time (PT/PTT), complete blood count (CBC), von Willebrand testing, factor 8 and factor 9 levels. Testing best done in collaboration with a CAP or pediatric hematologist.[13]
- Detection of occult abdominal trauma—Liver function tests (LFTs), amylase, lipase, urinalysis; CT of abdomen recommended if laboratory results are elevated or urinalysis positive for blood.[14]
- Detection of occult fractures—Skeletal survey (including oblique views of the ribs) in children younger than 2 years of age or nonverbal children; consider radionuclide bone scan to look for acute fractures, or a follow-up skeletal survey 2 weeks after initial presentation.[15]

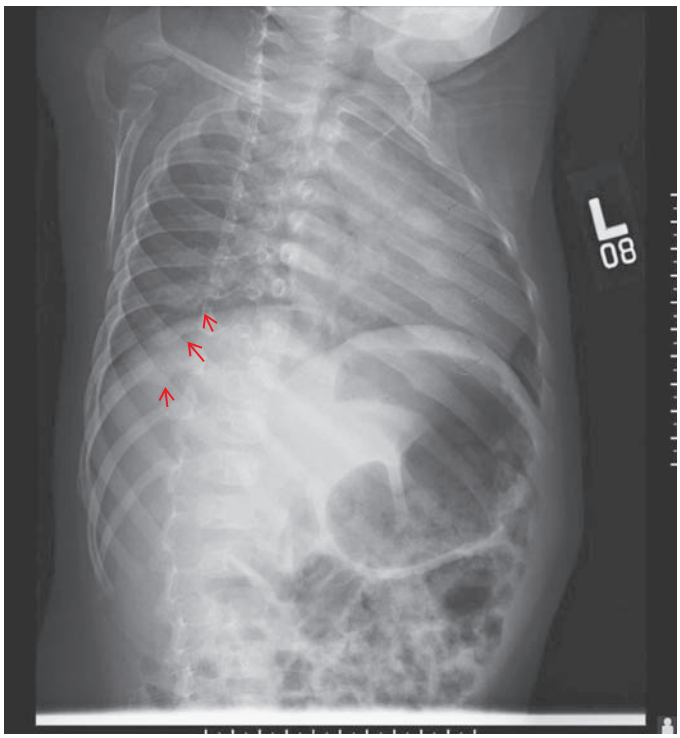

FIGURE 8-5 Same boy from **Figure 8-3** with oblique X-ray showing healing rib fractures with callus in eight different locations as marked by the *arrows*. The degree of callus formation shows that these rib fractures are not new. Oblique radiographs should be requested in addition to a "skeletal survey" because lateral rib fractures are best seen with this view. (*Courtesy of James Anderst, MD, MS.*)

FIGURE 8-6 Linear ecchymosis on the cheek of a baby who was slapped in the face by an abusive parent. (*Courtesy of James Anderst, MD, MS.*)

- Detection of occult intracranial injury—CT/MR of head in all young children, even if there are no clinical signs of intracranial injury; ophthalmology examination for retinal hemorrhages.[16]

DIFFERENTIAL DIAGNOSIS

- Bruises and other skin findings:
  - Accidental bruises—Any bruising in an infant or precruiser is very concerning for abuse. Accidental bruising is much more common in cruising or walking children.[17] Any inflicted bruising or skin markings (including those from spanking or other punishment) lasting more than 24 hours constitutes abuse.[18] Ear bruising is very specific for abuse (**Figure 8-8**).[19] It is not possible to accurately date bruises.[20] Accidental bruising is typically located on the shins, lower arms, under chin, forehead, hips, elbows, ankles, and bony prominences. Loop-like bruising is suspicious for blows with a cord or a looped belt (**Figure 8-9**).
  - Bruising with tracking of blood (subgaleal hematoma) can be seen with severe injuries to the head from violent hair pulling (**Figure 8-10**).
  - Bleeding disorders—Familial history, abnormal coagulation laboratory test results, vitamin K deficiency.
  - Other rare diseases associated with bruising—Ehlers-Danlos, Henoch-Schönlein purpura, phytophotodermatitis (skin reaction to psoralens, most commonly found in limes), osteogenesis imperfecta (brittle bones).
  - Skin discoloration—Common examples are allergic shiners (dark, puffy lower eyelids) and Mongolian spots (macular blue-gray pigmentation usually on the sacral area of normal infants, usually present at birth or appear within the first weeks of life; (see Chapter 108, Normal Skin Changes).
- Burns:
  - Accidental burns (splash marks usually seen).
  - Bullous impetigo, cellulitis, scalded skin syndrome, diaper rash.
  - Chemical burn caused by senna containing laxatives.
  - Drug reaction.
- Fractures from other diseases occurring in infants and young children:
  - Osteogenesis imperfecta—A congenital disorder with bone fragility; patients may have repeated fractures after mild trauma that heal readily. Other features seen in some cases include blue sclera, easy bruising, and deafness.
  - Rickets—Usually from vitamin D deficiency, consider in exclusively breastfed infants, dark skinned children, children with little sun exposure. The metaphyses show widening and cupping with irregular calcification as a result of poor calcification of osteoid.
- Failure to thrive from other causes including improper mixing of formula, breastfeeding difficulty, organic diseases such as cystic fibrosis, HIV, metabolic disorders, celiac disease, and renal disease.[21]

Intracranial bleeding—Other causes include accidental injury, infection, coagulation disorders, birth injury, and rare metabolic conditions (glutaric aciduria).

Cultural practices—Coining (**Figure 8-11**), cupping, moxibustion (cultural practice of burning herbs on skin).

FIGURE 8-7 Toddler being seen for a burn caused by hair straightener. The family claimed the iron fell onto the leg but further investigation seemed to indicate that the iron was applied to the child by an angry parent to control a crying child. Although the iron falling could explain the injury on the calf, it does not explain the additional injury higher up on the leg. (*Courtesy of James Anderst, MD, MS.*)

FIGURE 8-8 Bruising of the ear in a young boy who was physically abused by a parent. Ear bruising is rarely accidental. The additional bruising on the cheek suggests this child was hit with a hand or another object to produce the bruising seen in this photo. (*Courtesy of James Anderst, MD, MS.*)

MANAGEMENT

- Emergent care first; treat injuries, burns, failure to thrive accordingly.
- Careful examination of the skin and oral cavity, palpation for bony tenderness or callus formation, signs of abdominal trauma or neurologic abnormalities, ophthalmologic evaluation for retinal hemorrhages.
- Document the history provided by caregivers and physical findings accurately, including pictures.
- Consider consultation with a CAP or a family physician with additional training or expertise. Child abuse pediatrics is a new subspecialty of pediatrics requiring an additional 3 years of fellowship training.
- In cases where the injury was truly caused by an accidental mechanism, the role of neglect must be considered.
- Mandated reporting:
  - All 50 states require that all professionals who work with children report suspected child abuse and neglect.
  - Reporter of abuse is granted legal immunity.
  - Once the case is reported, further collaboration with CPS or law enforcement is usually necessary to ensure appropriate outcomes.[22]

FIGURE 8-9 Young girl with linear bruising on the back, buttocks, and thigh from being hit with a belt. One bruise appears to have a loop-like form (*arrow*) and was likely caused by blows with a cord or a looped belt. Blows with flexible objects produce patterns that tend to conform to the curved surfaces of the body, whereas inflexible objects may produce a discontinuous pattern over curved surfaces. (*Courtesy of Nancy Kellogg, MD.*)

PATIENT EDUCATION

- Prevention programs:
  - Home visitation programs have been shown to reduce child abuse and child mortality.[23]
  - Nursery-based prevention of abusive head trauma.[24]
  - Specific models of primary care may reduce abuse.[25]
  - Population-based prevention.[26]
  - Parent–child interactive therapy (PCIT) reduces repeat abuse.[27]

FOLLOW-UP

- If there is suspicion of fractures, obtain repeat skeletal X-ray in 2 weeks to look for evidence of healing fractures.
- Siblings of abused children should be interviewed and examined for findings concerning for abuse.
- Counseling for child and family as appropriate.
- Frequent follow-up with primary care provider to evaluate for signs of abuse and neglect.
- Report to CPS.

PATIENT RESOURCES

- Child Help—**http://childhelp.org/.**
- Prevent Child Abuse America—**http://www.preventchildabuse.org/index.shtml.**

FIGURE 8-10 Young girl with severe subgaleal hematoma with extensive blood tracking into the upper face after being lifted off the ground by her hair. Blood tracking after significant injury is most commonly seen on the face, although some injuries to the genitals may also track into the perineum. (*Courtesy of James Anderst, MD, MS.*)

PROVIDER RESOURCES

- Mechanisms of Injury in Childhood phone app/computer program—**http://www.childrensmercy.org/mic/.**
- The American Academy of Pediatrics Evaluation of Suspected Child Physical Abuse—**http://pediatrics.aappublications.org/cgi/content/full/119/6/1232.**
- The American Professional Society on the Abuse of Children—**www.apsac.fmhi.usf.edu/index.asp.**
- Child Abuse Evaluation & Treatment for Medical Providers—**http://www.childabusemd.com/index.shtml.**

REFERENCES

1. U.S. Department of Health and Human Services, Administration for Children and Families, Administration on Children, Youth and Families, Children's Bureau, 2010. *Child Maltreatment 2009*. http://www.acf.hhs.gov/programs/cb/stats_research/index.htm#can. Accessed March 2012.
2. Giardino AP, Alexander R. *Child Maltreatment: A Clinical Guide and Reference*. St. Louis, MO: G.W. Medical; 2005.
3. Bavolek S. *The Nurturing Parent Programs*. Washington, DC: Office of Juvenile Justice and Delinquency Prevention, U.S. Department of Justice; 2000.
4. Helfer RM. The etiology of child abuse. *Pediatrics.* 1973;51 (Suppl 4):777-779.
5. Kellogg ND; American Academy of Pediatrics, Committee on Child Abuse and Neglect. Evaluation of suspected child physical abuse. *Pediatrics.* 2007;119(6):1232-1241.
6. Maguire S, Mann MK, Sibert J, Kemp A. Are there patterns of bruising in childhood which are diagnostic or suggestive of abuse? A systematic review. *Arch Dis Child.* 2005;90:182-186.
7. Maguire S, Moynihan S, Mann M, et al. A systematic review of the features that indicate intentional scalds in children. *Burns.* 2008;34(8):1072-1081.
8. Maguire S. Which injuries may indicate child abuse? *Arch Dis Child Educ Pract Ed.* 2010;95:170-177.
9. Maguire S, Pickerd N, Farewell D, et al. Which clinical features distinguish inflicted from non-inflicted brain injury? A systematic review. *Arch Dis Child.* 2009;94:860-867.
10. Maguire S, Kemp AM, Lumb R, Farewell D. Estimating the probability of abusive head trauma: A pooled analysis. *Pediatrics.* 2011; 128(3):e550-e564.
11. Jenny C, Hymel KP, Ritzen A, et al. Analysis of missed cases of abusive head trauma. *JAMA.* 1999;282(7):621-626.
12. Kellogg ND; American Academy of Pediatrics, Committee on Child Abuse and Neglect. Oral and dental aspects of child abuse and neglect. *Pediatrics.* 2005;116(6):1565-1568.
13. Jackson J, Carpenter S, Anderst J. Challenges in the evaluation for possible abuse: presentations of congenital bleeding disorders in childhood. *Child Abuse Negl.* 2012;36:127-134.
14. Lindberg D, Makoroff K, Harper N, et al. Utility of hepatic transaminases to recognize abuse in children. *Pediatrics.* 2009;124(2): 509-516.

FIGURE 8-11 Young boy with the marks of coining on his back. A coin was rubbed across his back leaving ecchymoses over bony prominences with the intent to help the child heal from an acute illness. This cultural practice is more common among Asian immigrants to this country and mimics child abuse. (*Courtesy of Maria McColgan, MD.*)

15. American Academy of Pediatrics Section on Radiology. Diagnostic imaging of child abuse. *Pediatrics.* 2009;123(5):1430-1435.
16. Rubin DM, Christian CW, Bilaniuk L, et al. Occult head injury in high risk abused children. *Pediatrics.* 2003;111(6):1382-1386.
17. Sugar NF, Taylor JA, Feldman KW. Bruises in infants and toddlers: those who cruise rarely bruise. *Arch Pediatr Adolesc Med.* 1999;153: 399-403.
18. American Academy of Pediatrics, Committee on Child Abuse and Neglect. When inflicted skin injuries constitute child abuse. *Pediatrics.* 2002;110(3):644-645.
19. Dunstan FD, Guildea ZE, Kontos K, et al. A scoring system for bruise patterns: a tool for identifying abuse. *Arch Dis Child.* 2002; 86:330-333.
20. Maguire S, Mann MK, Sibert J, Kemp A. Can you age bruises accurately in children? A systematic review. *Arch Dis Child.* 2005; 90:187-189.
21. Block RW, Krebs NF. Failure to thrive as a manifestation of child neglect. *Pediatrics.* 2005;116(5):1234-1237.
22. Anderst J, Kellogg N, Jung I. Is the diagnosis of physical abuse changed when Child Protective Services consults a Child Abuse Pediatrics subspecialty group as a second opinion? *Child Abuse Negl*. 2009;33(8):481-489.
23. American Academy of Pediatrics, Council on Child and Adolescent Health. The role of home-visitation programs in improving health outcomes for children and families. *Pediatrics.* 1998;101(3): 486-489.
24. Barr RG, Barr M, Fujiwara T, et al. Do educational materials change knowledge and behavior about crying and shaken baby syndrome? A randomized controlled trial. *CMAJ.* 2009;180(7): 727-733.
25. Dubowitz H, Feigelman S, Lane W, Kim J. Pediatric primary care to help prevent child maltreatment: the safe environment for every kid (SEEK) model. *Pediatrics.* 2009;123(3):858-864.
26. Prinz RJ, Sanders MR, Shapiro CJ, et al. Population-based prevention of child maltreatment: the U.S. triple p system population trial. *Prev Sci*. 2009;10(1):1-12.
27. Timmer SG, Urquiza AJ, Zebell NM, McGrath JM. Parent-child interaction therapy: application to maltreating parent-child dyads. *Child Abuse Negl.* 2005;29(7):825-842.

9 CHILD SEXUAL ABUSE

Nancy D. Kellogg, MD
Maria D. McColgan, MD

PATIENT STORY

A 12-year-old girl is being seen for chronic abdominal pain by her family physician. The physician asks the mother to step out of the room and does a complete history including the HEADSS (home life, education level, activities, drug use, sexual activity, suicide ideation/attempts) questions. The girl tearfully reports that her stepfather has been touching her in her private areas when her mother is not home. On examination with a female nurse chaperone in the room, the physician finds that the girl's hymen initially appears normal (**Figure 9-1**). However, when the girl is more carefully examined with a cotton-tip applicator, a healed posterior hymenal transection is seen (**Figure 9-2**). When the girl is asked whether any other types of sexual abuse occurred with her stepfather, she admits to repeated penile penetration. Although rare, sometimes the examination reveals more than what the child is willing to disclose about the abuse. Partial disclosures of abuse are common in children. In addition, the findings of sexual abuse tend to be subtle and are easily missed if a careful examination and special techniques are not used. Attempts are made to reassure the girl that this should never happen and that this is not her fault. Her mother is brought back into the room and after a sensitive discussion, the police are called and Child Protective Services notified.

HEADSS is an acronym that provides a framework for interviewing adolescents and children about health risks. The questions start from easiest and least sensitive to more sensitive questions that need to be asked:

H—home

E—education

A—activities

D—depression and drugs

S—sex and sexual abuse

S—suicide

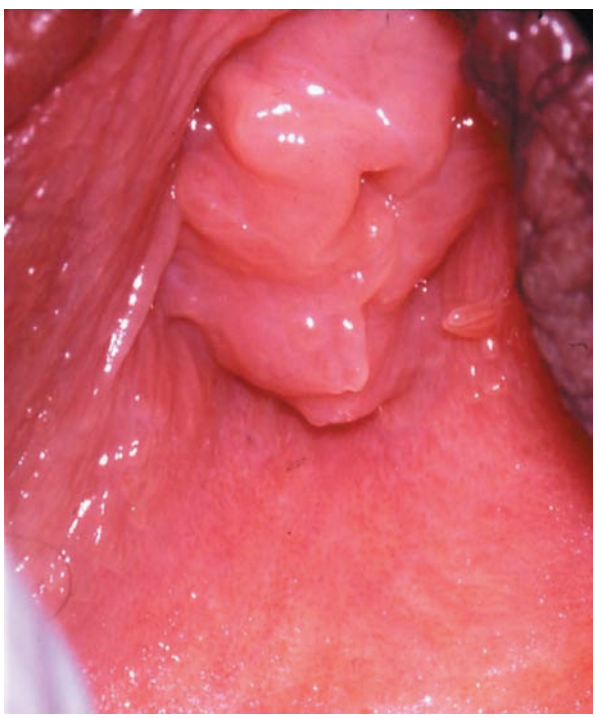

FIGURE 9-1 Typical appearance of the hymen and perihymenal tissues in a 12-year-old girl. Once females have entered puberty, the hymen becomes redundant with overlapping folds and is more difficult to examine for subtle signs of acute or healed injury. (*Courtesy of Nancy D. Kellogg, MD.*)

EPIDEMIOLOGY

- The U.S. Department of Health and Human Services compilation of Child Protective Services (CPS) data from 48 states in 2008 indicates there were 772,000 children confirmed as victims of abuse.[1] Of these, 9% were victims of sexual abuse. Not included in these numbers are several thousand additional victims who are sexually assaulted by nonfamily members; these cases are reported to law enforcement but not CPS.
- Sexual abuse of girls occurs at much higher rate than boys: 2.3 per 1000 females versus 0.6 per 1000 males.[2]
- Up to 50% of abusive sexual acts involve penetration of the vagina, anus, or oral cavity, or oral–genital contact.[3] In general, penetrative types of abuse are associated with poorer medical and mental health outcomes.

ETIOLOGY AND PATHOPHYSIOLOGY

Child sexual abuse occurs when a child is involved in sexual activities that he or she cannot comprehend, for which the child is developmentally unprepared and cannot or does not give consent, and/or that violate laws. All states have laws that require physicians to report a suspicion of abuse to child protection or law enforcement agencies.

Most sexual abuse involves an adult perpetrator the child knows and is expected to trust who uses deception and position of authority to gain the child's acquiescence and accommodation to the abuse;[4] it is not unusual for the abuse to progress from less to more severe and intrusive sexual acts, and for the child to wait months or years to disclose the abuse.

DIAGNOSIS

CLINICAL FEATURES

- Child victims of sexual abuse may have behavior changes, depression, increased sexual behaviors, somatic complaints (e.g., headaches or abdominal pain, constipation, enuresis/encopresis, genital/anal pain), or may be asymptomatic.
- Child may present to a medical provider for the following reasons:
  - Child has disclosed abuse (most common); it is rare for the abuse to be witnessed. Referrals to specialized programs with clinicians trained in the assessment of child sexual abuse is recommended, and are generally accessible in most areas of the United States.
  - Caregiver suspects abuse and presents to the clinician because of behavioral or physical symptoms.
  - Child is brought for routine care and sexual abuse is suspected based on clinical findings (e.g., acute or healed genital injuries, vaginal discharge in a prepubertal child, lesions suggestive of human papillomavirus [HPV] or herpes simplex virus [HSV]).
- Recent studies show that less than 5% of child sexual abuse victims have physical examination findings indicative of penetrative trauma because the type of sexual act either does not result in tissue damage or because when tissue damage occurs, most injuries heal quickly and completely.[5–7] In a study of 36 pregnant adolescents, only two had evidence of penetrative trauma.[8] The medical diagnosis relies predominantly on the child's history and clinicians should remember that "normal" does not mean "nothing happened."
- Tips for doing the physical examination:
  - The anogenital inspection should utilize optimal direct light source, magnification, and appropriate examination positions and techniques.
  - Recommended examination positions include supine frogleg or lithotomy and prone knee-chest; the latter position is particularly important to confirm any posterior (between the 4 and 8 o'clock positions of the hymen in supine) defects of the hymen that are seen in supine position.
  - Various examination techniques include labial separation and traction (gently pulling the labia outward and inferiorly), gluteal lifting in prone knee-chest and using cotton-tipped applicator for separating tissues.
  - In some cases, it may help to have an assistant gently squirt a small amount of nonbacteriostatic saline onto the hymen as the

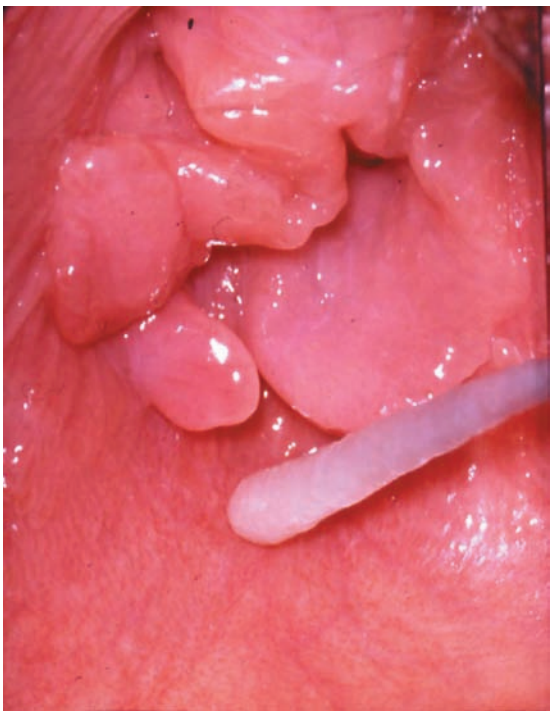

FIGURE 9-2 Hymenal cleft visible when the girl in **Figure 9-1** is more carefully examined using a saline moistened cotton-tip applicator to gently separate and demonstrate the edges of the hymen. This injury was caused by sexual abuse and may have been missed without the more careful examination. (*Courtesy of Nancy D. Kellogg, MD.*)

FIGURE 9-3 A 10-year-old girl with an acute tear of the posterior vestibule after recent sexual assault by a stranger. The posterior vestibule is the most common location for acute penetrative trauma in females. (*Courtesy of Nancy D. Kellogg, MD.*)

examiner uses gentle labial traction; this procedure is used to free folded hymenal edges.
  - A speculum examination and use of a cotton-tipped applicator to separate hymenal edges are traumatic procedures for prepubertal females and should not be used.
  - Most findings of anal trauma can be visualized by gently spreading the anal folds.
- Physical findings concerning for abuse include:[9]
  - Abrasions or bruising of the hymen, perihymenal structures, or anus (**Figures 9-3** and **9-4**).
  - Acute or healed tear in the posterior aspect of the hymen extending to, or nearly to, the base of the hymen or further to the posterior vestibule (see **Figure 9-2**).
  - Anal bruising or lacerations (**Figure 9-5**).
  - Petechiae or bruising on the soft palate following a history of forced oral penetration.

LABORATORY TESTS AND IMAGING

- Forensic evidence collection if sexual assault occurred less than 72 to 96 hours (protocols vary from region to region) prior to clinical presentation (consider referring to an emergency department or rape crisis center skilled in performing forensic evidence collection on children).
- Approximately 5% of sexually abused children and adolescents acquire a sexually transmitted infection (STI) from the abuse[9] (**Figure 9-6**).
- Consider STI testing in all postpubescent patients and in prepubescent children with a history of genital contact with any orifice.
- HIV, hepatitis B (if unimmunized), rapid plasma reagin (RPR) (for syphilis), cultures or nucleic acid amplification tests (with confirmation) for chlamydia, and gonorrhea and culture or polymerase chain reaction (PCR) for trichomonas.
- Culture or PCR for HSV1 and HSV2 if ulcers or vesicles are present (see **Figure 9-6**).
- Condylomata acuminata is a clinical diagnosis and biopsy is required only if lesions are atypical or resistant to treatment (molluscum contagiosum is a mimic and not sexually transmitted in children).
- Pregnancy testing in postpubescent children; consider prophylaxis (e.g., plan B) if the event occurred less than 96 hours prior to evaluation.
- Follow-up examinations 2 to 3 weeks after an acute assault to complete testing for STIs with prolonged incubation periods (especially HPV), assess resolution of injuries, and ensure emotional recovery.

DIFFERENTIAL DIAGNOSIS

In females, the following may be confused with abuse:

- Straddle injury (or other accidental trauma)—This occurs when a child falls onto an object. Bruising or lacerations to the labia majora, labia minora, or posterior fourchette may be seen. Although rare, accidental penetrating injury involving perihymenal tissues occurs, but rarely.

FIGURE 9-4 Acute hymenal hematoma in a prepubertal girl from penile penetration/contact. One reason why the considerable majority of examinations are normal may be that contact is more common than complete penetration and injuries resulting from penile contact are uncommon or are minor injuries that heal quickly and completely within days. (*Courtesy of Nancy D. Kellogg, MD.*)

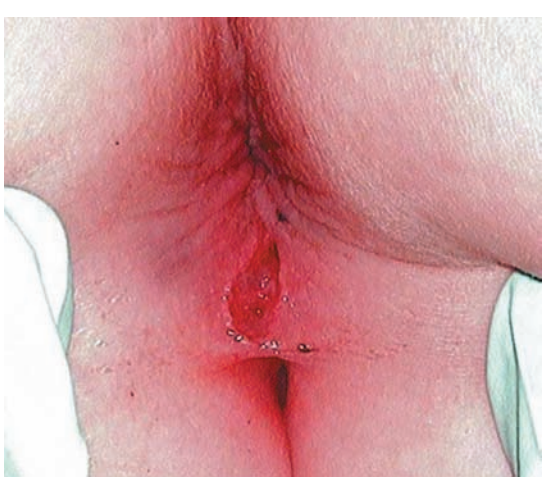

FIGURE 9-5 Acute rectal laceration in a young boy who was sexually abused by a relative. More than 95% of anal examinations in children with a history of anal penetration are normal or nonspecific. (*Courtesy of Nancy D. Kellogg, MD.*)

- Anatomic variants of normal, including shallow hymenal notches, anterior hymenal clefts, midline vestibule white lines, perineal defects, and narrow hymenal rims.
- Vulvar dermatitis—This may be caused by atopy, contact irritation, or seborrhea.
- Vulvovaginitis (e.g., nonspecific vaginal flora, shigella, streptococcus, poor hygiene, candidiasis)—Complaints include vaginal irritation or itching and vaginal discharge; wet prep and/or culture may be helpful.
- Lichen sclerosus et atrophicus is a cutaneous disease not caused by sexual abuse. It may present with bleeding, bruising, and/or vulvar itching, and the examination shows subepidermal hemorrhages and/or atrophic changes with areas of hypopigmentation over the vulva, perineum, and/or anus, an "hourglass" configuration (**Figure 9-7**).
- Anogenital irritation or bleeding—Causes may be infectious (pinworms, candidiasis, group B streptococcal infection), irritative (overgrowth of normal flora, sensitivity to laundry detergent or fabric softeners, sequelae of pubic hair shaving) or anatomic (urethral prolapse, dehiscence of a labial adhesion) (**Figure 9-8**).
- Normal physiologic leukorrhea—Scant, whitish tenacious discharge in pubertal females. Wet mount is normal.

In males, the following may be confused with abuse:

- Accidental trauma (e.g., penis caught in zipper)—History should support pattern of injury. Most intentionally inflicted injuries of male genitals are physical, not sexual, abuse.
- Phimosis—Unretractable foreskin. Irritation and redness occurs as a result of trapped debris.

Additional findings that may be confused with abuse:

- Anal fissure(s), which is a superficial excoriation or tear that extends from the anal verge into the anal canal; may or may not cause pain or bleeding during bowel movements. Sometimes, but not always, associated with diarrhea or constipation.
- Perianal venous pooling is sometimes mistaken for bruising.

MANAGEMENT

- Children may present with nonspecific behavioral and physical symptoms (but no disclosure of abuse) that include chronic stomachaches or headaches, school difficulties, mood changes, and sleeping difficulties. These children should be questioned in a careful and nonleading manner about the possibility of sexual abuse. For example, the clinician may state: "I treat other children who have problems like you do with school and headaches. Some of these children have told me about things that have happened to their body or feelings that made them sad, scared, or confused. Has anything like that ever happened to you?"
- Take a history from the child if necessary to make a medical diagnosis and to determine appropriate testing, treatment, and the need to report suspected abuse to child protection or law enforcement. The clinician may opt not to take a history if the child was or will be interviewed elsewhere; in this case, information necessary to determine what type of medical assessment and testing should be obtained from other sources.

FIGURE 9-6 Herpes simplex virus (HSV) type 1 infection on the vulva of the prepubertal girl caused by sexual abuse. HSV type 1 of the genitals from sexual contact is increasing in prevalence relative to HSV type 2 infections of the genitals. (*Courtesy of Nancy D. Kellogg, MD.*)

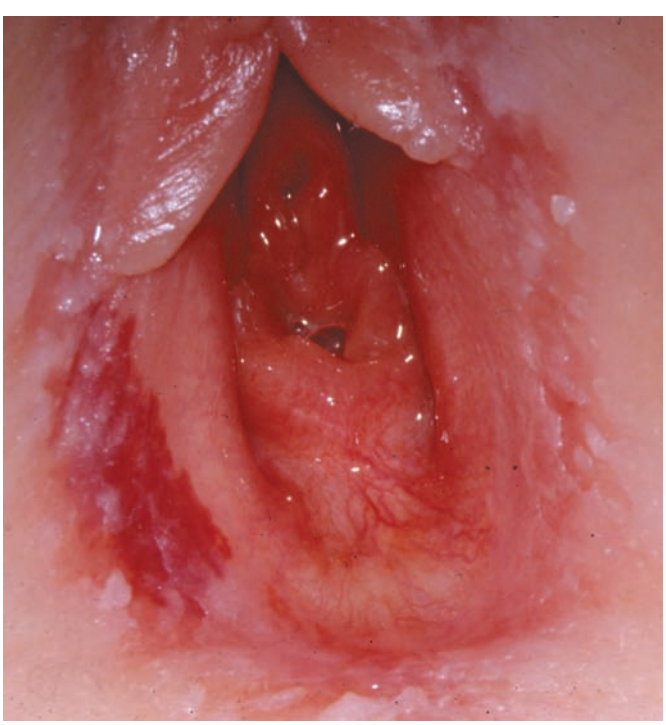

FIGURE 9-7 Lichen sclerosus et atrophicus in a young girl. This is a cutaneous disease, but commonly confused with sexual abuse because of the subepidermal hemorrhages. (*Courtesy of Nancy D. Kellogg, MD.*)

- Ensure that the parent is not in the room for the history. Parents may be present for the physical examination.
- Use open-ended questions, such as "What happened?" or "Tell me more" as opposed to suggestive questions such as "Did Daddy touch your private parts?"
- Take careful notes and document with quotations whenever possible.

- Conduct a full physical examination including genitalia. Elicit cooperation from the child by explaining all procedures and earning his or her trust.
- Consider STI and pregnancy prophylaxis for postpubertal patients.
- Withhold STI treatment in asymptomatic prepubescent children until STI tests are confirmed positive, as the incidence of STI in asymptomatic prepubertal children is relatively low.
- Consult with an infectious disease specialist regarding HIV prophylaxis. If HIV prevalence is high in local regions, assailant risk factors are unknown or high for HIV, and if the child is evaluated within 72 hours of a high-risk exposure, then HIV prophylaxis may be appropriate.
- Examine closely for signs of physical and emotional abuse and neglect.

FOLLOW-UP

- Laws vary by state; however, all states have mandated reporting laws (see Child Welfare Information Gateway, http://www.childwelfare.gov/).
- All victims of sexual abuse and their families should be referred to local counseling agencies and to a Children's Advocacy Center, or other child abuse agency if available in the community.

PATIENT EDUCATION

At well-child visits, provider should discuss touches that make children sad, scared, or confused, or that give them an "uh-oh" feeling inside, and encourage parents to reinforce these themes at home.

PATIENT RESOURCES

- Child Help—http://childhelp.org/.
- National Child Abuse Hotline, 1-800-422-4453
- Prevent Child Abuse America—http://www.preventchildabuse.org/index.shtml.
- National Center for Missing and Exploited Children—http://www.missingkids.com/.

PROVIDER RESOURCES

- The American Academy of Pediatrics Guidelines for the Evaluation of Sexual Abuse of Children—http://pediatrics.aappublications.org/content/103/1/186.full.
- National Guideline Clearing House—When to suspect child maltreatment. http://www.guideline.gov/content.aspx?id=15523.
- Child Welfare Information Gateway provides state statutes on child abuse and neglect—http://www.childwelfare.gov/systemwide/laws_policies/state/can/.

FIGURE 9-8 Labial adhesion can be confused with scarring secondary to child sexual abuse. This acquired condition is common in prepubertal girls and thought to be related to hygiene, irritation, and possibly trauma. (*Courtesy of Maria D. McColgan, MD.*)

REFERENCES

1. U.S. Department of Health and Human Services. Administration of Children, Youth and Families. *Child Maltreatment: 2008*. Washington, DC: Government Printing Office, 2010.
2. U.S. Department of Health and Human Services, Youth and Families. *Child Maltreatment 1998*. Washington, DC: Government Printing Office, 1999.
3. Finkelhor D. Current information on the scope and nature of child sexual abuse. *Future Child*. 1994;4(2):31-53.
4. Summit R. Child sexual abuse accommodation syndrome. *Child Abuse Negl*. 1983;7(2):177-193.
5. Berenson AB, Chacko MR, Weimann CM, et al. A case-control study of anatomic changes resulting from sexual abuse. *Am J Obstet Gynecol*. 2000;182(4):820-831.
6. Heger A, Ticson L, Velasquez O, et al. Children referred for possible sexual abuse: Medical findings in 2384 children. *Child Abuse Negl*. 2002;26(6-7):645-659.
7. Adams JA, Harper K, Knudson S, Revilla J. Examination findings in legally confirmed child sexual abuse: It's normal to be normal. *Pediatrics*. 1994;94(3):310-317.
8. Kellogg ND, Menard SW, Santos A. Genital anatomy in pregnant adolescents: "normal" does not mean "nothing happened." *Pediatrics*. 2004;113(1):e67-e69.
9. Kellogg ND. The evaluation of sexual abuse in children. *Pediatrics*. 2005;116(2):506-512.

10 INTIMATE PARTNER VIOLENCE

Mindy A. Smith, MD, MS

PATIENT STORY

A woman who fled her abusive boyfriend is observed sitting at a table with other women in a residential chemical dependency treatment program. Her bruised face could not be missed (**Figure 10-1**). The program physician asked to speak with her and learned that her boyfriend beat her when she told him that she was voluntarily entering this program. The boyfriend was also an addict and had been physically abusive to her before. The violence escalated when she said that she needed help to stop the alcohol and drugs. She left him and did not believe that he would follow her. The program management assured her that they would not let him on the premises and would do all they could to keep her safe while she was recovering. **Figure 10-2** was taken 2 months later, when her face was healing along with her mind and spirit. She completed the 90-day program and is currently working and actively following a 12-step program.

FIGURE 10-1 Bruising caused by intimate partner violence in a woman who fled her abusive boyfriend. (*Courtesy of Richard P. Usatine, MD.*)

FIGURE 10-2 Photograph of the woman in **Figure 10-1** taken 2 months later. Her facial and psychological wounds are healing. (*Courtesy of Richard P. Usatine, MD.*)

INTRODUCTION

Intimate partner violence (IPV) is defined as an intimate partner's physical, emotional, or sexual abuse. Physical violence is the intentional use of physical force with the potential for causing death, disability, injury, or harm. Physical violence includes scratching; pushing; biting; punching; use of a weapon; and use of restraints or one's body, size, or strength against another person.[1]

EPIDEMIOLOGY

IPV affects up to half of the women in the United States during their lifetime.[2]

- An estimated 4.9 million IPV rapes and physical assaults occur each year among U.S. women (age 18 years and older) and 2.9 million assaults occur among U.S. men. Most of these assaults include pushing, grabbing, shoving, slapping, and hitting and do not result in major injury.[3] In a national telephone survey of 8000 women and 8000 men, 41.5% of the women who were physically assaulted by an intimate partner were injured during their most recent assault, compared with 19.9% of men.[4]
- Physical violence by an intimate partner can result in direct injury including death (1181 women and 329 men in 2005; Bureau of Justice, 2007), adverse psychological, and social consequences, and impaired endocrine and immune systems through chronic stress and other mechanisms.[4]
- In the family practice setting, the lifetime prevalence of abuse of women was 38.8%, with current abuse reported by 2% to 48% of women.[1]

- A national survey estimated that 503,485 women and 185,496 men are stalked by intimate partners each year.[4]
- Clinicians identify only a small number of victims (1.5% to 8.5%).[1] Only approximately 20% of IPV rapes or sexual assaults, 25% of physical assaults, and 50% of stalking directed toward women are reported; fewer events against men are reported.[4]
- Between 4% and 8% of women are battered during pregnancy.[5]
- According to the National Violence Against Women Survey, more than 200,000 women age 18 years and older were raped by intimate partners in the 12 months preceding the survey.[6]
- Annually, 10 million children witness wife-battering.[1] Children may become injured themselves. One study found that children of abused mothers were 57 times more likely to have been harmed because of IPV between their parents, compared to children of nonabused mothers.[7]

RISK FACTORS

Risk factors for IPV include the following:[8]

- Individual factors—Individual factors include prior history of IPV, witnessing or experiencing violence as a child, being female, young, pregnant, less educated, unemployed, heavy user of alcohol or illicit drugs, mental health problems (e.g., depression, borderline or antisocial personality traits), and engaging in aggressive or delinquent behavior as a youth.
- For women, having a greater education level than their partner, being American Indian/Alaska Native or African American, and having a verbally abusive, jealous, or possessive partner increased risk. In addition, a risk of IPV by either a past or a new offender was almost double for women who had recently changed residence compared with those who had not moved.[9]
- For men, having a different ethnicity from their partner's increased the risk of IPV.
- Relationship factors—Relationship factors include couples with income, educational, or job status disparities or in which there is dominance and control of the relationship by one partner over the other, and marital conflict or instability.
- Community factors—Community factors include poverty and associated factors or weak community sanctions against IPV (e.g., police unwilling to intervene).

DIAGNOSIS

Asking patients directly about violence at routine visits or when presenting with clues (as below) is recommended by some for identifying patients suffering from IPV,[1,4] SOR C although data are lacking that identification produces positive outcomes. It is important to use patient-centered approaches.

- Questions that may be asked include general questions about how things are going at home or more specific questions about experiences of nonviolent (e.g., insulting, threatening) or violent (e.g., grabbing, punching, beating, forced sex) abusive acts.

- Several self-administered instruments are available for detecting IPV including the Woman Abuse Screening Tool (WAST).[10] In a study of screening tools, women preferred self-completed approaches (versus face-to-face), although no differences in prevalence was found for method or screening instrument.[11] In a predominantly Hispanic population, investigators found the Spanish version of the 4-question instrument HITS (Hurt-Insult-Threaten-Scream) to be moderately reliable with good validity compared with WAST for Spanish-speaking patients[12]; HITS has also been validated with male victims.[13]

CLINICAL FEATURES

Clues on patient history include the following:

- Chronic pain syndromes (e.g., headache, backache, stomachache, or pelvic pain).
- Depression.
- Drug and alcohol abuse.

Up to 42% of women and 20% of men who were physically assaulted as adults sustained injuries during their most recent victimization.[3] Clues on physical examination:

- Physical injury—Most physical injuries are minor (e.g., contusions, lacerations, abrasions) but include broken bones, traumatic brain injury, and knife wounds (see **Figures 10-1** to **10-3**).
  - Ocular injuries can include soft-tissue injuries, corneal abrasions, orbital fractures, lens dislocation, retinal detachment, visual field loss, double vision, and blindness (see **Figure 10-1**).
  - Trauma to the mouth and lips may be accompanied by fractures, broken teeth, tongue lacerations, and altered taste and smell.
  - Injuries suspicious for abuse are those only in areas covered by clothing, injuries in different stages of healing, and injuries that show a defensive wound pattern particularly on the hands or arms.
  - Upper torso injury carries a high risk of injury to cervical spine, large vessels of the neck and chest and lungs.
- Depression or symptoms of posttraumatic stress disorder (e.g., emotional detachment, sleep disturbances, flashbacks, replaying assault in mind).
- Evidence of forced sexual assault.
- Presence of sexually transmitted infections.

MANAGEMENT

- Initial evaluation, following identification of abuse, is to assess for immediate danger to the woman and any children (e.g., Do you feel it is safe to go home tonight? Where is your partner?). If danger is perceived, assist the woman in finding a safe place to go (**Figures 10-4** and **10-5**).
- Document all findings and include photographs (with date), if possible (**Figure 10-6**).
- Develop a safety plan. This should include:
  - A safe physical location that is not known to the abuser,
  - Transportation to that location, and

FIGURE 10-3 A woman with a large craniotomy wound that was needed to evacuate her intracranial bleeding secondary to being beaten over the head with a board by her fiancé. (*Courtesy of Richard P. Usatine, MD.*)

FIGURE 10-4 Frontal view of the woman in **Figure 10-3** at a homeless shelter. She was putting her life back together again with the help of the shelter and the providers at the clinic. (*Courtesy of Richard P. Usatine, MD.*)

- A list of items to take or a packed suitcase—clothes, keys, cash, valuable documents, telephone numbers, prescriptions, something meaningful for each child.

- Address the needs of any children—30% to 40% of children are also injured physically.[1]
- Data on effective intervention programs are scarce.
  - In a community intervention program in rural South Africa, providing loans to poor women combined with a participatory learning and action curriculum integrated into loan meetings every 2 weeks reduced IPV.[14]
  - Women residents in a domestic violence shelter showed improvement in psychological distress symptoms and less health care utilization following a social support intervention.[15]
  - An advocacy intervention for Chinese women who were victims of IPV did not reduce depression symptoms in a clinically meaningful way.[16]
  - A randomized controlled trial (RCT) of a psychobehavioral intervention for pregnant women reported reduced recurrent episodes of IPV victimization (odds ratio [OR] 0.48, 95% confidence interval [CI], 0.29, 0.80); number needed to treat = 17). Women who reported minor episodes of IPV were less likely to experience further episodes during pregnancy and women with either minor or major IPV episodes were less likely to experience further IPV postpartum.[17] Early childhood visitation may also be helpful in reducing IPV.[18]
  - Community-provided trauma-focused cognitive behavior therapy (CBT) was effective in reducing stress symptoms and anxiety in a RCT of 7- to 14-year-old children exposed to IPV.[19]
  - In a Cochrane review of CBT for abusive men, only four small trials could be combined and no significant effect was found for reduced risk of violence (relative risk [RR], 0.86; 95% CI, 0.54, 1.38); the authors concluded that there were too few trials to determine effectiveness.[20]

FIGURE 10-5 A young, Hispanic mom with her baby at a clinic in a homeless shelter. She had fled her abusive husband with her child. (*Courtesy of Richard P. Usatine, MD.*)

SCREENING AND PREVENTION

- With respect to screening, the U.S. Preventive Services Task Force and the AAFP conclude that there is insufficient evidence for or against routine screening of women for IPV.[21,22] However, the Institute for Clinical Systems Improvement recommends domestic violence screening at preconception and first trimester and 28 week visits.[23]
- In one RCT, computer screening increased detection and opportunities to discuss IPV in a busy family medicine practice.[24]
- In an observational study of a convenience sample of 2134 patients presenting to an emergency room (25.7% screened positive), there were no harms identified from screening for IPV at 1 week post-visit and at 3 months, 35% of those screening positive reported having contacted community resources.
- With respect to outcomes, a Canadian RCT (N = 6743 English-speaking women ages18 to 64 years) conducted in 11 emergency departments, 12 family practices, and 3 obstetrics/gynecology clinics, screening for IPV did not significantly reduce IPV recurrence (46% vs. 53% in screened vs. unscreened patients [OR, 0.82; 95%

FIGURE 10-6 A copy of a photograph, which the woman had in her purse, showing her black eyes after being beaten by her husband the month before. Out of fear for her life and the well-being of her child, she left her husband. (*Courtesy of Richard P. Usatine, MD.*)

CI, 0.32, 2.12]) or quality of life scores; loss to follow-up, however, was high (approximately 40%).[25]

PROGNOSIS

- Many women are not ready to leave an abusive relationship for a variety of reasons. In one study, duration of abuse was less than 1 year to 5 median years, and in 5% to 3% of the instances, IPV persisted for longer than 20 years.[26]
- Women who are abused have a higher risk of posttraumatic stress disorder, depression (1 in 6 abused women will attempt suicide[1]), insomnia, nightmares, and alcohol (16-fold risk of alcohol use[1]) and drug abuse (9-fold risk over nonabused patient[1]).
- IPV for women also decreases the odds of completing substance abuse treatment.[27]
- In one study, women reporting IPV in the year prior to pregnancy were at increased risk for high blood pressure or edema (adjusted OR 1.37 to 1.40), vaginal bleeding (adjusted OR 1.54 to 1.66), severe nausea, vomiting or dehydration (adjusted OR 1.48 to 1.63), kidney infection or urinary tract infection (adjusted OR 1.43 to 1.55), in addition to preterm delivery (adjusted OR 1.37), low-birth-weight infant (adjusted OR 1.17), and an infant requiring intensive care unit care (adjusted OR 1.31 to 1.33) compared with those not reporting IPV.[28]

FOLLOW-UP

- Plan for the next visit and provide ongoing support as it often takes time for women to leave an abusive relationship.
- Monitor for depression, insomnia, nightmares, and alcohol and drug abuse.
- If pregnant, monitor for miscarriage, preterm delivery, and low birth weight.
- Children exposed to IPV also should be monitored because they are at risk of behavioral problems including aggression, anxiety/depression, and inattention/hyperactivity; especially, if maternal mental health disorders or substance abuse are also present.[29]

PATIENT EDUCATION

- Assist patients in recognizing the cycle of abuse, that is, violence followed by remorse/apology, tension-building period (patient may experience fear, isolation, forced dependency, intermittent reward), followed by another episode of violence.
- Provide victim education and information on community resources (see Patient Resources below).
- Acknowledge that leaving may take time.
- Recovery from abuse may include shame and guilt, but often leads to an improved sense of self and self-worth.
- In a follow-up study of women exiting a shelter, women who were employed, reported higher quality of life, and had people in their

networks who provided practical help and/or were available to talk about personal matters were less likely to be re-victimized.[30]

PATIENT RESOURCES

- National Domestic Violence Hotline connects individuals to help in their area by using a nationwide database that includes detailed information about domestic violence shelters, other emergency shelters, legal advocacy and assistance programs, and social service programs. Help is more than 170 languages, 24 hours a day, 7 days a week—**www.ndvh.org.**
  Hotline: 800-779-SAFE (7233)
  TTY: 800-787-3224 available for the Deaf, Deaf-Blind and Hard of Hearing.
  Administrative phone: 512-453-8117
- National Coalition Against Domestic Violence is a membership organization that includes service programs, reading lists, advocacy, educational materials, and coordinates a national collaborative effort to assist battered women in removing the physical scars of abuse—**www.ncadv.org.**
- Centers for Disease Control and Prevention—**http://www.cdc.gov/ViolencePrevention/pdf/IPV_factsheet-a.pdf**

PROVIDER RESOURCES

- CDC—**http://www.cdc.gov/ViolencePrevention/intimatepartnerviolence/index.html.**
- Futures without Violence—**http://www.futureswithoutviolence.org/**
- Institute on Domestic Violence in the African American Community—**http://www.dvinstitute.org.**

REFERENCES

1. Centers for Disease Control. *Intimate Partner Violence: Definitions*. http://www.cdc.gov/ViolencePrevention/intimatepartnerviolence/definitions.html. Accessed October 2011.
2. Gilchrest VJ. Abuse of women. In: Smith MA, Shimp LA, eds. *20 Common Problems in Women's Health Care*. New York: McGraw-Hill; 2000:197-224.
3. Tjaden P, Thoennes N. *Extent, Nature, and Consequences of Intimate Partner Violence: Findings from the National Violence Against Women Survey*. Washington, DC: Department of Justice (US); 2000. Publication No. NCJ 181867. Office of Justice Programs. www.ojp.usdoj.gov/nij/pubs-sum/181867.htm. Accessed October 2011.
4. Centers for Disease Control. *Intimate Partner Violence: Consequences*. http://www.cdc.gov/ViolencePrevention/intimatepartnerviolence/consequences.html.
5. Centers for Disease Control. *Intimate Partner Violence During Pregnancy, A Guide for Clinicians: Download Instructions*. http://www.cdc.gov/reproductivehealth/violence/IntimatePartnerViolence/ipvdp_download.htm. Accessed October 2011.
6. Centers for Disease Control. *CDC Injury Fact Book*. www.cdc.gov/ncipc/fact_book/24_Sexual_Violence.htm. Accessed October 2011.
7. Parkinson GW, Adams RC, Emerling FG. Maternal domestic violence screening in an office-based pediatric practice. *Pediatrics*. 2001;108(3):E43.
8. Centers for Disease Control. *Intimate Partner Violence: Risk and Protective Factors*. http://www.cdc.gov/ViolencePrevention/intimatepartnerviolence/riskprotectivefactors.html. Accessed October 2011.
9. Waltermaurer E, McNutt LA, Mattingly MJ. Examining the effect of residential change on intimate partner violence risk. *J Epidemiol Community Health*. 2006;60(11):923-927.
10. Fogarty CT, Burge S, McCord EC. Communicating with patients about intimate partner violence: screening and interviewing approaches. *Fam Med*. 2002;34(5):369-375.
11. MacMillan HL, Wathen CN, Jamieson E, et al. Approaches to screening for intimate partner violence in health care settings: A randomized trial. *JAMA*. 2006;296(5):530-536.
12. Chen PH, Rovi S, Vega M, et al. Screening for domestic violence in a predominantly Hispanic clinical setting. *Fam Pract*. 2005; 22(6):617-623.
13. Shakil A, Donald S, Sinacore JM, Krepcho M. Validation of the HITS domestic violence screening tool with males. *Fam Med*. 2005;37(3):193-198.
14. Pronyk PM, Hargreaves JR, Kim JC, et al. Effect of a structural intervention for the prevention of intimate-partner violence and HIV in rural South Africa: a cluster randomised trial. *Lancet*. 2006;368(9551):1973-1983.
15. Contantino R, Kim Y, Crane PA. Effects of a social support intervention on health outcomes in residents of a domestic violence shelter: a pilot study. *Issues Ment Health Nurs*. 2005;26(6):575-590.
16. Tiwari A, Fong DY, Yuen KH, et al. Effect of an advocacy intervention on mental health in Chinese women survivors of intimate partner violence: a randomized controlled trial. *JAMA*. 2010; 304(5):536-543.
17. Kiely M, El-Mohandes AA, El-Khorazaty MN, et al. An integrated intervention to reduce intimate partner violence in pregnancy: a randomized controlled trial. *Obstet Gynecol*. 2010;115(2 Pt 1): 273-283.
18. Bair-Merritt MH, Jennings JM, Chen R, et al. Reducing maternal intimate partner violence after the birth of a child: a randomized controlled trial of the Hawaii Healthy Start Home Visitation Program. *Arch Pediatr Adolesc Med*. 2010;164(1):16-23.
19. Cohen JA, Mannarino AP, Iyengar S. Community treatment of posttraumatic stress disorder for children exposed to intimate partner violence: a randomized controlled trial. *Arch Pediatr Adolesc Med*. 2011;165(1):16-21.
20. Smedslund G, Dalsbø TK, Steiro AK, et al. Cognitive behavioural therapy for men who physically abuse their female partner. *Cochrane Database Syst Rev*. 2007 Jul 18;(3):CD006048.
21. United States Preventive Services Task Force. *Screening for Family and Intimate Partner Violence*. http://www.uspreventiveservicestaskforce.org/uspstf/uspsfamv.htm. Accessed October 2011.
22. Family Violence and Intimate Partner Violence. American Academy of Family Physicians. Available at http://www.aafp.org/

online/en/home/clinical/exam/familyviolence.html. Accessed May 2012.

23. Routine prenatal care. Institute for Clinical Systems Improvement. Available at http://www.guideline.gov/content.aspx?id=24138. Accessed May 2012.
24. Ahmad F, Hogg-Johnson S, Stewart DE, et al. Computer-assisted screening for intimate partner violence and control: a randomized trial. *Ann Intern Med*. 2009;151(2):93-102.
25. MacMillan HL, Wathen CN, Jamieson E, et al. Screening for intimate partner violence in health care settings: a randomized trial. *JAMA*. 2009;302(5):493-501.
26. Thompson RS, Bonomi AE, Anderson M, et al. Intimate partner violence: prevalence, types, and chronicity in adult women. *Am J Prev Med*. 2006;30(6):447-457.
27. Lipsky S, Krupski A, Roy-Bryne P, et al. Effect of co-occurring disorders and intimate partner violence on substance abuse treatment outcomes. *J Subst Abuse Treat*. 2010;38(3):231-244.
28. Silverman JG, Decker MR, Reed E, Raj A. Intimate partner violence victimization prior to and during pregnancy among women residing in 26 U.S. states: associations with maternal and neonatal health. *Am J Obstet Gynecol*. 2006;195(1):140-148.
29. Whitaker RC, Orzol SM, Kahn RS. Maternal mental health, substance use, and domestic violence in the year after delivery and subsequent behavior problems in children at age 3 years. *Arch Gen Psychiatry*. 2006;63(5):551-560.
30. Bybee D, Sullivan CM. Predicting re-victimization of battered women 3 years after exiting a shelter program. *Am J Community Psychol*. 2005;36(1-2):85-96.

11 ADULT SEXUAL ASSAULT

Mindy A. Smith, MD, MS

PATIENT STORIES

CASE 1

A 19-year-old college girl presents to the office after being raped 3 weeks ago. She went out on a date and was forced to have sex against her will. She states that she had been a virgin and that he made her bleed by penetrating her vagina with his penis. She tried to stop him, but was afraid to fight too hard because he was a strong man and was drunk. She is in tears as she tells her story. She waited so long to come in for help because she did not know where to turn. She took emergency contraception (EC) immediately, and a home pregnancy test taken last night was negative. She wants to be checked for any sexually transmitted infections (STIs). Upon examination, there is a tear of her hymen at the 5-o'clock position that has healed (**Figure 11-1**). There are no signs of infection and STI screening is performed. She is afraid to prosecute but would like to be referred to a rape-counseling program.

FIGURE 11-1 External genitalia of a 19-year-old college girl showing the tear of her hymen at approximately the 5-o'clock position. This was the result of date rape 3 weeks before the photograph was taken. (*Courtesy of Nancy D. Kellogg, MD.*)

CASE 2

A 47-year-old woman is seen in follow-up for depression. She admits to being raped in a parking lot several months prior but did not report it to the police. She is continuing to have intrusive nightmares and flashbacks of the event. She is having difficulty concentrating at work and does not feel comfortable in social situations.

INTRODUCTION

Sexual violence is a sex act completed or attempted against a victim's will or when a victim is unable to consent because of age, illness, disability, or the influence of alcohol or other drugs.[1] It may involve actual or threatened physical force, use of guns or other weapons, coercion, intimidation, or pressure. Sexual violence includes unwanted intercourse (completed sex act defined as contact between the penis and the vulva or penis and anus involving penetration); an attempted sex act, abusive sexual contact (intentional touching either directly or through clothing of the genitals, anus, groin, breast, inner thigh, or buttocks against a victim's will or when a victim is unable to consent); and noncontact sexual abuse, such as voyeurism, intentional exposure to exhibitionism, undesired exposure to pornography, verbal or behavioral sexual harassment, threats of sexual violence, or taking nude photographs of a sexual nature of another person without his or her consent or knowledge or of a person unable to consent or refuse.

EPIDEMIOLOGY

- Based on the National Intimate Partner and Sexual Violence Survey (NISVS; 2010) of more than 16,000 adults, nearly 1 in 5 women

(18.3%) and 1 in 71 men (1.4%) in the United States has been raped.[2] More than half of the women were raped by an intimate partner (see Chapter 10, Intimate Partner Violence) and 40.8% were raped by an acquaintance. Among men, more than half were raped by an acquaintance and 15.1% by a stranger.[2]

- Unwanted sexual contact was reported in the NISVS by 27.2% of women and 11.7% of men.[2]
- Lifetime stalking victimization was reported by 1 in 6 women (16.2%) and 1 in 19 men (5.2%) in the NISVS.[2]
- Most victims of sexual assault are young:
  - In the NISVS, most women (79.6%) experienced their first completed rape before age 25 years and 42.2% before the age of 18 years.[2] More than one-quarter of male victims of completed rape (27.8%) experienced their first rape before they were 11 years of age.
  - Similar findings were reported in another national survey where 60.4% of female and 69.2% of male victims were first raped before age 18 years.[3] A quarter of females were first raped before age 12 years.
- In surveys of college students, annually 10% of women described a rape, 17% reported an attempted rape, 26% reported unwanted sexual coercion, and 63% experienced unwanted sexual contact.[4]
- Women in substance abuse treatment are a particularly high-risk group for having experienced violence. In one study, 89% reported a history of interpersonal violence and 70% reported a history of sexual assault.[5]
- Men are most often the perpetrators of sexual violence;[2] even among male victims, predominantly male perpetrators committed the rape or noncontact unwanted sexual experiences reported, and almost half of stalking victimizations of men were perpetrated by men.
- According to the FBI Uniform Crime Reports, there were an estimated 84,767 forcible rapes reported to law enforcement in 2010 or 54.2 per 100,000 women, a decrease of 5% from 2009 and 6.7% lower than 2001.[6] Most women, however, do not report being raped to the police:
  - As in the cases presented in this chapter, most cases of sexual assault go unreported (only about 1 in 5 women report their rape to police).[7] Reasons for failing to report include fear of reprisal, shame, fear of the justice system, and failure to define the act as rape. Furthermore, according to victim accounts in the NISVS, only 37% of the rapes reported to police resulted in the rapist being criminally prosecuted, and of those prosecuted, less than half (46.2%) were convicted of a crime.[2]

ETIOLOGY AND PATHOPHYSIOLOGY

- Two types of factors are believed to contribute to sexual violence—*Vulnerability factors* that increase the likelihood that a person will suffer harm and *risk factors* that increase the likelihood that a person will cause harm. Neither vulnerability nor risk factors are direct causes of sexual violence.[3]

RISK FACTORS

Vulnerability factors for sexual assault, in addition to young age and female gender, include:[8,9]

- Prior history of sexual violence.
- Being disabled (physical, psychiatric illness, or cognitive impairment).
- Pregnancy.
- Poverty, homelessness.
- Having many sexual partners or involved in sex work.
- Consuming alcohol or illicit drugs.

Risk factors for perpetration include:[8,10]

- Alcohol and drug use.
- Childhood history of physical or sexual abuse and/or witnessed family violence as a child.
- Coercive sexual fantasies.
- Preference for impersonal sex.
- Hostility toward women.
- Association with sexually aggressive and delinquent peers.
- Family environment characterized by physical violence and few resources.
- Poverty and lack of employment opportunities.
- Societal norms that support sexual violence, male superiority, and sexual entitlement.
- Weak laws and policies related to gender equity.

DIAGNOSIS

It is recommended that patients are asked directly about violence during routine visits, when seen in the emergency department, or when presenting with substance abuse, depression, and/or physical clues (as listed below) so as to identify those who are suffering from the aftermath of sexual or physical violence.

CLINICAL FEATURES

- Approximately 33% of women and 16% of men have physical injuries as a result of a rape; 36.2% of injured women received medical treatment.[1]
- Women who are raped are significantly more likely than nonraped women to experience genital injuries and STIs, and have significantly greater difficulties with aspects of reproductive/sexual functioning, including dyspareunia, endometriosis, menstrual irregularities, and chronic pelvic pain.[11]
- Many women suffer psychological trauma following sexual assault such as posttraumatic stress disorder (PTSD) symptoms:[1]
  - Immediate psychological consequences include confusion, anxiety, withdrawal, fear, guilt, intrusive recollections, emotional detachment, and flashbacks.
  - Some victims may attempt suicide after being raped (**Figure 11-2**).

FIGURE 11-2 The mutilated arm of a 26-year-old woman who was raped 5 years prior to this photograph. After being raped, she became suicidal and began cutting her arm repeatedly. The additional malformation of the arm is secondary to osteomyelitis from previous intravenous drug use. (*Courtesy of Richard P. Usatine, MD.*)

MANAGEMENT

NONPHARMACOLOGIC

Following a sexual assault, many women report that they thought they were going to be killed. The survivor may be terrified and unable to provide a complete history of the assault. It is important to provide support, reassurance of immediate safety, and obtain informed consent for examination, procedures, and contact of others. With permission, the clinician should contact a rape crisis worker and the police, although the survivor decides whether or not to file criminal charges; in general, notification of law enforcement is not required if the patient is an adult age 18 years or older and is not disabled, mentally ill, or elderly. In these cases, reporting is done only if the patient gives his or her consent. Injury caused by any weapon or incidents involving life-threatening assault, however, must be reported to the law enforcement agency (per statute) irrespective of reporting the sexual assault.[12]

- A guideline developed for the state of Oregon is available from the United States Department of Justice for the emergency medical evaluation of a sexual assault victim.[12] Steps in the evaluation are reviewed briefly below. A medical forensic evaluation is appropriate if the assault occurred within 84 hours of presentation. A Standard Sexual Assault Forensic Evidence (SAFE) Kit should be used for gathering forensic evidence.
- The patient should be assessed for safety and immediate mental health needs. The history includes details of the assault (e.g., date, time, location, descriptors of assailant[s]), type of bodily and sexual contact (orifice[s] penetrated, objects used), and sexual activity or bathing/washing since the assault.[9,12] Laws in all 50 states strictly limit the evidentiary use of a survivor's previous sexual history, including evidence of previously acquired sexually transmitted diseases (STDs), as part of an effort to undermine the credibility of the survivor's testimony.[13]
- Treat traumatic injuries—Physical examination should include observations of emotional state and descriptions of clothing and stains. Gently, and with permission, examine for lacerations, abrasions, ecchymoses, and bites. A body chart may be useful for documenting the size, type, color, and location of any injuries. A genital examination should be conducted by an experienced clinician in a way that minimizes further trauma to the survivor; examination is directed by history.
- Test and treat for STI—A guideline for managing STI following sexual assault is available through the Centers for Disease Control and Prevention (CDC).[13]
  - Trichomoniasis, bacterial vaginosis (BV), gonorrhea, and chlamydial infection are the most frequently diagnosed infections following sexual assault. As the prevalence of these infections is high among sexually active women, their presence after an assault does not necessarily signify acquisition during the assault.
  - Nucleic acid amplification tests (NAATs) are recommended for *Neisseria gonorrhoeae* and *Chlamydia trachomatis*. These tests are preferred for the diagnostic evaluation of sexual assault victims, regardless of the sites of penetration or attempted penetration.[13]
  - Wet mount or point-of-care testing of a vaginal swab specimen for *Trichomonas vaginalis* infection. The wet mount also should be

examined for evidence of BV and candidiasis, especially if vaginal discharge, malodor, or itching is present.
  - Collect a serum sample for immediate evaluation for HIV, hepatitis B, and syphilis, and obtain serum or urine for a pregnancy test in reproductive-aged women. Obtain toxicology and/or alcohol test if a patient has altered mental status, reports blackouts, or is concerned that he/she may have been drugged.[12]

MEDICATIONS

The following prophylactic regimen is suggested as preventive therapy:

- Hepatitis B vaccination, without hepatitis B immune globulin, is administered to sexual assault victims at the time of the initial examination if they have not been previously vaccinated. Follow-up doses of vaccine should be administered 1 to 2 and 4 to 6 months after the first dose.
- An empiric antimicrobial regimen for *Chlamydia*, gonorrhea, and *Trichomonas* is ceftriaxone 250 mg IM in a single dose **or** cefixime 400 mg orally single dose **plus** metronidazole 2 g orally (single dose) **plus** azithromycin 1 g orally (single dose) **or** doxycycline 100 mg orally twice daily for 7 days. Clinicians should counsel patients about the possible benefits and toxicities associated with these treatment regimens, such as gastrointestinal (GI) side effects.
- HIV seroconversion has occurred in persons whose only known risk factor was sexual assault or sexual abuse, but the risk is probably low (in consensual sex, the risk for HIV transmission from vaginal intercourse is 0.1% to 0.2%, for receptive rectal intercourse the risk is 0.5% to 3%, and for oral sex the risk is substantially lower).[13]
- The healthcare provider should assess available information concerning HIV-risk behaviors of the assailant(s) (e.g., a man who has sex with other men and/or injected drug or crack cocaine use), local epidemiology of HIV/AIDS, and exposure characteristics of the assault. Specific circumstances of an assault that might increase risk for HIV transmission are trauma, including bleeding, with vaginal, anal, or oral penetration; exposure to ejaculate to mucous membranes; viral load in ejaculate (e.g., multiple assailants); and the presence of an STI or genital lesions in the assailant or survivor.
- If HIV postexposure prophylaxis (PEP) is offered, the following information should be discussed with the patient: (a) the unproven benefit and known toxicities of antiretrovirals; (b) the close follow-up that will be necessary; (c) the benefit of adherence to recommended dosing; (d) the necessity of early initiation to optimize potential benefits (as soon as possible after and up to 72 hours after the assault). Providers should emphasize that PEP appears to be well-tolerated and that severe adverse effects are rare.
- Specialist consultation on PEP regimens is recommended. If the survivor and clinician decide that PEP is warranted, provide enough medication to last until the next return visit and reevaluate the survivor 3 to 7 days after initial assessment and assess tolerance of medications.[13]
- If PEP is started, perform a complete blood count (CBC) and serum chemistry at baseline (initiation of PEP should not be delayed, pending results).
- Collect samples for legal evidence. Most emergency departments have rape or sexual assault kits containing instructions for gathering material to support legal charges; all samples must be carefully labeled and kept under supervision. Details of these procedures may be found elsewhere.[12]
- Reproductive-age female survivors should be evaluated for pregnancy, if appropriate, and offered EC if desired. Providers might also consider antiemetic medications, particularly if an EC containing estrogen is provided.
- Consider tetanus prophylaxis if skin wounds occurred and the patient is not up-to-date on tetanus immunization. Offer hepatitis vaccine if the patient has not been previously fully immunized for hepatitis B, has a negative history for hepatitis B and secretion-mucosal contact occurred during the assault.[12]
- Arrange for safety.
- Provide written information about the visit and any instructions given to the patient.

REFERRAL

- If the victim is amenable, refer for advocacy or counseling.
- If you are not the primary healthcare provider, arrange for follow-up medical care.

PREVENTION

- Women who have been physically assaulted as adolescents are at greater risk for revictimization during their college years.[14] Although dating violence prevention–intervention programs have not been uniformly successful, women should be counseled about strategies for avoiding future victimization (e.g., recognition of dangerous situations, limiting use of alcohol, safety with friends). One program, Safe Dates, has been shown in a randomized controlled trial (RCT) to be effective in preventing or interrupting sexual violence perpetration.[15]
- Life skills and educational programs are conducted to encourage men to take greater responsibility for their actions, relate better to others, have greater respect for women, and communicate more effectively. Although not many programs have been formally evaluated, there are reports of reduced violence against women in communities in Cambodia, the Gambia, South Africa, Uganda, and the United Republic of Tanzania attributed to these programs.[8]
- Other prevention efforts include media campaigns, written materials, victim risk-reduction techniques (e.g., self-defense, awareness), men's activism groups (e.g., Men Can Stop Rape), school-based programs, and legal and policy responses (e.g., encourage reporting, broadening the definition of rape and sexual assault).[8,16] In designing programs, information provided in documents prepared for the CDC may be useful.[16]

Health providers can also become involved in prevention activities at multiple levels:

- Strengthening individual knowledge and skills through skill-building programs in high schools or training bystanders to safely interrupt sexist and harassing behavior.
- Promoting community education by sponsoring activities such as plays that reinforce positive cultural norms and portray responsible sexual behavior or developing awards to recognize responsible media coverage.

- Educating other community leaders and providers, such as little league coaches, prison guards, nursing home providers.
- Fostering coalitions and networks to promote community understanding and strategies to prevent sexual violence.
- Changing organizational practices such as implementation and enforcement of sexual harassment policies in schools and workplaces, implementing environmental safety measures such as adequate lighting and emergency call boxes.
- Influencing policies and legislation such as offering comprehensive sex education programs in middle and high schools, including violence prevention.

PROGNOSIS

- More than 32,000 pregnancies result yearly from rape (approximately 5% of rapes result in pregnancy).[8]
- Chronic psychological consequences—In a metaanalysis of 17 case-control and 20 cohort studies (N = 3,162,318 participants), there was an association between sexual abuse and a lifetime diagnosis of anxiety disorder (odds ratio [OR], 3.09; 95% confidence interval [CI], 2.43 to 3.94), depression (OR, 2.66; 95% CI, 2.14 to 3.30), eating disorders (OR, 2.72; 95% CI, 2.04 to 3.63), posttraumatic stress disorder (OR, 2.34; 95% CI, 1.59 to 3.43), sleep disorders (OR, 16.17; 95% CI, 2.06 to 126.76), and suicide attempts (OR, 4.14; 95% CI, 2.98 to 5.76).[17]
- Chronic somatic consequences—Authors of a metaanalysis of 23 studies found associations between sexual abuse and lifetime diagnosis of functional GI disorders (OR, 2.43; 95% CI, 1.36 to 4.31), nonspecific chronic pain (OR, 2.20; 95% CI, 1.54 to 3.15), psychogenic seizures (OR, 2.96; 95% CI, 1.12 to 4.69), and chronic pelvic pain (OR, 2.73; 95% CI, 1.73 to 4.30).[18] Significant associations with rape included lifetime diagnosis of fibromyalgia (OR, 3.35; 95% CI, 1.51 to 7.46), chronic pelvic pain (OR, 3.27; 95% CI, 1.02 to 10.53), and functional GI disorders (OR, 4.01; 95% CI, 1.88 to 8.57).

FOLLOW-UP

Follow-up visits provide an opportunity to (a) provide support and advocacy; (b) evaluate for resolution and healing of injury and current symptoms; (c) detect new infections acquired during or after the assault; (d) complete hepatitis B immunization, if indicated; (e) complete counseling and treatment for other STIs; and (f) monitor side effects and adherence to PEP, if prescribed.[12]

- Initial follow-up should be within 1 to 2 weeks following the assault.
- Provide ongoing support—Survivors of sexual abuse report strained relationships with family, friends, and intimate partners, including less emotional support and less frequent contact with friends and relatives.[8] In addition, only about half of victims keep this appointment, so outreach efforts may be needed.
- Review results of tests and discuss the plan for redraw of Venereal Disease Research Laboratory (VDRL) 3 months after exposure and HIV in 6 weeks and 3 and 6 months (if initial test results were negative).
- Long-term support, monitoring, and treatment:
  - For women suffering from PTSD, medications that may be useful include selective serotonin reuptake inhibitors and risperdal.[19] Cognitive-Processing Therapy and Prolonged Exposure have been the most useful therapies for treating PTSD, depression, and anxiety in female rape victims.[20,21] However, more than one-third of women retain the diagnosis of PTSD or drop out of treatment.[21]
  - Imagery rehearsal therapy appears useful in decreasing chronic nightmares, improving sleep quality, and decreasing PTSD symptom severity.[22]

PATIENT EDUCATION

- Recovery from sexual assault is a slow process. In one study, one-third of survivors reported recovery within 1 year but one-quarter thought that they had not recovered after 4 to 6 years.[23]
- Counseling, and sometimes medication, is available to help control symptoms and treat depression and PTSD and patients should be encouraged to report and seek help for continuing difficulties.

PATIENT RESOURCES

- National Sexual Violence Resource Center serves as a comprehensive collection and distribution center for information, statistics, and resources related to sexual violence—**http://www.nsvrc.org.**
- Centers for Disease Control and Prevention. *Sexual Violence*—**http://www.cdc.gov/ViolencePrevention/sexualviolence/index.htm.**
- National Domestic Violence Hotline, 1-800-799-SAFE; National Sexual Assault Hotline, 1-800-656-HOPE.

PROVIDER RESOURCES

- *Recommended Medical Guideline Acute Sexual Assault Emergency Medical Evaluation for the State of Oregon*—**http://www.doj.state.or.us/crimev/pdf/guidelines05_000.pdf**.
- United States Department of Justice—Office on Violence Against Women, offers links to resources—**http://www.ovw.usdoj.gov/sexassault.htm.**
- Assistance with PEP decisions can be obtained by calling the National Clinician's Post-Exposure Prophylaxis Hotline (PEPLine), 1-888-448-4911.
- National Sexual Violence Resource Center serves as a comprehensive collection and distribution center for information, statistics, and resources related to sexual violence—**http://www.nsvrc.org.**
- The American College of Obstetricians and Gynecologists provides publications about violence against women, intimate partner violence, sexual violence, adolescent dating violence, and patient education materials in both English and Spanish—**http://www.acog.org.**

- A directory of sexual assault centers in the United States can be obtained from the following URL—**http://www.nsvrc.org/publications/nsvrc-publications/directory-sexual-assault-centers-united-states.**

REFERENCES

1. Centers for Disease Control and Prevention. *Sexual Violence. Scientific Information*. http://www.cdc.gov/ViolencePrevention/sexualviolence/index.html. Accessed February 2012.
2. Black MC, Basile KC, Breiding MJ, et al. *The National Intimate Partner and Sexual Violence Survey (NISVS): 2010 Summary Report*. Atlanta, GA: National Center for Injury Prevention and Control, Centers for Disease Control and Prevention; 2011. http://www.cdc.gov/ViolencePrevention/pdf/NISVS_Executive_Summary-a.pdf. Accessed February 2012.
3. Basile KC, Chen J, Lynberg MC, Saltzman LE. Prevalence and characteristics of sexual violence victimization. *Violence Vict*. 2007;22(4):437-448.
4. Koss MP. Detecting the scope of rape: a review of prevalence research methods. *J Interpers Violence*. 1993;8:198-222.
5. Lincoln AK, Liebschutz JM, Chernoff M, et al. Brief screening for co-occurring disorders among women entering substance abuse treatment. *Subst Abuse Treat Prev Policy*. 2006;1:26.
6. Federal Bureau of Investigation. *Uniform Crime Reports for the United States*. Washington, DC: U.S. Department of Justice; 2010. http://www.fbi.gov/about-us/cjis/ucr/crime-in-the-u.s/2010/crime-in-the-u.s.-2010/violent-crime/rapemain. Accessed March 2012.
7. National Institute of Justice. *Extent Nature and Consequences of Rape Victimization: Findings from the National Violence Against Women Survey (2006)*. https://www.ncjrs.gov/pdffiles1/nij/210346.pdf. Accessed March 2012.
8. World Health Organization. *World Report on Violence and Health, Sexual Violence*. Chapter 6. http://www.who.int/violence_injury_prevention/violence/global_campaign/en/chap6.pdf. Accessed March 2012.
9. Williams A. Managing adult sexual assault. *Aust Fam Physician*. 2004;33(10):825-828.
10. Centers for Disease Control and Prevention. *Sexual Violence. Risk and Protective Factors*. http://www.cdc.gov/ViolencePrevention/sexualviolence/riskprotectivefactors.html. Accessed March 2012.
11. Weaver TL. Impact of rape on female sexuality: review of selected literature. *Clin Obstet Gynecol*. 2009;52(4):702-711.
12. *Recommended Medical Guideline Acute Sexual Assault Emergency Medical Evaluation for the State of Oregon*. http://www.doj.state.or.us/crimev/pdf/guidelines05_000.pdf. Accessed March 2012.
13. Workowski KA, Berman S; Centers for Disease Control and Prevention. Sexual assault and STDs. In: Sexually Transmitted Diseases Treatment Guidelines, 2010. *MMWR Recomm Rep*. 2010;59(RR-12):90-95. http://www.guideline.gov/content.aspx?id=25597&search=sexual+assault. Accessed March 2012.
14. Smith PH, White JW, Holland LJ. A longitudinal perspective on dating violence among adolescent and college-age women. *Am J Public Health*. 2003;93(7):1104-1109.
15. Foshee V, Bauman KE, Ennett ST, et al. Assessing the long-term effects of the Safe Dates program and a booster in preventing and reducing adolescent dating violence victimization and perpetration. *Am J Public Health*. 2004;94:619-624.
16. Centers for Disease Control and Prevention. *Sexual Violence: Prevention Strategies*. http://www.cdc.gov/ViolencePrevention/sexualviolence/prevention.html. Accessed March 2012.
17. Chen LP, Murad MH, Paras ML, et al. Sexual abuse and lifetime diagnosis of psychiatric disorders: systematic review and meta-analysis. *Mayo Clin Proc*. 2010;85(7):618-629.
18. Paras ML, Murad MH, Chen LP, et al. Sexual abuse and lifetime diagnosis of somatic disorders: a systematic review and meta-analysis. *JAMA*. 2009;302(5):550-561.
19. Padala PR, Madison J, Monnahan M, et al. Risperidone monotherapy for post-traumatic stress disorder related to sexual assault and domestic abuse in women. *Int Clin Psychopharmacol*. 2006;21(5):275-280.
20. Nishith P, Nixon RD, Resick PA. Resolution of trauma-related guilt following treatment of PTSD in female rape victims: a result of cognitive processing therapy targeting comorbid depression? *J Affect Disord*. 2005;86(2-3):259-265.
21. Vickerman KA, Margolin G. Rape treatment outcome research: empirical findings and state of the literature. *Clin Psychol Rev*. 2009;29:431-448.
22. Krakow C, Hollifield M, Johnston L, et al. Imagery rehearsal therapy for chronic nightmares in sexual assault survivors with posttraumatic stress disorder: a randomized controlled trial. *JAMA*. 2001;286(5):537-545.
23. Burgess AW, Holmstrom LL. Adaptive strategies and recovery from rape. *Am J Psychiatry*. 1979;136:1278-1282.

PART 4

OPHTHALMOLOGY

Strength of Recommendation (SOR)	Definition
A	Recommendation based on consistent and good-quality patient-oriented evidence.*
B	Recommendation based on inconsistent or limited-quality patient-oriented evidence.*
C	Recommendation based on consensus, usual practice, opinion, disease-oriented evidence, or case series for studies of diagnosis, treatment, prevention, or screening.*

*See Appendix A on pages 1447–1450 for further information.

12 PTERYGIUM

Heidi Chumley, MD

PATIENT STORY

A 50-year-old man had spent most of his adult life working outdoors in southern Texas near the Mexico border. He denies any problems with his vision, but wonders what is growing on his eye and if it should be removed (**Figure 12-1**). His eyes are often dry and irritated. He is diagnosed with a pterygium and instructed that it does not need to be removed unless it interferes with his vision in the future. Liquid tears are suggested for his dry and irritated eyes. He is also instructed to wear wraparound sunglasses to avoid UV exposure and irritation from wind and dust.

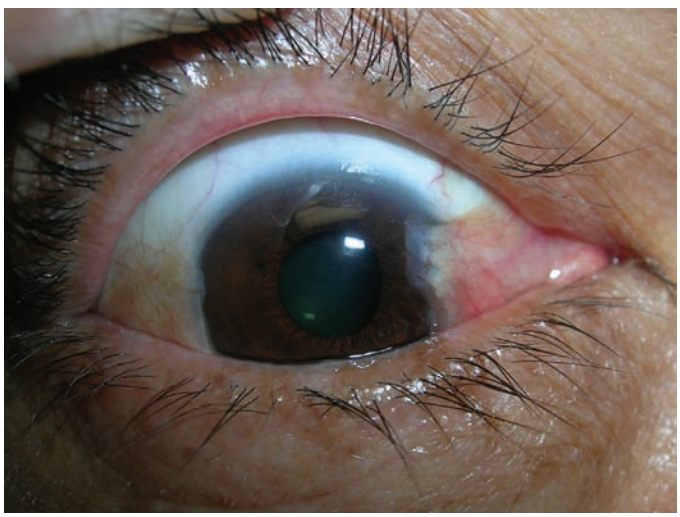

FIGURE 12-1 A nasal pterygium. (*Courtesy of Richard P. Usatine, MD.*)

INTRODUCTION

A pterygium is a generally benign growth of fibroblastic tissue on the eye of an adult with chronic UV exposure. Pterygia can be unilateral or bilateral, are usually located on the nasal side, and extend to the cornea. Pterygia often require no treatment, but can be removed surgically if they interfere with vision. Patients with dry eyes are prone to the development and progression of pterygia.

EPIDEMIOLOGY

- Pterygium most often develops between the ages 20 and 50 years.
- The frequency of pterygium increases with sun exposure and age. In a population-based study (Indonesia), it was found that the prevalence ranged from 3% (in 21- to 29-year-olds) to 18% (older than 50 years of age).[1] In rural China, the prevalence was 3.76% and also increased with age.[2]
- In one study carried out in Australia, it was found that sun exposure is consistently the greatest risk factor, contributing 43% of the risk.[3]

ETIOLOGY AND PATHOPHYSIOLOGY

- A pterygium is a proliferation of fibrovascular tissue on the surface of the eye, which extends onto the cornea.
- The etiology of pterygium is incompletely understood; however, chronic UV exposure is accepted as a causative agent. Chronic inflammation and oxidative stress may also play a role in pathogenesis.
- Pterygia have features seen in malignant tissues, such as normal tissue invasion and high recurrence rate.[4] Pterygia can be associated with premalignant lesions.[4]

RISK FACTORS

Risk factors are related to chronic UV exposure:

- Living in low latitude, low precipitation area.[2]
- Male gender.[2]

DIAGNOSIS

CLINICAL FEATURES

- Redness, itching, and/or irritation of the involved eyes (some are symptom free).
- Visual blurring if the pterygium grows over the visual axis. Even if not obscuring the visual axis, the pterygium can cause poor vision by leading to irregular and high astigmatism.
- Pterygia are diagnosed clinically by their distinctive appearance (**Figures 12-1** to **12-4**).

TYPICAL DISTRIBUTION

- Unilateral or bilateral.
- Nasal or nasal and temporal.
- Consider another diagnosis with a unilateral temporal distribution.

BIOPSY

Not indicated; however, excised pterygium are sent for histologic examination because of their association with premalignant lesions.[4]

DIFFERENTIAL DIAGNOSIS

- Pinguecula is a yellowish patch or nodule on the conjunctiva and does not extend onto the cornea **(Figure 12-5)**.
- Conjunctivitis is conjunctival injection with discomfort and eye discharge (see Chapter 16, Conjunctivitis).
- Squamous cell carcinoma of the conjunctiva is rare. Consider carcinoma when a unilateral growth is noted on the temporal side. Also consider malignancy if there are grossly aberrant-appearing blood vessels on the surface of the eye. Patients with abnormal immune systems (e.g.,cancer, HIV) are at particular risk for ocular surface malignancy.

MANAGEMENT

NONPHARMACOLOGIC

Avoid sun exposure and use UV filtering sunglasses when sun exposure is unavoidable.

MEDICATIONS

Nonprescription artificial tears and/or topical lubricating drops to soothe the inflammation. Ophthalmologists will occasionally

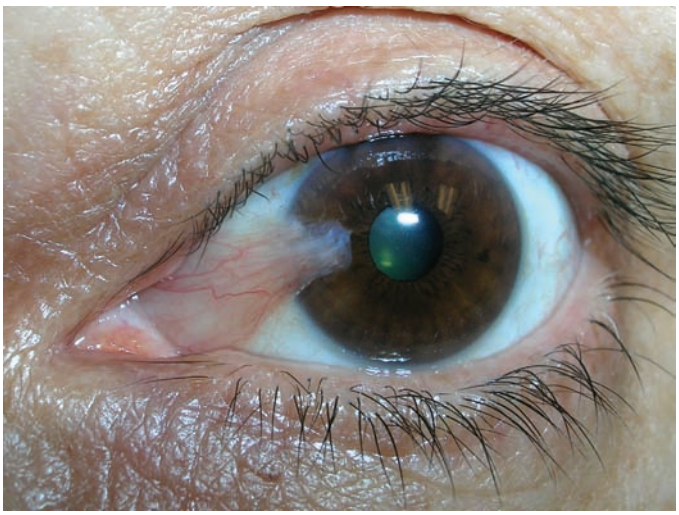

FIGURE 12-2 Pterygium that has grown onto the cornea but not covered the visual axis. This fibrovascular tissue has the shape of a bird's wing (literal definition of pterygium). The small vessels are prominent in this view. (*Courtesy of Richard P. Usatine, MD.*)

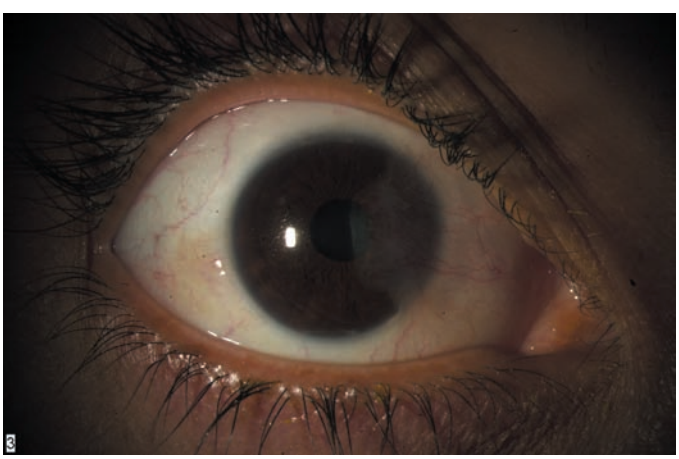

FIGURE 12-3 A pterygium that has grown over the visual axis and is interfering with this person's vision. The patient plans to undergo surgery. (*Courtesy of Paul D. Comeau.*)

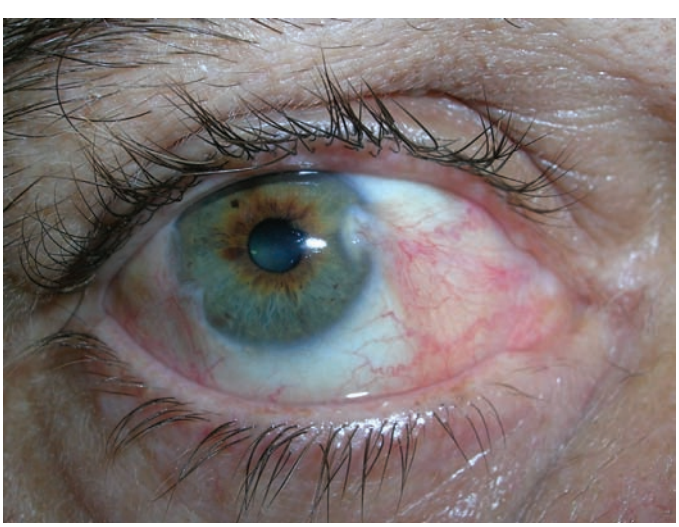

FIGURE 12-4 Bilateral pterygia growing over the cornea. (*Courtesy of Richard P. Usatine, MD.*)

prescribe a short course of topical corticosteroid antiinflammatory drops when symptoms of the pterygia are more intense.

SURGICAL

- Pterygia are usually treated when they interfere with vision or when they cause significant irritation or pain (**Figure 12-3**). The standard therapy is surgical removal.
- Pterygia have a high rate of recurrence. Conjunctival autografting and an antifibrotic treatment (e.g., mitomycin-C) can be used intraoperatively to lower recurrence.[5]

ASSOCIATED RISKS

- Pterygia affect astigmatism[6,7] and are associated with increased rates of macular degeneration; however, it is unclear whether treatment reduces this risk.
- Eyes with a pterygium or previous pterygium surgery (but not pinguecula) have a higher risk of incident late age-related maculopathy (ARM) (odds ratio [OR] 3.3, 95% confidence interval [CI], 1.1 to 10.3) and early ARM (OR 1.8, 95% CI, 1.1 to 2.9).[8]

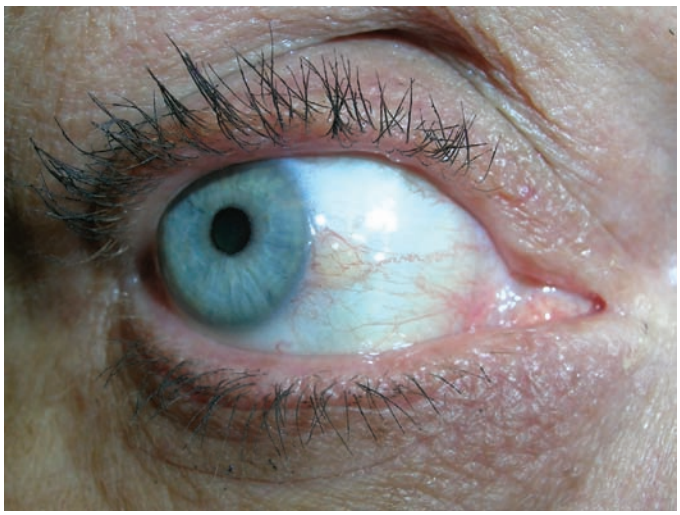

FIGURE 12-5 Pinguecula nodule on conjunctiva that does not extend to the cornea. Note the yellow color. (*Courtesy of Richard P. Usatine, MD.*)

PREVENTION

Sunglasses with 100% UV protection should be used by everyone to protect the eyes from UV damage **(Figure 12-6)**. Sunglasses should fit close to the eye to block scattered or reflected light in addition to direct light.[9]

PROGNOSIS

Most pterygia do not require surgical treatment. Pterygia that interfere with vision and are removed have a high chance of recurrence.

FOLLOW-UP

No specific follow-up is needed; however, consider monitoring vision during annual examinations because of the increased risk of age-related macular degeneration.

PATIENT EDUCATION

Wraparound sunglasses are helpful to avoid UV exposure and irritation from wind and dust. Liquid tears are suggested for dry and irritated eyes.

PATIENT RESOURCES

- PubMed Health. *Pterygium*—**http://www.ncbi.nlm.nih.gov/pubmedhealth/PMH0002006/.**

PROVIDER RESOURCES

- Fisher JP. *Pterygium*—**http://emedicine.medscape.com/article/1192527.**

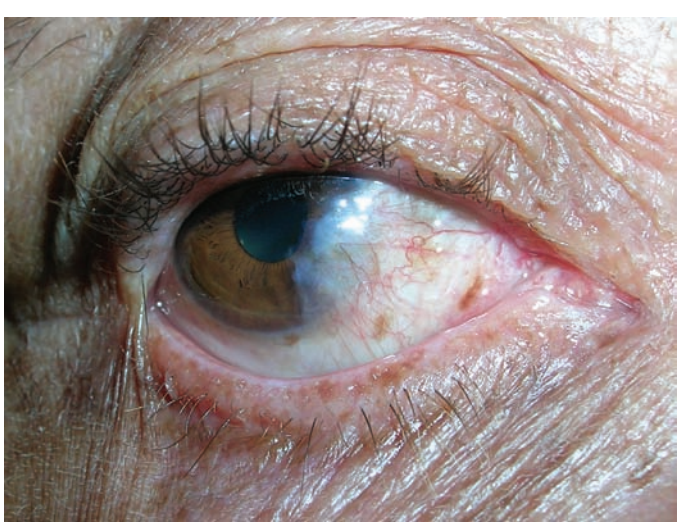

FIGURE 12-6 Nasal pterygium growing over the visual axis in a man living close to the equator. The patient did not use sunglasses. The melanosis within the pterygium is benign. (*Courtesy of Richard P. Usatine, MD.*)

REFERENCES

1. Gazzard G, Saw SM, Farook M, et al. Pterygium in Indonesia: prevalence, severity and risk factors. *Br J Ophthalmol.* 2002;86(12): 1341-1346.
2. Liang QF, Xu L, Jin XY, et al. Epidemiology of pterygium in aged rural population of Beijing, China. *Chin Med J (Engl).* 2010;123(13): 1699-1701.
3. McCarty CA, Fu CL, Taylor HR. Epidemiology of pterygium in Victoria, Australia. *Br J Ophthalmol.* 2000;84(3):289-292.
4. Chui J, Coroneo MT, Tat LT, et al. Ophthalmic pterygium: a stem cell disorder with premalignant features. *Am J Pathol.* 2011; 178(2):817-827.
5. Detorakis ET, Spandidos DA. Pathogenetic mechanisms and treatment options for ophthalmic pterygium: Trends and perspectives. *Int J Mol Med.* 2009;23(4):439-447.
6. Ashaye AO. Refractive astigmatism and size of pterygium. *Afr J Med Med Sci.* 2002;31(2):163-165.
7. Kampitak K. The effect of pterygium on corneal astigmatism. *J Med Assoc Thai.* 2003;86(1):16-23.
8. Pham TQ, Wang JJ, Rochtchina E, Mitchell P. Pterygium/pinguecula and the five-year incidence of age-related maculopathy. *Am J Ophthalmol.* 2005;139(3):536-537.
9. Wang SQ, Balaqula Y, Osterwalder U. Photoprotection: a review of the current and future technologies. *Dermatol Ther.* 2010;23(1): 31-47.

13 HORDEOLUM AND CHALAZION

Heidi Chumley, MD

PATIENT STORY

A 35-year-old woman presented with a tender nodule on the upper eyelid along with crusting and erythema to both eyelids (**Figure 13-1**). The upper eyelid had a large external hordeolum. When the lower eyelid was inverted, an internal hordeolum was also present. The physician recommended that she apply warm moist compresses to her eyelids 4 times a day. Her hordeola resolved within 7 days.

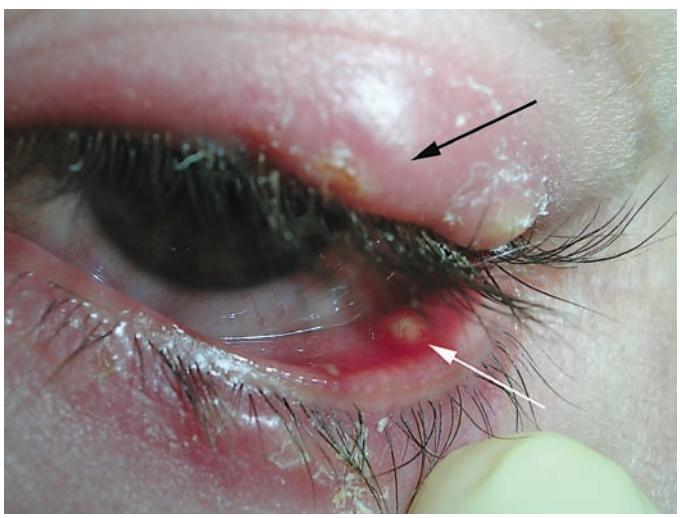

FIGURE 13-1 External hordeolum (*black arrow*) and an internal hordeolum (*white arrow*) (*Courtesy of Richard P. Usatine, MD.*)

INTRODUCTION

A hordeolum is an acute painful infection of the glands of the eyelid, usually caused by bacteria. Hordeola can be located on the internal or external eyelid. Internal hordeola that do not completely resolve become cysts called chalazia. External hordeola are commonly known as styes.

SYNONYMS

Stye (external hordeolum).

EPIDEMIOLOGY

- Unclear incidence or prevalence in the United States, but often stated to be more common in school-age children and adults 30 to 50 years old.
- In one study of school-age children in Brazil, the prevalence of chalazion was found to be 0.2% and that of hordeolum was 0.3%.[1]

ETIOLOGY AND PATHOPHYSIOLOGY

HORDEOLUM (ACUTELY TENDER NODULE IN THE EYE)

- Infection in the meibomian gland (internal hordeolum), often resolves into a chalazion (**Figure 13-1**).
- Infection in the Zeiss or Moll gland (external hordeolum) (**Figures 13-2** and **13-3**).
- *Staphylococcus aureus* is the causative agent in most cases.

CHALAZION

- Meibomian gland becomes blocked, often in a patient with blepharitis.
- Blocked meibomian gland's duct releases gland contents into the soft tissue of eyelid.

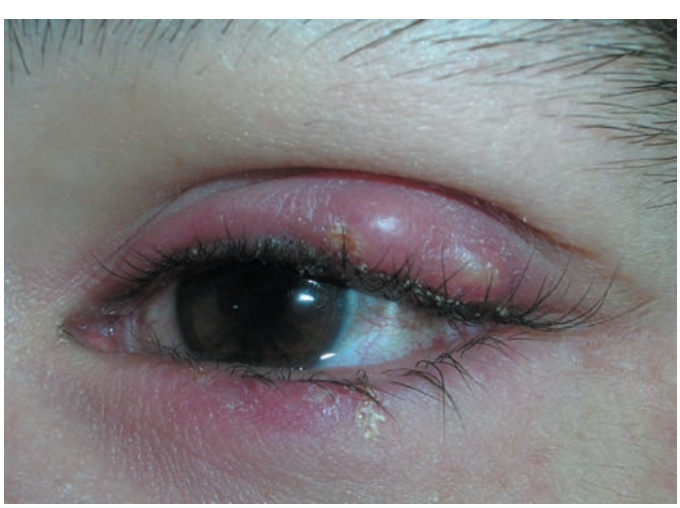

FIGURE 13-2 External hordeolum on upper lid with surrounding erythema. (*Courtesy of Richard P. Usatine, MD.*)

- Gland contents cause a lipogranulomatous reaction (**Figure 13-4**).
- Reaction can cause acute tenderness and erythema, which then resolves into a chronic nodule (**Figure 13-5**).

RISK FACTORS

- Hordeolum: *S. aureus* blepharitis, previous hordeolum.
- Chalazion: Seborrheic blepharitis and rosacea.

DIAGNOSIS

- Chalazion and hordeolum are clinical diagnoses.
- Chalazion is a nontender nodule on the eyelid.
- Hordeolum
  - Tenderness and erythema localized to a point on the eyelid (**Figures 13-1** to **13-3**).
  - Conjunctival injection may be present.
  - Fever, preauricular nodes, and vision changes should be absent.
  - Laboratory tests are generally not indicated.

DIFFERENTIAL DIAGNOSIS

- Hidrocystoma—Benign cystic lesion that grows on the edge of the eyelids and is filled with clear fluid (**Figure 13-6**).
- Xanthelasma—Yellowish plaques, generally near medial canthus (see Chapter 223, Hyperlipidemia).
- Molluscum contagiosum—Waxy nodules with central umbilication; generally multiple (see Chapter 130, Molluscum Contagiosum).
- Sebaceous cell carcinoma—Rare cancer seen in middle-age and elderly patients; difficult to distinguish from recurrent chalazion or unilateral chronic blepharitis without biopsy.
- Basal cell carcinoma—Pearly nodule, often with telangiectasias or central ulceration; more common on lower medial eyelid (see Chapter 170, Basal Cell Carcinoma).

MANAGEMENT

- Hordeolum (internal):
  - No studies of nonsurgical interventions (compresses, lid scrubs, antibiotics, steroids) met criteria for inclusion in a Cochrane study. No evidence for or against nonsurgical interventions for acute internal hordeolum.[1] SOR A
  - Treat as described below for external hordeolum.
- Hordeolum (external):
  - Warm soaks, 3 to 4 times a day for 15 minutes, will elicit drainage in most cases. SOR C
  - Topical antibiotics (e.g., bacitracin ophthalmic ointment) may be beneficial for recurrent or spontaneously draining hordeolum. SOR C
  - Cases that do not respond to warm soaks or that are extremely painful and swollen may be incised and drained with a small

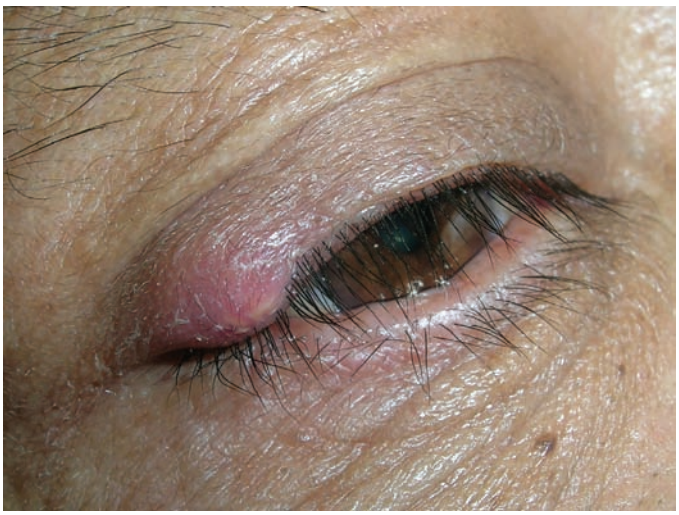

FIGURE 13-3 External hordeolum with visible purulence and the normal contour of the eyelid is disrupted. (*Courtesy of Richard P. Usatine, MD.*)

FIGURE 13-4 Chalazion viewed from internal eyelid showing the yellow lipogranulomatous material. (*Courtesy of Richard P. Usatine, MD.*)

FIGURE 13-5 Chalazion present for 4 months with minimal symptoms but cosmetically unappealing. (*Courtesy of Richard P. Usatine, MD.*)

incision using a #11 blade. Make the incision on either the internal or external eyelid depending on where the hordeolum is pointing. A chalazion clamp can be used to protect the globe from damage. SOR B
  - Antibiotics do not provide benefit after incision and drainage.[3] SOR B
  - Systemic antibiotics are usually not needed unless patient has preseptal cellulitis. SOR C
- Chalazion
  - Can be treated conservatively with lid hygiene and warm compresses. Warm compresses can be applied 2 to 3 times daily but may take weeks to months to work. SOR C
  - One study demonstrated a 58% response rate of 1% topical chloramphenicol with warm compresses.[3] SOR B
  - Higher percentages of resolution can be achieved with either incision and curettage or injection with steroid (e.g., 0.3 mL triamcinolone acetonide) (80% to 92%).[4-6] SOR B The chalazion is usually drained from the internal eyelid using a chalazion clamp to protect the globe. After anesthetizing the area, a #11 blade is carefully used to open the chalazion. A chalazion curette helps to scoop out the lipogranulomatous material. No suturing is needed.
  - A study of 136 patients compared triamcinolone injection, incision and curettage, and warm compresses, and found resolution rates of 84%, 87%, and 46%, respectively.[6] SOR B
  - One study demonstrated a better response to incision and curettage in the following situations: patients 35.1 years of age or older, with lesion duration equal to or greater than 8.5 months and size equal to or greater than 11.4 mm.[5] SOR B

REFERRAL

Refer to an ophthalmologist if the hordeolum or chalazion is interfering with vision and not responding to therapy. If a surgical intervention is needed and you lack experience doing such a procedure, refer to ophthalmology.

PREVENTION

Eyelid hygiene, keeping the area around the eyelid clean, may prevent hordeola.

PROGNOSIS

Chalazia can persist for years if untreated. Some patients are prone to recurrence of hordeola and chalazia.

FOLLOW-UP

A hordeolum with significant purulence and swelling should be reevaluated in 2 to 3 days or referred to an ophthalmologist. Warm compresses are slow to work for a chalazion, so follow-up should be no sooner than 1 month if nonsurgical treatment is prescribed.

FIGURE 13-6 Hidrocystoma showing telangiectasias. The cyst was easily resected and the fluid was clear. (*Courtesy of Richard P. Usatine, MD.*)

PATIENT EDUCATION

Hordeolum commonly responds to warm soaks and topical antibiotics. It often recurs and can develop into a chronic chalazion, which may need to be treated with surgical removal or a steroid injection.

PATIENT RESOURCES

- The American Academy of Ophthalmology—**http://www.geteyesmart.org/eyesmart/diseases/chalazion-stye.cfm.**
- The American Academy of Family Physicians has a patient handout in English or Spanish on stye—**http://familydoctor.org/familydoctor/en/diseases-conditions/sty.html.**

PROVIDER RESOURCES

- *Hordeolum and Stye in Emergency Medicine*—**http://emedicine.medscape.com/article/798940.**
- *Chalazion*—**http://emedicine.medscape.com/article/1212709.**
- *Chalazion Injection Demonstration*—**http://www.youtube.com/watch?v=yYCCkDZwKgg.**
- *Chalazion Incision and Curettage*—**http://www.youtube.com/watch?v=tdKw_zjYCf8.**

REFERENCES

1. Garcia CA, Pinheiro FI, Montenegro DA, et al. Prevalence of biomicroscopic findings in the anterior segment and ocular adnexa among schoolchildren in Natal, Brazil. *Arq Bras Oftalmol.* 2005; 68(2):167-170.
2. Lindsley K, Nichols JJ, Dickersin K. Interventions for acute internal hordeolum. *Cochrane Database Syst Rev.* 2010;(9):CD00742.
3. Hirunwiwatkul P, Wachirasereechai K. Effectiveness of combined antibiotic ophthalmic solution in the treatment of hordeolum after incision and curettage: a randomized, placebo-controlled trial: a pilot study. *J Med Assoc Thai.* 2005;88(5):647-650.
4. Chung CF, Lai JS, Li PS. Subcutaneous extralesional triamcinolone acetonide injection versus conservative management in the treatment of chalazion. *Hong Kong Med J.* 2006;12(4):278-281.
5. Ahmad S, Baig MA, Khan MA, et al. Intralesional corticosteroid injection vs surgical treatment of chalazia in pigmented patients. *J Coll Physicians Surg Pak.* 2006;16(1):42-44.
6. Goawalla A, Lee V. A prospective randomized treatment study comparing three treatment options for chalazia: triamcinolone acetonide injections, incision and curettage and treatment with hot compresses. *Clin Experiment Ophthalmol.* 2007;35(8):706-712.
7. Dhaliwal U, Bhatia A. A rationale for therapeutic decision-making in chalazia. *Orbit.* 2005;24(4):227-230.

14 SCLERAL AND CONJUNCTIVAL PIGMENTATION

Heidi Chumley, MD

PATIENT STORY

A 40-year-old white man came to see his physician about a brown spot in his eye (**Figure 14-1**). He noticed this spot many years ago, but after recently reading information on the Internet about brown spots in the eye, became concerned about ocular melanoma. He thinks the spot has changed in size. He denies any eye discomfort or visual changes. He was referred for a biopsy, and the pathology showed a benign nevus that did not require further treatment.

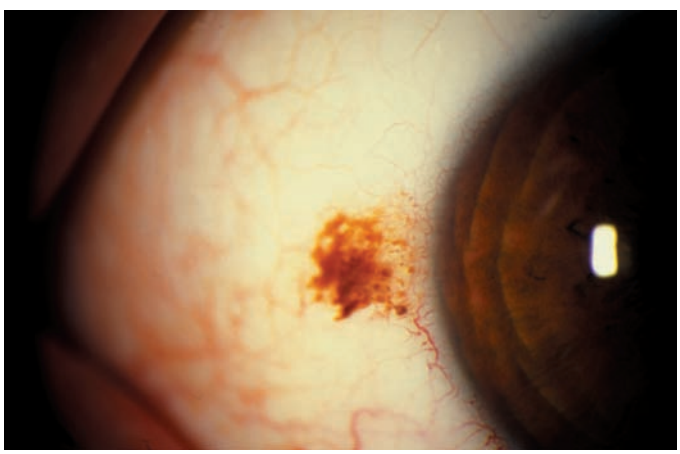

FIGURE 14-1 Scleral nevus. Unilateral localized distinct area of dark pigmentation on sclera. (*Courtesy of Paul D. Comeau.*)

INTRODUCTION

Scleral and conjunctival pigmentation is common and usually benign. Nevi can be observed and referred if they change in size. Primary acquired melanosis (PAM) must be biopsied because PAM with atypia has malignant potential, whereas PAM without atypia does not. Conjunctival melanoma is rare, but deadly.

EPIDEMIOLOGY

Although there is little information on the prevalence of ocular pigmentation other than physiologic (racial) melanosis, in a study of pigmented lesions referred for biopsy, investigators reported that 52% were nevi, 21% were PAM, and 25% were melanoma.[1]

- Scleral and conjunctival nevi (see **Figures 14-1** and **14-2**) are the most common cause of ocular pigmentation in light-skinned races. The pigmentation is generally noticeable by young adulthood, and is more common in whites.[2]
- Physiologic (racial) melanosis (**Figure 14-3**) is seen in 90% of black patients.[3] It can be congenital, and often presents early in life.
- PAM (**Figure 14-4**) is generally noted in middle-aged to older adults,[4,5] and is also more common in whites.
- Conjunctival melanoma (**Figures 14-5** to **14-7**) is rare, occurring in 0.000007% (7 per 1,000,000) of whites; it is even less common in other races.[5]

FIGURE 14-2 Conjunctival nevus. Unilateral localized distinct area of dark pigmentation on conjunctiva. (*Courtesy of Paul D. Comeau.*)

ETIOLOGY AND PATHOPHYSIOLOGY

The etiology of scleral or conjunctival nevi is not well understood. Racial melanosis is genetically determined. Conjunctival melanoma can arise from PAM with severe atypia, nevi, or de novo.[6,7]

RISK FACTORS

- In non-Hispanic whites, the incidence of conjunctival melanoma increases as latitude decreases.[8]
- Fair-skinned individuals are at higher risk for conjunctival melanoma.

DIAGNOSIS

Definitive diagnosis of pigmented ocular lesions is by biopsy.

CLINICAL FEATURES

- Benign nevi and physiologic or racial melanosis are stable over time, whereas PAM and melanoma change.
- Intrinsic cysts are common in conjunctival nevi and rare in racial melanosis, PAM, and melanoma. Seen with slit-lamp biomicroscopy.[9]

TYPICAL DISTRIBUTION

- Physiologic melanosis is typically bilateral and symmetrical.
- Nevi, PAM, and melanoma are typically unilateral; however, one study found that 13% of PAM cases were bilateral.[7]

LABORATORY TESTING

- None indicated, other than biopsy.

IMAGING

- Often not helpful, as diagnosis is made by biopsy.
- Anterior segment coherence tomography is being studied as a diagnostic aid for conjunctival nevus because cysts are detectable. In one study, there was 100% positive predictive value (PPV) but only 60% negative predictive value (NPV).[9]

BIOPSY

- Eighty-seven percent of biopsy-proven nevi do not change over time.[4]
- Features seen more commonly in malignancy: ulceration, hemorrhage, change in color, and formation of new vessels around the lesion.
- Pathologic factors of conjunctival melanoma with a higher mortality rate include increased tumor thickness, location on the palpebral, caruncular or forniceal conjunctiva, increased mitotic activity, lymphocytic invasion, and association with PAM.[10]

DIFFERENTIAL DIAGNOSIS

Pigmented areas on the sclera or conjunctiva include the following:

- Benign nevi—Unilateral and stable over time (see **Figures 14-1** and **14-2**).
- Physiologic or racial melanosis—Bilateral and symmetric, most common circumlimbally, and relatively consistent throughout patient's life (see **Figure 14-3**).

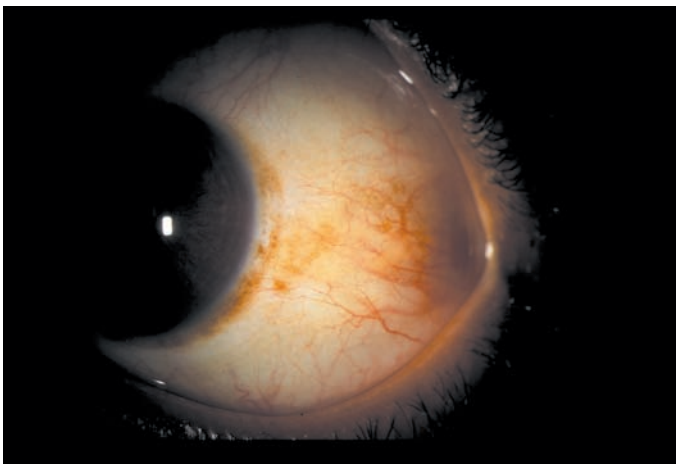

FIGURE 14-3 Physiologic (racial) melanosis. Flat conjunctival pigmentation present bilaterally starting at the limbus and most prominent in the interpalpebral zone is likely to be racial melanosis in a darkly pigmented patient. (*Courtesy of Paul D. Comeau.*)

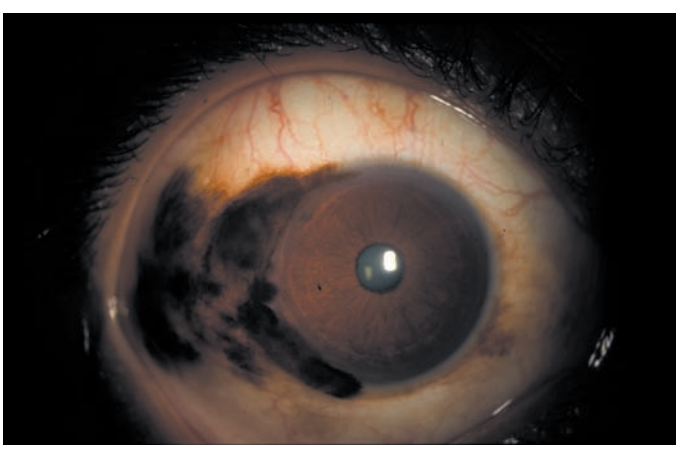

FIGURE 14-4 Primary acquired melanosis (PAM). Multiple unilateral indistinct areas of dark pigmentation. (*Courtesy of Paul D. Comeau.*)

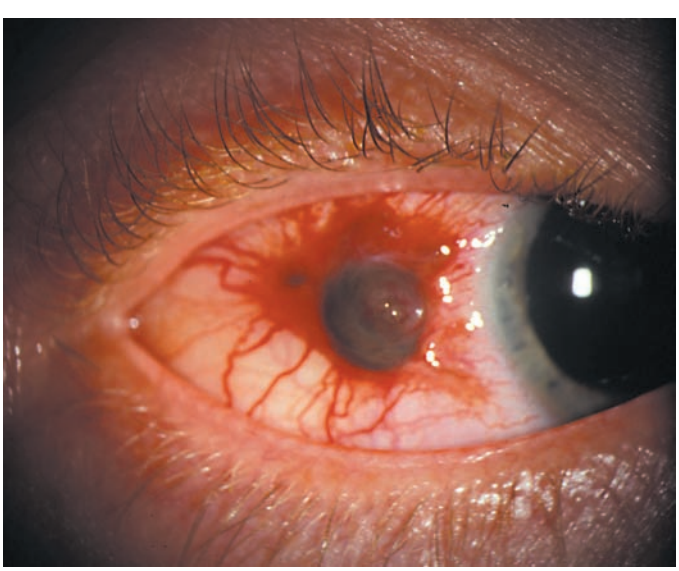

FIGURE 14-5 Conjunctival melanoma. Unilateral, nodular lesion with irregular contours and colors, and surrounded by hyperemic vessels. (*Courtesy of Paul D. Comeau.*)

- PAM—Typically unilateral, often multifocal indistinct areas of dark pigmentation, and can progress to malignancy over time (**Figure 14-4**). This term is used clinically when the histology is not known.
- Secondary acquired melanosis—Seen with hormonal changes or after trauma to the conjunctiva with irradiation, chemical irritation, or chronic inflammation.
- Conjunctival melanoma—Unilateral, nodular, with variegated color and size changes (**Figures 14-5** to **14-7**).
- Alkaptonuria—Rare disease accompanied by dark urine and arthritis.
- Nevus of Ota (also known as oculodermal melanocytosis)—Blue-gray scleral pigment involving the periorbital skin as well (**Figure 14-8**). It is more common in the Asian population but can be seen in any population. It can also be bilateral. Most importantly these persons should be followed by an ophthalmologist because they are at higher risk for glaucoma and possibly melanoma.

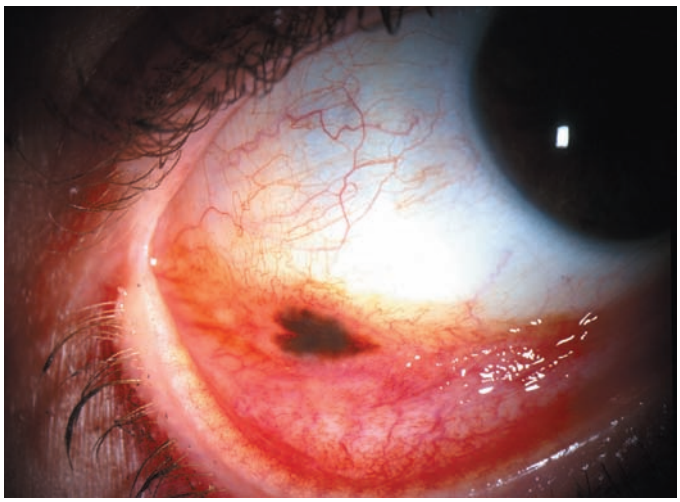

FIGURE 14-6 Early photo of conjunctival melanoma with irregular borders and variations in color. (*Courtesy of Paul D. Comeau.*)

MANAGEMENT

- Racial melanosis and nevi are two lesions that can be monitored for changes without a biopsy.
- Refer any changing pigmented lesion in the eye to a specialist who can perform a biopsy.
- Biopsy-proven PAM without atypia does not require excision, but must be monitored for stability. SOR C
- Melanosis with atypia is generally removed with large margins because of its potential for conversion into melanoma.[4] SOR C
- The primary treatment for conjunctival melanoma is surgical removal. Cryotherapy, radiotherapy, and chemotherapy may be used as adjunct therapy. SOR C

PREVENTION

To decrease risk of conjunctival melanoma, use sunglasses that protect the eye from UV radiation. SOR C

PROGNOSIS

In one study, PAM without atypia or with mild atypia did not progress into melanoma. Thirteen percent of PAM cases with severe atypia did progress. The risk of melanoma increases as PAM covers more of the iris circumference (**Figure 14-4**).[6] In one study, conjunctival melanoma arose from PAM, nevi, and de novo. Melanoma arising de novo had a worse prognosis. Other bad factors were fornix location and nodular tumor.[7]

FOLLOW-UP

Follow-up is based on the type of lesion. Nevi and physiologic melanosis that have not changed can be monitored without biopsy. PAM requires close follow-up because of its potential conversion to melanoma. Patients with nevus of Ota should be monitored for glaucoma and melanoma.

FIGURE 14-7 Conjunctival melanoma, 1 year after the previous photo, in a patient who initially declined treatment. (*Courtesy of Paul D. Comeau.*)

PATIENT EDUCATION

Most pigmentation in the eye is benign and does not change over time. Discuss the importance of reporting any changing pigmented lesion, even in the eye.

PATIENT RESOURCES

- American Academy of Ophthalmology (**http://www.aao.org**). Information on nevi and ocular melanoma. *What Is a Nevus?*—**http://www.geteyesmart.org/eyesmart/diseases/nevus.cfm.**
- Ocular Melanoma Foundation. *About Ocular Melanoma*—**http://www.ocularmelanoma.org/disease.htm.**

PROVIDER RESOURCES

- *Conjunctival Melanoma*—**http://emedicine.medscape.com/article/1191840.**

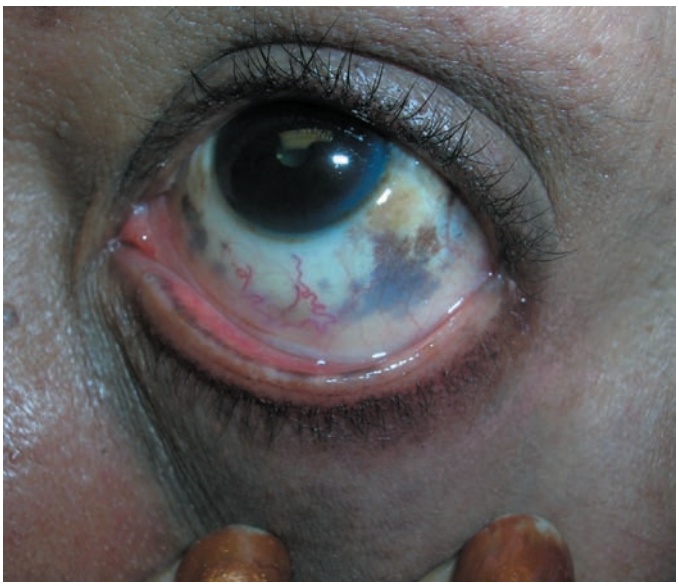

FIGURE 14-8 Nevus of Ota (also known as oculodermal melanocytosis). Unilateral blue-gray ocular pigmentation with periorbital hyperpigmentation. (*Courtesy of Richard P. Usatine, MD.*)

REFERENCES

1. Shields CL, Demirci H, Karatza E, Shields JA. Clinical survey of 1643 melanocytic and nonmelanocytic conjunctival tumors. *Ophthalmology*. 2004;111(9):1747-1754.
2. Shields CL, Fasiudden A, Mashayekhi A, Shields JA. Conjunctival nevi: clinical features and natural course in 410 consecutive patients. *Arch Ophthalmol*. 2004;122(2):167-175.
3. Singh AD, Campos OE, Rhatigan RM, et al. Conjunctival melanoma in the black population [review]. *Surv Ophthalmol*. 1998;43(2):127-133.
4. Folberg R, Mclean IW, Zimmerman LE. Conjunctival melanosis and melanoma. *Ophthalmology*. 1984;91(6):673-678.
5. Seregard S, af Trampe E, Månsson-Brahme E, et al. Prevalence of primary acquired melanosis and nevi of the conjunctiva and uvea in the dysplastic nevus syndrome. A case-control study. *Ophthalmology*. 1995;102(10):1524-1529.
6. Shields CL, Markowitz JS, Belinsky I, et al. Conjunctival melanoma: outcomes based on tumor origin in 382 consecutive cases. *Ophthalmology*. 2011;118(2):389-395.
7. Shields JA, Shields CL, Mashayekhi A, et al. Primary acquired melanosis of conjunctiva: risks for progression to melanoma in 311 eyes. *Ophthalmology*. 2008;115(3):511-519.
8. Yu GP, Hu DN, McCormick SA. Latitude and incidence of ocular melanoma. *Photochem Photobiol*. 2006;82(6):1621-1626.
9. Shields CL, Belinsky I, Romanelli-Gobbi M, et al. Anterior segment optical coherence tomography of conjunctival nevus. *Ophthalmology*. 2011;118(5):915-919.
10. Shields CL, Shields JA, Gunduz K, et al. Conjunctival melanoma: Risk factors for recurrence, exenteration, metastasis, and death in 150 consecutive patients [comment]. *Arch Ophthalmol*. 2000;118(11):1497-1507.

15 CORNEAL FOREIGN BODY AND CORNEAL ABRASION

Heidi Chumley, MD

PATIENT STORY

A 28-year-old man felt something fly into his eye while he was using a table saw without wearing protective eye gear. He presented with pain, tearing, photophobia, and thought that something was still in his eye. On examination with a slit lamp, the physician noted that he had a wood chip that had penetrated the cornea (**Figures 15-1** and **15-2**). He was referred to an ophthalmologist who successfully removed the foreign body. He was treated with a short course of topical NSAIDs for pain relief, and had complete healing.

FIGURE 15-1 Wood chip is visible in the cornea on close inspection of the eye. (*Courtesy of Paul D. Comeau.*)

INTRODUCTION

Corneal abrasions are often caused by eye trauma and can cause an inflammatory response. Corneal abrasions are detected using fluorescein and a UV light. A corneal foreign body can be seen during a careful physical examination with a good light source or slit lamp. Nonpenetrating foreign bodies can be removed by an experienced physician in the office using topical anesthesia. Refer all penetrating foreign bodies to an ophthalmologist.

SYNONYMS

Corneal abrasion is sometimes referred to as a corneal epithelial defect.

EPIDEMIOLOGY

- Corneal abrasions with or without foreign bodies are common; however, the prevalence or incidence of corneal abrasions in the general population is unknown.
- Corneal abrasions accounted for 85% of closed-eye injuries in adults presenting to an emergency department.[1]

ETIOLOGY AND PATHOPHYSIOLOGY

- The cornea overlies the iris and provides barrier protection, filters UV light, and refracts light onto the retina.
- Abrasions in the cornea are typically caused by direct injury from a foreign body, resulting in an inflammatory reaction.
- The inflammatory reaction causes the symptoms and can persist for several days after the foreign object is out.

FIGURE 15-2 Slit-lamp examination reveals this wood chip has penetrated the cornea. (*Courtesy of Paul D. Comeau.*)

RISK FACTORS

- Those with occupations such as metal workers, woodworkers, miners, and landscapers have an increased risk of corneal injuries from foreign bodies.[2]
- Participating in sports such as hockey, lacrosse, or racquetball raises the risk of corneal abrasions from ocular trauma.[2]
- Ventilated neonates (as a result of mask pressure on the orbit) or sedated patients (as a result of disruption of the blink reflex, and subsequent corneal exposure) are at increased risk for corneal abrasions.[2]

Contact lenses, especially soft extended wear, increase the risk of developing an infected abrasion that ulcerates.[2]

DIAGNOSIS

CLINICAL FEATURES

History and physical

- History of ocular trauma or eye rubbing (although corneal abrasions can occur with no trauma history).
- Symptoms of pain, eye redness, photophobia, and a foreign-body sensation.
- Foreign body seen with direct visualization or a slit lamp (**Figure 15-3**).
- Fluorescein application demonstrates green area (which represents the disruption in the corneal epithelium) under cobalt-blue filtered light (**Figure 15-4**).
- History of contact lens wear.
- History of ocular or perioral herpes virus infection.

LABORATORY TESTING

- Culture if an infection is suspected.

IMAGING

- If physical examination is equivocal, imaging may be useful to determine if a foreign body has perforated the cornea. An object that has fully perforated the cornea has passed through the cornea and will be located in the anterior segment or posterior segment of the eye, making it difficult to see without imaging technology.
- CT or spiral CT can detect nonmetallic and metallic foreign bodies.
- A metallic foreign body can be seen on an orbital radiograph. Avoid MRI if the history suggests the foreign body may be metallic.

Ultrasound and ultrasound biomicroscopy can also visualize intraocular foreign bodies and may be useful in some cases.

DIFFERENTIAL DIAGNOSIS

- Uveitis or iritis—Usually unilateral 360-degree perilimbal injection, eye pain, photophobia, and vision loss (see Chapter 18, Uveitis and Iritis).

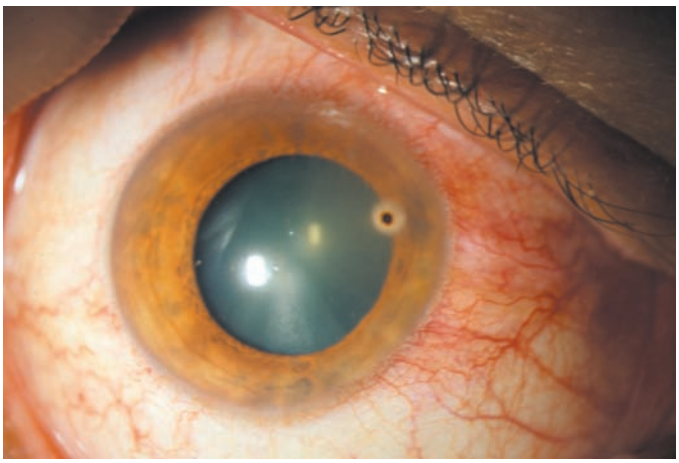

FIGURE 15-3 Metallic foreign body with rust ring within the corneal stroma and conjunctival injection. (*Courtesy of Paul D. Comeau.*)

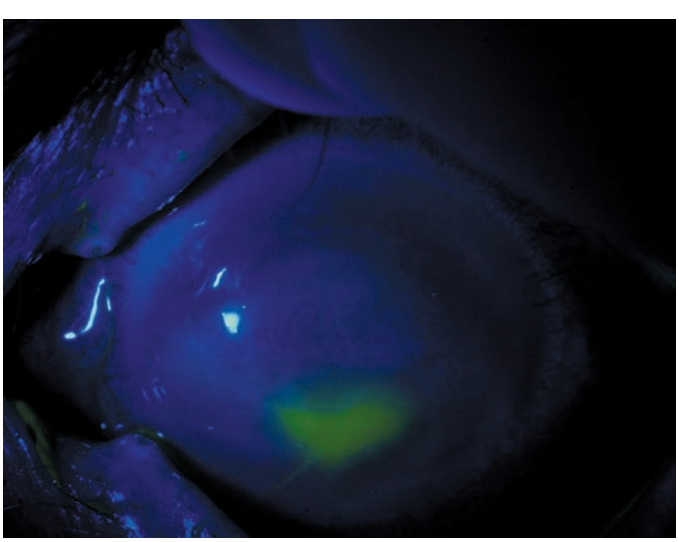

FIGURE 15-4 Fluorescein stains green, indicating corneal abrasion. (*Courtesy of Paul D. Comeau.*)

- Keratitis or corneal ulcerations—Diffuse erythema with ciliary injection often with miosis; eye discharge; pain, photophobia, and vision loss depending on the location of ulceration (**Figures 15-5** and **15-6**). There is often a history of trauma, herpes simplex virus (HSV), or contact lens wear. Patients should see an ophthalmologist urgently.
- Conjunctivitis—Conjunctival injection; eye discharge; gritty or uncomfortable feeling; no vision loss, history of respiratory infection, or contacts with others who have red eyes (see Chapter 16, Conjunctivitis).
- Acute-angle closure glaucoma—Cloudy cornea and scleral injection; eye pain with ipsilateral headache; severe vision loss, acutely elevated intraocular pressure (see Chapter 19, Glaucoma).

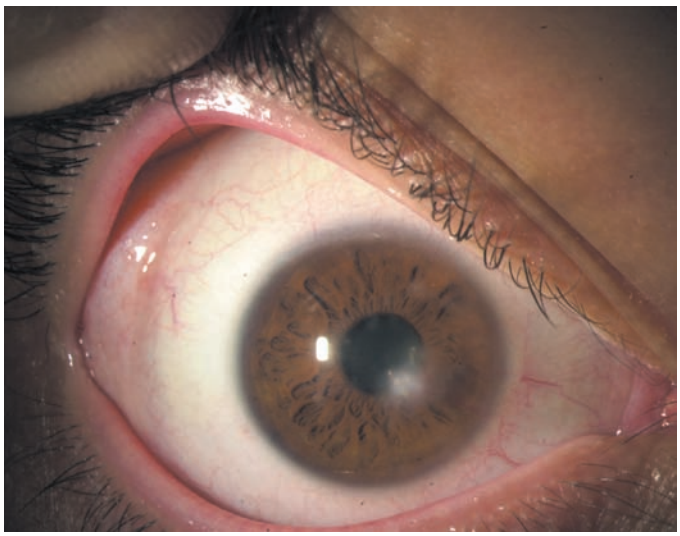

FIGURE 15-5 Small corneal ulcer in the visual axis. (*Courtesy of Paul D. Comeau.*)

MANAGEMENT

NONPHARMACOLOGIC

- Confirm diagnosis with fluorescein and a UV light (for abrasion) if no foreign body is readily visible (see **Figure 15-4**).
- Carefully inspect for a foreign body. Invert the upper eyelid for full visualization. Slit-lamp visualization may be needed to determine if the cornea has been penetrated (see **Figure 15-2**).
- Remove (or refer for removal) nonpenetrating foreign bodies. Apply a topical anesthetic, such as proparacaine or tetracaine. Remove with irrigation, a wet-tipped cotton applicator, or a fine-gauge needle.
- Remove contact lenses until cornea is healed.[3] SOR C
- Avoid patching in corneal abrasions smaller than 10 mm; it does not help.[4] SOR A

MEDICATIONS

- Prescribe ophthalmic NSAIDs for pain if needed.[5] SOR A
- Consider topical antibiotics. SOR C Chloramphenicol ointment reduced the risk of recurrent ulcer in a prospective, nonplacebo, controlled trial.[6] Although chloramphenicol is rarely used in the United States, other ophthalmic antibiotics, such as erythromycin ointment, are used for corneal abrasions. SOR C

REFERRAL

- Refer penetrating foreign bodies to an experienced eye surgeon.

PREVENTION

Eye protection should be worn for high-risk occupational and recreational activities.

PROGNOSIS

Prognosis is generally good. Development of infection or a rust ring worsens prognosis.

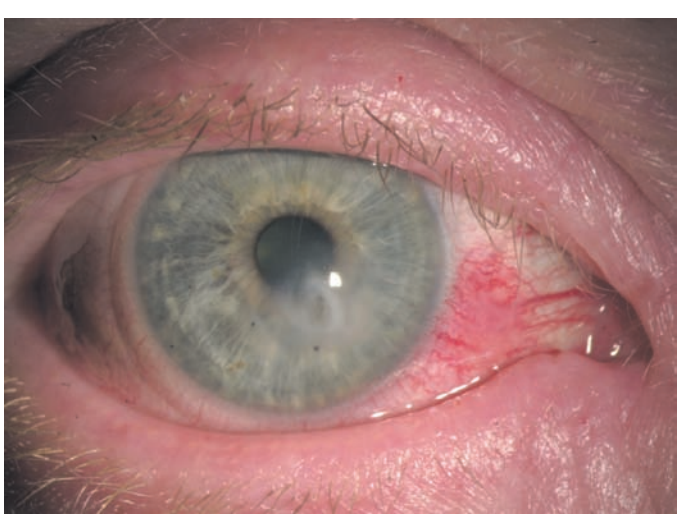

FIGURE 15-6 Larger corneal ulcer partially obscuring the visual axis. (*Courtesy of Paul D. Comeau.*)

FOLLOW-UP

See all patients in 24 hours for reassessment. If there is no improvement, look for an initially overlooked foreign body or a full-thickness injury. Don't hesitate to refer to ophthalmology if patient is not improving.

PATIENT EDUCATION

- Advise patients in specific professions (e.g., woodworking, metal working) and those who play sports, such as racquetball or hockey, to wear eye protection for primary prevention.
- Advise patients with corneal abrasions that healing usually occurs within 2 to 3 days, and they should report persistent pain, redness, and photophobia.
- Patients should be advised not to sleep in contact lenses, even if labeled "extended wear."

PATIENT RESOURCES

- FamilyDoctor.org. Patient handout on *Corneal Abrasions*—**http://familydoctor.org/familydoctor/en/prevention-wellness/staying-healthy/first-aid/corneal-abrasions.html.**

PROVIDER RESOURCES

- Cao C. *Corneal Foreign Body Removal*—**http://emedicine.medscape.com/article/82717.**

REFERENCES

1. Oum BS, Lee JS, Han YS. Clinical features of ocular trauma in emergency department. *Korean J Ophthalmol.* 2004;18(1):70-78.
2. Wilson SA, Last A. Management of corneal abrasions. *Am Fam Physician.* 2004;1(70):123-128.
3. Weissman BA. *Care of the Contact Lens Patient: Reference Guide for Clinicians*. St Louis, MO: American Optometric Association; 2000.
4. Turner A, Rabiu M. Patching for corneal abrasion. *Cochrane Database Syst Rev.* 2006 Apr 19;(2):CD004764.
5. Weaver CS, Terrell KM. Evidence-based emergency medicine. Update: do ophthalmic nonsteroidal anti-inflammatory drugs reduce the pain associated with simple corneal abrasion without delaying healing [review]? *Ann Emerg Med.* 2003;41(1):134-140.
6. Upadhyaya MP, Karmacharyaa PC, Kairalaa S, et al. The Bhaktapur eye study: ocular trauma and antibiotic prophylaxis for the prevention of corneal ulceration in Nepal. *Br J Ophthalmol.* 2001;85:388-392.

16 CONJUNCTIVITIS

Heidi Chumley, MD
Richard P. Usatine, MD

PATIENT STORY

A 35-year-old woman presents with 2 days of redness and tearing in her eyes (**Figure 16-1**). She has some thin matter in eyes, but neither eye has been glued shut when she awakens. She does not have any trouble seeing once she blinks to clear any accumulated debris. Both eyes are uncomfortable and itchy, but she is not having any severe pain. She does not wear contact lenses and has not had this problem previously. The patient was diagnosed with viral conjunctivitis and scored −1 on the clinical scoring system (see "Diagnosis" below). She was instructed about eye hygiene and recovered in 3 days.

FIGURE 16-1 Viral conjunctivitis demonstrating bilateral conjunctival injection with little discharge. The patient has an incidental left eye conjunctival nevus. (*Courtesy of Richard P. Usatine, MD.*)

INTRODUCTION

Conjunctivitis, inflammation of the membrane lining the eyelids and globe, presents with injected pink or red eye(s), eye discharge ranging from mild to purulent, eye discomfort or gritty sensation, and no vision loss. Conjunctivitis is most commonly infectious (viral or bacterial) or allergic, but can be caused by irritants. Diagnosis is clinical, based on differences in symptoms and signs.

SYNONYMS

Pink eye.

EPIDEMIOLOGY

- Infectious conjunctivitis is common and often occurs in outbreaks, making the prevalence difficult to estimate.
- In the United States, the estimated annual incidence rate for bacterial conjunctivitis is 135 per 10,000 people.[1]
- Viral conjunctivitis is more common than bacterial conjunctivitis.
- Allergic conjunctivitis had a point prevalence of 6.4% and a lifetime prevalence of 40% in a large population study in the United States from 1988 to 1994.[2]

ETIOLOGY AND PATHOPHYSIOLOGY

Conjunctivitis is predominately infectious (bacterial or viral) or allergic, and the most common etiologies vary by age.

- Neonatal conjunctivitis is often caused by *Chlamydia trachomatis* and *Neisseria gonorrhoeae*.[3]
- Children younger than 6 years are more likely to have a bacterial than viral conjunctivitis (**Figure 16-2**). In the United States, the

FIGURE 16-2 Unilateral conjunctivitis in a 4-year-old child. The child's age and purulent discharge are consistent with a bacterial etiology. (*Courtesy of Richard P. Usatine, MD.*)

most common bacterial causes are *Haemophilus* species and *Streptococcus pneumoniae* accounting for almost 90% of cases in children.[4]

- Children age 6 years or older are more likely to have viral or allergic causes for conjunctivitis.[4] Adenovirus is the most common viral cause.

DIAGNOSIS

- To distinguish conjunctivitis from other causes of a red eye, ask about pain and check for vision loss. Patients with a red eye and intense pain or vision loss that does not clear with blinking are unlikely to have conjunctivitis and should undergo further evaluation.
- Always ask about contact lens use as this can be a risk factor for all types of conjunctivitis, including bacterial conjunctivitis (**Figure 16-3**).
- Typical clinical features of any type of conjunctivitis may include eye discharge, gritty or uncomfortable feeling, one or both pink eyes, and no vision loss. The infection usually starts in one eye, and progresses to involve the other eye days later.
- Bacterial conjunctivitis (see **Figures 16-2** to **16-4**) has a more purulent discharge than viral or allergic conjunctivitis.
- A clinical scoring system has been developed to distinguish bacterial from other causes of conjunctivitis in healthy adults who did not wear contact lenses. A score of +5 to −3 is determined as follows:
  - Two glued eyes (+5); one glued eye (+2); history of conjunctivitis (−2); eye itching (−1).
  - A score of +5, +4, or +3 is useful in ruling in bacterial conjunctivitis with specificities of 100%, 94%, and 92%, respectively.
  - Scores of −1, −2, or −3 are useful in ruling out bacterial conjunctivitis with sensitivities of 98%, 98%, and 100%, respectively.[5]

Allergic conjunctivitis is typically bilateral and accompanied by eye itching. Giant papillary conjunctivitis is a type of allergic reaction, most commonly to soft contact lenses (**Figure 16-5**).

LABORATORY TESTING

- An in-office rapid test for adenoviral conjunctivitis (RPS Adeno Detector) has a sensitivity of 88% and a specificity of 91% compared to viral cell culture with confirmatory immunofluorescence staining.[6]

DIFFERENTIAL DIAGNOSIS

- Episcleritis—Segmental or diffuse inflammation of episclera (pink color), mild or no discomfort but can be tender to palpation, and no vision disturbance (see also Chapter 17, Episcleritis and Scleritis).
- Scleritis—Segmental or diffuse inflammation of sclera (dark red, purple, or blue color), severe boring eye pain often radiating to head and neck, and photophobia and vision loss (see also Chapter 17, Episcleritis and Scleritis).
- Uveitis or iritis—360-degree perilimbal injection, eye pain, photophobia, and vision loss. Frequently treated initially as conjunctivitis without resolution (see also Chapter 18, Uveitis and Iritis).

FIGURE 16-3 Bacterial conjunctivitis with a small amount of discharge. The patient was unable to clean her contacts while being evacuated from a hurricane-threatened Houston and the conjunctivitis was bilateral. (*Courtesy of Richard P. Usatine, MD.*)

FIGURE 16-4 Gonococcus conjunctivitis has a copious discharge. This severe case resulted in partial blindness. (*Courtesy of Centers for Disease Control and Prevention [CDC].*)

- Keratitis or corneal ulcerations—Diffuse conjunctival injection, often with miosis (constriction of pupil), eye discharge, pain, photophobia, and vision loss depending on the location of ulceration. Herpes keratitis is a diagnosis that should not be missed (**Figures 16-6** and **16-7**). The use of fluorescein and a UV light can help identify dendritic ulcers or other corneal damage and prompt an emergent referral to an ophthalmologist (**Figure 16-7**). Contact lens wearers should urgently see an ophthalmologist for keratitis.
- Acute-angle closure glaucoma—Cloudy cornea and scleral injection, eye pain with ipsilateral headache, elevated intraocular pressure, and severe vision loss (see also Chapter 19, Glaucoma).
- A foreign body in the eye can cause conjunctival injection and lead to a bacterial superinfection. If the foreign body is not easily dislodged with conservative measures, or appears to be superinfected with ulceration or leukocyte infiltrate, prompt referral to an ophthalmologist is required (**Figure 16-8**).

Trachoma is an eye infection caused by *C. trachomatis* that is rare in the United States but common in the rural areas of some developing countries. It is a leading cause of blindness in the developing world. Poverty and poor hygiene are major risk factors. Once the eye is infected, follicles can be seen on the upper tarsal conjunctiva upon eyelid eversion (**Figure 16-9**). Superior tarsal conjunctival scarring leads to entropion, which causes corneal scarring and ultimately blindness (**Figure 16-10**).

Vernal conjunctivitis is a severe recurrent form of allergic conjunctivitis that is more common in the summer (not the spring). The term *vernal* refers to the spring time, and therefore it is now referred to as "warm weather conjunctivitis" rather than "spring catarrh." Giant papillae that look like a cobblestone pattern may be seen in this condition. It occurs primarily in young boys, and typically ceases to recur seasonally with age.

MANAGEMENT

Hand hygiene can control the spread of infectious conjunctivitis.

Most acute conjunctival infections are viral and resolve without treatment. Following are the categories of patients who have a high probability of bacterial conjunctivitis and who are treated with topical antibiotics:

- Children younger than age 6 years.[4]
  - Azithromycin 1.5% ophthalmic solution twice daily for 3 days resulted in a clinical and microbiologic cure in more than 80% of children. This dosing regimen provides equivalent efficacy to 4 times a day dosing of tobramycin.[7,8]
- Adults who score +3 or above on the clinical scoring system for bacterial conjunctivitis.
- Studies show that more than 80% of patients show improvements with 0.3% ciprofloxacin, tobramycin, norfloxacin, or gentamicin.[9,10]
- Levofloxacin 0.5% is dosed 3 times a day.[11]
- Delayed antibiotic prescription decreased antibiotic use by nearly 50% and provided similar symptom control compared to immediate antibiotics.[12]

Allergic conjunctivitis can be treated with antihistamines, mast-cell stabilizers, nonsteroidal antiinflammatory agents, corticosteroids, and immunomodulatory agents.[13]

FIGURE 16-5 Giant papillary conjunctivitis in a contact lens wearer. (*Courtesy of Mike Johnson, MD.*)

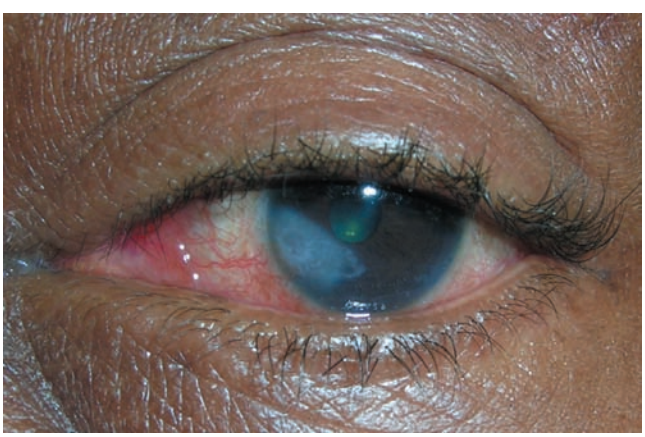

FIGURE 16-6 Herpetic keratitis in a 56-year-old woman staying in a shelter after Hurricane Katrina. (*Courtesy of Richard P. Usatine, MD.*)

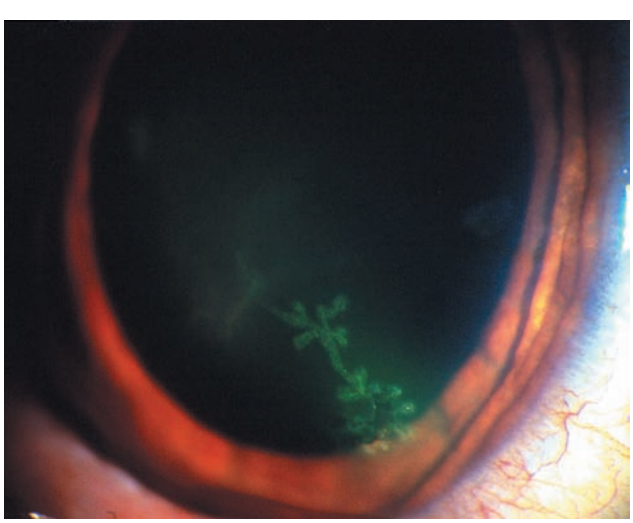

FIGURE 16-7 Slit-lamp view of a dendritic ulcer with fluorescein uptake from herpetic keratitis. (*Courtesy of Paul D. Comeau.*)

REFERRAL

- Refer patients who have vision loss, copious purulent discharge (this could represent gonococcal disease, which must be cultured, and which can cause vision loss), severe pain, lack of response to therapy, or a history of herpes simplex or zoster eye disease to an ophthalmologist.
- Any patient who may need ocular steroid should be seen by an ophthalmologist. There is a severe risk for complications with the use of ocular steroids.

PREVENTION

Good hygiene practices with washing of the hands and face with soap and water.

FOLLOW-UP/RETURN TO SCHOOL

Routine follow-up is generally not needed if symptoms resolve in 3 to 5 days.

State health departments have no consensus on when children with conjunctivitis can return to school. A literature-based review suggests the best strategy is excluding children from school until they are asymptomatic.[14]

PATIENT EDUCATION

- Most adults and children older than age 6 years have a nonbacterial cause of conjunctivitis.
- Remove contact lenses until conjunctivitis has resolved.
- Avoid touching the face or rubbing the eyes and wash hands immediately afterwards.
- Do not share face towels, eye make-up, or contact lens cases.
- Inform your physician immediately if you experience eye pain or vision loss.

PATIENT RESOURCES

- PubMed Health. *Conjunctivitis*—**http://www.ncbi.nlm.nih.gov/pubmedhealth/PMH0002005/.**
- American Academy of Ophthalmology has patient information under For Patients and the Public at **http://www.aao.org.**
- American Academy of Ophthalmology. *Conjunctivitis: What Is Pink Eye?*—**http://www.geteyesmart.org/eyesmart/diseases/conjunctivitis.cfm.**
- Centers for Disease Control and Prevention has patient information in English and Spanish at **http://www.cdc.gov.**
- Centers for Disease Control and Prevention. *Conjunctivitis (Pink Eye)*—**http://www.cdc.gov/conjunctivitis/index.html.**
- The Livestrong foundation has auditory patient information on YouTube. *Conjunctivitis Health Byte*— **http://www.youtube.com/watch?v=O8LkDfbLCaY**; and *A Healthy Byte: Pink Eye*—**http://www.youtube.com/watch?v=Hp28hS7XYCo&feature=relmfu.**

FIGURE 16-8 Conjunctivitis caused by a foreign body in the eye of a machinist. The ground metal speck is seen on the cornea, and the corneal infiltrate, along with a purulent discharge, indicate a bacterial superinfection. (*Courtesy of Richard P. Usatine, MD.*)

FIGURE 16-9 Trachoma showing many white follicles on the underside of the upper eyelid. (*Courtesy of Richard P. Usatine, MD.*)

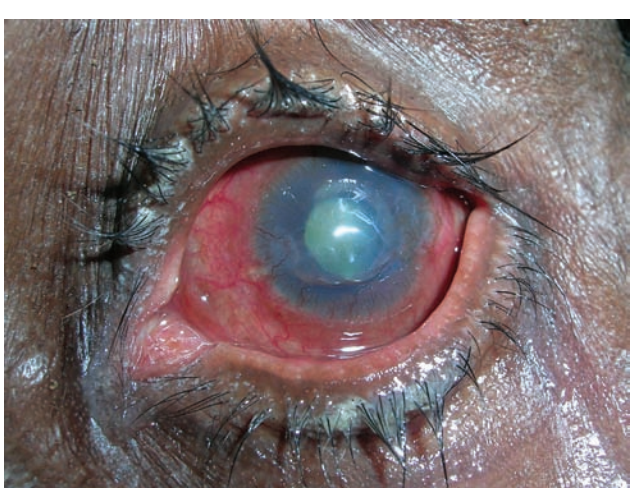

FIGURE 16-10 Advanced trachoma with blindness as a consequence of cornea opacities. Note the deep conjunctival injection and purulent discharge from the *C. trachomatis* infection. (*Courtesy of Richard P. Usatine, MD.*)

PROVIDER RESOURCES

- Agency for Healthcare Research and Quality. *Conjunctivitis* guidelines—**http://www.guidelines.gov/content.aspx?id=13501.**

REFERENCES

1. Smith AF, Waycaster C. Estimate of the direct and indirect annual cost of bacterial conjunctivitis in the United States. *BMC Ophthalmol.* 2009;9:13.
2. Singh K, Axelrod S, Bielory L. The epidemiology of ocular and nasal allergy in the United States, 1988-1994. *J Allergy Clin Immunol.* 2010;126(4):778-783.
3. Gigliotti F, Williams WT, Hayden FG, et al. Etiology of acute conjunctivitis in children. *J Pediatr.* 1981;98(4):531-536.
4. Meltzer JA, Kunkov D, Crain EF. Identifying children at low risk for bacterial conjunctivitis. *Arch Pediatr Adolesc Med.* 2010;164:263-267.
5. Rietveld RP. Predicting bacterial cause in infectious conjunctivitis: cohort study on informativeness of combinations of signs and symptoms. *BMJ.* 2004;329:206-210.
6. Sambursky R, Tauber S, Schirra F, et al. The RPS adeno detector for diagnosing adenoviral conjunctivitis. *Ophthalmology.* 2006; 113(10):1758-1764.
7. Bremond-Gignac D, Mariani-Kurkdjian P, Beresniak A, et al. Efficacy and safety of azithromycin 1.5% eye drops for purulent bacterial conjunctivitis in pediatric patients. *Pediatr Infect Dis J.* 2010;29(3):222-226.
8. Cochereau I, Meddeb-Ouertani A, Khairallah M, et al. 3-day treatment with azithromycin 1.5% eye drops versus 7-day treatment with tobramycin 0.3% for purulent bacterial conjunctivitis: multicentre, randomized and controlled trial in adults and children. *Br J Ophthalmol.* 2007;91(4):465-469.
9. Gross RD, Hoffman RO, Lindsay RN. A comparison of ciprofloxacin and tobramycin in bacterial conjunctivitis in children. *Clin Pediatr (Phila).* 1997;36(8):435-444.
10. Miller IM, Vogel R, Cook TJ, Wittreich J. Topically administered norfloxacin compared with topically administered gentamicin for the treatment of external ocular bacterial infections. The Worldwide Norfloxacin Ophthalmic Study Group. *Am J Ophthalmol.* 1992;113(6):638-644.
11. Szaflik J, Szaflik JP, Kaminska A. Clinical and microbiological efficacy of levofloxacin administered three times a day for the treatment of bacterial conjunctivitis. *Eur J Ophthalmol.* 2009; 19(1):1-9.
12. Everitt HA, Little PS, Smith PW. A randomized controlled trial of management strategies for acute infective conjunctivitis in general practice. *BMJ.* 2006;333(7563):321.
13. Mishra GP, Tamboli V, Jwala J, Mitra AK. Recent patents and emerging therapeutics in the treatment of allergic conjunctivitis. *Recent Pat Inflamm Allergy Drug Discov.* 2011;5(1):26-36.
14. Ohnsman CM. Exclusion of students with conjunctivitis from school: policies of state departments of health. *J Pediatr Ophthalmol Strabismus.* 2007;44(2):101-105.

17 SCLERITIS AND EPISCLERITIS

Heidi Chumley, MD
Kelly Green, MD

PATIENT STORY

A 45-year-old woman presents with 1 day of increasing eye pain, eye redness, and difficulty in seeing. On examination there was scleral injection and exquisite globe tenderness (**Figure 17-1**). Her review of systems is positive for morning stiffness and swelling in both of her hands. The patient was urgently referred to an ophthalmologist who diagnosed her with scleritis. Her visual acuity was reduced minimally. A slit lamp exam revealed injected sclera with a bluish hue in the affected eye and a rare anterior chamber cell. The posterior segment was normal.

The ophthalmologist prescribed an oral NSAID, specifically indomethacin, as it effectively crosses the blood-brain barrier and gets good levels in the eye.

Her rheumatoid factor was positive, so she was also referred to a rheumatologist.

FIGURE 17-1 Scleritis in a patient with eye pain and exquisite globe tenderness. Untreated this can result in loss of vision. (*Courtesy of Paul D. Comeau.*)

INTRODUCTION

Episcleritis and scleritis are inflammation of the deeper layers of the eye, the vascular episclera, and the avascular sclera. Episcleritis pre-sents with segmental eye redness, discomfort but not severe pain, and no vision loss. Scleritis can have overlying episcleritis, but also has a violaceous hue, is painful, and may cause vision loss. Scleritis typically has an associated underlying condition (autoimmune or infectious) that should be identified and treated. Scleritis is treated with NSAIDs, systemic glucocorticoids, or immunosuppressive medications. Patients with scleritis are often referred to an ophthalmologist as vision loss is common.

EPIDEMIOLOGY

Scleritis

- Scleritis usually presents between the ages of 30 and 50 years and is twice as common in women compared to men.[1]
- Forty-four percent of patients presenting with scleritis to specialty health centers were found to have an associated systematic disease (37% rheumatic, 7% infection), most commonly (15%) rheumatoid arthritis.[2]

Episcleritis

- Prevalence is unknown.
- Usually presents between the ages of 20 and 50 years and may be more common in women.
- Nodular or recurrent episcleritis is more likely to be associated with an underlying systemic condition than is an isolated episode of simple episcleritis.

ETIOLOGY AND PATHOPHYSIOLOGY

- Scleritis and episcleritis are inflammatory conditions causing congestion of the deeper 2 of the 3 vascular layers (conjunctival, episcleral, and scleral plexuses) overlying the avascular sclera.
- Scleritis often occurs with episcleritis; episcleritis does not involve the sclera and does not progress to scleritis.
- Scleritis disrupts vascular architecture and may cause vision loss; episcleritis does not.
- Causes of scleritis:
  - Systemic autoimmune diseases such as rheumatoid arthritis, Wegener granulomatosis, seronegative spondyloarthropathies, relapsing polychondritis, systemic lupus erythematosus (SLE). **Figure 17-2** shows a young woman with SLE and scleritis.
  - Infections (*Pseudomonas*, tuberculosis, syphilis, herpes zoster).
  - Less common causes include gout and sarcoidosis.
  - Idiopathic.
- Causes of episcleritis
  - Most often idiopathic.
  - May be associated with any of the conditions listed above, especially if the presentation is nodular or recurrent.

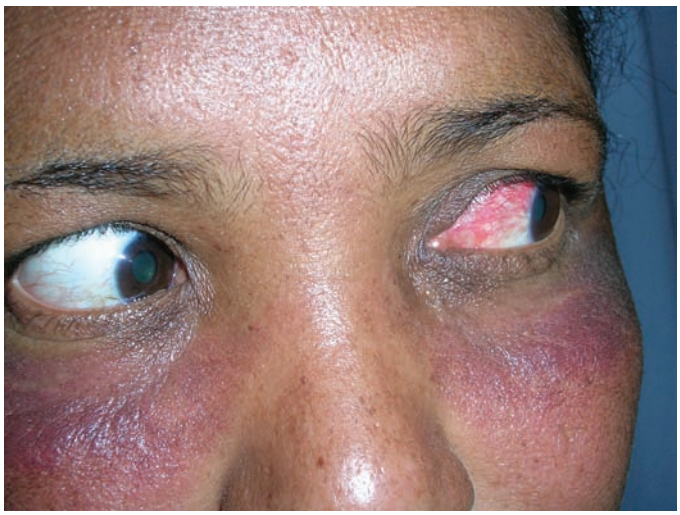

FIGURE 17-2 Scleritis in a young woman with systemic lupus erythematosus. Note the malar rash that is also present. (*Courtesy of Richard P. Usatine, MD.*)

DIAGNOSIS

CLINICAL FEATURES

Scleritis

- Segmental or diffuse inflammation of sclera (dark red, purple, or blue color), with overlying episclera and conjunctival inflammation (**Figures 17-1** to **17-3**).
- Severe, boring eye pain often radiating to head and neck that worsens with eye movement. However, 20% of patients may not have pain, including those with the necrotizing type (scleromalacia perforans) and those taking immunosuppressive agents prior to the onset of scleritis.[1]
- Photophobia and vision loss.

Episcleritis

- Segmental or diffuse inflammation of episclera (pink color) and overlying conjunctival vessel injection (**Figures 17-4** and **17-5**).
- Mild if any discomfort but can be tender to palpation.
- No vision disturbance.
- Scleritis and episcleritis are often distinguished by history and physical examination features; however, when scleritis has extensive overlying episcleritis, the diagnosis becomes more difficult. Scleritis must be differentiated from episcleritis because scleritis requires treatment and an evaluation for underlying medical conditions.
- Ten percent phenylephrine blanches inflamed episcleral and conjunctival vessels, but not scleral vessels; in scleritis, this can reveal a focus of scleral engorgement covered by episcleral injection.
- Scleritis and episcleritis, as opposed to iritis with overlying episcleral injection, often have areas of focal tenderness to palpation. These can be elicited with a sterile cotton swab after applying a topical anesthetic.

FIGURE 17-3 Scleritis in a patient with Wegener granulomatosis. Deep vessels are affected, giving the eye a purplish or blue hue. (*Courtesy of Everett Allen, MD.*)

Typical distribution

- Scleritis can be posterior (posterior to the medial and lateral rectus muscles) or anterior:
  - Posterior scleritis can produce retinal detachments and subretinal exudates and is often associated with uveitis (inflammation of the iris, ciliary body, or choroid).
  - Anterior scleritis can be diffuse, nodular, necrotizing with inflammation or necrotizing without inflammation.[1]
- Scleritis is bilateral in 50% of patients.[1]
- Episcleritis is often segmental, but can be diffuse, and is typically benign.

LABORATORY TESTING

In scleritis, if an associated systemic disease has not been previously diagnosed, consider ordering these tests: complete blood count, metabolic panel, urinalysis, antineutrophil cytoplasmic antibody, antinuclear antibody, rheumatoid factor, anticyclic citrullinated peptide antibodies, rapid plasma reagin, and Lyme antibody in Lyme infested regions. Also consider tuberculin skin test, viral hepatitis panel, and cultures for bacteria, virus, and fungi.

IMAGING

In scleritis, if an associated systemic disease has not been previously diagnosed, consider the following: chest radiographs, sinus CT, or sacroiliac joint radiographs.

To diagnose posterior scleritis, ultrasound or orbital CT can demonstrate sclera thickening.

BIOPSY

An ophthalmologist may perform a biopsy when it is important to distinguish among scleritis caused by rheumatic diseases, infections, or sarcoidosis.

- Rheumatic—Zonal necrotizing granulomatous scleral inflammation with loss of anterior scleral tissue.
- Infectious—Necrotizing scleritis with microabscesses.
- Sarcoid—Sarcoidal granulomatous inflammation can be identified in cases of sarcoidosis.

DIFFERENTIAL DIAGNOSIS

Causes of red eye, other than scleritis and episcleritis:

- Uveitis or iritis—360 degrees perilimbal injection, which is most intense at the limbus; eye pain, photophobia, and vision loss (see also Chapter 18, Uveitis and Iritis).
- Keratitis or corneal ulcerations—Diffuse erythema with ciliary injection often with pupillary constriction; eye discharge; pain, photophobia, and vision loss depending on location of ulceration.
- Conjunctivitis—Conjunctival injection, eye discharge, gritty or uncomfortable feeling, no vision loss (see Chapter 16, Conjunctivitis).
- Acute-angle closure glaucoma—Cloudy cornea and scleral injection; eye pain with ipsilateral headache; severe vision loss (see Chapter 19, Glaucoma).

FIGURE 17-4 Episcleritis showing inflammation of the conjunctival and episcleral tissue with associated vascular engorgement. A sector of this eye is involved and that is typical. Vessels were blanched with 2.5% phenylephrine, which helped distinguish this from scleritis. (*Courtesy of Paul D. Comeau.*)

FIGURE 17-5 Episcleritis showing inflammation of only the conjunctival and episcleral tissue. Note the absence of violaceous color that is seen in scleritis. (*Courtesy of Richard P. Usatine, MD.*)

MANAGEMENT

For patients presenting with scleritis who do not have a previously diagnosed associated systemic condition, a search for an underlying cause is indicated.

- Evaluate for signs and symptoms of rheumatoid arthritis, Wegener's granulomatosis (respiratory or renal symptoms), relapsing polychondritis (vasculitis around ear or nose cartilage or trachea), and seronegative spondyloarthropathies (inflammatory back pain, arthritis, and inflammatory bowel symptoms).
- Evaluate for signs, symptoms, and risk factors for infection including eye trauma, recent ocular surgery, recurrent herpes simplex or varicella zoster, or risk factors for tuberculosis.
- Evaluate for signs and symptoms of gout and sarcoidosis.

MEDICATIONS

- Scleritis is initially treated with systemic NSAIDs and/or topical steroids; however, in one study only 47% of patients responded to 2 drops of 1% prednisolone every 2 hours for up to 2 weeks.[3] SOR B
- Scleritis that does not respond to NSAIDs and/or topical steroids; may need systemic steroids, subconjunctival steroids, or immune modulators. SOR C
- Episcleritis often resolves spontaneously. Eye redness and irritation improve by 50% in less than a week. Treatment with topical NSAIDs was no better than artificial tears on measures of redness and comfort.[4] SOR B

REFERRAL

- If you suspect scleritis, refer the patient to an ophthalmologist immediately. This is especially important if there is any visual loss or eye pain.
- If episcleritis is not resolved, refer to an ophthalmologist.

PROGNOSIS

Simple episcleritis improves in 7 to 10 days. Episcleritis that is nodular or associated with an underlying disease may take 2 to 3 weeks to resolve.

Patients who smoke may take longer to recover from episcleritis or scleritis. One retrospective trial demonstrated that patients who smoked and had episcleritis or scleritis were 5.4 times more likely to have a delayed response of more than 4 weeks to any medication (95% CI = 1.9 to 15.5).[5]

Vision loss with scleritis is common and the risk is dependent on the type of scleritis: diffuse anterior, 9%; nodular, 26%; necrotizing, 74%; posterior, 84%.[6]

FOLLOW-UP

- Advise patients with episcleritis to return for any increases in eye pain, changes in vision, or no improvement in 1 week.
- Advise patients with scleritis to follow-up testing for underlying systemic illnesses. If none is found, consider retesting as patients with idiopathic scleritis develop a systemic illness at a 4% annual rate.[2]

PATIENT EDUCATION

- Reassure patients with episcleritis of its generally benign nature and that oral NSAIDs may be used for discomfort.
- Advise patients with scleritis of its association with systemic illnesses and the need for further work-up.

PATIENT RESOURCES

- Scleritis—**http://www.ncbi.nlm.nih.gov/pubmedhealth/PMH0001998/**.
- Episcleritis—**http://www.ncbi.nlm.nih.gov/pubmedhealth/PMH0002014/**.

PROVIDER RESOURCES

- **http://www.patient.co.uk/doctor/Scleritis-and-Episcleritis.htm**.

REFERENCES

1. Galor A, Thorne JE. Scleritis and peripheral ulcerative keratitis. *Rheum Dis Clin North Am*. 2007;33(4):835-854.
2. Akpek EK, Thorne JE, Qazi FA, et al. Evaluation of patients with scleritis for systemic disease. *Ophthalmology*. 2004;111(3):501-506.
3. McMullen M, Kovarik G, Hodge WG. Use of topical steroid therapy in the management of nonnecrotizing anterior scleritis. *Can J Ophthalmol*. 1999;34(4):217-221.
4. Williams CP, Browning AC, Sleep TJ, et al. A randomised, double-blind trial of topical ketorolac vs artificial tears for the treatment of episcleritis. *Eye (Lond)*. 2005;19(7):739-742.
5. Boonman ZF, de Keizer RJ, Watson PG. Smoking delays the response to treatment in episcleritis and scleritis. *Eye (Lond)*. 2005;19(9):945-955.
6. Tuft SJ, Watson PG. Progression of sclera disease. *Ophthalmology*. 1991;98(4):467-471.

18 UVEITIS AND IRITIS

Heidi Chumley, MD

PATIENT STORY

A 28-year-old man presented with sudden onset of a right red eye, severe eye pain, tearing, photophobia, and decreased vision. He denied eye trauma. His review of systems was positive for lower back pain and stiffness over the past year. On examination, he had a ciliary flush (**Figure 18-1**) and decreased vision. He was referred to an ophthalmologist who confirmed the diagnosis of acute anterior uveitis. He was found to be HLA-B27 positive with characteristics of ankylosing spondylitis. His uveitis was treated with topical steroids.

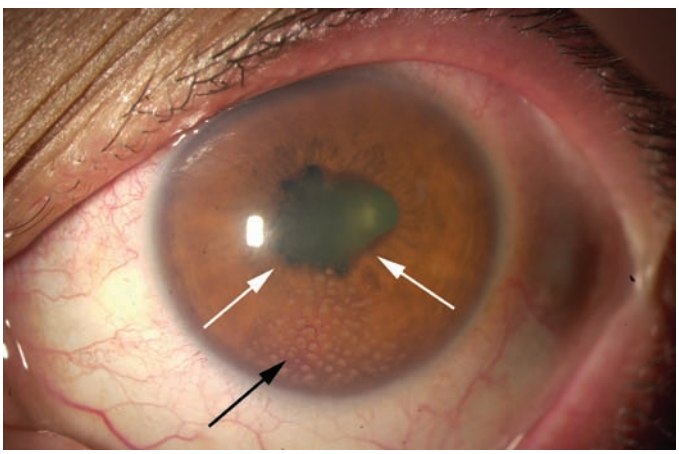

FIGURE 18-1 Acute anterior uveitis with corneal endothelial white cell aggregates (*black arrow*) and posterior synechiae formation (iris adhesions to the lens, *white arrows*). (*Courtesy of Paul D. Comeau.*)

INTRODUCTION

Uveitis is inflammation of any component of the uveal tract: iris (anterior), ciliary body (intermediate), or choroid (posterior). Most uveitis is anterior and is also called iritis. Uveitis is caused by trauma, inflammation, or infection and the most common etiologies vary by location in the uveal tract. Patients present with vision changes and, if uveitis is anterior, eye pain, redness, tearing, and photophobia. All patients with uveitis should be referred to an ophthalmologist.

SYNONYMS

Anterior uveitis includes iritis and iridocyclitis. *Iritis* is when the inflammation is limited to the iris. If the ciliary body is involved too, then it is called *iridocyclitis*. Posterior uveitis includes choroiditis and chorioretinitis.

EPIDEMIOLOGY

- Annual incidence of uveitis is 17 to 52 per 100,000 population and prevalence is 38 to 714 per 100,000 population.[1]
- Occurs at any age, but most commonly between 20 and 59 years.[1]
- Anterior uveitis (iritis) accounts for approximately 90% of uveitis as seen in primary care settings.[1]
- Eighty percent of uveitis cases seen in children are caused by juvenile rheumatoid arthritis.[2]
- In the United States, noninfectious uveitis accounts for 10% of legal blindness.[3]

ETIOLOGY AND PATHOPHYSIOLOGY

- Uveitis can be caused by trauma, infections, inflammation, or, rarely, neoplasms. Most likely causes differ by location.[4]
- Iritis—Trauma is common (**Figure 18-2**). In nontraumatic cases, causes include idiopathic (50%); seronegative spondyloarthropathies, that is, ankylosing spondylitis, reactive arthritis, psoriatic

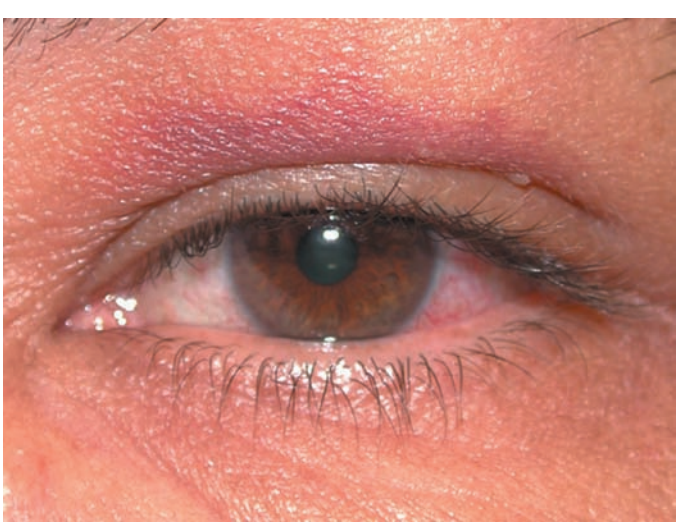

FIGURE 18-2 A young man with traumatic iritis (anterior uveitis) after being hit in the eye with a baseball. He has photophobia and eye pain. (*Courtesy of Richard P. Usatine, MD.*)

arthritis, inflammatory bowel disease (20%); and juvenile idiopathic arthritis (10%). Infections are less common and include herpes, syphilis, and tuberculosis.[4]

- Intermediate—Most are idiopathic[4] (**Figure 18-3**).
- Posterior—Toxoplasmosis is the most common, followed by idiopathic.[4]
- Panuveitis (affecting all layers)—Idiopathic (22% to 45%) and sarcoidosis (14% to 28%).[4] Unilateral panuveitis is often endophthalmitis (endogenous or related to trauma or surgery). Bilateral panuveitis can be caused by sarcoidosis or syphilis.

RISK FACTORS

Patients with Behçet disease and ankylosing spondylitis have uveitis more commonly than the general population (relative risk of 4 to 20) because of human leukocyte antigen (HLA) associations.[5]

DIAGNOSIS

CLINICAL FEATURES

Anterior acute uveitis presents with:

- Usually unilateral eye pain, redness, tearing, photophobia, and decreased vision.
- 360-Degree perilimbal injection, which is most intense at the limbus (see **Figures 18-1,** 18-**2**, and 18-**4**).
- History of eye trauma, an associated systemic disease, or risk factors for infection.
- Severe anterior uveitis may cause a hypopyon from layering of leukocytes and fibrous debris in the anterior chamber (**Figure 18-4**). Behçet syndrome and HLA-B27 disease are the only two common noninfectious causes of hypopyon.

Intermediate and posterior uveitis:

- Presents with altered vision or floaters.
- Often there is no pain, redness, tearing, or photophobia.

Sarcoid uveitis presents with:

- Panuveitis (anterior, intermediate, and posterior).
- Gradual and usually a bilateral onset.
- Few vision complaints unless cataracts or glaucoma develops.
- Characteristic findings on slit-lamp examination (i.e., mutton-fat keratic precipitates, posterior iris synechiae).[6]

Typical distribution

- Anterior uveitis is typically unilateral and sarcoid uveitis is typically bilateral.

DIFFERENTIAL DIAGNOSIS

Causes of red eye, other than uveitis:

- Scleritis—Segmental or diffuse inflammation of sclera (dark red, purple, or blue color); severe, boring eye pain often radiating to

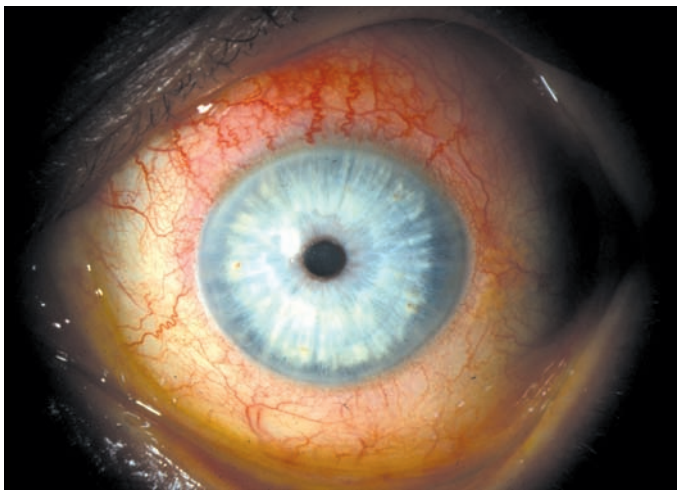

FIGURE 18-3 Idiopathic intermediate uveitis. The ciliary flush is perilimbal injection from dilation of blood vessels adjacent to the cornea, extending 3 mm into the sclera. Perilimbal injection may appear as a violet hue around the limbus with blurring of individual vessels. (*Courtesy of Paul D. Comeau.*)

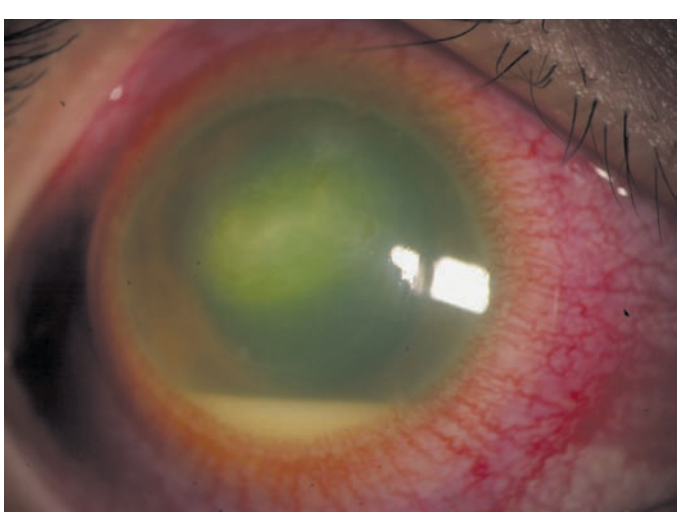

FIGURE 18-4 Hypopyon with severe anterior uveitis, showing layering of leukocytes and fibrinous debris in the anterior chamber. May be sterile or infectious. An intense ciliary flush is seen. Most commonly seen in HLA-B27-positive patients with uveitis. Hypopyon may also be a presenting sign of malignancy (retinoblastoma and lymphoma). (*Courtesy of Paul D. Comeau.*)

head and neck; and photophobia and vision loss (see Chapter 17, Scleritis and Episcleritis).

- Episcleritis—Segmental or diffuse inflammation of episclera (pink color), mild or no discomfort but can be tender to palpation, and no vision disturbance (see Chapter 17, Scleritis and Episcleritis).
- Keratitis or corneal ulcerations—Diffuse erythema with ciliary injection often with constricted pupil; eye discharge; and pain, photophobia, and vision loss depending on the location of ulceration. Frequently associated with trauma, a history of herpes simplex virus (HSV) infection, or contact lens wear. Needs urgent evaluation by an ophthalmologist. There will be staining of the cornea with fluorescein.
- Conjunctivitis—Conjunctival injection, eye discharge, gritty or uncomfortable feeling, and no vision loss (see Chapter 16, Conjunctivitis). Recent history of red eye contacts or URI symptoms.
- Acute-angle closure glaucoma—Cloudy cornea and scleral injection, eye pain with ipsilateral headache, and severe vision loss (see Chapter 19, Glaucoma). May be a family history of same.

MANAGEMENT

Refer patients for any red eye along with loss of vision to an ophthalmologist. Patients with uveitis warrant additional examinations by the ophthalmologist.

- Traumatic uveitis—Dilated funduscopy for other ocular trauma, measurement of intraocular pressure, gonioscopy to evaluate for angle recession and risk for future glaucoma, and treatment may include steroid and/or cycloplegics for comfort.
- Nontraumatic uveitis—Slit-lamp examination and laboratory tests to assist with diagnosis of underlying cause; treatment is based on underlying cause but is usually topical steroid drops with or without cycloplegia.
- Therapeutic dilation is used to break the posterior synechiae that can occur (**Figure 18-5**).

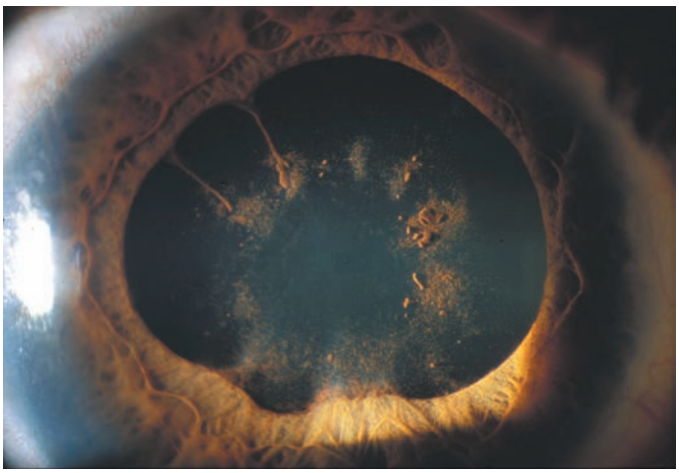

FIGURE 18-5 This patient with uveitis had posterior synechiae that are attachments of the iris to the anterior capsule of the lens. Therapeutic dilation broke the synechiae, but left residual pigment on the anterior capsule. (*Courtesy of Paul D. Comeau.*)

PROGNOSIS

Uveitis causes vision loss, cataract, and often glaucoma if treatment is delayed or not provided. HLA-B27 disease is the most common etiology for anterior uveitis, and is associated with recurrent, bilateral anterior uveitis.

FOLLOW-UP

Appropriate follow-up is based on the underlying cause.

PATIENT EDUCATION

- See a physician immediately for a red eye with loss of vision.
- A series of tests may be performed to determine the cause of the uveitis; however, the underlying cause is often elusive.

PATIENT RESOURCES

- **http://www.ncbi.nlm.nih.gov/pubmedhealth/PMH0002000/**.

PROVIDER RESOURCES

- **http://emedicine.medscape.com/article/798323**.

REFERENCES

1. Wakefield D, Chang JH. Epidemiology of uveitis. *Int Ophthalmol Clin.* 2005;45(2):1-13.
2. Foster CS. Diagnosis and treatment of juvenile idiopathic arthritis-associated uveitis. *Curr Opin Ophthalmol.* 2003;14(6):395-398.
3. Gritz DC, Wong IG. Incidence and prevalence of uveitis in northern California; the Northern California Epidemiology of Uveitis Study. *Ophthalmology.* 2004;111(3):491-500.
4. Brazis PW, Stewart M, Lee AG. The uveo-meningeal syndromes. *Neurologist.* 2004;10(4):171-184.
5. Capsi RR. A look at autoimmunity and inflammation in the eye. *J Clin Invest.* 2010;120(9):3073-3083.
6. Uyama M. Uveitis in sarcoidosis. *Int Ophthalmol Clin.* 2002;42(1):143-150.

19 GLAUCOMA

Heidi Chumley, MD

PATIENT STORY

A 50-year-old black man was noted to have a large cup-to-disc ratio during a funduscopic examination by his primary care provider (**Figure 19-1**). The patient reported no visual complaints. Further evaluation revealed elevated intraocular pressure and early visual field defects. He was started on medication to lower his intraocular pressure. He remained asymptomatic, and his visual field defects did not progress for the next several years.

FIGURE 19-1 A 50-year-old man with glaucoma has an increased optic cup-to-disc ratio of 0.8. Median cup-to-disc ratio is 0.2 to 0.3, but varies considerably among individuals. (*Courtesy of Paul D. Comeau.*)

INTRODUCTION

Glaucoma is a leading cause of blindness in the United States and globally. Open-angle glaucoma is an acquired loss of retinal ganglion cells characterized by either normal or increased intraocular pressure, a large cup-to-disc ratio, and visual field defects. Open-angle glaucoma is treated by reducing intraocular pressure, most commonly with eye drops. Angle-closure glaucoma, which is much less common, is an acute increase in intraocular pressure from a mechanical obstruction that must be treated emergently to preserve vision.

EPIDEMIOLOGY

- Approximately 2.5 million persons in the United States have glaucoma.
- Glaucoma is the second leading cause of blindness in the United States and the leading cause of blindness among African Americans.[1]
- Population studies predict there will be 60.5 million people worldwide with glaucoma by 2010, and of these, 74% will have open-angle glaucoma.[2]
- Women comprise approximately 60% of all glaucoma cases, but 70% of patients with acute angle-closure glaucoma.[2]
- Asians comprise approximately 47% of all glaucoma cases, but 87% of acute angle-closure glaucoma.[2]
- The incidence of primary open-angle glaucoma was 8.3 per 100,000 population in people older than 40 years in a Minnesota population study.[3]
- According to a population-based study, a family history of glaucoma increased the risk of having glaucoma (odds ratio [OR] = 3.08).[4]

ETIOLOGY AND PATHOPHYSIOLOGY

- Glaucoma pathophysiology is incompletely understood, but the end point is the acquired loss of retinal ganglion cells and axons with resulting irreversible vision loss.

- Increased intraocular pressure (IOP) is a well known risk factor; however, recent attention has turned to ocular perfusion pressure (OPP), the difference between blood pressure (BP) and IOP. OPP is essentially BP minus IOP. As such, OPP is decreased by either high IOP or low BP.[5] If a patient with apparently well-controlled IOP continues to have progressive visual field loss, it may be because of lack of perfusion of the optic nerve from aggressively lowered diastolic BPs. Therefore the management of glaucoma requires attention to diastolic BP.
- Glaucoma is categorized as either:
  - Open-angle—Dysfunction of the aqueous humor drainage system with no visible pathology to the anterior chamber angle.
  - Angle-closure—Occlusion of the anterior chamber angle.
- Impaired outflow of aqueous humor elevates IOP in some patients, but many patients with open-angle glaucoma have normal IOPs.
- Optic nerve atrophy is seen as optic disc cupping and irreversible visual field loss. Compare **Figures 19-1** and **19-2** to see the difference between abnormal (**Figure 19-1**) and normal (**Figure 19-2**) optic disc cupping.

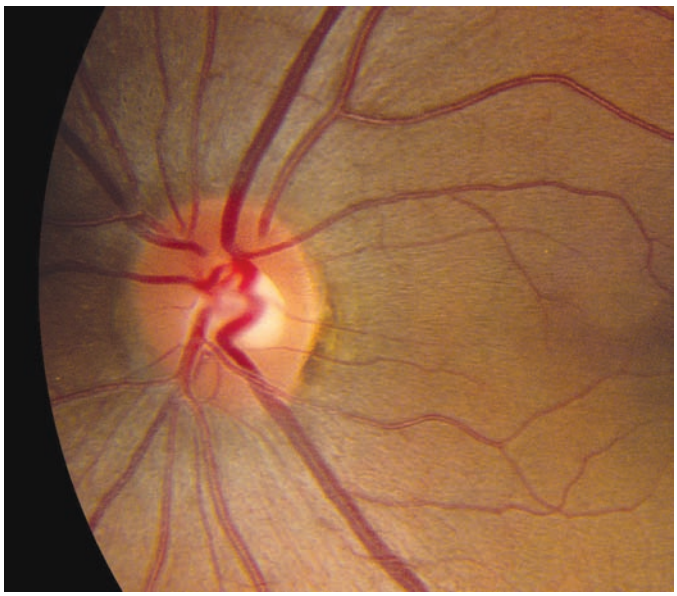

FIGURE 19-2 Normal eye with a normal cup-to-disc ratio of 0.4. A cup-to-disc ratio of more than 0.5 requires further evaluation. (*Courtesy of Paul D. Comeau.*)

RISK FACTORS

Open-angle risk factors include:

- Nonmodifiable: age older than 50 years, first-degree family history, and African ancestry.[6]
- Modifiable: high IOP, high or low BP, and maybe diabetes mellitus.[6]

Acute closed-angle glaucoma is more common in persons of Asian descent.

DIAGNOSIS

CLINICAL FEATURES

- Open-angle glaucoma:
  - History—Usually asymptomatic, occasionally "tunnel vision."
  - Physical examination—Optic cupping and/or elevated IOP (glaucomatous changes can occur with IOPs in the normal range), loss of peripheral vision by automated perimetry (typically bilateral, but may be asymmetric).
- Acute closed-angle glaucoma:
  - History—Painful red eye (unilateral), vision loss, headache, nausea, halos around lights, and vomiting (**Figure 19-3**).
  - Physical examination—Shallow anterior chamber, optic cupping and elevated IOP, injection of the conjunctiva, and cloudy cornea (**Figure 19-3**).
- Typical distribution
  - Open-angle glaucoma is typically bilateral.
  - Closed-angle glaucoma is typically unilateral. However, there is risk for the other eye to undergo the same process, as the abnormal anatomically narrow angle is usually present in the other eye too.

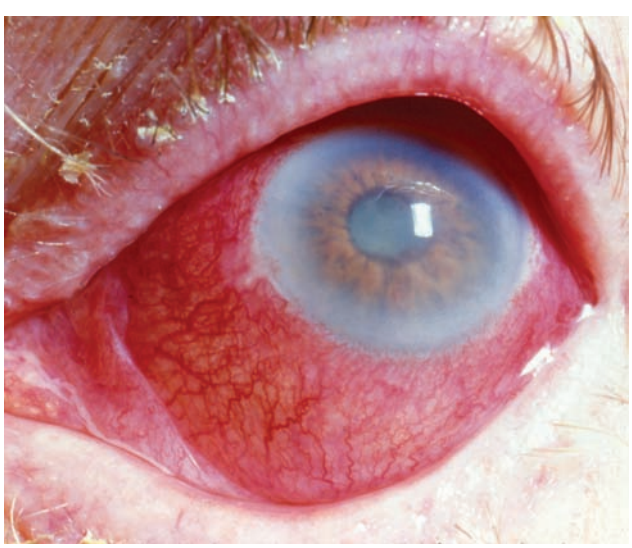

FIGURE 19-3 Acute closed-angle glaucoma with a painful red eye, vision loss, headache, nausea, and vomiting. This is a phacomorphic (i.e., lens induced) secondary acute angle closure. The mature cataract increased in anteroposterior (AP) diameter thus moving the lens-iris diaphragm forward and closing off the angle as well as the pupil thus resulting in high intraocular pressure, injected conjunctiva, and a cloudy cornea. (Used with permission from *The American Academy of Ophthalmology.*)

DIFFERENTIAL DIAGNOSIS

Glaucoma is the most common cause of optic disc cupping and is sometimes accompanied by elevated IOP.

- Optic disc cupping without elevated IOP can be caused by:[7]
  - Physiologic cupping (**Figure 19-2**).
  - Congenital optic-disc anomalies (i.e., coloboma or tilted discs).
  - Ischemic (i.e., compression by tumors), traumatic (closed-head injury), or hereditary optic neuropathies.
- Glaucomatous optic disc cupping compared to other causes has:[7]
  - Larger cup-to-disc ratios (compare **Figure 19-1** to **Figure 19-2**).
  - Vertical (as opposed to horizontal) elongation of the cup.
  - Disc hemorrhages.

MANAGEMENT

- Treat with topical agents to decrease IOP by 20% to 40%, which has been demonstrated to decrease glaucoma progression.[8] SOR A
  Many medications are available including:
  - Nonspecific β-blockers (e.g., timolol 0.5%, once or twice a day).
  - Prostaglandin analogs (e.g., latanoprost 0.005%, once a day).
  - Carbonic anhydrase inhibitors (e.g., dorzolamide 2%, 2 to 3 times a day).
  - α-Agonists (e.g., brimonidine 1.0%, 2 to 3 times a day).

REFERRAL

- Emergently refer patients with suspected angle-closure glaucoma to an ophthalmologist (see **Figure 19-3**).
- Evaluate (or refer for evaluation) patients with abnormal optic nerve cupping (cup-to-disc ratio of greater than 0.5; difference in cup-to-disc ratio of 0.2 or greater between eyes; asymmetric cup), or increased IOP measured by tonometry, or visual field deficits.
- Document the location and extent of visual field deficits with automated perimetry.
- Refer patients with shallow anterior chambers, severe far-sightedness (hyperopia) or previous history of acute angle closure glaucoma to an ophthalmologist.
- Refer for surgical evaluation if you are unable to medically reduce the IOP.

PREVENTION

- Screening—According to the U.S. Preventive Services Task Force update in 2005 (**http://www.ahrq.gov/clinic/uspstf/uspsglau.htm**), there is insufficient evidence to recommend for or against population screening for open-angle glaucoma. However, African Americans have been underrepresented in trials. Previously screening has been recommended for African Americans older than age 40 years, whites older than age 65 years, and patients with a family history of glaucoma.[1] SOR C

PROGNOSIS

Most patients with open-angle glaucoma, provided they are treated, will not lose vision.

Angle-closure glaucoma must be treated emergently to prevent vision loss.

FOLLOW-UP

Patients with glaucoma should have regular measurements of their IOP and visual fields to follow treatment efficacy.

PATIENT EDUCATION

Advise patients that glaucoma is a progressive disease requiring continued therapy to prevent vision loss.

PATIENT RESOURCES

- Glaucoma research foundation Web site has information on treatment, research progress, personal stories, and practical tips at **www.glaucoma.org.**
- **http://www.ncbi.nlm.nih.gov/pubmedhealth/PMH0002587/**.

PROVIDER RESOURCES

- Acute angle-closure glaucoma—**http://emedicine.medscape.com/article/798811**.
- Primary open-angle glaucoma—**http://emedicine.medscape.com/article/1206147**.

REFERENCES

1. Distelhorst JS, Hughes GM. Open-angle glaucoma. *Am Fam Physician.* 2003;67(9):1937-1944.
2. Quigley HA, Broman AT. The number of people with glaucoma worldwide in 2010 and 2020. *Br J Ophthalmol.* 2006;90(3):262-267.
3. Erie JC, Hodge DO, Gray DT. The incidence of primary angle-closure glaucoma in Olmsted County, Minnesota. *Arch Ophthalmol.* 1997;115(2):177-181.
4. Leske MC, Warheit-Roberts L, Wu SY. Open-angle glaucoma and ocular hypertension: the Long Island Glaucoma Case-control Study. *Ophthalmic Epidemiol.* 1996;3(2):85-96.
5. He Z, Vingrys AJ, Armitage JA, Bui BV. The role of blood pressure in glaucoma. *Clin Exp Optom.* 2011;94(2):133-149.
6. Leske MC, Wu SY, Hennis A, et al. Risk factors for incident open-angle glaucoma: the Barbados Eye Studies. *Ophthalmology.* 2008;115:85-93.
7. Piette SD, Sergott RC. Pathological optic-disc cupping. *Curr Opin Ophthalmol.* 2006;17(1):1-6.
8. Heijl A, Leske MC, Bengtsson B, et al. Reduction of intraocular pressure and glaucoma progression: results from the Early Manifest Glaucoma Trial. *Arch Ophthalmol.* 2002;120(10):1268-1279.

20 DIABETIC RETINOPATHY

Heidi Chumley, MD
Kelly Green, MD

PATIENT STORY

A 38-year-old man saw a physician for the first time in 10 years after noticing visual loss in his left eye. His history revealed many risk factors for and symptoms of diabetes mellitus (DM). On an undilated funduscopic examination, his physician was able to see some hemorrhages and hard exudates. A fingerstick in the office showed a blood glucose level of 420 mg/dL. He was treated for DM and referred to an ophthalmologist to be evaluated for his diabetic retinopathy (**Figure 20-1**).

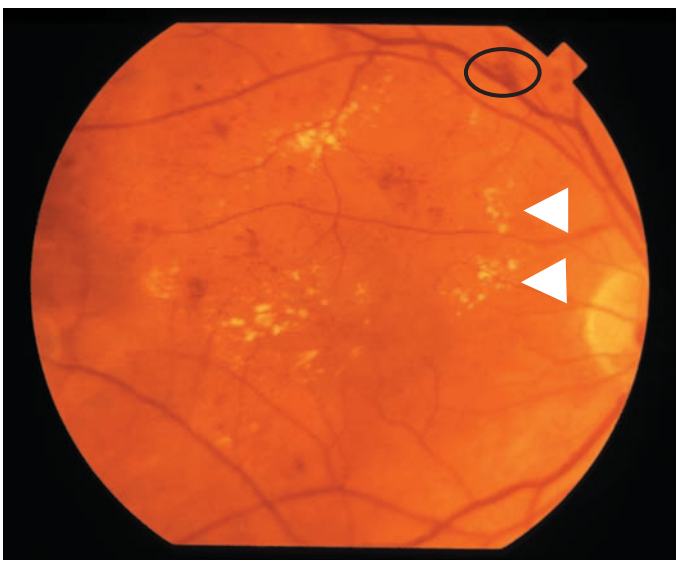

FIGURE 20-1 Dilated funduscopic photograph demonstrating microaneurysms (small red swellings attached to vessels), which are often the first change in diabetic retinopathy. Also present are flame hemorrhages (*black oval*) hemorrhages and hard exudates (*yellow*). Some of the hard exudates are demonstrated with white arrowheads. This case is an example of diabetic nonproliferative retinopathy. (*Courtesy of Paul D. Comeau.*)

INTRODUCTION

Diabetic retinopathy (DR) is a leading cause of blindness in the United States. Nonproliferative DR is characterized by microaneurysms, macular edema, cotton-wool spots, superficial (flame) or deep (dot-blot) hemorrhages, and exudates. Proliferative DR also has neovascularization of the retina, optic nerve head, or iris. Because patients may be asymptomatic until vision loss occurs, screening is indicated in all diabetic patients. Excellent glycemic control lowers a patient's risk of developing DR.

EPIDEMIOLOGY

- In developed nations, DR is the leading cause of blindness among people younger than age 40 years.[1]
- In a community-based study, 29% of adults older than age 40 years with DM had DR. Prevalence in black patients was higher than in white patients (38.8% vs. 26.4%).[2]
- Twenty-one percent of patients have retinopathy at the time type 2 diabetes is diagnosed.[3]
- More than 60% of patients with type 2 DM have retinopathy within 20 years of diagnosis.[3]
- After 40 years of type 1 DM, 84% of patients have retinopathy.[4]

ETIOLOGY AND PATHOPHYSIOLOGY

- Hyperglycemia results in microvascular complications including retinopathy.
- Several biochemical pathways linking hyperglycemia and retinopathy have been proposed.[3]
- In nonproliferative retinopathy, microaneurysms weaken vessel walls. Vessels then leak fluid, lipids, and blood resulting in macular edema, exudates, and hemorrhages (**Figures 20-1** and **20-2**).
- Cotton-wool spots result when small vessel occlusion causes focal ischemia to the superficial nerve fiber layer of the retina.

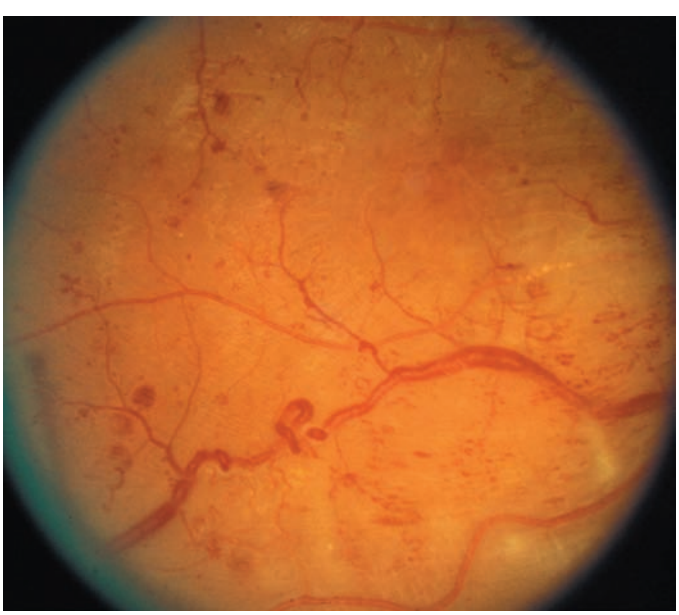

FIGURE 20-2 Very severe nonproliferative diabetic retinopathy with multiple deep dot-blot hemorrhages, venous beading, and looping. This patient may benefit from panretinal photocoagulation. (*Courtesy of Paul D. Comeau.*)

- In proliferative retinopathy, new blood vessels form in response to ischemia (**Figure 20-3**).

RISK FACTORS

- In type 1 DM, identified risk factors include: longer diabetes duration, high hemoglobin (Hgb) A_{1c}, hypertension, smoking, and male gender.[4,5]
- In type 2 DM, identified risk factors include: longer diabetes duration, high $HgbA_{1c}$, elevated systolic blood pressure, male gender, presence of albuminuria, and pharmacologic therapy.[6]

DIAGNOSIS

Definitive diagnosis is made by an eye specialist:

- Gold standard is grading of stereoscopic color fundus photographs in seven standard fields.[3]
- In comparison with the gold standard, a single monochromatic digital photo through a nondilated eye is sufficient to determine the presence or absence of DR with a sensitivity and specificity of 71% and 96%, respectivey.[7] SOR B

CLINICAL FEATURES

- Central vision loss as a result of macular edema or macular ischemia.
- Nonproliferative retinopathy—Microaneurysms are seen initially (mild), followed by macular edema, cotton-wool spots, superficial (flame) or deep (dot-blot) hemorrhages, and exudates (**Figure 20-1** shows moderate, and **Figure 20-2** shows severe).
- Proliferative retinopathy—Neovascularization, that is, growth of new blood vessels on the optic disc (**Figure 20-3**), the retina, or iris.

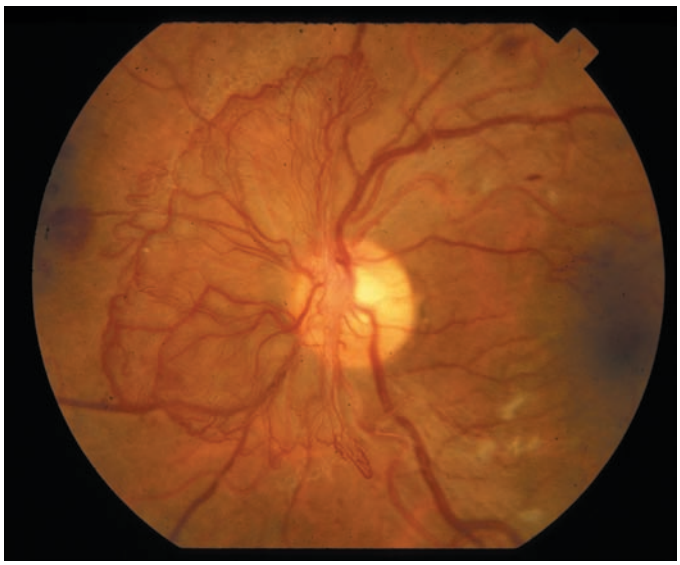

FIGURE 20-3 Proliferative diabetic retinopathy showing newly developed, porous, friable blood vessels. New vessels can be seen on the optic disc and peripheral retina. Panretinal photocoagulation may help prevent vitreous hemorrhage, retinal detachment, and neovascular glaucoma. (*Courtesy of Paul D. Comeau.*)

DIFFERENTIAL DIAGNOSIS

Retinopathy is also seen with other systemic illnesses and infections including:

- Hypertensive retinopathy—Arterial narrowing or atrioventricular nicking in addition to cotton-wool spots (see Chapter 21, Hypertensive Retinopathy).
- HIV retinopathy—Cotton-wool spots and infections such as *Cytomegalovirus*.

MANAGEMENT

Control diabetes and vascular risk factors:

- Glycemic control lowers the risk of retinopathy (35% risk reduction per 1 point $HgbA_{1C}$ reduction).[3] SOR A
- Blood pressure control improves visual outcomes (34% risk reduction in retinopathy progression; 47% risk reduction for declines in visual acuity).[3] SOR A

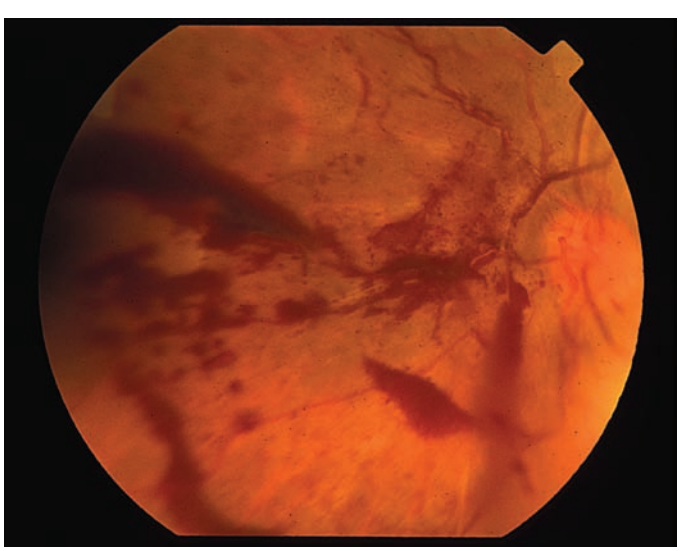

FIGURE 20-4 This vitreous hemorrhage occurred when friable neovascular membranes broke spontaneously. The patient described a "shower of red dots" obscuring the vision and then loss of vision in that eye. (*Courtesy of Paul D. Comeau.*)

- Treatment with angiotensin-converting enzyme inhibitors (ACEIs) or angiotensin receptor blockers (ARBs) in type 1 DM or an ARB in type 2 DM have been shown to reduce retinopathy progression independent of blood pressure control.[8,9] SOR B
- Patients with high lipids have more hard exudates and a higher risk of vision loss, but it is unclear if lipid control changes outcomes. SOR C

REFERRAL

Work with an ophthalmologist to prevent vision loss:

- Complications of DR are vitreous hemorrhage (**Figure 20-4**), retinal detachment, and neovascular glaucoma. Each of these complications can result in devastating vision loss.
- Ophthalmologists will determine when peripheral retinal photocoagulation is indicated (**Figure 20-5**). Photocoagulation reduces the risk of severe visual loss by more than 50% with side effects of peripheral and night vision loss.[14] SOR A Other surgical treatments, including vitrectomy, have been less successful.[3]

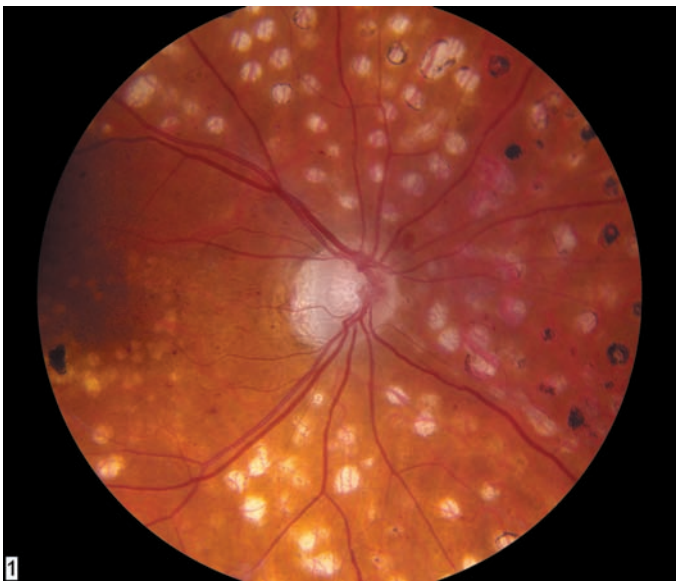

FIGURE 20-5 Panretinal photocoagulation is the application of laser burns to the peripheral retina. The ischemic peripheral retina is treated with thousands of laser spots to presumably eliminate vasogenic factors responsible for the development of neovascular vessels. Laser spots cause scarring of the retina and choroid. The scars may be hypotrophic (*white spots*) or hypertrophic (*black spots*). (*Courtesy of Paul D. Comeau.*)

PREVENTION

Prevent DR by preventing development of type 2 DM or tightly controlling type 1 or type 2 DM.

Screen patients with DM for DR based on national recommendations:[10]

- Type 1 DM—Adults and children older than age 10 years: Screen for retinopathy 5 years after diagnosis and at regular intervals as recommended by an eye specialist.
- Type 2 DM—Screen for retinopathy at diagnosis and then annually.

Patients can be referred to an eye specialist, or screened using telemedicine or retinal photographs taken during outreach screenings or in primary care offices.[11,12]

Mathematical models are being developed to individualize screening frequency. In one study, screening intervals ranged from 6 to 60 months (mean: 29 months). This resulted in 59% fewer visits than with fixed annual screening without compromising safety.[13]

FOLLOW-UP

Once DR is diagnosed, frequency of examination is set by the ophthalmologist.

PATIENT EDUCATION

Preventing retinopathy by controlling diabetes and hypertension leads to better vision outcomes than any available treatment.[3,14]

PATIENT RESOURCES

- National Eye Institute—**http://www.nei.nih.gov/health/diabetic/**.

PROVIDER RESOURCES

- **http://emedicine.medscape.com/article/1225122.**

REFERENCES

1. Congdon NG, Friedman DS, Lietman T. Important causes of visual impairment in the world today. *JAMA.* 2003;290(15): 2057-2060.
2. Zhang X, Saaddine JB, Chou CF, et al. Prevalence of diabetic retinopathy in the United States, 2005–2008. *JAMA.* 2010; 304(6):649-656.
3. Fong DS, Aiello LP, Ferris FL III, Klein R. Diabetic retinopathy. *Diabetes Care.* 2004;27(10):2540-2553.
4. Hammes HP, Kerner W, Hofer S, et al. Diabetic retinopathy in type 1 diabetes—a contemporary analysis of 8,784 patients. *Diabetologia.* 2011;54(8):1977-1984.
5. Romero-Aroca P, Baget-Bernaldiz M, Fernandez-Ballart J, et al. Ten-year incidence of diabetic retinopathy and macular edema. Risk factors in a sample of type 1 diabetes patients. *Diabetes Res Clin Pract.* 2011;94(1):126-132.
6. Semeraro F, Parrinello G, Cancarini A, et al. Predicting the risk of diabetic retinopathy in type 2 diabetic patients. *J Diabetes Complications.* 2011;25(5):292-297.
7. Vujosevic S, Benetti E, Massignan F, et al. Screening for diabetic retinopathy: 1 and 3 nonmydriatic 45-degree digital fundus photographs vs 7 standard early treatment diabetic retinopathy study fields. *Am J Ophthalmol.* 2009;148(1):111-118.
8. Chaturvedi N, Sjolie AK, Stephenson JM, et al. Effect of lisinopril on progression of retinopathy in normotensive people with type 1 diabetes. EURODIAB Controlled Trial of Lisinopril in Insulin-Dependent Diabetes Mellitus. *Lancet.* 1998;351:28-31.
9. Sjolie AK, Klein R, Porta M, et al. Effect of candesartan on progression and regression of retinopathy in type 2 diabetes (DIRECT-Protect 2): a randomised placebo-controlled trial. *Lancet.* 2008;372:1385-1393.
10. American Diabetes Association. Standards of medical care in diabetes—2009. *Diabetes Care.* 2009;32(Suppl 1):S13-S61.
11. Sanchez CR, Silva PS, Cavallerano JD, et al. Ocular telemedicine for diabetic retinopathy and the Joslin Vision Network. *Semin Ophthalmol.* 2010;25(5–6):218-224.
12. Bragge P, Gruen RL, Chau M, et al. Screening for presence or absence of diabetic retinopathy: a meta-analysis. *Arch Ophthalmol.* 2011;129(4):435-444.
13. Aspelund T, Thornórisdóttir O, Olafsdottir E, et al. Individual risk assessment and information technology to optimise screening frequency for diabetic retinopathy. *Diabetologia.* 2011;54(10): 2525-2532.
14. Photocoagulation treatment of proliferative diabetic retinopathy: the second report of diabetic retinopathy study findings. *Ophthalmology.* 1978;85(1):82-106.

21 HYPERTENSIVE RETINOPATHY

Heidi Chumley, MD
Kelly Green, MD

PATIENT STORY

A 37-year-old man comes in for a physical examination and is noted to have a blood pressure of 198/142 mm Hg. He has no symptoms at the time. The physician performs a dilated funduscopic examination and notes optic disc edema, cotton wool spots, flame hemorrhages, dot-blot hemorrhages, arteriovenous nicking, and exudates (**Figure 21-1**). Fortunately, the remainder of the neurological exam and the EKG are normal. The patient is sent to the emergency room to be evaluated further and treated for a hypertensive emergency.

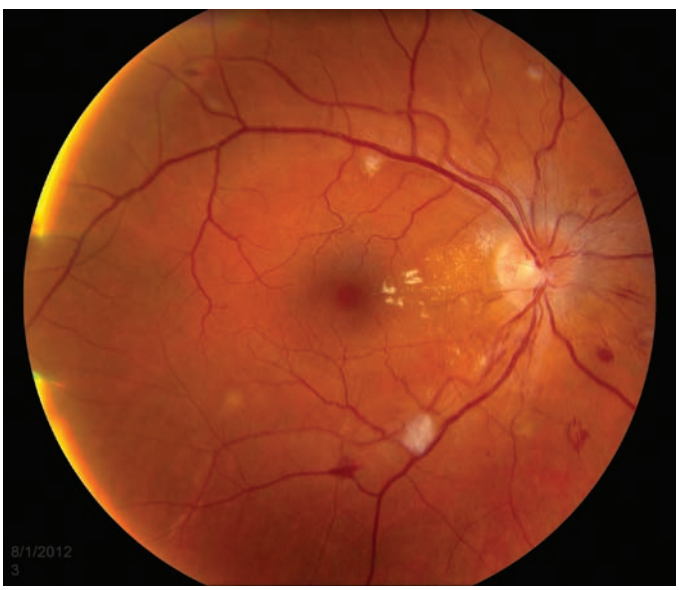

FIGURE 21-1 Hypertensive retinopathy with optic disc edema, cotton wool spots, flame hemorrhages, dot-blot hemorrhages, arteriovenous nicking, and exudates. (*Used with permission from EyeRounds.org and The University of Iowa.*)

INTRODUCTION

Hypertensive retinopathy (HR) develops from elevated blood pressure. HR is diagnosed clinically by the presence of classic retina findings seen on funduscopic examination or digital retinal photographs in a patient with hypertension. HR can result in vision loss. Treatment is control of blood pressure.

EPIDEMIOLOGY

- Prevalence of 7.7% (black) versus 4.1% (white) in a population study of men and women between 49 and 73 years of age without diabetes.[1]
- Multiple studies show that patients with moderate HR are 2 to 3 times more likely to have a stroke than those without HR at the same level of blood pressure control independent of other risk factors.[2]

ETIOLOGY AND PATHOPHYSIOLOGY

High blood pressure results in these retinal findings:[3]

- Retinal vessels become narrow and straighten at diastolic blood pressure (DBP) of 90 to 110 mm Hg.
- Arteriovenous "nicking" (white oval in **Figure 21-1**) occurs when the arteriolar wall enlarges from arteriosclerosis, compressing the vein. Patients with hypertension are at risk for central and branch retinal vein occlusions, which can result in significant vision loss.
- Microaneurysms and flame hemorrhages (**Figures 21-1** and **21-2**) result from the increased intravascular pressure. Cotton-wool spots (dashed arrow in **Figure 21-2**) represent ischemia of the nerve fiber layer. Hard exudates indicate vascular leakage (*white arrowheads* in Chapter 20, **Figure 20-1**).
- DBP 110 to 115 mm Hg causes leakage of plasma proteins and blood products resulting in retinal hemorrhages and hard exudates (**Figures 21-1** to **21-4**).

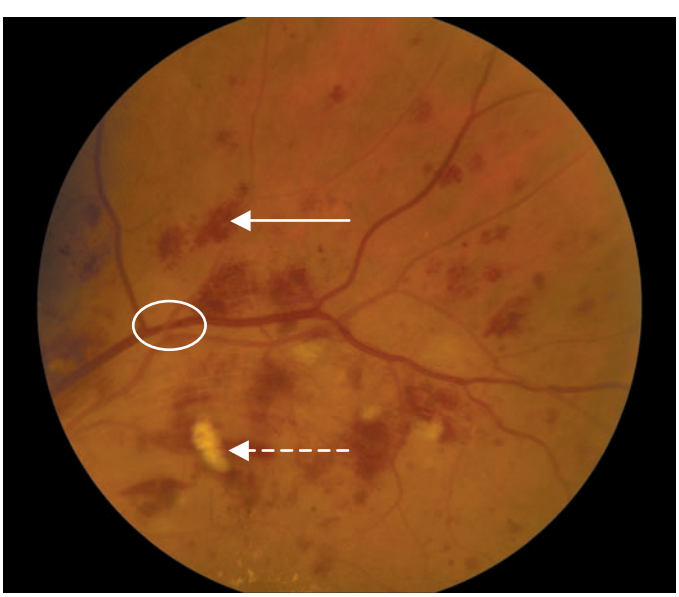

FIGURE 21-2 More advanced hypertensive retinopathy with flame hemorrhages (*white arrow*), arteriovenous nicking (*white oval*), and cotton-wool spots (*dashed arrow*). (*Courtesy of Paul D. Comeau.*)

- Optic nerve swelling occurs at DBP of 130 to 140 mm Hg (**Figure 21-3**).

DIAGNOSIS

The diagnosis is made clinically from typical retinal findings in a patient with hypertension. These findings can be seen using funduscopic examination or by viewing retinal digital images. Retinal digital images have a higher inter-observer reliability than funduscopic examination.[4]

CLINICAL FEATURES

In order of increasing severity:

- Mild arteriolar narrowing.
- Severe arteriolar narrowing plus arteriovenous nicking.
- Retinal hemorrhages, microaneurysms, hard exudation, cotton-wool spots.
- Swelling of the optic nerve head and macular star, also called accelerated or malignant HR.

TYPICAL DISTRIBUTION

- Bilateral and symmetrical

LABORATORY TESTING

- Laboratory tests are not needed to make the diagnosis.
- Recommended tests for patients with hypertension include urinalysis, blood glucose, hematocrit, serum potassium, creatinine, calcium, and a fasting lipid profile.
- 12-Lead ECG is also recommended.[5]

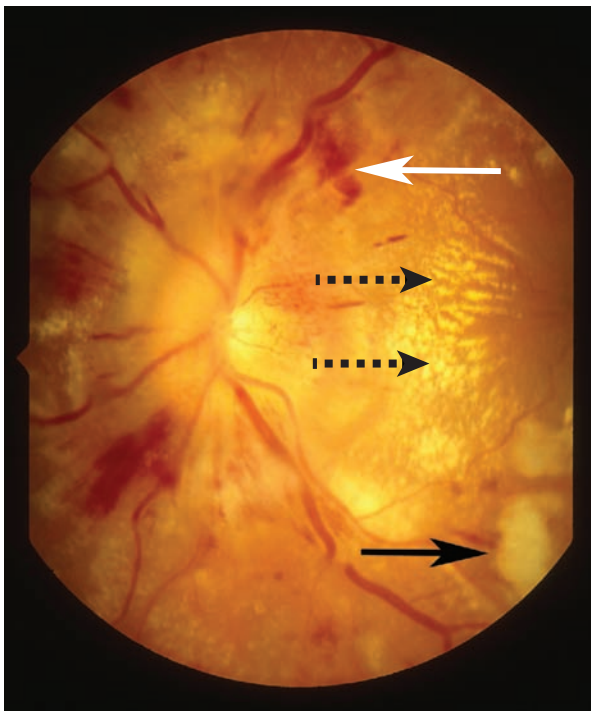

FIGURE 21-3 Malignant hypertensive retinopathy with optic nerve head edema (papilledema), flame hemorrhages (*white arrow*), cotton-wool spots (*black arrow*), and macular edema with exudates (*dashed arrows*). The patient was admitted to the hospital to treat malignant hypertension aggressively. (*Courtesy of Paul D. Comeau.*)

DIFFERENTIAL DIAGNOSIS

Retinal vessel narrowing, atrioventricular nicking, microaneurysms, retinal hemorrhages, hard exudates, and cotton-wool spots are also seen in other conditions that impair blood flow, including:

- Diabetic retinopathy (see Chapter 20, Diabetic Retinopathy).
- Radiation retinopathy.
- Venous or carotid artery occlusive disease.
- Systemic illnesses such as collagen vascular disease.
- Hematologic diseases such as anemia and leukemia.
- Systemic infectious diseases such as HIV.

Optic nerve swelling and a macular star (blurring of the macula in a star-like pattern) also occur in:

- Neuroretinitis.
- Diabetic papillopathy.
- Radiation optic retinopathy.
- Optic neuritis.
- Intracranial disease.

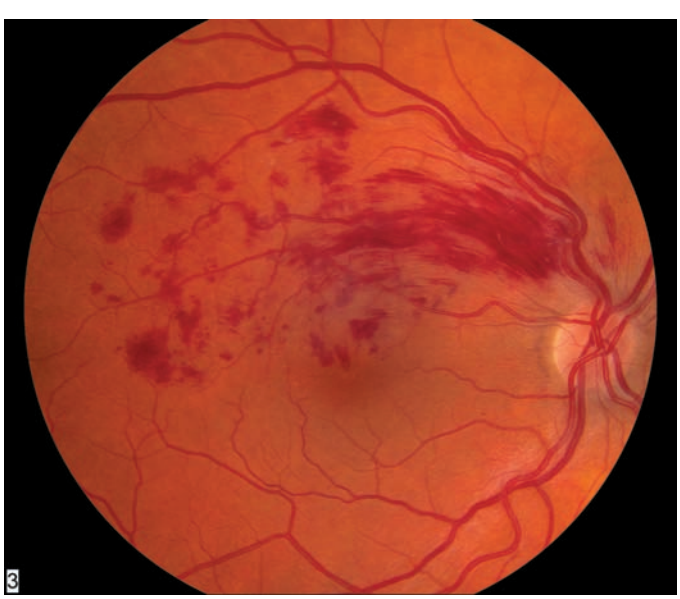

FIGURE 21-4 Branch retinal vein occlusion of a major retinal vein associated with hypertension. The patient noted new onset of blurred vision and visual field constriction. Flame hemorrhages are seen along the course of the obstructed vein. (*Courtesy of Paul D. Comeau.*)

MANAGEMENT

Patients with funduscopic findings of HR should have their blood pressure measured and treated to reduce the risk of heart and cerebrovascular disease.[5] SOR A

- Nonpharmacologic:
  - Assist patients in smoking cessation. This will result in the greatest benefit in morbidity and mortality.
  - Reduce weight or maintain normal body mass index (BMI).
  - Eat a diet rich in fruits and vegetables and low in saturated fats.
  - Reduce sodium to less than 6 g of sodium chloride per day.
  - Engage in regular physical activity for 30 minutes most days of the week.
  - Limit alcohol to 2 drinks per day in men and 1 drink per day in women.
- Medications
  - Start a thiazide diuretic to achieve blood pressure of less than 140/90 mm Hg unless contraindicated; a blood pressure goal of 130/80 mm Hg should be used for patients with diabetes. Consider an angiotensin-converting enzyme inhibitor (ACEI) as an initial medication for patients with diabetes. Consider other medications only for patients with compelling indications.
  - Although the largest benefit in outcomes is seen with the first medication, additional medications should be considered to achieve blood pressure less than 140/90 mm Hg after weighing the risks and benefits with the patient.
  - Evaluate and manage other risk factors for cardiovascular disease, including high cholesterol and diabetes.

REFERRAL

Patients experiencing acute visual disturbances should be referred for evaluation of hemorrhage or optic nerve edema (**Figures 21-3** and **21-4**).

PREVENTION

- Maintain normal blood pressure through a healthy lifestyle and medications when needed.
- Patients with hypertension alone do not require routine funduscopic examination, unless they also have diabetes mellitus.[6] SOR A
- Prevention is obtained by preventing and controlling high blood pressure.

PROGNOSIS

- Prognosis is associated with severity of hypertension retinopathy.
- Three-year survival in patients with mild arteriolar narrowing is 70% compared to 6% in patients with swelling of the optic nerve or macular star.[7]

FOLLOW-UP

Once diagnosed with hypertension, patients should be seen every month until blood pressure is controlled and then every 3 to 6 months.[4] SOR C

PATIENT EDUCATION

- HR does not require treatment other than lowering blood pressure unless acute vision changes occur.
- Control of blood pressure typically reverses HR findings, except for optic nerve edema, which may result in permanent vision loss.
- Control of blood pressure also reduces the risk of heart attack and stroke.

PATIENT RESOURCES

- **http://www.ncbi.nlm.nih.gov/pubmedhealth/PMH0001994/.**

PROVIDER RESOURCES

- **http://emedicine.medscape.com/article/1201779.**
- The Eighth Report of the Joint National Committee on Prevention, Detection, Evaluation, and Treatment of High Blood Pressure (JNC 8), 2012: **http://www.nhlbi.nih.gov/guidelines/hypertension/jnc8/index.htm**

REFERENCES

1. Wong TY, Klein R, Duncan BB, et al. Racial differences in the prevalence of hypertensive retinopathy. *Hypertension.* 2003;41(5):1086-1091.
2. Baker ML, Hand PJ, Wang JJ, Wong TY. Retinal signs and stroke: revisiting the link between the eye and brain. *Stroke.* 2008;39(4):1371-1379.
3. Luo BP, Brown GC. Update on the ocular manifestations of systemic arterial hypertension. *Curr Opin Ophthalmol.* 2004;15(3):203-210.
4. Castro AF, Silva-Turnes JC, Gonzalez F. Evaluation of retinal digital images by a general practitioner. *Telemed J E Health.* 2007;13(3):287-292.
5. NIH, NHLBI, and National High Blood Pressure Education Program. *The Seventh Report of the Joint National Committee on the Prevention, Detection, Evaluation, and Treatment of High Blood Pressure,* 2004. Washington, DC: U.S. Department of Health and Human Services, 2006.
6. van den Born BJ, Hulsman CA, Hoekstra JB, et al. Value of routine funduscopy in patients with hypertension: systematic review. *BMJ.* 2005;331(7508):73.
7. Keith NM, Wagener HP, Barker NW. Some different types of essential hypertension: their course and prognosis. *Am J Med Sci.* 1939;197:332-343.

22 PAPILLEDEMA

Heidi Chumley, MD

PATIENT STORY

A 29-year-old obese woman presented with chronic headaches that were worse in the morning or while lying down. She denied nausea or other neurologic symptoms. She had no other medical problems and took no medications. On examination, she had a visual acuity of 20/20 in both eyes, bilateral papilledema (**Figure 22-1**), no spontaneous venous pulsations (SVPs), and no other neurologic signs. She had a brain MRI showing no mass or hydrocephalus, and elevated intracranial pressure measured by lumbar puncture. She was diagnosed with idiopathic intracranial hypertension and was followed closely for any changes in her vision. She was started on acetazolamide and assisted with a weight-loss program. Her symptoms resolved over the course of 18 months.

FIGURE 22-1 Papilledema from increased intracranial pressure. The optic disc is elevated and hyperemic with engorged retinal veins. The entire optic disc margin is blurred. Optic neuropathies can also have blurring of the entire disc margin, but often, only part of the disc is blurred. (*Courtesy of Paul D. Comeau.*)

INTRODUCTION

The term *papilledema* refers specifically to optic disc swelling related to increased intracranial pressure. When no localizing neurological signs or space-occupying lesion is present, idiopathic intracranial hypertension (IIH) is a likely cause in patients younger than age 45 years, especially obese women. Patients with IIH usually present with daily pulsatile headache with nausea and often have transient visual disturbances and/or pulsatile tinnitus. Patients often report a "whooshing" sound that they hear. Bilateral papilledema and visual field defects on a perimetry test are found in almost all patients. Elevated opening pressure on lumbar puncture is required for the diagnosis.

SYNONYMS

Pseudotumor cerebri or benign intracranial hypertension.

EPIDEMIOLOGY

IIH occurs in:

- 1 per 100,000 people.[1]
- 20 per 100,000 obese females ages 15 to 44 years.[1]
- Prevalence may be increasing with increasing obesity. A UK population study found a prevalence of 85.7 per 100,000 in obese women.[2]
- Mean age of diagnosis is approximately 30 years.

ETIOLOGY AND PATHOPHYSIOLOGY

The optic disc swells because of elevated intracranial pressure. In IIH, the cerebral spinal fluid pressure is increased. The cause of this

increase in unknown, but a current hypothesis is that IIH is a syndrome of reduced cerebrospinal fluid (CSF) absorption.

RISK FACTORS

IIH is much more common in obese women of childbearing age.

DIAGNOSIS

Patients with papilledema should undergo imaging, preferably MRI, followed by lumbar puncture. IIH is a diagnosis of exclusion with the following criteria:[3]

- Signs and symptoms of increased intracranial pressure (headache, transient visual disturbances, papilledema).
- Normal neurologic examination, except a sixth nerve palsy may be present. This will lead to a complaint of diplopia.
- Elevated intracranial pressure is present, as measured by lumbar puncture opening pressure greater than 250 mm of water in the lateral decubitus position, with normal CSF on microscopic examination.
- No evidence of mass, hydrocephalus, or vascular lesions by MRI.
- No other identifiable cause of increased intracranial hypertension.

CLINICAL FEATURES

- More than 90% of patients with IIH are obese women of childbearing age. Look for a different diagnosis in children, men, and older patients.[3]
- Headaches and visual changes are the most common symptoms.
- Difficulty in thinking or concentrating is frequently reported. New studies indicate cognitive impairment, particularly in learning and memory.[4]
- SVP are retinal vein pulsations at the optic disc and are typically absent in IIH patients. SVP are seen in 90% of patients with normal intracranial pressure, and are absent when the CSF pressure is above 190 mm Hg. As the CSF pressure may be transiently normal in IIH, the presence of SVP does not preclude IIH, but indicates that the CSF pressure is normal at that moment.[5]

TYPICAL DISTRIBUTION

Papilledema is bilateral in the overwhelming majority of cases (see **Figures 22-1** and **22-2**). Unilateral optic disc swelling has been rarely noted with elevated intracranial pressure.

LABORATORY TESTING

Cerebral spinal fluid is typically sent for cell count and culture.

IMAGING

- Traditionally, imaging was used to rule out intracranial mass or venus sinus obstruction; however, several imaging modalities show promise as tools that may mitigate the need for recurrent lumbar punctures to monitor pressures.

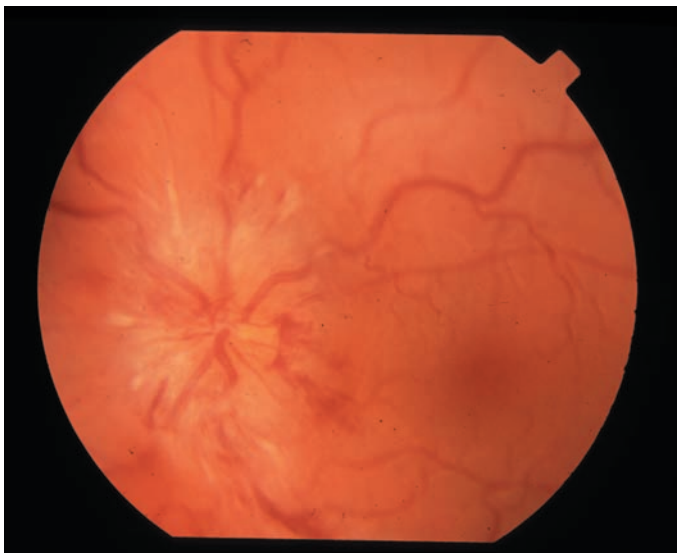

FIGURE 22-2 Severe acute papilledema with papillary flame hemorrhages and cotton-wool spots that obscure the disc vessels. The blurred edges of the optic disc appear as a starburst. (*Courtesy of Paul D. Comeau.*)

- Transorbital sonography measurements of optic nerve sheath diameter detected raised intracranial pressure (ICP) with a sensitivity of 90% and a specificity of 84%.[6]
- Optical coherence tomography (OCT) is an imaging modality used in the ophthalmology office that can distinguish between a normal optic disc, moderate elevation, and papilledema in patients with IIH based on differences in retinal nerve fiber layer thickness.[7]
- MRI findings in IIH include optic nerve tortuosity, partial empty sella, and transverse sinus narrowing. These changes reverse after pressure is reduced and return if pressure increases.[8]

DIFFERENTIAL DIAGNOSIS

- Pseudopapilledema or optic disc drusen, an optic nerve anomaly that elevates the optic disc surface and blurs the disc margins, which can be caused by calcifications in the optic nerve head.
- Optic neuropathies, swelling of all or parts of one or both discs, which can be caused by ischemia or demyelination (as in multiple sclerosis), and may be seen in 1% to 2% of patients with diabetes mellitus type 1 or 2.[9]

Elevated intracranial pressure can also be caused by obstructing lesions, medical conditions, or medications:[3]

- Mass lesions, hydrocephalus, venus sinus or jugular venus thrombosis, and meningeal infections.
- Addison disease, hypoparathyroidism, chronic obstructive pulmonary disease (COPD), sleep apnea, renal failure, pulmonary hypertension, and severe anemia.
- Antibiotics in the tetracycline family, vitamin A, anabolic steroids, lithium, and corticosteroid withdrawal.

MANAGEMENT

In many cases, IIH is self-limiting, presents without visual symptoms, and will resolve over several years without loss of vision. However, when patients present with persistent or worsening visual disturbances, treatment is required to lower the intracranial pressure to prevent optic nerve damage and irreversible loss of vision. Management of the headache is a key factor when choosing a therapeutic plan. Management includes the following:

- Nonpharmacologic
  - Careful observation (often by an ophthalmologist) with documentation of any visual changes. Formal visual field testing is indicated.
  - Weight loss of 15% of body weight is beneficial but will not decrease intracranial pressure quickly enough if visual compromise is present.[1] SOR C
- Medications
  - Acetazolamide 1000 to 2000 mg/day; early studies indicate that topiramate may also be effective; other diuretics such as furosemide are less effective.[10] SOR C
  - High-dose corticosteroids for short time periods for rare cases of rapidly advancing vision loss.[1,10] SOR C

- Refer or hospitalize
  - Surgical interventions for severe, recalcitrant cases include optic nerve sheath fenestration and lumbar peritoneal shunt. Surgery is also considered in special populations such as pregnant women and dialysis patients.[1,10] SOR C
  - Transverse sinus stenting is a newer surgical technique that holds promise.[11]

PREVENTION

Maintenance of ideal body weight may prevent IIH.

PROGNOSIS

Although approximately two-thirds of patients with IIH present with visual impairment, the majority of patients improve. One study reported 9% of patients had permanent visual loss.[12]

FOLLOW-UP

Patients should be followed every 3 to 6 months by a physician who can adequately view the entire optic disc and document visual acuity and visual field deficits. They should be seen immediately for any visual changes.

PATIENT EDUCATION

Advise patients with new papilledema of the need for an evaluation for dangerous causes of increased intracranial pressure, such as intracranial masses or underlying medical illnesses. Also advise patients that IIH often resolves spontaneously over several years, but they should report any visual changes immediately.

PATIENT RESOURCES

- The Intracranial Hypertension Research Foundation has information for patients at **www.ihrfoundation.org**.

PROVIDER RESOURCES

- The Intracranial Hypertension Research Foundation has information for medical professionals including ongoing research studies and information on patient registries at **www.ihrfoundation.org**.

REFERENCES

1. Mathews MK, Sergott RC, Savino PJ. Pseudotumor cerebri. *Curr Opin Ophthalmol*. 2003;14(6):364-370.
2. Raoof N, Sharrack B, Pepper IM, Hickman SJ. The incidence and prevalence of idiopathic intracranial hypertension in Sheffield, UK. *Eur J Neurol*. 2011;18(10):1266-1268.
3. Friedman DI, Jacobson DM. Diagnostic criteria for idiopathic intracranial hypertension. *Neurology*. 2002;59(10):1492-1495.
4. Kharkar S, Hernandez R, Batra S, et al. Cognitive impairment in patients with pseudotumor cerebri syndrome. *Behav Neurol*. 2011;24(2):143-148.
5. Jacks AS, Miller NR. Spontaneous retinal venous pulsation: aetiology and significance. *J Neurol Neurosurg Psychiatry*. 2003;74(1):7-9.
6. Bauerle J, Nedelmann M. Sonographic assessment of the optic nerve sheath in idiopathic intracranial hypertension. *J Neurol*. 2011;258(11):2014-2019.
7. Waisbourd M, Leibovitch I, Goldenberg D, Kesler A. OCT assessment of morphological changes of the optic nerve head and macula in idiopathic intracranial hypertension. *Clin Neurol Neurosurg*. 2011;113(10):839-843.
8. George U, Bansal G, Pandian J. Magnetic resonance "flip-flop" in idiopathic intracranial hypertension. *J Neurosci Rural Pract*. 2011;2(1):84-86.
9. Bayraktar Z, Alacali N, Bayraktar S. Diabetic papillopathy in type II diabetic patients. *Retina*. 2002;22(6):752-758.
10. Friedman DI, Jacobson DM. Idiopathic intracranial hypertension. *J Neuroophthalmol*. 2004;24(2):138-145.
11. Ahmed RM, Wilkinson M, Parker GD, et al. Transverse sinus stenting for idiopathic intracranial hypertension: a review of 52 patients and of model predictions. *AJNR Am J Neuroradiol*. 2011;32(8):1408-1414.
12. Baheti NN, Nair M, Thomas SV. Long-term visual outcome in idiopathic intracranial hypertension. *Ann Indian Acad Neurol*. 2011;14(1):19-22.

23 AGE-RELATED MACULAR DEGENERATION

Heidi Chumley, MD

PATIENT STORY

A 78-year-old white woman presents with loss of central vision that has gradually worsened over the last 6 months. Fully independent before, she can no longer drive and has difficulty with activities of daily living. Her peripheral vision remains normal. Funduscopic examination reveals macular depigmentation and drusen (yellowish-colored subretinal deposits on the macula) (**Figure 23-1**). She is diagnosed with dry, age-related macular degeneration. After her physician discusses the available information about antioxidants and therapeutic options, she decides to start antioxidants and see an ophthalmologist to discuss laser, surgical, or medical treatments.

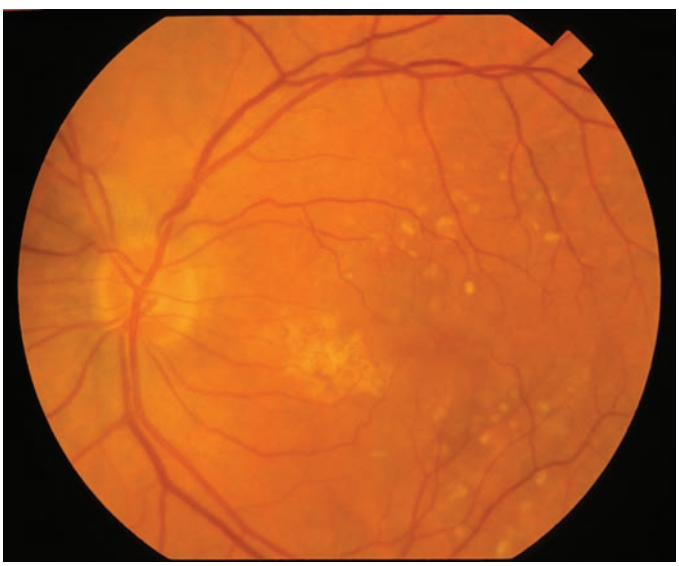

FIGURE 23-1 Intermediate, dry, age-related macular degeneration with macular depigmentation and drusen (yellowish-colored subretinal deposits on the macula). This patient has central vision distortion. (*Courtesy of Paul D. Comeau.*)

INTRODUCTION

Age-related macular degeneration (AMD) causes central vision loss in elderly patients. The pathophysiology of AMD is incompletely understood, but involves chronic changes in the retina and retinal pigment epithelium mediated by environmental and genetic factors. AMD is diagnosed by ophthalmoscopic detection of drusen. Healthy lifestyle decreases the risk of development and progression of AMD. Refer patients to an ophthalmologist to evaluate for intravitreal injections, laser photocoagulation or photodynamic therapy, or surgery.

EPIDEMIOLOGY

AMD is the leading cause of irreversible vision loss in the industrialized world.

- Prevalence of advanced AMD is 1.4% in patients older than 40 years of age and 15% in white women older than 80 years of age.[1]
- AMD that causes significant vision loss is more common in whites than blacks or Hispanics.[2]
- Smoking increases risk in women (relative risk [RR] 2.5 for current smokers; 2.0 for former smokers).[2]
- AMD aggregates in families, but the specific genetic and familial risk factors are not clear.[2]

ETIOLOGY AND PATHOPHYSIOLOGY

AMD affects central but not peripheral vision. Environment and genetic attributes increase risk of these pathologic changes with aging.[3]

- Oxidative stress from the buildup of free oxygen radicals causes retinal pigment epithelial (RPE) injury.

- RPE injury evokes a chronic inflammatory response. The complement system is involved and specific polymorphisms of complement genes are associated with advanced disease and progression.[4]
- RPE injury/inflammation forms an abnormal extracellular matrix (ECM), which alters diffusion of nutrients to the retina and RPE.
- The abnormal ECM and diffusion leads to retinal atrophy and new vessel growth.

RISK FACTORS

- For advanced AMD, strong risk factors are age, current cigarette smoking, previous cataract surgery (replaced lens provides less eye protection from sunlight), and family history of AMD.
- Moderate risk factors include higher body mass index, history of cardiovascular disease, hypertension, and high plasma fibrinogen.
- Weak or inconsistent risk factors include gender, ethnicity, diabetes, iris color, history of cerebrovascular disease, total cholesterol, high-density lipoprotein, and triglyceride levels.[5]

DIAGNOSIS

Diagnosis is made by ophthalmoscopy. AMD can be dry (early, intermediate, or advanced) or wet (always considered advanced).

- Early dry—May have no vision change; drusen present (**Figure 23-2**).
- Intermediate dry—Distortion in the center of vision; multiple medium-size drusen (see **Figure 23-1**).
- Advanced dry—(Nonexudative) Significant central vision loss from breakdown of support tissues around the macula.
- Advanced wet—(Exudative) Gradual or sudden significant loss of vision; new onset of distortion in vision (straight lines appear wavy); abnormal blood vessels grow under the macula and can cause hemorrhage (**Figure 23-3**). Late changes include subretinal scarring and retinal atrophy (**Figure 23-4**).

CLINICAL FEATURES

- Symptoms that occur before vision loss include metamorphopsia (distorted vision) and central scotoma (impaired vision at the point of fixation).[6]
- Vision loss is central. Peripheral and night vision are generally not affected.
- Drusen is the classic physical examination finding:
  - Hard: small, yellow punctuate nodules.
  - Soft: large pale yellow or grayish white with less distinct borders.

TYPICAL DISTRIBUTION

- Bilateral, although usually one eye is affected before the other.

ANCILLARY TESTING

Macular function is impaired before visual loss and can be detected by tests including: macular recovery function and central visual field

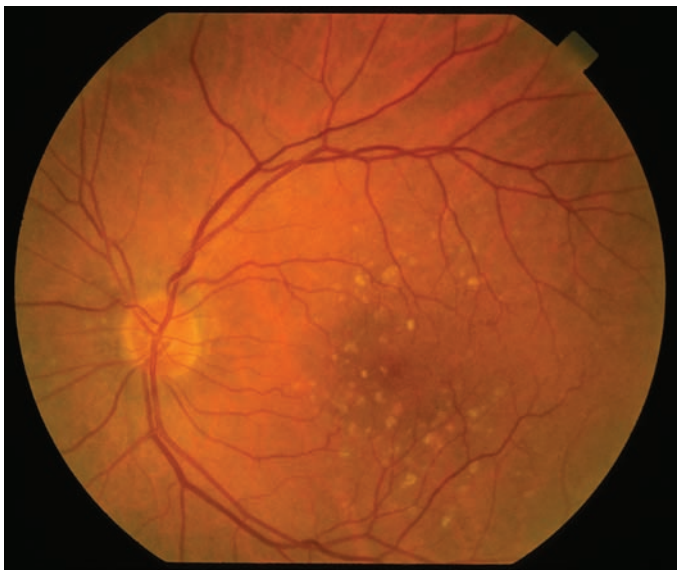

FIGURE 23-2 Early, dry, age-related macular degeneration demonstrating drusen, yellowish-colored subretinal deposits on the macula. Patients may have no visual complaints at this stage. (*Courtesy of Paul D. Comeau.*)

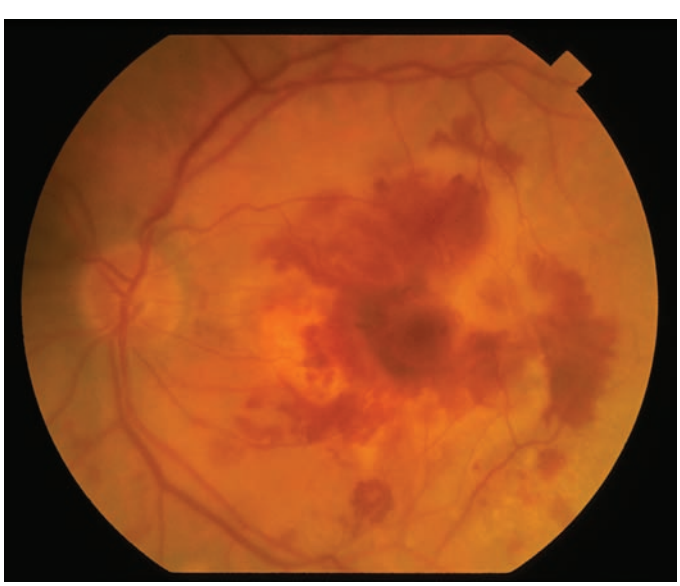

FIGURE 23-3 Late, wet, age-related macular degeneration (exudative) with subretinal hemorrhages. Patients usually have significant central vision loss. (*Courtesy of Paul D. Comeau.*)

sensitivity.[7] Optical coherence tomography (OCT) and fluorescein angiography are most commonly used to assess for leakage from abnormal blood vessels. If leakage is present, this indicates that anti-vascular endothelial growth factor (VEGF) treatment may help.

DIFFERENTIAL DIAGNOSIS

Vision loss in the elderly can also be caused by any of the following:[8]

- Glaucoma (open-angle)—Often asymptomatic until late in the disease, but then has visual field defects instead of central vision loss; funduscopic examination may reveal a large cup-to-disc ratio (see Chapter 19, Glaucoma).
- Diabetic retinopathy—May have central vision loss with macular edema; funduscopic examination demonstrates microaneurysms, cotton-wool spots, hemorrhages, and exudates (see Chapter 20, Diabetic Retinopathy).
- Cataracts—Blurred vision or glare; lens opacities seen when examining the red reflex.

Drusen can also be seen with:

- Pigmented nevi and choroidal malignant melanoma.
- Retinal detachment.
- Glomerulonephritis, particularly membranoproliferative glomerulonephritis type II.[6]

MANAGEMENT

Refer to ophthalmologist to evaluate for treatments such as intravitreal injections, laser photocoagulation or photodynamic therapy, or surgery.

- Nonpharmacologic:
  - Healthy lifestyle that includes diet, exercise, and no smoking.
- Medications:
  - Intraocular injections of pegaptanib and ranibizumab (anti-VEGFs) reduce the risk of visual acuity loss in patients with advanced neovascular AMD, number needed to treat (NNT) 3–14.[9] SOR A
  - Bevacizumab performs similarly to ranibizumab.[10]
  - Serious ocular/nonocular adverse events and mild ocular adverse events occur in 1% and 5% of injections, respectfully.[11]
- Complementary/alternative therapy:
  - Consider antioxidants (vitamin C, 500 mg; vitamin E, 400 IU; and beta-carotene, 15 mg) plus 80 mg zinc per day to decrease the risk of worsening vision loss in patients with intermediate to advanced AMD.[12] SOR B These antioxidants are available in single-tablet formulations. Avoid beta-carotene for smokers or people who have smoked in the last 10 years.

REFERRAL

- Most patients are treated by an ophthalmologist, and treatment may include intravitreal injections, laser photocoagulation or photodynamic therapy, or surgery.
- Urgently refer a patient with a history of dry AMD and acute changes in vision (distortion of lines, objects) to an ophthalmologist for evaluation and treatment.

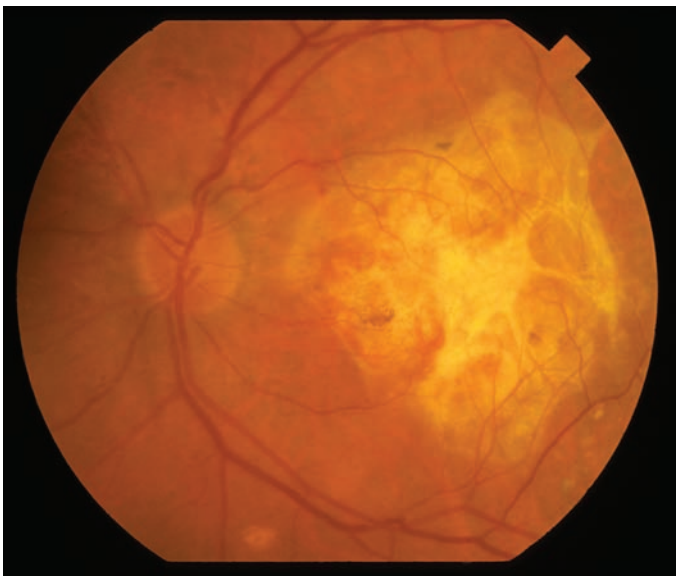

FIGURE 23-4 Late, wet, age-related macular degeneration (exudative) with subretinal scarring. Patients usually have significant central vision loss resulting from destruction of tissue around the macula. (*Courtesy of Paul D. Comeau.*)

PREVENTION

- Healthy diet—People with healthy diets, compared with non-healthy diets, were 46% less likely to develop AMD.[13]
- Physical activity—Active people, compared to inactive people, were 54% less likely to develop AMD.[13]
- Healthy behaviors—People with a healthy diet who exercised and did not smoke, compared with people without these healthy behaviors, were 71% less likely to develop AMD.[13]
- Regular intake of age-related eye disease study (AREDS) formula (vitamins A, C, and E, and zinc) may reduce the risk of AMD.[14]

PROGNOSIS

Twenty-five percent to 33% of patients with early ARM (age-related maculopathy, a precursor to AMD) progressed over a 7-year period. Smoking, elevated C-reactive protein, and specific complement genotypes increase the risk of progression.[4]

FOLLOW-UP

Patients with ARM and AMD should have regular follow-up with an ophthalmologist.

PATIENT EDUCATION

- AMD can cause a loss of vision leading to an inability to read and drive, thereby affecting many activities of daily living.
- A healthy lifestyle may prevent development or progression of AMD.
- Treatment options are available that decrease the risk of vision loss.
- Most patients with AMD need to see an ophthalmologist regularly in addition to their primary care physician.

PATIENT RESOURCES

- The National Eye Institute has information for patients—**http://www.nei.nih.gov/health/maculardegen/index.asp**.

PROVIDER RESOURCES

- A tool for calculating the risk of advanced AMD is available at: **http://caseyamdcalc.ohsu.edu/**.
- Exudative AMD—**http://emedicine.medscape.com/article/1236030**.
- Nonexudative AMD—**http://emedicine.medscape.com/article/1233154**.

REFERENCES

1. Friedman DS, O'Colmain BJ, Muñoz B, et al. Prevalence of age-related macular degeneration in the United States. *Arch Ophthalmol*. 2004;123:564-572.
2. Seddon JM, Chen CA. The epidemiology of age-related macular degeneration. *Int Ophthalmol Clin*. 2004;44(4):17-39.
3. Zarbin MA. Current concepts in the pathogenesis of age-related macular degeneration. *Arch Ophthalmol*. 2004;123(4):598-614.
4. Robman L, Baird PN, Dimitrov PN, et al. C-reactive protein levels and complement factor H polymorphism interaction in age-related macular degeneration and its progression. *Ophthalmology*. 2010;117(10):1982-1988.
5. Chakravarthy U, Wong TY, Fletcher A, et al. Clinical risk factors for age-related macular degeneration: a systematic review and meta-analysis. *BMC Ophthalmol*. 2010;10:31.
6. Kokotas H, Grigoriadou M, Petersen MB. Age-related macular degeneration: genetic and clinical findings. *Clin Chem Lab Med*. 2011;49(4):601-616.
7. Midena E, Degli Angeli C, Blarzino MC, et al. Macular function impairment in eyes with early age-related macular degeneration. *Invest Ophthalmol Vis Sci*. 1997;38(2):469-477.
8. Kroll P, Meyer CH. Which treatment is best for which AMD patient? *Br J Ophthalmol*. 2006;90(2):128-130.
9. Vedula SS, Krystolik MG. Antiangiogenic therapy with anti-vascular endothelial growth factor modalities for neovascular age-related macular degeneration. *Cochrane Database Syst Rev*. 2008;16(2):CD005139.
10. Fadda V, Maratea D, Trippoli S, Messori A. Treatments for macular degeneration: summarizing evidence using network meta-analysis. *Br J Ophthalmol*. 2011;95(10):1476-1477.
11. Van der Reis MI, La Heij EC, De Jong-Hesse Y, et al. A systematic review of the adverse events of intravitreal anti-vascular endothelial growth factor injections. *Retina*. 2011;31(8):1449-1469.
12. Age-Related Eye Disease Study Research Group. A randomized, placebo-controlled, clinical trial of high-dose supplementation with vitamins C and E, beta carotene, and zinc for age-related macular degeneration and vision loss: AREDS Report No. 8. *Arch Ophthalmol*. 2001;119(10):1417-1436.
13. Mares JA, Voland RP, Sondel SA, et al. Healthy lifestyles related to subsequent prevalence of age-related macular degeneration. *Arch Ophthalmol*. 2011;129(4):470-480.
14. Wong IY, Koo SC, Chan CW. Prevention of age-related macular degeneration. *Int Ophthalmol*. 2011;31(1):73-82.

24 EYE TRAUMA—HYPHEMA

Heidi Chumley, MD

PATIENT STORY

A 22-year-old man was hit in the eye with a baseball and presented to the emergency department with eye pain and redness and decreased visual acuity. There was a collection of blood in his anterior chamber (**Figure 24-1**) and he was diagnosed with a hyphema. He was given an eye shield for protection, advised to take acetaminophen for pain, and counseled not to engage in sporting activities until his hyphema resolved. He saw his physician daily for the next 2 days, during which his vision improved. His hyphema resolved in 5 days.

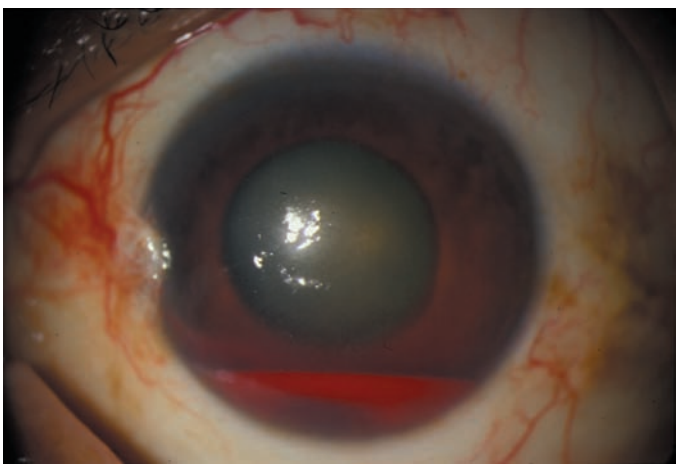

FIGURE 24-1 Layering of red blood cells in the anterior chamber following blunt trauma. This grade 1 hyphema has blood filling in less than one-third of the anterior chamber. (*Courtesy of Paul D. Comeau.*)

INTRODUCTION

Hyphema, blood in the anterior chamber, can be seen following eye trauma or as a result of clotting disturbances, vascular abnormalities, or mass effects from neoplasms. Traumatic hyphema occurs more often in boys and men, often related to work or sports. Hyphema typically resolves in 5 to 7 days, but some cases are complicated by rebleeding.

EPIDEMIOLOGY

- Hyphema occurs in 17 to 20 per 100,000 persons per year in the United States.[1]
- Sixty percent of hyphemas result from sports injuries.[2] Sports with higher risk for eye injuries include paintball, baseball/softball, basketball, soccer, fishing, ice hockey, racquet sports, fencing, lacrosse, and boxing.

ETIOLOGY AND PATHOPHYSIOLOGY

- A hyphema is a collection of blood, mostly erythrocytes, that layer within the anterior chamber.
- Trauma is the most common cause, often resulting from a direct blow from a projectile object such as a ball, air pellet or BB, rock, or fist.
- Direct force to the eye (blunt trauma) forces the globe inward, distorting the normal architecture.
- Intraocular pressure rises instantaneously causing the lens/iris/ciliary body to move posteriorly, thus disrupting the vascularization with resultant bleeding.
- Intraocular pressure continues to rise and bleeding stops when this pressure is high enough to compress the bleeding vessels.
- A fibrin-platelet clot forms and stabilizes in 4 to 7 days; this is eventually broken down by the fibrinolytic system and cleared through the trabecular meshwork.

DIAGNOSIS

The diagnosis of hyphema is clinical, depending on the classic appearance of blood layering in the anterior chamber.

CLINICAL FEATURES

History and physical:

- Layered blood in the anterior chamber.
- History of eye trauma or risk factor for nontraumatic hyphema.
- Increased intraocular pressure (32%).
- Decreased vision.
- Hyphemas are classified according to the amount of blood in the anterior chamber:[1]
  - Grade 1: Less than one-third of the anterior chamber (see **Figure 24-1**); 58% of all hyphemas.
  - Grade 2: One-third to one-half of the anterior chamber; 20% of all hyphemas.
  - Grade 3: One-half to almost completely filled anterior chamber; 14% of all hyphemas.
  - Grade 4: Completely filled anterior chamber; 8% of all hyphemas.
- Eye trauma without hyphema (**Figure 24-2** and **24-3**) can lead to subconjunctival hemorrhage, anterior uveitis, and/or distortion of the normal architecture, including globe rupture.

LABORATORY TESTING (INCLUDE ANCILLARY TESTING, TOO)

- Consider laboratory tests to evaluate for bleeding disorders: Bleeding time, electrophoresis for sickle cell trait, platelet count, prothrombin and partial thromboplastin time, and liver tests.

IMAGING

- Consider CT imaging if a mechanism of injury suggests an associated orbital fracture or concern for orbital or intraocular foreign body.

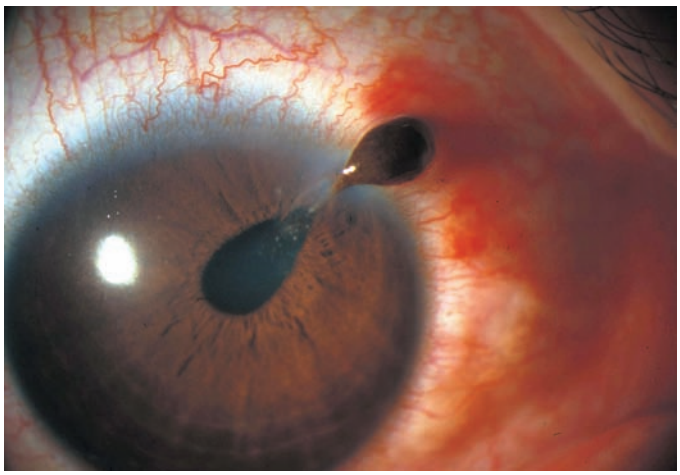

FIGURE 24-2 This young patient was hit in the eye with the corner of a laminated name card. The sharp edge perforated the cornea and pulled a portion of the iris out of the wound. Note the abnormal configuration of the pupil (dyscoria). No hyphema noted. This patient required emergent surgical repair. (*Reprinted with permission from Lo MW, Chalfin S. Retrobulbar anesthesia for repair of ruptured globes. Am J Ophthalmol. 1997;123(6):833-835. Photo by Paul D. Comeau.*)

DIFFERENTIAL DIAGNOSIS

Hyphema is an unmistakable physical examination finding that can be caused by any of the following:

- Trauma—History of trauma, including nonaccidental trauma (i.e., child abuse).
- Blood clotting disturbances—Personal or family history of bleeding disorder, little or no trauma, and black race (increased incidence of sickle trait and disease).
- Medication-induced anticoagulation—Chronic use of aspirin or warfarin and little or no trauma.
- Neovascularization—Diabetes with diabetic retinopathy, history of other ocular disease (central retinal vein occlusion), or history of prior eye surgery (cataract); without trauma, often painless, sudden, blurry vision.

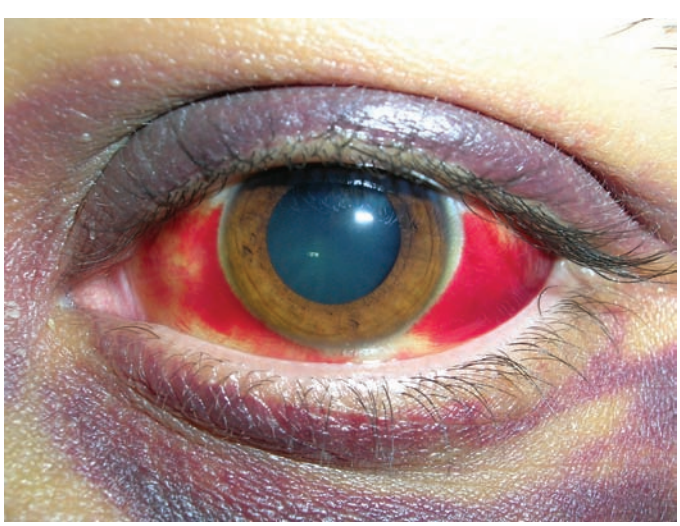

FIGURE 24-3 Subconjunctival hemorrhage and eyelid ecchymosis following accidental trauma. There was no hyphema present. *(Courtesy of Richard P. Usatine, MD.)*

- Melanoma or retinoblastoma—Variety of presentations depending on the size and location; hyphema occurs when mass effect sheers the lens/iris/ciliary body causing bleeding.
- Abnormal vasculature, that is, juvenile xanthogranuloma—Red to yellow papules and nodules in the eyes, skin, and viscera, most often present by 1 year of age.

MANAGEMENT

- Most hyphemas resolve in 5 to 7 days; management strategies protect the eye and decrease complications, including rebleeding.
- Evaluate or refer for evaluation for elevated intraocular pressure and other associated injuries. Urgent referral if concern for globe rupture.

A recent Cochrane review evaluated these interventions: antifibrinolytic agents, corticosteroids, cycloplegics, miotics, aspirin, conjugated estrogens, eye patching, head elevation, and bed rest.

- No interventions had a significant effect on visual acuity.
- Aminocaproic acid (antifibrinolytic) use resulted in a slower resolution of the primary hyphema.
- Antifibrinolytics: aminocaproic acid, tranexamic acid, and aminomethylbenzoic acid reduced the rate of secondary hemorrhage.[3]

NONPHARMACOLOGIC

- Eye patching, head elevation, and bed rest do not independently affect visual acuity. However, experts recommend to patch and shield the injured eye and allow the patient to remain ambulatory as part of a comprehensive treatment plan.[1] SOR C

MEDICATIONS

- Although controversy remains about the best treatment, each of the following has been demonstrated to lower the risk of rebleeding in randomized-controlled trials:
  - Oral antifibrinolytic agents (aminocaproic acid 50 mg/kg every 4 hours for 5 days, not to exceed 30 g/day, or tranexamic acid 75 mg/kg per day divided into 3 doses).[4] SOR C
  - Topical aminocaproic acid (30% in a gel vehicle 4 times a day) is as effective as oral.[4] SOR C
  - Avoid aspirin and NSAIDs, which have been associated with higher rates of rebleeding.
  - Use acetaminophen, if needed, for pain.

REFERRAL OR HOSPITALIZATION

- Signs of a violated globe, such as a perforation of the cornea, conjunctiva or sclera, distorted ocular architecture, or exposed and/or distorted uveal tissue such as the iris (causing a peaked pupil), require immediate surgical evaluation and repair (see **Figure 24-2**).
- Surgical intervention has been recommended for patients with persistent total hyphema or prolonged elevated intraocular pressure.
- Outpatient management is acceptable for adults and children if patient is likely to be able to follow treatment plan.[4,5] SOR B

PREVENTION

Ninety percent of sports-related eye injuries can be prevented with appropriate eyewear.[6]

PROGNOSIS

The percentage of patients who regain 20/40 vision varies by severity of the hyphema: grade I, 80%; grade III, 60%; grade IV, 35%.[1]

FOLLOW-UP

Patients should be monitored daily for the first 5 or more days by a provider familiar with caring for hyphemas. Patient with a hyphema should be followed subsequently for signs of angle recession and high intraocular pressure, which predisposes the patient to traumatic glaucoma, an insidious cause of blindness in patients with a history of trauma.

PATIENT EDUCATION

- Complications include rebleeding, decreased visual acuity, posterior or peripheral anterior synechiae, corneal bloodstaining, glaucoma, and optic atrophy. Patients may need surgical or medical management for glaucoma.
- Patients who are more likely to rebleed include black patients (irrespective of sickle cell/trait status),[7,8] patients with a grade 3 or 4 hyphema, and patients with high initial intraocular pressure.
- Warn patients that they may have angle recession from traumatic causes of the hyphema. This will predispose the patient to a lifetime risk of traumatic glaucoma, which can cause blindness without any symptoms. These patients need to be monitored regularly by an ophthalmologist for increased pressure and glaucomatous nerve changes.

PATIENT RESOURCES

- Play Hard Play Safe Web site has recommended eye protection by sport at **http://www.lexeye.com.**
- The National Eye Institute has information for parents, teachers, and coaches at **http://www.nei.nih.gov/sports.**

PROVIDER RESOURCES

- Coalition to prevent eye injuries has a variety of handouts suitable for displaying or giving to patients at **http://www.sportseyeinjuries.com.**

REFERENCES

1. Sheppard J, Hyphema. *Medscape Reference*. http://emedicine.medscape.com/article/119016. Accessed June 15, 2012.
2. Schein OD, Hibberd PL, Shingleton BJ, et al. The spectrum and burden of ocular injury. *Ophthalmology*. 1988;95(3):300-305.
3. Gharaibeh A, Savage HI, Scherer RW, et al. Medical interventions for traumatic hyphema. *Cochrane Database Syst Rev*. 2011 Jan 19; 19(1):CD005431.
4. Walton W, Von HS, Grigorian R, Zarbin M. Management of traumatic hyphema. *Surv Ophthalmol*. 2002;47(4):297-334.
5. Rocha KM, Martins EN, Melo LA Jr, Moraes NS. Outpatient management of traumatic hyphema in children: Prospective evaluation. *J AAPOS*. 2004;8(4):357-361.
6. Harrison A, Telander DG. Eye injuries in the youth athlete: a case-based approach. *Sports Med*. 2002;l31(1):33-40.
7. Lai JC, Fekrat S, Barron Y, Goldberg MF. Traumatic hyphema in children: risk factors for complications. *Arch Ophthalmol*. 2001; 119(1):64-70.
8. Spoor TC, Kwitko GM, O'Grady JM, Ramocki JM. Traumatic hyphema in an urban population. *Am J Ophthalmol*. 1990;109(1):23-27.

25 DIFFERENTIAL DIAGNOSIS OF THE RED EYE

Heidi Chumley, MD
Richard P. Usatine, MD

PATIENT STORY

A 41-year-old man wakes up with eyes that are reddened bilaterally (**Figure 25-1**). He has some burning and itching in the eyes, but no pain. He describes minimal crusting on his eyelashes. Examination shows no loss of vision, no foreign bodies, and pupils that are equal, round, and reactive to light. He is diagnosed with viral conjunctivitis, which does not require antibiotic treatment. He is advised about methods to prevent spreading conjunctivitis to others and is asked to notify the physician immediately if he experiences eye pain or loss of vision. He recovers spontaneously without complications after a few days.

FIGURE 25-1 Bilateral viral conjunctivitis in a 41-year-old man. (*Courtesy of Richard P. Usatine, MD.*)

INTRODUCTION

A red eye signifies ocular inflammation. The differential diagnosis includes both benign and sight-threatening conditions. The pattern of redness; presence/absence of eye pain or photophobia, vision loss, or eye discharge; involvement of cornea; and visual acuity are helpful in differentiating among causes (see **Table 25-1**). Although most red eyes seen in the primary care setting are a result of viral conjunctivitis, several causes of red eye require urgent referral.

EPIDEMIOLOGY

- An acute red eye or eyes is a common presentation in ambulatory and emergency departments.
- Conjunctivitis is the most common cause of a nontraumatic red eye in primary care.

ETIOLOGY AND PATHOPHYSIOLOGY

Red eye is caused by any of the following:

- Infectious or noninfectious inflammation of any layer of the eye (conjunctivitis, episcleritis, scleritis, uveitis, keratitis).
- Eyelid pathology (blepharitis, entropion, i.e., inward turning of the eyelid, or other eyelid malposition).
- Acute glaucoma (usually angle closure).
- Trauma.
- Subconjunctival hemorrhage.

TABLE 25-1 Clinical Features in the Diagnosis of Red Eye

	Conjunctivitis	Episcleritis	Scleritis	Uveitis	Keratitis	Closed-Angle Glaucoma	Subconjunctival Hemorrhage	Ocular Rosacea
Redness	Diffuse	Segmental; pink	Segmental or diffuse; dark red, purple, or blue	360-Degree perilimbal (worse at limbus)	Diffuse, ciliary injection	Diffuse, scleral	Blotchy, outside vessels	Diffuse
Eye pain	No	Mild, may be tender to touch	Severe, boring	Sometimes	Usually	Yes	No, unless caused by trauma	No
Vision loss	No	No	Sometimes	Sometimes	Maybe, depending on location	Yes	No	In severe cases
Discharge	Usually	No	No	No	Maybe	No	No	No
Photophobia*	No	No	Yes	Yes, if anterior	Yes	Yes	No	Sometimes
Pupil	Normal	Normal	Normal	Constricted	Normal to constricted	Mild dilation, less responsive	Normal; unless affected by trauma	Normal
Cornea	Clear	Clear	Clear	Clear to hazy	Hazy	Usually hazy	Clear	Clear or neovascularization, cloudy
Associated diseases	URI, allergy, exposure	Occasional systemic disease	Systemic disease	Systemic disease, idiopathic	Contact lenses, HSV or varicella, rosacea	Causes headaches, nausea, vomiting, GI symptoms	HTN, trauma, Valsalva, cough, blood thinners	Acne rosacea (can exist without also), blepharitis

Abbreviations: *HSV,* Herpes simplex virus; *HTN,* hypertension; *URI,* upper respiratory infection.
*For identifying serious causes of red eye, the presence of photophobia elicited with a penlight in a general practice had a positive predictive value of 60% and a negative predictive value of 90%.[1]

DIFFERENTIAL DIAGNOSIS

An acute red eye can be caused by any of the following:

- Conjunctivitis—Conjunctival injection, eye discharge, gritty or uncomfortable feeling, and no vision loss (**Figures 25-1** to **25-4**) (see also Chapter 16, Conjunctivitis).
- Episcleritis—Segmental or diffuse inflammation of episclera (pink color), mild or no discomfort, but can be tender to palpation, and no vision disturbance (**Figure 25-5**) (see also Chapter 17, Episcleritis and Scleritis).
- Scleritis—Segmental or diffuse inflammation of sclera (dark red, purple, or blue color), severe boring eye pain often radiating to head and neck, and photophobia and vision loss (**Figure 25-6**) (see also Chapter 17, Episcleritis and Scleritis).
- Keratitis or corneal ulcerations—Diffuse erythema with ciliary injection often with pupillary constriction; eye discharge; and pain, photophobia, vision loss depending on the location of ulceration (**Figure 25-7**). Often associated with the use of contact lenses.
- Subconjunctival hemorrhage (**Figure 25-8**)—Bright red subconjunctival blood; usually not painful; can present after significant coughing/sneezing, after trauma, or in the setting of dry eyes with minor trauma from rubbing with a finger. Not vision-threatening.
- Ocular rosacea—Eye findings present in more than 50% of people with facial rosacea. Can present as blepharitis, conjunctivitis, or episcleritis or cause corneal ulcerations and neovascularization (**Figures 25-9** and **25-10**).
- Uveitis or Iritis—A 360-degree injection, which is most intense at the limbus, eye pain, photophobia, and vision loss (**Figure 25-11**) (see also Chapter 18, Uveitis and Iritis).
- Trauma causing globe injury, or hemorrhage into the anterior chamber called hyphema (**Figures 25-12** and **25-13**) (see Chapter 24, Eye Trauma—Hyphema).
- Pterygium—Fibrovascular tissue on the surface of the eye extending onto the cornea (**Figure 25-14**) (see also Chapter 12, Pterygium).
- Hypopyon is a term for visible white cells (pus) layered out in the anterior chamber. It may be caused by inflammation of the iris or an eye infection. The inflammation and/or infection also causes the conjunctiva and sclera to become red (**Figure 25-15**).
- Acute-angle closure glaucoma—Cloudy cornea and scleral injection, shallow anterior chamber (check other eye if difficult to assess chamber depth in the red eye), eye pain with ipsilateral headache, and severe vision loss (see also Chapter 19, Glaucoma).
- Eyelid pathology—Blepharitis (inflammation of the eyelid) (**Figure 25-16**). Entropion is a turning inward of the eyelid and can cause irritation to the conjunctiva and cornea.

MANAGEMENT

Treatment for specific causes is discussed in the corresponding chapters.

Refer patients with any of the following to an ophthalmologist:[2,3]
SOR C

- Visual loss.
- Moderate or severe pain.

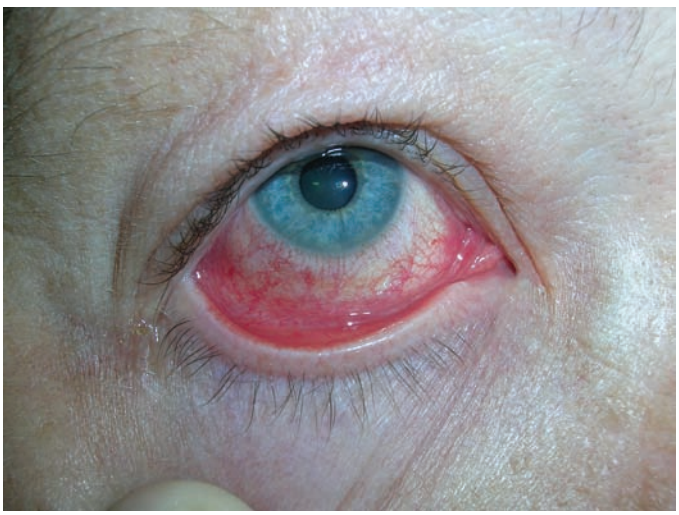

FIGURE 25-2 Bacterial conjunctivitis in a contact lens user. (*Courtesy of Richard P. Usatine, MD.*)

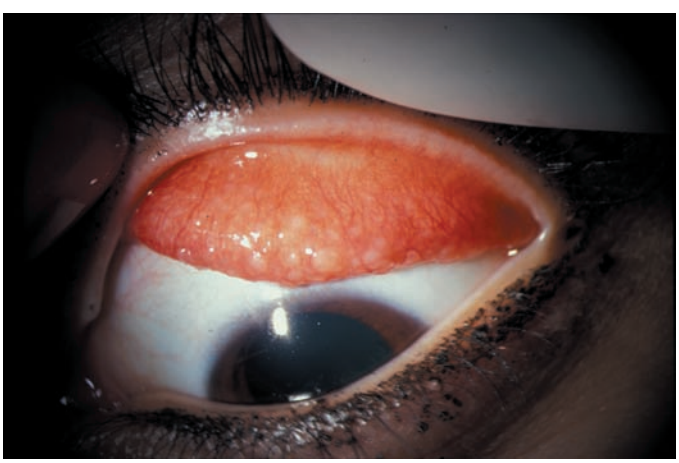

FIGURE 25-3 Giant papillary conjunctivitis secondary to contact lens use. (*Courtesy of Paul D. Comeau.*)

FIGURE 25-4 Conjunctival irritation caused by a fleck of metal (at 9-o'clock position) that was embedded in the eye of a man who was grinding steel. (*Courtesy of Richard P. Usatine, MD.*)

FIGURE 25-5 Episcleritis showing a sector of erythema. (*Courtesy of Richard P. Usatine, MD.*)

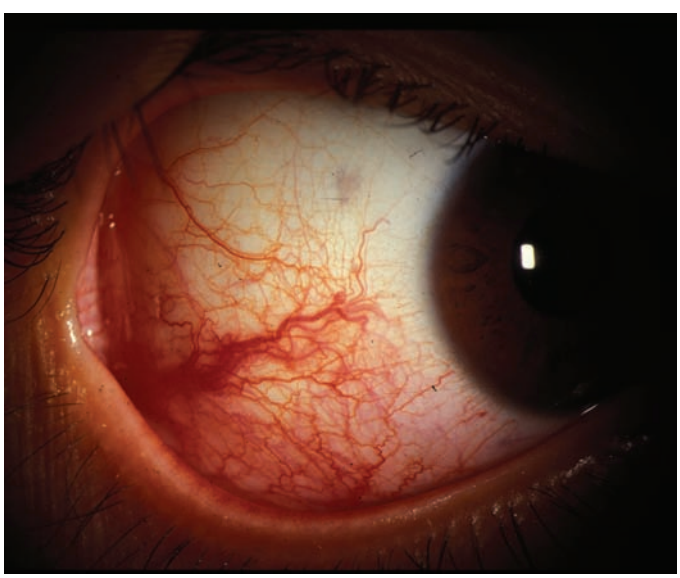

FIGURE 25-6 Scleritis with deeper, darker vessels than the episcleritis. (*Courtesy of Paul D. Comeau.*)

FIGURE 25-7 Diffuse ciliary injection and cloudy cornea demonstrating keratitis with corneal ulcer formation and a leucocyte infiltrate. (*Courtesy of Paul D. Comeau.*)

FIGURE 25-8 Subconjunctival hemorrhage secondary to trauma. (*Courtesy of Paul D. Comeau.*)

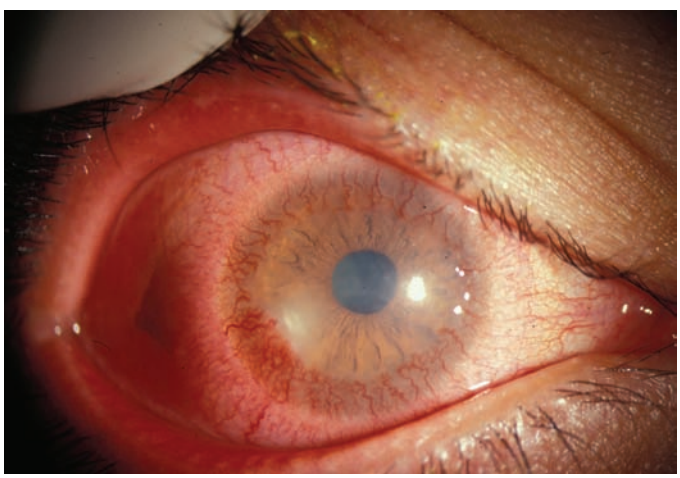

FIGURE 25-9 Ocular rosacea with new vessels growing onto the cornea. Many patients with rosacea have some ocular findings including blepharitis (inflammation of the eyelid), conjunctivitis (most common), episcleritis (rare), keratitis, or corneal ulceration/neovascularization. (*Courtesy of Paul D. Comeau.*)

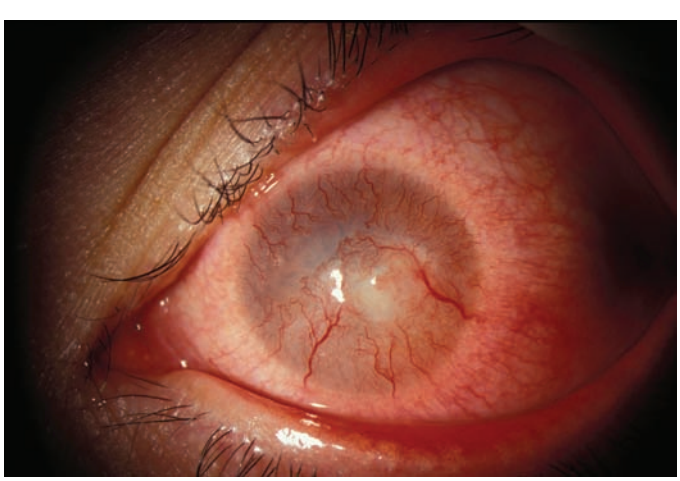

FIGURE 25-10 Severe ocular rosacea with blood vessels growing over the cornea leading to blindness. (*Courtesy of Paul D. Comeau.*)

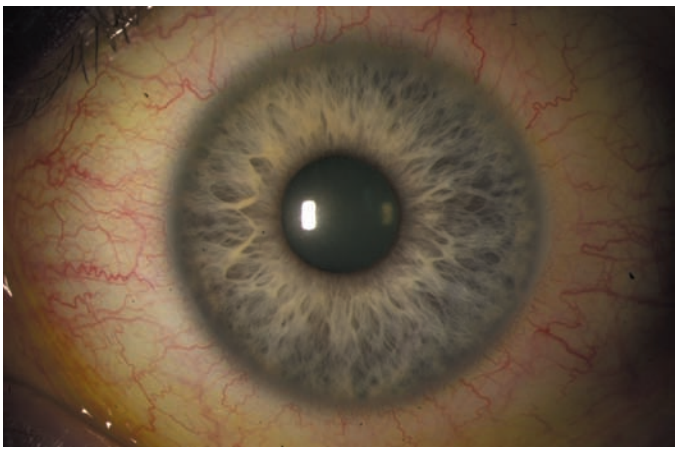

FIGURE 25-11 Iritis (anterior uveitis) with a limbal flush, red to purple perilimbal ring. For contrast, note the perilimbal area is not involved in conjunctivitis, as best seen in **Figure 25–2**. This patient has eye pain and vision loss, which are also absent in conjunctivitis. (*Courtesy of Paul D. Comeau.*)

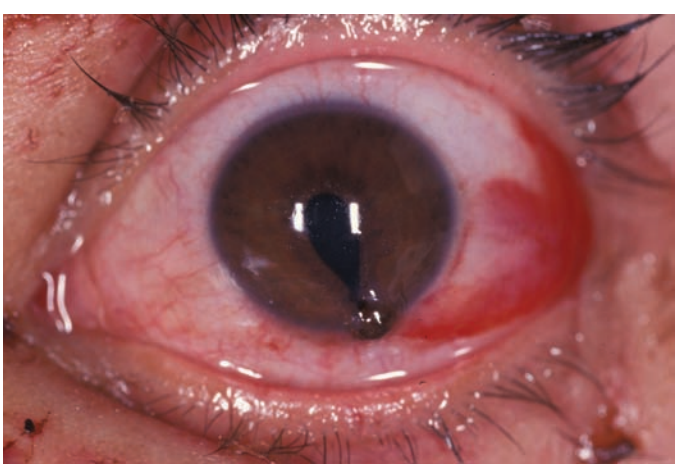

FIGURE 25-12 Trauma to the eye resulting in an open globe injury with extrusion of some of the iris through the cornea and an abnormal pupil. There is conjunctival injection and hemorrhage causing this red eye. (*Courtesy of Paul D. Comeau.*)

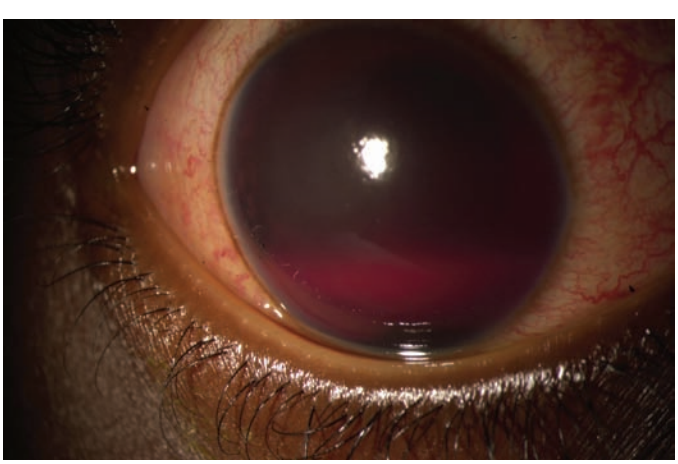

FIGURE 25-13 Hyphema with red cells in the anterior chamber and an inferior blood clot. (*Courtesy of Paul D. Comeau.*)

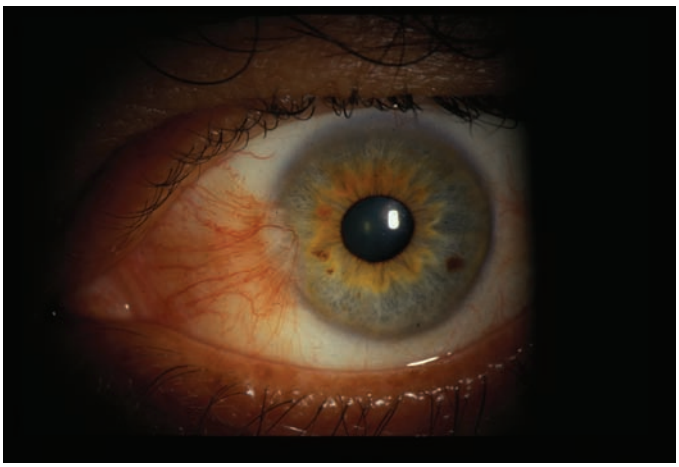

FIGURE 25-14 Pterygium that often becomes irritated and injected. (*Courtesy of Paul D. Comeau.*)

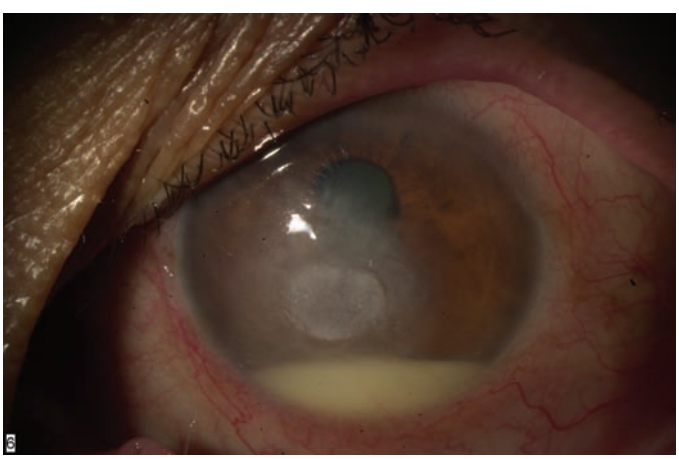

FIGURE 25-15 Hypopyon with white cells layered in the anterior chamber. (*Courtesy of Paul D. Comeau.*)

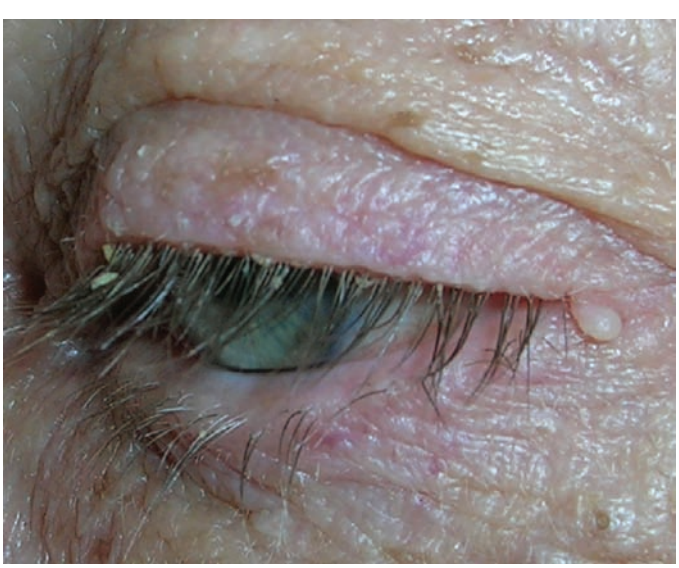

FIGURE 25-16 Blepharitis showing erythema of the eyelids and flaking in the eyelashes. Note the scale that has accumulated in the eyelashes. (*Courtesy of Richard P. Usatine, MD.*)

- Severe, purulent discharge.
- Corneal involvement.
- Conjunctival scarring.
- Lack of response to therapy.
- Topical steroid therapy.
- Recurrent episodes.
- Open globe or perforation.
- History of herpes simplex virus (HSV) eye disease.
- History of contact lens wear.

PROGNOSIS

Prognosis depends on underlying cause (see corresponding chapters).

FOLLOW-UP

Timing of follow-up and need for further testing is determined by the underlying cause (see corresponding chapters).

PATIENT EDUCATION

Advise patients to notify their physician immediately for eye pain (other than gritty discomfort) and/or loss of vision.

PATIENT RESOURCES

- FamilyDoctor.org. An algorithm to help patients determine when to seek care: *Eye Problems*—**http://familydoctor.org/familydoctor/en/health-tools/search-by-symptom/eye-problems.html.**

REFERENCES

1. Yaphe J, Pandher K. The predictive value of the penlight test for photophobia for serious eye pathology in general practice. *Fam Pract*. 2003;20(4):425-427.
2. American Academy of Ophthalmology Cornea/External Disease Panel, Preferred Practice Patterns Committee. *Conjunctivitis*. San Francisco, CA: American Academy of Ophthalmology; 2003:25.
3. Cronau H, Kankanala RR, Mauger T. Diagnosis and management of red eye in primary care. *Am Fam Physician*. 2010;81(2):137-144.

PART 5

EAR, NOSE, AND THROAT

Strength of Recommendation (SOR)	Definition
A	Recommendation based on consistent and good-quality patient-oriented evidence.*
B	Recommendation based on inconsistent or limited-quality patient-oriented evidence.*
C	Recommendation based on consensus, usual practice, opinion, disease-oriented evidence, or case series for studies of diagnosis, treatment, prevention, or screening.*

*See Appendix A on pages 1447–1450 for further information.

SECTION 1 EAR

26 OTITIS MEDIA: ACUTE OTITIS AND OTITIS MEDIA WITH EFFUSION

Brian Z. Rayala, MD

PATIENT STORY

A 15-month-old boy is brought by both parents to his family physician with a 2-day history of fever, irritability, and frequent tugging of his left ear. This was preceded by a 1-week history of nasal congestion, cough, and rhinorrhea. On otoscopy, his left tympanic membrane (TM) appears erythematous, cloudy, bulging, and exudative (**Figure 26-1**). His left TM fails to move on pneumatic otoscopy. The physician diagnoses acute otitis media and decides with the parents to prescribe a 10-day course of amoxicillin; the child recovers uneventfully.

In follow-up 2 months later, the child appears healthy and is meeting all his developmental milestones. On otoscopic examination, air–fluid levels are seen in the right ear (**Figure 26-2**). The physician explains the diagnosis of otitis media with effusion to the parents and arranges follow-up. Three months later the effusion is completely resolved.

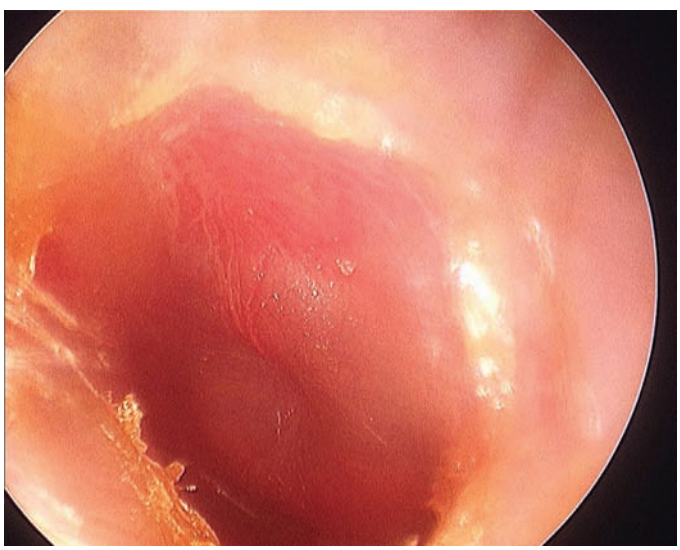

FIGURE 26-1 Acute otitis media in the left ear of a 15-month-old patient with marked erythema and bulging of the tympanic membrane. The malleus and light reflex are not visible. (*Courtesy of William Clark, MD.*)

INTRODUCTION

Acute otitis media (AOM) is the most common diagnosis for acute office visits for children.[1] AOM is characterized by middle-ear effusion in a patient with signs and symptoms of acute illness (e.g., fever, irritability, otalgia). Otitis media with effusion (OME) is a disorder characterized by fluid in the middle ear in a patient without signs and symptoms of acute ear infection; it is also very common in childhood.

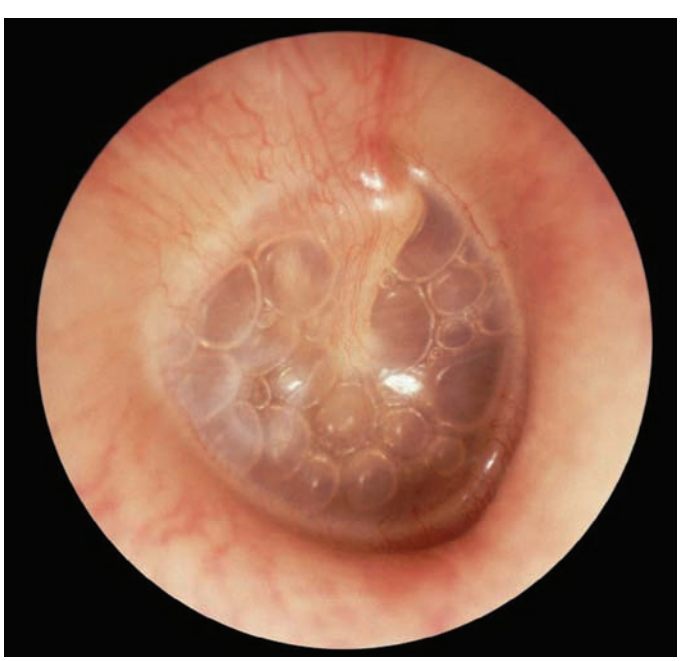

FIGURE 26-2 Otitis media with effusion (OME) in the right ear. Note multiple air–fluid levels in this slightly retracted, translucent, nonerythematous tympanic membrane. (*Courtesy of Frank Miller, MD.*)

EPIDEMIOLOGY

- AOM accounted for $5 billion of the total national health expenditure in 2000; more than 40% was incurred for children between 1 and 3 years of age.[1]
- It is estimated that 60% to 80% of children in the United States develop AOM by 1 year of age and that 80% to 90% develop AOM by 2 to 3 years of age.[2,3]
- The highest incidence occurs between 6 and 24 months of age.[2,3]
- AOM is the most common reason for outpatient antibiotic treatment in the United States.[4] A national survey in 1992 revealed that 30% of all antibiotics prescribed for children younger than age 18 years was for treatment of AOM.[5]
- OME is diagnosed in 2.2 million children yearly in the United States.[6]

- Approximately 90% of children (80% of individual ears) have OME at some time before school age, most often between ages 6 months and 4 years.[6]
- The combined direct and indirect health care costs of OME amount to $4 billion annually.[6]

ETIOLOGY AND PATHOPHYSIOLOGY

AOM is often preceded by upper respiratory symptoms such as cough and rhinorrhea.

- Pathogenesis of AOM includes:[7]
  - Eustachian tube dysfunction (usually a result of an upper respiratory infection) and subsequent tube obstruction.
  - Increased negative pressure in the middle ear.
  - Accumulation of middle-ear fluid.
  - Microbial growth.
  - Suppuration (that leads to clinical signs of AOM).
- Most common pathogens in the United States and United Kingdom are:[8,9]
  - Strains of *Streptococcus pneumoniae* not in the heptavalent pneumococcal vaccine (PCV7) (after introduction of PCV7 vaccine in 2000).
  - Nonencapsulated (nontypable) *Haemophilus influenzae* (NTHi).
  - *Moraxella catarrhalis.*
  - *Staphylococcus aureus.*
- Viruses account for 16% of cases. Respiratory syncytial viruses, rhinoviruses, influenza viruses, and adenoviruses have been the most common isolated viruses.[10]

OME most commonly follows AOM; it may also occur spontaneously.

- Fluid limits sound conduction through the ossicles and results in decreased hearing.
- Reasons for the persistence of fluid in otitis media remain unclear, although potential etiologies include allergies, biofilm, and physiologic features.
- "Glue ear" refers to extremely viscous mucoid material within the middle ear and is a distinct subtype of OME.

RISK FACTORS

- The most important risk factors for AOM include young age and attendance at daycare centers.
- Other risk factors include:[11]
  - White race.
  - Male gender.
  - History of enlarged adenoids, tonsillitis, or asthma.
  - Multiple previous episodes.
  - Bottle feeding.
  - History of ear infections in parents or siblings.
  - Use of a soother or pacifier.
- Second-hand smoke is a risk factor when parents smoke at home.
- Risk factors for OME include age 6 years or younger, large number of siblings, low socioeconomic group, frequent upper respiratory tract infection, tobacco exposure, daycare attendance, and bottle feeding.[12]

FIGURE 26-3 Otitis media with effusion in the left ear showing retraction of the TM and straightening of the handle of the malleus as the retraction pulls the bone upward. (*Courtesy of Glen Medellin, MD.*)

DIAGNOSIS

CLINICAL FEATURES OF AOM

- To diagnose AOM, the clinician should confirm a history of acute onset, identify signs of middle-ear effusion (MEE), *and* evaluate for the presence of signs and symptoms of middle-ear inflammation.[6] SOR C
- Elements of the definition of AOM are *all* of the following:[6]
  1. Recent, usually abrupt, onset of signs and symptoms of middle-ear inflammation and MEE.
  2. The presence of MEE. Although MEE is often presumed by bulging of the TM (**Figure 26-1**) or air–fluid level behind the TM (**Figure 26-2**), the guideline stresses use of objective measures of confirming MEE such as:[6]
     a. Limited or absent mobility of the TM established by pneumatic otoscopy—The TM does not move during air insufflation; often initially seen as retraction of the TM (**Figures 26-3** and **26-4**).
     b. Objective measures such as tympanometry.
     c. Otorrhea.
  3. Signs or symptoms of middle-ear inflammation as indicated by either:
     a. Distinct erythema of the TM (**Figure 26-1**) in contrast to the normal TM (**Figure 26-5**), or
     b. Distinct otalgia (discomfort clearly referable to the ear[s] that results in interference with or precludes normal activity or sleep).

CLINICAL FEATURES OF OME

- The most common symptom, present in more than half of patients, is mild hearing loss. This is usually identified when parents express concern regarding their child's behavior, performance at school, or language development.[12]
- Absence of signs and symptoms of acute illness assists in differentiating OME from AOM.
- Common otoscopic findings include:
  - Air–fluid level or bubble (**Figure 26-2**).
  - Cloudy TM (**Figures 26-4** and **26-6**) in contrast to the normal TM (**Figure 26-5**).
  - Redness of the TM may be present in approximately 5% of ears with OME.
- Clinicians should use pneumatic otoscopy as the primary diagnostic method for OME SOR A.[13]
  - Impaired mobility of the TM is the hallmark of MEE.
  - According to a metaanalysis, impaired mobility on pneumatic otoscopy has a pooled sensitivity of 94% and specificity of 80%, and positive likelihood ratio of 4.7 and negative likelihood ratio of 0.075.[13]

LABORATORY TESTS AND IMAGING

- Because AOM and OME are clinical diagnoses, diagnostic testing has a limited role. When clinical presentation and physical examination (including otoscopy) do not establish the diagnosis, the following can be used as adjunctive techniques:
  - Tympanometry—This procedure records compliance of the TM by measuring reflected sound. AOM and OME will plot as a reduced or flat waveform. This technique requires patient cooperation but provides more objective data.

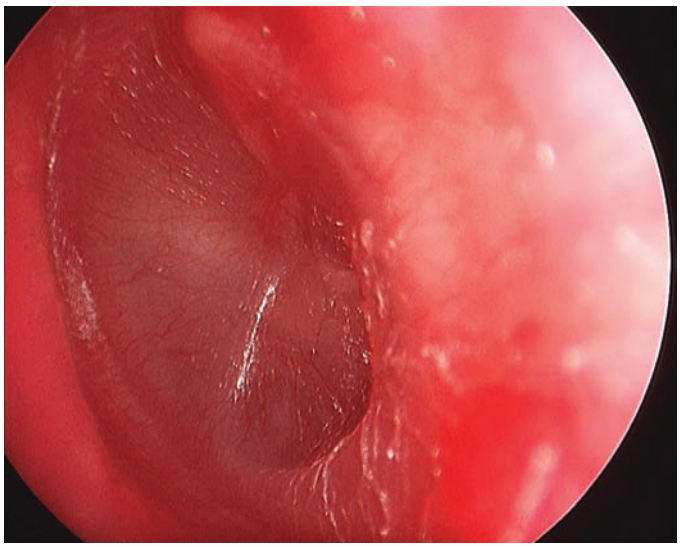

FIGURE 26-4 Early acute otitis media at the stage of eustachian tube obstruction. Note the slight retraction of the TM, the more horizontal position of the malleus, and the prominence of the lateral process. (*Courtesy of William Clark, MD.*)

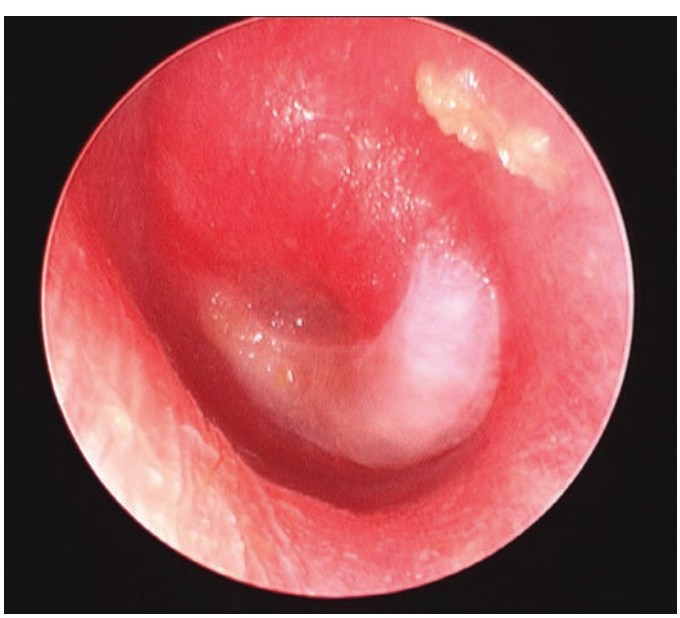

FIGURE 26-5 Acute otitis media, stage of suppuration. Note presence of purulent exudate behind the TM, the outward bulging of the TM, prominence of the posterosuperior portion of the drum, and generalized TM edema. The *white area* is tympanosclerosis from a previous infection. (*Courtesy of William Clark, MD.*)

- Acoustic reflectometry—This procedure, very similar to tympanometry, measures sound reflectivity from the middle ear. With this test, the clinician is able to distinguish air- or fluid-filled space without requiring an airtight seal of the ear canal.
- Middle ear aspiration—For patients with AOM, aspiration may be warranted if patient is toxic, is immunocompromised, or has failed prior courses of antibiotics.

DIFFERENTIAL DIAGNOSIS

The key differentiating feature between AOM and OME is the absence of signs and symptoms of acute illness in OME (e.g., fever, irritability, otalgia). Otoscopic findings may be similar. Other clinical entities that may be confused with AOM and OME include:

- Otitis externa—Otitis externa presents with otalgia, otorrhea and mild hearing loss, all of which can be present in AOM. Tragal pain on physical exam and signs of external canal inflammation on otoscopic exam differentiate it from AOM. Careful ear irrigation if tolerated may be helpful to visualize the TM to differentiate otitis externa from AOM (see Chapter 27, Otitis Externa).
- Otitic barotrauma—This often presents with severe otalgia. Key historical features include recent air travel, scuba diving, or ear trauma, preceded by an upper respiratory infection.
- Cholesteatoma—Unlike AOM, this is a clinically silent disease in its initial stages. Presence of white keratin debris in the middle ear cavity (on otoscopy) is diagnostic (**Figures 26-7** and **26-8**).
- Foreign body—A foreign body may present with otalgia. Otoscopy reveals presence of foreign body (see Chapter 28, Ear: Foreign Body).
- Bullous myringitis—Bullous myringitis is often associated with viral or mycoplasma infection as well as usual AOM pathogens; in approximately one-third of patients, there is a component of sensorineural hearing loss. Otoscopy shows serous-filled bulla on the surface of the TM (**Figure 26-9**). Patients present with severe otalgia.
- Chronic suppurative otitis media (CSOM)—Otoscopy shows TM perforation and otorrhea; history reveals a chronically draining ear and recurrent middle-ear infections with or without hearing loss.
- Referred otalgia—This is rare in children and in cases of bilateral otalgia. Should be considered in cases of otalgia that do not fit clinical features of AOM. Referred pain usually from other head and neck structures (e.g., teeth, jaw, cervical spine, lymph and salivary glands, nose and sinuses, tonsils, tongue, pharynx, meninges).
- Mastoiditis—Mastoiditis may be differentiated from simple AOM by presence of increasing pain and tenderness over mastoid bone in a patient with AOM who has not been treated by antibiotics, or recurrence of mastoid pain and tenderness in patients treated with antibiotics. Recurrence or persistence of fever, as well as progressive otorrhea, are other historical clues. The mastoid swelling may cause the pinna to protrude further than normal (**Figure 26-10**).
- Traumatic perforation of the TM (**Figure 26-11**)—A hole in the TM is seen without purulent drainage.

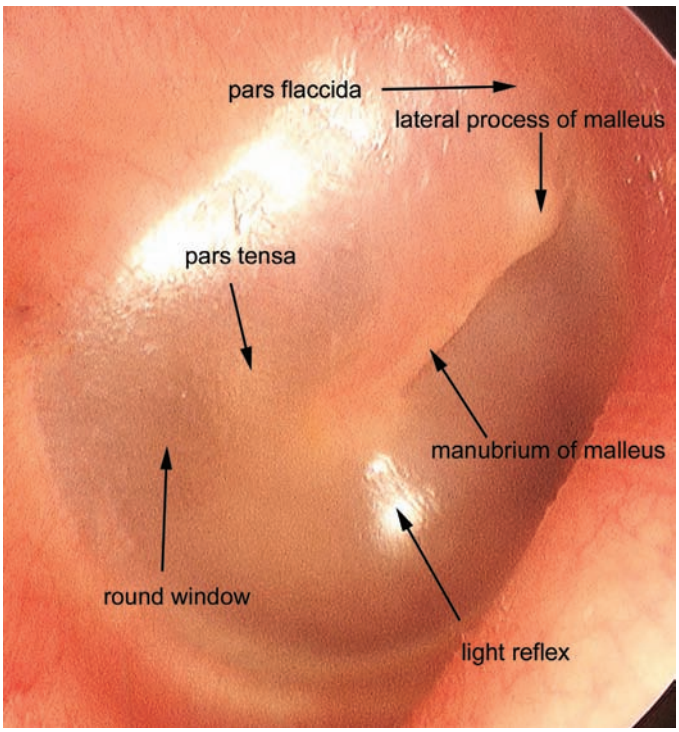

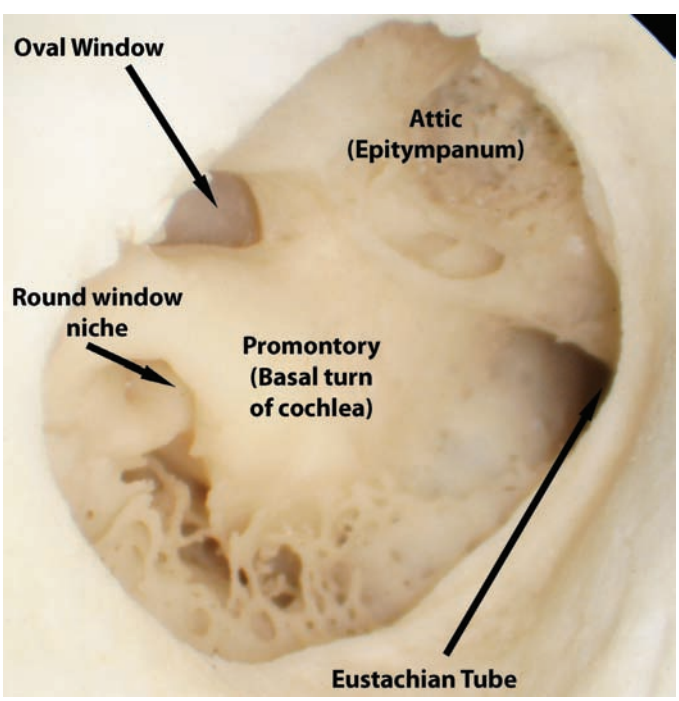

FIGURE 26-6 Normal right tympanic membrane with comparison using normal bony landmarks of the inner ear. The ossicles were removed in this dissection. (*Courtesy of William Clark, MD.*)

MANAGEMENT

NONPHARMACOLOGIC

Antibiotics are not necessary to treat uncomplicated AOM in an otherwise healthy child.[14] SOR A

Management of OME primarily consists of watchful waiting. Most cases resolve spontaneously within 3 months; only 5% to 10% last 1 year or longer. Treatment depends on duration and associated conditions. The following options should be considered:

- Document the laterality, duration of effusion, and presence and severity of associated symptoms at each assessment of the child with OME.[6] SOR C
- Distinguish the child with OME who is at risk for speech, language, or learning problems from other children with OME and more promptly evaluate hearing, speech, language, and need for intervention in children at risk.[6] SOR C Risk factors for developmental difficulties include:
  - Permanent hearing loss independent of OME.
  - Suspected or diagnosed speech and language delay or disorder.
  - Autism-spectrum disorder and other pervasive developmental disorders.
  - Syndromes (e.g., Down syndrome) or craniofacial disorders that include cognitive, speech, and language delays.
  - Blindness or uncorrectable visual impairment.
  - Cleft palate with or without associated syndrome.
  - Developmental delay.
- Manage the child with OME who is not at risk with watchful waiting for 3 months from the date of effusion onset (if known) or diagnosis (if onset is unknown).[6] SOR B
- Hearing testing is recommended when OME persists for 3 months or longer or at any time if language delay, learning problems, or significant hearing loss is suspected in a child with OME.[6] SOR B
- Autoinflation with nasal balloon, in one systematic review, provided short-term benefits, although 12% of children ages 3 to 10 years were unable to use it.[12]

MEDICATIONS

- Oral acetaminophen (paracetamol) and ibuprofen may reduce earache when given with antibiotics.[15] There is insufficient data to evaluate the effectiveness of topical analgesics in AOM.[16] SOR B
- Antibiotics seem to be most beneficial in children younger than 2 years of age with bilateral AOM, high fever, or vomiting, and in children with both AOM and otorrhea. For most other children with mild disease, an observational policy seems justified.[14,17] SOR B
- Antibiotics may lead to more rapid reduction in symptoms of AOM, but increase the risk of adverse effects, including diarrhea, vomiting, and rash.[15] SOR B
  - Antibiotics seem to reduce pain at 2 to 7 days, and may prevent development of contralateral AOM, but increase the risks of adverse effects compared with placebo.[13]
  - There is insufficient effectiveness data regarding which antibiotic regimen is better than another.[13,15]

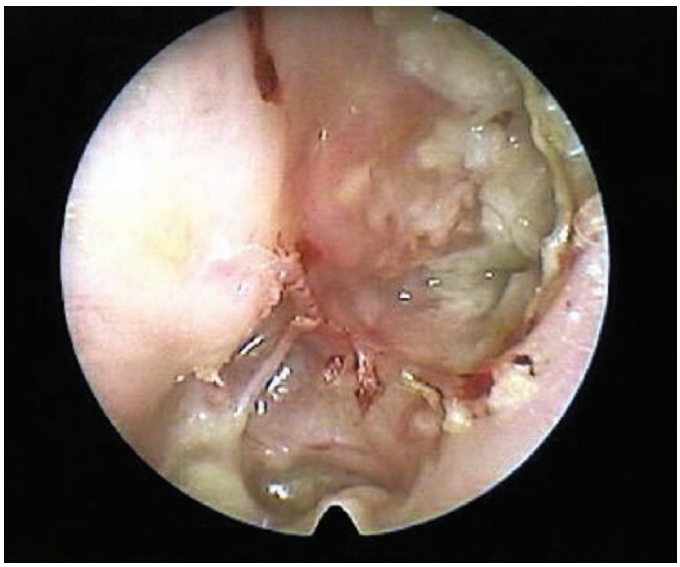

FIGURE 26-7 Cholesteatoma. (*Courtesy of Vladimir Zlinsky, MD, in Roy F. Sullivan, PhD. Audiology Forum: Video Otoscopy, www.rcsullivan.com.*)

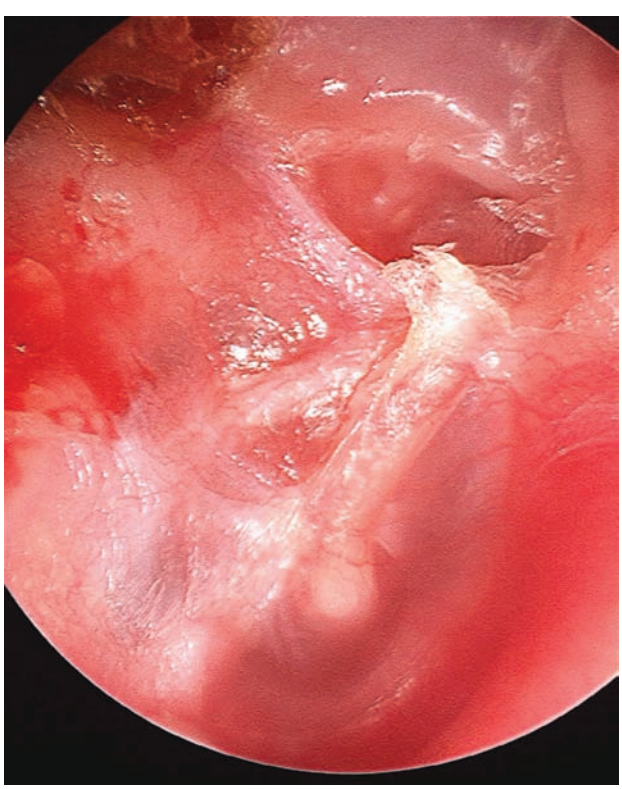

FIGURE 26-8 Primary acquired cholesteatoma with debris removed from the attic retraction pocket. (*Courtesy of William Clark, MD.*)

- Antibiotics found to be effective in AOM include amoxicillin, amoxicillin/clavulanic acid, ampicillin, penicillin, erythromycin, azithromycin, trimethoprim-sulfamethoxazole, and cephalosporins. Amoxicillin is a good first-line treatment because it is inexpensive and children tolerate the bubblegum taste well.
- Longer (8- to 10-day) courses of antibiotics reduce short-term treatment failure but have no long-term benefits compared with shorter regimens (5-day courses).[15,18]
- An observational approach substantially reduces unnecessary use of antibiotics in children with AOM and may be an alternative to routine use of antimicrobials for treatment of such children.[19]

- Immediate antibiotic treatment (i.e., given at initial consultation) may reduce the duration of symptoms of AOM, but increases the risk of vomiting, diarrhea, and rash compared with delayed treatment (i.e., given after 72 hours).[15] SOR B
- Treatment of AOM with decongestants and antihistamines is not recommended.[20] SOR B
- Antihistamines and decongestants are not effective for OME.[6] SOR A
- Antimicrobials and corticosteroids are not recommended for OME.[6] SOR A

COMPLEMENTARY AND ALTERNATIVE THERAPY

- Evidence on whether zinc supplementation can reduce the incidence of otitis media in healthy children younger than the age of 5 years living in low- and middle-income countries is mixed.[21] SOR B

REFERRAL

- Refer to specialist (otolaryngologist, audiologist, or speech-language pathologist) if:[6] SOR C
  - Persistent fluid for 4 or more months with persistent hearing loss.
  - Associated speech delay.
  - Structural damage to TM or middle-ear.
- Tympanostomy tubes for children with recurrent AOM (3 or more episodes of AOM in 6 months, or 4 or more AOM in 1 year) have a significant role in maintaining a "disease-free" state in the first 6 months after insertion. Because long-term effectiveness is uncertain, clinicians should consider possible adverse effects before surgery is undertaken.[22] SOR B
- Insertion of tympanostomy tubes in young children with persistent middle-ear infection does not improve cognitive development, language acquisition, or speech development compared with waiting 6 to 9 months for the effusion to resolve before placing the tubes.[23] Moreover, delayed insertion of tubes helps children avoid getting tubes altogether and does not result in worse developmental outcomes.[24] SOR A
- When a child becomes a surgical candidate, tympanostomy tube insertion is the preferred initial procedure; adenoidectomy should not be performed unless a distinct indication exists (e.g., nasal obstruction, chronic adenoiditis).[6] SOR B
- Repeat surgery consists of adenoidectomy plus myringotomy, with or without tube insertion. Tonsillectomy alone or myringotomy alone should not be used to treat OME.[6] SOR B

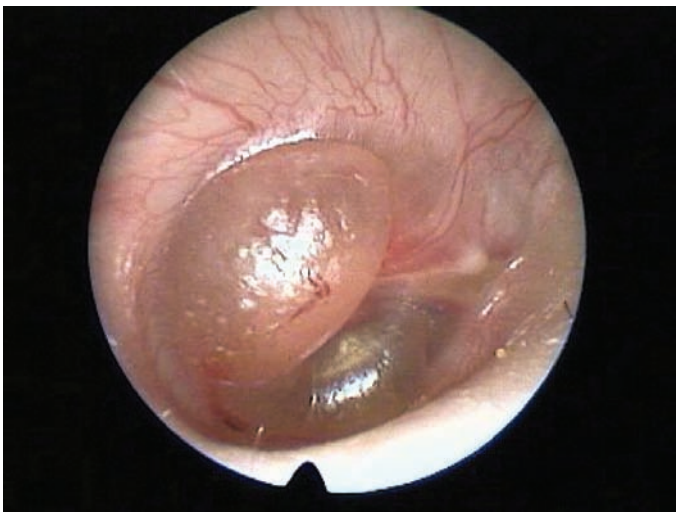

FIGURE 26-9 Bullous myringitis can be differentiated from otitis media with effusion by identifying serous-filled bulla on the surface of the TM. (*Courtesy of Vladimir Zlinsky, MD, in Roy F. Sullivan, PhD. Audiology Forum: Video Otoscopy, www.rcsullivan.com.*)

PREVENTION

- The currently licensed PCV7 administered during infancy has marginal beneficial effects for the prevention of AOM.[25] Although PCV7 only confers a marginal decrease in AOM episodes for the individual, it may still have a substantial impact on the healthcare burden of AOM. Administering PCV7 in older children with a history of AOM appears to have no benefit in preventing further episodes.[25] SOR A
- For children at risk, antibiotics given once or twice daily reduces the probability of AOM while the child is on treatment. In similar populations, antibiotics reduce the number of episodes of AOM per year from around 3 to around 1.5. Although this appears as a marginal reduction for the individual, it may have larger absolute benefits from a population standpoint. These benefits need to be balanced with the increased risks of vomiting, diarrhea, and rash.[15,26] SOR A
- Xylitol chewing gum or syrup given 5 times daily has a small preventive effect on recurrence of AOM, but the compliance issues in giving a medicine to such young children 5 times daily render it an unrealistic treatment option.[15] SOR B
- Tympanostomy tubes lead to short-term reduction in the number of episodes of AOM but increase the risk of complications (i.e., tympanosclerosis; **Figures 26-12** and **26-13**).[15] SOR B

PROGNOSIS

- Without antibiotics, AOM resolves within 24 hours in approximately 60% of children and within 3 days in approximately 80% of children. Rate of suppurative complications if antibiotics are withheld is 0.13%.[27]
- Most cases of OME resolve spontaneously within 3 months; only 5% to 10% last 1 year or longer. However, effusion will recur in 30% to 40% of patients.[6]

FOLLOW-UP

- If a patient with AOM fails to respond to the initial management option within 48 to 72 hours, the clinician should reassess the patient to confirm AOM and exclude other causes of illness. If AOM is confirmed in a patient initially managed with observation, the clinician should begin antibiotics. If the patient was initially managed with antibiotics, the clinician should change antibiotics.[6] SOR B
- Potentially serious complications of AOM, such as mastoiditis or facial nerve involvement, require urgent referral.
- There is no consensus in the medical community regarding timing of posttreatment follow-up of AOM or who should be receiving follow-up. There is some evidence that parents can be reliable predictors in the resolution or persistence of AOM following antibiotic treatment.[28]
- Children with persistent OME who are not thought to be at significant risk should be reexamined at 3- to 6-month intervals until the effusion is gone, significant hearing loss is identified, or structural abnormalities of the eardrum or middle ear are suspected.[6] SOR B

FIGURE 26-10 **A.** Mastoiditis in a young boy with recurrent otitis media. Note the erythema and swelling behind the ear. The ear is sticking out more than the other side. **B.** Surgical drainage was performed. (*Courtesy of William Clark, MD.*)

PATIENT EDUCATION

- Patient education should focus on identification, prevention, and control of risk factors (see above).
- Parents should be made aware of the high rates of spontaneous resolution of AOM and potential adverse effects of antibiotics. Providing a prescription for an antibiotic at the initial visit but advising delay of initiation of medication (i.e., observational approach for up to 48 hours) is an alternative to immediate treatment and is associated with lower antibiotic use.[19]
- Patients should be informed that the natural history of OME is spontaneous resolution.
  - Periodic follow-up to monitor resolution of MEE is extremely important.
  - If MEE is persistent and signs and symptoms of hearing loss, language difficulties, and learning problems arise, additional treatment may be considered.

PATIENT RESOURCES

AOM

- **http://www.nlm.nih.gov/medlineplus/ency/article/000638.htm.**
- **http://www.nidcd.nih.gov/health/hearing/earinfections.**
- **http://familydoctor.org/online/famdocen/home/common/ear/055.html.**
- **http://www.kidshealth.org/PageManager.jsp?dn=familydoctor&lic=44&article_set=22743.**
- **http://www.nhs.uk/conditions/Otitis-media/Pages/Introduction.aspx.**

OME

- **http://familydoctor.org/online/famdocen/home/common/ear/330.html.**
- **http://www.nlm.nih.gov/medlineplus/ency/article/007010.htm.**

PROVIDER RESOURCES

AOM

- Guideline: diagnosis and management of acute otitis media. Clinical Practice Guideline by the American Academy of Family Physicians, American Academy of Otolaryngology-Head and Neck Surgery, and American Academy of Pediatrics Subcommittee on Management of Acute Otitis Media. *Pediatrics.* 2004;113:1451-1465.
- **http://www.npc.nhs.uk/merec/infect/commonintro/resources/merec_bulletin_vol17_no3_acute_otitis_media.pdf.**
- **http://www.bcguidelines.ca/pdf/otitaom.pdf**.
- **http://www.gpnotebook.co.uk/simplepage.cfm?ID=1926234161.**

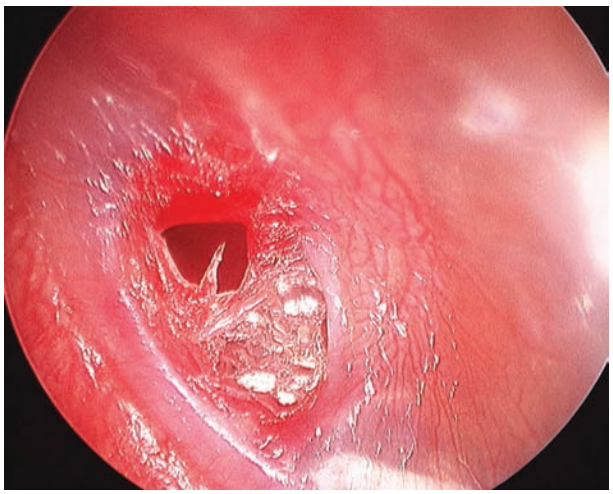

FIGURE 26-11 Traumatic perforation of the left tympanic membrane. (*Courtesy of William Clark, MD.*)

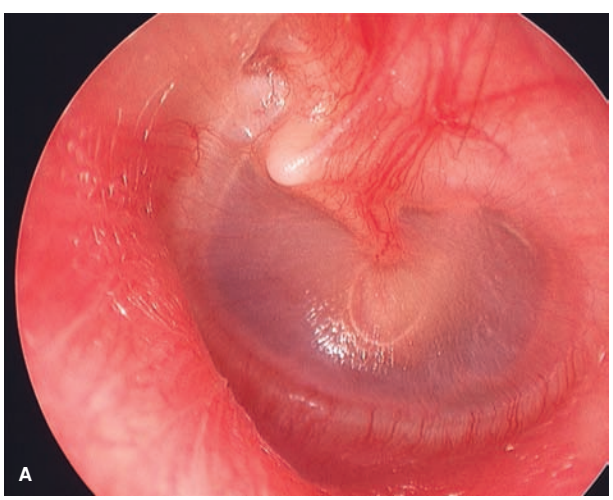

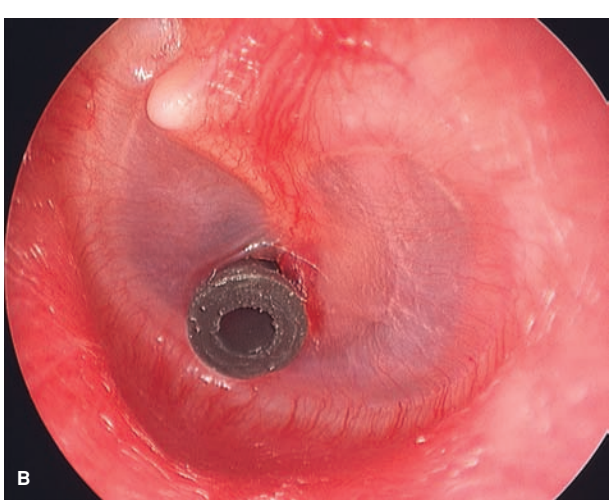

FIGURE 26-12 **A.** Left TM of a 9-year-old girl with recurrent acute otitis media and chronic TM retractions prior to polyethylene (PE) tube placement. The circular area near the center of the TM is caused by the TM being retracted against the promontory of the medial wall of the middle ear. **B.** A fluoroplastic polyethylene (PE) tube is placed in the anterior-inferior quadrant of the TM of a 9-year-old girl with recurrent acute otitis media. It is black because it is impregnated with silver oxide to retard the growth of bacterial microfilms. (*Courtesy of William Clark, MD.*)

OME

- Guideline: otitis media with effusion. Clinical Practice Guideline by the American Academy of Family Physicians, American Academy of Otolaryngology-Head and Neck Surgery, and American Academy of Pediatrics Subcommittee on Otitis Media With Effusion. *Pediatrics*.2004;113:1412-1429.
- **http://www.bcguidelines.ca/pdf/otitome.pdf.**

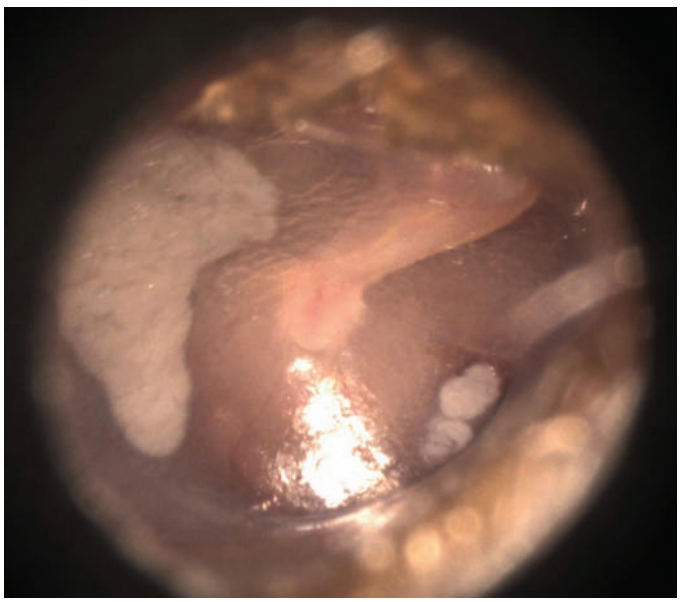

FIGURE 26-13 Tympanosclerosis as the result of previous recurrent episodes of otitis media and polyethylene (PE) tube placement. (*Courtesy of Glen Medellin, MD.*)

REFERENCES

1. Bondy J, Berman S, Glazner J, Lezotte D. Direct expenditures related to otitis media diagnoses: extrapolations from a pediatric medicaid cohort. *Pediatrics.* 2000;105(6):E72.
2. Teele DW, Klein JO, Rosner BA. Epidemiology of otitis media during the first seven years of life in children in greater Boston: a prospective, cohort study. *J Infect Dis.* 1989;160(1):83-94.
3. Paradise JL, Rockette HE, Colborn DK, et al. Otitis media in 2253 Pittsburgh-area infants: prevalence and risk factors during the first two years of life. *Pediatrics.* 1997;99(3):318-333.
4. Del Mar C, Glasziou P, Hayem M. Are antibiotics indicated as initial treatment for children with acute otitis media? A meta-analysis. *BMJ.* 1997;314:1526-1529.
5. Nyquist AC, Gonzales R, Steiner JF, Sande MA. Antibiotic prescribing for children with colds, upper respiratory tract infections, and bronchitis. *JAMA.* 1998;279:875.
6. Guideline: otitis media with effusion. Clinical practice guideline by the American Academy of Family Physicians, American Academy of Otolaryngology-Head and Neck Surgery, and American Academy of Pediatrics Subcommittee on Otitis Media With Effusion. *Pediatrics.* 2004;113:1412-1429.
7. Rovers MM, Schilder AG, Zielhuis GA, Rosenfeld RM. Otitis media. *Lancet.* 2004;363:465.
8. Casey JR, Adlowitz DG, Pichichero ME. New patterns in the otopathogens causing acute otitis media six to eight years after introduction of pneumococcal conjugate vaccine. *Pediatr Infect Dis J.* 2010;29(4):304-309.
9. McEllistrem MC. Acute otitis media due to penicillin-nonsusceptible *Streptococcus pneumoniae* before and after the introduction of the pneumococcal conjugate vaccine. *Clin Infect Dis.* 2005;40(12):1738-1744.
10. Ruuskanen O, Arola M, Heikkinen T, Ziegler T. Viruses in acute otitis media: increasing evidence for clinical significance. *Pediatr Infect Dis J.* 1991;10:425.9.
11. Froom J, Culpepper L, Jacobs M, et al. Antimicrobials for acute otitis media? A review from the International Primary Care Network. *BMJ.* 1997;315:98-102.
12. Williamson I. Otitis media with effusion in children. *Clin Evid.* 2011;01:502-531.
13. Takata GS, Chan LS, Morphew T, et al. Evidence assessment of the accuracy of methods of diagnosing middle ear effusion in children with otitis media with effusion. *Pediatrics.* 2003;112:1379-1387.

14. Gamboa S, Park MK, Wanserski G, Lo V. Clinical inquiries. Should you use antibiotics to treat acute otitis media in children? *J Fam Pract.* 2009;58(11):602-604.

15. Damoiseaux RA, Rovers MM. AOM in children. *Clin Evid (Online).* 2011 May 10;2011. pii: 0301.

16. Foxlee R, Johansson A, Wejfalk J, Dawkins J, Dooley L, Del Mar C. Topical analgesia for acute otitis media. *Cochrane Database Syst Rev.* 2006;3:CD005657.

17. Rovers MM, Glasziou P, Appelman CL, et al. Antibiotics for acute otitis media: a meta-analysis with individual patient data. *Lancet.* 2006;368:1429-1435.

18. Kozyrskyj AL, Hildes-Ripstein GE, Longstaffe SE, et al. Short-course antibiotics for acute otitis media. *Cochrane Database Syst Rev.* 2000;(2):CD001095.

19. Spiro DM, Tay KY, Arnold DH, et al. Wait-and-see prescription for the treatment of acute otitis media: a randomized controlled trial. *JAMA.* 2006;296:1235-1241.

20. Flynn CA, Griffin GH, Schultz JK. Decongestants and antihistamines for acute otitis media in children. *Cochrane Database Syst Rev.* 2004;3:CD001727.

21. Abba K, Gulani A, Sachdev HS. Zinc supplements for preventing otitis media. *Cochrane Database Syst Rev.* 2010;(2):CD006639.

22. McDonald S, Langton Hewer CD, Nunez DA. Grommets (ventilation tubes) for recurrent acute otitis media in children. *Cochrane Database Syst Rev.* 2008;(4):CD004741.

23. Paradise JL, Dollaghan CA, Campbell TF, et al. otitis media and tympanostomy tube insertion during the first three years of life: developmental outcomes at the age of four years. *Pediatrics.* 2003;112:265-277.

24. Paradise JL, Feldman HM, Campbell TF, et al. Tympanostomy tubes and developmental outcomes at 9 to 11 years of age. *N Engl J Med.* 2007;356:300-302.

25. Jansen AGSC, Hak E, Veenhoven RH, et al. Pneumococcal conjugate vaccines for preventing otitis media. *Cochrane Database Syst Rev.* 2009;(2):CD001480.

26. Leach AJ, Morris PS. Antibiotics for the prevention of acute and chronic suppurative otitis media in children. *Cochrane Database Syst Rev.* 2006;(4):CD004401.

27. Rosenfeld RM. Natural history of untreated otitis media. *Laryngoscope.* 2003;113:1645-1657.

28. Raimer PL. *Parents Can Be Reliable Predictors in the Resolution or Persistence of Acute Otitis Media Following Antibiotic Treatment.* University of Michigan Department of Pediatrics Evidence-based Pediatrics Web site. 2005. http://www.med.umich.edu/pediatrics/ebm/cats/omparent.htm. Accessed February 2012.

27 OTITIS EXTERNA

Brian Z. Rayala, MD

PATIENT STORY

A 40-year-old woman with type 2 diabetes presents to her family physician with a 2-day history of bilateral otalgia, otorrhea, and hearing loss. Symptoms started in the right ear and then rapidly spread to the left ear. She had a low-grade fever and was systemically ill. The external ear was swollen with honey-crusts (**Figures 27-1** and **27-2**). The external auditory canal (EAC) was narrowed and contained purulent discharge (**Figure 27-3**). Ear, nose, and throat (ENT) was consulted and she was admitted to the hospital for the presumptive diagnosis of malignant otitis externa. The MRI showed some destruction of the temporal bone. She was started on IV ciprofloxacin and the ear culture grew out *Pseudomonas aeruginosa* sensitive to ciprofloxacin. The patient responded well to treatment and was able to go home on oral ciprofloxacin 5 days later.

FIGURE 27-1 Malignant/necrotizing otitis externa in a 40-year-old woman with diabetes. Note the swelling and honey-crusts of the pinna. The EAC and temporal bone were involved. (*Courtesy of E.J. Mayeaux, MD.*)

INTRODUCTION

Otitis externa (OE) is common in all parts of the world. OE is defined as inflammation, often with infection, of the EAC.[1]

EPIDEMIOLOGY

- Incidence of OE is not known precisely; its lifetime incidence was estimated at 10% in one study.[2]
- Occurs more in adults than in children.

ETIOLOGY AND PATHOPHYSIOLOGY

- Common pathogens, which are part of normal EAC flora, include aerobic organisms predominantly (*P. aeruginosa and Staphylococcus aureus*) and, to a lesser extent, anaerobes (*Bacteroides* and *Peptostreptococcus*). Up to a third of infections are polymicrobial. A small proportion (2% to 10%) of OE is caused by fungal overgrowth (e.g., *Aspergillus niger* usually occurs with prolonged antibiotic use).[1]
- Pathogenesis of OE includes the following:
  - Trauma, the usual inciting event, leads to breech in the integrity of EAC skin.
  - Skin inflammation and edema ensue, which, in turn, leads to pruritus and obstruction of adnexal structures (e.g., cerumen glands, sebaceous glands, and hair follicles).
  - Pruritus leads to scratching, which results in further skin injury.
  - Consequently, the milieu of the EAC is altered (i.e., change in quality and quantity of cerumen, increase in pH of EAC, and dysfunctional epithelial migration).
  - Finally, the EAC becomes a warm, alkaline, and moist environment—ideal for growth of different pathogens.

FIGURE 27-2 Another view of the malignant/necrotizing otitis externa. (*Courtesy of E.J. Mayeaux, MD.*)

RISK FACTORS[3]

- Environmental factors:
  - Moisture—Macerates skin of EAC, elevates pH, and removes protective cerumen layer (from swimming, perspiration, high humidity).
  - Trauma—Leads to injury of EAC skin (from cotton buds, fingernails, hearing aids, ear plugs, paper clips, match sticks, mechanical removal of cerumen).
  - High environmental temperatures.
- Host factors:
  - Anatomical—Wax and debris accumulate and lead to moisture retention (e.g., a narrow ear canal, hairy ear canal).
  - Cerumen—Absence or overproduction of cerumen (leads to loss of the protective layer and moisture retention, respectively).
  - Chronic dermatologic disease (e.g., atopic dermatitis, psoriasis, seborrheic dermatitis).
  - Immunocompromise (e.g., chemotherapy, HIV, AIDS).

DIAGNOSIS

CLINICAL FEATURES

- OE can either be localized, like a furuncle, or generalized (**Figure 27-4**). The latter is known as "diffuse OE," or simply OE. Seborrheic dermatitis of the external ear and EAC can be diffuse or generalized (see **Figure 27-4**).
- Forms of (diffuse) OE:[1]
  - Acute (<6 weeks; **Figures 27-5** and **27-6**).
  - Chronic (>3 months)—May cause hearing loss and stenosis of the EAC (**Figure 27-7**).
  - Necrotizing or malignant form—Defined by destruction of the temporal bone, usually in diabetics or immunocompromised people; often life-threatening (see **Figure 27-1**).
- Key historical features include:
  - Otalgia, including pruritus.
  - Otorrhea (see **Figure 27-3**).
  - Mild hearing loss.
- Key physical findings include:
  - Pain with tragal pressure or pain when the auricle is pulled superiorly; this may be absent in very mild cases.
  - Signs of EAC inflammation (edema, erythema, aural discharge) (see **Figures 27-5** through **27-7**).
  - Fever, periauricular erythema, and lymphadenopathy point to severe disease.
  - Complete obstruction of EAC occurs in advanced OE.
- Establishing the integrity of the tympanic membrane (TM) (through direct visualization) and the absence of middle-ear effusion (through pneumatic otoscopy) is crucial in differentiating OE from other diagnoses (e.g., suppurative otitis media, cholesteatoma).

LABORATORY AND IMAGING

- Because OE is mostly a clinical diagnosis, diagnostic testing has a limited role. When a patient fails to respond to empiric treatment,

FIGURE 27-3 Chronic suppurative otitis media with purulent discharge chronically draining from the ear of this 25-year-old man. This image could be seen in acute otitis media with perforation of the tympanic membrane or in a purulent otitis externa. (*Courtesy of Richard P. Usatine, MD.*)

FIGURE 27-4 Seborrheic dermatitis causing erythema and greasy scale of the external ear and ear canal. The seborrheic dermatitis itself causes breaks in the skin and the coexisting pruritus may lead the patient to damage their own ear canal. All this can become secondarily infected. (*Courtesy of Eric Kraus, MD.*)

obtaining a culture of aural discharge may help guide proper choice of treatment (antibacterial vs. antifungal agents).

- If necrotizing or malignant OE is suspected, CT or MRI of the ear/skull base is warranted.

DIFFERENTIAL DIAGNOSIS

- Chronic suppurative otitis media—Otoscopy shows TM perforation; history reveals a chronically draining ear and recurrent middle-ear infections with or without hearing loss (see **Figure 27-3**).
- Seborrheic dermatitis involving the external ear and EAC can lead to inflammation and breaks in the skin (see **Figure 27-4**). The coexisting pruritus may lead the patient to damage their own ear canal. This can all become secondarily infected and become an infected OE.
- Acute otitis media with perforated TM—Presents with purulent drainage from the canal in the setting of ear pain and clinical signs or symptoms of acute illness such as fever. If the TM is visible, it will be red with a perforation.
- Foreign body in the EAC—Otoscopy, with or without aural toilet, confirms presence of foreign body (that incites an inflammatory response, leading to otalgia and otorrhea); see Chapter 28, Ear: Foreign Body.
- Otomycosis—Pruritus is generally more prominent and EAC inflammation (otalgia and otorrhea) is less pronounced; fungal organisms have a characteristic appearance in the EAC.
- Contact dermatitis—Usually caused by ototopical agents (e.g., neomycin, benzocaine, propylene glycol); seen in patients with poor response to empiric OE treatment; prominent clinical features include pruritus, erythema of conchal bowl, crusting, and excoriations.

FIGURE 27-5 Acute otitis externa showing purulent discharge and narrowing of the ear canal. (*Courtesy of Roy F. Sullivan, PhD. Audiology Forum: Video Otoscopy, www.rcsullivan.com.*)

MANAGEMENT

NONPHARMACOLOGIC

- The effectiveness of ear cleaning is unknown.[3] SOR B
- The effectiveness of specialist aural toilet (use of operating microscope to mechanically remove material from external canal) for treating OE is unknown.[1] SOR B

MEDICATIONS

- The management of acute OE should include an assessment of pain. The clinician should recommend analgesic treatment based on the severity of pain.[4] SOR B
- Topical treatments alone are effective for uncomplicated acute OE. Additional oral antibiotics are not required.[3] SOR B
- The evidence for steroid-only drops is very limited.[3] SOR B
- Given that most topical treatments are equally effective, it would appear that in most cases the preferred choice of topical treatment may be determined by other factors, such as risk of ototoxicity, risk of contact sensitivity, risk of developing resistance, availability, cost, and dosing schedule.[3] SOR B

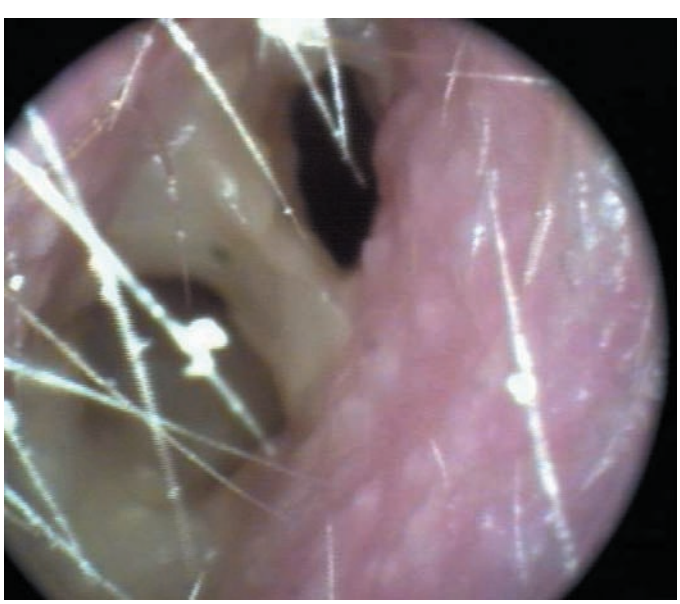

FIGURE 27-6 Acute otitis externa in an older man who wears a hearing aid. Note the viscous purulent discharge and narrowing of the ear canal. (*Courtesy of Roy F. Sullivan, PhD. Audiology Forum: Video Otoscopy, www.rcsullivan.com.*)

- Evidence from one trial of low quality found no difference in clinical efficacy between quinolone and nonquinolone drops. Quinolones are more expensive than nonquinolones.[3] SOR B
- There is some evidence indicating that patients treated with topical preparations containing antibiotics and steroids benefit from reduced swelling, severe redness, secretion, and analgesic consumption compared to preparations without steroids . There is a suggestion that high-potency steroids may be more effective than low-potency steroids (in terms of severe pain, inflammation, and swelling).[3] SOR B
- Acetic acid was effective and comparable to antibiotic/steroid at week 1. However, when treatment needed to be extended beyond this point it was less effective. In addition, patient symptoms lasted 2 days longer in the acetic acid group compared to antibiotic/steroid group.[3] SOR B
- Topical aluminum acetate may be as effective as a topical antibiotic/steroid at improving cure rates in people with acute OE.[1] SOR B

- Patients prescribed antibiotic/steroid drops can expect their symptoms to last for approximately 6 days after treatment has begun. Although patients are usually treated with topical medication for 7 to 10 days, it is apparent that this will undertreat some patients and overtreat others. It may be more useful when prescribing ear drops to instruct patients to use them for at least a week. If they have symptoms beyond the first week they should continue the drops until their symptoms resolve (and possibly for a few days after), for a maximum of an additional 7 days.[3] SOR B
- Evidence from one low-quality trial suggests a glycerine-ichthammol medicated wick may provide better pain relief in early severe acute OE than a triamcinolone/gramicidin/neomycin/nystatin medicated wick.[3] SOR B
- There is no evidence on the use of topical antifungal agents (with or without steroids) in OE.[1] SOR B

PREVENTION

- Prophylactic treatments to prevent OE (topical acetic acid, topical corticosteroids, or water exclusion) have not been evaluated in clinical trials.[1] SOR B

PROGNOSIS

- Acute OE often resolves within 6 weeks but can recur.

FOLLOW-UP

- If the patient fails to respond to empiric therapy within 48 to 72 hours, the clinician should reassess the patient to confirm the diagnosis of OE and to exclude other causes of illness.[4] SOR B
- Patients with persisting symptoms beyond 2 weeks should be considered treatment failures and alternative management initiated.[3] SOR B

FIGURE 27-7 Chronic otitis externa in an older woman who wears a hearing aid. The ear canal is not narrowed but is coated with a purulent discharge. (*Courtesy of Roy F. Sullivan, PhD. Audiology Forum: Video Otoscopy, www.rcsullivan.com.*)

PATIENT EDUCATION

- To avoid recurrent infections:[5]
  - Recommend that patients not use cotton swabs inserted into the ear canal.
  - Avoid frequent washing of the ears with soap as this leaves an alkali residue that neutralizes the normal acidic pH of the ear canal.
  - Avoid swimming in polluted waters.
  - Ensure that the canals are emptied of water after swimming or bathing—This can be done by turning the head or holding a facial tissue on the outside of the ear to act as a wick.
- Consider ear drops for swimmers who get frequent OE. A combination of a 2:1 ratio of 70% isopropyl alcohol and acetic acid may be used after each episode of swimming to assist in drying and acidifying the ear canal.[5] SOR C
- Do not use earplugs while swimming because they may cause trauma to the ear canal leading to OE.[5]

PATIENT RESOURCES

- **http://familydoctor.org/online/famdocen/home/common/ear/657.html.**

PROVIDER RESOURCES

- **http://emedicine.medscape.com/article/84923-overview.**
- **http://emedicine.medscape.com/article/763918-overview.**

REFERENCES

1. Hajioff D, MacKeith S. Otitis externa. *Clin Evid (Online).* 2010 Aug 03;2010. pii: 0510.
2. Raza SA, Denholm SW, Wong JC. An audit of the management of otitis externa in an ENT casualty clinic. *J Laryngol Otol.* 1995;109: 130-133.
3. Kaushik V, Malik T, Saeed SR. Interventions for acute otitis externa. *Cochrane Database Syst Rev.* 2010 Jan 20;(1):CD004740.
4. Rosenfeld RM, Brown L, Cannon CR, et al; American Academy of Otolaryngology—Head and Neck Surgery Foundation. Clinical practice guideline: acute otitis externa. *Otolaryngol Head Neck Surg.* 2006;134(4 Suppl):S4-S23.
5. Garry JP, Bhalla SK. Otitis Externa. Updated Feb. 28, 2010. http://emedicine.medscape.com/article/84923-overview. Accessed on August 8, 2011.

28 EAR: FOREIGN BODY

Brian Z. Rayala, MD

PATIENT STORY

A 3-year-old girl is brought by her parents to an urgent care facility after a day of crying, irritability, scant otorrhea, and frequent pulling of her right ear. Otoscopy reveals an erythematous, swollen external auditory canal (EAC) where a bead is wedged (**Figure 28-1**). The patient is referred to an otolaryngologist and the bead is removed using an operating microscope for visualization.

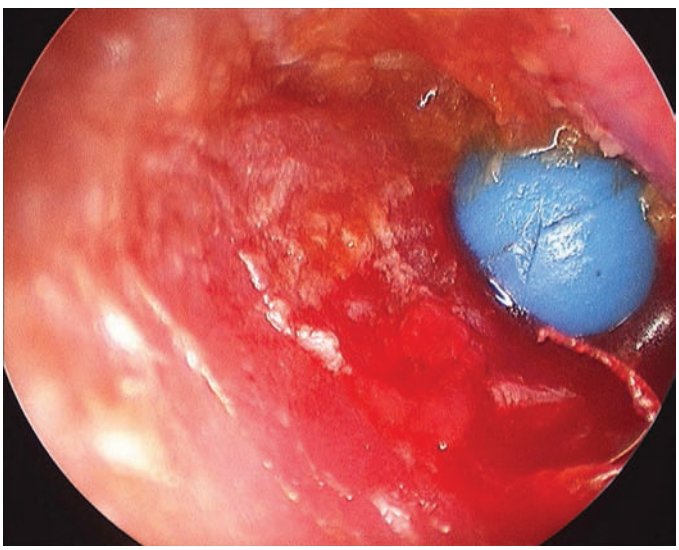

FIGURE 28-1 Foreign body (bead) in the ear canal of a 3-year-old girl with reactive tissue around it. (*Courtesy of William Clark, MD.*)

INTRODUCTION

- Children with ear foreign bodies (FBs) usually present with otalgia, otorrhea, or decreased hearing. At times, symptoms may be nonspecific, like irritability and crying. Other times, presentation may be asymptomatic.

EPIDEMIOLOGY

- Ear FBs are commonly seen in children ages 1 to 6 years.[1–3]
- Equal male-to-female ratio in the pediatric population.[4]

ETIOLOGY AND PATHOPHYSIOLOGY

- Most common FBs in children include:[5]
  - Inanimate objects such as beads (see **Figure 28-1**), cotton tips, paper, toy parts, crayons (**Figure 28-2**), eraser tips, food, or organic matter, including sand (**Figure 28-3**), sticks, and stones.
  - Insects (**Figure 28-4**).
- Pathogenesis includes some of the key elements of otitis externa (see Chapter 27, Otitis Externa):
  - Initial breakdown of the skin-cerumen barrier (caused by presence of FB).
  - Skin inflammation and edema leading to subsequent obstruction of adnexal structures (e.g., cerumen glands, sebaceous glands, and hair follicles).
  - FB reaction leading to further skin injury.
  - In the case of alkaline battery electrochemical reaction, severe alkaline burns may occur.

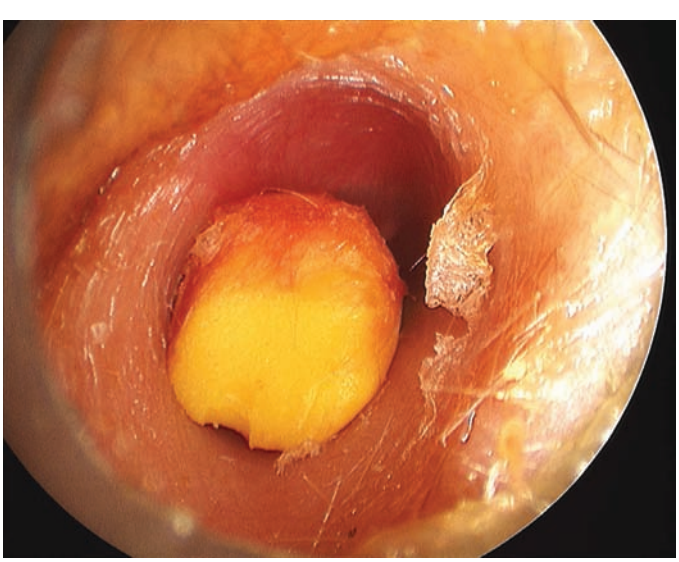

FIGURE 28-2 Piece of a crayon in the ear canal of a 4-year-old boy. (*Courtesy of William Clark, MD.*)

RISK FACTORS

- Children with attention deficit hyperactivity disorder (ADHD) may be more likely to self-insert FBs and ADHD should be considered in children with ear FBs who are older than age 5 years.[6]

DIAGNOSIS

CLINICAL FEATURES

- Key historical features include:
  - Otalgia.
  - Otorrhea or otorrhagia.
  - Mild hearing loss.
  - Irritability, crying.
  - History suspicious for FB insertion or witnessed FB insertion.
- Some children may be asymptomatic.
- Hallmark of diagnosis includes visualization of FB on otoscopy (see **Figures 28-1** through **28-4**).
- Otoscopy may reveal signs of EAC inflammation (e.g., edema, erythema, aural discharge) (see **Figure 28-1**).

LABORATORY AND IMAGING

- Aural FB is a clinical diagnosis. Laboratory and imaging studies have very limited use.

DIFFERENTIAL DIAGNOSIS

- Otitis externa—Presents with otalgia, otorrhea, and mild hearing loss, all of which can be present in ear FB. Absence of FB (on otoscopic exam) is the key differentiating factor (see Chapter 27, Otitis Externa).
- Acute otitis media (with or without perforated tympanic membrane [TM])—Otoscopy shows absence of FB and presence of middle-ear inflammation and effusion (i.e., bulging, erythematous, cloudy, immobile TM). Patients present with clinical signs or symptoms of acute illness like fever (see Chapter 26, Otitis Media: Acute Otitis and Otitis Media with Effusion).
- Chronic Suppurative Otitis Media—Otoscopy shows absence of FB and presence of TM perforation; history reveals a chronically draining ear and recurrent middle-ear infections with or without hearing loss.

MANAGEMENT

PROCEDURES

- Adequate immobilization of the child (sedation if necessary) and proper instrumentation allow the uncomplicated removal of many ear FBs in the pediatric population.[7] SOR C
  - The use of general anesthesia is preferred in very young children and in children of any age with ear FBs whose contour, composition, or location predispose to traumatic removal in the ambulatory setting.[7] SOR C
- Ear FBs can be removed by irrigation, suction, or instrumentation. The type of procedure depends on the type of FB being removed.
  - Small inorganic objects can be removed from the EAC by irrigation. Contraindication to irrigation includes:
    - Perforated TM.
    - Vegetable matter—Irrigation causes swelling of the vegetable matter which leads to further obstruction.

FIGURE 28-3 Beach sand granules with exostosis in the ear of a cold water surfer. The exostoses are common in cold water swimmers and surfers. (*Courtesy of Roy F. Sullivan, PhD. Audiology Forum: Video Otoscopy, www.rcsullivan.com.*)

FIGURE 28-4 Ant in the ear canal. (*Courtesy of Vladimir Zlinsky, MD in Roy F. Sullivan, PhD. Audiology Forum: Video Otoscopy, www.rcsullivan.com.*)

  - Alkaline (button) battery—Irrigation enhances leakage and potential for liquefaction necrosis and severe alkaline burns.
- Objects with protruding surfaces or irregular edges may be removed with alligator forceps under direct visualization.
- Objects that are round or breakable can be removed using a wire loop, a curette, or a right-angle hook that is slowly advanced beyond the object and carefully withdrawn.
- Cyanoacrylate adhesive (e.g., "superglue") has been used to remove tightly wedged, smooth, round FBs.
- Live insects should be killed before removing them (by irrigation or forceps). Instilling alcohol or mineral oil into the auditory canal can kill them.

REFERRAL

Referral to otolaryngology should be considered if:

- More than one attempt has been carried out without success.[8]
- More than one instrument is needed for removal.[7]
- Patients who have firm, rounded FBs (see **Figure 28-1**).[9]
- Patients who have FBs with smooth, nongraspable surfaces (see **Figure 28-1**).[10]

PREVENTION

- Efforts should focus on preventing small children from having access to tiny objects (e.g., beads, small toys, etc.).

PROGNOSIS

- Several retrospective studies from urban emergency departments showed that emergency physicians successfully removed most FBs (53% to 80%) with minimal complications and no need for operative removal.[7,8-10]

FOLLOW-UP

- Follow-up is very important, especially in cases where EAC inflammation or infection is likely (e.g., numerous attempts, use of numerous instruments, protracted exposure to the FB).

PATIENT EDUCATION

- Parents should be informed that successful removal depends a great deal on the length of time the FB has remained in the EAC.

PATIENT RESOURCES

- **http://www.emedicinehealth.com/foreign_body_ear/article_em.htm.**
- **http://www.webmd.com/a-to-z-guides/foreign-body-in-the-ear.**

PROVIDER RESOURCES

- **http://www.entusa.com/external_ear_canal.htm.**
- **http://www.nlm.nih.gov/medlineplus/ency/article/000052.htm.**
- **http://emedicine.medscape.com/article/763712-overview.**

REFERENCES

1. Balbani AP, Sanchez TG, Butugan O, et al. Ear and nose foreign body removal in children. *Int J Pediatr Otorhinolaryngol.* 1998;46:37-42.
2. Mishra A, Shukla GK, Bhatia N. Aural foreign bodies. *Indian J Pediatr.* 2000;67:267-269.
3. Ansley JF, Cunningham MJ. Treatment of aural foreign bodies in children. *Pediatrics.* 1998;101:638-641.
4. Baker MD. Foreign bodies of the ears and nose in childhood. *Pediatr Emerg Care.* 1987;3:67-70.
5. Ryan C, Ghosh A, Wilson-Boyd B, et al. Presentation and management of aural foreign bodies in two Australian emergency departments. *Emerg Med Australas.* 2006;18:372-378.
6. Perera H, Fernando SM, Yasawardena AD, et al. Prevalence of attention deficit hyperactivity disorder (ADHD) in children presenting with self-inserted nasal and aural foreign bodies. *Int J Pediatr Otorhinolaryngol.* 2009;73(10):1362-1364.
7. Ansley JF, Cunningham MJ. Response to O'Donovan. Glue ear and foreign body. *Pediatrics.* 1999;103(4):857.
8. Marin JR, Trainor JL. Foreign body removal from the external auditory canal in a pediatric emergency department. *Pediatr Emerg Care.* 2006;22:630-634.
9. Thompson SK, Wein RO, Dutcher PO. External auditory canal foreign body removal: management practices and outcomes. *Laryngoscope.* 2003;113:1912-1915.
10. DiMuzio J Jr, Deschler DG. Emergency department management of foreign bodies of the external ear canal in children. *Otol Neurotol.* 2002;23:473-475.

29 CHONDRODERMATITIS NODULARIS HELICIS AND PREAURICULAR TAGS

Linda French, MD

PATIENT STORY

A 44-year-old white man presents with a painful nodule on his right ear for 1 year (**Figure 29-1**). He has a long history of occupational sun exposure but no skin cancers. He states that it is too painful to sleep on his right side because of the ear nodule. He tried to remove it once with nail clippers but it bled too much. The patient is told that this is likely a benign condition called chondrodermatitis nodularis helicis. A shave biopsy/removal is performed for diagnostic and therapeutic purposes. It is explained to the patient that this could be a skin cancer as a result of his sun exposure history. The biopsy confirms chondrodermatitis nodularis helicis and he is counseled to use sun protection.

FIGURE 29-1 Chondrodermatitis nodularis helicis on the right ear of a 44-year-old man. (*Courtesy of Richard P. Usatine, MD.*)

INTRODUCTION

Chondrodermatitis nodularis helicis is a benign neoplasm of the ear cartilage commonly believed to be related to excessive pressure, for example, during sleep, and sun exposure. The result is a localized overgrowth of cartilage, and subsequent skin changes. Preauricular tags are malformations of the external ear.

SYNONYMS

Chondrodermatitis nodularis chronica helicis.

EPIDEMIOLOGY

CHONDRODERMATITIS NODULARIS

- The incidence of chondrodermatitis nodularis has not been determined.
- Occurs most commonly in men older than 40 years of age, but older women can also be affected.

PREAURICULAR TAGS

- Occur in approximately 1 of 10,000 to 12,500 births without predilection for gender or race.
- Ear malformations may occur in isolation or as part of a constellation of abnormalities, often involving the renal system. Children have a 5-fold risk of hearing impairment (8 of 10,000 vs. 1.5 of 10,000).[1]
- Several chromosomal abnormalities include preauricular tags as one of the phenotypic expressions.
- The Goldenhar syndrome includes preauricular skin tags, bilateral limbal dermoids of the eye and eyelid colobomas (**Figure 29-2**).

FIGURE 29-2 Chondrodermatitis nodularis on the helix of the right ear in a 62-year-old man. Note the pearly appearance, which may be seen with a basal cell carcinoma. (*Courtesy of Richard P. Usatine, MD.*)

ETIOLOGY AND PATHOPHYSIOLOGY

CHONDRODERMATITIS NODULARIS HELICIS

- In rare cases, especially when occurring at younger ages, the lesion may be related to an underlying disease associated with microvascular injury, such as vasculitis or other necrobiotic collagen disease.[2]

PREAURICULAR TAGS

- Arise from remnants of supernumerary brachial hillocks.[3]
- Early stage embryology involves the formation of several slit-like structures on the side of the head, the branchial clefts. The three hillocks between the first four clefts eventually form the structure of the outer ear. Preauricular tags are generally minor malformations arising from remnants of supernumerary branchial hillocks.[4]

DIAGNOSIS

CLINICAL FEATURES OF CHONDRODERMATITIS

- Firm, painful nodule 3-20 mm in size (**Figures 29-1** to **29-4**).
- The helix is most often affected especially in men (**Figures 29-1** and **29-2**). The antihelix is affected more often in women (**Figures 29-3** and **29-4**).
- Overlying skin normal in color or erythematous; a central ulcer may be present.

CLINICAL FEATURES OF PREAURICULAR TAGS

- Fleshy knob in front of the ear (**Figures 29-5** and **29-6**).
- Present from the time of birth.
- Generally asymptomatic.

TYPICAL DISTRIBUTION

- Chondrodermatitis is located at the helix or antihelix of the ear. The right ear is more often affected than the left.
- Preauricular tags may be unilateral or bilateral, more often present on the left.

BIOPSY

- Often required for chondrodermatitis nodularis to rule out malignancy, especially when occurring in individuals with actinic damage and/or history of other skin cancers.
- Not indicated for preauricular tag.

DIFFERENTIAL DIAGNOSIS

- Chondrodermatitis nodularis helicis may be confused with skin cancer, especially squamous cell carcinoma (SCC; see Chapter 171, Squamous Cell Carcinoma). In SCC, the overlying skin is often ulcerated and the tumor has poorly defined margins.
- The key issue in diagnosis of preauricular tags is whether the ear tags are an isolated anomaly or part of a syndrome involving vital

FIGURE 29-3 Chondrodermatitis nodularis on the antihelix of the right ear of an 86-year-old woman. Note the erythema and scale. A shave biopsy was performed to make sure this was not a squamous cell carcinoma. (*Courtesy of Richard P. Usatine, MD.*)

FIGURE 29-4 Chondrodermatitis nodularis on the antihelix of the right ear of a 52-year-old woman. Note the pearly nodule with central scale. A shave biopsy was performed to rule out basal cell carcinoma and squamous cell carcinoma. (*Courtesy of Richard P. Usatine, MD.*)

organs, especially the kidneys. There is no consensus about whether children with ear tags who otherwise appear to be healthy should be evaluated with renal ultrasound.[4,5]

MANAGEMENT

Chondrodermatitis nodularis is treated with the following:

NONPHARMACOLOGICAL

- A pressure-relieving prosthesis or donut-shaped pillow can be used.[6,7] SOR C This can also be created by cutting a hole from the center of a bath sponge. The sponge can then be held in place with a headband if needed. A special prefabricated pillow is available from **http://www.cnhpillow.com/.**

PROCEDURES

- Shave biopsy can be used to make the diagnosis and may relieve symptoms temporarily. SOR C
- Cryotherapy, intralesional steroids, or curettage and electrodesiccation can be performed after the result from the shave biopsy is known and there is no malignancy. SOR C
- Photodynamic therapy (combines a photosensitizer with a specific type of light to kill nearby cells) has been reported to decrease pain in case reports.[8] SOR C
- A small elliptical excision of the nodule with removal of inflamed cartilage provides excellent results (**Figure 29-7**).[9,10] SOR C
- Preauricular tags can be left alone or surgically excised for cosmetic reasons. SOR C

FOLLOW-UP FOR CHONDRODERMATITIS NODULARIS

- Recurrences are common and may require further treatment.

PATIENT EDUCATION

- Chondrodermatitis nodularis is a benign lesion that tends to recur; therapeutic options can be discussed.
- There is a low risk of urinary tract abnormalities in children who have apparently isolated preauricular tags and an increased risk of hearing impairment.

PATIENT RESOURCES

- A special prefabricated pillow is available that helps relieve pressure on the ear. For more information, contact: CNH Pillow, PO Box 1247, Abilene, TX 79604; phone (800) 255-7487; **http://www.cnhpillow.com/.**
- Preauricular tags—**http://nlm.nih.gov/medlineplus/ency/article/003304.htm.**

FIGURE 29-5 Preauricular tags in a young boy. (*Courtesy of Richard P. Usatine, MD.*)

FIGURE 29-6 Preauricular tag present since birth in a 59-year-old man. The patient has never had any renal abnormalities or related medical problems. He wants it removed for cosmetic purposes. (*Courtesy of Richard P. Usatine, MD.*)

PROVIDER RESOURCES

- To learn how to perform an easy elliptical excision of chondrodermatitis nodularis helicis refer to the text and DVD: Usatine R, Pfenninger J, Stulberg D, Small R. *Dermatologic and Cosmetic Procedures in Office Practice*. Text and DVD. Philadelphia, PA: Elsevier; 2012.
- Marks VJ, Papa CA. **http://www.emedicine.com/derm/topic76.htm.**
- Preauricular tags—**http://www.emedicine.com/ent/topic200.htm.**

REFERENCES

1. Roth DA, Hildesheimer M, Bardenstein S, et al. Preauricular skin tags and ear pits are associated with permanent hearing impairment in newborns. *Pediatrics.* 2008;122(4):e844-e890.
2. Magro CM, Frambach GE, Crowson AN. Chondrodermatitis nodularis helices as a marker of internal disease associated with microvascular injury. *J Cutan Pathol.* 2005;32:329-333.
3. Ostrower ST. Preauricular cysts, pits, and fissures. http://emedicine.medscape.com/article/845288-overview#a05. Accessed July 20, 2011.
4. Deshpande SA, Watson H. Renal ultrasound not required in babies with isolated minor ear abnormalities. *Arch Dis Child Fetal Neonatal Ed.* 2006;91:F29-F30.
5. Kohelet D, Arbel E. A prospective search for urinary tract abnormalities in infants with isolated preauricular tags. *Pediatrics.* 2000;105:E61.
6. Sanu A, Koppana R, Snow DG. Management of chondrodermatitis nodularis chronica helicis using a "donut pillow". *J Laryngol Otol.* 2007;121(11):1096-1098.
7. Moncrieff M, Sassoon EM. Effective treatment of chondrodermatitis nodularis chronica helices using a conservative approach. *Br J Dermatol.* 2004;150:892-894.
8. Pellegrino M, Taddeucci P, Mei S, et al. Chondrodermatitis nodularis chronics helicis and photodynamic therapy: a new therapeutic option? *Dermatol Ther.* 2011;24(1):144-147.
9. Rex J, Ribera M, Bielsa I, et al. Narrow elliptical skin excision and cartilage shaving for treatment of chondrodermatitis nodularis. *Dermatol Surg.* 2006;32:400-404.
10. Hudson-Peacock MJ, Cox NH, Lawrence CM. The long-term results of cartilage removal alone for the treatment of chondrodermatitis nodularis. *Br J Dermatol.* 1999;141:703-705.

FIGURE 29-7 Elliptical excision of chondrodermatitis nodularis helicis. (*Courtesy of Richard P. Usatine, MD.*)

SECTION 2 NOSE AND SINUS

30 NASAL POLYPS

Linda French, MD

PATIENT STORY

A 35-year-old man complains of unilateral nasal obstruction for the past several months of gradual onset. On examination of the nose, a nasal polyp is found (**Figure 30-1**).

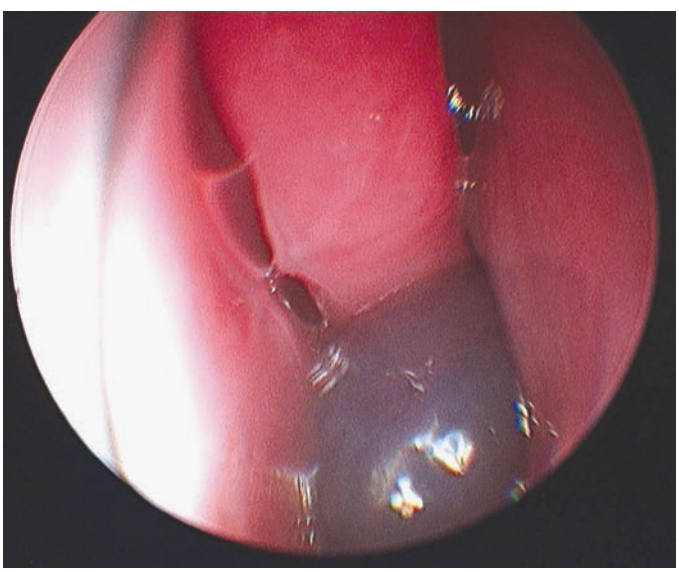

FIGURE 30-1 Nasal polyp in left middle meatus with normal surrounding mucosa. (*Courtesy of William Clark, MD.*)

INTRODUCTION

Nasal polyps are benign lesions arising from the mucosa of the nasal passages including the paranasal sinuses. They are most commonly semitransparent.

EPIDEMIOLOGY[1]

- Prevalence of 1% to 4% of adults; 0.1% of children of all races and classes.
- The male-to-female ratio in adults is approximately 2:1.
- Peak age of onset is 20 to 40 years old; rare in children younger than 10 years old.
- Associated with the following conditions:
  - Nonallergic and allergic rhinitis and rhinosinusitis.
  - Asthma—In 20% to 50% of patients with polyps.
  - Cystic fibrosis.
  - Aspirin intolerance—In 8% to 26% of patients with polyps.
  - Alcohol intolerance—In 50% of patients with polyps.

ETIOLOGY AND PATHOPHYSIOLOGY

- The precise cause of nasal polyp formation is unknown.
- Infectious agents causing desquamation of the mucous membrane may play a triggering role.
- Activated epithelial cells appear to be the major source of mediators that induce an influx of inflammatory cells, including eosinophils prominently; these in turn lead to proliferation and activation of fibroblasts.[2] Cytokines and growth factors play a role in maintaining the mucosal inflammation associated with polyps.
- Food allergies are strongly associated with nasal polyps.

DIAGNOSIS

CLINICAL FEATURES

- The appearance is usually smooth and rounded (**Figure 30-1**).
- Moist and translucent (**Figure 30-2**).
- Variable size.
- Color ranging from nearly none to deep erythema.

TYPICAL DISTRIBUTION

- The middle meatus is the most common location.

LABORATORY AND IMAGING

- Consider allergy testing.
- In children with multiple polyps, order sweat test to rule out cystic fibrosis.
- CT of the nose and paranasal sinuses may be indicated to evaluate extent of lesion(s) (**Figure 30-3**).

BIOPSY

- Not usually indicated. Histology typically shows pseudostratified ciliary epithelium, edematous stroma, epithelial basement membrane, and proinflammatory cells with eosinophils present in 80% to 90% of cases.

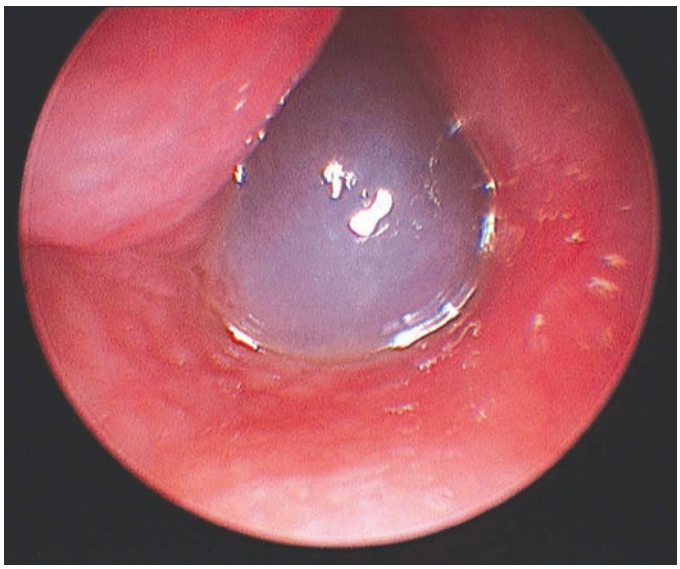

FIGURE 30-2 Nasal polyp in right nasal cavity in a patient with inflamed mucosa from allergic rhinitis. (*Courtesy of William Clark, MD.*)

DIFFERENTIAL DIAGNOSIS

Many relatively rare conditions can cause an intranasal mass including (in adults):

- Papilloma—About 1% of nasal tumors, affecting 1 in 100,000 adults per year. Locally invasive, these tend to recur especially if excision is not complete. Papillomas are of unknown etiology but are associated with chronic sinusitis, air pollution, and viral infections. They are irregular and friable in appearance and bleed easily.[3]
- Meningoencephalocele—Grayish gelatinous appearance.[4]
- Nasopharyngeal carcinoma—Firm, often ulcerated.
- Pyogenic granuloma—Relatively common benign vascular neoplasm of skin and mucous membranes (see Chapter 161, Pyogenic Granuloma).[5]
- Chordoma—Locally invasive neoplasms with gelatinous appearance that arise from notochordal (embryonic) remnants. Occurs in all age groups (mean age: 48 years).[6]
- Glioblastoma—Rare manifestation of the most common kind of brain tumor in adults.

Conditions that may mimic nasal polyp in children include:

- Rhabdomyosarcoma—Malignant tumor of childhood originating from striated muscle.
- Dermoid tumor—Inclusion cysts of ectodermal epithelial elements, usually manifest before 20 years of age. May grow slowly.
- Hemangioma—Congenital, abnormal proliferation of blood vessels that may occur in any vascularized tissue (see Chapter 109, Childhood Hemangiomas and Vascular Malformations).

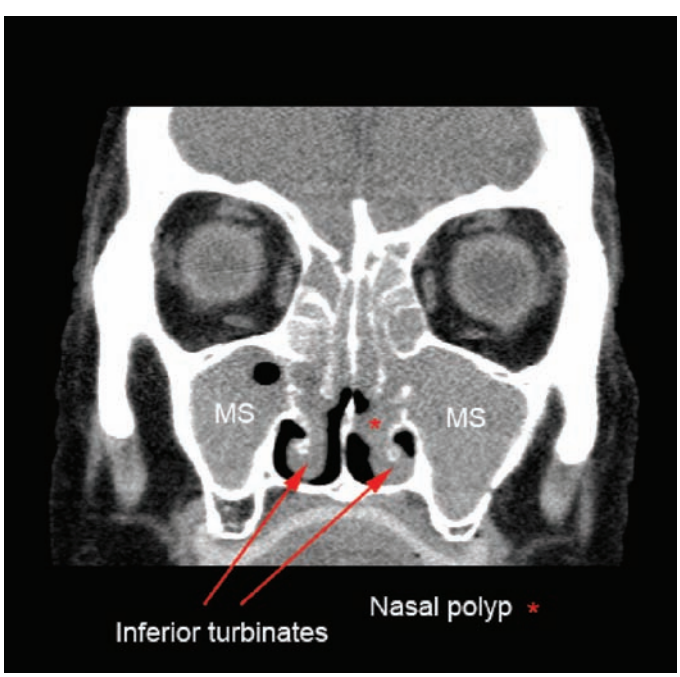

FIGURE 30-3 CT scan showing polyps (*asterisk*) and bilateral opacified maxillary sinuses (*MS*). Note the nasal polyp appears to be coming from the left maxillary sinus and is above the inferior turbinate. (*Courtesy of Richard P. Usatine, MD.*)

- Neuroblastoma—Unusual presentation of relatively common malignancy of childhood.
- Meningoencephalocele—Grayish gelatinous appearance.
- Angiofibroma—Locally invasive neoplasm that appears as a firm grayish mass. Bleeds easily. Occurs in adolescent males ages 14 to 18 years. Undetermined etiology.[7]
- Pyogenic granuloma (see Chapter 161, Pyogenic Granuloma).[5]

MANAGEMENT

MEDICATIONS

- Medical treatment consists of intranasal corticosteroids.[8] SOR A
- An initial short course (2 to 4 weeks) of oral steroids may be considered in severe cases.[9,10] SOR A
- Steroid treatment reduces polyp size, but does not generally resolve them. Corticosteroid treatment is also useful preoperatively to reduce polyp size.
- Oral doxycycline 100 mg daily for 20 days was shown to decrease polyp size, providing benefit for 12 weeks in one randomized controlled trial.[11] SOR B
- Topical nasal decongestants may provide some symptom relief, but do not reduce polyp size.[12] SOR B
- Montelukast reduces symptoms when used as an adjunct to oral and inhaled steroid therapy in patients with bilateral nasal polyposis.[13] SOR B

PROCEDURES

- Surgical excision is often required to relieve symptoms.
- Consider immunotherapy for patients with allergies.

PROGNOSIS

Lesions are benign and tend to recur.

FOLLOW-UP

- Periodic reevaluation is recommended because recurrence rates are high.[14]

PATIENT EDUCATION

- Patients should be informed about the benign nature of nasal polyps and their tendency to recur.

PATIENT RESOURCES

- **http://www.mayoclinic.com/health/nasal-polyps/DS00498.**
- **http://www.nlm.nih.gov/medlineplus/ency/article/001641.htm.**

PROVIDER RESOURCES

- **http://emedicine.medscape.com/article/994274.**
- **http://emedicine.medscape.com/article/861353.**

REFERENCES

1. McClay JE. *Nasal Polyps*. http://emedicine.medscape.com/article/994274. Accessed July 20, 2011.
2. Pawliczak R, Lewandowska-Polak A, Kowalski ML. Pathogenesis of nasal polyps: an update. *Curr Allergy Asthma Rep.* 2005;5:463-471.
3. Sadeghi N. *Sinonasal Papillomas*. http://emedicine.medscape.com/article/862677. Accessed July 20, 2011.
4. Kumar KK, Ganapathy K, Sumathi V, et al. Adult meningoencephalocele presenting as a nasal polyp. *J Clin Neurosci.* 2005;12:594-596.
5. Hoving EW. Nasal encephaloceles. *Childs Nerv Syst.* 2000;16:702-706.
6. Palmer CA. *Chordoma*. http://emedicine.medscape.com/article/250902. Accessed July 20, 2011.
7. Tewfik TL. *Angiofibroma*. http://emedicine.medscape.com/article/872580. Accessed July 20, 2011.
8. Joe SA, Thambi R, Huang J. A systematic review of the use of intranasal steroids in the treatment of chronic rhinosinusitis. *Otolaryngol Head Neck Surg.* 2008;139(3):340-347.
9. Martinez-Devesa P, Patiar S. Oral steroids for nasal polyps. *Cochrane Database Syst Rev.* 2011;6(7):CD005232.
10. Vaidyanathan S, Barnes M, Williamson P, et al. Treatment of chronic rhinosinusitis with nasal polyposis with oral steroids followed by topical steroids: a randomized trial. *Ann Intern Med.* 2011;154(5):293-302.
11. Van Zele T, Gevaert P, Holtappels G, et al. Oral steroids and doxycycline: two different approaches to treat nasal polyps. *J Allergy Clin Immunol.* 2010;125(5):1069-1076.e4.
12. Johansson L, Oberg D, Melem I, Bende M. Do topical nasal decongestants affect polyps? *Acta Otolaryngol.* 2006:126:288-290.
13. Stewart RA, Ram B, Hamilton G, et al. Montelukast as an adjunct to oral and inhaled steroid therapy in chronic nasal polyposis. *Otolaryngol Head Neck Surg.* 2008;139(5):682-687.
14. Vento SI, Ertama LO, Hytonen ML, et al. Nasal polyposis: clinical course during 20 years. *Ann Allergy Asthma Immunol.* 2000;85:209-214.

31 SINUSITIS

Mindy A. Smith, MD, MS

PATIENT STORY

A 55-year-old woman complains of sinus pressure for the past 2 weeks along with headache, rhinorrhea, postnasal drip, and cough. This all started with a cold 3 weeks ago. She has chronic allergic rhinitis, but now the pressure on the right side of her face has become intense and her right upper molars are painful. The nasal discharge has become discolored and she feels feverish. She is diagnosed clinically with right maxillary sinusitis and is prescribed an antibiotic. Two weeks later when her symptoms have persisted, a CT is ordered and she is found to have air-fluid levels in both maxillary sinuses and loculated fluid on the right side. (**Figures 31-1** and **31-2**.) The antibiotic is changed to amoxicillin/clavulanate and she is given information about nasal saline irrigation for symptom relief. If the symptoms don't improve the clinician plans to send her to ENT for further evaluation.

FIGURE 31-1 Bilateral maxillary sinusitis on axial CT. Note that fluid levels are greater on the right. (*Courtesy of Chris McMains, MD.*)

INTRODUCTION

Rhinosinusitis is symptomatic inflammation of the sinuses, nasal cavity, and their epithelial lining.[1] Mucosal edema blocks mucous drainage, creating a culture medium for viruses and bacteria. Rhinosinusitis is classified by duration as acute (<4 weeks), subacute (4 to 12 weeks), or chronic (>12 weeks).

EPIDEMIOLOGY

- Rhinosinusitis is common in the United States, with an estimated prevalence of 14% to 16% of the adult population annually.[1,2] The prevalence is increased in women and in individuals living in the southern United States.
- Only one-third to one-half of primary care patients with symptoms of sinusitis actually have bacterial infection.[3]
- Sinusitis is the fifth-leading diagnosis for which antibiotics are prescribed in the United States.[1]
- Children average 6 to 8 colds per year. Of those, 0.5% to 8% will develop a sinus infection.[4,5]
- This problem is responsible for millions of office visits to primary care physicians each year.[1]

FIGURE 31-2 Maxillary sinusitis on coronal CT of same patient. (*Courtesy of Chris McMains, MD.*)

ETIOLOGY AND PATHOPHYSIOLOGY

- Sinus cavities are lined with mucous-secreting respiratory epithelium. The mucus is transported by ciliary action through the sinus ostia (openings) to the nasal cavity. Under normal conditions, the paranasal sinuses are sterile cavities and there is no mucous retention.

- Bacterial sinusitis occurs when ostia become obstructed or ciliary action is impaired, causing mucus accumulation and secondary bacterial overgrowth.
- The causes of sinusitis include:[6]
  - Infection – most commonly viral (e.g., rhinovirus, parainfluenza, and influenza) followed by bacteria infection (e.g., community-acquired acute cases – about half from *S. pneumoniae* and *Haemophilus influenzae* followed by *Moraxella catarrhalis*). In immunocompromised patients, fulminant fungal sinusitis may occur (e.g., rhinocerebral mucormycosis – **Figure 31-3**).
  - Noninfectious obstruction—Allergic, polyposis, barotrauma (e.g., deep-sea diving, airplane travel), chemical irritants, tumors (e.g., squamous cell carcinoma, granulomatous disease, inverting papilloma), and conditions that alter mucous composition (e.g., cystic fibrosis).

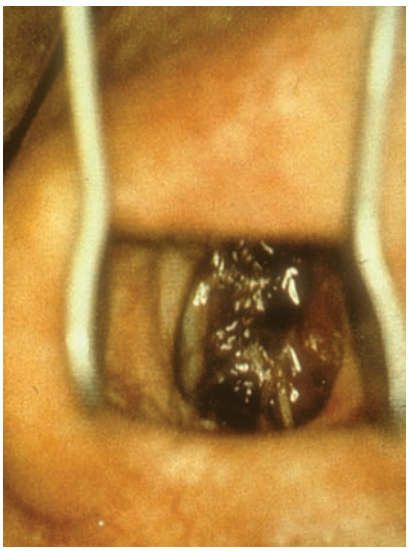

FIGURE 31-3 Mucormycosis sinusitis in a patient with diabetes showing the classic black nasal discharge. (*Courtesy of Randal A. Otto, MD.*)

DIAGNOSIS

The diagnosis is based on the clinical picture with typical symptoms listed below. Symptoms arising from viral infection generally peak by day 5 or before. Acute bacterial rhinosinusitis is diagnosed when symptoms are present for 10 days or longer or when symptoms worsen after initial stability or improvement ("double worsening" or "double sickening"); it can also be presumed in patients with unusually severe presentations or extrasinus manifestations of infection.[1] Superimposed bacterial infection is estimated to occur in 0.5% to 2% of cases of viral rhinosinusitis.[1]

CLINICAL FEATURES

- Most cases are seen in conjunction with viral upper respiratory infections and represent sinus inflammation rather than infection.[3]
- Nonspecific symptoms include cough, sneezing, fever, nasal discharge (may be purulent or discolored), congestion, and headache.
- The American Academy of Otolaryngology guideline and the European Position Paper on Rhinosinusitis and Nasal Polyps recommend a diagnosis of rhinosinusitis with a combination (2 or more) of purulent nasal drainage associated with nasal obstruction, facial pain-pressure-fullness, or both; the latter also recognizes reduction/loss of smell as a cardinal feature.[1,7] There are no prospective trials that validate this approach.
- Other localizing symptoms include facial pain or pressure over the involved sinus when bending over or supine (i.e., forehead in frontal sinusitis, cheek with maxillary sinusitis, between the eyes with ethmoid sinusitis, and neck and top of the head with sphenoid sinusitis) and maxillary tooth pain, most commonly the upper molars; the latter is seen more often with bacterial sinusitis. Halitosis is also attributed to bacterial causes.
- In a study of patients with chronic rhinosinusitis, diagnosis based on symptoms was problematic and only dysosmia (impairment in the sense of smell) and the presence of polyps could distinguish between normal and abnormal radiographs.[8]

TYPICAL DISTRIBUTION

- Most sinus infections involve the maxillary sinus followed in frequency by the ethmoid (anterior), frontal, and sphenoid sinuses; however, most cases involve more than one sinus.[5]

- Children are more likely to have inflammation in the posterior ethmoid and sphenoid sinuses.[9]

LABORATORY AND IMAGING

- Culture of nasal or nasopharyngeal secretions is not recommended as these have not been shown to differentiate between bacterial and viral rhinosinusitis.[1]
- If culture is needed because of suspected bacterial resistance or persistence of infection, a recent metaanalysis found endoscopically directed middle meatal cultures to be reasonably sensitive (80.9%), specific (90.5%), and accurate (87.0%; 95% confidence interval, 81.3% to 92.8%) compared with maxillary sinus taps.[10]
- Radiography should not be obtained for patients meeting diagnostic criteria for acute rhinosinusitis, unless a complication or alternate diagnosis is suspected.[1] If performed in cases of clinical uncertainty or for complications (e.g., orbital, intracranial, or soft-tissue involvement), plain sinus radiography is considered positive for acute sinusitis with the presence of air-fluid level, complete opacification, or at least 6 mm of mucosal thickening; it has a reported sensitivity of 76% and specificity 79%.[11] There are considerable limitations to the sensitivity of plain films, especially in diagnosing ethmoid and sphenoid disease.
- For children, ultrasound compared favorably to plain film for suspected maxillary sinusitis (94.9% sensitivity, 98.4% specificity).[12]
- Nasal endoscopy, identifying purulent material within the drainage area of the sinuses, may be comparable to plain sinus radiography in diagnosing acute sinusitis.[10] In one case series of patients with suspected chronic rhinosinusitis, the addition of endoscopy to symptom criteria had similar sensitivity (88.7% vs. 84.1%) but significantly improved specificity (66% vs. 12.3%) using CT as the gold standard.[13]
- In acute disease, CT scanning is generally reserved for persistent or recurrent symptoms to confirm sinusitis, or to investigate infectious complications (**Figures 31-4** and **31-5**). Radiation dose (about 10 times that of plain radiography) can be lowered with careful choice of technical factors.[1]

REFER OR HOSPITALIZE

- Potentially life threatening complications include subperiosteal orbital abscess, meningitis, epidural or cerebral abscess, and cavernous sinus thrombosis (**Figures 31-6** and **31-7**).
- The risks of frontal sinusitis includes eroding through the frontal bone forward and causing a Pott's puffy tumor, inward and spreading into the brain and cavernous sinuses (**Figure 31-5**).
- Orbital abscess is highly dangerous and can be the result of spread from the frontal or ethmoid sinuses (**Figure 31-6**).
- In immunocompromised patients, fulminant fungal sinusitis may cause orbital swelling, cellulitis, proptosis, ptosis, impairment of extra-ocular motion, nasopharyngeal ulceration, and epistaxis. Bony erosion may be evident.[7] Nasal mucosa may appear black (**Figure 31-3**), blanched white, or erythematous.
- In hospitalized patients, patients may be critically ill and without localizing symptoms. Infections in these patients are often polymicrobial including *S. aureus, Pseudomonas aeruginosa, Serratia marcescens, Klebsiella pneumoniae,* and *Enterobacter*.[7]

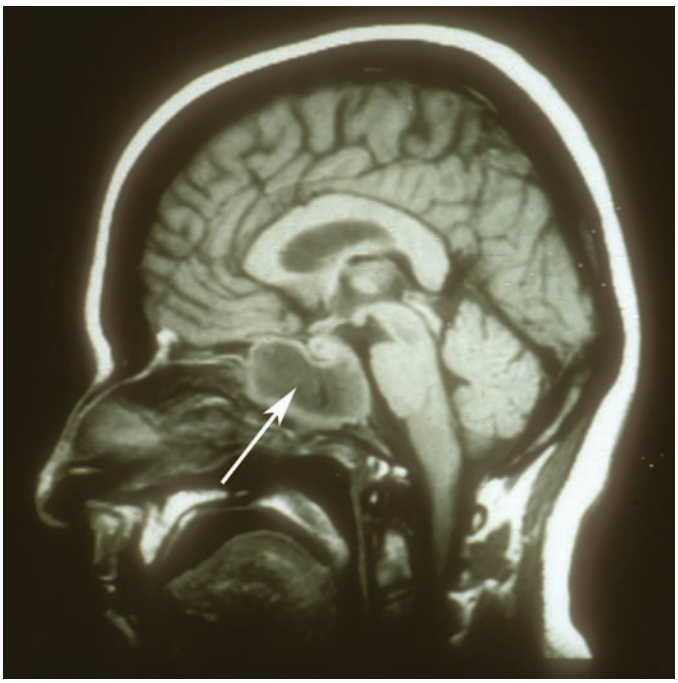

FIGURE 31-4 Mucopyocele in the sphenoid sinus (*arrow*) as a complication of bacterial sinusitis. (*Courtesy of Randal A. Otto, MD.*)

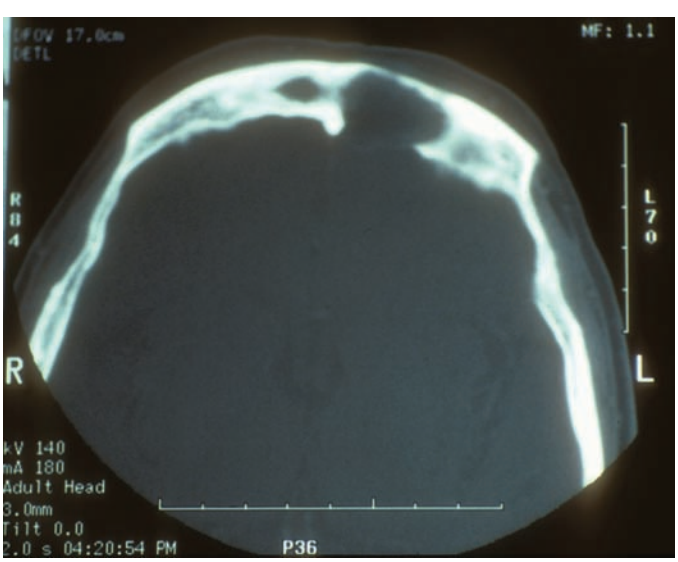

FIGURE 31-5 Frontal sinusitis eroded through the frontal bone inward toward the brain threatening such complications as a brain abscess and cavernous sinus thrombosis. Seen on CT scan. (*Courtesy of Randal A. Otto, MD.*)

DIFFERENTIAL DIAGNOSIS

- Upper respiratory tract infections—These are common infections, primarily viral (most commonly rhinovirus), that cause 2 to 4 infections per year in adults and 6 to 8 infections per year in children. Infections are self-limited (lasting approximately 7 to 10 days) and typical symptoms include rhinorrhea, nasal congestion, sore throat, and cough. Upper respiratory infection (URI) often precedes acute sinusitis.
- Allergic rhinitis—Sneezing, itching, watery rhinorrhea.
- Tumor (usually squamous cell carcinoma)—Rare; unilateral epistaxis or discharge and obstruction, recurrent sinusitis, sinus pain.

Other causes of facial pain include:

- Migraine headache or cluster headache—Moderate to severe head pain that is usually deep seated, persistent, and pulsatile. There is a history of multiple occurrences and head pain may be associated with nausea, vomiting, photophobia, and scotomata. Attacks last 4 to 72 hours.
- Trigeminal neuralgia—Painful condition characterized by excruciating, paroxysmal, shock-like pain lasting seconds to minutes along the distribution of the trigeminal nerve (ophthalmic, maxillary and/or mandibular branches). Pain may be triggered by face washing, air draft, and chewing.
- Dental pain—Tooth pain may be secondary to caries or gingivitis. When caries extend into the tooth pulp, the tooth becomes sensitive to percussion and hot and cold food and beverages. If pulp necrosis occurs, pain becomes severe, sharp, throbbing, and often worse when supine. Abscess formation results in pain, swelling and erythema of the gum and surrounding tissue, and possibly purulent drainage.
- Temporal arteritis—Unilateral pounding headache that may be associated with visual changes and systemic symptoms (e.g., fever, weight loss, muscle aches). Onset is usually older adults (older than age 50 years) and laboratory testing reveals an elevated erythrocyte sedimentation rate (>50).

MANAGEMENT

Duration of illness assists in decision making as most patients improve without specific treatment; a period of watchful waiting for up to 7 days is consistent with guidelines.[1] Treatment of symptoms, including pain, is important.

NONPHARMACOLOGIC

- Nasal saline irrigation for acute upper respiratory tract infection in adults is generally not helpful, although data are limited[14]; two trials suggested modest benefit from buffered hypertonic (3% to 5%) saline irrigation for acute rhinosinusitis.[1] SOR B In adults with chronic sinusitis, nasal saline irrigation provides symptom relief, both alone and as an adjunct to nasal steroids, and is well tolerated.[15] SOR B

MEDICATIONS

- Analgesics (acetaminophen or nonsteroidal antiinflammatory drugs alone or in combination with an opioid) should be used for pain.[1]
- Oral and topical (nasal) decongestants may be offered for symptomatic relief; however, there are no randomized controlled trials

FIGURE 31-6 Right orbital abscess with proptosis as a complication of frontal sinusitis eroding through the superior orbital bones. (*Courtesy of Randal A. Otto, MD.*)

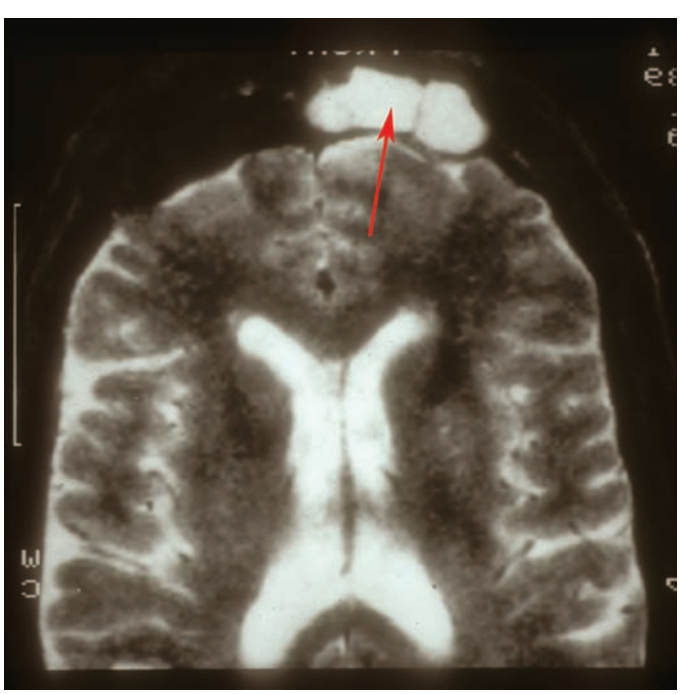

FIGURE 31-7 Mucopyocele (*red arrow*) in the right frontal sinus seen on MRI scan as a complication of frontal sinusitis. (*Courtesy of Randal A. Otto, MD.*)

(RCTs) demonstrating effectiveness for sinusitis and the effect is limited to the nasal cavity.[16] Topical agents are more potent but rebound nasal congestion may develop after discontinuation; use for 3 days only is suggested.[1]

- Topical corticosteroids appear to be of benefit in improvement and resolution of symptoms for acute sinusitis.[17] SOR B
- There have been no clinical trials of mucolytics reported in nonatopic children or adults with acute bacterial sinusitis. However, they may be useful in preventing crust formation and liquefying secretions. SOR C
- Patients who fail to improve or have severe symptoms may be offered oral antibiotics. SOR A Although 10 days is usually recommended for adults, a shorter course (3 to 5 days) may be equally effective.[1]
  - Adults (after 7 days)—Amoxicillin (500 mg three times daily or 875 mg twice daily) for 10 days[1]; alternatives include trimethoprim-sulfamethoxazole (TMS-SMX) (1 DS twice daily) or a macrolide for 10 days.[1]
  - Children (after 10 to 14 days of symptoms)—Amoxicillin (45 to 90 mg/kg divided twice daily), cefuroxime axetil (30 mg/kg divided twice daily), or cefdinir (14 mg/kg daily) for 10 to 14 days.[4,6,18]
- In a Cochrane review of 59 trials evaluating antibiotic treatment for acute maxillary sinusitis, antibiotics decreased clinical failure by approximately 10%.[19] Comparisons between classes of antibiotics showed no significant differences; therefore, narrow-spectrum antibiotics should be first-line therapy.[19]
- Based on the Otolaryngology Head and Neck Surgery clinical guideline, the modest benefit of antibiotics for improving rates of clinical cure or improvement at 7 to 12 days (number needed to treat = 7) must be weighed against the risks of harm (primarily gastrointestinal, but also skin rash, vaginal discharge, headache, dizziness, and fatigue [number needed to harm = 9]).[1]

PROCEDURES

- Surgery and intravenous antibiotics are used for complications, including abscess and cases with orbital involvement.[6]
- Patients with fungal sinusitis are treated with aggressive debridement and adjunctive antifungals (e.g., amphotericin).[6]
- Based on three RCTs, endoscopic sinus surgery is not superior to medical treatment; in one study there was a lower relapse rate (2.4% vs. 5.6% without surgery).[20] SOR B Patients should be selected based on the severity of disease (frequency of antibiotics/oral steroid use), comorbidities (asthma, aspirin sensitivity, etc.), and overall clinical picture (presence of polyps or fungal disease).

COMPLEMENTARY AND ALTERNATIVE MEDICINE

- With respect to alternative therapy, there is limited evidence that Sinupret and bromelain may be effective adjunctive treatments in acute rhinosinusitis.[21] SOR B

PREVENTION

- Smoking increases the risk for sinusitis; patients should be counseled about cessation.[1]

PROGNOSIS

- Based on a Cochrane review, cure or improvement rate for acute sinusitis within 2 weeks was high in both the placebo group (80%) and the antibiotic group (90%).[19]
- For patients with chronic sinusitis, a retrospective study of medical treatment reported treatment success in about half of patients (N = 74); 26 patients had partial resolution and 45 patients underwent surgery. Facial pressure/pain, mucosal inflammation, and higher endoscopic severity grade predicted treatment failure.[22]

FOLLOW-UP

- For those adults who fail treatment after 7 days of antibiotic therapy,[1] a nonbacterial cause or resistant organism should be considered; amoxicillin-clavulanate (4 g per day amoxicillin equivalent) twice daily for 10 days, or a respiratory fluoroquinolone (e.g., levofloxacin, 500 mg daily) for 7 days are alternatives.[1,6] SOR C

PATIENT EDUCATION

- Nasal congestion, purulent rhinitis, and facial pain following a cold may indicate a sinus infection. Symptoms due to a cold usually abate within 1 week.
- Methods to improve sinus drainage include oral and nasal decongestants and nasal saline irrigation. Patients should be cautioned against using nasal decongestants for more than three days to avoid rebound symptoms. For longer-term management, topical nasal steroids may prove useful.
- Patients should be encouraged to see their primary care provider if symptoms persist or worsen after 10 days, suggesting bacterial infection that may benefit from antibiotic treatment.

PATIENT RESOURCES

- **http://www.niaid.nih.gov/topics/sinusitis/Pages/Index.aspx.**
- **http://familydoctor.org/online/famdocen/home/common/ear/686.html.**

PROVIDER RESOURCES

- Clinical practice guideline: management of sinusitis. *Pediatrics.* 2001;108(3):798-808.
- Rosenfeld RM, Andes D, Neil B, et al. Clinical practice guideline: adult sinusitis. *Otolaryngol Head Neck Surg.* 2007;137:365-377.

REFERENCES

1. Rosenfeld RM, Andes D, Neil B, et al. Clinical practice guideline: adult sinusitis. *Otolaryngol Head Neck Surg.* 2007;137:365-377.
2. Anand VK. Epidemiology and economic impact of rhinosinusitis. *Ann Otol Rhinol Laryngol.* 2004;193(Suppl):3-5.
3. Holleman DR Jr, Williams JW Jr, Simel DL. Usual care and outcomes in patients with sinus complaints and normal results of sinus roentgenography. *Arch Fam Med.* 1995;4:246-251.
4. Ramadan HH. Pediatric sinusitis: update. *J Otolaryngol.* 2005; 34(Suppl 1):S14-S17.
5. Revai K, Dobbs LA, Nair S, et al. Incidence of acute otitis media and sinusitis complicating upper respiratory tract infection: the effect of age. *Pediatrics.* 2007;119(6):e1408-e1412.
6. Rubin MA, Gonzales R, Sande MA. Infections of the upper respiratory tract. In: Kasper DL, Braunwald E, Fauci AS, Hauser SL, Longo DL, Jameson, JL, eds. *Harrison's Principles of Internal Medicine.* New York: McGraw-Hill; 2005:185-188.
7. Daudia A, Jones NS. Sinus headaches. *Rhinology.* 2007;45:1-2.
8. Bhattacharyya N. Clinical and symptom criteria for the accurate diagnosis of chronic rhinosinusitis. *Laryngoscope.* 2006;116 (7 Pt 2 Suppl 110):1-22.
9. Gordts F, Clement PA, Destryker A, et al. Prevalence of sinusitis signs on MRI in a non-ENT pediatric population. *Rhinology.* 1997; 35:154-157.
10. Benninger MS, Payne SC, Ferguson BJ, et al. Endoscopically directed middle meatal cultures versus maxillary sinus taps in acute bacterial maxillary rhinosinusitis: a meta-analysis. *Otolaryngol Head Neck Surg.* 2006;134(1):3-9.
11. Berger G, Steinberg DM, Popoytzer A, Ophir D. Endoscopy versus radiography for the diagnosis of acute bacterial rhinosinusitis. *Eur Arch Otorhinolaryngol.* 2005;262(5):416-422.
12. Fufezan O, Asavoaie C, Cherecheş Panta P, et al. The role of ultrasonography in the evaluation of maxillary sinusitis in pediatrics. *Med Ultrason.* 2010;12(1):4-11.
13. Bhattacharyya N, Lee LN. Evaluating the diagnosis of chronic rhinosinusitis based on clinical guidelines and endoscopy. *Otolaryngol Head Neck Surg.* 2010;143(1):147-151.
14. Kassel JC, King D, Spurling GKP. Saline nasal irrigation for acute upper respiratory tract infections. *Cochrane Database Syst Rev.* 2010;(3):CD006821.
15. Harvey R, Hannan SA, Badia L, Scadding G. Nasal saline irrigations for the symptoms of chronic rhinosinusitis. *Cochrane Database Syst Rev.* 2007;(3):CD006394.
16. Shaikh N, Wald ER, Pi M. Decongestants, antihistamines and nasal irrigation for acute sinusitis in children. *Cochrane Database Syst Rev.* 2010;(12):CD007909.
17. Zalmanovici Trestioreanu A, Yaphe J. Intranasal steroids for acute sinusitis. *Cochrane Database Syst Rev.* 2009;(4):CD005149.
18. American Academy of Pediatrics. *Clinical Practice Guideline: Management of Sinusitis.* http://aappolicy.aappublications.org/cgi/reprint/pediatrics;108/3/798.pdf. Accessed May 2011.
19. Ahovuo-Saloranta A, Rautakorpi U-M, Borisenko OV, et al. Antibiotics for acute maxillary sinusitis. *Cochrane Database Syst Rev.* 2008;(2):CD000243.
20. Khalil HS, Nunez DA. Functional endoscopic sinus surgery for chronic rhinosinusitis. *Cochrane Database Syst Rev.* 2006;3:CD004458.
21. Guo R, Canter PH, Ernst E. Herbal medicines for the treatment of rhinosinusitis: a systematic review. *Otolaryngol Head Neck Surg.* 2006;135(4):496-506.
22. Lal D, Scianna JM, Stankiewicz JA. Efficacy of targeted medical therapy in chronic rhinosinusitis, and predictors of failure. *Am J Rhinol Allergy.* 2009;23:396-400.

SECTION 3 MOUTH AND THROAT

32 ANGULAR CHEILITIS

Linda French, MD
Richard P. Usatine, MD

PATIENT STORY

A middle-aged woman presents to your office with soreness at the corners of her mouth for 4 months (**Figure 32-1**). On examination, she has cracking and fissures at the right corner of her mouth. She is diagnosed with angular cheilitis and treated with nonprescription nystatin ointment twice daily. Within 2 weeks she was fully healed.

FIGURE 32-1 Angular cheilitis (perlèche). Note dry, erythematous, and fissured appearance. (*Courtesy of Richard P. Usatine, MD.*)

INTRODUCTION

Angular cheilitis is an inflammatory lesion of the commissure or corner of the lip characterized by scaling and fissuring.

SYNONYM

Perlèche, angular cheilosis, commissural cheilitis, angular stomatitis

EPIDEMIOLOGY

- Most common in the elderly. In one study of institutionalized elderly patients in Scotland, angular cheilitis was present in 25% of patients.[1]

ETIOLOGY AND PATHOPHYSIOLOGY

- Maceration is the usual predisposing factor. Microorganisms, most often *Candida albicans*, can then invade the macerated area (**Figure 32-2**).[2]
- It may also occur in infants and children related to drooling, thumb sucking, and lip licking (**Figure 32-3**).
- Lip licking can cause a contact dermatitis to the saliva along with perlèche (**Figure 32-4**). Perlèche is derived from the French word, "lecher," meaning to lick.
- Historically associated with vitamin B deficiency, which is rare in developed countries.

FIGURE 32-2 *Candida albicans* seen under the microscope after gently scraping a case of angular cheilitis and using KOH on the slide. (*Courtesy of Richard P. Usatine, MD.*)

RISK FACTORS

- Maceration which can be related to poor dentition, deep facial wrinkles, orthodontic treatment, or poorly fitting dentures in the elderly (**Figure 32-5**).

- Other risk factors include incorrect use of dental floss causing trauma or diseases that enlarge the lips such as orofacial granulomatosis.
- Atopic dermatitis (**Figure 32-6**).
- HIV or other types of immunodeficiency may lead to more severe case of angular cheilitis with overgrowth of *Candida* (**Figure 32-7**).
- Use of isotretinoin which dries the lips and predisposes to angular cheilitis.

DIAGNOSIS

CLINICAL FEATURES

- Erythema and fissuring at the corners of the mouth, without exudates or ulceration (**Figures 32-3** to **32-7**).

TYPICAL DISTRIBUTION

- Corners of the mouth (oral commissures or angles of the mouth) hence the names commissural cheilitis and angular cheilitis.

LABS

- A light scraping of the corner of the mouth can be placed on a slide with KOH to look for *Candida* (**Figure 32-2**).

BIOPSY

- Not usually indicated.

DIFFERENTIAL DIAGNOSIS

- Impetigo—Yellowish crusts or exudates are characteristic of impetigo but not angular cheilitis (see Chapter 116, Impetigo).
- Herpes simplex (cold sores)—Initial blisters, followed by shallow ulcers, are characteristic of herpes simplex, but not angular cheilitis (see Chapter 129, Herpes Simplex).

MANAGEMENT

NONPHARMACOLOGIC

- Attempt to relieve precipitating causes such as poorly fitting dentures.
- Counsel patients to stop licking their lips if this is part of the cause (**Figure 32-4**).
- Recommend protective petrolatum or lip balm as needed.
- Counsel patients to stop using tobacco, either chewing or smoking.

MEDICATIONS

- Recommend topical antifungal creams or ointments, such as clotrimazole, to be applied twice daily.[3] SOR B
- Low-potency topical corticosteroid, such as 1% hydrocortisone cream twice daily, may be added to treat the inflammatory component. SOR B
- Nystatin lozenges work well but their use is limited because of their unpleasant taste.[3] SOR C If thrush is also present, prescribe clotrimazole troches for treatment of both conditions.

FIGURE 32-3 Angular cheilitis in a one-year-old girl with widespread atopic dermatitis on her extremities. (*Courtesy of Richard P. Usatine, MD.*)

FIGURE 32-4 Perlèche in a woman with contact dermatitis related to lip licking. (*Courtesy of Richard P. Usatine, MD.*)

FIGURE 32-5 Angular cheilitis in an elderly woman. Note the wrinkles line extending downward from the corner of her mouth indicating some change in her facial anatomy that can predispose to this condition. The perlèche started while she was waiting for her dentures to be repaired. (*Courtesy of Richard P. Usatine, MD.*)

- One randomized controlled study showed that medicated chewing gum can decrease the risk of angular cheilitis in older occupants of nursing homes. Consider recommending xylitol-containing gum to elderly patients with angular cheilitis.[4] SOR B

PREVENTION

Attempt to identify predisposing factors and correct if possible, such as:

- Edentulousness.
- Poorly fitting dentures.
- Drooling.
- Lip licking (**Figure 32-4**)
- Atopic dermatitis (**Figures 32-3** and **32-6**)

Protective lip balm may be helpful to prevent recurrences as long as the patient is not allergic to chemicals within the product. Plain petrolatum is often the safest product for dry lips.

PATIENT EDUCATION

- Encourage patients to identify and correct predisposing factors (as above). Protective lip balm may be helpful.

PATIENT AND PROVIDER RESOURCES

- **http://www.stevedds.com/toppage2.htm#Angular Chelitis.**
- **http://www.ncemi.org/cse/cse0409.htm.**

REFERENCES

1. Samaranayake LP, Wilkieson CA, Lamey PJ, MacFarlane TW. Oral disease in the elderly in long-term hospital care. *Oral Dis*. 1995;1(3):147-151.
2. Sharon V, Fazel N. Oral candidiasis and angular cheilitis. *Dermatol Ther*. 2010;23(3):230-242.
3. Skinner N, Junker JA, Flake D, Hoffman R. Clinical inquiries. What is angular cheilitis and how is it treated? *J Fam Pract*. 2005 May;54(5):470-471.
4. Simons D, Brailsford SR, Kidd EA, Beighton D. The effect of medicated chewing gums on oral health in frail older people: a 1-year clinical trial. *J Am Geriatr Soc*. 2002 Aug;50(8):1348-1353.

FIGURE 32-6. Angular cheilitis in a woman with atopic dermatitis. (*Courtesy of Richard P. Usatine, MD.*)

FIGURE 32-7. Severe angular cheilitis in an HIV positive man with thrush. Note the obvious white *Candida* growth on both corners of his mouth. (*Courtesy of Richard P. Usatine, MD.*)

33 TORUS PALATINUS

Linda French, MD
Mindy A. Smith, MD, MS

PATIENT STORY

An elderly woman is in the office for a physical examination. While looking in her mouth, a torus is seen at the midline on the hard palate (**Figure 33-1**). She states that she has had this for her whole adult life and it does not bother her. You explain to her that it is a torus palatinus and that nothing needs to be done. She is pleased to know the name of this lump and even happier to know that it is not harmful.

FIGURE 33-1 Torus palatinus in a 66-year-old woman. The patient was asymptomatic and this was an incidental finding. (*Courtesy of Richard P. Usatine, MD.*)

INTRODUCTION

Torus palatinus is a benign bony exostosis (bony growth) occurring in the midline of the hard palate. Torus mandibularis often presents as multiple benign bony exostoses on the floor of the mouth.

EPIDEMIOLOGY

- Most common bony maxillofacial exostosis, unclear origin.
- Usually in adults older than 30 years of age.
- Prevalence ranges from 9.5% to 26.9%; among ethnic groups, the range is wider (0.9% in Vietnamese to 33.8% among African Americans).[1]
- More common in women than men.
- Some populations seem to be more predisposed (e.g., Middle Eastern).[2]

DIAGNOSIS

CLINICAL FEATURES

- Hard lump protruding from the hard palate into the mouth covered with normal mucous membrane (**Figure 33-2**).
- Small size (<2 mm) appear most frequent (70% to 91%).[1]
- Shapes include flat, nodular, lobular, or spindle-shaped; nodular appear most common.[1]

TYPICAL DISTRIBUTION

- Midline hard palate.

FIGURE 33-2 Torus mandibularis seen under the tongue caused by bony exostoses. Note these are bilateral and appear similar to a torus palatinus. Although this patient had multiple untreated dental problems, the tori were asymptomatic and this was an incidental finding. (*Courtesy of Richard P. Usatine, MD.*)

DIFFERENTIAL DIAGNOSIS

- Torus mandibularis is also a bony exostosis but is found under the tongue. These appear similar to a torus palatinus but are usually bilateral rather than midline (**Figure 33-2**).

- Squamous cell carcinoma is not as hard and the mucous membranes are usually ulcerated. Mucous membranes are normal in appearance with torus palatinus unless traumatized.
- Adenoid cystic carcinoma is a rare tumor that can start in a minor salivary gland over the hard palate. Note that this tumor will not be midline as found in the torus palatinus. If a suspected torus is not midline a biopsy is needed to rule out this potentially fatal carcinoma (**Figure 33-3**).

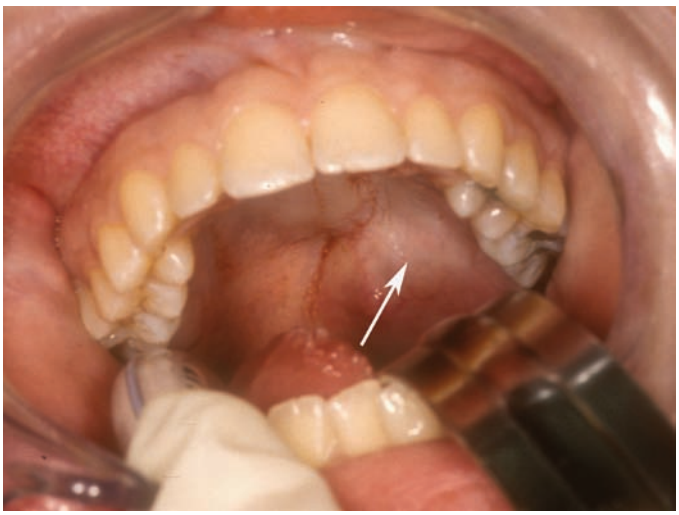

FIGURE 33-3 Adenoid cystic carcinoma in a 22-year-old woman. The arrow points to this unilateral tumor that should not be confused with a torus palatinus. (*Courtesy of Randal A. Otto, MD.*)

MANAGEMENT

- Excision can be considered if the lesion interferes with function, such as the fit of dentures. This is performed as an outpatient procedure.[3,4]
- Sometimes removed because of disturbances of phonation, traumatic inflammation or ulcer, aesthetic reasons, or as source of autogenous cortical bone for grafts in periodontal surgery.[1]

PROGNOSIS

- Very slow growing; can stop growth spontaneously.[1]
- Surgical complications include perforation of nasal cavities, palatine nerve damage, bone necrosis, hemorrhage and fracture of palatine bone.[1]

PATIENT EDUCATION

- Patients should be informed about the benign nature of the lesion and that removal can be considered, if bothersome.

PATIENT RESOURCES

- **http://www.fpnotebook.com/DEN21.htm.**
- **http://www.breadentistry.com/files/pdf/OPG_tor_pal.pdf.**

REFERENCES

1. García-García AS, Martínez-González JM, Gómez-Font R, et al. Current status of the torus palatinus and torus madibularis. *Med Oral Patol Oral Cir Bucal.* 2010;15(2):e353-e360.
2. Yildiz E, Deniz M, Ceyhan O. Prevalence of torus palatinus in Turkish school children. *Surg Radiol Anat.* 2005;27:368-371.
3. Al-Quran FA, Al-Dwairi ZN. Torus palatinus and torus mandibularis in edentulous patients. *J Contemp Dent Pract.* 2006; 7:112-119.
4. Cagirankaya LB, Dansu O, Hatipoglu MG. Is torus palatinus a feature of a well-developed maxilla? *Clin Anat.* 2004;17: 623-625.

34 SCARLET FEVER AND STRAWBERRY TONGUE

Mark Jason Sanders, MD
Linda French, MD

PATIENT STORY

A 7-year-old boy is brought to the family physician's office with a rough red rash on his trunk (**Figures 34-1** and **34-2**) along with fever and a sore throat. The sandpaper rash and signs consistent with strep pharyngitis lead the physician to diagnose scarlet fever. The physician explains the diagnosis to the mother and oral Pen VK is prescribed. The boy feels markedly better by the next day, and the mother continues to give the penicillin for the full 10 days as directed to prevent rheumatic fever.

INTRODUCTION

Scarlet fever is an illness caused by toxin-producing group A β-hemolytic streptococci. Most commonly, scarlet fever evolves from an exudative pharyngitis.

Strawberry tongue may be observed in patients with scarlet fever, and usually develops within the first 2 to 3 days of illness. A white or yellowish coating usually precedes the classic red tongue with white papillae (**Figure 34-3**).

EPIDEMIOLOGY

- Scarlet fever is predominately seen in school-age children with no gender predilection.
- Majority related to strep pharyngitis, with 1 in 10 developing scarlet fever (**Figures 34-1**, **34-2**, and **34-4**).
- Prevalent in late fall to early spring.
- Strawberry tongue (**Figure 34-4**) is most commonly seen in children in association with scarlet fever or Kawasaki disease.
- Can be present with other group A *Streptococcus* (strep) infection.
- In cases of strep, a white membrane through which the papillae are seen can initially cover the tongue followed by desquamation of the membrane (with the appearance as in **Figure 34-4**).

ETIOLOGY AND PATHOPHYSIOLOGY

- Transmission of *Streptococcus* occurs via respiratory secretions.
- Virulent *Streptococcus pyogenes* (group A *Streptococcus* or GAS) incubate more than 2 to 7 days. M protein serotypes of GAS are typically more invasive with greater potential for progression to rheumatic fever or acute glomerulonephritis if untreated.[1]

FIGURE 34-1 Sandpaper rash on the trunk and in the axilla of a 7-year-old boy with scarlet fever. (*Courtesy of Richard P. Usatine, MD.*)

FIGURE 34-2 Scarlatiniform rash comprising small papules and erythema on the trunk of a febrile child with strep pharyngitis. (*Courtesy of Richard P. Usatine, MD.*)

- Fever and rash are related to pyrogenic A–C and erythrogenic exotoxins produced by GAS.[2]
- Infection may originate from other sites like skin (e.g., cellulitis), and seed blood (bacteremia) or organ systems (e.g., pneumonia).
- Strawberry tongue results from a general inflammatory response during the early course of the disease.

DIAGNOSIS

CLINICAL FEATURES

- Headache, sore throat, cervical lymphadenopathy, abdominal pain, nausea and vomiting, decreased oral intake, malaise, and fever may precede rash. Cough is usually not present.
- Oropharyngeal findings include:
  - Strawberry tongue—Erythematous and sometimes edematous tongue with prominent papillae (**Figure 34-4**).
- May be covered by a white membrane/coating through which the papillae can be seen.
- Not typically painful.
- Forchheimer spots—Palatal and uvular petechiae and erythematous macules.
- Initial sandpaper rash, associated with blanching erythema and occasional pruritus, erupts in 1 to 2 days (**Figures 34-1** to **34-3**).[2]
- Pastia's lines are pink or red lines seen in the body folds (especially elbows and axilla) during scarlet fever. Linear hyperpigmentation may persist after the rash fades (**Figure 34-1**).
- Desquamation of the skin (especially of the hands and feet) ensues in 3 to 4 days as rash fades and can persist for 2 to 4 weeks.[1]

TYPICAL DISTRIBUTION

- Progresses centrally (torso) to peripherally (extremities) and can be prominent on the face, chest, palms, fingers, and toes.[1]

LABORATORY TESTS AND IMAGING

- Throat swab for rapid strep testing (screening) and/or culture (confirmation) is usually performed.
- Complete blood count (CBC), if indicated, to look for:
  - Elevation of white blood cell count with left shift.
  - Elevated platelet count—Seen with Kawasaki disease (after 1 week).
- Antistreptolysin-*O* titer is obtained to confirm prior infection or support suspected poststreptococcal complication, such as rheumatic fever.[3]
- Acute phase reactants (C-reactive protein [CRP] and erythrocyte sedimentation rate [ESR]) may be elevated, and may be useful in monitoring nonsuppurative complications such as rheumatic fever.[4]
- If Kawasaki disease is suspected, two-dimensional echocardiography or angiography is obtained to detect coronary artery abnormalities. The initial echocardiogram should be performed as soon as the diagnosis is suspected to establish a baseline for longitudinal follow-up of coronary artery morphology, left ventricular and left valvular function, and the evolution and resolution of pericardial effusion when present.[4] SOR C

FIGURE 34-3 Sandpaper rash (scarlatiniform) seen prominently on the hand of a child recovering from strep pharyngitis. (*Courtesy of Richard P. Usatine, MD.*)

FIGURE 34-4 Strawberry tongue in a child with scarlet fever caused by strep pharyngitis; note marked erythema and prominent papillae. (*Courtesy of Richard P. Usatine, MD.*)

DIFFERENTIAL DIAGNOSIS

The rash of scarlet fever may be confused with the following:

- Allergic/contact dermatitis—Often localized to areas of contact; prominent pruritus and skin vesicles often in linear streaks (see Chapter 145, Atopic Dermatitis and Chapter 146, Contact Dermatitis).
- Viral exanthem—Many viral exanthems have prodromal phases with fever followed by skin rashes that can be macular or maculopapular including measles (see Chapter 126, Measles), rubella (tender retroauricular, cervical, and occipital lymphadenopathy, and rash starts on face and spreads and fades quickly), and roseola (rash occurs at the end of a period of 3 to 5 days of high fever). Lack of sandpaper feel and oral findings help distinguish.
- Staphylococcal scalded skin syndrome—Rash may also follow a prodrome of malaise and fever but is macular, brightly erythematous, and initially involves the face, neck axilla, and groin. Skin is markedly tender and large areas of the epidermis peel away.
- Erythema toxicum—Rash of newborns; often blotchy, evanescent, macular erythema that can include pale yellow or white wheals or papules on an erythematous base (see Chapter 108, Normal Skin Changes).

The differential diagnosis for strawberry tongue includes:

- Kawasaki disease (**Figure 34-5**)—Fever persists at least 5 days and there must be the presence of at least four principal features including the following:[4]
  - Changes in extremities—Acute: Erythema of palms, soles; edema of hands and feet. Subacute: Periungual peeling of fingers and toes in weeks 2 and 3.
  - Polymorphous exanthem.
  - Bilateral bulbar conjunctival injection without exudate.
  - Changes in lips and oral cavity—Erythema, lips cracking, strawberry tongue, diffuse injection of oral and pharyngeal mucosae.
  - Cervical lymphadenopathy (>1.5 cm diameter), usually unilateral.
- Viral stomatitis with eruptive lingual papillitis—Lack of other features for scarlet fever or Kawasaki's will assist in differentiating.
- Red-colored food dyes—History is helpful; edema and prominent papillae will be absent.

FIGURE 34-5 Child recovering from Kawasaki's disease. Note the conjunctival injection that still remains. (*Courtesy of Greg Thompson, MD.*)

MANAGEMENT

NONPHARMACOLOGICAL

- Supportive care with oral fluids and age-appropriate symptomatic measures, such as salt-water gargles, and an antipyretic as needed are recommended.

MEDICATIONS

- For scarlet fever and strawberry tongue caused by group A *Streptococcus*:
  - Oral penicillin (penicillin VK 500 mg divided twice daily or 250 mg divided 4 times daily for 10 days for adults or 25 to

50 mg/kg per day divided 4 times daily for 10 days for children) or macrolide (erythromycin base 500 mg 4 times daily for 10 days for adults or erythromycin estolate 20 mg/kg per day or succinate 40 mg/kg per day divided twice daily for 10 days for children) in penicillin-allergic patients for 10 days.[5] SOR A
  - Cephalosporins are an efficacious alternative (e.g., cefuroxime axetil 250 mg twice daily for 10 days for adults or 20 mg/kg per day divided twice daily for 10 days for children); cephalosporins were better than penicillin in a metaanalysis.[6] SOR A
  - Symptoms typically resolve in 4 to 7 days.
- For strawberry tongue caused by Kawasaki disease:
  - Intravenous gammaglobulin (IVIG), 2 g/kg in a single infusion, within 7 to 10 days of onset for Kawasaki disease to reduce subsequent coronary artery abnormalities.[4] SOR A Additional IVIG infusion may be considered if defervescence is not achieved in the first 1 to 2 days.[7]
  - In the acute phase, aspirin is also administered at 80 to 100 mg/kg per day in 4 doses with IVIG followed by low-dose aspirin (3 to 5 mg/kg per day) until the patient shows no evidence of coronary changes by 6 to 8 weeks after the onset of illness.[4] SOR C

REFERRAL OR HOSPITALIZE

- Hospitalization should be considered if a patient is dehydrated or exhibits cardiorespiratory instability. It should also be considered for cases of complicated scarlet fever, streptococcal toxic shock, staphylococcal scalded skin, rheumatic fever, acute glomerulonephritis, or Kawasaki disease (when suspected).
- Cardiology, infectious disease, or nephrology consultation may be indicated in the most severe cases.

PROGNOSIS

Scarlet fever usually follows a benign course. Rarely it is complicated by septic shock and multi-organ failure, suppurative complications such as peritonsillar abscess, or nonsuppurative complications such as rheumatic fever or poststreptococcal glomerulonephritis

FOLLOW-UP

- Routine follow-up is not required unless illness is protracted or a complication is suspected.
- For patients with uncomplicated Kawasaki disease, echocardiographic evaluation should be performed at the time of diagnosis, at 2 weeks, and at 6 to 8 weeks after onset of the disease.[4] SOR C Recent studies show that repeat echocardiography performed 1 year after the onset of the illness is unlikely to reveal coronary artery enlargement in patients whose echocardiographic findings were normal at 4 to 8 weeks.[4]

PATIENT EDUCATION

- Contact physician for fever recurrence, atypical or persistent rash, and new symptoms or potential complications (meningitis, sinusitis,

otitis media, oropharyngeal abscess, pneumonia, acute glomerulonephritis, or rheumatic fever).

- Completion of a prescribed antibiotic course is encouraged to decrease the incidence of recurrence and potential complications.[3]

REFERENCES

1. Cunningham MW. Pathogenesis of group A streptococcal infections. *Clin Microbiol Rev.* 2000;13(3):470-511.
2. Cherry JD. Contemporary infectious exanthems. *Clin Infect Dis.* 1993;16(2):199-205.
3. Hahn RG, Knox LM, Forman TA. Evaluation of poststreptococcal illness. *Am Fam Physician.* 2005;71(10):1949-1954.
4. Newburger JW, Takahashi M, Gerber MA, et al. Diagnosis, treatment, and long-term management of Kawasaki disease: a statement for health professionals from the committee on rheumatic fever, endocarditis and Kawasaki disease, council on cardiovascular disease in the young, American Heart Association. *Circulation.* 2004;110(17):2747-2771.
5. Gilbert DN, Moellering RC, Eliopoulos GM, et al. *The Sanford Guide to Antimicrobial Therapy 2010.* 40th ed. Sperryville, VA: Antimicrobial Therapy, Incorporated; 2010.
6. Casey JR, Pichichero ME. Meta-analysis of cephalosporin versus penicillin treatment of group A streptococcal tonsillopharyngitis in children. *Pediatrics.* 2004;113(4):866-882.
7. Freeman AF, Shulman ST. Kawasaki disease: summary of the American Heart Association guidelines. *Am Fam Physician.* 2006;74(7):1141-1148.

35 PHARYNGITIS

Brian Williams, MD
Richard P. Usatine, MD
Mindy A. Smith, MD

PATIENT STORY

A 27-year-old woman complains of 2 days of sore throat, fever, and chills. She is unable to swallow anything other than liquids because of severe odynophagia. She denies any congestion or cough. On examination, she has bilateral tonsillar erythema and exudate (**Figure 35-1**). Her anterior cervical lymph nodes are tender. Based on the presence of fever, absence of cough, tender lymphadenopathy, and tonsillar exudate, she is diagnosed with a high probability of group A β-hemolytic *Streptococcus* (GABHS) pharyngitis and prescribed antibiotics.

FIGURE 35-1 Strep pharyngitis showing tonsillar exudate and erythema. (*Courtesy of Michael Nguyen, MD.*)

INTRODUCTION

Pharyngitis is inflammation of the pharyngeal tissues, and is usually associated with pain. The complaint of "sore throat" is a common one in the primary care office, and can be accompanied by other symptoms and signs including throat scratchiness, fever, headache, malaise, rash, joint and muscle pains, and swollen lymph nodes.

EPIDEMIOLOGY

- Pharyngitis accounts for 1% of primary care visits.[1]
- Viral infections account for an estimated 60% to 90% of cases of pharyngitis.
- Bacterial infections are responsible for between 5% and 30% of pharyngitis cases, depending upon the age of the population and the season.
- The GABHS accounts for 5% to 10% of pharyngitis in adults and 15% to 30% in children.[2] Up to 38% of cases of tonsillitis are because of GABHS.
- Highest prevalence in winter.
- Highest incidence in children between the ages of 4 and 7 years.
- Acute rheumatic fever is currently rare in the United States.
- Up to 14% of deep neck infections result from pharyngitis.[3]

FIGURE 35-2 Scarlatiniform rash in scarlet fever. This 7-year-old boy has a typical sandpaper rash with his strep throat and fever. The erythema is particularly concentrated in the axillary area. (*Courtesy of Richard P. Usatine, MD.*)

ETIOLOGY AND PATHOPHYSIOLOGY

- Some viruses, such as adenovirus, cause inflammation of the pharyngeal mucosa by direct invasion of the mucosa or secondary to suprapharyngeal secretions.[4] Other viruses, such as rhinovirus, cause pain through stimulation of pain nerve endings by mediators, such as bradykinin.
- The GABHS releases exotoxins and proteases. Erythrogenic exotoxins are responsible for the development of the scarlatiniform exanthem (**Figure 35-2**).[5] Secondary antibody formation because of cross-reactivity may

result in rheumatic fever and valvular heart disease.[6] Antigen–antibody complexes may lead to acute poststreptococcal glomerulonephritis.

- Untreated GABHS pharyngitis can result in suppurative complications including bacteremia, otitis media, meningitis, mastoiditis, cervical lymphadenitis, endocarditis, pneumonia, or peritonsillar abscess formation (**Figure 35-3**). Nonsuppurative complications include rheumatic fever and poststreptococcal glomerulonephritis.

RISK FACTORS

- Immune deficiency.
- Chronic irritation (e.g., allergies, cigarette smoking).

DIAGNOSIS

CLINICAL FEATURES

- Rhinorrhea and cough are more consistent with viral etiology.
- Rapid onset odynophagia, tonsillar exudates, anterior cervical lymphadenopathy, and fever are consistent with streptococcal pharyngitis.
- Not all tonsillar exudates are caused by streptococcal pharyngitis. Mononucleosis and other viral pharyngitis can cause tonsillar exudates (**Figures 35-4** and **35-5**). The positive predictive value for tonsillar exudate in strep throat is only 31%; that is, 69% of patients with tonsillar exudate will have a nonstreptococcal cause.
- Para- and supratonsillar edema with medial and/or anterior displacement of the involved tonsil and uvular displacement to the contralateral side suggest peritonsillar abscess (**Figure 35-3**). Trismus and anterior cervical lymphadenopathy with severe tenderness to palpation are additional findings.
- Palatal petechiae can be seen in all types of pharyngitis (**Figure 35-6**).
- A sandpaper rash is suggestive of scarlet fever (**Figure 35-2**, and Chapter 34, Scarlet Fever and Strawberry Tongue).
- Lymphoid hyperplasia can cause a cobblestone pattern on the posterior pharynx or palate from viral infections, gastroesophageal reflux disease (GERD), or allergies (**Figure 35-7**). Although it usually is more suggestive of a viral infection or allergic rhinitis, lymphoid hyperplasia can be seen in strep pharyngitis (**Figure 35-8**).
- The following criteria are helpful in the diagnosis of GABHS pharyngitis:[7–10]
  - History of fever or temperature of 38°C (100.4°F) (1 point).
  - Absence of cough (1 point).
  - Tender anterior cervical lymph nodes (1 point).
  - Tonsillar swelling or exudates (1 point).
  - Age:
    - <15 years (1 point).
    - 15 to 45 years (0 points).
    - >45 years (−1 point).

The probability of GABHS is approximately 1% with −1 to 0 points and approximately 51% with 4 to 5 points.[11]

FIGURE 35-3 **A.** Peritonsillar abscess on the left showing uvular deviation away from the side with the abscess. **B.** Peritonsillar abscess with swelling and anatomic distortion of the right tonsillar region. (*Courtesy of Charlie Goldberg, MD, and The Regents of the University of California.*)

FIGURE 35-4 Mononucleosis in a young adult with considerable tonsillar exudate. (*Courtesy of Tracey Cawthorn, MD.*)

FIGURE 35-6 Viral pharyngitis with visible palatal petechiae. Palatal petechiae can be seen in all types of pharyngitis. (*Courtesy of Richard P. Usatine, MD.*)

FIGURE 35-5 Viral pharyngitis in a young adult showing enlarged cryptic tonsils with some erythema and exudate. (*Courtesy of Richard P. Usatine, MD.*)

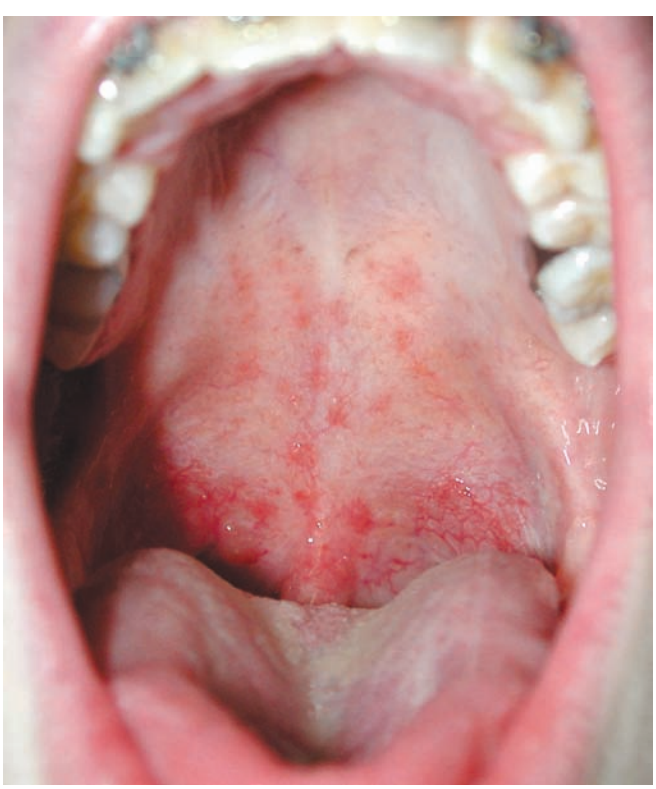

FIGURE 35-7 Viral pharyngitis with prominent vascular injection of the soft palate and lymphoid hyperplasia. (*Courtesy of Richard P. Usatine, MD.*)

LABORATORY TESTS AND IMAGING

- Rapid antigen detection is often used to diagnose GABHS. Test options include enzyme immunoassays, latex agglutination, liposomal method, and immunochromatograph assays; the latter has the highest reported sensitivity (0.97), specificity (0.97), and positive (32.3) and negative (0.03) likelihood ratios.[12]
- The gold standard for the diagnosis of streptococcal infection is a positive throat culture. However, GABHS is part of the normal oropharyngeal flora in many patients and the diagnosis of acute streptococcal pharyngitis must include both the clinical signs of acute infection and a positive throat culture.
- False-positive tests for streptococcal infection can occur when the patient is colonized with GABHS but is not the cause of the acute disease.
- False-negative tests for streptococcal infection can occur when poor sampling technique with the throat swab fails to recover the streptococcal organism when it is the cause of the acute infection.
- A positive mono spot (likelihood ratio in the first week of illness 5.7) and/or greater than 40% atypical lymphocytes on the peripheral smear (likelihood ratio: 39) indicate mononucleosis.[12]
- Viral cultures obtained from vesicles can be obtained in Coxsackievirus and herpes infections, but the diagnosis is usually based on clinical suspicion and findings.
- Head–neck CT scan can assist in the diagnosis and localization of peritonsillar abscess and should be obtained if further extension into the deeper neck is suspected.[13]

FIGURE 35-8 Strep pharyngitis with dark necrotic area on right tonsil and prominent lymphoid hyperplasia in a cobblestone pattern on the posterior pharynx. (*Courtesy of Richard P. Usatine, MD.*)

DIFFERENTIAL DIAGNOSIS

- Infectious mononucleosis—Nausea, anorexia without vomiting, uvular edema, generalized symmetric lymphadenopathy, and lethargy particularly in teenagers and young adults, is more suggestive of acute mononucleosis (Epstein-Barr virus [EBV]) although the pharyngeal examination has a similar appearance to GABHS (**Figure 35-4**). Hepatosplenomegaly is indicative of EBV in this group.
- Herpangina/Coxsackievirus infection—Oropharyngeal vesicles and ulcers indicate herpangina, which is caused by Coxsackievirus A16 in the majority of cases (**Figure 35-9**).
- Oral *Candida*—Whitish plaques of the oropharyngeal mucosa indicate oral *Candida*/thrush, which is mainly found in infants but can be found in adults with immunosuppression (see Chapter 136, *Candidiasis*).
- Sexually transmitted infections—Primary human immunodeficiency virus, gonococcal and syphilitic pharyngitis can all present with the symptom of sore throat. Although uncommon, these diagnoses should be considered in high-risk populations.
- Primary herpes gingivostomatitis causes oral ulcers and pain in the mouth. The wide distribution of ulcers with the first case of herpes simplex virus (HSV)-1 distinguishes this infection from other types of pharyngitis (see Chapter 129, Herpes Simplex).
- *Cytomegalovirus* (CMV)—Primary CMV infection in the immunocompetent host is usually asymptomatic. In the immunocompromised host, CMV may present with a mononucleosis-like syndrome clinically indistinguishable from EBV infection.

FIGURE 35-9 Herpangina caused by Coxsackievirus A16.

- Deep neck infections—Asymmetry of the neck, neck masses, and any displacement if the peripharyngeal wall should raise suspicion. Associated shortness of breath may be a warning sign of impending airway obstruction. Other complications include aspiration, thrombosis, mediastinitis, and septic shock.[13]
- Epiglottitis—Rapid-onset fever, malaise, sore throat, and drooling in the absence of coughing characterize acute epiglottitis, especially when presenting in children. Progression of the disease can lead to life-threatening airway obstruction. Fortunately, this is a rare condition because of the preventive effect of the *Haemophilus influenzae* type b (HIB) vaccine.
- Supraglottitis—Similar symptoms to epiglottitis, although seen in adults. Sore throat and painful swallowing are the most common presenting symptoms, seen in more than 90% of cases. Muffled voice and drooling, dyspnea, stridor, and cough reported in less than 50% of cases. No definite organism is identified in the majority of cases. Unlike epiglottitis in children, HIB is responsible for less than 20% of adult cases but still accounts for the majority of positive cultures. Mortality rates have been reported up to 20%. Currently more common than epiglottitis, because of HIB vaccine.
- Diphtheria—A rare condition in the United States today, as most patients have been immunized. However, it needs to be considered, especially in unvaccinated and immigrant populations. Pharyngeal diphtheria presents with sore throat, low-grade fever, and malaise. The pharynx is erythematous with a grayish pseudomembrane that cannot be scraped off. Complications include myocarditis resulting in acute and severe congestive heart failure (CHF), endocarditis, and neuropathies.
- Other bacterial causes— Non–group A *Streptococcus*, *Fusobacterium necrophorum*, *Mycoplasma pneumoniae*, *Chlamydophila pneumoniae*, and *Arcanobacterium haemolyticum* have all been isolated as bacterial causes of pharyngitis; not as clinically significant, but all generally respond to treatments prescribed for strep pharyngitis.

MANAGEMENT

NONPHARMACOLOGICAL

- Hydration with plenty of liquids (children and adults).
- Salt-water gargles (children and adults).
- Lozenges for comfort (adults only).

MEDICATIONS

- Age-appropriate dosing of acetaminophen and ibuprofen may be used for symptomatic relief of fever and pain. Doses can be alternated as needed.
- Steroids (e.g., dexamethasone single 10-mg injection) are indicated in severe tonsillitis in patients without immunocompromise.[12] SOR C However, there is no good evidence to recommend steroids in infectious mononucleosis.[14]
- In extreme cases of pharyngitis, 1 teaspoon of viscous lidocaine 2% in a half glass of water gargled 20 to 30 minutes before meals helps the odynophagia. This is typically only recommended in rare cases because of risk of aspiration, potential toxicity of lidocaine, and the

risk for oral mucosal burns—consider hospitalization if symptoms are this severe.

- Antibiotic use—Use the clinical prediction rule (given above [see "Clinical Features"]) for estimating the probability of GABHS:[7–11]
  - Low probability (no test, no treatment for GABHS): Patients scoring 0 points should be treated symptomatically and not given antibiotics.
  - Intermediate probability (test and treatment based on result): Patients with 1 to 3 points (probability of GABHS is approximately 18%) should undergo a rapid antigen test and be treated with antibiotics if positive.
  - High probability (no test, treatment for GABHS): Patients with 4 to 5 points should be considered for empiric antibiotic treatment.
- For suspected or proven GABHS, penicillin V 500 mg orally 2 to 3 times daily for 10 days continues to be the treatment of choice for adults.[15] Erythromycin 500 mg orally 4 times daily may be used in penicillin allergic patients. Penicillin G 1.2 million U IM single dose may be used if unable to tolerate oral medication. Pediatric doses are Pen VK 25 to 50 mg/kg per day divided 3 to 4 times daily and erythromycin 30 to 50 mg/kg per day divided 4 times daily for 10 days. In some cases amoxicillin 25 mg/kg per day in divided doses every 12 hours is preferred because of palatability.
- Penicillin G (600 mg IV every 6 hours for 24 to 48 hours) in combination with metronidazole (15 mg/kg IV more than 1 hour followed by 7.5 mg/kg IV more than 1 hour every 6 to 8 hours) is recommended for peritonsillar abscess.

REFERRAL

- If signs of airway impairment are present, the patient should be immediately transported to an emergency department. Intubation can be extremely difficult and risky.
- Refer patients with peritonsillar abscess to ear, nose, and throat (ENT). Incision and drainage is the treatment of choice in addition to using systemic antibiotics.
- Consider ENT referral for tonsillectomy in proven recurrent GABHS cases, or under certain other conditions (e.g., antibiotic allergies/intolerances) with recurrence.[16] However, there is no evidence to support tonsillectomy for isolated cases.[17]

PROGNOSIS

- Sore throat, regardless of the cause, is typically self-limiting. Typical symptoms last 3 to 4 days.
- Longer-term complications are rare but antibiotic treatment to prevent these sequelae remains justification for treatment. Antibiotics shorten the duration of illness by approximately 1 day and can reduce the risk of rheumatic fever by approximately two-thirds in communities where this complication is common.[15] However, GI symptoms like mild diarrhea are common side effects of antibiotic therapy. The number needed to treat to prevent 1 sore throat at day 3 is less than 6; at week 1 it is 21.[15]

FOLLOW-UP

Follow up if clinically deteriorating, especially if swallowing or breathing becomes more difficult or severe headache develops.

PATIENT EDUCATION

- The treatment for most cases of non-GABHS pharyngitis is education. Explain to patients the difference between a viral and a bacterial infection to help them understand why antibiotics were prescribed or not prescribed. Antibiotic treatment for a patient with an obvious viral infection is inappropriate, despite patient requests. Studies demonstrate that spending time with the patient to explain the disease process is associated with greater patient satisfaction than prescribing an antibiotic.[18,19]
- Rest, liquids, and analgesics should be encouraged.
- Patients receiving antibiotics should be reminded to complete the entire course, even if symptoms improve. Common antibiotic side effects, like rash, nausea, and diarrhea, should be reviewed.
- Patients with mononucleosis and splenomegaly should be warned to avoid contact sports because of the risk of splenic rupture.

PATIENT RESOURCES

- **http://familydoctor.org/familydoctor/en/diseases-conditions/sore-throat.html.**
- **www.nlm.nih.gov/medlineplus/ency/article/000639.htm.**
- Mononucleosis information for patients—**http://familydoctor.org/familydoctor/en/diseases-conditions/mononucleosis.html.**

PROVIDER RESOURCES

- Free clinical calculator online: Modified Centor Score for Strep Pharyngitis—**http://www.mdcalc.com/modified-centor-score-for-strep-pharyngitis**.

REFERENCES

1. Vital Health and Statistics. US Department of Health and Human Services, Series 13, Number 169 April 2011; Ambulatory Medical Care Utilization Estimates for 2007.
2. Bisno AL, Gerber MA, Gwaltney JM, et al. Practice guidelines for the diagnosis and management of group A streptococcal pharyngitis. *Clin Infect Dis.* 2002;35:(2):113-125.
3. Bottin R, Marioni G, Rinaldi R, et al. Deep neck infection: A present-day complication. A retrospective review of 83 cases (1998-2001). *Eur Arch Otorhinolaryngol.* 2003;260(10):576-579.
4. Aung K, Ojha A, Lo C. *Viral Pharyngitis*. http://www.emedicine.medscape.com/article/22562. Accessed November, 2011.
5. Halsey E. *Bacterial Pharyngitis*. http://emedicine.medscape.com/article/225243. Accessed November 2011.

6. Guilherme L, Kalil J, Cunningham M. Molecular mimicry in the autoimmune pathogenesis of rheumatic heart disease. *Autoimmunity*. 2006;39(1):31-39.
7. Singh S, Dolan JG, Centor RM. Optimal management of adults with pharyngitis: a multi-criteria decision analysis. *BMC Med Inform Decis Mak*. 2006;6:14.
8. Choby BA. Diagnosis and treatment of streptococcal pharyngitis. *Am Fam Physician*. 2009;79(5):383-390.
9. Aalbers J, O'Brien KK, Chan WS, et al. Predicting streptococcal pharyngitis in adults in primary care: a systematic review of the diagnostic accuracy of symptoms and signs and validation of the Centor score. *BMC Med*. 2011 Jun 1;9:67.
10. Merrill B, Kelsberg G, Jankowski TA, Danis P. Clinical inquiries. What is the most effective diagnostic evaluation of streptococcal pharyngitis? *J Fam Pract*. 2004;53(9):734, 737-738, 740.
11. McIsaac WJ, Goel V, To T, Low DE. The validity of a sore throat score in family practice. *CMAJ*. 2000;163:811-815.
12. Ebell MH. Sore throat. In: Sloane PD, Slatt LM, Ebell MH, Jacques LB, eds. *Essentials of Family Medicine*. Baltimore, MD: Lippincott Williams & Wilkins; 2002:727-738.
13. Wang LF, Kuo WR, Tsai SM, Huang KJ. Characterizations of life-threatening deep cervical space infections: a review of one hundred ninety-six cases. *Am J Otolaryngol*. 2003;24(2):111-117.
14. Candy B, Hotopf M. Steroids for symptom control in infectious mononucleosis. *Cochrane Database Syst Rev*. 2006;3:CD004402.
15. Spinks A, Glasziou PP, Del Mar CB. Antibiotics for sore throat. *Cochrane Database Syst Rev*. 2006;(4):CD000023.
16. Baugh RF, Archer SM, Mitchell RB, et al. Clinical practice guideline: tonsillectomy in children. *Otolaryngol Head Neck Surg*. 2011;144(1 Suppl):S1-S30.
17. Neill RA, Scoville C. Clinical inquiries. What are the indications for tonsillectomy in children? *J Fam Pract*. 2002;51(4):314.
18. Hamm RM, Hicks RJ, Bemben DA. Antibiotics and respiratory infections: Are patients more satisfied when expectations are met. *J Fam Pract*. 1996;43(1):56-62.
19. Ong S, Nakase J, Moran GJ, et al. Antibiotic use for emergency department patients with upper respiratory infections: prescribing practices, patient expectations, and patient satisfaction. *Ann Emerg Med*. 2007;50(3):213-220.

36 THE LARYNX (HOARSENESS)

Laura Matrka, MD
C. Blake Simpson, MD
J. Michael King, MD

PATIENT STORY

A 47-year-old man with a 40-pack-year history of smoking presents with worsening hoarseness that began approximately 6 weeks ago. He complains of globus sensation and difficulty swallowing solid foods. He denies odynophagia, otalgia, hemoptysis, and hematemesis. There is no associated cough, and he has not had any constitutional symptoms such as fevers, chills, or recent weight loss.

Hoarseness in a middle-aged man with the above symptoms is very common, and the differential diagnosis is long (all the diseases below are possibilities in this case scenario). The patient's smoking history and duration of symptoms should raise concern for a possible laryngeal malignancy. However, there is a higher incidence of laryngopharyngeal reflux (LPR) followed by benign vocal fold (cord) lesions.

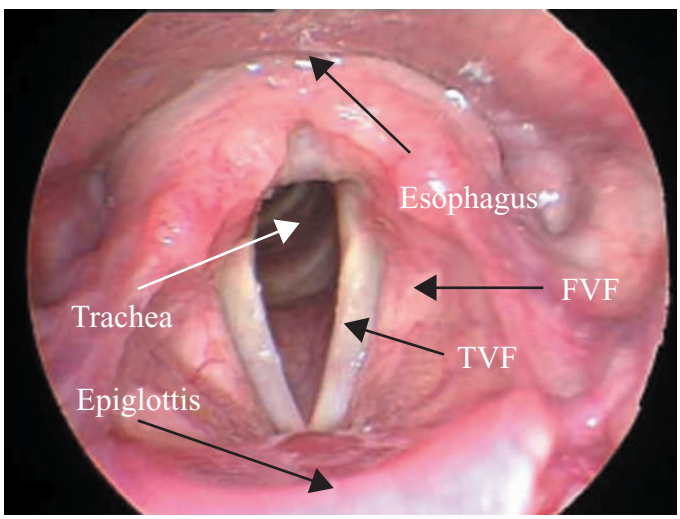

FIGURE 36-1 Normal larynx (true and false vocal folds). *FVF*, False vocal fold; *TVF*, true vocal fold (cord). (*Courtesy of C. Blake Simpson, MD.*)

INTRODUCTION

The evaluation of hoarseness typically involves first ruling out the most serious pathologies, such as laryngeal squamous cell carcinoma, in adults or recurrent respiratory papillomatosis in children, and then proceeding with a more focused and subtle evaluation to uncover any of the many benign pathologies that affect the larynx. Treatment of these benign pathologies must take into account the patient's lifestyle and voice needs. It also often incorporates education on vocal hygiene, which involves increasing hydration, decreasing mucus and vocal abuse, and reducing acid reflux if a factor.

SYNONYMS AND DEFINITIONS

- Hoarseness, dysphonia, vocal strain, breathiness, raspiness.
- Vocal cords, true vocal cords, true vocal folds, glottis (**Figure 36-1**).
- False vocal folds, false vocal cords (mucosal folds in the supraglottis, just superior to the true vocal folds and separated from the true folds by the ventricle).
- Flexible fiberoptic laryngoscopy, direct laryngoscopy, nasopharyngeal scope (NP scope), transnasal fiberoptic laryngoscopy.
- Stroboscopy, videolaryngostroboscopy (VLS), strobe exam.

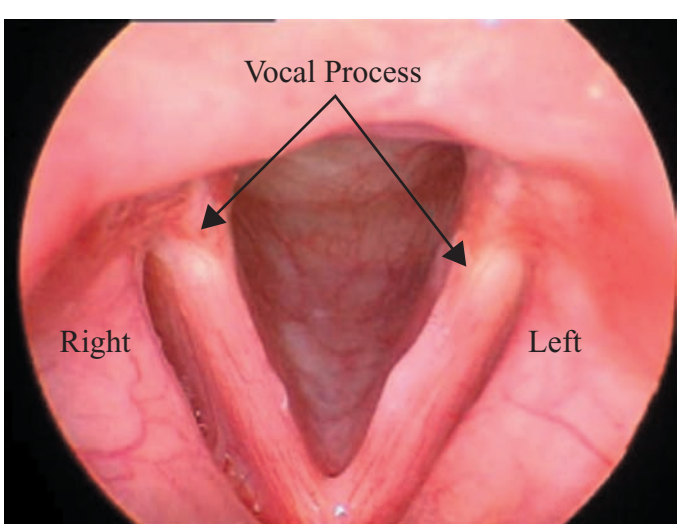

FIGURE 36-2 Laryngitis—diffuse erythema and inflammation, irregular vocal fold edges. (*Courtesy of C. Blake Simpson, MD.*)

EPIDEMIOLOGY

- The most common cause of hoarseness in adults and children overall is viral infection causing laryngitis (**Figure 36-2**).

- LPR disease may be present in up to 50% of patients presenting with voice and laryngeal disorders.[1] It is less commonly the sole cause of hoarseness.
- Squamous cell carcinoma (SCC) accounts for 95% of laryngeal cancer. Approximately 11,000 new cases are diagnosed in the United States each year. Peak incidence is in the sixth and seventh decades of life with a strong male predominance.[1]
- Recurrent respiratory papillomatosis (RRP) represents the most common benign neoplasm of the larynx among children and should be considered in children with chronic hoarseness. A known risk factor for juvenile onset is the triad of a firstborn child (75%), teenage mother, and vaginal delivery. The incidence is 4.3 per 100,000 children and 1.8 per 100,000 adults.[2] There is a known association between cervical human papillomavirus (HPV) infection in the mother and juvenile onset RRP, but the precise mode of transmission is unclear. The risk of a child contracting RRP after delivery from an actively infected mother with genital HPV ranges from 0.25% to 3%.[3] Because cesarean section does not prevent RRP in all cases, routine prophylactic cesarean section in mothers with active condyloma acuminata is currently *not* recommended.

ETIOLOGY AND PATHOPHYSIOLOGY

- Laryngitis is a nonspecific term to describe inflammation of the larynx from any cause. Most commonly this is due to a viral upper respiratory infection. Compare the anatomy of the normal larynx (**Figure 36-1**) with that of acute laryngitis (**Figure 36-2**), with the primary differences being in the diffuse erythema and edema of the vocal folds and the often transient irregularities of the vocal fold medial edge as compared to the straight medial edge of the normal vocal fold. Laryngeal symptoms result from dry throat, mucous stasis, and recurrent trauma from coughing and throat clearing.
- LPR must be differentiated from gastroesophageal reflux disease (GERD), in which acid reflux is more likely to cause heartburn, indigestion, and regurgitation and does not necessarily reach the larynx or upper aerodigestive tract. LPR is more likely to present with frequent throat clearing, dry cough, hoarseness, and globus sensation, and does not include heartburn in more than 60% of patients. The larynx is highly sensitive to even small amounts of acid or pepsin. Thus, patients who do not have severe enough reflux to cause esophagitis, with its associated symptoms of GERD, may still develop symptomatic laryngeal mucosal injury, with its associated symptoms of LPR.[1,4,5,8]
- SCC has a multifactorial etiology, but 90% of patients have a history of heavy tobacco and/or alcohol use. These risk factors have a synergistic effect. Other independent risk factors include employment as a painter or metalworker, exposure to diesel or gasoline fumes, and exposure to therapeutic doses of radiation.
- RRP is caused by HPV-6 and HPV-11. Onset is predominantly in young children, although an adult-onset variant exists. Its course is unpredictable and highly variable. Tracheal and bronchopulmonary spread can occur, as can malignant transformation to SCC; the latter is rare. Bronchopulmonary spread is uniformly fatal as a consequence of the lack of surgical options.

- Vocal cord nodules are benign lesions arising from mechanical trauma (vocal abuse or misuse) and are often described as a "callous" of the vocal folds. Vocal cord polyps or cysts can arise from vocal abuse, a blocked mucous gland, vocal fold hemorrhage, a background of polypoid corditis (see below), or idiopathic etiologies. They are a common cause of dysphonia in singers, teachers, and other professional voice users. Vocal cord granulomas are associated with LPR and/or intubation trauma and rarely require surgery.
- Causes of vocal cord paresis or paralysis are myriad:[1,6]
  - Iatrogenic surgical injury (anterior spine fusion, carotid endarterectomy, thyroidectomy) is most common (25%).
  - Nonlaryngeal malignancy (mediastinal, bronchopulmonary, and skull base) (24%).
  - No identifiable cause (idiopathic), often assumed to be viral (20%).
  - Nonsurgical trauma (penetrating/blunt injury and intubation injury) (10%).
  - Neurologic causes (stroke, central nervous system [CNS] tumors, multiple sclerosis [MS], and amyotrophic lateral sclerosis [ALS]) (8%).
  - Inflammatory/infectious disease (2% to 5%).
- Presbyphonia is a diagnosis of exclusion denoting vocal changes from aging of the larynx (gradually weakening voice, poor vocal projection, and vocal "roughness"). Hoarseness in patients older than 60 years of age is most commonly a result of benign vocal fold lesions followed by malignancy and vocal fold paralysis. Once a thorough evaluation has been done to rule out organic causes, presbyphonia is the cause of hoarseness in approximately 10% of elderly patients; it is characterized by atrophied vocal folds.[7]

DIAGNOSIS

CLINICAL FEATURES

- Key historical and physical examination findings can help differentiate benign pathology from potentially more serious problems:
  - Otalgia (ear pain)—Often a source of referred pain from primary laryngeal and pharyngeal carcinomas; it is not typically seen with benign pathologies.
  - Dysphagia and odynophagia (pain when swallowing)—Nonspecific complaints, but potentially worrisome for obstructing lesions or reactive pharyngeal edema.
  - Stridor or dyspnea—"Noisy breathing" with respiratory distress should be evaluated urgently to rule out impending airway obstruction. Less-severe dyspnea may be noted by patients with vocal cord paralysis caused by air escape during speech; a detailed history should reveal that it occurs only during speech or from the inability to perform adequate Valsalva maneuver as a result of loss of tight glottic closure.
  - Globus pharyngeus—The persistent or intermittent nonpainful sensation of a lump or foreign body in the throat. This is commonly associated with LPR.
  - Neck mass—Associated unilateral or bilateral lymphadenopathy is suspicious for a laryngeal neoplasm until proven otherwise.
  - Timing—Onset, duration, and frequency of symptoms is important.
- Red flags for laryngeal carcinoma include a history of smoking and/or alcohol abuse, associated neck mass, weight loss or severe

dysphagia, presence of stridor (often initially noted with sleep or when lying flat), and otalgia.

- LPR symptoms include hoarseness, throat clearing, "postnasal drip," chronic cough, dysphagia, globus pharyngeus, and sore throat. "Heartburn" is *not* a requisite symptom!
- Hallmark of diagnosis is direct visualization of the larynx, often performed by an otolaryngologist with a flexible laryngoscopic exam. Stroboscopy is added to the evaluation when visualization of the mucosal wave of the vocal folds is necessary. Assessment of the mucosal wave aids in determining the depth of a lesion within the vocal fold and the severity of its effect on the voice.

LABORATORY AND IMAGING

- Laboratory studies are not usually helpful, except in the rare case that a previously undiagnosed rheumatologic disease presents with vocal complaints as the initial symptom.
- Plain films of the chest are useful to rule out bronchopulmonary or mediastinal masses as a cause of vocal cord paralysis, but are generally not helpful for primary laryngeal lesions.
- A CT of the neck and chest with contrast is useful in ruling out pathology along the length of the recurrent laryngeal nerve in cases of unexplained vocal cord paralysis and in cases suspicious for carcinoma, especially if there is associated cervical lymphadenopathy. A chest X-ray is sometimes used to replace the chest CT.
- An MRI with and without gadolinium offers the best imaging for suspected primary CNS or skull base lesions; this is typically added to the work-up for vocal cord paralysis when evidence of high vagal injury such as weakness in palate elevation is present.
- Referral to a gastroenterologist for *dual-channel* 24-hour pH probe monitoring (*while on antireflux medications*) is a useful diagnostic tool for patients with suspected LPR.

DIFFERENTIAL DIAGNOSIS

- Laryngitis (**Figure 36-2**).
- Laryngopharyngeal reflux (**Figures 36-3** and **36-4**).
- SCC (**Figure 36-5**).
- Laryngeal papillomatosis (**Figures 36-6** and **36-7**).
- Vocal cord nodule (**Figure 36-8**).
- Vocal cord polyp (**Figure 36-9**).
- Vocal cord cyst.
- Vocal cord paresis or paralysis.
- Presbyphonia.
- Neurologic disorders (MS, Parkinson disease, ALS, and essential tremor).
- Systemic diseases (Wegener granulomatosis, sarcoidosis, rheumatoid arthritis).

MANAGEMENT

- Laryngitis—Empiric treatment is aimed at alleviating symptoms such as cough and thinning nasal/pharyngeal secretions. Hydration

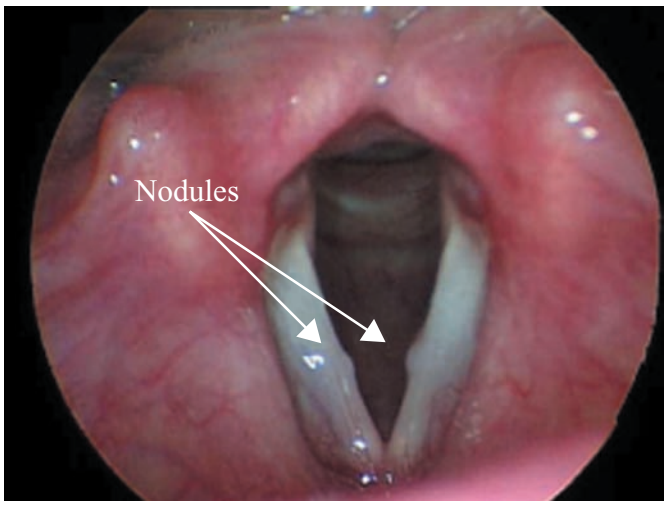

FIGURE 36-3 Laryngopharyngeal reflux. Postcricoid region edema (normal is less full and nearly concave) and edema just inferior to the true vocal fold edge (infraglottic edema) indicative of chronic inflammation from reflux, often called "pseudosulcus." Other findings of LPR not seen in this image include thick mucus and mucosal erythema. (*Courtesy of C. Blake Simpson, MD.*)

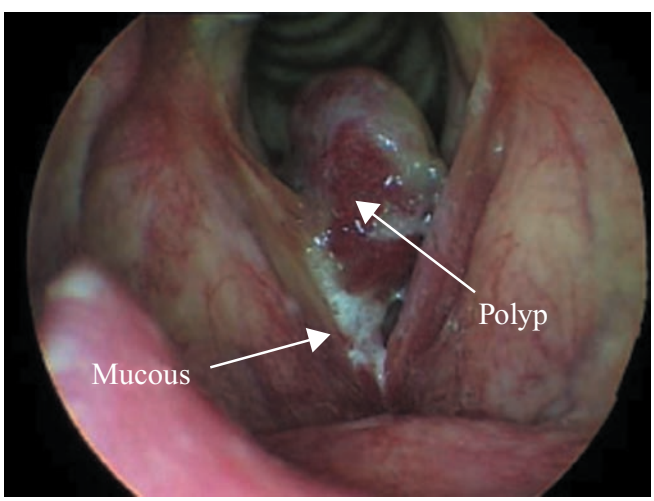

FIGURE 36-4 Laryngopharyngeal reflux during phonation with diffuse erythema, inflammation, and thick mucus. (*Courtesy of C. Blake Simpson, MD.*)

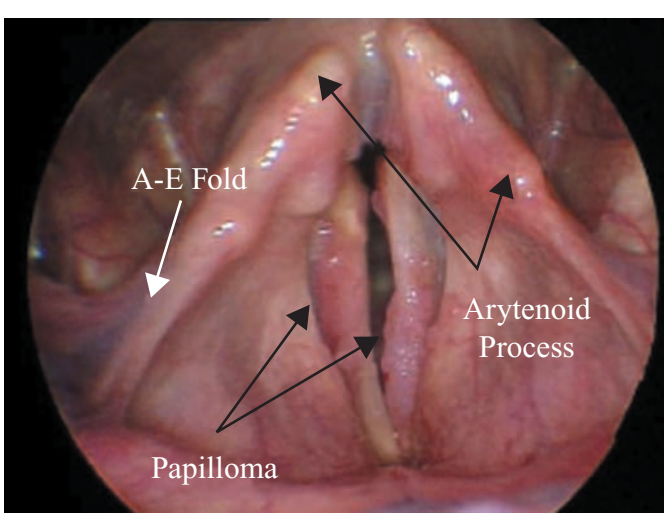

FIGURE 36-5 Squamous cell carcinoma, advanced stage with left true vocal cord paralysis. (*Courtesy of C. Blake Simpson, MD.*)

is critical for healing (increased water intake, steam showers, humidifiers, and saunas may help). Throat clearing should be discouraged and voice rest encouraged. Talking should be conserved, not prohibited. Inform patients that whispering causes even more vocal strain than normal speech.

- Vocal cord nodules, polyps, and cysts—Initial management involves speech therapy accompanied by medical treatment of dehydration, allergies, sinonasal secretions (postnasal drip), and LPR. Refractory disease may require surgical excision.
- Laryngeal papillomatosis—Most children have a recalcitrant course that requires periodic surgical debridement by an otolaryngologist to prevent airway obstruction. Spontaneous remission may occur. Adjuvant therapy, such as intraepithelial injection of cidofovir at the time of surgery, is commonly utilized in more aggressive disease. It is hoped that the administration of the Gardasil vaccine will decrease the incidence of RRP over time. Some practitioners administer the Gardasil vaccine in a nonprophylactic manner to patients with existing RRP, although there is no strong evidence currently to support a treatment effect of the vaccine.[2,3]
- LPR—Mainstay treatment involves patient education to modify diet and behavior (avoidance of acidic or greasy foods, tobacco cessation, limiting alcohol and caffeine, weight loss, and avoiding meals shortly before lying down). Medical therapy consists of *twice* daily proton pump inhibitors (PPIs) 30 to 60 minutes before meals, which can often be weaned after several months of therapy. Some patients benefit from adding an H_2-blocker, such as ranitidine 300 mg, at bedtime.
- SCC—Multidisciplinary management is best. Depending on the staging and extent of disease, patients often receive one or more modalities of treatment including surgery, radiation, and chemotherapy.
- Vocal cord paresis or paralysis—Treatment is targeted at the underlying disorder. Some patients may be candidates for surgical intervention to reposition the paralyzed cord medially with an implant. With a mobile vocal fold on the contralateral side, airway is rarely compromised by medialization of the paralyzed vocal fold. These procedures restore voice quality and often alleviate chronic aspiration problems.
- Neurologic diseases—Laryngeal complaints can be associated with MS, myasthenia gravis, Parkinson disease, ALS, and essential tremor. In addition to managing the underlying disorder, a trial of voice therapy is sometimes useful.
- Systemic diseases—Diseases such as Wegener granulomatosis, sarcoidosis, relapsing polychondritis, and rheumatoid arthritis rarely may involve the larynx. Voice and swallowing problems in these patients should be evaluated by an otolaryngologist for possible therapies to improve the voice and to rule out associated airway stenosis.
- Presbyphonia—This is a diagnosis of exclusion. Once organic etiologies have been ruled out, a trial of voice therapy is recommended before considering surgical options, such as vocal fold injection augmentation to plump the atrophied vocal fold.

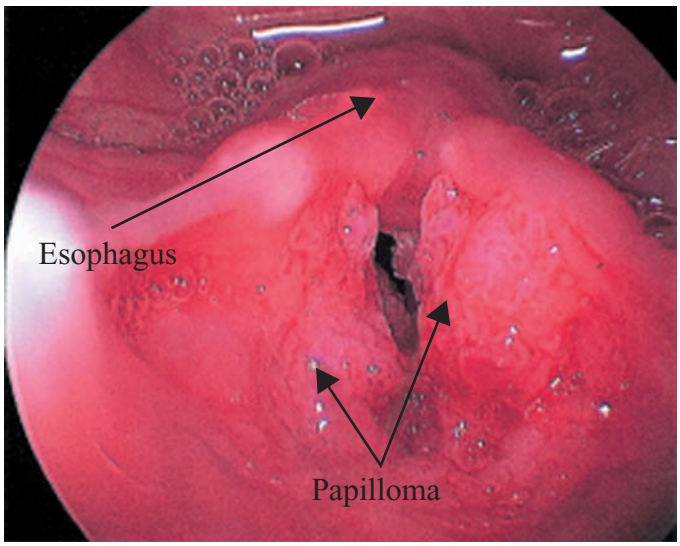

FIGURE 36-6 Adult recurrent respiratory papillomatosis. Aryepiglottic fold (*A-E fold*). (*Courtesy of C. Blake Simpson, MD.*)

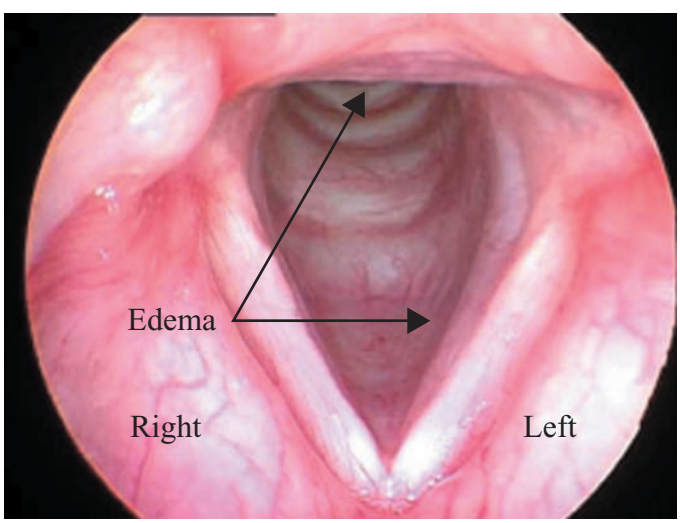

FIGURE 36-7 Recurrent respiratory papillomatosis in a 3-year-old child. The papillomas are nearly obstructing the airway and have required debridement. (*Courtesy of C. Blake Simpson, MD.*)

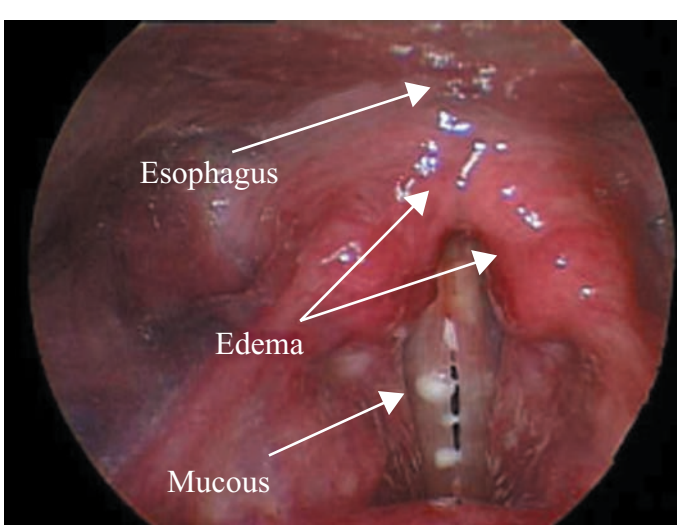

FIGURE 36-8 Vocal cord nodules. (*Courtesy of C. Blake Simpson, MD.*)

FOLLOW-UP

- Urgent referral to an otolaryngologist for flexible laryngoscopic examination of the larynx is advisable when the history and physical are suspicious for carcinoma.
- When symptoms worsen or fail to resolve, referral to an otolaryngologist (or laryngologist) is indicated (see "Provider Resources" below to find a laryngologist in your area).
- Patients suspected of having LPR should be seen approximately 6 to 8 weeks after initiating empiric therapy with a PPI and lifestyle measures. An otolaryngology and/or gastroenterology consultation is indicated when symptoms do not improve after optimized behavioral and medical management or for patients who require long-term PPI therapy (longer than 12 months). Some of these patients, particularly those with chronic cough or longstanding requirement for PPIs, may require transnasal esophagoscopy (performed in the otolaryngologist's office) or esophagogastroduodenoscopy (performed by a gastroenterologist in the endoscopy suite). Recent evidence has pointed to chronic cough as an independent indicator of esophageal adenocarcinoma, and Barrett esophagus should be ruled out in any patient requiring long-term PPI use.[9]

PATIENT EDUCATION

- In cases of nonmalignant pathology, vocal hygiene and other lifestyle measures often play an important role in treatment. Efforts should focus on increasing hydration, decreasing caffeine intake, tobacco cessation, and prevention of excessive alcohol use.
- Vocal cord nodules, polyps, and cysts typically occur in professional voice users (ministers, auctioneers, teachers, singers, etc.). Speech therapists can be integral in preventing and healing lesions by teaching patients how to avoid vocal misuse.
- Benign laryngeal pathology may be improved, but not necessarily resolved, by controlling both gastroesophageal and LPR disease. Patients should be educated about GERD/LPR risk factors:
  - Spicy, acidic, or greasy foods.
  - Tobacco and alcohol abuse.
  - Caffeinated beverages (especially carbonated sodas).
  - Citric juices, tomato sauces, chocolate, mints.
  - Obesity.
  - Eating meals within 2 to 3 hours of lying down.

PATIENT RESOURCES

- **http://www.entnet.org/healthinfo/index.cfm.**
- **http://www.entusa.com.**
- **http://www.voiceproblem.org.**

PROVIDER RESOURCES

- **http://www.voiceproblem.org.**
- **http://www.ucdvoice.org/gallery.html.**
- Information about laryngeal pathology as well as an extensive list of laryngologists worldwide—**http://www.voicedoctor.net/links/physicians.html.**

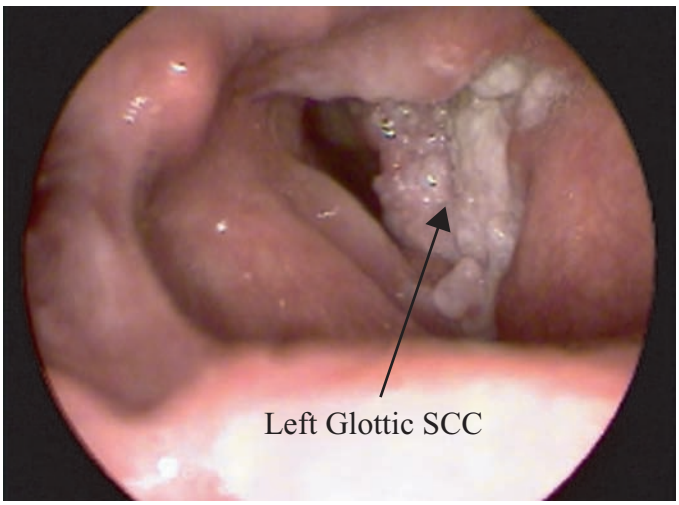

FIGURE 36-9 Large obstructing laryngeal polyp with thick mucus collecting around it. (*Courtesy of C. Blake Simpson, MD.*)

REFERENCES

1. Ossoff R, Shapshay S, Woodson G, Netterville J. *The Larynx*. Philadelphia: Lippincott Williams & Wilkins; 2003.
2. Derkay CS. Recurrent respiratory papillomatosis. *Laryngoscope*. 2001;111:57-69.
3. Gallagher TQ, Derkay CS. Recurrent respiratory papillomatosis: update 2008. *Curr Opin Otolaryngol Head Neck Surg.* 2008;16:536-542.
4. Simpson CB. Patient of the month program: breathy dysphonia. *American Academy of Otolaryngol Head Neck Surg.* 2002;31(7): 19-28.
5. Koufmann JA, Amin MA, Panetti M. Prevalence of reflux in 113 consecutive patients with laryngeal and voice disorders. *Otolaryngol Head Neck Surg*. 2000;123:385-388.
6. Benninger MS, Gillen JB, Altman JS. Changing etiology of vocal fold immobility. *Laryngoscope.* 1998;108:1346-1349.
7. Kendall K. Presbyphonia: a review. *Curr Opin Otolaryngol Head Neck Surg*. 2007;15:137-140.
8. Koufman JA, Aviv JE, Casiano RR, Shaw GY. Laryngopharyngeal reflux: position statement of the committee on speech, voice, and swallowing disorders of the American Academy of Otolaryngology-Head and Neck Surgery. *Otolaryngol Head Neck Surg*. 2002;127: 32-36.
9. Reavis KM, Morris CD, Gopal DV, et al. Laryngopharyngeal reflux symptoms better predict the presence of esophageal adenocarcinoma than typical gastroesophageal reflux symptoms. *Ann Surg*. 2004;239(6):849-858.

PART 6

ORAL HEALTH

Strength of Recommendation (SOR)	Definition
A	Recommendation based on consistent and good-quality patient-oriented evidence.*
B	Recommendation based on inconsistent or limited-quality patient-oriented evidence.*
C	Recommendation based on consensus, usual practice, opinion, disease-oriented evidence, or case series for studies of diagnosis, treatment, prevention, or screening.*

*See Appendix A on pages 1447–1450 for further information.

37 BLACK HAIRY TONGUE

Richard P. Usatine, MD
Wanda C. Gonsalves, MD

PATIENT STORY

A 60-year-old man who smokes presents to the physician's office smelling of alcohol. He complains of a black discoloration of his tongue and a gagging sensation on occasion. He admits to smoking 1 to 2 packs per day along with drinking at least 6 to 8 beers per day. The patient brushes his teeth infrequently and has not seen a dentist for a long time. On physical exam, his teeth are stained and his tongue shows elongated papillae with brown discoloration (**Figure 37-1**). Diagnoses include black hairy tongue (BHT), poor oral hygiene, and tobacco and alcohol addiction.

FIGURE 37-1 Black hairy tongue showing elongated filiform papillae with brown discoloration in a man who is a heavy smoker and drinker. Note the tobacco-stained teeth. (*Courtesy of Brad Neville, DDS.*)

INTRODUCTION

BHT is a benign disorder of the tongue characterized by abnormally hypertrophied and elongated filiform papillae on the surface of the tongue.[1] In addition, there is defective desquamation of the papillae on the dorsal tongue resulting in a hair-like appearance.[2]

SYNONYMS

Hyperkeratosis of the tongue, lingua villosa nigra.

EPIDEMIOLOGY

The prevalence of BHT varies depending upon the risk factors in the population being studied.

- It can be as high as 57% in persons incarcerated or addicted to drugs.[3]
- The prevalence in Minnesota schoolchildren was 0.06%.[4]
- Turkish dental patients showed higher rates of BHT in men, smokers, and black tea drinkers. The highest prevalence was 54% in heavy smokers.[5]

ETIOLOGY AND PATHOPHYSIOLOGY

- BHT (**Figure 37-1**) is a disorder characterized by elongation and hypertrophy of filiform papillae and defective desquamation of the papillae.[2,6]
- These papillae, which are normally about 1 mm in length, may become as long as 12 mm.
  - The elongated filiform papillae can then collect debris, bacteria, fungus, or other foreign materials.[1]
- In an extensive literature review of reported cases of drug-induced BHT, 82% of the cases were caused by antibiotics (**Figure 37-2**).[1]

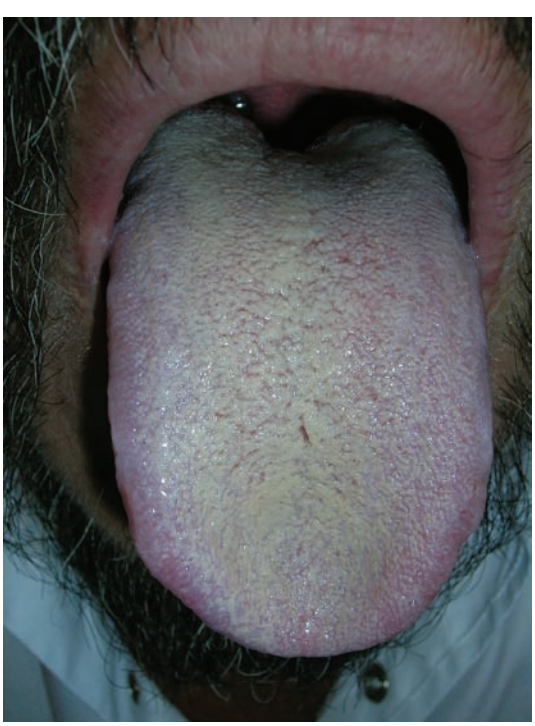

FIGURE 37-2 Drug-induced black hairy tongue with yellowish-brown elongated filiform papillae in a patient taking a broad spectrum antibiotic. (*Courtesy of Richard P. Usatine, MD.*)

- Dry mouth (xerostomia) from medications, tobacco, and radiation therapy can lead to BHT.[1]

RISK FACTORS[1]

- Tobacco (smoking and chewing).
- Alcoholism and drug abuse (especially drugs that are smoked).
- Poor oral hygiene.
- Medications (especially antibiotics and those causing xerostomia).
- Oxidizing mouthwashes (containing peroxide).
- Cancer, especially with radiation therapy.
- Drinking black tea or coffee.

DIAGNOSIS

CLINICAL FEATURES

- Patients may be asymptomatic. However, the accumulation of debris in the elongated papillae may cause taste alterations, nausea, gagging, halitosis, and pain or burning of the tongue.[1]

The diagnosis is made by visual inspection:

- BHT may exhibit a thick coating of black, brown, or yellow discoloration, depending on foods ingested, tobacco use, and amount of coffee or tea consumed (**Figure 37-3**).

TYPICAL DISTRIBUTION

The lesion is restricted to the dorsum of the tongue, anterior to the circumvallate papillae, rarely involving the tip or sides of the tongue.

LABORATORY TESTS

Consider performing a KOH preparation to rule out associated candidiasis.

DIFFERENTIAL DIAGNOSIS

- Black tongue can occur with the ingestion of bismuth subsalicylate or minocycline. Although the tongue has a black coating, the papillae are not elongated. Without the hypertrophy of papillae this is not a BHT (**Figure 37-4**).
- Hairy leukoplakia—Appears as faint white vertical keratotic streaks typically on the lateral side of the tongue (**Figure 37-5**). Do not confuse BHT with oral hairy leukoplakia, an Epstein-Barr virus–related condition typically affecting the lateral tongue bilaterally in immunocompromised patients, especially those with HIV infection.
- Oral candidiasis—White plaques typically found on the buccal mucosa, tongue, and palate when removed has an erythematous base. The white color should make this easy to distinguish from BHT (see Chapter 136, Candidiasis).

FIGURE 37-3 Black hairy tongue that also is furrowed in a heavy smoker. Note this man also has angular cheilitis, poor dentition and halatosis. (*Courtesy of Richard P. Usatine, MD.*)

FIGURE 37-4 Black tongue without elongated papillae in a woman with untreated pemphigus vulgaris. Note the palatal erosions along with the black color of the tongue. The black color was gone in 2 days after prednisone was initiated and the patient was able to eat again. (*Courtesy of Richard P. Usatine, MD.*)

MANAGEMENT

NONPHARMACOLOGIC

- Avoidance of predisposing risk factors (e.g., tobacco, alcohol, and antibiotics). SOR C
- Stop the offending medication in drug-induced BHT whenever possible.[1] SOR B
- Regular tongue brushing using a soft toothbrush or tongue scraper. SOR C

MEDICATIONS

If candidiasis is present, an oral antifungal is indicated. If there is no liver disease, the preferred regimen for oral candidiasis is fluconazole 100 mg daily for 14 days. An alternative is clotrimazole troches 5 times a day for 14 days. Nystatin is less effective. Fluconazole-treated HIV patients with oropharyngeal candidiasis were more likely to remain disease-free than were those treated with other antifungal agents.[7] SOR A

REFERRAL

Patients with poor oral hygiene should be referred to a dentist. All patients should be encouraged to see a dentist at least twice yearly.

PREVENTION

Good oral hygiene and avoidance of risk factors.

PROGNOSIS

BHT is generally a self-limited disorder, so the prognosis should be excellent with good oral hygiene and treatment.

PATIENT EDUCATION

Tell patients to brush their teeth and tongue twice a day or to use a tongue scraper. Address addictions and offer help to quit. Suggest that patients eat firm foods, like fresh apples, that will help to clean the tongue.

PATIENT RESOURCES

- Mayo Clinic. *Black, Hairy Tongue*—**http://www.mayoclinic.com/health/black-hairy-tongue/DS01134.**

PROVIDER RESOURCES

- Medscape. *Hairy Tongue*—**http://emedicine.medscape.com/article/1075886.**

FIGURE 37-5 Oral hairy leukoplakia caused by Epstein-Barr virus on the tongue of a man with AIDS. (*Courtesy of Richard P. Usatine, MD.*)

REFERENCES

1. Thompson DF, Kessler TL. Drug-induced black hairy tongue. *Pharmacotherapy*. 2010;30(6):585-593.
2. Harada Y, Gaafar H. Black hairy tongue. A scanning electron microscopic study. *J Laryngol Otol.* 1977;91:91-96.
3. Bouquot JE. Common oral lesions found during a mass screening examination. *J Am Dent Assoc.* 1986;112(1):50-57.
4. Redman RS. Prevalence of geographic tongue, fissured tongue, median rhomboid glossitis, and hairy tongue among 3,611 Minnesota schoolchildren. *Oral Surg Oral Med Oral Pathol.* 1970; 30:390-395.
6. Sarti GM, Haddy RI, Schaffer D, Kihm J. Black hairy tongue. *Am Fam Physician.* 1990;41:1751-1755.
7. Albougy HA, Naidoo S. A systematic review of the management of oral candidiasis associated with HIV/AIDS. *SADJ*. 2002;57(11): 457-466.

38 GEOGRAPHIC TONGUE

Ernest E. Valdez, DDS
Richard P. Usatine, MD
Wanda C. Gonsalves, MD

PATIENT STORY

A 23-year-old male medical student presents to the physician's office complaining of his tongue's "strange appearance." He denies pain or discomfort and is unsure how long the lesions have been present. The lesions seem to change areas of distribution on the tongue. The examination reveals large, well-delineated, shiny and smooth, erythematous spots on the surface of the tongue (**Figure 38-1**). The diagnosis is geographic tongue (benign migratory glossitis). The physician explains that it is benign and that no treatment is needed unless symptoms develop.

FIGURE 38-1 Geographic tongue (benign migratory glossitis). Note the pink continents among the white oceans. (*Reprinted with permission from Gonsalves WC, Chi AC, Neville BW. Common oral lesions: part II. Am Fam Phys 2007;75(4):501-508. Copyright © 2007 American Academy of Family Physicians. All rights reserved.*)

INTRODUCTION

Geographic tongue is a recurrent, benign, usually asymptomatic, inflammatory disorder of the mucosa of the dorsum and lateral borders of the tongue. Geographic tongue is characterized by circinate, irregularly shaped erythematous patches bordered by a white keratotic band. The central erythematous patch represents loss of filiform papillae of tongue epithelium. Geographic tongue can, although rarely, present as symptomatic.

SYNONYMS

Benign migratory glossitis, geographic stomatitis.

EPIDEMIOLOGY

- Geographic tongue has an estimated prevalence of 1% to 3% of the population.[1]
- It may occur in either children or adults, and exhibits a female predilection.
- Geographic tongue in the United States has a greater prevalence among white and black persons than among Mexican Americans.[2]

ETIOLOGY AND PATHOPHYSIOLOGY

- Geographic tongue is a common oral inflammatory condition of unknown etiology.
- Some studies have shown an increased frequency in patients with allergies, pustular psoriasis, stress, type 1 diabetes, fissured tongue, and hormonal disturbances.[3]
- Histopathologic appearance resembles psoriasis.[4]
- Oddly, geographic tongue has an inverse association with cigarette smoking.[2,5]

DIAGNOSIS

CLINICAL FEATURES

- The diagnosis is made by visual inspection and history of the lesion. The lesions are suggestive of a geographic map (hence geographic tongue) with pink continents surrounded by whiter oceans (**Figure 38-1**).
- Geographic tongue consists of large, well-delineated, shiny, and smooth, erythematous patches surrounded by a white halo (**Figure 38-2**).
- Tongue lesions exhibit central erythema because of atrophy of the filiform papillae and are usually surrounded by slightly elevated, curving, white-to-yellow elevated borders (**Figures 38-1** and **38-2**).
- The condition typically waxes and wanes over time so the lesions appear to be migrating (hence migratory glossitis).
- Lesions may last days, months, or years. The lesions do not scar.
- Most patients are asymptomatic, but some patients may complain of pain or burning, especially when eating spicy foods.
- Suspect systemic intraoral manifestations of psoriasis or reactive arthritis if the patient has psoriatic skin lesions or has conjunctivitis, urethritis, arthritis, and skin involvement suggestive of reactive arthritis (see Chapter 155, Reactive Arthritis).

TYPICAL DISTRIBUTION

- The lesions are typically found on the anterior two-thirds of the dorsal tongue mucosa.
- Geographic tongue usually affects the tongue, although other oral sites may be involved such as the buccal mucosa, the labial mucosa, and, less frequently, the soft palate.[3]

FIGURE 38-2 Geographic tongue lesions in a 71-year-old woman. Note the white halos around the pink areas of atrophy of filiform papillae. (*Courtesy of Michael Huber, DMD.*)

DIFFERENTIAL DIAGNOSIS

- Erythroplakia or leukoplakia—May be suspected when lesions affect the soft palate (see Chapter 42, Leukoplakia).
- Lichen planus—Reticular forms are characterized by interlacing white lines commonly found on the buccal mucosa, or erosive forms, characterized by atrophic erythematous areas with central ulceration and surrounding radiating striae (see Chapter 154, Lichen Planus) (**Figure 38-3**).
- Psoriasis—Intraoral lesions have been described as red or white plaques associated with the activity of cutaneous lesions (see Chapter 152, Psoriasis) (**Figure 38-4**).
- Reactive arthritis—A condition characterized by the triad of "urethritis, arthritis, and conjunctivitis," may have rare intraoral lesions described as painless ulcerative papules on the buccal mucosa and palate (see Chapter 155, Reactive Arthritis).
- Fissured tongue—An inherited condition in which the tongue has fissures that are asymptomatic. Although it has been called a *scrotal tongue* in the past, the term *fissured tongue* is preferred by patients (**Figure 38-5**).

FIGURE 38-3 Lichen planus of the tongue. There are white striae; the surface is smooth in the affected area because of the loss of papillae. (*Courtesy of Richard P. Usatine, MD.*)

MANAGEMENT

Most individuals are asymptomatic and do not require treatment (**Figure 38-6**).

- For symptomatic cases, several treatments have been proposed but not proven effective with good clinical trials:[6,7]
  - Topical steroids such as triamcinolone dental paste (Oralone or Kenalog in Orabase). SOR C
  - Supplements such as zinc, vitamin B_{12}, niacin, and riboflavin. SOR C
  - Antihistamine mouth rinses (e.g., diphenhydramine elixir 12.5 mg per 5 mL diluted in a 1:4 ratio with water). SOR C
  - Topical anesthetic rinses.[6,7] SOR C

Geographic tongue can rarely present as persistent and painful (**Figure 38-7**). In one case report, 0.1% tacrolimus ointment was applied twice daily for 2 weeks with significant improvement of symptoms.[8] SOR C

No treatment has been proven to be uniformly effective.[9]

FIGURE 38-4 White plaques on the tongue of a black woman with severe cutaneous plaque psoriasis. A histologic specimen would appear similar to geographic tongue. (*Courtesy of E.J. Mayeaux, Jr., MD.*)

FOLLOW-UP

Tell the patient to contact you if the symptoms continue past 10 days and to go to the emergency department immediately if:

- The tongue swells significantly;
- The patient has trouble breathing; or
- The patient has trouble talking or chewing/swallowing.

PATIENT EDUCATION

Patients should be reassured of the conditions benign nature. Tell patients with geographic tongue to avoid irritating spicy foods and liquids.

PATIENT RESOURCES

- Medline Plus. *Geographic Tongue*—**http://www.nlm.nih.gov/medlineplus/ency/article/001049.htm.**

PROVIDER RESOURCES

- Medscpe. *Geographic Tongue*—**http://emedicine.medscape.com/article/1078465.**
- Mayo Clinic. *Geographic Tongue*—**http://www.mayoclinic.com/health/geographic-tongue/DS00819.**

FIGURE 38-5 Fissured tongue present since birth. Although this has also been called a *scrotal tongue*, the preferred terminology is now *fissured tongue*, for obvious reasons. (*Courtesy of Richard P. Usatine, MD.*)

REFERENCES

1. Redman RS. Prevalence of geographic tongue, fissured tongue, median rhomboid glossitis, and hairy tongue among 3,611 Minnesota schoolchildren. *Oral Surg Oral Med Oral Pathol.* 1970;30:390-395.

2. Shulman JD, Carpenter WM. Prevalence and risk factors associated with geographic tongue among US adults. *Oral Dis.* 2006;12:381-386.
3. Assimakopoulos D, Patrikakos G, Fotika C, Elisaf M. Benign migratory glossitis or geographic tongue: an enigmatic oral lesion. *Am J Med.* 2002;113:751-755.
4. Espelid M, Bang G, Johannessen AC, et al. Geographic stomatitis: report of 6 cases. *J Oral Pathol Med.* 1991;20:425-428.
5. Darwazeh AM, Almelaih AA. Tongue lesions in a Jordanian population. Prevalence, symptoms, subject's knowledge and treatment provided. *Med Oral Patol Oral Cir Bucal.* 2011;16:e745-e749.
6. Abe M, Sogabe Y, Syuto T, et al. Successful treatment with cyclosporin administration for persistent benign migratory glossitis. *J Dermatol.* 2007;34:340-343.
7. Reamy BV, Derby R, Bunt CW. Common tongue conditions in primary care. *Am Fam Physician.* 2010; 81:627-634.
8. Ishibashi M, Tojo G, Watanabe M, et al. Geographic tongue treated with topical tacrolimus. *J Dermatol Case Rep.* 2010;4:57-59.
9. Gonsalves W, Chi A, Neville B. Common oral lesions: part 1. Superficial mucosal lesions. *Am Fam Physician.* 2007;75:501-507.

FIGURE 38-6 A mild asymptomatic case of geographic tongue. Note the atrophic filiform papillae and the subtle white halo. (*Courtesy of Richard P. Usatine, MD.*)

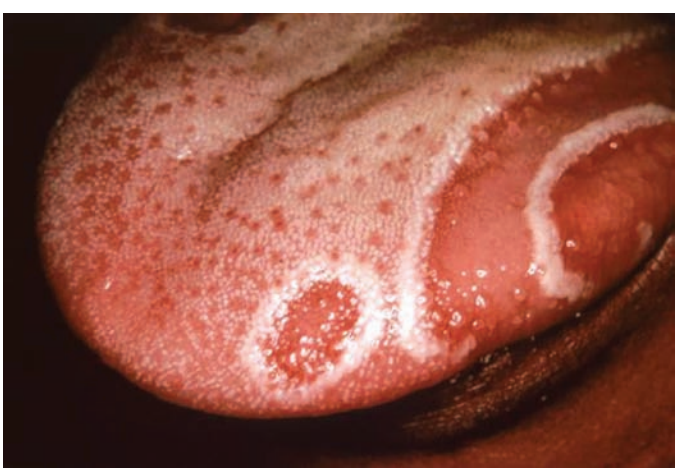

FIGURE 38-7 Geographic tongue with more severe symptomatology, including pain and a burning sensation when eating spicy foods. The contrast between the normal tongue tissue and the pink atrophic papillae is striking. (*Courtesy of Ellen Eisenberg, DMD.*)

39 GINGIVITIS AND PERIODONTAL DISEASE

Richard P. Usatine, MD
Wanda C. Gonsalves, MD

PATIENT STORY

A 35-year-old woman presents to clinic for a routine physical examination. She says that for the last 6 months her gums bleed when she brushes her teeth. She reports smoking 1 pack of cigarettes per day. The oral examination finds generalized plaque and red swollen intradental papilla (**Figure 39-1**). The physician explains to her that she has gingivitis and that she should brush twice daily and use floss daily. The physician tells her that smoking is terrible for her health in all ways, including her oral health. The physician offers her help to quit smoking and refers her to a dentist for a cleaning and full dental examination.

FIGURE 39-1 Chronic gingivitis in which the intradental papillae are edematous and blunted. There is some loss of gingival tissue. The gums bleed with brushing. (*Reproduced with permission from Gerald Ferretti, DMD.*)

INTRODUCTION

Gingivitis is the inflammation of the gingiva (gums). Gingivitis alone does not affect the underlying supporting structures of the teeth and is reversible (**Figure 39-1**).

Periodontitis (periodontal disease) is a chronic inflammatory disease, which includes gingivitis along with loss of connective tissue and bone support for the teeth. It damages alveolar bone (the bone of the jaw in which the roots of the teeth are connected) and the periodontal ligaments that hold the roots in place. It is a major cause of tooth loss in adults (**Figures 39-2** to **39-4**).

EPIDEMIOLOGY

- Gingivitis and periodontal diseases are the most common oral diseases in adults.
- It is estimated that 35% of adults 30 years of age or older in the United States have periodontal disease: 22% have a severe form and 13% have a moderate-to-severe form.[1]
- Homeless persons are a very high-risk group for gingivitis, periodontitis, and all dental disease (**Figure 39-4**).
- Periodontal disease has been shown in some studies to be an associated factor in coronary heart disease and chronic kidney disease.[2]
- Periodontal disease in pregnancy is associated with an increase in preterm birth.[3,4]

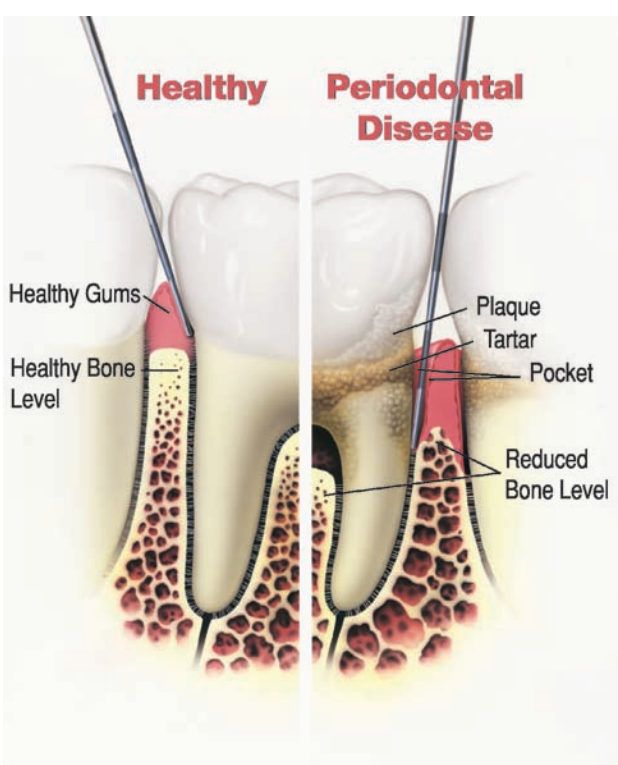

FIGURE 39-2 Healthy periodontal anatomy versus periodontal disease. (*Reproduced with permission from the American Academy of Periodontology; http://www.perio.org/consumer/2a.html.*)

ETIOLOGY AND PATHOPHYSIOLOGY

- Periodontal diseases are caused by bacteria in dental plaque that create an inflammatory response in gingival tissues (gingivitis) or in the soft tissue and bone supporting the teeth (periodontitis).

- The normal healthy gingival attachments form the gingival cuff around the tooth to help protect the underlying bone and teeth from the bacteria of the mouth.
- Gingivitis is caused by a reversible inflammatory process that occurs as the result of prolonged exposure of the gingival tissues to plaque and tartar (**Figure 39-2**).
- Gingivitis may be classified by appearance (e.g., ulcerative, hemorrhagic), etiology (e.g., drugs, hormones), duration (e.g., acute, chronic), or by quality (e.g., mild, moderate, or severe).
- A severe form, acute necrotizing ulcerative gingivitis (ANUG) (**Figure 39-5**), also known as Vincent disease or trench mouth, is associated with α-hemolytic streptococci, anaerobic fusiform bacteria, and nontreponemal oral spirochetes. The term *trench mouth* was coined in World War I when ANUG was common among soldiers in the trenches. Predisposing factors now include diabetes, HIV, and chemotherapy.[2]
- The most common form of gingivitis is chronic gingivitis induced by plaque (**Figure 39-1**). This type of gingivitis occurs in half of the population 4 years of age or older. The inflammation worsens as mineralized plaque forms calculus (tartar) at and below the gum surface (sulcus). The plaque that covers calculus causes destruction of bone (an irreversible condition) and loose teeth, which result in tooth mobility and tooth loss.
- Gingivitis may persist for months or years without progressing to periodontitis. This suggests that host susceptibility plays an important role in the development of periodontal disease.[5]

RISK FACTORS

Risk factors that contribute to the development of periodontal disease include poor oral hygiene, smoking, alcohol dependence, environmental factors (e.g., crowded teeth and mouth breathing), and comorbid conditions, such as a weakened immune status (e.g., HIV, steroids, or diabetes), low educational attainment, and low income.[6–8]

DIAGNOSIS

CLINICAL FEATURES

- Simple or marginal gingivitis first cause swelling of the intradental papillae and later affect the gingiva and dental interface (see **Figures 39-1** to **39-4**).
- Mild gingivitis is painless and may bleed when brushing or eating hard foods.
- ANUG (**Figure 39-5**) is painful, ulcerative, and edematous, and produces halitosis and bleeding gingival tissue. Patients with ANUG may have systemic symptoms such as myalgias and fever.

TYPICAL DISTRIBUTION

Gingivitis begins at the gingival and dental margins and may extend onto the alveolar ridges.

LABORATORY STUDIES AND IMAGING

Radiographs of the mouth are used to evaluate for bone loss in periodontal disease.

FIGURE 39-3 Severe periodontal disease in a woman who smokes and is addicted to cocaine. Note the blunting of the intradental papillae and the dramatic loss of gingival tissue. (*Reproduced with permission from Richard P. Usatine, MD.*)

FIGURE 39-4 Severe periodontal disease in an alcoholic smoker with very edematous and blunted intradental papilla. This homeless man has already lost two teeth secondary to his severe periodontal disease. (*Reproduced with permission from Richard P. Usatine, MD.*)

FIGURE 39-5 Acute necrotizing ulcerative gingivitis (ANUG) with intense erythema and ulcerations around the teeth. This is an acute infectious process. (*Reproduced with permission from Gerald Ferretti, DMD.*)

DIFFERENTIAL DIAGNOSIS

- Gingivitis can be from poor dental hygiene only or secondary to conditions that affect the immune system such as diabetes, Addison disease, HIV, and pregnancy.
- Gingival hyperplasia is an overgrowth of the gingiva with various etiologies, including medications such as calcium channel blockers, phenytoin, and cyclosporine. This can occur with or without coexisting gingivitis (see Chapter 40, Gingival Hyperplasia).

MANAGEMENT

- Recommend smoking cessation for all patients who smoke.[7] SOR A Offer help to support the patients' smoking cessation efforts with behavioral counseling and pharmacologic methods (see Chapter 236, Tobacco Addiction). SOR A
- Recommend alcohol cessation for patients with alcoholism and refer to Alcoholics Anonymous (AA) or another resource. For patients in whom alcohol use is heavy but addiction has not been diagnosed, at least recommend a decrease in alcohol use (see Chapter 237, Alcoholism).[8] SOR B
- Dental experts recommend tooth brushing twice a day and flossing daily. SOR C However, a Cochrane systematic review failed to show a benefit for daily flossing on plaque and clinical parameters of gingivitis.[9] SOR A
- Some experts suggest that electric toothbrushes may have additional benefit over manual brushing, but this remains unproven. SOR C In fact, one study of dental students showed that one electric toothbrush was no better than two different manual toothbrushes with respect to plaque control.[10] SOR B
- Systematic reviews indicate that there is strong evidence supporting the efficacy of chlorhexidine as an antiplaque, antigingivitis mouthrinse.[11] SOR A Mouthwashes should not be used as a replacement for tooth brushing. Chlorhexidine oropharyngeal 0.12% is available as a generic mouthrinse. Recommended dosing is 15 mL to swish (for 30 seconds) and spit twice daily.
- The treatments with chlorhexidine (gel and spray) achieved a significant reduction in plaque and gingival bleeding in children with special needs. The parents/caregivers preferred the administration of chlorhexidine in spray form.[12] SOR B
- In patients with ANUG, treatment involves antibiotics, NSAIDs, and topical 2% viscous lidocaine for pain relief. Oral rinses with saline, hydrogen peroxide 3% solution, or chlorhexidine 0.12% may be of benefit. SOR C
- Antibiotics recommended for ANUG include penicillin VK, erythromycin, doxycycline, and clindamycin. SOR C
- Everyone should receive ongoing care from a dental professional for prevention and treatment of periodontal disease.

PREVENTION

- No smoking or tobacco use at all.
- Avoid alcohol and drug abuse.
- Good oral hygiene with tooth brushing and flossing.
- Dental visits at least twice yearly even during pregnancy.

PATIENT EDUCATION

- There is no safe level of smoking. Quitting is crucial to good health.
- Drink alcohol in moderation or not at all.
- Practice good oral hygiene to remove plaque (i.e., brush twice a day and use floss daily).
- Consider use of chlorhexidine-containing mouthrinse.
- Consult a dentist for regular check-ups, especially when the condition does not improve after using good oral hygiene.
- Pregnancy is not a contraindication for dental visits and cleaning.

FOLLOW-UP

Follow up patients with ANUG closely. All patients need regular dental care and follow-up with their dentist.

PATIENT RESOURCES

- PubMed Health. *Gingivitis*—**http://www.ncbi.nlm.nih.gov/pubmedhealth/PMH0002051/.**
- The American Academy of Periodontology. *Types of Gum Disease*—**http://www.perio.org/consumer/2a.html.**

PROVIDER RESOURCES

- Stephen JM. *Gingivitis*—**http://emedicine.medscape.com/article/763801.**

REFERENCES

1. Albandar JM, Brunelle JA, Kingman A. Destructive periodontal disease in adults 30 years of age and older in the United States, 1988-1994. *J Periodontol.* 1999;70:13-29.
2. Fisher MA, Borgnakke WS, Taylor GW. Periodontal disease as a risk marker in coronary heart disease and chronic kidney disease. *Curr Opin Nephrol Hypertens.* 2010;19:519-526.
3. Corbella S, Taschieri S, Francetti L, et al. Periodontal disease as a risk factor for adverse pregnancy outcomes: a systematic review and meta-analysis of case-control studies. *Odontology.* 2011. [Epub ahead of print]
4. Chambrone L, Pannuti CM, Guglielmetti MR, Chambrone LA. Evidence grade associating periodontitis with preterm birth and/or low birth weight: II: a systematic review of randomized trials evaluating the effects of periodontal treatment. *J Clin Periodontol.* 2011;38:902-914.
5. Kornman KS, Crane A, Wang HY, et al. The interleukin-1 genotype as a severity factor in adult periodontal disease. *J Clin Periodontol.* 1997;24:72-77.
6. Boillot A, El Halabi B, Batty GD, et al. Education as a predictor of chronic periodontitis: a systematic review with meta-analysis population-based studies. *PLoS One.* 2011;6(7):e21508.

7. Hanioka T, Ojima M, Tanaka K, et al. Causal assessment of smoking and tooth loss: a systematic review of observational studies. *BMC Public Health.* 2011;11:221.
8. Amaral CS, Vettore MV, Leao A. The relationship of alcohol dependence and alcohol consumption with periodontitis: a systematic review. *J Dent.* 2009;37:643-651.
9. Berchier CE, Slot DE, Haps S, Van der Weijden GA. The efficacy of dental floss in addition to a toothbrush on plaque and parameters of gingival inflammation: a systematic review. *Int J Dent Hyg.* 2008;6:265-279.
10. Parizi MT, Mohammadi TM, Afshar SK, et al. Efficacy of an electric toothbrush on plaque control compared to two manual toothbrushes. *Int Dent J.* 2011;61:131-135.
11. Gunsolley JC. Clinical efficacy of antimicrobial mouthrinses. *J Dent.* 2010;38 Suppl 1:S6-S10.
12. Chibinski AC, Pochapski MT, Farago PV, et al. Clinical evaluation of chlorhexidine for the control of dental biofilm in children with special needs. *Community Dent Health.* 2011;28:222-226.

40 GINGIVAL OVERGROWTH

Richard P. Usatine, MD
Wanda C. Gonsalves, MD

PATIENT STORY

A 31-year-old woman with a history of seizure disorder notices increasing gum enlargement (**Figure 40-1**). She is unemployed and does not have dental insurance. She has not been to a dentist in at least 10 years. She brushes her teeth only once a day and does not floss at all. She has been on phenytoin (Dilantin) since early childhood, and this does prevent her seizures. You talk to her about dental hygiene and refer her to a low-cost dental clinic that cares for persons with limited resources.

FIGURE 40-1 Gingival overgrowth secondary to phenytoin (Dilantin) in a woman with epilepsy. (*Courtesy of Richard P. Usatine, MD.*)

INTRODUCTION

Gingival overgrowth (hyperplasia) can be hereditary or induced as a side effect of systemic drugs, such as phenytoin, cyclosporine, or calcium channel blockers. Besides the cosmetic effect it can make good oral hygiene more difficult to maintain.

SYNONYMS

Gingival hyperplasia, drug-induced gingival overgrowth (DIGO), hereditary gingival fibromatosis.

EPIDEMIOLOGY

- The prevalence of phenytoin-induced gingival hyperplasia is estimated at 15% to 50% in patients taking the medication[1,2] (**Figures 40-1** and **40-2**).
- In patients receiving cyclosporine for more than 3 months, the incidence of gingival overgrowth (GO) can approach 70%[3] (**Figure 40-3**).
- The incidence of gingival hyperplasia has been reported as 10% to 20% in patients treated with calcium channel blockers in the general population.[2]

FIGURE 40-2 Multiple tiny hamartomas on the gums from Cowden disease with gingival overgrowth secondary to phenytoin. (*Courtesy of Richard P. Usatine, MD.*)

ETIOLOGY AND PATHOPHYSIOLOGY

- Although the etiology of GO is not entirely known, risk factors known to contribute to GO include the following: nonspecific chronic inflammation associated with poor hygiene, hormonal changes (pregnancy), medications (calcium channel blockers, phenytoin, and cyclosporine), and systemic diseases (leukemia, sarcoidosis, and Crohn disease).
  - Studies suggest that phenytoin, cyclosporine, and nifedipine interact with epithelial keratinocytes, fibroblasts, and collagen to lead to an overgrowth of gingival tissue in susceptible individuals.[2]

- More than 15 drugs have been shown to cause GO.
- The most common nonreversible DIGO is caused by phenytoin (**Figures 40-1** and **40-2**).

- Histopathologically, tissue enlargement is the result of proliferation of fibroblasts, collagen, and chronic inflammatory cells.

RISK FACTORS

- Prolonged use of phenytoin, cyclosporine, or calcium-channel blockers (especially nifedipine).
- Pregnancy.
- Systemic diseases (leukemia, sarcoidosis, and Crohn disease).
- Poor oral hygiene and the presence of periodontal disease.

DIAGNOSIS

SIGNS AND SYMPTOMS

- The diagnosis is made by visual inspection and by obtaining a thorough history (**Figures 40-1** to **40-3**).
- The gingiva appears edematous and bulky with loss of its stippling. It may be soft or firm.
- Nonspecific chronic inflammation, hormonal and systemic causes such as leukemia appear red and inflamed and may bleed.

TYPICAL DISTRIBUTION

Lobular gingiva enlargement occurs first at the interdental papillae and anterior facial gingiva approximately 2 to 3 months after starting the drug, and increases in maximum severity in 12 to 18 months (**Figure 40-3**).

LABORATORY TESTS

Consider checking a complete blood count (CBC) with differential count to investigate for leukemia if there is not an obvious etiology.

IMAGING

The periodontist or oral medicine specialist may order bitewing radiographs and periapical films to evaluate for the presence of periodontal disease.

DIFFERENTIAL DIAGNOSIS

- Generalized gingivitis—Gums around the teeth become inflamed. This condition often occurs with poor oral hygiene (see Chapter 39, Gingivitis and Periodontal Disease).
- Pregnancy gingivitis—Inflamed gums. More than half of pregnant women will develop gingivitis during pregnancy because of hormonal changes.
- Pyogenic granuloma—A small red bump that may bleed and grow to approximately half an inch. These are most often found on the skin but can occur in the mouth secondary to trauma or pregnancy. When they occur in pregnancy, they are sometimes called a pregnancy

FIGURE 40-3 Gingival overgrowth secondary to cyclosporine use for 1 year to treat severe plaque psoriasis. Note the blunted and thickened interdental papillae. (*Courtesy of Richard P. Usatine, MD.*)

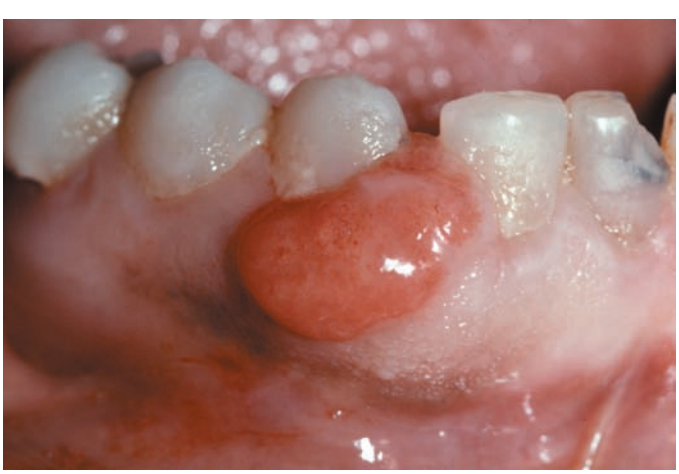

FIGURE 40-4 Pyogenic granuloma growing rapidly on the gums after minor trauma. (*Reprinted with permission from Gonsalves WC, Chi AC, Neville BW. Common oral lesions: part II. Masses and neoplasia. Am Fam Physician. 2007;75(4):509-512. Copyright © 2007 American Academy of Family Physicians. All Rights Reserved.*)

tumor. In reality, these are not pyogenic nor granulomatous but are a type of lobular capillary hemangioma (see Chapter 161, Pyogenic Granuloma) (**Figure 40-4**).

- Leukemia—Leukemic cells may infiltrate the oral soft tissues producing a diffuse, boggy, nontender swelling of the gingiva that may ulcerate or bleed.

MANAGEMENT

NONPHARMACOLOGIC

- Teach and emphasize good oral hygiene including cleanings at least every 3 months to control plaque. SOR C
- The use of a powered toothbrush, together with oral hygiene instruction, reduces GO for pediatric transplantation patients on cyclosporine. In one study, the sonic toothbrushing and oral hygiene instruction group had less severe GO after 12 months than did the control group.[4] SOR B
- If possible, stop drugs that induce gingival hyperplasia as discontinuing the medications may reverse the condition in most cases (except phenytoin).
- If drugs cannot be stopped, try reducing the dose, if possible, as gingival hyperplasia can be dose dependent.

MEDICATIONS

- Tacrolimus is an alternative to cyclosporine to prevent transplant rejection; it causes less GO. In one study on the prevalence of gingival growth after renal transplantation, GO occurred in 29% of patients treated with tacrolimus and in 60% of patients treated with cyclosporine.[5] SOR B In another study, switching patients from cyclosporine to tacrolimus reduced GO in the first month after the change was made.[6] SOR B
- Case reports have reported regression of overgrowth with both oral metronidazole and azithromycin. In one randomized controlled trial (RCT), patients with GO were randomized to receive either 1 course of 5 days of azithromycin or 7 days of metronidazole. The extent of GO was measured at 0, 2, 4, 6, 12, and 24 weeks, and azithromycin was found to be more effective than metronidazole.[3] SOR B
- Azithromycin with an oral hygiene program resulted in a reduction in cyclosporine-induced GO, whereas oral hygiene alone improved oral symptoms (pain, halitosis, and gum bleeding) but did not decrease cyclosporine-induced GO.[7] Patients were randomized into 2 groups, both receiving oral hygiene instructions, with the treatment group receiving 3 days of azithromycin 500 mg daily. They were evaluated after 15 and 30 days and only the azithromycin group had a reduction in GO.[7] SOR B
- Chlorhexidine 12% (Peridex) once before going to bed or Biotene mouthwash after meals is recommended for patients who are known to be at risk for gingivitis.[2] SOR C Warn patients that chlorhexidine 12% will taste bad and can stain the teeth. This staining can be removed with a dental cleaning. This information should help improve adherence to the use of this mouthwash.

REFERRAL

- For patients who do not respond to the above measures, refer to a dental health professional for possible gingivectomy. This can be done with a scalpel or a laser.

PREVENTION

Ensure healthy periodontal tissue prior to starting calcium channel blockers or phenytoin, or before any organ transplantation in which cyclosporine will be prescribed.

Folic acid supplementation, 0.5 mg per day, is associated with prevention of GO in children taking phenytoin monotherapy. Of patients in the folic acid arm, 21% developed GO, as compared with 88% receiving placebo.[1] SOR B

PATIENT EDUCATION

Advise patients to practice good oral hygiene (i.e., brush at least twice a day and floss at least once a day) and have regular follow-up with their dental health professional to monitor for worsening periodontal disease.

FOLLOW-UP

- Patients should be monitored by a periodontist or an oral medicine specialist as long as the patients are taking medicines that induce gingival hyperplasia.

PATIENT RESOURCES

- The Merck Manual of Health and Aging. *Periodontal Disease*—**http://www.merck.com/pubs/mmanual_ha/sec3/ch40/ch40c.html.**

PROVIDER RESOURCES

- Mejia L. *Drug-induced Gingival Hyperplasia*—**http://emedicine.medscape.com/article/1076264.**

REFERENCES

1. Arya R, Gulati S, Kabra M, et al. Folic acid supplementation prevents phenytoin-induced gingival overgrowth in children. *Neurology*. 2011; 76:1338-1343.
2. Mejia L. *Drug-Induced Gingival Hyperplasia*. http://emedicine.medscape.com/article/1076264. Accessed January 23, 2012.
3. Chand DH, Quattrocchi J, Poe SA, et al. Trial of metronidazole vs. azithromycin for treatment of cyclosporine-induced gingival overgrowth. *Pediatr Transplant*. 2004;8:60-64.
4. Smith JM, Wong CS, Salamonik EB, et al. Sonic tooth brushing reduces gingival overgrowth in renal transplant recipients. *Pediatr Nephrol*. 2006;21:1753-1759.

5. Cota LO, Aquino DR, Franco GC, et al. Gingival overgrowth in subjects under immunosuppressive regimens based on cyclosporine, tacrolimus, or sirolimus. *J Clin Periodontol*. 2010;37:894-902.
6. Parraga-Linares L, Almendros-Marques N, Berini-Aytes L, Gay-Escoda C. Effectiveness of substituting cyclosporin A with tacrolimus in reducing gingival overgrowth in renal transplant patients. *Med Oral Patol Oral Cir Bucal*. 2009;14:e429-e433.
7. Ramalho VL, Ramalho HJ, Cipullo JP, et al. Comparison of azithromycin and oral hygiene program in the treatment of cyclosporine-induced gingival hyperplasia. *Ren Fail*. 2007;29:265-270.

41 APHTHOUS ULCER

Richard P. Usatine, MD
Wanda C. Gonsalves, MD

PATIENT STORY

A 58-year-old man presents with a 1-year history of painful sores in his mouth. (**Figures 41-1** to **41-4**). He has lost 20 pounds over the past year because it hurts to eat. The ulcers come and go, but are found on his tongue, gums, buccal mucosa, and inner lips. Prior to the onset of these lesions the patient had been in good health and was not on any medications. The physician recognized his condition as recurrent aphthous ulcers with giant ulcers. No underlying systemic diseases were found on work-up. The patient was started on oral prednisone and given dexamethasone oral elixir to swish and swallow. Within 1 week the patient was able to eat and drink liquids comfortably and began regaining his lost weight. Long-term management of his problem required the use of other medications so as to successfully taper him off prednisone without recurrences.

FIGURE 41-1 Major aphthous ulcer on the buccal mucosa of a 58-year-old man who has been suffering with recurrent aphthous stomatitis for the past year. (*Courtesy of Richard P. Usatine, MD.*)

INTRODUCTION

Aphthous ulcers are painful ulcerations in the mouth which can be single, multiple, occasional, or recurrent. These ulcers can be small or large but are uniformly painful and may interfere with eating, speaking, and swallowing. Oral trauma, stress, and systemic diseases can contribute to the occurrence of these ulcers but no precise etiology is apparent. Recurrent aphthous stomatitis (RAS) is a frustrating condition that merits aggressive treatment aimed at pain relief and prevention.

SYNONYMS

Canker sores, recurrent aphthous ulcer (RAU), aphthous stomatitis, RAS.

EPIDEMIOLOGY

- Incidence rates of RAUs of 0.85% among adults and 1.5% among children and adolescents have been reported.[1]
- RAS is more common in women, in people younger than age 40 years, in whites, in nonsmokers, and in people of high socioeconomic status.[1]

ETIOLOGY AND PATHOPHYSIOLOGY

- The precise etiology and pathogenesis of this condition remains unknown, although a variety of host and environmental factors have been implicated.

FIGURE 41-2 Two aphthous ulcers on the tongue of a 58-year-old man with recurrent aphthous stomatitis. (*Courtesy of Richard P. Usatine, MD.*)

- A positive family history is seen in about one-third of RAS patients. A genetic predisposition is suggested by an increased frequency of HLA types A2, A11, B12, and DR2.[1]
- In one study, Th1 (T-helper subtype 1) activation was more intense in the patients with RAUs. Many conditions that increase the incidence of RAUs, such as psychologic stress, NSAIDs, Crohn disease, and celiac disease, also shift the immune response toward the Th1 subtype. Conditions and medications that inhibit the Th1 immune response pathway, such as pregnancy, thalidomide, glucocorticoids, and tetracycline, decrease the incidence of RAUs.[2]
- Another study found significantly higher-than-normal serum level of tumor necrosis factor (TNF)-α in 20% to 39% of patients in the ulcerative stage of RAUs.[3] Medications that have anti–TNF-α effects, such as pentoxifylline, levamisole, and thalidomide, have also been found to be useful in the treatment of RAUs.[1-3]
- Although studies show that there are active immune mechanisms associated with RAUs, there is still much to learn regarding their etiology and pathogenesis.

RISK FACTORS

- Oral trauma.
- Stress and anxiety.
- Systemic diseases (celiac disease, Crohn disease, Behçet syndrome, HIV, reactive arthritis).
- Medications (NSAIDs, β-blockers, angiotensin-converting enzyme inhibitors [ACEIs]).
- Vitamin deficiencies (zinc, iron, B_{12}, folate).
- Food and chemical sensitivities.

DIAGNOSIS

CLINICAL FEATURES

History:

- Symptoms may begin with a burning sensation and the pain is exacerbated by moving the area affected by the ulcer.
- Eating often hurts, especially foods and drinks with a high acid content.
- Ask about recurrences and onset in relation to the use of medications.
- Ask about GI symptoms, genital ulcers, HIV risk factors, and joint pain.

Physical:

- Three clinical variations are described based on the size of the ulcers: Minor (4 to 9 mm), major (>1 cm), and herpetiform (<3 mm). The most common minor form appears as rounded, well-demarcated, single or multiple ulcers less than 1 cm in diameter that usually heal in 10 to 14 days without scarring (**Figure 41-5**).
- The ulcers are solitary or multiple covered by a white-to-yellow pseudomembrane and surrounded by an erythematous halo (**Figure 41-5**).

FIGURE 41-3 Minor aphthous ulcer occurring simultaneously with major aphthous ulcers on the buccal mucosa and tongue of a 58-year-old man with recurrent aphthous ulcers. (*Courtesy of Richard P. Usatine, MD.*)

FIGURE 41-4 Aphthous ulcer located on unkeratinized (movable) mucosa in a 5-year-old girl. It is slightly raised, round, with a white-yellow necrotic center and surrounding erythema. (*Courtesy of Richard P. Usatine, MD.*)

FIGURE 41-5 Behçet disease characterized by recurrent oral and genital ulcers in a 17-year-old girl. (*Courtesy of Richard P. Usatine, MD.*)

TYPICAL DISTRIBUTION

RAS usually involves nonkeratinizing mucosa (e.g., labial mucosa, buccal mucosa, ventral tongue). Aphthous ulcers spare the attached gingiva and the hard palate (nonmovable mucosa).

LABORATORY TESTS

Consider complete blood count (CBC), ferritin, B_{12}, folate, erythrocyte sedimentation rate (ESR), viral culture, KOH, skin biopsy, and HIV testing, if indicated.

DIFFERENTIAL DIAGNOSIS

- Primary oral herpes simplex virus (primary gingivostomatitis)—Begins as vesicular lesions, which quickly ulcerate on all mucosal lesions in the mouth. It is accompanied by systemic manifestations such as fever, malaise, anorexia, and sore throat. The ulcers are located on movable and nonmovable oral mucosa (includes attached gingiva and hard palate). Lesions may also appear on keratinized surfaces such as the lip (see Chapter 129, Herpes Simplex).
- Herpangina causes multiple ulcers in the mouth, especially on the soft palate and the anterior fauces. It is caused by coxsackievirus A16 in most cases. The distribution of the ulcers is different than in aphthous ulcers.
- Candidiasis—White plaque, when removed, appears red. Scrape white plaque and a KOH preparation will be positive for yeast. (see Chapter 136, Candidiasis).
- Oral cancer—Ulcerative lesion that will not resolve by 2 weeks (see Chapter 43, Oral Cancer).
- Erythema multiforme (EM)—Mucocutaneous lesion proceeded by infection of herpes simplex virus (HSV), *Mycoplasma pneumoniae*, or exposure to certain drugs or medications. Oral lesions begin as patches and evolve into large shallow erosions and ulcerations with irregular borders. Common sites include the lip, tongue, buccal mucosa, floor of the mouth, and soft palate. The presence of targetoid skin lesions should help differentiate EM from RAS (see Chapter 177, Erythema Multiforme, Stevens-Johnson Syndrome, and Toxic Epidermal Necrolysis).
- Erosive lichen planus—Erythematous ulcerative lesion with surrounding striae (see Chapter 154, Lichen Planus).
- Behçet syndrome—A condition with multiple ulcerative lesions that resemble aphthae involving the soft palate and oropharynx, infrequent sites for routine aphthae. Common cutaneous lesions include the genital and ocular mucosa (**Figure 41-6**).
- Hand, foot, and mouth disease presents as mucocutaneous lesions involving the hand, foot, and mouth caused by enterovirus. Any area of mucosa may be involved. Lesions resolve within 1 week (see Chapter 128, Hand, Foot, and Mouth Disease).

FIGURE 41-6 Ulcer on penis in a patient with Behcet Syndrome. (*Courtesy of Richard P. Usatine, MD.*)

MANAGEMENT

NONPHARMACOLOGIC

- Most isolated aphthae require no treatment or only periodic topical therapy.

MEDICATIONS

Topical corticosteroids, such as fluocinonide gel or dexamethasone elixir, can promote healing and lessen the severity of RAS.[4] Patients should be instructed to dab the area of ulcer dry, apply the gel, paste, or cream after rinsing, and avoid eating or drinking for at least 30 minutes. SOR C

- Amlexanox 5% paste (Aphthasol) reduces ulcer size, pain duration, and healing time.[5] It is nonprescription and the paste is applied directly to ulcers four times a day until ulcers heal.[5] SOR B
- Lidocaine 1% cream applied to aphthous ulcers was found to reduce pain intensity compared to the placebo cream.[6] SOR B

In severe RAS cases, systemic therapy with oral steroids, montelukast, colchicine, pentoxifylline, azathioprine, clofazimine, or thalidomide may need to be considered:

- Both prednisone and montelukast were effective in reducing the number of aphthous ulcers and improving pain relief and ulcer healing when compared with placebo in a randomized controlled trial (RCT).[7] Prednisone was more effective than montelukast in pain cessation ($P < 0.0001$) and in accelerating ulcer healing ($P < 0.0001$). Montelukast may be useful in cases of RAS where pharmacologic therapy for long periods is needed and prednisone is to be avoided.[7] In this study, prednisone was given 25 mg daily for 15 days, 12.5 mg daily for 15 days, 6.25 mg daily for 15 days, and then 6.25 mg on alternate days for 15 days. Montelukast 10 mg daily was given every evening and then on alternate days for the second month.[7] SOR B
- In one RCT, 5 mg per day prednisolone was compared with 0.5 mg per day colchicine in the treatment of RAS. Both colchicine and prednisolone treatments significantly reduced RAS. No significant differences in size and number of lesions, recurrence and severity of pain, and duration of pain-free period were seen between the two treatment groups. Colchicine (52.9%) had significantly more side effects than prednisolone (11.8%), so the prednisolone seems to be a better alternative in reducing the signs and symptoms of RAS.[8] SOR B
- Clofazimine 100 mg daily for 30 days and then 100 mg every other day has been studied in a partially blinded RCT for the prevention of RAS. A greater percentage of individuals in the clofazimine group had no further aphthous episodes (17% to 44%) compared with the other groups (<6%).[9]
- A multicenter cohort analysis of thalidomide for severe RAS was recently published. The authors conclude that low-dose maintenance regimens of thalidomide appear to be effective, and relatively well tolerated. However, adverse events were reported by 84% (77 of 92) of patients. If thalidomide is needed, refer the patient to a specialist with experience using this toxic drug.[10] SOR B

COMPLEMENTARY AND ALTERNATIVE THERAPY

Vitamin C was shown to reduce the frequency of minor RAS and the severity of pain by 50% in a small group of teens. They were given 2000 mg/m^2 per day of ascorbate.[11]

REFERRAL

Consider referring children with periodic fever with aphthous stomatitis, pharyngitis, and adenitis (PFAPA) syndrome for tonsillectomy

or adenotonsillectomy. A metaanalysis found little evidence to support surgery, but the authors concluded that surgery is an option when symptoms markedly interfere with the child's quality of life and medical treatment has failed.[12] SOR C

PREVENTION

Oral vitamin B_{12} was studied in a RCT of primary care patients. A sublingual dose of 1000 mcg of vitamin B_{12} was used by patients in the intervention group for 6 months. During the last month of treatment more participants in the intervention group reached a status of "no aphthous ulcers" (74.1% vs. 32.0%; $P < 0.01$). The treatment worked regardless of the serum vitamin B_{12} level.[13] SOR B

See data on clofazimine and thalidomide under "Medications" above.

PATIENT EDUCATION

Recurrent lesions that do not respond to treatment and severe cases should be seen by their oral health provider or primary care physician to look for an underlying cause. Foods that are spicy or acidic worsen pain and should be avoided.

PATIENT RESOURCES

- MedicineNet.com. *Canker Sores (Aphthous Ulcers)*—**http://www.medicinenet.com/canker_sores/article.htm.**

PROVIDER RESOURCES

- Dermnet NZ. *Aphthous Ulcers*—**http://www.dermnetnz.org/site-age-specific/aphthae.html.**
- eMedicine. *Aphthous Ulcers*—**http://emedicine.medscape.com/article/867080.**
- eMedicine. *Aphthous Stomatitis*—**http://emedicine.medscape.com/article/1075570.**

REFERENCES

1. Messadi DV, Younai F. Aphthous ulcers. *Dermatol Ther*. 2010;23:281-290.
2. Borra RC, Andrade PM, Silva ID, et al. The Th1/Th2 immune-type response of the recurrent aphthous ulceration analyzed by cDNA microarray. *J Oral Pathol Med*. 2004;33:140-146.
3. Sun A, Wang JT, Chia JS, Chiang CP. Levamisole can modulate the serum tumor necrosis factor-alpha level in patients with recurrent aphthous ulcerations. *J Oral Pathol Med*. 2006;35:111-116.
4. Casiglia JM. Recurrent aphthous stomatitis: etiology, diagnosis, and treatment. *Gen Dent*. 2002;50:157-166.
5. Bailey J, McCarthy C, Smith RF. Clinical inquiry. What is the most effective way to treat recurrent canker sores? *J Fam Pract*. 2011;60:621-632.
6. Descroix V, Coudert AE, Vige A, et al. Efficacy of topical 1% lidocaine in the symptomatic treatment of pain associated with oral mucosal trauma or minor oral aphthous ulcer: a randomized, double-blind, placebo-controlled, parallel-group, single-dose study. *J Orofac Pain*. 2011;25:327-332.
7. Femiano F, Buonaiuto C, Gombos F, et al. Pilot study on recurrent aphthous stomatitis (RAS): a randomized placebo-controlled trial for the comparative therapeutic effects of systemic prednisone and systemic montelukast in subjects unresponsive to topical therapy. *Oral Surg Oral Med Oral Pathol Oral Radiol Endod*. 2010;109:402-407.
8. Pakfetrat A, Mansourian A, Momen-Heravi F, et al. Comparison of colchicine versus prednisolone in recurrent aphthous stomatitis: a double-blind randomized clinical trial. *Clin Invest Med*. 2010;33:E189-E195.
9. de Abreu MA, Hirata CH, Pimentel DR, Weckx LL. Treatment of recurrent aphthous stomatitis with clofazimine. *Oral Surg Oral Med Oral Pathol Oral Radiol Endod*. 2009;108:714-721.
10. Hello M, Barbarot S, Bastuji-Garin S, et al. Use of thalidomide for severe recurrent aphthous stomatitis: a multicenter cohort analysis. *Medicine (Baltimore)*. 2010;89:176-182.
11. Yasui K, Kurata T, Yashiro M, et al. The effect of ascorbate on minor recurrent aphthous stomatitis. *Acta Paediatr*. 2010;99:442-445.
12. Garavello W, Pignataro L, Gaini L, et al. Tonsillectomy in children with periodic fever with aphthous stomatitis, pharyngitis, and adenitis syndrome. *J Pediatr*. 2011;159:138-142.
13. Volkov I, Rudoy I, Freud T, et al. Effectiveness of vitamin B12 in treating recurrent aphthous stomatitis: a randomized, double-blind, placebo-controlled trial. *J Am Board Fam Med*. 2009;22:9-16.

42 LEUKOPLAKIA

Michaell A. Huber, DDS
Wanda C. Gonsalves, MD

PATIENT STORY

A 57-year-old male smoker presents at the physician's clinic with a 7-month history of a nonpainful white patch below his tongue. He admits to drinking 2 to 3 beers in the evening and smoking 1 pack of cigarettes per day. Your examination reveals a painless white, thick lesion with fissuring below the tongue (**Figure 42-1**). A biopsy shows this to be premalignant and the patient is told that he must stop smoking and drinking. He is also referred to an oral surgeon for further evaluation of his dysplasia.

FIGURE 42-1 Homogenous leukoplakia on the lateral tongue presenting with a uniform surface plaque and surface cracks in a patient with a long smoking history. A 4-mm punch biopsy was performed and showed moderate dysplasia. (*Courtesy of Richard P. Usatine, MD.*)

INTRODUCTION

The World Health Organization defines leukoplakia as a clinical term used to recognize "white plaques of questionable risk having excluded (other) known diseases or disorders that carry no increased risk for cancer."[1,2] For all types of leukoplakia (see "Clinical Features" below) the risk of malignant transformation is approximately 1%, with a much higher risk associated with leukoplakias manifesting a red and/or highly variable surface texture component.

The term *erythroplakia* is reserved for a purely red lesion, which is described as a "fiery red patch that cannot be characterized clinically or pathologically as any other definable disease."[1,2] It may be flat or slightly depressed and exhibits a smooth or granular surface texture. The majority of erythroplakias will undergo malignant transformation.

SYNONYMS

Homogenous leukoplakia; nonhomogenous leukoplakia; speckled leukoplakia; nodular leukoplakia; verrucous leukoplakia; erythroleukoplakia; erythroplakia; erythroplasia.

EPIDEMIOLOGY

- Leukoplakia occurs in 0.5% to 2.0% of adults and is most frequently seen in middle-age and older men.[1]
- Erythroplakia occurs in approximately 0.02% to 0.83% of adults and is most commonly observed in middle-age and elderly persons, with no gender distinction.[1]

ETIOLOGY AND PATHOPHYSIOLOGY

- Both leukoplakia and erythroplakia likely represent clinical changes associated with the underlying multistep progression of alterations

at the molecular level underlying the development of dysplasia and subsequent carcinoma.

- For all types of leukoplakia, the risk of malignant transformation is approximately 1%, with a much higher risk associated with leukoplakias manifesting a red component.[1]
- For erythroplakia, the risk of malignant transformation is extremely high, with 85% of cases demonstrating either dysplasia or carcinoma in situ at the time of biopsy.[3]

RISK FACTORS

- Smoking and alcohol exposure are the most prominent risk factors for leukoplakia and erythroplakia, and create a synergistic effect when combined.[1]
- Human papillomavirus (HPV) is a recognized risk factor for oropharyngeal cancer, but its association with leukoplakia and erythroplakia is undetermined.[4]
- Up to 27% of leukoplakias are idiopathic.[4]

DIAGNOSIS

- Both leukoplakia and erythroplakia are clinical working diagnoses of exclusion, to be applied when other conditions have been excluded.

CLINICAL FEATURES

- Leukoplakia may be characterized as either homogenous or nonhomogenous.[1,2]
- Homogenous leukoplakia (**Figure 42-1**) presents uniformly as a thin surface plaque with possible shallow surface cracks.[2]
- Nonhomogenous leukoplakia (**Figures 42-2** and **42-3**) may be further characterized as speckled (white predominant with interspersed red component); nodular (small polypoid outcrops, may be red or white); or verrucous (corrugated or folded surface appearance).[2]
- Erythroplakia (**Figure 42-4**) presents as distinct flat or slightly depressed red lesion with a smooth or granular surface texture.[1,2]

TYPICAL DISTRIBUTION

- Both leukoplakia and erythroplakia may occur on any oropharyngeal mucosal site.[4]
- Lesions affecting the floor of the mouth, ventral/lateral tongue, and possibly the soft palatal complex, are associated with a increased risk for malignant transformation.[4,5]
- Idiopathic leukoplakias demonstrate a significantly higher risk of malignant transformation compared to risk-associated variants.[4]

LABORATORY

A biopsy is required to determine the histologic characterization of the lesion. Usually a 4-mm punch biopsy is a good start, but be wary of a false negative as a consequence of sampling error. If the lesion appears suspicious, refer to an oral surgeon, even with a negative result.

FIGURE 42-2 Nonhomogenous leukoplakia of the right ventral tongue in a 54-year-old white woman. Although she is a nonsmoker, she did have moderate alcohol exposure. Previous biopsy 6 years ago revealed hyperkeratosis. New biopsy indicated moderate to severe dysplasia. Patient was managed with total excision of the leukoplakia and an AlloDerm graft. (*Courtesy of Michaell Huber, DDS.*)

FIGURE 42-3 Leukoplakia (nonhomogenous) with moderate dysplasia on the lateral border of the tongue of a 65-year-old woman with a long history of smoking. She presented with discomfort and a noticeable white plaque on her tongue; a biopsy proved this to be moderate dysplasia. This was the third white dysplastic lesion she had developed in this area. A new excision will be performed and close follow-up is needed. Even though she quit smoking a few years ago, the damage done has led to a relentless dysplastic process. (*Courtesy of Ellen Eisenberg, DMD.*)

DIFFERENTIAL DIAGNOSIS[1,2]

- Aspirin/chemical burn—Determined by history.
- Candidosis—Typically symmetrical and wipes off.
- Discoid lupus—Concurrent cutaneous lesions, circumscribed mucosal lesion with central erythema, radiating white lines, histopathology.
- Hairy leukoplakia—Characteristic clinical presentation (bilateral tongue), histopathologic evidence Epstein-Barr virus (EBV).
- Lichen planus—Presence of striations, symmetrical presentation.
- Lichenoid lesion—Presence of striations, temporal association with trigger agent (e.g., new drug, dental material, home care product).
- Linea alba—Parallel to line of occlusion, often bilateral.
- Morsicatio—Habitual chewing or biting habit of the oral mucosa, often bilateral (**Figure 42-5**).
- Nicotine stomatitis—Smoking habit, characteristic appearance (**Figure 42-6**).
- Snuff patch—Characteristic folded, corrugated appearance at site of tobacco placement.
- White sponge nevus—Familial history, symmetrical pattern, and other mucosal sites often involved.

MANAGEMENT

MEDICATIONS

- There are no pharmacologic regimens to manage either leukoplakia or erythroplakia.

SURGERY

- All leukoplakias and erythroplakias should be excised and biopsied to determine the presence of epithelia dysplasia, carcinoma in situ, or squamous cell carcinoma.[1,6,7] SOR C
- Watchful waiting is not recommended.

REFERRAL

- Refer as appropriate to an oral and maxillofacial surgeon, an oral medicine expert, or an ear, nose, and throat (ENT) surgeon.

PREVENTION AND SCREENING

- Risk reduction measures are to be encouraged.
- Ensure a thorough and disciplined soft-tissue examination is accomplished on a routine basis.

PROGNOSIS

- Highly variable for leukoplakia; it may ultimately regress and disappear, persist, or progress to eventual carcinoma. Leukoplakia may recur after excision.[6–8]
- Erythroplakia almost always progresses to cancer.[1,3]

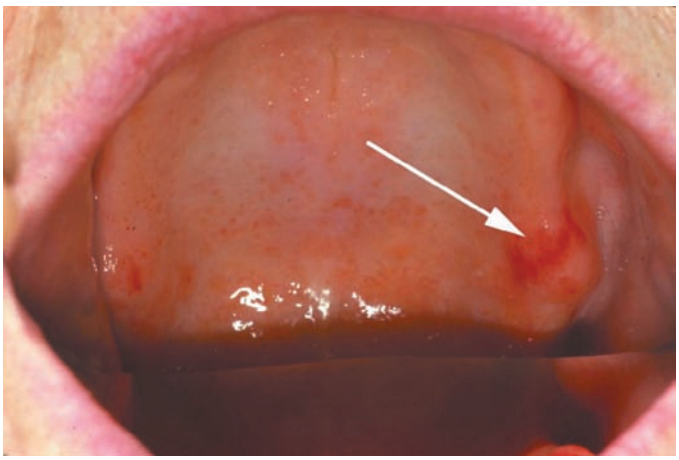

FIGURE 42-4 Erythroplakia with red patch (*arrow*) on the upper alveolar ridge of an edentulous person. (*Courtesy of Gerald Ferritti, DMD.*)

FIGURE 42-5 Morsicatio—leukoplakia caused by habitual chewing and biting of the oral mucosa. This young man only reluctantly acknowledged this habit upon further questioning of his bilateral leukoplakia. (*Courtesy of Richard P. Usatine, MD.*)

FIGURE 42-6 Nicotine stomatitis is observed in smokers. Note the hyperkeratosis affecting the hard palate and the erythematous minor salivary duct orifices. (*Courtesy of Michaell Huber, DDS.*)

FOLLOW-UP

- Routine monitoring (e.g., every 3 to 6 months) for recurrence should be done.[6–8] SOR C
- Risk factor elimination may reduce the risk of recurrence.[1,6,9]

PATIENT EDUCATION

- Counsel patients who use tobacco (e.g., smoke or smokeless tobacco) to quit. Ask if they are ready to quit at each visit, and sign a contract with them that specifies the date and time they will quit. Provide tools (see "Patient Resources" below) they can use to quit (see Chapter 236, Tobacco Addiction).

PATIENT RESOURCES

- American Lung Association. *Getting Help to Quit Smoking*—**http://www.lung.org/stop-smoking/how-to-quit/getting-help/.**
- QuitSmokingSupport.com. **http://www.quitsmokingsupport.com/.**
- Centers for Disease Control and Prevention. *Quit Smoking*—**http://www.cdc.gov/tobacco/quit_smoking/index.htm.**

PROVIDER RESOURCES

- Tobacco Use and Dependence Guideline Panel. *Treating Tobacco Use and Dependence: 2008 Update.* Rockville, MD: US Department of Health and Human Services; 2008. **http://www.ncbi.nlm.nih.gov/books/NBK63952/.**
- National Cancer Institute. *Cigarette Smoking: Health Risks and How to Quit (PDQ®)*—**http://www.cancer.gov/cancertopics/pdq/prevention/control-of-tobacco-use/HealthProfessional.**

REFERENCES

1. van der Waal I. Potentially malignant disorders of the oral and oropharyngeal mucosa; terminology, classification and present concepts of management. *Oral Oncol.* 2009;45:317-323.
2. Warnakulasuriya S, Johnson NW, van der Waal I. Nomenclature and classification of potentially malignant disorders of the oral mucosa. *J Oral Pathol Med.* 2007;36:575-580.
3. Scully C, Bagan JV, Hopper C, Epstein JB. Oral cancer: current and future diagnostic techniques. *Am J Dent.* 2008;21:199-209.
4. Napier SS, Speight PM. Natural history of potentially malignant oral lesions and conditions: an overview of the literature. *J Oral Pathol Med.* 2008;37:1-10.
5. Reibel J. Prognosis of oral pre-malignant lesions: significance of clinical, histopathological, and molecular biological characteristics. *Crit Rev Oral Biol Med.* 2003;14:47-62.
6. Lodi G, Porter S. Management of potentially malignant disorders: evidence and critique. *J Oral Pathol Med.* 2008;37:63-69.
7. Holmstrup P, Vedtofte P, Reibel J, Stoltze K. Oral premalignant lesions: is a biopsy reliable? *J Oral Pathol Med.* 2007;36:262-266.
8. Holmstrup P, Vedtofte P, Reibel J, Stoltze K. Long-term treatment outcome of oral premalignant lesions. *Oral Oncol.* 2006;42:461-474.
9. Vladimirov BS, Schiodt M. The effect of quitting smoking on the risk of unfavorable events after surgical treatment of oral potentially malignant lesions. *Int J Oral Maxillofac Surg* 2009;38:1188-1193.

43 OROPHARYNGEAL CANCER

Michaell A. Huber, DDS
Wanda C. Gonsalves, MD

PATIENT STORY

A 66-year-old man presents to the physician's office with a nonhealing painful lesion on the roof of his mouth (**Figure 43-1**). The lesion has increased in size recently and he is worried because his dad died from oral cancer. Your patient has smoked since he was 11 years old by getting cigarettes from his dad. He admits to being a heavy drinker. A biopsy shows squamous cell carcinoma and the patient is referred to a head and neck surgeon.

FIGURE 43-1 Squamous cell carcinoma of the palate of a 66-year-old man who smokes and drinks. (*Courtesy of Frank Miller, MD.*)

INTRODUCTION

In spite of the relative ease for the healthcare provider to accomplish a visual and tactile examination of the oropharyngeal cavity, fully two-thirds of oropharyngeal cancers (OPCs) will present with advanced disease at the time of diagnosis.[1] Ninety percent of OPCs are of the squamous cell type. Concern has been raised that practitioners are missing early disease by not accomplishing a thorough soft-tissue examination on a routine basis.[2] However, the fact that more than 35% of patients do not see a dentist on a routine basis likely contributes to the diagnostic delay.[3] The 5-year survival rate is 62% for whites and 42% for blacks.[1]

SYNONYMS

Oral cancer; oral squamous cell carcinoma; mouth cancer; site specific (e.g., gingival cancer, tongue cancer, lip cancer).

EPIDEMIOLOGY

- In the United States, an estimated 40,000 OPC cases occur annually, accounting for approximately 3.3% of malignancies among men and 1.5% of malignancies among women.[1]
- The median age at diagnosis is 62 years and more than 70% of cases occur after the age of 55 years.[4]
- Incidence rates vary from a low of 3.9 per 100,000 Hispanic women to a high of 16.1 per 100,000 white men.[4]
- Up to 35% of OPC patients will develop a new primary tumor within 5 years.[5]

ETIOLOGY AND PATHOPHYSIOLOGY

- Typical OPC develops from a complex multistep progression marked by alterations at the molecular level, followed by

phenotypic changes and subsequent clinically observable changes affecting the squamous epithelium.[6]

RISK FACTORS

- Tobacco use is the major risk factor for OPC and is implicated in approximately 75% of cases.[7]
- Alcohol use is a major risk factor and the combined use of tobacco and alcohol increases the risk of OPC far more than either alone.[7]
- Human papillomavirus (HPV) (especially HPV 16) is a newly recognized major risk factor for carcinomas affecting the lingual and palatine tonsils.[8]
- Other risk factors include betel quid chewing, low intake of fruits and vegetables, immunosuppression, and maté drinking.[9]
- Excess sun exposure is the major risk factor for cancer of the lip.[7]

DIAGNOSIS

- A scalpel biopsy is required to establish the diagnosis.[5,10]

CLINICAL FEATURES

- OPC may affect any area of the oropharyngeal cavity.
- Early OPC often presents as a leukoplakia or erythroplakia (**Figure 43-1**). High-risk sites are the floor of the mouth and ventrolateral tongue (**Figure 43-2**).
- Features of more advanced disease include induration, persistent ulceration, tissue proliferation or erosion, pain or paresthesia, loss of function, and lymphadenopathy (**Figures 43-3** to **43-5**).[10]
- HPV-associated carcinomas are often less visible and share signs and symptoms (e.g., sore throat, hoarseness, earaches, enlarged lymph nodes) of tonsillitis and pharyngitis. More advanced symptoms include dysphagia, hemoptysis, and weight loss.[10]
- Lip cancer typically presents as a relapsing or persistent chronic scab, plaque, crust, or ulceration (**Figure 43-6**). Antecedent actinic cheilosis is commonly observed.
- Nonsquamous type cancers (e.g., salivary gland tumors, melanoma, sarcomas) often present as a submucosal nodular swelling or mass (**Figures 43-7** and **43-8**).

TYPICAL DISTRIBUTION

- OPCs occur most commonly (in order of frequency) on the tongue, floor of mouth, and lower lip vermilion. The lymphoepithelial tissues of the Waldeyer ring (lateral tongue extending to the lateral soft palate and tonsillar area) has the greatest risk of developing an HPV-associated OPC.[8]

LABORATORY

- A scalpel biopsy is required to establish the diagnosis. An excisional biopsy is preferred to better ensure all suspicious tissue is available for histologic assessment. Confirmed cases are staged utilizing the TNM (tumor, nodes, metastases) scheme.

FIGURE 43-2 Squamous cell carcinoma on the lateral side of the tongue. This is a broad erythroleukoplakic plaque with surface ulcerations. (*Courtesy of Ellen Eisenberg, DMD.*)

FIGURE 43-3 Squamous cell carcinoma arising on the buccal mucosa. (*Courtesy of Gerald Ferritti, DDS.*)

FIGURE 43-4 Exophytic cancer of the mouth. (*Courtesy of Gerald Ferritti, DDS.*)

DIFFERENTIAL DIAGNOSIS

- OPC is capricious and may initially mimic any number of benign conditions such as aphthae, chronic ulcerative conditions, pharyngitis, and tonsillitis.
- Any lesion deemed suspicious or equivocal at discovery should be referred to an expert (oral and maxillofacial surgeon, an oral medicine expert, or an ear, nose, and throat [ENT] surgeon) for further assessment or immediate biopsy.
- Findings deemed innocuous should be reevaluated within 2 weeks for resolution and referred to an expert for further assessment or undergo biopsy if still present (**Figure 43-9**).

MANAGEMENT

- Confirmed OPC is best managed by the oncology team whose members deliver all indicated therapeutic antitumor modalities and provide appropriate adjunctive services such as dental care and nutritional, psychological, and social support. TNM staging is useful for treatment planning and prognostication.
- The principal therapeutic modalities are surgery, radiotherapy, and chemotherapy.[11,12]
- The use of one treatment over another depends on the size, location, and stage of the primary tumor, the patient's ability to tolerate treatment, and the patient's desires.[11,12]
- Surgical excision is the preferred modality for most well-defined and accessible solid tumors; however, it has its limitations for inaccessible or more advanced tumors demonstrating lymph node involvement and/or metastasis.[11,12]
- Radiotherapy may be either an effective alternative to surgery or a valuable adjunct to surgery and/or chemotherapy in the locoregional treatment of malignant head and neck tumors.[11,12]
- Protocols utilizing concomitant chemoradiotherapy improve both locoregional control and survival.[12]

PROGNOSIS

- Early OPCs (stage I and stage II) of the lip and oral cavity are highly curable with 5-year survival rates exceeding 90%.[11]
- Later stage OPCs (stage III and stage IV) have a more guarded prognosis with 5-year survival rates ranging from 23% to 58%.[1]

FOLLOW-UP

- Vigilant posttherapy follow-up is required (every 6 months).
- Posttherapy OPC patients are at risk for developing a second primary tumor, 3% to 7% per year.[12]

PATIENT EDUCATION

Advise patients to discontinue smoking and/or drinking alcohol.

FIGURE 43-5 Squamous cell carcinoma manifesting chronic ulceration with induration on the right side of the tongue in a homeless patient. (*Courtesy of Richard P. Usatine, MD.*)

FIGURE 43-6 Squamous cell carcinoma of the lower lip in a 51-year-old male, managed with vermilionectomy. (*Courtesy of Michaell Huber, DDS*).

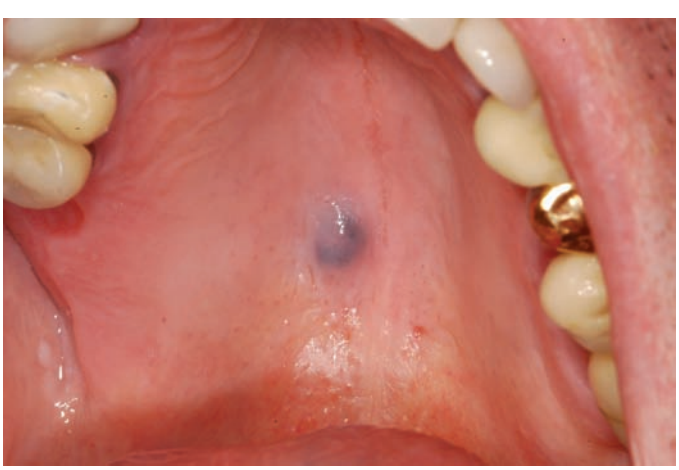

FIGURE 43-7 A 58-year-old male with well-defined soft bluish diascopy positive nodule of unknown duration. Although a benign vascular lesion is the most likely diagnosis, a minor salivary gland tumor or a Kaposi sarcoma should also be considered. (*Courtesy of Michaell Huber, DDS.*)

PATIENT RESOURCES

- The Oral Cancer Foundation—**http://www.oralcancerfoundation.org/.**
- Centers for Disease Control and Prevention, National Oral Health Surveillance System. *Cancer of the Oral Cavity and Pharynx*—**http://www.cdc.gov/nohss/guideCP.htm.**

PROVIDER RESOURCES

- The Oral Cancer Foundation—**http://www.oralcancerfoundation.org/.**
- National Cancer Institute. *Lip and Oral Cavity Cancer (PDQ®): Treatment*—**http://www.cancer.gov/cancertopics/pdq/treatment/lip-and-oral-cavity/HealthProfessional.**
- National Cancer Institute. *Oropharyngeal Cancer (PDQ®): Treatment*—**http://www.cancer.gov/cancertopics/pdq/treatment/oropharyngeal/HealthProfessional.**
- Medscape Reference. *Cancers of the Oral Mucosa*—**http://emedicine.medscape.com/article/1075729-overview.**

REFERENCES

1. Siegel R, Naishadham D, Jemal A. Cancer statistics, 2012. *CA Cancer J Clin*. 2011;62:10-29.
2. Mignogna MD, Fedele S, Lo Russo L, et al. Oral and pharyngeal cancer: lack of prevention and early detection by health care providers. *Eur J Cancer Prev*. 2001;10(4):381-383.
3. Pleis JR, Ward BW, Lucas JW. Summary health statistics for U.S. adults: National Health Interview Survey, 2009. National Center for Health Statistics. *Vital Health Stat 10*. 2010;(249):1-207.
4. National Cancer Institute, Surveillance Epidemiology and End Results. *SEER Stat Fact Sheets: Oral Cavity and Pharynx*. http://seer.cancer.gov/statfacts/html/oralcav.html. Accessed February 17, 2012.
5. Lingen MW, Kalmar JR, Karrison T, Speight PM. Critical evaluation of diagnostic aids for the detection of oral cancer. *Oral Oncol*. 2008;44(1):10-22.
6. Haddad RI, Shin DM. Recent advances in head and neck cancer. *N Engl J Med*. 2008;359:1143-1154.
7. National Cancer Institute. *Oral Cancer Prevention (PDQ®)*. http://www.cancer.gov/cancertopics/pdq/prevention/oral/HealthProfessional. Accessed February 27, 2012.
8. Cleveland JL, Junger ML, Saraiya M, et al. The connection between human papillomavirus and oropharyngeal squamous cell carcinomas in the United States. *J Am Dent Assoc*. 2011;142:915-924.
9. Warnakulasuriya S. Causes of oral cancer—an appraisal of controversies. *Br Dent J*. 2009;207:471-475.
10. Rethman MP, Carpenter W, Cohen EEW, et al. Evidence-based clinical recommendations regarding screening for oral squamous cell carcinomas. *J Am Dent Assoc*. 2010;141:509-520.
11. National Cancer Institute. *Lip and Oral Cancer Treatment (PDQ®)*. http://www.cancer.gov/cancertopics/pdq/treatment/lip-and-oral-cavity/HealthProfessional. Accessed February 17, 2012.
12. National Cancer Institute. *Oropharyngeal Cancer Treatment (PDQ®)*. http://www.cancer.gov/cancertopics/pdq/treatment/oropharyngeal/HealthProfessional. Accessed February 17, 2012.

FIGURE 43-8 An 80-year-old Hispanic female with a 25-year history of palatal mass, which she stated only recently started getting bigger. A low-grade adenocarcinoma of the palate was confirmed with biopsy. (*Courtesy of Michaell Huber, DDS.*)

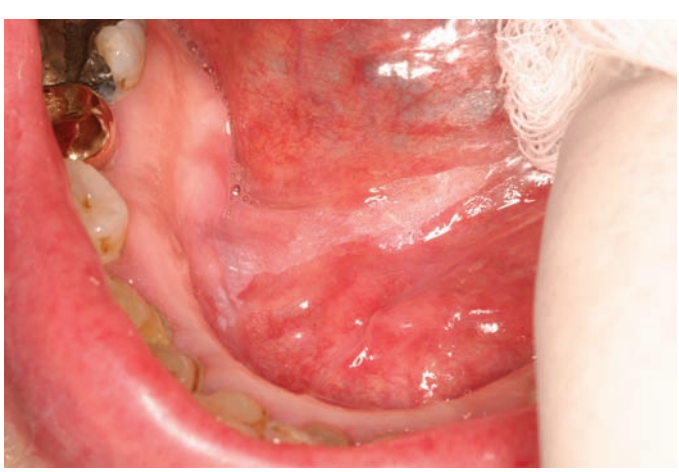

FIGURE 43-9 A 64-year-old woman with faint leukoplakia and a history of a hot coffee burn. Upon 2-week follow-up, the leukoplakia was still present and an excisional biopsy revealed carcinoma in situ completely excised. She was recommended for close monitoring. (*Courtesy of Michaell Huber, DDS.*)

44 EARLY CHILDHOOD CARIES

Adriana Segura, DDS, MS
Wanda C. Gonsalves, MD

PATIENT STORY

A mother brings her 18-month-old son to the physician's clinic for his well-child examination. He is almost weaned from his bottle, but still drinks from a bottle to go to sleep. During the day, he uses a sippy cup to drink everything—from milk to soda. His mother has started giving him apple juice in the bottle instead of milk because he tends to get constipated. On performing an oral examination, the physician notices that several of his teeth have "white spots" (**Figure 44-1**). The physician discusses dental hygiene and treats him with topical fluoride gel.

FIGURE 44-1 Demineralization at gingiva margins characterized by whitish discolorations. (*Courtesy of Gerald Ferretti, DMD.*)

INTRODUCTION

Dental caries continues to be the most prevalent chronic disease problem facing infants and children. The American Academy of Pediatric Dentistry, American Academy of Pediatrics, and American Dental Association recommend that a child's first visit to a dentist should occur 6 months after the eruption of the first tooth or at 1 year of age. Providing a dental home by age 1 year allows the health provider to complete a risk assessment, provide an introduction to dentistry, and provide anticipatory guidance. It is important to be able to recognize disease and to provide prevention strategies early on to the parents/caregivers.

SYNONYMS

Nursing bottle caries, baby bottles caries.

EPIDEMIOLOGY

- Early childhood caries (ECC; tooth decay) is the single most common chronic childhood disease. It is 5 times more common than asthma and 7 times more common than hayfever among children 5 to 7 years of age.[1]
- Tooth decay affects more than 25% of U.S. children between 2 and 5 years of age and about half of those 12 to 15 years of age.
- Disparities in oral health exist—In 2002, 32% of Mexican American and 27% of non-Hispanic black children 2 to 11 years of age had untreated decay in their primary teeth, compared to 18% of non-Hispanic white children.[2,3]
- ECC is defined as "the presence of one or more decayed (noncavitated or cavitated lesions), missing (as a consequence of caries), or filled tooth surfaces in any primary tooth in a child 71 months of age or younger (**Figures 44-2** to **44-4**)."[4]

FIGURE 44-2 Central maxillary incisors with severe tooth decay, and bilateral maxillary lateral incisors with demineralized area near gingival line (yellow-brownish discolorations). The upper incisors are often the first teeth involved in nursing bottle caries. (*Courtesy of Gerald Ferretti, DMD.*)

- Consequences of ECC include poor self-esteem, diminished physical development, decreased ability to learn, higher risk of new caries, and added cost.[4]

ETIOLOGY AND PATHOPHYSIOLOGY

- Dental caries is a multifactorial, infectious, communicable disease caused by the demineralization of tooth enamel (**Figure 44-1**) in the presence of a sugar substrate and acid-forming cariogenic bacteria, *Streptococcus mutans* (also known as *mutans streptococci*), which is considered to be the primary strain causing decay that are found in the soft gelatinous biofilm.
- Caries can develop at any time after tooth eruption. Early teeth are principally susceptible to caries caused by the transmission of *S. mutans* from the mouth of the caregiver or sibling(s) to the mouth of the infant or toddler. This type of tooth decay is called baby bottle tooth decay, nursing bottle caries, or ECC.

RISK FACTORS

Risk factors for caries development include:

- Frequent consumption of liquids.
- Repetitive use of a "sippy cup" containing sugars (juice, milk, formula, soda).
- Consumption of sticky foods.
- Human breast milk is uniquely superior in providing the best possible nutrition to infants and, by itself, has been shown to be noncariogenic.[3]

Nighttime bottle feeding and caregiver with caries.

- Drinking unfluoridated community water or bottled water, which usually lacks fluoride.
- Low socioeconomic status.
- Taking medications that contain sugar or cause dryness.

Lack of good oral hygiene practices.
Subnormal saliva and function.

DIAGNOSIS

CLINICAL FEATURES

- Demineralized areas develop on the tooth surfaces, between teeth, and on pits and fissures. These areas are painless and appear clinically as opaque or brown spots (**Figure 44-1**). White-spot lesions are the first indication the demineralization has started.
- Infection that is allowed to progress forms a cavity that can spread to and through the dentin (the component of the tooth located below the enamel) and to the pulp (composed of nerves and blood vessels; an infection of the pulp is called pulpitis) causing pain, necrosis, and, perhaps, an abscess.

FIGURE 44-3 Severe ECC in a 4-year-old with severe decay of all four maxillary incisors. (*Courtesy of Richard P. Usatine, MD.*)

FIGURE 44-4 Severe ECC in a 3-year-old with multiple areas of cavitary lesions involving the mandibular incisors and missing maxillary incisors secondary to decay. (*Courtesy of Richard P. Usatine, MD.*)

TABLE 44-1 Supplemental Fluoride Dosage Schedule

Age	Concentration of Fluoride in Water		
	<0.3 ppm F	0.3 to 0.6 ppm F	>0.6 ppm F
Birth to 6 months	0	0	0
6 months to 3 years	0.25 mg	0	0
3 to 6 years	0.50 mg	0.25 mg	0
6 to at least 16 years	1.00 mg	0.50 mg	0

Source: The Guideline on Fluoride Therapy (2008 revision) is Copyright © 2007-2008 by the American Academy of Pediatric Dentistry and is reproduced with their permission. http://www.aapd.org/media/policies_guidelines/g_fluoridetherapy.pdf.

TYPICAL DISTRIBUTION

Demineralized (white or brown spots) and carious lesions generally occur at the margins of the gingiva upper incisors, and later first and second molars in pits and grooves of occlusal surfaces. Lower incisors are rarely affected.

LABORATORY AND IMAGING

Demineralized lesions may not be seen on radiographs, but advanced carious lesions between and on the occlusal surfaces are detected by X-ray.

MANAGEMENT

- Counsel patients about the importance of good oral hygiene practices and perform a caries risk assessment during well-child examination visits.[5,6] SOR B
- Refer to the dental health professional for the application of pit and fissure sealants.[5,6] SOR B
- Before prescribing supplemental fluoride, the primary care provider must determine the fluoride concentration in the child's primary source of drinking water. If fluoridated water is not available in the community, natural sources of fluoride are well water exposed to fluorite minerals and certain fruits and vegetables grown in soil irrigated with fluoridated water.[7] SOR B
- Fluoride supplementation is not recommended for use by persons who live in communities whose water is optimally fluoridated (0.7 to 1.2 parts per million [ppm] or >0.6 mg/L). See **Table 44-1** for fluoride supplementation.[7] SOR A
- Advise the caregiver to take the child to a dentist by age 1 year.[6] SOR C
- Application of fluoride varnishes twice per year in moderate to high-risk children have been shown to prevent caries in demineralized enamel.[8] SOR A

FOLLOW-UP

Ensure that any child whose teeth has "white spots" or visible caries is taken to a dentist for evaluation and treatment so the teeth can be saved from decay or repaired.

PATIENT EDUCATION[6]

- Give the child's caregiver anticipatory guidance that is appropriate to the child's age and dental development. Before the teeth erupt, the caregiver should use a washcloth or cotton gauze to clean a baby's mouth and to transition the child to tooth brushing. SOR C
- A "smear" of fluoridated toothpaste (approximately 0.1 mf fluoride) should be considered for children younger than 2 years of age who are at moderate risk or high risk for caries (**Figure 44-5**).[6] SOR B
- A "pea size" amount of toothpaste (approximately 0.2 mg fluoride) is appropriate for children 2 through 5 years of age.[6] SOR B
- The caregiver should brush the child's teeth until the child is capable of doing an adequate job (usually around age 7 years).
- Educate caregivers about the benefits of fluoride and fluorosis, and the possible side effects of using too much fluoride (see **Table 44-1**).
- Advise caregivers to teach the child to drink from a "sippy cup" as soon as possible and to avoid giving the child milk, juice, or soda in either a bottle or sippy cup when putting the child to bed.

Breastfeeding by itself is noncariogenic but when supplemented with other carbohydrates can place the child at risk for caries.[9,10]

The American Academy of Pediatric Dentistry (AAPD) promotes breastfeeding for infants but recommends cessation of ad libitum breastfeeding as the first primary tooth begins to erupt and other dietary carbohydrates are introduced.[9] SOR C

FIGURE 44-5 Comparison of a "smear" (*left*) with a "pea-sized" (*right*) amount of toothpaste. (*Courtesy of Richard P. Usatine, MD.*)

PATIENT RESOURCES

- Centers for Disease Control and Prevention. *Brush Up on Healthy Teeth*—**http://www.cdc.gov/OralHealth/pdfs/BrushUpPoster.pdf.**
- Douglass JM, Douglass AB, Silk HJ. Your baby's teeth. *Am Fam Physician.* 2004;70:2121. **http://www.aafp.org/afp/20041201/2121ph.html.**

PROVIDER RESOURCES

- American Academy of Pediatric Dentistry—**http://www.aapd.org/.**
- Smiles for Life: A National Oral Health Curriculum—**http://www.smilesforlifeoralhealth.org/.**
- Centers for Disease Control and Prevention. *Preventing Cavities, Gum Disease, Tooth Loss, and Oral Cancers at a Glance 2011*—**http://www.cdc.gov/chronicdisease/resources/publications/AAG/doh.htm.**

REFERENCES

1. U.S. Department of Health and Human Services. *Oral Health in America: A Report of the Surgeon General-Executive Summary*. Rockville, MD: US Department of Health and Human Services, National Institute of Dental and Craniofacial Research, National Institutes of Health, 2000. http://www.nidr.nih.gov/sgr/execsumm.htm. Accessed April 20, 2012.

2. Centers for Disease Control and Prevention. *Oral Health: Preventing Cavities, Gum Disease, and Tooth Loss, and Oral Cancers*. http://www.cdc.gov/chronicdisease/resources/publications/AAG/doh.htm. Accessed April 20, 2012.
3. Centers for Disease Control and Prevention. *Oral Health Resources: New Report Finds Improvements in Oral Health of Americans*. http://www.cdc.gov/oralhealth/publications/library/pressreleases/improvements.htm. Accessed April 20, 2012.
4. American Academy of Pediatric Dentistry, Council on Clinical Affairs. *Policy on Early Child Caries (ECC: Classifications, Consequences, and Prevention Strategies) (Revised 2011)*. http://www.aapd.org/media/policies_guidelines/p_eccclassifications.pdf. Accessed April 20, 2012.
5. National Institutes of Health, Consensus Development Conference Statement, March 26-28, 2001. *Diagnosis and Management of Dental Caries Throughout Life*. http://consensus.nih.gov/2001/2001DentalCaries115html.htm. Accessed April 20, 2012.
6. American Academy of Pediatric Dentistry, Clinical Affairs Committee—Infant Oral Health Subcommittee. *Guideline on Infant Oral Health Care (Revised 2011)*. http://www.aapd.org/media/policies_guidelines/g_infantoralhealthcare.pdf. Accessed April 20, 2012.
7. American Academy of Pediatric Dentistry, Liaison with Other Groups Committee, Council on Clinical Affairs. *Guideline on Fluoride Therapy*, p. 90. http://www.aapd.org/media/Policies_Guidelines/G_FluorideTherapy.pdf. Accessed April 20, 2012.
8. Adair SM. Evidence base use of fluoride in contemporary pediatric dental medicine. *Pediatr Dent*. 2006;28(2):133-142, discussion 192-198.
9. American Academy of Pediatric Dentistry, Council on Clinical Affairs. *Policy on Dietary Recommendation for Infants, Children and Adolescents (Revised 2008)*. http://www.aapd.org/media/policies_guidelines/p_dietaryrec.pdf. Accessed April 20, 2012.
10. Iada H, Auinger P, Billings RJ, Weitzman M. Association between infant breast feeding and early childhood caries in the United States. *Pediatrics*. 2007;120(4):944-952.

45 ADULT DENTAL CARIES

Juanita Lozano-Pineda, DDS, MPH
Wanda C. Gonsalves, MD

PATIENT STORY

A 41-year-old homeless man presents to a clinic on "skid row" with a toothache (**Figure 45-1**). He has a history of alcoholism and smoking. Many of his teeth are loose and a number of his teeth have fallen out in the past year. He acknowledges that he does not floss or brush his teeth regularly. He has been sober for 60 days now and wants help to get his teeth fixed. He states that no one will hire him with his teeth as they are. He also has pain in a molar and wants something for the pain until he can see a dentist. On oral examination, you see missing teeth, generalized plaque, and teeth with multiple brown caries.

FIGURE 45-1 Severe caries in a homeless man. (*Courtesy of Richard P. Usatine, MD.*)

INTRODUCTION

Dental caries is a multifactorial disease that is primarily caused by an interaction between bacteria and fermentable carbohydrates producing acid that has potential to demineralize the tooth surface over time. Host factors, such as the plaque (biofilm) adherence, quality and quantity of saliva, immune system response, use of fluoride, and a diet that is caries-promoting, play a role in the formation of incipient demineralized lesions that progress to dental caries. Caries risk is impacted by factors that may be behavioral, biologic, environmental, lifestyle-related, and physical. Age, diabetes, ethnic origin, gingival recession, smoking, and socioeconomic status are frequently associated with high caries prevalence.[1]

SYNONYMS

Dental decay, dental cavities, cavitated lesions.

EPIDEMIOLOGY

- Many adults (e.g., 31% of those 20 to 34 years of age, 27% of those 35 to 49 years of age, 24% of those 50 to 64 years of age, and 20% of those 65 years of age and older) have untreated dental caries (**Figure 45-1**).[2]
- Black and Hispanic adults, younger adults, and those with lower incomes and less education have more untreated decay.[3]
- Many older adults suffer from root caries (decay on the roots of their teeth) (**Figure 45-2**). The percentage of adults with root caries increased with age: 8% of adults 20 to 39 years of age had root decay, compared with 11% of adults 40 to 59 years of age, and 13% of adults 60 years of age and older. The prevalence is greater for black non-Hispanics (20%) and adults below 100% poverty level (19%).[4]
- More than twice as many current smokers (19%) as nonsmokers (7%) had root caries.[4]

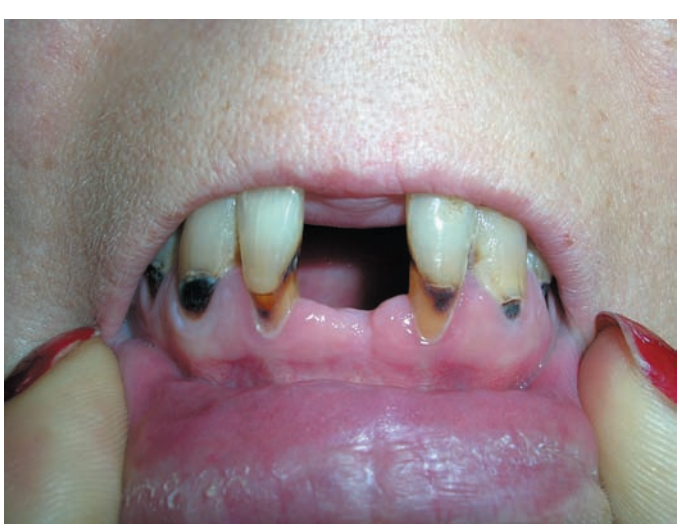

FIGURE 45-2 Root caries in a woman with a history of substance abuse. She has lost all of her upper teeth and is beginning to lose her lower teeth. Note the exposed and darkened roots. (*Courtesy of Richard P. Usatine, MD.*)

ETIOLOGY AND PATHOPHYSIOLOGY

- Dental caries result from the activity of dental bacterial plaque, a complex biofilm containing microorganisms that demineralize and proteolyse tooth enamel and dentin through their action on the fermentation of sucrose and other sugars. The main organism is *Streptococcus mutans*.
- A caries-promoting diet that is high in sugar or acid increases the demineralization process. A cariostatic diet that contains calcium helps buffer the acidity and increase remineralization of the tooth's enamel surface.
- Low saliva flow and low pH also increase demineralization; the lack of saliva to buffer the acidity from plaque and diet increases caries risk.
- Dental caries progression or reversal depends on the balance between demineralization and remineralization. If caries is untreated and progresses, it eventually destroys enough tooth structure to either have the unsupported tooth fracture, or the caries reaches the tooth's pulp (nerve tissue) and leads to infection that can progress through the pulp to the tooth's root apex and surrounding bone.
- Plaque also impacts the gingival tissues; if it is not removed regularly, it may calcify with the minerals in the saliva and form calculus (tartar).

RISK FACTORS

The risk factors for adult caries include:[5–7]

- Increased acidic environment that may be a result of:
  - A diet that is high in fermentable carbohydrates and/or acid.
  - High quantity of bacteria/poor oral hygiene.
  - Physical and medical disabilities that often prevent proper oral hygiene.
  - Medications that decrease pH.[6]
  - Acid reflux.
  - Bulimia.
- Low saliva flow and dry mouth:
  - Medications that decrease saliva flow (tricyclic antidepressants, antihistamines, steroids, diuretics).
  - Illicit drugs such as methamphetamine and cocaine dry the mouth.
  - Radiation to the head and neck that may damage salivary glands.
  - Sjögren syndrome affects saliva glands and decreases flow rate.
- The presence of existing restorations or oral appliances.
- Gingival recession exposing root surfaces that demineralize at a higher pH.
- Low socioeconomic status with limited or no access to medical or dental care.

DIAGNOSIS

Caries can be diagnosed clinically through visual examination of the teeth, where lesions range from a white spot (incipient) to a large

cavitated lesion. Radiographically, the carious lesion appears radiolucent (as a consequence of demineralization or cavitation) within a radiopaque, calcified tooth structure.

CLINICAL FEATURES

- Dental caries initially present as a painless white spot (demineralization of enamel) and if contributing risk factors are not modified, it progresses to a brownish discoloration, with eventual cavitation into the dentin. Pain is usually not felt until the caries progresses into the dentin and/or approximates the pulp. It presents only when stimulated with cold or sweets, and rarely with heat, subsiding shortly after stimulus removal. Once the caries infects the nerve, it leads to pulpal necrosis. The patient may present with pain that is spontaneous, triggered with heat and lingers, is more severe, and may be accompanied with soft-tissue swelling.

TYPICAL DISTRIBUTION

Any enamel, exposed dentin or cementum surface, including occlusal, interproximal, and root surfaces.

LABORATORY AND IMAGING

An X-ray will show the extent of the cavity, but not all demineralized areas.

DIFFERENTIAL DIAGNOSIS

- Fluorosis—Mild fluorosis may present as white spot lesions with an appearance that is similar to the "white-spot" incipient carious lesions.
- Dark staining in the tooth's deep pits and fissures that may be a result of tobacco use or tartar build up.
- Trauma—Usually involves maxillary incisors common in sports, accidents, violence, and epilepsy.
- Tooth erosion—Results from consumption of carbonated beverages and fruit drinks, repeated vomiting associated with eating disorders, gastroesophageal reflux, and alcoholism.
- Tooth attrition—Wearing down of teeth because of tooth grinding (bruxism) or an abrasive diet.
- Tooth abrasion—Caused by brushing with a hard toothbrush and using abrasive toothpaste.
- Bulimia can cause destruction of the teeth because of the gastric acids (**Figure 45-3**).

FIGURE 45-3 Destruction of the teeth in woman with bulimia. The gastric acids have dissolved the enamel. (*Courtesy of Gerald Ferretti, DMD.*)

MANAGEMENT

- Demineralized lesions ("white spots") and caries—Topical fluorides such as varnishes (5% NaF; 23,000 parts per million [ppm] F^-) that are applied by dental health providers or the primary care physician twice a year have been shown to decrease dental caries by 21%.[7]
- Fluoride mouth rinses (0.2% NaF, 900 ppm F^-) are effective in controlling caries when used daily.[7]
- Refer to a dental health professional for sealant treatment of pits and fissures.[8]

- Refer patients with "white spots" and dental caries to a dental professional for treatment and/or restoration.[5]
- Patients with xerostomia may be treated with saliva substitutes such as Oralbalance in the Biotene product range.[5]

PREVENTION AND SCREENING

Most oral disease, including cavities, is preventable. Proper oral hygiene (daily brushing and flossing), daily exposure to fluoride (systemic or topical), along with a healthy diet that is not high in sugar, can prevent the formation and/or progression of dental caries. Visual screening can detect caries at the early stages.

PROGNOSIS

The prognosis for lesions that are detected during their early stages or prior to approximating the tooth's nerve is very good. Removal of the carious portion of the tooth and placement of a filling will restore the tooth to function and prevent further progression of the cavity.

FOLLOW-UP

Remind adult patients who have incipient "white-spot" caries or active caries to go to a dentist for treatment. Patients with large caries should be referred for immediate treatment.

PATIENT EDUCATION

- Advise patients to maintain good oral hygiene by brushing their teeth twice daily with a small-headed, soft to medium hardness brush using a toothpaste that contains fluoride. Electric toothbrushes may be useful for those with poor manual dexterity. Counsel patients to floss once daily to remove plaque and food particles from between the teeth.
- Suggest that patients use antiplaque mouthwashes containing chlorhexidine to inhibit *S. mutans*, but caution coffee, tea, and red wine drinkers that such mouthwashes may increase dental staining.[5]
- Patients with xerostomia (dry mouth) should be advised to practice good oral hygiene, increase water intake, and avoid sugary foods. Chewing sugar-free gum will induce salivation.[5]
- Patients with xerostomia should also be advised to avoid alcohol-containing mouth rinses, as alcohol also dries the mouth.
- Advise patients that plaque formation may be reduced by chewing sugar-free gum and eating raw fruits and vegetables, which reduces bacteria through mechanical cleansing of the tooth surfaces.
- Patients who use asthma inhalers should be advised to rinse their mouth out with water after inhaler use to decrease the amount of residue that is left in the oral cavity. Many inhalers contain lactose, a fermentable sugar.
- Eating calcium-containing foods, such as milk and cheese, helps buffer the acidic environment and helps with remineralization.

- Advise patients to visit a dental professional at least once a year for a cleaning and examination.

PATIENT RESOURCES

- American Dental Association. *Public Resources*—**http://www.ada.org/public.aspx.**
- New York State Department of Health. *Oral Health Resources and Links*—**http://www.health.state.ny.us/prevention/dental/weblinks_oral_health.htm.**

PROVIDER RESOURCES

- Smiles for Life: A National Oral Health Curriculum—**http://www.smilesforlifeoralhealth.org/.**
- Centers for Disease Control and Prevention. *Preventing Cavities, Gum Disease, Tooth Loss, and Oral Cancers at a Glance 2011*—**http://www.cdc.gov/chronicdisease/resources/publications/AAG/doh.htm.**
- World Health Organization. *Oral Health*—**http://www.who.int/oral_health/en/.**

REFERENCES

1. Ritter AV, Preisser JS, Chung Y, et al; X-ACT Collaborative Research Group. Risk indicators for the presence and extent of root caries among caries-active adults enrolled in the Xylitol for Adult Caries Trial (X-ACT). *Clin Oral Investig*. 2011 Dec 24 [Epub ahead of print].
2. Griffin SO, Barker LK, Griffin PM, et al. Oral health needs among adults in the United States with chronic diseases. *J Am Dent Assoc*. 2009;140;1266-1274.
3. National Institute of Dental and Craniofacial Research. *Dental Caries (Tooth Decay) in Adults (Age 20 to 64)*. http://www.nidcr.nih.gov/DataStatistics/FindDataByTopic/DentalCaries/DentalCariesAdults20to64.htm. Accessed April 3, 2012.
4. National Health and Nutrition Examination Survey (NHANES), 1999-2002. *NIDCR/CDC Oral Health Data Query System*. http://apps.nccd.cdc.gov/dohdrc/dqs/entry.html. Accessed April 5, 2012.
5. Johnson V, Chalmers J. *Oral Hygiene Care for Functionally Dependent and Cognitively Impaired Older Adults*. Iowa City, IA: University of Iowa College of Nursing, John A. Hartford Foundation Center of Geriatric Nursing Excellence; 2011 Jul. 61 p. http://www.guideline.gov/content.aspx?id=34447&search=oral+hygiene+care+for+functionally+dependent+and+cognitively+impaired+older+adults. Accessed April 5, 2012.
6. Stookey GK. The effect of saliva on dental caries. *J Am Dent Assoc*. 2008;139(suppl):S11-S17.
7. Cappelli, DP, Mobley CC. *Prevention in Clinical Oral Health Care*. St. Louis, MO: Elsevier; 2008.
8. National Institutes of Health, Consensus Development Conference Statement, March 26-28, 2001. *Diagnosis and Management of Dental Caries Throughout Life*. http://consensus.nih.gov/2001/2001DentalCaries115html.htm

PART 7

THE HEART AND CIRCULATION

Strength of Recommendation (SOR)	Definition
A	Recommendation based on consistent and good-quality patient-oriented evidence.*
B	Recommendation based on inconsistent or limited-quality patient-oriented evidence.*
C	Recommendation based on consensus, usual practice, opinion, disease-oriented evidence, or case series for studies of diagnosis, treatment, prevention, or screening.*

*See Appendix A on pages 1447–1450 for further information.

SECTION 1 CENTRAL

46 CORONARY ARTERY DISEASE

Heidi Chumley, MD

PATIENT STORY

A 45-year-old man began having chest pressure with exertion that was relieved with rest. He did not have diabetes, high blood pressure, or high cholesterol, and had never had a myocardial infarction. His examination and resting ECG were normal. On the basis of the testing modalities available, he was scheduled for exercise stress testing. After a positive test, he underwent coronary angiography that demonstrated a significant stenosis in the left coronary artery (**Figure 46-1**). He underwent a stenting procedure and was placed on aspirin and cholesterol-lowering medication.

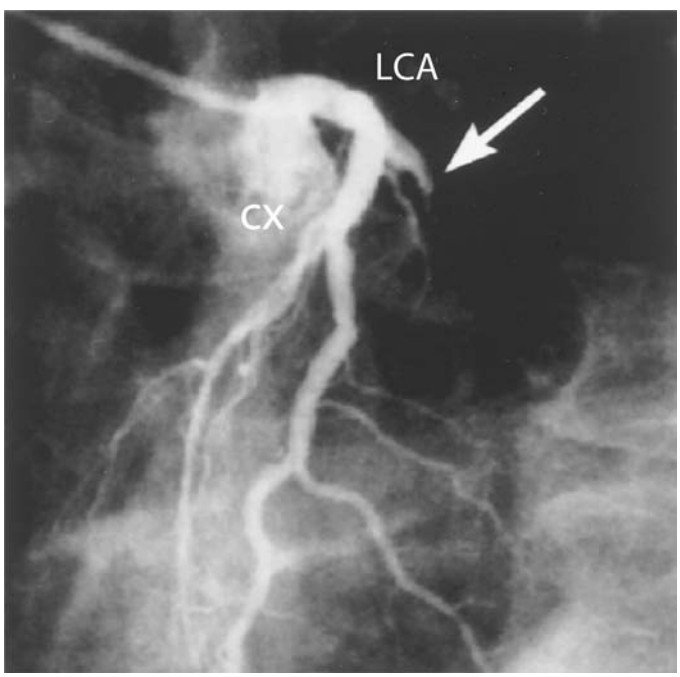

FIGURE 46-1 Coronary arteriogram demonstrating severe stenosis (*white arrow*) in the left coronary artery. Note that the circumflex artery (CX) is patent.

INTRODUCTION

In the United States, a person dies of coronary heart disease every 39 seconds. Coronary heart disease is a manifestation of atherosclerotic disease and has many modifiable risk factors. Patients with and without coronary heart disease should be advised to stop smoking, maintain normal blood pressure and cholesterol levels, exercise, achieve or maintain a normal weight, and control diabetes mellitus if present.

EPIDEMIOLOGY

- Coronary heart disease (CHD) is the leading cause of death in the United States, responsible for approximately 400,000 deaths in 2008.[1]
- Each year, 1.5 million myocardial infarctions occur (first and recurrent) with a 33% mortality rate.[1]
- In 2005, the prevalence of CHD among U.S. adults older than 18 years of age was higher in men than woman (8.2% vs. 5.0%) and higher in people with a less-than-high-school-diploma education (9.8% vs. 5.0% for college graduates).[2]

In 2005, prevalence among white and black persons was similar.[2]

ETIOLOGY AND PATHOPHYSIOLOGY

- CHD is one of several manifestations of atherosclerotic disease, which begins with endothelium dysfunction.[3]
- Endothelium, when normal, balances vasoconstrictors and vasodilators, impedes platelet aggregation, and controls fibrin production.

- Dysfunctional endothelium encourages macrophage adhesion, plaque growth, and vasoconstriction by recruiting inflammatory cells into the vessel walls, the initiating step of atherosclerosis.
- The vessel wall lesions develop a cap of smooth muscle cells and collagen to become fibroadenomas.
- The vessels with these lesions undergo enlargement, allowing progression of the plaque without compromising the lumen.
- Plaque disruption and thrombus formation, instead of progressive narrowing of the coronary artery lumen, is responsible for two-thirds of acute coronary events.[2]
- Plaques most likely to rupture (high-risk plaques) have a large core of lipids, many macrophages, decreased vascular smooth muscle cells, and a thin fibrous cap.
- After plaque rupture, the exposed lipid core triggers a superimposed thrombus that occludes the vessel.
- Increased thrombosis is triggered by known cardiac risk factors including elevated low-density lipoprotein (LDL) cholesterol, cigarette smoking, and hyperglycemia.
- The other one-third of acute coronary events occurs at the site of very stenotic lesions (**Figure 46-2**).[3]

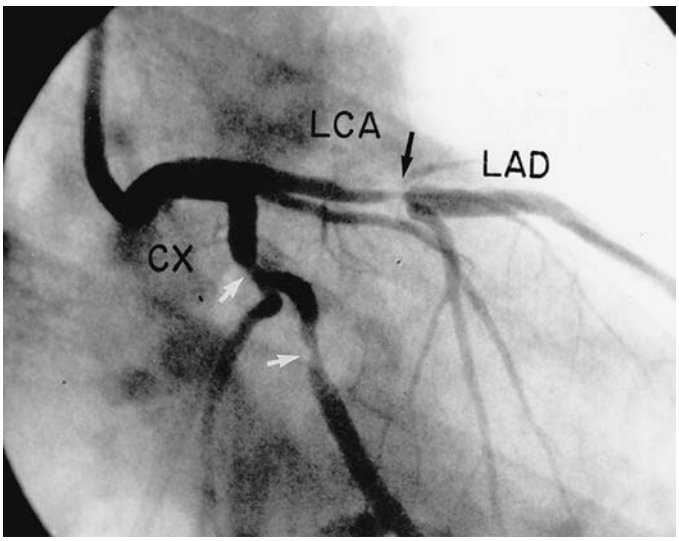

FIGURE 46-2. Coronary angiogram of a left coronary artery (*LCA*) with a tight stenosis in the proximal left anterior descending (*LAD*) artery (*black arrow*). The circumflex artery (*CX*) has 2 moderately severe stenoses (*white arrows*).

RISK FACTORS

- Family history of premature paternal or sibling myocardial infarction increases risk of heart disease by 50%.[1]
- Tobacco use and secondhand smoke exposure increase the risk of CHD and smoking cessation reduces risk.[1]
- High total cholesterol, high LDL, and/or low high-density lipoprotein (HDL) are independent risk factors.
- Physical inactivity has a relative risk of CHD of 1.5 to 2.4.[1]
- Overweight and obesity increases risk of heart disease by 20% (men and women) and 46% (men)/64% (women), respectively.[1]
- Diabetes mellitus increases risk of heart disease (hazard ratio 2.5).[1]

DIAGNOSIS

CLINICAL FEATURES

- Typical angina is chest pain or pressure, brought on by exertion or stress, and relieved with rest or nitroglycerin.
- Atypical angina has two of the three features of typical angina; however, women with coronary artery disease report more neck, throat, or jaw pain.[4]
- Noncardiac chest pain has zero to one of the three features of typical angina.

LABORATORY TESTING

- Risk factor assessment—Lipid profile and fasting blood glucose.
- Acute coronary syndrome—Cardiac-specific troponin is now preferred; when troponin cutoff is 0.1 g/L, sensitivity is 93%,

specificity is 91%, positive likelihood ratio (LR+) is 10.33, and negative likelihood ratio (LR−) is 0.08.

COMMON NONINVASIVE TESTING[5]

- Exercise treadmill testing—Sensitivity 52% and specificity 71%, LR+ 1.79, LR− 0.68.
- Stress echocardiogram—Sensitivity 85% and specificity 77%, LR+ 3.70, LR− 0.19.
- Stress thallium—Sensitivity 87% and specificity 64%, LR+ 2.42, LR− 0.20.

Newer methods being tested include CT for diagnosis:[6]

- A 4- or 16-slice study—Sensitivity 95% and specificity 84%, LR+ 5.94, LR− 0.06, with 78% and 91% of segments evaluable.
- A 64-slice study—Sensitivity 100% and specificity 100% with 100% of segments evaluable.

DIFFERENTIAL DIAGNOSIS

Chest pain can be caused by several conditions including:

- Cardiac—Pericarditis—slower onset of pain, pain aggravated by movement or inspiration, characteristic ECG changes.
- Respiratory—Pneumothorax—acute onset with shortness of breath and characteristic radiographic findings; pneumonia—often accompanied by fever, cough, shortness of breath/hypoxia, and/or radiographic findings; pulmonary embolism—acute onset of shortness of breath, positive ventilation-perfusion scan, or spiral CT.
- GI—Gastroesophageal reflux—related to eating, responds to H_2 blockers or proton pump inhibitor (PPI).
- Musculoskeletal—Costochondritis—chest muscles tender to palpation.

MANAGEMENT

NONPHARMACOLOGIC

- Advise patients with coronary artery disease to stop smoking.[7] SOR A
- Recommend 30 minutes of physical activity 5 to 7 days per week.[1,7] SOR B
- Advise patients in weight management with a goal body mass index (BMI) of 18.5 to 24.9.[7] SOR B

MEDICATIONS

Managing risk factors:

- Lower LDL cholesterol using lifestyle modification and hydroxymethylglutaryl coenzyme A (HMG-CoA) reductase inhibitors to decrease all-cause mortality (relative risk [RR] 0.90), cardiovascular mortality (RR 0.80), fatal and nonfatal myocardial infarction (MI) (RR 0.82 and 0.74).[8] SOR A
- Lower blood pressure to 140/90 or 130/80 mm Hg (with diabetes or chronic renal disease); treat patients who are post-MI with a β-blocker, thiazide diuretic, or aldosterone antagonist.[9] SOR A
- Prescribe aspirin in patients with prior ST elevation or non-ST elevation acute coronary event or chronic stable angina. Prescribe clopidogrel alone in chronic stable angina or with aspirin in non-ST elevation acute coronary syndrome.[10] SOR A
- Prescribe a β-antagonist—Several trials demonstrate mortality decreases of 25% to 40% with various β-blockers used in the acute MI or post-MI period.[11]

Treat symptoms:

- Nitroglycerin sublingual or spray for immediate relief of angina.[12] SOR B
- Long-acting nitrates or calcium antagonists if β-blockers are contraindicated, do not control symptoms, or have unacceptable side effects.[12] SOR B

REFERRAL OR HOSPITALIZATION

- Refer patients with positive noninvasive testing to be evaluated for cardiac catheterization.
- Consult with cardiologists and cardiothoracic surgeons to determine optimal management.
- Traditionally, patients with greater than 50% stenosis of left main, proximal stenosis of three major arteries, or significant stenosis of the proximal left anterior descending and one other major artery have been treated with coronary bypass surgery.[13] SOR A
- Advancements with drug-eluting stents may increase the numbers and types of patients who benefit from stenting.[13]

PREVENTION

Prevention of CHD is accomplished by risk factor control. In a study of older men that examined the risk factors of smoking, high LDL, high blood pressure, and no aspirin use, the number needed to treat (NNT) to prevent one cardiovascular outcome were: 22, 8, 6, and 5 for 1, 2, 3, and 4 risk factors controlled, respectively.[14]

FOLLOW-UP

Follow-up frequency is based on the extent of illness and symptoms and may include primary care and subspecialty care. Patients should have ongoing evaluation of risk factors and symptoms every 4 to 12 months. Expert guidelines recommend annual exercise stress testing for patients with chronic stable angina.[12] SOR C

PATIENT EDUCATION

Advise patients in the importance of lifestyle modification and medications in the long-term management of CHD.

PATIENT RESOURCES

- PubMed Health. *Coronary Heart Disease*—**http://www.ncbi.nlm.nih.gov/pubmedhealth/PMH0004449/.**
- The American Heart Association has information about the warning signs of heart attacks and living a healthy lifestyle at **http://www.americanheart.org.**

PROVIDER RESOURCES

- Boudi FB. *Coronary Artery Atherosclerosis*—**http://emedicine.medscape.com/article/153647.**
- Online calculator for pre- and posttest probability of coronary artery disease based on history and physical—**http://www.soapnote.org/cardiovascular/chest-pain-evaluation/.**
- The National Heart, Lung, and Blood Institute—**http://www.nhlbi.nih.gov/index.htm.**

REFERENCES

1. Roger VL, Go AS, Lloyd-Jones DM, et al. Heart Disease and Stroke Statistics—2012 Update: A Report From the American Heart Association. *Circulation*. 2012;125(1):188-197. Available online at http://circ.ahajournals.org/content/early/2011/12/15/CIR.0b013e31823ac046.citation. Accessed September 3, 2012.
2. Centers for Disease Control and Prevention. Prevalence of Heart Disease—United States, 2005. *MMWR Morb Mortal Wkly Rep*. 2007;56(6):113-118.
3. Viles-Gonzalez JF, Fuster V, Badimon JJ. Atherothrombosis: a widespread disease with unpredictable and life-threatening consequences. *Eur Heart J*. 2004;25(14):1197-1207.
4. Philpott S, Boynton PM, Feder G, Hemingway H. Gender differences in descriptions of angina symptoms and health problems immediately prior to angiography: the ACRE study. Appropriateness of Coronary Revascularisation study. *Soc Sci Med*. 2001;52(10):1565-1575.
5. Pryor DB, Shaw L, McCants CB, et al. Value of the history and physical in identifying patients at increased risk for coronary artery disease. *Ann Intern Med*. 1993;118(2):81-90.
6. Stein PD, Stein PD, Beemath A, et al. Multidetector computed tomography for the diagnosis of coronary artery disease: a systematic review. *Am J Med*. 2006;119(3):203-216.
7. Smith SC Jr, Allen J, Blair SN, et al. AHA/ACC guidelines for secondary prevention for patients with coronary and other atherosclerotic vascular disease: 2006 update. *Circulation*. 2006;113:2363-2372.
8. Mills EJ, Wu P, Chong G, et al. Efficacy and safety of statin treatment for cardiovascular disease: a network meta-analysis of 170,255 patients from 76 randomized trials. *QJM*. 2011;104(2):109-124.
9. *The Seventh Report of the Joint National Committee on Prevention, Detection, Evaluation and Treatment of High Blood Pressure (JNC 7)*. http://www.nhlbi.nih.gov/guidelines/hypertension/index.htm. Accessed September 3, 2012.
10. Tran H, Anand SS. Oral antiplatelet therapy in cerebrovascular disease, coronary artery disease, and peripheral arterial disease. *JAMA*. 2004;292(15):1867-1874.
11. Ellison KE, Gandhi G. Optimising the use of beta-adrenoceptor antagonists in coronary artery disease. *Drugs*. 2005;65(6):787-797.
12. Gibbons RJ, Abrams J, Chatterjee K, et al. ACC/AHA 2002 guideline update for the management of patients with chronic stable angina: a report of the American College of Cardiology/American Heart Association Task Force on Practice Guidelines (Committee to Update the 1999 Guidelines for the Management of Patients with Chronic Stable Angina). 2002. www.acc.org/clinical/guidelines/stable/stable.pdf. Accessed September 3, 2012.
13. Schofield PM. Indications for percutaneous and surgical revascularisation: How far does the evidence base guide us? *Heart*. 2003;89(5):565-570.
14. Robinson JG, Rahill-Tierney C, Lawler E, Gaziano JM. Benefits associated with achieving optimal risk factor levels for the primary prevention of cardiovascular disease in older men. *J Clin Lipidol*. 2012;6(1):58-65.

47 HYPERTENSION

Heidi Chumley, MD

PATIENT STORY

A 40 year-old man presents after his blood pressure was measured as 180/100 mm Hg at a health screening. He has no complaints. His blood pressure today was 178/98 mm Hg. Based on these two readings, he is diagnosed with stage 2 hypertension. His family history is very positive for essential hypertension. His examination is normal other than an enlarged and laterally displaced point of maximal impulse. His body mass index is normal. The provider sends him for a urinalysis, complete blood count (CBC), fasting lipid profile, and a chemistry panel that includes blood glucose, potassium, serum creatinine, and calcium. An ECG shows left ventricular hypertrophy (**Figure 47-1**). He is counseled regarding lifestyle change, started on 2 medications, and asked to follow-up within a couple of weeks.

INTRODUCTION

Hypertension (HTN) is a major risk factor for both myocardial infarction and stroke. Primary HTN constitutes 90% of HTN cases. Initial

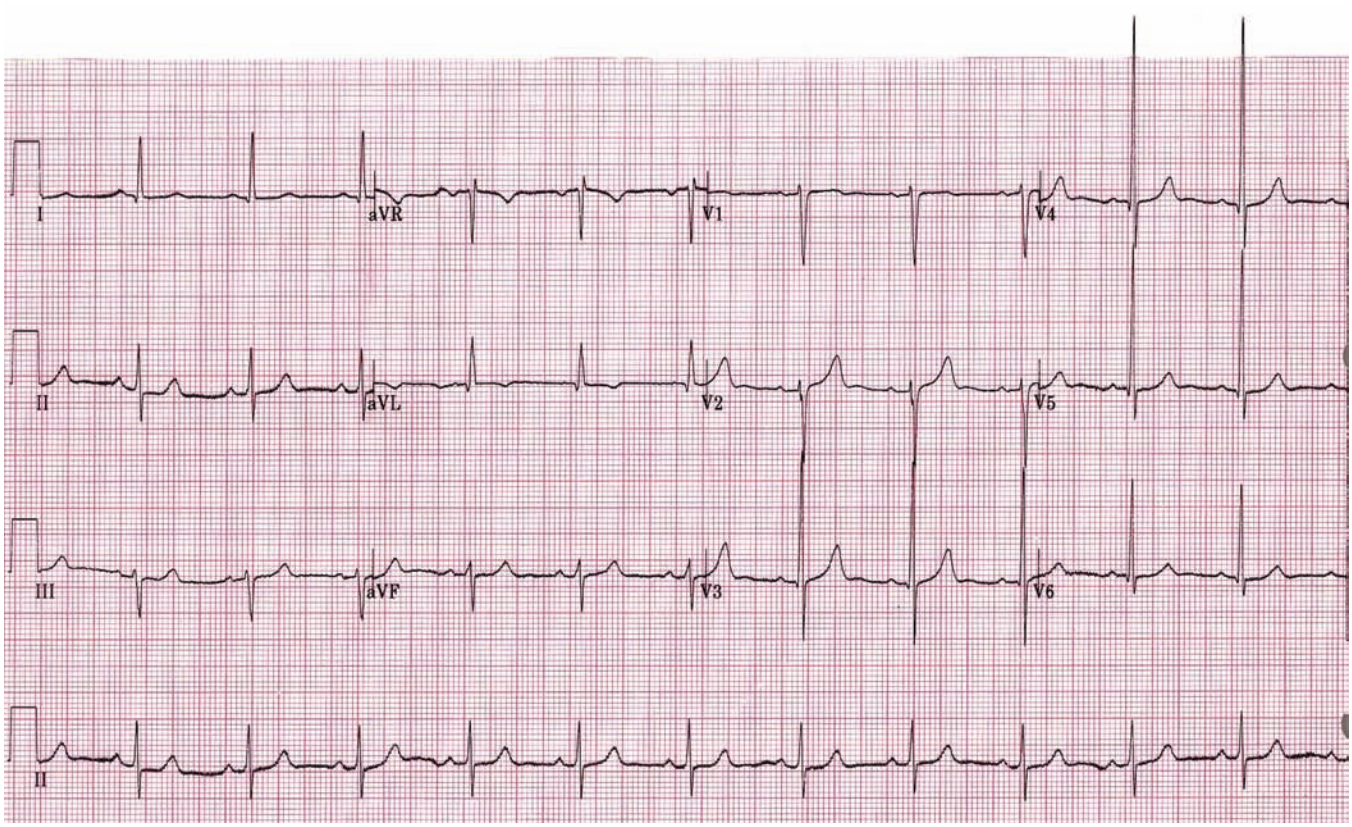

FIGURE 47-1 EKG showing left ventricular hypertrophy in this 58-year-old man with current blood pressure of 178/98. Note how S V_1 + R V_5 > 35 mm. Also his EKG shows left axis deviation and non-specific ST changes in the high lateral leads (I and aVL). (*Courtesy of Gary Ferenchick, MD.*)

treatment includes lifestyle modifications and medications. Most patients require at least 2 medications to achieve control. Patients who are not controlled on 3 medications should undergo a work-up for secondary causes.

EPIDEMIOLOGY

- Of U.S. adults older than age 18 years, 29% have HTN.[1]
- Blood pressure is controlled in approximately 50% of adults with HTN.[1]
- Blood pressure control is lowest among those without health insurance (29%), Mexican Americans (37%), and adults ages 18 to 39 years (31%).[1,2]
- In the United States, HTN contributes to 1 of every 7 deaths and to half of the cardiovascular disease-related deaths.[2]
- Cost of HTN to the U.S. healthcare system is estimated to be $93.5 billion per year.[2]

ETIOLOGY AND PATHOPHYSIOLOGY

- Primary HTN (>90% of patients)—The specific cause is unknown, but environmental factors (i.e., salt intake, excess alcohol intake, obesity) and genetics both play a role.
- Secondary HTN (5% to 10% of patients)—Causes include medications, kidney disease, renal artery stenosis (**Figure 47-2**), thyroid disease, hyperaldosteronism, and sleep apnea. Rare causes include coarctation of the aorta, Cushing syndrome and pheochromocytoma.

RISK FACTORS

- Family history/genetic predisposition.
- Obesity.
- High sodium chloride intake.
- Medications, including oral contraceptives, NSAIDs, decongestants, and some antidepressants.
- Substances, including caffeine, licorice, amphetamines, cocaine, tobacco.

DIAGNOSIS

Average of 2 or more seated blood pressure readings on each of 2 or more office visits, based on systolic (SBP) and diastolic (DBP) blood pressures.

- Prehypertension—SBP 120 to 139 mm Hg or DBP 80 to 89 mm Hg.
- Stage 1 HTN—SBP 140 to 159 mm Hg or DBP 90 to 99 mm Hg.
- Stage 2 HTN—SBP equal to or greater than 160 mm Hg or DBP equal to or greater than 100 mm Hg.

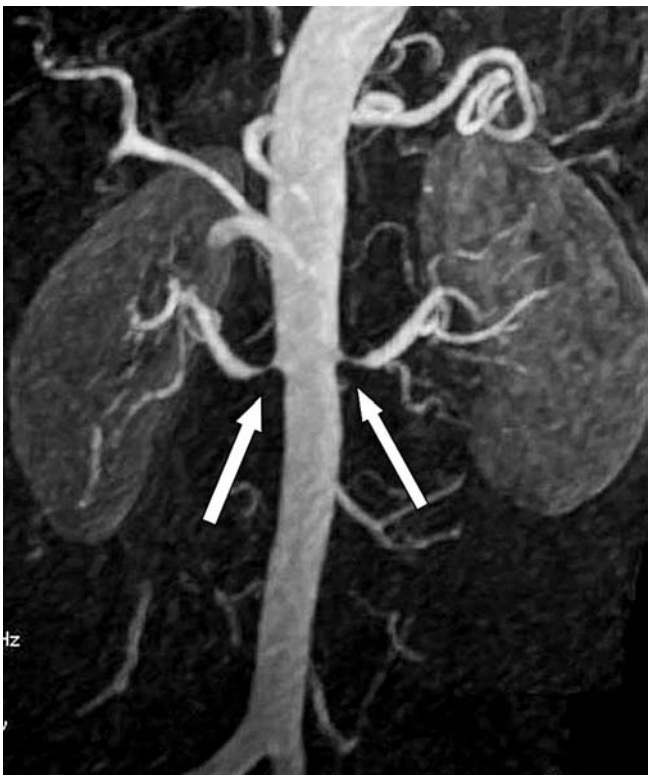

FIGURE 47-2 Angiogram revealing bilateral renal artery stenosis (*arrows*), one of the more common causes of secondary hypertension, most often a result of atherosclerotic disease in older patients. (*From Figure 111-15A in Hurst's the Heart 13th ed.*)

CLINICAL FEATURES

- No symptoms may be present.
- When blood pressure is high, patients may have headaches, vision changes, confusion, chest pain/myocardial infarction, pulmonary edema, stroke or hematuria.
- Hypertensive retinopathy may be present (**Figure 47-3** and Chapter 21, Hypertensive retinopathy).
- An S4 can be an early physical examination finding.
- Left ventricular hypertrophy may be manifest as an enlarged laterally displaced point of maximal impulse, abnormal ECG (**Figure 47-1**), or abnormal chest radiograph.
- Abdominal bruits may be present with renal artery stenosis.

LABORATORY TESTING

- Before initiating therapy for presumed primary HTN perform the following tests: urinalysis, CBC, fasting lipid profile, and chemistry panel, including fasting blood glucose, potassium, creatinine, and calcium.
- Consider testing for thyroid disorders with a thyroid-stimulating hormone (TSH) if other signs or symptoms are present.
- For patients with abnormal screening tests, signs indicating a secondary cause, or inadequate control on 3 medications:
  - Serum aldosterone and plasma renin activity are useful in patients with hypokalemia.
  - 24-hour urine protein and creatinine for suspected renal disease.
  - A 24-hour urine free cortisol or a dexamethasone suppression test for suspected Cushing syndrome.
  - Plasma and urine catecholamines or metanephrines for suspected pheochromocytoma.
  - Parathyroid hormone level for suspected hyperparathyroidism.

IMAGING AND ANCILLARY TESTS

- ECG on all patients with HTN.
- Chest radiograph is usually not ordered for primary HTN; however, if obtained, cardiomegaly may be present. If coarctation of the aorta is expected, rib notching may be present.
- Echocardiogram may also demonstrate left ventricular hypertrophy.
- Renal artery stenosis can be seen on magnetic resonance angiography or by angiography (**Figure 47-2**).
- Renal ultrasound may demonstrate small or absent kidney.

FIGURE 47-3 Hypertensive and diabetic retinopathy with dot-blot hemorrhages, a flame hemorrhage, and hard exudates. The arterioles are attenuated from the hypertension. (*Courtesy of Carrie Cooke.*)

DIFFERENTIAL DIAGNOSIS

- Falsely elevated blood pressure readings can be a result of improper cuff size (too small with a large arm diameter) or method (patient not seated, arm in incorrect position, etc).
- Acute elevations in blood pressure may be caused by substances (e.g., tobacco).
- White coat HTN is defined as blood pressure that is consistently over 140/90 mm Hg in the presence of a healthcare provider with an ambulatory monitoring average of less than 135/85 mm Hg.

MANAGEMENT

NONPHARMACOLOGIC

- Weight reduction if overweight or obese
- DASH (dietary approaches to stop hypertension) diet, rich in fruits and vegetables, aimed at reducing sodium intake and eating a variety of foods rich in nutrients that help lower blood pressure, such as potassium, calcium, and magnesium.
- Low-fat diet.
- Low dietary sodium chloride.
- Regular aerobic exercise.
- Moderate alcohol intake: no more than 2 drinks per day for men and 1 drink per day for women.
- Smoking cessation for cardiovascular risk reduction (see Chapter 236, Tobacco Addiction).

MEDICATIONS

- Start a thiazide-type diuretic in most patients. An angiotensin converting enzyme inhibitor (ACEI) may be the initial choice in white males.
- Consider starting 2 medications when blood pressure is 20/10 mm Hg higher than goal. Goal is 140/90 mm Hg or 130/80 mm Hg in patients with diabetes or chronic kidney disease.
- Add an ACEI, angiotensin receptor blocker (ARB), β-blocker (BB), or calcium channel blocker (CCB) if control is not achieved with initial agent.
- Specific medications have compelling indications in these situations:
  - Heart failure—Diuretic, BB, ACEI, ARB, aldosterone antagonist (AA).
  - Postmyocardial infarction—BB, ACEI, AA.
  - Diabetes—Diuretic, BB, ACEI, ARB, CCB.
  - Chronic kidney disease—ACEI, ARB.
  - Recurrent stroke prevention—Diuretic, ACEI.

REFERRAL OR HOSPITALIZATION

- Refer patients in whom adequate blood pressure control is not obtained.
- Women with HTN who are planning a pregnancy or who become pregnant should be referred to a provider with experience managing chronic HTN in pregnancy.

PREVENTION

Healthy lifestyle for all persons, including weight reduction (if overweight or obese), use of DASH, initiation and maintenance of adequate physical activity, and moderate alcohol intake.

PROGNOSIS

- Risk of cardiovascular disease increases as blood pressure increases.

- Between 115/75 and 185/115 mm Hg, every 20 mm Hg systolic BP or 10 mm Hg diastolic BP doubles the risk of cardiovascular disease for adults ages 40 to 70 years.[3]

FOLLOW-UP

- Schedule visits monthly until blood pressure goal is obtained.
- Consider more frequent visits for patients with stage 2 HTN or significant comorbid conditions.
- See patients with controlled HTN every 3 to 6 months.

PATIENT EDUCATION

- HTN is a chronic disease requiring lifelong lifestyle modifications and 1 or more daily medications for most patients.
- Adequate control of HTN reduces the risk for heart attack and stroke.

PATIENT RESOURCE

- The National Heart Lung and Blood Institute. *What Is High Blood Pressure?*—**http://www.nhlbi.nih.gov/health/health-topics/topics/hbp/.**

PROVIDER RESOURCES

- The Seventh Report of the Joint National Committee on Prevention, Detection, Evaluation, and Treatment of High Blood Pressure (JNC 7)—**http://www.nhlbi.nih.gov/guidelines/hypertension/express.pdf.**
- The Eighth Report of the Joint National Committee on Prevention, Detection, Evaluation, and Treatment of High Blood Pressure (JNC 8)—**http://www.nhlbi.nih.gov/guidelines/hypertension/jnc8/index.htm.**

REFERENCES

1. Egan BM, Zhao Y, Axon RN. US trends in prevalence, awareness, treatment and control of hypertension, 1988-2008. *JAMA*. 2010; 303(2):2043-2050.
2. Centers for Disease Control and Prevention. Vital Signs: Prevalence, Treatment, and Control of Hypertension—United States, 1999-2002 and 2005-2008. *MMWR Morb MortalWkly Rep.* 2011;60:103-108.
3. Lewington S, Clarke R, Qizilbash N, et al. Age-specific relevance of usual blood pressure to vascular mortality: a metaanalysis of individual data for one million adults in 61 prospective studies. *Lancet*. 2002;360:1903-1913.

48 HEART FAILURE

Heidi Chumley, MD

PATIENT STORY

A 60-year-old man presents to the emergency department with shortness of breath increasing in severity over the past several days, along with paroxysmal nocturnal dyspnea and orthopnea. He does not have a history of heart failure or previous myocardial infarction. On examination it was found that he had a third heart sound and an elevated jugular venous pressure. His chest radiograph showed cardiomegaly (**Figure 48-1**) and his B-type natriuretic peptide (BNP) was elevated at 600 pg/mL. He was diagnosed with heart failure, evaluated for underlying causes including coronary artery disease, and treated initially with an angiotensin-converting enzyme inhibitor (ACEI) and a diuretic. Later, he will be started on a β-blocker and an aldosterone inhibitor.

FIGURE 48-1 Cardiomegaly demonstrated in a posteroanterior (PA) view. The widest part of the heart is greater than 50% of the diameter of the chest. (*Courtesy of Heidi Chumley, MD.*)

INTRODUCTION

Heart failure (HF) is common and increases with age. Multiple etiologies can cause the decrease in heart pumping capacity that leads to HF. ACEIs and β-blockers with or without aldosterone agonists and angiotensin II blockers are the main pharmacologic therapies.

SYNONYMS

Congestive heart failure (CHF).

EPIDEMIOLOGY

- The prevalence of HF in the community increases with age: 0.7% (45 to 54 years); 1.3% (55 to 64 years); 1.5% (65 to 74 years); and 8.4% (75 years or older).[1]
- More than 40% of patients in the community with HF have an ejection fraction greater than 50%.[1]
- At age 40 years, the lifetime risk for HF is 21.0% (95% confidence interval [CI] 18.7% to 23.2%) for men and 20.3% (95% CI 18.2% to 22.5%) for women.[2]

ETIOLOGY AND PATHOPHYSIOLOGY

- Heart pumping capacity declines from any cause (i.e., myocardial infarction or ischemia, hypertension, valvular dysfunction, cardiomyopathy, or infections such as endocarditis or myocarditis).
- Cardiac dysfunction activates the adrenergic and renin-angiotensin-aldosterone systems.
- These systems provide short-term compensation, but chronic activation leads to myocardial remodeling and eventually worsening cardiac function.

- Norepinephrine, angiotensin II, aldosterone, and tissue necrosis factor each contribute to disease progression.
- Angiotensin II directly causes cell death through necrosis and apoptosis, as well as cardiac hypertrophy.

DIAGNOSIS

Many history, examination, radiographic, ECG, and laboratory features are helpful in making the diagnosis of HF for patients presenting with dyspnea in the emergency department:[3]

CLINICAL FEATURES

- History and physical
  - History of HF (LR + [likelihood ratio] = 5.8), myocardial infarction (LR+ = 3.1).[3]
  - Symptoms of paroxysmal nocturnal dyspnea (LR+ = 2.6), orthopnea (LR+ = 2.2), edema (LR+ = 2.1).[3]
  - Examination finding of third heart sound (LR+ = 11), hepatojugular reflex (LR+ = 6.4), jugular venous distention (LR+ = 5.1).[3]

LABORATORY AND ANCILLARY TESTING

- Laboratory value of BNP ≥250 (LR+ = 4.6); BNP <100 decreases likelihood of HF.[3]
- ECG finding of atrial fibrillation (LR+ = 3.8), T-wave changes (LR+ = 3.0), any abnormality (LR+ = 2.2). A normal ECG lowers likelihood (LR− = 0.640).[3]

IMAGING

- Radiographic finding of pulmonary venous congestion (**Figure 48-2**) (LR+ = 12.0), interstitial edema (LR+ = 12.0), alveolar edema (LR+ = 6.0), cardiomegaly (**Figures 48-1** to **48-3**) (LR+ = 3.3).[3]

DIFFERENTIAL DIAGNOSIS

Gradually increasing shortness of breath can also be caused by:

- Chronic obstructive pulmonary disease may have dyspnea with exertion but does not have orthopnea; chest radiograph shows a normal size heart, hyperinflated lungs, and flattened diaphragm; pulmonary function tests may be abnormal.
- Deconditioning has a normal chest radiograph.
- Metabolic acidosis from any cause can be differentiated with an arterial blood gas.
- Anxiety has episodic shortness of breath, not associated with exertion and a normal chest radiograph.
- Neuromuscular weakness may have abnormal pulmonary function tests and a normal chest radiograph.
- Pneumonia may have fever and an infiltrate on chest radiograph.

MANAGEMENT

NONPHARMACOLOGIC

- Telemonitoring of patients with known HF reduced all-cause mortality (relative risk [RR] 0.66). Telemonitoring and structure

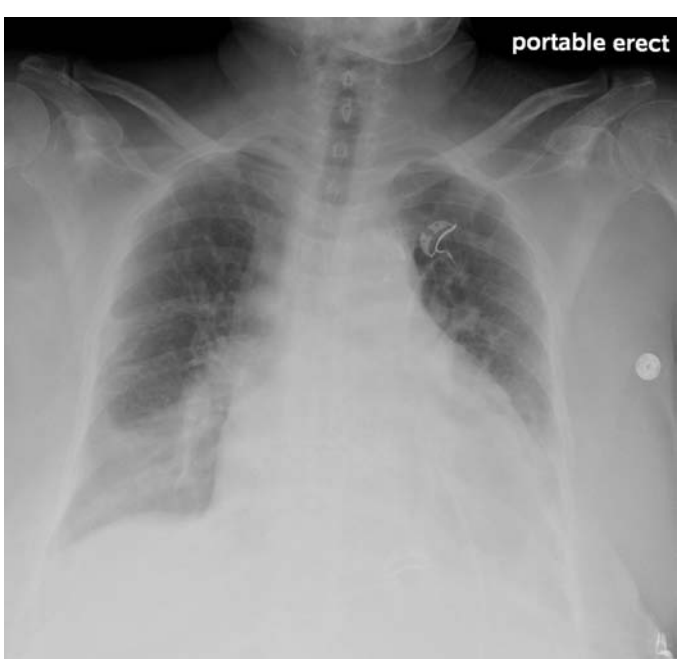

FIGURE 48-2 Cardiomegaly with pulmonary venous congestion and bilateral pleural effusions. (*Courtesy of Heidi Chumley, MD.*)

telephone support reduced HF related hospitalization (RR 0.79 and 0.77, respectively).[4]

- Exercise rehabilitation increases quality of life and decreases hospital admissions in patients with left ventricular systolic dysfunction.[5]
- Salt restriction *increased* all-cause mortality in patients with HF (RR 0.84).[6]

MEDICATIONS

Individually, ACEIs, β-blockers, and aldosterone antagonists (AAs) lower mortality and should be considered for all patients without contraindications.

- Prescribe an ACEI. SOR A ACEIs lower mortality rates by 23% overall. Use in patients with asymptomatic left ventricular dysfunction and all other stages of HF.[7]
- Prescribe a β-blocker. SOR A β-Blockers reduce mortality by 32%.[8] Begin at a small dose and double the dose every 2 to 4 weeks until the target dose is reached or the patient cannot tolerate the increased dose. One study demonstrating a decrease in mortality had a large percentage of patients in the control and intervention groups already on an ACEI, indicating that the two together may decrease mortality more than an ACEI alone.[7] SOR B
- Prescribe an AA when the creatinine is less than 2.0; monitor renal function and potassium.[7] SOR A AAs lowered mortality in patients already on ACEI.[8] SOR B
- Consider an angiotensin II receptor blocker (ARB) for patients who cannot tolerate an ACEI.[4] Patients with moderate, severe, or advanced HF may benefit from an ACEI plus an ARB or AA SOR B, but the safety of all three is unknown.[7]
- After a myocardial infarction, an ARB has shown equivalent reductions in mortality to an ACEI, but the combination does not improve outcomes.

Nonpotassium sparing diuretics, calcium channel blockers, and digoxin may improve symptoms but do not lower mortality.

- Nonpotassium sparing diuretics (e.g., furosemide) have been associated with worse outcomes, including higher mortality when used alone. Use for volume overload with ACEI, β-blocker, AA ± ARB as above.[8]
- Calcium channel blockers (verapamil and nifedipine) are avoided in systolic HF. Calcium channel blockers improve symptoms in diastolic HF, but do not lower mortality.[9] SOR A
- Digoxin reduces hospitalizations and improves clinical symptoms, but does not lower mortality.[8] Consider adding digoxin when patients have symptoms despite adequate therapy with ACEI, β-blockers, AA ± ARB.

REFERRAL OR HOSPITALIZE

- Refer for evaluation for cardiac resynchronization therapy in patients with left ventricular ejection fraction (LVEF) less than 35% and QRS greater than 150 milliseconds.[5] A recent metaanalysis demonstrated that cardiac resynchronization therapy decreased all-cause mortality and hospitalizations for HF in patients with

FIGURE 48-3 Cardiomegaly with increased pulmonary vasculature and Kerley B lines (2- to 3-cm horizontal lines in the lower lung fields). (*Courtesy of Heidi Chumley, MD.*)

New York Heart Association (NYHA) class II. Number needed to treat (NNT) = 12 to prevent 1 hospitalization.[10]

- Refer for evaluation for implantable cardiac defibrillator (ICD) placement in patients with NYHA class II-IV and LVEF less than 35%. SOR C ICDs have been shown to reduce mortality up to 30% and may offer greater risk reduction than antiarrhythmic medical therapy for some patients.[11]

PROGNOSIS

Absolute mortality is high in patients with HF.

- Patients with preserved ejection fraction (>50%) have a mortality rate of 121 per 1000 patient years.[12]
- Patients with reduced ejection fraction (<40%) have a mortality rate of 141 per 1000 patient years.[12]

FOLLOW-UP

Close follow-up in many forms, including telemedicine and structured telephone visits, can reduce hospitalizations and mortality.[4]

PATIENT EDUCATION

Fluid and sodium restriction are often advised, but a recent Cochrane review demonstrated an increased mortality with sodium restriction.

PATIENT RESOURCES

- **http://www.ncbi.nlm.nih.gov/pubmedhealth/PMH0001211/.**
- The National Heart, Lung, and Blood Institute has patient information on HF at **http://www.nhlbi.nih.gov/health/health-topics/topics/hf/.**

PROVIDER RESOURCES

- The 2010 Heart Failure Society of America Comprehensive Heart Failure Practice Guideline—**http://www.heartfailureguideline.org/.**
- Management of Chronic Heart Failure. A National Clinical Guideline (Scottish)—**http://www.ngc.gov/content.aspx?id=10587.**

REFERENCES

1. Redfield MM, Jacobsen SJ, Burnett JC Jr, et al. Burden of systolic and diastolic ventricular dysfunction in the community: appreciating the scope of the heart failure epidemic [see comment]. *JAMA.* 2003;289(2):194-202.
2. Lloyd-Jones DM, Larson MG, Leip EP, et al. Lifetime risk for developing congestive heart failure: The Framingham Heart Study [see comment]. *Circulation.* 2002;106(24):3068-3072.
3. Wang CS, FitzGerald JM, Schulzer M, et al. Does this dyspneic patient in the emergency department have congestive heart failure [review]? *JAMA.* 2005;294(15):1944-1956.
4. Inglis SC, Clark RA, McAlister FA, et al. Which components of heart failure programmes are effective? A systematic review and meta-analysis of the outcomes of structured telephone support or telemonitoring as the primary component of chronic heart failure management in 8323 patients: Abridged Cochrane Review. *Eur J Heart Fail.* 2011;139(9):1028-1040.
5. Mant J, Al-Mohammad A, Swain S, Laramée P; Guideline Development Group. Management of chronic heart failure in adults: synopsis of the national institute for health and clinical excellence guideline. *Ann Intern Med.* 2011;155(4):252-259.
6. Taylor RS, Ashton KE, Moxham T, et al. Reduced dietary salt for the prevention of cardiovascular disease. *Cochrane Database Syst Rev.* 2011;(7):CD009217.
7. Mielniczuk L, Stevenson LW. Angiotensin-converting enzyme inhibitors and angiotensin II type I receptor blockers in the management of congestive heart failure patients: what have we learned from recent clinical trials [review]? *Curr Opin Cardiol.* 2005;20(4):250-255.
8. Yan AT, Yan RT, Liu PP. Narrative review: pharmacotherapy for chronic heart failure: Evidence from recent clinical trials [review]. *Ann Intern Med.* 2005;142(2):132-145. [Summary for patients in *Ann Intern Med.* 2005;142(2):I53.]
9. Haney S, Sur D, Xu Z. Diastolic heart failure: a review and primary care perspective [review]. *J Am Board Fam Pract.* 2005;18(3):189-198.
10. Adabag S, Roukoz H, Anand IS, Moss AJ. Cardiac resynchronization therapy in patients with minimal heart failure a systematic review and meta-analysis. *J Am Coll Cardiol.* 2011;58(9):935-941.
11. Kadish A, Mehra M. Heart failure devices: Implantable cardioverter-defibrillators and biventricular pacing therapy [review]. *Circulation.* 2005;111(24):3327-3335.
12. Meta-analysis Global Group in Chronic Heart Failure. The survival of patients with heart failure with preserved or reduced left ventricular ejection fraction: an individual patient data meta-analysis. *Eur Heart J.* 2011; Aug 6 [epub ahead of print].

49 PERICARDIAL EFFUSION

Heidi Chumley, MD

PATIENT STORY

A 30-year-old woman presented to her family physician with increasing shortness of breath over the past 2 weeks. Prior to this, she had a flu-like illness and felt like she never recovered. She denied chest pain and edema, did not take any medications, and had not had any recent trauma or surgery. She had a normal examination. Her chest radiograph showed a classic globular heart as demonstrated in **Figure 49-1**. She had nonspecific ST changes on her ECG. An echocardiogram confirmed pericardial effusion (**Figure 49-2**). The underlying etiology was not elucidated and she recovered spontaneously over the next several months.

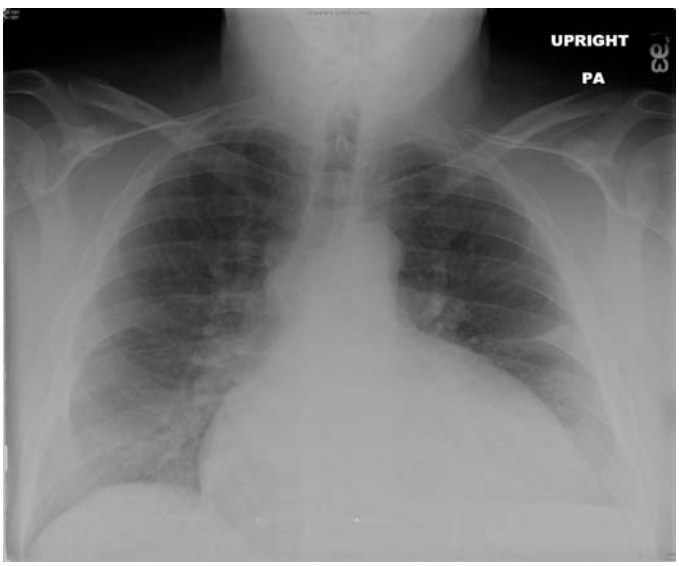

FIGURE 49-1 Globular cardiac silhouette or classic "water-bottle heart" seen with a pericardial effusion can be difficult to distinguish from cardiomegaly on plain radiographs. (*Courtesy of Heidi Chumley, MD.*)

INTRODUCTION

Pericardial effusions are commonly found in the general population and the incidence increases with age. They can be caused by cardiac disease or surgery, connective tissue disorders, neoplasms, infections, renal disease, hypothyroidism, or medications; however, a cause is identified only 50% of the time. The definitive diagnosis is made by echocardiography.

EPIDEMIOLOGY

- Six-and-a-half percent of adults (<1% ages 20 to 30 years; 15% older than 80 years of age) had echocardiogram findings consistent with pericardial effusion in a population-based study of 5652 adults and adult family members of participants in the Framingham Heart Study.[1]
- Seventy-seven percent of patients after cardiac surgery for valves or bypass have pericardial effusions, which rarely (<1%) require therapy.[2]
- Forty percent of healthy pregnant women have small, asymptomatic pericardial effusions in the third trimester.[3]

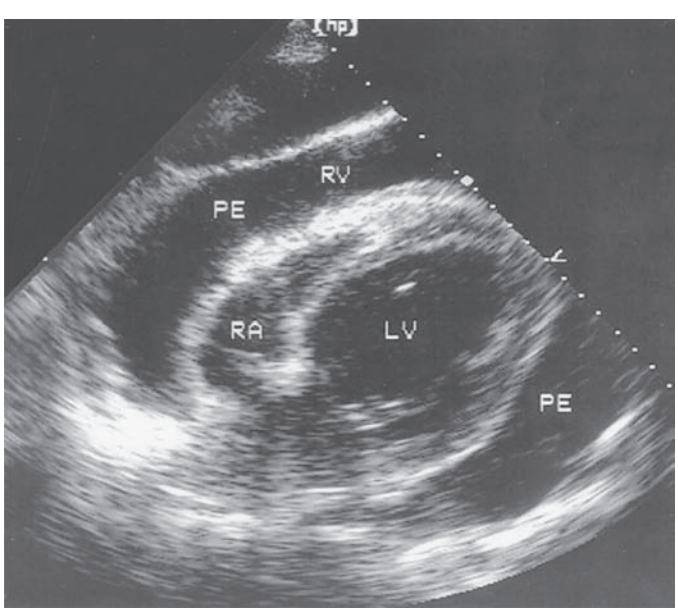

FIGURE 49-2 Echocardiogram showing right ventricular (*RV*) compression from a pericardial effusion (*PE*). *LV*, Left ventricle; *RA*, right atrium. (*Courtesy of Heidi Chumley, MD.*)

ETIOLOGY AND PATHOPHYSIOLOGY

Pericardial effusion, acute or chronic, occurs when there is increased production or decreased drainage of pericardial fluid allowing accumulation in the pericardial space.

The underlying etiology is apparent clinically approximately 25% of the time and can be determined with testing in another 25% of cases, leaving 50% of cases idiopathic.[4] Most idiopathic cases have small effusions. Moderate to large pericardial effusions have an identifiable cause in 90%.[5]

RISK FACTORS

Underlying causes include:

- Congestive heart failure from other cardiac diseases, such as rheumatic heart disease, cor pulmonale, or cardiomyopathy.[6]
- After cardiac surgery or after a myocardial infarction.[2]
- Connective tissue disorders (scleroderma, lupus erythematosus, rheumatoid arthritis).[6]
- Neoplasms: benign (atrial myxoma); primary malignant (mesothelioma); secondary malignant (i.e., lung or breast cancer).[6]
- Chronic renal disease (uremia or hemodialysis) or other causes of hypoalbuminemia.
- Infections: acute (enterovirus, adenovirus, influenza virus, *Streptococcus* pneumonia, *Coxiella burnetii*—responsible for Q fever) or chronic (tuberculosis, fungus, parasites).[4]
- Medications (procainamide, hydralazine) or after radiation.[6]
- Severe hypothyroidism with myxedema.[6]

DIAGNOSIS

Clinical features, chest radiograph, and electrocardiogram suggest pericardial effusion, which is confirmed by echocardiogram. The underlying etiology is identifiable in approximately 50% of cases.

CLINICAL FEATURES

Signs and symptoms occur when the volume of fluid is large enough to affect hemodynamics. This occurs at 150 to 200 mL in acute pericardial effusion. Chronic pericardial effusion allows stretching overtime and may require up to 2 L to cause significant symptoms:[6]

- Hypotension, increased jugular venous pressure, and soft heart sounds form the classic triad of acute cardiac tamponade, but all three are present only in approximately 30% of cases.[6]
- Common symptoms include anorexia (90%), dyspnea (78%), cough (47%), and chest pain (27%).[6]
- Common physical examination findings include pulsus paradoxus (77% with acute tamponade, 30% with chronic effusions), sinus tachycardia (50%), jugular venous distention (45%), hepatomegaly and peripheral edema (35%).[6]

LABORATORY AND ANCILLARY TESTING

- Electrocardiogram is abnormal in 90%. Findings include low QRS voltage and nonspecific ST-T changes (59% to 63%) and electrical alternans (0% to 10%).[6]

When the diagnosis remains unclear, pericardial fluid can be sent for cell count and differential, protein, lactate dehydrogenase, glucose, Gram stain, bacterial cultures, fungal cultures, mycobacterial acid-fast stain and culture, and tumor cytology. Measure rheumatoid factor, antinuclear antibody, and complement levels when collagen vascular disease is suspected.[6] Check HIV status in at-risk patients.

When there is no obvious cause, ordering this set of specific tests determined the underlying etiology more often than seen in historic controls (27.3% vs. 3.9%; $p < 0.001$).[7]

- Aerobic and anaerobic blood cultures.
- Throat swab cultures for influenza, adenovirus, and enterovirus.
- Serologic tests for *Cytomegalovirus*, influenza, *C. burnetii*, *Mycoplasma* pneumonia, and *Toxoplasma*.
- Blood tests for antinuclear antibody (ANA) and thyroid-stimulating hormone (TSH).

IMAGING

- Chest radiograph shows a globular enlarged cardiac silhouette (**Figure 49-1**) (sensitivity 78%, specificity 34% with moderate or severe effusions) and pericardial fat stripe (**Figure 49-3**) (sensitivity 22%, specificity 92%).[6]
- Echocardiography is the preferred imaging test. Echo can be used to quantify volume of pericardial effusion (correlation to amount of fluid withdrawn 0.7).[8] Echo-free, as opposed to echogenic fluid, is associated with a lower risk of constrictive pericarditis or recurrent pleural effusion.[9]
- CT scanning, typically done for another purpose, can demonstrate the presence of a pericardial effusion, but does not qualify volume as well as echocardiography (correlation to amount of fluid withdrawn 0.4).[8]

DIFFERENTIAL DIAGNOSIS

- Congestive heart failure has many similar signs and symptoms (dyspnea, jugular venous distention, hepatomegaly, and edema) but may have pulmonary rales, which are unusual in pericardial

FIGURE 49-3 Moderate pericardial effusion is seen as a wide pericardium (*arrow*). (*Courtesy of Heidi Chumley, MD.*)

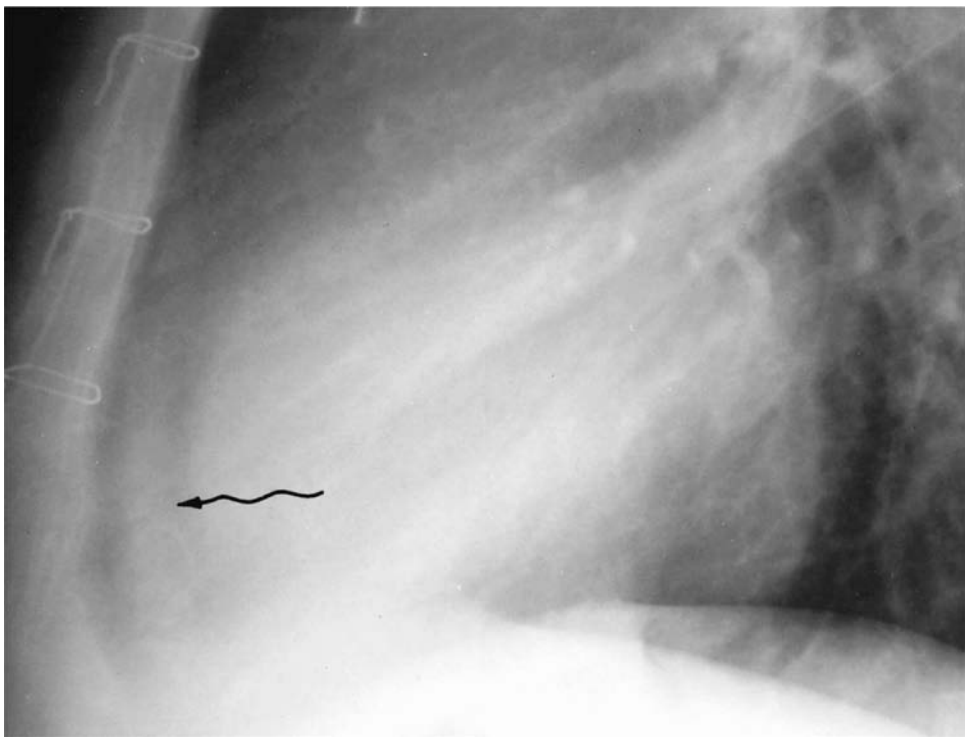

FIGURE 49-4 The lateral view demonstrates the normal thin pericardium (*arrow*), which should be less than 2 mm. (*Courtesy of Heidi Chumley, MD.*)

effusions. A lateral radiograph in a patient with congestive heart failure (without pleural effusion) should have a normal thin pericardium (**Figure 49-4**).

- Pleural effusions may also present with dyspnea, but have different physical examination and radiographic findings.
- Acute pericarditis (without pericardial effusion) can present with chest pain and nonspecific ECG changes also seen with pericardial effusion. In contrast, acute pericarditis often has elevated inflammatory markers and a normal chest radiograph.

MANAGEMENT

- Treat any identified underlying cause.
- When the diagnosis is unclear and the patient is hemodynamically stable, NSAIDs may be beneficial, especially if inflammatory markers are elevated.
- Pericardiocentesis is required when there is hemodynamic compromise. A pericardiocentesis is also useful when the pericardial effusion is large or suspected to be secondary to a bacterial infection or neoplastic process.
- Pericardiocentesis is performed by a specialist under local anesthesia as follows: Elevate the patient to a 45-degree angle. Insert a needle in the angle between the left costal arch and the xiphoid process, directed 15-degrees posterior, and angled toward the head or either shoulder. Complications are reduced when this procedure is guided by echocardiography. Fluid often reaccumulates. An

indwelling catheter can be placed for up to 72 hours without increasing the risk of infection, until a more permanent procedure can be performed to decrease the likelihood of reaccumulation.

- Sclerosing therapy reduces the recurrence of symptoms from reaccumulation or the need for a repeat procedure for 30 days in more than 70% of patients. A caustic substance such as bleomycin or tetracycline is instilled into the pericardial space and held there for up to 4 hours.
- Other options to reduce recurrence include balloon pericardiotomy performed in a cardiac catheterization laboratory, radiation therapy, and surgery (i.e., pericardial window).

PROGNOSIS

Prognosis depends on the underlying cause.

In a study of older adults undergoing echocardiography for reasons other than a pericardial effusion, patients with an incidental small pericardial effusion had a higher 1-year mortality (26%) than did patients without an effusion (11%).[10]

FOLLOW-UP

Follow-up is based on the underlying cause. Pericardial effusions often disappear when the underlying illness resolves, and reappear when the underlying illness does not resolve (metastatic cancer).

PATIENT EDUCATION

- The underlying cause of a pericardial effusion is identified only 50% of the time; however, specific tests should be done to find treatable causes.
- In patients without an obvious underlying illness, infections (like the flu, Q fever, or tuberculosis) and cancer are the two most commonly identified causes of pericardial effusions.

PATIENT RESOURCES

- Mayo Clinic—**http://www.mayoclinic.com/health/pericardial-effusion/DS01124.**

PROVIDER RESOURCES

- **http://emedicine.medscape.com/article/157325.**

REFERENCES

1. Savage DD, Garrison RJ, Brand F, et al. Prevalence and correlates of posterior extra echocardiographic spaces in a free-living population based sample (the Framingham study). *Am J Cardiol.* 1983; 51(7):1207-1212.
2. Ikaheimo MJ, Huikuri HV, Airaksinen KE, et al. Pericardial effusion after cardiac surgery: Incidence, relation to the type of surgery,

antithrombotic therapy, and early coronary bypass graft patency. *Am Heart J.* 1988;116(1 Pt 1):97-102.

3. Ristic AD, Seferovic PM, Ljubic A, et al. Pericardial disease in pregnancy. *Herz.* 2003;28(3):209-215.
4. Levy PY, Corey R, Berger P, et al. Etiologic diagnosis of 204 pericardial effusions. *Medicine (Baltimore).* 2003;82(6):385-391.
5. Imazio M, Spodick DH, Brucato A, et al. Controversial issues in the management of pericardial diseases. *Circulation.* 2010;121(7): 916-928.
6. Karam N, Patel P, deFilippi C. Diagnosis and management of chronic pericardial effusions. *Am J Med Sci.* 2002;322(2):79-87.
7. Levy PY, Moatti JP, Gauduchon V, et al. Comparison of intuitive versus systematic strategies for aetiological diagnosis of pericardial effusion. *Scand J Infect Dis.* 2005;37(3):216-220.
8. Liebowitz D, Perlman G, Planer D, et al. Quantification of pericardial effusions by echocardiography and computed tomography. *Am J Cardiol.* 2011;107(2):331-335.
9. Kim SH, Song JM, Jung IH, et al. Initial echocardiographic characteristics of pericardial effusion determine the pericardial complications. *Int J Cardiol.* 2009;136(2):151-155.
10. Mitiku TY, Heidenreich PA. A small pericardial effusion is a marker of increased mortality. *Am Heart J.* 2011; 161(1):152-157.

50 BACTERIAL ENDOCARDITIS

Heidi Chumley, MD

PATIENT STORY

A 25-year-old man presented to the office because he had been feeling tired and feverish for several weeks. He admitted to injecting heroin regularly in the last 2 months. On examination, he was febrile and had a heart murmur of which he was previously unaware. His fingernails showed splinter hemorrhages (**Figure 50-1**). His funduscopic examination revealed Roth spots (**Figures 50-2** and **50-3**). An echocardiogram demonstrated vegetation on the tricuspid valve. He was hospitalized and treated empirically for bacterial endocarditis. After his blood cultures returned *Staphylococcus aureus*, his regimen was adjusted based on sensitivities and continued for 6 weeks.

FIGURE 50-1 Splinter hemorrhages appearing as red linear streaks under the nail plate and within the nail bed. Although endocarditis can cause this, splinter hemorrhages are more commonly seen in psoriasis and trauma. (*Courtesy of Richard P. Usatine, MD.*)

INTRODUCTION

Bacterial endocarditis is a serious infection seen most commonly in patients with prosthetic valves; injection drug users; patients with HIV, especially those who use intravenous (IV) drugs; and patients who are immunosuppressed. Diagnosis is made based on Duke Criteria. Treatment is IV antibiotics. Mortality, despite treatment, is 26% to 37%.

EPIDEMIOLOGY

- 5.0 to 7.9 cases per 100,000 patient-years.[1]
  - Historically more common in men; however, the incidence in women is increasing. Men and women 8.6 to 12.7 and 1.4 to 6.7 cases per 100,000 person-years, respectively.[1]
  - Average age has increased from 46.5 years (1980-1984) to 70 years (2001-2006).[1]
  - Incidence in IV drug users is 3 per 1000 person-years or 1% to 5% per year.[2]
  - Incidence in HIV-positive IV drug users is 13.8 per 1000 person-years.[2]
- Seen in immunosuppressed patients with central venous catheters or hemodialysis patients.
  - Fifty percent healthcare-associated, 43% community-acquired, and 7.5% nosocomial.[1]
  - Mortality ranges from 16% to 37%.[3]
- Prosthetic valve endocarditis makes up 10% to 15% of endocarditis cases.[4]
  - Incidence of 0.1% to 2.3% person-year.[4]
  - Can occur early (2 months after surgery) or late.

FIGURE 50-2 Roth spots that are retinal hemorrhages with white centers seen in bacterial endocarditis. These can also be seen in leukemia and diabetes. (*Courtesy of Paul D. Comeau.*)

ETIOLOGY AND PATHOPHYSIOLOGY

- Endothelium is injured by mechanical or inflammatory processes.
- Microbes adhere to compromised endothelium during transient bacteremia.

- Common organisms include *S. aureus* (IV drug users, nosocomial infections, prosthetic valve patients), *Streptococcus bovis* (elderly patients), enterococci (nosocomial infections), and *Staphylococcus epidermis* (early infection in prosthetic valve patients).
- Blood contacts subendothelial factors, which promotes coagulation.
- Pathogens bind and activate monocyte, cytokine, and tissue factor production, enlarging the vegetations on the heart valves.
- The vegetations enlarge and damage the heart valves (**Figure 50-4**). This process can lead to death if not treated adequately in time.
- Septic emboli can occur, most commonly in the brain, spleen, or kidney.[4]

RISK FACTORS

- Prosthetic valve.
- Injection drug use.
- HIV infection.
- Immunodeficiency.

DIAGNOSIS

- Duke criteria use a combination of history, physical examination, laboratory, and echocardiogram findings, and have a sensitivity of approximately 80% across several studies.[5]
- Diagnosis is considered definite when patients have two major, one major and three minor, or five minor criteria.[5]
- Diagnosis is considered possible with one major and one minor or three minor criteria.[5]
- Major criteria include:[5]
  - Two separate blood cultures positive with:
    - *Streptococcus viridans*, *S. bovis*, *Haemophilus, Actinobacillus, Cardiobacterium, Eikenella, Kingella.*
    - Community-acquired *S. aureus* or *Enterococcus* without a primary focus.
    - Microorganisms consistent with prior positive blood cultures in infective endocarditis.
  - Endocardial involvement as evidenced by:
    - Echocardiogram evidence of vegetation, abscess, or new partial dehiscence of a prosthetic valve.
    - New valvular regurgitation.
  - Minor criteria include:[5]
    - Predisposition (e.g., heart condition such as a congenital or acquired valvular defect, injection drug use, prior history of endocarditis).
    - Temperature >38°C (100.4°F).
    - Clinical signs: arterial emboli, septic pulmonary infarcts, mycotic aneurysms, intracranial hemorrhages, Janeway lesions (**Figures 50-5** and **50-6**).
    - Glomerulonephritis, Osler nodes, Roth spots, or positive rheumatoid factor (**Figures 50-2**, **50-3**, and **50-6**).
    - Positive blood culture not meeting major criteria.
    - Echocardiographic findings consistent with infective endocarditis that do not meet major criteria.

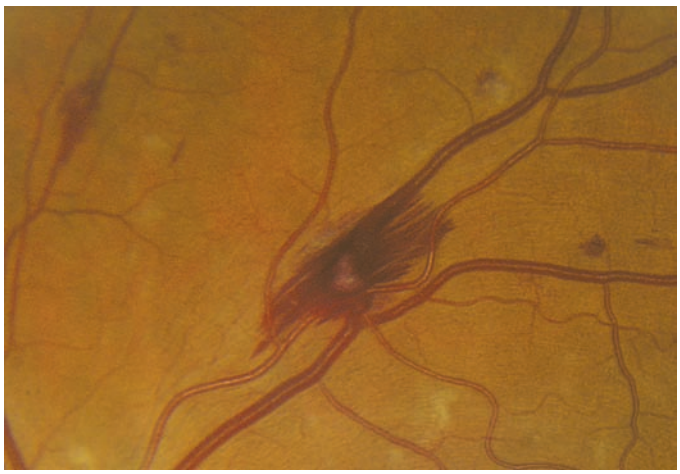

FIGURE 50-3 Close-up of a Roth spot, which is actually a cotton-wool spot surrounded by hemorrhage. The cotton-wool comes from ischemic bursting of axons and the hemorrhage comes from ischemic bursting of an arteriole. (*Courtesy of Paul D. Comeau.*)

FIGURE 50-4 Pathology specimen of a patient who died of bacterial endocarditis. Bacterial growth can be seen on the three cusps of this heart valve. (*Courtesy of Larry Fowler, MD.*)

CLINICAL FEATURES

- Fever—Seen in 85% to 99% of patients, typically low-grade, approximately 39°C (102.2°F).
- New or changing heart murmur—Seen in 20% to 80% of patients.
- Septic emboli—Seen in up to 60%, largely dependent on the size (>10 mm) and mobility of the vegetation.
- Intracranial hemorrhages—Seen in 30% to 40% of patients, bleeding from septic emboli or cerebral mycotic aneurysms.
- Mycotic aneurysms—Aneurysms resulting from infectious process in the arterial wall, most commonly in the thoracic aorta, also found in the cerebral arteries.
- Janeway lesions—Very rare, flat, painless, red to bluish-red spots on the palms and soles (**Figures 50-5** and **50-6**).
- Splinter hemorrhages—Red, linear streaks in the nail beds of the fingers or toes (**Figure 50-1**).
- Glomerulonephritis—Immune mediated that can result in hematuria and renal insufficiency, occurs in approximately 15% of patients with endocarditis.
- Osler nodes—Tender, subcutaneous nodules in the pulp of the digits (**Figure 50-6**).
- Roth spots—Retinal hemorrhages from microemboli, seen in approximately 5% of endocarditis (**Figures 50-2** and **50-3**).
- Positive rheumatoid factor—Seen in up to 50% of patients.

TYPICAL DISTRIBUTION

- Native endocarditis: Mitral valve (prior rheumatic fever or mitral valve prolapse), followed by aortic (prior rheumatic fever, calcific aortic stenosis of bicuspid valve).
- Prosthetic valve endocarditis: Site of any prosthetic valve.
- In IV drug users: Tricuspid valve, followed by aortic.

LABORATORY AND ANCILLARY TESTING

In addition to blood cultures, consider a complete blood count for anemia and leukocytosis, erythrocyte sedimentation rate (ESR) (elevated in approximately 90%), and urinalysis for proteinuria or microscopic hematuria (seen in approximately 50%).

- Positive blood culture—First two sets of cultures are positive in 90%.[4]

IMAGING

- Abnormal echocardiogram in 85%.[5]
- If transthoracic echocardiogram is normal and endocarditis is still suspected, order a transesophageal echo.[6] SOR A

DIFFERENTIAL DIAGNOSIS

Fever without a clear cause may be seen with:

- Connective tissue disorders—Typically with other signs depending on the disorder, negative blood cultures, normal echocardiogram.
- Fever of unknown origin—Negative blood cultures or positive cultures with atypical organisms, normal echocardiogram in noncardiac causes.

FIGURE 50-5 Janeway lesions on the palm of a woman hospitalized with acute bacterial endocarditis. These were not painful. (*Courtesy of David A. Kasper DO, MBA.*)

FIGURE 50-6 Osler node causing pain within pulp of the big toe in the same woman hospitalized with acute bacterial endocarditis. (Osler nodes are painful—remember "O" for Ouch and Osler.) Note the multiple painless flat Janeway lesions over the sole of the foot. (*Courtesy of David A. Kasper DO, MBA.*)

- Intraabdominal infections—Fever and positive blood cultures, normal echocardiogram.

Echocardiogram findings similar to bacterial endocarditis may be seen with:

- Noninfective vegetations—No fever and negative blood cultures.
- Cardiac tumors—Embolic complications, right or left heart failure, often located off valves in cardiac chambers, negative blood cultures.
- Cusp prolapse—No fever and negative blood cultures.
- Myxomatous changes—Extra connective tissue in the valve leaflets.
- Lamb excrescences—Stranding from wear and tear on the valve, most commonly aortic, no fever, and negative blood cultures.

MANAGEMENT

- Draw blood cultures (two to three sets) and admit suspected cases to the hospital for IV antibiotics.
- Start antibiotics empirically (SOR C for specific regiments).

MEDICATIONS

- Cover *Streptococcus* in native valve endocarditis: penicillin G 12 to 18 million units divided every 4 hours and gentamicin 1.5 mg/kg loading dose, then 1 mg/kg every 8 hours.
- Cover *Staphylococcus* in IV drug abusers: nafcillin 2 g every 4 hours and gentamicin; use vancomycin instead of nafcillin when concerned about methicillin-resistant *Staphylococcus aureus* (MRSA) (prior history of MRSA infection).
- Cover MRSA in prosthetic valve endocarditis: vancomycin 30 mg/kg per day divided every 8 hours and gentamicin.
- Alter antibiotics based on culture results. SOR A
- Treat Gram-positive with a β-lactam; current evidence does not support adding an aminoglycaside.[7] SOR A
- Surgical consultation.
- Surgical excision of infected tissue has a 10% to 16% mortality rate in the immediate post-op period.[8,9] Consider surgical consultation when:
  - Congestive heart failure is severe with mitral or aortic regurgitation.
  - Fever and/or bacteremia persist for 7 to 10 days despite adequate antibiotic therapy, abscesses or perivalvular involvement occurs, or fungal organisms are identified.
  - Embolic events recur on adequate antibiotic therapy or the risk of embolic events is high because of vegetations larger than 10 mm. SOR C
- Anticoagulation and aspirin are not indicated for infective endocarditis and are contraindicated with cerebral complications or aneurysms.

PREVENTION

- Bacterial endocarditis is a serious life-threatening disease requiring long-term antibiotics and close follow-up.
- Educate patients with high risk for endocarditis of the importance of prophylactic antibiotics before certain procedures. Following are the 2007 American Heart Association recommendations:[10]
  - Prescribe prophylactic antibiotics only to patients at the highest risk: SOR B
    - Patients with prosthetic cardiac valves.
    - Patients with previous bacterial endocarditis.
    - Cardiac transplant recipients with cardiac valvuloplasty.
    - Patients with these congenital heart defects (CHDs): unrepaired cyanotic CHD, CHD repaired with prosthetic material within the last 6 months, repaired CHD with a residual defect at or adjacent to the site of a prosthetic device.
  - Prophylactic antibiotics are *no longer recommended* for patients with mitral valve prolapse.
  - Prescribe prophylactic antibiotics only to patients undergoing one of the following:
    - Any dental procedure that involves manipulation of gingival tissue or the periapical region of teeth or perforation of the oral mucosa. SOR C
    - Respiratory procedures involving incision or biopsy of the respiratory mucosa such as a tonsillectomy or adenoidectomy. SOR C
    - Procedures on infected skin or musculoskeletal tissue.
  - Endocarditis prophylaxis is *no longer recommended* for patients undergoing gastrointestinal or genitourinary procedures. SOR B
  - Prescribe a one-dose regimen to be taken 30 minutes to 1 hour before the procedure:[10]
    - Amoxicillin 2.0 g orally for adults, 50 mg/kg for children.
    - Unable to take oral medications: ampicillin 2.0 g IM or IV for adults, 50 mg/kg for children 30 minutes before the procedure; *or* cefazolin or ceftriaxone 1 g IM or IV for adults, 50 mg/kg for children.
    - Penicillin allergic: clindamycin 600 mg po, IM, or IV for adults; 20 mg/kg po, IM, or IV for children; *or* azithromycin or clarithromycin 500 mg po for adults, 15 mg/kg po for children. If allergy to penicillin is *not* anaphylaxis, angioedema, or urticaria, may also use cephalexin 2.0 g po for adults, 50 mg/kg po for children; *or* cefazolin or ceftriaxone 1 g IM or IV for adults, 50 mg/kg for children.

PROGNOSIS

Bacterial endocarditis requires early detection and aggressive antibiotic therapy to decrease mortality.

- Thirty-day mortality is 16% to 25%.[3]
- Ninety-day mortality is 14.5%.[3]
- Greater than 6-month mortality is 20% to 37%.[3]

FOLLOW-UP

- Most patients with bacterial endocarditis will require 4 to 6 weeks of IV antibiotics.
- Depending on the antibiotics, some patients will need to have medication levels monitored.
- Repeat blood cultures to ensure response to therapy.
- An echocardiogram at the end of treatment provides baseline imaging, as patients with endocarditis are at risk for another episode.[6] SOR C

PATIENT EDUCATION

- Bacterial endocarditis is a serious disease with a significant mortality rate.
- Finish all antibiotics and keep follow-up appointments to ensure adequate treatment.
- Mortality remains elevated even 6 months after an episode.
- Recurrence is common, especially if risk factors remain (i.e., continued immunosuppression or IV drug use).

PATIENT RESOURCES

- Family Doctor has written and auditory information on bacterial endocarditis in English and Spanish—**http://familydoctor.org/familydoctor/en/diseases-conditions/bacterial-endocarditis.html.**
- The American Heart Association has information about who is at risk for bacterial endocarditis and a printable wallet card for at-risk patient, available in English or Spanish—**http://www.heart.org/HEARTORG/Conditions/CongenitalHeartDefects/TheImpactofCongenitalHeartDefects/Infective-Endocarditis_UCM_307108_Article.jsp.**

PROVIDER RESOURCES

- The American Heart Association guidelines on endocarditis prophylaxis—**http://circ.ahajournals.org/content/116/15/1736.full.pdf.**
- Guidelines on Infective Endocarditis: Diagnosis, Antimicrobial Therapy, and Management of Complications—**http://circ.ahajournals.org/content/111/23/e394.full.**
- MedCalc has an interactive Web site with Duke criteria for Infective Endocarditis—**www.medcalc.com/endocarditis.html.**

REFERENCES

1. de Sa DD, Tleyjeh IM, Anavekar NS, et al. Epidemiological trends of infective endocarditis: a population-based study in Olmsted County, Minnesota. *Mayo Clin Proc.* 2010;85(5):422-426.
2. Wilson LE, Thomas DL, Astemborski J, et al. Prospective study of infective endocarditis among injection drug users. *J Infect Dis.* 2002;185(12):1761-1766.
3. Nomura A, Omata F, Furukawa K. Risk factors of mid-term mortality of patients with infective endocarditis. *Eur J Clin Microbiol Infect Dis.* 2010;29(11):1355-1360.
4. Prendergast BD. The changing face of infective endocarditis. *Heart.* 2006;92(7):879-885.
5. Habib G. Management of infective endocarditis. *Heart.* 2006;92(1):124-130.
6. Baddour LM, Wilson WR, Bayer AS, et al. American Heart Association Scientific Statement on Infective Endocarditis. *Circulation.* 2005;111:e394-e434.
7. Falagas ME, Matthaiou DK, Bliziotis IA. The role of aminoglycosides in combination with a beta-lactam for the treatment of bacterial endocarditis: a meta-analysis of comparative trials. *J Antimicrob Chemother.* 2006;57(4):639-647.
8. Fayad G, Leroy G, Devos P, et al. Characteristics and prognosis of patients requiring valve surgery during active infective endocarditis. *J Heart Valve Dis.* 2011;20(2):223-228.
9. Mokhles MM, Ciampichetti I, Head SJ, et al. Survival of surgically treated infective endocarditis: a comparison with the general Dutch population. *Ann Thorac Surg.* 2011;91(5):1407-1412.
10. Wilson W, Taubert KA, Gewitz M, et al. Prevention of infective endocarditis: a guideline from the American Heart Association. *Circulation.* 2007;116:1736-1754.

SECTION 2 PERIPHERAL

51 CLUBBING

Heidi Chumley, MD

PATIENT STORY

A 31-year-old man with congenital heart disease has had these clubbed fingers since his childhood (**Figures 51-1** and **51-2**). A close view of the fingers shows a widened club-like distal phalanx. He has learned to live with the limitations from his congenital heart disease and his fingers do not bother him at all.

INTRODUCTION

Clubbing is a physical examination finding first described by Hippocrates in 400 BC. Clubbing can be primary (pachydermoperiostosis or hypertrophic osteoarthropathy) or secondary (pulmonary, cardiac, or GI disease or HIV). Diagnosis is clinical based on nail fold angles and phalangeal depth ratios. The treatment is to correct the underlying cause, after which clubbing may resolve.

SYNONYMS

Hippocratic nails or fingers, drumstick fingers.

EPIDEMIOLOGY

Prevalence in the general population is unknown:

- Two percent of adult patients admitted to a Welsh general medicine or surgery service.[1]
- Thirty-eight percent and 15% of patients with Crohn disease and ulcerative colitis, respectively.[2]
- Thirty-three percent and 11% of patients with lung cancer and chronic obstructive pulmonary disease (COPD), respectively.[3]

ETIOLOGY AND PATHOPHYSIOLOGY

- The etiology of clubbing is poorly understood.
- Increased connective tissue growth and angiogenesis in the nail bed result in the remodeling of the finger into a club shape.
- Current explanations include megakaryocyte release of platelet-activated growth factor, hypoxia, vasodilators in circulation, a neurocirculatory mechanism, and chronic activation of macrophages with production of profibrotic factors.[4]

FIGURE 51-1 Clubbing of all the fingers in a 31-year-old man with congenital heart disease. Note the thickening around the proximal nail folds. (*Courtesy of Richard P. Usatine, MD.*)

FIGURE 51-2 Close-up view of a clubbed finger. (*Courtesy of Richard P. Usatine, MD.*)

RISK FACTORS

- Family history.
- History of a disease associated with clubbing.

DIAGNOSIS

CLINICAL FEATURES

- History of present illness: Gradual onset of painless enlargement at the ends of the fingers and toes.
  - Family history suggests primary hypertrophic osteoarthropathy/familial clubbing.
  - Social history to identify exposure to asbestos, coal mine dust, and pigeons; tobacco use as risk factor for lung cancer; HIV and tuberculosis risk factors.
- Review of systems: Constitutional, pulmonary, GI, and musculoskeletal symptoms for clues to an underlying disease.[5]

PHYSICAL EXAMINATION

- Abnormal nail fold angles[6] (**Figure 51-3**).
  - Profile angle (*ABC*) ≥180 degrees.
  - Hyponychial (*ABD*) ≥192 degrees.
  - Phalangeal depth ratio (*BE:GF*) ≥1[6] (**Figure 51-3**).
- Schamroth sign, obliteration of the diamond shape normally created when dorsal surfaces of 2 corresponding fingers are opposed (**Figure 51-4**). LR+ (likelihood ratio) 7.60 to 8.40 and LR− 0.14 to 0.25.[7]

TYPICAL DISTRIBUTION

- Bilateral; involves all fingers and often toes.
- Rarely unilateral or involving only one or some digits (consider neurologic or traumatic insult to extremity).

LABORATORY TESTING

Laboratory testing is useful to evaluate for secondary causes. Consider:

- HIV testing if risk factors present.
- Complete blood count (CBC) and blood cultures if systemic symptoms (fever, night sweats, weight loss) are present.
- Thyroid-stimulating hormone (TSH)/thyroxine (T_4) if exophthalmos or pretibial myxedema is present.
- Liver function tests (LFTs), hepatitis serologies for right upper quadrant (RUQ) tenderness or jaundice.

IMAGING

- Screening chest radiograph if an underlying cause is not identified.
- Plain radiograph of the hand can distinguish clubbed from non-clubbed by measuring nail bed greater than or equal to to 3 mm.[8]

DIFFERENTIAL DIAGNOSIS

PRIMARY CLUBBING

- Hypertrophic osteoarthropathy (HOA)—Clubbing, periostosis, and arthritis or arthralgias.

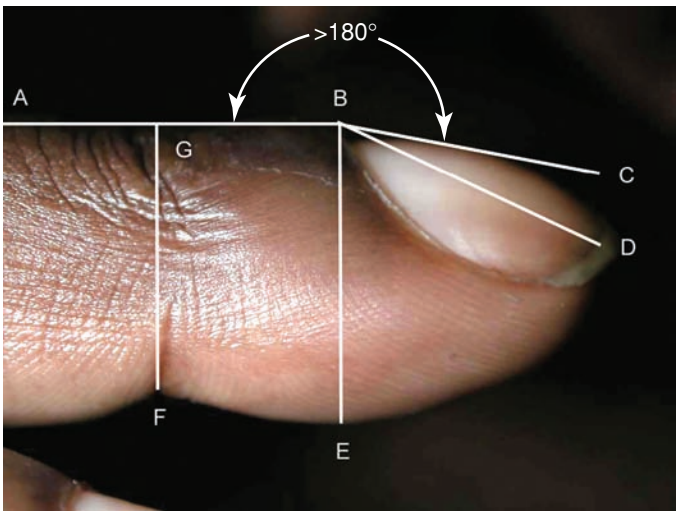

FIGURE 51-3 Clubbing of fingers in a 55-year-old man with chronic obstructive pulmonary disease. Abnormal profile angle (*ABC*) and hyponychial angle (*ABD*); distal phalangeal depth (*BE*) greater than interphalangeal depth (*GF*). (*Courtesy of Richard P. Usatine, MD.*)

FIGURE 51-4 Schamroth sign. Loss of the normal diamond shape formed when right and left thumbs are opposed in a person with clubbing of the fingers. (*Courtesy of Richard P. Usatine, MD.*)

- Primary HOA, also known as pachydermoperiostosis, is an autosomal dominant disorder.
- Secondary HOA is often associated with pulmonary neoplasms.

- Familial clubbing, now thought to be an incomplete form of primary HOA.

SECONDARY CLUBBING

Secondary clubbing can be caused by many conditions, including:[5]

- Pulmonary—Idiopathic pulmonary fibrosis, malignancy, asbestosis, COPD, and cystic fibrosis.
- Cardiac—Congenital heart disease, endocarditis, atrioventricular malformations, or fistulas.
- GI—Inflammatory bowel disease, cirrhosis, and celiac disease.
- HIV infection—Clubbing was found in 36% of patients with HIV in one study.[9]

MANAGEMENT

- Clubbing improves with the management of the underlying disease.[2]
- Evaluate patients without an obvious associated disease for lung cancer.[5] SOR C
- Evaluate patients with COPD and a phalangeal depth ratio greater than 1 for lung cancer.[3] (LR 3.9) SOR B

PROGNOSIS

Prognosis depends on the underlying process. Clubbing usually completely reverses after successful treatment of the underlying process.

FOLLOW-UP

Follow-up is dependent on the underlying disease process.

PATIENT EDUCATION

Clubbing may be secondary to many different types of disease, some very serious.

PATIENT RESOURCES

- Medline Plus—**http://www.nlm.nih.gov/medlineplus/ency/article/003282.htm.**

PROVIDER RESOURCES

- Spicknall, et al.[5] provide an algorithm useful in identifying the underlying cause of clubbing.

REFERENCES

1. White HA, Alcolado R, Alcolado JC. Examination of the hands: an insight into the health of a Welsh population. *Postgrad Med J.* 2003; 79(936):588-589.
2. Kitis G, Thompson H, Allan RN. Finger clubbing in inflammatory bowel disease: its prevalence and pathogenesis. *Br Med J.* 1979; 2(6194):825-828.
3. Baughman RP, Gunther KL, Buchsbaum JA, Lower EE. Prevalence of digital clubbing in bronchogenic carcinoma by a new digital index. *Clin Exp Rheumatol.* 1998;16(1):21-26.
4. Toovy OT, Eisenhauer HJ. A new hypothesis on the mechanism of digital clubbing secondary to pulmonary pathologies. *Med Hypotheses.* 2010;759(6):511-513.
5. Spicknall NE, Zirwas MJ, English JC. Clubbing: an update on diagnosis, differential diagnosis, pathophysiology, and clinical relevance. *J Am Acad Dermatol.* 2005;52(6):1020-1028.
6. Myers KA, Farquhar DR. The rational clinical examination. Does this patient have clubbing [comment]? *JAMA.* 2001;286(3): 341-347.
7. Pallares-Sanmartin A, Leiro-Fernandez V, Cebreiro TL, et al. Validity and reliability of the Schamroth sign for the diagnosis of clubbing. *JAMA.* 2010;304(2):159-161.
8. Moreira AL, Porto NS, Moreira JS, et al. Clubbed fingers: radiological evaluation of the nail bed thickness. *Clin Anat.* 2008;21(4): 314-318.
9. Dever LL, Matta JS. Digital clubbing in HIV-infected patients: an observational study. *AIDS Patient Care STDS.* 2009;23(1):19-22.

52 VENOUS INSUFFICIENCY

Maureen K. Sheehan, MD, MHA

PATIENT STORY

A 45-year-old woman presents to her physician's office with complaints of heaviness and fatigue in her legs (**Figure 52-1**). She does not experience the symptoms in the morning but they become more noticeable as the day progresses and with prolonged standing. When she stands for many hours, she develops swelling in both of her legs. The symptoms are concentrated over her medial calf where she has prominent tortuous veins. She first noted the veins approximately 20 years ago when she was pregnant. Initially, they did not cause her any discomfort but have progressively enlarged now and over the past 10 years have become increasingly painful. She recalls that her mother had similar veins in her legs.

FIGURE 52-1 Uncomplicated varicose veins of thigh. (*Courtesy of Maureen K. Sheehan, MD.*)

INTRODUCTION

Venous insufficiency, or improperly functioning valves in the venous system, can lead to variety of symptoms, including, but not limited to, heaviness and/or swelling in the legs with prolonged standing, leg fatigue or aching, bleeding from leg varices, skin changes, and ulcerations. The prevalence is higher in industrialized nations and ranges from 15% to 30% of the U.S. population.

SYNONYMS

Varicose veins, venous stasis

EPIDEMIOLOGY

- Varies by definition and region, but generally venous insufficiency affects 27% of the population.[1]
- Prevalence estimates vary by some reports, indicating a prevalence of 10.4% to 23% in men and 29.5% to 39% in women.[2,3]
- More frequent in women as compared to men.
- Symptomatic in more than two-thirds of those affected.
- Varicose veins are notable only in half of patients with venous insufficiency.[4]

ETIOLOGY AND PATHOPHYSIOLOGY

- Most frequently it is a result of valvular dysfunction.
- Valvular dysfunction may be primary or secondary (result of trauma, deep venous thrombosis [DVT], or May-Thurner syndrome).
- It may affect deep system (i.e., femoral veins), superficial system (i.e., saphenous vein), or both.

- The superficial system is involved in 88% of cases either alone or in conjunction with the deep system.
- Dysfunction leads to loss of compartmentalization of veins, leading to distention and increased pressure (**Figures 52-1** and **52-2**).
- Increased pressure in veins is transmitted to microvasculature leading to basement membrane thickening, increased capillary elongation, and visual skin changes (**Figures 52-3** and **52-4**).

RISK FACTORS

- Family history.
- Deep venous thrombosis.
- Female gender.
- Estrogen increase (hormone replacement, pregnancy, oral contraceptive pills).
- Age.
- Obesity.
- Prolonged standing.

DIAGNOSIS

SYMPTOMS

- Heaviness, fatigue, and edema; not present immediately in the morning; gets worse with prolonged standing or walking; relieved with elevation.

TYPICAL DISTRIBUTION

- Varicose veins can be present anywhere on the leg depending upon affected segments or branches; ulcers from venous disease tend to be near the medial malleoli (**Figure 52-5**).

TESTS

- Duplex scanning to assess valve closure; normal valve closure takes 0.5 to 1.0 seconds.

DIFFERENTIAL DIAGNOSIS

- Arterial ulcers—Tend to be at toes, shin, and pressure points (heels or sides of feet).
- Diabetic ulcers—Occur at ambulatory pressure points, mostly at first metatarsal head.
- Malignancy (basal cell or squamous cell carcinoma).
- Chronic infectious diseases (osteomyelitis, leprosy).
- Vasculitides—Irregular border, black necrosis, erythema, or bluish or purplish discoloration of adjacent tissue.

MANAGEMENT

- Graduated compression hose for superficial or deep system insufficiency: SOR C

FIGURE 52-2 Varicose veins of posterior calf *without* hemosiderin deposition, lipodermatosclerosis, or ulceration. (*Courtesy of Maureen K. Sheehan, MD.*)

FIGURE 52-3 Lipodermatosclerosis with hemosiderin deposition. (*Courtesy of Maureen K. Sheehan, MD.*)

- 15 to 20 mm Hg—Minor reflux and minimal symptoms.
- 20 to 30 mm Hg—Moderate to severe reflux and symptoms; moderate edema; postsurgical.
- 30 to 40 mm Hg—Severe reflux and symptoms; severe edema.

- Compression for open ulcer.[5] SOR B
- Compression hose treat symptoms, not underlying pathophysiology. Effective only when being worn.
- Surgical intervention is available either with endovenous ablation or with stripping and ligation if superficial system involved.
- If only deep system involvement, then compression hose is the mainstay of therapy. SOR C
- When superficial and deep systems are affected, treatment of superficial system leads to improvement of deep system reflux in one-third of the patients.
- A study randomizing patients to stripping and ligation versus compression therapy demonstrated an improved quality of life in the surgical arm.[7] SOR A
- Endovenous therapy uses radiofrequency or laser energy to ablate vein. Because the vein is usually accessed with a needle under ultrasound guidance, an incision is avoided in most instances.
- Decreased postoperative pain and analgesic use in patients undergoing endovenous ablation compared to those undergoing stripping and ligation.[8] SOR A
- Adjunctive phlebectomies or sclerotherapy for branch varicosities may be necessary with either operative approach.

FIGURE 52-4 Healed ulcers with hemosiderin deposition. (*Courtesy of Maureen K. Sheehan, MD.*)

PREVENTION

Patients at risk for developing venous insufficiency (genetics, occupations with prolonged standing, etc.) may benefit from compression hose use.

PROGNOSIS

Majority of patients with venous insufficiency live a full and complete life without significant sequelae. Those with only superficial involvement tend to have greater relief with treatment than those with superficial and deep or only deep system involvement. Most patients obtain relief from interventions such as compression hose or surgery.

FOLLOW-UP

- It depends on the treatment and severity of disease.
- Unna boots for ulceration need to be changed at least weekly.
- Compression hose needs to be replaced every 6 months.
- Following surgical intervention, follow-up depends upon intervention. Stripping and ligation require wound checks, whereas endovenous ablations require ultrasound monitoring.

FIGURE 52-5 Venous stasis ulcer in the typical location around the medial malleolus. (*Courtesy of Maureen K. Sheehan, MD.*)

PATIENT EDUCATION

Venous insufficiency is not merely a cosmetic concern. Longstanding disease can give rise to skin changes (**Figures 52-3** and **52-4**) and ulcers (**Figure 52-5**). Compliance with compression hose is necessary. Compression hose only treats symptoms, not the underlying disease process. Even after surgical intervention, new varicose veins may appear as the process is chronic.

PATIENT RESOURCES

- MedlinePlus. *Venous Insufficiency*—**http://www.nlm.nih.gov/medlineplus/ency/article/000203.htm.**
- MedlinePlus. *Varicose Veins*—**http://www.nlm.nih.gov/medlineplus/ency/article/001109.htm.**
- MedlinePlus. *Stasis Dermatitis and Ulcers*—**http://www.nlm.nih.gov/medlineplus/ency/article/000834.htm.**

PROVIDER RESOURCES

- Medscape. *Venous Insufficiency*—**http://emedicine.medscape.com/article/1085412**.
- American College of Phlebology—**http://www.phlebology.org/.**

REFERENCES

1. White JV, Ryjewski C. Chronic venous insufficiency. *Perspect Vasc Surg Endovasc Ther.* 2005;17:319-327.
2. Beebe-Dimmer JL, Pfeifer JR, Engle JS, Schottenfeld D. The epidemiology of chronic venous insufficiency and varicose veins. *Ann Epidemiol.* 2005;15:175-184.
3. Mundy L, Merlin TL, Fitridge RA, Hiller JE. Systematic review of endovenous laser treatment for varicose veins. *Br J Surg.* 2005;92:1189-1194.
4. Reichenberg J, Davis M. Venous ulcers. *Semin Cutan Med Surg.* 2005;24:216-226.
5. Cullum N, Nelson EA, Fletcher AW, Sheldon TA. Compression for venous leg ulcers. *Cochrane Database Syst Rev.* 2000;3:CD000265.
6. Puggioni A, Lurie F, Kistner RL, et al. How often is deep venous reflux eliminated after saphenous vein ablation? *J Vasc Surg.* 2003;38:517-521.
7. Michaels JA, Brazier JE, Campbell WB, et al. Randomized clinical trial comparing surgery with conservative treatment for uncomplicated varicose veins. *Br J Surg.* 2006;93:175-181.
8. Rautio T, Ohinmaa A, Perala J, et al. Endovenous obliteration versus conventional stripping operation in the treatment of primary varicose veins: a randomized controlled trial with the comparison of the costs. *J Vasc Surg.* 2002;35:958-965.

PART 8

THE LUNGS

Strength of Recommendation (SOR)	Definition
A	Recommendation based on consistent and good-quality patient-oriented evidence.*
B	Recommendation based on inconsistent or limited-quality patient-oriented evidence.*
C	Recommendation based on consensus, usual practice, opinion, disease-oriented evidence, or case series for studies of diagnosis, treatment, prevention, or screening.*

*See Appendix A on pages 1447–1450 for further information.

53 PNEUMONIA

Mindy A. Smith, MD, MS

PATIENT STORY

Max is a 65-year-old man who presents with a "terrible cough" and fever of several days' duration. He has just returned from a business trip and is feeling quite run down. His cough is productive with rusty colored sputum. He is otherwise healthy and is a nonsmoker. His chest x-ray is similar to the one shown in **Figure 53-1**. He is diagnosed with probable bacterial pneumonia and is placed on antibiotics. You note that he has never had vaccinations against influenza or pneumococcus and you offer these to him at a follow-up visit when he is well.

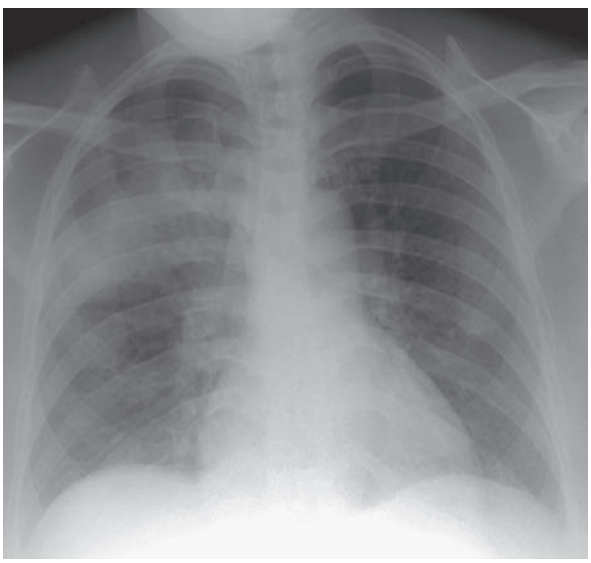

FIGURE 53-1 Chest x-ray (CXR) showing right upper lobe consolidation. (*From Miller WT Jr. Diagnostic Thoracic Imaging. New York, NY: McGraw-Hill; 2006:218, Figure 5-1 B. Copyright 2006.*)

INTRODUCTION

Pneumonia refers to an infection in the lower respiratory tract (distal airways, alveoli, and interstitium of the lung). Community-acquired pneumonia (CAP) has traditionally referred to pneumonia occurring outside of the hospital setting. More recently, a subgroup of CAP has been identified that is associated with healthcare risk factors (e.g., prior hospitalization, dialysis, nursing home residence, immunocompromised state); this form of pneumonia has been classified as a healthcare-associated pneumonia (HCAP), although definitions of HCAP vary. While severity and excess mortality are associated with HCAP, as well as a slight increase in multidrug resistant (MDR) pathogens, most studies do not support either a causal relationship between MDR and excess mortality or demonstrate benefit from broad-spectrum antibiotic coverage.[1] It is likely that excess mortality is a result of underlying patient-related factors (e.g., older age, comorbidities, higher initial severity).[1,2]

EPIDEMIOLOGY

- Three to 4 million adults per year in United States are diagnosed with CAP (8 to 15 per 1000 persons/year).[3,4]
- Annual incidence rate of CAP requiring hospitalization: 267 per 100,000 population and 1012 per 100,000 individuals older than 65 years of age.[5]
- Ten percent to 20% of patients are admitted to the hospital.[3,4,6] Of those, 10% to 20% are admitted to the intensive care unit (ICU).[7]
- Increased incidence in men and in blacks versus whites.[3]
- CAP is the most frequent cause of death caused by infectious disease in the United States and the eighth leading cause of death overall (2007).[7,8]
- Economic burden associated with CAP is estimated at more than $12 billion annually in the United States.[7]

ETIOLOGY AND PATHOPHYSIOLOGY[3]

- In a study of children hospitalized with CAP (N = 254), the cause of the disease (identified in 85% of cases) was most often viral (62%, with 30% having evidence of both viral and bacterial pathogens).[9] The most common pathogens were *Streptococcus pneumoniae* (37%), respiratory syncytial virus (29%), and rhinovirus (24%). Dual bacterial infections were found in 19 patients; only 1 patient of 125 tested had a positive blood culture.
- In a single U.S. hospital study, pathogens identified in adult patients with CAP separate from HCAP (N = 208) were *S. pneumoniae* (40.9%), *Haemophilus influenzae* (17.3%), *Staphylococcus aureus* (13.5%) and methicillin-resistant *S. aureus* (MRSA, 12%).[10] For HCAP, the most common pathogens were MRSA (30.6%) and *Pseudomonas aeruginosa* (25.5%). This distribution of pathogens for HCAP may be unique to this setting.
- Most common route of infection is microaspiration of oropharyngeal secretions colonized by pathogens. In this setting, *S. pneumoniae* and *H. influenzae* are the most common pathogens.
- Pneumonia secondary to gross aspiration occurs postoperatively or in those with central nervous system disorders; anaerobes and Gram-negative bacilli are common pathogens.
- Hematogenous spread, most often from the urinary tract, results in *Escherichia coli* pneumonia, and hematogenous spread from intravenous catheters or in the setting of endocarditis may cause *S. aureus* pneumonia.
- *Mycobacterium tuberculosis* (TB), fungi, *Legionella,* and many respiratory viruses are spread by aerosolization. Reported incidence rates of atypical pathogens vary greatly; for example, *Legionella* species were identified in patients with CAP in 1.3% (defined as positive urine antigen),[10] 1.4% (defined as 4-fold rise in antibody titer or a single titer of ≥400),[11] and 18.9% (defined as 4-fold rise in antibody titer of 128),[12] with coinfection with another pathogen in approximately 10%.
- Etiology is unknown in up to 70% of cases of CAP.

RISK FACTORS[3,4,13]

- Age older than 70 years (relative risk [RR], 1.5 vs. 60- to 69-year-olds).
- Smoking more than 20 cigarettes/day (odds ratio [OR], 2.77; 95% confidence interval [CI], 1.14 to 6.7)
- Alcohol consumption (RR, 9).
- Asthma (RR, 4.2), chronic bronchitis (OR, 2.22; 95% CI, 1.13 to 4.37), and other chronic lung diseases or pulmonary edema.
- Previous respiratory infection (OR, 2.73; 95% CI, 1.75 to 4.26).
- Uremia.
- Immune suppression (RR, 1.9).
- Malnutrition.
- Acid-suppressing drugs (proton pump inhibitors and histamine-2 receptor antagonist; OR, 1.27; 95% CI, 1.11 to 1.46 and OR, 1.22; 95% CI, 1.09 to 1.36, respectively).[14]

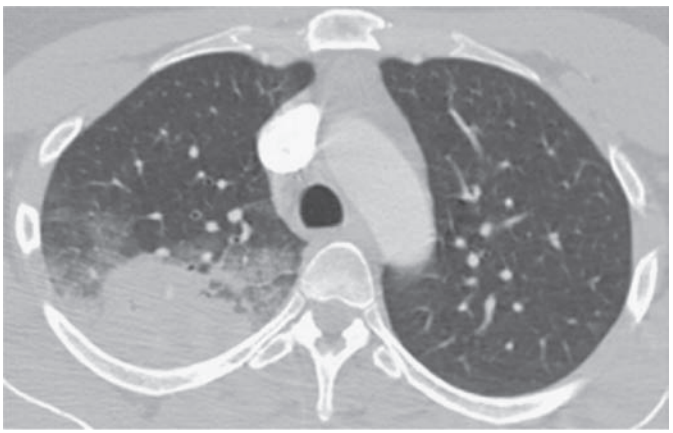

FIGURE 53-2 CT scan of the patient in **Figure 53-1** demonstrating a confluent region of lung consolidation with ground-glass opacification on the margins of the consolidated lung commonly seen in bacterial pneumonia. (*From Miller WT Jr. Diagnostic Thoracic Imaging. New York, NY: McGraw-Hill; 2006:218, Figure 5-1 C. Copyright 2006.*)

DIAGNOSIS

The history can provide clues to the likely pathogen[3]:

- Alcoholism—Consider *S. pneumoniae, Klebsiella, S. aureus*, and anaerobes.
- Chronic obstructive pulmonary disease—Consider *S. pneumoniae, H. influenzae,* and *Moraxella*.
- Uncontrolled diabetes mellitus—Consider *S. pneumoniae* and *S. aureus*.
- Sickle-cell disease—Consider *S. pneumoniae*.
- HIV with low CD4 count—Consider *S. pneumoniae, Pneumocystis carinii, H. influenzae, Cryptococcus*, and TB.

CLINICAL FEATURES

- Constellation of symptoms includes cough, fever, chills, pleuritic chest pain, and sputum production. Patients may also complain of fatigue, myalgia, and headache.[4] Patients with viral or atypical pathogens (e.g., *Mycoplasma*, *Chlamydia*) often present with fever, nonproductive cough, and constitutional symptoms developing over several days; patients with *Legionella* pathogens may present initially with GI symptoms.[4]
- Signs include increased respiratory rate, dullness to percussion, bronchial breathing, egophony, crackles, wheezes, and pleural-friction rub. Lung findings in atypical pneumonia may be more diffuse.

LABORATORY STUDIES

- Sputum Gram stain may be helpful in determining etiology in hospitalized patients. Pretreatment Gram stain and culture of expectorated sputum should be performed only if a good-quality specimen is obtained; indications are the same as for blood cultures listed below.[15] An adequate specimen has a more than 25 white blood cells (WBCs) and less than 10 epithelial cells per high-powered field. For intubated patients with severe CAP, an endotracheal aspirate sample should be obtained.[15]
- Testing of induced sputum has established merit primarily for detection of TB and *P. carinii*. SOR A Special stains are needed for detecting TB, *P. carinii*, and fungi.
- Blood cultures are not recommended routinely for nontoxic, fully immunized children with CAP managed in the outpatient setting.[16] SOR B Blood cultures should be obtained in children who fail to demonstrate clinical improvement, and in those who have progressive symptoms or clinical deterioration after initiation of antibiotics.[16] SOR B
- Blood cultures are recommended for children requiring hospitalization for presumed bacterial CAP that is moderate to severe, particularly those with complicated pneumonia.[16] SOR C
- Routine diagnostic tests to identify an etiologic agent are optional for adult outpatients with CAP.[15] SOR C Blood cultures should be considered in ambulatory patients with a temperature higher than 38.5°C (101.3°F) or lower than 36°C (96.8°F) and in those who are homeless or abusing alcohol.[3] SOR C
- Blood cultures (2 sets prior to administration of antibiotics) are suggested for hospitalized patients who meet clinical indications (i.e., cavitary infiltrates, leukopenia, active alcohol abuse, chronic

severe liver disease, asplenia, positive pneumococcal urinary antigen, or pleural effusion) or are admitted to the ICU.[15] SOR A Blood cultures are positive in 6% to 20% of hospitalized patients.[3] Investigators in a Canadian study found that blood cultures had limited usefulness in the routine management of patients admitted to the hospital with uncomplicated CAP; only 1.97% (15 of 760 patients) had a change of therapy directed by blood culture results.[17]

- Sensitive and specific tests for the rapid diagnosis of influenza virus and other respiratory viruses should be used in the evaluation of children with CAP.[16] A positive influenza test may decrease both the need for additional diagnostic studies and antibiotic use, while guiding appropriate use of antiviral agents in both outpatient and inpatient settings.[16] SOR A Serology (4-fold rise in immunoglobulin [Ig] M titer) may also be useful in diagnosing *Mycoplasma pneumoniae*, *Chlamydia pneumoniae*, *Legionella pneumoniae*, *Legionella pneumophila,* and other viral pneumonia.[15] SOR C
- Urinary antigens may be useful in diagnosing Legionnaires disease (*L. pneumophila*) and *S. pneumoniae,* and are recommended in patients with severe CAP.[15] SOR B Urinary antigen detection tests are not recommended for the diagnosis of pneumococcal pneumonia in children as false-positive tests are common.[16]
- Procalcitonin, a peptide precursor of calcitonin used as a biomarker of bacterial infection and sepsis, has been used in the emergency room setting to distinguish between pneumonia (increased level) and an exacerbation of asthma [18] In one study, use of guidelines including measurement of procalcitonin versus standard guidelines in patients with lower respiratory infection reduced exposure to antibiotics (mean duration: 5.7 vs. 8.7 days).[19]
- Pulse oximetry should be performed in patients with pneumonia and suspected hypoxemia. The presence of hypoxemia should guide decisions regarding site of care and further diagnostic testing. SOR B

IMAGING

Routine chest x-ray (CXR) is not necessary for the confirmation of suspected CAP in children who are well enough to be treated in the outpatient setting (after evaluation in the office, clinic, or emergency department setting).[16] SOR A CXR, posteroanterior and lateral, should be obtained in patients with suspected or documented hypoxemia, significant respiratory distress, those who failed initial antibiotic therapy, and hospitalized patients. SOR B

The diagnosis of pneumonia in adults based on clinical history and examination is only 47% to 69% sensitive and 58% to 75% specific, thus CXR is considered a standard part of evaluation.[3,15] The presence of new infiltrate in conjunction with clinical features is diagnostic.[6] If the initial CXR is negative in a patient with clinical features of pneumonia, the CXR should be repeated in 24 to 48 hours or a chest CT be considered. SOR C Ultrasound may be useful for evaluation of pleural effusion.[20]

There are 4 general patterns of pneumonia seen on CXR[3]:

- Lobar—Consolidation involves the entire lobe (**Figures 53-1** to **53-5**). A cavity with an air–fluid level is sometimes seen within the area of consolidation representing abscess formation (**Figure 53-5**).
- Bronchopneumonia—Patchy involvement of one or several lobes that may be extensive (**Figures 53-6** and **53-7**), usually in the dependent lower and posterior lungs (**Figure 53-3**).

FIGURE 53-3 Posteroanterior CXR consolidation in the left lower lobe occupying all 3 basilar segments. There is blunting of the left costophrenic angle indicating a parapneumonic effusion. (*From Miller WT Jr. Diagnostic Thoracic Imaging. New York, NY: McGraw-Hill; 2006:219, Figure 5-2 C. Copyright 2006.*)

FIGURE 53-4 Lateral CXR of the patient in **Figure 53-3** showing posterior displacement of the major fissure indicating some atelectasis of the left lower lobe. (*From Miller WT Jr. Diagnostic Thoracic Imaging. New York, NY: McGraw-Hill; 2006:219, Figure 5-2 D. Copyright 2006.*)

- Interstitial pneumonia—Inflammatory process involves the interstitium; usually patchy and diffuse (**Figure 53-8**). A nodular interstitial pattern is seen in patients with histoplasmosis (**Figure 53-9**), miliary TB, pneumoconiosis, and sarcoidosis.
- Miliary pneumonia—Numerous discrete lesions from hematogenous spread (see tuberculosis) (see Chapter 54, Tuberculosis).

DIFFERENTIAL DIAGNOSIS

- Upper respiratory illnesses, including bronchitis, can cause cough, fever, chills, and sputum production with a negative CXR.
- Pulmonary embolus should be considered in patients with pleuritic chest pain or hypoxia and a negative CXR (see Chapter 57, Pulmonary Embolus).
- Asthma can cause cough, wheezing, dyspnea, and hypoxia, with the CXR negative unless mucous plugging causes collapse of airways (see Chapter 55, Asthma).

MANAGEMENT

Initial determination of severity of illness is used to identify patients with CAP who may be candidates for outpatient treatment[15]:

- Respiratory rate more than 30 breaths/min without underlying disease is single best predictor.
- British Thoracic Society (BTS) rule—The presence of one or more of the following 4: confusion; blood urea nitrogen greater than 7 mmol/L; respiratory rate greater than 30 breaths/min; systolic blood pressure lower than 90 mm Hg or diastolic blood pressure lower than 60 mm Hg. If none are present, mortality rate is 2.4%; 1 present, 8%; 2 present, 23%; 3 present, 33%; and all 4 present, 80%.
- A number of other severity scores are available (e.g., CURB-65 criteria [confusion, uremia, respiratory rate, low blood pressure, age 65 years or greater] and prognostic models such as the Pneumonia Severity Index),[4,15] but one study found that the modified BTS performed best, although they recommend validation in each clinical setting.[21]
- Assessment of oxygen consumption/hypoxia.

NONPHARMACOLOGIC

- Based on limited data, chest physiotherapy can't be recommended as part of routine care for adults with pneumonia.[22] Positive expiratory pressure (versus no physiotherapy) and osteopathic manipulative treatment (OMT versus placebo therapy) appear to slightly reduce the duration of hospital stay (by 2.02 and 1.4 days, respectively). OMT may also reduce duration of antibiotic use by 1 to 2 days.[22]
- The Infectious Diseases Society of America/American Thoracic Society recommend a cautious trial of noninvasive ventilation for patients with hypoxemia or respiratory distress unless they require immediate intubation because of severe hypoxemia (arterial oxygen pressure/fraction of inspired oxygen [PaO_2/FiO_2] ratio <150) and bilateral alveolar infiltrates.[15]

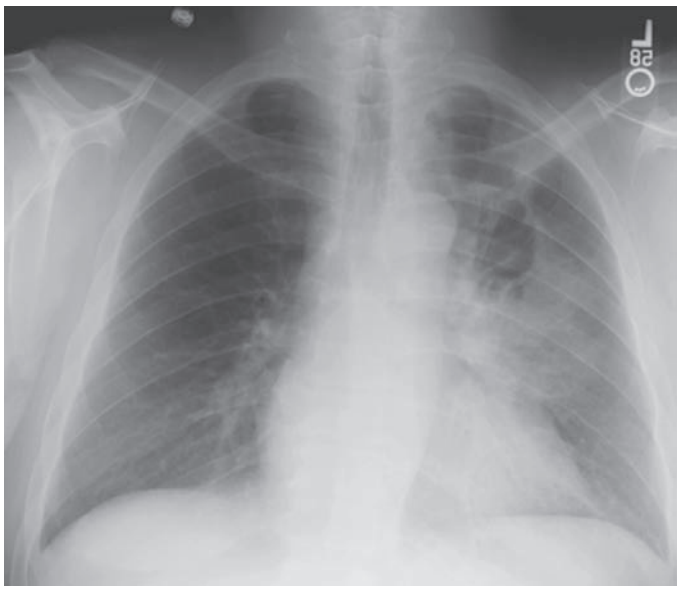

FIGURE 53-5 CXR showing a consolidation in the left upper lobe; note oval lucency that represents cavitation within the infiltrate. This patient had *Klebsiella* pneumonia. (*From Miller WT Jr. Diagnostic Thoracic Imaging. New York, NY: McGraw-Hill; 2006:223, Figure 5-6 A. Copyright 2006.*)

- On small randomized controlled trial (RCT) (N = 40) found continuous positive airway pressure (CPAP) delivered by helmet improved oxygenation more quickly than oxygen therapy alone (median: 1.5 vs. 48 hours, respectively) in patients with CAP and moderate hypoxemic acute respiratory failure.[23]

MEDICATIONS

Antimicrobial therapy is not routinely required for preschool-age children with CAP because of the high proportion with viral disease.[16] SOR A When antibiotics are prescribed, treatment courses of 10 days are recommended.

- Amoxicillin should be used as first-line therapy for previously healthy, appropriately immunized infants and preschool-age children with mild to moderate CAP suspected to be of bacterial origin.[16] SOR B A Cochrane review supported use of amoxicillin (or co-trimoxazole) as first-line therapy with amoxicillin clavulanate and cefpodoxime considered as alternative second-line drugs; limited data were available on other antibiotics.[24]
- Amoxicillin is also recommended for previously healthy, appropriately immunized school-age children and adolescents with mild to moderate CAP with consideration of atypical pathogens.[16] SOR B If atypical pathogens are suspected clinically, macrolide antibiotics should be prescribed and diagnostic testing performed.
- Influenza antiviral therapy should be administered as soon as possible (within 48 hours) to children with moderate to severe CAP consistent with influenza virus infection during widespread local circulation of influenza viruses.[16] SOR B
- For children with CAP who are inpatients, ampicillin or penicillin G should be administered to the fully immunized infant or school-age child when local epidemiologic data document lack of substantial high-level penicillin resistance for invasive *S. pneumoniae*.[16,24] Empiric therapy with a third-generation parenteral cephalosporin (ceftriaxone or cefotaxime) should be prescribed for hospitalized infants and children who are not fully immunized, in regions where local epidemiology of invasive pneumococcal strains documents high-level penicillin resistance, or for infants and children with life-threatening infection.[16] SOR B
- For children who are inpatients, empiric combination therapy with a macrolide (oral or parenteral) in addition to a β-lactam antibiotic, should be prescribed when *M. pneumoniae* and *C. pneumoniae* are significant considerations; diagnostic testing should be performed.[16] SOR B For children hospitalized with severe and very severe CAP, penicillin/ampicillin plus gentamicin is superior to chloramphenicol.[24]
- Vancomycin or clindamycin (based on local susceptibility data) should be provided in addition to β-lactam therapy for hospitalized children if clinical, laboratory, or imaging characteristics are consistent with infection caused by *S. aureus*.[16] SOR C

Empiric antibiotic treatment for adults with CAP includes[15]:

- Outpatient, uncomplicated (previously healthy, no risk factors for drug-resistant *S. pneumoniae* [DRSP] infection)—Macrolide (erythromycin, azithromycin, or clarithromycin) SOR A or doxycycline. SOR C Authors of a Cochrane review did not find sufficient evidence to determine antibiotic choice for the treatment of

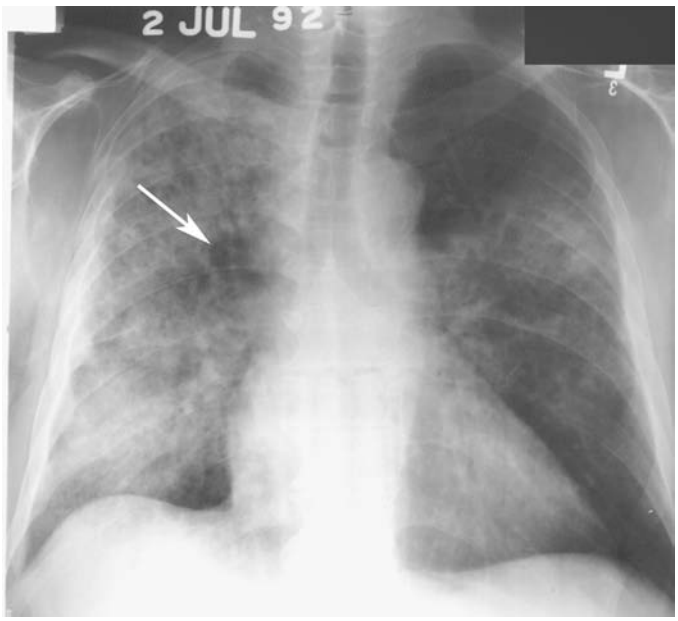

FIGURE 53-6 This patient has bilateral pulmonary infiltrates worsening despite antibiotics characteristic of severe bronchopneumonia. Note air bronchograms (arrows) on the right side. He was diagnosed with *Legionella* pneumonia. (*From Miller WT Jr. Diagnostic Thoracic Imaging. New York, NY: McGraw-Hill; 2006:221, Figure 5-4 B. Copyright 2006.*)

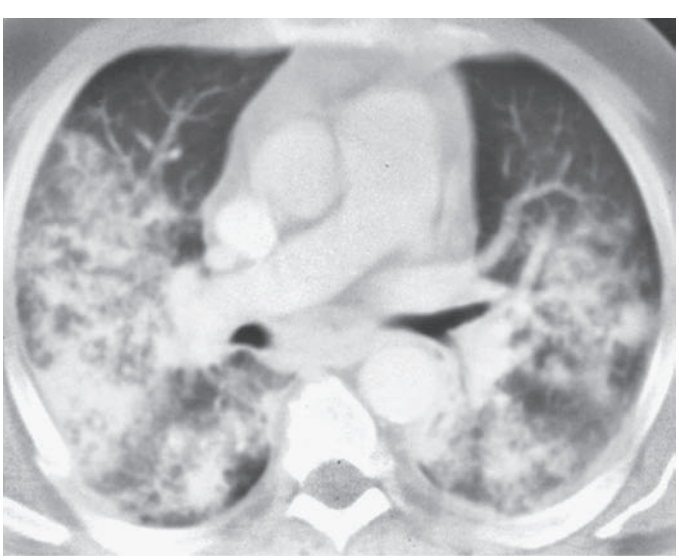

FIGURE 53-7 CT scan of the patient in **Figure 53-6** at the level of the main pulmonary arteries showing extensive pulmonary consolidation in both lungs. (*From Miller WT Jr. Diagnostic Thoracic Imaging. New York, NY: McGraw-Hill; 2006:221, Figure 5-4 D. Copyright 2006.*)

CAP in ambulatory patients; individual study results did not demonstrate significant differences in efficacy between various antibiotics and antibiotic groups.[25]

- Outpatient with comorbidities (e.g., cardiac disease, diabetes mellitus) or risk factors for DRSP—Respiratory fluoroquinolone (i.e., levofloxacin [750 mg], moxifloxacin, and gemifloxacin) or β-lactam **plus** macrolide. SOR A In regions with high rate (>25%) of macrolide-resistant *S. pneumoniae*, consider use of an alternate agent.
- Hospitalized patient (non-ICU)—Respiratory fluoroquinolone **or** β-lactam (preferred agents include cefotaxime, ceftriaxone, and ampicillin; ertapenem for selected patients) **plus** macrolide combination. SOR A Doxycycline can be considered as an alternative to the macrolide. Treatment should be started in the emergency room for patients admitted from there. A Cochrane review, however, did not find benefit in survival or clinical efficacy using empirical atypical coverage (quinolone monotherapy or β-lactams or cephalosporins) in hospitalized patients with CAP.[26]
- If the etiology of CAP is identified on the basis of reliable microbiologic methods, antimicrobial therapy should be directed at that pathogen.
- Early treatment (within 48 hours of the onset of symptoms) with oseltamivir or zanamivir is recommended for influenza A.[15]
- Duration of therapy—A minimum of 5 days. SOR A The patient should be afebrile for 48 to 72 hours and have no more than 1 CAP-associated sign of instability (e.g., temperature higher than 37.8°C [100°F], tachycardia, respiratory rate >24 breaths/min, hypotension, oxygen saturation <90%, unable to maintain oral intake, altered mental status) before discontinuing antibiotics.[15]
- Dexamethasone reduced hospital length of stay (LOS) by about 1 day when added to antibiotic treatment in nonimmunocompromised patients with CAP.[27] There were no differences in in-hospital mortality or severe adverse events in this study. Among children hospitalized with CAP, adjunctive steroids also appears to reduce hospital stay but only in conjunction with concomitant β-agonist therapy (i.e., likely only children with acute wheezing benefit).[28] Steroid use increased LOS and readmission when used in patients who did not receive concomitant β-agonist therapy.

HOSPITALIZATION

- Children and infants who have moderate to severe CAP, as defined by several factors including respiratory distress and hypoxemia, should be hospitalized for management, including skilled pediatric nursing care.[16] SOR A
- Infants younger than 3 to 6 months of age with suspected bacterial CAP, children and infants with suspected or documented CAP caused by a pathogen with increased virulence (e.g., community-acquired MRSA), and children and infants for whom there is concern about careful observation at home or who are unable to comply with therapy or follow-up are likely to benefit from hospitalization.[16] SOR C
- For adults, severity-of-illness scores can be used to identify patients with CAP who may be candidates for outpatient treatment. SOR A Consider hospitalization if the patients has severe CAP (CURB-65 ≥2 or BTS score >0) or has hypoxia, worsening symptoms, preexisting conditions that compromise safety of home care or for patients who fail to improve in more than 72 hours.[3,15]

FIGURE 53-8 CXR showing basilar predominant interstitial lung disease in this 70-year-old woman; given her age, idiopathic pulmonary fibrosis is the most likely diagnosis. (*From Miller WT Jr. Diagnostic Thoracic Imaging. New York, NY: McGraw-Hill; 2006:81, Figure 3-10 A. Copyright 2006.*)

FIGURE 53-9 Nodular interstitial pattern with many calcified granulomas in a patient with histoplasmosis. (*From Schwartz DT, Reisdorff EJ. Emergency Radiology. New York, NY: McGraw-Hill; 2000:460, Figure 17-15. Copyright 2000.*)

PREVENTION

- Vaccination—Children should be immunized with vaccines for bacterial pathogens including *S. pneumoniae*, *H. influenzae* type b, and pertussis to prevent CAP.[16] SOR A The use of pneumococcal conjugate vaccine is associated with an overall decreased incidence of invasive disease among children younger than 5 years of age (from approximately 99 cases per 100,000 population [1998–1999] to 21 cases per 100,000 population [2008]).[29] Pneumococcal polysaccharide vaccine is recommended for persons 65 years of age and older, and for those with selected high-risk concurrent diseases.[15] SOR B All infants 6 months of age or older, children, adolescents, persons 50 years of age or older, others at risk for influenza complications, and healthcare workers should be immunized annually with vaccines for influenza virus to prevent CAP.[15,16] SOR A Vaccination status should be assessed at the time of hospital admission for all patients and appropriate vaccines offered at discharge.[15] SOR C
- Smoking cessation assistance should be offered to patients who smoke (see Chapter 236, Tobacco Addiction).
- To prevent spread of respiratory pathogens, respiratory hygiene measures should be practiced.[15] These include the coughing into the elbow and use of hand hygiene and masks or tissues for patients with cough, particularly in outpatient settings and emergency departments.

PROGNOSIS

- Patients on adequate therapy for CAP should demonstrate clinical (and laboratory) signs of improvement within 48 to 72 hours.[16]
- Outpatient mortality rate is 1%. The mortality rate for those who require admission to the hospital averages 12%, and the mortality rate for patients with severe CAP in the ICU setting approaches 40%.[3] In a multihospital study in Canada, 9% (N = 89) of patients died in-hospital, 10% died at 30 days, and 247 (26%) died by 1 year. In-hospital mortality was higher among patients with admission hypoglycemia.[30]
- Using a large database, guideline concordant therapy for CAP (65% of cases) was associated with decreased in-hospital mortality (OR, 0.70; 95% CI, 0.63 to 0.77), sepsis (OR, 0.83; 95% CI, 0.72 to 0.96), renal failure (OR, 0.79; 95% CI, 0.67 to 0.94), and reduced hospital LOS and duration of parenteral therapy (0.6 days for both).[31]

FOLLOW-UP

- Assess need and provide pneumococcal and influenza vaccination at hospital discharge or follow-up.
- Monitor improvement and treat comorbid illness (which may worsen).
- In children, repeat CXRs (inpatient or outpatient) are not routinely required if recovery from an episode of CAP is uneventful.[16] SOR B Follow-up chest radiographs should be obtained in patients with complicated pneumonia with worsening respiratory distress or clinical instability, or in those with persistent fever that is not

responding to therapy over 48 to 72 hours. SOR C Repeat CXR at 4 to 6 weeks after the diagnosis of CAP should be obtained in patients with recurrent pneumonia involving the same lobe and in patients with lobar collapse at initial CXR with suspicion of an anatomic anomaly, chest mass, or foreign-body aspiration.[16] SOR B

- In adults, repeat CXRs until clear if the patient is older than 40 years or smokes as 2% of them may have underlying cancer.[3]

PATIENT EDUCATION

- Patients who smoke should be offered cessation assistance.
- Improvement is expected in healthy outpatients younger than age 65 years in 48 to 72 hours with their returning to work or school in approximately 4 to 5 days and complete improvement within 2 weeks.
- In hospitalized patients, clinical stability is expected in 3 to 7 days; mortality is 12% with 70% developing a complication such as respiratory failure, congestive heart failure, shock, dysrhythmia, myocardial infarction, GI bleeding, or renal insufficiency.[3]

REFERENCES

1. Ewig S, Welte T, Torres A. Is healthcare-associated pneumonia a distinct entity needing specific therapy? *Curr Opin Infect Dis.* 2012; 25(2):166-175.
2. Chalmers JD, Taylor JK, Singanayagam A, et al. Epidemiology, antibiotic therapy, and clinical outcomes in health care-associated pneumonia: a UK cohort study. *Clin Infect Dis.* 2011;53(2): 107-113.
3. Marrie TJ, Campbell GD, Walker DH, Low DE. Pneumonia. In: Kasper DL, Braunwald E, Fauci AS, Hauser SL, Longo DL, Jameson JL, eds. *Harrison's Principles of Internal Medicine*, 16th ed. New York, NY: McGraw-Hill; 2005:1528-1541.
4. Butt S, Swiatlo E. Treatment of community-acquired pneumonia in an ambulatory setting. *Am J Med.* 2011;124(4);297-300.
5. Marston BJ, Plouffe JF, File TM Jr, et al; Community-Based Pneumonia Incidence Study Group. Incidence of community-acquired pneumonia requiring hospitalization: results of a population-based active surveillance study in Ohio. *Arch Intern Med.* 1997;157:1709-1718.
6. File TM Jr, Marrie TJ. Burdon of community-acquired pneumonia in North American adults. *Postgrad Med.* 2010;122(2):130-141.
7. File TM. Case studies of lower respiratory tract infections: community-acquired pneumonia. *Am J Med.* 2010;123(4 Suppl): S4-S15.
8. Xu J, Kochanek MA, Murphy SL, Tejada-Vera B. Deaths: final data for 2007. *Natl Vital Stat Rep.* 2010;58(19):1-136.
9. Juvén T, Mertsola J, Waris M, et al. Etiology of community-acquired pneumonia in 254 hospitalized children. *Pediatr Infect Dis J.* 2000;19(4):293-298.
10. Micek ST, Kollef KE, Reichley RM, et al. Health care-associated pneumonia and community-acquired pneumonia: a single-center experience. *Antimicrob Agents Chemother.* 2007;51(10):3568-3573.
11. Marrie TJ, Raoult D, La Scola B. *Legionella*-like and other amoebal pathogens as agents of community-acquired pneumonia. *Emerg Infect Dis.* 2001;7(6):1026-1029.
12. Benson RF, Drozanski WJ, Rowbatham TJ, et al. Serologic evidence of infection with 9 *Legionella*-like amoebal pathogens in pneumonia patients. Proceedings of the 95th ASM General Meeting; May 21-25, 1995; Washington, DC. [Abstract C-200. p. 35.]
13. Almirall J, Bolibar I, Balanzo X, Gonzalez CA. Risk factors for community-acquired pneumonia in adults: a population-based case control study. *Eur Respir J.* 1999;13(2):349-355.
14. Eom CS, Jeon CY, Lim JW, et al. Use of acid-suppressive drugs and risk of pneumonia: a systematic review and meta-analysis. *CMAJ.* 2011;183(3):310-319.
15. Mandell LA, Wunderink RG, Anzueto A, et al. Infectious Diseases Society of America/American Thoracic Society consensus guidelines on the management of community-acquired pneumonia in adults. *Clin Infect Dis.* 2007;44 Suppl 2:S27-S72.
16. Bradley JS, Byington CL, Shah SS, et al. The management of community-acquired pneumonia in infants and children older than 3 months of age: clinical practice guidelines by the Pediatric Infectious Diseases Society and the Infectious Diseases Society of America. *Clin Infect Dis.* 2011;53(7):e25-e76.
17. Campbell SG, Marrie TJ, Anstey R, et al. The contribution of blood cultures to the clinical management of adult patients admitted to the hospital with community-acquired pneumonia: a prospective observational study. *Chest.* 2003;123(4):1142-1150.
18. Badfadhel M, Clark TW, Reid C, et al. Procalcitonin and C-reactive protein in hospitalized adult patients with community-acquired pneumonia or exacerbation of asthma or COPD. *Chest.* 2011; 139(6):1410-1418.
19. Schuetz P, Christ-Crain M, Thomann R, et al. Effect of procalcitonin-based guidelines vs standard guidelines on antibiotic use in lower respiratory tract infections: the ProHOSP randomized controlled trial. *JAMA.* 2009;302(10):1059-1066.
20. Reynolds JH, McDonald G, Alton H, Gordon SB. Pneumonia in the immunocompetent patient. *Br J Radiol.* 2010;83(996): 998-1009.
21. Buising KL, Thursky KA, Black JF, et al. Reconsidering what is meant by severe pneumonia: a prospective comparison of severity scores for community-acquired pneumonia. *Thorax.* 2006;61(5): 419-424.
22. Yang M, Yan Y, Yin X, et al. Chest physiotherapy for pneumonia in adults. *Cochrane Database Syst Rev.* 2010;(2):CD006338.
23. Cosentini , Brambilla AM, Aliberti S, et al. Helmet continuous positive airway pressure vs oxygen therapy to improve oxygenation in community-acquired pneumonia: a randomized, controlled trial. *Chest.* 2010;138(1):114-120.
24. Kabra SK, Lodha R, Pandey RM. Antibiotics for community-acquired pneumonia in children. *Cochrane Database Syst Rev.* 2010;(3):CD004874.
25. Bjerre LM, Verheij TJM, Kochen MM. Antibiotics for community acquired pneumonia in adult outpatients. *Cochrane Database Syst Rev.* 2009;(4):CD002109.

26. Robenshtok E, Shefet D, Gafter-Gvili A, et al. Empiric antibiotic coverage of atypical pathogens for community-acquired pneumonia in hospitalized adults. *Cochrane Database Syst Rev*. 2008;(1): CD004418.

27. Meijvis SC, Hardeman H, Remmelts HH, et al. Dexamethasone and length of hospital stay in patients with community-acquired pneumonia: a randomised, double-blind, placebo-controlled trial. *Lancet*. 2011;377(9782):2023-2030.

28. Weiss AK, Hall M, Lee GE, et al. Adjunct corticosteroids in children hospitalized with community-acquired pneumonia. *Pediatrics*. 2011;127(2):e255-e263.

29. Centers for Disease Control and Prevention. *Pneumococcal Disease*. http://www.cdc.gov/vaccines/pubs/pinkbook/pneumo.html. Accessed February 2012.

30. Gamble JM, Eurich DT, Marrie TJ, Majumdar SR. Admission hypoglycemia and increased mortality in patients hospitalized with pneumonia. *Am J Med*. 2010;123(6):556.e11-e16.

31. McCabe C, Kirchner C, Zhang H, et al. Guideline-concordant therapy and reduced mortality and length of stay in adults with community-acquired pneumonia: playing by the rules. *Arch Intern Med*. 2009;169(16):1525-1531.

54 TUBERCULOSIS

Mindy A. Smith, MD, MS

PATIENT STORY

A 20-year-old man from Mexico presents to the emergency room in a South Texas hospital with a persistent cough for 3 weeks, low-grade fever, and night sweats. His chest x-ray shows mediastinal and right hilar lymphadenopathy and right upper lobe consolidation concerning for primary tuberculosis (**Figure 54-1**). Upon review of the radiograph, the emergency room staff admits the patient to a single room with negative pressure. The patient is placed in respiratory isolation, sputum is sent for acid-fast bacillus (AFB) stain and cultures, and the results show acid-fast bacilli consistent with *Mycobacterium spp.* (**Figure 54-2**). While culture results are pending, the patient is started on 4 antituberculosis drugs. Fortunately, the sputum culture result shows *pan susceptible Mycobacterium tuberculosis*, and his treatment continues with directly observed therapy through the local city health department.

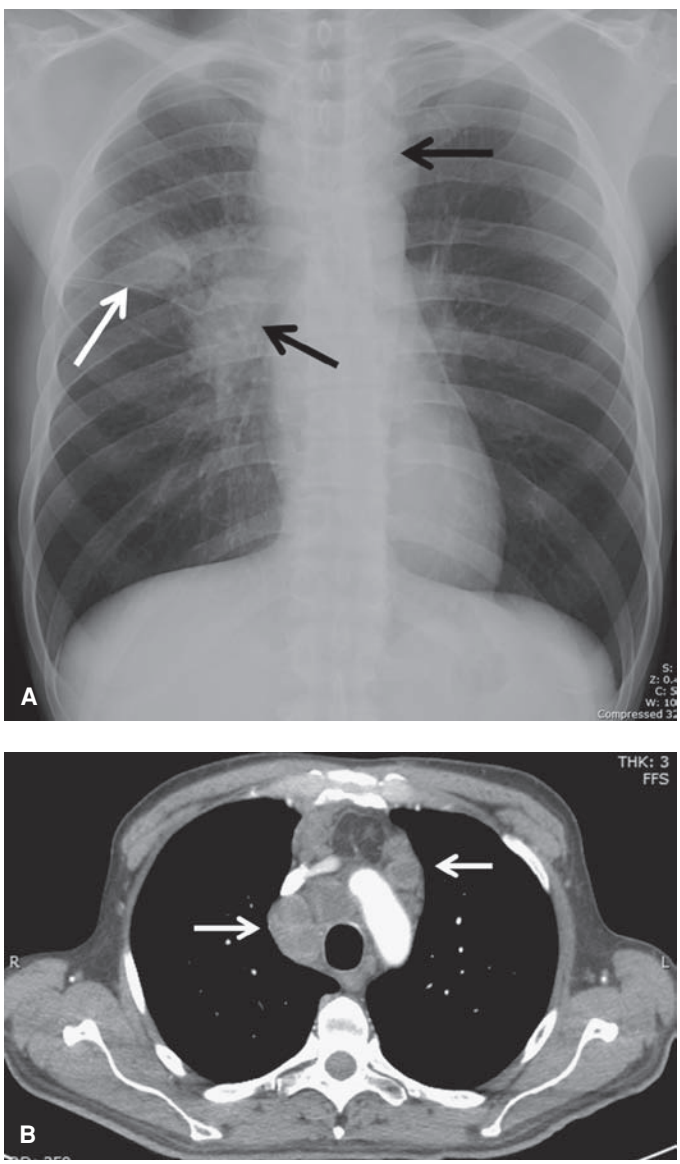

FIGURE 54-1 Typical presentation of a primary pulmonary tuberculosis infection in a 20-year-old man. **A.** Frontal chest radiograph shows mediastinal and right hilar lymphadenopathy (*black arrows*) and right upper lobe consolidation (*white arrow*). **B.** Contrast-enhanced CT demonstrates low-density enlarged mediastinal lymph nodes with rim peripheral enhancement consistent with necrotizing lymphadenopathy (*arrows*). (*Courtesy of Carlos Santiago Restrepo, MD.*)

INTRODUCTION

Tuberculosis (TB) is a bacterial infection caused by *M. tuberculosis,* an obligate intracellular pathogen that is aerobic, acid fast, and nonencapsulated. TB primarily involves the lungs, although other organs are involved in one-third of cases. Improvements in diagnostics, drugs, vaccines, and understanding of biomarkers of disease activity are expected to change future management of this devastating worldwide disease.

EPIDEMIOLOGY

- More than 8 million cases occur annually around the world, with nearly 2 million TB-related deaths[1]; 95% of TB deaths occur in low- and middle-income countries.
- A total of 11,182 TB cases (3.6 per 100,000 persons) were reported in the United States in 2010. This represents the lowest incidence rate since recording began in 1953.[2] An estimated 2 billion people worldwide have latent TB.[3]
- The multiple-drug resistant (MDR) TB rate in the United States was 1.2% (88 cases) in 2010; a rate that remains relatively stable in the United States.[1] MDR TB rates are highest in India, China, the Russian federation, South Africa, and Bangladesh.[3]
- Based on the 2010 data, 60% of reported U.S. cases of *M. tuberculosis* occurred in foreign-born individuals (case rate 11 times higher than U.S.-born individuals).[1]
- There were 547 reported deaths from TB in the United States in 2009 (a 7% decrease from 2008).[1]
- Prophylactic treatment of those with latent TB (infection without active disease—diagnosed by tuberculin skin test conversion from negative to positive or by an interferon gamma release assay performed on blood) can reduce the risk of active TB by 90% or more.[4] SOR A

ETIOLOGY AND PATHOPHYSIOLOGY[4]

- Infection is transmitted by aerosolized respiratory droplet nuclei.
- Approximately 10% of those infected develop active TB, usually within 1 to 2 years of exposure; risk factors for the development of active TB are listed below.
- There are 3 host responses to infection—Immediate nonspecific macrophage and likely neutrophil ingestion of those bacilli reaching the alveoli, later tissue-damaging response (delayed-type hypersensitivity reaction), and specific macrophage activating and potentially neutrophil-related response, the latter, if effective, walling off infection into granulomas. Recent evidence suggests that mycobacteria themselves may promote granuloma formation and these granulomas are dynamic, blurring distinctions between latent and active TB.[3]
- In areas of high prevalence, TB is often seen in children. The disease process usually localizes to the middle and upper lung zones accompanied by hilar and paratracheal lymphadenopathy (as the tubercle bacilli spread from lung to lymphatic vessels). The primary focus usually heals spontaneously and may disappear entirely or, if encapsulated by fibroblasts and collagen fibers, be visible as a calcified lung nodule (Ghon complex) (**Figure 54-3**).

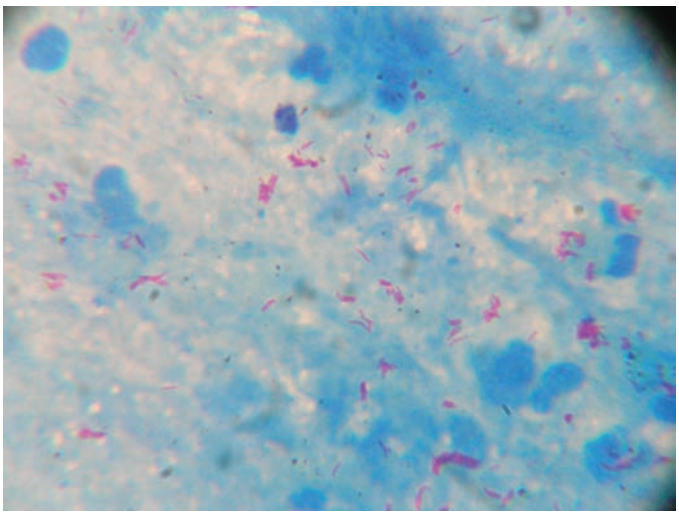

FIGURE 54-2 The acid-fast bacilli of *Mycobacterium tuberculosis* seen with acid-fast staining at 100 power with oil immersion microscopy. (*Courtesy of Richard P. Usatine, MD.*)

RISK FACTORS

Risk factors for infection or progression to active TB include[2–4]:

- Minority and foreign-born populations (subject to overcrowding and malnutrition).
- HIV (relative risk [RR] for progression to active TB 100) and other immunocompromised states (e.g., cancer, treatment with tumor necrosis factor antagonists) (RR [progression to active TB] 10). As a result of the high susceptibility of HIV-infected patients, 12% of worldwide TB cases are HIV-associated with sub-Saharan Africa accounting for 4 of every 5 of these cases.[3]
- Chronic diseases such as diabetes mellitus (RR 3) or chronic renal failure/hemodialysis (RR [infection and progression to active TB] 10 to 25 for renal failure).
- Malignancy.
- Genetic susceptibility.
- Bariatric surgery or jejunoileal bypass (RR [progression to active TB] 30 to 60) recipients.
- Injection drug users (RR [progression to active TB] 10 to 30).
- Smoking (RR 2 for progression and infection).
- Personnel who work or live in high-risk settings (e.g., prisons, long-term care facilities, and hospitals).
- Adult women (ratio 2:1 adult man).
- Older age (both infection and progression).
- Children younger than 4 years of age who are exposed to high-risk individuals.
- Recent infection (<1 year) (RR [progression to active TB] 12.9 vs. old infection).

FIGURE 54-3 Primary tuberculosis may coalesce into a small granuloma in the upper lobe referred to as a Ghon complex. (*From Miller WT, Jr. Diagnostic Thoracic Imaging. New York, NY: McGraw-Hill; 2006:289, Figure 6-5 E,.*)

- Fibrotic lung lesions (spontaneously healed) (RR [progression to active TB] 2 to 20).
- Silicosis (RR [infection] 3 and RR [progression to active TB] 30).
- Malnutrition (RR [progression to active TB] 2).
- In a study of hospital personnel, only the percentage of low-income persons within the employee's residential postal zone was independently associated with conversion (odds ratio [OR] 1.39, 95% confidence interval [CI], 1.09 to 1.78).[5]

DIAGNOSIS

The diagnosis of active TB requires a high index of suspicion. In addition, targeted testing for latent TB in vulnerable populations that would benefit from treatment (recent [<5 years] immigrants, immunosuppressed patients, patients with diabetes mellitus and/or chronic renal disease, recent TB or close contact with someone with TB such as household members and healthcare workers) is suggested.[6] Manifestations of active TB can be classified as pulmonary or extrapulmonary. TB can affect any organ system.

CLINICAL FEATURES

The disease may be asymptomatic (1 in 4 culture-confirmed cases from active case finding in Asia).[3]

Pulmonary:

- Early nonspecific signs and symptoms: fever, night sweats, fatigue, anorexia, weight loss.
- Later nonproductive cough (lasting 2 to 3 weeks) or cough with purulent sputum.
- Patients with extensive disease may develop dyspnea or acute respiratory distress syndrome.
- Physical examination findings also nonspecific with crackles or rhonchi.

Extrapulmonary TB, caused by hematogenous spread, occurs in the following order of frequency[4]:

- Lymph nodes: painless swelling of cervical and supraclavicular nodes (scrofula) (**Figure 54-4**).
- Pleura: pleural effusion with exudates.
- Genitourinary tract: may cause urethral stricture, kidney damage or infertility (in women, affects the fallopian tubes and endometrium).
- Bones and joints: pain in the spine (Pott disease, **Figure 54-5**), hips, or knees.
- Other less common sites are meninges, peritoneum, intestines, skin, eye, ear, and pericardium.
- TB of the skin (scrofuloderma) shows ulcerations of the skin (**Figures 54-4** and **54-6**) in the inguinal or cervical region along with lymphadenopathy.

SKIN TESTING AND RAPID TESTING

Positive results on either a tuberculin skin test (TST) or an interferon-γ release assay (IGRA) in the absence of active TB establish a diagnosis of latent TB infection.

- TST with purified protein derivative (PPD) is not useful in diagnosing active TB but is used to detect latent infection in exposed or

FIGURE 54-4 Young boy in Africa with scrofuloderma and large cervical and submandibular lymphadenopathy from tuberculosis. (*Courtesy of Richard P. Usatine, MD.*)

FIGURE 54-5 Pott disease from tuberculosis infection of the spine resulting in a severe kyphoscoliosis. Note to continue skin ulceration on the right and a severe deformity caused by this disease. (*Courtesy of Richard P. Usatine, MD.*)

high-risk individuals. A positive test is 10 mm induration at the inoculation site or 5 mm induration in a patient who is immunocompromised; evaluated in 48 to 72 hours after test placement.

- Two commercially produced IGRAs are licensed for use in the United States and in many other countries: QuantiFERON-TB Gold (QFT-G, Cellestis Limited, Carnegie, Victoria, Australia) and TSPOT.TB (Oxford Immunotec, Inc; Oxford, England) as an aid for diagnosing *M. tuberculosis* infection.[3]
- IGRAs detect the release of interferon-γ in fresh heparinized whole blood from sensitized persons when it is incubated with mixtures of synthetic peptides using antigens present in *M. tuberculosis*. Advantages include no need for a return visit and greater specificity than skin testing. Disadvantages include cost, availability, and lack of supporting data that these tests improve patient outcomes.
- IGRAs have limited accuracy in diagnosing active TB in HIV-infected patients and should not be used alone to rule out or rule in disease.[7] In one study of children investigated for TB in 6 U.K. pediatric centers, TST had a sensitivity of 82%, QuantiFERON-TB Gold in tube (QFT-IT) had a sensitivity of 78% and TSPOT.TB of 66%; combining TST and IGRA results increased sensitivity for both tests (ability to rule out TB).[8] In practice, IGRA have become standard of care for *M. tuberculosis* screening in some HIV clinics.
- Nucleic acid amplification tests (NAATs) on sputum specimens are under investigation and are being used to confirm diagnosis in some institutions.[3]

LABORATORY AND ANCILLARY TESTING

- Nonspecific findings include mild anemia and leukocytosis.
- Urinalysis may show "sterile" pyuria and hematuria with urinary tract involvement.
- Acid-fast bacilli may be seen on acid-fast staining from sputum or pleural or peritoneal fluid (**Figure 54-2**). They may also be seen upon staining tissue from fine-needle aspiration or biopsy of lymph nodes or other tissues as above. Sputum processing with bleach or sodium hydroxide and centrifugation and use of fluorescent microscopy is associated with increased sensitivity of smear microscopy.[3]
- Definitive diagnosis is based on culture of sputum (3 sets of samples collected 8 to 24 hours apart), urine (3 morning specimens—positive in 90% with urinary tract infection), or from tissue or bone biopsy using automated liquid culture systems. *M. tuberculosis* is slow growing and may take 4 to 8 weeks to identify. Authors of a recent review note that one specimen should be tested with NAAT.[9] Once identified, testing for drug sensitivity should be performed.
- Obtaining baseline liver enzymes is recommended for patients older than age 35 years, or for those with a history of liver disease, HIV infection, pregnancy (or within 3 months postdelivery), concomitant hepatotoxic therapy, or regular alcohol use.
- Testing vision, including color vision, is suggested prior to initiating and throughout treatment with ethambutol, which can cause irreversible cumulative toxicity to the optic nerve.
- Biomarkers of disease activity are an area of active investigation; however, a simple, inexpensive point-of-care test is still not available.

FIGURE 54-6 Young adult man in Africa with scrofuloderma showing an ulcerated lesion on one side and inguinal adenopathy on the other side. (*From Schwartz DT, Reisdorff EJ. Emergency Radiology. New York, NY: McGraw-Hill; 2006:469, Figure 17-28. Copyright 2006.*)

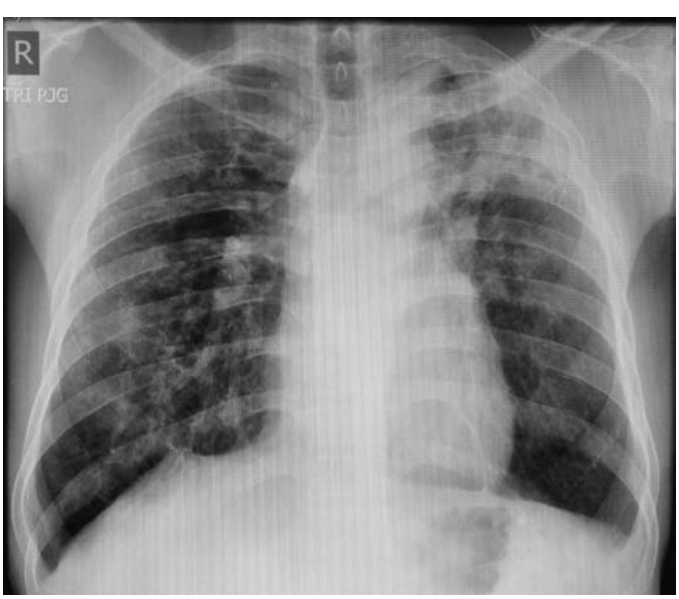

FIGURE 54-7 A 36-year-old man with pulmonary tuberculosis. There is an opacity in the left pulmonary apex associated with a cavity consistent with fibrosis and scarring changes of pulmonary tuberculosis. Also there is an infiltrate in the right lung. (*From Schwartz DT, Reisdoff EJ. Emergency Radiology. New York, NY: McGraw-Hill; 2006:470, Figure 17-30 (upper block only). Copyright 2006.*)

IMAGING

- Chest x-ray (CXR) is the diagnostic test of choice and classically shows upper lobe infiltrates with cavitation and/or lymphadenopathy (**Figures 54-1** and **54-7).**
- Other patterns of TB seen on CXR include a solitary nodule (Ghon complex) (**Figure 54-3**) and diffuse infiltrates that may represent bronchogenic spread (**Figure 54-8**).
- CXR pattern in children and young adults often shows an infiltrate with hilar and paratracheal lymphadenopathy (**Figures 54-1** and **54-9**).
- In disseminated (miliary) TB, innumerable tiny nodules are seen throughout both lungs on CXR and CT (**Figure 54-10**).
- Reactivation TB may show large cavities in both upper lobes associated with bronchiectasis and fibronodular opacities (**Figure 54-11**).
- X-ray, CT, or MRI of bone may show destructive lesions. Spinal MRI has a sensitivity of approximately 100% and specificity of 88% for detecting tuberculous lesions before deformity develops.[10]

BIOPSY

Histology reveals granulomas with caseating necrosis.

FIGURE 54-8 A 23-year-old woman with pulmonary tuberculosis. There is increased density of the lung parenchyma in the upper left lobe with a heterogeneous pattern showing areas of consolidation, fibrosis and bullae. Other sections of the long show a micronodular pattern. There is a retraction of the mediastinum toward the left. This whole pattern is consistent with pulmonary tuberculosis. (*Courtesy of Richard P. Usatine, MD.*)

DIFFERENTIAL DIAGNOSIS

Because any pattern on CXR may be seen with active TB, the differential diagnosis includes:

- Bacterial or viral pneumonia—Sputum or blood culture may reveal the infecting organism, and the patient will usually respond to antibacterial drugs and/or time.
- Fungal respiratory infections—These patients usually have a history of travel to or living in an area where histoplasmosis or coccidiomycosis is endemic.
- Acute histoplasmosis is usually asymptomatic or causes only mild symptoms and CXR typically shows hilar adenopathy with or without pneumonitis (**Figure 54-11**); patients with chronic pulmonary histoplasmosis have gradually increasing cough, weight loss, and night sweats, and CXR shows uni- or bilateral fibronodular, apical infiltrates; positive serology or culture, immunodiffusion test, or lung biopsy can be diagnostic.
- Coccidiomycosis has similar clinical features to TB and CXR may show infiltrate, hilar adenopathy, and pleural effusion; serologic tests are useful in the diagnosis.
- Sarcoidosis—No TB contacts, dyspnea and cough, hilar adenopathy on CXR, skin lesions help differentiate along with serum angiotensin-converting enzyme level or biopsy. Pathology shows noncaseating granulomata (see Chapter 175, Sarcoidosis).

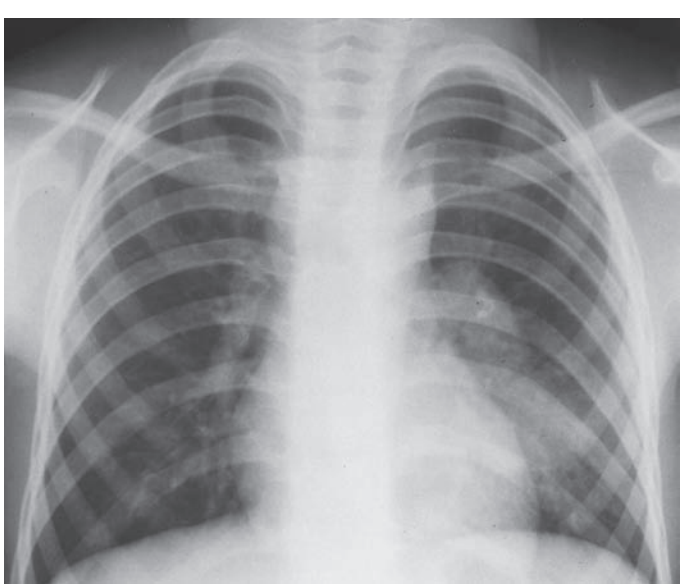

FIGURE 54-9 Primary tuberculosis in a child; note the left lower lobe infiltrate and the left hilar lymphadenopathy and right paratracheal adenopathy. (*From Schwartz DT and Reisdorff EJ. Emergency Radiology. New York, NY: McGraw-Hill; 2000:469, Figure 17-28.*)

MANAGEMENT

Patients may be managed by their primary care provider, by public health departments, or jointly, but in all cases the health department is ultimately responsible for ensuring availability of appropriate diagnostic and treatment services and for monitoring the results of therapy.

NONPHARMACOLOGIC

- There are insufficient data to support use of free food or nutritional supplements on improving treatment outcome or quality of life in individuals with TB in the United States.[11] However, attention to nutrition has shown to be beneficial in a study of TB treatment in Haiti.[12]
- Vitamin D deficiency has been linked to TB susceptibility and there is evidence that vitamin D suppresses intracellular growth of *M. tuberculosis* in vitro. Data are insufficient to determine if vitamin D supplementation is useful as an adjunct to TB treatment. One randomized controlled trial (RCT) found no differences in time to sputum culture conversion with adjunctive vitamin D in the whole study population, but reported a significant hastening of sputum culture conversion in participants with the tt genotype of the TaqI vitamin D receptor polymorphism.[13] Many experts recommend screening and treatment for vitamin D deficiency in all TB patients. SOR C

MEDICATIONS

For adult patients with *active TB* there are 4 major drugs used for treatment. The firstline anti-TB medications should be administered together; split dosing should be avoided. Review the patient's current medications to avoid drug interactions. A few combination medications are available but are more costly. The following regimen is suggested by the American Thoracic Society, Infectious Diseases Society of America, and the Centers for Disease Control and Prevention (2003)[14]: SOR B

- Two-month initial treatment phase with all 4 medications (isoniazid 5 mg/kg daily [maximum 300 mg] or 15 mg/kg thrice weekly [maximum 900 mg]); rifampin (10 mg/kg daily or thrice weekly [maximum 600 mg]); pyrazinamide (20 to 25 mg/kg daily [maximum 2 g] or 30 to 40 mg/kg thrice weekly [maximum 3 g]); and ethambutol (15 to 20 mg/kg daily or 25 to 30 mg/kg thrice weekly). A RCT found a fixed-dose 4-drug combination was noninferior to treatment with 4 drugs separately.[15]
- Four-month continuation phase with isoniazid (INH) and rifampin; treatment is extended to 7 months for patients with cavitary pulmonary TB who remain sputum-positive after initial treatment or if pregnant. The World Health Organization 2010 recommendations agree with continuing rifampin for 6 months and emphasize the importance of drug sensitivity testing to guide individual patient management.[16]
- To prevent INH-related neuropathy, pyridoxine 10 to 25 mg/day may be given, especially to those at risk for vitamin B_6 deficiency (i.e., alcoholic, malnourished, pregnant or lactating women, HIV-positive, and those with chronic disease). SOR A
- Drug-resistant TB is treated with a variety of injectable drugs including streptomycin, kanamycin, and amikacin, or oral drugs, including fluoroquinolones, ethionamide, cycloserine, and *p*-aminosalicylic acid.[4] In a Cochrane review of 11 small trials on the use of fluoroquinolones in TB regimens, investigators found no difference in trials substituting ciprofloxacin, ofloxacin, or moxifloxacin for firstline drugs in relation to cure (416 participants, 3 trials), treatment failure (388 participants, 3 trials), or clinical or radiologic improvement (216 participants, 2 trials).[17] Substituting ciprofloxacin into firstline regimens in drug-sensitive TB led to a higher incidence of relapse in HIV-positive patients.

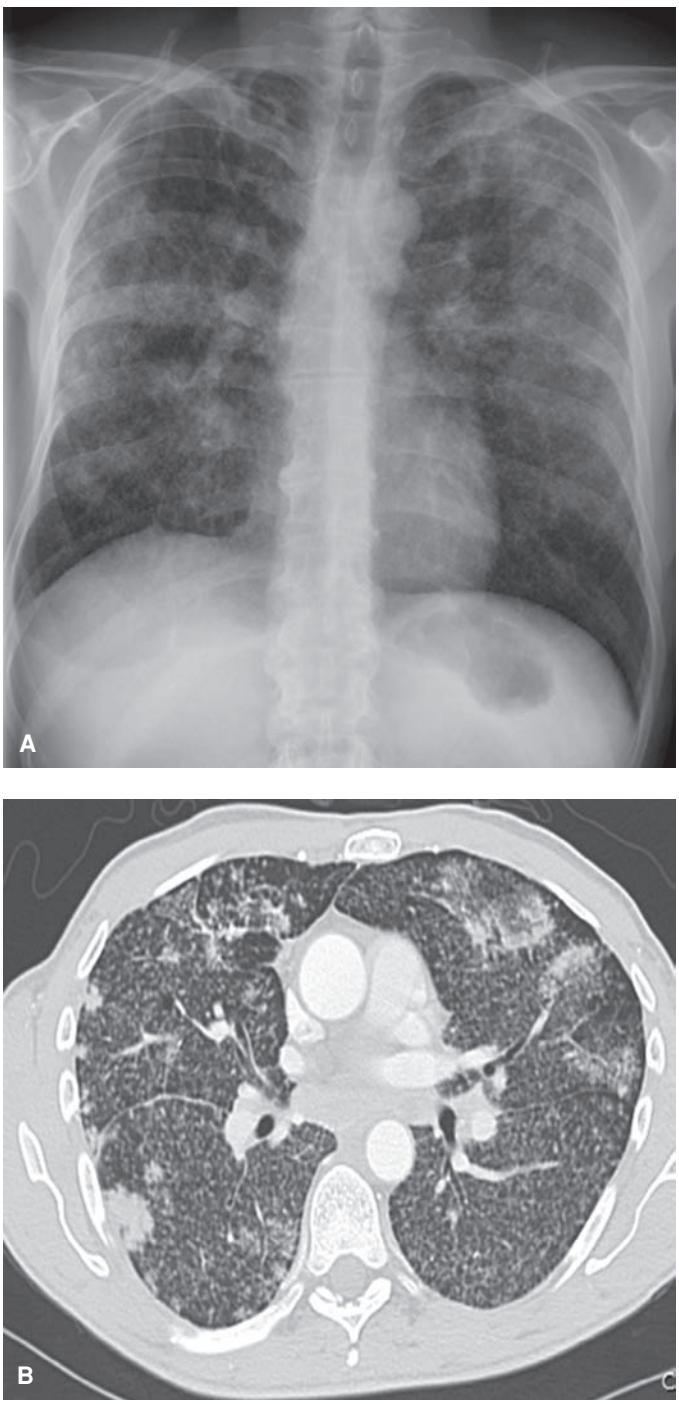

FIGURE 54-10 Disseminated (miliary) tuberculosis with tiny innumerable nodules throughout both lungs. **A.** Chest x-ray. (*Courtesy of Richard P. Usatine, MD.*) **B.** CT scan. (*Courtesy of Carlos Santiago Restrepo, MD.*)

- Research into adjuvant immunotherapy (e.g., antitumor necrosis factor therapies) is underway to determine whether this treatment will accelerate the response to treatment.
- In patients with HIV infection, treatment with antiretroviral therapy (ART) should be started during the first 2 to 8 weeks of TB treatment.[16] SOR B In a RCT of early ART treatment (2 weeks after initiating TB treatment) versus later (8 weeks after) in patients with TB and HIV, investigators found a significantly reduced risk of death in the earlier ART treatment group (18% vs. 27% in delayed treatment group).[18] Rates of immune reconstitution inflammatory syndrome, however, were higher when starting earlier.
- An open-label RCT in South Africa of patients with TB and HIV (plus CD4+ T-cell count <500 per cubic millimeter) found similar AIDS or death rates in the groups assigned to early ART (within 4 weeks) versus later ART (within the first 4 weeks of the continuation phase) (18 vs. 19 cases, respectively) and also reported higher rates of immune reconstitution inflammatory syndrome when starting earlier (20.1 vs. 7.7 cases/100 person-years).[19] AIDS and death rates were higher, however, for those with very low CD4 counts (<50 per cubic millimeter) randomized to later initiation of ART (26.3 vs. 8.5 cases per 100 person-years).[19]
- Treatment may be given daily or intermittently (3 times a week throughout or twice weekly after the initial phase). For patients who are HIV-seronegative with noncavitary pulmonary TB and negative cultures at 2-months, treatment may be given once weekly.

For adult patients with *latent TB*, a treatment decision is made considering the benefits of treatment based on individual's risk for developing TB disease (see Risk Factors above) and the person's level of commitment to completion of treatment and resources available to ensure adherence.[20] Persons with no known risk factors for TB may be considered for treatment of latent TB if they have either a positive IGRA result *or* if their reaction to the TST is 15 mm or larger. The following options are used:

- INH 5 mg/kg daily (maximum 300 mg) for 9 months; SOR A twice weekly regimens (15 mg/kg [maximum 900 mg]) may be considered if the patient is under direct observation therapy and 6-month therapy may be considered for adults who are not HIV-infected and have no fibrotic lesions on CXR. SOR B The standard treatment regimen is preferred for HIV-infected people taking ART, and children 2 to 11 years of age.
- Rifampin (10 mg/kg daily [maximum 600 mg]) for 4 months if INH-resistant TB or allergy.
- Rifapentine (900 mg; a rifamycin derivative) plus INH (900 mg) for 3 months of directly observed once-weekly therapy. The Centers for Disease Control and Prevention (CDC) recommends this regimen for otherwise healthy patients 12 years of age or older who have latent tuberculosis infection and factors that are predictive of TB developing (e.g., recent exposure to contagious TB).[21] SOR A
- In an open-label, randomized noninferiority trial comparing 3 months of directly observed once-weekly therapy with rifapentine plus INH with 9 months of self-administered daily INH (300 mg) in subjects at high risk for tuberculosis, rates of TB were comparable (7 of 3986 subjects in the combination-therapy group [cumulative rate, 0.19%] and in 15 of 3745 subjects in the INH-only group

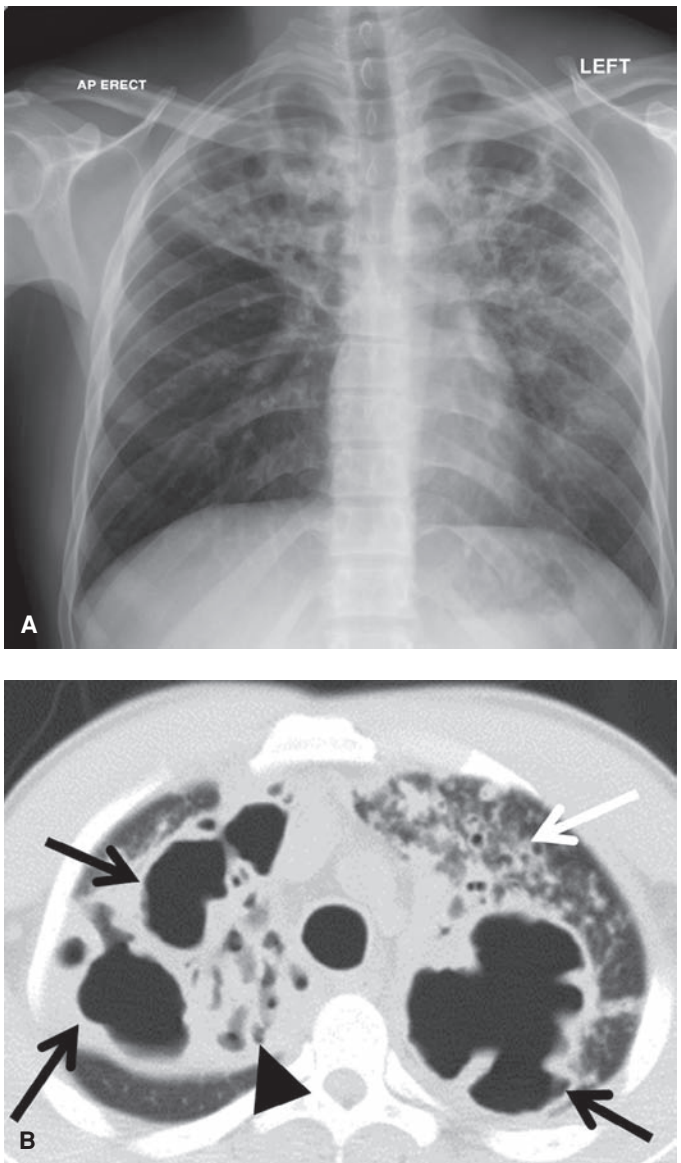

FIGURE 54-11 Reactivation tuberculosis with cavitary lesions in the upper lobes of a 35-year-old man. **A.** Frontal chest radiograph depicts large cavitary lesions in both upper lobes associated with bronchiectasis and fibronodular opacities. **B.** Noncontrast chest CT confirms the presence of irregular cavities in both upper lobes (*black arrows*), nodules (*white arrow*), and bronchiectasis (*black arrowhead*). (*Courtesy of Carlos Santiago Restrepo, MD.*)

[cumulative rate, 0.43%]) and completion rates were higher.[22] Three additional RCTs (Brazil, South Africa, and International) have shown that this combination regimen administered weekly for 12 weeks as directly observed therapy is as effective for preventing TB as other regimens and is more likely to be completed than the U.S. standard regimen of 9 months of INH daily without directly observed therapy.[21]

- Refusal of treatment for latent TB in another study at 32 clinics was 17.1% (95% CI, 14.5% to 20.0%) and 52.7% (95% CI, 48.5% to 56.8%) failed to complete the recommended course.[23]

PREVENTION

- There is no currently available vaccine with adequate effectiveness for the prevention of TB,[3] although approximately 10 vaccines are in the clinical trial phase.[24] Bacille Calmette-Guérin (BCG) vaccine, first released in 1921, can prevent up to 50% of TB cases.[25]
- BCG vaccine also has a protective effect against meningitis and disseminated TB in children, although it does not appear to prevent primary infection or reactivation of latent pulmonary infection, the principal source of bacillary spread in many communities.
- In clinical trials in Guinea-Bissau, vaccination at birth of low-birthweight infants decreased mortality, while revaccination of children with BCG appeared to increase mortality, resulting in early discontinuation of the trial.[26,27] The CDC recommends that BCG vaccine only be considered for very select persons who meet specific criteria and in consultation with a TB expert.[28]
- In a RCT, the use of primary INH prophylaxis did not improve tuberculosis disease-free survival among HIV-infected children or tuberculosis infection-free survival among HIV-uninfected children immunized with BCG vaccine.[29]
- CDC consensus-based recommendations to prevent TB spread include: not routinely hospitalizing patients with TB for diagnostic tests or care; separating patients with respiratory TB from immunocompromised patients; use of masks, gowns, or barrier nursing techniques if MDR TB is suspected or an aerosol-generating procedure is being performed; instructing patients with smear-positive pulmonary, laryngeal, or respiratory tract disease to avoid unnecessary contact with people from outside the household (e.g., avoid work, daycare facilities, or schools) for the first 2 weeks of treatment, and considering chemoprophylaxis for young children who are close contacts to avoid parental separation.[30]

PROGNOSIS

- Without treatment, approximately one-third of individuals with active TB will die within 1 year and half within 5 years. Of those who survive 5 years, 60% will have undergone spontaneous remission and the remaining will continue to be infectious.[31]

FOLLOW-UP SOR C

- Patients are considered contagious until they have been on adequate chemotherapy for a minimum of 2 weeks, have 3 negative

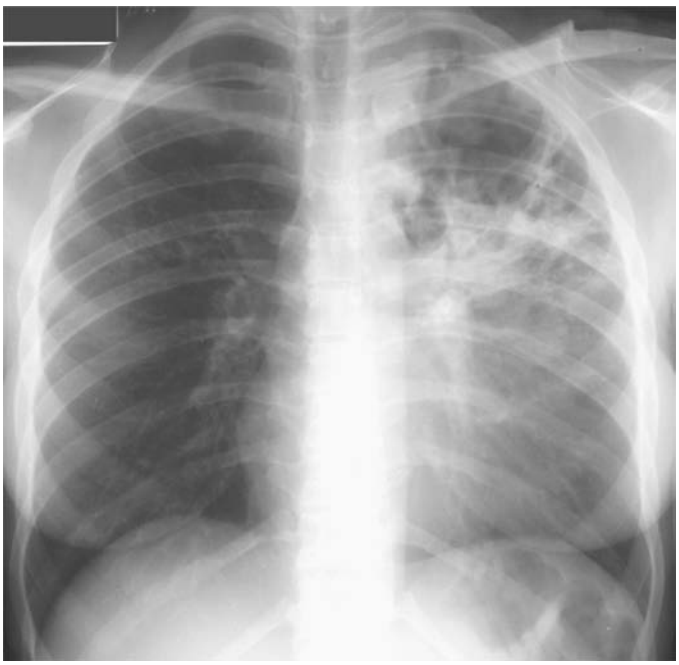

FIGURE 54-12 Histoplasmosis in a 33-year-old man with a 6-month history of fatigue. Chest x-ray shows a 4-cm mass overlying the right hilum and a lumpy contour of the left hilum that indicates lymphadenopathy. Histoplasmosis was diagnosed on bronchoscopy. (*From Miller WT, Jr. Diagnostic Thoracic Imaging. New York, NY: McGraw-Hill; 2006:357, Figure 7-54 A.*)

AFB sputum cultures (collected in 8- to 24-hour intervals with 1 early morning specimen), and show clinical improvement.[32]

- Monitor clinical recovery, medication adverse effects and compliance with treatment monthly[19]; risk factors for noncompliance include lack of motivation, lack of perceived vulnerability, and poverty.
- Monitor response to treatment—Monthly sputum cultures should be obtained until culture negative (80% expected by 2 months). If culture positive at 3 or more months, consider drug resistance or treatment failure and institute additional evaluation and treatment. For those with extrapulmonary TB, monitor clinically.[4]
- CXR is not used for monitoring treatment as clearing lags behind clinical improvement. A CXR should be completed at the end of treatment for later comparison if reactivation is suspected.[4]
- Monitor drug toxicity[4]:
  - GI side effects and pruritus are common and can generally be managed without suspending treatment.
  - Hepatitis is the most common serious adverse event (symptoms include dark urine and decreased appetite); elevation of liver enzymes up to 3 times normal occurs in 20% and is of no clinical importance. Treatment (INH, pyrazinamide, or rifampin) should be discontinued for elevations of 5 times or more or with symptoms and drugs reintroduced one at a time after liver function has normalized.
  - Hypersensitivity reactions usually require discontinuing treatment.
  - Hyperuricemia and arthralgias may occur with pyrazinamide and can be managed with aspirin; the drug should be discontinued if the patient develops gouty arthritis.
  - Autoimmune thrombocytopenia may be caused by rifampin and requires discontinuing the drug.
  - Optic neuritis may occur with ethambutol and the drug should be discontinued. Visual acuity and color vision testing monthly if ethambutol is used for more than 2 months or in doses greater than 15 to 20 mg/kg.[29]
- Routine measurements of hepatic and renal function and platelet count are not necessary during treatment unless patients have baseline abnormalities or are at increased risk of hepatotoxicity (e.g., hepatitis B or C virus infection, alcohol abuse).

PATIENT EDUCATION

- Identifying and testing household and other intimate contacts and maintaining follow-up are extremely important for preventing spread, insuring cure, and monitoring for drug toxicity (as below). The potential severity of TB should be emphasized.
- If available, patients should consider receiving treatment through a (directly observed therapy) short course program composed of 5 distinct elements: political commitment; microscopy services; drug supplies; surveillance and monitoring systems and use of highly efficacious regimens; and direct observation of treatment.[33] Although data are conflicting about the benefits of such programs, they may be better equipped to provide the intense services needed, especially in resource poor communities. Directly observed therapy is recommended for the 3-month combination rifampin and INH treatment.
- TB is not spread through direct contact, sharing food, or kissing. The best prevention of progression and spread is to take the prescribed medications regularly for the recommended duration and to avoid unnecessary contact with people from outside the household (e.g., avoid work, daycare facilities, or schools) for the first 2 weeks of treatment and until you have 3 negative AFB sputum cultures and feel better.

PATIENT RESOURCES

- Centers for Disease Control and Prevention. *Tuberculosis (TB)*—**http://www.cdc.gov/tb/.**
- MedlinePlus. *Tuberculosis*—**http://www.nlm.nih.gov/medlineplus/tuberculosis.html.**

PROVIDER RESOURCES

- Centers for Disease Control and Prevention. *Tuberculosis (TB)*—**http://www.cdc.gov/tb/.**
- Lawn SD, Zumla AI. Tuberculosis. *Lancet*. 2011;378(9785):57-72, **http://www.thelancet.com/journals/lancet/article/PIIS0140-6736(10)62173-3/abstract.**
- American Thoracic Society, CDC, and Infectious Diseases Society of America. Treatment of tuberculosis. *MMWR Recomm Rep*. 2003;54(RR-11):1-77, **http://www.cdc.gov/mmwr/preview/mmwrhtml/rr5211a1.htm.**
- Occupational Safety & Health Administration. *Tuberculosis*—**http://www.osha.gov/SLTC/tuberculosis/index.html.**

REFERENCES

1. Centers for Disease Control and Prevention. *A Global Perspective on Tuberculosis (Fact Sheet)*, http://www.cdc.gov/tb/events/WorldTBDay/resources_global.htm, accessed January 2012.
2. Centers for Disease Control and Prevention. *Trends in Tuberculosis, 2010 (Fact Sheet)*, http://www.cdc.gov/tb/publications/factsheets/statistics/TBTrends.htm, accessed January 2012.
3. Lawn SD, Zumla AI. Tuberculosis. *Lancet*. 2011;378(9785):57-72.
4. Escalante P. In the clinic. Tuberculosis. *Ann Intern Med*. 2009;150(11):ITC61-614.
5. Bailey TC, Fraser VJ, Spitznagel EL, Dunagan WC. Risk factors for a positive tuberculin skin test among employees of an urban, midwestern teaching hospital. *Ann Intern Med*. 1995;122(8):580-585.
6. Targeted tuberculin testing and treatment of latent tuberculosis infection. This official statement of the American Thoracic Society was adopted by the ATS Board of Directors, July 1999. This is a Joint Statement of the American Thoracic Society (ATS) and the Centers for Disease Control and Prevention (CDC). This statement was endorsed by the Council of the Infectious Diseases Society of America. (IDSA), September 1999, and the sections of this statement. *Am J Respir Crit Care Med*. 2000;161(4 Pt 2):S221-S247.
7. Chen J, Zhang R, Wang J, et al. Interferon-gamma release assays for the diagnosis of active tuberculosis in HIV-infected patients: a systematic review and meta-analysis. *PLoS One*. 2011;6(11):e26827.

8. Bamford AR, Crook AM, Clark JE, et al. Comparison of interferon-gamma release assays and tuberculin skin test in predicting active tuberculosis (TB) in children in the UK: a paediatric TB network study. *Arch Dis Child.* 2010;95(3):180-186.
9. Sia IG, Wieland ML. Current concepts in the management of tuberculosis. *Mayo Clin Proc.* 2011;86(4):348-361.
10. Jain AK. Tuberculosis of the spine: a fresh look at an old disease. *J Bone Joint Surg Br.* 2010;92(7):905-913.
11. Sinclair D, Abba K, Grobler L, Sudarsanam TD. Nutritional supplements for people being treated for active tuberculosis. *Cochrane Database Syst Rev.* 2011;(11):CD006086.
12. Farmer P, Robin S, Ramilus SL, Kim JY. Tuberculosis, poverty, and "compliance": lessons from rural Haiti. *Semin Respir Infect.* 1991;6(4):254-260.
13. Martineau AR, Timms PM, Bothamley GH, et al. High-dose vitamin D(3) during intensive-phase antimicrobial treatment of pulmonary tuberculosis: a double-blind randomised controlled trial. *Lancet.* 2011;377(9761):242-250.
14. American Thoracic Society; Centers for Disease Control and Prevention; Infectious Diseases Society of America. Treatment of tuberculosis. *MMWR Recomm Rep.* 2003;52(RR-11):1-77.
15. Lienhardt C, Cook SV, Burgos M, et al. Efficacy and safety of a 4-drug fixed-dose combination regimen compared with separate drugs for treatment of pulmonary tuberculosis: the Study C randomized controlled trial. *JAMA.* 2011;305(14):1415-1423.
16. WHO. Treatment of Tuberculosis: Guidelines—4th ed. Geneva, Switzerland: World Health Organization; 2010, http://whqlibdoc.who.int/publications/2010/9789241547833_eng.pdf, accessed January 2012.
17. Ziganshina LE, Squire SB. Fluoroquinolones for treating tuberculosis. *Cochrane Database Syst Rev.* 2008;(1):CD004795.
18. Blanc FX, Sok T, Laureillard D, et al. Earlier versus later start of antiretroviral therapy in HIV-infected adults with tuberculosis. *N Engl J Med.* 2011;365(16):1471-1481.
19. Abdool Karim SS, Naidoo K, Grobler A, et al. Integration of antiretroviral therapy with tuberculosis treatment, *N Engl J Med.* 2011;365(16):1492-1501.
20. Centers for Disease Control and Prevention. *Treatment Options for Latent Tuberculosis Infection*, http://www.cdc.gov/tb/publications/factsheets/treatment/LTBItreatmentoptions.htm, accessed January 2012.
21. Centers for Disease Control and Prevention. Recommendations for use of an isoniazid-rifapentine regimen with direct observation to treat latent *Mycobacterium tuberculosis* infection weekly. *MMWR Morb Mortal Wkly Rep.* 2011;60(48);1650-1653.
22. Sterling TR, Villarino ME, Borisov AS, et al. Three months of rifapentine and isoniazid for latent tuberculosis infection. *N Engl J Med.* 2011;365(23):2155-2166.
23. Horsburgh CR Jr, Goldberg S, Bethel J, et al. Latent TB infection treatment acceptance and completion in the United States and Canada. *Chest.* 2010;137(2):401-409.
24. Kaufmann SH, Hussey G, Lambert PH. New vaccines for tuberculosis. *Lancet.* 2010;375(9731):2110-2119.
25. Colditz GA, Brewer TF, Berkley CS, et al. Efficacy of BCG vaccine in the prevention of tuberculosis. Meta-analysis of the published literature. *JAMA.* 1994;271(9):698-702.
26. Aaby P, Roth A, Ravn H, et al. Randomized trial of BCG vaccination at birth to low-birth-weight children: beneficial nonspecific effects in the neonatal period? *J Infect Dis.* 2011;204(2):245-52.
27. Roth AE, Benn CS, Ravn H, et al. Effect of revaccination with BCG in early childhood on mortality: randomised trial in Guinea-Bissau. *BMJ.* 2010;340:c671.
28. Centers for Disease Control and Prevention. *Vaccine and Immunizations: TB Vaccine (BCG)*, http://www.cdc.gov/tb/topic/vaccines/default.htm, accessed May 2012.
29. Madhi SA, Nachman S, Violari A, et al. Primary isoniazid prophylaxis against tuberculosis in HIV-exposed children. *N Engl J Med.* 2011;365(1):21-31.
30. Harrison SW, Ganzhorn F, Radner A. Tuberculosis. In: Sloane P, Slatt L, Ebell M, et al, eds. *Essentials of Family Medicine*, 6th ed. Philadelphia, PA: Lippincott, Williams & Wilkins.
31. Raviglione MC, O'Brien RJ. Tuberculosis. In: Kasper DL, Braunwald E, Fauci AS, Hauser SL, Longo DL, Jameson, JL eds. *Harrison's Principles of Internal Medicine*, 16th ed. New York, NY: McGraw-Hill; 2005:953-966.
32. Centers for Disease Control and Prevention. *Infection Control in Health-Care Settings (Fact Sheet)*, http://www.cdc.gov/tb/publications/factsheets/prevention/ichcs.htm, accessed January 2012.
33. Davies PD. The role of DOTS in tuberculosis treatment and control. *Am J Respir Med.* 2003;2(3):203-209.

55 ASTHMA

Mindy A. Smith, MD, MS

PATIENT STORY

A 32-year-old Hispanic woman presents to your office with a chronic cough for 3 months. She states the cough is dry and started with a cold 3 months ago. She denies fever, chills, and night sweats. She has never been diagnosed with asthma or lung disease in the past. She does admit to having had persistent dry coughs that linger on after getting colds in the past. She is not sure what wheezing is but she has noticed a tight feeling in her chest at night with some whistling sound. On physical examination, her lungs are clear and she is moving air well. She is 5 feet tall and weighs 220 pounds, giving her a body mass index (BMI) of 43. Her peak expiratory flow (PEF) in the office is at 80% of predicted. Even though she is not wheezing her history and physical exam are highly suspicious for asthma. You prescribe a short-acting β_2-agonist rescue inhaler with spacer and order pulmonary function tests (PFTs). You have your nurse provide asthma education (including proper use of an inhaler) and suggestions for weight loss.

The patient returns 1 week later and the cough is much improved. You review her PFTs (**Figure 55-1**) and note that she has reversible bronchospasm especially in the small airways ($FEF_{25\%–75\%}$ shows a 70% improvement with inhaled albuterol). **Table 55-1** lists the meaning of typical abbreviations used with PFTs. Her lung volumes (**Figure 55-1B**) show hyperinflation with a high residual volume and her diffusing capacity is normal. The whole picture is consistent with asthma. An asthma action plan is created and a referral to a nutritionist is offered to help the patient with her obesity.

INTRODUCTION

Asthma is a chronic inflammatory airway disorder with variable airflow obstruction and bronchial hyperresponsiveness that is at least partially reversible, spontaneously or with treatment (e.g., β_2-agonist treatment). Patients with asthma have recurrent episodes of wheezing, breathlessness, chest tightness, and cough (particularly at night or in the early morning).

EPIDEMIOLOGY

- Estimated prevalence of asthma in noninstitutionalized adults older than age 18 years in the United States (2010) is approximately 8.2% (18.7 million cases).[1] There are 7 million children (9.4%) who currently have asthma. Rates of asthma are increasing; the greatest rise in rates is among black children, an almost 50% increase between 2001 and 2009.[2]
- The number of deaths from asthma in 2009 was 3388 (1.1/100,000 population).[1]
- Asthma accounts for 17 million visits per year (physician offices, emergency departments, and hospital outpatient sites).[1]

	Pre-Bronch			Post-Bronch		
	Pred	Actual	%Pred	Actual	%Pred	%Chng
— SPIROMETRY —						
FVC (L)	3.14	3.27	104	3.69	117	+12
FEV_1 (L)	2.64	2.16	81	2.68	101	+24
FEV_1/FVC (%)	85	66	77	73	85	+9
$FEF_{25-75\%}$ (L/s)	3.14	1.44	45	2.47	78	+70
FEF_{Max} (L/s)	6.14	4.83	78	6.73	109	+39
$FEF_{25\%}$ (L/s)	5.06	2.88	56	4.70	92	+62
$FEF_{50\%}$ (L/s)	4.36	1.72	39	2.82	64	+64
$FEF_{75\%}$ (L/s)	1.79	0.69	38	1.28	71	+86
FIVC (L)		3.24		3.75		+15
$FIF_{50\%}$ (L/s)	4.18	5.09	121	5.45	130	+6

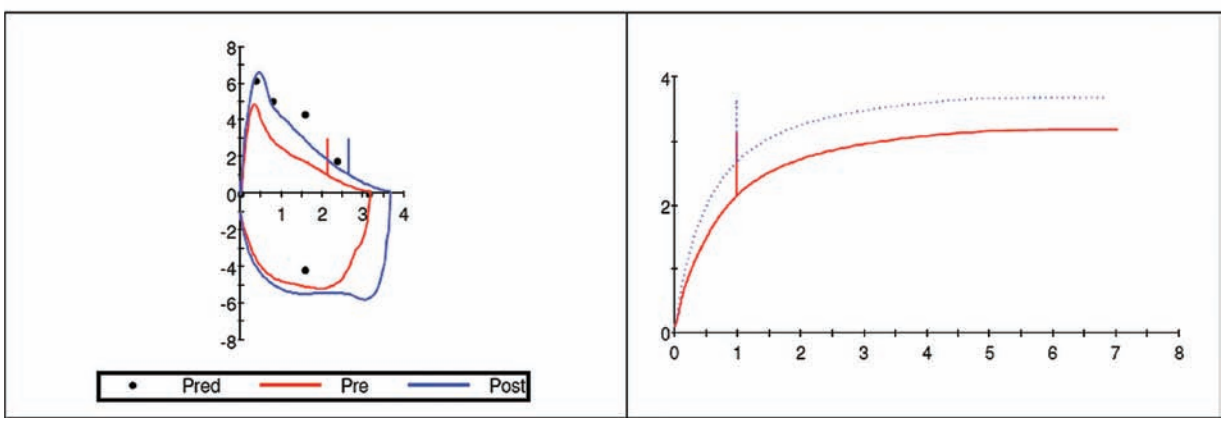

A

	Pre-Bronch			Post-Bronch		
	Pred	Actual	%Pred	Actual	%Pred	%Chng
— LUNG VOLUMES —						
SVC (L)	3.14	3.17	101			
TLC (Pleth) (L)	4.30	5.12	119			
RV (Pleth) (L)	1.23	1.95	158			
RV/TLC (Pleth) (%)	29	38	131			
TGV (L)	2.32	3.33	143			
Raw (cmH_2O/L/s)	1.86	3.71	199			
ERV (L)	1.16	1.38	118			
IC (L)	1.98	1.79	90			
— DIFFUSION —						
DLCOunc (mL/min/mm H_2)	17.53	27.25	155			
DLCOcor (mL/min/mm H_2)	17.53					
VA (L)	4.30	5.11	118			
DL/VA (mL/min/mm Hg)	4.08	5.33	130			

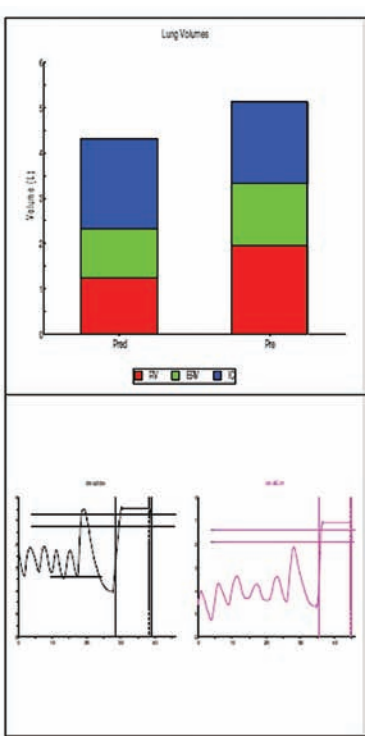

B

FIGURE 55-1 Pulmonary function tests in a woman with suspected asthma. **A.** Spirometry before and after bronchodilation with flow volumes loops and graph of forced vital capacity. The FEV_1 is normal, but the FEV_1/FVC ratio and $FEF_{25-75\%}$ are reduced. Following administration of bronchodilators, there is a good response especially in the small airways as represented by $FEF_{25-75\%}$. **B.** Lung volumes are all increased (especially the residual volume), indicating overinflation and air trapping. The diffusing capacity is normal. Conclusions: Minimal airway obstruction, overinflation, and a response to bronchodilators are consistent with a diagnosis of asthma. The patient has minimal obstructive airways disease of the asthmatic type.*%Chng*, Percent change;*%Pred*, percent predicted; *Pre-Bronch*, prebronchodilation; *Pred*, predicted; *Post-Bronch*, postbronchodilation. See **Table 55-1** for additional abbreviation explanations. (*Courtesy of Richard P. Usatine, MD.*)

TABLE 55-1 Pulmonary Function Tests: Key to Abbreviations

DLCO	Diffusing capacity of lung (using carbon monoxide measuring)
DL/VA	Diffusing capacity divided by alveolar volume
ERV (L)	Expiratory reserve volume
$FEF_{25\%}$ (L/s)	Forced expiratory flow rate when 25% of the FVC has been exhaled (slope of FVC curve at 25% exhaled)
$FEF_{25–75\%}$ (L/s)	Forced expiratory flow between 25% and 75% of capacity—same as maximal mid expiratory flow (MMFR)
$FEF_{50\%}$ (L/s)	Forced expiratory flow rate when 50% of the FVC has been exhaled
$FEF_{75\%}$ (L/s)	Forced expiratory flow rate when 75% of the FVC has been exhaled
FEF_{max} (L/s)	Forced expiratory flow maximum
FEV_1 (L)	Forced vital capacity at 1 second
FEV_1/FVC %	FEV_1 divided by FVC
$FIF_{50\%}$ (L/s)	Forced inspiratory flow at 50% capacity
FITC (L)	Forced inspiratory vital capacity
FVC (L)	Forced vital capacity
IC (L)	Inspiratory capacity
Raw	Airway resistance
RV (L)	Residual volume
RV/TLC	Residual volume divided by total lung capacity
SVC (L)	Slow vital capacity
TGV (L)	Thoracic gas volume
TLC (L)	Total lung capacity
VA (L)	Alveolar volume

- Asthma was the first-listed diagnosis for 479,000 hospital discharges in 2009 with an average length of stay of 4.3 days.[1]
- Estimated direct costs associated with asthma in the United States grew from approximately $53 billion in 2002 to approximately $56 billion in 2007 (6% increase).[2]

ETIOLOGY AND PATHOPHYSIOLOGY

- Although the precise cause is unknown, early exposure to airborne allergens (e.g., house-dust mite, cockroach antigens) and childhood respiratory infections (e.g., respiratory syncytial virus, parainfluenza) are associated with asthma development.
- In addition to environmental factors, asthma has an inherited component, although the genetics involved remain complex.[3] The gene ADAM33 (A Disintegrin And Metalloproteinase) may increase risk of asthma as metalloproteinases appear to affect airway remodeling.[4] A recent nested case-control study found that genetic variation in the ATPAF1 gene predisposed children of different racial backgrounds to asthma.[5]

- The pulmonary obstruction characterizing asthma results from combinations of mucosal swelling, mucous production, constriction of bronchiolar smooth muscles and neutrophils (the latter, particularly important in smokers or those with occupational asthma).[4] The smaller airways of children make them particularly susceptible. Over time, airway smooth muscle hypertrophy and hyperplasia, remodeling (thickening of the subbasement membrane, subepithelial fibrosis, and vascular proliferation and dilation), along with mucous plugging complicate the disease.[4]
- Allergen-induced acute bronchospasm involves immunoglobulin-E (IgE)-dependent release of mast cell mediators.[4]

RISK FACTORS

Based on a cohort study, early life (first 5 years) risk factors for diagnosed asthma at age 10 years includes:[6]

- Family history of asthma (maternal [odds ratio (OR), 2.26; 95% confidence interval (CI), 1.24 to 3.73]; paternal [OR, 2.30; 95% CI, 1.17 to 4.52]; sibling [OR, 2.00; 95% CI, 1.16 to 3.43]).
- Recurrent chest infections at 1 year of age (OR, 2.67; 95% CI, 1.12 to 6.40) and 2 years of age (OR, 4.11; 95% CI, 2.06 to 8.18).
- Atopy at 4 years of age (OR, 7.22; 95% CI, 4.13 to 12.62).
- Parental smoking at 1 year of age (OR, 1.99; 95% CI, 1.15 to 3.45).
- Male gender (OR, 1.72; 95% CI, 1.01 to 2.95).
- Recent use of acetaminophen has also been associated with asthma symptoms in adolescents (OR, 1.43; 95% CI, 1.33 to 1.53 and OR, 2.51; 95% CI, 2.33 to 2.70 for at least once a year and at least once a month use vs. no use, respectively).[7] One possible mechanism is through acetaminophen reducing the immune response and prolonging rhinovirus infection.[8]
- Modifiable risk factors include obesity (OR 3.3 for adult-onset asthma) and tobacco smoking; the latter also increases the risk of occupational asthma.[4] In one study, consumption of salty snacks (OR 4.8; 95% CI, 1.50 to 15.8) was strongly associated with the presence of asthma symptoms, especially in children with television/video-game viewing of more than 2 hours per day.[9]

DIAGNOSIS

The diagnosis of asthma is made on clinical suspicion (presence of symptoms of recurrent and partially reversible airflow obstruction and airway hyperresponsiveness) and confirmed with spirometry.[3] Alternative diagnoses should be excluded.

CLINICAL FEATURES

Asthma's most common symptoms are recurrent wheezing, difficulty breathing, chest tightness, and cough. An absence of wheezing or normal physical exam does not exclude asthma.[3] In fact, up to 25% of patients with asthma have normal physical exams even though abnormalities are seen on pulmonary function testing.[4] As part of the diagnosis of asthma, ask about the following:[3]

- Pattern of symptoms and precipitating factors. Symptoms often occur or worsen at night and during exercise, viral infection, exposure to inhalant allergens or irritants (e.g., tobacco smoke, wood smoke, airborne chemicals), changes in weather, strong emotional expression (laughing hard or crying), menstrual cycle, and stress.[3]
- Family history of asthma, allergy, or atopy in close relatives.
- Social history (e.g., daycare, workplace, social support).
- History of exacerbations (e.g., frequency, duration, treatment) and impact on patient and family.

Findings on physical exam may include:[3]

- Upper respiratory tract—Increased nasal secretion, mucosal swelling, and/or nasal polyp.
- Lungs—Decreased intensity of breath sounds is the most common (33% to 65% of patients).[4] Additional findings may include wheezing, prolonged phase of forced exhalation, use of accessory respiratory muscles, appearance of hunched shoulders, and chest deformity. During a severe exacerbation of asthma, minimal airflow may result in no audible wheezing.
- Skin—Atopic dermatitis and/or eczema (Chapters 145, Atopic Dermatitis, 147, Hand Eczema, and 148, Nummular Eczema). There is a strong association between asthma, allergic rhinoconjunctivitis, and eczema (**Figure 55-2**), although the "atopic or allergic triad," with the coexistence of all three conditions at one time (**Figure 55-3**), is not very common. Children with asthma are also more likely to develop pityriasis alba, a chronic skin disorder characterized by patches of lighter skin mainly on the face (**Figure 55-4**). In a U.S. study of children with physician-confirmed atopic dermatitis (N = 2270), 38% reported symptoms of asthma and allergic rhinitis on a survey[10]; similarly in a population study in Taiwan using the National Insurance register, of the 66,446 individuals diagnosed with atopic dermatitis, approximately 50% had a concomitant diagnosis of allergic rhinitis and/or asthma.[11] Data support a sequence of atopic manifestations beginning typically with atopic dermatitis in infancy followed by allergic rhinitis and/or asthma in later stages.[12]

Findings in patients with status asthmaticus (prolonged/severe asthma attack that is not responsive to standard treatment) may include:[4]

- Tachycardia (heart rate >120 beats/min) and tachypnea (respiratory rate >30 breaths/min).
- Use of accessory respiratory muscles.
- Pulsus paradoxus (inspiratory decrease in systolic blood pressure >10 mm Hg).
- Mental status changes (as a consequence of hypoxia and hypercapnia).
- Paradoxical abdominal and diaphragmatic movement on inspiration.

LABORATORY TESTING

Spirometry is recommended by National Asthma Education Program (NAEP) for all patients older than 4 years of age to determine airway obstruction that is at least partially reversible (**Figures 55-1, 55-5,** and **55-6**).[3] SOR B

FIGURE 55-2 Patient with severe asthma, atopic dermatitis, and allergic rhinitis—atopic triad. (*Courtesy of Richard P. Usatine, MD.*)

FIGURE 55-3 Two-year-old child with the "atopic triad" showing skin manifestations of atopic dermatitis. (*Courtesy of Richard P. Usatine, MD.*)

- Assess severity—Severity is defined as the intrinsic intensity of the disease process.[3] The NAEP divides severity into four groups: intermittent, persistent-mild, persistent-moderate, and persistent-severe (**Table 55-2**).
- Initially, severity can be assessed in the office, urgent, or emergency care setting with predicted forced expiratory volume in 1 second (FEV_1) or PEF; a value of less than 40% indicates a severe exacerbation. A value of equal to or greater than 70% predicted FEV_1 or PEF is a goal for discharge from the emergency care setting.
- Once asthma control is achieved, severity can be assessed by the step of care required for control (i.e., amount of medication) (**Table 55-2**).

Additional tests that may be useful include:[3]

- Pulmonary function testing if a diagnosis of chronic obstructive pulmonary disease (COPD), restrictive lung disease, or vocal cord dysfunction is considered.
- Bronchoprovocation (using methacholine, histamine, cold air, or exercise challenge) if spirometry is normal or near-normal and asthma is still suspected; a negative test is helpful in ruling out asthma.
- Pulse oximetry or arterial blood gas if hypoxia is suspected (e.g., cyanosis, rapid respiratory rate).
- In the emergency room setting, B-type natriuretic peptide can help distinguish between heart failure and pulmonary disease.[4]

FIGURE 55-4 Ten-year-old girl with pityriasis alba, atopic dermatitis, and asthma under control. (*Courtesy of Richard P. Usatine, MD.*)

IMAGING

A chest X-ray (CXR) is not useful for diagnosis but is helpful for excluding other diseases (e.g., pneumonia) or identifying comorbidity (e.g., heart failure). The main finding on CXR is hyperinflation (occurring in approximately 45% of patients with asthma).[4] Hyperinflation is manifested by the following:

- Increased anteroposterior (AP) diameter.
- Increased retrosternal air space (**Figure 55-7**).
- Infracardiac air.
- Low-set flattened diaphragms (best assessed in lateral chest).
- Vertical heart.

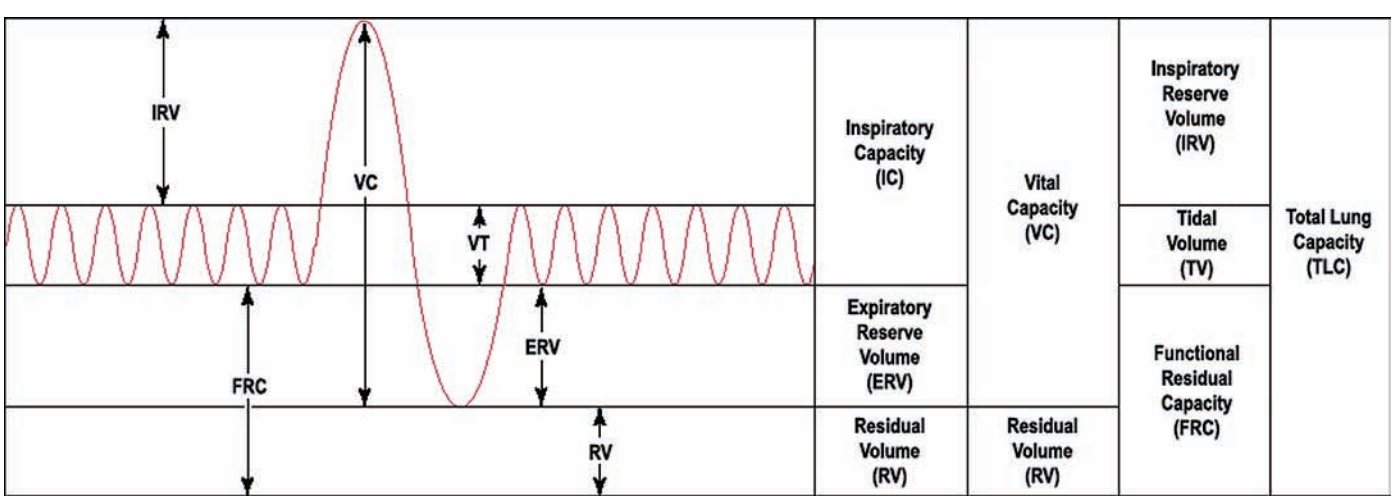

FIGURE 55-5 Graph of lung volumes showing the relationship of tidal volume to vital capacity and other important lung volumes. (*Courtesy of Wikimedia Commons and Vihsadas at http://commons.wikimedia.org/wiki/File:LungVolume.jpg*)

Atelectasis is another finding seen during acute severe episodes (**Figure 55-8**).

DIFFERENTIAL DIAGNOSIS

The differential diagnosis of an infant or child with wheezing includes:[3]

- Upper airway disease (e.g., allergic rhinitis, sinusitis)—Exam or imaging helps differentiate.
- Airway obstruction (foreign body, vascular rings, vocal cord dysfunction, tracheal stenosis, enlarged lymph node or tumor, infection, cystic fibrosis, heart disease)—Imaging helps differentiate.
- Other causes, such as recurrent cough or reflux. Cough-variant asthma (only cough) occurs especially in young children.

The differential diagnosis of an adult with episodic wheezing, chest-tightness, cough, and difficulty breathing includes:

- COPD—Usually begins after age 40 years with dyspnea (persistent or progressive or worse with exercise), chronic cough (even if intermittent or nonproductive) and/or sputum production, and/or a history of COPD risk factors, including a family history of COPD (Chapter 56, Chronic Obstructive Pulmonary Disease).
- Chronic bronchitis—A clinical diagnosis defined as the presence of cough and sputum production of at least 3 months in two consecutive years[13]; although often seen in patients with COPD, chronic bronchitis can occur in patients with normal spirometry.
- Pneumonia—Symptoms include fever, chills, and pleuritic chest pain; physical findings include dullness to percussion, bronchial breathing, egophony (E to A change), and crackles with area of infiltrate/pneumonia usually confirmed on CXR (Chapter 53, Pneumonia).
- Tuberculosis—Any age; symptoms of chronic cough. CXR shows infiltrate; positive culture confirms (Chapter 54, Tuberculosis).

FIGURE 55-6 Patient having pulmonary function tests (*Courtesy of Richard P. Usatine, MD.*)

TABLE 55-2 Classification of Asthma Severity

	Intermittent	Mild Persistent	Moderate Persistent	Severe Persistent
Symptoms	≤2 times/week	More than 2 days per week	Daily	Throughout the day
Nighttime Awakenings	≤2 times/month	3–4 × per month	Greater than once per week but not nightly	Nightly
Inhaler Use for symptom control (rescue use)	≤2 days/week	> 2 days per week, but not daily	Daily	Several times per day
Interference with Normal Activity	None	Minor limitation	Some limitation	Extremely limited
Lung Function	FEV_1 >80% predicted and normal between exacerbations	FEV_1 >80% predicted	FEV_1 >60%–80% predicted	FEV_1 less than 60% predicted

Source: National Asthma Education and Prevention Program. *Guidelines for the Diagnosis and Management of Asthma*—http://www. nhlbi.nih.gov/guidelines/asthma/asthsumm.pdf.

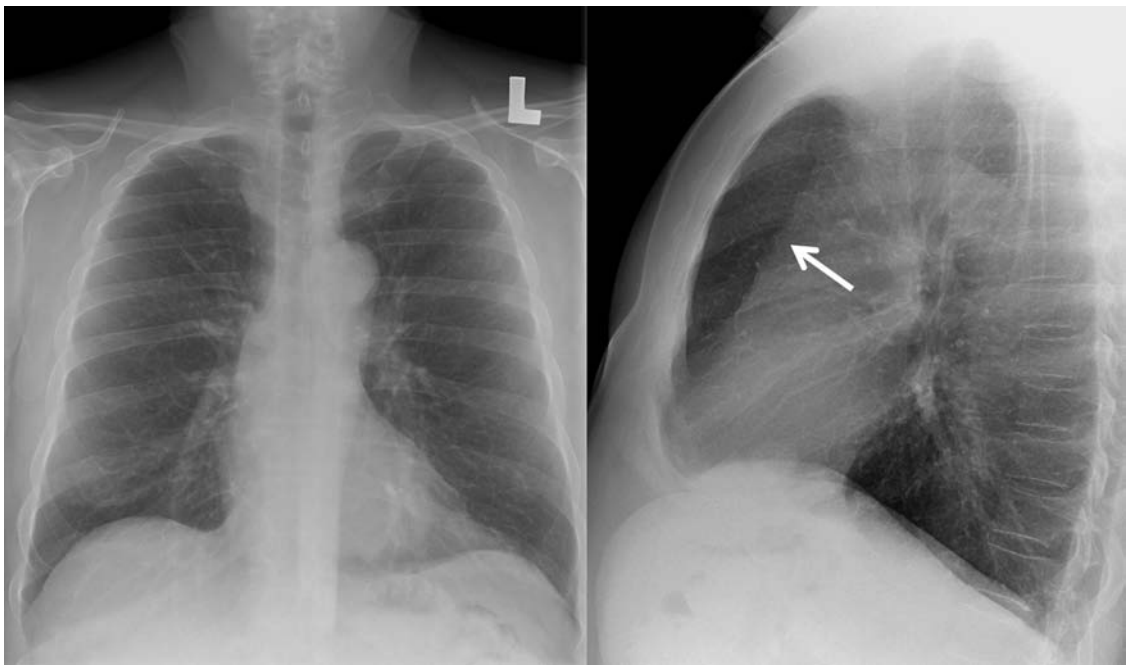

FIGURE 55-7 Acute asthma exacerbation with increased lung volumes on chest X-ray. The lateral projection reveals enlargement of the retrosternal clear space (*arrow*). (*Courtesy of Carlos Santiago Restrepo, MD.*)

- Congestive heart failure—Nonspecific basilar crackles, CXR shows cardiomegaly, echocardiogram confirms (Chapter 48, Heart Failure).
- Cough secondary to drugs (e.g., angiotensin-converting enzyme inhibitor), vocal cord dysfunction—Identified on medication history or PFT.
- Asthma may occur in conjunction with these conditions.

MANAGEMENT

NAEP outlines four components of care: assessment and monitoring, provision of education, control of environmental factors and comorbid conditions, and use of medications.[3] The goals of asthma therapy are two-fold:[3]

- Reduce impairment—Prevent chronic symptoms, require infrequent (twice weekly or less) use of rescue inhaler, maintain near normal pulmonary function, maintain normal activity levels, meet patient and family expectations and satisfaction with care.
- Reduce risk—Prevent recurrent exacerbations and minimize need for emergency or hospital care, prevent loss of lung function (for children, prevent reduced lung growth), and provide optimal pharmacotherapy while minimizing side effects and adverse effects.

NONPHARMACOLOGIC

- Exercise should be encouraged. In a randomized clinical trial (RCT) of aerobic exercise in patients with persistent asthma, the group randomized to exercise showed significant improvements in physical limitations, frequency of symptoms, health-related quality

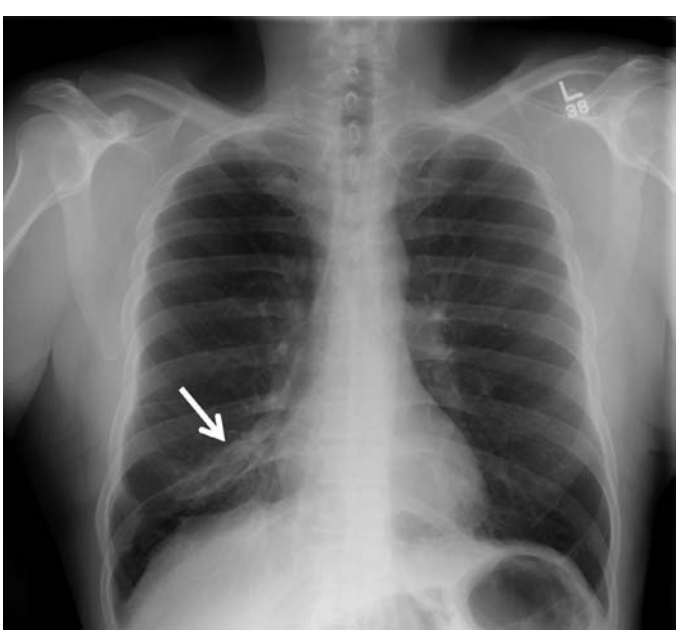

FIGURE 55-8 Acute asthma exacerbation in a 28-year-old man. Frontal chest radiograph demonstrates increased lung volumes and ill-defined opacity in the right infrahilar region consistent with middle lobe segmental atelectasis (*arrow*). (*Courtesy of Carlos Santiago Restrepo, MD.*)

of life, number of asthma-symptom-free days, and anxiety and depression levels over the control group (education and breathing exercises only).[14]

- For patients exposed to secondhand smoke in the home, use of high-efficiency particulate-arresting (HEPA) air cleaners was shown in one RCT to decrease unscheduled asthma visits for children ages 6 to 12 years; there was no difference between groups in parent-reported symptoms.[15]
- Dietary changes may also be useful. In a cross-sectional study, greater adherence to a Mediterranean-type diet was associated with a lower prevalence of asthma symptoms.[16]
- Provide patient education. SOR A Pediatric asthma education was shown in a metaanalysis to reduce mean number of hospitalizations and emergency department (ED) visits and the odds of an ED visit for asthma[17]; there was no influence of education on the odds of hospitalization or mean number of urgent physician visits. Reduction in hospital and ED visits and missed work/school also has been shown for self-management education with written asthma action plans and physician review.[4] In one RCT, peer-led asthma education compared to adult-led education was associated with more positive attitudes at 6 months and higher quality of life at 6 and 9 months.[18]
- Consider interventions to control home environmental triggers; comprehensive individual programs may reduce symptom days.[4] SOR B
  - Many people who have asthma are allergic to dust mites **(Figure 55-9)**. Two relatively easy interventions to decrease dust mite exposure are to encase pillows and mattresses in special dust-mite-proof covers and wash the sheets and blankets on the bed each week in hot water.[3]
  - Other suggestions for reducing environmental triggers can be found in the NAEP reference[3] at http://www.nhlbi.nih.gov/guidelines/asthma/asthsumm.pdf.



FIGURE 55-9 Dust mites under the microscope. Dust mites are a common allergen for patients who suffer from asthma and allergic rhinitis. Environmental control to minimize dust mite exposure can help control asthma for some individuals. (*Courtesy of Richard P. Usatine, MD.*)

MEDICATIONS

To determine appropriate medication management, assess severity based on symptoms, medication usage, and lung function (**Figure 55-1**). In addition, assess risk based on number of exacerbations requiring systemic steroids (**Figure 55-1**). For children, severity is assessed through symptoms, night time awakenings, interference with normal activity, and lung function; the latter if the child is older than 4 years of age. Risk is assessed by exacerbations requiring systemic steroids and treatment-related adverse effects.[3] A chart for children is available in the NAEP reference to facilitate these assessments and includes treatment protocols.[3]

For youths age 12 years and up and adults, persistent asthma can then be divided into mild, moderate, or severe; these categories are matched to steps of medications described below and shown in **Figure 55-1**. Children are categorized as controlled, not-well controlled, or very poorly controlled with steps of care suggested as well. The NAEP six steps of care with respect to asthma medications are:[3]

- **Step 1:** For all patients of all ages with intermittent asthma, an inhaled short-acting β_2-agonist (SABA) is recommended. SOR A Metered-dose inhalers with spacers are at least as effective (with fewer side effects) as nebulized treatment for most patients.

- **Step 2:** Low-dose inhaled corticosteroids (ICSs) are the preferred long-term control therapy for all ages with persistent asthma. SOR A Alternatives include cromolyn inhaler, leukotriene receptor antagonist (LTRA), nedocromil, or theophylline.
  - LTRAs are less effective than ICSs but better than placebo.[3] SOR A
  - In a RCT of preschool-age children with recurrent wheezing (N = 278), intermittent budesonide inhalation suspension (1 mg twice daily for 7 days, starting early during a predefined respiratory tract illness) was as effective as a daily low-dose regimen (0.5 mg nightly) in preventing acute exacerbations (about 1 fewer per patient-year) while reducing mean exposure to budesonide.[19]
- **Step 3:** Combination low-dose ICSs and long-acting β_2-agonist (LABA) or medium-dose ICSs are equally preferred options in patients older than 4 years of age.[3] SOR A Alternatives include low-dose ICS plus LTRA (less effective than ICS and LABA), theophylline, or zileuton. Theophylline requires monitoring serum concentration levels. Zileuton is less desirable because of limited supporting data and the need to monitor liver function. Authors of a Cochrane review found the combination ICS-LABA modestly more effective in reducing the risk of exacerbations requiring oral corticosteroids than higher-dose ICSs for adolescents and adults, but a trend toward increased risks of exacerbation and hospitalization among children.[20]
  - For patients age 4 years and younger, low-dose ICSs and LABA are suggested initially by NAEP, followed by increasing the ICS dose if persistent low lung function and more than 2 days per week of impairment[3]; the ICS-LABA combination may not reduce exacerbations but appears to improve PEF and growth.[21] Although serious asthma-related events (asthma-related deaths, intubations, and hospitalizations) attributable to LABAs appear to be greatest among children, in a metaanalysis, there was no statistically significant difference in serious events by age group for the subgroup on both ICS and LABA.[22]
  - One trial of step-up therapy for children with not-well-controlled persistent asthma on ICSs found that although combination ICS-LABA was most likely to result in a best response, some children had a best response to doubling ICSs or combination ICSs-LTRA.[23]
- **Step 4:** Combination medium-dose ICS and LABA. Alternatives are combination medium-dose ICS plus LTRA, theophylline, or zileuton (see above).
- **Step 5:** Combination high-dose ICS and LABA.
- **Step 6:** Combination high-dose ICS and LABA plus oral corticosteroid.

Other drug options:

- In a RCT, the addition of tiotropium bromide (a long-acting anticholinergic agent approved for the treatment of COPD but not asthma) to inhaled ICSs was superior to doubling the ICS dose in improving lung function and symptoms and noninferior to the addition of a LABA to ICSs (step 3 above).[24]
- Omalizumab should be considered for patients older than 11 years of age who have allergies or for adults who require step 5 or 6 care (severe asthma).[3] In a RCT with inner-city children, adolescents, and young adults (N = 419) with persistent asthma, omalizumab reduced symptom days and the proportion of subjects who had 1 or more exacerbations (30.3% vs. 48.8% on placebo).[25]

- To assist with smoking cessation, consider nicotine-replacement therapy (bupropion [150 mg, twice daily], varenicline [1 mg twice daily], nortriptyline [75 to 100 mg daily], or nicotine replacement [gum, inhaler, spray, patch]) and supportive counseling and follow-up; using these interventions improves rates of smoking cessation by up to two-fold (Chapter 236, Tobacco Addiction).[26–28] SOR A
- In patients with persistent asthma attributed to allergies, consider allergy immunotherapy.[3] SOR B One metaanalysis concluded that specific immunotherapy for patients with positive skin tests resulted in a reduction in need for increased medications (number needed to treat = 5) and another study in patients with high IgE found immunotherapy reduced exacervations.[4]
- Using proton pump inhibitor therapy in adults with asthma is unlikely to add significant benefit.[29] Among children with uncontrolled asthma on ICSs but without GI reflux symptoms, the addition of a lansoprazole (versus placebo) resulted in no improvement in symptoms or lung function, but increased adverse events.[30]

For patients with a mild *exacerbation* of asthma (dyspnea with activity, PEF ≥70% predicted or personal best), SABAs, and sometimes oral corticosteroids, are used for home management of patients following their action plan. NAEP does not recommend doubling the dose of ICSs for home management versus oral steroids for exacerbations.[3] A Cochrane review concluded that a short course of oral steroids was effective in reducing the number of relapses to additional care, hospitalizations, and use of SABA without an apparent increase in side effects.[31]

- Moderate exacerbation (dyspnea interferes with usual activity, PEF 40% to 69% predicted or personal best) usually requires an office or ED visit; SABA and oral corticosteroids (typically 40 to 60 mg prednisone for adults and 1 to 2 mg/kg per day of prednisolone liquid in two divided doses) are recommended for 3 to 10 days. SOR A SABA can be administered every 20 minutes as needed and the addition of inhaled ipratropium bromide may reduce the need for hospitalization (0.68 to 0.75).[4] SOR A Symptoms usually abate in 1 to 2 days.
- Severe exacerbation (dyspnea at rest, PEF <40% predicted or personal best) usually requires an ED visit and hospitalization is likely; combination SABA-anticholinergic nebulized treatment hourly or continuously as needed, oral corticosteroids, adjunctive treatment as needed (see below). Symptoms last for longer than 3 days after treatment begins.
- Life-threatening exacerbation (too dyspneic to speak, diaphoresis, PEF <25% predicted or personal best) requires an ED visit and/or hospitalization; consider intensive care unit, SABA-anticholinergic, intravenous corticosteroids, and adjunctive therapies.
- Oxygen therapy—Use to correct hypoxia in patients with moderate to life-threatening exacerbations; maintain O_2 saturation above 90%.[3,4] SOR C
- Consider intravenous magnesium sulfate or heliox-driven albuterol nebulization if severe exacerbation and unresponsive to treatment after initial assessments.
- Monitor response to treatment with serial assessments of FEV_1 or PEF. Pulse oximetry may be useful in children for assessing initial severity—a result of less than 92% to 94% after 1 hour is an indication for hospitalization.[3] For adults, pulse oximetry may be useful for severe episodes or when unable to perform lung function testing; repeat assessments for hypoxia are useful for predicting need for hospitalization, as are signs and symptoms at 1 hour posttreatment.
- Patients with severe or life-threatening exacerbation unresponsive to initial treatments may require intubation and mechanical ventilation. Drowsiness may be a symptom of impending respiratory failure.
- The following should not be used as they have no supporting evidence and may delay effective treatment: drinking large volumes of liquids; breathing warm, moist air; using nonprescription products, such as antihistamines or cold remedies; and pursed-lip and other forms of breathing.[3] In addition, the NAEP does not recommend use of methylxanthines, antibiotics (except as needed for comorbid conditions), aggressive hydration, chest physical therapy, mucolytics, or sedation in the ED or hospital setting.[3]

REFERRAL

- Consider referral to an asthma specialist if signs and symptoms are atypical, there are problems in assessing other diagnoses, or if additional specialized testing is needed.
- Referral or consultation should also be considered if there are difficulties achieving or maintaining control of asthma, if the patient required more than two bursts of oral systemic corticosteroids in 1 year or has an exacerbation requiring hospitalization, or if immunotherapy or omalizumab is considered.[3]
- Consultation with an asthma specialist should be conducted for patients with persistent asthma requiring step 4 care or higher and considered if a patient requires step 3 care.[3]

PREVENTION AND SCREENING

- Smoking cessation and avoidance of secondhand smoke, limiting occupational exposures and exposure to indoor air pollution may be preventive.
- Influenza and pneumococcal vaccination are recommended.[3] SOR B
- Despite limited data, vitamins A, D, and E; zinc; fruits and vegetables; and a Mediterranean diet may be useful for the prevention of asthma.[32] In addition, raw cow's milk consumption appears protective (adjusted OR, 0.59; 95% CI, 0.46 to 0.74).[33]

PROGNOSIS

- More than half of children with asthma will no longer have symptoms by age 6 years.[4]
- In a metaanalysis, maternal asthma was associated with an increased risk of low birthweight (relative risk [RR], 1.46; 95% CI 1.22 to 1.75), small for gestational age (RR, 1.22; 95% CI 1.14 to 1.31), preterm delivery (RR, 1.41; 95% CI 1.22 to 1.61), and preeclampsia (RR, 1.54; 95% CI 1.32 to 1.81).[34] The RR of preterm delivery and preterm labor became nonsignificant by active asthma management. Pregnancy does not appear to increase asthma severity, provided women continue to use their prescribed medications.[35]

- Among children, factors predictive of an asthma exacerbation include bronchiolitis or pneumonia during infancy, maternal eczema, paternal history of hay fever, asthma symptoms lasting 3 or more months/year, more than four scheduled physician visits for asthma in the previous year, and use of certain medications (SABAs, antiinflammatory medications, and one or more courses of oral steroids) in the prior year.[36] A 17-item checklist assessing asthma symptoms, use of medications and health-care services, and history has been demonstrated to be helpful for identifying children at high- or low-risk for asthma exacerbations.[36]
- For patients with an asthma exacerbation, the following factors place a patient at higher risk of asthma-related death; these patients should be advised to seek medical care early during an exacerbation:[3]
  - Previous severe exacerbation (e.g., intubation or intensive care unit admission for asthma).
  - Two or more hospitalizations or more than three ED visits in the past year.
  - Use of more than two canisters of SABA per month.
  - Difficulty perceiving airway obstruction or the severity of worsening asthma.
  - Low socioeconomic status or inner-city resident.

FOLLOW-UP

Many patients have asthma that is not well-controlled. In a cross-sectional study of 29 pediatric practices (n = 2429), 46% reported uncontrolled asthma (defined as a Childhood Asthma Control Test [C-ACT] or the Asthma Control Test [ACT] less than or equal to 19).[37]

One of the new aspects of the NAEP 2007 guideline is the focus on monitoring asthma severity and control, the latter defined as the degree to which manifestations of asthma are minimized by therapeutic interventions and the therapy goals are met.

- At each visit ask about frequency and intensity of symptoms and functional limitations currently or recently experienced (impairment). A self-assessment sheet for follow-up visits is available in the NAEP document and a simple symptom checklist can be downloaded from http://www.qvar.com/asthma/asthma-symptoms-checklist.aspx (accessed February 2012). Severity can be measured by the step of care required to maintain control (**Figure 55-1**).[3] SOR C
- In addition, at each visit, assess the likelihood of either asthma exacerbations, progressive decline in lung function (or lung growth for children), or risk of medication adverse effects. A patient self-assessment sheet rating asthma control (e.g., symptoms, PEF) and medication use is available in the NAEP reference.[3] Provision of a visually standardized, interpreted peak-flow graph to assist in understanding when to add medication or contact a healthcare provider may reduce need for oral steroids and urgent care visits.[38]
- For patients on medications, monitor treatment effectiveness ("Have you noticed a difference, for example, less breathlessness?") and side effects. Observe inhaler technique at least once to ensure optimal delivery.
- For smokers, encourage cessation.
- Document exacerbations/hospitalizations—This may indicate a need for additional treatment.
- Monitor for comorbidities (e.g., heart disease, chronic lung disease) and maximize control of those conditions.
- Measurement of fractional nitric oxide (NO) concentration in exhaled breath (Fe[NO]) is a quantitative, noninvasive method of measuring airway inflammation.[39] It is under investigation as a complementary tool to other ways of assessing airways disease, including asthma.

PATIENT EDUCATION

- Smoking cessation should be strongly and repeatedly encouraged. Exercise should also be encouraged along with weight loss, if obese, or maintenance of a healthy weight.
- The NAEP suggests that key educational messages include basic facts about asthma, the role of medications (i.e., rescue/short-term vs. control/long-term), and patient skills (e.g., correct inhaler technique, self-monitoring).
- Creation of an asthma action plan can be helpful in promoting self-management and greater understanding of warning signs of worsening asthma. An example of an action plan can be found in the NAEP document.[3] Asthma action plans usually use three zones, similar to traffic lights, with green zone representing good control (i.e., few symptoms, PEF 80% to 100%), yellow zone representing worsening or not-well-controlled asthma (i.e., mild to moderate symptoms, PEF 50% to 80%), and red zone representing an alert or warning (i.e., severe symptoms, PEF <50%), with advice to seek emergency care if not better after 15 minutes of rescue medication use and unable to reach their health-care provider. Each zone contains instructions for management that the primary care provider can modify.

PATIENT RESOURCES

For general information, these sites are helpful:

- American Lung Association. *Asthma*—**http://www.lung.org/lung-disease/asthma/.**
- MedlinePlus. *Asthma*—**http://www.nlm.nih.gov/medlineplus/asthma.html.**

PROVIDER RESOURCES

- National Asthma Education and Prevention Program. *Guidelines for the Diagnosis and Management of Asthma*—**http://www.nhlbi.nih.gov/guidelines/asthma/asthsumm.pdf.**
- Centers for Disease Control and Prevention. *FastStats: Asthma*—**http://www.cdc.gov/nchs/fastats/asthma.htm.**

REFERENCES

1. Centers for Disease Control and Prevention. *Asthma FastStats*. http://www.cdc.gov/nchs/fastats/asthma.htm. Accessed February 2012.
2. Centers for Disease Control and Prevention. *Asthma in the U.S.* http://www.cdc.gov/VitalSigns/Asthma/index.html. Accessed February 2012.

3. *National Asthma Education and Prevention Program Expert Panel Report 3 (2007)*. http://www.nhlbi.nih.gov/guidelines/asthma/asthsumm.pdf. Accessed February 2012.
4. Roett MA, Gillespie C. Asthma. In: Sloane PD, Slatt LM, Ebell MH, Smith MA, Power D, Viera AJ, eds. *Essential of Family Medicine*. Philadelphia: Lippincott Williams & Wilkins; 2011:607-623.
5. Schauberger EM, Ewart SL, Arshad SH, et al. Identification of ATPAF1 as a novel candidate gene for asthma in children. *J Allergy Clin Immunol*. 2011;128(4):753-760.
6. Arshad SH, Kurukulaaratchy RJ, Fenn M, Matthews S. Early life risk factors for current wheeze, asthma, and bronchial hyperresponsiveness at 10 years of age. *Chest*. 2005;127(2):502-508.
7. Beasley RW, Clayton TO, Crane J, et al. Acetaminophen use and risk of asthma, rhinoconjunctivitis, and eczema in adolescents: International Study of Asthma and Allergies in Childhood Phase Three. *Am J Respir Crit Care Med*. 2011;183(2):171-178.
8. Holgate ST. The acetaminophen enigma in asthma. *Am J Respir Crit Care Med*. 2011;183(2):147-151.
9. Arvaniti F, Priftis KN, Papadimitriou A, et al. Salty-snack eating, television or video-game viewing, and asthma symptoms among 10- to 12-year-old children: the PANACEA study. *J Am Diet Assoc*. 2011;111(2):251-257.
10. Kapoor R, Menon C, Hoffstad O, et al. The prevalence of atopic triad in children with physician-confirmed atopic dermatitis. *J Am Acad Dermatol*. 2008;58(1):66-73.
11. Hwang CY, Chen YJ, Lin MW, et al. Prevalence of atopic dermatitis, allergic rhinitis and asthma in Taiwan: a national study 2000-2007. *Acta Derm Venereol*. 2010;90(6):589-594.
12. Spergel JM. From atopic dermatitis to asthma. *Ann Allergy Asthma Immunol*. 2010;105(2):99-106.
13. Global Initiative for Chronic Obstructive Lung Disease (GOLD). *Global Strategy for the Diagnosis, Management and Prevention of COPD*. 2011. http://www.goldcopd.org/. Accessed January 2012.
14. Mendes FA, Goncalves RC, Nunes MP, et al. Effects of aerobic training on psychosocial morbidity and symptoms in patients with asthma: a randomized clinical trial. *Chest*. 2010;138(2):331-337.
15. Lanphear BP, Hornung RW, Khoury J, et al. Effects of HEPA air cleaners on unscheduled asthma visits and asthma symptoms for children exposed to secondhand tobacco smoke. *Pediatrics*. 2011;127(1):93-101.
16. Arvaniti F, Priftis KN, Papadimitriou A, et al. Adherence to the Mediterranean type of diet is associated with lower prevalence of asthma symptoms, among 10-12 year old children: the PANACEA study. *Pediatr Allergy Immunol*. 2011;22(3):283-289.
17. Coffman JM, Cabana MD, Halpin HA, Yelin EH. Effects of asthma education on children's use of acute care services: a meta-analysis. *Pediatrics*. 2008;121(3):575-586.
18. Rhee H, Belyea MJ, Hunt JF, Brasch J. Effects of a peer-led asthma self-management program for adolescents. *Arch Pediatr Adolesc Med*. 2011;165(6):513-519.
19. Zeiger RS, Mauger D, Bacharier LB, et al. Daily or intermittent budesonide in preschool children with recurrent wheezing. *N Engl J Med*. 2011;365(21):1990-2001.
20. Ducharme FM, Ni Chroinin M, Greenstone I, Lasserson TJ. Addition of long-acting beta2-agonists to inhaled steroids versus higher dose inhaled steroids in adults and children with persistent asthma. *Cochrane Database Syst Rev*. 2010;(4):CD005533.
21. Ni Chroinin M, Lasserson TJ, Greenstone I, Ducharme FM. Addition of long-acting beta-agonists to inhaled corticosteroids for chronic asthma in children. *Cochrane Database Syst Rev*. 2009;(3):CD007949.
22. McMahon AW, Levenson MS, McEvoy BW, et al. Age and risks of FDA-approved long-acting β_2-adrenergic receptor agonists. *Pediatrics*. 2011;128(5):e1147-e1154.
23. Lemanske RF Jr, Mauger DT, Sorkness CA, et al. Step-up therapy for children with uncontrolled asthma receiving inhaled corticosteroids. *N Engl J Med*. 2010;362(11):975-985.
24. Peters SP, Kunselman SJ, Icitovic N, et al. Tiotropium bromide step-up therapy for adults with uncontrolled asthma. *N Engl J Med*. 2010;363(18):1715-1726.
25. Busse WW, Morgan WJ, Gergen PJ, et al. Randomized trial of omalizumab (anti-IgE) for asthma in inner-city children. *N Engl J Med*. 2011;364(11):1005-1015.
26. Hughes JR, Stead LF, Lancaster T. Antidepressants for smoking cessation. *Cochrane Database Syst Rev*. 2007;(1):CD000031.
27. Stead LF, Perera R, Bullen C, Mant D, Lancaster T. Nicotine replacement therapy for smoking cessation. *Cochrane Database Syst Rev*. 2008;(1):CD000146.
28. Stead LF, Bergson G, Lancaster T. Physician advice for smoking cessation. *Cochrane Database Syst Rev*. 2008;(2):CD000165.
29. Chan WW, Chiou E, Obstein KL, et al. The efficacy of proton pump inhibitors for the treatment of asthma in adults: a meta-analysis. *Ann Intern Med*. 2011;171(7):620-629.
30. Writing Committee for the American Lung Association Asthma Clinical Research Centers, Holbrook JT, Wise RA, Gold BD, et al. Lansoprazole for children with poorly controlled asthma: a randomized controlled trial. *JAMA*. 2012;307(4):373-381.
31. Rowe BH, Spooner CH, Ducharme FM, et al. Corticosteroids for preventing relapse following acute exacerbations of asthma. *Cochrane Database Syst Rev*. 2007;(3):CD000195.
32. Nurmatov U, Devereux G, Sheikh A. Nutrients and foods for the primary prevention of asthma and allergy: systematic review and meta-analysis. *J Allergy Clin Immunol*. 2011;127(3):724-733.e1-e30.
33. Loss G, Apprich S, Waser M, et al. The protective effect of farm milk consumption on childhood asthma and atopy: the GABRIELA study. *J Allergy Clin Immunol*. 2011;128(4):766-773.e4.
34. Murphy VE, Namazy JA, Powell H, et al. A meta-analysis of adverse perinatal outcomes in women with asthma. *BJOG*. 2011;118(11):1314-1323.
35. Belanger K, Hellenbrand ME, Holford TR, Bracken M. Effect of pregnancy on maternal asthma symptoms and medication use. *Obstet Gynecol*. 2010;115(3):559-567.
36. Forno E, Fuhlbrigge A, Soto-Quiros ME, et al. Risk factors and predictive clinical scores for asthma exacerbations in childhood. *Chest*. 2010;138(5):1156-1165.

37. Liu AH, Gilsenan AW, Stanford RH, et al. Status of asthma control in pediatric primary care: results from the pediatric Asthma Control Characteristics and Prevalence Survey Study (ACCESS). *J Pediatr*. 2010;157(2):276-281.

38. Janson SL, McGrath KW, Covington JK, et al. Objective airway monitoring improves asthma control in the cold and flu season: a cluster randomized trial. *Chest*. 2010;138(5):1148-1155.

39. Dweik RA, Boggs PB, Erzurum SC, et al. American Thoracic Society Committee on Interpretation of Exhaled Nitric Oxide Levels (FENO) for Clinical Applications. An official ATS clinical practice guideline: interpretation of exhaled nitric oxide levels (FENO) for clinical applications. *Am J Respir Crit Care Med*. 2011;184(5):602-615.

56 CHRONIC OBSTRUCTIVE PULMONARY DISEASE

Mindy A. Smith, MD, MS

PATIENT STORY

A 74-year-old woman and longtime smoker presents with fatigue and shortness of breath. She has not seen a physician for many years and says she has been basically healthy. On physical examination, she is found to be pale, mildly cachectic, and her lips are cyanotic. Her breath sounds are distant, although crackles can be heard in both lung bases. Her heart sounds are best heard in the epigastrium; a third heart sound is present. She has mild peripheral edema. Her resting pulse oximetry is 74%. Her chest X-ray (CXR) shows emphysema (**Figure 56-1**) and her echocardiogram confirms heart failure.

FIGURE 56-1 Emphysema with mild hyperinflation and increased interstitial markings. (*From Miller WT Jr. Diagnostic Thoracic Imaging. New York: McGraw-Hill; 2006:106, Figure 3-37 A. Copyright 2006.*)

INTRODUCTION

Chronic obstructive pulmonary disease (COPD) is defined as a disease state characterized by airflow limitation that is usually progressive and associated with an abnormal inflammatory response of the lung to noxious particles or gases.[1] COPD is preventable and treatable. Some patients have significant extrapulmonary effects (particularly cardiac) that may contribute to disease severity. Worldwide, tobacco smoke is the primary cause of COPD (**Figure 56-2**).

SYNONYMS

Emphysema (technically refers to destruction of the alveoli).

EPIDEMIOLOGY

- Estimated prevalence of COPD in adults older than age 18 years in the United States (2008) is about 13.2 million cases, or 4% of the population (95% confidence interval [CI], 3.8 to 4.1).[2]
- Fourth leading cause of death both in United States and worldwide. Mortality rates have declined for men from 1999 to 2006 (57 per 100,000 to 46.4 per 100,000) and remained fairly stable for women (35.3 per 100,000 to 34.2 per 100,000).[3]
- In a study in Latin America, prevalence rates ranged from 7.8% to 19.7% of the population;[4] a prevalence of between 3% and 11% has been reported in never-smokers.[1] This high rate among never-smokers is most likely related to indoor cooking with open wood fires.
- In a Swedish study of COPD (birth cohorts from 1919 to 1950), the 10-year cumulative incidence rate of COPD was 13.5% using Global Initiative for Chronic Obstructive Lung Disease (GOLD) criteria (**Table 56-1**) based on 1109 patients with baseline

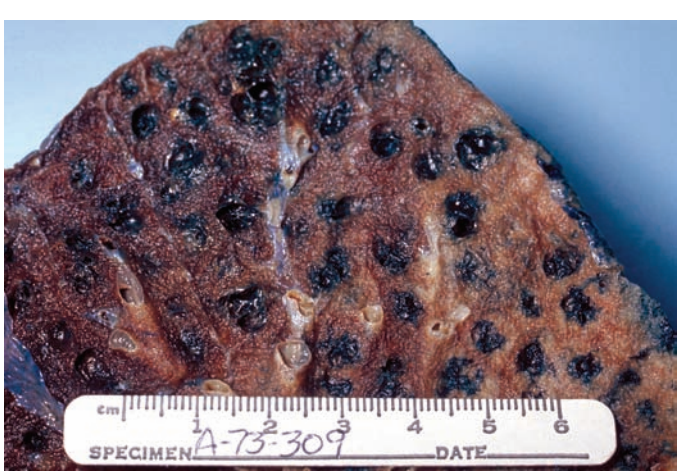

FIGURE 56-2 Gross pathology of lung showing centrilobular emphysema caused by tobacco smoking. Close-up of cut surface shows multiple cavities lined by heavy black carbon deposits. (*Courtesy of Centers for Disease Control and Prevention [CDC] and Dr. Edwin P. Ewing, Jr.*)

TABLE 56-1 COPD Severity—GOLD Grade

Grade	FEV_1/FVC	FEV_1
Mild COPD (GOLD 1)	<0.7	≥80% predicted
Moderate COPD (GOLD 2)	<0.7	<80% but ≥50% predicted
Severe COPD (GOLD 3)	<0.7	<50% but ≥30% predicted
Very severe COPD (GOLD 4)	<0.7	<30% predicted or FEV_1 <50% with respiratory failure or right-sided heart failure

Abbreviations: FEV_1, forced expiratory volume in 1 second; *FVC*, forced vital capacity.

respiratory symptoms (76.6% of the original symptomatic cohort and 16.7% of the total cohort).[5]

- Estimated direct costs associated with COPD in the United States are more than $29 billion with additional indirect costs of $20.4 billion.[1]

ETIOLOGY AND PATHOPHYSIOLOGY

- Mediated by chronic inflammatory responses to environmental factors, especially cigarette smoke, that results in recruitment of inflammatory cells in terminal airspaces and release of elastolytic proteinases that damage the extracellular lung matrix and cause ineffective repair of elastin and other matrix components.
- Oxidative stress may be an important amplifying mechanism in COPD development and exacerbations.[1] In addition, there appears to be an imbalance between proteases and antiproteases in the lungs of patients with COPD.
- The inflammatory process leads to obstruction and later fibrosis of small airways and the destruction of lung parenchyma. Circulating inflammatory mediators may contribute to muscle wasting and cachexia and worsen comorbidities such as heart failure and diabetes.[1]
- Gas exchange abnormalities result in hypoxemia and hypercapnia.
- Pulmonary hypertension may occur as a result of hypoxic vasoconstriction of small pulmonary arteries.
- Genetic mutations (e.g., α_1-antitrypsin deficiency [1% to 2% of cases; affects 1 in 2000 to 5000 individuals]) are present in some patients. Suspect a genetic mutation when emphysema is found in a patient age 45 to 50 years or younger, a positive family history of COPD, primarily basilar disease, or a minimal smoking history.[6] Single-nucleotide polymorphisms at three loci—TNS1, GSTCD, and HTR4—are associated with COPD, as is genetic variation in the transcription factor SOX5.[7,8]

RISK FACTORS

- Smoking (direct and passive)—COPD relative risk (RR) for ever smoking is 2.89 (95% CI, 2.63 to 3.17) and RR for current smoking is 3.51 (95% CI, 3.08 to 3.99).[9]

- Airway hypersensitivity (15% of the population attributable risk).[1]
- Occupational exposures (e.g., gold and coal mining, cotton textile dust).[1,2,6] The estimated fraction of COPD symptoms or functional impairment attributed to these exposures is 10% to 20%.[1]
- Indoor air pollution from burning wood and other biomass fuels, particularly with open fires, poorly functioning stoves, and poorly ventilated dwellings.[1]
- Reduced maximal attained lung function (e.g., preterm vs. full-term infants).[1]
- Infections (e.g., early childhood infection, chronic bronchitis, HIV, tuberculosis).[1]
- Poverty.
- Parental history of COPD (odds ratio [OR] 1.73).[10]
- α_1-antitrypsine deficiency (genetic disorder).

DIAGNOSIS

A diagnosis of COPD should be considered in a patient older than age 40 years with dyspnea (persistent or progressive or worse with exercise), chronic cough (even if intermittent or nonproductive) and/or sputum production, and/or a history of COPD risk factors including a family history of COPD.[1]

CLINICAL FEATURES

- COPD's three most common symptoms are cough, sputum production, and exertional dyspnea. In one study of newly diagnosed patients, most presented with cough (85%) and exertional dyspnea (70%); almost half (45%) reported increased sputum production.[11] Most patients were classified in GOLD stage 0 to 1 (42%) or 2 (46%) (see **Table 56-1**).
- Patients may also report chest tightness, often following exertion; fatigue, weight loss, and anorexia are symptoms later in the disease.
- Several validated questionnaires are available to assess symptoms in patients with COPD; GOLD recommends the Modified British Medical Research Council (MMRC) questionnaire (**Box 56-1**) or the 8-question COPD Assessment Test (CAT; http://catestonline.org).[1]
- Physical findings may include:
  - Tobacco odor and nicotine staining of fingernails.
  - Increased expiratory phase or expiratory wheezing.
  - Signs of hyperinflation—Barrel chest, poor diaphragmatic excursion.
  - Use of accessory muscles of respiration—Intercostals, sternocleidomastoid, and scalene muscles.
  - Late in illness—Cyanosis of the lips and nail beds, wasting, and *cor pulmonale* (right-sided heart failure—signs include increased jugular-venous distention, right ventricular heave, third heart sound, ascites, and peripheral edema).

BOX 56-1 MMRC Dyspnea Scale

0 – Not troubled with breathlessness except with strenuous exercise.

1 – Troubled by shortness of breath when hurrying on the level or walking up a slight hill.

2 – Walks slower than people of the same age on the level because of breathlessness or has to stop for breath when walking at own pace on the level.

3 – Stops for breath after walking about 100 yards or after a few minutes on the level.

4 – Too breathless to leave the house or breathless when dressing or undressing.

LABORATORY TESTING

Postbronchodilator spirometry secures the diagnosis and provides the severity classification:[1,12] SOR B

- At risk—Chronic cough and sputum production with normal spirometry.

Additional tests that may be useful in management are sputum culture (in acute exacerbations to assist in confirming pneumonia), complete blood count (to identify anemia or polycythemia), and blood gases (confirms hypoxia when peripheral oxygen saturation is <92% or respiratory failure [PCO_2 >45]).[1,13]

- A serum level of α_1-antitrypsin should be measured if you suspect a genetic mutation (young age at presentation [≤45 years], lower lobe emphysema, family history, minimal smoking history).
- Exercise (walking) tests to assess disability or response to rehabilitation.[1]

IMAGING

A CXR is not useful for diagnosis but is helpful for excluding other diseases or identifying comorbidity (e.g., heart failure). Findings on CXR include:[3]

Hyperinflation manifested by the following (**Figures 56-1** to **56-3**):

- Increased anteroposterior (AP) diameter.
- Increased retrosternal air space.
- Infracardiac air.
- Low-set flattened diaphragms (best assessed in lateral chest).
- Vertical heart.
- Bullae are difficult to recognize in CXR but are easily seen on CT (**Figures 56-4** to **56-8**).
- Paucity of vascular markings in periphery (**Figure 56-2**).
- Pulmonary hypertension (CXR shows enlarged central pulmonary arteries).
- α_1-Antitrypsine deficiency leads to early COPD even in nonsmokers. See **Figure 56-9** for advanced pulmonary emphysema in a 30-year-old woman with α_1-antitrypsine deficiency. The CXR shows increased lung volumes, flattening of the diaphragms, and a vertical heart. A CT may show extensive panlobular emphysema of the mid and lower lung zones (**Figure 56-10**). The vascular markings are prominent in the upper lobes, demonstrating "cephalization" of flow.

A chest CT scan is the current definitive test for emphysema, but the findings do not influence treatment.[6] Cystic and bullous lesions are better delineated with CT scan (**Figures 56-4**, **56-5**, and **56-7**), and collapsing airways with inspiration and expiration can also be demonstrated with CT. Chest CT is recommended if surgery is contemplated.[1]

Echocardiography is suggested if features of cor pulmonale are present.[13]

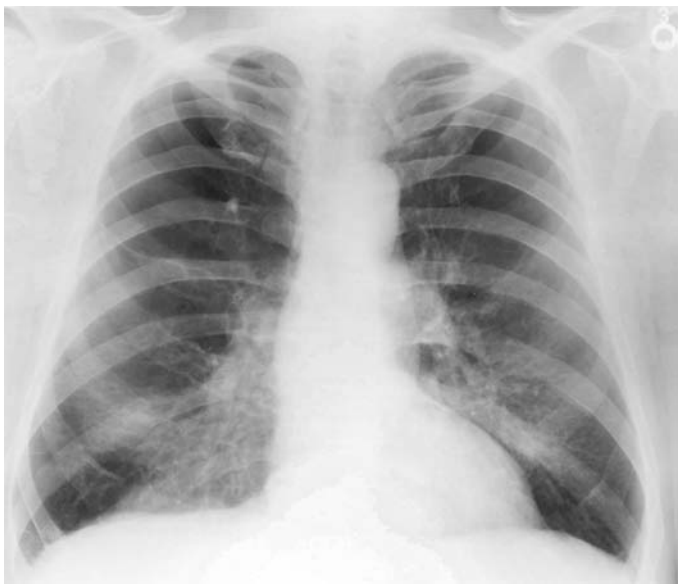

FIGURE 56-3 Posteroanterior (PA) radiograph showing flattened hemidiaphragms and decreased vascular markings from hyperinflation as a result of air trapping in a patient with COPD. (*From Miller WT Jr. Diagnostic Thoracic Imaging. New York: McGraw-Hill; 2006:108, Figure 3-40 A and B. Copyright 2006.*)

FIGURE 56-4 Lateral view in the patient in *Figure 56-2* showing increased anteroposterior (AP) diameter from hyperinflation as a result of air trapping in a patient with COPD. (*From Miller WT Jr. Diagnostic Thoracic Imaging. New York: McGraw-Hill; 2006:108, Figure 3-40 A and B. Copyright 2006.*)

DIFFERENTIAL DIAGNOSIS

The differential diagnosis of an individual with persistent productive cough and dyspnea includes:

- Asthma—Begins before age 40 years in most (often in childhood), usually episodic and characterized by increased responsiveness to stimuli (e.g., allergens, occupational exposures). Nocturnal awakenings with symptoms are common. This condition is reversible with bronchodilators (see Chapter 55, Asthma).
- Chronic bronchitis—A clinical diagnosis defined as the presence of cough and sputum production of at least 3 months in 2 consecutive years;[1] although often seen in patients with COPD and associated with development and/or acceleration of fixed airflow limitation, chronic bronchitis can occur in patients with normal spirometry.
- Pneumonia—Symptoms include fever, chills, and pleuritic chest pain; physical findings include dullness to percussion, bronchial breathing, egophony (E to A change), and crackles with area of infiltrate/pneumonia usually confirmed on CXR (see Chapter 53, Pneumonia).
- Tuberculosis—Any age; symptoms of chronic cough. CXR shows infiltrate; positive culture confirms (see Chapter 54, Tuberculosis).
- Congestive heart failure—Nonspecific basilar crackles; CXR shows cardiomegaly; echocardiogram confirms (see Chapter 48, Heart Failure).
- Lung cancer—Symptoms may occur with central or endobronchial growth of the tumor (e.g., cough, hemoptysis, wheeze, stridor, dyspnea), collapse of airways from tumor obstruction (e.g., post-obstructive pneumonitis), involvement of the pleura or chest wall (e.g., pleuritic chest pain), or from regional spread of the tumor (e.g., dysphagia, hoarseness from recurrent laryngeal nerve paralysis, dyspnea, and elevated hemidiaphragm from phrenic nerve paralysis). Findings on CXR or chest CT may be focal or unilateral and tissue confirms diagnosis (see Chapter 58, Lung Cancer).

Any of these processes/illnesses may occur in conjunction with emphysema.

FIGURE 56-5 Centrilobular emphysema seen on high resolution CT of the chest. Diffuse emphysematous changes throughout both lungs are seen as darker round areas of cyst-like lesions. (*Courtesy of Carlos S. Restrepo, MD.*)

MANAGEMENT

Management of COPD is based on symptoms, risk or history of exacerbations, and severity/predicted survival. GOLD places patients into four categories as shown in **Table 56-2**.

NONPHARMACOLOGIC

Nonpharmacologic therapies that should be considered for all patients are:[1,5]

- Influenza and pneumococcal vaccination, which are most effective in the elderly. SOR B Also consider vaccination against herpes zoster as patients with COPD are at increased risk (adjusted hazard ratio [HR] 1.68, 95%CI, 1.45 to 1.95), especially if using inhaled steroids (adjusted HR 2.09, 95% CI, 1.38 to 3.16) or oral steroids (adjusted HR 3.00, 95% CI, 2.40 to 3.75).[14]
- Patient education (multidisciplinary and self-management training) improves patient outcomes and reduces costs and hospitalizations.[1,15] SOR A
- Pulmonary rehabilitation programs decrease hospitalization at 6 to 12 months, increase quality of life, and improve dyspnea and exercise capacity.[1,5] SOR A Pulmonary rehabilitation may increase survival and improve recovery following hospitalization.[1] SOR B

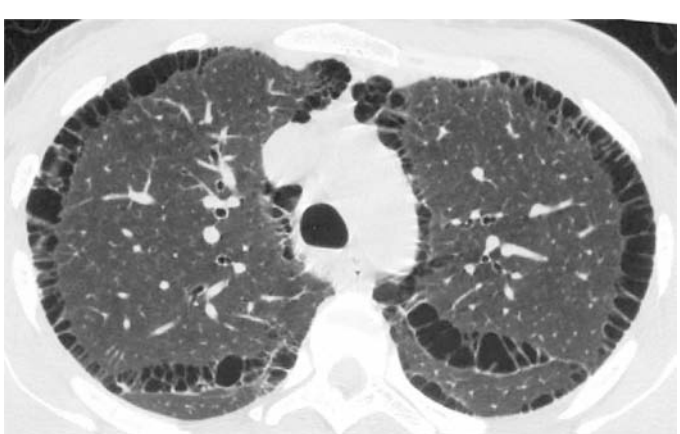

FIGURE 56-6 CT at the level of the aortic arch showing a pattern of cysts in the subpleural lung with an upper-lung zone predominance characteristic of mild paraseptal emphysema. (*From Miller WT Jr. Diagnostic Thoracic Imaging. New York: McGraw-Hill; 2006:110, Figure 3-41 D. Copyright 2006.*)

- There are no clear benefits of continuous positive pressure ventilation in patients with COPD unless they have coexisting sleep apnea, in which case there is an associated improvement in survival and decrease in risk of hospitalization.[1]

For patients with an *acute exacerbation* of COPD (defined as an increase in symptoms and change in the amount and character of the sputum and anticipated to occur about 1 to 3 times a year in patients with moderate or severe COPD), the following assessments and nonpharmacologic interventions are recommended:[1,13]

- Assess severity SOR C—Physical signs of a more severe exacerbation include use of accessory muscles of respiration, paradoxical chest wall movements, worsening (or new onset) cyanosis, new peripheral edema, hemodynamic instability, or worsening mental status. Consider pulse oximetry.
- Consider CXR for those with moderate to severe symptoms and focal lung findings to exclude other diagnoses.
- Consider an ECG if suspecting cardiac complication or comorbidity.
- Consider a complete blood count (to identify anemia, polycythemia, or leukocytosis) and a theophylline level if on theophylline at admission. Consider sputum or blood cultures if clinically appropriate (e.g., purulent sputum, fever).
- Consider blood gas for those with moderate to severe symptoms, advanced COPD, history of hypercarbia, or mental status changes.
- Hospitalize—Based on clinical judgment; recommended in those with marked increase in symptom intensity or onset of new physical signs (e.g., cyanosis); frequent exacerbations; older age; the presence of respiratory acidosis, hypercarbia, hypoxemia; severe underlying COPD or serious comorbidities (e.g., heart failure); failure to respond to outpatient treatment; or poor home support.[1] SOR C

MEDICATIONS

For patients with *stable COPD*, only smoking cessation and oxygen therapy for those with hypoxia at rest have been shown to improve outcome.[1] SOR A

- To assist with smoking cessation, consider nicotine replacement therapy (bupropion [150 mg, twice daily], varenicline [1 mg twice daily], nortriptyline [75 to 100 mg daily], or nicotine replacement [gum, inhaler, spray, patch]) and supportive counseling and follow-up; using these interventions improves rates of smoking cessation by up to 2-fold (see Chapter 236, Tobacco Addiction).[1,16–18] SOR A
- Oxygen therapy is initiated for patients who have a resting O_2 saturation less than 89% (PaO_2 at or below 55 mm Hg [7.3 kPa], confirmed twice over a 3-week period or <89% in a patient with pulmonary hypertension or right-sided heart failure); chronic administration (<15 hours/day) in patients with chronic respiratory failure is associated with greater survival.[1] SOR B

The following are recommended for symptomatic relief:

- Short-acting inhaled bronchodilators—β-agonists (e.g., albuterol) or anticholinergic agents (e.g., ipratropium bromide)—intermittent use; SOR A these agents are comparable in efficacy and the choice of agent should be based on side effects, cost, and patient preference.[1]
- Inhaled long-acting β-agonists (e.g., salmeterol, indacaterol)—Regular treatment is more effective, but more costly and may be associated

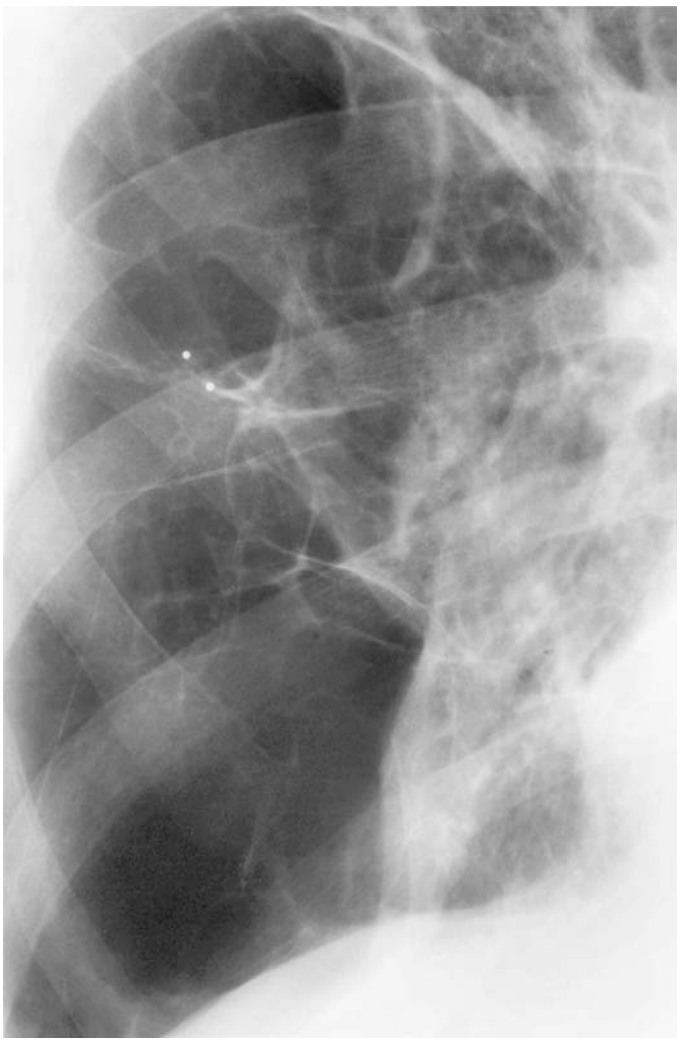

FIGURE 56-7 Close-up of CXR showing multiple large bullae in a patient with COPD. (*From Miller WT Jr. Diagnostic Thoracic Imaging. New York: McGraw-Hill; 2006:111, Figure 3-42. Copyright 2006.*)

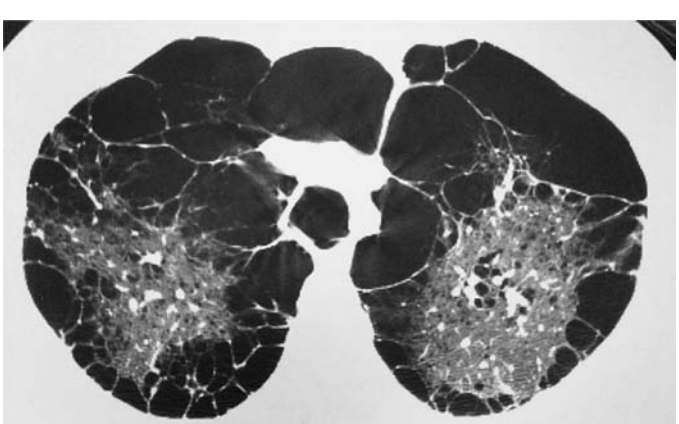

FIGURE 56-8 CT scan of the patient in **Figure 56-6** (at the level of the pulmonary veins) showing multiple large peripheral bullae; the patient was diagnosed with severe paraseptal emphysema. (*From Miller WT Jr. Diagnostic Thoracic Imaging. New York: McGraw-Hill; 2006:111, Figure 3-42. Copyright 2006.*)

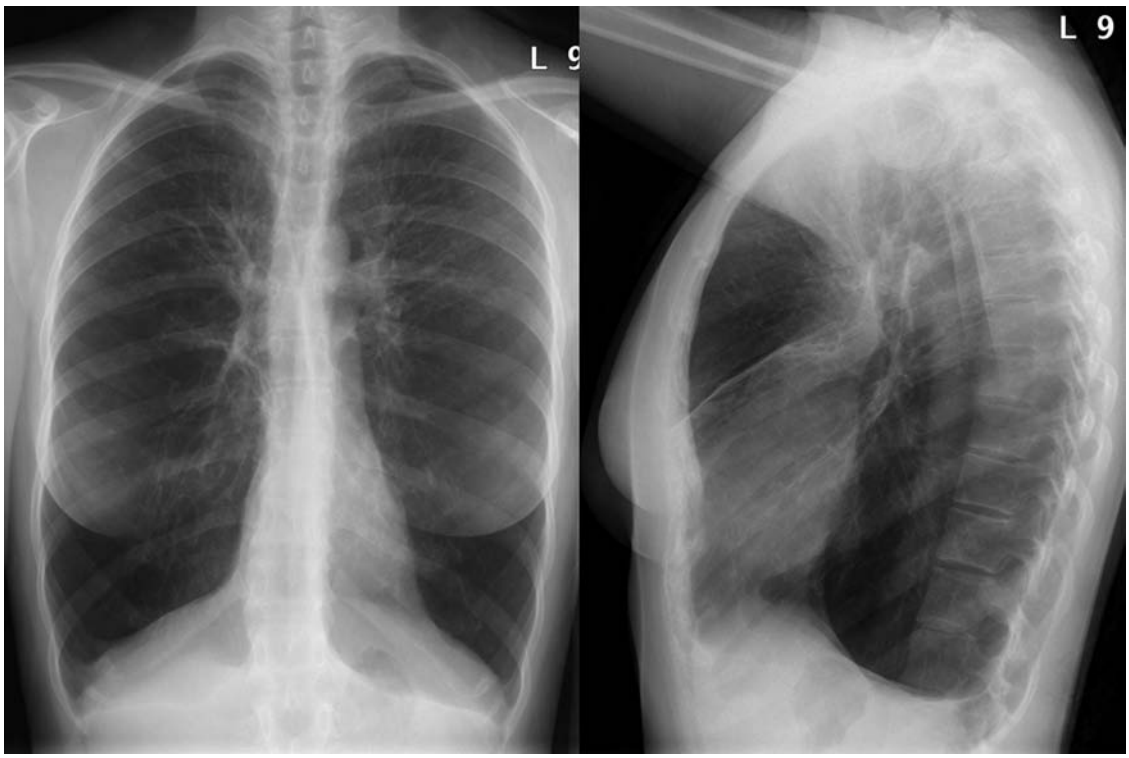

FIGURE 56-9 Advanced pulmonary emphysema in a 30-year-old woman with α_1-antitrypsine deficiency. The CXR shows increased lung volumes, flattening of the diaphragms, and a vertical heart. (*Courtesy of Carlos S. Restrepo, MD.*)

with tachycardia and tremor.[1] SOR A Salmeterol reduces the risk of hospitalization but has no effect on mortality or the rate of lung function decline. Adverse effects include tachycardia, tremor.

- Combination long-acting β-agonists with inhaled anticholinergic agents can provide incremental benefit for symptoms.[1] SOR B They may also be used in combination with inhaled corticosteroids to improve health status and reduce exacerbations in patients with moderate SOR B to severe COPD SOR A.[1]
- Inhaled long-acting anticholinergic (tiotropium)—Tiotropium has a duration of action of 24 hours and reduces exacerbations and improves symptoms.[1] SOR A Adverse effects include dry mouth;[1] a recent metaanalysis concluded that mortality was increased with use of this medication (2.4% vs. 1.6% on placebo; number needed to harm over 1 year = 124).[19]
- Inhaled glucocorticoids—Regular use is associated with improved quality of life and a small decrease in the frequency of exacerbations (approximately half-a-day per month), but an increase in oral candidiasis, easy bruising, and bone loss (the latter shown for long-term triamcinolone acetonide).[1] SOR A These agents are recommended for patients with moderate to severe COPD or for frequent exacerbations. Parenteral steroids do not benefit patients with stable COPD. In a Cochrane review comparing inhaled glucocorticoids with long-acting β-agonists, the authors concluded that effects were comparable on most outcomes, including reduced frequency of exacerbation, with β-agonists conferring a small additional benefit in lung function while inhaled corticosteroid therapy showed a small advantage in health-related quality of life but increased the risk of pneumonia.[20]

FIGURE 56-10 CT of the chest in the same 30-year-old woman with α_1-antitrypsine deficiency. Coronal reformation of the CT demonstrates extensive panlobular emphysema of the mid and lower lung zones, which is a typical distribution of this condition. The vascular markings are more prominent in the upper lobes showing "cephalization" of flow. (*Courtesy of Carlos S. Restrepo, MD.*)

TABLE 56-2 Recommended Management of COPD Based on GOLD Grade and Exacerbation History

Patient Group	Description	Non-Pharmacological Treatment	Medications (First choice)
A	Few symptoms (MMRC grade 0-1 or CAT score <10) and 0-1 exacerbations per year, and/or mild impairment (GOLD 1 or 2)*	Smoking cessation, physical activity, vaccinations	Short-acting bronchodilator (anticholinergic OR beta2-agonist as needed)
B	More symptoms (MMRC >= 2 or CAT score >= 10) and 0-1 exacerbations per year; and or mild impairment (GOLD 1 or 2).*	Smoking cessation, physical activity, vaccinations, pulmonary rehabilitation	Long-acting bronchodilator (anticholinergic OR beta2-agonist)
C	Few symptoms (MMRC grade 0-1 or CAT score <10) and >= 2 exacerbations per year, and/or severe impairment (GOLD 3 or 4).*	Smoking cessation, physical activity, vaccinations, pulmonary rehabilitation	Inhaled corticosteroid AND Long acting bronchodilator (beta2-agonist OR anticholinergic)
D	More symptoms (MMRC >= 2 or CAT score >= 10) and >= 2 exacerbations per year, and/or severe impairment (GOLD 3 or 4).*	Smoking cessation, physical activity, vaccinations, pulmonary rehabilitation	Inhaled corticosteroid AND Long acting bronchodilator (beta2-agonist OR anticholinergic)

*See laboratory testing.
Abbreviations: MMRC = Modified British Medical Research Council; CAT = COPD Assessment Test; GOLD = Global Initiative for Chronic Obstructive Lung Disease.

- Theophylline—Mildly effective for symptoms SOR A and reduction in exacerbations SOR B, but associated with nausea and risk of toxicity with high blood levels.[1,21]
- Mucolytic agents (e.g., guaifenesin, carbocysteine, potassium iodide)—Produce a small decrease in the frequency of exacerbations (0.5 fewer exacerbations/year) and in disability days.[22] SOR A GOLD does not recommend these medications for routine use.[1]
- Early investigation has begun on a phosphodiesterase-4 inhibitor (roflumilast) in patients with moderate to severe COPD already on an inhaled bronchodilator. There may be some improvement in exacerbations but other relevant patient outcome data are unevaluated; side effects include nausea, diarrhea, weight loss, and headache.[23]

For patients with *an acute exacerbation* of COPD, the three classes of medications commonly used are bronchodilators, corticosteroids, and antibiotics.

- Inhaled bronchodilators—Both β-agonist and anticholinergics can be used alone or in combination; metered-dose inhalers with proper patient instruction perform as well as nebulized treatments and are less expensive; nebulizers can be considered for sicker patients.[1] SOR A
- Glucocorticoid—Use oral (prednisone 30 to 40 mg/day for 10 to 14 days) or intravenous glucocorticoids if the patient is unable to tolerate oral medication. Steroids decrease recovery time, hospital length of stay, and relapse rates.[1] SOR A
- Antibiotics—Treating COPD with antibiotics is controversial. In a systematic review, investigators found four placebo-controlled clinical trials and a metaanalysis that demonstrated significant improvements in outcome for patients treated with an antibiotic versus placebo.[24] In contrast, six studies failed to demonstrate statistical differences. GOLD recommends the use of antibiotics for 5 to 10 days for

patients with increased dyspnea, sputum volume, and sputum purulence, and for patients who require mechanical ventilation.[1] SOR B Antibiotics should also be considered for patients with increased purulent sputum and either increased sputum volume or dyspnea.[1] SOR C

- The choice of antibiotic does not appear to influence outcome and should be based on local bacterial resistance and severity of disease. For exacerbations of lesser severity, use narrow-spectrum antibiotics such as amoxicillin, doxycycline, or trimethoprim-sulfamethoxazole. For exacerbations of greater severity use broad-spectrum antibiotic such as azithromycin, amoxicillin-clavulanate, levofloxacin, cefuroxime axetil or hospitalize for IV antibiotics. SOR C
- Oxygen therapy—Use to maintain O_2 saturation above 88%.[1] SOR C
- Noninvasive mechanical ventilation (NIV) decreases mortality, decreases the need for intubation, and reduces hospital length of stay.[1] SOR A However, patients may find it difficult to tolerate. It should be considered for patients with moderate to severe dyspnea, moderate to severe acidosis (pH <7.35), hypercapnia ($PaCO_2$ >6.0 kPa, 45 mm Hg), and respiratory rate greater than 25 breaths/min.[1]
- Mechanical ventilation support should be considered for patients with the above indications who are unable to tolerate NIV and for those with severe dyspnea, massive aspiration or inability to remove respiratory secretions, respiratory failure [life-threatening hypoxemia (PaO_2 <5.3 kPa, 40 mm Hg or PaO_2/FiO_2 <200 mm Hg), severe acidosis (pH <7.25) and hypercapnia ($PaCO_2$ > 8.0 kPa, 60 mm Hg)], heart rate less than 50 beats per minute with loss of alertness, severe ventricular arrhythmias, and respiratory arrest.[1] SOR C

COMPLEMENTARY AND ALTERNATIVE THERAPY

- There is supporting evidence for immunostimulant therapy (reduced hospital days), cineole (a constituent of eucalyptus oil on reducing severity and duration of exacerbations and improved lung function, dyspnea, and quality of life), and ginseng (on lung function and quality of life) in patients with COPD.[25–27] SOR B
- Tai Chi and Qigong (twice weekly 60-minute sessions) significantly improved exercise tolerance and 3-month exacerbation rate compared with either exercise or no intervention in patients with COPD.[28] SOR B

SURGERY

Two surgical therapies with the best supporting evidence may be considered for patients with severe disease despite optimal medical therapy:

- Lung volume reduction surgery (LVRS)—Patients with upper lobe predominant disease and low postrehabilitation exercise capacity appear to gain the most symptom benefit.[1] LVRS in contrast to medical treatment improves survival (54% vs. 38.7%) in patients with severe upper-lobe emphysema and low postrehabilitation exercise capacity.[1] SOR A
- Lung transplantation—Considered for patients who are 65 years of age or younger with no comorbid disease. GOLD lists a BODE (body mass, obstruction, dyspnea, exercise index (see Prognosis) greater than 5 as an indication for transplantation.[1,29] However, investigators from Norway found no obvious survival benefit from lung transplantation in a cohort of 219 patients accepted onto the lung transplant waiting list.[30]

REFERRAL

Reasons to consider referral include diagnostic uncertainty; severe disease, including onset of cor pulmonale; assessment for oxygen, corticosteroid, or pulmonary rehabilitation therapy; surgical assessment (bullous lung disease, severe disease); rapid decline in FEV_1; early onset or family history of COPD; frequent infections; and hemoptysis.[13] There are new treatments for α_1-antitrypsine deficiency and these patients should be referred to a pulmonologist for evaluation and treatment.

PREVENTION AND SCREENING

- The best prevention for COPD is to not smoke or to quit smoking. Limiting occupational exposures and exposure to indoor air pollution is also preventive.
- GOLD recommends active case finding but not general population screening.[1] The U.S. Preventive Services Task Force also recommends against screening adults for COPD using spirometry.[31]

PROGNOSIS

- In a longitudinal study of 227 patients with COPD in Japan, 5-year survival was 73%; level of dyspnea and not FEV_1 was correlated with survival rates.[32]
- Severity classification (see "Laboratory Testing" above) can be used in predicting risk of exacerbations (1.1 to 1.3 for severe and 1.2 to 2.0 for very severe), hospitalizations per year (0.11 to 0.2 for moderate, 0.25 to 0.3 for severe, and 0.4 to 0.54 for very severe), or 3-year mortality (11% for moderate, 15% for severe, 24% for very severe).[1]
- The BODE index is a composite measure using body mass, obstruction (FEV_1, % predicted), dyspnea (MMRC score), and exercise (6-minute walking distance) to predict mortality. The risk of death from respiratory causes increases by more than 60% for each 1 point increase in BODE score.[33] An online calculator is available at **http://www.newleaf.com/ns/c/calculator-bode.htm?storeID=j3qsseqx5cs92j2000akhmccqja05t39** (accessed January 2012).
- In-hospital mortality of patients admitted for hypercapnic exacerbation with acidosis is approximately 10% and mortality at 1-year postdischarge for those requiring mechanical ventilation is 40%.[1]

FOLLOW-UP

Patients should be followed regularly for disease progression or development of complications.

- At each visit ask about symptoms, activity, and sleep. For smokers, encourage cessation. Symptom questionnaires can be used (every 2 to 3 months suggested by GOLD) for monitoring.

- Spirometry is recommended by GOLD at least yearly.[1] SOR C
- For patients on medications, monitor treatment effectiveness ("have you noticed a difference, for example less breathlessness") and side effects. Observe inhaler technique at least once to ensure optimal delivery.
- Document exacerbations/hospitalizations; this may indicate a need for additional treatment.
- Monitor for comorbidities (e.g., heart disease, hypertension, osteoporosis, anxiety/depression, lung cancer, infections, metabolic syndrome, and diabetes) and maximize control of those conditions. The GOLD reference provides information on management of these conditions in patients with COPD.[1]
- Additional concerns for patients with severe COPD include need for long-term oxygen, need for specialist referral, including social services; biyearly evaluation should be considered.[13] Hospice referral may also be appropriate.

PATIENT EDUCATION

Smoking cessation should be strongly and repeatedly encouraged. Progressive exercise should also be encouraged, activities that brace the arms and allow use of accessory muscles of respiration are better tolerated—these include pushing a cart, walker, or wheelchair, and use of a treadmill.

PATIENT RESOURCES

For general information, these sites are helpful:

- American Lung Association—**http://www.lungusa.org/lung-disease/copd/.**
- Journal of the American Medical Association, Chronic Obstructive Pulmonary Disease, Patient Page with good diagram—**http://jama.ama-assn.org/content/300/20/2448.full.pdf.**
- The Family of COPD Support Programs, COPD Support, Inc. This Web site provides information and links to support groups—**http://www.copd-support.com.**

PROVIDER RESOURCES

- Several evidence-based guidelines are available at—**http://www.guideline.gov/** and search on *COPD*.
- Evidence-based guidelines are also available on GOLD (GOLD) at—**http://www.goldcopd.org/.**
- Another Web site that has links to National Heart, Lung, and Blood Institute, American Academy of Family Physicians, and others, patient education materials and an interactive tutorial is—**www.nlm.nih.gov/medlineplus/copdchronicobstructivepulmonarydisease.html.**

REFERENCES

1. Global Initiative for Chronic Obstructive Lung Disease (GOLD). *Global Strategy for the Diagnosis, Management and Prevention of COPD,* 2011. http://www.goldcopd.org/uploads/users/files/GOLD_Report_2011_Feb21.pdf. Accessed January 2012.
2. Centers for Disease Control and Prevention. *Chronic Obstructive Pulmonary Disease Morbidity* (Table 10.3). http://www2a.cdc.gov/drds/WorldReportData/FigureTableDetails.asp?FigureTableID=944&GroupRefNumber=T10-09. Accessed January 2012.
3. Centers for Disease Control and Prevention. *Chronic Obstructive Pulmonary Disease (COPD). Data and Statistics.* http://www.cdc.gov/copd/data.htm. Accessed January 2012.
4. Menezes AM, Perez-Padilla R, Jardim JR, et al. Chronic obstructive lung disease in five Latin American cities (the PLATINO study): a prevalence study. *Lancet.* 2005;366:1875-1881.
5. Lindberg A, Jonsson AC, Ronmark E, et al. Ten-year cumulative incidence of COPD and risk factors for incident disease in asymptomatic cohort. *Chest.* 2005;127:1544-1552.
6. Reilly JJ, Silverman EK, Shapiro SD. Chronic obstructive pulmonary disease. In: Kasper DL, Braunwald E, Fauci AS, Hauser SL, Longo DL, Jameson JL, eds. *Harrison's Principles of Internal Medicine*, 16th ed. New York: McGraw-Hill; 2005: 1547-1554.
7. Soler Artigas M, Wain LV, Repapi E, et al. Effect of five genetic variants associated with lung function on the risk of chronic obstructive lung disease, and their joint effects on lung function. *Am J Respir Crit Care Med.* 2011;184(7):786-795.
8. Hersh CP, Silverman EK, Gascon J, et al. SOX5 is a candidate gene for chronic obstructive pulmonary disease susceptibility and is necessary for lung development. *Am J Respir Crit Care Med.* 2011;183(11):1482-1489.
9. Forey BA, Thornton AJ, Lee PN. Systematic review with meta-analysis of the epidemiological evidence relating smoking to COPD, chronic bronchitis and emphysema. *BMC Pulm Med.* 2011;11:36.
10. Hersh CP, Hokanson JE, Lynch DA, et al. Family history is a risk factor for COPD. *Chest.* 2011;140(2):343-350.
11. Kornmann O, Beeh KM, Beier J, et al. Global Initiative for Obstructive Lung Disease. Newly diagnosed chronic obstructive pulmonary disease. Clinical features and distribution of the novel stages of the Global Initiative for Obstructive Lung Disease. *Respiration.* 2003;70:67-75.
12. Qaseem A, Wilt TJ, Weinberger SE, et al. Diagnosis and management of stable chronic obstructive pulmonary disease: a clinical practice guideline update from the American College of Physicians, American College of Chest Physicians, American Thoracic Society, and European Respiratory Society. *Ann Intern Med.* 2011; 155(3):179-191.
13. National Guideline Clearinghouse, Agency for Healthcare Research and Quality. *Chronic Obstructive Pulmonary Disease. Management of Chronic Obstructive Pulmonary Disease in Adults in Primary and Secondary Care.* http://www.guideline.gov/content.aspx?id=23801&search=chronic+obstructive+pulmonary+disease. Accessed January 2012.
14. Yang YW, Chen YH, Wang KH, et al. Risk of herpes zoster among patients with chronic obstructive pulmonary disease: a population-based study. *CMAJ.* 2011;183:E275-E280.
15. Gadoury MA, Schwartzman K, Rouleau M, et al. Chronic Obstructive Pulmonary Disease axis of the Respiratory Health

Network, Fonds de la recherche en sante du Quebec (FRSQ). Self-management reduces both short- and long-term hospitalisation in COPD. *Eur Respir J.* 2005;26(5):853-857.

16. Hughes JR, Stead LF, Lancaster T. Antidepressants for smoking cessation. *Cochrane Database Syst Rev.* 2007;(1):CD000031.
17. Stead LF, Perera R, Bullen C, et al. Nicotine replacement therapy for smoking cessation. *Cochrane Database Syst Rev.* 2008;(1): CD000146.
18. Stead LF, Bergson G, Lancaster T. Physician advice for smoking cessation. *Cochrane Database Syst Rev.* 2008;(2):CD000165.
19. Singh S, Loke YK, Enright PL, Furberg CD. Mortality associated with tiotropium mist inhaler in patients with chronic obstructive pulmonary disease: systematic review and meta-analysis of randomised controlled trials. *BMJ.* 2011;342:d3215.
20. Spencer S, Evans DJ, Karner C, Cates CJ. Inhaled corticosteroids versus long-acting beta(2)-agonists for chronic obstructive pulmonary disease. *Cochrane Database Syst Rev.* 2011;(12): CD007033.
21. Ram FS. Use of theophylline in chronic obstructive pulmonary disease: Examining the evidence. *Curr Opin Pulm Med.* 2006;12(2): 132-139.
22. Poole P, Black PN. Mucolytic agents for chronic bronchitis or chronic obstructive pulmonary disease. *Cochrane Database Syst Rev.* 2010;(2):CD001287.
23. Rennard SI, Calverley PM, Goehring UM, et al. Reduction of exacerbations by the PDE4 inhibitor roflumilast—the importance of defining different subsets of patients with COPD. *Respir Res.* 2011;12:18.
24. Russo RL, D'Aprile M. Role of antimicrobial therapy in acute exacerbations of chronic obstructive pulmonary disease. *Ann Pharmacother.* 2001;35(5):576-581.
25. Collet JP, Shapiro P, Ernst P, et al. Effects of an immunostimulating agent on acute exacerbations and hospitalizations in patients with chronic obstructive pulmonary disease. The PARI-IS Study Steering Committee and Research Group. Prevention of Acute Respiratory Infection by an Immunostimulant. *Am J Respir Crit Care Med.* 1997;156:1719-1724.
26. Worth H, Schacher C, Dethlefsen U. Concomitant therapy with Cineole (Eucalyptole) reduces exacerbations in COPD: a placebo-controlled double-blind trial. *Respir Res.* 2009;10:69.
27. An X, Zhang AL, Yang AW, et al. Oral ginseng formulae for stable chronic obstructive pulmonary disease: a systematic review. *Respir Med.* 2011;105:165-176.
28. Chan AW, Lee A, Suen LK, Tam WW. Tai chi Qigong improves lung functions and activity tolerance in COPD clients: a single blind, randomized controlled trial. *Complement Ther Med.* 2011;19:3-11.
29. Puhan MA, Garcia-Aymerich J, Frey M, et al. Expansion of the prognostic assessment of patients with chronic obstructive pulmonary disease: the updated BODE index and the ADO index. *Lancet.* 2009;374:704-711.
30. Stavem K, Bjortuft O, Borgan O, et al. Lung transplantation in patients with chronic obstructive pulmonary disease in a national cohort is without obvious survival benefit. *J Heart Lung Transplant.* 2006;25(1):75-84.
31. United States Preventive Services Task Force. *Screening for Chronic Obstructive Pulmonary Disease Using Spirometry.* http://www.uspreventiveservicestaskforce.org/uspstf/uspscopd.htm. Accessed January 2012.
32. Nishimura K, Izumi T, Tsukino M, Oga T. Dyspnea is a better predictor of 5-year survival than airway obstruction in patients with COPD. *Chest.* 2002;121:1434-1440.
33. Celli BR, Cote CG, Martin JM, et al. The body-mass index, airflow obstruction, dyspnea, and exercise capacity index in chronic obstructive pulmonary disease. *N Engl J Med.* 2004;350(10): 1005-1012.

57 PULMONARY EMBOLUS

Mindy A. Smith, MD, MS

PATIENT STORY

A 52-year-old woman developed acute shortness of breath 3 weeks after a hysterectomy. She denied leg pain or swelling. She has no chronic medical problems and takes no medications. Her pulse is 105 beats/min, respiratory rate is 20 breaths/min, and the rest of her examination is unremarkable. She had an elevated hemidiaphragm on chest X-ray (CXR). These findings placed her at moderate risk for pulmonary embolism (PE) based on the Geneva score. Chest CT demonstrated a moderate-sized PE similar to the one shown in **Figure 57-1**. She was treated with anticoagulation without complications.

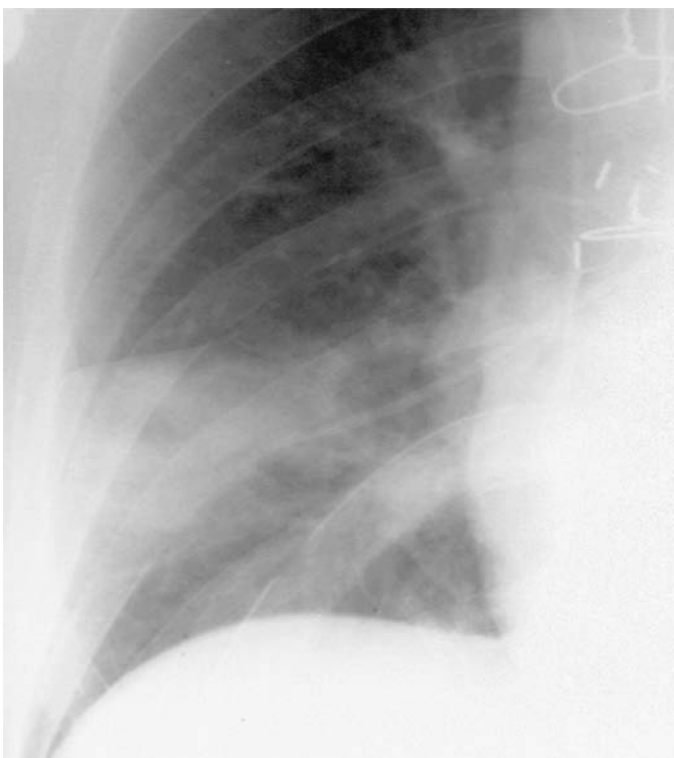

FIGURE 57-1 CXR showing a wedge-shaped pulmonary infarction with the base on the pleural surface and the apex at the tip of a pulmonary artery catheter; the catheter caused the occlusion of a peripheral artery. (*From Miller WT Jr. Diagnostic Thoracic Imaging. New York: McGraw-Hill; 2006:272, Figure 5-61. Copyright 2006.*)

INTRODUCTION

PE is a thromboembolic occlusion (total or partial) of one or more pulmonary arteries, usually arising from a deep venous thrombosis (DVT).

EPIDEMIOLOGY

- Population estimate of the age- and sex-adjusted annual incidence of DVT is 48 per 100,000 and 69 per 100,000 for PE; the incidence increases with age.[1]
- PEs are noted as incidental findings in 1% to 4% of chest CT studies.[2]
- One metaanalysis concluded that nearly 1 in every 4 to 5 patients presenting with an exacerbation of chronic obstructive pulmonary disease has a PE; presenting signs and symptoms did not distinguish patients with and without PE.[3]
- In a metaanalysis of randomized controlled trials (RCTs) of patients on venous thromboembolism (VTE) prophylaxis, the pooled rates of symptomatic DVT were 0.63% (95% confidence interval [CI], 0.47% to 0.78%) following knee arthroplasty and 0.26% (95% CI, 0.14% to 0.37%) following hip arthroplasty. The pooled rates for PE were 0.27% (95% CI, 0.16% to 0.38%) following knee arthroplasty and 0.14% (95% CI, 0.07% to 0.21%) following hip arthroplasty.[4]

ETIOLOGY AND PATHOPHYSIOLOGY

- PE is most commonly caused by embolization of a thrombus from a proximal leg or pelvic vein that enters the pulmonary artery circulation and obstructs a vessel. PE may also be caused by:[1]
  - An upper-extremity thrombus (from indwelling catheters or pacemakers) (**Figure 57-1**).
  - Fat embolus (following surgery or trauma).
  - Hair/talc/cotton embolus (from intravenous drug use).
  - Amniotic fluid embolus (from a tear at the placental margin in a pregnant woman).

- PE results from vascular endothelial injury, which promotes platelet adhesion, blood flow stasis, and/or hypercoagulation causing more coagulants to accumulate than usual and resulting obstruction. Although most PEs are asymptomatic and do not alter physiology, PE can cause:
  - Increased pulmonary, vascular, and airway resistance (from obstruction of vessels or distal airways).
  - Impaired gas exchange (from increased dead space and right to left shunting).
  - Alveolar hyperventilation (from stimulation of irritant receptors).
  - Decreased pulmonary compliance (from lung edema, hemorrhage, or loss of surfactant).
  - Right ventricular (RV) dysfunction (from increased pulmonary vascular resistance, increased RV wall tension, and reduced right coronary artery flow).
  - Only approximately 10% of emboli cause pulmonary infarction; most PEs are multiple and involve the lower lobes.[5]

RISK FACTORS

In a population study, independent risk factors for DVT included:[6]

- Surgery (odds ratio [OR], 21.7; 95% CI, 9.4 to 49.9).
- Trauma (OR, 12.7; 95% CI, 4.1 to 39.7).
- Hospital or nursing home confinement (OR, 8.0; 95% CI, 4.5 to 14.2).
- Malignant neoplasm with (OR, 6.5; 95% CI, 2.1 to 20.2) or without (OR, 4.1; 95% CI, 1.9 to 8.5) chemotherapy.
- Central venous catheter or pacemaker (OR, 5.6; 95% CI, 1.6 to 19.6).
- Superficial vein thrombosis (OR, 4.3; 95% CI, 1.8 to 10.6). A recent study found a slightly higher OR, 6.3 (95% CI, 5.0 to 8.0) for DVT and 3.9 (95% CI, 3.0 to 5.1) for PE.[7]
- Neurologic disease with extremity paresis (OR, 3.0; 95% CI, 1.3 to 7.4).
- Other risk factors for PE include hormonal treatment (i.e., combined estrogen/progestogen oral contraceptives [OCs] or menopausal hormone therapy), pregnancy, obesity, smoking, chronic obstructive pulmonary disease, immobility, bed rest for more than 3 days, and clotting disorders. In a Danish population study, the risk of venous thrombosis in current users of combined OCs decreased with duration of use (OR <1 year 4.17 [95% CI, 3.73 to 4.66]; OR 1 to 4 years 2.98 [95% CI, 2.73 to 3.26] and OR >4 years 2.76 [95% CI, 2.53 to 3.02]) and decreasing oestrogen dose.[8] OCs with desogestrel, gestodene, or drospirenone were associated with a significantly higher risk of venous thrombosis than those with levonorgestrel, while progestogen-only pills and hormone-releasing intrauterine devices were not associated with an increased risk.
- Genetic predisposition includes factor V Leiden and prothrombin gene mutations.
- Use of an antipsychotic agent (particularly atypical antipsychotics) increased risk of DVT in a population nested case-control study (OR 1.32, 95% CI, 1.23 to 1.42).[9]

DIAGNOSIS

A history and physical examination should be completed to assess risk factors and determine whether the patient is clinically stable. If unstable (e.g., hemodynamic instability [including systolic blood pressure <90 mm Hg, or a drop of 40 mm Hg], syncope, severe hypoxemia, or respiratory distress), thrombolytic therapy should be considered (**Figure 57-1**).[2,10]

Diagnostic strategy begins with the determination of a patient's (pretest) probability of PE using a clinical decision rule (**Figure 57-2**). The two most frequently used rules are the Geneva and the Wells score.[11,12] Online calculators are available for the Wells score (http://www.mdcalc.com/wells-criteria-for-pulmonary-embolism-pe/). The Geneva score appears to be the most consistent across experience of examiner;[13] and the revised Geneva scoring system performs as well

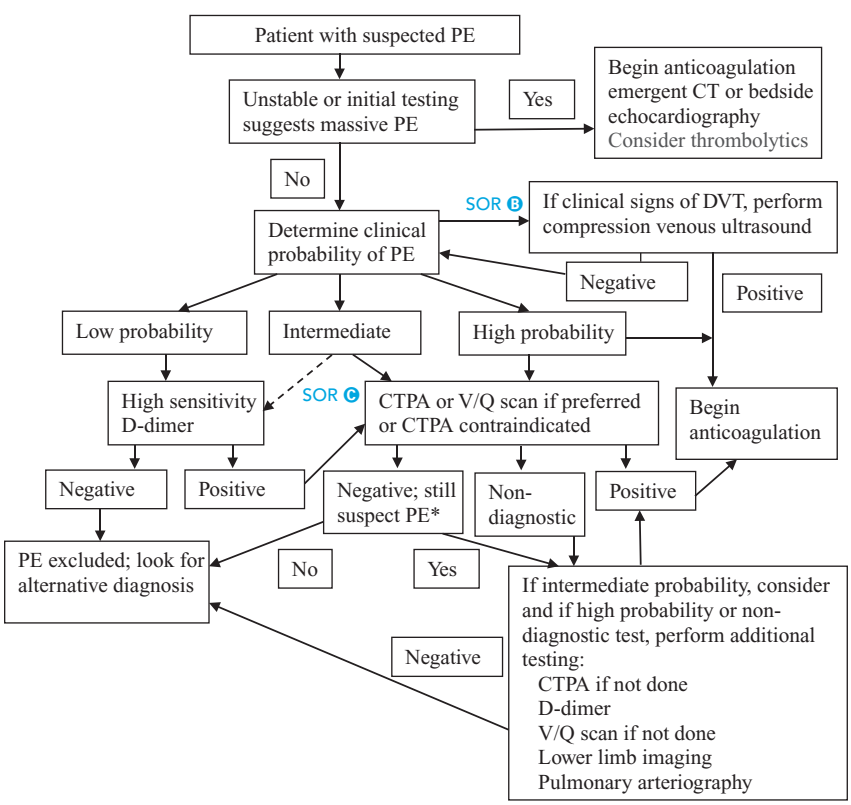

*Based on clinical impression, high probability with positive D-dimer and negative CTPA, or confusing presentation.

FIGURE 57-2 Approach to the patient with suspected pulmonary embolus. *Abbreviations: CT*, computed tomography; *CTPA*, computed tomographic pulmonary arteriography; *DVT*, deep venous thrombosis; *PE*, pulmonary embolism; *V/Q*, ventilation–perfusion. (Dotted lines indicate differences in guidelines). (Information from Fesmire FM, Brown MD, Espinosa JA, et al.; American College of Emergency Physicians. Critical issues in the evaluation and management of adult patients presenting to the emergency department with suspected pulmonary embolism. *Ann Emerg Med.* 2011;57(6):628-652; Institute for Clinical Systems Improvement (ICSI). *Venous Thromboembolism Diagnosis and Treatment.* Bloomington, MN: Institute for Clinical Systems Improvement (ICSI); 2011 Mar. 93 p. Available at http://www.guideline.gov/content.aspx?id=32482&search=pulmonary+embolism.)

as the Wells and does not require laboratory testing or imaging.[14] A score of 0 to 3 indicates a low probability of PE (8%); 4 to 10 indicates intermediate probability of PE (28%); and greater than 10 indicates a high probability of PE (74%). The revised Geneva score is derived by summing the following points:

- Age older than 65 years (+1).
- Previous DVT or PE (+3).
- Surgery or fracture within 1 month (+2).
- Active malignant condition (+2).
- Unilateral lower limb pain (+3).
- Hemoptysis (+2).
- Heart rate 75 to 94 beats/min (+3) or equal to or greater than 95 beats/min (+5).
- Pain on lower-limb deep venous palpation and unilateral edema (+4).

The Wells score is derived by summing the factors below; a score less than 2 indicates a low probability of PE (15%); 2 to 6 indicates intermediate probability of PE (29%); and greater than 6 indicates a high probability of PE (59%). Alternatively, the Wells score can be dichotomized as PE less likely or likely (the latter with score >4):[2]

- Clinically suspected DVT (+3).
- Alternative diagnosis is less likely than PE (+3).
- Tachycardia (+1.5).
- Immobilization/surgery in previous 4 weeks (+1.5).
- History of DVT or PE (+1.5).
- Hemoptysis (+1.0).
- Malignancy (treatment for within 6 months, palliative) (+1.0).

Patients with a high pretest probability of PE or high risk because of comorbidities (e.g., pulmonary hypertension) should be started on anticoagulation during the workup.[2,10]

CLINICAL FEATURES

- Dyspnea—The most common symptom; tachycardia is the most common sign. Sudden onset of dyspnea is the best single predictor (positive likelihood ratio [LR+] 2.7).
- Chest pain—May be caused by a small, peripheral PE with pulmonary infarction.
- Other signs—Include fever, neck vein distention, and accentuated pulmonic component of the second heart sound.
- Massive PE—May present with shock, syncope, and cyanosis.

LABORATORY STUDIES AND ECG

- The combination of clinical decision rules and sensitive plasma D-dimer is used to rule out a PE (sensitive but not specific).[15,16] SOR B The test is suggested for patients with a low or moderate probability of a PE: if low probability and negative (<500 ng/mL), there is only approximately a 0.4% chance that the patient has a PE.[14] If low or intermediate probability, a negative D-dimer concentration is associated with a posttest probability of PE below 5% (negative likelihood ratio [LR−] 0.08 [0.04 to 0.18]).[17] Of patients with a PE, 90% will have a value greater than 500 ng/mL. Use of

an age-adjusted D-dimer (patient's age × 10 mcg/L) was shown in one study to increase the percentage of patients in whom PE could be safely excluded (from 13% to 14% to 19% to 22%).[18] If the D-dimer is positive, further testing is needed (**Figure 57-2**).[2]

- An ECG may be indicated to search for alternative diagnoses. The most frequent, sensitive, and specific ECG finding for PE is T-wave inversion in leads V1 to V4, which is indicative of RV strain. Other findings include tachycardia, new-onset atrial fibrillation or flutter, S in Lead I, Q and inverted T in lead III, and a QRS axis greater than 90 degrees.
- Arterial blood gas is obtained if clinically indicated. A platelet count should be obtained prior to initiation of fondaparinux.[10]

IMAGING

- CXR is often nonspecific; dyspnea with a near normal CXR should suggest PE. Findings that may be seen on CXR include:
  - Triad of basal infiltrate, blunted costophrenic angle, and elevated hemidiaphragm.
  - Infiltrates similar to pneumonia (**Figure 57-3**) that may be diagnosed using CT (**Figure 57-4**).
  - A peripheral wedge-shaped density (**Figure 57-1**).
  - Decreased vascular markings (**Figure 57-5**).
  - When a patient has an intermediate or high PE probability score, PE is confirmed by a positive CT pulmonary angiography (CTPA) or high-probability lung scan, and ruled out by a negative CTPA or normal lung scan (**Figure 57-1**). The American College of Radiology (ACR) and Institute for Clinical Systems Improvement recommend CTPA over ventilation–perfusion (V/Q) scan for patients with suspected PE, unless the former is contraindicated or nondiagnostic (**Figure 57-1**).[2,19] CT (**Figure 57-4**) can also provide evidence of alternate diagnoses.
  - A V/Q scan is considered the initial test for patients with high probability of PE who have renal insufficiency or dye allergy. A high-probability scan for PE (positive predictive value of 90%) has 2 or more segmental perfusion defects with normal ventilation.
  - For pregnant women with suspected PE, the American Thoracic Society/Society of Thoracic Radiology recommend CXR as the initial study followed by lung scintigraphy (V/Q scan) if the CXR is normal, and CTPA if the V/Q scan is nondiagnostic.[20]
  - If the CTPA or lung scan is nondiagnostic, a leg ultrasound with compression is usually performed. If positive for a DVT, proceed with treatment as below. If normal or nondiagnostic, other testing such as a pulmonary angiogram is suggested (**Figure 57-1**).
  - Pulmonary angiography is generally reserved for patients with nondiagnostic CTPA, lung scans, or leg ultrasound, and for patients who will undergo embolectomy or catheter-directed thrombolysis. ACR also recommends pulmonary angiography in circumstances where a specific diagnosis (i.e., PE) is considered necessary for the proper patient management and before placement of an inferior vena cava (IVC) filter.[10] An intraluminal filling defect may be seen along with truncated arteries associated with regions of diminished perfusion (**Figure 57-6**).
  - Although MRI is not indicated in the routine evaluation of suspected PE, magnetic resonance angiography (MRA) is used in certain centers with particular interest and expertise, and in patients in whom contrast administration for CTPA or

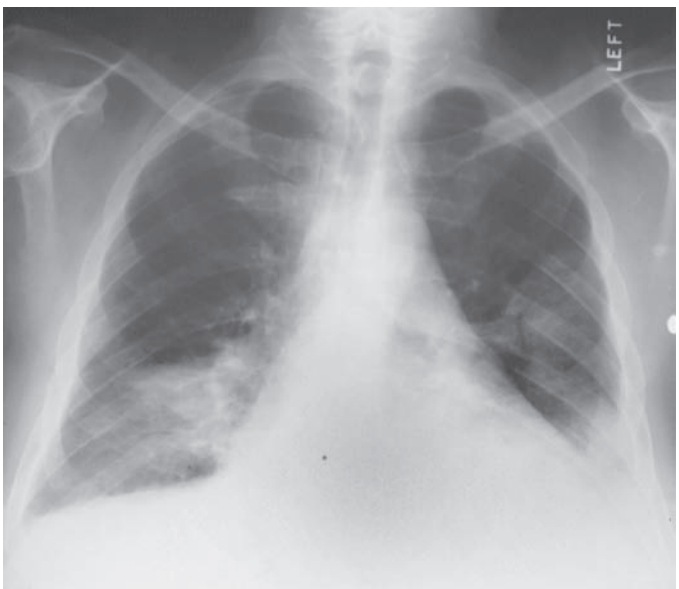

FIGURE 57-3 CXR showing bilateral pulmonary infiltrates thought to represent pneumonia. (*From Miller WT Jr. Diagnostic Thoracic Imaging. New York: McGraw-Hill; 2006:273, Figure 5-63 A. Copyright 2006.*)

FIGURE 57-4 CT scan from the patient in **Figure 57-2** demonstrates several large, wedge-shaped pulmonary opacities with air bronchograms characteristic of pulmonary infarcts. (*From Miller WT Jr. Diagnostic Thoracic Imaging. New York: McGraw-Hill; 2006:273, Figure 5-63 B. Copyright 2006.*)

pulmonary angiography is thought to be contraindicated because of renal failure, prior reaction to iodinated contrast, pulmonary hypertension, or for other reasons.[19]

DIFFERENTIAL DIAGNOSIS

The differential diagnosis of a symptomatic PE includes:

- Pneumonia—Symptoms include chills, fever, and pleuritic chest pain (the latter two can occur with PE); physical findings include dullness to percussion, bronchial breathing, egophony (E-to-A change), and crackles with area of infiltrate/pneumonia usually confirmed on CXR (see Chapter 53, Pneumonia).
- Congestive heart failure—History of previous heart failure or myocardial infarction; symptoms of paroxysmal nocturnal dyspnea, orthopnea, or the presence of bilateral lower extremity edema, third heart sound, hepatojugular reflex, and jugular venous distention. CXR may show pulmonary venous congestion, interstitial or alveolar edema, and cardiomegaly (see Chapter 48, Heart Failure).
- Pneumothorax—History of previous pneumothorax or chronic obstructive pulmonary disease, or current rib fracture; physical findings include absence of breath sounds and CXR may show free air, an elevated hemidiaphragm, or a shift of the mediastinum to the contralateral side with a tension pneumothorax.

MANAGEMENT

NONPHARMACOLOGIC

- Knee-high compression stockings (30 to 40 mm Hg) are recommended to reduce recurrence and prevent post-thrombotic syndrome.[10] SOR A
- Psychological support may be needed.

MEDICATION

- Primary treatment of PE is considered for patients with hemodynamic instability, RV dysfunction, or infarct. In selected patients with massive PE, systemic administration of thrombolytic therapy (via a peripheral vein with a 2-hour infusion) is suggested.[2,10] SOR B Brain natriuretic peptide and troponin testing, combined with echocardiography, can help identify patients at high risk of deterioration who would be candidates for thrombolytic therapy.[2]
- Moderate to large PE may be treated similarly or with anticoagulation only. In a recent Cochrane review, the authors found no trials comparing thrombolytic therapy to surgical intervention and were unable to determine whether thrombolytic therapy was better than heparin for PE.[21]
- Acute PEs or proximal DVT are treated with oral anticoagulation to prevent future PEs. In addition to beginning oral anticoagulation (e.g., warfarin 5 mg daily, adjusted based on international normalized ratio [INR]), treatment options include intravenous unfractionated heparin (UFH) using a weight-based nomogram, SQ low-molecular-weight heparin (LMWH; 1 mg/kg twice daily) or SQ fondaparinux (a selective factor Xa inhibitor) for a minimum of 5 days.[2,10] SOR A The American College of Chest

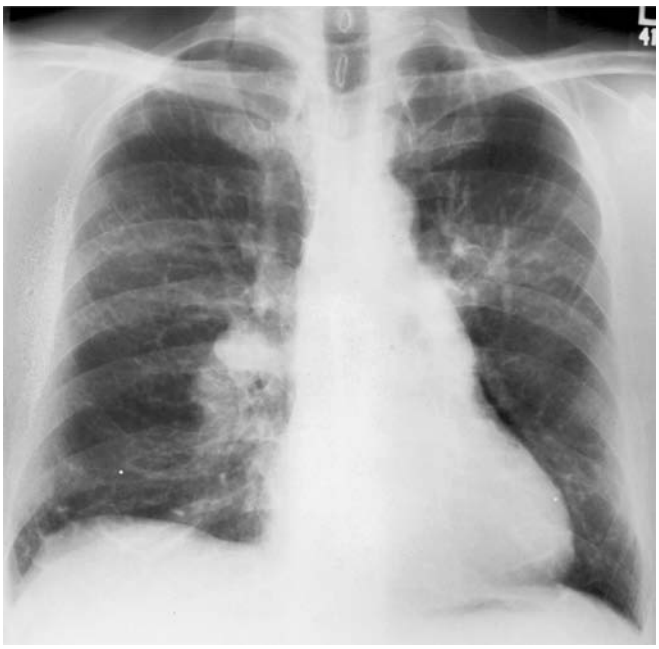

FIGURE 57-5 Pulmonary embolism: Westermark sign, an avascular zone because of obstructed vessel from a blood clot. In this patient, both lung apices and the mid to lower thorax have decreased vascular markings. Note the fusiform enlargement of both hila and the prominent pulmonary artery mediastinal shadow characteristic of pulmonary hypertension. (*From Miller WT Jr. Diagnostic Thoracic Imaging. New York: McGraw-Hill; 2006:748, Figure 14-19 A. Copyright 2006.*)

FIGURE 57-6 Pulmonary angiogram in the patient in **Figure 57-4** showing abruptly truncated pulmonary arteries associated with regions of diminished perfusion typical of chronic pulmonary emboli. (*From Miller WT Jr. Diagnostic Thoracic Imaging. New York: McGraw-Hill; 2006:748, Figure 14-19 B. Copyright 2006.*)

Physicians (ACCP) recommends LMWH as first choice unless there is a massive PE, concern about SQ absorption, severe renal insufficiency, or thrombolytic therapy is under consideration or planned; IV UFH is then the preferred agent.[10] If UFH is used, therapeutic levels (activated partial thromboplastin time [aPTT] 1.5 to 2.5 times normal) should be achieved within 24 hours.[22]

- Once the INR is therapeutic (range: 2 to 3) for at least 24 hours prior to discontinuing above treatment, oral anticoagulation is continued for a minimum of 3 to 12 months or indefinitely unless there is a known reversible or time-limited risk factor (e.g., recent surgery) when oral anticoagulation may be discontinued after 3 months.[2,10] SOR A For additional recommendations on duration of therapy, see the ACCP guideline.[10] A Cochrane review reported no excess recurrence of VTE after stopping therapy and while absolute risk of recurrence declines over time, the risk for major bleeding remains.[23]
- In another Cochrane review based on 15 RCTs, fixed-dose SQ UFH could not be proven non-inferior to standard treatment with respect to DVT and PE at 3 months (trend favored standard arm), but was safe and effective with regard to rates of major bleeding and death.[24]
- Patients with a history of heparin-induced thrombocytopenia (HIT) should not be treated with either UFH or LMWH. Fondaparinux is an option, although several cases of fondaparinux-associated HIT have been reported.[10]
- Direct thrombin inhibitors (e.g., ximelagatran) appear to be as effective as LMWH in prevention of VTE and treatment of PE, may have fewer side effects, and do not require routine monitoring. They are not considered initial therapy using current guidelines. In one trial, idraparinux was not as effective as heparin for PE treatment.[25] In another trial, oral ximelagatran was as effective as enoxaparin followed by warfarin in patients with PE.[26]

SURGERY AND PROCEDURES

Highly compromised patients who are unable to receive thrombolytic therapy or whose critical status does not allow sufficient time to infuse thrombolytic therapy may be treated with pulmonary embolectomy.[10] SOR C In a Japanese case series of 19 patients undergoing embolectomy, most for massive or submassive PEs in the main pulmonary trunk or bilateral main pulmonary arteries, operative mortality was 5.3%.[27] No patients exhibited newly developed neurologic damage.

- IVC filter placement is reserved for patients with contraindications to anticoagulation or for failure of anticoagulation (i.e., recurrence or progression of thromboembolism despite anticoagulation).[2,10] SOR C Although they decrease recurrent PE, they do not appear to improve long-term survival.
- Adjunctive therapy, if needed, includes pain relief and supplemental oxygen. RV failure/shock may be treated with dobutamine.

REFERRAL OR HOSPITALIZATION

- Consider consultation with a coagulation specialist for patients with recurrent VTE, if alternative anticoagulants are being considered, if there is an increased risk of bleeding, and for pregnant women.
- Patients with cardiovascular or respiratory compromise should be admitted to the intensive care unit. Patients with symptomatic PE

are usually hospitalized because of decreased cardiopulmonary reserve.[10] One open-label trial (N = 344) found no significant differences between inpatient and outpatient treatment with only 1 patient dying in each group.[28] However, 2 outpatients had major bleeding in the first 14 days and 3 by 90 days versus no patients in the inpatient group.

PREVENTION

- Mechanical methods (graduated compression stockings [GCS] and/or intermittent pneumatic compression) are recommended for thromboprophylaxis in hospitalized patients who are at high risk of bleeding or possibly as an adjunct to anticoagulant-based prophylaxis.[10] SOR A For more detailed information on prophylaxis (e.g., surgical or cancer patients), see the ACCP guidelines.
- A Cochrane review found GCS effective in reducing the risk of DVT in hospitalized patients from 26% without GCS to 13% with GCS and from 16% with another method of prophylaxis alone to 4% with GCS with another method of prophylaxis.[29]
- The American College of Physicians recommends assessment of the risk for thromboembolism and bleeding and pharmacologic prophylaxis with heparin or a related drug unless the assessed risk for bleeding outweighs the likely benefits for hospitalized nonsurgical patients. They recommend against use of GCS for routine hospitalized nonsurgical patients.[30]
- For long-distance travelers (e.g., flights >8 hours) avoidance of constrictive clothing around the lower extremities or waist, maintenance of adequate hydration, and frequent calf muscle contraction are recommended.[10] SOR C In high-risk individuals, consider use of GCS providing 15 to 30 mm Hg of pressure at the ankle or a single prophylactic dose of LMWH, injected prior to departure.[10] SOR C

PROGNOSIS

- In a large multicenter study of patients with acute PE (N = 1880), mortality rate directly attributed to PE was 1% (95% CI, 0% to 1.6%).[31] Mortality from hemorrhage was 0.2% and the all-cause 30-day mortality rate was 5.4% (95% CI, 4.4% to 6.6%). Delay in initiating anticoagulation appeared to be a mortality factor as only 3 of 20 patients with fatal PE had systemic anticoagulation initiated before diagnostic confirmation; another 3 of these 20 received a fibrinolytic agent. These figures were much improved over a 3-country registry of patients (N = 2110) with acute PE from 1999 where the 3-month mortality rate was 15.3%.[32]
- In a retrospective Japanese study of patients with PE treated surgically, the 10-year survival rate was 83.5% ± 8.7%.[29]
- In one study with a rate of adverse events of 7.4% (N = 42) at 30 days following acute PE, factors associated with those events included altered mental state (OR 6.8; 95% CI, 2.0 to 23.3), shock on admission (OR 2.8; 95% CI, 1.1 to 7.5), and cancer (OR 2.9; 95% CI, 1.2 to 6.9).[33]
- In an Italian prospective cohort study of patients with DVT or PE following discontinuation of anticoagulation therapy (N = 1626), 22.9% had a recurrence of VTE.[34]
- Pulmonary hypertension develops in approximately 5% of patients following PE.[35]

FOLLOW-UP

- Patients on warfarin should be monitored using a standard protocol. Patients on LMWH do not require routine monitoring except for pregnant women where monitoring with anti-Xa levels is recommended.[10] SOR C
- For patients with serious bleeding complications, management includes holding warfarin, giving vitamin K_1 10 mg slow IV plus fresh-frozen plasma or prothrombin complex concentrate, and repeating vitamin K_1 every 12 hours as needed. SOR C
- PE is slow to resolve; based on 4 imaging studies, the percentage of patients with residual pulmonary thrombi was 87% at 8 days after diagnosis, 68% after 6 weeks, 65% after 3 months, 57% after 6 months, and 52% after 11 months.[36]

PATIENT EDUCATION

- Patients taking warfarin should be instructed about the importance of remaining on oral anticoagulation for at least 3 months and use of compression stockings to decrease the likelihood of recurrence. Patients should also be counseled about the signs and symptoms of bleeding, to ask about potential drug interactions before starting a new medication, and the importance of laboratory monitoring.
- Use of an anticoagulation service or home self-monitoring[37] may be considered to improve adherence and reduce complications.
- Avoidance of periods of prolonged immobilization is suggested.

PATIENT RESOURCES

- National Heart, Lung, and Blood Institute. *What Is Pulmonary Embolism?*—**http://www.nhlbi.nih.gov/health/health-topics/topics/pe/.**

PROVIDER RESOURCES

- MedlinePlus. *Pulmonary Embolism*—**www.nlm.nih.gov/medlineplus/pulmonaryembolism.html.**
- Agency for Healthcare Research and Quality. *Venous Thromboembolism Diagnosis and Treatment*—**http://www.guideline.gov/content.aspx?id=32482&search=pulmonary+embolism.**
- American Thoracic Society. *Evaluation of Suspected Pulmonary Embolism in Pregnancy*—**http://www.thoracic.org/statements/resources/respiratory-disease-adults/evaluation-of-suspected-pulmonary-embolism-in-pregnancy.pdf.**

REFERENCES

1. Silverstein MD, Heit JA, Mohr DN, et al. Trends in the incidence of deep vein thrombosis and pulmonary embolism. A 25-year population-based study. *Arch Intern Med.* 1998;158:585-593.

2. Institute for Clinical Systems Improvement (ICSI). *Venous thromboembolism diagnosis and treatment*. Bloomington, MN: Institute for Clinical Systems Improvement (ICSI); 2011 Mar. 93 p. http://www.guideline.gov/content.aspx?id=32482&search=pulmonary+embolism. Accessed February 2012.
3. Rizkallah J, Man SF, Sin DD. Prevalence of pulmonary embolism in acute exacerbations of COPD: a systematic review and meta-analysis. *Chest.* 2009;135(3):786-793.
4. Januel JM, Chen G, Ruffieux C, et al. Symptomatic in-hospital deep vein thrombosis and pulmonary embolism following hip and knee arthroplasty among patients receiving recommended prophylaxis: a systematic review. *JAMA.* 2012;307(3):294-303.
5. Moser KM. Venous thromboembolism. *Am Rev Respir Dis.* 1990;141:235-249.
6. Heit JA, Silverstein MD, Mohr DN, et al. Risk factors for deep vein thrombosis and pulmonary embolism: a population-based case-control study. *Arch Intern Med.* 2000;160(6):809-815.
7. van Langevelde K, Lijfering WM, Rosendaal FR, Cannegieter SC. Increased risk of venous thrombosis in persons with clinically diagnosed superficial vein thrombosis: results from the MEGA study. *Blood.* 2011;118(15):4239-4241.
8. Lidegaard Ø, Løkkegaard E, Svendsen AL, Agger C. Hormonal contraception and risk of venous thromboembolism: national follow-up study. *BMJ.* 2009;339:b2890.
9. Parker C, Coupland C, Hippisley-Cox J. Antipsychotic drugs and risk of venous thromboembolism: nested case-control study. *BMJ.* 2010;341:c4245.
10. Ansell J, Hirsh J, Hylek E, et al. Pharmacology and management of the vitamin K antagonists: American College of Chest Physicians Evidence-Based Clinical Practice Guidelines (8th Edition). *Chest.* 2008;133(6 Suppl):160S-198S.
11. Wicki J, Perneger TV, Junod AF, et al. Assessing clinical probability of pulmonary embolism in the emergency ward: a simple score. *Arch Intern Med.* 2001;161:92-97.
12. Wells PS, Anderson DR, Rodger M, et al. Derivation of a simple model to categorize patients probability of pulmonary embolism: Increasing the model's utility with the SimpliRED D-dimer. *Thromb Haemost.* 2000;83:416-420.
13. Iles S, Hodges AM, Darley JR, et al. Clinical experience and pretest probability scores in the diagnosis of pulmonary embolism. *Q J Med.* 2003;96:211-215.
14. Le Gal G, Righini M, Roy PM, et al. Prediction of pulmonary embolism in the emergency department: the revised Geneva score. *Ann Intern Med.* 2006;144(3):165-171.
15. American College of Emergency Physicians Clinical Policies Committee; Clinical Policies Committee Subcommittee on Suspected Pulmonary Embolism. Clinical policy: critical issues in the evaluation and management of adult patients presenting with suspected pulmonary embolism. *Ann Emerg Med.* 2003;41(2):257-270.
16. Lucassen W, Geersing GJ, Erkens PM, et al. Clinical decision rules for excluding pulmonary embolism: a meta-analysis. *Ann Intern Med.* 2011;155(7):448-460.
17. Roy PM, Colombet I, Durieux P, et al. Systematic review and meta-analysis of strategies for the diagnosis of suspected pulmonary embolism. *BMJ.* 2005;331(7511):259.
18. van Es J, Mos I, Douma R, et al. The combination of four different clinical decision rules and an age-adjusted D-dimer cut-off increases the number of patients in whom acute pulmonary embolism can safely be excluded. *Thromb Haemost.* 2012;107(1):167-171.
19. Bettmann MA, Lyders EM, Yucel EK, et al; Expert Panel on Cardiac Imaging. *Acute Chest Pain—Suspected Pulmonary Embolism*. Reston, VA: American College of Radiology (ACR); 2011. 7 p. Available at http://www.guideline.gov/content.aspx?id=35135. Accessed February 2012.
20. Leung AN, Bull TM, Jaeschke R, et al. An official American Thoracic Society/Society of Thoracic Radiology clinical practice guideline: evaluation of suspected pulmonary embolism in pregnancy. *Am J Respir Crit Care Med.* 2011;184(10):1200-1208.
21. Dong B, Hao Q, Yue J, et al. Thrombolytic therapy for pulmonary embolism. *Cochrane Database Syst Rev.* 2009;(3):CD004437.
22. Hull RD, Raskob GE, Brant RF, et al. Relation between the time to achieve the lower limit of the APTT therapeutic range and recurrent venous thromboembolism during heparin treatment for deep vein thrombosis. *Arch Intern Med.* 1997;157:2562-2568.
23. Hutten BA, Prins MH. Duration of treatment with vitamin K antagonists in symptomatic venous thromboembolism. *Cochrane Database Syst Rev.* 2006;(1):CD001367.
24. Vardi M, Zittan E, Bitterman H. Subcutaneous unfractionated heparin for the initial treatment of venous thromboembolism. *Cochrane Database Syst Rev.* 2009;(4):CD006771.
25. The van Gogh Investigators, Buller HR, Cohen AT, et al. Idraparinux versus standard therapy for venous thromboembolic disease. *N Engl J Med.* 2007;357:1094-1104.
26. Fiessinger JN, Huisman MV, Davidson BL, et al; THRIVE, Treatment Study Investigators. Ximelagatran vs low-molecular-weight heparin and warfarin for the treatment of deep vein thrombosis: a randomized trial. *JAMA.* 2005;293:681-689.
27. Fukuda I, Taniguchi S, Fukui K, et al. Improved outcome of surgical pulmonary embolectomy by aggressive intervention for critically ill patients. *Ann Thorac Surg.* 2011;91(3):728-732.
28. Aujesky D, Roy PM, Verschuren F, et al. Outpatient versus inpatient treatment for patients with acute pulmonary embolism: an international, open-label, randomised, non-inferiority trial. *Lancet.* 2011;378(9785):41-48.
29. Sachdeva A, Dalton M, Amaragiri SV, Lees T. Elastic compression stockings for prevention of deep vein thrombosis. *Cochrane Database Syst Rev.* 2010;(7):CD001484.
30. Qaseem A, Chou R, Humphrey LL, et al. Venous thromboembolism prophylaxis in hospitalized patients: a clinical practice guideline from the American College of Physicians. *Ann Intern Med.* 2011;155(9):625-632.
31. Pollack CV, Schreiber D, Goldhaber SZ, et al. Clinical characteristics, management, and outcomes of patients diagnosed with acute pulmonary embolism in the emergency department: initial report of EMPEROR (Multicenter Emergency Medicine Pulmonary

Embolism in the Real World Registry). *J Am Coll Cardiol.* 2011;57(6):700-706.

32. Goldhaber SZ, Visani L, De Rosa M. Acute pulmonary embolism: clinical outcomes in the International Cooperative Pulmonary Embolism Registry (ICOPER). *Lancet.* 1999;353:1386-1389.
33. Sanchez O, Trinquart L, Caille V, et al. Prognostic factors for pulmonary embolism: the prep study, a prospective multicenter cohort study. *Am J Respir Crit Care Med.* 2010;181(2):168-173.
34. Prandoni P, Noventa F, Ghirarduzzi A, et al. The risk of recurrent venous thromboembolism after discontinuing anticoagulation in patients with acute proximal deep vein thrombosis or pulmonary embolism. A prospective cohort study in 1,626 patients. *Haematologica.* 2007;92(2):199-205.
35. Kearon C. Natural history of venous thromboembolism. *Circulation.* 2003;107:I22-I30.
36. Nijkeuter M, Hovens MM, Davidson BL, Huisman MV. Resolution of thromboemboli in patients with acute pulmonary embolism: a systematic review. *Chest.* 2006;129:192-197.
37. Menéndez-Jándula B, Souto JC, Oliver A, et al. Comparing self-management of oral anticoagulant therapy with clinic management. *Ann Intern Med.* 2005;142(1):1-10.

58 LUNG CANCER

Mindy A. Smith, MD, MS

PATIENT STORY

A 60-year-old woman presents with a solid, nontender, movable mass on her upper chest that's been there for 6 months. It began as a dime-size mass and has been growing more rapidly over the past month (**Figure 58-1A**). She has lost 10 pounds over the last year without dieting. She has smoked 1 pack of cigarettes per day since age 18 years and gets short of breath easily. Her "smoker's cough" has gotten worse in the last few months and occasionally she coughs up some blood-tinged sputum. Her family physician excised the mass in the office and sent it to pathology (**Figure 58-1B**). When the result demonstrated squamous cell carcinoma of the lung, a chest x-ray (CXR) was ordered (**Figure 58-2A**). The radiologist suggested a CT to confirm the diagnosis (**Figure 58-2B**). The patient chose to have no treatment and passed away in 10 months of her lung cancer.

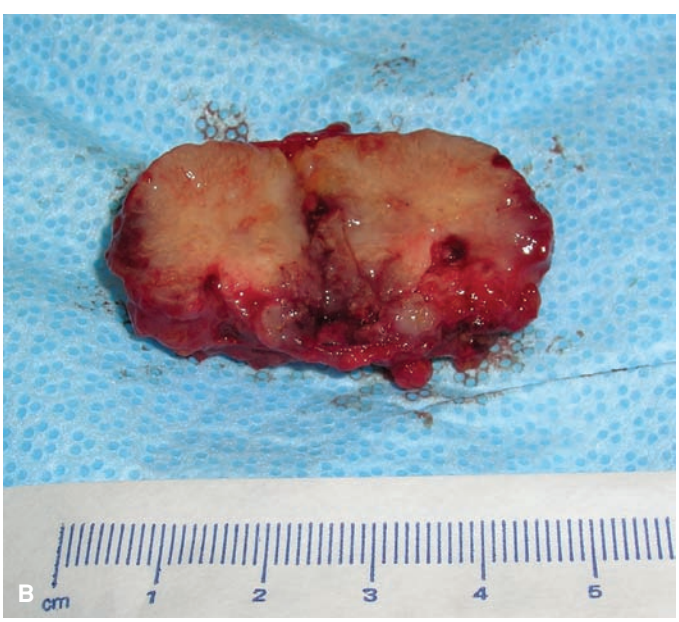

FIGURE 58-1 **A.** Growing chest nodule in a 60-year-old woman who smoked tobacco her whole adult life. The pathology demonstrated metastatic squamous cell carcinoma from the lung. **B.** The resected nodule was surgically removed by the family physician in the office. (*Courtesy of Leonard Chow, MD, and Ross Lawler, MD.*)

INTRODUCTION

Lung cancer is a malignant neoplasm of the lung arising from respiratory epithelium (bronchi, bronchioles/alveoli), most commonly adenocarcinoma or squamous cell carcinoma.

EPIDEMIOLOGY

- In 2007, lung cancer was diagnosed in 203,546 people in the United States (109,643 men and 93,893 women).[1] Both incidence and mortality rates have been decreasing since 1999 for men, but remain level for women.
- Black men have the highest age-adjusted incidence rates (99.8/100,000) followed by white men (75.3/100,000), and then black women (54.7/100,000) and white women (54.6/100,000); Hispanic men (41.5/100,000) and women (26.1/100,000) have the lowest incidence rates.[2]
- Risk increases with age; at age 60 years, 2.29% of men will develop lung cancer in 10 years and 5.64% in 20 years.[1] Among women at age 60 years, 1.74% will develop lung cancer in 10 years and 4.27% in 20 years. Median age at diagnosis is 71 years.[2]
- In 2007, lung cancer was the leading cause of cancer deaths, accounting for 14% of all cancer diagnoses and 28% of all cancer deaths.[3]
- The 2011 estimate for new cases of lung cancer in the United States was 221,130 with 156,940 deaths from the disease.[4]

ETIOLOGY AND PATHOPHYSIOLOGY

- Lung cancer begins in the lungs spreading to regional lymph nodes and regional structures (e.g., trachea, esophagus). Extrathoracic

metastases are common (found at autopsy in 50% to 95%) and sites include brain, bone, and liver.[5]

- Likely caused by a multistep process involving both carcinogens and tumor promoters; a number of genetic mutations (e.g., epidermal growth factor receptor [EGFR] mutations) are present in lung cancer cells, including activation of dominant oncogenes and inactivation of tumor-suppressor oncogenes.[5]
- There are two main groupings of lung cancer: non–small cell lung cancer (NSCLC; most common) and small cell lung cancer (SCLC). The four major cell types responsible for 88% of cases[5] are:
  - Adenocarcinoma (including bronchoalveolar)—32% of cases.
  - Squamous or epidermoid carcinoma—29% of cases.
  - Small cell (or oat cell) carcinoma—18% of cases.
  - Large cell (or large cell anaplastic)—9% of cases.
- Adenocarcinoma, squamous carcinoma, and large cell are classified together under NSCLC because of similar diagnostic, staging, and treatment approaches.[4]
- Adenocarcinoma and squamous carcinoma have defined premalignant precursor lesions with lung tissue morphology ranging from hyperplasia to dysplasia and carcinoma in situ.[3]

RISK FACTORS

- Smoking is the major risk factor; a smoking history (current or former) is present in 90%, with a relative risk ratio of 13 (passive smoke exposure has a risk ratio of 1.5).[3] Currently, 28% of men, 25% of women, and 38% of high school seniors smoke in the United States. Women have a higher susceptibility to the carcinogens in tobacco (Chapter 236, Tobacco Addiction).
- Occupations and exposures that increase risk of lung cancer include asbestos mining and processing, welding, pesticide manufacturing (arsenic), metallurgy (chromium), polycyclic hydrocarbons (through coke oven emissions), iron oxide, vinyl chloride, and uranium.[3] Home exposure to asbestos or radon and diesel exhaust also increase risk.[2,6]
- Radiation therapy to the breast or chest.[4]
- Family history of lung cancer.
- Beta-carotene supplementation in current smokers (small increased risk).
- Hormone therapy (women). In the Women's Health Initiative, although incidence of lung cancer was not significantly increased, death from lung cancer (primarily NSCLC) was increased (73 vs. 40 deaths; 0.11% vs. 0.06%).[7]

DIAGNOSIS

Signs and symptoms depend on location, tumor size and type, and the presence of local or distant spread.

- Five percent to 15% of patients are asymptomatic—The cancer is found on chest imaging performed for another reason.[5]
- Systemic symptoms (e.g., anorexia, cachexia, weight loss [seen in 30% of patients]) may be seen, but the cause is unknown.

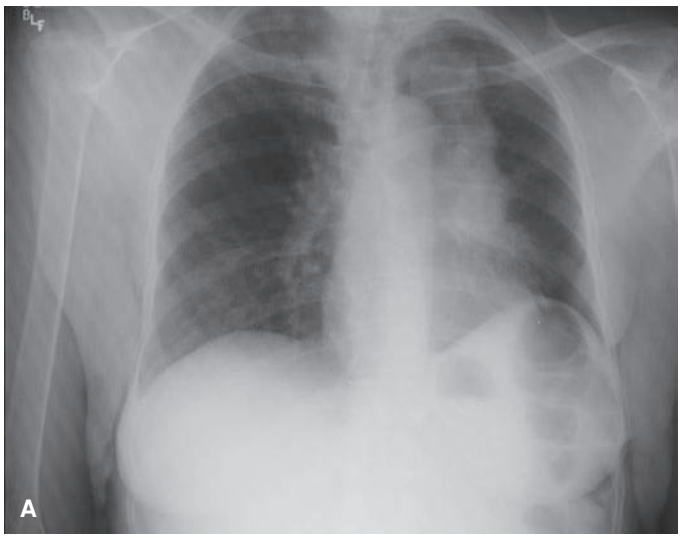

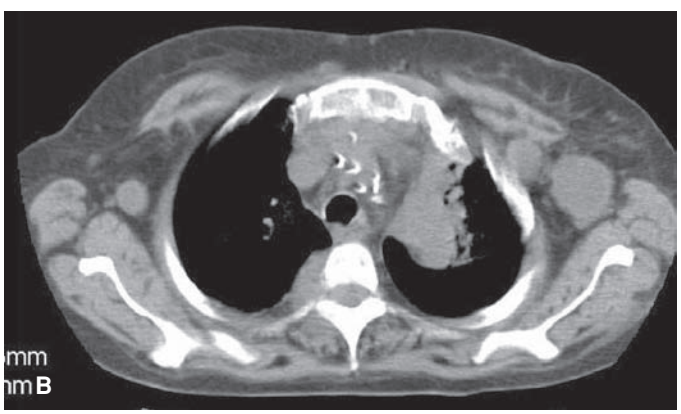

FIGURE 58-2 **A.** Chest x-ray showing squamous cell carcinoma of the lung. **B.** CT scan demonstrating the architecture of the squamous cell carcinoma of the lung. (*Courtesy of David A. Kasper DO, MBA.*)

The diagnosis of lung cancer requires tissue confirmation through the safest and least-invasive procedure. Procedures include sputum cytology, bronchoscopy, lymph node biopsy, operative specimen, needle aspiration (e.g., endobronchial ultrasound-guided transbronchial approach for mediastinal or hilar lymph nodes or CT-guided transthoracic approach for peripheral tumors), biopsy under CT guidance, or cell block from pleural effusion.[5,8]

- Immunohistochemistry (e.g., thyroid transcription factor 1 for adenocarcinoma or P63 for squamous carcinoma) is now being used to help differentiate between cell types when morphologic criteria used in resections are not apparent.[8] Differentiation is important as different cell types respond differently to treatment.
- For suspicious central lung lesions, sputum cytology (at least three specimens) is a reasonable first step followed by bronchoscopy if needed.[5] SOR B
- In patients with a suspicious peripheral lung lesion (especially <2 cm), if sputum cytology fails to confirm the diagnosis, transthoracic needle aspiration has a higher sensitivity than bronchoscopy.[5] SOR A
- In patients with a lesion that is moderately suspicious for lung cancer who appear to have limited disease, excisional biopsy and subsequent lobectomy if a lung cancer is confirmed is recommended.[5] SOR B

CLINICAL FEATURES

- The most common symptoms at diagnosis are worsening cough or chest pain.[4] Symptoms may occur in the following situations:[5]
  - Central or endobronchial growth of the tumor may produce cough, hemoptysis, wheezing, stridor, and dyspnea.
  - Collapse of airways from tumor obstruction may cause post-obstructive pneumonitis.
  - Involvement of the pleura or chest wall may cause pleuritic chest pain, dyspnea on a restrictive basis, or lung abscess from tumor cavitation.
  - Regional spread of the tumor may cause tracheal obstruction; dysphagia from esophageal spread; hoarseness from recurrent laryngeal nerve paralysis; dyspnea and elevated hemidiaphragm from phrenic nerve paralysis; and Horner syndrome (enophthalmos, ptosis, miosis, ipsilateral loss of sweating from sympathetic nerve paralysis).
  - Spread to lymph nodes may be detected as firm masses in the supraclavicular area, axilla, or groin.
  - Extrathoracic metastases are common (found at autopsy in 50% to 95%) and may cause neurologic symptoms with brain metastases; pain and fracture with bone metastases; cytopenias or leukoerythroblastosis from bone marrow involvement; and liver dysfunction from metastases to the liver.
  - Paraneoplastic syndromes are common in SCLC and include endocrine syndromes (seen in 12%), such as hypercalcemia and hypophosphatemia from elevated parathyroid hormone or parathyroid-hormone related peptide; hyponatremia from secretion of antidiuretic hormone; electrolyte disturbances as seen with secretion of adrenocorticotropic hormone; and Lambert-Eaton myasthenic syndrome (primarily proximal muscle weakness, abnormal gait, fatigue, autonomic dysfunction, paresthesias). The most common paraneoplastic syndromes in SCLC are the syndrome of inappropriate antidiuresis (15% to

40% of patients with SCLC) and Cushing syndrome (2% to 5% of patients with SCLC).[8]
- Skeletal and connective tissue syndromes including clubbing (seen in 30%, especially with non–small cell carcinoma) and hypertrophic pulmonary osteoarthropathy with pain and swelling from periostitis (1% to 10%, especially with adenocarcinoma).
- Skin nodules from lung cancer metastases may not be painful but are a poor prognostic sign (**Figures 58-1** and **58-2**).

LABORATORY TESTING

- Molecular testing for mutational profiles is becoming more common for NSCLC with the rapid development of targeted therapies. Specifically, identification of activating EGFR mutations is the best predictor for response to EGFR-tyrosine kinase inhibitors.[9] In one multicenter study in Spain, EGFR mutations were found in 16.6% (350 of 2105) of patients and were more frequent in women (69.7%), in never smokers (66.6%), and in those with adenocarcinomas (80.9%).[10]

IMAGING

- For an incidental lung nodule not believed to be lung cancer, the American College of Radiology (ACR) recommends either percutaneous lung biopsy or whole-body fluorine-18-2-fluoro-2-deoxy-D-glucose-positron emission tomography (FDG-PET), the latter if the patient has lung cancer risk factors.[11] Follow-up imaging only is recommended for selected patients with no lung cancer risk factors.
- If a tumor is associated with mediastinal adenopathy, endoscopic/bronchoscopic mediastinal biopsy is recommended.[11] In one study, endobronchial ultrasound-guided transbronchial needle aspiration was found to be comparable to mediastinoscopy for mediastinal staging in patients with potentially resectable NSCLC.[12]
- CXR may be useful as baseline if not already performed and a chest CT scan should be performed; these tests may show a nodule (**Figures 58-3** and **58-4**) or diffuse lung abnormalities often confused with pneumonia (**Figures 58-5** to **58-7**).

TYPICAL DISTRIBUTION[5]

- Squamous and small cell carcinoma tend to present as central masses with endobronchial growth.
- Adeno- and large cell carcinoma tend to present as peripheral masses, frequently with pleural involvement.

BIOPSY: HISTOLOGY[5]

- SCLCs have scant cytoplasm, hyperchromatic nuclei with fine chromatin pattern, nucleoli that are indistinct, and diffuse sheets of cells.
- NSCLCs have abundant cytoplasm, pleomorphic nuclei with coarse chromatin pattern, prominent nucleoli, and glandular or squamous architecture.

DIFFERENTIAL DIAGNOSIS

The differential diagnosis of an individual with lung findings (e.g., productive cough and dyspnea) includes:

FIGURE 58-3 Chest x-ray demonstrating a 2.5-cm irregular nodule in the left upper lobe.

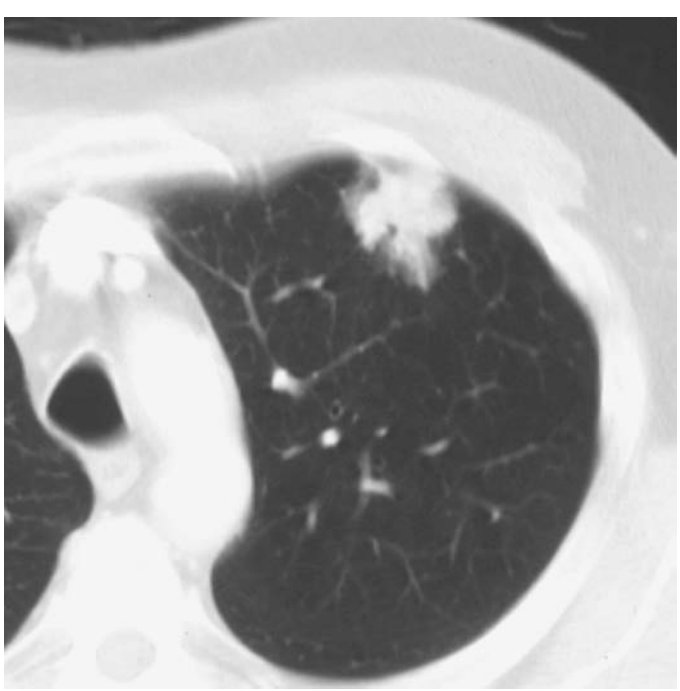

FIGURE 58-4 CT scan of the patient in Figure 58-3 shows a spiculated mass confirmed at surgery to be an adenocarcinoma. (*From Diagnostic Thoracic Imaging Courtesy of Miller, W. Diagnostic Thoracic Imaging. New York. McGraw-Hill. 2006.*)

- Chronic obstructive pulmonary disease—Most common symptoms are cough, sputum production and exertional dyspnea. Although hemoptysis may occur, imaging (chest CT is most definitive) will not show a tumor. There is an increased risk of lung cancer in these patients (Chapter 56, Chronic Obstructive Pulmonary Disease).
- Pneumonia—Symptoms include fever, chills, and pleuritic chest pain; physical findings include dullness to percussion, bronchial breathing, egophony (E to A change), and crackles with area of infiltrate (pneumonia usually confirmed on CXR; Chapter 53, Pneumonia).

Both these processes may occur in conjunction with lung cancer.

MANAGEMENT

Treatment is based on staging and cell type; both anatomic (e.g., physical location of tumor) and physiologic (e.g., patient's ability to withstand treatment) factors are considered. All patients should undergo the following:[5,8] SOR C

- Complete history and physical.
- Laboratory tests—Complete blood count with differential and platelets, electrolytes, glucose, calcium, phosphorus, and renal and liver function tests.

For staging purposes for NSCLC the ACR recommends the following imaging:[13]

- CT chest scan with contrast, if there are no strong contraindications, and a FDG-PET from skull base to midthigh. Use of FDG-PET has been shown to identify more patients with mediastinal and extrathoracic disease than conventional staging.[14] Although this approach spares more patients from stage-inappropriate surgery, the strategy appears to incorrectly upstage disease in some patients and, in one randomized controlled trial (RCT), did not affect overall mortality.[15]
- If a patient has neurologic symptoms or an adenocarcinoma larger than 3 cm or mediastinal adenopathy, an MRI of the head without and with contrast are recommended.[11]
- In addition, for patients with non–small cell tumors who may be candidates for curative surgery or radiotherapy, obtain pulmonary function tests, coagulation tests, and possibly cardiopulmonary exercise testing.[5]

For staging of patients with SCLC, ACR recommends:[11]

- CT chest scan with contrast, if there are no strong contraindications, FDG-PET from skull base to midthigh, MRI of the head without and with contrast, and CT scan of the abdomen (liver metastases are common at diagnosis). The use of FDG-PET scanning is controversial for patients with SCLC as most chemoradiation studies were performed prior to use of this scan.[8]

Staging for patients with lung cancer is based on the TNM classification system where T describes the size of the tumor, N describes any regional lymph node involvement, and M notes the presence or absence of distant metastases (**Box 58-1**).[16] At diagnosis, approximately 15% have localized disease, 22% have regional disease (spread to regional lymph nodes), and 56% have distant metastases.[2]

FIGURE 58-5 Diffuse lung abnormality seen on chest x-ray best characterized as ground-glass opacity, slightly worse in the right upper lobe. Open biopsy demonstrated bronchoalveolar carcinoma. (*From Diagnostic Thoracic Imaging Courtesy of Miller, W. Diagnostic Thoracic Imaging. New York. McGraw-Hill. 2006.*)

FIGURE 58-6 Chest x-ray showing local area of consolidation in the left lower lobe. Worsening consolidation for the subsequent 2 months despite antibiotic treatment lead to a surgical biopsy, which confirmed bronchoalveolar carcinoma. (*From Diagnostic Thoracic Imaging Courtesy of Miller, W. Diagnostic Thoracic Imaging. New York. McGraw-Hill. 2006.*)

NONPHARMACOLOGIC

Supportive care for the patient and family and palliative care of the patient should be provided, including adequate pain relief.

- Early palliative care was shown in one trial to improve quality of life and mood and increased median survival (11.6 months vs. 8.9 months) for patients with metastatic NSCLC compared to those receiving standard care.[17]
- Smoking cessation—In a metaanalysis, continued smoking was associated with a significantly increased risk of all-cause mortality and recurrence in early stage NSCLC and of all-cause mortality, development of a second primary tumor and recurrence in limited stage (all but stage IV) SCLC.[18] Using life-table modeling, these investigators estimated that 5-year survival in 65-year-old patients with early stage NSCLC who quit smoking would increase from 33% (for those who continued to smoke) to 70% and for those with limited stage SCLC, from 29% (continued smokers) to 63% (quitters) (Chapter 236, Tobacco Addiction).

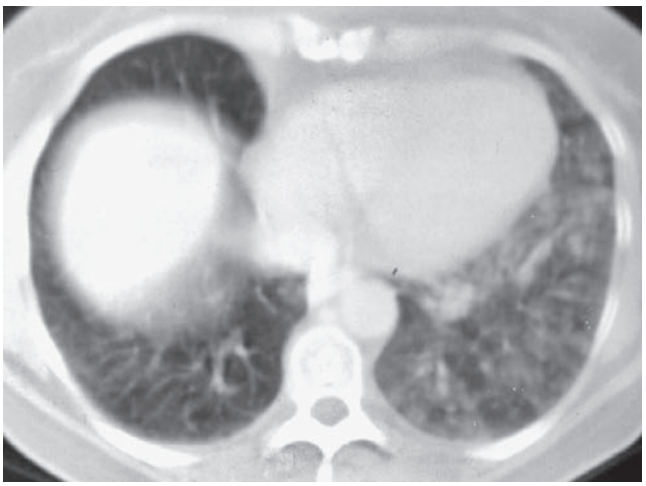

FIGURE 58-7 CT at the level of the bases in the patient in Figure 58-6 showing areas of ground-glass opacification in the left lower lobe and lingula. (*From Diagnostic Thoracic Imaging Courtesy of Miller, W. Diagnostic Thoracic Imaging. New York. McGraw-Hill. 2006.*)

BOX 58-1 TNM Staging of Lung Cancer

- Stage 0 – Carcinoma in situ (Tis N0 M0)
- Stage IA – Tumor size 2 centimeters (cm) or smaller (1a) or tumor size >2 cm but <3 cm (1b) (T1a,b N0 M0)
- Stage IB – Tumor size >3 cm but <5 cm (2a) and has any of the following: involves the main bronchus (>2 cm distal to the carina), invades visceral pleura, or associated with atelectasis or obstructive pneumonitis extending to the hilar region (T2a N0 M0)
- Stage IIA – Tumor size >5 cm but <7 cm (2b) (T2b N0 M0, T1a,b N1 M0, T2a N1 M0)
- Stage IIB – Tumor size >5 cm but <7 cm (2b) or tumor size >7 cm or directly invades the chest wall, diaphragm, phrenic nerve, mediastinal pleura, parietal pericardium; or tumour in the main bronchus <2 cm distal to the carina but without carina involvement; or associated atelectasis or obstructive pneumonitis of the entire lung or separate tumour nodule(s) in the same lobe as the primary (T3) (T2b N1 M0, T3 N0 M0)
- Stage IIIA – Any size tumor including a tumor that invades the mediastinum, heart, great vessels, trachea, recurrent laryngeal nerve, oesophagus, vertebral body, carina or separate tumor in a different ipsilateral lobe to that of the primary (T4) (T1a,b or T2a,b N2 M0, T3 N1or 2 M0, T4 N0 or 1 M0)
- Stage IIIB – T4 N2 M0, any T N3 M0
- Stage IV – tumor has spread to distant sites (Any T any N M1)

T, Tumor (size and extent); N, regional lymph nodes (N0 no regional lymph node metastasis, N1 metastasis in ipsilateral peribronchial and/or ipsilateral hilar lymph nodes and intrapulmonary nodes, including involvement by direct extension, N2 metastasis in ipsilateral mediastinal and/or subcarinal lymph node[s], N3 metastasis in contralateral mediastinal, contralateral hilar, ipsilateral or contralateral scalene, or supraclavicular lymph node[s]); M, metastases (M0 no distant metastasis, M1 distant metastasis).

MEDICATIONS

- Pain medication should be provided as needed (Chapter 5, End of Life). Opioids, such as codeine or morphine, may reduce cough.
- Adjuvant chemotherapy in patients with NSCLC, with or without postoperative radiotherapy, increases 5-year survival by approximately 4% to 5%.[8,19]
- Preoperative chemotherapy in patients with NSCLC increases survival by approximately 6% (absolute benefit) at 5 years.[20] Advantages of preoperative chemotherapy include early start on potential micrometastases and higher adherence to therapy.[8]
- Maintenance therapy with either cytotoxic agents or tyrosine kinase inhibitor agents (or switch therapy) can be considered as it appears to increase overall survival for patients with nonprogressive NSCLC.[21]
- Management of patients with SCLC includes combination, platinum-based chemotherapy (see Surgery and Radiation, management of very limited SCLC.).[5,22] SOR A Targeted therapies have not proved beneficial for patients with SCLC.[22]

COMPLEMENTARY AND ALTERNATIVE THERAPY

- In a small RCT of patients with NSCLC on chemotherapy, nutritional intervention with 2.2 g of fish oil per day provided a benefit on maintenance of weight and muscle mass over standard care.[23] Fish oil also increased the response to chemotherapy in those with advanced NSCLC, and may provide a survival benefit (trend).[24]

SURGERY AND RADIATION

Management of patients with NSCLC includes the following:

- Localized stages I and II—Pulmonary resection. SOR A
  Evidence is conflicting about whether video-assisted thoracoscopic surgery offers advantages over standard lobectomy; either technique can be used.[8,25,26]
- In patients undergoing resection, intraoperative systematic mediastinal lymph node sampling or dissection is recommended for accurate staging.[25] Although data are limited, a Cochrane review concluded that resection combined with complete mediastinal lymph node dissection is associated with a modest survival improvement compared with resection combined with systematic sampling of mediastinal nodes in patients with stages I to IIIA NSCLC.[27]
- For patients with stage I disease who are not surgical candidates, external-beam radiotherapy is recommended[28]; stereotactic body radiation therapy or percutaneous ablation can be considered as a treatment option.[25,26] SOR B
- Adjuvant chemotherapy is recommended for patients with stage II disease.[25,29]
- Stage IIIA and favorable age, cardiovascular function, and anatomy—Possible surgery and/or concurrent chemo/radiation therapy.
- Stage IIIB—Concurrent chemo/radiation therapy.[25]
- Stage IV—Options include radiation therapy to symptomatic local sites, chemotherapy or molecular targeted agents, chest tube for malignant effusion, and consideration of resection of primary or isolated brain or adrenal metastases.[5,25] A Cochrane review

concluded that chemotherapy improves overall survival in patients with advanced NSCLC (absolute improvement in survival of 9% at 12 months [20% to 29%] or absolute increase in median survival of 1.5 months [from 4.5 months to 6 months]).[30]

- Curative radiotherapy should be considered for patients with good performance status and inoperable stages I to III disease.[25]

Management of patients with very limited (stage I) SCLC is surgical resection and adjuvant combined cisplatin-based chemotherapy, possibly with prophylactic cranial irradiation.[22]

- Other patients with limited-stage SCLC (stages II to III) should be offered thoracic irradiation concurrently with the first or second cycle of chemotherapy or following completion of chemotherapy if there has been at least a good partial response within the thorax.[5,22] Prophylactic cranial irradiation should be considered if nonprogressive after induction treatment.[22]
- For patients with extensive disease (stage IV), limited data support prolonged survival (added 63 to 84 days) using chemotherapy.[31] Supportive care plus palliative thoracic irradiation should be considered following chemotherapy (combination etoposide and cisplatin for non-Asian patients and irinotecan and cisplatin for Asian patients).[22]
- For patients who are not candidates for chemotherapy, palliative radiotherapy should be considered.[22] Palliative radiotherapy is associated with a modest increase in survival (5% at 1 year) in patients with better performance status who are given higher-dose radiotherapy.[32] Other targeted therapies, based on molecular testing of tumor mutational profiles (e.g., erlotinib for mutant EGFR) should be considered.
- External-beam radiotherapy could also be considered for the relief of breathlessness, cough, hemoptysis, or chest pain.[5]

PREVENTION

- Avoid smoking/smoking exposure or quit, if already smoking (Chapter 236, Tobacco Addiction). Avoid workplace and home exposures (listed in risk factors).
- Daily aspirin appears to protect against lung adenocarcinoma.[33]
- Routine screening for lung cancer is not currently recommended; the U.S. Preventive Services Task Force concluded that there is insufficient evidence to support screening with any modality.[34] Results of the Prostate, Lung, Colorectal, and Ovarian (PLCO) Cancer Screening Trial (N = 154,901) demonstrated no benefit of annual CXR screening on reducing lung cancer mortality compared with usual care.[35]
- However, the National Lung Screening Trial (N = 53,454 patients at high-risk for lung cancer) reported lower mortality from lung cancer after three annual screenings for patients randomized to low-dose CT versus single-view posteroanterior chest radiography (247 deaths from lung cancer per 100,000 person-years and 309 deaths per 100,000 person-years, respectively).[36] There was also reduced all-cause mortality in this group by 6.7%. As the risk of false positives with low-dose CT is high (33% after two screenings),[37] and there is potential for radiation-induced cancer, it is not clear that routine screening for high-risk patients should be conducted.

PROGNOSIS

- Perioperative mortality from a large database of over 18,000 lung cancer resections performed at 111 participating centers was 2.2% and composite morbidity and mortality occurred in 8.6%.[38] Predictive factors of mortality included pneumonectomy, bilobectomy, performance status, induction chemoradiation, steroids, age, and renal dysfunction among other factors.
- Adverse prognostic factors for NSCLC include presence of pulmonary symptoms, large tumor size (>3 cm), nonsquamous histology, metastases to multiple lymph nodes within a TNM-defined nodal station, and vascular invasion.[4]
- The overall 5-year relative survival from lung cancer (SEER data 2001-2007) was 15.6%. Five-year relative survival by race and sex was 18.3% for white women, 14.5% for black women, 13.7% for white men, and 11.6% for black men.[2]
- Five-year survival decreases by stage at diagnosis ranging from 52.2% for localized disease to 3.6% for those with distant metastases.[2] Estimates for 5-year survival by stage are: Stage IA 73%, Stage IB 65%, Stage IIA 46%, Stage IIB 36%, Stage IIIA 24%, Stage IIIB 9%, and Stage IV 13%.[16]
- For SCLC, median survival for patients with limited-stage disease is approximately 15 to 20 months (20% to 40% survive to 2 years). For those with extensive-stage SCLC disease, median survival is approximately 8 to 13 months with 2-year survival of 5%.[8]
- Following lung cancer resection, there is a 1% to 2% risk per patient per year that a second lung cancer will occur.[5] One author reported higher risks of second tumors in long-term survivors, including rates of 10% for second lung cancers and 20% for all second cancers.[39] For patients with SCLC, second primary tumors are reported in 2% to 10% of patients per year.[22]

FOLLOW-UP

Surveillance for the recognition of a recurrence of the original lung cancer and/or the development of a metachronous tumor should be coordinated through a multidisciplinary team approach.

- This team should develop a lifelong surveillance plan appropriate for the individual circumstances of each patient immediately following initial curative-intent therapy.[5] SOR C
- In patients following curative-intent therapy for lung cancer, the use of blood tests, FDG-PET scanning, sputum cytology, tumor markers, and fluorescence bronchoscopy is not currently recommended for surveillance.[2]

PATIENT EDUCATION

- Smoking cessation, never initiating smoking, and avoidance of occupational and environmental exposure to carcinogenic substances are recommended to reduce the risk of recurrence or a second primary in curatively treated patients. In patients with metastatic disease, although smoking cessation has little effect on overall prognosis, it may improve respiratory symptoms.

- Information about local hospice services and support groups should be provided. The Lung Cancer Alliance website, listed in "Patient Resources" below, can be used to find support groups.

PATIENT RESOURCES

- National Cancer Institute. *Lung Cancer*—**http://www.cancer.gov/cancertopics/types/lung.**
- Mayo Clinic. *Lung Cancer*—**www.mayoclinic.com/health/lung-cancer/DS00038.**
- American Lung Association—**www.lungusa.org.**
- Lung Cancer Alliance. Support groups for patients and families can be found at the following website—**http://www.lungcanceralliance.org/get-help-and-support/coping-with-lung-cancer/support-groups.html.**

PROVIDER RESOURCES

- MedlinePlus. *Lung Cancer*—**www.nlm.nih.gov/medlineplus/lungcancer.html.**
- National Cancer Institute. *Lung Cancer*—**www.cancer.gov/cancertopics/types/lung.**

REFERENCES

1. Centers for Disease Control and Prevention. *Lung Cancer Statistics*. http://www.cdc.gov/cancer/lung/statistics/index.htm. Accessed January 2012.
2. National Cancer Institute. *SEER Stat Fact Sheets: Lung and Bronchus*. http://seer.cancer.gov/statfacts/html/lungb.html. Accessed January 2012.
3. Centers for Disease Control and Prevention. *Basic Information About Lung Cancer*. http://www.cdc.gov/cancer/lung/basic_info/index.htm. Accessed January 2012.
4. National Cancer Institute. *Non-Small Cell Lung Cancer Treatment (PDQ)*. http://cancer.gov/cancertopics/pdq/treatment/non-small-cell-lung/healthprofessional. Accessed January 2012.
5. Minna JD. Neoplasms of the lung. In: Kasper DL, Braunwald E, Fauci AS, Hauser SL, Longo DL, Jameson JL, eds. *Harrison's Principles of Internal Medicine*, 16th ed. New York: McGraw-Hill; 2005:506-516.
6. Olsson AC, Gustavsson P, Kromhout H, et al. Exposure to diesel motor exhaust and lung cancer risk in a pooled analysis from case-control studies in Europe and Canada. *Am J Respir Crit Care Med.* 2011;183(7):941-948.
7. Chlebowski RT, Schwartz AG, Wakelee H, et al. Oestrogen plus progestin and lung cancer in postmenopausal women (Women's Health Initiative trial): a post-hoc analysis of a randomised controlled trial. *Lancet.* 2009;374(9697):1243-1251.
8. Goldstraw P, Ball D, Jett JR, et al. Non-small-cell lung cancer. *Lancet.* 2011;378(9804):1727-1740.
9. Dacic S. Molecular diagnostics of lung carcinomas. *Arch Pathol Lab Med.* 2011;135(5):622-629.
10. Rosell R, Moran T, Queralt C, et al. Screening for epidermal growth factor receptor mutations in lung cancer. *N Engl J Med.* 2009;361(10):958-967.
11. Ray CE Jr, English B, Funaki BS, et al. Expert Panel on Interventional Radiology. ACR Appropriateness Criteria biopsies of thoracic nodules and masses. Reston, VA: American College of Radiology; 2011. 7 p. http://www.guideline.gov/content.aspx?id=32616&search=lung+neoplasm. Accessed February 2012.
12. Yasufuku K, Pierre A, Darling G, et al. A prospective controlled trial of endobronchial ultrasound-guided transbronchial needle aspiration compared with mediastinoscopy for mediastinal lymph node staging of lung cancer. *J Thorac Cardiovasc Surg.* 2011;142(6):1393-1400.e1.
13. Ravenel JG, Mohammed TH, Movsas B, et al. Expert Panel on Thoracic Imaging and Radiation-Oncology-Lung. ACR Appropriateness Criteria non-invasive clinical staging of bronchogenic carcinoma. Reston, VA: American College of Radiology; 2010. 11 p. http://www.guideline.gov/content.aspx?id=32627&search=lung+neoplasm. Accessed February 2012.
14. Maziak DE, Darling GE, Inculet RI, et al. Positron emission tomography in staging early lung cancer: a randomized trial. *Ann Intern Med.* 2009;151(4):221-228, W-48.
15. Fischer B, Lassen U, Mortensen J, et al. Preoperative staging of lung cancer with combined PET-CT. *N Engl J Med.* 2009;361(1):32-39.
16. Goldstraw P, Crowley J, Chansky K, et al. The IASLC Lung Cancer Staging Project: proposals for the revision of the TNM stage groupings in the forthcoming (seventh) edition of the TNM Classification of malignant tumours. *J Thorac Oncol.* 2007;2(8):706-714.
17. Temel JS, Greer JA, Muzikansky A, et al. Early palliative care for patients with metastatic non-small-cell lung cancer. *N Engl J Med.* 2010;363(8):733-742.
18. Parsons A, Daley A, Begh R, Aveyard P. Influence of smoking cessation after diagnosis of early stage lung cancer on prognosis: systematic review of observational studies with meta-analysis. *BMJ.* 2010;340:b5569.
19. NSCLC Meta-Analysis Collaborative Group, Arriagada R, Auperin A, Burdett S, et al. Adjuvant chemotherapy, with or without postoperative radiotherapy, in operable non-small-cell lung cancer: two meta-analyses of individual patient data. *Lancet.* 2010;375(9722):1267-1277.
20. Burdett S, Stewart L, Rydzewska L. Chemotherapy and surgery versus surgery alone in non-small cell lung cancer. *Cochrane Database Syst Rev.* 2007;(3):CD006157.
21. Zhang X, Zhang J, Xu J, et al. Maintenance therapy with continuous or switch strategy in advanced non-small cell lung cancer: a systematic review and meta-analysis. *Chest.* 2011;140(1):117-126.
22. van Meerbeeck JP, Fennell DA, DeRuysscher DKM. Small-cell lung cancer. *Lancet.* 2011;378(9804):1741-1755.
23. Murphy RA, Mourtzakis M, Chu QS, et al. Nutritional intervention with fish oil provides a benefit over standard of care for weight and skeletal muscle mass in patients with nonsmall cell lung cancer receiving chemotherapy. *Cancer.* 2011;117(8):1775-1782.

24. Murthy RA, Mourizakis M, Chu QS, et al. Supplementation with fish oil increases first-line chemotherapy efficacy in patients with advanced nonsmall cell lung cancer. *Cancer*. 2011;117(16): 3774-3780.

25. Carr LL, Finigan JH, Kern JA. Evaluation and treatment of patients with non-small cell lung cancer. *Med Clin North Am*. 2011;95(6):1041-1054.

26. Scott WJ, Howington J, Feigenberg S, et al. American College of Chest Physicians. Treatment of non-small cell lung cancer stage I and stage II: ACCP evidence-based clinical practice guidelines (2nd edition). *Chest* 2007;132(3 Suppl):234S-242S. http://www.guideline.gov/content.aspx?id=11415&search=lung+cancer. Accessed February 2012.

27. Manser R, Wright G, Hart D, et al. Surgery for local and locally advanced non-small cell lung cancer. *Cochrane Database Syst Rev*. 2005;(1):CD004699.

28. Gewanter RM, Movsas B, Rosenzweig KE, et al. Expert Panel on Radiation Oncology-Lung. ACR Appropriateness Criteria nonsurgical treatment for non-small-cell lung cancer: good performance status/definitive intent. Reston, VA: American College of Radiology; 2010. 11 p. http://www.guideline.gov/content.aspx?id=23840&search= lung+cancer+acr. Accessed February 2012.

29. Decker RH, Langer CJ, Movsas B, et al. Expert Panel on Radiation Oncology-Lung. ACR Appropriateness Criteria postoperative adjuvant therapy in non-small-cell lung cancer. Reston, VA: American College of Radiology; 2010. 10 p. http://www.guideline.gov/content.aspx?id=32607&search=lung+cancer+acr. Accessed February 2012.

30. Non-Small Cell Lung Cancer Collaborative Group. Chemotherapy and supportive care versus supportive care alone for advanced non-small cell lung cancer. *Cochrane Database Syst Rev*. 2010;(5): CD007309.

31. Pelayo Alvarez M, Gallego Rubio Ó, Bonfill Cosp X, Agra Varela Y. Chemotherapy versus best supportive care for extensive small cell lung cancer. *Cochrane Database Syst Rev*. 2009;(4):CD001990.

32. Lester JF, MacBeth F, Toy E, Coles B. Palliative radiotherapy regimens for non-small cell lung cancer. *Cochrane Database Syst Rev*. 2006;(4):CD002143.

33. Rothwell PM, Fowkes FG, Belch JF, et al. Effect of daily aspirin on long-term risk of death due to cancer: analysis of individual patient data from randomised trials. *Lancet*. 2011;377(9759):31-41.

34. United States Preventive Services Task Force. *Lung Cancer Screening*. http://www.uspreventiveservicestaskforce.org/uspstf/uspslung.htm. Accessed January 2012.

35. Oken NM, Hocking WG, Kvale PA, et al. PLCO Project Team. Screening by chest radiograph and lung cancer mortality: the Prostate, Lung, Colorectal, and Ovarian (PLCO) randomized trial. *JAMA*. 2011;306(17):1865-1873.

36. National Lung Screening Trial Research Team, Aberle DR, Adams AM, Bery CD, et al. Reduced lung-cancer mortality with low-dose computed tomographic screening. *N Engl J Med*. 2011; 365(5):395-409.

37. Croswell JM, Baker SG, Marcus PM, et al. Cumulative incidence of false-positive test results in lung cancer screening: a randomized trial. *Ann Intern Med*. 2010;152(8):505-512.

38. Kozower BD, Sheng S, O'Brien SM, et al. STS database risk models: predictors of mortality and major morbidity for lung cancer resection. *Ann Thorac Surg*. 2010;90(3):875-881.

39. Fry WA, Menck HR, Winchester DP. The National Cancer Data Base report on lung cancer. *Cancer*. 1996;77(9):1947-1955.

PART 9

GASTROINTESTINAL

Strength of Recommendation (SOR)	Definition
A	Recommendation based on consistent and good-quality patient-oriented evidence.*
B	Recommendation based on inconsistent or limited-quality patient-oriented evidence.*
C	Recommendation based on consensus, usual practice, opinion, disease-oriented evidence, or case series for studies of diagnosis, treatment, prevention, or screening.*

*See Appendix A on pages 1447–1450 for further information.

59 PEPTIC ULCER DISEASE

Hend Azhary, MD
Mindy A. Smith, MD, MS

PATIENT STORY

A 41-year-old man presents with a 4-month history of epigastric pain. The pain is dull, achy, and intermittent; there is no radiation of the pain and it has not changed in character since it began. Coffee intake seems to exacerbate the symptoms while eating or drinking milk helps. Infrequently, he is awakened at night from the pain. He reports no weight loss, vomiting, melena, or hematochezia. On examination, there is mild epigastric tenderness with no rebound or guarding. The reminder of the examination is unremarkable. A stool antigen test is positive for *Helicobacter pylori*, and the patient is treated for peptic ulcer disease with eradication therapy.

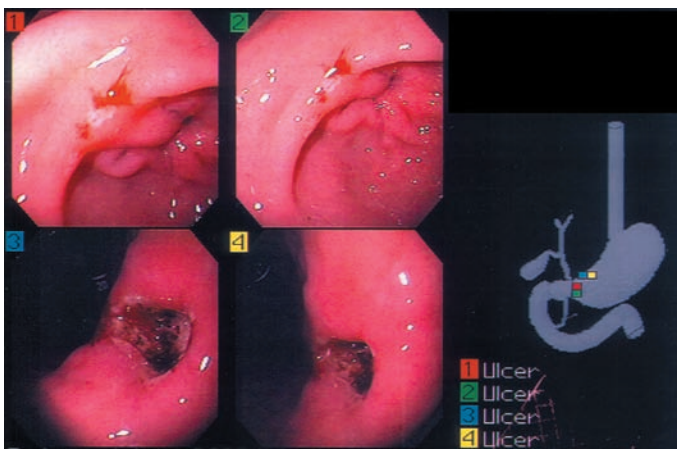

FIGURE 59-1 Endoscopic pictures of a gastric ulcer. Plates 1 and 2 show erosions. Note that the bleeding is from biopsy. Plates 3 and 4 show a large crater with evidence of recent bleeding. Both are consistent with severe ulcer disease. (*Courtesy of Michael Harper, MD.*)

INTRODUCTION

Peptic ulcer disease (PUD) is a disease of the gastrointestinal (GI) tract characterized by a break in the mucosal lining of the stomach or duodenum secondary to pepsin and gastric acid secretion, this damage is greater than 5 mm in size and with a depth reaching the submucosal layer.[1]

EPIDEMIOLOGY

- PUD is a common disorder affecting approximately 4.5 million people annually in the United States. It encompasses both gastric and duodenal ulcers (**Figures 59-1** and **59-2**).[2]
- One-year point prevalence is 1.8%, and the lifetime prevalence is 10% in the United States.[2]
- Prevalence is similar in both sexes, with increased incidence with age.[1] Duodenal ulcers most commonly occur in patients between the ages of 30 and 55 years, whereas gastric ulcers are more common in patients between the ages of 55 and 70 years.[2]
- PUD incidence in *H. pylori*-infected individuals is approximately 1% per year (6- to 10-fold higher than uninfected subjects).[1]
- Physician office visit and hospitalization for PUD have decreased in the last few decades.[1]
- The current U.S. annual direct and indirect health care costs of PUD are estimated at approximately $10 billion. However, the incidence of peptic ulcers keeps declining, possibly as a result of the increasing use of proton pump inhibitors and eradication of *H. pylori* infection.[3]

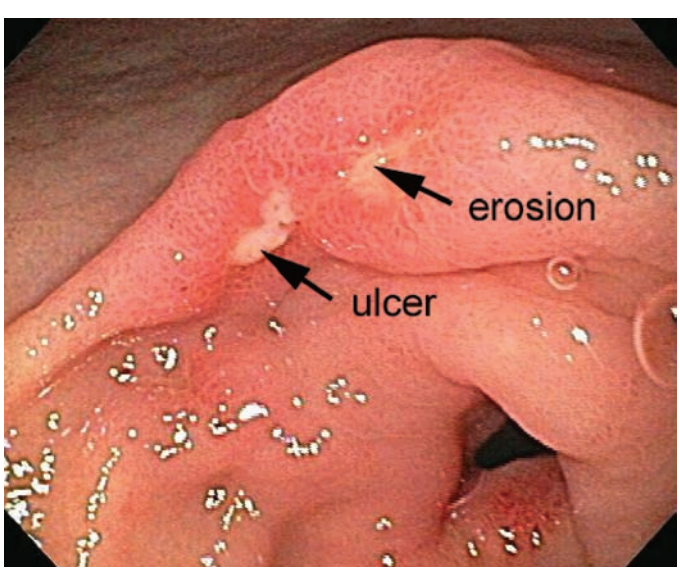

FIGURE 59-2 Endoscopic view of a pyloric ulcer and an erosion of the mucosa. The ulcer and erosion are benign peptic ulcer disease and not malignant. (*Courtesy of Marvin Derezin, MD.*)

ETIOLOGY AND PATHOPHYSIOLOGY

- Causes of PUD include:
  - NSAIDs, chronic *H. pylori* infection, and acid hypersecretory states such as Zollinger-Ellison syndrome.[2]

- Uncommon causes include *Cytomegalovirus* (especially in transplantation recipients), systemic mastocytosis, Crohn disease, lymphoma, and medications (e.g., alendronate).[2]
- Up to 10% of ulcers are idiopathic.[2]

- Infection with *H. pylori*, a short, spiral-shaped, microaerophilic Gram-negative bacillus, is the leading cause of PUD. It is associated with up to 70% to 80% of duodenal ulcers.[2]
- *H. pylori* colonize the deep layers of the gel that coats the mucosa and disrupt its protective properties causing release of certain enzymes and toxins. These make the underlying tissues more vulnerable to damage by digestive juices and thus cause injury to the stomach (**Figures 59-1** to **59-3**) and duodenum cells.[1]
- NSAIDs are the second most common cause of PUD and account for many *H. pylori*-negative cases.
- NSAIDs and aspirin inhibit mucosal cyclooxygenase activity reducing the level of mucosal prostaglandin causing defects in the protective mucous layer.
- There is a 10% to 20% prevalence of gastric ulcers and a 2% to 5% prevalence of duodenal ulcers in long-term NSAID users.[2] The annual risk of a life-threatening ulcer-related complication is 1% to 4% in long-term NSAID users, with older patients having the highest risk.[7]

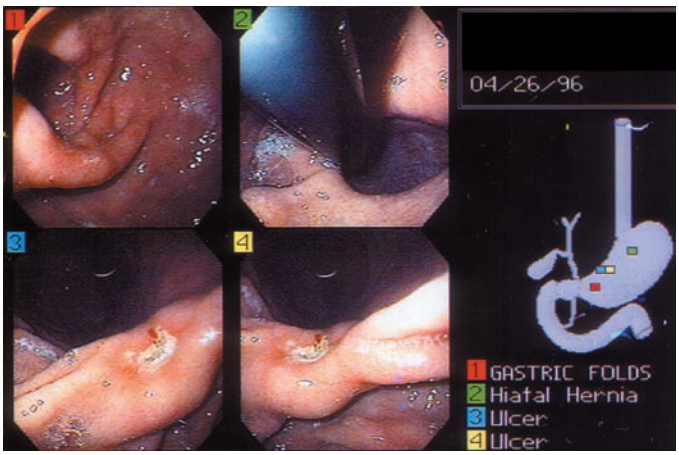

FIGURE 59-3 Stomach ulcer in a patient with a hiatal hernia. (*Courtesy of Michael Harper, MD.*)

RISK FACTORS

- Severe physiologic stress—Burns, central nervous system trauma, surgery, and severe medical illness increase the risk for secondary (stress) ulceration.[4]
- Smoking—Evidence that tobacco use is a risk factor for duodenal ulcers in not conclusive, with several studies producing contradictory findings. However, smoking in the setting of *H. pylori* infection may increase the risk of relapse of PUD.[5]
- Alcohol use—Ethanol is known to cause gastric mucosal irritation and nonspecific gastritis. Evidence that consumption of alcohol is a risk factor for duodenal ulcer is inconclusive.[5]
- Medications—Corticosteroids alone do not increase the risk for PUD; however, they can potentiate ulcer risk in patients who use NSAIDs concurrently.[4]

DIAGNOSIS

CLINICAL FEATURES

- Epigastric pain (dyspepsia), the hallmark of PUD, is present in 80% to 90% of patients; however, this symptom is not sensitive or specific enough to serve as a reliable diagnostic criterion for PUD. Pain is typically described as gnawing or burning, occurring 1 to 3 hours after meals and relieved by food or antacids. It can occur at night, and sometimes radiates to the back.[2] Less than 25% of patients with dyspepsia have ulcer disease at endoscopy.[4]
- Other dyspeptic symptoms including belching, bloating, and distention are common but also not specific features of PUD as they are commonly encountered in many other conditions.

- Additional symptoms include fatty food intolerance, heartburn, and chest discomfort.
- Nausea and anorexia may occur with gastric ulcers.
- Significant vomiting and weight loss are unusual with uncomplicated ulcer disease and suggest gastric outlet obstruction or gastric malignancy.[2]
- Twenty percent of patients with ulcer complications such as bleeding and nearly 61% of patients with NSAID-related ulcer complications have no antecedent symptoms.
- Rare and nonspecific physical findings include:
  - Epigastric tenderness.
  - Heme-positive stool.
  - Hematemesis or melena in cases of GI bleeding.

TYPICAL DISTRIBUTION

- Duodenal ulcers occur most often in the first portion of the duodenum (>95%), with approximately 90% of ulcers located within 3 cm of the pylorus.[1]
- Benign gastric ulcers are located most commonly in the antrum (60%) and at the junction of the antrum and body on the lesser curvature (25%) (**Figure 59-3**).[1]

LABORATORY STUDIES

- In most patients with uncomplicated PUD, routine laboratory tests are not helpful.[4]
- Noninvasive tests include serum *H. pylori* antibody detection, fecal antigen tests, and urea breath tests; the latter two, if positive, indicate active disease.[6]
- Serum enzyme-linked immunosorbent assay (ELISA) is the least accurate test and is useful only for diagnosing the initial infection.
- The stool antigen test is less convenient but is highly accurate and also can be used to confirm *H. pylori* eradication, as can the urea breath test.[6]
- Obtaining a serum gastrin may be useful in patients with recurrent, refractory, or complicated PUD and in patients with a family history of PUD to screen for Zollinger-Ellison syndrome.[1]

IMAGING

- Upper endoscopy is the procedure of choice for the diagnosis of duodenal and gastric ulcers (**Figures 59-1** to **59-3**).[2]
- Endoscopy provides better diagnostic accuracy than barium radiography and affords the ability to biopsy for the presence of malignancy and *H. pylori* infection. Endoscopy is usually reserved for the following situations:
  - Patients with red flag signs (e.g., bleeding, dysphagia, severe pain, abdominal mass, recurrent vomiting, weight loss) or age older than 55 years.
  - Patients who fail initial therapy.
  - Patients whose symptoms recur after appropriate therapy.
- Duodenal ulcers are virtually never malignant and do not require biopsy.[2]
- Gastric ulcers should be biopsied because 3% to 5% of benign-appearing gastric ulcers prove to be malignant.[2]
- Barium upper gastrointestinal (UGI) series is an acceptable alternative to endoscopy but is not as sensitive for the diagnosis of small ulcers (<0.5 cm) and does not allow for biopsy with gastric ulcer.[6]
- Patient's testing positive for PUD should undergo noninvasive testing for *H. pylori*.
- UGI series has limited accuracy in distinguishing benign from malignant gastric ulcers; therefore, all patients diagnosed this way should be reevaluated with endoscopy after 8 to 12 weeks of therapy.

DIFFERENTIAL DIAGNOSIS

Disease processes that may present with "ulcer-like" symptoms include:

- Nonulcer or functional dyspepsia (FD)—The most common diagnosis among patients seen for upper abdominal discomfort; it is a diagnosis of exclusion. Dyspepsia has been reported to occur in up to 30% of the U.S. population.
- Gastroesophageal reflux—Classic symptoms are heartburn (i.e., substernal pain that may be associated with acid regurgitation or a sour taste) aggravated by bending forward or lying down, especially after a large meal. Endoscopy is considered if symptoms fail to respond to treatment (e.g., histamine-2-receptor agonist, proton pump inhibitor [PPI]) or red flag signs and symptoms occur.
- Gastric cancer—Most patients do not become symptomatic until late in the disease; symptoms include upper abdominal pain, postprandial fullness, anorexia and mild nausea, vomiting (especially with pyloric tumors), weight loss and a palpable mass. Endoscopic biopsy is used to make this diagnosis (see Chapter 60, Gastric Cancer).
- Biliary colic is characterized by discrete, intermittent episodes of pain that should not be confused with other causes of dyspepsia.
- Gastroduodenal Crohn disease—Symptoms include epigastric pain, nausea, and vomiting. On endoscopy, patients often have *H. pylori*-negative gastritis and may develop gastric outlet obstruction. Extraintestinal manifestations include erythema nodosum, peripheral arthritis, conjunctivitis, uveitis, and episcleritis. Endoscopy shows an inflammatory process with skip lesions, fistulas, aphthous ulcerations, and rectal sparing. Small bowel involvement is seen on imaging with longitudinal and transverse ulceration (cobblestoning) in addition to segmental colitis and frequent stricture (see Chapter 65, Inflammatory Bowel Disease).

MANAGEMENT

- The approach to patients with dyspepsia includes performing endoscopy for patients with red flag symptoms or who are older than age 55 years. For patients who have an ulcer identified on endoscopy, eradication of *H. pylori* is attempted (as below) and a PPI is continued for 4 to 8 weeks. For those without an ulcer on endoscopy, treatment with a PPI or H_2 blocker is provided.[7]
- For patients without red flag findings, testing and treating for *H. pylori*; counseling to avoid smoking, alcohol, and NSAIDs; and

appropriate use of antisecretory therapy for 4 weeks will be successful in the majority of patients.[7]

- The goals of treatment of active *H. pylori*-associated ulcers are to relieve dyspeptic symptoms, to promote ulcer healing, and to eradicate *H. pylori* infection. Eradication of *H. pylori* is better than ulcer-healing drug therapy for duodenal ulcer healing[8] and greatly reduces the incidence of ulcer recurrence from 67% to 6% in patients with duodenal ulcers and from 59% to 4% in patients with gastric ulcers.[7]
- The worldwide empiric use of traditional triple therapy with PPI, clarithromycin, and amoxicillin no longer provides an acceptable cure rate (cure rate below 80%) because of the increasing prevalence of clarithromycin resistance.[9]
- Four drug combinations currently provide the best results and consist of two general combinations: (a) a PPI, amoxicillin, clarithromycin, metronidazole/tinidazole given either sequentially or concomitantly, or (b) a PPI, a bismuth, tetracycline HCL, and metronidazole/tinidazole. [9] SOR A
- A PPI, levofloxacin, and amoxicillin for 10 days appears to be more effective and better tolerated than a PPI, bismuth, tetracycline, and metronidazole in patients with persistent *H. pylori* infection but requires validation in North America.[6]
- The European Helicobacter Study Group consensus guideline states that triple therapy (PPI-clarithromycin-amoxicillin/metronidazole) or Bismuth quadruple therapy remain first-line treatment in areas with low clarithromycin resistance. For areas with high clarithromycin resistance (>20%), Bismuth or non-Bismuth quadruple therapy are preferred.[10]
- Treat NSAID-induced ulcers with cessation of NSAIDs, if possible, and an appropriate course of standard ulcer therapy with a H_2-receptor antagonist or a PPI. If NSAIDs are continued, prescribe a PPI. SOR A
- *H. pylori*-negative ulcers that are not caused by NSAIDs can be treated with appropriate antisecretory therapy, either H_2-receptor antagonist or PPI. SOR A
- For patients with bleeding peptic ulcers, high-dose PPIs do not reduce rates of rebleeding, surgical intervention, or mortality after endoscopic treatment compared with non–high-dose PPIs.[11]

PREVENTION

- In a large randomized controlled trial (RCT) (N = 2426) of PUD prevention in patients taking low-dose acetylsalicylic acid who were at risk for ulcer development (e.g., prior ulcer, GI symptoms and erosions, age older than 65 years), esomeprazole 40 mg or 20 mg reduced the rate of endoscopically confirmed peptic ulcer development (1.5% and 1.1%, respectively) versus placebo (7.4%).[12]
- Authors of a metaanalysis found the use of prophylactic H_2 blockers to prevent stress ulcers was not necessary in patients receiving enteral nutrition and that such therapy was associated with pneumonia and higher risk of hospital mortality.[13] In another metaanalysis, PPIs were similar to H_2-receptor antagonists in terms of stress-related UGI bleeding prophylaxis, pneumonia, and mortality among patients admitted to intensive care units.[14]

PROGNOSIS

- Hospitalization rate is approximately 30 per 100,000 cases.[4]
- Mortality rate is approximately 1 per 100,000 cases.[4]
- When the underlying cause is addressed the prognosis is excellent.
- With the eradication of *H. pylori* infection there has been decrease in the ulcer recurrence rate from 60% to 90% to approximately 10% to 20% with the regard to NSAID-related ulcers.[4]
- The incidence of perforation is approximately 0.3% per patient year, and the incidence of obstruction is approximately 0.1% per patient year.[4]

FOLLOW-UP

- Endoscopy is required to document healing of gastric ulcers and to rule out gastric cancer; this is performed 6 to 8 weeks after the initial diagnosis.
- Confirmation of *H. pylori* eradication in patients with uncomplicated ulcers is not necessary.
- Confirmation of healing with endoscopy is required in all patients with ulcer complicated by bleeding, perforation, or obstruction.
- For patients without initial endoscopy who have persistent symptoms following initial treatment, the PPI or H_2 blocker can be continued for another 4 to 8 weeks.[7] If there is inadequate response to therapy, endoscopy and evaluation for hypersecretory states should be considered.

PATIENT EDUCATION

- Patients with PUD should be encouraged to eat balanced meals at regular intervals, avoid heavy alcohol use, and avoid smoking (which has been shown to retard the rate of ulcer healing and increase the frequency of recurrences); stress reduction counseling might be helpful in individual cases.

PATIENT RESOURCES

- National Digestive Diseases Information Clearing House—**http://digestive.niddk.nih.gov/ddiseases/pubs/pepticulcers_ez/index.htm.**
- Centers for Disease Control and Prevention—**http://www.cdc.gov/ulcer/.**

PROVIDER RESOURCES

- **http://emedicine.medscape.com/article/181753-overview.**

REFERENCES

1. Del Valle J. Peptic ulcer disease and related disorders. In: Kasper DL, Braunwald E, Fauci AS, Hauser SL, Longo DL, Jameson JL, eds. *Harrison's Principles of Internal Medicine*, 16th ed. New York, NY: McGraw-Hill; 2005:1746-1762.

2. McPhee SJ, Papadakis MA, Tierney LW Jr. *Current Medical Diagnosis and Treatment*. New York, NY: McGraw-Hill; 2007.
3. University of Michigan Health System. *Peptic Ulcer Disease*. http://www.cme.med.umich.edu/pdf/guideline/PUD05.pdf. Accessed October 2011.
4. Anand BS, Bank S, Qureshi WA, et al. *Peptic Ulcer* Disease. http://emedicine.medscape.com/article/181753-overview. Accessed October 2011.
5. Aldoori WH, Giovannucci EL, Stampfer MJ, et al. A prospective study of alcohol, smoking, caffeine, and the risk of duodenal ulcer in men. *Epidemiology*. 1997;8(4):420-424.
6. Chey WD, Wong BCY; Practice Parameters Committee of the American College of Gastroenterology. American College of Gastroenterology guideline on the management of *Helicobacter pylori* infection. *Am J Gastroenterol*. 2007;102:1808-1825.
7. Ramakrishnan K, Salinas RC. Peptic ulcer disease. *Am Fam Physician*. 2007;76(7):1005-1012.
8. Ford AC, Delaney B, Forman D, Moayyedi P. Eradication therapy for peptic ulcer disease in *Helicobacter pylori* positive patients. *Cochrane Database Syst Rev*. 2006;(2):CD003840.
9. Graham DY, Rugge M. Diagnosis and evaluation of dyspepsia: clinical practice. *J Clin Gastroenterol.* 2010;44(3):167-172.
10. Malfertheiner P, Megraud F, O'Morain CA, et al; The European Helicobacter Study Group (EHSG). Management of *Helicobacter pylori* infection—The Maastricht IV/Florence Consensus Report. *Gut*. 2012;61:646-664.
11. Wang CH, Ma MH, Chou HC, et al. High-dose vs non-high-dose proton pump inhibitors after endoscopic treatment in patients with bleeding peptic ulcer: a systematic review and meta-analysis of randomized controlled trials. *Arch Intern Med.* 2010;170(9):751-758.
12. Scheiman JM, Devereaux PJ, Herlitz J, et al. Prevention of peptic ulcers with esomeprazole in patients at risk of ulcer development treated with low-dose acetylsalicylic acid: a randomised, controlled trial (OBERON). *Heart.* 2011;97(10):797-802.
13. Marik PE, Vasu T, Hirani A, Pachinburavan M. Stress ulcer prophylaxis in the new millennium: a systematic review and meta-analysis. *Crit Care Med.* 2010;38(11):2222-2228.
14. Lin PC, Chang CH, Hsu PI, et al. The efficacy and safety of proton pump inhibitors vs histamine-2 receptor antagonists for stress ulcer bleeding prophylaxis among critical care patients: a meta-analysis. *Crit Care Med.* 2010;38(4):1197-1205.

60 GASTRIC CANCER

Mindy A. Smith, MD, MS

PATIENT STORY

A 72-year-old Japanese immigrant was brought in by his family with complaints of difficulty in eating, vague abdominal pain, and weight loss. Endoscopy and biopsy confirmed gastric adenocarcinoma (**Figure 60-1**). Liver metastases were found on abdominal CT. The family and the patient chose only comfort measures and the patient died 6 months later.

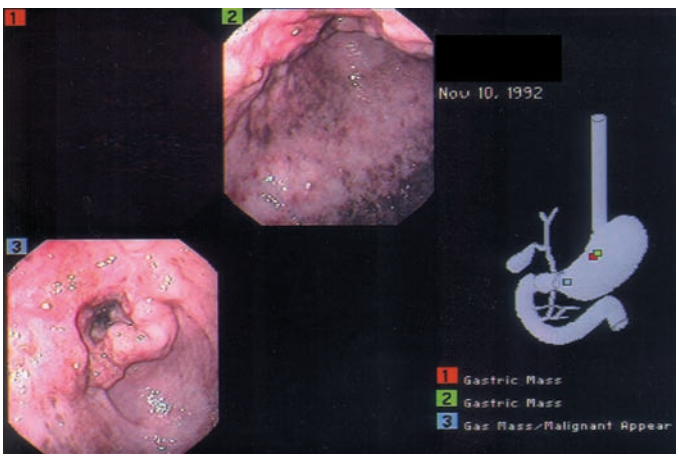

FIGURE 60-1 Endoscopy showing a raised and irregular mass in the antrum of the stomach deforming the pylorus. It fills the distal one-half of the antrum. The lesion was hard when probed with biopsy forceps. Biopsy indicated adenocarcinoma. (*Courtesy of Michael Harper, MD.*)

INTRODUCTION

Gastric cancer is a malignant neoplasm of the stomach, usually adenocarcinoma.

EPIDEMIOLOGY

- Based on Surveillance Epidemiology and End Results (SEER) data, an estimated 12,730 men and 8270 women will be diagnosed with gastric cancer, and 10,570 men and women will die of this cancer in 2012 (2010).[1] The median age at diagnosis is 70 years and median age at death from gastric cancer is 73 years.[1]
- Stomach cancer occurs in 10.8 per 100,000 men and 5.4 per 100,000 women in a year. In 2008, the United States prevalence was 37,739 men and 28,271 women, with a lifetime risk of 0.88%.[1]
- High rates of stomach cancer occur in Japan, China, Chile, and Ireland.[2]

ETIOLOGY AND PATHOPHYSIOLOGY

- Eighty-five percent of stomach cancers are adenocarcinomas with 15% lymphomas and GI stromal tumors.[2] Adenocarcinoma is further divided into two types:
  - Diffuse type—Characterized by absent cell cohesion, these tumors affect younger individuals infiltrating and thickening the stomach wall; the prognosis is poor. Several susceptibility genes have been identified for this type of cancer.[3]
  - Intestinal type—Characterized by adhesive cells forming tubular structures, these tumors frequently ulcerate.
- Tumor grade can be well (4.1%), moderate (23.1%), or poorly differentiated (54.9%), or undifferentiated (2.9%) (SEER data from 1988–2001; unknown type accounted for 15%).[4]
- Most tumors are thought to arise from ingestion of nitrates that are converted by bacteria to carcinogens. Exogenous and endogenous factors (see "Risk Factors" below) contribute to this process.[2]
  - Exogenous sources of nitrates—Sources include foods that are dried, smoked, and salted. *Helicobacter pylori* infection may

contribute to carcinogenicity by creating gastritis, loss of acidity, and bacterial growth.
- Oncogenic pathways identified in most gastric cancers are the proliferation/stem cell, nuclear factor-κB, and Wnt/β-catenin; interactions between them appear to influence disease behavior and patient survival.[5]
- Gastric tumors are classified for staging using the T (tumor) N (nodal involvement) M (metastases) system. Two important prognostic factors are depth of invasion through the gastric wall (less than T2 [tumor invades muscularis propria]) and presence or absence of regional lymph node involvement (N0). Changes made to the classification system in the seventh edition of the American Joint Commission's *Cancer Staging Manual* for gastric cancer[6] demonstrate better survival discrimination.[7]
- Gastric cancer spreads in multiple ways:[2]
  - Local extension through the gastric wall to the perigastric tissues, omenta, pancreas, colon, or liver.
  - Lymphatic drainage through numerous pathways leads to multiple nodal group involvement (e.g., intraabdominal, supraclavicular) or seeding of peritoneal surfaces with metastatic nodules occurring on the ovary, periumbilical region, or peritoneal cul-de-sac.
  - Hematogenous spread is also common with liver metastases.

RISK FACTORS

- Previous gastric surgery—As a result of alteration of the normal pH or with biopsy showing high-grade dysplasia.[2,8]
- Other endogenous risk factors—Atrophic gastritis (including postsurgical vagotomized patients) and pernicious anemia are conditions that favor the growth of nitrate-converting bacteria. In addition, intestinal-type cells that develop metaplasia and possibly atypia can replace the gastric mucosa in these patients. Genetic polymorphisms (e.g., interleukin-1B-511, interleukin-1RN, and tumor necrosis factor-α) also appear to play a role. Familial adenomatous polyposis and hereditary nonpolyposis colorectal cancer are also risk factors.[8]
- Individuals infected with certain *H. pylori* bacteria (cytotoxin-associated gene A) are at increased risk of gastric adenocarcinoma (especially noncardia) and gastric mucosa-associated lymphoid tissue (MALT) lymphoma.[9]
- Additional risk factors—Smoking, low socioeconomic class, lower educational level, exposure to certain pesticides (e.g., those who work in the citrus fruit industry in fields treated with 2,4-dichlorophenoxyacetic acid [2,4-D], chlordane, propargite, and triflurin[10]), radiation exposure, and blood type A.

DIAGNOSIS

CLINICAL FEATURES[2]

- Asymptomatic, if superficial and/or early.
- Upper abdominal pain that ranges from vague to severe.
- Postprandial fullness.
- Anorexia and mild nausea are common.

- Nausea and vomiting occur with pyloric tumors.
- Late symptoms include weight loss and a palpable mass (regional extension).
- Late complications include peritoneal and pleural effusions; obstruction of the gastric outlet; bleeding from esophageal varices or postsurgical site; and jaundice.[11]
- Physical signs are also late features and include:[11]
  - Palpable enlarged stomach with succussion splash (splashing sound on shaking, indicative of the presence of fluid and air in a body cavity).
  - Primary mass (rare).
  - Enlarged liver.
  - Enlarged, firm to hard, lymph nodes (i.e., left supraclavicular [Virchow]), periumbilical region (Sister Mary Joseph node), and peritoneal cul-de-sac (Blumer shelf; palpable on vaginal or rectal examination).

TYPICAL DISTRIBUTION

- Based on SEER data from 1988–2001, gastric tumors occur most often in the cardia (25.5%) and gastric antrum (20.7%), followed by the lesser curvature (9.9%), body (7.4%) and greater curvature (4.3%), and fundus (4.1%). Overlapping lesions were reported in 9.8% and no specific information was available in 15.2%.[4]
- Rates of noncardia gastric cancer appear to be decreasing.[9]

IMAGING AND ENDOSCOPY

- Diagnosis can be made on endoscopy (**Figures 60-1** and **60-2**) with biopsy of suspicious lesions. Confocal laser endomicroscopy may improve detection of early lesions.[12]
- Urgent referral for endoscopy (within 2 weeks) is recommended for patients with dyspepsia who also have GI bleeding, dysphagia, progressive unexplained weight loss, persistent vomiting, iron-deficiency anemia, epigastric mass, family history of gastric cancer (onset <50 years), or whose dyspepsia is persistent and they are older than age 55 years.[13] SOR C
- Double-contrast radiography is an alternative to endoscopy and can detect large primary tumors but distinguishing benign from malignant disease is difficult.[2]
- Although endoscopy is not necessary when radiography demonstrates a benign-appearing ulcer with evidence of complete healing at 6 weeks, some authors recommend routine endoscopy, biopsy, and brush cytology when any gastric ulcer is identified.[2]
- Some gastric polyps (adenomas, hyperplastic) have malignant potential and should be removed.[14]
- Work-up for metastases includes:[15] SOR C
  - Chest radiograph.
  - CT scan or MRI of the abdomen and pelvis.
- Endoscopic sonography is useful as a staging tool when the CT scan fails to find evidence of locally advanced or metastatic disease.[2]

LABORATORY STUDIES

- A hemoglobin or hematocrit can identify anemia, present in approximately 30% of patients.[11]

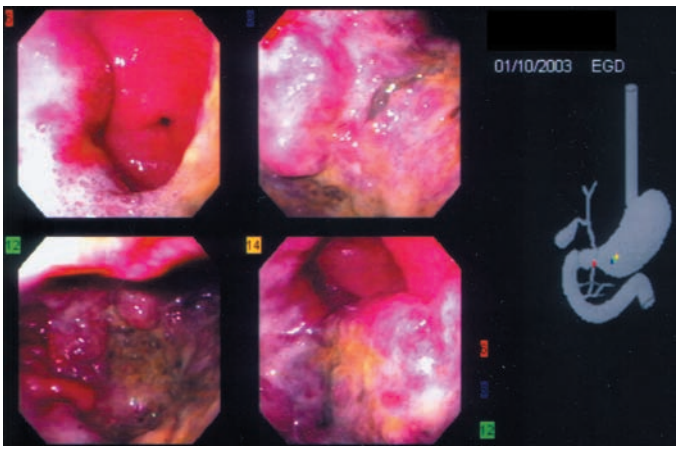

FIGURE 60-2 Endoscopy showing a deep ulcer with yellow-brown exudate in center of mass, consistent with cancer. Pathology confirmed a high-grade, diffuse, large B-cell lymphoma of the stomach. (*Courtesy of Michael Harper, MD.*)

- Electrolyte panels and liver function tests can assist in assessing the patient's clinical state and any liver involvement.[11]
- Carcinoembryonic antigen (CEA) is increased in about half of cases.[11]

DIFFERENTIAL DIAGNOSIS

- Peptic ulcer—Typical symptoms include epigastric pain (described as a gnawing or burning), occurring 1 to 3 hours after meals and relieved by food or antacids. Patients may also have nausea and vomiting, bloating, abdominal distention, and anorexia. Endoscopy confirms diagnosis (see Chapter 59, Peptic Ulcer Disease).
- Nonulcer dyspepsia—Includes gastroesophageal reflux disease and functional dyspepsia. Classic symptoms of gastroesophageal reflux disease are heartburn (i.e., substernal pain that may be associated with acid regurgitation or a sour taste) aggravated by bending forward or lying down, especially after a large meal; individual symptoms, however, do not help to distinguish these patients from those with peptic ulcer disease. Endoscopy is considered if symptoms fail to respond to treatment (e.g., histamine-2 receptor agonist, proton pump inhibitor) or red flag signs/symptoms occur (e.g., bleeding, dysphagia, severe pain, weight loss).
- Chronic gastritis—Includes autoimmune (body-predominant) and *H. pylori*-related (antral-predominant) types; mucosal inflammation (primarily lymphocytes) may progress to atrophy and metaplasia. Abdominal pain and dyspepsia are common symptoms and patients may have pernicious anemia.
- Esophagitis—May be mechanical or infectious (primarily viral and fungal). Symptoms include heartburn (retrosternal wave-like pain that may radiate to the neck or jaw) and painful swallowing (odynophagia); regurgitation of sour or bitter tasting material may occur with obstruction. Barium swallow or esophagoscopy can be used to establish the diagnosis.
- Esophageal cancer—Relatively uncommon malignancy of two cell types: squamous cell cancers (largely related to smoking, excessive alcohol consumption, and other agents causing mucosal trauma) and adenocarcinomas (usually arising in the distal esophagus related to reflux disease). Symptoms include progressive dysphagia and weight loss; the diagnosis is confirmed on esophagoscopy and biopsy.

MANAGEMENT

- Patients may be best managed by an experienced multidisciplinary team.[16] Based on SEER data from 1988–2001, only 20% of tumors had not spread beyond the stomach, one third had spread to adjacent structures and lymph nodes and another third had distant metastases.[4]

PHARMACOLOGIC

- Chemotherapy using 5-fluorouracil (FU) and doxorubicin with or without cisplatin or mitomycin C is somewhat helpful (partial response in 30% to 50%).[2] The European Organization for Research and Treatment of Cancer (EORTC)-Gastrointestinal Cancer Group notes improved outcomes for resectable gastric cancer using a strategy of perioperative (pre- and postoperative) chemotherapy or postoperative chemoradiotherapy.[16] SOR A
- In a metaanalysis, three-drug regimens containing FU, an anthracycline, and cisplatin administered as adjunct therapy appeared to have the best survival rates,[17] and another metaanalysis confirmed that postoperative adjuvant chemotherapy based on FU regimens was associated with reduced risk of death in gastric cancer in patients with resectable cancer compared with surgery alone (hazard ratio [HR] 0.82; 95% CI 0.76 to 0.90) with an absolute 5-year survival benefit of 5.7%.[18] SOR C
- EORTC-Gastrointestinal Cancer Group found no chemotherapy combination was an accepted gold standard and that in the treatment of unresectable, locally advanced or metastatic gastric or gastroesophageal junction adenocarcinoma, response rates were poor.[16]

REFERRAL FOR SURGERY OR PROCEDURES

- Complete resection including adjacent lymph nodes is recommended.[3] For resectable gastric adenocarcinoma, EORTC-Gastrointestinal Cancer Group recommends free-margin surgery with at least D1 resection (perigastric lymph nodes) combined to removal of a minimum of 15 lymph nodes.[16]
- In a metaanalysis of six trials comparing D1 with D2 (extended lymph node dissection—hepatic, left gastric, celiac, and splenic arteries, as well as those in the splenic hilum) gastrectomy for patients with resectable gastric cancer, postoperative morbidity and 30-day mortality rate were higher in the D2 group; 5-year survival was similar.[19]
- In a metaanalysis, laparoscopy-assisted distal gastrectomy compared to conventional distal gastrectomy was associated with lower morbidity, less pain, faster bowel function recovery, and shorter hospital stay; anastomotic and wound complications and mortality rates were similar.[20]
- Radiation is useful for palliation for pain.

PREVENTION

- Aspirin use reduces the risk of GI cancers (20-year cancer death HR 0.65; 95% CI 0.54, 0.78); the latent period before an effect on death was seen for stomach cancer was more than 5 years.[21]
- Adherence to a relative Mediterranean diet is associated with a reduced risk of gastric cancer (HR 0.67; 95% CI 0.47, 0.94).[22]
- Limited data are available regarding prevention of gastric cancer, but in a population of poorly nourished Chinese subjects, combined supplementation with beta-carotene, α-tocopherol, and selenium reduced the incidence of and mortality rate from gastric cancer and the overall mortality rate from cancer by 13% to 21%.[23]
- In a metaanalysis, consumption of large amounts of allium vegetables (onions, garlic, shallots, leeks, chives) was associated with a reduced risk of gastric cancer (odds ratio [OR] 0.54; 95% CI 0.43 to 0.65).[24]

- Despite limited data, a metaanalysis of six studies conducted primarily in Asia found a reduced gastric cancer risk (0.6% absolute risk reduction) with eradication of *H. pylori* infection.[25]
- Screening for gastric cancer in Japan has led to a greater number of cases of gastric cancer being detected in an early stage.

PROGNOSIS

- Surgical morbidity (e.g., anastomotic leaks, infection) occurs in approximately 25% of patients and operative mortality is approximately 3%.[26]
- Overall 5-year relative survival based on SEER 2001–2007 data was 26.3%. Five-year relative survival by race and gender was: 23.2% for white men; 27.5% for white women; 22.5% for black men; 29.4% for black women.[1]
- Five-year relative survival for localized disease is 61.5%, for spread to regional nodes is 27.8%, and for metastatic disease is 3%.[1]
- Median survival for grade of tumor decreases from well-differentiated tumors (22.6 months) to undifferentiated (7.6 months).[4]

FOLLOW-UP

- Recurrences occur in the first 8 years.
- Follow-up varies from evaluation based on clinical suspicion of relapse to intensive investigations to detect early recurrences; unfortunately there are no data to show that early detection of local recurrence by endoscopy or CT improves survival or quality of life because these recurrences are invariably incurable.[27]
- Isolated liver metastasis identified on CT, however, may be resectable.
- Tumor markers have been used with some success to detect subclinical recurrences and could be used to target more invasive or expensive procedures.[27,28] The National Academy of Clinical Biochemistry does not recommend the routine use of CEA or carbohydrate antigen 19–9 for postoperative monitoring of patients with gastric cancer.[29] SOR B

PATIENT EDUCATION

- Surgery with perioperative chemotherapy is potentially curative; operative mortality is approximately 3%.[21]
- Early postoperative complications include anastomotic failure, bleeding, ileus, cholecystitis, pancreatitis, pulmonary infections, and thromboembolism. Further surgery may be required for anastomotic leaks.[11]
- Late mechanical and physiologic complications include dumping syndrome, vitamin B_{12} deficiency, reflux esophagitis, and bone disorders, especially osteoporosis.
- Postgastrectomy patients often are immunologically deficient.

PATIENT RESOURCES

- National Cancer Institute—**http://www.cancer.gov/cancertopics/types/stomach/.**
- Medline Plus—**http://www.nlm.nih.gov/medlineplus/stomachcancer.html.**

PROVIDER RESOURCES

- National Cancer Institute—**http://www.cancer.gov/cancertopics/types/stomach/.**

REFERENCES

1. Howlader N, Noone AM, Krapcho M, Neyman N, Aminou R, Waldron W, Altekruse SF, Kosary CL, Ruhl J, Tatalovich Z, Cho H, Mariotto A, Eisner MP, Lewis DR, Chen HS, Feuer EJ, Cronin KA, Edwards BK, eds. *SEER Cancer Statistics Review, 1975-2008*. Bethesda, MD: National Cancer Institute. http://seer.cancer.gov/csr/1975_2008/, based on November 2010 SEER data submission, posted to the SEER Web site, 2011. http://seer.cancer.gov/statfacts/html/stomach.html. Accessed October 2011.
2. Mayer R. Gastrointestinal tract cancer. In: Kasper DL, Braunwald E, Fauci AS, Hauser SL, Longo DL, Jameson JL, eds. *Harrison's Principles of Internal Medicine*, 16th ed. New York: McGraw-Hill; 2005:523-533.
3. Saeki N, Saito A, Choi IJ, et al. A functional single nucleotide polymorphism in mucin 1, at chromosome 1q22, determines susceptibility to diffuse-type gastric cancer. *Gastroenterology*. 2011;140(3):892-902.
4. Key C, Meisner ALW. *Cancers of the Esophagus, Stomach, and Small Intestine*. http://seer.cancer.gov/publications/survival/surv_esoph_stomach.pdf. Accessed October 2011.
5. Ooi CH, Ivanova T, Wu J, et al. Oncogenic pathway combinations predict clinical prognosis in gastric cancer. *PLoS Genet*. 2009; 5(10):e1000676.
6. *Understanding the Changes from the Sixth to the Seventh Edition of the AJCC Cancer Staging Manual*. http://www.cancerstaging.org/staging/changes2010.pdf. Accessed October 2011.
7. Mcghan LJ, Pockai BA, Gray RJ, et al. Validation of the updated 7th edition AJCC TNM staging criteria for gastric adenocarcinoma. *J Gastrointest Surg*. 2012;16(1):53-61, discussion 61.
8. Layke JC, Lopez PP. Gastric cancer: diagnosis and treatment options. *Am Fam Physician*. 2004;69(5):1133-1141.
9. National Cancer Institute. *Cancer Topics Fact Sheet*. http://www.cancer.gov/cancertopics/factsheet/Risk/h-pylori-cancer. Accessed October 2011.
10. Mills PK, Yang RC. Agricultural exposures and gastric cancer risk in Hispanic farm workers in California. *Environ Res*. 2007;104(2): 282-289.
11. Cabebe EC. Mehta VK, Fisher G. *Gastric Cancer*. http://emedicine.medscape.com/article/278744-clinical. Accessed October 2011.

12. Li WB, Zuo XL, Li CQ, et al. Diagnostic value of confocal laser endomicroscopy for gastric superficial cancerous lesions. *Gut.* 2011;60(3):299-306.

13. Gastrointestinal cancer. In: New Zealand Guidelines Group. *Suspected Cancer in Primary Care: Guidelines for Investigation, Referral and Reducing Ethnic Disparities*. Wellington, New Zealand: New Zealand Guidelines Group (NZGG); 2009:33-51. http://www.guideline.gov/content.aspx?id=15447&search=gastric+cancer. Accessed October 2011.

14. Goddard AF, Badreldin R, Pritchard DM, et al. The management of gastric polyps. *Gut.* 2010;59(9):1270-1276.

15. Society for Surgery of the Alimentary Tract (SSAT). *Surgical Treatment of Gastric Cancer*. Manchester, MA: Society for Surgery of the Alimentary Tract (SSAT); 2004:15:4.

16. Van Cutsem E, Van de Velde C, Roth A, et al. Expert opinion on management of gastric and gastro-oesophageal junction adenocarcinoma on behalf of the European Organisation for Research and Treatment of Cancer (EORTC)—gastrointestinal cancer group. *Eur J Cancer.* 2008;44(2):182-194.

17. Wagner AD, Grothe W, Haerting J, et al. Chemotherapy in advanced gastric cancer: A systematic review and meta-analysis based on aggregate data. *J Clin Oncol.* 2006;24(18):2903-2909.

18. GASTRIC (Global Advanced/Adjuvant Stomach Tumor Research International Collaboration) Group, Paoletti X, Oba K, Burzykowski T, et al. Benefit of adjuvant chemotherapy for resectable gastric cancer: a meta-analysis. *JAMA.* 2010;303(17):1729-1737.

19. Memon MA, Subramanya MS, Khan S, et al. Meta-analysis of D1 versus D2 gastrectomy for gastric adenocarcinoma. *Ann Surg.* 2011;253(5):900-911.

20. Hosono S, Arimoto Y, Ohtani H, Kanamiya Y. Meta-analysis of short-term outcomes after laparoscopy-assisted distal gastrectomy. *World J Gastroenterol.* 2006;12(47):7676-7683.

21. Rothwell PM, Fowkes FG, Belch JF, et al. Effect of daily aspirin on long-term risk of death due to cancer: analysis of individual patient data from randomised trials. *Lancet.* 2011;377(9759):31-41.

22. Buckland G, Agudo A, Luján L, et al. Adherence to a Mediterranean diet and risk of gastric adenocarcinoma within the European Prospective Investigation into Cancer and Nutrition (EPIC) cohort study. *Am J Clin Nutr.* 2010;91(2):381-390.

23. Huang HY, Caballero B, Chang S, et al. The efficacy and safety of multivitamin and mineral supplement use to prevent cancer and chronic disease in adults: a systematic review for a National Institutes of Health state-of-the-science conference. *Ann Intern Med.* 2006;145(5):372-385.57(1):69-74.

24. Zhou Y, Zhuang W, Hu W, et al. Consumption of large amounts of Allium vegetables reduces risk for gastric cancer in a meta-analysis. *Gastroenterology.* 2011;141(1):80-89.

25. Fuccio L, Zagari RM, Eusebi LH, et al. Meta-analysis: can *Helicobacter pylori* eradication treatment reduce the risk for gastric cancer? *Ann Intern Med.* 2009;151(2):121-128.

26. Zilberstein B, Abbud Ferreira J, Cecconello I. Management of postoperative complications in gastric cancer. *Minerva Gastroenterol Dietol.* 2011;57(1):69-74

27. Whiting J, Sano T, Saka M, et al. Follow-up of gastric cancer: a review. *Gastric Cancer.* 2006;9(2):74-81.

28. Fareed KR, Kaye P, Soomro IN, et al. Biomarkers of response to therapy in oesophago-gastric cancer. *Gut.* 2009;58(1):127-143.

29. Sturgeon CM, Diamandis E, eds. *Use of Tumor Markers in Liver, Bladder, Cervical, and Gastric Cancers*. Washington, DC: National Academy of Clinical Biochemistry (NACB); 2010:57. http://www.guideline.gov/content.aspx?id=23861&search=gastric+cancer. Accessed October 2011.

61 LIVER DISEASE

Mindy A. Smith, MD, MS
Angie Mathai, MD

PATIENT STORY

A 64-year-old woman presents with complaints of itchy skin and fatigue. She is noted on physical examination to have scleral icterus and jaundice (**Figure 61-1**). Laboratory testing revealed elevated liver enzymes, particularly the serum alkaline phosphatase and γ-glutamyltranspeptidase, and positive antinuclear and antimitochondrial antibodies. A liver biopsy confirmed primary biliary cirrhosis. Two months later, she vomited up some blood and on endoscopy was found to have esophageal varices from her portal hypertension (**Figure 61-2**).

FIGURE 61-1 Scleral icterus in a 64-year-old Hispanic woman with primary biliary cirrhosis. (*Courtesy of Javid Ghandehari, MD.*)

INTRODUCTION

Liver disease can be caused by any number of metabolic, toxic, microbial, circulatory, or neoplastic insults resulting in direct liver injury or from obstruction of bile flow or both. Liver injury falls anywhere on the spectrum from transient abnormalities in biomarkers to life-threatening multiorgan failure.

SYNONYMS

The following terms refer to various types of liver diseases: hepatic failure, hepatic dysfunction, alcoholic hepatitis, viral hepatitis, cirrhosis, hepatocellular disease, cholestatic disease, liver fibrosis.

EPIDEMIOLOGY

Common causes of liver disease include:

- Nonalcoholic fatty liver disease (NAFLD)—Present in 10% to 30% of adults in the general population; now the most common cause of chronic liver disease in Western countries.[1] NAFLD is believed responsible for 90% of cases of elevated liver enzymes without an identifiable cause (e.g., viral hepatitis, alcohol, genetic, medications).[2]
- Alcohol, excessive use—Approximately 5% of the population are at risk; this includes women who drink more than two drinks per day and men who drink more than three drinks per day.[3]
- Drug-induced liver disease:[4]
  - Drugs causing hepatitis include phenytoin, captopril, enalapril, isoniazid, amitriptyline, and ibuprofen.
  - Drugs causing cholestasis include oral contraceptives, erythromycin, and nitrofurantoin.
  - Drugs causing both of the above include azathioprine, carbamazepine, statins, nifedipine, verapamil, amoxicillin/clavulanic acid, and trimethoprim-sulfamethoxazole.

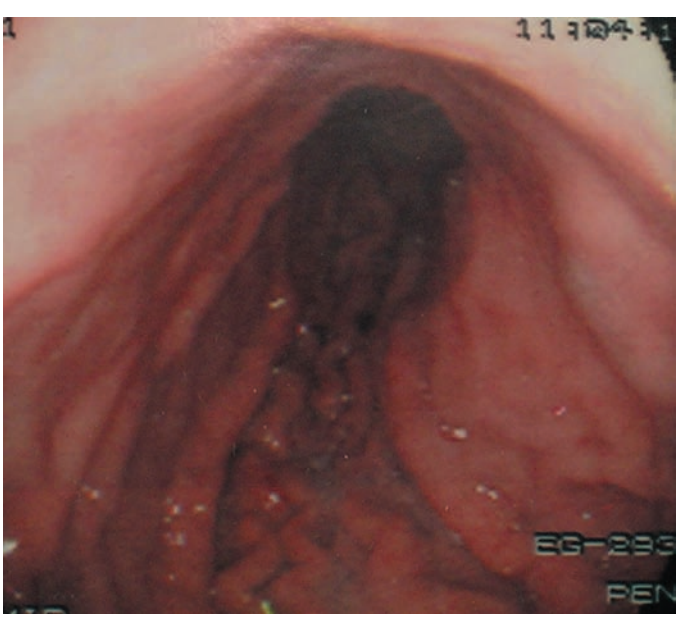

FIGURE 61-2 Esophageal varices in the patient in Figure 61-1 secondary to her cirrhosis and portal hypertension. (*Courtesy of Javid Ghandehari, MD.*)

- Infectious disease—Viral hepatitis, infectious mononucleosis, *Cytomegalovirus*, and coxsackievirus are most common. Viral hepatitis infections include:
  - Hepatitis A—Twenty-nine percent to 33% of patients have ever been infected with hepatitis A; there are no chronic infections.[5] Incidence rates in recent years have declined with approximately 1987 cases reported and 9000 estimated in 2009.[6]
  - Hepatitis B—Five percent to 10% of volunteer blood donors in the United States have evidence of prior infection, with 1% to 10% of those infected progressing to chronic hepatitis B virus (HBV) infection.[5] Up to 1.4 million people have chronic hepatitis B.[6]
  - Hepatitis C—In the United States, 1.8% of the general population have had hepatitis C, with 50% to 70% developing chronic hepatitis and 80% to 90% chronic infection.[5] Nearly 3.9 million have chronic hepatitis C.[6]
  - Hepatitis D—Transmitted through contact with infectious blood and can occur as a coinfection or as a superinfection in persons with HBV infection.[6]
  - Hepatitis E— Outbreaks are usually associated with contaminated water supply in countries with poor sanitation.[6]

Less common disorders include:

- Genetic inheritance—Wilson disease (defective copper transport with copper toxicity; autosomal recessive with 1 per 40,000 affected), hemochromatosis (disorder of iron storage; autosomal recessive—among individuals of northern European heritage, 1 in 10 individuals is a heterozygous carrier and 0.3% to 0.5% have the disease), α_1-antitrypsin deficiency (autosomal recessive with 1% to 2% of patients with chronic obstructive pulmonary disease affected).
- Autoimmune liver disease—Eleven percent to 23% of patients with chronic liver disease and accounts for approximately 6% of liver transplantations in the United States.[7]
- Primary biliary cirrhosis (approximately 5 per 100,000 persons worldwide)—A disease of unknown etiology characterized by inflammatory destruction of the small bile ducts and gradual liver cirrhosis (**Figures 61-1** and **61-2**).

ETIOLOGY AND PATHOPHYSIOLOGY

To understand liver disease, the anatomy and key functions are briefly described here.

- The hepatic artery (20%) and the portal vein (80%) provide the vascular supply of the liver.[3] The liver is organized functionally into acini, which are divided into three zones[3]:
  - Zone 1—The portal areas where blood enters from both sources.
  - Zone 2—The hepatocytes and sinusoids where blood flows.
  - Zone 3—The terminal hepatic veins.
- Hepatocytes, the predominant cells in the liver, perform several vital functions, including the synthesis of essential serum proteins (e.g., albumin, coagulation factors); production of bile and its carriers (e.g., bile acids, cholesterol); regulation of nutrients (e.g., glucose, lipids, amino acids); and metabolism and conjugation of

lipophilic compounds (e.g., bilirubin, various drugs) for excretion into the bile or urine.[3]

- There are two basic patterns of liver disease and one mixed pattern:[3]
  - Hepatocellular—Features of this type are direct liver injury, inflammation, and necrosis. Examples are alcoholic and viral hepatitis.
  - Cholestatic (obstructive)—Involves inhibition of bile flow. Examples are gallstone disease, malignancy, primary biliary cirrhosis, and some drug-induced disease.
  - Both patterns—Evidence of direct damage and obstruction. Examples are cholestatic form of viral hepatitis and some drug-induced diseases.
- Cirrhosis occurs following irreversible hepatic injury with hepatocyte necrosis resulting in fibrosis and distortion of the vascular bed. This, in turn, can cause portal hypertension.
- The spectrum of NAFLD ranges from hepatic steatosis (fat deposition in liver cells) to nonalcoholic steatohepatitis (NASH) and cirrhosis.[2] In NAFLD, steatosis occurs when free fatty acids, released in the setting of insulin resistance, are taken up by the liver; the same process can occur in alcoholism. The presence of these fatty acids leads to inflammation from other insults to the liver including oxidative stress, upregulation of inflammatory mediators, and dysregulated apoptosis, producing NASH, fibrosis, and sometimes cirrhosis (occurs in approximately 20% of patients with NASH).[2]

RISK FACTORS

- Risk factors for liver disease include:[3]
  - Alcohol and intravenous drug use.
  - Drugs (e.g., oral contraceptives).
  - Personal and sexual habits.
  - Travel to underdeveloped countries.
  - Exposure to contaminant in food (e.g., shellfish) or individuals with liver disease (includes needle stick injuries).
  - Family history.
  - Blood transfusion prior to 1992.
- Obesity and the metabolic syndrome are risk factors for NAFLD and the more advanced form NASH.

DIAGNOSIS

The goals of diagnosis are to determine the etiology and severity of the liver disease, and, where appropriate, the stage of the disease, including whether it is acute or chronic, early or late in the course of the disease, and whether there is cirrhosis present and to what degree.

CLINICAL FEATURES

- Patients with NAFLD are usually asymptomatic.
- Constitutional symptoms in patients with liver disease include fatigue (most common; especially following activity), weakness, anorexia, and nausea.
- Skin alterations:[3]
  - Jaundice (hallmark of obstructive pattern)—Best seen in the sclera or below the tongue; the latter is particularly useful in

dark-skinned individuals. Not detected until serum bilirubin levels reach 2.5 mg/dL (43 μmol/L). Early, jaundice may manifest as dark (tea colored) urine and later with light-colored stools. Jaundice without dark urine is usually from indirect hyperbilirubinemia, as seen in patients with hemolytic anemia or Gilbert syndrome.
  - Palmar erythema—Can be seen in both acute and chronic disease but also seen in normal individuals and during pregnancy (**Figure 61-3**).
  - Spider angiomas (superficial, tortuous arterioles that flow outward from the center)—Also seen in both acute and chronic disease, in normal individuals, and during pregnancy (**Figure 61-4**).
  - Excoriations—Pruritus is prominent in acute obstructive disease and in chronic cholestatic diseases such as primary biliary cirrhosis.
  - Palpable purpura—Seen with hepatitis C and chronic HBV.
- Abdominal distention/bloating—Secondary to ascites (accumulation of excess fluid within the peritoneal cavity) (**Figure 61-5**).
  - Ascites may be detected on examination by shifting dullness on percussion (ascitic fluid will flow to the most dependent portions of the abdomen and the air-filled intestines will float on top of this fluid. The fluid–air interface is detected with the patient supine and then turned onto the side where the "line" shifts upward) (**Figures 61-6** and **61-7**).
- Pain in the right upper quadrant (caused by stretching or irritation of the Glisson capsule surrounding the liver) with tenderness on examination in the liver area. Pain and fever in a patient with ascites should suggest the diagnosis of spontaneous bacterial peritonitis (SBP).
- Hepatomegaly and splenomegaly (congestive splenomegaly from portal hypertension)—Seen in patients with cirrhosis, venoocclusive disease, malignancy, and alcoholic hepatitis.[3]
- Features of hyperestrogenemia in men including gynecomastia (**Figure 61-8**) and testicular atrophy.
- Physical signs of specific liver disease include:
  - Kayser-Fleischer rings—Brown copper pigment deposits around the periphery of the cornea seen in Wilson disease (**Figure 61-9**).
  - Excessive skin pigmentation (slate gray hue/bronzing), diabetes mellitus, polyarticular arthropathy, congestive heart failure, and hypogonadism (hemochromatosis).
  - Cachexia, wasting, and firm hepatomegaly (primary hepatocellular carcinoma or metastatic liver disease).
- Features of patients with advanced disease include muscle wasting, ascites, edema, dilated abdominal veins (e.g., caput medusa—collateral veins seen radiating from the umbilicus), bruising, hepatic fetor (i.e., sweet, ammonia odor), asterixis (i.e., flapping of the hands when extended), and mental confusion, stupor, or coma.[3]
- Hepatic failure, defined as the occurrence of signs and symptoms of hepatic encephalopathy, may begin with sleep disturbance, personality changes, irritability, and mental slowness.[3] Mental confusion, disorientation, or coma may occur later along with physical signs as above.

LABORATORY TESTING

- Initial evaluation with bilirubin, albumin, alanine aminotransferase (ALT), aspartate aminotransferase (AST), γ-glutamyl transpeptidase

FIGURE 61-3 Palmar erythema in a man with cirrhosis secondary to alcoholism. (*Courtesy of Richard P. Usatine, MD.*)

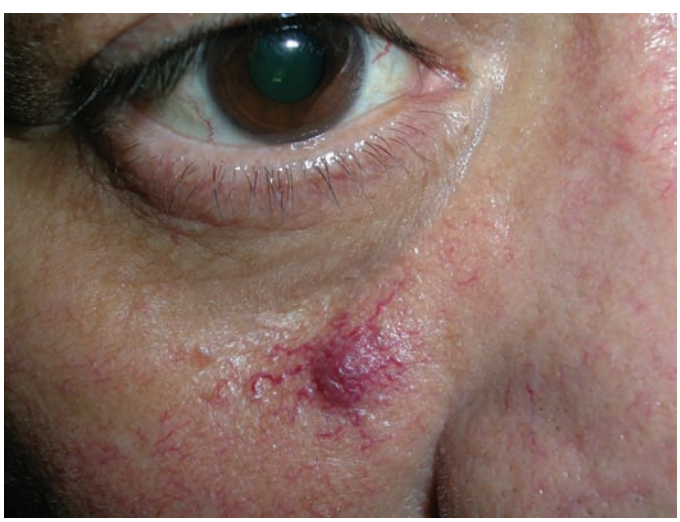

FIGURE 61-4 Spider angioma on the face of a woman with cirrhosis secondary to chronic hepatitis C. (*Courtesy of Richard P. Usatine, MD.*)

FIGURE 61-5 Tense ascites in a woman with cirrhosis from her alcoholism. An umbilical hernia is also seen from the increased intraabdominal pressure. (*Courtesy of Richard P. Usatine, MD.*)

(GGT), and alkaline phosphatase (AlkP).[3] **Table 61-1** provides the diagnostic interpretation of the patterns of liver biochemical markers.

- In acute disease (duration <6 months) with a hepatocellular pattern (see **Table 61-1**) consider infections, ingestions, or Wilson disease.
- In acute disease with a cholestatic pattern (see Table 61-1) consider obstructing gallstones or masses, primary biliary cirrhosis and cholangitis
- In chronic disease (duration >6 months) with hepatocellular pattern (see **Table 61-1**) or mixed pattern (↑ ALT, ↑ AlkP), consider hemochromatosis, Wilson disease, and α_1-antitrypsin deficiency. Because many of the acute processes can also cause a chronic picture, consider workup for hepatitis B or C, autoimmune hepatitis, alcoholic disease, chronic drug ingestion, or structural abnormalities.
- In chronic disease with cholestatic pattern, consider primary sclerosing cholangitis (see **Table 61-1**).
- In patients with NAFLD, elevations in ALT and AST are usually no more than 4 times the upper limit of normal; ALT usually predominates.[2]
- Bilirubin, albumin, and prothrombin time along with the presence or absence of ascites and hepatic encephalopathy are part of the Child-Pugh classification of cirrhosis that has been used to estimate the likelihood of survival and complications of cirrhosis; it is also used to determine candidacy for liver transplantation.[8] Another scoring system, the model for end-stage liver disease (MELD), which uses the international normalized ratio, serum bilirubin, and serum creatinine, is a reliable measure of mortality risk in patients with end-stage liver disease and used to prioritize liver transplantations.[9] In 2011, the MeSO index was published; it adjusts the MELD score by including serum sodium and may be more useful in determining prognosis in patients with decompensated cirrhosis than the MELD alone.[10]

- Suspected SBP can be confirmed following paracentesis of the ascitic fluid showing a polymorphonuclear leukocyte count greater than or equal to 250 cells/mm.[5]
- It may be possible to predict significant fibrosis and inflammation among patients with chronic hepatitis B using noninvasive markers, thereby limiting the number of biopsies needed. Serum microRNA profiles may serve as noninvasive biomarkers for HBV infection.[11] The aspartate aminotransferase-to-platelet ratio index (APRI) is a new marker that can identify hepatitis C-related fibrosis with a moderate degree of accuracy. This information may limit biopsies in patients with chronic hepatitis C.[12]
- In one study, significant liver fibrosis was predicted in patients who were hepatitis B e antigen (HBeAg)-negative using the HBV DNA levels, AlkP, albumin, and platelet counts with an area under Receiver Operating Characteristic curve of 0.91 for the training group and 0.85 for the validation group.[13]
- The best model for predicting significant inflammation included the variables age, HBV DNA levels, AST, and albumin with an area under the curve of 0.93 in the training and 0.82 in the validation group. In HBeAg-positive patients, no factor could accurately predict stages of liver fibrosis, but the best factor for predicting significant inflammation was AST with an area under the curve of 0.87.

FIGURE 61-6 Patient with ascites and jaundice; lines drawn demonstrate the position of the fluid dullness to percussion (*solid stripes*), intestines (*tubular structure*), and the fluid intestine interface (*dotted line*). (*Courtesy of Charlie Goldberg, MD, copyrighted by the University of California, San Diego.*)

FIGURE 61-7 When patient is turned to the right side, the fluid intestine interface is shifted upward as shown; this is the sign called *shifting dullness*. (*Courtesy of Charlie Goldberg, MD, copyrighted by the University of California, San Diego.*)

FIGURE 61-8 Gynecomastia in a man with cirrhosis secondary to alcoholism. (*Courtesy of Richard P. Usatine, MD.*)

IMAGING

Ultrasound is best for detection of NAFLD. It is most accurate when there is greater than 30% steatosis; use of liver elasticity can help distinguish severe from mild fibrosis.[2] MRI reliably detects lesser degrees of steatosis (down to 3%). NAFLD can usually be diagnosed by history, serologies, and abdominal imaging, although biopsy may be needed to judge severity.

BIOPSY

Liver biopsy is the gold standard for diagnosing those with acute disease where the etiology is unclear or for those with chronic disease (e.g., chronic hepatitis B, hepatitis C) to assist in staging the disease and for prognosis.

FIGURE 61-9 Kayser-Fleischer ring around the cornea in a patient with Wilson disease. (*Courtesy of Marc Solioz, University of Berne.*)

MANAGEMENT

Management decisions are based on the etiology, acuity, and severity of the disease.

- NAFLD/NASH—Diet and exercise have been shown to decrease liver enzymes, although it is not known if there is histologic improvement as well.[2] Other treatments for obesity, such as medication or bariatric surgery, may also be useful. Because NAFLD increases risk of cardiovascular disease,[1] treatment of other risk factors, such as hypertension and hyperlipidemia, should be undertaken. It is not known whether use of insulin sensitizers, such as metformin, and thiazolidinediones or statins specifically for NAFLD are beneficial.
- Alcoholic cirrhosis—Discontinue alcohol and provide supportive therapy. Alcoholic hepatitis is treated with either glucocorticoids or pentoxifylline based on Maddrey Discriminant Function (MDF).[14]
- Drug-induced disease—Withdrawal of agent. Routine screening of asymptomatic patients on statins is no longer recommended. Withdrawal of statins usually results in resolution of elevated transaminases within 2 months. The same statin could be continued at a lower dose or another statin could be started.[15]
- Viral hepatitis—Hepatitis A and acute hepatitis B are treated supportively; virtually all patients recover without specific treatment. Chronic hepatitis B may be treated with antiviral therapy (interferon) and the nucleoside analog lamivudine or the acyclic nucleotide analog adefovir.[5,16] Hepatitis C is currently treated with pegylated interferon and ribavirin.[5] All persons with chronic hepatitis B who are not immune to hepatitis A should receive 2 doses of hepatitis A vaccine 6 to 18 months apart.[15] Patients with hepatitis C should be vaccinated against hepatitis A and hepatitis B if they are seronegative for these other forms of hepatitis. SOR B Newborns of HBV-infected mothers should receive hepatitis B immunoglobulin and hepatitis B vaccine at delivery and complete the recommended vaccination series.[15] SOR A
- Wilson disease is treated with zinc acetate (50 mg 3 times daily) with or without trientine, a chelating agent (500 mg twice daily).[17]
- Hemochromatosis is treated with weekly or twice weekly phlebotomy.
- Primary biliary cirrhosis is managed with ursodiol (13 to 15 mg/kg per day) single dose in the presence of abnormal liver function tests

TABLE 61-1 Patterns of Liver Disease with Usual Laboratory Features, Differential Diagnosis, and Key Components of Diagnostic Workup

Liver Pattern	AST	ALT	AlkP	GGT	TB	Differential Dx	Diagnostic Workup
Acute—Hepatocellular	↑	↑↑	Usually normal	↑	Usually normal	Hepatitis A/B/C	Hepatitis panel
						Autoimmune hepatitis	Antinuclear Ab Smooth muscle Ab
						Mononucleosis	Monospot
						Wilson disease	Ceruloplasmin screen Urinary copper
						Tylenol overdose	Tylenol level
						Alcoholic hepatitis	Ammonia level History of alcohol use
						Drug ingestion	Toxicology screen History of drug use
Acute—Cholestatic	Often normal	↑	↑↑	↑↑	↑	Gall stones	Ultrasound
						Mass, hepatic or biliary	MRI MRCP
						Fatty infiltration	
						Biliary duct dilatation	
						Primary biliary cirrhosis	Antimitochondrial Ab
						Primary sclerosing cholangitis	ERCP with biopsies
Chronic—Hepatocellular	↑	↑↑	Usually normal	Usually normal	Usually normal	Hepatitis B/C	Hepatitis panel
						Hemochromatosis	Iron saturation and ferritin
						Wilson disease	Ceruloplasmin screen Urinary copper
						α_1-Antitrypsin deficiency	α_1-Antitrypsin serum level
Chronic—Cholestatic	Usually normal	↑	↑↑	↑↑	↑	Primary sclerosing cholangitis	Antimitochondrial Ab pANCA Ultrasound MRCP ERCP

Abbreviations: Ab, antibody; AST, aspartate aminotransferase; AlkP, alkaline phosphatase; ALT, alanine aminotransferase; dx, diagnosis; ERCP, endoscopic retrograde cholangiopancreatography; GGT, γ-glutamyl transferase; MRCP, magnetic resonance cholangiopancreatography; pANCA, peripheral antinuclear cytoplasmic antibody; TB, total bilirubin.

regardless of histologic stage and eventual liver transplantation.[18,19] SOR A In a metaanalysis of 7 trials, ursodeoxycholic acid treatment resulted in a significant reduction of the incidence of liver transplantation (odds ratio [OR] 0.65, $p = 0.01$) and a marginally significant reduction of the rate of death or liver transplantation.[20] Bile acid sequestrants can be used for pruritis.[20]

- Autoimmune hepatitis is treated with glucocorticoid therapy with or without azathioprine. Oral budesonide, in combination with azathioprine, induces and maintains remission in patients with noncirrhotic autoimmune hepatitis, with a low rate of steroid-specific side effects.[21]

Management of the complications of cirrhosis include:

- Control ascites with salt restriction (2g per day of NaCl), fluid restriction if hyponatremic (1000 mL per day), gentle diuresis to avoid electrolyte disturbance (spironolactone 100 to 400 mg per day) with or without furosemide (40 to 160 mg per day).[18] SOR A
- SBP is treated with empiric antibiotic therapy (e.g., intravenous cefotaxime 2 g every 8 hours).[22] SOR A
- Portal hypertension may be managed with shunting.

PREVENTION AND SCREENING

- Maintaining normal weight and treating obstructive sleep apnea and diabetes may help prevent NAFLD.
- Screen for alcohol abuse using structured questionnaires (e.g., CAGE [cutting, annoyance, guilt, eye-opener], Alcohol Use Disorders Identification Test [AUDIT]). Encourage abstinence and consider naltrexone or acamprosate in combination with counseling.[23]
- Risk for hepatitis A can be minimized by avoidance of susceptible foods in high-risk countries.
- For hepatitis B, recommendations include avoidance of high-risk behavior and blood contact, vaccination of risk groups, postexposure prophylaxis with anti–hepatitis B immunoglobulin, and cleaning of wound after exposure to infectious blood.[24]
- Screen for HBV infection in pregnant women at their first prenatal visit.[25] Patients with chronic liver disease should be vaccinated with hepatitis A and hepatitis B vaccines.[26]
- Hepatitis C risk can be decreased by avoidance of intravenous drug use, tattooing, and unprotected sexual intercourse.
- Screen patients with mild elevations of liver enzymes (above normal but less than 5 times the upper limit of normal) for hepatitis B and hepatitis C.[27]

PROGNOSIS

- Thirty percent of patients with NAFLD show histologic progression of fibrosis over 5 years and approximately 3% eventually develop cirrhosis.[2] Of those with NASH, 15% to 20% may develop cirrhosis. Leading causes of death appear to be cardiovascular disease, cancer (including hepatocellular carcinoma), and liver-related disease. Recurrence of hepatocellular carcinoma is higher in patients with NASH.[2]
- Patients presenting with a high clinical suspicion of alcoholic hepatitis should have their risk for poor outcome stratified using the MDF. Continued alcohol use is associated with disease progression.[23]
- Most cases of hepatitis B are self limiting. If the hepatitis B surface antigen (HBsAg) test remains positive 6 months after the disease onset, the patient is likely to have become a hepatitis B carrier. The carrier status is confirmed by a positive HBsAg test at 12 months.[24]
- Hepatitis C becomes chronic more often than hepatitis B; this occurs in approximately 50% to 80% of patients. The average time from primary infection to liver disease to cirrhosis is 21 years. Twenty percent to 30% develop cirrhosis as early as 5 to 7.5 years after contracting the disease. Treatment is more effective for genotypes 2 and 3 than for genotypes 1 and 4.[24]
- Approximately 50% of patients with autoimmune hepatitis will die within 5 years without treatment. Steroids can induce remission with survival rates similar to the general population.[7] The majority of patients with autoimmune hepatitis achieves complete remission within 3 months but requires long-term or permanent immunosuppressive therapy; such therapy is usually well tolerated. Long-term survival in well-managed patients is excellent.[28]
- In the absence of cirrhosis and diabetes, phlebotomy prevents further tissue damage and guarantees a normal life expectancy in patients with hemochromatosis.[29]
- Primary sclerosing cholangitis is a progressive process with a probability of transplant-free survival of 18 years in asymptomatic patients and of 8.5 years in symptomatic patients.[30]

FOLLOW-UP

- Hepatitis B virus carriers with high risk for hepatocellular carcinoma (HCC) (e.g., men older than 45 years of age, those with cirrhosis, and individuals with a family history of HCC), should be screened periodically with both α-fetoprotein and ultrasonography.[16] SOR C
- Patients who have survived an episode of SBP should receive long-term prophylaxis with daily norfloxacin or trimethoprim-sulfamethoxazole.[22] SOR A

PATIENT EDUCATION

- Patients with liver disease should be counseled about avoidance of alcohol and medications that may cause liver injury. They should avoid aspirin use (coagulation impaired) and use acetaminophen at lower doses (2 g per day).
- For those with infectious causes of liver disease, prevention of the spread of disease should be emphasized including limiting alcohol, safe-sex practices, and avoiding needle sharing. Screening for sexual contacts and household members should be offered along with vaccination for hepatitis B, if nonimmune and noninfected.[16] SOR A

PATIENT RESOURCES

MedlinePlus has a wealth of information for patients with kinds of liver diseases—**http://www.nlm.nih.gov/medlineplus/.**

PROVIDER RESOURCES

A number of disease-specific evidence-based guidelines can be found through the National Guideline Clearinghouse—**http://www.guideline.gov.**

O'Shea RS, Dasarathy S, McCullough AJ; Practice Guideline Committee of the American Association for the Study of Liver. Alcoholic liver disease. *Hepatology*. 2010;51(1):307-328.

REFERENCES

1. Targher G, Day CP, Bonora E. Risk of cardiovascular disease in patients with nonalcoholic fatty liver disease. *N Engl J Med*. 2010;363(14):1341-1350.
2. Lewis JR, Mohanty SR. Nonalcoholic fatty liver disease: a review and update. *Dig Dis Sci*. 2010;55(3):560-578.
3. Ghany M, Hoofnagle JH. Approach to the patient with liver disease. In: Kasper DL, Braunwald E, Fauci AS, Hauser SL, Longo DL, Jameson JL, eds. *Harrison's Principles of Internal Medicine*, 16th ed. New York: McGraw-Hill; 2005:1808-1813.
4. Dientag JL, Isselbacher KJ. Toxic and drug-induced hepatitis. In: Kasper DL, Braunwald E, Fauci AS, Hauser SL, Longo DL, Jameson JL, eds. *Harrison's Principles of Internal Medicine*, 16th ed. New York: McGraw-Hill; 2005:1840.
5. Dienstag JL, Isselbacher KJ. Acute viral hepatitis. In: Kasper DL, Braunwald E, Fauci AS, Hauser SL, Longo DL, Jameson JL, eds. *Harrison's Principles of Internal Medicine*, 16th ed. New York: McGraw-Hill; 2005:1822-1838.
6. Centers for Disease Control and Prevention. *Viral Hepatitis Statistics and Surveillance*. http://www.cdc.gov/hepatitis/Statistics/index.htm. Accessed November 2011.
7. Wolf DC, Raghuraman UV. *Autoimmune Hepatitis*. http://emedicine.medscape.com/article/172356-overview. Accessed November 2011.
8. Kamath PS, Wiesner RH, McDiarmid SV, et al. A model to predict survival in patients with end-stage liver disease. *Hepatology*. 2001;33(2):464-470.
9. Asrani SK, Kim WR. Model for end-stage liver disease: end of the first decade. *Clin Liver Dis*. 2011;15(4):685-698.
10. Lv XH, Liu HB, Wang Y, Wang BY. Validation of model for end stage liver disease score to serum sodium ratio index as a prognostic predictor in patients with cirrhosis. *J Gastroenterol Hepatol*. 2009;24(9):1547-1553.
11. Li LM, Hu ZB, Zhou ZX, Chen X. Serum microRNA profiles serve as novel biomarkers for HBV infection and diagnosis of HBV-positive hepatocarcinoma. *Cancer Res*. 2010;70(23):798-807.
12. Lin ZH, Xin YN, Dong QJ, Wang Q. Performance of the aspartate aminotransferase-to-platelet ratio index for the staging of hepatitis C-related fibrosis: an updated meta-analysis. *Hepatology*. 2011;53(3):726-736.
13. Mohamadnejad M, Montazeri G, Fazlollahi A, et al. Noninvasive markers of liver fibrosis and inflammation in chronic hepatitis B-virus related liver disease. *Am J Gastroenterol*. 2006;101(11):2537-2545.
14. Mailliard ME, Sorrell NF. Alcoholic liver disease. In: Kasper DL, Braunwald E, Fauci AS, Hauser SL, Longo DL, Jameson JL, eds. *Harrison's Principles of Internal Medicine*, 16th ed. New York: McGraw-Hill; 2005:1855-1857.
15. Gillett RC Jr, Norrell A. Considerations for safe use of statins: liver enzyme abnormalities and muscle toxicity. *Am Fam Physician*. 2011;83(6):711-716.
16. Lok AS, McMahon BJ. Chronic hepatitis B: update 2009. *Hepatology*. 2009;50(3):661-662. http://www.guideline.gov/content.aspx?id=15475&search=chronic+hepatitis+b. Accessed December 2011.
17. Brewer GJ. Wilson disease. In: Kasper DL, Braunwald E, Fauci AS, Hauser SL, Longo DL, Jameson JL, eds. *Harrison's Principles of Internal Medicine*, 16th ed. New York: McGraw-Hill; 2005:2313-2315.
18. Chung RT, Podolsky DK. Cirrhosis and its complications. In: Kasper DL, Braunwald E, Fauci AS, Hauser SL, Longo DL, Jameson JL, eds. *Harrison's Principles of Internal Medicine*, 16th ed. New York: McGraw-Hill; 2005:1808-1813.
19. Lindor KD, Gershwin ME, Poupon R, et al; American Association for Study of Liver Diseases. Primary biliary cirrhosis. *Hepatology*. 2009;50(1):291-308.
20. Shi J, Wu C, Lin Y, et al. Long-term effects of mid-dose ursodeoxycholic acid in primary biliary cirrhosis: a meta-analysis of randomized controlled trials. *Am J Gastroenterol*. 2006;101(7):1529-1538.
21. Manns MP, Woynarowski M, Kreisel W, Lurie Y. Budesonide induces remission more effectively than prednisone in a controlled trial of patients with autoimmune hepatitis. *Gastroenterology*. 2010;139(4):1198-1206.
22. Runyon BA. Management of adult patients with ascites due to cirrhosis. *Hepatology*. 2004;39(3):841-856.
23. O'Shea RS, Dasarathy S, McCullough AJ; Practice Guideline Committee of the American Association for the Study of Liver. Alcoholic liver disease. *Hepatology*. 2010;51(1):307-328.
24. Finnish Medical Society Duodecim. *Viral Hepatitis*. http://www.guidelines.gov/content.aspx?id=12806&search=viral+hepatitis+b. Accessed November 2011.
25. U.S. Preventive Services Task Force. Screening for hepatitis B virus infection in pregnancy: U.S. Preventive Services Task Force reaffirmation recommendation statement. *Ann Intern Med*. 2009;150(12):869-873.
26. Kumar M, Herrera JL. Importance of hepatitis vaccination in patients with chronic liver disease. *South Med J*. 2010;103(12):1223-1231.
27. Senadhi V. A paradigm shift in the outpatient approach to liver function tests. *South Med J*. 2011;104(7):521-525.
28. Kanzler S, Löhr H, Gerken G, et al. Long-term management and prognosis of autoimmune hepatitis (AIH): a single center experience. *Gastroenterology*. 2001;39(5):339-341, 344-348.
29. Barton JC, McDonnell SM, Adams PC, Brissot P. Management of hemochromatosis. Hemochromatosis Management Working Group. *Ann Intern Med*. 1998;129(11):932-939.
30. Parés A. Primary sclerosing cholangitis: diagnosis, prognosis and treatment. *Gastroenterol Hepatol*. 2011;34(1):41-52.

62 GALLSTONES

Mindy A. Smith, MD, MS

PATIENT STORY

A 44-year-old woman reports frequent episodes of severe pain in the mid and upper right-side of her abdomen that usually occurs shortly after her evening meal and sometimes at night. She is obese, but otherwise healthy. The pain lasts for several hours and is steady and often causes vomiting. On physical examination she complains of slight tenderness in the right upper quadrant (RUQ). An ultrasound confirms the presence of gallstones (**Figure 62-1**).

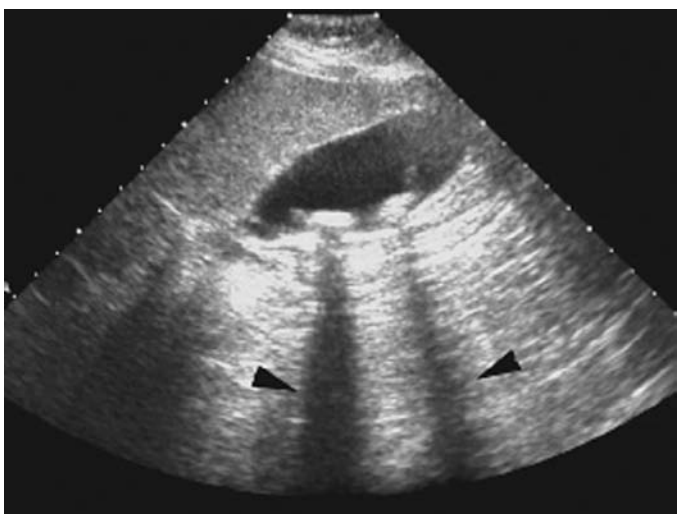

FIGURE 62-1 Ultrasound showing two echogenic gallstones in the gallbladder. Note the absence of echoes posterior to the gallstone called "shadowing" (*arrowheads*). (*From Schwartz's Principles of Surgery, Ninth Edition, New York, NY: McGraw-Hill; 2010:1141, Fig. 32-6. Copyright 2010, McGraw-Hill.*)

INTRODUCTION

Gallstones are concretions (inorganic masses), usually composed of cholesterol, that form in the gallbladder or bile duct. They are formed by concretion (joining together of adjacent parts and hardening) or accretion (growth by addition or adherence of parts normally separated) of normal and/or abnormal bile constituents.

EPIDEMIOLOGY

- Based on autopsy data, 20% of women and 8% of men have gallstones.[1]
- Approximately 20 million people in the United States are affected, with 1 million new cases each year.[1]
- In a Swedish incidence study of 621 randomly selected individuals ages 35 to 85 years, 42 (8.3%) of the 503 subjects available at 5 years developed gallstones; this yielded an incidence for newly developed gallstones of 1.39 per 100 person-years.[2]
- Among pregnant women, 5% to 12% have gallstones and 20% to 30% have gallbladder sludge (thick mucous material containing cholesterol crystals and mucin thread or mucous gels). Gallbladder sludge is a possible precursor form of gallstone disease.[1]
- Patients with asymptomatic gallstones have a 1% to 2% risk per year of developing symptoms or complications of gallstones. Based on data primarily for men, this will occur in 10% by 5 years, 15% by 10 years, and 18% by 15 years following diagnosis.[1]
- Gallstone disease is responsible for approximately 10,000 deaths per year in the United States. Most (7000) of these deaths are attributable to acute gallstone complications (e.g., cholecystitis, pancreatitis, cholangitis).[3]
- Although gallbladder cancers most often occur in the setting of stones (91% of 34 patients with gallbladder cancer in one study),[4] gallbladder cancer is rare. An incidence rate of 0.28% for incidental gallbladder carcinoma was reported in a Swiss database study of a population of more than 30,000 patients undergoing laparoscopic cholecystectomy.[5]

ETIOLOGY AND PATHOPHYSIOLOGY

- There are two types of gallstones: cholesterol stones (80%) and pigmented stones (primarily calcium bilirubinate, 20%).
- The solute components of bile include bile acids (80%), lecithin and other phospholipids (16%), and unesterified cholesterol (4%).[1] Cholesterol gallstones form when there is excess cholesterol or an abnormal ratio of cholesterol, bile acids, and lecithin.
- Excess biliary cholesterol can occur from a secondary increase in secretion of cholesterol caused by obesity, high cholesterol diet, clofibrate therapy, or a genetic predisposition to increased hydroxymethylglutaryl-coenzyme A reductase.
- The excess cholesterol becomes supersaturated and can precipitate out of solution in a process called *nucleation*, forming solid cholesterol monohydrate crystals that can become trapped in gallbladder mucus, producing sludge, and/or grow and aggregate to form cholesterol gallstones.
- Gallbladder hypomotility is a predisposing and possibly necessary factor in stone formation because of the failure to completely empty supersaturated or crystal-containing bile.[1] Situations associated with hypomotility include pregnancy, prolonged parenteral nutrition, surgery, burns, and use of oral contraceptives or estrogen therapy.
- Pigmented stones occur when increasing amounts of unconjugated bilirubin in bile precipitate to form stones. Bilirubin, a yellow pigment derived from the breakdown of heme, is actively secreted into bile by liver cells. In situations of high heme turnover, such as chronic hemolytic states (e.g., sickle cell anemia), calcium bilirubinate can crystallize from solution and form stones.
- Chronic gallstones may cause progressive fibrosis of the gallbladder wall and loss of function.

RISK FACTORS

- Genetic mutations can result in reduction of bile acids and lecithin that predispose some patients to stone formation. A high prevalence of gallstones is found in first-degree relatives of patients with gallstones and among Native Americans, Chilean Indians, and Chilean Hispanics.[1]
- In a case-control study, the prevalence of gallstones was 28.6% in first-degree relatives of subjects with gallstones versus 12.4% in first-degree relatives of subjects without gallstones (relative risk [RR] 1.80, 95% confidence interval [CI] 1.29 to 2.63).[3]
- Other risk factors for gallstones include rapid weight loss (10% to 20% of these patients form stones),[1] increasing age, liver or ileal disease, and cystic fibrosis.

DIAGNOSIS

CLINICAL FEATURES

- Symptoms of gallstones are caused from inflammation or obstruction as stones migrate into the cystic or common bile duct (CBD).

- Biliary colic is a steady, severe pain or ache, usually of sudden onset, located in the epigastrium or RUQ. Pain episodes last between 30 minutes and 5 hours and may radiate to the interscapular area, right scapula, or right shoulder.
- Gallstone-related pain may be precipitated by a fatty meal, a regular meal or a large meal followed by a prolonged fast.
- Pain is recurrent and often nocturnal.

- RUQ tenderness may be elicited on physical examination.
- Nausea and vomiting are common.
- Accompanying fever and chills suggests a complication of gallstones. Complications are more common in patients with a calcified gallbladder or in those who have had a previous episode of acute cholecystitis.[1]

LABORATORY STUDIES

- No laboratory testing is usually indicated as the results are usually normal. However, an elevated γ-glutamyl transpeptidase suggests a CBD stone. In a study of patients with acute calculous gallbladder disease, investigators found a 1-in-3 chance of CBD stones when the γ-glutamyl transpeptidase level was above 90 U/L and a 1-in-30 chance when the level was less than 90 U/L.[6]

IMAGING

- Ultrasound is the diagnostic test of choice and is 95% accurate for stones as small as 2 mm in diameter (**Figure 62-1**).[1] Shadowing, a discrete acoustic shadow caused by the absorption and reflection of sound by the stone that changes with patient positioning, is an important diagnostic feature that is shown in **Figures 62-1** and **62-2**.
- In one study, high-resolution ultrasound was more accurate than endoscopic ultrasonography or CT in differentiating benign disease from malignancy in cases with gallbladder polypoid lesions.[7]
- Gallstones may be seen on plain film, but only calcified stones are seen (**Figures 62-3** and **62-4**). This includes only 10% to 15% of cholesterol stones and 50% of pigmented stones.[1] Stones may be single or multiple and the gallbladder wall may be calcified (referred to as a *Porcelain gallbladder*), indicating severe chronic cholecystitis or adenocarcinoma.
- CT is less sensitive and more expensive than ultrasound for the detection of gallstones (**Figures 62-5** and **62-6**). However, CT can detect both radiopaque stones and radiolucent stones.
- An oral cholecystogram can be used to assess cystic duct patency and emptying function. This test has largely been replaced by gallbladder ultrasound.
- Radioisotope scans (e.g., technetium [Tc]-99m hepatoiminodiacetic acid [HIDA]) can be used to confirm acute cholecystitis (nonvisualizing gallbladder) and can be useful in evaluating functional abnormalities.
- Endoscopic retrograde cholangiopancreatography is used for imaging bile ducts. Stones in bile appear as filling defects in the opacified ducts. Endoscopic retrograde cholangiopancreatography is usually performed in conjunction with endoscopic retrograde sphincterotomy and gallstone extraction.

FIGURE 62-2 Gallstones visible in the gallbladder of a 43-year-old woman with right upper quadrant pain and a positive Murphy sign. (*Courtesy of Jeff Russell, MD.*)

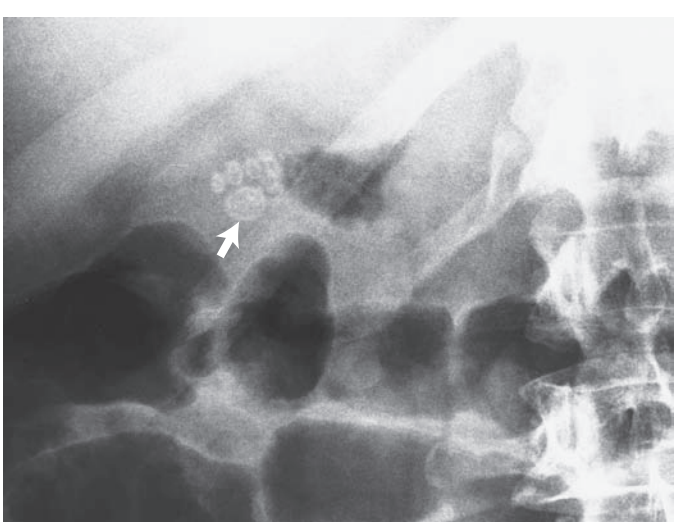

FIGURE 62-3 Plain film showing multiple gallstones (*white arrow*). (*From Schwartz DT, Reisdorff EJ. Emergency Radiology. New York: McGraw-Hill; 2000:536, Fig. 19-37. Copyright 2000, McGraw-Hill.*)

DIFFERENTIAL DIAGNOSIS

Severe epigastric and RUQ pain can be seen in the following conditions:

- Acute cholecystitis—Pain may radiate to the back, and fever is usually present. Physical examination can reveal RUQ rigidity and guarding with a positive Murphy sign (RUQ pain worsening with deep inspiration while the examiner maintains steady pressure below the right costal margin). White blood count, serum amylase, aspartate transaminase, and alanine transaminase may all be elevated.
- Pancreatitis—Pain is located in the midepigastrium and left upper quadrant, but may radiate to the RUQ. Abdominal distention and diminished bowel sounds may be present. Elevations in lipase and amylase are found and pancreatic pseudocysts or abscess may be present on ultrasound.
- Peptic ulcer disease—Pain may be described as burning and is usually epigastric and often relieved by antacids. Onset is 1 to 3 hours after meals or following nonsteroidal antiinflammatory drug usage. Stool hemoccult testing may be positive. An ulcer may be visualized on upper GI barium swallow or endoscopy (Chapter 59, Peptic Ulcer Disease).
- Hepatitis—Other symptoms and signs include malaise, anorexia, pruritus, tender liver, and low-grade fever. Jaundice may be present and urine may be dark (i.e., bilirubinuria). Aspartate transaminase and alanine transaminase are elevated (Chapter 61, Liver Disease).

MANAGEMENT

- Silent gallstones may be managed expectantly; prophylactic cholecystectomy is unwarranted based on the few who develop symptoms over time and the very low rate of complications (3% to 4%).[8] There are no randomized controlled trials comparing cholecystectomy to watchful waiting for silent gallstones.[9] SOR C
- Cholecystectomy should be considered for patients with:[1]
  - Frequent symptoms that interfere with daily life.
  - A prior complication of gallstone disease.
  - The presence of an underlying condition (e.g., calcified gallbladder) that predisposes the patient to increased risk of complications.
- Laparoscopic cholecystectomy is the surgical treatment of choice because of the low rate of complications (4%) and mortality (<0.1%), shortened hospital stay, and reduced cost.[1] Conversion to an open laparotomy is infrequent (5%).[1] A Cochrane review found no differences in mortality or complications among open, small-incision, and laparoscopic cholecystectomy, but quicker recovery favors minimally invasive procedures; small-incision cholecystectomies appear to have shorter operative time and lower cost.[10]
- Early laparoscopic cholecystectomy (<7 days from symptom onset) during acute cholecystitis has comparable outcomes to delayed cholecystectomy and shortens hospital stay.[11]
- Single versus four-port laparoscopic cholecystectomy may reduce postoperative pain.[12]
- For patients with gallbladder and CBD stones, intraoperative endoscopic sphincterotomy during laparoscopic cholecystectomy appears as safe and effective as preoperative endoscopic

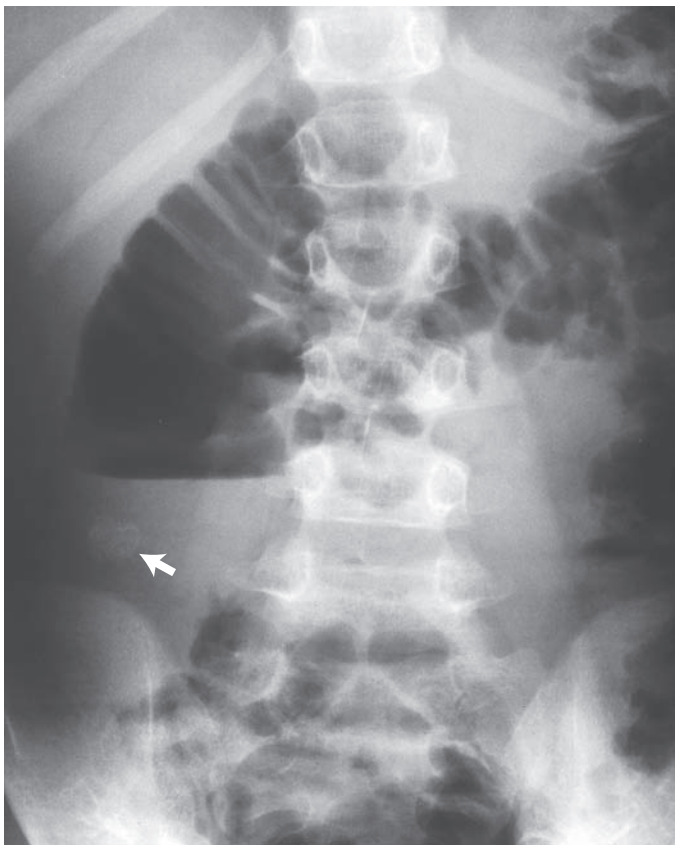

FIGURE 62-4 Gallstone ileus in an elderly patient with diabetes; note dilated loops of small bowel and an ectopic gallstone (*arrow*). (*From Schwartz DT, Reisdorff EJ. Emergency Radiology. New York: McGraw-Hill; 2000:527, Fig. 19-21. Copyright 2000, McGraw-Hill.*)

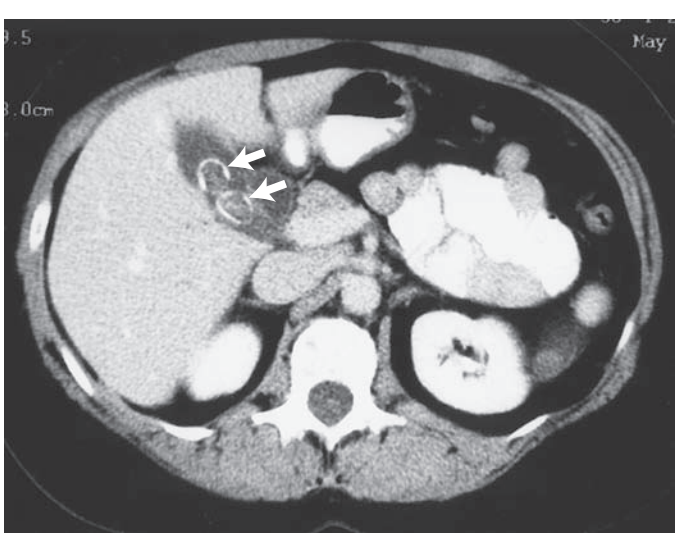

FIGURE 62-5 CT scan showing two large gallstones that have a rim of calcification (*large arrows*). (*From Schwartz DT, Reisdorff EJ. Emergency Radiology. New York: McGraw-Hill; 2000:538, Fig. 19-41A. Copyright 2000, McGraw-Hill.*)

sphincterotomy followed by laparoscopic cholecystectomy and is associated with significantly shorter hospital stay.[13]

- Medical therapy with ursodeoxycholic acid may be considered for patients with functioning gallbladders and small stones (<10 mm).[1] Approximately 50% of these patients will have complete dissolution of stones in 6 to 24 months, but recurrences are common (see "Prognosis" below).[1]
- Medical therapy can also be used to prevent gallstone formation in patients with expected rapid weight loss caused by very-low-calorie diets or bariatric surgery. In one study, ursodeoxycholic acid at a dose of 500 mg daily for 6 months reduced the incidence of gallstones over placebo (3% vs. 22%, respectively, at 12 months) and cholecystectomy (4.7% vs. 12%, respectively).[14]
- Extracorporeal shock wave lithotripsy combined with medical therapy may be considered for patients with radiolucent, solitary stones less than 2 cm, and a functional gallbladder.[1]

PROGNOSIS

- Abdominal pain resembling biliary colic may persist in up to 30% of patients despite cholecystectomy (called postcholecystectomy syndrome).[15] In one follow-up survey of 1300 patients following cholecystectomy (44% response rate), preoperative pain resolved in 90% but postoperative pain was reported in 25%; in 10% of these patients the post-operative pain was the same quality and location as the preoperative pain, and in 17% a new abdominal pain developed, most often in the periumbilical area.[16] In a study of 100 consecutive patients, 13% had persistent pain following laparoscopic cholecystectomy.[17]
- In the follow-up survey noted above (N = 573), nonpain symptoms all decreased in prevalence following cholecystectomy, including indigestion (14%), fatty food intolerance (19%), and heartburn (13%). Diarrhea, however, was present in similar percentages pre- and postoperatively (19% and 21%, respectively).[16]
- Following medical therapy, recurrences are common (30% to 50% at 3- to 5-year follow-up).[1]

FOLLOW-UP

- Approximately 5% to 10% of patients develop chronic diarrhea, attributed to increased bile salts reaching the colon, following cholecystectomy. Diarrhea is usually mild and can be managed with over-the-counter antidiarrheal agents (e.g., loperamide).
- Postcholecystectomy pain may be related to recurrent stones, choledocholithiasis, biliary dyskinesia, inflammatory scarring or strictures involving the sphincter of Oddi or the CBD, and dilation of cystic duct remnants; ultrasound, CT, cholangiography, or magnetic resonance cholangiopancreatography may be useful in identification of the cause and some may be amenable to surgical management.[18,19]

PATIENT EDUCATION

- Patients with asymptomatic gallstones may be managed expectantly—The rates of developing symptoms and complications should be

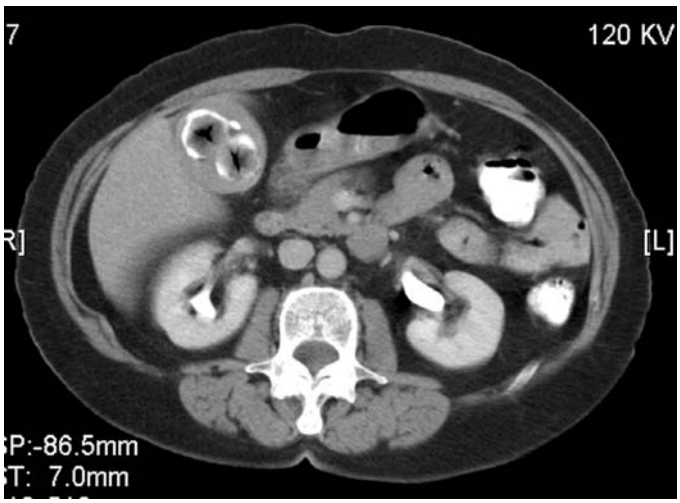

FIGURE 62-6 Radiographic Mercedes-Benz sign seen on a CT cut through the gallbladder (the gallstones produce a black pattern that resembles a Mercedes-Benz logo in the center). (*Courtesy of Mike Freckleton, MD.*)

reviewed. They should be encouraged to report symptoms of biliary colic and acute cholecystitis or pancreatitis (described above).

- Laparoscopic cholecystectomy appears to be very successful for symptom resolution, although chronic diarrhea may occur and abdominal pain may persist or new pain develop in approximately one-quarter of patients.[15]

PATIENT RESOURCES

- National Digestive Diseases Information Clearinghouse Gallstones (NDDIC)—**http://digestive.niddk.nih.gov/ddiseases/pubs/gallstones/index.aspx.**
- American Academy of Family Physicians (AAFP)—**http://familydoctor.org/online/famdocen/home/common/digestive/disorders/555.html.**

PROVIDER RESOURCES

- Ahmed A, Cheung RC, Keeffe EB. Management of gallstones and their complications—**http://www.aafp.org/afp/20000315/1673.html.**
- Heuman DM, Greenwald D, Soweid AM, et al. Cholelithiasis—**http://emedicine.medscape.com/article/175667-overview.**
- National Institute of Diabetes and Digestive and Kidney Diseases—**http://www2.niddk.nih.gov/Research/ScientificAreas/DigestiveDiseases/Gastrointestinal/GBBD.htm.**

REFERENCES

1. Greenberger NJ, Paumgartner G. Diseases of the gallbladder and bile ducts. In: Kasper DL, Braunwald E, Fauci AS, Hauser SL, Longo DL, Jameson, JL, eds. *Harrison's Principles of Internal Medicine*, 16th ed. New York: McGraw-Hill; 2005:1880-1884.
2. Halldestam I, Kullman E, Borch K. Incidence of and potential risk factors for gallstone disease in a general population sample. *Br J Surg.* 2009;96(11):1315-1322.
3. Attili AF, De Santis A, Attili F, et al. Prevalence of gallstone disease in first-degree relatives of patients with cholelithiasis. *World J Gastroenterol.* 2005;11(41):6508-6511.
4. Ishak G, Ribeiro FS, Costa DS, et al. Gallbladder cancer: 10 years of experience at an Amazon reference hospital. *Rev Col Bras Cir.* 2011;38(2):100-104.
5. Glauser PM, Strub D, Käser SA, et al. Incidence, management, and outcome of incidental gallbladder carcinoma: analysis of the database of the Swiss association of laparoscopic and thoracoscopic surgery. *Surg Endosc.* 2010;24(9):2281-2286.
6. Peng WK, Sheikh Z, Paterson-Brown S, Nixon SJ. Role of liver function tests in predicting common bile duct stones in acute calculous cholecystitis. *Br J Surg.* 2005;92(10):1241-1247.
7. Jang JY, Kim SW, Lee SE, et al. Differential diagnostic and staging accuracies of high resolution ultrasonography, endoscopic ultrasonography, and multidetector computed tomography for gallbladder polypoid lesions and gallbladder cancer. *Ann Surg.* 2009;250(6):943-949.

8. Gracie WA, Ransohoff DF. The natural history of asymptomatic gallstones: the innocent gallstone is not a myth. *N Engl J Med.* 1982;307:798-800.
9. Gurusamy KS, Samraj K. Cholecystectomy for patients with silent gallstones. *Cochrane Database Syst Rev.* 2007;(1):CD006230.
10. Keus F, Gooszen HG, van Laarhoven CJHM. Open, small-incision, or laparoscopic cholecystectomy for patients with symptomatic cholecystolithiasis. An overview of Cochrane Hepato-Biliary Group reviews. *Cochrane Database Syst Rev.* 2010;(1):CD008318.
11. Gurusamy KS, Samraj K. Early versus delayed laparoscopic cholecystectomy for acute cholecystitis. *Cochrane Database Syst Rev.* 2006;(4):CD005440.
12. Asakuma M, Hayashi M, Komeda K, et al. Impact of single-port cholecystectomy on postoperative pain. *Br J Surg.* 2011;98(7): 991-995.
13. Gurusamy K, Sahay SJ, Burroughs AK, Davidson BR. Systematic review and meta-analysis of intraoperative versus preoperative endoscopic sphincterotomy in patients with gallbladder and suspected common bile duct stones. *Br J Surg.* 2011;98(7):908-916.
14. Miller K, Hell E, Lang B, Lengauer E. Gallstone formation prophylaxis after gastric restrictive procedures for weight loss: a randomized double-blind placebo-controlled trial. *Ann Surg.* 2003;238(5):697-702.
15. Gui GP, Cheruvu CV, West N, et al. Is cholecystectomy effective treatment for symptomatic gallstones? Clinical outcomes after long-term follow-up. *Ann R Coll Surg Engl.* 1998;80:25-32.
16. Lublin M, Crawford DL, Hiatt JR, Phillips EH. Symptoms before and after laparoscopic cholecystectomy for gallstones. *Am Surg.* 2004;70(10):863-866.
17. Luman W, Adams WH, Nixon SN, et al. Incidence of persistent symptoms after laparoscopic cholecystectomy: a prospective study. *Gut.* 1996;39(6):863-866.
18. Perera E, Bhatt S, Dogra VS. Cystc duct remnant syndrome. *J Clin Imaging Sci.* 2011;1:2.
19. Girometti R, Brondani G, Cereser L, et al. Post-cholecystectomy syndrome: spectrum of biliary findings at magnetic resonance cholangiopancreatography. *Br J Radiol.* 2010;83(988): 351-361.

63 COLON POLYPS

Cathy Abbott, MD
Mindy A. Smith, MD, MS

PATIENT STORY

A 62-year-old woman presents to her physician for routine annual examination. She has no known family history of colon disease and is asymptomatic. Stool cards and flexible sigmoidoscopy were recommended and on flexible sigmoidoscopy a 2.4-cm polyp was noted at 35 cm. A colonoscopy was performed and additional polyps were identified in the descending colon and cecum (**Figure 63-1**).

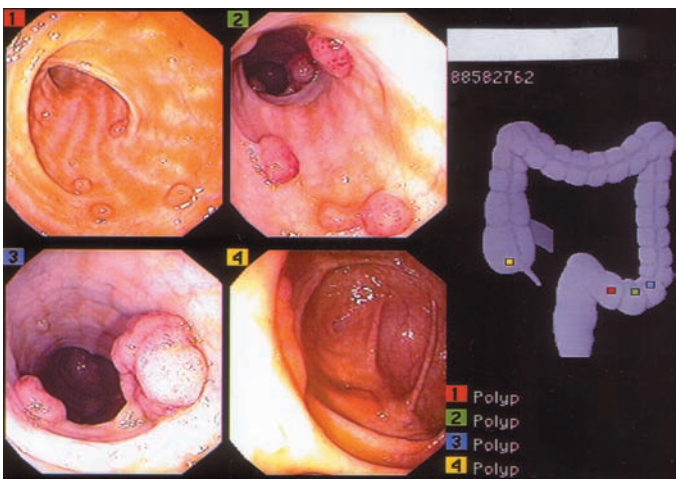

FIGURE 63-1 Colon polyps seen on colonoscopy. (*Courtesy of Michael Harper, MD.*)

INTRODUCTION

Colon polyps are growths that arise from the epithelial cells lining the colon.

EPIDEMIOLOGY

- More than 30% of middle-aged and elderly patients are found to have adenomatous polyps on screening and based on autopsy surveys; fewer than 1% will become malignant.[1] The lifetime risk of colon cancer is 5.12%.[2]
- Patients with an adenomatous polyp have a 30% to 50% risk for developing another adenoma and are at higher risk for colon cancer. This risk is greatest in the first 4 years after diagnosis of the first polyp, and greater if a villous adenoma or more than 3 polyps were found.
- Familial adenomatous polyposis of the colon is a rare autosomal dominant disorder. Thousands of adenomatous polyps appear in the large colon, generally by age 25 years, and colorectal cancer develops in almost all of these patients by age 40 years.[1] Other hereditary polyposis syndromes include Gardner syndrome, Turcot syndrome, Peutz-Jeghers syndrome, Cowden disease, familial juvenile polyposis, and hyperplastic polyposis.[3]

ETIOLOGY AND PATHOPHYSIOLOGY

- There are several types of colon polyps, including:
  - Hyperplastic polyps—These contain increased numbers of glandular cells with decreased cytoplasmic mucus and an absence of nuclear hyperchromatism, stratification, or atypia. Traditionally thought to be benign, recent evidence suggests malignant potential particularly for right-sided polyps, especially proximal hyperplastic serrated polyps[1] and those associated with hyperplastic polyposis syndrome (a familial disorder with multiple [>30] hyperplastic polyps proximal to the sigmoid colon with 2 or more >10 mm).[3] The percentage of polyps reported to be in this category ranges from 12% to 90%.[3,4]

- Adenomatous polyps—These may be tubular, villous (papillary), or tubulovillous. In a case series of 582 patients who had a polyp removed, 81% were adenomatous, including 65.0% that were tubular, 25.8% tubulovillous, 7.2% villous adenomas, and 0.5% mixed adenomatous hyperplastic polyps; 12 (1.4%) were invasive carcinomas.[4]
  - Adenomatous polyps may be pedunculated or sessile; cancers more frequently develop in sessile polyps.[1]
- Villous polyps can cause hypersecretory syndromes characterized by hypokalemia and profuse mucous discharge; these more frequently harbor carcinoma in situ or invasive carcinoma than other adenomas.[3]
- Nonneoplastic hamartoma (juvenile polyp)—These are benign cystic polyps with mucous-filled glands, most commonly found in male children, ages 2 to 5 years, and are often found as singular lesions, but additional polyps are found on panendoscopy in 40% to 50% of children. Juvenile polyps in adolescence may be associated with hereditary syndromes that carry malignant potential.[5]

- A series of genetic/molecular changes have been found that are thought to represent a multistep process from normal colon mucosa to malignant tumor.[3] These include:
  - Point mutations in the K-*ras* protooncogene leading to gene activation and deletion of DNA at the site of tumor-suppressor gene.
  - This results in an altered proliferative pattern and polyp formation.
  - Mutational activation of an oncogene, coupled with loss of tumor-suppressor genes, leads to malignant transformation.
  - Serrated polyps, which have in the past been characterized as hyperplastic polyps, are now known to have epigenetic alterations that may develop into colon cancers by another pathway—the CpG-island-methylation-phenotype pathway.[6]
  - Patients with familial polyposis inherit a germline alteration that leads into the above pathway.
- Insulin resistance, with increased concentrations of insulin-like growth factor type I, may also stimulate proliferation of the intestinal mucosa.

RISK FACTORS

- Older age—99% of cases occur in people older than age 40 years and 85% in those older than age 60 years.[7]
- Family history—Present in 10% to 20% of cases.[7]
- Diet appears to be associated with colon polyps and colon cancer. Animal fats may alter anaerobes in the gut microflora, increasing conversion of normal bile acids to carcinogens. Also, increased cholesterol is associated with an enhanced risk of development of adenomas.
- There may be an association between *Helicobacter* exposure and colonic polyps.[8,9]

DIAGNOSIS

CLINICAL FEATURES

- Usually asymptomatic.
- Patients may experience overt or occult rectal bleeding.

- Change in bowel habits—Diarrhea or constipation can occur, often with decreased stool caliber.
- Secretory villous adenomas can occasionally manifest as a syndrome of severe diarrhea with massive fluid and electrolyte loss.[3]

TYPICAL DISTRIBUTION

- Cancer distribution is approximately equal between the right and left colon. Juvenile polyps are usually found in the rectosigmoid region.

LABORATORY TESTING

- Occult blood in the stool is found in less than 5% of patients with polyps.[1] Of the 2% to 4% of asymptomatic patients who have heme positive stool on screening, 20% to 30% will have polyps.[1]
- For patients with a family history of familial adenomatous polyposis, DNA testing may be performed to detect the adenomatous polyposis coli *(APC)* gene mutation; this can lead to a definitive diagnosis before the development of polyps.[1] SOR C A positive test finding only indicates susceptibility, not the actual presence of a polyp.[3]
- Genetic testing can also be considered for patients with a family history of hereditary nonpolyposis colorectal cancer (HNPCC), which is caused by germline mutation of the DNA mismatch repair genes (*hMLH1*, *hMSH2*, *hPMS1*, *hPMS2*, *hMSH6*).[10] SOR C

IMAGING AND ENDOSCOPIC FEATURES

- Polyps may be identified on barium enema (**Figures 63-2** and **63-3**), flexible sigmoidoscopy, or colonoscopy (including virtual computer tomography colonoscopy) (**Figures 63-1** and **63-4**).
- A polyp is defined as grossly visible protrusion from the mucosal surface, although adenomas can also be flat or even depressed.[11]
- Colonoscopy must be subsequently performed to identify additional lesions and remove all lesions.
- Synchronous lesions occur in one-third of cases (**Figure 63-1**).

BIOPSY

- Polyps upon removal are sent for histology to determine type and whether dysplasia or carcinoma in situ is present (**Figure 63-5**).

DIFFERENTIAL DIAGNOSIS

Other causes of rectal bleeding include:

- Infectious agents—*Salmonella*, *Shigella*, certain *Campylobacter* species, enteroinvasive *Escherichia coli*, *Clostridium difficile*, and *Entamoeba histolytica* can cause bloody, watery diarrhea and are identified by culture. Bacterial toxins may be identified with *C. difficile*. Additional symptoms include fever and abdominal pain, and the disease is often self-limited.
- Hemorrhoids and fissures—Bleeding is usually bright red blood and seen in the toilet or with wiping after bowel movements. Hemorrhoids can sometimes be visible as a protruding mass often associated with pruritus and fissures are identified as a cut or tear

FIGURE 63-2 A 69-year-old female with a family history of colon cancer presented for screening. Her hemoccult test was positive. Her double-contrast barium enema (air contrast) demonstrated a large colonic polyp, which was found on surgery to be highly dysplastic. (*Courtesy of E.J. Mayeaux, Jr., MD.*)

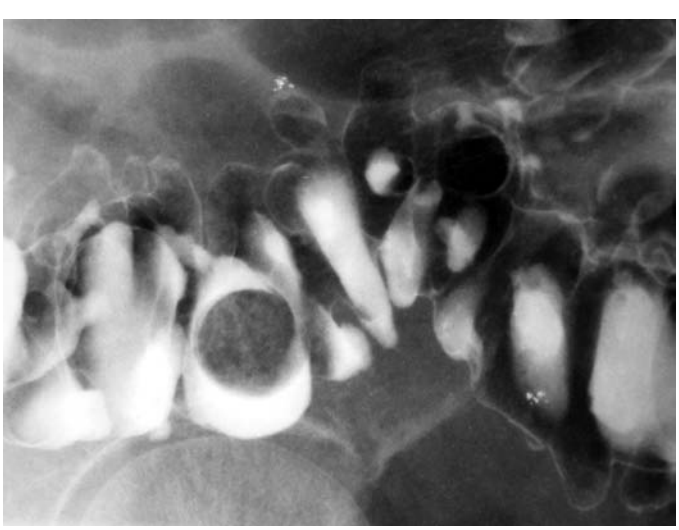

FIGURE 63-3 While getting a barium enema for other reasons, this patient was found to have a large colonic polyp. Biopsy of the polyp demonstrated early stage colon cancer, which was treated by surgical resection. (*Courtesy of E.J. Mayeaux, Jr., MD.*)

occurring in the anus (see Chapter 66, Hemorrhoids). Hemorrhoidal pain is described as a dull ache, but may be severe if thrombosed.

- Diverticula—Bleeding is usually abrupt in onset, painless, and may be massive but often stops spontaneously. These may be seen on endoscopy or on radiographic study.
- Vascular colonic ectasias—Bleeding tends to be chronic, resulting in anemia. Bleeding source may be identified during colonoscopy but a radionuclide scan or angiography may be needed.
- Colon cancer—Other symptoms include abdominal cramping, tenesmus (i.e., urgency with a feeling of incomplete evacuation), narrow caliber stool, occasional obstruction, and, rarely, perforation. Imaging studies often can distinguish and biopsy confirms malignancy (see Chapter 64, Colon Cancer).
- Inflammatory bowel disease—This includes ulcerative colitis and Crohn disease; symptoms include diarrhea, tenesmus, passage of mucus, and cramping abdominal pain (see Chapter 65: Inflammatory Bowel Disease). Extraintestinal manifestations are more common in Crohn disease and include skin involvement (e.g., erythema nodosum), rheumatologic symptoms (e.g., peripheral arthritis, symmetric sacroiliitis), and ocular problems (e.g., uveitis, iritis). Diagnosis may be made on endoscopy.

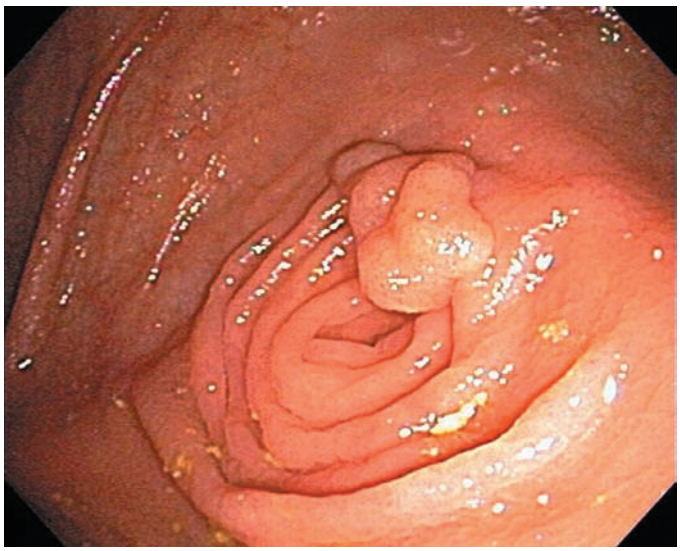

FIGURE 63-4 Polyp in the cecum seen on colonoscopy. (*Courtesy of Marvin Derezin, MD.*)

MANAGEMENT

- Removal of a solitary polyp may be completed during sigmoidoscopy or colonoscopy (**Figure 63-5**).

PREVENTION

- Primary prevention of colon cancer should be encouraged.
  - Dietary alterations may be useful.
    - Decreasing animal fats as diets high in animal fats are thought to be a major risk factor based on epidemiologic studies. However, in the Women's Health Initiative study, a low-fat dietary intervention did not reduce the risk of colorectal cancer in postmenopausal women during 8.1 years of follow-up.[12]
    - Additional dietary fiber has not shown to be helpful in controlled studies.[13]
    - Increasing water consumption to 8 glasses per day may be helpful.
    - Diets high in flavonols (fruits, vegetables, and tea) are associated with decreased risk of colon polyps, possibly by reducing serum interleukin (IL)-6, which is associated with inflammation and carcinogenesis.[14]
  - Calcium supplements (1200 mg per day) have been shown to reduce the development of adenomatous polyps.[15] SOR A
  - Hormone therapy in women reduces colon cancer incidence.[16] SOR B
  - A metaanalysis failed to show that folic acid supplementation reduced the risk of recurrent colon adenomas.[17]
  - Low-dose aspirin (81 mg per day) was found to decrease recurrent adenomas, including those containing advanced neoplasms.[18] SOR B In patients with familial adenomatous polyposis, once-daily treatment with 25 mg rofecoxib significantly

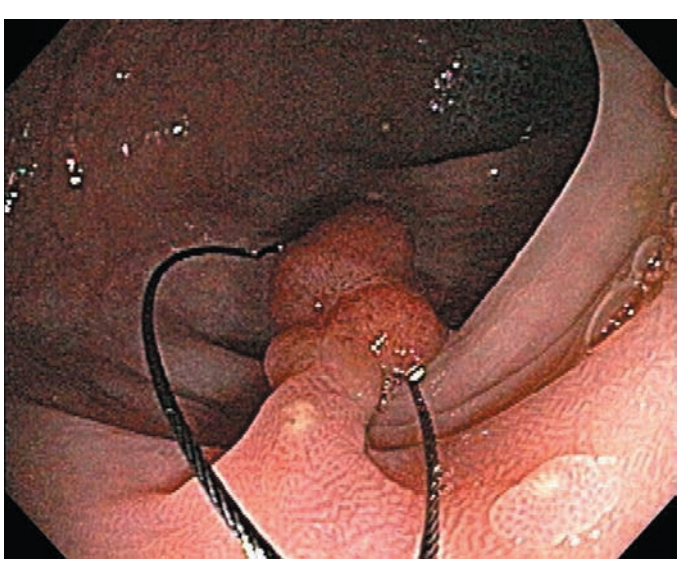

FIGURE 63-5 Polypectomy being performed through the colonoscope. (*Courtesy of Marvin Derezin, MD.*)

decreased the number and size of rectal polyps in one randomized trial.[19]
  - Smoking cessation.[20]
  - Increasing physical activity reduces the risk of advanced polyps and neoplasia, possibly by decreasing insulin resistance.[21]

PROGNOSIS

- Patients with a polyp with tubulovillous features or with more than 3 polyps larger than 10 mm are at increased risk for further aggressive lesions on follow-up colonoscopy, and untreated patients with polyps larger than 10 mm are at increased risk for colon cancer both at the site of polyp and at other sites.[22]

FOLLOW-UP

- Secondary prevention of colon cancer should be maximized through screening and removal of additional or recurrent polyps or colon cancer in these patients (see Chapter 64, Colon Cancer). Although there is debate regarding the frequency of screening, the American Cancer Society, the U.S. Multi-Society Task Force on Colorectal Cancer, and the American College of Radiology updated guideline recommends repeat colonoscopy at the following intervals:
  - Every 5 to 10 years for those with 1 to 2 small tubular adenomas with low-grade dysplasia after initial polypectomy.
  - Every 3 years for patients with 3 to 10 adenomas or 1 adenoma larger than 1 cm or any adenoma with villous features or high-grade dysplasia.
  - Less than every 3 years for patients with more than 10 adenomas.
  - At 2 to 6 months to verify complete removal in patients with sessile adenomas that are removed piecemeal.[23]
- Although screening options that enable detection of both adenomatous polyps and colon cancer include flexible sigmoidoscopy, colonoscopy, double-contrast barium enema, and CT colonography (use of dyes or other visual enhancements during colonoscopy), authors of a Cochrane review found that chromoscopic colonoscopy enhances the detection of polyps in the colon and rectum.[24] This form of colonoscopy can be used to identify flat polyps, increasing the sensitivity of colonoscopy, and may allow for detection of high-risk polyps without the need for biopsy.

PATIENT EDUCATION

- Attention to lifestyle factors can contribute to decreasing the risk of colon polyps.
- Patients should be encouraged to undergo screening for colon cancer, including use of high-sensitivity hemoccult cards, flexible sigmoidoscopy, or colonoscopy.[25] SOR A
- Patients diagnosed with polyps should be encouraged to engage in continued surveillance for polyps and colon cancer. Those at increased risk for a subsequent advanced neoplasia (see above) should have a follow-up colonoscopy at 3 or fewer years.[23] SOR B For other patients, follow-up is recommended at 5 to 10 years.[10] SOR C

PATIENT RESOURCES

- **http://digestive.niddk.nih.gov/ddiseases/pubs/colonpolyps_ez/index.htm.**
- **http://www.mayoclinic.com/health/colon-polyps/DS00511/DSECTION=4.**

PROVIDER RESOURCES

- **http://emedicine.medscape.com/article/172674.**

REFERENCES

1. Mayer R. Gastrointestinal tract cancer. In: Kasper DL, Braunwald E, Fauci AS, Hauser SL, Longo DL, Jameson, JL, eds. *Harrison's Principles of Internal Medicine*, 16th ed. New York: McGraw-Hill; 2005:523-533.
2. National Cancer Institute. http://seer.cancer.gov/statfacts/html/colorect.html. Accessed September 2011.
3. Enders GH. *Colon Polyps*. http://emedicine.medscape.com/article/172674-overview. Accessed September 2011.
4. Khan A, Shrier I, Gordon PH. The changed histologic paradigm of colorectal polyps. *Surg Endosc.* 2002;16(3):436-440.
5. Barnard J. Gastrointestinal polyps and polyp syndromes in adolescents. *Adolesc Med Clin.* 2004;15(1):119-129.
6. Noffsinger AE. Serrated polyps and colorectal cancer: new pathway to malignancy. *Annu Rev Pathol.* 2009;4:343-364.
7. Ballinger AB, Anggiansah C. Colorectal cancer. *BMJ.* 2007;335:715-718.
8. Mizuno S, Morita Y, Inui T, et al. *Helicobacter pylori* infection is associated with colon adenomatous polyps detected by high-resolution colonoscopy. *Int J Cancer.* 2005;117(6):1058-1059.
9. Abbass K, Gul W, Beck G, et al. Association of *Helicobacter pylori* infection with the development of colorectal polyps and colorectal cancer. *South Med J.* 2011;104(7):473-476.
10. American Gastroenterological Association medical position statement: hereditary colorectal cancer and genetic testing. *Gastroenterology.* 2001;121(1):195-197.
11. Anderson JC. Risk factors and diagnosis of flat adenomas of the colon. *Expert Rev Gastroenterol Hepatol.* 2011;5(1):25-32.
12. Beresford SA, Johnson KC, Ritenbaugh C, et al. Low-fat dietary pattern and risk of colorectal cancer: the Women's Health Initiative Randomized Controlled Dietary Modification Trial. *JAMA.* 2006;295(6):643-654.
13. Asano TK., McLeod RS. Dietary fibre for the prevention of colorectal adenomas and carcinomas. *Cochrane Database Syst Rev.* 2002;(2):CD003430.
14. Bobe G, Albert PS, Sansbury LB, et al. Interleukin-6 as a potential indicator for prevention of high risk adenoma recurrence by dietary flavonols in the polyp prevention trial. *Cancer Prev Res (Phila).* 2010;3(6):764-775.
15. Weingarten MAMA, Zalmanovici Trestioreanu A, Yaphe J. Dietary calcium supplementation for preventing colorectal cancer and adenomatous polyps. *Cochrane Database Syst Rev.* 2008;(1):CD003548
16. Nelson HS, Humphrey LL, Nygren P, et al. Postmenopausal hormone replacement therapy. *JAMA.* 2002;288(7):872-881.
17. Ibrahim EM, Zekri JM. Folic acid supplementation for the prevention of colorectal adenomas: metaanalysis of interventional trials. *Med Oncol.* 2010;27(3):915-918.
18. Baron JA, Cole BF, Sandler RS, et al. A randomized trial of aspirin to prevent colorectal adenomas. *N Engl J Med.* 2003;348(10):891-899.
19. Higuchi T, Iwama T, Yoshinaga K, et al. A randomized, double-blind, placebo-controlled trial of the effects of rofecoxib, a selective cyclooxygenase-2 inhibitor, on rectal polyps in familial adenomatous polyposis patients. *Clin Cancer Res.* 2003;9(13):4756-4760.
20. Botteri E, Iodice S, Raimondi S. Cigarette smoking and adenomatous polyps: a meta-analysis. *Gastroenterology.* 2008;134:388-395.
21. Wolin KY, Yan Y, Colditz GA. Physical activity and risk of colon adenoma: a meta-analysis. *Br J Cancer.* 2011;104(5):882-885.
22. Hassan C, Pickhardt PJ, Kim DH, et al. Systematic review: distribution of advanced neoplasia according to polyp size at screening colonoscopy. *Aliment Pharmacol Ther.* 2010;31(2):210-217.
23. Levin B, Lieberman DA, McFarland B, et al. Screening and surveillance for the early detection of colorectal cancer and adenomatous polyps, 2008: a joint guideline from the American Cancer Society, the US Multi-Society Task Force on Colorectal Cancer, and the American College of Radiology. *Gastroenterology.* 2008;134:1570-1595.
24. Brown SR, Baraza W. Chromoscopy versus conventional endoscopy for the detection of polyps in the colon and rectum. *Cochrane Database Syst Rev.* 2010;(10):CD006439.
25. United States Preventive Services Task Force. *Colorectal Cancer Screening. Summary*. http://www.ahrq.gov/clinic/colorsum.htm. Accessed September 2011.

64 COLON CANCER

Mindy A. Smith, MD, MS
Bonnie Wong, MD

PATIENT STORY

A 72-year-old man reports rectal bleeding with bowel movements over the past several months and the stool seems narrower with occasional diarrhea. He has a history of hemorrhoids but at this time is not experiencing rectal irritation or itching, as with previous episodes. His medical history is significant for controlled hypertension and a remote history of smoking. On digital rectal examination, his stool sample tests positive for blood but anoscopy fails to identify the source of bleeding. On colonoscopy, a mass is seen at 30 cm (**Figure 64-1**). A biopsy was obtained and pathology confirmed adenocarcinoma.

FIGURE 64-1 A sessile colon mass seen at 30 cm. At surgery, this was found to be a Duke stage A adenocarcinoma. (*Courtesy of Michael Harper, MD.*)

INTRODUCTION

Colon cancer is a malignant neoplasm of the colon, most commonly adenocarcinoma. With the establishment of screening programs and treatment improvements, there has been a slow decline in both the incidence and mortality from colon cancer, although it is still a leading cause of cancer death.[1]

EPIDEMIOLOGY

- Colon cancer is the third most common cancer in both men and women in the United States, second only to lung cancer as a cause of death.[1]
- The incidence and mortality have been slowly but steadily declining in the United States for the past decade.[2] The American Cancer Society estimated there were 142,570 new cases of colorectal cancer (102,900 colon cancer cases) and 51,370 deaths in 2010.[3]
- Onset is after age 50 years and peaks at around age 65 years.
- Proximal colon carcinoma rates in blacks are higher than in whites.[4]

ETIOLOGY AND PATHOPHYSIOLOGY

- Colon cancer appears to be a multipathway disease with tumors usually arising from adenomatous polyps or serrated adenomas; mutational events occur within the polyp including activation of oncogenes and loss of tumor-suppressor genes.[1,5]
- The probability of a polyp undergoing malignant transformation increases for the following cases:[1]
  - The polyp is sessile, especially if villous histology or flat.
  - Larger size—Malignant transformation is rare if smaller than 1.5 cm, 2% to 10% if 1.5 to 2.5 cm, and 10% if larger than 2.5 cm.
- Important genes involved in colon carcinogenesis include adenomatous polyposis gene mutations, *KRAS* oncogene, chromosome 18 loss of heterozygosity leading to inactivation of *SMAD4*, and *DCC*

tumor-suppression genes (deleted in colon cancer). Other mutations in genes, such as *MSH2, MLH1,* and *PMS2,* result in what is known as high-frequency microsatellite instability (H-MSI), which is found in cases of hereditary nonpolyposis colon cancer and in approximately 20% of sporadic colon cancers.[4]

RISK FACTORS[1,6]

- Ingestion of red and processed meat.
- Hereditary syndromes—Polyposis coli and nonpolyposis syndromes (40% lifetime risk).[4]
- Inflammatory bowel disease.
- Bacteremia with *Streptococcus bovis*—Increased incidence of occult tumors.
- Following ureterosigmoidostomy procedures (5% to 10% incidence over 30 years).
- Smoking.
- Alcohol consumption.
- Family history of colon cancer in a first-degree relative.
- Obesity.

DIAGNOSIS

The diagnosis of colon cancer is sometimes made following a positive screening test [i.e., digital rectal examination, fecal occult blood test (FOBT), sigmoidoscopy, colonoscopy, or barium enema]. For patients who have symptoms and signs suggestive of colon cancer, the confirmative diagnostic test most commonly performed is colonoscopy with biopsy. Colonoscopy allows direct visualization of the lesion, examination of the entire large bowel for synchronous and metachronous lesions, and an ability to obtain tissue for histologic diagnosis.

CLINICAL FEATURES

Symptoms vary, primarily based on anatomic location, as follows:[1]

- Right-sided colon tumors more commonly ulcerate, occasionally causing anemia without change in stool or bowel habits.
- Tumors in the transverse and descending colon often impede stool passage causing abdominal cramping, occasional obstruction, and rarely perforation (**Figure 64-5**).
- Tumors in the rectosigmoid region are associated more often with hematochezia, tenesmus (i.e., urgency with a feeling of incomplete evacuation), narrow caliber stool, and uncommonly, anemia.

Physical signs often appear later in the course of the disease and can include:[4]

- Weight loss and cachexia.
- Abdominal distention, discomfort, or tenderness.
- Abdominal or rectal mass.
- Ascites.
- Rectal bleeding or occult blood on rectal examination.

TYPICAL DISTRIBUTION

Colon cancers are approximately equally distributed between the right and left colon.[7]

IMAGING, ENDOSCOPY, AND WORK-UP

- Colonoscopy of the entire colon is recommended to identify additional neoplasms or polyps (**Figures 64-1** and **64-2**).
- Evaluation for metastatic disease includes:[8]
  - Local metastasis: Abdominal/pelvic CT scans.
  - Lung metastasis: Chest x-ray or chest CT.
  - Liver metastasis: MRI (pelvis), CT (abdomen and pelvis) or positron emission tomography (PET) CT scan (whole body).
  - The American College of Radiology also recommends transrectal rectum ultrasound for pretreatment staging for patients with rectal cancer and the addition of MRI of the abdomen for patients with large rectal tumors.[9]
  - Preoperative carcinoembryonic antigen (CEA)—An elevated CEA level can be used to monitor for recurrence. Pretreatment CEA (C-stage) is an independent predictor of overall mortality (60% increased risk) in patients with colon cancer.[10] CEA may be elevated for reasons other than colon cancer, such as pancreatic or hepatobiliary disease; elevation does not always reflect cancer or disease recurrence.
  - At surgery, surgeons perform an examination of the liver, pelvis, hemidiaphragm, and full length of the colon for evidence of tumor spread.[1]

BIOPSY

Colonic adenocarcinomas may be microscopically well-differentiated or poorly differentiated glandular structures.[4] The addition of cytology brushings to forceps biopsies may increase the diagnostic yield, especially in the setting of obstructing tumors that cannot be traversed.[11]

DIFFERENTIAL DIAGNOSIS

Other causes of abdominal pain in patients in this age group:

- Inflammatory bowel disease, which includes ulcerative colitis and Crohn disease (see Chapter 65, Ulcerative Colitis); symptoms include bloody diarrhea, tenesmus, passage of mucus, and cramping abdominal pain. Extraintestinal manifestations, more common in Crohn disease, include skin involvement (e.g., erythema nodosum), rheumatologic symptoms (e.g., peripheral arthritis, symmetric sacroiliitis), and ocular problems (e.g., uveitis, iritis). Diagnosis may be made on the basis of endoscopy.
- Diverticulitis—Patients present with fever, anorexia, lower left-sided abdominal pain, and diarrhea. Abdominal distention and peritonitis may be found on physical examination. Diagnosis is clinical or made on the basis of abdominal CT scan.
- Appendicitis—Initial symptoms include periumbilical or epigastric abdominal pain that over time becomes more severe and localized to the right lower quadrant. Additional symptoms include fever, nausea, vomiting, and anorexia.

Other causes of rectal bleeding:

- Infectious agents—*Salmonella*, *Shigella*, certain *Campylobacter* species, enteroinvasive *Escherichia coli*, *Clostridium difficile*, and *Entamoeba histolytica* can cause bloody, watery diarrhea, and are identified by culture test. Bacterial toxins may be identified with *C. difficile*. Additional symptoms include fever and abdominal pain and the disease is often self-limited.
- Hemorrhoids (see Chapter 66, Hemorrhoids) and fissures—Bleeding is usually bright red blood and seen in the toilet or with wiping after bowel movements. Hemorrhoids can sometimes be visible as a protruding mass often associated with pruritus, and fissures are identified as a cut or tear occurring in the anus. Hemorrhoidal pain is described as a dull ache but may be severe if thrombosed.
- Diverticula—Bleeding is usually abrupt in onset, painless, and may be massive, but often stops spontaneously. These may be seen in endoscopy or in radiographic study.
- Vascular colonic ectasias—Bleeding tends to be chronic resulting in anemia. Bleeding source may be identified during colonoscopy, but a radionuclide scan or angiography may be needed.
- Colon polyp (see Chapter 63, Colon Polyps)—Usually asymptomatic, although abdominal pain, diarrhea, or constipation can occur often with decreased stool caliber. Imaging studies often can distinguish and biopsy confirms absence of malignancy.

Other causes of intestinal obstruction include adhesions, peritonitis, inflammatory bowel disease, fecal impaction, strangulated bowels, and ileus.[2]

MANAGEMENT

MEDICATIONS

- Chemotherapy with fluorouracil (5-FU), irinotecan, with or without leucovorin is of marginal benefit with overall response in approximately 15% to 20% of patients.[1] For patients with stage II (Duke B) tumors (invasion into or through muscularis propria), authors of a systematic review found similar mortality rates with and without adjuvant chemotherapy.[12]
- Six months of postoperative treatment with 5-FU and leucovorin decreased recurrence for stage III (Duke C) tumors (lymph node involvement) by 40% and increased survival[1]; the absolute survival benefit in one trial over leucovorin alone was approximately 12% (49% vs. 37%, respectively).[13] A reduction in relapse rate and a modest increase in 3-year disease-free survival were also seen in patients with Duke B and C colon cancer by adding oxaliplatin to 5-FU–leucovorin; however, overall survival is only improved for a subgroup of patients.[14]
- For patients with metastatic disease (stage IV/Duke D), first-line multiagent chemotherapy can be considered. Three randomized controlled trials have demonstrated improved response rates, progression-free survival, and overall survival when a biologic agent (irinotecan or oxaliplatin) was combined with 5-FU–leucovorin.[15]

SURGERY OR OTHER TREATMENTS

- Total resection of the tumor is completed for attempted cure or for symptoms; open surgery or laparoscopic techniques may be used.[16]
- For superficial lesions, local excision or polypectomy with clear margins is performed; for other localized disease, wide surgical resection and reanastomosis is used.
- For patients with metastatic disease (stage IV/Duke D), treatment options include surgical resection, resection of liver metastases, palliative radiation or chemotherapy, first-line multiagent chemotherapy (see above), or participation in clinical trials.
- Total colonic resection is performed for patients with familial polyposis and multiple colonic polyps.
- For rectal carcinoma, sharp dissection is recommended (versus blunt) for rectal tumors to reduce recurrence to approximately 10%.[1] In addition, radiation therapy of the pelvis also decreases regional recurrence.[1] Postoperative treatment with 5-FU and radiation decreases recurrence for stages B2 and C tumors.[1]
- Preoperative radiation therapy can be used to shrink large tumors prior to resection.

PREVENTION AND SCREENING

- Primary prevention—Increased dietary fiber (conflicting evidence) and possibly increased ingestion of fruit, vegetables, fish, and milk.[6,17] High levels of physical activity also appear protective.[6,17] Low-dose aspirin is also associated with a lower risk of colon cancer and death from colon cancer.[18] Other medications possibly associated with a lower colon cancer risk include hormone therapy and oral contraceptives.
- Individuals who undergo at least one round of screening for colon cancer have a reduced risk of death from bowel cancer. In addition, early polyp removal by colonoscopy with polypectomy is associated with a reduced risk for colorectal cancer in the population setting.[19] Of the screening tests, high-sensitivity fecal occult blood testing, flexible sigmoidoscopy (FSG) with fecal occult blood testing, and colonoscopy are recommended options.[20] The U.S. Preventive Services Task Force (USPSTF) recommends screening for colorectal cancer in adults, beginning at age 50 years and continuing until age 75 years.[20] SOR A
- FOBT—This test will be positive in 2% to 4% of asymptomatic patients; less than 10% will have colon cancer.[1] There is good evidence that periodic fecal occult blood testing reduces mortality from colorectal cancer; annual screening is recommended.[20]
- FSG—There is good evidence that sigmoidoscopy in combination with fecal occult blood testing reduces mortality from colon cancer.[11] The ideal interval for surveillance is unknown, but the USPSTF recommends a 5-year interval of surveillance by FSG combined with a high-sensitivity FOBT every 3 years.[20]
- Colonoscopy—There is emerging evidence that screening colonoscopy is effective in reducing colorectal cancer mortality. Population-based observational study shows a declining incidence of colon cancer and gains in life-years where colonoscopy screening programs are in place. Colonoscopy also allows inspection of the

proximal colon and early removal of polyps.[11,21] Examples of colonoscopy pictures are shown in **Figures 64-1** to **64-3**.

- Double-contrast barium enema—This test offers an alternative means of whole-bowel examination, but is less sensitive than colonoscopy and there is no direct evidence that it is effective in reducing mortality rates. **Figures 64-4** and **64-5** display classic "apple-core deformities" of the colon from colon cancers.
- Other tests—CT colonography and stool DNA tests have been available for colorectal cancer screening. However, more research is needed to study their potential benefits and harms before widespread clinical use of these tests can be recommended as screening tools.[22]
- Secondary prevention—Low-dose aspirin (81 mg) prevents adenomas in patients with previous colon cancer.[23]

PROGNOSIS[1,24]

- Duke A (T1N0M0)—Cancer limited to mucosa and submucosa; 5-year survival: 90.1%.
- Duke B1 (T2N0M0)—Cancer extends into muscularis; 5-year survival: 85%.
- Duke B2 (T3N0M0)—Cancer extends into or through serosa; 5-year survival: 70% to 80%.
- Duke C (TxN1M0)—Cancer involves regional lymph nodes; 5-year survival: 35% to 69.2%.
- Duke D (TxNxM1)—Distant metastases (i.e., lung, liver); 5-year survival: 5% to 11.7%.
- In addition to node involvement and metastases, poor outcome is associated with:[1]
  - Number of regional lymph nodes involved.
  - Tumor penetration or perforation through the bowel wall.
  - Histology of poor differentiation.
  - Tumor adherence to adjacent organs.
  - Venous invasion.
  - Elevated preoperative CEA (i.e., >5 ng/mL).
  - Aneuploidy.
- Specific chromosomal deletion (e.g., allelic loss on chromosome 18q).

FOLLOW-UP

- Staging is based on tumor depth and spread and predicts survival as above.[1]
- Surveillance recommendations are as follows:[25]
  - Office visits and CEA evaluations should be performed at a minimum of 3 times per year for the first 2 years of follow-up. SOR A
  - There is insufficient data to recommend for or against chest x-ray (CXR) as a part of routine colorectal cancer follow-up. SOR C
  - Posttreatment colonoscopy should be performed at 3-year intervals. SOR A
  - Periodic anastomotic evaluation is recommended for patients who have undergone resection/anastomosis or local excision of rectal cancer. SOR B

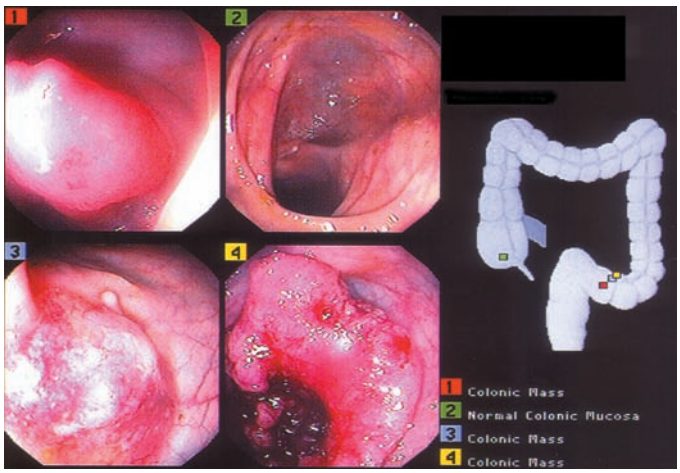

FIGURE 64-2 Plate 2 in this series shows normal cecum. The remaining frames show a large friable mass. Biopsy confirmed adenocarcinoma. The tumor was resected and determined to be Duke stage B adenocarcinoma. Colonoscopy 3 years later was negative. (*Courtesy of Michael Harper, MD.*)

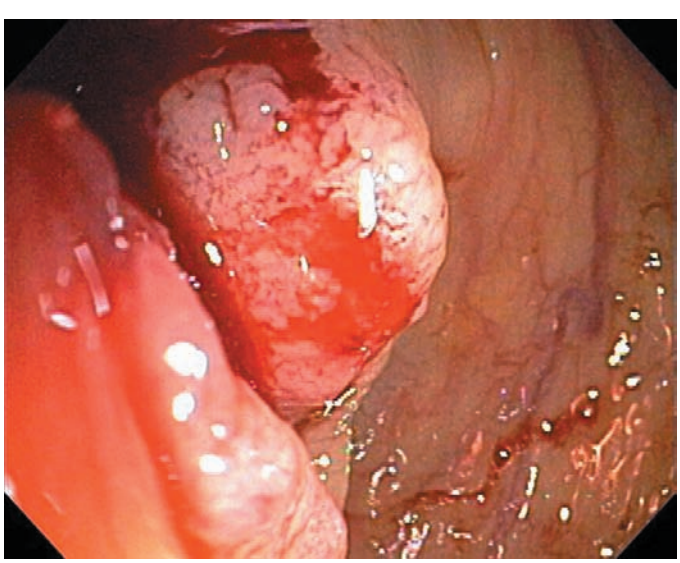

FIGURE 64-3 Adenocarcinoma in the cecum found on colonoscopy. (*Courtesy of Marvin Derezin, MD.*)

- Serum hemoglobin, hemoccult II (FOBT), and liver function tests (hepatic enzymes tests) should not be routine components of a follow-up program. SOR A
- For patients with progressive disease, options for further therapy must be discussed, including discontinuing therapy, intrahepatic chemotherapy (if appropriate), and experimental (i.e., phase I) therapy.

PATIENT EDUCATION

- Most recurrences occur within the first 3 to 4 years, so survival at 5 years is a good indication of cure.[1]
- Surveillance for recurrence should be conducted over the first 5 years following treatment as noted above. In addition to identifying recurrence, a second tumor is found in 3% to 5% and adenomatous polyps will be found in more than 15% of patients over that period.[1]

PATIENT RESOURCES

- **www.nlm.nih.gov/medlineplus/ency/article/000262.htm.**
- **http://www.cancer.gov/cancertopics/pdq/treatment/colon/patient.**

PROVIDER RESOURCES

- **http://www.cancer.gov/cancertopics/pdq/treatment/colon/HealthProfessional.**
- **http://emedicine.medscape.com/article/277496-overview.**

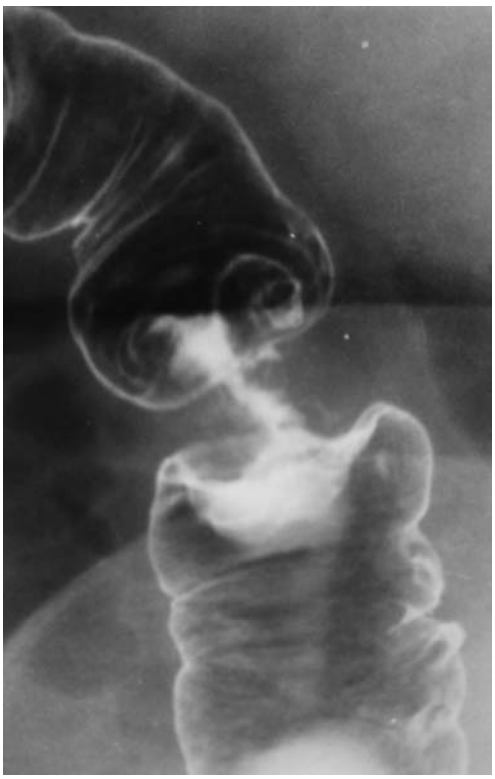

FIGURE 64-4 An "apple core" lesion on barium enema is consistent with colon cancer. The patient is a 72-year-old African American man who presented with weight loss. A complete blood count demonstrated moderate anemia and his hemoccult cards were positive. (*Courtesy of E.J. Mayeaux, Jr., MD.*)

REFERENCES

1. Mayer R. Gastrointestinal tract cancer. In: Kasper DL, Braunwald E, Fauci AS, Hauser SL, Longo DL, Jameson JL, eds. *Harrison's Principles of Internal Medicine,* 16th ed. New York, NY: McGraw-Hill; 2005:523-533.
2. Edwards B, Ward E, Kohler B, et al. Annual report to the nation on the status of cancer, 1975-2006, featuring colorectal cancer trends and impact of interventions (risk factors, screening, and treatment) to reduce future rates. *Cancer*. 2010;116(3):544-573.
3. Jemal A, Siegel R, Xu J, Ward E. Cancer statistics, 2010. *CA Cancer J Clin*. 2010;60(5):277-300.
4. Dragovich T. *Colon Adenocarcinoma*. http://www.emedicine.com/med/topic413.htm. Accessed November 2011.
5. Jass JR. Classification of colorectal cancer based on correlation of clinical, morphological, and molecular features. *Histopathology*. 2007;50:113-130.
6. Cancer Research UK. *Bowel Cancer*. http://info.cancerresearchuk.org/cancerstats/types/bowel/riskfactors./ Accessed December 2011.
7. Topazian M. Gastrointestinal endoscopy. In: Kasper DL, Braunwald E, Fauci AS, Hauser SL, Longo DL, Jameson JL, eds. *Harrison's*

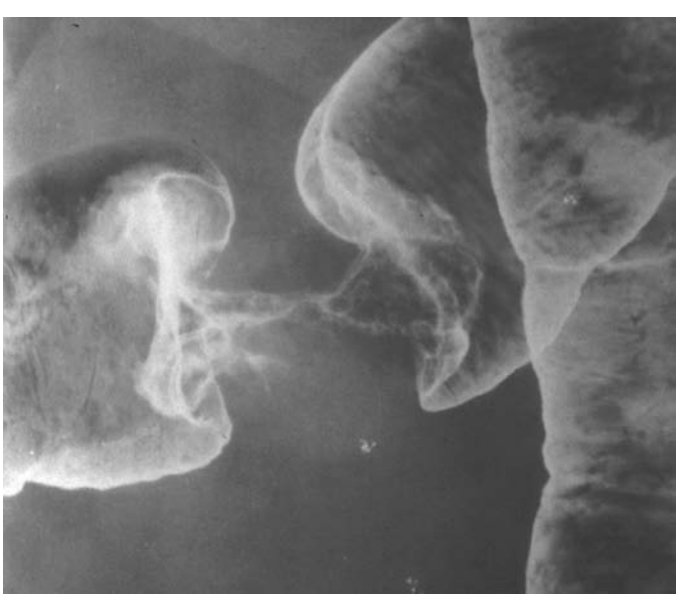

FIGURE 64-5 A barium enema reveals a large "apple core" lesion consistent with colon cancer. The patient is a 64-year-old man who had a barium enema performed as part of the work-up for weight loss and vague abdominal pain. (*Courtesy of E.J. Mayeaux, Jr., MD.*)

Principles of Internal Medicine, 16th ed. New York, NY: McGraw-Hill; 2005:1730-1739.

8. Niekel MC, Bipat S, Stoker J. Diagnostic imaging of colorectal liver metastases with CT, MR imaging, FDG PET, and/or FDG PET/CT: a meta-analysis of prospective studies including patients who have not previously undergone treatment. *Radiology*. 2010;257(3):674-684.
9. Rosen MP, Bree RL, Foley WD, et al; Expert Panel on Gastrointestinal Imaging. *ACR Appropriateness Criteria Pretreatment Staging of Colorectal Cancer*. http://www.guideline.gov/content.aspx?id=13629&search=colon+cancer. Accessed December 2011.
10. Thirunavukarasu P, Sukumar S, Sathaiah M, et al. C-stage in colon cancer: implications of carcinoembryonic antigen biomarker in staging, prognosis, and management. *J Natl Cancer Inst*. 2011;103(8):689-697.
11. Davila RE, Rajan E, Adler D, et al. ASGE guideline: The role of endoscopy in the diagnosis, staging, and management of colorectal cancer. *Gastrointest Endosc*. 2005;61(1):1-7.
12. Figueredo A, Charette ML, Maroun J, et al. Adjuvant therapy for stage II colon cancer: a systematic review from the Cancer Care Ontario Program in evidence-based care's gastrointestinal cancer disease site group. *J Clin Oncol*. 2004;22(16):3395-3407.
13. Laurie JA, Moertel CG, Fleming TR, et al. Surgical adjuvant therapy of large-bowel carcinoma: an evaluation of levamisole and the combination of levamisole and fluorouracil. The North Central Cancer Treatment Group and the Mayo Clinic. *J Clin Oncol*. 1989;7(10):1447-1456.
14. André T, Boni C, Navarro M, et al. Improved overall survival with oxaliplatin, fluorouracil, and leucovorin as adjuvant treatment in stage II or III colon cancer in the MOSAIC trial. *J Clin Oncol*. 2009;27 (19):3109-3116.
15. National Cancer Institute. http://www.cancer.gov/cancertopics/pdq/treatment/colon/HealthProfessional/page9. Accessed December 2011.
16. National Cancer Institute. http://www.cancer.gov/cancertopics/pdq/treatment/colon/HealthProfessional/page4. Accessed December 2011.
17. National Cancer Institute. *Colorectal Cancer Prevention*. http://cancer.gov/cancertopics/pdq/prevention/colorectal/HealthProfessional. Accessed November 2011.
18. Rothwell PM, Wilson M, Elwin CE, et al. Long-term effect of aspirin on colorectal cancer incidence and mortality: 20-year follow-up of five randomised trials. *Lancet*. 2010;376(9754):1741-1750.
19. Brenner H, Chang-Claude J, Seiler CM, et al. Protection from colorectal cancer after colonoscopy: a population-based, case-control study. *Ann Intern Med*. 2011;154(1):22-30.
20. U.S. Preventive Services Task Force. *Screening for Colorectal Cancer*. http://www.uspreventiveservicestaskforce.org/uspstf08/colocancer/colosum.htm. Accessed November 2011.
21. Meza R, Jeon J, Renehan AG, Luebeck EG. Colorectal cancer incidence trends in the United States and United Kingdom: evidence of right- to left-sided biological gradients with implications for screening. *Cancer Res*. 2010;70(13):5419-5429.
22. Zauber AG, Lansdorp-Vogelaar I, Knudsen AB, et al. Evaluating test strategies for colorectal cancer screening: a decision analysis for the U.S. Preventive Services Task Force. *Ann Intern Med*. 2008;149(9):659-669.
23. Sandler RS, Halabi S, Baron JA, et al. A randomized trial of aspirin to prevent colorectal adenomas in patients with previous colorectal cancer. *N Engl J Med*. 2003;348(10):883-890.
24. National Cancer Institute. *Surveillance Epidemiology and End Results*. http://seer.cancer.gov/statfacts/html/colorect.html. Accessed December 2011.
25. Anthony T, Simmang C, Hyman N, et al. Practice parameters for the surveillance and follow-up of patients with colon and rectal cancer. *Dis Colon Rectum*. 2004;47(6):807-817.

65 INFLAMMATORY BOWEL DISEASE

Mindy A. Smith, MD, MS

PATIENT STORY

A 20-year-old man presents with several days of diarrhea with a small amount of rectal bleeding with each bowel movement. This is his second episode of bloody diarrhea; the first seemed to resolve after several days and occurred several weeks ago. He has cramps that occur with each bowel movement, but feels fine between bouts of diarrhea. He has no travel history outside of the United States. He is of Jewish descent and has a cousin with Crohn disease. Colonoscopy shows mucosal friability with superficial ulceration and exudates confined to the rectosigmoid colon, and he is diagnosed with ulcerative colitis (**Figure 65-1**).

FIGURE 65-1 Ulcerative colitis in the rectosigmoid colon as viewed through the colonoscope. (*Courtesy of Marvin Derezin, MD.*)

INTRODUCTION

Inflammatory bowel disease (IBD) comprises ulcerative colitis (UC) and Crohn disease. The intestinal inflammation in UC is usually confined to the mucosa and affects the rectum with or without parts or the entire colon (pancolitis) in an uninterrupted pattern. In Crohn disease, inflammation is often transmural and affects primarily the ileum and colon, often discontinuously. Crohn disease, however, can affect the entire GI tract from mouth to anus.

EPIDEMIOLOGY

- Incidence of UC in the West is 8 to 14 per 100,000 people and 6 to 15 per 100,000 people for Crohn disease.[1] Prevalence for UC and Crohn disease in North America (one of the highest rates in the world) is 37.5 to 238 per 100,000 people and 44 to 201 per 100,000 people, respectively; IBD therefore affects an estimated 1.3 million people in the United States.[1] Rates of IBD are increasing in both the West and in developing countries.[1]
- Age of onset is 30 to 40 years for UC and 20 to 30 years for Crohn disease. A bimodal distribution with a second peak at ages 60 to 70 years has been reported but not confirmed.[1] Pediatric patients account for up to 20% of cases.
- Predilection for those of Jewish ancestry (especially Ashkenazi Jews) followed in order by non-Jewish whites and African Americans, Hispanics, and Asians.[1]
- Inheritance (polygenic) plays a role with a concordance of 20% in monozygous twins and a risk of 10% in first-degree relatives of an incidence case.[2]

ETIOLOGY AND PATHOPHYSIOLOGY

- Unknown etiology—Current theory is that colitis is an inappropriate response to microbial gut flora or a lack of regulation of intestinal

immune cells in a genetically susceptible host with failure of the normal suppression of the immune response and tissue repair.[2,3]

- Genetic regions containing nucleotide oligomerization domain 2 (NOD2; encodes an intracellular sensor of peptidoglycan), autophagy genes (regulate clearing of intracellular components like organelles), and components of the interleukin-23–type 17 helper T-cell (Th17) pathway are associated with IBD; the autophagy gene, *ATG16L1,* is associated with Crohn disease.[3]
- Multiple bowel pathogens (e.g., *Salmonella, Shigella* species, and *Campylobacter*) may trigger UC. This is supported by a large cohort study where the hazard ratio of developing IBD was 2.4 (95% confidence interval [CI], 1.7 to 3.3) in the group who experienced a bout of infectious gastroenteritis compared with the control group; the excess risk was greatest during the first year after the infective episode.[4] People with IBD also have depletion and reduced diversity of some members of the mucosa-associated bacterial phyla, but it is not known whether this is causal or secondary to inflammation.[3]
- Other abnormalities found in patients with IBD include increased permeability between mucosal epithelial cells, defective regulation of intercellular junctions, infiltration into the lamina propria of innate (e.g., neutrophils) and adaptive (B and T cells) immune cells with increased production of tumor necrosis factor α and increased numbers of CD4+ T cells, dysregulation of intestinal CD4+ T-cell subgroups, and the presence of circulating antimicrobial antibodies (e.g., antiflagellin antibodies).[3] Many of the therapeutic approaches target these areas.
- Psychological factors (e.g., major life change, daily stressors) are associated with worsening symptoms.
- Patients with longstanding UC are at higher risk of developing colon dysplasia and cancer; this is believed to be a developmental sequence (see "Prognosis" below).

RISK FACTORS

- Smokers are at increased risk for Crohn disease and tend to have more severe disease, whereas former smokers and nonsmokers are at greater risk for UC.[1,2]
- Environmental factors appear to be important triggers, especially of Crohn disease in children.[1]
- Appendectomy reduces the risk of UC.[1]

DIAGNOSIS

The diagnosis depends on the clinical evaluation, sigmoid appearance, histology, and a negative stool for bacteria, *Clostridium difficile* toxin, and ova and parasites.[2]

CLINICAL FEATURES

- Major symptoms of UC—Diarrhea, rectal bleeding, tenesmus (i.e., urgency with a feeling of incomplete evacuation), passage of mucus, and cramping abdominal pain.
- Symptoms in patients with Crohn disease depend on the location of disease; patients become symptomatic when lesions are extensive

or distal (e.g., colitis), systemic inflammatory reaction is present, or when disease is complicated by stricture, abscess, or fistula. Gross blood and mucus in the stool are less frequent and systemic symptoms, extracolonic features, pain, perineal disease, and obstruction are more common.[2] There is no relationship between symptoms and anatomic damage.[1]

- UC is classified by severity based on the clinical picture and results of endoscopy;[5] treatment is based on disease classification.
  - Mild: Less than 4 stools per day, with or without blood, no signs of systemic toxicity, and a normal erythrocyte sedimentation rate (ESR).
  - Moderate: More than 4 stools per day but with minimal signs of toxicity.
  - Severe: More than 6 bloody stools per day, and evidence of toxicity demonstrated by fever, tachycardia, anemia, and elevated ESR.
  - Fulminant: May have more than 10 bowel movements daily, continuous bleeding, toxicity, abdominal tenderness and distention, a blood transfusion requirement, and colonic dilation on abdominal plain films.
- Extraintestinal manifestations are present in 25% to 40% of patients with IBD, but are more common in Crohn disease than UC:[2,6]
  - Dermatologic (2% to 34%)—Erythema nodosum (10%) that correlates with disease activity and pyogenic gangrenosum (pustule that spreads concentrically and ulcerates surrounded by violaceous borders) in 1% to 12% of patients.[2]
  - Rheumatologic—Peripheral arthritis (5% to 20%), spondylitis (1% to 26%, but nearly all of those positive for human leukocyte antigen B27), and symmetric sacroiliitis (<10%).
  - Ocular—Conjunctivitis, uveitis, iritis, and episcleritis (0.3% to 5%)[6]
  - Hepatobiliary—The most serious complication in this category is primary sclerosing cholangitis; although 75% of patients with this disease have UC, only 5% of those with UC and 2% of patients with Crohn disease develop it.[6] Hepatic steatosis (fatty liver) and cholelithiasis can also occur.
  - Cardiovascular—Increased risk of deep venous thrombosis, pulmonary embolus, and stroke (because of a hypercoagulable state from thrombocytosis and gut losses of antithrombin III among other factors); endocarditis; myocarditis; and pleuropericarditis.[2]
  - Bone—Osteoporosis and osteomalacia from multiple causes including medications, reduced physical activity, inflammatory-mediated bone resorption, vitamin D deficiency, and calcium and magnesium malabsorption. Fracture risk in patients with IBD is 1 per 100 patient-years (40% higher than the general population).[6]
  - Renal—Nephrolithiasis, obstructive uropathy, and fistulization of the urinary tract occur in 6% to 23%.[6]
- Extraintestinal manifestations may occur prior to the diagnosis of IBD. For example, 10% to 30% of patients with IBD-related arthritis develop arthritis prior to IBD diagnosis.[6]
- Severe complications include toxic colitis (15% initially present with catastrophic illness), massive hemorrhage (1% of those with severe attacks), toxic megacolon (i.e., transverse colon diameter >5 to 6 cm) (5% of attacks; may be triggered by electrolyte abnormalities and narcotics), and bowel obstruction (caused by strictures and occurring in 10% of patients).[1]

- On endoscopy in patients with Crohn disease, rectal sparing is frequent and cobblestoning of the mucosa is often seen. Small bowel involvement is seen on imaging in addition to segmental colitis and frequent strictures (**Figure 65-5**).
- Diagnosis is changed from UC to Crohn disease over time in 5% to 10% of patients.[7]

TYPICAL DISTRIBUTION

- At presentation, about a third of patients with UC have disease localized to the rectum, another third have disease present in the colorectum distal to the splenic flexure, and the remainder with disease proximal to the splenic flexure; pancolitis is present in one quarter.[1] Adults appear to always have rectal involvement, which is not the case for children. Over time (20 years), half will have pancolitis (**Figure 65-1**).[8]
- In patients with Crohn disease, lesions occur in equal proportions in the ileum, colon, or both; 10% to 15% have upper GI lesions, 20% to 30% present with perianal lesions and about half eventually develop perianal disease. Fifteen percent to 20% of patients have or have had a fistula.[1]

LABORATORY TESTS

- Acute disease can result in a rise of acute phase reactants (e.g., C-reactive protein) and elevated ESR (rare in patients with just proctitis). C-reactive protein is elevated in nearly all patients with Crohn disease and in approximately half the patients with UC.[9]
- Obtain hemoglobin (to assess for anemia) and platelets (to assess for reactive thrombocytosis).
- Of the biomarkers available to detect IBD, fecal calprotectin and lactoferrin are most commonly used.[9] The former is an indirect measure of neutrophil infiltrate in the bowel mucosa and the later is an iron-binding protein secreted by mucosal membranes and found in neutrophil granules and serum. Although the optimal threshold value for calprotectin in detecting IBD is unknown, a study of adult patients suspected of having IBD based on clinical evaluation reported a sensitivity and specificity of the test of 93% and 96%, respectively.[10] Test characteristics for lactoferrin are lower at 80% and 82%.
- Stool should be examined to rule out infectious causes including *C. difficile*; the incidence of *C. difficile* is increasing in patients with UC and is associated with a more severe course in those with IBD.[11]

ENDOSCOPY AND IMAGING

Imaging has become more important for patients with IBD, not only for diagnosis in symptomatic patients but for early detection and treatment of inflammation in asymptomatic patients with Crohn disease and for monitoring inflammation and disease complications.[12]

- Colonoscopy with ileoscopy and mucosal biopsy should be performed in the evaluation of IBD and for differentiating UC from Crohn disease (**Figures 65-1** to **65-5**).[13] SOR B It is the best test for detection of colonic inflammation.[5,10]
- Colonoscopy can show pseudopolyps in both active UC (**Figure 65-3**) and inactive UC (**Figure 65-4**). Risks of ileocolonoscopy include perforation, limited small bowel evaluation and inability to stage penetrating disease.[12]

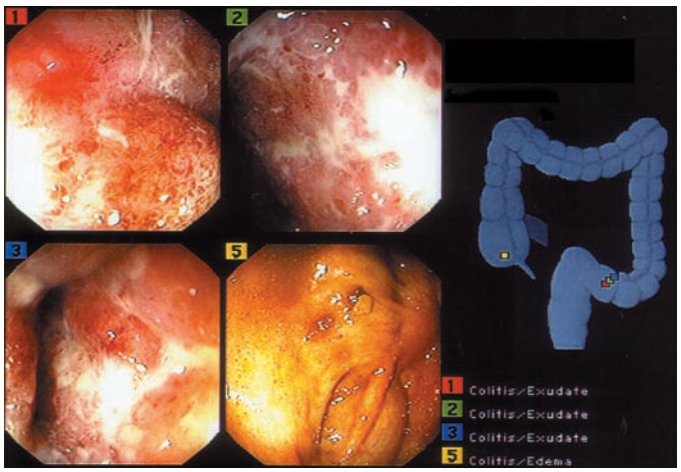

FIGURE 65-2 Endoscopic image showing friability and exudates over superficial ulceration in the sigmoid colon. There is edema in the cecum that, all together, indicates pan colitis. Biopsy confirmed ulcerative colitis. (*Courtesy of Michael Harper, MD.*)

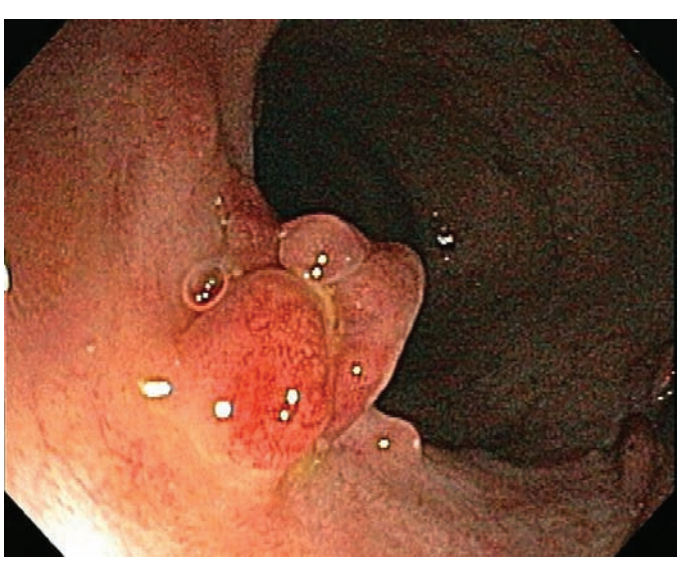

FIGURE 65-3 Pseudopolyps in active comprises ulcerative colitis viewed through colonoscope. (*Courtesy of Marvin Derezin, MD.*)

- Capsule endoscopy (CE) is a less-invasive technique for evaluating the small intestine in patients with Crohn disease and is more sensitive than radiologic and endoscopic procedures for detecting small bowel lesions and mucosal inflammation.[12,13] SOR B CE should not be performed in patients with Crohn disease known or suspected to have a high-grade stricture. In that case, consider CT enterography.[13] The major risk is retention.[12]
- In patients with initial presentation of symptomatic Crohn disease, the American College of Radiology (ACR) recommends CT enterography.[14] Magnetic resonance (MR) enterography may be substituted based on institutional preference as this test appears to have similar test characteristics and avoids radiation exposure; it is the preferred test for investigating perianal disease.[13] In addition to radiation, risks of CT enterography are related to the iodine dye and for MR enterography, image quality can be suboptimal in some patients; both tests have limited ability to detect colonic cancer.[12]
- In patients with severe disease, a plain supine film may show edematous, irregular colon margins, mucosal thickening, and toxic dilation.[2]

FIGURE 65-4 Pseudopolyps in inactive comprises ulcerative colitis viewed through colonoscope. (*Courtesy of Marvin Derezin, MD.*)

DIFFERENTIAL DIAGNOSIS

- Infections of the colon—*Salmonella, Shigella* species, and *Campylobacter* have a similar appearance with bloody diarrhea and abdominal pain but disease is usually self-limited and stool culture can confirm the presence of these bacteria. *C. difficile* and *Escherichia coli* can also mimic IBD.
- Numerous infectious agents including *Mycobacterium*, *Cytomegalovirus*, and protozoan parasites can mimic UC in immunocompromised patients.
- Ischemic colitis—May present with sudden onset of left lower quadrant pain, urgency to defecate, and bright red blood via rectum. It can be chronic and diffuse and should be considered in elderly patients following abdominal aorta repair or when a patient has a hypercoagulable state. Endoscopic examination often demonstrates normal rectal mucosa with a sharp transition to an area of inflammation in the descending colon or splenic flexure (**Figure 65-6**).
- Colitis associated with NSAIDs—Clinical features of diarrhea and pain, but may be complicated by bleeding, stricture, obstruction, and perforation. History is helpful and symptoms improve with withdrawal of the agent.

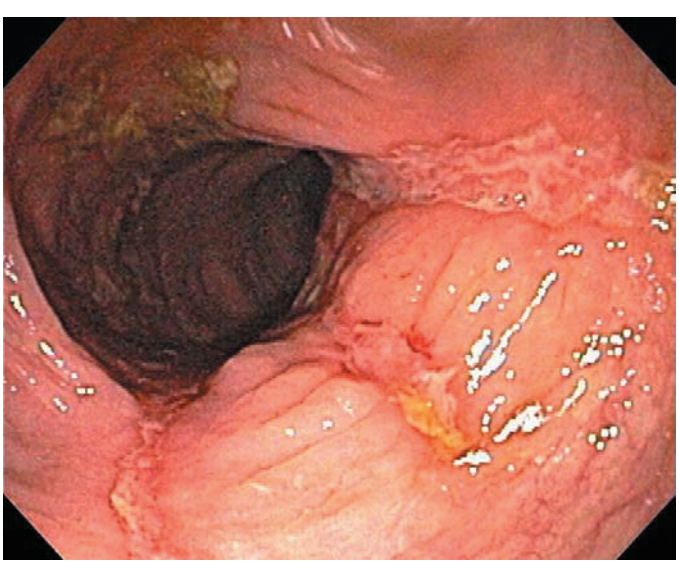

FIGURE 65-5 Crohn colitis with deep longitudinal ulcers and normal-appearing tissue between. The biopsies that showed normal tissue between the ulcers clinched the diagnosis for Crohn disease. Ulcerative colitis is diffuse whereas Crohn disease often skips areas as seen in this patient's colon. (*Courtesy of Marvin Derezin, MD.*)

MANAGEMENT

MEDICATION

Treatment of acute disease in patients with UC (treatment algorithms can be found in the reference provided) is based on disease activity as follows[15]:

- Mild to moderate distal disease—Oral aminosalicylates (ASAs), topical mesalamine or topical steroids.[5] SOR A An oral 5-ASA agent can be a prodrug (e.g., sulfasalazine, 4 to 6 g/day), a drug with a pH-dependent coating (e.g., Asacol, 2.4 to 4.8 g/day), or a slow-release agent (Pentasa, 2 to 4 g/day). Mesalamine suppositories (1 g/day) are the best way to induce remission in patients

with proctitis.[15] Rectal suppositories or enemas should also be used to improve medication delivery when treating active distal colitis, and a combination of oral and rectal mesalamine is better than monotherapy for stopping rectal bleeding (89% vs. 46% [oral only] or 69% [rectal only]).[5,15] SOR A Fifty percent to 75% of patients will show clinical improvement with 2 g/day of 5-ASA and a similar percentage will maintain remission with doses of 1.5 to 4 g/day.[2]

- For patients with mild to moderate active proctitis who do not respond to topical mesalamine, adding a topical corticosteroid should be considered. In patients refractory to oral ASAs or topical corticosteroids, mesalamine enemas or suppositories may still be effective.[5] SOR A An oral steroid (e.g., prednisone, 40 to 60 mg/day) or infliximab (induction regimen of 5 mg/kg at weeks 1, 2, and 6) can be added for patients with mild-moderate local disease who have an inadequate response to initial therapy; the latter is often reserved for patients who do not respond to or tolerate steroids.[5,13] SOR C
- Mild to moderate extensive colitis— Oral sulfasalazine (titrated to 4 to 6 g/day) or 5-ASA (up to 4.8 g/day) with or without topical therapy. SOR A Oral steroids are generally reserved for patients refractory to combined oral and topical ASA therapy or for those with severe symptoms requiring more prompt improvement.[5] SOR A Immunomodulators (6-mercaptopurine and azathioprine) are effective for patients who do not respond to oral steroids and continue to have moderate disease.[5] SOR A Patients who are steroid refractory, intolerant, or steroid-dependent despite adequate doses of a thiopurine can be considered for infliximab induction as above.[5] SOR A Infliximab is contraindicated in patients with active infection, untreated latent tuberculosis, preexisting demyelinating disorder or optic neuritis, moderate to severe congestive heart failure, or current or recent malignancies.
- Severe colitis—Patients presenting with toxicity should be admitted to the hospital for IV steroids (methylprednisolone, 40 to 60 mg/day, or hydrocortisone, 200 to 300 mg/day) following hospitalization.[5,15] SOR C Otherwise, treat with oral prednisone, oral ASA drugs, and topical medications with the addition of infliximab (5 mg/kg) if refractory to treatment and urgent hospitalization is not necessary.[5] SOR A If patient fails to improve within 3 to 5 days, colectomy SOR B or IV cyclosporine SOR A should be considered. Antibiotics have no proven efficacy without proven infection and parenteral nutrition has not been shown to be of benefit as primary therapy for UC.[5]
- Fulminant disease—Patients should be treated as above with IV glucocorticoid and maintained without oral intake and with use of a decompression tube if small bowel ileus is present.[5] IV cyclosporine (2 to 4 mg/kg per day) or infliximab may be considered for patients who are not improving on maximal medical therapy as above.
- Patients with Crohn disease are treated similarly except that there is limited response to mesalamine or cyclosporin and better response to nutritional therapy. A research tool called the Crohn Disease Activity Index can be used to monitor disease activity (online calculator available at http://www.ibdjohn.com/cdai/. Accessed October 2011).
- Mild to moderate active ileocolic Crohn disease—Budesonide (9 mg) or prednisone if distal colonic disease is present.[15] Nutrition

FIGURE 65-6 Ischemic colitis in an elderly patient. (*Courtesy of Marvin Derezin, MD.*)

therapy is the first-line treatment for children. For patients who do not tolerate steroids or in cases where steroids are ineffective, biologic therapy with infliximab, adalimumab, or certolizumab pegol is appropriate. Methotrexate (25 mg/week) is also effective.[15] Patients with weight loss or strictures may benefit from early introduction of biologic or immunomodulator therapy.[15]

- Severe Crohn disease in any location-Initial treatment with oral or intravenous steroids; antitumor necrosis factor therapy is reserved for patients who do not respond to initial therapy. In a single-center cohort study of 614 patients treated with infliximab, only 10.9% were not primary responders by 12 weeks, and sustained benefit was seen in 63% who received long-term treatment (mean follow-up: 55 months).[16] Management also includes nutritional support and treatment of iron deficiency.
- Side effects of biologic therapy include serious infections, induction of autoimmune phenomena, and neurotoxicity.[17] However, in a report of a cohort of 734 patients with IBD treated with infliximab, the most commonly observed systemic side effects were skin eruptions including psoriasiform eruptions in 20%; two patients developed tuberculosis but none of the 16 patients with positive skin tests who received prophylaxis.[18]

SURGERY

Surgery (total proctocolectomy with ileostomy or continence-preserving operation (i.e., ileal pouch-anal anastomosis [IPAA]) is performed in approximately half of patients with UC within 10 years of disease onset. Indications for surgery include the following[2,5]: SOR C

- Intractable or fulminant disease.
- Toxic megacolon.
- Massive hemorrhage.
- Colonic obstruction or perforation.
- Colon cancer or dysplasia in flat mucosa,[8] SOR B or for cancer prophylaxis.

PROGNOSIS

- In UC (**Figure 65-7**), disease flares and remissions with mucosal healing occur; remission is seen in about half of the patients within a year of onset.[1] Those who have complete clinical and endoscopic remission have a significantly decreased risk of colectomy.[1] Disease activity lessens over time with longer periods of remission. In a population study of 1575 patients with UC in Denmark, 13% had no relapse, 74% had 2 or more relapses, and 13% had active disease every year for 5 years after diagnosis.[19]
- The probability of colectomy over 25 years for those with UC is 20% to 30%.[1] Colectomy is not necessarily curative as pouchitis episodes occur in half of these patients by 5 years postoperatively, and in up to 10% of cases, pouchitis is chronic and often refractory to antibiotic treatment.[1]
- Overall mortality is not increased for patients with UC, unless there is severe disease.[1] Although UC-related mortality from liver disease or colorectal cancer is increased, there is a decreased rate of death from pulmonary cancer and other tobacco-related diseases.[1]

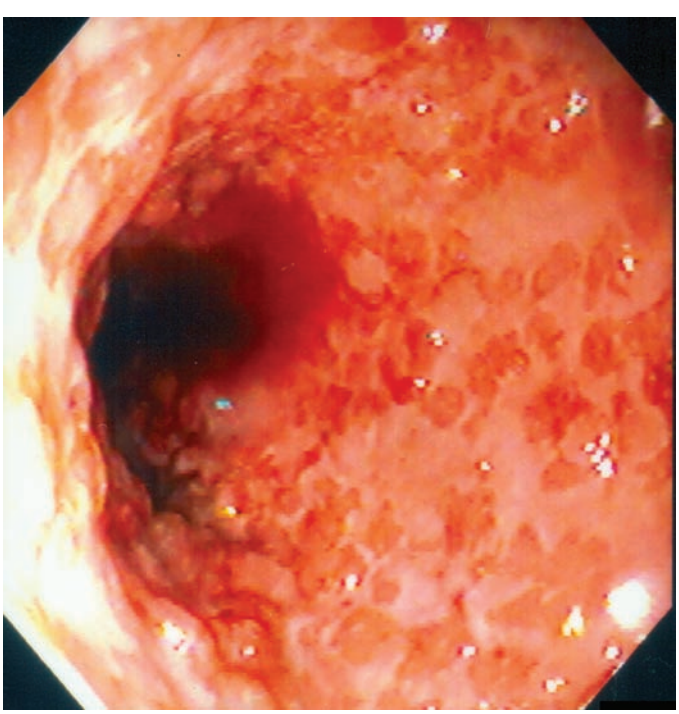

FIGURE 65-7 Ulcerative colitis in a 27-year-old man presenting with rectal bleeding. (*Courtesy of Mark Koch, MD.*)

- Recurrence postoperatively is the norm for patients with Crohn disease; only 5% have normal endoscopy at 10 years follow-up and symptoms occur about 2 to 3 years after anatomic lesions are found.[20] Natural progression of the disease with or without surgery is variable with spontaneous and treatment-related remissions, especially of more superficial lesions. Only approximately 10% to 15% of patients have chronic continuous disease.[1]
- Most patients with Crohn disease (60% to 80%) require surgery by the time they have had the disease for 20 to 30 years (estimated at 3% to 5% per year) and greater than 10% eventually require fecal diversion, especially in patients with colorectal disease or anal stenosis.[1]
- Factors associated with poor prognosis in IBD are younger age and more extensive disease. Other factors associated with poor prognosis are pouchitis and extraintestinal manifestations at surgery (IPAA) for UC and need for steroids at presentation for Crohn disease.[1]
- Mortality rate for Crohn disease is slightly increased (standardized mortality ratio = 1.52); most deaths are connected to malnutrition, postoperative complications, and intestinal cancer.
- Both patients with UC and Crohn disease are at increased risk for colorectal cancer. The risk increases with duration and extent of disease and decreases following successful treatment.[21] Colorectal cancer is rare within the first 7 years of colitis onset and increases at a rate of approximately 0.5% to 1% per year thereafter, which is likely associated with histologic disease activity.[9] It is not clear if antiinflammatory medications reduce this risk.[9]
- Patients with cholestasis should be evaluated for primary sclerosing cholangitis and subsequent cholangiocarcinoma.[5]

FOLLOW-UP

- Support and patient education should be provided to address medication side effects, the uncertain nature of the disease, and potential complications. Discuss medication adherence in patients with apparent inadequate response to treatment.
- For maintenance of remission of mild to moderate distal disease—Mesalamine suppositories (proctitis) or enemas (distal colitis) can be dosed as infrequently as every third night.[5] SOR A Patients, however, prefer oral therapy.[15] Sulfasalazine, mesalamine compounds, and balsalazide are also effective in maintaining remission; the combination of oral and topical mesalamine is more effective than either one alone.[5] SOR A If these fail, thiopurines and infliximab may be effective.[5] SOR A
- For maintenance of remission of mild to moderate extensive colitis—Sulfasalazine, olsalazine, mesalamine (2.4 g/day), and balsalazide are effective in reducing relapses; chronic steroid use should be avoided.[5] SOR A Infliximab can be used for maintenance of remission in patients who respond to infliximab induction.[5] SOR A For patients who relapse despite therapy, azathioprine or 6-mercaptopurine can be used (number needed to treat to prevent 1 recurrence is 5).[15]
- For patients with severe colitis, long-term remission is significantly enhanced with the addition of maintenance 6-mercaptopurine.[5] SOR B
- Periodic bone mineral density assessment is recommended for patients on long-term corticosteroid therapy (>3 months).[22] SOR A
- Annual ophthalmologic examinations are recommended for patients on long-term corticosteroid therapy.[22] SOR C
- Patients with longstanding IBD are at higher risk of developing colon dysplasia and cancer. For patients with pancolitis, the risk is 0.5% to 1% per year after 8 to 10 years of disease.[1,2] Surveillance colonoscopy with multiple biopsies should be performed every 1 to 2 years beginning after 8 to 10 years of disease.[5] SOR B There is evidence that cancers are detected at an earlier stage in patients who are undergoing surveillance.[23]
- In the near future, it may be possible to monitor patients for intestinal ulcerations or thickening using noninvasive techniques (assays for C-reactive protein, fecal calprotectin and lactoferrin; videocapsule and magnetic resonance imaging) and treat them as early as possible to prevent disease progression.[1,12] In addition, biomarkers may be useful for assessing mucosal healing, predicting relapse, and making therapeutic adjustments.[9]

PATIENT EDUCATION

- Patients should be informed about the unpredictable course of IBD and the need for frequent contact with an experienced provider for medical management, support, and surveillance.
- Smoking cessation should be stressed, particularly for patients with Crohn disease.[2]

PATIENT RESOURCES

- National Digestive Diseases Information Clearinghouse, *Ulcerative Colitis*—**http://digestive.niddk.nih.gov/ddiseases/pubs/colitis/.**
- National Digestive Diseases Information Clearinghouse, *Crohn Disease*—**http://digestive.niddk.nih.gov/ddiseases/pubs/crohns/.**
- Crohn's and Colitis Foundation of America—**www.ccfa.org.**

PROVIDER RESOURCES

- Kornbluth A, Sachar D; Practice Committee of the American College of Gastroenterology. Ulcerative colitis practice guidelines in adults: American College of Gastroenterology, Practice Parameters Committee. *Am J Gastroenterol*. 2010;105:501-523.
- Burger D, Travis S. Conventional medical management of IBD. *Gastroenterology*. 2011;140(6):1827-1837.

REFERENCES

1. Cosnes J, Gower-Rousseau C, Seksik P, Cortot A. Epidemiology and natural history of inflammatory bowel diseases. *Gastroenterology*. 2011;140(6):1785-1794.
2. Friedman S, Blumberg RS. Inflammatory bowel disease. In: Kasper DL, Braunwald E, Fauci AS, Hauser SL, Longo DL, Jameson JL, eds. *Harrison's Principles of Internal Medicine*, 16th ed. New York, NY: McGraw-Hill; 2005:1776-1789.

3. Abraham C, Cho J. Inflammatory bowel disease. *N Engl J Med.* 2009;361:2066-2078.
4. Garcia Rodriguez LA, Ruigomez A, Panes J. Acute gastroenteritis is followed by an increased risk of inflammatory bowel disease. *Gastroenterology*. 2006;130(6):1588-1594.
5. Kornbluth A, Sachar D; Practice Committee of the American College of Gastroenterology. Ulcerative colitis practice guidelines in adults: American College of Gastroenterology, Practice Parameters Committee. *Am J Gastroenterol.* 2010;105:501-523.
6. Levine JS, Burakoff R. Extraintestinal manifestations of inflammatory bowel disease. *Gastroenterol Hepatol (N Y)*, 2011;7(4):235-241.
7. Langholz E, Munkholm P, Davidsen M, et al. Course of ulcerative colitis: analysis of changes in disease activity over years. *Gastroenterology*. 1994;107:3-11.
8. Langholz E, Munkholm P, Davidsen M, et al. Changes in extent of ulcerative colitis: a study on the course and prognostic factors. *Scand J Gastroenterol.* 1996;31:260-266.
9. Lewis JD. The utility of biomarkers in the diagnosis and therapy of inflammatory bowel disease. *Gastroenterology*. 2011;140(6):1817-1826.
10. van Rheenen PF, Van de Vijver E, Fidler V. Faecal calprotectin for screening of patients with suspected inflammatory bowel disease: diagnostic meta-analysis. *BMJ.* 2010;341:c3369.
11. Ananthakrishnan AN , McGinley EL, Binion DG. Excess hospitalization burden associated with Clostridium difficile in patients with inflammatory bowel disease. *Gut.* 2008;57:205-210.
12. Fletcher JG, Fider JL, Bruining DH, Huprich JE, New concepts in intestinal imaging for inflammatory bowel disease. *Gastroenterology*. 2011;140(6):1795-1806.
13. Leighton JA, Shen B, Baron TH, et al; Standards of Practice Committee, American Society for Gastrointestinal Endoscopy. ASGE guideline: endoscopy in the diagnosis and treatment of inflammatory bowel disease. *Gastrointest Endosc.* 2006;63(4):558-565.
14. *ACR Appropriateness Criteria Crohn's Disease*. http://www.guideline.gov/content.aspx?id=35137. Accessed October 2012.
15. Burger D, Travis S. Conventional medical management of inflammatory bowel disease. *Gastroenterology*. 2011;140(6):1827-1837.
16. Schnitzler F, Fidder H, Ferrante M, et al. Long-term outcome of treatment with infliximab in 614 patients with Crohn's disease: results from a single-centre cohort. *Gut.* 2009;58:492-500.
17. Van Assche G, Vermeire S, Rutgeerts P. Safety issues with biological therapies for inflammatory bowel disease. *Curr Opin Gastroenterol.* 2006;22(4):370-376.
18. Fidder H, Schnitzler F, Ferrante M, et al. Long-term safety of infliximab for the treatment of inflammatory bowel disease: a single-centre cohort study. *Gut.* 2009;58(4):501-508.
19. Jess T, Riis L, Vind I, et al. Changes in clinical characteristics, course, and prognosis of inflammatory bowel disease during the last 5 decades: a population-based study from Copenhagen, Denmark. *Inflamm Bowel Dis.* 2007;13:481-489.
20. Olaison G, Smedh K, Sjodahl R. Natural course of Crohn's disease after ileocolic resection: endoscopically visualized ileal ulcers preceding symptoms. *Gut.* 1992;33:331-335.
21. Ullman TA, Itzkowitz SH. Intestinal inflammation and cancer. *Gastroenterology*. 2011;140(6):1807-1816.
22. Lichtenstein GR, Abreu MT, Cohen R, Tremaine W. American gastroenterological association institute medical position statement on corticosteroids, immunomodulators, and infliximab in inflammatory bowel disease. *Gastroenterology*. 2006;130(3):935-939.
23. Collins PD, Mpofu C, Watson AJ, Rhodes JM. Strategies for detecting colon cancer and/or dysplasia in patients with inflammatory bowel disease. *Cochrane Database Syst Rev.* 2006;(2):CD000279.

66 HEMORRHOIDS

Mindy A. Smith, MD, MS

PATIENT STORY

A 42-year-old woman presents to the office with rectal pressure and occasional bright red blood on the toilet paper when wiping after bowel movements (**Figure 66-1**). She has had difficulty with constipation off and on for many years and had large hemorrhoids during her last pregnancy. Physical examination confirms the diagnosis of external hemorrhoids.

FIGURE 66-1 External hemorrhoid that is symptomatic. The patient had some bleeding with bowel movements. (*Courtesy of Richard P. Usatine, MD.*)

INTRODUCTION

Hemorrhoids are cushions of highly vascular structures found within the submucosa of the anal canal. They become pathologic when swollen or inflamed.

SYNONYMS

Piles.

EPIDEMIOLOGY

- More than 1 million people in Western civilization suffer from hemorrhoids each year.[1]
- Estimated at 5% prevalence in the general population.[2]
- Approximately half of those older than age 50 years have experienced hemorrhoidal symptoms at some time.[2]
- More frequent in whites and in those of higher socioeconomic status.[2]

ETIOLOGY AND PATHOPHYSIOLOGY

- Three hemorrhoidal cushions (comprised of subepithelial connective tissue, elastic tissue, blood vessels, and smooth muscle) surround and support distal anastomoses between the terminal branches of the superior and middle rectal arteries and the superior, middle, and inferior rectal veins.[2] The hemorrhoidal cushions have several functions, including maintaining fecal continence by engorging with blood and closing the anal canal and by protecting the anal sphincter during defecation.
- Hemorrhoidal tissue provides important sensory information, enabling the differentiation between solid, liquid, and gas and subsequent decision to evacuate.[2]
- Abnormal swelling of the anal cushions can occur from a number of causes (see "Risk Factors" below) resulting in increased pressure, with dilation and engorgement of the arteriovenous plexuses. Increased pressure can lead to stretching of the suspensory muscles, laxity of connective tissue, and eventual prolapse of rectal tissue

through the anal canal.[2] The engorged anal mucosa is easily traumatized, leading to rectal bleeding. Prolapse predisposes to incarceration and strangulation.

- Hemorrhoids are classified with respect to their position relative to the dentate line.
  - Internal hemorrhoids (**Figure 66-2**) develop above the dentate line and are covered by columnar epithelium of anal mucosa. Internal hemorrhoids lack somatic sensory innervation.
  - External hemorrhoids (**Figure 66-1**) arise distal to the dentate line. They are covered by stratified squamous epithelium and receive somatic sensory innervation from the inferior rectal nerve.
- Hemorrhoids are further classified into four stages of disease severity:[1,2]
  - Stage I—Enlargement and bleeding.
  - Stage II—Protrusion of hemorrhoids with spontaneous reduction.
  - Stage III—Protrusion of hemorrhoids with manual reduction possible.
  - Stage IV—Irreducible protrusion of hemorrhoids usually containing both internal and external components with or without acute thrombosis or strangulation.

FIGURE 66-2 A large prolapsed internal hemorrhoid. (*Courtesy of Charlie Goldberg, MD, and the Regents of the University of California.*)

RISK FACTORS

- Family history of hemorrhoids.
- Personal history of constipation, diarrhea, and/or prolonged straining at stool.
- Pregnancy.
- Prolonged sitting or heavy lifting.

DIAGNOSIS

CLINICAL FEATURES

- Bleeding described as bright red blood (a result of the high blood oxygen content within the arteriovenous anastomoses) seen in the toilet or with wiping after bowel movements.
- Protrusion/mass (**Figure 66-1**).
- Pain described as a dull ache or severe if thrombosed.
- Inability to maintain personal hygiene/staining/soiling secondary to prolapse.
- Pruritus, also secondary to prolapse.
- Diagnosis is made on visual inspection and anoscopy, with and without straining:
  - Physical findings of swollen blood vessels protruding from the anus (**Figure 66-1**).
  - Excoriations may also be seen on the skin surrounding the anus.
  - A thrombosed hemorrhoid will be tender and firm and appear as a circular purplish bulge adjacent to the anal opening (**Figure 66-3**). There may be a black discoloration if there is accompanying necrosis.
  - Internal hemorrhoids may be visualized on anoscopy as swollen purple blood vessels arising above the dentate line.
- Other physical findings that may accompany hemorrhoids are redundant tissue and skin tags (**Figure 66-4**) from old thrombosed external hemorrhoids.

FIGURE 66-3 Thrombosed external hemorrhoid prior to elliptical excision and healing by secondary intention. Note how the hemorrhoid is at the typical 5 o'clock position. (*Courtesy of Yu Wah, MD.*)

DIFFERENTIAL DIAGNOSIS

- Rectal prolapse—Full-thickness circumferential protrusion appearing as a bluish, tender perianal mass. More common in women (six-fold higher incidence) and associated with other pelvic-floor disorders (e.g., cystocele, urinary incontinence). It can present as an anal mass with bleeding.[1]
- Condyloma acuminata (see Chapter 133, Genital Warts)—Appear as flesh-colored, exophytic lesions on perianal skin. They may be flat, verrucous, or pedunculated.
- Anal tumors—Tumors in the rectosigmoid region are associated with hematochezia, tenesmus (i.e., urgency with a feeling of incomplete evacuation), and arrow-caliber stool; a firm mass may be found on rectal examination or seen outside the rectum.
- Inflammatory bowel disease (see Chapter 65, Inflammatory Bowel Disease)—Associated diarrhea, rectal bleeding, tenesmus, passage of mucus, and cramping abdominal pain.
- Signs of infection or abscess formation—Tender mass, sometimes feeling fluctuant, with overlying skin erythema (**Figure 66-5**). If cellulitis is also present, skin may have a woody, hard feel. Fistulas may also form and an opening may be seen on the buttock.
- Fissures—A cut or tear occurring in the anus that extends upwards into the anal canal. Common and occurring at all ages; fissures cause pain during bowel movements in addition to bleeding (**Figure 66-4**).

FIGURE 66-4 Rectal fissure with prominent skin tag. (*Courtesy of Charlie Goldberg, MD, copyrighted by the University of California, San Diego.*)

MANAGEMENT

NONPHARMACOLOGIC

- Patients with hemorrhoids should be encouraged to increase dietary fiber and/or add a fiber supplement to reduce severity and duration of symptoms. In a Cochrane review of seven small randomized controlled trials (RCTs), fiber supplements decreased symptoms (e.g., pain, itching, and bleeding) by 53% in the group receiving fiber.[3] SOR A
- There are no data supporting use of sitz baths.

MEDICATIONS

- Short course of a topical steroid cream or suppositories, twice daily. SOR C
- For acute thrombosed external hemorrhoids, a small RCT of 98 patients treated nonsurgically found improved complete pain relief at 7 days with a combination of topical nifedipine 0.3% and lidocaine 1.5% compared with lidocaine alone (86% vs. 50%, respectively).[4] Resolution at 14 days was reported for 92% versus 45.8%, respectively.
- Use stool softener and encourage adequate fluid intake if constipation is a factor. SOR C

PROCEDURES

- Internal hemorrhoids
  - Data are limited to retrospective studies and case series for most procedures.

FIGURE 66-5 Perirectal abscess: Note surrounding erythema that extends onto the right buttock. (*Courtesy of Charlie Goldberg, MD, copyrighted by the University of California, San Diego.*)

- Stages I to II hemorrhoids can be treated with sclerotherapy (1 to 5 mL of sclerosing agent such as sodium tetradechol sulfate injected via a 25-gauge needle into the submucosa of the hemorrhoidal complex).[1] Sclerotherapy, however, carries a high risk of postprocedure pain (70%). Urinary retention, abscess formation, and sepsis have also been reported; the author of a review recommends that only two sites be sclerosed at one time to reduce risk.[2] Recurrence rates are as high as 30%.[2]
- Stages II and III internal hemorrhoids can be treated with rubber band ligation. Two bands are placed around the engorged tissue producing ischemia and fibrosis of the hemorrhoid.
  - In a Cochrane review of three methodologically poor trials comparing excisional hemorrhoidectomy with banding for grade III hemorrhoids, results with hemorrhoidectomy were better than banding for resolution of symptoms but were associated with increased postprocedural pain, higher complication rate, and more time off work.[5]
  - Patients on anticoagulants may be better candidates for another procedure with less bleeding risk.[2]
  - Success rates of 50% to 100% are reported, depending on time to follow-up; there is a recurrence rate of 68% at 4 to 5 years.[2]
  - Complications are uncommon (<1%) and include pain, abscess formation, urinary retention, bleeding, band slippage, and sepsis.[2]
- Lower stage hemorrhoids can also be treated with infrared photocoagulation (IPC), bipolar electrocautery, laser therapy, or low-voltage direct current (the latter works for higher-grade hemorrhoids). IPC is initially successful in 88% to 100% of patients.[2]

- External hemorrhoids
  - Based on retrospective studies, excision is the most effective treatment for thrombosed external hemorrhoids. This procedure is associated with lower recurrence rates (6.5% in one study) and faster symptom resolution.[6] SOR B
  - Acutely thrombosed external hemorrhoids may also be safely excised in the office or emergency room for patients who present within 48 to 72 hours of symptom onset. A local anesthetic containing epinephrine is used followed by elliptical incision (not extending beyond the anal verge or deeper than the cutaneous layer) and excision of the thrombosed hemorrhoid and overlying skin. Simple incision and clot evacuation is inadequate therapy for complete resolution, although it may relieve pain. A pressure dressing is applied for several hours, after which time the wound is left to heal by secondary intention.
  - Intrasphincteric injection of botulinum toxin provided more effective pain relief at 24-hours than saline injection for patients with thrombosed external hemorrhoids not undergoing surgery.[7]

REFERRAL FOR SURGERY

- Surgeries for hemorrhoids include open and closed excision, harmonic scalpel, LigaSure tissue-sealing device, Doppler-guided transanal hemorrhoidal ligature, and stapled hemorrhoidopexy.[2] The ultimate need for surgical management is uncommon (5% to 10%).[2] The major complication is postoperative pain that can delay work return for 2 to 4 weeks.[2]

- Indications for surgery include:
  - Failure of nonsurgical treatment (persistent bleeding or chronic symptoms).[6]
  - Grades III and IV hemorrhoids with severe symptoms.[6]

- Presence of other anorectal conditions (e.g., anal fissure or fistula) requiring surgery.
- Patient preference.

- Stage IV hemorrhoids can be treated with traditional excision or surgery using stapling. A Cochrane review of 12 RCTs comparing conventional hemorrhoidectomy with stapling hemorrhoidopexy in patients with grades I to III hemorrhoids found a lower long-term recurrence rate (9 out of 476 [1.9%] vs. 37 out of 479 [7.7%], respectively) in patients who had conventional hemorrhoidectomy (number needed to treat [NNT] = 17).[8] Another metaanalysis of 14 RCTs confirmed higher rates of prolapse recurrence with stapling (odds ratio [OR]: 5.5).[9]
- Use of perianal local anesthetic infiltration provides significant postoperative pain relief.[10] SOR A
  - Combination acetaminophen and nonsteroidal antiinflammatory agents or cyclooxygenase (COX)-2–selective inhibitors should be used when possible for pain control as opioids may be constipating. There are no data supporting any particular drug over another.[8] SOR B
  - Stapled hemorrhoidectomy reduces pain compared with other surgical techniques.[8] SOR A
  - Other medications that can be considered as analgesic adjuncts are laxatives and metronidazole started before surgery.[8] SOR A
- Complications of surgery include transient urinary retention (up to 34%), infection (rare), bleeding (2%), fecal incontinence (if sphincter muscle damage), anal stenosis, and rectal prolapse.

PROGNOSIS

Most hemorrhoids resolve spontaneously or with medical therapy alone. The recurrence rate with nonsurgical therapy is 10% to 50% (over a 5-year period), and for surgical treatment, less than 10%.

FOLLOW-UP

- After excision of a thrombosed hemorrhoid, patient instructions should include initial bed rest for several hours, sitz baths 3 times daily, stool softeners, and topical or systemic analgesia. SOR C The patient should return in 48 to 72 hours for a wound check.
- Similar instructions are used for patients postoperatively with respect to bed rest (1 to 2 days), sitz baths, stool softeners, and adequate fluid intake. Pain control is discussed above.

PATIENT EDUCATION

- Patients should be counseled to avoid aggravating factors including constipation and prolonged sitting.
- Advise patients who elect rubber band ligation that complications, based on one follow-up study, include pain (at 1 week, 75% of patients were pain-free and 7% were still experiencing moderate-to-severe pain), rectal bleeding (in 65% on the day after banding, persisting in 24% at 1 week), and relatively low satisfaction (only 59% were satisfied with their experience and would undergo the procedure again).[11]
- Advise patients who elect or are recommended for surgery about potential complications of infection, thrombosis, ulceration, and incontinence.

PATIENT RESOURCES

- **http://www.nlm.nih.gov/medlineplus/hemorrhoids.html.**
- **http://digestive.niddk.nih.gov/ddiseases/pubs/hemorrhoids/index.aspx.**

PROVIDER RESOURCES

- Hemorrhoids—**http://emedicine.medscape.com/article/775407.**
- Hemorrhoid surgery—**http://emedicine.medscape.com/article/195401.**

REFERENCES

1. Gerhart SL, Bulkley G. Common diseases of the colon and anorectum and mesenteric vascular insufficiency. In: Kasper DL, Braunwald E, Fauci AS, Hauser SL, Longo DL, Jameson JL, eds. *Harrison's Principles of Internal Medicine*, 16th ed. New York: McGraw-Hill; 2005:1801-1802.
2. Sneider EB, Maykel JA. Diagnosis and management of symptomatic hemorrhoids. *Surg Clin North Am.* 2010;90(1):17-32.
3. Alonso-Coello P, Guyatt G, Heels-Ansdell D, et al. Laxatives for the treatment of hemorrhoids. *Cochrane Database Syst Rev.* 2005 Oct 19;(4):CD004649.
4. Perrotti P, Antropoli C, Molino D, et al. Conservative treatment of acute thrombosed external hemorrhoids with topical nifedipine. *Dis Colon Rectum.* 2001;44:405-409.
5. Shanmugam V, Thaha MA, Rabindranath KS, et al. Rubber band ligation versus excisional haemorrhoidectomy for haemorrhoids. *Cochrane Database Syst Rev.* 2005 Jul 20;3:CD005034.
6. Mounsey AL, Henry SL. Clinical inquiries. Which treatments work best for hemorrhoids? *J Fam Pract.* 2009;58(9):492-493.
7. Patti R, Arcara M, Bonventre S, et al. Randomized clinical trial of botulinum toxin injection for pain relief in patients with thrombosed external haemorrhoids. *Br J Surg.* 2008;95(11):1339-1343.
8. Jayaraman S, Colquhoun PH, Malthaner RA. Stapled versus conventional surgery for hemorrhoids. *Cochrane Database Syst Rev.* 2006 Oct 18;(4):CD005393.
9. Giordano P, Gravante G, Sorge R, et al. Long-term outcomes of stapled hemorrhoidopexy vs conventional hemorrhoidectomy: a meta-analysis of randomized controlled trials. *Arch Surg.* 2009;144(3):266-272.
10. Joshi GP, Neugebauer EA; PROSPECT Collaboration. Evidence-based management of pain after haemorrhoidectomy surgery. *Br J Surg.* 2010;97(8):1155-1168.
11. Watson NF, Liptrott S, Maxwell-Armstrong CA. A prospective audit of early pain and patient satisfaction following out-patient band ligation of haemorrhoids. *Ann R Coll Surg Engl.* 2006;88(3):275-279.

PART 10

GENITOURINARY

Strength of Recommendation (SOR)	Definition
A	Recommendation based on consistent and good-quality patient-oriented evidence.*
B	Recommendation based on inconsistent or limited-quality patient-oriented evidence.*
C	Recommendation based on consensus, usual practice, opinion, disease-oriented evidence, or case series for studies of diagnosis, treatment, prevention, or screening.*

*See Appendix A on pages 1447–1450 for further information.

67 URINARY SEDIMENT

Mindy A. Smith, MD, MS
Richard P. Usatine, MD

PATIENT STORY

A 47-year-old woman presents to the office with severe right flank pain that does not radiate. Dipstick urinalysis shows hematuria, and microscopic examination confirms the presence of many red blood cells per high-power field (**Figure 67-1**). There is no pyuria or bacteriuria. The physician gives her some pain medication and sends her to get a CT urogram. The CT urogram shows a stone in the right ureter and some mild hydronephrosis. Fortunately for the patient, she passes the stone when urinating after the imaging study is complete.

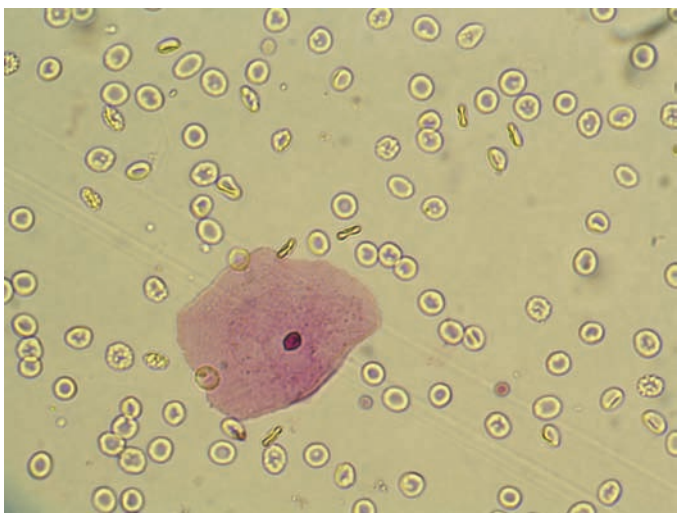

FIGURE 67-1 Red blood cells (RBCs) seen in the urine of a woman passing a kidney stone. Some of the RBCs are crenated and there is one epithelial cell visible. (*Courtesy of Richard P. Usatine, MD.*)

INTRODUCTION

Examination of the urinary sediment is a test frequently done for evaluation of patients with suspected genetic/intrinsic (e.g., systemic lupus nephritis, renal sarcoidosis, sickle cell disease, glomerulonephritis, interstitial nephritis), anatomic (e.g., arteriovenous malformation), obstructive (e.g., kidney or bladder stones, benign prostatic hypertrophy), infectious, metabolic (e.g., coagulopathy), traumatic, or neoplastic disease of the urinary tract. Potential findings of red or white blood cells, casts, bacteria, or neoplastic cells help in directing further evaluation of a patient's problem.

EPIDEMIOLOGY

- A finding of hematuria (2 to 5 red blood cells [RBCs]/high-power field [HPF]) on a single urinalysis in an asymptomatic person is common and most often a result of menses, allergy, exercise, viral illness, or mild trauma.[1]
- One study of servicemen, conducted for a period of 10 years, found an incidence of 38%.[1]
- In one UK population study, first episode of hematuria resulted in a noncancer or cancer diagnosis within 90 days in 17.5% of women (95% confidence interval [CI], 16.4% to 18.6%) and 18.3% of men (95% CI, 17.4% to 19.3%).[2]
- Persistent (>3 RBCs/HPF over 3 specimens) and significant hematuria (>100 RBCs/HPF or gross hematuria) was associated with significant lesions in 9.1% of more than 1000 patients.[1]
- In a review of hematuria, approximately 5% of patients with significant microscopic hematuria (>3 RBCs/HPF on 2 of 3 properly collected specimens during a 2- to 3-week period)[3] and up to 40% of patients with gross hematuria have a neoplasm.[4]
- Isolated pyuria (>2 to 10 white blood cells per high-power field [WBCs/HPF]) is uncommon, as inflammatory processes in the urinary tract are usually associated with hematuria.[1]
- In a laboratory study from 88 institutions, 62.5% of urinalysis tests received a manual microscopic evaluation of the urinary sediment,

usually triggered by an abnormal urinalysis. New information was obtained 65% of the time as a result of the manual examination.[5]

ETIOLOGY AND PATHOPHYSIOLOGY

- Hematuria (**Figure 67-1**) has many causes including:[1]
  - Idiopathic (increasing incidence in the young).
  - Stones.
  - Neoplasms (increasing incidence with increase in age).
  - Trauma.
  - Infection/inflammation including acute cystitis, urethritis, pyelonephritis, and prostatitis.
  - Benign prostatic hypertrophy.
  - Metabolic abnormalities, including hypercalcemia and hyperuricemia.
  - Glomerular diseases such as immunoglobulin (Ig) A nephropathy, hereditary nephritis, and thin basement membrane disease.
- Hematuria with dysmorphic RBCs or RBC casts (**Figure 67-2**) and excess protein excretion (>500 mg/dL) indicates glomerulonephritis.
- Gross hematuria suggests a postrenal source in the collecting system.
- Pyuria (**Figure 67-3**) is often the result of urinary tract infection.
  - The presence of bacteria (>10^2 organisms per mL or >10^5 using a midstream urine specimen) suggests infection. A urinalysis with 10 bacteria per HPF is highly suggestive (specificity 99%) of infection (positive likelihood ratio [LR+] 85).[2]
  - Asymptomatic bacteruria is found in 4% to 15% of pregnant women, usually *Escherichia coli*.
  - The presence of WBC casts (**Figure 67-4**) with bacteria indicates pyelonephritis.
- WBCs and/or WBC casts can be seen in tubulointerstitial processes like interstitial nephritis, systemic lupus erythematosus, or transplant rejection.
- Urinary casts are formed only in the distal convoluted tubule (DCT) or in the collecting duct (distal nephron).
- Hyaline casts are formed from mucoprotein secreted by the tubular epithelial cells within the nephrons. These translucent casts are the most common type of cast and can be seen in normal persons after vigorous exercise or with dehydration. Low urine flow and concentrated urine from dehydration can contribute to the formation of hyaline casts (**Figure 67-5**).
- Granular casts are the second most common type of cast seen (**Figure 67-6**). These casts can result from the breakdown of cellular casts or the inclusion of aggregates of albumin or immunoglobulin light chains. They can be classified as fine or coarse based on the size of the inclusions. There is no diagnostic significance to the classification of fine or coarse.

RISK FACTORS

- Constipation (for urinary tract infection [UTI] in children).
- Risk factors for cancer in patients with microscopic hematuria include:[4]
  - Smoking.
  - Age older than 40 years.

FIGURE 67-2 A RBC cast caused by bleeding into the tubule from the glomerulus. These casts are seen in glomerulonephritis, IgA nephropathy, lupus nephritis, Goodpasture syndrome, and Wegener granulomatosis. RBC casts are always pathologic. (*Courtesy of Agnes B. Fogo, MD, Vanderbilt University.*)

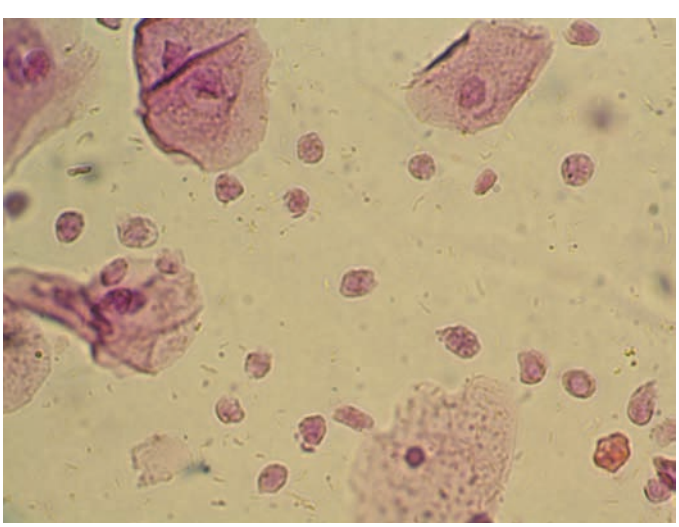

FIGURE 67-3 Pyuria and bacteriuria in a woman with a urinary tract infection. A simple stain was added to the wet mount of spun urine. Although there are epithelial cells present, the culture demonstrated a true urinary tract infection (UTI) and not merely a contaminated urine. (*Courtesy of Richard P. Usatine, MD.*)

- Medical history of gross hematuria, urologic disease, or pelvic radiation.
- Occupational history of exposure to chemicals or dyes.
- Analgesic abuse.

DIAGNOSIS

CLINICAL FEATURES

- Other signs and symptoms of glomerular disease include various degrees of renal failure, edema, oliguria, and hypertension.
- Hematuria is often asymptomatic in patients with glomerular disease or metabolic abnormalities. Renal stones can cause pain in the ipsilateral flank and/or abdomen with radiation to the ipsilateral groin, testicle or vulva or irritative symptoms of frequency, urgency and dysuria, if located in the bladder.
- Symptoms of UTI include dysuria, nocturia, urgency, frequency, offensive odor of urine, or a combination of these; positive likelihood ratios, however, are low (1.3 to 2.3).[6] In children, pain (abdominal pain [LR+ 6.3; 95% CI, 2.5 to 16.0] or back pain [LR+ 3.6; 95% CI, 2.1 to 6.1]), in addition to dysuria, frequency, or both (LR+ 2.2 to 2.8), and new-onset urinary incontinence (LR+ 4.6; 95% CI, 2.8 to 7.6) increased the likelihood of a UTI.[7]
- In infants, findings of previous UTI (LR+ 2.3 to 2.9), fever higher than 40°C (104°F) (LR+ 3.2 to 3.3), and suprapubic tenderness (LR+ 4.4) were the findings most useful for identifying UTI.
- Symptoms of pyelonephritis include chills and rigor, fever, nausea and vomiting, and flank pain; positive likelihood ratios are 1.5 to 2.5.
- Family history of renal failure or microscopic hematuria or history of trauma, weight loss, and changes in urine volume may be useful.

LABORATORY TESTING AND IMAGING

The work-up for persistent or significant hematuria includes the following:[1]

- Urinary sediment looking for dysmorphic cells or RBC casts (**Figure 67-2**) and a 24-hour urine sample for proteinuria.
  - If positive, suspect glomerular disease and consider blood cultures, antiglomerular basement membrane (GBM) antibody, antineutrophil cytoplasmic antibody (ANCA), complement, cryoglobulins, hepatitis serologies, Venereal Disease Research Laboratory (VDRL), HIV, and antistreptolysin O; a renal biopsy may be indicated.
  - If negative and the sediment contains WBCs (**Figure 67-3**) or WBC casts (**Figure 67-4**), suspect infection and obtain a urine culture and susceptibility test if pyelonephritis is suspected; *E. coli* is the most common organism (more than 80%) in uncomplicated cystitis. WBCs seen in conjunction with many epithelial cells, particularly in women, can indicate a contaminated specimen and a new clean catch urine specimen should be obtained if possible.
  - If negative and no WBCs, obtain a hemoglobin electrophoresis, urine cytology, urinalysis (UA) from family members looking for hematuria or signs of glomerular disease, and a 24-hour urine for calcium and uric acid.

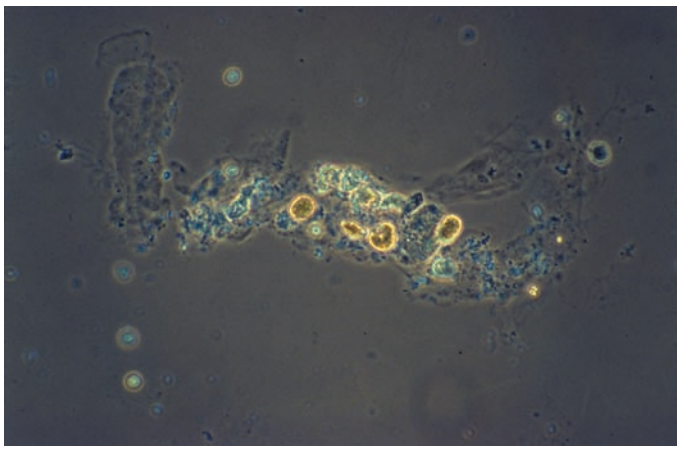

FIGURE 67-4 WBC casts seen in pyelonephritis. These can be differentiated from a clump of WBCs by their cylindrical shape and the presence of a hyaline matrix. (*Courtesy of Agnes B. Fogo, MD, Vanderbilt University.*)

FIGURE 67-5 Hyaline casts are translucent and proteinaceous. These are the most common casts found in the urine and can be seen in normal individuals. Concentrated urine with low flow, usually caused by dehydration, exercise, and/or diuretics, can lead to hyaline cast formation. (*Courtesy of Agnes B. Fogo, MD, Vanderbilt University.*)

- In all adult patients with hematuria (except for those with generalized renal parenchymal disease or young women with hemorrhagic cystitis), the American College of Radiology (ACR) recommends obtaining CT urography.[8] In patients with generalized renal parenchymal disease and in children, ultrasound of the kidneys and bladder is recommended. For painful hematuria, a CT of the abdomen and pelvis without contrast and/or an ultrasound of the kidneys and bladder is most appropriate.[8] For hematuria associated with trauma, obtain a CT of the abdomen and pelvis with contrast.
  - If the above is negative or high risk for cancer, perform cystoscopy.
  - If the above is positive, an open renal biopsy may be indicated.
  - If the above is negative, consider periodic follow-up (6, 12, 24, and 36 months).
- If RBC casts (**Figure 67-2**) are seen on UA in addition to proteinuria, also consider nephrotic syndrome caused by diabetes or amyloidosis.
- Note that RBC casts are fragile and are best seen in a fresh urine specimen (**Figure 67-2**).

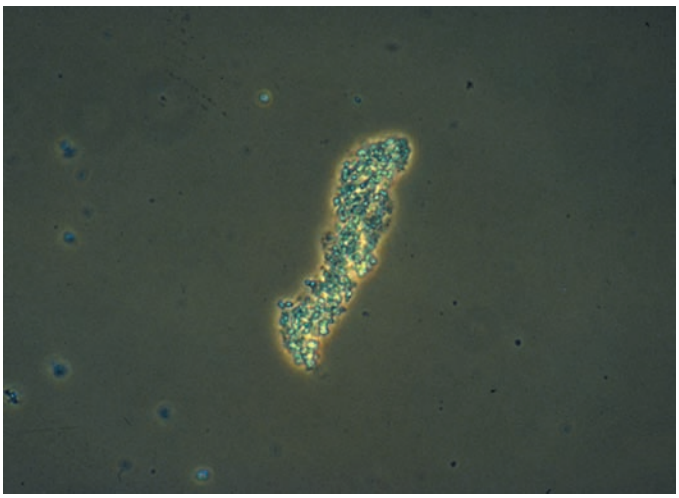

FIGURE 67-6 Coarse granular cast. All granular casts indicate underlying renal disease. These are nonspecific and may be seen in diverse renal conditions. (*Courtesy of Agnes B. Fogo, MD, Vanderbilt University.*)

MANAGEMENT

Treatment will depend on the underlying etiology:

- Cystitis is treated with appropriate antibiotics based on knowledge of the sensitivities of *E. coli* in your practice location (nitrofurantoin [100 mg twice daily for 5 days], trimethoprim-sulfamethoxazole [1 double-strength tablet twice-daily for 3 days], or fosfomycin [3 g single dose] are first-line agents).[9] Symptoms usually improve within 24 to 36 hours.
- Uncomplicated pyelonephritis is treated with appropriate antibiotics as an outpatient (oral ciprofloxacin [500 mg twice daily]) for 7 days with or without an initial 400-mg intravenous dose when resistance is not known to exceed 10%).[9] The urine should always be cultured in pyelonephritis to help guide therapy. Pregnant women may need hospitalization.
- See Chapter 68 (Kidney Stones) for management of patients with kidney stones, Chapter 71 (Renal Cell Carcinoma) for renal cell carcinoma, and Chapter 72 (Bladder Cancer) for bladder cancer.

PREVENTION AND SCREENING

- The United States Preventive Services Task Force concluded that there was insufficient evidence to assess the balance of benefits and harms of screening for bladder cancer in asymptomatic adults.[10] The positive predictive value of screening is less than 10% in asymptomatic persons, including higher-risk populations.

PROVIDER RESOURCES

- *Urinalysis*—**http://library.med.utah.edu/WebPath/TUTORIAL/URINE/URINE.html.**

REFERENCES

1. Denker BM, Brenner BM. Azotemia and urinary abnormalities. In: Kasper DL, Braunwald E, Fauci AS, Hauser SL, Longo DL, Jameson JL, eds. *Harrison's Principles of Internal Medicine*, 16th ed. New York: McGraw-Hill; 2005:250-251.
2. Jones R, Charlton J, Latinovic R, Gulliford MC. Alarm symptoms and identification of non-cancer diagnoses in primary care: cohort study. *BMJ*. 2009;339:b3094. doi: 10.1136/bmj.b3094.
3. Grossfeld GD, Litwin MS, Wolf JS, et al. Evaluation of asymptomatic microscopic hematuria in adults: the American Urological Association best practice policy—part I: definition, detection, prevalence, and etiology. *Urology*. 2001;57(4): 599-603.
4. Margulis V, Sagalowsky AI. Assessment of hematuria. *Med Clin North Am*. 2011;95:153-159.
5. Tworek JA, Wilkinson DS, Walsh MK. The rate of manual microscopic examination of urine sediment: a College of American Pathologists Q-Probes study of 11,243 urinalysis tests from 88 institutions. *Arch Pathol Lab Med*. 2008;132(12): 1868-1873.
6. Bergus GR. Dysuria. In: Sloane PD, Slatt LM, Ebell MH, Smith MA, Power D, Viera AJ, eds. *Essentials of Family Medicine*, 6th ed. Baltimore: Lippincott Williams & Wilkins; 2012:327-336.
7. Shaikh N, Morone NE, Lopez J, et al. Does this child have a urinary tract infection? *JAMA*. 2007;298(24):2895-2904.
8. Ramchandani P, Kisler T, Francis IR, et al; Expert Panel on Urologic Imaging. *ACR Appropriateness Criteria® Hematuria*. Reston, VA: American College of Radiology; 2008 [online publication]. http://www.guideline.gov/content.aspx?id=15763&search=hematuria. Accessed December 30, 2011.
9. Gupta K, Hooton TM, Naber KG, et al; Infectious Diseases Society of America, European Society for Microbiology and Infectious Diseases. International clinical practice guidelines for the treatment of acute uncomplicated cystitis and pyelonephritis in women: a 2010 update by the Infectious Diseases Society of America and the European Society for Microbiology and Infectious Diseases. *Clin Infect Dis*. 2011;52(5):e103-e120.
10. Moyer VA; U.S. Preventive Services Task Force. Screening for bladder cancer: U.S. Preventive Services Task Force recommendation statement. *Ann Intern Med*. 2011;155(4):246-251.

68 KIDNEY STONES

Karl T. Rew, MD
Mindy A. Smith, MD, MS

PATIENT STORY

A 55-year-old woman presents with severe pain in the right flank. The pain began suddenly after supper and increased dramatically over the next hour. Urinalysis shows blood but no signs of infection. Abdominal X-ray reveals bilateral renal stones (**Figure 68-1**). A non-contrast CT scan confirms multiple bilateral renal stones, with an obstructing right distal ureteral stone and enlargement of the right kidney (**Figure 68-2**). She is subsequently found to have hyperparathyroidism, which is the cause of her multiple stones.

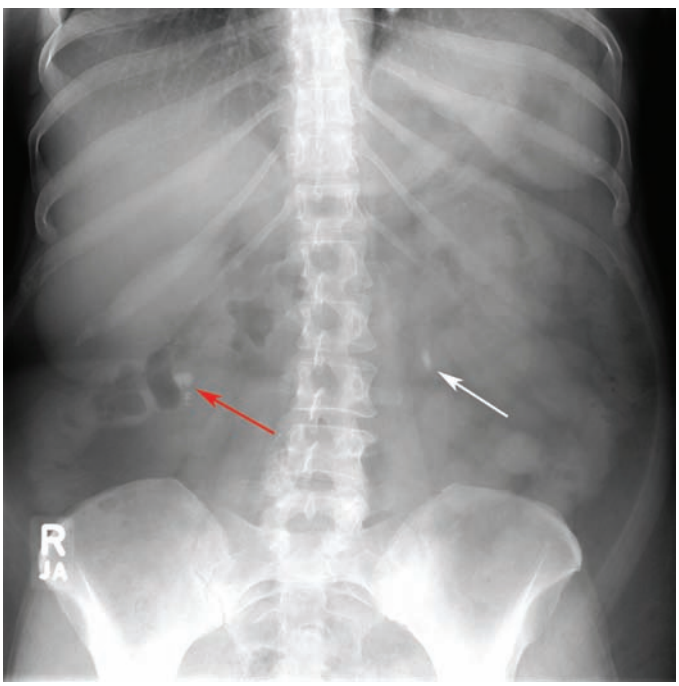

FIGURE 68-1 Plain X-ray of the abdomen in a 55-year-old woman showing several stones in the right kidney (*red arrow*) and a large left ureteral stone (*white arrow*) adjacent to the L2-L3 disc space.

INTRODUCTION

A kidney stone is a solid mass that forms when minerals crystallize and collect in the urinary tract. Kidney stones can cause pain and hematuria, and may lead to complications, such as urinary tract obstruction and infection.

SYNONYMS

Kidney stone, nephrolithiasis, renal calculus, renal stone, urinary tract stone, ureterolithiasis, urolithiasis.

EPIDEMIOLOGY

- The prevalence of kidney stones is increasing in the United States.[1] More than 5% of adults have kidney stone disease, with a lifetime risk of 13% for men and 7% for women.
- Men between the ages of 40 and 60 years have the highest risk of stones; for women, the risk peaks in their 50s.[2]
- African Americans have a lower rate of kidney stones than white Americans.[1]
- Calcium oxalate and calcium phosphate stones are the most common, occurring in 75% to 85% of patients. Struvite (magnesium ammonium phosphate) stones occur in 5% of cases. Uric acid stones occur in 5% to 10% of patients and cystine stones occur in 1% of cases. Other types of stones are less common.[3]
- Calcium stones are more common in men than in women (ratio 2:1), whereas struvite stones are more common in women than in men (ratio 3:1).[3]

ETIOLOGY AND PATHOPHYSIOLOGY

- Kidney stones form when there is supersaturation of otherwise soluble materials, usually from increased excretion of these

compounds or dehydration. Urine pH is a factor in stone formation because urinary phosphate increases in alkaline urine, whereas uric acid predominates in acidic urine (pH <5.5). Higher urine citrate can decrease stone formation.

- Struvite stones are caused by infection with urea-splitting bacteria, mainly *Proteus*.
- Uric acid stones form in patients with gout or hyperuricemia caused by other causes, including myeloproliferative disorders, chemotherapy, and Lesch-Nyhan syndrome.
- Cystine stones occur in patients with an inherited defect of dibasic amino acid transport.
- Struvite, cystine, and uric acid stones can grow large, filling the renal pelvis and extending into the calyces to form staghorn calculi **Figure 68-3**.

RISK FACTORS

Infections, genetic defects, and certain drugs can increase the risk of stones, but most stones are idiopathic. Risk factors vary with type of stone, as follows:

- Calcium stones are more likely in patients who are obese[4] and in those with diets higher in animal protein, salt, and oxalate-containing foods. Contrary to popular belief, calcium in the diet does not lead to calcium stones; in fact, calcium supplementation can prevent calcium stones by trapping oxalate in the GI tract.
- Patients with poor urinary drainage or indwelling catheters are at risk for *Proteus* urinary tract infections and struvite stones.
- Uric acid stones are associated with acidic urine, which is more common in obese patients with metabolic syndrome and insulin resistance, and in patients with chronic diarrhea.

DIAGNOSIS

CLINICAL FEATURES

- Kidney stones are often asymptomatic. Stone passage into the ureter usually causes pain and hematuria. The pain of renal colic typically begins suddenly in the ipsilateral flank or abdomen and progresses in waves, gradually increasing in intensity over the next 20 to 60 minutes. As the stone moves downward, pain may be felt in the ipsilateral groin, testis, or vulva.
- Obstructing stones cause hydronephrosis, with an associated constant dull flank pain. Stones in the bladder may cause frequency, urgency, dysuria, or recurrent urinary tract infections.

LABORATORY

- Urinalysis usually reveals microscopic hematuria and limited pyuria. Gross hematuria is possible.
- Because treatment depends on stone type, stone capture and analysis is recommended SOR C.
- Additional work-up is recommended for adults with recurrent stones and for children with a first stone.[1] This includes a 24-hour urine collection for pH, volume, oxalate, and citrate, with simultaneous serum tests for calcium, uric acid, electrolytes, and creatinine.

FIGURE 68-2 Noncontrast CT of the abdomen and pelvis of the same woman showing several of the stones seen in **Figure 68-1**, including a nonobstructing stone in the interpolar region of the right kidney. Because the right ureter is obstructed by a distal stone (not visible on this image), the right kidney is enlarged, with collecting system dilation and perinephric stranding. The large left proximal ureteral stone seen in this image is only partially obstructing, causing mild dilation in the left kidney collecting system. Several small stones are visible in the left kidney, and the left kidney is somewhat atrophied from chronic obstruction.

FIGURE 68-3 Bilateral staghorn calculi. (From Doherty GM. Current Surgical Diagnosis and Treatment; Figure 40-17, p. 1023. *Copyright 2006, McGraw-Hill.*)

In patients with elevated serum calcium, parathyroid hormone (PTH) should be measured.

IMAGING

- Plain abdominal X-ray will demonstrate most calcium, struvite, and cystine stones. It is recommended for patients with a prior radiopaque stone (**Figure 68-1**).
- Noncontrast helical CT (**Figures 68-4** and **68-5**) has largely replaced intravenous urography for patients with a suspected urinary tract stone because it is rapid, exposes patients to less radiation, requires no contrast, and may provide clues to diagnoses outside the urinary system. Although uric acid stones are radiolucent, they often can be detected with CT.
- Ultrasound can be used to monitor uric acid stones (typically radiolucent), to assess hydronephrosis, or to avoid using X-rays in pregnant women. Ultrasound also may provide clues to diagnoses outside the urinary system.

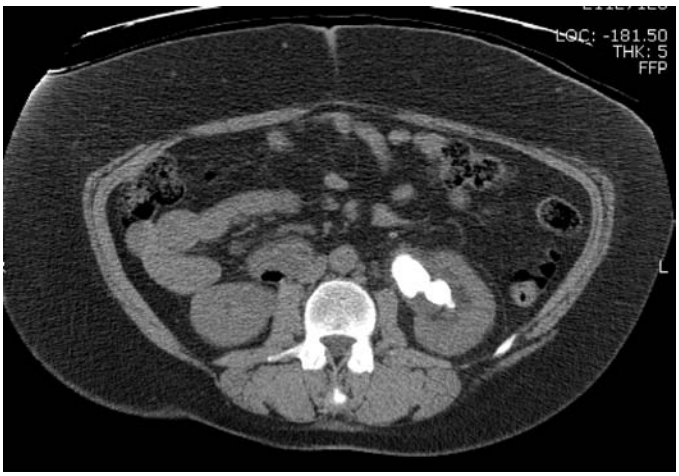

FIGURE 68-4 An unenhanced CT performed on a 49-year-old woman with known renal stones reveals a large left staghorn calculus. The striated appearance of the left renal cortex is seen in obstruction, infection, and ischemia. (*Courtesy of Michael Freckleton, MD.*)

DIFFERENTIAL DIAGNOSIS

Other causes of flank and lower pelvic/groin pain include:

- Gynecologic conditions in women (ovarian torsion, cyst, or ectopic pregnancy)—These can often be distinguished on ultrasound. Pelvic inflammatory disease can also present with pain and is diagnosed based on clinical examination and culture.
- In men, epididymitis, prostatitis, or testicular torsion may cause pain that can be confused with kidney stones. Testicular tumors rarely cause pain. Physical examination can help differentiate these conditions.
- Cholelithiasis—Biliary colic is usually described as a steady, severe pain or ache, usually of sudden onset, located in the epigastrium or right upper quadrant (RUQ) (see Chapter 62, Gallstones). RUQ tenderness may be elicited on physical examination and ultrasound usually shows stones in the gallbladder.
- Urologic disorders including ureteropelvic junction obstruction, renal subcapsular hematoma, and renal cell carcinoma (see Chapter 71, Renal Cell Carcinoma). Imaging assists in differentiating these from kidney stones.

Abdominal pain from renal stones may be confused with:

- Colitis, appendicitis, and diverticulitis—Systemic symptoms such as fever are often seen. Symptoms of colitis include diarrhea, rectal bleeding, tenesmus (i.e., urgency with a feeling of incomplete evacuation), passage of mucus, and cramping abdominal pain (see Chapter 65, Ulcerative Colitis). GI symptoms with kidney stones are limited to nausea and vomiting from stimulation of the celiac plexus.
- Peptic ulcer disease—Epigastric pain is the hallmark, along with dyspeptic symptoms (see Chapter 59, Peptic Ulcer Disease). Stool antigen test can confirm *Helicobacter pylori* infection. Upper endoscopy is the preferred procedure for diagnosing ulcers.
- Abdominal aortic aneurysm—Peak incidence is later, usually in the sixth and seventh decades. Pain is described as severe and tearing localized to the front or back of the chest and associated with diaphoresis. Syncope and weakness may also occur.

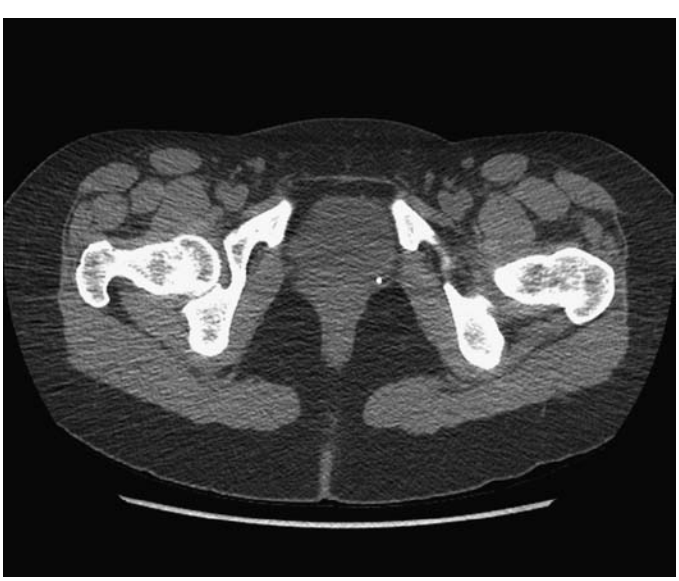

FIGURE 68-5 Noncontrast CT of the abdomen and pelvis in a 33-year-old woman showing a 3-mm obstructing stone in the distal ureter, just proximal to the ureterovesical junction.

Stones within the bladder may mimic urinary tract infection (UTI). Helpful indictors of UTI are a urine dipstick positive for nitrates (positive likelihood ratio [LR+] 26.5) and urinary sediment showing 10 or more bacteria/ high-power field (LR+ 85).

Hematuria is also seen in patients with infection (e.g., UTI, sexually transmitted infection, schistosomiasis), cancer of the bladder (see Chapter 72, Bladder Cancer) or kidney (see Chapter 71, Renal Cell Carcinoma), renal disease (glomerulonephritis, immunoglobulin [Ig] A nephropathy, lupus nephritis, hemolytic uremic syndrome), in men with prostatitis, benign prostatic hypertrophy, or prostate cancer (see Chapter 73, Prostate Cancer), or following trauma.

MANAGEMENT

NONPHARMACOLOGIC

- Adequate fluid intake is essential—2 to 3 L of water per day for most patients.[5] SOR B
- Stones smaller than 5 mm are likely to pass spontaneously. About three-fourths of distal ureteral stones and about half of proximal ureteral stones will pass spontaneously. The 3-mm distal ureteral stone shown in **Figure 68-3** passed spontaneously.

MEDICATIONS

- Medical expulsive therapy with α-adrenergic blockers (such as tamsulosin) or calcium-channel blockers can increase the chance of stone passage.[6] SOR B
- Effective pain control should be provided using NSAIDs and narcotics if needed. NSAIDs may need to be avoided if planning lithotripsy because of increased risk of perinephric bleeding.

COMPLEMENTARY AND ALTERNATIVE THERAPY

- For prevention of struvite stones, urine can be acidified with cranberry juice.[5] Other supplements have been suggested as potentially protective against renal stones, but study results are conflicting.

PROCEDURES

- Stones that do not pass spontaneously or with medical expulsive therapy can be treated with lithotripsy or removed via ureteroscopy. Large stones may require percutaneous nephrolithotomy (PCNL) or open surgery.

REFERRAL

- Urgent urologic consultation is recommended for patients with stones and urosepsis, anuria, or renal failure. Urologic consultation is recommended for patients with refractory pain and nausea, extremes of age, major comorbidities, stones larger than 5 mm. SOR C

Indications for operative intervention:

- Infection.
- Persistent symptoms of flank pain, nausea, and vomiting.
- Failure to pass a ureteral stone after an appropriate trial of observation (2 to 4 weeks).

PREVENTION

- Foods high in oxalate should be avoided by those who form calcium oxalate stones, including rhubarb, spinach, Swiss chard, beets, apricots, figs, kiwi, many soy products, chocolate, and many nuts and seeds.
- Uric acid stones are prevented with allopurinol and a low-purine diet. High-purine foods to avoid include most fish, shellfish, and meats (especially game meats and organ meats), and protein supplements such as brewer's yeast.
- Low-calcium diets should not be used in patients with calcium stones. A low-calcium diet can increase stone formation and lower bone mineral density.

Additional treatments may be warranted based on the type of stone:

- Patients with recurrent calcium-containing stones caused by idiopathic hypercalciuria can be treated with a thiazide diuretic (reduces recurrence by 50% over 3 years). Hypokalemia should be avoided; low potassium reduces urinary citrate.
- Idiopathic stone disease can be treated with fluids and potassium citrate (2 g/day).
- For cystine stones, increasing fluid intake, alkalinizing the urine to a pH ≥7.5, and a low-sodium diet are recommended. D-Penicillamine has also been used.

PROGNOSIS

- Half of the patients with a first calcium-containing stone have a recurrence within 10 years. Twenty-five percent of struvite stones recur if there was incomplete removal of the stone.
- Long-term complications are uncommon. The proportion of nephrolithiasis-related end-stage renal disease (ESRD) appears small (3.2%).

FOLLOW-UP

- A follow-up consultation to discuss kidney stone prevention is important for all patients with an initial stone. Patients started on medical therapy should be reevaluated with a 24-hour urine in 3 months. Those with a history of recurrent stones should be seen at least annually.

PATIENT EDUCATION

Maintaining water intake of at least 2 to 3 L/day (to keep urine specific gravity around 1.005) is recommended for most patients as this fluid level has been shown to reduce recurrences by half. Dietary information is available (see "Patient Resources" below).

PATIENT RESOURCES

- National Kidney and Urologic Diseases Information Clearinghouse. *Kidney Stones in Adults*—**http://kidney.niddk.nih.gov/Kudiseases/pubs/stonesadults/.**
- National Kidney and Urologic Diseases Information Clearinghouse. *Diet for Kidney Stone Prevention*—**http://kidney.niddk.nih.gov/kudiseases/pubs/kidneystonediet/.**
- *The Oxalate Content of Food*—**http://www.ohf.org/docs/Oxalate2008.pdf.**

PROVIDER RESOURCES

- American Urologic Association. *2007 Guideline for the Management of Ureteral Calculi*—**http://www.auanet.org/content/clinical-practice-guidelines/clinical-guidelines.cfm?sub=uc.**
- European Association of Urology. *Guidelines on Urolithiasis*, update March 2011—**http://www.uroweb.org/gls/pdf/18_Urolithiasis.pdf.**

REFERENCES

1. Worcester EM, Coe FL. Calcium kidney stones. *N Engl J Med*. 2010:363:954-963.
2. Curhan GC. Epidemiology of stone disease. *Urol Clin North Am*.2007;34(3):287-293.
3. Asplin JR, Coe FL, Favus MJ. Nephrolithiasis. In: Longo DL, Fauci AS, Kasper DL, Hauser SL, Jameson JL, Loscalzo J, eds. *Harrison's Principles of Internal Medicine*, 18th ed. New York: McGraw-Hill; 2012. http://www.accessmedicine.com/content.aspx?aID=9131116. Accessed December 28, 2011.
4. Taylor EN, Stampfer MJ, Curhan GC. Obesity, weight gain, and the risk of kidney stones. *JAMA*. 2005;293(4):455-462.
5. Frasetto L, Kohlstadt I. Treatment and prevention of kidney stones: an update. *Am Fam Physician*. 2011;84(11):1234-1242.
6. Hollingsworth JM, Rogers MA, Kaufman SR, et al. Medical therapy to facilitate urinary stone passage: a metaanalysis. *Lancet*. 2006;368:1171-1179.

69 HYDRONEPHROSIS

Mindy A. Smith, MD, MS

PATIENT STORY

A 74-year-old man presented with a 2-day history of severe, steady pain radiating down to the lower abdomen and left testicle. He has had urinary frequency, nocturia, hesitancy, and urinary dribbling for several years with slight worsening with time. CT scan revealed left-sided hydronephrosis (**Figure 69-1**). In this patient, an irregular mass was seen at the left ureterovesical junction compressing the bladder. Prostate cancer was found on biopsy.

FIGURE 69-1 Intravenous urogram showing left hydronephrosis and hydroureter. (*From Schwartz DT, Reisdorff EJ. Emergency Radiology. New York: McGraw-Hill; 2000:540, Fig. 19-45. Copyright 2000.*)

INTRODUCTION

Hydronephrosis refers to distention of the renal calyces and pelvis of one or both kidneys by urine. Hydronephrosis is not a disease but a physical result of urinary blockage that may occur at the level of the kidney, ureters, bladder, or urethra. The condition may be physiologic (e.g., occurring in up to 80% of pregnant women) or pathologic.

EPIDEMIOLOGY

- The most common cause of congenital bilateral hydronephrosis is posterior urethral valves (in males). Other causes include narrowing of the ureteropelvic or ureterovesicular junction.
- Using a large European database for surveillance of congenital malformations (EUROCAT), authors found a prevalence of congenital hydronephrosis of 11.5 cases per 10,000 births; the majority (72%) was in males.[1]
- Ureteropelvic junction obstruction is one of the most common congenital abnormalities of the urinary tract causing hydronephrosis, occurring in approximately 1 in 5000 to 8000 live births.[2]
- Authors of one systematic review reported a mean prevalence of 15% for postnatal primary vesicoureteral reflux (VUR) in children after prenatally detected hydronephrosis.[3] Of the remaining cases, 53% had no postnatal anomalies and 29% had other anomalies (e.g., duplicate collecting systems; **Figure 69-2**).
- Among acquired causes in adults, pelvic tumors, renal calculi, and urethral stricture predominate.[4] If renal colic is present, renal stone is likely present (90% in one study).[5]
- Hydronephrosis is common in pregnancy because of the compression from the enlarging uterus and functional effects of progesterone.

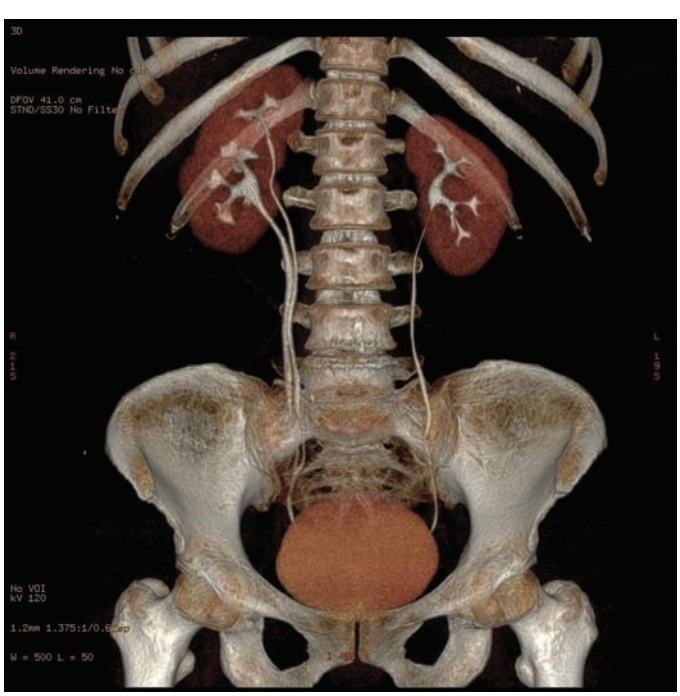

FIGURE 69-2 Duplicate right ureter seen with three-dimensional rendering of a CT urogram. (*Courtesy Karl T. Rew, MD.*)

ETIOLOGY AND PATHOPHYSIOLOGY

- Bilateral hydronephrosis is caused by a blockage to urine flow occurring at or below the level of the bladder or urethra.
- Unilateral hydronephrosis is caused by a blockage to urine flow occurring above the level of the bladder.

- Multiple causes result in this condition including congenital (e.g., VUR), acquired intrinsic (e.g., calculi, inflammation, and trauma), and acquired extrinsic (e.g., pregnancy or uterine leiomyoma, retroperitoneal fibrosis). Within these groupings, obstruction may be a result of mechanical (e.g., benign prostatic hypertrophy) or functional (e.g., neurogenic bladder) defects.
- Urinary obstruction causes a rise in ureteral pressure leading to declines in glomerular filtration, tubular function (e.g., ability to transport sodium and potassium or adjust urine concentration), and renal blood flow.
- If obstruction persists, tubular atrophy and permanent nephron loss can occur.

DIAGNOSIS

- In children, the diagnosis of hydronephrosis or megaureter is often made by a routine ultrasound.
- A work-up for hydronephrosis in adults is often triggered by the discovery of azotemia (caused by impaired excretory function of sodium, urea, and water). Sudden or new onset of hypertension (because of the increased renin release with unilateral obstruction) may also trigger an investigation. A first step in the evaluation is to perform bladder catheterization. If diuresis occurs, the obstruction is below the bladder neck.

CLINICAL FEATURES

- Pain is the symptom that most commonly leads an adult patient to seek medical attention. This is caused by distention of the collecting system or renal capsule. The pain is often described as severe, steady, and radiating down to the lower abdomen, testicles, or labia. Flank pain with urination is pathognomonic for VUR.
- Disturbed excretory function or difficulty in voiding: Oliguria and anuria are symptoms of complete obstruction whereas polyuria and nocturia occur with partial obstruction (impaired concentrating ability causes osmotic diuresis).
- Fever or dysuria can occur with associated urinary tract infection (UTI).
- The physical examination may reveal distention of the kidney or bladder. Rectal exam may show an enlarged prostate or rectal/pelvic mass and pelvic examination may reveal an enlarged uterus or pelvic mass.

LABORATORY TESTING

- Urinalysis may show hematuria, pyuria, proteinuria, or bacteruria but the sediment is often normal.[3]
- Assess renal function (blood urea nitrogen [BUN], creatinine).
- Urodynamic testing may be indicated for patients with neurogenic bladder or other suspected bladder causes of hydronephrosis.

IMAGING

- Ultrasound imaging has a sensitivity and specificity of 90% for identifying the presence of hydronephrosis if no diuresis occurs following bladder catheterization.[4]

- If a source remains unidentified, an IV urogram (**Figures 69-1** and **69-3**) and/or CT scan (**Figure 69-4**) should be obtained to diagnose intraabdominal or retroperitoneal causes.
- One study of magnetic resonance (MR) pyelography (vs. ultrasound and urography) reported a sensitivity in detecting stones, strictures, and congenital ureteropelvic junction obstructions of 68.9%, 98.5%, and 100%, respectively, with a specificity of 98%.[6] Accuracy regarding the level of obstruction was high (100%).
- Antegrade urography (percutaneous placement of ureteral catheter) or retrograde urography (cystoscopic placement of ureteral catheter) may be needed in patients with azotemia and poor excretory function or in those at high risk of acute renal failure from IV contrast (i.e., diabetes, multiple myeloma).
- A voiding cystourethrogram is useful in the diagnosis of VUR and bladder neck and urethral obstructions.
- For children identified in the prenatal period with hydronephrosis, the American Urologic Association (AUA) recommends a voiding cystourethrogram if there is high-grade hydronephrosis, hydroureter, or an abnormal bladder on ultrasound (late-term prenatal or postnatal), or for children who develop a UTI on observation.[7] SOR C Given the unproven value in diagnosing and treating VUR, an observational approach without screening may be taken for children with lesser grades of prenatally detected hydronephrosis (Society for Fetal Urology [SFU] grade 1 or 2).

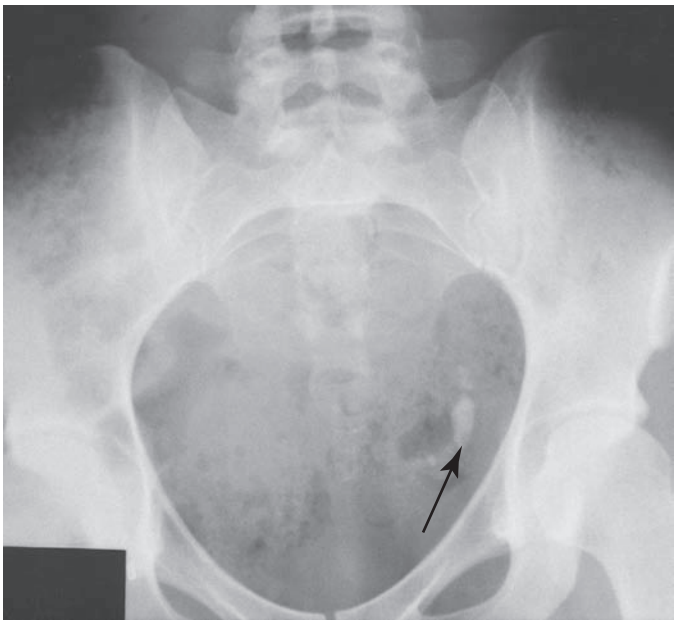

FIGURE 69-3 Large irregular calcification (*arrow*) representing ureterolithiasis in the left side of the pelvis in the patient in Figure 69-1. (*From Schwartz DT, Reisdorff EJ. Emergency Radiology. New York: McGraw-Hill; 2000:539, Fig. 19-43. Copyright 2000.*)

DIFFERENTIAL DIAGNOSIS

Hydronephrosis is usually found during an investigation for symptoms such as flank pain or renal failure. Following are other causes of flank pain:

- Pyelonephritis—Fever, chills, nausea, vomiting, and diarrhea often occurring with or without symptoms of cystitis.
- Cholelithiasis—Pain is more typical in the epigastrium and right upper quadrant (biliary colic) and often nausea and vomiting occurs (see Chapter 62, Gallstones).
- Other urologic disorders include ureteropelvic junction obstruction, renal subcapsular hematoma, and renal cell carcinoma (see Chapter 71, Renal Cell Carcinoma).

Causes of unexplained renal failure in adults:

- Hypoperfusion (prerenal failure).
- Acute tubular necrosis (ATN), interstitial, glomerular, or small vessel disease (intrarenal failure).
- Hypoperfusion and ATN account for the majority of cases of acute renal failure.

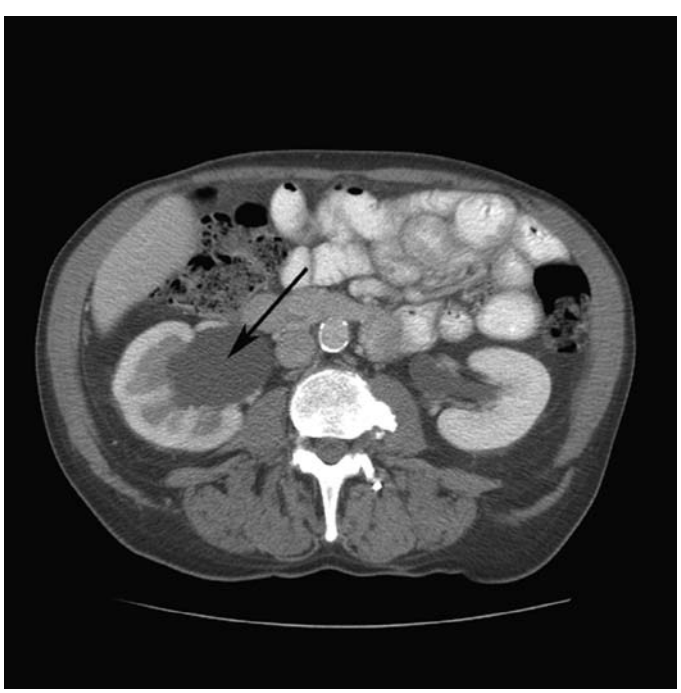

FIGURE 69-4 Right-sided hydronephrosis (arrow) seen on CT. (*Courtesy Karl T. Rew, MD.*)

MANAGEMENT

NONPHARMACOLOGIC

- Spontaneous resolution or decrease in urinary tract dilation is expected for most cases of neonatal hydronephrosis and primary megaureter diagnosed prenatally.[8,9]

- Functional causes may be treated by frequent voiding or catheterization (intermittent preferred).[10] SOR B

MEDICATIONS

- Children younger than 1 year of age with VUR complicated by a history of febrile UTI or higher grades of VUR (grades III to V) should be placed on prophylactic antibiotics (sulfamethoxazole/trimethoprim or nitrofurantoin).[11] SOR B
- Adult patients with hydronephrosis, complicated by infection, should be treated with appropriate antibiotics for 3 to 4 weeks. Chronic or recurrent unilateral infections may require nephrectomy. SOR A
- Anticholinergic drugs (e.g., oxybutynin, tolterodine) are recommended for patients with neurogenic bladder.[10] SOR B
- α-Adrenergic blockade in children with neurogenic bladder can also be considered, but studies are lacking.[10] SOR C

PROCEDURES AND SURGERY

- Hydronephrosis with infection is a urologic emergency that can be treated by prompt drainage using retrograde stent insertion or percutaneous nephrostomy.[12]
- Pyeloplasty is a surgical technique for repairing an obstruction between the ureter and kidney that involves excising the obstructing segment with reanastomosis of the ureter. For children with ureteropelvic junction obstruction, three basic procedures (open pyeloplasty [OP], endopyelotomy, and laparoscopic pyeloplasty [LP]) can be used for treatment; early surgery is only needed in approximately 15% to 20% of patients.[13] In one review of largely retrospective data, OP and LP had higher success rates than endopyelotomy (94.1% and 95.9% to 97.2% vs. 62% to 83%, respectively).[14]
- Treatment for VUR includes surgical repair (ureteral reimplantation or ureteroneocystostomy) or endoscopic injection of a bulking agent. Surgical repair reduces rates of pyelonephritis compared to medical treatment, but not UTI or renal scarring.[15]
- Stenting (conventional and metallic) is also used for bypassing ureteral obstruction to alleviate hydronephrosis.[16] The American College of Radiology (ACR) recommends percutaneous antegrade ureteral stenting or percutaneous nephrostomy for afebrile nonanuric patients with acute hydronephrosis.[17] In a septic patient with acute obstruction, ACR recommends urgent percutaneous nephrostomy (preferred) or urgent retrograde ureteral stenting.[17]
- Patients with renal failure can be treated with dialysis. SOR A
- Elective surgery for drainage is performed for persistent pain or progressive loss of renal function. SOR C

PREVENTION AND SCREENING

- The prevalence of VUR in siblings of an index case is 27.4% and in offspring 35.7%; severe reflux is identified in approximately 10% of screened patients.[18] Because of the lack of randomized controlled trials of treated versus untreated screened siblings with VUR regarding health outcomes, the best screening strategy is not known. One cost analysis estimated that it would require screening 30 to 430 asymptomatic siblings 1 year of age to prevent 1 febrile UTI at a cost of $56,000 to $820,000 per averted episode.[19]

PROGNOSIS

Prognosis depends on the underlying etiology.

FOLLOW-UP

- Neonates and children with unresolved hydronephrosis or megaureter should be followed periodically with urine cultures, serum creatinine, ultrasonography, and possibly renal scan.[11]
- Prognosis for an adult patient depends on the duration and completeness of the obstruction and associated complications like infection; complete obstruction for 1 to 2 weeks may be followed by partial return of renal function, but after 8 weeks, recovery is unlikely.[4]
- Postobstructive diuresis can cause loss of sodium, potassium, and magnesium that may require replacement in the setting of hypovolemia, hypotension, or electrolyte imbalance.

PATIENT EDUCATION

- Education regarding VUR should include a discussion of the treatment rationale, treatment approaches, and likely adherence with the care plan.[10]

PATIENT RESOURCES

- National Kidney Foundation (800-622-9010) or **www.kidney.org.**
- National Institutes of Health, MedlinePlus. *Bilateral Hydronephrosis*—**http://www.nlm.nih.gov/medlineplus/ency/article/000474.htm.**

PROVIDER RESOURCES

- Lusaya DG, Lerma EV. *Hydronephrosis and Hydroureter*—**http://emedicine.medscape.com/article/436259-overview.**
- Guideline: Screening of the neonate/infant with prenatal hydronephrosis. In: American Urologic Association Education and Research. *Management and Screening of Primary Vesicoureteral Reflux in Children: AUA Guideline*. Linthicum, MD: American Urologic Association Education and Research; 2010:1-12. **http://www.guideline.gov/content.aspx?id=24030&search=hydronephrosis.**
- Guideline: Vatakencherry G, Funaki BS, Ray CE Jr, et al; Expert Panel on Interventional Radiology. *ACR Appropriateness Criteria® Treatment of Urinary Tract Obstruction*. [online publication]. Reston, VA: ACR; 2010. 7 p. **http://www.guideline.gov/content.aspx?id=23819&search=hydronephrosis.**

REFERENCES

1. van Eerde AM, Meutgeert MH, de Jong TP, Giltay JC. Vesicoureteral reflux in children with prenatally detected hydronephrosis: a systematic review. *Ultrasound Obstet Gynecol.* 2007;29(4):463-469.
2. Turk TMT, Polcari AJ, Sharma SK, Fulmer BR. *Pyeloplasty*. http://emedicine.medscape.com/article/448299-overview#a0199. Accessed January 2012.
3. Garne E, Loane M, Wellesley D, et al. Congenital hydronephrosis: prenatal diagnosis and epidemiology in Europe. *J Pediatr Urol.* 2009;5(1):47-52.
4. Seifter JL, Brenner BM. Urinary tract obstruction. In: Kasper DL, Braunwald E, Fauci AS, Hauser SL, Longo DL, Jameson JL, eds. *Harrison's Principles of Internal Medicine*, 16th ed. New York: McGraw-Hill; 2005:1722-1724.
5. Pepe P, Motta L, Pennisi M, Aragona F. Functional evaluation of the urinary tract by color-Doppler ultrasonography (CDU) in 100 patients with renal colic. *Eur J Radiol.* 2005;53(1):131-135.
6. Blandino A, Gaeta M, Minutoli F, et al. MR pyelography in 115 patients with a dilated renal collecting system. *Acta Radiol.* 2001;42(5):532-536.
7. Screening of the neonate/infant with prenatal hydronephrosis. In: American Urological Association Education and Research. *Management and Screening of Primary Vesicoureteral Reflux in Children: AUA Guideline*. Linthicum, MD: American Urological Association Education and Research; 2010:1-12. http://www.guideline.gov/content.aspx?id=24030&search=hydronephrosis. Accessed January 2012.
8. Shukla AR, Cooper J, Patel RP, et al. Prenatally detected primary megaureter: a role for extended followup. *J Urol.* 2005;173(4):1353-1356.
9. Upadhyay J, McLorie GA, Bolduc S, et al. Natural history of neonatal reflux associated with prenatal hydronephrosis: long-term results of a prospective study. *J Urol.* 2003;169(5):1837-1841.
10. Management of neurogenic bladder in children. In: Tekgül S, Riedmiller H, Gerharz E, et al. *Guidelines on Paediatric Urology*. Arnhem, The Netherlands: European Association of Urology, European Society for Paediatric Urology; 2009:31-41. http://www.guideline.gov/content.aspx?id=14433&search=hydronephrosis. Accessed January 2012.
11. Management of infants less than one year of age with vesicoureteral reflux. In: American Urological Association Education and Research. *Management and Screening of Primary Vesicoureteral Reflux in Children: AUA Guideline*. Linthicum, MD: American Urological Association Education and Research; 2010:1-11. http://www.guideline.gov/content.aspx?id=24027&search=hydronephrosis. Accessed January 2012.
12. Ramsey S, Robertson A, Ablett MJ, et al. Evidence-based drainage of infected hydronephrosis secondary to ureteric calculi. *J Endourol.* 2010;24(2):185-189.
13. Madsen MG, Nørregaard R, Frøkiær J, Jørgensen TM. Urinary biomarkers in prenatally diagnosed unilateral hydronephrosis. *J Pediatr Urol.* 2011;7(2):105-112.
14. Gallo F, Schenone M, Giberti C. Ureteropelvic junction obstruction: which is the best treatment today? *J Laparoendosc Adv Surg Tech A.* 2009;19(5):657-652.
15. Estrada CR, Cendron M. *Vesicoureteral Reflux Treatment and Management*. http://emedicine.medscape.com/article/439403-treatment#a1128. Accessed January 2012.

16. Modi AP, Ritch CR, Arend D, et al. Multicenter experience with metallic ureteral stents for malignant and chronic benign ureteral obstruction. *J Endourol*. 2010;24(7):1189-1193.

17. Vatakencherry G, Funaki BS, Ray CE Jr; Expert Panel on Interventional Radiology. *ACR Appropriateness Criteria® Treatment of Urinary Tract Obstruction* [online publication]. Reston, VA: American College of Radiology; 2010. 7 p. http://www.guideline.gov/content.aspx?id=23819&search=hydronephrosis. Accessed January 2012.

18. Skoog SJ, Peters CA, Arant BS Jr, et al. Pediatric Vesicoureteral Reflux Guidelines Panel summary report: clinical practice guidelines for screening siblings of children with vesicoureteral reflux and neonates/infants with prenatal hydronephrosis. *J Urol.* 2010; 184(3):1145-1151.

19. Routh JC, Grant FD, Kokorowski P, et al. Costs and consequences of universal sibling screening for vesicoureteral reflux: decision analysis. *Pediatrics.* 2010;126(5):865-871.

70 POLYCYSTIC KIDNEYS

Mindy A. Smith, MD, MS

PATIENT STORY

A 43-year-old woman with newly diagnosed hypertension reports persistent bilateral flank pain. She has a family history of "kidney problems." On urinalysis, she is noted to have microscopic hematuria. An ultrasound and abdominal CT scan show bilateral polycystic kidneys (**Figure 70-1**).

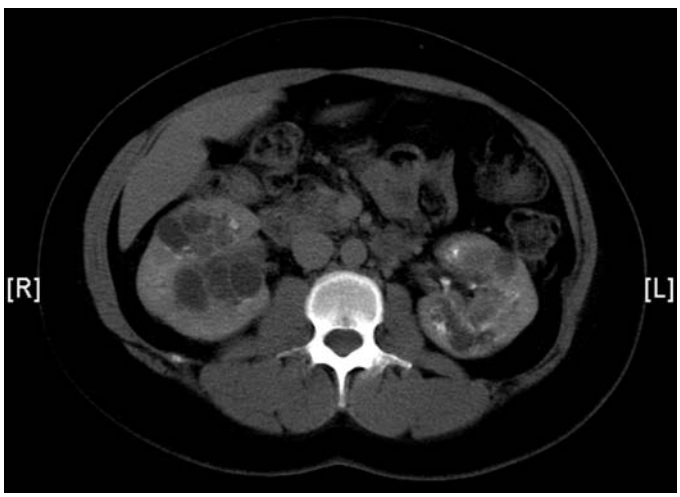

FIGURE 70-1 Polycystic kidneys in a 43-year-old woman with hematuria. (*Courtesy of Michael Freckleton, MD.*)

INTRODUCTION

Polycystic kidney disease (PKD) is a manifestation of a group of inherited disorders resulting in renal cyst development. In the most common form, autosomal-dominant polycystic kidney disease (ADPKD), extensive epithelial-lined cysts develop in the kidney; in some cases, abnormalities also occur in the liver, pancreas, brain, arterial blood vessels, or a combination of these sites.

EPIDEMIOLOGY

- Most common tubular disorder of the kidney, affecting 1 in 300 individuals.
- Autosomal dominant in 90% of cases, rarely as an autosomal recessive trait.[1]
- Sporadic mutation in approximately 1:1000 individuals.
- ADPKD accounts for approximately 5% to 10% of cases of end-stage renal disease (ESRD) in the United States.
- Most frequently seen in the third and fourth decades of life, but can be diagnosed at any age.

ETIOLOGY AND PATHOPHYSIOLOGY

- ADPKD results from mutations in either of 2 genes that encode plasma membrane–spanning polycystin 1 (PKD1) and polycystin 2 (PKD2).[2] Polycystins regulate tubular and vascular development in the kidneys and other organs (liver, brain, heart, and pancreas). PKD1 and PKD2 are colocalized in primary cilia and appear to mediate Ca^{2+} signaling as a mechanosensor, essential for maintaining the differentiated state of epithelia lining tubules in the kidney and biliary tract.[3] These mutations result in many abnormalities including increased proliferation and apoptosis and loss of differentiation and polarity.[4]
- Few (1% to 5%) nephrons actually develop cysts.
- Remaining renal parenchyma shows varying degrees of tubular atrophy, interstitial fibrosis, and nephrosclerosis.
- Cysts are also found in other organs such as liver (**Figure 70-2**), spleen, pancreas, and ovaries. Liver cysts are found in up to 80% of

patients with ADPKD.[2] There is also an increased incidence of intracranial aneurysms (5% to 12%).

- Autosomal-recessive PKD (ARPKD) is the neonatal form of PKD that is associated with enlarged kidneys and biliary dysgenesis.[3] The genetic mutation in PKHD1 (polycystic kidney hepatic disease 1) involves a protein, fibrocystin, that is also localized to cilia/basal body and complexes with PKD2. This large, receptor-like protein is thought to be involved in the tubulogenesis and/or maintenance of duct-lumen architecture of epithelium.
- Rare syndromic forms of PKD include defects of the eye, central nervous system, digits, and/or neural tube.[3]
- A variant of PKD is glomerulocystic kidney (GCK), which refers to a kidney with greater than 5% cystic glomeruli.[5] This condition is usually diagnosed in young patients. Although PKD-associated gene mutations have been excluded in many cases, there is a familial form of GCK presenting with cystic kidneys, hyperuricemia, and isosthenuria (concentration similar to plasma).[5]

DIAGNOSIS

Family history is a useful tool for diagnosing early ADPKD.

CLINICAL FEATURES

- Chronic flank pain as a result of the mass effect of enlarged kidneys.
- Acute pain with infection, obstruction, or hemorrhage into a cyst.
- Enlarged liver.
- Hypertension is common in adults (75%) and may be present in 10% to 30% of children.
- Kidney stones (calcium oxalate and uric acid) develop in 15% to 20% of affected individuals because of urinary stasis from distortion of the collecting system, low urine pH, and low urinary citrate.
- Nocturia may also be present from impaired renal concentrating ability.

LABORATORY TESTING

- Gross or microscopic hematuria (60%).[2] Obtain a urinalysis to document hematuria and a complete blood count or hemoglobin to identify anemia.

IMAGING

- Diagnosis often made with ultrasound. More than 80% of patients have cysts present by age 20 years and 100% by age 30 years. In one study, the sensitivity of ultrasound in at-risk individuals younger than age 30 years was 70% to 95%, depending on the type of PKD present.[6] For younger patients or those with small cysts, CT scan (**Figures 70-1** and **70-2**) or MRI may be preferred.
- Cysts are commonly found in the liver (50% to 80%) (**Figure 70-2**), spleen, pancreas, and ovaries.
- The diagnosis of PKD can usually be made from ultrasound characteristics, the presence or absence of extrarenal abnormalities, and screening of parents older than 40 years of age.[7] Age-dependent ultrasound criteria have been established for both diagnosis and disease exclusion in subjects at risk of PKD1 (the more severe disorder).[8]

FIGURE 70-2 CT scan showing multiple liver cysts and multiple cysts in both kidneys in a patient with polycystic kidney disease (*Courtesy of Ves Dimov, MD, Section of Allergy, Asthma and Immunology, Department of Pediatrics, Department of Medicine, University of Chicago, ClinicalCases.org.*)

- If the diagnosis is uncertain, genetic testing is available for both ADPKD and ARPKD.

DIFFERENTIAL DIAGNOSIS[2]

- Simple cyst—Diagnosed at any age; few cysts seen; benign features.
- Acquired cystic disease—Diagnosed in adulthood; few to many cysts; cyst development preceded by renal failure.
- Tuberous sclerosis—Diagnosed at any age; few to many renal angiomyolipomas; inherited nonmalignant tumors grow in the skin, brain/nervous system, kidneys, and heart.

MANAGEMENT

The current role of therapy in PKD is to slow the rate of progression of renal disease and minimize symptoms. However, specific treatments are on the horizon.

NONPHARMACOLOGIC

- Neither protein restriction nor tight blood pressure control decreased the decline in glomerular filtration rate (GFR) in clinical trials.[9,10] However, in a UK population study, increasing coverage (from 7% to 46% of the population prescribed an antihypertensive agent) showed a trend towards decreasing mortality and increased intensity of antihypertensive therapy was associated with decreasing mortality in people with ADPKD.[11]
- For episodes of gross hematuria, one author recommends bed rest, analgesics, and hydration sufficient to increase the urinary flow rate to 2 to 3 L/day; hematuria generally declines to microscopic levels in a few days.[2] SOR C

MEDICATIONS

- Control blood pressure to reduce the risk of associated cardiovascular disease. SOR A
- In one randomized controlled trial (RCT) (N = 46 patients with ADPKD and hypertension), no differences in renal function, urinary albumin excretion, or left ventricular mass index were detected between those treated with ramipril versus metoprolol, during 3 years of follow-up.[12] Renal function declined significantly in both groups. Angiotensin-converting enzyme inhibitors and angiotensin receptor blockers are the traditionally used agents for patients with chronic kidney disease and hypertension. SOR A
- Treat infection as early as possible. If pyocyst is suspected, agents that penetrate cysts such as trimethoprim-sulfamethoxazole, chloramphenicol, and ciprofloxacin are used. SOR C
- Future therapies focus on exploiting signaling mechanisms underlying disease pathogenesis. Experimental and observational studies suggest that the mammalian target of rapamycin (mTOR) pathway plays a critical role in cyst growth.
- A 2-year RCT of the mTOR inhibitor everolimus for patients with ADPKD (N = 46) demonstrated a slowing of the increase in total kidney volume over placebo but not the progression of renal impairment.[13] An open-label trial (N = 100 patients with ADPKD and early chronic kidney disease) of the mTOR inhibitor sirolimus did not show slowing of kidney growth or improved function over standard care.[14]
- In a RCT of octreotide (a long-acting somatostatin analog) versus placebo for patients with polycystic liver disease (some of whom had ADPKD), patients with ADPKD randomized to octreotide had a stabilization of kidney volume (versus an increase in the control group) and all patients randomized to treatment showed a reduced liver volume; there was no difference between groups in GFR.[15]

SURGERY AND OTHER PROCEDURES

- Cyst puncture and a sclerosing agent (i.e., ethanol) can be used in painful cysts. SOR C
- For painful liver enlargement, partial hepatectomy can be performed, with good outcomes reported at experienced centers.[2] SOR C
- For patients with ESRD as a result of PKD, transplantation and dialysis are options.
- In a nationwide study of 15-year outcomes following renal transplantation (N = 534 patients with ADPKD and 4779 patients without ADPKD), patients with ADPKD had better graft survival and no difference in infections, but more thromboembolic complications, more metabolic complications, and increased incidence of hypertension.[16]

REFERRAL

- Patients with PKD with progressive renal failure and/or ESRD should be managed by a team of providers as they often require dialysis or kidney transplantation and can develop multiple complications; other considerations include anemia management, aneurysm screening pretransplantation, and nephrectomy of the native ADPKD kidneys.[17] SOR C
- Consider hospitalization for patients with PKD who develop acute pyelonephritis and symptomatic cyst infection.[2]

PROGNOSIS

- Approximately 50% of patients with ADPKD progress slowly to ESRD; kidney failure requiring renal-replacement therapy typically develops in the fourth to sixth decade of life.[2] Patients with ADPKD and ESRD may have more favorable outcomes compared to those with other causes of kidney failure.[16]
- The following are the characteristics that predict a faster rate of decline in GFR in persons with ADPKD[18]:
  - Greater serum creatinine (independent of GFR).
  - Greater urinary protein excretion.
  - Higher mean arterial pressure (MAP).
  - Young age.
  - Increased kidney volume (>1500 mL).[2]
  - Disease caused by PKD1 mutation.[19]
  - The presence of tubulointerstitial fibrosis.[20]
- The ARPKD phenotype is highly variable ranging from causing neonatal death to causing minimal kidney disease presenting later in life.[3]
- Patients with ADPKD are also more prone to kidney stones (Chapter 68, Kidney Stones).[21]

FOLLOW-UP

- Monitor patients renal function and watch for hypertension and posttransplantation diabetes mellitus; imaging to assess the rate of increased kidney and total cyst volume may be useful in prognosis.[22]
- Avoid exogenous estrogen use for women with ADPKD and liver cystic enlargement; consider limiting use in women with liver cysts.[2]
- For all patients with PKD with renal dysfunction, review medications to adjust for level of kidney function and avoid nephrotoxic drugs if possible. SOR C
- The prognosis for patients following renal transplant is fairly good. In a follow-up study of patients with autosomal dominant PKD, adult cadaveric renal transplant survival at 5 years was found to be 79%.[23]
- In the absence of a family history of aneurysm, screening is not routinely recommended for asymptomatic patients; diagnostic testing should be considered in patients with ADPKD and new-onset or severe headache or other central nervous system symptoms or signs.[2]
- Posttransplantation, patients with ADPKD may be more prone to the development of diabetes mellitus (odds ratio 2.3, 95% confidence interval, 1.008 to 5.14).[24]

PATIENT EDUCATION

- Explain the genetics (among patients with ADPKD disease will develop in half of their offspring) and prognosis to patients. Referral to a genetic counselor may be useful for patients considering childbearing.
- Hypertension is common and should be treated.
- Kidney dysfunction is also common and should be monitored.
- Avoid high-impact sports in which abdominal trauma may occur (e.g., boxing).[2]
- In otherwise healthy women with ADPKD, pregnancy is usually uncomplicated but the risks of severe hypertension and preeclampsia are higher than those in the general population when elevated blood pressure or renal insufficiency is present before conception.[25]

PATIENT RESOURCES

- National Kidney Foundation (800-622-9010)—**http://www.kidney.org.**
- National Kidney Disease Education Program—**http://www.nkdep.nih.gov.**
- National Institutes of Health, PubMed Health. *Polycystic Kidney Disease*—**http://www.ncbi.nlm.nih.gov/pubmedhealth/PMH0001531/.**

PROVIDER RESOURCES

- Roser T. *Polycystic Kidney Disease*—**http://emedicine.medscape.com/article/244907.**

REFERENCES

1. Asplin JR, Coe FL. Tubular disorders. In: Kasper DL, Braunwald E, Fauci AS, Hauser SL, Longo DL, Jameson JL, eds. *Harrison's Principles of Internal Medicine*, 16th ed. New York, NY: McGraw-Hill; 2005:1694-1696.
2. Grantham JJ. Autosomal dominant polycystic kidney disease. *Ann Transplant.* 2009;14(4):86-90.
3. Harris PC, Torres VE. Polycystic kidney disease. *Annu Rev Med.* 2009;60:321-337.
4. Park EY, Woo YM, Park JH. Polycystic kidney disease and therapeutic approaches. *BMB Rep.* 2011;44(6):359-368.
5. Lennerz JK, Spence DC, Iskandar SS, et al. Glomerulocystic kidney: one hundred-year perspective. *Arch Pathol Lab Med.* 2010;134(4):583-605.
6. Nicolau C, Torra R, Bandenas C, et al. Autosomal dominant polycystic kidney disease types 1 and 2: assessment of US sensitivity for diagnosis. *Radiology.* 1999;213(1):273-276.
7. Sweeney WE Jr, Avner ED. Diagnosis and management of childhood polycystic kidney disease. *Pediatr Nephrol.* 2011;26(5):675-692.
8. Barua M, Pei Y. Diagnosis of autosomal-dominant polycystic kidney disease: an integrated approach. *Semin Nephrol.* 2010;30(4):356-365.
9. Klahr S, Breyer JA, Beck GJ, et al. Dietary protein restriction, blood pressure control, and the progression of polycystic kidney disease. Modification of Diet in Renal Disease Study Group. *J Am Soc Nephrol.* 1995;6(4):1318.
10. Schrier R, McFann K, Johnson A, et al. Cardiac and renal effects of standard versus rigorous blood pressure control in autosomal-dominant polycystic kidney disease: results of a seven-year prospective randomized study. *J Am Soc Nephrol.* 2002;13(7):1733-1739.
11. Patch C, Charlton J, Roderick PJ, Gulliford MC. Use of antihypertensive medications and mortality of patients with autosomal dominant polycystic kidney disease: a population-based study. *Am J Kidney Dis.* 2011;57(6):856-862.
12. Zeltner R, Poliak R, Stiasny B, et al. Renal and cardiac effects of antihypertensive treatment with ramipril vs metoprolol in autosomal dominant polycystic kidney disease. *Nephrol Dial Transplant.* 2008;23(2):573-579.
13. Walz G, Budde K, Mannaa M, et al. Everolimus in patients with autosomal dominant polycystic kidney disease. *N Engl J Med.* 2010;363(9):830-840.
14. Serra AL, Poster D, Kistler AD, et al. Sirolimus and kidney growth in autosomal dominant polycystic kidney disease. *N Engl J Med.* 2010;363(9):820-829.
15. Hogan MC, Masyuk TV, Page LJ, et al. Randomized clinical trial of long-acting somatostatin for autosomal dominant polycystic kidney and liver disease. *J Am Soc Nephrol.* 2010;21(6):1052-1061.
16. Jacquet A, Pallet N, Kessler M, et al. Outcomes of renal transplantation in patients with autosomal dominant polycystic kidney disease: a nationwide longitudinal study. *Transpl Int.* 2011;24(6):582-587.

17. Alam A, Perrone RD. Management of ESRD in patients with autosomal dominant polycystic kidney disease. *Adv Chronic Kidney Dis.* 2010;17(2):164-172.

18. Klahr S, Breyer JA, Beck GJ, et al. Dietary protein restriction, blood pressure control, and the progression of polycystic kidney disease. Modification of Diet in Renal Disease Study Group. *J Am Soc Nephrol.* 1995;6(4):1318.

19. Pei Y. Practical genetics for autosomal dominant polycystic kidney disease. *Nephron Clin Pract.* 2011;118(1):c19-c30.

20. Norman J. Fibrosis and progression of autosomal dominant polycystic kidney disease (ADPKD). *Biochim Biophys Acta.* 2011; 1812(10):1327-1336.

21. Nishiura JL, Neves RF, Eloi DR, et al. Evaluation of nephrolithiasis in autosomal dominant polycystic kidney disease patients. *Clin J Am Soc Nephrol.* 2009;4(4):838-844.

22. Bae KT, Grantham JJ. Imaging for the prognosis of autosomal dominant polycystic kidney disease. *Nat Rev Nephrol.* 2010;6(2): 96-106.

23. Johnston O, O'Kelly P, Donohue J, et al. Favorable graft survival in renal transplant recipients with polycystic kidney disease. *Ren Fail.* 2005;27(3):309-314.

24. Gonclaves S, Guerra J, Santana A, et al. Autosomal-dominant polycystic kidney disease and kidney transplantation: experience of a single center. *Transplant Proc.* 2009;41(3):887-890.

25. Vora N, Perrone R, Bianchi DW. Reproductive issues for adults with autosomal dominant polycystic kidney disease. *Am J Kidney Dis.* 2008;51(2):307-318.

71 RENAL CELL CARCINOMA

Mindy A. Smith, MD, MS

PATIENT STORY

A 56-year-old man with hypertension presents with a 2-week history of left-sided flank pain. Urinalysis shows microscopic hematuria and a CT scan (**Figures 71-1** and **71-2**) demonstrates a solid left renal mass. Work-up for metastatic disease was negative. A biopsy confirmed renal cell carcinoma and a radical nephrectomy was performed.

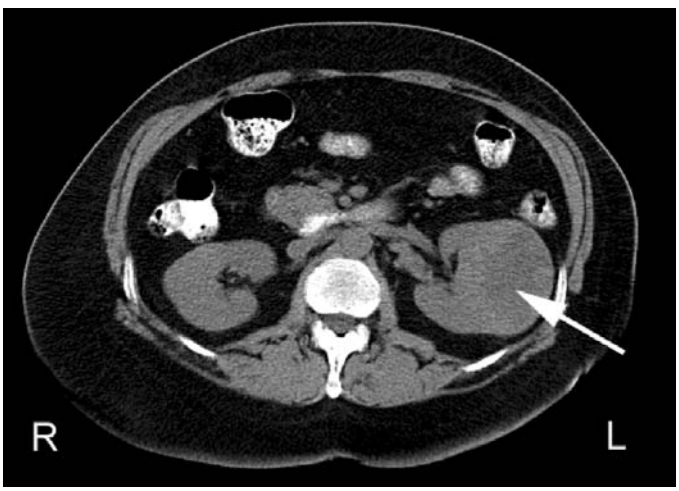

FIGURE 71-1 Renal cell carcinoma. CT shows solid mass in the left kidney (*arrow*). (*Courtesy of Michael Freckleton, MD.*)

INTRODUCTION

Renal tumors are a heterogeneous group of kidney neoplasms derived from the various parts of the nephron. Each type of tumor possesses distinct genetic characteristics, histologic features, and, to some extent, clinical phenotypes that range from benign (approximately 20% of small masses) to high-grade malignancy. Ninety percent to 95% of kidney neoplasms are renal cell carcinomas (RCCs).[1,2]

EPIDEMIOLOGY

- RCC comprises 2% to 3% of all malignant diseases in adults and is the seventh most common cancer in men and ninth most common cancer in women.[2]
- An estimated 60,920 cases were diagnosed and approximately 13,120 deaths occurred in 2011 from kidney and renal pelvis cancer.[3] The age-adjusted incidence rate was 14.6 per 100,000 persons with a median age at diagnosis of 64 years.[3]
- Lifetime risk of kidney and renal pelvis cancer is 1.56% (1 in 63 people will be diagnosed during their lifetime).[3] These cancers are more common in men than women (approximately 2:1).
- Approximately 2% to 3% of cases are familial (e.g., von Hippel-Lindau syndrome).[2]
- Metastatic disease at presentation occurs in 23% to 33%; the most common sites of distant metastases (in descending order) are lung (with or without mediastinal or hilar nodes), bone, upper abdomen (including the tumor bed, adrenal gland, contralateral kidney, and liver), brain, and other sites (e.g., skin, spleen, heart, diaphragm, gut, connective tissue, and pancreas).[4]

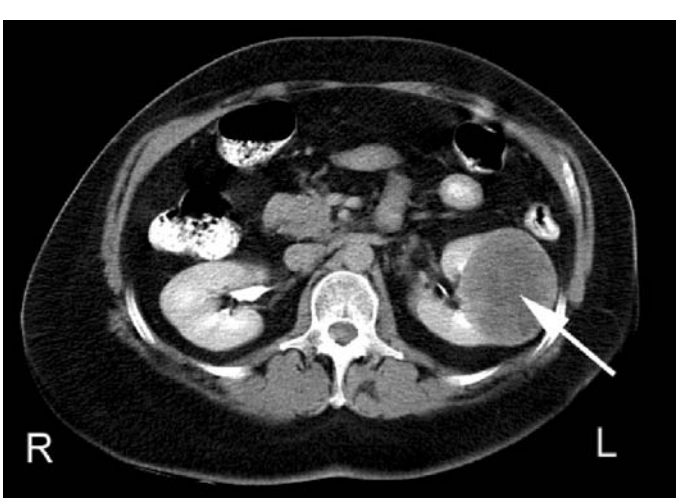

FIGURE 71-2 CT with contrast in the same patient shows the solid hypodense renal cell carcinoma mass (*arrow*) in the left kidney and contrasting normal parenchyma. The contrast is taken up better by the remaining normal kidney tissue and the tumor becomes more visible. (*Courtesy of Michael Freckleton, MD.*)

ETIOLOGY AND PATHOPHYSIOLOGY

The majority of renal tumors fall into the following categories:[1,2]

- Clear cell carcinoma (from high lipid content) (60% to 80%).
- Papillary carcinoma (5% to 15%), further delineated into type 1 and the more aggressive type 2.

- Chromophobic tumors (3% to 10%) and other rare subtypes, such as medullary, which occurs almost exclusively in patients with sickle cell trait.

RISK FACTORS[1,2]

- Smoking (relative risk 2 to 3).
- Obesity.
- Hypertension.
- Acquired cystic disease and end-stage renal disease, including dialysis treatment.
- Family history of the disease.

DIAGNOSIS

Most presentations are incidental (identified during other tests) and, consequently, although the incidence has increased, more cancers are diagnosed at early stages.[2] Despite this fact, mortality rates have also increased.

CLINICAL FEATURES

- Hematuria (40%) and flank pain (40%).
- Weight loss and anemia (approximately 33%).
- Flank mass (approximately 25%).
- The classic triad of hematuria, flank pain, and flank mass occurs in 5% to 10% of patients.[1]
- Other reported symptoms include night sweats, bone pain, fatigue, and sudden onset of left varicocele.
- Systemic symptoms may be caused by metastases or paraneoplastic syndromes, such as parathyroid hormone-related protein (causing hypercalcemia and renal stones), renin (causing hypertension), or erythropoietin (causing erythrocytosis).[2]

LABORATORY TESTING

Potentially useful studies: SOR C

- Hemoglobin (anemia).
- Liver chemistries (metastatic disease or paraneoplastic syndrome).
- Urinalysis (hematuria—gross or microscopic).
- Urine cytology (neoplastic cells).
- The National Comprehensive Cancer Network (NCCN) also suggests a metabolic panel including lactate dehydrogenase (LDH) as part of the initial work-up.[5]

IMAGING

- The work-up for indeterminate renal masses suggested by the American College of Radiology (ACR) includes either CT scan of the abdomen (**Figures 71-1** to **71-3**) (solid renal mass; signs suggestive of renal vein or caval thrombus include filling defects, enlargement of the vessel, and rim enhancement) or abdominal MRI (slightly more sensitive and tends to upgrade cystic lesions; **Figure 71-4**); either scan should be done without and with contrast.[6]

FIGURE 71-3 CT in a 70-year-old man demonstrating a heterogeneous solid mass in the midportion to lower pole of the right kidney (arrow), consistent with a primary renal cancer. The mass contains low-attenuation, likely necrotic, components and is exophytic. (*Courtesy of Karl T. Rew, MD.*)

FIGURE 71-4 Patient with tuberous sclerosis. MRI shows multiple angiomyolipomas in the kidneys with several lesions suspicious for renal cancer. (*Courtesy of Karl T. Rew, MD.*)

- An ultrasound (US) of the kidney retroperitoneal may help to clarify a mass that is probably a hyperdense cyst (the most common renal mass).
- Angiography may be used to define vascular anatomy before nephron-sparing surgery.[6]

For the purpose of staging a RCC, ACR recommends:[6]

- Multidetector CT without and with contrast.
- Chest X-ray (CXR, tumor may extend into the hilar lymph nodes) or chest CT.
- MRI if patient is unable to undergo CT with contrast.
- Bone scans and brain MRI should be reserved for patients with abnormal blood chemistries, symptoms, or large and locally aggressive or metastatic primary renal cancers.

BIOPSY

A renal biopsy is only needed on occasion based on the appearance and size of the mass; US, CT, or MRI can be used for image guidance.[4] ACR indications for biopsy include:

- Confirming an infected cyst.
- Identifying lymphoma.
- Determining a metastasis.
- Confirming RCC in certain circumstances, including prior to ablative therapies.

DIFFERENTIAL DIAGNOSIS

The differential diagnosis of a renal mass includes:

- Simple cysts.
- Renal calculi/nephrolithiasis (see Chapter 68, Kidney Stones).
- Benign neoplasms (infrarenal hematoma, adenoma, angiomyolipoma [see **Figure 71-4**], and oncocytoma).
- Inflammatory lesions (focal bacterial nephritis, abscess, pyelonephritis, and renal tuberculosis); patients often present with systemic signs and symptoms of infection such as fever and chills.
- Other primary or metastatic tumors (neoplastic tumors involving the kidney include squamous cell carcinoma of the collecting system, transitional cell carcinomas of the renal pelvis or collecting system, sarcoma, lymphoma, nephroblastoma, and melanoma).

These can frequently be differentiated from RCC on CT scan, but biopsy may be necessary.

MANAGEMENT

Because an increasing number of tumors are identified early (tumor size <4 cm) and may be slow growing with low risk of early progression, some authors are advocating initial active surveillance.[7]

MEDICATIONS

- Investigational therapy should be considered for patients with advanced disease because chemotherapy and immunotherapy are not known to be effective.

TABLE 71-1 Stages of Renal Cell Carcinoma

Stage	Characteristics	TNM* Staging System
I	Tumor size 7 cm or smaller and found only in the kidney	T1 N0 M0
II	Tumor size larger than 7 cm and found only in the kidney	T2 N0 M0
III	Any size tumor and cancer is found only in the kidney and in 1 or more nearby lymph nodes OR Cancer is found in the main kidney blood vessels or in the fatty tissue around the kidney; cancer may be found in 1 or more nearby lymph nodes	T1 or T2 N1 M0 T3 N0 or N1 M0
IV	Tumor has spread to distant sites	T4 and N M0 Any T and N M1

**T*, tumor (size and extent; T4 tumors invade beyond Gerota fascia); *N*, regional lymph nodes (NX unable to assess, N0 no regional lymph node metastasis, N1 metastasis in a single regional lymph node); *M*, metastases (M0 no distant metastasis, M1 distant metastasis).[5]

- There is some evidence that high-dose intravenous interleukin-2 results in complete remission in 7% to 8% of patients with metastatic RCC; interferon-α has also conferred minimal improvement in overall survival (3.8 months) versus control group.[2]
- The NCCN recommends high-dose interleukin-2 as first-line therapy for predominantly clear cell carcinoma.[5]
- Similar improvement in survival (4 to 5 months), but not cure, has been reported for targeted therapies, primarily those using antivascular epithelial growth factor agents (bevacizumab, sorafenib, sunitinib, pazopanib, tivozanib, or axitinib) or mammalian target of rapamycin (mTOR) inhibitors (temsirolimus or everolimus) usually compared to interferon-α.[8] No placebo-controlled trial has reported a benefit on health-related quality of life.
- The European Society of Medical Oncologists recommend either sunitinib or combination of bevacizumab and interferon in good-risk and intermediate-risk patients, and temsirolimus in patients with poor-risk features and clear cell renal carcinoma.[10] The NCCN recommends any of these as first-line therapy for predominantly clear cell carcinoma and enrollment in a clinical trial as the preferred strategy for non–clear cell cancers, although temsirolimus has shown some promise.[5]
- Presurgical treatment with sunitinib was reported in one case series; the drug decreased the size of primary RCC in 17 of 20 patients treated.[9]

SURGERY

- For localized disease, partial nephrectomy for small tumors and radical nephrectomy (complete removal of the kidney and Gerota fascia) for large tumors is the gold standard.[2,10] SOR B For T1 tumors (**Table 71-1**), the NCCN recommends either partial (preferred) or radical nephrectomy, active surveillance for selected patients, or thermal ablation for nonsurgical candidates.[5]
- Similar to lumpectomy for localized breast cancer, partial nephrectomy for small tumors in the presence of a normal contralateral kidney appears to have similar outcomes to radical nephrectomy,

based on observational data.[11] Complications are uncommon and include urinary leak (3% to 5%) and hemorrhage (1%).[2] Advantages include better preservation of renal function, which is associated with fewer hospitalizations and lower risk of cardiac events and mortality.[2] In one long-term follow-up study, 5- and 10-year cancer-specific survival for nephron-sparing surgery in these cases was 98.5% and 96.7% for tumors less than 4 cm, respectively, and for imperative indications (solitary kidney) they were 89.6% and 76%, respectively. Chronic renal failure requiring dialysis was reported in 9 patients (11.2%) with a solitary kidney.[12]

- Percutaneous cryoablation or radiofrequency ablation of smaller (≤3.5 cm) renal masses is an alternative treatment[13,14]; outcomes for the 2 methods appear comparable, but the procedures have not been compared in a randomized trial.[15] Limitations of thermoablation include high local recurrence compared to surgery, lack of long-term data, and subsequent fibrosis that may compromise subsequent surgery if needed.
- For patients with larger tumors or local extension, radial nephrectomy offers a 40% to 60% chance of cure.[2] Laparoscopic approaches are used more recently, but there are no RCTs supporting this approach.[16]
- For patients with metastatic disease, cytoreductive nephrectomy (similar to radical nephrectomy with removal of the kidney and possibly other surrounding structures) should be considered.[10] NCCN recommends nephrectomy and surgical metastasectomy for a potentially surgically resectable solitary metastatic site.[5]
- In a combined analysis of trials, survival was longer in patients with metastatic RCC randomized to radical nephrectomy followed by interferon versus interferon alone (13.6 months vs. 7.8 months, respectively).[17]
- Regional lymphadenectomy is controversial.
- Resection of solitary metastasis should be considered.[18] In a systematic review of data on 311 surgically and 73 nonsurgically treated patients with RCC metastatic to pancreas, metastases were single in approximately 60% of both groups. Surgery appeared to improve overall survival at 2 and 5 years (80.6% and 72.6%, respectively, for the surgical group, and 41% and 14%, respectively, in unresected patients).[19]

FOLLOW-UP

There is no standardized follow-up regimen based on evidence. The ACR recommends a follow-up CXR and CT of the abdomen without and with contrast for patients who have been treated for RCC by radical nephrectomy or nephron-sparing surgery.[4] The NCCN recommends chest and abdominal imaging at 2 to 6 months.[5] An MRI can be used for patients unable to undergo CT with contrast.[4] Most recurrences occur within 2 to 3 years after initial resection.[4]

- For patients with T1 tumors, most surveillance protocols recommend a history, physical examination, laboratory tests, and CXR be obtained every 6 to 12 months for 3 years and then yearly until year 5.[4] Others have suggested no imaging if the tumor is less than 2.5 cm. Most protocols do not recommend surveillance with abdominal CT for patients with T1 tumors.

- For patients with T2 primary tumors, a history, physical examination, laboratory tests, and CXR is recommended annually or every 6 months for 3 years, then annually thereafter till year 5.[4] Protocols vary widely with some not recommending abdominal CT at all, while others recommend CT at intervals ranging from annually for 3 years to once in year 2 and year 5.
- For patients with T3 or T4 primary tumors, most protocols recommend a history, physical examination, laboratory tests, and CXR be obtained every 6 months for a few years, then annually thereafter.[4] Most also recommend abdominal CT every 3 to 6 months for 3 years after surgery and less frequently (yearly or every other year) thereafter.

PROGNOSIS

- The clinical course is highly variable and spontaneous remissions have occurred.
- In a metaanalysis of 300 cases, small tumors had an average growth rate of 0.28 cm per year.[20] Although follow-up for most patients was only 2 to 3 years, only 1% of these patients developed metastases.
- Among patients initially treated with partial or radical nephrectomy, local or metastatic recurrences develop in approximately 20% to 50% of them.
- Five-year survival rates are 90.8% for localized disease (stage I, confined to the kidney), 63.1% for regional disease (spread to regional lymph nodes), and 11% for metastatic disease (stage IV).[3]
- In one retrospective study across 5 European centers (N = 1124), prognostic factors for survival following nephrectomy for RCC on univariate analysis were TNM (tumor, nodes, metastases) stage, Fuhrman grade (based on cell morphology), symptoms, Eastern Cooperative Oncology Group performance status, tumor size, and urinary collecting system invasion.[21]
- For papillary RCC, one study found incidental detection, T classification, M classification, vascular invasion, and tumor necrosis extent were independent prognostic factors of disease-specific survival.[22]
- For advanced RCC, a multivariate analysis with 246 patients found performance status 1 versus 0 (hazard ratio [HR] 1.95, $p < 0.0001$), high alkaline phosphatase (HR 1.5, $p = 0.002$), and lung metastasis only (HR 0.73, $p = 0.028$) were overall survival predictors.[23]

PATIENT EDUCATION

Several prognostic algorithms, or nomograms, for RCC survival are available that may be useful in counseling patients about their probable clinical course and facilitating treatment planning.[22,24]

PATIENT RESOURCES

- National Kidney Foundation (800-622-9010 or e-mail **http://www.kidney.org/about/contact.cfm**)—**http://www.kidney.org.**
- National Institutes of Health, MedlinePlus. *Kidney Cancer*—**http://www.nlm.nih.gov/medlineplus/kidneycancer.html.**

PROVIDER RESOURCES

- National Cancer Institute Surveillance Epidemiology and End Results. *SEER Stat Fact Sheets: Kidney and Renal Pelvis*—**http://seer.cancer.gov/statfacts/html/kidrp.html.**
- Kidney Cancer Trial Search Tool (800) 850-9132—**http://www.kidneycancer.org/knowledge/clinical-trials/about-clinical-trials.**

REFERENCES

1. Scher HI, Motzer RJ. Bladder and renal cell carcinomas. In: Kasper DL, Braunwald E, Fauci AS, Hauser SL, Longo DL, Jameson JL, eds. *Harrison's Principles of Internal Medicine*, 16th ed. New York: McGraw-Hill; 2005:541-543.
2. Rini BI, Campbell SC, Escudier B. Renal cell carcinoma. *Lancet.* 2009;373:1119-1132.
3. National Cancer Institute. *SEER Stat Fact Sheets: Kidney and Renal Pelvis*. http://seer.cancer.gov/statfacts/html/kidrp.html. Accessed January 2012.
4. Casalino DD, Francis IR, Arellano RS, et al; Expert Panel on Urologic Imaging. *ACR Appropriateness Criteria® Follow-Up of Renal Cell Carcinoma* [online publication]. Reston, VA: American College of Radiology; 2009. 6 p. http://www.guideline.gov/content.aspx?id=15762&search=renal+cell+carcinoma. Accessed January 2012.
5. Motzer RJ, Agarwal N, Beard C, et al. NCCN clinical practice guidelines in oncology: kidney cancer. *J Natl Compr Canc Netw.* 2009;7(6):618-630.
6. Israel GM, Casalino DD, Remer EM, et al; Expert Panel on Urologic Imaging. *ACR Appropriateness Criteria® Indeterminate Renal Masses* [online publication]. Reston, VA: American College of Radiology; 2010. 7 p. http://www.guideline.gov/content.aspx?id=32641&search=renal+cell+carcinoma. Accessed January 2012.
7. Jewett MA, Zuniga A. Renal tumor natural history: the rationale and role for active surveillance. *Urol Clin North Am.* 2008;35(4):627-634.
8. Coppin C, Kollmannsberger C, Le L, et al. Targeted therapy for advanced renal cell cancer (RCC): a Cochrane systematic review of published randomised trials. *BMJ (Int Ed).* 2011;108(10):1556-1563.
9. Hellenthal NJ, Underwood W, Penetrante R, et al. Prospective clinical trial of preoperative sunitinib in patients with renal cell carcinoma. *J Urol.* 2010;184(3):859-864.
10. Escudier B, Kataja V; ESMO Guidelines Working Group. Renal cell carcinoma: ESMO clinical practice guidelines for diagnosis, treatment and follow-up. *Ann Oncol.* 2010;21 Suppl 5:v137-v139.
11. Butler BP, Novick AC, Miller DP, et al. Management of small unilateral renal cell carcinomas: radical versus nephron-sparing surgery. *Urology*. 1995;45:34-40.
12. Roos FC, Pahernik S, Brenner W, Thuroff JW. Imperative and elective indications for nephron-sparing surgery for renal tumors: long-term oncological follow-up. *Aktuelle Urol*. 2010;(Suppl 1):S70-S76.

13. Uppot RN, Harisinghani MG, Gervais DA. Imaging-guided percutaneous renal biopsy: rationale and approach. *AJR Am J Roentgenol.* 2010;194(6):1443-1449.
14. Venkatesan AM, Wood BJ, Gervais DA. Percutaneous ablation in the kidney. *Radiology.* 2011;261(2):375-391.
15. Pirasteh A, Snyder L, Boncher N, et al. Cryoablation vs. radiofrequency ablation for small renal masses. *Acad Radiol.* 2011;18(1):97-100.
16. Nabi G, Cleves A, Shelley M. Surgical management of localised renal cell carcinoma. *Cochrane Database Syst Rev.* 2010;(3):CD006579.
17. Flanigan RC, Mickisch G, Sylvester R, et al. Cytoreductive nephrectomy in patients with metastatic renal cancer: a combined analysis. *J Urol.* 2004;171:1071-1076.
18. Karam JA, Rini BI, Varella L, et al. Metastasectomy after targeted therapy in patients with advanced renal cell carcinoma. *J Urol.* 2011;185(2):439-444.
19. Tanis PJ, van der Gaag NA, Busch OR, et al. Systematic review of pancreatic surgery for metastatic renal cell carcinoma. *Br J Surg.* 2009;96(6):579-592.
20. Chawla SN, Crispen PL, Hanlon AL, et al. The natural history of observed enhancing renal masses: meta-analysis and review of the world literature. *J Urol.* 2006;175:425-431.
21. Verhoest G, Avakian R, Bensalah K, et al. Urinary collecting system invasion is an independent prognostic factor of organ confined renal cell carcinoma. *J Urol.* 2009;182(3):854-859.
22. Klatte T, Remzi M, Zigeuner RE, et al. Development and external validation of a nomogram predicting disease specific survival after nephrectomy for papillary renal cell carcinoma. *J Urol.* 2010;184(1):53-58.
23. Lars PN, Tangen CM, Conlon SJ, et al. Predictors of survival of advanced renal cell carcinoma: long-term results from Southwest Oncology Group Trial S8949. *J Urol.* 2009;181(2):512-516.
24. Lane BR, Kattan MW. Predicting outcomes in renal cell carcinoma. *Curr Opin Urol.* 2005;15(5):289-297.

72 BLADDER CANCER

Mindy A. Smith, MD, MS

PATIENT STORY

A 68-year-old man, who is a retired painter and in good health, comes to the office at the insistence of his wife. He reports that his urinary stream is smaller and he has occasional dysuria. He has no major medical problems, although he continues to smoke one pack of cigarettes per day. His urinalysis in the office shows microscopic hematuria and an irregular mass is seen in the bladder on CT scan (**Figure 72-1**). Cystoscopy shows a bladder tumor (**Figure 72-2**). Complete endoscopic resection is performed and confirms transitional cell carcinoma.

FIGURE 72-1 CT with contrast reveals a bladder cancer in a 68-year-old man with hematuria. (*Courtesy of Michael Freckleton, MD.*)

INTRODUCTION

Bladder cancer is a malignant neoplasm of the bladder, almost exclusively urothelial (transitional cell) carcinoma.

EPIDEMIOLOGY

- In 2008, there were approximately 398,329 men and 139,099 women alive in the United States who had a history of cancer of the urinary bladder.[1]
- Almost 70,000 new cases (52,020 men and 17,230 women) were diagnosed and approximately 14,990 deaths occurred from bladder cancer in 2011.[1] Mean age at diagnosis is 73 years.
- The age-adjusted incidence rate (based on 2004 to 2008 data) was 21.1 per 100,000 men and women per year with a male-to-female ratio of approximately 4:1. Among men, bladder cancer is more prevalent in whites than in blacks or Hispanics (ratio of 2:1) and more prevalent in whites than in Asian/Pacific Islander or American Indian/Alaska Natives (ratio 2.4:1); for white women, incidence rates are also higher but the differences are not as great.[1]

ETIOLOGY AND PATHOPHYSIOLOGY

- Ninety percent to 95% are transitional cell cancers and the remainder are nonurothelial neoplasms, including primarily squamous cell, adenocarcinoma, and small cell carcinoma[2,3] (**Figures 72-1** to **72-4**). Rare forms include nonepithelial neoplasms (approximately 1%), including benign tumors, such as hemangiomas or lipomas, and malignant tumors, such as angiosarcomas.[3]
- Transitional cells line the urinary tract from the renal pelvis to the proximal two-thirds of the urethra. Ninety percent of transitional cell tumors develop in the bladder and the others develop in the renal pelvis, ureters, or urethra.[2]
- Most tumors are superficial (75% to 85%).[4] At diagnosis, approximately 51% are in situ and 35% are localized (confined to primary

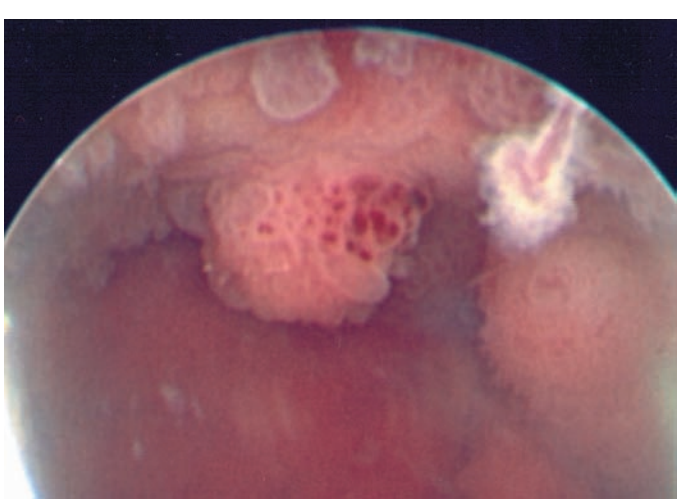

FIGURE 72-2 Cystoscopic view of the transitional cell carcinoma in the man in **Figure 72-1**. (*Courtesy of Carlos Enrique Bermejo, MD.*)

site) with an additional 7% of cases having regional spread and 4% having distant metastases at diagnosis (3% unknown).[2]

- Multiple tumors are seen in 30% of cases.[4]
- Bladder tumor cells are also graded based on their appearance and behavior into well differentiated or low grade (grade 1), moderately well differentiated or moderate grade (grade 2), and poorly differentiated or high grade (grade 3).
- The most common sites of hematogenous spread are lung, bone, liver, and brain. Superficial lesions do not metastasize until they invade deeply and may remain indolent for years.[2]

RISK FACTORS

- Risk factors include smoking (odds ratio increased by 3- to 4-fold; 50% attributable risk) and exposure to pelvic radiation,[5] the drugs phenacetin and chlornaphazine, external-beam radiation, and chronic infection, including *Schistosoma haematobium* and genitourinary tuberculosis.[2,3]
- There is an increased risk in certain occupations, particularly those involving exposure to metals (e.g., aluminum), paint and solvents, polycyclic aromatic hydrocarbons, diesel engine emissions, aniline dyes (e.g., workers in chemical plants exposed to benzidine or *o*-toluidine),[2] and textiles.[6]
- An increased risk was also seen with drinking tap water (odds ratio [OR] for >2 L/day vs. ≤0.5 L/day was 1.46 [1.20 to 1.78]), with a higher risk among men (OR = 1.50, 1.21 to 1.88).[7]
- Familial cases indicate a genetic predisposition.[8]

DIAGNOSIS

CLINICAL FEATURES

- Hematuria in 80% to 90%; with microscopic hematuria approximately 2% have bladder cancer and with gross hematuria approximately 20% have bladder cancer.[3]
- Irritative symptoms (i.e., dysuria, frequency) are the most common presentation.
- Obstructive symptoms may occur if the tumor is located near the urethra or bladder neck.

LABORATORY

- Urine microscopy and culture to rule out bladder infection.[3]
- Urine cytology (high specificity [90% to 95%] but low sensitivity [23% to 60%]), CT scan of the pelvis (**Figures 72-1**,**72-3**, and **72-4**) or intravenous urography (IVU), and cystoscopy with biopsy (**Figure 72-2**) comprise the basic work-up.[2] Fluorescence cystoscopy (use of photosensitizer instilled into the bladder, can enhance detection of flat neoplastic lesions like carcinoma in situ (CIS).[4] When CIS is found in a cystectomy specimen, 9% to 13% of patients have upper urinary tract disease.[4]
- Bladder wash cytology during cystoscopy detects most CIS.[3]
- A complete blood count, blood chemistry tests (including alkaline phosphatase tests), liver function tests, CT or MRI of the chest or

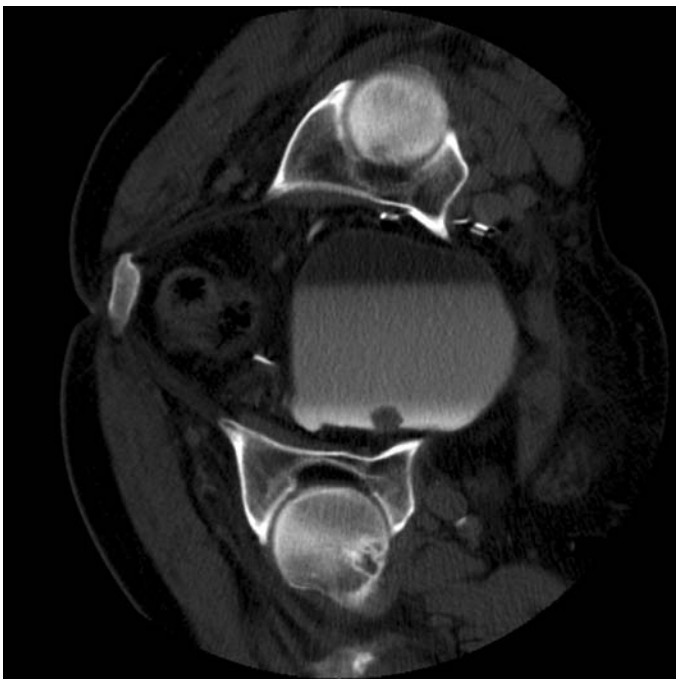

FIGURE 72-3 CT with contrast of a small transitional cell carcinoma of the bladder that was barely visible until the patient was scanned on side. A small bladder diverticulum is visible as well. (*Courtesy of Michael Freckleton, MD.*)

FIGURE 72-4 CT of locally invasive transitional cell carcinoma (arrow) of the bladder extending outside of the bladder in a 71-year-old man. The carcinoma on the patient's right is displacing the contrast toward the left side of the patient's bladder. (*Courtesy of Michael Freckleton, MD.*)

abdomen and a bone scan may be needed for suspected metastatic disease.[2,3] Bone scanning may be limited to patients with bone pain and/or elevated levels of serum alkaline phosphatase.[4]

- Tumor markers such as fluorescence in situ hybridization (FISH) analysis and nuclear matrix protein (NMP) 22 identify changes in cells in the urine and are more sensitive than urine cytology for low-grade tumors with equivalent sensitivity for high-grade tumors and CIS.[9] As specificity is low, tumor markers should not be used for diagnosis.

IMAGING

- For pretreatment staging of invasive bladder cancer, the American College of Radiology (ACR) recommends a chest X-ray (with chest CT if equivocal), CT of the abdomen and pelvis (without and with contrast) or MRI of the pelvis (especially in cases where patients are unable to undergo contrast injection), and possibly IVU; contrast-enhanced MRI is preferred over CT for local staging.[4] SOR C
- The European Association of Urology (EAU) recommends multidetector-row CT (MDCT) of the chest, abdomen, and pelvis as the optimal form of staging for patients with confirmed muscle-invasive bladder cancer, including MDCT urography for examination of the upper urinary tracts.[9] If MDCT is not available, alternatives are excretory urography and a chest X-ray. SOR B
- EAU recommends renal and bladder ultrasonography, and IVU or CT prior to transurethral resection for presumed invasive bladder cancer.[10] SOR B ACR agrees that ultrasound is useful for local tumor staging.[4] For patients with verified invasive bladder cancer, EAU recommends either MRI with fast dynamic contrast-enhancement or MDCT with contrast enhancement for patients considered suitable for radical treatment. SOR B

BIOPSY

- Diagnosis is made by cystoscopy, biopsy, and histology.

DIFFERENTIAL DIAGNOSIS

- Among adult patients with microscopic hematuria, most patients have benign pathology, such as urinary tract infection, with 25% having prostate cancer and only 2% having bladder cancer.[2]
- Among adult patients with gross hematuria, 22% have benign cystitis and 15% to 20% have bladder cancer.[2]

MANAGEMENT

MEDICATIONS

Neoadjuvant cisplatin-containing combination chemotherapy (administered prior to main treatment) improves overall 5-year survival by 5% to 7% and should be considered in muscle-invasive bladder cancer irrespective of definitive treatment.[9,11] SOR A It is not recommended for patients with performance status of 2 or more and impaired renal function or for primary therapy for localized bladder cancer.[9]

- The role of adjuvant chemotherapy (usually administered after surgery) for invasive bladder cancer is under debate. A Cochrane review based on 6 small trials (N = 491) found a 25% relative reduction in the risk of death for chemotherapy compared to control patients (hazard ratio for survival 0.75; 95% CI 0.60, 0.96), suggesting a benefit for these patients.[12]
- Cisplatin-containing combination chemotherapy is first-line therapy for patients with metastatic disease and treated patients can achieve a median survival of up to 14 months.[9,13] SOR A

SURGICAL

Depends on the extent (depth and grade) or spread of the disease (**Table 72-1**). Recommendations have been provided by the American Urological Association (AUA, 2007)[13] and the EAU (2009)[9] as given below:

- Non–muscle-invasive disease (70% to 75% of cases)—Complete endoscopic resection with or without intravesical treatment (bacille Calmette-Guérin [BCG] weekly for 6 weeks or interferon or mitomycin C). SOR C Low-grade tumors (Ta tumors) can be treated with resection alone or with a single postoperative dose of intravesical chemotherapy. SOR B In a metaanalysis of three trials, tumor recurrence was significantly lower with intravesical BCG but there was no difference in disease progression or survival.[14] SOR B BCG treatment causes urinary frequency (71%), cystitis (67%), hematuria (23%), fever (25%),[15] and, rarely, systemic granulomatous infection requiring antituberculosis treatment.
- For Ta, Tis, or T1 tumors that are initially histologically confirmed as high grade, the AUA recommends repeat resection and additional intravesical therapy (induction course of BCG followed by maintenance therapy).[13] SOR A A Cochrane review based on five small trials found that immunotherapy with intravesical BCG following surgery benefits patients with medium/high risk Ta or T1 bladder cancer on delaying tumor recurrence.[15] Additional Cochrane reviews found intravesical BCG more effective than intravesical epirubicin or mitomycin C in reducing tumour recurrence (the latter only for patients at high risk of recurrence) [16,17]; mitomycin C, however, was equivalent to BCG for disease progression and survival. SOR A
- Persistent or recurrent superficial disease—Repeat resection with an induction course of BCG; maintenance BCG or mitomycin C is recommended or consideration of intravesical chemotherapy (valrubicin or gemcitabine). SOR B For treatment failure of patients with non–muscle-invasive bladder tumors, EAU recommends radical cystectomy for those with high-grade tumors and cystectomy for other patients with T1 tumors.[9] SOR B Delay in cystectomy for these patients increases the risk of progression and cancer-specific death.[9]
- Recurrent high-grade T1 tumors or invasive-muscle disease (extends to muscle or lymph nodes)—Radical cystectomy and pelvic lymphadenectomy with or without systemic chemotherapy.[2,9] SOR C In men, radical cystectomy includes removal of the prostate, seminal vesicles, and proximal urethra resulting in impotence. In women, the uterus, ovaries, and anterior vaginal wall are removed. Most patients receive cutaneous reservoirs (bowel or orthotopic neobladder) drained by intermittent self-catheterization.
- Chemotherapy is not used for nonurothelial cancers, such as squamous cell carcinoma or adenocarcinoma, which are primarily treated with cystectomy.[2]

TABLE 72-1 Bladder Cancer Categories, Stage, and 5-Year Survival Rate

Tumor Category	Stage of Tumor*	Description	5-Year Survival
Non–muscle-invasive disease			
Ta	Stage 0 (N0,M0)	Nonmuscle-invasive papillary carcinoma	90%
Tis	Stage 0 (N0,M0)	Carcinoma in situ	96.6%
T1	Stage I (N0,M0)	Tumor invading the lamina propria	
Muscle-invasive disease			
T2a	Stage II (N0,M0)	Tumor grown into inner half of muscle layer	70.7%
T2b	Stage II (N0,M0)	Tumor grown into outer half of muscle layer	
T3†	Stage III (N0,M0)	Tumor through muscle layer into fatty tissue	
T4a	Stage III (N0,M0)	Tumor beyond fatty tissue into nearby organs‡	
T4b	Stage IV (N0,M0)	Tumor beyond into pelvic or abdominal wall‡	
Lymph node			
N0	Stage IV	No lymph node involvement	34.6%
N1	Stage IV	Spread to single lymph node in true pelvis	
N2	Stage IV	Spread to 2 or more lymph nodes in true pelvis	
N3		Spread to nodes along the common iliac artery	
Metastatic disease			
M0	Stage IV	No distant spread	5.4%
M1		Cancer has spread to distant sites*	

*Determined by combining the tumor category with presence or absence and number of lymph nodes involved (N), and presence or absence or distant spread (e.g., distant lymph nodes, bones, lungs, and liver).
†Also divided into *a* (microscopic spread into fatty tissue) and *b* (visible spread on imaging or to the eye).
‡Also divided into *a* (spread to prostate or uterus/vagina) and *b* (spread to pelvic or abdominal wall).
Information based on SEER data. http://seer.cancer.gov/statfacts/html/urinb.html. Accessed November 2011.

- Upper urinary tract recurrence—Radical nephroureterectomy. SOR B

OTHER THERAPY

- In a Cochrane review of three trials comparing radical radiotherapy followed by surgery (salvage cystectomy) versus radical cystectomy, overall survival was better with radical cystectomy.[18] SOR A
- External-beam radiotherapy alone is considered an option for patients unfit for cystectomy or to stop the bleeding from a tumor when local control can't be achieved by transurethral manipulation because of extensive local tumor growth.[9] SOR C

PREVENTION

Eliminate active and passive smoking.[9] SOR C

PROGNOSIS

- Most recurrences are also superficial tumors with only approximately 10% to 15% of tumors progressing to invasive disease.[4]
- Performance status, ranging from 0 (fully active) to 4 (completely disabled), and the presence or absence of visceral metastases are independent prognostic factors for survival.
- The EAU working group suggests use of a weighted scoring system to estimate recurrence and progression risk.[19] Factors include number, size, category, and grade of tumors; recurrence; and concomitant CIS. Scores range from 0 to 17 for recurrence and 0 to 23 for progression. These scores are translated into probabilities for 1-year and 5-year recurrence (15% and 31%, respectively, for a score of 0, and 61% to 78%, respectively, for a score of 10 to 17) and 1-year and 5-year progression (0.2% and 0.8%, respectively, for a score of 0, and 17% to 45%, respectively, for a score of 14 to 23).
- Risk of disease progression by tumor grade: 10% to 15% progress with grade 1 tumors, 14% to 37% with grade 2, and 33% to 64% with grade 3 tumors.[20]
- Five-year survival rates for superficial disease are 90%; infiltrating (stage II or III), 35% to 70%; metastatic disease (stage IV), 5.4% to 20% (see **Table 72-1**).[1] Long-term disease-free survival is reported in approximately 15% of patients with nodal disease and good performance status.

FOLLOW-UP

- Recurrence rates overall are 50% with a median recurrence at 1 year (0.4 to 11 years), and 5% to 20% progress to a more advanced stage. Patients should be seen every 3 months for the first year. SOR C The ACR and EAU recommend stopping oncologic surveillance after 5-years of normal follow-up to be replaced by functional surveillance (e.g., renal function).[4,9]
- For patients with high-grade Ta and T1 disease, cystoscopy, urinalysis and urine cytology are recommended every 3 months for 2 years, then every 6 months for 2 years, then annually. Imaging of the upper tract collecting system is performed every 1 to 2 years.[2,4]

- For patients with muscle-invasive disease, laboratory tests (liver function test, creatinine clearance, electrolyte panel) in addition to a chest X-ray are recommended every 6 to 12 months with imaging of upper urinary tract, abdomen, and pelvis for recurrence every 3 to 6 months for 2 years, and then as clinically indicated.[3]
- For patients undergoing bladder-sparing surgery, urine cytology with or without biopsy is conducted every 3 months for 1 year, then at increasing intervals.[3]
- For patients undergoing cystectomy, urine cytology is conducted every 6 to 12 months, and for those undergoing cystectomy and cutaneous diversion, urethral wash cytology is recommended every 6 to 12 months.[3]
- For patients with cystectomy and continent orthotopic diversion, vitamin B_{12} level should be checked annually.[3,21]
- Bladder tumor markers from voided urine will likely improve detection of recurrence in the future, but data are still insufficient to warrant substitution of cystoscopic follow-up.[4,22]

PATIENT EDUCATION

- The most important primary prevention for muscle-invasive bladder cancer is to eliminate active and passive smoking.
- Tumor recurrence and progression risk can be estimated from clinical and pathologic factors;[4] this information may help in joint decision-making for primary treatment and follow-up intervals.

PATIENT RESOURCES

- **www.nlm.nih.gov/medlineplus/bladdercancer.html.**
- **http://cancerhelp.cancerresearchuk.org/type/bladder-cancer/about/.**
- **http://www.macmillan.org.uk/Cancerinformation/Cancertypes/Bladder/Bladdercancer.aspx.**

PROVIDER RESOURCES

- *SEER Cancer Statistics Review*—**http://seer.cancer.gov/statfacts/html/urinb.html.**

REFERENCES

1. *SEER Cancer Statistics Review*. http://seer.cancer.gov/statfacts/html/urinb.html. Accessed November 2011.
2. Scher HI, Motzer RJ. Bladder and renal cell carcinomas. In: Kasper DL, Braunwald E, Fauci AS, Hauser SL, Longo DL, Jameson JL, eds. *Harrison's Principles of Internal Medicine*, 16th ed. New York: McGraw-Hill; 2005:539-540.
3. Sharma S, Ksheersagar P, Sharma P. Diagnosis and treatment of bladder cancer. *Am Fam Physician*. 2009;80(7):717-723.
4. American College of Radiology (ACR), Expert Panel on Urologic Imaging. *ACR Appropriateness Criteria® Pretreatment Staging of Invasive Bladder Cancer (2009)*. http://www.guidelines.gov/content.aspx?id=15767&search=bladder+cancer. Accessed November 2011.
5. Quilty PM, Kerr GR. Bladder cancer following low or high dose pelvic irradiation. *Clin Radiol*. 1987;38(6):583-585.
6. Band PR, Le ND, MacArthur AC, et al. Identification of occupational cancer risks in British Columbia: a population-based case-control study of 1129 cases of bladder cancer. *J Occup Environ Med*. 2005;47(8):854-858.
7. Villanueva CM, Cantor KP, King WD, et al. Total and specific fluid consumption as determinants of bladder cancer risk. *Int J Cancer*. 2006;118(8):2040-2047.
8. Aben KK, Witjes JA, Schoenberg MP, et al. Familial aggregation of urothelial cell carcinoma. *Int J Cancer*. 2002;98(2):274-278.
9. Gutiérrez Baños JL, Rebollo Rodrigo MH, Antolín Juárez FM, Martín García B. NMP 22, BTA stat test and cytology in the diagnosis of bladder cancer: a comparative study. *Urol Int*. 2001;66(4):185-190.
10. European Association of Urology. *Guidelines on Bladder Cancer: Muscle-Invasive and Metastatic*. http://www.guidelines.gov/content.aspx?id=12524&search=bladder+cancer. Accessed November 2011.
11. Advanced Bladder Cancer Meta-analysis Collaboration. Neoadjuvant chemotherapy for invasive bladder cancer. *Cochrane Database Syst Rev*. 2005 Apr 18;(2):CD005246.
12. Vale CL, Advanced Bladder Cancer Meta-analysis Collaboration. Adjuvant chemotherapy for invasive bladder cancer (individual patient data). *Cochrane Database Syst Rev*. 2006 Apr 19;(2):CD006018.
13. American Urological Association guideline. http://www.guidelines.gov/content.aspx?id=11795&search=bladder+cancer. Accessed November 2011.
14. Shelley MD, Wilt TJ, Court J, et al. Intravesical bacillus Calmette-Guerin is superior to mitomycin C in reducing tumour recurrence in high-risk superficial bladder cancer: a meta-analysis of randomized trials. *BJU Int*. 2004;93(4):485-490.
15. Shelley M, Court JB, Kynaston H, et al. Intravesical bacillus Calmette-Guérin in Ta and T1 bladder cancer. *Cochrane Database Syst Rev*. 2000;(4):CD001986.
16. Shang PF, Kwong J, Wang ZP, et al. Intravesical Bacillus Calmette-Guérin versus epirubicin for Ta and T1 bladder cancer. *Cochrane Database Syst Rev*. 2011 May 11;(5):CD006885.
17. Shelley M, Court JB, Kynaston H, et al. Intravesical bacillus Calmette-Guérin versus mitomycin C for Ta and T1 bladder cancer. *Cochrane Database Syst Rev*. 2003;(3):CD003231.
18. Shelley M, Barber J, Wilt T, Mason M. Surgery versus radiotherapy for muscle invasive bladder cancer. *Cochrane Database Syst Rev*. 2002;(1):CD002079.
19. European Association of Urology. *Guidelines on TaT1 (Non-Muscle Invasive) Bladder Cancer*. http://www.guidelines.gov/content.aspx?id=14798&search=bladder+cancer. Accessed December 2011.
20. Canadian Cancer Society. http://info.cancer.ca/cce-ecc/default.aspx?Lang=E&cceid=7593&toc=5. Accessed November 2011.
21. Ganesan T, Khadra MH, Wallis J, Neal DE. Vitamin B12 malabsorption following bladder reconstruction or diversion with bowel segments. *ANZ J Surg*. 2002;72(7):479-482.
22. Lokeshwar VB, Habuchi T, Grossman HB, et al. Bladder tumor markers beyond cytology: International consensus panel on bladder tumor markers. *Urology*. 2005;66:35-63.

73 PROSTATE CANCER

Rowena A. DeSouza, MD
Melanie Ketchandji, MD

PATIENT STORY

A 65-year-old man in good health comes to the office having had a prostate specific antigen (PSA) test performed at a local health fair. He reports a normal voiding pattern and normal erectile function with no evidence of weight loss or bone pain. He has no major medical problems but does have a strong family history of prostate cancer. His PSA is 9.3 ng/mL and he chooses to have a prostate biopsy. Pathology demonstrates prostate cancer with a Gleason score of 6 (**Figure 73-1**).

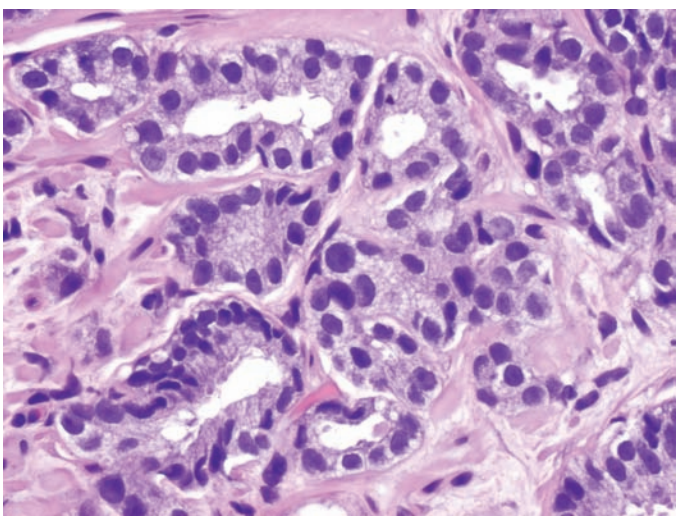

FIGURE 73-1 Microscopic image of biopsy demonstrating glands with enlarged nuclei and prominent nucleoli (hematoxylin and eosin [H&E] staining). The patient was diagnosed with prostate cancer with a Gleason score of 6. (*Courtesy of E.J. Mayeaux, Jr., MD.*)

INTRODUCTION

Prostate cancer is a very common cancer in men. Secondary to widespread testing, we have seen a stage migration in prostate cancer. Most patients are diagnosed with asymptomatic, clinically localized disease. Multiple factors such as Gleason score, PSA level, stage at diagnosis, and life expectancy are all factors applied to risk stratify patients associated with varying possibilities of achieving a cure. It is especially important to consider life expectancy prior to offering PSA screening.

EPIDEMIOLOGY

- Prostate cancer (**Figure 73-2**) is the leading cancer in U.S. men and the second leading cause of cancer deaths in men.[1]
- It is the second most common cancer in men worldwide, with an estimated 900,000 cases and 258,000 deaths in 2008.[2]
- Incidence is increased with age.
- The risk of developing prostate cancer increases at age 40 years in black men and in those who have a first-degree relative with prostate cancer.
- The risk of developing prostate cancer begins to increase at age 50 years in white men who have no family history of the disease.[3]
- There is no peak age or modal distribution.
- The highest incidence of prostate cancer in the world is found in African American men, who have approximately a 9.8% lifetime risk of developing prostate cancer. There is accompanied by a high rate of prostate cancer mortality (**Figure 73-3**).
- The lifetime risk of prostate cancer for white men in the United States is 8%.[3]
- Japanese and mainland Chinese populations have the lowest rates of prostate cancer.
- Socioeconomic status appears to be unrelated to the risk of prostate cancer.

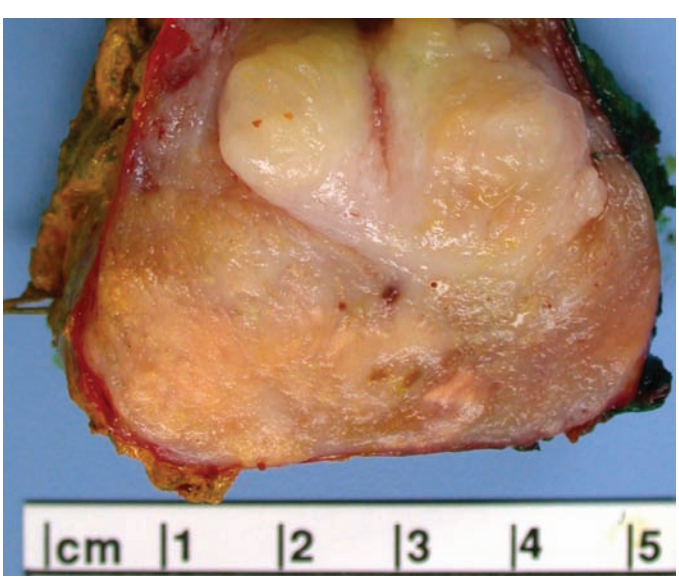

FIGURE 73-2 Photograph showing adenocarcinoma on the left lower side of the specimen and bilateral benign prostatic hypertrophy toward the top. (*Courtesy of E.J. Mayeaux, Jr., MD.*)

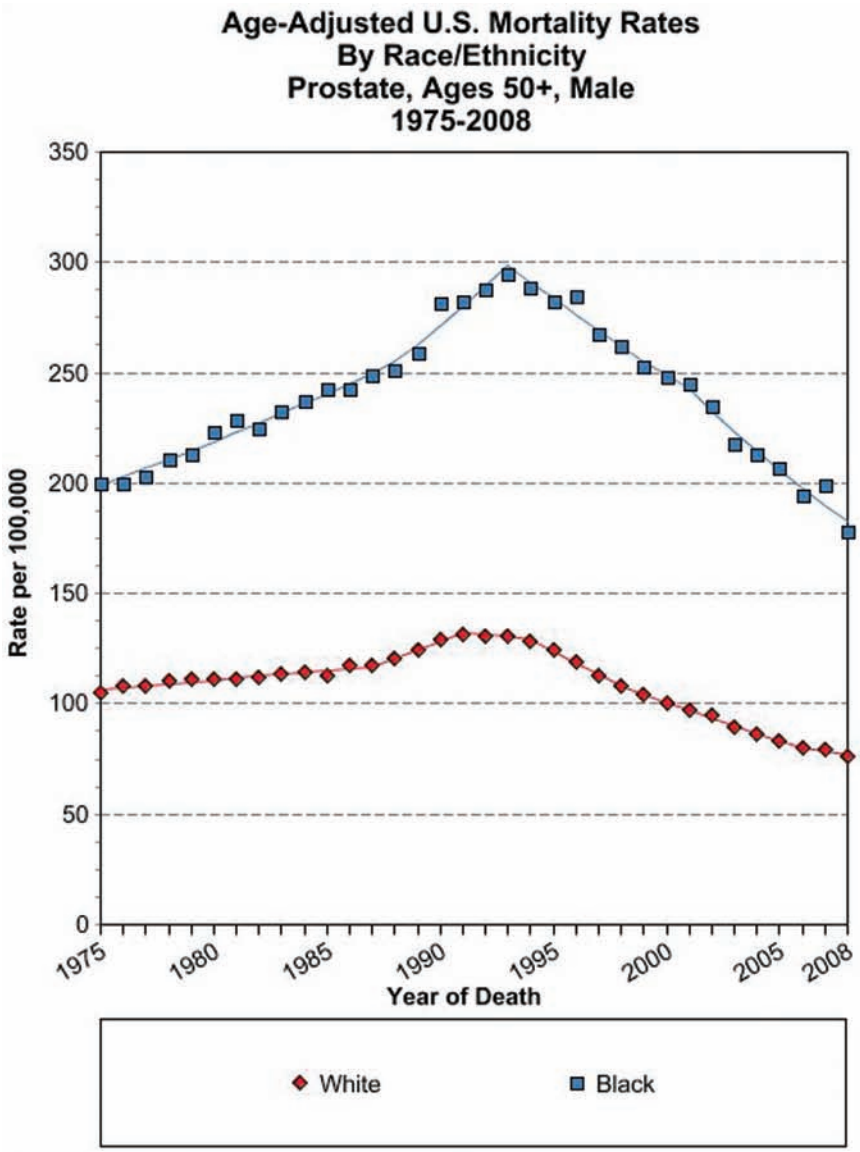

FIGURE 73-3 Age-adjusted U.S. prostate cancer mortality rates by race and ethnicity in males older than the age of 50 years. Note the higher mortality in blacks.

ETIOLOGY AND PATHOPHYSIOLOGY

- Greater than 95% of prostate cancers are adenocarcinomas.
- Histologic variants include ductal or endometrioid carcinoma, mucinous adenocarcinoma, signet cell carcinoma, small cell carcinoma, squamous and adenosquamous carcinoma, basaloid and adenoid cystic carcinoma.
- Of prostate adenocarcinomas, 70% occur in the peripheral zone, 20% in the transitional zone, and approximately 10% in the central zone (**Figure 73-4**).
- Biologic behavior is affected by histologic grade as described by the Gleason Grade and Score (**Figure 73-5**). The Gleason grade is

based on the architectural pattern of prostate cancer cells. Based upon the growth pattern and differentiation, tumors are graded from 1 to 5, with grade 1 being the most differentiated and grade 5 the least differentiated. One grade is assigned to the most common tumor pattern, and a second grade to the next most common tumor pattern. The Gleason Score is obtained by adding the two grades together and ranges from 2 to 10. A higher score indicates a greater likelihood of having non–organ-confined disease, as well as a worse outcome after treatment of localized disease.

- Patterns of spread include direct extension, hematogenous, and lymphatic.
- Lymphatic spread occurs to the hypogastric, obturator, external iliac, presacral, common iliac, and paraaortic nodes.[4]
  - Of distant metastases, 90% are osseous.
  - Visceral metastases to lung, liver, and adrenals are less commonly seen without bone involvement.[4]

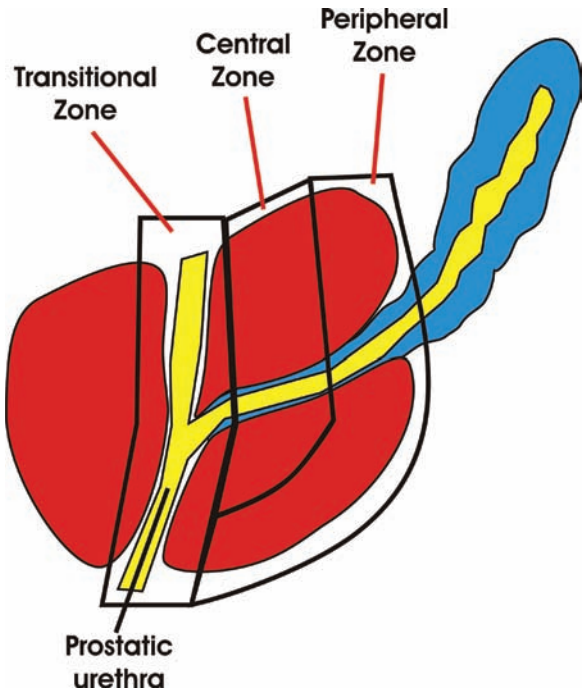

FIGURE 73-4 Diagram of prostate zones. Most prostate adenocarcinomas occur in the peripheral zone. (*Courtesy of E.J. Mayeaux, Jr., MD.*)

RISK FACTORS

- Men who have a first-degree relative with prostate cancer have approximately a two-fold increased risk of developing prostate cancer during their lifetime.
- African American ethnicity.

DIAGNOSIS

CLINICAL FEATURES

- Prostate cancer can be associated with urinary obstructive symptoms or hematuria, but these are usually a result of other causes.

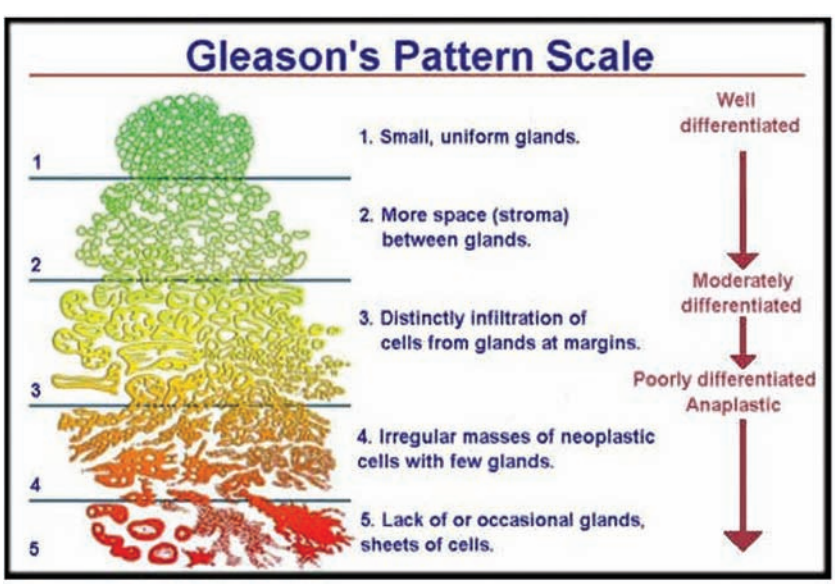

FIGURE 73-5 Gleason scoring of prostate cancer. (*From Gleason, DF. Histologic grading and clinical staging of prostatic carcinoma. In Tannenbaum M. Urologic Pathology: The Prostate. Philadelphia, PA: Lea and Febiger; 1977:171–197.*)

- Rarely, bone pain can be an initial symptom, but it generally represents very advanced disease. Prior to PSA screening, men commonly presented with this symptom.
- A prostatic nodule on digital rectal examination (DRE) is not always specific for a carcinoma and can underestimate the extent of disease when it does represent a carcinoma.

LABORATORY TESTING

PSA Screening

- PSA is a glycoprotein produced primarily by the epithelial cells that line the acini and ducts of the prostate gland.
- PSA is concentrated in prostatic tissue, and serum PSA levels are normally very low.
- Disruption of the normal prostatic architecture, such as by prostatic disease, inflammation, or trauma, allows greater amounts of PSA to enter the general circulation.[5]
- The sensitivity and specificity for PSA as a detection tool is 80% and 65%, respectively.[5] After treatment PSA is the primary tool used to evaluate for persistent disease or metastatic disease before imaging is employed.
- The American Urological Association guidelines support screening from age 40 years old to 75 years old.[6]
- The U.S. Prevention Task Force (USPSTF) has published final recommendations against PSA-based screening for prostate cancer in asymptomatic men.[7] They gave the guidance a D recommendation, which means there is moderate or high certainty that the service has no net benefit or that the harms outweigh the benefits, and the task force discourages use of the service. In May 2012, they concluded that many men are harmed as a result of prostate cancer screening [with PSA] and few, if any, benefit. A better test and better treatment options are needed. Until these are available, the USPSTF has recommended against screening for prostate cancer.[7]

IMAGING

Transrectal Ultrasound

- Transrectal ultrasound (TRUS) is a sensitive but nonspecific method of detecting prostate cancer.
- A hypoechoic lesion as seen on TRUS has a 30% chance of being carcinoma.
- TRUS should not be used as a screening tool.
- The most important use of TRUS is in combination with 12-core prostate needle biopsy.[3]

Bone Scan

- Radionuclide imaging is routinely used to evaluate for disseminated disease.
- Recent studies show that the likelihood of a positive bone scan in patients with a PSA value less than 10 ng/mL and no bone symptoms is 1 per 1000.[8]

CT Scan and MRI

- CT scans and body-surface-coil MRI of the pelvis have poor performance characteristics for assessing metastatic disease and are not part of standard screening or staging.
- MRI with an endorectal coil is sometimes used to evaluate disease beyond the capsule, in focal therapy, and for surgical planning.

Prostate Biopsy

- Performed with local anesthesia and ultrasound guidance using a spring-loaded biopsy needle to obtain 12 prostate biopsy specimens. The patient may experience significant discomfort despite the anesthetic.
- There is an estimated false negative rate of 0 to 9.3% and an estimated false positive rate of 0 to 3.8% amongst pathologists.[9]
- The percentage of positive cores, length or percentage of cancer per core can provide predictive information.
- Lower GI tract cleansing enemas and prophylactic antibiotics are routinely used.

DIFFERENTIAL DIAGNOSIS

- Prostatitis—Infection or inflammation of the prostate. This is often associated with perineal or suprapubic pain, dysuria frequency while prostate cancer is often asymptomatic.
- Benign prostatic hyperplasia—Enlarged prostate that may cause obstructive symptoms. There is no relative increase in the risk of developing prostate cancer.
- Prostatic intraepithelial neoplasia (PIN)—High-grade PIN has been noted as a precursor to prostate carcinoma.[10]
- Atypical glands on biopsy—The probability of detecting cancer following an atypical diagnosis is approximately 40%. Often a repeat biopsy is recommended with increased sampling of the atypical site.

MANAGEMENT

- General considerations include age, and general performance status, Gleason score, initial serum PSA, estimated tumor volume, tumor stage, and patient life expectancy.
- Options should be explained to patients so that patients can make an informed decision about which treatment best fits their values and goals.
- Active surveillance—Monitoring for disease progression over time in low-risk individuals who are likely to die with the disease rather than from the disease. Treatment is considered if significant disease progression is detected. This involves PSA testing and periodic rebiopsy.[11] SOR B
- Radical prostatectomy—Treatment of choice for patients with organ-defined disease and a life expectancy of more than 10 years. Walsh has shown that the cavernosal nerves that mediate erectile function can be identified and avoided, reducing postoperative erectile dysfunction. Rarely, significant urinary incontinence may be encountered.[3]

- Robotic-assisted laparoscopic prostatectomy (RALRP)—RALRP was developed to overcome of the difficulties of the standard laparoscopic prostatectomy. The robotic technique allows for magnified high definition three-dimensional visualization of the operative field and wider range of motion. The majority of men opting for radical prostatectomy in the United States are having RALRP (**Figure 73-6**).[12] SOR B

- External beam radiation therapy (EBRT)—EBRT is also a viable treatment option for localized disease and is the choice treatment option for T3 disease. EBRT utilizes high-energy electrons to destroy cancer cells by damaging cellular DNA. Side effects can include rectal and bladder symptomatology. Short-term androgen deprivation therapy (1 to 3 years) may increase efficacy.[13,14] SOR B
- Brachytherapy—Outpatient, ultrasound-guided, transperineal placement of ^{125}I or Pd radioactive seeds into the prostate. Optimal candidates have low-risk prostate cancer. Many centers utilize short-term neoadjuvant hormonal blockade given the difficulty in treated glands larger than 50 gs.[15] SOR B
- Androgen ablation in combination with EBRT—There may be some synergy between the apoptotic response induced by androgen deprivation and radiotherapy. Androgen deprivation results in an average 20% decrease in prostate volume to reduce the number of target cells, and thereby improve tumor treatment. Shrinking the prostate can decrease side effects by diminishing the volume of rectum and bladder irradiated.[13,16] SOR B
- For recurrent or advanced disease—Docetaxel (Taxotere)-based regimens can be included among the most effective treatment options for the management of patients with advanced, androgen independent prostate cancer. Results with docetaxel as a single agent and in combination regimens with estramustine (Emcyt) have provided patient benefit through an improved palliative response and improvement in quality of life as assessed through quality of life questionnaires. In addition, treatment with Docetaxal based regimens have produced objective responses such as reduced serum PSA levels by 50%, reduction in measurable disease on imaging, pain and health related quality of life. Progression-free survival was significantly increased in patients receiving docetaxel plus estramustine compared to those receiving mitoxantrone and prednisone (6.3 verses 3.2 months).[17,18] SOR B

FIGURE 73-6 The DaVinci robot: three working arms and a camera. The robot allows for better visualization of the pelvic anatomy. (*Courtesy of Intuitive Surgical.*)

PREVENTION

- The Prostate Cancer Prevention Trial (PCPT) aimed to determine the prevalence of histologically proven prostate cancer among men randomized to receive daily finasteride or placebo.[19]
- The authors described a 24.8% reduction in the prevalence of prostate cancer among men taking finasteride; however, the cancers detected in these men were significantly higher risk cancers.[19]
- More recently, the Selenium and Vitamin E Cancer Prevention Trial (SELECT) found that although selenium does not prevent prostate cancer, vitamin E is associated with a significantly increased risk of prostate cancer.[20]

PROGNOSIS

- The optimal management of patients with prostate cancer varies widely and is highly dependent upon a patient's age, overall health, and tumor risk assessment.

PATIENT EDUCATION

- Patients should be provided balanced and objective information about the risks and benefits of PSA screening, prostate biopsies, and the various options for prostate cancer treatment. This is challenging as there are conflicting opinions and interpretations of existing data. New studies are published frequently, which can change evidence-based recommendations and expert opinions. It is the physician's job to help patients navigate through the vast data and varied opinions to find a course of prevention and treatment that fits their individual needs. Although some patients will want the physician to make decisions about whether or not to get a PSA test or which cancer treatment is best, many others will appreciate balanced information so they may decide for themselves. See Patient and Provider Resources below to help inform patient–doctor discussions on these matters.
- Risk assessment calculations can be useful in discussions with patients to help them decide about screening, biopsy and treatment. Links to prostate cancer online prediction tools are listed under Provider Resources below.

PATIENT RESOURCES

- National Alliance of State Prostate Cancer Coalitions—**http://www.naspcc.org.**
- Men's Health Network—**http://www.menshealthnetwork.org.**
- Links to prostate cancer online prediction tools are listed under Provider Resources below and are useful for patients in their discussions with physicians.

PROVIDER RESOURCES

- The Prostate Cancer Prevention Trial Prostate Cancer Risk Calculator (PCPTRC) provides a person's estimated risk of biopsy-detectable prostate cancer and high grade prostate cancer—**http://deb.uthscsa.edu/URORiskCalc/Pages/uroriskcalc.jsp.**
- Prostate cancer gene 3 (PCA3) data and use of finasteride can be entered into a more advanced version of this calculator on the same site.
- Prostate cancer online prediction tools are available from Memorial Sloan-Kettering Cancer Center. They can be used to in conjunction with patients to decide which treatment approaches will result in the greatest benefit at various stages of prostate cancer. The four nomograms are found at **http://www.mskcc.org/mskcc/html/10088.cfm.**

1. Pre-Treatment (Diagnosed with Cancer But Not Yet Begun Treatment)

2. Post-Radical Prostatectomy (Recurrence After Surgery)
3. Salvage Radiation Therapy (Considering Radiation Therapy After Surgery)
4. Hormone Refractory (Progression of Metastatic Prostate Cancer That Can No Longer Be Controlled by Hormones Alone)

- Additional tools for measuring PSA doubling time, male life expectancy and tumor volume are found at: **http://nomograms.mskcc.org/Prostate/index.aspx.**
- National Cancer Institute (NCI). *Prostate Cancer*—**http://www.cancer.gov/cancertopics/types/prostate.**
- National Comprehensive Cancer Network (NCCN)—**http://www.nccn.org/professionals/physician_gls/f_guidelines.asp.**
- National Prostate Cancer Coalition (NPCC)—**http://www.4npcc.org.**
- *Screening for Prostate Cancer: A Review of the Evidence for the U.S. Preventive Services Task Force*—**http://www.uspreventiveservicestaskforce.org/uspstf12/prostate/prostateart.htm.**

REFERENCES

1. Lim LS, Sherin K. Screening for prostate cancer in U.S. men ACPM position statement on preventive practice. *Am J Prev Med*. 2008;34(2):164-170.
2. Jemal A, Bray F, Center MM, et al. Global cancer statistics. *CA Cancer J Clin*. 2011;61:69.
3. Morey A, Shoskes D. *The American Urological Association Educational Review Manual in Urology*. 1st ed. New York, NY: Castle Connolly Graduate Medical Publishing; 2007.
4. Wein A. *Clinical Manual of Urology*. 3rd ed. New York, NY: McGraw Hill; 2001.
5. Greene KL, Albertsen PC, Babaian RJ, et al. Prostate specific antigen best practice statement: 2009 update. *J Urol*. 2009; 182(5):2232-2241.
6. Williams SB, Salami S, Regan MM, et al. Selective detection of histologically aggressive prostate cancer: an Early Detection Research Network Prediction model to reduce unnecessary prostate biopsies with validation in the Prostate Cancer Prevention Trial. *Cancer*. 2012;118(10):2651-2658, http://www.ncbi.nlm.nih.gov/pubmed/22006057, accessed October 25, 2011.
7. U.S. Preventive Services Task Force. Screening for Prostate Cancer. Current Recommendation. May 2012. http://www.uspreventiveservicestaskforce.org/prostatecancerscreening.htm, accessed September 1, 2012.
8. Oxley JD, Sen C. Error rates in reporting prostatic core biopsies. *Histopathology*. 2011;58(5):759-765.
9. Tanaka N, Fujimoto K, Shinkai T, et al. Bone scan can be spared in asymptomatic prostate cancer patients with PSA of <= 20 ng/ml and Gleason Score of <= 6 at the initial stage of diagnosis. *Jpn J Clin Oncol*. 2011;41(10):1209-1213, http://www.ncbi.nlm.nih.gov/pubmed/21862505, accessed September 12, 2011.
10. Epstein JI, Herawi M. Prostate needle biopsies containing prostatic intraepithelial neoplasia or atypical foci suspicious for carcinoma: implications for patient care. *J Urol*. 2006;175(3 Pt 1): 820-834.
11. Albertsen PC, Hanley JA, Fine J. 20-year outcomes following conservative management of clinically localized prostate cancer. *JAMA*. 2005;293(17):2095-2101.
12. Parsons JK, Bennett JL. Outcomes of retropubic, laparoscopic, and robotic-assisted prostatectomy. *Urology*. 2008;72(2): 412-416.
13. Payne H, Mason M. Androgen deprivation therapy as adjuvant/neoadjuvant to radiotherapy for high-risk localised and locally advanced prostate cancer: recent developments. *Br J Cancer*. 2011;105(11):1628-1634, http://www.ncbi.nlm.nih.gov/pubmed/22009028, accessed October 25, 2011.
14. Potosky AL, Davis WW, Hoffman RM, et al. Five-year outcomes after prostatectomy or radiotherapy for prostate cancer: the prostate cancer outcomes study. *J Natl Cancer Inst*. 2004;96(18): 1358-1367.
15. Merrick GS, Butler WM, Wallner KE, Galbreath RW, Adamovich E. Permanent interstitial brachytherapy in younger patients with clinically organ-confined prostate cancer. *Urology*. 2004;64(4): 754-759.
16. Bolla M, Collette L, Blank L, et al. Long-term results with immediate androgen suppression and external irradiation in patients with locally advanced prostate cancer (an EORTC study): a phase III randomised trial. *Lancet*. 2002;360(9327):103-106.
17. Logothetis CJ. Docetaxel in the integrated management of prostate cancer. Current applications and future promise. *Oncology (Williston Park, N.Y.)*. 2002;16(6 Suppl 6):63-72.
18. Machiels J-P, Mazzeo F, Clausse M, et al. Prospective randomized study comparing docetaxel, estramustine, and prednisone with docetaxel and prednisone in metastatic hormone-refractory prostate cancer. *J Clin Oncol*. 2008;26(32):5261-5268.
19. Crawford ED, Andriole GL, Marberger M, Rittmaster RS. Reduction in the risk of prostate cancer: future directions after the Prostate Cancer Prevention Trial. *Urology*. 2010;75(3):502-509.
20. Klein EA, Thompson IM Jr, Tangen CM, et al. Vitamin E and the risk of prostate cancer: the Selenium and Vitamin E Cancer Prevention Trial (SELECT). *JAMA*. 2011;306(14):1549-1556.

PART 11

WOMEN'S HEALTH

Strength of Recommendation (SOR)	Definition
A	Recommendation based on consistent and good-quality patient-oriented evidence.*
B	Recommendation based on inconsistent or limited-quality patient-oriented evidence.*
C	Recommendation based on consensus, usual practice, opinion, disease-oriented evidence, or case series for studies of diagnosis, treatment, prevention, or screening.*

*See Appendix A on pages 1447–1450 for further information.

SECTION 1 PREGNANCY

74 SKIN FINDINGS IN PREGNANCY

E.J. Mayeaux, Jr., MD

PATIENT STORY

A 32-year-old G3P2 woman presents with persistent itching in her 31st week of pregnancy. The itching is constant and worse at night. Her pregnancy had been uncomplicated and she has no past history of medical problems. Many excoriations are noted and there are no blisters (**Figure 74-1**). She has no jaundice or scleral icterus. Her transaminases were greater than 300 and her total bilirubin was elevated at 2.1. Her bile salts were elevated and her hepatitis panel was negative. The ultrasound showed gallstones but no obstruction was seen. A diagnosis of "intrahepatic cholestasis of pregnancy" was made and the patient was treated with oral ursodiol (a bile salt binding agent) and topical 1% hydrocortisone cream. The bile salts and transaminases were decreased and the patient's pruritus improved but did not resolve until after delivery.[1]

FIGURE 74-1 Pruritus and excoriations in a patient with intrahepatic cholestasis of pregnancy. All the lesions are secondary to patient scratching. (*Courtesy of Richard P. Usatine, MD.*)

INTRODUCTION

Maternal skin and skin structures undergo numerous changes during pregnancy. There are two general categories of pregnancy-associated skin conditions: (a) benign skin conditions associated with normal hormonal changes of pregnancy (striae gravidarum, hyperpigmentation, hair and vascular changes), and (b) pregnancy-specific dermatoses (prurigo of pregnancy, intrahepatic cholestasis of pregnancy).

SYNONYMS

- Striae gravidarum—Stretch marks.
- Prurigo of pregnancy—Atopic eruption of pregnancy.
- Spider telangiectasias—Spider nevi or spider angiomas.
- Intrahepatic cholestasis of pregnancy—Pruritus gravidarum.

EPIDEMIOLOGY

- Almost all pregnant women develop some increase in skin pigmentation. This usually occurs in discrete areas, probably because of differences in melanocyte density.
- Striae gravidarum (stretch marks) occur in up to 90% of pregnant women by the third trimester.[2]
- Spider telangiectasias occur in approximately 66% of light-complected and 10% of dark-complected pregnant women,

primarily appearing on the face, neck, and arms. The condition is most common during the first and second trimesters.[3] Palmar erythema occurs in approximately two-thirds of light-complected and up to one-third of dark-complected pregnant women.[2]

- Hemorrhoidal, saphenous, and vulvar varicosities occur in approximately 40% of pregnant women.[3]
- Prurigo of pregnancy (now called atopic eruption of pregnancy) occurs with an incidence of approximately 1 in 300 to 1 in 450 pregnancies.[4,5]
- Intrahepatic cholestasis of pregnancy occurs in approximately 1 of 146 to 1293 pregnancies in the United States.[3]

ETIOLOGY AND PATHOPHYSIOLOGY

- The most common skin pigmentary change is darkening of the linea alba (**Figure 74-2**), which is then called the linea nigra.[6] It may span from the pubic symphysis to the umbilicus or all the way to the xiphoid process.
- The skin around the areola may also darken and develop a reticular type pattern. Other anatomic areas that develop hyperpigmentation are the nipples, axillae, vulva, perineum, anus, inner thighs, and neck.[7] Darkening may also occur in nevi during pregnancy.
- As pregnancy progresses, increased eccrine activity may result in hyperhidrosis (increased sweating) and/or miliaria ("prickly heat").[8] Apocrine activity decreases during pregnancy but increases postpartum, so hidradenitis suppurativa improves during pregnancy but may rebound later.[8]
- Hypertrophy of sebaceous glands produces small, brown papules on the areolae (Montgomery tubercles, **Figure 74-3**) in up to half of pregnant women. They usually regress postpartum.[8]
- Stretch marks (striae distensae, striae gravidarum) begin as pink/violaceous linear patches in the sixth to seventh month of gestation and are a common cosmetic concern among pregnant women (**Figure 74-4**). They evolve into hypopigmented linear depressions. They are most common on the abdomen, breasts, and thighs, but may also arise on the lower back, buttocks, and upper arms.[8] The cause of striae is multifactorial and includes physical factors (e.g., actual stretching of the skin) and hormonal factors adrenocortical (e.g., steroids, estrogen, and relaxin). Although striae fade postpartum, they do not completely disappear.
- Spider angiomas, arterial spiders, or spider nevi may develop, especially in whites. They occur mostly on the neck, face, upper chest, arms, and hands.[6] Almost all regress postpartum.
- Palmar erythema may develop and may be limited to the thenar or hypothenar eminence, or may be diffuse and mottled.[8]
- Acrochordons (skin tags) may develop, enlarge, or increase on the face, neck, axillae, chest, groin, and inframammary area during the second half of pregnancy. Some may regress postpartum.[9]
- Keloids, leiomyomas, dermatofibromas, and neurofibromas may enlarge during pregnancy.[9]
- Scalp hair appears thicker during pregnancy as a result of slowing of the normal progression of hairs to the telogen ("resting") stage, thereby creating a relative increase in anagen hair. Hair loss (telo-

FIGURE 74-2 Darkened linea alba (linea nigra) in a pregnant patient. (*Courtesy of Dan Stulberg, MD.*)

FIGURE 74-3 Montgomery tubercles in a pregnant woman. The brown papules on the areola are caused by hypertrophy of the normal sebaceous glands. (*Courtesy of Richard P. Usatine, MD.*)

gen effluvium) is common 1 to 5 months postpartum as the percentage of telogen hairs in the scalp normalizes or increases (**Figure 74-5**).[9] Telogen effluvium resolves within 15 months postpartum, but the scalp hair may never return to prepregnancy thickness.[9]

- Hirsutism may occur on the face, arms, legs, back, and suprapubic region.[9] Hirsutism appears to be a result of increased levels of ovarian and placental androgens. Frontoparietal hair loss (androgenic alopecia) may develop late in pregnancy but usually resolves postpartum.
- Saphenous, vulvar, and hemorrhoidal varicosities may increase in number and/or size (see Chapter 66, Hemorrhoids). This may be because of increased blood volume, increased venous pressure, or genetic predisposition. Jacquemier sign refers to venous distention in the vestibule and vagina and is associated with vulvar varicosities, which are particularly difficult to treat.[8] Varicosities regress, at least partially, postpartum.
- Vascular type tumors may develop or enlarge during pregnancy. Pyogenic granulomas (**Figure 74-6**) (granuloma gravidarum, pregnancy tumor, pregnancy epulis) are reddish purple papules that are made up of granulation tissue (see Chapter 161, Pyogenic Granuloma). They usually begin in the first half of pregnancy and then partially regress postpartum. They most commonly appear on the gingiva, but are also common on fingers. Hemangiomas, subcutaneous hemangioendotheliomas, and glomangiomas (glomus tumors) may also occur.
- Atopic eruption of pregnancy is most common in the second or third trimester, but has been reported in all trimesters. It presents with erythematous, excoriated papules on the extensor surfaces of the limbs and trunk.[4,5] Lesions are grouped and may appear eczematous. The eruption usually resolves in the immediate postpartum period, although it can persist for months. This should not be confused with intrahepatic cholestasis of pregnancy, which is most common in the third trimester and has no primary skin lesions (**Figure 74-4**).
- Intrahepatic cholestasis of pregnancy is usually diagnosed based on clinical history and presentation. Patients demonstrate pruritus (with or without jaundice) and no primary skin lesions. Laboratory findings consistent with cholestasis (elevated serum bile acid levels and alkaline phosphatase levels) confirms the diagnosis. Elevated bilirubin levels may or may not be found.[2] The etiology remains controversial. It usually resolves postpartum without specific treatment (**Figure 74-1**).

RISK FACTORS

Striae gravidarum are more common in women who are younger, nonwhite, have larger babies, and have higher body mass indices.[2] There is a familial predisposition to striae gravidarum, and women with preexisting breast or thigh striae are also more prone to this condition.[10]

Intrahepatic cholestasis of pregnancy is associated with a family history of the condition is common, human leukocyte antigen-A31 and -B8.[3] It often recurs in subsequent pregnancies and patients have a higher risk of gallstones or a family history of gallstones. It is associated with a higher risk of premature delivery, meconium-stained amniotic fluid, and intrauterine demise.

FIGURE 74-4 Atopic eruption of pregnancy. Note the erythematous, excoriated papules on the trunk. This patient's lesions resolved about 2 weeks postpartum. She also demonstrates pink/violaceous linear patches known as striae distensae or striae gravidarum. (*Courtesy of E.J. Mayeaux, Jr., MD.*)

FIGURE 74-5 Telogen effluvium causing a hair loss in a young woman 1 month postpartum. The hair loss was most visible near the temples. There was no scalp inflammation or scarring. A gentle hair pull test produced four hairs in the telogen phase (with a visible bulb). Her hair returned to normal within 1 year of this visit. (*Courtesy of Richard P. Usatine, MD.*)

MANAGEMENT

NONPHARMACOLOGIC

- Changes such as hypertrophy of sebaceous glands, spider angiomas, palmar erythema, and varicosities usually regress postpartum and often require only symptomatic or no therapy. SOR C
- Varicosities may be treated with leg elevation, compression with support hose, sleeping on the left side to ease uterine pressure on the great veins, exercise, and avoidance of long periods of standing or sitting. SOR C (see Chapter 52, Venous Stasis). [2]

MEDICATIONS

- The primary treatment for pruritus in pregnancy is symptomatic. SOR C Topical low-potency to mid-potency corticosteroids are safe and can give symptomatic relief of itching.
- Oral antihistamines such as diphenhydramine may be used to relieve itching.[2] SOR C See Chapters 75, Pruritic Urticarial Papules and Plaques of Pregnancy and 76, Pemphigoid Gestationis for specific treatment of various pruritic diseases in pregnancy.
- Treatment of stretch marks after pregnancy with 0.1% tretinoin was reported to be beneficial but should not be used during pregnancy because of the risk of birth defects with any retinoid.[11] SOR B
- The pruritus of intrahepatic cholestasis of pregnancy may be treated with oral antihistamines. More severe cases require ursodeoxycholic acid (ursodiol [Actigall]) to relieve pruritus and improve cholestasis while reducing adverse fetal outcomes. [2]

SURGICAL

- Persistent, bothersome pyogenic granulomas can be excised and should be sent to pathology to rule out amelanotic melanoma (see Chapter 161, Pyogenic Granuloma). SOR C
- Physical lesions such as skin tags, fibromas, and angiomas may be treated by local surgical or destructive therapies. SOR C
- Laser treatment (585-nm and pulsed-dye laser) may be used to treat striae after pregnancy.[2]

COMPLEMENTARY AND ALTERNATIVE THERAPY

- Many creams, emollients, and oils containing vitamin E, cocoa butter, aloe vera lotion, and olive oil are used to attempt to prevent striae. However, there is no evidence that these treatments are effective. Limited evidence suggests that *Centella asiatica* extract plus α-tocopherol and collagen-elastin hydrolysates and tocopherol, essential fatty acids, panthenol, hyaluronic acid, elastin, and menthol may be helpful.[12] The safety of using *Centella asiatica* and other components during pregnancy are unclear.[13]

FOLLOW-UP

Conditions should be monitored during pregnancy and the patient regularly reassured. Postpartum, the patient may be followed or treated as needed.

FIGURE 74-6 Pyogenic granuloma in a pregnant woman. (*Courtesy of Richard P. Usatine, MD.*)

PATIENT EDUCATION

The primary aim of treatment for most skin conditions in pregnancy is to relieve symptoms, as many conditions improve or resolve postpartum. Those conditions that do not resolve can usually be safely treated postpartum when there is no risk to the pregnancy.

PATIENT RESOURCES

- ACOG Education Pamphlet. *Skin Conditions During Pregnancy*—**www.acog.org/publications/patient_education/bp169.**
- Netdoctor—**http://www.netdoctor.co.uk/womenshealth/facts/skinrash_pregnancy.htm.**
- MedicineNet.com. *Skin Problems of Pregnancy*—**http://www.medicinenet.com/script/main/art.asp?articlekey=52164.**

PROVIDER RESOURCES

- Dermnet NZ. *Pregnancy Skin Problems* —http://www.dermnetnz.org/.
- Common skin conditions during pregnancy. *Am Fam Physician.* 2007;75(2):211-218. **http://www.aafp.org/afp/2007/0115/p211.html.**

REFERENCES

1. Orr B, Usatine RP. Pruritus in pregnancy. *J Fam Pract.* 2007;56(11):913-916.
2. Tunzi M, Gray GR. Common skin conditions during pregnancy. *Am Fam Physician.* 2007;75:211-218.
3. Kroumpouzos G, Cohen LM. Dermatoses of pregnancy. *J Am Acad Dermatol.* 2001;45:1-19.
4. Roger D, Vaillant L, Fignon A, et al. Specific pruritic diseases of pregnancy: a prospective study of 3192 pregnant women. *Arch Dermatol.* 1994;130:734-739.
5. Holmes RC, Black MM. The specific dermatoses of pregnancy. *J Am Acad Dermatol.* 1983;8(3):1405-1412.
6. Esteve E, Saudeau L, Pierre F, et al. Physiological cutaneous signs in normal pregnancy: a study of 60 pregnant women. *Ann Dermatol Venereol.* 1994;121:227-231.
7. Muzaffar F, Hussain I, Haroon TS. Physiologic skin changes during pregnancy: a study of 140 cases. *Int J Dermatol.* 1998;37(6):429-431.
8. Martin AG, Leal-Khouri S. Physiologic skin changes associated with pregnancy. *Int J Dermatol.* 1992;31(6):375-378.
9. Winton GB, Lewis CW. Dermatoses of pregnancy. *J Am Acad Dermatol.* 1982;6(6):977-998.
10. Chang AL, Agredano YZ, Kimball AB. Risk factors associated with striae gravidarum. *J Am Acad Dermatol.* 2004;51(6):881-885.
11. Kang S, Kim KJ, Griffiths CE, et al. Topical tretinoin (retinoic acid) improves early stretch marks. *Arch Dermatol.* 1996;132(5):519-526.
12. Young GL, Jewell D. Creams for preventing stretch marks in pregnancy. *Cochrane Database Syst Rev.* 2000;(2):CD000066.
13. Ernst E. Herbal medicinal products during pregnancy: are they safe? *BJOG.* 2002;109:227-235.

75 PRURITIC URTICARIAL PAPULES AND PLAQUES OF PREGNANCY

E.J. Mayeaux, Jr., MD

PATIENT STORY

A 26-year-old pregnant woman presents at 36 weeks of gestation with a progressive itchy rash. The rash started within the abdominal striae (**Figure 75-1**) and spread to her proximal extremities. This is her first pregnancy and she has never had any rashes like this before. The itching "is maddening." The patient is diagnosed with pruritic urticarial papules and plaques of pregnancy (PUPPP) and treated with topical steroids and oral antihistamines.

FIGURE 75-1 Pruritic urticarial papules and plaques of pregnancy (PUPPP) presenting as pruritic striae on the abdomen. (*Courtesy of University of Texas Health Sciences Center, Division of Dermatology.*)

INTRODUCTION

PUPPP is a dermatosis of pregnancy characterized by a papulovesicular or urticarial eruption on the abdomen, trunk, and limbs. Other than maternal itching, PUPPP poses no increased risk of fetal or maternal morbidity.[1]

SYNONYMS

- Polymorphic eruption of pregnancy (in the United Kingdom).
- Toxic erythema of pregnancy.
- Linear immunoglobulin (Ig) M dermatosis of pregnancy.
- Bourne toxemic rash of pregnancy.
- Nurse's late-onset prurigo.

EPIDEMIOLOGY

- The incidence of PUPPP is 1 out of 160 to 1 out of 300 pregnancies, making it the most common defined dermatosis of pregnancy.[2]
- Nulliparous patients account for more than 75% of patients with classic PUPPP.[3]
- PUPPP is also more common with multiple gestations, possibly because of increased abdominal distention or higher hormone levels.[4]

The rate of recurrence with subsequent pregnancies is unknown.

ETIOLOGY AND PATHOPHYSIOLOGY

- The etiology of PUPPP is unknown. PUPPP is more common with excessive stretching of the skin, possibly because of damage to connective tissue, which could result in exposure of antigens that

trigger an inflammatory response.[2,5] The disease may also represent an immunologic reaction to circulating fetal antigens.

- Onset of PUPPP is usually late in the third trimester, but may develop postpartum.[1,3] There are case reports of first and second trimester disease.[3] Pruritus may worsen after delivery, but generally resolves by 15 days postpartum. The PUPPP may resolve prior to delivery.

RISK FACTORS

- The disorder is more common with first pregnancies.[6]
- Multiple gestations.[6]
- Familial occurrences have been reported.[4]

DIAGNOSIS

CLINICAL FEATURES

PUPPP is usually diagnosed by its characteristic findings on history and physical examination. PUPPP typically presents with erythematous papules and plaques within striae with periumbilical sparing (**Figures 75-1** and **75-2**). Extreme pruritus is a hallmark of the disease and is present in all patients.[1]

TYPICAL DISTRIBUTION

Abdominal striae are the most common initial site.[3] The lesions usually spread to the extremities and coalesce to form urticarial plaques (**Figures 75-3** and **75-4**). The face, palms, soles, and periumbilical region are usually spared. White halos often surround the erythematous papules and are target-like, exhibiting three distinct rings or color.[3]

LABORATORY TESTING

There are no related laboratory abnormalities.

BIOPSY

Biopsy is not necessary when the clinical picture is classic. When the diagnosis is uncertain, perform a punch biopsy and consider immunofluorescent studies. IgM or IgA deposits may be found at the dermoepidermal junction or around blood vessels. It is preferable to biopsy a lesion off the abdomen to avoid wound-healing problems on a distended abdomen.

DIFFERENTIAL DIAGNOSIS

- Pemphigoid gestationis can be differentiated from PUPPP by its bullous lesions (see Chapter 76, Pemphigoid Gestationis).
- Erythema multiforme produces target lesions that may affect the palms and soles (see Chapter 177, Erythema Multiforme, Stevens-Johnson Syndrome, and Toxic Epidermal Necrolysis).
- Drug reactions produce various types of erythematous eruptions on the trunk and extremities. History of a new drug exposure helps to distinguish this from PUPPP (see Chapter 203, Cutaneous Drug Reactions).

FIGURE 75-2 PUPPP occurring in the first pregnancy of a 20-year-old woman during her third trimester. Note how it involves the striae of her abdomen. She also has darkening of her linea alba and umbilicus. (*Courtesy of Rachel Giese, MD.*)

FIGURE 75-3 Pruritic urticarial papules and plaques of pregnancy (PUPPP) on the arm. (*Courtesy of Richard P. Usatine, MD.*)

- Scabies infestations produce severe itching from the mite burrows that are common between the fingers and in areas of skin folds (see Chapter 143, Scabies).
- Viral exanthems may produce all types of erythematous eruptions that can be pruritic at times. The history of a fever along with upper respiratory symptoms should help to differentiate these eruptions from PUPPP (see Chapters 126, Measles and 127, Fifth Disease).

FIGURE 75-4 Pruritic urticarial papules and plaques of pregnancy (PUPPP) on the leg. (*Courtesy of Richard P. Usatine, MD.*)

MANAGEMENT

NONPHARMACOLOGIC

- Symptom control is the main goal. Aggressive therapy is not recommended since the condition is self-limiting. SOR C
- Early delivery to relieve symptoms is rarely required.

General symptom relief measures such as cool baths, frequent application of emollients, wet soaks or cool packs applied to the skin provide some symptomatic relief.[7] SOR C

MEDICATIONS

- First-line therapy consists of topical steroids and oral antihistamines to alleviate symptoms. Systemic corticosteroids are occasionally required in cases of extreme pruritus. SOR C
- Start with a mid-potency topical corticosteroid such as 0.1% triamcinolone bid to tid. Pregnancy class B. SOR C High-potency, topical, corticosteroids such as fluocinonide may be applied sparingly bid to tid as severity warrants. Pregnancy class B. SOR C
- Diphenhydramine 25 to 50 mg PO bid to qid or similar antihistamines may be used for symptomatic relief of pruritus. Pregnancy class B. SOR C

In severe cases, oral prednisolone, 40 to 60 mg daily, may induce a rapid resolution of symptoms.[7] SOR C

PROGNOSIS

Apart from itching and related discomfort, the prognosis for the mother is unaffected. Recurrence of the condition in subsequent pregnancies is rare and tends to be less severe than the first episode.[7]

Pruritus may worsen immediately after delivery, but generally resolves by 2 weeks postpartum.

FOLLOW-UP

Routine prenatal and postpartum care should be continued.

PATIENT EDUCATION

- When discussing treatment options, inform the patient that the condition is self-limited, so therapy is based on making the patient comfortable while minimizing the potential risks involved in the use of medications.[6]

- Symptom control with topical steroids and antihistamines is the main goal.

PATIENT RESOURCES

- About.com. *PUPPP*—**http://dermatology.about.com/cs/pregnancy/a/puppp.htm.**
- DermNet NZ. *PUPPP*—**http://dermnetnz.org/reactions/puppp.html.**

PROVIDER RESOURCES

- EMedicine. *Pruritic Urticarial Papules and Plaques of Pregnancy*—**http://www.emedicine.com/derm/topic351.htm.**
- Medscape Today. *Specific Pregnancy Dermatoses: Pruritic Urticarial Papules and Plaques of Pregnancy*—**http://www.medscape.com/viewarticle/707663_3.**
- Tunzi M, Gray GR. Common skin conditions during pregnancy. *Am Fam Physician*. 2007;75:211-218. **http://www.aafp.org/afp/2007/0115/p211.html.**

REFERENCES

1. Yancey KB, Hall RP, Lawley TJ. Pruritic urticarial papules and plaques of pregnancy. Clinical experience in twenty-five patients. *J Am Acad Dermatol*. 1984;10:473.
2. Vaughan Jones SA, Black MM. Pregnancy dermatoses. *J Am Acad Dermatol*. 1999;40:233.
3. Aronson IK, Bond S, Fiedler VC, et al. Pruritic urticarial papules and plaques of pregnancy: Clinical and immunopathologic observations in 57 patients. *J Am Acad Dermatol*. 1998;39:933.
4. Kroumpouzos G, Cohen LM. Specific dermatoses of pregnancy: An evidence-based systematic review. *Am J Obstet Gynecol*. 2003;188:1083.
5. Beckett MA, Goldberg NS. Pruritic urticarial plaques and papules of pregnancy and skin distention. *Arch Dermatol*. 1991;127:125.
6. Tunzi M, Gray GR. Common skin conditions during pregnancy. *Am Fam Physician*. 2007;75:211-218.
7. Ahmadi S, Powell FC. Pruritic urticarial papules and plaques of pregnancy: current status. *Australas J Dermatol*. 2005;46:53-60.

76 PEMPHIGOID GESTATIONIS

E.J. Mayeaux, Jr., MD

PATIENT STORY

A 37-year-old pregnant woman presented to the hospital with severe preeclampsia. After all medical methods were tried and failed to control her severe preeclampsia, a joint decision was made to induce labor to save the life of the mother. The pregnancy was too early for the fetus to survive. The following day she began to develop the lesions seen in **Figures 76-1** through **76-4**. A diagnosis of pemphigoid gestationis was made. Her past history includes antiphospholipid syndrome with multiple pregnancy losses but two live children. This was her third episode of pemphigoid gestationis. A photograph of her previous episode is included to see how similar the periumbilical bulla was to her current episode of pemphigoid gestationis. A new biopsy was not performed given that her previous biopsy was on file and the clinical picture was consistent with a recurrence of this disease. She was treated with oral prednisone and began to improve rapidly (**Figure 76-5**).

FIGURE 76-1 Pemphigoid gestationis in the pruritic papular stage. The lesions resemble the target lesions of erythema multiforme. (*Courtesy of Richard P. Usatine, MD.*)

INTRODUCTION

Pemphigoid gestationis is a rare autoimmune bullous dermatosis of pregnancy. The disease was originally known as herpes gestationis because of it visual similarities to herpes simplex infection. However, that term has fallen out of favor because pemphigoid gestationis is not associated with active or prior herpes virus infection.

SYNONYMS

Herpes gestationis.

EPIDEMIOLOGY

- Pemphigoid gestationis is a rare disease that occurs in 1 in 1700 to 1 in 50,000 pregnancies.[1,2]
- Pemphigoid gestationis has an estimated prevalence of 1 case in 50,000 to 60,000 pregnancies in the United States.
- It has been linked to the presence of human leukocyte antigen (HLA)-DR3, HLA-DR4, or both.[3]
- It is rarely associated with molar pregnancies and choriocarcinoma.[3]

FIGURE 76-2 Pemphigoid gestationis with bullous lesions on the wrist. (*Courtesy of Richard P. Usatine, MD.*)

ETIOLOGY AND PATHOPHYSIOLOGY

- Pemphigoid gestationis, which has classically been called herpes gestationis, is defined as a bullous or blistering disease that is associated with pregnancy or with trophoblastic tumors.

- As there is no connection with a herpes virus, the preferred name is now pemphigoid gestationis. It is associated with an increased risk of fetal morbidity and mortality.
- The pathophysiology of the disease involves immunoglobulin (Ig) G antibodies that attack cells in the skin.
- The IgG attacks the same antigen (bullous pemphigoid antigen) as in bullous pemphigoid.[2] This antigen is a transmembrane protein that is part of the hemidesmosome, which connects the basal cells of the epidermis to the basement membrane.
- When the inflammatory response is activated, the hemidesmosomes are destroyed and the epidermis separates from the dermis.[2]
- It is unknown why some patients form these antibodies.
- Rarely, pemphigoid gestationis persists for years postpartum.[1,2]
- There is no scarring from the lesions.

FIGURE 76-3 Pemphigoid gestationis. Close-up of a bullous lesion on the abdomen. (*Courtesy of Richard P. Usatine, MD.*)

RISK FACTORS

Pemphigoid gestationis in a prior pregnancy.

DIAGNOSIS

CLINICAL FEATURES: HISTORY AND PHYSICAL

- Pemphigoid gestationis typically erupts during the second or third trimester and, rarely, postpartum and first trimester. Symptoms may abate at the end of pregnancy; however, flares can occur immediately after delivery.
- Pruritus sometimes precedes the rash and vesicles may develop early.
- The initial manifestations are erythematous urticarial patches and plaques, which typically start around the umbilicus. The lesions progress to tense vesicles. (**Figures 76-1** to **76-5**).

TYPICAL DISTRIBUTION

The rash begins on the trunk around the umbilicus as pruritic papules or plaque and may progress to bullae (**Figures 76-4** to **76-5**).[1,2] Lesions may occasionally be seen on the palms and soles, and rarely on the face or mucous membranes.

LABORATORY TESTING

There are no diagnostic laboratory tests.

BIOPSY

Skin biopsy including the edge of a blistering lesion reveals a subepidermal vesicle with a perivascular lymphocytic and eosinophilic infiltrate.

- Eosinophils may appear at the dermoepidermal junction and inside the vesicle; the degree of eosinophilia correlates with disease severity.
- Basal cell necrosis and papillae edema are usually present.

A skin biopsy of perilesional skin for indirect immunofluorescent staining shows complement 3 in a homogeneous linear band at the basement membrane. This is pathognomonic for pemphigoid gestationis.

FIGURE 76-4 Pemphigoid gestationis with a bulla in the umbilicus. Lesions typically begin in the periumbilical region. (*Courtesy of Richard P. Usatine, MD.*)

DIFFERENTIAL DIAGNOSIS

- Papular urticarial papules and plaques of pregnancy (PUPPP) may mimic pemphigoid gestationis, especially early in the disease. However, PUPPP usually begin in the striae, whereas pemphigoid gestationis is usually periumbilical. Most importantly, PUPPP does not develop large bullae as does pemphigoid gestations (see Chapter 75, Pruritic Urticarial Papules and Plaques of Pregnancy).
- Dermatitis herpetiformis is a very pruritic, vesicular skin eruption. It is a chronic recurrent symmetric vesicular eruption that is usually associated with gluten-induced enteropathy. Men are more often affected than women (see Chapter 186, Other Bullous Disease).
- Erythema multiforme secondary to pregnancy, infection, or drug exposure can mimic pemphigoid gestationis. Biopsy with routine histology can usually distinguish between these disorders (see Chapter 177, Erythema Multiforme, Stevens-Johnson Syndrome, and Toxic Epidermal).
- Contact dermatitis and drug reactions may have a similar appearance and history of exposure to a contact allergen or medication can help to distinguish between these reactions and pemphigoid gestationis (see Chapters 146, Contact Dermatitis and 203, Cutaneous Drug Reactions).
- Bullous pemphigoid produces similar lesions, but rarely starts in pregnancy or starts around the umbilicus (see Chapter 184, Bullous Pemphigoid).
- Urticaria may appear similar to early pemphigoid gestationis (see Chapter 150, Urticaria and Angioedema).

FIGURE 76-5 Close-up of a large bulla in the umbilicus in a previous case of pemphigoid gestationis in the same patient 5 years before. (*Courtesy of University of Texas Health Sciences Center, Division of Dermatology.*)

MANAGEMENT

NONPHARMACOLOGIC

Tepid baths, compresses, and emollients may help alleviate pruritus.

MEDICATIONS

- Topical steroids and oral antihistamines should be administered in early or mild cases, but are usually ineffective in more severe cases. SOR C
- Systemic steroids, such as prednisone (0.5 mg/kg per day), are effective to control most cases.[4] SOR C The dose may be tapered and eventually discontinued in many pregnancies.

PROGNOSIS

Pemphigoid gestationis typically regresses spontaneously without scarring within weeks to months after delivery. It may recur in subsequent pregnancies or may be precipitated by the use of oral contraceptives.

FOLLOW-UP

- Follow-up of the mother and child are essential because of the following issues:

- The fetus during a pregnancy in which the mother has pemphigoid gestationis is at risk for growth restriction and prematurity.
- Mild placental insufficiency may result from an immune response between placental antigens and the disease-related antibodies.[7]

- Cutaneous involvement in infants of affected mothers is rare (5% to 10% have urticarial, vesicular, or bullous lesions) and abates with clearance of the maternal antibodies.[6]
- The mother is at high risk of recurrent pemphigoid gestationis with subsequent pregnancies and at an increased lifetime risk of Graves disease.[2,5]

PATIENT EDUCATION

- Pemphigoid gestationis may abate prior to delivery, but 75% of patients flare postpartum requiring reinstatement of treatment.
- At least 25% of patients will flare with oral contraceptive pill use.
- Most cases spontaneously resolve in the weeks to months following delivery.
- The disease usually recurs with future pregnancies and often worsens with repeated episodes, but may also skip some pregnancies.[2,5]

PATIENT RESOURCES

- About.com. *Pemphigoid Gestationis*—**http://dermatology.about.com/cs/pregnancy/a/pemphgest.htm.**
- DermNet NZ—**http://www.dermnetnz.org/immune/pemphigoid-gestationis.html.**
- Patient.co.uk. *Pemphigoid Gestationis*—**http://www.patient.co.uk/doctor/Pemphigoid-Gestationis-(PG).htm.**
- European Academy of Dermatology and Venereology. *Pemphigoid (Herpes) Gestationis (PG)*—**http://www.eadv.org/patient-corner/leaflets/eadv-leaflets/pemphigoid-herpes-gestationis-pg/.**

PROVIDER RESOURCES

- EMedicine. *Pemphigoid Gestationis*—**http://emedicine.medscape.com/article/1063499-overview.**
- ARUP. *Pemphigoid Gestationis: Herpes Gestationis*—**http://www.arupconsult.com/Topics/PemphigoidGestationis.html.**
- Tunzi M, Gray GR. Common skin conditions during pregnancy. *Am Fam Physician*. 2007;75:211-218—**http://www.aafp.org/afp/2007/0115/p211.pdf.**

REFERENCES

1. Roger D, Vaillant L, Fignon A, et al. Specific pruritic diseases of pregnancy. A prospective study of 3192 pregnant women. *Arch Dermatol*. 1994;130:734.
2. Shornick JK. Dermatoses of pregnancy. *Semin Cutan Med Surg*. 1998;17:172.
3. Tunzi M, Gray GR. Common skin conditions during pregnancy. *Am Fam Physician*. 2007;75:211-218.
4. Jenkins RE, Hern S, Black MM. Clinical features and management of 87 patients with pemphigoid gestationis. *Clin Exp Dermatol*. 1999;24(4):255-259.
5. Jenkins RE, Hern S, Black MM. Clinical features and management of 87 patients with pemphigoid gestationis. *Clin Exp Dermatol*. 1999;24:255.
6. Shimanovich I, Brocker EB, Zillikens D. Pemphigoid gestationis: New insights into pathogenesis lead to novel diagnostic tools. *BJOG*. 2002;109:970-976.
7. Jenkins RE, Shornick JK, Black BL. Pemphigoid gestationis. *J Eur Acad Dermatol Venereol*. 1993;2:163.

77 FIRST TRIMESTER OBSTETRICAL ULTRASOUND

E.J. Mayeaux, Jr., MD
Danielle Cooper, MD

PATIENT STORY

A 22-year-old woman presents with no menstrual period for approximately 2 months (she has irregular menses.) She is complaining of morning sickness but is otherwise feeling well. A urine pregnancy test confirms she is pregnant. **Figure 77-1** shows a fetus of 9 weeks estimated gestational age (EGA).

FIGURE 77-1 Ultrasound examination of a fetus of 9 weeks estimated gestational age. The ultrasound was performed with a vaginal probe and the membranes are visible. (*Courtesy of E.J. Mayeaux, Jr., MD.*)

INTRODUCTION

Obstetrical ultrasound has become a vital tool in our ability to properly care for the pregnant patient. Vast technologic improvements have made visualization of the pregnancy even better and improved our diagnostic capabilities, ranging from the normal pregnancy to the extremely early ectopic pregnancy. Ultrasonography (US) allows for a relatively detailed assessment of fetal gestational age, development, number of fetuses, and anatomy in utero. Most pregnancies in the United States undergo ultrasound imaging for various indications.

EPIDEMIOLOGY

- Women who receive antenatal care have lower maternal and perinatal mortality and better pregnancy outcomes.[1] However, the optimal components of prenatal care have not been rigorously examined in well-designed studies.
- In the United States in 2003, 84.1% of pregnant women obtained prenatal care in the first trimester, and only 3.5% received no care or initiated prenatal care in the third trimester.

ETIOLOGY AND PATHOPHYSIOLOGY

- Ultrasound is used to estimate gestational age and to calculate the expected date of delivery (EDD). Ultrasound is especially helpful when menses are irregular, the last menstrual period (LMP) is unknown, or in patients who conceived while using hormonal contraceptives. A Cochrane review noted with more accurate dating there was a reduction in intervention for postterm pregnancy.[2]
- The Routine Antenatal Diagnostic Imaging with Ultrasound (RADIUS) trial was a randomized trial of routine obstetrical ultrasound screening.[3] It included more than 15,000 women in the United States. The trial showed that routine ultrasound screening was associated with a significantly increased detection of fetal anomalies, but no improvement in any perinatal outcome, including mortality, preterm birth, birth weight, and neonatal morbidity.

- First trimester vaginal bleeding is found in 20% to 40% of pregnancies. The differential diagnoses include possible spontaneous abortion, ectopic pregnancy, and gestational trophoblastic disease.
- Ectopic pregnancy causes a significant degree of morbidity and mortality if untreated, often through tubal rupture with potentially life-threatening hemorrhage. Identification of an intrauterine pregnancy effectively excludes the possibility of an ectopic in almost all cases, unless conception involved assisted reproductive technology.
- Threatened, inevitable, incomplete, or complete spontaneous abortion may cause first trimester bleeding. Up to one-third of recognized pregnancies end in early pregnancy loss. Ectopic pregnancy may also be a concern. US may be used to determine if a gestational sac or yolk sac is present in the uterus.
- First trimester transvaginal ultrasound used in conjunction with serum screening is the most sensitive noninvasive technique to detect aneuploidy. When performed in the first trimester, nuchal translucency as well as serum pregnancy-associated plasma protein A (PAPP-A) and β-human chorionic gonadotropin (β-hCG) levels are evaluated, which effectively detect 82% to 87% of trisomy 21. Integrated screening would also include a quad screen in second trimester, which carries a 94% to 96% detection rate.[4]

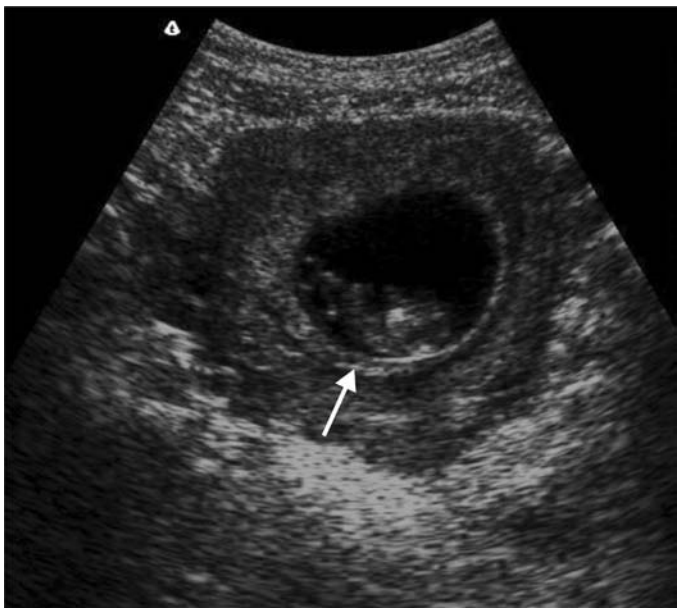

FIGURE 77-2 Ultrasound examination of a 9-week EGA twin with abdominal probe. The *arrow* is pointing to the yolk sac. Only one of the twins is visible. (*Courtesy of E.J. Mayeaux, Jr., MD.*)

DIAGNOSIS

- The goals of a basic first trimester ultrasound examination include[3]:
  - Confirm the presence of an intrauterine (or evaluate suspected extrauterine) pregnancy.
  - Assess gestational age.
  - Determine fetal viability.
  - Determine the cause of vaginal bleeding.
  - Evaluate pelvic or lower abdominal pain.
  - Determine whether a multiple gestation is present.
  - Evaluate maternal pelvic organs for congenital or acquired abnormalities.
- Fetal crown-rump length is used to calculate gestational age and may be performed via the transvaginal or the transabdominal route. Because the variation in size from fetus to fetus is minimal in the first trimester and minimal flexion, this is the optimal time to obtain an estimate of gestational age. Transvaginal US is typically used early for evaluation of the gestational sac, yolk sac, and developing embryo, while transabdominal US usually provides better visualization later in the first trimester. In obese patients, transvaginal US in early pregnancy can provide better visualization for more accurate dating.
- During the first 5 weeks of pregnancy, the endometrium has a "trilaminar" appearance, and usually does not show distinct evidence of an intrauterine pregnancy. The gestational sac is the first detectable sign on ultrasound. Initial gestational age measurements are based on diameter of the sac. The yolk sac (**Figure 77-2**) is the first anatomic structure to appear within the gestational sac around the fifth week of gestation. A gestational sac diameter of 8 mm or greater with an empty or no fetal pole yolk sac indicates an abnormal gestation.[5]
- The embryonic disc becomes visible at about a gestational age of 5 to 6 weeks.[6] If the embryo is visible, but too small to measure, detection of cardiac activity establishes a gestational age of

FIGURE 77-3 Ultrasound examination of a 13-week 3-day fetus by dates showing the head and spine with crown-to-rump length measurement of 6.98 cm. This represents an EGA of 13-weeks 3-days by ultrasound estimation. (essentially equal to dates.) (*Courtesy of E.J. Mayeaux, Jr., MD.*)

approximately 6 weeks. Direct measurement of the crown-rump length of the embryo provides the most accurate estimate of gestational age once the fetal pole is evident (**Figure 77-3**). The crown-rump length is the mean of three measurements of the longest straight-line length of the embryo from the outer margin of the cephalic pole to the rump.

- The biparietal diameter may be used later in the first trimester (**Figure 77-4**). It is highly reproducible and can predict gestational age within 7 days when measured between 14 and 20 weeks of gestation. The biparietal diameter should be measured on a plane of section that intersects both the third ventricle and thalami. The falx cerebri should be visible. The cursors are placed on the outer edge of the proximal skull and the inner edge of the distal skull to take the measurement. The femur length can be assessed by 10 weeks gestational age, but is more accurate after 20 weeks' gestation.

FIGURE 77-4 Ultrasound examination of the same 13-week 3-day fetus showing the biparietal diameter of 2.51 cm producing an EGA of 14 weeks and 2 days. A 1-week disparity is within the measurement error of ultrasound at this stage of the pregnancy. (*Courtesy of E.J. Mayeaux, Jr., MD.*)

PATIENT RESOURCES

- Obstetric ultrasound by Dr. Joseph Woo—**http://www.ob-ultrasound.net/.**
- RadiologyInfo—**http://www.radiologyinfo.org/en/info.cfm?pg=obstetricus&bhcp=1.**

PROVIDER RESOURCES

- Obstetric Ultrasound by Dr. Joseph Woo—**http://www.ob-ultrasound.net/.**

REFERENCES

1. Villar J, Bergsjo P. Scientific basis for the content of routine antenatal care. Philosophy, recent studies, and power to eliminate or alleviate adverse maternal outcomes. *Acta Obstet Gynecol Scand.* 1997;76:1.
2. Whitworth M, Bricker L, Neilson J P, Dowsell T. Ultrasound for fetal assessment in early pregnancy. Cochrane Database Systematic Review. 2010. CD007058 http://www2.cochrane.org/reviews/en/ab007058.html. Accessed August 14, 2011.
3. Ewigman BG, et al. Effect of prenatal ultrasound screening on perinatal outcome. RADIUS Study Group. *N Engl J Med.* 1993; 329:821.
4. Screening for fetal chromosomal abnormalities. ACOG Practice Bulletin No. 77. American College of Obstericians and Gynecologists. *Obstet Gynecol.* 2007;109:217-227.
5. American Institute of Ultrasound in Medicine. AIUM Standards and Guidelines. http://www.aium.org/publications/clinical/obstetrical.pdf. Accessed May 10, 2011.
6. Levi CS, Lyons EA, Lindsay DJ. Early diagnosis of nonviable pregnancy with endovaginal US. *Radiology.* 1988;167:383.
7. Goldstein SR, Wolfson R. Endovaginal ultrasonographic measurement of early embryonic size as a means of assessing gestational age. *J Ultrasound Med.* 1994;13:27.

78 SECOND TRIMESTER OBSTETRICAL ULTRASOUND

E.J. Mayeaux, Jr., MD
Danielle B. Cooper, MD

PATIENT STORY

A 23-year-old pregnant gravida 2, para 1 woman is being seen for ultrasound because of her uncertain dates. Her best recollection of her last period gave her an estimated gestational age (EGA) of 19 weeks. Her vital signs are normal and her fundal height is 20 cm. **Figures 78-1** to **78-3** are still images taken from her ultrasound examination demonstrating an EGA of 21 weeks and 6 days by measurement of the baby's biparietal diameter (BPD), head circumference (HC), abdominal circumference (AC), and femur length (FL). All four measurements allow the computer to calculate an estimated fetal weight of 431 g. The pregnancy proceeded without complications and the patient delivered a healthy boy at 40$^{3}/_{7}$ weeks based on the ultrasound calculated estimated date of delivery. No interventions were needed for postdates because of the ultrasound calculations earlier in the pregnancy.

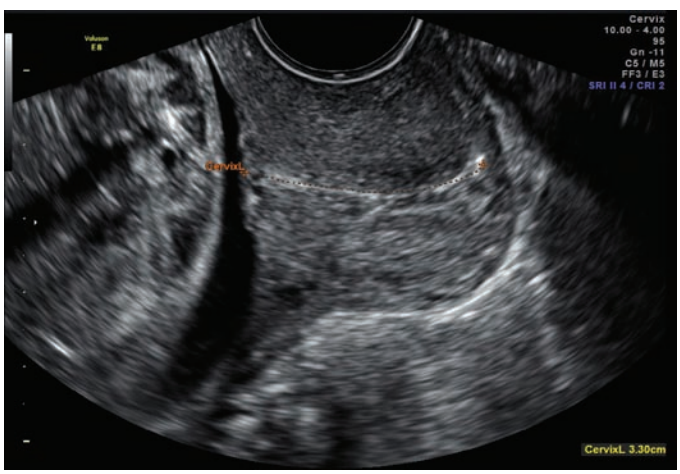

FIGURE 78-1 Transvaginal cervical length of a 24-week uterus. The hyperechoic line identifies the glandular tissue of the cervix and correct positioning to include the entire cervix. Measurement is from the internal os traced out to the external os. The fetal head is visible in this shot but not necessary for the measurement. (*Courtesy of Danielle Cooper, MD.*)

INTRODUCTION

The ideal time to perform an obstetric ultrasound is between 18 and 20 weeks' gestation. The fetus has developed all of its organ systems and is large enough to visualize these in detail. If resources are limited or patient costs are an issue, the second trimester ultrasound provides the most bang for the buck.

INDICATIONS FOR ULTRASOUND

- Second and third trimester ultrasound examination can be used to determine fetal number and presentation, and for documentation of fetal cardiac activity, placental location, and amniotic fluid volume.
- Second trimester is a good time to perform ultrasound for fetal assessment for gestational age and weight, and it is also an integral part of performing diagnostic amniocentesis.
- If only a single ultrasound can be performed on a patient, optimal timing is 18 to 20 weeks. Fetal anatomy is best seen during this interval. If fetal abnormalities are detected, a more detailed examination (level 2 ultrasound) by a specialized sonographer is indicated.
- Ultrasound examination is indicated to establish the number of fetuses when a multiple gestation pregnancy is suspected. Risk factors for a multiple gestation pregnancy include assisted reproductive technology, family history of twins (or higher multiples), and uterine size larger than that expected by menstrual dating.

FIGURE 78-2 Ultrasound examination of a 21-week EGA fetus showing measurement of the baby's biparietal diameter (*BPD*) and head circumference (*HC*). Note the presence of the *falx cerebri* and the thalamus (*TH*) to ensure the measurement is at the right anatomic level. (*Courtesy of E.J. Mayeaux, Jr., MD.*)

The number of fetuses can be best established by obtaining an image that includes a cross-section of all fetal poles that have distinct cardiac activity within a single frame.

- The cervix and lower uterine segment may be imaged in the second trimester to look for funneling (membranes protruding into the cervical canal), a short cervix that is a significant risk factor for preterm labor.

The placental location, appearance and relationship to the internal cervical os should be recorded.[1]

PATHOPHYSIOLOGY

- Fetal abnormalities that may be reliably diagnosed by ultrasound include achondroplasia, anencephaly, cleft lip, clubfoot, duodenal atresia, fetal hydrops, gastroschisis, hydrocephalus, omphalocele, transposition of the great vessels, cardiac, pulmonary and renal abnormalities, and spina bifida. If anomalies are suspected, a level 2 ultrasound with a perinatologist is indicated.
- Up to 5% of pregnancies will have placentas that partially or completely cover the internal cervical os at 16 to 18 weeks of gestation. Only 1 in 10 of these will continue to cover the internal os in the late third trimester.[2] Placentas that are clear of the cervix in early pregnancy will not encroach upon it later.

INDICATIONS FOR OB ULTRASOUNDS IN SECOND TRIMESTER

- Evaluating the possibility of a fetal anomaly is best done by ultrasound examination after 16 weeks of gestation as earlier examination may be limited by fetal size and development.
- The sensitivity and specificity of the procedure for detecting congenital abnormalities varies depending upon the specific defect, the gestational age, the quality of the ultrasound unit, and the skill of the ultrasonographer.
- Ultrasound examination is the main diagnostic modality used to evaluate second and third trimester bleeding. The major placental causes of vaginal bleeding at this time are placenta previa and abruptio placentae. A transvaginal obstetric ultrasound examination can identify placental location, and is safe even when placenta previa is present. Preterm labor is another cause of vaginal bleeding and the cervical length can be measured transvaginally to assess this risk. The normal cervical length can be seen in **Figure 78-1**. The images should be obtained after the mother has emptied her bladder to avoid displacement of the anterior lower uterine segment thus producing a false-positive test.[3]
- Fetal intrauterine growth limiting disorders are more likely when the uterine size is less than appropriate for gestational age, a prior pregnancy has been affected by growth restriction, with maternal hypertension, and in multiple gestations. Ultrasound cannot distinguish between a constitutionally small fetus and a pathologically small fetus. Decreased amniotic fluid volume and below normal interval growth make placental insufficiency more likely.

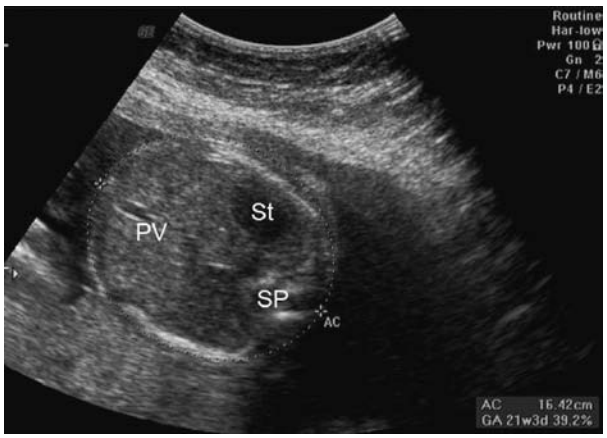

FIGURE 78-3 Ultrasound examination of a 21-week EGA fetus showing measurement of the baby's abdominal circumference (*AC*). Note how the stomach (*St*), spine (*SP*), and portal vein (*PV*) are all visible to ensure that the measurement is at the right anatomic level. (*Courtesy of E.J. Mayeaux, Jr., MD.*)

FIGURE 78-4 Ultrasound measurement of the same baby's femur length giving an EGA of 21 weeks and 6 days. Note the buttocks and penis are visible. All four measurements from **Figures 78-1** to **78-3** and this figure allow the computer to calculate an estimated fetal weight (EFW) of 431 grams. (*Courtesy of E.J. Mayeaux, Jr., MD.*)

FIGURE 78-5 Ultrasound examination of a 15-week EGA fetus showing the baby's face. (*Courtesy of E.J. Mayeaux, Jr., MD.*)

PERFORMING THE PROCEDURE

- The four standard biometric parameters commonly used to estimate gestational age and/or fetal weight in the second trimester are: BPD, HC (**Figure 78-2**), AC (**Figure 78-3**), and FL (**Figure 78-4**).[4] They are usually obtained by transabdominal ultrasound examination, and the fetal weight is calculated.
- The BPD (**Figure 78-2**) is a highly reproducible measurement and can predict gestational age within ±7 days when the ultrasound is performed between 14 and 20 weeks' gestation, although the best time to get an accurate date is in the first trimester. The BPD should be measured on a plane that includes both the third ventricle and the thalamus. The cursors are placed on the outer edge of the proximal skull and the inner edge of the distal skull and the BPD measured.
- The cephalic index is ratio of the BPD and the occipitofrontal diameter multiplied by 100. It should be used where the BPD may be inaccurate, such as with breech presentations, oligohydramnios, premature rupture of the membranes, and neural tube abnormalities.
- The measurement of fetal HC also accurately estimates gestational age, and is especially useful in the setting of growth disorders (**Figure 78-2**). The accuracy decreases in the second half of pregnancy. The HC should be measured on a plane that includes the third ventricle, the thalamus, the cavum septum pellucidum anteriorly, and the tentorial hiatus posteriorly. Unlike the BPD measurements, the HC measurement is obtained by placing the cursors on the outer margins of the calvarium bilaterally.
- The AC (**Figure 78-3**) is the least accurate in predicting gestational age, being accurate within 2 weeks in the second trimester. It is most often used for estimations of fetal weight and interval growth evaluations rather than fetal dating. The measurement should be taken at the level of the largest diameter of the fetal liver where the right and left portal veins join. The four calipers are placed around the abdomen on the skin edge to draw a circular line for AC measurement.
- FL (**Figure 78-4**) can be measured and is accurate to within 1 week before 20 weeks' gestation. Align the transducer along the long axis of the femoral bone and visualize either the femoral head or the greater trochanter proximally, and the end of the femur or the femoral condyle distally. Make sure you are measuring the femur and not another long bone in the arm or leg. Place the calipers at the bone and cartilage junction and measure only ossified bone, not including the femoral head.
- Many providers will often show expectant parents images of the baby's face (**Figures 78-5** and **78-6**), hands (**Figure 78-7**), and sex (**Figures 78-8** and **78-9**).
- The placenta and its relationship to the cervix should be examined for signs of placenta previa.

Cervical length or funneling of the cervix should be measured if there is a history of or current evidence of preterm labor or history of incompetent cervix. Cervical length is determined as the distance between the internal and external os. In patients at risk for cervical shortening or incompetence the operator can apply fundal pressure or scan the patient in the standing position to help identify these women[3] (**Figure 78-10**).

FIGURE 78-6 Ultrasound examination of a 15-week EGA fetus showing another view of the baby's face. (*Courtesy of E.J. Mayeaux, Jr., MD.*)

FIGURE 78-7 Ultrasound examination of a 19-week EGA fetus showing the baby's hands and forearms. *Arrow* is pointing at the right hand. (*Courtesy of E.J. Mayeaux, Jr., MD.*)

PATIENT RESOURCES

- Obstetric ultrasound by Dr. Joseph Woo—**http://www.ob-ultrasound.net/.**
- RadiologyInfo—**http://www.radiologyinfo.org/en/info.cfm?pg=obstetricus&bhcp=1.**

PROVIDER RESOURCES

- The Society of Obstetricians and Gynaecologists of Canada (SOGC) recommends a single "routine" ultrasound evaluation at 16 to 20 weeks in all pregnancies and suggests that 8 markers be evaluated based on an EBM review of the literature—**http://www.sogc.org/guidelines/pdf/JOGC-june05-Fetalmarkers-revised-ENG-CPG.pdf.**
- Perinatology.com. Level 2 Ultrasound—**http://www.perinatology.com/ultrasound.htm.**
- Obstetric ultrasound by Dr. Joseph Woo—**http://www.ob-ultrasound.net/.**

REFERENCES

1. American Institute of Ultrasound in Medicine. AIUM Standards and Guidelines. http://www.aium.org/publications/clinical/obstetrical.pdf. Accessed May 10, 2011.
2. Townsend RR, Laing FC, Nyberg DA, et al. Technical factors responsible for "placental migration": sonographic assessment. *Radiology* 1986;160:105.
3. Expert Panel of Women's Imaging. Assessment of the Gravid Cervix. American College of Radiology. Date of origin 1999, last review date 2008. http://www.acr.org/SecondaryMainMenuCategories/quality_safety/app_criteria/pdf/ExpertPanelonWomensImaging. Accessed September 19, 2011.
4. Hadlock FP. Sonographic estimation of fetal age and weight. *Radiol Clin North Am.* 1990;28:39.

FIGURE 78-8 Ultrasound examination of a 19-week EGA fetus showing the baby is a boy (*arrow*). (*Courtesy of E.J. Mayeaux, Jr., MD.*)

FIGURE 78-9 Ultrasound examination of a 19-week EGA fetus sucking his thumb (*arrow*). The two hemispheres of the brain are visible with the falx cerebri in between. (*Courtesy of E.J. Mayeaux, Jr., MD.*)

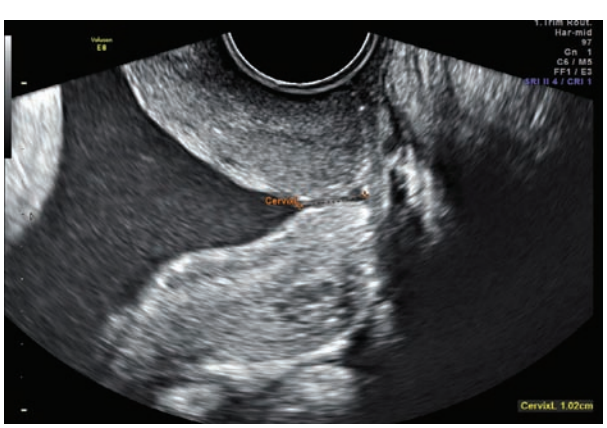

FIGURE 78-10 Transvaginal cervical length (CL) of a 27-week uterus at risk for preterm labor. CL is 1.02 cm. The "V" quality of the lower uterine segment and opening of the internal os, significantly increases this patient's risk for preterm labor. (*Courtesy of Danielle Cooper, MD.*)

79 THIRD TRIMESTER OBSTETRIC ULTRASOUND

E.J. Mayeaux, Jr., MD
Danielle B. Cooper, MD

PATIENT STORY

A 26-year-old woman gravida 3, para 2-0-0-2 with a singleton pregnancy at 27 weeks' gestation is concerned because her sister had a fetal demise and she thinks her baby is moving less. An ultrasound demonstrating normal anatomy (**Figures 79-1** to **79-3**) and strong fetal heart motion is very reassuring (**Figure 79-4**).

INTRODUCTION

Ultrasound usage in the third trimester of pregnancy is most often utilized to determine fetal number, presentation, and growth issues. This later pregnancy scan is also used to document fetal cardiac activity, placental location, and amniotic fluid volume, as well as provide a method for antenatal fetal assessment.

INDICATIONS FOR USE

- A Cochrane review of 7 studies showed no difference in obstetric, antenatal, or neonatal interventions between women undergoing routine late ultrasound examination after 24 weeks and those who did not.[1] In addition, there was no difference in perinatal outcome measures, such as admission to a neonatal intensive care unit, birthweight less than 10th percentile, or perinatal mortality.
- Hydrops fetalis is the accumulation of fluid in fetal tissues and body cavities, usually a result of immune pathologic conditions (**Figure 79-5**). Serial ultrasound examinations are useful for following pregnancies at risk for developing hydrops or to evaluate treatment. As well as utilizing middle cerebral artery peak-systolic velocity as a noninvasive tool to predict fetal anemia.[2]
- Ultrasound may also be used to evaluate third trimester bleeding. The major placental causes of vaginal bleeding at this time are placenta previa (**Figure 79-6**) and abruptio placentae.
- Ultrasound can safely image maternal abdominal organs during pregnancy. Ovarian cysts, uterine leiomyoma, renal obstruction, and gallbladder or liver disease can be evaluated without using ionizing radiation.

In pregnancies complicated by fetal growth restriction and maternal hypertensive disorders, umbilical artery Doppler sonography can be used for fetal surveillance and monitoring well-being. The values measured are peak-systolic frequency shift (S) and end-diastolic frequency shift (D). This S-to-D ratio gives information about downstream impedance to flow. For example uteroplacental insufficiency will show rising impedance to fetal placental vascular bed, which shows a decline in end-diastolic velocity and an overall increase in these Doppler indices.[3]

FIGURE 79-1 Ultrasound examination of a 27-week estimated gestational age (EGA) fetus showing measurement of the baby's humerus. (*Courtesy of E.J. Mayeaux, Jr., MD.*)

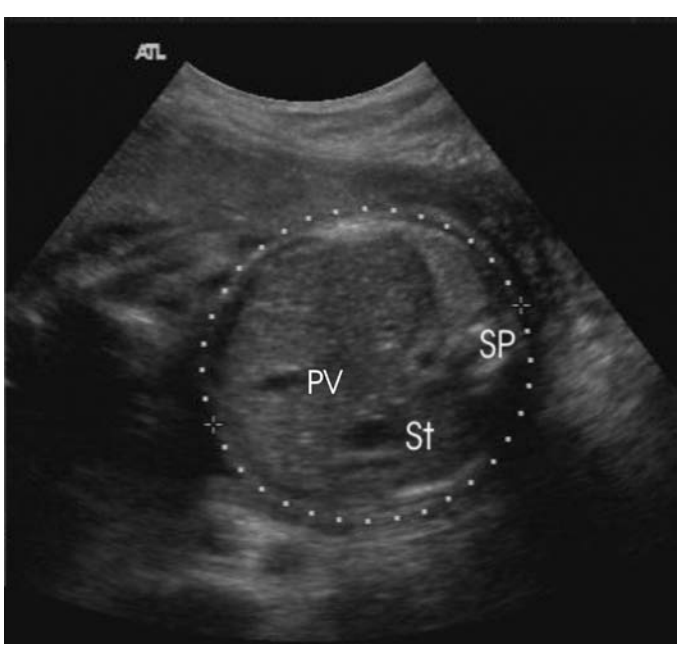

FIGURE 79-2 Ultrasound examination of a 27-week EGA fetus showing the baby's stomach (*St*), abdomen, spine (*SP*), and left portal vein (*PV*). (*Courtesy of E.J. Mayeaux, Jr., MD.*)

If there is an increased risk for in utero fetal demise or significant risk factors for fetal anemia then fetal surveillance can be performed with the biophysical profile (BPP). This is the sonographic assessment of four fetal variables: fetal movement, fetal tone, fetal breathing, and the amniotic fluid volume, plus the results of the nonstress testing.[3]

VALUE OF ULTRASOUND IN THIRD TRIMESTER

- Ultrasound-based determination of estimated date of delivery (EDD) has been shown to improve dating and thus reduce intervention for postterm pregnancy. One randomized controlled trial evaluated the effect of routine ultrasound examinations at 18 and 32 weeks of gestation on the accuracy of dating and pregnancy outcome in a low-risk population.[4] They found that ultrasound screening reduced the incidence of induced labor for postterm pregnancy by 70%, and also reduced the incidence of induction for all causes. They also found that the proportion of 5-minute Apgar scores less than 8 and the need for positive pressure ventilation were both lower in the screened group.
- Although ultrasound EDD determination as late as 34 weeks can reduce the number of pregnancies diagnosed as postterm, first trimester ultrasound in a low-risk population is more effective than later ultrasound in decreasing postterm pregnancy.
- Accurate assessment of gestational age is important so as not to inappropriately initiate tocolysis for near-term labor.
- Signs suggestive of fetal maturity may also be found on ultrasound. The femoral epiphyseal ossification center can be visualized by 32 weeks' gestational age, and proximal tibial center can be visualized by 35 weeks' gestational age. The proximal humeral epiphysis also appears in the late third trimester and correlates well with fetal lung maturity.
- Twin pregnancies are at increased risk of complications, such as fetal heart rate abnormalities and complications as a result of malpresentation. When both twins are found on ultrasound to be vertex (42% of twins) a trial of labor with the goal of a vaginal delivery is appropriate. When one twin is nonvertex (38% of twins) options include cesarean delivery of both twins, or attempted vaginal delivery of one or both twins.[5,6]
- Parents are now paying for 4D ultrasounds (3D images in real time, time being the fourth dimension) so that they can see and get pictures of their developing child. Although the 4D ultrasound is not a standard medical device (**Figure 79-7**), it is being utilized to better characterize certain anomalies, such as facial clefts, neural tube defects, and skeletal malformations.[7]

If there is suspicion of unusual fetal growth, restricted or macrosomic, a third trimester growth scan is obtained for evaluation and continued plan of care.

The BPP is a noninvasive, easily performed, accurate means for predicting the presence of significant fetal anemia. Approximately 70% to 90% of late fetal deaths display evidence of fetal compromise prior to demise.[3] Ultrasound detection of these fetal signs can allow appropriate intervention to ideally prevent adverse fetal sequelae.

Umbilical artery and middle cerebral artery Doppler measurements should be integrated with other existing modalities of antepartum fetal monitoring to determine their clinical usefulness.[3]

FIGURE 79-3 Ultrasound examination of a 27-week EGA fetus showing measurement of the baby's biparietal diameter (BPD). (*Courtesy of E.J. Mayeaux, Jr., MD.*)

FIGURE 79-4 Ultrasound examination of a 27-week EGA fetus showing all four chambers of the baby's heart. (*Courtesy of E.J. Mayeaux, Jr., MD.*)

FIGURE 79-5 Ultrasound examination showing scalp edema (*E*) associated with hydrops fetalis. (*Courtesy of E.J. Mayeaux, Jr., MD.*)

FOLLOW-UP

- Once BPPs are initiated in women requiring fetal surveillance, this test should be repeated on a weekly or twice weekly basis until delivery.

When a patient has placenta previa diagnosed on ultrasound, advise patient to avoid coitus, digital cervical examination, and exercise. Counsel her to seek immediate medical attention if there is any vaginal bleeding or uterine contractions. Advise her that cesarean delivery is the delivery route of choice.[8]

PATIENT RESOURCES

- Obstetric ultrasound by Dr. Joseph Woo—**http://www.ob-ultrasound.net/.**
- March of Dimes pregnancy education center—**http://www.marchofdimes.com/pnhec/159_523.asp.**

PROVIDER RESOURCES

- OB-GYN ultrasound online—**http://www.fetalsono.com/index.html.**
- Perinatology.com. Level 2 ultrasound—**http://www.perinatology.com/ultrasound.htm.**
- Obstetric ultrasound by Dr. Joseph Woo—**http://www.ob-ultrasound.net/.**

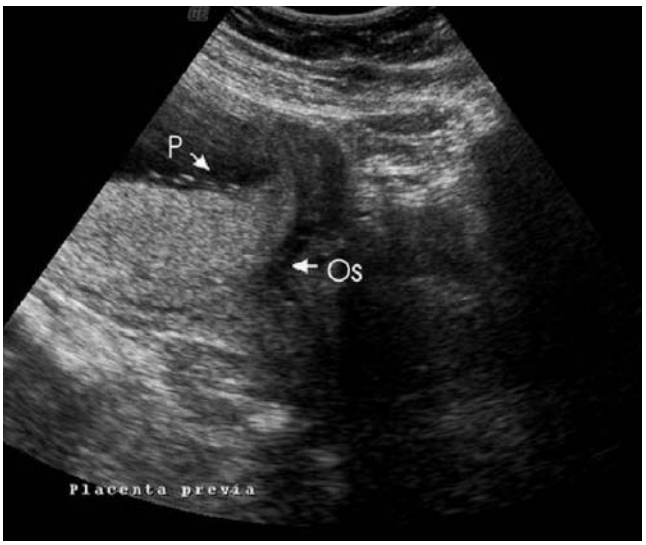

FIGURE 79-6 Ultrasound examination showing the placenta (*P*) covering the cervical os (*Os*) in placenta previa. (*Courtesy of E.J. Mayeaux, Jr., MD.*)

REFERENCES

1. Bricker L, Neilson JP. Routine ultrasound in late pregnancy (after 24 weeks' gestation). *Cochrane Database Syst Rev.* 2000;(2): CD001451.
2. Mari G; Collaborative Group for Doppler Assessment of the Blood Velocity in Anemic Fetuses. Noninvasive diagnosis by Doppler ultrasonography of fetal anemia due to maternal red-cell alloimmunization. *N Engl J Med.* 2000;342:9-14.
3. ACOG practice bulletin. Antepartum Fetal Surveillance. Number 9, October 1999. Clinical Management guidelines for obstetricians-gynecologists. *Int J Gynaecol Obstet.* 2000;68:175-185.
4. Eik-Nes SH, Salvesen KA, Okland O, Vatten LJ. Routine ultrasound fetal examination in pregnancy: the "Alesund" randomized controlled trial. *Ultrasound Obstet Gynecol.* 2000;15:473.
5. Chasen ST, Spiro SJ, Kalish RB, Chervenak FA. Changes in fetal presentation in twin pregnancies. *J Matern Fetal Neonatal Med.* 2005;17:45.
6. Dodd JM, Crowther CA. Evidence-based care of women with a multiple pregnancy. *Best Pract Res Clin Obstet Gynaecol.* 2005; 19:131.
7. Goncalves LF, Lee W, Espinoza J, Romero R. Three and four dimensional ultrasound in obstetric practice does it help? *J Ultrasound Med.* 2005;24:1599-1624.
8. Bhide A, Prefumo F, Moore J, et al. Placental edge to internal os distance in the late third trimester and mode of delivery in placenta praevia. *BJOG.* 2003;110:860.

FIGURE 79-7 Three-dimensional (3D) ultrasound showing a 25-week fetus. (*Courtesy of E.J. Mayeaux, Jr., MD.*)

SECTION 2 VAGINITIS AND CERVICITIS

80 OVERVIEW OF VAGINITIS

E.J. Mayeaux, Jr., MD

PATIENT STORY

A 39-year-old woman presented to her physician with a malodorous vaginal discharge. On exam, a thin white discharge was seen covering the introitus (**Figure 80-1).** A speculum exam revealed a thin whitish gray discharge and a distinct fishy odor. The pH of the discharge was 4.6, and 40% of the epithelial cells on her wet prep were clue cells (**Figure 80-2**). She was diagnosed with bacterial vaginosis and treated with oral metronidazole.

FIGURE 80-1 Thin white discharge from bacterial vaginosis seen covering the introitus prior to speculum exam. (*Courtesy of Seattle STD/HIV Prevention Training Center, University of Washington.*)

INTRODUCTION

Vaginal discharge is a frequent presenting complaint in primary care. The three most common causes are bacterial vaginosis, candidiasis, and trichomoniasis. However, a significant number of patients with vaginal discharge will have some other condition, such as atrophic vaginitis. Providers must refrain from "diagnosing" a vaginitis based solely on the color and consistency of the discharge, as this may lead to misdiagnosis and may miss concomitant infections.[1]

EPIDEMIOLOGY

The reported rates of chlamydia and gonorrhea are highest among females ages 15 to 19 years. Adolescents are at greater risk for sexually transmitted diseases (STDs) because they frequently have unprotected intercourse, are biologically more susceptible to infection, are often engaged in partnerships of limited duration, and face multiple obstacles to utilization of health care.[1]

ETIOLOGY AND PATHOPHYSIOLOGY

- The quantity and quality of normal vaginal discharge in healthy women vary. Physiologic leukorrhea refers to generally nonmalodorous, mucousy, white or yellowish vaginal discharge in the absence of a pathologic cause. It is not accompanied by signs and symptoms, such as pain, pruritus, burning, erythema, or tissue friability. However, slight malodor and irritative symptoms can be normal for some women at certain times.[2] Physiologic leukorrhea is usually a result of estrogen-induced changes in cervicovaginal secretions.
- Noninfectious causes of vaginitis include irritants (e.g., scented panty liners, spermicides, povidone-iodine, soaps and perfumes, and some topical drugs) and allergens (e.g., latex condoms, topical

antifungal agents, chemical preservatives) that produce hypersensitivity reactions.

- Before starting an examination, determine whether the patient douched recently, because this can lower the yield of diagnostic tests and increase the risk of pelvic inflammatory disease.[3] Patients who have been told not to douche will sometimes start wiping the vagina with soapy washcloths, which also irritates the vagina and cervix and may cause a discharge. Douching is associated with increases in bacterial vaginosis and acquisition of sexually transmitted infections when exposed. However, recent studies indicate that douching with plain water once a week or less did not disturb normal flora.[4,5]
- There are many causes of vaginitis in humans. Infectious causes include bacterial vaginosis (40% to 50% of cases) (see **Figures 80-1 and 80-2**), vulvovaginal candidiasis (20% to 25%), and trichomonas (15% to 20%) (**Figure 80-3**).[6] Less common causes include atrophic vaginitis, foreign body (especially in children), cytolytic or desquamative inflammatory vaginitis, streptococcal vaginitis, ulcerative vaginitis, and idiopathic vulvovaginal ulceration associated with HIV infection.
- Rarer noninfectious causes include chemicals, allergies, hypersensitivity, contact dermatitis, trauma, postpuerperal atrophic vaginitis, erosive lichen planus, collagen vascular disease, Behçet syndrome, and pemphigus syndromes.

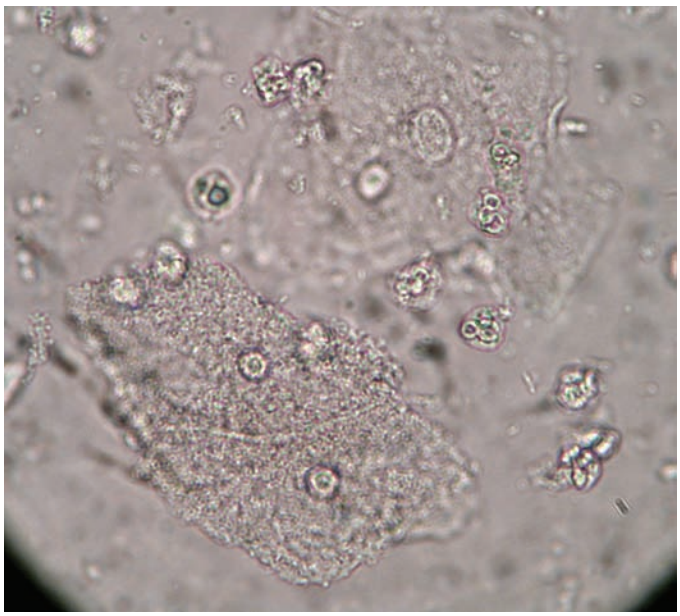

FIGURE 80-2 A wet mount of vaginal discharge in saline under high-power light microscopy. Note the presence of vaginal epithelial cells, smaller white blood cells (polymorphonucleocytes), and bacteria. The bacteria are the coccobacilli of *Gardnerella vaginalis* covering the cell membranes of the two vaginal epithelial cells near the lower end of the field. These are clue cells seen in patients with bacterial vaginosis. (*Courtesy of Richard P. Usatine, MD.*)

DIAGNOSIS

CLINICAL FEATURES

- Examine the external genitalia for irritation or discharge (see **Figure 80-2).** Speculum examination is done to determine the amount and character of the discharge (**Figure 80-4**). A chlamydia and gonorrhea test should always be done in sexually active females with a vaginal discharge. Look closely at the cervix for discharge and signs of infection, dysplasia, or cancer (**Figure 80-3**). Bimanual examination may show evidence of cervical, uterine, or adnexal tenderness. **Table 80-1** shows diagnostic values for examination of vaginitis.
- Vaginal pH testing can be helpful in the diagnosis of vaginitis. The pH can be checked by applying pH paper to the vaginal sidewall. Do not place the pH paper in contact with the cervical mucus. A pH above 4.5 is seen with menopausal patients, trichomonas infection, or bacterial vaginosis.
- Wet preps are obtained by applying a cotton-tipped applicator to the vaginal sidewall and placing the sample into normal saline. A drop of the suspension is then placed on a slide and examined for the presence and number of white blood cells (WBCs), trichomonads, candidal hyphae, or clue cells (**Figure 80-1**).
- A KOH prep is made by adding a drop of KOH solution to a drop of saline suspension of the discharge. The KOH lyses epithelial cells in 5 to 15 minutes (faster if the slide is warmed briefly) and allows easier visualization of candidal hyphae. The use of KOH with DMSO allows for quicker lyses of the epithelial cells and immediate examination of the smear.
- Another diagnostic procedure is the "whiff" test, which is performed by placing a drop of KOH on a slide of the wet prep and

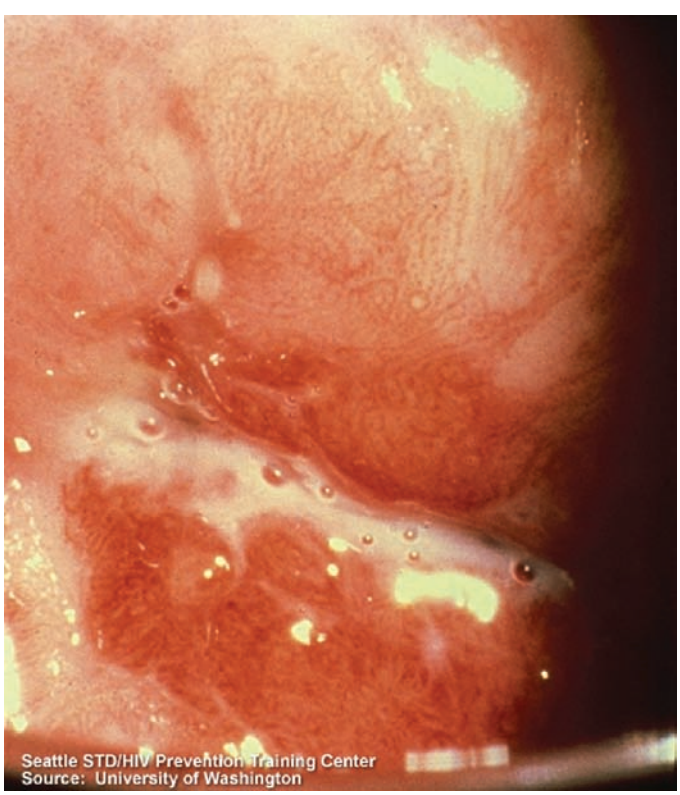

FIGURE 80-3 Colposcopic view of the cervix in a patient infected with trichomonas vaginalis. Note the frothy discharge with visible bubbles and the cervical erythema. (*Courtesy of Seattle STD/HIV Prevention Training Center, University of Washington.*)

TABLE 80-1 Diagnostic Values for Vaginal Infections

Diagnostic Criteria	Normal	Bacterial Vaginosis	Trichomonas Vaginitis	Candida Vulvovaginitis
Vaginal pH	3.8 to 4.2	>4.5	4.5	<4.5 (usually)
Discharge	White, thin, flocculent	Thin, white, gray	Yellow, green, or gray, frothy	White, curdy, "cottage cheese"
Amine odor "whiff" test	Absent	Fishy	Fishy	Absent
Microscopic	Lactobacilli, epithelial cells	Clue cells, adherent cocci, no white blood cells	Trichomonads, white blood cells >10/hpf	Budding yeast, hyphae, Pseudohyphae

(*Courtesy of E.J. Mayeaux, Jr., MD.*)

smelling for a foul, fishy odor. The odor is indicative of anaerobic overgrowth or infection. The "whiff" test is positive if the fishy amine odor is detected during the exam and it is then not necessary to add KOH and "whiff" again.

LABORATORY TESTING (INCLUDE ANCILLARY TESTING TOO)

- Nucleic acid amplification tests are highly sensitive tests for *Neisseria gonorrhoeae*, *Chlamydia*, and *Chlamydia trachomatis* that can be performed on genital specimens or urine. Urine screening for gonorrhea, chlamydia, or both using nucleic acid amplification test can be used successfully in difficult-to-reach adolescents.[7]

MANAGEMENT

- Management is based on the identification of the causative agent.
- Treatment for physiologic leukorrhea is unnecessary.
- Management of vaginal irritants and allergens involves identifying and eliminating the offending agents. However, irritants and allergens can often be difficult to identify.
- Health food store lactobacilli are the wrong strain and do not adhere well to the vaginal epithelium. Ingestion of live-culture, nonpasteurized yogurt does not significantly change the incidence of candidal vulvovaginitis or bacterial vaginosis. [8]

FIURE 80-4 Speculum exam showing mucopurulent discharge with a friable appearing cervix. (*Courtesy of Richard P. Usatine, MD.*)

PATIENT RESOURCES

- Centers for Disease Control and Prevention. *Sexually Transmitted Diseases* page—**http://www.cdc.gov/std/.**
- Planned Parenthood—**http://www.plannedparenthood.org/cameron-willacy/images/South-Texas/What_Every_Woman_Needs_to_Know_English.pdf.**
- Illinois Department of Public Health. *Vaginitis*—**www.idph.state.il.us/public/hb/hbvaginitis.htm.**

PROVIDER RESOURCES

- Centers for Disease Control and Prevention. *2010 Guidelines for Treatment of Sexually Transmitted Diseases*—**http://www.cdc.gov/std/treatment/2010/STD-Treatment-2010-RR5912.pdf.**
- Centers for Disease Control and Prevention. *Self-Study STD Module–Vaginitis*—**www2a.cdc.gov/stdtraining/self-study/vaginitis.asp.**
- Centers for Disease Control and Prevention. Vaginitis slides—**http://www2a.cdc.gov/stdtraining/ready-to-use/Manuals/Vaginitis/vaginitis-slides-2010.pdf.**
- eMedicine—**http://emedicine.medscape.com/article/257141-overview.**
- American Family Physician—**http://www.aafp.org/afp/20000901/1095.html.**

REFERENCES

1. Centers for Disease Control and Prevention. *Sexually Transmitted Disease Surveillance 2001*. Atlanta, GA: U.S. Department of Health and Human Services, CDC, 2002.
2. Anderson M, Karasz A, Friedland S. Are vaginal symptoms ever normal? A review of the literature. *MedGenMed*. 2004;6:49.
3. Zhang J, Thomas AG, Leybovich E. Vaginal douching and adverse health effects: A meta-analysis. *Am J Public Health*. 1997;87:1207-1211.
4. Hassan S, Chatwani A, Brovender H, et al. Douching for perceived vaginal odor with no infectious cause of vaginitis: a randomized controlled trial. *J Low Genit Tract Dis*. 2011;15(2):128-133.
5. Zhang J, Hatch M, Zhang D, et al. Frequency of douching and risk of bacterial vaginosis in African-American women. *Obstet Gynecol*. 2004;104(4):756-760.
6. Sobel JD. Vaginitis. *N Engl J Med*. 1997;337:1896-1903.
7. Monroe KW, Weiss HL, Jones M, Hook EW 3rd. Acceptability of urine screening for *Neisseria gonorrheae* and *Chlamydia trachomatis* in adolescents at an urban emergency department. *Sex Transm Dis*. 2003;30:850-853.
8. Pirotta M, Gunn J, Chondros P, et al. Effect of lactobacillus in preventing post-antibiotic vulvovaginal candidiasis: A randomised controlled trial. *BMJ*. 2004;329:548.

81 ATROPHIC VAGINITIS

E.J. Mayeaux, Jr., MD

PATIENT STORY

A 60-year-old woman with vaginal dryness and irritation is seen to follow-up on an inflammatory Pap smear. She denies discharge, odor, douching, and sexually transmitted disease (STD) exposure. She does admit to some postcoital bleeding. Her cervix has atrophic changes and an endocervical polyp (**Figure 81-1**). The polyp was removed easily with a ring forceps and no dysplasia was found on pathology.

FIGURE 81-1 Colposcopic photograph (scanning objective with 10× eyepiece) demonstrating atrophic vaginitis. Note thinned white epithelium, friable epithelium with bleeding, and a cervical polyp. (*Courtesy of E.J. Mayeaux, Jr., MD.*)

INTRODUCTION

Vaginal atrophy caused by estrogen deficiency is common and usually is asymptomatic except for vaginal dryness.

SYNONYMS

Vaginal atrophy, vulvovaginal atrophy, urogenital atrophy, senile vaginitis.

EPIDEMIOLOGY

- The average age of menopause is 51 years in the United States.
- Approximately 5% of women experience menopause after age 55 years (late menopause), and another 5% experience the transition between the ages of 40 and 45 years (early menopause). This means that in the United States, most women will live a significant portion of their lives during menopause. Women who in menopause have surgical menopause or have ovarian suppression without estrogen supplementation (progestin-only contraceptives) are susceptible to atrophic changes in their lower genital tract.
- Vaginal dryness occurs in approximately 3% of women of reproductive age, 4% to 21% of women in the menopausal transition, and 47% of women 3 years postmenopause.[1] Internationally, 39% of women experience menopause-related vaginal discomfort.[2]

ETIOLOGY AND PATHOPHYSIOLOGY

- After menopause, circulating estrogen levels dramatically decrease to a level at least one-sixth their premenopausal levels.[3] Changes that occur in the vaginal and cervical epithelium include proliferation of connective tissue, loss of elastin, thinning of the epithelium (**Figure 81-2**), and hyalinization of collagen.
- A long-term decrease in estrogen is generally necessary before symptoms become apparent. Genital symptoms include decreased vaginal lubrication, dryness, burning, dyspareunia, leukorrhea, itching, and yellow malodorous discharge.

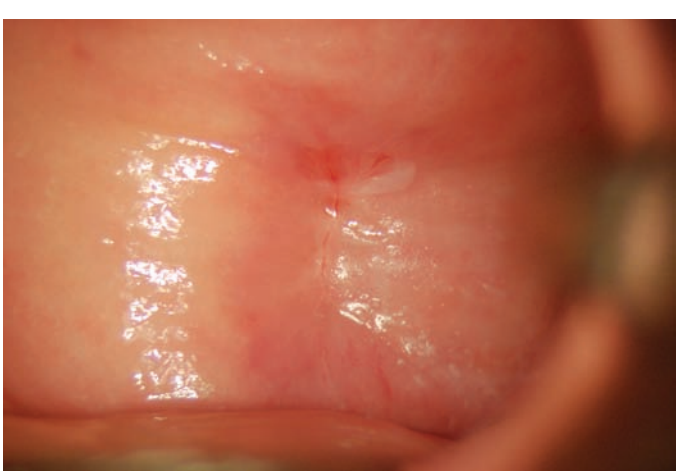

FIGURE 81-2 Colposcopic photograph (scanning objective with 10× eyepiece) demonstrating atrophic cervicovaginitis. Note thin white epithelium, relative dryness, and a barely visible cervical os. (*Courtesy of E.J. Mayeaux, Jr., MD.*)

- Urinary symptoms, such as frequency, hematuria, urinary tract infection, dysuria, and stress incontinence, are usually late symptoms. Over time, the lack of vaginal lubrication often results in sexual dysfunction.
- Cervical polyps (**Figure 81-1**) are pedunculated tumors that usually arise from the endocervical canal mucosa, and are common in patients with atrophic vaginitis. Many will show squamous metaplasia, and they may develop squamous dysplasia. Polyps are most commonly asymptomatic unless they bleed.
- Menopause is the most common cause of atrophic vaginitis. In premenopausal women, radiation therapy, chemotherapy, immunologic disorders, and oophorectomy may greatly decrease production of ovarian estrogen and lead to atrophic vaginitis. Antiestrogen medications may also result in atrophic vaginitis. Women who are naturally premenopausally estrogen deficient, smoke cigarettes, or have not given vaginal birth tend to have more severe symptoms.[3]

RISK FACTORS

- Age.
- Family history of early menopause.
- Bilateral oophorectomy.
- Spontaneous premature ovarian failure.
- Antiestrogenic medications effects, such as tamoxifen, danazol, medroxyprogesterone acetate.
- Gonadotropin-releasing hormone agonists (leuprolide, nafarelin, goserelin), or antagonists (ganirelix).
- Prolactin elevation as a result of hypothalamic-pituitary disorders with secondary reduction of estrogen secretion.
- Certain chemotherapeutic agents.
- Pelvic radiation therapy.
- Severe systemic lupus erythematosus or rheumatoid arthritis (because of hypothalamic hypogonadism or primary ovarian insufficiency) combined with glucocorticoid therapy cause combined suppression of ovarian and adrenal activity.

DIAGNOSIS

CLINICAL FEATURES

- Diagnosis is clinical, based upon characteristic symptoms and findings. Many women with symptoms of vaginal atrophy do not discuss their condition with a health care provider because they believe their symptoms are a normal part of the aging process.[4]
- Atrophic vaginal and cervical epithelium appears pale, smooth, relatively dry, and shiny (**Figure 81-2**). Inflammation with patchy erythema, petechiae, and friability is common in more advanced cases. The external genitalia may demonstrate diminished elasticity, turgor of skin, sparsity of pubic hair, dryness of labia, erythema (**Figure 81-3**), and fusion of the labia minora.[5]

LABORATORY TESTING

- Laboratory tests to confirm hypoestrogenic findings are typically not necessary.

FIGURE 81-3 The vulva of a postmenopausal woman demonstrating thinning of the hair and thinning and erythema of vulvar skin associated with atrophic vulvitis. (*Courtesy of Gordon Davis, MD, Arizona Vulva Clinic, Inc.*)

- Serum estradiol levels of less than 20 pg/mL support a clinical diagnosis of a low-estrogenic state. However, values are very laboratory dependent and most assays are neither sufficiently sensitive nor reliable for diagnosis of hypoestrogenic states without clinical signs and symptoms.
- A serum follicle-stimulating hormone (FSH) level greater than 40 mIU/mL is diagnostic of menopause.
- A Papanicolaou smear can confirm the presence of urogenital atrophy. Cytologic examination of smears from the upper one-third of the vagina shows an increased proportion of parabasal cells and a decreased percentage of superficial cells.
- An elevated vaginal pH level (>5), monitored by a pH strip in the vaginal vault, may also be a sign of vaginal atrophy.[3]

IMAGING

- Testing for associated osteoporosis should be considered if not previously performed.

DIFFERENTIAL DIAGNOSIS

- Atrophic vaginitis symptoms can be mimicked or exacerbated by coinfection of candidiasis, trichomoniasis, or bacterial vaginosis. These can be identified by wet prep, pH, and whiff test (see Chapter 82, Bacterial Vaginosis).
- Sexually transmitted diseases, including gonorrhea, trichomonas, and chlamydia, also may coexist with or mimic atrophic vaginitis. Cultures or nucleic acid amplification tests can identify these infections. It is important not to assume a diagnosis of solely atrophic vaginitis in the postmenopausal patient who presents with urogenital complaints. (Chapter 80, Overview of Vaginitis).
- Contact dermatitis because of environmental agents (e.g., perfumes, deodorants, soaps, panty liners, perineal pads, spermicides, lubricants, or tight fitting/synthetic clothing) may cause erythema, itching, burning, or pain. (Chapter 146, Contact Dermatitis).
- Vulvovaginal lichen planus, which may produce labial fusion. (Chapter 154. Lichen Planus).
- Lichen sclerosus et atrophicus (LSEA) does produce atrophy of the vulva and can be mistaken for the atrophy of estrogen deficiency. It can be recognized by the hour-glass configuration of the atrophy around the vulva and perianal region **(Figure 81-4)**. LSEA is treated with a high-potency steroid ointment rather than estrogen.

FIGURE 81-4 Lichen sclerosus et atrophicus with atrophy of the vulva in this 53-year-old woman. Lichen sclerosus et atrophicus can be recognized by the hour-glass configuration of the atrophy around the vulva and perianal region. (*Courtesy of Richard P. Usatine, MD.*)

MANAGEMENT

NONPHARMACOLOGIC

- Nonhormonal local vaginal moisturizers and lubricants may be used to help maintain natural secretions and comfort during intercourse. Sexual activity has been shown to encourage vaginal elasticity and pliability, and the lubricative response to sexual stimulation. One open-label study indicated that Replens, a bioadhesive vaginal moisturizer, was a safe and effective alternative to estrogen vaginal cream, with both therapies exhibiting statistically significant increases in vaginal moisture, vaginal fluid volume, and vaginal elasticity.[6] SOR A

- Water-based vaginal lubricants include:
  - Slippery Stuff (polyoxyethylene, methylparaben, propylene glycol, isopropanol).
  - Astroglide (glycerin, methylparaben, propylparaben, polypropylene glycol, polyquaternium, hydroxyethylcellulose).
  - K-Y Jelly (glycerin, hydroxyethylcellulose, parabens, and chlorhexidine).
  - Pre-Seed (hydroxyethylcellulose, arabinogalactan, paraben, and Pluronic copolymers), which is promoted for women who are trying to conceive.
- Silicone-based:
  - ID Millennium (cyclomethicone, dimethicone, and dimethiconol).
  - Pjur Eros (cyclopentasiloxane, dimethicone, and dimethiconol).
  - Pink (dimethicone, vitamin E, aloe vera, dimethiconol, and cyclomethicone.
- Oil-based:
  - Elégance Women's Lubricant.
  - Natural oils (such as olive oil).
- Water-based and silicone-based vaginal lubricants are compatible with condom use. Oil-based lubricants may damage latex-based condoms.
- Patients should stop smoking, as women who smoke cigarettes are relatively estrogen-deficient.[7] SOR A

MEDICATIONS

- Estrogen replacement therapy relieves menopausal symptoms including atrophic vaginitis.[8] SOR A Routes of administration include oral, transdermal, and intravaginal. Risks associated with estrogen use include breast cancer, coronary heart disease, stroke, and venous thromboembolism.
- A Cochrane review found that estrogen creams, pessaries, vaginal tablets, and the estradiol vaginal ring appeared to be equally effective for the symptoms of vaginal atrophy.[8] SOR A One trial found significant side effects following conjugated equine estrogen cream administration when compared to tablets causing uterine bleeding, breast pain, and perineal pain. Another trial found significant endometrial overstimulation following use of the conjugated equine estrogen cream when compared to the estrogen vaginal ring. Women appeared to favor the estradiol-releasing vaginal ring for ease of use, comfort of product, and overall satisfaction.[8] SOR A
- The amount of estrogen and the duration of time required to eliminate symptoms depend on the degree of vaginal atrophy, and varies among patients. Progestin therapy should be considered in any woman with an intact uterus to avoid causing endometrial cancer. When oral estrogen is used at typical doses, atrophic symptoms will persist in 10% to 25% of patients.[9]
- Topical administration of estrogen is an excellent treatment for genitourinary symptoms of atrophy, because exposure of other organs can be minimized if low doses of topical estrogens are used. Absorption rates with topical therapy increase with treatment duration because of the enhanced vascularity of the epithelium.
- Vaginal estrogen therapy available in the United States are conjugated estrogens cream (0.625 mg conjugated estrogens/g, 0.5 g of cream intravaginally twice weekly) and estradiol cream (100 mcg estradiol/g of cream, 2 to 4 g of cream intravaginally administered daily for 2 weeks, then decreased to 1 g of cream 1 to 3 times per week), tablet (10 mcg estradiol/tablet intravaginally daily for 2 weeks then twice weekly), and ring (0.5 mcg estradiol/day, released over 90 days). In Europe and some other countries, estriol cream is also available.
- Vaginal estrogen therapy results in some estrogen absorption into the circulation, although to a lesser degree than oral or transdermal estrogen treatment. In one study, systemic absorption was 30% lower in a study of vaginal versus conjugated estrogen therapy.[10] SOR B
- Progestin therapy is probably not necessary to protect against endometrial hyperplasia in women treated with the low-dose ring or intravaginal tablet when used as approved. The systemic estrogen absorption with use of the vaginal creams is difficult to quantify, so some experts recommend use of an opposing progestin for women treated with vaginal estrogen cream.[11] SOR C

FOLLOW-UP

- Follow-up is needed for all patients placed on estrogen therapy to monitor for estrogen-related side effects. Otherwise, follow-up can be as needed.

PATIENT EDUCATION

- Discuss the risks and benefits of estrogen replacement therapy with patients interested in the use of estrogens. Vaginal lubricants (nonprescription) may safely help prevent pain during intercourse.

PATIENT RESOURCES

- NCBI. *Atrophic Vaginitis*—**www.ncbi.nlm.nih.gov.**
- MedlinePlus. *Atrophic Vaginitis*—**www.nlm.nih.gov/medlineplus/ency/article/000892.htm.**
- Harvard Medical School. *Atrophic Vaginitis*—**www.health.harvard.edu/fhg/updates/update0703c.shtml.**

PROVIDER RESOURCES

- eMedicine. *Vaginitis*—**http://emedicine.medscape.com/article/257141.**
- eMedicine. *Vulvovaginitis in Emergency Medicine*—**http://emedicine.medscape.com/article/797497.**
- Bachmann GA, Nevadunsky NS. Diagnosis and treatment of atrophic vaginitis. *Am Fam Physician.* 2000;61(10):3090-3096.—**http://www.aafp.org/afp/2000/0515/p3090.html.**
- American Family Physician—**http://www.aafp.org/afp/20000515/3090.html.**

REFERENCES

1. Dennerstein L, Dudley EC, Hopper JL, et al. A prospective population-based study of menopausal symptoms. *Obstet Gynecol.* 2000;96:351.

2. Nappi RE, Kokot-Kierepa M. Women's voices in the menopause: results from an international survey on vaginal atrophy. *Maturitas*. 2010;67:233.
3. Pandit L, Ouslander JG. Postmenopausal vaginal atrophy and atrophic vaginitis. *Am J Med Sci.* 1997;314:228-231.
4. Bachmann GA, Nevadunsky NS. Diagnosis and treatment of atrophic vaginitis. *Am Fam Physician.* 2000;61:3090.
5. Johnston SL, Farrell SA, Bouchard C, et al. The detection and management of vaginal atrophy. *J Obstet Gynaecol Can.* 2004;26:503.
6. Nachtigall Le. Comparative study: Replens versus local estrogen in menopausal women. *Fertil Steril.* 1994;61:178.
7. Tansavatdi K, McClain B, Herrington DM. The effects of smoking on estradiol metabolism. *Minerva Ginecol.* 2004;56:105.
8. Suckling J, Lethaby A, Kennedy R. Local oestrogen for vaginal atrophy in postmenopausal women. *Cochrane Database Syst Rev.* 2006 Oct 18;(4):CD001500. Doi: 10.1002/14651858.Cd001500.Pub2.
9. Smith P, Heimer G, Lindskog M, Ulmsten U. Oestradiol-releasing vaginal ring for treatment of postmenopausal urogenital atrophy. *Maturitas.* 1993;16:145-154.
10. Dorr MB, Nelson AL, Mayer PR, et al. Plasma estrogen concentrations after oral and vaginal estrogen administration in women with atrophic vaginitis. *Fertil Steril.* 2010;94:2365.
11. Bachmann G, Bouchard C, Hoppe D, et al. Efficacy and safety of low-dose regimens of conjugated estrogens cream administered vaginally. *Menopause.* 2009;16:719.

82 BACTERIAL VAGINOSIS

E.J. Mayeaux, Jr., MD
Richard P. Usatine, MD

PATIENT STORY

A 31-year-old woman presents with a malodorous vaginal discharge for 3 weeks. There is no associated vaginal itching or pain. She is married and monogamous. She admits to douching about once per month to prevent odor but it is not working this time. On examination, her discharge is visible (**Figure 82-1**). It is thin and off-white. Wet prep examination shows that more than 50% of the epithelial cells are clue cells (**Figure 82-2**). The patient is treated with oral metronidazole 500 mg bid for 7 days with good results.

FIGURE 82-1 A 31-year-old woman with homogeneous, thin white malodorous vaginal discharge. (*Courtesy of Richard P. Usatine, MD.*)

INTRODUCTION

Bacterial vaginosis (BV) is a clinical syndrome resulting from alteration of the vaginal ecosystem. It is called a vaginosis, not a vaginitis, because the tissues themselves are not actually infected, but only have superficial involvement. Women with BV are at increased risk for the acquisition of HIV, *Neisseria gonorrhoeae*, *Chlamydia trachomatis*, and herpes simplex virus (HSV)-2, and they have increased risk of complications after gynecologic surgery.[1]

BV is associated with adverse pregnancy outcomes, including premature rupture of membranes, preterm labor, preterm birth, intraamniotic infection, and postpartum endometritis. However, the only established benefit of BV therapy in pregnant women is the reduction of symptoms and signs of vaginal infection.[1]

SYNONYMS

- Vaginal bacteriosis.
- *Corynebacterium* vaginosis/*vaginalis*/*vaginitis*.
- *Gardnerella vaginalis*/vaginosis.
- *Haemophilus vaginalis*/vaginitis.
- Nonspecific vaginitis.
- Anaerobic vaginosis.

EPIDEMIOLOGY

- BV is estimated to be the most prevalent cause of vaginal discharge or malodor in women presenting for care in the United States. However, more than 50% of women with BV are asymptomatic.[1] It accounts for more than 10 million outpatient visits per year.[2] The worldwide prevalence is unknown.

ETIOLOGY AND PATHOPHYSIOLOGY

- Hydrogen peroxide-producing *Lactobacillus* is the most common organism composing normal vaginal flora.[1] In BV, normal vaginal lactobacilli are replaced by high concentrations of anaerobic bacteria such as *Mobiluncus*, *Prevotella*, *Gardnerella*, *Bacteroides*, and *Mycoplasma* species.[1,2]
- The hydrogen peroxide produced by the *Lactobacillus* may help in inhibiting the growth of atypical flora.
- The odor of BV is caused by the aromatic amines produced by the altered bacterial flora in the vagina. These aromatic amines include putrescine and cadaverine—aptly named to describe their foul odor.

RISK FACTORS

- Multiple male or female partners.[1,3]
- A new sex partner.[1]
- Douching.[4]
- Lack of condom use.[1]
- Lack of vaginal lactobacilli.[1]
- Prior BV infection.[1]

DIAGNOSIS

CLINICAL FEATURES

- Symptomatic patients present with an unpleasant, "fishy smelling" discharge that is more noticeable after coitus (the basic pH of seminal fluid is like doing the whiff test with KOH). There may be pruritus but not as often as seen with *Candida* vaginitis. The physical examination should include inspection of the external genitalia for irritation or discharge. Speculum examination is done to determine the amount and character of the discharge. A nucleic acid amplification test for *N. gonorrhoeae*, *Chlamydia*, and/or *C. trachomatis* (or similar test) should be performed on genital specimens (urethral or cervical) or urine.
- BV is usually clinically diagnosed by finding three of the following four signs and symptoms:
  - Homogeneous, thin, white discharge that smoothly coats the vaginal walls (**Figure 82-3** and **82-4**).
  - Presence of clue cells on microscopic examination (**Figure 82-2**).
  - pH of vaginal fluid >4.5.
  - A fishy odor of vaginal discharge before or after addition of 10% KOH (i.e., the whiff test).[1]

LABORATORY TESTING

- Vaginal pH testing can be very helpful in the diagnosis of vaginitis. The normal vaginal pH is usually 3.5 to 4.5. A pH above 4.5 is seen with menopausal patients, *Trichomonas* infection, or BV. A small piece of pH paper is touched to the vaginal discharge during the exam or on the speculum. Do not test a wet-prep sample if saline has been added because the saline alters the pH.

FIGURE 82-2 Clue cell and bacteria seen in bacterial vaginosis. The lower cell is a clue cell covered in bacteria while the upper cell is a normal epithelial cell. Light microscope under high power. (*Courtesy of E.J. Mayeaux, Jr., MD.*)

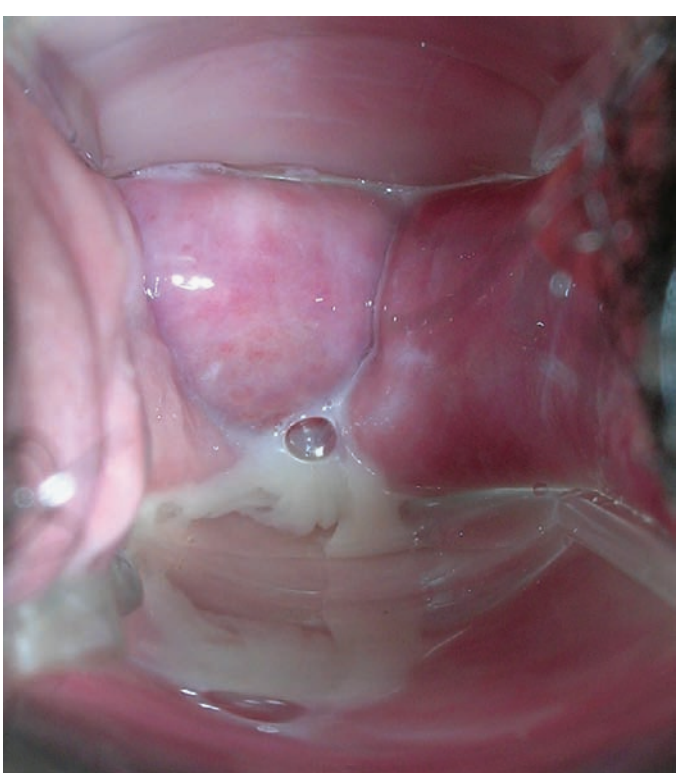

FIGURE 82-3 A homogeneous, off-white creamy malodorous discharge that adheres to the vaginal walls and pools in the vaginal vault in a woman with bacterial vaginosis. (*Courtesy of Richard P. Usatine, MD.*)

- Wet preps are obtained using a cotton-tipped applicator applied to the vaginal sidewall, placing the sample of discharge into normal saline (not water). Observe for clue cells, number of white blood cells, trichomonads, and candidal hyphae. Clue cells are squamous epithelial cells whose borders are obscured by attached bacteria. More than 20% to 25% of epithelial cells seen in BV should be clue cells (**Figure 82-2**).
- A proline aminopeptidase test card (Pip Activity Test Card), a DNA probe-based test for high concentrations of *G. vaginalis* (Affirm VP III), and the OSOM BVBLUE test have shown acceptable performance characteristics compared with Gram stain (gold standard).[1] However, they are more costly than traditional testing without clear advantages.
- Although a test card is available for the detection of elevated pH and trimethylamine, it has low sensitivity and specificity and is not recommended by the Centers for Disease Control and Prevention (CDC).[1]
- Culture of *G. vaginalis* is not recommended as a diagnostic tool because it is not specific.
- Pap tests are not useful for the diagnosis of BV because of their low sensitivity.[1]

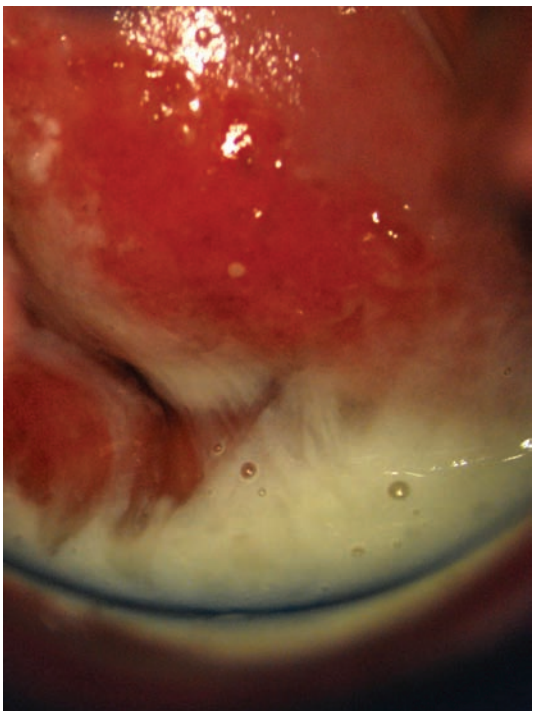

FIGURE 82-4 Close up view of the cervix showing the white homogeneous discharge. Note the lack of clumping or "cottage-cheese" appearance usually found with *Candida* infections. (*Courtesy of E.J. Mayeaux, Jr., MD.*)

DIFFERENTIAL DIAGNOSIS

- *Trichomonas* also may have the odor of aromatic amines and, therefore, easily confused with BV at first glance. Look for the strawberry cervix on examination and moving trichomonads on the wet prep (Chapter 84, Trichomonas Vaginitis).
- *Candida* vaginitis tends to present with a cottage-cheese-like discharge and vaginal itching (Chapter 83, *Candida* Vulvovaginitis).
- Gonorrhea and chlamydia should not be missed in patients with vaginal discharge. Consider testing for these sexually transmitted diseases (STDs) based on patients' risk factors and the presence of purulence clinically and white blood cells on the wet prep (Chapter 85, Chlamydia Cervicitis).

MANAGEMENT

- Treatment is recommended for women with symptoms.
- Treatment of male sex partners has not been beneficial in preventing the recurrence of BV.[1] SOR A

MEDICATIONS

- The established benefits of therapy for BV in nonpregnant women are to (a) relieve vaginal symptoms and signs of infection and (b) reduce the risk for infectious complications after abortion or hysterectomy.[1] SOR A Other potential benefits might include a reduction in risk for other sexually transmitted infections (STIs).[1] SOR B **Table 82-1** shows CDC recommended treatments.
- Metronidazole 2 g single-dose therapy has the lowest efficacy for BV and is no longer a recommended or alternative regimen. Clindamycin cream is oil-based and might weaken latex condoms and diaphragms for 5 days after use. Topical clindamycin

TABLE 82-1 CDC Recommended Regimens SOR A

Metronidazole 500 mg orally twice a day for 7 days
OR
Metronidazole gel 0.75%, 1 full applicator (5 g) intravaginally, once a day for 5 days
OR
Clindamycin cream 2%, 1 full applicator (5 g) intravaginally at bedtime for 7 days
CDC Alternative Regimens SOR A
Tinidazole 2 g orally once daily for 3 days
OR
Tinidazole 1 g orally once daily for 5 days
OR
Clindamycin 300 mg orally twice a day for 7 days
OR
Clindamycin ovules 100 mg intravaginally once at bedtime for 3 days
OR
Metronidazole 750-mg extended-release tablets once daily for 7 days
CDC Recommended Regimens for Pregnant Women SOR A
Metronidazole 500 mg orally twice a day for 7 days
OR
Metronidazole 250 mg orally three times a day for 7 days
OR
Clindamycin 300 mg orally twice a day for 7 days

Data from Centers for Disease Control and Prevention.[1]

preparations should not be used in the second half of pregnancy.[1] Multiple studies and metaanalyses have not demonstrated an association between metronidazole use during pregnancy and teratogenic or mutagenic effects in newborns.[1] SOR A

- The only established benefit of therapy for BV in pregnant women is to relieve vaginal symptoms and signs of infection.[1] SOR A Additional potential benefits of therapy include (a) reducing the risk for infectious complications associated with BV during pregnancy and (b) reducing the risk for other infections (e.g., other STDs or HIV). Multiple studies and metaanalyses have not demonstrated an association between metronidazole use during pregnancy and teratogenic or mutagenic effects in newborns.[5]
- One randomized trial for persistent BV indicated that metronidazole gel 0.75% twice per week for 6 months after completion of a recommended regimen was effective in maintaining a clinical cure for 6 months.[6] SOR B
- Limited data suggest that oral nitroimidazole followed by intravaginal boric acid and suppressive metronidazole gel for those women in remission might be an option in women with recurrent BV. SOR B[7]
- Intravaginal clindamycin cream has been associated with adverse outcomes if used in the latter half of pregnancy.[1]

COMPLEMENTARY AND ALTERNATIVE THERAPY

- Extended ingestion of live culture, nonpasteurized yogurt may theoretically increase colonization by lactobacilli and decrease the episodes of BV.[8] SOR C However, health food store lactobacilli are the wrong strain and are not well-retained by the vagina.
- The efficacy of exogenous lactobacillus recolonization with probiotic lactobacilli vaginal gelatin capsules has been reported in two small trials.[9,10]

PREVENTION

- Avoidance of risk factors is recommended, although asymptomatic BV is common.
- The evidence is insufficient to assess the impact of screening for BV in pregnant women at high risk for preterm delivery.[1]

FOLLOW-UP

- Follow-up visits are unnecessary in nonpregnant women if symptoms resolve.[1]
- Treatment of BV in asymptomatic pregnant women who are at high risk for preterm delivery might prevent adverse pregnancy outcomes. Therefore, a follow-up evaluation 1 month after completion of treatment should be considered to evaluate whether therapy was effective.[1] SOR C
- If symptoms do recur, consider a treatment regimen different from the original regimen to treat recurrent disease.[1] SOR C

PATIENT EDUCATION

- Avoid consuming alcohol during treatment with metronidazole and for 24 hours thereafter. Women should be advised to return for additional therapy if symptoms recur because recurrence of BV is not unusual.

PATIENT RESOURCES

- Centers for Disease Control and Prevention. *Bacterial Vaginosis Fact Sheet*—**http://www.cdc.gov/std/BV/STDFact-Bacterial-Vaginosis.htm.**
- Family Doctor.org from the AAFP—**http://familydoctor.org/234.xml.**
- MedicineNet.com—**http://www.medicinenet.com/bacterial_vaginosis/article.htm.**

PROVIDER RESOURCES

- Centers for Disease Control and Prevention. *2010 Guidelines for Treatment of Sexually Transmitted Diseases*—**http://www.cdc.gov/std/treatment/2010/STD-Treatment-2010-RR5912.pdf.**

REFERENCES

1. Centers for Disease Control and Prevention. *Guidelines for Treatment of Sexually Transmitted Diseases*. http://www.cdc.gov/std/treatment/2010/STD-Treatment-2010-RR5912.pdf. Accessed December 24, 2011.
2. Martius J, Krohn MA, Hillier SL, et al. Relationships of vaginal lactobacillus species, cervical chlamydia trachomatis, and bacterial vaginosis to preterm birth. *Obstet Gynecol.* 1988;71:89-95.
3. Gorgos LM, Marrazzo JM. Sexually transmitted infections among women who have sex with women. *Clin Infect Dis.* 2011;53 Suppl 3: S84-S91.
4. Klebanoff MA, Nansel TR, Brotman RM, et al. Personal hygienic behaviors and bacterial vaginosis. *Sex Transm Dis.* 2010;37:94.
5. Burtin P, Taddio A, Ariburnu O, et al. Safety of metronidazole in pregnancy: a meta-analysis. *Am J Obstet Gynecol.* 1995;172 (2 Pt 1):525-529.
6. Sobel JD, Ferris D, Schwebke J, et al. Suppressive antibacterial therapy with 0.75% metronidazole vaginal gel to prevent recurrent bacterial vaginosis. *Am J Obstet Gynecol.* 2006;194: 1283-1289.
7. Reichman O, Akins R, Sobel JD. Boric acid addition to suppressive antimicrobial therapy for recurrent bacterial vaginosis. *Sex Transm Dis.* 2009;36:732-734.
8. Baylson FA, Nyirjesy P, Weitz MV. Treatment of recurrent bacterial vaginosis with tinidazole. *Obstet Gynecol.* 2004;104 (5 Pt 1):931-932.
9. Anukam KC, Osazuwa E, Osemene GI, et al. Clinical study comparing probiotic Lactobacillus GR-1 and RC-14 with metronidazole vaginal gel to treat symptomatic bacterial vaginosis. *Microbes Infect.* 2006;8:2772.
10. Ya W, Reifer C, Miller LE. Efficacy of vaginal probiotic capsules for recurrent bacterial vaginosis: a double-blind, randomized, placebo-controlled study. *Am J Obstet Gynecol.* 2010;203:120.

83 *CANDIDA* VULVOVAGINITIS

E.J. Mayeaux, Jr., MD
Richard P. Usatine, MD

PATIENT STORY

A 35-year-old woman presents with severe vaginal and vulvar itching. She also complains of a thick white discharge. **Figure 83-1** demonstrates the appearance of her vagina and cervix and **Figure 83-2** shows her vulva. **Figure 83-3** shows her wet prep. Treatment with a nonprescription intravaginal preparation was successful.

INTRODUCTION

Vulvovaginal candidiasis (VVC) is a common fungal infection in women of childbearing age. Pruritus is accompanied by a thick, odorless, white vaginal discharge. VVC is not a sexually transmitted disease. On the basis of clinical presentation, microbiology, host factors, and response to therapy, VVC can be classified as either uncomplicated or complicated.[1] Uncomplicated VVC is characterized by sporadic or infrequent symptoms, mild-to-moderate symptoms, and the patient is nonimmunocompromised. Complicated VVC is characterized by recurrent (four or more episodes in 1 year) or severe VVC, non-albicans candidiasis, or the patient has uncontrolled diabetes, debilitation, or immunosuppression.[1]

SYNONYMS

Yeast vaginitis, yeast infection, candidiasis, moniliasis.

EPIDEMIOLOGY

- VVC accounts for approximately one third of vaginitis cases.[1]
- *Candida* species are part of the lower genital tract flora in 20% to 50% of healthy asymptomatic women.[2]
- Seventy-five percent of all women in the United States will experience at least one episode of VVC. Of these, 40% to 45% will have two or more episodes within their lifetime.[3] Approximately 10% to 20% of women will have complicated VVC that necessitates diagnostic and therapeutic considerations.
- It is a frequent iatrogenic complication of antibiotic treatment, secondary to altered vaginal flora.
- Nearly half of all women experience multiple episodes, and up to 5% experience recurrent disease.[1]
- Recurrent vulvovaginal candidiasis (RVVC) is defined as four or more episodes of symptomatic VVC in 1 year. It affects a small percentage of women (<5%).[4] Recurrent yeast vaginitis is usually caused by relapse, and less often by reinfection. Recurrent infection may be caused by *Candida* recolonization of the vagina from the rectum.[5]

FIGURE 83-1 *Candida* on the vulva and introitus showing whitish patches with erythema. (*Courtesy of Richard P. Usatine, MD.*)

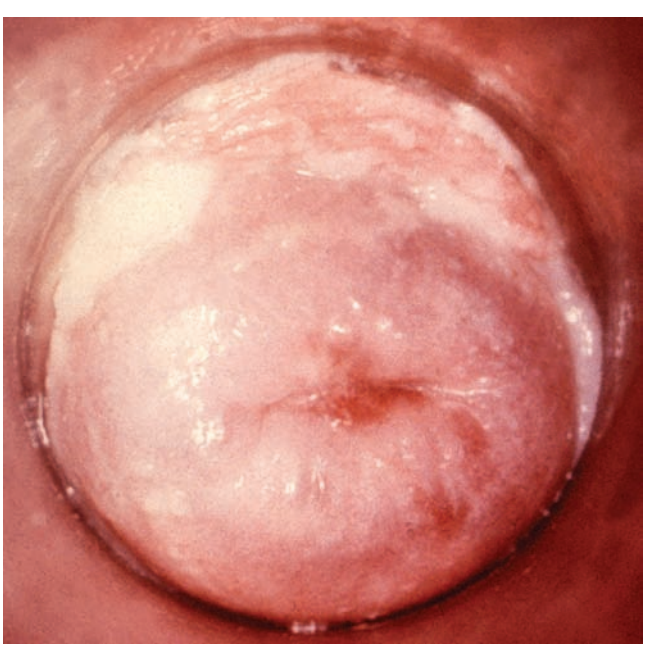

FIGURE 83-2 *Candida* vaginitis. Note the thick white adherent "cottage-cheese-like" discharge. (*Courtesy of the Centers for Disease Control and Prevention and Stuart Brown, MD.*)

ETIOLOGY AND PATHOPHYSIOLOGY

- Most vulvovaginal Candidiasis is caused by *Candida albicans* (**Figure 83-3**).[1,6] *Candida glabrata* now causes a significant percentage of all *Candida* vulvovaginal infections. This organism is resistant to the nonprescription imidazole creams. It can mutate out of the activity of treatment drugs much faster than *albicans* species.[7]
- The disease is suggested by pruritus in the vulvar area, together with erythema of the vagina and vulva (**Figures 83-1** and **83-2**). The familiar reddening of the vulvar tissues is caused by an ethanol by-product of the *Candida* infection. This ethanol compound also produces pruritic symptoms. A scalloped edge with satellite lesions is characteristic of the erythema on the vulva.
- VVC can occur concomitantly with sexually transmitted diseases (STDs).
- The pathogenesis of recurrent VVC is poorly understood, and most women with these recurrences have no apparent predisposing or underlying conditions.[1]

FIGURE 83-3 Wet mount with KOH of *Candida albicans* in a woman with *Candida* vaginitis. Seen under high power demonstrating branching pseudohyphae and budding yeast. (*Courtesy of Richard P. Usatine, MD.*)

RISK FACTORS[8,9]

- Diabetes mellitus.
- Recent antibiotic use.
- Increased estrogen levels.
- Immunosuppression.
- Contraceptive devices (vaginal sponges, diaphragms, and intrauterine devices).
- Genetic susceptibility.
- Behavioral factors—VVC may be linked to orogenital and, less commonly, anogenital sex.
- Wearing diapers.
- Spermicides are **not associated** with *Candida* infection.
- There is no high-quality evidence showing a link between VVC and hygienic habits or wearing tight or synthetic clothing.

DIAGNOSIS

CLINICAL FEATURES

- The diagnosis is usually suspected by characteristic findings (**Figures 83-1** and **83-2**). Typical symptoms include pruritus, vaginal soreness, dyspareunia, and external dysuria. Typical signs include vulvar edema, fissures, excoriations, or thick, curdy vaginal discharge.[1]

LABORATORY TESTING (INCLUDE ANCILLARY TESTING TOO)

- Vaginitis solely caused by *Candida* generally has a normal vaginal pH of less than 4.5.
- The wet prep, KOH smear, or Gram stain may demonstrate yeast and/or pseudohyphae (**Figures 83-3** and **83-4**). Wet preps may

FIGURE 83-4 Wet mount with saline showing *Candida* in a woman with *Candida* vaginitis. Note how the branching pseudohyphae and budding yeast can be seen even though the epithelial cells have not been lysed by KOH. (*Courtesy of Richard P. Usatine, MD.*)

also demonstrate white blood cells, trichomonads, candidal hyphae, or clue cells.

- The KOH prep is made by adding a drop of KOH solution to a drop of saline suspension of the discharge. The KOH lyses epithelial cells in 5 to 15 minutes (faster if the slide is warmed) and allows easier visualization of candidal hyphae or yeast.[1] Swartz-Lamkins stain (potassium hydroxide, a surfactant, and blue dye) may facilitate diagnosis by staining the yeast organisms a light blue.[10]
- Rapid antigen testing is also available for *Candida*. The detection of vaginal yeast by rapid antigen testing is feasible for office practice and more sensitive than wet mount. A negative test result, however, was not found to be sensitive enough to rule out yeast and avoid a culture.[6] SOR A
- Fungal culture with Sabouraud agar, Nickerson medium, or Microstix-*Candida* medium should be considered in patients with symptoms and a negative KOH because *C. glabrata* does not form pseudohyphae or hyphae and is not easily recognized on microscopy. If the wet mount is negative and *Candida* cultures cannot be done, empiric treatment can be considered for symptomatic women with any sign of VVC on examination.[1] SOR C Asymptomatic women should not be cultured as 10% to 20% of women harbor *Candida* sp. and other yeasts in the vagina.[1] SOR A
- Vaginal cultures should be obtained from patients with RVVC to confirm the clinical diagnosis and to identify unusual species, including non-*albicans* species, particularly *C. glabrata* (*C. glabrata* does not form pseudohyphae or hyphae and is not easily recognized on microscopy).[1] SOR B *C. glabrata* and other non-*albicans Candida* species are observed in 10% to 20% of patients with RVVC.[1]
- Given the frequency at which RVVC occurs in the immunocompetent healthy population, the occurrence of RVVC alone should not be considered an indication for HIV testing.[1] SOR C

DIFFERENTIAL DIAGNOSIS

- Trichomoniasis can be confused with candidiasis because patients may report itching and a discharge in both diagnoses. Look for the strawberry cervix on examination and moving trichomonads on the wet prep (Chapter 84, *Trichomonas* Vaginitis).
- Bacterial vaginosis can be confused with candidiasis because patients may report a discharge and an odor in both diagnoses. The odor is usually much worse in bacterial vaginosis and the quality of the discharge can be different. The wet prep should allow for differentiation between these two infections (Chapter 82, Bacterial Vaginosis).
- Gonorrhea and *Chlamydia* should not be missed in patients with vaginal discharge. Consider testing for these STDs based on patients' risk factors and the presence of purulence clinically and white blood cells on the wet prep (Chapter 85, *Chlamydia* Cervicitis).
- Cytolytic vaginosis, or Döderlein cytolysis, can be confused with candidiasis. Cytolytic vaginosis is produced by a massive desquamation of epithelial cells related to excess lactobacilli in the vagina. The signs and symptoms are similar to *Candida* vaginitis, except no yeast are found on wet prep. The wet prep will show an overgrowth

of lactobacilli. The treatment is to discontinue all antifungals and other agents or procedures that alter the vaginal flora.

MANAGEMENT

NONPHARMACOLOGIC

- VVC is not usually acquired through sexual intercourse; treatment of sex partners is not recommended but may be considered in women who have recurrent infection. Some male sex partners might have balanitis (Chapter 136, Candidiasis) and might benefit from treatment.[1] SOR A
- Any woman whose symptoms persist after using a nonprescription preparation or who has a recurrence of symptoms within 2 months should be evaluated with office-based testing as they are not necessarily more capable of diagnosing themselves even with prior diagnosed episodes of VVC and delay in the treatment of other vulvovaginitis etiologies can result in adverse clinical outcomes.[1] SOR A

MEDICATIONS

- Women with typical symptoms and a positive test result should receive treatment. Short-courses of topical formulations effectively treat uncomplicated VVC (**Table 83-1**).[1] SOR A Topical azole drugs are more effective than nystatin, and result in clinical cure and negative cultures in 80% to 90% of patients who complete therapy. SOR A The creams and suppositories in **Table 83-1** are oil-based and might weaken latex condoms and diaphragms.[1]
- The cure rates with single-dose oral fluconazole and all the intravaginal treatments are equal.[11] Fluconazole (Diflucan) 150-mg single dose has become very popular, but may have clinical cure rates of approximately only 70%. SOR A Systemic allergic reactions are possible with the oral agents.
- The oral agents fluconazole, ketoconazole, and itraconazole also appear to be effective.[1] SOR B
- VVC frequently occurs during pregnancy. Only topical azole therapies, applied for 7 days, are recommended for use among pregnant women.[1] SOR C
- The optimal treatment of non-*albicans* VVC remains unknown. Options include longer duration of therapy (7 to 14 days) with topical therapy or a 100-mg, 150-mg, or 200-mg oral dose of fluconazole every third day for a total of 3 doses.[1] SOR C
- Severe VVC (i.e., extensive vulvar erythema, edema, excoriation, and fissure formation) is associated with lower clinical response rates in patients treated with short courses of topical or oral therapy. Either 7 to 14 days of topical azole or 150 mg of fluconazole in two sequential doses (second dose 72 hours after initial dose) is recommended.[1] SOR C

COMPLEMENTARY AND ALTERNATIVE THERAPY

- If recurrence VVC occurs, 600 mg of boric acid in a gelatin capsule is recommended, administered vaginally once daily for 2 weeks. This regimen has clinical and mycologic eradication rates of approximately 70%.[1] SOR B

TABLE 83-1 Centers for Disease Control and Prevention Recommended Treatment Regimens

Intravaginal Agents:
Butoconazole 2% cream 5 g intravaginally for 3 days
Butoconazole 2% cream 5 g (Butaconazole1-sustained release), single intravaginal application*
Clotrimazole 1% cream 5 g intravaginally for 7 to 14 days
Clotrimazole 2% cream 5 g intravaginally for 3 days
Clotrimazole 100 mg vaginal suppositories, one intravaginally for 3 days
Miconazole 2% cream 5 g intravaginally for 7 days
Miconazole 100 mg vaginal suppository, 1 suppository for 7 days
Miconazole 200 mg vaginal suppository, 1 suppository for 3 days
Miconazole 1200 mg vaginal suppository, 1 suppository for 1 day
Nystatin 100,000-U vaginal tablet, 1 tablet for 14 days*
Tioconazole 6.5% ointment 5 g intravaginally in a single application
Terconazole 0.4% cream 5 g intravaginally for 7 days*
Terconazole 0.8% cream 5 g intravaginally for 3 days*
Terconazole 80 mg vaginal suppository, 1 suppository for 3 days*
Oral Agent:
Fluconazole 150-mg oral tablet, 1 tablet in single dose*

*Prescription only in the United States.
Data from the Centers for Disease Control and Prevention.[1]

- *Lactobacillus acidophilus* does not adhere well to the vaginal epithelium, and it does not significantly change the incidence of candidal vulvovaginitis.[5,12]
- There is no evidence from randomized trials that other complementary and alternative (CAM) therapies, such as garlic, tea tree oil, yogurt, or douching, are effective for the treatment or prevention of VVC caused by *C. albicans*.[13,14]

PREVENTION

MAINTENANCE REGIMENS

- Oral fluconazole (i.e., 100-mg, 150-mg, or 200-mg dose) weekly for 6 months is the first line of treatment. If this regimen is not feasible, some specialists recommend topical clotrimazole 200 mg twice a week, clotrimazole (500-mg dose vaginal suppositories once weekly), or other topical treatments used intermittently.[1] SOR C
- Suppressive maintenance antifungal therapies are effective in reducing RVVC.[1] SOR A However, 30% to 50% of women will have recurrent disease after maintenance therapy is discontinued. Routine treatment of sex partners is controversial. *C. albicans* azole resistance is rare in vaginal isolates, and susceptibility testing is usually not warranted for individual treatment guidance.

PROGNOSIS

- Women with underlying debilitating medical conditions (e.g., those with uncontrolled diabetes or those receiving corticosteroid treatments) do not respond as well to short-term therapies. Efforts to correct modifiable conditions should be made, and more prolonged (i.e., 7 to 14 days) conventional antimycotic treatment is necessary.[1] SOR C
- Symptomatic VVC is more frequent in HIV-seropositive women and correlates with severity of immunodeficiency. In addition, among HIV-infected women, systemic azole exposure is associated with the isolation of non–*C. albicans* species from the vagina. According to the available data, therapy for VVC in HIV-infected women should not differ from that for seronegative women.[1] SOR C

FOLLOW-UP

- Patients should be instructed to return for follow-up visits only if symptoms persist or recur within 2 months of onset of initial symptoms.[1]

PATIENT EDUCATION

- Studies show that women who were previously diagnosed with VVC are not necessarily more likely to be able to diagnose themselves.[1] Any woman whose symptoms persist after using an nonprescription preparation, or who has a recurrence of symptoms within 2 months, should be evaluated with office-based testing. Explain that unnecessary or inappropriate use of nonprescription preparations can lead to a delay in the treatment of other vulvovaginitis etiologies, which can result in adverse clinical outcomes.[1]

PATIENT RESOURCES

- FamilyDoctor.org from AAFP. *Yeast Infections*—**http://familydoctor.org/online/famdocen/home/women/reproductive/vaginal/206.htm.**
- MedicineNet. *Vaginal Yeast Infection (Yeast Vaginitis)*—**http://www.medicinenet.com/yeast_vaginitis/article.htm.**
- WebMD. *Vaginal Yeast Infections*—**http://women.webmd.com/tc/vaginal-yeast-infections-topic-overview.**
- Womenshealth.gov. *Vaginal Yeast Infections Fact Sheet*—**http://www.womenshealth.gov/publications/our-publications/fact-sheet/vaginal-yeast-infections.cfm.**
- MedLinePlus. *Yeast Infections*—**http://www.nlm.nih.gov/medlineplus/yeastinfections.html.**
- eMedicine Health. *Candidiasis*—**http://www.emedicine-health.com/candidiasis_yeast_infection/article_em.htm.**

PROVIDER RESOURCES

- Centers for Disease Control and Prevention. *2010 Guidelines for Treatment of Sexually Transmitted Diseases*—**http://www.cdc.gov/std/treatment/2010/STD-Treatment-2010-RR5912.pdf.**
- American Family Physician. Management of vaginitis. *Am Fam Physician*. 2004;70:[11]2125-2132.—**http://www.aafp.org/afp/20041201/2125.html.**
- eMedicine. *Candidiasis*—**emedicine.medscape.com/article/213853-overview.**
- eMedicine. *Vulvovaginitis in Emergency Medicine*—**emedicine.medscape.com/article/797497-overview.**

REFERENCES

1. Centers for Disease Control and Prevention. *2010 Guidelines for Treatment of Sexually Transmitted Diseases*. http://www.cdc.gov/std/treatment/2010/STD-Treatment-2010-RR5912.pdf. Accessed November 2, 2011.
2. Goldacre MJ, Watt B, Loudon N, et al. Vaginal microbial flora in normal young women. *Br Med J*. 1979;1:1450.
3. Hurley R, De Louvois J. *Candida* vaginitis. *Postgrad Med J*. 1979;55:645.
4. Sobel JD. Epidemiology and pathogenesis of recurrent vulvovaginal candidiasis. *Am J Obstet Gynecol*. 1985;152:924.
5. Shalev E, Battino S, Weiner E, et al. Ingestion of yogurt containing acidophilus compared with pasteurized yogurt as prophylaxis for recurrent candidal vaginitis and bacterial vaginosis. *Arch Fam Med*. 1996;5:593-596.
6. Cohen DA, Nsuami M, Etame RB, et al. A school-based chlamydia control program using DNA amplification technology. *Pediatrics*. 1998;(1):101.
7. Horowitz BJ, Giaquinta D, Ito S. Evolving pathogens in vulvovaginal candidiasis: implications for patient care. *J Clin Pharmacol*. 1992;32:248.
8. Foxman B. The epidemiology of vulvovaginal candidiasis: risk factors. *Am J Public Health*. 1990;80:329.
9. Sobel JD. *Candida* vaginitis. *Infect Dis Clin Pract (Baltim Md)*. 1994;3:334.
10. Swartz JH, Lamkins BE. A rapid, simple stain for fungi in skin, nail scrapings, and hair. *Arch Dermatol*. 1964;89:89.
11. Sobel JD, Brooker D, Stein GE, et al. Single oral dose fluconazole compared with conventional clotrimazole topical therapy of candida vaginitis. *Am J Obstet Gynecol*. 1995;172:1263-1238.
12. Pirotta M, Gunn J, Chondros P, et al. Effect of lactobacillus in preventing post-antibiotic vulvovaginal candidiasis: a randomised controlled trial. *BMJ*. 2004;329:548.
13. Van Kessel K, Assefi N, Marrazzo J, Eckert L. Common complementary and alternative therapies for yeast vaginitis and bacterial vaginosis: a systematic review. *Obstet Gynecol Surv*. 2003;58(5):351-358.
14. Boskey ER. Alternative therapies for bacterial vaginosis: a literature review and acceptability survey. *Altern Ther Health Med*. 2005;11(5):38-43.

84 *TRICHOMONAS* VAGINITIS

E.J. Mayeaux Jr., MD
Richard P. Usatine, MD

PATIENT STORY

A 27-year-old woman presents with a vaginal itching, odor, and discharge for 1 week. She has one partner who is asymptomatic. Speculum examination shows a strawberry cervix seen with *Trichomonas* infections (**Figure 84-1**). This strawberry pattern is caused by inflammation and punctate hemorrhages on the cervix. There is a scant white discharge with a fishy odor. Wet mount shows trichomonads swimming in saline (**Figures 84-2** and **84-3**). The trichomonads are larger than white blood cells (WBCs) and have visible flagella and movement. She is diagnosed with trichomoniasis and treated with 2 g of metronidazole in a single dose. The patient is tested for other sexually transmitted diseases (STDs) and her partner is treated with the same regimen.

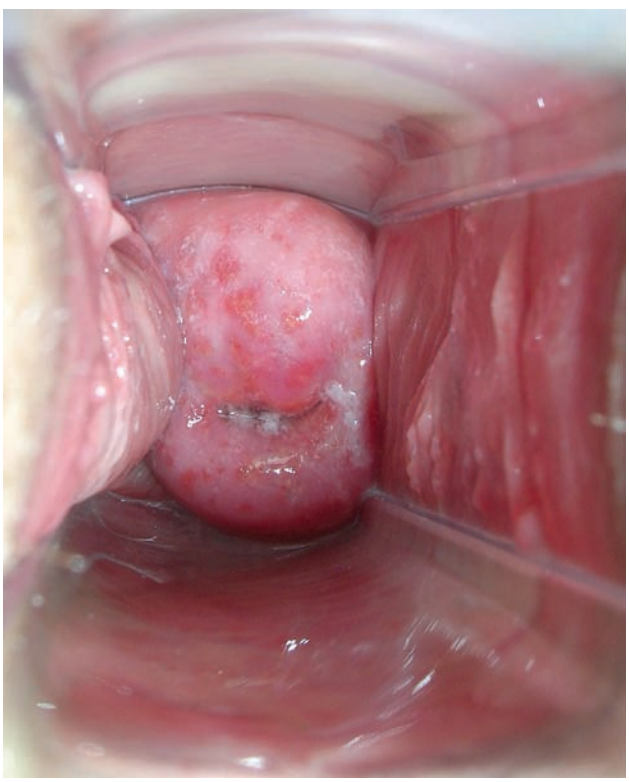

FIGURE 84-1 Speculum examination showing the strawberry cervix pattern seen with *Trichomonas* infections. This strawberry pattern is caused by inflammation and punctate hemorrhages on the cervix. There is a scant white discharge. (*Courtesy of Richard P. Usatine, MD.*)

INTRODUCTION

Trichomonas vaginitis is a local infection caused by the protozoan *Trichomonas vaginalis* that is associated with vaginal discharge. The woman often has an itch and an odor along with the discharge but may be asymptomatic.

SYNONYMS

Trichomoniasis, trich, tricky monkeys.

EPIDEMIOLOGY

- An estimated 3 to 5 million cases of trichomoniasis occur each year in the United States.[1]
- The worldwide prevalence of trichomoniasis is estimated to be 180 million cases per year; and these cases account for 10% to 25% of all vaginal infections.[2]

ETIOLOGY AND PATHOPHYSIOLOGY

- *Trichomonas* infection is caused by the unicellular protozoan *T. vaginalis*.[3]
- The majority of men (90%) infected with *T. vaginalis* are asymptomatic, but many women (50%) report symptoms.[4]
- The infection is predominantly transmitted via sexual contact. The organism can survive up to 48 hours at 10°C (50°F) outside the body, making transmission from shared undergarments or from infected hot spas possible although extremely unlikely.

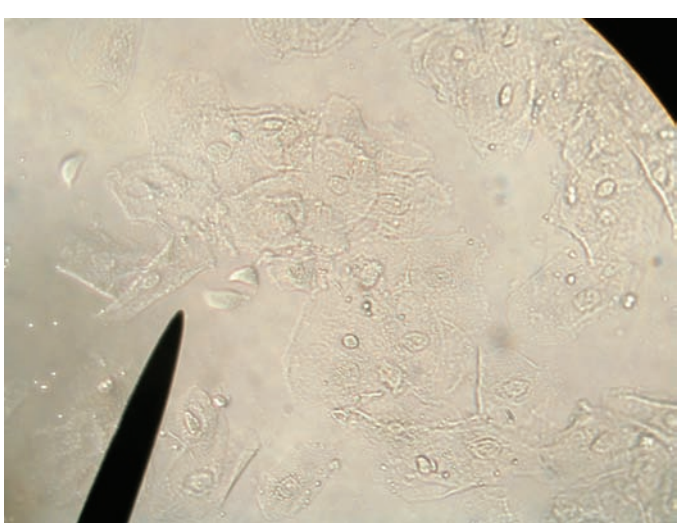

FIGURE 84-2 Wet mount showing *Trichomonas* in saline under low power. There are two visible trichomonads to the right and above the tip of the pointer. The largest cells are vaginal epithelial cells with visible nuclei. (*Courtesy of Richard P. Usatine, MD.*)

- *Trichomonas* infection is associated with low-birth-weight infants, premature rupture of membranes, and preterm delivery in pregnant patients.[5]
- In a person coinfected with HIV, the pathology induced by *T. vaginalis* infection can increase HIV shedding. *Trichomonas* infection may also act to expand the portal of entry for HIV in an HIV-negative person. Studies from Africa have suggested that *T. vaginalis* infection may increase the rate of HIV transmission by approximately two-fold.[6]

RISK FACTORS[3]

- New or multiple partners.
- A history of STDs.
- Exchanging sex for payment or drugs.
- Injection drug use.

DIAGNOSIS

CLINICAL FEATURES

- The physical examination should include inspection of the external genitalia for irritation or discharge. Speculum examination is done to determine the amount and character of the discharge and to look for the characteristic strawberry cervix (**Figures 84-1** and **84-3**).
- Typically, women with trichomoniasis have a diffuse, malodorous, yellow-green discharge (**Figure 84-4**) with vulvar irritation.[3] Vaginal and vulvar itching and irritation are common.
- It should be determined whether the patient douched recently, because this can lower the yield of diagnostic tests. Patients who have been told not to douche will sometimes start wiping the vagina with soapy washcloths to "keep clean" as an alternative. This greatly irritates the vagina and cervix, lowers test sensitivity, and may cause a discharge.

TYPICAL DISTRIBUTION

- In women, *Trichomonas vaginalis* may be found in the vagina, urethra, and paraurethral glands of infected women. Other sites include the cervix and Bartholin and Skene glands.

LABORATORY TESTING

- Because of the high prevalence of trichomoniasis, testing should be performed in women seeking care for vaginal discharge. Screening should be considered for women with risk factors.[3]
- Wet preps are obtained using a cotton-tipped applicator applied to the vaginal side-wall, placing the sample of discharge into normal saline (not water). A drop of the suspension is then placed on a slide, covered with a coverslip, and carefully examined with the low-power and high-dry objective lenses. Under the microscope, observe for motile trichomonads, which are often easy to visualize because of their lashing flagella (**Figure 84-2**).
- Wet prep has a sensitivity of only approximately 60% to 70% and requires immediate evaluation of wet preparation slide for optimal results.[3]
- The OSOM Trichomonas Rapid Test and the Affirm VP III are FDA-cleared for trichomoniasis in women. Both tests are performed

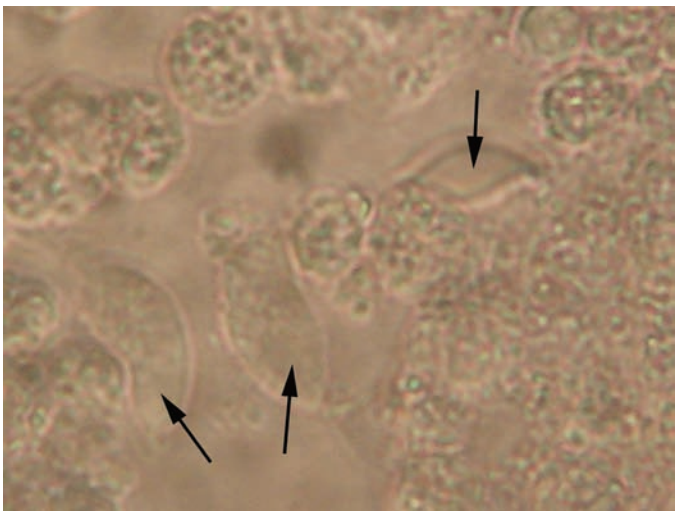

FIGURE 84-3 Wet mount showing *Trichomonas* (*arrows*) in saline under high power. The smaller more granular cells are white blood cells. (*Courtesy of Richard P. Usatine, MD.*)

FIGURE 84-4 Close-up of strawberry cervix in a *Trichomonas* infection demonstrating inflammation and punctate hemorrhages. (*Courtesy of Richard P. Usatine, MD.*)

on vaginal secretions at the point of care and have a sensitivity greater than 83% and a specificity greater than 97%. The results of the OSOM Trichomonas Rapid Test are available in approximately 10 minutes, and results of the Affirm VP III are available within 45 minutes. False-positive tests might occur, especially in populations with a low prevalence of disease.[3]

- An FDA-approved polymerase chain reaction (PCR) assay for detection of gonorrhea and chlamydial infection (Amplicor, manufactured by Roche Diagnostic Corp.) has been modified to test for *T. vaginalis* in vaginal or endocervical swabs and in urine from women and men, with sensitivity ranges from 88% to 97% and specificity from 98% to 99%.[7]
- APTIMA *T. vaginalis* Analyte Specific Reagents (ASR; manufactured by Gen-Probe, Inc.) also can detect *T. vaginalis* RNA using the same instrumentation platforms available for the FDA-cleared APTIMA Combo2 assay for diagnosis of gonorrhea and chlamydial infection. Published validation studies found sensitivity ranging from 74% to 98% and specificity from 87% to 98%.[8]
- A vaginal pH above 4.5 is seen with menopausal patients, *Trichomonas* infection, or bacterial vaginosis.[4]
- Culture is a sensitive and highly specific method of diagnosis. In women in whom trichomoniasis is suspected but not confirmed by microscopy, vaginal secretions should be cultured for *T. vaginalis*.[3]
- A nucleic acid amplification test for *Neisseria gonorrhoeae*, and/or *Chlamydia trachomatis* should be performed on all patients with *Trichomonas*.

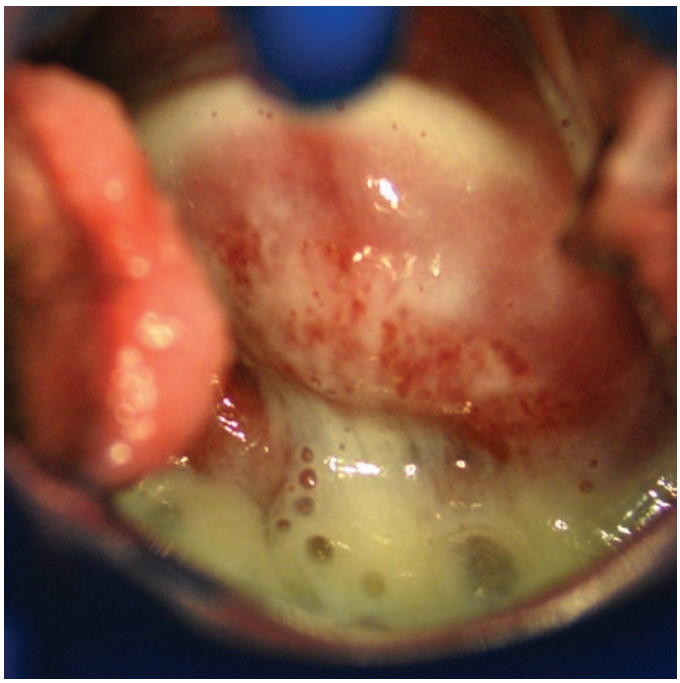

FIGURE 84-5 Speculum examination demonstrating the thick yellow-green discharge that may be seen in *Trichomonas* infection. The discharge can also be frothy white. (*Courtesy of E.J. Mayeaux, Jr., MD.*)

DIFFERENTIAL DIAGNOSIS

- Bacterial vaginosis and *Trichomonas* may have the odor of aromatic amines, and therefore may easily be confused with each other. Look for clue cells and trichomonads on the wet prep to differentiate between the two (Chapter 82, Bacterial Vaginosis).
- *Candida* vaginitis tends to present with a cottage-cheese-like discharge and vaginal itching (Chapter 83, *Candida* Vaginitis).
- Gonorrhea and *Chlamydia* and should not be missed in patients with vaginal discharge. Consider testing for these STDs based on patients' risk factors and the presence of purulence clinically and WBCs on the wet prep (Chapter 85, *Chlamydia* Cervicitis).

MANAGEMENT

MEDICATIONS

- **Table 84-1** shows treatments for *T. vaginalis* infections. Metronidazole 2 g orally as a single dose, or 500 mg bid for 7 days (including pregnant patients) are the best treatments by Cochrane analysis.[9] SOR A
- Tinidazole (Tindamax), a second-generation nitroimidazole, is indicated as a one-time dose of 2 g for the treatment of trichomoniasis (including metronidazole-resistant trichomoniasis).[3] SOR A It is effective therapy in nonresistant and resistant *T. vaginalis*.[10,11] The contraindications (including ethyl alcohol [ETOH]) to the use of tinidazole are similar to those for metronidazole.
- Pregnant women may be treated with 2 g of metronidazole in a single dose. Metronidazole is pregnancy category B. Vaginal

TABLE 84-1 Centers for Disease Control and Prevention Recommended Regimens for Pregnant and Nonpregnant Patients. SOR A

Metronidazole 2 g orally in a single dose
OR
Tinidazole 2 g orally in a single dose
CDC Alternative Regimen SOR A
Metronidazole 500 mg orally twice a day for 7 days

Data from Centers for Disease Control and Prevention.[2,3]

trichomoniasis is associated with adverse pregnancy outcomes, particularly premature rupture of membranes, preterm delivery, and low birth weight. Unfortunately, data do not suggest that metronidazole treatment results in a reduction in perinatal morbidity and treatment may even increase prematurity or low birth weight.[3] Treatment of *T. vaginalis* might relieve symptoms of vaginal discharge in pregnant women and might prevent respiratory or genital infection of the newborn and further sexual transmission. The Centers for Disease Control and Prevention (CDC) recommends that clinicians counsel patients regarding the potential risks and benefits of treatment during pregnancy.[3]

- Some strains of *T. vaginalis* can have diminished susceptibility to metronidazole. Low-level metronidazole resistance has been identified in 2% to 5% of cases of vaginal trichomoniasis. These infections should respond to tinidazole or higher doses or longer durations of metronidazole. High-level resistance is rare.
- Metronidazole gel is 50% less efficacious for the treatment of trichomoniasis than oral preparations and is not recommended.[3]

PREVENTION

- Patients should be instructed to avoid sex until they and their sex partners are cured (i.e., when therapy has been completed and patient and partner[s] are asymptomatic).[3]
- Spermicidal agents such as nonoxynol-9 reduce the rate of transmission of *Trichomonas*.[12]
- The risk of acquiring infection can be reduced by consistent use of condoms and limiting the number of sexual partners.

FOLLOW-UP

- Because of the high rate of reinfection among patients in whom trichomoniasis was diagnosed, rescreening at 3 months following initial infection can be considered for sexually active women.[3]

PATIENT EDUCATION

- Sexual partners of patients with *Trichomonas* should be treated. Patients can be sent home with a dose for a partner when it is believed that the partner will not come in on his own.

PATIENT RESOURCES

- Centers for Disease Control and Prevention information—**http://www.dpd.cdc.gov/dpdx/HTML/Trichomoniasis.htm.**
- Medline-plus—**http://www.nlm.nih.gov/medlineplus/ency/article/001331.htm.**
- Centers for Disease Control and Prevention. *STDs: Trichomoniasis*—**http://www.cdc.gov/std/trichomonas/default.htm.**
- PubMed Health. *Trichomoniasis*—**http://www.ncbi.nlm.nih.gov/pubmedhealth/PMH0002307/.**
- MedLinePlus. *Trichomoniasis*—**http://www.nlm.nih.gov/medlineplus/trichomoniasis.html.**

- eMedicine Health. *Trichomoniasis*—**http://www.emedicinehealth.com/trichomoniasis/article_em.htm.**

PROVIDER RESOURCES

- **http://emedicine.medscape.com/article/230617.**
- Trichomoniasis in Emergency Medicine—**http://emedicine.medscape.com/article/787722.**
- Centers for Disease Control and Prevention. *2010 Guidelines for Treatment of Sexually Transmitted Diseases*—**http://www.cdc.gov/std/treatment/2010/STD-Treatment-2010-RR5912.pdf.**

REFERENCES

1. Sutton M, Sternberg M, Koumans EH, et al. The prevalence of *Trichomonas vaginalis* infection among reproductive-age women in the United States, 2001-2004. *Clin Infect Dis.* 2007;45:1319.
2. Weinstock H, Berman S, Cates W Jr. Sexually transmitted diseases among American youth: incidence and prevalence estimates, 2000. *Perspect Sex Reprod Health*. 2004;36(1):6-10.
3. Centers for Disease Control and Prevention. *2010 Guidelines for Treatment of Sexually Transmitted Diseases*. http://www.cdc.gov/std/treatment/2010/STD-Treatment-2010-RR5912.pdf. Accessed 12-1-11.
4. Gjerdngen D, Fontaine P, Bixby M, et al. The impact of regular vaginal pH screening on the diagnosis of bacterial vaginosis in pregnancy. *J Fam Pract.* 2000;49:3-43.
5. Cotch MF, Pastorek JG 2nd, Nugent RP, et al. *Trichomonas vaginalis* associated with low birth weight and preterm delivery: the Vaginal Infections and Prematurity Study Group. *Sex Transm Dis.* 1997;24:353-360.
6. Sorvillo F, Smith L, Kerndt P, Ash L. *Trichomonas vaginalis*, HIV, and African-Americans. *Emerg Infect Dis.* 2001;7(6):927-932.
7. Van Der PB, Kraft CS, Williams JA. Use of an adaptation of a commercially available PCR assay aimed at diagnosis of chlamydia and gonorrhea to detect *Trichomonas vaginalis* in urogenital specimens. *J Clin Microbiol.* 2006;44:366-373.
8. Nye MB, Schwebke JR, Body BA. Comparison of APTIMA *Trichomonas vaginalis* transcription-mediated amplification to wet mount microscopy, culture, and polymerase chain reaction for diagnosis of trichomoniasis in men and women. *Am J Obstet Gynecol.* 2009;200:188-197.
9. Epling J. What is the best way to treat trichomoniasis in women? (Cochrane review) *Am Fam Physician.* 2001;64:1241-1243.
10. Mammen-Tobin A, Wilson JD. Management of metronidazole-resistant *Trichomonas vaginalis*—a new approach. *Int J STD AIDS.* 2005;16(7):488-490.
11. Hager WD. Treatment of metronidazole-resistant *Trichomonas vaginalis* with tinidazole: case reports of three patients. *Sex Transm Dis.* 2004;31(6):343-345.
12. d'Oro LC, Parazzini F, Naldi L, La Vecchia C. Barrier methods of contraception, spermicides, and sexually transmitted diseases: a review. *Genitourin Med.* 1994;70:410.

85 CHLAMYDIA CERVICITIS

E.J. Mayeaux, Jr., MD
Richard P. Usatine, MD

PATIENT STORY

A 17-year-old girl presents to the sexually transmitted disease (STD) clinic because her boyfriend was diagnosed with a *Chlamydia* urethritis. Both she and her boyfriend admit to having had sexual partners in the past before starting to be sexually active with each other. On physical examination, there is ectopy and some mucoid discharge (**Figure 85-1**). The cervix bled easily while obtaining discharge and cells for a wet mount and genetic probe test. The wet mount showed many white blood cells (WBCs) but no visible pathogens. The patient was treated with 1 g of azithromycin taken in front of a clinic nurse. She was sent to the laboratory for rapid plasma reagin (RPR) and HIV tests and given a follow-up appointment in 1 week. The genetic probe test was positive for *Chlamydia* and all the other examinations were negative. This information was given to the patient on her return visit and safe sex was discussed.

FIGURE 85-1 Chlamydial cervicitis with ectopy, mucoid discharge, and bleeding. The cervix is inflamed and friable. (*Courtesy of Connie Celum and Walter Stamm, Seattle STD/HIV Prevention Training Center, University of Washington.*)

INTRODUCTION

Chlamydia trachomatis causes genital infections that can result in pelvic inflammatory disease (PID), ectopic pregnancy, and infertility. Asymptomatic infection is common among both men and women so healthcare providers must rely on screening tests to detect disease. The Centers for Disease Control and Prevention (CDC) recommends annual screening of all sexually active women ages 25 years and younger, and of older women with risk factors, such as having a new sex partner or multiple sex partners.[1]

EPIDEMIOLOGY

- A very common STD, *Chlamydia* is the most frequently reported infectious disease in the United States (excluding human papillomavirus [HPV]).[1] An estimated 1.2 million cases are reported to the CDC annually in the United States.[2]
- The World Health Organization (WHO) estimates there are 140 million cases of Chlamydia trachomatis infection worldwide every year.[3]
- The CDC estimates screening and treatment programs can be conducted at an annual cost of $175 million. Every dollar spent on screening and treatment saves $12 in complications that result from untreated *Chlamydia*.[4]
- It is common among sexually active adolescents and young adults.[5] As many as 1 in 10 adolescent girls tested for *Chlamydia* is infected. Based on reports to the CDC provided by states that collect age-specific data, teenage girls have the highest rates of chlamydial infection. In these states, 15- to 19-year-old girls represent 46% of infections and 20- to 24-year-old women represent another 33%.[4]

ETIOLOGY AND PATHOPHYSIOLOGY

- *C. trachomatis* is a small Gram-negative bacterium with unique biologic properties among living organisms. *Chlamydia* is an obligate intracellular parasite that has a distinct life-cycle consisting of two major phases: The small elementary bodies attach and penetrate into cells, and the metabolically active reticulate bodies that form large inclusions within cells.
- It has a long growth cycle, which explains why extended courses of treatment are often necessary. Immunity to infection is not long-lived, so reinfection or persistent infection is common.
- The infection may be asymptomatic and the onset often indolent. It can cause cervicitis, endometritis, PID, urethritis, epididymitis, neonatal conjunctivitis, and pediatric pneumonia. Of exposed babies, 50% develop conjunctivitis and 10% to 16% develop pneumonia.[1]
- *Chlamydia* infections may lead to reactive arthritis, which presents with arthritis, conjunctivitis, and urethritis (Chapter 155, Reactive Arthritis). Past or ongoing *C. trachomatis* infection may be a risk factor for ovarian cancer.[6,7]
- Up to 40% of women with untreated *Chlamydia* will develop PID. Undiagnosed PID caused by *Chlamydia* is common. Of those with PID, 20% will become infertile; 18% will experience debilitating, chronic pelvic pain; and 9% will have a life-threatening tubal pregnancy. Tubal pregnancy is the leading cause of first-trimester, pregnancy-related deaths in American women.[4]

RISK FACTORS[1,2,8]

- Adolescents and young adults.
- Nonwhite populations.
- Multiple sexual partners.
- Poor socioeconomic conditions.
- Single marital status.
- Nonbarrier contraceptive use.
- History of prior STD.

DIAGNOSIS

CLINICAL FEATURES

- The cervix is inflamed, friable, and may bleed easily with manipulation. The cervix may show ectopy (columnar cells on the ectocervix). The discharge is usually mucoid or mucopurulent (**Figure 85-1**).
- Swab test—A white cotton-tip applicator is placed in the endocervical canal and removed to view. A visible mucopurulent discharge constitutes a positive swab test for *Chlamydia* (**Figure 85-2**). This is not specific for *Chlamydia* as other genital infections can cause a mucopurulent discharge, and is not recommended for diagnosis.

LABORATORY TESTING

- A significant proportion of patients with *Chlamydia* are asymptomatic, providing a reservoir for infection. All pregnant women and

FIGURE 85-2 Mucopurulent discharge on the left swab from a cervix infected with *Chlamydia* (positive swab test). (*Courtesy of Claire Stevens and Ronald Roddy, Seattle STD/HIV Prevention Training Center, University of Washington.*)

sexually active women younger than 25 years of age should be screened with routine examinations. A wet prep is usually negative for other organisms. Only WBCs and normal flora are seen.

- *Chlamydia* cannot be cultured on artificial media because it is an obligate intracellular organism. Tissue culture is required to grow the live organism. When testing for *Chlamydia*, a wood-handled swab must not be used, as substances in wood may inhibit *Chlamydia* organism. Culture has sensitivity of 70% to 100% and a specificity of almost 100%, which makes it the gold standard.[1]
- The enzyme-linked immunosorbent assay (ELISA) technique (Chlamydiazyme) has a sensitivity of 70% to 100% and a specificity of 97% to 99%.[5] Fluorescein-conjugated monoclonal antibodies test (MicroTrak) has a sensitivity of 70% to 100% and a specificity of 97% to 99%.[5]
- *C. trachomatis* can be detected using nucleic acid amplification techniques (NAATs) on swabs or voided urine specimens. These tests are often used for testing to detect gonorrhea and *Chlamydia*. Nucleic acid amplification tests have been used successfully in difficult-to-reach adolescents ("street kids") as well as in pediatric emergency departments and school-based settings.[9,10] Screening in school-based settings was associated with significant reduction in *Chlamydia* rates during a 1-year period. Self-collected vaginal swab specimens perform at least as well as with other approved specimens using NAATs.[11]
- Rectal and oropharyngeal *C. trachomatis* infection in persons engaging in anal or oral intercourse can be diagnosed by testing at the site of exposure. Although not FDA-cleared for this use, NAATs have demonstrated improved sensitivity and specificity compared with culture for the detection at rectal sites[12] and at oropharyngeal sites in men.[13]
- Certain NAATs have been FDA-cleared for use on liquid-based cytology specimens, although test sensitivity using these specimens might be lower.[14]
- Persons who undergo testing for *Chlamydia* should be tested for other STDs as well.[1]

DIFFERENTIAL DIAGNOSIS

- Gonorrhea frequently coexists with *Chlamydia* and should be tested for when a patient is thought to have *Chlamydia*. The discharge of gonorrhea may be more purulent but this is not always the case (Chapter 215, Gonococcal Urethritis)
- Bacterial vaginosis—The aromatic amine odor and clue cells help to distinguish between these infections (Chapter 82, Bacterial Vaginosis).
- Trichomoniasis—Look for the strawberry cervix and *Trichomonas* on the wet prep. There may also be a positive whiff test (see Chapter 84, *Trichomonas* Vaginitis).

MANAGEMENT

NONPHARMACOLOGIC

- Patients diagnosed with *Chlamydia* cervicitis should be tested for other STDs.[1]

TABLE 85-1 Centers for Disease Control and Prevention Recommended Regimens SOR A

Azithromycin 1 g orally in a single dose
OR
Doxycycline 100 mg orally twice a day for 7 days
CDC Alternative Regimens
Erythromycin base 500 mg orally 4 times a day for 7 days
OR
Erythromycin ethylsuccinate 800 mg orally 4 times a day for 7 days
OR
Ofloxacin 300 mg orally twice a day for 7 days
OR
Levofloxacin 500 mg orally once daily for 7 days
CDC Recommended Regimens in Pregnancy
Azithromycin 1 g orally in a single dose
OR
Amoxicillin 500 mg orally 3 times a day for 7 days
Alternative Regimens in Pregnancy
Erythromycin base 500 mg orally 4 times a day for 7 days
OR
Erythromycin base 250 mg orally 4 times a day for 14 days
OR
Erythromycin ethylsuccinate 800 mg orally 4 times a day for 7 days
OR
Erythromycin ethylsuccinate 400 mg orally 4 times a day for 14 days

Data from the Centers for Disease Control and Prevention.[1]

MEDICATIONS

- **Table 85-1** shows CDC recommended treatments for *Chlamydia*. Azithromycin (Zithromax) 1000 mg one-time dose is easy and may be directly observed in the clinic.[1] SOR A It is the first-line therapy for *Chlamydia* during pregnancy.
- Other treatments include doxycycline 100 mg PO bid × 7 days.[1] SOR A Avoid dairy products around time of dosing.
- Erythromycin might be less efficacious than either azithromycin or doxycycline, mainly because of the frequent occurrence of GI side effects that can lead to nonadherence.
- Ofloxacin (Floxin) 300 mg po bid × 7 days is an alternative that should be taken on an empty stomach.[1] SOR A It is contraindicated in children or pregnant and lactating women, but may also cover *Neisseria gonorrhoeae* infection. Levofloxacin 500 mg orally for 7 days is another fluoroquinolone alternative.[1] SOR A
- A metaanalysis of 12 randomized clinical trials of azithromycin versus doxycycline for the treatment of genital chlamydial infection demonstrated that the treatments were equally efficacious, with microbial cure rates of 97% and 98%, respectively.[15]
- Partners need treatment. If concerns exist that sex partners will not seek evaluation and treatment, then delivery of antibiotic therapy (either a prescription or medication) to their partners is an option.[1]
- Medications for chlamydial infections should be dispensed on site and the first dose directly observed to maximize medication adherence.[1]

REFERRAL OR HOSPITALIZATION

- With evidence of complications such as a tuboovarian abscess or severe PID.

PREVENTION

- Individuals who are sexually active should be aware of the risk of STDs and that ways of avoiding infection include mutual monogamy and appropriate barrier protection.

PROGNOSIS

- Treatment failures with full primary therapies are quite rare. Reinfection is very common and is related to nontreatment of sexual partners or acquisition from a new partner.

FOLLOW-UP

- Test-of-cure (repeat testing 3 to 4 weeks after completing therapy) is not recommended for persons treated with the recommended or alterative regimens, unless therapeutic compliance is in question, symptoms persist, or reinfection is suspected. However, test of cure is recommended in pregnant women.[1]

PATIENT EDUCATION

- To minimize transmission, persons treated for *Chlamydia* should be instructed to abstain from sexual intercourse for 7 days after single-dose therapy or until completion of a 7-day regimen.
- To minimize the risk for reinfection, patients also should be instructed to abstain from sexual intercourse until all of their sex partners are treated.[1]

PATIENT RESOURCES

- eMedicine Health. *Cervicitis*—**http://www.emedicinehealth.com/cervicitis/article_em.htm.**
- eMedicine Health. *Chlamydia*—**http://www.emedicinehealth.com/chlamydia/article_em.htm.**
- CDC patient information—**http://www.cdc.gov/std/Chlamydia/STDFact-Chlamydia.htm.**

PROVIDER RESOURCES

- CDC. *Sexually Transmitted Diseases (STDs) 2010: Diseases Characterized by Urethritis and Cervicitis*—**http://www.cdc.gov/std/treatment/2010/urethritis-and-cervicitis.htm.**
- *Chlamydial Genitourinary Infections*—**http://emedicine.medscape.com/article/214823-overview.**
- *Cervicitis*—**http://emedicine.medscape.com/article/253402.**

REFERENCES

1. Centers for Disease Control and Prevention. *Sexually Transmitted Diseases (STDs) 2010: Diseases Characterized by Urethritis and Cervicitis*. http://www.cdc.gov/std/treatment/2010/urethritis-and-cervicitis.htm. Accessed December 2, 2011.
2. Centers for Disease Control and Prevention. *Sexually Transmitted Disease Surveillance, 2009—Chlamydia*. http://www.cdc.gov/std/stats09/default.htm. Accessed December 25, 2011.
3. World Health Organization. *Chlamydia Trachomatis. Initiative for Vaccine Research*. http://www.who.int/vaccine_research/diseases/soa_std/en/index.html. Accessed December 2, 2011.
4. Centers for Disease Control and Prevention. http://www.cdc.gov/std/Chlamydia/STDFact-Chlamydia.htm. Accessed December 2, 2011.
5. Skolnik NS. Screening for *Chlamydia trachomatis* infection. *Am Fam Physician*. 1995;51:821-826.
6. Martius J, Krohn MA, Hillier SL, et al. Relationships of vaginal lactobacillus species, cervical *Chlamydia trachomatis*, and bacterial vaginosis to preterm birth. *Obstet Gynecol*. 1988;71:89-95.
7. Ness RB, Goodman MT, Shen C, Brunham RC. Serologic evidence of past infection with *Chlamydia trachomatis*, in relation to ovarian cancer. *J Infect Dis*. 2003;187:1147-1152.
8. Datta SD, Sternberg M, Johnson RE, et al. Gonorrhea and *Chlamydia* in the United States among persons 14 to 39 years of age, 1999 to 2002. *Ann Intern Med*. 2007;147:89.
9. Monroe KW, Weiss HL, Jones M, Hook EW 3rd. Acceptability of urine screening for *Neisseria gonorrheae* and *Chlamydia trachomatis* in adolescents at an urban emergency department. *Sex Transm Dis*. 2003;30:850.
10. Rietmeijer CA, Bull SS, Ortiz CG, et al. Patterns of general health care and STD services use among high-risk youth in Denver participating in community-based urine *Chlamydia* screening. *Sex Transm Dis*. 1998;25:457.
11. Doshi JS, Power J, Allen E. Acceptability of chlamydia screening using self-taken vaginal swabs. *Int J STD AIDS*. 2008;19:507-509.
12. Bachmann LH, Johnson RE, Cheng H, et al. Nucleic acid amplification tests for diagnosis of *Neisseria gonorrhoeae* and *Chlamydia trachomatis* rectal infections. *J Clin Microbiol*. 2010;48:1827-1832.
13. Bachmann LH, Johnson RE, Cheng H, et al. Nucleic acid amplification tests for diagnosis of *Neisseria gonorrhoeae* oropharyngeal infections. *J Clin Microbiol*. 2009;47:902-907.
14. Chernesky M, Freund GG, Hook E, III, et al. Detection of *Chlamydia trachomatis* and *Neisseria gonorrhoeae* infections in North American women by testing SurePath liquid-based Pap specimens in APTIMA assays. *J Clin Microbiol*. 2007;45:2434-2438.
15. Lau C-Y, Qureshi AK. Azithromycin versus doxycycline for genital chlamydial infections: A meta-analysis of randomized clinical trials. *Sex Transm Dis*. 2002;29:497-502.

SECTION 3 VULVA

86 PAGET DISEASE OF THE EXTERNAL GENITALIA

E.J. Mayeaux, Jr., MD

PATIENT STORY

A 60-year-old woman presented with vulvar pruritus for 1 year that is now constant. On physical examination, there is one large red lesion surrounded by white epithelium (**Figure 86-1**). A 3-mm punch biopsy was done of the white island within the red lesion using local anesthesia. The pathology showed Paget disease of the vulva. The patient underwent a wide local excision of the involved area and no malignancy was found.

FIGURE 86-1 Paget disease of the vulva. Note the red lesion with the "white island." (*Courtesy of Hope Haefner, MD.*)

INTRODUCTION

Paget disease of the external genitalia is an uncommon primary cutaneous adenocarcinoma of apocrine gland-bearing skin. The most commonly involved site is the vulva, although perineal, perianal, scrotal, and penile skin may also be affected. Less commonly, the axilla, buttocks, thighs, eyelids, and external auditory canal may be found.[1] It is morphologically and histologically identical to Paget disease of the nipple except for the anatomic location.

SYNONYMS

Extramammary Paget disease.

EPIDEMIOLOGY

- The frequency of malignancy in extramammary Paget disease is approximately 20%, which is less than that of Paget disease of the nipple.
- It accounts for less than 5% of all vulvar malignancies.[2]
- The female-to-male ratio is 3 to 4.5 to 1.[3]
- Most patients are white and in their sixth or seventh decade of life.[4]
- Approximately 4% to 25% of patients with genital Paget disease have an underlying neoplasm.[4-6] Associated malignancies include carcinomas of the Bartholin glands, urethra, bladder, vagina, cervix, endometrium, or adnexal apocrine tissue. Only a minority of cases represent a direct extension of an underlying carcinoma.
- Perianal Paget disease (**Figure 86-2**) is associated with underlying colorectal carcinoma in 25% to 35% of cases.

ETIOLOGY AND PATHOPHYSIOLOGY

- It arises from apocrine gland tissue, usually as a primary cutaneous adenocarcinoma. The epidermis becomes infiltrated with neoplastic cells showing glandular differentiation. The tumor cells may originate from apocrine gland ducts or from keratinocytic stem cells.

RISK FACTORS

- Extramammary Paget disease should be considered in any patient with chronic dermatitis of the groin, vulva, scrotal, or perianal area. Patients with Paget disease of the external genitalia often present with nonresolving eczematous lesions in the groin, genitalia, perineum, or perianal area.[7]

DIAGNOSIS

CLINICAL FEATURES

- Lesions present on the vulva as geographic red macules that often appear excoriated or have an eczematoid appearance (**Figures 86-1** to **86-3**). The lesions are often dotted with small, white patches (islands of tissue). Other lesions may be erythematous, eczematous, or leukoplakic plaques (**Figure 86-4**).[2]
- Pruritus occurs in approximately 70% of patients.[2] Patients may also experience burning, pain, or no symptoms other than the lesion.[6]
- The lesions are well-demarcated and have slightly raised edges.
- Vulvar Paget disease is similar in gross appearance to Paget disease of the breast.

TYPICAL DISTRIBUTION

- It is usually multifocal and may occur anywhere on the vulva, mons, perineum, perianal area, inner thigh, nipple, or bladder. It occurs less often in males (**Figures 86-3** and **86-4**).

LABORATORY TESTING

- The appearance is similar to superficial melanoma, and sometimes special stains using markers that separate malignant melanocytes from Pagetoid cells may be necessary to identify the correct neoplasm.

IMAGING

- Imaging studies should be used to augment physical and endoscopic examination to assess possible undetected internal malignancy.

BIOPSY

- Biopsy of gross lesions must be performed to determine the diagnosis and the depth and nature of stromal invasion. A punch biopsy should be taken from the center of the lesion and include underlying dermis and connective tissue so the depth of stromal invasion can be determined. If multiple abnormal areas are present, then multiple biopsies should be taken.
- The diagnosis is made by identification of "pagetoid" cells in the epidermis.
  - These cells are round in shape and considerably larger than the surrounding keratinocytes or melanocytes.

FIGURE 86-2 Perianal Paget disease. Note the appearance is very similar to vulvar Paget disease. (*Courtesy of University of Texas Health Sciences Center, Division of Dermatology.*)

FIGURE 86-3 Paget disease of the scrotum. (*Courtesy of University of Texas Health Sciences Center, Division of Dermatology.*)

- The cytoplasm is pink and the nuclei are large, round, and have prominent nucleoli.
- The pagetoid cells cluster and form small nests in the rete pegs, but single cells spread into the superficial epidermis.

DIFFERENTIAL DIAGNOSIS[2,8]

- Leukoplakia is an elevated white plaque seen before applying of acetic acid (see Chapter 87, Vulvar Intraepithelial Neoplasia).
- Squamous cell carcinoma of the vulva, which can appear as expanding ulcerative lesions but without the "white islands" (see Chapter 171, Squamous Cell Carcinoma).
- Hidradenitis suppurativa also tends to form in apocrine areas but usually presents as chronic recurring abscesses (see Chapter 115, Hidradenitis Suppurativa).
- Amelanotic melanoma of the vulva can occur, although vulvar melanoma is usually a pigmented lesion with irregular borders. Vulvar melanoma accounts for 5% of primary vulvar neoplasms, and occurs predominantly in postmenopausal white women (see Chapter 172, Melanoma).
- Condylomata acuminata (genital condylomas) are common and, when flat or excoriated, may be confused with vulvar Paget disease. More than one third of women have associated cervical intraepithelial neoplasia. Exophytic condylomas are typically verrucous, and usually occur in clusters along the vulvar surface (see Chapter 133, Genital Warts).
- Herpes simplex viruses 1 and 2 are associated with ulcerative genital lesions and characteristic systemic symptoms (see Chapter 129, Herpes Simplex).
- Fungal infections commonly affect the vulva and are usually caused by *Candida albicans*. Patients present with vulvar itching and burning. On inspection, the skin surface is red and may demonstrate small satellite lesions. A white "cottage cheese" discharge may also be present. Tinea cruris presents as a reddened area with raised sharp borders that occurs along the inner aspect of the thigh and often extends into the perianal and perineal region (see Chapter 136, Candidiasis).
- Lichen sclerosus is grossly and histologically similar to morphea (circumferential or localized scleroderma), which appears as white sclerotic or atrophic areas (**Figure 86-5**).
- Other dermatoses, including seborrheic or contact dermatitis, psoriasis, lichen planus, and lichen simplex chronicus, can resemble Paget disease when these conditions occur in the vulva or perineum.

MANAGEMENT

MEDICATIONS

- Topical imiquimod 5% cream applied 3 times weekly for 16 weeks has been shown to induce complete resolution in a patient with perineal disease.[9,10] SOR B However, more studies are needed to define the exact role for this off-label therapy in this disease.

FIGURE 86-4 Paget disease of the scrotum and inguinal area. Note the white plaques with erythema that could be mistaken for *Candida* or tinea. (*Courtesy of University of Texas Health Sciences Center, Division of Dermatology.*)

FIGURE 86-5 Lichen sclerosus (et atrophicus) of vulva showing white sclerotic plaques and epidermal atrophy. This was biopsy proven to rule out Paget disease of the vulva and other possible malignancies. (*Courtesy of Richard P. Usatine, MD.*)

SURGICAL

- Treatment usually consists either of wide local excision with frozen sections or vulvectomy, if the disease is more extensive.[2,5,6] SOR B Local recurrence is common even in the face of negative surgical margins, presumably because the disease tends to be multicentric or from microscopic extension of disease beyond the margins.[5]
- Treatment with Mohs micrographic surgery may have a lower recurrence rate.[8] SOR B
- The role of radiation therapy and chemotherapy (topical and systemic) in the treatment of vulvar Paget disease is not well-defined, but may be an option for some patients. SOR C

PROGNOSIS

- The prognosis for Paget disease of the external genitalia confined to the epidermis is excellent. The rate of invasive malignant conversion is low, and the cutaneous disease may extend over a period of 10 to 15 years without evidence of metastases. The prognosis depends mainly on the early diagnosis with definitive surgical treatment. Full recovery is possible in patients with purely epidermal disease and negative margins after micrographic surgery.
- Perianal disease, male genital disease, dermal invasion, and lymph node metastasis are poor prognostic indicators.[2]
- The recurrence rate of primary tumors after standard surgical excision is 30% to 60%. The rate after excision with Mohs micrographic surgery is 8% to 26%.[8,11]

FOLLOW-UP

- Long-term follow-up is indicated because of the 8% to 60% risk of recurrence (even years after initial therapy) and the increased risk of noncontiguous carcinoma.[8,11]
- The patient's vulva should be inspected annually and biopsy performed with any suggestion of abnormality.
- Screening and surveillance for tumors at other sites (breast, lung, colorectum, gastric, pancreas, and ovary) following national guidelines and U.S. Preventive Services Task Force guidelines should be considered.

PATIENT RESOURCES

- OncoLink. *Paget's Disease of the Vulva*—**http://www.oncolink.org/experts/article.cfm?c=3&s=16&ss=96&id=2012.**
- University of Arkansas for Medical Sciences. *Paget's Disease of the Vulva*—**http://obgyn.uams.edu/?id=6366&sid=19.**
- Williams College Women's Health Site. *Vulva Self-Examination*—**http://wso.williams.edu/orgs/peerh/women/wsexam.html.**

PROVIDER RESOURCES

- Medscape. *Extramammary Paget Disease*—**http://emedicine.medscape.com/article/1100397-overview.**
- DermNet NZ. *Extramammary Paget Disease*—**http://dermnetnz.org/site-age-specific/extra-mammary-paget.html.**
- DermQuest. *Extramammary Paget Disease*—**http://www.dermquest.com/therapeutic_strategies/extramammary_pagets/_pagets_disease.html**.

REFERENCES

1. Heymann WR. Extramammary Paget's disease. *Clin Dermatol.* 1993;11(1):83-87.
2. Shepherd V, Davidson EJ, Davies-Humphreys J. Extramammary Paget's disease. *Br J Obstet Gynaecol.* 2005;112:273-279.
3. Chanda JJ. Extramammary Paget's disease: prognosis and relationship to internal malignancy. *J Am Acad Dermatol.* 1985;13(6):1009-1014.
4. Parker LP, Parker JR, Bodurka-Bevers D, et al. Paget's disease of the vulva: pathology, pattern of involvement, and prognosis. *Gynecol Oncol.* 2000;77:183.
5. Fanning J, Lambert HC, Hale TM, et al. Paget's disease of the vulva: prevalence of associated vulvar adenocarcinoma, invasive Paget's disease, and recurrence after surgical excision. *Am J Obstet Gynecol.* 1999;180:24.
6. Bakalianou K, Salakos N, Iavazzo C, et al. Paget's disease of the vulva. A ten-year experience. *Eur J Gynaecol Oncol.* 2008;29(4):368-370.
7. Bagby CM, MacLennan GT. Extramammary Paget's disease of the penis and scrotum. *J Urol.* 2009;182(6):2908-2909.
8. Hendi A, Brodland DG, Zitelli JA. Extramammary Paget's disease: surgical treatment with Mohs micrographic surgery. *J Am Acad Dermatol.* 2004;51:767.
9. Sendagorta E, Herranz P, Feito M, et al. Successful treatment of three cases of primary extramammary Paget's disease of the vulva with Imiquimod – proposal of a therapeutic schedule. *J Eur Acad Dermatol Venereol.* 2010;24(4):490-492.
10. Hatch KD, Davis JR. Complete resolution of Paget disease of the vulva with imiquimod cream. *J Low Genit Tract Dis.* 2008;12(2):90-94.
11. Coldiron BM, Goldsmith BA, Robinson JK. Surgical treatment of extramammary Paget's disease. A report of six cases and a reexamination of Mohs micrographic surgery compared with conventional surgical excision. *Cancer.* 1991;67(4):933-938.

87 VULVAR INTRAEPITHELIAL NEOPLASIA

E.J. Mayeaux, Jr., MD

PATIENT STORY

A 63-year-old black woman presents with a "knot" on her labia majora (**Figures 87-1** and **87-2**). She is a smoker but is otherwise healthy. The lesion is occasionally pruritic but is generally asymptomatic. She found it approximately 6 months ago, and it has been slowly increasing in size. There is no significant family history of cancer. On physical exam she is found to have exophytic condyloma acuminata around the introitus and a growth labelled vulvar intraepithelial neoplasia (VIN) that the patient called a "knot." A 3-mm punch biopsy is performed and demonstrates VIN III. The patient is referred to gynecologic oncology.

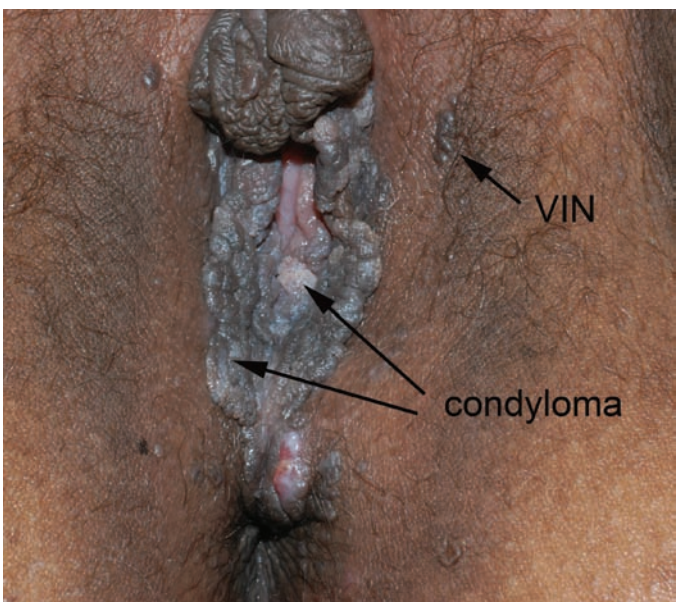

FIGURE 87-1 Patient with multiple exophytic condyloma and vulvar intraepithelial neoplasia III. The large clitoral hood is an incidental finding unrelated to the vulvar intraepithelial neoplasia. (*Courtesy of Hope Haefner, MD.*)

INTRODUCTION

Vulvar dysplasia and cancer is less common than cervical cancer. It is associated with high-risk human papillomavirus (HPV) infection, but not to the same extent as cervical disease.

EPIDEMIOLOGY

- Vulvar cancer is the fourth most common gynecologic cancer (following cancer of the endometrium, ovary, and cervix) and accounts for 5% of lower female genital tract malignancies.[1] There are approximately 3900 new cases and 870 deaths each year in the United States from this disease.[1]
- Worldwide, vulvar cancer is rare, especially in developing countries. Approximately 27,000 cases are reported annually, making the incidence rate between 1 and 1.5 per 100,000 women.[2]
- Seventy-five percent of VIN cases occur in premenopausal women, with no racial predisposition.
- Although the rate of invasive vulvar carcinoma has remained stable in the past two decades, the incidence of in situ disease (VIN) has more than doubled. This may be the result of improved surveillance and treatment of VIN, or the apparent increase in cases of VIN in younger women.[3]

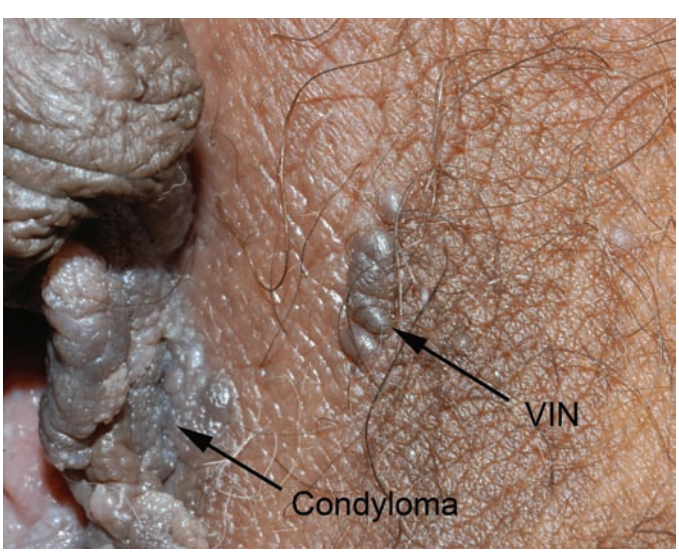

FIGURE 87-2 Close-up of the same patient with vulvar intraepithelial neoplasia III on the labia majora. (*Courtesy of Hope Haefner, MD.*)

ETIOLOGY AND PATHOPHYSIOLOGY

- VIN is the associated preneoplastic condition that is associated with the loss of epithelial cell maturation and nuclear abnormalities.
- The cervix, vagina, vulva, anus, and lower 3 cm of rectal mucosa is derived from the embryonic cloaca. Most squamous intraepithelial lesions in this area affect multiple anatomic sites.
- HPV 16 is estimated to contribute to approximately 77% of VIN lesions.[4]

- The risk of neoplastic progression appears to be lower with VIN than with cervical intraepithelial neoplasia. VIN I probably has minimal malignant potential, but VIN III often progresses to invasive cancer if left untreated (see "Biopsy" below).[5]

RISK FACTORS[6]

- Risk factors are similar to those for vaginal and cervical dysplasia:
  - High-risk HPV infection.
  - Cigarette smoking.
  - Altered immune status.

DIAGNOSIS

CLINICAL FEATURES

- The vulva is best examined using a good source of white light and magnification from a handheld magnifying lens or a colposcope. The examination should be systematic and incorporate all aspects of the vulvar surface. Vulvar examination may be aided by dilute acetic acid solution, which acts on the vulva much the same way as it does on the cervix and vagina. More acetic acid solution and a longer soaking time are required to achieve the acetowhite effect.
- VIN often appears as raised plaques and papules on the surface of the vulva and perineum (**Figures 87-1** and **87-2**).
- Approximately one quarter of these lesions are pigmented (usually brown).
- Fifty percent of VINs are white (leukoplakia) or become acetowhite after soaking with dilute acetic acid (**Figure 87-3**).
- Lesions may occasionally be red and ulcerate (**Figure 87-4**). White areas may also indicate malignant changes (**Figures 87-5** and **87-6**).
- VIN can appear warty, so lesions that are diagnosed as condyloma but do not respond to conservative therapy should be biopsied to rule out VIN.
- More than 50% of patients presenting with vulvar dysplasia are without symptoms. Of patients with symptoms, pruritus is the most common.
- Lesions may become confluent, involving the labia majora, minora, and perianal skin.

TYPICAL DISTRIBUTION

- Unlike cervical intraepithelial neoplasia, VIN is usually multifocal and can be located throughout the vulva, anus, and perineum. The interlabial grooves, posterior fourchette, and perineum are the most frequent locations (**Figures 87-1** to **87-6**).

BIOPSY

- Tissue biopsy is necessary for a definitive diagnosis of abnormal or ambiguous areas. After infiltration with lidocaine and epinephrine, 3-mm punch biopsies are performed in all suspicious areas. Bleeding can be stopped with a chemical hemostatic agent or electrocautery. Small biopsy sites usually do not need to be sutured and will heal well by secondary intention. Areas of ulceration should be sampled along the edge (**Figure 87-4**).

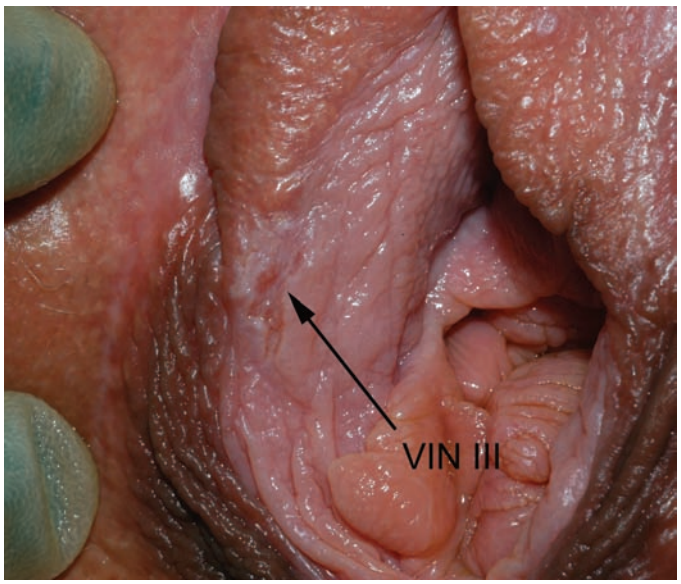

FIGURE 87-3 Diffuse white vulvar intraepithelial neoplasia III with ulceration. (*Courtesy of Hope Haefner, MD.*)

FIGURE 87-4 A small painful ulcer turned out to be vulvar intraepithelial neoplasia II on punch biopsy. A 3-mm punch biopsy was performed on the edge of the ulcer. (*Courtesy of Richard P. Usatine, MD.*)

- On histology, VIN may be graded as VIN I (mild dysplasia), VIN II (moderate dysplasia), or VIN III (severe dysplasia, carcinoma in situ) based upon the depth of epithelial involvement.
- VIN lesions are subdivided into three morphologic types: the basaloid type, which shows a thickened epithelium with a relatively flat, smooth surface; the warty type, which is characterized by a surface that has a condylomatous appearance; and the differentiated type, in which the epithelium is thickened and parakeratotic with elongated and anastomosing rete ridges.

DIFFERENTIAL DIAGNOSIS

- Micropapillae of the inner labia minora have commonly been misinterpreted as being secondary to HPV. Micropapillomatosis is a condition in which the vestibular papillae are atypically prominent. It is a benign normal variant.
- Sebaceous hyperplasia may be found as multiple small yellowish papules from Hart line (junction of the keratinized skin and mucosa) to the junction of the hair-bearing skin. This is a benign condition.
- HPV causes condylomata acuminata (genital condyloma). More than one third of women have associated cervical intraepithelial neoplasia. Exophytic condylomas are typically verrucous, and usually occur in clusters. They can be found at any site along the vulvar surface, and diagnosis is usually made by their characteristic appearance (see Chapter 133, Genital Warts).
- Herpes simplex viruses 1 and 2 produce grouped vesicles and ulcers, and are associated with genital lesions (see Chapter 129, Herpes Simplex).
- Molluscum contagiosum lesions appear as small papules with central umbilicated cores that contain a cheesy material (see Chapter 130, Molluscum Contagiosum).
- Secondary syphilis usually appears as a gray, plaque-like lesion (condyloma lata) (see Chapter 216, Syphilis).
- Granuloma inguinale produces small red lesions that appear from 3 weeks to 3 months after inoculation. These evolve into erosive ulcerations resulting in fibrosis and loss of superficial labial structures.
- Fungal infections commonly affect the vulva and are usually caused by *Candida albicans*. Patients present with vulvar itching and burning. On inspection, the skin surface is red and may demonstrate small satellite lesions. A white "cottage cheese" discharge may also be present (see Chapter 83, *Candida* Vulvovaginitis).
- Tinea cruris presents as a reddened area with raised sharp borders that occurs along the inner aspect of the thigh and often extends into the perianal and perineal region (see Chapter 139, Tinea Cruris).
- Lichen sclerosus is grossly and histologically similar to morphea (circumferential or localized scleroderma) and appears as white atrophic patches with erythema and loss of hair. Areas suspicious for VIN should be biopsied (**Figure 87-7**).
- Other dermatoses including psoriasis, lichen planus, and lichen simplex chronicus may present on the vulva and be confused with VIN.
- Nevi are benign melanocytic skin tumors that may occur in any area of the body, including the vulva.

FIGURE 87-5 A 59-year-old woman with long history of condyloma presents with a vaginal irritation. In addition to her cystocele after her hysterectomy, she is found to have *Trichomonas* and evidence of atrophic changes. However, the most concerning areas are the leukoplakia at the 6-, 11-, and 12-o'clock positions. These are most suspicious for vulvar intraepithelial neoplasia. (*Courtesy of Richard P. Usatine, MD.*)

FIGURE 87-6 The woman in **Figure 87-5** after punch biopsies are performed of the most suspicious areas. Both biopsies show moderate epithelial dysplasia, vulvar intraepithelial neoplasia II along with associated human papillomavirus changes. (*Courtesy of Richard P. Usatine, MD.*)

MANAGEMENT

NONPHARMACOLOGIC

- If the biopsy reveals condyloma, either observation or treatment with topical medications or surgical modalities (see Chapter 133, Genital Warts). Patients with VIN I can be followed by close observation.[7] SOR A

MEDICATIONS

- 5-Fluorouracil (5-FU) cream has been a traditional treatment for VIN that causes a chemical desquamation of the lesion.[8] It may result in significant burning, pain, inflammation, edema, and occasional painful ulcerations. Biopsy to exclude invasive disease is mandatory prior to 5-FU treatment.[8] SOR B
- Imiquimod cream is a topical immune response modifier that is FDA-approved for the treatment of anogenital warts, actinic keratosis, and certain basal cell carcinomas.[9] It has been used to treat multifocal VIN II or III in a few small pilot studies. The cream is self-administered 3 times per week for periods of 6 to 34 weeks.[9] SOR B

SURGICAL

- Patients with VIN II or III should have their lesions removed. Basaloid and warty VINs may be treated with ablation on non–hair-bearing epithelium. CO_2 laser is most commonly performed, although some providers perform loop electrosurgical excision procedure.[7] SOR B
- Differentiated VINs and any lesions in hair-bearing areas are generally treated with a wide local excision. Resected VIN specimens should be examined for residual disease in the margin.[10] SOR B

FIGURE 87-7 A 55-year-old woman with lichen sclerosus (et atrophicus). A biopsy was taken at the site indicated by the arrow to confirm the diagnosis and make sure that there was no vulvar intraepithelial neoplasia arising in that area. (*Courtesy of Richard P. Usatine, MD.*)

PREVENTION

- The bivalent vaccine (Cervarix) containing HPV types 16 and 18 and the quadrivalent vaccine (Gardasil) vaccine containing HPV types 6, 11, 16, and 18 are effective at preventing VIN when given prophylactically. Vaccine efficacy against any VIN lesion (regardless of HPV type) in HPV-naïve patients was 75% (22% to 94%).[11]

PROGNOSIS

- Surgical excision success is dependent upon margin status. Most recurrences will occur within 2 years.

FOLLOW-UP

- Because of the potential for disease persistence and recurrence, patients should be followed every 6 months for at least a year after treatment.[7]

PATIENT EDUCATION

- The diagnosis of high-grade dysplasia of the lower genital tract confers an increased risk of additional dysplasias and cancers for at least 20 years.[12] Continuing surveillance is necessary.

PATIENT RESOURCES

- Oncolink. *Vulvar Cancer*—**http://oncolink.org/types/article.cfm?c=6&s=21&ss=804&id=9509&CFID=49327043&CFTOKEN=65186180.**
- Information on patient education is available with the International Society for the Study of Vulvovaginal Disease—**http://www.issvd.org/document_library/VulvarCancer.pdf.**
- *Vulva Self-Examination*—**http://wso.williams.edu/orgs/peerh/women/wsexam.html.**

PROVIDER RESOURCES

- Practice management materials from the American Society for Colposcopy and Cervical Pathology—**http://www.asccp.org/PracticeManagement/Vulva/tabid/7430/Default.aspx.**
- eMedicine. *Malignant Vulvar Lesions*—**http://emedicine.medscape.com/article/264898-overview.**

REFERENCES

1. Jemal A, Murray T, Ward E, et al. Cancer statistics, 2005. *CA Cancer J Clin.* 2005;55:10-30.
2. Ferlay J, Shin HR, Bray F, et al. Estimates of worldwide burden of cancer in 2008: GLOBOCAN 2008. *Int J Cancer.* 2010;127(12):2893-2917. DOI:10.1002/ijc.25516.
3. Sturgeon SR, Brinton LA, Devesa SS, Kurman RJ. In situ and invasive vulvar cancer incidence trends (1973-87). *Am J Obstet Gynecol.* 1992;166:1482-1485.
4. Insinga RP, Liaw KL, Johnson LG, Madeleine MM. A systematic review of the prevalence and attribution of human papillomavirus types among cervical, vaginal, and vulvar precancers and cancers in the United States. *Cancer Epidemiol Biomarkers Prev.* 2008;17(7):1611-1622.
5. Jones RW, Rowan DM. Vulvar intraepithelial neoplasia III: A clinical study of the outcome in 113 cases with relation to the later development of invasive vulvar carcinoma. *Obstet Gynecol.* 1994;84:741-745.
6. Modesitt SC, Waters AB, Walton L, et al. Vulvar intraepithelial neoplasia III: occult cancer and the impact of margin status on recurrence. *Obstet Gynecol.* 1998;92:962-966.
7. Haefner H, Mayeaux EJ Jr. Vulvar abnormalities. In: Mayeaux EJ Jr, Cox T, eds. *Modern Colposcopy*, 3rd ed. Philadelphia: Lippincott Williams, & Wilkins; 2011:432-471.
8. Krupp PJ, Bohm JW. 5-fluorouracil topical treatment of in situ vulvar cancer. A preliminary report. *Obstet Gynecol.* 1978;51:702-706.

9. Le T, Menard C, Hicks-Boucher W, et al. Final results of a phase 2 study using continuous 5% Imiquimod cream application in the primary treatment of high-grade vulva intraepithelial neoplasia. *Gynecol Oncol.* 2007;106:579-584.
10. Di Saia PJ, Rich WM. Surgical approach to multifocal carcinoma in situ of the vulva. *Am J Obstet Gynecol.* 1981;140:136-145.
11. The FUTURE I/II Study Group; Dillner J, Kjaer SK, Wheeler CM, et al. Four year efficacy of prophylactic human papillomavirus quadrivalent vaccine against low grade cervical, vulvar, and vaginal intraepithelial neoplasia and anogenital warts: randomised controlled trial. *BMJ.* 2010;340:c3493.
12. Soutter WP, Sasieni P, Panoskaltsis T. Long-term risk of invasive cervical cancer after treatment of squamous cervical intraepithelial neoplasia. *Int J Cancer.* 2006;118:2048-2055.

SECTION 4 COLPOSCOPY

88 COLPOSCOPY—NORMAL AND NONCANCEROUS FINDINGS

E.J. Mayeaux, Jr., MD

PATIENT STORY

A 21-year-old woman presents for her well-woman examination. She has been followed by her physician for many years and has no complaints. She has been sexually active for a little more than 2 years with one mutually monogamous partner. She does not smoke, has never had a sexually transmitted disease (STD), and uses oral contraceptive pills for contraception. On speculum examination, her cervix appears normal (**Figure 88-1**) and a Papanicolaou (Pap) test is performed.

FIGURE 88-1 Normal cervix as seen through a colposcope without the application of vinegar. The red color around the os is produced by columnar cells and the lighter pink on the remainder of the cervix result from normal squamous cells. The presence of visible columnar cells outside the internal os is called ectropion and is a normal finding in young women and women on estrogen-containing contraception. The junction between the two cell types and colors is the squamo-columnar junction. (*Courtesy of E.J. Mayeaux, Jr., MD.*)

INTRODUCTION

The colposcope is an optical instrument using light and magnification that helps distinguish dysplasia and cervical cancer from benign cervical findings (**Figure 88-2**). Colposcopy (*colpo:* vagina; *scope:* to look) literally means to look into the vagina. Primary indications for colposcopy include certain abnormal Pap results or an abnormal appearing cervix. Colposcopically directed biopsies have a higher yield than biopsies done without the benefit of a colposcope, thereby decreasing the risk of false-negative biopsies.

FIGURE 88-2 The family physician is looking at the cervix directly through the colposcope lenses and the image is also visible on the monitor for learners and/or the patient to see. (*Courtesy of E.J. Mayeaux, Jr., MD.*)

SYNONYMS

Nabothian cysts are also called mucinous retention cysts or epithelial cysts.

An ectropion is also known as a persistent juvenile transformation zone or cervical erosion.

EPIDEMIOLOGY

- The Papanicolaou smear (Pap smear, Pap test) is a commonly employed screening test for dysplasia and cancer of the uterine cervix. More than 50 million Pap smears are performed each year in the United States.[1] The Pap test is a cytologic examination of cells taken from the cervical transformation zone (**Figures 88-3** and **88-4**). Colposcopy is the diagnostic test to evaluate patients with an abnormal cervical cytologic smear or abnormal-appearing cervix.
- Nabothian cysts are common and benign and are considered a normal feature of the adult cervix. They may occur singly or multiple cysts may be found simultaneously (**Figure 88-4**).[2]

- Infections of the lower female genital tract are common and can produce a number of cervical epithelial changes (**Figure 88-5**).
- Cervical epithelial atrophy may occur in hypoestrogenic states and cause the cervix to appear pale and the squamocolumnar junction to retract into the cervical os (**Figure 88-6**).
- Endocervical polyps are the most common benign neoplasms of the uterine cervix (**Figures 88-6** and **88-7**) and are most commonly found incidentally during pelvic examination. They are most common in the fourth to sixth decades of life and usually are asymptomatic, but may cause vaginal discharge or postcoital spotting.[3] Most polyps are benign with the incidence of malignancy being approximately 1 in 1000.[4]

ETIOLOGY AND PATHOPHYSIOLOGY

- Colposcopy entails the use of a field microscope to examine the cervix. The cervix and vagina are examined under magnification, and all abnormal areas are identified.
- If the colposcopy is satisfactory, the entire transformation zone (TZ) is examined and the extent of all lesions is seen (**Figure 88-3**). Directed biopsies of the most abnormal areas are performed to obtain a tissue diagnosis.
- Colposcopy begins after visualization of the cervix prior to application of acetic acid to look for leukoplakia and abnormal vessels. Acetic acid 3% to 5% is applied with a cotton ball held in a ring forceps or with a rectal swab. Scan the cervix with low power (typically 5×) and determine if the entire TZ, including the entire squamocolumnar junction (SCJ) can be seen. The borders of all lesions must be entirely visible (not disappearing into the canal) for the examination to be adequate.
- Most of the normal cervical findings are derived from the physiologic transformation of the exposed columnar epithelium to squamous epithelium (**Figures 88-1** and **88-3**). Noncancerous findings may include epithelial thinning and whitening as a result of lack of estrogen, and polyp formations. The damage to the cervical epithelium from various infections often produces inflammation, friability, discharge, and bleeding.

DIAGNOSIS

CLINICAL FEATURES

- Normal colposcopic findings include:[5]
  - Original squamous epithelium, which is a featureless, smooth, pink epithelium without gland openings or nabothian cysts (**Figure 88-4**).
  - Columnar epithelium is a single-cell layer, mucous-producing epithelium that extends between the endometrium and the squamous epithelium. Columnar epithelium appears red and irregular with stromal papillae and clefts (**Figure 88-4**). With acetic acid application and magnification, columnar epithelium has a grape-like or "sea-anemone" appearance.
  - SCJ is a clinically visible line seen on the ectocervix or within the distal canal, which demarcates endocervical tissue from squamous (or squamous metaplastic) tissue (**Figure 88-4**).

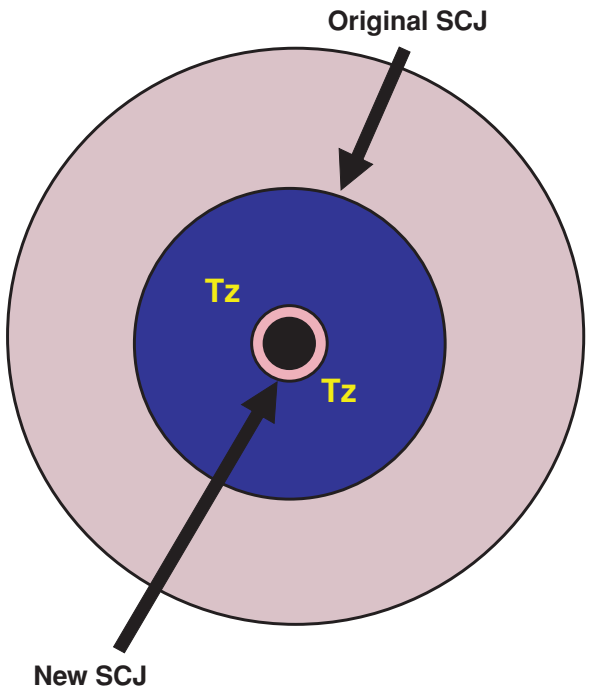

FIGURE 88-3 Schematic demonstration of the development of the transformation zone. The transformation zone extends from the original (prepubertal) squamocolumnar junction to the new (current) squamocolumnar junction. This transformation zone in the area at highest risk for cervical cancer. (*Courtesy of E.J. Mayeaux, Jr., MD.*)

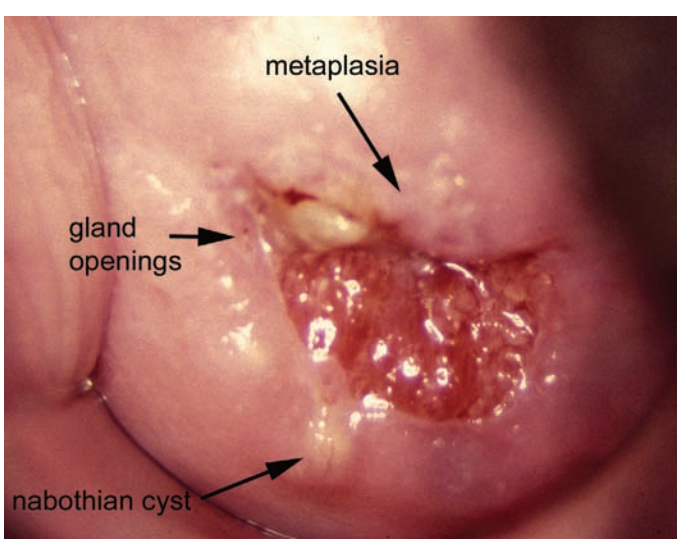

FIGURE 88-4 Normal transformation zone viewed with colposcopy. Note the squamocolumnar junction separating the red columnar epithelium from the pink squamous epithelium. Gland openings, nabothian cysts, and metaplasia are all part of this normal transformation zone. There is a white area of normal metaplasia on the anterior lip and a yellowish nabothian cyst on the posterior lip. (*Courtesy of E.J. Mayeaux, Jr., MD.*)

- Squamous metaplasia is the physiologic, normal process whereby columnar epithelium transforms into squamous epithelium. At the SCJ, it appears as a "ghostly white" or white-blue film with the application of acetic acid. It is usually sharply demarcated toward the cervical os and has very diffuse borders peripherally (**Figure 88-4**).
- TZ is the geographic area between the original squamous epithelium (before puberty) and the current SCJ. It may contain gland openings, nabothian cysts, and islands of columnar epithelium surrounded by metaplastic squamous epithelium (**Figures 88-3** and **88-4**).
- In some women, the juvenile type TZ persists into adulthood or is present after trauma or childbirth and is termed an ectropion (**Figure 88-8**). It has a reddish appearance similar to granulation tissue. Ectropion is common in adolescents, pregnant women, and those taking estrogen-containing contraceptives. Although usually asymptomatic, vaginal discharge and postcoital bleeding may occur.[6]

- Other nondysplastic colposcopic findings:
  - Nabothian cysts are normal areas of mucus-producing epithelium that are "roofed over" with squamous epithelium (**Figure 88-4**). They may appear translucent or opaque, whitish to yellow, and can range from a few millimeters to several centimeters in size. They always occur in the cervical TZ. They are usually asymptomatic and do not require any treatment.[2]
  - Cervicitis from an infection may make colposcopic assessment for dysplasia and cervical cancer difficult. Cervicitis appears as friable, inflamed epithelium, often in the presence of a vaginal discharge. *Trichomonas* may cause an inflamed cervix that has a strawberry appearance (**Figure 88-5** and Chapter 84, *Trichomonas* Vaginitis).
  - Atrophic vaginal or cervical epithelium is frequently white and easily traumatized (**Figure 88-6** and Chapter 81, Atrophic Vaginitis).
  - Cervical polyps are focal benign hyperplastic protrusions of the endocervical folds. They usually appear as polypoid growths protruding for the cervical os.[3]

BIOPSY

- The colposcope is used to examine the cervix for signs of dysplasia or cancer before performing cervical biopsies (see Chapters 89, Colposcopy of Low-Grade Lesions, 90, Colposcopy of High-Grade Lesions, and 91, Colposcopy of Cervical Cancer for details of suspicious colposcopic findings).

DIFFERENTIAL DIAGNOSIS

- Friability from infections must be differentiated from dysplastic changes by a history of possible exposure to STDs, presence of discharge, wet prep, and STD testing.

MANAGEMENT

NONPHARMACOLOGIC

- Nabothian cysts do not require any treatment. If you tell patients that they have a nabothian cyst, please tell them that this is a normal finding.

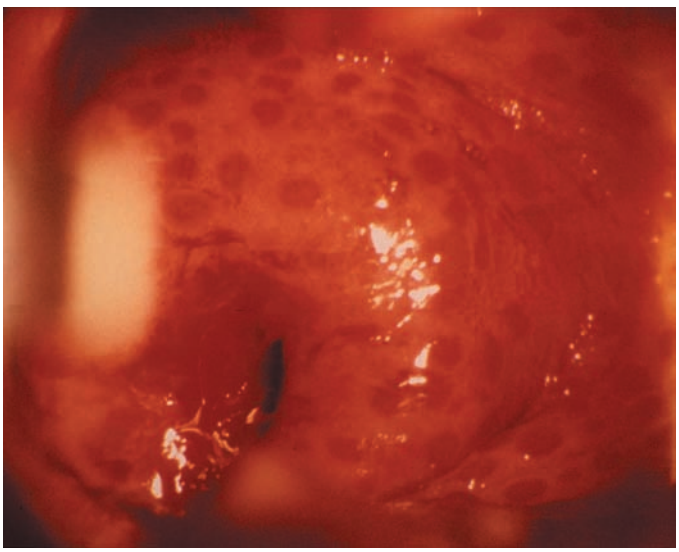

FIGURE 88-5 Colposcopic view of *Trichomonas* infection. Note disruption of the epithelium with petechiae and pinpoint bleeding producing the "strawberry" cervix. (*Courtesy of E.J. Mayeaux, Jr., MD.*)

FIGURE 88-6 Colposcopic view of cervical atrophy and a benign endocervical polyp in a postmenopausal woman. Note the pale epithelium and the polyp extending from the cervical os. (*Courtesy of E.J. Mayeaux, Jr., MD.*)

MEDICATIONS

- Atrophic vaginal or cervical epithelium can be treated with intravaginal estrogen for 2 to 4 weeks before colposcopy in order to "normalize" the epithelium. SOR C This is generally safe, even if dysplasia or cancer is present, because the duration of therapy is short, and these lesions do not express any more estrogen receptors than a normal cervix.[7]
- Vaginocervicitis is treated with antiinfectives once the source is diagnosed.
- Treatment for cervical polyps is removal by twisting the polyp with ringed forceps. Smaller polyps may be removed with colposcopy biopsy forceps. Polyps with a thick stalk may require surgical or electrosurgical removal. If polyps are removed after a recently abnormal Pap test, the polyp should be sent for analysis as dysplasia may be found on the polyp.[8]
- Cervical dysplastic changes should be handled according to national evidence-based guidelines (see Chapters 89, Colposcopy of Low-Grade Lesions and 90, Colposcopy of High-Grade Lesions).[9]
- An ectropion may be treated with ablation (such as cervical cryotherapy) if significant discharge or postcoital bleeding is present after dysplasia and cancer have been ruled out.[2]

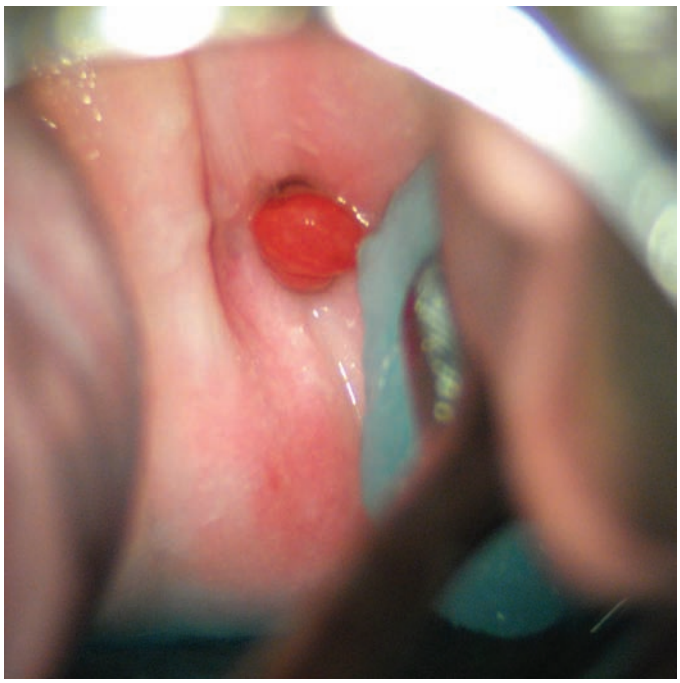

FIGURE 88-7 Colposcopic view of an endocervical polyp. Ring forceps were used to identify the base of the polyp, and after the polyp was found to be arising from the wall of the cervical canal, it was twisted off without complications. (*Courtesy of E.J. Mayeaux, Jr., MD.*)

FOLLOW-UP

- If an infection coexists with an abnormal Pap smear or grossly abnormal appearing cervix, the infection should be treated and the colposcopic assessment should be performed 1 month later.

PATIENT EDUCATION

- Patients should be discouraged from douching as it irritates the mucous membranes, disrupts normal flora, and makes acquisition of an STD more likely if exposed. Safer-sex education should be given to all patients at risk of acquiring an STD.

PATIENT RESOURCES

- National Cancer Institute. *Cervical Cancer Screening*—**http://www.cancer.gov/cancertopics/screening/cervical.**
- WebMD. *Colposcopy and Cervical Biopsy*—**http://www.webmd.com/cancer/cervical-cancer/colposcopy-and-cervical-biopsy.**
- MedlinePlus. *Nabothian Cyst*—**http://www.nlm.nih.gov/medlineplus/ency/article/001514.htm.**

PROVIDER RESOURCES

- American Society for Colposcopy and Cervical Pathology (includes colposcopy and treatment algorithms)—**http://www.asccp.org.**
- Medscape. *Colposcopy*—**http://emedicine.medscape.com/article/265097.**

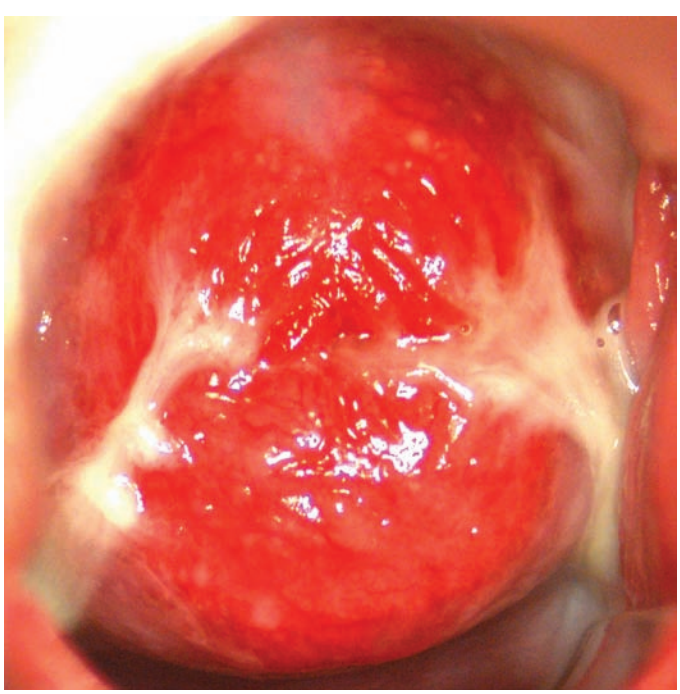

FIGURE 88-8 Colposcopic view of an ectropion. This patient was 22 years of age, but her cervix had the appearance of the cervix of a younger female. She was asymptomatic. (*Courtesy of E.J. Mayeaux, Jr., MD.*)

REFERENCES

1. Sirovich BE, Welch HG. The frequency of Pap smear screening in the United States. *J Gen Intern Med.* 2004;19:243-250.
2. Casey PM, Long ME, Marnach ML. Abnormal cervical appearance: what to do, when to worry? *Mayo Clin Proc.* 2011;86(2):147-150.
3. Aaro LA, Jacobson LJ, Soule EH. Endocervical polyps. *Obstet Gynecol.* 1963;21:659-665.
4. Schnatz PF, Ricci S, O'Sullivan DM. Cervical polyps in postmenopausal women: is there a difference in risk? *Menopause.* 2009;16(3):524-528.
5. Stafl A, Wilbanks GD. An international terminology of colposcopy: report of the nomenclature committee of the International federation of cervical pathology and colposcopy. *Obstet Gynecol.* 1991;77:313-314.
6. Goldacre MJ, Loudon N, Watt B, et al. Epidemiology and clinical significance of cervical erosion in women attending a family planning clinic. *Br Med J.* 1978;1(6115):748-750.
7. Sadan O, Frohlich RP, Driscoll JA, et al. Is it safe to prescribe hormonal contraception and replacement therapy to patients with premalignant and malignant uterine cervices? *Gynecol Oncol.* 1986;34:159-163.
8. Chin N, Platt AB, Nuovo GJ. Squamous intraepithelial lesions arising in benign endocervical polyps: a report of 9 cases with correlation to the Pap smears, HPV analysis, and immunoprofile. *Int J Gynecol Pathol.* 2008;27(4):582-590.
9. Wright TC Jr, Cox JT, Massad LS, et al. For the 2001 ASCCP-sponsored consensus conference. Consensus guidelines for the management of women with cervical cytological abnormalities and cervical cancer precursors. Part I: cytological abnormalities. *JAMA.* 2002;287(18):2120-2129.

89 COLPOSCOPY OF LOW-GRADE LESIONS

E.J. Mayeaux, Jr., MD

PATIENT STORY

A 23-year-old woman has a low-grade squamous intraepithelial lesion on her Papanicolaou (Pap) test. One colposcopic view of her cervix shows acetowhite changes consistent with a cervical intraepithelial neoplasia grade 1 lesion (CIN 1) (**Figure 89-1**). She has no other suspicious findings and biopsy of the acetowhite area confirms CIN 1. The endocervical curettage is negative for disease. During the follow-up visit, the doctor and patient together decide to proceed with watchful waiting and repeat Pap tests at 6 and 12 months.

INTRODUCTION

Our knowledge of the genesis and development of cervical cancer has grown greatly over the last 20 years. It was once believed that human papillomavirus (HPV) infection and CIN 1 disease were the first steps in cancer formation. We now know that HPV infection and CIN 1 are essentially the same thing and will resolve without treatment in most immunocompetent women.

EPIDEMIOLOGY

- In low-grade squamous intraepithelial lesion (LGSIL) tests, the abnormalities are typically associated with HPV infection or CIN grade 1 lesions.[1] Overall rates of Pap test abnormalities are often estimated from regional studies. For example, in an observational cohort study of routine cervical tests in the Northwest United States, in women of all ages (n = 150,052), atypical squamous cells was diagnosed at a rate of 9.8 per 1000, LGSIL was diagnosed at a rate of 3.5 per 1000, and negative routine tests occurred at a rate of 278.5 per 1000.[2]

ETIOLOGY AND PATHOPHYSIOLOGY

- Essentially all CIN is caused by HPV. Ten percent to 15% of CIN 1 lesions progress to CIN 2-3I, and 0.3% progress to cervical cancer.[3]
- There is no way to determine which CIN 1 lesions (**Figures 89-1** to **89-3**) or simple HPV lesions (**Figures 89-4** and **89-5**) will regress or progress.
- Colposcopy is the standard of care for assessing abnormal Pap tests and cervical dysplasia. It entails the use of a field microscope to examine the cervix after acetic acid (**Figures 89-1** to **89-4**) and Lugol iodine (**Figure 89-5**.) Ten percent to 15% of CIN 1 lesions progress to CIN 2 or 3, and 0.3% progress to cervical cancer.[3]
- An atypical transformation zone is defined as a transformation zone with findings suggesting cervical dysplasia or neoplasia. Differences in thickness, density of the cells, degree of differentiation, and

FIGURE 89-1 Colposcopic view of acetowhite changes on the cervix of cervical intraepithelial neoplasia grade 1 lesions after the application of acetic acid. Note the irregular geographic borders. (*Courtesy of E.J. Mayeaux, Jr., MD.*)

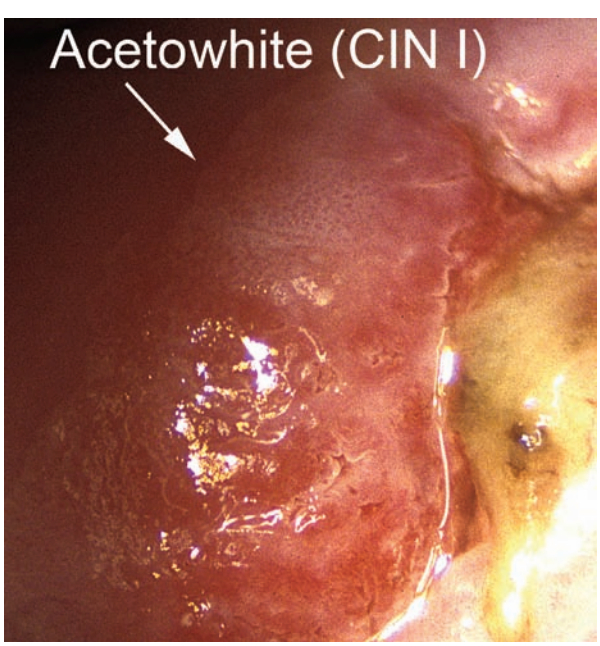

FIGURE 89-2 Another colposcopy view of acetowhite changes on the cervix of cervical intraepithelial neoplasia grade 1 lesions. (*Courtesy of E.J. Mayeaux, Jr., MD.*)

keratin production determine the color and opacity of the epithelium, and may produce the abnormal findings of leukoplakia and acetowhite epithelium.

RISK FACTORS

- Sexual intercourse.
- Other types of sexual activity including digital/anal, oral/anal, and digital/vaginal contact.
- Immunosuppression.

DIAGNOSIS

CLINICAL FEATURES

- The diagnosis of low-grade cervical abnormalities is made on colposcopic examination. Findings consistent with this diagnosis include:[1]
  - Acetowhite changes (**Figures 89-1** to **89-4**). A transient, white-appearing epithelium following the application of acetic acid may be abnormal and correlates with higher nuclear density. The more sharp and angular the margin is, the likelier it is to be dysplastic. The margins of low-grade disease are usually feathery or geographic borders. Most low-grade lesions are snowy white with a shiny surface. A uniformly papillary surface is often indicative of HPV disease.
  - Punctation is a stippled appearance of small looped capillaries seen end-on, often found within acetowhite area, appearing as fine-to-coarse red dots. Fine punctuation has fine-caliber vessels that are regularly spaced, and is usually associated with benign conditions or low-grade disease (**Figures 86-3** and **86-4**).
  - Lack of iodine staining (Schiller test) may be used when further clarification of potential biopsy sites is necessary (**Figure 89-5**). It need not be used in all cases. The sharp outlining afforded by Lugol solution can be dramatic and very helpful.

LABORATORY TESTING[4]

- High-risk HPV testing can be used to further define a patient's risk for dysplasia and cancer after an atypical squamous cell (ASC) Pap result. Patients with ASC and a positive high-risk HPV test should be triaged to immediate colposcopy and patients with a negative HPV test may be triaged to re-Pap in 1 year.
- High-risk HPV testing may also be used in conjunction with cytology testing to screen low-risk women at 3-year intervals.

BIOPSY

- Biopsy is usually indicated to establish the histologic grade of the abnormalities present.

DIFFERENTIAL DIAGNOSIS

- CIN 1 and HPV lesions must be differentiated from nonmalignant inflammatory lesions such as yeast vaginitis and sexually transmitted diseases, which usually present with vaginal itching, odor, and/or discharge (see Chapter 83, *Candida* Vulvovaginitis).

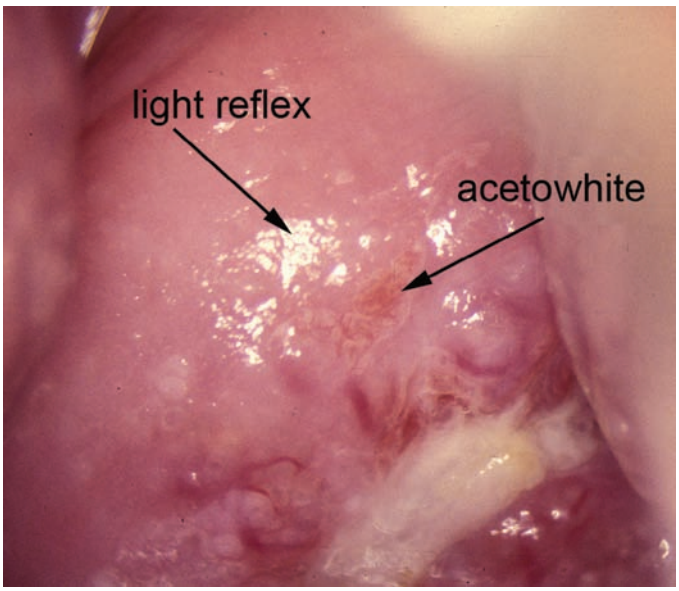

FIGURE 89-3 Colposcopy view of an indistinct acetowhite lesion on the anterior lip. Note the light reflex just above the lesion that may be confused with an actual lesion. (*Courtesy of E.J. Mayeaux, Jr., MD.*)

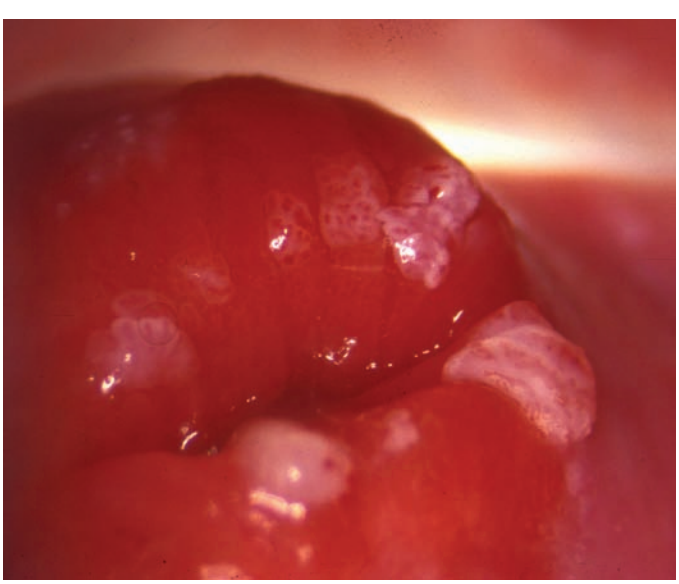

FIGURE 89-4 Colposcopy view of condyloma of the cervix. Note the bright acetowhite effect that is common on condyloma. (*Courtesy of E.J. Mayeaux, Jr., MD.*)

- High-grade dysplasia (CIN 2 and CIN 3) and cancer must also be ruled out, usually by colposcopic examination and biopsy (see Chapter 90, Colposcopy of High-Grade Lesions).

MANAGEMENT

NONPHARMACOLOGIC

- According to the 2006 consensus guideline, the preferred treatment for women with CIN 1 and satisfactory colposcopy is repeat cytology at 6 and 12 months or DNA testing for HPV types at 12 months.[3,5] SOR B Most cases of CIN 1 spontaneously regress.
- Observation without treatment is acceptable in pregnant women with CIN 1 and in women with unsatisfactory colposcopy.[3,5] SOR B
- Pap test screening is not recommended for females younger than the age of 21 years, but if they are inappropriately screened, observation without treatment is recommended for CIN 1 disease.

COMPLEMENTARY AND ALTERNATIVE THERAPY

- In one study, oral supplements of indole-3-carbinol were shown to promote regression in high-grade cervical dysplasias when administered orally for 12 weeks.[6] SOR B Indole-3-carbinol occurs naturally in cruciferous vegetables, such as broccoli, cabbage, cauliflower, Brussels sprouts, collard greens, and kale, or can be purchased as a supplement.

SURGICAL

- Treatment options for CIN can be grouped into chemically destructive, surgical ablative, and surgical excisional methods. Cryotherapy, laser, and loop electrosurgical methods are commonly employed when treatment is selected.
- Candidates for outpatient cervical cryotherapy are patients with smaller lesions that do not enter the cervical os. Endocervical sampling is recommended before applying any ablative treatment.[3,5] SOR B
- Large lesions (more than 1 inch in diameter, more than a 0.5 inch from the os, or involving more than 2 cervical quadrants) may be more appropriate for loop or laser therapy.[3,5] SOR B

PREVENTION

- The patient should also be counseled that an HPV vaccine may still be of benefit, if indicated. The U.S. Advisory Committee on Immunization Practices (ACIP) recommends giving the vaccine to girls and women in the indicated age group (11 to 26 years of age) even if they have had an abnormal Pap test; although it will not change the course of the current infection, it will protect from any HPV types to which the patient has not yet been exposed.[7]
- According to the National Cancer Institute, scientific evidence supports the following for prevention of HPV infection.[8]
  - Abstinence from sexual activity.
  - Barrier protection and/or spermicidal gel during sexual intercourse.
  - Vaccination against HPV-16/HPV-18.

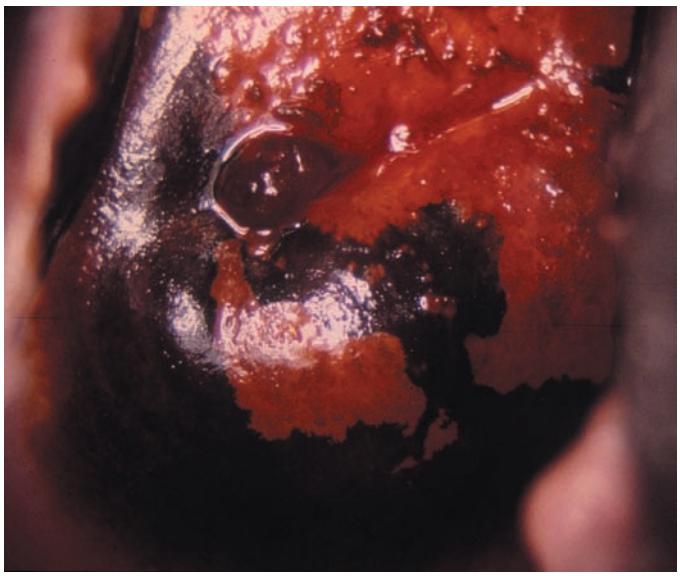

FIGURE 89-5 Colposcopic view of a cervix after Lugol solution is applied. The abnormal cervical intraepithelial neoplasia grade 1 lesion is the area on the cervix that does not stain brown with the iodine in the Lugol solution. The areas that do not stain can then be biopsied. This is called the Schiller test. (*Courtesy of E.J. Mayeaux, Jr., MD.*)

FOLLOW-UP

- Follow-up is in 4- to 6-month intervals until the patient has two serial normal examinations, with colposcopy or colposcopy interspersed with Pap tests. Recurrence is most common in the first 2 years after therapy. Recurrences are most common in the os and on the outside margins.
- After two consecutive negative Pap tests or one negative high-risk HPV DNA test, patients should continue to be routinely screened.

PATIENT EDUCATION

- Smoking cessation counseling is an important part of therapy for women who continue to smoke (see Chapter 236, Tobacco Addiction).

PATIENT RESOURCES

- American Social Health Association. *HPV*—**http://www.ashastd.org/std-sti/hpv.html.**
- Centers for Disease Control and Prevention. *HPV Vaccine Information For Young Women—Fact Sheet*—**http://www.cdc.gov/std/hpv/stdfact-hpv-vaccine-young-women.htm.**
- Oncolink. *Cervical, Vaginal, Vulvar Cancers*—**http://oncolink.upenn.edu/types/types.cfm?c=6.**

PROVIDER RESOURCES

- Treatment algorithms based on the American Society for Colposcopy and Cervical Pathology 2006 Consensus guidelines for the management of women with abnormal Cervical Cancer Screening Tests—**http://www.asccp.org/consensus/cytological.shtml.**
- National Cancer Institute. *Cervical Cancer Prevention (PDQ®)*—**http://www.cancer.gov/cancertopics/pdq/prevention/cervical/HealthProfessional.**
- Medscape. *Colposcopy*—**http://emedicine.medscape.com/article/265097.**

REFERENCES

1. Stafl A, Wilbanks GD. An international terminology of colposcopy: report of the nomenclature committee of the International federation of cervical pathology and colposcopy. *Obstet Gynecol.* 1991;77:313-314.
2. Insinga RP, Glass AG, Rush BB. Diagnoses and outcomes in cervical cancer screening: a population-based study. *Am J Obstet Gynecol.* 2004;191:105-113.
3. Spitzer M, Apgar BS, Brotzman GL. Management of histologic abnormalities of the cervix. *Am Fam Physician.* 2006;73:105-112.
4. *2006 Consensus Guidelines for the Management of Women with Abnormal Cervical Screening Tests*. http://www.asccp.org/ConsensusGuidelines/AbnormalCervicalScreeningTests/tabid/5958/Default.aspx. Accessed March 4, 2012.

5. Wright TC Jr, Massad LS, Dunton CJ, et al. 2006 American Society for Colposcopy and Cervical Pathology-sponsored Consensus Conference. 2006 Consensus guidelines for the management of women with cervical intraepithelial neoplasia or adenocarcinoma in situ. *Am J Obstet Gynecol.* 2007;197(4):340-345. http://www.asccp.org/consensus/histological.shtml.
6. Bell MC, Crowley-Nowick P, Bradlow HL, et al. Placebo-controlled trial of indole-3-carbinol in the treatment of CIN. *Gynecol Oncol.* 2000;78(2):123-129.
7. Advisory Committee on Immunization Practices (ACIP). *ACIP Recommendations for the Use of Quadrivalent HPV Vaccine*. http://www.cdc.gov/nip/recs/provisional_recs/hpv.pdf. Accessed February 28, 2012.
8. National Cancer Institute. *Cervical Cancer Prevention (PDQ)*. http://www.cancer.gov/cancertopics/pdq/prevention/cervical/HealthProfessional. Accessed March 4, 2012.

90 COLPOSCOPY OF HIGH-GRADE LESIONS

E.J. Mayeaux, Jr., MD

PATIENT STORY

A 36-year-old woman presented for follow-up of a persistently abnormal Papanicolaou (Pap) test. She is a smoker and has had multiple new sexual partners in the last few years. Although she has had several "abnormal Pap tests" in the past, she states she has never needed treatment. She was found to have a dense acetowhite (AW) lesion on colposcopy that was biopsied (**Figure 90-1**). The pathology returned cervical intraepithelial neoplasia grade 3 (CIN 3) and the patient was treated with loop electrosurgery. She had negative margins on the loop electrosurgical excision procedure specimen and remained recurrence-free at 3 years.

FIGURE 90-1 Dense acetowhite (white after application of vinegar) lesions with "rolled" edges in a patient with high-grade disease. Her colposcopically directed biopsies showed cervical intraepithelial neoplasia grade 3. (*Courtesy of E.J. Mayeaux, Jr., MD.*)

INTRODUCTION

High-grade squamous intraepithelial lesions in adult women are considered true cancer precursors because if left untreated, they have a significant chance of developing into invasive cancer.

SYNONYMS

Cervical intraepithelial neoplasia (CIN 3 and CIN 2) are high-grade lesions.

EPIDEMIOLOGY

- Overall rates of Pap test abnormalities are usually estimated from local or regional studies. For example, in an observational cohort study of routine cervical tests in the Northwest United States, in women of all ages (n = 150,052), high-grade squamous intraepithelial lesion was diagnosed at a rate of 0.8 per 1000 compared to negative routine tests that were diagnosed at a rate of 278.5 per 1000.[1]

ETIOLOGY AND PATHOPHYSIOLOGY

- In high-grade squamous intraepithelial lesions, the abnormalities are immature parabasilar cell types. They have an increased nuclear-to-cytoplasmic ratio, enlarged hyperchromatic nucleoli, few nucleoli, and a reticular or granular appearance.
- On histology, abnormal maturation and nuclear atypia defines CIN. Koilocytosis (perinuclear cytoplasmic vacuolization) is indicative of human papillomavirus (HPV) infection and may be found with high-grade CIN. High-grade CIN is diagnosed when immature basaloid cells with nuclear atypia occupy greater than the lower one third of the epithelium. With increasing lesion severity, there is also increased nuclear crowding, pleomorphism, normal and abnormal mitosis, and loss of polarity.[2]

- Traditionally, high-grade CIN is thought to arise as a small focus within a larger area of low-grade CIN that expands and eventually replaces much of the low-grade lesion.
- This "monoclonal" theory is supported by the fact that there is a 5-year difference between the peak prevalence of CIN 1 and CIN 2 or 3, and detection of a low-grade squamous intraepithelial lesion. Pap greatly increases the risk that a high-grade CIN will be found on subsequent tests.
- It has been difficult to document the rate of progression because most studies use cervical biopsy to establish an accurate diagnosis, which influences the rate of disease progression.
- With the discovery that most CIN 1 lesions regress or persist, the question has been raised as to whether high-grade CIN might be a process that develops concurrently and somewhat independently from low-grade CIN.
- This theory is supported by the fact that CIN 3 can develop without a detectable preceding low-grade CIN lesion, and high-grade CIN is almost always found closer to the squamocolumnar junction than concomitant low-grade lesions. It has also been found that women who turned HPV-16/-18–positive had a 39% rate of high-grade CIN at 2 years compared to HPV-negative women.
- Schiffman et al. reported that both CIN 1 and CIN 2 or 3 lesions developed within the same time frame in a large group of women who turned HPV-positive and were followed for 4 years.[3]
- Which theory is most correct is a matter of debate. Many practitioners still treat CIN 1 level lesions on the basis of the monoclonal theory or on the theory that if both lesions arise concomitantly, then treating CIN 1 lesions may be the best way of eliminating high-grade CIN. Others promote the idea of observing CIN 1 lesions and treating only high-grade CIN lesions.

RISK FACTORS[4]

- HPV infection.
- Nonuse of barrier protection and/or spermicidal gel during sexual intercourse.
- No Pap testing within the last 3 years in low-risk women with a cervix or within 1 year for high-risk women.
- Nonvaccination status for HPV-16 and HPV-18.
- Tobacco smoking.

DIAGNOSIS

CLINICAL FEATURES

- Leukoplakia, as shown in **Figure 90-2**, is typically an elevated, white plaque seen prior to the application of acetic acid. It is caused by a thick keratin layer that obscures the underlying epithelium and may signal severe dysplasia or cancer. Although it may be associated with benign findings, it always warrants a biopsy.
- AW epithelium following the application of acetic acid is typical for CIN 2 and 3 lesions (**Figure 90-1**). The AW effect tends to develop more slowly than in lower-grade lesions and to persist

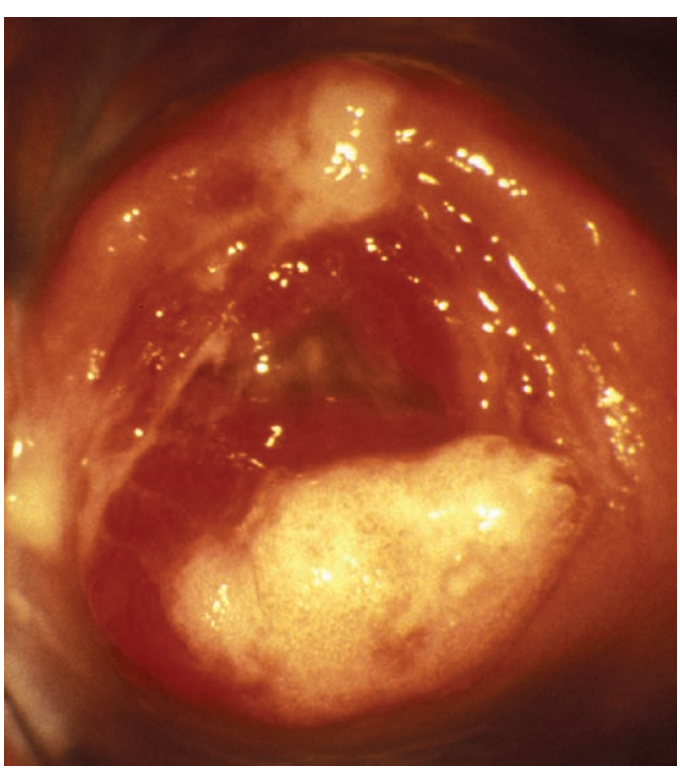

FIGURE 90-2 Leukoplakia (white lesion before application of vinegar) of the cervix seen with colposcopy in a patient with high-grade squamous intraepithelial lesion. (*Courtesy of E.J. Mayeaux, Jr., MD.*)

longer. The margins of high-grade CIN are straighter and sharper compared to the vague, feathery, geographic borders of CIN 1 or HPV disease.

- With increasing levels of CIN, desmosomes (intracellular bridges) that attach the epithelium to the basement membrane are often lost, producing an edge that easily peels. This loss of tissue integrity should raise the suspicion of high-grade dysplasia. The extreme expression of this effect is the ulceration that sometimes forms with invasive disease.
- High-grade CIN lesions are usually proximal to or touch the squamocolumnar junction, even when contained in larger lesions (**Figures 90-1** to **90-5**).
- Nodular elevations on the surface of lesions and ulceration are suspicious for high-grade or invasive cancer.
- Increases in local factors such as tumor angiogenesis factor or vascular endothelial growth factor, which are much more commonly produced by CIN 3 lesions, cause growth of abnormal surface vasculature, producing punctuation (**Figures 90-3** and **90-4**), mosaicism (**Figures 90-5** and **90-6**), and frankly abnormal vessels. However, most high-grade lesions do not develop any abnormal vessels.
- Punctation is a stippled appearance of small looped capillaries seen end-on, often found within AW area, appearing as fine-to-coarse red dots (**Figures 90-3** and **90-4**). Course punctation represents increased caliber vessels that are spaced at irregular intervals, and is more highly associated with increasing levels of dysplasia.
- Mosaicism is an abnormal pattern of small blood vessels suggesting a confluence of "tiles" or a "chicken-wire pattern" with reddish borders. Mosaicism represents capillaries that grow on or near the surface of the lesion that forms partitions between blocks of proliferating epithelium (**Figures 90-5** and **90-6**). It develops in a manner very similar to punctation and is often found in the same lesions. Course mosaic forms a consistently irregular cobblestone effect with dilated coarse vessels which is highly associated with CIN 2 and 3.

TYPICAL DISTRIBUTION

- CIN 2 or 3 disease usually touches the active squamocolumnar junction (SCJ).
- When CIN 2 or 3 coexists in the same lesion with a lower-grade lesion, the higher-grade lesion often presents with a sharply defined internal border (also known as a border-within-a-border). The higher-grade disease is usually proximal to the os.

LABORATORY TESTING

- High-risk HPV testing is not useful for the diagnosis of CIN 2 or 3. It can be useful for posttreatment follow-up.[5]

BIOPSY

- Biopsy is usually indicated to establish the histologic grade of the abnormalities present. Biopsies are performed under colposcopic direction.

DIFFERENTIAL DIAGNOSIS

- CIN 2 and 3 lesions must be differentiated from nonmalignant inflammatory lesions, especially trichomoniasis and *Chlamydia*

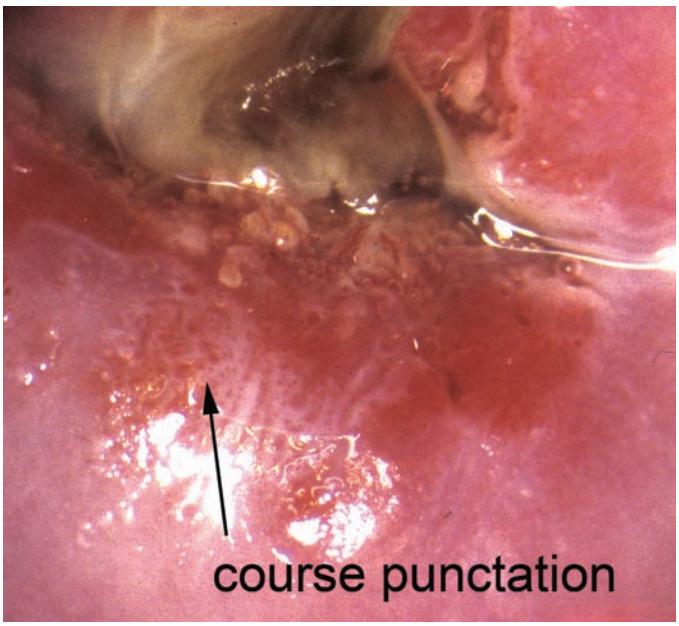

FIGURE 90-3 Course punctuation of the cervix seen through the colposcope in a patient with high-grade disease. (*Courtesy of E.J. Mayeaux, Jr., MD.*)

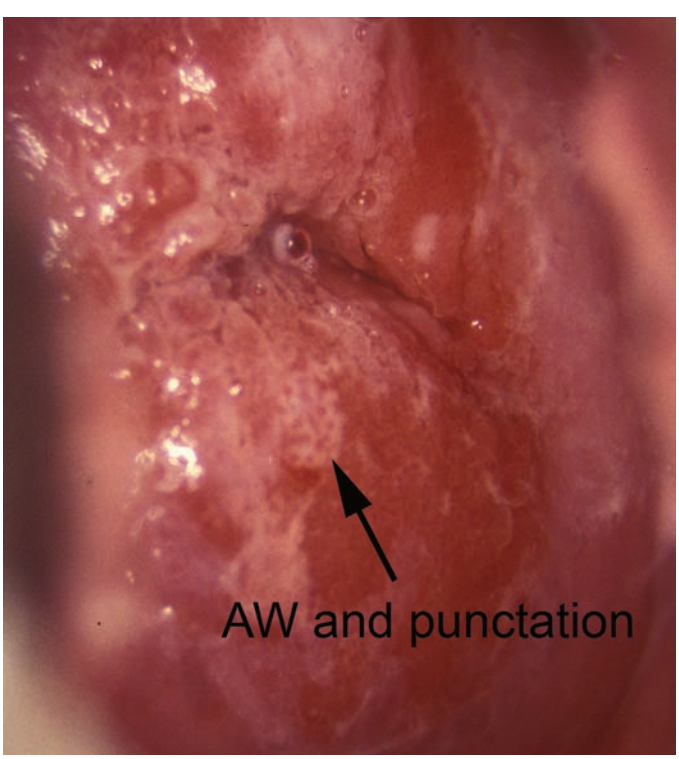

FIGURE 90-4 Acetowhite epithelium and course punctuation on the same cervix (*arrow*). The biopsies of this area showed cervical intraepithelial neoplasia grade 3. (*Courtesy of E.J. Mayeaux, Jr., MD.*)

infections, which usually present with vaginal itching, odor, and/or discharge (see Chapter 84, *Trichomonas* Vaginitis, and Chapter 85, *Chlamydia* Cervicitis).

- Flat HPV lesions may mimic the dense AW lesions of CIN 2 and 3.
- CIN 2 and 3 lesions must be differentiated from both CIN 1 and cancer (see Chapter 89, Colposcopy of Low-Grade Lesions, and Chapter 91, Colposcopy of Cervical Cancer).

MANAGEMENT

- Except in special circumstances, women with biopsy-confirmed CIN 2 or 3 should be treated. CIN 2 may be followed with colposcopy and Pap tests in patients who have not attained their 21st birthday.[5,6]
- Effective treatment of CIN 2 and 3 requires the removal of the entire transformation zone rather than just the removal of the lesion. When colposcopy is satisfactory, any ablative or excisional modality will treat CIN effectively.[5] SOR A However, because excisional modalities allow for the pathologic identification of unanticipated microinvasive or occult invasive cancer, some physicians prefer these methods to treat biopsy-confirmed CIN 2 and 3.[2] SOR C
- Both excision and ablation are acceptable treatment choices for nonpregnant adult women with a histologic diagnosis of CIN 2 and 3 and satisfactory colposcopy. For adolescents and young women with a histologic diagnosis of CIN 2, observation with colposcopy and cytology at 6-month intervals is preferred, but treatment is acceptable.
- Observation is unacceptable in women with CIN 2 except during pregnancy and in very compliant adolescents with satisfactory colposcopy and negative results on endocervical curettage.[6] SOR C
- A randomized clinical trial demonstrated that condom use promotes regression of CIN and clearance of HPV.[7] SOR B
- Because a small number of women with biopsy-confirmed CIN 2 or 3 and unsatisfactory colposcopy have occult invasive cancer, excisional procedures should be performed. Cold knife and loop electrosurgical excision procedure conizations effectively diagnose and treat these women.[6] SOR B

COMPLEMENTARY AND ALTERNATIVE THERAPY

- In one study, oral supplements of indole-3-carbinol have been shown to promote regression in high-grade cervical dysplasias when administered orally for 12 weeks.[8] SOR B Indole-3-carbinol occurs naturally in cruciferous vegetables, such as broccoli, cabbage, cauliflower, Brussels sprouts, collard greens, and kale, or can be purchased as a supplement.

PREVENTION

- The patient should also be counseled that an HPV vaccine may still be of benefit if indicated. The U.S. Advisory Committee on Immunization Practices (ACIP) recommends giving the vaccine to women in the indicated age group (11 to 26 years of age) even if they have had an abnormal Pap test. Although it will not change the course of the current infection, it will protect her from other HPV types to which she has not yet been exposed.[6]

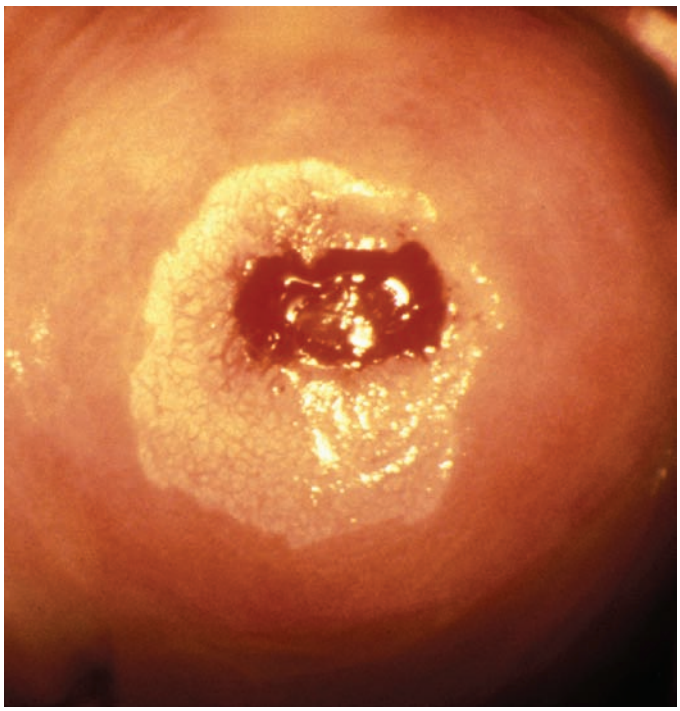

FIGURE 90-5 Colposcopy with findings of mosaicism in a patient with cervical intraepithelial neoplasia grade 3. (*Courtesy of E.J. Mayeaux, Jr., MD.*)

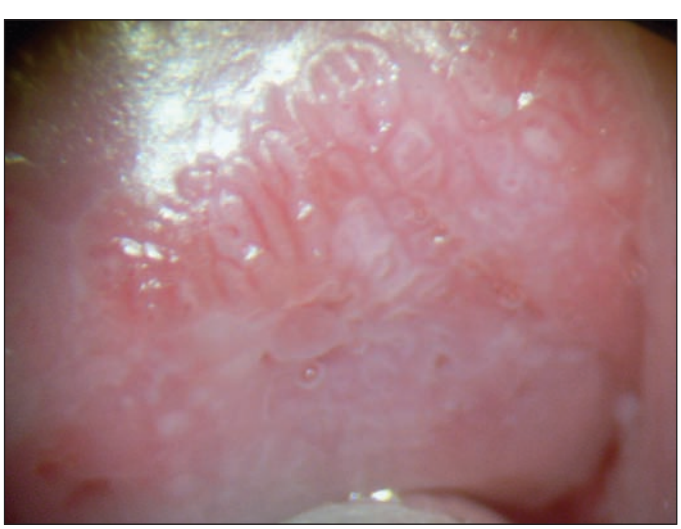

FIGURE 90-6 High-power colpophotograph of mosaicism in a patient with cervical intraepithelial neoplasia grade 3. Note the course pattern consisting of large caliber vessels, irregular tile shapes, and irregular sizes. There are also a few punctations contained within the mosaic pattern, which is common. (*Courtesy of E.J. Mayeaux, Jr., MD.*)

- According to the National Cancer Institute (NCI), scientific evidence supports the following for prevention of cervical cancer:[9]
  - Prevention of HPV infection through abstinence from sexual activity and barrier protection and/or spermicidal gel during sexual intercourse.
  - Vaccination against HPV-16/HPV-18.
  - Screening via gynecologic examinations and cytologic screening.
- Avoidance of all tobacco smoke.

PROGNOSIS

- For untreated CIN 2, approximately 43% will spontaneously regress, 35% will persist, and 22% will progress to carcinoma in situ or invasive cancer.[2] The regression rate of CIN 2 is higher in adolescents.
- For untreated CIN 3, approximately 32% will regress, 56% will persist, and 14% of CIN 3 will progress to carcinoma in situ or invasive cancer.[2]

FOLLOW-UP

- After treatment for CIN 2 or 3, acceptable management methods include cytology with or without colposcopy at 4- to 6-month intervals until three negative evaluations have been obtained, or HPV DNA testing no sooner than 6 months after treatment.[5,6] SOR C
- The preferred management for CIN identified at the margin of a diagnostic excisional procedure or in postprocedure endocervical sampling is colposcopy and endocervical sampling at the 4- to 6-month follow-up evaluation.[5,6] SOR C

PATIENT EDUCATION

- Tobacco smoking has been linked to the development and recurrence of CIN. Part of any treatment program should include smoking cessation.

PATIENT RESOURCES

- National Cancer Institute. *What You Need to Know About Cancer of the Cervix*—**http://www.cancer.gov/cancertopics/wyntk/cervix.**
- Oncolink. *Cervical, Vaginal, Vulvar Cancers*— **http://oncolink.upenn.edu/types/types.cfm?c=6.**

PROVIDER RESOURCES

- National Cancer Institute. *Cervical Cancer Prevention (PDQ®)*—**http://www.cancer.gov/cancertopics/pdq/prevention/cervical/HealthProfessional.**
- Treatment algorithms based on the American Society for Colposcopy and Cervical Pathology 2006 Consensus guidelines for the management of women with CIN—**http://www.asccp.org/ConsensusGuidelines/tabid/7436/Default.aspx.**

REFERENCES

1. Insinga RP, Glass AG, Rush BB. Diagnoses and outcomes in cervical cancer screening: a population-based study. *Am J Obstet Gynecol.* 2004;191:105-113.
2. Spitzer M, Apgar BS, Brotzman GL. Management of histologic abnormalities of the cervix. *Am Fam Physician.* 2006;73:105-112.
3. Schiffman MH, Bauer HM, Hoover RN, et al. Epidemiological evidence showing that human papillomavirus infection causes most cervical intraepithelial neoplasia. *J Natl Cancer Inst.* 1994;85:958-964.
4. National Cancer Institute. *Cervical Cancer Prevention*. http://www.cancer.gov/cancertopics/pdq/prevention/cervical/HealthProfessional. Accessed February 17, 2011.
5. Wright TC Jr, Massad LS, Dunton CJ, et al. 2006 Consensus guidelines for the management of women with cervical intraepithelial neoplasia or adenocarcinoma in situ. *Am J Obstet Gynecol.* 2007;197(4):340-345.
6. Wright TC Jr, Massad LS, Dunton CJ, et al. 2006 Consensus guidelines for the management of women with abnormal cervical cancer screening tests. *Am J Obstet Gynecol.* 2007;197(4):346-355.
7. Hogewoning CJ, Bleeker MC, van den Brule AJ, et al. Condom use promotes regression of cervical intraepithelial neoplasia and clearance of human papillomavirus: a randomized clinical trial. *Int J Cancer.* 2003;107:811-816.
8. Bell MC, Crowley-Nowick P, Bradlow HL, et al. Placebo-controlled trial of indole-3-carbinol in the treatment of CIN. *Gynecol Oncol.* 2000;78(2):123-129.
9. National Institutes of Health-National Cancer Institute. *Cervical Cancer Prevention (PDQ)*. http://www.cancer.gov/cancertopics/pdq/prevention/cervical/HealthProfessional. Accessed March 4, 2012.

91 COLPOSCOPY OF CERVICAL CANCER

E.J. Mayeaux, Jr., MD

PATIENT STORY

A 51-year-old woman presents with postcoital bleeding. She has not had a period in 3 years, but has started spotting after intercourse. Her last Papanicolaou (Pap) smear was after the birth of her last child 25 years ago and was normal. Other than an occasional mild hot flash, she has no other complaints. On colposcopy she was found to have a densely acetowhite lesion with abnormal vessel near the cervical os (**Figure 91-1**). Biopsy demonstrated invasive squamous cell carcinoma. The patient then had a radical hysterectomy with pelvic/paraaortic lymphadenectomy. Fortunately her lymph nodes were all negative.

FIGURE 91-1 Colposcopic view of invasive squamous cell carcinoma. The lesion is densely acetowhite with abnormal vessels on the anterior lip just above the cervical os. (*Courtesy of E.J. Mayeaux, Jr., MD.*)

INTRODUCTION

Colposcopy is an important visualization technique used to investigate abnormal Pap smears and to direct biopsies for histologic diagnosis of cervical cancer. Because human papillomavirus (HPV) is present in 95% to 100% of all squamous cell cancers (SCCs), the International Agency for Research on Cancer proclaimed cervical cancer to be the first human cancer known to have a single necessary cause.[1,2]

EPIDEMIOLOGY

- Carcinoma of the cervix is the second most common cancer in women worldwide with an estimated 400,000 to 500,000 cases of cervical cancer diagnosed each year.[3,4]
- In the United States, an estimated 12,170 new cases and approximately 4220 deaths occur annually, even though more than 50 million Pap smears are performed each year.[5]
- Half of the cases occur in women never screened and an additional 10% in women not screened within the past 5 years.[6]
- Ninety-three percent of invasive cervical cancers are SCCs (**Figures 91-1** to **91-4**). They almost all contain HPV DNA, and 90% are subtypes 16 or 18, which are most virulent.[7]
- Approximately 7% of cases are adenocarcinomas but these are on the rise[7] (**Figure 91-5**).
- It is rare to find invasive cancer of the uterine cervix in pregnancy. The incidence varies from 1 to 15 cases per 10,000 pregnancies, and the prognosis is similar to that of nonpregnant patients.[8]
- The peak prevalence of invasive cervical cancer is 40 to 50 years of age.[9]

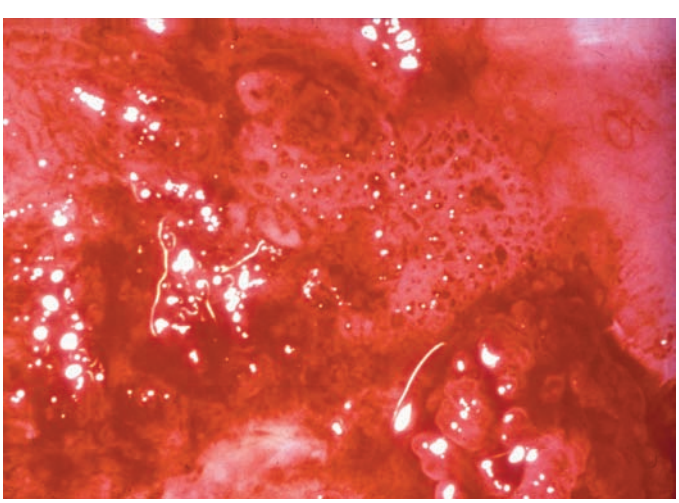

FIGURE 91-2 Colposcopic view of invasive squamous cell cancer with abnormal vessels. (*Courtesy of E.J. Mayeaux, Jr., MD.*)

ETIOLOGY AND PATHOPHYSIOLOGY

- Oncogenic HPV serve as initiators, and other factors relating to immune status, such as cigarette smoking, nutrition, or other genital infections, may be promoters.[10]
- Cervical cancer is unique in that no other human cancer has been shown to have such a clearly identified cause, which are oncogenic strains of HPV.[1]

RISK FACTORS[11]

- HPV infection.
- Nonuse of barrier protection and/or spermicidal gel during sexual intercourse.
- No Pap testing within the last 3 years in low-risk women with a cervix or within 1 year for high-risk women.
- Nonvaccination status for HPV-16 and HPV-18.
- Tobacco smoking.

DIAGNOSIS

CLINICAL FEATURES

- Leukoplakia is typically an elevated, white plaque seen prior to the application of acetic acid. It is caused by a thick keratin layer that obscures the underlying epithelium (**Figure 91-1**). It always warrants a biopsy.
- Early invasion often is associated with a decline in the acetowhite reaction. Yellow hued color change is also a marker for early or frank invasive lesions (**Figure 91-4**).
- With increasing levels of cervical intraepithelial neoplasia (CIN), desmosomes (intracellular bridges) that attach the epithelium to the basement membrane are often lost, producing an edge that easily peels. This loss of tissue integrity should raise the suspicion of high-grade dysplasia. The extreme expression of this effect is the ulceration that sometimes forms with invasive disease. The ulcer can have a rolled edge around the ulcer without vessels visible in the ulcer cavity.
- Nodular elevations and ulceration are suspicious for high-grade or invasive cancer.
- Course punctation and course mosaic patterns may be associated with high-grade dysplasia or cancer (see Chapter 90, Colposcopy of High-Grade Lesions).
- Abnormal blood vessels are atypical irregular surface vessels that have lost their normal arborization or branching pattern (**Figures 91-1** and **91-2**). This represents an exaggeration of the abnormalities of punctation and mosaicism, and it usually represents increasing severity of the lesion. They can be indicative of invasive cancer, but can occasionally be seen with high-grade CIN. These vessels are often best seen before application of acetic acid. They are usually nonbranching, appear with abrupt courses and patterns, and often appear as commas, corkscrews,

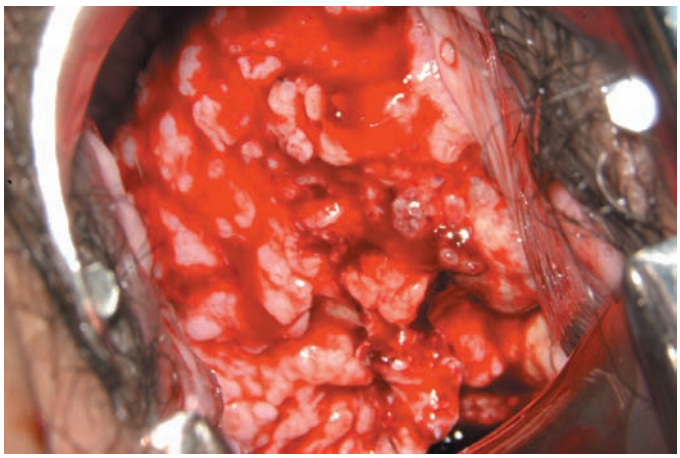

FIGURE 91-3 Colposcopic view of invasive squamous cell cancer. Note how the cancer has replaced the entire surface of the cervix with friable epithelium. (*Courtesy of Daron Ferris, MD.*)

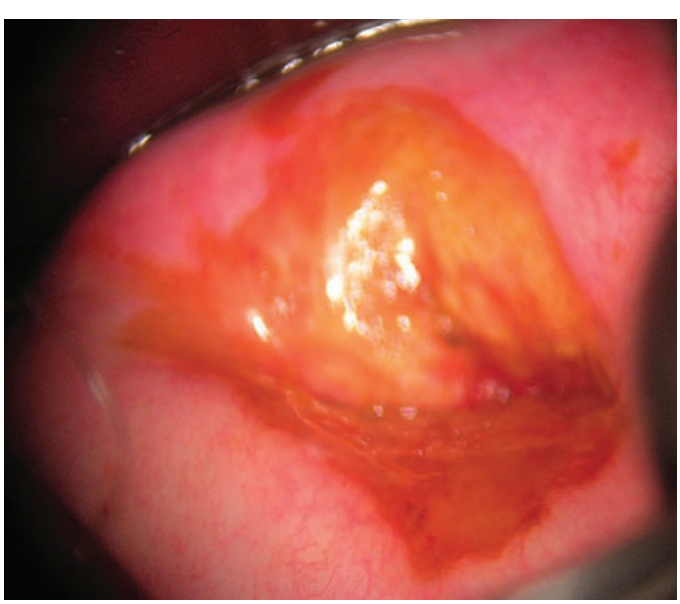

FIGURE 91-4 Colposcopic view of a rarer yellow-hued invasive squamous cell cancer of the cervix. (*Courtesy of E.J. Mayeaux, Jr., MD.*)

hairpins, or spaghetti. They may also appear as coarse parallel vessels. There is no definite repetitive pattern as with punctation or mosaic.

- A thin watery vaginal discharge is the most common early complaint of a woman with cervical cancer. As the lesions progress or enlarge, complaints occur of postcoital bleeding or painless intermenstrual bleeding.
- More advanced lesions present with heavier and frequent bleeding until it may become continuous. Pain, hematuria, obstipation, and rectal bleeding are symptoms of late disease because of local direct invasion of surrounding paracervical structures. Lower-extremity edema may occur with pelvic sidewall involvement of tumor. Hemorrhage and uremia are preterminal events.
- Findings on speculum examination include an exophytic mass (**Figures 91-3** and **91-5**), cervical ulcer, or barrel-shaped cervix.

LABORATORY TESTING

- Although HPV testing is used for screening for cervical cancer, it is not useful in the diagnosis of the disease.

IMAGING

- The staging of biopsy proven cervical cancer remains clinical. Physical examination with cystoscopy and proctoscopy usually starts the process. Routine x-ray studies are also used, including chest x-ray, intravenous pyelogram, and barium enema.

BIOPSY

- Colposcopy and biopsy are needed to make the diagnosis. A histologic biopsy that is suspicious, but not confirmatory, of invasion requires cervical conization for definitive diagnosis. A biopsy of microinvasive carcinoma requires conization for definitive diagnosis and to rule out a more invasive lesion. A biopsy with definitive invasion greater than 5 mm does not require conization to plan therapy. Any frank lesion of the cervix requires biopsy for diagnosis.

FIGURE 91-5 Adenocarcinoma of the cervix. (*Courtesy of E.J. Mayeaux, Jr., MD.*)

DIFFERENTIAL DIAGNOSIS

- Because some cancers of the cervix ulcerate, cervical cancer must be differentiated from nonmalignant ulcerative diseases such as herpes virus infections (see Chapter 129, Herpes Simplex).
- Cervical cancer must be differentiated from CIN II and CIN III lesions (see Chapter 90, Colposcopy of High-Grade Lesions).
- Flat HPV lesions may mimic dense acetowhite lesions or leukoplakia (see Chapter 133, Genital Warts). A colposcopically directed biopsy can distinguish between these conditions.

MANAGEMENT

- **Table 91-1** shows the staging and treatment methods for cervical cancer.

TABLE 91-1 Staging and Treatment of Cervical Cancer*,†

Stage	Description	Treatment	5-Year Survival (%)
0	Carcinoma in situ	Surgical excision or ablation	
I	Tumor is confined to the cervix		91.3
IA	Microinvasive disease with the lesion not grossly visible. No deeper than 5 mm and no wider than 7 mm	Simple hysterectomy or careful observation after cone biopsy (with clear margins)	98.1
IB	Larger tumor than in IA or grossly visible, confined to cervix	Radical hysterectomy with pelvic node dissection or external-beam and intracavitary radiotherapy (equally effective)	88.2
II	Extends beyond the cervix, but does not involve the pelvic sidewall or lowest third of the vagina		60.7
IIA	Involvement of the upper two-thirds of vagina, without lateral extension into the parametrium	Radical hysterectomy with pelvic node dissection or pelvic radiotherapy	67.2
IIB	Lateral extension into parametrial tissue	Pelvic radiotherapy	57.9
III	Involves the lowest third of the vagina or pelvic sidewall or causes hydronephrosis		46.8
IIIA	Involvement of the lowest third of the vagina	Pelvic radiotherapy with or without cisplatin-based therapy	38.6
IIIB	Involvement of pelvic sidewall or hydronephrosis or nonfunctioning kidney	Pelvic radiotherapy with or without cisplatin-based therapy	47.7
IV	Extensive local infiltration or has spread to a distant site		
IVA	Spread of the tumor onto adjacent pelvic organs	Pelvic radiotherapy with cisplatin-based therapy	15.5
IVB	Distant metastases	Chemotherapy with or without pelvic radiotherapy	14.6

*Staging system based on the Federation of International Gynecologists and Obstetricians. *Treatment Option Overview*. http://www.cancer.gov/cancertopics/pdq/treatment/cervical/HealthProfessional/page4#Section_61. Accessed February 18, 2012.
†Survival data based on the SEER Survival Monograph: *Cancer Survival Among Adults: US SEER Program, 1988-2001, Patient and Tumor Characteristics. Chapter 14: Cancer of the Cervix Uteri*. http://seer.cancer.gov/publications/survival/surv_cervix_uteri.pdf.

PREVENTION

- Most cases are detected in the precancerous stages or as early disease in industrialized countries through the use of the Pap test and HPV testing.[12] The current death rate, however, is far higher than it should be because the Pap test and HPV testing are not performed on approximately 33% of eligible women.

PROGNOSIS

- The prognosis for patients with cervical cancer is mostly defined by the extent of disease at the time of diagnosis (see **Table 91-1**).[13] Clinical stage, volume and grade of tumor, histologic type, lymphatic spread, and vascular invasion also affect prognosis. The factors that best predict decreased disease-free survival are depth of stromal invasion, capillary-lymphatic space involvement by tumor, and increased tumor size.

FOLLOW-UP

- Early stage (International Federation of Gynecology and Obstetrics stages IA to IIA) SCC is treated with radical hysterectomy and pelvic/paraaortic lymphadenectomy or radiation therapy. In patients with positive resection margins or positive lymph nodes, postoperative chemotherapy and/or radiotherapy is often used.

- Stages IB2 and IIA disease is treated with either chemoradiotherapy alone, surgery followed by chemoradiotherapy, or chemotherapy and radiotherapy followed by hysterectomy.
- For patients with stages IIB, III, and IVA cervical SCC, chemotherapy plus radiotherapy is usually recommended over radiation therapy alone.

PATIENT EDUCATION

- Fertility-sparing surgery is available for very early stage cervical cancer. Menopausal symptoms are a common side-effect of chemotherapy.

PATIENT RESOURCES

- Oncolink. *Cervical, Vaginal, Vulvar Cancers*—**http://oncolink.org/types/article.cfm?c=6&s=17&ss=129&id=8226.**
- National Cancer Institute. *General Information About Cervical Cancer*—**http://www.cancer.gov/cancertopics/pdq/treatment/cervical/Patient.**
- National Cancer Institute. **What You Need To Know About Cancer of the Cervix**—http://www.cancer.gov/cancertopics/wyntk/cervix.

PROVIDER RESOURCES

- American Society for Colposcopy and Cervical Pathology-sponsored Consensus Conference. *2006 Consensus Guidelines for the Management of Women with Cervical Intraepithelial Neoplasia or Adenocarcinoma in Situ*—**http://www.asccp.org/consensus/histological.shtml.**
- National Cancer Institute. *General Information About Cervical Cancer*—**http://www.cancer.gov/cancertopics/pdq/treatment/cervical/HealthProfessional.**

REFERENCES

1. Tjalma WA, Van Waes TR, Van den Eeden LE, Bogers JJ. Role of human papillomavirus in the carcinogenesis of squamous cell carcinoma and adenocarcinoma of the cervix. *Best Pract Res Clin Obstet Gynaecol.* 2005;19:469-483.
2. Bosch FX, Munoz N. The viral etiology of cervical cancer. *Virus Res.* 2002;89:183-190.
3. Schiffman M, Herrero R, Hildesheim A, et al. HPV DNA testing in cervical cancer screening: results from women in a high-risk province of Costa Rica. *JAMA.* 2000;283(1):87-93.
4. Parkin DM, Bray F. The burden of HPV-related cancers. *Vaccine.* 2006;24(Suppl 3):511-525.
5. American Cancer Society. *Cancer Facts and Figures 2012*. Atlanta, GA: American Cancer Society; 2012. http://www.cancer.org/acs/groups/content/@epidemiologysurveilance/documents/document/acspc-031941.pdf. Accessed February 17, 2012.
6. NIH Consensus Statement Online 1996 April 1-3. http://consensus.nih.gov/1996/1996cervicalcancer102html.htm. Accessed August 25, 2012.
7. Schiffman MH, Bauer HM, Hoover RN, et al. Epidemiological evidence showing that human papillomavirus infection causes most cervical intraepithelial neoplasia. *J Natl Cancer Inst.* 1994;85:958-964.
8. Campion MJ, Sedlacek TV. Colposcopy in pregnancy. *Obstet Gynecol Clin North Am.* 1993;20(1):153-163.
9. Moscicki AB, Schiffman M, Kjaer S, Villa LL. Chapter 5: Updating the natural history of HPV and anogenital cancer. *Vaccine.* 2006;24 Suppl 3:S3/42-51.
10. Berrington DE, Gonzalez A, Green J. Comparison of risk factors for invasive squamous cell carcinoma and adenocarcinoma of the cervix: collaborative reanalysis of individual data on 8,097 women with squamous cell carcinoma and 1,374 women with adenocarcinoma from 12 epidemiological studies. *Int J Cancer.* 2007;120:885.
11. National Cancer Institute. *Cervical Cancer Prevention*. http://www.cancer.gov/cancertopics/pdq/prevention/cervical/HealthProfessional. Accessed February 17, 2011.
12. The 1988 Bethesda System for reporting cervical/vaginal cytological diagnoses. National Cancer Institute Workshop. *JAMA.* 1989;262(7):931-934.
13. Zaino RJ, Ward S, Delgado G, et al. Histopathologic predictors of the behavior of surgically treated stage IB squamous cell carcinoma of the cervix. A Gynecologic Oncology Group study. *Cancer.* 1992;69(7):1750-1758.

SECTION 5 BREAST

92 BREAST ABSCESS AND MASTITIS

E.J. Mayeaux, Jr., MD

PATIENT STORY

A 23-year-old woman, who is currently breastfeeding and 6 weeks postpartum, presents with a hard, red, tender, indurated area medial to her right nipple (**Figure 92-1**). She also has a low-grade fever. Because there is a local area of fluctuance, incision and drainage is recommended. The area is anesthetized with 1% lidocaine and epinephrine and drained with a #11 scalpel. A lot of purulence is expressed and the wound is packed. The patient is started on cephalexin 500 mg qid for 10 days to treat the surrounding cellulitis and seen in follow-up the next day. The patient was already feeling better the next day and went on to full resolution in the following weeks.

FIGURE 92-1 Localized cellulitis and breast abscess in a breastfeeding mother. Note the Peau d' orange appearance of the edematous breast tissue. (*Courtesy of Nicolette Deveneau, MD.*)

INTRODUCTION

Mastitis, defined as an infection of the breast, and breast abscesses are typically found in breastfeeding women (**Figure 92-1**). A breast abscess and mastitis unrelated to pregnancy and breastfeeding can occur in older women (**Figure 92-2**).

EPIDEMIOLOGY

- The prevalence of mastitis is estimated to be 2% to 3% of lactating women.[1]
- Breast abscess is an uncommon problem in breastfeeding women, with an incidence of approximately 0.1%.[2]

ETIOLOGY AND PATHOPHYSIOLOGY

- Mastitis is most commonly caused by *Staphylococcus aureus*, *Streptococcus* species, and *Escherichia coli*.
- Recurrent mastitis can result from poor selection or incomplete use of antibiotic therapy, or failure to resolve underlying lactation management problems. Mastitis that repeatedly recurs in the same location, or does not respond to appropriate therapy, may indicate the presence of breast cancer.[3]

RISK FACTORS

- Risk factors for mastitis include a history of mastitis with a previous child, cracks and nipple sores, use of an antifungal nipple cream in the same month, and use of a manual breast pump.[4]

FIGURE 92-2 Breast abscess and cellulitis in a 40-year-old woman. Pus was already draining at the time of presentation, but a further incision and drainage through the openings yielded another 30 cc of pus. The patient was treated with oral antibiotics and scheduled to get a mammogram when the infection is cleared. (*Courtesy of Richard P. Usatine, MD.*)

- Risk factors for breast abscess include maternal age older than 30 years, primiparity, gestational age of 41 weeks, and mastitis.[2,3] Breast abscess develops in 5% to 11% of women with mastitis, often caused by inadequate therapy.[3]

DIAGNOSIS

CLINICAL FEATURES

- Mastitis causes a hard, red, tender, swollen area on the breast (**Figures 92-1** to **92-3**). Erythema is less visible in darker skin but the swelling is still prominent (**Figure 92-3**).
- Usually unilateral, so the breast size difference can be obvious (**Figure 92-3**).
- Fever is common.
- Pain usually extends beyond the indurated area.
- It is often associated with other systemic complaints, including myalgia, chills, malaise, and flu-like symptoms.
- Breast abscess can occur with mastitis, except a fluctuant mass is palpable. (In **Figure 92-2**, the fluctuant mass is close to the midline with two openings of spontaneous drainage. The remainder of the erythema is the mastitis.)

TYPICAL DISTRIBUTION

- The typical distribution is usually unilateral.

LABORATORY TESTING

- In persistent cases, a mid-stream milk sample may be cultured and antibiotics prescribed based upon the identification and sensitivity of the specific pathogen.

IMAGING

- Ultrasonography may be used to distinguish abscesses from other types of lesions. Abscesses appear as ill-defined masses and have central hypoechoic areas with either septations or low-level internal echoes, and posterior enhancement.[5]

BIOPSY

- Biopsy is needed if a palpable mass remains after the infection is cleared.

DIFFERENTIAL DIAGNOSIS

- Mastitis should be distinguished from plugged lacrimal ducts, which present as hard, locally tender, red areas without associated regional pain or fever.
- Tinea corporis can cause erythema and scaling on any part of the body, including breast. It is often annular and pruritic (see Chapter 138, Tinea Corporis).
- Paget disease of the breast is an intraepithelial neoplasia that may appear as an erythematous patch on the nipple or breast (see Chapter 94, Paget Disease of the Breast).

FIGURE 92-3 Mastitis in a postpartum breastfeeding woman. The right breast was warm, tender, enlarged, and painful. Erythema is barely visible on the areola because of the naturally darker pigmentation of the skin. (*Courtesy of Richard P. Usatine, MD.*)

MANAGEMENT

NONPHARMACOLOGIC

- Management of mastitis includes supportive measures, such as analgesics, warm compresses, and continued breastfeeding. SOR C If the infant cannot relieve breast fullness during nursing, breast massage during nursing or pumping afterwards may help reduce discomfort.
- Frequent breast emptying helps both infectious and noninfectious mastitis.[6] SOR A Breastfeeding may continue on both breasts if the incision isn't too painful and it does not interfere with the baby latching on. Otherwise a breast pump may be used on the affected breast for 3 to 4 days until nursing can resume.

MEDICATIONS

- Acetaminophen or an antiinflammatory agent such as ibuprofen may be used for pain control.
- Antibiotic treatment should be initiated with dicloxacillin or cephalexin (500 mg PO 4 times daily) for 10 to 14 days.[7] SOR A Consider clindamycin if the patient is allergic to penicillin and/or cephalosporins.[7] Clindamycin 600 mg PO q6h may be a good choice if methicillin-resistant *S. aureus* (MRSA) is suspected. All of the antibiotics recommended are safe for the baby during pregnancy and lactation. Trimethoprim-sulfamethoxazole 1 DS tablet bid is an alternative for MRSA and/or penicillin-allergic patients, but it should be avoided near term pregnancy and in the first 2 months of breastfeeding because of a risk to the baby of kernicterus. Shorter courses of antibiotic therapy may be associated with higher relapse rates. SOR C
- For mastitis not associated with breastfeeding, use clindamycin 300 mg PO q6h, or amoxicillin/clavulanate 500 mg PO tid.[8]

COMPLEMENTARY AND ALTERNATIVE THERAPY

- Preliminary data suggests that administration of lactobacilli strains that are naturally occurring in breast milk may be of therapeutic benefit for the management of mastitis during lactation.[9] SOR C

SURGICAL

- The management of a breast abscess consists of drainage of the abscess.[7] SOR A Antibiotic therapy should be considered and is especially important if there is surrounding cellulitis (see **Figures 92-2** and **92-4**).
- Drainage can usually be performed on abscesses smaller than 3 cm by needle aspiration, with the addition of ultrasound guidance if needed. Abscesses larger than 3 cm treated with needle aspiration have a high reoccurrence rate.[10]
- If needle aspiration is not effective, incision and drainage should be performed. Incision and drainage is often preferred because it allows for continued drainage through the opening. In many cases a cotton wick is placed to keep the abscess open while the purulence drains over the following days.

REFERRAL OR HOSPITALIZATION

- Hospitalization and intravenous antibiotics are rarely needed but should be considered if the patient is systemically ill and not able to tolerate oral antibiotics.

FIGURE 92-4 Healing after drainage of an abscess and antibiotics for cellulitis. (*Courtesy of E.J. Mayeaux, Jr., MD.*)

FOLLOW-UP

- If no response is seen within 48 hours or if MRSA is a possibility, antibiotic therapy should be switched to trimethoprim-sulfamethoxazole 1 DS tablet PO bid, or clindamycin 300 mg orally q6h. Avoid trimethoprim-sulfamethoxazole near term pregnancy and in the first 2 months of breastfeeding.

PATIENT EDUCATION

- The patient may take acetaminophen or ibuprofen for pain as these medications are safe while breastfeeding and are indicated for use in children.
- Warm compresses applied before and after feedings can provide some pain relief. A warm bath may also help.
- Instruct the patient to finish the antibiotic prescription, even if the patient feels better in a few days, to lower the risk of bacterial resistance or relapse.
- Continue feedings and, if necessary, use a breast pump to completely empty the breast.
- Educate the parents that the mastitis or the antibiotics will not harm the baby, and that the source of the infection was probably the baby's own mouth.
- Continue to drink plenty of water and eat well-balanced meals.

PATIENT RESOURCES

- MedlinePlus. *Breast Infection*—**http://www.nlm.nih.gov/medlineplus/ency/article/001490.htm.**
- PubMed Health, *Breast Infection*—**http://www.ncbi.nlm.nih.gov/pubmedhealth/PMH0002460/.**

PROVIDER RESOURCES

- Medscape. *Breast Abscess and Masses*—**http://www.emedicine.com/EMERG/topic68.htm.**
- Andolsek KM, Copeland JA. Benign breast conditions and disease: mastitis. In: Tayor RB, ed. *Family Medicine Principles and Practice*, 6th ed. New York: Springer; 2003:898.

REFERENCES

1. Mass S. Breast pain: Engorgement, nipple pain and mastitis. *Clin Obstet Gynecol.* 2004;47(3):676-682.
2. Kvist LJ, Rydhstroem H. Factors related to breast abscess after delivery: a population-based study. *BJOG.* 2005;112:1070.
3. Berens PD. Prenatal, intrapartum, and postpartum support of the lactating mother. *Pediatr Clin North Am.* 2001;48:365.
4. Foxman B, D'Arcy H, Gillespie B, et al. Lactation mastitis: occurrence and medical management among 946 breastfeeding women in the united states. *Am J Epidemiol.* 2002;155:103.
5. Muttarak M, Chaiwun B. Imaging of giant breast masses with pathological correlation. *Singapore Med J.* 2004;45(3):132-139.

6. Cabou A, Babineau S, St Anna L. Clinical inquiry: what's the best way to relieve mastitis in breastfeeding mothers? *J Fam Pract.* 2011;60(9):551-552.
7. Stevens DL, Bisno AL, Chambers HF, et al. Practice guidelines for the diagnosis and management of skin and soft-tissue infections. *Clin Infect Dis.* 2005;41:1373-1406.
8. Barbosa-Cesnik C, Schwartz K, Foxman B. Lactation mastitis. *JAMA.* 2003;289(13):1609-1612.
9. Arroyo R, Martín V, Maldonado A, et al. Treatment of infectious mastitis during lactation: antibiotics versus oral administration of lactobacilli isolated from breast milk. *Clin Infect Dis.* 2010;50(12):1551-1558.
10. Ozseker B, Ozcan UA, Rasa K, Cizmeli OM. Treatment of breast abscesses with ultrasound-guided aspiration and irrigation in the emergency setting. *Emerg Radiol.* 2008;15(2):105-108.

93 BREAST CANCER

E.J. Mayeaux, Jr., MD

PATIENT STORY

A 55-year-old woman presents for routine screening mammogram. The patient does not have any complaints but has a family history of breast cancer in a sister at age of 40 years. Her mammogram demonstrates an irregular mass with possible local spread (**Figures 93-1** and **93-2**). She is referred to a breast surgeon and the biopsy confirms the diagnosis of breast cancer.

INTRODUCTION

Breast cancer is a major health concern for all women. It is the most common female cancer in the United States, and the second most common cause of cancer death in women after lung cancer.[1]

EPIDEMIOLOGY

- In 2007, approximately 178,000 women in the United States were diagnosed with breast cancer.[1] Breast cancer incidence in the United States has doubled over the past 60 years. Since the early 1980s, most of the increase has been in early stage and in situ cancers because of mammogram screening (**Figures 93-1** to **93-4**).
- Approximately 232,620 new cases of invasive breast cancer were expected to be diagnosed in the United States in 2011, and 39,970 were expected to die from the disease.[1]
- Globally, breast cancer is the most common cancer, and the leading cause of cancer death in females. Breast cancer incidence rates are highest in North America, Australia-New Zealand, and Europe, and lowest in Asia and sub-Saharan Africa.[2]
- Locally advanced breast cancer (LABC) has been decreasing in frequency over the past several decades, at least partially as a result of earlier diagnosis because of better screening (**Figures 93-5** to **93-8**). It represents 30% to 50% of newly diagnosed breast cancers in medically underserved populations.[3]
- Primary inflammatory breast cancer (IBC) is relatively rare, accounting for 0.5% to 2% invasive breast cancers.[4] However, it accounts for a greater proportion of cases presenting with more advanced disease. IBC is a clinical diagnosis. At presentation, almost all women with primary IBC have lymph node involvement and approximately one third have distant metastases.[5]

ETIOLOGY AND PATHOPHYSIOLOGY

- The incidence of breast cancer increases with age. White women are more likely to develop breast cancer than black women. One percent of breast cancers occur in men.

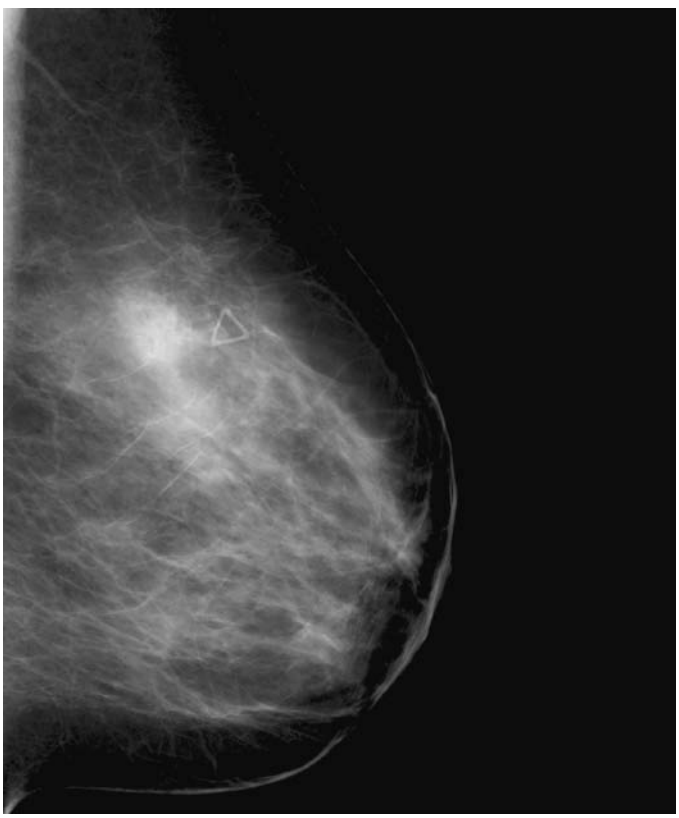

FIGURE 93-1 A mammogram that demonstrates an irregular mass with possible local spread. (*Courtesy of John Braud, MD.*)

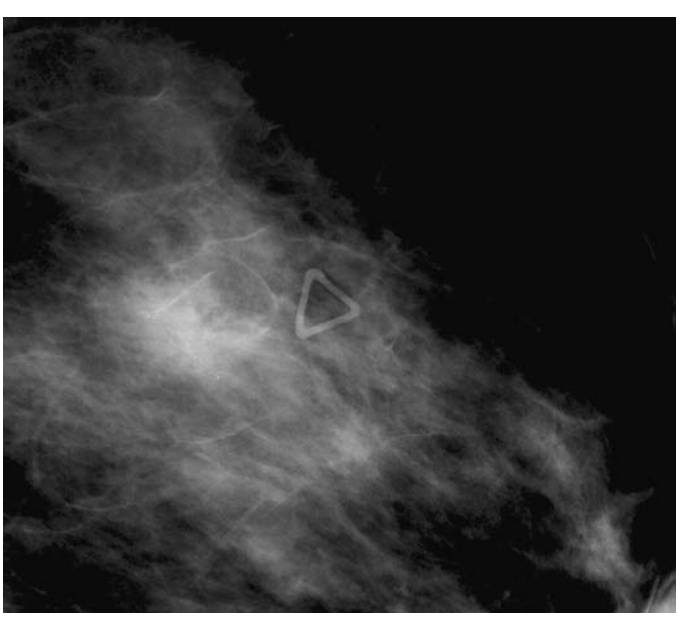

FIGURE 93-2 A close-up view of the lesion shown in **Figure 93-1**. (*Courtesy of John Braud, MD.*)

- Primary risk factors for the development of breast cancer include age older than 50 years, female sex, increased exposure to estrogen (including early menarche and late menopause), and a family history in a first-degree maternal relative (especially if diagnosed premenopausally.).
- Approximately 8% of breast cancers are hereditary and of these one-half are associated with mutations in genes BRCA1 and BRCA2. It is more common in premenopausal women, multiple family generations, and bilateral breasts.[6] Typically, several family members are affected over at least three generations and can include women from the paternal side of the family.
- A history of a proliferative breast abnormality, such as atypical hyperplasia, may increase a woman's risk for developing breast cancer.
- The selective estrogen receptor modulator tamoxifen (and possibly raloxifene) reduces the risk of developing breast cancer.
- The American Cancer Society, American College of Radiology, American Medical Association, and American College of Obstetrics and Gynecology all recommend starting routine screening at age 40 years.[7]
- The United States Preventive Services Task Force and the 2002 statement by the American Academy of Family Physicians recommend screening mammography every 1 to 2 years for women ages 40 years and older.[8]
- Women who have a family history of BRCA mutation should begin annual mammography between 25 and 35 years of age.[9] SOR A
- MRI screening is more sensitive for detecting breast cancers than mammography and is being used to screen women with BRCA mutations.[10] It is not proven that surveillance regimens that include MRI will reduce mortality from breast cancer in high-risk women.[10]
- Although the sensitivity of MRI is higher than that of conventional imaging, MRI has a lower specificity. One study suggests that unnecessary biopsies can be avoided with second-look ultrasound when MRI is positive and mammography is not. Second-look ultrasound can be used to recognize false-positive MRI results and guide biopsies.[11]

RISK FACTORS

- Positive family history of breast and/or ovarian cancer (especially with BRCA mutations).
- Personal history of breast cancer.
- Increasing age in women.
- Early age at menarche and late menopause.
- Prolonged exposure to and higher concentrations of endogenous or exogenous estrogen.
- Exposure to ionizing radiation.
- Dense breast tissue and atypical hyperplasia.
- Women who have had no children or who had their first child after age 30 have a slightly higher breast cancer risk.
- Low physical activity levels.
- High-fat diet.
- Alcohol intake of two or more drinks daily.

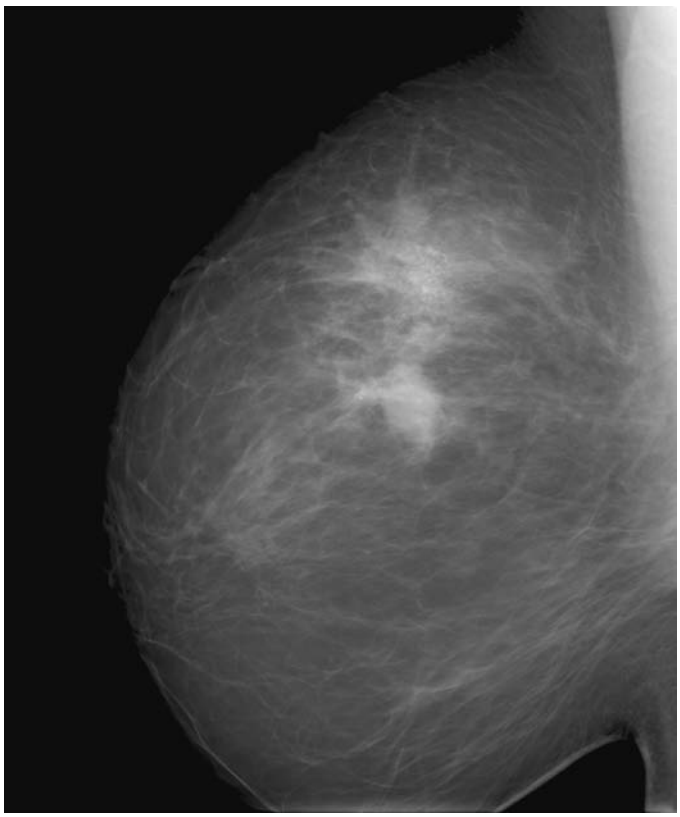

FIGURE 93-3 A screening mammogram of a 55-year-old woman who is without breast complaints. The mammogram demonstrates a significant mass with spiculations. (*Courtesy of John Braud, MD.*)

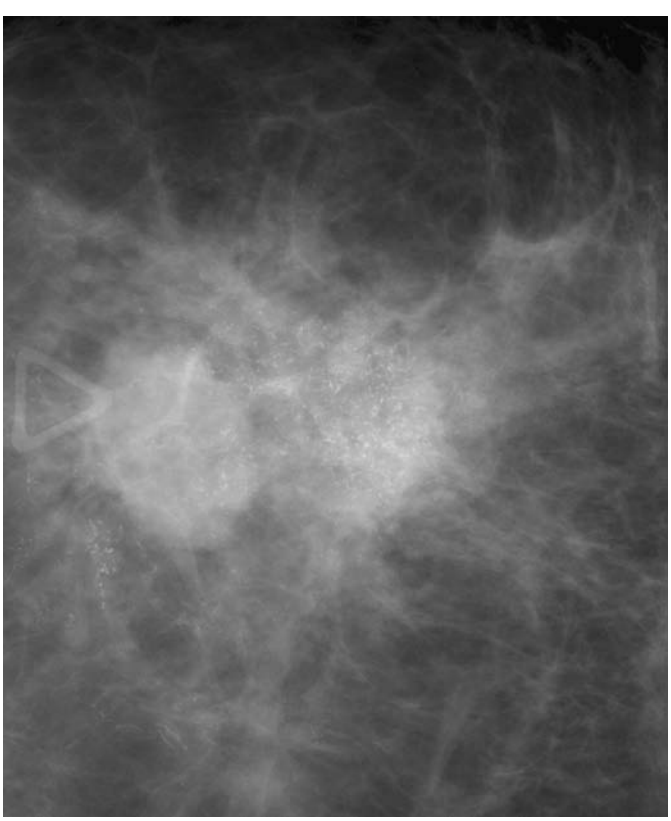

FIGURE 93-4 Close-up view of the mass shown in **Figure 93-3** demonstrating clear spiculations and microcalcifications. (*Courtesy of John Braud, MD.*)

DIAGNOSIS

CLINICAL FEATURES

- Detection of a breast mass is the most common presenting breast complaint. However, 90% of all breast masses are caused by benign lesions. Breast pain is also a common presenting problem. Physical examination of the breast should be performed in the upright (sitting) and supine positions. Inspect for differences in size, retraction of the skin or nipple (**Figures 93-5** and **93-6**), prominent venous patterns, and signs of inflammation (**Figures 93-5** and **93-6**). Palpate the breast tissue, axillary area, and supraclavicular areas for masses or adenopathy. Gently squeeze the nipple to check for discharge.
- Most LABCs are both palpable and visible (**Figures 93-7** and **93-8**). Careful palpation of the skin, breasts, and regional lymph nodes is the initial step in diagnosis. The patient in **Figure 93-8** had five palpable lymph nodes at the time of presentation.
- IBC usually presents clinically as a diffuse brawny induration of the skin of the breast with an erythematous edge, and usually without an underlying palpable mass. Patients with de novo IBC typically present with pain and a rapidly enlarging breast. The skin over the breast is warm, and thickened, with a "peau d'orange" (skin of an orange) appearance (**Figures 93-5** and **93-6**). The skin color can range from a pink flushed discoloration to a purplish hue.

TYPICAL DISTRIBUTION

- A mass that is suspicious for breast cancer is usually solitary, discrete, hard, unilateral, and nontender. It may be fixed to the skin or the chest wall.

IMAGING

- More than 90% of breast cancers are identified mammographically.[12] When an abnormality is found, supplemental mammographic views and possibly ultrasound are usually done. Diagnostic mammography is associated with higher sensitivity but lower specificity as compared to screening mammography.[13]

BIOPSY

- Fine-needle aspiration biopsy generally uses a 20- to 23-gauge needle to obtain samples from a solid mass for cytology. Ultrasound or stereotactic guidance is used to assist in collecting a fine-needle aspiration from a nonpalpable lump. Core biopsy uses a 14-gauge or similar needle to remove cores of tissue from a mass. Excisional biopsy is done as the initial procedure or when needle biopsies are negative when the clinical suspicion is high. Guided biopsy and nonguided biopsy are also commonly used to make a definitive diagnosis.

DIFFERENTIAL DIAGNOSIS

- Fibroadenoma usually present as smooth, rounded, rubbery masses in women in their 20s and 30s. A clinically suspicious mass should be biopsied even if mammography findings are normal.
- Benign cysts are rubbery and hollow feeling in women in their 30s and 40s. A cyst can be diagnosed by ultrasound imaging. A simple

FIGURE 93-5 Woman with advanced breast cancer and peau d'orange sign. The skin looks like the skin of an orange as a consequence of lymphedema. (*Courtesy of Richard P. Usatine, MD.*)

FIGURE 93-6 The patient in **Figure 93-5** showing breast retraction and brawny edema of the breast and arm. (*Courtesy of Richard P. Usatine, MD.*)

cyst can be aspirated, but a residual mass requires further evaluation. Ultrasound is useful to differentiate between solid and cystic breast masses, especially in young women with dense breast tissue.

- Bilateral mastalgia is rarely associated with breast cancer, but it does not eliminate the possibility. It is usually related to fibrocystic changes in premenopausal women that are associated with diffuse lumpy breasts. A unilateral breast lump with pain must be evaluated for breast cancer.
- Nipple discharge may be from infection which is usually purulent, and from pregnancy, stimulation, or prolactinoma which produces a thin, milky, often bilateral discharge. A pregnancy test may be helpful. A suspicious discharge from a single duct can be evaluated with a ductogram.
- Infectious mastitis and breast abscess, which typically occur in lactating women, appear similar to IBC but are generally associated with fever and leukocytosis (see Chapter 92, Breast Abscess and Mastitis).
- Ductal ectasia with inflammation appears similar but is usually localized.
- Leukemic involvement of the breast may mimic IBC, but the peripheral blood smear is typically diagnostic.

FIGURE 93-7 Advanced breast cancer with fungating mass and distortion of the normal breast anatomy. (*Courtesy of Kristen Sorensen, MD.*)

MANAGEMENT

NONPHARMACOLOGIC

- Surgical resection is required in all patients with invasive breast cancer. Oncologic outcomes are similar with mastectomy and breast conserving therapy (lumpectomy plus breast radiation therapy) in appropriately selected patients. For women undergoing mastectomy, breast reconstruction may be performed at the same time as the initial breast cancer surgery, or deferred to a later date.[14] SOR A
- Long-term survival can be achieved in approximately 50% of women with LABC who are treated with a multimodality approach.[15] Prognostic factors include age, menopausal status, tumor stage and histologic grade, clinical response to neoadjuvant therapy, and estrogen receptor status.
- In general, women with IBC are approached similarly to those with noninflammatory LABC except that breast conservation therapy is generally considered inappropriate for these women.[16] SOR A

MEDICATIONS

- Adjuvant systemic therapy consists of administration of hormone therapy, chemotherapy, and/or trastuzumab (a humanized monoclonal antibody directed against HER-2/neu) after definitive local therapy for breast cancer. It benefits most women with early stage breast cancer, but the magnitude of benefit is greatest for those with node-positive disease.[17] SOR A
- The most common approach for advanced breast cancer is preoperative chemotherapy followed by surgery and radiotherapy. Questions regarding sequencing and choice of specific chemotherapy regimens and extent of surgery (including the utility of the sentinel node biopsy) persist. SOR A

FIGURE 93-8 Ethiopian woman with breast cancer and five enlarged firm left axillary lymph nodes. Note the breast asymmetry and the peau d'orange skin on the left breast. The dark black area was caused by a "traditional healer" who burned the skin. Unfortunately the woman could not afford to get care at the local hospital, making her prognosis very grave. (*Courtesy of Richard P. Usatine, MD.*)

- Preoperative (as opposed to postoperative) chemotherapy has several advantages for advanced breast cancer (**Figure 93-7**) treatment. It can reduce the size of the primary tumor, thus allowing for breast conserving surgery, permits assessing an identified mass to determine the sensitivity of the tumor cells to drugs with discontinuation of ineffective therapy (thus avoiding unnecessary toxicity), and enables drug delivery through an intact tumor vasculature.[18] SOR A
- Tamoxifen and aromatase inhibitors may be used in selective patients as neoadjuvant hormone therapy of decrease overall tumor volume. SOR A

REFERRAL OR HOSPITALIZATION

- With the emergence of breast-conserving therapy (BCT), many women now have the option of preserving a cosmetically acceptable breast without sacrificing survival for early stage invasive breast cancer.

PREVENTION

- Healthy lifestyle choices can decrease the risk of breast cancer, including a low-fat diet, regular exercise, and no more than one drink daily.
- Having children before age 30 years and prolonged breastfeeding may be of help in primary prevention, but will not be a commonly used strategy for most women.
- Secondary prevention involves screening for breast cancer with physical exams and mammography. There is a strong consensus based on consistent findings from multiple randomized trials that routine screening mammography should be offered to women ages 50 to 69 years. Consensus is less strong for routine screening among women ages 40 to 49 years, women older than age 70 years, or for how frequently to screen.
  - The American Cancer Society,[19] the National Cancer Institute,[20] the American College of Obstetricians and Gynecologists,[21] and the National Comprehensive Cancer Network[22] recommend starting routine screening at age 40 years.
  - The United States Preventive Services Task Force (USPSTF)[23] and the Canadian Task Force on the Periodic Health Examination[24] recommend beginning routine screening at age 50 years.
- Prophylactic mastectomy is an effective and accepted method by some BRCA-positive women after childbearing when their risk of lifetime breast cancer without this intervention is high (e.g., over 60%).
- Chemoprevention with tamoxifen or raloxifene is an option for women who are high risk for breast cancer.

FOLLOW-UP

- Regular follow-up will usually be maintained during treatment. After treatment, life-long regular follow-up for surveillance should be maintained. Metastases can present in many ways including difficulty breathing, back pain, or a new skin nodule (**Figure 93-9**). These complaints should be taken seriously and worked up carefully in any patient with a history of breast cancer.

FIGURE 93-9 Metastatic breast cancer with firm palpable nodules on the back. (*Courtesy of Richard P. Usatine, MD.*)

PATIENT EDUCATION

- The contralateral breast is at increased risk of breast cancer and should be monitored. Patients on tamoxifen should be monitored for endometrial hyperplasia or cancer.

PATIENT RESOURCES

- Breast cancer support group for survivors—**http://bcsupport.org/.**
- Breastcancer.org—**http://www.breastcancer.org/.**

PROVIDER RESOURCES

- American Academy of Family Physicians. *Breast Cancer*—**http://www.aafp.org/online/en/home/clinical/exam/breastcancer.html.**
- U.S. Preventive Services Task Force. *Screening for Breast Cancer*—**http://www.uspreventiveservicestaskforce.org/uspstf/uspsbrca.htm.**
- National Cancer Institute. *Breast Cancer*—**http://www.cancer.gov/cancertopics/types/breast.**

REFERENCES

1. Siegel R, Ward E, Brawley O, Jemal A. Cancer statistics, 2011: the impact of eliminating socioeconomic and racial disparities on premature cancer deaths. *CA Cancer J Clin.* 2011;61(4):212-236.
2. Jemal A, Bray F, Center MM, et al. Global cancer statistics. *CA Cancer J Clin.* 2011;61(2):69-90.
3. Hortobagyi GN, Sinigletary SE, Strom EA. Treatment of locally advanced and inflammatory breast cancer. In: Harris JR, Lippman ME, Morrow M, Osborne CK, eds. *Diseases of the Breast*, 2nd ed. Philadelphia: Lippincott Williams & Wilkins; 2000:645-660.
4. Hance KW, Anderson WF, Devesa SS, et al. Trends in inflammatory breast carcinoma incidence and survival: The surveillance, epidemiology, and end results program at the national cancer institute. *J Natl Cancer Inst.* 2005;97(13):966-975.
5. Kleer CG, van Golen KL, Merajver SD. Molecular biology of breast cancer metastasis: inflammatory breast cancer: Clinical syndrome and molecular determinants. *Breast Cancer Res.* 2000; 2(6):423-429.
6. Krainer M, Silva-Arrieta S, FitzGerald MG, et al. Differential contributions of BRCA1 and BRCA2 to early-onset breast cancer. *N Engl J Med.* 1997;336(20):1416-1421.
7. Smith RA, Saslow D, Sawyer KA, et al. American Cancer Society guidelines for breast cancer screening: update 2003. *CA Cancer J Clin.* 2003;53(3):141-169.
8. U.S. Preventive Services Task Force. *Guide to Clinical Preventive Services*, 3rd ed. http://www.ahrq.gov/clinic/uspstfix.htm. Accessed February 24, 2012.
9. Burke W, Daly M, Garber J, et al. Recommendations for follow-up care of individuals with an inherited predisposition to cancer. II. BRCA1 and BRCA2. *JAMA.* 1997;277(12):997-1003.
10. Warner E, Plewes DB, Hill KA, et al. Surveillance of BRCA1 and BRCA2 mutation carriers with magnetic resonance imaging, ultrasound, mammography, and clinical breast examination. *JAMA.* 2004;292(11):1317-1325.
11. Trecate G, Vergnaghi D, Manoukian S, et al. MRI in the early detection of breast cancer in women with high genetic risk. *Tumori.* 2006;92(6):517-523.
12. Smart CR, Hartmann WH, Beahrs OH, Garfinkel L. Insights into breast cancer screening of younger women. Evidence from the 14-year follow-up of the Breast Cancer Detection Demonstration Project. *Cancer.* 1993;72(4 Suppl):1449-1456.
13. Barlow WE, Lehman CD, Zheng Y, et al. Performance of diagnostic mammography for women with signs or symptoms of breast cancer. *J Natl Cancer Inst.* 2002;94(15):1151-1159.
14. Vandeweyer E, Hertens D, Nogaret JM, Deraemaecker R. Immediate breast reconstruction with saline-filled implants: No interference with the oncologic outcome? *Plast Reconstr Surg.* 2001; 107(6):1409-1412.
15. Brito RA, Valero V, Buzdar AU, et al. Long-term results of combined-modality therapy for locally advanced breast cancer with ipsilateral supraclavicular metastases: The University of Texas M.D. Anderson Cancer Center experience. *J Clin Oncol.* 2001; 19(3):628-633.
16. Lyman GH, Giuliano AE, Somerfield MR, et al. American Society of Clinical Oncology. American Society of Clinical Oncology guideline recommendations for sentinel lymph node biopsy in early-stage breast cancer. *J Clin Oncol.* 2005;23(30):7703-7720.
17. Goldhirsch A, Glick JH, Gelber RD, et al. Meeting highlights: international expert consensus on the primary therapy of early breast cancer 2005. *Ann Oncol.* 2005;16(10):1569-1583.
18. Fisher B, Gunduz N, Saffer EA. Influence of the interval between primary tumor removal and chemotherapy on kinetics and growth of metastases. *Cancer Res.* 1983;43(4):1488-1492.
19. Smith RA, Cokkinides V, Brawley OW. Cancer screening in the United States, 2009: a review of current American Cancer Society guidelines and issues in cancer screening. *CA Cancer J Clin.* 2009;59(1):27-41.
20. National Cancer Institute. *Breast Cancer Screening (PDQ).* http://www.cancer.gov/cancertopics/pdq/screening/breast/HealthProfessional/page2. Accessed February 24, 2012.
21. American College of Obstetricians-Gynecologists. Practice bulletin no. 122: breast cancer screening. *Obstet Gynecol.* 2011; 118(2 Pt 1):372-382.
22. Bevers TB, Anderson BO, Bonaccio E, et al. National Comprehensive Cancer Network. NCCN clinical practice guidelines in oncology: breast cancer screening and diagnosis. *J Natl Compr Canc Netw.* 2009;7(10):1060-1096.
23. US Preventive Services Task Force. Screening for breast cancer: U.S. Preventive Services Task Force recommendation statement. *Ann Intern Med.* 2009;151(10):716-726, W-236.
24. Canadian Task Force on the Periodic Health Examination. *Screening for Breast Cancer.* http://www.canadiantaskforce.ca/recommendations/2011_01_eng.html. Accessed February 24, 2012.

94 PAGET DISEASE OF THE BREAST

E.J. Mayeaux, Jr., MD

PATIENT STORY

A 62-year-old woman presents with a 6-month history of an eczematous, scaly, rash near her nipple. It is mildly pruritic. On physical examination, the nipple and the areola are involved (**Figure 94-1**). Also, a hard mass is present in the lateral lower quadrant of the same breast. A 4-mm punch biopsy of the affected area including the nipple demonstrates Paget disease. The mammogram is suspicious for breast cancer at the site of the mass and the patient is referred to a breast surgeon.

FIGURE 94-1 Paget disease of the breast of a 62-year-old woman that presented as a persistent eczematous lesion. (*Courtesy of the University of Texas Health Sciences Center, Division of Dermatology.*)

INTRODUCTION

Paget disease of the breast is a low-grade malignancy of the breast that is often associated with other malignancies. It is an important consideration when working up a chronic persistent abnormality of the nipple.

SYNONYMS

Paget's disease, Mammary Paget disease.

EPIDEMIOLOGY

- The incidence of Paget disease of the breast is approximately 0.6% in women in the United States, according to National Cancer Institute Surveillance, Epidemiology, and End Results (SEER) data.[1] Paget disease, like all breast cancers, is rare in men.
- The peak incidence is between 50 and 60 years of age.[2]
- It is associated with underlying in situ and/or invasive breast cancer 85% to 88% of the time.[3]

ETIOLOGY AND PATHOPHYSIOLOGY

- Most patients delay presentation, assuming the abnormality is a benign condition of some sort. The median duration of signs and symptoms prior to diagnosis is 6 to 8 months.[2]
- Presenting symptoms are sometimes limited to persistent pain, burning, and/or pruritus of the nipple (**Figures 94-1** and **94-2**).
- A palpable breast mass is present in 50% of cases, but is often located more than 2 cm from the nipple–areolar complex.[4]
- Twenty percent of cases will have a mammographic abnormality without a palpable mass, and 25% of cases will have neither a mass nor abnormal mammogram, but will have an occult ductal carcinoma.

FIGURE 94-2 Close-up of Paget disease of the breast. Note the erythematous, eczematous, scaly appearance of the lesion. (*Courtesy of the University of Texas Health Sciences Center, Division of Dermatology.*)

- In less than 5% of cases, Paget disease of the breast is an isolated finding.[4]
- There are two theories regarding the pathogenesis of Paget disease of the breast, the choice of which affects treatment choices.
  - The more widely accepted epidermotropic theory proposes that the Paget cells arise from an underlying mammary adenocarcinoma that migrates through the ductal system of the breast to the skin of the nipple. It is supported by the fact that Paget disease is usually associated with an underlying ductal carcinoma, and both Paget cells and mammary ductal cells usually express similar immunochemical staining patterns and molecular markers. This could mean that there is a common genetic alteration and/or a common progenitor cell for both Paget cells and the underlying ductal carcinoma.
  - The less widely accepted transformation theory proposes that epidermal cells in the nipple transform into malignant Paget cells, and that Paget disease of the breast represents an independent epidermal carcinoma in situ. It is supported by the fact that there is no parenchymal cancer identified in a small percentage of cases, and underlying breast carcinomas are often located at some distance to the nipple. Most pathologists disagree with the transformation theory.

FIGURE 94-3 Paget disease of the breast of a 29-year-old woman that presented as a persistent eczematous lesion for 8 months prior to biopsy. The patient did not have a palpable breast mass. (*Courtesy of Richard P. Usatine, MD.*)

DIAGNOSIS

CLINICAL FEATURES

- Paget disease of the breast presents clinically in the nipple–areolar complex as a dermatitis that may be erythematous, eczematous, scaly, raw, vesicular, or ulcerated (**Figures 94-1** to **94-4**). The nipple is usually initially involved, and the lesion then spreads to the areola. Spontaneous improvement or healing of the nipple dermatitis can occur and should not be taken as an indication that Paget disease is not present. The diagnosis is made by finding malignant, intraepithelial adenocarcinoma cells on pathology. Rarely, nipple retraction is found.
- Pain, burning, and/or pruritus may be present or even precede clinically apparent disease develops on the skin.

TYPICAL DISTRIBUTION

- Paget disease of the breast is almost always unilateral, although bilateral cases have been reported.
- Work-up must also be directed toward identifying any underlying breast cancer.

LABORATORY TESTING

- The diagnosis is made by finding intraepithelial adenocarcinoma cells (Paget cells) either singly or in small groups within the epidermis of the nipple complex.

IMAGING

- Bilateral mammography is mandatory to asses for associated cancers. MRI may disclose occult cancer in some women with Paget disease of the breast and normal mammography and/or physical examination.[5]

FIGURE 94-4 Close-up of Paget disease of the breast in the young woman in Figure 94-3. Note the erythematous, scaly, and ulcerated appearance of the lesion. (*Courtesy of Richard P. Usatine, MD.*)

BIOPSY

- The diagnosis is usually made by full-thickness punch or wedge biopsy that shows Paget cells. Nipple scrape cytology can diagnose Paget disease and may be considered for screening eczematous lesion of the nipple.

DIFFERENTIAL DIAGNOSIS

- Eczema of the areola is the most common cause of scaling of the breast (**Figure 94-5**). If the patient (**Figure 94-5**) had new nipple inversion with the onset of skin changes, this would be more suspicious for Paget disease.
- Bowen disease is squamous cell carcinoma in situ and can differentiate from Paget disease by histology. Also, Bowen disease expresses high-molecular-weight keratins, whereas Paget disease expresses low-molecular-weight keratins (see Chapter 166, Actinic Keratosis and Bowen Disease and Chapter 171, Squamous Cell Carcinoma).
- Superficial spreading malignant melanoma may be confused with Paget disease but histologic study and immunohistochemical staining can separate the two (**Figure 94-6**) (see Chapter 172, Melanoma).
- Seborrheic keratoses and benign lichenoid keratoses can occur on and around the areola and be suspicious for Paget disease (**Figure 94-7**). A biopsy is the best way to make the diagnosis (see Chapter 158, Seborrheic Keratosis).
- Nipple adenoma, which usually presents as an isolated mass with redness, can be diagnosed with biopsy.

MANAGEMENT

SURGICAL

- The treatment and prognosis of Paget disease of the breast is first based on the stage of any underlying breast cancer. Simple mastectomy has traditionally been the standard treatment for isolated Paget disease of the breast, but breast-conserving treatment is being used more often. Breast-conserving surgery combined with breast irradiation is gaining wider acceptance. The surgically conservative approaches include excision of the complete nipple–areolar complex with margin evaluation. Sentinel lymph node biopsy should be performed to evaluate axillary lymph node status.[6] SOR B

PROGNOSIS

- Patients with only noninvasive Paget disease of the nipple have excellent cancer outcome with conservative surgery, with survival rates similar to those achieved with mastectomy.[7,8] SOR B The prognosis of Paget disease with synchronous cancer is dependent upon the tumor stage of the underlying cancer.

PATIENT EDUCATION

- All lesions of the breast that do not heal should be checked for cancer.

FIGURE 94-5 Eczema of the areola in a 43-year-old woman who has had an inverted nipple her whole adult life. She remembers having difficulty breastfeeding her children. The current eczema has been present on the areola on and off for more than 10 years and always responds to topical corticosteroids. Breast examination and mammography are negative. (*Courtesy of Richard P. Usatine, MD.*)

FIGURE 94-6 Superficial spreading melanoma adjacent to the areola. (*Courtesy of the University of Texas Health Sciences Center, Division of Dermatology.*)

- The patient's prognosis is based on the underlying cancer, if present, not the Paget disease itself.

PATIENT RESOURCES

- Breastcancer.org. *Paget Disease of the Nipple*—**www.breastcancer.org/symptoms/types/pagets/.**
- Imaginis. *Paget Disease of the Nipple*—**http://imaginis.com/breasthealth/pagets_disease.asp.**
- Macmillan Cancer Support. *Paget Disease of the Breast*—**http://www.macmillan.org.uk/Cancerinformation/Cancertypes/Breast/Aboutbreastcancer/Typesandrelatedconditions/Pagetsdisease.aspx.**

PROVIDER RESOURCES

- Medscape. *Mammary Paget Disease*—**http://emedicine.medscape.com/article/1101235-overview.**
- National Cancer Institute. *Paget Disease of the Nipple*—**http://www.cancer.gov/cancertopics/factsheet/Sites-Types/pagets-breast.**

FIGURE 94-7 Benign lichenoid keratosis on the areola proven by biopsy. (*Courtesy of Richard P. Usatine, MD.*)

REFERENCES

1. SEER Brest Cancer. *Cancer Statistics Review 1975-2008. Table 4.1. Cancer of the Female Breast (Invasive).* http://seer.cancer.gov/csr/1975_2008/results_merged/sect_04_breast.pdf. Accessed January 7, 2012.
2. Chaudary MA, Millis RR, Lane EB, Miller NA. Paget's disease of the nipple: a ten year review including clinical, pathological, and immunohistochemical findings. *Breast Cancer Res Treat.* 1986;8(2):139-146.
3. Chen CY, Sun LM, Anderson BO. Paget disease of the breast: changing patterns of incidence, clinical presentation, and treatment in the U.S. *Cancer.* 2006;107(7):1448-1458.
4. Ashikari R, Park K, Huvos AG, Urban JA. Paget's disease of the breast. *Cancer.* 1970;26(3):680-685.
5. Morrogh M, Morris EA, Liberman L, et al. MRI identifies otherwise occult disease in select patients with Paget disease of the nipple. *J Am Coll Surg.* 2008;206(2):316-321.
6. Caliskan M, Gatti G, Sosnovskikh I, et al. Paget's disease of the breast: the experience of the European institute of oncology and review of the literature. *Breast Cancer Res Treat.* 2008;112(3):513-521. http://www.springerlink.com/content/6270v27346461v08/. Accessed February 25, 2008.
7. Marshall JK, Griffith KA, Haffty BG, et al. Conservative management of Paget disease of the breast with radiotherapy: 10- and 15-year results. *Cancer.* 2003;97(9):2142-2149.
8. Pezzi CM, Kukora JS, Audet IM, et al. Breast conservation surgery using nipple-areolar resection for central breast cancers. *Arch Surg.* 2004;139(1):32-37.

PART 12

MUSCULOSKELETAL PROBLEMS

Strength of Recommendation (SOR)	Definition
A	Recommendation based on consistent and good-quality patient-oriented evidence.*
B	Recommendation based on inconsistent or limited-quality patient-oriented evidence.*
C	Recommendation based on consensus, usual practice, opinion, disease-oriented evidence, or case series for studies of diagnosis, treatment, prevention, or screening.*

*See Appendix A on pages 1447–1450 for further information.

95 ARTHRITIS OVERVIEW

Heidi Chumley, MD
Richard P. Usatine, MD

PATIENT STORY

A 50-year-old woman presents with new complaint of pain in several fingers. She has had psoriasis for many years; however, she only developed joint pain last year. Her examination is significant for swelling and tenderness at the distal interphalangeal (DIP) joints of her second, third, and fourth fingers (**Figure 95-1**, ***A***). She had an elevated erythrocyte sedimentation rate (ESR) and radiographs with erosive changes (**Figure 95-1**, ***B***). Choices for therapy include methotrexate and the new biologic anti-tumor necrosis factor (TNF)-α medications.

FIGURE 95-1 Psoriatic arthritis at initial presentation in a 50-year-old woman with psoriasis and new-onset hand pain. **A.** Note the prominent involvement of the distal interphalangeal joints. **B.** Radiography showing early psoriatic arthritis changes with periarticular erosions seen at the distal interphalangeal joints. (*Courtesy of Richard P. Usatine, MD.*)

INTRODUCTION

Arthritis means joint inflammation of the joints; however, the term is used for any disease or condition that affects joints or the tissues around the joints. Joint pain can be classified as monoarticular or polyarticular and inflammatory or noninflammatory. Diagnosis is based on a combination of clinical presentation, synovial fluid analysis, other laboratory tests, and radiographic findings. Management goals include minimizing joint damage, controlling pain, maximizing function, and improving quality of life.

EPIDEMIOLOGY

- Fifty million adults in the United States (22%) report doctor-diagnosed arthritis.[1]
- Arthritis is the most common cause of disability in the United States. Twenty-one million adults have functional limitations because of arthritis.[1]
- Fifty percent of adults age 65 years or older have been diagnosed with arthritis.[1]
- One in every 250 children younger than the age of 18 have some form of arthritis.[2]
- In 2003, the total cost attributable to arthritic conditions was $128 billion.[3]

ETIOLOGY AND PATHOPHYSIOLOGY

Arthritis can be caused by one of several mechanisms.

- Noninflammatory arthritis (i.e., osteoarthritis) is caused by bony overgrowth (osteophytes) and degeneration of cartilage and underlying bone (**Figures 95-2** and **95-3**).
- Autoimmune arthritis (i.e., rheumatoid arthritis, systemic lupus erythematosus [SLE], psoriatic arthritis) is caused by an inappropriate immune response.

- Crystalline arthritis (i.e., gout, calcium pyrophosphate dehydrate deposition disease) is caused by deposition of uric acid crystals (gout) or calcium pyrophosphate dehydrate crystals (CPPD) resulting in episodic flares with periods of remission.
- Septic arthritis is most commonly caused by bacteria (*Neisseria gonorrhoeae*, *Staphylococcus*, or *Streptococcus*; also gram-negative bacilli in immunocompromised patients and *Salmonella* in patients with sickle cell disease). Several viral illnesses may also have an associated arthritis.
- Postinfectious (reactive) arthritis is caused by an immune reaction several weeks after a urethritis or enteric infection.
- Fibromyalgia has an unknown etiology but includes abnormal pain perception processing.

DIAGNOSIS

CLINICAL FEATURES

- Two features help limit the differential diagnosis: mono- or polyarticular and inflammatory or noninflammatory.
  - Monoarticular noninflammatory—Osteoarthritis, trauma, atrioventricular node (AVN).
  - Monoarticular inflammatory—Infectious (gonococcal, nongonococcal, Lyme disease) or crystalline (gout or CPPD).
  - Polyarticular noninflammatory—Osteoarthritis.
  - Polyarticular inflammatory—Rheumatologic (rheumatoid arthritis [RA], SLE, psoriatic, ankylosing spondylitis [AS], and others) or infectious (bacterial, viral, postinfectious) or crystalline later in the disease.

TYPICAL DISTRIBUTION

- Most commonly affected joints
  - Osteoarthritis (see Chapter 96, Osteoarthritis)—Knees, hips, hands (DIP and proximal interphalangeal [PIP]), and spine (**Figures 95-2** to **95-4**).
  - RA (see Chapter 97, Rheumatoid Arthritis)—Wrists, metacarpophalangeal (MCP), PIP, metatarsophalangeal (MTP) early in the disease with larger joints affected later in the disease (**Figures 95-5** and **95-6**). Rheumatoid nodules may be found over the fingers, hands, wrists, or elbows (**Figures 95-6** and **95-7**).
  - SLE—Hands, wrists, and knees (see Chapter 180, Lupus: Systemic and Cutaneous) (**Figure 95-8**).
  - AS—Lower back and hips, costosternal junctions, shoulders (see Chapter 98, Ankylosing Spondylitis).
  - Psoriatic arthritis—Hands, feet, knees, spine, sacroiliac; typically with a personal or family history or psoriasis (**Figures 95-9** to **95-11**); **Table 95-1** describes the five types of psoriatic arthritis.
  - Gonococcal—Migratory with a single joint affected, such as knee, wrist, ankle, hand, or foot.
  - Lyme disease—Knee and/or other large joints.
  - Gout (see Chapter 100, Gout)—Begins as monoarticular with MTP joint of the first toe; hands, ankles, tarsal joints, and knee may also be affected (**Figures 95-12** to **95-14**); gout may present with tophi over any joint; olecranon bursitis can also be the result of gout (**Figure 95-15**).

FIGURE 95-2 Osteoarthritis in an elderly woman with Heberden nodes at the distal interphalangeal joints. There is some swelling beginning at the proximal interphalangeal joints creating Bouchard nodes. (*Courtesy of Richard P. Usatine, MD.*)

FIGURE 95-3 Osteoarthritis with visible Heberden (DIP) and Bouchard (PIP) nodes. (*Courtesy of Ricardo Zuniga-Montes, MD.*)

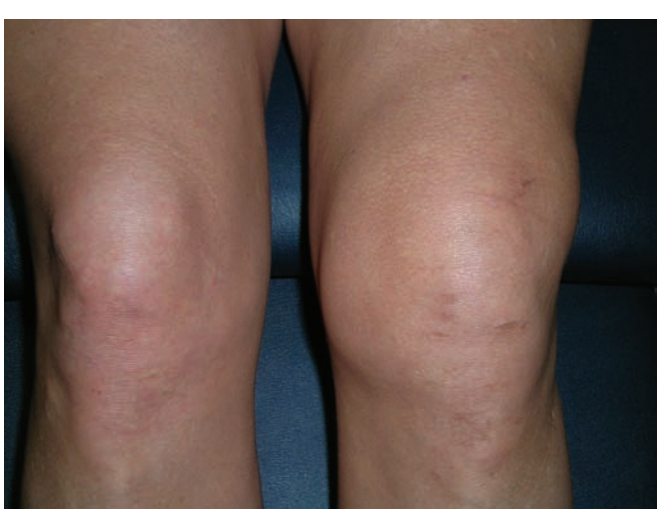

FIGURE 95-4 Osteoarthritis with visible unilateral knee effusion. The effusion was tapped and the synovial fluid was consistent with osteoarthritis. An intraarticular steroid injection was given and provided great relief to the pain and stiffness. (*Courtesy of Richard P. Usatine, MD.*)

FIGURE 95-5 Rheumatoid arthritis showing typical ulnar deviation at the metacarpophalangeal joints. (*Courtesy of Richard P. Usatine, MD.*)

FIGURE 95-6 Rheumatoid arthritis involving the whole upper-extremity joints with nodules on the elbow, wrist, and hand joints. (*Courtesy of Ricardo Zuniga-Montes, MD.*)

FIGURE 95-7 Rheumatoid arthritis with rheumatoid nodules over the PCP joints along with deformities of the digits. (*Courtesy of Ricardo Zuniga-Montes, MD.*)

FIGURE 95-8 Longstanding lupus erythematosus has caused swan-neck deformities without bone erosions. This is called Jaccoud arthropathy and is caused by synovitis and inflammatory capsular fibrosis. (*Courtesy of Everett Allen, MD.*)

FIGURE 95-9 Psoriatic arthritis of both knees. This patient has asymmetric psoriatic arthritis in his hands. (*Courtesy of Richard P. Usatine, MD.*)

FIGURE 95-10 Psoriatic arthritis with dactylitis and significant distal interphalangeal joint involvement. Note the destruction of the nails. Almost all patients with psoriatic arthritis have nail involvement. (*Courtesy of Ricardo Zuniga-Montes, MD.*)

TABLE 95-1 Five Types of Psoriatic Arthritis (PsA)

Type	Characteristics
Symmetric arthritis	Affects approximately 15% of PsA patients. Involves multiple symmetric pairs of joints in the hands and feet; resembles rheumatoid arthritis.
Asymmetric arthritis	The most common type of PsA, found in approximately 80% of patients. Usually involves only 1–3 joints in an asymmetric pattern and may affect any joint (e.g., knee, hip, ankle, and wrist). Hands and feet may have enlarged "sausage" digits.
Distal interphalangeal predominant (DIP)	This "classic type" occurs in only approximately 5% of PsA patients. Primarily involves distal joints of the fingers and toes. It is sometimes confused with osteoarthritis, but nail changes are common in PsA.
Spondylitis (Axial)	Inflammation of the spinal column causing a stiff neck and pain in the lower back and sacroiliac area. Peripheral disease may be seen in the hands, arms, hips, legs, and feet.
Arthritis mutilans	A severe, deforming type of PsA affecting <5% of patients with PsA. Usually affects a few joints in the hands and feet. Has been associated with pustular psoriasis.

Adapted from Van Voorhees A, Feldman SR, Koo JYM, et al; National Psoriasis Foundation: *The Psoriasis and Psoriatic Arthritis Pocket Guide: Treatment Algorithms and Management Options*, 3rd ed. http://www.psoriasis.org/document.doc?id=354.

- CPPD—Knee, but also seen in shoulder, elbow, wrist, hands, and ankle joints; most patients have polyarticular disease.
- Septic arthritis can involve any joint; acute onset of pain, swelling, and joint immobility; fever may be present; must be recognized and treated immediately as joint destruction occurs within days (**Figure 95-16**).

LABORATORY TESTING

- Not indicated for noninflammatory arthritis.
- Inflammatory polyarthritis: Use laboratory tests to supplement the clinical impression. Initial tests to consider include:
  - ESR or C-reactive protein as a nonspecific measure of inflammation.
  - Rheumatoid factor or anti-CCP (anti-cyclic citrullinated peptide) antibody when RA is expected. Anti-CCP antibody is more sensitive and specific than rheumatoid factor.
  - Antinuclear antibody (ANA), anti–double-stranded DNA (dsDNA) and anti-Ro when SLE is expected.
  - Human leukocyte antigen (HLA)-B27 when AS is expected.
  - Serum uric acid can be used, especially to follow hypouricemic therapy; levels can be normal or low during an attack.
- Joint aspiration:
  - Synovial fluid analysis is critical when septic or crystalline arthritis are suspected.
  - Assess for clarity/color, cell count, crystals, and culture. Gram stain may give quick information, but a culture should also be done. If there is clinical suspicion for septic arthritis, empiric antibiotics should be started even if the Gram stain is negative.
  - White blood cell (WBC)—Normal <200 cells/μL; noninflammatory arthritis <2000 cells/μL; inflammatory, crystalline, or septic arthritis >2000 cells/μL, often 30,000 to 50,000 cells/μL.
  - Crystals—Monosodium urate (gout) are needle-shaped and negatively birefringent; CPPD are rhomboid-shaped positively birefringent.
  - Culture—Gonococcal arthritis synovial fluid cultures can be negative in two-thirds of cases (synovial biopsy is positive);

FIGURE 95-11 Psoriatic arthritis mutilans with severe destruction of the fingers. (*Courtesy of Ricardo Zuniga-Montes, MD.*)

FIGURE 95-12 An acute gouty arthritis attack of multiple finger joints in a 75-year-old man with gout. His joints have been painful for 3 weeks. The erythema of the acute inflammation is evident. (*Courtesy of R. Treadwell, MD.*)

tuberculosis, fungal, and anaerobic infections may also be difficult to identify on culture.

IMAGING

- Osteoarthritis—Osteophytes, sclerosis, narrowed joint space (**Figure 95-17**).
- Rheumatoid arthritis—Soft-tissue swelling, erosions, and loss of joint space; severe destruction and subluxation in advanced disease. MRI changes may appear first and include synovitis, effusions, and bone marrow changes.
- SLE—Soft-tissue swelling; erosions are rare and joint deformities are uncommon.
- AS—Symmetric sacroiliitis, erosions, sclerosis; active sacroiliitis is best seen on MRI.
- Psoriatic arthritis—Erosions with adjacent proliferation, "pencil-in-cup" deformity, osteolysis, digit telescoping, asymmetric sacroiliitis.
- Gout—Only soft-tissue swelling until advanced disease when erosions with sclerotic margins may be present.
- CPPD—Can mimic other types of arthritis; chondrocalcinosis, linear or punctate radiodense deposits in cartilage or menisci may be present.

Table 95-2 provides a comparison of psoriatic arthritis with RA, osteoarthritis, and AS.

FIGURE 95-13 Severe tophaceous gout with chronic gouty arthritis causing hand deformities and disabilities. (*Courtesy of Jack Resneck, Sr., MD.*)

DIFFERENTIAL DIAGNOSIS

- Bursitis is inflammation of a bursa. Pain and tenderness is localized to the bursa. Common locations include subdeltoid, trochanteric, olecranon.
- Tendinitis is inflammation of a tendon that produces a localized pain aggravated by stretching of the affected tendon.
- Inflammatory myopathy or myositis is inflammation of the muscle most commonly caused by an autoimmune or infectious process. Pain is in the muscles instead of the joints.
- Polymyalgia rheumatica is a systematic inflammatory disease with aching and stiffness in the torso and proximal extremities. Pain is in the muscles, but synovitis or tenosynovitis may also be present. Passive joint range of motion is preserved. ESR is elevated. Normocytic anemia and thrombocytosis can be present.
- Fibromyalgia—Widespread pain not limited to joints. Joint swelling is absent. Laboratory tests and imaging if obtained are normal.

MANAGEMENT

The goals of treatment are to control pain, maximize function, improve quality of life, and, for inflammatory causes, minimize joint damage.

NONPHARMACOLOGIC

- Recommend an exercise program. Aerobic exercise, strength training, or both improves pain and function in arthritis and other rheumatic diseases.[4] SOR A

FIGURE 95-14 Severe tophaceous gout with large tophi and joint destruction of the hands. (*Courtesy of Ricardo Zuniga-Montes, MD.*)

- Splints or braces may be used to offload stress on a particular joint.
- Weight loss reduces joint load for weight-bearing joints.

MEDICATIONS

See specific chapters.

REFERRAL OR HOSPITALIZATION

- Hospitalize patients with suspected septic arthritis and begin empiric therapy with appropriate intravenous antibiotics.
- Refer patients in whom the diagnosis is unclear, especially if RA is suspected as early diagnosis and treatment improves outcomes.
- Refer patients in whom surgical management is indicated.

FIGURE 95-15 Olecranon bursitis bilaterally in a man with gout. (*Courtesy of Richard P. Usatine, MD.*)

PROGNOSIS

Prognosis depends on the type of arthritis as well as psychosocial factors and socioeconomic status.

FOLLOW-UP

Acute arthritis should be followed closely until resolution. Chronic arthritis is managed as other chronic diseases with the frequency of follow-up dependent upon the type of arthritis and the severity of the disease.

PATIENT EDUCATION

For chronic arthritic conditions, the goals of treatment are to control pain, maximize function, improve quality of life and minimize joint damage. Self-management is an important part of chronic arthritic conditions.

PATIENT RESOURCES

- Centers for Disease Control and Prevention: Information on the Arthritis Self-Management Program is available in English and Spanish—**http://www.cdc.gov/arthritis/interventions/self_manage.htm#1.**

PROVIDER RESOURCES

- Centers for Disease Control and Prevention: Information on arthritis and other rheumatologic conditions—**http://www.cdc.gov/arthritis/.**
- American College of Rheumatology: Clinical support, including practice guidelines, classification criteria, and clinical forms—**http://www.rheumatology.org/practice/clinical/index.asp.**

FIGURE 95-16 Septic left knee joint in a young girl who presented with knee pain, fever, and limited ability to ambulate. (*Courtesy of Richard P. Usatine, MD.*)

TABLE 95-2 Comparison of Psoriatic Arthritis with Rheumatoid Arthritis, Osteoarthritis, and Ankylosing Spondylitis

	PsA	RA	OA	AS
Peripheral disease	Asymmetric	Symmetric	Asymmetric	No
Sacroiliitis	Asymmetric	No	No	Symmetric
Stiffness	In morning and/or with immobility	In morning and/or with immobility	With activity	Yes
Female-to-male ratio	1:1	3:1	Hand/foot more common in female patients	1:3
Enthesitis	Yes	No	No	No
High-titer rheumatoid factor	No	Yes	No	No
HLA association	CW6, B27	DR4	No	B27
Nail lesions	Yes	No	No	No
Psoriasis	Yes	Uncommon	Uncommon	Uncommon

Abbreviations: *AS*, ankylosing spondylitis; *OA*, osteoarthritis; *PsA*, psoriatic arthritis; *RA*, rheumatoid arthritis.
Adapted from Gottlieb A, Korman NJ, Gordon KB, et al. Guidelines of care for the management of psoriasis and psoriatic arthritis: Section 2. Psoriatic arthritis: overview and guidelines of care for treatment with an emphasis on the biologics. *J Am Acad Dermatol*. 2008;58(5):851-864.

REFERENCES

1. Centers for Disease Control and Prevention (CDC). Prevalence of doctor-diagnosed arthritis and arthritis-attributable activity limitation—United States, 2007-2009. *MMWR Morb Mortal Wkly Rep*. 2010;59(39):1261-1265. http://www.cdc.gov/mmwr/preview/mmwrhtml/mm5939a1.htm?s_cid=mm5939a1_w. Accessed May 1, 2012.
2. Sacks JJ, Helmick CG, Luo YH, et al. Prevalence of and annual ambulatory health care visits for pediatric arthritis and other rheumatologic conditions in the United States in 2001-2004. *Arthritis Rheum*. 2007;57:1439-1445.
3. Yelin E, Murphy L, Cisternas MG, et al. Medical care expenditures and earnings losses among persons with arthritis and other rheumatic conditions in 2003, and comparisons to 1997. *Arthritis Rheum*. 2007;56(5):1397-1407.
4. Kelley GA, Kelley KS, Hootman JM, Jones DL. Effects of community-deliverable exercise on pain and physical function in adults with arthritis and other rheumatic diseases: a meta-analysis. *Arthritis Care Res (Hoboken)*. 2011;63(1):79-93.

FIGURE 95-17 Radiograph showing osteoarthritis of the knee with asymmetric joint space narrowing. (*Courtesy of Ricardo Zuniga-Montes, MD.*)

96 OSTEOARTHRITIS

Jana K. Zaudke, MD
Heidi Chumley, MD

PATIENT STORY

A 70-year-old woman presents with pain and swelling in the joints of both hands, which impedes her normal activities. Her pain is better in the morning after resting and worse after she has been working with her hands. She denies stiffness. On examination, you find bony enlargement of some distal interphalangeal (DIP) and proximal interphalangeal (PIP) joints on both hands (**Figure 96-1**). Radiographs confirm the presence of Heberden and Bouchard nodes. She begins taking 1 g of acetaminophen twice a day and has significant improvement in her pain and function.

FIGURE 96-1 Bony enlargement of some distal interphalangeal (DIP) and proximal interphalangeal (PIP) joints consistent with Heberden (DIP) and Bouchard (PIP) nodes. (*Courtesy of Richard P. Usatine, MD.*)

INTRODUCTION

Osteoarthritis is the most common type of arthritis. It involves degeneration of the articular cartilage accompanied by osteophytes (hypertrophic bone changes) around the joints. Osteoarthritis leads to pain in the joints with movement and relief with rest.

SYNONYMS

Degenerative joint disease.

EPIDEMIOLOGY

- Osteoarthritis is the most common type of arthritis, affecting 10% of men and 13% of women age 60 years or older.[1,2]
- Incidence and prevalence will likely increase given the obesity epidemic and the aging of the population.[2]
- In the Framingham cohort (mean age 71 years at baseline) women and men developed symptomatic knee osteoarthritis at the rate of 1% and 0.7% per year, respectively.[1]
- Risk of developing osteoarthritis increases with knee injury in adolescence or adulthood (relative risk [RR] = 2.95) and obesity (RR = 1.51 to 2.07).[1]
- Occupational physical activity and abnormal joint loading also increase the risk.[1,2]

ETIOLOGY AND PATHOPHYSIOLOGY

- Biomechanical factors and inflammation upset the balance of articular cartilage biosynthesis and degradation.
- Chondrocytes attempt to repair the damage; eventually, however, enzymes produced by the chondrocytes digest the matrix and accelerate cartilage erosion.

- Inflammatory molecules related to cytokine production, prostaglandin and arachidonic acid metabolism may be involved in susceptibility to osteoarthritis.[3]

RISK FACTORS

- Advanced age.
- Female gender.
- Genetics.
- Obesity.
- Knee injury in adolescence and adulthood.
- Abnormal joint loading.
- Occupational history.

DIAGNOSIS

The American College of Rheumatology uses the following criteria for the most common joints involved in osteoarthritis.

- Knee—Knee pain, osteophytes on radiograph, and 1 of 3: age older than 50 years, stiffness less than 30 minutes, or crepitus on physical examination (sensitivity = 91%, specificity = 86%).[4]
- Hip—Hip pain and 2 of 3: erythrocyte sedimentation rate (ESR) less than 20 mm/h; femoral or acetabular osteophytes by radiograph; superior, axial, or medial joint space narrowing by radiograph (sensitivity = 89%, specificity = 91%).[5]
- Hand—Hand pain, aching, or stiffness and 3 of 4: hard tissue enlargement of 2 or more DIP joints, fewer than 3 swollen metacarpophalangeal (MCP) joints, hand tissue enlargement of 2 or more selected joints, deformity of 1 or more selected joints. Selected joints include second and third DIP, second and third PIP, first carpometacarpal (CMC) on both hands (sensitivity = 94%, specificity = 87%).[6]

CLINICAL FEATURES

- Typically, joint pain is worsened with movement and relieved by rest. A small subset may demonstrate inflammatory symptoms including prolonged stiffness.
- Loss of function (i.e., impaired gait with knee or hip osteoarthritis, impaired manual dexterity with hand osteoarthritis).
- Radicular pain when vertebral column osteophytes impinge nerve roots.
- Bony enlargement of the DIP joints (Heberden nodes) or PIP joints (Bouchard nodes) (**Figure 96-1**).

TYPICAL DISTRIBUTION

Most common joints affected include knees, hands, hips, and back.

LABORATORY TESTING

- Not typically indicated. Normal ESR and synovial fluid white blood cell count (WBC) less than 2000/mm.[3,4]
- Imaging.
- Loss of joint space or osteophytes on radiographs (**Figures 96-2** to **96-5**).

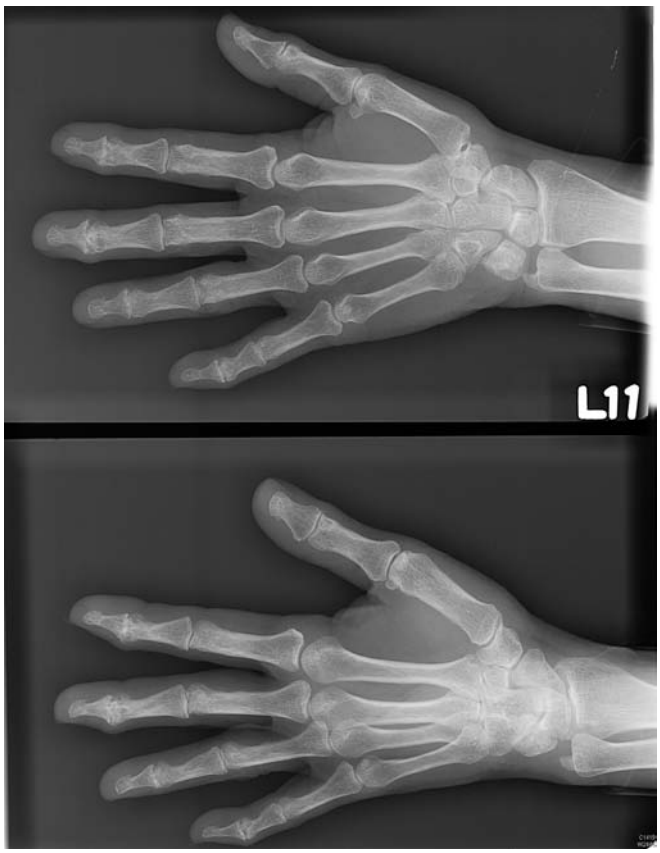

FIGURE 96-2 Joint space narrowing, marginal osteophytes, and Heberden nodes at the distal interphalangeal joints of the second through fifth fingers. (*Courtesy of Heidi Chumley, MD.*)

FIGURE 96-3 Osteoarthritis of the knee causing joint space narrowing, sclerosis, and bony spurring in all 3 compartments of the right knee, most pronounced in the medial compartment. (*Courtesy of Heidi Chumley, MD.*)

DIFFERENTIAL DIAGNOSIS

Musculoskeletal pain can also be caused by:

- Connective tissue diseases (scleroderma and lupus) that have other specific systemic signs.
- Fibromyalgia—Pain at trigger points instead of joints.
- Polyarticular gout—Erythematous joints and crystals in joint aspirate (see Chapter 100, Gout).
- Polymyalgia rheumatica—Proximal joint pain without deformity, elevated ESR.
- Seronegative spondyloarthropathies—Asymmetric joint involvement, spine often involved (see Chapter 98, Ankylosing Spondylitis).
- Reactive arthritis—History of infection, sexually transmitted disease, or bowel complaints. The patient may have conjunctivitis, iritis, urethritis in addition to joint pain and arthritis (see Chapter 155, Reactive Arthritis).
- Rheumatoid arthritis—Symmetric soft-tissue swelling in distal joints, stiffness after inactivity, positive rheumatoid factor. Ulnar deviation of the fingers at the MCP joints is a distinct finding in rheumatoid arthritis (**Figure 96-6**; Chapter 97, Rheumatoid Arthritis).
- Bursitis—Pain at one site, often increased with direct pressure.

FIGURE 96-4 Articular space narrowing, sclerosis, and subchondral cyst formation of both hips because of osteoarthritis. (*From Chen MYM, Pope TL Jr, Ott DJ. Basic Radiology. New York NY: McGraw-Hill; 2004:189, Figure 7-34.*)

MANAGEMENT

NONPHARMACOLOGIC

Table 96-1 lists the nonpharmacologic options for management of osteoarthritis.

- Recommend therapeutic land-based or aquatic exercise to maintain range of motion and strengthen muscles surrounding affected joints.[7,9] SOR A
- Recommend weight loss for knee or hip osteoarthritis. Weight loss may not improve current pain, but may slow progression and can be recommended for numerous other health reasons.[9] SOR C
- Consider a knee brace that alters knee mechanics (i.e., Counter-Force brace).[10] SOR B

MEDICATIONS

Table 96-2 lists the pharmacologic therapy for osteoarthritis.

- Prescribe acetaminophen (2 to 4 g/day) for pain relief in patients at higher risk for GI complications. In a pooled analysis, acetaminophen improved pain by 5%, number needed to treat (NNT) 4 to 14.[8] SOR A
- Prescribe a NSAID for moderate to severe hip or knee osteoarthritis in patients who are at low risk for GI complications. GI bleeding is a significant risk to many elderly patients with osteoarthritis (see **Table 96-3**). A 2006 Cochrane review found NSAIDs were slightly more effective than acetaminophen, although more likely to produce adverse GI events.[8] SOR A

FIGURE 96-5 Loss of disc space and facet arthropathy at L5-S1 and small osteophytes, best seen on L4 and L5. These changes are caused by osteoarthritis. (*Courtesy of Heidi Chumley, MD.*)

- If NSAIDs are to be used in patients with risk factors (see **Table 96-3**), consider giving a misoprostol or a proton pump inhibitor for protection.[9] Note that H_2-blockers may decrease gastric symptoms from NSAIDs but are not protective against GI bleeding.
- Consider opioid analgesics for patients with severe osteoarthritis who have not responded to NSAIDs (be careful to not prescribe narcotics to patients in recovery from substance abuse).[9] SOR C
- Consider a topical NSAID rather than an oral NSAID for hand or knee osteoarthritis, especially in patients 75 years of age or older. SOR C There is not yet enough data to recommend topical NSAID for hip osteoarthritis.[9]
- Consider topical capsaicin 0.025% cream 4 times a day for hand osteoarthritis.[2] SOR B
- Consider an intraarticular corticosteroid injection for acute pain related to knee or hip osteoarthritis.[9,11] SOR B
- Consider an intraarticular hyaluronic injection for symptomatic chronic knee osteoarthritis. A 2006 Cochrane review of 76 clinical trials concluded that these injections were effective for treating knee osteoarthritis.[11] SOR A

COMPLEMENTARY AND ALTERNATIVE THERAPY

- Consider participation in tai chi programs for knee or hip osteoarthritis.[9]
- Consider traditional Chinese acupuncture or transcutaneous electrical stimulation for patients with knee osteoarthritis who choose not to have or are not candidates for a total-knee arthroplasty.[9]
- In their newest guidelines, the American College of Rheumatology does not recommend use of chondroitin sulfate and glucosamine for osteoarthritis.[9]

FIGURE 96-6 Rheumatoid arthritis showing ulnar deviation of the fingers at the metacarpophalangeal joints. (*Courtesy of Richard P. Usatine, MD.*)

TABLE 96-1 Nonpharmacologic Options for Osteoarthritis

Weight loss (if overweight)
Aerobic exercise
Range-of-motion exercises
Muscle-strengthening
Assistive devices for walking
Yoga and Tai Chi
Safe shoes
Lateral-wedged insoles (for genu varum) bracing
Physical and Occupational therapy
Joint protection such as braces
Assistive devices for activities of daily living
Arthritis Foundation Self-Management Program
Social support

TABLE 96-2 Pharmacologic Options for Osteoarthritis

Oral
• Acetaminophen
• COX-2-specific inhibitor
• NSAID plus a proton pump inhibitor
• Opioids (e.g. hydrocodone)
• Salsalate
• Tramadol
Topical
• Methylsalicylate
• Topical NSAID (e.g diclofenac gel)
Intraarticular
• Glucocorticoids (e.g. triamcinolone)
• Hyaluronic acid

REFERRAL

Refer patients who do not respond to conservative therapy to:

- Any physician with experience doing joint injections if this is not within your skillset.
- Rheumatologist for evaluation and treatment.
- Orthopedic surgeon for evaluation for arthroplasty or joint replacement.

FOLLOW-UP

There are no recommended intervals for follow-up; however, it is reasonable to see patients periodically to assess pain management and function.

PATIENT EDUCATION

Osteoarthritis is a chronic, progressive disease. Nonpharmacologic and pharmacologic therapies can reduce pain and preserve function.

PATIENT RESOURCES

- Arthritis Foundation. *Osteoarthritis*—**http://www.arthritis.org/osteoarthritis.php.**
- PubMed Health. *Osteoarthritis*—**http://www.ncbi.nlm.nih.gov/pubmedhealth/PMH0001460/.**
- FamilyDoctor.org. *Osteoarthritis*—**http://familydoctor.org/familydoctor/en/diseases-conditions/osteoarthritis.html.**

PROVIDER RESOURCES

- American College of Rheumatology Subcommittee on Osteoarthritis Guidelines. *Recommendations for the Medical Management of Osteoarthritis of the Hip and Knee*—**http://www.rheumatology.org/practice/clinical/guidelines/oa-mgmt.asp.**

REFERENCES

1. Sharma L, Kapoor D, Issa S. Epidemiology of osteoarthritis: an update [review]. *Curr Opin Rheumatol.* 2006;18(2):147-156.
2. Zhang Y, Jordan JM. Epidemiology of osteoarthritis. *Clin Geriatr Med.* 2010;26(3):355-369.
3. Valedez AM, Spector TD. The clinical relevance of genetic susceptibility to osteoarthritis. *Best Pract Res Clin Rheumatol.* 2010;24(1):3-14.
4. American College of Rheumatology. http://www.rheumatology.org/practice/clinical/classification/oaknee.asp. Accessed April 6, 2012.
5. http://www.rheumatology.org/practice/clinical/classification/oa-hip/oahip.asp. Accessed April 6, 2012.

TABLE 96-3 Risk Factors for Upper GI Adverse Effects in Persons Taking NSAIDs

- Age 65 years or older
- Anticoagulants
- Comorbid medical conditions
- History of peptic ulcer disease
- History of upper gastrointestinal bleeding
- Oral steroids
- Taking NSAIDs with an empty stomach

6. http://www.rheumatology.org/practice/clinical/classification/oa-hand/oshand.asp. Accessed April 6, 2012.
7. Ottawa panel evidence-based clinical practice guidelines for therapeutic exercises and manual therapy in the management of osteoarthritis [review] [178 refs]. *Phys Ther.* 2005;85:907-971.
8. Towheed TE, Maxwell L, Judd MG, et al. Acetaminophen for osteoarthritis. *Cochrane Database Syst Rev.* 2006 Jan 25;(1): CD004257.
9. Hochberg MC, Altman RD, April KT, et al. American College of Rheumatology 2012 recommendations for the use of nonpharmacologic and pharmacologic therapies in osteoarthritis of the hand, hip and knee. *Arthritis Care Res.* 2012;64(4):465-474.
10. Barnes CL, Cawley PW, Hederman B. Effect of CounterForce brace on symptomatic relief in a group of patients with symptomatic unicompartmental osteoarthritis: a prospective 2-year investigation. *Am J Orthop.* 2002;31:396-401.
11. Sinusas, K. Osteoarthritis: diagnosis and treatment. *Am Fam Physician.* 2012;85(1):49-56.

97 RHEUMATOID ARTHRITIS

Heidi Chumley, MD

PATIENT STORY

A 79-year-old woman with late-stage rheumatoid arthritis comes for routine follow-up (**Figures 97-1** to **97-4**). She began having hand pain and stiffness approximately 40 years ago. She took nonprescription medications for pain for approximately 10 years before seeing a physician. She was diagnosed with rheumatoid arthritis on the basis of combination of clinical, laboratory, and radiograph findings. She was treated with prednisone and tried most of the disease-modifying agents as they became available; however, her disease progression continued. Approximately 10 years ago, she began having increased foot pain and difficulty walking. Today, she works with a multidisciplinary team to control pain and preserve hand function and independence.

FIGURE 97-1 Ulnar deviation at metacarpophalangeal joints in advanced rheumatoid arthritis. Also note the swelling at the distal interphalangeal joints, seen best on the first finger. (*Courtesy of Richard P. Usatine, MD.*)

INTRODUCTION

Rheumatoid arthritis (RA) is a progressive chronic illness that causes significant pain and disability. RA is a polyarticular inflammatory arthritis that causes symmetrical joint pain and swelling and typically involves the hands. Early recognition and treatment with nonbiologic and/or biologic disease-modifying antirheumatologic agents (DMARDs) can induce remission and preserve function.

EPIDEMIOLOGY

- RA is found in 0.8% of the adult population worldwide.[1]
- It is more than twice as common in women as compared to men (54 per 100,000 vs. 25 per 100,000).[1]
- Typical age of onset is 30 to 50 years.[1]

ETIOLOGY AND PATHOPHYSIOLOGY

- Genetic predisposition coupled with an autoimmune or infection-triggering incident.
- Synovial macrophages and fibroblasts proliferate, leading to increased lymphocytes and endothelial cells.
- Increased cellular material occludes small blood vessels, causing ischemia, neovascularization, and inflammatory reactions.
- Inflamed tissue grows irregularly, causing joint damage.
- Damage causes further release of cytokines, interleukins, proteases, and growth factors, resulting in more joint destruction and systemic complications including a higher risk for cardiovascular disease

FIGURE 97-2 Rheumatoid arthritis in the foot of a 79-year-old woman with subluxation of the first metatarsophalangeal joint. (*Courtesy of Richard P. Usatine, MD.*)

RISK FACTORS

Genetic predisposition signified by a positive family history.

DIAGNOSIS

The 2010 American College of Rheumatology/European League Against Rheumatism classification criteria uses a scoring system to designate patients as definite RA. A score of 6 or greater out of 10 meets criteria for definite RA.[2]

- Joint involvement—1 large joint (0 points); 2 to 10 large joints (1 point); 1 to 3 small joints with or without large joints (2 points); 4 to 10 small joints with or without large joints (3 points); more than 10 joints with at least 1 small joint (5 points).
- Serology—Negative rheumatoid factor (RF) and anticitrullinated protein antibody (ACPA) (0 points); low positive RF or ACPA (2 points); high positive RF or ACPA (3 points).
- Acute-phase reactants—Normal C-reactive protein (CRP) and erythrocyte sedimentation rate (ESR) (0 points); abnormal CRP or ESR (1 point).
- Duration of symptoms—Less than 6 weeks (0 points); 6 or more weeks (1 point).

American Rheumatism Association criteria (with positive likelihood ratio abbreviated as LR+):[3]

- Stiffness around joint for 1 hour after inactivity (LR+1.9).
- Three or more of these have soft-tissue swelling—Wrist, proximal interphalangeal (PIP), metacarpophalangeal (MCP), elbow, knee, ankle, metatarsophalangeal (MTP) (LR+1.4).
- Hand joints involved (LR+1.5) (**Figures 97-1, 97-4,** and **97-5**).
- Symmetrical involvement of one of these: wrist, PIP, MCP, elbow, knee, ankle, MTP (LR+1.2).
- Subcutaneous nodules (LR+3.0) (**Figures 97-5** and **97-6**).
- Positive serum RF (LR+8.4).
- Osteopenia or erosion of surrounding joints on hand or wrist films (LR+11) (**Figures 97-7** and **97-8**).

CLINICAL FEATURES

Joint pain and swelling, polyarticular and symmetrical.

TYPICAL DISTRIBUTION

- Hands are typically involved (**Figures 97-1, 97-4,** and **97-5**).
- Commonly involved joints include wrist, PIP, MCP, elbow, knee, ankle, MTP.
- Subcutaneous nodules (**Figures 97-5** and **97-6**).

LABORATORY TESTING

- RF (negative in 30% of patients; positive in many connective tissue, neoplastic, and infectious diseases).
- ACPA, high specificity, often present before definitive diagnosis can be made; presence predicts arthritis development.
- CRP (>0.7 pg/mL) or ESR (>30 mm/h).
- Complete blood count (normocytic or microcytic anemia, thrombocytosis).

FIGURE 97-3 Deviation at the metatarsophalangeal joints from bony destruction in advanced rheumatoid arthritis. (*Courtesy of Richard P. Usatine, MD.*)

FIGURE 97-4 Ulnar deviation at metacarpophalangeal joints seen in a 79-year-old woman with advanced rheumatoid arthritis. (*Courtesy of Kelly Foster, MD.*)

IMAGING

- Hand or wrist radiographs may show soft tissue swelling, osteopenia, erosions, subluxations, and deformities (**Figures 97-7** and **97-8**).

DIFFERENTIAL DIAGNOSIS

RA can mimic many systemic diseases and should be differentiated from the following:[1]

- Connective tissue diseases (scleroderma and lupus), which have other specific systemic signs.
- Fibromyalgia—Pain at trigger points instead of joints.
- Hemochromatosis—Abnormal iron studies and skin changes.
- Infectious endocarditis—Heart murmurs, high fever, risk factors, such as IV drug use.
- Polyarticular gout—Erythematous joints and crystals in joint aspirate.
- Polymyalgia rheumatica—Proximal joint pain without deformity.
- Seronegative, spondyloarthropathies—Asymmetric joint involvement, spine often involved.
- Reactive arthritis—History of infection, sexually transmitted disease, or bowel complaints.

MANAGEMENT

Target outcome is remission through use of disease-modifying agents. Monitor for complications:

- Patients with RA are twice as likely to have serious GI complications; monitor carefully.
- Anemia—Twenty-five percent will respond to iron therapy.
- Cancer—Twofold increase risk of lymphomas and leukemias.
- Cardiac complications such as pericarditis or pericardial effusion (30% at diagnosis).
- Cervical spine disease—Atlas instability; careful with intubation and avoid flexion films after trauma until atlas visualized.

NONPHARMACOLOGIC

- Use of multidisciplinary team improves outcomes.[4] SOR B
- Exercise improves aerobic capacity and strength without increases in pain or disease activity.[5] SOR B

MEDICATIONS

- NSAIDs can be used for pain control,[5] SOR A but do not alter disease progression and should not be used alone.
- Systemic corticosteroids relieve pain and slow progression,[5] SOR A but have serious side effects and should be used at lowest dose possible with added bone protection (e.g., calcium and vitamin D or a bisphosphonate).
- Nonbiologic DMARDs such as methotrexate, leflunomide, hydroxychloroquine, sulfasalazine, and minocycline reduce disease

FIGURE 97-5 Rheumatoid nodules in the hands. (*Courtesy of Richard P. Usatine, MD.*)

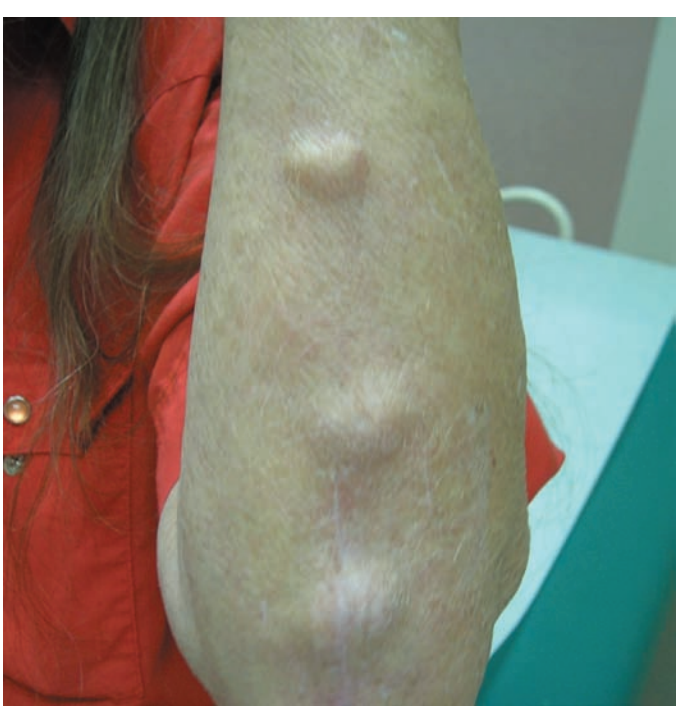

FIGURE 97-6 Rheumatoid nodules on the arm of a patient with rheumatoid arthritis. (*Courtesy of Richard P. Usatine, MD.*)

progression and should be considered in all patients without contraindications. SOR A

- Biologic DMARDs, such as antitumor necrosis factor (TNF) drugs, rituximab, abatacept, adalimumab, etanercept, and infliximab, reduce disease progression and should be considered in patients with high disease activity and poor prognostic features. SOR C

COMPLEMENTARY AND ALTERNATIVE THERAPY

- Diet modifications—Omega-3 polyunsaturated fatty acids may decrease antiinflammatory medication use.[1] SOR B

REFERRAL

- Refer patients with new diagnosis of or with a suspicion of RA to a physician experienced in the use of nonbiologic and biologic DMARDs.

Recommendations for initiating DMARDs are based on:[6]

- Disease duration.
- Presence of poor prognostic factors (functional limitations, extraarticular disease, positive RF and/or anti-CCP [anti-cyclic citrullinated peptide], bony erosions).
- Classification of low, moderate, or high disease activity, based on one of several validated instruments (e.g., Rheumatoid Arthritis Disease Activity Index).

DMARDs reduce disease progression, but have several contraindications and must be followed closely.

- Do not start nonbiologic or biologic DMARDs when the patient has an active bacterial infection, active or latent (before preventive therapy is initiated) tuberculosis (TB), acute hepatitis B or C, active herpes zoster, or a systemic fungal infection.[6]
- Avoid DMARDs if white blood cell count (WBC) is less than $3000/mm^3$ or platelets are under $50,000/mm^3$, New York Heart Association class III or IV heart failure, or liver transaminases more than twice the normal value.[6]
- Start methotrexate or leflunomide monotherapy for any disease duration, with or without poor prognostic factors, and any classification of disease activity.[6]
- Combination DMARD therapy (e.g., methotrexate [MTX] and sulfasalazine) may be used in patients with any duration of disease, poor prognostic features, and moderate or high disease activity.[6]
- Consider biologic DMARDs for patients with any disease duration, high disease activity, and poor prognostic features. Etanercept, infliximab, and adalimumab improve function and quality of life as monotherapy or in combination with nonbiologic DMARDs.[6]

PROGNOSIS

- Poor prognostic features include functional limitations, extraarticular disease, positive RF and/or anti-CCP [anti-cyclic citrullinated peptide], and bony erosions.[6]
- RA patients have an increased risk of cardiovascular disease.

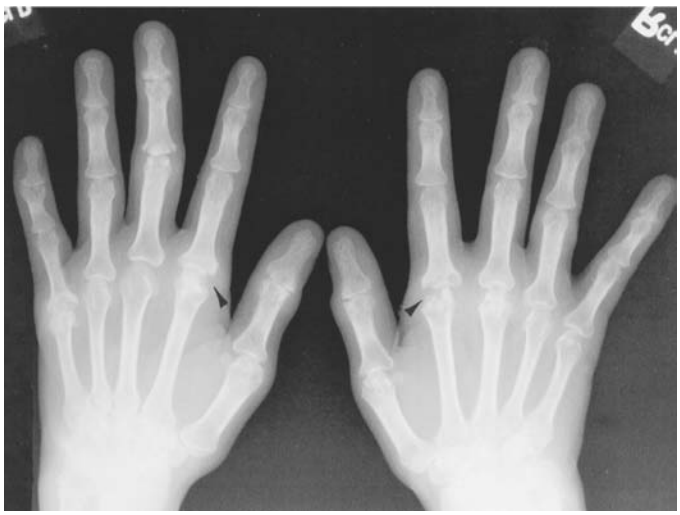

FIGURE 97-7 Hand radiographs in longstanding rheumatoid arthritis demonstrating carpal destruction, radiocarpal joint narrowing, bony erosion (*arrowheads*), and soft-tissue swelling. (*From Chen MYM, Pope TL Jr, Ott DJ. Basic Radiology. New York: McGraw-Hill; 2004:194, Figure 7-42. Copyright 2004.*)

FIGURE 97-8 Severe changes of late rheumatoid arthritis including radiocarpal joint destruction, ulnar deviation, erosion of the ulnar styloid bilaterally, dislocation of the left thumb PIP joint, and dislocation of the right fourth and fifth MCP joints. (*From Brunicardi CF, Andersen DK, Billiar TR, et al. Schwartz's Principles of Surgery. New York: McGraw-Hill; 2005:1666, Figure 42-40. Copyright 2005.*)

FOLLOW-UP

Multidisciplinary follow-up with primary care, rheumatologist, occupational and physical therapists, and patient educators improves outcomes.

PATIENT EDUCATION

RA is a chronic illness. Twenty percent to 40% of patients will have remission with therapy. Early treatment can prevent complications and allow the person to maintain function. It is best to stay active and exercise to the best of your ability.

PATIENT RESOURCES

- Information on RA is available at **http://www.rheumatoid-arthritis.com/ra/** and **http://www.ra.com/.**
- American College of Rheumatology. *Rheumatoid Arthritis*—**http://www.rheumatology.org/practice/clinical/patients/diseases_and_conditions/ra.asp.**

PROVIDER RESOURCES

- Saag KG, Teng GG, Patkar NM, et al. American College of Rheumatology 2008 recommendations for the use of nonbiologic and biologic disease-modifying antirheumatic drugs in RA. *Arthritis Rheum* 2008;59(6):762-784—**http://www.rheumatology.org/practice/clinical/guidelines/recommendations.pdf.**

REFERENCES

1. Rindfleisch JA, Muller D. Diagnosis and management of rheumatoid arthritis. *Am Fam Physician*. 2005;72(6):1037-1047, 1049-1050.
2. American College of Rheumatology/European League Against Rheumatism. 2010 Rheumatoid arthritis classification criteria. *Arthritis Rheum*. 2010;62(9):2569-2581.
3. Saraux A, Berthelot JM, Chales G, et al. Ability of the American College of Rheumatology 1987 criteria to predict rheumatoid arthritis in patients with early arthritis and classification of these patients two years later. *Arthritis Rheum*. 2001;44(11):2485-2491.
4. Vliet Vlieland TP, Breedveld FC, Hazes JM. The 2-year follow-up of a randomized comparison of in-patient multidisciplinary team care and routine out-patient care for active rheumatoid arthritis. *Br J Rheum*. 1997;36(1):82-85.
5. American College of Rheumatology Subcommittee on Rheumatoid Arthritis Guidelines. Guidelines for the management of rheumatoid arthritis: 2002 Update. [see comment]. *Arthritis Rheum*. 2002;46(2):328-346.
6. Saag KG, Teng GG, Patkar NM, et al. American College of Rheumatology 2008 recommendations for the use of nonbiologic and biologic disease-modifying antirheumatic drugs in rheumatoid arthritis. *Arthritis Rheum*. 2008;59(6):762-784.

98 ANKYLOSING SPONDYLITIS

Heidi Chumley, MD

PATIENT STORY

A 43-year-old man falls and presents with acute back and diffuse abdominal pain. He has had back pain on and off for years. Also, his wife notes that he has become "stooped" forward in the last few years. The radiographs show flowing ligamentous ossification and syndesmophyte formation about the cervical, thoracic, and lumbar spine consistent with ankylosing spondylitis (bamboo spine) (**Figure 98-1**). The KUB (kidneys, ureters, bladder) view film also shows fusion of the sacroiliac joints consistent with ankylosing spondylitis (**Figure 98-2**). No fracture, dislocation, or abdominal pathology is identified. The patient's symptoms are treated and nonsteroidal antiinflammatory drugs (NSAIDs) are started. On follow-up a blood test reveals that he is human leukocyte antigen (HLA)-B27–positive.

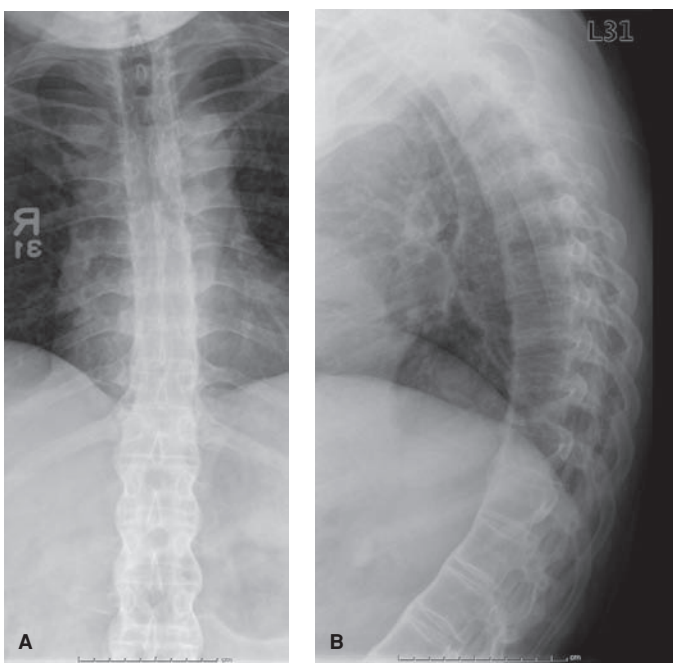

FIGURE 98-1 **A.** Fusion of the vertebral bodies and posterior elements gives the spine the classic "bamboo" appearance seen in ankylosing spondylitis. **B.** Note the marked kyphosis and the syndesmophytes that are the thin vertical connections between the anterior aspects of the vertebral bodies. They are located in the outer layers of the annulus fibrosis. (*Courtesy of Richard P. Usatine, MD.*)

INTRODUCTION

Ankylosing spondylitis is an inflammatory disease of the axial spine associated with the HLA-B27 genotype. Symptoms of low back and/or hip pain begin in late adolescence or early adulthood. Diagnosis is based on clinical features and radiographic findings.

EPIDEMIOLOGY

- Prevalence in general population is approximately 0.2% to 0.5%.
- Five percent of patients in primary care with low back pain have a spondyloarthritis, a spectrum of diseases that includes ankylosing spondylitis.[1]
- More common in males than in females (approximate ratio: 4:1).
- Ninety percent of patients are HLA-B27–positive.[2] However, many people with HLA-B27 do not develop the disease.

FIGURE 98-2 KUB view showing bamboo spine and fusion of both sacroiliac joints. (*Courtesy of Richard P. Usatine, MD.*)

ETIOLOGY AND PATHOPHYSIOLOGY

- Inflammatory arthritis with a poorly understood pathology.
- Environment and genetic factors result in inflammation.
- Chronic inflammation causes in extensive new bone formation.

RISK FACTORS

- Male gender.
- HLA-B27–positive genotype.

DIAGNOSIS

Mean delay of 7 to 8 years until diagnosis. Consider screening patients younger than 45 years of age with chronic low back pain for more than 3 months.[3]

CLINICAL FEATURES

- Younger patient (younger than 40 years of age at start of disease).
- Inflammatory (pain and stiffness worsen with immobility and improve with motion; symptoms are worse at night or early morning).
- Good response to NSAIDs—Sensitivity = 77%, specificity = 85%, positive likelihood ratio (LR+) 5.1.[1]
- Symptoms of inflammatory back pain have fair sensitivity (75%) and specificity (75%). LR+ 3.1. Number needed to screen is 7.[1,3]

PHYSICAL EXAM

- Limited range of motion of the spine.
- Tenderness over the spine and sacroiliac joints.
- In the advanced stages, kyphosis may occur with a stooped posture (**Figure 98-1**).
- Uveitis of the eye is the most common extraarticular manifestation occurring in 20% to 30% of patients. This can present with a red painful eye along with photophobia. The involved eye may have an irregular pupil and a 360-degree perilimbal injection (see Chapter 18, Uveitis and Iritis).

TYPICAL DISTRIBUTION

- Pain in lower back and/or sacroiliac joints.

LABORATORY TESTING

- HLA-B27 has good sensitivity (90%) and specificity (90%). LR+ 9.0. Number needed to screen is 3. Test is expensive.[1,3]
- May also consider HLA-B27 for patients with inflammatory back pain only.[1]

IMAGING

- Radiologic findings confirm the diagnosis; however, these may occur years after the onset of symptoms.
- Plain films—Typical spinal features include erosions, squaring, sclerosis, syndesmophytes, and fractures; may also see sacroiliac joint fusion (**Figure 98-3**). Flowing ligamentous ossification and syndesmophyte formation about the cervical, thoracic, and lumbar spine form the classic bamboo spine described in ankylosing spondylitis (**Figures 98-1** and **98-2**).
- MRI—Detects inflammation, such as acute sacroiliitis, which occurs prior to bony change visible by radiographs.

DIFFERENTIAL DIAGNOSIS

Causes of back pain in patients younger than age 45 years:

- Lumbar strain or muscle spasm—Acute onset often with precipitating event.

FIGURE 98-3 Ankylosing spondylitis with near fusion of right sacroiliac (SI) joint and pseudowidening (from erosive changes) of the left SI joint. (*Courtesy of Everett Allen, MD.*)

- Herniated disc—Acute onset with pain radiating below the knee into lower leg or foot with numbness, weakness, and/or loss of ankle jerk reflex.
- Vertebral fractures—Risk factors are osteoporosis or significant trauma.
- Abdominal pathology such as pancreatitis—Associated with GI symptoms.
- Kidney diseases—Nephrolithiasis (pain radiating into groin); pyelonephritis (fever, nausea, and urinary symptoms).
- Osteoarthritis—Worse after working; less commonly has inflammatory symptoms.
- Other spondyloarthritides (SpA) include psoriatic spondyloarthritis (**Figure 98-4**), SpA associated with inflammatory bowel disease, reactive SpA, and undifferentiated SpA.

FIGURE 98-4 Psoriatic arthritis showing swan-neck deformities, involvement of proximal interphalangeal (PIP) and distal interphalangeal (DIP) joints and skin plaques. (*Courtesy of Richard P. Usatine, MD.*)

MANAGEMENT

- NSAIDs and physical therapy reduce pain. Continuous NSAIDs reduce radiographic progression.[4] SOR B
- Disease-modifying antirheumatic drugs (methotrexate, leflunomide) have not been demonstrated to have patient-oriented outcomes.[4] SOR B
- Tissue necrosis factor blockers are recommended for patients who fail NSAIDs and physical therapy. Consider treating or referring for treatment with shorter duration of symptoms, elevated acute phase reactants (i.e., C-reactive protein), or rapid radiographic progression. SOR C
  - Infliximab improves pain scores and quality of life within 2 weeks (61% vs. 19% placebo).[4] SOR B Many relapse; high cost, but economic analysis is favorable compared to estimated cost of loss of function.[4]
  - Adalimumab improves quality-of-life and function scores by 12 weeks. Improvement continues for up to a year and remains stable through 3 years.[5] SOR B
  - Etanercept improves pain scores (60% vs. 12%).[4] SOR B Relief within 2 weeks. Many relapse; reinitiation works.[4] Seventy-six percent of patients treated with Etanercept, compared to 53% of patients treated with sulfasalazine, improved by 20% within 4 months.[6] Improvements in pain, function, and mobility were sustained at 5 years.[7]

PROGNOSIS

Mortality is increased in male patients with ankylosing spondylitis. Leading cause of death was cardiovascular. Risk factors for reduced survival include absence of NSAID use (odds ratio [OR] 4.35), work disability (OR 3.65), increased C-reactive protein (OR 2.68), and diagnostic delay (OR 1.05).[8]

FOLLOW-UP

Follow patients for progression of pain or decreased function using standard ankylosing spondylitis, such as the Ankylosing Spondylitis

Disease Activity Score or the Bath Ankylosing Spondylitis Disease Activity Index or Functional Index.

PATIENT EDUCATION

Ankylosing spondylitis is a chronic disease. NSAIDs and physical therapy and exercise are important in controlling pain and slowing progression of disease. If these are ineffective, tissue necrosis factor blockers are effective; however, these are expensive and pain recurs when they are stopped.

PATIENT RESOURCES

- American College of Rheumatology. Patient education handout: *Spondylarthritis (Spondylarthropathy)*—**http://www.rheumatology.org/practice/clinical/patients/diseases_and_conditions/spondyloarthritis.asp.**
- The Spondylitis Association of America—**http://www.spondylitis.org/main.asp.**
- PubMed Health. *Ankylosing Spondylitis*—**http://www.ncbi.nlm.nih.gov/pubmedhealth/PMH0001457/.**

PROVIDER RESOURCES

- Assessment of SpondyloArthritis International Society. *Ankylosing Spondylitis Disease Activity Score Information and Online Calculator*—**http://www.Asas-Group.Org/Research.Php?Id=01#Null.**
- Medscape. Brent LH. *Ankylosing Spondylitis and Undifferentiated Spondyloarthropathy*—**http://emedicine.medscape.com/article/332945.**
- Assessment of SpondyloArthritis International Society (ASAS) and European League Against Rheumatism (EULAR); Zochling J, van der Heijde D, Burgos-Vargas R, et al. ASAS/EULAR recommendations for the management of ankylosing spondylitis. *Ann Rheum Dis.* 2006;65(4):442-452.—**http://www.ncbi.nlm.nih.gov/pmc/articles/PMC1798102/.**

REFERENCES

1. Rudwaleit M, van der HD, Khan MA, et al. How to diagnose axial spondyloarthritis early. *Ann Rheum Dis.* 2004;63(5):535-543.
2. Kim Th, Uhm WS, Inman RD. Pathogenesis of ankylosing spondylitis and reactive arthritis [review] [73 refs]. *Curr Opin Rheumatol.* 2005;17(4):400-405.
3. Sieper J, Rudwaleit M. Early referral recommendations for ankylosing spondylitis (including pre-radiographic and radiographic forms) in primary care [review]. *Ann Rheum Dis.* 2005; 64(5):659-663.
4. Zochling J, Braun J. Management and treatment of ankylosing spondylitis [review]. *Curr Opin Rheumatol.* 2005;17(4):418-425.
5. Kimel M, Revicki D, Rao S, et al. Norms-based assessment of patient-reported outcomes associated with adalimumab monotherapy in patients with ankylosing spondylitis. *Clin Exp Rheumatol.* 2011;29(4):624-632.

6. Braun J, van der Horst-Bruinsma IE, Huang F, et al. Clinical efficacy and safety of etanercept versus sulfasalazine in patients with ankylosing spondylitis: a randomized, double-blind trial. *Arthritis Rheum.* 2011;63(6):1543-1551.
7. Martin-Mola E, Sieper J, Leirisalo-Repo M, et al. Sustained efficacy and safety, including patient-reported outcomes, with etanercept treatment over 5 years in patients with ankylosing spondylitis. *Clin Exp Rheumatol.* 2010;28(2):238-245.
8. Bakland G, Gran JT, Nossent JC. Increased mortality in ankylosing spondylitis is related to disease activity. *Ann Rheum Dis.* 2011; 70(11):1921-1925.

99 BACK PAIN

Heidi Chumley, MD

PATIENT STORY

A 60-year-old woman presents with chronic low back pain that began many years ago. Her back pain waxes and wanes and she has taken acetaminophen and ibuprofen with some relief. About 3 months ago, she began to have daily pain. She recalls no trauma. Her examination is unremarkable other than some decreased flexion. Straight leg raise test is negative. As the patient is older than 55 years of age, radiographs are ordered and they demonstrate degenerative changes in her lumbar spine (**Figure 99-1**). She is started on scheduled acetaminophen and ibuprofen along with an exercise program.

FIGURE 99-1 Lateral view shows grade 1 degenerative spondylolisthesis at L4-L5 (*arrow*), moderate facet osteoarthritis of L5-S1. Marked T12-L1 disc degeneration (arrowhead) and mild L4-L5 disc degeneration.

INTRODUCTION

Back pain is one of the most common reasons that adults see their physician. Most acute back pain is a result of mechanical causes. Serious pathology can be recognized by the presence of red flags. Acute back pain is treated with reassurance, returning to activities, and acetaminophen with or without an NSAID. Psychological factors increase the risk of development of chronic pain. Chronic back pain is difficult to treat and the best outcomes are typically achieved by an interprofessional team.

EPIDEMIOLOGY

- Six percent of visits to primary care physicians are for back pain.[1]
- Low back pain 1-year incidence is 20% and 1-year prevalence is 40% in adults.[2]
- Thoracic back pain 1-year prevalence is 15% to 27% in adults.[3]
- Treatment for back and neck problems accounted for approximately $86 billion in health care expenditures in the United States in 2005.[4]
- Prevalence of malignancy in patients with LBP presenting to a primary care office or emergency room is 0.1% to 1.5%.[5]

ETIOLOGY AND PATHOPHYSIOLOGY

- LBP can be caused by pain in the muscles, ligaments, joints, bones, discs, nerves, or blood vessels.[2]
- In 90% of cases, the specific cause of LBP is unclear.[2]
- In 10% of cases, a specific cause such as an infection, fracture, or cancer is identified.

RISK FACTORS

- Older age—Prevalence of LBP increases with age into the sixth decade.[2]

- Low educational status.[2]
- Occupational factors—Manual labor, bending, twisting, and whole-body vibration.[2]
- Psychosocial factors increase the risk of transition from acute to chronic pain.[2]
- Risk factors for cancer—Previous history of cancer (positive likelihood ratio [LR+] 23.7), elevated erythrocyte sedimentation rate (ESR) (LR+ 18.0), reduced hematocrit (LR+ 18.3).[5]

DIAGNOSIS

The diagnosis can be classified into three categories:

1. Nonspecific back pain—Pain for less than 6 weeks (acute), 6 to 12 weeks (subacute), or more than 12 weeks (chronic); negative straight-leg raise test; absence of red flags.
2. Radicular syndrome—LBP with radiation down leg; positive straight-leg raise test; absence of red flags.
3. Serious pathology—Further work-up required for presence of red flags, including age younger than 20 or older than 55 years; significant trauma; fever; unexplained weight loss; neurologic signs of cauda equina; progressive neurologic deficit.

TYPICAL DISTRIBUTION

Lumbar pain is about twice as common as thoracic pain.

LABORATORY TESTING

Helpful in the presence of red flags:

- Complete blood count (CBC) to evaluate for anemia (malignancy) or leukocytosis (infection).
- Consider human leukocyte antigen (HLA)-B27 in younger patients with inflammatory symptoms.

IMAGING

- In acute back pain without red flags, imaging can be delayed for 6 weeks.
- Radiographs may show degenerative joint disease changes in osteoarthritis; vertebral fractures; malignancies; and findings of ankylosing spondylitis including erosions, sclerosis, syndesmophytes (see Chapter 98, Ankylosing Spondylitis).
- MRI is the best imaging test for disc herniation and imaging of the spinal cord. Emergent MRI is indicated in patients with suspected spinal cord compromise or cauda equina syndrome.
- CT myelogram is a useful alternative to evaluate disc herniation in patients who cannot undergo MRI.

DIFFERENTIAL DIAGNOSIS

- Osteoporotic vertebral fracture—Acute onset of pain, typically seen in older patients or those at risk for osteoporosis, point tenderness at the level of the fracture, confirmation by plain radiographs demonstrating compression or burst fracture (**Figure 99-2**).

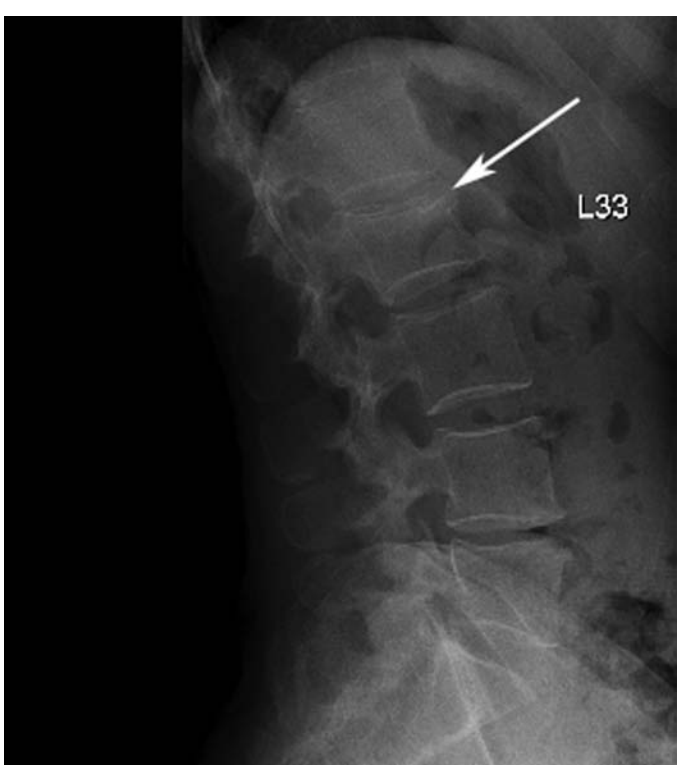

FIGURE 99-2 Lateral view demonstrating the loss of vertebral body height seen with a compression fracture deformity (*arrow*) of the superior end plate of the L2 vertebral body. There is also a mild concave compression deformity of the superior end plate of the L5 vertebral body.

- Spinal stenosis—Pain worse with extension, presence of unilateral or bilateral leg symptoms worse with walking and better with sitting, confirmation by CT or MRI.
- Herniated disc—Radicular pain that is worse with flexion or sitting, may be accompanied by numbness or weakness of foot plantar flexion (L5/S1) or dorsiflexion (L4/L5), MRI confirms the level and shows the type of herniation (**Figures 99-3** and **99-4**).
- Spinal infection/abscess—Most commonly seen in patients who use IV drugs, have diabetes mellitus, have cancer, or have a transplant; symptoms include fever, night pain, night sweats, and elevated ESR. MRI is the study of choice. If neurologic deficit is present, obtain an urgent MRI to evaluate for an abscess, which would require hospitalization and consultation with a spinal surgeon.
- Ankylosing spondylitis (see Chapter 98, Ankylosing Spondylitis)—Pain, most commonly in the low back or sacroiliac joints, usually begins in late adolescence or early adulthood. Pain and stiffness worsen with immobility and improve with motion. HLA-B27 may be positive. Radiographic findings confirm the diagnosis, but occur years after symptoms.
- Malignancy—Typically seen in an older patient; symptoms of weight loss and night pain; significant anemia; history of cancer; nonresponse to therapy. Often seen on plain radiographs. Bone scan is the most sensitive test.
- Abdominal pathology such as pancreatitis, pyelonephritis, and cholecystitis can present as back pain or pain radiating to the back.

FIGURE 99-3 MRI showing herniated nucleus pulposus (*arrow*) at L5-S1 in a patient with radicular pain and a poor response to 6 weeks of conservative therapy.

MANAGEMENT

ACUTE BACK PAIN

Most national guidelines agree on the following:[6]

- Nonpharmacologic:
  - Reassure patients without red flags that they do not have a serious condition, advise them to remain active, discourage bed rest, and encourage an early return to work while back pain is still present.
  - Exercise is considered no more effective than return to normal activities for LBP within the first 4 to 6 weeks.[6]
- Medications:
  - Acetaminophen
  - Add NSAID if needed (ask about GI problems and protect against ulcers as needed).
  - Consider a short course of opiates or muscle relaxers if pain is severe and inadequately treated with acetaminophen and NSAIDs.
  - Consider antidepressants (such as amitriptyline) or anticonvulsants (such as gabapentin) for radicular pain.
- Complementary and alternative therapy:
  - National guidelines differ; some recommend and some do not recommend spinal manipulative therapy for acute back pain.
  - Spinal manipulative therapy has a similar effect on pain relief and functional status as other interventions.[7]
- Referral or hospitalization:
  - Patients with cauda equina syndrome should have expedient imaging and urgent referral to a spinal surgeon.

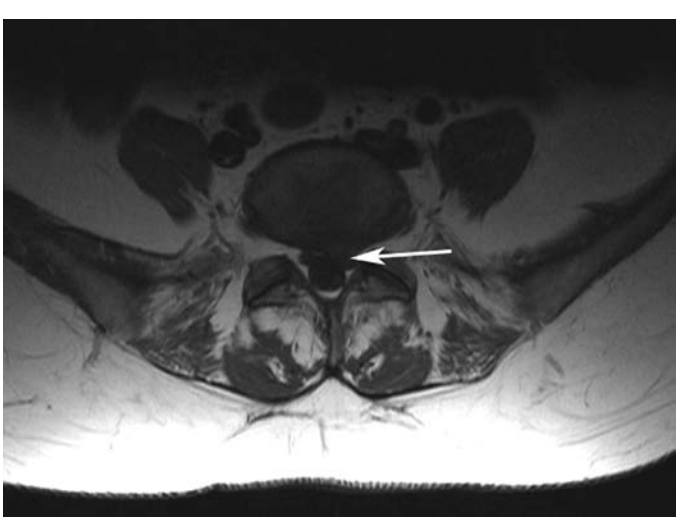

FIGURE 99-4 MRI cross section demonstrates that the herniated disc (*arrow*) is compressing S1 nerve root.

- Refer patients with serious pathology such as infection, tumor, or fracture to appropriate consultants.

SUBACUTE (6 TO 12 WEEKS) OR CHRONIC (>12 WEEKS) BACK PAIN

Most national guidelines agree on these recommendations:[6]

- Nonpharmacologic:
  - Encourage an exercise program.
  - Recommend cognitive-behavioral therapy.
  - Discourage ultrasound or electrotherapy.
- Medications:
  - National guidelines vary on medication recommendations.
  - Start with acetaminophen then add NSAIDs if needed.
  - Consider adding one of these medications: tramadol, an antidepressant, a benzodiazepine, or an opiate.
- Complementary and alternative therapy:
  - Yoga—There have been a number of randomized controlled trials (RCTs) and metaanalyses that have found yoga to be an excellent treatment for chronic and recurrent LBP.[1–4] SOR A A 12-week yoga program for adults with chronic or recurrent LBP led to greater improvements in back function than did usual care.[4] Yoga classes were more effective than a self-care book, but not more effective than stretching classes, in improving function and reducing symptoms caused by chronic LBP, with lasting benefits.[3]
- Referral or hospitalization:
  - Chronic pain is difficult to treat. Use an interdisciplinary team to maximize effectiveness if possible.
  - Consider referring patients who do not respond to conservative therapy to a pain management specialist or a spine surgeon.

PREVENTION

Good posture, appropriate lifting techniques, maintaining a healthy weight, and enjoying an active lifestyle may help prevent back pain. Adding yoga to an active lifestyle has the potential to prevent recurrent back pain and diminish the pain of chronic back pain.[1–4] SOR A

PROGNOSIS

- Patients with nonradicular acute back pain—By 12 months, 40% recover fully.[8]
- Patients with acute back pain that have psychological factors at baseline are more likely to develop chronic LBP.[9]

FOLLOW-UP

Follow-up is determined by etiology. Patients with acute back pain, without red flags, especially those at risk to develop chronic pain, should be followed closely. Patients with chronic pain benefit from ongoing treatment by an interprofessional team.

PATIENT EDUCATION

- Reassure patients without red flags that most acute back pain is not a result of a serious cause and can be treated conservatively.
- Advise patients with chronic back pain that a comprehensive approach to pain management is more likely to result in pain improvement than medications alone.
- Yoga and stretching can be a valuable adjunct to other treatments.[1–4]

PATIENT RESOURCES

- Written and auditory patient information is available in English and Spanish at Family Doctor.org—**http://familydoctor.org/familydoctor/en/diseases-conditions/low-back-pain.html.**
- Yoga therapy for back pain. Audio and visual instructions for patients wanting to use yoga—**http://www.samata.com/video4.php.**
- Gentle yoga routine for lower back relief on YouTube—**http://www.youtube.com/watch?v=u0BLxSY2L3Y.**

PROVIDER RESOURCES

- A comprehensive list of red flags for back pain can be found in family practice notebook—**http://www.fpnotebook.com/Ortho/Sx/LwBckPnRdFlg.htm.**
- WebMD Back Pain Health Center. Useful for patients and providers—**http://www.webmd.com/back-pain/default.htm.**

REFERENCES

1. Jordan KP, Kadam UT, Hayward R, et al. Annual consultation prevalence of regional musculoskeletal problems in primary care: an observational study. *BMC Musculoskelet Disord.* 2010; 11:144.
2. Hoy D, Brooks P, Blyth F, Buchbinder R. The epidemiology of low back pain. *Best Pract Res Clin Rheumatol.* 2010;24(6): 769-781.
3. Briggs AM, Smith AJ, Straker LM, Bragge P. Thoracic spine pain in the general population: prevalence, incidence and associated factors in children, adolescents and adults. A systematic review. *BMC Musculoskelet Disord.* 2009;10:77.
4. Martin BI, Deyo RA, Mirza SK, et al. Expenditures and health status among adults with back and neck problems. *JAMA.* 2008;299: 656-664.
5. Henschke N, Maher CG, Refshauge KM. Screening for malignancy in low back pain patients: a systematic review. *Eur Spine J.* 2007; 16(10):1673-1679.

6. Koes BW, van Tulder M, Lin CW, et al. An updated overview of clinical guidelines for the management of non-specific low back pain in primary care. *Eur Spine J.* 2010;19(12):2075-2094.
7. Rubinstein SM, van Middelkoop M, Assendelft WJ, et al. Spinal manipulative therapy for chronic low-back pain. *Cochrane Database Syst Rev.* 2011:CD008112.
8. Costa Lda C, Maher CG, McAuley JH, et al. Prognosis for patients with chronic low back pain: inception cohort study. *BMJ.* 2009; 339:b3829.
9. Mello M, Elfering A, Egli Presland C, et al. Predicting the transition from acute to persistent low back pain. *Occup Med (Lond).* 2011; 61(2):127-131.

100 GOUT

Mindy A. Smith, MD
Heidi Chumley, MD

PATIENT STORY

A 91-year-old woman arrives by ambulance to the emergency department because she was experiencing severe pain in her right middle finger (**Figure 100-1**). History reveals that she has had swelling of her finger for approximately 1 year. Palpation of the distal interphalangeal joint demonstrated firmness rather than fluctuance. A radiograph of the finger was ordered (**Figure 100-2**). The radiograph and physical examination are consistent with acute gouty arthritis superimposed on tophaceous gout. The diagnosis was confirmed by an aspirate of the finger that demonstrated negatively birefringent, needle-like crystals, both intracellularly and extracellularly. She was given 1.2 mg of colchicine followed by a second dose of 0.6 mg after 1 hour. Her pain was markedly decreased in 4 hours. Her serum uric acid level was determined to be 10.7 mg/dL. The colchicine was used in this case because the risk of using NSAIDs was considered to be high because of her previous history of gastric bleeding secondary to NSAIDs.

FIGURE 100-1 Acute gouty arthritis superimposed on tophaceous gout. (*Courtesy of Geiderman JM. An elderly woman with a warm, painful finger. West J Med. 2000;172(1):51-52.*)

INTRODUCTION

Gout is an inflammatory crystalline arthritis. Elevated uric acid leads to deposition of monosodium urate (MSU) crystals in the joints resulting in a red, hot, swollen joint. Gout typically begins as a monoarthritis, but can become polyarthritic. Treatment of acute episodes include NSAIDs, colchicine, or intraarticular steroids. Chronic therapy includes lowering the uric acid level using dietary modifications and urate-lowering drugs.

EPIDEMIOLOGY

- Gout affects 1% to 2% of the U.S. population and approximately 6% of men older than 80 years of age.[1]
- Gout is more prevalent in men than women.
- Gout usually begins after age 30 years in men and after menopause in women; it is familial in approximately 40% of patients.[1]

ETIOLOGY AND PATHOPHYSIOLOGY

- Defective uric acid metabolism with inefficient renal urate excretion leads to underexcretion of uric acid and an elevated serum uric acid level.
- Overproduction of uric acid, instead of underexcretion, occurs in approximately 10% of patients with gout, and also leads to elevated serum uric acid levels.

- Elevated serum uric acid leads to deposition of MSU crystals in the joints and the kidneys.
- Crystals trigger proinflammatory cytokines, which cause local inflammation, tissue necrosis, fibrosis, and subchondral bone destruction.

RISK FACTORS

- Medications that cause hyperuricemia—Thiazide diuretics, cyclosporine, aspirin (<1 g/day).[2]
- Conditions associated with gout—Insulin resistance, obesity, hypertension, hypertriglyceridemia, hypercholesterolemia, congestive heart failure, renal insufficiency, early menopause, organ transplant.[2,3]
- Dietary—Increased intake of meat and seafood, alcohol, soft drinks, and fructose.[2]

DIAGNOSIS

Diagnostic characteristics useful in predicting gout, based on the 1977 criteria developed by the American College of Rheumatology, are:

- Monoarthritis.
- Redness over the joints.
- First metatarsophalangeal (MTP) joint involved (**Figure 100-3**).
- Unilateral first MTP joint attack.
- Unilateral tarsal joint attack.
- Tophi identified (**Figures 100-1**, **100-4**, and **100-5**).
- Hyperuricemia.
- Asymmetric swelling in joint on radiograph.
- Subcortical cysts on radiograph.
- MSU crystals in joint fluid (**Figure 100-6**).
- Joint fluid culture negative.

The presence of 6 of these 11 criteria helps confirm gout (positive likelihood ratio [LR+] 20, negative likelihood ratio [LR−] 0.02).[4]

CLINICAL FEATURES

- Gout usually begins at night as an acute attack over several hours.
- Fever, chills, and arthralgias sometimes precede gout.
- The affected joint is swollen, red, hot, and painful to touch and movement (**Figures 100-1**, **100-3**, and **100-6**). Symptoms subside in 3 to 10 days.
- Dietary or alcohol excess, trauma, surgery, and serious medical illness can precipitate gout attacks.

TYPICAL DISTRIBUTION

Initially, only one joint may be affected, but other joints commonly involved are fingers and toes (75%) and knees and ankles (50%).

- The most common site is the first MTP joint and the name for gout at this site is podagra (**Figure 100-3**).
- Joint involvement is often asymmetric.

FIGURE 100-2 This x-ray of the finger in **Figure 100-1** shows several tophi (monosodium urate [MSU] deposits) in the soft tissue over the third distal interphalangeal joint. Note the typical punched out lesions under the tophi. This is subchondral bone destruction. (*Courtesy of Geiderman JM. An elderly woman with a warm, painful finger. West J Med. 2000;172(1):51-52.*)

FIGURE 100-3 Podagra. Typical inflammatory changes of gout at first MTP joint. (*Courtesy of Richard P. Usatine, MD.*)

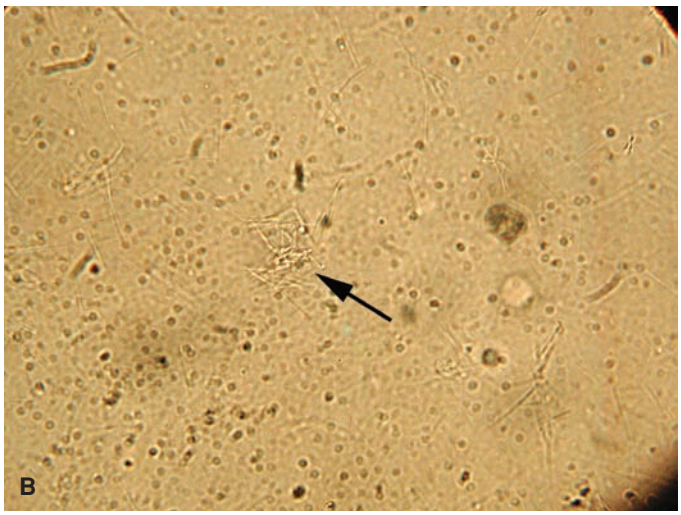

FIGURE 100-4 **A.** A 52-year-old homeless man with acute monoarticular gouty arthritis presenting with knee pain and swelling. Knee aspiration revealed a straw-colored effusion. **B.** With light microscopy numerous refractile needle-shaped crystals of uric acid were visualized in the joint fluid. The *arrow* points to a cluster of needle-shaped uric acid crystals. (*Reproduced with permission from Usatine RP, Sacks B, Sorci J. A swollen knee. J Fam Pract. 2003;52(1):53-55. Reproduced with permission from Frontline Medical Communications.*)

FIGURE 100-5 Severe tophaceous gout causing major deformities in the hands. (*Courtesy of Eric Kraus, MD.*)

FIGURE 100-6 Tophaceous deposits on both elbows and one finger in a man with gout. (*Courtesy of Richard P. Usatine, MD.*)

- Tophi may be seen at the MTP joint, elbow, hands, and ears (**Figures 100-1**, **100-4**, and **100-5**).

LABORATORY TESTING

- Serum uric acid is often elevated, but is variable from week to week and normal in 25% of patients with gout.
- Measure 24-hour urine for excretion of uric acid.
- On microscopy, the presence of MSU crystals from synovial fluid or a tophus that are negatively birefringent in polarized light (yellow against a red background) helps to confirm the diagnosis, but there are limited data on the accuracy of crystal identification.
- Even with light microscopy refractile needle-shaped crystals of uric acid can be visualized in the joint fluid (**Figure 100-6**).

IMAGING

Although radiographs are negative early in the disease, punched-out erosions ("rat bites") are seen later and can be diagnostic, especially if seen adjacent to tophi (**Figure 100-2**).

DIFFERENTIAL DIAGNOSIS

In addition to gout, the differential diagnosis of inflammatory monoarthritis includes the following:

- Cellulitis—Joint motion is not painful; synovial culture is negative (see Chapter 120, Cellulitis).
- Septic arthritis—Fever; painful motion; synovial fluid has many white blood cells and a positive culture.
- Rheumatic arthritis—Symmetric joint involvement (usually hands); slow onset; synovial culture is negative (see Chapter 97, Rheumatoid Arthritis).
- Pseudogout—Findings like gout; synovial fluid with short rods; crystal refraction blue on red background (calcium pyrophosphate dihydrate).

MANAGEMENT

ACUTE GOUT

- Prescribe an NSAID, such as indomethacin 50 to 75 mg every 6 to 8 hours, in patients without renal impairment (serum creatinine should be <2) or peptic ulcer disease.[5] SOR B
- Colchicine can be used in patients who cannot take NSAIDs. Colchicine 1.2 mg followed by 0.6 mg after 1 hour has equivalent efficacy and lower side effects compared to a high dose of 4.8 mg given over 6 hours. One third of patients will respond.[6] SOR B
- In monoarticular gout, consider an intraarticular injection with long-acting steroid (e.g., triamcinolone acetonide, 10 to 40 mg, depending on the size of the joint).[5] SOR C

CHRONIC GOUT

The treatment of chronic gout includes modifications in diet and existing medications (if possible) and lowering urate levels. Treatment measures include:[1]

- Nonpharmacologic:
  - Reduce the intake of purine-rich foods (e.g., organ meats, red meats, and seafood).
  - Increase fluid intake to 2000 mL/day.
  - Lower alcohol intake.
  - Consume dairy products as these may be protective against gout.[1]
- Medications:
  - Change medications—Discontinue aspirin (low dose up to 2 g/day causes uric acid retention) and consider stopping a thiazide diuretic.
  - Lower urate levels with xanthine oxidase inhibitors (e.g., allopurinol), uricosuric agents (e.g., probenecid) or uricase agents (e.g., pegloticase).
  - The level of urinary uric acid helps to determine which medication should be used with levels ≥600 mg/24 hours indicating a need to halt production with xanthine oxidase inhibitors and levels less than 600 mg/24 hours indicating a need for uricosuric drugs.
  - Allopurinol (100 to 300 mg/day for mild gout; for patients with moderate to severe tophaceous gout give 400 to 600 mg/day with a maximum daily dose of 800 mg/day). Titrate allopurinol to a serum uric acid level less than 6.[7] SOR B
  - Give colchicine (0.6 mg twice daily for the first 6 months of therapy) concomitantly during initiation of allopurinol to reduce the frequency and severity of acute flares.[8] SOR B
  - Consider uricosuric agents (probenecid, 250 mg twice daily increasing to 2 to 3 g/day or sulfinpyrazone, 50 to 100 mg twice daily increasing to 200 to 400 twice daily) in patients with uric acid excretion of less than 600 mg/24 hours, with normal renal function, younger than age 60 years, and no history of renal calculi.[5] SOR C
  - Consider oral potassium citrate (10 to 20 mEq 3 to 4 times a day) to prevent crystal precipitation in the urine as uricosuric agents increase urinary uric acid excretion.
  - Pegloticase, a mammalian recombinant uricase, is a medication that degrades urate when administered by intravenous infusion. Early randomized controlled trials show improvements in pain and quality of life; however, adverse events are high. This may be an option for patients with severe gout, allopurinol intolerance or refractoriness, and serum uric acid greater than 8 mg/dL despite conventional therapy.[9]
- Complementary and alternative therapy:
  - A number of Chinese and Vietnamese medicinal plants and herbs have xanthine oxidase inhibitory activity, but few have been tested for clinical effectiveness.

PREVENTION

- Intake of dairy products, folate, and coffee lowers risk of gout.[3]
- In a patient with a prior episode of gout, avoid medications that cause hyperuricemia—Thiazide diuretics, cyclosporine, aspirin (<1 g/day).[2]

PROGNOSIS

- Untreated, recurrent, and more severe attacks are common with 60% of patients experiencing a recurrence in year 1 and 25% in year 2.
- Colchicine 0.5 mg up to 3 times a day decreases attacks, but may not decrease joint destruction.[7] SOR B

FOLLOW-UP

- Follow patients with an acute flare through resolution and initiation of prophylactic therapy if indicated.

PATIENT EDUCATION

Advise patients to lose weight, minimize alcohol use, eat less meat and seafood, and obtain more protein from dairy.[5]

PATIENT RESOURCES

- The Arthritis Foundation. *Gout Living*—**http://www.arthritis.org/goutliving-basics.php.**
- MedlinePlus. *Gout*—**http://www.nlm.nih.gov/medlineplus/goutandpseudogout.html.**
- The American College of Rheumatology. *Gout*—**http://www.rheumatology.org/practice/clinical/patients/diseases_and_conditions/gout.asp.**

PROVIDER RESOURCES

- Medscape. *Gout and Pseudogout*—**http://emedicine.medscape.com/article/329958**.

REFERENCES

1. Choi HK, Curhan G. Gout: epidemiology and lifestyle choices. *Curr Opin Rheumatol.* 2005;17(3):341-345.
2. Neogi T. Gout. *N Engl J Med.* 2011;362:443-452.
3. Singh JA, Reddy SG, Kundukulam J. Risk factors for gout and prevention: a systematic review of the literature. *Curr Opin Rheumatol.* 2011;23(2):192-202.
4. Silman AJ, Hochberg MC. *Epidemiology of the Rheumatic Diseases.* New York, NY: Oxford University Press; 1993.
5. Wortmann RL. Recent advances in the management of gout and hyperuricemia. *Curr Opin Rheumatol.* 2005;17(3):319-324.

6. Terkeltaub RA, Furst DE, Bennett K, et al. High versus low dosing of oral colchicine for early acute gout flare: twenty-four-hour outcome of the first multicenter, randomized, double-blind, placebo-controlled, parallel-group, dose-comparison colchicine study. *Arthritis Rheum.* 2010;62(4):1060-1080.
7. Winklerprins VJ, Weismantel AM, Trinh TH. Clinical inquiries. How effective is prophylactic therapy for gout in people with prior attacks? *J Fam Pract.* 2004;53(10):837-838.
8. Borstad GC, Bryant LR, Abel MP, et al. Colchicine for prophylaxis of acute flares when initiating allopurinol for chronic gouty arthritis. *J Rheumatol.* 2004;31(12):2429-2432.
9. Sundy JS, Baraf HS, Yood RA, et al. Efficacy and tolerability of pegloticase for the treatment of chronic gout in patients refractory to conventional treatment. *JAMA.* 2011;306(7):711-720.

101 OLECRANON BURSITIS

Heidi Chumley, MD

PATIENT STORY

A 60-year-old man presents with swelling in his elbow for the last 2 months. He does not have pain unless he leans on his elbow. He denies any trauma. **Figure 101-1** demonstrates a "goose egg" swelling over the olecranon bursa that is not warm and is tender only to palpation. He has full range of motion. His olecranon bursitis was treated with ice, rest, and NSAIDs and he was told to avoid leaning on his elbow.

FIGURE 101-1 Chronic aseptic olecranon bursitis in a 60-year-old man showing typical swelling over the olecranon. There is no erythema or tenderness. (*Courtesy of Richard P. Usatine, MD.*)

INTRODUCTION

Olecranon bursitis can be aseptic, from repetitive trauma or systemic disease, or septic, most commonly from Gram-positive bacteria. Differences in clinical presentation help differentiate aseptic from septic olecranon bursitis; however, analysis of fluid may be necessary. Aseptic olecranon bursitis is treated with an elbow pad, NSAIDs, and ice. Septic olecranon bursitis is treated with drainage and antibiotics.

SYNONYMS

Popeye elbow, student elbow, baker elbow.

EPIDEMIOLOGY

Prevalence of aseptic olecranon bursitis is unknown, but is estimated to be twice as common as septic olecranon bursitis.[1]

- Prevalence of septic olecranon bursitis is at least 10 per 100,000 in the general population.[2]
- Peak age of onset is 40 to 50 years.
- Eighty-one percent are male.
- Fifty percent have antecedent trauma.

ETIOLOGY AND PATHOPHYSIOLOGY

Inflammation or degeneration of the sac overlying the olecranon bursa from:

- Repetitive motion or trauma, such as direct pressure on the elbow.
- Systemic diseases such as gout, pseudogout, and rheumatoid arthritis.
- Infection, typically by *Staphylococcus aureus* or another Gram-positive organism.

RISK FACTORS

- Aseptic bursitis—Occupation-related activities such as leaning on the elbow.
- Septic bursitis—Immunocompromised state.

DIAGNOSIS

The diagnosis of olecranon bursitis is made clinically, by its typical appearance (**Figures 101-1** and **101-2**). When necessary, joint aspiration verifies the diagnosis and separates septic from aseptic bursitis.

CLINICAL FEATURES OF SEPTIC BURSITIS[2]

- Common symptoms—Pain (87%), redness (77%), and subjective fever or chills (45%).
- Common signs—Erythema (92%), swelling (85%), edema (75%), tenderness (59%), and fluctuance (50%).
- Less common signs—Decreased range of motion (27%) and temperature greater than or equal to 37.8°C (100.04°F) (20%).

CLINICAL FEATURES OF ASEPTIC BURSITIS

- Swelling with minimal pain and tenderness.
- Erythema may be present (**Figure 101-2**).
- Fever is typically absent.

LABORATORY TESTING

- Erythrocyte sedimentation rate and C-reactive protein may be elevated in both septic and aseptic presentations.[3]
- Bursal fluid findings that help differentiate septic from aseptic olecranon bursitis:[3]
  - White blood cell (WBC) count greater than 30,000 in septic bursitis; less than 28,000 in aseptic bursitis; however, elevated WBC count is also seen in rheumatoid arthritis or gout.
  - Neutrophils seen in septic bursitis; monocytes seen in aseptic bursitis.
  - Glucose less than 50% of serum glucose in septic bursitis; greater than 70% of serum glucose in aseptic bursitis.
  - Gram-positive organisms on gram stain in septic bursitis.

IMAGING

- Usually not indicated.
- In traumatic bursitis, radiographs may identify a foreign body.
- In atypical cases, MRI may be needed to determine the extent of soft-tissue involvement.

ASPIRATION

- Aspirate when there is suspicion of infection or crystal disease (moderate pain, fever, warmth over the olecranon)[4] or for discomfort caused by extensive swelling.[5]

FIGURE 101-2 Aseptic olecranon bursitis secondary to repetitive elbow leaning in this computer programmer. There is some erythema and minimal tenderness. The aspirated fluid was clear. Most patients (70%) retain full extension in the elbow despite swelling over the olecranon. (*Courtesy of Richard P. Usatine, MD.*)

DIFFERENTIAL DIAGNOSIS

Pain and swelling around the elbow joint may be caused by:

- Gout or pseudogout (acute pain with signs of inflammation), prior history of gout (pseudogout).
- Rheumatoid arthritis (pain, inflammation, loss of range of motion, often involves other joints).
- Septic joint (acute pain, loss of range of motion, fever).
- Hemorrhage into the bursa (history of trauma, bruising).

Other causes of elbow pain typically without swelling include:

- Lateral or medial epicondylitis (pain lateral or medial, not over olecranon).
- Ulnar nerve entrapment (concurrent numbness in fingers).

MANAGEMENT

SEPTIC BURSITIS

- Identify organism using Gram stain and culture (**Figure 101-3**).
- If the WBC is slightly elevated and no organisms are seen on Gram stain, treat empirically with oral antibiotics active against Gram positives until culture results are available (i.e., cephalexin 500 mg twice a day or levofloxacin 500 mg/day).[6] SOR C
- If WBCs are moderately elevated and organisms are seen on Gram stain, use intravenous medications such as oxacillin or nafcillin 2 g every 6 hours or cephazolin 1 to 2 g every 8 hours.[6] SOR C
- Vancomycin can be considered for penicillin- or cephalosporin-allergic patients or in communities with high rates of methicillin-resistant *S. aureus* (MRSA).[6] SOR C
- Home IV therapy is safe and effective for immunocompetent patients.[2] SOR B
- Hospitalize immunosuppressed patients or those who do not respond to therapy.[6] SOR C
- Aspirate after several days of treatment and continue antibiotics for 5 days after fluid is sterile.[6] SOR C
- Refer to an orthopedic specialist if incision and debridement of the bursa is needed. SOR C

ASEPTIC BURSITIS

- The first line of treatment should be wearing an elbow pad at all times in addition to modification of activities (no leaning on elbows) and NSAIDs as tolerated.
- Patient education about aggravating factors.
- Ice and rest.
- Consider corticosteroid injection for severe pain, persistent, or recurrent fluid accumulation.[6] SOR C Because there is a risk of converting an aseptic olecranon bursitis to a septic one with aspiration and steroid injection, the treatment options noted above should be exhausted prior to consideration of steroid injection.
- Consider surgical referral for recalcitrant fluid accumulation.

FIGURE 101-3 Septic olecranon bursitis in an immunosuppressed patient with pemphigus vulgaris. Aspiration showed gram positive cocci on gram stain and MRSA grew out of the culture. Patient was treated in the hospital with IV vancomycin and then discharged on oral doxycycline when the sensitivities were available and the patient was stable. (*Courtesy of Richard P. Usatine, MD.*)

ASPIRATION

When indicated, aspirate fluid as follows:[5]

- Flex elbow to 45 degrees.
- Locate triangle formed by lateral olecranon, the head of the radius, and the lateral epicondyle.
- Using sterile technique, insert needle into the soft tissue in the middle of the triangle, pointing toward the medial epicondyle. (If there is a significant amount of fluid, it is hard to miss the fluid regardless of the direction of the needle as long as the needle gauge is sufficient for aspiration. Consider a 20- to 22-gauge needle, and if an 18-gauge needle is to be used, give the patient some local anesthetic first.
- Aspirate fluid and send for complete blood count (CBC), Gram stain, culture, and evaluate for crystals if gout or pseudogout is expected.
- Consider injecting with steroid (see below) only if aspirate is clear and history does not suggest infection.

PROGNOSIS

- Aseptic olecranon bursitis often resolves with conservative therapy.[7]
- Septic bursitis has a recurrence rate of 15% in hospitalized patients treated with surgical interventions and antibiotics.[7]

FOLLOW-UP

Follow septic bursitis until fluid is sterile. Reaspirate after 4 to 5 days of antibiotics and continue antibiotics for 5 days after fluid is sterile.

PATIENT EDUCATION

Limit bursa aggravation by not leaning on elbows or pushing off on elbows when arising. Aseptic and septic bursitis may require multiple aspirations.

PATIENT RESOURCES

- **http://www.patient.co.uk/health/Olecranon-Bursitis.htm.**

PROVIDER RESOURCES

- Includes a description of aspiration technique—**http://www.aafp.org/afp/2002/1201/p2097.html.**

REFERENCES

1. Stell IM. Septic and non-septic olecranon bursitis in the accident and emergency department–an approach to management. *J Accid Emerg Med*. 1996;13(5):351-353.
2. Laupland KB, Davies HD. Calgary home parenteral therapy program study group. Olecranon septic bursitis managed in an

ambulatory setting. The Calgary home parenteral therapy program study group. *Clin Invest Med.* 2001;24:171-178.

3. Wasserman AR, Melville LD, Birkhahn RH. Septic bursitis: a case report and primer for the emergency clinician. *J Emerg Med.* 2009; 37(3):269-272.
4. Work Loss Data Institute. *Elbow (Acute and Chronic)*. National Guidelines Institute. http://guidelines.gov/content.aspx?id=33179. Updated April 28, 2011. Accessed November 21, 2011.
5. Cardone DA, Tallia AF. Diagnostic and therapeutic injection of the elbow region. *Am Fam Physician.* 2002;66(11):2097-2100.
6. Sheon RP, Kotton CN. Septic bursitis. UpToDate. http://www.utdol.com/utd/content/topic.do?topicKey=skin_inf/12648. Accessed February 24, 2008.
7. Perez C, Huttner A, Assal M, et al. Infectious olecranon and patellar bursitis: short-course adjuvant antibiotic therapy is not a risk factor for recurrence in adult hospitalized patients. *J Antimicrob Chemother*. 2010;65(5):1008-1014.

102 CLAVICULAR FRACTURE

Heidi Chumley, MD

PATIENT STORY

A 17-year-old boy presents after falling off his skateboard and landing directly on his lateral shoulder. He had immediate pain and swelling in the middle of his clavicle. His examination revealed a bump in the middle of his clavicle. A radiograph confirmed a midclavicular fracture (**Figure 102-1**). He was treated conservatively with a sling, which he wore for approximately 1 of the recommended 3 weeks. A follow-up radiograph demonstrated good healing. The bump on his clavicle is still palpable; however, this does not bother him.

INTRODUCTION

Clavicular fractures are common in both children and adults and are most commonly caused by accidental trauma. The clavicle most commonly fractures in the midshaft (**Figures 102-1** to **102-3**), but can also fracture distally (**Figure 102-4**). Many fractures can be treated conservatively. Refer patients with significant displacement or distal fractures for surgical evaluation.

EPIDEMIOLOGY

- Clavicular fractures account for 2.6% of all fractures in adults, with an overall incidence of 64 per 100,000 people per year; midshaft fractures account for approximately 69% to 81% of all clavicle fractures.[1]
- Accounts for 10% to 15% of fractures in children; 90% are midshaft fractures.[2]

ETIOLOGY AND PATHOPHYSIOLOGY

- Most are caused by accidental trauma from fall against the lateral shoulder or an outstretched hand or direct blow to the clavicle; however, stress fractures in gymnasts and divers have been reported.
- Pathologic fractures (uncommon) can result from lytic lesions, bony cancers or metastases, or radiation.
- Birth trauma (neonatal).
- Physical assaults, intimate partner violence, and child abuse can cause clavicular fractures.

DIAGNOSIS

CLINICAL FEATURES

- History of trauma with a mechanism known to result in clavicle fractures (i.e., fall on an outstretched hand or lateral shoulder, or direct blow).

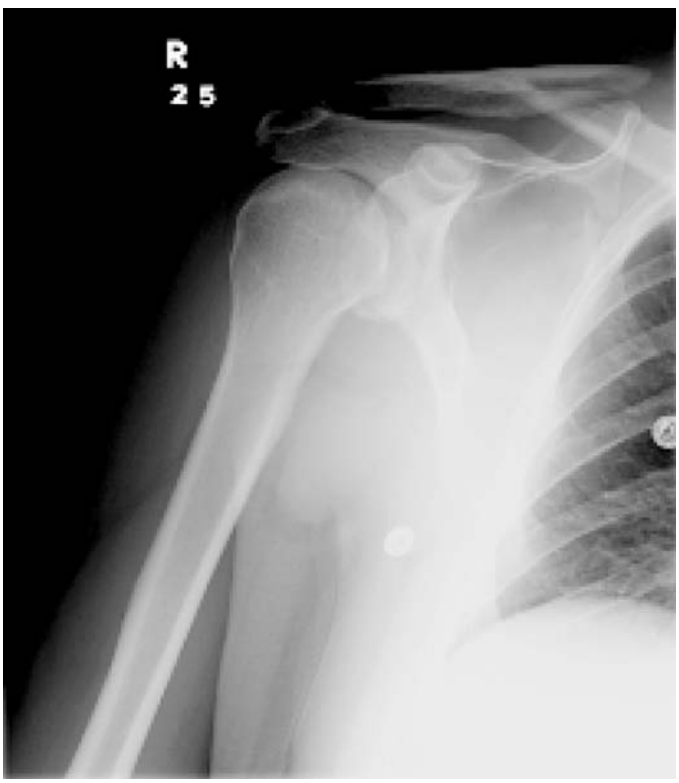

FIGURE 102-1 Midshaft clavicle fracture. Clavicle fractures are designated midshaft (in the middle third), distal (distal third), or medial (medial third). (*From Simon RR, Sherman SC, Koenigsknecht SJ. Emergency Orthopedics the Extremities. New York, NY: McGraw-Hill; 2007:286, Fig. 11-35. Copyright 2007.*)

FIGURE 102-2 Midshaft clavicle fracture with angulation. (*From Simon RR, Sherman SC, Koenigsknecht SJ. Emergency Orthopedics the Extremities. New York, NY: McGraw-Hill; 2007:297, Fig. 11-54. Copyright 2007.*)

TABLE 102-1 Typical Distribution/Classification

Group (Approx. %)	Fracture Location	Radiographic Appearance
Group I (80%)	Middle third	Upward displacement (**Figures 102-1** to **102-3**)
Group II (15%)	Distal third	Medial side of fragment is displaced upward (**Figure 102-4**)
Type I		Minimal displacement
Type II		Fracture medial to coracoclavicular ligaments; some overlapping of fragments
Type III		Fracture at the articular surface of the acromioclavicular (AC) joint; can look like AC separation
Group III (5%)	Medial third	Medial side of fragment up; distal side down

- Pain and swelling at the fracture site.
- Gross deformity at site of fracture.

TYPICAL DISTRIBUTION

- For the typical distribution and classification of clavicular fractures, see **Table 102-1**.

IMAGING

- Obtain plain films of the clavicle for radiographic evidence of fracture.

FIGURE 102-3 Midshaft clavicular fracture with proximal fragment displaced superiorly from the pull of the sternocleidomastoid muscle. (*From Simon RR, Sherman SC, Koenigsknecht SJ. Emergency Orthopedics the Extremities. New York, NY: McGraw-Hill; 2007:283, Fig. 11-32. Copyright 2007.*)

DIFFERENTIAL DIAGNOSIS

- Acromioclavicular (AC) separation (**Figure 102-5**)—Fall directly on the "point" of the shoulder or a direct blow, pain with overhead movement, tenderness at the AC joint, and AC joint separation on radiographs.
- Sternoclavicular dislocation—Fall on the shoulder, chest and shoulder pain exacerbated by arm movement or when lying down, and a prominence from the superomedial displacement of the clavicle (uncommon).
- Pseudoarthrosis of the clavicle—Painless mass in the middle of the clavicle from failure of the central part of the clavicle to ossify (extremely rare).

MANAGEMENT

For all adults and children:

- Assess neurovascular status of injured extremity.
- Assess for damage to lungs (pneumothorax or hemothorax).
- Determine the classification and amount of displacement by radiograph (**Figure 102-1**; see also **Table 102-1**).

NONPHARMACOLOGIC

Most clavicular fractures can be treated nonoperatively, other options include fixation with plates or pins.

FIGURE 102-4 Distal clavicular fracture. (*From Simon RR, Sherman SC, Koenigsknecht SJ. Emergency Orthopedics the Extremities. New York, NY: McGraw-Hill; 2007:286, Fig. 11-35. Copyright 2007.*)

Child clavicle fracture

- Treat most children with any type of clavicle fracture conservatively, without immobilization.[2] SOR C
- Treat children nonoperatively even with 90-degree displacement and several inches of overlap.[2] SOR C

Adult midclavicular fractures

- Treat adults with non- or minimally displaced midshaft clavicular fractures nonoperatively. SOR B
- Place adults in a sling instead of a figure-of-eight. Patients treated with a sling had higher treatment satisfaction than those treated with a figure-of-eight bandage.[3] SOR B
- Midclavicular fractures can be treated with a clavicle brace; treat until radiographic evidence of healing has occurred. SOR C Wearing the brace frees the upper extremities for activities of daily living. The clavicle brace may improve the alignment of the midclavicular fracture.
- Refer patients with initial fracture shortening over 2 cm to discuss operative and conservative options. SOR B These patients have a higher risk of a nonunion associated with poor functional outcomes.[4]

Adult distal clavicular fractures

- Treat patients with nondisplaced distal clavicle fractures conservatively.
- Distal clavicle fractures are commonly treated by wearing a sling for 6 weeks to minimize the weight of the arm pulling on the distal clavicle fragment.
- Some patients with displaced distal clavicle fracture may benefit from surgery. Refer patients, other than the very elderly, to discuss risks and benefits of operative and nonoperative options.[5]

MEDICATIONS

- Treat pain as needed with acetaminophen or NSAIDs.

REFERRAL

- Refer for surgical evaluation, children with impingement of soft tissue/muscle, instability of shoulder girdle, displacement with skin perforation/necrosis, or risk to mediastinal structures.[2] SOR C
- Consider referring patients with displaced fractures. Nonoperative treatment has a 15.1% nonunion rate, whereas operative rates are 0% to 2%.[1]
- Consider consulting with a physician skilled in managing clavicular fractures in patients with a distal clavicle fracture. These fractures have a high rate of nonunion; however, only a portion of nonunions are painful or inhibit function. If the patient continues to have a symptomatic nonunion after many months, surgery may be considered.

FIGURE 102-5 Acromioclavicular joint separation (third degree) with a wide AC joint and the clavicle displaced from the acromion. (*From Simon RR, Sherman SC, Koenigsknecht SJ. Emergency Orthopedics the Extremities. New York, NY: McGraw-Hill; 2007:297, Fig. 11-54. Copyright 2007.*)

PROGNOSIS

- Midclavicular displaced fractures treated nonoperatively have a nonunion rate of up to 15% and a poor functional outcome in up to 5%. Operative nonunion rates are 0% to 2%.[1]

- Patients with distal clavicle fractures treated nonoperatively had nonunion rates of 21%; however, there was no difference in function between those who healed and those with a nonunion.[6] SOR B

FOLLOW-UP

- Monitor with examination and radiographs until pain has resolved, any lost function has returned, and there is radiographic evidence of healing. Initially, repeat x-ray every 1 to 2 weeks to evaluate for any change in alignment. If the fracture is stable, repeat x-ray every 4 to 6 weeks until the clavicle has healed. If there is no evidence of healing after 2 to 3 months, referral should be considered.

PATIENT EDUCATION

Most clavicle fractures heal without surgery, especially if the fracture is not displaced. Fractures in adults take 6 to 8 weeks to heal and fractures in children take approximately 3 to 4 weeks to heal. Often, there will be a bump at the site of the healed fracture, which typically does not interfere with any activities.

PATIENT RESOURCES

- American Academy of Orthopedic Surgeons. Patient information handout under *Broken Collarbone*—**http://orthoinfo.aaos.org/topic.cfm?topic=A00072.**

PROVIDER RESOURCES

- **http://emedicine.medscape.com/article/1260953.**
- Duke University online. *Wheeless' Textbook of Orthopaedics*—**http://www.wheelessonline.com/ortho/clavicle_fractures.**

REFERENCES

1. Zlowodzki M, Zelle BA, Cole PA, et al; Evidence-Based Orthopaedic Trauma Working Group. Treatment of acute midshaft clavicle fractures: systematic review of 2144 fractures: on behalf of the Evidence-Based Orthopaedic Trauma Working Group. *J Orthop Trauma.* 2005;19(7):504-507.
2. Kubiak R, Slongo T. Operative treatment of clavicle fractures in children: a review of 21 years. *J Pediatr Orthop.* 2002;22:736-739.
3. Andersen K, Jensen PO, Lauritzen J. Treatment of clavicular fractures. Figure-of-eight bandage versus a simple sling. *Acta Orthop Scand.* 1987;58(1):71-74.
4. Preston CF, Egol KA. Midshaft clavicle fractures in adults. *Bull NYU Hosp Jt Dis.* 2009;67(1):52-57.
5. Khan LA, Bradnock TJ, Scott C, Robinson CM. Fractures of the clavicle. *J Bone Joint Surg Am.* 2009;91(2):447-460.
6. Robinson CM, Cairns DA. Primary nonoperative treatment of displaced lateral fractures of the clavicle. *J Bone Joint Surg Am.* 2004;86-A(4):778-782.

103 DISTAL RADIUS FRACTURE

Heidi Chumley, MD
Richard P. Usatine, MD

PATIENT STORY

A 65-year-old woman tripped on a rug in her home and fell on her outstretched hand with her wrist dorsiflexed (extended). She felt immediate pain in her wrist and has difficulty in moving her wrist or hand. She has been postmenopausal for 15 years and has never taken hormone replacement therapy or bisphosphates. She presented with pain and swelling in her wrist. Her arm had a "dinner-fork" deformity. Radiographs showed a distal radius fracture with dorsal angulation on the lateral view (**Figure 103-1**).

INTRODUCTION

Distal radius fractures are common, especially in postmenopausal women. Patients present with wrist pain and a "dinner-fork" deformity. Diagnosis is confirmed by radiographs. Treatment is either operative or nonoperative, based on the degree of displacement and the age of the patient.

SYNONYMS

Colles fracture is the most common type. Other types of distal radius fractures include Smith fracture, Barton fracture and Hutchinson fracture.

EPIDEMIOLOGY

- More common in older women—Female-to-male ratio of 3.2:1.[1]
- Prevalence—In a community study of 452 people older than age 40 years in the United Kingdom, 10.8% of women and 2.6% of men had a prior distal radius fracture.[2]
- Incidence—In Sweden, the incidence is 115 per 100,000 women and 29 per 100,000 men.[1]

ETIOLOGY AND PATHOPHYSIOLOGY

- Classic history is a fall on an outstretched hand.
- In patients older than 40 years of age, there is a strong association with osteoporosis. Patients with low-impact distal radius fractures have higher rates of osteoporosis than age-matched controls without fractures by bone density measured at the wrist (60% vs. 35%; $p < 0.001$; odds ratio [OR], 5.7; 95% confidence interval [CI], 1.2 to 27.2) and lumbar spine (47% vs. 20%; $p < 0.005$; OR, 3.9; 95% CI, 1.1 to 14.3).[3]

FIGURE 103-1 Colles fracture. This occurred after a fall on an extended wrist. **A.** Lateral view shows a distal radius fracture with dorsal angulation. **B.** Anterior–posterior view demonstrating a transverse distal radius fracture. (*Courtesy of Rebecca Loredo-Hernandez, MD.*)

- Postmenopausal women and older men with distal radius fractures have an increased risk for a future hip fracture (relative risk [RR] = 1.53; 95% CI, 1.34 to 1.74; p <0.001; RR = 3.26; 95% CI, 2.08 to 5.11; p <0.001, respectively).[4]

RISK FACTORS

Osteoporosis for men or women.[5]

DIAGNOSIS

Diagnosis is suspected by a compatible history, such as falling on a dorsiflexed wrist and confirmed with a plain radiograph showing the fracture of the distal radius (**Figure 103-1**).

CLINICAL FEATURES

Patients present with wrist pain and are not able to use the wrist or hand. The distal radius typically angles dorsally, creating the "dinner-fork" deformity (**Figure 103-1**). Swelling is usually present.

IMAGING

Wrist radiographs (two views) confirm the fracture and demonstrate the degree of displacement and angulation.

While Colles fracture is the most common distal radius fracture, there are 3 other types that can be classified based upon their radiographic appearance, history and physical exam:

1. Smith fracture is a reverse Colles fracture in which the angulation is in the palmar direction. It usually occurs after a fall on a flexed wrist or a direct blow to the dorsal wrist. The distal radial metaphysis it is displaced and angulated in the palmar direction and an associated ulna styloid fracture may be seen (**Figure 103-2**).
2. Barton fracture is an intraarticular dorsal or volar rim fracture. It occurs with forced wrist dorsiflexion and pronation. A triangular fragment of the distal radial styloid occurs as seen in **Figure 103-3**.
3. Hutchinson fracture (chauffeur's fracture) is a fracture through the base of the radial styloid. It occurs with forced hyperextension of the wrist. There will be tenderness at the radial styloid on exam and the radiograph indicates a radial styloid fracture (**Figure 103-4**). It is also named a chauffeur's fracture from the past when a chauffeur would crank a car manually and the kick back could break the wrist in this pattern.

FIGURE 103-2 Smith fracture (Reverse Colles fracture). **A.** Lateral view of a fracture of the distal radial metaphysis that is displaced and angulated in the palmar direction. This occurred after a fall on a flexed wrist. (*Courtesy of Rebecca Loredo-Hernandez, MD.*)

DIFFERENTIAL DIAGNOSIS

Other causes of pain at the wrist include:

- Scaphoid fracture—Forced hyperextension, tenderness in anatomic snuffbox; radiograph demonstrates scaphoid fracture (70%).
- de Quervain tenosynovitis—No acute injury, pain on radial side of wrist from abductor pollicis longus and extensor pollicis brevis involvement, pain over the tendon when the thumb is placed into the patient's fist and the wrist is deviated to the ulnar side; radiographs (not usually done) are normal.

FIGURE 103-3 Barton fracture. **A.** Lateral view showing a marginal fracture of the dorsal rim of the radius that is displaced along with the carpus producing a fracture-subluxation. **B.** AP view showing the triangular fragment of the radial styloid (*arrow*). (*Courtesy of Rebecca Loredo-Hernandez, MD.*)

FIGURE 103-4 Hutchinson fracture or chauffeur's fracture. This oblique view demonstrates a fracture through the base of the radial styloid (*arrow*). (*Courtesy of Rebecca Loredo-Hernandez, MD.*)

TABLE 103-1 Universal Classification of Radial Fractures

Fracture Classification	Management
I Nonarticular, nondisplaced	Immobilization with cast or splint[6] for 4 to 6 weeks
II Nonarticular, displaced	Reduction with cast or splint immobilization; surgical management if irreducible or unstable fracture
III Articular, nondisplaced	Immobilization; pinning if unstable
IV Articular, displaced	Surgical management (**Figure 103-5** and **Figure 103-6**)

MANAGEMENT

Examine patients for the following associated complications:

- Flexor tendon injuries.
- Median and ulnar nerve injuries.

Examine radiographs for the following associated injuries:

- Ulnar styloid or neck fractures.
- Carpal fractures.
- Distal radioulnar subluxation.

Management is based on whether the fracture is nonarticular or articular, displaced or nondisplaced, reducible or irreducible (**Figure 103-5**). Although there are multiple accepted classification schemes, the Universal Classification of radial fractures, shown in **Table 103-1**, is the most straightforward when determining management.[6] See **Figure 103-6** for a successful open reduction and internal fixation on a distal radial fracture. Note that this fracture was articular with displacement (**Figure 103-5**).

- The patient's wrist in most cases is splinted for the first few days after injury to allow swelling to decrease prior to casting.
- On the basis of the type of fracture, the patient's wrist is typically cast from 4 to 6 weeks and followed with serial radiographs.
- The patient should be referred to a musculoskeletal or orthopedic specialist if a fracture requires reduction. Management of displaced fractures is controversial, with surgical and nonsurgical treatments demonstrating similar outcomes.
  - External fixation, compared to cast immobilization, reduces displacement, but does not result in an improved functional outcome in adults.[7]
  - Open reduction and internal fixation was compared to closed reduction and cast fixation in patients older than age 65 years with an unstable displaced radial fracture. At 12 months, there was no difference in range of motion, pain, or function.[8]
- All patients with a low-impact distal radius fracture are at a higher risk for osteoporosis and clinicians should consider screening for osteoporosis.

FIGURE 103-5 31-year-old woman fell on a flexed wrist. **A.** Lateral view shows a distal radius comminuted intra-articular fracture with palmar displacement and volar angulation occurred (Smith fracture). This Type IV fracture is best managed with surgery. **B.** PA view shows an associated ulna styloid process fracture that is mildly displaced (*arrow*). (*Courtesy of Richard P. Usatine, MD.*)

PREVENTION

Screening for and treatment of osteoporosis may reduce fractures, including distal radial fractures.

PROGNOSIS

Most patients recover adequate function and do not have chronic pain, whether treated nonsurgically or surgically. In nonsurgically treated patients, higher degree of displacement leads to increased risk of poor function or pain 10 years after fracture.[9]

FOLLOW-UP

- Management and follow-up often involve a physician with expertise in managing distal radial fractures.
- Evaluate for osteoporosis.

PATIENT EDUCATION

- Distal radial fractures may result in limitations of wrist function.
- Nontraumatic fractures, in patients older than 40 years of age, may indicate osteoporosis.

PATIENT RESOURCES

- WebMD has information on distal radial fractures—**http://www.webmd.com/a-to-z-guides/colles-fracture.**

PROVIDER RESOURCES

- *Wheeless' Textbook of Orthopaedics* has additional information about the types of distal radius fractures, classification systems, and radiographic findings—**http://www.wheelessonline.com/ortho/12591.**

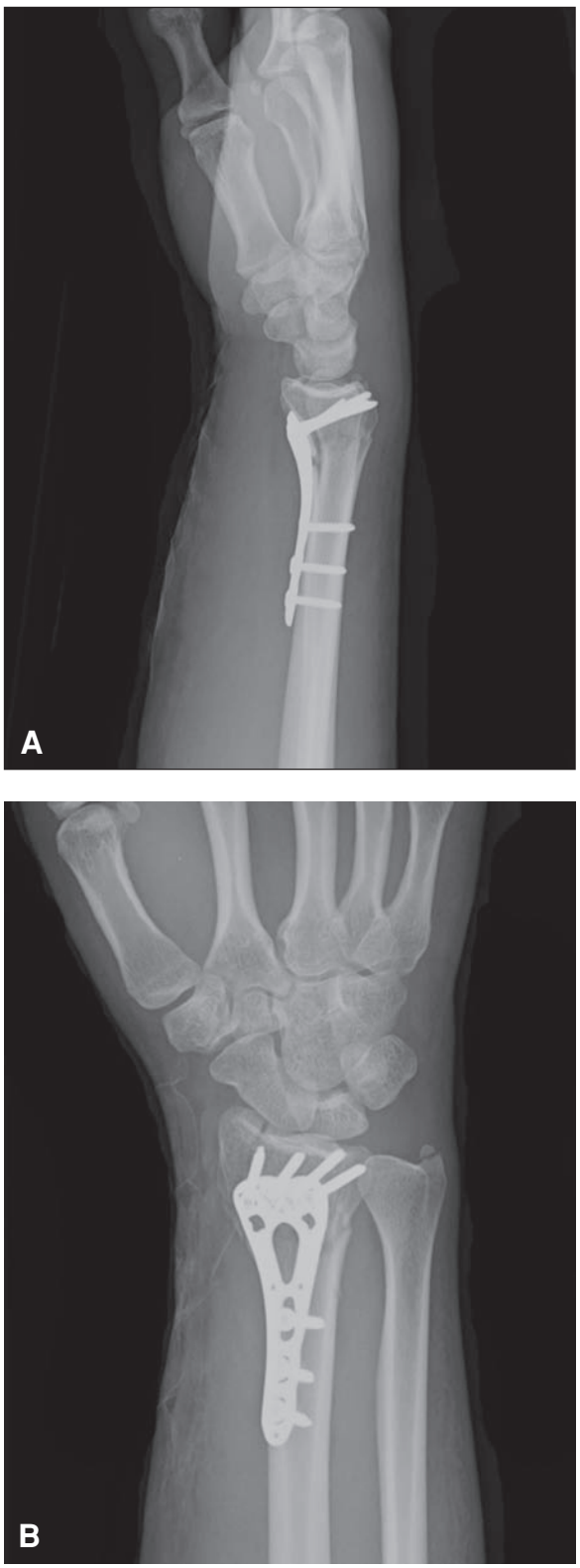

FIGURE 103-6 Open reduction and internal fixation of the distal radius fracture in **Figure 103-5**. Volar plate and screw fixation has placed the wrist in anatomic alignment for healing. **A.** Lateral view. **B.** Oblique view. (*Courtesy of Richard P. Usatine, MD.*)

REFERENCES

1. Masud T, Jordan D, Hosking DJ. Distal forearm fracture history in an older community-dwelling population: the Nottingham Community Osteoporosis (NOCOS) Study. *Age Ageing.* 2001; 30:255-258.
2. Mallmin H, Ljunghall S. Incidence of Colles' fracture in Uppsala. A prospective study of a quarter-million population. *Acta Orthop Scand.* 1992;63(2):213-215.
3. Kanterewicz E, Yanez A, Perez-Pons A, et al. Association between Colles' fracture and low bone mass: age-based differences in post-menopausal women. *Osteoporos Int.* 2002;13(10):824-828.
4. Haentjens P, Autier P, Collins J, et al. Colles fracture, spine fracture, and subsequent risk of hip fracture in men and women. A meta-analysis. *J Bone Joint Surg Am.* 2003;85-A(10):1936-1943.
5. Oyen J, Brudvik C, Gjesdal CG, et al. Osteoporosis as a risk factor for distal radial fractures: a case-control study. *J Bone Joint Surg Am.* 2011;93(4):348-356.
6. Newport ML. Upper extremity disorders in women. *Clin Orthop.* 2000;(372):85-94.

7. Handoll HH, Huntley JS, Madhok R. External fixation versus conservative treatment for distal radial fractures in adults. *Cochrane Database Syst Rev.* 2007;18(3):CD006194.
8. Arora R, Lutz M, Deml C, et al. A prospective randomized trial comparing nonoperative treatment with volar locking plate fixation for displaced and unstable distal radial fractures in patients sixty-five years of age and older. *J Bone Joint Surg Am.* 2011;93(23):2146-2153.
9. Foldhazy Z, Törnkvist H, Elmstedt E, et al. Long-term outcome of nonsurgically treated distal radial fractures. *J Hand Surg Am.* 2007;32(9):1374-1384.

104 METATARSAL FRACTURE

Heidi Chumley, MD

PATIENT STORY

A 37-year-old man inverted his ankle while playing basketball with his teenagers in their driveway. He felt a pop and had immediate pain. He had tenderness over the base of his fifth metatarsal. Having met the Ottawa ankle rules for radiographs (see later), a radiograph was obtained, which revealed a nondisplaced fracture at the base of the fifth metatarsal (**Figure 104-1**).

FIGURE 104-1 Fifth metatarsal tuberosity avulsion fracture (dancer fracture). (*From Simon RR, Sherman SC, Koenigsknecht SJ. Emergency Orthopedics, The Extremities, 5th ed. New York: McGraw-Hill; 2007: 488, Fig. 18-21B. Copyright 2007.*)

INTRODUCTION

Most metatarsal fractures involve the fifth metatarsal and include avulsion fractures at the base, acute diaphyseal fractures (Jones fracture), and diaphyseal stress fractures. Fractures of the first through fourth metatarsals are less common but can be associated with a Lisfranc injury. Diagnosis is based on the mechanism of injury or type of overuse activity and radiographic appearance. Treatment depends on the type of fracture. Most metatarsal fractures have a good prognosis; however, Jones fractures have a high rate of nonunion and Lisfranc injuries can result in chronic symptoms.

SYNONYMS

Avulsion fracture at base of fifth metatarsal: fifth metatarsal tuberosity fracture, dancer fracture, pseudo-Jones fracture.

Jones fracture: acute diaphyseal fracture of the fifth metatarsal.

EPIDEMIOLOGY

- Foot fractures are common injuries among recreational and serious athletes; however, incidence and prevalence in most populations is unknown.
- In women older than age 70 years, the incidence of foot fractures is 3.1 per 1000 woman-years, and more than 50% of these are fifth metatarsal fractures.[1]
- Fifty percent of metatarsal fractures in adults ages 16 to 75 years involve the fifth metatarsal.[2]
- The majority of fifth metatarsal fractures are avulsion injuries (**Figure 104-1**).
- Twenty-three percent of elite military personnel sustain metatarsal stress fracture; most of these occur after 6 months of training.[3]

ETIOLOGY AND PATHOPHYSIOLOGY

- Avulsion fractures result when the peroneus brevis tendon and the lateral plantar fascia pull off the base of the fifth metatarsal, typically during an inversion injury while the foot is in plantar flexion.

- Jones (acute diaphyseal) fracture results from landing on the outside of the foot with the foot plantar flexed.
- Diaphyseal stress fractures are caused by chronic stress from activities such as jumping and marching.
- Fractures of the first through fourth metatarsals are caused by direct blows or falling forward over a plantar-flexed foot. These fractures may be associated with a Lisfranc injury.

DIAGNOSIS

The diagnosis of avulsion or Jones fractures is made on plain radiographs in a patient with a history of injury and acute lateral foot pain. Diaphyseal stress fractures may require CT imaging.

CLINICAL FEATURES

- Avulsion injury—Sudden onset of pain (and tenderness on examination) at the base of the fifth metatarsal after forced inversion with the foot and ankle in plantar flexion.
- Acute Jones fracture—Sudden pain at the base of the fifth metatarsal, with difficulty bearing weight on the foot, after a laterally directed force on the forefoot during plantar flexion of the ankle.
- Stress fracture—History of chronic foot pain with repetitive motion.

IMAGING

- Avulsion fracture—Fracture line at base of fifth metatarsal oriented perpendicularly to the metatarsal shaft (**Figure 104-1**). May extend into joint with cuboid bone, but does not extend into the intermetatarsal joint.
- Acute Jones fractures (**Figure 104-2**) and stress fractures both have a fracture line through the proximal 1.5 cm of the fifth metatarsal shaft. These should be classified into type I, II, or III as below:[4]
  - Type I fractures have a sharp, narrow fracture line, no intramedullary sclerosis, and minimal cortical hypertrophy.
  - Type II fractures (delayed unions) have a widened fracture line with radiolucency, involve both cortices, and have intramedullary sclerosis.
  - Type III fractures (nonunions) have a wide fracture line, periosteal new bone and radiolucency, and obliteration of the medullary canal by sclerotic bone.
- Early stress fractures may have normal radiographs and can be seen on CT, MRI, or bone scan. Ultrasound may be a less expensive option—sensitivity 83%, specificity 76%, positive predictive value 59% and negative predictive value 92% in one small study.[5]

FIGURE 104-2 Jones fracture, a transverse fracture at the junction of the diaphysis and metaphysic. (*From Simon RR, Sherman SC, Koenigsknecht SJ. Emergency Orthopedics, The Extremities, 5th ed. New York: McGraw-Hill; 2007:488, Fig. 18-21A. Copyright 2007.*)

DIFFERENTIAL DIAGNOSIS

Pain at the fifth metatarsal can also be caused by:

- Diaphyseal stress fracture—May be radiographically similar to Jones fracture but is often seen more distally in the shaft; occurs in patients with no injury and history of overuse (e.g., ballet dancing, marching).

- Lisfranc injury—Disruption of the tarsal metatarsal joints. This pain is typically in the midfoot and more commonly medial. May be associated with fractures in the first through fourth metatarsals.

X-ray findings that can be confused with foot fractures include:

- Apophysis, a secondary center of ossification at the proximal end of the fifth metatarsal seen in girls, ages 9 to 11 years, and boys, ages 11 to 14 years. The apophysis is oblique to the metatarsal shaft, whereas avulsion fractures are perpendicular.
- Accessory ossicles (i.e., os peroneum, located at the lateral border of the cuboid) have smooth edges, whereas avulsion fractures have rough edges.

MANAGEMENT

Apply the Ottawa ankle rules to determine which patients with an injury and ankle/foot pain should have an X-ray.[6] SOR A Ottawa rules: X-ray patients who cannot walk four steps immediately after the injury or who have localized tenderness at the posterior edge or tip of either malleolus, the navicular, or the base of the fifth metatarsal.[6]

- Treat nondisplaced avulsion fractures with an ankle splint or walking boot with ambulation for 3 to 6 weeks.[7] SOR B Refer displaced avulsion fractures.
- Consider referring Jones fractures because of the high rate of nonunion caused by the poor blood supply. Type I or II may be treated with immobilization for at least 6 to 8 weeks. Type II can also be treated with surgery. Type III requires surgical repair. Elite athletes or patients needing a faster recovery are often surgically treated.[8] SOR B
- Treat stress fractures with elimination of the causative activity for 4 to 8 weeks. Immobilization is often not required. If walking is painful, partial or non–weight bearing for 1 to 3 weeks may be necessary.[9]

Refer patients with:[9]

- Neurovascular compromise, compartment syndrome or open fractures.
- First metatarsal fracture, multiple metatarsal fractures, displaced fracture, intraarticular fracture, or Lisfranc injury.
- Inadequate response to treatment.

PROGNOSIS

Metatarsal fractures have an excellent outcome, with most patients symptom free at 33 months. Patients with higher body mass index (BMI), diabetes mellitus, women, and a dislocation with the fracture have less-positive outcomes.[2]

FOLLOW-UP

Patients should be followed every 1 to 3 weeks to evaluate for appropriate clinical and radiographic response to treatment.

PATIENT EDUCATION

Patients with nondisplaced avulsion fractures require a splint or boot, but can remain ambulatory. Jones fractures have a poor blood supply and often do not reconnect, even with immobilization. Surgery may result in a faster return to activities in some cases.

PATIENT RESOURCES

- Patient.co.uk has patient information on metatarsal fractures—**http://www.patient.co.uk/health/Metatarsal-Fractures.htm.**

PROVIDER RESOURCES

- The Ottawa ankle rules are available in several places online including—**http://www.mdcalc.com/ottawa-ankle-rules.**

REFERENCES

1. Hasselman CT, Vogt MT, Stone KL, et al. Foot and ankle fractures in elderly white women. Incidence and risk factors. *J Bone Joint Surg Am.* 2003;85-A(5):820-824.
2. Cakir H, Van Vliet-Koppert ST, Van Lieshout EM, et al. Demographics and outcome of metatarsal fractures. *Arch Orthop Trauma Surg.* 2011;131(2):241-245.
3. Finestone A, Milgrom C, Wolf O, et al. Epidemiology of metatarsal stress fractures versus tibial and femoral stress fractures during elite training. *Foot Ankle Int.* 2011;32(1):16-20.
4. Lehman RC, Torg JS, Pavlov H, Delee JC. Fractures of the base of the fifth metatarsal distal to the tuberosity: A review. *Foot Ankle.* 1987;7:245-252.
5. Banal F, Gandjbakhch F, Foltz V, et al. Sensitivity and specificity of ultrasonography in early diagnosis of metatarsal bone stress fractures: a pilot study of 37 patients. *J Rheumatol.* 2009;36(8):1715-1719.
6. Stiell IG, Greenberg GH, Mcknight RD, et al. Decision rules for the use of radiography in acute ankle injuries. Refinement and prospective validation. *JAMA.* 1993; 269:1127-1132.
7. Konkel KF, Menger AG, Retzlaff SA. Nonoperative treatment of fifth metatarsal fractures in an orthopaedic suburban private multispeciality practice. *Foot Ankle Int.* 2005;26:704-707.
8. Portland G, Kelikian A, Kodros S. Acute surgical management of jones' fractures. *Foot Ankle Int.* 2003;24:829-833.
9. Hatch RL, Alsobrook JA, Clugston JR. Diagnosis and management of metatarsal fractures. *Am Fam Physician.* 2007;76(6):817-826.

105 HIP FRACTURE

Heidi Chumley, MD

PATIENT STORY

A 60-year-old woman comes to the emergency room for hip pain. She felt a pop in her hip accompanied by the immediate onset of pain that prohibited her from walking. She had fallen 2 days prior. **Figure 105-1** shows a transcervical left femoral neck fracture with varus angulation and superior offset of the distal fracture fragment. She was evaluated by an orthopedic surgeon and underwent surgery the next day (**Figure 105-2**). After many months of rehabilitation, she was able to walk again.

FIGURE 105-1 Transcervical left femoral neck fracture with varus angulation and superior offset of the distal fracture fragment. The femoral head is within the acetabular cup. Degenerative changes of the left hip are also present. (*Courtesy of John E. Delzell, Jr., MD.*)

EPIDEMIOLOGY

- Approximately 300,000 hip fractures per year occur in the United States.[1]
- Seventy percent to 80% of hip fractures occur in women.[1]
- Average age is 70 to 80 years; risk increases with age.[1]
- Half of the patients with a hip fracture have osteoporosis.[2]

ETIOLOGY AND PATHOPHYSIOLOGY

- Approximately 95% of hip fractures are caused by a fall.

RISK FACTORS

- Low body mass index (BMI) and low physical activity in postmenopausal women.[3]
- Low physical activity.[3]

Long-term use of proton pump inhibitor (PPI) is associated with increased risk of any fracture, including hip fracture.[4]

DIAGNOSIS

CLINICAL FEATURES: HISTORY AND PHYSICAL

- In a population study, major risk factors for hip fracture include:
  - Low bone mineral density (3.6-fold [95% confidence interval (CI), 2.6 to 4.5] in women and 3.4-fold [95% CI, 2.5 to 4.6] in men for each standard deviation [SD] [0.12 g/cm^2] reduction in bone mineral density).[5]
  - Postural instability and/or quadriceps weakness.
  - A history of falls.
  - Prior hip fracture.[5]
  - Other factors associated with increased risk include: dementia, tobacco use, physical inactivity, impaired vision, and alcohol use.

Physical examination—Abducted and externally rotated hip; limp or refusal to walk.

TYPICAL DISTRIBUTION

- Hip fractures are classified according to anatomic location.[6]
  - Intracapsular (femoral neck fracture; **Figures 105-1** and **105-3**).
  - Extracapsular (intertrochanteric or subtrochanteric fracture; **Figure 105-4**).

IMAGING

- Radiographs—Plain radiographs show most hip fractures.
- Consider MRI, bone scan, or CT for indeterminate radiographs.

DIFFERENTIAL DIAGNOSIS

Hip pain can be caused by bone or joint pathology, soft-tissue injuries, spine pathology, or can be referred. Some causes include:[6]

- Pelvic fractures, bone cancers, or metastases; osteoarthritis, inflammatory, crystal, or septic arthritis.
- Iliotibial band syndrome, trochanteric bursitis, iliopsoas bursitis, pyriformis syndrome, muscle strain.
- Lumbar disc herniation, lumbar spinal stenosis, sciatica.
- Hernia, abdominal or pelvic pathology.

MANAGEMENT

Preventing hip fracture is important; 50% of patients with a hip fracture do not regain previous level of function; 20% die within a year.

Lower risk of hip fracture by:

- Screening for osteoporosis.[7] SOR B
- Treating osteoporosis with bisphosphonates. SOR A
- Preventing falls by monitoring vision; assessing gait, strength, and balance; and minimizing the use of psychotropic medications in the elderly. SOR C
- Encouraging exercise, such as tai chi, for lower-body strengthening and balance.
- Calcium and vitamin D supplementation do not decrease risk of hip fracture, but should be part of an osteoporosis prevention and treatment strategy.[8] SOR A
- Providing hip protectors to older residents of nursing home facilities may reduce the number of hip fractures; however, the clinical significance of the intervention is unclear.[9] SOR A

Refer to an orthopedic surgeon unless the patient is not healthy enough to withstand surgery.

PREVENTION

- Thiazide diuretics may reduce the risk of hip fracture by 24%, based on metaanalysis of observational studies.[10]
- Population interventions are effective. Kaiser Permanente decreased hip fractures by 40% by identifying patients who had not

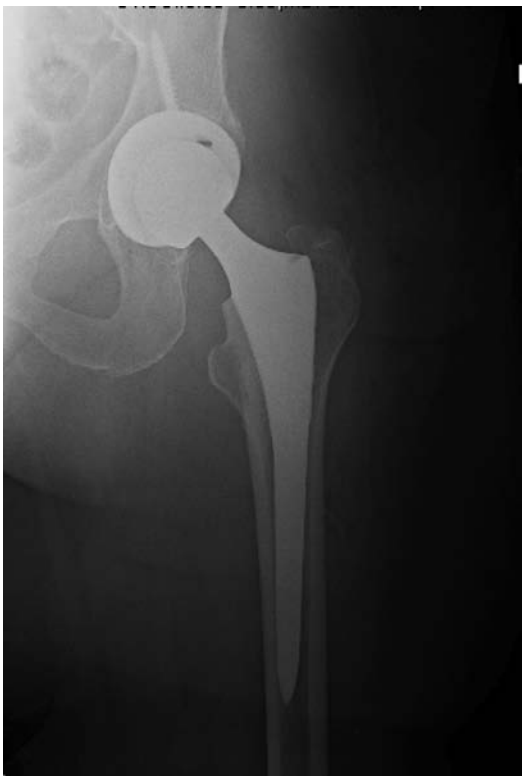

FIGURE 105-2 Postsurgical portable radiograph demonstrating good positioning of artificial hip. (*Courtesy of John E. Delzell, Jr., MD.*)

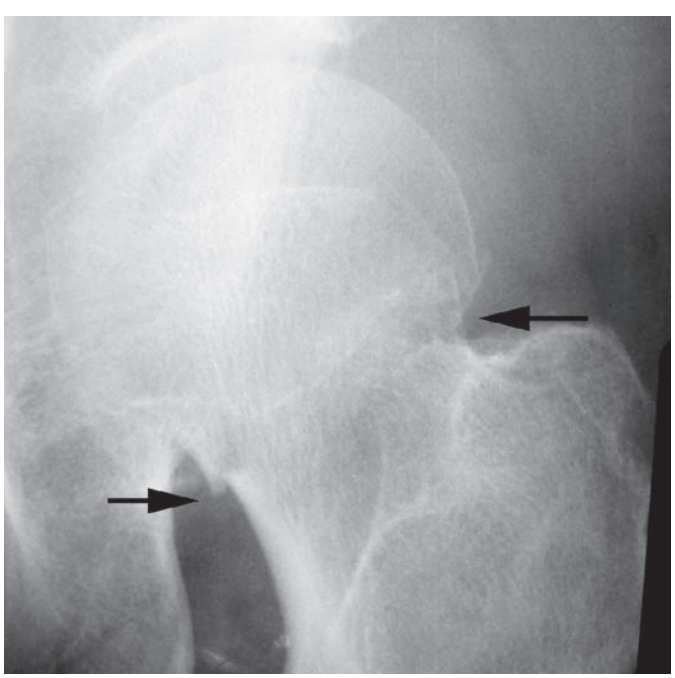

FIGURE 105-3 Nondisplaced, complete, femoral neck fracture (*black arrows*). Nondisplaced fractures can be incomplete (fracture through part of the femoral neck) or complete (fracture through the entire femoral neck). (*From Simon RR, Sherman SC, Koenigsknecht SJ. Emergency Orthopedics, The Extremities, 5th ed. New York: McGraw-Hill; 2007:358, Fig. 13-8. Copyright 2007.*)

received recommended bone density screening and treating as appropriate.[11]

PROGNOSIS

- One-year postoperation mortality of 27.3%.[12]
- All-cause mortality is three times higher in patients with a hip fracture than in the general population.[12]

FOLLOW-UP

Patients with hip fracture may benefit from multidisciplinary follow-up, including monitoring for complications such as avascular necrosis, identifying and treating osteoporosis, modifying risk factors for further falls, and maximizing function through therapy.

PATIENT EDUCATION

It is much easier to prevent hip fractures than to treat hip fractures. After a hip fracture, patients often need prolonged time (months) in a nursing care facility. Physical therapy is crucial in regaining as much function as possible.

PATIENT RESOURCES

- FamilyDoctor.org has written and auditory information in English and Spanish—**http://familydoctor.org/familydoctor/en/diseases-conditions/hip-fractures.html.**
- The American Academy of Orthopedic Surgeons (**http://www.aaos.org/**) has a patient handout called "Live it Safe—Prevent Broken Hips"—**http://orthoinfo.aaos.org/topic.cfm?topic=A00305.**
- Mayo Health on hip fractures with the option to view with larger type—**http://www.mayoclinic.com/health/hip-fracture/DS00185.**

PROVIDER RESOURCES

- eMedicine article: Davenport M. *Hip Fracture in Emergency Medicine*—**http://emedicine.medscape.com/article/825363-overview.**

FIGURE 105-4 Unstable intertrochanteric fracture demonstrating displacement and a reverse oblique fracture line. Intertrochanteric fractures are unstable when there are multiple fracture lines, displacement between the femoral shaft and neck, or when the fracture line runs in an oblique reverse direction, with the most superior part of the fracture on the medial surface of the femur. The patient experiences severe pain, hip swelling, and shortening of the involved leg. (*From Simon RR, Sherman SC, Koenigsknecht SJ. Emergency Orthopedics, The Extremities, 5th ed. New York: McGraw-Hill; 2007:361, Fig. 13-12. Copyright 2007.*)

REFERENCES

1. National Center for Health Statistics. Center for Disease Control. Department of Health and Human Services. National Health and Nutrition Examination Survey (NHANES) 2005-2006. http://www.cdc.gov/nchs. Accessed June 2, 2008.
2. Robbins JA, Schott AM, Garnero P, et al. Risk factors for hip fracture in women with high BMD: EPIDOS study. *Osteoporos Int.* 2005;16(2):149-154.
3. Armstrong ME, Spencer EA, Cairns BJ, et al. Body mass index and physical activity in relation to the incidence of hip fracture in postmenopausal women. *J Bone Miner Res.* 2011;26(6):1330-1338.

4. Eom Cs, Park SM, Myung DK, et al. Use of acid-suppressive drugs and risk of fracture: a meta-analysis of observational studies. *Ann Fam Med.* 2011;9(3):257-267.
5. Nguyen ND, Pongchaiyakul C, Center JR, et al. Identification of high-risk individuals for hip fracture: a 14-year prospective study. *J Bone Miner Res.* 2005;20(11):1921-1928.
6. Brunner LC, Eshilian-Oates L, Kuo TY. Hip fractures in adults. *Am Fam Physician.* 2003;67(3):537-542.
7. Kern LM, Powe NR, Levine MA, et al. Association between screening for osteoporosis and the incidence of hip fracture. *Ann Intern Med.* 2005;142(3):173-181.
8. Porthouse J, Cockayne S, King C, et al. Randomised controlled trial of calcium and supplementation with cholecalciferol (vitamin D3) for prevention of fractures in primary care. *BMJ.* 2005;330(7498):1003.
9. Gillespie WJ, Gillespie LD, Parker MJ. Hip protectors for preventing hip fractures in older people. *Cochrane Database Syst Rev.* 2010;(10):CD001255.
10. Aung K, Htay T. Thiazine diuretics and the risk of hip fracture. *Cochrane Database Syst Rev.* 2011;(10):CD005185.
11. Dell R. Fracture prevention in Kaiser Permanente Southern California. *Osteoporos Int.* 2011;22(Suppl 3):457-460.
12. Panula J, Pihlajamäki H, Mattila VM, et al. Mortality and cause of death in hip fracture patients aged 65 or older: a population-based study. *BMC Musculoskelet Disord.* 2011;12:105.

106 THE KNEE

Heidi Chumley, MD

PATIENT STORY

A 33-year-old woman felt a pop in her knee while skiing around a tree. She felt immediate pain and had difficulty walking when paramedics removed her from the slopes. Within a couple of hours, her knee was swollen. On examination the next day, she was able to walk 4 steps with pain. She had a moderate effusion without gross deformity and full range of motion. She had no tenderness at the joint line, the head of the fibula, over the patella, or over the medial or lateral collateral ligaments. She had a positive Lachman test, a negative McMurray test, and no increased laxity with valgus or varus stress. The physician suspected an anterior cruciate ligament (ACL) tear, placed her in a long leg range of motion brace, and advised her to use crutches until an evaluation by her physician within the next several days. She was treated with acetaminophen for pain and advised to rest, apply ice, and keep her leg elevated. Later, an MRI confirmed an ACL tear (**Figure 106-1**).

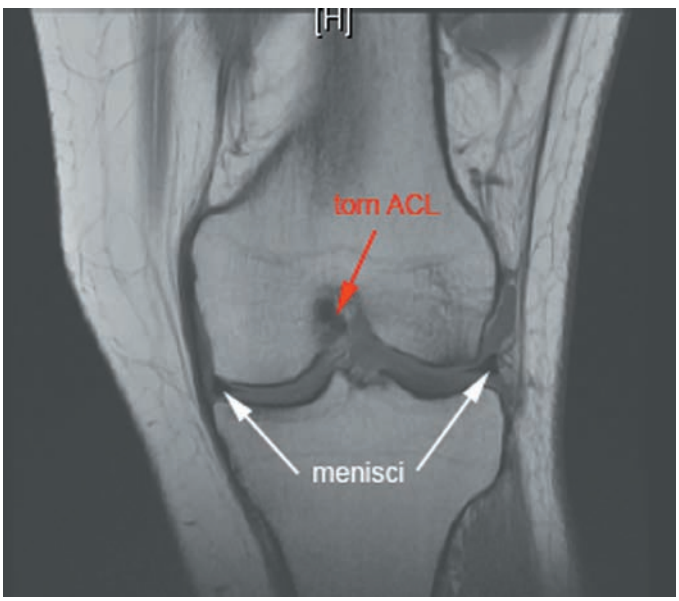

FIGURE 106-1 MRI of ACL tear in the frontal view. Note the normal menisci, which are black throughout. (*Courtesy of John E. Delzell, Jr., MD, MSPH.*)

INTRODUCTION

Knee injuries are common, especially in adolescents. Women have a greater risk of knee injuries because of body mechanics. Most knee injuries involve the ACL, meniscus, or medial or lateral collateral ligaments. The mechanism of injury and physical examination findings suggest the type of injury, which can be confirmed by MRI. Treatment includes rest, ice, compression, elevation, and referral to an orthopedic surgeon.

EPIDEMIOLOGY

- Knee injuries are the second most common adolescent sporting injury (after ankle injuries)[1] and typically are seen in sports requiring pivoting, such as basketball or football. **Figure 106-2** shows the normal anatomy of the knee.
- The risk of ACL injury while playing soccer, is 2 to 3 times higher in females than in males after the age of 12 years.[2]
- The risk of ACL injury was 3.79 times greater in girls in a prospective study of boy and girl high school basketball players in Texas.[1]
- Incidence of ACL injuries was approximately 3 per 1000 person-years in United States active military personnel, with no difference in gender.[3]
- Meniscal injuries commonly occur with ACL tears (23% to 65%).[4]
- Meniscal tears were seen on MRI in 91% of patients with symptomatic osteoarthritis, but also seen in 76% of age-matched controls without knee pain.[5]
- Collateral ligament injuries account for approximately 25% of acute knee injuries.

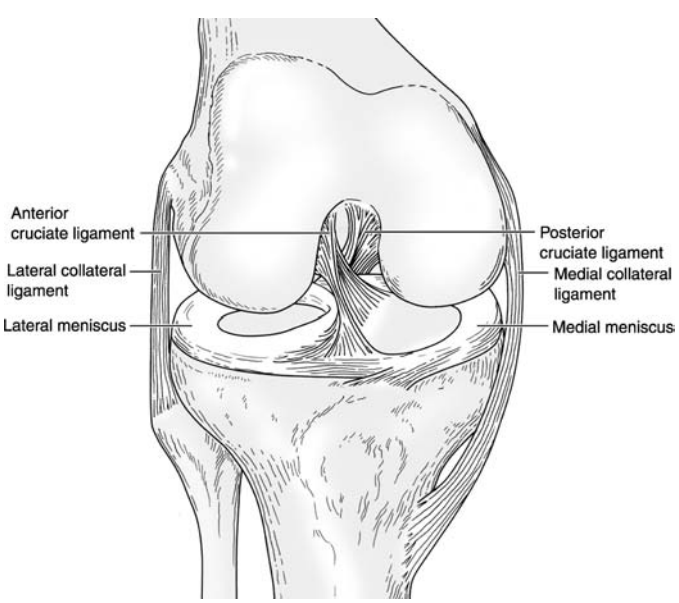

FIGURE 106-2 Anatomy of a normal knee. (*From Simon RR, Sherman SC, Koenigsknecht SJ. Emergency Orthopedics, The Extremities, 5th ed. New York, NY: McGraw-Hill; 2007:392, Fig. 15-5. Copyright 2007.*)

ETIOLOGY AND PATHOPHYSIOLOGY

- ACL injuries occur with sudden deceleration with a rotational maneuver, usually without contact.
- ACL injuries are thought to occur more commonly in women because of decreased leg strength, increased ligamentous laxity, and differences in lumbopelvic core control.
- Acute meniscal injuries occur with a twisting motion on the weight-bearing knee.
- Chronic meniscal tears occur from mechanical grinding of osteophytes on the meniscus in older patients with osteoarthritis.
- Medial collateral and lateral collateral injuries occur from valgus and varus stress, respectively.

RISK FACTORS

Women are at higher risk for ACL injuries.

DIAGNOSIS

CLINICAL FEATURES ON HISTORY

ACL:

- Rotational injury.
- "Pop" reported by patient.
- Unable to bear full weight.
- Effusion within the first few hours.

Meniscal injury:

- Foot planted with femur rotated internally with valgus stress (medial) or femur rotated externally with varus stress (lateral).
- Joint line pain.
- Effusion over the first several hours.
- Usually ambulatory with instability or locking (mechanical) symptoms.

Collateral injury:

- Valgus or varus stress injury.
- Usually ambulatory without instability or locking symptoms.

PHYSICAL EXAMINATION

A complete physical exam of the knee is demonstrated online from the University of British Columbia at **http://www.youtube.com/user/BJSMVideos**.

- Inspect the knee for effusions—Usually present for an ACL tear.
- Test range of motion—Often normal; inability to extend fully can indicate either a medial meniscal tear or an ACL tear displaced posteriorly.
- Palpate for tenderness—Joint line tenderness may indicate a meniscal tear (likelihood ratio, LR+ = 1.1; LR− = 0.8).[6] Tenderness at the head of the fibula or at the patella are 2 of the 5 Ottawa

rules for obtaining radiographs; tenderness along the medial or lateral collateral ligament may indicate damage to those ligaments.

- Perform tests for ACL tear—Lachman test (LR+ = 12.4; LR− = 0.14),[6] anterior drawer test (LR+ = 3.7; LR− = 0.6),[6] pivot shift test (LR+ = 20.3; LR− = 0.4).[6]
- Patients with ACL tears typically have a history of rotational injury; inability to bear weight; positive provocative tests; normal plain radiographs; and abnormal MRI.
- Perform tests for meniscal tears—McMurray test (LR+ = 17.3; LR− = 0.5).[6]
- Patients with meniscal tears typically have history of rotational injury with valgus/varus stress or history of osteoarthritis; able to bear weight, commonly with instability or locking; positive McMurray test; normal plain radiographs; and abnormal MRI.
- Perform varus and valgus stress to test the lateral and medial collateral ligaments.
- Patients with injuries to the collateral ligaments typically have a history of valgus/varus stress to extended knee; able to bear weight without instability or locking; laxity with valgus or varus stress testing; normal plain radiographs and abnormal MRI.

IMAGING

- Determine whether or not to obtain plain radiographs (anteroposterior, lateral, intercondylar notch, and sunrise views) to assess for a fracture based on either the Pittsburgh or Ottawa knee rules (the Ottawa rules may be less sensitive in children):
  - Pittsburg (99% sensitivity, 60% specificity; tested in population ages 6 to 96 years)[6]—Obtain x-ray for:
    - Recent significant fall or blunt trauma.
    - Age younger than 12 years or older than 50 years.
    - Unable to take 4 unaided steps.
  - Ottawa (98.5% sensitivity, 48.6% specificity; LR− = 0.05; tested in 6 studies of 4249 adult patients)[7]—Obtain x-ray for:
    - Age 55 years or older.
    - Tenderness at the head of the fibula.
    - Isolated tenderness of the patella.
    - Inability to flex knee to 90 degrees.
    - Inability to bear weight for 4 steps both immediately and in the examination room regardless of limping.
- MRI is 95% and 90% accurate in identifying ACL tears and meniscal injuries, respectively (**Figures 106-2** to **106-4**).[8]

FIGURE 106-3 Medial meniscal tear on the frontal view, seen as a small white line through the black meniscus. (*Courtesy of Heidi Chumley, MD.*)

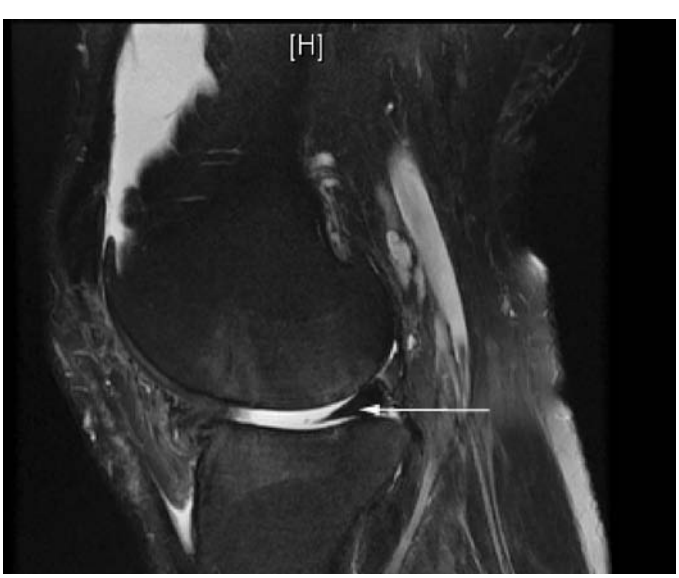

FIGURE 106-4 Lateral meniscal tear on a sagittal view, seen as a small white line in the black meniscus. (*Courtesy of Heidi Chumley, MD.*)

DIFFERENTIAL DIAGNOSIS

Acute knee pain can be caused by trauma affecting structures of the knee other than ligaments and menisci, arthritis, infection, or tumors including:

- Trauma.
- Intraarticular fractures (patella, femoral condyles, tibial eminence, tibial tuberosity, and tibial plateau)—history of trauma or chronic overuse; edema, ecchymosis, point tenderness, or deformity may be present; visible on plain radiographs (**Figures 106-5** and **106-6**).

- Patellar dislocation—Severe hyperextension (anterior dislocation), fall on a bent knee or knee hitting the dashboard (posterior dislocation), valgus or varus stress (medial or lateral dislocation); visible deformity; effusion and immobility; neurovascular complications (peroneal nerve and popliteal artery); visible on plain radiographs.
- Arthritis—No history of trauma.
- Reactive arthritis—Fever/malaise; oligoarthritis involving the knee, ankle, feet and/or wrist involvement, urethritis, conjunctivitis or iritis; elevated C-reactive protein or erythrocyte sedimentation rate (ESR); arthritic changes on radiographs (see Chapter 155, Reactive Arthritis).
- Juvenile rheumatoid arthritis (JRA)—Children younger than age 16 years; acute pain and swelling without trauma; fever or skin rashes (systemic JRA); knee is commonly involved; arthritic changes on plain radiographs.
- Rheumatoid arthritis—Adults ages 30 to 50 years, more commonly women; polyarthritis involving hands, wrists, feet, and knees; fever/malaise; positive rheumatoid factor; erosive arthritis changes on radiographs (see Chapter 97, Rheumatoid Arthritis).
- Gout or pseudogout—Adults ages 30 to 60 years, more commonly men; single joint erythema, warmth and tenderness without trauma; abnormal joint fluid with elevated white blood cell count (WBC); radiographs may be normal or abnormal (sclerotic regions, degenerative changes, or soft tissue calcifications) (see Chapter 100, Gout).
- Osteoarthritis—Older adults; gradual onset; symptoms worse after use; radiographic osteophytes (see Chapter 96, Osteoarthritis).
- Infections such as cellulitis, septic arthritis (**Figure 106-7**), osteomyelitis—May have history of skin break by bite or puncture wound; fever; erythema, warmth with cellulitis; decreased range of motion, inability to walk, abnormal fluid aspirate with septic arthritis; chronic symptoms and abnormal radiograph with osteomyelitis.
- Malignant tumors (e.g., osteosarcoma, chondroblastoma) or benign tumors (e.g., bone cysts, osteochondroma)—No (or insignificant) history of trauma; chronic symptoms or acute symptoms caused by pathologic fracture; abnormal radiographs and MRI.

MANAGEMENT

Initial management for traumatic knee pain includes rest, ice, compression, and elevation.

- Provide pain relief with acetaminophen. Add a nonsteroidal antiinflammatory medication if needed.[9] SOR C
- Prevent further injury (e.g., limit activities to toe-touch weight bearing and place in a long leg range of motion brace)[8] until evaluation by a provider trained to manage acute knee injuries. SOR C
- Obtain plain radiographs if indicated by the Pittsburg or Ottawa rules.[7] SOR A
- Consider an MRI for suspected ACL, meniscal, or collateral ligament tear based on the mechanism of injury and physical examination findings.[8] SOR C

FIGURE 106-5 Nondisplaced patellar fracture seen best on the lateral view. (*From Simon RR, Sherman SC, Koenigsknecht SJ. Emergency Orthopedics, The Extremities, 5th ed. New York, NY: McGraw-Hill; 2007:405, Fig. 15-26, bottom photo only. Copyright 2007.*)

FIGURE 106-6 Lateral condylar split fracture (type 1) has no depression of the articular surface and is usually the result of low-impact trauma. More common in children. (*From Simon RR, Sherman SC, Koenigsknecht SJ. Emergency Orthopedics, The Extremities, 5th ed. New York, NY: McGraw-Hill; 2007:398,Fig. 15-14. Copyright 2007.*)

FOR ACL TEARS

- Refer to a physician trained in surgical repair as repair results in 80% to 95% return to normal activity in 4 to 6 months.[9] SOR C
- Surgical repair is typically done at least 3 weeks after the injury. Repair within the first 3 weeks results in a high incidence of arthrofibrosis.
- Refer to physical therapy if available to institute early knee range of motion (before surgery).[9] SOR C

FOR MENISCAL TEARS

- Refer to a physician for discussion of nonsurgical and surgical treatments as rates of healing vary by location of meniscal tear and associated injuries.[10] SOR C

FOR COLLATERAL TEARS

- The treatment is based on the severity of the tear. SOR C
- For all grades, instruct in early range of motion exercises (or refer to physical therapy).
- Grade I medial collateral ligament (MCL) or lateral collateral ligament (LCL) (≤5 cm laxity on valgus or varus stress), weight-bearing as tolerated with early ambulation.
- Grade II MCL or LCL (5 to 10 cm laxity), place in a brace blocking the last 20 degrees of flexion, weight-bearing as tolerated.
- Grade III MCL (>10 cm laxity), place in a hinged brace, initially non–weight bearing, advancing to weight bearing over 4 weeks. Grade III LCL tears often require surgery.

PREVENTION

- Neuromuscular retraining programs reduce the incidence of ACL injuries in female basketball, soccer, and basketball players.[11]
- The Prevent Injury, Enhance Performance Program achieved a 75% to 88% reduction in ACL injuries among female soccer players ages 14 to 18 years. The program includes warm-up, stretching, strengthening, plyometrics, and agility exercises.[12]
- Structured warm-up program to improve cutting, jumping, balance and strength decreased acute knee injuries, number needed to treat was 43 over 8 months.[13]

PROGNOSIS

Of children and adolescents who have had ACL surgery, 84.2% achieve excellent or good knee function.[14]

Nonsurgical management of ACL tears have a good prognosis from 1 to 5 years, but patients reduce their activity level by 21%.[15]

FOLLOW-UP

Timing of follow-up is determined by the orthopedic surgeon, sports medicine specialist, or other provider skilled in acute knee injury management.

FIGURE 106-7 Septic arthritis in a young girl who presented with a painful swollen left knee, decreased range of motion and difficulty walking. A knee aspiration revealed turbid fluid with elevated leukocytes. The joint fluid culture grew *Staphylococcus aureus*. (*Courtesy of Richard P. Usatine, MD.*)

PATIENT EDUCATION

- ACL tears often require surgery, take 4 to 6 months to heal, and require a commitment to rehabilitation for the best results.
- Meniscal tears may require surgery when mechanical symptoms are present. The location of the tear determines how likely surgical repair is to be effective because of the blood supply available for healing.
- Meniscal tears are commonly seen on MRI in patients with osteoarthritis who do not have pain and meniscal tears seen on MRI may not be contributing to arthritic pain.
- Collateral tears can often be treated conservatively, while protecting the knee in a brace and preserving range of motion. Complete tears to the LCL often require surgery.

PATIENT RESOURCES

- The American Academy of Family Physicians has a patient algorithm for knee pain—**http://familydoctor.org/family-doctor/en/health-tools/search-by-symptom/knee-problems.html.**
- The National Institute of Health through the National Institute for Arthritis and Musculoskeletal and Skin Diseases has patient information on several types of knee problems—**http://www.niams.nih.gov/Health_Info/Knee_Problems/default.asp.**

PROVIDER RESOURCES

- The Ottawa and Pittsburgh Knee Rules are available in an online calculator—**http://www.mdcalc.com/ottawa-and-pittsburg-knee-rules.**
- Dr. Hutchinson's Knee Exam from the University of British Columbia—**http://www.youtube.com/user/BJSMVideos.**

REFERENCES

1. Messina DF, Farney WC, DeLee JC. The incidence of injury in Texas high school basketball. A prospective study among male and female athletes. *Am J Sports Med*. 1999;27(3):294-299.
2. Walden M, Hagglund M, Werner J, Ekstrand J. The epidemiology of anterior cruciate ligament injury in football(soccer): a review of the literature from a gender-related perspective. *Knee Surg Sports Traumatol Arthrosc*. 2011;19(1):3-10.
3. Owens BD, Mountcastle SB, Dunn WR, et al. Incidence of anterior cruciate ligament injury among active duty U.S. military servicemen and servicewomen. *Mil Med*. 2007;172(1):90-91.
4. Cimino PM. The incidence of meniscal tears associated with acute anterior cruciate ligament disruption secondary to snow skiing accidents. *Arthroscopy*. 1994;10(2):198-200.
5. Bhattacharya T, Gale D, Dewire P, et al. The clinical importance of meniscal tears demonstrated by magnetic resonance imaging in osteoarthritis of the knee. *J Bone Joint Surg Am*. 2003;85-A:4-9.
6. Ebell MH. Evaluating the patient with a knee injury. *Am Fam Physician*. 2005;71(6):1169-1172.
7. Bachmann KM, Haberzeth S, Steurer J, Ter Riet G. The accuracy of the Ottawa knee rule to rule out knee fractures: a systematic review. *Ann Intern Med*. 2004;140(2):121-124.
8. David K, Frank B. Anterior cruciate ligament rupture. *Br J Sports Med*. 2005;39:324-329.
9. New Zealand Guidelines Group (NZGG). *The Diagnosis and Management of Soft Tissue Knee Injuries: Internal Derangements*. Wellington, NZ: New Zealand Guidelines Group (NZGG), 2003:100.
10. Greis PE, Bardana DD, Holmstrom MC, Burks RT. Meniscal injury I: basic science and evaluation. *J Am Acad Orthop Surg*. 2002;10(2):168-176.
11. Barber-Westin SD, Noyes FR, Smith ST, Campbell TM. Reducing the risk of noncontact anterior cruciate ligament injuries in the female athlete. *Phys Sportsmed*. 2009;37(3):49-61.
12. Mandelbaum BR, Silvers HJ, Watanabe DS, et al. Effectiveness of a neuromuscular and proprioceptive training program in preventing anterior cruciate ligament injuries in female athletes: 2-year follow-up. *Am J Sports Med*. 2005;33(7):1003-1010.
13. Olsen OE, et al. Exercises to prevent lower limb injuries in youth sports: cluster randomised controlled trial. *BMJ*. 2005;330(7489):449.
14. Frosch KH, Stengel D, Brodhun T, et al. Outcomes and risks of operative treatment of rupture of the anterior cruciate ligament in children and adolescents. *Arthroscopy*. 2010;26(11):1539-1550.
15. Muaidi QI, Nicholson LL, Refshauge KM, et al. Prognosis of conservatively managed anterior cruciate ligament injury: a systematic review. *Sports Med*. 2007;37(8):703-716.

107 DUPUYTREN DISEASE

John E. Delzell, Jr., MD, MSPH
Heidi Chumley, MD

PATIENT STORY

A 53-year-old man presented with stiffness in his hands. He said his hands began to feel stiff several years ago, and now he finds that he cannot straighten many of his fingers (**Figure 107-1**). He delayed seeing a physician because he did not feel any pain in his hands. He recently began having difficulty holding his woodworking tools and wants to regain the function he has lost in his hands. The physician diagnosed him with Dupuytren contracture and discussed the disease with him along with his options for treatment.

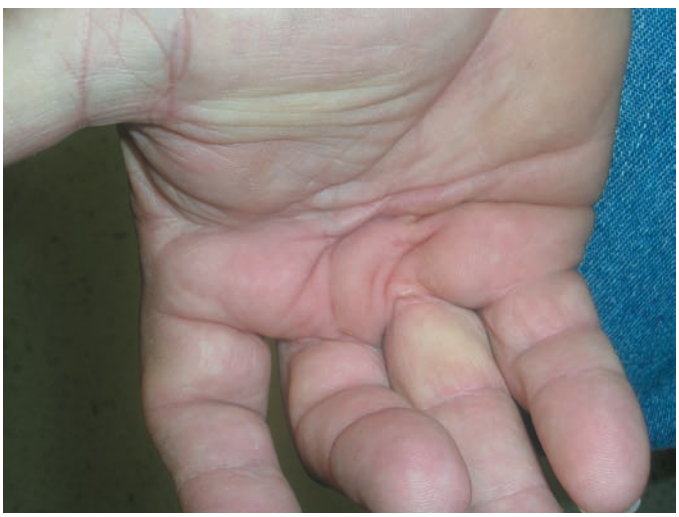

FIGURE 107-1 Dupuytren contracture in a 53-year-old man showing flexion contractures at the proximal interphalangeal joints of the third digit and a palmar cord. (*Courtesy of Richard P. Usatine, MD.*)

INTRODUCTION

Dupuytren contracture is a flexion contracture of one or more of the fingers in the hand. Patients develop a progressive thickening of the palmar fascia, which causes the fingers to bend in toward the palm and limits extension. Diagnosis is clinical and the palpable nodules in the palm are considered diagnostic. Treatment has historically been surgical, but a new nonsurgical treatment with a collagenase has been approved.

SYNONYMS

Dupuytren disease, Dupuytren contractures, palmar fibromatosis, morbus Dupuytren, Ledderhose disease.

EPIDEMIOLOGY

- Dupuytren contracture is an autosomal dominant disease with incomplete penetrance (**Figure 107-2**).
- Higher prevalence among whites, particularly of Northern European descent. There is an increasing incidence related to aging.[5]
- More common in men than women (approximately 6:1).[1,3]
- Incidence in the United States is estimated to be approximately 3 per 10,000 adults with an estimated prevalence of 7%.
- Higher incidence in people who use tobacco and alcohol or who have diabetes mellitus or epilepsy.[2]

FIGURE 107-2 Dupuytren contracture in a 60-year-old man showing a flexion contracture of the fifth digit and a palmar cord. All of his brothers have Dupuytren contractures. (*Courtesy of Richard P. Usatine, MD.*)

ETIOLOGY AND PATHOPHYSIOLOGY

Dupuytren contractures form in three stages:

- Myofibroblasts in the palmar fascia proliferate to form nodules.
- Myofibroblasts then align along the lines of tension, forming cords.
- Tissue becomes acellular leaving thick cords of collagen that tighten resulting in flexion contractures at the metacarpal phalangeal joint,

the proximal interphalangeal joint, and, occasionally, the distal interphalangeal joint.

RISK FACTORS

- Tobacco use.
- Alcohol consumption.
- Epilepsy.
- Diabetes mellitus.
- Carpal tunnel syndrome.
- History of manual labor.
- History of hand injury.

DIAGNOSIS

CLINICAL FEATURES

- Clinical diagnosis that is based on the history and physical examination.
- Patients complain of a slowly progressive tightness in the hands and a lack of the ability to fully extend their fingers.
- Typically painless.
- Examination findings—Nodules with flexion contractures are considered diagnostic, particularly in older white males; however, nodules may disappear late in the disease.[2]

TYPICAL DISTRIBUTION

- Can be either hand.
- More commonly seen in the fourth and fifth digits (**Figure 107-3**).

LABORATORY TESTING

- Not indicated.

IMAGING

- MRI of the contractures may be helpful prior to surgical intervention, but is not needed to confirm a clinical diagnosis.

BIOPSY

- Typically not indicated.
- Early diagnosis or diagnosis in atypical populations, such as children, may require histologic confirmation.

DIFFERENTIAL DIAGNOSIS

Consider the other causes of hand contractures and palmar nodules including:

- Intrinsic joint contractures—Loss of range of motion from any primary joint disease.
- Trigger finger, stenosing tenosynovitis—Localized swelling of the flexor tendon limits movement within the sheath with resulting "triggering"; digit catches, but can be straightened.

FIGURE 107-3 Dupuytren contracture in a 58-year-old man showing flexion contractures of the fourth and fifth digits and a palmar cord. (*Courtesy of Richard P. Usatine, MD.*)

- Rheumatoid arthritis—Bony deformities resulting in ulnar deviation at the metacarpophalangeal joints and/or the wrist.
- Ganglion cysts and palmar nodules.
- Occupational hyperkeratosis and callous formation.
- Hand tumors including epithelioid sarcomas and soft-tissue giant cell tumors.

MANAGEMENT

The treatment goal of Dupuytren contracture is to maintain or restore hand function by increasing range of motion at involved joints.

NONPHARMACOLOGIC

- Physical therapy with splinting does not seem to be helpful as a sole treatment. SOR C
- Radiation therapy has been used but there is little evidence to support it and significant potential side effects of the treatment. SOR C
- Hyperbaric oxygen is being studied with mixed results. SOR C

MEDICATIONS

- Intralesional injection of corticosteroids is only mildly successful and may place the patient at risk for tendon rupture. SOR C
- Collagenase injection, a nonsurgical treatment, shows promise in phase II and phase III trials.[4] SOR B

REFERRAL FOR SURGERY

- Surgical correction is considered when there is at least 30 degrees of contracture at the metacarpophalangeal (MCP) joint. SOR C
- Surgical fasciotomy decreases the degree of flexion deformity and results in modest improvements in hand function. Studies indicated that improvements in function are best correlated to changes at the proximal interphalangeal joint.[5] SOR B

PROGNOSIS

- Recurrence rate is related to the amount of fascia that is removed on surgery.
- There is an increased risk for recurrence with time.

FOLLOW-UP

- Postoperative follow-up should include hand therapy with a goal of increasing extension in the affected digits.

PATIENT EDUCATION

- Modifying risk factors (e.g., smoking, alcohol intake) known to contribute to the development of Dupuytren contracture is prudent, but are not shown to alter the course of the disease.

- After surgery, postoperative hand therapy may improve function and use of the hand. However, initial decreases in joint deformity and improvements in hand function may be lost over time.

PATIENT RESOURCES

- PubMed Health. *Dupuytren's Contracture*—**http://www.ncbi.nlm.nih.gov/pubmedhealth/PMH0002213/.**
- American Family Physician (AAFP). *Dupuytren's Disease: What You Should Know*—**http://www.aafp.org/afp/2007/0701/p90.html.**

PROVIDER RESOURCES

- Mayo Clinic. *Dupuytren's Contracture*—**http://www.mayoclinic.com/health/dupuytrens-contracture/DS00732.**
- American Family Physician (AAFP). Trojian TH, Chu SM. Dupuytren's disease: diagnosis and treatment *Am Fam Physician.* 2007;76(1):86-89—**http://www.aafp.org/afp/2007/0701/p86.html.**
- Medscape. *Dupuytren Contracture*—**http://emedicine.medscape.com/article/329414.**

REFERENCES

1. Gudmundsson KG, Arngrimsson R, Sigfusson N, et al. Epidemiology of Dupuytren's disease: clinical, serological, and social assessment. The Reykjavik study. *J Clin Epidemiol.* 2000;53(3):291-296.
2. Saar JD, Grothaus PC. Dupuytren's disease: an overview. *Plast Reconstr Surg.* 2000;106(1):125-134.
3. Hindocha S, McGrouther DA, Bayat A. Epidemiological evaluation of Dupuytren's disease incidence and prevalence rates in relation to etiology. *Hand (N Y).* 2009;4(3):256-269.
4. Badalamente MA, Hurst LC, Hentz VR. Collagen as a clinical target: nonoperative treatment of Dupuytren's disease. *J Hand Surg Am.* 2002;27(5):788-798.
5. Draviaraj KP, Chakrabarti I. Functional outcome after surgery for Dupuytren's contracture: a prospective study. *J Hand Surg Am.* 2004;29(5):804-808.

PART 13

DERMATOLOGY

Strength of Recommendation (SOR)	Definition
A	Recommendation based on consistent and good-quality patient-oriented evidence.*
B	Recommendation based on inconsistent or limited-quality patient-oriented evidence.*
C	Recommendation based on consensus, usual practice, opinion, disease-oriented evidence, or case series for studies of diagnosis, treatment, prevention, or screening.*

*See Appendix A on pages 1447–1450 for further information.

SECTION 1 CHILDHOOD DERMATOLOGY

108 NORMAL SKIN CHANGES

Cristina Fernandez, MD
Mindy Smith, MD, MS

PATIENT STORY

A 2-week-old infant is brought to the office for her first well-baby check. The parents noticed a rash on the face. You diagnose the white spots on the bridge of the nose as milia and neonatal acne on the cheeks. The parents are happy to hear that the neonatal acne and milia will go away without treatment (**Figures 108-1** and **108-2**).

INTRODUCTION

- Rashes are common in newborns. Physicians will be consulted frequently as they are a common parental concern. Almost all newborn rashes are benign; however, a few are associated with more serious conditions. A newborn's skin shows a variety of changes during the first 2 months of life and most are self-limited. Physicians must be prepared to identify common rashes and advise parents.[1]
- Milia are inclusion cysts that appear as tiny white papules in the skin (**Figure 108-1**) or on the roof of the mouth.
- Neonatal acne is an acneiform eruption appearing as small red papules or whiteheads with surrounding erythema on the skin of newborns (**Figure 108-2**).
- A mongolian spot is a hereditary, congenital macule of bluish-black or bluish-gray pigment usually in the sacral area, back, and buttocks of infants (**Figures 108-3** and **108-4**).
- Erythema toxicum neonatorum (ETN) is a benign, self-limited skin eruption appearing as small yellow-white papules or vesicles with surrounding skin erythema (**Figures 108-5** and **108-6**).

SYNONYMS

- Milia are also called milk spots or oil seed.
- Neonatal acne is also called acne neonatorum.
- Mongolian spots are also known as mongolian blue spots, congenital dermal melanocytosis, and dermal melanocytosis.

EPIDEMIOLOGY

- Approximately 40% of newborn infants in the United States develop milia.[2] This condition is mainly associated with newborns carried to full term or near term.

FIGURE 108-1 Milia on the face of a 2-week-old infant with greatest number of milia on the nose. (*Courtesy of Richard P. Usatine, MD.*)

FIGURE 108-2 Neonatal acne on the same infant. (*Courtesy of Richard P. Usatine, MD.*)

- Neonatal acne occurs in up to 20% of the newborns. It typically consists of close comedones of the forehead, nose, and cheeks, although other locations are possible. It is most frequent in boys in the first week of life.[3]
- The prevalence of mongolian spots varies among different ethnic groups. They have been reported in approximately 96% of black infants, 90% of Native American infants, 81% to 90% of Asian infants, 46% to 70% of Hispanic infants, and 1% to 10% of white infants.[2,4,5]
- ETN occurs in 30% to 70% of full-term infants and in 5% of premature infants. The incidence rises with increasing gestational age and birth weight.[6,7]

ETIOLOGY AND PATHOPHYSIOLOGY

- Milia are inclusion cysts that contain trapped keratinized stratum corneum surrounded by a dense lymphocytic infiltrate. Milia are caused by retention of keratin within the dermis. They may rarely be associated with other abnormalities in syndromes such as epidermolysis bullosa and the orofacial digital syndrome (type 1).[2,8]
- Maternal androgenic hormones that stimulate sebaceous glands likely cause neonatal acne.[9]
  - Hyperactivity of sebaceous glands, stimulated by neonatal androgens, has been implicated as the underlying pathogenic mechanism.
  - Histologic examination shows hyperplastic sebaceous glands with keratin-plugged orifices.
- The mongolian spot is a hereditary, congenital, developmental condition exclusively involving the skin. It results from entrapment of melanocytes in the dermis during their migration from the neural crest into the epidermis.
  - Mongolian spots are associated with cleft lip, spinal meningeal tumor, melanoma, and phakomatosis pigmentovascularis types 2 and 5.[2,10]
  - A few cases of extensive mongolian spots have been reported with inborn errors of metabolism, the most common being Hurler syndrome, followed by gangliosidosis type 1, Niemann-Pick disease, Hunter syndrome, and mannosidosis. In such cases, they are likely to persist rather than resolve.[2,4]
- The etiology of ETN is not known. ETN is thought to be an immune system reaction; the condition is associated with increased levels of immunologic and inflammatory mediators (e.g., interleukins 1 and 8, eotaxin).[11]
  - The eosinophilic infiltrate of ETN suggests an allergic-related or hypersensitivity-related etiology, but no allergens have been identified. Newborn skin appears to respond to any injury with an eosinophilic infiltrate.
  - Because ETN rarely is seen in premature infants, it is believed that mature newborn skin is required to produce this reaction pattern.

DIAGNOSIS

CLINICAL FEATURES

- Milia are characterized as tiny, pearly white papules (see **Figure 108-1**) that are actually small inclusion cysts ranging from 1 to 2 mm in diameter. No visible opening is present.[2]

FIGURE 108-3 Large mongolian spots covering the buttocks and back of a Hispanic infant. (*Courtesy of Richard P. Usatine, MD.*)

FIGURE 108-4 Prominent mongolian spots on the back of a 1-year-old black child. (*Courtesy of Richard P. Usatine, MD.*)

- Milia usually appear after 4 to 5 days of life in full-term newborns. Manifestations of milia may be delayed from days to weeks in infants born before term.[8,10]

- Neonatal acne (**Figure 108-2**) includes comedones (i.e., whiteheads), papules, and pustules.
  - Papules and pustules are the most frequent types of lesions (72.7%), followed by comedones only (22.7%).[2,9]
- A mongolian spot (**Figures 108-3** and **108-4**) is a bluish-black macule or patch typically a few centimeters in diameter, although much larger lesions also can occur. Lesions may be solitary or numerous.
  - Generalized mongolian spots involving large areas covering the entire posterior or anterior trunk and the extremities have been reported.
  - Several variants exist including:[2,4]
    - Persistent mongolian spots—These are larger, have sharper margins, and persist for many years (**Figure 108-4**).
    - Aberrant mongolian spots involve unusual sites such as the face or extremities.
    - Persistent aberrant mongolian spots also are referred to as macular-type blue nevi.
- ETN commonly presents with a blotchy, evanescent, macular erythema (**Figures 108-5** and **108-6**).
  - The macules are irregular, blanchable, and vary in size.
  - In more severe cases (**Figure 108-6**), pale yellow or white wheals or papules on an erythematous base may follow. In approximately 10% of patients, 2- to 4-mm pustules develop.[2,7]
  - ETN occurs within the first 4 days of life in full-term infants, with the peak onset within the first 48 hours following birth. Rare cases have been reported at birth.
  - Delayed onset can rarely occur in full-term and preterm infants up to 14 days of age.
  - Infants with ETN otherwise are healthy and lack systemic symptoms.

TYPICAL DISTRIBUTION

- Milia are found on the forehead, nose, upper lip, cheeks, and scalp. They can, however, occur anywhere and may be present at birth or appear subsequently. The milia on the child in **Figure 108-1** were present at birth.
- Neonatal acne occurs on the face with the cheeks being the most common site (81.8%) (**Figure 108-2**).[2]
- Mongolian spots most commonly involve the lumbosacral area (**Figure 108-3**), but the buttocks, flanks, and shoulders (**Figure 108-4**) may be affected with extensive lesions.
- ETN sites of predilection include the forehead, face, trunk, and proximal extremities, but lesions may occur anywhere, including the genitalia. Involvement of the mucous membranes and palms and soles rarely occurs (**Figures 108-5** and **108-6**).

LABS AND IMAGING

- No laboratory studies are required.
- In extensive mongolian spots involving the back, radiographic studies are needed to rule out a spinal meningeal tumor or anomaly.[4]

FIGURE 108-5 One small spot of ETN on a 2-day-old infant. (*Courtesy of Richard P. Usatine, MD.*)

FIGURE 108-6 More widespread case of ETN covering the infant. ETN is completely benign and will resolve spontaneously. (*Courtesy of the University of Texas Health Sciences Center, Division of Dermatology.*)

- ETN is often diagnosed clinically, based on history and physical examination, but a peripheral smear of intralesional contents can be done to confirm the diagnosis.[2,7]
  - A Tzanck smear or Gram stain shows inflammatory cells with greater than 90% eosinophils and variable numbers of neutrophils.
  - A complete blood count (CBC) also shows eosinophilia (up to 18%) in approximately 15% of patients. Eosinophilia may be more pronounced when the eruption shows a marked pustular component.

DIFFERENTIAL DIAGNOSIS

Other diagnoses that may be confused with milia, neonatal acne, and ETN include:

- Miliaria—Heat rash (prickly heat) with tiny papules that can be red (miliaria rubra) or clear (miliaria crystallina) or pustular (miliaria pustulosa) (**Figure 108-7**). Miliaria results from sweat retention caused by partial closure of eccrine structures. Both milia and miliaria result from immaturity of the skin structures, but they are clinically distinct entities.
- Neonatal pustular melanosis—This eruption, present at birth, consists of 2- to 4-mm nonerythematous vesicles filled with a milky fluid. This rash occurs in 5% of African American newborns and in less than 1% of white newborns, and fades in the first 3 to 4 weeks of life (see Chapter 110, Pustular Diseases of Childhood).

Mongolian spots may be confused with the following lesions also present at birth or shortly after:

- Congenital melanocytic nevi—These lesions are much less common (1% to 2% of newborns). They are of variable color from tan or brown to red or black, often within a single lesion and the pigment may fade off into surrounding skin. The borders are often irregular and the lesion can appear slightly raised over time (although a macular portion is usually found at the edges). Most congenital melanocytic nevi have a darker color and more discrete borders than mongolian spots. A biopsy is only needed if melanoma is suspected (see Chapter 163, Congenital Nevi).
- There are reports of Mongolian spots being confused for the bruising that occurs in child abuse. A good history and a clear knowledge of the pattern of mongolian spots should help to differentiate between these two entities.

ETN can also be confused with the following:

- Miliaria—See information above.
- Folliculitis—Primary lesion is a papule or pustule pierced by a central hair, although the hair may not always be visualized. Deeper lesions present as erythematous, often fluctuant, nodules. Folliculitis rarely occurs in the first few days of life when ETN is most commonly seen (see Chapter 117, Folliculitis).
- Chickenpox—The characteristic rash appears in crops of lesions beginning with red macules and passing through stages of papule, vesicle (on an erythematous base), pustule, and crust. Simultaneous presence of different stages of the rash is a hallmark. Infants are mostly born with adequate maternal antibodies to varicella, so that timing should differentiate between these two conditions (see Chapter 123, Chickenpox).

FIGURE 108-7 Miliaria (heat rash) in a 6-month-old infant on a warm summer day. (*Courtesy of Richard P. Usatine, MD.*)

- Cutis marmorata (**Figure 108-8**) is reticulated mottled skin with symmetric involvement of the trunk and extremities produced by a vascular response to cold; the change resolves with heat. This entity can persist for weeks or months. No treatment is indicated.
- Harlequin color change affects 10% of full-term babies and occurs when the newborn lies on one side and erythema develops on one side of the body, while blanching is seen on the contralateral side. The color change fades after 30 seconds to 20 minutes and resolves with increased muscle activity or crying. It begins between the second to fifth days of life and lasts up to 3 weeks.[12]
- Neonatal lupus is a rare syndrome in which maternal autoantibodies are passively transferred to the baby producing well-demarcated, erythematous, scaling patches that are often annular, predominately on the scalp, neck or face (**Figure 108-9**). The condition is self-limited and resolves without scarring by 6 to 7 months of age. It is associated with congenital heart block. Treatment includes photoprotection; mild topical steroids may be helpful.

FIGURE 108-8 Cutis marmorata in a 4-month-old infant in a cold exam room. Notice the reticular pattern. This resolved when the infant was warmed. (*Courtesy of Richard P. Usatine, MD.*)

MANAGEMENT

- Milia, neonatal acne, mongolian spots, and ETN are benign conditions and parents should be reassured that they resolve with time.
- Although acne treatment generally is not indicated, infants can be treated with a 2.5% benzoyl peroxide lotion if lesions are extensive and persist for several months.[9]

PROGNOSIS

- Milia usually disappear within several weeks.
- Neonatal acne may come and go until the baby is between 4 and 6 months of age.
- Mongolian spots may persist for many years but usually disappear within 3 to 5 years and almost always by puberty.
- ETN usually lasts for several days but can change rapidly, with lesions appearing and disappearing in different areas over hours.

PARENT EDUCATION

- Milia is a benign self-limiting rash that disappears within a few months without leaving any scars. No drug therapy is required and use of nonprescription rash medications is not recommended.
- Neonatal acne resolves on its own in weeks. Oils and lotions do not help and may actually aggravate the acne.
- Mongolian spots are likely to fade over time and may disappear by age 7 to 13 years.
- ETN will usually disappear within 2 weeks.

PATIENT RESOURCES

- Milia—**http://www.ncbi.nlm.nih.gov/pubmedhealth/PMH0002343/.**
- Neonatal acne—**http://www.womenshealthcaretopics.com/baby_acne.htm.**

FIGURE 108-9 Neonatal lupus from acquired antibodies through transplacental transmission from the mother with active systemic lupus erythematosus (SLE). Note the annular patterns of scale. (*From Warner AM, Frey KA, Connolly S. Photo rounds: annular rash on a newborn. J Fam Pract. 2006;55(2):127-129. Reproduced with permission from Frontline Medical Communications.*)

- Mongolian spot—**http://www.nlm.nih.gov/medlineplus/ency/article/001472.htm.**
- ETN—**http://www.nlm.nih.gov/medlineplus/ency/article/001458.htm.**

PROVIDER RESOURCES

- **http://www.adhb.govt.nz/newborn/teachingresources/dermatology/BenignLesions.htm.**
- **http://www.aafp.org/afp/2008/0101/p47.html.**

REFERENCES

1. McLaughlin MR, O'Connor NR, Ham P. Newborn skin: part II. Birthmarks. *Am Fam Physician.* 2008;77(1):56-60.
2. Agrawal R. *Pediatric Milia*. http://emedicine.medscape.com/article/910405-overview. Accessed September 2011.
3. Katsambas AD, Kotoulis AC, Stravropoulus P. Acne neonatorum: a study of 22 cases. *Int J Dermatol.* 1999;38(2):128-130.
4. Ashrafi MR, Shabanian R, Mohammadi M, Kavusi S. Extensive Mongolian spots: a clinical sign merits special attention. *Pediatr Neurol.* 2006;34(2):143-145.
5. Cordova A. The Mongolian spot: a study of ethnic differences and a literature review. *Clin Pediatr (Phila).* 1981;20(11): 714-719.
6. Clemons RM. Issues in newborn care. *Prim Care.* 2000;27(1): 251-267.
7. Liu C, Feng J, Qu R. Epidemiologic study of the predisposing factors in erythema toxicum neonatorum. *Dermatology.* 2005; 210(4):269-272.
8. Johr RH, Schachner LA. Neonatal dermatologic challenges. *Pediatr Rev.* 1997;18(3):86-94.
9. Van Praag MC, Van Rooij RW, Folkers E, et al. Diagnosis and treatment of pustular disorders in the neonate. *Pediatr Dermatol.* 1997;14(2):131-143.
10. Mallory SB. Neonatal skin disorders. *Pediatr Clin North Am.* 1991; 38(4):745-761.
11. Keitel HG, Yadav V. Etiology of toxic erythema. Erythema toxicum neonatorum. *Am J Dis Child.* 1963;106:306-309.
12. Selmogul MA, Dilmen U, Karkelleoglu C, et al. Picture of the month. Harlequin color change. *Arch Pediatr Adolesc Med.* 1995; 149(10):1171-1172.

109 CHILDHOOD HEMANGIOMAS AND VASCULAR MALFORMATIONS

Richard P. Usatine, MD
Megha Madhukar, MD

PATIENT STORY

A baby girl is brought to the office because her mother is concerned over the growing strawberry hemangioma on her face. Her mother is reassured that most of these childhood hemangiomas regress over time and that there is no need for immediate treatment (**Figure 109-1**).

FIGURE 109-1 Strawberry hemangioma on the face causing no functional problems. Treatment is reassurance and watchful waiting. (*Courtesy of Richard P. Usatine, MD.*)

INTRODUCTION

Hemangiomas are the most common benign tumors of infancy. They can be problematic if they block vision or interfere with any vital function. Most hemangiomas are small and of cosmetic concern only.

SYNONYMS

Infantile hemangiomas, angiomas. Strawberry hemangiomas are also called superficial hemangiomas of infancy. Cavernous hemangiomas are also called deep hemangiomas of infancy.

EPIDEMIOLOGY

- Approximately 30% of hemangiomas are present at birth; the other 70% appear within the first few weeks of life.
- Hemangiomas occur more commonly in fair-skinned, premature, female infants. In one study, the mothers of children with hemangiomas are of higher maternal age, have a higher incidence of preeclampsia and placenta previa, and are more likely to have had multiple gestation pregnancies.[1]
- There is an increased incidence of vascular anomalies in the families of children born with hemangiomas.[1]
- The data are mixed as to whether chorionic villus sampling may play a role in the formation of hemangiomas.[1]
- Females are affected more often than males (2.4:1).[1]

ETIOLOGY AND PATHOPHYSIOLOGY

- Hemangiomas consist of an abnormally dense group of dilated blood vessels. Most childhood hemangiomas are thought to occur sporadically.
- Hemangiomas are characterized by an initial phase of rapid proliferation, followed by spontaneous and slow involution, often

leading to complete regression. Most childhood hemangiomas are small and innocuous, but some grow to threaten a particular function (**Figure 109-2**) or even life.

- Rapid growth during the first month of life is the historical hallmark of hemangiomas, when rapidly dividing endothelial cells are responsible for the enlargement of these lesions. The hemangiomas become elevated and may take on numerous morphologies (dome-shaped, lobulated, plaque-like, and/or tumoral). The proliferation phase occurs during the first year, with most growth taking place during the first 6 months of life. Proliferation then slows and the hemangioma begins to involute.
- The involutional phase may be rapid or prolonged. No specific feature has been identified in explaining the rate or completeness of involution. However, in one type of hemangioma, the rapidly involuting congenital hemangioma, the proliferation phase occurs entirely in utero such that the lesion is fully developed at birth, followed by complete involution during the second year of life.[1]
- A good rule of thumb is 50% of childhood hemangiomas will involute by age 5 years, 70% by age 7 years, and the remainder of childhood hemangiomas will take an additional 3 to 5 years to complete the process of involution.[1]
- Of the lesions that have involuted by age 6 years, 38% will leave residual evidence of the hemangioma in the form of a scar, telangiectasia, or redundant, "bag-like" skin. The chance of a permanent scar increases the longer it takes to involute. For example, of the lesions that involute after age 6 years, 80% may exhibit a cosmetic deformity.[1]

FIGURE 109-2 Large hemangioma on the face needing immediate treatment to prevent amblyopia in the left eye. Although this hemangioma follows the V1 dermatome, this is not a port-wine stain and the patient does not have Sturge-Weber syndrome. (*Courtesy of Richard P. Usatine, MD.*)

DIAGNOSIS

CLINICAL FEATURES

Early lesions may be subtle, resembling a scratch or bruise, or alternatively may look like a small patch of telangiectasias or an area of hypopigmentation. Hemangiomas can start off as a flat red mark, but as proliferation ensues, it grows to become a spongy mass protruding from the skin. The earliest sign of a hemangioma is blanching of the involved skin with a few fine telangiectasias followed by a red macule. Rarely, a shallow ulceration may be the first sign of an incipient hemangioma.[1] Hemangiomas are typically diagnosed based on appearance, rarely warranting further diagnostic tests.

Hemangiomas may be superficial, deep, or a combination of both. Superficial hemangiomas are well defined, bright red, and appear as nodules or plaques located above clinically normal skin (**Figures 109-1** to **109-3**). Deep hemangiomas are raised flesh-colored nodules, which often have a bluish hue and feel firm and rubbery (**Figure 109-4**).

Most are clinically insignificant unless they impinge on vital structures, ulcerate, bleed, incite a consumptive coagulopathy, or cause high output cardiac failure or structural abnormalities. Blocking vision is a common reason needed for treatment (**Figure 109-2**).

TYPICAL DISTRIBUTION

Anywhere on the body, most often on the face, scalp, back, or chest.

IMAGING

Most hemangiomas of infancy do not need imaging. If the hemangioma is very large, deep or undefined, MRI with and without IV

FIGURE 109-3 Strawberry hemangioma present since birth on the face of a 22-month-old girl. Although it is close to her eye, her vision has never been occluded. She has been followed by ophthalmology and no active treatment was recommended. The hemangioma grew larger during the first year of life and is now beginning to involute without treatment. (*Courtesy of Richard P. Usatine, MD.*)

gadolinium helps delineate the location and extent of the hemangioma while also differentiating them from high flow vascular lesions, like arteriovenous malformations.[1] Ultrasound is a useful tool to differentiate hemangiomas from other subcutaneous structures such as cysts and lymph nodes as well as from other soft-tissue masses.[1]

Plain radiography may be useful for evaluating hemangiomas that impinge on an airway.[1]

BIOPSY

Biopsies are rarely needed and can be risky because vascular lesions may bleed profusely. If a biopsy is being considered, it might be best to refer to a specialist.

DIFFERENTIAL DIAGNOSIS

- Superficial capillary malformations that are frequently seen in infants include those above the eyelids and nape of the neck. These are called *salmon patches* and are not dangerous. The "angel's kisses" on the eyelids usually disappear by age 2 years. The "stork bites" may last into adulthood but are rarely an issue because they often get covered by hair (**Figures 109-5** and **109-6**). These capillary malformations are a variant of nevus flammeus or port-wine stain. They are macular, sharply circumscribed, pink to purple, and varied in size (see Chapter 202, Hereditary and Congenital Vascular Skin Lesions).
- Blue rubber bleb nevus syndrome—Bluish cutaneous vascular malformations that empty with pressure, texture resembles rubbery nodules, similar to deep hemangiomas.[2]
- Maffucci syndrome—Rare congenital nonhereditary mesodermal dysplasia characterized by multiple enchondromata, cutaneous hemangiomas, and more recently spindle cell hemangiomas.[3] It is important to identify Maffucci syndrome early because it is associated with an increased risk of malignancy. May appear as multiple vascular malformations of the skin with a "grape-like" appearance (see Chapter 202, Hereditary and Congenital Vascular Skin Lesions).
- Angiosarcoma—Rare, malignant endothelial tumor characterized as ill-defined red patches, plaques, or nodules (see Chapter 201, Acquired Vascular Skin Lesions).[4]
- Arteriovenous malformation—Benign, single red papules on head or neck, may be cutaneous or mucosal.[4]
- Infantile fibrosarcoma—A rare and highly malignant tumor of childhood that may take on the form of a highly vascularized mass, resembling a hemangioma, especially after a hemangioma has ulcerated as a result of rapid proliferation.[5]

MANAGEMENT

- The majority of hemangiomas will eventually involute without complications and require no treatment, but approximately 20% cause complications like ulcerations, irreversible cutaneous expansion, or threaten vital structures such as the eyes, nose, or airways.[6]
- Any large segmental hemangioma on the face could be part of the PHACE (posterior fossa malformations, hemangiomas, arterial anomalies, coarctation of aorta, cardiac defects, eye abnormalities)

FIGURE 109-4 Deep (cavernous) hemangioma on the arm in a 9-month-old child. Treatment is watchful waiting. (*Courtesy of Richard P. Usatine, MD.*)

FIGURE 109-5 Salmon patch (a variant of nevus flammeus) on the upper eyelid called an "angel's kiss." These resolve by age 2 years. (*Courtesy of Richard P. Usatine, MD.*)

FIGURE 109-6 Salmon patch (a variant of nevus flammeus) on the neck of this young child called a "stork bite." These vascular malformations persist into adulthood. (*Courtesy of Richard P. Usatine, MD.*)

syndrome and therefore will need evaluation of the eyes, central nervous system (CNS), and heart.
  - ***P***osterior fossa—Brain malformations present at birth.
  - ***H***emangioma—Segmental hemangioma covers a large area on the head or neck (greater than 5 cm).
  - ***A***rterial lesions—Abnormalities of the blood vessels in the neck or head.
  - ***C***ardiac abnormalities/aortic coarctation.
  - ***E***ye abnormalities.
- Any lower face or beard hemangioma can be a marker for laryngeal hemangiomatosis. Snoring in such a child can be a bad sign. Refer to a head and neck surgeon.
- Hemangiomas in trauma-prone areas are most likely to ulcerate. These include the diaper area (**Figure 109-7**) and the back of the head. Small ulcerations can be treated with topical mupirocin in morning and metronidazole gel in the evening. SOR C
- Propranolol is now the first line of therapy for function-impairing and rapidly proliferating infantile hemangiomas.[2–4] It has been successfully used to treat periorbital infantile hemangiomas and other problematic infantile hemangiomas (**Figure 109-8**).[2–4] SOR B
- Propranolol (20 mg/5 mL) is given orally starting with 1 mg/kg per day divided into qid dosing. It is advisable to monitor for hypoglycemia and low blood pressure even though this treatment has been found to be safe in a number of studies.[2–4] If the child is tolerating the treatment well, the dose may be increased to the recommended maintenance dose of 1.5 to 2 mg/kg per day in divided doses.[2,4] Treatment should be maintained until the lesion is completely involuted or the child is 1 year of age.

FIGURE 109-7 Strawberry hemangioma in the perianal area of a 5-month-old girl. This is at high risk of ulceration. (*Courtesy of Richard P. Usatine, MD.*)

FIGURE 109-8 Large infantile hemangioma in which the child does not have the PHACE syndrome. However, urgent therapy was needed to shrink this hemangioma. **A.** Before propranolol therapy. **B.** After propranolol therapy. (*Courtesy of John Browning, MD.*)

- Prior to the discovery of the benefits and safety of propranolol as a first-line treatment, prednisone 3 to 5 mg/kg per day had been shown to provide an effective and rapid way of treating hemangiomas.[7] SOR B In a study, 68% of patients receiving systemic corticosteroid treatment with oral prednisone experienced rapid and virtually complete involution of hemangiomas.[7] Another 25% experienced significant regression, and treatment demonstrated no effect in 7% of patients. The authors recommended treating with oral prednisone for 6 to 8 weeks, and in more severe cases, for 12 weeks. Side effects include moon facies and irritability, which resolved once therapy was discontinued.[7] Growth may be retarded temporarily.
- Ultrapotent topical corticosteroids have been found especially helpful in the treatment of small hemangiomas, especially periocular hemangiomas and those at sites prone to ulceration and disfigurement. Seventy-four percent of patients demonstrated good or at least partial response to treatment with the majority experiencing cessation of growth before what would have been expected for their age. Thinner, more superficial hemangiomas demonstrated better improvement than thicker, deeper lesions.[8] SOR B
- Intralesional corticosteroid injections, composed of a mixture containing triamcinolone acetonide (20 mg average dose) and betamethasone acetate (3 mg average dose) with varying number of injections, have been found to successfully treat head and neck childhood hemangiomas in properly selected infants. In a research study, 13% of the hemangiomas treated with intralesional injections almost completely involuted, 32% showed greater than 50% reduction in volume, 32% showed definite but less than 50% reduction in volume, and 23% showed little to no decrease in size.[9] SOR B Avoid intralesional steroids around eye.
- Treatment with flashlamp-pumped pulsed-dye laser has been found to be an effective treatment method for superficial cutaneous hemangiomas at sites of potential functional impairment and on the face. In a study, 76% of patients were found to have excellent or good results with the flashlamp-pumped pulsed-dye laser. Hemangiomas with a deep component do not seem to benefit from flashlamp-pumped pulsed-dye laser therapy to the same degree as a truly superficial hemangioma, as the laser is limited by its depth of vascular injury.[12] SOR B
- Facial hemangiomas causing severe functional disturbance and serious psychological distress are strong reasons to consider surgical excision before the child reaches the expected age of spontaneous regression. SOR C
- Large periocular hemangiomas demand prompt treatment to prevent debilitating consequences such as amblyopia (**Figure 109-2**). Early treatment is also recommended for proliferative labial tumors because not only do they have a tendency to bleed, but they also make eating difficult. Additionally, early treatment with a consideration for surgery is advised for hemangiomas located on the nasal tip as they regress slowly and may ultimately result in distortion of the nasal framework.[13]
- Laser surgery may be considered for selective ablation of vascular tissue, like ulcerated hemangiomas and thin superficial hemangiomas, especially when their locations may result in psychosocial distress for the patient, that is, facial hemangiomas. The pulsed-dye laser seems especially promising with its ability to selectively damage blood vessels with minimal damage to surrounding tissues.[14] This procedure is also associated with decreased pain and increased healing.[14] SOR B
- Surgical excision of involuted hemangiomas is not uncommon to remove the residual tissue that may be causing cosmetic or functional impairment. Excision is performed in late involution to reduce the risk of hemorrhage.
- Depending on the location and how complex the hemangioma is, consultations with pediatric dermatologists, ophthalmologists, otolaryngologists, plastic surgeons, and pediatric neurosurgeons may be necessary to ensure proper care.

NEW TOPICAL THERAPY

- Topical timolol ophthalmic gel or solution has been shown in a number of studies to effectively treat infantile hemangiomas.[15,16,17] SOR B One of the studies noted that predictors of better response were superficial type of hemangioma ($p = 0.01$), 0.5% timolol concentration ($p = 0.01$), and duration of use longer than 3 months ($p = 0.04$).[16] SOR B Another study using 0.5% ophthalmic solution 3-4 times daily in patients with small superficial hemangiomas found that treatment was most effective in the early proliferative stage.[15] SOR B

FOLLOW-UP

Watchful waiting and serial observations during well-child examinations are recommended for uncomplicated hemangiomas of infancy. Hemangiomas with complicating factors need close follow-up on an individual basis.

PATIENT EDUCATION

Hemangiomas are benign and not cancer. They are common and up to 1 in 10 white babies will have one. Most hemangiomas will go away spontaneously and not need treatment. For those needing treatments, there are new treatments that are safe and effective (oral propranolol and topical timolol).

PATIENT RESOURCES

- The Texas Children's Dermatology Clinic Web site is excellent—**http://www.texaschildrens.org/carecenters/dermatology/infantile-hemangioma.aspx.**
- Vascular Birthmarks Foundation—**http://www.birthmark.org/.**

PROVIDER RESOURCES

- National Organization of Vascular Anomalies (NOVA)—**http://www.novanews.org/.**

REFERENCES

1. Antaya R. *Infantile Hemangioma*. http://emedicine.medscape.com/article/1083849. Accessed July 16, 2011.

2. Elewski BE, Hughey LC, Parsons ME. *Differential Diagnosis in Dermatology*. St. Louis, MO: Elsevier; 2005:545.
3. McDermott AL, Dutt SN, Shavda SV, Morgan DW. Maffucci's syndrome: clinical and radiological features of a rare condition. *J Laryngol Otol.* 2001;115(10):845-847.
4. Barnhill RL. Vascular tumors. In: Hunt SJ, Santa Cruz DJ, Barnhill RL, eds. *Textbook of Dermatopathology*. New York: McGraw-Hill; 1998:821.
5. Yan AC, Chamlin SL, Liang MG, et al. Fibrosarcoma: a masquerader of ulcerated hemangioma. *Pediatr Dermatol.* 2006;23(4):330-334.
6. Enjolras O, Wassef M, Mazoyer E, et al. Infants with Kasabach-Merritt syndrome do not have "true" hemangiomas. *J Pediatr.* 1997;130(4):631-640.
7. Sadan N, Wolach B. Treatment of hemangiomas of infants with high doses of prednisone. *J Pediatr.* 1996;128 (1);141-146.
8. Garzon MC, Lucky AW, Hawrot A, Frieden IJ. Ultrapotent topical corticosteroid treatment of hemangiomas of infancy. *J Am Acad Dermatol.* 2005;52:281-286.
9. Sloan G, Reinisch J, Nichter L, et al. Intralesional corticosteroid therapy for infantile hemangiomas. *Plast Reconstr Surg.* 1989;83:459-466.
12. Poetke M, Phillip C, Berlien HP. Flashlamp-pumped pulsed dye laser for hemangiomas in infancy: treatment of superficial vs. mixed hemangiomas. *Arch Dermatol.* 2000;136(5):628-632.
13. Demiri EC, Pelissier P, Genin-Etcheberry T, et al. Treatment of facial haemangiomas: the present status of surgery. *Br J Plast Surg.* 2001;54(8):665-674.
14. Eedy DJ, Breathnach SM, Walker NPJ. *Surgical Dermatology*. Oxford, UK: Blackwell Science; 1996:245.
15. Oranje AP, Janmohamed SR, Madern GC, de Laat PC. Treatment of small superficial haemangioma with timolol 0.5% ophthalmic solution: a series of 20 cases. *Dermatology*. 2011;223:330-334.
16. Chakkittakandiyil A, Phillips R, Frieden IJ, et al. Timolol maleate 0.5% or 0.1% gel-forming solution for infantile hemangiomas: a retrospective, multicenter, cohort study. *Pediatr Dermatol.* 2012;29:28-31.
17. Semkova K, Kazandjieva J. Topical timolol maleate for treatment of infantile haemangiomas: preliminary results of a prospective study. *Clin Exp Dermatol.* 2012.

110 PUSTULAR DISEASES OF CHILDHOOD

Andrew Shedd, MD
Richard P. Usatine, MD
Heidi Chumley, MD

PATIENT STORY

A 1-year-old boy is brought for a second opinion about the recurrent pruritic vesicles and pustules on his hands and feet. This is the third episode, and in both previous episodes, the physicians thought the child had scabies. The child was treated with permethrin both times and within 2 to 3 weeks the skin cleared. No other family members have had lesions or symptoms. **Figures 110-1** to **110-3** demonstrate a typical case of infantile acropustulosis that is often misdiagnosed as scabies. Although the condition can be recurrent, it is ultimately self-limited and will resolve.

FIGURE 110-1 Infantile acropustulosis (acropustulosis of infancy) on the foot of a 1-year-old boy. (*Courtesy of Richard P. Usatine, MD.*)

INTRODUCTION

Acropustulosis and transient neonatal pustular melanosis (TNPM) are pustular diseases that typically present in infancy. Acropustulosis is a pruritic vesiculopustular disease presenting between 2 and 10 months of age and remitting spontaneously by 36 months of age. TNPM is present at birth and characterized by 2- to 3-mm hyperpigmented macules and pustules. Acropustulosis may require symptomatic treatment of pruritus, but otherwise both illnesses are self-limiting.

EPIDEMIOLOGY

Acropustulosis:

- Rare, intensely pruritic, vesiculopustular disease of young children.[1]
- Typically begins in the second or third months[1] of life and as late as 10 months of age.[2]
- Occur slightly more often in darker-skinned patients and males.[1]
- Typically spontaneously remits by 6 to 36 months of life.[2]

Transient neonatal pustular melanosis:

- A disease of newborns.[3]
- Equal male-to-female ratio.[3]
- Seen in 4.4% of black infants and 0.6% of white infants.[4]
- Early, spontaneous remission.[3]

FIGURE 110-2 Acropustulosis with vesiculopustular eruption on the toes of the boy shown in **Figure 110-1**. (*Courtesy of Richard P. Usatine, MD.*)

ETIOLOGY AND PATHOPHYSIOLOGY

Acropustulosis:

- The exact cause and mechanism have yet to be determined.[5]
- Some physicians speculate that it is a persistent reaction to scabies ("postscabies syndrome"). Suggestive of this infectious etiology,

infantile acropustulosis will occasionally be concurrently present amongst siblings. Also, patients diagnosed with this disorder frequently have received prior treatment for scabies, which may either provide evidence of an infectious etiology or demonstrate the frequent misdiagnosis, as in the patient above. Odom et al. concludes that in some cases, this disease may represent a hypersensitivity reaction to *Sarcoptes scabiei*.[4]

Transient neonatal pustular melanosis:

- The etiology is uncertain[6]; however, it may result from an obstruction of the pilosebaceous orifice.[3]

DIAGNOSIS

- Acropustulosis—A workup to rule out potentially serious infectious causes should be considered whenever confronted with a new pustular dermatosis early in a child's life. A workup might include a scraping for scabies, and KOH preparation as rapid diagnostic tests. If these studies are negative, the diagnosis may be made clinically as described below.
- TNPM—This diagnosis can often be made clinically. However, if performed, a Wright stain of the exudate will reveal a predominance of neutrophils with an occasional eosinophil, and the Gram stain will be negative.[3]

CLINICAL FEATURES

Acropustulosis:

- These vesiculopustular lesions begin around the second or third months of life and are typically concentrated on the hands and feet (**Figures 110-1** to **110-3**).[1]
- They begin acutely as small pink papules and progress within 24 hours to pustules[1] of less than 5 mm in diameter.[2]
- Recurrent episodes of these intensely pruritic lesions typically last 10 days and may recur every 2 to 5 weeks,[1,2] decreasing in frequency and severity[2] until spontaneous remission around 3 years of age.[1]
- There may be a residual scale and postinflammatory hyperpigmentation.[2]

Transient neonatal pustular melanosis:

- This condition is characterized by the presence at birth of 2- to 3-mm macules and pustules[4] on a nonerythematous base (**Figures 110-4** and **110-5**).[7]
- The lesions probably evolve prenatally[7] and subsequently rupture postnatally in 1 to 2 days.
- They heal with hyperpigmented macules that fade by 3 months of age,[3] with lighter-skinned patients experiencing less hyperpigmentation.[7]
- Sometimes, the only evidence of the disease is the presence of small, brown macules with a rim of scale at birth.[7]

TYPICAL DISTRIBUTION

- Acropustulosis—Although most commonly found on the palms and soles, the pustules may also be found on the dorsal surfaces of the hands and feet and occasionally the face, scalp, and trunk.[5]

FIGURE 110-3 Acropustulosis with pruritic eruption on the hand and wrist of the boy shown in **Figures 110-1** and **110-2**. (*Courtesy of Richard P. Usatine, MD.*)

FIGURE 110-4 Neonatal pustular melanosis on the hand of a newborn. (*Courtesy of Dan Stulberg, MD.*)

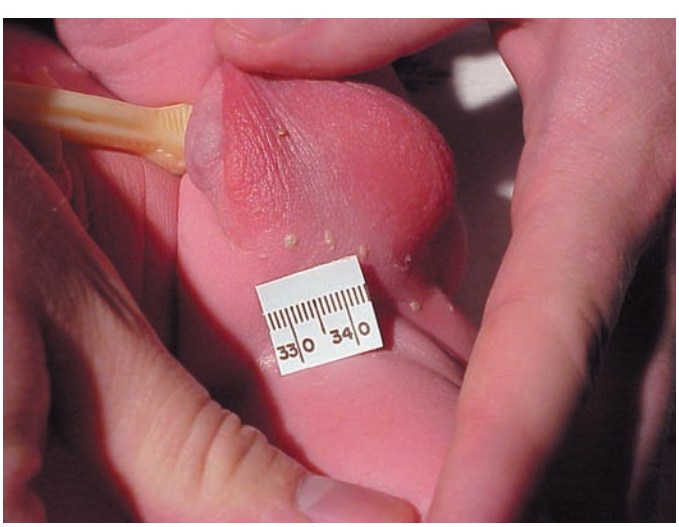

FIGURE 110-5 Neonatal pustular melanosis on scrotum of the same newborn. (*Courtesy of Dan Stulberg, MD.*)

- TNPM—They are most common on the face and chin; however, they may also be present on the neck, chest, sacrum, abdomen, and thighs.[7]

LABORATORY TESTING

- Acropustulosis—A blood count is not needed but might reveal a slight leukocytosis and frequently an eosinophilia. Stained smears of the lesions are also not needed but will demonstrate many neutrophils,[1] with some eosinophils possible early in the course.[2]
- TNPM—A Wright stain will reveal numerous neutrophils and some eosinophils, with a negative Gram stain.[3] Blood counts should be normal and no laboratory workup is generally indicated.

DIFFERENTIAL DIAGNOSIS

- Scabies infestation—Characterized by pruritic, intraepidermal burrows and vesicles with scale and crust, most commonly found in the web spaces of the digits, wrists, elbow, genitals, and lower extremities. May be present in other family members, and is not present at birth. Microscopic examination of the scrapings of the burrows may reveal mites, feces, eggs, or all of the above.[3] Acropustulosis will be refractory to all scabies therapies but scabies therapy may appear to work because each episode of acropustulosis is self-limited (see Chapter 143, Scabies).
- Erythema toxicum neonatorum—Appearing on the neonate 1 to 2 days after birth, this disease of unknown etiology causes 2- to 3-cm diffuse blotchy macules with 1- to 4-mm central vesicles. The lesions, which spare the palms and soles, contain a predominance of eosinophils and resolve spontaneously by 2 weeks of age (see Chapter 108, Normal Skin Changes).[3]
- Impetigo—A superficial infection of the skin with vesicles, bullae, and honey-colored crusts, caused by group A *Streptococcus*, or *Staphylococcus aureus*. Gram stain and culture should be positive (see Chapter 116, Impetigo).[3]
- Cutaneous candidiasis—Slightly pruritic areas of intensely erythematous papules, pustules, and plaques, possibly with white exudate, found around the genitals and folds of skin. *Candida* yeast forms present on KOH preparation or culture (see Chapter 136, Candidiasis).[3]
- Varicella—Characteristic "dewdrops on a rose petal" that develop in childhood. Uniformly distributed, pruritic, with known contacts likely. Now less common because of immunization (see Chapter 123, Chickenpox).
- Herpes—Grouped, painful vesicles on an erythematous base. May occur as gingivostomatitis in young children but rarely seen in the distribution of the pustular diseases of childhood. More likely to be vesicular rather than pustular (see Chapter 129, Herpes Simplex).
- Hand, foot, and mouth disease—This illness is caused by the coxsackievirus and produces papules and macules of the hands and feet that progress to flat vesicles before ulceration and eventual resolution. They typically affect the dorsum of the hands and feet and are also accompanied by painful oral lesions (see Chapter 128, Hand, Foot, and Mouth Disease).[3]
- Psoriasis, pustular—This severe form of psoriasis is rare in children and is characterized by the acute appearance of diffuse, painful, pinpoint pustules with high fever, fatigue, and anorexia (see Chapter 152, Psoriasis).[1]

MANAGEMENT

Acropustulosis:

- Corticosteroids (topical and oral) generally are not effective,[1] and not necessary in management.[5] SOR C
- Oral antihistamines may be helpful in controlling pruritus.[1] SOR C
- Pramoxine, lotion or cream, may be used topically for control of itching as it works by a different mechanism than antihistamines.[5] SOR C
- Dapsone (1 to 2 mg/kg per day, maximum dose of 100 mg/day)[5] has been used with good results. However, the risks of complications are generally considered to outweigh the benefits, unless the pruritus is debilitating.[1] SOR C

Transient neonatal pustular melanosis:

- No treatment is necessary. The parents should be reassured that the condition is benign and will resolve spontaneously with eventual normalization of any hyperpigmented macules.[6] SOR B

PROGNOSIS

- Acropustulosis resolves spontaneously by 6 to 36 months of age.
- TNPM resolves spontaneously by 3 months of age.

FOLLOW-UP

Acropustulosis may require initial follow-up for control of symptoms and assurance of a stable disease course. With symptoms controlled, follow-up may be unnecessary as the child ages and the disease decreases in severity and frequency. If dapsone is prescribed, proper monitoring is indicated.

TNPM needs no specific follow-up other than normal well-child care.

PATIENT EDUCATION

Once other conditions have been ruled out, reassurance that these diseases are self-limited is the most important piece of information to communicate to the family.

PATIENT AND PROVIDER RESOURCES

- Medscape. *Acropustulosis of Infancy*—**http://emedicine.medscape.com/article/1109935.**
- Medscape. *Transient Neonatal Pustular Melanosis*—**http://emedicine.medscape.com/article/1112258.**

REFERENCES

1. Ruggero C, Gelmetti C. *Pediatric Dermatology and Dermatopathology: A Concise Atlas*. London, UK: Martin Dunitz; 2002.
2. Weinberg S, Prose NS, Leonard K. *Color Atlas of Pediatric Dermatology*, 3rd ed. New York: McGraw-Hill; 1998.
3. Kane KS, Bissonette J, Baden HP, et al. *Color Atlas and Synopsis of Pediatric Dermatology*. New York: McGraw-Hill; 2002.
4. Odom RB, James WD, Timothy GB. *Andrews' Diseases of the Skin, Clinical Dermatology*, 9th ed. Philadelphia: Saunders; 2000.
5. Pride H. *Acropustulosis of Infancy*. http://www.emedicine.com/derm/topic8.htm. Accessed March 30, 2012.
6. Silverman RA. *Neonatal Pustular Melanosis*. http://www.emedicine.com/ped/topic698.htm. Accessed March 5, 2012.
7. Cohen BA. *Pediatric Dermatology*, 3rd ed. Philadelphia: Elsevier Mosby; 2005.

111 DIAPER RASH AND PERIANAL DERMATITIS

Bridget Malit, MD
Julie Scott Taylor, MD, MSc

PATIENT STORY

A 2-month-old baby girl was brought to the office with a severe diaper rash that was not getting better with Desitin. Upon examination, the physician noted a white coating on the tongue and buccal mucosa. The diaper area was red with skin erosions and satellite lesions (**Figure 111-1**). The whole picture is consistent with candidiasis of the mouth (thrush) and the diaper region. The child was treated with oral nystatin suspension and topical clotrimazole cream in the diaper area with good results.

FIGURE 111-1 *Candida* diaper dermatitis in an infant who has oral thrush. (*Courtesy of Richard P. Usatine, MD.*)

INTRODUCTION

Diaper rash is a general term used to describe any type of red or inflammatory skin rash that is located in the diaper area.

SYNONYMS

Diaper dermatitis, napkin dermatitis.

EPIDEMIOLOGY

- Diaper dermatitis is the most common dermatitis of infancy.
- Variability in prevalence of 4% to 35% among children in their first 2 years of life in different studies.[1]
- Diaper rash is thought to be present in 25% of children presenting for outpatient visits.[2]
- No differences in prevalence between genders or among ethnic groups.
- One study showed an incidence of 19.4% in children ages 3 to 6 months.[1]
- Higher incidence among formula-fed compared with breastfed infants.[1]
- Condition typically begins around age 3 weeks, peaks at age 9 to 12 months, and then decreases with age until it resolves completely with toilet training.
- Individual episodes last from 1 day to 2 weeks.
- Aggravating factors include poor skin care, diarrhea, recent antibiotic use, and urinary tract abnormalities.
- Perianal streptococcal dermatitis occurs in children between 6 months and 10 years of age (**Figures 111-2** and **111-3**).

ETIOLOGY AND PATHOPHYSIOLOGY

- Primary diaper dermatitis—An acute skin inflammation in the diaper area with a multifactorial etiology.[3] The main cause is irritation of thin skin as a result of prolonged contact with moisture including feces and urine. The multiple factors involved are:
  1. Occlusion/lack of exposure to air.
  2. Friction and mechanical trauma.
  3. Local irritants—Fecal proteases and lipases.
  4. Increased pH.
  5. Maceration of the stratum corneum with loss of the protective barrier function of skin.
- Irritant diaper dermatitis (IDD) is a combination of intertrigo (wet skin damaged from chafing) and miliaria (heat rash) when eccrine glands become obstructed from excessive hydration. It is a noninfectious, nonallergic, often asymptomatic contact dermatitis that typically lasts for less than 3 days after a change in diaper practices.
- Candidal diaper dermatitis—Within 3 days, 45% to 75% of diaper rashes are colonized with *Candida albicans* of fecal origin.
- Bacterial diaper dermatitis may be a secondary infection caused by *Staphylococcus aureus* or *Streptococcus pyogenes*. Other common bacterial isolates include *Escherichia coli, Peptostreptococcus*, and *Bacteroides*. Usually occurs during the warm summer months.
- Perianal streptococcal dermatitis is caused by group A β-hemolytic streptococci (**Figures 111-2** and **111-3**).

RISK FACTORS

- Diarrhea.
- Formula-fed infants.
- Recent antibiotic use.
- Urinary tract abnormalities.
- Poor skin care.

DIAGNOSIS

CLINICAL FEATURES

- IDD begins with shiny erythema with or without scale and poorly demarcated margins on the convex skin surfaces in areas covered by diapers. Moderate cases can have papules, plaques, vesicles, and small superficial erosions that can progress to well-demarcated ulcerated nodules typically with sparing of skin folds (**Figure 111-4**).
- Pustules or papules beyond the rash border (called "satellite lesions"), involvement of the skin folds, and white scaling all indicate a fungal infection with *Candida* (**Figure 111-5**).
- Secondary bacterial infections can have redness, honey-colored crusting, swelling, red streaking, and/or purulent discharge. With impetigo in the diaper area, bullae are not usually intact but instead present as superficial erosions.
- Perianal streptococcal dermatitis is a bright red, sharply demarcated rash sometimes associated with blood-streaked stools (**Figure 111-2**).

FIGURE 111-2 Perianal dermatitis caused by group A β-hemolytic streptococci. (*From Sheth S, Schechtman AD. Itchy perianal erythema. J Fam Pract. 2007;56(12):1025-1027. Reproduced with permission from Frontline Medical Communications.*)

FIGURE 111-3 A positive rapid strep test taken from a swab of the perianal area of the infant in the previous photo. (*From Sheth S, Schechtman AD. Itchy perianal erythema. J Fam Pract. 2007;56(12): 1025-1027. Reproduced with permission from Frontline Medical Communications.*)

FIGURE 111-4 Irritant diaper dermatitis precipitated by diarrhea secondary to amoxicillin-clavulanate prescribed to treat otitis media. Note the absence of satellite lesions. (*Courtesy of Richard P. Usatine, MD.*)

TYPICAL DISTRIBUTION

Diaper dermatitis is primarily found on the buttocks, the genitalia, the mons pubis and lower abdomen, and the medial thighs. Be sure to evaluate for rashes outside of the diaper area as well. If *Candida* is suspected, the oropharynx should be inspected for signs of thrush, such as adherent white plaques on the mucosa.

LABORATORY STUDIES

Clinical diagnosis is based primarily on the physical examination. Rarely indicated tests that are occasionally used in more complicated cases include potassium hydroxide preparation for fungal elements, mineral oil preparation for scabies, complete blood count with differential, zinc level, or skin biopsy (**Figure 111-6**). A rapid strep test can be used to diagnose perianal streptococcal dermatitis (**Figures 111-2** and **111-3**).

FIGURE 111-5 Close-up of a *Candida* diaper dermatitis in a 5-month-old infant. Note the superficial scaling around the satellite lesions. (*Courtesy of Richard P. Usatine, MD.*)

DIFFERENTIAL DIAGNOSIS

There are two distinctive severe variants of IDD. Jacquet's diaper dermatitis (dermatitis syphiloides posterosiva or erosive variant) is a term used to describe severe, slow-healing, noduloerosive lesions with heaped-up borders seen in children with persistent diarrhea.[4] Granuloma gluteale infantum is a rare and poorly understood primary diaper dermatitis that presents with granulomatous nodules that can have large, raised, purple erosions with rolled margins. It resolves spontaneously over the course of a few months once the causative agent is discovered and removed, often with residual scarring and hyperpigmentation.[5]

Perianal pseudoverrucous papules are shiny, smooth, red, moist, flat-topped lesions that are commonly confused with the genital warts that occur in the context of Hirschsprung disease.

Secondary diaper dermatitis is an eruption in the diaper area with a defined etiology. Atopic dermatitis, seborrheic dermatitis, and psoriasis are examples of rashes that can appear anywhere on the body and can be exaggerated in the groin as a result of wearing diapers. Family history of atopy or psoriasis and rash in other locations besides the groin can be helpful.

Congenital syphilis, scabies, HIV, Langerhans cell histiocytosis, and acrodermatitis enteropathica are examples of rashes in the diaper area unrelated to the diaper. Allergic contact dermatitis as a result of an allergen in the diaper itself is possible but rare.

Suspect acrodermatitis enteropathica caused by zinc deficiency when the diaper dermatitis is severe and accompanied by perioral dermatitis (**Figure 111-6**). The serum zinc level will be low and zinc supplementation will be needed.

FIGURE 111-6 Acrodermatitis enteropathica caused by zinc deficiency. The child also had perioral dermatitis that appeared similar to the diaper dermatitis. (*Courtesy of Richard P. Usatine, MD.*)

MANAGEMENT

TREATMENT

- Parental behavior change to keep the skin as exposed and dry as possible. SOR B Frequent diaper changes (as soon as they are wet or soiled and at least every 3 to 4 hours); use disposable diapers. SOR B Frequent gentle cleaning of the affected area with lukewarm tap water instead of commercial wipes containing alcohol

and pat dry. A squeeze bottle with lukewarm water can be used to avoid rubbing the delicate skin.

- Superabsorbent diapers that pull moisture away from the skin are helpful.[1] SOR B
- Apply barrier preparations, including zinc oxide paste, petroleum jelly, Vitamin A & D ointment, or Burow solution, to affected area after each diaper change.[1] SOR B Pastes are better than ointments, which, in turn, are better than creams or lotions. Avoid products with fragrances or preservatives to minimize allergic potential. Apply thickly like "icing on a cake." These barrier preparations should be used *on top* of other indicated therapies.
- For moderate to severe inflammation, consider a nonfluorinated, low-potency topical steroid such as 1% hydrocortisone ointment (up to 3 times daily) to the affected area until the dermatitis is gone. To avoid skin erosions, atrophy, and striae, it is best to not go beyond 2 weeks of therapy with any topical steroid on a baby's bottom.
- For *Candida*, use topical nonprescription antifungal creams such as clotrimazole, miconazole after every diaper change until the rash resolves. SOR B For concomitant oral thrush, treat with oral nystatin swish and swallow 4 times daily.
- Avoid combination antifungal–steroid agents that contain steroids stronger than hydrocortisone (e.g., Lotrisone). Potent topical steroids can cause striae and skin erosions, hypothalamus–pituitary–adrenal axis suppression, and Cushing syndrome.[1]
- For mild bacterial infections, use topical antibiotic ointments such as bacitracin or mupirocin after every diaper change until the rash resolves. SOR B
- For more severe bacterial infections, consider a broad-spectrum oral antibiotic such as amoxicillin-clavulanate. Perianal bacterial dermatitis has been reported to be predominantly caused by *S. aureus.*[6] Oral cephalexin is a good choice because it covers *S. aureus* and group A β-hemolytic streptococcus. If methicillin-resistant *S. aureus* (MRSA) is suspected, consider trimethoprim-sulfamethoxazole. SOR B
- Ciclopirox 0.77% topical suspension (Loprox), a broad-spectrum agent with antifungal, antibacterial, and antiinflammatory properties, was used safely and effectively in 1 trial of 44 children to treat diaper dermatitis caused by *Candida*.[1] SOR B
- Recommend dye-free diapers for allergic contact dermatitis. SOR B

PREVENTION AND ROUTINE SKIN CARE

- Keep the diaper region as dry and clean as possible.
- Promote the use of barrier preparations daily to maintain skin integrity.
- There is no evidence to suggest that topical vitamin A prevents diaper dermatitis.[7] SOR B
- Disposable diapers—Although many individual trials show benefits, a 2006 Cochrane Review found that there is not enough evidence from good quality, randomized, controlled trials to support or refute the use and type of disposable diapers for the prevention of diaper dermatitis in infants.[8] SOR B

PROGNOSIS

Diaper dermatitis has an excellent prognosis when treated as above.

FOLLOW-UP

No follow-up needed unless the rash worsens or persists. The exception is severe bacterial infection where follow-up is recommended because recurrences are common.

PATIENT (PARENT) EDUCATION

Prevention and early treatment are the best strategies. Keep the child's diaper area as clean, cool, and dry as possible with frequent diaper changes. Do *not* use creams that contain boric acid, camphor, phenol, methyl salicylate, compound of benzoin, or talcum powder or cornstarch. Reassure parents that, although this common condition is sometimes distressing for parents and uncomfortable for children, it is rarely dangerous.

PATIENT RESOURCES

- FamilyDoctor.org. *Diaper Rash*—**http://familydoctor.org/familydoctor/en/diseases-conditions/diaper-rash.html.**
- WebMD. *Diaper Rash–Topic Overview*—**http://children.webmd.com/tc/diaper-rash-topic-overview.**

PROVIDER RESOURCES

- Medscape. *Diaper Rash*—**http://emedicine.medscape.com/article/801222.**

REFERENCES

1. Dib R. *Diaper Rash*. http://emedicine.medscape.com/article/801222-overview#a0199. Updated March 17, 2010.
2. Adalat S, Wall D, Goodyear H. Diaper dermatitis-frequency and contributory factors in hospital attending children. *Pediatr Dermatol*. 2007:24(5):483-488.
3. Adam R. Skin care of the diaper area. *Pediatr Dermatol*. 2008:25(4):427-433.
4. Paradisi A, Capizzi R, Ghitti F, et al. Jacquet erosive diaper dermatitis: a therapeutic challenge. *Clin Exp Dermatol*. 2009:34(7):e385-e386.
5. Al-Faraidy N, Al-Natour S. A forgotten complication of diaper dermatitis: granuloma Gluteale Infantum. *J Family Community Med*. 2010;17(2):107-109.
6. Heath C, Desai N, Silverberg N. Recent microbiological shifts in perianal bacterial dermatitis: *Staphylococcus aureus* predominance. *Pediatr Dermatol*. 2009:26(6):696-700.
7. Davies MW, Dore AJ, Perissinotto KL. Topical vitamin A, or its derivatives, for treating and preventing napkin dermatitis in infants. *Cochrane Database Syst Rev*. 2005 Oct 19;(4):CD004300.
8. Baer EL, Davies MW, Easterbrook KJ. Disposable nappies for preventing napkin dermatitis in infants. *Cochrane Database Syst Rev*. 2006 Jul 19;(3):CD004262.

SECTION 2 ACNEIFORM DISORDERS

112 ACNE VULGARIS

Richard P. Usatine, MD

PATIENT STORY

A 16-year-old boy (**Figure 112-1**) with severe nodulocystic acne and scarring presents for treatment. After trying oral antibiotics, topical retinoids, and topical benzyl peroxide with no significant benefit, the patient and his mother request isotretinoin (Accutane). After 4 months of isotretinoin, the nodules and cysts cleared and there remained only a few papules (**Figure 112-2**). He is much happier and more confident about his appearance. The skin cleared fully after the last month of isotretinoin.

FIGURE 112-1 Severe nodulocystic acne with scarring in a 16-year-old boy. (*Courtesy of Richard P. Usatine, MD.*)

INTRODUCTION

Acne is an obstructive and inflammatory disease of the pilosebaceous unit predominantly found on the face of adolescents. However, it can occur at any age and often involves the trunk in addition to the face.

EPIDEMIOLOGY

Acne vulgaris affects more than 80% of teenagers, and persists beyond the age of 25 years in 3% of men and 12% of women.[1]

ETIOLOGY AND PATHOPHYSIOLOGY

The four most important steps in acne pathogenesis:

1. Sebum overproduction related to androgenic hormones and genetics.
2. Abnormal desquamation of the follicular epithelium (keratin plugging).
3. *Propionibacterium acnes* proliferation.
4. Follicular obstruction, which can lead to inflammation and follicular disruption.

Neonatal acne is thought to be related to maternal hormones and is temporary (**Figure 112-3**).

Acne can be precipitated by mechanical pressure as with a helmet strap (**Figure 112-4**) and medications such as phenytoin and lithium (**Figure 112-5**).

There are some studies that suggest that consumption of large quantities of milk (especially skim milk) increase the risk for acne in teenagers.[2]

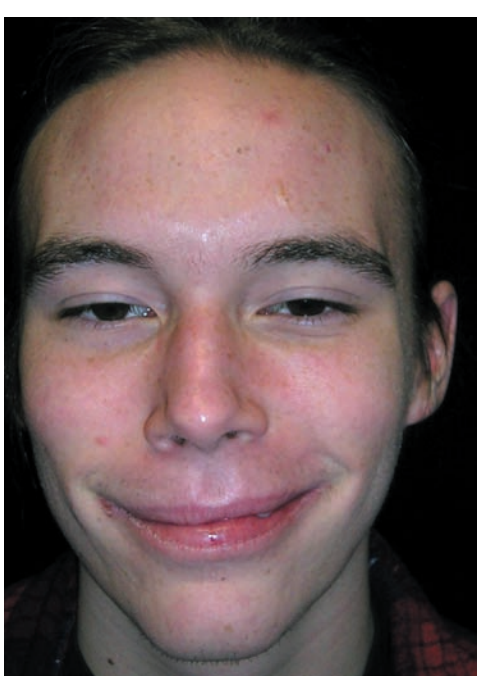

FIGURE 112-2 A happier boy now that his nodules and cysts have cleared at the start of the fifth month of isotretinoin treatment. (*Courtesy of Richard P. Usatine, MD.*)

DIAGNOSIS

CLINICAL FEATURES

Morphology of acne includes comedones, papules, pustules, nodules, and cysts.

- Obstructive acne = comedonal acne = noninflammatory acne and consists of only comedones (**Figure 112-6**).
- Open comedones are blackheads and closed comedones are called whiteheads and look like small papules.
- Inflammatory acne has papules, pustules, nodules, and cysts in addition to comedones (**Figure 112-5**).

TYPICAL DISTRIBUTION

Face, back, chest, and neck.

LABORATORY STUDIES

None unless you suspect androgen excess and/or polycystic ovarian syndrome (PCOS).[3] SOR A Obtain testosterone and DHEA-S levels if you suspect androgen excess and/or PCOS.

Consider follicle-stimulating hormone (FSH) and luteinizing hormone (LH) levels if you suspect PCOS.

FIGURE 112-3 Neonatal acne in a healthy 2-week-old infant that resolved without treatment. (*Courtesy of Richard P. Usatine, MD.*)

DIFFERENTIAL DIAGNOSIS

- Acne conglobata is an uncommon and unusually severe form of acne characterized by multiple comedones, cysts, sinus tracks, and abscesses. The inflammatory lesions and scars can lead to significant disfigurement.[4] Sinus tracks can form with multiple openings that drain foul-smelling purulent material (**Figures 112-7, 112-8** and **112-9**). The comedones and nodules are usually found on the chest, the shoulders, the back, the buttocks, and the face. In some cases acne conglobata is part of a follicular occlusion triad including hidradenitis and dissecting cellulitis of the scalp (**Figure 112-9**).
- Acne fulminans is characterized by sudden onset ulcerative crusting cystic acne, mostly on the chest and back (**Figures 112-10** and **112-11**).[5] Fever, malaise, nausea, arthralgia, myalgia, and weight loss are common. Leukocytosis and elevated erythrocyte sedimentation rate are usually found. There may also be focal osteolytic lesions. The term *acne fulminans* may also be used in cases of severe aggravation of acne without systemic features.[5]
- Rosacea can resemble acne by having papules and pustules on the face. It is usually seen in older adults with prominent erythema and telangiectasias. Rosacea does not include comedones and may have ocular or nasal manifestations (Chapter 113, Rosacea). Rosacea fulminans or pyoderma faciale has features of severe acne and rosacea (**Figure 112-12**).
- Folliculitis on the back may be confused with acne. Look for hairs centrally located in the inflammatory papules of folliculitis to help distinguish it from acne. Acne on the back usually accompanies acne on the face as well (Chapter 117, Folliculitis).
- Acne keloidalis nuchae consists of papules, pustules, nodules, and keloidal tissue found at the posterior hairline. It is most often seen in men of color after shaving the hair at the nape of the neck (Chapter 114, Pseudofolliculitis and Acne Keloidalis Nuchae).

FIGURE 112-4 Inflammatory acne showing pustules and nodules in a 17-year-old boy who uses a helmet while playing football in high school. (*Courtesy of Richard P. Usatine, MD.*)

FIGURE 112-5 Severe inflammatory acne in a young adult. His acne worsened when he was started on phenytoin for his seizure disorder. (*Courtesy of Richard P. Usatine, MD.*)

FIGURE 112-6 Comedonal acne in a 15-year-old girl. Open comedones (blackheads) and closed comedones (whiteheads) are visible on her forehead. (*Courtesy of Richard P. Usatine, MD.*)

FIGURE 112-7 **A.** Acne conglobata in a 16-year-old boy. He has severe cysts on his face with sinus tracks between them. He required many weeks of oral prednisone before isotretinoin was started. His acne cleared completely with his treatment. **B.** Acne conglobata cleared with minimal scarring after oral prednisone and 5 months of isotretinoin therapy. (*Courtesy of Richard P. Usatine, MD.*)

FIGURE 112-8 Acne conglobata in a 42-year-old woman showing communicating sinus tracks between cysts. There is pus draining from one of the sinus tracts on the right side of the neck. (*Courtesy of Richard P. Usatine, MD.*)

- Actinic comedones (blackheads) are related to sun exposure and are seen later in life (**Figure 112-13**).

MANAGEMENT

Treatment is based on type of acne and severity. Categories to choose from are topical retinoids, topical antimicrobials, systemic antimicrobials, hormonal therapy, oral isotretinoin, and injection therapy.

MEDICATIONS FOR ACNE THERAPY

In a review of 250 comparisons, the Agency for Healthcare Research and Quality found 14 had evidence of level A.[6] These comparisons demonstrated the efficacy over vehicle or placebo control of topical clindamycin, topical erythromycin, benzoyl peroxide, topical tretinoin, oral tetracycline, and norgestimate/ethinyl estradiol.[4] Level A conclusions demonstrating equivalence include: Benzoyl peroxide at various strengths was equally efficacious in mild/moderate acne; adapalene and tretinoin were equally efficacious.[6] SOR A

Topical

- Benzoyl peroxide—Antimicrobial effect (gel, cream, lotion) (2.5%, 5%, 10%) 10% causes more irritation and is not more effective.[1] SOR A
- Topical antibiotics—Clindamycin and erythromycin are the mainstays of treatment.
- Erythromycin—Solution, gel.[3] SOR A
- Clindamycin—Solution, gel, lotion.[3] SOR A
- Benzamycin gel—Erythromycin 3%, benzoyl peroxide 5%.[3] SOR A
- BenzaClin gel—Clindamycin 1%, benzoyl peroxide 5%.[3] SOR A
- Dapsone 5% gel.[7] SOR B

Retinoids:

- Tretinoin (Retin-A) gel, cream, liquid, micronized.[1] SOR A
- Adapalene gel—Less irritating than tretinoin.[1] SOR A
- Tazarotene—Strongest topical retinoid with greatest risk of irritation.[8] SOR A

Topical retinoids will often result in skin irritation during the first 2 to 3 months of treatment, but new systematic reviews do not demonstrate that they worsen acne lesion counts during the initial period of use.[2]

- Azelaic acid—Useful to treat spotty hyperpigmentation and acne (**Figure 112-14**).[3] SOR B

Systemic

- Oral antibiotics.
  - Tetracycline 500 mg qd-bid—Inexpensive, absorbed best on an empty stomach.[3] SOR A
  - Doxycycline 40 to 100 mg qd bid—Inexpensive, well tolerated, can take with food and increases sun sensitivity.[3] SOR A
  - Minocycline 50 to 100 mg qd bid—Expensive, not proven to be better than other systemic antibiotics including tetracycline.[3,9] SOR A
  - Erythromycin 250 to 500 mg bid—Inexpensive, frequent gastrointestinal (GI) disturbance but can be used in pregnancy.[3] SOR A

FIGURE 112-9 Acne conglobata in a 53-year-old man covered with open comedones and cysts on his back. He has the follicular occlusion triad including hidradenitis, dissecting cellulitis of the scalp and acne conglobata. (*From Grunwald MH, Amichai B. Nodulo-cystic eruption with musculoskeletal pain. J Fam Pract. 2007;56(3):205-206, Reproduced with permission from Frontline Medical Communications.*)

FIGURE 112-10 Acne fulminans in a 17-year-old boy. He was on isotretinoin when he developed worsening of his acne with polymyalgia and arthralgia. He presented with numerous nodules and cysts covered by hemorrhagic crusts on his chest and back. (*From Grunwald MH, Amichai B. Nodulo-cystic eruption with musculoskeletal pain. J Fam Pract. 2007;56:205-206, Reproduced with permission from Frontline Medical Communications.*)

FIGURE 112-11 Acne fulminans with severe rapidly worsening truncal acne in a 15-year-old-boy. He did not have fever or bone pain but had a white blood cell count of 17,000. He responded rapidly to prednisone and was started on isotretinoin. The ulcers and granulation tissue worsened initially on isotretinoin but prednisone helped to get this under control. (*Courtesy of Richard P. Usatine, MD.*)

- Trimethoprim/sulfamethoxazole DS bid—Effective but risk of Stevens-Johnson syndrome is real. Reserve for short courses in particularly severe and resistant cases.[3] SOR A

Oral azithromycin has been prescribed in pulse dosing for acne in a number of small poorly done studies and has not been found to be better than oral doxycyline.[10]

- Isotretinoin (Accutane) is the most powerful treatment for acne. It is especially useful for cystic and scarring acne that has not responded to other therapies.[3] SOR A Dosed at approximately 1 mg/kg per day for 5 months. Women of childbearing age must use two forms of contraception. Monitor for depression.
- The U.S. Food and Drug Administration requires that prescribers of isotretinoin, patients who take isotretinoin, and pharmacists who dispense isotretinoin all must register with the iPLEDGE system (**www.ipledgeprogram.com**).
- Hormonal treatments:
  - Oral contraceptives only for females—Choose ones with low androgenic effect.[3] SOR A FDA-approved oral contraceptives are Ortho Tri-Cyclen, Yaz, and Estrostep. Other oral contraceptives with similar formulations also help acne in women even though these have not received FDA approval for this indication. Note Yaz and Yasmin have progestin drospirenone, which is derived from 17α-spirolactone. It shares an antiandrogenic effect with spironolactone.
  - Spironolactone may be used for adult women when other therapies fail.[3,11,12] This may be especially useful if the patient has hirsutism. Standard dosing is 50 to 200 mg/day. May start with 25 mg bid and monitor for hyperkalemia. The risk of hyperkalemia increases with a higher dose. Titrate up as needed and tolerated.[3] SOR B A recent systematic review failed to show a benefit for spironolactone in acne even though it was found to decrease hirsutism.[13]
  - One small prospective study of 27 women with severe papular and nodulocystic acne used a combination of EE/DRSP (Yasmin) and spironolactone 100 mg daily. Eighty-five percent of subjects were entirely clear of acne lesions or had excellent improvement and there was no significant elevation of serum potassium.[14]

COMPLEMENTARY AND ALTERNATIVE THERAPY

Tea tree oil 5% gel.[15] SOR B

Steroid injection therapy

For painful nodules and cysts. SOR C Be careful to avoid producing skin atrophy.

- Dilute 0.1 cc of 10 mg/cc triamcinolone acetonide (Kenalog) with 0.4 cc of sterile saline for a 2 mg/cc suspension.
- Inject 0.1 cc with a 1-cc tuberculin syringe into each nodule using a 30-gauge needle (**Figure 112-15**).

ACNE THERAPY BY SEVERITY

Comedonal acne (Figure 112-6).

- Topical retinoid or azelaic acid.
- No need for antibiotics or antimicrobials—Do not need to kill *P. acnes*.

FIGURE 112-12 Pyoderma faciale is almost exclusively seen in adult women. It can present with severe cystic facial acne often in a malar distribution. It also is called rosacea fulminans. It started abruptly 6 months before and her antinuclear antibody was normal. (*Courtesy of Richard P. Usatine, MD.*)

FIGURE 112-13 Actinic comedones related to sun exposure in an older man. These are typically seen on the side of the face clustering around the eyes. (*Courtesy of Richard P. Usatine, MD.*)

Mild papulopustular

- Topical antibiotics and benzoyl peroxide.
- Topical retinoid or azelaic acid.
- May add oral antibiotics if topical agents are not working.

Papulopustular or nodulocystic acne—moderate to severe—inflammatory

- Topical antibiotic, benzoyl peroxide, and oral antibiotic.
- Oral antibiotics are often essential at this stage.
- Topical retinoid or azelaic acid.
- Steroid injection therapy—For painful nodules and cysts.

Severe cystic or scarring acne

- Isotretinoin if there are no contraindications.
- Steroid injection therapy—For painful nodules and cysts.

Acne fulminans (Figures 112-9 to 112-11)

- Start with systemic steroids (prednisone 40 to 60 mg/day—approximately 1 mg/kg per day).[16] SOR C
- Systemic steroid treatment rapidly controls the skin lesions and systemic symptoms. The duration of steroid treatment in one Finnish series was 2 to 4 months to avoid relapses.[16] SOR C
- Therapy with isotretinoin, antibiotics, or both was often combined with steroids, but the role of these agents is still uncertain.[16] SOR C
- One British series used oral prednisolone 0.5 to 1 mg/kg daily for 4 to 6 weeks (thereafter slowly reduced to zero).[17] SOR C
- Oral isotretinoin was added to the regimen at the fourth week, initially at 0.5 mg/kg daily and gradually increased to achieve complete clearance.[17] SOR C
- Consider introducing isotretinoin at approximately 4 weeks into the oral prednisone if there are no contraindications. SOR C

Acne conglobata and pyoderma faciale may be treated like acne fulminans but the course of oral prednisone does not need to be as long. SOR C

COMBINATION THERAPIES

- Combination therapy with multiple topical agents can be more effective than single agents.[3] SOR B
- Topical retinoids and topical antibiotics are more effective when used in combination than when either are used alone.[3] SOR B
- Benzoyl peroxide and topical antibiotics used in combination are effective treatment for acne by helping to minimize antibiotic resistance.[3] SOR B
- The adjunctive use of clindamycin/benzoyl peroxide gel with tazarotene cream promotes greater efficacy and may also enhance tolerability.[18]
- Combination therapy with topical retinoids and oral antibiotics can be helpful at the start of acne therapy. However, maintenance therapy with combination tazarotene and minocycline therapy showed a trend for greater efficacy but no statistical significance vs. tazarotene alone.[19]

FIGURE 112-14 Obstructive or comedonal acne with spotty hyperpigmentation. Azelaic acid was helpful to treat the acne and the hyperpigmentation. (*Courtesy of Richard P. Usatine, MD.*)

FIGURE 112-15 Injection of acne nodules with 2 mg/cc triamcinolone acetonide. (*Courtesy of Richard P. Usatine, MD.*)

MEDICATION COST

The most affordable medications for acne include topical benzoyl peroxide, erythromycin, clindamycin, and oral tetracycline and doxycycline. The most expensive acne medications are the newest brand-name combination products of existing topical medication. These medications are convenient for those with insurance that covers them (Epiduo contains benzoyl peroxide and adapalene; Ziana contains clindamycin and tretinoin).

NEWER EXPENSIVE MODES OF THERAPY

Intense pulsed light and photodynamic therapy (PDT) use lasers, special lights, and topical chemicals to treat acne.[20–22] These therapies are very expensive and the data do not suggest that these should be first-line therapies at this time. Light and laser treatments have been shown to be of short-term benefit if patients can afford therapy and tolerate some discomfort. These therapies have not been shown to be better than simple topical treatments.[2]

One comparative trial demonstrated that PDT was less effective than topical adapalene in the short-term reduction of inflammatory lesions.[2]

FOLLOW-UP

Isotretinoin requires monthly follow-up visits but other therapies can be monitored every few months at first and then once to twice a year. Keep in mind that many treatments for acne take months to work, so quick follow-up visits may be disappointing.

PATIENT EDUCATION

Adherence with medication regimens is crucial to the success of the therapy. Adequate face washing twice a day is sufficient. Do not scrub the face with abrasive physical or chemical agents. If benzoyl peroxide is not being used as a leave-on product, it can be purchased to use for face washing.

PATIENT RESOURCES

- PubMed Health has a good patient education information—**http://www.ncbi.nlm.nih.gov/pubmedhealth/PMH0001876/.**

PROVIDER RESOURCES

- Usatine R, Pfenninger J, Stulberg D, Small R. *Dermatologic and Cosmetic Procedures in Office Practice*. Philadelphia: Elsevier; 2012—Covers how to do acne surgery, steroid injections for acne, chemical peels, PDT and laser treatment for acne. It is also available as an app: **www.usatinemedia.com.**

REFERENCES

1. Purdy S, de Berker D. Acne vulgaris. *Clin Evid (Online)*. 2011;2011.
2. Smith EV, Grindlay DJ, Williams HC. What's new in acne? An analysis of systematic reviews published in 2009-2010. *Clin Exp Dermatol*. 2011;36:119-122.

3. Strauss JS, Krowchuk DP, Leyden JJ, et al. Guidelines of care for acne vulgaris management. *J Am Acad Dermatol.* 2007;56:651-663.
4. Shirakawa M, Uramoto K, Harada FA. Treatment of acne conglobata with infliximab. *J Am Acad Dermatol.* 2006;55:344-346.
5. Grunwald MH, Amichai B. Nodulo-cystic eruption with musculoskeletal pain. *J Fam Pract.* 2007;56:205-206.
6. AHRQ. *Management of Acne*. http://www ahrq gov/clinic/epcsums/acnesum htm [serial online]. 2001.
7. Draelos ZD, Carter E, Maloney JM, et al. Two randomized studies demonstrate the efficacy and safety of dapsone gel, 5% for the treatment of acne vulgaris. *J Am Acad Dermatol.* 2007;56:439-410.
8. Webster GF, Guenther L, Poulin YP, et al. A multicenter, double-blind, randomized comparison study of the efficacy and tolerability of once-daily tazarotene 0.1% gel and adapalene 0.1% gel for the treatment of facial acne vulgaris. *Cutis.* 2002;69(2 Suppl):4-11.
9. Garner SE, Eady EA, Popescu C, et al. Minocycline for acne vulgaris: efficacy and safety. *Cochrane Database Syst Rev.* 2003; CD002086.
10. Maleszka R, Turek-Urasinska K, Oremus M, et al. Pulsed azithromycin treatment is as effective and safe as 2-week-longer daily doxycycline treatment of acne vulgaris: a randomized, double-blind, noninferiority study. *Skinmed.* 2011;9:86-94.
11. Shaw JC. Low-dose adjunctive spironolactone in the treatment of acne in women: a retrospective analysis of 85 consecutively treated patients. *J Am Acad Dermatol.* 2000;43:498-502.
12. Sato K, Matsumoto D, Iizuka F, et al. Anti-androgenic therapy using oral spironolactone for acne vulgaris in Asians. *Aesthetic Plast Surg.* 2006;30:689-694.
13. Brown J, Farquhar C, Lee O, et al. Spironolactone versus placebo or in combination with steroids for hirsutism and/or acne. *Cochrane Database Syst Rev.* 2009;CD000194.
14. Krunic A, Ciurea A, Scheman A. Efficacy and tolerance of acne treatment using both spironolactone and a combined contraceptive containing drospirenone. *J Am Acad Dermatol.* 2008;58:60-62.
15. Enshaieh S, Jooya A, Siadat AH, Iraji F. The efficacy of 5% topical tea tree oil gel in mild to moderate acne vulgaris: a randomized, double-blind placebo-controlled study. *Indian J Dermatol Venereol Leprol.* 2007;73:22-25.
16. Karvonen SL. Acne fulminans: report of clinical findings and treatment of twenty-four patients. *J Am Acad Dermatol.* 1993;28: 572-579.
17. Seukeran DC, Cunliffe WJ. The treatment of acne fulminans: a review of 25 cases. *Br J Dermatol.* 1999;141:307-309.
18. Tanghetti E, Dhawan S, Green L, et al. Randomized comparison of the safety and efficacy of tazarotene 0.1% cream and adapalene 0.3% gel in the treatment of patients with at least moderate facial acne vulgaris. *J Drugs Dermatol.* 2010;9:549-558.
19. Leyden J, Thiboutot DM, Shalita AR, et al. Comparison of tazarotene and minocycline maintenance therapies in acne vulgaris: a multicenter, double-blind, randomized, parallel-group study. *Arch Dermatol.* 2006;142:605-612.
20. Yeung CK, Shek SY, Bjerring P, et al. A comparative study of intense pulsed light alone and its combination with photodynamic therapy for the treatment of facial acne in Asian skin. *Lasers Surg Med.* 2007;39:1-6.
21. Wiegell SR, Wulf HC. Photodynamic therapy of acne vulgaris using 5-aminolevulinic acid versus methyl aminolevulinate. *J Am Acad Dermatol.* 2006;54:647-651.
22. Horfelt C, Funk J, Frohm-Nilsson M, et al. Topical methyl aminolaevulinate photodynamic therapy for treatment of facial acne vulgaris: results of a randomized, controlled study. *Br J Dermatol.* 2006;155:608-613.

113 ROSACEA

Richard P. Usatine, MD

PATIENT STORY

A 34-year-old woman with extensive papulopustular rosacea (**Figures 113-1** to **113-3**) has a history of easy facial flushing since her teen years. Her face has been persistently redder in the past 5 years and she is bothered by this. She acknowledges that her mom has similar redness in her face and that she is from northern European heritage. In the last 6 months, since her daughter was born, she has developed many "pimples." Physical examination reveals papules, pustules, and telangiectasias. No comedones are seen. She knows that the sun makes it worse but finds that many sunscreens are irritating to her skin. The patient is started on oral tetracycline daily and 0.75% metronidazole cream to use once daily. She agrees to wear a hat and stay out of the sun during the middle of the day. She will continue to look for a sunscreen she can tolerate. She knows that precipitating factors for her include hot and humid weather, alcohol, hot beverages, and spicy foods. She will do her best to avoid those factors.

FIGURE 113-1 Rosacea in a 34-year-old woman showing erythema, papules, and pustules covering much of the face. Note her fair skin and blue eyes from her northern European heritage. (*Courtesy of Richard P. Usatine, MD.*)

INTRODUCTION

Rosacea is an inflammatory condition of the face and eyes that mostly affects adults. Most commonly the face becomes reddened over the cheeks and nose and this is often accompanied by telangiectasias and a papulopustular eruption.

SYNONYMS

Rosacea is also called acne rosacea.

EPIDEMIOLOGY

- Common in fair-skinned people of Celtic and northern European heritage.
- Women are more often affected than men.
- Men are more prone to the extreme forms of hyperplasia, which causes rhinophymatous rosacea (**Figures 113-4** and **113-5**).

ETIOLOGY AND PATHOPHYSIOLOGY

- Although the exact etiology is unknown, the pathophysiology involves nonspecific inflammation followed by dilation around follicles and hyperreactive capillaries. These dilated capillaries become telangiectasias (**Figures 113-6** and **113-7**).
- As rosacea progresses, diffuse hypertrophy of the connective tissue and sebaceous glands ensues (**Figures 113-4** and **113-5**).
- Alcohol may accentuate erythema, but does not cause the disease. Rosacea runs in families.

FIGURE 113-2 Close-up of papules and pustules in the same woman. Note the absence of comedones. This is not acne. This is papulopustular rosacea. (*Courtesy of Richard P. Usatine, MD.*)

- Sun exposure may precipitate an acute rosacea flare, but flare-ups can happen without sun exposure.
- A significant increase in the hair follicle mite *Demodex folliculorum* is sometimes found in rosacea.[1] It is theorized that these mites play a role because they incite an inflammatory or allergic reaction by mechanical blockage of follicles.

RISK FACTORS

Genetics, *Demodex* infestation,[1] sun exposure.

DIAGNOSIS

CLINICAL FEATURES

Rosacea has four stages or subtypes:

1. ***Erythematotelangiectatic rosacea*** (**Figures 113-6** and **113-7**)—This stage is characterized by frequent mild to severe flushing with persistent central facial erythema.
2. ***Papulopustular rosacea*** (**Figures 113-1** to **113-3, 113-8** and **113-9**)—This is a highly vascular stage that involves longer periods of flushing than the first stage, often lasting from days to weeks. Minute telangiectasias and papules start to form by this stage, and some patients begin having very mild ocular complaints such as ocular grittiness or conjunctivitis. These patients may have many unsightly pustules with severe facial erythema. They are more prone to develop a hordeolum (stye) (see Chapter 13, Hordeolum and Chalazion).
3. ***Phymatous or Rhinophymatous rosacea*** (**Figures 113-4** and **113-5**)—Characterized by hyperplasia of the sebaceous glands that form thickened confluent plaques on the nose known as rhinophyma. This hyperplasia can cause significant disfigurement to the forehead, eyelids, chin, and nose. The nasal disfiguration is seen more commonly in men than women. W. C. Fields is famous for his rhinophyma and intake of alcohol. Rhinophyma can occur without any alcohol use, as seen in the patient in **Figure 113-5**.
4. ***Ocular rosacea*** (**Figures 113-10** to **113-12**)—An advanced subtype of rosacea that is characterized by impressive, severe flushing with persistent telangiectasias, papules, and pustules. The patient may complain of watery eyes, a foreign-body sensation, burning, dryness, vision changes, and lid or periocular erythema. The eyelids are most commonly involved with telangiectasias, blepharitis, and recurrent hordeola and chalazia (**Figures 113-10** and **113-11**). Conjunctivitis may be chronic. Although corneal involvement is least common, it can have the most devastating consequences. Corneal findings may include punctate erosions, corneal infiltrates, and corneal neovascularization. In the most severe cases, blood vessels may grow over the cornea and lead to blindness (**Figure 113-12**).

TYPICAL DISTRIBUTION

Rosacea occurs on the face, especially on the cheeks and nose. However, the forehead, eyelids, and chin can also be involved (**Figure 113-13**).

FIGURE 113-3 Close-up showing telangiectasias on the nose and papules around the mouth and chin. (*Courtesy of Richard P. Usatine, MD.*)

FIGURE 113-4 Rhinophymatous rosacea with hypertrophy of the skin of the nose of a 51-year-old Hispanic man. The patient acknowledges previous heavy alcohol intake. (*Courtesy of Richard P. Usatine, MD.*)

LABORATORY STUDIES

Not needed when the clinical picture is clear. If you are considering lupus or sarcoid, an antinuclear antibody (ANA), chest X-ray, or punch biopsy may be needed.

DIFFERENTIAL DIAGNOSIS

- Acne–The age of onset for rosacea tends to be 30 to 50 years, much later than the onset for acne vulgaris. Comedones are prominent in most cases of acne and generally absent in rosacea (see Chapter 112, Acne Vulgaris).
- Sarcoidosis on the face is much less common than rosacea, but the inflamed plaques can be red and resemble the inflammation of rosacea (see Chapter 175, Sarcoidosis).
- Seborrheic dermatitis tends to produce scale, whereas rosacea does not. Although both cause central facial erythema, papules and telangiectasias are present in rosacea and are not part of seborrheic dermatitis (see Chapter 151, Seborrheic Dermatitis).
- Systemic lupus erythematosus (SLE) can be scarring, does not usually produce papules or pustules, and it spares the nasolabial folds and nose (see Chapter 180, Lupus: Systemic and Cutaneous). The patient in **Figure 113-13** has a butterfly distribution of her rosacea, but her right nasolabial fold is involved along with her chin.

The following three diagnoses were once considered variants of rosacea but a recent classification system identified these as separate entities:[2]

- Rosacea fulminans (known as pyoderma faciale) is characterized by the sudden appearance of papules, pustules, and nodules, along with fluctuating and draining sinuses that may be interconnecting. The condition appears primarily in women in their 20s, and intense redness and edema also may be prominent (**Figure 113-14**).[2]
- Steroid-induced acneiform eruption is not a variant of rosacea and can occur as an inflammatory response in any patient during or after chronic corticosteroid use. The same inflammatory response may also occur in patients with rosacea (**Figure 113-15**).
- Perioral dermatitis without rosacea symptoms should not be classified as a variant of rosacea. Perioral dermatitis is characterized by microvesicles, scaling, and peeling around the mouth (**Figure 113-16**).

MANAGEMENT

- A Cochrane Database systematic review examined the efficacy of rosacea interventions.[3] Oral doxycycline appeared to be significantly more effective than placebo and there was no statistically significant difference in effectiveness between the 100-mg and 40-mg doses.[2] SOR A They found some evidence to support the effectiveness of topical metronidazole (0.75% or 1%), azelaic acid (15% or 20%) for the treatment of moderate to severe rosacea.[2] SOR A Cyclosporine ophthalmic emulsion was significantly more effective than artificial tears for treating ocular rosacea (for all outcomes).[2] SOR A
- When there are a limited number of papules and pustules, start with topical metronidazole (0.75% or 1%) or topical azelaic acid (15% or 20%).[3]

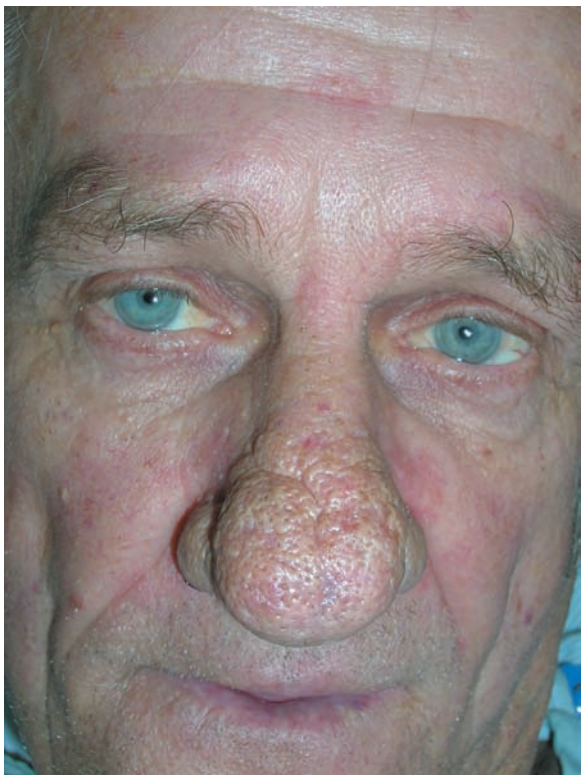

FIGURE 113-5 Rhinophymatous rosacea in an older man who does not drink alcohol. Although this is often called a W. C. Field nose, it is not necessarily related to heavy alcohol use. (*Courtesy of Richard P. Usatine, MD.*)

FIGURE 113-6 Erythematotelangiectatic subtype of rosacea in a middle-aged Hispanic woman. (*Courtesy of Richard P. Usatine, MD.*)

- There are no substantial differences between topical metronidazole of 0.75% and 1%, or between once daily and twice daily regimens.[4] Metronidazole cream, gel, and lotion have similar efficacies as well.[4]

- Azelaic acid in a 15% gel applied bid appeared to offer some modest benefits over 0.75% metronidazole gel in a manufacturer-sponsored study.[4] Azelaic acid was not as well tolerated, so both medications are reasonable options with the choice depending on patient preference and tolerance.[3] SOR B One study found that once-daily azelaic acid 15% gel was as effective as twice-daily application, which can translate into a significant cost saving.[5]
- If the skin lesions are more extensive, oral antibiotics, such as doxycycline (40 mg or 100 mg daily) is recommended.[2] SOR A When attempting to avoid the photosensitivity side effects of doxycycline it is reasonable to prescribe oral tetracycline (250 mg to 500 mg daily) or oral metronidazole (250 mg to 500 mg daily). SOR C
- Patients who are started on oral antibiotics alone and improve may be switched to topical agents such as metronidazole or azelaic acid for maintenance.
- The *Demodex* mite may be one causative agent in rosacea. One study found permethrin 5% cream to be as effective as metronidazole 0.75% gel and superior to placebo in the treatment of rosacea.[5] SOR B
- Severe papulopustular disease refractory to antibiotics and topical treatments can be treated with oral isotretinoin at a low dose of 0.3 mg/kg per day.[6] SOR B
- Simple electrosurgery or laser without anesthesia can be used to treat the telangiectasias associated with rosacea. SOR C
- Rhinophyma can be excised with radiofrequency electrosurgery or laser. Isotretinoin is also used to treat rhinophyma.[6] SOR B
- Traditional therapies for mild ocular rosacea include oral tetracyclines, lid hygiene, and warm compresses.[1] SOR C Topical ophthalmic cyclosporine 0.05% (Restasis) is more effective than artificial tears for the treatment of rosacea-associated lid and corneal changes.[7] SOR B Ocular rosacea that involves the cornea should be immediately referred to an ophthalmologist to prevent blindness (**Figure 113-12**).

FOLLOW-UP

Follow-up can be in 1 to 3 months as needed.

PATIENT EDUCATION

Sun protection, including use of a hat and daily application of sunscreen, should be emphasized. Choose a sunscreen that is nonirritating and protects against UVA and UVB rays. Advise patients to keep a diary to identify and avoid precipitating factors such as hot and humid weather, alcohol, hot beverages, spicy foods, and large hot meals.

FIGURE 113-7 Rosacea in a middle-aged man showing deep erythema and many telangiectasias. (*Courtesy of Richard P. Usatine, MD.*)

FIGURE 113-8 Papulopustular rosacea in a middle-aged woman. (*Courtesy of Richard P. Usatine, MD.*)

FIGURE 113-9 Papulopustular rosacea in a woman who has a history of recurrent hordeola. (*Courtesy of Richard P. Usatine, MD.*)

FIGURE 113-10 Ocular rosacea showing blepharitis, conjunctival hyperemia, and telangiectasias of the lid. (*Courtesy of Richard P. Usatine, MD.*)

FIGURE 113-11 Ocular rosacea with blepharitis, conjunctivitis and crusting around the eyelashes. This patient has meibomian gland dysfunction. (*Courtesy of Richard P. Usatine, MD.*)

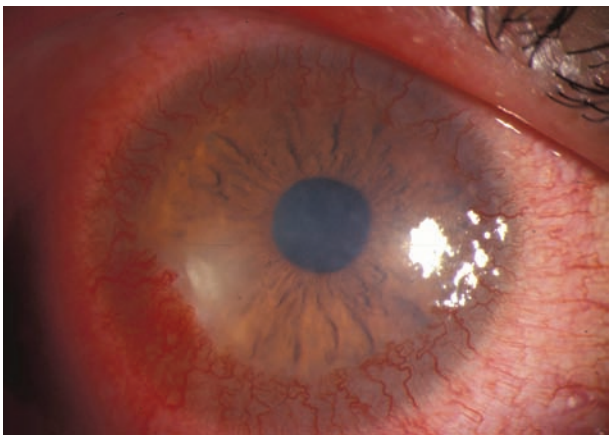

FIGURE 113-12 Neovascularization involving the cornea in a patient with severe ocular rosacea. This type of corneal involvement can lead to blindness. (*Courtesy of Paul Comeau.*)

FIGURE 113-13 Rosacea in a young woman with a butterfly pattern along with chin involvement. This is not lupus. (*Courtesy of Richard P. Usatine, MD.*)

FIGURE 113-14 Rosacea fulminans (known as pyoderma faciale) is characterized by the sudden appearance of papules, pustules, and nodules, along with fluctuating and draining sinuses that may be interconnecting. (*Courtesy of Richard P. Usatine, MD.*)

PATIENT RESOURCES

- National Rosacea Society. Its mission is to improve the lives of people with rosacea by raising awareness, providing public health information, and supporting medical research—**http://www.rosacea.org/.**

PROVIDER RESOURCES

- The National Rosacea Society also has an excellent set of materials that are geared for physicians—**http://www.rosacea.org/.**

REFERENCES

1. Zhao YE, Wu LP, Peng Y, Cheng H. Retrospective analysis of the association between Demodex infestation and rosacea. *Arch Dermatol.* 2010;146:896-902.
2. Wilkin J, Dahl M, Detmar M, et al. Standard classification of rosacea: report of the National Rosacea Society Expert Committee on the Classification and Staging of Rosacea. *J Am Acad Dermatol.* 2002;46:584-587.
3. van Zuuren EJ, Kramer S, Carter B, et al. Interventions for rosacea. *Cochrane Database Syst Rev.* 2011;(3):CD003262.
4. Yoo J, Reid DC, Kimball AB. Metronidazole in the treatment of rosacea: do formulation, dosing, and concentration matter? *J Drugs Dermatol.* 2006;5:317-319.
5. Kocak M, Yagli S, Vahapoglu G, Eksioglu M. Permethrin 5% cream versus metronidazole 0.75% gel for the treatment of papulopustular rosacea. A randomized double-blind placebo-controlled study. *Dermatology.* 2002;205:265-270.
6. Gollnick H, Blume-Peytavi U, Szabo EL, et al. Systemic isotretinoin in the treatment of rosacea - doxycycline- and placebo-controlled, randomized clinical study. *J Dtsch Dermatol Ges.* 2010;8:505-515.
7. Schechter BA, Katz RS, Friedman LS. Efficacy of topical cyclosporine for the treatment of ocular rosacea. *Adv Ther.* 2009;26:651-659.

FIGURE 113-15 Steroid-induced acneiform eruption caused by the use of topical fluocinonide daily in this woman who probably had some underlying rosacea. (*Courtesy of Richard P. Usatine, MD.*)

FIGURE 113-16 Perioral dermatitis in this 23-year-old woman with microvesicles, scaling, and peeling around the mouth. (*Courtesy of Richard P. Usatine, MD.*)

114 PSEUDOFOLLICULITIS AND ACNE KELOIDALIS NUCHAE

E.J. Mayeaux, Jr., MD

PATIENT STORY

A 17-year-old young African American man comes to the office because, for the past 2 years, he has been bothered by the uncomfortable bumps on the back of his neck (**Figure 114-1**). He is an athletic young man, more than 6 feet tall, and likes to keep his hair short for his sports. He notices the bumps get irritated and larger when he shaves his hair. He also has bumps on his face that get worse when he shaves his face (**Figure 114-2**). He is diagnosed with pseudofolliculitis barbae and acne keloidalis nuchae. His treatment consisted of patient education and twice-daily tretinoin cream and 0.1% triamcinolone cream to the neck area and nightly tretinoin cream to the beard area. He was told he could use 1% hydrocortisone cream on his face as needed. It was suggested that he minimize shaving, if possible.

FIGURE 114-1 Acne keloidalis nuchae in a 17-year-old African American man. (*Courtesy of Richard P. Usatine, MD.*)

INTRODUCTION

Pseudofolliculitis is a common skin condition affecting the hair-bearing areas of the body that are shaved (**Figures 114-2** to **114-4**). Potential complications include postinflammatory hyperpigmentation, bacterial superinfection, and keloid formation.

SYNONYMS

- Pseudofolliculitis—Razor bumps, shave bumps.
- Acne keloidalis nuchae—Folliculitis keloidalis.

EPIDEMIOLOGY

- Pseudofolliculitis is most common in black men, with at least 50% of black men who shave being prone to the condition.[1] In the beard area it is called *pseudofolliculitis barbae*, and when it occurs after pubic hair is shaved, it is referred to as *pseudofolliculitis pubis*. It may also occur in the neck area.
- Acne keloidalis nuchae occurs most often in black men but can be seen in all ethnicities (**Figures 114-3** and **114-5**). The lesions are often painful and cosmetically disfiguring.
- Both conditions are seen in women but far less often than in men (**Figure 114-6**).

FIGURE 114-2 Pseudofolliculitis barbae along the jawline and neck in the patient in Figure 114-1. (*Courtesy of Richard P. Usatine, MD.*)

ETIOLOGY AND PATHOPHYSIOLOGY

- Pseudofolliculitis develops when, after shaving, the free end of tightly coiled hair reenters the skin, causing a foreign-body–like

inflammatory reaction. Shaving produces a sharp free end below the skin surface. Tightly curled hair has a greater tendency for the tip to pierce the surface of the skin and form ingrown hairs. This explains the relative predominance of this condition in patients of African ethnicity. The hair eventually forms a loop and if the embedded tip is pulled out there may be spontaneous resolution of symptoms.

- The exact cause of acne keloidalis is uncertain. It often develops in areas of pseudofolliculitis or folliculitis. It may be associated with haircuts where the posterior hairline is shaved with a razor and with tightly curved hair shafts. Other possible etiologies include irritation from shirt collars, chronic bacterial infections, and an autoimmune process. It is a form of primary scarring alopecia.[2] As such, multiple hairs can be seen growing from single follicle (hair tufts) in the midst of the keloidal scarring (**Figure 114-7**).

RISK FACTORS

- Pseudofolliculitis:
  - African ethnicity.
  - Curly hair.
- Acne keloidalis nuchae:
  - Shaving the hair on the neck.
  - Pseudofolliculitis.

DIAGNOSIS

CLINICAL FEATURES

- The diagnosis of pseudofolliculitis is based upon clinical appearance. A piece of hair often may be identified protruding from a lesion. Inflammation results in the formation of firm, skin-colored, erythematous or hyperpigmented papules that occur after shaving (**Figures 114-2** to **114-4**). Pustules may develop secondarily. The severity varies from a few papules or pustules to hundreds of lesions.
- Patients with acne keloidalis initially develop a folliculitis or pseudofolliculitis, which heals with keloid-like lesions, sometimes with discharging sinuses. It starts after puberty as 2- to 4-mm firm, follicular papules (**Figure 114-1**). More papules appear and enlarge over time (**Figure 114-5**). Papules may coalesce to form keloid-like plaques, which are usually arranged in a band-like distribution along the posterior part of the hairline (**Figures 114-7** and **114-8**).

TYPICAL DISTRIBUTION

- Pseudofolliculitis affects the hair-bearing areas of the body that are shaved, especially the face, neck, and pubic area (**Figures 114-2** to **114-4**).
- Acne keloidalis occurs on the occipital scalp and the posterior part of the neck (**Figures 114-1**, **114-5**, and **114-7**).

BIOPSY

- Histologic evaluation of a biopsy may confirm either diagnosis but is usually not necessary.

FIGURE 114-3 Pseudofolliculitis barbae in a Dominican man. Note the active pustules on the neck. (*Courtesy of Richard P. Usatine, MD.*)

FIGURE 114-4 Pseudofolliculitis barbae on the face of a 28-year-old African man who works providing aid to Darfur refugees. The painful nodules become worse every time he shaves. (*Courtesy of Richard P. Usatine, MD.*)

FIGURE 114-5 Acne keloidalis with multiple firm keloidal papules in a Hispanic man who prefers to keep his hair short. (*Courtesy of Richard P. Usatine, MD.*)

DIFFERENTIAL DIAGNOSIS

- True folliculitis, which is an acute pustular infection of a hair follicle with more localized inflammation (see Chapter 117, Folliculitis).
- Impetigo, which presents with yellowish pustules or bullae that rupture and develop honey crusts, sometimes with adenopathy (see Chapter 116, Impetigo).
- Acne vulgaris, which presents with comedones and pustules usually including the forehead (see Chapter 112, Acne Vulgaris).

MANAGEMENT

NONPHARMACOLOGIC

- Avoid close shaving, avoid all shaving, or permanently remove hair.[3] Some occupations, however, such as the military and law enforcement, require facial shaving. Occasionally, a doctor's note will allow these men to go without shaving. In mild cases, shaving should be discontinued for a month. The beard can be coarsely trimmed with scissors or electric clippers during this time. Shaving should not resume until all inflammatory lesions have resolved. Warm Burow solution compresses may be applied to the lesions for 10 minutes, 2 times per day. Instruct the patient to search for ingrown hairs each day using a magnifying mirror and release them gently using a sterilized needle or tweezers. The hairs should not be plucked as this may cause recurrence of symptoms with hair regrowth (**Figure 114-6**). SOR C
- Chemical depilatories (Ali, Royal Crown, Magic Shave, and others) cause fewer symptoms than shaving.[4] SOR B However, these creams can cause severe irritation, so testing a small amount on the forearm is important. They work by breaking the disulfide bonds in hair, which results in the hair being bluntly broken at the follicular opening instead of sharply cut below the surface. They should be used every second or third day to avoid skin irritation, although this can be controlled with hydrocortisone cream. Barium sulfide 2% powder depilatories can be made into a paste with water, applied to the beard, and removed after 3 to 5 minutes. Calcium thioglycolate preparations are left on 10 to 15 minutes, but the fragrances can cause an allergic reaction and chemical burns can result if it is left for too long.
- People who have acne keloidalis nuchae should avoid anything that causes folliculitis or pseudofolliculitis, such as getting their neck or hairline shaved with a razor.

MEDICATIONS

- Topical eflornithine HCL 13.9% cream (Vaniqa; by prescription only) may be used to inhibit hair growth. It decreases the rate of hair growth and may make the hair finer and lighter. Unfortunately, this medication is expensive and requires daily application for continued efficacy. SOR C
- Twice-daily treatment with a class 2 or 3 corticosteroid may be sufficient to shrink pseudofolliculitis lesions and relieve symptoms (see Appendix 2: Topical and Intralesional Corticosteroids). SOR C
- When pustules, crust formation, or drainage is present, use topical clindamycin or erythromycin. Unresponsive patients may be changed to a systemic antibiotic. SOR C

FIGURE 114-6 Pseudofolliculitis barbae in a black woman with hirsutism. The scarring is related to plucking and shaving the hairs on the neck. (*Courtesy of Richard P. Usatine, MD.*)

FIGURE 114-7 Acne keloidalis nuchae with large keloidal mass in a Hispanic man. Note multiple hairs can be seen growing from single follicles (hair tufts). Surgery is the only treatment that can remove this keloidal mass. (*Courtesy of Richard P. Usatine, MD.*)

FIGURE 114-8 Acne keloidalis nuchae after injection with intralesional triamcinolone. Although the keloid is smaller and softer, some hypopigmentation has occurred. (*Courtesy of Richard P. Usatine, MD.*)

- Topical erythromycin, clindamycin, and combination clindamycin-benzoyl peroxide (BenzaClin, Duac) and erythromycin-benzoyl peroxide (Benzamycin) may be used once or twice daily.[5] SOR B
- Oral doxycycline 100 mg bid, tetracycline 500 mg bid, or erythromycin 500 mg bid may be used for patients with more severe secondary inflammation. SOR C
- Tretinoin cream, 0.025%, may be useful in patients with mild disease, but is rarely helpful in moderate to severe cases.[6] It is applied nightly for a week then reduced to every second or third night. Tretinoin may be used in conjunction with a mid-potency topical corticosteroid applied each morning. The mechanism of action is thought to be by relieving hyperkeratosis and "toughening" the skin. Topical combination cream (tretinoin 0.05%, fluocinolone acetonide 0.01%, and hydroquinone 4%) (Tri-Luma) adds an additional postinflammatory hyperpigmentation treatment. SOR C
- Intralesional steroid injections (10 to 20 mg/mL) may be used to soften and shrink keloids. Warn patients that this therapy may cause hypopigmentation (**Figure 114-8**). SOR C

SURGICAL

- The only definitive cure for pseudofolliculitis is permanent hair removal. Electrolysis is expensive, painful, and sometimes unsuccessful. Laser hair removal is fairly successful for treating pseudofolliculitis.[7] SOR B Diode laser (810 nm) treatments have been proven safe and effective in patients with skin phototypes I to IV.[8]
- Excision of acne keloidalis lesions may be attempted. Recalcitrant keloidal lesions may be treated with removing individual papules with a small punch, or large keloids (**Figure 114-9**) with an elliptical excision closed with sutures. After removal, the wound edges should be injected with a mixture of equal amount of triamcinolone acetonide 40 mg/mL and sterile saline. Remove the sutures in 1 to 2 weeks and inject the edges every month with the above mixture for 3 to 4 times. SOR C Excision should extend into the subcutaneous tissue and the wound edges can be injected with 10 to 40 mg/mL of triamcinolone acetonide and be reapproximated. SOR C Recurrence is common, especially with shallow excisions or not treating with steroids.
- Other therapies that may be considered are laser therapy (carbon dioxide or Nd:YAG [neodymium:yttrium-aluminum-garnet]) followed by intralesional triamcinolone injections or cryotherapy for two 20-second bursts that are allowed to thaw and are then applied again a minute later. These methods may produce more pain and hypopigmentation. SOR C

FIGURE 114-9 Hypertrophic scarring after the excision of acne keloidalis nuchae. (*Courtesy of Richard P. Usatine, MD.*)

PREVENTION

- Termination of shaving prevents the development of pseudofolliculitis.

PROGNOSIS

- No specific cure exists. If the patient is able to stop shaving, the problem usually disappears (except for any scar formation).

FOLLOW-UP

- Instruct patients to return if any complications occur. Otherwise have them return for possible initiation of intralesional steroid injections or topical steroid/retinoic acid therapy once the area has healed.

PATIENT EDUCATION

- For those who must shave, have the patient clip hairs no shorter than needed for maintenance. Use fine scissors or facial hair clippers if possible. When shaving, have the patient rinse with warm tap water for several minutes, use generous amounts of a highly lubricating shaving gel, and allow it to soften the skin for 5 to 10 minutes before shaving. The patient should always use sharp razors and shave in the direction of hair growth. Specialized guarded razors (e.g., PFB Bump Fighter) are available in pharmacies and by mail order. After shaving rinse the face with tap water, and then apply cold water compresses.
- With acne keloidalis, instruct males who play football to make sure their helmets fit properly and do not cause irritation on the posterior part of the scalp. They should avoid having the posterior part of the hairline shaved with a razor as part of a haircut, and discontinue wearing garments that rub or irritate the posterior parts of the scalp and the neck.

PATIENT RESOURCES

- American Osteopathic College of Dermatology. *Pseudofolliculitis*—**http://aocd.org/skin/dermatologic_diseases/pseudofolliculitis.html.**
- Skin Channel. *Acne Keloidalis Nuchae*—**http://skinchannel.com/acne/acne-keloidalis-nuchae/.**

PROVIDER RESOURCES

- eMedicine. *Pseudofolliculitis*—**http://emedicine.medscape.com/article/1071251.**
- eMedicine. *Acne Keloidalis*—**http://emedicine.medscape.com/article/1072149.**
- DermNet NZ. *Acne Keloidalis*—**http://dermnetnz.org/acne/keloid-acne.html.**

REFERENCES

1. Coquilla BH, Lewis CW. Management of pseudofolliculitis barbae. *Mil Med.* 1995;160(5):263-269.
2. Sperling LC, Homoky C, Pratt L, Sau P. Acne keloidalis is a form of primary scarring alopecia. *Arch Dermatol.* 2000;136(4):479-484.
3. Chui CT, Berger TG, Price VH, Zachary CB. Recalcitrant scarring follicular disorders treated by laser-assisted hair removal: A preliminary report. *Dermatol Surg.* 1999;25(1):34-37.
4. Hage JJ, Bowman FG. Surgical depilation for the treatment of pseudofolliculitis or local hirsutism of the face: experience in the first 40 patients. *Plast Reconstr Surg.* 1991;88:446-451.

5. Cook-Bolden FE, Barba A, Halder R, Taylor S. Twice-daily applications of benzoyl peroxide 5% clindamycin 1% gel versus vehicle in the treatment of pseudofolliculitis barbae. *Cutis.* 2004;73(6 Suppl): 18-24.
6. Brown LA Jr. Pathogenesis and treatment of pseudofolliculitis barbae. *Cutis.* 1983;32(4):373-375.
7. Ross EV, Cooke LM, Timko AL, et al. Treatment of pseudofolliculitis barbae in skin types IV, V, and VI with a long-pulsed neodymium: yttrium aluminum garnet laser. *J Am Acad Dermatol.* 2002; 47(2):263-270.
8. Kauvar AN. Treatment of pseudofolliculitis with a pulsed infrared laser. *Arch Dermatol.* 2000;136(11):1343-1346.

115 HIDRADENITIS SUPPURATIVA

Richard P. Usatine, MD

PATIENT STORY

A 25-year-old woman presents with new tender lesions in her axilla (**Figure 115-1**). She admits to years of similar outbreaks in both axilla and occasional painful bumps in the groin. She states that it is painful to have them opened and just wants to get some relief without surgery. We elected to inject the nodules with triamcinolone and start the patient on doxycycline 100 mg twice daily. Smoking cessation was emphasized and the patient agreed to start on a nicotine patch that evening. She had relief within 24 hours from the steroid injection.

FIGURE 115-1 Mild hidradenitis suppurativa in the axilla of a young woman. She has a history of recurrent lesions in her axilla. (*Courtesy of Richard P. Usatine, MD.*)

INTRODUCTION

Hidradenitis suppurativa (HS) is an inflammatory disease of the pilosebaceous unit in the apocrine gland-bearing skin. HS is most common in the axilla and inguinal area, but may be found in the inframammary area as well. It produces painful inflammatory nodules, cysts, and sinus tracks with mucopurulent discharge and progressive scarring.

SYNONYMS

It is called acne inversa because it involves intertriginous areas and not the regions affected by acne (similar to inverse psoriasis).

EPIDEMIOLOGY

- Occurs after puberty in approximately 1% of the population.[1]
- Incidence is higher in females, in the range of 4:1 to 5:1. Flare-ups may be associated with menses.[1]

ETIOLOGY AND PATHOPHYSIOLOGY

- Disorder of the terminal follicular epithelium in the apocrine gland-bearing skin.[1]
- Starts with occlusion of hair follicles that lead to occlusion of surrounding apocrine glands.
- Chronic relapsing inflammation with mucopurulent discharge (**Figures 115-2** to **115-7**).
- Can lead to sinus tracts, draining fistulas and progressive scarring (**Figures 115-2** to **115-7**).

RISK FACTORS

Obesity, smoking, and tight-fitting clothing.

DIAGNOSIS

CLINICAL FEATURES

- Most common presentation is painful, tender, firm, nodular lesions in axillae (**Figures 115-1** to **115-3**).
- Nodules may open and drain pus spontaneously and heal slowly, with or without drainage, over 10 to 30 days.[1]
- Nodules may recur several times yearly, or in severe cases new lesions form as old ones heal.
- Surrounding cellulitis may be present and require systemic antibiotic treatment.
- Chronic recurrences result in thickened sinus tracts, which may become draining fistulas (**Figures 115-3** to **115-7**).
- HS can cause disabling pain, diminished range of motion, and social isolation (**Figure 115-5**).

TYPICAL DISTRIBUTION

- Axillary, inguinal, periareolar, intermammary zones, pubic area, infraumbilical midline, gluteal folds, top of the anterior thighs, and the perianal region.[1]

LABORATORY STUDIES

Culture of purulence is likely to yield staphylococci and streptococci and is usually unnecessary to determine treatment. Culture may be useful if you suspect methicillin-resistant *Staphylococcus aureus*.

DIFFERENTIAL DIAGNOSIS

- Bacterial infections, including folliculitis, carbuncles, furuncles, abscess, and cellulitis, may resemble HS but are less likely to be recurrent in the intertriginous areas.
- Epidermal cysts in the intertriginous regions may resemble HS. Theses cysts contain malodorous keratin contents.
- Granuloma inguinale and lymphogranuloma venereum are sexually transmitted infections that can produce inguinal ulcers and adenopathy that could be mistaken for HS.

MANAGEMENT

- Lifestyle changes are recommended, including weight loss if obesity is present. SOR C
- Smoking is a risk factor for HS and cessation is highly recommended for many reasons.[1] See SOR B for HS and SOR A for other health reasons.
- Frequent bathing and wearing loose-fitting clothing may help.

FIGURE 115-2 Moderate HS in a young woman. The lesions are deeper and there have been some chronic changes with scarring and fibrosis from previous lesions. (*Courtesy of Richard P. Usatine, MD.*)

FIGURE 115-3 A 33-year-old Hispanic woman with sinus tracts, draining fistulas, and scarring secondary to her chronic HS. Note the mucopurulent discharge. (*Courtesy of Richard P. Usatine, MD.*)

Medical treatment is similar to acne treatment:

- Oral antibiotics are used in acute and chronic treatment. Oral tetracyclines, clindamycin, rifampin, and dapsone have been touted as beneficial. If there is methicillin-resistant *S. aureus* present, trimethoprim/sulfamethoxazole or clindamycin should be used.
- Tetracycline 500 mg bid and doxycycline 100 mg bid can be used acutely and to prevent new lesions in the mildest of cases. Many patients do not find these antibiotics to be of great help. SOR C
- Topical clindamycin bid may be used in the mildest of cases. In one randomized controlled trial (RCT), systemic therapy with tetracyclines did not show better results than topical therapy with clindamycin.[1] SOR B
  - Combination of systemic clindamycin (300 mg twice daily) and rifampin (600 mg daily) is recommended for patients with more severe HS.[2,3] In a series of 116 patients, parameters of severity improved, as did the quality-of-life score.[2] In another study, 28 of 34 patients (82%) experienced at least partial improvement, and 16 (47%) showed a total remission.[3] The maximum effect of treatment appeared within 10 weeks. Following total remission, 8 of 13 (61.5%) patients experienced a relapse after a mean period of 5 months. Nonresponders were predominantly patients with severe disease. The most frequent side effect is diarrhea.[2,3]
  - Oral dapsone may be considered in milder cases. In one study, only 38% of patients experienced improvement.[4] SOR B Rapid recurrence after stopping treatment suggests that antiinflammatory effects may predominate over antimicrobial effects. The total effect appears to be smaller than that reported with combination therapy using clindamycin and rifampicin.
- Isotretinoin can reduce the severity of attacks in some patients but is not a reliable cure for HS.[5] SOR C
- Acitretin can be an effective treatment for refractory HS. In one study, all 12 patients achieved remission and experienced a significant decrease in pain. Long-lasting improvement was observed in 9 patients, with no recurrence of lesions after 6 months (n = 1), 1 year (n = 3), more than 2 years (n = 2), more than 3 years (n = 2), and more than 4 years (n = 1).[5] SOR B
- Antitumor necrosis factor (TNF) agents are being studied for severe, recalcitrant HS (**Figure 115-8**). In one series, infliximab therapy (weight based) was shown to be effective and well tolerated in 6 of 7 patients with HS who were resistant to previous therapy.[6] This was in agreement with preexisting literature showing that 52 of 60 patients (87%) were improved after infliximab therapy.[6] SOR B Adalimumab helps in the short-term, but no long-term curative effect was uniformly seen.[7]
- Intense pulsed light (IPL) with laser may be worth considering for patients who can afford the cost and time for treatment. In one study of 18 patients who were randomized to treatment of one axilla, groin, or inframammary area with IPL 2 times per week for 4 weeks, there was a significant improvement in the mean examination score, which was maintained at 12 months. Patients reported high levels of satisfaction with the IPL treatment.[8] SOR B

Surgical treatments include the following:

- Intralesional steroids with 5 to 10 mg/mL of triamcinolone may help to decrease inflammation and pain within 24 to 48 hours. SOR C

FIGURE 115-4 Longstanding painful severe HS between the breasts of a 45-year-old woman. (*Courtesy of Richard P. Usatine, MD.*)

FIGURE 115-5 Severe disabling HS in a 34-year-old white man who is morbidly obese. He finds it painful to walk. (*Courtesy of Richard P. Usatine, MD.*)

- Incision and drainage of acute lesions are suggested for the large fluctuant abscesses that can occur in HS. Although this may give some relief of the pressure, the surgical treatment and repacking of the wound is painful, and there is no evidence that it speeds healing. SOR C
- Lancing small nodules is more painful than helpful and is not recommended.
- Surgical excision of affected area with or without skin grafting is used for recalcitrant disabling disease and should be individualized based on the stage and location of the disease.[9] SOR B One surgical group has been using a medial thigh lift for immediate defect closure after radical excision of localized inguinal hidradenitis.[10]

FOLLOW-UP

If there is cellulitis or a large abscess was drained, follow-up should be within days. Chronic relapsing disease can ultimately be managed with appointments every 3 to 6 months depending upon the treatment and its success.

PATIENT EDUCATION

Smoking cessation, weight loss if overweight, and avoidance of tight-fitting clothes.

PATIENT RESOURCES

- Patient education materials at Medline Plus—**http://www.nlm.nih.gov/medlineplus/hidradenitissuppurativa.html.**

PROVIDER RESOURCES

- **http://emedicine.medscape.com/article/1073117-overview.**

REFERENCES

1. Jemec GB, Wendelboe P. Topical clindamycin versus systemic tetracycline in the treatment of hidradenitis suppurativa. *J Am Acad Dermatol.* 1998;39:971-974.
2. Gener G, Canoui-Poitrine F, Revuz JE, et al. Combination therapy with clindamycin and rifampicin for hidradenitis suppurativa: a series of 116 consecutive patients. *Dermatology.* 2009;219:148-154.
3. van der Zee HH, Boer J, Prens EP, Jemec GBE. The effect of combined treatment with oral clindamycin and oral rifampicin in patients with hidradenitis suppurativa. *Dermatology.* 2009;219:143-147.
4. Yazdanyar S, Boer J, Ingvarsson G, et al. Dapsone therapy for hidradenitis suppurativa: a series of 24 patients. *Dermatology.* 2011;222(4):342-346.
5. Boer J, Nazary M. Long-term results of acitretin therapy for hidradenitis suppurativa. Is acne inversa also a misnomer? *Br J Dermatol.* 2011;164:170-175.

FIGURE 115-6 Severe HS in the vulva and on the mons pubis. The skin is thickened and hyperpigmented from the ongoing inflammatory lesions present in the area. (*Courtesy of Suraj Reddy, MD.*)

FIGURE 115-7 Thirty-year history of severe hidradenitis in a 54-year-old woman. Note the scars from previous plastic surgeries. Note the draining cysts, fistulas, and the acute abscess on her left buttocks. (*Courtesy of Richard P. Usatine, MD.*)

6. Delage M, Samimi M, Atlan M, et al. Efficacy of infliximab for hidradenitis suppurativa: assessment of clinical and biological inflammatory markers. *Acta Derm Venereol.* 2011;91:169-171.
7. Miller I, Lynggaard CD, Lophaven S, et al. A double-blind placebo-controlled randomized trial of adalimumab in the treatment of hidradenitis suppurativa. *Br J Dermatol.* 2011;165:391-398.
8. Highton L, Chan WY, Khwaja N, Laitung JK. Treatment of hidradenitis suppurativa with intense pulsed light: a prospective study. *Plast Reconstr Surg.* 2011;128:459-466.
9. Kagan RJ, Yakuboff KP, Warner P, Warden GD. Surgical treatment of hidradenitis suppurativa: a 10-year experience. *Surgery.* 2005;138:734-740.
10. Rieger UM, Erba P, Pierer G, Kalbermatten DF. Hidradenitis suppurativa of the groin treated by radical excision and defect closure by medial thigh lift: aesthetic surgery meets reconstructive surgery. *J Plast Reconstr Aesthet Surg.* 2009;62:1355-1360.

FIGURE 115-8 Severe recalcitrant hidradenitis in this 42-year-old woman with sinus tracts and scarring. **A.** Axillary involvement. **B.** Inframammary involvement. (*Courtesy of Richard P. Usatine, MD.*)

SECTION 3 BACTERIAL

116 IMPETIGO

Richard P. Usatine, MD

PATIENT STORIES

A young woman presented to the office with a 3-day history of an uncomfortable rash on her lip and chin (**Figure 116-1**). She denied any trauma or previous history of oral herpes. This case of impetigo resolved quickly with oral cephalexin.

An 11-year-old-child presented with a 5-day history of a skin lesion that started after a hiking trip (**Figure 116-2**). This episode of bullous impetigo was found to be secondary to methicillin-resistant *Staphylococcus aureus* (MRSA). The lesion was rapidly progressive and was developing a surrounding cellulitis. She was admitted to a hospital and treated with intravenous clindamycin with good results.[1]

FIGURE 116-1 Typical honey-crusted plaque on the lip of an adult with impetigo. (*Courtesy of Richard P. Usatine, MD.*)

INTRODUCTION

Impetigo is the most superficial of bacterial skin infections. It causes honey crusts, bullae, and erosions.

EPIDEMIOLOGY

- Most frequent in children ages 2 to 6 years, but it can be seen in patients of any age.
- Common among homeless people living on the streets.
  - Seen often in third world countries in persons living without easy access to clean water and soap.
- Contagious and can be spread within a household.

ETIOLOGY AND PATHOPHYSIOLOGY

- Impetigo is caused by *S. aureus* and/or group A β-hemolytic *Streptococcus* (GABHS).
- Bullous impetigo is almost always caused by *S. aureus* and is less common than the typical crusted impetigo.
- Impetigo may occur after minor skin injury, such as an insect bite, abrasion, or dermatitis.

DIAGNOSIS

CLINICAL FEATURES

- Vesicles, pustules, honey-colored (**Figure 116-1**), brown or dark crusts, erythematous erosions (**Figure 116-3**), ulcers in ecthyma (**Figure 116-4**), bullae in bullous impetigo (**Figures 116-5** to **116-7**).

FIGURE 116-2 Bullous impetigo secondary to methicillin-resistant *Staphylococcus aureus* (MRSA) on the leg of an 11-year-old child. Note the surrounding cellulitis. (*With permission from Studdiford J, Stonehouse A. Bullous eruption on the posterior thigh 1. J Fam Pract. 2005;54:1041-1044. Reproduced with permission from Frontline Medical Communications.*)

TYPICAL DISTRIBUTION

- Face (**Figures 116-1, 116-4** to **116-6**, and **116-8**) is most common, followed by hands, legs (**Figures 116-2** and **116-9**), trunk, and buttocks.

CULTURE

- Culture should be considered in severe cases because of the rising incidence of MRSA-causing impetigo.

DIFFERENTIAL DIAGNOSIS

Many of the conditions below can become impetigo after being secondarily infected (**Figures 116-10** and **116-11**) with bacteria. This process is called impetiginization.

- Atopic dermatitis—A common inflammatory skin disorder characterized by itching and inflamed skin. It can become secondarily infected with bacteria (**Figure 116-11**) (see Chapter 145, Atopic Dermatitis).
- Herpes simplex virus infection anywhere on the skin or mucous membranes can become secondarily infected (see Chapter 129, Herpes Simplex).
- Eczema herpeticum is eczema superinfected with herpes rather than bacteria (**Figure 145-4**).
- Scabies—Pruritic contagious disease caused by a mite that burrows in skin (see Chapter 143, Scabies).
- Folliculitis—Inflammation and/or infection of hair follicles that may be bacterial (see Chapter 117, Folliculitis).
- Tinea corporis—A cutaneous fungal infection caused by dermatophytes, frequently with ring-like scale (see Chapter 138, Tinea Corporis).
- Pemphigus vulgaris—Somewhat rare bullous autoimmune condition with flaccid vesicles and bullae that rupture easily, affecting people between 40 and 60 years of age (see Chapter 185, Pemphigus).
- Bullous pemphigoid—An autoimmune condition with multiple tense bullae that primarily affects people older than 60 years of age (see Chapter 184, Bullous Pemphigoid).
- Acute allergic contact dermatitis—Dermatitis from direct cutaneous exposure to allergens such as poison ivy. Acute lesions are erythematous papules and vesicles in a linear pattern (see Chapter 146, Contact Dermatitis).
- Insect bites—Scratched, open lesions can become secondarily infected with bacteria (impetiginized) (**Figure 116-9**).
- Second-degree burn or sunburn—The blisters when opened leave the skin susceptible to secondary infection (**Figure 116-10**).
- Staphylococcal scalded skin syndrome—Life-threatening syndrome of acute exfoliation of the skin caused by an exotoxin from a staphylococcal infection. This condition is seen almost entirely in infants and young children (**Figure 116-12**).

MANAGEMENT

- There is good evidence that topical mupirocin is equally or more effective than oral treatment for people with limited impetigo. SOR A Mupirocin also covers MRSA.[2]

FIGURE 116-3 Widespread impetigo with honey-crusted erythematous lesions on the back of a 7-year-old child. (*Courtesy of Richard P. Usatine, MD.*)

FIGURE 116-4 Impetigo on the face and hand of a homeless man. Note the ecthyma (ulcerated impetigo) on the dorsum of the hand. (*Courtesy of Richard P. Usatine, MD.*)

FIGURE 116-5 Bullous impetigo around the mouth of a young boy that progressed to desquamation of the skin on his hands and feet. (*Courtesy of Richard P. Usatine, MD.*)

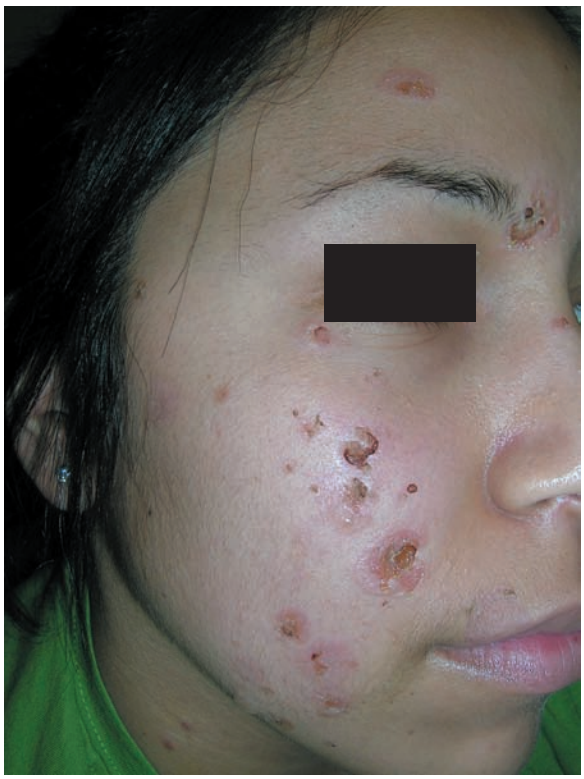

FIGURE 116-6 Bullous impetigo on the face of a 14-year-old girl. Methicillin-resistant *Staphylococcus aureus* was cultured from the impetigo. (*Courtesy of Richard P. Usatine, MD.*)

FIGURE 116-8 Impetigo on the face and neck of an infant. (*Courtesy of Richard P. Usatine, MD.*)

FIGURE 116-7 Bullous impetigo on the abdomen of an 8-year-old boy. (*Courtesy of Richard P. Usatine, MD.*)

FIGURE 116-9 Impetigo secondary to flea bites on the legs of a young girl. (*Courtesy of Richard P. Usatine, MD. Previously published in the Western Journal of Medicine.*)

- Extensive impetigo could be treated for 7 days with antibiotics that cover GABHS and *S. aureus*, such as cephalexin or dicloxacillin.[3] SOR A
- Community-acquired MRSA can present as bullous impetigo in children (**Figures 116-2** and **116-6**) or adults.
- If you suspect MRSA, culture the lesions and start one of the following oral antibiotics: trimethoprim-sulfamethoxazole, clindamycin, tetracycline, or doxycycline.[4] SOR A Trimethoprim-sulfamethoxazole achieved 100% clearance in the treatment of impetigo in children cultured with MRSA and GABHS in one small randomized controlled trial (RCT).[6]
- If there are recurrent MRSA infections, one might choose to prescribe intranasal mupirocin ointment and chlorhexidine bathing to decrease MRSA colonization.[5] SOR B

PREVENTION

Practice good hygiene with soap and water. Avoid sharing towels and wash clothes.

FOLLOW-UP

Arrange follow-up based on severity of case and the age and immune status of the patient.

PATIENT EDUCATION

Discuss hygiene issues and how to avoid spread within the household or other living situations such as homeless shelters.

REFERENCES

1. Studdiford J, Stonehouse A. Bullous eruption on the posterior thigh 1. *J Fam Pract.* 2005;54:1041-1044.
2. Koning S, Verhagen AP, van-Suijlekom-Smit LWA, et al. Interventions for impetigo. *Cochrane Database Syst Rev*. 2012; CD003261.
3. Stevens DL, Bisno AL, Chambers HF, et al. Practice guidelines for the diagnosis and management of skin and soft-tissue infections. *Clin Infect Dis.* 2005;41:1373-1406.
4. Naimi TS, LeDell KH, Como-Sabetti K, et al. Comparison of community- and health care-associated methicillin-resistant *Staphylococcus aureus* infection. *JAMA.* 2003;290:2976-2984.
5. Wendt C, Schinke S, Württemberger M, et al. Value of whole-body washing with chlorhexidine for the eradication of methicillin-resistant *Staphylococcus aureus:* a randomized, placebo-controlled, double-blind clinical trial. *Infect Control Hosp Epidemiol.* 2007; 28(9):1036-1043.
6. Tong SY, Andrews RM, Kearns T, et al. Trimethoprim-sulfamethoxazole compared with benzathine penicillin for treatment of impetigo in aboriginal children: a pilot randomised controlled trial. *J Paediatr Child Health.* 2010;46(3):131-133.

FIGURE 116-10 Secondary impetiginization of a second-degree sunburn in a homeless man. (*Courtesy of Richard P. Usatine, MD.*)

FIGURE 116-11 Atopic dermatitis complicated by secondary impetiginization. (*Courtesy of Richard P. Usatine, MD.*)

FIGURE 116-12 Staphylococcal scalded skin syndrome in a young child. A severe form of bullous impetigo with large areas of skin exfoliation. Note the prominent involvement of the neck as this condition tends to involve areas with skin folds. (*Courtesy of Deborah Henderson, MD.*)

117 FOLLICULITIS

Richard P. Usatine, MD
Khalilah Hunter-Anderson, MD

PATIENT STORY

A 42-year-old woman is seen for multiple papules and pustules on her back (**Figure 117-1**). Further questioning demonstrates that she was in a friend's hot tub twice over the previous weekend. The outbreak on her back started after she went into the hot tub the second time. This is a case of *Pseudomonas* folliculitis or "hot tub" folliculitis. The patient avoided this hot tub and the folliculitis disappeared spontaneously. Another option is to treat with an oral fluoroquinolone that covers *Pseudomonas*.

FIGURE 117-1 "Hot-tub" folliculitis from *Pseudomonas aeruginosa* in a hot tub. (*Courtesy of Richard P. Usatine, MD.*)

INTRODUCTION

Folliculitis is an inflammation of hair follicles usually from an infectious etiology. Multiple species of bacteria have been implicated, as well as fungal organisms.

EPIDEMIOLOGY

- Folliculitis is a cutaneous disorder that affects all age groups and races, and both genders.
- It can be infectious or noninfectious. It is most commonly of bacterial origin (**Figures 117-2** and **117-3**).
- Pseudofolliculitis or sycosis barbae is most frequently seen in men of color and made worse by shaving (**Figure 117-4**).[1]
- Acne keloidalis nuchae or keloidal folliculitis is commonly seen in black patients, but can be seen in patients of any ethnic background (**Figures 117-5** and **117-6**).[2]
- Eosinophilic folliculitis is described in patients with HIV infection (**Figure 117-7**).
- Methicillin-resistant *Staphylococcus aureus* (MRSA) can pose a challenge to the treatment of folliculitis (**Figure 117-8**).

ETIOLOGY AND PATHOPHYSIOLOGY

- Folliculitis is an infection of the hair follicle and can be superficial, in which it is confined to the upper hair follicle, or deep, in which inflammation spans the entire depth of the follicle.
- Infection can be of bacterial, viral, or fungal origin. *S. aureus* is by far the most common bacterial causative agent.
- The noninfectious form of folliculitis is often seen in adolescents and young adults who wear tight-fitting clothes. Folliculitis can also be caused by chemical irritants or physical injury.
- Topical steroid use, ointments, lotions, or makeup can swell the opening to the pilosebaceous unit and cause folliculitis.

FIGURE 117-2 Close-up of bacterial folliculitis showing hairs coming through pustules. (*Courtesy of Richard P. Usatine, MD.*)

- Bacterial folliculitis or *Staphylococcus* folliculitis typically presents as infected pustules most prominent on the face, buttocks, trunk, or extremities. It can progress to a deeper infection with the development of furuncles or boils (**Figure 117-9**). Infection can occur as a result of mechanical injury or via local spread from nearby infected wounds. An area of desquamation is frequently seen surrounding infected pustules in *S. aureus* folliculitis.[1-3]
- Parasitic folliculitis usually occurs as a result of mite infestation (*Demodex*). These are usually seen on the face, nose, and back and typically cause an eosinophilic pustular-like folliculitis.[1]
- Folliculitis decalvans is a chronic form of folliculitis involving the scalp, leading to hair loss or alopecia (**Figure 117-10**). Staphylococci infection is the usual causative agent, but there also has been a suggested genetic component to this condition.[1] It is also called tufted folliculitis because some of the hair follicles will have many hairs growing from them simultaneously (**Figure 117-11**) (see Chapter 189, Scarring Alopecia).
- Acne keloidalis nuchae is a chronic form of folliculitis found on the posterior neck that can be extensive and lead to keloidal tissue and alopecia.[1-3] Although it is often thought to occur almost exclusively in black men, it can be seen in men of all ethnic backgrounds and occasionally in women (**Figures 117-5** and **117-6**) (see Chapter 114, Pseudofolliculitis and Acne Keloidalis Nuchae).
- Fungal folliculitis is epidermal fungal infections that are seen frequently. Tinea capitis infections are a form of dermatophytic folliculitis (see Chapter 137, Tinea Capitis). *Pityrosporum* folliculitis is caused by yeast infection (*Malassezia* species) and is seen in a similar distribution as bacterial folliculitis on the back, chest, and shoulders (**Figure 117-12**) (see Chapter 141, Tinea Versicolor). Candidal infection is less common and is usually seen in individuals who are immunosuppressed, present in hairy areas that are moist, and unlike most cases of folliculitis, may present with systemic signs and symptoms.[1-4]
- *Pseudomonas* folliculitis or "hot tub" folliculitis is usually a self-limited infection that follows exposure to water or objects that are contaminated with *Pseudomonas aeruginosa* (**Figure 117-1**). This occurs when hot tubs are inadequately chlorinated or brominated. This also occurs when loofah sponges or other items used for bathing become a host for pseudomonal growth. Onset of symptoms is usually within 6 to 72 hours after exposure, with the complete resolution of symptoms in a couple of days, provided that the individual avoids further exposure.[4]
- Gram-negative folliculitis is an infection with Gram-negative bacteria that most typically occurs in individuals who have been on long-term antibiotic therapy, usually those taking oral antibiotics for acne. The most frequently encountered infective agents include *Klebsiella*, *Escherichia coli*, *Enterobacter,* and *Proteus*.[5]
- Pseudofolliculitis barbae (razor bumps) is most commonly seen in black males who shave. Papules develop when the sharp edge of the hair shaft reenters the skin (ingrown hairs), and is seen on the cheeks and neck as a result of curled ingrown hair.[2] It can also occur in women with hirsutism who shave or pluck their hairs (**Figure 117-4**) (see Chapter 114, Pseudofolliculitis and Acne Keloidalis Nuchae).[6]
- Viral folliculitis seen is primarily caused by herpes simplex virus and molluscum contagiosum.[4] Herpetic folliculitis is seen primarily

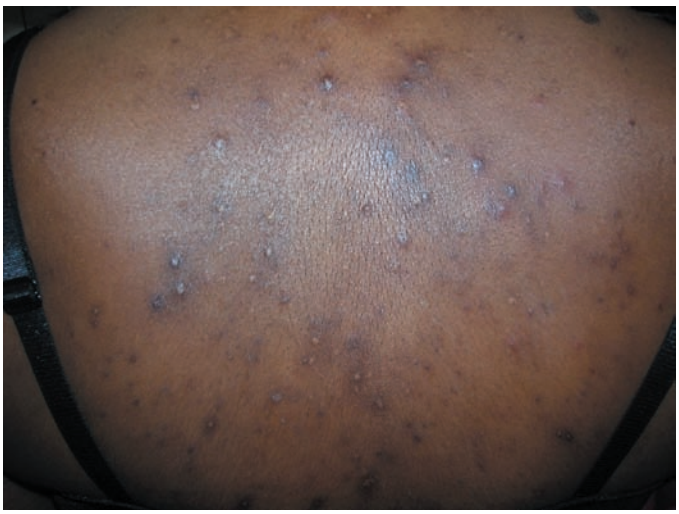

FIGURE 117-3 Chronic bacterial folliculitis on the back with scarring and hyperpigmentation. (*Courtesy of E.J. Mayeaux, Jr., MD.*)

FIGURE 117-4 Pseudofolliculitis barbae in a black man. Shaving makes it worse and he notes many problems with ingrown hairs. (*Courtesy of Jonathan Karnes, MD.*)

FIGURE 117-5 Acne keloidalis nuchae with inflamed papules and pustules on the neck of a young Hispanic man. (*Courtesy of Richard P. Usatine, MD.*)

FIGURE 117-6 Acne keloidalis nuchae in a woman demonstrating the folliculitis around the hair follicles and the scarring alopecia that has occurred. (*Courtesy of Richard P. Usatine, MD.*)

FIGURE 117-7 Eosinophilic folliculitis on the back of an HIV-positive man. (*Courtesy of Richard P. Usatine, MD.*)

FIGURE 117-8 MRSA folliculitis in the axilla of a 29-year-old woman. The lesions were present for 4 weeks in the axilla, left forearm, and right thigh. The MRSA was sensitive to tetracyclines and resolved with oral doxycycline. (*Courtesy of Alisha N. Plotner, MD, and Robert T. Brodell, MD, and used with permission from Plotner AN, Brodell RT. Bilateral axillary pustules. J Fam Pract. 2008;57(4):253-255. Reproduced with permission from Frontline Medical Communications.*)

FIGURE 117-9 Isolated single furuncle in an adult woman. (*Courtesy of Richard P. Usatine, MD.*)

FIGURE 117-10 Early folliculitis decalvans showing scalp inflammation, pustules around hair follicles and scarring alopecia. (*Courtesy of Richard P. Usatine, MD.*)

FIGURE 117-11 Tufted folliculitis with visible tufts of hair (multiple hairs from one follicle) growing from a number of abnormal follicles. This is one example of scarring alopecia. (*Courtesy of Richard P. Usatine, MD.*)

in individuals with a history of herpes simplex infections type I or II. But most notably, it may be a sign of immunosuppression, as is the case with HIV infection.[7] The expression of herpes folliculitis in HIV infection ranges from simple to necrotizing folliculitis and ulcerative lesions. Molluscum is a pox virus and molluscum contagiosum has been well-documented in similar patient populations (i.e., HIV and AIDS) and in children (see Chapters 129, Herpes Simplex and 130, Molluscum Contagiosum).[7-9]

- Actinic superficial folliculitis is a sterile form of folliculitis seen predominantly in warm climates or during hot or summer months. Pustules occur primarily on the neck, over the shoulders, upper trunk, and upper arms, usually within 6 to 36 hours after sun exposure.[10]
- Eosinophilic folliculitis is associated with HIV infection and can occur as a result of the viral infection itself, in which case the exact mechanism by which this occurs is uncertain (though thought to be autoimmune) (**Figure 117-7**).[9,11,12,14] It is associated with diminished CD4 cell counts. Eosinophilic folliculitis generally improves with the initiation of highly active antiretroviral therapy (HAART), but can occur during the restoration of immune function with HAART.[12]

DIAGNOSIS

Often the diagnosis of folliculitis is based on a good history and physical.

CLINICAL FEATURES

Folliculitis has its characteristic presentation as the development of papules or pustules that are thin-walled and surrounded by a margin of erythema or inflammation. Look for a hair at the center of the lesions (**Figure 117-2**). There is usually an absence of systemic signs and patients, symptoms range from mild discomfort and pruritus to severe pain with extensive involvement.

TYPICAL DISTRIBUTION

Any area of the skin may be affected and often location may be related to the pathogen or cause of folliculitis. The face, scalp, neck, trunk, axillae, extremities, and groin are some of the more common areas affected.

LABORATORY TESTS

Laboratory testing may be unnecessary in simple superficial folliculitis and where the history is clear and quick resolution occurs. Clinical diagnosis of herpes and fungal folliculitis may be difficult and diagnosis may be made based on strong clinical suspicion or as a result of failed antimicrobial therapy. KOH preps can be used to look for tinea versicolor or other fungal organisms. Herpes culture or a quick test for herpes can be used when herpes is suspected.[1] SOR A

DIFFERENTIAL DIAGNOSIS

- *Grover disease* is a very pruritic condition of unknown cause that produces reddish papules and slight scale on the backs of middle-aged men. It is also called "transient acantholytic dermatosis" and may resolve spontaneously in a period of years. It resembles folliculitis but the papules are not centered on hair follicles (**Figure 117-13**).

FIGURE 117-12 **A.** *Pityrosporum* folliculitis on the chest, shoulders, and arms of a young man; biopsy proven. **B.** *Pityrosporum* folliculitis on the chest of a young woman. KOH preparation showed *Pityrosporum* looking like ziti and meatballs. (*Courtesy of Richard P. Usatine, MD.*)

FIGURE 117-13 Grover's disease on the back of a middle-aged man. This is also called "transient acantholytic dermatosis." It is very pruritic with reddish papules and slight scale. (*Courtesy of Richard P. Usatine, MD.*)

- *Miliaria* is blockage of the sweat glands that can resemble the small papules of folliculitis. The eccrine sweat glands become blocked so that sweat leaks into the dermis and epidermis. Clinically, skin lesions may range from clear vesicles to pustules. These skin lesions primarily occur in times of increased heat and humidity, and are self-limited (see Chapter 108, Normal Skin Changes).[1]
- *Impetigo* is a bacterial infection of the skin that affects the superficial layers of the epidermis as opposed to hair follicles. It is contagious, unlike folliculitis. It has a bullous and nonbullous form, and honey-crusted lesions frequently predominate as opposed to the usual pustules seen in folliculitis (see Chapter 116, Impetigo).[4,6]
- *Keratosis pilaris* consists of papules that occur as a result of a buildup of keratin in the openings of hair follicles, especially on the lateral upper arms and thighs. It is not an infection but can develop into folliculitis if lesions become infected (see Chapter 145, Atopic Dermatitis).[1,6]
- *Acne vulgaris* is characterized by the presence of comedones, papules, pustules, and nodules that are a result of follicular hyperproliferation and plugging with excessive sebum. Inflammation occurs when *Propionibacterium acnes* and other inflammatory substances get extruded from the blocked pilosebaceous unit.[15] Although acne on the face is rarely confused with folliculitis, acne on the trunk can resemble folliculitis. To distinguish between them look for facial involvement and comedones seen in acne (see Chapter 112, Acne Vulgaris).

MANAGEMENT

- Management of folliculitis varies by causative agent and underlying pathophysiology.
- Antivirals, antibiotics, and antifungals are used as topical and/or systemic agents. Approaches to nonpharmacologic therapy include patient education on the prevention of chemical and mechanical skin irritation. Glycemic control in diabetic patients may help treat folliculitis.[1–3] Good hygiene helps to control symptoms and prevent recurrence.
- With superficial bacterial folliculitis, treatment with topical preparations such as mupirocin (Bactroban) or fusidic acid may be sufficient.[1] SOR A Additionally, topical clindamycin may be considered in the mildest cases in which MRSA is involved.[1] SOR A
- Deep or extensive bacterial folliculitis warrants oral therapy with first-generation cephalosporins (cephalexin), penicillins (amoxicillin/clavulanate and dicloxacillin), macrolides, or fluoroquinolones.[1,4,6] SOR A
- *Pseudomonas* or "hot tub" folliculitis usually resolves untreated within a week of onset (**Figure 117-1**). For severe cases, treatment with ciprofloxacin provides adequate antipseudomonal coverage.[1,4] SOR B Application of a warm compress to affected areas also provides symptomatic relief.
- *Pityrosporum* folliculitis and/or tinea versicolor can be treated with systemic antifungals, topical azoles, and/or with shampoos containing azoles, selenium, or zinc (**Figure 117-12**) (see Chapter 141, Tinea Versicolor).
- Candidal folliculitis in immunosuppressed persons may be treated with oral itraconazole (see Chapter 136, Candidiasis).[1] SOR A
- *Demodex* folliculitis can be treated with ivermectin or topically with 5% permethrin cream.[4] SOR B
- Herpes folliculitis can be treated with acyclovir, valacyclovir, and famciclovir. Regimens may frequently include acyclovir 200 mg 5 times a day for 5 days (see Chapter 129, Herpes Simplex).[1] SOR A
- Eosinophilic folliculitis associated with HIV is treated with HAART, topical steroids, antihistamines, itraconazole, metronidazole, oral retinoids, and UV light therapy.[11] Topical steroids and NSAIDs and isotretinoin are treatments of choice for HIV-associated eosinophilic folliculitis.[9–13] SOR B Relief with systemic antihistamines are variable and UV therapy is time-consuming and expensive.[11,12] SOR C

FOLLOW-UP

Most cases of folliculitis are superficial and resolve easily with treatment. Dermatologic and surgical consultation may be required in cases of chronic folliculitis with scarring.

PATIENT EDUCATION

Prevention is most important, and centers on good personal hygiene and proper laundering of clothing. Patients should be encouraged to avoid tight-fitting clothing. Hot tubs should be properly cleaned and the chemicals should be maintained appropriately. Electric razors for shaving can help prevent pseudofolliculitis barbae and should be cleaned regularly with alcohol. Patients with acne keloidalis nuchae should avoid shaving the hair in the involved area.

PATIENT RESOURCE

- **http://www.ncbi.nlm.nih.gov/pubmedhealth/PMH0001826/.**

PROVIDER RESOURCE

- **http://emedicine.medscape.com/article/1070456.**

REFERENCES

1. Luelmo-Aguilar J, Santandreu MS. Folliculitis recognition and management. *Am J Clin Dermatol.* 2004;5(5):301-310.
2. Habif T. Clinical Dermatology, 5th ed. Philadelphia, 2010.
3. Levy AL, Simpson G, Skinner RB Jr. Medical pearl: circle of desquamation, a clue to the diagnosis of folliculitis and furunculosis caused by *Staphylococcus aureus*. *J Am Acad Dermatol.* 2006;55(6):1079-1080.
4. Stulberg DL, Penrod MA, Blatny RA. Common bacterial skin infections. *Am Fam Physician.* 2002;66(1):119-124.
5. Neubert U, Jansen T, Plewig G. Bacteriologic and immunologic aspects of Gram-negative folliculitis: a study of 46 patients. *Int J Dermatol.* 1999;38(4):270-274.
6. *Ferri's Clinical Advisor* 2012, Elsevier, Philadelphia, 2012.

7. Boer A, Herder N, Winter K, Falk T. Herpes folliculitis: clinical histopathological, and molecular pathologic observations. *Br J Dermatol.* 2006;154(4):743-746.
8. Weinberg JM, Mysliwiec A, Turiansky GW, et al. Viral folliculitis. Atypical presentations of herpes simplex, herpes zoster, and molluscum contagiosum. *Arch Dermatol.* 1997;133(8):983-986.
9. Fearfield LA, Rowe A, Francis N, et al. Itchy folliculitis and human immunodeficiency virus infection: clinicopathological and immunological features, pathogenesis and treatment. *Br J Dermatol.* 1999;141(1):3-11.
10. Labandeira J, Suarez-Campos A, Toribio J. Actinic superficial folliculitis. *Br J Dermatol.* 1998;138(6):1070-1074.
11. Nervi SJ, Schwartz RA, Dmochowski M. Eosinophilic pustular folliculitis: a 40 year retrospect. *J Am Acad Dermatol.* 2006;55(2):285-289.
12. Rajendran PM, Dolev JC, Heaphy MR Jr, Maurer T. Eosinophilic folliculitis: before and after the introduction of antiretroviral therapy. *Arch Dermatol.* 2005;141(10):1227-1231.
13. Jang KA, Kim SH, Choi JH, et al. Viral folliculitis on the face. *Br J Dermatol.* 2000;142(3):555-559.
14. Toutous-Trellu L, Abraham S, Pechère M, et al. Topical tacrolimus for effective treatment of eosinophilic folliculitis associated with human immunodeficiency virus infection. *Arch Dermatol.* 2005;141(10):1203-1208.
15. Strauss JS, Krowchuk DP, Leyden JJ, et al. Guidelines of care for acne vulgaris management. *J Am Acad Dermatol.* 2007;56(4):651-663.
16. Gupta AK, Batra R, Bluhm R, et al. Skin diseases associated with *Malassezia* species. *J Am Acad Dermatol.* 2004;51(5):785-798.

118 PITTED KERATOLYSIS

Michael J. Babcock, MD
Richard P. Usatine, MD

PATIENT STORY

A 34-year-old man comes to the office with a terrible foot odor problem. He is wearing cowboy boots and he says that his feet are always sweaty. He is embarrassed to remove his boots, but when the physician convinces him to do so the odor is overwhelming. While breathing through the mouth, the physician sees the typical pits of pitted keratolysis. His socks are moist and the skin is somewhat macerated from the hyperhidrosis. His foot has many crateriform pits on the heel (**Figure 118-1**). He is prescribed topical erythromycin solution for the pitted keratolysis and topical aluminum chloride for the hyperhidrosis. It is suggested that he wear a lighter and more breathable shoe until this problem improves.

FIGURE 118-1 Many crateriform pits on the heel of a foot in a man with pitted keratolysis and hyperhidrosis. (*Courtesy of Richard P. Usatine, MD.*)

INTRODUCTION

Pitted keratolysis is a superficial foot infection caused by Gram-positive bacteria. These bacteria degrade the keratin of the stratum corneum leaving visible pits on the soles of the feet.

EPIDEMIOLOGY

- Seen more commonly in men.
- Often a complication of hyperhidrosis.
- Seen more often in hot and humid climates.
- Prevalence can be as high as 42.5% among paddy field workers.[1]
- May be common in athletes with moist, sweaty feet.[2]

ETIOLOGY AND PATHOPHYSIOLOGY

- *Kytococcus sedentarius* (formerly *Micrococcus* spp.), *Corynebacterium* species, and *Dermatophilus congolensis* have all been shown to cause pitted keratolysis.[3]
- Proteases produced by the bacteria degrade keratins to give the clinical appearance.[4]
- The associated malodor is likely secondary to the production of sulfur byproducts.[3]

DIAGNOSIS

CLINICAL FEATURES

Pitted keratolysis usually presents as painless, malodorous, crateriform pits coalescing into larger superficial erosions of the stratum corneum (**Figures 118-1** to **118-4**). It may be associated with itching and a burning sensation in some patients (**Figure 118-3**).

FIGURE 118-2 Pitted keratolysis on the pressure-bearing areas of the toes and the ball of the foot. (*Courtesy of Richard P. Usatine, MD.*)

TYPICAL DISTRIBUTION

Pitted keratolysis usually involves the callused pressure-bearing areas of the foot, such as the heel, ball of the foot, and plantar great toe. It can also be found in friction areas between the toes.[5]

LABORATORY STUDIES

Typically a clinical diagnosis but biopsy will reveal keratin pits lined by bacteria.

DIFFERENTIAL DIAGNOSIS

- Characteristic clinical features make the diagnosis easy, but it is possible to have other diseases causing plantar pits, which can be included in the differential. These other diseases include plantar warts, basal cell nevus syndrome, and arsenic toxicity.
- Plantar warts are typically not as numerous. They have a firm callus ring around a soft core with small black dots from thrombosed capillaries (see Chapter 134, Plantar Warts).
- Basal cell nevus syndrome typically has pits involving the palms and soles, bone abnormalities, a history of many basal cell carcinomas, and a characteristic facies with frontal bossing, hypoplastic maxilla, and hypertelorism (wide-set eyes) (see Chapter 170, Basal Cell Carcinoma).
- Arsenic toxicity can result in pits on the palms and soles, but it can also have hyperpigmentation, many skin cancers, Mees lines (white lines on the fingernails), or other nail disorders.

MANAGEMENT

- Treatment is based on bacterial elimination and reducing the moist environment in which the bacteria thrive. Various topical antibiotics are effective for pitted keratolysis.
- Topical erythromycin or clindamycin solution or gel can be applied twice daily until the condition resolves. SOR C Generic 2% erythromycin solution with an applicator top is a very inexpensive and effective preparation. It may take 3 to 4 weeks to clear the odor and skin lesions.
- Topical mupirocin is more expensive but also effective. SOR C
- Oral erythromycin is effective and may be considered if topical therapy fails. SOR C
- Treating underlying hyperhidrosis is also important to prevent recurrence. This can be done with topical aluminum chloride of varying concentrations. SOR C Drysol is 20% aluminum chloride solution and can be prescribed with an applicator top.
- Botulinum toxin injection is an expensive and effective treatment for hyperhidrosis.[6] SOR C It should be reserved for treatment failures because of the cost, the discomfort of the multiple injections, and the need to repeat the treatment every 3 to 4 months.

FOLLOW-UP

Follow-up is needed for treatment failures, recurrences, and the treatment of underlying hyperhidrosis if present. Follow-up can be

FIGURE 118-3 Pitted keratolysis with hyperpigmented crateriform pits on the pressure-bearing areas of the foot. The patient complained of itching and burning on the feet. (*Courtesy of Richard P. Usatine, MD.*)

FIGURE 118-4 Pitted keratolysis with many crateriform pits on the heel. (*Courtesy of Richard P. Usatine, MD.*)

performed annually for prescription aluminum chloride or approximately every 4 months for botulinum toxin injections.

PATIENT EDUCATION

Patients should be taught about the etiology of this disorder to help avoid recurrence. Helpful preventive strategies include avoiding occlusive footwear and using moisture-wicking socks or changing sweaty socks frequently.

PATIENT RESOURCES

- International Hyperhidrosis Society—**http://www.sweathelp.org.**

PROVIDER RESOURCES

- Medscape. *Pitted Keratolysis*—**http://emedicine.medscape.com/article/1053078-overview.**

REFERENCES

1. Shenoi SD, Davis SV, Rao S, et al. Dermatoses among paddy field workers—a descriptive, cross-sectional pilot study. *Indian J Dermatol Venereol Leprol.* 2005;71:254-258.
2. Conklin RJ. Common cutaneous disorders in athletes. *Sports Med.* 1990;9:100-119.
3. Bolognia J, Jorizzo J, Rapini R. *Dermatology*, 2nd ed. Philadelphia: Mosby; 2008:1088-1089.
4. Takama H, Tamada Y, Yano K, et al. Pitted keratolysis: clinical manifestations in 53 cases. *Br J Dermatol.* 1997;137(2):282-285.
5. Longshaw C, Wright J, Farrell A, et al. Kytococcus sedentarius, the organism associated with pitted keratolysis, produces two keratin-degrading enzymes. *J Appl Microbiol.* 2002;93(5):810-816.
6. Vadoud-Seyedi J. Treatment of plantar hyperhidrosis with botulinum toxin type A. *Int J Dermatol.* 2004;43(12):969-971.

119 ERYTHRASMA

Anna Allred, MD
Richard P. Usatine, MD
Mindy A. Smith, MD, MS

PATIENT STORY

A 12-year-old Hispanic girl, accompanied by her mother, presents with a 1-year history of a red irritated rash in both axillae (**Figure 119-1**). She has been seen by multiple physicians and many antifungal creams had been tried with no results. Even hydrocortisone did not help. She had stopped wearing deodorant for fear that she was allergic to all deodorants. Although the rash barely fluoresced at all, the physical examination and history were most consistent with erythrasma. The patient was given a prescription for oral erythromycin and the erythrasma cleared to the great delight of the patient and her mother.

FIGURE 119-1 Erythrasma in the axilla of a 12-year-old Hispanic girl. (*Courtesy of Richard P. Usatine, MD.*)

INTRODUCTION

Erythrasma is a chronic superficial bacterial skin infection that usually occurs in a skin fold.

EPIDEMIOLOGY

- The incidence of erythrasma is approximately 4%.[1]
- Both sexes are equally affected.
- The inguinal location is more common in men.

ETIOLOGY AND PATHOPHYSIOLOGY

- *Corynebacterium minutissimum*, a lipophilic Gram-positive non–spore-forming rod-shaped organism, is the causative agent.
- Under favorable conditions, such as heat and humidity, this organism invades and proliferates the upper one-third of the stratum corneum.
- The organism produces porphyrins that result in the coral red fluorescence seen under a Wood lamp (**Figure 119-2**).

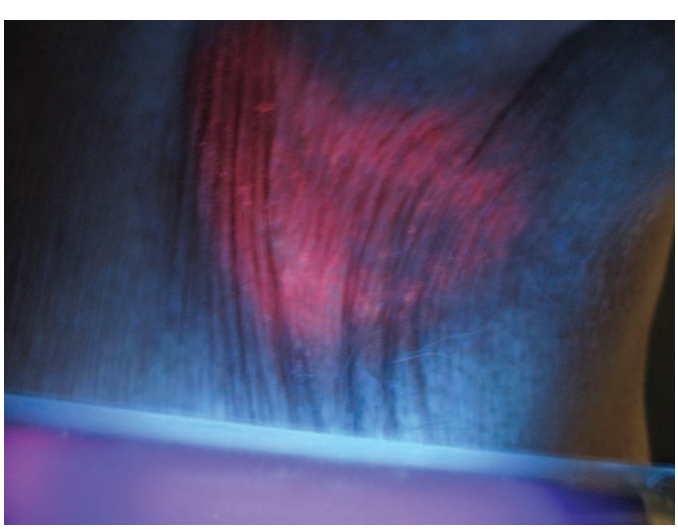

FIGURE 119-2 Coral red fluorescence seen with a Wood lamp held in the axilla of a patient with erythrasma. (*Courtesy of the University of Texas Health Sciences Center, Division of Dermatology.*)

RISK FACTORS[1]

- Warm climate.
- Diabetes mellitus.
- Immunocompromised states.
- Obesity.
- Hyperhidrosis.
- Poor hygiene.
- Advanced age.

DIAGNOSIS

CLINICAL FEATURES

- Erythrasma is a sharply delineated, dry, red-brown patch with slightly scaling patches. Some lesions appear redder, whereas others have a browner color (**Figures 119-3** and **119-4**).
- The lesions may appear with central clearing and be slightly raised from the surrounding skin (**Figure 119-5**).
- The lesions are typically asymptomatic; however, patients sometimes complain of itching and burning when lesions occur in the groin (**Figure 119-6**).

TYPICAL DISTRIBUTION

Erythrasma is characteristically found in the intertriginous areas, especially the axilla and the groin. Patches of erythrasma may also be found in the interspaces of the toes, intergluteal cleft, perianal skin, and inframammary area.

LABORATORY STUDIES

- Illumination of the plaque with a Wood lamp reveals coral-red fluorescence. It should be noted that washing the area before examination may eliminate the fluorescence.
- The diagnosis may be confirmed by applying Gram stain or methylene blue stain to scrapings from the skin to reveal Gram-positive rods and dark blue granules, respectively. However, if the presentation is typical and the plaque reveals fluorescence then microscopic examination and cultures are not needed.
- Microscopic examination is useful if erythrasma is suspected but the plaque does not fluoresce.

DIFFERENTIAL DIAGNOSIS

- Psoriasis—Inverse psoriasis occurs in the same areas as erythrasma and also causes pink to red plaques with well-demarcated borders. The best way to distinguish psoriasis from erythrasma is to look for other clues of psoriasis in the patient, including nail pitting or onycholysis and hyperkeratotic plaques on the elbows, knees, or scalp. Also, inverse psoriasis may be seen in the intergluteal cleft as well as below the breasts or pannus in overweight individuals (see Chapter 152, Psoriasis). The Wood lamp may help differentiate between these diagnoses.
- Dermatophytosis—Cutaneous fungal infections also closely resemble erythrasma when they occur in the axillary and inguinal areas. Tinea infections also have well-demarcated borders that can be raised with central clearing. This distinctive ringworm look is more obvious with tinea than erythrasma but a scraping for microscopic examination should be able to distinguish between the two conditions. Examination of the feet will frequently show tinea pedis and onychomycosis when there are tinea infections elsewhere on the body (see Chapters 138, Tinea Corporis and 139, Tinea Cruris).
- Candidiasis—Look for satellite lesions to help distinguish candidiasis from erythrasma. Candidiasis will not fluoresce and a microscopic examination of a *Candida* infection should show branching pseudohyphae (see Chapter 136, Candidiasis).

FIGURE 119-3 Light brown erythrasma in the groin of a young man. It does not have the degree of scaling usually seen with tinea cruris. (*Courtesy of Dan Stulberg, MD.*)

FIGURE 119-4 Brown erythrasma in the groin of a man with diabetes. (*Courtesy of the University of Texas Health Sciences Center, Division of Dermatology.*)

- Intertrigo—This is a term for inflammation in intertriginous areas (skin folds). It is caused or exacerbated by heat, moisture, maceration, friction, and lack of air circulation. It is frequently made worse by infection with *Candida*, bacteria, or dermatophytes, and therefore overlaps with the erythrasma, *Candida*, and dermatophytosis. Obesity and diabetes especially predispose to this condition. All efforts should be made to find coexisting infections and treat them.
- Contact dermatitis to deodorants can mimic erythrasma. The history and Wood lamp should help to differentiate the two conditions (see Chapter 146, Contact Dermatitis).

MANAGEMENT

NONPHARMACOLOGIC

- It has been advocated that the areas should be vigorously washed with soap and water prior to application of topical antibiotics.[5] SOR C
- Consider loose-fitting cotton undergarments during treatment and to help prevent recurrence.[5] SOR C

MEDICATIONS

- Although the bacteria responds to a variety of antibacterial agents (e.g., penicillins, first-generation cephalosporins), the treatment of choice is oral erythromycin 250 mg 4 times a day for 14 days. Erythromycin shows cure rates as high as 100%.[2–4] SOR B
- However, some advocate that oral erythromycin is only required for the treatment of extensive or resistant cases.[5] SOR C
- Topical therapy (antibacterial, antifungal, benzoic acid 6%) has been recommended in addition to oral therapy in patients with hidden reservoirs of infection (i.e., interdigital involvement). SOR C
- Topical clindamycin may be applied once daily during the course of oral erythromycin therapy and for 2 weeks after physical clearance of the lesions for treatment and prophylaxis.[3,6] SOR C
- Topical erythromycin 2% solution applied twice daily.[4,5,7] SOR C
- In a Turkish study, topical fusidic acid was more effective than erythromycin or single-dose clarithromycin based on Wood light reflection scores.[8]
- Optimal blood glucose control is recommended in the management of a diabetic patient with erythrasma.[2] SOR C

PROGNOSIS

- Usually a benign condition; however, in immunocompromised individuals, *Corynebacterium* can cause abscess formation, bacteremia, endocarditis, pyelonephritis, cellulitis, and meningitis.[1]
- The condition tends to recur if the predisposing condition is not addressed.

FOLLOW-UP

Have the patient follow up in 2 to 4 weeks as needed to determine if erythrasma has resolved.

FIGURE 119-5 Pinkish erythrasma in the axilla of a 32-year-old man with some central clearing and elevated borders. (*Courtesy of Richard P. Usatine, MD.*)

FIGURE 119-6 Pinkish erythrasma in the groin of the man in **Figure 119-5**. Men are more likely to have erythrasma in the crural region. (*Courtesy of Richard P. Usatine, MD.*)

PATIENT EDUCATION

Reassure the patient that erythrasma is curable with antibiotic treatment.

PATIENT RESOURCES

- PubMed Health. *Erythrasma*—**http://www.ncbi.nlm.nih.gov/pubmedhealth/PMH0002441/.**
- Dermnet NZ. *Erythrasma*—**http://www.dermnetnz.org/bacterial/erythrasma.html.**

PROVIDER RESOURCES

- Medscape. *Erythrasma*—**http://emedicine.medscape.com/article/1052532.**

REFERENCES

1. Kibbi AG, Bahhady RF, Saleh Z, Haddad FG. *Erythrasma*. http://emedicine.medscape.com/article/1052532-overview#a0199. Accessed April 2, 2012.
2. Ahmed I, Goldstein B. Diabetes mellitus. *Clin Dermatol.* 2006; 24(4):237-246.
3. Holdiness MR. Management of cutaneous erythrasma. *Drugs.* 2002;62(8):1131-1141.
4. James WD, Berger TG, Elston DM. *Andrew's Diseases of the Skin Clinical Dermatology*, 10th ed. London, UK: Saunders/Elsevier; 2006.
5. Karakatsanis G, Vakirlis E, Kastoridou C, Devliotou-Panagiotidou D. Coexistence of pityriasis versicolor and erythrasma. *Mycoses.* 2004;47(7):343-345.
6. Holdiness MR. Erythrasma and common bacterial skin infections. *Am Fam Physician.* 2003;15:67(2):254.
7. Miller SD, David-Bajar K. Images in clinical medicine. A brilliant case of erythrasma. *N Engl J Med.* 2004;14:351(16):1666.
8. Avci O, Tanyildizi T, Kusku E. A comparison between the effectiveness of erythromycin, single-dose clarithromycin and topical fusidic acid in the treatment of erythrasma. *J Dermatolog Treat.* 2011 Sep 18 [Epub ahead of print].

120 CELLULITIS

Richard P. Usatine, MD

PATIENT STORY

A 4-year-old child presents with a fever and a red and swollen foot (**Figure 120-1**). The patient injured her foot 3 days before with a door. On physical examination, the foot was warm, tender, red, and swollen, and the child's temperature was 39.4°C (103°F). This is classic cellulitis and the child was admitted for IV antibiotics.

FIGURE 120-1 Cellulitis of the foot after an injury with a door in a 4-year-old girl. (*Courtesy of Richard P. Usatine, MD.*)

INTRODUCTION

Cellulitis is an acute infection of the skin that involves the dermis and subcutaneous tissues.

EPIDEMIOLOGY

- Facial cellulitis occurs more often in adults ages 50 years or older, or in children ages 6 months to 3 years.
- Perianal cellulitis occurs more commonly in young children but can be seen in adults as well (see Chapter 111, Diaper Rash and Perianal Dermatitis).

ETIOLOGY AND PATHOPHYSIOLOGY

- Often begins with a break in the skin caused by trauma, a bite, or an underlying dermatosis (e.g., tinea pedis, stasis dermatitis) (**Figures 120-2** to **120-4**).
- Is most often caused by group A β-hemolytic *Streptococcus* (GABHS) or *Staphylococcus aureus*. The most common etiology of cellulitis with intact skin, when it has been determined through needle aspiration and/or punch biopsy, is *S. aureus*, outnumbering GABHS by a ratio of nearly 2:1.[1]

There are increasing concerns about the role of community-acquired methicillin-resistant *S. aureus* (MRSA) in all soft-tissue infections including cellulitis.[2-5]

- After a cat or dog bite, cellulitis is often caused by *Pasteurella multocida*.
- After saltwater exposure, cellulitis can be secondary to *Vibrio vulnificus* in warm climates (**Figure 120-5**). A *Vibrio vulnificus* infection can be especially deadly.

Erysipelas is a specific type of superficial cellulitis with prominent lymphatic involvement and leading to a sharply defined and elevated border (**Figure 120-6**).

FIGURE 120-2 Cellulitis and abscess of the finger after a clenched fist injury in which the patient cut his finger on the tooth of the man he assaulted. (*Courtesy of Richard P. Usatine, MD.*)

DIAGNOSIS

CLINICAL FEATURES

Rubor (red), calor (warm), tumor (swollen), and dolor (painful).

TYPICAL DISTRIBUTION

Can occur on any part of the body, but is most often seen on the extremities and face (**Figures 120-1** to **120-8**). Periorbital cellulitis can be life-threatening (**Figure 120-9**). Cellulitis can also occur around the anus. This is called perianal cellulitis (**Figure 120-10**).

LABORATORY TESTS

- Aspiration—If there is fluctuance within the area of erythema, a needle aspiration or incision and drainage should be performed (**Figure 120-11**). If pus is aspirated, perform a culture to guide antibiotic use.
- Blood cultures—Results are positive in only 5% of cases and the results of culture of needle aspirations of the inflamed skin are variable and not recommended.[4]

DIFFERENTIAL DIAGNOSIS

- Thrombophlebitis—Inflammation of a vein caused by a blood clot. The pain and tenderness are over the involved vein.
- Venous stasis—Swelling, discoloration, and pain of the lower extremities that can lead to cellulitis. Venous stasis dermatitis can add erythema and scaling to the picture and resemble cellulitis (**Figure 120-4**) (see Chapter 52, Venous Stasis).
- Allergic reactions—Allergic reactions to vaccines or bug bites may resemble cellulitis because of the erythema and swelling (**Figure 120-12**).
- Acute gout—May resemble cellulitis if there is significant cutaneous inflammation beyond the involved joint (see Chapter 100, Gout).
- Necrotizing fasciitis—Deep infection of the subcutaneous tissues and fascia with diffuse swelling, severe pain, and bullae in a toxic-appearing patient. It is important to recognize the difference between standard cellulitis and necrotizing fasciitis. Imaging procedures can detect gas in the soft tissues. Rapid progression from mild erythema to violaceous or necrotic lesions and/or bullae in a number of hours is a red flag for necrotizing fasciitis. The toxicity of the patient and the other physical findings should encourage rapid surgical consultation (see Chapter 122, Necrotizing Fasciitis).

MANAGEMENT

- The first decision is whether or not the patient needs hospitalization and IV antibiotics. It is often best to hospitalize any immunocompromised patients (e.g., HIV, transplant recipient, chronic renal or liver disease, on prednisone, diabetes out of control) with cellulitis because they may decompensate quickly. SOR C
- Evidence comparing different durations of treatment, oral versus intravenous antibiotics is lacking.[6] Randomized controlled trials (RCTs) comparing different antibiotic regimens found clinical cure in 50% to 100% of people, but provided insufficient information on differences between regimens.[6] SOR A
- One quasi-randomized trial in 73 hospitalized people with erysipelas, but excluding patients with clinical signs of septicemia, compared oral versus intravenous penicillin and found no significant difference in clinical efficacy.[6] SOR B

FIGURE 120-3 Cellulitis of the foot of a diabetic person in which there is possible necrosis and gangrene of the second toe, requiring hospitalization and a podiatry consult. (*Courtesy of Richard P. Usatine, MD.*)

FIGURE 120-4 Cellulitis in an older man with venous stasis dermatitis. (*Courtesy of Richard P. Usatine, MD.*)

FIGURE 120-5 Fatal *Vibrio vulnificus* infection with widespread cellulitis and bullae. The violaceous bullae should be a red flag for this infection and/or necrotizing fasciitis. Even though the infection was identified early, the overwhelming sepsis resulted in death. (*Courtesy of Donna Nguyen, MD.*)

FIGURE 120-6 Erysipelas of the central face that responded well to oral antibiotic therapy. (*Courtesy of Ernesto Samano Ayon, MD.*)

FIGURE 120-7 Cellulitis of the leg in a 55-year-old man that developed after a minor abrasion and a long plane flight. Petechiae and ecchymoses are visible and not infrequently seen in cellulitis. (*Courtesy of Richard P. Usatine, MD.*)

FIGURE 120-8 Ascending lymphangitis characterized by lymphatic streaking up the leg in the same patient. (*Courtesy of Richard P. Usatine, MD.*)

FIGURE 120-9 Life-threatening staphylococcal periorbital cellulitis requiring operative intervention. (*Courtesy of Frank Miller, MD.*)

FIGURE 120-10 Severe perianal cellulitis in an adult man. (*Courtesy of Jack Resneck Sr., MD.*)

- Standard oral therapy for cellulitis not requiring hospitalization (in the pre-MRSA era) involves covering GABHS and *S. aureus* with cephalexin or dicloxacillin.[4] SOR A The standard dose is 500 mg orally every 6 hours for each antibiotic and the typical duration is 7 to 10 days. SOR C
- Penicillin-allergic patients may be treated with clindamycin rather than erythromycin because of macrolide resistance and increasing MRSA prevalence.[4] SOR A
- Parenteral treatment is usually done with penicillinase-resistant penicillins or first-generation cephalosporins such as cefazolin, or, for patients with life-threatening penicillin allergies, clindamycin, or vancomycin.[4] SOR A
- In cases of uncomplicated cellulitis, 5 days of antibiotic treatment with levofloxacin is as effective as a 10-day course.[7] SOR B This is not a good choice if MRSA is suspected.

Two recent studies (published in 2009 and 2010) addressed concerns over community-acquired MRSA (CAMRSA) in cellulitis and came up with different conclusions:

- An electronic chart review of patients seen in a Texas emergency department with cellulitis in 2000 and 2005 was performed. Exclusion criteria were incision and drainage, surgery, or admission on initial visit. Treatment failure was defined as a repeat visit in the subsequent 30 days and a change in antibiotics, admission to the hospital, incision and drainage of abscess, or surgical intervention. There was a significant decrease in β-lactam antibiotics and an increase in CAMRSA-effective antibiotics prescribed in 2005 versus 2000. The difference in treatment failure rates of the β-lactams and CAMRSA antibiotics was statistically insignificant. The β-lactam antibiotics performed as well as "CAMRSA antibiotics" in their setting.[5] SOR B
- A 3-year retrospective cohort study of outpatients with cellulitis empirically treated in Hawaii was performed. Exclusion criteria included patients who received more than one oral antibiotic or were hospitalized. The overall treatment success rate of trimethoprim-sulfamethoxazole was significantly higher than the rate of cephalexin (91% vs. 74%; $P < 0.001$). Clindamycin success rates were higher than those of cephalexin in patients who had subsequently culture-confirmed MRSA infections ($P = 0.01$), had moderately severe cellulitis ($P = 0.03$), and were obese ($P = 0.04$). MRSA was recovered in 72 of 117 positive culture specimens from 405 included patients. The researchers concluded that trimethoprim-sulfamethoxazole and clindamycin are preferred empiric therapy for outpatients with cellulitis in the CAMRSA-prevalent setting.[2] SOR B
- Although MRSA is increasing in its prevalence in skin and soft-tissue infections,[3] the difficulty in obtaining microbiologic cultures for cellulitis still makes it difficult to know how much MRSA is a problem in cellulitis with intact skin. If there is a coexisting abscess or crusting lesion, it is best to obtain a culture to guide therapy and start empiric therapy with trimethoprim-sulfamethoxazole and clindamycin.[2] SOR B
- Do not miss necrotizing fasciitis. Patients with severe pain, bullae, crepitus, skin necrosis, or significant toxicity merit imaging and immediate surgical consultation (see Chapter 122, Necrotizing Fasciitis).

FIGURE 120-11 Cellulitis and abscess of the neck and chest in a 2-year-old girl in Ethiopia. Incision and drainage of the fluctuance over the neck revealed pus. A drain was placed to allow the pus to continue to drain from the incision site. She was treated with IV ceftriaxone and she survived. (*Courtesy of Richard P. Usatine, MD.*)

FIGURE 120-12 Redness and swelling after a pneumococcal vaccine the day before in a 66-year-old woman. This allergic reaction looks like bacterial cellulitis. It resolved with oral diphenhydramine. (*Courtesy of Richard P. Usatine, MD.*)

- Treat underlying conditions (e.g., tinea pedis, lymphedema) that predispose the patient to the infection. SOR C

PATIENT EDUCATION

Recommend that the patient rest and elevate the involved extremity. If outpatient therapy is followed, then provide precautions (e.g., vomiting and unable to hold medicine down) for which the patient should seek more immediate follow-up.

FOLLOW-UP

If prescribing oral outpatient therapy, consider follow-up in 1 to 2 days to assess response to the antibiotic and to determine the adequacy of outpatient therapy.

PATIENT RESOURCES

- Medline Plus for patients—**http://www.nlm.nih.gov/medlineplus/cellulitis.html.**

PROVIDER RESOURCES

- Guidelines on the management of cellulitis in adults from Ireland—**http://www.gain-ni.org/Library/Guidelines/cellulitis-guide.pdf.**
- Practice Guidelines for the Diagnosis and Management of Skin and Soft-Tissue Infections from the Infectious Diseases Society of America—**http://cid.oxfordjournals.org/content/41/10/1373.full.**

REFERENCES

1. Chira S, Miller LG. *Staphylococcus aureus* is the most common identified cause of cellulitis: a systematic review. *Epidemiol Infect.* 2010;138:313-317.
2. Khawcharoenporn T, Tice A. Empiric outpatient therapy with trimethoprim-sulfamethoxazole, cephalexin, or clindamycin for cellulitis. *Am J Med.* 2010;123:942-950.
3. Moran GJ, Krishnadasan A, Gorwitz RJ, et al. Methicillin-resistant *S. aureus* infections among patients in the emergency department. *N Engl J Med.* 2006;355:666-674.
4. Stevens DL, Bisno AL, Chambers HF, et al. Practice guidelines for the diagnosis and management of skin and soft-tissue infections. *Clin Infect Dis.* 2005;41:1373-1406.
5. Wells RD, Mason P, Roarty J, Dooley M. Comparison of initial antibiotic choice and treatment of cellulitis in the pre- and post-community-acquired methicillin-resistant *Staphylococcus aureus* eras. *Am J Emerg Med.* 2009;27:436-439.
6. Morris AD. Cellulitis and erysipelas. *Clin Evid (Online).* 2008 Jan 2; 2008.
7. Hepburn MJ, Dooley DP, Skidmore PJ, et al. Comparison of short-course (5 days) and standard (10 days) treatment for uncomplicated cellulitis. *Arch Intern Med.* 2004;164:1669-1674.

121 ABSCESS

Richard P. Usatine, MD

PATIENT STORY

A young man is seen in a shelter in San Antonio after being evacuated from New Orleans after the devastating floods of Hurricane Katrina (**Figure 121-1**). He has facial pain and swelling and noticeable pus near the eye. His vision is normal. The area is anesthetized with lidocaine and epinephrine. The abscess is drained with a #11 blade. The patient is started on an oral antibiotic because of the proximity to the eye and the local swelling that could represent early cellulitis. A culture to look for methicillin-resistant *Staphylococcus aureus* (MRSA) was not available in the shelter, but close follow-up was set for the next day and the patient was doing much better.

FIGURE 121-1 Abscess seen on the face of a man after evacuation from the flood waters of New Orleans following Hurricane Katrina. (*Courtesy of Richard P. Usatine, MD.*)

INTRODUCTION

An abscess is a collection of pus in the infected tissues. The abscess represents a walled-off infection in which there is a pocket of purulence. In abscesses of the skin the offending organism is almost always *S. aureus*.

EPIDEMIOLOGY

- MRSA was the most common identifiable cause of skin and soft-tissue infections among patients presenting to emergency departments in 11 U.S. cities. *S. aureus* was isolated from 76% of these infections and 59% were community-acquired MRSA (CAMRSA).[1]
- Risk factors for MRSA infection and other abscesses—Intravenous drug abuse, homelessness, dental disease, contact sports, incarceration, and high prevalence in the community (**Figure 121-2**).

ETIOLOGY AND PATHOPHYSIOLOGY

- Most cutaneous abscesses are caused by *S. aureus*.
- Risk factors for developing an abscess with MRSA include patients who work or are exposed to a healthcare system, intravenous drug use, previous MRSA infection and colonization, recent hospitalization, being homeless, African American, and having used antibiotics within the last 6 months.[2]
- CAMRSA has become so prevalent in our community that both the patients shown in **Figures 121-3** and **121-4** had no special risk factors and both had abscesses that grew out MRSA. One study that evaluated management of skin abscesses drained in the emergency department showed that there was no significant association between amount of surrounding cellulitis or abscess size with the likelihood of MRSA-positive cultures.[2]
- A dental abscess can spread into tissue outside the mouth, as in the homeless person in **Figure 121-2**.

FIGURE 121-2 Neck abscess secondary to dental abscess in a homeless man. This was drained in the operating room by an ear, nose, and throat (ENT) specialist. (*Courtesy of Richard P. Usatine, MD.*)

DIAGNOSIS

CLINICAL FEATURES

Collection of pus in or below the skin. Patients often feel pain and have tenderness at the involved site. There is swelling, erythema, warmth, and fluctuance in most cases (**Figures 121-1** to **121-5**). Determine if the patient is febrile and if there is surrounding cellulitis.

TYPICAL DISTRIBUTION

Skin abscesses can be found anywhere from head to feet. Frequent sites include the hands, feet, extremities, head, neck, buttocks, and breast (**Figure 121-5**).

LABORATORY STUDIES

Clinical cure is often obtained with incision and drainage alone so the benefits of pathogen identification and sensitivities are low in low-risk patients.[2] Most clinical studies have excluded patients who were immunocompromised, diabetic, or had other significant comorbidities.[2] Consequently, it may be reasonable to obtain wound cultures in high-risk patients, those with signs of systemic infection, and in patients with history of high recurrence rates.[2,3]

FIGURE 121-3 MRSA abscess on the back of the neck that patient thought was a spider bite. Note that a ring block was drawn around the abscess with a surgical marker to demonstrate how to perform this block. (*Courtesy of Richard P. Usatine, MD.*)

DIFFERENTIAL DIAGNOSIS

- Epidermal inclusion cyst with inflammation/infection—These cysts (also known as sebaceous cysts) can become inflamed, swollen, and superinfected. Although the initial erythema may be sterile inflammation, these cysts can become infected with *S. aureus*. The treatment consists of incision and drainage and antibiotics if cellulitis is also present. If these are removed before they become inflamed, the cyst may come out intact (**Figure 121-6**).
- Cellulitis with swelling and no pocket of pus—When it is unclear if an area of infected skin has an abscess, needle aspiration with a large-gauge needle may be helpful to determine whether to incise the skin. Cellulitis alone should have no area of fluctuance (see Chapter 120, Cellulitis).
- Hidradenitis suppurativa—Recurrent inflammation surrounding the apocrine glands of the axilla and inguinal areas (see Chapter 115, Hidradenitis Suppurativa).
- Furuncles and carbuncles—A furuncle or boil is an abscess that starts in hair follicle or sweat gland. A carbuncle occurs when the furuncle extends into the subcutaneous tissue.
- Acne cysts—More sterile inflammation than true abscess, often better to inject with steroid rather than incise and drain (see Chapter 112, Acne Vulgaris).

MANAGEMENT

- The evidence strongly supports the incision and drainage of an abscess.[2,4] SOR A Inject 1% lidocaine with epinephrine into the skin at the site you plan to open using a 27-gauge needle. A ring block can be helpful rather than injecting into the abscess itself (**Figure 121-3**). Open the abscess with a linear incision using a #11 blade scalpel following skin lines if possible.[5]

FIGURE 121-4 Large MRSA abscess on the leg in a 62-year-old man beginning to drain spontaneously. The abscess cavity was large and patient was placed on trimethoprim-sulfamethoxazole (TMP-SMX) to cover the surrounding cellulitis. (*Courtesy of Richard P. Usatine, MD.*)

Although many physicians still pack a drained abscess with ribbon gauze, there is limited data on whether or not packing of an abscess cavity improves outcomes. A small study concluded that routine packing of simple cutaneous abscesses is painful and probably unnecessary.[6] SOR C The author of this chapter often packs abscesses lightly and has the patient remove the packing in the shower 2 days later, avoiding additional visits and painful repacking of the healing cavity. SOR C However, if a large abscess is not packed it can seal over and the pus may reaccumulate.

Routine use of antibiotics for an initial abscess in addition to incision and drainage is not supported by current evidence.[2,7-9] SOR A Three randomized controlled trials (RCTs) performed since the emergence of CAMRSA have demonstrated that antibiotics do not significantly improve healing rates of superficial skin abscesses, but two of these studies suggest that antibiotics do decrease short-term rates of new lesion development.[7–9]

Consider the use of oral antibiotics to treat an abscess with suspected CAMRSA in patients who are febrile or have systemic symptoms, have significant surrounding cellulitis, have failed incision and drainage alone, have frequent recurrences, or have a history of close contacts with abscesses.[2] SOR C

If an antibiotic is to be used, CAMRSA is close to 100% sensitive to trimethoprim-sulfamethoxazole.[2] SOR B Although standard dosing of oral trimethoprim-sulfamethoxazole for an infection in adults is 1 DS tablet bid, one study suggests that 2 DS tablets should be used bid for 7 days.[10] SOR B Alternative antibiotics include oral clindamycin, tetracycline, or doxycycline. Local sensitivity data should be consulted when available.[2] SOR B

There is no current data to support the use of an antimicrobial medication (mupirocin or rifampin) in the eradication of MRSA colonization.[2] SOR C

FIGURE 121-5 A large abscess of the hand in a 2-year-old girl in Ethiopia. Incision and drainage was performed and antibiotics were given to cover the surrounding cellulitis and any deeper infections. (*Courtesy of Richard P. Usatine, MD.*)

PATIENT EDUCATION

Patients may shower daily 24 to 48 hours after incision and drainage and then reapply dressings. Patients should be given return precautions for worsening of symptoms or continued redness, pain, or pus.

FOLLOW-UP

In patients or wounds at higher risk for complications, follow-up should be scheduled in 24 to 48 hours. If packing was placed, it can be removed by the patient or a family member.

PATIENT RESOURCES

- Skinsight article on abscess–**http://www.skinsight.com/adult/abscess.htm.**

PROVIDER RESOURCES

- Gillian R. How do you treat an abscess in the era of increased community-associated MRSA (MRSA)? *J Emerg Med*. 2011;41:276-281.
- **http://www.sciencedirect.com/science/article/pii/S0736467911004252#ref_bib17.**

FIGURE 121-6 Epidermal inclusion cyst removed intact. There is no need for antibiotics in this case. (*Courtesy of Richard P. Usatine, MD.*)

REFERENCES

1. Moran GJ, Krishnadasan A, Gorwitz RJ, et al. Methicillin-resistant *S. aureus* infections among patients in the emergency department. *N Engl J Med.* 2006;355:666-674.
2. Gillian R. How do you treat an abscess in the era of increased community-associated methicillin-resistant *Staphylococcus aureus* (MRSA)? *J Emerg Med.* 2011;41:276-281.
3. Abrahamian FM, Shroff SD. Use of routine wound cultures to evaluate cutaneous abscesses for community-associated methicillin-resistant *Staphylococcus aureus*. *Ann Emerg Med.* 2007;50:66-67.
4. Sorensen C, Hjortrup A, Moesgaard F, Lykkegaard-Nielsen M. Linear incision and curettage vs. deroofing and drainage in subcutaneous abscess. A randomized clinical trial. *Acta Chir Scand.* 1987;153:659-660.
5. Usatine R, Pfenninger J, Stulberg D, Small R. *Dermatologic and Cosmetic Procedures in Office Practice.* Philadelphia: Elsevier; 2012.
6. O'Malley GF, Dominici P, Giraldo P, et al. Routine packing of simple cutaneous abscesses is painful and probably unnecessary. *Acad Emerg Med.* 2009;16:470-473.
7. Duong M, Markwell S, Peter J, Barenkamp S. Randomized, controlled trial of antibiotics in the management of community-acquired skin abscesses in the pediatric patient. *Ann Emerg Med.* 2010;55:401-407.
8. Schmitz GR, Bruner D, Pitotti R, et al. Randomized controlled trial of trimethoprim-sulfamethoxazole for uncomplicated skin abscesses in patients at risk for community-associated methicillin-resistant *Staphylococcus aureus* infection. *Ann Emerg Med.* 2010;56:283-287.
9. Rajendran PM, Young D, Maurer T, et al. Randomized, double-blind, placebo-controlled trial of cephalexin for treatment of uncomplicated skin abscesses in a population at risk for community-acquired methicillin-resistant Staphylococcus aureus infection. *Antimicrob Agents Chemother.* 2007;51:4044-4048.
10. Markowitz N, Quinn EL, Saravolatz LD. Trimethoprim-sulfamethoxazole compared with vancomycin for the treatment of *Staphylococcus aureus* infection. *Ann Intern Med.* 1992;117:390-398.

122 NECROTIZING FASCIITIS

Richard P. Usatine, MD
Jeremy A. Franklin, MD

PATIENT STORY

A 54-year-old woman with diabetes was brought to the emergency department with right leg swelling, fever, and altered mental status.[1] The patient noted a pimple in her groin 5 days earlier and over the past few days had increasing leg pain. Her right leg was tender, red, hot, and swollen (**Figure 122-1**). Large bullae were present. Her temperature was 38.9°C (102°F) and her blood sugar was 573. The skin had a "woody" feel and a radiograph of her leg showed gas in the muscles and soft tissues (**Figure 122-2**). She was taken to the operating room for debridement of her necrotizing fasciitis. Broad-spectrum antibiotics were also started but the infection continued to advance quickly. The patient died the following day; her wound culture later grew *Escherichia coli, Proteus vulgaris, Corynebacterium, Enterococcus, Staphylococcus sp.*, and *Peptostreptococcus.*[1]

FIGURE 122-1 Necrotizing fasciitis on the leg and groin showing erythema, swelling, and bullae. (*From Dufel S, Martino M. Simple cellulitis or a more serious infection? J Fam Pract. 2006;55(5):396-400. Reproduced with permission from Frontline Medical Communications.*)

INTRODUCTION

Necrotizing fasciitis (NF) is a rapidly progressive infection of the deep fascia, with necrosis of the subcutaneous tissues. It usually occurs after surgery or trauma. Patients have erythema and pain disproportionate to the physical findings. Immediate surgical debridement and antibiotic therapy should be initiated.[2]

SYNONYMS

- Flesh-eating bacteria, necrotizing soft-tissue infection (NSTI), suppurative fasciitis, hospital gangrene, and necrotizing erysipelas. Fournier gangrene is a type of NF or NSTI in the genital and perineal region.[3]

EPIDEMIOLOGY

- Incidence in adults is 0.40 cases per 100,000 population.[4]
- NF caused by *Streptococcus pyogenes* is the most common form of NF.[4]

ETIOLOGY AND PATHOPHYSIOLOGY

- Type I NF is a polymicrobial infection with aerobic and anaerobic bacteria:
  - Frequently caused by enteric Gram-negative pathogens including *Enterobacteriaceae* organisms and *Bacteroides*.
  - Can occur with Gram-positive organisms such as non–group A streptococci and *Peptostreptococcus.*[5]

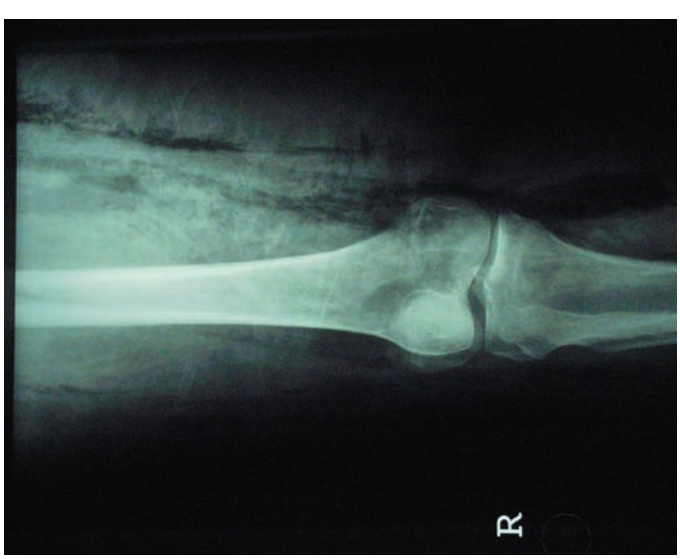

FIGURE 122-2 Radiograph of the patient's leg showing gas in the soft tissues and muscles. (*Courtesy of Susan Dufel, MD.*)[1]

- Saltwater variant can occur with penetrating trauma or an open wound contaminated with saltwater containing marine vibrios. *Vibrio vulnificus* is the most virulent (**Figure 122-3**).[6]
- Up to 15 pathogens have been isolated in a single wound.
- Average of five different isolates per wound.[7]

- Type II NF occurs from common skin organisms:
  - Generally a monomicrobial infection caused by *S. pyogenes:*
    - May occur in combination with *Staphylococcus aureus.*
    - Methicillin-resistant *S. aureus* is no longer a rare cause of NF.[5]
    - *S. pyogenes* strains may produce pyrogenic exotoxins, which act as superantigens to stimulate production of tumor necrosis factor (TNF)-α, TNF-β, interleukin (IL)-1, IL-6, and IL-2.[7]

RISK FACTORS

- Risk factors for type I NF (polymicrobial):
  - Diabetes mellitus.
  - Severe peripheral vascular disease.
  - Obesity.
  - Alcoholism and cirrhosis.
  - Intravenous drug use.
  - Decubitus ulcers.
  - Poor nutritional status.
  - Postoperative patients or those with penetrating trauma.
  - Abscess of the female genital tract.
- Risk factors of type II NF (group A β-hemolytic *Streptococcus* [GABHS] and *S. aureus*):
  - Diabetes mellitus.
  - Severe peripheral vascular disease.
  - Recent parturition (**Figure 122-4**).
  - Trauma.
  - Varicella.[5]

DIAGNOSIS

Early recognition based on signs and symptoms is potentially life-saving. Although lab tests and imaging studies can confirm ones' clinical impression, rapid treatment with antibiotics and surgery are crucial to improving survival.

CLINICAL FEATURES

- Rapid progression of erythema to bullae (**Figures 122-3** and **122-5**), ecchymosis, and necrosis or gangrene (**Figure 122-6**).
- The erythematous skin may develop a dusky blue discoloration. Vesicular and bullous lesions form over the erythematous skin, with some serosanguineous drainage. The bullae may become violaceous. The skin can become gangrenous and develop a black eschar.[2]
- Edematous, wooden feel of subcutaneous tissues extending beyond the margin of erythema.
- High fevers and severe systemic toxicity.
- Unrelenting intense pain out of proportion to cutaneous findings.
- Pain progresses to cutaneous anesthesia as disease evolves. Anesthesia of the skin develops as a result of infarction of cutaneous nerves.[2]

FIGURE 122-3 Saltwater variant of necrotizing fasciitis due to *Vibrio vulnificus*. Note the bullae and dusky skin. This case was fatal. (*Courtesy of Donna Nguyen, MD.*)

FIGURE 122-4 Necrotizing fasciitis with violaceous color of the skin on the affected skin above the C-section. (*Courtesy of Michael Babcock, MD.*)

FIGURE 122-5 Necrotizing fasciitis that started when patient stepped on a nail. A large flaccid bulla is visible along with swelling and erythema. A rapid below the knee amputation allowed this patient to survive. (*Subramaniam R, Shirley OB. Oozing puncture wound on foot. J Fam Pract. 2009 Jan;58(1):37-39.*

- Crepitus occurs when there is gas in the soft tissues.
- Unresponsive to empiric antimicrobial therapy.

TYPICAL DISTRIBUTION

- May occur at any anatomic location.
- Majority of cases occur on the lower extremities (**Figures 122-5** and **122-7**) but can occur on the upper extremities.
- Also common on abdominal wall (**Figure 122-4**) and in perineum (Fournier gangrene).

LABORATORY AND IMAGING

- Routine laboratory tests are nonspecific but common findings include an elevated white blood cell count (WBC), a low serum sodium, and a high blood urea nitrogen (BUN).
- Histology and culture of deep tissue biopsy are essential; surface cultures cannot be relied on alone. Gram staining of the exudate may provide clues about the pathogens while the physician awaits culture results.[2]
- Standard radiographs are of little value unless air is demonstrated in the tissues (**Figure 122-2**).
- Radiography, CT, ultrasonography, and MRI can be used to detect gas within soft tissues or muscles.[2]
- Although imaging may help delineate the extent of disease, it should not delay surgical consultation.

BIOPSY

- Gross examination reveals swollen, dull, gray fascia with stringy areas of necrosis.[6]
- Necrosis of superficial fascia and fat produces watery, foul-smelling "dishwater pus."[2]
- Histology demonstrates subcutaneous fat necrosis, vasculitis, and local hemorrhage.[2]

DIFFERENTIAL DIAGNOSIS

- Cellulitis—Acute spreading infection of skin and soft tissues characterized by erythema, edema, pain, and calor. Rapid progression of disease despite antibiotics, systemic toxicity, intense pain, and skin necrosis suggest NF rather than cellulitis (see Chapter 120, Cellulitis).
- Pyomyositis—Suppuration within individual skeletal muscle groups. Synergistic necrotizing cellulitis is a NSTI that involves muscle groups in addition to superficial tissues and fascia.[7] Although pyomyositis may occur with NF, it can occur independent of cutaneous and soft-tissue infections. Imaging of the muscle confirms the diagnosis.
- Clostridial myonecrosis—Acute necrotizing infection of muscle tissue caused by clostridial organisms. Surgical exploration and cultures are required to differentiate from NF.
- Erythema induratum—Tender, erythematous subcutaneous nodules occurring on the lower legs (especially the calves). Lack of fever, systemic toxicity, and skin necrosis suggest erythema

FIGURE 122-6 Necrotizing fasciitis with gangrene. Even with a radical hemipelvectomy this patient did not survive. (*Courtesy of Fred Bongard, MD.*)

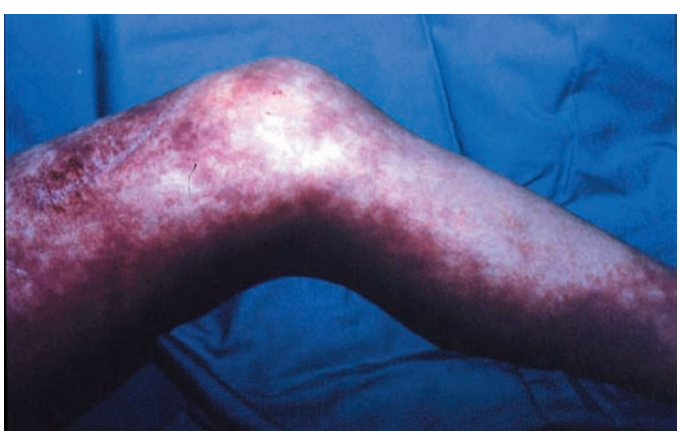

FIGURE 122-7 Necrotizing fasciitis with violaceous color of the skin on the affected leg. (*Courtesy of Fred Bongard, MD.*)

induratum rather than NF. Lesions of erythema induratum may have a chronic, recurrent course and the patient frequently has a history of tuberculosis or a positive purified protein derivative (PPD) test.

- Streptococcal or staphylococcal toxic shock syndrome—Systemic inflammatory response to a toxin-producing bacteria characterized by fever, hypotension, generalized erythroderma, myalgia, and multisystem organ involvement. NF may occur as part of the toxic shock syndrome.

MANAGEMENT

Start by maintaining a high index of suspicion for NF. If the first debridement occurs within 24 hours from the onset of symptoms, there is a significantly improved chance of survival.[8]

- Surgical debridement is the primary therapeutic modality.[2,3,5,7–10] SOR A
  - Extensive, definitive debridement should be the goal with the first surgery. This may require amputation of an extremity to control the disease. Surgical debridement is repeated until all infected devitalized tissue is removed.
- Antibiotics are the main adjunctive therapy to surgery. Broad-spectrum empiric antibiotics should be started immediately when NF is suspected and should include coverage of Gram-positive, Gram-negative, and anaerobic organisms.[7] SOR A
  - Antimicrobial therapy must be directed at the known or suspected pathogens and used in appropriate doses until repeated operative procedures are no longer needed, the patient has demonstrated obvious clinical improvement, and fever has been absent for 48 to 72 hours.[7] SOR A
  - Ampicillin is useful for coverage of susceptible enteric aerobic organisms, such as *E. coli*, as well as for Gram-positive organisms, such as *Peptostreptococcus* species, group B, C, or G streptococci, and some anaerobes.[7] SOR A
  - Clindamycin is useful for coverage of anaerobes and aerobic Gram-positive cocci, including most *S. aureus* serogroups.
  - Clindamycin should be considered in initial coverage for its effects on exotoxin production in group A *Streptococcus* (GAS) infections. NF and/or streptococcal toxic shock syndrome caused by group A streptococci should be treated with clindamycin and penicillin.[7] SOR A
    - The rationale for clindamycin is based on in vitro studies demonstrating both toxin suppression and modulation of cytokine (i.e., TNF) production, on animal studies demonstrating superior efficacy versus that of penicillin, and on two observational studies demonstrating greater efficacy for clindamycin than for β-lactam antibiotics.[7] SOR A
  - Metronidazole has the greatest anaerobic spectrum against the enteric Gram-negative anaerobes, but it is less effective against the Gram-positive anaerobic cocci. Gentamicin or a fluorinated quinolone, ticarcillin-clavulanate, or piperacillin-sulbactam is useful for coverage against resistant Gram-negative rods.[7]
  - The best choice of antibiotics for community-acquired mixed infections is a combination of ampicillin-sulbactam plus clindamycin plus ciprofloxacin.[7] SOR A

- Another commonly used combination is a continuous infusion of penicillin G in combination with clindamycin and an aminoglycoside if renal function permits.[10]
- Empiric vancomycin should be considered during pending culture results to cover for the increasing incidence of community-acquired methicillin-resistant *Staphylococcus aureus* (MRSA).[5,7]
- One preferred antimicrobial therapy for *V. vulnificus* is doxycycline in combination with ceftazidime and surgery for NSTI.[6]
- Hyperbaric oxygen (HBO_2) may have beneficial effects when used postoperatively in NSTIs. One recent study demonstrated decreased morbidity (amputations 50% vs. 0%) and mortality (34% vs. 11.9%) with the use of postoperative HBO_2.[11] SOR B

- Aggressive fluid resuscitation is often necessary because of massive capillary leak syndrome. Supplemental enteral nutrition is often necessary for patients with NSTIs.
- Vacuum-assisted closure devices may be helpful in secondary wound management after debridement of NSTIs.[10]
- A recommendation to use intravenous gammaglobulin (IVIG) to treat NF or toxic shock syndrome cannot be made with certainty.[7] SOR B

PROGNOSIS AND FOLLOW-UP

- Overall case fatality rate remains 20% to 47% despite aggressive, modern therapy.[5,6]
  - However, in a retrospective chart review of patients with NSTIs treated at six academic hospitals in Texas between 2004 and 2007 mortality rates varied between hospitals from 9% to 25% (n = 296).[12]
- Early diagnosis and treatment can reduce case fatality rate to 12%.[5]
- Carrying out the first fasciotomy and radical debridement within 24 hours of symptom onset is associated with significantly improved survival.[8]

PATIENT EDUCATION

The serious life-threatening nature of NF should be explained to the patient and family when informed consent is given prior to surgery. The risk of losing life and limb should be explained while giving hope for recovery. For those patients who survive but have lost a limb, counseling should be offered to help them deal with the psychological effects of the amputation.

PATIENT RESOURCES

- **http://www.cdc.gov/ncidod/dbmd/diseaseinfo/groupastreptococcal_g.htm.**
- **http://www.pamf.org/health/healthinfo/index.cfm?A=C&hwid=hw140405.**

PROVIDER RESOURCES

- Practice Guidelines for the Diagnosis and Management of Skin and Soft-Tissue Infections—**http://cid.oxfordjournals.org/content/41/10/1373.full#sec-6.**

REFERENCES

1. Dufel S, Martino M. Simple cellulitis or a more serious infection? *J Fam Pract.* 2006;55:396-400.
2. Usatine RP, Sandy N. Dermatologic emergencies. *Am Fam Physician.* 2010;82:773-780.
3. Koukouras D, Kallidonis P, Panagopoulos C, et al. Fournier's gangrene, a urologic and surgical emergency: presentation of a multi-institutional experience with 45 cases. *Urol Int.* 2011;86:167-172.
4. Trent JT, Kirsner RS. Diagnosing necrotizing fasciitis. *Adv Skin Wound Care.* 2002;15:135-138.
5. Cheng NC, Chang SC, Kuo YS, et al. Necrotizing fasciitis caused by methicillin-resistant *Staphylococcus aureus* resulting in death. A report of three cases. *J Bone Joint Surg Am.* 2006;88:1107-1110.
6. Horseman MA, Surani S. A comprehensive review of *Vibrio vulnificus*: an important cause of severe sepsis and skin and soft-tissue infection. *Int J Infect Dis.* 2011;15:e157-e166.
7. Stevens DL, Bisno AL, Chambers HF, et al. Practice guidelines for the diagnosis and management of skin and soft-tissue infections. *Clin Infect Dis.* 2005;41:1373-1406.
8. Cheung JP, Fung B, Tang WM, Ip WY. A review of necrotising fasciitis in the extremities. *Hong Kong Med J.* 2009;15:44-52.
9. Angoules AG, Kontakis G, Drakoulakis E, et al. Necrotising fasciitis of upper and lower limb: a systematic review. *Injury.* 2007;38 Suppl 5:S19-S26.
10. Endorf FW, Cancio LC, Klein MB. Necrotizing soft-tissue infections: clinical guidelines. *J Burn Care Res.* 2009;30:769-775.
11. Escobar SJ, Slade JB Jr, Hunt TK, Cianci P. Adjuvant hyperbaric oxygen therapy (HBO2) for treatment of necrotizing fasciitis reduces mortality and amputation rate. *Undersea Hyperb Med.* 2005;32:437-443.
12. Kao LS, Lew DF, Arab SN, et al. Local variations in the epidemiology, microbiology, and outcome of necrotizing soft-tissue infections: a multicenter study. *Am J Surg.* 2011;202:139-145.

SECTION 4 VIRAL

123 CHICKENPOX

E.J. Mayeaux, Jr., MD

PATIENT STORY

A 12-year-old girl presents with a 3-day history of a body-wide pruritic vesicular rash (**Figure 123-1**). The episode started 24 hours before the rash with fever and malaise. The patient is diagnosed with varicella and no antiviral medications are given. Acetaminophen or ibuprofen are recommended for fever and comfort.

INTRODUCTION

Chickenpox is a highly contagious viral infection that can become reactivated in the form of zoster.

EPIDEMIOLOGY

- Varicella-zoster virus (VZV) is distributed worldwide.
- The rate of secondary household attack is more than 90% in susceptible individuals (**Figure 123-2**).[1]
- Adults and immunocompromised patients generally develop more severe disease than normal children.
- Traditionally, primary infection with VZV occurred during childhood (**Figure 123-3**). In childhood, it is usually a benign, self-limited illness in immunocompetent hosts. It occurs throughout the year in temperate regions, but the incidence peaks in the late spring and summer months.
- Prior to the introduction of the varicella vaccine in 1995, the yearly incidence of chickenpox in the United States was approximately 4 million cases with approximately 11,000 hospital admissions and 100 deaths.[2]
- As the vaccination rates steadily increased in the United States, there has been a corresponding 4-fold decrease in the number of cases of chickenpox cases down to disease rates of from 0.3 to 1.0 per 1000 population in 2001.[2]

ETIOLOGY AND PATHOPHYSIOLOGY

- Chickenpox is caused by a primary infection with the VZV, which is a double-stranded, linear DNA herpesvirus.
- Transmission occurs via contact with aerosolized droplets from nasopharyngeal secretions or by direct cutaneous contact with vesicle fluid from skin lesions.

FIGURE 123-1 Chickenpox in a child. Note lesions in various stages (papules, intact vesicles, pustules, and crusted papules) caused by multiple crops of lesions. The vesicles are on a red base. (*Courtesy of Richard P. Usatine, MD.*)

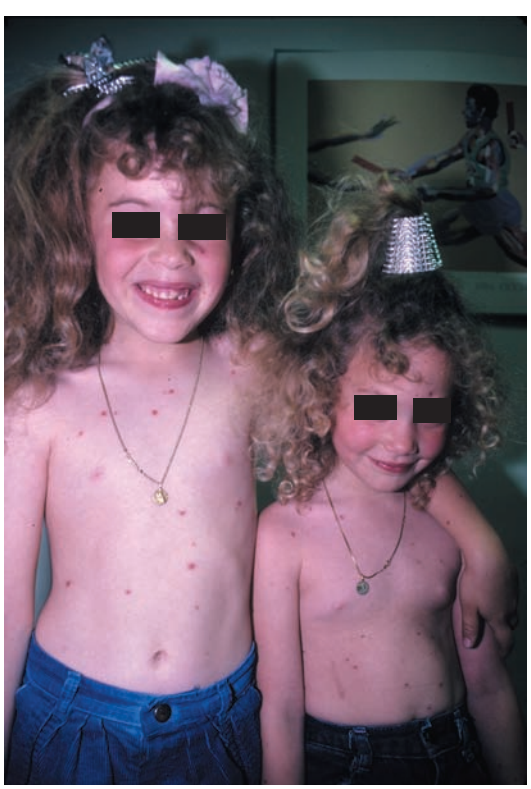

FIGURE 123-2 Chickenpox in sisters seen before the varicella vaccine was available. The girls are feeling better now that the disease is resolving. (*Courtesy of Richard P. Usatine, MD.*)

- The incubation period for VZV is approximately 15 days, during which the virus undergoes replication in regional lymph nodes, followed by two viremic phases, the second of which persists through the development of skin lesions generally by day 14.[3]
- The vesicular rash appears in crops for several days. The lesions start as vesicle on a red base, which is classically described as a dewdrop on a rose petal (**Figure 123-4**). The lesions gradually develop a pustular component (**Figure 123-5**) followed by the evolution of crusted papules (**Figure 123-6**). The period of infectivity is generally considered to last from 48 hours prior to the onset of rash until skin lesions have fully crusted.
- The most frequent complication in healthy children is bacterial skin superinfection (**Figure 123-7**). Less-common skin complications (seen more frequently in immunosuppressed hosts) include bullous varicella, purpura fulminans, and necrotizing fasciitis.
- Encephalitis is a serious potential complication of chickenpox that develops toward the end of the first week of the exanthema. One form, acute cerebellar ataxia, occurs mostly in children and is generally followed by complete recovery. A more diffuse encephalitis most often occurs in adults and may produce delirium, seizures, and focal neurologic signs. It has significant rates of long-term neurologic sequelae and death.
- Pneumonia is rare in healthy children but accounts for the majority of hospitalizations in adults, where it has up to a 30% mortality rate.[4] It usually develops insidiously within a few days after the rash has appeared with progressive tachypnea, dyspnea, and dry cough. Chest X-rays reveal diffuse bilateral infiltrates. Treat with prompt administration of intravenous acyclovir. The use of adjunctive steroid therapy is controversial.
- Varicella hepatitis is rare, and typically only occurs in immunosuppressed individuals. It is frequently fatal.
- Reactivation of latent VZV results in herpes zoster or shingles.

FIGURE 123-3 Chickenpox in a child. Note the widespread distribution of the lesions. The honey-crusted lesion on the eyebrow suggests a secondary bacterial infection (impetigo). (*Courtesy of Richard P. Usatine, MD.*)

DIAGNOSIS

CLINICAL FEATURES

- The typical clinical manifestations of chickenpox include a prodrome of fever, malaise, or pharyngitis, followed in 24 hours by the development of a generalized vesicular rash.
- The lesions are pruritic and appear as successive crops of vesicles more than 3 to 4 days.
- Coexisting lesions in different stages of development on the face, trunk, and extremities are common (**Figure 123-8**).
- New lesions stop forming in approximately 4 days, and most lesions have fully crusted by 7 days.

TYPICAL DISTRIBUTION

- Bodywide—No laboratory tests are needed unless the diagnosis is uncertain. For children or adults in which there is uncertainty about previous disease and it is important to establish a quick diagnosis, a direct fluorescent antibody test can be done on a scraping of a lesion. In many laboratories, a result can be obtained within 24 hours (**Figure 123-9**).

FIGURE 123-4 Dewdrop on a rose petal is the classic description of a varicella vesicle on a red base. (*Courtesy of Richard P. Usatine, MD.*)

LABORATORY TESTING

- Diagnosis is usually based on classic presentation. Culture of vesicular fluid provides a definitive diagnosis, but is positive in less than 40% of cases. Direct immunofluorescence has good sensitivity and is more rapid than tissue culture. Latex agglutination blood testing may be used to determine exposure and immunity to VZV.

DIFFERENTIAL DIAGNOSIS

- Pemphigus and bullous pemphigoid are usually seen in adults, whereas varicella is a disease of children.
- Dermatitis herpetiformis is characterized by pruritic papulovesicles over the extremities and on the trunk, and granular immunoglobulin (Ig) A deposits on the basement membrane (see Chapter 186, Other Bullous Disease).
- Herpes simplex infection presents with similar lesions, but is generally restricted to the genital and oral areas. The vesicles of herpes simplex tend to be more clustered in a group rather than the wide distribution of varicella (see Chapter 129, Herpes Simplex).
- Impetigo can have bullous or crusted lesions anywhere on the body. The lesions often have mild erythema and a yellowish color to the crusts (see Chapter 116, Impetigo).
- Insect bites are often suspected by history and can occur on the entire body.

MANAGEMENT

NONPHARMACOLOGIC

- Pruritus can be treated with calamine lotion, pramoxine gel, or powdered oatmeal baths.
- Fingernails should be closely cropped to avoid significant excoriation and secondary bacterial infection.

MEDICATIONS

- Antihistamines are helpful in the symptomatic treatment of pruritus.
- Acetaminophen should be used to treat fever in children, as aspirin use is associated with Reye syndrome in the setting of viral infections.[5] SOR A
- Superinfection may be treated with topical or oral antibiotics.
- Prophylactic use of varicella zoster immune globulin (125 U/10 kg, up to 625 U IM) in recently exposed susceptible individuals can prevent or attenuate the disease. However, the immune globulin is extremely hard to obtain at times.[6]
- Acyclovir (20 mg/kg PO 4 times daily) is U.S. Food and Drug Administration approved for treatment of varicella in healthy children. It should be given during the first 24 hours of rash.[1] However, the Committee on Infectious Disease of the American Academy of Pediatrics issued a statement saying they did not consider the routine administration of acyclovir to all healthy children with varicella to be justified.[7] SOR C
- For adults, acyclovir 20 mg/kg PO 4 times daily (800 mg maximum) for 5 days may be used for treatment if started in the first 24 hours of the rash.[6] SOR A

FIGURE 123-5 Pustules and crusted lesions on the face of a homeless man with varicella. Note how varicella has lesions simultaneously visible at different stages. (*Courtesy of Richard P. Usatine, MD.*)

FIGURE 123-6 Varicella on the leg of an infant after the lesions have crusted over. The patient is probably not contagious at this time. (*Courtesy of the University of Texas Health Sciences Center, Division of Dermatology.*)

- Early treatment with intravenous acyclovir may be effective for treatment of varicella hepatitis and pneumonia, and may also be useful in the treatment of immunosuppressed patients. SOR B
- Adults who get varicella should be assessed for neurologic and pulmonary disease.

PREVENTION

- Varicella immunization (Varivax) can be used to prevent chickenpox. SOR A It is contraindicated in individuals allergic to gelatin or neomycin and in immunosuppressed individuals (it is a live vaccine). In 2006, and again in 2010, the Advisory Committee on Immunization Practices recommended that all children younger than 13 years of age should be routinely administered 2 doses of varicella-containing vaccine, with the first dose administered at 12 to 15 months of age and the second dose at 4 to 6 years of age (i.e., before first grade). The second dose can be administered at an earlier age provided the interval between the first and second dose is at least 3 months.[8]

FOLLOW-UP

- Follow-up is unnecessary for immunocompetent children and adults who are having no complications. All patients or parents should report any respiratory or neurologic problems immediately.

PATIENT EDUCATION

- Avoid scratching the blisters and keep fingernails short. Scratching may lead to superinfection.
- Calamine lotion and oatmeal (Aveeno) baths may help relieve itching.
- Do not use aspirin or aspirin-containing products to relieve fever. The use of aspirin is associated with development of Reye syndrome, which may cause death.

PATIENT RESOURCES

- KidsHealth. *Chickenpox*—**http://www.kidshealth.org/parent/infections/skin/chicken_pox.html.**
- MedlinePlus. *Chickenpox*—**http://www.nlm.nih.gov/medlineplus/chickenpox.html.**

PROVIDER RESOURCES

- Centers for Disease Control and Prevention. *Varicella (Chickenpox) Vaccination*—**http://www.cdc.gov/vaccines/vpd-vac/varicella/default.htm.**
- Centers for Disease Control and Prevention. *Slide Set: Overview of VZV Disease & Vaccination for Healthcare Professionals*—**http://www.cdc.gov/vaccines/vpd-vac/shingles/downloads/VZV_clinical_slideset_Jul2010.ppt.**

FIGURE 123-7 Honey-crusted lesions of superinfected varicella. This is impetiginized chickenpox caused by a secondary bacterial infection (impetigo). (*Courtesy of Richard P. Usatine, MD.*)

FIGURE 123-8 Varicella on the trunk of a nonimmunized man demonstrating the simultaneous appearance of papules, pustules and crusted lesions. (*Courtesy of Richard P. Usatine, MD.*)

REFERENCES

1. Wharton M. The epidemiology of varicella-zoster infections. *Infect Dis Clin North Am.* 1996;10(3):571-581.
2. Centers for Disease Control and Prevention (CDC). Decline in annual incidence of varicella—selected states, 1990-2001. *MMWR Morb Mortal Wkly Rep.* 2003;52(37):884-885.
3. Grose C. Variation on a theme by Fenner: the pathogenesis of chickenpox. *Pediatrics.* 1981;68(5):735-737.
4. Schlossberg D, Littman M. Varicella pneumonia. *Arch Intern Med.* 1988;148(7):1630-1632.
5. Belay ED, Bresee JS, Holman RC, et al. Reye's syndrome in the United States from 1981 through 1997. *N Engl J Med.* 1999; 340(18):1377-1382.
6. Ogilvie MM. Antiviral prophylaxis and treatment in chickenpox. A review prepared for the UK advisory group on chickenpox on behalf of the british society for the study of infection. *J Infect.* 1998;36 Suppl 1:31-38.
7. Prevention of varicella: recommendations of the Advisory Committee on Immunization Practices (ACIP). Centers for Disease Control and Prevention. *MMWR Morb Mortal Wkly Rep.* 1996; 45(RR-11):1-36.
8. CDC Varicella Vaccination: Information for Health Care Providers-Routine Varicella Vaccination. http://www.cdc.gov/vaccines/vpd-vac/varicella/hcp-routine-vacc.htm. Accessed August 5, 2012.

FIGURE 123-9 A 29-year-old woman with mild case of varicella. Her previous history of varicella in childhood was uncertain so a direct scraping of a lesion was performed and the varicella virus was identified quickly with a direct fluorescent antibody test. (*Courtesy of Richard P. Usatine, MD.*)

124 ZOSTER

E.J. Mayeaux, Jr., MD
Richard P. Usatine, MD

PATIENT STORY

A 14-year-old boy presents with deep burning pain and a vesicular eruption in a band starting at the left chest and ending just across the midline of the back (**Figure 124-1**). The varicella-zoster virus (VZV) leaves the dorsal root ganglion to travel down the spinal nerves to the cutaneous nerves of the skin. The vesicles do cross the midline by a few centimeters because the posterior primary ramus of the spinal nerve includes a small cutaneous medial branch that reaches across the midline.[1] The boy was treated with analgesics and an antiviral medication. The zoster healed with scarring.

FIGURE 124-1 A 14-year-old boy with severe case of herpes zoster in a thoracic distribution. (*Courtesy of Richard P. Usatine, MD.*)

INTRODUCTION

Herpes zoster (shingles) is a syndrome characterized by a painful, usually unilateral vesicular eruption that develops in a restricted dermatomal distribution (**Figures 124-1** and **124-2**).[2,3]

SYNONYMS

Shingles.

EPIDEMIOLOGY

- According to the Centers for Disease Control and Prevention (CDC), 32% of persons in the United States will experience zoster during their lifetimes accounting for about 1 million cases annually.[4] Older age groups account for the highest incidence of zoster. Approximately 4% of patients will experience a second episode of herpes zoster.[5]
- More zoster cases have been observed among women, even when controlling for age.[6]
- Herpes zoster occurs more frequently and more severely in immunosuppressed patients, including transplantation patients.

ETIOLOGY AND PATHOPHYSIOLOGY

- After primary infection with either chickenpox or vaccine-type VZV, a latent infection is established in the sensory dorsal root ganglia. Reactivation of this latent VZV infection results in herpes zoster (shingles).
- Both sensory ganglia neurons and satellite cells surrounding the neurons serve as sites of VZV latent infection. During latency, the virus only expresses a small number of viral proteins.

FIGURE 124-2 Close-up of herpes zoster lesions. Note grouped vesicles on a red base. (*Courtesy of Richard P. Usatine, MD.*)

- How the virus emerges from latency is not clearly understood. Once reactivated, virus spreads to other cells within the ganglion. The dermatomal distribution of the rash corresponds to the sensory fields of the infected neurons within the specific ganglion.[3]
- Loss of VZV-specific cell-mediated immune response is responsible for reactivation.[3]
- The pain associated with zoster infections and postherpetic neuralgia (PHN) is thought to result from injury to the peripheral nerves and altered central nervous system processing.
- The most common complications are PHN and bacterial superinfection that can delay healing and cause scarring of the zoster lesions.
- Approximately 19% of patients develop complications that may include:[7]
  - PHN—The most common complication is seen in 10% at 90 days[7] (see below).
  - Ocular complications, including uveitis and keratitis (seen in 4%)[7] (see Chapter 125, Zoster Ophthalmicus).
  - Bell palsy and other motor nerve plastic (seen in 3%).[7]
  - Bacterial skin infection (seen in 2%).[7]
  - Meningitis caused by central extension of the infection.
  - Herpes zoster oticus (Ramsay Hunt syndrome) (**Figure 124-3**) includes the triad of ipsilateral facial paralysis, ear pain, and vesicles in the auditory canal and auricle.[8] Disturbances in taste perception, hearing (tinnitus, hyperacusis), lacrimation, and vestibular function (vertigo) may occur.
  - Other rare complications may include acute retinal necrosis, transverse myelitis, encephalitis, leukoencephalitis, contralateral thrombotic stroke syndrome, and granulomatous vasculitis.[9]
- Immunosuppressed patients are at increased risk for complications, including severe complications such as broader dermatomal involvement (**Figure 124-4**), disseminated infection, visceral involvement, pneumonitis, and/or meningoencephalitis.
- PHN is the persistence of pain, numbness, and/or dysesthesias precipitated by movement or in response to nonnoxious stimuli in the affected dermatome for more than 1 month after the onset of zoster. The incidence of PHN in the general population is 1.38 per 1000 person-years, and it occurs more commonly in individuals older than age 60 years and in immunosuppressed individuals.[3]
- In a large study, rates of zoster-associated pain (PHN) persisting at least 90 days were:
  - Ten percent overall; 12% in women and 7% in men.
  - Ages 22 to 59 years—Five percent overall; 6% in women and 5% in men.
  - Ages 60 to 69 years—Ten percent overall; 14% in women and 5% in men.
  - Ages 70 to 79 years—Seventeen percent overall; 18% in women and 15% in men.
  - Age 80 years and older—Twenty percent overall; 23% in women and 13% in men.[7]

RISK FACTORS

ZOSTER[3]

- Older age.
- Underlying malignancy.

FIGURE 124-3 Herpes zoster oticus (Ramsay Hunt syndrome) with the classic presentation of vesicles on the auricle. (*Courtesy of the University of Texas Health Sciences Center, Division of Dermatology.*)

FIGURE 124-4 Herpes zoster in a 4-year-old boy with HIV disease. Note multiple dermatomes are involved. (*Courtesy of Richard P. Usatine, MD.*)

- Disorders of cell-mediated immunity.
- Chronic lung or kidney disease.
- Autoimmune disease.

PHN

- Age older than 60 years.
- Negative vaccine status.

DIAGNOSIS

CLINICAL FEATURES

- A deep burning pain and sometimes redness in a dermatomal pattern is the most common first symptom and can precede the rash by days to weeks (**Figure 124-5**). A prodrome of fever, dysesthesias, malaise, and headache leads in several days to a dermatomal vesicular eruption. The rash starts as grouped vesicles or bullae which evolve into pustular or hemorrhagic lesions within 3 to 4 days (**Figures 124-1** to **124-8**). The lesions typically crust in approximately a week, with complete resolution within 3 to 4 weeks.[5]

TYPICAL DISTRIBUTION

- Generally limited to one dermatome in immunocompetent patients, but sometimes affects neighboring dermatomes. Rarely, a few scattered vesicles located away from the involved dermatome as a result of release of VZV from the infected ganglion into the bloodstream.[3] If there are more than 20 lesions distributed outside the dermatome affected, the patient has disseminated zoster. The thoracic and lumbar dermatomes are the most commonly involved. Occasionally zoster will be seen on the extremities (**Figure 124-6**).

LABORATORY TESTING

- Meningitis associated with VZV infection can be diagnosed by cerebrospinal fluid showing pleocytosis.

DIFFERENTIAL DIAGNOSIS

- Pemphigus and other bullous diseases present with blisters, but not the classic dermatomal distribution (see Chapters 183, Overview of Bullous Disease and 185, Pemphigus).
- Molluscum contagiosum presents with white or yellow flat topped papules with central umbilication caused by a pox virus. The lesions are more firm and unless irritated do not have a red base as seen with zoster (see Chapter 130, Molluscum Contagiosum).
- Scabies may present as a pustular rash that is not confined to dermatomes and usually has characteristic lesions in the webs of the fingers (see Chapter 143, Scabies).
- Insect bites are often suspected by history and can occur over the entire body.

FIGURE 124-5 Herpes in the axilla of a young women. Notice the redness in the dermatome that has started producing blisters. (*Courtesy of Richard P. Usatine, MD.*)

FIGURE 124-6 Herpes zoster on the arm that follows a dermatomal pattern. (*Courtesy of E.J. Mayeaux, Jr., MD.*)

FIGURE 124-7 Herpes zoster of the C4-C5 dermatomal distribution. (*Courtesy of Richard P. Usatine, MD.*)

- Folliculitis presents with characteristic pustules arising from hair shafts (see Chapter 117, Folliculitis).
- Zoster mimics coronary artery disease when it presents with chest pain before the vesicles are visible.
- Herpes simplex infection presents with similar lesions but is usually restricted to the perioral region, genital area, buttocks, and fingers (see Chapter 129, Herpes Simplex).

FIGURE 124-8 Herpes zoster in the thoracic distribution in an African child. (*Courtesy of Richard P. Usatine, MD.*)

MANAGEMENT

NONPHARMACOLOGIC

- Calamine lotion and topically administered lidocaine may be used to reduce pain and itching. SOR C

MEDICATIONS

- The objectives of treatment of herpes zoster include (a) hastening the resolution of the acute viral infection, (b) treatment of the associated pain, and (c) prevention of PHN.
- Antiviral agents used in the treatment of herpes zoster include acyclovir (Zovirax), famciclovir (Famvir), and valacyclovir (Valtrex), all started within 72 hours of the onset of the rash (**Table 124-1**).[10] SOR A
- Adding corticosteroids to acyclovir therapy may accelerate times to crusting and healing, return to uninterrupted sleep, resumption of full activity, and discontinuation of analgesic. Data is lacking for combining corticosteroids with other antivirals.
- Pain can be managed with nonprescription analgesics or narcotics. Pain should be treated aggressively. This may actually prevent or lessen the severity of PHN. Narcotic analgesics with hydrocodone are appropriate when needed. SOR C
- Treatment of herpes zoster with steroids does not reduce the prevalence of PHN.
- Treatment of herpes zoster early with valacyclovir, famciclovir, or amitriptyline does reduce pain of PHN at 6 months.
- Treatment of PHN includes tricyclic antidepressants, gabapentin (Neurontin), pregabalin (Lyrica), and/or opioid analgesics (**Table 124-2**).

TABLE 124-1 Treatments for Herpes Zoster

Medication	Dosage
Acyclovir (Zovirax)	800 mg orally 5 times daily for 7 to 10 days or 10 mg/kg intravenously every 8 hours for 7 to 10 days
Famciclovir (Famvir)	500 mg orally 3 times daily for 7 days
Valacyclovir (Valtrex)	1000 mg orally 3 times daily for 7 days
Prednisone (Deltasone)	30 mg orally twice daily for 1 week followed by a tapering dose for approximately 2 weeks

PREVENTION

- Use of varicella (chickenpox) vaccine has not led to an increase in vaccine-associated herpes zoster in immunized patients or in the general population, and has led to an overall decrease in herpes zoster.[8]
- The herpes zoster vaccine contains a much higher dose of the live-attenuated virus than the varicella vaccine. In adults 60 years of age or older, immunization reduces the incidence of herpes zoster by 51% compared with placebo.[3] In those who do develop zoster, the duration of pain and discomfort is shorter and the incidence of PHN is greatly reduced. It reduces the incidence of PHN from 1.38 to 0.46 per 1000 person-years.[3]

TABLE 124-2 Effective Treatments for Postherpetic Neuralgia

Treatment	Benefit/Risk	Risks	NNT for ≥50% Pain Reduction	Dose/Duration
Lidocaine patch 5%	Reduces pain and acts as mechanical barrier	Application site sensitivity	2	Apply up to 3 patches for up to 12 hours
Tricyclic antidepressants (including amitriptyline) (strongest evidence)	Reduce pain, better sleep, decreases anxiety and depression	Multiple side effects, including sedation and dry mouth	2.7	25 to 150 mg qhs
Gabapentin (Neurontin) (strongest evidence)	Reduces pain, improves sleep, mood, and quality of life	Somnolence, dizziness, decreased memory	2.8–5.3	300 to 600 mg tid (can go as high as 1200 mg tid)
Pregabalin (Lyrica)	May reduce pain	Peripheral edema and weight gain	5	75 mg bid
Opioids (morphine, oxycodone, methadone)	Reduce pain	Somnolence, constipation, tolerance	Variable	Start low and titrate to effective dose
Tramadol	Reduces pain and is not a true narcotic	Dizziness, nausea, somnolence, constipation	4.8	50 to 100 mg qid

Abbreviation: NNT, number needed to treat.
Adapted from Garroway N, Chhabra S, Landis S, Skolnik DC. Clinical inquiries: what measures relieve postherpetic neuralgia? J Fam Pract. 2009;58(7):384 and Tyring SK. Management of herpes zoster and postherpetic neuralgia. J Am Acad Dermatol. 2007;57(6 Suppl):S136-142.

FOLLOW-UP

- Follow-up is based on the severity of the case and the immune status of the patient.

PATIENT EDUCATION

- Herpes zoster in an immunocompetent host is only contagious from contact with open lesions.
- Patients with disseminated zoster or with zoster and are immunocompromised should be isolated from nonimmune individuals with primary varicella infection (in which airborne spread is possible).
- Individuals who have not had varicella and are exposed to a patient with herpes zoster are only at risk of developing primary varicella and not herpes zoster.

PATIENT RESOURCES

- Centers for Disease Control and Prevention. *Vaccine Information Statements*—**http://www.cdc.gov/vaccines/pubs/vis/.**
- Medinfo UK. *Shingles (Herpes Zoster)*—**http://www.medinfo.co.uk/conditions/shingles.html.**
- The Skin Site. *Herpes Zoster (Shingles)*—**http://www.skinsite.com/info_herpes_zoster.htm.**
- MedlinePlus. *Shingles*—**http://www.nlm.nih.gov/medlineplus/ency/article/000858.htm.**

PROVIDER RESOURCES

- MedlinePlus. *Shingles*—**http://emedicine.medscape.com/article/218683.**
- Stankus SJ, Dlugopolski M, Packer D. Management of herpes zoster (shingles) and PHN. *Am Fam Physician*. 2000;61[8]:2437-2444—**http://www.aafp.org/afp/20000415/2437.html.**

REFERENCES

1. Usatine RP, Clemente C. Is herpes zoster unilateral? *West J Med*. 1999;170(5):263.
2. Gnann JW Jr, Whitley RJ. Clinical practice. Herpes zoster. *N Engl J Med*. 2002;347(5):340-346.
3. Oxman MN. Immunization to reduce the frequency and severity of herpes zoster and its complications. *Neurology*. 1995; 45(12 Suppl 8):S41-S46.
4. Harpaz R, Ortega-Sanchez IR, Seward JF; Advisory Committee on Immunization Practices (ACIP) Centers for Disease Control and Prevention (CDC). Prevention of herpes zoster: recommendations of the Advisory Committee on Immunization Practices (ACIP). *MMWR Recomm Rep*. 2008;57(RR-5):1-30.
5. Stankus SJ, Dlugopolski M, Packer D. Management of herpes zoster (shingles) and postherpetic neuralgia. *Am Fam Physician*. 2000;61(18):2437-2444, 2447-2448.
6. Opstelten W, Van Essen GA, Schellevis F, et al. Gender as an independent risk factor for herpes zoster: a population-based prospective study. *Ann Epidemiol*. 2006;16(9):692-695.

7. Yawn BP, Saddier P, Wollan PC, et al. A population-based study of the incidence and complication rates of herpes zoster before zoster vaccine introduction. *Mayo Clin Proc.* 2007;82(11):1341-1349.
8. Adour KK. Otological complications of herpes zoster. *Ann Neurol.* 1994;35 Suppl:S62-S64.
9. Arvin AM, Pollard RB, Rasmussen LE, Merigan TC. Cellular and humoral immunity in the pathogenesis of recurrent herpes viral infections in patients with lymphoma. *J Clin Invest.* 1980;65(4):869-878.
10. Tyring SK, Beutner KR, Tucker BA, et al. Antiviral therapy for herpes zoster: randomized, controlled clinical trial of valacyclovir and famciclovir therapy in immunocompetent patients 50 years and older. *Arch Fam Med.* 2000;9(9):863-869.

125 ZOSTER OPHTHALMICUS

E.J. Mayeaux, Jr., MD
Richard P. Usatine, MD

PATIENT STORY

A 44-year-old HIV-positive Hispanic man presented with painful herpes zoster of his right forehead (**Figure 125-1**). He was particularly worried because his right eye was red, painful, and very sensitive to light (**Figure 125-2**). On physical examination there was significant conjunctival injection, corneal punctate epithelial erosions, and clouding, and a small layer of blood in the anterior chamber (hyphema). The pupil was somewhat irregular. Along with the hyphema and ciliary flush, this indicated an anterior uveitis. The patient had a unilateral ptosis on the right side with limitations in elevation, depression, and adduction of the eye secondary to cranial nerve III palsy from the zoster. The patient was immediately referred to ophthalmology and the anterior uveitis, corneal involvement, and cranial nerve III palsy were confirmed. The ophthalmologist started the patient on topical ophthalmic preparations of erythromycin, moxifloxacin, prednisolone, and atropine. Oral acyclovir was also prescribed. Unfortunately, the patient did not return for follow up until 6 months later when he returned to the ophthalmologist with significant corneal scarring (**Figure 125-3**). The patient is currently on a waiting list for a corneal transplantation.

FIGURE 125-1 A 44-year-old HIV-positive Hispanic man with painful herpes zoster of his right forehead.

FIGURE 125-2 Acute zoster ophthalmicus of the same patient with conjunctival injection, corneal punctation (keratitis), and a small layer of blood in the anterior chamber (hyphema). A diagnosis of anterior uveitis was suspected based on the irregularly shaped pupil, the hyphema, and ciliary flush. A slit-lamp examination confirmed the anterior uveitis (iritis).

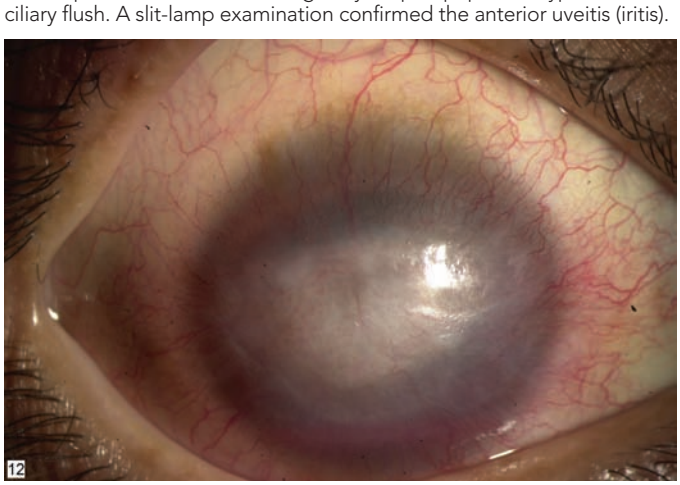

FIGURE 125-3 Corneal scarring and conjunctival injection of the same patient 6 months later after being lost to follow up.

INTRODUCTION

Herpes zoster is a common infection caused by varicella-zoster virus, the same virus that causes chickenpox. Reactivation of the latent virus in neurosensory ganglia produces the characteristic manifestations of herpes zoster (shingles). Herpes zoster outbreaks may be precipitated by aging, poor nutrition, immunocompromised status, physical or emotional stress, and excessive fatigue. Although zoster most commonly involves the thoracic and lumbar dermatomes, reactivation of the latent virus in the trigeminal ganglia may result in herpes zoster ophthalmicus (HZO) (**Figures 125-1** to **125-6**).

SYNONYMS

Ocular herpes zoster.

EPIDEMIOLOGY

- Incidence rates of HZO complicating herpes zoster range from 8% to 56%.[1]
- Ocular involvement is not correlated with age, gender, or severity of disease.

ETIOLOGY AND PATHOPHYSIOLOGY

- Serious sequelae may occur including chronic ocular inflammation, vision loss, and disabling pain. Early diagnosis is important

to prevent progressive corneal involvement and potential loss of vision.[2]

- Because the nasociliary branch of the first (ophthalmic) division of the trigeminal (fifth cranial) nerve innervates the globe (**Figure 125-7**), the most serious ocular involvement develops if this branch is involved.
- Classically, involvement of the side of the tip of the nose (Hutchinson sign) has been thought to be a clinical predictor of ocular involvement via the external nasal nerve (**Figures 125-4** and **125-5**). The Hutchinson sign is a powerful predictor of ocular inflammation and corneal denervation with relative risks of 3.35 and 4.02, respectively. In one study, the manifestation of herpes zoster skin lesions at the dermatomes of both nasociliary branches (at the tip, the side, and the root of the nose) was invariably associated with the development of ocular inflammation.[3]
- Epithelial keratitis is the earliest potential corneal finding (**Figure 125-2**). On slit-lamp examination, it appears as multiple, focal, swollen spots on the cornea that stain with fluorescein dye. They may either resolve or progress to dendrite formation. Herpes zoster virus dendrites form branching or frond-like patterns that have tapered ends and stain with fluorescein dye. These lesions can lead to anterior stromal corneal infiltrates.
- Stromal keratitis occurs in 25% to 30% of patients with HZO, and is characterized by multiple fine granular infiltrates in the anterior corneal stroma. The infiltrates probably arise from antigen–antibody reaction and may be prolonged and recurrent.[4]
- Anterior uveitis evolves to inflammation of the iris and ciliary body and occurs frequently with HZO (**Figure 125-2**). The inflammation is usually mild, but may cause a mild intraocular pressure elevation. The course of disease may be prolonged, especially without timely treatment, and may lead to glaucoma and cataract formation.
- Herpes zoster virus is the most common cause of acute retinal necrosis. Symptoms include blurred vision and/or pain in one or both eyes and signs include peripheral patches of retinal necrosis that rapidly coalesce, occlusive vasculitis, and vitreous inflammation. It commonly causes retinal detachment. Bilateral involvement is observed in one-third of patients, but may be as high as 70% in patients with untreated disease. Treatment includes long courses of oral and intravenous acyclovir (Zovirax), and corticosteroids.[5]
- Varicella-zoster virus is a member of the same family (Herpesviridae) as herpes simplex virus, Epstein-Barr virus, and cytomegalovirus.
- The virus damages the eye and surrounding structures by neural and secondary perineural inflammation of the sensory nerves. This often results in corneal anesthesia.
- Conjunctivitis, usually with *Staphylococcus aureus*, is a common complication of HZO.

RISK FACTORS

- Immunocompromised persons, especially when caused by human immunodeficiency virus infection, have a much higher risk of developing zoster complications, including HZO.

FIGURE 125-4 This 5-year-old girl had herpes zoster involving the ophthalmic branch of the trigeminal nerve. Note the vesicles and bullae on the forehead and eyelid and the crust on the nasal tip (Hutchinson sign). Fortunately, she did not have ocular complications and her case of zoster fully healed with oral acyclovir and acyclovir eye ointment. (*Courtesy of Amor Khachemoune, MD.*)

FIGURE 125-5 Herpes zoster ophthalmicus involving the first and second branch of the trigeminal nerve and the eyelids. There is conjunctival hyperemia and purulent left eye discharge. The nasociliary branch of the ophthalmic branch of the trigeminal nerve is involved, producing the black crusting on the tip of the nose. (*Courtesy of Richard P. Usatine, MD.*)

DIAGNOSIS

CLINICAL FEATURES

- The syndrome usually begins with a prodrome of low-grade fever, headache, and malaise that may start up to 1 week before the rash appears.
- Unilateral pain or hypesthesia in the affected eye, forehead, top of the head, and/or nose may precede or follow the prodrome. The rash starts with erythematous macules along the involved dermatome, then rapidly progresses over several days to papules, vesicles and pustules (**Figures 125-4** to **125-6**). The lesions rupture and typically crust over, requiring several weeks to heal completely.
- With the onset of a vesicular rash along the trigeminal dermatome, hyperemic conjunctivitis, episcleritis, and lid droop (ptosis) can occur (**Figure 125-6**).
- Approximately two-thirds of patients with HZO develop corneal involvement (keratitis).[1] The epithelial keratitis may feature punctate or dendritiform lesions (**Figure 125-2**). Complications of corneal involvement can lead to corneal scarring (**Figure 125-3**).[6]
- Iritis (anterior uveitis) occurs in approximately 40% of patients and can be associated with hyphema and an irregular pupil (**Figure 125-2**).[1]
- Rarely, zoster can be associated with cranial nerve palsies.

FIGURE 125-6 Herpes zoster ophthalmicus causing eyelid swelling and ptosis. Note the positive Hutchinson sign. (*Courtesy of Richard P. Usatine, MD.*)

TYPICAL DISTRIBUTION

- The frontal branch of the first division of the trigeminal nerve (which includes the supraorbital, supratrochlear, and external nasal branch of the anterior ethmoidal nerve) is most frequently involved, and 50% to 72% of patients experience direct eye involvement (**Figure 125-7**).[1]
- Although HZO most often produces a classic dermatomal rash in the trigeminal distribution, a minority of patients may have only cornea findings.

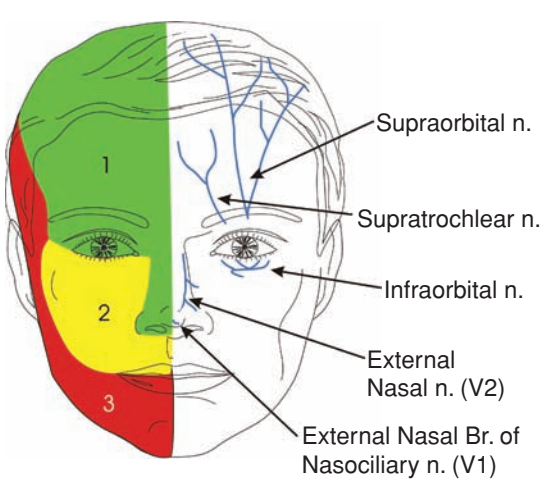

FIGURE 125-7 Diagram demonstrating the sensory distribution of the trigeminal (fifth cranial) nerve, and major peripheral nerves of the first (ophthalmic) division that may be involved with herpes zoster ophthalmicus. The infraorbital nerve from the second division is also shown. (*Courtesy of E.J. Mayeaux, Jr., MD.*)

DIFFERENTIAL DIAGNOSIS

- Bacterial or viral conjunctivitis presents as eye pain and foreign body sensation associated with discharge but no rash (see Chapter 16, Conjunctivitis).
- Trigeminal neuralgia presents with facial pain but without the rash or conjunctival findings.
- Glaucoma that presents as inflammation, pain, and injection, but without the rash or conjunctival findings (see Chapter 19, Glaucoma).
- Traumatic abrasions usually present with a history of trauma and corneal findings but no other zoster findings (see Chapter 15, Corneal Foreign Body and Abrasion).
- Pemphigus and other bullous diseases present with blisters, but not in a dermatomal distribution (see Chapter 183, Overview of Bullous Disease).

MANAGEMENT

MEDICATIONS

- The standard treatment for HZO is to initiate antiviral therapy with acyclovir (800 mg, 5 times daily for 7 to 10 days), valacyclovir (1000 mg 3 times daily for 7 or 14 days), or famciclovir (500 mg orally 3 times a day for 7 days), as soon as possible so as to decrease the incidence of dendritic and stromal keratitis as well as anterior uveitis.[7] SOR A
- Oral acyclovir, valacyclovir, and famciclovir in patients with ophthalmic involvement have comparable outcomes. Treatment is most commonly oral acyclovir but intravenous acyclovir (10 mg/kg 3 times daily for 7 days) may be considered in immunocompromised patients or the rare patient who is extremely ill.[8] SOR A
- Topical steroid ophthalmic drops are applied to the involved eye, after examination by the ophthalmologist, to reduce the inflammatory response and control immune keratitis and iritis.[1,2] SOR B
- The ophthalmologist may prescribe a topical cycloplegic (such as atropine) to treat the ciliary muscle spasm that is painful in iritis. SOR C
- Topical ophthalmic antibiotics may also be prescribed to prevent secondary infection of the eye. SOR C
- As in all cases of zoster, pain should be treated effectively with oral analgesics and other appropriate medications. Early and effective treatment of pain may help to prevent postherpetic neuralgia (see Chapter 124, Zoster).
- Topical anesthetics should never be used with ocular involvement because of their corneal toxicity. SOR B
- Secondary infection, usually *S. aureus*, may develop and should be treated with broad-spectrum topical and/or systemic antibiotics.

REFERRAL OR HOSPITALIZATION

- Referral to an ophthalmologist urgently should be initiated when eye involvement is seen or suspected.
- Hospital admission should be considered for patients with loss of vision, severe symptoms, immunosuppression, involvement of multiple dermatomes, or with significant facial bacterial superinfection.

PREVENTION

- The herpes zoster vaccine reduces the incidence of herpes zoster by 51% compared with placebo.[9] In those who do develop zoster, the duration of pain and discomfort is shorter and the incidence of postherpetic neuralgia (PHN) is greatly reduced. It reduces the incidence of PHN from 1.38 to 0.46 per 1000 person-years.[9]

PROGNOSIS

- HZO can become chronic or relapsing. Recurrence is a characteristic feature of HZO.

- Approximately 50% of patients with HZO develop complications. Systemic antiviral therapy can lower the emergence of complications.[10,11]

FOLLOW-UP

- Early diagnosis is critical to prevent progressive corneal involvement and potential loss of vision. Patients with herpes zoster should be informed that they should present for medical care with any zoster involving the first (ophthalmic) division of the trigeminal nerve or the eye itself.

PATIENT EDUCATION

- Zoster of the eye is a very serious vision-threatening illness that requires strict adherence to medical therapy and close follow-up.
- Viral transmission to nonimmune individuals from patients with herpes zoster can occur, but it is less frequent than with chickenpox. Virus can be transmitted through contact with secretions.

PATIENT RESOURCES

- American Family Physician. *What You Should Know About HZO*—**http://www.aafp.org/afp/2002/1101/p1732.html.**
- EyeMDLink.com. *Eye Herpes (Ocular Herpes)*—**http://www.eyemdlink.com/Condition.asp?ConditionID=223.**

PROVIDER RESOURCES

- Medscape. *Herpes Zoster Ophthalmicus*—**http://emedicine.medscape.com/article/783223.**
- Shaikh S, Ta CN. Evaluation and management of HZO. *Am Fam Physician*. 2002;66[9]:1723-1730—**http://www.aafp.org/afp/20021101/1723.html.**

REFERENCES

1. Pavan-Langston D. Herpes zoster ophthalmicus. *Neurology*. 1995;45(12 Suppl 8):S50-S51.
2. Severson EA, Baratz KH, Hodge DO, Burke JP. Herpes zoster ophthalmicus in Olmsted County, Minnesota: Have systemic antivirals made a difference? *Arch Ophthalmol*. 2003;121(3):386-390.
3. Zaal MJ, Völker-Dieben HJ, D'Amaro J. Prognostic value of Hutchinson's sign in acute herpes zoster ophthalmicus. *Graefes Arch Clin Exp Ophthalmol*. 2003;241(3):187-191.
4. Liesegang TJ. Corneal complications from herpes zoster ophthalmicus. *Ophthalmology*. 1985;92(3):316-324.
5. Liesegang TJ. Herpes zoster ophthalmicus natural history, risk factors, clinical presentation, and morbidity. *Ophthalmology*. 2008;115(2 Suppl):S3-S12.
6. Albrecht Ma. *Clinical Features of Varicella-Zoster Virus Infection: Herpes Zoster*. http://www.uptodate.com/contents/clinical-manifestations-of-varicella-zoster-virus-infection-herpes-zoster. Accessed September 3, 2012.
7. McGill J, Chapman C, Mahakasingam M. Acyclovir therapy in herpes zoster infection. A practical guide. *Trans Ophthalmol Soc U K*. 1983;103(Pt 1):111-114.
8. Gnann JW Jr, Whitley RJ. Clinical practice. Herpes zoster. *N Engl J Med*. 2002;347(5):340-346.
9. Oxman MN. Immunization to reduce the frequency and severity of herpes zoster and its complications. *Neurology*. 1995;45 (12 Suppl 8):S41-S46.
10. Miserocchi E, Waheed NK, Dios E, et al. Visual outcome in herpes simplex virus and varicella zoster virus uveitis: a clinical evaluation and comparison. *Ophthalmology*. 2002;109(8): 1532-1537.
11. Zaal MJ, Volker-Dieben HJ, D'Amaro J. Visual prognosis in immunocompetent patients with herpes zoster ophthalmicus. *Acta Ophthalmol Scand*. 2003;81(3):216-220.

126 MEASLES

E.J. Mayeaux, Jr., MD
Luke M. Baudoin, MD

PATIENT STORY

An 18-month-old boy, who is visiting family in San Antonio with his parents from Central America, presents with a 3-day history of fever, malaise, conjunctivitis, coryza, and cough. He had been exposed to a child with similar symptoms approximately 2 weeks prior. A day before, he developed a maculopapular rash that blanches under pressure (**Figures 126-1** and **126-2**). His shot records are unavailable but his mother states that his last vaccine was before age 1 year. He is diagnosed with measles and supportive care is provided.

INTRODUCTION

Measles is a highly communicable, acute, viral illness that is still one the most serious infectious diseases in human history. Until the introduction of the measles vaccination, it was responsible for millions of deaths worldwide annually. Although the epidemiology of this disease makes eradication a possibility, the ease of transmission and the low percentage of nonimmunized population that is required for disease survival have made eradication of measles extremely difficult.

EPIDEMIOLOGY

- Last major outbreak in the United States was during 1989 to 1990 and prompted a change in immunization policy in 1991, so that all children are to have two measles, mumps, rubella (MMR) vaccines before starting kindergarten.
- This practice interrupted the transmission of indigenous measles in the United States by 1993 and reduced incidence of measles to a historic low (<0.5 cases per 1 million persons) by 1997 to 1999.[1]
- After an all-time low of 34 cases were reported in 2004, the annual incidence began to increase with most cases linked to international travel of inadequately vaccinated Americans to endemic areas. Incomplete vaccination rates facilitate the spread once the virus is imported to the United States causing clusters of periodic outbreaks.[1]
- The worldwide incidence of death from measles was effectively reduced from an estimated 873,000 in 1999 to 164,000 by 2008 with mass vaccination campaigns by the member countries of the World Health Assembly.[2] In 2008, approximately 83% of the world's children received one dose of measles vaccine by their first birthday through routine health services—up from 72% in 2000.[3]

ETIOLOGY AND PATHOPHYSIOLOGY

- Measles is caused by the measles virus, a member of the family paramyxoviridae, genus *Morbillivirus* (hence the name, morbilliform rash).

FIGURE 126-1 Typical measles rash that began on the face and became confluent. (*Courtesy of the University of Texas Health Sciences Center, Division of Dermatology.*)

FIGURE 126-2 The typical measles rash on the trunk. (*Courtesy of the University of Texas Health Sciences Center, Division of Dermatology.*)

- It is highly contagious, transmitted by airborne droplets, and commonly causes outbreaks.
- Classic measles infection starts with the incubation phase that is usually asymptomatic and lasts for 10 to 14 days. It starts after entry of the virus into the respiratory mucosa with local viral replication. The infection then spreads to regional lymphatic tissues, and then throughout the body through the bloodstream.
- The prodrome phase starts with the appearance of systemic symptoms including fever, malaise, anorexia, conjunctivitis, coryza, and cough (**Figure 126-3**). The respiratory symptoms are caused by mucosal inflammation from viral infection of epithelial cells. Patients may develop Koplik spots, which are small whitish, grayish, or bluish papules with erythematous bases that develop on the buccal mucosa usually near the molar teeth (**Figure 126-4**). The prodrome usually lasts for 2 to 3 days.
- The classic measles rash (**Figures 126-1**, **126-2**, and **126-5**) is maculopapular and blanches under pressure. Clinical improvement in symptoms typically ensues within 2 days. Three to 4 days after the rash first appears, it begins to fade to a brownish color, which is followed by fine flaking. The cough may persist for up to 2 weeks.
- Fever persisting beyond the third day of rash suggests a measles-associated complication.
- Immunity after measles infection is thought to be lifelong in most cases. Measles reinfection occasionally occurs, but it is extremely rare.
- Atypical measles is a measles variant that occurs in previously vaccinated persons. Patients develop high fever and headache 7 to 14 days after exposure, and often present with a dry cough and pleuritic chest pain. Two to 3 days later, a rash develops that spreads from the extremities to the trunk. The rash may be vesicular, petechial, purpuric, or urticarial. Patients may develop respiratory distress, peripheral edema, hepatosplenomegaly, paresthesias, or hyperesthesia.
- The measles virus can cause a variety of clinical syndromes, including the classic childhood illness and a less intense form in persons with suboptimal levels of antimeasles antibodies.
- Measles virus infection can also result in more severe illness, including lymphadenopathy, splenomegaly, laryngotracheobronchitis (croup), giant cell pneumonia, and measles inclusion body encephalitis in immunocompromised patients.[2] This form occurs in the very old and young, those with vitamin A deficiency, and in pregnant women.
- Postinfection neurologic syndromes can occur. Postinfectious encephalomyelitis is a demyelinating disease that presents during the recovery phase, and is thought to be caused by a postinfectious autoimmune response.[3] The major manifestations include fever, headache, neck stiffness, ataxia, mental status changes, and seizures. Cerebrospinal fluid (CSF) analysis demonstrates lymphocytosis and elevated proteins. Postinfectious encephalomyelitis has a 10% to 20% mortality rate, and residual neurologic abnormalities are common.[3]
- Subacute sclerosing panencephalitis (SSPE) is a progressive, fatal, neurologic degenerative disease that may represent a persistent infection of the central nervous system with a variant of the virus. It usually occurs in patients younger than 20 years of age and 7 to 10 years after natural measles.[4] Patients develop neurologic

FIGURE 126-3 Measles in an Ethiopian infant during a measles outbreak. The rash is faint but her cough is prominent and subcostal retractions are seen during this cough. She also has rhinorrhea and conjunctivitis. (*Courtesy of Richard P. Usatine, MD.*)

FIGURE 126-4 Koplik spots occur 1 to 2 days before to 1 to 2 days after the cutaneous rash. Their presence is considered to be pathognomonic for measles, and appear as punctate blue-white spots on the bright red background of the oral buccal (cheek) mucosa. (*Courtesy of the Centers for Disease Control and Prevention.*)

symptoms, myoclonus, dementia, and eventually flaccidity or decorticate rigidity.

- Measles in pregnancy is a rare entity in areas that practice vaccination. Premature births may be more common in gravid women with measles, but there is no clear evidence of teratogenicity.[5]

RISK FACTORS

For developing measles:

- Failure to receive immunization.
- Failure to receive second immunization dose.
- Travel to endemic areas.
- Exposure to travelers from endemic areas.

For developing severe measles or for developing complications:

- Immunodeficiency.
- Malnutrition.
- Pregnancy.
- Vitamin A deficiency.
- Age younger than 5 years or older than 20 years.

DIAGNOSIS

Measles is a distinct disease characterized by fever, malaise, conjunctivitis, coryza, cough, rash, and Koplik spots.

CLINICAL FEATURES

Koplik spots appear during the prodrome phase and are pathognomonic for measles infection; they occur approximately 48 hours before the characteristic measles exanthem. The classic blanching rash is usually adequate to make a tentative diagnosis. The most rapid and accurate test to confirm acute measles is a blood test for measles specific immunoglobulin (Ig) M antibodies. By waiting until the third day of the rash, a false-negative IgM result can be avoided.[1]

TYPICAL DISTRIBUTION

The rash begins on the face and spreads centrifugally to involve the neck, trunk, and, finally, the extremities. The lesions may become confluent, especially on the face. This cranial-to-caudal rash progression is characteristic of measles.

DIFFERENTIAL DIAGNOSIS

- Upper respiratory tract infections—The prodrome stage of measles can be confused with a upper respiratory infection (URI) except that significant fever is typically present with measles infection.
- Fordyce spots—Tiny yellow-white granules on the buccal or lip mucosa caused by benign ectopic sebaceous glands that may be mistaken for Koplik spots. Fordyce spots do not have an erythematous base.

FIGURE 126-5 A South American child with a measles exanthem that has spread down the trunk. (*Courtesy of Eric Kraus, MD.*)

- Alternative diagnoses that may be confused with the measles rash include Rocky Mountain spotted fever, infectious mononucleosis, scarlet fever, Kawasaki disease, toxic shock syndrome, dengue fever, and simple drug eruption (see Chapter 203, Cutaneous Drug Reactions).
- Measles can usually be distinguished clinically from rubella, erythema infectiosum (parvovirus B19 infection), roseola, and enteroviral infection by the intensity of the measles rash, its subsequent brownish coloration, and the disease course.

MANAGEMENT

NONPHARMACOLOGIC

- The treatment of measles is mostly supportive. Suspected cases of measles should be immediately reported to the local or state department of health.

MEDICATIONS

- Measures to control spread of infection should not be delayed for laboratory confirmation. Vaccine should be promptly administered to all susceptible persons, or they should be removed from the outbreak setting for a minimum of 3 weeks. SOR C
- Giving serum immune globulin 0.25 mL/kg of body weight to a maximum dose of 15 mL to a susceptible person within 6 days of exposure to measles can prevent or modify disease. This is especially important in patients in whom the risk of complications of measles is higher, such as pregnant women, children younger than 1 year of age, and immunocompromised patients. SOR C
- Vitamin A reduces morbidity and mortality and is recommended by the World Health Organization (WHO) for children in areas where vitamin A deficiency is prevalent or where the mortality from measles exceeds 1%.[5] SOR B

REFERRAL OR HOSPITALIZATION

Consider hospitalization in the following scenarios:

- Difficulty breathing or noisy breathing—Bronchopneumonia occurs in 5% to 10% of patients.
- Changes in behavior, confusion—May be a harbinger of acute disseminated encephalomyelitis.
- There is dehydration, which can be the result of diarrhea, vomiting, and poor oral intake.

Refer to ophthalmology if there are changes in vision as measles keratitis can lead to permanent scarring and blindness.

PREVENTION

- Measures to control spread of infection should not be delayed for laboratory confirmation. Vaccine should be promptly administered to all susceptible persons, or they should be removed from the outbreak setting for a minimum of 3 weeks.
- Initial and booster immunization.
- Avoidance of endemic areas without being fully immunized.
- Adequate nutrition and hand washing.

PROGNOSIS

- The disease is typically self-limited. Measles typically lasts approximately 10 to 14 days from the beginning of the prodrome to the fading of the eruption.
- Approximately 30% of measles cases have one or more complications. Complications of measles are more common among patients younger than 5 years of age and adults 20 years of age and older. Centers for Disease Control and Prevention (CDC)-reported measles complications include:[6]
  - Diarrhea—8%.
  - Otitis media—7%.
  - Pneumonia—6%.
  - Encephalitis—0.1%.
  - Seizures—0.6% to 0.7%.
  - Death—0.2%.

FOLLOW-UP

- Have patients watched for changes that indicate more severe disease or complications and follow-up if these occur.
- Make sure return appointments for full vaccination are scheduled.

PATIENT EDUCATION

- Drink plenty of fluids to avoid dehydration. Use antipyretics/analgesics to control fever and discomfort. Avoid aspirin to prevent Reye syndrome.
- Avoid exposure to other individuals, particularly unimmunized children and adults, pregnant women, and immunocompromised persons, until at least 4 days after rash onset.

PATIENT RESOURCES

- Measles from "KidsHealth"—**http://kidshealth.org/parent/infections/bacterial_viral/measles.html#cat20028.**
- Centers for Disease Control and Prevention. *Two Options for Protecting Your Child Against Measles, Mumps, Rubella, and Varicella*—**http://www.cdc.gov/vaccines/vpd-vac/combo-vaccines/mmrv/vacopt-factsheet-parent.htm.**
- Centers for Disease Control and Prevention. *Measles: Make Sure Your Child Is Fully Immunized*—**http://www.cdc.gov/Features/Measles/.**
- Centers for Disease Control and Prevention. *Who Should NOT Get Vaccinated with the MMRV (Measles, Mumps, Rubella, and Varicella) Vaccine*—**http://www.cdc.gov/vaccines/vpd-vac/should-not-vacc.htm#mmrv.**
- World Health Organization. *Measles*—**http://www.who.int/topics/measles/en/.**

PROVIDER RESOURCES

- MedlinePlus. *Measles*—**http://www.nlm.nih.gov/medlineplus/measles.html.**
- Centers for Disease Control and Prevention. *Measles*—**http://www.cdc.gov/measles/index.html.**
- Centers for Disease Control and Prevention. *Manual for the Surveillance of Vaccine-Preventable Diseases,* 4th ed. (2008). *Chapter 7: Measles*—**http://www.cdc.gov/vaccines/pubs/surv-manual/chpt07-measles.html.**
- Centers for Disease Control and Prevention. *Epidemiology and Prevention of Vaccine-Preventable Diseases, The Pink Book: Course Textbook,* 12th ed (April 2011): *Measles*—**http://www.cdc.gov/vaccines/pubs/pinkbook/meas.html.**

REFERENCES

1. Centers for Disease Control and Prevention. *Manual for the Surveillance of Vaccine-Preventable Diseases*, 4th ed (2008). *Chapter 7: Measles*. http://www.cdc.gov/vaccines/pubs/surv-manual/chpt07-measles.html. Accessed November 25, 2011.
2. Kaplan LJ, Daum RS, Smaron M, McCarthy CA. Severe measles in immunocompromised patients. *JAMA*. 1992;267:1237-1241.
3. Johnson RT, Griffin DE, Hirsch RL, et al. Measles encephalomyelitis—clinical and immunologic studies. *N Engl J Med*. 1984;310:137-141.
4. Bellini WJ, Rota JS, Lowe LE, et al. Subacute sclerosing panencephalitis: More cases of this fatal disease are prevented by measles immunization than was previously recognized. *J Infect Dis*. 2005;192:1686-1693.
5. Siegel M, Fuerst HT. Low birth weight and maternal virus diseases. A prospective study of rubella, measles, mumps, chickenpox, and hepatitis. *JAMA*. 1966;197:680-684.

127 FIFTH DISEASE

E.J. Mayeaux, Jr., MD

PATIENT STORY

A 2-year-old boy presents with mild flu-like symptoms and a rash. He had erythematous malar rash and a "lace-like" erythematous rash on the trunk and extremities (**Figures 127-1** and **127-2**). The "slapped cheek" appearance made the diagnosis easy for fifth disease. The parents were reassured that this would go away on its own. The child returned to daycare the next day.

FIGURE 127-1 Classic erythematous malar rash with "slapped cheek" appearance of fifth disease (erythema infectiosum). (*Courtesy of Richard P. Usatine, MD.*)

INTRODUCTION

Fifth disease is also commonly referred to as erythema infectiosum. The name derives from the fact that it represents the fifth of the six common childhood viral exanthems described. Transmission occurs through respiratory secretions, possibly through fomites, and parenterally via vertical transmission from mother to fetus and by transfusion of blood or blood products.

SYNONYMS

Erythema infectiosum, parvovirus B19 infections, slapped cheek disease.

EPIDEMIOLOGY

- Fifth disease is common throughout the world. Antiparvovirus B19 immunoglobulin (Ig) G is found equally among Americans, Asians, and Europeans.[1] The only known host for B19 is humans.
- Most individuals become infected during their school years.
- Fifth disease is very contagious via the respiratory route and occurs more frequently between late winter and early summer. Up to 60% of the population is seropositive for antiparvovirus B19 IgG by age 20 years.[2] In some communities, there are cycles of local epidemics every 4 to 10 years.[3]
- Thirty percent to 40% of pregnant women lack measurable IgG to the infecting agent and are, therefore, presumed to be susceptible to infection. Infection during pregnancy can in some cases lead to fetal death.

FIGURE 127-2 Classic fifth disease "lace-like" erythematous rash on the trunk and extremities. (*Courtesy of Richard P. Usatine, MD.*)

ETIOLOGY AND PATHOPHYSIOLOGY

- Fifth disease is a mild viral febrile illness with an associated rash caused by parvovirus B19 (**Figure 127-3**).
- Most persons with parvovirus B19 infection never develop the clinical picture of fifth disease.

- Parvovirus B19 infects rapidly dividing cells and is cytotoxic for erythroid progenitor cells.
- After initial infection, a viremia occurs with an associated precipitous drop in the reticulocyte count and anemia. The anemia is rarely clinically apparent in healthy patients, but can cause serious anemia if the red blood cell count is already low. Patients with a chronic anemia such as sickle cell or thalassemia may experience a transient aplastic crisis.[4]
- Vertical transmission can result in congenital infection if a woman becomes infected during her pregnancy.[5] The risk of a fetal loss or hydrops fetalis is greatest (loss rate of 11%) when the infection occurs within the first 20 weeks of gestation.[6]

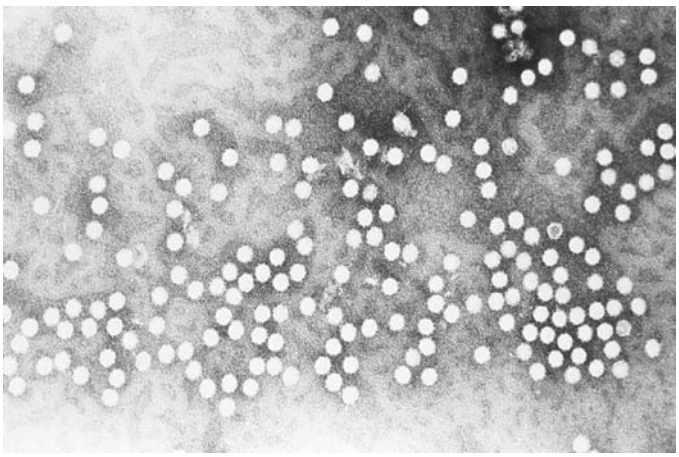

FIGURE 127-3 Transmission electron microscopy of parvovirus B19. (*Courtesy of the Centers for Disease Control and Prevention.*)

RISK FACTORS

- Exposure to infected children.
- Reception of blood products.

DIAGNOSIS

CLINICAL FEATURES

- Fifth disease is usually a biphasic illness, starting with upper respiratory tract symptoms that may include headache, fever, sore throat, pruritus, coryza, abdominal pain, diarrhea, and/or arthralgias. These constitutional symptoms coincide with onset of viremia and they usually resolve for about a week before the next stage begins.
- The second stage is characterized by a classic erythematous malar rash with relative circumoral pallor or "slapped cheek" appearance in children (**Figures 127-1** and **127-4**) followed by a "lace-like" erythematous rash on the trunk and extremities (**Figures 127-2** and **127-5**). Arthropathy affecting the hands, wrists, knees, and ankles may precede the development of a rash in adults. The course is usually self-limited.

TYPICAL DISTRIBUTION

- The rash starts with the classic slapped cheek appearance (**Figures 127-1** and **127-4**). Then an erythematous macular rash occurs on the extremities. After several days, the extremities rash fades into a lacy pattern (**Figures 127-2** and **127-5**). The exanthem may recur over several weeks in association with exercise, sun exposure, bathing in hot water, or stress.

LABORATORY TESTING

- Laboratory studies are not usually needed as the diagnosis can be made by history and physical exam. Serum B19-specific IgM may be ordered in pregnant women exposed to fifth disease. After 3 weeks, infection is also indicated by a four-fold or greater rise in serum B19-specific IgG antibody titers.
- Patients with symptoms of anemia, a history of increased red blood cell (RBC) destruction (e.g., sickle cell disease, hereditary spherocytosis), or with decreased RBC production (e.g., iron-deficiency anemia) should be tested for anemia.
- Pregnant women who are exposed to or have symptoms of parvovirus infection should have serologic testing. SOR C Prior to

FIGURE 127-4 Classic erythematous malar rash with "slapped cheek" appearance of fifth disease in an 18-month-old child. (*Courtesy of Richard P. Usatine, MD.*)

20 weeks' gestation, women testing positive for acute infection (i.e., positive IgM and negative IgG) should be counseled concerning the low risk of fetal loss and congenital anomalies.

IMAGING

- If serologic testing in pregnant women is positive, some experts recommend that the patient should receive ultrasounds to look for signs of fetal hydrops. SOR C Intrauterine transfusion is currently the only effective treatment to alleviate fetal anemia.[7]

DIFFERENTIAL DIAGNOSIS

- Acute rheumatic fever presents as a fine papular (sandpaper) rash in association with a *Streptococcus* infection (see Chapter 34, Scarlet Fever and Strawberry Tongue).
- Allergic-hypersensitivity reactions (erythema multiforme, erythema nodosum, and cutaneous vasculitis) often involve the arms and legs but rarely affect the face (see Section 14, Hypersensitivity Syndromes).
- Lyme disease presents with an expanding rash with central clearing (see Chapter 218, Lyme Disease).
- Measles produces a blanching rash that begins on the face and spreads centrifugally to involve the neck, trunk, and finally the extremities. It tends to become more confluent instead of lacy with time (see Chapter 126, Measles).

MANAGEMENT

NONPHARMACOLOGIC

- Fifth disease is usually self-limited and requires no specific therapy.
- See "Patient Education" below for further information about parvovirus B19 infections in pregnancy.

MEDICATIONS

- NSAID or acetaminophen therapy may alleviate fevers and arthralgias. SOR C
- Transient aplastic anemia is very rare but may be severe enough to require transfusion until the patient's red cell production recovers. SOR C

PREVENTION

- Because it is spread through respiratory secretions and possibly through fomites, good hand sanitation and infection-control techniques are recommended.
- Infected individuals should avoid excessive heat or sunlight, which can cause rash flare-ups.

PROGNOSIS

- The rash of erythema infectiosum usually is self-limiting, but may last weeks to months with exacerbations.
- Aplastic anemia usually lasts up to 2 weeks but may become chronic. The onset of erythema infectiosum rash usually indicates that reticulocytosis has returned and aplastic crisis will not occur.

FIGURE 127-5 Classic reticular eruption on the extremities. (*Courtesy of Jeffrey Meffert, MD.*)

PATIENT EDUCATION

- Explain to parents that the disease is usually self-limited. Normal activities may be pursued as tolerated with sun protection or avoidance.
- Children who present with the classic findings of fifth disease are past the infectious state and can attend school and daycare.
- During pregnancy, a woman who has an acute infection prior to 20 weeks' gestation should be counseled concerning the low risks of fetal loss and congenital anomalies. Beyond 20 weeks' gestation, some physicians recommend repeated ultrasounds to look for signs of fetal hydrops.

PATIENT RESOURCES

- Centers for Disease Control and Prevention (CDC). *Parvovirus B19 and Fifth Disease*—**http://www.cdc.gov/parvovirusB19/fifth-disease.html.**
- Centers for Disease Control and Prevention (CDC). *Pregnancy and Fifth Disease*—**http://www.cdc.gov/parvovirusB19/pregnancy.html.**
- eMedicine health. *Fifth Disease*—**http://www.emedicine-health.com/fifth_disease/article_em.htm.**
- PubMed Health. *Fifth Disease*—**http://www.ncbi.nlm.nih.gov/pubmedhealth/PMH0001972/.**

PROVIDER RESOURCES

- Medscape. *Fifth Disease or Erythema Infectiosum*—**http://emedicine.medscape.com/article/801732.**

REFERENCES

1. Young NS, Brown KE. Parvovirus B19. *N Engl J Med.* 2004; 350(6):586-597.
2. American Academy of Pediatrics. Parvovirus B19 (Erythema Infectiosum, Fifth Disease). *Red Book: 2006 Report on the Committee of Infectious Diseases*. Elk Grove Village, IL: American Academy of Pediatrics; 2006:484-487.
3. Naides SJ. Erythema infectiosum (fifth disease) occurrence in Iowa. *Am J Public Health.* 1988;78(9):1230-1231.
4. Serjeant GR, Serjeant BE, Thomas PW, et al. Human parvovirus infection in homozygous sickle cell disease. *Lancet.* 1993; 341(8855):1237-1240.
5. Jordan JA. Identification of human parvovirus B19 infection in idiopathic nonimmune hydrops fetalis. *Am J Obstet Gynecol.* 1996; 174(1 Pt 1):37-42.
6. Enders M, Weidner A, Zoellner I, et al. Fetal morbidity and mortality after acute human parvovirus B19 infection in pregnancy: prospective evaluation of 1018 cases. *Prenat Diagn.* 2004;24(7):513-518.
7. de Jong EP, de Haan TR, Kroes ACM, et al. Parvovirus B19 infection in pregnancy. *J Clin Virol.* 2006;36(1):1-7.

128 HAND, FOOT, AND MOUTH DISEASE

E.J. Mayeaux, Jr., MD

PATIENT STORY

A 4-year-old boy presents to a free clinic for homeless families with a low-grade fever and lesions on his hands and feet (**Figures 128-1** and **128-2**). The mother notes that two other kids in the transitional living center also have a similar rash. Upon further investigation, the mouth lesions are noted (**Figure 128-3**). The mother is reassured that this is nothing more than hand, foot, and mouth disease and will go away on its own. Treatment includes fluids and antipyretics as needed.

FIGURE 128-1 Typical flat vesicular lesions on the hand of a 4-year-old boy with hand, foot, and mouth disease. (*Courtesy of Richard P. Usatine, MD.*)

INTRODUCTION

Hand, foot, and mouth disease (HFMD) is a viral illness that may affect humans and some animals, and presents with a distinct clinical presentation. The disease occurs worldwide.

SYNONYMS

Hand, foot, mouth syndrome.

EPIDEMIOLOGY

- Epidemics tend to occur every 3 years worldwide. In temperate climates, the peak incidence is in late summer and early fall.
- HFMD generally has a mild course, but it may be more severe in infants and young children.[1,2]
- There is no racial or gender predilection. Most cases affect children younger than 10-year-old.[3]

ETIOLOGY AND PATHOPHYSIOLOGY

- HFMD is most commonly caused by members of the enterovirus genus, especially coxsackie viruses. Epidemic infections are usually caused by coxsackievirus A16, and less commonly by other coxsackievirus A, coxsackievirus B, or enterovirus 71.[2,3] Sporadic cases occur caused by other coxsackie viruses.
- Coxsackievirus infections are highly contagious. Transmission occurs via aerosolized droplets of nasal and/or oral secretions via the fecal–oral route, or from contact with skin lesions. During epidemics, the virus is spread from child to child and from mother to fetus.
- The incubation period averages 3 to 6 days. Initial viral implantation is in the GI tract mucosa, and it then spreads to lymph nodes within 24 hours. Viremia rapidly ensues, with spread to the oral mucosa and skin. Rarely, aseptic meningitis may occur. Usually by

FIGURE 128-2 Foot of the boy in **Figure 128-1** with hand, foot, and mouth disease. Lesions tend to be on palms and soles, fingers, and toes. (*Courtesy of Richard P. Usatine, MD.*)

day 7, a neutralizing antibody response develops, and the virus is cleared from the body.

- When HFMD is caused by enteroviruses, it may also result in neurologic problems such as a polio-like syndrome, aseptic meningitis, encephalitis, acute cerebellar ataxia, acute transverse myelitis, Guillain-Barré syndrome, and benign intracranial hypertension. Rarely, cardiopulmonary complications such as myocarditis, interstitial pneumonitis, and pulmonary edema may occur.[4,5] Rarely death may occur.[6]
- Infection in the first trimester of pregnancy may lead to spontaneous abortion or intrauterine growth retardation.

RISK FACTORS

- Attendance at child care centers.
- Contact with HFMD.
- Large family.
- Rural residence.

DIAGNOSIS

CLINICAL FEATURES

- A prodrome lasting 12 to 36 hours is usually the first sign of HFMD, and it usually consists of typical general viral infection symptoms with anorexia, abdominal pain, and sore mouth. Lesions are present for 5 to 10 days, and heal spontaneously in 5 to 7 days.
- Each lesion begins as a 2- to 10-mm erythematous macule, which develops a gray, oval vesicle that parallels the skin tension lines in its long axis (**Figures 128-1** and **128-2**). The oral lesions (**Figure 128-3**) begin as erythematous macules, evolve into 2- to 3-mm vesicles on an erythematous base, and then rapidly become ulcerated. The vesicles are painful and may interfere with eating. They are not generally pruritic.
- Cervical or submandibular lymphadenopathy may be present.

TYPICAL DISTRIBUTION

- Skin lesions develop on the hands, feet, and/or buttocks and oral lesions may involve the palate, buccal mucosa, gingiva, and/or tongue.

LABORATORY TESTING

- Laboratory tests are not needed.

DIFFERENTIAL DIAGNOSIS

- Aphthous stomatitis presents as single or multiple painful ulcers in the mouth without skin eruptions (see Chapter 41, Aphthous Ulcer).
- Chickenpox presents with body-wide vesicular lesions in multiple crops (see Chapter 123, Chickenpox).

FIGURE 128-3 Mouth lesions in same boy with hand, foot, and mouth disease appear as small ulcers on the lips and oral mucosa. (*Courtesy of Richard P. Usatine, MD.*)

- Erythema multiforme demonstrates body-wide target lesions that also involve the skin of the palms and soles (see Chapter 177, Erythema Multiforme, Stevens-Johnson Syndrome, and Toxic Epidermal).
- Herpes simplex presents with painful recurrent ulcerations of the lips or genitals without simultaneous hand or foot lesions unless there is herpetic whitlow on the hand (see Chapter 129, Herpes Simplex).

MANAGEMENT

NONPHARMACOLOGIC

- The treatment of HFMD is usually supportive. Usually the mouth lesions are not as painful as in herpes gingivostomatitis. If there is a lot of mouth pain leading to poor oral intake, the following medications may be considered. Topical oral anesthetics such as 2% viscous lidocaine by prescription or 20% topical benzocaine (Orabase) nonprescription may be used to treat painful oral ulcers. SOR C
- A solution combining aluminum and magnesium hydroxide (liquid antacid) and 2% viscous lidocaine has been reported as helpful when swished and spit out several times a day as needed for pain. SOR C

MEDICATIONS

- Acetaminophen or NSAIDs/cyclooxygenase (COX)-2's may be used to manage fever, and analgesics may be used to treat arthralgias. SOR C Aspirin should not be used in viral illnesses in children younger than 12 years of age, to prevent Reye syndrome. SOR C
- A case report of enterovirus HFMD in an immunocompromised patient reported a faster resolution of symptoms and lesions with oral acyclovir.[6] SOR C

REFERRAL OR HOSPITALIZATION

- Patients with central nervous system (CNS) manifestations may require hospitalization.

PREVENTION

- Good hand washing should be encouraged to reduce the spread of disease.

PROGNOSIS

- HFMD caused by coxsackie viruses is generally a mild self-limited illness that resolves in around 7 to 10 days. HFMD may rarely recur, persist, or cause serious complications.

PATIENT EDUCATION

- Educate parents of young children to watch for signs of dehydration owing to decreased oral intake secondary to mouth pain.
- To reduce viral spreading, do not rupture blisters.
- The patient may attend school once symptoms subside.
- The virus that causes hand, foot, and mouth disease may be present in the patient's stool for 1 month.
- Report any neurologic symptoms to healthcare providers immediately.

PATIENT RESOURCES

- Centers for Disease Control and Prevention. *CDC Feature: Hand, Foot, and Mouth Disease*—**http://www.cdc.gov/Features/HandFootMouthDisease/.**
- Centers for Disease Control and Prevention. *About Hand, Foot, and Mouth Disease (HFMD)*—**http://www.cdc.gov/hand-foot-mouth/about/.**
- eMedicine. *Hand, Foot and Mouth Disease*—**http://www.emedicinehealth.com/hand_foot_and_mouth_disease/article_em.htm.**

PROVIDER RESOURCES

- Centers for Disease Control and Prevention. *Hand, Foot and Mouth Disease References & Resources*—**http://www.cdc.gov/hand-foot-mouth/references-resources.html.**
- NHS Clinical Knowledge Summaries. *Hand, Foot and Mouth Disease*—**http://www.cks.nhs.uk/hand_foot_and_mouth_disease/evidence/references#.**
- Frydenberg A, Starr M. Hand, foot and mouth disease. *Aust Fam Physician.* 2003;32(8):594-595. **http://www.racgp.org.au/afp/200308/20030805starr2.pdf.**

REFERENCES

1. Chang LY, King CC, Hsu KH, et al. Risk factors of enterovirus 71 infection and associated hand, foot, and mouth disease/herpangina in children during an epidemic in Taiwan. *Pediatrics.* 2002;109(6):e88.
2. Chong CY, Chan KP, Shah VA, et al. Hand, foot and mouth disease in Singapore: a comparison of fatal and non-fatal cases. *Acta Paediatr.* 2003;92(10):1163-1169.
3. Frydenberg A, Starr M. Hand, foot and mouth disease. *Aust Fam Physician.* 2003;32(8):594-595.
4. Chan KP, Goh KT, Chong CY, et al. Epidemic hand, foot and mouth disease caused by human enterovirus 71, Singapore. *Emerg Infect Dis.* 2003;9(1):78-85.
5. Chen SC, Chang HL, Yan TR, et al. An eight-year study of epidemiologic features of enterovirus 71 infection in Taiwan. *Am J Trop Med Hyg.* 2007;77(1):188-191.
6. Faulkner CF, Godbolt AM, DeAmbrosis B, Triscott J. Hand, foot and mouth disease in an immunocompromised adult treated with aciclovir. *Australas J Dermatol.* 2003;44(3):203-206.

129 HERPES SIMPLEX

E.J. Mayeaux, Jr., MD
Kevin J. Carter, MD

PATIENT STORY

A 32-year-old man presents with complains of a 1-week history of multiple painful vesicles on the shaft of his penis associated with tender groin adenopathy (**Figure 129-1**). The vesicles broke 2 days ago and the pain has increased. He had similar lesions 1 year ago but never went for healthcare examination at that time. He has had 3 different female sexual partners in the last 2 years but has no knowledge of them having any sores or diseases. He was given the presumptive diagnosis of genital herpes and a course of acyclovir. His herpes culture came back positive and his rapid plasma reagin (RPR) and HIV tests were negative.

FIGURE 129-1 Recurrent genital herpes simplex virus on the penis showing grouped ulcers (deroofed vesicles). (*Courtesy of Richard P. Usatine, MD.*)

INTRODUCTION

Herpes simplex virus (HSV) infection can involve the skin, mucosa, eyes and central nervous system. HSV establishes a latent state followed by viral reactivation and recurrent local disease. Perinatal transmission of HSV can lead to significant fetal morbidity and mortality.

EPIDEMIOLOGY

HSV affects more than one-third of the world's population, with the 2 most common cutaneous manifestations being genital (**Figures 129-1** to **129-4**) and orolabial herpes (**Figures 129-5** to **129-7**).[1]

The Centers for Disease Control and Prevention (CDC) reports that at least 50 million persons in the United States have genital HSV-2 infection. Over the past decade, the percentage of Americans with genital herpes infection in the United States has remained stable. Most persons infected with HSV-2 have not been diagnosed with genital herpes.[2]

Genital HSV-2 infection is more common in women (approximately 1 out of 5 women 14 to 49 years of age) than in men (approximately 1 out of 9 men 14 to 49 years of age). Transmission from an infected male to his female partner is believed to be more likely than from an infected female to her male partner.

Orolabial herpes is the most prevalent form of herpes infection and often affects children younger than 5 years of age (**Figure 121-7**). The duration of the illness is 2 to 3 weeks, and oral shedding of virus may continue for as long as 23 days.[1]

Herpetic whitlow is an intense painful infection of the hand involving the terminal phalanx of one or more digits. In the United States, the estimated annual incidence is 2.4 cases per 100,000 persons.[3]

FIGURE 129-2 Herpes simplex on the penis with intact vesicles and visible crusts. (*Courtesy of Jack Rezneck, Sr., MD.*)

ETIOLOGY AND PATHOPHYSIOLOGY

- HSV belongs to the family Herpesviridae and is a double-stranded DNA virus.

- HSV exists as 2 separate types (types 1 and 2), which have affinities for different epithelia.[3] Ninety percent of HSV-2 infections are genital, whereas 90% of those caused by HSV-1 are oral–labial.
- HSV enters through abraded skin or intact mucous membranes. Once infected, the epithelial cells die, forming vesicles and creating multinucleated giant cells.
- Retrograde transport into sensory ganglia leads to lifelong latent infection.[1] Reactivation of the virus may be triggered by immunodeficiency, trauma, fever, and UV light.
- Genital HSV infection is usually transmitted through sexual contact. When it occurs in a preadolescent, the possibility of abuse must be considered.
- Evidence indicates that 21.9% of all persons in the United States, 12 years or older, have serologic evidence of HSV-2 infection, which is more commonly associated with genital infections.[4]
- As many as 90% of those infected are unaware that they have herpes infection and may unknowingly shed virus and transmit infection.[5]
- Primary genital herpes has an average incubation period of 4 days, followed by a prodrome of itching, burning, or erythema.
- With both types, systemic symptoms are common in primary disease and include fever, headache, malaise, abdominal pain, and myalgia.[6] Recurrences are usually less severe and shorter in duration than the initial outbreak.[1,6]
- Maternal–fetal transmission of HSV is associated with significant morbidity and mortality. Manifestations of neonatal HSV include localized infection of the skin, eyes, and mouth, central nervous system (CNS) disease, or disseminated multiple organ disease (**Figure 129-8**). The CDC and the American College of Obstetricians and Gynecologists recommend that cesarean delivery should be offered as soon as possible to women who have active HSV lesions or, in those with a history of genital herpes, symptoms of vulvar pain or burning at the time of delivery.
- Herpetic whitlow occurs as a complication of oral or genital HSV infection and in medical personnel who have contact with oral secretions (**Figures 129-9** and **129-10**).
- Toddlers and preschool children are susceptible to herpetic whitlow if they have herpes labialis and engage in thumb-sucking or finger-sucking behavior.
- Like all HSV infections, herpetic whitlow usually has a primary infection, which may be followed by subsequent recurrences. The virus migrates to the peripheral ganglia and Schwann cells where it lies dormant. Recurrences observed in 20% to 50% of cases are usually milder and shorter in duration.

RISK FACTORS

- Multiple sexual partners.
- Female gender.
- Low socioeconomic status.
- HIV infection.

FIGURE 129-3 Vulvar herpes simplex virus at the introitus showing small punched out ulcers. (*Courtesy of the Centers for Disease Control and Prevention and Susan Lindsley.*)

FIGURE 129-4 Recurrent herpes simplex virus on the buttocks of a woman in the ulcerative stage. Women are prone to getting buttocks involvement owing to sleeping with partners that have genital involvement. (*Courtesy of Richard P. Usatine, MD.*)

FIGURE 129-5 Primary herpes gingivostomatitis in a teenager presenting with multiple ulcers on the tongue and lower lip. (*Courtesy of Richard P. Usatine, MD.*)

FIGURE 129-6 Close-up of recurrent herpes simplex virus-1 showing vesicles on a red base at the vermillion border in a young girl. (*Courtesy of Richard P. Usatine, MD.*)

FIGURE 129-7 Orolabial herpes simplex virus in an adult woman showing deroofed blisters (ulcer). (*Courtesy of Richard P. Usatine, MD.*)

FIGURE 129-8 Hospitalized baby with a recurrence of skin lesions after neonatal herpes simplex virus-2 infection and central nervous system involvement. (*Courtesy of Jack Resneck, Sr., MD.*)

FIGURE 129-9 Herpetic whitlow lesion on distal index finger. (*Courtesy of Richard P. Usatine, MD.*)

FIGURE 129-10 Severely painful herpetic whitlow on the thumb. (*Courtesy of Eric Kraus, MD.*)

DIAGNOSIS

CLINICAL FEATURES

- The diagnosis of HSV infection may be made by clinical appearance. Many patients have systemic symptoms, including fever, headache, malaise, and myalgias.
- Orolabial herpes typically takes the form of painful vesicles and ulcerative erosions on the tongue, palate, gingiva, buccal mucosa, and lips (**Figures 129-5** to **129-7**).
- Genital herpes presents with multiple transient, painful vesicles that appear on the penis (**Figures 129-1** and **129-2**), vulva (**Figure 129-3**), buttocks (**Figures 129-4** and **129-11**), perineum, vagina or cervix, and tender inguinal lymphadenopathy.[6] The vesicles break down and become ulcers that develop crusts while these are healing.
- Recurrences typically occur 2 to 3 times a year. The duration is shorter and less painful than in primary infections. The lesions are often single and the vesicles heal completely by 8 to 10 days.
- UV radiation in the form of sunlight may trigger outbreaks. Another reason to use sun protection when outdoors triggers recurrence of orolabial HSV-1, an effect which is not fully suppressed by acyclovir.

LABORATORY STUDIES

- The gold standard of diagnosis is viral isolation by tissue culture and polymerase chain reaction (PCR) testing.[2]
  - The culture sensitivity rate is only 70% to 80% and depends upon the stage at which the specimen is collected. The sensitivity is highest at first in the vesicular stage and declines with ulceration and crusting. The tissue culture assay can be positive within 48 hours but may take longer.
  - PCR is extremely sensitive (96%) and specific (99%). PCR testing is generally used for cerebrospinal fluid (CSF) testing in suspected HSV encephalitis or meningitis.[2]
- Older type-specific HSV serologic assays that do not accurately distinguish HSV-1 from HSV-2 antibody are still on the market. Both laboratory-based assays and point-of-care tests that provide results for HSV-2 antibodies from capillary blood or serum with sensitivities of 80% to 98% are available. Because nearly all HSV-2 infections are sexually acquired, the presence of type-specific HSV-2 antibody implies anogenital infection. Type-specific HSV serologic assays might be useful in patients with recurrent symptoms and negative HSV cultures and an asymptomatic patient with a partner with genital herpes. Screening for HSV-1 and HSV-2 in the general population is not indicated.[2]
- The Tzanck test and antigen detection tests have lower sensitivity rates than viral culture and should not be relied on for diagnosis.[2]
- The CDC does not currently recommend routine type 2 HSV testing in someone with no symptoms suggestive of herpes infection (i.e., for the general population).[7]
- If the herpes was acquired by sexual contact, screening should be performed for other sexually transmitted diseases (STDs), such as syphilis and HIV.

FIGURE 129-11 Recurrent herpes simplex virus on the buttocks of a woman. Note the vesicles and crusts in a unilateral cluster. (*Courtesy of Richard P. Usatine, MD.*)

- Biopsy is usually unnecessary unless no infectious etiology is found for a genital lesion and a malignancy is suspected.

DIFFERENTIAL DIAGNOSIS

- Syphilis produces a painless or mildly painful, indurated, clean-based ulcer (chancre) at the site of exposure. It is best to investigate for syphilis or coexisting syphilis in any patient presenting for the first time with a genital ulcer of unproven etiology (see Chapter 216, Syphilis).
- Chancroid produces a painful deep, undermined, purulent ulcer that may be associated with painful inguinal lymphadenitis (see Chapter 216, Syphilis).
- Drug eruptions produce pruritic papules or blisters without associated viral symptoms (see Chapter 203, Cutaneous Drug Reactions).
- Behçet disease produces ulcerative disease around the mouth and genitals, possibly before onset of sexual activity (**Figure 129-12**).
- Acute paronychia which presents as a localized abscess in a nail fold and is the main differential diagnosis in the consideration of herpetic whitlow (see Chapter 194, Paronychia).
- Felon—A red, painful infection, usually bacterial, of the fingertip pulp. It is important to distinguish whitlow from a felon (where the pulp space usually is tensely swollen) as incision and drainage of a felon is needed, but should be avoided in herpetic whitlow because it may lead to an unnecessary secondary bacterial infection.

FIGURE 129-12 Young man with Behçet syndrome presenting with a painful penile ulcer and aphthous ulcers in his mouth. (*Courtesy of Richard P. Usatine, MD.*)

MANAGEMENT

NONPHARMACOLOGIC

- Women with active primary or recurrent genital herpetic lesions at the onset of labor should deliver by cesarean section to lower the chance of neonatal HSV infection.[2] SOR A

MEDICATIONS

- Acyclovir is a guanosine analog that acts as a DNA chain terminator which, when incorporated, ends viral DNA replication. Valacyclovir is the *l*-valine ester prodrug of acyclovir that has enhanced absorption after oral administration and high oral bioavailability. Famciclovir is the oral form of penciclovir, a purine analog similar to acyclovir. They must be administered early in the outbreak to be effective, but are safe and extremely well-tolerated.[6] SOR A

Genital herpes:

- Antiviral therapy is recommended for an initial genital herpes outbreak. **Table 129-1** shows the dosages for antiherpes drugs. Although systemic antiviral drugs can partially control the signs and symptoms of herpes episodes, they do not eradicate latent virus.
- Acyclovir, famciclovir, and valacyclovir are equally effective for episodic treatment of genital herpes, but famciclovir appears somewhat less effective for suppression of viral shedding.[2] SOR B
- Effective episodic treatment of herpes requires initiation of therapy during the prodrome period or within 1 day of lesion onset.

TABLE 129-1 Dosages of Treatments for Genital Herpes Infection[2]

Drug	Primary Infection Dosage	Recurrent Infection Dosage	Chronic Suppressive Therapy
Acyclovir (Zovirax)	400 mg 3 times daily for 7 to 10 days or 200 mg 5 times daily	400 mg 3 times daily for 5 days or 800 mg twice daily for 5 days or 800 mg 3 times daily for 2 days	400 mg twice daily
Famciclovir (Famvir)	250 mg 3 times daily for 10 days*	125 mg twice daily for 5 days or 1 g twice daily for 1 day or 500 mg once, followed by 250 mg twice daily for 2 days	250 mg PO twice daily
Valacyclovir (Valtrex)	1 g twice daily for 10 days	500 mg twice daily for 3 days or 1 g daily for 5 days	500 mg to 1 g once daily

*Famciclovir is not FDA-labeled for this indication.

Providing the patient with a prescription for the medication with instructions to initiate treatment immediately when symptoms begin improves efficacy.[2] SOR B

- IV acyclovir therapy at 5 to 10 mg/kg IV every 8 hours for 2 to 7 days followed by oral antiviral therapy to complete at least 10 days of total therapy should be provided for patients who have severe HSV disease or complications.[2] SOR C
- HSV strains resistant to acyclovir have been detected in immunocompromised patients so that other antivirals (e.g., famciclovir) need to be considered in these patients. SOR C
- Topical medication for HSV infection is generally not effective. Topical penciclovir applied every 2 hours for 4 days, reduces clinical healing time by approximately 1 day.[1,2]
- All patients with a first episode of genital herpes should receive antiviral therapy as even with mild clinical manifestations initially, they can develop severe or prolonged symptoms.
- Toxicity of these 3 antiviral drugs is rare, but in patients who are dehydrated or who have poor renal function, the drug can crystallize in the renal tubules, leading to a reversible creatinine elevation or, rarely, acute tubular necrosis. Adverse effects, usually mild, include nausea, vomiting, rash, and headache. Lethargy, tremulousness, seizures and delirium have been reported rarely in studies of renally impaired patients.[9]

Oral herpes:

Table 129-2 provides an overview of treatments for herpes labialis.

- In the treatment of primary orolabial herpes, oral acyclovir (200 mg 5 times daily for 5 days) accelerates healing by 1 day and can reduce the mean duration of pain by 36%.[8] SOR A
- The oral lesions in primary herpes gingivostomatitis can lead to poor oral intake especially in children (**Figures 129-5** and **129-13**). To prevent dehydration, the following medications may be considered. Topical oral anesthetics such as 2% viscous lidocaine by prescription or 20% topical benzocaine OTC may be used to treat painful oral ulcers. SOR C A solution combining aluminum and magnesium hydroxide (liquid antacid) and 2% viscous lidocaine

FIGURE 129-13 Primary herpes gingivostomatitis in a 4-year-old girl. Note the cluster of ulcers inside the lower lip typical of herpes simplex virus. The patient also had involvement of her gingiva, which were swollen and painful. (*Courtesy of Richard P. Usatine, MD.*)

TABLE 129-2 Treatments for Herpes Labialis

Drug	Dose or Dosage	Evidence Rating†	References
Episodic oral treatment for recurrences‡			
Acyclovir (Zovirax)	200 mg 5 times per day or 400 mg 3 times per day for 5 days	A	12,13
Famciclovir (Famvir)	1500 mg once for 1 day	B	14
Valacyclovir (Valtrex)	2 g twice for 1 day	B	15
Episodic topical treatment for recurrences‡			
Acyclovir cream	Apply 5 times per day for 4 days	B	18
Docosanol cream (Abreva)	Apply 5 times per day until healed	B	17
Penciclovir cream (Denavir)	Apply every 2 hours while awake for 4 days	B	16
Treatment to prevent recurrences			
Acyclovir	400 mg twice per day (ongoing)	A	13,19
Valacyclovir	500 mg once per day (ongoing)	B	20

Abbreviation: NA, not available.
†*A*, Consistent, good-quality, patient-oriented evidence; *B*, inconsistent or limited-quality, patient-oriented evidence; *C*, consensus, disease-oriented evidence, usual practice, expert opinion, or case series.
‡ Most effective if treatment is started at the onset of symptoms.
Source: Reprinted with permission from Usatine RP, Tinitigan R. Nongenital herpes simplex virus. *Am Fam Physician.* 2010;82(9):1075-1082.

has been reported as helpful when swished and spit out several times a day as needed for pain. SOR C

- Docosanol cream (Abreva) is available without prescription for oral herpes. One randomized controlled trial (RCT) of 743 patients with herpes labialis showed a faster healing time in patients treated with docosanol 10% cream compared with placebo cream (4.1 vs. 4.8 days), as well as reduced duration of pain symptoms (2.2 vs. 2.7 days).[11] More than 90% of patients in both groups healed completely within 10 days.[11] Treatment with docosanol cream, when applied 5 times per day and within 12 hours of episode onset, is safe and somewhat effective.[12]

PREVENTION

- Barrier protection using latex condoms is recommended to minimize exposure to genital HSV infections (see "Patient Education" below).
- Suppressive therapy with antiviral drugs reduces the frequency of genital herpes recurrences by 70% to 80% in patients with frequent recurrences.[2] SOR A Traditionally this is reserved for use in patients who have more than 4 to 6 outbreaks per year (see **Table 129-1**).

- Short-term prophylactic therapy with acyclovir for orolabial HSV may be used in patients who anticipate intense exposure to UV light. Early treatment of recurrent orolabial HSV infection with Famciclovir 250 mg 3 times daily for 5 days can markedly decrease the size and duration of lesions.[10] SOR A

FOLLOW-UP

The patient should return for follow-up if pain is uncontrolled or superinfection is suspected. The patient should be periodically evaluated for the need for suppressive therapy based on the number of recurrences per year.

PATIENT EDUCATION

Measures to prevent genital HSV infection:

- Abstain from sexual activity or limit number of sexual partners to prevent exposure to the disease.
- Use condoms to protect against transmission, but this is not foolproof as ulcers can occur on areas not covered by condoms.
- Prevent autoinoculation by patting dry affected areas, not rubbing with towel.
- Studies show that patients may shed virus when they are otherwise asymptomatic. A link between HSV genital ulcer disease and sexual transmission of HIV has been established. Safer sex practices should be strongly encouraged to prevent transmission of HSV to others and acquiring HIV by the patient.

PATIENT RESOURCES

- National Institute of Allergy and Infectious Diseases. *Genital Herpes*—**http://www.niaid.nih.gov/topics/genitalherpes/Pages/default.aspx.**
- Centers for Disease Control and Prevention. *Genital Herpes–CDC Fact Sheet*—**http://www.cdc.gov/std/Herpes/STDFact-Herpes.htm.**
- Skinsight. *Herpetic Whitlow–Information for Adults*—**http://www.skinsight.com/adult/herpeticWhitlow.htm.**

PROVIDER RESOURCES

- Medscape. *Herpes Simplex*—**http://emedicine.medscape.com/article/218580.**
- Medscape. *Dermatologic Manifestations of Herpes Simplex*—**http://emedicine.medscape.com/article/1132351.**
- Usatine RP, Tinitigan R. Nongenital HSV. *Am Fam Physician*. 2010;82[9]:1075-1082—**http://www.aafp.org/afp/2010/1101/p1075.html.**
- Emmert DH. Treatment of common cutaneous HSV infections. *Am Fam Physician*. 2000;61[6]:1697-1704—**http://www.aafp.org/afp/20000315/1697.html.**

REFERENCES

1. Whitley RJ, Kimberlin DW, Roizman B. Herpes simplex viruses. *Clin Infect Dis.* 1998;26:541-555.
2. Centers for Disease Control and Prevention. *2010 Guidelines for Treatment of Sexually Transmitted Diseases*. http://www.cdc.gov/std/treatment/2010/STD-Treatment-2010-RR5912.pdf. Accessed December 1, 2011.
3. Gill MJ, Arlette J, Buchan K. Herpes simplex virus infection of the hand. A profile of 79 cases. *Am J Med.* 1988;84:89-93.
4. Fleming DT, McQuillan GM, Johnson RE, et al. Herpes simplex virus type 2 in the United States, 1976 to 1994. *N Engl J Med.* 1997;337:1105-1111.
5. Mertz GJ. Epidemiology of genital herpes infections. *Infect Dis Clin North Am.* 1993;7:825-839.
6. Clark JL, Tatum NO, Noble SL. Management of genital herpes. *Am Fam Physician.* 1995;51:175-182, 187-188.
7. Centers for Disease Control and Prevention (CDC). Seroprevalence of herpes simplex virus type 2 among persons aged 14-49 years—United States, 2005-2008. *MMWR Morb Mortal Wkly Rep.* 2010;59(15):456-459.
8. Spruance SL, Stewart JC, Rowe NH, et al. Treatment of recurrent herpes simplex labialis with oral acyclovir. *J Infect Dis.* 1990;161:185-190.
9. Emmert DH. Treatment of common cutaneous herpes simplex virus infections. *Am Fam Physician.* 2000;61(6):1697-1706, 1708.
10. Spruance SL, Rowe NH, Raborn GW, et al. Perioral famciclovir in the treatment of experimental ultraviolet radiation-induced herpes simplex labialis: A double-blind, dose-ranging, placebo-controlled, multicenter trial. *J Infect Dis.* 1999;179:303-310.
11. Sacks SL, Thisted RA, Jones TM, et al. Docosanol 10% Cream Study Group. Clinical efficacy of topical docosanol 10% cream for herpes simplex labialis: a multi-center, randomized, placebo-controlled trial. *J Am Acad Dermatol.* 2001;45(2):222-230.
12. Usatine RP, Tinitigan R. Nongenital herpes simplex virus. *Am Fam Physician.* 2010;82(9):1075-1082.

130 MOLLUSCUM CONTAGIOSUM

E.J. Mayeaux, Jr., MD

PATIENT STORIES

An 8-year-old girl is brought to the office because of an outbreak of bumps on her face for the past 3 months (**Figure 130-1**). Occasionally she scratches them, but she is otherwise asymptomatic. The mother and child are unhappy with the appearance of the molluscum contagiosum and chose to try topical imiquimod 5% cream. Fortunately, her health insurance covered this expensive treatment. A topical treatment was chosen to avoid the risk of hypopigmentation that can occur in dark-skinned individuals with cryotherapy.

An 11-year-old girl was also seen with molluscum on her face. The child and her mother decided to try cryotherapy as her treatment. She very bravely tolerated the treatment with liquid nitrogen in a Cryogun (**Figure 130-2**). The molluscum disappeared without scarring or hypopigmentation after two treatments.

FIGURE 130-1 Molluscum contagiosum on the face of an 8-year-old girl. (*Courtesy of Richard P. Usatine, MD.*)

INTRODUCTION

Molluscum contagiosum is a viral skin infection that produces pearly papules that often have a central umbilication. It is seen most commonly in children, but can also be transmitted sexually among adults.

EPIDEMIOLOGY

- Molluscum contagiosum infection has been reported worldwide. An Australian seroepidemiology study found a seropositivity rate of 23%.[1]
- Up to 5% of children in the United States have clinical evidence of molluscum contagiosum infection.[2] It is a common, nonsexually transmitted condition in children (**Figures 130-1** to **130-4**).
- The number of cases in U.S. adults increased in the 1980s, probably as a result of the HIV/AIDS epidemic. Since the introduction of highly active antiretroviral therapy (HAART), the number of molluscum contagiosum cases in HIV/AIDS patients has decreased substantially.[3] However, the prevalence of molluscum contagiosum in patients who are HIV-positive may still be as high as 5% to 18% (**Figures 130-5** and **130-6**).[4,5]
- In adults, molluscum occurs most commonly in the genital region (**Figure 130-7**). In this case, it is considered a sexually transmitted disease. Subclinical cases may occur and may be more common in the general community than is generally recognized.

FIGURE 130-2 Cryotherapy of molluscum on the face of an 11-year-old girl. The central umbilication is easily seen in the two papules that were just frozen. (*Courtesy of Richard P. Usatine, MD.*)

ETIOLOGY AND PATHOPHYSIOLOGY

- Molluscum contagiosum is a benign condition that is often transmitted through close contact in children and through sexual contact in adults.

- It is a large DNA virus of the *Poxviridae* family of poxvirus. It is related to the orthopoxviruses (variola, vaccinia, smallpox, and monkeypox viruses).
- Molluscum replicates in the cytoplasm of epithelial cells. It causes a chronic localized skin infection consisting of dome-shaped pearly papules on the skin. Like most of the viruses in the poxvirus family, molluscum is spread by direct skin-to-skin contact. It can also spread by autoinoculation when scratching, touching, or treating lesions.
- Any one single lesion is usually present for approximately 2 months, but autoinoculation often causes continuous crops of lesions.

RISK FACTORS

- Common childhood disease.
- Molluscum contagiosum may be more common in patients with atopic dermatitis (**Figure 130-8**).[2]
- The disease also may be spread by participation in contact sports.[2]
- It is also associated with immunodeficient states such as in HIV infection (**Figures 130-5** and **130-6**) and with immunosuppressive drug treatment.

DIAGNOSIS

CLINICAL FEATURES

- Firm, multiple, 2- to 5-mm dome-shaped papules with a characteristic shiny surface and umbilicated center (**Figure 130-9**). Not all the papules have a central umbilication, so it helps to take a moment and look for a papule that has this characteristic morphology. If all features point to molluscum and no single lesion has central umbilication, do not rule out molluscum as the diagnosis.
- The lesions range in color from pearly white, to flesh-colored, to pink or yellow.
- Pruritus may be present or absent.

TYPICAL DISTRIBUTION

- The lesions may appear anywhere on the body except the palms and soles. The number of lesions may be greater in an HIV-infected individual. In adults, they are often found around the genitalia, inguinal area, buttocks, or inner thighs (**Figure 130-7**). In children, the lesions are often on the trunk or face.
- If a child is found to have molluscum contagiosum in the genital area, a history and physical examination should be directed at looking for other clues that might indicate sexual abuse (see Chapter 9, Child Sexual Abuse). Not all cases of molluscum in this area will be secondary to sexual abuse (**Figure 130-10**).

LABORATORY TESTING

- Laboratory testing is not typically indicated.
- Sexually active adolescents and adults with genital lesions should be evaluated for other sexually transmitted diseases, including for HIV infection.

FIGURE 130-3 A group of molluscum contagiosum lesions on the abdomen of a 4-year-old boy. (*Courtesy of Richard P. Usatine, MD.*)

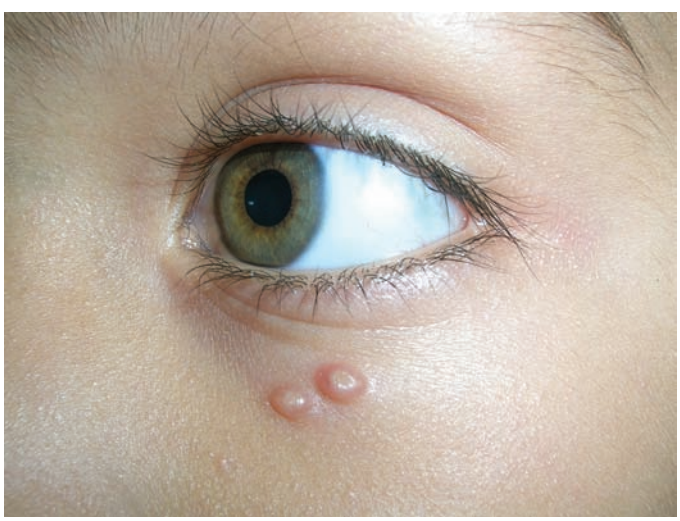

FIGURE 130-4 Molluscum contagiosum under the eye of a young girl with central umbilication. (*Courtesy of Richard P. Usatine, MD.*)

FIGURE 130-5 Molluscum contagiosum on the face of a woman with human immunodeficiency virus. Note the large molluscum on the scalp. (*Courtesy of Richard P. Usatine, MD.*)

BIOPSY

- If confirmation is needed, smears of the caseous material expressed from the lesions can be examined directly under the microscope looking for molluscum bodies (enlarged keratinocytes that are engorged with viral inclusion bodies). Hematoxylin and eosin (H&E) staining from a shave biopsy usually reveals keratinocytes that contain eosinophilic cytoplasmic inclusion bodies.[5] If a single lesion is suspicious for basal cell carcinoma (BCC), perform a shave biopsy.

DIFFERENTIAL DIAGNOSIS

- Scabies is caused by *Sarcoptes scabiei* mite and can be transmitted through close or sexual contact. Early lesions are flesh-colored to red papules that produce significant itching. The itching and excoriations are greater than seen with molluscum. Scabies lesions also usually appear in the finger webs, ventral wrist fold, and underneath the breasts in women (see Chapter 143, Scabies).
- Dermatofibromas—Firm to hard nodules ranging in color from flesh to black that typically dimple downward when compressed laterally. Usually not seen in crops as in molluscum. These nodules are deeper in the dermis and don't appear stuck on like molluscum (see Chapter 160, Dermatofibroma).
- BCCs are also pearly and raised. Usually not seen in crops as in molluscum. If a single lesion could be a BCC or molluscum, a biopsy is warranted (see Chapter 170, Basal Cell Carcinoma).
- Genital warts may be flat and grossly resemble molluscum but they lack the characteristic shiny surface and central umbilication (see Chapter 133, Genital Warts).

MANAGEMENT

NONPHARMACOLOGIC

- Treatment of nongenital lesions is usually not medically necessary as the infection is usually self-limited and spontaneously resolves after a few months. Treatment may be performed in an attempt to decrease autoinoculation. Patients and parents of children often want treatment for cosmetic reasons and when watchful waiting fails.
- A 2009 Cochrane Database systematic review investigated the efficacy of treatments for nongenital molluscum contagiosum in healthy individuals and found insufficient evidence to conclude that any treatment was definitively effective.[6] SOR A
- In the HIV-infected patient, molluscum may resolve after control of HIV disease with HAART.[3] SOR B

MEDICATIONS

- Podophyllotoxin 0.5% (Condylox) is an antimitotic agent that is indicated for the treatment of genital warts. The efficacy of podophyllotoxin was established in a randomized trial of lesions located on the thighs or genitalia. SOR B Local erythema, burning, pruritus, inflammation, and erosions can occur with the use of this agent. The safety and efficacy of this drug has not been established in young children.[7]

FIGURE 130-6 Extensive molluscum contagiosum on the face of a young girl who has been human immunodeficiency virus-positive from birth. (*Courtesy of Richard P. Usatine, MD.*)

FIGURE 130-7 Molluscum contagiosum on and around the penis. His girlfriend has them on the buttocks. (*Courtesy of Richard P. Usatine, MD.*)

FIGURE 130-8 Molluscum contagiosum in the antecubital fossa of a 6-year-old girl with atopic dermatitis. (*Courtesy of Richard P. Usatine, MD.*)

- Topical imiquimod 5% (Aldara) cream has been shown (not FDA approved) to be better than vehicle alone to treat molluscum.[8,9] SOR B It can be well tolerated, although application site irritation can be uncomfortable and lead to discontinuation of therapy. It has been shown not to have systemic or toxic effects in children.[9] In one study, 23 children ranging in age from 1 to 9 years with molluscum contagiosum infection were randomized to either imiquimod cream 5% (12 patients) or vehicle (11 patients). Parents applied the study drug to the patient's lesions 3 times a week for 12 weeks. Complete clearance at week 12 was noted in 33.3% (4/12) of imiquimod patients and in 9.1% (1/11) of vehicle patients.[10]
- Tretinoin cream[11] 0.1% or gel 0.025% applied daily are commonly used but not FDA-approved for this indication. SOR B
- Cantharidin[12] and trichloroacetic acid[13] are topical chemicals that can be applied by the physician in the office (**Figure 130-11**). SOR B Many children will fear treatment with a curette or with any form of cryotherapy.

SURGICAL

- Curettage and cryotherapy are physical methods used to eradicate molluscum.[14,15] SOR B

COMPLEMENTARY AND ALTERNATIVE THERAPY

- ZymaDermis a nonprescription, topical, homeopathic agent that is marketed for the treatment of molluscum contagiosum, but no published studies have evaluated its efficacy or safety.

PREVENTION

- Molluscum contagiosum is a common childhood disease.
- Limiting sexual exposure or number of sexual contact may help prevent exposure.
- Genital lesions should be treated to prevent spread by sexual contact.

PROGNOSIS

- In immunocompetent patients, lesions usually spontaneously resolve within several months. In a minority of cases, disease persists for a few years.[16]

FOLLOW-UP

- Have patients watch for complications that may include irritation, inflammation, and secondary infections. Lesions on eyelids may be associated with follicular or papillary conjunctivitis, so eye irritation should prompt a visit to an eye care specialist.

PATIENT EDUCATION

- Instruct patients to avoid scratching to prevent autoinoculation.

FIGURE 130-9 Close-up of a molluscum lesion on the back of a child showing a dome-shaped pearly papule with a characteristic umbilicated center. (*Courtesy of Richard P. Usatine, MD.*)

FIGURE 130-10 Molluscum contagiosum on and around the penis of a young boy. There was no evidence for sexual abuse. (*Courtesy of Richard P. Usatine, MD.*)

FIGURE 130-11 Blisters that formed the next day after treating molluscum contagiosum with cantharidin. The blisters are not always so large but are supposed to form as the cantharidin is derived from the blister beetle. The blistering helps eradicate the molluscum. (*Courtesy of Richard P. Usatine, MD.*)

PATIENT RESOURCES

- Centers for Disease Control and Prevention. *Molluscum (Molluscum Contagiosum)*—**http://www.cdc.gov/ncidod/dvrd/molluscum/.**
- Pubmed Health. *Molluscum Contagiosum*—**http://www.ncbi.nlm.nih.gov/pubmedhealth/PMH0001829/.**
- American Academy of Dermatology. *Molluscum Contagiosum*—**http://www.aad.org/skin-conditions/dermatology-a-to-z/molluscum-contagiosum.**
- eMedicine Health. *Molluscum Contagiosum*—**http://www.emedicinehealth.com/molluscum_contagiosum/article_em.htm.**
- MedlinePlus. *Molluscum Contagiosum*—**http://www.nlm.nih.gov/medlineplus/ency/article/000826.htm.**

PROVIDER RESOURCES

- eMedicine. *Molluscum Contagiosum*—**http://emedicine.medscape.com/article/910570.**
- Centers for Disease Control and Prevention. *Clinical Information: Molluscum Contagiosum*—**http://www.cdc.gov/ncidod/dvrd/molluscum/clinical_overview.htm.**

REFERENCES

1. Konya J, Thompson CH. Molluscum contagiosum virus: antibody responses in persons with clinical lesions and seroepidemiology in a representative Australian population. *J Infect Dis.* 1999; 179(3):701-704.
2. Dohil MA, Lin P, Lee J, et al. The epidemiology of molluscum contagiosum in children. *J Am Acad Dermatol.* 2006;54(1):47-54.
3. Calista D, Boschini A, Landi G. Resolution of disseminated molluscum contagiosum with highly active anti-retroviral therapy (HAART) in patients with AIDS. *Eur J Dermatol.* 1999;9(3):211-213.
4. Schwartz JJ, Myskowski PL. Molluscum contagiosum in patients with human immunodeficiency virus infection. *J Am Acad Dermatol.* 1992;27(4):583-588.
5. Cotell SL, Roholt NS. Images in clinical medicine. Molluscum contagiosum in a patient with the acquired immunodeficiency syndrome. *N Engl J Med.* 1998;338(13):888.
6. van der Wouden JC, van der Sande R, van Suijlekom-Smit LW, et al. Interventions for cutaneous molluscum contagiosum. *Cochrane Database Syst Rev.* 2009 Oct 7;(4):CD004767.
7. Syed TA, Lundin S, Ahmad M. Topical 0.3% and 0.5% podophyllotoxin cream for self-treatment of molluscum contagiosum in males. A placebo-controlled, double-blind study. *Dermatology.* 1994;189(1):65-68.
8. Hengge UR, Esser S, Schultewolter T, et al. Self-administered topical 5% imiquimod for the treatment of common warts and molluscum contagiosum. *Br J Dermatol.* 2000;143(5):1026-1031.
9. Barba AR, Kapoor S, Berman B. An open label safety study of topical imiquimod 5% cream in the treatment of Molluscum contagiosum in children. *Dermatol Online J.* 2001;7(1):20.

10. Theos AU, Cummins R, Silverberg NB, Paller AS. Effectiveness of imiquimod cream 5% for treating childhood molluscum contagiosum in a double-blind, randomized pilot trial. *Cutis.* 2004;74 (2):134-138, 141-142.

11. Papa CM, Berger RS. Venereal herpes-like molluscum contagiosum: treatment with tretinoin. *Cutis.* 1976;18(4):537-540.

12. Silverberg NB, Sidbury R, Mancini AJ. Childhood molluscum contagiosum: experience with cantharidin therapy in 300 patients. *J Am Acad Dermatol.* 2000;43(3):503-507.

13. Yoshinaga IG, Conrado LA, Schainberg SC, Grinblat M. Recalcitrant molluscum contagiosum in a patient with AIDS: combined treatment with CO(2) laser, trichloroacetic acid, and pulsed dye laser. *Lasers Surg Med.* 2000;27(4):291-294.

14. Hanna D, Hatami A, Powell J, et al. A prospective randomized trial comparing the efficacy and adverse effects of four recognized treatments of molluscum contagiosum in children. *Pediatr Dermatol.* 2006;23(6):574-579.

15. Wetmore SJ. Cryosurgery for common skin lesions. Treatment in family physicians' offices. *Can Fam Physician.* 1999;45:964-974.

16. Lee R, Schwartz RA. Pediatric molluscum contagiosum: reflections on the last challenging poxvirus infection, part 1. *Cutis.* 2010;86(5):230-236.

131 COMMON WARTS

E.J. Mayeaux, Jr., MD

PATIENT STORY

An 11-year-old girl presents with warts on her fingers that have not responded to nonprescription wart medications (**Figure 131-1**). It causes her and her mother some social embarrassment and they would like to be rid of them. Her mother is also worried that it is affecting her daughter's nails. The girl was able to tolerate the discomfort of liquid nitrogen treatment and wanted all her warts treated. The mother was instructed to purchase 40% salicylic acid to continue treatment of any residual warts at home.

FIGURE 131-1 Common warts on the hands of an 11-year-old girl. These periungual warts are particularly difficult to eradicate. (*Courtesy of Richard P. Usatine, MD.*)

INTRODUCTION

Human papillomaviruses (HPVs) are DNA viruses that infect skin and mucous membranes. Infection is usually confined to the epidermis and does not result in disseminated systemic infection. The most common clinical manifestation of these viruses is warts (verrucae). There are more than 100 distinct HPV subtypes based on DNA testing. Some tend to infect specific body sites or types of epithelium. Some HPV types have a potential to cause malignant change but transformation is rare on keratinized skin.

SYNONYMS

Verrucae, verruca vulgaris, common warts.

EPIDEMIOLOGY

- Nongenital cutaneous warts are widespread worldwide and are more common in children, with a peak incidence in the teenage years and a sharp decline thereafter.[1]
- They are most commonly caused by HPV types 1 to 5, 7, 27, 29.[1]
- Common warts account for approximately 70% of nongenital cutaneous warts.[2]
- Common warts occur most commonly in children and young adults (**Figures 131-1** and **131-2**).[3]

FIGURE 131-2 Many common warts on the hand of an human immunodeficiency virus-negative young adult. (*Courtesy of Richard P. Usatine, MD.*)

ETIOLOGY AND PATHOPHYSIOLOGY

- Infection with HPV occurs by skin-to-skin contact. It starts with a break in the integrity of the epithelium caused by maceration or trauma that allows the virus to infect the basal layers.
- Warts may infect the skin on opposing digits causing "kissing warts" (**Figure 131-3**).
- Individuals with subclinical infection may serve as a reservoir for HPVs.

- An incubation period following inoculation lasts for approximately 2 to 6 months.

RISK FACTORS[1]

- Young age.
- Disruption to the normal epithelial barrier.
- More common among meat handlers.
- Atopic dermatitis.
- Nail biters more commonly have multiple periungual warts.
- Conditions that decrease cell-mediated immunity such as HIV (**Figure 131-4)** and immunosuppressant drugs (**Figure 131-5)**.

DIAGNOSIS

CLINICAL FEATURES

- The diagnosis of warts is based upon clinical appearance. The wart will obscure normal skin markings.
- Common warts are well-demarcated, rough, hard papules with irregular papillary surface. They are usually asymptomatic unless located on a pressure point.
- Warts may form cylindrical of filiform projections (**Figure 131-6**).

TYPICAL DISTRIBUTION

- Common anatomic locations include the dorsum of the hand, between the fingers, flexor surfaces, and adjacent to the nails (periungual) (**Figures 131-1** and **131-2**).

LABORATORY TESTING

- HPV testing is not useful for this condition.[4]
- HIV testing may be useful if the warts are severe and there are risk factors present (**Figure 131-4**).

BIOPSY

- Paring the surface with a surgical blade may expose punctate hemorrhagic capillaries, or black dots, which are thrombosed capillaries. If the diagnosis is in doubt, a shave biopsy is indicated to confirm the diagnosis.

DIFFERENTIAL DIAGNOSIS

- Seborrheic keratosis are usually more darkly pigmented, have a stuck-on appearance, and "horn cysts" may be visible on close examination. They also have a wide distribution on the body (see Chapter 158, Seborrheic Keratosis). Typical dermoscopic patterns include comedo-like openings and milia-like cysts (see Appendix C, Dermoscopy)
- Acrochordon (skin tags) are pedunculated flesh-colored papules that are more common in obese persons. They lack the surface roughness of common warts. Filiform warts also may be pedunculated, but typically have a characteristic filiform appearance (see Chapter 157, Skin Tag).

FIGURE 131-3 Warts may infect the skin on opposing digits causing "kissing warts." (*Courtesy of Richard P. Usatine, MD.*)

FIGURE 131-4 Large cluster of warts on the foot of a child in Africa suspected of being human immunodeficiency virus-positive. (*Courtesy of Richard P. Usatine, MD.*)

- Squamous cell carcinoma (SCC) should be considered when lesions have irregular growth, pigmentation, ulceration, or resist therapy, particularly in sun-exposed areas and in immunosuppressed patients (see Chapter 171, Squamous Cell Carcinoma). The patient in **Figure 131-7** had a wart that was not going away and a biopsy demonstrated SCC in situ with in an HPV-induced lesion.
- Amelanotic melanoma—Although rare, lesions that are treatment resistant or atypical should be monitored closely or biopsied to establish the diagnosis (see Chapter 172, Melanoma).
- Early warts may appear similar to actinic keratosis in sun-exposed areas (see Chapter 166, Actinic Keratosis and Bowen Disease)
- Advanced warts may appear similar to a keratoacanthoma to casual inspection. The characteristic findings of the keratoacanthoma and biopsy will separate the two conditions. (see Chapter 167, Keratoacanthoma)

FIGURE 131-5 Biopsy-proven warts on the neck and chest of a woman on azathioprine after a renal transplantation. Human papillomaviruses lesions can proliferate as a result of immunosuppressive medications. This patient is also being monitored for squamous cell carcinoma, as this is a more significant risk in posttransplantation patients. (*Courtesy of Richard P. Usatine, MD.*)

MANAGEMENT

NONPHARMACOLOGIC

- Because spontaneous regression occurs in two-thirds of warts within 2 years, observation without treatment is always an option. In 17 trials, the average reported cure rate was 30% within 10 weeks.[5] Observational studies show that one-half of cutaneous warts resolve spontaneously within 1 year, and about two-thirds within 2 years.[6]
- Treatment does not decrease transmissibility of the virus.[7]

MEDICATIONS

- Therapies for common warts do not specifically treat the HPV virus. They work by destruction of virus-containing skin while preserving uninvolved tissue. This usually exposes the blood and its immune cells to the virus, which may promote an immune response against the virus.
- The least-painful methods should be used first, especially in children. SOR C
- A Cochrane review found that there is a considerable lack of evidence on which to base the rational use of the local treatments for common warts.[5] The trials are highly variable in method and quality. There is evidence that simple topical treatments containing salicylic acid have a therapeutic effect.[5] SOR A There is less evidence for the efficacy of cryotherapy and no convincing evidence that it is any more effective than simple topical treatments.
- Seventeen percent salicylic acid is a useful first-line agent, especially for thick or multiple warts.[5] SOR A It is safe in children. Combined results from 5 randomized controlled trials (RCTs) showed a 73% cure rate with 6 to 12 weeks of salicylic acid treatment, compared with a 48% cure rate with placebo (number needed to treat [NNT] = 4).[5] A number of preparations are available without a prescription. Topical 17% salicylic acid is applied overnight and is now the most commonly used form for this type of wart. Soak the wart area with warm water for 5 minutes, then gently file down any thick skin with a pumice stone or emery board. The salicylic acid product should be applied to the wart. Repeat the first two steps daily with liquid or gel preparations, or

FIGURE 131-6 Filiform warts are identified by their multiple projections as opposed to a unified papule. This wart was on the face of an elderly woman and was removed by shave excision and sent for pathology. It was proven to be a wart and not squamous cell carcinoma. (*Courtesy of Richard P. Usatine, MD.*)

every other day with the patch. Tape may be used to cover the wart after application of salicylic acid liquid. Repeat treatment until the wart has cleared, or for up to 12 weeks. Discontinue the treatment if severe redness or pain occurs in the treated area. Do not use salicylic acid on the face because of an increased risk of hypopigmentation.[1]

- Forty percent salicylic acid plasters (Mediplast) are available over the counter for larger and thicker warts. The plasters are cut to fit and then applied a few millimeters beyond the wart for 48 hours. Then the patch is removed; the wart pared down with a nail file, pumice stone, or scalpel; and the process repeated as needed.
- Imiquimod 5% is an expensive topical immunomodulator that is indicated for treatment of anogenital warts but is also used on nongenital warts.[8–10] SOR B It is nonscarring and painless, although local irritation is common. Debriding heavily keratinized warts may enhance penetration of the medication. The cream is applied in a thin layer to the lesions three times a week (every other night) and covered with an adhesive bandage or tape. The medication is removed with soap and water in the morning. It can also be used as adjunctive therapy. A lower concentration of imiquimod (3.75% cream) is also available, but data for common warts is lacking.
- Intralesional injections with *Candida* antigen induces a localized, cell-mediated, and HPV-specific response that may target the injected wart as well as more distant warts (**Figure 131-8**). This method has moderate effectiveness (60% cure rates) for treatment of recalcitrant warts in patients with a positive skin antigen pretest.[1] SOR B The *Candida* antigen must be diluted before used (see **Table 132-1**). Inject 0.1 to 0.3 mL into the largest warts using a 30-gauge needle and up to 1 mL per treatment. Warn the patient to expect itching in the area, burning, or peeling. Repeat every 4 weeks, up to 3 treatments or until warts are gone.
- Photodynamic therapy with aminolevulinic acid plus topical salicylic acid is a moderately effective option for treatment of recalcitrant warts.[1] SOR B Although it is likely to be beneficial, it is expensive and often requires referral.
- Cantharidin 0.7% is an extract of the blister beetle that is applied to the wart, after which blistering occurs on the following day. It may be used in resistant cases. It is also useful in young children because application is painless in the office. However, painful blisters often occur within a day after application. Be careful not to overtreat with cantharidin because the blistering can be quit severe. Carefully apply to multiple lesions using the wooden end of a cotton-tipped applicator (**Figure 131-9**). SOR C
- Contact immunotherapy using dinitrochlorobenzene, squaric acid dibutylester, and diphenylcyclopropenone may be applied to the skin to sensitize the patient and then to the lesion to induce an immune response. SOR C
- Intralesional injection with bleomycin can be considered for treatment of recalcitrant warts, although the effectiveness is unproven.[1] SOR B
- Early open-label, uncontrolled studies indicate cimetidine might be useful in treating warts. However, three placebo-controlled, double-blind studies and two open-label comparative trials demonstrate that its efficacy is equal to placebo.[11] SOR A

FIGURE 131-7 Squamous cell carcinoma in situ that started from an human papillomaviruses-positive lesion. When cryotherapy is not working on what appears to be a wart, consider performing a biopsy. (*Courtesy of Richard P. Usatine, MD.*)

FIGURE 131-8 Candida antigen is being injected into a cluster of warts on the knee of a teenage boy. His warts did not respond to multiple therapies, including topical salicylic acid and cryotherapy. (*Courtesy of Richard P. Usatine, MD.*)

SURGICAL

- Cryotherapy, most commonly with liquid nitrogen, is useful but is somewhat painful for younger children.[5] SOR B Chemical cryogens are now available over the counter but are not as cold or effective as liquid nitrogen. Most trials comparing cryotherapy with salicylic acid found similar effectiveness, with overall cure rates of 50% to 70% after 3 or 4 treatments.[1] Aggressive cryotherapy (10 to 30 seconds) is more effective than less-aggressive cryotherapy, but may increase complications.[1] SOR B Anesthesia is usually unnecessary but may be achieved with 1% lidocaine or EMLA (eutectic mixture of local anesthetics) cream. Liquid nitrogen is applied for 10 to 20 seconds via a Cryogun or a cotton swab so that the freeze ball extends 2 mm beyond the lesion (**Figure 131-10**). Two freeze cycles may improve resolution, but it is better to underfreeze than overfreeze as overfreezing may lead to permanent scarring or hypopigmentation. Best results of cryotherapy can be achieved when the patient is treated every 2 or 3 weeks. There is no therapeutic benefit beyond 3 months.[1] SOR B Because HPV can survive in liquid nitrogen, cotton swabs and residual liquid nitrogen should be properly discarded to avoid spreading the virus to other patients or contaminating the liquid nitrogen reservoir.[13] After cryotherapy, the skin shows erythema and may progress to hemorrhagic blistering. Healing occurs in approximately a week and hypopigmentation may occur. Ring warts may result from an inadequate margin of treatment of a common wart (**Figure 131-11**). Common adverse effects of cryotherapy include pain, blistering, and hypo- or hyperpigmentation. Cryotherapy must be used cautiously where nerves are located superficially (such as on the fingers) to prevent pain and neuropathy. Overfreezing in the periungual region can result in permanent nail dystrophy.
- Simple excision is used for small or filiform warts (**Figure 131-7**). The area is injected with lidocaine and the wart is excised with sharp scissors or a scalpel blade. SOR C
- Pulsed-dye laser can be considered for treatment of recalcitrant warts, although the effectiveness is unproven.[1] SOR B

COMPLEMENTARY AND ALTERNATIVE THERAPY

- Although preliminary studies were promising, duct tape is of uncertain efficacy for wart treatment.[1] A randomized controlled trial in adults showed it to be no better than moleskin and both groups only had a 21% to 22% success rate.[12] SOR B

PREVENTION

- Tools used for paring down warts, such as nail files and pumice stones, should not be used on normal skin or by other people.
- Hair-bearing areas with warts should be shaved with depilatories, electric razors, or not at all to help limit spread of warts.

PROGNOSIS

- Sixty percent to 70% of cutaneous warts resolve in 3 to 24 months without treatment.[14,15]

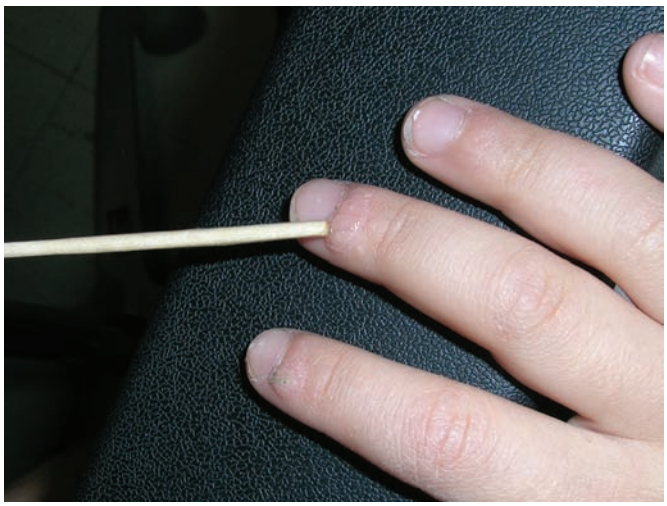

FIGURE 131-9 Cantharidin is being applied to periungual warts on the fingers of a 5-year-old child. Note the use of the wooden stick of a cotton-tipped applicator. If the cotton tip is used, the cantharidin stays within the cotton and the application is insufficient. (*Courtesy of Richard P. Usatine, MD.*)

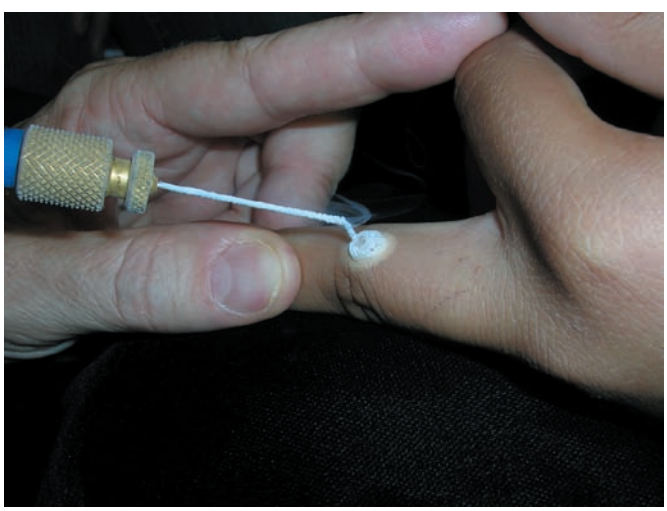

FIGURE 131-10 Cryotherapy showing an adequate free zone (halo) around the wart. (*Courtesy of Richard P. Usatine, MD.*)

FIGURE 131-11 Ring wart that resulted from inadequate cryotherapy of a common wart. (*Courtesy of Richard P. Usatine, MD.*)

- New warts may appear while others are regressing. This is not a treatment failure but part of the natural disease process with HPV.

FOLLOW-UP

- Schedule patients for return visits after treatment to limit loss of follow-up and to assess therapy.
- Follow-up visits can be left to the patient's discretion when self-applied therapy is being used.

PATIENT EDUCATION

- Therapy often takes weeks to months, so patience and perseverance are essential for successful therapy.

PATIENT RESOURCES

- AFP Patient Information. *Am Fam Physician*. 2011;84(3):296.—**http://www.aafp.org/afp/2011/0801/p296.html.**
- eMedicine Health—**http://www.emedicinehealth.com/warts/article_em.htm.**
- BUPA. *Warts and verrucas patient information*—**http://www.bupa.co.uk/individuals/health-information/directory/w/warts-and-verrucas?tab=Resources.**
- FamilyDoctor.org. American Academy of Family Physicians. *Warts*—**http://familydoctor.org/209.xml.**
- MayoClinic.com. *Common warts*—**http://www.mayoclinic.com/health/common-warts/DS00370.**

PROVIDER RESOURCES

- eMedicine. *Nongenital Warts*—**http://emedicine.medscape.com/article/1133317.**
- For information on treating warts including how to dilute Candida antigen: Usatine R, Pfenninger J, Stulberg D, Small R. *Dermatologic and Cosmetic Procedures in Office Practice*. Philadelphia, PA: Elsevier; 2012. This can also be purchased as an electronic application at **www.usatinemedia.com**
- Cutaneous warts: An evidence-based approach to therapy. *Am Fam Physician*. 2005;72:647-652. Available online at **http://www.aafp.org/afp/20050815/647.html.**
- Medline Plus—**http://www.nlm.nih.gov/medlineplus/ency/article/000885.htm.**
- Cochrane review. *Topical Treatments for Cutaneous Warts*—**http://www.cochrane.org/reviews/en/ab001781.html.**

REFERENCES

1. Mulhem E, Pinelis S. Treatment of nongenital cutaneous warts. *Am Fam Physician*. 2011;84(3):288-293.
2. Micali G, Dall'Oglio F, Nasca MR, et al. Management of cutaneous warts: an evidence-based approach. *Am J Clin Dermatol*. 2004;5(5):311-317.
3. Kilkenny M, Marks R. The descriptive epidemiology of warts in the community. *Australas J Dermatol*. 1996;37:80-86.
4. Sterling JC, Handfield-Jones S, Hudson PM; British Association of Dermatologists. Guidelines for the management of cutaneous warts. *Br J Dermatol*. 2001;144(1):4-11.
5. Gibbs S, Harvey I, Sterling JC, Stark R. Local treatments for cutaneous warts. *Cochrane Database Syst Rev*. 2001;(2):CD001781.
6. Massing AM, Epstein WL. Natural history of warts. A two-year study. *Arch Dermatol*. 1963;87:306-310.
7. Rivera A, Tyring SK. Therapy of cutaneous human papillomavirus infections. *Dermatol Ther*. 2004;17(6):441-448.
8. Micali G, Dall'Oglio F, Nasca MR. An open label evaluation of the efficacy of imiquimod 5% cream in the treatment of recalcitrant subungual and periungual cutaneous warts. *J Dermatolog Treat*. 2003;14:233-236.
9. Hengge UR, Esser S, Schultewolter T, et al. Self-administered topical 5% imiquimod for the treatment of common warts and molluscum contagiosum. *Br J Dermatol*. 2000;143:1026-1031.
10. Grussendorf-Conen EI, Jacobs S. Efficacy of imiquimod 5% cream in the treatment of recalcitrant warts in children. *Pediatr Dermatol*. 2002;19:263-266.
11. Yilmaz E, Alpsoy E, Basaran E. Cimetidine therapy for warts: a placebo-controlled, double-blind study. *J Am Acad Dermatol*. 1996;34(6):1005-1007.
12. Wenner R, Askari SK, Cham PM, et al. Duct tape for the treatment of common warts in adults: a double-blind randomized controlled trial. *Arch Dermatol*. 2007;143(3):309-313.
13. Tabrizi SN, Garland SM. Is cryotherapy treating or infecting? *Med J Aust*. 1996;164(5):263.
14. Allen AL, Siegfried EC. What's new in human papillomavirus infection. *Curr Opin Pediatr*. 2000;12:365-369.
15. Sterling JC, Handfield-Jones S, Hudson PM. Guidelines for the management of cutaneous warts. *Br J Dermatol*. 2001;144:4-11.

132 FLAT WARTS

E.J. Mayeaux, Jr., MD

PATIENT STORY

A 16-year-old girl presents with multiple flat lesions on her forehead (**Figure 132-1**). It started with just a few lesions but has spread over the past 3 months. She is diagnosed with flat warts and topical imiquimod is prescribed as the initial treatment.

FIGURE 132-1 Flat warts on a patient's forehead. (*Courtesy of Richard P. Usatine, MD.*)

INTRODUCTION

Flat warts are characterized as flat or slightly elevated flesh-colored papules. They may be smooth or slightly hyperkeratotic. They range in size from 1 to 5 mm or more, and numbers range from a few to hundreds of lesions, which may become grouped or confluent. They occur most commonly on the face, hands, and shins. They may appear in a linear distribution as a result of scratching, shaving, or trauma (Koebner phenomenon) (**Figure 132-2**).

SYNONYMS

Plane warts, verruca plana, verruca plana juvenilis.

EPIDEMIOLOGY

- Flat warts (verruca plana) are most commonly found in children and young adults (**Figures 132-1** to **132-?**).
- Flat warts are the least common variety of wart, but are generally numerous on an individual.[1]
- Flat warts are usually caused by human papillomavirus (HPV) types 3, 10, 28, and 29.[2]

ETIOLOGY AND PATHOPHYSIOLOGY

- Like all warts, flat warts are caused by HPV.[2]
- Flat warts may spread in a linear pattern secondary to spread by scratching or trauma, such as shaving.
- Flat warts present a special treatment problem because they persist for a long time, they are generally located in cosmetically important areas, and they are resistant to therapy.

RISK FACTORS

- Shaving next to infected areas (**Figures 132-2** and **132-3**).
- HIV infection or other types of immunosuppression (**Figure 132-3**).

FIGURE 132-2 Flat warts just above the knee of a young woman. Probably spread by shaving. (*Courtesy of Richard P. Usatine, MD.*)

DIAGNOSIS

CLINICAL FEATURES

- Multiple small, flat-topped papules that may be pink, light brown, or light yellow colored. They may be polygonal in shape (**Figure 132-4**).

TYPICAL DISTRIBUTION

- Flat warts typically appear on the forehead (**Figure 132-1**), around the mouth (**Figure 132-5**), the backs of the hands, and shaved areas, such as the lower face and neck in men (**Figure 132-3**) and the lower legs in women (**Figure 132-2**).

LABORATORY TESTING

- HPV testing is not useful for this condition.[3]

BIOPSY

- Although usually not necessary, a shave biopsy can confirm the diagnosis.

DIFFERENTIAL DIAGNOSIS

- Lichen planus produces flat-topped papules that may be confused with flat warts. Look for characteristic signs of lichen planus such as the symmetric distribution, purplish coloration, and oral lacy lesions. (Wickham striae are white, fine, reticular scale seen on the lesions.) The distribution of lichen planus is different, with the most common sites being the ankles, wrists, and back (see Chapter 154, Lichen Planus).
- Seborrheic keratoses are often more darkly pigmented and have a stuck-on appearance; "horn cysts" may be visible on close examination (see Chapter 158, Seborrheic Keratosis).
- Squamous cell carcinoma should be considered when lesions have irregular growth or pigmentation, ulceration, or resist therapy, particularly in sun-exposed areas and in immunosuppressed patients (see Chapter 171, Squamous Cell Carcinoma).

MANAGEMENT

NONPHARMACOLOGIC

- Regression of these lesions may occur, which usually is heralded by inflammation.
- There are no current therapies for HPV that are virus specific.

MEDICATIONS

- Topical salicylic acid treatments by topical liquid or patch are the most effective treatment for all types of warts with a success rate average of 73% from five pooled placebo-controlled trials.[4] Number needed to treat (NNT) = 4. SOR A Salicylic acid may be more acceptable on the legs than the face.[2] Often, 17% salicylic acid topicals are applied overnight daily until the warts resolve.

FIGURE 132-3 Flat warts on the neck of an HIV-positive man. The warts have been spread by shaving. Cryotherapy and imiquimod were not successful but intralesional Candida antigen injections cleared all the warts. (*Courtesy of Richard P. Usatine, MD.*)

FIGURE 132-4 Close-up of a flat wart. Note typical small, flat-topped papule. (*Courtesy of Richard P. Usatine, MD.*)

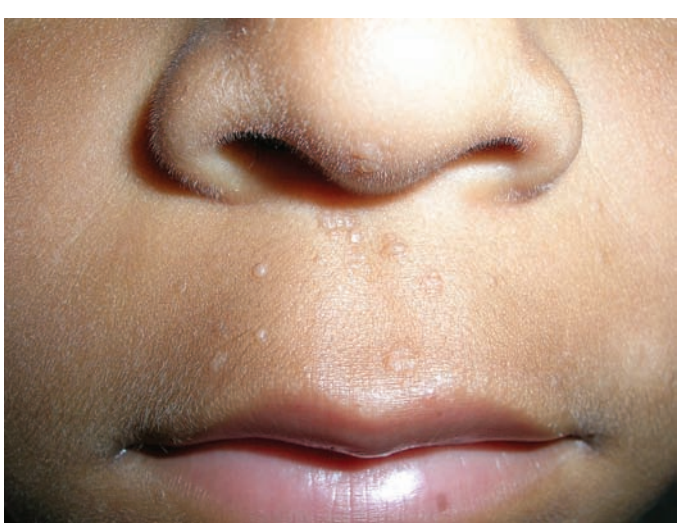

FIGURE 132-5 Flat warts on the upper lip and nose of a young girl. (*Courtesy of Richard P. Usatine, MD.*)

- Fluorouracil (Efudex 5% cream, Fluoroplex 1%) may be used to treat flat warts. Apply the cream to affected areas twice daily for 3 to 4 weeks. Sun protection is essential because the drug is photosensitizing. Persistent hypo- or hyperpigmentation may occur following use, but applying it with a cotton-tipped applicator to individual lesions instead of to the area may minimize this adverse reaction.[5,6] SOR B
- Imiquimod 5% cream is an expensive topical immunomodulator that has shown some efficacy in treating flat warts.[7,8] It is nonscarring and painless to apply. There are rare reports of systemic side effects. The cream is applied to the lesions 3 times a week (every other day). The cream may be applied to the affected area, not strictly to the lesion itself.[9] It can be used on all external HPV-infected sites, but not on occluded mucous membranes. Therapy can be temporarily halted if symptoms become problematic. Imiquimod has the advantage of having almost no risk of scarring.[7,8] SOR B A lower concentration of imiquimod (3.75% cream) is also available, but data for its use with flat or common warts is lacking.
- Tretinoin cream, 0.025%, 0.05%, or 0.1%, applied at bedtime over the entire involved area is one accepted treatment. The frequency of application is then adjusted so as to produce a mild, fine scaling and erythema. Sun protection is important. Treatment may be required for weeks or months and may not be effective. No published studies were found to support this treatment. SOR C
- Intralesional injections with *Candida* antigen induces a localized, cell-mediated, and HPV-specific response that may target the injected wart as well as more distant warts. This method has moderate effectiveness (60% cure rates) for treatment of recalcitrant warts (**Figure 132-3**).[2] The *Candida* antigen must be diluted before used (see **Table 132-1**). Inject 0.1 to 0.3 mL into the largest warts using a 30-gauge needle and up to 1 mL per treatment. Warn the patient to expect itching in the area, burning, or peeling. Repeat every 4 weeks, up to three treatments or until warts are gone.[10] SOR B
- Photodynamic therapy with aminolevulinic acid plus topical salicylic acid is a moderately effective option for treatment of recalcitrant warts. Although it is likely to be beneficial, it is expensive and often requires dermatologic referral.[2] SOR B
- Cantharidin 0.7% is an extract of the blister beetle that is applied to the wart after which blistering occurs. It may be used in resistant cases.[11] It is also useful in young children because application is painless in the office. However, painful blisters often occur within a day after application. Be careful not to overtreat with cantharidin because the blistering can be quite severe. Carefully apply to multiple lesions using the wooden end of a cotton-tipped applicator. SOR C

SURGICAL

- Cryotherapy, most commonly with liquid nitrogen, is useful but is somewhat painful for younger children.[6] SOR B Chemical cryogens are now available over the counter but are not as cold or effective as liquid nitrogen. Most trials comparing cryotherapy with salicylic acid found similar effectiveness.[2] Liquid nitrogen is applied for 5 to 10 seconds via a Cryogun or a cotton swab so that the freeze ball extends 1 to 2 mm beyond the lesion. Because flat warts are thinner than common warts, the freeze times needed are shorter. Two freeze cycles may improve resolution, but it is better

TABLE 132-1 Candida Dilutions

Creating 1.0 mL for Injection	Candida Antigen (mL)	2% Lidocaine (no Epinephrine) (mL)
Generic 1:1000	0.25	0.75
Candin 1:500	0.5	0.5

Reprinted with permission from: Usatine R, Pfenninger J, Stulberg D, Small R. Dermatologic and Cosmetic Procedures in Office Practice. Elsevier, Inc., Philadelphia. 2012.

to underfreeze than overfreeze since overfreezing may lead to permanent scarring or hypopigmentation. Best results of cryotherapy can be achieved when the patient is treated every 2 or 3 weeks. There is no therapeutic benefit beyond 3 months.[2] SOR B Because HPV can survive in liquid nitrogen, cotton swabs and residual liquid nitrogen should be properly discarded to avoid spreading the virus to other patients or contaminating the liquid nitrogen reservoir.[12] After cryotherapy, the skin shows erythema and may progress to hemorrhagic blistering. Healing occurs in approximately a week and hypopigmentation may occur. Common adverse effects of cryotherapy include pain, blistering, and hypo- or hyperpigmentation.

- Pulsed-dye laser can be considered for treatment of recalcitrant warts, although the effectiveness is unproven.[2] SOR B

PREVENTION

- Hair-bearing areas with warts should be shaved with depilatories, electric razors, or not at all to help limit spread of warts.

FOLLOW-UP

- Schedule patients for a return visit in 2 to 3 weeks after therapy to assess efficacy.

PATIENT EDUCATION

- To help avoid spreading warts, patients should avoid touching or scratching the lesions.
- Razors that are used in areas where warts are located should not be used on normal skin or by other people to prevent spread.

PATIENT RESOURCES

- KidsHealth—**http://www.kidshealth.org/parent/infections/skin/wart.html.**
- American Academy of Dermatology—**http://www.aad.org/public/Publications/pamphlets/Warts.htm.**
- MedlinePlus. *Warts*—**http://www.nlm.nih.gov/medlineplus/ency/article/000885.htm.**

PROVIDER RESOURCES

- Bacelieri R, Johnson SM. Cutaneous warts. An evidence-based approach to therapy. *Am Fam Physician.* 2005;72:647-652. **http://www.aafp.org/afp/20050815/647.html.**
- Cochrane Review. *Topical Treatments for Cutaneous Warts*—**http://www.cochrane.org/reviews/en/ab001781.html.**
- Treatment of warts is covered extensively in: Usatine R, Pfenninger J, Stulberg D, Small R. Dermatologic and Cosmetic Procedures in Office Practice. Elsevier, Inc., Philadelphia. 2012. This can also be purchased as an electronic application at **www.usatinemedia.com**

REFERENCES

1. Williams H, Pottier A, Strachan D. Are viral warts seen more commonly in children with eczema? *Arch Dermatol.* 1993;129:717-720.
2. Mulhem E, Pinelis S. Treatment of nongenital cutaneous warts. *Am Fam Physician.* 2011;84(3):288-293.
3. Sterling JC, Handfield-Jones S, Hudson PM; British Association of Dermatologists. Guidelines for the management of cutaneous warts. *Br J Dermatol.* 2001;144(1):4-11.
4. Gibbs S, Harvey I. Topical treatments for cutaneous warts. *Cochrane Database Syst Rev*. 2006;(3):CD001781.
5. Lockshin NA. Flat facial warts treated with fluorouracil. *Arch Dermatol.* 1979;115:929-1030.
6. Lee S, Kim J-G, Chun SI. Treatment of verruca plana with 5% 5-fluorouracil ointment. *Dermatologica.* 1980;160:383-389.
7. Cutler K, Kagen MH, Don PC, et al. Treatment of facial verrucae with topical imiquimod cream in a patient with human immunodeficiency virus. *Acta Derm Venereol.* 2000;80:134-135.
8. Kim MB. Treatment of flat warts with 5% imiquimod cream. *J Eur Acad Dermatol Venereol.* 2006;20(10):1349-1350.
9. Schwab RA, Elston DM. Topical imiquimod for recalcitrant facial flat warts. *Cutis.* 2000;65:160-162.
10. Ritter SE, Meffert J. Successful treatment of flat warts using intralesional *Candida* antigen. *Arch Dermatol.* 2003;139(4):541-542.
11. Kartal Durmazlar SP, Atacan D, Eskioglu F. Cantharidin treatment for recalcitrant facial flat warts: a preliminary study. *J Dermatolog Treat.* 2009;20(2):114-119.
12. Tabrizi SN, Garland SM. Is cryotherapy treating or infecting? *Med J Aust.* 1996;164(5):263.

133 GENITAL WARTS

E.J. Mayeaux, Jr., MD
Richard P. Usatine, MD

PATIENT STORY

An 18-year-old woman presents with a concern that she might have genital warts (**Figure 133-1**). She has never had a sexually transmitted disease (STD) but admits to two new sexual partners in the last 6 months. She has not been vaccinated against human papillomavirus (HPV). The patient is told that her concern is accurate and she has condyloma caused by HPV (an STD). The treatment options are discussed and she chooses to have cryotherapy with liquid nitrogen followed by imiquimod self-applied beginning 2 weeks after cryotherapy. A urine test for gonorrhea and *Chlamydia* is performed and the patient is sent to the lab to have blood tests for syphilis and HIV. Fortunately, all the additional tests are negative. Further patient education is performed and follow-up is arranged.

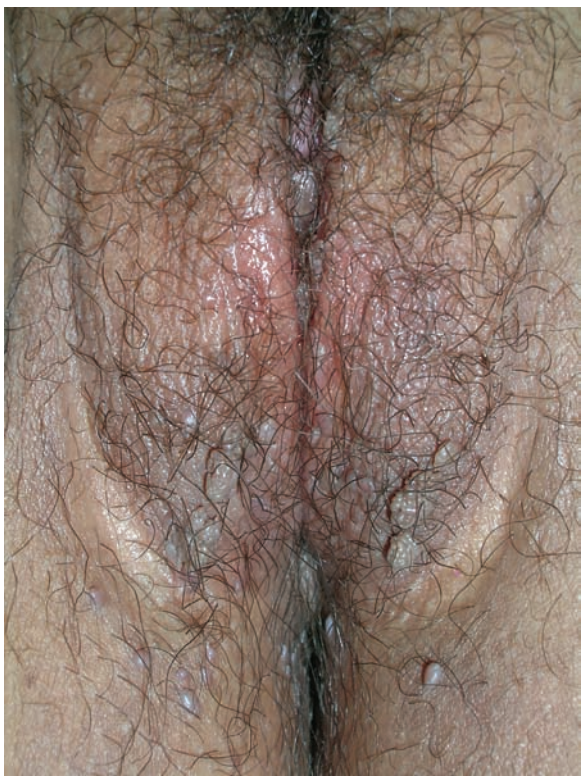

FIGURE 133-1 Multiple vulvar exophytic condyloma in an 18-year-old woman. (*Courtesy of Richard P. Usatine, MD.*)

INTRODUCTION

More than 100 types of HPV exist, with more than 40 that can infect the human genital area. Most HPV infections are asymptomatic, unrecognized, or subclinical. Low-risk HPV types (e.g., HPV types 6 and 11) cause genital warts, although coinfection with HPV types associated with squamous intraepithelial neoplasia can occur. Asymptomatic genital HPV infection is common and usually self-limited.[1]

SYNONYMS

Condyloma acuminata.

EPIDEMIOLOGY

- Anogenital warts are the most common viral STD in the United States. There are approximately 1 million new cases of genital warts per year in the United States.[2]
- Most infections are transient and cleared within 2 years.[2]
- Some infections persist and recur and cause much distress for the patients.

ETIOLOGY AND PATHOPHYSIOLOGY

- Genital warts are caused by HPV infection. HPV encompasses a family of primarily sexually transmitted double-stranded DNA viruses. The incubation period after exposure ranges from 3 weeks to 8 months.

RISK FACTORS[3]

- Sexual intercourse and oral sex.
- Other types of sexual activity including digital–anal, oral–anal, and digital–vaginal contact.
- Immunosuppression, especially HIV (**Figure 133-2**).

FIGURE 133-2 Multiple exophytic condyloma on the penis of a man with AIDS. (*Courtesy of Richard P. Usatine, MD.*)

DIAGNOSIS

CLINICAL FEATURES

- Diagnosis of genital warts is usually clinical based on visual inspection.[1]
- Genital warts are usually asymptomatic, and typically present as flesh-colored, exophytic lesions on the genitalia, including the penis, vulva, vagina, scrotum, perineum, and perianal skin.
- External warts can appear as small bumps, or they may be flat, verrucous, or pedunculated (**Figures 133-2** to **133-4**).
- Less commonly, warts can appear as reddish or brown, smooth, raised papules, or as dome-shaped lesions on keratinized skin.

TYPICAL DISTRIBUTION

- In women, the most common sites of infection are the vulva (85%) (**Figure 133-1**), perianal area (58%), and the vagina (42%) (**Figure 133-3**).
- In men, the most common sites of infection are the penis (**Figures 133-4** to **133-5**) and scrotum.
- Perianal warts (**Figure 133-6**) can occur in men or women who have a history of anal intercourse, and in those who do not have any such history (**Figure 133-7**).[1]
- Condyloma acuminata may be seen on the abdomen or upper thighs in conjunction with genital warts (**Figure 133-8**).
- Condyloma caused by HPV can be seen in obese individuals within the folds of the pannus (**Figure 133-9**).
- An RPR or VDRL should be ordered to screen for syphilis and a HIV test should be ordered as well. Genital warts are a sexually transmitted disease and patients who have one STD should be screened for others.

LABORATORY TESTING

- HPV viral typing is not recommended because test results would not alter clinical management of the condition. The application of 3% to 5% acetic acid to detect mucosal changes attributed to HPV infection is not recommended.[1]

BIOPSY

- Diagnosis may be confirmed by shave or punch biopsy if necessary.[1] Biopsy is indicated if:
  - The diagnosis is uncertain.
  - The patient has a poor response to appropriate therapy.
  - Warts are atypical in appearance (unusually pigmented, indurated, fixed, or ulcerated).
  - The patient has compromised immunity and squamous cell carcinoma is suspected (one type of HPV-related malignancy).

FIGURE 133-3 Condyloma around the clitoris, labia minor, and opening of the vagina. (*Courtesy of Richard P. Usatine, MD.*)

FIGURE 133-4 Condyloma acuminata demonstrating a cauliflower appearance with typical papillary surface seen when the foreskin is retracted in an uncircumcised man. Note that the top wart is pedunculated with a narrow base. (*Courtesy of Richard P. Usatine, MD.*)

FIGURE 133-6 Perianal warts in a gay man with history of anal-receptive intercourse. These lesions responded to cryotherapy. (*Courtesy of Richard P. Usatine, MD.*)

FIGURE 133-5 Smooth-topped condyloma on the well-keratinized skin of a circumcised man. (*Courtesy of Richard P. Usatine, MD.*)

FIGURE 133-7 Extensive perianal warts in a 17-year-old boy who denies sexual abuse and anal intercourse. Patient failed imiquimod therapy and was referred to surgery. (*Courtesy of Richard P. Usatine, MD.*)

DIFFERENTIAL DIAGNOSIS

- Pearly penile papules, which are small papules around the edge of the glans penis (**Figure 133-10**).
- Common skin lesions, such as seborrheic keratoses and nevi—These are rare in the genital area (**Figure 133-11**) (see Chapters 158, Seborrheic Keratosis and 162, Nevus).
- Giant condyloma or Buschke-Lowenstein tumor is a low-grade, locally invasive malignancy that can appear as a fungating condyloma (**Figure 133-12**). Persons with HIV/AIDS have a higher risk of giant condyloma and malignant transformation (**Figure 133-13**).
- Molluscum contagiosum—Waxy umbilicated papules around the genitals and lower abdomen (see Chapter 130, Molluscum Contagiosum).
- Malignant neoplasms, such as basal cell carcinoma and squamous cell carcinomas (see Chapters 170, Basal Cell Carcinoma and 171, Squamous Cell Carcinoma).
- Condyloma lata is caused by secondary syphilis infection; lesions appear flat and velvety (see Chapter 216, Syphilis). A full work-up for other STDs, including syphilis, should be done for any patient with genital warts (**Figure 133-14**).
- Micropapillomatosis of the vulva is a normal variant and appears as distinct individual papillary projections from the labia in a symmetrical pattern.

FIGURE 133-8 Condyloma that started on the penis and spread up the abdomen and on to the thighs. Note how these warts are hyperpigmented in this Latino man. (*Courtesy of Richard P. Usatine, MD.*)

MANAGEMENT

- The primary reason for treating genital warts is the amelioration of symptoms and ultimately removal of the warts.[1]
- The choice of therapy is based on the number, size, site, and morphology of lesions, as well as patient preference, treatment cost, convenience, adverse effects, and physician experience.
- Although available therapies for genital warts are likely to reduce HPV infectivity, they probably do not eradicate transmission.[1]

MEDICATIONS AND SURGICAL METHODS

- Treatments for external genital warts include topical medications, cryotherapy (**Figure 133-15**), and surgical methods, and are shown in **Table 133-1**.
- Cryotherapy is best applied with a bent-tipped spray applicator that allows for precise application with a less painful attenuated flow (**Figure 133-15**).[8] Application may be repeated every 2 weeks if necessary.
- Treatment with 5% fluorouracil cream (Efudex) is no longer recommended because of severe local side effects and teratogenicity.[1]

REFERRAL OR HOSPITALIZATION

- Consider consultation for patients with very large or recalcitrant lesions.

FIGURE 133-9 Panus condyloma from HPV growing between the folds of heavy adipose tissue in this obese woman. (*Courtesy of Richard P. Usatine, MD.*)

PREVENTION

- A bivalent vaccine (Cervarix) containing HPV types 16 and 18 and a quadrivalent vaccine (Gardasil) vaccine containing HPV types 6, 11, 16, and 18 are licensed in the United States. The quadrivalent

FIGURE 133-10 Condyloma coexisting with pearly penile papules (PPPs), which are a normal variant on the edge of the corona. (*Courtesy of Richard P. Usatine, MD.*)

FIGURE 133-11 Two large condylomas that resemble seborrheic keratoses. Shave biopsy was positive for HPV. (*Courtesy of Richard P. Usatine, MD.*)

FIGURE 133-12 Buschke-Lowenstein tumor (giant condylomata acuminata) at the base of the penis. This was treated with surgical resection. The margins were clear and there was no squamous cell carcinoma found. (*Courtesy of Suraj Reddy, MD.*)

FIGURE 133-13 Giant condylomata acuminata in a man with AIDS. (*Courtesy of Jack Resneck, Sr., MD.*)

FIGURE 133-14 This 22-year-old IV heroine addict presented with many condyloma in the anogenital region. An RPR was positive for syphilis. The patient was treated with penicillin as well as cryotherapy. The visible condyloma in this image are most likely HPV and not condyloma lata based on their verrucous morphology. (*Courtesy of Richard P. Usatine, MD.*)

TABLE 133-1 Treatments for External Genital Warts

Treatment	Possible Adverse Effects	Clearance (%)	Recurrence (%)
Patient-Applied Therapy			
Imiquimod (Aldara) is applied at bedtime for 3 days, then rest 4 days; alternatively, apply every other day for 3 applications; may repeat weekly cycles for up to 16 weeks[5] SOR A	Erythema, irritation, ulceration, pain, and pigmentary changes; minimal systemic absorption	30 to 50	15
Sinecatechins 15% ointment—Apply a 0.5-cm strand of ointment to each wart 3 times daily[6] SOR A	Erythema, pruritus/burning, pain, ulceration, edema, induration, and vesicular rash	53 to 57	3.7
Podofilox (Condylox) is applied twice daily for 3 days, then rest 4 days; may repeat for 4 cycles[7] SOR A	Burning, pain, inflammation; low risk for systemic toxicity unless applied to occluded membranes	45 to 80	5 to 30
Provider-Applied Therapy			
Cryotherapy performed with liquid nitrogen or a cryoprobe[6] SOR B	Pain or blisters at application site, scarring	60 to 90	20 to 40
Podophyllin resin is applied to each wart and allowed to dry, and is repeated weekly as needed[6,7] SOR A	Local irritation, erythema, burning, and soreness at application site; neurotoxic and oncogenic if absorbed	30 to 80	20 to 65
Surgical treatment for warts involves removal to the dermal–epidermal junction; options include scissor excision, shave excision, laser vaporization, and loop electrosurgical excision procedure (LEEP) excision[6] SOR B	Pain, bleeding, scarring; risk for burning and allergic reaction from local anesthetic; laser and LEEP have risk for spreading HPV in plume	35 to 70	5 to 50
Trichloroacetic acid (TCA) and bichloracetic acid (BCA) are applied to each wart and allowed to dry; repeated weekly[6] SOR B	Local pain and irritation; no systemic side effects	50 to 80	35

HPV vaccine protects against the HPV types that cause 90% of genital warts (i.e., types 6 and 11) in males and females when given prophylactically. Both vaccines offer protection against the HPV types that cause 70% of cervical cancers (i.e., types 16 and 18). In the United States, the quadrivalent (Gardasil) HPV vaccine can also be used in males and females ages 9 to 26 years to prevent genital warts.[4]

PROGNOSIS

- Many genital warts will eventually resolve without treatment. Resolution can usually be hastened with therapy (see **Table 133-1**).

FOLLOW-UP

- Patients should be offered a follow-up evaluation 2 to 3 months after treatment to check for new lesions.[1] SOR C

PATIENT EDUCATION

- HPV is transmitted mainly by skin-to-skin contact. Although condoms may decrease the levels of transmission, they are imperfect

barriers at best as they can fail, and they do not cover the scrotum or vulva, where infection may reside.

PATIENT RESOURCES

- eMedicineHealth. *Genital Warts (HPV Infection)*—**http://www.emedicinehealth.com/genital_warts/article_em.htm.**
- PubMed Health. *Genital Warts*—**http://www.ncbi.nlm.nih.gov/pubmedhealth/PMH0001889/.**
- American Academy of Dermatology. *Genital Warts*—**http://www.aad.org/skin-conditions/dermatology-a-to-z/genital-warts.**
- MedlinePlus. *Genital Warts*—**http://www.nlm.nih.gov/medlineplus/ency/article/000886.htm.**

PROVIDER RESOURCES

- Centers for Disease Control and Prevention. *Genital Warts*—**http://www.cdc.gov/std/treatment/2010/genital-warts.htm.**
- Medscape. *Genital Warts*—**http://emedicine.medscape.com/article/1133201.**
- Medscape. *Genital Warts in Emergency Medicine*—**http://emedicine.medscape.com/article/763014.**

FIGURE 133-15 Cryotherapy of penile warts using a liquid nitrogen spray technique and a bent-tipped applicator.

REFERENCES

1. Centers for Disease Control and Prevention. *2010 Guidelines for Treatment of Sexually Transmitted Diseases*. http://www.cdc.gov/std/treatment/2010/STD-Treatment-2010-RR5912.pdf. Accessed December 1, 2011.
2. Burk RD, Kelly P, Feldman J, et al. Declining prevalence of cervicovaginal human papillomavirus infection with age is independent of other risk factors. *Sex Transm Dis.* 1996;23:333-341.
3. Palefsky JM. Cutaneous and genital HPV-associated lesions in HIV-infected patients. *Clin Dermatol.* 1997;15:439-447.
4. Centers for Disease Control and Prevention (CDC). FDA licensure of quadrivalent human papillomavirus vaccine (HPV4, Gardasil) for use in males and guidance from the Advisory Committee on Immunization Practices (ACIP). *MMWR Morb Mortal Wkly Rep.* 2010;59(20):630-632.
5. Gotovtseva EP, Kapadia AS, Smolensky MH, Lairson DR. Optimal frequency of imiquimod (Aldara) 5% cream for the treatment of external genital warts in immunocompetent adults: a meta-analysis. *Sex Transm Dis.* 2008;35(4):346-351.
6. Mayeaux EJ Jr, Dunton C. Modern management of external genital warts. *J Low Genit Tract Dis.* 2008;12:185-192.
7. Langley PC, Tyring SK, Smith MH. The cost effectiveness of patient-applied versus provider-administered intervention strategies for the treatment of external genital warts. *Am J Manag Care.* 1999;5(1):69-77.
8. Usatine R, Stulberg D. Cryosurgery. In: Usatine R, Pfenninger J, Stulberg D, Small R, eds. *Dermatologic and Cosmetic Procedures in Office Practice*. Philadelphia: Elsevier; 2012:182-198.

134 PLANTAR WARTS

E.J. Mayeaux, Jr., MD

PATIENT STORY

A 15-year-old boy presents with painful growths on his right heel for approximately 6 months (**Figure 134-1**). It is painful to walk on and he would like it treated. He was diagnosed with multiple large plantar warts called *mosaic warts*. The lesions were treated with gentle paring with a #15 blade scalpel and liquid nitrogen therapy over a number of sessions. He and his mom were instructed on how to use salicylic acid plasters on the remaining warts.

FIGURE 134-1 Plantar warts. Note small black dots in the warts that represent thrombosed vessels. Large plantar warts such as these are called *mosaic warts*. (*Courtesy of Richard P. Usatine, MD.*)

INTRODUCTION

Plantar warts (verruca plantaris) are human papilloma virus (HPV) lesions that occur on the soles of the feet (**Figures 134-1** to **134-5**) and palms of the hands (**Figure 134-6**).

SYNONYMS

Palmoplantar warts, myrmecia.

EPIDEMIOLOGY

- Plantar warts affect mostly adolescents and young adults, affecting up to 10% of people in these age groups.[1]
- Prevalence studies demonstrate a wide range of values, from 0.84% in the United States[2] to 3.3% to 4.7% in the United Kingdom,[3] to 24% in 16- to 18-year-olds in Australia.[4]

ETIOLOGY AND PATHOPHYSIOLOGY

- Plantar warts are caused by HPV.
- They usually occur at points of maximum pressure, such as on the heels (**Figures 134-1** to **134-4**) or over the heads of the metatarsal bones (**Figure 134-5**), but may appear anywhere on the plantar surface including the tips of the fingers (**Figure 134-7**).
- A thick, painful callus forms in response to the pressure that is induced as the size of the lesion increases. Even a minor wart can cause a lot of pain.
- A cluster of many warts that appear to fuse is referred to as a *mosaic wart* (**Figures 134-1** and **134-4**).

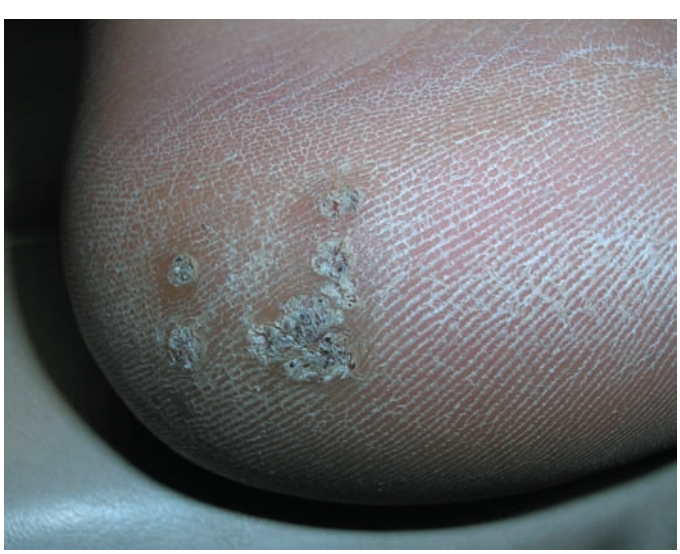

FIGURE 134-2 Close-up of plantar wart on the side of the heel. Note the disruption of skin lines and black dots. (*Courtesy of Richard P. Usatine, MD.*)

RISK FACTORS

- Young age.
- Decreased immunity.

DIAGNOSIS

CLINICAL FEATURES

Plantar warts present as thick, painful endophytic plaques located on the soles and/or palms. Warts have the following features:

- Begin as small shiny papules.
- Lack skin lines crossing their surface (**Figure 134-3**).
- Have a highly organized mosaic pattern on the surface when examined with a hand lens.
- Have a rough keratotic surface surrounded by a smooth collar of callused skin
- Painful when compressed laterally.
- May have centrally located black dots (thrombosed vessels) that may bleed with paring (**Figures 134-1** to **134-7**).

TYPICAL DISTRIBUTION

- They occur on the palms of the hands and soles of the feet. They are more commonly found on weight-bearing areas, such as under the metatarsal heads or on the heel.[5]

BIOPSY

- If the diagnosis is doubtful, a shave biopsy is indicated to confirm the diagnosis.[6]

DIFFERENTIAL DIAGNOSIS

- Corns and calluses are pressure-induced skin thickenings that occur on the feet and can be mistaken for plantar warts. Calluses are generally found on the sole and corns are usually found on the toes. Calluses and corns have skin lines crossing the surface, and are painless with lateral pressure (see Chapter 207, Corn and Callus).
- Black heel presents as a cluster of blue-black dots that result from ruptured capillaries. They appear on the plantar surface of the heel following the shearing trauma of sports that involve sudden stops or position changes. Examination reveals normal skin lines, and paring does not cause additional bleeding. The condition resolves spontaneously in a few weeks.
- Black warts are plantar warts undergoing spontaneous resolution, which may turn black and feel soft when pared with a blade.[7]
- Squamous cell carcinoma should be considered when lesions have irregular growth or pigmentation, ulceration, or resist therapy, particularly in immunosuppressed patients (see Chapter 171, Squamous Cell Carcinoma).
- Amelanotic melanoma, although extremely rare, can look similar to HPV lesions. Lesions that are treatment resistant or atypical, particularly on the palms or soles, should be monitored closely. A biopsy is required to establish the diagnosis (see Chapter 172, Melanoma).
- Palmoplantar keratoderma describes a rare heterogeneous group of disorders characterized by thickening of the palms and the soles that can also be an associated feature of different syndromes. They can be classified as having uniform involvement versus

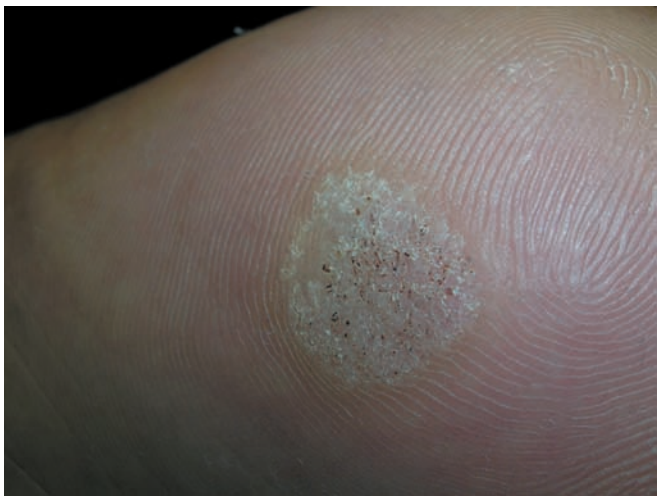

FIGURE 134-3 Close-up of a plantar wart demonstrating disruption of normal skin lines. Corns and callus do not disrupt normal skin lines. The black dots are thrombosed vessels, which are frequently seen in plantar warts. (*Courtesy of Richard P. Usatine, MD.*)

FIGURE 134-4 A mosaic wart is formed when several plantar warts become confluent. (*Courtesy of Richard P. Usatine, MD.*)

FIGURE 134-5 Multiple plantar warts on the ball of the foot and toes. The thrombosed vessels within the warts appear as black dots. (*Courtesy of Richard P. Usatine, MD.*)

focal hyperkeratosis located mainly on pressure points and sites of recurrent friction (**Figure 134-8**). This latter type can be differentiated from plantar warts by the more diffuse locations on the palmoplantar surfaces, the mainly epidermal involvement, and biopsy, if necessary (**Figure 134-9**).

MANAGEMENT

NONPHARMACOLOGIC

- Painless plantar warts do not require therapy. Minimal discomfort can be relieved by periodically removing the hyperkeratosis with a blade or pumice stone.
- Painful warts should be treated using a technique that causes minimal scarring as scars on the soles of the feet are usually permanent and painful.
- Patients with diabetes must be treated with the utmost care to minimize complications.

MEDICATIONS

- Topical salicylic acid solutions are available in nonprescription form and provide conservative keratolytic therapy. These preparations are nonscarring, minimally painful, and relatively effective, but require persistent application of medication once each day for weeks to months. The wart is first pared with a blade, pumice stone, or emery board, and the area soaked in warm water. The solution is then applied, allowed to dry, reapplied, and occluded with adhesive tape.[8] White, pliable, keratin forms and should be pared away carefully until pink skin is exposed.[9] SOR B
- Seventeen percent to 50% salicylic acid solution and plasters are available in nonprescription and prescription forms. However, the 17% solutions are more prevalent and easier to find in nonprescription form. The treatment is similar to the previous process, except that with plasters the salicylic acid has been incorporated into a pad. They are particularly useful in treating mosaic warts covering a large area. Pain is quickly relieved in plantar warts, because a large amount of keratin is removed during the first few days of treatment.[9] SOR B A recent multicenter, open-label, randomized, controlled trial found that 50% salicylic acid and the cryotherapy were equally effective for clearance of plantar warts.[10] SOR A
- Acid chemotherapy with trichloroacetic acid (TCA) or bichloracetic acid (BCA) is commonly employed to treat plantar warts in the office. They are considered safe during pregnancy for external lesions. The excess keratin is first pared with a scalpel, then the entire lesion is coated with acid, and the acid is worked into the wart with a sharp toothpick. The process is repeated every 7 to 10 days. SOR C
- Cryotherapy with liquid nitrogen therapy is commonly used, but plantar warts are more resistant than other HPV lesions. The liquid nitrogen is applied to form a freeze ball that covers the lesion and 2 mm of surrounding normal tissue, usually 10 to 20 seconds per freeze. SOR C There is no evidence that two freezing episodes are better than one, other than it allows for more freeze time in a way that is more acceptable to the patient. It is always better to underfreeze than to overfreeze in areas where scarring can produce permanent disability.

FIGURE 134-6 Multiple plantar warts on the palms of an HIV-positive man. (*Courtesy of Richard P. Usatine, MD.*)

FIGURE 134-7 Close up of plantar wart on a finger that also shows disruption of skin lines and black dots. (*Courtesy of Richard P. Usatine, MD.*)

- Treatments for resistant lesions are often carried out in referral practices that have a high enough volume to use more expensive or specialized therapy. Cantharidin is an extract of the blister beetle that is applied to the wart after which blistering occurs. Intralesional immunotherapy with skin-test antigens (i.e., mumps, *Candida*, or *Trichophyton* antigens) may lead to the resolution both of the injected wart and other warts that were not injected. Contact immunotherapy using dinitrochlorobenzene, squaric acid dibutylester, and diphenylcyclopropenone may be applied to the skin to sensitize the patient and then to the lesion to induce an immune response. Intralesional bleomycin or laser therapy are also useful for recalcitrant warts. SOR C

COMPLEMENTARY AND ALTERNATIVE THERAPY

- Although many complementary and alternative therapies are promoted for wart therapy, there is no significant data supporting their use in the treatment of plantar warts.

PREVENTION

- Tools used for paring down warts, such as nail files and pumice stones, should not be used on normal skin or by other people.

PROGNOSIS

Most plantar warts will spontaneously disappear without treatment. Treatment often hastens resolution of lesions.

FOLLOW-UP

- Regular follow-up to assess treatment efficacy, adverse reactions, and patient tolerance are recommended to minimize treatment dropouts.

PATIENT EDUCATION

- Because spontaneous regression occurs, observation of painless lesions without treatment is preferable.
- Therapy often takes weeks to months, so patience and perseverance are essential for successful therapy.

PATIENT RESOURCES

- MayoClinic. *Plantar Warts*—**http://www.mayoclinic.com/health/plantar-warts/DS00509.**
- MedlinePlus. Warts—**http://www.nlm.nih.gov/medlineplus/warts.html.**
- Fort Drum Medical Activity. *Patient Education Handouts: Warts and Plantar Warts*—**http://www.drum.amedd.army.mil/pt_info/handouts/warts_Plantar.pdf.**

FIGURE 134-8 Focal palmoplantar keratoderma of the palms (**A**) and soles (**B**). This is an inherited genodermatosis. Note lesions are located mainly on higher pressure areas. (*Courtesy of Richard P. Usatine, MD.*)

PROVIDER RESOURCES

- Bacelieri R, Johnson SM. Cutaneous warts: an evidence-based approach to therapy. *Am Fam Physician*. 2005;72[4]:647-652—**http://www.aafp.org/afp/20050815/647.html.**
- Medscape. *Nongenital Warts*—**http://emedicine.medscape.com/article/1133317.**

REFERENCES

1. Laurent R, Kienzler JL. Epidemiology of HPV infections. *Clin Dermatol*. 1985;3(4):64-70.
2. Johnson ML, Roberts J. Skin conditions and related need for medical care among persons 1-74 years. Rockville, MD: US Department of Health, Education, and Welfare; 1978:1-26.
3. Williams HC, Pottier A, Strachan D. The descriptive epidemiology of warts in British schoolchildren. *Br J Dermatol*. 1993;128:504-511.
4. Kilkenny M, Merlin K, Young R, Marks R. The prevalence of common skin conditions in Australian school students: 1. Common, plane and plantar viral warts. *Br J Dermatol*. 1998;138:840-845.
5. Holland TT, Weber CB, James WD. Tender periungual nodules. Myrmecia (deep palmoplantar warts). *Arch Dermatol*. 1992;128(1):105-106, 108-109.
6. Beutner, KR. Nongenital human papillomavirus infections. *Clin Lab Med*. 2000;20:423-430.
7. Berman A, Domnitz JM, Winkelmann RK. Plantar warts recently turned black. *Arch Dermatol*. 1982;118:47-51.
8. Landsman MJ, Mancuso JE, Abramow SP. Diagnosis, pathophysiology, and treatment of plantar verruca. *Clin Podiatr Med Surg*. 1996;13(1):55-71.
9. Gibbs S, Harvey I. *Cochrane Summaries*. *Topical Treatments for Cutaneous Warts*. http://www.cochrane.org/reviews/en/ab001781.html. Accessed April 1, 2008.
10. Cockayne S, Hewitt C, Hicks K, et al. Cryotherapy versus salicylic acid for the treatment of plantar warts (verrucae): a randomized controlled trial. *BMJ*. 2011;342:d3271.

FIGURE 134-9 Diffuse palmoplantar keratoderma of the palms (**A**) and soles (**B**) in an 11-year-old girl. This is an inherited genodermatosis with severe functional consequences. (*Courtesy of Richard P. Usatine, MD.*)

SECTION 5 FUNGAL

135 FUNGAL OVERVIEW

Richard P. Usatine, MD

PATIENT STORY

A 55-year-old woman presents with a red pruritic area on her face for 3 months (**Figure 135-1**). The annular distribution immediately is suspicious for a dermatophyte infection. Further investigation demonstrates that the patient has severe tinea pedis in a moccasin distribution. The patient is treated with an oral antifungal agent and her fungal infection clears over the coming month.

FIGURE 135-1 Tinea faciei on the face of a 55-year-old woman with typical scaling and ringlike pattern (ringworm). Note the well-demarcated raised border and central clearing. (*Courtesy of Richard P. Usatine, MD.*)

INTRODUCTION

Fungal infections of the skin and mucous membranes are ubiquitous and common. There are many types of fungus that grow on humans but they all share a predilection for warm and moist areas. Consequently, hot and humid climates promote fungal infections, but many areas of the skin can get warm and sweaty even in cold climates, such as the feet and groin.

SYNONYMS

Pityriasis versicolor equals tinea versicolor.

PATHOPHYSIOLOGY

Mucocutaneous fungal infections are caused by:

- Dermatophytes in three genera: *Microsporum*, *Epidermophyton,* and *Trichophyton*. There are approximately 40 species in the three genera and these fungi cause tinea pedis and manus, tinea capitis, tinea corporis, tinea cruris, tinea faciei, and onychomycosis (**Figures 135-1** to **135-6**).
- Yeasts in the genera of *Candida* and *Pityrosporum* (*Malassezia*)—There are also multiple types of species and the *Pityrosporum* that cause seborrhea and tinea versicolor (**Figures 135-7** and **135-8**). Although tinea versicolor has the name tinea in it, it is not a true dermatophyte and may be best called pityriasis versicolor.

FIGURE 135-2 Annular pruritic lesion with concentric rings in the axilla of a young woman caused by tinea corporis. The concentric rings have a high specificity for tinea infections. (*Courtesy of Richard P. Usatine, MD.*)

DIAGNOSIS

CLINICAL FEATURES OF TINEA INFECTIONS

Scaling, erythema, pruritus, central clearing, concentric rings, and maceration (**Table 135-1**). Changes in pigmentation are not uncommon in various types of tinea especially tinea versicolor.

- **Figure 135-1** shows tinea faciei on the face with typical scaling and ring-like pattern, hence, the name ringworm. There is also erythema and central clearing. The patient was experiencing pruritus.
- **Figure 135-2** shows annular pruritic lesion with concentric rings in the axilla of a young woman caused by tinea corporis. The concentric rings have a high specificity (80%) for tinea infections.
- Note that tinea infections will not show central clearing in 58% of cases, as in **Figure 135-3** in which tinea cruris has no central clearing.
- Post-inflammatory hyperpigmentation is common in skin of color, as seen in **Figure 135-4**. Note the hyperpigmentation is seen within the area affected by the tinea corporis.
- Hypopigmentation is frequently seen in tinea versicolor (**Figure 135-8**).

TYPICAL DISTRIBUTION

Literally found from head to toes:

- **Figure 135-5** shows tinea capitis in a 5-year-old black girl with hair loss and an inflammatory response. Her kerion is healing after initiating oral griseofulvin.
- The two-foot, one-hand syndrome is a curious phenomenon with tinea manus of one hand and tinea pedis of both feet (**Figure 135-6**). It is not clear why only one hand is involved in these cases. In this case, it was the nondominant hand.

LABORATORY STUDIES

Creating a KOH Prep:

- Scrape the leading edge of the lesion on to a slide using the side of a #15 scalpel or another microscope slide (**Figure 135-9**).
- Use your coverslip to push the scale into the center of the slide.
- Add two drops of KOH (or fungal stain) to the slide and place coverslip on top.
- Gently heat with flame from an alcohol lamp or lighter if you are using plain KOH without dimethyl sulfoxide (DMSO). Avoid boiling.
- DMSO acts as a surfactant that helps to break up the cell membranes of the epithelial cells without heating. Fungal stains that come with KOH and a surfactant in the solution are very simple to use. These inexpensive stains come conveniently in small plastic squeeze bottles that have a shelf life of 1 to 3 years. Two useful stains that can that make it easier to identify fungus are chlorazol and Swartz-Lamkins stains. Swartz-Lamkins stain has a longer shelf life and is my preferred stain.
- Examine with microscope starting with 10 power to look for the cells and hyphae and then switch to 40 power to confirm your findings (**Figures 135-10** to **135-13**). The fungal stain helps the hyphae to stand out among the epithelial cells.
- It helps to start with 10 power to find the clumps of cells and look for groups of cells that appear to have fungal elements within them (**Figure 135-10**).
- Do not be fooled by cell borders that look linear and branching. True fungal morphology at 40 power should confirm that you are looking at real fungus and not artifact. The fungal stains bring out

FIGURE 135-3 Tinea cruris with well-demarcated raised border and no central clearing. (*Courtesy of Richard P. Usatine, MD.*)

FIGURE 135-4 Tinea corporis on the right flank of a woman bending forward. Note that post-inflammatory hyperpigmentation is seen in the skin affected by the tinea corporis. (*Courtesy of Richard P. Usatine, MD*)

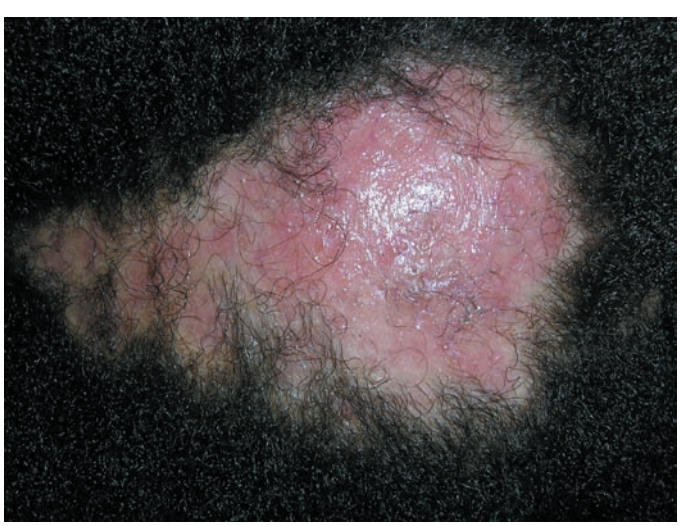

FIGURE 135-5 Tinea capitis in a 5-year-old black girl with hair loss and an inflammatory response. Her kerion is healing after initiating oral griseofulvin. (*Courtesy of Richard P. Usatine, MD.*)

FIGURE 135-6 Two-foot, one-hand syndrome with tinea manus of one hand and tinea pedis of both feet. (*Courtesy of Richard P. Usatine, MD.*)

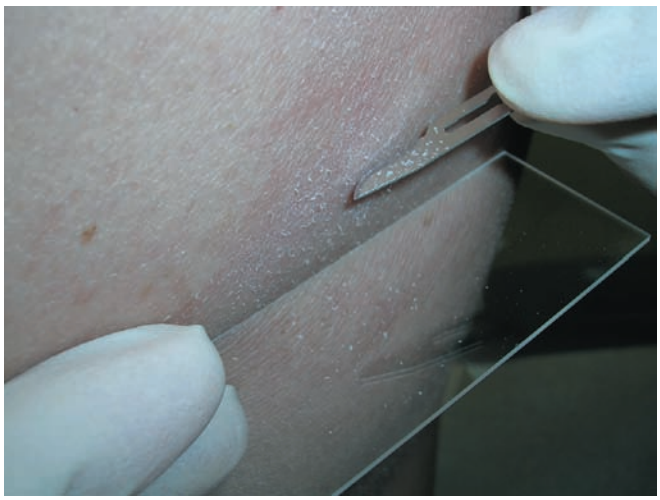

FIGURE 135-9 Making a KOH preparation by scraping in area of scale with a #15 blade. This was a case of tinea versicolor. (*Courtesy of Richard P. Usatine, MD.*)

FIGURE 135-7 Thrush in the mouth of an infant caused by *Candida*. (*Courtesy of Richard P. Usatine, MD.*)

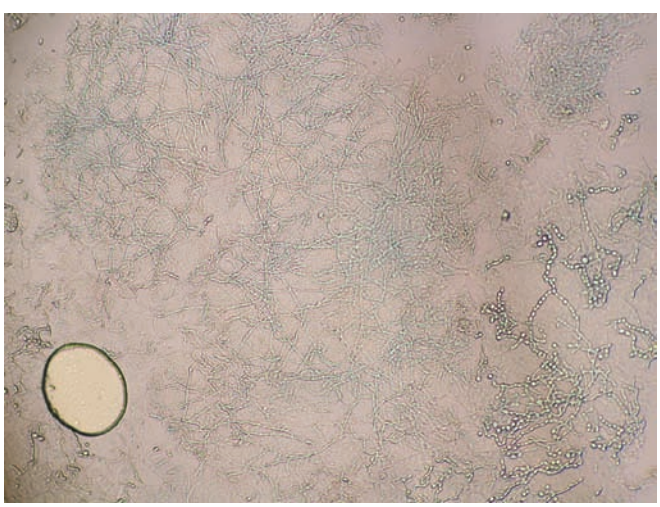

FIGURE 135-10 *Trichophyton rubrum* from tinea cruris visible among skin cells using light microscopy at 10 power and Swartz-Lamkins fungal stain. Start your search on 10 power and move to 40 power to confirm your findings. (*Courtesy of Richard P. Usatine, MD.*)

FIGURE 135-8 Tinea versicolor showing hypopigmentation on the chest. (*Courtesy of Richard P. Usatine, MD.*)



FIGURE 135-11 *Trichophyton rubrum* from tinea cruris using Swartz-Lamkins fungal stain at 40 power. Straight hyphae with visible septae. (*Courtesy of Richard P. Usatine, MD.*)

TABLE 135-1 Diagnostic Value of Selected Signs and Symptoms in Tinea Infection*

Sign/Symptom	Sensitivity (%)	Specificity (%)	PV+ (%)	PV– (%)	LR+	LR–
Scaling	77	20	17	80	0.96	1.15
Erythema	69	31	18	83	1.00	1.00
Pruritus	54	40	16	80	0.90	1.15
Central clearing	42	65	20	84	1.20	0.89
Concentric rings	27	80	23	84	1.35	0.91
Maceration	27	84	26	84	1.69	0.87

*Signs and symptoms were compiled by 27 general practitioners prior to submission of skin for fungal culture. Specimens were taken from 148 consecutive patients with erythematosquamous lesions of glabrous skin. Culture results were considered the gold standard; level of evidence = 2b.
LR–, Negative likelihood ratio; *LR+*, positive likelihood ratio; *PV–*, negative predictive value; *PV+*, positive predictive value.
Source: From J Fam Pract. 1999;48:611-615. Reproduced with permission from Frontline Medical Communications.

these characteristics including cell walls, nuclei, and Arthroconidia (**Figures 135-11** to **135-13**).

- KOH test characteristics[1] (without fungal stains)—Sensitivity 77% to 88%, specificity 62% to 95% (**Table 135-2**). The sensitivity and specificity should be higher with fungal stains and the experience of the person performing the test.

OTHER LABORATORY STUDIES

- Fungal culture—Send skin scrapings, hair, or nail clippings to the laboratory in a sterile container such as a urine cup. These will be plated out on fungal agar and the laboratory can report the species if positive.
- Biopsy specimens can be sent in formalin for periodic acid-Schiff (PAS) staining when KOH and fungal cultures seem to be falsely negative.
- UV light (Woods lamp), looking for fluorescence. The *Microsporum* species are most likely to fluoresce. However, the majority of tinea infections are caused by *Trichophyton* species that do not fluoresce.

MANAGEMENT

There is a wide variety of topical antifungal medications (**Table 135-3**). A Cochrane systematic review of 70 trials of topical antifungals for tinea pedis showed good evidence for efficacy compared to placebo[2] for:

- Allylamines (naftifine, terbinafine, butenafine).
- Azoles (clotrimazole, miconazole, econazole).
- Allylamines cure slightly more infections than azoles but are more expensive.[2]
- No differences in efficacy found between individual topical allylamines or individual azoles.[2] SOR A

Evidence for the management onychomycosis by topical treatments is sparse. There is some evidence that ciclopiroxolamine and

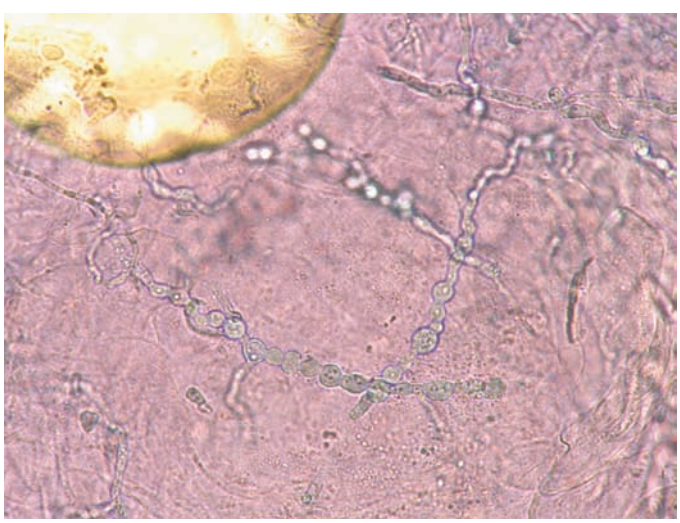

FIGURE 135-12 Arthroconidia visible from tinea cruris using Swartz-Lamkins fungal stain at 40 power. (*Courtesy of Richard P. Usatine, MD.*)

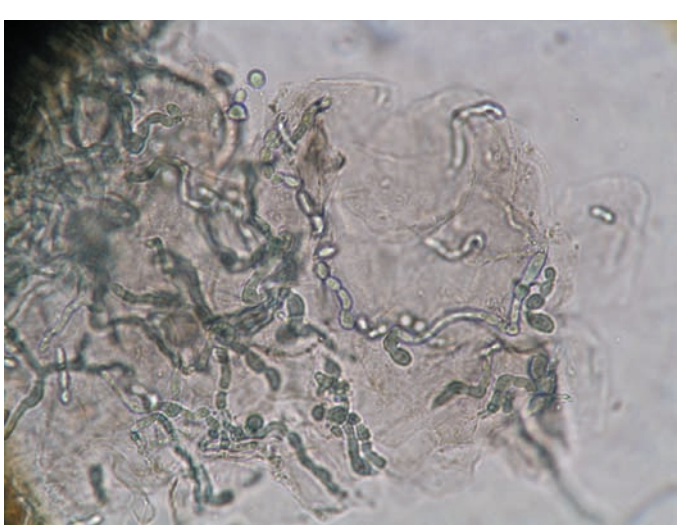

FIGURE 135-13 *Trichophyton rubrum* from tinea cruris using chlorazol black fungal stain at 40 power. (*Courtesy of Richard P. Usatine, MD.*)

TABLE 135-2 Diagnostic Value of Clinical Diagnosis and KOH Prep in Tinea Infection

Test	Sensitivity (%)	Specificity (%)	PV+ (%)	PV– (%)	LR+	LR–
Clinical diagnosis*	81	45	24	92	1.47	0.42
KOH prep (study one)†	88	95	73	98	17.6	0.13
KOH prep (study two)†	77	62	59	79	2.02	0.37

*The clinical diagnosis set was compiled by 27 general practitioners prior to submission of skin for fungal culture. Specimens were taken from consecutive patients with erythrosquamous lesions. Culture results were considered the gold standard; study quality = 2b.
†Both studies of KOH preps were open analyses of patients with suspicious lesions. Paired fungal culture was initiated simultaneously with KOH prep and was considered the gold standard; study quality = 2b.
LR–, Negative likelihood ratio; *LR+*, positive likelihood ratio; *PV–*, negative predictive value; *PV+*, positive predictive value.
Source: From Thomas B. Clear choices in managing epidermal tinea infections. J Fam Pract. 2003;52(11):850-862. Reproduced with permission from Frontline Medical Communications.

TABLE 135-3 Topical Antifungal Preparations

Generic Name	Brand Name	OTC or R_x	Class
Butenafine	Mentax Lotrimin Ultra	R_x OTC	Allylamine
Ciclopirox	Loprox	R_x	Pyridone
Clotrimazole	Lotrimin AF Cream Lotrimin AF Spray	OTC	Azole
Econazole	Spectazole	R_x	Azole
Ketoconazole	Nizoral	2% R_x	Azole
Miconazole	Micatin Generic	OTC	Azole
Naftifine	Naftin	R_x	Allylamine
Oxiconazole	Oxistat	R_x	Azole
Sertaconazole	Ertaczo	R_x	Azole
Terbinafine	Lamisil AT	OTC	Allylamine
Tolnaftate*	Tinactin cream Lamisil AF defense and Tinactin powder spray Generic cream	OTC	Miscellaneous

*All the above antifungals will treat dermatophytes and *Candida*. Tolnaftate is effective only for dermatophytes and not *Candida*. Nystatin is effective only for *Candida* and not the dermatophytes.
OTC, over-the-counter.

butenafine are both effective, but they both need to be applied daily for at least 1 year.[3]

Oral antifungals are needed for all tinea capitis infections and for more severe infections of the rest of the body.[4] True dermatophyte infections that do not respond to topical antifungals may need an oral agent.

- A Cochrane systematic review of 12 trials of oral antifungals for tinea pedis showed oral terbinafine for 2 weeks cures 52% more patients than oral griseofulvin.[5] SOR A

- Terbinafine is equal to itraconazole in patient outcomes.[5]
- No significant differences in comparisons between a number of other oral agents.[5]

Oral antifungals used for fungal infections of the skin, nails, or mucous membranes:

- Itraconazole (Sporanox).
- Fluconazole (Diflucan).
- Griseofulvin.
- Ketoconazole (Nizoral).
- Terbinafine (Lamisil).

One metaanalysis suggests that terbinafine is more efficacious than griseofulvin in treating tinea capitis caused by *Trichophyton* species, whereas griseofulvin is more efficacious than terbinafine in treating tinea capitis caused by *Microsporum* species.[6] SOR A

Details of treatments for multiple types of fungal skin infections are supplied in the following chapters.

PATIENT RESOURCES

- Doctor fungus—**http://www.doctorfungus.org/.**

PROVIDER RESOURCES

- Fungal skin from New Zealand—**http://www.dermnetnz.org/fungal/.**
- Doctor fungus from the United States—**http://www.doctorfungus.org/.**
- World of dermatophytes from Canada—**http://www.provlab.ab.ca/mycol/tutorials/derm/dermhome.htm.**
- Swartz Lamkins fungal stain can be easily purchased online at—**http://www.delasco.com/pcat/1/Chemicals/Swartz_Lamkins/dlmis023/.**

REFERENCES

1. Thomas B. Clear choices in managing epidermal tinea infections. *J Fam Pract.* 2003;52:850-862.
2. Crawford F, Hart R, Bell-Syer S, et al. Topical treatments for fungal infections of the skin and nails of the foot. *Cochrane Database Syst Rev.* 2000;(2):CD001434.
3. Crawford F, Hollis S. Topical treatments for fungal infections of the skin and nails of the foot. *Cochrane Database Syst Rev.* 2007 Jul 18;(3):CD001434.
4. Gonzalez U, Seaton T, Bergus G, et al. Systemic antifungal therapy for tinea capitis in children. *Cochrane Database Syst Rev.* 2007 Oct 17;(4):CD004685.
5. Bell-Syer SE, Hart R, Crawford F, et al. Oral treatments for fungal infections of the skin of the foot. *Cochrane Database Syst Rev.* 2002;(2):CD003584.
6. Tey HL, Tan AS, Chan YC. Meta-analysis of randomized, controlled trials comparing griseofulvin and terbinafine in the treatment of tinea capitis. *J Am Acad Dermatol.* 2011;64:663-670.

136 CANDIDIASIS

Richard P. Usatine, MD

PATIENT STORY

The 42-year-old man (**Figure 136-1**) was admitted to the hospital for community-acquired pneumonia and type 2 diabetes out of control. On the second day of admission, when he was feeling a bit better, he asked about the itching he was having on his penis. Physical examination revealed an uncircumcised penis with white discharge on the glans and inside the foreskin consistent with *Candida* balanitis. KOH prep was positive for the pseudohyphae of *Candida*. The patient was treated with a topical azole and the balanitis resolved.

FIGURE 136-1 Candida balanitis in a man with uncontrolled diabetes. (*Courtesy of Richard P. Usatine, MD.*)

INTRODUCTION

Cutaneous and mucosal *Candida* infections are seen commonly in persons with obesity, diabetes, hyperhidrosis, and/or immunodeficiency.

SYNONYMS

Perlèche = angular cheilitis.

EPIDEMIOLOGY

Candida thrush is common in normal infants and in adults may be a sign of immunosuppression (**Figure 136-2**).

Candida balanitis is more common in uncircumcised men than in those that have been circumcised (**Figure 136-1**).

FIGURE 136-2 Thrush in an otherwise healthy infant. (*Courtesy of Richard P. Usatine, MD.*)

ETIOLOGY AND PATHOPHYSIOLOGY

- Infections caused by *Candida* species are primarily *Candida albicans*.[1]
- *C. albicans* has the ability to exist in both hyphal and yeast forms (termed *dimorphism*). If pinched cells do not separate, a chain of cells is produced and is termed *pseudohyphae*.[1]

RISK FACTORS

Obesity, diabetes, hyperhidrosis, immunodeficiency, HIV, heat, use of oral antibiotics, and use of inhaled or systemic steroids.[1]

DIAGNOSIS

CLINICAL FEATURES

- Typical distribution—Groin, glans penis, vulva, inframammary, under abdominal pannus, between fingers, in the creases of the neck, corners of mouth, nailfolds in chronic paronychia.

- Morphology—Macules, patches, plaques that are pink to bright red with small peripheral satellite lesions.
- Candidiasis of the nipple in the nursing mother is associated with infantile thrush (**Figures 136-2** and **136-3**). Nipple candidiasis is almost always bilateral, with the nipples appearing bright red and inflamed. In this case, the inflammation was made worse by the application of a topical antibiotic that caused a secondary contact dermatitis.
- The *Candida* infection in the corners of the mouth are called perlèche or angular cheilitis (**Figure 136-4**). When accompanied by thrush it may be a sign of HIV/AIDS.
- Thrush can be caused be *Candida* growing on the upper plate of a denture and the roof of the mouth (**Figure 136-5**).
- Ask about recent antibiotic use if there is a new onset of a rash with satellite lesions. In **Figure 136-6**, the man with diabetes had a course of antibiotics before he developed a *Candida* infection in his groin.

FIGURE 136-3 *Candida* rash with superimposed contact dermatitis in a breastfeeding woman. Her baby has thrush and both need treatment to eradicate the infection. The contact dermatitis was to the neomycin-containing topical antibiotic she applied to her sore breasts. (*Courtesy of Jack Resneck, Sr., MD.*)

LABORATORY STUDIES

Scrape involved area and add to a slide with KOH (DMSO optional). *C. albicans* exist in both hyphal and yeast forms (dimorphism). Look for pseudohyphae and/or budding yeast (**Figure 136-7**).

DIFFERENTIAL DIAGNOSIS

- Intertrigo is a nonspecific inflammatory condition of the skin folds. It is induced or aggravated by heat, moisture, maceration, and friction. The condition frequently is worsened by infection with *Candida* or dermatophytes (**Figures 136-8** and **136-9**). In **Figure 136-8** there is significant hyperpigmentation secondary to the inflammation.
- Tinea corporis or cruris—Can be distinguished from *Candida* when you see an annular pattern or concentric circles in the tinea (**Figure 136-9**). There is no scrotal involvement in tinea cruris. *Candida* intertrigo may have scrotal involvement (see Chapters 138, Tinea Corporis and 139, Tinea Cruris).
- Erythrasma—May be brown and glows a coral red with UV light (see Chapter 119, Erythrasma).
- Inverse psoriasis—Psoriasis in the intertriginous areas as seen in **Figure 136-10** (see Chapter 152, Psoriasis).
- Seborrhea—Inflammation related to overgrowth of *Pityrosporum*, a yeast-like organism (see Chapter 151, Seborrheic Dermatitis).

FIGURE 136-4 Thrush and perlèche in a man with AIDS. The *Candida* infection in the corners of the mouth are called perlèche or angular cheilitis. (*Courtesy of Richard P. Usatine, MD.*)

MANAGEMENT

PRIMARY CANDIDAL SKIN INFECTIONS

- Topical azoles, including clotrimazole, miconazole, and nystatin (polyenes), are effective.[3] SOR B
- Keeping the infected area dry is important.[2] SOR C
- For more details of the topical antifungals, see Table 135-3 in Chapter 135, Fungal Overview.

FIGURE 136-5 *Candida* on the roof of the mouth in an elderly woman using dentures. This is a common complication of denture use and should be suspected if a patient presents with new onset pain under the dentures. (*Courtesy of Richard P. Usatine, MD.*)

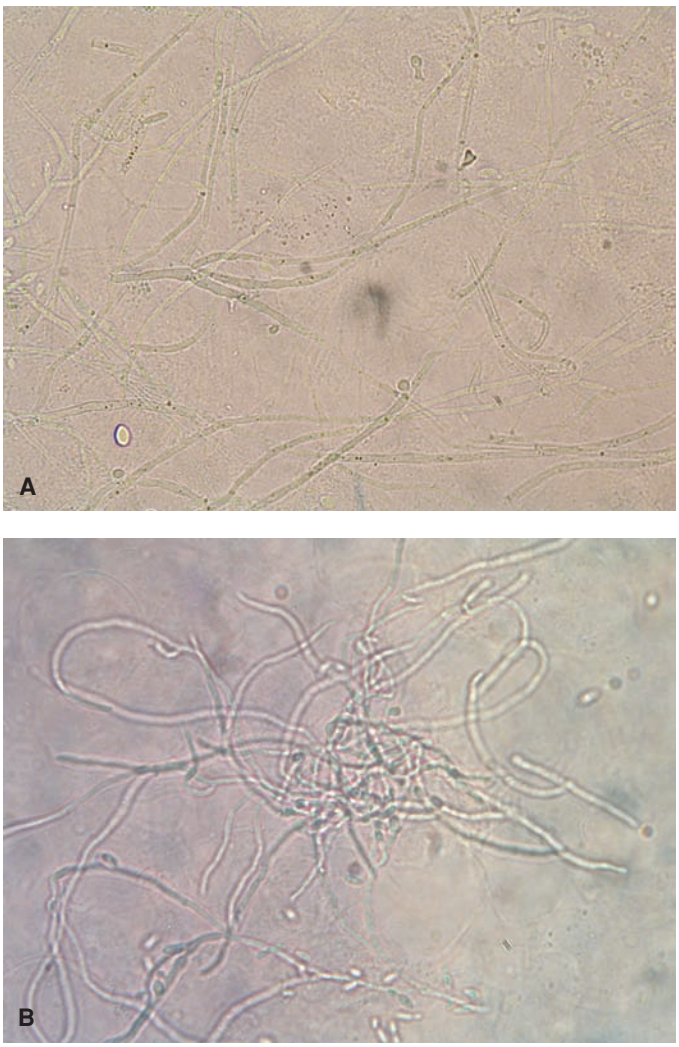

FIGURE 136-7 The branching pseudohyphae and budding yeast of *Candida* under high power. **A.** *Candida* from thrush. **B.** *Candida* from vaginitis. (*Courtesy of Richard P. Usatine, MD.*)

FIGURE 136-6 *Candida* inguinal eruption in a 61-year-old man after a course of antibiotics for bronchitis. Note the satellite lesions. (*Courtesy of Richard P. Usatine, MD.*)

FIGURE 136-8 *Candida* under the breasts of an overweight Hispanic woman showing hyperpigmentation. The border is not well-demarcated and there are satellite lesions. (*Courtesy of Richard P. Usatine, MD.*)

- In one study, miconazole ointment was well tolerated and significantly more effective than the zinc oxide/petrolatum vehicle control for treatment of diaper dermatitis complicated by candidiasis.[3]
- Do not use tolnaftate, which is active against dermatophytes but not *Candida*.
- If recurrent or recalcitrant, consider fluconazole 150 mg qwk × 2 or ketoconazole 200 mg qd for 1 to 2 weeks.

OROPHARYNGEAL CANDIDIASIS

- Treat initial episodes with clotrimazole troches (one 10-mg troche 5 times per day for adults) or nystatin (available as a suspension of 100,000 U/mL [dosage, 4 to 6 mL qid] or as flavored 200,000 U pastilles [dosage, 1 or 2 pastilles 4 to 5 times per day for 7 to 14 days]).[2] SOR B
- Oral fluconazole (100 mg/day for 7 to 14 days) is as effective as—and, in some studies, superior to—topical therapy.[2] SOR A
- Itraconazole solution (200 mg/day for 7 to 14 days) is as effective as fluconazole.[2] SOR A
- Ketoconazole and itraconazole capsules are less effective than fluconazole, because of variable absorption.[2] SOR A
- Fluconazole-refractory oropharyngeal candidiasis will respond to oral itraconazole therapy (>200 mg/day, preferably in solution form) approximately two thirds of the time.[2] SOR A
- Children with thrush are usually treated with oral nystatin suspension.[2] SOR B
- HIV/AIDS patients with oral candidiasis may be treated with clotrimazole troches. If unresponsive to topical therapy, fluconazole may be needed.[2] SOR A
- Denture-related disease may require extensive and aggressive disinfection of the denture for definitive cure.[2] SOR C

MAMMARY CANDIDIASIS IN BREASTFEEDING

- Most mammary candidiasis does not present with the red breasts seen in **Figure 136-3**.
- Nipple pain and discomfort along with thrush are adequate data to treat the mother and child.
- Topical nystatin and oral fluconazole are safe for infants and the mother.[2]

CHRONIC MUCOCUTANEOUS CANDIDIASIS

- Chronic mucocutaneous candidiasis (**Figure 136-11**) requires a long-term approach that is analogous to that used in patients with AIDS.[2]
- Systemic therapy is needed, and azole antifungal agents (ketoconazole, fluconazole, and itraconazole) have been used successfully.[2]
- As with HIV-infected patients, development of resistance to these agents has been described.[2]

PATIENT EDUCATION

Keep the infected area clean and dry. For thrush in a baby, treat sources of infection such as the mother's breasts and bottle nipples. If the baby is bottle fed, boil the nipples between uses.

FIGURE 136-9 Tinea corporis under the breasts of a 55-year-old woman. Note the annular pattern with well-demarcated borders. KOH was positive for dermatophytes and not *Candida*. (*Courtesy of Richard P. Usatine, MD.*)

FIGURE 136-10 Inverse psoriasis that closely resembles *Candida* intertrigo in the submammary folds. This patient did not improve with topical antifungals and finally a biopsy showed that this was inverse psoriasis. Inverse psoriasis is often mistaken for a fungal infection unless the physician is aware of this condition. Frequently there are other clues to the diagnosis of psoriasis in the skin and nails so that a biopsy is not needed. (*Courtesy of Richard P. Usatine, MD.*)

FIGURE 136-11 Severe chronic cutaneous candidiasis in a 22-year-old man with immunosuppression. (*Courtesy of Richard P. Usatine, MD.*)

PATIENT AND PROVIDER RESOURCES

- *Cutaneous Candidiasis*—**http://emedicine.medscape.com/article/1090632.**
- *Intertrigo*—**http://emedicine.medscape.com/article/1087691.**

REFERENCES

1. Scheinfeld N. *Cutaneous Candidiasis*. Updated August 2, 2011. http://emedicine.medscape.com/article/1090632. (Accessed September 5, 2011)
2. Pappas PG, Rex JH, Sobel JD, et al. Guidelines for treatment of candidiasis. *Clin Infect Dis.* 2004;38:161-189.
3. Spraker MK, Gisoldi EM, Siegfried EC, et al. Topical miconazole nitrate ointment in the treatment of diaper dermatitis complicated by candidiasis. *Cutis*. 2006;77(2):113-120.

137 TINEA CAPITIS

Richard P. Usatine, MD
Congjun Yao, MD, PhD

PATIENT STORY

An 11-year-old boy has a history of 2 months of progressive patchy hair loss (**Figure 137-1**). He has some itching of the scalp but his mother is worried about his hair loss. Physical examination reveals alopecia with scaling of the scalp and broken hairs looking like black dots in the areas of hair loss. A KOH preparation is created by scraping an area of alopecia onto a slide. A few loose hairs are added to the slide before the KOH and cover slip are placed. Fungal elements are seen under the microscope. After 6 weeks of griseofulvin, the tinea capitis is fully resolved.

FIGURE 137-1 Tinea capitis in a young black boy. The most likely organism is *Trichophyton tonsurans*. (*Courtesy of Richard P. Usatine, MD.*)

INTRODUCTION

Tinea capitis is a fungal infection involving the scalp and hair. It is the most common type of dermatophytoses in children younger than 10 years of age. Common signs include hair loss, scaling, erythema, and impetigo-like plaques.

SYNONYMS

Ringworm of the scalp and tinea tonsurans.

EPIDEMIOLOGY

- Tinea capitis is more common in young, black boys.
- Tinea capitis is the most common type of dermatophytoses in children younger than 10 years (**Figures 137-1** to **137-5**). It rarely occurs after puberty or in adults.[1] The infection has a worldwide distribution.
- Combs, brushes, couches, and sheets may harbor the live dermatophyte for a long period of time.
- Spread from person to person with direct contact or through fomites.
- Occasionally spread from cats and dogs to humans.

FIGURE 137-2 Tinea capitis with patchy hair loss and scaling of the scalp in a young boy. (*Courtesy of Richard P. Usatine, MD.*)

ETIOLOGY AND PATHOPHYSIOLOGY

- Tinea capitis is a superficial fungal infection affecting hair shafts and follicles on the scalp but could involve the eyebrows and eyelashes.
- Caused by *Trichophyton* and *Microsporum* dermatophytes. The most common organism in the United States is *Trichophyton tonsurans,* which is associated with black dot alopecia. *Microsporum canis* is less common now than decades ago. *M. canis* is still highly prevalent in developing countries. The natural reservoir of *M. canis* is dogs and cats.

RISK FACTORS

- Lack of access to clean water and soap.
- Poverty and living in rural areas.
- African descent as the dermatophytes grow well in the follicles of short curly hairs.
- Crowded living arrangements in which infected individuals spread the tinea to others.
- Sharing combs, brushes, and hair ornaments.

DIAGNOSIS

- The clinical appearance is often adequate to make the diagnosis.
- Confirm the diagnosis by scraping the scaling areas on the scalp and placing a few loose hairs on a microscope slide with KOH. (DMSO and a fungal stain will help.) Look for hyphae and spores (**Figure 137-6**). Look for endoectothrix invasion of the hair shaft with fungus.

CLINICAL FEATURES

- Alopecia and scaling of the scalp (**Figures 137-1** and **137-2**).
- A kerion occurs when there is an inflammatory response to the tinea. The scalp gets red, swollen, and boggy. There may be serosanguineous discharge and some crusting as this dries (**Figure 137-3**).
- There may be broken hairs that look like black dots in the areas of hair loss (**Figure 137-4**).
- Cervical lymphadenopathy is common from the tinea capitis (**Figure 137-5**).
- Tinea capitis can even be annular and have the rings of ringworm (**Figure 137-6**).

TYPICAL DISTRIBUTION

By definition it occurs on the head, but usually is found on the scalp. Rarely involves the eyebrows and eyelashes.

LABORATORY STUDIES

Whenever possible it is very important to confirm or dispel ones' clinical suspicion with mycologic evidence before starting weeks of oral antifungal medicines.

- KOH preparation—Scrape the scale and infected hairs using a #15 blade. Then use KOH or a fungal stain to dissolve the keratin. Use the microscope to look for septate, branching hyphae under 10 and 40 power (**Figure 137-7**). The hyphae of *Microsporum* may also be found on the exterior of the hair (exothrix) as in **Figure 137-8**. The hyphae of *Trichophyton* is found in the interior of the hair (endothrix).
- If the diagnosis is uncertain, send a few loose hairs and a scraping of the scalp scale for a fungal culture.
- You may look at the scalp with a UV light (Woods lamp), looking for fluorescence, but the yield is low. Only the *Microsporum* species

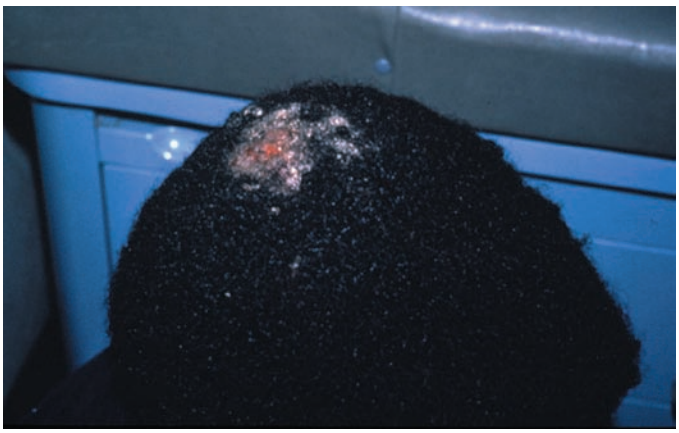

FIGURE 137-3 A kerion resulting from inflammation of the tinea capitis on this young boy. The kerion looks superinfected but it is nothing more than an exuberant inflammatory response to the dermatophyte. (*Courtesy of Richard P. Usatine, MD.*)

FIGURE 137-4 Close-up of black dot alopecia in a 7-year-old girl showing the black dots where infected hairs have broken off. (*Courtesy of Richard P. Usatine, MD.*)

FIGURE 137-5 Lymphadenopathy visible in the neck of this young boy with tinea capitis. The fungal infection shows more scaling and crusting than actual hair loss. The lymphadenopathy is a reaction to the tinea and not a bacterial superinfection. (*Courtesy of Richard P. Usatine, MD.*)

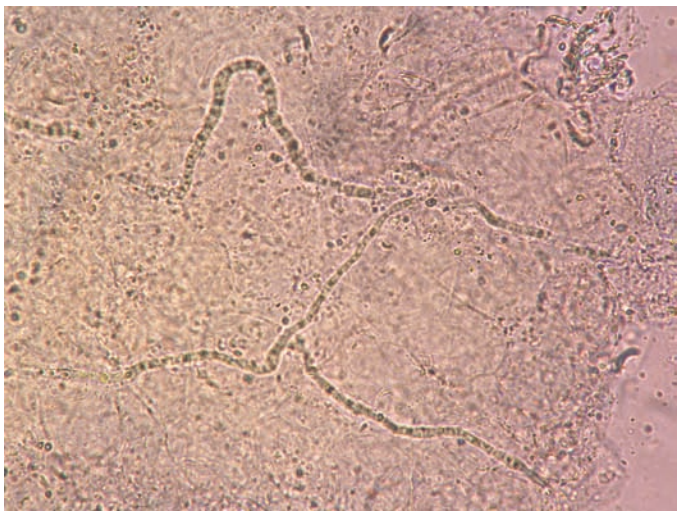

FIGURE 137-7 *T. tonsurans* from tinea capitis visible among skin cells at 40 power after adding Swartz-Lamkins fungal stain. (*Courtesy of Richard P. Usatine, MD.*)

FIGURE 137-6 Tinea capitis with an annular configuration. (*Courtesy of Richard P. Usatine, MD.*)

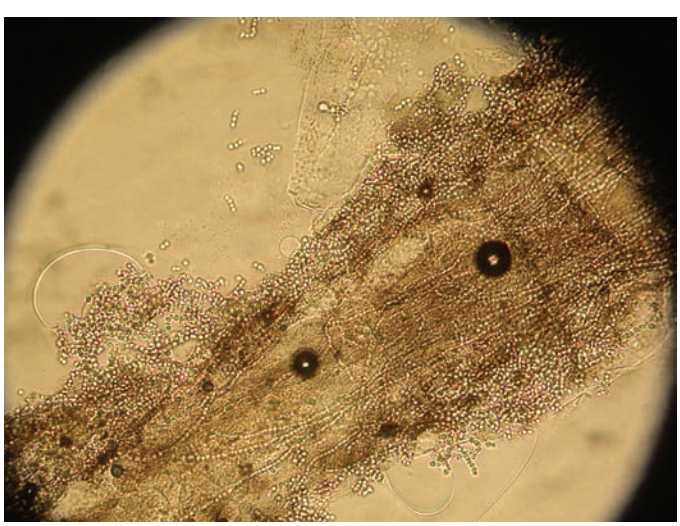

FIGURE 137-8 *M. canis* showing hyphae on the exterior of the hair (exothrix) at 40 power after adding Swartz-Lamkins fungal stain. (*Courtesy of Eric Kraus, MD.*)

will fluoresce (**Figure 137-9)** and this organism is the involved dermatophyte less than 30% of the time.

DIFFERENTIAL DIAGNOSIS

- Alopecia areata—Produces areas of hair loss with no scaling, inflammation, or scarring in the underlying scalp. It is an autoimmune process in which the immune system attacks the person's own hair follicles (see Chapter 187, Alopecia Areata).
- Seborrhea of the scalp (dandruff)—Is caused by the *Pityrosporum* yeast, resulting in scaling and inflammation but rarely causing hair loss. The scalp involvement tends to be more widespread than patchy and localized as seen in tinea capitis (see Chapter 151, Seborrheic Dermatitis).
- Scalp psoriasis—Rarely causes alopecia. There are mild cases with slight, fine scaling on the scalp, or severe cases with silvery, thick, crusted plaques covering the majority of the scalp. Often psoriatic plaques are seen elsewhere on the body and nail changes are visible.
- Trichotillomania—Self-inflicted alopecia caused when the patient pulls and twists her/his own hair (see Chapter 188, Traction Alopecia and a Trichotillomania).
- Traction alopecia—Alopecia that occurs when the patient or parent pulls the hair to style it into braids or ponytails. There should be no scaling of the scalp (unless there is coexisting seborrhea) and the pattern of hair loss should match the hairstyle (**Figure 137-10**) (see Chapter 188, Traction Alopecia and Trichotillomania).
- Scarring alopecia—Seen with systemic lupus erythematosus (SLE) and discoid lupus. Scarring and hypopigmentation should differentiate this from tinea capitis (see Chapter 189, Scarring Alopecia).
- Tinea barbae (**Figure 137-11**) is a type of tinea infection of the hair follicles of the beard.

MANAGEMENT

- Topical antifungal therapy is not adequate and oral treatment is needed.
- Griseofulvin remains the treatment of choice for tinea capitis even if it requires a somewhat longer course than the newer antifungal agents.[2–5] SOR B Most importantly, it is less expensive and available in a liquid form for children. Prescribe a 6- to 8-week course or longer (12-week course) of griseofulvin for tinea capitis.
- A 2- to 4-week course of terbinafine, fluconazole, and itraconazole are at least as effective as a 6- to 8-week course of griseofulvin for the treatment of *Trichophyton* infections of the scalp. Griseofulvin is likely to be superior to terbinafine for the rare cases caused by *Microsporum* species; its efficacy is matched by itraconazole and fluconazole.[5] SOR B
- Griseofulvin is available in many forms, including liquid (125 mg microsize/5 cc) for children. Taking the drug with fatty food increases absorption and aids bioavailability. The dose for microsize griseofulvin is 20 mg/kg per day and ultramicrosize griseofulvin is 10 mg/kg per day. Ultramicrosize preparations are stronger per mg

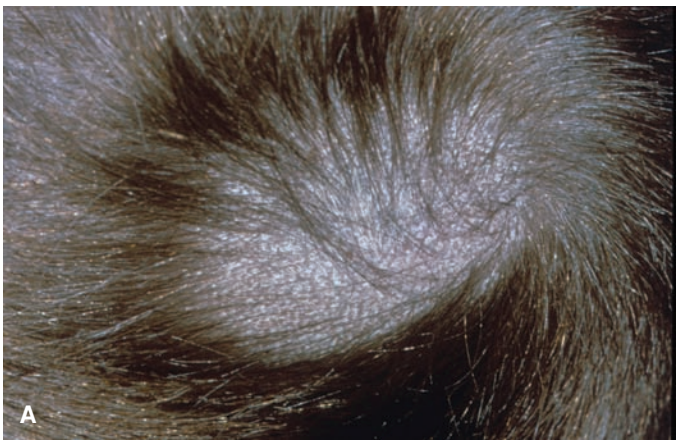

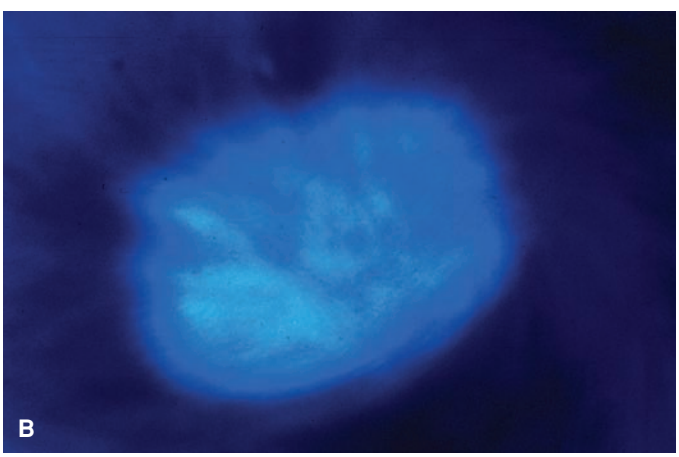

FIGURE 137-9 **A.** Tinea capitis in a young boy. **B.** Fluorescence with an ultraviolet light indicating that this is a *Microsporum* species causing the tinea capitis. (*Courtesy of Jeff Meffert, MD.*)

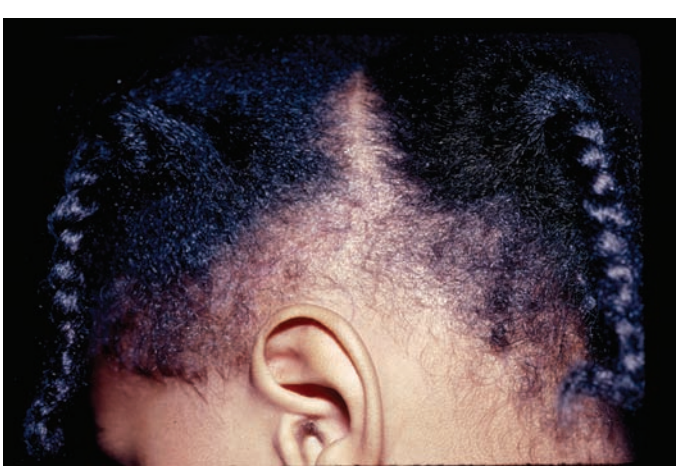

FIGURE 137-10 Traction alopecia that is related to the tight braids that put pressure on the hair follicle. The slight scaling was caused by seborrhea but tinea capitis must be in the differential diagnosis. (*Courtesy of Richard P. Usatine, MD.*)

than the microsize, but do not come in liquid form. The tablets are less expensive than the liquids and can be used for children that can swallow a pill. The standard course should be 6 to 12 weeks for tinea capitis to deal with increasing resistance patterns.

- Terbinafine is effective and offers a shorter course of therapy than griseofulvin. It is not available in liquid form. Recommended dosage for 10- to 20-kg children is 62.5 mg/day; for 20- to 40-kg children, 125 mg daily; and for children who weigh more than 40 kg, 250 mg daily. Treatment duration for *Trichophyton* is 2 to 4 weeks; it is 8 to 12 weeks for *Microsporum* infection.
- Fluconazole is available in liquid form and appears to be effective and safe to treat cutaneous fungal infections. Recommended dosage is 5 to 6 mg/kg per day. Treatment duration for *Trichophyton* is 3 to 6 weeks; 8 to 12 weeks for *Microsporum* infection.
- Itraconazole is also available in liquid form. The recommended dose is 3 mg/kg per day for liquid form. For capsules: 5 mg/kg per day. Treatment duration is 2 to 6 weeks.
- None of these agents require laboratory monitoring at the recommended lengths of treatment for tinea capitis.[1]
- A kerion may resolve with oral antifungal treatment alone. If it is severe and painful, consider a short pulse of oral steroids to speed up resolution. SOR C
- Although oral therapy is still the recommended treatment for tinea capitis, topical treatment can be used as adjuvant therapy: 1% or 2.25% selenium sulfide, 1% ciclopirox, or 2% ketoconazole shampoo should be applied to the scalp and hair for 5 minutes 2 or 3 times a week for 8 weeks.[6–7] SOR B Another use for antifungal shampoo is empirical treatment while waiting for a culture to come back in an equivocal case. SOR C

FIGURE 137-11 Tinea barbae involving the hair follicles of the beard in a 63-year-old man with cutaneous lupus. The annular eruption on the neck was initially confused for his lupus until a potassium hydroxide scraping confirmed a fungal infection. The tinea barbae became inflammatory like a kerion with swelling of the upper lip before it was cured with oral terbinafine. (*Courtesy of Richard P. Usatine, MD.*)

PREVENTION

Family members or playmates should be screened and asymptomatic carriers should be treated. Close physical contact and sharing of toys or combs/hairbrushes should be avoided.[8] SOR B

PROGNOSIS

Severe hair loss and scarring alopecia can occur if tinea capitis is left untreated.

PATIENT EDUCATION

Patients and parents need to exercise care to avoid spreading the infection to others. Explain the importance of not sharing combs, brushes, and towels.

FOLLOW-UP

Follow-up may be scheduled to check for full resolution of the infection by negative culture or hair regrowth.

PATIENT RESOURCE

- Medline Plus article for patients—**http://www.nlm.nih.gov/medlineplus/ency/article/000878.htm.**

PROVIDER RESOURCE

- **http://www.emedicine.com/DERM/topic420.htm.**

REFERENCES

1. Johnston KL, Chambliss ML, DeSpain J. Clinical inquiries. What is the best oral antifungal medication for tinea capitis? *J Fam Pract.* 2001;50:206-207.
2. Tey HL, Tan AS, Chan YC. Meta-analysis of randomized, controlled trials comparing griseofulvin and terbinafine in the treatment of tinea capitis. *J Am Acad Dermatol.* 2011;64(4):663-670.
3. Gupta AK, Cooper EA, Bowen JE. Meta-analysis: griseofulvin efficacy in the treatment of tinea capitis. *J Drugs Dermatol.* 2008;7(4):369-372.
4. González U, Seaton T, Bergus G, et al. Systemic antifungal therapy for tinea capitis in children. *Cochrane Database Syst Rev.* 2007 Oct 17;(4):CD004685.
5. Kakourou T, Uksal U; European Society for Pediatric Dermatology. Guidelines for the management of tinea capitis in children. *Pediatr Dermatol.* 2010;27(3):226-228.
6. Greer DL. Successful treatment of tinea capitis with 2% ketoconazole shampoo. *Int J Dermatol.* 2000;39(4):302-304.
7. Chen C, Koch LH, Dice JE, et al. A randomized, double-blind study comparing the efficacy of selenium sulfide shampoo 1% and ciclopirox shampoo 1% as adjunctive treatments for tinea capitis in children. *Pediatr Dermatol.* 2010;27(5):459-462.
8. Higgins EM, Fuller LC, Smith CH. Guidelines for the management of tinea capitis. British Association of Dermatologists. *Br J Dermatol.* 2000;143(1):53-58.

138 TINEA CORPORIS

Richard P. Usatine, MD
Adeliza Jimenez, MD

PATIENT STORY

A 6-year-old girl is brought to the office for a round, itchy rash on her body (**Figure 138-1**). It was first noted 2 weeks ago. The family cat does have some patches of hair loss. Note the concentric rings with scaling, erythema, and central sparing. UV light showed green fluorescence (*Microsporum* species) and the KOH is positive for branching and septate hyphae. The child was treated with a topical antifungal cream bid and the tinea resolves in 3 to 4 weeks. The family cat was taken to the veterinarian for treatment, too.

FIGURE 138-1 Tinea corporis on the shoulder of this young girl. This is a very typical annular pattern and the cat on a sweatshirt might be a clue to an infected pet at home spreading a *Microsporum* dermatophyte to its owner. Note the concentric rings with scaling, erythema, and central sparing. (*Courtesy of Richard P. Usatine, MD.*)

INTRODUCTION

Tinea corporis is a common superficial fungal infection of the body, characterized by well-demarcated, annular lesions with central clearing, erythema, and scaling of the periphery.

EPIDEMIOLOGY

Dermatophytes are the most prevalent agents causing fungal infections in the United States, with *Trichophyton rubrum* causing the majority of cases of tinea corporis, tinea cruris, tinea manuum, and tinea pedis.

- Excessive heat and humidity make a good environment for fungal growth.
- Dermatophytes are spread by exposure to infected animals or persons and contact with contaminated items.

ETIOLOGY AND PATHOPHYSIOLOGY

Tinea corporus is caused by fungal species from any one of the following three dermatophyte genus's: *Trichophyton*, *Microsporum*, and *Epidermophyton*. *T. rubrum* is the most common causative agent of tinea corporis.

- Dermatophytes produce enzymes such as keratinase that penetrate keratinized tissue. Their hyphae invade the stratum corneum and keratin and spread centrifugally outward.

RISK FACTORS

- Participation in daycare centers.
- Living in a nursing home.
- Poor personal hygiene.
- Living conditions with poor sanitation.
- Warm, humid environments.

- Conditions that cause weakening of the immune system (e.g., AIDS, cancer, organ transplantation, diabetes).

DIAGNOSIS

The diagnosis can be made from history, clinical presentation, culture, and direct microscopic observation of hyphae in infected tissue and hairs after KOH preparation.

CLINICAL FEATURES

- Pruritus of affected area.
- Well-demarcated, annular lesions with central clearing, erythema, and scaling of the periphery. Concentric rings are highly specific (80%) for tinea infections (**Figure 138-1**).
- Central clearing is not always present (**Figure 138-2**).
- Although scale is the most prominent morphologic characteristic, some tinea infections will actually cause pustules from the inflammatory response (**Figure 138-3**).

TYPICAL DISTRIBUTION

Any part of the body including the face and axilla (**Figures 138-1** to **138-4**).

Tinea incognito is a type of tinea infection that was previously not recognized by the physician or patient and topical steroids were used on the site. While applying the steroid, the dermatophyte continues to grow and form concentric rings (**Figures 138-5** and **138-6**).

Tinea corporis can cover large parts of the body as in **Figures 138-7** to **138-9**.

In some cases the infection may cause hyperpigmentation (**Figures 138-7** to **138-9**).

LABORATORY STUDIES

- KOH preparation of skin scraping can be very useful to confirm a clinical impression or when the diagnosis is not certain. Scrape the skin with the side of a slide or scalpel, making sure to scrape the periphery and the erythematous part. Scrape hard enough to get some stratum corneum without causing significant bleeding. False negatives can occur secondary to inadequate scraping, patient using topical antifungals, or an inexperienced microscopist.
- Use KOH (plain, with dimethyl sulfoxide [DMSO], or in a fungal stain) to break up the epithelial cells more rapidly without heating (**Figure 138-10**). It is easy to purchase a small bottle of Swartz-Lamkins fungal stain that includes KOH, a surfactant, and blue ink. The blue ink allows the hyphae to stand out, thereby saving time and decreasing the chance of a false-negative result (**Figure 138-11**). If the epithelial cells are not breaking up sufficiently, use a flame under the slide for approximately 5 seconds to speed up the process.
- Skin scraping and culture—Gold standard, but more costly and may take up to 2 weeks for the culture to grow. Consider culture if the KOH is negative but tinea is still suspected, or when a microscope is not available.
- Skin biopsy sent in formalin for periodic acid-Schiff (PAS) staining when the KOH and culture remain negative but the clinical picture is consistent with a fungal infection.

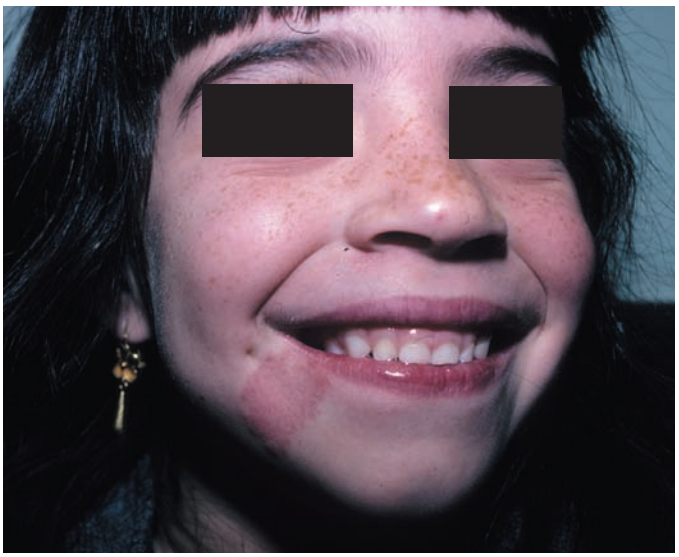

FIGURE 138-2 Tinea faciei in a young girl. There is no central clearing or annular pattern here but the KOH preparation was positive for branching hyphae. It resolved with a topical antifungal medicine. (*Courtesy of Richard P. Usatine, MD.*)

FIGURE 138-3 Tinea corporis with pustules and scale. KOH preparation was positive for branching hyphae. The pustules are a manifestation of an inflammatory response to the dermatophyte infection. (*Courtesy of Richard P. Usatine, MD.*)

FIGURE 138-4 Extensive tinea corporis in the axilla and arm of this older adult. (*Courtesy of Richard P. Usatine, MD.*)

FIGURE 138-5 Tinea incognito on the chest and arm of this black woman. This tinea infection continued to grow as the patient applied the topical steroids given to her by her physician. There is an extensive amount of postinflammatory hyperpigmentation. **A.** Tinea incognito on the arm with concentric rings as this dermatophyte infection continued to grow under the influence of the topical steroids. **B.** Tinea incognito on the chest. (*Courtesy of Richard P. Usatine, MD.*)

FIGURE 138-6 Tinea incognito in the axillary region of a young man who was prescribed topical steroids. Although there is some hyperpigmentation, erythema is most prominent. (*Courtesy of Chris Wenner, MD.*)

FIGURE 138-7 Tinea corporis covering the back and showing well-demarcated borders. (*Courtesy of Richard P. Usatine, MD.*)

DIFFERENTIAL DIAGNOSIS

- Granuloma annulare—Inflammatory, benign dermatosis of unknown cause, characterized by both dermal and annular papules (**Figure 138-12**) (see Chapter 173, Granuloma Annulare).
- Psoriasis—Plaque with scale on extensor surfaces and trunk. Occasionally, the plaques can have an annular appearance (**Figure 138-13**). Inverse psoriasis in intertriginous areas can also mimic tinea corporis (see Chapter 152, Psoriasis).
- Erythema annulare centrifugum (EAC)—Scaly red rings with normal skin in the center of the rings. The scale is trailing the erythema as the ring expands while the scale is leading in tinea corporis (**Figure 138-14**) (see Chapter 206, Erythema Annulare Centrifugum).
- Cutaneous larva migrans has serpiginous burrows made by the hookworm larvae, and these burrows can look annular and be confused with tinea corporis (see Chapter 144, Cutaneous Larva Migrans).
- Nummular eczema—Round coin-like red scaly plaques without central clearing (see Chapter 145, Atopic Dermatitis).
- Erythrasma—Found in the axilla and groin without an annular configuration and central clearing. Fluoresces coral red under UV lamp (see Chapter 119, Erythrasma).

MANAGEMENT

- Use topical antifungal medications for tinea corporis that involves small areas of the body such as seen in **Figures 138-1** and **138-2**.
- Although all the topical antifungal agents may be effective, the evidence supports the greater effectiveness of the allylamines (terbinafine) over the less-expensive azoles for tinea pedis and corporis. Allylamines cure slightly more infections than azoles and are now available over the counter.[1,2] SOR A
- Studies show that terbinafine 1% cream or solution applied once daily for 7 days is highly effective for tinea corporis/cruris.[3,4] The 1% cream (which is available over the counter as Lamisil AF) produced a mycologic cure of 84.2% versus 23.3% with placebo. Number needed to treat (NNT) = 1.6.[3] SOR A
- Oral antifungal agents should be considered for first-line therapy for tinea corporis covering large areas of the body, as seen in **Figures 138-6** and **138-7**. However, it is not wrong to attempt topical treatment if the size of the area infected is on the borderline. The patient with tinea incognito in **Figures 138-4** and **138-5** did need oral therapy to resolve her infection. Unfortunately, the postinflammatory hyperpigmentation did not resolve well.
- One randomized controlled trial (RCT) showed that oral itraconazole 200 mg daily for 1 week is similarly effective, equally well tolerated, and at least as safe as itraconazole 100 mg for 2 weeks in the treatment of tinea corporis or cruris.[5] SOR B
- In one study, patients with mycologically diagnosed tinea corporis and tinea cruris were randomly allocated to receive either 250 mg of oral terbinafine once daily or 500 mg of griseofulvin once daily for 2 weeks. The cure rates were higher for terbinafine at 6 weeks.[6] SOR B

FIGURE 138-8 Tinea corporis on the back, shoulder, and arm with erythema and hyperpigmentation. (*Courtesy of Richard P. Usatine, MD.*)

FIGURE 138-9 Tinea corporis from the trunk down both legs with significant hyperpigmentation. (*Courtesy of Richard P. Usatine, MD.*)

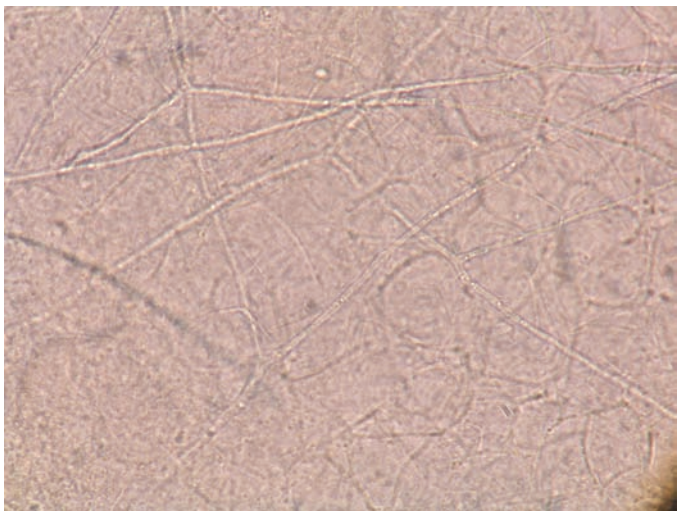

FIGURE 138-10 Branching hyphae at 40× power from KOH preparation of tinea corporis. (*Courtesy of Richard P. Usatine, MD.*)

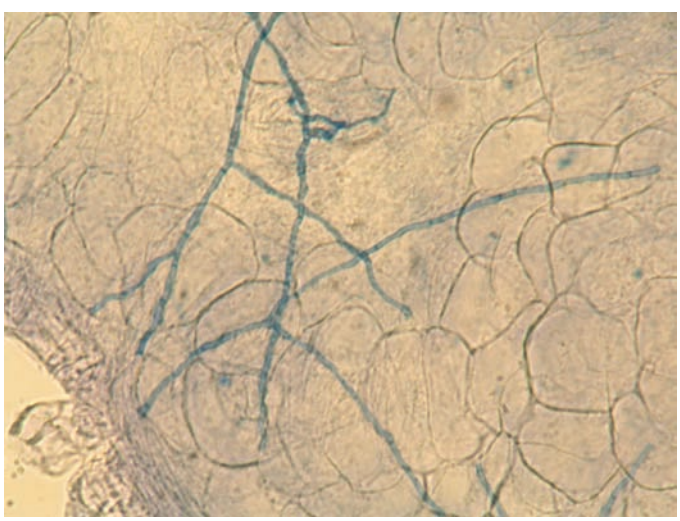

FIGURE 138-11 Branching hyphae easily seen at 40× power using fungal stain (Swartz-Lamkins) from a scraping of tinea corporis. Note how the hyphae stand out with the blue ink color. (*Courtesy of Richard P. Usatine, MD.*)

FIGURE 138-12 Multiple annular lesions caused by granuloma annulare. No scale is visible. (*Courtesy of Richard P. Usatine, MD.*)

FIGURE 138-13 Widespread annular lesions caused by psoriasis. Not all lesions that are annular with scale are tinea corporis. (*Courtesy of Richard P. Usatine, MD.*)

FIGURE 138-14 Erythema annulare centrifugum (EAC) in the axilla of a 28-year-old man. After multiple failed trials of antifungal medicines, a punch biopsy showed this to be EAC. Note the trailing scale rather than leading scale seen in tinea corporis. (*Courtesy of Richard P. Usatine, MD.*)

- In summary, if an oral agent is needed, the evidence is greatest for the use of:
  - Terbinafine 250 mg daily for 2 weeks.[6] SOR B (Terbinafine is available as an inexpensive generic prescription on the $4 and $5 plans in the United States. It also has less drug interactions than itraconazole. For these reasons it is usually the preferred treatment when an oral agent is needed.)
  - Itraconazole 200 mg daily for 1 week.[5] SOR B (More expensive with more drug interactions than terbinafine.)
  - Itraconazole 100 mg daily for 2 weeks.[5] SOR B

PREVENTION

Tinea corporis and cruris are dermatophyte infections that are particularly common in areas of excessive heat and moisture. A dry, cool environment may play a role in reducing infection. In addition, avoiding contact with farm animals and other individuals infected with tinea corporis and cruris may help in preventing infection. Preventative measures for tinea infections include practicing good personal hygiene; keeping the skin dry and cool at all times; and avoiding sharing towels, clothing, or hair accessories with infected individuals.[7]

In individuals involved in contact sports such as wrestling, a comprehensive skin disease prevention protocol includes some combination of the following: washing of wrestling mats before and after each practice and competition; showers before and after each practice; use of clean clothing before each practice; and exclusion of infected athletes.[8]

PATIENT EDUCATION

Keep the skin clean and dry. Infected pets should be treated.

FOLLOW-UP

Consider follow-up appointments in 4 to 6 weeks for difficult and more widespread cases. If there are concerns about bacterial superinfection, follow-up should be sooner.

PATIENT RESOURCES

- VisualDxHealth. *Ringworm*—**http://www.visualdxhealth.com/adult/tineaCorporis.htm.**
- Medline Plus Medical Encyclopedia—**http://www.nlm.nih.gov/medlineplus/ency/article/000877.htm.**

PROVIDER RESOURCES

- eMedicine topic—**http://www.emedicine.com/DERM/topic421.htm.**
- Doctor Fungus Web site—**http://www.doctorfungus.org/.**
- Swartz-Lamkins fungal stain can be easily purchased online at: **http://www.delasco.com/pcat/1/Chemicals/Swartz_Lamkins/dlmis023/.**

REFERENCES

1. Thomas B. Clear choices in managing epidermal tinea infections. *J Fam Pract.* 2003;52:850-862.
2. Crawford F, Hollis S. Topical treatments for fungal infections of the skin and nails of the foot. *Cochrane Database Syst Rev.* 2007;3:CD001434.
3. Budimulja U, Bramono K, Urip KS, et al. Once daily treatment with terbinafine 1% cream (Lamisil) for one week is effective in the treatment of tinea corporis and cruris. A placebo-controlled study. *Mycoses.* 2001;44:300-306.
4. Lebwohl M, Elewski B, Eisen D, Savin RC. Efficacy and safety of terbinafine 1% solution in the treatment of interdigital tinea pedis and tinea corporis or tinea cruris. *Cutis.* 2001;67:261-266.
5. Boonk W, de Geer D, de Kreek E, et al. Itraconazole in the treatment of tinea corporis and tinea cruris: comparison of two treatment schedules. *Mycoses.* 1998;41:509-514.
6. Voravutinon V. Oral treatment of tinea corporis and tinea cruris with terbinafine and griseofulvin: A randomized double blind comparative study. *J Med Assoc Thai.* 1993;76:388-393.
7. Gupta AK, Chaudhry M, Elewski B. Tinea corporis, tinea cruris, tinea nigra, and piedra. *Dermatol Clin.* 2003;21(3):395-400.
8. Hand JW, Wroble RR. Prevention of tinea corporis in collegiate wrestlers. *J Athl Train.* 1999;34(4):350-352.

139 TINEA CRURIS

Richard P. Usatine, MD
Mindy A. Smith, MD, MS

PATIENT STORY

A 59-year-old man presents with itching in the groin (**Figure 139-1**). On examination, he was found to have scaly erythematous plaques in the inguinal area. A skin scraping was treated with Swartz-Lamkins stain and the dermatophyte was highly visible under the microscope (**Figure 139-2**). He was treated with a topical antifungal medicine until his tinea cruris resolved.

INTRODUCTION

Tinea cruris is an intensely pruritic superficial fungal infection of the groin and adjacent skin.

SYNONYMS

Crotch rot and jock itch.

EPIDEMIOLOGY

- Using data from the National Ambulatory Medical Care Survey and the National Hospital Ambulatory Medical Care Survey (NHAMCS) (1995-2004), there were more than 4 million annual visits for dermatophytoses and 8.4% were for tinea cruris.[1]
- Tinea cruris is more common in men than women (three-fold) and rare in children.

ETIOLOGY AND PATHOPHYSIOLOGY

- Most commonly caused by the dermatophytes: *Trichophyton rubrum, Epidermophyton floccosum, Trichophyton mentagrophytes,* and *Trichophyton verrucosum. T. rubrum* is the most common organism.[2]
- Can be spread by fomites, such as contaminated towels.
- The fungal agents cause keratinases, which allow invasion of the cornified cell layer of the epidermis.[2]
- Autoinoculation can occur from fungus on the feet or hands.

RISK FACTORS

- Wearing tight-fitting or wet clothing or underwear has traditionally been suggested; however, in a study of Italian soldiers, none of the risk factors analyzed (e.g., hyperhidrosis, swimming pool attendance) were significantly associated with any fungal infection.[3]
- Obesity and diabetes mellitus may be risk factors.[4]

FIGURE 139-1 Tinea cruris in a 59-year-old Hispanic man present for 1 year. (*Courtesy of Richard P. Usatine, MD.*)

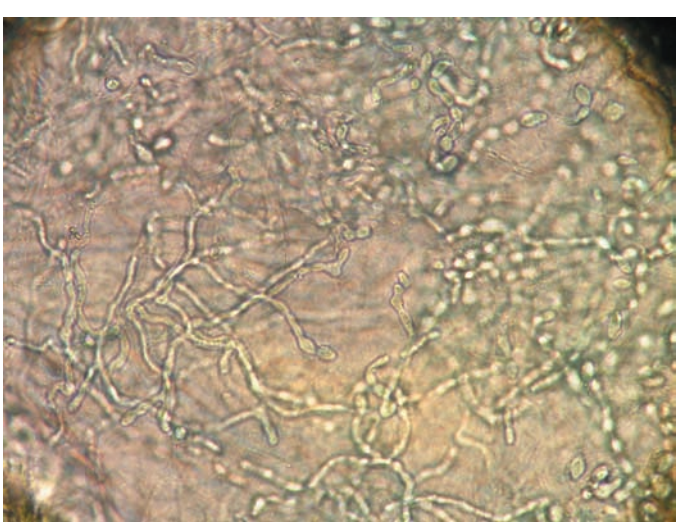

FIGURE 139-2 Microscopic view of the scraping of the groin in a man with tinea cruris. The hyphae are easy to see under 40 power with Swartz-Lamkins stain. (*Courtesy of Richard P. Usatine, MD.*)

DIAGNOSIS

CLINICAL FEATURES

The cardinal features are scale and signs of inflammation. In light-skinned persons inflammation often appears pink or red and in dark-skinned persons the inflammation often leads to hyperpigmentation (**Figures 139-3** and **139-4)**. Occasionally, tinea cruris may show central sparing with an annular pattern as in **Figure 139-5**, but most often is homogeneously distributed as in **Figures 139-3** and **139-4**.

TYPICAL DISTRIBUTION

By definition tinea cruris is in the inguinal area. However, the fungus can grow outside of this area to involve the abdomen and thighs (**Figures 139-4** and **139-6**). Tinea can be present in multiple locations, as in the patient in **Figure 139-7** who had tinea in the groin, on her feet and face, and under her breasts.

LABORATORY STUDIES

Diagnosis is often made based on clinical presentation, but a skin scraping treated with KOH and a fungal stain analyzed under the microscope can be helpful (**Figure 139-2**). False negatives may occur if scraping is inadequate, patient is using topical antifungals, or the viewer is inexperienced.

Skin scraping and culture is definitive but expensive, and may take up to 2 weeks for the culture to grow.

UV lamp can be used to look for the coral red fluorescence of erythrasma (see Chapter 119, Erythrasma). Most tinea cruris is caused by *T. rubrum* so will not fluoresce.

FIGURE 139-3 Tinea cruris in an older black man with hyperpigmentation secondary to the inflammatory response. A silvery scale is also seen and psoriasis should be considered in the differential diagnosis. In such a case, performing a potassium hydroxide preparation is crucial to making an accurate diagnosis as it is not possible to know the diagnosis by appearance only. (*Courtesy of Richard P. Usatine, MD.*)

DIFFERENTIAL DIAGNOSIS

- Cutaneous *Candida* in the groin can become red and have scaling that extends to the thigh and scrotum. Tinea cruris does not often involve the scrotum. *Candida* often has satellite lesions. However, tinea cruris can also have a few satellite lesions (see Chapter 136, Candidiasis).
- Erythrasma in the groin appears similar to tinea cruris. It is less common than tinea cruris and may show coral red fluorescence with a UV light (**Figure 139-8**) (see Chapter 119, Erythrasma).
- Contact dermatitis can occur anywhere on the body. If the contact is near the groin this can be mistaken for tinea cruris (see Chapter 146, Contact Dermatitis).
- Inverse psoriasis causes inflammation in the intertriginous areas of the body. It does not have the thick plaques of plaque psoriasis. Inverse psoriasis is frequently misdiagnosed as a fungal infection until an astute clinician recognizes the pattern or does a biopsy (**Figure 139-9**; see Chapter 152, Psoriasis).
- Intertrigo is an inflammatory condition of the skin folds. It induced or aggravated by heat, moisture, maceration, and friction.[5] The condition frequently is worsened by infection with *Candida* or dermatophytes so there is some overlap with tinea cruris.

FIGURE 139-4 Tinea cruris that has expanded beyond the inguinal area in this 35-year-old black man. Postinflammatory hyperpigmentation is visible throughout the infected area. (*Courtesy of Richard P. Usatine, MD.*)

FIGURE 139-5 An 18-year-old woman with tinea cruris showing erythema and scale in an annular pattern. Central clearing is less common in tinea cruris than tinea corporis but can occur. (*Courtesy of Richard P. Usatine, MD.*)

FIGURE 139-6 A 54-year-old man with tinea cruris and corporis for decades despite multiple treatments with oral antifungal medications. His cultures show *T. rubrum* sensitive to all the typical oral antifungal medications, but his tinea never completely clears. He does not have a known immunodeficiency but his immune system appears not to recognize the *T. rubrum* as foreign. (*Courtesy of Richard P. Usatine, MD.*)

FIGURE 139-7 A 55-year-old woman with tinea cruris showing erythema and scale. Although less common in women, women do get tinea cruris. This patient had tinea on her feet, face, and under her breasts. She was treated with oral terbinafine for 3 weeks. (*Courtesy of Richard P. Usatine, MD.*)

FIGURE 139-8 Erythrasma in the groin can be mistaken for tinea cruris. This erythrasma fluoresced coral red with a ultraviolet light. (*Courtesy of Richard P. Usatine, MD.*)

FIGURE 139-9 Inverse psoriasis in a man who also has the nail changes of psoriasis. (*Courtesy of Richard P. Usatine, MD.*)

MANAGEMENT

- Tinea cruris is best treated with a topical allylamine or an azole antifungal (SOR A, based on multiple randomized controlled trials [RCTs]).[6] Differences in current comparison data are insufficient to stratify the two groups of topical antifungals.[7] In one RCT, cure rates were higher at 1 week with butenafine (once daily for 2 weeks) versus clotrimazole (twice daily for 4 weeks) (26.5% vs. 2.9%, respectively), but were not significantly different at 4 or 8 weeks.[8]
- The fungicidal allylamines (naftifine and terbinafine) and butenafine (allylamine derivative) are a more costly group of topical tinea treatments, yet they are more convenient as they allow for a shorter duration of treatment compared with fungistatic azoles (clotrimazole, econazole, ketoconazole, oxiconazole, miconazole, and sulconazole).[7]
- Topical azoles should be continued for 4 weeks and topical allylamines for 2 weeks or until clinical cure.[6–8] SOR A
- Fluconazole 150 mg once weekly for 2 to 4 weeks appears to be effective in the treatment of tinea cruris.[9] SOR B
- One RCT showed that itraconazole 200 mg for 1 week is similarly effective, equally well tolerated, and at least as safe as itraconazole 100 mg for 2 weeks in the treatment of tinea corporis or cruris (clinical response: 73% and 80% at the end of follow-up, respectively).[10] SOR B
- Patients with mycologically diagnosed tinea corporis and tinea cruris were randomly allocated to receive either 250 mg of oral terbinafine once daily or 500 mg of griseofulvin once daily for 2 weeks. The cure rates were higher for terbinafine at 6 weeks.[11] SOR B
- If there are multiple sites infected with fungus, treat all active areas of infection simultaneously to prevent reinfection of the groin from other body sites. If the tinea is widespread as in the patient in **Figure 139-5**, an oral agent is warranted.

FOLLOW-UP

As needed.

PATIENT EDUCATION

- Advise patients with tinea pedis to put on their socks before their undershorts to reduce the possibility of direct contamination. SOR C
- Dry the groin completely after bathing. SOR C

PATIENT RESOURCES

- Medscape Family Medicine. *Tinea Cruris in Men: Bothersome But Treatable*—**http://www.medscape.com/viewarticle/512992.**
- Medline Plus. *Jock Itch*—**http://www.nlm.nih.gov/medlineplus/ency/article/000876.htm.**

PROVIDER RESOURCES

- DermNet NZ. *Fungal Skin Infections*—**http://www.dermnetnz.org/fungal/.**
- Doctor Fungus—**http://www.doctorfungus.org/.**
- Medscape. *Tinea Cruris*—**http://emedicine.medscape.com/article/1091806**.

REFERENCES

1. Panackal AA, Halpern EF, Watson AJ. Cutaneous fungal infections in the United States: analysis of the National Ambulatory Medical Care Survey (NAMCS) and National Hospital Ambulatory Medical Care Survey (NHAMCS), 1995-2004. *Int J Dermatol.* 2009;48(7):704-712.
2. Wiederkehr M, Schwartz RA. *Tinea Cruris*, http://emedicine.medscape.com/article/1091806-overview, accessed April 2, 2012.
3. Ingordo V, Naldi L, Fracchiolla S, Colecchia B. Prevalence and risk factors for superficial fungal infections among Italian Navy cadets. *Dermatology.* 2004;209(3):190-196.
4. Patel GA, Wiederkehr M, Schwartz RA. Tinea cruris in children. *Cutis.* 2009;84(3):133-137.
5. Selden ST. *Intertrigo*, http://emedicine.medscape.com/article/1087691-overview, accessed April 2, 2012.
6. Drake LA, Dinehart SM, Farmer ER, et al. Guidelines of care for superficial mycotic infections of the skin: tinea corporis, tinea cruris, tinea faciei, tinea manuum, and tinea pedis. Guidelines/Outcomes Committee. American Academy of Dermatology. *J Am Acad Dermatol.* 1996;34(2 Pt 1):282-286.
7. Nadalo D, Montoya C, Hunter-Smith D. What is the best way to treat tinea cruris? *J Fam Pract.* 2006;55:256-258.
8. Singal A, Pandhi D, Agrawal S, Das S. Comparative efficacy of topical 1% butenafine and 1% clotrimazole in tinea cruris and tinea corporis: a randomized, double-blind trial. *J Dermatolog Treat.* 2005;16(506):331-335.
9. Nozickova M, Koudelkova V, Kulikova Z, Malina L, Urbanowski S, Silny W. A comparison of the efficacy of oral fluconazole, 150 mg/week versus 50 mg/day, in the treatment of tinea corporis, tinea cruris, tinea pedis, and cutaneous candidosis. *Int J Dermatol.* 1998;37:703-705.
10. Boonk W, de Geer D, de Kreek E, Remme J, van Huystee B. Itraconazole in the treatment of tinea corporis and tinea cruris: comparison of two treatment schedules. *Mycoses.* 1998;41:509-514.
11. Voravutinon V. Oral treatment of tinea corporis and tinea cruris with terbinafine and griseofulvin: a randomized double blind comparative study. *J Med Assoc Thai.* 1993;76:388-393.

140 TINEA PEDIS

Richard P. Usatine, MD
Katie Reppa, MD

PATIENT STORY

A 38-year-old man presents with an itchy rash on his hands and blisters on his feet for 1 week duration (**Figure 140-1**). Vesicular tinea pedis with bullae were present. The papules and vesicles between the fingers were typical of an autoeczematization reaction (Id reaction) (**Figure 140-2**). The patient was treated with an oral antifungal medication and a short burst of oral prednisone for the autosensitization reaction.

FIGURE 140-1 Vesicular tinea pedis with bullae present. This is an inflammatory reaction to the tinea pedis. (*Courtesy of Richard P. Usatine, MD.*)

INTRODUCTION

Tinea pedis is a common cutaneous infection of the feet caused by dermatophyte fungus. The clinical manifestation presents in 1 of 3 major patterns: interdigital, moccasin, and inflammatory. Concurrent fungal infection of the nails (onychomycosis) occurs frequently.

SYNONYMS

Athlete's foot

EPIDEMIOLOGY

- Tinea pedis is thought to be the world's most common dermatophytosis.[1]
- 70% of the population will be infected with tinea pedis at some time.[1]
- More commonly affects males than females.[1]
- Prevalence increases with age and it is rare before adolescence.[1]

ETIOLOGY AND PATHOPHYSIOLOGY

- A cutaneous fungal infection most commonly caused by *Trichophyton rubrum*.[1]
- *Trichophyton mentagrophytes* and *Epidermophyton floccosum* follow in that order.
- *T. rubrum* causes most tinea pedis and onychomycosis.

RISK FACTORS

- Male gender.
- Use of public showers, baths or pools.[2]
- Household member with tinea pedis infection.[2]

FIGURE 140-2 The hand shows an autoeczematization reaction to the inflammatory tinea pedis in the previous figure. The vesicles between the fingers are typical of an autoeczematization reaction, also known as an Id reaction. (*Courtesy of Richard P. Usatine, MD.*)

- Certain occupations (miners, farmers, soldiers, meat factory workers, marathon runners).[2]
- Use of immunosuppressive drugs.

DIAGNOSIS

TYPICAL DISTRIBUTION AND MORPHOLOGY

Three types of tinea pedis

- Interdigital type—most common (**Figure 140-3**).
- Moccasin type (**Figure 140-4** and **140-5**).
- Inflammatory/vesicular type—least common (**Figure 140-1**).

Some authors describe an ulcerative type (**Figure 140-6**).

CLINICAL FEATURES

- Interdigital—white or green fungal growth between toes with erythema, maceration, cracks, and fissures—especially between fourth and fifth digits (**Figure 140-3**). The dry type has more scale and the moist type becomes macerated.
- Moccasin—scale on sides and soles of feet (**Figure 140-4** and **140-5**).
- Vesicular—vesicles and bullae on feet (**Figure 140-6**).
- Ulcerative tinea pedis is characterized by rapidly spreading vesiculopustular lesions, ulcers, and erosions, typically in the web spaces (**Figure 140-7**). It is accompanied by a secondary bacterial infection. This can lead to cellulitis or lymphangitis.
- Autosensitization (dermatophytid reaction; ID reaction) is a hypersensitivity response to the fungal infection causing papules on the hands (**Figure 140-2**).
- Examine nails for evidence of onychomycosis—fungal infections of nails may include subungual keratosis, yellow or white discolorations, dysmorphic nails (Chapter 193, Onychomycosis).
- Examine to exclude cellulitis that may show erythema, swelling, tenderness with red streaks tracking up the foot and lower leg (Chapter 120, Cellulitis).

TYPICAL DISTRIBUTION

Between the toes, on the soles, and lateral aspects of the feet.

LABORATORY STUDIES

Diagnosis is often made based on clinical presentation but a skin scraping treated with KOH and a fungal stain analyzed under the microscope can be helpful (**Figure 140-8**).

In the patient with tinea incognito on his foot and lower leg, the physicians were set astray by his diagnosis of systemic lupus erythematosus (SLE) (**Figure 140-9**). It took a skin scraping to demonstrate that this was tinea and not lupus to get the patient the treatment he needed (**Figure 140-8**).

Skin scraping and culture is definitive but expensive, and may take up to 2 weeks for the culture to grow.

FIGURE 140-3 Tinea pedis seen in the interdigital space between the fourth and fifth digits. This is the most common area to see tinea pedis. (*Courtesy of Richard P. Usatine, MD.*)

FIGURE 140-4 Tinea pedis in the moccasin distribution. (*Courtesy of Richard P. Usatine, MD.*)

FIGURE 140-5 Tinea pedis in a moccasin distribution that has spread up the leg. (*Courtesy of Richard P. Usatine, MD.*)

DIFFERENTIAL DIAGNOSIS

- Pitted keratolysis: well-demarcated pits or erosions in the sole of the foot caused by bacteria (**Figure 140-10**) (Chapter 118, Pitted Keratolysis).
- Contact dermatitis: tends to be seen on the dorsum and sides of the foot (**Figure 140-11**) (Chapter 146, Contact Dermatitis).
- Keratodermas: thickening of the soles of the feet that can be caused by a number of etiologies, including menopause (**Figure 140-12**). This condition looks a lot like tinea pedis in the moccasin distribution.
- Dyshidrotic eczema is characterized by scale and tapioca-like vesicles on the hands and feet (**Figure 140-13**) (Chapter 147, Hand Eczema).
- Friction blisters: blisters on the feet of persons leading an active athletic lifestyle.
- Psoriasis: can mimic tinea pedis but will usually be present in other areas as well (**Figure 140-14**) (Chapter 152, Psoriasis).

MANAGEMENT

Table 140-1 discusses management of tinea pedis.

TOPICAL ANTIFUNGALS

- Systematic review of 70 trials of topical antifungals showed good evidence for efficacy compared to placebo for the following:
  - Allylamines (naftifine, terbinafine, butenafine)[3] SOR A
  - Azoles (clotrimazole, miconazole, econazole)[3] SOR A
  - Allylamines cure slightly more infections than azoles but are more expensive[3] SOR A
  - No differences in efficacy found between individual allylamines or individual azoles (**Table 140-2**) SOR A
  - In one metaanalysis, topical terbinafine was found to be equally effective as other topical antifungals but the average duration of treatment was shorter. (1 week instead of 2 weeks). Additionally, terbinafine is effective as a single-application film-forming solution.[4] SOR A

ORAL ANTIFUNGALS

- Systematic review of 12 trials, involving 700 participants: oral terbinafine for 2 weeks cures 52% more patients than oral griseofulvin.[5] SOR A
- Terbinafine is equal to itraconazole in patient outcomes.[5] SOR A
- No significant differences in comparisons between a number of oral agents.[5] SOR A

Dosing for tinea pedis needing oral therapy:

- Itraconazole two 100 mg tablets daily for 1 week.[6]
- Terbinafine 250 mg PO daily for 1 to 2 weeks.[6]

Patients with onychomycosis may have recurrences of the skin infection related to the fungus that remains in the nails and, therefore, may need oral treatment for 3 months to achieve better results.

FIGURE 140-6 Vesicular tinea pedis with vesicles and bullae over the arch region of the foot. The arch is a typical location for vesiculobullous tinea pedis. (*Courtesy of Richard P. Usatine, MD.*)

FIGURE 140-7 Ulcerative tinea pedis with spreading vesicles related to a bacterial superinfection. The patient was treated with antifungals and antibiotics. (*Courtesy of Richard P. Usatine, MD.*)

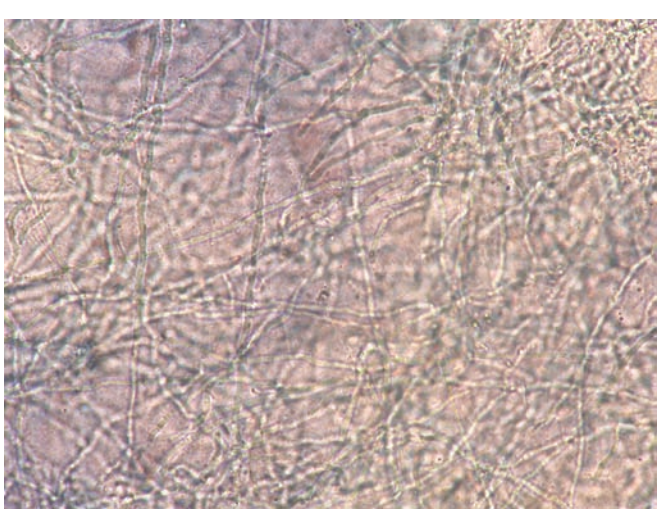

FIGURE 140-8 Microscopic view of the scraping of the foot in the man with tinea incognito in the next figure. The hyphae have proliferated and are easy to see under 40 power with Swartz-Lamkins stain. (*Courtesy of Richard P. Usatine, MD.*)

FIGURE 140-9 Tinea incognito on the foot of a 63-year-old black man with lupus. He was given topical steroids that allowed this fungus to spread and thrive. (*Courtesy of Richard P. Usatine, MD.*)

FIGURE 140-10 Pitted keratolysis on the sole of the foot with some interdigital tinea pedis. The pits are caused by bacteria and if not treated with an antibiotic will not resolve. (*Courtesy of Richard P. Usatine, MD.*)

FIGURE 140-11 Contact dermatitis to an allergen in tennis shoes with typical distribution that crosses the dorsum of the foot. (*Courtesy of Richard P. Usatine, MD.*)

FIGURE 140-12 Keratoderma climactericum, which started when this woman entered menopause. (*Courtesy of Richard P. Usatine, MD.*)

FIGURE 140-13 Dyshidrotic eczema on the foot showing tapioca vesicles with peeling of skin on the tip of the second toe. The patient also has typical tapioca vesicles between the fingers. (*Courtesy of Richard P. Usatine, MD.*)

TABLE 140-1 Management of Tinea Pedis

Tinea Pedis Type	Treatment for Mild Cases	Treatment for Recalcitrant Cases	SOR
Interdigital type	Topical antifungal	Another topical antifungal or an oral antifungal	A
Moccasin type	Topical antifungal	Oral antifungal	A
Inflammatory/vesicular type	Oral antifungal	Oral antifungal	A

Reprinted with permission from Thomas B. Clear choices in managing epidermal tinea infections. *J Fam Pract* 2003;52(11):857. Reproduced with permission from Frontline Medical Communications.

TABLE 140-2 Topical Antifungal Medications

Agent	Formulation	Frequency*	Duration* (weeks)	NNT†
Imidazoles				
Clotrimazole	1% cream 1% solution 1% swabs	Twice daily	2 to 4	2.9
Econazole	1% cream	Twice daily	2 to 4	2.6
Ketoconazole	2% cream	Once daily	2 to 4	No data available
Miconazole	2% cream 2% spray 2% powder	Twice daily	2 to 4	2.8 (at 8 weeks)
Oxiconazole	1% cream 1% lotion	Once to twice daily	2 to 4	2.9
Sulconazole	1% cream 1% solution	Once to twice daily	2 to 4	2.5
Allylamines				
Naftifine	1% cream 1% gel	Once to twice daily	1 to 4	1.9
Terbinafine	1% cream 1% solution	Once to twice daily	1 to 4	1.6 (1.7 for tinea cruris/tinea corporis at 8 weeks)
Benzylamine				
Butenafine	1% cream	Once to twice daily	1 to 4	1.9 (1.4 for tinea corporis and 1.5 for tinea cruris)
Other				
Ciclopirox	0.77% cream 0.77% lotion	Twice daily	2 to 4	2.1
Tolnaftate	1% powder 1% spray 1% swabs	Twice daily	4	3.6 (at 8 weeks)

*Manufacturer guidelines.
†NNT, number needed to treat. NNT is calculated from systematic review of all randomized controlled trials for tinea pedis at 6 weeks after the initiation of treatment except where otherwise noted.
Reprinted with permission from Thomas B. Clear choices in managing epidermal tinea infections. *J Fam Pract* 2003;52(11):857. Reproduced with permission from Frontline Medical Communications.

Topical urea (Carmol, Keralac), available in 10% to 40% concentrations, may be useful to decrease scaling in patients with hyperkeratotic soles.[5]

ALTERNATIVE THERAPY

One small pilot study with 56 participants showed significant improvement or resolution of symptoms in patients treated by wearing socks containing copper-oxide fibers daily for a minimum of 8 to 10 days.[7] SOR B

PATIENT EDUCATION

- Do not go barefoot in public showers and locker rooms. SOR C
- Keep feet dry and clean, and use clean socks and shoes that allow the feet to get fresh air. SOR C
- Use the topical medication beyond the time in which the feet look clear to prevent relapse.

PATIENT RESOURCES

- eMedicineHealth. *Athlete's Foot*—**http://www.emedicinehealth.com/athletes_foot/article_em.htm.**

PROVIDER RESOURCES

- Medscape. *Tinea Pedis*—**http://emedicine.medscape.com/article/1091684.**

FIGURE 140-14 Plantar psoriasis in a patient with other areas of psoriasis also present. (*Courtesy of Richard P. Usatine, MD.*)

REFERENCES

1. Robbins C. *Tinea Pedis*, http://www.emedicine.com/DERM/topic470.htm, accessed June 24, 2007.
2. Seebacher C, Bouchara JP, Mignon B. Updates on the epidemiology of dermatophyte infections. *Mycopathologia* 2008;166(5-6):335-352.
3. Crawford F, Hart R, Bell-Syer S, Torgerson D, Young P, Russell I. Topical treatments for fungal infections of the skin and nails of the foot. *Cochrane Database Syst Rev* 2000;CD001434.
4. Kienke P, Korting HC, Nelles S, Rychlik R. Comparable efficacy and safety of various topical formulations of terbinafine in tinea pedis irrespective of the treatment regimen: results of a meta-analysis. *Am J Clin Dermatol* 2007;8(6):357-364.
5. Bell-Syer SE, Hart R, Crawford F, Torgerson DJ, Tyrrell W, Russell I. Oral treatments for fungal infections of the skin of the foot. *Cochrane Database Syst Rev* 2002;CD003584.
6. Thomas B. Clear choices in managing epidermal tinea infections. *J Fam Pract* 2003;52:850-862.
7. Zatcoff RC, Smith MS, Borkow G. Treatment of tinea pedis with socks containing copper-oxide impregnated fibers. *Foot (Edinb)* 2008;18(3):136-141.

141 TINEA VERSICOLOR

Richard P. Usatine, MD
Melissa M. Chan, MD

PATIENT STORY

A young black man presents to the office with a 5-year history of white spots on his trunk (**Figure 141-1**). He denies any symptoms but worries if this could spread to his girlfriend. These spots get worse during the summer months but never go away completely. He was relieved to receive a treatment for his tinea versicolor and to find out that it is rarely spread to others through contact.

FIGURE 141-1 Tinea versicolor showing areas of hypopigmentation. (*From the Usatine RP. What is in a name? West J Med. 2000;173(4): 231-232.*)

INTRODUCTION

Tinea versicolor is a common superficial skin infection caused by the dimorphic lipophilic yeast *Pityrosporum* (*Malassezia furfur*). The most typical presentation is a set of hypopigmented macules and patches with fine scale over the trunk in a cape-like distribution.

SYNONYMS

Pityriasis versicolor is actually a more accurate name as "tinea" implies a dermatophyte infection. Tinea versicolor is caused by *Pityrosporum* and not a dermatophyte.

EPIDEMIOLOGY

- Seen more commonly in men than in women.
- Seen more often during the summer, and is especially common in warm and humid climates.

ETIOLOGY AND PATHOPHYSIOLOGY

- Tinea versicolor is caused by *Pityrosporum* (*M. furfur*), which is a lipophilic yeast that can be normal human cutaneous flora.
- *Pityrosporum* exists in two shapes—*Pityrosporum ovale* (oval) and *Pityrosporum orbiculare* (round).
- Tinea versicolor starts when the yeast that normally colonizes the skin changes from the round form to the pathologic mycelial form and then invades the stratum corneum.[1]
- *Pityrosporum* is also associated with seborrhea and *Pityrosporum* folliculitis.
- The white and brown colors are secondary to damage caused by the *Pityrosporum* to the melanocytes, while the pink is an inflammatory reaction to the organism.
- *Pityrosporum* thrive on sebum and moisture; they tend to grow on the skin in areas where there are sebaceous follicles secreting sebum.

DIAGNOSIS

CLINICAL FEATURES

Tinea versicolor consists of hypopigmented, hyperpigmented, or pink macules and patches on the trunk that are finely scaling and well-demarcated. Versicolor means a variety of or variation in colors; tinea versicolor tends to come in white, pink, and brown colors (**Figures 141-1** to **141-5**).

TYPICAL DISTRIBUTION

Tinea versicolor is found on the chest, abdomen, upper arms, and back, whereas seborrhea tends to be seen on the scalp, face, and anterior chest.

LABORATORY STUDIES

A scraping of the scaling portions of the skin may be placed onto a slide using the side of another slide or a scalpel. KOH with DMSO (DMSO helps the KOH dissolve the keratinocytes faster and reduces the need for heating the slide) is placed on the slide and covered with a coverslip. Microscopic examination reveals the typical "spaghetti-and-meatballs" pattern of tinea versicolor. The "spaghetti," or more accurately "ziti," is the short mycelial form and the "meatballs" are the round yeast form (**Figures 141-6** and **141-7**). Fungal stains such as the Swartz-Lamkins stain help make the identification of the fungal elements easier.

DIFFERENTIAL DIAGNOSIS

- Pityriasis rosea has a fine collarette scale around the border of the lesions and is frequently seen with a herald patch. Negative KOH (see Chapter 153, Pityriasis Rosea).
- Secondary syphilis is usually not scaling and tends to have macules on the palms and soles. Negative KOH (see Chapter 216, Syphilis).
- Tinea corporis is rarely as widespread as tinea versicolor and each individual lesion usually has central clearing and a well-defined, raised, scaling border. The KOH preparation in tinea corporis shows hyphae with multiple branch points and not the "ziti-and-meatballs" pattern of tinea versicolor (see Chapter 138, Tinea Corporis).
- Vitiligo—The degree of hypopigmentation is greater and the distribution is frequently different with vitiligo involving the hands and face (see Chapter 198, Vitiligo).
- Pityriasis alba—Lightly hypopigmented areas with slight scale that tend to be found on the face and trunk of children with atopy. These patches are frequently smaller and rounder than tinea versicolor (see Chapter 145, Atopic Dermatitis).
- *Pityrosporum* folliculitis is caused by the same organism but presents with pink or brown papules on the back. The patient complains of itchy rough skin and the KOH is positive (**Figure 141-8**).

MANAGEMENT

TOPICAL

- Because tinea versicolor is usually asymptomatic, the treatment is mostly for cosmetic reasons.

FIGURE 141-2 Patches of hypopigmentation across the back caused by tinea versicolor in a young Latino man. Vitiligo is on the differential diagnosis in this case. A KOH preparation confirmed tinea versicolor. (*Courtesy of Richard P. Usatine, MD.*)

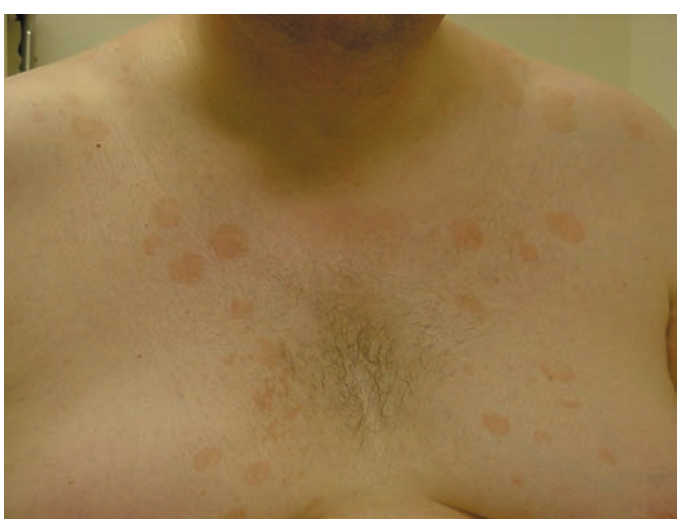

FIGURE 141-3 Pink scaly patches caused by tinea versicolor. Seborrhea may be seen in this location, but tends to be worse in the presternal region. (*Courtesy of Richard P. Usatine, MD.*)

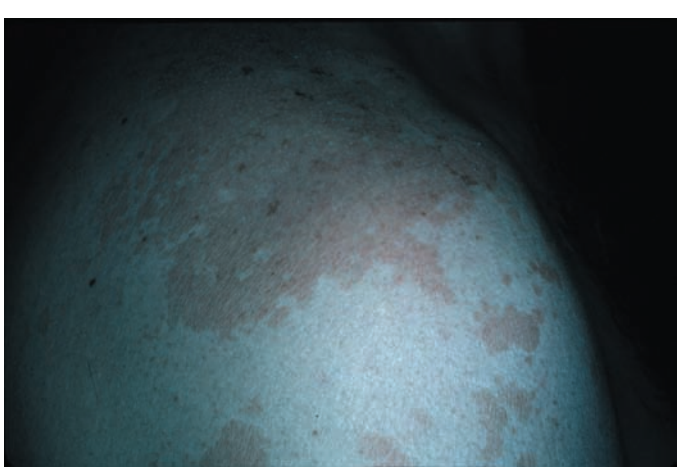

FIGURE 141-4 Large areas of pink tinea versicolor on the shoulder in a cape-like distribution. (*Courtesy of Richard P. Usatine, MD.*)

FIGURE 141-5 Hyperpigmented variant of tinea versicolor in a Hispanic woman. (*Courtesy of Richard P. Usatine, MD.*)

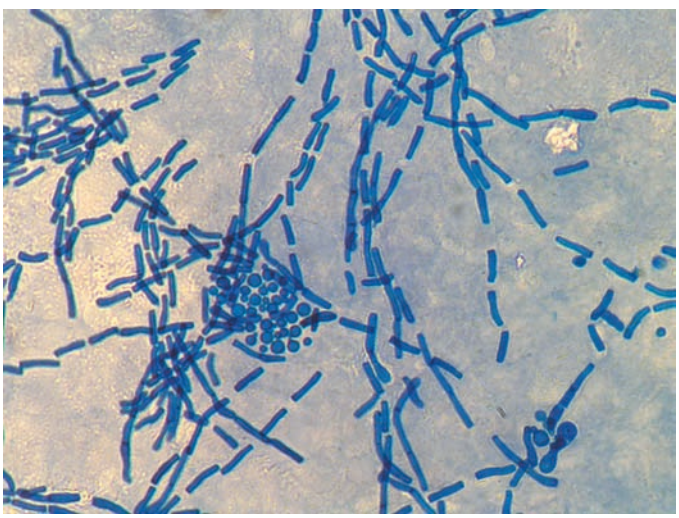

FIGURE 141-7 Close-up of *Malassezia furfur* (*Pityrosporum*) showing the ziti-and-meatball appearance after Swartz-Lamkins stain was applied to the scraping of tinea versicolor in a young woman. (*Courtesy of Richard P. Usatine, MD.*)

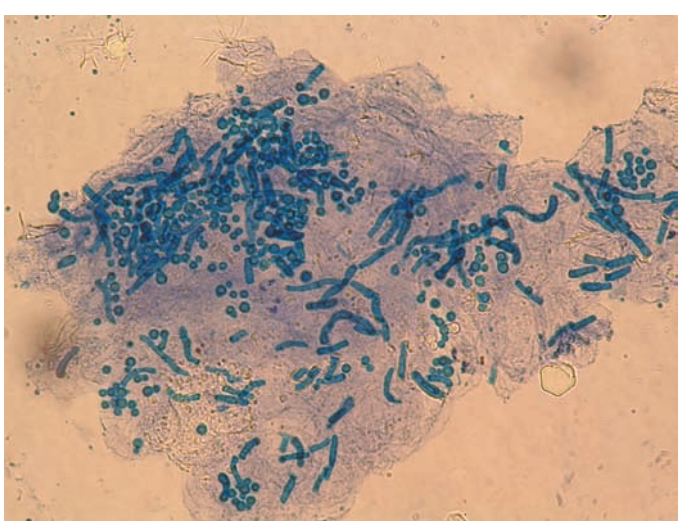

FIGURE 141-6 Microscopic examination of scrapings done from previous patient showing short mycelial forms and round yeast forms suggestive of spaghetti and meatballs. Swartz-Lamkins stain was used. (*Courtesy of Richard P. Usatine, MD.*)

FIGURE 141-8 *Pityrosporum* folliculitis on the back of a man with pruritus. (*Courtesy of Richard P. Usatine, MD.*)

- The mainstay of treatment has been topical therapy using antidandruff shampoos, because the same *Pityrosporum* species that cause seborrhea and dandruff also cause tinea versicolor.[1,2]
- Patients may apply selenium sulfide 2.5% lotion or shampoo, or zinc pyrithione shampoo to the involved areas daily for 1 to 2 weeks. Various amounts of time are suggested to allow the preparations to work, but there are no studies that show a minimum exposure time needed. A typical regimen involves applying the lotion or shampoo to the involved areas for 10 minutes and then washing it off in the shower. SOR C
- One study used ketoconazole 2% shampoo (Nizoral) as a single application or daily for 3 days and found it safe and highly effective in treating tinea versicolor.[3] SOR B
- Topical antifungal creams for smaller areas of involvement can include ketoconazole and clotrimazole. SOR C

ORAL TREATMENT AND PREVENTION

- A single-dose 400-mg oral fluconazole provided the best clinical and mycologic cure rate, with no relapse during 12 months of follow-up.[4] SOR B
- A single dose of 300 mg of oral fluconazole repeated weekly for 2 weeks was equal to 400 mg of ketoconazole in a single dose repeated weekly for 2 weeks. No significant differences in efficacy, safety, and tolerability between the two treatment regimens were found.[5] SOR B
- A single-dose 400-mg oral ketoconazole to treat tinea versicolor is safe and cost-effective compared to using the newer, more expensive, oral antifungal agents, such as itraconazole.[6,7] SOR B
- Oral itraconazole 200 mg given twice a day for 1 day a month has been shown to be safe and effective as a prophylactic treatment for tinea versicolor.[8] SOR B
- There is no evidence that establishes the need to sweat after taking oral antifungals to treat tinea versicolor.

PATIENT EDUCATION

Patients should be told that the change in skin color will not reverse immediately. The first sign of successful treatment is the lack of scale. The yeast acts like a sunscreen in the hypopigmented macules. Sun exposure will hasten the normalization of the skin color in patients with hypopigmentation.

FOLLOW-UP

None needed unless it is a stubborn or recurrent case. Recurrent cases can be treated with monthly topical or oral therapy.

PATIENT RESOURCES

- **http://www.skinsight.com/adult/tineaVersicolor.htm.**

PROVIDER RESOURCES

- **http://emedicine.medscape.com/article/1091575.**

REFERENCES

1. Bolognia J, Jorizzo J, Rapini R. *Dermatology*. St. Louis, MO: Mosby; 2003.
2. Hu SW, Bigby M. Pityriasis versicolor: a systematic review of interventions. *Arch Dermatol.* 2010;146(10):1132-1140.
3. Lange DS, Richards HM, Guarnieri J, et al. Ketoconazole 2% shampoo in the treatment of tinea versicolor: a multicenter, randomized, double-blind, placebo-controlled trial. *J Am Acad Dermatol.* 1998;39(6):944-950.
4. Bhogal CS, Singal A, Baruah MC. Comparative efficacy of ketoconazole and fluconazole in the treatment of pityriasis versicolor: a one year follow-up study. *J Dermatol.* 2001;28(10):535-539.
5. Farschian M, Yaghoobi R, Samadi K. Fluconazole versus ketoconazole in the treatment of tinea versicolor. *J Dermatolog Treat.* 2002;13(2):73-76.
6. Gupta AK, Del Rosso JQ. An evaluation of intermittent therapies used to treat onychomycosis and other dermatomycoses with the oral antifungal agents. *Int J Dermatol.* 2000;39(6):401-411.
7. Wahab MA, Ali ME, Rahman MH, et al. Single dose (400 mg) versus 7 day (200 mg) daily dose itraconazole in the treatment of tinea versicolor: a randomized clinical trial. *Mymensingh Med J.* 2010;19(1):72-76.
8. Faergemann J, Gupta AK, Mofadi AA, et al. Efficacy of itraconazole in the prophylactic treatment of pityriasis (tinea) versicolor. *Arch Dermatol.* 2002;138:69-73.

SECTION 6 INFESTATIONS

142 LICE

E.J. Mayeaux, Jr., MD
Richard P. Usatine, MD

PATIENT STORY

A 64-year-old homeless woman with schizophrenia presented to a homeless clinic for itching all over her body. She stated that she could see creatures feed on her and move in and out of her skin. The physical examination revealed that she was unwashed and had multiple excoriations over her body (**Figure 142-1**). Body lice and their progeny were visible along the seams of her pants (**Figure 142-2**). Treatment of this lousy infestation required giving her new clothes and a shower.[1]

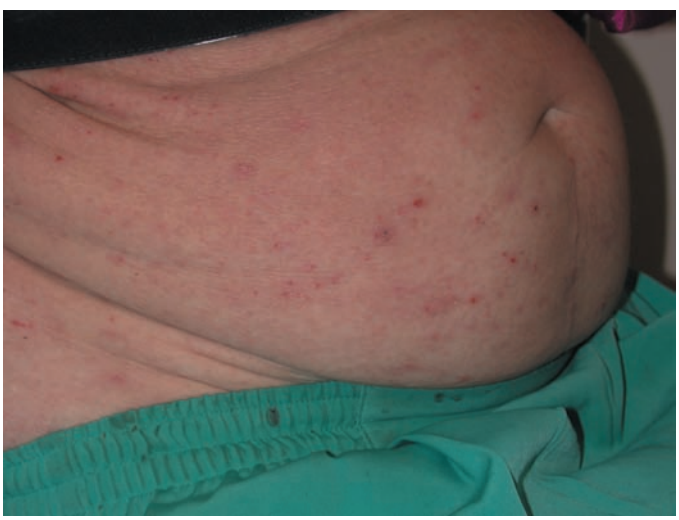

FIGURE 142-1 Body lice in a 64-year-old homeless woman with schizophrenia. (*Courtesy of Richard P. Usatine, MD and Usatine RP, Halem L. A terrible itch. J Fam Pract. 2003;52(5):377-379. Reproduced with permission from Frontline Medical Communications.*)

INTRODUCTION

Lice are ectoparasites that live on or near the body. They will die of starvation within 10 days of removal from their human host. Lice have coexisted with humans for at least 10,000 years.[2] Lice are ubiquitous and remain a major problem throughout the world.[3]

SYNONYMS

Pediculosis, crabs (pubic lice).

EPIDEMIOLOGY

- Human lice (pediculosis corporis, pediculosis pubis, and pediculosis capitis) are found in all countries and climates.[3]
- Head lice are most common among school-age children. Each year, approximately 6 to 12 million children, ages 3 to 12 years, are infested.[4]
- Head lice infestation is seen across all socioeconomic groups and is not a sign of poor hygiene.[5]
- In the United States, black children are affected less often as a result of their oval-shaped hair shafts that are difficult for lice to grasp.[4]
- Body lice infest the seams of clothing (**Figure 142-2**) and bed linen. Infestations are associated with poor hygiene and conditions of crowding.
- Pubic lice are most common in sexually active adolescents and adults. Young children with pubic lice typically have infestations of the eyelashes. Although infestations in this age group may be an indication of sexual abuse, children generally acquire the crab lice from their parents.[6]

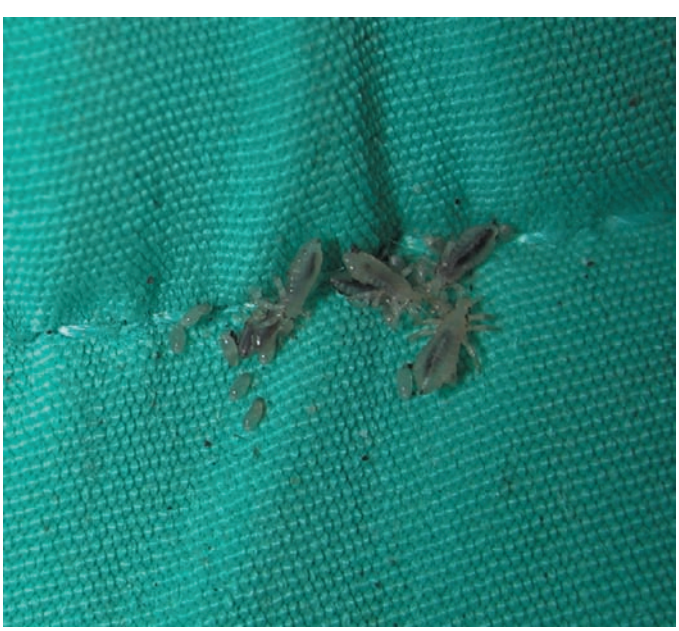

FIGURE 142-2 Adult body lice and nymphs visible along the pant seams of the woman in **Figure 142-1**. (*Courtesy of Richard P. Usatine, MD.*)

ETIOLOGY AND PATHOPHYSIOLOGY

- Lice are parasites that have six legs with terminal claws that enable them to attach to hair and clothing. There are three types of lice responsible for human infestation. All three kinds of lice must feed daily on human blood and can only survive 1 to 2 days away from the host. The three types of lice are as follows:
  - Head lice (*Pediculus humanus capitis*)—Measure 2 to 4 mm in length (**Figure 142-3**).
  - Body lice (*Pediculus humanus corporis*)—Body lice similarly measure 2 to 4 mm in length (**Figure 142-4**).
  - Pubic or crab lice (*Phthirus pubis*)—Pubic lice are shorter, with a broader body and have an average length of 1 to 2 mm (**Figure 142-5**).
- Female lice have a lifespan of approximately 30 days and can lay approximately 10 eggs (nits) a day.[4]
- Nits are firmly attached to the hair shaft or clothing seams by a glue-like substance produced by the louse (**Figures 142-6** to **142-8**).
- Nits are incubated by the host's body heat.
- The incubation period from laying eggs to hatching of the first nymph is 7 to 14 days.
- Mature adult lice capable of reproducing appear 2 to 3 weeks later.[5]
- Transmission of head lice occurs through direct contact with the hair of infested individuals. The role of fomites (e.g., hats, combs, brushes) in transmission is negligible.[6] Head lice do not serve as vectors for transmission of disease among humans.
- Transmission of body lice occurs through direct human contact or contact with infested material. Unlike head lice, body lice are well-recognized vectors for transmission of the pathogens responsible for epidemic typhus, trench fever, and relapsing fever.[5]
- Pubic or crab lice are transmitted primarily through sexual contact. In addition to pubic hair (**Figure 142-9**), infestations of eyelashes, eyebrows, beard, upper thighs, abdominal, and axillary hairs may also occur.

RISK FACTORS

- Contact with an infected individual.
- Living in crowded quarters such as homeless shelters.
- Poor hygiene and mental illness.

DIAGNOSIS

CLINICAL FEATURES

- Nits can be seen in active disease or treated disease. Nits closer to the base of the hairs are generally newer and more likely to be live and unhatched. Unfortunately, nits that were not killed by pediculicides can hatch and start the infestation cycle over again. Note that nits are glued to the hairs and are hard to remove, whereas flakes of dandruff can be easily brushed off.

FIGURE 142-3 Adult head louse with elongated body. (*Courtesy of Centers for Disease Control and Prevention and Dennis D. Juranek.*)

FIGURE 142-4 A body louse feeding on the blood of the photographer. The dark mass inside the abdomen is a previously ingested blood meal. (*Courtesy of Centers for Disease Control and Prevention and Frank Collins, PhD.*)

FIGURE 142-5 The crab louse has a short body and its large claws are responsible for the "crab" in its name. (*Courtesy of Centers for Disease Control and Prevention and World Health Organization.*)

- Pruritus is the hallmark of lice infestation. It is the result of an allergic response to louse saliva.[7] Head lice are associated with excoriated lesions that appear on the scalp, ears, neck, and back.
- Occipital and cervical adenopathy may develop, especially when lesions become superinfected.
- Body lice result in small maculopapular eruptions that are predominantly found on the trunk (**Figure 142-1**) and the clothing (**Figure 142-2**).
- Chronic infestations often result in hyperpigmented, lichenified plaques known as "vagabond's skin."[8]
- Pubic lice produce bluish-gray spots (macula cerulea) that can be found on the chest, abdomen, and thighs.[8]

TYPICAL DISTRIBUTION

- Head lice—Look for nits and lice in the hair especially above the ears, behind the ears, and at the nape of the neck. There are many more nits present than live adults. Finding nits without an adult louse does not mean that the infestation has resolved (**Figures 142-6** and **142-7**). Systematically combing wet or dry hair with a fine toothed nit comb (teeth of comb are 0.2 mm apart) better detects active louse infestation than visual inspection of the hair and scalp alone.[9]
- Body lice—Look for the lice and larvae in the seams of the clothing (**Figure 142-2**).
- Pubic lice—Look for nits and lice on the pubic hairs (**Figure 142-9**). These lice and their nits may also be seen on the hairs of the upper thighs, abdomen, axilla, beard, eyebrows, and eyelashes. Little specks of dried blood may be seen in the underwear as a clue to the infestation.

LABORATORY TESTING

- Direct visualization and identification of live lice or nits are sufficient to make a diagnosis (**Figures 142-2** to **142-7** and **142-9**).
- The use of a magnification lens may aid in the detection or confirmation of lice infestation.
- Under Wood light the head lice nits fluoresce a pale blue.
- If you find an adult louse put it on a slide with a cover slip loosely above it. Look at it under the microscope on the lowest power (**Figures 142-4** and **142-5**). You will see the internal workings of the live organs. If the louse was not found in a typical location, you can use the morphology of the body and legs to determine the type of louse causing the infestation.
- In cases of pubic lice infestations, individuals should be screened for other sexually transmitted diseases.[5]

DIFFERENTIAL DIAGNOSIS

- Dandruff, hair casts, and debris should be ruled out in cases of suspected lice infestations. Unlike nits, these particles are easily removed from the hair shaft. In addition, adult lice are absent.
- Scabies is also characterized by intense pruritus and papular eruptions. Unlike lice infestations, scabies may be associated with vesicles, and the presence of burrows is pathognomonic. Diagnosis is

FIGURE 142-6 Pearly nits on the hair of a schoolgirl. (*Courtesy of Richard P. Usatine, MD.*)



FIGURE 142-7 Massive infestation of head lice on a mentally ill homeless person. (*Courtesy of Richard P. Usatine, MD.*)

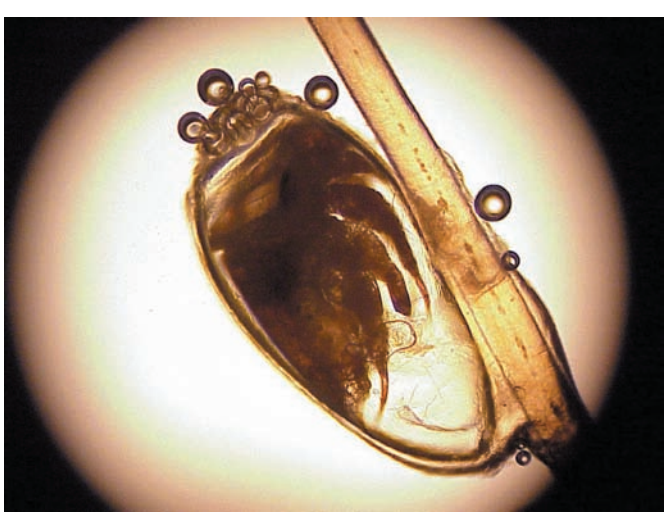

FIGURE 142-8 Microscopic view of a nit cemented to the hair and about to hatch. (*Courtesy of Dan Stulberg, MD.*)

confirmed by microscopic examination of the scrapings from lesions for the presence of mites or eggs (see Chapter 143, Scabies).

MANAGEMENT

NONPHARMACOLOGIC

- In young children or others who wish to avoid topical pediculicides for head lice, mechanical removal of lice by wet combing is an alternative therapy. A 1:1 vinegar: water rinse (left under a conditioning cap or towel for 15 to 20 minutes) or 8% formic acid crème rinse may enhance removal of tenacious nits.[8] Combing is performed until no lice are found for 2 weeks. SOR B
  - Nits are also removed with a fine-toothed comb following the application of all treatments. This step is critical in achieving resolution.
  - Combs and hairbrushes should be discarded, soaked in hot water (at a temperature of at least 55°C [130°F]) for 5 minutes, or treated with pediculicides.[10]

MEDICATIONS

- *Pediculus humanus capitis* (head lice):
  - Nonprescription 1% permethrin cream rinse (Nix), pyrethrins with piperonyl butoxide (which inhibits pyrethrin catabolism; RID) shampoo, or permethrin 1% is applied to the hair and scalp and left on for 10 minutes then rinsed out.[11] SOR A
  - Pyrethrins are only pediculicidal, whereas permethrin is both pediculicidal and ovicidal. It is important to note that treatment failure is common with these agents owing to the emergence of resistant strains of lice.
  - After 7 to 10 days repeating the application is optional when permethrin is used, but is a necessary for pyrethrin. Lice persisting after treatment with a pyrethroid may be an indication of resistance.
  - Malathion 0.5% (Ovide) is available by prescription only, and is a highly effective pediculicidal and ovicidal agent for resistant lice. Malathion may have greater efficacy than pyrethrins.[12] It is approved for use in children age 6 years and older. The lotion is applied to dry hair for 8 to 12 hours and then washed. Repeat application is recommended after 7 to 10 days if live lice are still present. When used appropriately, malathion is 78% to 95% effective.[12] SOR A
  - Benzyl alcohol 5% lotion (Ulesfia) is a newer treatment option in patients 6 months of age and older. It works by asphyxiating the parasite. It is applied for 10 minutes with saturation of the scalp and hair, and then rinsed off with water. The treatment is repeated after 7 days.[13] SOR A
  - Spinosad (Natroba) is a new topical prescription medication approved by the FDA in 2011 for the treatment of lice. Spinosad is a fermentation product of the soil bacterium *Saccharopolyspora spinosa* that compromises the central nervous system of lice. It is approximately 85% effective in lice eradication, usually after one application. It is applied to completely cover the dry scalp and hair, and rinsed off after 10 minutes. Treatment should be repeated if live lice remain 7 days after the initial application.[14] SOR A
  - In February 2012, the U.S. FDA approved ivermectin 0.5% lotion for the treatment of head lice. It is applied as a single

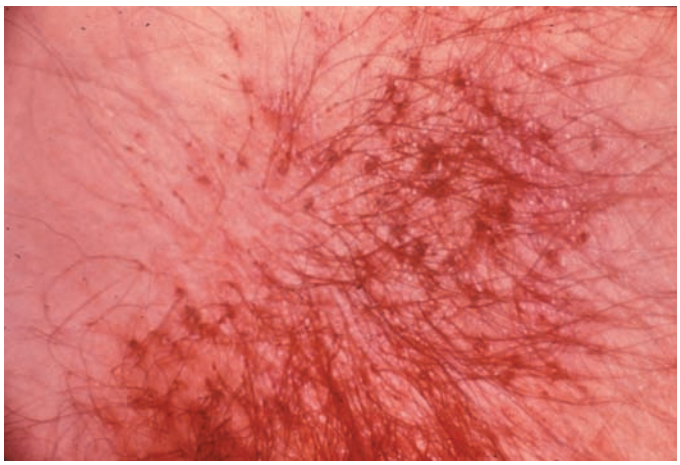

FIGURE 142-9 Crab lice infesting pubic hair. (*Courtesy of the University of Texas Health Sciences Center, Division of Dermatology.*)

10-minute topical application. The safety of ivermectin in infants younger than age 6 months has not been established.[15] SOR A
  - Hair conditioners should not be used prior to the application of pediculicides; these products may result in reduced efficacy.[16]
  - A Cochrane review found no evidence that any one pediculicide was better than another; permethrin, synergized pyrethrin, and malathion were all effective in the treatment of head lice.[17] SOR A
  - Other therapeutic options include permethrin 5% cream and lindane 1% shampoo. Permethrin 5% is conventionally used to treat scabies; however, it is anecdotally recommended for treatment of recalcitrant head lice.[5] SOR C
  - Lindane is considered a second-line treatment option owing to the possibility of central nervous system toxicity, which is most severe in children.
  - Oral therapy options include a 10-day course of trimethoprim-sulfamethoxazole or 2 doses of ivermectin (200 mcg/kg) 7 to 10 days apart. SOR C Trimethoprim-sulfamethoxazole is postulated to kill the symbiotic bacteria in the gut of the louse.[4] Combination therapy with 1% permethrin and trimethoprim-sulfamethoxazole is recommended in cases of multiple treatment failure or suspected cases of resistance to therapy.[5,10] SOR C
- *Pediculus humanus corporis* (body lice):
  - Improving hygiene, and laundering clothing and bed linen at temperatures of 65°C (149°F) for 15 to 30 minutes will eliminate body lice.[8]
  - In settings where individuals cannot change clothing (e.g., indigent population), a monthly application of 10% lindane powder can be used to dust the lining of all clothing.[8]
  - Additionally, lindane lotion or permethrin cream may be applied to the body for 8 to 12 hours to eradicate body lice.
- *Phthirus pubis* (pubic lice):
  - Pubic lice infestations are treated with a 10-minute application of the same topical pediculicides used to treat head lice.
  - Retreatment is recommended 7 to 10 days later.
  - Petroleum ointment applied 2 to 4 times a day for 8 to 10 days will eradicate eyelash infestations.
  - Clothing, towels, and bed linen should also be laundered to eliminate nit-bearing hairs.[8]

PREVENTION

- Washing clothing and linen used by the head or pubic lice-infested person during the 2 days prior to therapy in hot water and/or drying the items on a high-heat dryer cycle (54.5°C [130°F].) Items that cannot be washed may be dry cleaned or stored in a sealed plastic bag for 2 weeks.

FOLLOW-UP

- Patients should be reexamined upon completion of therapy to confirm eradication of lice.

PATIENT EDUCATION

- Patients should be instructed to wash potentially contaminated articles of clothing, bed linen, combs, brushes, and hats.
- Nit removal is important in preventing continued infestation as a result of new progeny. Careful examination of close contacts, with appropriate treatment for infested individuals is important in avoiding recurrence.
- In cases of pubic lice, all sexual contacts should be treated.

PATIENT RESOURCES

- eMedicineHealth. *Lice*—**http://www.emedicinehealth.com/lice/article_em.htm.**
- Centers for Disease Control and Prevention. *Parasites–Lice*—**http://www.cdc.gov/parasites/lice/index.html.**

PROVIDER RESOURCES

- Centers for Disease Control and Prevention. *Parasites*—**http://www.cdc.gov/ncidod/dpd/parasites/lice/default.htm.**
- Medscape. *Pediculosis (Lice)*—**http://emedicine.medscape.com/article/225013.**

REFERENCES

1. Usatine RP, Halem L. A terrible itch. *J Fam Pract*. 2003;52(5):377-379.
2. Araujo A, Ferreira LF, Guidon N, et al. Ten thousand years of head lice infection. *Parasitol Today*. 2000;16(7):269.
3. Roberts RJ. Clinical practice. Head lice. *N Engl J Med*. 2002;346:1645.
4. Frankowski BL, Weiner LB. Head Lice. *Pediatrics*. 2002;110(3):638-643.
5. Pickering LK, Baker CJ, Long SS, McMillan JA. *Red Book: 2006 Report of the Committee on Infectious Diseases*, 27th ed. Elk Grove Village, IL: American Academy of Pediatrics; 2006:488-493.
6. Maguire JH, Pollack RJ, Spielman A. Ectoparasite infestations and arthropod bites and stings. In: Kasper DL, Fauci AS, Longo DL, Braunwald EB, Hauser SL, Jameson JL, eds. *Harrison's Principles of Internal Medicine*, 16th ed. New York, NY: McGraw-Hill; 2005:2601-2602.
7. Flinders DC, De Schweinitz P. Pediculosis and scabies. *Am Fam Physician*. 2004;69(2):341-348.
8. Darmstadt GL. Arthropod bites and infestations. In: Behrman RE, Kliegman RM, Jenson HB, eds. *Nelson Textbook of Pediatrics,* 16th ed. Philadelphia, PA: Saunders; 2000:2046-2047.
9. Jahnke C, Bauer E, Hengge UR, Feldmeier H. Accuracy of diagnosis of pediculosis capitis: visual inspection vs wet combing. *Arch Dermatol*. 2009;145(3):309-313.
10. Hipolito RB, Mallorca FG, Zuniga-Macaraig ZO, et al. Head lice infestation: single drug versus combination therapy with one percent permethrin and trimethoprim/sulfamethoxazole. *Pediatrics*. 2001;107(3):E30.
11. Meinking TL, Clineschmidt CM, Chen C, et al. An observer-blinded study of 1% permethrin creme rinse with and without adjunctive combing in patients with head lice. *J Pediatr*. 2002;141(5):665-670.
12. Meinking TL, Serrano L, Hard B, et al. Comparative in vitro pediculicidal efficacy of treatments in a resistant head lice population in the United States. *Arch Dermatol*. 2002;138(2):220-224.
13. Meinking TL, Villar ME, Vicaria M, et al. The clinical trials supporting benzyl alcohol lotion 5% (Ulesfia): a safe and effective topical treatment for head lice (pediculosis humanus capitis). *Pediatr Dermatol*. 2010;27(1):19-24.
14. Stough D, Shellabarger S, Quiring J, Gabrielsen AA Jr. Efficacy and safety of spinosad and permethrin creme rinses for pediculosis capitis (head lice). *Pediatrics*. 2009;124(3):e389-e395.
15. *Ivermectin Lotion 0.5% (Sklice) Clinical Review (NDA)*. http://www.fda.gov/downloads/Drugs/DevelopmentApprovalProcess/DevelopmentResources/UCM295584.pdf. Accessed April 13, 2012.
16. Lebwohl M, Clark L, Levitt J. Therapy for head lice based on life cycle, resistance, and safety considerations. *Pediatrics*. 2007;119(5):965-974.
17. Dodd CS. Interventions for treating head lice. *Cochrane Database Syst Rev*. 2006;(4):CD001165.

143 SCABIES

Richard P. Usatine, MD
Pierre Chanoine, MD
Mindy A. Smith, MD, MS

PATIENT STORY

A 2-year-old boy is seen with severe itching and crusting of his hands (**Figures 143-1** and **143-2**). He also has a pruritic rash over the rest of his body. The child has had this problem since 2 months of age and has had a number of treatments for scabies. Other adults and children in the house have itching and rash. Various attempts at treatment have only included topical preparations. A scraping was done and scabies mites and scybala (feces) were seen (**Figures 143-3** and **143-4**). The child and all the family members were put on ivermectin simultaneously and the Norwegian scabies cleared from the child. The family cleared as well and the child was given a repeat dose of ivermectin to avoid relapse.

FIGURE 143-1 Crusted scabies (Norwegian scabies) in a 2-year-old boy. (*Courtesy of Richard P. Usatine, MD.*)

SYNONYMS

Seven-year itch.

EPIDEMIOLOGY

- Three hundred million cases per year are estimated worldwide.[1] In some tropical countries, scabies is endemic.
- The incidence of scabies in a study performed in general practices in England and Wales was 351 per 100,000 person-years in men and 437 per 100,000 person-years in women.[2]
- Data from the Royal Infirmary in Edinburgh show that 5% of patients with skin disease between 1815 and 2000 had scabies; the prevalence during wartime reached over 30%.[3]

ETIOLOGY AND PATHOPHYSIOLOGY

- Human scabies is caused by the mite *Sarcoptes scabei*, an obligate human parasite (**Figure 143-3**).[1,4]
- Adult mites spend their entire life cycle, around 30 days, within the epidermis. After copulation the male mite dies and the female mite burrows through the superficial layers of the skin excreting feces (**Figure 143-4**) and laying eggs (**Figure 143-5**).
- Mites move through the superficial layers of skin by secreting proteases that degrade the stratum corneum.
- Infected individuals usually have less than 100 mites. In contrast, immunocompromised hosts can have up to 1 million mites, and are susceptible to crusted scabies also called Norwegian scabies (**Figures 143-1**, **143-2**, and **143-6** to **143-10**).[1]
- Transmission usually occurs via direct skin contact. Scabies in adults is frequently sexually transmitted.[5] Scabies mites can also be transmitted from animals to humans.[1]

FIGURE 143-2 The boy in **Figure 143-1** with a close-up of his hand showing crusting and a fissure. (*Courtesy of Richard P. Usatine, MD.*)

- Mites can also survive for 3 days outside of the human epidermis allowing for infrequent transmission through bedding and clothing.
- The incubation period is on average 3 to 4 weeks for an initial infestation. Sensitized individuals can have symptoms within hours of reexposure.

RISK FACTORS

- Scabies is more common in young children, healthcare workers, homeless and impoverished persons, and individuals who are immunocompromised or suffering from dementia.[1]
- Institutionalized individuals and those living in crowded conditions also have a higher incidence of the infestation.[1]

DIAGNOSIS

CLINICAL FEATURES

- Pruritus is a hallmark of the disease.[1]
- Skin findings include papules (**Figure 143-10**), burrows (**Figure 143-11** and **143-12**) nodules (**Figures 143-13**), and vesiculopustules (**Figure 143-14**).
- Burrows are the classic morphologic finding in scabies and the best location to find the mite (**Figures 143-11** and **143-12**).
- Infants and young children can also exhibit irritability and poor feeding.
- Pruritic papules/nodules around the axillae (**Figure 143-13**), umbilicus, or on the penis and scrotum (**Figure 143-15** and **143-16**) are highly suggestive of scabies.

TYPICAL DISTRIBUTION

- Classic distribution in scabies includes the interdigital spaces (**Figure 143-17**), wrists, ankles (**Figure 143-18**), waist (**Figures 143-19** and **143-20**), groin, axillae (**Figure 143-13**), palms, and soles (**Figures 143-1**, **143-2**, **143-6**, and **143-7**).
- Genital involvement can also occur (**Figures 143-15** and **143-16**).
- In children, the head can also be involved (**Figure 143-21**).

LABORATORY STUDIES AND IMAGING

- Light microscopy of skin scrapings provides a definitive diagnosis when mites, eggs, or feces are identified (**Figures 143-3** to **143-5**). This can be challenging and time-consuming, even when mites, eggs, or feces are present. Packing tape stripping of skin has also been used instead of a scalpel to find mites for examination under the microscope.[6] The inability to find these items should not be used to rule out scabies in a clinically suspicious case. In what is believed to be a recurrent case, it is helpful to find definitive evidence that your diagnosis is correct.
- Dermoscopy is a useful and rapid technique for identifying a scabies mite at the end of a burrow (see Appendix 3: Dermoscopy).[7] The mite has been described as an arrowhead or a jet plane in its appearance (**Figure 143-22**). The advantage of the dermoscope is

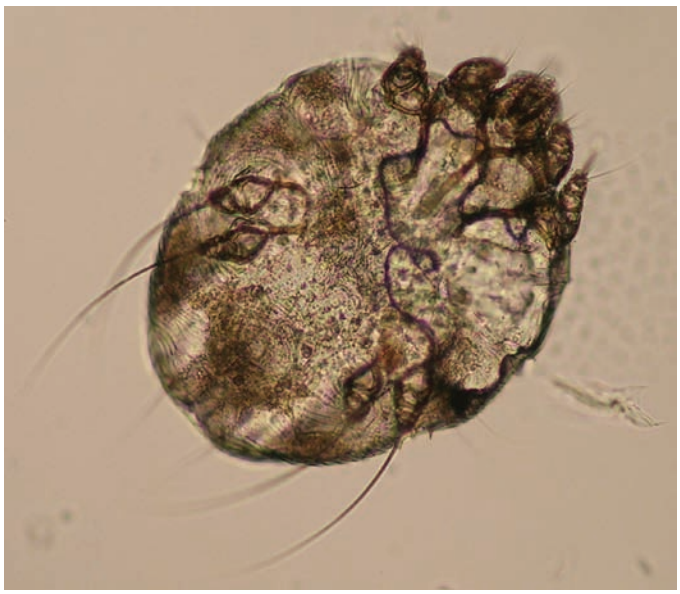

FIGURE 143-3 Microscopic view of the scabies mite from a patient with crusted scabies. (*Courtesy of Richard P. Usatine, MD.*)

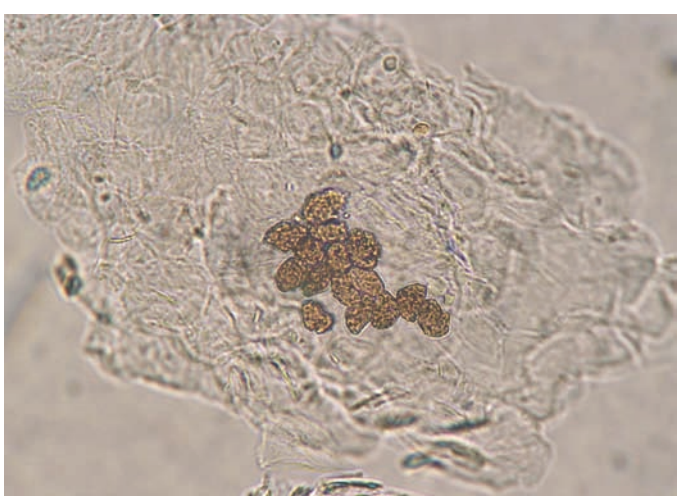

FIGURE 143-4 Scraping of the patient's hand produced a good view of the scybala (the mites' feces). (*Courtesy of Richard P. Usatine, MD.*)

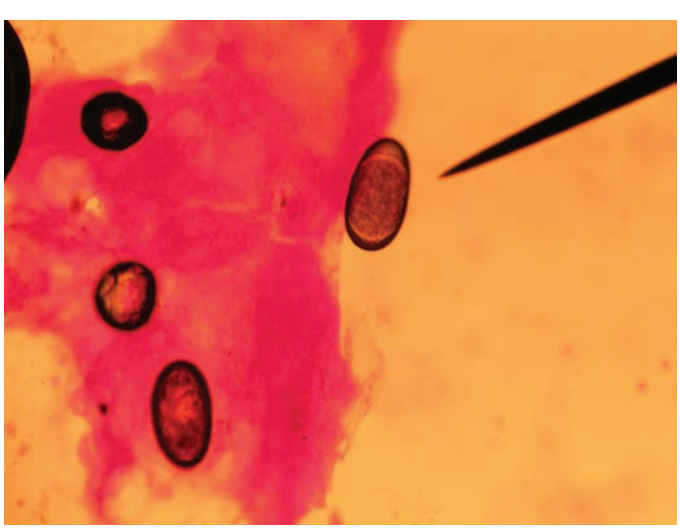

FIGURE 143-5 Scabies eggs from a scraping. (*Courtesy of Richard P. Usatine, MD.*)

FIGURE 143-6 Norwegian scabies with crusting on the hand. (*Courtesy of Jack Resneck, Sr., MD.*)

FIGURE 143-7 Crusted scabies on the feet of an immunosuppressed transplantation patient in the hospital. (*Courtesy of Deborah Henderson, MD.*)

FIGURE 143-8 Crusted scabies on the feet of a malnourished girl in Haiti. (*Courtesy of Richard P. Usatine, MD.*)

FIGURE 143-9 Crusted scabies on the foot of a 5-year-old boy with Down syndrome. (*Courtesy of Richard P. Usatine, MD.*)

FIGURE 143-10 Crusted scabies on the foot of a disabled man who had experienced a stroke previously. (*Courtesy of Richard P. Usatine, MD.*)

FIGURE 143-11 Scabies infestation on the hand of an incarcerated woman. *Arrow* points to 1 burrow. (*Courtesy of Richard P. Usatine, MD.*)

FIGURE 143-12 Burrows prominently visible between the fingers of this homeless man with scabies. Burrows are a classic manifestation of scabies. (*Courtesy of Richard P. Usatine, MD.*)

FIGURE 143-13 Scabetic nodules in the axilla of a toddler with scabies. (*Courtesy of Richard P. Usatine, MD.*)

FIGURE 143-14 Scabies on the foot of a 9-month-old infant with pustules. Although this also looks like acropustulosis, the mother also had scabies. (*Courtesy of Richard P. Usatine, MD.*)

FIGURE 143-15 Pruritic papules on the foreskin of the penis, hands, and groin acquired as a sexually transmitted disease. (*Courtesy of Richard P. Usatine, MD.*)

FIGURE 143-16 Pruritic papules on the glans of the penis and scrotum secondary to sexually transmitted scabies in a gay man. (*Courtesy of Richard P. Usatine, MD.*)

FIGURE 143-17 Scabies found in the classic location between the fingers in this interdigital webspace. (*Courtesy of Richard P. Usatine, MD.*)

FIGURE 143-18 Ethiopian child with widely distributed scabies seen prominently on the wrists and ankles. (*Courtesy of Richard P. Usatine, MD.*)

FIGURE 143-21 Scabies on the head and face of a young breastfeeding boy. (*Courtesy of Richard P. Usatine, MD.*)

FIGURE 143-19 Scabies papules found prominently around the waist in this incarcerated woman. (*Courtesy of Richard P. Usatine, MD.*)

FIGURE 143-20 Scabies around the waist showing postinflammatory hyperpigmentation along with multiple papules and some crusting. (*Courtesy of Richard P. Usatine, MD.*)

FIGURE 143-22 Two scabies mites visible with dermoscopy. Note how the darkest most visible aspect of the mite looks like an arrowhead or jet plane. In this case the oval bodies of the mites are also visible. The *upper right inset* shows the same burrows without dermoscopy. (*Courtesy of Richard P. Usatine, MD.*)

that multiple burrows can be examined quickly without causing any pain to the patient. Children are more likely to stay still for this than scraping with a scalpel or skin stripping with tape.

- If a dermoscope is available, start with this noninvasive examination. If the findings are typical, then a microscopic examination is not needed. If the findings are not convincing, or a dermoscope is not available, perform a scraping. It is best to scrape the skin at the end of a burrow. Use a #15 scalpel that has been dipped into mineral oil or microscope immersion oil. Scrape holding the blade perpendicular to the skin until the burrow (or papule) is opened (some slight bleeding is usual). Transfer the material to a slide and add a cover slip.
- Tips for microscopic examination—Start by examining the slide with the lowest power available as mites may be seen under 4 power and the slide can be scanned most quickly with the lowest power. If no mites are seen switch to 10 power and scan the slide again looking for mites, eggs, and feces. Forty power may be used to confirm findings under 10 power.
- In one study comparing dermoscopic mite identification with microscopic examination of skin scrapings, found the former technique to be of comparable sensitivity (91% and 90%, respectively) with specificity of 86% (vs. 100% by definition), even in inexperienced hands.[8] Another study reported sensitivity of dermoscopy at 83% (95% confidence interval, 0.70 to 0.94).[9] In this study, the negative predictive value was identical for dermoscopy and the adhesive tape test (0.85), making the latter a good screening test in resource-poor areas.
- Videodermatoscopy can also be used to diagnose scabies.[10] Videodermatoscopy allows for skin magnification with incidental lighting at high magnifications for viewing mites and eggs. The technique is noninvasive and does not cause pain.
- *S. scabiei* recombinant antigens have diagnostic potential and are under investigation for identifying antibodies in individuals with active scabies.[11]

BIOPSY

Rarely necessary unless there are reasons to suspect another diagnosis.

DIFFERENTIAL DIAGNOSIS

- Atopic dermatitis—Itching is a prominent symptom in atopic dermatitis and scabies. The distribution of involved skin can help to differentiate the 2 diagnoses. Look for burrows in scabies and a history of involved family members. In children, atopic dermatitis is often confined to the flexural and extensor surfaces of the body. In adults, the hands are a primary site of involvement (see Chapter 145, Atopic Dermatitis).
- Contact dermatitis—Characterized by vesicles and papules on bright red skin, which are rare in scabies. Chronic contact dermatitis often leads to scaling and lichenification and may not be as pruritic as scabies (see Chapter 146, Contact Dermatitis).
- Seborrheic dermatitis—A papulosquamous eruption with scales and crusts that is limited to the sebum rich areas of the body; namely, the scalp, the face the postauricular areas, and the

intertriginous areas. Pruritus is usually mild or absent (see Chapter 151, Seborrheic Dermatitis).

- Impetigo—Honey-crusted plaques are a hallmark of impetigo. Scabies can become secondarily infected, so consider that both diagnoses can occur concomitantly with papules and pustules present (**Figure 143-23**) (see Chapter 116, Impetigo).
- Arthropod bites—Bites may exhibit puncta that allow for differentiation from scabies.
- Acropustulosis of infancy (**Figure 143-24**)—A vesicopustular recurrent eruption limited to the hands, wrists, feet, and ankles. It is rare after 2 years of age (see Chapter 110, Pustular Diseases of Childhood).

FIGURE 143-23 **A.** Superinfected scabies from head to toe in this young boy. **B.** Note the large pustules on the foot of this boy demonstrating the bacterial superinfection. (*Courtesy of Richard P. Usatine, MD.*)

FIGURE 143-24 Infantile acropustulosis in a 9-month-old child that was mistakenly treated for scabies. No one else in the household had lesions and the scabies treatment did not lead to resolution of the pustules and vesicles. (*Courtesy of Richard P. Usatine, MD.*)

MANAGEMENT

NONPHARMACOLOGIC

- Environmental decontamination is a standard component of all therapies. SOR B Clothing, bed linens, and towels should be machine washed in hot water. Clothing or other items (e.g., stuffed animals) that cannot be washed may be dry cleaned or stored in sealed bags for at least 72 hours.[12]

MEDICATIONS

Treatment includes administration of an antiscabicide and an antipruritic.[1,13]

- Permethrin 5% cream (Elimite, Acticin) is the most effective treatment based upon a systematic review in the Cochrane Database.[13] SOR A The cream is applied from the neck down (include the head when it is involved) and rinsed off 8 to 14 hours later. Usually, this is done overnight. Repeating the treatment in 1 to 2 weeks may be more effective. SOR C In patients with crusted scabies, use of a keratolytic cream may facilitate the breakdown of skin crusts and improve penetration of the cream.[14] Unfortunately, scabies resistance to permethrin is increasing.
- Ivermectin is an oral treatment for resistant or crusted scabies. Studies have demonstrated its safety and efficacy. Most studies used a single dose of ivermectin at 200 mcg/kg.[13] SOR A Taking the drug with food may enhance drug penetration into the epidermis.[14] Some experts advocate repeating a dose 1 week later. It is worth noting that the FDA has not labeled this drug for use in children weighing less than 15 kg. Ivermectin is currently available only in 3- and 6-mg tablets, so dosing often needs to be rounded up to accommodate the use of whichever tablets are available. As there is no oral suspension available, tablets may need to be cut and given with food for use in children.
- Diphenhydramine, hydroxyzine, and mid-potency steroid creams can be used for symptomatic relief of itching. SOR C. It is important to note that pruritus may persist for 1 to 2 weeks after successful treatment because the dead scabies mites and eggs still have antigenic qualities that may cause persistent inflammation.
- All household or family members living in the infested home and sexual contacts should be treated. SOR C Failure to treat all involved individuals often results in recurrences within the family. Use of insecticide sprays and fumigants is not recommended.

- Other less-effective medications include topical benzyl benzoate, crotamiton, lindane (no longer used in the United States because of concerns regarding neurotoxicity), and synergized natural pyrethrins.[9] SOR A Topical agents used more commonly in other countries include 5% to 10% sulfur in paraffin (widely in Africa and South America), 10% to 25% benzyl benzoate (often used in Europe and Australia), and malathion.[14] In infants younger than 2 months of age, crotamiton or a sulfur preparation is recommended by one author instead of permethrin because of theoretical concerns of systemic absorption of permethrin.[14]
- Antibiotics are needed if there is evidence of a bacterial superinfection (**Figure 143-23**). SOR C

COMPLEMENTARY AND ALTERNATIVE THERAPY

- Tea tree oil contains oxygenetic terpenoids, found to have rapid scabicidal activity.[15]

PREVENTION

- Avoid direct skin-to-skin contact with an infested person or with items such as clothing or bedding used by an infested person.
- Treat members of the same household and other potentially exposed persons at the same time as the infested person to prevent possible reexposure and reinfestation.

PROGNOSIS

- The prognosis with proper diagnosis and treatment is excellent unless the patient is immunocompromised; reinfestation, however, often occurs if environmental risk factors continue.[1]
- Postinflammatory hyper- or hypopigmentation can occur.[1]

FOLLOW-UP

- Routine follow-up is indicated when symptoms do not resolve.
- Consider an immunologic work-up for individuals with crusted scabies.

PATIENT EDUCATION

- Patients should avoid direct contact including sleeping with others until they have completed the first application of the medicine.
- Patients may return to school and work 24 hours after first treatment.
- Patients should be warned that itching may persist for 1 to 2 weeks after successful treatment but that if symptoms are still present by the third week, the patient should return for further evaluation.

PATIENT RESOURCES

- **http://www.cdc.gov/parasites/scabies/.**
- **http://www.ncbi.nlm.nih.gov/pubmedhealth/PMH0001833/.**

PROVIDER RESOURCES

- **http://emedicine.medscape.com/article/1109204.**
- **http://dermnetnz.org/arthropods/scabies.html.**

REFERENCES

1. Hengge UR, Currie B, Jäger G, et al. Scabies: a ubiquitous neglected skin disease. *Lancet Infect Dis.* 2006;6(12):769-779.
2. Pannell RS, Fleming DM, Cross KW. The incidence of molluscum contagiosum, scabies and lichen planus. *Epidemiol Infect.* 2005; 133(6):985-991.
3. Savin JA. Scabies in Edinburgh from 1815 to 2000. *J R Soc Med.* 2005;98(3):124-129.
4. Paller AS, Mancini AJ. Scabies. In: Paller AS, Mancini AJ, eds. *Hurwitz Clinical Pediatric Dermatology: A Textbook of Skin Disorders of Childhood and Adolescence*. Philadelphia, PA: Saunders; 2006:479-488.
5. Centers for Disease Control and Prevention. *Scabies: Epidemiology and Risk Factors*. http://www.cdc.gov/parasites/scabies/epi.html. Accessed April 2012.
6. Albrecht J, Bigby M. Testing a test. Critical appraisal of tests for diagnosing scabies. *Arch Dermatol.* 2011;147(4):494-497.
7. Fox GN, Usatine RP. Itching and rash in a boy and his grandmother. *J Fam Pract.* 2006;55(8):679-684.
8. Dupuy A, Dehen L, Bourrat E, et al. Accuracy of standard dermoscopy for diagnosing scabies. *J Am Acad Dermatol.* 2007;56(1): 53-62.
9. Walter B, Heukelbach J, Fengler G, et al. Comparison of dermoscopy, skin scraping, and the adhesive tape test for the diagnosis of scabies in a resource-poor setting. *Arch Dermatol.* 2011;147(4):468-473.
10. Lacarrubba F, Musumeci ML, Caltabiano R, et al. High-magnification videodermatoscopy: a new noninvasive diagnostic tool for scabies in children. *Pediatr Dermatol.* 2001;18(5):439-441.
11. Walton SF, Currie BJ. Problems in diagnosing scabies, a global disease in human and animal populations. *Clin Microbiol Rev.* 2007;20(2):268-279.
12. Centers for Disease Control and Prevention. *Scabies: Treatment*. http://www.cdc.gov/parasites/scabies/treatment.html. Accessed April 2012.
13. Strong M, Johnstone PW. Interventions for treating scabies. *Cochrane Database Syst Rev.* 2007;3:CD000320.
14. Currie BJ, McCarthy JS. Permethrin and ivermectin for scabies, *N Engl J Med.* 2010;362(8):717-725.
15. Carson CF, Hammer KA, Riley TV. *Melaleuca alternifolia* (Tea Tree) oil: a review of antimicrobial and other medicinal properties. *Clin Microbiol Rev.* 2006;19(1):50-62.

144 CUTANEOUS LARVA MIGRANS

Jennifer A. Keehbauch, MD

PATIENT STORY

A mother brought her 18-month-old son to the physician's office for an itchy rash on his feet and buttocks (**Figures 144-1** and **144-2**).[1] The first physician examined the child and made the incorrect diagnosis of tinea corporis. The topical clotrimazole cream failed. The child was unable to sleep because of the intense itching and was losing weight secondary to his poor appetite. He was taken to an urgent care clinic where the physician learned that the family had returned from a trip to the Caribbean prior to the visit to the first physician. The child had played on beaches that were frequented by local dogs. The physician recognized the serpiginous pattern of cutaneous larva migrans (CLM) and successfully treated the child with oral ivermectin. The child was 15 kg so the dose was 3 mg (0.2 mg/kg) and the tablet was ground up and placed in applesauce.

FIGURE 144-1 The serpiginous rash of cutaneous larva migrans on the foot of an 18-month-old boy after a family trip to the beaches of the Caribbean. (*Courtesy of Richard P. Usatine, MD. Usatine RP. A rash on the feet and buttocks. West J Med. 1999;170(6):344-335.*)

SYNONYMS

Creeping eruption, Plumber's itch.

EPIDEMIOLOGY

- Endemic in developing countries, particularly Brazil, India, South Africa, Somalia, Malaysia, Indonesia, and Thailand.[2,3]
- Peak incidence in the rainy seasons.[3]
- During peak rainy seasons, the prevalence in children is as high as 15% in resource poor areas, but much less common in affluent communities in these same countries with only 1 to 2 per 10,000 individuals per year.[4]
- In the United States, it is found predominantly in Florida, southeastern Atlantic states, and the Gulf Coast.[2]
- Children are more frequently affected than adults.[4]

ETIOLOGY AND PATHOPHYSIOLOGY

- Caused most commonly by dog and cat hookworms (i.e., *Ancylostoma braziliense*, *Ancylostoma caninum*, *Uncinaria stenocephala*).[4]
- Eggs are passed in cat or dog feces.[2]
- Larvae are hatched in moist, warm, sand/soil.[2]
- Infective stage larvae penetrate the skin.[2]

DIAGNOSIS

The diagnosis is based on history and clinical findings.

FIGURE 144-2 Cutaneous larva migrans on the buttocks and thigh of the same boy showing significant excoriations. (*Courtesy of Richard P. Usatine, MD. Usatine RP. A rash on the feet and buttocks. West J Med. 1999;170(6):344-335.*)

CLINICAL FEATURES

- Elevated, serpiginous, or linear reddish-brown tracks 1 to 5 cm long (**Figures 144-1** to **144-3**).[2,5]
- Intense pruritus, which often disrupts sleep.[3]
- Symptoms last for weeks to months, and, rarely, years. Most cases are self-limiting.[5]

TYPICAL DISTRIBUTION

- Feet and lower extremities (73%), buttocks (13% to 18%), and abdomen (16%).[6,7]
- Areas that come in contact with contaminated skin.
  - Most commonly the feet, buttocks, and thigh.[3]

LABORATORY AND IMAGING

- Not indicated, but rarely blood tests shows Eosinophilia or elevated immunoglobulin E levels.[5]

FIGURE 144-3 Close-up of a serpiginous burrow from cutaneous larva migrans on the leg. The actual larva is 2 to 3 cm beyond the visible tracks. (*Courtesy of John Gonzalez, MD.*)

DIFFERENTIAL DIAGNOSIS

May be confused with the following conditions:

- Cutaneous fungal infections—Lesions are typically scaling plaques and annular macules with central clearing. If the serpiginous track of CLM is circular, this can lead to the incorrect diagnosis of "ringworm." The irony is that ringworm is a dermatophyte fungus whereas CLM really is a worm (see Chapter 138, Tinea Corporis).
- Contact dermatitis—Differentiate by distribution of lesions, presence of vesicles, and absence of classical serpiginous tracks (see Chapter 146, Contact Dermatitis).
- Erythema migrans of Lyme disease—Lesions are usually annular macules or patches and are not raised and serpiginous (see Chapter 218, Lyme Disease).
- Phytophotodermatitis—The acute phase of phytophotodermatitis is erythematous with vesicles; this later develops into postinflammatory hyperpigmented lesions. This may be acquired while preparing drinks with lime on the beach and not from the sandy beach infested with larvae (see Chapter 199, Photosensitivity).

MANAGEMENT

- Oral thiabendazole was the first proven therapy with FDA approval. It was removed from the market in 2010.
- Ivermectin (Stromectol) lacks FDA indication, but has been well studied and is the current drug of choice.[3]
  - A single dose of ivermectin 0.2 mg/kg is recommended.[3] SOR B
  - Cure rates of 77% to 100% with a single dose.[3]
  - Ivermectin has been used worldwide on millions with an excellent safety profile.[3]
  - Ivermectin is contraindicated in pregnancy, breastfeeding mothers, and in children weighing less than 15 kg.[3]
- Albendazole has been successfully prescribed for more than 25 years, and is the Centers for Disease Control and Prevention (CDC) drug of choice.[5]

- Albendazole also lacks FDA indication and the recommended dose is 400 mg daily for 3 to 7 days.[3,5]
- Cure rates with albendazole exceed 92%, but it is less with single dosage.[3]
- Studies on compounded ivermectin and albendazole for topical use are limited, but promising for use in children.[3]

- Cryotherapy is ineffective and harmful and should be avoided.[3] SOR B

ADJUNCT THERAPY

- Antihistamines may relieve itching.
- Antibiotics may be used if secondary infection occurs.

PATIENT EDUCATION

- Wear shoes on beaches where animals are allowed.
- Keep covers on sand boxes.
- Pet owners should keep pets off the beaches, deworm pets, and dispose of feces properly.

FOLLOW-UP

- Follow-up if lesions persist.

PATIENT AND PROVIDER RESOURCES

- eMedicine. *Dermatology*—**http://emedicine.medscape.com/article/1108784.**
- eMedicine. *Pediatrics*—**http://emedicine.medscape.com/article/998709.**
- CDC—**http://www.cdc.gov/parasites/zoonotichookworm/health_professionals/index.html**

REFERENCES

1. Usatine RP. A rash on the feet and buttocks. *West J Med*. 1999;170(6):334-335.
2. Bowman D, Montgomery S, Zajac A, et al. Hookworms of dogs and cats as agents of cutaneous larva migrans *Trends Parasitol*. 2010;26(4):162-167.
3. Heukelbach J, Feldmeier H. Epidemiological and clinical characteristics of hookworm-related cutaneous larva migrans. *Lancet Infect Dis*. 2008;8(5):302-309.
4. Feldmeier H, Heukelbach J. Epidermal parasitic skin diseases: a neglected category of poverty-associated plagues. *Bull World Health Organ*. 2009;87(2):152-159.
5. Montgomery S. Cutaneous larva migrans. In: *Infectious Disease Related to Travel. CDC Yellow Book*. 2012. http://wwwnc.cdc.gov/travel/yellowbook/2012/chapter-3-infectious-diseases-related-to-travel/cutaneous-larva-migrans.htm. Accessed October 26, 2012.
6. Hotez P, Brooker S, Bethony J, et al. Hookworm infection. *N Engl J Med*. 2004;351(8):799-807.
7. Jelinek T, Maiwald H, Nothdurft H, Loscher T. Cutaneous larva migrans in travelers: Synopsis of histories, symptoms and treating 98 patients. *Clin Infect Dis*. 1994;19:1062-1066.

SECTION 7 DERMATITIS/ALLERGIC

145 ATOPIC DERMATITIS

Richard P. Usatine, MD
Lindsey B. Finklea, MD

PATIENT STORY

A 1-year-old Asian American girl is brought to her family physician for a new rash on her face and legs (**Figures 145-1** and **145-2**). The child is scratching both areas but is otherwise healthy. There is a family history of asthma, allergic rhinitis, and atopic dermatitis (AD) on the father's side. The child responded well to low-dose topical corticosteroids and emollients.

FIGURE 145-1 Atopic dermatitis on the cheeks of an infant. (*With permission from Milgrom EC, Usatine RP, Tan RA, Spector SL. Practical Allergy. Philadelphia, PA: Elsevier; 2004.*)

INTRODUCTION

AD is a chronic and relapsing inflammatory skin disorder characterized by itching and inflamed skin that is triggered by the interplay of genetic, immunologic, and environmental factors.

SYNONYMS

Eczema, atopic eczema.

EPIDEMIOLOGY

- AD is the most frequent inflammatory skin disorder in the United States and the most common skin condition in children.[1]
- Worldwide prevalence in children is 15% to 20% and is increasing in industrialized nations.[2]
- Sixty percent of cases begin during the first year of life and 90% by 5 years of age.[1] One third will persist into adulthood.[2]
- Sixty percent of adults with AD have children with AD (**Figure 145-3**).[1]

FIGURE 145-2 Atopic dermatitis on the leg of the infant in **Figure 145-1**. The coin-like pattern is that of nummular eczema. (*With permission from Milgrom EC, Usatine RP, Tan RA, Spector SL. Practical Allergy. Philadelphia, PA: Elsevier; 2004.*)

ETIOLOGY AND PATHOPHYSIOLOGY

- Strong familial tendency, especially if atopy is inherited from the maternal side.
- Associated with elevated T-helper (Th) 2 cytokine response, elevated serum immunoglobulin (Ig) E, hyperstimulatory Langerhans cells, defective cell-mediated immunity, and loss of function mutation in filaggrin, an epidermal barrier protein.
- Exotoxins of *Staphylococcus aureus* act as superantigens and stimulate activation of T-cells and macrophages, worsening AD without actually showing signs of superinfection.

- Patients may have a primary T-cell defect. This may be why they can get more severe skin infections caused by herpes simplex virus (eczema herpeticum as seen in **Figure 145-4**) or bacteria (widespread impetigo). They are also at risk of a bad reaction to the smallpox vaccine with dissemination of the attenuated virus beyond the vaccination site. Eczema vaccinatum is a potentially deadly complication of smallpox vaccination (**Figure 145-5**).

DIAGNOSIS

- History—Pruritus is the hallmark symptom of AD. It is referred to as "the itch that rashes" as patients will often feel the need to scratch before a primary lesion appears. If it does not itch, it is not AD. Persons with AD often have a personal or family history of other allergic conditions, namely asthma and allergic rhinitis.
- The atopic triad is AD, allergic rhinitis, and asthma. Atopic persons have an exaggerated inflammatory response to factors that irritate the skin.
- Physical examination—Primary lesions include vesicles, scale, papules, and plaques.
- Secondary (or sequential) lesions include linear excoriations from scratching or rubbing which may result in lichenification (thickened skin with accentuation of skin lines), fissuring, and prurigo nodularis. Crust may indicate that a secondary infection has occurred. Postinflammatory hyperpigmentation and follicular hyperaccentuation (more prominent hyperkeratotic follicles) (**Figure 145-6**) may also be identified.

TYPICAL DISTRIBUTION

- AD often starts on the face in infancy and childhood (**Figures 145-1** and **145-7**) and then appears in the flexural folds, especially the antecubital and popliteal fossa (**Figures 145-8** to **145-10**).
- Involvement of the neck, wrists, and ankles also may occur (**Figures 145-11** and **145-12**).
- AD in adults can occur on the hands, around the mouth, or eyelids as well as all the other areas (**Figures 145-13** and **145-14**).
- In one series, the prevalence of hand involvement in patients with active AD was 58.9%. There was a significant trend toward an increasing prevalence of hand involvement with increasing age.[3]

OTHER FEATURES OR CONDITIONS ASSOCIATED WITH ATOPIC DERMATITIS

- Keratosis pilaris (**Figure 145-15).**
- Ichthyosis (**Figure 145-16**).
- Pityriasis alba (**Figures 145-17** and **145-18**).
- Palmar or plantar hyperlinearity.
- Dennie-Morgan lines (infraorbital fold) (**Figure 145-14**).
- Hand or foot dermatitis (see Chapter 147, Hand Eczema).
- Cheilitis (see Chapter 32, Angular Cheilitis).
- Susceptibility to cutaneous infections (**Figures 145-4** and **145-5**).
- Xerosis (dry skin) (**Figure 145-19**).
- Eye findings—Recurrent conjunctivitis, keratoconus (**Figure 145-20**), cataracts, orbital darkening.

FIGURE 145-3 The child and his mother both have atopic dermatitis but not in the most typical distribution. (*Courtesy of Richard P. Usatine, MD.*)

FIGURE 145-4 An 18-year-old woman with atopic dermatitis superinfected by herpes (eczema herpeticum). (*From Buccolo LS. Severe rash after dermatitis. J Fam Pract. 2004;53(8):613-615. Reproduced with permission from Frontline Medical Communications.*)

FIGURE 145-5 Eczema vaccinatum in a 17-year-old woman with atopic dermatitis who was given the smallpox vaccine. This eruption became this severe 8 days after her vaccination. (*Courtesy of CDC and Arthur E. Kaye.*)

FIGURE 145-6 A young black girl with atopic dermatitis showing follicular hyperaccentuation on the neck. This pattern of atopic dermatitis is more common in persons of color. (*Courtesy of Richard P. Usatine, MD.*)

FIGURE 145-7 An infant with atopic dermatitis on the face that has become superinfected. (*With permission from Milgrom EC, Usatine RP, Tan RA, Spector SL. Practical Allergy. Philadelphia, PA: Elsevier; 2004.*)

FIGURE 145-8 The same infant with superinfected atopic dermatitis of the popliteal fossa. (*With permission from Milgrom EC, Usatine RP, Tan RA, Spector SL. Practical Allergy. Philadelphia, PA: Elsevier; 2004.*)

FIGURE 145-9 Atopic dermatitis in the antecubital fossae of a 6-year-old boy. Note the erythematous plaques with excoriations. (*Courtesy of Richard P. Usatine, MD.*)

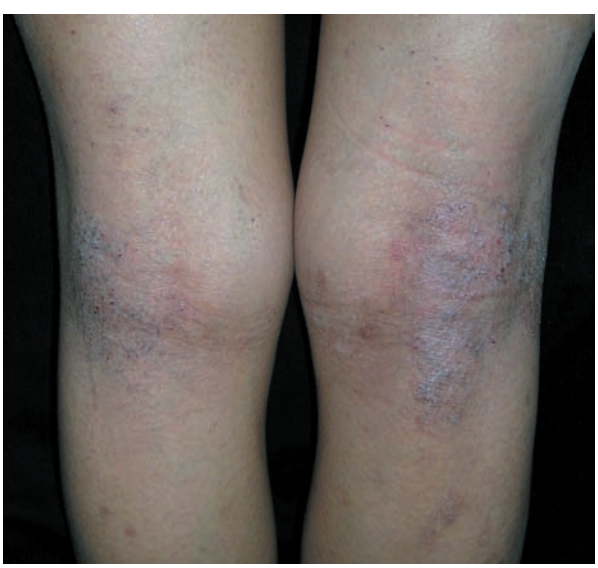

FIGURE 145-10 A 20-year-old young woman with severe chronic atopic dermatitis showing lichenification and hyperpigmentation in the popliteal fossa. (*Courtesy of Richard P. Usatine, MD.*)

FIGURE 145-11 A 2-year-old girl with atopic dermatitis visible on her hands, wrists, and arms. (*Courtesy of Richard P. Usatine, MD.*)

FIGURE 145-12 The girl in **Figure 145-11** with an exacerbation of her atopic dermatitis on the ankle showing many excoriations. (*Courtesy of Richard P. Usatine, MD.*)

FIGURE 145-13 A young nurse with atopic dermatitis made worse by wearing the stethoscope around her neck. (*With permission from Milgrom EC, Usatine RP, Tan RA, Spector SL. Practical Allergy. Philadelphia, PA: Elsevier; 2004.*)

FIGURE 145-14 A young woman with chronic atopic dermatitis around her eyes and mouth. In addition to the eyelid involvement the patient has Denny Morgan lines visible on the lower eyelids. (*Courtesy of Richard P. Usatine, MD.*)

FIGURE 145-15 Keratosis pilaris on the lateral upper arm. Note how the papules can vary in color from pink to brown to white depending upon the skin color of the person. (*Courtesy of Richard P. Usatine, MD.*)

FIGURE 145-17 Pityriasis alba on the face of a young boy. (*Courtesy of Richard P. Usatine, MD.*)

FIGURE 145-16 Acquired ichthyosis on the leg of a 9-year-old boy with atopic dermatitis. Note the fish-scale appearance along with the dry skin. (*Courtesy of Richard P. Usatine, MD.*)

FIGURE 145-18 An 18-month-old girl with atopic dermatitis visible in her popliteal fossa and pityriasis alba on her arm. (*Courtesy of Richard P. Usatine, MD.*)

- A horizontal nasal crease may be seen over the bridge of the nose in a patient with allergic rhinitis prone to performing the allergic salute. In some patients this crease may become hyperpigmented (**Figure 145-21**).

LABORATORY STUDIES

Labs are rarely needed if the history and physical examination support the diagnosis. Occasionally, a KOH preparation may be needed to rule out tinea or a skin scraping to rule out scabies. Of course, both of these conditions can occur on top of AD. RAST (radioallergosorbent test) testing for food allergies and serum IgE levels are not of proven benefit.

DIFFERENTIAL DIAGNOSIS

- Dyshidrotic eczema—Dry inflamed scaling skin on the hands and feet with tapioca-like vesicles, especially seen between the fingers (see Chapter 147, Hand Eczema).
- Seborrheic dermatitis—Greasy, scaly lesions on scalp, face, and chest (see Chapter 151, Seborrheic Dermatitis).
- Psoriasis—Thickened plaques on extensor surfaces, scalp, and buttocks; pitted nails (see Chapter 152, Psoriasis).
- Lichen simplex chronicus (sometimes called neurodermatitis)—Usually, a single patch in an area accessible to scratching such as the ankle, wrist, and neck (see Chapter 149, Self-Inflicted Dermatoses).
- Contact dermatitis—Positive exposure history, rash in area of exposure; absence of family history. Patch testing may be helpful in distinguishing from AD (see Chapter 146, Contact Dermatitis).
- Scabies—Papules, burrows, finger web involvement, positive skin scraping (see Chapter 143, Scabies).
- Dermatophyte infection—On the hands or feet can look just like hand or foot dermatitis; a positive KOH preparation for hyphae can help make the diagnosis (see Chapter 140, Tinea Pedis).

MANAGEMENT

- There is some evidence suggesting that controlling house dust mites reduces severity of symptoms in patients with the atopic triad. Bedding covers were found to be the most effective method to control dust mites and AD symptoms in this subgroup of AD patients. Unfortunately, dust mite interventions are not proven to be effective for patients with AD that do not have the full atopic triad.[1] SOR B
- Dietary restriction is controversial but may be useful for infants with proven egg allergies. SOR B There is insufficient evidence that dietary manipulation in children or adults reduces symptom severity and may cause iatrogenic malnourishment.
- Patient education, avoidance of possible triggers (enzyme-rich detergents, wool clothing), and dry skin care should be optimized.
- Dilute bleach baths (0.5 cup of 6% bleach in tub of bath water) lower the *S. aureus* burden on the skin, decreasing severity of AD.[4] SOR B

FIGURE 145-19 Severe atopic dermatitis in a 2-year-old black boy with very dry (xerotic) skin. He is spontaneously scratching and crying out in discomfort. (*Courtesy of Richard P. Usatine, MD.*)

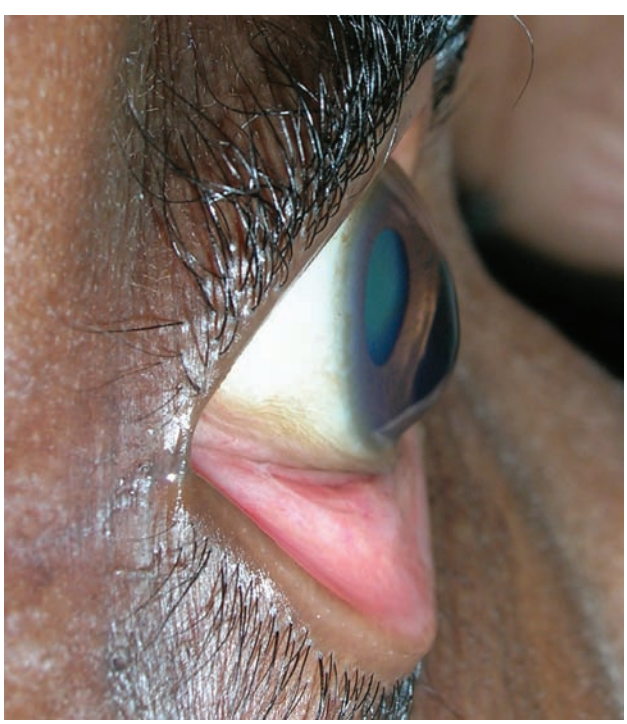

FIGURE 145-20 Keratoconus in a young woman with severe atopic dermatitis. She admits to rubbing her eyes frequently. In keratoconus the cornea bulges out in the middle like a cone and can adversely affect the health of the eye. (*Courtesy of Richard P. Usatine, MD.*)

- There is some evidence suggesting probiotic treatment of pregnant mother and prolonged nursing of child may delay onset of AD.[1] SOR B

TOPICAL THERAPIES

- Topical steroids and emollients have been proven to work for AD and are the mainstay of treatment.[1] SOR A
- Vehicle selection and steroid strength area based on age, body location, and lesion morphology. The ointments are best for dry and cracked skin and are more potent. Creams are easier to apply and are better tolerated by some patients.
- Use stronger steroids for thicker skin, severe outbreaks, or lesions that have not responded to weaker steroids. Avoid strong steroids on face, genitals, and armpits and in infants and small children.
- To avoid adverse effects, the highest potency steroids (e.g., clobetasol) should not be used for longer than 2 weeks continuously. However, they can be used intermittently for recurring AD in a pulse-therapy mode (e.g., apply every weekend, with no application on weekdays).
- Topical calcineurin inhibitors (immunomodulators, such as pimecrolimus and tacrolimus) reduce the rash severity and symptoms in children and adults.[1] SOR A These work by suppressing antigen-specific T-cell activation and inhibiting inflammatory cytokine release. These are steroid-sparing medications that are helpful for eyelid eczema and in other areas when steroids may thin the skin (**Figure 145-22**). These agents are now only approved for persons older than 2 years of age and the FDA states that they should not be used as first-line agents because of a possible risk of causing cancer. The American Academy of Dermatology (AAD) has released a statement that the "data does not prove that the proper topical use of pimecrolimus and tacrolimus is dangerous."
- Short-term adjunctive use of topical doxepin may aid in the reduction of pruritus.[1] SOR A
- Topical and systemic antibiotics are used for AD that has become secondarily infected with bacteria. The most common infecting organism is *S. aureus*. Weeping fluid and crusting during an exacerbation should prompt consideration of antibiotic use[1] (**Figures 145-7**, **145-8**, and **145-23**). SOR A

ORAL/SYSTEMIC THERAPIES

- For extensive flares, consider oral prednisone or an IM shot of triamcinolone (40 mg in 1 mL of 40 mg/mL suspension for adults).[1] SOR C
- The value of antihistamines in AD is controversial. If antihistamines are to be used, the sedating agents are most effective and can be given at night.[1] SOR B
- Cyclosporine for severe refractory AD can be used in long-term maintenance therapy to treat and avoid relapse.[1] SOR A Cyclosporine is approved for 1 year of lifetime therapy for skin diseases in the United States and 2 years in Europe (**Figure 145-24**).
- UV phototherapy may also be used in severe refractory AD with some success.[1] SOR A
- Azathioprine, methotrexate, and mycophenolate mofetil are of possible benefit, but there is less evidence for their effectiveness.[1] SOR C

FIGURE 145-21 Hyperpigmented horizontal nasal crease in a patient with the atopic triad who repeatedly performs the allergic salute when her nose is feeling itchy. (*Courtesy of Richard P. Usatine, MD.*)

FIGURE 145-22 Atopic dermatitis involving the eyelids in this 19-year-old woman with relatively severe atopic dermatitis since infancy. A topical calcineurin inhibitor helped to get the eyelid eczema under control. (*Courtesy of Richard P. Usatine, MD.*)

TABLE 145-1 Written Action Plan to Be Given to Patients (or Their Parents)

No skin lesions or dry skin	Prevention: Emollients, dry skin care, fragrance-free detergent, no drier sheets, once weekly bleach bath
Mild flare	Prevention plus low-mid potency topical steroid and/or calcineurin inhibitors (e.g., hydrocortisone 2.5% or tacrolimus 0.1% to face, axillae, genitals; desonide 0.1% or triamcinolone 0.1% to body)
Moderate flare	Prevention plus mid-high potency topical steroids and/or calcineurin inhibitor (e.g., triamcinolone under wet pajamas bid to clobetasol for short course)
Severe flare	Systemic therapy

Source: Adapted from Rance F, Boguniewicz M, and Lau S,[2] and from Chisolm SS, Taylor SL, Balkrishnan R, et al.[5]

FIGURE 145-23 Superinfected atopic dermatitis on the cheeks. The crusting is a sign of secondary infection usually caused by Staph. aureus or Strep. pyogenes. (*Courtesy of Richard P. Usatine, MD.*)

PATIENT EDUCATION

Patients need to know that scratching their AD makes is worse. Behavior modification is especially challenging in young children and may involve cutting fingernails short and occluding hands/body at night with cotton gloves or clothing. Because of its chronicity and cyclic nature, AD patients may have poor adherence. In one recent study, overall adherence was 32%. A written action plan may be employed to improve adherence (**Table 145-1**).

FOLLOW-UP

Regular follow-up should be given to patients with chronic and difficult-to-control AD. Establishing a good regimen is crucial to good control and then visits may be adjusted to longer intervals between visits.

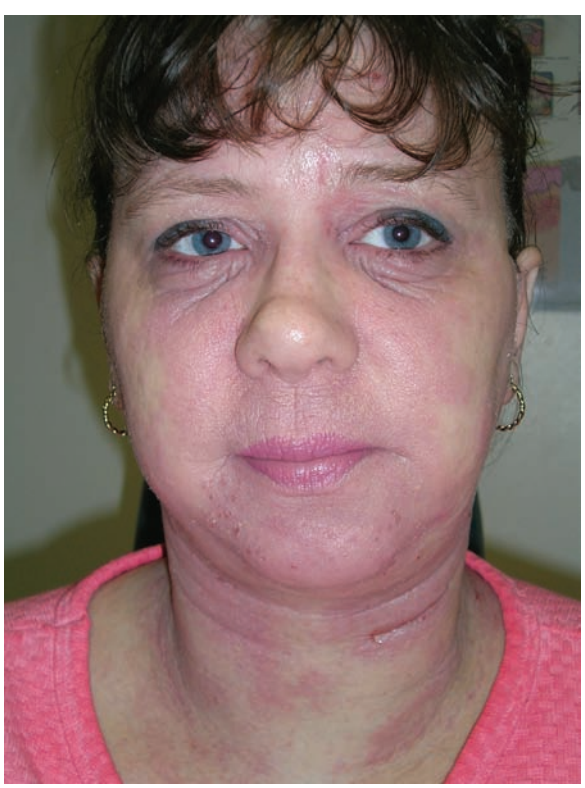

FIGURE 145-24 Atopic dermatitis was so flared up that this woman was started on oral cyclosporine 2 days ago. Her response to cyclosporine over the ensuing months was excellent. (*Courtesy of Richard P. Usatine, MD.*)

REFERENCES

1. Hanifin JM, Cooper KD, Ho VC, et al. Guidelines of care for atopic dermatitis. *J Am Acad Dermatol.* 2004;50:391-404.
2. Rance F, Boguniewicz M, Lau S. New visions for atopic eczema: an iPAC summary and future trends. *Pediatr Allergy Immunol.* 2008;19 Suppl 19:17-25.
3. Simpson EL. Prevalence and morphology of hand eczema in patients with atopic dermatitis. *Dermatitis.* 2006;17:123-127.
4. Huang JT, Abrams M, Tlougan B, et al. Dilute bleach baths for *Staphylococcus aureus* colonization in atopic dermatitis to decrease disease severity. *Pediatrics.* 2009;123(5):e808-e814.
5. Chisolm SS, Taylor SL, Balkrishnan R, et al. Written action plans: potential for improving outcomes in children with atopic dermatitis. *J Am Acad Dermatol.* 2008;59:677-683.

146 CONTACT DERMATITIS

Richard P. Usatine, MD

PATIENT STORY

A 38-year-old woman twisted her right ankle and applied a Chinese medicine patch to relieve the pain. The following day the patient developed a severe contact dermatitis (CD) with many small vesicles (<5 mm) and bullae (>5 mm) (**Figure 146-1**). The erythema had a well-demarcated border and was traced by the doctor's pen. Cold compresses and a high potency topical steroid were prescribed. When the patient showed little improvement a 2-week course of oral prednisone was given starting with 60 mg daily and tapering down to 5 mg daily. The patient responded rapidly and the CD fully resolved.[1,2]

FIGURE 146-1 Severe acute allergic contact dermatitis on the ankle of a woman after application of a Chinese topical medicine for a sprained ankle. (*With permission from Milgrom EC, Usatine RP, Tan RA, Spector SL. Practical Allergy. Philadelphia, PA: Elsevier, Inc; 2004.*)

INTRODUCTION

CD is a common inflammatory skin condition characterized by erythematous and pruritic skin lesions resulting from the contact of skin with a foreign substance. Irritant contact dermatitis (ICD) is caused by the non–immune-modulated irritation of the skin by a substance, resulting in a skin changes. Allergic contact dermatitis (ACD) is a delayed-type hypersensitivity reaction in which a foreign substance comes into contact with the skin, and upon reexposure, skin changes occur.[3]

EPIDEMIOLOGY

- Some of the most common types of CD are secondary to exposures to poison ivy, nickel, and fragrances.[4]
- Patch testing data indicate that the five most prevalent contact allergens out of more than 3700 known contact allergens are nickel (14.3% of patients tested), fragrance mix (14%), neomycin (11.6%), balsam of Peru (10.4%), and thimerosal (10.4%).[5]
- Occupational skin diseases (chiefly CD) rank second only to traumatic injuries as the most common type of occupational disease. Chemical irritants such as solvents and cutting fluids account for most ICD cases. Sixty percent were ACD and 32% were ICD. Hands were primarily affected in 64% of ACD and 80% of ICD[4] (**Figure 146-2**).

FIGURE 146-2 Occupational irritant contact dermatitis in a woman whose hands are exposed to chemicals while making cowboy hats in Texas. (*Courtesy of Richard P. Usatine, MD.*)

ETIOLOGY AND PATHOPHYSIOLOGY

- CD is a common inflammatory skin condition characterized by erythematous and pruritic skin lesions resulting from the contact of skin with a foreign substance.
- ICD is caused by the non–immune-modulated irritation of the skin by a substance, resulting in a skin rash.

- ACD is a delayed-type hypersensitivity reaction in which a foreign substance comes into contact with the skin, and is linked to skin protein forming an antigen complex that leads to sensitization. Upon reexposure of the epidermis to the antigen, the sensitized T cells initiate an inflammatory cascade, leading to the skin changes seen in ACD.

DIAGNOSIS

HISTORY

Ask about contact with known allergens (i.e., nickel, fragrances, neomycin, and poison ivy/oak).

- Nickel exposure is often related to the wearing of rings, jewelry, and metal belt buckles **(Figures 146-3** through **146-6).**
- Fragrances in the forms of deodorants and perfumes (**Figure 146-7).**
- Neomycin applied as a triple antibiotic ointment by patients (**Figures 146-8** and **146-9).**
- Poison ivy/oak in outdoor settings. Especially ask when the distribution of the reaction is linear (**Figures 146-10** and **146-11**).
- Ask about occupational exposures, especially solvents. For example, chemicals used in hat making can cause ICD on the hands (**Figure 146-2**).
- Tapes applied to skin after cuts or surgery are frequent causes of CD (**Figure 146-12**).
- If the CD is on the feet, ask about new shoes (**Figures 146-13** and **146-14**).

A detailed history of products used on the skin may reveal a suspected allergen. In **Figure 146-15,** this truck driver was using baby wipes to clean his skin during long drives. Patch testing ultimately revealed that he was allergic to one of the ingredients in those wipes.

CLINICAL FEATURES

All types of CD have erythema. Although it is not always possible to distinguish between ICD and ACD, here are some features that might help:

- ICD:
  - Location—usually the hands.
  - Symptoms—burning, pruritus, pain.
  - Dry and fissured skin (**Figure 146-2**).
  - Indistinct borders.
- ACD:
  - Location—usually exposed area of skin, often the hands.
  - Pruritus is the dominant symptom.
  - Vesicles and bulla (**Figures 146-1** and **146-8**).
  - Distinct angles, lines, and borders (**Figures 146-8** through **146-12**).

Both ICD and ACD may be complicated by bacterial superinfection showing signs of exudate, weeping, and crusts.

Toxicodendron (Rhus) dermatitis (poison ivy, poison oak, and poison sumac) is caused by urushiol, which is found in the saps of this plant family. Clinically, a line of vesicles can occur from brushing against one of the plants. Also, the linear pattern occurs from scratching oneself and dragging the oleoresin across the skin with the fingernails (**Figures 146-10** and **146-11**).

FIGURE 146-3 Patient moved up his ring to show the allergic contact dermatitis secondary to a nickel allergy to the ring. (*With permission from Milgrom EC, Usatine RP, Tan RA, Spector SL. Practical Allergy. Philadelphia, PA: Elsevier, Inc; 2004.*)

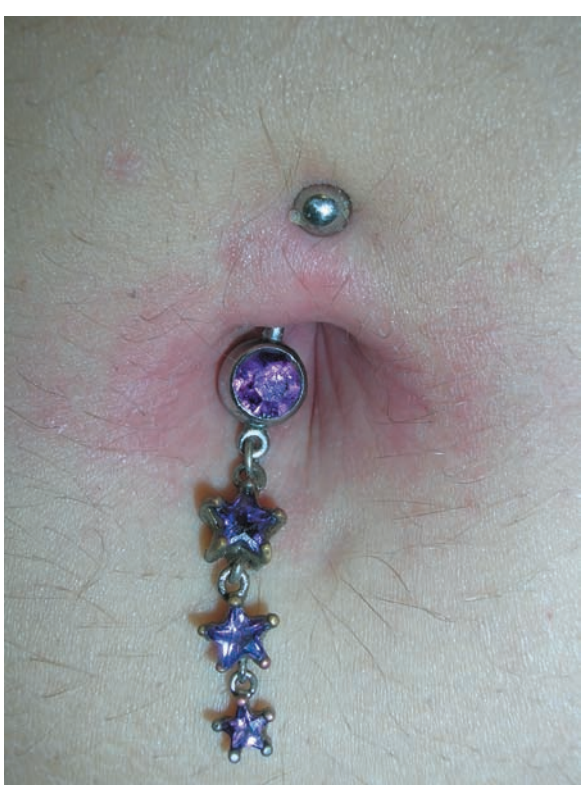

FIGURE 146-4 Allergic contact dermatitis to the metal in the bellybutton ring of a young woman. (*Courtesy of Richard P. Usatine, MD.*)

FIGURE 146-5 Allergic contact dermatitis to the metal in the belt buckle causing erythema, scaling, and hyperpigmentation. (*Courtesy of Richard P. Usatine, MD.*)

FIGURE 146-6 A 12-year-old girl with atopic dermatitis and allergy to the metal in her pants' fastener and metal belts when she wears them. (*Courtesy of Richard P. Usatine, MD.*)

FIGURE 146-7 Allergic contact dermatitis to the fragrance in a new deodorant. (*With permission from Milgrom EC, Usatine RP, Tan RA, Spector SL. Practical Allergy. Philadelphia, PA: Elsevier, Inc; 2004.*)

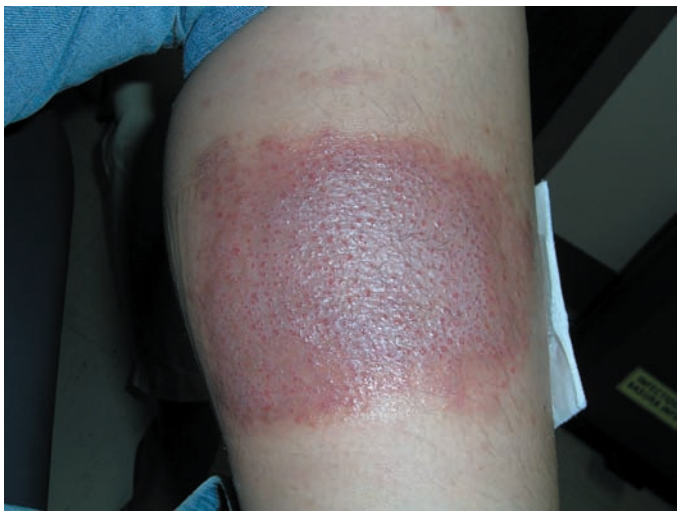

FIGURE 146-8 Allergic contact dermatitis to neomycin applied to the leg of a young woman. Her mom gave her triple antibiotic ointment to place over a bug bite with a large nonstick pad. The contact allergy follows the exact size of the pad and only occurs where the antibiotic was applied. (*Courtesy of Richard P. Usatine, MD.*)

FIGURE 146-9 Allergic contact dermatitis to a neomycin containing topical antibiotic on the breasts. This woman applied this medicine to treat her breast discomfort that began when her breastfeeding baby developed thrush. (*Courtesy of Jack Resneck, Sr., MD.*)

FIGURE 146-10 A linear pattern of allergic contact dermatitis from poison ivy. (*Courtesy of Jack Resneck, Sr., MD.*)

FIGURE 146-11 Multiple lines of vesicles from poison oak on the arm. (*With permission from Milgrom EC, Usatine RP, Tan RA, Spector SL. Practical Allergy. Philadelphia, PA: Elsevier, Inc; 2004.*)

FIGURE 146-12 Allergic contact dermatitis to the tape used after an abdominal hysterectomy. (*With permission from Milgrom EC, Usatine RP, Tan RA, Spector SL. Practical Allergy. Philadelphia, PA: Elsevier, Inc; 2004.*)

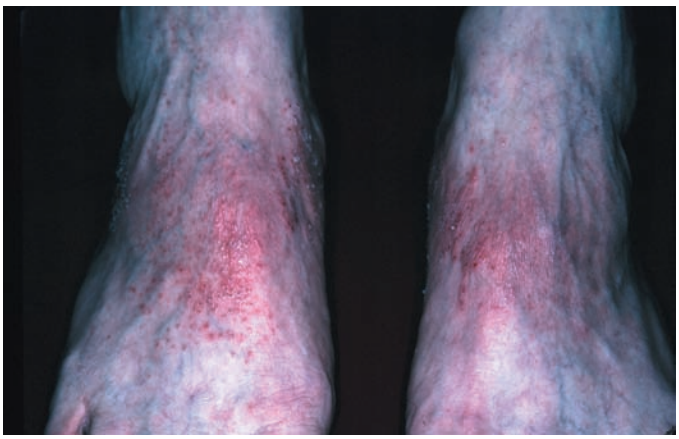

FIGURE 146-13 Allergic contact dermatitis from new shoes. This is the typical distribution found on the dorsum of the feet. (*With permission from Milgrom EC, Usatine RP, Tan RA, Spector SL. Practical Allergy. Philadelphia, PA: Elsevier, Inc; 2004.*)

FIGURE 146-14 A 25-year-old man with allergic contact dermatitis to a chemical in his boots. His boots were higher but he cut them down to try to alleviate the discomfort coming from the boots higher on his leg. (*With permission from Milgrom EC, Usatine RP, Tan RA, Spector SL. Practical Allergy. Philadelphia, PA: Elsevier, Inc; 2004.*)

Systemic CD is a rare form of CD seen after the systemic administration of a substance, usually a drug, to which topical sensitization has previously occurred.[6]

LABORATORY STUDIES

The diagnosis is most often made by history and physical examination. Consider culture if there are signs of superinfection and there is a concern for methicillin-resistant *Staphylococcus aureus* (MRSA). The following tests may be considered when the diagnosis is not clear.

- KOH preparation and/or fungal culture if tinea is suspected.
- Microscopy for scabies mites and eggs.
- Latex allergy testing—This type of reaction is neither ICD (nonimmunologic) nor ACD. The latex allergy type of reaction is a type I, or immunoglobulin (Ig)E-mediated response to the latex allergen.
- Patch testing—Common antigens are placed on the skin of a patient. The T.R.U.E. Test comes in three tape strips that are easy to apply to the back (**Figure 146-16**). There is no preparation needed to test for the 29 common allergens embedded into these strips (**Table 146-1** for a list of the 29 allergens). The strips are removed in 2 days and read at that time and again in 2 more days (**Figure 146-17**). The T.R.U.E. Test website provides detailed information on how to perform the testing and how to counsel patients about the meaning of their results. Any clinician with an interest in patch testing can easily perform this service in the office.
  - A metaanalysis of the T.R.U.E. Test shows that nickel (14.7% of tested patients), thimerosal (5.0%), cobalt (4.8%), fragrance mix (3.4%), and balsam of Peru (3.0%) are the most prevalent allergens detected using this system.[5]
  - Critics of the T.R.U.E. Test state that it misses other important antigens. There are a number of dermatologists who create their own more extensive panels in their office. If the suspected allergen is not in the T.R.U.E. Test, refer to a specialist who will customize the patch testing. Also, personal products, such as cosmetics and lotions, can be diluted for special patch testing.
  - A metaanalysis of children patch tested for ACD showed the top five allergens to be nickel, ammonium persulfate, gold sodium thiosulfate, thimerosal, and toluene-2,5-diamine (*p*-toluenediamine).[7] Only two of these five allergens are in the T.R.U.E. Test, so it may be best to not use this standardized patch testing for children.
  - Once the patch test results are known, it is important to determine if the result is "relevant" to the patient's dermatitis. One method for classifying clinical relevance of a positive patch test reaction is: (a) current relevance—the patient has been exposed to allergen during the current episode of dermatitis and improves when the exposure ceases; (b) past relevance—past episode of dermatitis from exposure to allergen; (c) relevance not known—not sure if exposure is current or old; (d) cross-reaction—the positive test is a result of cross-reaction with another allergen; and (e) exposed—a history of exposure but not resulting in dermatitis from that exposure, or no history of exposure but a definite positive allergic patch test.[6]
- Punch biopsy—When another underlying disorder is suspected that is best diagnosed with histology (e.g., psoriasis).

FIGURE 146-15 A 49-year-old truck driver developed pruritic erythematous eruption on his arms and trunk that persisted for 1 year despite various treatments. Patch testing ultimately revealed that he was allergic to isothiazolinone. He went home and discovered this was one of the ingredients in the baby wipes he used to clean his skin during long drives. His allergic contact dermatitis resolved once he stopped using the wipes. (*Courtesy of Richard P. Usatine, MD.*)

FIGURE 146-16 The T.R.U.E. Test is an easy-to-use standardized patch test that is applied to the back using 3 tape strips to test for 36 common allergens. Extra hypoallergenic tape is applied to keep the strips from peeling off for 2 days. (*Courtesy of Richard P. Usatine, MD.*)

FIGURE 146-17 This positive patch test result for nickel shows small vesicles on an erythematous base. The T.R.U.E. Test reading strip is held against the skin to identify the positive antigen. (*Courtesy of Richard P. Usatine, MD.*)

TABLE 146-1 Allergens in T.R.U.E. Test (Patch Test for Contact Dermatitis)

Panel 1.2	Panel 2.2	Panel 3.2
1. Nickel Sulfate	13. *p*-tert-Butylphenol Formaldehyde Resin	25. Diazolidinyl urea
2. Wool Alcohols	14. Epoxy Resin	26. Quinoline mix
3. Neomycin Sulfate	15. Carba Mix	27. Tixocortol-21-pivalate
4. Potassium Dichromate	16. Black Rubber Mix	28. Gold sodium thiosulfate
5. Caine Mix	17. Cl^+ Me^- Isothiazolinone (MCI/MI)	29. Imidazolidinyl urea
6. Fragrance Mix	18. Quaternium-15	30. Budesonide
7. Colophony	19. Methyldibromo glutaronitrile	31. Hydrocortizone-17-butyrate
8. Paraben Mix	20. *p*-Phenylenediamine	32. Mercaptobenzothiazole
9. Negative Control	21. Formaldehyde	33. Bacitracin
10. Balsam of Peru	22. Mercapto Mix	34. Parthenolide
11. Ethylenediamine Dihydrochloride	23. Thimerosal	35. Disperse blue 106
12. Cobalt Dichloride	24. Thiuram Mix	36. 2-Bromo-2-nitropropane-1,3-diol (Bronopol)

DIFFERENTIAL DIAGNOSIS

- Atopic dermatitis is usually more widespread than CD. There is often a history of other atopic conditions, such as allergic rhinitis and asthma. There may be family history of allergies. However, persons with atopic dermatitis are more prone to CD (**Figure 146-6**; Chapter 145, Atopic Dermatitis).
- Dyshidrotic eczema—Seen on the hands and feet with tapioca vesicles, erythema, and scale. Although this is not primarily caused by contact to allergens, various irritating substances can make it worse (see Chapter 147, Hand Eczema).
- Immediate IgE contact reaction (e.g., latex glove allergy)—Immediate erythema, itching, and possibly systemic reaction after contact with a known (or suspected) allergen.
- Fungal infections—A dermatophyte infection that can closely resemble CD when it occurs on the hands and feet. Tinea pedis is usually seen between the toes, on the soles or on the sides of the feet. CD of the feet is often on the dorsum of the foot and related to rubber or other chemicals in the shoes (**Figures 146-13** and **146-14**; Chapter 140, Tinea Pedis).
- Scabies on the hands can be mistaken for CD. Look for burrows and for the typical distribution of the scabies infestation to distinguish this from CD (see Chapter 143, Scabies).
- Allergies to the dyes used in tattoos can occur. Although this is not strictly a CD because the dye is injected below the skin, the allergic process is similar (**Figure 146-18**).

MANAGEMENT

- Identify and avoid the offending agent(s).[4] SOR A
  - Be aware that some patients are actually allergic to topical steroids. This unfortunate situation can be diagnosed with patch testing.

FIGURE 146-18 Man with allergy to red dye in tattoo. Everywhere that the red dye was used, the patient developed pain and swelling. (*Courtesy of Richard P. Usatine, MD.*)

- In cases of nickel ACD, we recommend the patient cover the metal tab of their jeans with an iron-on patch or a few coats of clear nail polish.

- Cool compresses can soothe the symptoms of acute cases of CD.[4] SOR C
- Calamine and colloidal oatmeal baths may help to dry and soothe acute, oozing lesions.[3,4] SOR C
- Localized acute ACD lesions respond best with mid-potency to high-potency topical steroids such as 0.1% triamcinolone to 0.05% clobetasol, respectively.[4] SOR A
- On areas of thinner skin (e.g., flexural surfaces, eyelids, face, anogenital region) lower-potency steroids such as desonide ointment can minimize the risk of skin atrophy.[3,4] SOR B
- There is insufficient data to support the use of topical steroids for ICD, but because it is difficult to distinguish clinically between ACD and ICD, these agents are frequently tried. SOR C
- If ACD involves extensive skin areas (>20%), systemic steroid therapy is often required and offers relief within 12 to 24 hours. The recommended dose is 0.5 to 1 mg/kg daily for 5 to 7 days, and if the patient is comfortable at that time, the dose may be reduced by 50% for the next 5 to 7 days. The rate of reduction of steroid dosage depends on factors such as severity, duration of ACD, and how effectively the allergen can be avoided.[4] SOR B
- Oral steroids should be tapered over 2 weeks because rapid discontinuance of steroids can result in rebound dermatitis. Severe poison ivy/oak is often treated with oral prednisone for 2 to 3 weeks. Avoid using a Medrol dose-pack, which has insufficient dosing and duration.[4] SOR B
- The efficacy of topical immunomodulators (tacrolimus and pimecrolimus) in ACD or ICD has not been well established.[4] However, one randomized controlled trial (RCT) did demonstrate that tacrolimus ointment is more effective than vehicle in treating chronically exposed, nickel-induced ACD.[8] SOR B
- Although antihistamines are generally not effective for pruritus associated with ACD, they are commonly used. Sedation from more soporific antihistamines may offer some degree of palliation (diphenhydramine, hydroxyzine).[4] SOR C
- Bacterial superinfection should be treated with an appropriate antibiotic that will cover *Streptococcus pyogenes* and *S. aureus*. Treat for MRSA if suspected.
- Once the diagnosis of any CD is established, emollients and moisturizers may help soothe irritated skin.[4] SOR C

For ICD and occupational CD of the hands:

- Wear protective gloves when working with known allergens or potentially irritating substances such as solvents, soaps, and detergents.[6,9] SOR A
- Use cotton liners under the gloves for both comfort and the absorption of sweat. Wearing cotton glove liners can prevent the development of an impaired skin barrier function caused by prolonged wearing of occlusive gloves.[9] SOR B
  - There is insufficient evidence to promote the use of barrier creams to protect against contact with irritants.[6,9] SOR A
  - After work, conditioning creams can improve skin condition in workers with damaged skin.[9] SOR A

FIGURE 146-19 Severe occupational contact dermatitis to petroleum products in a man who works as a car mechanic. (*Courtesy of Richard P. Usatine, MD.*)

- Keep hands clean, dry, and well-moisturized whenever possible.
- Petrolatum applied twice a day is a great way to moisturize dry and cracked skin without exposing the patient to new irritants.

If the CD is severe enough (**Figure 146-19**), the patient may need to change work to completely avoid the offending irritant or antigen.

FOLLOW-UP

May need frequent follow-up if the offending substance is not found, the rash does not resolve and if patch testing will be needed.

PATIENT EDUCATION

Avoid the offending agent and take the medications as prescribed to relieve symptoms.

PATIENT RESOURCES

- PubMed Health. *Contact Dermatitis*—**http://www.ncbi.nlm.nih.gov/pubmedhealth/PMH0001872/.**
- The T.R.U.E. Test website has a wealth of information on reading labels, common allergens and patch testing for patients—**http://www.truetest.com/.**

PROVIDER RESOURCES

- American Family Physician. *Diagnosis and Management of Contact Dermatitis*—**http://www.aafp.org/afp/2010/0801/p249.html.**
- The T.R.U.E. Test website has a wealth of information on patch testing for healthcare professionals—**http://www.truetest.com/.**

REFERENCES

1. Usatine RP. A red twisted ankle. *West J Med.* 1999;171:361-362.
2. Halstater B, Usatine RP. Contact dermatitis. In: Milgrom E, Usatine RP, Tan R, Spector S, eds. *Practical Allergy*. Philadelphia, PA: Elsevier; 2004.
3. Usatine RP, Riojas M. Diagnosis and management of contact dermatitis. *Am Fam Physician.* 2010;82:249-255.
4. Beltrani VS, Bernstein IL, Cohen DE, Fonacier L. Contact dermatitis: a practice parameter. *Ann Allergy Asthma Immunol.* 2006;97: S1-S38.
5. Krob HA, Fleischer AB Jr, D'Agostino R Jr, Haverstock CL, Feldman S. Prevalence and relevance of contact dermatitis allergens: a meta-analysis of 15 years of published T.R.U.E. test data. *J Am Acad Dermatol.* 2004;51:349-353.
6. Bourke J, Coulson I, English J. Guidelines for the management of contact dermatitis: an update. *Br J Dermatol.* 2009;160:946-954.

7. Bonitsis NG, Tatsioni A, Bassioukas K, Ioannidis JP. Allergens responsible for allergic contact dermatitis among children: a systematic review and meta-analysis. *Contact Dermatitis.* 2011;64:245-257.
8. Belsito D, Wilson DC, Warshaw E, et al. A prospective randomized clinical trial of 0.1% tacrolimus ointment in a model of chronic allergic contact dermatitis. *J Am Acad Dermatol.* 2006;55:40-46.
9. Nicholson PJ, Llewellyn D, English JS. Evidence-based guidelines for the prevention, identification and management of occupational contact dermatitis and urticaria. *Contact Dermatitis.* 2010;63:177-186.

147 HAND ECZEMA

Richard P. Usatine, MD

PATIENT STORY

An Asian American physician presents with dry scaling on her hands. Frequent hand washing makes it worse and it sometimes cracks. She has allergic rhinitis and she had more widespread atopic dermatitis in her youth. This is a case of chronic atopic hand dermatitis (**Figure 147-1**). The treatment suggested was use of Cetaphil (or equivalent nonsoap cleanser) instead of soap and water. She was directed to soak her hands 3 to 5 minutes in warm water every night, apply triamcinolone 0.1% ointment, and cover with cotton gloves overnight. Her hands cleared 90% with this treatment and she was pleased with the results.

FIGURE 147-1 An Asian American physician with chronic atopic hand dermatitis. She has allergic rhinitis and she had more widespread atopic dermatitis in her youth. (*Courtesy of Richard P. Usatine, MD.*)

INTRODUCTION

Hand eczema refers to a wide spectrum of inflammatory skin diseases of the hands, including atopic dermatitis, contact dermatitis, pompholyx, and dyshidrotic eczema.

SYNONYMS

Hand dermatitis, pompholyx, dyshidrotic eczema, vesicular palmoplantar eczema. Although some people use pompholyx and dyshidrotic eczema synonymously, others reserve pompholyx for hand eczema with vesicles and bullae on the palms and dyshidrotic eczema for conditions with smaller vesicles between the fingers and toes.

EPIDEMIOLOGY

- The prevalence of hand dermatitis is estimated at approximately 2% to 8.9% in the general population.[1]

ETIOLOGY AND PATHOPHYSIOLOGY

- There are many clinical variants of hand dermatitis and a number of different classification schemas. Here is one accepted classification scheme:
  1. Contact (i.e., allergic and irritant) (**Figure 147-2**).
  2. Hyperkeratotic (i.e., psoriasiform) (**Figure 147-3**).
  3. Frictional (**Figure 147-4**).
  4. Nummular (**Figure 147-5**).
  5. Atopic (**Figure 147-6**).
  6. Pompholyx (i.e., dyshidrosis) (**Figures 147-7** and **147-8**).
  7. Chronic vesicular hand dermatitis.[1] (**Figure 147-9**)

FIGURE 147-2 Contact dermatitis to fragrance mix on the dorsum of the hand secondary to using the back of the hand to apply perfume to neck. (*From Usatine RP. New rash on the right hand and neck. J Fam Pract. 2003;52(11):863-865. Reproduced with permission from Frontline Medical Communications.*)

FIGURE 147-3 Hyperkeratotic hand dermatitis in a black woman. (*Courtesy of Richard P. Usatine, MD.*)

FIGURE 147-4 Frictional hand eczema that is worse on the hand that is used for the cane. The other side was affected by a stroke so only one hand is usable for ambulating with a cane. (*Courtesy of Richard P. Usatine, MD.*)

FIGURE 147-5 Nummular hand dermatitis with tiny papules, papulovesicles, and "coin-shaped" eczematous plaques on the distal fingers of a 14-year-old girl. (*Courtesy of Richard P. Usatine, MD.*)

FIGURE 147-6 Atopic hand dermatitis on palms in Asian American woman with long history of atopic dermatitis. (*Courtesy of Richard P. Usatine, MD. Previously published in Practical Allergy.*)

FIGURE 147-7 Dyshidrotic eczema with acute outbreak of tapioca vesicles on the sides of the fingers. (*Courtesy of Richard P. Usatine, MD.*)

FIGURE 147-8 Severe pompholyx worsening with topical steroids. Patch testing showed she was allergic to topical steroids. Her hands finally cleared with oral cyclosporine and avoidance of all topical and oral steroids. (*Courtesy of Richard P. Usatine, MD.*)

- Another way of looking at hand dermatitis is to break it down into three categories:[2]
  1. Endogenous—Atopic, psoriasis, pompholyx, dyshidrotic (we do not include psoriasis as a type of hand eczema in this chapter).
  2. Exogenous—Allergic and irritant contact dermatitis.
  3. Infectious—Tinea, *Candida*, and/or superimposed *S. aureus* (**Figure 147-10**).
- Most contact dermatitis of the hands is secondary to irritants such as soap, water, solvents, and other chemicals.
- Allergic contact dermatitis (ACD) is a type IV, delayed-type, cell-mediated, hypersensitivity reaction.
- The nine most frequent allergens related to hand contact dermatitis were identified by patch testing from 1994 to 2004.[3] These are quaternium-15 (16.5%), formaldehyde (13.0%), nickel sulfate (12.2%), fragrance mix (11.3%), thiuram mix (10.2%), balsam of Peru (9.6%), carba mix (7.8%), neomycin sulfate (7.7%), and bacitracin (7.4%).[3]
- Rubber allergens were commonly associated with occupation. One third of patients with ACD had identifiable relevant irritants.[3]
- Most common allergens are preservatives, metals, fragrances, topical antibiotics, or rubber additives.[3]

FIGURE 147-9 Chronic vesicular hand dermatitis going on for decades in this 51-year-old Hispanic woman. It is particularly bad in the hypothenar area. (*Courtesy of Richard P. Usatine, MD.*)

DIAGNOSIS

CLINICAL FEATURES[1]

Contact (i.e., allergic and irritant) (**Figure 147-2**).

- Symptoms include burning, stinging, itching, and tenderness at the site of exposure to the irritant or allergen.[1]
- Acute signs include papules, vesicles, bullae, and edema.
- Weeping and crusting can occur with or without superinfection.
- Chronic signs include plaques with fissuring, hyperpigmentation, and/or lichenification.
- Irritant contact dermatitis may predispose to ACD.

Hyperkeratotic (i.e., psoriasiform) (**Figure 147-3**).

- Symmetric hyperkeratotic plaques.
- May be localized to the proximal or middle part of the palms.
- Painful fissures are common.

Frictional (**Figure 147-4**).

- Mechanical factors, often from work, such as trauma, friction, pressure, and vibration, induce skin changes with erythema and scale.
- "Wear-and-tear dermatitis."[1]
- Can be caused by contact with paper and fabrics.

Nummular (**Figure 147-5**).

- Nummular hand dermatitis (also called discoid hand dermatitis).
- Tiny papules, papulovesicles, or "coin-shaped" eczematous plaques.
- Dorsal hands and distal fingers are often involved.

FIGURE 147-10 Contact hand dermatitis in a Chinese cook superinfected with *Candida*. See white scale between the fingers. The *Candida* in the interdigital space is also called erosio interdigitalis blastomycetica and is seen in patients with diabetes. (*Courtesy of Richard P. Usatine, MD.*)

Atopic

- Patients with childhood atopic dermatitis are predisposed to develop hand dermatitis as adults (**Figure 147-6**).
- There is no characteristic pattern and it can occur on any part of the hand.
- Extension to or involvement of the wrist is common (**Figure 147-11**).

Pompholyx (i.e., dyshidrosis, dyshidrotic eczema).

- Has recurrent crops of papules, vesicles, and bullae on the lateral aspects of the fingers, as well as the palms and soles, on a background of nonerythematous skin (**Figures 147-7** and **147-8**).
- These are described as tapioca vesicles as they look like the small spheres in tapioca. The vesicles open and the skin then peels (mild desquamation).
- There may be pruritus or pain.
- Although some use the names pompholyx and dyshidrotic eczema interchangeably, others only use the name pompholyx to describe an explosive onset of large bullae, usually on the palms (**Figure 147-8**) and dyshidrotic eczema to mainly describe chronic small tapioca vesicles on the sides of the fingers (**Figure 147-7**).
- Both conditions may last 2 to 3 weeks and resolve, leaving normal skin, only to recur again at varying intervals.
- Both conditions are idiopathic and closely related, if not identical.
- Symptoms may be associated with exogenous factors (e.g., nickel or hot weather) or endogenous factors (e.g., atopy or stress).

Chronic vesicular hand dermatitis (**Figure 147-9**).

- Chronic vesicles that are mostly palmar and pruritic.
- Differentiated from pompholyx by a more chronic course and the presence of vesicles with an erythematous base.
- The soles of the feet may also be involved.
- Poorly responsive to treatments.
- In one series, 55% of patients with this type of hand dermatitis were found to have positive patch test results.[4]

TYPICAL DISTRIBUTION

Of course, hand dermatitis is on the hands, but both hands and feet can be involved in dyshidrotic eczema and chronic vesicular hand dermatitis.

LABORATORY STUDIES

Scraping and using microscopy with KOH (with or without a fungal stain) to look for dermatophytes is helpful (see Chapter 129, Cutaneous Fungal Infections).

Patch testing can be crucial to the diagnosis and treatment of hand eczema. Patch testing is described in detail in the previous chapter (Chapter 146, Contact Dermatitis). The patient in **Figure 147-8** had severe pompholyx worsening with topical steroids. Patch testing showed she was allergic to topical steroids (**Figure 147-12**). Her hands finally cleared with oral cyclosporine and avoidance of all topical and oral steroids.

FIGURE 147-11 Hand dermatitis with prominent wrist involvement in a 20-year-old Hispanic woman with moderately severe widespread atopic dermatitis. (*Courtesy of Richard P. Usatine, MD.*)

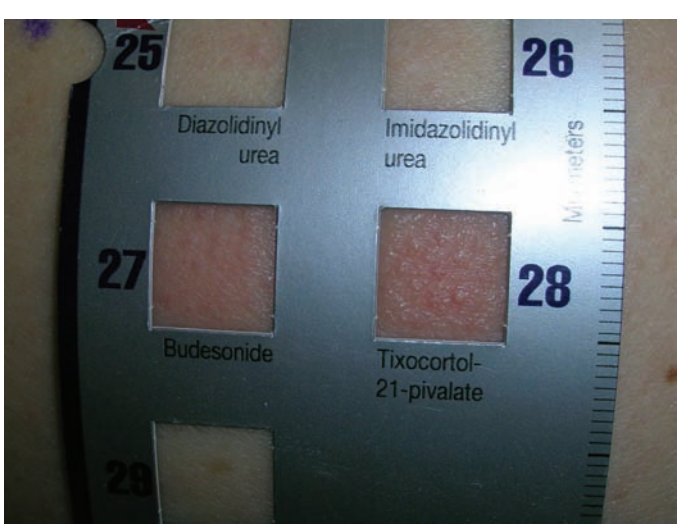

FIGURE 147-12 Patch testing positive to two types of topical steroids in a patient with severe pompholyx and topical steroid allergic contact dermatitis. Reading of T.R.U.E. test. (*Courtesy of Richard P. Usatine, MD.*)

DIFFERENTIAL DIAGNOSIS

- Tinea manus is often found as part of the two-foot, one-hand syndrome in which both feet have scaling tinea pedis and one hand has scale as well (**Figure 147-13**) (see Chapter 129, Cutaneous Fungal Infections, and Chapter 140, Tinea Pedis).
- *Candida* can be seen in between the fingers with erythema and scale over the fingers and hand (**Figure 147-10**) (see Chapter 136, Candidiasis).
- Psoriasis often involves the hand. It can present with plaques on the dorsum of hand and over the knuckles of the fingers or on the palm of the hand. Palmoplantar psoriasis will involve the hands and feet (see Chapter 152, Psoriasis).
- Knuckle pads are thickening of the skin over the knuckles. These can be accompanied by hyperpigmentation.

FIGURE 147-13 Tinea manus in a patient with two-foot, one-hand syndrome. The scraping showed hyphae under the microscope with a KOH preparation. (*Courtesy of Richard P. Usatine, MD.*)

MANAGEMENT

- Lifestyle modifying factors, as listed in **Table 147-1**, are essential.
- Avoid irritants and "wet work" at home and at work as much as possible. SOR C
- Wear protective gloves when working with known allergens or potentially irritating substances such as solvents, soaps, and detergents.[5,6] SOR A
- Use cotton liners under the gloves for both comfort and the absorption of sweat. Wearing cotton glove liners can prevent the development of an impaired skin barrier function caused by prolonged wearing of occlusive gloves.[5,6] SOR B

There is insufficient evidence to promote the use of barrier creams to protect against contact with irritants.[5,6] SOR A

Applying conditioning creams after work can improve skin condition in workers with damaged skin on the hands.[6] SOR A

- Avoid latex gloves because of a high risk of latex allergy among patients with hand dermatitis. SOR C
- Frequent and liberal use of emollients can help restore normal skin-barrier function. Simple, inexpensive, petrolatum-based emollients were found to be equally as effective as an emollient containing skin-related lipids in a 2-month study of 30 patients with mild to moderate hand dermatitis.[7] SOR B
- For patients with very dry skin that is not irritated by water, it may help to soak hands 3 to 5 minutes in warm water at night, apply triamcinolone 0.1% ointment, and cover with cotton gloves overnight. The cotton gloves may be used repeatedly even though they will soak up some of the ointment. SOR C
- Do not wash hands with soap. Use Cetaphil, a nonsoap cleanser. SOR C

See **Table 147-2** for a summary of the recommended therapeutic agents for different types of hand dermatitis.

TOPICAL AGENTS

- Topical steroids are first-line agents for inflammatory hand dermatitis. Ointments are considered more effective and contain fewer

TABLE 147-1 Sample Patient Handout on Lifestyle Management of Hand Dermatitis

Hand washing and moisturizing:
- Use lukewarm or cool water, and mild cleansers without perfume, coloring, or antibacterial agents, and with minimal preservatives. In general, bar soaps tend to have fewer preservatives than liquid soaps (Cetaphil or Aquanil liquid cleansers or generic equivalents are exceptions to this statement).
- Pat hands dry, especially between fingers.
- Immediately following partial drying of hands (e.g., within 3 minutes), apply a generous amount of a heavy cream or ointment (not lotion); petroleum jelly, a one-ingredient lubricant, works well.
- It is helpful to have containers of creams or ointments next to every sink in your home (next to the bed, next to the TV, in the car, and at multiple places at work).
- Moisturizing should be repeated as often as possible throughout the day, ideally 15 times per day.
- Avoid using washcloths, rubbing, scrubbing, or overuse of soap or water.

Occlusive therapy at night for intensive therapy:
- Apply a generous amount of your doctor's recommended emollient or prescribed medicine on your hands.
- Then put on cotton gloves and wear overnight.

When performing "wet work":
- Wear cotton gloves under vinyl or other nonlatex gloves.
- Try not to use hot water and decrease exposure to water to less than 15 minutes at a time, if possible.
- Use running water rather than immersing hands, if possible.
- Remove rings before wet or dry work.

Wear protective gloves in cold weather and for dusty work. For frictional exposures, wear tight-fitting leather gloves (e.g., riding or golfing gloves).

Avoid direct contact with the following, if possible:
- Shampoo;
- Peeling fruits and vegetables, especially citrus fruits;
- Polishes of all kinds;
- Solvents (e.g., white spirit, thinners, and turpentine);
- Hair lotions, creams, and dyes;
- Detergents and strong cleansing agents;
- Fragranced chemicals;
- "Unknown" chemicals.

Heavy-duty vinyl gloves are better than rubber, nitrile, or other synthetic gloves because vinyl is less likely to cause allergic reactions.

Source: Reprinted with permission from Fig. 9 in Warshaw E, Lee G, Storrs FJ. Hand dermatitis: a review of clinical features, therapeutic options, and long-term outcomes. *Am J Contact Dermat*. 2003;14:126.

preservatives and additives than creams. Some patients will prefer a cream vehicle, so that patient preference should be considered in prescribing topical steroids. It is better to have a patient use a cream than not use an ointment.

- Start with 0.1% triamcinolone ointment bid as it is inexpensive and effective. SOR C Cut back on use when possible to avoid skin atrophy, striae, and telangiectasias.
- Topical calcineurin inhibitors, tacrolimus and pimecrolimus, are effective in the treatment of atopic and other allergic types of hand dermatitis.[8,9] SOR B Skin burning or an unpleasant sensation of warmth is reported by approximately 50% of patients using topical tacrolimus and 10% with pimecrolimus.[10]

PHOTOTHERAPY AND IONIZING RADIATION

- Psoralen and UVA irradiation (PUVA) has been used to treat patients with all forms of hand dermatitis.[10] SOR C
- Grenz rays (ionizing radiation with ultra-soft X-rays or Bucky rays) usually requires 200 to 400 rad (2 to 4 Grays or Gy) every 1 to 3 weeks for up to a total of 6 treatments, followed by a 6-month hiatus.[10] SOR C

SYSTEMIC STEROIDS AND IMMUNOMODULATORS

- Oral prednisone may be used to treat the most severe and recalcitrant case of hand dermatitis. Pulse dosing of 40 to 60 mg daily for 3 to 4 days may be valuable.[10] For atopic dermatitis of the hands, an injection of 40 mg triamcinolone acetonide is another option when topical meds are not fully working. SOR C
- Cyclosporine is a potent immunomodulating agent used to treat severe and recalcitrant cases of atopic dermatitis and hand dermatitis. In a systematic review, cyclosporin consistently decreased the severity of atopic dermatitis. The decrease in disease severity was greater at 2 weeks with dosages greater than or equal to 4 mg/kg.

TABLE 147-2 Recommended Therapies for Hand Dermatitis Variants

Therapeutic Agent	Hand Dermatitis Variant						
	Irritant Contact	Allergic Contact	Hyper-keratotic	Nummular	Pompholyx (Dyshidrosis)	Frictional	Chronic Vesicular
Corticosteroids:							
Topical	✓	✓		✓	✓	✓	✓
Oral		✓			✓*		✓
Cyclosporine		✓			✓		✓
Methotrexate		✓	✓		✓		✓
Mycophenolate mofetil		✓		✓	✓		✓
Tacrolimus or pimecrolimus (topical)	✓	✓		✓	✓		✓
Phototherapy (UVB, psoralen UVA, and Grenz)	✓	✓	✓	✓	✓	✓	✓
Retinoids (topical and/or oral)			✓			✓	✓
Calcipotriene (topical)			✓			✓	✓

*Acute flares.
Source: Reprinted with permission from Warshaw E, Lee G, Storrs FJ. Hand dermatitis: a review of clinical features, therapeutic options, and long-term outcomes. *Am J Contact Dermat. 2003;14:128.*

After 6 to 8 weeks the relative effectiveness was 55%.[11] For patients with severe functional problems this can be a great relief (**Figure 147-8**). Unfortunately, relapse rates are high after discontinuation of the cyclosporine.[10] SOR B

- Mycophenolate mofetil and methotrexate have been reported to be beneficial in case reports.[10] SOR C
- Alitretinoin (9-*cis*-retinoic acid) is an effective treatment for severe chronic hand eczema.[12] SOR B Like all systemic retinoids it is teratogenic and requires careful monitoring. This medication is not yet available in the United States, but is being used in Canada and the United Kingdom.

PATIENT EDUCATION

- See **Table 147-1**.

FOLLOW-UP

Patients with chronic hand dermatitis are often desperately looking for help and often appreciate frequent follow-up until the dermatitis is controlled. Patch testing requires three visits within a 1-week period.

PATIENT RESOURCES

- DermNet New Zealand—**http://www.dermnetnz.org/dermatitis/hand-dermatitis.html.**

PROVIDER RESOURCES

- *Dyshidrotic eczema*—**http://emedicine.medscape.com/article/1122527.**
- *Vesicular Palmoplantar Eczema*—**http://emedicine.medscape.com/article/1124613.**

REFERENCES

1. Warshaw E, Lee G, Storrs FJ. Hand dermatitis: a review of clinical features, therapeutic options, and long-term outcomes. *Am J Contact Dermat.* 2003;14:119-137.
2. Bolognia J. *Dermatology*. St. Louis, MO: Mosby; 2003.
3. Warshaw EM, Ahmed RL, Belsito DV, et al; North American Contact Dermatitis Group. Contact dermatitis of the hands: cross-sectional analyses of North American Contact Dermatitis Group Data, 1994-2004. *J Am Acad Dermatol.* 2007;57(2):301-314.
4. Li LF, Wang J. Contact hypersensitivity in hand dermatitis. *Contact Dermatitis.* 2002;47:206-209.
5. Bourke J, Coulson I, English J. Guidelines for the management of contact dermatitis: an update. *Br J Dermatol.* 2009;160:946-954.
6. Nicholson PJ, Llewellyn D, English JS. Evidence-based guidelines for the prevention, identification and management of occupational contact dermatitis and urticaria. *Contact Dermatitis.* 2010;63:177-186.
7. Kucharekova M, Van De Kerkhof PC, Van Der Valk PG. A randomized comparison of an emollient containing skin-related lipids with a petrolatum-based emollient as adjunct in the treatment of chronic hand dermatitis. *Contact Dermatitis.* 2003;48:293-299.

8. Belsito DV, Fowler JF Jr, Marks JG Jr, et al; Multicenter Investigator Group. Pimecrolimus cream 1%: a potential new treatment for chronic hand dermatitis. *Cutis.* 2004;73(1):31-38.
9. Belsito D, Wilson DC, Warshaw E, et al. A prospective randomized clinical trial of 0.1% tacrolimus ointment in a model of chronic allergic contact dermatitis. *J Am Acad Dermatol.* 2006;55:40-46.
10. Warshaw EM. Therapeutic options for chronic hand dermatitis. *Dermatol Ther.* 2004;17:240-250.
11. Schmitt J, Schmitt N, Meurer M. Cyclosporin in the treatment of patients with atopic eczema—a systematic review and meta-analysis. *J Eur Acad Dermatol Venereol.* 2007;21:606-619.
12. Ruzicka T, Lynde CW, Jemec GBE, et al. Efficacy and safety of oral alitretinoin (9-cis retinoic acid) in patients with severe chronic hand eczema refractory to topical corticosteroids: results of a randomized, double-blind, placebo-controlled, multicentre trial. *Br J Dermatol.* 2008;158:808-817.

148 NUMMULAR ECZEMA

Yu Wah, MD
Richard P. Usatine, MD

PATIENT STORY

A 2-year-old Hispanic male presents to the clinic with erythematous, round, moist, crusted lesions on the left thigh (**Figure 148-1**) and right arm. His mother noted several small bumps initially, which developed into coin-shaped lesions over the next few weeks. The child is scratching them but is otherwise healthy. A KOH preparation of the scraping from the lesions did not show fungal structures. The child responds well to treatment with topical midpotency corticosteroids, emollients, and dressing in long-sleeve clothes to prevent scratching the lesions. His nummular eczema resolved in 6 weeks.

FIGURE 148-1 A 2-year-old child with nummular eczema on the left thigh. The lesion shows abrasions and excoriations from scratching. He has another similar lesion on the right arm. (*Courtesy of Yu Wah, MD.*)

INTRODUCTION

Nummular eczema (NE) is a type of eczema characterized by circular or oval-shaped scaling plaques with well-defined borders. The term *nummular* refers to the shape of a coin (Latin for coin is *nummus*).The lesions are typically multiple and most commonly found on the dorsa of the hands, arms, and legs. It often overlaps with other clinical types of eczema: atopic dermatitis, stasis dermatitis, and asteatotic eczema.[1,2]

SYNONYMS

Nummular dermatitis, discoid eczema, microbial eczema, and orbicular eczema.

EPIDEMIOLOGY

- Prevalence is reported to range widely from 0.1% to 9.1%.[1]
- It is slightly more common in males than in females.[1]
- Males are also affected at a later age (peak older than age 50 years) than females (peak younger than age 30 years).[1]
- It is less common in children.

ETIOLOGY AND PATHOPHYSIOLOGY

Many factors have been reported in association with NE but their role in the etiology and pathogenesis is not well established:

- NE has been viewed as microbial in origin, either secondary to bacterial colonization or hematogenous spread of bacterial toxins,[1,3] but an infectious source is not identified in most cases of NE.
- NE is reported to be associated with xerosis of the skin that subsequently weakens the skin barrier function and sensitizes it to environmental allergens.[4]

- NE is frequently reported in association with contact sensitization to various agents, including nickel, chromate, balsam of Peru, and fragrances. Allergic or chronic contact dermatitis has been frequently reported to manifest as NE on the dorsa of the hands.[1,5]
- Onset of NE has been reported in association with various medications, including interferon and ribavirin therapy for hepatitis C[6,7] and isotretinoin.[8] Most of these reports are based on single or limited number of cases.
- Mercury in the dental amalgam was reported to induce NE in two cases with relapsing NE.[9]

DIAGNOSIS

HISTORY

- Onset is reported to be within days to week. Simultaneous or subsequent development of multiple lesions is often reported.
- Intense pruritus or burning is common.
- Lesions may last months to years without treatment and may be recurrent.
- History of medications, atopy, and exposure to allergens may be helpful to tailor the management of NE.

PHYSICAL EXAMINATION

- Primary morphology includes small papules and vesicles that coalesce to form circular to oval shape patches and plaques (**Figures 148-2** and **148-3**).
- Secondary morphology includes abrasion and excoriations from scratching (**Figure 148-1**), weeping and crusting after the vesicles leak (**Figures 148-2** to **148-4**), and scaling and lichenification in more chronic lesions (**Figures 148-5** and **148-6**). Excessive weeping and crusting may indicate secondary bacterial infection.

TYPICAL DISTRIBUTION

- Dorsal hand is most commonly affected (**Figures 148-2** and **148-7**). The extensor aspects of the forearm (**Figures 148-3** and **148-6**) and the lower leg (**Figure 148-5**), the thighs (**Figure 148-1**), and the flanks are frequently involved, but NE may be seen in any part of the body (**Figures 148-4**, **148-8**, and **148-9**).

LABORATORY TESTING

- Diagnosis in most cases is made from clinical features.
- KOH preparation is helpful to investigate for tinea corporis.
- Patch testing may be considered if contact allergy is suspected.

BIOPSY

- Biopsy is rarely needed, but should be performed if there is suspicion of other serious clinical entities (e.g., mycosis fungoides, psoriasis) or if the diagnosis is uncertain.

DIFFERENTIAL DIAGNOSIS

- Tinea corporis may present as pruritic annular lesions with scales and vesicles. Vesicles are typically at the periphery of the lesion compared to NE, where they are also seen in the center. A positive

FIGURE 148-2 Multiple nummular lesions on the dorsum of the hand, a common site of nummular eczema. The lesions show multiple papules and vesicles that coalesce to form coin-shaped plaques; oozing and crusting can be seen from ruptured vesicles. (*Courtesy of Richard P. Usatine, MD.*)

FIGURE 148-3 Nummular eczema on the forearm of a 22-year-old man. The lesions show multiple papules and vesicles that coalesce to form coin-shaped plaques; oozing and crusting can be seen from ruptured vesicles. (*Courtesy of Richard P. Usatine, MD.*)

FIGURE 148-4 Nummular eczema on the face of a young man. (*Courtesy of Richard P. Usatine, MD.*)

FIGURE 148-5 Multiple nummular lesions on the lower leg of a 15-year-old girl. Lesions of nummular eczema can be dry and scaly. The lesions prevented the patient from shaving her legs. (*Courtesy of Richard P. Usatine, MD.*)

FIGURE 148-6 Nummular eczema on the extensor surface of the forearms and elbows. Thickened, scaly lesions resemble psoriatic plaques. A biopsy was perform to confirm the diagnosis of nummular eczema. (*Courtesy of Richard P. Usatine, MD.*)

FIGURE 148-7 Nummular eczema on the dorsum of the hand and wrist. (*Courtesy of Richard P. Usatine, MD.*)

FIGURE 148-8 Nummular eczema on the dorsum of the foot. Contact dermatitis and tinea pedis were also in the differential diagnosis. (*Courtesy of Richard P. Usatine, MD.*)

FIGURE 148-9 Nummular eczema on the abdomen of a 27-year-old man. (*Courtesy of Richard P. Usatine, MD.*)

KOH preparation for hyphae can help with the diagnosis (see Chapter 138, Tinea Corporis).

- Psoriasis typically presents with thickened plaques on the extensor surfaces of arms and legs, scalp and sacral areas. Nail changes may be present (see Chapter 152, Psoriasis).
- Lichen simplex chronicus usually presents as a single plaque in an area easily accessible to scratching such as the ankle, wrist, and neck (see Chapter 149, Self-Inflicted Dermatoses).
- Mycosis fungoides is a type of cutaneous T-cell lymphoma, which may present with scaly patches or plaques that are often pruritic and usually erythematous. A biopsy can help make the diagnosis (see Chapter 176, Mycosis Fungoides).
- Nummular lesions of atopic dermatitis may have features similar to NE. Presence of other lesions typically on flexural surfaces, and a history of atopy, asthma, or seasonal allergies may help make the diagnosis (see Chapter 145, Atopic Dermatitis).
- Contact dermatitis (CD) may present with nummular lesions. History of exposure to contact allergens at the affected areas can raise the suspicion for CD. Patch testing may be used to confirm the clinical suspicion (see Chapter 146, Contact Dermatitis).
- Asteatotic dermatitis may have overlapping features with NE but has a less-well-defined margin.

MANAGEMENT

- Emollients are beneficial to help restore and maintain normal skin barrier function. SOR C
- Hydration by bathing before bedtime followed by ointment application to wet skin is reported as an effective method of skin care in patients with eczema.[10] SOR B
- A medium- to high-potency topical corticosteroid ointment is the first line of treatment. A cream preparation may be used if patient compliance is a concern with ointments. SOR C
- Topical calcineurin inhibitors such as topical tacrolimus and pimecrolimus have the benefit of not causing skin atrophy and have been shown to be effective in many types of eczema.[1] SOR B They have a higher cost compared to topical corticosteroids and have a black box warning because of a reported risk of malignancies.
- Short courses of systemic corticosteroids may be necessary in severe or acute cases. SOR C
- Methotrexate is reported to be safe, effective, and well-tolerated in treatment of moderate to severe childhood NE.[11] This was reported in a case series of 25 pediatric patients with refractory NE treated with 5 or 10 mg of methotrexate per week. Sixty-four percent had total clearance after an average of 10.5 months. No serious adverse events were observed in this study.[11] SOR B
- Phototherapy may be used in generalized, severe, or refractory cases.[1,2] Narrow-band UVB is commonly used and psoralen UVA has been used in more severe cases.[2] SOR C
- Topical and oral antihistamines are often needed to treat pruritus. Topical doxepin is reported to be effective in treatment of pruritus associated with eczematous conditions and has a favorable safety profile.[12] SOR B
- Topical and systemic antibiotics may be needed to treat secondary or associated bacterial infection. SOR C
- Complementary therapy with probiotics is not effective in treatment of eczema and carries a small risk of adverse events.[13] SOR A

FOLLOW-UP

Regular follow-up is needed for the patient with chronic, refractory, or relapsing nummular dermatitis until remission or resolution is achieved.

PATIENT EDUCATION

Hydration and protection of skin form irritants is important. Apply moisturizer or topical medications immediately after bathing while the skin is still moist. Avoid strong soaps and use mild fragrance-free soap, or soap alternatives. Avoid tight clothing and fabrics that irritate the skin.

PATIENT RESOURCES

- American Academy of Dermatology. *Nummular Dermatitis*—**http://www.aad.org/skin-conditions/dermatology-a-to-z/nummular-dermatitis.**
- British Association of Dermatologists. *Discoid Eczema*—**http://www.bad.org.uk/site/811/Default.aspx.**

PROVIDER RESOURCE

- Medscape. *Nummular Dermatitis*—**http://emedicine.medscape.com/article/1123605.**

REFERENCES

1. Bolognia J. *Dermatology*. St. Louis, MO: Mosby/Elsevier; 2008.
2. Miller J. *Nummular Dermatitis*, http://emedicine.medscape.com/article/1123605, updated May 20, 2011, accessed November 12, 2011.
3. Tanaka T, Satoh T, Yokozeki H. Dental infection associated with nummular eczema as an overlooked focal infection. *J Dermatol*. 2009;36(8):462-465.
4. Aoyama H, Tanaka M, Hara M, Tabata N, Tagami H. Nummular eczema: an addition of senile xerosis and unique cutaneous reactivities to environmental aeroallergens. *Dermatology*. 1999;199(2):135-139.
5. Wilkinson DS. Discoid eczema as a consequence of contact with irritants. *Contact Dermatitis*. 1979;5(2):118-119.
6. Moore MM, Elpern DJ, Carter DJ. Severe, generalized nummular eczema secondary to interferon alfa-2b plus ribavirin combination therapy in a patient with chronic hepatitis C virus infection. *Arch Dermatol*. 2004;140(2):215-217.

7. Shen Y, Pielop J, Hsu S. Generalized nummular eczema secondary to peginterferon Alfa-2b and ribavirin combination therapy for hepatitis C infection. *Arch Dermatol.* 2005;141(1):102-103.
8. Bettoli V, Tosti A, Varotti C. Nummular eczema during isotretinoin treatment. *J Am Acad Dermatol.* 1987;16(3 Pt 1):617.
9. Adachi A, Horikawa T, Takashima T, Ichihashi M. Mercury-induced nummular dermatitis. *J Am Acad Dermatol.* 2000;43(2):383-385.
10. Gutman AB, Kligman AM, Sciacca J, James WD. Soak and smear: a standard technique revisited. *Arch Dermatol.* 2005;141(12): 1556-1569.
11. Roberts H, Orchard D. Methotrexate is a safe and effective treatment for paediatric discoid (nummular) eczema: a case series of 25 children. *Australas J Dermatol.* 2010;51(2):128-130.
12. Drake LA, Millikan LE. The antipruritic effect of 5% doxepin cream in patients with eczematous dermatitis. Doxepin Study Group. *Arch Dermatol.* 1995;131(12):1403-1408.
13. Boyle RJ, Bath-Hextall FJ, Leonardi-Bee J, Murrell DF, Tang ML. Probiotics for treating eczema. *Cochrane Database Syst Rev.* 2008;(4):CD006135.

149 SELF-INFLICTED DERMATOSES

Richard P. Usatine, MD
Anne E. Johnson, MD

PATIENT STORY

A 55-year-old woman presents with severe itching on her arms and legs. The itching disrupts her sleep and she sometimes scratches her arms and legs until exhaustion (**Figures 149-1** and **149-2**).[1] She had used moisturizers, emollients, and topical corticosteroids, but they only alleviated the itching temporarily. The itching began 10 months earlier after finalizing the divorce from her husband of 20 years. The patient's right leg had been amputated above the knee after a car accident, and she now wore a prosthetic leg. The patient readily admitted to a great deal of psychological distress. She described feeling depressed since her divorce, and the loss of her leg further aggravated her situation. She has had difficulty securing a job and had high anxiety about being able to pay for rent and bills. The diagnosis made was neurotic excoriations (neurodermatitis) and the patient understood that she was doing this to her own skin. The patient improved with nail cutting, acknowledging the self-inflicted nature of her excoriations and topical clobetasol. One year later, the patient was working in the hospital laboratory with a tremendous improvement in her skin condition (**Figure 149-3**).

FIGURE 149-1 Neurotic excoriations (neurodermatitis) seen on 3 of 4 extremities. The fourth extremity is a prosthetic leg. (*From Usatine RP, Saldana-Arregui MA. Excoriations and ulcers and legs. J Fam Pract. 2004;53(9):713-716. Reproduced with permission from Frontline Medical Communications.*)

INTRODUCTION

The self-inflicted dermatoses (sometimes referred to as psychogenic dermatoses) include neurotic excoriations, lichen simplex chronicus, and prurigo nodularis. These conditions are caused by pruritus for which no medical cause is apparent, which initiates an itch–scratch cycle. The self-inflicted dermatoses can present a challenge to the clinician, as multiple underlying medical etiologies must be ruled out to arrive at their diagnosis and the pathophysiology of these diseases is not well understood. In addition, they may be difficult to treat successfully. There is no clear standard of care for treatment, although a vast array of treatments targeting different etiologies has been tried clinically, and many have some amount of research to support them. As with other psychosomatic conditions, non-pharmacologic interventions, including the physician–patient relationship itself, can be important to treatment.

FIGURE 149-2 Neurotic excoriations with close-up of arm. (*From Usatine RP, Saldana-Arregui MA. Excoriations and ulcers and legs. J Fam Pract. 2004;53(9):713-716. Reproduced with permission from Frontline Medical Communications.*)

SYNONYMS

- Neurotic excoriations—Neurodermatitis.
- Lichen simplex chronicus—Neurodermatitis circumscripta.
- Prurigo nodularis—Picker's nodules; lichen simplex chronicus, prurigo nodularis type; atypical nodular form of neurodermatitis circumscripta.

EPIDEMIOLOGY

- Studies show that neurotic excoriations primarily affect females, with a mean onset between the ages of 30 and 45 years[1] (**Figures 149-1** to **149-5**).
- Neurotic excoriations are present in 2% of patients seen in dermatologic clinics.[1]
- Lichen simplex chronicus (LSC) is observed more commonly in females than in males (**Figures 149-6** to **149-9**). Lichen nuchae is a form of lichen simplex that occurs on the midposterior neck (**Figures 149-8** and **149-9**).
- LSC occurs mostly in mid-to-late adulthood, with highest prevalence in persons ages 30 to 50 years.[2]
- For prurigo nodularis (PN) there is no documented difference in frequency between males and females. PN most often occurs in middle-aged and older persons[3] (**Figures 149-10** to **149-15**).

ETIOLOGY AND PATHOPHYSIOLOGY

- All 3 conditions are found on the skin in regions accessible to scratching.
- Pruritus provokes scratching that produces clinical lesions.
- The underlying pathophysiology is unknown for all 3 conditions. Central nervous system (CNS)[4] and peripheral nervous system[5–7] dysfunction have been implicated in the pathogenesis of the pruritus underlying the self-inflicted dermatoses.
- Some skin types are more prone to lichenification, such as skin that tends toward eczematous conditions (i.e., atopic dermatitis).[2]
- One study showed an association between LSC and a certain genotype (short/short) at the serotonin transporter gene-linked polymorphic region.[8]
- Neurotic excoriations (neurodermatitis) is a result of a psychodermatologic disorder in which patients inflict excoriations and ulcers on their skin and admit to their involvement.
- The pathogenesis of PN is still unknown. PN shares some histologic features (epidermal proliferation) with psoriasis and ichthyosis but is largely self-inflicted.[3] There is some evidence to suggest immune dysregulation is involved, as PN is more common in patients with HIV/AIDS and other forms of immunosuppression than in the general population.[9]

DIAGNOSIS

CLINICAL FEATURES

Itching is the common historical theme for all three self-inflicted dermatoses.

Common psychiatric problems associated with all self-inflicted dermatoses include significant social stress, depression, anxiety, and obsessive–compulsive disorder.

FIGURE 149-3 Same patient 1 year later after successful therapy. Hypopigmented scarring remains. (*Courtesy of Richard P. Usatine, MD.*)

FIGURE 149-4 Neurotic excoriations on the leg with significant postinflammatory hyperpigmentation. (*Courtesy of Richard P. Usatine, MD.*)

FIGURE 149-5 Neurotic excoriations on the upper arm with hypopigmented scarring. (*Courtesy of Richard P. Usatine, MD.*)

FIGURE 149-7 Lichen simplex chronicus on the ankle. (*Courtesy of Richard P. Usatine, MD.*)

FIGURE 149-6 Lichen simplex chronicus on the hand of a middle-aged woman with thick lichenification, erythema, and hyperpigmentation. She was continually scratching at her hand. (*Courtesy of Richard P. Usatine, MD.*)

FIGURE 149-8 Lichen simplex chronicus on the neck of a Hispanic woman who also has acanthosis nigricans. (*Courtesy of Richard P. Usatine, MD.*)

FIGURE 149-9 Lichen simplex chronicus on the neck of a Hispanic woman with thick plaque formation that resembles prurigo nodularis. (*Courtesy of Richard P. Usatine, MD.*)

FIGURE 149-11 Prurigo nodularis on the arms and legs after 9 months of unsuccessful treatment in the patient in **Figure 149-10**. (*Courtesy of Richard P. Usatine, MD.*)

FIGURE 149-10 Prurigo nodularis on the arms and legs of a 42-year-old Hispanic woman. (*Courtesy of Richard P. Usatine, MD.*)

FIGURE 149-12 Severe prurigo nodularis on the arm. The nodules are somewhat linear from years of scratching. (*Courtesy of Richard P. Usatine, MD.*)

FIGURE 149-13 Prurigo nodularis on the upper back of a man. (*Courtesy of Richard P. Usatine, MD.*)

Patients are often observed scratching and rubbing their skin. This results in:

- Lichenification of the skin (skin thickening with exaggerated skin lines) (**Figures 149-6** and **149-9**).
- Pigmentary changes (especially hyperpigmentation) (**Figures 149-4**, **149-5**, **149-9**, **149-11**, and **149-15**).
- Excoriations, erosions, and ulcerations.

Common physical examination findings for all three disorders include:

- Neurotic excoriations—May vary from dug-out erosions, to ulcers covered with crusts and surrounded by erythema to areas receding into hypopigmented depressed scars (**Figure 149-5**).
- LSC—One or more slightly erythematous, scaly, well-demarcated, lichenified, firm, rough plaques[2] (**Figures 149-6** to **149-9**).
- Prurigo nodularis—Raised nodules from 2 to 20 mm, colors vary from shades of red to brown (**Figures 149-10** to **149-15**).

Excoriations are almost always present on initial presentation. With treatment the excoriations may subside and the nodules may remain.

TYPICAL DISTRIBUTION

- Neurotic excoriations occur on areas easily reached by the patient, such as the arms, legs, and upper back (**Figures 149-1** to **149-5**).
- LSC occurs on:
  - Hands, wrists, extensor forearms, and elbows (**Figure 149-6**).
  - Knees, lower legs, and ankles (**Figure 149-7**).
  - Nape of neck (**Figures 149-8** and **149-9**).
  - Vulva and scrotum.
- In PN, nodules occur on the extensor surfaces of the arms, the legs, and sometimes the trunk (**Figures 149-10** to **149-15**).

LABORATORY STUDIES

Punch biopsy may be helpful when the diagnosis is uncertain.

FIGURE 149-14 A cluster of nodules on the back of the same patient with prurigo nodularis. (*Courtesy of Richard P. Usatine, MD.*)

DIFFERENTIAL DIAGNOSIS

- Acne keloidalis nuchae—Acneiform eruption at the hairline from ingrown hairs, worse with shaving and short haircuts (see Chapter 114, Pseudofolliculitis and Acne Keloidalis Nuchae).
- Atopic dermatitis—An allergic skin disorder in patients with a personal or family history of atopic conditions. Patients with atopic dermatitis are more likely to get LSC (see Chapter 145, Atopic Dermatitis).
- Contact dermatitis—A common inflammatory skin condition characterized by erythematous and pruritic skin lesions resulting from the contact of skin with a foreign substance (see Chapter 146, Contact Dermatitis).
- Delusions of parasitosis—Delusions that tiny bugs or parasites are living on or below the patient's skin leading them to try to dig them out with their nails and fingers. This condition looks just like

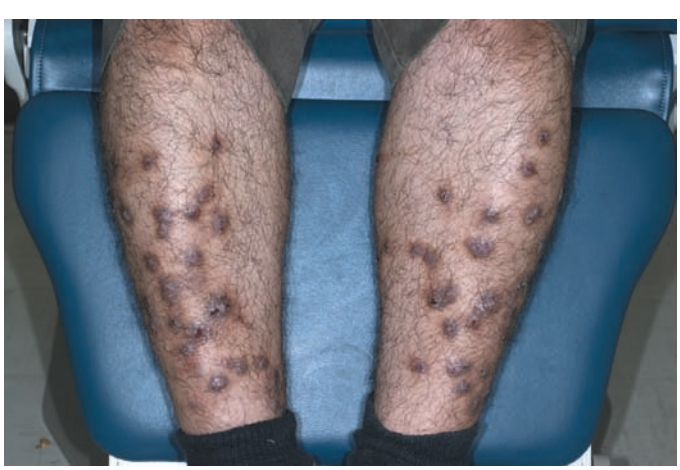

FIGURE 149-15 Severe prurigo nodularis on the legs with prominent hyperpigmentation of the nodules and some secondary infection. (*Courtesy of Richard P. Usatine, MD.*)

neurotic excoriations; however, the patient believes there are parasites causing the pruritus and it is very difficult to convince them otherwise.

- Nummular eczema—Eczematous lesions in the shape of coins seen most often on the legs.
- Scabies—Look for burrows between the fingers and the typical distribution of scabies on the hands, feet, wrists, waist, and axillae to differentiate scabies from a self-inflicted dermatosis. If you do a scraping and find evidence of the scabies mite that is the best way to confirm a true scabies infestation. Often family members have itching and lesions as well when the real diagnosis is scabies (see Chapter 143, Scabies).

MANAGEMENT

For all 3 self-inflicted dermatoses there is little evidence to guide therapy. The following 3 treatments can be used in all 3 conditions and are based on expert opinion and a few small studies: SOR C

- Topical corticosteroids—Use mid-potency to high-potency steroids except in areas of thin skin.
- Oral antihistamines—Sedating H_1 blockers and consider doxepin (start with 10 to 25 mg PO qhs and titrate to response) for refractory cases.
- Oral antibiotics, if secondary infection is present.
- One small study of 3 patients with inflammatory skin diseases and severe nocturnal pruritus who underwent treatment with mirtazapine (Remeron) suggests that this may be an effective alternative for the treatment of nocturnal pruritus.[10] SOR C

Get a good psychosocial history and offer the patient treatment for any problems uncovered. It may help for patients to understand the connection between their self-inflicted lesions and their stressors. Some patients will have anxiety disorders or depression, whereas others will be suffering with great psychosocial stressors like loss of work, homelessness, or grief. Offer pharmacotherapy (including selective serotonin reuptake inhibitors [SSRIs]) and counseling if indicated. Refer as needed for these therapies.

Other specific treatments to consider are as follows:

- LSC
  - Doxepin 5% cream has been studied in patients with LSC, nummular eczema, and contact dermatitis. Applied 4 times per day for a period of 7 days led to an 84% response rate in reduction of pruritus (not lesions).[11] SOR B
  - Tacrolimus 0.1% ointment applied twice daily for approximately 2 months, then once daily for an additional 3 months was effective in achieving remission from LSC in 1 case report.[12]
  - In one study of 22 patients with LSC, transcutaneous electrical nerve stimulation (TENS) reduced pruritus by greater than more than 50% in 80% of the patients.[5]
- Prurigo nodularis—A difficult condition to treat with mild-to-moderate success at best. Here are some treatments to consider:
  - Intralesional steroids—Triamcinolone 5 to 10 mg/cc. SOR C

- Cryotherapy—Applied to each nodule to flatten the nodules and decrease pruritus. SOR C
- Calcipotriol—After 8 weeks of calcipotriol treatment, the reduction in the number and size of nodules was 49% and 56%, respectively, compared with 18% and 25% for the betamethasone valerate.[13] SOR B
- UV light (narrow-band UVB) is sometimes useful when the condition is widespread. SOR C
- Monochromatic excimer light (308 nm) showed partial or complete remission from PN in 9 (81%) of 11 patients.[14] SOR C
- Oral dapsone has been tried with some reported success in this difficult condition. SOR C

Gabapentin has some reported success in reducing pruritus in patients with PN and LSC.[6] One case series of oral cyclosporine showed some benefit for PN.[15]

In AIDS patients with PN, maintaining a CD4+ count over 50 may improve pruritus.[9]

PATIENT EDUCATION

Help patients to understand that they are unintentionally hurting their own skin. Patients need to minimize touching, scratching, and rubbing affected areas. Suggest that patients gently apply their medication or a moisturizer instead of scratching the pruritic areas. Give patients hope and show them **Figures 149-1** to **149-3** to demonstrate that even the most severe cases can heal if they stop manipulating their skin.

FOLLOW-UP

Follow-up is essential because these problems are chronic and difficult to treat. Patients need to know that you will not abandon them and will continue to work with them to get relief. This is especially important when the patient is suffering from anxiety, depression, or other psychological problems.

PATIENT RESOURCES

- LSC—**http://www.ncbi.nlm.nih.gov/pubmedhealth/PMH0001875/**.
- PN—**http://www.aocd.org/skin/dermatologic_diseases/prurigo_nodularis.html**.
- *Neurotic Excoriations*—**http://www.aafp.org/afp/2001/1215/p1981.html.**

PROVIDER RESOURCES

- LSC—**http://emedicine.medscape.com/article/1123423.**
- PN—**http://emedicine.medscape.com/article/1088032**.
- *Neurotic Excoriations*—**http://emedicine.medscape.com/article/1122042**.

REFERENCES

1. Scheinfeld, N. *Neurotic Excoriations*. http://emedicine.medscape.com/article/1122042. Updated August 3, 2011. Accessed November 15, 2011.
2. Hogan, D. *Lichen Simplex Chronicus*. http://emedicine.medscape.com/article/1123423. Updated June 4, 2010. Accessed November 15, 2011.
3. Hogan, D. *Prurigo Nodularis*. http://emedicine.medscape.com/article/1088032. Updated July 9, 2010. Accessed November 17, 2011.
4. Krishnan A, Koo J. Psyche, opioids, and itch: therapeutic consequences. *Dermatol Ther*. 2005;18(4):314-322.
5. Engin B, Tufekci O, Yazici A, Ozdemir M. The effect of transcutaneous electrical nerve stimulation in the treatment of lichen simplex: a prospective study. *Clin Exp Dermatol*. 2009;34:324-328.
6. Gencoglan G, Inanir I, Gunduz K. Treatment of prurigo nodularis and lichen simplex chronicus with gabapentin. *Dermatol Ther*. 2010;23:194-198.
7. Solak O, Kulac M, Yaman M, et al. Lichen simplex chronicus as a symptom of neuropathy. *Clin Exp Dermatol*. 2008;34:476-480.
8. Kirtak N, Inaloz S, Akcali C, et al. Association of serotonin transporter gene-linked polymorphic region and variable number of tandem repeat polymorphism of the serotonin transporter gene in lichen simplex chronicus patients with psychiatric status. *Int J Dermatol*. 2008;47:1069-1072.
9. Maurer T. Dermatologic manifestations of HIV infection. *Top HIV Med*. 2005 Dec-2006 Jan;13(5):149-154.
10. Hundley JL, Yosipovitch G. Mirtazapine for reducing nocturnal itch in patients with chronic pruritus: a pilot study. *J Am Acad Dermatol*. 2004;50:889-891.
11. Drake LA, Millikan LE. The antipruritic effect of 5% doxepin cream in patients with eczematous dermatitis. Doxepin Study Group. *Arch Dermatol*. 1995;131:1403-1408.
12. Aschoff R, Wozel G. Topical tacrolimus for the treatment of lichen simplex chronicus. *J Dermatolog Treat*. 2007;18:115-117.
13. Wong SS, Goh CL. Double-blind, right/left comparison of calcipotriol ointment and betamethasone ointment in the treatment of prurigo nodularis. *Arch Dermatol*. 2000;136:807-808.
14. Saraceno R, Nistico SP, Capriotti E, et al. Monochromatic excimer light (308 nm) in the treatment of prurigo nodularis. *Photodermatol Photoimmunol Photomed*. 2008;24(1):43-45.
15. Siepmann, D Luger T, Stander S. Antipruritic effect of cyclosporine microemulsion in prurigo nodularis: results of a case series. *J Dtsch Dermatol Ges*. 2008;6:941-945.
16. Brodin M. Neurotic excoriations. *J Am Acad Dermatol*. 2010;2:341-342.
17. Konuk N, Koca R, Atik L, et al. Psychopathology, depression and dissociative experiences in patients with lichen simplex chronicus. *Gen Hosp Psychiatry*. 2007;29:232-235.
18. Lotti T, Buggiani G, Prignano F. Prurigo nodularis and lichen simplex chronicus. *Dermatol Ther*. 2008;21:42-46.
19. Saporito L, Florena A, Colomba C, et al. Prurigo nodularis due to *Mycobacterium tuberculosis*. *J Med Microbiol*. 2009;58:1649-1651.
20. Usatine RP, Saldana-Arregui MA. Excoriations and ulcers on the arms and legs. *J Fam Pract*. 2004;53:713-716.

150 URTICARIA AND ANGIOEDEMA

Richard P. Usatine, MD

PATIENT STORY

A 26-year-old man was given trimethoprim-sulfamethoxazole for sinusitis and broke out in hives 1 week later. The hives were all over his trunk and arms (**Figures 150-1** and **150-2**). He had no airway compromise and had only urticaria without angioedema. His sinus symptoms were mostly resolved, so he was told to stop the antibiotic and take an oral antihistamine. The H_1-blocker gave him relief of symptoms and the wheals disappeared over the next 2 days.

FIGURE 150-1 A 26-year-old man with acute urticaria due to trimethoprim-sulfamethoxazole. (*Courtesy of Richard P. Usatine, MD.*)

INTRODUCTION

Urticaria and angioedema are a heterogeneous group of diseases that cause swelling of the skin and other soft tissues. They both result from a large variety of underlying causes, are elicited by a great diversity of factors, and present clinically in a highly variable way.[1] Standard hives with transient wheals is the most common manifestation of urticaria.

SYNONYMS

Hives.

EPIDEMIOLOGY

- It is estimated that 15% to 25% of the population may have urticaria sometime during their lifetime.[2]
- Urticaria affects 6% to 7% of preschool children and 17% of children with atopic dermatitis.[2]
- Among all age groups, approximately 50% have both urticaria and angioedema, 40% have isolated urticaria, and 10% have angioedema alone.[2]
- Acute urticaria is defined as less than 6 weeks' duration. A specific cause is more likely to be identified in acute urticaria.[2]
- The cause of chronic urticaria (>6 weeks' duration) is determined in less than 20% of cases.[2]
- Chronic urticaria is twice as common in women as in men.[3]
- Chronic urticaria predominantly affects adults.[3]
- Up to 40% of patients with chronic urticaria of more than 6 months' duration still have urticaria 10 years later.[3]

FIGURE 150-2 Note the confluence of wheals with a well-demarcated border on the arm of the man with acute urticaria due to trimethoprim-sulfamethoxazole. (*Courtesy of Richard P. Usatine, MD.*)

ETIOLOGY AND PATHOPHYSIOLOGY

- The pathophysiology of angioedema and urticaria can be immunoglobulin (Ig) E mediated, complement mediated, related to physical stimuli, autoantibody mediated, or idiopathic.

- These mechanisms lead to mast cell degranulation resulting in the release of histamine. The histamine and other inflammatory mediators produce the wheals, edema, and pruritus.
- Urticaria is a dynamic process in which new wheals evolve as old ones resolve. These wheals result from localized capillary vasodilation, followed by transudation of protein-rich fluid into the surrounding skin. The wheals resolve when the fluid is slowly reabsorbed.
- Angioedema is an edematous area that involves transudation of fluid into the dermis and subcutaneous tissue (**Figures 150-3** and **150-4**).

The following etiologic types exist:

- Immunologic—IgE mediated, complement mediated. Occurs more often in patients with an atopic background. Antigens are most commonly foods or medications. The most common foods are milk, nuts, wheat, and shellfish.
- Physical urticaria—Dermatographism, cold, cholinergic, solar, pressure, vibratory urticaria (**Figures 150-5** and **150-6**).
- Urticaria caused by mast cell-releasing agents—Mastocytosis, urticaria pigmentosa (**Figures 150-7** and **150-8**).
- Urticaria associated with vascular/connective tissue autoimmune disease.
- Hereditary angioedema is a potentially life-threatening disorder that is inherited in an autosomal dominant manner. In this disease, angioedema occurs without urticaria (**Figure 150-9**).

DIAGNOSIS

CLINICAL FEATURES

- Symptoms include itching, burning, and stinging.
- Wheals vary in size from small, 2-mm papules of cholinergic urticaria (**Figure 150-6**) to giant hives where a single wheal may cover a large portion of the trunk.
- The wheal may be all red or white, or the border may be red with the remainder of the surface white.
- Wheals may be annular (**Figures 150-10** and **150-11**).
- If dermatographism is present, one can write on the skin and be able to see the resulting words or shapes (**Figure 150-5**).
- If you suspect urticaria pigmentosa, stroke a lesion with the wooden end of a cotton-tipped applicator. This induces erythema of the plaque and the wheal is confined to the stroke site. This is called Darier sign (**Figure 150-12**).

TYPICAL DISTRIBUTION

- Angioedema is seen more often on the face and is especially found around the mouth and eyes (**Figures 150-3** and **150-4**). Sometimes angioedema can occur on the genitals or the trunk (**Figure 150-13**).
- Urticaria can be found anywhere on the body and is often on the trunk and extremities (**Figures 150-1** and **150-2**).

FIGURE 150-3 Young black woman with angioedema after being started on an angiotensin-converting enzyme (ACE) inhibitor for essential hypertension. (*Courtesy of Adrian Casillas, MD.*)

FIGURE 150-4 Severe angioedema around the eyes and mouth in a high school girl. (*Courtesy of Daniel Stulberg, MD.*)

FIGURE 150-5 Dermatographism in a 21-year-old man with chronic urticaria. Note the exaggerated triple reaction. (*Courtesy of Richard P. Usatine, MD.*)

FIGURE 150-6 Cholinergic urticaria showing small wheals. The patient would get this urticaria after exercising. (*Courtesy of Philip C. Anderson, MD.*)

FIGURE 150-8 Urticaria pigmentosa in a 4-month-old black boy. His lesions started on day 2 of life and have proliferated. (*Courtesy of Richard P. Usatine, MD.*)

FIGURE 150-7 Urticaria pigmentosa on the chest of this 9-month-old girl. She has a positive Darier sign in which stroking the lesion results in edema. (*Courtesy of Richard P. Usatine, MD.*)

FIGURE 150-9 Hereditary angioedema. **A.** Severe edema of the face during an episode, leading to grotesque disfigurement. **B.** Angioedema will subside within hours. The patient had a positive family history and had multiple similar episodes including colicky abdominal pain. (*With permission from Fitzpatrick's Color Atlas and Synopsis of Clinical Dermatology, 5th ed. New York, NY: McGraw-Hill; 2005.*)

LABORATORY STUDIES

Consider tests that might help reveal the cause of the urticaria and/or angioedema.

- Order complement studies to investigate for hereditary or acquired C1 esterase inhibitor deficiency when angioedema occurs repeatedly without urticaria (**Figure 150-9**).
- Consider allergen skin testing and/or in vitro tests for when the history reveals that urticaria/angioedema occurs after direct contact with a suspected allergen.
- Punch biopsy of the involved area may be used to diagnose urticarial vasculitis or mastocytosis.

DIFFERENTIAL DIAGNOSIS

- Insect bites—A good history and physical examination should help to distinguish between insect bites and urticaria.
- Erythema multiforme like urticaria can occur in response to an allergic/immunologic reaction to medications, infections, and neoplasms. The classic lesion of erythema multiforme is the target lesion in which there is disruption of the epithelium in the center. This disruption may be a vesicle, bulla, or erosion. Do not confuse annular lesions or concentric rings with erythema multiforme if the epidermis is intact (**Figure 150-11** is *not* erythema multiforme) (see Chapter 177, Erythema Multiforme, Stevens-Johnson Syndrome, and Toxic Epidermal Necrolysis).
- Urticarial vasculitis typically has lesions that last longer than 24 hours. The lesions are found more commonly on the lower extremities, and when they heal, they often leave hyperpigmented areas. Causes range from a hypersensitivity vasculitis, such as Henoch-Schönlein purpura, to underlying connective tissue disease (**Figure 150-14**).[2]
- Mast cell releasability syndromes are syndromes in which there are too many mast cells in the skin or other organs of the body. These include cutaneous mastocytosis and urticaria pigmentosa (**Figures 150-5**, **150-6**, and **150-11**).
- Pruritic urticarial papules and plaques of pregnancy can be differentiated from urticaria in pregnancy because the eruption remains fixed and increases in intensity until delivery (**Figure 150-15**) (see Chapter 75, Pruritic Urticarial Papules and Plaques of Pregnancy).
- Pemphigoid gestationis can have lesions that are urticarial. However, it also has bullae that distinguish it from urticaria and of course the patient is pregnant or postpartum (see Chapter 76, Pemphigoid Gestationis).

MANAGEMENT

NONPHARMACOLOGIC THERAPY

- Avoid any causative agent, medication, stimulus, or antigen if found. SOR B
- Angiotensin-converting enzyme inhibitors (ACEIs) are especially prone to causing angioedema so should be stopped as soon as possible when suspected to be causative of angioedema or urticaria

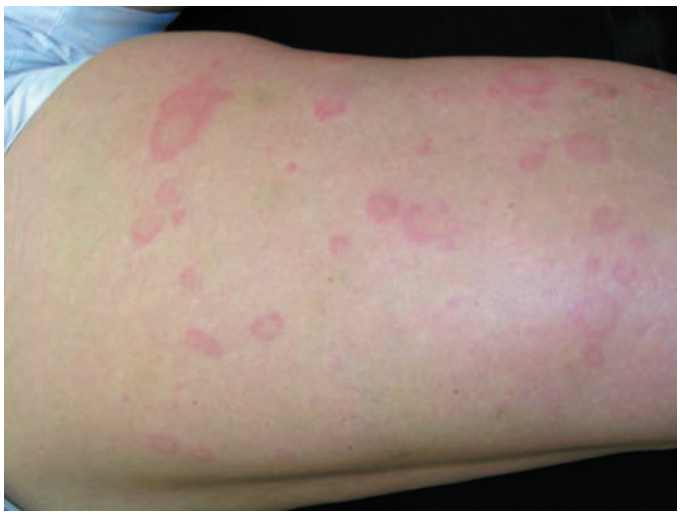

FIGURE 150-10 Chronic urticaria with annular urticarial plaques. (*Courtesy of Richard P. Usatine, MD.*)

FIGURE 150-11 Giant urticaria (urticaria multiforme). Although this appears to have targets the real target lesions of erythema multiforme have a central lesion and have a scaling or bullous component affecting the epidermis. The history suggests that this may have been a serum sickness type reaction. (*With permission from Milgrom EC, Usatine RP, Tan RA, Spector SL. Practical Allergy. Philadelphia, PA: Elsevier; 2003; and Daniel Stulberg, MD.*)

FIGURE 150-12 Positive Darier sign in which stroking the lesion of urticaria pigmentosum results in edema. (*Courtesy of Richard P. Usatine, MD.*)

FIGURE 150-14 Henoch-Schönlein purpura on the leg of a 20-year-old woman. This is a type of urticarial vasculitis. (*With permission from Milgrom EC, Usatine RP, Tan RA, Spector SL. Practical Allergy. Philadelphia, PA: Elsevier; 2003; and Richard P. Usatine, MD.*)

FIGURE 150-13 Angioedema and urticaria of the back. The thicker deeper wheals are angioedema. (*With permission from Milgrom EC, Usatine RP, Tan RA, Spector SL. Practical Allergy. Philadelphia, PA: Elsevier; 2003; and Daniel Stulberg, MD.*)

FIGURE 150-15 Pruritic urticarial papules and plaques of pregnancy on the arm of a pregnant woman. The wheals are indistinguishable from other types of urticaria. (*With permission from Milgrom EC, Usatine RP, Tan RA, Spector SL. Practical Allergy. Philadelphia, PA: Elsevier; 2003; and Richard P. Usatine, MD.*)

(**Figure 150-3**).[1] SOR A Even an angiotensin receptor blocker (ARB) can cause angioedema and should be suspected in a patient on this class of medication (**Figure 150-16**).

- In chronic urticaria, patients may benefit from avoidance of potential urticarial precipitants such as aspirin, NSAIDs (**Figure 150-17**), opiates, and alcohol.[1] SOR B
- Infections may be a cause, an aggravating factor, or an unassociated bystander.[1] Look for sources of chronic infections such as parasitic infections, dental infections, GI infections, respiratory infections, and tinea pedis. Treat these, as it is possible, but unproven, that they can contribute to the chronic urticaria. SOR C
- Stop all unnecessary nonprescription medications, supplements, and vitamins in chronic urticaria. SOR C
- Avoidance of physical stimuli for the treatment of physical urticaria is desirable, but not always possible (observational studies only).[1] SOR B
- Stress reduction techniques may help in chronic urticaria but this is unproven. SOR C

ANTIHISTAMINES

- Low-sedating, second-generation antihistamines should be prescribed as a first-line treatment for chronic urticaria.[4–6] SOR A
- Increasing the dose of cetirizine from 10 mg to 20 mg daily produced a significant improvement in the severity of wheal and itching in urticaria refractory to the standard doses of antihistamines.[7] SOR B
- The British guidelines even suggest using antihistamines at up to quadruple the manufacturers' recommended dosages before changing to an alternative therapy. They also recommend waiting up to 4 weeks to allow full effectiveness of the antihistamines before considering referral to a specialist.[1] SOR C
- All patients should be offered the choice of at least two low-sedating H_1 antagonists because responses and tolerance vary between individuals.[8] SOR A
- Addition of a sedating antihistamine at night may help patients sleep better, although they probably add little to existing H_1 receptor blockade.[8]
- The addition of an H_2 antagonist may give better control of urticaria than H_1 antagonists alone, SOR B although a benefit is not always seen.[8] In one study, adding H_2 blockers to H_1 antagonists resulted in improvement of certain cutaneous outcomes for patients presenting with acute allergic syndromes to an emergency department.[9] SOR B
- When initial antihistamines are not working, consider doxepin, an antidepressant and potent H_1 antagonist.[10] SOR B Its use is limited by the side effects of sedation and dry mouth. Start with 10 mg doxepin in the evening and titrate up as needed and tolerated.
- Low-sedating antihistamines seem to be effective in the treatment of acquired cold urticaria by significantly reducing the presence of wheals and pruritus after cold exposure.[11] SOR A

CORTICOSTEROIDS

- Oral corticosteroids should be restricted to short courses for severe acute urticaria or angioedema affecting the mouth (e.g., prednisone 60 mg/day for 3 to 4 days in adults).[8,12] SOR B

FIGURE 150-16 Angioedema secondary to an angiotensin receptor blocker given for hypertension. The angioedema resolved and did not return once the patient stopped the offending medication. (*Courtesy of Richard P. Usatine, MD.*)

FIGURE 150-17 Urticaria that occurred within an hour after a boy was given ibuprofen to treat a high fever. (*Courtesy of Richard P. Usatine, MD.*)

- Short tapering courses of oral steroids over 3 to 4 weeks may be necessary for urticarial vasculitis and severe delayed pressure urticaria.
- Long-term oral corticosteroids should not be used in chronic urticaria. It is better to use oral cyclosporine if needed as it has a far better risk-to-benefit ratio compared with steroids.[1,8]
- A randomized controlled trial showed that clobetasol 0.05% in a foam formulation was safe and effective in the short-term treatment of patients with delayed pressure urticaria.[13] SOR B

IMMUNOMODULATORY AGENTS

- Immunosuppressive therapies for autoimmune urticaria should be restricted to patients with disabling disease who have not responded to optimal conventional treatments.[6]
- A retrospective study of methotrexate in 8 patients with recalcitrant chronic urticaria indicated that methotrexate was both safe and effective, with a mean dose of 15 mg methotrexate/week. Seven of 8 patients achieved a complete response and 5 of 8 remained disease-free after methotrexate was stopped.[14] SOR B
- Cyclosporine, plasmapheresis, anti-IgE (Omalizumab), and intravenous immunoglobulin have been used in severe recalcitrant cases.[1] SOR C
- Plasmapheresis is very costly and should be reserved for autoantibody-positive chronic spontaneous urticaria patients.[1]

OTHERS

- Epinephrine is valuable in severe acute urticaria or angioedema, especially if there is a suspicion of airway compromise or anaphylaxis.
- The evidence for leukotriene modifiers in the treatment of urticaria is poor. SOR C
- Ecallantide is a new plasma kallikrein inhibitor for the subcutaneous treatment of acute attacks of hereditary angioedema.[15] SOR B
- Antiinflammatory drugs, such as colchicine, dapsone and sulfasalazine, have been reported as helpful in uncontrolled trials or case series.[1]

PATIENT EDUCATION

In most cases, we are not able to find the cause of urticaria. This is especially true for chronic urticaria. Fortunately, most chronic urticaria will subside over time and there are medicines to treat the condition until it runs its course. If one medication doesn't work keep your follow-up visits to try other medications. Carefully observe for causative agents.

FOLLOW-UP

Follow-up is especially needed when the urticaria/angioedema persist or recur.

PATIENT RESOURCES

- eMedicineHealth.com is a consumer health site with information and support groups—**http://www.emedicinehealth.com/hives_and_angioedema/article_em.htm.**

PROVIDER RESOURCES

- Well written guideline based upon a joint initiative of a number of European dermatology, allergy, and immunology organizations—**http://onlinelibrary.wiley.com/doi/10.1111/j.1398-9995.2009.02178.x/full.**

REFERENCES

1. Zuberbier T, Asero R, Bindslev-Jensen C, et al. EAACI/GA(2)LEN/EDF/WAO guideline: management of urticaria. *Allergy.* 2009;64:1427-1443.
2. Baxi S, Dinakar C. Urticaria and angioedema. *Immunol Allergy Clin North Am.* 2005;25:353-367, vii.
3. Usatine RP. Urticaria and agioedema. In: Milgrom E, Usatine RP, Tan R, Spector S, eds. *Practical Allergy*. Philadelphia, PA: Elsevier; 2003:78-96.
4. Finn AF Jr, Kaplan AP, Fretwell R, et al. A double-blind, placebo-controlled trial of fexofenadine HCl in the treatment of chronic idiopathic urticaria. *J Allergy Clin Immunol.* 1999;104:1071-1078.
5. Ortonne JP, Grob JJ, Auquier P, Dreyfus I. Efficacy and safety of desloratadine in adults with chronic idiopathic urticaria: a randomized, double-blind, placebo-controlled, multicenter trial. *Am J Clin Dermatol.* 2007;8:37-42.
6. Ortonne JP. Chronic urticaria: a comparison of management guidelines. *Expert Opin Pharmacother.* 2011;12(17):2683-2693.
7. Okubo Y, Shigoka Y, Yamazaki M, Tsuboi R. Double dose of cetirizine hydrochloride is effective for patients with urticaria resistant: a prospective, randomized, non-blinded, comparative clinical study and assessment of quality of life. *J Dermatolog Treat.* 2011. [Epub ahead of print]
8. Grattan C, Powell S, Humphreys F. Management and diagnostic guidelines for urticaria and angio-oedema. *Br J Dermatol.* 2001;144:708-714.
9. Lin RY, Curry A, Pesola GR, et al. Improved outcomes in patients with acute allergic syndromes who are treated with combined H1 and H2 antagonists. *Ann Emerg Med.* 2000;36:462-468.
10. Goldsobel AB, Rohr AS, Siegel SC, et al. Efficacy of doxepin in the treatment of chronic idiopathic urticaria. *J Allergy Clin Immunol.* 1986;78:867-873.
11. Weinstein ME, Wolff AH, Bielory L. Efficacy and tolerability of second- and third-generation antihistamines in the treatment of acquired cold urticaria: a meta-analysis. *Ann Allergy Asthma Immunol.* 2010;104:518-522.
12. Pollack CV Jr, Romano TJ. Outpatient management of acute urticaria: the role of prednisone. *Ann Emerg Med.* 1995;26:547-551.
13. Vena GA, Cassano N, D'Argento V, Milani M. Clobetasol propionate 0.05% in a novel foam formulation is safe and effective in the short-term treatment of patients with delayed pressure urticaria: a randomized, double-blind, placebo-controlled trial. *Br J Dermatol.* 2006;154:353-356.
14. Sagi L, Solomon M, Baum S, et al. Evidence for methotrexate as a useful treatment for steroid-dependent chronic urticaria. *Acta Derm Venereol.* 2011;91:303-306.
15. Stolz LE, Horn PT. Ecallantide: a plasma kallikrein inhibitor for the treatment of acute attacks of hereditary angioedema. *Drugs Today (Barc).* 2010;46:547-555.

SECTION 8 PAPULOSQUAMOUS CONDITIONS

151 SEBORRHEIC DERMATITIS

Meredith M. Hancock, MD
Yoon-Soo Cindy Bae-Harboe, MD
Richard P. Usatine, MD

PATIENT STORY

A 59-year-old man presents with a 3-month history of an itchy rash on his face (**Figures 151-1** and **151-2**). He states that he has had this rash intermittently for many years, but that it had recently worsened. He denies any major risk factors for HIV and does not have Parkinson disease. He has been under more stress lately and has noticed that this rash flares when under increased stress. Note the scale visible on the forehead and under the eyebrows and beard. There is also some mild erythema on the cheeks and around the nasolabial folds. The diagnosis of seborrheic dermatitis is made and treatment is begun with appropriate topical agents to treat the inflammation and the *Malassezia*. On the following visit, the patient has complete clearance of his seborrheic dermatitis.

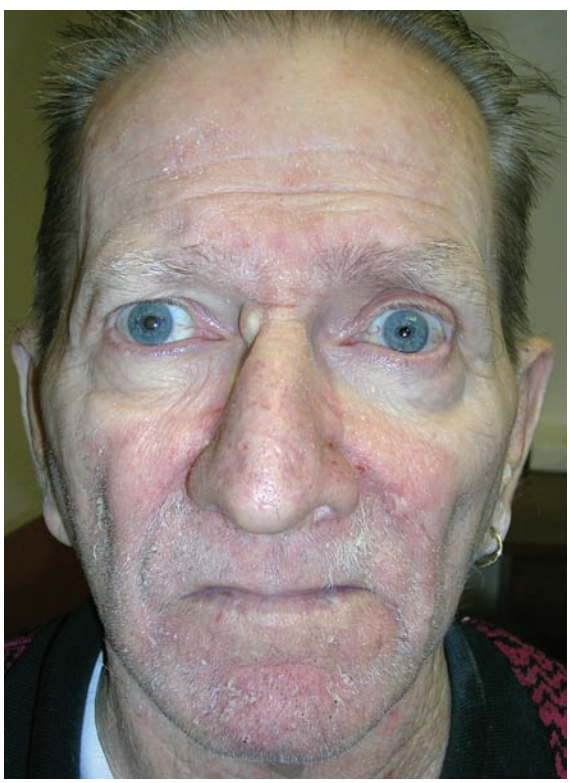

FIGURE 151-1 Seborrheic dermatitis following the typical distribution on the face of a 59-year-old man. Note the prominent scale and erythema on his forehead, glabella, and beard region. (*Courtesy of Richard P. Usatine, MD.*)

INTRODUCTION

Seborrheic dermatitis is a common, chronic, relapsing dermatitis affecting sebum-rich areas of the body. Infants and adults, men and women may be affected. Presentation may vary from mild erythema to greasy scales, and, rarely, as erythroderma. Treatment is targeted to reduce inflammation and irritation, as well as to eliminate *Malassezia* fungus, whose exact role is not completely understood.

SYNONYMS

Seborrhea, seborrheic eczema, dandruff, and cradle cap.

EPIDEMIOLOGY

- Seborrheic dermatitis is most commonly seen in male patients ages 20 to 50 years. The prevalence is approximately 3% to 5% in healthy young adults who are HIV-negative.[1] More people may be affected, but many do not seek medical attention for mild cases.
- The prevalence is higher in immunocompromised persons (e.g. HIV-positive/AIDS); however, the vast majority of affected persons have a normal immune system.
- More common in persons with Parkinson disease.
- Infants can have seborrhea of the scalp (cradle cap), face, and diaper area.

ETIOLOGY AND PATHOPHYSIOLOGY

- Seborrheic dermatitis is a chronic, superficial, localized inflammatory dermatitis that is found in sebum-producing areas of the body.
- The actual cause of seborrheic dermatitis is not well-understood. It appears to be related to the interplay between host susceptibility, environmental factors, and local immune response to antigens.[2–4]
- Patients with seborrheic dermatitis may be colonized with certain species of lipophilic yeast of the genus *Malassezia* (also called *Pityrosporum)*. However, *Malassezia* is considered normal skin flora and unaffected persons also may be colonized.
- Recent evidence suggests that *Malassezia* may produce different irritants or metabolites on affected skin.[4]

RISK FACTORS

- Male gender
- Immunocompromise (HIV/AIDS, Parkinson disease)
- Stress
- Environmental factors (cold, dry weather)
- Certain medications, including captopril, cimetidine, interleukin-2, isotretinoin, nicotine, and psoralens, may cause seborrheic dermatitis to flare.[5–9]

DIAGNOSIS

The clinical diagnosis is made by history and physical examination. **Figures 151-1** and **151-2** reveal erythema and scale across the eyebrows, cheeks, and under beard. Biopsy is not generally indicated unless ruling out other possibilities (see Differential Diagnosis below).

CLINICAL FEATURES

- Chronic skin condition characterized by remissions and exacerbations.
- Poorly demarcated, erythematous plaques of greasy, yellow scale (**Figure 151-3**), in the characteristic seborrheic distribution (see description below).
- Common precipitating factors are stress, immunosuppression, and cold weather.
- Face, scalp, and ears may be very pruritic.
- May be the presenting sign of HIV seropositivity
- In dark-skinned individuals, the involved skin and scale may become hyperpigmented (**Figure 151-4**).

TYPICAL DISTRIBUTION

Scalp (i.e., dandruff), eyebrows (**Figures 151-5** and **151-6**), nasolabial creases, forehead, cheeks, around the nose, behind the ears (**Figure 151-7**), external auditory meatus, and under facial hair (**Figure 151-8**). Seborrhea can also occur over the sternum and in the axillae, submammary folds, umbilicus, groin, and gluteal creases.

FIGURE 151-2 Close-up of seborrheic dermatitis showing the flaking scale and erythema around the beard region. (*Courtesy of Richard P. Usatine, MD.*)

FIGURE 151-3 Severe seborrheic dermatitis on the face of a hospitalized man. The stress of his illness has worsened his otherwise mild seborrhea. (*Courtesy of Richard P. Usatine, MD.*)

Infants may develop scales on the scalp, known as cradle cap (**Figure 151-9**). The eyebrows may also be affected (**Figure 151-5**). Some infants have a wider distribution involving the neck creases, armpits, or groin.

LABORATORY STUDIES

Test for HIV and/or syphilis if patient has risk factors (**Figures 151-10** and **151-11**).

Also consider testing for systemic lupus erythematosus (SLE) in setting of associated systemic symptoms or if treatment-resistant.

Consider KOH test to rule out tinea.

Consider zinc level or alkaline phosphatase to rule out nutritional/zinc deficiency.

DIFFERENTIAL DIAGNOSIS

- Psoriasis—The scale of psoriasis tends to be thicker, on well-demarcated plaques distributed over extensor surfaces along with the scalp. Look for signs of nail involvement that may support the diagnosis of psoriasis (see Chapter 152, Psoriasis).
- SLE with butterfly rash—Rash across nasal bridge in patient with associated systemic symptoms and abnormal blood tests (see Chapter 180, Lupus: Systemic and Cutaneous).
- Rosacea—The erythema on the face is often associated with papules, pustules, telangiectasia, and an absence of scales. May also present with chalazia or hordeola (see Chapter 113, Rosacea).
- Tinea capitis—Scale and erythema commonly with associated hair loss. KOH and/or culture can help make the distinction (see Chapter 137, Tinea Capitis).
- Secondary syphilis—Skin presentation may mimic seborrheic dermatitis. Examine patient for mucosal or palmar involvement. Lab testing for syphilis may be necessary.
- Perioral dermatitis—Usually restricted around the mouth with minimal scale.
- Tinea versicolor (trunk)—The scale of tinea versicolor is fine and white and scales with scraping.
- Allergic or irritant contact dermatitis- may present with a well demarcated lesion with fine white scale, secondarily impetiginized lesions may have associated yellow colored crust, not scale.
- Candidiasis—May be found in intertriginous areas, but present bright red with satellite lesions.
- Nutritional deficiency (i.e., zinc)—May present with facial lesions and acral rash.

MANAGEMENT

As seborrheic dermatitis is a recurrent, chronic condition, repeated and/or maintenance therapy is often required.

- Mainstay of treatment is topical antifungals.
- For seborrheic dermatitis of the scalp, patients should wash their hair with antifungal shampoos (containing selenium sulfide, ketoconazole, or ciclopirox) several times per week, each time leaving the lather on the affected areas for several minutes until remission

FIGURE 151-4 Seborrhea in a black woman with hyperpigmentation related to the inflammation. Note the prominent involvement in the nasolabial folds. (*Courtesy of Richard P. Usatine, MD.*)

FIGURE 151-5 Mild seborrheic dermatitis with subtle flaking around the eyebrows of a 2-month-old girl who also has cradle cap. (*Courtesy of Richard P. Usatine, MD.*)

FIGURE 151-6 Seborrheic dermatitis with erythema and scale under the eyebrows and in the glabella region on a young man. (*Courtesy of Richard P. Usatine, MD.*)

FIGURE 151-8 Seborrhea of the beard and mustache distribution with prominent erythema. (*Courtesy of Richard P. Usatine, MD.*)

FIGURE 151-7 Seborrheic dermatitis behind the ear in a young woman. This is a good place to look for evidence of seborrhea. (*Courtesy of Richard P. Usatine, MD.*)

FIGURE 151-9 Cradle cap in an infant that also has atopic dermatitis. (*Courtesy of Richard P. Usatine, MD.*)

is attained. Patients may continue to use antifungal shampoo as maintenance therapy.[3]

- Shampoos containing ketoconazole, selenium sulfide or zinc pyrithione (ZPT) are active against the *Malassezia* and are effective in the treatment of moderate to severe dandruff.[10,11] SOR A
- Ketoconazole 2% shampoo was found to be superior to ZPT 1% shampoo when used twice weekly. Ketoconazole led to a 73% improvement in the total dandruff severity score compared with 67% for ZPT 1% at 4 weeks.[11] SOR B
- Ciclopirox shampoo 1% is effective and safe in the treatment of seborrheic dermatitis of the scalp.[12,13] SOR A It is by prescription only and is very expensive.
- Ketoconazole 2% cream, gel, or emulsion is safe and effective for facial seborrheic dermatitis.[14–16] SOR B
- Ciclopirox 1% cream is also safe and effective for facial seborrheic dermatitis and is equivalent to ketoconazole 2% cream.[14,17] SOR B
- Oral terbinafine 250 mg daily for 4 weeks is effective for moderate to severe seborrhea.[18,19] SOR A However, because of the potential for harmful side effects of oral antifungals and the limited study of their efficacy, they are not first-line treatments.[3] Oral terbinafine may be considered in erythroderma caused by seborrhea.

Topical corticosteroids are useful in treating associated erythema and pruritis.[3] Long-term use may lead to skin atrophy[3] and should be used with caution.

- Lotion or solution is preferable on hair-covered area for patient comfort and usability.
- Hydrocortisone 1% cream or lotion can be used bid on the face, scalp, and other affected areas.[16,20] SOR B
- Desonide 0.05% lotion is safe and effective for short-term treatment of seborrheic dermatitis of the face.[18] SOR B It is a nonfluorinated low to midpotency steroid that is higher in potency than hydrocortisone 1%.
- For moderate to severe seborrheic dermatitis on the scalp.
  - Fluocinonide 0.05% solution once daily is affordable and beneficial. SOR C
  - Clobetasol 0.05% shampoo, solution, spray, or foam works well but is more costly. SOR C

OTHER TREATMENTS

- Pimecrolimus cream 1% is an effective and well-tolerated treatment for facial seborrheic dermatitis.[20,22,23] SOR B In one study, there was more burning noted with the pimecrolimus than with the betamethasone 17-valerate 0.1% cream.[22]
- Metronidazole gel—Two small studies have found different results in the treatment of seborrheic dermatitis on the face. One suggests it works better than the vehicle alone and the other found no statistically significant difference from placebo.[24,25] SOR B

COMPLEMENTARY AND ALTERNATIVE THERAPY

- Tea tree oil 5% shampoo showed a 41% improvement in the quadrant-area-severity score compared with 11% in the placebo.

FIGURE 151-10 Seborrheic dermatitis on the face of a man with acquired immune deficiency syndrome. Note the involvement of the forehead, cheeks, and chin causing hypopigmentation and scaling. (*Courtesy of Yoon-Soo Cindy Bae-Harboe, MD.*)

FIGURE 151-11 Seborrheic dermatitis on the face of a man with acquired immune deficiency syndrome. Note erythema and scale on the forehead, nose and cheeks. (*Courtesy of Richard P. Usatine, MD.*)

Statistically significant improvements were also observed in the total area of involvement score, the total severity score, and the itchiness and greasiness components of the patients' self-assessments.[26] SOR B

- One small randomized controlled trial using homeopathic medication consisting of potassium bromide, sodium bromide, nickel sulfate, and sodium chloride for 10 weeks showed significant improvement over placebo.[27] SOR C

FOLLOW-UP

Patients with longstanding and severe seborrhea will appreciate a follow-up visit in most cases. Milder cases can be followed as needed.

PATIENT EDUCATION

For improved treatment results, encourage patients to wash the hair and scalp daily with an antifungal shampoo. Some patients fear that washing their hair too often will cause a "dry" scalp and need to understand that the scaling and flaking will improve rather than worsen with more frequent hair washing.

PATIENT RESOURCE

- PubMed Health. *Seborrheic Dermatitis*—**http://www.ncbi.nlm.nih.gov/pubmedhealth/PMH0001959/.**

PROVIDER RESOURCE

- Medscape. *Seborrheic Dermatitis*—**http://emedicine.medscape.com/article/1108312.**

REFERENCES

1. Usatine RP. A red rash on the face. *J Fam Pract.* 2003;52:697-699.
2. Gaitanis G, Magiatis P, Hantschke M, Bassukas ID, Velegraki A. The Malassezia genus in skin and systemic diseases. *Clin Microbiol Rev.* 2012;25(1):106-141.
3. Naldi L, Alfredo Rebora A. Seborrheic dermatitis. *N Engl J Med.* 2009;360;4:387-396.
4. Hay RJ. Malassezia, dandruff and seborrheic dermatitis: an overview. *Br J Dermatol.* 2011;165 (Suppl. 2):2-8.
5. Yamamoto T, Tsuboi R. Interleukin-2-induced seborrheic dermatitis-like eruption. *J Eur Acad Dermatol Venereol.* 2008;22(2):244-245.
6. Sudan BJ, Brouillard C, Sterboul J, Sainte-Laudy J. Nicotine as a hapten in seborrheic dermatitis. *Contact Dermatitis.* 1984;11(3):196-197.
7. Kitamura K, Aihara M, Osawa J, Naito S, Ikezawa Z. Sulfhydryl drug-induced eruption: a clinical and histological study. *J Dermatol.* 1990;17(1):44-51.
8. Tegner E. Seborrheic dermatitis of the face induced by PUVA treatment. *Acta Derm Venereol.* 1983;63(4):335-339.
9. Barzilai A, David M, Trau H, Hodak E. Seborrheic dermatitis-like eruption in patients taking isotretinoin therapy for acne: retrospective study of five patients. *Am J Clin Dermatol.* 2008;9(4):255-261.
10. Danby FW, Maddin WS, Margesson LJ, Rosenthal D. A randomized, double-blind, placebo-controlled trial of ketoconazole 2% shampoo versus selenium sulfide 2.5% shampoo in the treatment of moderate to severe dandruff. *J Am Acad Dermatol.* 1993;29:1008-1012.
11. Pierard-Franchimont C. A multicenter randomized trial of ketoconazole 2% and zinc pyrithione 1% shampoos in severe dandruff and seborrheic dermatitis. *Skin Pharmacol Appl Skin Physiol.* 2002;15(6):434-441.
12. Aly R. Ciclopirox gel for seborrheic dermatitis of the scalp. *Int J Dermatol.* 2003;42(Suppl 1):19-22.
13. Lebwohl M, Plott T. Safety and efficacy of ciclopirox 1% shampoo for the treatment of seborrheic dermatitis of the scalp in the US population: results of a double-blind, vehicle-controlled trial. *Int J Dermatol.* 2004;43(Suppl 1):17-20.
14. Chosidow O, Maurette C, Dupuy P. Randomized, open-labeled, non-inferiority study between ciclopiroxolamine 1% cream and ketoconazole 2% foaming gel in mild to moderate facial seborrheic dermatitis. *Dermatology.* 2003;206:233-240.
15. Pierard GE, Pierard-Franchimont C, Van CJ, Rurangirwa A, Hoppenbrouwers ML, Schrooten P. Ketoconazole 2% emulsion in the treatment of seborrheic dermatitis. *Int J Dermatol.* 1991;30:806-809.
16. Katsambas A, Antoniou C, Frangouli E, Avgerinou G, Michailidis D, Stratigos J. A double-blind trial of treatment of seborrheic dermatitis with 2% ketoconazole cream compared with 1% hydrocortisone cream. *Br J Dermatol.* 1989;121:353-357.
17. Dupuy P, Maurette C, Amoric JC, Chosidow O. Randomized, placebo-controlled, double-blind study on clinical efficacy of ciclopiroxolamine 1% cream in facial seborrheic dermatitis. *Br J Dermatol.* 2001;151:1033-1037.
18. Vena GA, Micali G, Santoianni P, Cassano N, Peruzzi E. Oral terbinafine in the treatment of multi-site seborrheic dermatitis: a multicenter, double-blind placebo-controlled study. *Int J Immunopathol Pharmacol.* 2005;18:745-753.
19. Scaparro E, Quadri G, Virno G, Orifici C, Milani M. Evaluation of the efficacy and tolerability of oral terbinafine (Daskil) in patients with seborrheic dermatitis. A multicentre, randomized, investigator-blinded, placebo-controlled trial. *Br J Dermatol.* 2001;151(4):854-857.
20. Firooz A, Solhpour A, Gorouhi F, et al. Pimecrolimus cream, 1%, vs hydrocortisone acetate cream, 1%, in the treatment of facial seborrheic dermatitis: a randomized, investigator-blind, clinical trial. *Arch Dermatol.* 2006;142:1066-1067.
21. Freeman SH. Efficacy, cutaneous tolerance and cosmetic acceptability of desonide 0.05% lotion (Desowen) versus vehicle in the short-term treatment of facial atopic or seborrheic dermatitis. *Australas J Dermatol.* 2002;43(3):186-189.
22. Rigopoulos D, Ioannides D, Kalogeromitros D, Gregoriou S, Katsambas A. Pimecrolimus cream 1% vs. betamethasone

17-valerate 0.1% cream in the treatment of seborrheic dermatitis. A randomized open-label clinical trial. *Br J Dermatol.* 2004;151:1071-1075.

23. Warshaw EM, Wohlhuter RJ, Liu A, et al. Results of a randomized, double-blind, vehicle-controlled efficacy trial of pimecrolimus cream 1% for the treatment of moderate to severe facial seborrheic dermatitis. *J Am Acad Dermatol.* 2007;57(2):257-264.
24. Parsad D, Pandhi R, Negi KS, Kumar B. Topical metronidazole in seborrheic dermatitis—a double-blind study. *Dermatology*. 2001;202:35-37.
25. Koca R. Is topical metronidazole effective in seborrheic dermatitis? A double-blind study. *Int J Dermatol.* 2003;42(8):632-635.
26. Satchell AC, Saurajen A, Bell C, Barnetson RS. Treatment of dandruff with 5% tea tree oil shampoo. *J Am Acad Dermatol.* 2002;47(6):852-855.
27. Smith SA, Baker AE, Williams JH. Effective treatment of seborrheic dermatitis using a low dose, oral homeopathic medication consisting of potassium bromide, sodium bromide, nickel sulfate, and sodium chloride in a double-blind, placebo-controlled study. *Altern Med Rev.* 2002;7(1):59-67.

152 PSORIASIS

Richard P. Usatine, MD

PATIENT STORY

A 33-year-old woman presents with uncontrolled psoriasis for 20 years. In addition to the plaque psoriasis (**Figure 152-1**), she has inverse psoriasis (**Figure 152-2**). Topical ultrahigh-potency steroids and topical calcipotriol have not controlled her psoriasis. The options for phototherapy and systemic therapy were discussed. The patient chose to try narrowband UVB treatment in addition to her topical therapy.

FIGURE 152-1 Typical plaque psoriasis on the elbow and arm. (*Courtesy of Richard P. Usatine, MD.*)

INTRODUCTION

Psoriasis is a chronic inflammatory papulosquamous and immune-mediated skin disorder. It is also associated with joint and cardiovascular comorbidities. Psoriasis can present in many different patterns from the scalp to the feet and cause psychiatric distress and physical disabilities. It is crucial to be able to identify psoriasis in all its myriad presentations so that patients receive the best possible treatments to improve their quality of life and avoid comorbidities.

EPIDEMIOLOGY

Psoriasis affects approximately 2% of the world population.[1] The prevalence of psoriasis was 2.5% in white patients and was 1.3% in African American patients in one population study in the United States.[2]

- Sex—No gender preference.
- Age—Psoriasis can begin at any age. In one population study of the age of onset of psoriasis two peaks were revealed, one occurring at the age of 16 years (female) or 22 years (males) and a second peak at the age of 60 years (female) or 57 years (males).[3]

FIGURE 152-2 Inverse psoriasis in the inframammary folds of the patient in **Figure 152-1**. This is not a *Candida* infection. (*Courtesy of Richard P. Usatine, MD.*)

ETIOLOGY AND PATHOPHYSIOLOGY

- Immune-mediated skin disease, where the T cell plays a pivotal role in the pathogenesis of the disease.
- Langerhans cell (antigen-presenting cells in the skin) migrate from the skin to regional lymph nodes, where they activate T cells that migrate to the skin and release cytokines.
- Cytokines are responsible for epidermal and vascular hyperproliferation and proinflammatory effects.

TABLE 152-1 Factors that Trigger or Exacerbate Psoriasis

- Stress
- Physical trauma to the skin (Koebner phenomenon)
- Cold dry weather
- Sun exposure and hot weather
- Infections (e.g. strep throat, HIV)
- Medications (e.g. ACE-inhibitors, antimalarials, Beta-blockers, lithium, NSAIDs)

RISK FACTORS

- Family history.
- Obesity.
- Smoking and environmental smoke.
- Heavy alcohol use.

Table 152-1 lists the factors that trigger or exacerbate psoriasis.[4]

The risk of psoriasis is higher in:[5]

- Family history of psoriasis (odds ratio [OR] = 33.96; 95% confidence interval [CI] 14.14 to 81.57)
- Change in work conditions (OR = 8.34; 95% CI = 1.86 to 37.43)
- Divorce (OR = 5.69; 95% CI = 2.26 to 14.34)
- Urban dwellers (OR = 3.61; 95% CI = 0.99 to 13.18)
- Alcohol consumption (OR = 2.55; 95% CI = 1.26 to 5.17)
- Environmental tobacco smoke at home (OR = 2.29; 95% CI = 1.12 to 4.67)

DIAGNOSIS

Psoriasis has many forms and locations. These nine categories were used to describe psoriasis in a consensus statement of the American Academy of Dermatology (AAD):[6]

1. Plaque (80% to 90% of patients with psoriasis) (**Figures 152-1** and **152-3**).
2. Scalp psoriasis (**Figure 152-4**).
3. Guttate psoriasis (**Figure 152-5**).
4. Inverse psoriasis (**Figures 152-2** and **152-6**).
5. Palmar-plantar psoriasis (**Figure 152-7**). Also known as palmoplantar psoriasis.
6. Erythrodermic psoriasis (**Figure 152-8**).
7. Pustular psoriasis—localized and generalized (**Figure 152-9**).
8. Nail psoriasis (**Figure 152-10**) (see Chapter 195, Psoriatic Nails).
9. Psoriatic arthritis (**Figure 152-11**).

Typical distribution in general: elbows, knees, extremities, trunk, scalp, face, ears, hands, feet, genitalia and intertriginous areas, and

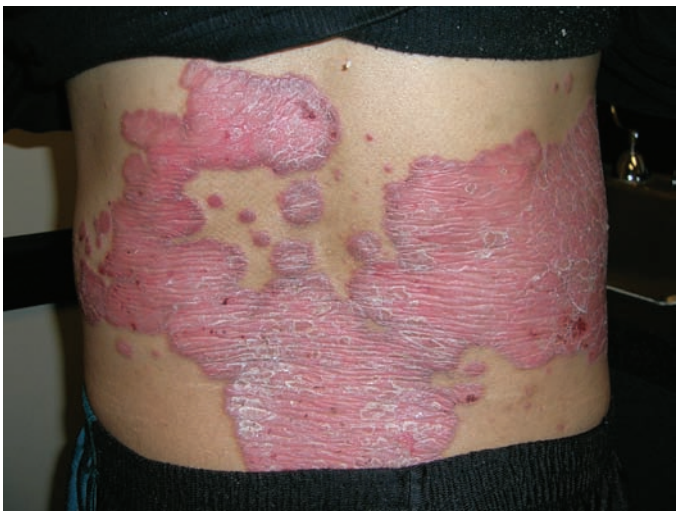

FIGURE 152-3 Well-demarcated plaques of plaque psoriasis in a 44-year-old man with severe psoriasis and psoriatic arthritis. (*Courtesy of Richard P. Usatine, MD.*)

FIGURE 152-4 Scalp psoriasis visible at the hairline. (*Courtesy of Richard P. Usatine, MD.*)

FIGURE 152-5 Two cases of guttate psoriasis that started 2 weeks after strep pharyngitis. **A.** Note the typical drop-like (guttate) lesions on the arm of this 11-year-old girl. **B.** The salmon patches of guttate psoriasis in a 7-year-old boy with prominent neck, ear, and scalp involvement. (*Courtesy of Richard P. Usatine, MD.*)

FIGURE 152-6 Inverse psoriasis in the axilla of this middle-aged woman. There is considerable erythema and very little scale. Prior to this visit her condition was misdiagnosed as fungal in origin. (*Courtesy of Richard P. Usatine, MD.*)

FIGURE 152-7 **A.** Palmoplantar psoriasis with pustulosis that started 3 months ago on the hands of a 62-year-old woman. **B.** Note the erythema, scale, brown macules (mahogany spots), and pustules that are typical of this condition. This is considered to be a localized form of pustular psoriasis. (*Courtesy of Richard P. Usatine, MD.*)

FIGURE 152-8 Erythrodermic psoriasis covering most of the body surface. (*Courtesy of Richard P. Usatine, MD.*)

FIGURE 152-10 Nail pitting from psoriasis. (*Courtesy of Richard P. Usatine, MD.*)

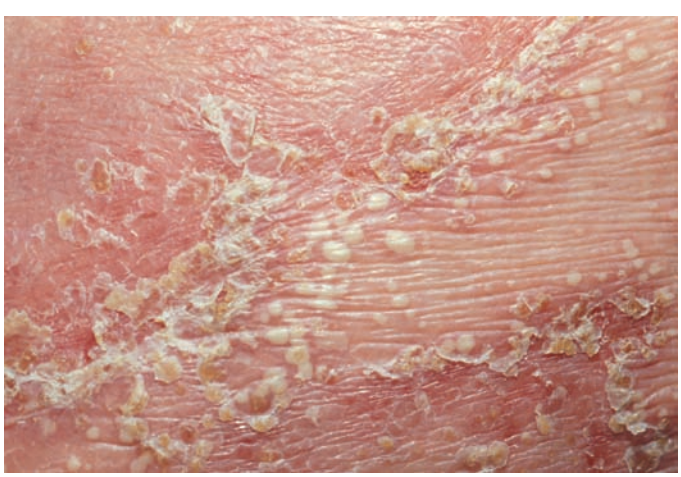

FIGURE 152-9 Pustular psoriasis on the back that occurred when oral prednisone was stopped. (*Courtesy of Jack Resneck, Sr., MD.*)

FIGURE 152-11 Psoriatic arthritis that has become crippling to this 44-year-old man. The shortening of the fingers fits the psoriatic arthritis mutilans subtype. (*Courtesy of Richard P. Usatine, MD.*)

TABLE 152-2 The Most Common Locations of Lesions in Patients With Psoriasis

Location	% of Psoriasis Patients
Scalp	80
Elbows	78
Legs	74
Knees	57
Arms	54
Trunk	53
Lower part of the body	47
Base of the back	38
Palms and soles	12

nails. **Table 152-2** provides percentages for the most common locations of lesions in patients with psoriasis.

Plaque psoriasis:

- White scale on an erythematous raised base with well-demarcated borders **(Figures 152-1** and **152-3)**.
- Silvery scale with hyperpigmentation may be seen in patients with darker skin **(Figures 152-12** and **152-13)**.
- Plaques can be appear in different colors including hypopigmented (**Figure 152-14**) and silvery gray (**Figure 152-15**). A tricolored presentation occurs when the inflammation leads to leukoderma (**Figure 152-16**).
- The thickness and extent of the scale is variable **(Figure 152-15)**.
- Positive Auspitz sign in which the peeling of the scale produces pinpoint bleeding on the plaque below.
- Typical distribution includes the elbows and knees and other extensor surfaces. The plaques can be found from head to toe including the penis (**Figure 15-17**).
- Plaques tend to be symmetrically distributed.
- Plaques can be annular with central clearing **(Figure 152-18)**.
- When plaques occur at a site of injury, it is known as the Koebner phenomenon (**Figure 152-19**).

Scalp psoriasis:

- Plaque on the scalp that may be seen at the hairline and around the ears (**Figure 152-4**).
- The thickness and extent of the plaques are variable as seen in plaque psoriasis.

Guttate psoriasis:

- Small round plaques that resemble water drops (guttate means like a water drop) (**Figure 152-20**).
- Classically described as occurring after strep pharyngitis or another bacterial infection. This is one type of psoriasis that occurs in childhood.

FIGURE 152-12 Plaque psoriasis with silvery scale on a black man. (*Courtesy of Richard P. Usatine, MD.*)

FIGURE 152-13 Psoriasis on the knee of a Hispanic man showing postinflammatory hyperpigmentation. (*Courtesy of Richard P. Usatine, MD.*)

FIGURE 152-14 Plaque psoriasis with hypopigmentation in this 12-year-old obese boy. (*Courtesy of Richard P. Usatine, MD.*)

FIGURE 152-16 Plaque psoriasis that has caused hypopigmentation in a band across the back. His original skin color is brown so that the brown, white, and pink colors produce the appearance of Neapolitan ice cream. (*Courtesy of Richard P. Usatine, MD.*)

FIGURE 152-17 Plaque psoriasis on the penis, covering the glans and part of the shaft. (*Courtesy of Richard P. Usatine, MD.*)

FIGURE 152-15 Thick plaque psoriasis covering the lower legs of this obese man. Note the silver gray color to his plaques. (*Courtesy of Richard P. Usatine, MD.*)

FIGURE 152-18 Plaque psoriasis with an annular configuration. (*Courtesy of Richard P. Usatine, MD.*)

- Typical distribution: the trunk and extremities but may include the face and neck (**Figure 152-21**).

Inverse psoriasis:

- Found in the intertriginous areas of the axilla, groin, inframammary folds, and intergluteal fold (**Figures 152-2, 152-6,** and **152-22**). It can also be seen below the pannus or within adipose folds in obese individuals.
- The term *inverse* refers to the fact that the distribution is not on extensor surfaces but in areas of body folds.
- Morphologically the lesions have little to no visible scale.
- Color is generally pink to red but can be hyperpigmented in dark-skinned individuals.

Palmar-plantar (palmoplantar) psoriasis:

- Psoriasis that occurs on the plantar aspects of the hands and feet (palms and soles) (**Figure 152-23**). The psoriasis can also be seen on other parts of the hands and feet.
- Patients with this type of psoriasis often experience severe foot and hand pain that can impair walking and other daily activities of living. Hand involvement can result in pain with many types of work.
- Morphologically this can be plaque-like, vesicular, or pustular (**Figure 152-24**). Brown spots may be present as macules or flat papules. These are called mahogany spots and although they are not always present, they are characteristic of palmar-plantar psoriasis. Exfoliation of the skin can occur on the palms and soles.

Erythrodermic psoriasis:

- Erythrodermic psoriasis is widespread and erythematosus covering most of the skin (**Figure 152-25**).
- Morphologically, it can have plaques and erythema or the erythroderma can appear with the desquamation of pustular psoriasis.
- Widespread distribution can impair the important functions of the skin and this can be a dermatologic urgency requiring hospitalization and IV fluids. Chills, fever, tachycardia, and orthostatic hypotension are all signs that the patient may need hospitalization.

Pustular psoriasis:

- Pustular psoriasis comes in localized and generalized types. One example of the local type is pustular psoriasis on the feet (**Figure 152-24**).
- In the generalized type, the skin initially becomes fiery red and tender and the patient experiences constitutional signs and symptoms such as headache, fever, chills, arthralgia, malaise, anorexia, and nausea (**Figure 152-26**). The desquamation that occurs in the generalized form can impair the important functions of the skin predisposing to dehydration and sepsis. This is a dermatologic emergency requiring hospitalization and IV fluids, preferably in a monitored bed with good nursing care.
- Typical distribution: Flexural and anogenital (**Figure 152-27**). Less often, facial lesions occur. Pustules may occur on the tongue and subungually, resulting in dysphagia and nail shedding, respectively.
- Time course: Within hours, clusters of nonfollicular, superficial 2- to 3-mm pustules may appear in a generalized pattern. These pustules coalesce within 1 day to form lakes of pus that dry and desquamate in sheets, leaving behind a smooth erythematous

FIGURE 152-19 Linear distribution of psoriasis on the arm secondary to the Koebner phenomenon. (*Courtesy of Richard P. Usatine, MD.*)

FIGURE 152-20 Guttate psoriasis in a 17-year-old young man following an episode of strep pharyngitis. (*Courtesy of Richard P. Usatine, MD.*)

FIGURE 152-21 This young boy developed guttate psoriasis after an upper respiratory infection. **A.** Note the drop-like pink plaques on the face and neck. **B.** Drop-like plaques on the arms and trunk. (*Courtesy of Richard P. Usatine, MD.*)

FIGURE 152-22 Inverse psoriasis in the inguinal area. This was mistaken for tinea cruris for a long time. (*Courtesy of Richard P. Usatine, MD.*)

FIGURE 152-23 Palmar-plantar psoriasis that was biopsy proven. Note the widespread erythema and scale that could be mistaken for tinea pedis and tinea manus. The patient does not have pustules or mahogany spots but those lesions are often not present in palmar-plantar psoriasis. (*Courtesy of Richard P. Usatine, MD.*)

FIGURE 152-24 Palmar-plantar psoriasis with extensive pustules and mahogany spots. (*Courtesy of UTHSCSA dermatology.*)

FIGURE 152-26 Generalized pustular psoriasis in a 47-year-old man with fever, exfoliation, and dehydration. This is the twentieth time for this patient in his life. His siblings also get severe generalized pustular psoriasis. (*Courtesy of Meng Lu, MD.*)

FIGURE 152-25 Erythrodermic psoriasis in a 45-year-old man. Note the extensive exfoliation of the skin along with the deep erythema. (*Courtesy of Richard P. Usatine, MD.*)

FIGURE 152-27 Localized pustular psoriasis in the groin. (*Courtesy of Jeffrey Meffert, MD.*)

surface on which new crops of pustules may appear. These episodes of pustulation may occur for days to weeks causing the patient severe discomfort and exhaustion. Upon remission of the pustular component, most systemic symptoms disappear; however, the patient may be in an erythrodermic state or may have residual lesions.[1]

Nail psoriasis:

- Nail involvement in psoriasis can lead to pitting, onycholysis, subungual keratosis, splinter hemorrhages, oil spots, and nail loss (**Figure 152-10** and Chapter 195, Psoriatic Nails).

Psoriatic arthritis:

- Asymmetric oligoarthritis typically involving the hands, feet, and knees. The arthritis can also be symmetric resembling rheumatoid arthritis. Distal interphalangeal joint (DIP) involvement is a classic finding, but DIP predominance is present in the minority of cases. The fingers may be swollen like sausages which is called dactylitis (**Figure 152-28**). See Table 95-1 in Chapter 95, Overview of Arthritis for a description of the five types of psoriatic arthritis.
- Hand involvement can be disabling (**Figure 152-11**). X-rays should be ordered when a person with psoriasis has joint pains suggesting psoriatic arthritis. Typical findings are juxtaarticular erosions and the pencil-cup deformity (**Figure 152-29**).
- There may be inflammation at the insertion of tendons onto bone (enthesopathy). This may occur at the Achilles tendon.
- Patients with psoriatic arthritis need to be treated with systemic agents (methotrexate or biologics) to prevent advancement of the disease.

FIGURE 152-28 Dactylitis with sausage-shaped fingers in this middle-aged woman with plaque psoriasis and psoriatic arthritis. Note the nail involvement along with distal interphalangeal joint involvement. (*Courtesy of Richard P. Usatine, MD.*)

DISEASE SEVERITY

- Moderate-to-severe disease is defined by psoriasis of the palms, soles, head and neck, or genitalia, and in patients with more than 5% body surface area (BSA) involvement. A person's palm is approximately 1% BSA and can be used to estimate BSA.
- Another grading system for severity uses the following numbers:
  - Mild: Up to 3% BSA
  - Moderate: 3% to 10% BSA
  - Severe: >10% BSA
- Patients with psoriatic arthritis may have limited skin disease but require more aggressive systemic therapies.
- Note that palmoplantar psoriasis is considered moderate-to-severe even if the BSA involved is not above 3% or 5% (**Figure 152-30**).

LABORATORY STUDIES

Laboratory studies are rarely needed. A punch biopsy or scoop shave is used for evaluating atypical cases. For pustular psoriasis, a 4-mm punch around an intact pustule is preferred (**Figure 132-31**).

IMAGING

Plain films should be ordered when a person with psoriasis has joint pains suggesting psoriatic arthritis (**Figure 152-29**). Early psoriatic arthritis often has no findings on plain films, but if history and physical exam suggest the diagnosis, one should not wait for irreversible visible joint damage to initiate therapy.

FIGURE 152-29 Radiograph showing the pencil-in-cup deformity at the distal interphalangeal joint of the second and third digits. (*Courtesy of Richard P. Usatine, MD.*)

DIFFERENTIAL DIAGNOSIS

- Cutaneous T-cell lymphoma (CTCL) can have plaques that resemble psoriasis. In most cases of psoriasis, the distribution and nail changes will help to differentiate between these diseases. Plaque-type CTCL tends to be more central and truncal, whereas psoriasis often involves the extremities along with the trunk. If needed, a punch biopsy can help to differentiate between these two conditions (see Chapter 176, Cutaneous T- cell Lymphoma).
- Lichen planus is another papulosquamous disease. Its distribution is more on flexor surfaces and around the wrists and ankles than the elbows and knees (see Chapter 154, Lichen Planus).
- Lichen simplex chronicus is a hyperkeratotic plaque with lichenification. It usually presents with fewer plaques than psoriasis and is typically found on the posterior neck, ankle, wrist, or lower leg. There is usually more lichenification than thick scale and it is always pruritic (see Chapter 149, Self-Inflicted Dermatoses).
- Nummular eczema presents with coin-like plaques. These are most commonly found on the legs and are usually not as thick as the plaques of psoriasis. Nummular eczema may also have vesicles and bullae. Psoriasis has a different distribution and often includes nail changes (see Chapter 145, Atopic Dermatitis).
- Pityriasis rosea is a self-limited process that has papulosquamous plaques. These plaques are less keratotic and have a collarette scale. Pityriasis rosea frequently has a herald patch (see Chapter 153, Pityriasis Rosea).
- Seborrheic dermatitis of the scalp can closely resemble psoriasis of the scalp, especially when it is severe. Psoriasis generally has thicker plaques on the scalp and the plaques often cross the hairline. Seborrhea and psoriasis can both involve the ear. Both conditions respond to topical steroids (see Chapter 151, Seborrheic Dermatitis).
- Syphilis is the great imitator and secondary syphilis can have a papulosquamous eruption similar to psoriasis. Secondary syphilis often involves the palms and soles and the rapid plasma reagin (RPR) will be positive (see Chapter 216, Syphilis).
- Tinea corporis or cruris can resemble inverse psoriasis in the intertriginous areas as both conditions tend to have erythema and thinner plaques without central clearing in these regions. Tinea corporis in non-intertriginous areas typically presents with annular plaques with central clearing. Psoriasis can do this as seen in **Figure 152-18**. Tinea corporis usually does not have as many plaques as psoriasis but a KOH preparation can be used to look for fungal elements to distinguish between these two conditions (see Chapter 138, Tinea Corporis).
- Cutaneous candidiasis appears similar to inverse psoriasis when found in intertriginous areas (see Chapter 136, Candidiasis).
- Reactive arthritis (see Chapter 155, Reactive Arthritis) is a noninfectious acute oligoarthritis that occurs in response to an infection, most commonly in the GI or urogenital tract. Patients present 1 to 4 weeks after the triggering infection, with joint pain in asymmetric large joints, eye disease such as conjunctivitis, and skin changes including erythema nodosum, keratoderma blennorrhagicum, and circinate balanitis. Diagnosis is based on the clinical presentation

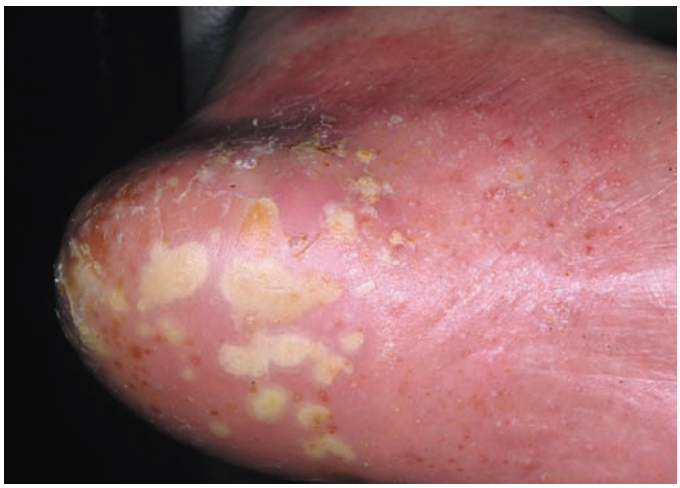

FIGURE 152-30 Palmoplantar psoriasis in a 31-year-old man with erythema, pustules, and lakes of pus. Note the typical brown macules that are called mahogany spots. High-potency topical steroids did not help at all. It is painful for him to walk and systemic therapy has just been started. This is a localized form of pustular psoriasis. (*Courtesy of Jeff Meffert, MD.*)

plus evidence of associated infection. The skin lesions closely resemble psoriasis so the diagnosis depends upon the constellation of the clinical involvement and the history.

MANAGEMENT

Treat precipitating and underlying factors when these are known. Encourage smoking cessation to all who smoke (Chapter 236, Tobacco Addiction). Avoid or minimize alcohol use (Chapter 237, Alcoholism). Stress management techniques can be suggested in patients whom admit that stress is an important factor in worsening their condition. Use preventive techniques as much as possible by avoiding known precipitants.

Patient perception of their disease and expectations for therapy are as important as the evidence and recommendations that follow. Some patients are willing to live with some skin changes rather than go on systemic treatment, whereas others want everything done with a goal of 100% clearance. Consequently, therapeutic choices are made in conjunction with patient's values and their life situation (economics and time issues surrounding treatment options).

Choice of topical vehicles:

- An ointment has a petrolatum base and will penetrate thick scale best.
- An emollient cream has some of the advantages of an ointment but is cosmetically more appealing to patients who find a basic ointment to be too greasy.
- Some patients prefer cream to avoid the oily feel of ointment even though it is less effective in general than an ointment. However, in many cases the most effective vehicle is the one the patient will use.
- Lotions and foams are good for hair-bearing areas when some moisturizing is desired.
- Steroid solutions work well for psoriasis of the scalp.
- New foam preparations have rapid absorption and are cosmetically appealing. These tend to be more expensive at this time.

Topical treatments:

- **Table 152-3** summarizes the strength of recommendations for the treatment of psoriasis using topical therapies.
- Research supports potent topical steroids as first-line therapy.[8] SOR A Clobetasol is an ultrahigh-potency steroid that is generic and comes in many vehicles for use on the body and scalp. A metaanalysis of the studies with clobetasol demonstrated 68% to 89% of patients had clear improvement or complete healing.[9] SOR A
- There are two vitamin D analogs available for topical use: calcipotriene (Dovonex and generic) and calcitriol (Vectical). These vitamin D preparations are recommended as first-line therapy with or without topical corticosteroids for the treatment of childhood psoriasis.[10] SOR A They are also useful for adults but most patients report that clobetasol is more effective.
- Comparable efficacy has been shown for topical calcipotriene (vitamin D analog) and tazarotene (retinoid) with a slight increase in adverse effects for tazarotene.[8] SOR A
- Using topical steroids and calcipotriene or tazarotene is an effective regimen. It has increased efficacy and fewer side effects.[8,9] SOR A However, in monotherapy studies of topical agents in psoriasis,

FIGURE 152-31 Pustular psoriasis in a 41-year-old woman. A 4-mm punch biopsy including at least one pustule helped to confirm the clinical diagnosis. The patient was stable for outpatient treatment and was started on cyclosporine and acitretin together with the plan to stop the cyclosporine once the pustules have cleared. **A.** Arm involvement. **B.** Close-up of pustules on the leg. (*Courtesy of Robert T. Gilson, MD.*)

TABLE 152-3 Strength of Recommendations for the Treatment of Psoriasis Using Topical Therapies[1]

Agent	Strength of Recommendation	Level of Evidence
Class I corticosteroids (highest potency)	A	I
Class II corticosteroids	B	II
Classes III/IV corticosteroids (medium potency)	A	I
Classes V/VI/VII corticosteroids (lowest potency)	A	I
Vitamin D analogs	A	I
Tazarotene	A	I
Tacrolimus and pimecrolimus	B	II
Anthralin	C	III
Coal tar	B	II
Combination corticosteroid and salicylic acid	B	II
Combination corticosteroid and vitamin D analog	A	I
Combination corticosteroid and tazarotene	A	I
Combination tacrolimus and salicylic acid	B	II

Adapted from Menter A, Korman NJ, Elmets CA, et al; American Academy of Dermatology. Guidelines of care for the management of psoriasis and psoriatic arthritis. Section 3. Guidelines of care for the management and treatment of psoriasis with topical therapies. *J Am Acad Dermatol*. 2009;60(4):643-659.

steroids caused fewer adverse reactions compared to vitamin D analogs and tazarotene.[11] SOR A

- One expensive topical preparation combines betamethasone and calcipotriene (Taclonex ointment) to be applied once daily. Another option is to prescribe generic clobetasol ointment and generic calcipotriene cream to be used simultaneously or in an alternating fashion.
- Clobetasol in the morning and tazarotene in the evening is a good combination to reduce irritation and increase efficacy.[9] SOR A
- Two trials randomized potent steroid treatment responders to either an intermittent maintenance regime (three applications each weekend) or to no maintenance. The results of more than 6 months indicate that patients receiving maintenance therapy were more than three times as likely to stay in remission.[12] SOR B
- Older treatments still in use include topical coal tar and topical anthralin.[9] Evidence does not support the use of coal tar alone or in combination at this time.[9] SOR A Topical anthralin is messy, not practical for long-term use and not supported by evidence.[1,5] SOR A
- Topical calcineurin inhibitors previously approved for eczema are being studied for use in psoriasis. Tacrolimus ointment seems most effective in treating psoriasis of the face and intertriginous areas where the skin is thin. Clinical trials suggest that tacrolimus (0.1%) ointment twice a day produces a good response in a majority of patients with facial and intertriginous (inverse) psoriasis (**Figure 152- 6**).[13–15] SOR B
- Emollients and keratolytics are safe and probably beneficial as adjunctive treatment. SOR C
- Intralesional steroids may help small plaques resolve (**Figure 152-32**). Use triamcinolone acetonide 5 to 10 mg/mL injected with a 27-gauge needle into the plaque. SOR C

FIGURE 152-32 Intralesional injection of small plaques over the knee that were resistant to treatment with high potency topical steroids. A 27-gauge needle was employed with 5 mg/mL triamcinolone. (*Courtesy of Richard P. Usatine, MD.*)

TABLE 152-4 Systemic Drugs Used in Treatment of Psoriasis[31]

Drug Name	Classification/ Mechanism of Action	Comments
Acitretin	Oral retinoid	First-line systemic drug for chronic palmoplantar or pustular psoriasis in patients of nonchildbearing potential. Limited benefit for plaque psoriasis.
Cyclosporine	Oral calcineurin inhibitor	Fast-acting systemic drug that is often used first-line for pustular psoriasis or erythrodermic psoriasis. For intermittent use in periods up to 12 wk as a short-term agent to control a flare of psoriasis.
Methotrexate sodium	Inhibitor of folate biosynthesis	May be used as a first-line systemic drug for plaque psoriasis and psoriatic arthritis. Compared with cyclosporine, has a more modest effect, but can be used continuously for years or decades.
Adalimumab	TNF inhibitor	May be used as first-line systemic treatment of plaque psoriasis and psoriatic arthritis. Has higher efficacy and lower rate of adverse effects compared with methotrexate.
Etanercept	TNF inhibitor	Commonly used as a first-line systemic drug for chronic plaque psoriasis and psoriatic arthritis.
Infliximab	TNF inhibitor	Intravenous infusion with high rates of effectiveness. Fast-acting drug that is often used as a second- or third-line biological for chronic plaque psoriasis.
Ustekinumab	Monoclonal antibody that binds the shared p40 protein subunit of IL-12 and IL-23	Favorable results when compared with etanercept in terms of efficacy and safety. May be used as first-line systemic treatment for chronic plaque psoriasis.

IL, interleukin; *TNF*, tumor necrosis factor.

Phototherapy:

- Is indicated in the presence of extensive and widespread disease (practically defined as more lesions than can be easily counted) and psoriasis not responding to topical therapy.
- Narrowband UVB is more effective than broadband UVB and approaches psoralen and UVA (PUVA) in efficacy for the treatment of psoriasis in patients with skin types I to III (lighter skin).[16] SOR A
- At present, there are no predictors of the type(s) of psoriasis most responsive to narrowband UVB.[16]
- Of patients with psoriasis, 63% to 80% will clear with a course of narrowband UVB with equivalent relapse rates compared with PUVA.[16]
- Lack of requirement for psoralen and convenience suggests that narrowband UVB could be considered as the first-line phototherapy option with PUVA reserved for treatment failures.[16]
- Methotrexate pretreatment (15 mg per week × 3) allowed physicians to clear psoriasis in fewer phototherapy sessions than when phototherapy was administered alone in one study.[17] SOR B
- According to one consensus conference, acitretin combined with UV therapy is safe and effective and limits treatment frequency, duration, and cumulative doses of both agents. They state this

combination is better tolerated, more convenient, less costly, and, perhaps, safer during long-term treatment than phototherapy alone.[18] SOR C

- Avoid use of cyclosporine with UV therapy because of an increased risk of skin cancer.[19]

Systemic:

- When topical agents (and/or phototherapy fail), systemic agents (including biologic agents) are the next step. **Table 152-4** summarizes the systemic drugs used in treatment of psoriasis.
- Methotrexate and biologic agents are especially valuable in patients with psoriatic arthritis and may be started early in the course of treatment to prevent permanent joint damage.
- Do not use systemic corticosteroid therapy for psoriasis. Pustular flares of disease may be provoked and these flares can be fatal (**Figure 152-18**).
- Methotrexate and oral retinoids can cause birth defects so appropriate counseling, contraception, and testing should accompany therapy with these agents.
- Methotrexate (MTX) is given as a weekly dose of 7.5 to 25 mg/week depending upon response and side effects.[20] SOR A Tuberculosis screening with purified protein derivative (PPD) or QuantiFERON-TB Gold blood test should precede treatment (if positive results, then the tuberculosis [TB] needs treatment before starting this therapy). Pretreatment laboratories should include a complete blood count (CBC), differential, liver function tests (LFTs), a chemistry profile, and hepatitides B and C serologies. A CBC and LFTs should be followed regularly. Patients should take folic acid 1 mg/day to prevent some of the possible adverse effects of MTX. For MTX, reliable contraceptive methods should be used during and for at least 3 months after therapy in both men and women.[5]
- The starting dose of MTX is between 5 and 10 mg/week for the first week based on expert experience.[21] The dose is escalated with monitoring to obtain a therapeutic target dose of 15 to 25 mg/week. Oral dosing is preferred but SQ dosing is an option in the event of poor GI tolerance (same dosing as oral). Type 2 diabetes and obesity appear to be significant risk factors in fibrosis.[21] A combination of fibrotests and fibroscans together with measurement of the type III serum procollagen aminopeptide are noninvasive methods to monitor for liver toxicity.[21] SOR C The question of whether or when to do a liver biopsy and/or stop MTX is controversial. The National Psoriasis Foundation has published that liver "biopsies are now advocated after a cumulative dose of 3.5 g in low-risk patients and 1.5 g in high-risk patients." The same recommendations are cited in the 2009 National Psoriasis Foundation Consensus Conference on MTX and psoriasis.[22] SOR C
- Cyclosporine (oral) is a T-cell inhibitor and is very effective in rapidly treating psoriasis. The recommended starting dose is 2.5 to 6 mg/kg per day (actual body weight) divided twice a day.[19] SOR C Serum creatinine and blood pressure should be monitored monthly. Also CBC, uric acid, potassium, lipids, LFTs, and magnesium should be monitored monthly. Cyclosporine can be used for long-term therapy in patients with severe psoriasis for up to 2 years lifetime maximum based on European guidelines and 1 year maximum based upon the U.S. guidelines.[9,19] SOR C Cyclosporine is pregnancy category C, with several studies indicating an increased risk of premature birth but no major malformations.[19]
- Oral retinoids: Acitretin is a potent systemic retinoid used for psoriasis.[23] SOR A Acitretin appears to provide better efficacy in pustular psoriasis (including palmoplantar psoriasis) than in plaque-type psoriasis as a single agent treatment (**Figure 152-31**).[24] SOR A Low-dose acitretin therapy (25 mg/day) seems to be better tolerated and associated with fewer abnormalities found after laboratory testing and fewer adverse effects than the 50 mg/day dosage.[23] Acitretin is known to cause fetal malformations just like isotretinoin so it is best to avoid use in women capable of pregnancy, especially as it may remain in the body for up to 3 years after stopping therapy.

Biologic agents:

There are 4 biologic agents available and FDA approved for treating psoriasis. See **Table 152-5** and **152-6** for information about mechanism of action and the effectiveness of these agents.

- Before starting therapy, obtain a PPD or QuantiFERON-TB *Gold* blood test. These agents can reactivate dormant TB. Screening for TB should continue yearly during biologic therapy.[26]
- The TNF inhibitors (adalimumab, etanercept, and infliximab) share a common mechanism of action that leads to safety concerns. Safety concerns include serious infections (e.g., sepsis, tuberculosis, and viral infections), autoimmune conditions (lupus and demyelinating disorders), and lymphoma.[27]
- Etanercept (subcutaneous): For adults the dose is 50 mg SQ twice weekly for 3 months then 50 mg weekly thereafter.[9] SOR A This

TABLE 152-5 FDA-Approved Biologic Agents for Treating Psoriasis

Biologic Agent	Product Name	Mechanism of Action	Route of Delivery	Frequency of Maintenance Dosing
Adalimumab	Humira	TNF inhibitor	SQ	Every 2 weeks
Etanercept	Enbrel	TNF inhibitor	SQ	Once to twice weekly
Infliximab	Remicade	TNF inhibitor	IV infusion	Every 6-8 weeks
Ustekinumab	Stelara	Monoclonal antibody that binds p40 protein subunit of IL-12 and IL-23	SQ	Every 3 months

IL, Interleukin; *TNF*, tumor necrosis factor.

TABLE 152-6 Biologic Agents as Treatment of Plaque Psoriasis—Estimated Probabilities of Response Based Upon Synthesis of Evidence

	PASI 50, mean (95% CrI)	PASI 75, mean (95% CrI)	PASI 90, mean (95% CrI)
Placebo	13% (12–14)	4% (3–4)	1% (0–1)
Etanercept 25 mg	65% (56–73)	39% (30–48)	15% (10–21)
Etanercept 50 mg	76% (71–81)	52% (45–59)	24% (19–30)
Adalimumab	81% (74–87)	58% (49–68)	30% (23–39)
Ustekinumab 45 mg	88% (84–91)	69% (62–75)	40% (33–48)
Ustekinumab 90 mg	90% (87–93)	74% (68–80)	46% (39–54)
Infliximab	93% (89–96)	80% (70–87)	54% (42–64)

CrI, Credible interval; *PASI*, Psoriasis Area and Severity Index is used to express the severity of psoriasis. It combines the severity (erythema, induration, and desquamation) and percentage of affected area (lower number is better and the highest number for worst disease is 72); PASI 50 = 50% reduction in PASI score—clinically meaningful improvement; PASI 75 = 75% reduction in PASI score—very good improvement; PASI 90 = 90% reduction in PASI score—excellent improvement.
Adapted from Reich K, Burden AD, Eaton JN, Hawkins NS. Efficacy of biologics in the treatment of moderate to severe psoriasis: a network meta-analysis of randomized controlled trials. *Br J Dermatol*. 2012;166:179-188.

agent is especially valuable in patients with psoriatic arthritis as well as psoriasis.[9] SOR A

- Ustekinumab is a new biologic agent that is given SQ every 3 months. It targets interleukin (IL)-12 and IL-23 in the treatment of moderate-to-severe psoriasis. The safety profile of continued ustekinumab exposure through up to 3 years is favorable including the risk for either infections or malignancies.[28,29]
- While the biologic agents are all very expensive, insurance often pays and there are patient assistance programs for uninsured patients with limited resources.

Methotrexate versus biologic agents:[20]

- MTX is a very inexpensive medication with more than a 40-year track record, but with known potential for hepatotoxicity. It is very effective, but requires monitoring of the LFTs and the blood count on a regular basis.
- The biologic agents are engineered proteins with a potentially safer profile than MTX. However, they are very expensive and require parenteral administration. Biologics have the advantage of requiring less monitoring with blood tests. The biologic agents are not side-effect free and some of the potential side effects, while rare, are quite dangerous, and include the risks of sepsis, malignancy, and demyelinating disease.

THERAPY BY TYPE OF PSORIASIS

PLAQUE TYPE

Mild-to-moderate plaque psoriasis: Clobetasol twice daily for 2 to 4 weeks. Then decrease use of clobetasol and consider adding a steroid-sparing topical agent such as a vitamin D topical product.

Severe plaque form psoriasis: One systematic review found 665 studies dealing with the treatment of severe plaque psoriasis.[17] Photochemotherapy showed the highest average proportion of patients with clearance (70% [6947/9925]) and good response (83% [8238/9925]), followed by UVB (67.9% [620/913]) and cyclosporine (64% [1030/1609]) therapy.[30] SOR A Expert consensus in a meeting following data analysis supported the following sequence for the treatments: UVB, photochemotherapy, MTX, acitretin, and cyclosporine.[30] SOR C

The Consensus guidelines for the management of plaque psoriasis published in 2012 is based on U.S. National Psoriasis Foundation review and update of the Canadian Guidelines for the Management of Plaque Psoriasis. It includes newly approved agents such as ustekinumab and the excimer laser. The management of psoriasis in special populations is discussed.[31] In particular, current evidence does support the use of tumor necrosis factor (TNF) antagonists for the treatment of psoriasis in patients with hepatitis C.[31] **Table 152-4** summarizes the systemic treatments for plaque type psoriasis.

SCALP

One head-to-head trial (no pun intended) in scalp psoriasis demonstrated no therapeutic difference between a topical vitamin D derivative and a topical potent steroid.[12] Generic fluocinonide solution daily to the scalp is effective. Derma-smooth is another affordable scalp product that combines a high-potency steroid with a peanut oil. Calcipotriene daily to scalp also helps but is more expensive. Mineral oil may be used to moisturize and remove scale. Shampoos with tar and/or salicylic acid (T-Gel and T-Sal) can help to dissolve and wash away some of the scale. Of course, systemic therapies for more severe psoriasis will help clear scalp psoriasis.

GUTTATE PSORIASIS

Phototherapy works particularly well for guttate psoriasis.[6] SOR C Narrow-band UVB therapy may produce clearing in less than one month. Topical therapies are a reasonable option when phototherapy is not available (**Figure 152-20**).[6] SOR C Although both antibiotics and tonsillectomy have frequently been advocated for patients with guttate psoriasis, there is no good evidence that either intervention is beneficial.[32]

INVERSE PSORIASIS

Mid- to high-potency topical steroids can be used for inverse psoriasis even though the disease occurs in skinfolds (**Figure 152-6**). A number of studies have shown that tacrolimus works well to treat inverse psoriasis when applied twice daily.[13–15] SOR B Some patients did report a warm sensation or pruritus upon application so patients should be warned of this and told not to stop using the tacrolimus as this may improve over time.[13–15]

PALMAR-PLANTAR PSORIASIS

For mild disease, start with topical treatments as in plaque psoriasis. For moderate to severe cases, systemic therapy such as oral acitretin, MTX, or one of the biologics may be needed.

ERYTHRODERMIC/GENERALIZED PSORIASIS

Treatment considerations include hospitalization for dehydration and close monitoring, cyclosporine, MTX, oral retinoids, phototherapy, or photochemotherapy.[6] SOR C Cyclosporine is very effective in rapidly treating the most severe erythrodermic psoriasis (**Figure 152-25**). The recommended starting dose is 2.5 to 6 mg/kg per day (actual body weight) divided twice a day.[19]

PUSTULAR PSORIASIS

Options include oral retinoids such as isotretinoin or acitretin (depends on sex and age of the patient), MTX, cyclosporine, phototherapy, and hospitalization as needed.[6] SOR C Cyclosporine is very effective in rapidly treating pustular psoriasis at 2.5 to 6 mg/kg per day (actual body weight) divided twice a day.[19] One strategy is to start cyclosporine and acitretin together and to stop the cyclosporine once the pustules have cleared (**Figure 152-31**).

PROGNOSIS

Prognosis is dependent upon the type of psoriasis with the palmar-plantar type being the most difficult to treat. While erythrodermic and generalized pustular psoriasis are the most immediately dangerous types the response to treatment may vary from excellent to disappointing. Widespread plaque psoriasis is challenging to treat but the prognosis is not easily predictable and patient adherence is a very important factor in the prognosis. Excellent control is always the goal and cure should not be expected (even guttate psoriasis in children can come back as plaque psoriasis later in life).

FOLLOW-UP

- Follow-up may need to be frequent for various therapies including cytotoxic drugs, the biologics, and light therapy.
- While there are many safety concerns with the biologic agents a recent integrated safety analysis of short- and long-term safety profiles of etanercept in patients with psoriasis concluded that rates of noninfectious and infectious adverse events were comparable between placebo and etanercept groups.[33] Also, there was no increase in overall malignancies with etanercept therapy compared with the psoriasis population.[33]

TABLE 152-7 Patient Education Topics for Discussion Over Time

- Psoriasis is not curable but can be controlled
- Adherence to treatment is important
- Importance of losing weight
- Smoking Cessation
- Drinking alcohol in moderation or not drinking if patient has alcohol abuse disorder
- Factors that trigger or exacerbate psoriasis
- Range of therapeutic options from topical agents to systemic medications
- Hereditary issues
- Possible systemic manifestations including arthritis
- Psychological issues
- Membership in the National Psoriasis Foundation

- Well-controlled psoriasis on topical agents does not require frequent follow-up.

PATIENT EDUCATION

This is a chronic disease that cannot be cured. There are many methods to control psoriasis. Patients need to develop a relationship with a family physician or dermatologist to control the psoriasis for maximum quality of life. **Table 152-7** lists important patient education topics for discussion over time.

PATIENT RESOURCES

- The National Psoriasis Foundation—**www.psoriasis.org/.**

PROVIDER RESOURCES

- Hsu S, Papp KA, Lebwohl MG, et al. Consensus guidelines for the management of plaque psoriasis. *Arch Dermatol*. 2012;148(1):95-102. **http://archderm.ama-assn.org/cgi/content/short/148/1/95.**
- Guidelines of Care for the Management of Psoriasis and Psoriatic Arthritis: 6 parts published in *Journal of the American Academy of Dermatology* from 2008 to 2010.
- National Guideline Clearinghouse. *Guidelines of Care for the Management of Psoriasis and Psoriatic Arthritis. Section 3. Guidelines of Care for the Management and Treatment of Psoriasis with Topical Therapies*—**http://www.guidelines.gov/content.aspx?id=14572&search=psoriasis.**
- The National Psoriasis Foundation. This includes a Pocket Guide that can be downloaded as a PDF. This excellent pocket guide includes treatment algorithms for specific patient types, combination therapies, and transitional strategies for switching meds. By joining the NPF you can get this printed guide for your pocket—**http://www.psoriasis.org/health-care-providers/treating-psoriasis.**
- Medscape. *Psoriasis*—**http://emedicine.medscape.com/article/1943419.**

REFERENCES

1. Menter A, Korman NJ, Elmets CA, et al. Guidelines of care for the management of psoriasis and psoriatic arthritis. Section 3. Guidelines of care for the management and treatment of psoriasis with topical therapies. *J Am Acad Dermatol.* 2009;60:643-659.
2. Gelfand JM, Stern RS, Nijsten T, et al. The prevalence of psoriasis in African Americans: results from a population-based study. *J Am Acad Dermatol.* 2005;52:23-26.
3. Henseler T, Christophers E. Psoriasis of early and late onset: characterization of two types of psoriasis vulgaris. *J Am Acad Dermatol.* 1985;13:450-456.
4. Menter A, Weinstein GD. An overview of psoriasis. In: Koo YM, Lebwohl MD, Lee CS, eds. *Therapy of Moderate-to-Severe Psoriasis*. London, UK: Informa Healthcare; 2008:1-26.
5. Jankovic S, Raznatovic M, Marinkovic J, et al. Risk factors for psoriasis: a case-control study. *J Dermatol.* 2009;36:328-334.
6. Callen JP, Krueger GG, Lebwohl M, et al. AAD consensus statement on psoriasis therapies. *J Am Acad Dermatol.* 2003;49:897-899.
7. van de Kerkhof PCM. Clinical features. In: van de Kerkhof PCM, ed. *Textbook of Psoriasis*. Oxford, UK: Blackwell Science; 2003:3-29.
8. Afifi T, de Gannes G, Huang C, Zhou Y. Topical therapies for psoriasis: evidence-based review. *Can Fam Physician.* 2005;51:519-525.
9. Nast A, Kopp I, Augustin M, et al. German evidence-based guidelines for the treatment of Psoriasis vulgaris (short version). *Arch Dermatol Res.* 2007;299:111-138.
10. de Jager ME, de Jong EM, van de Kerkhof PC, Seyger MM. Efficacy and safety of treatments for childhood psoriasis: a systematic literature review. *J Am Acad Dermatol.* 2010;62:1013-1030.
11. Bruner CR, Feldman SR, Ventrapragada M, Fleischer AB Jr. A systematic review of adverse effects associated with topical treatments for psoriasis. *Dermatol Online J.* 2003;9:2.
12. Mason J, Mason AR, Cork MJ. Topical preparations for the treatment of psoriasis: a systematic review. *Br J Dermatol.* 2002;146:351-364.
13. Brune A, Miller DW, Lin P, et al. Tacrolimus ointment is effective for psoriasis on the face and intertriginous areas in pediatric patients. *Pediatr Dermatol.* 2007;24:76-80.
14. Lebwohl M, Freeman AK, Chapman MS, et al. Tacrolimus ointment is effective for facial and intertriginous psoriasis. *J Am Acad Dermatol.* 2004;51:723-730.
15. Martin EG, Sanchez RM, Herrera AE, Umbert MP. Topical tacrolimus for the treatment of psoriasis on the face, genitalia, intertriginous areas and corporal plaques. *J Drugs Dermatol.* 2006;5:334-336.
16. Ibbotson SH, Bilsland D, Cox NH, et al. An update and guidance on narrowband ultraviolet B phototherapy: a British Photodermatology Group Workshop Report. *Br J Dermatol.* 2004;151:283-297.
17. Asawanonda P, Nateetongrungsak Y. Methotrexate plus narrowband UVB phototherapy versus narrowband UVB phototherapy alone in the treatment of plaque-type psoriasis: a randomized, placebo-controlled study. *J Am Acad Dermatol.* 2006;54:1013-1018.
18. Lebwohl M, Drake L, Menter A, et al. Consensus conference: acitretin in combination with UVB or PUVA in the treatment of psoriasis. *J Am Acad Dermatol.* 2001;45:544-553.
19. Rosmarin DM, Lebwohl M, Elewski BE, Gottlieb AB. Cyclosporine and psoriasis: 2008 National Psoriasis Foundation Consensus Conference. *J Am Acad Dermatol.* 2010;62:838-853.
20. Saporito FC, Menter MA. Methotrexate and psoriasis in the era of new biologic agents. *J Am Acad Dermatol.* 2004;50:301-309.
21. Montaudie H, Sbidian E, Paul C, et al. Methotrexate in psoriasis: a systematic review of treatment modalities, incidence, risk factors and monitoring of liver toxicity. *J Eur Acad Dermatol Venereol.* 2011;25 Suppl 2:12-18.
22. Kalb RE, Strober B, Weinstein G, Lebwohl M. Methotrexate and psoriasis: 2009 National Psoriasis Foundation Consensus Conference. *J Am Acad Dermatol.* 2009;60:824-837.
23. Pearce DJ, Klinger S, Ziel KK, et al. Low-dose acitretin is associated with fewer adverse events than high-dose acitretin in the treatment of psoriasis. *Arch Dermatol.* 2006;142:1000-1004.
24. Sbidian E, Maza A, Montaudie H, et al. Efficacy and safety of oral retinoids in different psoriasis subtypes: a systematic literature review. *J Eur Acad Dermatol Venereol.* 2011;25 Suppl 2:28-33.
25. Reich K, Burden AD, Eaton JN, Hawkins NS. Efficacy of biologics in the treatment of moderate to severe psoriasis: a network meta-analysis of randomized controlled trials. *Br J Dermatol.* 2012;166:179-188.
26. Sivamani RK, Goodarzi H, Garcia MS, et al. Biologic therapies in the treatment of psoriasis: a comprehensive evidence-based basic science and clinical review and a practical guide to tuberculosis monitoring. *Clin Rev Allergy Immunol.* 2012 Feb 5. [Epub ahead of print.]
27. Gottlieb A, Korman NJ, Gordon KB, et al. Guidelines of care for the management of psoriasis and psoriatic arthritis: section 2. Psoriatic arthritis: overview and guidelines of care for treatment with an emphasis on the biologics. *J Am Acad Dermatol.* 2008;58:851-864.
28. Gordon KB, Papp KA, Langley RG, et al. Long-term safety experience of ustekinumab in patients with moderate to severe psoriasis (part II of II): results from analyses of infections and malignancy from pooled phase II and III clinical trials. *J Am Acad Dermatol.* 2012;66:742-751.
29. Lebwohl M, Leonardi C, Griffiths CE, et al. Long-term safety experience of ustekinumab in patients with moderate-to-severe psoriasis (part I of II): results from analyses of general safety parameters from pooled phase 2 and 3 clinical trials. *J Am Acad Dermatol.* 2012;66:731-741.
30. Spuls PI, Bossuyt PM, van Everdingen JJ, et al. The development of practice guidelines for the treatment of severe plaque form psoriasis. *Arch Dermatol.* 1998;134:1591-1596.
31. Hsu S, Papp KA, Lebwohl MG, et al. Consensus guidelines for the management of plaque psoriasis. *Arch Dermatol.* 2012;148:95-102.
32. Owen CM, Chalmers RJ, O'Sullivan T, Griffiths CE. A systematic review of antistreptococcal interventions for guttate and chronic plaque psoriasis. *Br J Dermatol.* 2001;145:886-890.
33. Pariser DM, Leonardi CL, Gordon K, Gottlieb AB, Tyring S, Papp KA, Li J, Baumgartner SW. Integrated safety analysis: Short- and long-term safety profiles of etanercept in patients with psoriasis. *J Am Acad Dermatol.* 2012;67(2):245-256.

153 PITYRIASIS ROSEA

David Henderson, MD
Richard P. Usatine, MD

PATIENT STORY

A 17-year-old young woman is brought to the office by her mom because of a rash that appeared 3 weeks ago for no apparent reason (**Figures 153-1** to **153-3**). She was feeling well and the rash is only occasionally pruritic. With and without mom in the room, the young woman denied sexual activity. The diagnosis of pityriasis rosea was made by the clinical appearance even though there was no obvious herald patch. The collarette scale was visible and the distribution was consistent with pityriasis rosea. The young woman and her mom were reassured that this would resolve spontaneously. At a subsequent visit for a college physical the skin was found to be completely clear with no scarring.

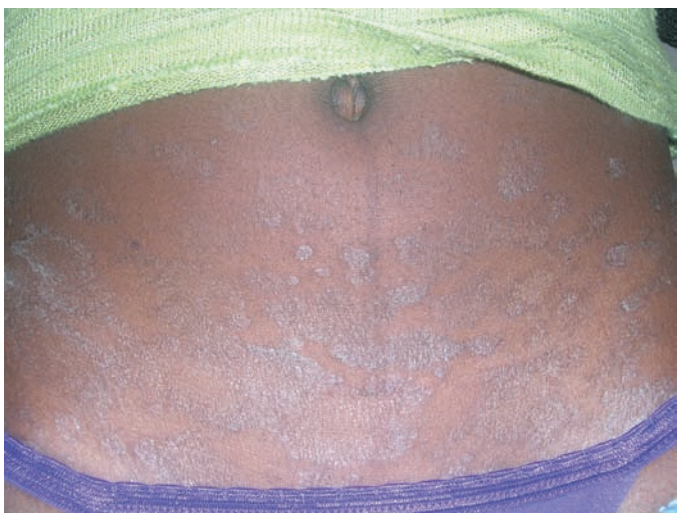

FIGURE 153-1 Pityriasis rosea in a 17-year-old young woman. Lesions are often concentrated in the lower abdominal area. (*Courtesy of Richard P. Usatine, MD.*)

INTRODUCTION

Pityriasis rosea is a common, self-limited, papulosquamous skin condition originally described in the 19th century. It is seen in children and adults. Despite the long history, its etiology remains elusive. A number of infectious etiologies have been proposed, but at present, supporting evidence is inconclusive. Pityriasis rosea has unique features including a herald patch in many cases and collarette scale that are useful in distinguishing it from other papulosquamous eruptions.

EPIDEMIOLOGY

- Pityriasis rosea is a papulosquamous eruption of unknown etiology.[1]
- It occurs throughout the life cycle. It is most commonly seen between the ages of 10 and 35 years.[3]
- The peak incidence is between 20 and 29 years of age.[1]
- The gender distribution is essentially equal.[1]
- The rash is most prevalent in winter months.[4]

ETIOLOGY AND PATHOPHYSIOLOGY

- The cause of pityriasis rosea is unknown, although numerous causes have been proposed.
- It has long been suspected that it may have a viral etiology because a viral-like prodrome often occurs prior to the onset of the rash. Human herpesviruses 6 and 7 have been proposed as causes, but numerous studies have failed to demonstrate conclusive supportive evidence.[1,2]
- *Chlamydia pneumoniae, Mycoplasma pneumoniae, and Legionella pneumophila* have been proposed as potential etiologic agents, but studies have not demonstrated any significant rise in antibody levels against any of these pathogens in patients with pityriasis rosea.[1]

FIGURE 153-2 Scaling lesions seen on the buttocks of the same young woman. Note how some of the lesions are annular. (*Courtesy of Richard P. Usatine, MD.*)

- Pityriasis rosea has also been associated with negative pregnancy outcomes, particularly premature birth. The risk seems to be greatest when the condition occurs in the first 15 weeks of gestation.[2]
- Pityriasis rosea may rarely occur as the result of a drug reaction. Documented drug reactions that have produced a pityriasis rosea-like eruption include barbiturates, captopril, clonidine, interferon, bismuth, gold, and the hepatitis B vaccine.[1,2]

DIAGNOSIS

CLINICAL FEATURES

- In approximately 20% to 50% of cases, the rash of pityriasis rosea is preceded by a viral-like illness consisting of upper respiratory or GI symptoms.
- This is followed by the appearance of a *herald patch* in 17% of cases (**Figures 153-4** to **153-6**).[4]
- The herald patch is a solitary, oval, flesh-colored to salmon-colored lesion with scaling at the border. It often occurs on the trunk, and is generally 2 to 10 cm in diameter (**Figures 153-4** and **153-5**).
- One to 2 weeks after the appearance of the herald patch, other papulosquamous lesions appear on the trunk and sometimes on the extremities.
- These lesions vary from oval macules to slightly raised plaques, 0.5 to 2 cm in size. They are salmon colored (or hyperpigmented in individuals with dark skin), and typically have a collarette of scaling at the border (**Figure 153-3**). It is common for some of the lesions to appear annular with central clearing.
- In many cases, the herald patch has resolved by the time the rest of the exanthem erupts which can make the diagnosis more difficult.
- There are no systemic symptoms.
- Itching occurs in approximately 25% of patients.
- The exanthem resolves in 8 weeks in 80% of patients.[1] However, it can last up to 3 to 5 months.[3]

TYPICAL DISTRIBUTION

- The rash is bilaterally symmetrical, generally most dense on the trunk, but also involves the upper and lower extremities.
- The lesions follow the cleavage, or Langer lines, and may create the typical *fir* or *Christmas tree* pattern over the back (**Figure 153-7**). Do not expect to always see a Christmas tree pattern.
- Over the chest, the lesions create a V-shaped pattern, and run transversely over the abdomen (**Figures 153-8** and **153-9**).
- An inverse form has been described, characterized by more intense involvement of the extremities and relative sparing of the trunk (**Figures 153-10** and **153-11**).

LABORATORY STUDIES

Pityriasis rosea is a clinical diagnosis. There are no laboratory tests that aid in the diagnosis. Biopsy of lesions typically reveals only nonspecific inflammatory changes. Because secondary syphilis is also a papulosquamous eruption and can be difficult to distinguish

FIGURE 153-3 Close-up of lesion showing collarette scale. Note how the lesions can be annular with some central clearing. (*Courtesy of Richard P. Usatine, MD.*)

FIGURE 153-4 Pityriasis rosea in a 25-year-old Hispanic man. *Arrow* points to herald patch. (*Courtesy of Scott Youngquist, MD. Previously published in Youngquist S, Usatine R. It's beginning to look a lot like Christmas. West J Med. 2001;175(4):227-228.*)

FIGURE 153-5 Pityriasis rosea in a 13-year-old boy. *Arrow* points to herald patch. (*Courtesy of Richard P. Usatine, MD.*)

FIGURE 153-7 Pityriasis rosea in a 16-year-old boy. The scaling lesions follow skin lines and resemble a Christmas tree. (*Courtesy of E.J. Mayeaux, Jr., MD.*)

FIGURE 153-6 Pityriasis rosea in a 15-year-old boy with the herald patch on the neck near the hairline. (*Courtesy of Richard P. Usatine, MD.*)

FIGURE 153-8 Pityriasis rosea in a 12-year-old boy showing classic scaling lesions across the chest and abdomen. Small annular lesions are visible. (*Courtesy of Jeffrey Meffert, MD.*)

from pityriasis rosea on clinical grounds, taking a sexual history is important when a diagnosis of pityriasis rosea is being considered. In patients with a history of sexually transmitted diseases, or sexual practices that place them at risk, a blood test for syphilis should be considered (**Figures 153-9** and **153-10**) (see Chapter 216, Syphilis).

DIFFERENTIAL DIAGNOSIS

- Tinea corporis is usually more localized than pityriasis rosea. However, the annular patterns, scale, and central clearing of some lesions in pityriasis rosea can mislead the clinician to misdiagnose tinea corporis. Tinea corporis tends to have fewer annular lesions and may have concentric circles rather than a single ring. Microscopy with KOH usually demonstrates branching hyphae (see Chapter 138, Tinea Corporis).
- Tinea versicolor has a distribution similar to pityriasis rosea, but is not associated with a herald patch. The pattern of scaling noted is generally more diffuse and not annular. Microscopy with KOH demonstrates the *spaghetti-and-meatball* pattern typical of *Pityrosporum* (see Chapter 141, Tinea Versicolor).
- Secondary syphilis is also a papulosquamous eruption. Lesions are often found on the palms and soles, which is not the case in pityriasis rosea; however, because the two conditions cannot always be accurately distinguished on clinical grounds, a blood test for syphilis is indicated if there is a significant doubt in the diagnosis (see Chapter 216, Syphilis).
- Nummular eczema has coin-like areas of scale that can resemble pityriasis rosea. The scale is not collarette and nummular eczema has a predilection for the legs, an area that is less often involved with pityriasis rosea (see Chapter 145, Atopic Dermatitis).
- Guttate psoriasis generally presents as oval to round, scaly macules on the trunk, and so can be confused with pityriasis rosea. However, the scaling is generally thicker and more adherent than in pityriasis rosea (see Chapter 152, Psoriasis).

MANAGEMENT

- Pityriasis rosea often requires no treatment at all other than reassurance.
- Topical steroids and oral diphenhydramine may be used to relieve itching when there is pruritus involved. SOR C
- One study found oral erythromycin to be effective in treating patients with pityriasis rosea,[5] although a subsequent study did not find erythromycin to be better than placebo.[6] SOR B
- Azithromycin did not cure pityriasis rosea in a study of children with this condition.[7]
- A Cochrane systematic review found inadequate evidence for efficacy for most treatments for pityriasis rosea.[8] Based on one small randomized controlled trial (RCT), the review authors noted that oral erythromycin may be effective in treating the rash and decreasing the itch.[5,8] The authors stated that this result should be treated with caution as it comes from only one small RCT.[5,8] SOR B

FIGURE 153-9 Pityriasis rosea on the chest and abdomen of a young woman. Blood test for syphilis was negative. (*Courtesy of the University of Texas Health Sciences Center, Division of Dermatology.*)

FIGURE 153-10 Pityriasis rosea in a 40-year-old man with an inverse pattern. Note how there is a higher density of lesions on the legs. Rapid plasma reagin (RPR) was negative and the diagnosis was confirmed with a punch biopsy. (*Courtesy of Richard P. Usatine, MD.*)

PATIENT EDUCATION

- Patients are often concerned about the duration of the rash and whether they are contagious. They should be reassured that pityriasis rosea is self-limited and not truly contagious. Although there have been reported clusters of pityriasis rosea in settings where people are living in close quarters (e.g., dormitories), it is not considered to be contagious. It has a reported recurrence rate of only 2%.[5]

FOLLOW-UP

- Patients should be instructed to follow up if the rash persists for longer than 3 months as reevaluation and consideration of an alternate diagnosis may be prudent.

PATIENT RESOURCES

- Mayo Clinic. *Pityriasis Rosea*—**http://www.mayoclinic.com/health/pityriasis-rosea/DS00720.**
- WebMD. *Pityriasis Rosea: Topic Overview*—**http://www.webmd.com/skin-problems-and-treatments/tc/pityriasis-rosea-topic-overview.**

PROVIDER RESOURCES

- Medscape. *Pityriasis Rosea in Emergency Medicine*—**http://emedicine.medscape.com/article/762725.**
- American Academy of Dermatology. *Pityriasis Rosea*—**http://www.aad.org/skin-conditions/dermatology-a-to-z/pityriasis-rosea.**

FIGURE 153-11 Pityriasis rosea on the arms with prominent erythematous lesions. (*Courtesy of the University of Texas Health Sciences Center, Division of Dermatology.*)

REFERENCES

1. Stulberg DH, Wolfrey J. Pityriasis rosea. *Am Fam Physician.* 2004;69:87-92, 94.
2. Browning JC. An update on pityriasis rosea and other similar childhood exanthems. *Curr Opin Pediatr.* 2009;21(4):481-485.
3. Youngquist S, Usatine R. It's beginning to look a lot like Christmas. *West J Med.* 2001;175(4):227-228.
4. Habif TP. *Clinical Dermatology*, 5th ed. St Louis, MO: Mosby; 2009:316-319.
5. Sharma PK, Yadav TP, Gautam RK, et al. Erythromycin in pityriasis rosea: a double-blind, placebo-controlled clinical trial. *J Am Acad Dermatol.* 2000;42(2 Pt 1):241-244.
6. Rasi A, Tajziehchi L, Savabi-Nasab S. Oral erythromycin is ineffective in the treatment of pityriasis rosea. *J Drugs Dermatol.* 2008;7(1):35-38.
7. Amer H, Fischer H. Azithromycin does not cure pityriasis rosea. *Pediatrics.* 2006;117(4):1702-1705.
8. Chuh AA, Dofitas BL, Comisel GG, et al. Interventions for pityriasis rosea. *Cochrane Database Syst Rev.* 2007;(2):CD005068.

154 LICHEN PLANUS

Robert L. Kraft, MD
Richard P. Usatine, MD

PATIENT STORY

A 38-year-old Hispanic woman presents with a rash on her forearms, wrists, ankle, and back (**Figures 154-1** to **154-4**). She states the rash is mildly itchy and she does not like the way it looks. She would like some medication to make this better. Lichen planus (LP) was diagnosed and clobetasol was prescribed to keep the LP under better control.

INTRODUCTION

LP is a self-limited, recurrent, or chronic autoimmune disease affecting the skin, oral mucosa, and genitalia. LP is generally diagnosed clinically with lesions classically described using the six Ps (planar, purple, polygonal, pruritic, papules, and plaques).

EPIDEMIOLOGY

- LP is an inflammatory dermatosis of skin or mucous membranes that occurs in approximately 1% of all new patients seen at health-care clinics.[1]
- Although most cases occur between ages 30 and 60 years, LP can occur at any age.[1,2]
- There may be a slight female predominance.[2–4]

ETIOLOGY AND PATHOPHYSIOLOGY

- Usually idiopathic, thought to be a cell-mediated immune response to an unknown antigen.[2,3,5]
- Possible human leukocyte antigen (HLA)-associated genetic predisposition.[2]
- Lichenoid-type reactions may be associated with medications (e.g., angiotensin-converting enzyme inhibitors [ACEIs], thiazide-type diuretics, tetracycline, chloroquine), metals (e.g., gold, mercury), or infections (e.g., secondary syphilis).[2,5]
- Associated with liver disease, especially related to hepatitis C virus.[2,5,6]
- LP may be found with other diseases of altered immunity (e.g., ulcerative colitis, alopecia areata, myasthenia gravis).[1]
- Malignant transformation has been reported in ulcerative oral lesions in men.[1]

RISK FACTORS

- Possible HLA-associated genetic predisposition.
- Hepatitis C virus infection, although causal relationship is not established.[6]
- Certain drugs (see "Etiology and Pathophysiology" above).

FIGURE 154-1 A 38-year-old Hispanic woman with lichen planus on her wrist. (*Courtesy of Richard P. Usatine, MD.*)

FIGURE 154-2 Close-up of wrist showing linearity of the lesions on the flexor surface. Lesions may be pink rather than purple. (*Courtesy of Richard P. Usatine, MD.*)

FIGURE 154-3 Ankle of the woman in **Figure 154-1** with typical lichen planus eruption. (*Courtesy of Richard P. Usatine, MD.*)

DIAGNOSIS

CLINICAL FEATURES[2,5]

- Classically, the six Ps of LP are planar, purple, polygonal, pruritic, papules, and plaques (**Figures 154-1** to **154-5**).
- These well-demarcated flat-topped violaceous lesions are often covered by lacy, reticular white lines (called Wickham striae or Wickham lines) (**Figure 154-4B**).
- An initial lesion is usually located on the flexor surface of the limbs, such as the wrists, followed by a generalized eruption with maximal spreading within 2 to 16 weeks.[1]
- Lesions may demonstrate the Koebner phenomenon (linear distribution) from scratching (**Figure 154-2**).
- Lesions are more often hyperpigmented rather than purple or pink in dark-skinned persons, and skin may remain hyperpigmented after lesions resolve (**Figures 154-6** and **154-7**).
- Skin variants
  - Hypertrophic—Typical papules develop into thicker reddish-brown to purple plaques (**Figures 154-5** and **154-7**) most commonly on the foot and shins. Seen more often in black men with hyperpigmented and hypertrophic lesions (**Figure 154-7**).
  - Follicular—Pinpoint hyperkeratotic projections often on scalp, may lead to cicatricial alopecia.
  - Vesicular—Vesicles or bullae occur alongside the more typical LP lesions (**Figure 154-8**).
  - Actinic—Typical lesions in sun-exposed areas, such as the face, back of hands and arms (**Figure 154-9**).
  - Atrophic—the lesions are atrophic rather than standard plaques (**Figure 154-10**).
  - Ulcerative—Ulcers develop within typical lesions or start as waxy semitranslucent plaques on palms and soles; may require skin grafting.
- Mucous membrane variants
  - May be reticular (net-like; **Figure 154-11**), atrophic, erosive (**Figures 154-12** and **154-13**), or bullous. It is almost always bilateral.
  - Oral lesions may be asymptomatic or have a burning sensation; pain occurs with ulceration.[1,4,6]
  - Oral LP is often associated with extraoral LP.[7,8]
- Genitalia variants
  - Reticular, annular (**Figure 154-14**), papular (**Figure 154-15**), or erosive lesions on penis, scrotum, labia, or vagina.
  - Vulvar/vaginal lesions may be associated with dyspareunia, a burning sensation, and/or pruritus.[1,7]
  - Vulvar and urethral stenosis can also be present.[1,7]
- Hair and nail variants; the latter present in 10% of patients.[1]
  - Violaceous, scaly, pruritic papules on the scalp can progress to scarring alopecia. Lichen planopilaris (LP of the scalp) can cause widespread hair loss (see Chapter 189, Scarring Alopecia).[9]
  - Nail plate thinning results in longitudinal grooving and ridging; rarely destruction of nailfold and nail bed with splintering (**Figure 154-16**).
  - Hyperpigmentation, subungual hyperkeratosis, onycholysis, and longitudinal melanonychia can result from LP.[1]

FIGURE 154-4 **A.** Lichen planus on the back of the woman in **Figure 154-1**. **B.** Close-up of lesions on the back showing Wickham striae crossing the flat papules of lichen planus. These lines are white and reticular like a net. (*Courtesy of Richard P. Usatine, MD.*)

FIGURE 154-5 Hypertrophic lichen planus on the foot of a man. Purple polygonal papules and plaques are visible. (*Courtesy of M. Craven, MD.*)

FIGURE 154-7 Hypertrophic lichen planus on the leg of a black man. Note the hyperpigmentation that is common when lichen planus occurs in a person with dark skin. (*Courtesy of Richard P. Usatine, MD.*)

FIGURE 154-6 Hyperpigmented lichen planus on the back proven by punch biopsy. (*Courtesy of Richard P. Usatine, MD.*)

FIGURE 154-8 Bullous lichen planus on the buttocks. (*Courtesy of Richard P. Usatine, MD.*)

FIGURE 154-9 Actinic lichen planus on the face. (*Courtesy of Richard P. Usatine, MD.*)

FIGURE 154-10 Atrophic lichen planus (biopsy proven) on the forearm showing multiple colors within the atrophic lesions. (*Courtesy of Richard P. Usatine, MD.*)

FIGURE 154-11 Asymptomatic white keratotic striae of lichen planus on left buccal mucosa of a 56-year-old woman. The patient had similar involvement of the right buccal mucosa and gingivae. Lichen planus in the mouth is bilateral. (*Courtesy of Richard P. Usatine, MD.*)

FIGURE 154-12 Erosive lichen planus, lateral surface of the tongue. This 52-year-old woman experiences tongue discomfort while eating acidic or spicy foods. (*Courtesy of Richard P. Usatine, MD.*)

FIGURE 154-13 Lichen planus in the mouth with erosions. The lips, tongue, and palate are all involved. (*Courtesy of Eric Kraus, MD.*)

FIGURE 154-14 Lichen planus on the penis showing a lacy white pattern. (*Courtesy of Dan Stulberg, MD.*)

FIGURE 154-15 Lichen planus on the penis that is more similar to the pattern seen on other parts of the body. This is an example of planar, purple, polygonal papules on the penis. (*Courtesy of John Gonzales, MD.*)

FIGURE 154-16 Hypertrophic lichen planus covering the dorsum of both feet with nail splintering. Note the purple color and Wickham lines. (*Courtesy of Eric Kraus, MD.*)

TYPICAL DISTRIBUTION

Wrists (**Figure 154-17**), ankles, lower back, eyelids, shins, scalp, penis, mouth (i.e., buccal mucosa, lateral tongue, and gingiva).[2,5]

LABORATORY STUDIES

- Wickham striae can be accentuated by a drop of oil on the skin plaque and magnification.[5] Not all LP has visible Wickham striae. This study is rarely needed. If the diagnosis is uncertain, a punch biopsy should be performed.

BIOPSY

- A punch biopsy is a valuable method to make as initial diagnosis if the clinical picture is not certain. A biopsy is rarely needed to evaluate for malignant transformation.[5,10]
- Mainly lymphocytic immunoinflammatory infiltrate with hyperkeratosis, increased granular layer and liquefaction of basal cell layer.[2,5]
- Linear fibrin and fibrinogen deposits along basement membrane.[2,5]
- Direct immunofluorescence on biopsy specimen reveals globular deposits of immunoglobulin (Ig) G, IgM, IgA, and complement at dermal–epidermal junction.[5]

FIGURE 154-17 Thick hypertrophic papules and plaques on the wrist of the man in **Figure 154-16**. (*Courtesy of Eric Kraus, MD.*)

DIFFERENTIAL DIAGNOSIS

Skin lesions that may be confused with LP:

- Eczematous dermatitis—"The itch that rashes:" dry skin, itching, often excoriations and lichenification of skin with predilection for flexor surfaces (see Chapter 145, Atopic Dermatitis).
- Psoriasis has more prominent silvery scale and is generally located on extensor surfaces.[5] A punch biopsy can be used to distinguish between these two when the clinical picture is not clear (see Chapter 152, Psoriasis).
- Stasis dermatitis—Lower-extremity eczematous dermatitis with inflammatory papules and often ulceration, in the setting of chronic venous insufficiency with dependent edema (see Chapter 52, Venous Stasis).
- Pityriasis rosea—Herald patch and subsequent pink papules and plaques with long axes along skin lines (Christmas tree pattern) (see Chapter 153, Pityriasis Rosea).
- Chronic cutaneous lupus erythematosus—Bright red sharply demarcated papules with adherent scale. Tend to regress centrally and can be light induced. Generally located on face, scalp, or forearms, and hands. Biopsy may be necessary to differentiate (see Chapter 180, Lupus: Systemic and Cutaneous).[5]
- Bowen disease—Sharply demarcated pink, red, brown, or black scaling or hyperkeratotic macule, papule, or plaque, usually mistaken for eczema or psoriasis, associated with ultraviolet radiation, human papilloma virus (HPV), chemicals, and chronic heat exposure. Biopsy is needed to make the diagnosis (see Chapter 166, Actinic Keratosis and Bowen Disease).
- Lichen simplex chronicus—Localized confluence of lichenification from excoriation; patients have a strong urge to scratch their skin (see Chapter 149, Self-Inflicted Dermatoses).

- Prurigo nodularis—Nodular form of lichen simplex chronicus, brown to red hard, domed nodules from scratching and picking of intense pruritus. LP is not usually so pruritic (see Chapter 149, Self-Inflicted Dermatoses).

Other mucous membrane lesions that may appear similar:[5]

- Leukoplakia—White adherent patch or plaque to oral mucosa. Less net-like pattern. Biopsy warranted because of the risk of malignancy (see Chapter 42, Leukoplakia).
- Thrush—Removable whitish plaques over an erythematous mucosal surface caused by *Candida* infection, confirmed by KOH preparation (see Chapter 136, Candidiasis).
- Bite trauma in the mouth—May result in white areas of the lip or buccal mucosa; Persons may have a white bite line where the upper and lower molars occlude and this can be confused with oral LP. If in doubt, a biopsy may be needed.

Genital lesions that may be differentiated from LP:[5]

- Psoriasis on the penis can look like LP on the penis. A shave biopsy can be used to differentiate between these two diagnoses (see Chapter 152, Psoriasis).
- Syphilis—Primary infection manifests as painless shallow ulcer (chancre) at site of inoculation, if untreated secondary syphilis presents with macular and then papular, pustular, or acneiform eruption on trunk, neck, palms, and soles, condyloma lata (soft, moist, flat-topped pink to tan papules) in the anogenital region (see Chapter 216, Syphilis).

MANAGEMENT

LP may persist for months to years. Hypertrophic LP and oral LP can last for decades.[2] Any type of LP can recur. Antihistamines can be used for symptomatic pruritus.[5] SOR C Symptomatic and severe cases can be treated as follows:

- Localized/topical treatment.
  - Topical corticosteroids twice a day.[11–13] SOR B Mid to high-potency steroids are usually needed. Clobetasol cream or ointment may be used on the skin and clobetasol ointment or gel may be used in the mouth.
  - Topical aloe vera gel has demonstrated efficacy against oral LP.[14,15] SOR B
  - Intralesional triamcinolone (3 to 5 mg/mL) for hypertrophic or mucous membrane lesions, may repeat every 3 to 4 weeks.[2,5,10,11] SOR B
  - Tacrolimus, pimecrolimus, retinoids, or cyclosporine in mouthwash or adhesive base for oral disease unresponsive to topical corticosteroids.[3,4,10,12,16–19] SOR B
  - Topical corticosteroids, tacrolimus and aloe vera gel have demonstrated efficacy for vulvar LP.[20,21] SOR B
- Systemic treatment can be considered for resistant, widespread, or severe cases.
  - Oral steroids may be used starting with a 3-week tapered course of oral prednisone (60 mg/day starting dose).[2,10,11,22,23] SOR B
  - Systemic retinoids, e.g., acitretin 25 mg/day. Monitor serum creatinine, liver function tests (LFTs), fasting lipids.[3,10,23] SOR B Contraindicated in women of childbearing potential.

- Cyclosporine (5 mg/kg per day). Monitor complete blood count, serum creatinine, LFTs, and blood pressure.[2] SOR B
- Azathioprine may be used as a steroid-sparing agent (50 mg po daily to start and titrate to 100 to 250 mg po daily). Monitor complete blood count and LFTs.[5,10] SOR C
- Psoralen UVA (PUVA) phototherapy may be effective but can cause phototoxic reactions and has long-term risks, including the development of squamous cell carcinoma.[24] SOR C
- Carbon dioxide laser and low-level laser therapy have reports of treatment success against oral LP.[25,26] SOR C

PROGNOSIS

- Generally self-limiting and spontaneous resolution may occur in 12 to 18 months.
- Recurrences are common.
- Mucosal LP is generally more persistent than cutaneous forms.
- Malignant transformation of LP is rare.

FOLLOW-UP

- Follow-up depends on severity and treatment course.
- Oral and vaginal disease may be most challenging to treat.
- Follow oral or vaginal lesions for possible malignant transformation. Because of low risk of transformation even with oral LP (best estimate: 0.2% per year), routine screening and biopsy is not recommended.[10] Biopsy if suspecting malignancy; lesion becomes larger, ulcerated, nodular, or lose reticular pattern.

PATIENT EDUCATION

- Patients should understand that LP is often self-limiting and may resolve in 12 to 18 months.
- There is a significant chance of recurrence.

PATIENT RESOURCES

- Handout available at **http://familydoctor.org/600.xml.**
- Online support group for LP at **http://www.mdjunction.com/lichen-planus.**
- Online support group for oral LP at **http://bcdwp.web.tamhsc.edu/iolpdallas/.**

PROVIDER RESOURCES

- Usatine RP, Tinitigan M. Diagnosis and treatment of LP. *Am Fam Physician.* 2011;84(1):53-60. Available online at: **http://www.aafp.org/afp/2011/0701/p53.html#afp20110701p53-b14.**

REFERENCES

1. Chuang T-Y, Stitle L. http://emedicine.medscape.com/article/1123213-overview. Accessed September 20, 2011.
2. Wolff K, Johnson RA. *Fitzpatrick's Color Atlas and Synopsis of Clinical Dermatology*, 6th ed. New York, NY: McGraw-Hill; 2009;128-133.
3. Zakrzewska JM, Chan ES-Y, Thornhill MH. A systematic review of placebo-controlled randomized clinical trials of treatments used in oral lichen planus. *Br J Dermatol.* 2005;153:336-341.
4. Laeijendecker R, Tank B, Dekker SK, Neumann HA. A comparison of treatment of oral lichen planus with topical tacrolimus and triamcinolone acetonide ointment. *Acta Derm Venereol.* 2006;86(3):227-229.
5. Habif TP. *Clinical Dermatology: A Color Guide to Diagnosis and Therapy*, 5th ed. Philadelphia, PA: Mosby; 2010.
6. Shengyuan L, Songpo Y, Wen W, et al. Hepatitis C virus and lichen planus: a reciprocal association determined by a meta-analysis. *Arch Dermatol.* 2009;145(9):1040-1047.
7. Di Fede O, Belfiore P, Cabibi D, et al. Unexpectedly high frequency of genital involvement in women with clinical and histological features of oral lichen planus. *Acta Derm Venereol.* 2006;86(5):433-438.
8. Imail SB, Kumar SK, Zain RB. Oral lichen planus and lichenoid reactions: etiopathogenesis, diagnosis, management and malignant transformation. *J Oral Sci.* 2007;49(2):89-106.
9. Cevacso NC, Bergfeld WF, Remzi BK, de Knott HR. A case-series of 29 patients with lichen planopilaris: the Cleveland Clinic Foundation experience on evaluation, diagnosis, and treatment. *J Am Acad Dermatol.* 2007;57(1):47-53.
10. Lodi G, Scully C, Carrozzo M, et al. Current controversies in oral lichen planus: report of an international consensus meeting, part 2. Clinical management and malignant transformation. *Oral Surg Oral Med Oral Pathol Oral Radiol Endod.* 2005;100:164-178.
11. Cribier B, Frances C, Chosidow O. Treatment of lichen planus. An evidence-based medicine analysis of efficacy. *Arch Dermatol.* 1998;134(12):1521-1530.
12. Corrocher G, Di Lorenzo G, Martinelli N, et al. Comparative effect of tacrolimus 0.1% ointment and clobetasol 0.05% ointment in patients with oral lichen planus. *J Clin Periodontol.* 2008;35(3):244-249.
13. Carbone M, Arduino PG, Carrozzo M, et al. Topical clobetasol in the treatment of atrophic-erosive oral lichen planus: a randomized controlled trial to compare two preparations with different concentrations. *J Oral Pathol Med.* 2009;38(2):227-233.
14. Choonhakarn C, Busaracome P, Sripanidkulchai B, Sarakam P. The efficacy of aloe vera gel in the treatment of oral lichen planus: a randomized controlled trial. *Br J Dermatol.* 2008;158(3):573-577.
15. Salazar SN. Efficacy of topical Aloe vera in patients with oral lichen planus: a randomized double-blind study. *J Oral Pathol Med.* 2010;39(10):735-740.
16. Conrotto D, Carbone M, Carrozzo M, et al. Ciclosporine vs. clobetasol in the topical management of atrophic and erosive oral lichen planus: a double-blind, randomized controlled trial. *Br J Dermatol.* 2006;154(1):139-145.
17. Swift JC, Rees TD, Plemons JM, et al. The effectiveness of 1% pimecrolimus cream in the treatment of oral erosive lichen planus. *J Periodontol.* 2005;76(4):627-635.

18. Volz T, Caroli U, Ludtke H, et al. Pimecrolimus cream 1% in erosive oral lichen planus—a prospective randomized double-blind vehicle-controlled study. *Br J Dermatol.* 2008;159(4):936-941.
19. Thongprasom K, Carrozzo M, Furness S, Lodi G. Interventions for treating oral lichen planus. *Cochrane Database Syst Rev.* 2011 Jul 6;(7):CD001168.
20. Rajar UD, Majeed R, Parveen N, et al. Efficacy of aloe vera gel in the treatment of vulval lichen planus. *J Coll Physicians Surg Pak*. 2008;18(10):612-614.
21. McPherson T, Cooper S. Vulval lichen sclerosis and lichen planus. *Dermatol Ther.* 2010;23(5):523-532.
22. Thongprasom K, Dhanuthai K. Steroids in the treatment of lichen planus: a review. *J Oral Sci.* 2008;50(4):377-385.
23. Asch S, Goldenberg G. Systemic treatment of cutaneous lichen planus: an update. *Cutis.* 2011;87(3):129-134.
24. Wackernagel A, Legat FJ, Hofer A, et al. Psoralen plus UVA vs. UVB-311 nm for the treatment of lichen planus. *Photodermatol Photoimmunol Photomed.* 2007;23(1):15-19.
25. van der Hem PS, Egges M, van der Wal JE, Roodenburg JL. CO_2 laser evaporation of oral lichen planus. *Int J Oral Maxillofac Surg.* 2008;37(7):630-633.
26. Cafaro A, Albanese G, Arduino PG, et al. Effect of low-level laser irradiation on unresponsive oral lichen planus: early preliminary results in 13 patients. *Photomed Laser Surg*. 2010;28 Suppl 2: S99-S103.

155 REACTIVE ARTHRITIS

Heidi Chumley, MD
Angela Shedd, MD
Suraj Reddy, MD
Richard P. Usatine, MD

PATIENT STORY

A 29-year-old man presented with concerns about an extensive rash that had developed over the previous month. The rash was reported to involve the scalp, abdomen, penis, hands, and feet (**Figures 155-1** to **155-5**). He also complained of severe joint pain, involving the back, knees, and feet. He denied ocular, GI, or genitourinary complaints, but was prescribed a course of antibiotics last month when his partner was diagnosed with *Chlamydia*.

The patient's young age, rapid onset of symptoms, dermatologic findings, and arthritis were suggestive of reactive arthritis. The patient's joint pain was treated with NSAIDs and skin lesions were treated with topical corticosteroids. No antibiotics were prescribed because no current infectious agent was identified. In conjunction with a dermatologist, acitretin 25 mg daily was started to treat his psoriasiform lesions.

FIGURE 155-1 Reactive arthritis in a young man showing annular scalp lesions (circinate plaques). (*From Shedd AD, Reddy SG, Meffert JJ, Kraus EW. Acute onset of rash and oligoarthritis. J Fam Pract. 2007;56(10):811-814. Reproduced with permission from Frontline Medical Communications.*)

INTRODUCTION

Reactive arthritis is a noninfectious acute oligoarthritis that occurs in response to an infection, most commonly in the GI or urogenital tract. Patients present 1 to 4 weeks after the triggering infection, with joint pain in asymmetric large joints; eye disease, such as conjunctivitis; and skin changes including erythema nodosum, keratoderma blennorrhagicum, and circinate balanitis. Diagnosis is based on the clinical presentation plus evidence of associated infection. Treatment includes antiinflammatory medications and treatment of triggering infection.

FIGURE 155-2 Keratoderma blennorrhagicum with hyperkeratotic papules, plaques, and pustules that have coalesced to form circular borders. (*From Shedd AD, Reddy SG, Meffert JJ, Kraus EW. Acute onset of rash and oligoarthritis. J Fam Pract. 2007;56(10):811-814. Reproduced with permission from Frontline Medical Communications.*)

SYNONYMS

Reiter syndrome is no longer the preferred name as Dr. Reiter was a Nazi physician that performed unethical experimentation on human subjects.

EPIDEMIOLOGY

- Incidence is 0.6 to 27 per 100,000 people.[1]
- Most common in young adults ages 30 to 40 years; rare in children.[1]
- Reactive arthritis after a genitourinary (GU) infection is more common in young men; reactive arthritis after a GI infection is equally common in men and women.[1]

ETIOLOGY AND PATHOPHYSIOLOGY

- Follows a GI (*Yersinia*, *Salmonella*, *Shigella*, *Campylobacter*, or rarely *Escherichia coli* or *Clostridium difficile*) or GU (*Chlamydia trachomatis*, *Ureaplasma urealyticum*) infection; less commonly follows a respiratory infection with *Chlamydia* pneumonia.
- Mechanism by which the triggering agent leads to development of arthritis is not fully understood.

RISK FACTORS

- Infection with a triggering agent.
- Presence of human leukocyte antigen (HLA)-B27 is associated with an increased risk of chronic disease and a more severe arthritis.
- HLA-B27 has been found in a high percentage of patients with severe disease, but there is no increase in HLA-B27 prevalence in population studies.

DIAGNOSIS

Definite reactive arthritis: Both major criteria and one minor criterion.

Probable reactive arthritis: one major criterion and one minor criterion.

Major criteria:

- Arthritis with two of three features: asymmetric, mono- or oligoarthritis, lower limbs predominately affected.
- Preceding enteritis or urethritis.

Minor criteria:

- Evidence of triggering infection.
- Evidence of synovial infection.

CLINICAL FEATURES

- The classic triad consists of urethritis, conjunctivitis (**Figure 155-6**), and arthritis; however few patients present with the classic triad.
- Tendinitis, bursitis or enthesitis, or low back pain may be present.
- Skin findings (psoriasiform) typically involve the palms, soles (keratoderma blennorrhagicum) (**Figures 155-2** and **155-7**), and the glans penis (balanitis circinata). Nail dystrophy, thickening, and destruction may occur (**Figures 155-3** and **155-8**). Many other body surfaces may be affected including the scalp (see **Figure 155-1**), intertriginous areas (**Figure 155-4**), and the oral mucosa (**Figure 155-9**). Erosive lesions on the tongue and hard palate may be seen.
- Rarely, carditis and atrioventricular conduction disturbances are present.

LABORATORY TESTING

- No specific laboratory test is used to confirm reactive arthritis.
- Erythrocyte sedimentation rate (ESR) and C-reactive protein are usually elevated.
- Urethral/cervical swab or urine test for *C. trachomatis* when a GU infection precedes the onset of symptoms.

FIGURE 155-3 Erythema and scale seen on the toes of the patient in **Figure 155-1**. Note the nail involvement with subungual keratosis and onycholysis. The fourth toe is red and swollen; this is called dactylitis. (*From Shedd AD, Reddy SG, Meffert JJ, Kraus EW. Acute onset of rash and oligoarthritis. J Fam Pract. 2007;56(10):811-814. Reproduced with permission from Frontline Medical Communications.*)

FIGURE 155-4 The patient in **Figure 155-1** with psoriasiform lesion on the corona and glans. The patient also has erythema in the inguinal area that resembles inverse psoriasis. This particular case does not exemplify classic balanitis circinata, which is characterized by annular or arcuate thin scaly plaques, as opposed to the nonspecific scaly plaques found on this patient. (*Courtesy of Suraj Reddy, MD.*)

FIGURE 155-5 Psoriatic-appearing plaque on the leg in the same patient with reactive arthritis in **Figure 155-1**. (*From Shedd AD, Reddy SG, Meffert JJ, Kraus EW. Acute onset of rash and oligoarthritis. J Fam Pract. 2007;56(10):811-814. Reproduced with permission from Frontline Medical Communications.*)

FIGURE 155-7 Keratoderma blennorrhagicum on the soles of the foot of a man with reactive arthritis. (*Courtesy of Ricardo Zuniga-Montes, MD.*)

FIGURE 155-6 Reactive arthritis with conjunctivitis as a result of chlamydial pelvic inflammatory disease in a 42-year-old woman. She presented with fever, chills, and generalized pain in her joints, abdomen, and pelvis. (*Courtesy of Joseph Mazziotta, MD, and from Mazziotta JM, Ahmed N. Conjunctivitis and cervicitis. J Fam Pract. 2004;53(2):121-123. Reproduced with permission from Frontline Medical Communications.*)

FIGURE 155-8 Nail dystrophy, thickening, and nail destruction in a man with reactive arthritis. (*Courtesy of Ricardo Zuniga-Montes, MD.*)

- Stool culture may detect an enteric pathogen when GI infection precedes the onset of symptoms.
- *Salmonella*, *Yersinia*, and *Campylobacter* antibodies can be detected in the serum after microbes are no longer detectable in the stool.
- Skin biopsy if performed resembles that of psoriasis with acanthosis of the epidermis, a neutrophilic perivascular infiltrate, and spongiform pustules.

DIFFERENTIAL DIAGNOSIS

- Spondyloarthropathies and reactive arthropathies may present with acute joint pain but often lack the skin findings seen with reactive arthritis (see Chapter 98, Ankylosing Spondylitis).
- Psoriatic arthritis may be easily confused especially in immunocompromised patients. Lack of constitutional symptoms and a more chronic course help differentiate from reactive arthritis.
- Gonococcal arthritis is characterized by migratory polyarthralgia that settles in one or more joints. Often erythematous macules or hemorrhagic papules on acral sites help distinguish from reactive arthritis.
- Rheumatoid arthritis often presents with a progressive, symmetric polyarthritis of the small joints of the hands and wrists. Females are affected more often than males (see Chapter 97, Rheumatoid Arthritis).

MANAGEMENT

- Treat patients with acute *C. trachomatis* with 1 g azithromycin single dose or 100 mg doxycycline twice a day for 7 days.[1,2] SOR A Treat partners when possible.[1]
- The current recommendation no longer calls for long-term antibiotics as studies do not support this previous treatment.[5,6] SOR B
- GI-triggering infections are typically self-limiting and do not require antibiotics.
- Treat inflammation with NSAIDs.[2] SOR B
- Consider glucocorticoid joint injections in patients with severe joint pain.
- For refractory arthritic disease, immunosuppressive agents, such as sulfasalazine at 2000 mg/day, have demonstrated some benefit.[3] SOR B
- Treat mucosal and skin lesions with topical corticosteroids.
- Psoriasiform skin lesions may be treated with some of the same medications used to treat psoriasis (including acitretin). SOR C
- Systemic steroids are indicated for patients with systemic symptoms (fever) or in those who develop carditis.
- Current evidence demonstrates that chronic antimicrobial therapy is not recommended.[5,6]

REFERRAL

- Refer patients with severe or nonresponsive joint pain to a rheumatologist.
- Refer patients who develop cardiac manifestations to a cardiologist.

FIGURE 155-9 Oral mucosal inflammation with reactive arthritis secondary to chlamydial pelvic inflammatory disease. The cervix was also inflamed on examination. (*Courtesy of Joseph Mazziotta, and from Mazziotta JM, Ahmed N. Conjunctivitis and cervicitis. J Fam Pract. 2004;53(2):121-123. Reproduced with permission from Frontline Medical Communications.*)

PROGNOSIS

- Arthritic symptoms typically resolve in 3 to 5 months.[1] Persistent symptoms that last longer than 6 months are associated with the development of chronic symptoms.
- Sixteen percent to 68% of patients developed chronic symptoms across several studies. Type of triggering infection and presence of HLA-B27 affect prognosis.

FOLLOW-UP

- Follow patients closely at the time of diagnosis to ensure response to therapy and timely referral for nonresponders.

PATIENT EDUCATION

There is no curative treatment. Symptoms may resolve permanently, relapse, or persist. Medications and physical/occupational therapy can help relieve pain and preserve function. Seek medical care for extraarticular symptoms, especially those involving the eye.

PATIENT RESOURCES

- FamilyDoctor.org. *Reactive Arthritis*—**http://familydoctor.org/familydoctor/en/diseases-conditions/reactive-arthritis.html.**

PROVIDER RESOURCES

- Medscape. *Reactive Arthritis*—**http://emedicine.medscape.com/article/331347.**

REFERENCES

1. Hannu T. Reactive arthritis. *Best Pract Res Clin Rheumatol.* 2011; 25(3):347-357.
2. Colmegna I, Cuchacovich R, Espinoza LR. HLA-B27-associated reactive arthritis: Pathogenetic and clinical considerations. *Clin Microbiol Rev.* 2004;17(2):348-369.
3. Clegg DO, Reda DJ, Weisman MH, et al. Comparison of sulfasalazine and placebo in the treatment of reactive arthritis (Reiter's syndrome). A Department of Veterans Affairs Cooperative Study. *Arthritis Rheum.* 1996;39(12):2021-2027.
5. Kvien TK, Gaston JS, Bardin I, et al. Three months treatment of reactive arthritis with azithromycin: a EULAR double blind, placebo controlled study. *Ann Rheum Dis.* 2004;63(9):1113-1119.
6. Putschky N, Pott HG, Kuipers JG, et al. Comparing 10-day and 4-month doxycycline courses for treatment of *Chlamydia trachomatis*–reactive arthritis: a prospective, double-blind trial. *Ann Rheum Dis.* 2006;65(11):1521-1524.

156 ERYTHRODERMA

David Henderson, MD

PATIENT STORY

A 34-year-old man presented with red skin from his neck to his feet for the last month (**Figure 156-1**). He was having a lot of itching and his skin was shedding so that wherever he would sit, there would be a pile of skin that would remain. He denied fever and chills. He admitted to smoking and drinking heavily. The patient's vital signs were stable with normal blood pressure and he preferred not to be hospitalized. He had some nail pitting but no personal or family history of psoriasis. The presumed diagnosis was erythrodermic psoriasis but a punch biopsy was done to confirm this. A complete blood count (CBC) and chemistry panel were ordered in anticipation of the patient needing systemic medications. A purified protein derivative (PPD) was also placed. The patient was started on total body 0.1% triamcinolone under wet wrap overnight and given a follow-up appointment for the next day. The patient was also counseled to quit smoking and drinking. The following day his labs showed mild elevation in his liver function tests (LFTs) only. The following day his PPD was negative and he was already feeling a bit better from the topical triamcinolone. Cyclosporine was started and the patient improved rapidly.

FIGURE 156-1 Erythrodermic psoriasis in a 34-year-old man. (*Courtesy of Richard P. Usatine, MD.*)

INTRODUCTION

Erythroderma is an uncommon condition that affects all age groups. It is characterized by a generalized erythematous rash with associated scaling. It is generally a manifestation of another underlying dermatosis or systemic disorder. It is associated with a range of morbidity, and can have life-threatening metabolic and cardiovascular complications. Therapy is usually focused on treating the underlying disease, as well as addressing the systemic complications.

SYNONYMS

Exfoliative dermatitis.

EPIDEMIOLOGY

Erythroderma or exfoliative dermatitis is an uncommon condition that is generally a manifestation of underlying systemic or cutaneous disorders.

- It affects all age groups, from infants to the elderly.
- In adults, the average age of onset is 41 to 61 years of age, with a male-to-female ratio of 2:1 to 4:1.[1]
- It accounts for approximately 1% of all dermatologic hospital admissions.[2]
- It can be a very serious condition resulting in metabolic, infectious, cardiorespiratory, and thermoregulatory complications.[3]

TABLE 156-1 Conditions Most Commonly Associated with Erythroderma

Dermatoses	Infections	Systemic/Cancer	Pediatric	Drugs
Psoriasis (**Figures 156-1, 156-2, 156-3,** and **156-8**)	HIV	Sarcoidosis	Omenn syndrome	Penicillins
Atopic dermatitis (**Figure 156-4**)	Norwegian scabies	Thyrotoxicosis	Kwashiorkor	Sulfonamides
Contact dermatitis (**Figure 156-5**)	Hepatitis	Graft versus host reaction	Cystic fibrosis	Tetracycline derivatives
Seborrhea (**Figure 156-5**)	Murine typhus (**Figure 156-6**)	Dermatomyositis	Amino acid disorders	Sulfonylureas
Pityriasis rubra pilaris	Human herpesvirus 6	Lung cancer	Immunodeficiency	Calcium channel blockers
Photosensitivity reaction	Toxic shock syndrome	Colon cancer		Captopril
Bullous pemphigoid	Staphylococcal scalded skin syndrome	Prostate cancer		Thiazides
Impetigo herpetiformis	Histoplasmosis Tuberculosis	Breast cancer B- and T-cell lymphoma (**Figure 156-7**) Leukemia		NSAIDs Barbiturates Vancomycin Lithium Antivirals Antimalarials

ETIOLOGY AND PATHOPHYSIOLOGY

In almost 50% of cases, erythroderma occurs in the setting of a preexisting dermatosis; however, it may also occur secondary to underlying systemic disease, malignancy, and drug reactions. It is classified as idiopathic in 9% to 47% of cases.[3]

- The pathophysiology is not fully understood, but it is related to the pathophysiology of the underlying disease. However, the factors that promote the development of erythroderma are not well defined.
- The rapid maturation and migration of cells through the epidermal layer results in excessive scaling. The rapid turnover of the epidermis also results in fluid, electrolyte, and protein losses that may have severe metabolic consequences, including heart failure and acute respiratory distress syndrome.[4]
- The underlying pathogenesis may be an interaction of immunologic modulators, including Interleukins 1, 2, and 8, as well as tumor necrosis factor.[2]

Table 156-1 presents the conditions most commonly associated with erythroderma. Dermatologic conditions commonly associated with erythroderma include:[1–5]

- Psoriasis, especially generalized pustular psoriasis with exfoliation (**Figures 156-1** to **156-3**).
- Atopic dermatitis (**Figure 156-4**).[2,3]
- Contact dermatitis (**Figure 156-5**).
- Seborrhea (**Figure 156-5**).

FIGURE 156-2 Erythrodermic psoriasis with sheets of exfoliation causing dehydration and life-threatening illness. This is secondary to generalized pustular psoriasis. (*Courtesy of Jack Resneck, Sr., MD.*)

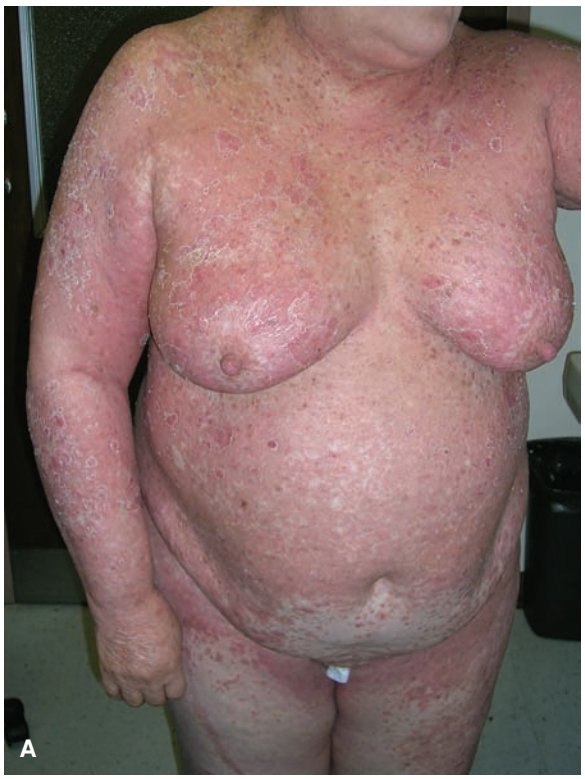

FIGURE 156-3 **A.** Generalized pustular psoriasis causing a life-threatening case of erythroderma in a 67-year-old woman. This all started 3 weeks before presentation and she had no previous history of psoriasis. Patient was hospitalized and treated with topical steroids and oral acitretin with good results. **B.** Close-up of posterior thigh showing pustules on an erythematous plaque in a new case of erythroderma from generalized pustular psoriasis. (*Courtesy of Richard P. Usatine, MD.*)

FIGURE 156-4 Erythroderma atopic dermatitis in a 55-year-old woman. (*Courtesy of Richard P. Usatine, MD.*)

- Pityriasis rubra pilaris.
- Bullous pemphigoid.[4]
- Impetigo herpetiformis.[4]
- Photosensitivity reaction.[4]

Erythroderma may also occur secondary to a number of infectious diseases, including:

- HIV.
- Tuberculosis.
- Norwegian scabies.
- Hepatitis.
- Murine typhus (**Figure 156-6**).
- Human herpesvirus 6.[4]
- Toxic shock syndrome.[4]
- Staphylococcal scalded skin syndrome.[4]
- Histoplasmosis.[3]

Systemic diseases associated with erythroderma include the following:

- Sarcoidosis.
- Thyrotoxicosis.
- Graft versus host reaction.
- Dermatomyositis.[3,4]

The exact incidence of erythroderma in association with underlying malignancy is not known but reticuloendothelial neoplasms are the most common, most notably T-cell lymphomas.[1,2] It may precede or follow the diagnosis of cutaneous T-cell lymphoma, and chronic idiopathic erythroderma carries a high risk of development of cutaneous T-cell lymphoma over time (**Figure 156-7**).[5] In addition colon, lung, prostate, and thyroid malignancies account for 1% of cases of erythroderma.[2] Specifically in children, it may be associated with:

- Kwashiorkor.
- Cystic fibrosis.
- Amino acid disorders.[1–5]

Drug reactions are a common cause of erythroderma. The list of drugs associated with erythroderma is extensive and includes both systemic and topical medications, many of which are very commonly used, including a number of herbal, homeopathic, and ayurvedic medications.[5] The list of medications includes the following:

- Penicillins.
- Sulfonamides.
- Tetracycline derivatives.
- Sulfonylureas.
- Calcium channel blockers.
- Captopril.
- Thiazides.
- NSAIDs.
- Barbiturates.
- Lithium.[2,3,5]

FIGURE 156-5 **A.** Erythroderma caused by seborrheic dermatitis and contact dermatitis. The biopsy showed changes consistent with seborrheic dermatitis but the history suggested that the erythroderma was worsened by contact with products used in auto maintenance. **B.** After the erythroderma cleared, the arms and hands would worsen every time the patient went back to working on cars. (*Courtesy of Richard P. Usatine, MD.*)

In children, an association with topical boric acid has been identified.[5]

The cause of erythroderma may not always be identified (**Figure 156-9**).

DIAGNOSIS

CLINICAL FEATURES

- The clinical presentation of erythroderma may be variable depending on the underlying cause. In association with drug reactions, the onset tends to be more abrupt and the resolution more rapid.
- Cutaneous manifestations begin with pruritic, erythematous patches that spread and coalesce into areas of erythema that cover the body. Scaling eventually develops. Large scales are seen more often in acute settings and in chronic erythroderma smaller scales predominate.
- Although the red color of erythroderma is very evident in light skin, erythroderma may be only light pink to brown in darker-skinned individuals (**Figure 156-9**).
- Scalp involvement is very common with alopecia occurring in 25% of patients.[2]
- Systemic manifestations associated with compromise of the protective cutaneous barrier and loss of vasoconstriction of vessels in the dermis that occurs in erythroderma include loss of fluid and electrolytes.
- Protein losses can be as high as 25% to 30% in psoriatic erythroderma, resulting in hypoalbuminemia and edema.[3] Increased perfusion to denuded inflamed skin may result in thermoregulatory disturbances and high output cardiac failure. In addition, there is an increased risk of staphylococcal infection and sepsis.[2,3] Any of these complications can be life threatening.

TYPICAL DISTRIBUTION

The distribution is variable, but there is usually sparing of mucous membranes, the palms, and the soles of the feet. Sparing of the nose and nasolabial region has also been reported.[2]

LABORATORY STUDIES

Skin biopsy is useful, but often nondiagnostic. Because 50% of individual biopsies fail to reveal a specific diagnosis, multiple biopsies are recommended when evaluating patients for erythroderma. In addition to conventional histopathologic evaluation, direct immunofluorescence may be helpful in immunobullous disease (e.g., pemphigus). T-cell receptor gene rearrangement studies may aid in the diagnosis of lymphoproliferative disorders.[3] Laboratory tests are often nonspecific; however, common findings include:

- Leukocytosis.
- Lymphocytosis.
- Mild anemia.
- Eosinophilia.
- Elevated sedimentation rate.
- Polyclonal gammopathy.
- Elevated immunoglobulin (Ig) E levels.

FIGURE 156-6 Murine typhus causing erythema and exfoliation in a febrile systemically ill man in southern Texas. (*Courtesy of Angela Peng, MD.*)

FIGURE 156-7 Erythema secondary to new-onset mycosis fungoides. (*Courtesy of the University of Texas Health Sciences Center, Division of Dermatology.*)

- Hypoalbuminemia.
- Elevated serum creatinine.
- Elevated uric acid levels.[1–5]

HIV testing should be considered in those with risk factors.[5] In children a sweat test, zinc, amino acid, and lipid levels should be considered.[5]

DIFFERENTIAL DIAGNOSIS

Erythroderma is the dermatologic manifestation of a number of underlying disease processes, including infectious diseases, lymphoproliferative disorders, malignancies, dermatoses, acquired and inborn metabolic disorders, and drug reactions. The key to proper diagnosis and treatment is contingent on identification of the underlying cause.[1–5] (For a list of underlying conditions, see "Etiology and Pathophysiology" above.)

MANAGEMENT

Hospitalization and urgent dermatologic referral should be considered for patients presenting with erythroderma acutely as the metabolic, infectious, thermoregulatory, and cardiovascular complications can be life threatening (**Figures 156-1** to **156-9**).[2,5]

Therapeutic interventions include:

- Topical skin care measures such as emollients, oatmeal baths, and wet dressings.[1–5] SOR C
- Mid-potency topical steroid ointments such as 0.1% triamcinolone applied to all the affected areas.[1–5] SOR C Using the wet wrap technique (see Chapter 145, Atopic Dermatitis) can help promote quicker absorption and faster onset of action. SOR C
- High potency topical steroids and topical immunomodulators should be avoided owing to risk of increased cutaneous absorption.[3] SOR C
- Systemic steroids are useful in drug reactions and eczema, but should be avoided in psoriasis.[2,3,5] SOR C
- Consider methotrexate, cyclosporine, for cases secondary to psoriasis. Infliximab has also been used (**Figures 156-3** to **156-5**).[2,4] SOR C Cyclosporine acts most rapidly in cases caused by psoriasis or atopic dermatitis. SOR C
- Immunosuppressive agents (methotrexate, azathioprine, infliximab).[2–4] SOR C
- Discontinuation of all nonessential medications.[2,3] SOR C
- Antibiotic therapy when infection is suspected.[2,3] SOR C
- Close monitoring of fluid, electrolyte, and nutritional status and replacement of deficits.[1–5] SOR C

PATIENT EDUCATION

Patients should be advised that erythroderma can be life-threatening because of the infectious, thermoregulatory, metabolic, and cardiovascular complications. This is important when it might be necessary

FIGURE 156-8 Erythrodermic psoriasis in a black man showing visible scaling but less obvious erythema secondary to the darker skin color. (*Courtesy of Richard P. Usatine, MD.*)

to hospitalize a patient that does not appreciate the seriousness of the condition. They should also be advised that with certain underlying etiologies, the condition may recur. This is particularly true of idiopathic erythroderma (**Figure 156-8**).

FOLLOW-UP

The prognosis in erythroderma is very much dependent on the underlying cause. Most deaths occur in malignancy-associated erythroderma. Drug-induced erythroderma carries the best prognosis and the lowest risk of recurrence. Relapses occur in 15% of patients with psoriatic erythroderma. Fifty percent of patients with idiopathic erythroderma experience partial remission, and one third complete remission.[3]

PATIENT RESOURCES

- Health-Disease—a family medical guide: **http://www.health-disease.org/skin-disorders/erythroderma.htm.**

PROVIDER RESOURCES

- Medscape. *Erythroderma (Generalized Exfoliative Dermatitis)*—**http://emedicine.medscape.com/article/1106906.**
- DermNet NZ. *Erythroderma*—**http://www.dermnetnz.org/reactions/erythroderma.html.**
- DermIS. *Congenital Ichthyosiform and Psoriatic Erythroderma*—**http://www.dermis.net/dermisroot/en/list/erythroderma/search.htm.**

REFERENCES

1. Rothe MJ, Bialy TL, Grant-Kels JM. Erythroderma. *Dermatol Clin*. 2000;18:405-415.
2. Karakayli G, Beckham G, Orengo I, Rosen T. Exfoliative dermatitis. *Am Fam Physician*. 1990;59(3):625-630.
3. Rothe JH, Bernstein ML, Grant-Kels JM. Life-threatening erythroderma: diagnosing and treating the "red man". *Clin Dermatol*. 2005;23(2):206-217.
4. Grant-Kels JM, Bernstein ML, Rothe MJ. Exfoliative dermatitis. In: Wolff K, Goldsmith LA, Katz SI, Gilchrest B, Paller AS, Leffell DJ, eds. *Fitzpatrick's Dermatology in General Medicine*, 7 ed. http://www.accessmedicine.com/content.aspx?aID=2984502#2984502.
5. Sehgal VN, Srivastava G. Erythroderma/generalized exfoliative dermatitis in pediatric practice: an overview. *Int J Dermatol*. 2006;45:831-839.

FIGURE 156-9 **A.** Complete erythroderma of unknown etiology with extreme reddening of the skin and exfoliation. **B.** The back of the same patient with a closer view of the exfoliation. (*Courtesy of Gwen Denton, MD.*)

SECTION 9 BENIGN NEOPLASMS

157 SKIN TAG

Mindy A. Smith, MD, MS

PATIENT STORY

A 55-year-old man requests removal of multiple skin tags around his neck. He is overweight and has diabetes and acanthosis nigricans. Although some of his skin tags occasionally get caught on his clothing, he just doesn't like the way they look. The patient chose to have many of them removed by the snip excision method.

FIGURE 157-1 Many skin tags and acanthosis nigricans on the neck of a man with diabetes. (*Courtesy of Richard P. Usatine, MD.*)

INTRODUCTION

Skin tags (acrochordons) are flesh-colored, pedunculated lesions that tend to occur in areas of skin folds especially around the neck and in the axillae.

SYNONYMS

- Also referred to as fibroepithelial polyps.

EPIDEMIOLOGY

- In an unselected population study, skin tags were found in 46% of patients, particularly in patients who were obese.[1]
- Skin tags increase in frequency through the fifth decade of life so that as many as 59% of individuals have them by the time they are 70 years old; however, the increase slows after age 50 years.[1]

ETIOLOGY AND PATHOPHYSIOLOGY

- Three types of skin tags are described:[1]
  - Small, furrowed papules of approximately 1 to 2 mm in width and height, located mostly on the neck and the axillae (**Figure 157-1**).
  - Single or multiple filiform lesions of approximately 2 mm in width and 5 mm in length occurring elsewhere on the body (**Figure 157-2**).
  - Large, pedunculated tumor or nevoid, bag-like, soft fibromas that occur on the lower part of the trunk (**Figure 157-3**).
- Etiology is unknown, but it is theorized that skin tags occur in localized areas with a paucity of elastic tissue resulting in sessile or atrophic lesions. In addition, hormone imbalances appear to facilitate their development (e.g., high levels of estrogen and progesterone seen during pregnancy) and other factors including epidermal

FIGURE 157-2 Filiform pedunculated skin tags on the eyelids. These were removed with a radiofrequency loop after local anesthesia with lidocaine and epinephrine to minimize bleeding. (*Courtesy of Richard P. Usatine, MD.*)

growth factor, tissue growth factor-α, and infection (e.g., human papillomavirus) have been implicated as cofactors.

- Acrochordons also appear to be associated with impaired carbohydrate metabolism and diabetes mellitus (**Figure 157-1**).[2]
- Pedunculated lesions may become twisted, infarcted, and fall off spontaneously.
- Very rarely neoplasms are found at the base of skin tags. In a study of consecutive cutaneous pathology reports, 5 of 1335 clinically diagnosed fibroepithelial polyp specimens were malignant (i.e., 4 were basal cell carcinomas and 1 was squamous cell carcinoma in situ).[3] There is selection bias in this study because most skin tags are not sent to the pathologist.

DIAGNOSIS

CLINICAL FEATURES

- Small, soft, usually pedunculated lesions.
- Skin colored or hyperpigmented.
- Most vary in size from 2 to 5 mm, but larger ones may be seen.
- Usually asymptomatic, but can be pruritic or become painful and inflamed by catching on clothing or jewelry.

TYPICAL DISTRIBUTION

- Most typically seen on the neck and in the axillae (**Figure 157-1**), but any skin fold may be affected. They are also seen on the trunk (**Figure 157-3**), the abdomen, and the back.

ANCILLARY TESTING

- Dermatoscopy may be a useful diagnostic tool to analyze acrochordon-like lesions in people with basal cell syndromes to facilitate early diagnosis and treatment.[4]

BIOPSY

- Not usually indicated unless the diagnosis is not clear. Typical skin tags do not need to be sent to pathology upon removal. Skin tags, on histology, are characterized by acanthotic, flattened, or frond-like epithelium. A papillary-like dermis is composed of loosely arranged collagen fibers and dilated capillaries and lymphatic vessels.

DIFFERENTIAL DIAGNOSIS

Lesions that can be confused with skin tags include:

- Warts—Cutaneous neoplasm caused by papilloma virus. Sessile, dome-shaped lesions approximately 1 cm in diameter with hyperkeratotic surface. Paring usually demonstrates a central core of keratinized debris and punctate bleeding points.
- Neurofibromas—Benign Schwann cell tumors; cutaneous tumors tend to form multiple, soft pedunculated masses (**Figure 157-4**).
- Epidermal hyperplasia in melanocytic nevi (also called keratotic melanocytic nevus [KMN])—Although most common moles are round, tan to brown, less than 6 mm, and flat to slightly elevated, some nevi have overlying hyperplastic epidermis resembling skin

FIGURE 157-3 Large pedunculated bag-like soft fibroma on the trunk. This is a large acrochordon or fibroepitheliomatous polyp. Local anesthetic was given prior to excision. (*Courtesy of Richard P. Usatine, MD.*)

FIGURE 157-4 Multiple soft neurofibromas on the neck of a patient with neurofibromatosis. (*Courtesy of Richard P. Usatine, MD.*)

tags. In a study of melanocytic nevi submitted for pathology over an 8-month period, 6% were KMN, most often located on the trunk (76%).[5] Dermal nevi, can be pedunculated but they are usually larger than skin tags and may appear warty above the stalk.

- Basal cell carcinomas in certain syndromes.[4,6]

MANAGEMENT

Skin tags may be removed for cosmetic reasons or because of irritation in a number of ways:

- Small lesions may be snipped with a sharp iris scissor with or without anesthesia (**Figure 157-5**).
- Larger skin tags and fibromas may be removed with shave excision after injecting with lidocaine and epinephrine.
- If there is any bleeding, aluminum chloride on a cotton-tipped applicator is applied for hemostasis.
- Electrodesiccation with or without anesthesia works for very tiny skin tags too small to grab with the forceps.
- Skin tags on the eyelids may be removed with a radiofrequency loop after local anesthesia with lidocaine and epinephrine to minimize bleeding.
- Cryotherapy can be applied directly to the skin tag with a Cryogun or a cotton-tipped applicator. One preferred method involves dipping forceps into liquid nitrogen and then grasping the skin tag until it turns white. This allows you to grasp the skin tag without freezing the skin around it. This is especially helpful on the eyelids. A special cryo forceps is made by Brymill, Inc. that has more metal at the end to hold the cold longer (**Figure 157-6**). This is a very efficient way to treat multiple skin tags quickly.
- An adhesive patch that applies pressure to the base of a skin tag was found effective in 65% of skin tags in one case series.[7]
- Most insurance companies will not pay for the cosmetic removal of skin tags.
- To avoid large healthcare costs, only send suspicious looking skin tags to the pathologist.

FOLLOW-UP

- Follow-up is not usually necessary.

PATIENT EDUCATION

- Advise patients that these are benign growths that can be removed if irritation occurs or for cosmetic purposes. Patients who are overweight should be encouraged to lose weight for their general health and to avoid new skin tags.

PATIENT RESOURCES

- **http://www.nlm.nih.gov/medlineplus/ency/article/000848.htm.**

FIGURE 157-5 Snip excision of skin tag with iris scissors and no anesthesia. (*Courtesy of Richard P. Usatine, MD.*)

FIGURE 157-6 Cryotherapy using Cryo Tweezers to grasp the skin tag without freezing the skin around it. This is especially helpful on the eyelids. (*Courtesy of Richard P. Usatine, MD.*)

PROVIDER RESOURCES

- For quick cryosurgery of skin tags, the Cryo Tweezer can be ordered from: **http://www.brymill.com/.**

REFERENCES

1. Banik R, Lubach D. Skin tags: localization and frequencies according to sex and age. *Dermatologica.* 1987;174(4):180-183.
2. Demir S, Demir Y. Acrochordon and impaired carbohydrate metabolism. *Acta Diabetol.* 2002;39(2):57-59.
3. Eads TJ, Chuang TY, Fabre VC, et al. The utility of submitting fibroepithelial polyps for histological examination. *Arch Dermatol.* 1996;132(12):1459-1462.
4. Feito-Rodríguez M, Sendagorta-Cudós E, Moratinos-Martínez M, et al. Dermatoscopic characteristics of acrochordon-like basal cell carcinomas in Gorlin-Goltz syndrome. *J Am Acad Dermatol.* 2009;60(5):857-861.
5. Horenstein MG, Prieto VG, Burchette JL Jr, Shea CR. Keratotic melanocytic nevus: a clinicopathologic and immunohistochemical study. *J Cutan Pathol.* 2000;27(7):344-350.
6. Lortscher DN, Sengelmann RD, Allen SB. Acrochordon-like basal cell carcinomas in patients with basal cell nevus syndrome. *Dermatol Online J.* 2007;13(2):21.
7. Fredriksson CH, Ilias M, Anderson CD. New mechanical device for effective removal of skin tags in routine health care. *Dermatol Online J.* 2009;15(2):9.

158 SEBORRHEIC KERATOSIS

Mindy Smith, MD, MS
Richard P. Usatine, MD

PATIENT STORY

An elderly woman noted a growth of a lesion on her chest (**Figure 158-1**). She was afraid that it might be melanoma. Her family physician recognized the typical features of a seborrheic keratosis (SK) (stuck-on with visible horn cysts) and attempted to reassure her. Dermoscopy was performed and the features were so typical of an SK; the physician was able to convince the patient to not have a biopsy (**Figure 158-2**). The black comedonal-like openings and white milia-like cysts are typical of an SK and can be seen with the naked eye and magnified with a dermatoscope.

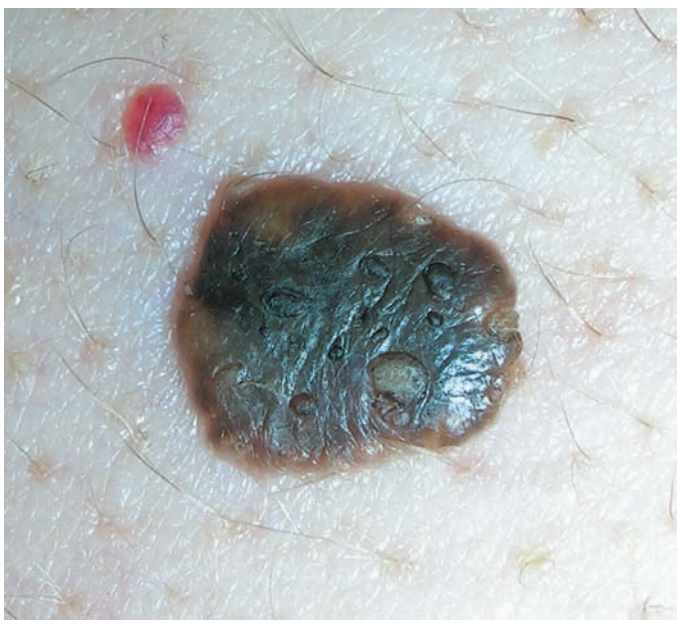

FIGURE 158-1 Seborrheic keratosis with associated horn cysts. (*Courtesy of Richard P. Usatine, MD.*)

INTRODUCTION

- A SK is a benign skin tumor and a form of localized hyperpigmentation as a result of epidermal alteration; it develops from the proliferation of epidermal cells, although the cause is unknown.

EPIDEMIOLOGY

- Most common benign tumor in older individuals; frequency increases with age.
- In an older study of individuals older than age 64 years in North Carolina, 88% had at least one SK. Ten or more SKs were found in 61% of the black men and women, 38% of the white women, and 54% of the white men in the study.[1]
- In an Australian study preformed in 2 general practices, 23.5% (40 out of 170) of individuals between ages 15 and 30 years had at least 1 SK; prevalence and size increased with age.[2]
- Approximately half of cases of multiple SKs occur within families, with an autosomal dominant mode of inheritance.[3]

ETIOLOGY AND PATHOPHYSIOLOGY

- In pigmented SKs, the proliferating keratinocytes secrete melanocyte-stimulating cytokines triggering activation of neighboring melanocytes.[3]
- A high frequency of mutations have been found in certain types of SKs in the gene encoding the tyrosine kinase receptor fibroblast growth factor receptor 3 (FGFR3).[3] One study found that FGFR3 and transcription factor forkhead box N1 (FOXN1) were highly expressed in SKs but close to undetectable in squamous cell skin cancer.[4] This may represent a positive regulatory loop between FGFR3 and FOXN1 that underlies a benign versus malignant skin tumor phenotype.
- Reticulated SKs, usually found on sun-exposed skin, may develop from solar lentigines.[3]

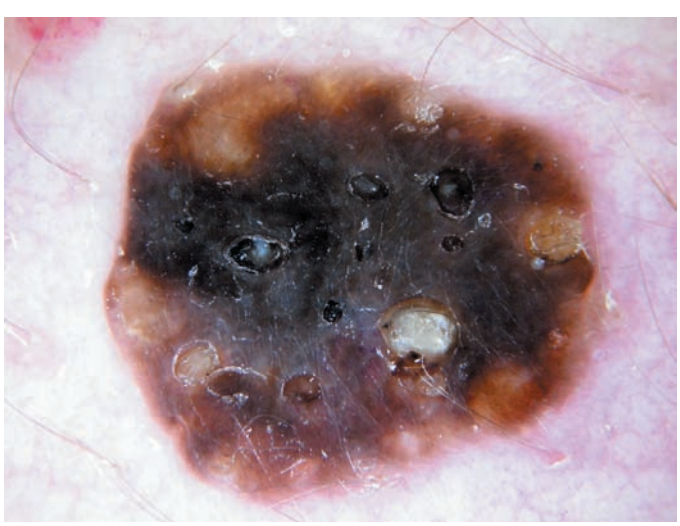

FIGURE 158-2 Dermoscopy of the seborrheic keratosis in the previous figure showing comedo-like openings (black-like blackheads) and milia-like cysts (white-like milia). (*Courtesy of Richard P. Usatine, MD.*)

- Multiple eruptive seborrheic keratoses (the sign of Leser-Trélat) can be associated with internal malignancy (most often adenocarcinoma of the GI tract) (**Figure 158-3**),[5] although this association has been questioned.[6]
- An eruption of seborrheic keratoses may develop after an inflammatory dermatosis such as severe sunburn or eczema.[3] There is also a report of exacerbation of a SK by topical fluorouracil.[7]

FIGURE 158-3 Multiple eruptive seborrheic keratoses as seen in the sign of Lesser-Trélat. In this case the malignancy workup was negative. (*Courtesy of Angela Shedd, MD.*)

DIAGNOSIS

SKs have a variety of appearances.

CLINICAL FEATURES

- Typically oval or round brown plaques with adherent greasy scale (**Figure 158-4**).
- Color ranges from black to tan (**Figures 158-4** to **158-6**).
- Most often have a velvety to finely verrucous surface and appear to be "stuck on."
- Some are so verrucous they can appear to be warty (**Figure 158-6**).
- Lesions may be large (up to 35 × 15 cm), pigmented, and have irregular borders (**Figure 158-5**).
- Lesions can also be flat (**Figure 158-7**).
- Many lesions show keratotic plugging of the surface (**Figures 158-1** and **158-2**).
- May have surface cracks and associated horn cysts (keratin-filled cystic structures). The dermoscopy terms for the horn cysts are comedo-like openings and milia-like cysts (**Figures 158-1** and **158-2**; see Appendix C, Dermoscopy).
- Occasionally, lesions become irritated and can itch, grow, and bleed; secondary infection may occur.
- Variants of SKs include:
  - Dermatosis papulosa nigra—Consists of multiple brown-black dome-shaped, smooth papules found on the face in young and middle-age persons of color, predominantly African Americans (**Figures 158-8** and **158-9**).
  - Stucco keratosis—Consists of large numbers of superficial gray-to-light brown flat keratotic lesions usually on the tops of the feet, the ankles, and the back of the hands and forearms (**Figure 158-10**).

TYPICAL DISTRIBUTION

- Trunk, face, back, abdomen, extremities; not present on the palms and soles or on mucous membranes. May be present on the areola and breasts (**Figures 158-11** and **158-12**).
- Dermatosis papulosa nigra is found on the face, especially the upper cheeks and lateral orbital areas (**Figures 158-8** and **158-9**).

IMAGING

- No imaging studies are needed unless there is a sudden appearance of multiple seborrheic keratoses as in the sign of Lesser-Trélat (**Figure 158-3**). These are associated with adenocarcinoma of the GI tract, lymphoma, Sézary syndrome, and acute leukemia.[3,8]

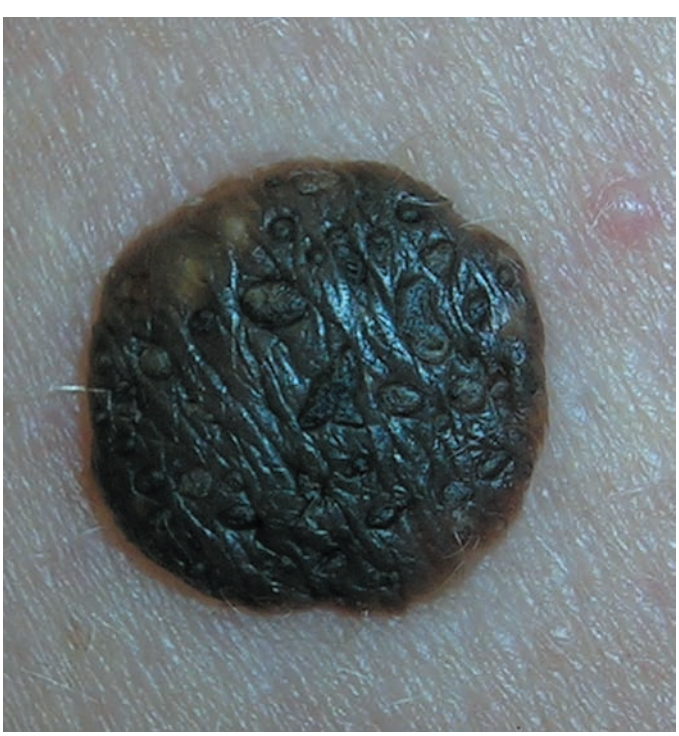

FIGURE 158-4 Round elevated seborrheic keratosis with very visible horn cysts. (*Courtesy of Richard P. Usatine, MD.*)

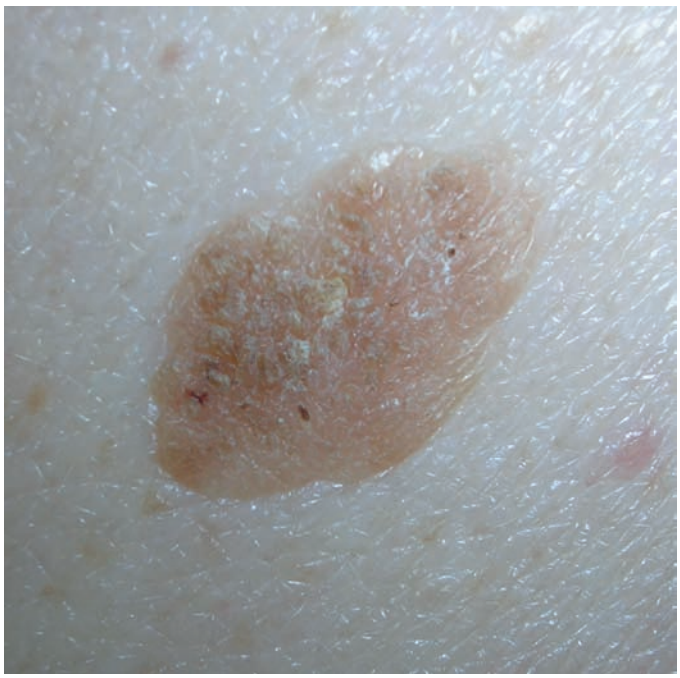

FIGURE 158-5 Seborrheic keratosis that is lightly pigmented, waxy, and appears stuck-on. (*Courtesy of Richard P. Usatine, MD.*)

FIGURE 158-6 Seborrheic keratosis with verrucous appearance on the forehead. (*Courtesy of Richard P. Usatine, MD.*)

FIGURE 158-7 Seborrheic keratosis with irregular borders and variation in color that suggest a possible melanoma. (*Courtesy of Richard P. Usatine, MD.*)

FIGURE 158-8 Dermatosis papulosa nigra with multiple seborrheic keratoses on the face of a Central American woman. (*Courtesy of Richard P. Usatine, MD.*)

FIGURE 158-9 Dermatosis papulosa nigra on the cheeks and in the hair line. The patient was treated effectively with cryotherapy and had a great cosmetic result. (*Courtesy of Richard P. Usatine, MD.*)

BIOPSY

- Should be performed if there is a suspicion of melanoma (**Figures 158-7** and **158-13**). Some melanomas resemble SKs and a biopsy is needed to avoid missing the diagnosis of melanoma. Do not freeze or curette a suspicious SK; these need surgical intervention to send tissue to the pathologist.

DIFFERENTIAL DIAGNOSIS

- Melanoma—When keratin plugs are visible in the surface of the SK, this helps to distinguish it from a melanoma. **Figure 158-7** is a SK that has the ABCDE features (Asymmetry, Border irregular, Color variation, Diameter >6 mm, Evolving) of melanoma (Chapter 172, Melanoma). A biopsy was performed and the lesion was proven to be benign. In **Figure 158-13**, a possible SK turned out to be a melanoma in situ.
- Solar lentigo—Flat, uniformly medium or dark brown lesion with sharp borders (Chapter 168, Lentigo Maligna). These are flat and seen in sun-exposed areas, typically on the face or back of the hands. Also called liver spots, these hyperpigmented areas are not palpable, whereas a SK is a palpable plaque even when the SK is thin (**Figure 158-7**).
- Wart—Cutaneous neoplasm caused by papilloma virus (Chapter 131, Common Warts). Sessile, dome-shaped lesions approximately 1 cm in diameter with hyperkeratotic surface.
  Paring usually demonstrates central core of keratinized debris and punctate bleeding points.
- Pigmented actinic keratosis (AK)—Although most AKs are nonpigmented and don't look like an SK, occasionally a biopsy of an unknown pigmented plaque will be a pigmented AK secondary to sun damage (Chapter 166, Actinic Keratosis and Bowen Disease).
- An inflamed SK may be confused with a malignant melanoma or a squamous cell carcinoma and should be biopsied to determine the diagnosis.
- Even a basal cell carcinoma (BCC) can have features that suggest a SK (**Figure 158-14**) (Chapter 170, Basal Cell Carcinoma).

MANAGEMENT

- Cryosurgery with liquid nitrogen, with a 1-mm halo, is a quick and easy treatment. The risks include pigmentary changes, incomplete resolution, and scarring. Hypopigmentation is the most common complication of this treatment, especially in dark-skinned individuals.
- Removal of benign lesions by curettage assures complete removal without taking the normal tissue below.
- Light electrofulguration can make the curettage so easy that it can be accomplished with a wet gauze pad.
- If the diagnosis is uncertain but there are no features suggesting a melanoma, a SK may be removed by shave biopsy and the tissue sent to pathology.
- If melanoma or other skin cancers are suspected, perform a full-thickness biopsy by punch or elliptical excision and send to pathology.

FIGURE 158-10 Stucco keratosis on the foot of an elderly man. (*Courtesy of Richard P. Usatine, MD.*)

FIGURE 158-11 Multiple seborrheic keratoses on the areola of a 46-year-old woman. Cryotherapy cleared the seborrheic keratoses easily. (*Courtesy of Richard P. Usatine, MD.*)

FIGURE 158-12 Waxy seborrheic keratoses on the breasts of this 70-year-old woman. (*Courtesy of Richard P. Usatine, MD.*)

FOLLOW-UP

- Some experts suggest follow-up for patients with multiple SKs because malignant tumors can develop elsewhere on the body and rarely within a SK.[3,8] SOR C

PATIENT EDUCATION

- Reassure patients that SKs are benign lesions that do not become cancer. Although these SKs may grow larger and thicker with time, this is not dangerous.
- Unless the SK is suspicious for cancer or inflamed, removal is for cosmetic purposes only and is often not covered by insurance.
- Although SKs may resolve on occasion, spontaneous resolution does not ordinarily occur.

PATIENT RESOURCES

- **http://www.nlm.nih.gov/medlineplus/ency/article/000884.htm.**
- **http://www.aad.org/public/Publications/pamphlets/SeborrheicKeratoses.htm.**

PROVIDER RESOURCES

- **http://emedicine.medscape.com/article/1059477-overview.**

FIGURE 158-13 Melanoma in situ on the lateral face of a 48-year-old man. This resembles a seborrheic keratosis but this large lesion also has all the ABCDEs (Color variation, Diameter >6 mm, Evolving) of melanoma and needed to be biopsied. (*Courtesy of Richard P. Usatine, MD.*)

REFERENCES

1. Tindall JP, Smith JG. Skin lesions of the aged and their association with internal changes. *JAMA*. 1963;186:1039-1042.
2. Gill D, Dorevitch A, Marks R. The prevalence of seborrheic keratoses in people aged 15 to 30 years. *Arch Dermatol*. 2000;136:759-762.
3. Balin AK. *Seborrheic Keratosis*. Available at http://emedicine.medscape.com/article/1059477-overview#a0104. Accessed May 29, 2011.
4. Mandinova A, Kolev V, Neel V, et al. A positive FGFR3/FOXN1 feedback loop underlies benign skin keratosis versus squamous cell carcinoma formation in humans. *J Clin Invest*. 2009;119(10):3127-3137.
5. Ponti G, Luppi G, Losi L. Leser-Trélat syndrome in patients affected by six multiple metachronous primitive cancers. *J Hematol Oncol*. 2010;3:2.
6. Lindelof B, Sigurgeirsson B, Melander S. Seborrheic keratoses and cancer. *J Am Acad Dermatol*. 1992;26(6):947-950.
7. Brodell EE, Smith E, Brodell RT. Exacerbation of seborrheic dermatitis by topical fluorouracil. *Arch Dermatol*. 2011;147(2):245-246.
8. Cascajo CD, Reichel M, Sanchez JL. Malignant neoplasms associated with seborrheic keratoses. An analysis of 54 cases. *Am J Dermatopathol*. 1996;18(3):278-282.

FIGURE 158-14 Basal cell carcinoma with surface cracks and a stuck-on appearance resembling an seborrheic keratosis. The shave biopsy demonstrated the diagnosis of basal cell carcinoma. (*Courtesy of Richard P. Usatine, MD.*)

159 SEBACEOUS HYPERPLASIA

Mindy Smith, MD, MS

PATIENT STORY

A 65-year-old man noted a new growth on his face for 1 year (**Figure 159-1**). On close examination, the growth was pearly with a few telangiectasias. The doughnut shape and presence of sebaceous hyperplasia scattered on other areas of the face were reassuring that this may be nothing but benign sebaceous hyperplasia. To reassure the patient and to remove the lesion a shave biopsy was performed to rule out basal cell carcinoma (BCC). The patient was relieved when the pathology result was in fact sebaceous hyperplasia. Additionally, he was pleased with the cosmetic result.

FIGURE 159-1 Large single lesion of sebaceous hyperplasia that was removed by shave biopsy to confirm that it was not a basal cell carcinoma. Doughnut shape visible. (*Courtesy of Richard P. Usatine, MD.*)

INTRODUCTION

Sebaceous hyperplasia (SH) is a common, benign condition of sebaceous glands consisting of multiple asymptomatic small yellow papules with a central depression. The sebaceous lobules of SH are greater in number and higher in the dermis than normal sebaceous glands and only 1 gland appears enlarged.[1] Consequently, the term *hyperplasia* appears to be a misnomer, and SH is more accurately classified as a hamartoma (disorganized overgrowth of tissue normally found at that site).[1]

EPIDEMIOLOGY

- SH occurs in approximately 1% to 26% of the adult population; the latter number is from a population study of hospitalized patients with a mean age of 82 years.[1]
- The prevalence of SH is increased in those with immunosuppression by 10-fold to 30-fold[1]; for example, 10% to 16% of patients receiving long-term immunosuppression with cyclosporine in one study had SH.[2]
- SH has also been reported in infants where they are considered physiologic,[3] and in young adults who may have a family history of SH.[1]
- SH has been reported overlying other skin lesions including neurofibromas, melanocytic nevi, verruca vulgaris, and skin tags.[1]
- Rare forms of SH include giant linear (up to 5 cm in diameter) and functional familial (also called premature or diffuse SH); the latter occurring typically around puberty as thick plaque-like lesions with pores resembling an orange peel.[1]

ETIOLOGY AND PATHOPHYSIOLOGY

- Sebaceous glands, a component of the pilosebaceous unit, are found throughout the skin, everywhere that hair is found. The greatest number is found on the face, chest, back, and the upper outer arms.

- The glands are composed of acini attached to a common excretory duct. In some areas, these ducts open directly to the epithelial surface, including the lips and buccal mucosa (i.e., Fordyce spots), glans penis or clitoris (i.e., Tyson glands), female areolae (i.e., Montgomery glands), and eyelids (i.e., meibomian glands).[1]
- Sebaceous glands are highly androgen sensitive and become increasingly active at puberty and reach their maximum by the third decade of life.
- The cells that form the sebaceous gland, sebocytes, accumulate lipid material as they migrate from the basal layer of the gland to the central duct where they release the lipid content as sebum. In younger individuals, turnover of sebocytes occurs approximately every month.
- With aging, the turnover of sebocytes slows; this results in crowding of primitive sebocytes within the sebaceous gland, causing a benign hamartomatous enlargement called SH.[1]
- Genetic factors include overexpression of the aging-associated gene Smad7 and parathormone-related protein.[4]
- There is no known potential for malignant transformation, but SH may be associated with nonmelanoma skin cancer in patients following organ transplantation.

FIGURE 159-2 Multiple lesions of sebaceous hyperplasia on the cheek and chin. Simultaneous appearance of multiple lesions makes them less likely to be basal cell carcinoma. (*Courtesy of Richard P. Usatine, MD.*)

RISK FACTORS

- Associated with Muir-Torre syndrome (concurrent or sequential development of a sebaceous neoplasm and an internal malignancy or multiple keratoacanthomas, an internal malignancy, and a family history of Muir-Torre syndrome).
- Immunosuppression
- Ultraviolet radiation[4]

DIAGNOSIS

CLINICAL FEATURES

- Lesions appear as yellowish, soft, small papules ranging in size from 2 to 9 mm (**Figures 159-1** to **159-3**).[1]
- Surface varies from smooth to slightly verrucous.
- Lesions can be single or multiple.
- Increasing number of lesions with aging; higher frequencies after 40 to 50 years of age.[1]
- In functional familial SH, lesions may appear thick and plaque-like, with pores that resemble an orange peel; the skin in these patients is quite oily.[1]
- Lesions may become red and irritated and bleed after scratching, shaving, or other trauma and may be associated with telangiectasias.
- Central umbilication (doughnut shape) from which a small amount of sebum can sometimes be expressed (**Figures 159-1** to **159-3**).

TYPICAL DISTRIBUTION

- Most commonly located on the face, particularly the nose, cheeks, and forehead. May also be found on the chest, areola, mouth, and, rarely, the vulva.[1,5]

FIGURE 159-3 Large sebaceous hyperplasia on the forehead with telangiectasias. Doughnut shape visible. (*Courtesy of Richard P. Usatine, MD.*)

IMAGING

- Dermoscopy may aid in distinguishing between nodular BCC and SH; a vascular pattern with orderly winding, scarcely branching vessels extending toward the center of the lesion is specific for hyperplastic sebaceous glands.[6]

BIOPSY

- Not usually necessary unless concerned about BCC.

DIFFERENTIAL DIAGNOSIS

- Nodular BCC—These lesions can appear as waxy papules with a central depression that may ulcerate, most commonly located on the head, neck, and upper back. They may have a pearly appearance, surface telangiectases, and bleed easily (**Figures 159-4** and **159-5**).
- Fibrous papule of the face is a benign, firm, papule of 1 to 5 mm that is usually dome-shaped and indurated with a shiny, skin-colored appearance. Most lesions are located on the nose and, less commonly, on the cheeks, chin, neck, and, rarely, the lip or forehead.
- Milia are common, benign, keratin-filled cysts (histologically identical to epidermoid cysts) that occur in persons of all ages. They are 1 to 2 mm, superficial, uniform, pearly white to yellowish, domed lesions usually occurring on the face (**Figure 159-6**).
- Molluscum contagiosum are firm, smooth, usually 2- to 6-mm umbilicated papules that may be present in groups or widely disseminated on the skin and mucosal surfaces. The lesions can be flesh colored, white, translucent, or even yellow in color. Lesions generally are self-limited but can persist for several years (Chapter 130, Molluscum Contagiosum).
- Syringoma is a benign adnexal neoplasm formed by well-differentiated ductal elements. They are 1- to 3-mm skin-colored or yellowish dermal papules with a rounded or flat top arranged in clusters, and symmetrically distributed primarily on the upper parts of the cheeks and lower eyelids (**Figure 159-6**).
- Xanthomas are deposits of lipid in the skin or subcutaneous tissue that manifest clinically as yellowish papules, nodules, or tumors. They are usually a consequence of primary or secondary hyperlipidemia and occur in patients older than age 50 years. The lesions are soft, velvety, yellow, flat, polygonal papules that are asymptomatic and usually bilateral and symmetric (Chapter 223, Hyperlipidemia).

MANAGEMENT

SH does not require treatment but can be removed for cosmetic purposes or if it becomes irritated. Evidence supporting treatment comes primarily from case series.

- Options for removal include cryotherapy, electrodesiccation, topical chemical treatments (e.g., with bichloracetic acid or trichloroacetic acid), oral isotretinoin (10 to 40 mg a day for 2 to 6 weeks), laser treatment (e.g., with argon, carbon dioxide, or pulsed-dye laser), photodynamic therapy (i.e., combined use of

FIGURE 159-4 Basal cell carcinoma on the forehead that could be mistaken for sebaceous hyperplasia. (*Courtesy of Richard P. Usatine, MD.*)

FIGURE 159-5 Close-up of same basal cell carcinoma on the forehead that shows irregular distribution of telangiectasias and lack of the doughnut shape. (*Courtesy of Richard P. Usatine, MD.*)

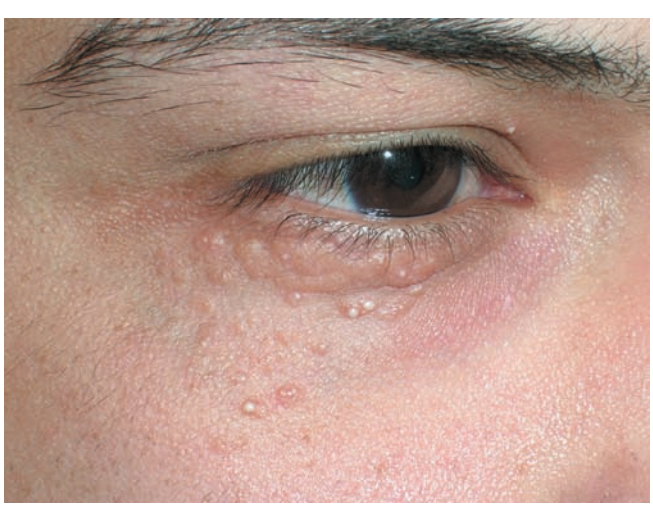

FIGURE 159-6 Syringomas and milia on the lower eyelid of a 23-year-old male. The milia are the white round epidermal cysts and the syringomas are flesh colored and larger. (*Courtesy of Richard P. Usatine, MD.*)

5-aminolevulinic acid and visible light),[7] shave excision, and punch excision.[1] Complications of these therapies include atrophic scarring and changes in pigmentation.

FOLLOW-UP

No follow-up is needed.

PATIENT RESOURCES

- **http://www.skinsight.com/adult/sebaceousHyperplasia.htm.**

PROVIDER RESOURCES

- **http://emedicine.medscape.com/article/1059368-overview.**

FIGURE 159-7 Single, large, elevated lesion of sebaceous hyperplasia on the nose of a 51-year-old man with rosacea. A shave biopsy ruled out basal cell carcinoma and gave the definitive diagnosis of sebaceous hyperplasia. The cosmetic result was excellent. *(Courtesy of Richard P. Usatine, MD.)*

REFERENCES

1. Eisen DB, Michael DJ. Sebaceous lesions and their associated syndromes: part 1. *J Am Acad Dermatol.* 2009;61:549-560.
2. Boschnakow A, May T, Assaf C, et al. Ciclosporin A-induced sebaceous gland hyperplasia. *Br J Dermatol.* 2003;149(1):198-200.
3. Oh ST, Kwon HJ. Premature sebaceous hyperplasia in a neonate. *Pediatr Dermatol.* 2007;24:443-445.
4. Zouboulis CC, Boschnakow A. Chronological ageing and photo-ageing of the human sebaceous gland. *Clin Exp Dermatol.* 2001; 26(7):600-607.
5. Al-Daraji WI, Wagner B, Ali RBM, McDonagh AJG. Sebaceous hyperplasia of the vulva: a clinicopathological case report with a review of the literature. *J Clin Pathol.* 2007;60(7):835-837.
6. Zaballos P, Ara M, Puig S, Malvehy J. Dermoscopy of sebaceous hyperplasia. *Arch Dermatol.* 2005;141:808.
7. Gold MH, Bradshaw WL, Boring MM, et al. Treatment of sebaceous hyperplasia by photodynamic therapy with 5-aminolevulinic acid and a blue light source or intense pulsed light source. *J Drugs Dermatol.* 2004;3(6 Suppl):S6-S9.

160 DERMATOFIBROMA

Mindy A. Smith, MD, MS
Richard P. Usatine, MD

PATIENT STORY

A 25-year-old woman reports a firm nodule on her leg that gets in the way of shaving her leg (**Figure 160-1**). Upon questioning, the nodule may have started there after she cut her leg shaving 1 year ago. She is worried it could be a cancer and wants it removed. Close observation showed a brown halo and a firm nodule that dimpled down when pinched. A diagnosis of a dermatofibroma (DF) was made and the choices for treatment were discussed.

FIGURE 160-1 Dermatofibroma on the leg of a 25-year-old woman that may have begun after she cut her leg shaving 1 year ago. Note the brown halo, pink hue, and raised center. (*Courtesy of Richard P. Usatine, MD.*)

INTRODUCTION

DF is a benign fibrohistiocytic tumor, usually found in the mid dermis, composed of a mixture of fibroblastic and histiocytic cells. These scar-like nodules are most commonly found on the legs and arms of adults.

SYNONYMS

Also called benign fibrous histiocytoma.

EPIDEMIOLOGY

- Occurs more often in women (male-to-female ratio is 1:4).[1]
- Found in patients of all races.
- Approximately 20% occur in patients younger than age 17 years.[1] In one case series, 80% occurred in people between the ages of 20 and 49 years.[2]

ETIOLOGY AND PATHOPHYSIOLOGY

- Uncertain etiology—Nodule may represent a fibrous reaction triggered by trauma, a viral infection, or insect bite; however, DFs show clonal proliferative growth seen in both neoplastic and inflammatory conditions.[3]
- Multiple DFs (i.e., >15 lesions) have been reported associated with systemic lupus erythematosus, HIV infection, Down syndrome, Graves disease, or leukemia, and may represent a worsening of immune function.[1] A case of familial eruptive DFs has also been reported associated with atopic dermatitis.[4]

DIAGNOSIS

CLINICAL FEATURES

- Firm to hard nodule; skin is freely movable over the nodule, except for the area of dimpling.

- Color of the overlying skin ranges from flesh to gray, pink, red, blue, brown, or black (**Figures 160-2** and **160-3**), or a combination of hues (**Figure 160-4**).
- Dimples downward when compressed laterally because of tethering of the overlying epidermis to the underlying nodule (**Figure 160-3**).
- Usually asymptomatic but may be tender or pruritic.
- Size ranges from 0.3 to 10 mm; usually less than 6 mm. Rarely, DFs grow to larger than 5 cm.[5]
- May have a hyperpigmented halo and a scaling surface (**Figure 160-4**).
- DFs can rarely be located entirely within subcutaneous tissue.[6]

IMAGING

- Dermoscopy is a useful adjunctive diagnostic technique for DF (**Figure 160-5**). Although the most common finding is a peripheral pigment network with a central white area (34.7% of cases), 10 dermoscopic patterns have been identified; in a large case series, pigment network was observed in 71.8% (3% atypical pigment network).[7] (See Appendix C: Dermoscopy.)

TYPICAL DISTRIBUTION

- May be found anywhere, but usually on the legs and arms, especially the lower legs. In one case series, 70% were on the lower extremities.[2]

BIOPSY

- A punch biopsy can be both diagnostic and therapeutic. DFs have been reported with overlying basal cell carcinoma and associated melanoma.[8,9]
- Histologically, DFs can be fibrocollagenous (40.1%), histiocytic (13.1%), cellular (11.5%), aneurysmal (7.4%), angiomatous (6.5%), sclerotic (6.5%), monster (4.9%), palisading (1.6%), keloidal (0.8%), or mixed type (7.3%).[2] Also reported are ossifying DFs[10] and a signet-ring cell DF.[11]
- Electron microscopy and immunohistochemistry may be needed to differentiate atypical or pigmented DFs from other lesions.[7]

DIFFERENTIAL DIAGNOSIS

DFs may be confused with the following malignant tumors; diagnosis based on histology and excision should be undertaken for enlarging or ulcerating tumors:

- Dermatofibrosarcoma protuberans—A low-grade malignant fibrotic tumor of the skin and subcutaneous tissues (**Figure 160-6**). A punch biopsy will provide adequate tissue to make the diagnosis.
- Pseudosarcomatous DF—A rare connective tissue tumor arising on the trunk and limbs in young adults.
- Malignant fibrous histiocytoma—A common soft-tissue sarcomas occurring in the extremities. Presentation as a primary cutaneous lesion is rare and more often presents as a metastasis from another location such as the breast.

FIGURE 160-2 Dermatofibroma on the thigh of black woman. Note the darker brown halo around the lighter center. (*Courtesy of Richard P. Usatine, MD.*)

FIGURE 160-3 Pinch test showing a deep dimpling of this dermatofibroma on the buttocks. (*Courtesy of Richard P. Usatine, MD.*)

Many benign lesions have a similar appearance, including:

- Pigmented seborrheic keratosis—May be macular and often larger than DF. Distinguished by surface cracks, verrucous features, stuck-on appearance, and adherent greasy scale (Chapter 158, Seborrheic Keratosis).
- Epidermal inclusion cyst—Sharply circumscribed, skin-colored nodule often with a central punctum. Most common on face, neck, or trunk. Composed of stratified epithelium surrounding a mass of keratinized material that has a foul odor when it drains.
- Hypertrophic scar—Occurs within previous wounds or lacerations.
- Neurofibroma—Benign Schwann cell tumors; single lesions are seen in normal individuals. Cutaneous tumors tend to form multiple, soft, pedunculated masses, whereas subcutaneous nodules are skin-colored soft nodules attached to peripheral nerves. The latter show similar invagination as DF (Chapter 235, Neurofibromatosis).

MANAGEMENT

- No treatment is necessary unless the diagnosis is questioned or symptoms warrant.
- Punch excision or shave excision may be used for small lesions; with the latter technique, the healed area may remain hard as a result of remaining fibrous tissue.
- Larger lesions may require an elliptical (fusiform) excision, down to the subcutaneous fat.
- One author noted that DFs occurring on the face often have involvement of deeper structures and an increased rate of local recurrences and therefore recommend excision with wider margins in comparison with DFs occurring on the extremities.[12]
- Cryotherapy has also been used, but the cure rate is low and lesions may recur.
- Several case reports found success in treating multiple DFs with carbon dioxide laser[13] or isotretinoin.[14]

PROGNOSIS

- Although DFs are usually unchanging and persist indefinitely, there are reports of spontaneous regression.[15]
- Following excision, DFs have a low recurrence rate of less than 2%, with higher recurrence believed to occur in cellular, aneurysmal, and atypical types.[7,10]
- A higher rate of recurrence has been noted in the subcutaneous and deep types, and in lesions located on the face, in which a recurrence rate of 15% to 19% has been reported.[16,17]

PATIENT EDUCATION

- DFs are best left alone if they are relatively asymptomatic and stable.

PATIENT RESOURCES

- **www.aocd.org/skin/dermatologic_diseases/DF.html.**
- **http://www.skinsight.com/adult/DF.htm.**

FIGURE 160-4 Dermatofibroma on the back. Note the brown halo around the lighter central nodule. (*Courtesy of Richard P. Usatine, MD.*)

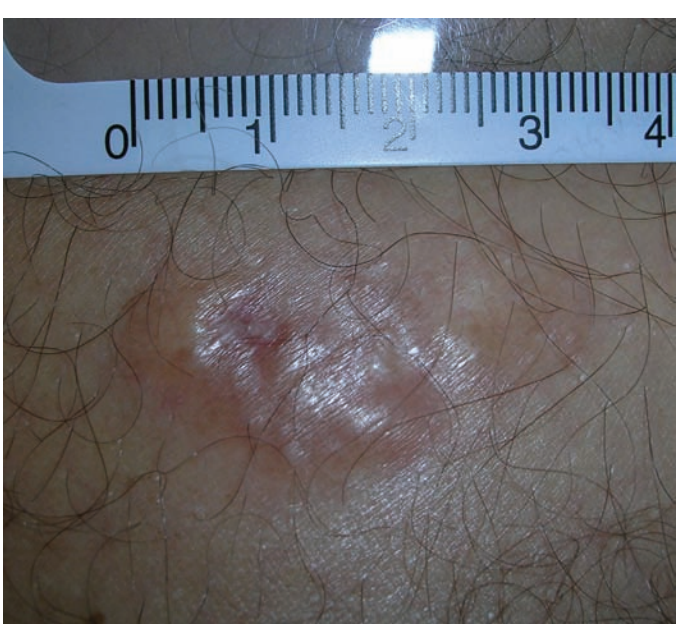

FIGURE 160-5 Large dermatofibrosarcoma protuberans growing on the thigh of this 55-year-old man. The first punch biopsy was read as a benign dermatofibroma. Continued growth prompted a second biopsy that detected the malignancy. The first excision did not achieve clear margins so the final treatment consisted of Mohs surgery. Note the shiny surface and multilobular look that can be characteristic of a dermatofibrosarcoma protuberans. (*Courtesy of Richard P. Usatine, MD.*)

FIGURE 160-6 **A.** Dermatofibroma on the leg that appears pink to red in color. **B.** Close-up of the dermatofibroma showing the pink center and brown halo. **C.** Dermoscopic view of the dermatofibroma showing the typical pattern with a radially streaking brown halo and a pink center with little pigment. (*Courtesy of Ashfaq Marghoob, MD.*)

PROVIDER RESOURCES

- **http://emedicine.medscape.com/article/1056742**

REFERENCES

1. Pierson JC. *Dermatofibroma*. http://emedicine.medscape.com/article/1056742-overview#a0104. Accessed July 2011.
2. Han TY, Chang HS, Lee JH, et al. A clinical and histopathological study of 122 cases of dermatofibroma (benign fibrous histiocytoma). *Ann Dermatol*. 2011;23(2):185-192.
3. Chen TC, Kuo T, Chan HL. Dermatofibroma is a clonal proliferative disease. *J Cutan Pathol.* 2000;27:36-39.
4. Yazici AC, Baz K, Ikizoglu G, et al. Familial eruptive dermatofibromas in atopic dermatitis. *J Eur Acad Dermatol Venereol.* 2006;20(1):90-92.
5. Lang KJ, Lidder S, Hofer M, et al. Rapidly evolving giant dermatofibroma. *Case Report Med*. 2010;2010:620910.
6. Jung KD, Lee DY, Lee JH, et al. Subcutaneous dermatofibroma. *Ann Dermatol*. 2011;23(2):254-257.
7. Zaballos P, Puig S, Llambrich A, Malvehy J. Dermoscopy of dermatofibromas: a prospective morphological study of 412 cases. *Arch Dermatol*. 2008;144(1):75-83.
8. Rosmaninho A, Farrajota P, Peixoto C, et al. Basal cell carcinoma overlying a dermatofibroma: a revisited controversy. *Eur J Dermatol.* 2011;21(1):137-138.
9. Kovach BT, Boyd AS. Melanoma associated with dermatofibroma. *J Cutan Pathol.* 2007;34(5):420-492.
10. Papalas JA, Balmer NN, Wallace C, Sangüeza OP. Ossifying dermatofibroma with osteoclast-like giant cells: report of a case and literature review. *Am J Dermatopathol.* 2009;31(4):379-833.
11. Garrido-Ruiz MC, Carrillo R, Enguita AB, Peralto JL. Signet-ring cell dermatofibroma. *Am J Dermatopathol.* 2009;31(1):84-87.
12. Mentzel T, Kutzner H, Rutten A, Hugel H. Benign fibrous histiocytoma (dermatofibroma) of the face: clinicopathologic and immunohistochemical study of 34 cases associated with an aggressive clinical course. *Am J Dermatopathol*. 2001;23(5):419-426.
13. Sardana K, Garg VK. Multiple dermatofibromas on face treated with carbon dioxide laser: the importance of laser parameters. *Indian J Dermatol Venereol Leprol.* 2008;74(2):170.
14. Kwinter J, DeKoven J. Generalized eruptive histiocytoma treated with isotretinoin. *J Cutan Med Surg.* 2009;4(4):490-491.
15. Niemi KM. The benign fibrohistiocytic tumours of the skin. *Acta Derm Venereol Suppl (Stockh)*. 1970;50(63):Suppl 63:1-66.
16. Fletcher CD. Benign fibrous histiocytoma of subcutaneous and deep soft tissue: a clinicopathologic analysis of 21 cases. *Am J Surg Pathol.* 1990;14:801-809.
17. Mentzel T, Kutzner H, Rütten A, Hügel H. Benign fibrous histiocytoma (dermatofibroma) of the face: clinicopathologic and immunohistochemical study of 34 cases associated with an aggressive clinical course. *Am J Dermatopathol.* 2001;23:419-426.

161 PYOGENIC GRANULOMA

Mindy A. Smith, MD, MS
Richard P. Usatine, MD

PATIENT STORY

A 20-year-old woman, who was being seen by her family physician for her prenatal care, presents to the office with a new growth on her lip. She stated that the growth on her lip bled very easily but was not painful. She was diagnosed with a pyogenic granuloma (PG) and preferred to wait until her pregnancy was over to have it removed. The lesion did not regress spontaneously after pregnancy and was surgically excised.

FIGURE 161-1 Pyogenic granuloma on the lower lip arising during pregnancy. *(With permission from Usatine RP, Moy RL, Tobinick EL, Siegel DM. Skin Surgery: A Practical Guide. St. Louis, MO: Mosby; 1998.)*

INTRODUCTION

PG is the name for a common, benign, acquired, vascular neoplasm of the skin and mucous membranes.

SYNONYMS

The term *lobular capillary hemangioma* has been suggested because PG is neither pyogenic (purulent bacterial infection) nor a granuloma.[1]

EPIDEMIOLOGY

- Most often seen in children and young adults (0.5% of children's skin lesions); 42% of cases occur by 5 years of age and approximately 1% are present at birth.[1]
- Oral lesions occur most often in the second and third decade, more commonly in women (female-to-male ratio is 2:1).[1]
- Also common during pregnancy.
- PG has also been reported in the GI tract, the larynx, and on the nasal mucosa, conjunctiva, and cornea.

ETIOLOGY AND PATHOPHYSIOLOGY

- Etiology is unknown but may be the result of trauma, infection, or preceding dermatoses.
- Consists of dense proliferation of capillaries and fibroblastic stroma that is infiltrated with polymorphonuclear leukocytes.
- Multiple PGs have been reported at burn sites and following use of oral contraceptives, protease inhibitors, and topical application of tretinoin for acne.[2]
- PGs are known to regress following pregnancy. Vascular endothelial growth factor (VEGF) was found in one study to be high in the granulomas during pregnancy, was almost undetectable after parturition, and was associated with apoptosis of endothelial cells and regression of granuloma.[3]

RISK FACTORS

- Trauma (up to 50%) or chronic irritation.[1]
- Multiple lesions can follow manipulation of a primary lesion.[4]
- Pregnancy or use of oral contraceptives for oral PGs; postulated caused by imbalance between angiogenesis enhancers and inhibitors.[1]
- Infection with *Bartonella*.[1]

DIAGNOSIS

CLINICAL FEATURES

- Usually solitary, erythematous, dome-shaped papule or nodule that bleeds easily (**Figures 161-1** to **161-8**); rarely causes anemia. Satellite lesions may rarely occur.
- Prone to ulceration, erosion, and crusting.
- Size ranges from a few millimeters to several centimeters (average size is 6.5 mm).[1]
- Rapid growth over a period of weeks to maximum size.
- Variants include cutaneous, oral mucosal (granuloma gravidarum), satellite, subcutaneous, intravenous, and congenital types.[1]

TYPICAL DISTRIBUTION

- Cutaneous PG most often found on the head and neck (62.5%) specifically the gingiva, lips as in **Figure 161-1**, nose (**Figure 161-2**), and face, trunk (20%) and extremities (18%) (**Figures 161-3** to **161-6**).[1]
- Pregnancy PG occurs most commonly along the maxillary intraoral mucosal surface (**Figure 161-1**).

IMAGING

- Reddish homogeneous area surrounded by a white collarette is the most frequent dermoscopic pattern in PGs (85%).[5] In more advanced lesions, white lines that intersect the central areas may be seen that are likely fibrous septa.

BIOPSY

- Early lesions resemble granulation tissue (numerous capillaries and venules with endothelial cells arrayed radially toward the skin surface; stroma is edematous).[1]
- The mature PG exhibits a fibromyxoid stroma separating the lesion into lobules. Proliferation of capillaries is present, with prominent endothelial cells. The epidermis exhibits inward growth at the lesion base.[1]
- A regressing PG has extensive fibrosis.

DIFFERENTIAL DIAGNOSIS

PG may be confused with a number of cutaneous malignancies, including atypical fibroxanthoma, basal cell carcinoma, Kaposi carcoma, metastatic cutaneous lesions, squamous cell carcinoma, and amelanotic melanoma (**Figure 161-7**). It is especially important to

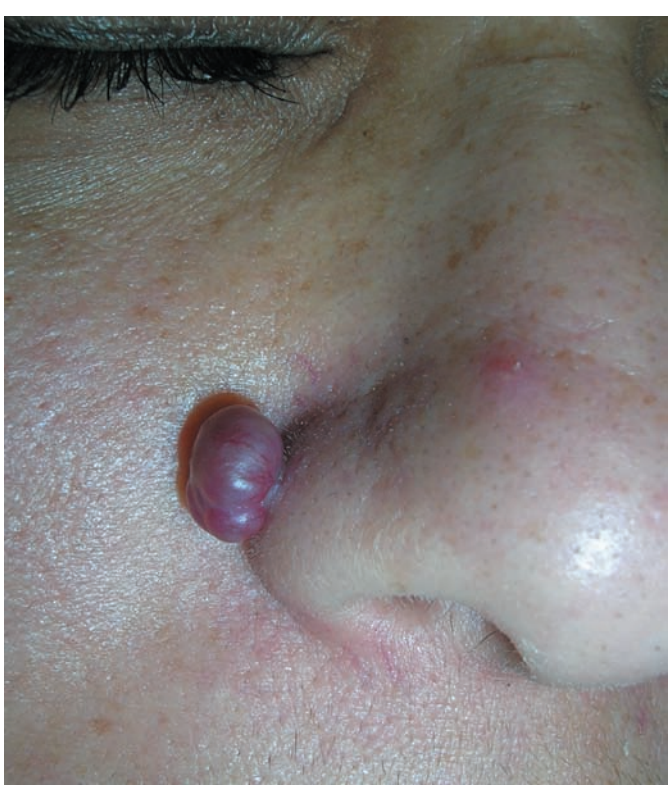

FIGURE 161-2 Pyogenic granuloma on the nose in a young adult. *(Courtesy of Richard P. Usatine, MD.)*

FIGURE 161-3 Large pyogenic granuloma on the hand of a 33-year-old man present for 3 months. *(Courtesy of Richard P. Usatine, MD.)*

FIGURE 161-4 Large pyogenic granuloma on the finger of a 22-year-old man present for 4 months. He was sent out of multiple clinical settings untreated until we excised this. *(Courtesy of Richard P. Usatine, MD.)*

FIGURE 161-5 Small pyogenic granuloma on the finger of a 17-year-old boy for 2 months. It started with a small injury to the finger. *(Courtesy of Richard P. Usatine, MD.)*

FIGURE 161-6 Pyogenic granuloma on the leg for 6 months before the patient presented for treatment. *(Courtesy of Richard P. Usatine, MD.)*

FIGURE 161-7 Amelanotic melanoma on the nose that could be confused with a pyogenic granuloma. Always send what you suspect to be a PG to the pathologist. *(Courtesy of the University of Texas Health Sciences Center, Division of Dermatology.)*

send the excised lesion that appears to be a PG for pathology to make sure that a malignancy is not missed.

Benign tumors that may be confused with PG include:

- Cherry hemangioma—Small, bright-red, dome-shaped papules that represent benign proliferation of capillaries (**Figure 161-8**).
- Fibrous papule of the nose is a benign tumor of the nose. Most are skin colored and not confused with PG. A benign clear cell variant of a fibrous papule can closely resemble a PG as seen in **Figure 161-9**.
- Bacillary angiomatosis—A systemic infectious disease caused by two *Bartonella* species. Globular angiomatous papules appear like PG (**Figure 217-6**). Nodules affect all age groups and may reach 10 cm in size. This infection is more likely to occur in persons with AIDS. Weight loss and lymphadenopathy may occur.

FIGURE 161-8 Hemangioma on the lip of a 67-year-old man. By appearance alone this is hard to differentiate from a pyogenic granuloma (lobular capillary hemangioma). This did not bleed extensively at time of excision and the pathology result confirmed that this was a hemangioma. *(Courtesy of Richard P. Usatine, MD.)*

MANAGEMENT

Removal of the lesion is indicated to alleviate any bleeding or discomfort, for cosmetic reasons, or when the diagnosis is uncertain.

NONPHARMACOLOGIC

- Untreated PGs eventually atrophy, become fibromatous, and slowly regress, especially if the causative agent is removed.

MEDICATIONS

- A case of successful treatment of a recurrent PG was reported using a 14-week course of twice-weekly imiquimod 5% topical application.[6] SOR C

PROCEDURES

A number of procedures have been used for elimination of PGs; data are limited to case series reports.[7]

- Simple surgical excision has a low recurrence rate (<4%) but is associated with scarring (55%).[7] SOR C
- Removal can be accomplished with shave excision and electrodesiccation; the latter reduces recurrence (approximately 10%) and scarring appears less than with either simple excision (31%) or cauterization alone (43.5%).[1,7] PGs bleed extensively when manipulated or cut. It is important to use lidocaine with epinephrine, wait 10 minutes for the epinephrine to work, and have an electrosurgery device to control bleeding. Cut the PG off with a blade and send to pathology. Curetting the base will also help stop the bleeding and prevent recurrence. The base is curetted and electrodesiccated until the bleeding stops. SOR C
- Both cryosurgery and laser surgery often require more than one treatment and rates of scarring may be high (12% to 42% and 44%, respectively).[1,7] SOR C
- In one case series, sclerotherapy was reported to leave no scarring or recurrence.[7] SOR C

FIGURE 161-9 Vascular growth on the nose of a pregnant woman that appears to be a pyogenic granuloma. Biopsy revealed a benign clear cell variant of a fibrous papule. *(Courtesy of Richard P. Usatine, MD.)*

PROGNOSIS

- PG develops over weeks and growth typically stabilizes over several months.[1] Eventually, it shrinks to become a fibrotic "angioma."

Some nodules spontaneously infarct and involute. In one pediatric retrospective case series with telephone follow-up, 4 untreated patients had spontaneous resolution within 6 to 18 months with no recurrences.[8]

- Congenital PG is an uncommon disseminated variant that presents with multiple lesions, is similar in appearance to the cutaneous form, and is present at birth. The condition appears to follow a benign course, with spontaneous resolution over 6 to 12 months.[1]

PATIENT EDUCATION

- Explain to patients that lesions may resolve spontaneously and that multiple successful treatments are available (note that most patients will be grateful to have treatment that day as the lesion tends to be a great nuisance by bleeding easily and having an undesirable appearance).
- Once treated, if the lesion begins to recur, patients should follow-up quickly before the lesion gets larger and harder to treat.

FOLLOW-UP

In 2 weeks to receive the result of the pathology and to check wound healing.

PATIENT RESOURCES

- **http://www.nlm.nih.gov/medlineplus/ency/article/001464.htm.**
- **http://www.ncbi.nlm.nih.gov/pubmedhealth/PMH0002435/.**

PROVIDER RESOURCES

- **http://emedicine.medscape.com/article/910112.**
- **http://emedicine.medscape.com/article/1077040.**
- Usatine R, Pfenninger J, Stulberg D, Small R. *Dermatologic and Cosmetic Procedures in Office Practice*. Philadelphia, PA: Elsevier; 2012. The book has many photographs and descriptions that provide details of how to surgically treat PGs. It is also available as an electronic application with video included: www.usatinemedia.com.

REFERENCES

1. Lin RL, Janniger CK. Pyogenic granuloma. *Cutis.* 2004;74(4):229-233.
2. Teknetzis A, Tonannides D, Vakali G, et al. Pyogenic granulomas following topical application of tretinoin. *J Eur Acad Dermatol Venereol.* 2004;18(3):337-339.
3. Yuan K, Lin MT. The roles of vascular endothelial growth factor and angiopoietin-2 in the regression of pregnancy pyogenic granuloma. *Oral Dis.* 2004;10(3):179-185.
4. Blickenstaff RD, Roenigk RK, Peters MS, et al. Recurrent pyogenic granuloma with satellitosis. *J Am Acad Dermatol.* 1989;21:1241-1244.
5. Zaballos P, Llambrich A, Cuellar F, et al. Dermoscopic findings in pyogenic granuloma. *Br J Dermatol.* 2006;154(6):1108-1111.
6. Goldenberg G, Krowchuk DP, Jorizzo JL. Successful treatment of a therapy-resistant pyogenic granuloma with topical imiquimod 5% cream. *J Dermatolog Treat.* 2006;17(2):121-123.
7. Gilmore A, Kelsberg G, Safranek S. Clinical inquiries. What's the best treatment for pyogenic granuloma? *J Fam Pract.* 2010;59(1):40-42.
8. Pagliai KA, Cohen BA. Pyogenic granuloma in children. *Pediatr Dermatol.* 2004;21:10-13.

SECTION 10 NEVI

162 BENIGN NEVI

Mindy A. Smith, MD, MS
Richard P. Usatine, MD

PATIENT STORY

A young woman comes to the office because her husband has noted that the moles on her back are changing **(Figure 162-1)**. A few have white halos around the brown pigmentation and some have lost their pigment completely, with a light area remaining. She has no symptoms but wants to make sure these are not skin cancers. Halo nevi are an uncommon variation of common nevi. These appear benign and the patient is reassured.

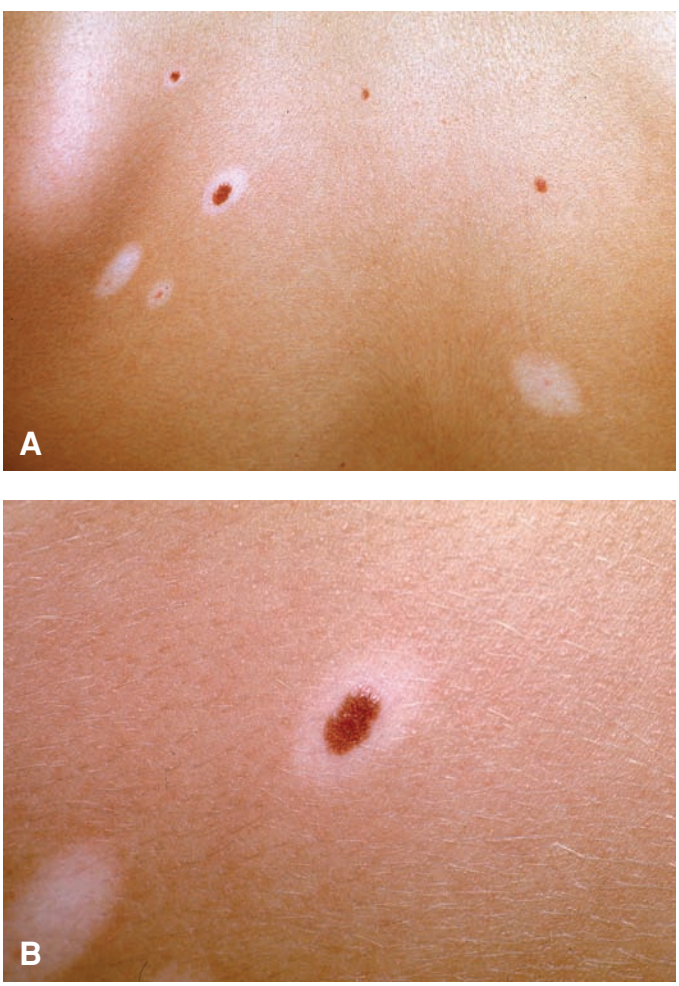

FIGURE 162-1 **A.** Multiple halo nevi on the back. **B.** Close-up of a halo nevus in transition. (*Courtesy of Richard P. Usatine, MD.*)

INTRODUCTION

Most nevi are benign tumors caused by the aggregation of melanocytic cells in the skin. However, nevi can occur on the conjunctiva, sclera and other structures of the eye. There are also nonmelanocytic nevi that are produced by other cells as seen in Becker nevi and comedonal nevi. Although most nevi are acquired, many nevi are present at birth.

SYNONYMS

Moles.

EPIDEMIOLOGY

- Acquired nevi are common lesions, forming during early childhood; few adults have none.
- Prevalence appears to be lower in dark-skinned individuals.
- Present in 1% of neonates increasing through childhood and peaking at puberty; new ones may continue to appear in adulthood. In a population study of children (N = 180, ages 1 to 15 years) in Barcelona, the mean number of nevi was 17.5.[1]
- Adults typically have 10 to 40 nevi scattered over the body. In a population study in Germany, 60.3% of 2823 adults (mean age: 49 years; 50% women) exhibited 11 to 50 common nevi and 5.2% had at least 1 atypical nevus.[2]
- The peak incidence of melanocytic nevi (MN) is in the fourth to fifth decades of life; the incidence decreases with each successive decade.[3]

ETIOLOGY AND PATHOPHYSIOLOGY

- Benign tumors composed of nevus cells derived from melanocytes, pigment-producing cells that colonize the epidermis.
- MN represent proliferations of melanocytes that are in contact with each other, forming small collections of cells known as nests. Genetic mutations present in common nevi as well as in melanomas include BRAF, NRAS, and *c*-kit.[4]
- Sun (UV) exposure, skin-blistering events (e.g., sunburn), and genetics play a role in the formation of new nevi.[3]
- Nevi commonly darken and/or enlarge during pregnancy. Melanocytes have receptors for estrogens and androgens and melanogenesis is responsive to these hormones.[3]
- Three broad categories of MN are based on location of nevus cells[2]:
  - Junctional nevi—Composed of nevus cells located in the dermoepidermal junction; may change into compound nevi after childhood (except when located on the palms, soles, or genitalia) (**Figure 162-2**).
  - Compound nevi—A nevus in which a portion of nevus cells have migrated into the dermis (**Figure 162-3**).
  - Dermal nevi—Composed of nevus cells located within the dermis (usually found only in adults). These are usually raised and have little to no visible hyperpigmentation (**Figures 162-4** and **162-5**).
- Special categories of nevi:
  - Halo nevus—Compound or dermal nevus that develops a symmetric, sharply demarcated, depigmented border (**Figure 162-1)** . Most commonly occurs on the trunk and develops during adolescence. Repigmentation may occur.
  - Blue nevus—A dermal nevus that contains large amounts of pigment so that the brown pigment absorbs the longer wavelengths of light and scatters blue light (Tyndall effect) (**Figure 162-6**). Blue nevi are not always blue and color varies from tan to blue, black, and gray. Types of blue nevi include amelanotic, desmoplastic, atypical, and malignant variants; genetic mutations seen in blue nevi are often different than those seen in common nevi and include the Gαq class of G-protein α subunits, Gnaq, and Gna11 proteins.[4] The nodules are firm because of associated stromal sclerosis. Usually appears in childhood on the extremities, dorsum of the hands and face. A rare variant, the cellular blue nevus is large (>1 cm), frequently located on the buttocks, and may undergo malignant degeneration.
  - Nevus spilus—Hairless, oval, or irregularly shaped brown lesion with darker brown to black dots containing nevus cells (**Figure 162-7**). May appear at any age or be present at birth; unrelated to sun exposure.
  - Spitz nevus (formerly called benign juvenile melanoma because of its clinical and histologic similarity to melanoma)—Hairless, red, or reddish brown dome-shaped papules generally appearing suddenly in children, sometimes following trauma (**Figures 162-8** and **162-9**). The pink color is caused by increased vascularity. Most importantly, these should be fully excised with clear margins.
  - Nevus of Ota—Dark brown nevus that occurs most commonly around the eye and can involve the sclera (**Figure 162-10).**

FIGURE 162-2 Two benign junctional nevi on the arm of a 19-year-old woman. Note how these are flat macules. (*Courtesy of Richard P. Usatine, MD.*)

FIGURE 162-3 Benign compound nevus proven by biopsy on the back of a 35-year-old woman. (*Courtesy of Richard P. Usatine, MD.*)

FIGURE 162-4 Dermal nevus (intradermal melanocytic nevus)—dome shaped with some scattered pigmentation. (*Courtesy of Richard P. Usatine, MD.*)

FIGURE 162-5 Dermal nevus pedunculated with small telangiectasias. (*Courtesy of Richard P. Usatine, MD.*)

FIGURE 162-7 Nevus spilus on the leg of a young woman from birth. It appears benign and needs no intervention. (*Courtesy of Richard P. Usatine, MD.*)

FIGURE 162-8 Spitz nevus that grew over the past year on the nose of this 18-year-old woman. It was fully excised with no complications. (*Courtesy of Richard P. Usatine, MD.*)

FIGURE 162-6 Blue nevus on the left cheek that could resemble a melanoma with its dark color. In this case it was fully excised with a 5-mm punch with a good cosmetic result. Blue nevi are benign and do not need to be excised unless there are suspicious changes. (*Courtesy of Richard P. Usatine, MD.*)

FIGURE 162-9 Spitz nevus on face of this 9-year-old boy. He very bravely allowed us to excise it with local anesthesia. (*Courtesy of Richard P. Usatine, MD.*)

- Both acquired and congenital MN hold some risk for the development of melanoma; the number of MN, especially more than 100, is an important independent risk factor for cutaneous melanoma.[5]

NONMELANOCYTIC NEVI

- Becker nevus—A brown patch often with hair located on the shoulder, back or submammary area, most often in adolescent men (**Figures 162-11** and **162-12**). The lesion may enlarge to cover an entire shoulder or upper arm. Although it is called a nevus, it does not actually have nevus cells and has no malignant potential. It is a type of hamartoma, an abnormal mixture of cells and tissues normally found in the area of the body where the growth occurs.
- Nevus depigmentosus is usually present at birth or starts in early childhood. There is a decrease number of melanosomes within a normal number of melanocytes. It typically has a serrated or jagged edge (**Figure 162-13**).
- Nevus anemicus—A congenital hypopigmented macule or patch that is stable in relative size and distribution. It occurs as a result of localized hypersensitivity to catecholamines and not a decrease in melanocytes. On diascopy (pressure with a glass slide) the skin is indistinguishable from the surrounding skin (**Figure 162-14**).
- Nevus comedonicus (comedonal nevus) is a rare congenital hamartoma characterized by an aggregation of comedones in one region of the skin (**Figure 162-15**).
- Epidermal nevi are congenital hamartomas of ectodermal origin classified on the basis of their main component: sebaceous, apocrine, eccrine, follicular, or keratinocytic. See Chapter 163, Congenital Nevi for a full discussion of this type of nevus.

Note nevus comedonicus and epidermal nevi tend to follow Blaschko lines, which come from embryologic development.

RISK FACTORS

- In the Barcelona study of children, male gender, past history of sunburns, facial freckling, and family history of breast cancer were independent risk factors for having a higher number of nevi.[1]
- In one study among very light-skinned (and not darker skinned) children without red hair, children who develop tans have greater numbers of nevi.[6]
- Neonatal blue-light phototherapy is not related to nevus count.[7]

DIAGNOSIS

CLINICAL FEATURES

Most benign MN are tan to brown, usually less than 6 mm, with round shape and sharp borders.

- Junctional nevi—Macular or slightly elevated mole of uniform brown to black pigmentation, smooth surface, and a round or oval border (**Figure 162-2**). Most are hairless and vary from 1 to 6 mm.
- Compound nevi—Slightly elevated, symmetric, uniformly flesh colored or brown with a round or oval border, often becoming

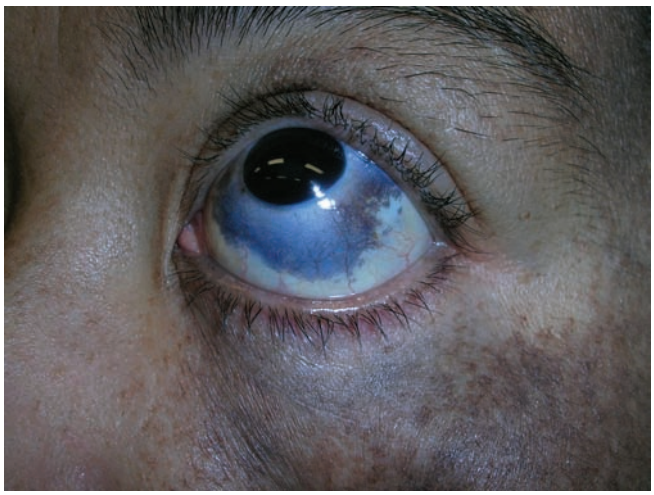

FIGURE 162-10 Nevus of Ota on the face of this young woman since early childhood. It involved both eyes and the skin around both eyes. The scleral pigmentation looks blue. (*Courtesy of Richard P. Usatine, MD.*)

FIGURE 162-11 Becker nevus that developed during adolescence. Hair is frequently seen on this type of nonmelanocytic nevus. (*Courtesy of Richard P. Usatine, MD.*)

FIGURE 162-12 Becker nevus on the back of a 16-year-old Hispanic boy for 2 years. While this nevus did not have hair, it did have increased acne within the area—another feature of the Becker nevus. (*Courtesy of Richard P. Usatine, MD.*)

more elevated with age (**Figure 162-3**). Hair may be present and a white halo may form.

- Dermal nevi (same as intradermal nevi)—Skin color or brown color that may fade with age; dome shaped is most common, but shapes vary, including polypoid, warty, and pedunculated. Often found on the face and may have telangiectasias (**Figures 162-4** and **162-5**). Size ranges from 1 to 10 mm.

TYPICAL DISTRIBUTION

- Most often above the waist on sun-exposed areas but may appear anywhere on the cutaneous surface; less commonly found on the scalp, breasts, or buttocks.
- Among the children in the Barcelona study, 61.1% had nevi on the face and neck, 17.2% on the buttocks, and 11.7% on the scalp; approximately one-third had congenital nevi (Chapter 163, Congenital Nevi).[1]
- In an Australian study of white children, MN of all sizes were highest on the outer forearms, followed by the outer upper arms, neck, and face.[8] Boys had higher densities of MN of all sizes on the neck than girls, and girls had higher densities of MN of 2 mm or greater on the lower legs and thighs than boys. Habitually sun-exposed body sites had higher densities of small MN and highest prevalence of larger MN.

IMAGING

- Dermoscopy can be a useful technique for diagnosing benign nevi. For MN, dermoscopic diagnosis relies on color; pattern (i.e., globular, reticular, starburst, and homogeneous blue pattern); pigment distribution (i.e., multifocal, central, eccentric, and uniform); and special sites (e.g., face, acral areas, nail, and mucosa), in conjunction with patient factors (e.g., history, pregnancy).[9] (See Appendix C: Dermoscopy.)
- In the Barcelona study, the most frequent dominant dermoscopic pattern was the globular type with the homogeneous pattern predominating in the youngest children and the reticular pattern predominating in adolescents.[1]

BIOPSY

Biopsy is necessary if you suspect melanoma or a Spitz nevus. A biopsy that cuts below the pigmented area is preferred if there is a reasonable suspicion for melanoma. This can be done with a scoop shave, a punch that gets the whole lesion, or an elliptical excision. If the patient wants a raised benign appearing nevus excised for cosmetic reasons, a shave excision may be adequate. Send all lesions (except skin tags) to the pathologist for examination, even when they appear benign, to avoid missing a melanoma.

DIFFERENTIAL DIAGNOSIS

Benign nevi may develop atypia or become melanoma. This should be suspected if a lesion has atypical features including asymmetry, border irregularity, color variability, diameter greater than 6 mm, and evolving (called the ABCDE approach [asymmetry, border irregularity, color irregularity, diameter >6 mm, evolution]). Any lesion that becomes symptomatic (e.g., itchy, painful, irritated, or

FIGURE 162-13 Nevus depigmentosus on the face of this young girl since birth. (*Courtesy of Richard P. Usatine, MD.*)

FIGURE 162-14 Nevus anemicus on the posterior neck. The localized hypersensitivity to catecholamines causes the area to stay lighter than the surrounding skin. (*Courtesy of the University of Texas Health Sciences Center, Division of Dermatology.*)

bleeding), or develops a loss or increase in pigmentation, should be evaluated and biopsied if needed. Dermoscopy can be used to increase one's accuracy in distinguishing between benign and malignant lesions (see Appendix C, Dermoscopy).

- Melanomas are skin cancers that may develop from a preexisting nevus. The most important skill to develop is how to distinguish a benign nevus from a nevus that might be malignant melanoma. Because clinical appearance can be misleading, a biopsy is necessary when there is a reasonable suspicion for cancer (Chapter 172, Melanoma).
- Dysplastic or atypical nevi are variants that are relatively flat, thinly papular, and relatively broad. Often, the lesions exhibit target-like or fried egg-like morphology, with a central papular zone and a macular surrounding area with differing pigmentation (Chapter 165, Dysplastic Nevus).
- Seborrheic keratoses are benign growths that appear more with increasing age and are often hyperpigmented as seen with many nevi. These are more superficial and stuck-on in their appearance (Chapter 158, Seborrheic Keratosis).
- Labial melanotic macules are benign dark macules on the lip that are not nevi and not melanomas (**Figure 162-16**). They can be removed for cosmetic purposes.

FIGURE 162-15 Nevus comedonicus on the chest of this 15-year-old boy since birth. This is a congenital hamartoma with open comedones. It is not acne. (*Courtesy of Richard P. Usatine, MD.*)

MANAGEMENT

Nevi are generally only removed for cosmetic reasons or because of concern over changes in the lesion suggestive of dysplasia or melanoma.

- A full excisional biopsy with a sutured closure is usually the best means to diagnose a lesion if concern exists regarding the possibility of melanoma. If the lesion is found to be benign, no further treatment is usually required.
- Punch excision can be used to excise smaller lesions.
- Scoop shave—Unfortunately, if a punch biopsy is used to sample a larger lesion it may miss a melanoma in another part of the lesion. A broad scoop shave is better than a punch biopsy when a full elliptical excision is not possible or desirable (e.g., a large flat pigmented lesion on the face).
- Nevi removed for cosmesis are often removed by shave excision.[3]

If a Spitz nevus is suspected, either biopsy it now or schedule the patient for a full excision. The histopathology is too close to a melanoma to just watch it.

- Becker nevi and comedonal nevi do not become melanoma because they lack melanocytes. Therefore, there is no reason to excise them. Generally, these are large and the risks of excision for cosmetic reasons outweigh the benefits.

FIGURE 162-16 Labial melanotic macule. These are benign but are not nevi. (*Courtesy of Richard P. Usatine, MD.*)

PREVENTION

- Sun protection to limit sunburn may help reduce the appearance of nevi. In a trial of 209 white children, children randomized to the sunscreen group, especially those with freckles, had significantly

fewer new nevi on the trunk than did children in the control group at 3-year follow-up.[10]

PROGNOSIS

- Degeneration of common nevi into melanoma is very rare.
- Patients with multiple or large MN appear to have an increased risk of melanoma.[3]
- Nevi may recur or persist following removal; in one study, dysplastic MN were the most likely to persist.[11] In another study, of 61 benign nevi biopsy sites reexamined, two (3.3%) recurred.[12]

FOLLOW-UP

- Patients with multiple or sizable MN should be followed by an experienced clinician because they appear to have an increased lifetime risk of melanoma, with the risk increasing in rough proportion to the size and/or number of lesions.[3]

PATIENT EDUCATION

- Patients should be encouraged to use sunscreen to prevent skin cancer as well as to reduce the development of new nevi.
- Patients with multiple or sizable MN should be taught to look for and report asymmetry, border irregularity, new symptoms, and color and size changes.

PATIENT RESOURCES

- VisualDxHealth. Good information with excellent photographs—**http://www.visualdxhealth.com/adult/nevus.htm.**
- MedlinePlus—**http://www.nlm.nih.gov/medlineplus/moles.html.**
- American Osteopathic College of Dermatology—**http://www.aocd.org/skin/dermatologic_diseases/moles.html.**
- American Academy of Dermatology—**http://www.aad.org/public/publications/pamphlets/common_moles.html.**

PROVIDER RESOURCES

- **http://emedicine.medscape.com/article/1058445-overview.**

REFERENCES

1. Aguilera P, Puig S, Guilabert A, et al. Prevalence study of nevi in children from Barcelona. Dermoscopy, constitutional and environmental factors. *Dermatology*. 2009;18(3):203-214.
2. Schafer T, Merkl J, Klemm E, et al. The Epidemiology of nevi and signs of skin aging in the adult general population: Results of the KORA-Survey 2000. *J Invest Dermatol*. 2006;126(7):1490-1496.

3. McCalmont T. *Melanocytic Nevi*. http://emedicine.medscape.com/article/1058445-overview#a0199. Accessed October 2011.
4. Zembowicz A, Phadke PA. Blue nevi and variants: an update. *Arch Pathol Lab Med.* 2011;135(3):327-336.
5. Gandini S, Sera F, Cattaruzza MS, et al. Meta-analysis of risk factors for cutaneous melanoma: I. Common and atypical nevi. *Eur J Cancer.* 2005;41(1):28-44.
6. Aalborg J, Morelli JG, Mokrohisky ST, et al. Tanning and increased nevus development in very-light-skinned children without red hair. *Arch Dermatol.* 2009;145(9):989-996.
7. Mahé E, Beauchet A, Aegerter P, Saiag P. Neonatal blue-light phototherapy does not increase nevus count in 9-year-old children. *Pediatrics.* 2009;123(5):e896-e900.
8. Harrison SL, Buettner PG, MacLennan R. Body-site distribution of MN in young Australian children. *Arch Dermatol.* 1999;135(1):47-52.
9. Zalaudek I, Docimo G, Argenziano G. Using dermoscopic criteria and patient-related factors for the management of pigmented melanocytic nevi. *Arch Dermatol.* 2009;145(7):816-826.
10. Lee TK, Rivers JK, Gallagher RP. Site-specific protective effect of broad-spectrum sunscreen on nevus development among white schoolchildren in a randomized trial. *J Am Acad Dermatol.* 2005;52(5):786-792.
11. Sommer LL, Barcia SM, Clarke LE, Helm KF. Persistent melanocytic nevi: a review and analysis of 205 cases. *J Cutan Pathol.* 2011;38(6):503-507.
12. Goodson AG, Florell SR, Boucher KM, Grossman D, Low rates of clinical recurrence after biopsy of benign to moderately dysplastic melanocytic nevi. *J Am Acad Dermatol.* 2010;62(4):591-596.

163 CONGENITAL NEVI

Mindy A. Smith, MD, MS

PATIENT STORY

A small congenital nevus (**Figure 163-1**) was noted on this 6-month-old child by his new family physician during a routine examination. The parents acknowledged that it was present from birth and asked if it needed to be cut out. They were reassured that nothing needs to be done about it at this time.

FIGURE 163-1 Small congenital nevus found on the foot of a 6-month-old child. The parents were counseled that this nevus does not need to be excised for the prevention of melanoma. (*Courtesy of Richard P. Usatine, MD.*)

INTRODUCTION

Congenital melanocytic nevi are benign pigmented lesions that have a wide variation in presentation and are composed of melanocytes, the pigment-forming cells in the skin (**Figures 163-1** to **163-7**).

SYNONYMS

- Garment nevus, bathing trunk nevus, giant hairy nevus, giant pigmented nevus, pigmented hairy nevus, nevus pigmentosus, nevus pigmentosus et pilosus, and Tierfell nevus.[1]
- Tardive congenital nevus refers to a nevus with similar features to congenital nevi, but appears at age 1 to 2 years.

EPIDEMIOLOGY

- Congenital melanocytic nevi develop in 1% to 6% of newborns and are present at birth or develop during the first year of life.[1]
- In an Italian prevalence study of more than 3000 children ages 12 to 17 years, congenital melanocytic nevi or congenital nevus-like nevi were found in 17.5%; most (92%) were small (<1.5 cm).[2]
- Congenital nevi are also seen in neurocutaneous melanosis, a rare syndrome characterized by the presence of congenital melanocytic nevi and melanotic neoplasms of the central nervous system.
- The development of melanoma within congenital nevi (**Figure 163-8**) is believed to occur at a higher rate than in normal skin. Estimates range from 4% to 10%, with smaller lesions having lowest risk.[1]
  - In a systematic review, 46 of 651 patients with congenital melanocytic nevi (0.7%), who were followed for 3.4 to 23.7 years, developed melanomas, representing a 465-fold increased relative risk of developing melanoma during childhood and adolescence.[3] The mean age at diagnosis of melanoma was 15.5 years (median: 7 years).
  - Patients with giant congenital melanocytic nevi appear to be at highest risk where subsequent melanoma has been reported in 5% to 7% by age 60 years.[4] In one study, 70% of patients with a large congenital melanocytic nevi diagnosed with melanoma were diagnosed within the first 10 years of life.[5]

FIGURE 163-2 Congenital nevus on the breast of a 24-year-old woman. It is verrucous, but entirely benign. (*Courtesy of Richard P. Usatine, MD.*)

- In a prospective study of 230 medium-size congenital nevi (1.5 to 19.9 cm) in 227 patients from 1955 to 1996, no melanomas occurred. The average follow-up period being 6.7 years to an average age of 25.5 years.[6]
- Other risk factors for melanoma include personal or family history of melanoma or other skin cancer, presence of multiple nevi, red hair, blue eyes, freckling, and history of radiation (see Chapter 172, Melanoma).[1]

ETIOLOGY AND PATHOPHYSIOLOGY

- The etiology of congenital nevi is unknown.
- Congenital nevi result from a proliferation of benign melanocytes in the dermis, epidermis, or both. Melanocytes of the skin originate in the neuroectoderm and migrate vertically to the skin and other locations such as the central nervous system and eye.[1] Defects in migration or maturation are hypothesized as causal.

DIAGNOSIS

Diagnosis is usually made based on clinical features and the history of the nevus being present at birth or develop during the first year of life.

CLINICAL FEATURES[1]

- Variable mixtures of color including pink-red (primarily at birth), tan, brown, black, or multiple shades within a single lesion (**Figures 163-1** to **163-7**); color usually remains constant over time but the nevus will grow as the person grows.
- Shapes are also highly variable, including oval, round, linear, and random; lesions have irregular but well-demarcated borders (**Figures 163-1** to **163-8**). The pigment may fade off into surrounding skin (**Figures 163-3** and **163-4**).
- Nevi may become raised over time (**Figures 163-2** and **163-3**) and the skin surface ranges from smooth to pebbly to hyperkeratotic (eczema-like appearance).
- Macular portion usually found at edges.
- Frequently exhibit hypertrichosis (**Figure 163-5**).
- Heavily pigmented large congenital melanocytic nevi over a limb may be associated with underdevelopment of the limb.[1]
- Lesions are classified by size in adulthood as:[1]
  - Small (<1.5 cm) (**Figure 163-1**).
  - Medium (1.5 cm to 19 cm) (**Figures 163-2** and **163-3**).
  - Large (>20 cm) (**Figures 163-5** to **163-7**). Giant nevi are often surrounded by several smaller satellite nevi (**Figures 163-5** to **163-7**).
  - Lesions on a child's head of less than 9 cm or body of greater than 6 cm are considered large based on likely eventual growth.[1]

IMAGING

- Dermoscopy findings depend on the age and location. In one study, the globular pattern was most common in children younger than age 11 years and on the trunk.[7] The majority of reticular lesions

FIGURE 163-3 A benign hairy congenital nevus on the upper buttocks of a 7-year-old boy. The parents requested a consult with plastic surgery to discuss removal. (*Courtesy of Richard P. Usatine, MD.*)

FIGURE 163-4 A speckled congenital nevus (nevus spilus) on the back of a young woman. (*Courtesy of Richard P. Usatine, MD.*)

FIGURE 163-5 Large bathing trunk nevus seen on the legs of this older child. (*Courtesy of Jack Resneck, Sr., MD.*)

FIGURE 163-7 Giant congenital bathing trunk nevus surrounded by satellite nevi in a 7-year-old Hispanic boy. The patient was referred to plastic surgery so that his parents might consider a staged removal of this large nevus. (*Courtesy of Richard P. Usatine, MD.*)

FIGURE 163-6 Infant born with large bathing trunk nevus covering most of the back and chest. (*Courtesy of the University of Texas Health Sciences Center, Division of Dermatology.*)

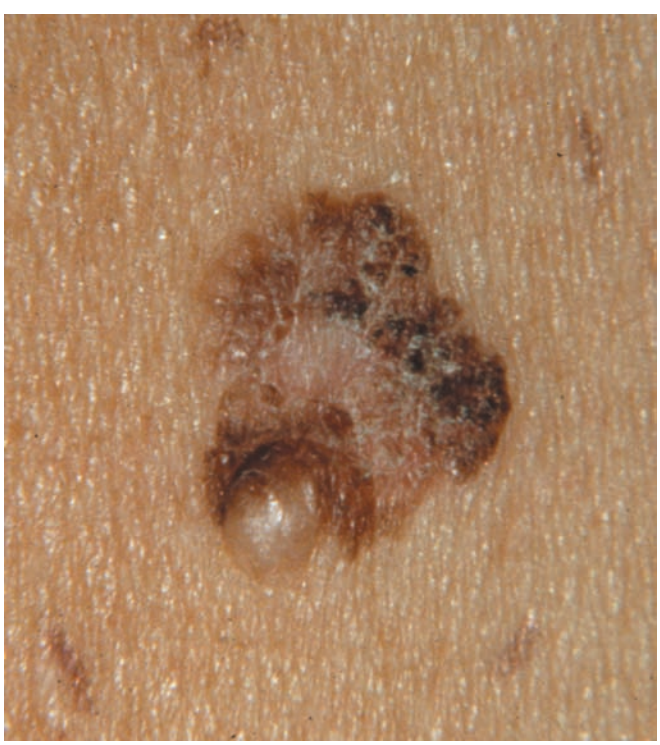

FIGURE 163-8 Melanoma arising in an acquired nevus showing features of central regression and a new elevated nodule. These are the same features that make a congenital nevus suspicious for melanoma. (*Courtesy of the University of Texas Health Sciences Center, Division of Dermatology.*)

were located on the limbs and the variegated pattern was the most specific for congenital nevi.

- MRI of the central nervous system can be a useful diagnostic tool in patients suspected of having neurocutaneous melanosis; one author recommended a screening MRI for patients with giant congenital melanocytic nevi.[8]

TYPICAL DISTRIBUTION

- Congenital nevi can be found anywhere on the body.

BIOPSY

- Although there are many histologic subtypes, distinguishing histologic features of congenital nevi include:[1]
  - Involvement by nevus cells of deep dermal appendages and neurovascular structures (e.g., hair follicles, sebaceous glands, arrector pili muscles, and within walls of blood vessels).
  - Infiltration of nevus cells between collagen bundles.

DIFFERENTIAL DIAGNOSIS

- Becker nevus—A brown macule, patch of hair, or both on the shoulder, back, or submammary area that develops in adolescence. The border is irregular and the lesion may enlarge to cover an entire shoulder or upper arm. It is a type of hamartoma and is not a melanocytic nevus (see Chapter 162, Nevus).
- Café-au-lait spots—Coffee-and-milk-colored patch that can be present at birth or develop during early childhood. Although a number of large café-au-lait spots are associated with neurofibromatosis, a few of them can occur in completely unaffected children. These light-brown patches have increased melanin but are not nevi (see Chapter 234, Neurofibromatosis).

MANAGEMENT

The management of congenital nevi depends on size and location of the lesion (difficulty in monitoring), associated symptoms, the age of the patient, the effect on cosmesis, and the potential for malignant transformation.

- For small- and medium-size congenital melanocytic nevi, the risk of malignant transformation is small and prophylactic removal is not recommended. For cosmesis, treatments include surgical excision or laser treatment.
- Larger congenital nevi can be surgically removed but may require tissue expanders, tissue grafts, and tissue flaps to close large defects. Excisions can also be staged in multiple steps. Because the melanocytes may extend deep into underlying tissues (including muscle, bone, and central nervous system), removing the cutaneous component may not eliminate the risk of malignancy.
  - There is also concern that surgical intervention may adversely affect congenital melanocytic nevi cells.[9]
- Laser treatment of the lesions has been performed with a number of different types of lasers.[10] Because of the lack of penetrance to deeper tissue levels, long-term recurrence or malignant transformation is also an issue with these techniques.
- Careful life long follow-up with photographs is an acceptable approach, especially now with the affordability of digital cameras.
- Garment or bathing trunk nevi (**Figures 163-5** to **163-7**):
  - Approximately half of the melanomas that develop in bathing trunk nevi do so before age 5 years.[11] These melanomas can be missed by observation because they can have nonepidermal origins.
  - Surgical excision is recommended by some experts to prevent melanoma.[11] SOR C.
- Changes to watch for that call for a biopsy include:
  - Partial regression (depressed white areas).
  - Inflammation.
  - Rapid growth or color change.
  - Development of a firm nodule (**Figure 163-8**).

PATIENT EDUCATION

- All patients should be told about the importance of protection from UV light exposure. This is especially important in people with giant congenital nevi, because they at a significantly increased risk of melanoma.
- Patients (or their parents) should be taught to look for signs of melanoma (ABCDE) (asymmetry, border irregularity, color irregularity, diameter >6 mm, evolution).

FOLLOW-UP

- Patients with giant congenital nevi or multiple congenital nevi may benefit from consultation with a neurologist, pediatrician, or both, because of the risk of neurocutaneous melanosis and its neurologic manifestations or obstructive hydrocephalus.
- Bathing trunk nevi can also be associated with spina bifida, meningocele, and neurofibromatosis.[11]
- Because patients with all forms of congenital nevi, especially giant congenital melanocytic nevi, have an increased risk of developing melanoma, physicians should consider baseline photography and regular follow-up with an experienced clinician for these patients.

PATIENT RESOURCES

- **http://www.ncbi.nlm.nih.gov/pubmedhealth/PMH0001831/.**
- Giant congenital nevi—**http://www.nlm.nih.gov/medlineplus/ency/article/001453.htm.**
- Support group—**http://www.nevus.org.**

PROVIDER RESOURCES

- **http://emedicine.medscape.com/article/1118659.**
- **http://www.dermatlas.org.**

REFERENCES

1. Lyon VB. Congenital melanocytic nevi. *Pediatr Clin North Am.* 2010;57:1155-1176.

2. Gallus S, Naldi L; Oncology Study Group of the Italian Group for Epidemiologic Research in Dermatology. Distribution of congenital melanocytic naevi and congenital naevus-like naevi in a survey of 3406 Italian schoolchildren. *Br J Dermatol.* 2008;159(2):433-438.
3. Krengel S, Hauschild A, Schafer T. Melanoma risk in congenital melanocytic naevi: a systematic review. *Br J Dermatol.* 2006; 155(1):1-8.
4. Bett BJ. Large or multiple congenital melanocytic nevi: occurrence of cutaneous melanoma in 1008 persons. *J Am Acad Dermatol.* 2005;52(5):793-797.
5. Marghoob AA, Agero AL, Benvenuto-Andrade C, et al. Large congenital melanocytic nevi, risk of cutaneous melanoma, and prophylactic surgery. *J Am Acad Dermatol.* 2006;54(5):868-870.
6. Sahin S, Levin L, Kopf AW, et al. Risk of melanoma in medium-sized congenital melanocytic nevi: a follow-up study. *J Am Acad Dermatol.* 1998;39:428-433.
7. Seidenari S, Pellacani G, Martella A, et al. Instrument-, age- and site-dependent variations of dermoscopic patterns of congenital melanocytic naevi: a multicentre study. *Br J Dermatol.* 2006;155(1): 56-61.
8. Arneia JS, Gosain AK. Giant congenital melanocytic nevi. *Plast Reconstr Surg.* 2009;124(1 Suppl):1e-13e.
9. Kinsler V, Bulstrode N. The role of surgery in the management of congenital melanocytic naevi in children: a perspective from Great Ormond Street Hospital. *J Plast Reconstr Aesthet Surg.* 2009;62(5):595-601.
10. Ferguson RE Jr, Vasconez HC. Laser treatment of congenital nevi. *J Craniofac Surg.* 2005;16(5):908-914.
11. Habif T. *Clinical Dermatology: A Color Guide to Diagnosis and Therapy*. 4th ed. St. Louis, MO: Mosby; 2003.

164 EPIDERMAL NEVUS AND NEVUS SEBACEOUS

Mindy A. Smith, MD, MS

PATIENT STORY

A 15-year-old boy is brought in by his mother with a concern about growth of his birthmark. It has become somewhat more raised and bumpy in the past year (**Figure 164-1**). The adolescent reports no symptoms and is not worried about the appearance. He is otherwise healthy with no neurologic symptoms. The joint decision of the family and the doctor was to not excise the epidermal nevus at this time. He may choose to have this removed by a plastic surgeon in the future.

FIGURE 164-1 Epidermal nevus on the face of a teenager. This nevus has been present since birth, and the patient is otherwise healthy. (*Courtesy of Richard P. Usatine, MD.*)

INTRODUCTION

- Epidermal nevi (EN) are congenital hamartomas of ectodermal origin classified on the basis of their main component: sebaceous, apocrine, eccrine, follicular, or keratinocytic.
- Nevus sebaceous (NS) is a hamartoma of the epidermis, hair follicles, and sebaceous and apocrine glands. A hamartoma is the disordered overgrowth of benign tissue in its area of origin.

SYNONYMS

- EN syndrome is also called Solomon syndrome and is a neurocutaneous disorder characterized by EN and an assortment of neurologic and visceral manifestations.
- NS is also called sebaceous nevus and nevus sebaceus of Jadassohn (**Figure 164-2**).
- An inflammatory linear verrucous epidermal nevus (ILVEN) (**Figure 164-3**) can be part of an epidermal nevus syndrome but some affected persons only have the cutaneous EN.

EPIDEMIOLOGY

- EN are uncommon (approximately 1% to 3% of newborns and children), sporadic, and usually present at birth, although they can appear in early childhood (**Figure 164-4**).
- EN are associated with disorders of the eye, nervous, and musculoskeletal systems in 10% to 30% of patients; in one study, 7.9% of patients with EN had 1 of the 9 syndromes—an estimated 1 per 11,928 pediatric patients.[1]
- In another review of 131 cases of EN, most (60%) had noninflammatory EN, one third had NS, and 6% had ILVEN.[2]
- NS is usually present at birth or noted in early childhood (**Figure 164-5**).[3] Most cases are sporadic but familial cases have been reported.[2]
- Linear NS is estimated to occur in 1 per 1000 live births.[4]

FIGURE 164-2 Nevus sebaceous on the scalp of a 14-year-old boy. (*Courtesy of Richard P. Usatine, MD.*)

- Linear NS syndrome includes a range of abnormalities, including the central nervous system (CNS); patients with CNS involvement typically have cognitive impairment and seizures[3]; other organ systems, including the cardiovascular, skeletal, ophthalmologic, and urogenital systems, may be involved.

ETIOLOGY AND PATHOPHYSIOLOGY

- EN histologically display hyperkeratosis and papillomatosis, similar microscopically to seborrheic keratosis (see Chapter 158, Seborrheic Keratosis).[2] Also similar to seborrheic keratosis, some EN of keratinocyte differentiation (approximately one third) have been found to have a mutation in the fibroblast growth factor receptor 3 (FGFR3) gene.
- Nine EN syndromes have been reported and are described in the referenced article.[5]
- EN frequently have a linear pattern that follows Blaschko lines (**Figures 164-1, 164-3**, and **164-4**), which are believed to represent epidermal migration during embryogenesis.
- EN tend to become thicker, verrucous (**Figure 164-4**), and hyperpigmented at puberty.[2]
- Similarly, NS demonstrates stages of evolution paralleling the histologic differentiation of normal sebaceous gland:[6]
  - Infancy and young children—Smooth to slightly papillated, waxy, hairless thickening (**Figure 164-5**).
  - Puberty—Epidermal hyperplasia resulting in verrucous irregularity of the surface covered with numerous closely aggregated yellow-to-brown papules (**Figure 164-6**).
  - Development of secondary appendageal tumors (**Figures 164-7** and **164-8**) occurs in 20% to 30% of patients, most are benign (most commonly basal cell epithelioma or trichoblastoma), but single (most commonly basal cell carcinoma) or multiple malignant tumors of both epidermal and adnexal origins may be seen and metastases have been reported.[2] Rarely, these malignancies are seen in childhood.
- NS was shown to have a high prevalence of human papillomavirus DNA and authors postulate that human papillomavirus (HPV) infection of fetal epidermal stem cells could play a role in the pathogenesis.[7]

MAKING THE DIAGNOSIS

Clinical features of EN

- EN are linear, round, or oblong; well-circumscribed; elevated; and flat-topped (**Figures 164-1** and **164-4**).
- Color is yellow-tan to dark brown.
- Surface is uniform velvety or warty (**Figures 164-4** and **164-5**).
- ILVEN, a less common type of EN, is pruritic and erythematous (**Figure 164-3**).

Clinical features of NS

- NS has an oval to linear shape ranging from 0.5 × 1 cm to 7 × 9 cm.
- NS is usually a solitary, smooth, waxy, hairless thickening noted on the scalp at birth or in early childhood (**Figures 164-2** and **164-6**).

FIGURE 164-3 Inflammatory linear verrucous epidermal nevus (ILVEN) on the trunk of an adult man. Topical steroids were not helpful in diminishing his pruritus. (*Courtesy of Robert T. Gilson, MD.*)

FIGURE 164-4 Linear epidermal nevus on the neck that appeared in early childhood. The patient had no neurologic, musculoskeletal, or vision problems. (*Courtesy of Richard P. Usatine, MD.*)

FIGURE 164-5 Nevous sebaceous behind the ear of an infant. Note the light color and the subtle presentation. (*Courtesy of Richard P. Usatine, MD.*)

FIGURE 164-6 Nevus sebaceous on the scalp of a teenage female that is verrucous and brown. (*Courtesy of Richard P. Usatine, MD.*)

FIGURE 164-7 Nevus sebaceous on the scalp of a young woman. The patient reported a new area of elevation and bleeding. A biopsy showed no malignant transformation. (*Courtesy of Richard P. Usatine, MD.*)

FIGURE 164-8 Nevus sebaceous with a benign tumor identified as a syringocystadenoma papilliferum by shave biopsy. Patient was referred for full removal of the nevus sebaceous. (*Courtesy of Richard P. Usatine, MD.*)

FIGURE 164-9 Extensive epidermal nevus following Blaschko lines on the trunk of this boy. Note how the lines are similar to the patient with inflammatory linear verrucous epidermal nevus (ILVEN) in Figure 164-2. (*Courtesy of Rick Hodes, MD.*)

- Early NS may be pink, orange, yellow, or tan; later lesions can appear verrucous and nodular (**Figure 164-5**).

TYPICAL DISTRIBUTION

- EN occur most commonly on the head and neck followed by the trunk and proximal extremities; only 13% have widespread lesions (**Figure 164-9**). Lesions may spread beyond their original distribution with age.
- NS are commonly found on the scalp followed by forehead and retroauricular region (**Figures 164-2** and **164-5** to **164-8**) and rarely involves the neck, trunk, or other areas.

BIOPSY

- Biopsy is the most definitive method for diagnosing these nevi. A biopsy is not needed if the clinical picture is clear and no operative intervention is planned. A shave biopsy should provide adequate tissue for diagnosis because the pathology is epidermal and in the upper dermis.
  - Histologic features of epidermolytic hyperkeratosis within an EN are associated with mutations in the keratin gene that may be transmitted to offspring; widespread cutaneous involvement may be seen.[2]

DIFFERENTIAL DIAGNOSIS

- Linear lichen planus (**Figure 164-10**)—Discrete, pruritic, violaceous papules are arranged in a linear fashion, usually extending along an entire limb.
- Syringoma (**Figure 164-11**)—Benign adnexal tumor derived from sweat gland ducts. Autosomal dominant transmission, soft, small, skin-colored to brown papules develop during childhood and adolescence, especially around the eyes, but may be found on the face, neck, and trunk.
- Lichen striatus—Discrete pink, tan, or skin-colored asymptomatic papules in a linear band that suddenly appear. The papules may be smooth, scaly, or flat topped. It is mostly seen in children. Although it is most commonly seen on an extremity, it can appear on the trunk (**Figure 164-12**). It can resemble a linear EN but lichen striatus will spontaneously regress within 1 year.
- Linear porokeratosis—Characterized by small, annular, hypertrophic verrucous plaques with a linear morphology usually limited to a single extremity. The annular morphology and dermatomal distribution should help distinguish this condition from EN and NS.

MANAGEMENT

MEDICATIONS

- There are no proven topical methods for treatment of these lesions. Topical retinoids may improve lesion appearance but recurrence is common.[2]

PROCEDURES

- Destructive modalities for EN, such as electrodessication and cryotherapy, may temporarily improve the appearance of the lesion, but recurrence is frequent.[2]

FIGURE 164-10 Lichen planus on the flexor aspect of the forearm in a linear pattern resembling a linear epidermal nevus. (*Courtesy of Richard P. Usatine, MD.*)

FIGURE 164-11 Syringoma on the lower eyelid. (*Courtesy of Richard P. Usatine, MD.*)

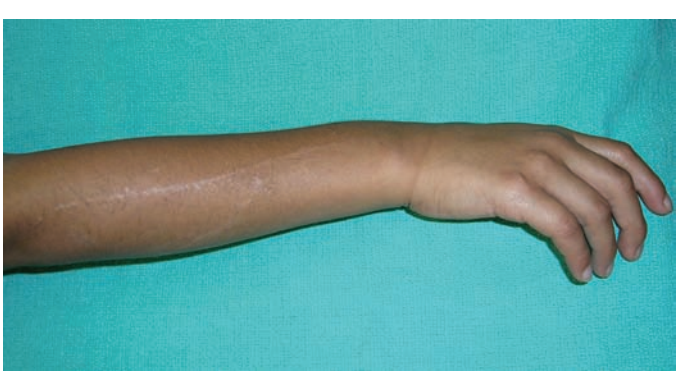

FIGURE 164-12 Lichen striatus that appeared suddenly on the arm of a young boy. (*Courtesy of Richard P. Usatine, MD.*)

- Carbon dioxide laser is an alternative option for EN; however, scarring and pigment changes are potential permanent complications, especially in patients with darker skin types.[8] This treatment does not completely remove NS and there is recurrence risk.[2]
- Surgical excision is an option that may be complicated by scarring.
- Because of the potential for malignant transformation particularly following puberty, some authors recommend early complete plastic surgical excision for NS; SOR C reconstructive surgery may be needed.
- Excision of large lesions may require reconstructive surgery with a rotation flap to close.[9]

PROGNOSIS

- There are reports of spontaneous improvement in patients with widespread involvement of EN.
- Malignant potential is low in EN.[2]
- Malignant potential in NS is uncertain. Reports range from 0% to 2.7%.[2]
  - Early reports suggested a high rate of developing basal cell carcinomas, whereas more recent studies identified trichoblastoma and syringocystadenoma papilliferum in NS, usually in adulthood.[2]
  - In a retrospective analysis of 757 cases of NS from 1996 to 2002 in children age 16 years or younger, investigators found no malignancies and question the need for prophylactic surgical removal.[10]
  - Squamous cell carcinoma has also been described in a NS.[11]

FOLLOW-UP

- Patients with NS should be examined for other associated findings. Consider a consultation with a neurologist and/or ophthalmologist.
  - In a study of 196 subjects with NS examined for clinical neurologic abnormalities, only 7% had abnormalities.[12] Abnormal exams were more frequent in individuals with extensive nevi (21% vs. 5%) and a centrofacial location (21% vs. 2%). The patients depicted in this chapter had no neurologic abnormalities.

PATIENT RESOURCES

- Nevus Outreach. *Other Kinds of Nevi*—**http://www.nevus.org/other-kinds-of-nevi_id559.html.**
- Genetics Home Reference. *Epidermal Nevus*—**http://ghr.nlm.nih.gov/condition/epidermal-nevus.**

PROVIDER RESOURCES

- Medscape. *Nevus Sebaceous*—**http://emedicine.medscape.com/article/1058733-overview.**
- Medscape. *Epidermal Nevus Syndrome*—**http://emedicine.medscape.com/article/1117506-overview.**

REFERENCES

1. Vidaurri-de la Cruz H, Tamayo-Sanchez L, Duran-McKinster C, et al. Epidermal nevus syndromes: clinical findings in 35 patients. *Pediatr Dermatol.* 2004;21(4):432-439.
2. Rogers M, McCrossin I, Commens C. Epidermal nevi and the epidermal nevus syndrome. A review of 131 cases. *J Am Acad Dermatol.* 1989;20(3):476-488.
3. Brandling-Bennett HA, Morel KD. Epidermal nevi. *Pediatr Clin North Am.* 2010;57:1177-1198.
4. Menascu S, Donner EJ. Linear nevus sebaceous syndrome: case reports and review of the literature. *Pediatr Neurol.* 2008;38(3):207-210.
5. Happle R. The group of epidermal nevous syndromes. Part I. Well-defined phenotypes. *J Am Acad Dermatol.* 2010;63:1-22.
6. Hammadi AA. *Nevus Sebaceous*. Last updated June 9, 2010. http://emedicine.medscape.com/article/1058733-overview. Accessed September 2011.
7. Carlson JA, Cribier B, Nuovo G, et al. Epidermodysplasia verruciformis-associated and genital-mucosal high-risk human papillomavirus DNA are prevalent in nevus sebaceus of Jadassohn. *J Am Acad Dermatol.* 2008;59(2):279-294.
8. Boyce S, Alster TS. CO_2 laser treatment of epidermal nevi: long-term success. *Dermatol Surg.* 2002;28(7):611-614.
9. Davison SP, Khachemoune A, Yu D, Kauffman LC. Nevus sebaceus of Jadassohn revisited with reconstruction options. *Int J Dermatol.* 2005;44(2):145-150.
10. Santibanez-Gallerani A, Marshall D, Duarte AM, et al. Should nevus sebaceus of Jadassohn in children be excised? A study of 757 cases, and literature review. *J Craniofac Surg.* 2003;14(5):658-660.
11. Aguayo R, Pallarés J, Casanova JM, et al. Squamous cell carcinoma developing in Jadassohn's sebaceous nevus: case report and review of the literature. *Dermatol Surg.* 2010;36(11):1763-1768.
12. Davies D, Rogers M. Review of neurological manifestations in 196 patients with sebaceous naevi. *Australas J Dermatol.* 2002;43(1):20-23.

165 DYSPLASTIC NEVUS

Mindy A. Smith, MD, MS
Richard P. Usatine, MD

PATIENT STORY

A 44-year-old man presents with concern over a mole on his back that his wife says is growing larger and more variable in color. The edges are irregular and the color almost appears to be "leaking" into the surrounding skin. He reports no symptoms related to this lesion. On physical exam, the nevus is 9 mm in diameter with asymmetry and variations in color and an irregular border (**Figure 165-1**). A full-body skin exam did not demonstrate any other suspicious lesions. Dermoscopy showed an irregular network with multiple asymmetrically placed dots off the network (**Figure 165-2**). A scoop saucerization was performed with a DermaBlade taking 2-mm margins of clinically normal skin (**Figure 165-3**). Although this could have been an early thin melanoma, the pathology showed a completely excised compound dysplastic nevus with no signs of malignancy. No further treatment was needed except yearly skin exams to monitor for melanoma.

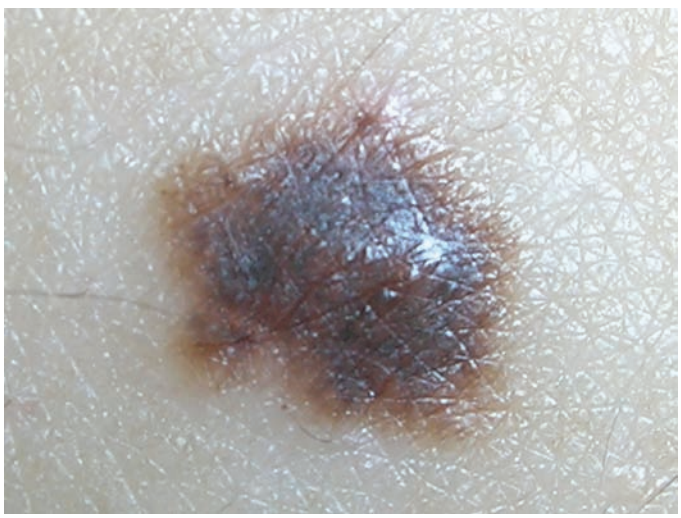

FIGURE 165-1 Growing 9-mm compound dysplastic nevus on the back of a 44-year-old man. There is asymmetry and variations in color and an irregular border. (*Courtesy of Richard P. Usatine, MD.*)

INTRODUCTION

Dysplastic nevi (DN)/atypical moles are acquired melanocytic lesions of the skin whose clinical and histologic definitions are controversial and still evolving. These lesions have some small potential for malignant transformation and patients with multiple DN have an increased risk for melanoma.[1]

The presence of multiple DN is a marker for increased melanoma risk just as red hair is, and, analogously, cutting off the red hair or cutting out all the DN does not change that risk of melanoma. The problem with DN is that any one lesion that is suspicious for melanoma must be biopsied to avoid missing melanoma, not to prevent melanoma from occurring in that nevus in the future.

SYNONYMS

Atypical nevus, atypical mole, Clark nevus, nevus with architectural disorder, and melanocytic atypia.[1]

EPIDEMIOLOGY

- Two percent to 9% of the population has atypical moles (AMs).[2,3] In a Swedish case-control study, 56% of cases (121 patients with melanoma) and 19% of 310 control subjects had nevi fulfilling the clinical criteria for DN.[4] Among patients with melanoma, the rate of DN ranges from 34% to 59%.[3] DN are uncommon in children; in a study of Swedish children (N = 524), none had DN.[5] In another study of pathology reports from nevi removed from

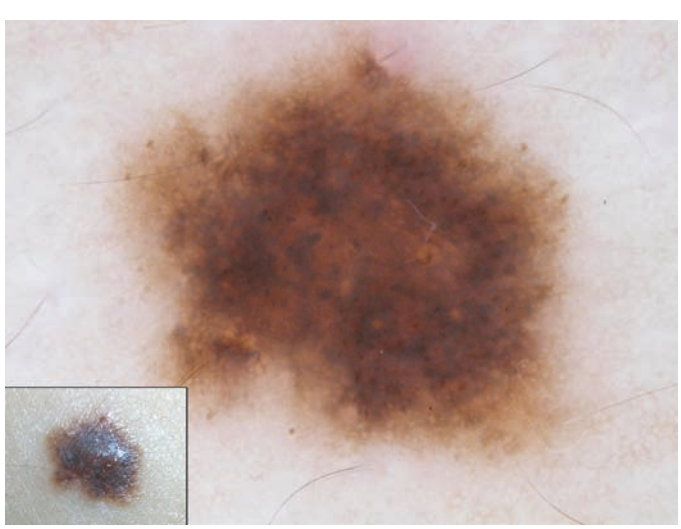

FIGURE 165-2 Dermoscopy of this compound dysplastic nevus shows an irregular network with multiple asymmetrically placed dots off the network. (*Courtesy of Richard P. Usatine, MD.*)

patients younger than 18 years old, 3 of 199 nevi submitted for histologic analysis met the histologic criteria for DN.[6]

- Individuals with fair skin types are at higher risk of DN.[3]
- The sudden eruption of benign and atypical melanocytic nevi has been reported and is associated with blistering skin conditions and a number of disease states, including immunosuppression. Subsets of patients with immunosuppression have increased numbers of nevi on the palms and soles.[7]
- The National Institute of Health Consensus Conference on the diagnosis and treatment of early melanoma defined a syndrome of familial atypical mole and melanoma (FAMM). The criteria of FAMM syndrome are:[8]
  - The occurrence of malignant melanoma in one or more first- or second-degree relatives.
  - The presence of numerous (often >50) melanocytic nevi, some of which are clinically atypical.
  - Many of the associated nevi show certain histologic features (see below under BIOPSY).

FIGURE 165-3 A scoop saucerization was performed with a DermaBlade taking 2-mm margins of clinically normal skin. Although this could have been an early thin melanoma, the pathology showed a completely excised compound dysplastic nevus with no signs of malignancy. (*Courtesy of Richard P. Usatine, MD.*)

ETIOLOGY AND PATHOPHYSIOLOGY

- Most DN are compound nevi (**Figure 165-1**) possessing a junctional and intradermal component (see Chapter 162, Nevus).[1] The junctional component is highly cellular and consists of an irregular distribution of melanocytes arranged in nests and lentiginous patterns along the dermoepidermal junction. The dermal component, located at the center, consists of nests and strands of melanocytes with distinct sclerotic changes.[1]
- DN exhibit a host response consisting of irregular rete ridge elongation, subepidermal sclerosis, proliferation of dermal capillaries, and a perivascular, lymphohistiocytic inflammatory infiltrate.[1]
- Individuals with DN may have deficient DNA repair, and DN lesions are associated with overexpression of pheomelanin (pigment produced by melanocytes), which may lead to increased oxidative DNA damage and tumor progression.[9]

DIAGNOSIS

CLINICAL FEATURES

- Variable mixtures of color including tan, brown, black, and red within a single lesion (**Figures 165-4** and **165-5**).
- Irregular, notched borders; pigment may fade off into surrounding skin (**Figure 165-5**).
- Flat or slightly raised (**Figures 165-4** to **165-6**) with the macular portion at edge. Not verrucous or pendulous.
- Lesions frequently surrounded by a reddish hue from reactive hyperemia making them appear target-like.
- Usually larger than 6 mm; may be larger than 10 mm (**Figures 162-1** and **162-4**).
- Patients with FAMM syndrome may have more than 100 lesions, far greater than the average number of common moles (<50) in most individuals.

FIGURE 165-4 Dysplastic nevus in a woman with malignant melanoma in a different region of her body. The size was greater than 6 mm and there was variation in color. This was fully excised to make sure there was no melanoma present. (*Courtesy of Richard P. Usatine, MD.*)

TYPICAL DISTRIBUTION

- Usually on sun-exposed areas, especially the back (**Figure 165-5**); may be found on sites where nevi are usually absent or rare such as the scalp, breasts, genital skin, buttocks, palm (**Figure 165-6**), and dorsa of feet.

IMAGING

- Although eccentric peripheral hyperpigmented and multifocal hyper- or hypopigmented types are more commonly seen in melanoma, no digital dermatoscopic criteria have been identified that can clearly distinguish DN from in situ melanomas.[10] However, dermoscopy increases diagnostic sensitivity and specificity of cutaneous melanoma from 60% to greater than 90%, especially using pattern recognition.[3]

BIOPSY

- The importance of histology is to distinguish DN from melanoma. Although not universally accepted, the World Health Organization Melanoma Program proposed a list of characteristics/criteria with individual lesions requiring two major and two minor criteria to be classified as a DN:[3]
  - Major criteria are basilar proliferation of atypical nevomelanocytes and organization of this proliferation in a lentiginous or epithelioid cell pattern.
  - Minor criteria are: (a) the presence of lamellar fibrosis or concentric eosinophilic fibrosis, (b) neovascularization, (c) inflammatory response, and (d) fusion of rete ridges. These established criteria yielded 92% mean concordance overall by panel members.

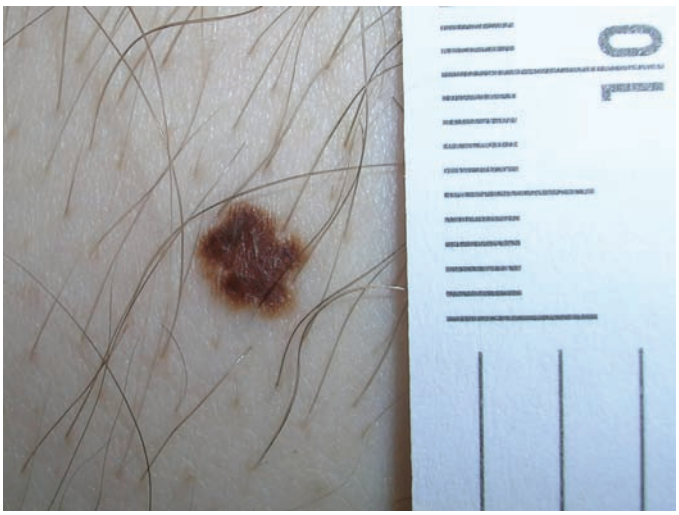

FIGURE 165-5 Dysplastic nevus on the chest of a 30-year-old man. A shave biopsy successfully removed the whole lesion and confirmed that it was not melanoma. Although it was less than 6 mm, it had irregular borders and variation of color. (*Courtesy of Richard P. Usatine, MD.*)

DIFFERENTIAL DIAGNOSIS

- Melanocytic nevi—Most common moles are tan to brown, smaller than 6 mm, round in shape, and with sharp borders (see Chapter 162, Nevus).
- Melanoma—Skin cancer is often asymmetric, with irregular border and varied colors. It is usually larger than 6 mm in diameter (see Chapter 172, Melanoma).

MANAGEMENT

NONPHARMACOLOGIC

- Obtain a family history of DN and melanoma for patients presenting with DN.
- Because of the low risk of any one DN developing malignant transformation, the prophylactic removal of all DN is not recommended. SOR C

MEDICATIONS

- Of the medications tested, including topical 5-fluorouracil, systemic isotretinoin, topical tretinoin with or without hydrocortisone, and topical imiquimod, none completely destroy DN.[3]

PROCEDURES

- Removal of at least one lesion is reasonable to histologically confirm the diagnosis and rule out melanoma. This should be accomplished

FIGURE 165-6 Junctional dysplastic nevus on the palm of a 43-year-old Hispanic man. Dermoscopically there was pigment on the top of the skin ridges making this suspicious for melanoma. Fortunately, the punch biopsy showed a dysplastic nevus only. (*Courtesy of Richard P. Usatine, MD.*)

with excisional biopsy and histologic confirmation of DN versus melanoma. DN is usually removed with conservative surgical margins (about 2 mm) to provide adequate tissue for the pathologist.[3] SOR C

- Scoop saucerizations (deep shave biopsy with a DermaBlade or razor blade) including at least a 2-mm margin of clinically normal skin surrounding the pigmented lesion is a rapid and acceptable method of excision for pathology (**Figure 165-7**).

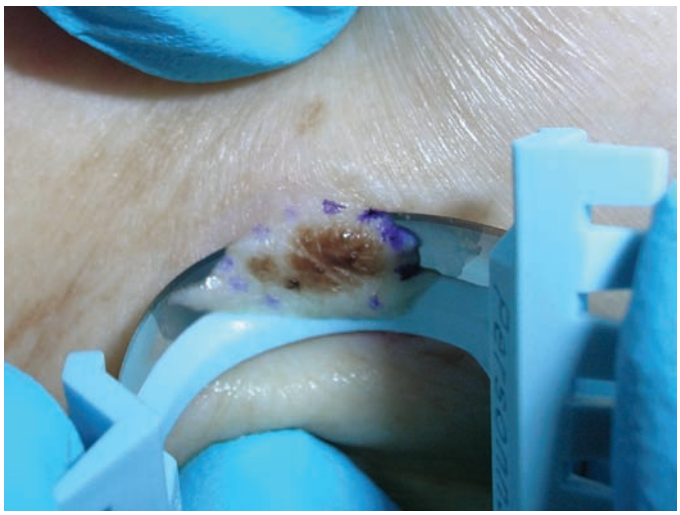

FIGURE 165-7 Scoop saucerization of a suspicious pigmented lesion that turned out to be a dysplastic junctional nevus with moderate atypia. The whole lesion was successfully excised with this deep shave. (*Courtesy of Richard P. Usatine, MD.*)

PREVENTION

- Avoid direct sunlight.

PROGNOSIS

- DNs appear to be dynamic throughout adulthood. In a study of the natural history of DN, investigators found that 51% of all evaluated nevi (297 of 593) showed clinical signs of change during an average follow-up of 89 months.[11] New nevi were common in adulthood, continuing to form in more than 20% of patients older than age 50 years, and some nevi disappeared.
- The risk of a melanoma arising within a DN is estimated at 1:3000 per year.[1] However, there is also an increased risk of melanoma arising elsewhere on the skin in patients with DN; the actual incidence rate is uncertain and ranges from 0.5% to 46%.[3] There is also a substantially increased risk of melanoma associated with the number of atypical nevi (relative risk [RR] = 6.36; 95% confidence interval [CI]: 3.80, 10.33; for 5 versus 0).[12]
- In one case-control study, the estimated 10-year cumulative risk for developing melanoma in patients with AM syndrome was 10.7% (versus 0.62% in a control population).[13]

FOLLOW-UP

- Patents with DN should have regular skin examinations with biopsy performed of any suspicious lesions (**Figure 165-7**).[3]
- Consider total-body photographs for monitoring (**Figures 165-8** and **165-9**).[3] In a study of 50 patients with 5 or more DN, the use of baseline digital photographs improved the diagnostic accuracy of skin self-examination on the back, chest, and abdomen, and improved detection of changing and new moles.[14] Individual DN can be monitored more precisely with digital dermoscopic photos added to the skin photographs (**Figure 165-9**).
- MelaFind, a lesion imaging device using multispectral imaging analysis, may be helpful in differentiating DN from melanoma.[15] It is a very expensive computerized device that is not affordable in a primary care office.
- Patients with numerous DN and who have a family history of melanoma are at a higher risk of developing melanoma and should be encouraged to have regular follow-up with a provider skilled in detecting melanoma.

FIGURE 165-8 Multiple dysplastic nevi on the back of a young physician. Multiple biopsies have all been negative, so patient is being followed by serial digital photography with numbering of the dysplastic nevi. (*Courtesy of Richard P. Usatine, MD.*)

- Patients with FAMM should also consider a baseline ophthalmologic examination because of a possible association between uveal melanoma and FAMM syndrome.[3]
- First-degree relatives of patients diagnosed with FAMM syndrome should be encouraged to be examined for DN and melanoma.

PATIENT EDUCATION

- Patients with DN should avoid excessive exposure to natural or artificial UV light and routinely use a broad-spectrum sunscreen with a sun protective factor of 30 or greater and/or sun-protective clothing.
- Patients should be taught self-examination to detect changes in existing moles and to recognize clinical features of melanomas. Patients should be taught to look for and report asymmetry, border irregularity, new symptoms (e.g., pain, pruritus, bleeding, or ulceration), and color and size changes.

PATIENT RESOURCES

- **http://www.nlm.nih.gov/medlineplus/moles.html.**
- **http://www.cancer.gov/cancertopics/wyntk/moles-and-dysplastic-nevi.**
- **http://www.ncbi.nlm.nih.gov/books/NBK7030/.**

PROVIDER RESOURCES

- **http://www.dermatlas.com.**
- **http://emedicine.medscape.com/article/1056283-overview.**

FIGURE 165-9 More than 14 dysplastic nevi are seen on the back of this 35-year-old woman with a history of 2 basal cell carcinomas on her back. She has never had a melanoma and has no family history of melanoma. Multiple biopsies so far have only shown dysplastic nevi, so she is being followed with serial digital photography of her nevi along with corresponding dermoscopic photographs. Note the dermoscopic images of nevi 3 and 4 in the bottom left corner. (*Courtesy of Richard P. Usatine, MD.*)

REFERENCES

1. Clarke LE. Dysplastic nevus. *Clin Lab Med*. 2011;31:255-265.
2. Mooi WJ. The dysplastic naevus. *J Clin Pathol*. 1997;50:711-715.
3. Friedman RJ, Farber MJ, Warycha MA, et al. The "dysplastic" nevus. *Clin Dermatol*. 2009;27:103-115.
4. Stierner U, Augustsson A, Rosdahl I, Suurküla M. Regional distribution of common and dysplastic naevi in relation to melanoma site and sun exposure. A case-control study. *Melanoma Res*. 1992;1(5-6):367-375.
5. Synnerstad I, Nilsson L, Fredrikson M, Rosdahl I. Frequency and distribution pattern of melanocytic naevi in Swedish 8-9-year-old children. *Acta Derm Venereol*. 2004;84(4):271-276.
6. Haley JC, Hood AF, Chuang TY, Rasmussen J. The frequency of histologically dysplastic nevi in 199 pediatric patients. *Pediatr Dermatol*. 2000;17(4):266-269.
7. Woodhouse J, Maytin EV. Eruptive nevi of the palms and soles. *J Am Acad Dermatol*. 2005;52(5 Suppl 1):S96-S100.
8. Friedman RJ, Farber MJ, Warycha MA, et al. The "dysplastic" nevus. *Clin Dermatol*. 2009;27:103-115.
9. Elder DE. Dysplastic naevi: an update. *Histopathology*. 2010;56(1):112-120.

10. Burroni M, Sbano P, Cevenini G, et al. Dysplastic naevus vs. in situ melanoma: digital dermoscopy analysis. *Br J Dermatol*. 2005;152(4):679-684.

11. Trock B, Synnestvedt M, Humphreys T. Natural history of dysplastic nevi. *J Am Acad Dermatol*. 1993;29(1):51-57.

12. Gandini S, Sera F, Cattaruzza MS, et al. Meta-analysis of risk factors for cutaneous melanoma: I. Common and atypical naevi. *Eur J Cancer*. 2005;41(1):28-44.

13. Marghoob AA, Kopf AW, Rigel DS, et al. Risk of cutaneous malignant melanoma in patients with "classic" atypical-mole syndrome. A case-control study. *Arch Dermatol*. 1994;130:993-998.

14. Oliveria SA, Chau D, Christos PJ, et al. Diagnostic accuracy of patients in performing skin self-examination and the impact of photography. *Arch Dermatol*. 2004;140(1):57-62.

15. Friedman RJ, Gutkowicz-Krusin D, Farber MJ, et al. The diagnostic performance of expert dermoscopists vs a computer-vision system on small-diameter melanomas. *Arch Dermatol*. 2008;144:476-482.

SECTION 11 PRE CANCER/EARLY CANCER

166 ACTINIC KERATOSIS AND BOWEN DISEASE

Richard P. Usatine, MD
Yu Wah, MD

PATIENT STORY

A 57-year-old woman presented with red and scaling skin on both arms (**Figure 166-1**) with a request for a prescription for 5-fluorouracil (5-FU). The patient had blue eyes and white hair and was found to have 2 basal cell carcinomas (BCCs) on her face and shoulder. The patient stated that 5-FU had helped her arms in the past, but that the scaly lesions had returned. She avoids sun exposure now, but acknowledges receiving too much sun exposure while growing up. Another course of 5-FU was prescribed for her arms to prevent new skin cancers from forming.

FIGURE 166-1 Actinic keratoses covering both arms and the dorsum of both hands in a fair-skinned woman who had significant sun exposure. Note that her left arm and hand are worse from driving a car and receiving more sun on the left arm. (*Courtesy of Richard P. Usatine, MD.*)

INTRODUCTION

Actinic keratoses (AKs) are precursors on the continuum of carcinogenesis toward squamous cell carcinomas (SCCs). However, each AK has a low risk of progression to malignancy and a high probability of spontaneous regression.[1] Bowen disease (BD) is SCC in situ confined to the epidermis.

SYNONYMS

AK is also known as solar keratosis. AK on the lips is known as actinic cheilitis (**Figure 166-2**). BD is also known as SCC in situ of the skin. SCC in situ involving the penis is known as erythroplasia of Queyrat (**Figure 166-3**).

FIGURE 166-2 Actinic cheilitis involving lower lips. Note the erythema and scale caused by the sun damage. (*Courtesy of Richard P. Usatine, MD.*)

EPIDEMIOLOGY

- AKs and BD are seen frequently in light-skinned individuals who have had significant sun exposure.
- The prevalence of AK is estimated at 11% to 25% in adults older than age 40 years in the northern hemisphere, and increases with age.[1] AKs are so common that they account for more than 10% of visits to dermatologists.
- The prevalence of BD is unknown.[1]

ETIOLOGY AND PATHOPHYSIOLOGY

AKs and BD are both caused by cumulative UV exposure, most commonly from sunlight.

UV rays induce mutation of the tumor-suppressor gene P53. Subsequent proliferation of mutated atypical epidermal keratinocytes give rise to the clinical lesion of AK.[2] Multiple clinical and subclinical lesions may exist in an area of sun-damaged skin, a concept known as "field cancerization."

AKs have the potential to become SCCs. The rate of malignant transformation has been variably estimated, but is probably no greater than 6% per AK over a 10-year period.[3]

In a large prospective cohort study, the risk of progression of AK to primary SCC (invasive or in situ) was 0.60% at 1 year and 2.57% at 4 years. Approximately 65% of all primary SCCs and 36% of all primary BCCs diagnosed in the study arose in lesions that previously were diagnosed clinically as AKs. Many AKs did resolve spontaneously, 55% AKs that were followed clinically were not present at 1 year and the 70% were not present at the 5-year follow-up.[4]

On a spectrum of malignant transformation, BD is SCC in situ before the SCC becomes invasive.

FIGURE 166-3 Bowen disease of the penis also known as erythroplasia of Queyrat. Human papillomavirus is a risk factor in this location. (*Courtesy of Richard P. Usatine, MD.*)

RISK FACTORS

- Total lifetime dose of UV radiation (natural sunlight, UV from tanning beds and radiation).1
- Fair skin.1
- Site-specific risk factors include tobacco for actinic cheilitis and human papilloma virus for genital and anal lesions.1
- Exposure to immunosuppressive drugs, especially organ transplant recipients.
- Personal or family history of skin cancers.

DIAGNOSIS

CLINICAL FEATURES

AKs are rough scaly spots seen on sun-exposed areas (**Figure 166-1** to **166-6**). They may be found by touch, as well as close visual inspection of the patient's skin. BD appears similar to an AK, but tends to be larger in size and thicker with a well-demarcated border (**Figure 166-7** and **166-8**).

TYPICAL DISTRIBUTION

Both lesions are seen in areas with greatest sun exposure such as the face, forearms, dorsum of hands, lower legs of women, and the balding scalp (**Figure 166-5**) and tops of the ears in men.

LABORATORY STUDIES

AKs that appear premalignant may be diagnosed by observation only and treated with destructive methods (e.g., excision, electrosurgery, or cryosurgery) without biopsy. BD requires a biopsy for diagnosis. BD or SCC should be biopsied prior to treatment. A shave biopsy should produce enough tissue for histopathology.

FIGURE 166-4 Large actinic keratoses over the eyebrow of an older adult. A biopsy was performed to make sure this was not already Bowen disease or squamous cell carcinoma. (*Courtesy of Richard P. Usatine, MD.*)

DIFFERENTIAL DIAGNOSIS

- Nummular eczema—a type of eczema in which the scaly patches are coin-shaped. The patches are often seen in patients who have already had some eczema or atopic conditions. The patches usually

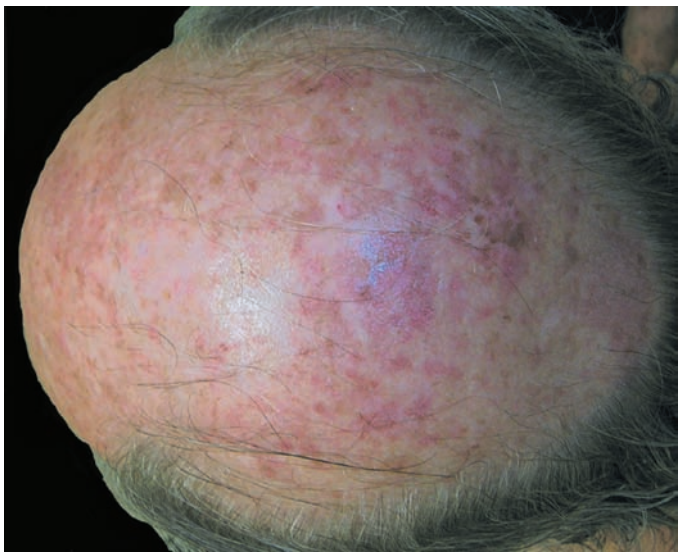

FIGURE 166-5 Actinic keratoses on the balding head of an older man. Hair loss results in less natural sun protection and is a risk factor for skin cancers on the scalp. The visible and palpable actinic keratoses were treated with cryotherapy. (*Courtesy of Richard P. Usatine, MD.*)

FIGURE 166-7 Lesions on the arm of an older man with Bowen disease in the central lesion and actinic keratosis on the upper lesion. (*Courtesy of Richard P. Usatine, MD.*)

FIGURE 166-6 Actinic keratoses on the dorsum of the hand with some lesions suspicious for Bowen disease (squamous cell carcinoma in situ). (*With permission from Usatine RP, Moy RL, Tobinick EL, Siegel DM. Skin Surgery: A Practical Guide. St. Louis, MO: Mosby; 1998,.*)

FIGURE 166-8 Bowen disease on the leg of an older woman. (*Courtesy of Richard P. Usatine, MD.*)

respond well to topical corticosteroids and are not related to sun damage (see Chapter 145, Atopic Dermatitis).

- Seborrheic keratoses—occur in aging adults but do not have any malignant potential. Typical seborrheic keratoses are brown in color and have a stuck on appearance. Seborrheic keratoses may look greasy or verrucous and have surface cracks. Their borders tend to be more well demarcated than AKs and their color is usually more brown than pink (see Chapter 158, Seborrheic Keratosis).
- Superficial BCCs—can look like an AK or BD. Look for the pearly and thready border that may distinguish a superficial BCC from an AK or BD. Histopathology is the proven method to diagnose (see Chapter 170, Basal Cell Carcinoma).
- When in doubt, perform a shave biopsy to differentiate between an AK, BD, SCC, and superficial BCC.

FIGURE 166-9 Cryosurgery of large actinic keratosis. The outside border was marked with a 1- to 2-mm margin. (*Courtesy of Richard P. Usatine, MD.*)

MANAGEMENT

ACTINIC KERATOSES

- No therapy or the application of an emollient is a reasonable option for mild AKs.[5] SOR A
- Sun screen applied twice daily for 7 months may protect against development of AKs.[2] SOR A
- AKs are most often treated by cryosurgery using liquid nitrogen (**Figure 166-9**). It is simple, rapid, and inexpensive, and may be used as first-line treatment.[1] SOR C One metaanalysis showed a 2-month cure rate of 97.0% with 2.1% recurrences in 1 year.[6]
- Treating AKs with liquid nitrogen using a 1-mm halo freeze demonstrated complete response of 39% for freeze times of less than 5 seconds, 69% for freeze times greater than 5 seconds, and 83% for freeze times greater than 20 seconds.[7] There is considerably more hypopigmentation caused by 20 seconds of freeze time. Determine the length of the freeze time based on the size and thickness of the lesion, using sufficient time for clearance while attempting to avoid hypopigmentation and scarring. SOR B
- Treat multiple AKs of the face, scalp, forearms, and hands topically with 5-FU, imiquimod, or diclofenac.[1,5] SOR A **Table 166-1**.
- Topical 5-FU is an efficient therapeutic method and may be used for treatment of isolated, as well as large, areas of AK. It may be applied by the patient, and is inexpensive compared with other topical modalities.[1] SOR A
- 5-FU cream used twice daily for 3 to 6 weeks is effective for up to 12 months in clearance of the majority of AKs (**Figure 166-10**).[5] SOR A Because of side-effects of soreness, less-aggressive regimens are often used, which may be effective, but have not been fully evaluated.[5]

TABLE 166-1 Comparison of Topical Agents for the Treatment of AK

Topical Agent for AK	Duration of Treatment	Irritation	Cost
5-fluorouracil generic 5%	3 to 6 weeks	High	Less than $100
Diclofenac 3%	10 to 12 weeks	Moderate	More than $130
Imiquimod	16 weeks	Moderate	More than $400

- Diclofenac gel applied twice daily for 10 to 12 weeks has moderate efficacy with low morbidity in mild AKs.[2] SOR B There are few follow-up data to indicate the duration of benefit.[2] In one study, diclofenac 3% gel was as effective as 5-FU cream for AK of the face and scalp and diclofenac produced fewer signs of inflammation.[8]
- Imiquimod 5% cream has been demonstrated to be effective over a 16-week course of treatment, but studies have only measured 8 weeks of follow up.[5] SOR B By weight, it is 19 times the cost of 5-FU. They have similar side effects.[5]
- One metaanalysis comparing imiquimod to 5-FU showed average complete clearance of AKs for each drug was 5-FU, 52 ± 18% and imiquimod, 70 ± 12%.[9]
- Imiquimod applied topically for 12 to 16 weeks produced complete clearance of AKs in 50% of patients compared to 5% with vehicle (number needed to treat [NNT] = 2.2). Adverse events included erythema (27%), scabbing or crusting (21%), flaking (9%), and erosions (6%) (number needed to harm [NNH] = 3.2 to 5.9).[10]
- Because of its immunostimulatory properties, imiquimod cream must be used with caution in transplant patients on immunosuppression therapy.[1] SOR C
- Topical tretinoin has some efficacy on the face, with partial clearance of AKs, but may need to be used for up to a year at a time to optimize benefit.[5] SOR B
- Cryosurgery was effective for up to 75% of lesions in trials comparing it with photodynamic therapy. It may be particularly superior for thicker lesions, but may leave scars.[5] SOR A
- Photodynamic therapy (PDT) was effective in up to 91% of AKs in trials comparing it with cryotherapy, with consistently good cosmetic results. It may be particularly good for superficial and confluent AKs, but is likely to be more expensive than most other therapies. It is of particular value where AKs are numerous or when located at sites of poor healing, such as the lower leg.[5] SOR B
- Other less accessible and expensive methods include lasers, dermabrasion, and chemical peels.
- Investigational treatment—ingenol mebutate. A short 2 to 3 days of treatment with daily topical ingenol mebutate from the sap of *Euphorbia peplus* plant, showed promising efficacy with a favorable safety profile in several randomized controlled trials (RCTs). One multicenter RCT showed 34.1% to 42.2% complete clearance of AKs with ingenol mebutate gel 0.05% for trunk and extremities, and 0.015% for face.[11] Another RCT with 0.05% gel showed a complete clearance of 71% of treated lesions.[12] Ingenol mebutate appears to have a dual mechanism of action by rapid lesion necrosis and subsequent immune mediated cellular cytotoxicity, providing efficacy with short treatment period. [13]

BOWEN DISEASE

- **Table 166-2** compares and summarizes the main treatment options.
- The risk of progression to invasive cancer is approximately 3%. This risk is greater in genital BD, and particularly in perianal BD. A high risk of recurrence, including late recurrence, is a particular feature of perianal BD and prolonged follow up is recommended for this variant.[14] SOR A
- There is reasonable evidence to support use of 5-FU.[14] SOR B It is more practical than surgery for large lesions, especially at potentially

FIGURE 166-10 **A.** Actinic keratoses reddened and crusted by the application of 5-fluorouracil topically twice daily. **B.** Face healed months after the course of 5-fluorouracil was completed. (*Courtesy of Richard P. Usatine, MD.*)

TABLE 166-2 Summary of the Main Treatment Options for Bowen Disease

Lesion Characteristics	Topical 5-FU	Topical Imiquimod*	Cryotherapy	Curettage	Excision	PDT	Radiotherapy	Laser†
Small, single/few, good healing site‡	4	3	2	1	3	3	5	4
Large, single, good healing site‡	3	3	3	5	5	2	4	7
Multiple, good healing site‡	3	4	2	3	5	3	4	4
Small, single/few, poor healing site‡	2	3	3	2	2	1–2	5	7
Large, single, poor healing site‡	3	2–3	5	4	5	1	6	7
Facial	4	7	2	2	4§	3	4	7
Digital	3	7	3	5	2§	3	3	3
Perianal	6	6	6	6	1¶	7	2 to 3	6
Penile	3	3	3	5	4§	3	2 to 3	3

5-FU, 5-fluorouracil; PDT, photodynamic therapy; *1,* probably treatment of choice; *2,* generally good choice; *3,* generally fair choice; *4,* reasonable but not usually required; *5,* generally poor choice; *6,* probably should not be used; *7,* insufficient evidence available. The suggested scoring of the treatments listed takes into account the evidence for benefit, ease of application or time required for the procedure, wound healing, cosmetic result, and current availability/costs of the method or facilities required. Evidence for interventions based on single studies or purely anecdotal cases is not included.
*Does not have a product license for Bowen disease.
†Depends on site.
‡Refers to the clinician's perceived potential for good or poor healing at the affected site.
§Consider micrographic surgery for tissue sparing or if poorly defined/recurrent.
¶Wide excision recommended.

poor healing sites, and has been used for "control" rather than cure in some patients with multiple lesions.[8]

- Topical imiquimod may be used off-label for BD for larger lesions or difficult/poor healing sites.[14] SOR B However, it is costly and the optimum regimen has yet to be determined.[14]
- One prospective study suggests a superiority of curettage and electrodesiccation over cryotherapy in treating BD, especially for lesions on the lower leg (**Figure 166-11**).[10] Curettage was associated with a significantly shorter healing time, less pain, fewer complications, and a lower recurrence rate when compared with cryotherapy.[15]

PREVENTION

- Protection from UV exposure by limiting outdoor activities, and using sunscreens and protective gears (hat, umbrella, long sleeve garments, etc).
- Avoid artificial tanning beds and tobacco.

PROGNOSIS

Prognosis of treated AK and BD is excellent.

FOLLOW-UP

Patients need skin examinations every 6 to 12 months to identify new precancers and cancers. SOR C More frequent examinations may be needed for those who have continued exposure to offending agents (eg. organ transplant recipients on immunosuppressant therapy), and those with history of recurrent skin malignancies.

PATIENT EDUCATION

Patients must understand that they acquired these conditions through cumulative sun damage, and they need to avoid further sun damage to minimize the likelihood of additional precancers and cancers. The sun damage is often from childhood and early adulthood, so the lesions are likely to form even with future sun protection. Self skin examination is recommended.

All topical treatments for AKs and BD will make the lesions look worse before they get better (**Figure 166-10**). The 5-FU treatments are often given with topical corticosteroid preparations to use after the treatment is over so as to minimize the symptoms of the inflammation.

PATIENT RESOURCE

- Skin Cancer Foundation has an excellent website with photos and patient information—**http://www.skincancer.org/ak/index.php.**

PROVIDER RESOURCE AND GUIDELINES

- Cox NH, Eedy DJ, Morton CA. Guidelines for management of Bowen's disease: 2006 update. *Br J Dermatol* 2007;156(1):11-21.

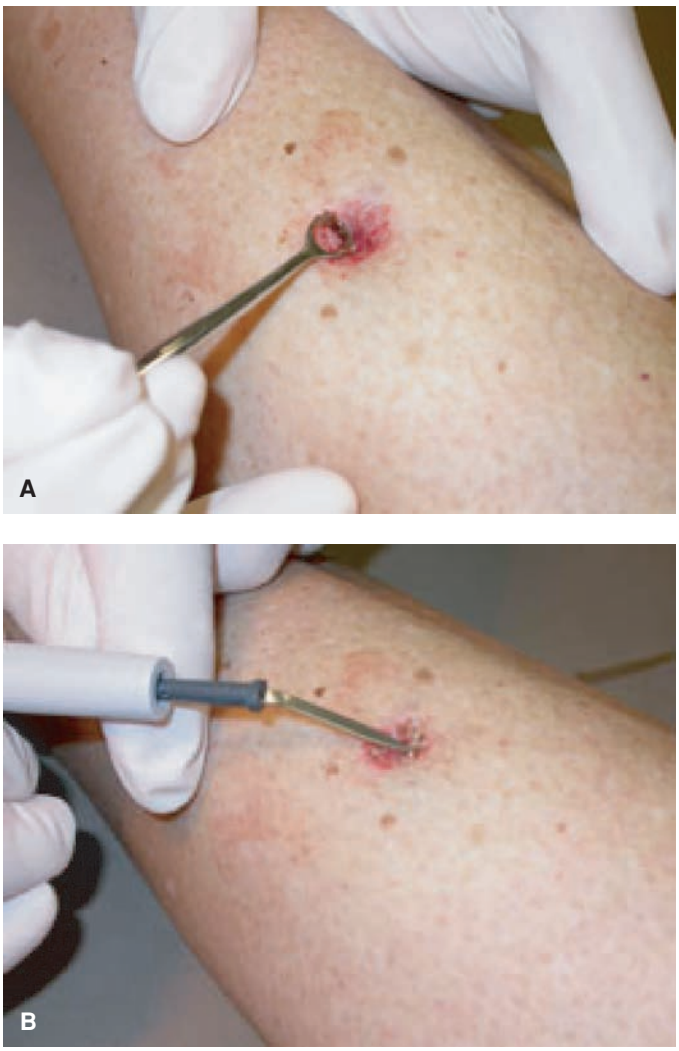

FIGURE 166-11 **A.** Curettage of Bowen disease on the leg. Each cycle begins with curettage and ends with electrodesiccation. **B.** Electrodesiccation of Bowen disease on the same leg. Three cycles were performed to complete the procedure. (*Courtesy of Richard P. Usatine, MD.*)

REFERENCES

1. Bonerandi JJ, Beauvillain C, Caquant L, et al. Guidelines for the diagnosis and treatment of cutaneous squamous cell carcinoma and precursor lesions. *J Eur Acad Dermatol Venereol* 2011;25 Suppl 5:1-51.
2. Leffell DJ. The scientific basis of skin cancer. *J Am Acad Dermatol* 2000;42(1 Pt 2):18-22.
3. Anwar J, Wrone DA, Kimyai-Asadi A, Alam M. The development of actinic keratosis into invasive squamous cell carcinoma: evidence and evolving classification schemes. *Clin Dermatol* 2004;22(3):189-196.
4. Criscione VD, Weinstock MA, Naylor MF, et al. Actinic keratoses: natural history and risk of malignant transformation in the Veterans Affairs Topical Tretinoin Chemoprevention Trial. *Cancer* 2009;115(11):2523-2530.

5. de Berker D, McGregor JM, Hughes BR. Guidelines for the management of actinic keratoses. *Br J Dermatol* 2007;156(2):222-230.
6. Zouboulis CC, Röhrs H. [Cryosurgical treatment of actinic keratoses and evidence-based review]. *Hautarzt* 2005;56(4):353-358.
7. Thai K-E, Fergin P, Freeman M, et al. A prospective study of the use of cryosurgery for the treatment of actinic keratoses. *Int J Dermatol* 2004;43(9):687-692.
8. Smith SR, Morhenn VB, Piacquadio DJ. Bilateral comparison of the efficacy and tolerability of 3% diclofenac sodium gel and 5% 5-fluorouracil cream in the treatment of actinic keratoses of the face and scalp. *J Drugs Dermatol* 2006;5(2):156-159.
9. Gupta AK, Davey V, Mcphail H. Evaluation of the effectiveness of imiquimod and 5-fluorouracil for the treatment of actinic keratosis: Critical review and meta-analysis of efficacy studies. *J Cutan Med Surg* 2005;9(5):209-214.
10. Hadley G, Derry S, Moore RA. Imiquimod for actinic keratosis: systematic review and meta-analysis. *J Invest Dermatol* 2006;126(6):1251-1255.
11. Lebwohl M, Swanson N, Anderson LL, et al. Ingenol mebutate gel for actinic keratosis. *N Engl J Med* 2012;366(11):1010-1019.
12. Siller G, Gebauer K, Welburn P, Katsamas J, Ogbourne SM. PEP005 (ingenol mebutate) gel, a novel agent for the treatment of actinic keratosis: results of a randomized, double-blind, vehicle-controlled, multicentre, phase IIa study. *Australas J Dermatol* 2009;50(1):16-22.
13. Rosen RH, Gupta AK, Tyring SK. Dual mechanism of action of ingenol mebutate gel for topical treatment of actinic keratoses: Rapid lesion necrosis followed by lesion-specific immune response. *J Am Acad Dermatol* 2012;66(3):486-493.
14. Cox NH, Eedy DJ, Morton CA. Guidelines for management of Bowen's disease: 2006 update. *Br J Dermatol* 2007;156(1):11-21.
15. Ahmed I, Berth-Jones J, Charles-Holmes S, O'Callaghan CJ, Ilchyshyn A. Comparison of cryotherapy with curettage in the treatment of Bowen's disease: a prospective study. *Br J Dermatol* 2000;143(4):759-766.

167 KERATOACANTHOMA

Alfonso Guzman, Jr. BSN, MD
Richard P. Usatine, MD

PATIENT STORY

A 71-year-old woman presented with a rapidly growing lesion on her face over the past 4 months (**Figure 167-1**). The lesion had features of a basal cell carcinoma with a pearly border and telangiectasias (**Figure 167-2**). Also the central crater with keratin gave it the appearance of a keratoacanthoma (KA). A shave biopsy was performed and the pathology showed squamous cell carcinoma (SCC)–KA type. A full elliptical excision with 4-mm margins was then performed.

FIGURE 167-1 Pearly keratoacanthoma with telangiectasias and a central keratin core on the face of a 71-year-old woman. (*Courtesy of Richard P. Usatine, MD.*)

INTRODUCTION

The KA is a unique epidermal tumor characterized by rapid, abundant growth and a spontaneous resolution, with the classic presentation in middle-aged, light-skinned individuals in hair-bearing, sun-exposed areas. In the late 1940s, Freudenthal of Wroclaw coined the term *keratoacanthoma*, owing to the considerable acanthosis observed in the tumor. Controversies have arisen since the 1950s about the real nature of the tumor; some KAs may metastasize, and there is debate over the relationship to SCC.[1,2] Many dermatopathologists now classify this tumor as a subtype of SCC.

SYNONYMS[1]

- Keratocarcinoma.
- Molluscum sebaceum.
- Molluscum pseudocarcinomatosum.
- Cutaneous sebaceous neoplasm.
- Self-healing squamous epithelioma.
- Intracutaneous cornifying epithelioma.
- Idiopathic cutaneous pseudoepitheliomatous hyperplasia.
- Verrugoma.

EPIDEMIOLOGY

- KA develops as a solitary nodule in sun-exposed areas.
- Seen more commonly later in life with a predilection for males.[1]
- Develops rapidly within 6 to 8 weeks.
- May spontaneously regress after 3 to 6 months or may continue to grow and rarely metastasize.[3]

FIGURE 167-2 Close-up of the keratoacanthoma with telangiectasias and a central keratin core on the face of the woman in **Figure 167-1**. (*Courtesy of Richard P. Usatine, MD.*)

ETIOLOGY AND PATHOPHYSIOLOGY

- KAs share features such as infiltration and cytologic atypia with SCCs.

- KAs have been reported to metastasize.
- KA is considered to be a variant of SCC, called SCC-KA type.
- Histologic criteria are not sensitive enough to discriminate reliably between KA and SCC.[4]

RISK FACTORS

- Ages 40s to 60s.
- Occurs on sun-exposed areas of skin.
- Light complexion.
- Male gender.

DIAGNOSIS

CLINICAL FEATURES

Solitary nodule in sun exposed areas. Often have a central keratin plug that resembles a volcano (**Figures 167-1** to **167-5**). KAs may grow rapidly (**Figure 167-6**). Rare cases of multiple eruptive KAs have been reported.[1]

TYPICAL DISTRIBUTION

Face, arms, hands, and trunk (**Figures 167-3** and **167-5**). KAs can be found anywhere on the head and neck, including the ears (**Figures 167-6** and **167-7**).

LABORATORY STUDIES

Biopsy is the only reliable method to make the diagnosis. KAs are well-differentiated squamoproliferative skin lesions.

DIFFERENTIAL DIAGNOSIS

- Actinic keratoses are precancerous lesions found on sun-exposed areas that may progress to SCC. Because these lesions are generally flat they are rarely confused with KAs (see Chapter 166, Actinic Keratosis and Bowen Disease).
- Cutaneous horn is a raised, keratinaceous lesion that can arise in actinic keratoses and in all types of nonmelanoma skin cancers. It generally does not have pearly raised skin around the keratin horn and therefore does not have the crater appearance of a KA (see Chapter 169, Cutaneous Horn).
- SCCs of the skin have many forms and KA is considered to be one type of SCC (see Chapter 171, Squamous Cell Carcinoma).

MANAGEMENT

- A shave biopsy may be used for diagnosis but is not an adequate final treatment. Options for definitive treatment should be discussed with patient.
- Although some KAs may regress spontaneously, there is no way to distinguish between these and the ones that are variants of SCC, which may go on to metastasize. Therefore, the standard of care is to remove or destroy the remaining tumor. SOR C

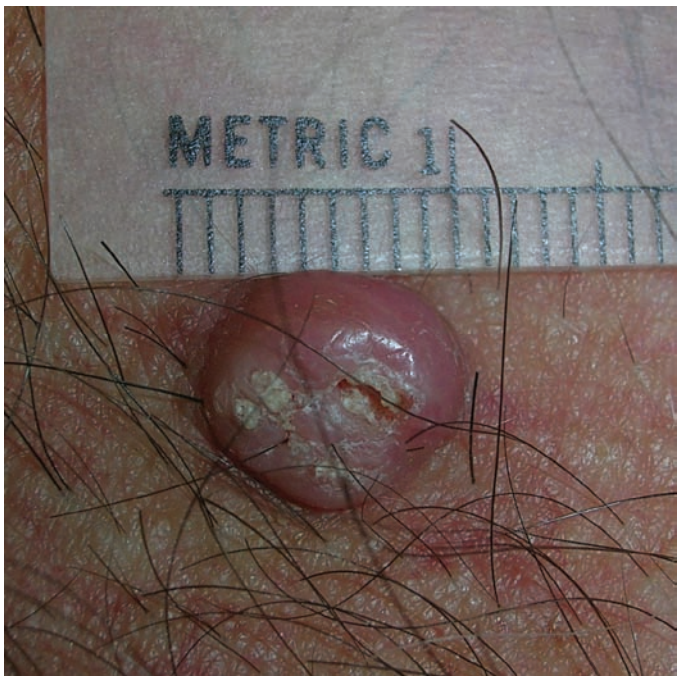

FIGURE 167-3 Keratoacanthoma on the chest of a 53-year-old man with central scaling. (*Courtesy of Richard P. Usatine, MD.*)

FIGURE 167-4 Giant keratoacanthoma under the clavicle. (*With permission from Usatine RP, Moy RL, Tobinick EL, Siegel DM. Skin Surgery: A Practical Guide. St. Louis: Mosby; 1998:235.*)

FIGURE 167-5 Keratoacanthoma on the chest of a 70-year-old man with central keratin core that resembles a volcano. (*Courtesy of Richard P. Usatine, MD.*)

FIGURE 167-7 Keratoacanthoma on the ear. (*Courtesy of Richard P. Usatine, MD.*)

FIGURE 167-6 Two SCCs in a 65-year-old man. **A.** The SCC over the temple was a keratoacanthoma type, whereas the SCC on the neck was a well-differentiated SCC. **B.** Rapid growth occurred in both tumors over the 6-week period that the patient waited to have head and neck surgery. (*Courtesy of Richard P. Usatine, MD.*)

- Elliptically excise a KA with margins of 3 to 5 mm as you would a SCC.[4] SOR C
- Smaller, less-aggressive KAs diagnosed with shave biopsy may be destroyed with curettage and desiccation or cryotherapy with 3- to 5-mm margins. SOR C
- Mohs surgery may be indicated for large or recurrent KAs or KAs located in anatomic areas with cosmetic or functional considerations.[4] SOR C
- Multiple eruptive KAs have been treated with oral retinoids, methotrexate, and cyclophosphamide.[1] SOR C

PROGNOSIS

When compared to other skin cancers, prognosis is good. Excision is typically curative.[5]

FOLLOW-UP

Patients should perform their own skin exams and have yearly clinical skin examinations to examine for recurrence and the development of new skin cancers.

PATIENT EDUCATION

KA is similar to other nonmelanoma skin cancers in that it occurs on sun-exposed areas and patients that have one are at increased risk of developing new skin cancers. Therefore, sun avoidance and sun protection should be emphasized.

PATIENT RESOURCES

- Skinsight. *Keratoacanthoma*—**http://www.skinsight.com/adult/KA.htm.**

PROVIDER RESOURCES

- Medscape. *Keratoacanthoma*—**http://emedicine.medscape.com/article/1100471.**

REFERENCES

1. Karaa A, Khachemoune A. Keratoacanthoma: A tumor in search of a classification. *Int J Dermatol.* 2007;46(7):671-678.
2. Ko CJ. Keratoacanthoma: facts and controversies. *Clin Dermatol.* 2010;28(3):254-261.
3. Clausen OP, Aass HC, Beigi M, et al. Are keratoacanthomas variants of squamous cell carcinomas? A comparison of chromosomal aberrations by comparative genomic hybridization. *J Invest Dermatol.* 2006;126(10):2308-2315.
4. Chuang TY. *Keratoacanthoma*. Updated July 2005. http://www.emedicine.com/derm/topic206.htm. Accessed on May 28, 2006.
5. Beham A, Regauer S, Soyer HP, Beham-Schmid C. Keratoacanthoma: a clinically distinct variant of well differentiated squamous cell carcinoma. *Adv Anat Pathol.* 1998;5(5):269-280.

168 LENTIGO MALIGNA

E.J. Mayeaux, Jr., MD
Richard P. Usatine, MD

PATIENT STORY

A 65-year-old woman noted that a brown spot on her face was growing larger and darker (**Figure 168-1**). A broad shave biopsy showed lentigo maligna (LM) (melanoma in situ). The patient was referred for Mohs surgery for definitive treatment.

INTRODUCTION

LM begins as a tan-brown macule melanoma usually in sun-damaged areas of the skin in older individuals. It is a subtype of melanoma in situ.

SYNONYMS

Hutchinson melanotic freckle.

EPIDEMIOLOGY

- The incidence of LM is directly related to sun exposure. In the United States, the incidence is greatest in Hawaii, intermediate in the central and southern states, and lowest in the northern states.[1]
- Generally, patients with LM are older than age 40 years, with a peak incidence between the ages of 65 and 80 years.[2]
- Persons with LM melanoma (LMM) tend to be older, fair-skinned persons with markers of actinic skin damage and prior skin cancers, and the incidence is increasing.[3]
- The lesions occur more commonly on the driver's side of the head and neck in men in Australia.[4]

ETIOLOGY AND PATHOPHYSIOLOGY

- LM is a subtype of melanoma in situ, a preinvasive lesion confined to the epidermis (**Figures 168-1** to **168-3**).
- It is caused by cumulative sun exposure and, therefore, seen later in life.
- LMM occurs when the lesion extends into the dermis (**Figure 168-4**).
- LM can be present for long periods (5 to 15 years) before invasion occurs, although rapid progression within months has been described.[5]
- The risk for progression to LMM appears to be proportional to the size of the lesion of LM.[5]

FIGURE 168-1 Lentigo maligna (melanoma in situ) on the face. (*With permission from Usatine RP, Moy RL, Tobinick EL, Siegel DM. Skin Surgery: A Practical Guide. St. Louis, MO: Mosby; 1998.*)

FIGURE 168-2 LM on the face, presenting as a single large evolving pigmented lesion with changing color. (*With permission from Usatine RP, Moy RL, Tobinick EL, Siegel DM. Skin Surgery: A Practical Guide. 1998, St. Louis: Mosby.*)

RISK FACTORS

- UV radiation exposure: risk increases with increased hours of exposure to sunlight, with the amount of actinic damage, and with a history of nonmelanoma skin cancer.
- Increased number of melanocytic nevi, including large or giant congenital nevi.
- Fair skin.
- History of severe sunburns.
- Porphyria cutanea tarda.
- Tyrosine-positive oculocutaneous albinism.
- Xeroderma pigmentosum.
- Occupational risk with sun exposure.

DIAGNOSIS

CLINICAL FEATURES

- Large pigmented patch with multiple colors, including brown, black, pink, and white (signifying regression) (**Figures 168-1** to **168-3**).
- May have ill-defined borders and microscopic extension that can determine the clinical borders and complete removal of the lesion difficult.
- One retrospective study revealed the four most important features of LM: asymmetric pigmented follicular openings, dark rhomboidal structures, slate-gray globules, and slate-gray dots with a sensitivity of 89% and a specificity of 96% (see Appendix 3, Dermoscopy).[6]

TYPICAL DISTRIBUTION

- Face, head, and neck. There is a predilection for the nose and cheek (**Figures 168-1** and **168-2**).

BIOPSY

- Complete excisional biopsy is rarely practical because these lesions are frequently large and are on the face (**Figure 168-1**). There is debate in the literature between doing broad shave biopsy, multiple punch biopsy, and incisional biopsy.[7] The goal is to avoid sampling error and misdiagnosing a LM or LMM as a benign lesion.
- A lesion suspicious for LM or LMM can be biopsied using a broad scoop shave biopsy approach with a Derma blade or sharp razor blade (**Figure 168-4**).[7] The goal is to sample the dermal–epidermal junction and still produce a good cosmetic result (especially if the lesion turns out to be benign).
- One option is multiple smaller biopsy samples of each morphologically distinct region of the lesion.[7]
- If an area suspicious for invasion is noted, or if there is an area of induration suspicious for associated desmoplastic melanoma, a deeper incisional biopsy of this area should be performed.[7]
- If sampling is incomplete, the presence of a solar lentigo, pigmented actinic keratosis, or reticulated seborrheic keratosis (SK) could mislead the pathologist and clinician to the wrong conclusion

FIGURE 168-3 LM on the ear (melanoma in situ). (*With permission from Usatine RP, Moy RL, Tobinick EL, Siegel DM. Skin Surgery: A Practical Guide. St. Louis, MO: Mosby; 1998.*)

FIGURE 168-4 LMM on the cheek. This lesion is invasive and no longer melanoma in situ. A partial broad scoop shave biopsy is a good way to make this diagnosis, as a full depth complete excisional biopsy would be prohibitively large and a punch biopsy might miss the diagnosis. (*Courtesy of the Skin Cancer Foundation. For more information www.skincancer.org.*)

that the incisional specimen is representative of the whole, and that no LM is present.[7]

- In a study of LM, contiguous pigmented lesions were present in 48% of the specimens obtained by broad shave biopsy or Mohs surgery. The most common lesion was a benign solar lentigo (30%), followed by pigmented actinic keratosis (24%).[7] This should be kept in mind when interpreting biopsy results to avoid false negatives.

DIFFERENTIAL DIAGNOSIS

- Solar lentigo—These hyperpigmented patches are very common on the faces and the dorsum of the hands of persons with significant sun exposure and the incidence increases with age. A possible solar lentigo is more suspicious for LM or LMM when it is larger, more asymmetric, has irregular borders and has more variation in colors. Pigmented lesions with these characteristics should be biopsied to determine the correct diagnosis. Many fair-skinned individuals have a number of solar lentigines making this a challenge. The use of dermoscopy and judicious biopsies is necessary to avoid missing LM and LMM (**Figures 168-5** and **168-6**).
- SKs are ubiquitous benign growths that occur more frequently with age. An early SK can be flat and easily resemble a solar lentigo or LM. The SKs on the back are less likely to be confused for LM, but a large flat SK on the face can easily be mistaken for a LM. More importantly, avoid missing a LM because it is assumed to be a flat early SK. When in doubt, biopsy the lesion with a quick and easy shave biopsy. Do not freeze a possible SK unless you are sure that it is truly benign (see Chapter 158, Seborrheic Keratosis).
- LMM is the feared outcome of missing an LM and not treating it properly. Any suspicious lesion requires biopsy. Don't be afraid to do a quick and easy shave biopsy rather than a full-thickness excision. If it turns out to be a LM or LMM, you can refer for definitive treatment and your biopsy technique does not change the prognosis. Early diagnosis does. LMM accounts for 4% to 15% of cutaneous melanoma (**Figure 168-4**) (see Chapter 172, Melanoma).

MANAGEMENT

- Therapy is directed toward preventing progression to invasive LMM.

NONSURGICAL

- Nonsurgical therapy for primary cutaneous melanomas should only be considered when surgical excision is not possible.
- Alternatives to surgery include topical imiquimod, cryosurgery, and observation. Efficacy of nonsurgical therapies for LM has not been fully established.[8] SOR C

MEDICATIONS

- Topical imiquimod 5% cream has been described in multiple studies to be effective in treating LM, especially in patients who are not surgical candidates. It is an immune response modifier that is indicated for the treatment of actinic keratosis and superficial basal cell

FIGURE 168-5 Solar lentigo on the face of a middle-aged Hispanic woman. (*Courtesy of Richard P. Usatine, MD.*)

FIGURE 168-6 Dermoscopy of the solar lentigo in the previous figure. The moth-eaten appearing edges are typical of a solar lentigo. There are no suspicious patterns and a shave biopsy confirmed that it was benign. (*Courtesy of Richard P. Usatine, MD.*)

carcinomas. Studies are limited by highly variable treatment regimens and lack of long-term follow-up.[8–10] SOR B

SURGICAL

- For melanoma in situ, wide excision with 0.5- to 1.0-cm margins is recommended. For LM histologic subtype may require larger than 0.5-cm margins to achieve histologically negative margins, because of characteristically broad subclinical extension.[8,10] SOR A
- Standard therapy is margin controlled surgical excision with Mohs surgery or rush permanent sections.[10,11] SOR B
- The perimeter technique is a method of margin-controlled excision of LM with rush permanent sections. The main advantage is that all margins are examined with permanent sections. The main drawback is that multiple operative sessions are required to complete the procedure.[12]
- Recommended margins for standard excision of melanoma in situ are 0.5 cm. This margin is often inadequate for LM because of the subclinical extension that can occur.[10] The average margin required to clear LM in 90% to 95% of cases in one study was greater than 0.5 cm.[11] Consequently, margin-controlled excision of LM is recommended.[11] SOR B
- Cryosurgery may be used in patients who are not good surgical candidates. In a study of 18 such patients with LM, the lesions resolved clinically in all cases, with no recurrence or metastasis detected during a mean follow-up of 75.5 months.[13] SOR C These patients were treated with two freeze–thaw cycles of liquid nitrogen under local anesthesia in a single sitting.

PREVENTION

- Because LMM is related to a lifetime of exposure to UV radiation, patients should limit sun exposure, especially between 10 AM and 4 PM. When in the sun, make sure to wear sunscreen with a high sun-protection factor (SPF) that blocks both UVA and UVB. It's also a good idea to protect skin by wearing a broad-brim hat and clothing that covers your arms and legs.

PROGNOSIS

- There is a 5% estimated lifetime risk of developing LMM in patients diagnosed with LM at age 45 years.[5]

FOLLOW-UP

- The National Comprehensive Cancer Network recommends that patients have regular clinical skin examinations at least yearly by their family physician or a dermatologist.[14]
- Regional lymph nodes should also be examined.

PATIENT EDUCATION

- Patients diagnosed with LM need to minimize sun exposure and do regular self-skin examinations.

PATIENT RESOURCES

- Medline Plus. *Melanoma*—**http://www.nlm.nih.gov/medlineplus/melanoma.html.**

PROVIDER RESOURCES

- The Skin Cancer Foundation. *Melanoma*—1-800-SKIN-490 or **http://www.skincancer.org.**
- National Cancer Institute. *Melanoma*—**http://www.cancer.gov/cancertopics/types/melanoma.**
- Dermoscopy. A website on dermoscopy to learn how to improve early diagnosis of melanoma—**http://www.dermoscopy.org/.**

REFERENCES

1. Clark WH Jr, Mihm MC Jr. Lentigo maligna and lentigo-maligna melanoma. *Am J Pathol*. 1969;55(1):39-67.
2. Cohen LM. Lentigo maligna and lentigo maligna melanoma. *J Am Acad Dermatol*. 1995;33(6):923-936.
3. Swetter SM, Boldrick JC, Jung SY, et al. Increasing incidence of lentigo maligna melanoma subtypes: northern California and national trends 1990-2000. *J Invest Dermatol*. 2005;125(4):685-691.
4. Jelfs PL, Giles G, Shugg D, et al. Cutaneous malignant melanoma in Australia, 1989. *Med J Aust*. 1994;161(3):182-187.
5. Weinstock MA, Sober AJ. The risk of progression of lentigo maligna to lentigo maligna melanoma. *Br J Dermatol*. 1987;116(3):303-310.
6. Schiffner R, Schiffner-Rohe J, Vogt T, et al. Improvement of early recognition of lentigo maligna using dermatoscopy. *J Am Acad Dermatol*. 2000;42(1 Pt 1):25-32.
7. Dalton SR, Gardner TL, Libow LF, Elston DM. Contiguous lesions in lentigo maligna. *J Am Acad Dermatol*. 2005;52:859-862.
8. Bichakjian CK, Halpern AC, Johnson TM, et al. Guidelines of care for the management of primary cutaneous melanoma. *J Am Acad Dermatol*. 2011;65(5):1032-1047.
9. Buettiker UV, Yawalkar NY, Braathen LR, Hunger RE. Imiquimod treatment of lentigo maligna: an open-label study of 34 primary lesions in 32 patients. *Arch Dermatol*. 2008;144(7):943-945.
10. Erickson C, Miller SJ. Treatment options in melanoma in situ: topical and radiation therapy, excision and Mohs surgery. *Int J Dermatol*. 2010;49(5):482-491.
11. Huang CC. New approaches to surgery of lentigo maligna. *Skin Therapy Lett*. 2004;9(5):7-11.
12. Mahoney MH, Joseph M, Temple CL. The perimeter technique for lentigo maligna: an alternative to Mohs micrographic surgery. *J Surg Oncol*. 2005;91(2):120-125.
13. de Moraes AM, Pavarin LB, Herreros F, et al. Cryosurgical treatment of lentigo maligna. *J Dtsch Dermatol Ges*. 2007;5(6):477-480.
14. The National Comprehensive Cancer Network. *National Clinical Guidelines in Oncology: Melanoma*, 2009. http://www.mmmp.org/mmmpFile/image/conv%20ther/NCCN%20guidelines_Melanoma.pdf. Accessed April 20, 2012.

169 CUTANEOUS HORN

Mindy A. Smith, MD, MS

PATIENT STORY

A 74-year-old man asks about a lesion on the back of his right ear (**Figure 169-1**). It has been present for approximately 5 years. Although the lesion does not bother him, his wife is concerned because it has been slowly growing. Shave biopsy revealed that the horn was from a basal cell carcinoma. The patient was referred for Mohs surgery to excise the remainder of the cancer.

FIGURE 169-1 Cutaneous horn on posterior right pinna arising in a basal cell carcinoma. (*With permission from Usatine RP, Moy RL, Tobinick EL, Siegel DM. Skin Surgery: A Practical Guide. St. Louis, MO: Mosby; 1998.*)

INTRODUCTION

Cutaneous horn (cornu cutaneum) is a morphologic (not pathologic) designation for a hyperkeratotic protuberant mass rising above the skin, resembling the horn of an animal.

EPIDEMIOLOGY

- Relatively rare lesion, most often occurring on sun-exposed areas of the skin in elderly men; a recent Brazilian case series, however, found a higher prevalence in women.[1]

ETIOLOGY AND PATHOPHYSIOLOGY

- Results from unusual cohesiveness of keratinized material from the superficial layers of the skin or deeply embedded in the cutis. Etiology is unknown but may be related to skin damage from sun exposure or trauma; infectious causes have also been reported including molluscum contagiosum and leishmaniasis.[2]
- Consists of marked retention of stratum corneum.
- May be benign, premalignant, or malignant (**Figures 169-1** to **169-3**) at the base; in 2 large series, 58.6% and 38.9% had malignant or premalignant base pathology.[1,3]
- A history of other malignant or premalignant lesions, tenderness at the base, large size, older age, and location on the penis increase the risk of underlying malignancy.[2–4]
- Associated with many types of skin lesions (at the base) that can retain keratin and produce horns including actinic keratosis, warts (**Figures 169-4** and **169-5**), seborrheic keratosis (**Figures 169-6** and **169-7**), keratoacanthoma (**Figure 169-3**), sebaceous gland, and basal or squamous cell carcinoma (**Figures 169-1** to **169-3**). In the more recent case series, actinic keratosis was found in 83.8% of the premalignant cases and squamous cell carcinoma was found in 93.75% of the malignant cases.[1]
- Rare cases have been described in association with metastatic renal cell carcinoma, lymphoma, dermatofibroma, pyogenic granuloma (**Figure 169-8**), and, recently, Kaposi sarcoma.[5]

FIGURE 169-2 Cutaneous horn in a squamous cell carcinoma in situ just lateral to the eye. (*Courtesy of Richard P. Usatine, MD.*)

RISK FACTORS

- Advanced age (>70 years).
- Sun/radiation exposure.

DIAGNOSIS

CLINICAL FEATURES

- Horn-like protuberance.
- Lesions are usually firm; have been described as flat, keratotic, nodular, pedunculated, and ulcerated.[3]
- Size may vary from a few millimeters to several centimeters; gigantic cutaneous horns (17 to 25 cm length and up to 2.5 cm width) have been reported, and in one series of 4 cases, all were benign.[6]
- Because of their height, cutaneous horns may be traumatized causing bleeding or pain.

TYPICAL DISTRIBUTION

- May occur on any area of the body; approximately 30% are found on the face (**Figures 169-2**, **169-6**, and **169-7**) and scalp and another 30% on the upper limbs.[1]

BIOPSY

- The horn itself consists of concentric layers of cornified epithelial cells (hyperkeratosis). The base may display features of the associated pathologic etiology.

DIFFERENTIAL DIAGNOSIS

- Common warts are well-demarcated, rough, hard papules with an irregular papillary surface. Although they may form cylindrical projections, these often fuse to form a surface mosaic pattern; paring the surface exposes punctate hemorrhagic capillaries (see Chapter 131, Common Warts).

MANAGEMENT

- Shave excision, ensuring that the base of the epithelium is obtained for histologic examination, and send to pathology; if benign, may freeze remainder of the lesion.
- Excisional biopsy may also be performed, with wider margins (tumor-free margin of at least 3 mm) if suspected malignancy.

FOLLOW-UP

- Routine follow-up is not needed provided complete removal is accomplished for malignant and premalignant lesions; in one case series of 48 eyelid cutaneous horns, there was no recurrence over a mean of 21 months.[7]
- Patients with any skin cancer should be seen yearly for skin exams because one cancer puts them at higher risk for all skin cancers. SOR C

FIGURE 169-3 Cutaneous horn on the arm of a 65-year-old woman, which grew rapidly over 6 months. Biopsy revealed a squamous cell carcinoma of the keratoacanthoma type. (*Courtesy of Richard P. Usatine, MD.*)

FIGURE 169-4 **A.** Cutaneous horn on the hand of a 33-year-old man for 8 years. He clipped it with nail clippers many times but it always grew back. A shave excision successfully removed it and the pathology showed a viral wart at the base. **B.** Close-up of the cutaneous horn. (*Courtesy of Richard P. Usatine, MD.*)

FIGURE 169-5 Cutaneous horn on the back of a 73-year-old woman within an endophytic wart. (*Courtesy of Richard P. Usatine, MD.*)

FIGURE 169-7 Another view of this amazing cutaneous horn. The patient had the lesion since her early 30s and attributed it to hot grease popping on her face. She had shown it to other physicians who declined to remove it. Patient stated it "made her feel 16 again" to have it removed. (*Courtesy of Scott Bergeaux, MD.*)

FIGURE 169-6 Large cutaneous horn on the face of an 88-year-old woman. After shave removal the pathology showed seborrheic keratosis with chronic inflammation and cutaneous horn formation. (*Courtesy of Scott Bergeaux, MD.*)

FIGURE 169-8 Cutaneous horn arising in a pyogenic granuloma. (*Courtesy of Suraj Reddy, MD.*)

PATIENT AND PROVIDER RESOURCES

- **http://emedicine.medscape.com/article/1056568-overview.**
- **http://www.accessmedicine.ca/search/searchAMResultImg.aspx?searchStr=acquired+brachial+cutaneous+dyschromatosis&rootTerm=cutaneous+horn&searchType=1&rootID=45192.**

REFERENCES

1. Mantese SA, Diogo PM, Rocha A, et al. Cutaneous horn: a retrospective histopathological study of 222 cases. *An Bras Dermatol*. 2010;85(2):157-163.
2. Vera-Donoso CD, Lujan S, Gomez L, et al. Cutaneous horn in glans penis: a new clinical case. *Scand J Urol Nephrol*. 2009;43(1):92-93.
3. Yu RC, Pryce DW, Macfarlane AW, Stewart TW. A histopathological study of 643 cutaneous horns. *Br J Dermatol*. 1991;124:499-452.
4. Solivan GA, Smith KJ, James WD. Cutaneous horn of the penis: its association with squamous cell carcinoma and HPV-16 infection. *J Am Acad Dermatol*. 1990;23(5 Pt 2):969-972.
5. Onak Kandemir N, Gun BD, Barut F, et al. Cutaneous horn-related Kaposi's Sarcoma: a case report. *Case Report Med*. 2010;2010. pii: 825949.
6. Michal M, Bisceglia M, Di Mattia A, et al. Gigantic cutaneous horns of the scalp: lesions with a gross similarity to the horns of animals: a report of four cases. *Am J Surg Pathol*. 2002;26:789-794.
7. Mencia-Gutiérrez E, Gutiérrez-Diaz E, Redondo-Marcos I, et al. Cutaneous horns of the eyelid: clinicopathological study of 48 cases. *J Cutan Pathol*. 2004;31:539-543.

SECTION 12 SKIN CANCER

170 BASAL CELL CARCINOMA

Jonathan B. Karnes, MD
Richard P. Usatine, MD

PATIENT STORY

A 52-year-old woman presented to the office with a "mole" that had been increasing in size over the last year (**Figure 170-1**). This "mole" had been on her face for at least 5 years. The differential diagnosis of this lesion was a nodular basal cell carcinoma (BCC) versus an intradermal nevus. A shave biopsy confirmed it was a nodular BCC and the lesion was excised with an elliptical excision.

FIGURE 170-1 Pearly nodular basal cell carcinoma on the face of a 52-year-old woman present for 5 years. (*Courtesy of Richard P. Usatine, MD.*)

INTRODUCTION

Basal cell carcinoma is the most common cancer in humans. Usually found on the head and neck, it is generally slow growing and almost never kills or metastasizes when treated in a timely fashion. However, the treatment necessary to eliminate it is often surgical and may cause scarring and changes in appearance and/or function.

EPIDEMIOLOGY

- BCC is the most common skin cancer but the exact incidence is not known.[1]
- Incidence of these cancers increases with age, related to cumulative sun exposure.
- Nodular BCCs—Most common type (70%) (**Figures 170-1** to **170-4**).
- Superficial BCCs—Next most common type (**Figures 170-5** and **170-6**).
- Sclerosing (or morpheaform) BCCs—The least common type (**Figures 170-7** and **170-8**).

Other clinical variants including pigmented, polypoid, giant, keloidal, linear, and fibroepithelioma of Pinkus have been recognized, but are less common to very rare.[2]

FIGURE 170-2 Nodular BCC on the nasal ala of an 82-year-old woman. The nose is a very common location for a basal cell carcinoma. (*Courtesy of Richard P. Usatine, MD.*)

ETIOLOGY AND PATHOPHYSIOLOGY

- BCCs spread locally and very rarely metastasize.
- Basal cell nevus syndrome, also known as Gorlin syndrome, is a rare autosomal dominant condition in which affected individuals have multiple BCCs that may clinically mimic nevi (**Figure 170-9**).

FIGURE 170-3 Nodular BCC on the lower eyelid. Patient referred for Mohs surgery. The differential diagnosis is a hidrocystoma. This basal cell carcinoma is a firm nodule and a hidrocystoma is fluid-filled and softer. (*Courtesy of Richard P. Usatine, MD.*)

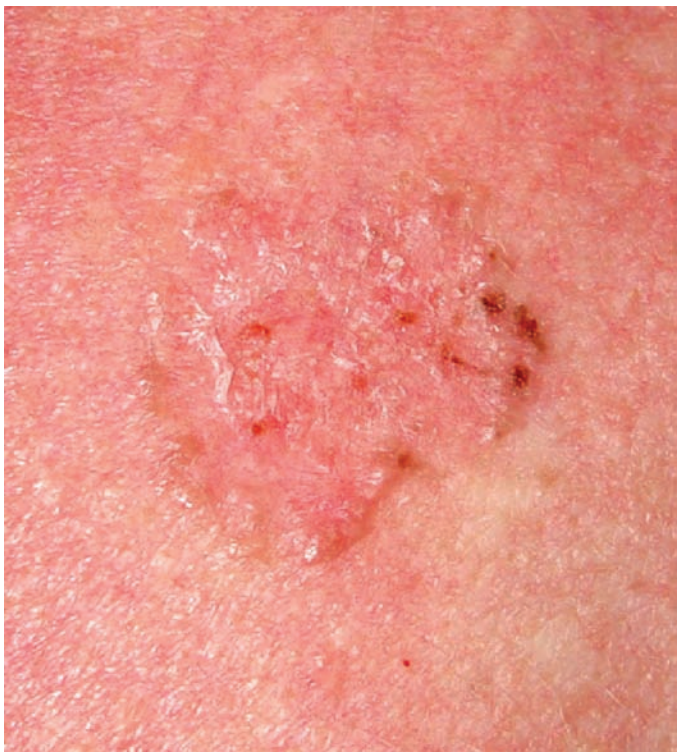

FIGURE 170-5 Superficial basal cell carcinoma on the back of a 45-year-old man who enjoys running in the California sun without his shirt. Note the diffuse scaling, thready border (slightly raised and pearly), and spotty hyperpigmentation. (*Courtesy of Richard P. Usatine, MD.*)

FIGURE 170-4 Large nodular basal cell carcinoma with an annular appearance on the face of a homeless woman. (*Courtesy of Richard P. Usatine, MD.*)

FIGURE 170-6 Superficial basal cell carcinoma on the arm of a fair skinned welder mimicking nummular eczema. (*Courtesy Jonathan B. Karnes, MD.*)

RISK FACTORS

- Advanced age.
- Cumulative sun exposure.
- Radiation exposure.
- Latitude.
- Immunosuppression.
- Genetic predisposition.
- Family history.
- Skin type.[3]

DIAGNOSIS

CLINICAL FEATURES

Common clinical features of the three most common morphologic types are listed below.

Nodular BCC

- Raised pearly white, smooth translucent surface with telangiectasias.
- Smooth surface with loss of the normal pore pattern (**Figures 170-1** to **170-4**).
- May be moderately to deeply pigmented (**Figures 170-10** to **170-12**).
- May ulcerate (**Figures 170-13** to **170-16**) and can leave a bloody crust.

Superficial BCC

- Red or pink patches to plaques often with mild scale and a thready border (slightly raised and pearly) (**Figure 170-5**).
- Found more commonly on the trunk and upper extremities than the face.

Sclerosing (morpheaform)

- Ivory or colorless, flat or atrophic, indurated, may resemble scars, are easily overlooked (**Figures 170-7** and **170-8**).
- Called morpheaform because of their resemblance to localized scleroderma (morphea).
- The border is not well demarcated and the tumor can spread far beyond what is clinically visible (**Figure 170-17**).
- These BCCs are the most dangerous and have the worst prognosis.

TYPICAL DISTRIBUTION

Ninety percent appear on face, ears, and head, with some found on the trunk and upper extremities (especially the superficial type).[1]

Recently lesions on the ears have been associated with a more aggressive behavior (**Figure 170-18**).[4]

DERMOSCOPY

Dermoscopic characteristics of BCCs (**Figures 170-19** and **170-20**) include:

- Large blue-gray ovoid nests.

FIGURE 170-7 Sclerosing basal cell carcinoma on the forehead of a man resembling a scar. Note the white color with shiny atrophic skin. (*Courtesy of the Skin Cancer Foundation. For more information www.skincancer.org.*)

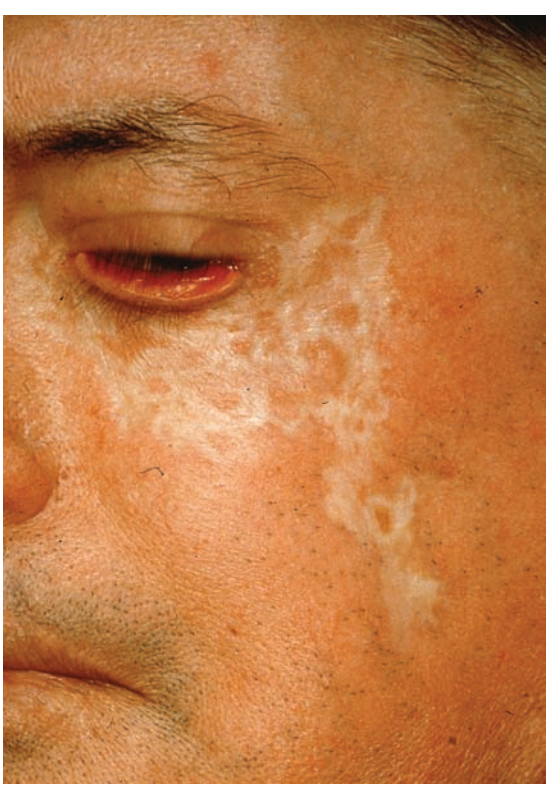

FIGURE 170-8 Advanced sclerosing basal cell carcinoma on the cheek of a man, causing ectropion (the eyelid is being pulled down by the sclerotic skin changes). (*With permission from Usatine RP, Moy RL, Tobinick EL, Siegel DM. Skin Surgery: A Practical Guide. St. Louis, MO: Mosby; 1998.*)

FIGURE 170-9 Basal cell nevus syndrome with multiple nevoid basal cell carcinomas on the face and neck of a young woman. This is a rare autosomal dominant condition. (*Courtesy of the University of Texas Health Sciences Center, Division of Dermatology.*)

FIGURE 170-10 Large pigmented nodular basal cell carcinoma on the face with ulceration mimicking melanoma. (*Courtesy Jonathan B. Karnes, MD.*)

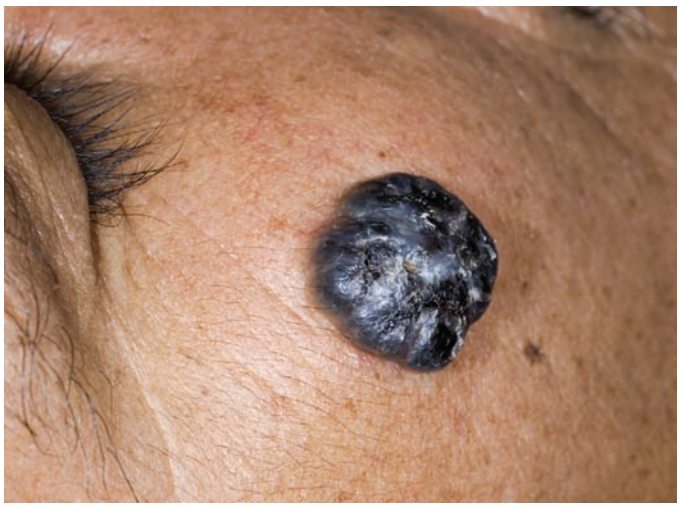

FIGURE 170-11 Darkly pigmented large basal cell carcinoma with raised borders and some ulceration in a 53-year-old Hispanic man. A biopsy was performed to rule out melanoma before this was excised. (*Courtesy of Richard P. Usatine, MD.*)

FIGURE 170-12 Darkly pigmented basal cell carcinoma with pearly borders and some ulceration in a 73-year-old Hispanic woman. A biopsy was performed to rule out melanoma before this was excised. (*Courtesy of Richard P. Usatine, MD.*)

FIGURE 170-13 Ulcerated basal cell carcinoma on the scalp of a 35-year-old woman. (*Courtesy of Richard P. Usatine, MD.*)

FIGURE 170-14 Basal cell carcinoma in the nasal alar groove. There is a high risk of recurrence at this site so Mohs surgery is indicated for removal. (*Courtesy of Richard P. Usatine, MD.*)

FIGURE 170-15 Large advanced basal cell carcinoma with ulcerations and bloody crusting infiltrating the upper lip. The patient was referred for Mohs surgery. (*Courtesy of Richard P. Usatine, MD.*)

FIGURE 170-16 **A.** Very large ulcerating basal cell carcinoma on the neck of a 65-year-old white man, which has been growing there for 6 years. It was excised in the operating room with a large flap from his chest used to close the big defect. **B.** The same man showing recurrence within the scar a few years later. (*Courtesy of Richard P. Usatine, MD.*)

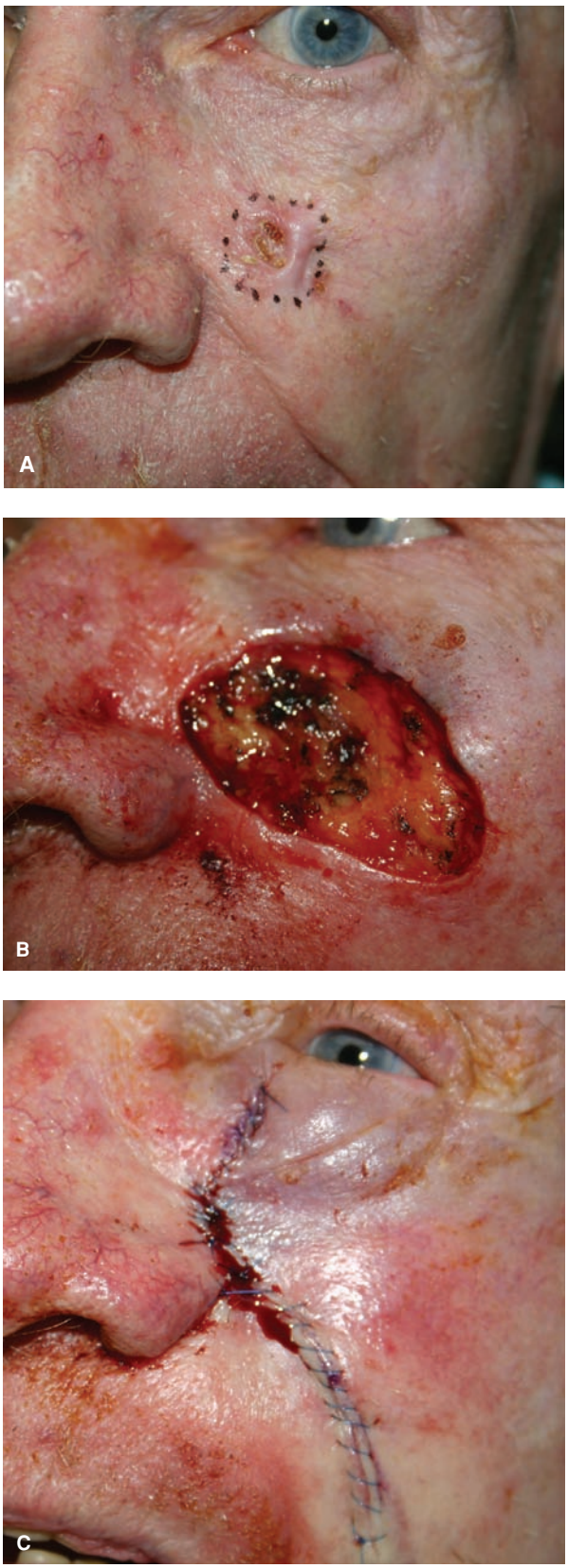

FIGURE 170-17 **A.** Sclerosing basal cell carcinoma in an elderly man. The size of the basal cell carcinoma did not appear large by clinical examination. **B.** Mohs surgery of the same sclerosing basal cell carcinoma. This took four excisions to get clean margins. Usual 4- to 5-mm margins with an elliptical excision would not have removed the full tumor. **C.** Repair by Mohs surgery to close the large defect. The cure rate should be close to 99%. (*Courtesy of Ryan O'Quinn, MD.*)

FIGURE 170-18 Ulcerated nodular basal cell carcinoma of the ear in a 67-year-old man. These may have more aggressive behavior. (*Courtesy of Richard P. Usatine, MD.*)

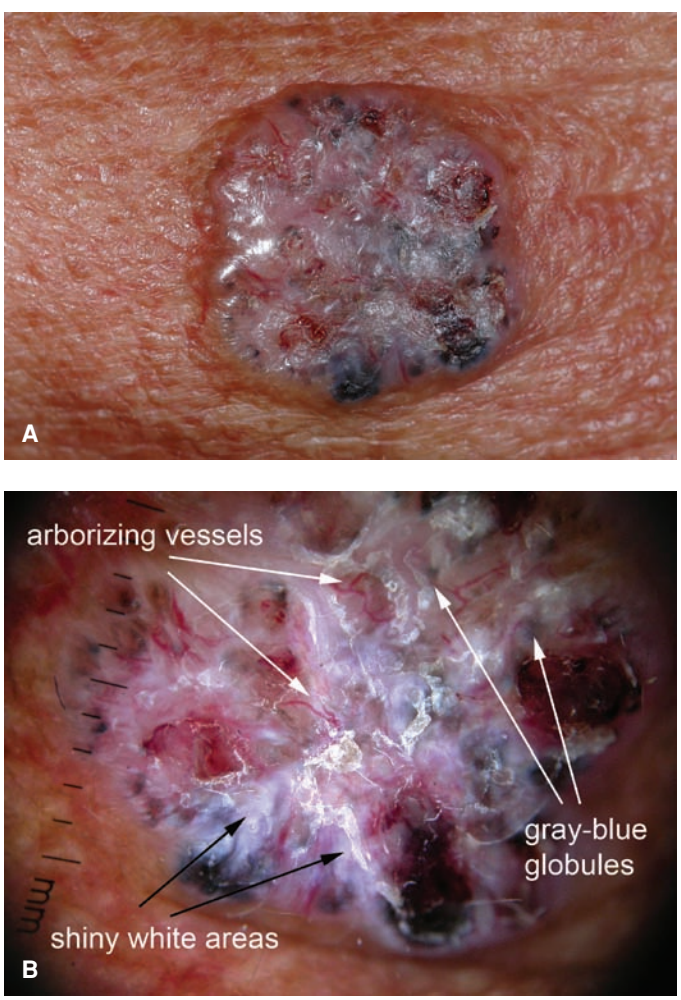

FIGURE 170-19 **A.** Large nodular basal cell carcinoma on the cheek of a 52-year-old man. There is a loss of normal pore pattern, pearly appearance, telangiectasias, and some areas of dark pigmentation. **B.** Dermoscopy of the nodular basal cell carcinoma. There are visible arborizing "tree-like" telangiectasias, ulcerations, shiny white areas, and gray-blue globules all consistent with a basal cell carcinoma. (*Courtesy of Richard P. Usatine, MD.*)

- Multiple blue-gray globules.
- Leaf-like areas, also called clods, that look like maple leaves.
- Spoke-wheel areas.
- Arborizing "tree-like" telangiectasia.
- Ulceration.
- Shiny white areas/stellate streaks (see Appendix C: Dermoscopy for further information).

BIOPSY

- A shave biopsy is adequate to diagnose a nodular BCC or a thick superficial BCC.
- A scoop shave or punch biopsy is preferred for a sclerosing BCC or a very flat superficial BCC.
- In many instances, excision at the time of definitive treatment reveals a different morphologic type in deeper tissue.[5]

DIFFERENTIAL DIAGNOSIS

Nodular BCC

- Intradermal (dermal) nevi may look very similar to nodular BCCs with telangiectasias and smooth pearly borders (**Figure 170-21**). A history of stable size and lack of ulceration may be helpful in distinguishing them from a nodular BCC. A simple shave biopsy is diagnostic and produces a good cosmetic result. Excisional biopsy is usually unnecessary and can be deforming. It is remarkable how similar **Figure 170-21** appears to **Figure 170-1** (both biopsies proven to be as labeled) (see Chapter 162, Benign Nevi).
- Sebaceous hyperplasia is a benign adnexal tumor common on the face in older adults and usually occurs with more than one lesion present (**Figure 170-22**). This benign overgrowth of the sebaceous glands produces small waxy yellow to pink papules with telangiectasias. Dermoscopy may show vessels that radiate out from the center like spokes on a wheel (see Chapter 159, Sebaceous Hyperplasia).
- Fibrous papule of the face is a benign condition with small papules that can be firm and pearly.
- Trichoepithelioma/trichoblastoma/trichilemmoma are benign tumors on the face that can appear around the nose. They may be pearly but usually do not have telangiectasias. These are best diagnosed with a shave biopsy, but trichoepitheliomas can even mimic a BCC on histology.
- Keratoacanthoma is a type of squamous cell carcinoma that is raised, nodular, and may be pearly with telangiectasias. A central keratin-filled crater may help to distinguish this from a BCC (see Chapter 167, Keratoacanthoma).

Superficial BCC

- Actinic keratoses are precancers that are flat, pink, and scaly. They lack the pearly and thready border of the superficial BCC (see Chapter 166, Actinic Keratosis and Bowen Disease).
- Bowen disease is a squamous cell carcinoma in situ that appears like a larger thicker actinic keratosis with more distinct well-demarcated borders. It also lacks the pearly and thready border of the superficial BCC (see Chapter 166, Actinic Keratosis and Bowen Disease).

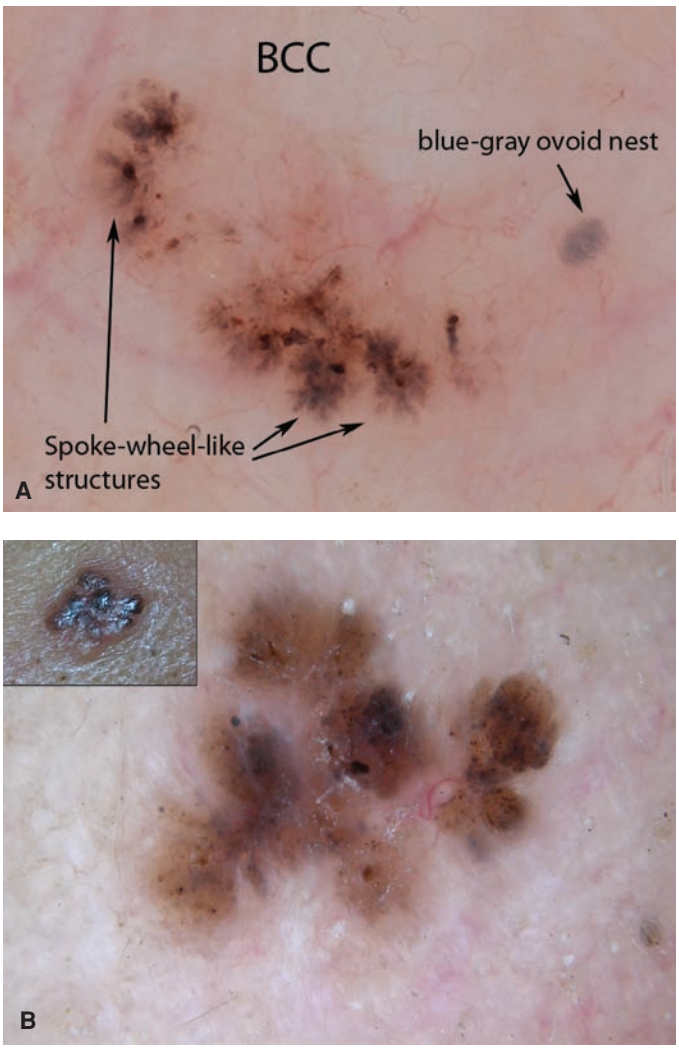

FIGURE 170-20 Dermoscopy of two different basal cell carcinomas. Characteristic findings of basal cell carcinomas include arborized vessels, blue-gray ovoid nests, spoke wheel structures, and leaf-like structures. **A.** (*Courtesy of Ashfaq Marghoob, MD.*) **B.** Note the leaf-like structures on the periphery of this BCC. (*Courtesy of Richard P. Usatine, MD.*)

FIGURE 170-21 Pearly dome-shaped intradermal nevus near the nose with telangiectasias closely resembling a basal cell carcinoma. A shave biopsy proved that this was an intradermal nevus. (*Courtesy of Richard P. Usatine, MD.*)

- Nummular eczema can usually be distinguished by its multiple coin-like shapes, transient nature, and rapid response to topical steroids. These lesions are extremely pruritic and most patients will have other signs and symptoms of atopic disease (see Chapter 145, Atopic Dermatitis).
- Discoid lupus erythematosus is a cutaneous manifestation of autoimmune disease and often presents with skin color change, scaling, and hair follicle destruction. These have characteristic predilection for the ears, scalp, and face, but may be found on the trunk and extremities.
- Benign lichenoid keratosis is a variably scaly flat or slightly raised benign reactive neoplasm on sun-damaged skin. It is often on the trunk or extremities and can have blue-gray globules on dermoscopy and some pearly color.

Sclerosing (morpheaform) BCC

- Scars may look like a sclerosing BCC. Ask about previous surgeries or trauma to the area. If the so-called scar is flat, shiny, and enlarging, a biopsy still may be needed to rule out a sclerosing BCC.

MANAGEMENT

- Mohs micrographic surgery (3 studies, $n = 2660$) is the gold standard but is not needed for all BCCs. Recurrence rate is 0.8% to 1.1% (**Figure 170-17*B***). Mohs micrographic surgery (pioneered by Dr. Frederick Mohs) entails surgical removal of tumors with immediate histologic processing in sequential horizontal layers preserving a continuous peripheral margin that is mapped to the clinical lesion. Concentric surgical margins are taken until all margins are clear (**Figure 170-17**). This is the treatment of choice for BCCs with poorly defined clinical margins or in areas of significant cosmetic or functional importance such as the face.[6] SOR A
- Surgical excision (3 studies, $n = 1303$): Recurrence rate was 2% to 8%. Mean cumulative 5-year rate[1] (all 3 studies) was 5.3%. Recommended margins are 4 to 5 mm. SOR A
- Cryosurgery (4 studies, $n = 796$): Recurrence rate was 3.0% to 4.3%. Cumulative 5-year rate (3 studies) ranged from 0% to 16.5%.[6] SOR A Recommended freeze times are 30 to 60 seconds with a 5-mm halo. This can be divided up into two 30-second freezes with a thaw in between. For such long freeze times, most patients will prefer a local anesthetic (**Figure 170-23**). SOR C
- Curettage and desiccation (6 studies, $n = 4212$): Recurrence rate ranged from 4.3% to 18.1%; cumulative 5-year rate ranged from 5.7% to 18.8%. Three cycles of curettage and desiccation can produce higher cure rates than one cycle (**Figure 170-24**).[6] SOR A
- Imiquimod is FDA approved for the treatment of superficial BCCs less than 2 cm in diameter.[7] SOR B Confirm diagnosis with biopsy and use when surgical methods are contraindicated. A recent study combining cryotherapy with imiquimod improved decreased the recurrence rate.[8]
- Vismodegib is an FDA-approved targeted chemotherapy for the treatment of metastatic or nonresectable BCCs that cannot be treated with radiation. It targets the smoothened pathway, which is damaged in basal cell nevus syndrome and altered in most BCCs.[9] SOR B

FIGURE 170-22 Extensive sebaceous hyperplasia on the cheek of a 52-year-old woman. The largest one has visible telangiectasias and could be mistaken for a basal cell carcinoma. (*Courtesy of Richard P. Usatine, MD.*)

FIGURE 170-23 Cryosurgery was a favored treatment modality in a 94-year-old female patient with Alzheimer dementia with a basal cell carcinoma on the cheek. The family appreciated how easy this was to complete and how well it healed. (*Courtesy of Richard P. Usatine, MD.*)

PREVENTION AND SCREENING

- All skin cancer prevention starts with sun protection.
- Unfortunately there is no proof that sunscreen use prevents BCC.[10]
- Sun protection should include sun avoidance, especially during peak hours of UV transmission, and protective clothing.
- United States Preventive Services Task Force has not found sufficient evidence to recommend regular screening for any skin cancer in the general population.[11]
- Most experts believe that persons at high risk for BCC (including previous personal history of BCC, high risk family history, and high risk skin types with significant sun exposure) should be screened regularly for skin cancer by a physician trained in such screening.
- Evidence for the value of self-screening is lacking but persons at high risk for skin cancer should also be encouraged to observe their own skin and to come in for evaluation if they see any suspicious changes or growths.

FIGURE 170-24 Curettage and electrodessication of a superficial basal cell carcinoma on the extremity is a rapid and effective treatment. The abnormal tumor tissue is softer than the surrounding normal skin and scoops out easily. (*Courtesy of Richard P. Usatine, MD.*)

PROGNOSIS

The prognosis for basal cell carcinoma is generally excellent with high cure rates with surgery and destructive modalities. Large lesions on the face or lesions that have spread to sites deep to the skin have a poorer prognosis.

FOLLOW-UP

Patients should be seen at least yearly after the diagnosis and treatment of a BCC. The 3-year risk of BCC recurrence after having a single BCC is 44%.[12]

PATIENT EDUCATION

Patients should practice skin cancer prevention by sun-protective behaviors such as avoiding peak sun, covering up, and using sunscreen.

PATIENT RESOURCES

The Skin Cancer Foundation—**http://www.skincancer.org/skin-cancer-information/basal-cell-carcinoma**

- **http://www.nlm.nih.gov/medlineplus/ency/article/000824.htm**
- **http://www.ncbi.nlm.nih.gov/pubmedhealth/PMH0001827/**

PROVIDER RESOURCES

- **http://emedicine.medscape.com/article/276624-overview**

Chapters and videos on diagnosing and surgically managing melanoma can be found in the following book/DVD or electronic application:

- Usatine R, Pfenninger J, Stulberg D, Small R. *Dermatologic and Cosmetic Procedures in Office Practice*. Philadelphia, PA: Elsevier, Inc.; 2012.
- Information about smartphone and tablet apps of this resource can be viewed at: **www.usatinemedia.com**

REFERENCES

1. Ormerod A, Rajpara S, Craig F. Basal cell carcinoma. *Clin Evid (Online)*. 2010;2010:1719.
2. Jackson SM, Nesbitt LT. *Differential Diagnosis for the Dermatologist*, 1st ed. Berlin, Germany: Springer; 2008:1360.
3. Madan V, Hoban P, Strange RC, et al. Genetics and risk factors for basal cell carcinoma. *Br J Dermatol*. 2006;154 Suppl 1:5-7.
4. Jarell AD, Mully TW. Basal cell carcinoma on the ear is more likely to be of an aggressive phenotype in both men and women. *J Am Acad Dermatol*. 2012;66(5):780-784.
5. Welsch MJ, Troiani BM, Hale L, et al. Basal cell carcinoma characteristics as predictors of depth of invasion. *J Am Acad Dermatol*. 2012;67(1):47-53.
6. Thissen MR, Neumann MH, Schouten LJ. A systematic review of treatment modalities for primary basal cell carcinomas. *Arch Dermatol*. 1999;135(10):1177-1183.
7. Geisse J, Caro I, Lindholm J, et al. Imiquimod 5% cream for the treatment of superficial basal cell carcinoma: results from two phase III, randomized, vehicle-controlled studies. *J Am Acad Dermatol*. 2004;50(5):722-733.
8. MacFarlane DF, Tal El AK. Cryoimmunotherapy: superficial basal cell cancer and squamous cell carcinoma in situ treated with liquid nitrogen followed by imiquimod. *Arch Dermatol*. 2011;147(11):1326-1327.
9. Hoff Von DD, LoRusso PM, Rudin CM, et al. Inhibition of the hedgehog pathway in advanced basal-cell carcinoma. *N Engl J Med*. 2009;361(12):1164-1172.
10. van der Pols JC, Williams GM, Pandeya N, et al. Prolonged prevention of squamous cell carcinoma of the skin by regular sunscreen use. *Cancer Epidemiol Biomarkers Prev*. 2006;15(12):2546-2548.
11. Wolff T, Tai E, Miller T. Screening for Skin Cancer: An Update of the Evidence for the U.S. Preventive Services Task Force [Internet]. Rockville (MD): Agency for Healthcare Research and Quality (US); 2009 Feb. Available from http://www.ncbi.nlm.nih.gov/books/NBK34051/
12. Marcil I, Stern RS. Risk of developing a subsequent nonmelanoma skin cancer in patients with a history of nonmelanoma skin cancer: a critical review of the literature and meta-analysis. *Arch Dermatol*. 2000;136(12):1524-1530.

171 SQUAMOUS CELL CARCINOMA

Jonathan B. Karnes, MD
Richard P. Usatine, MD

PATIENT STORY

A 66-year-old farmer presents with new growths on his scalp (**Figure 171-1**). The patient admits to lots of sun exposure and has already had one squamous cell carcinoma (SCC) excised from the scalp 5 years ago. On close inspection there are many suspicious areas for SCC (**Figure 171-1**). **Figure 171-2** demonstrates a shave biopsy of a SCC on a scalp using a dermablade. The pathology demonstrated that 2 of 3 biopsy sites were positive for SCC (E and G were SCC and F was read as actinic keratoses). The patient was referred for Mohs surgery. The Mohs surgeon recommended field treatment with 5-fluoruracil for 4 weeks before surgery to minimize the amount of cutting that would be needed to clear the SCC from this diffusely sun-damaged scalp.

FIGURE 171-1 Multiple squamous cell carcinomas on the scalp of a farmer with a lot of sun exposure. The pathology demonstrated that 2 of 3 biopsy sites were positive for squamous cell carcinoma (E and G were squamous cell carcinomas and F was read as actinic keratosis). (*Courtesy of Richard P. Usatine, MD.*)

INTRODUCTION

Cutaneous SCC is the second most common cancer in humans and arises most often as a result of cumulative sun damage. Although the mortality is declining, incidence is increasing in all populations making this cancer a common and significant burden on patients.

EPIDEMIOLOGY

- Mortality from SCC has been observed as 0.29 per 100,000 population.[1]
- Metastasis from SCC occurs in 2% to 9.9% of cases.[2]
- The incidence is increasing in all age groups and populations at a rate of 3% to 10%.[2]
- In the United States, approximately 2500 people die from SCC every year.[3]
- SCC is the second most common skin cancer and accounts for up to 25% of nonmelanoma skin cancers.[4]
- More than 250,000 new cases of invasive SCC are diagnosed annually in the United States.[4]

PATHOPHYSIOLOGY

SCC is a malignant tumor of keratinocytes. Most SCCs arise from precursor lesions called actinic keratoses. SCCs usually spread by local extension but are capable of regional lymph node metastasis and distant metastasis. Human papillomavirus (HPV)-related lesions may be found on the penis, labia, and perianal mucosa, or in the periungual region or elsewhere associated with immunosuppression.[5]

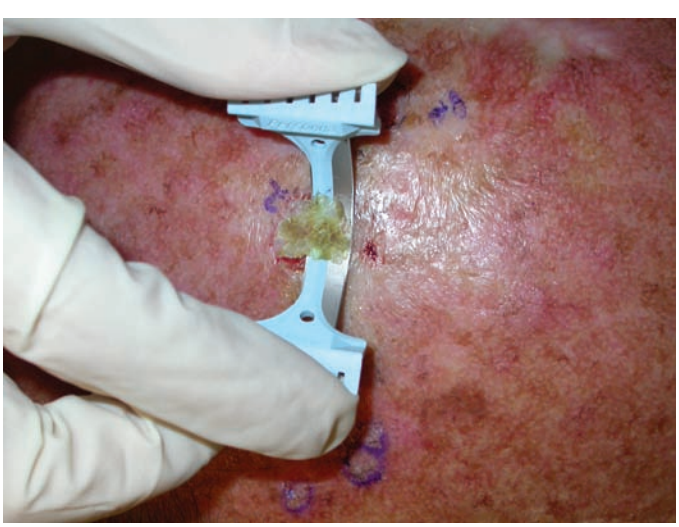

FIGURE 171-2 Shave biopsy of a squamous cell carcinoma on the scalp. (*Courtesy of Richard P. Usatine, MD.*)

SCCs that metastasize most often start on mucosal surfaces and sites of chronic inflammation.

RISK FACTORS

- Long-term cumulative UV exposure is the greatest risk factor.
- Childhood sunburns.
- Occupational exposure.
- Other UV exposure including PUVA therapy and tanning beds.
- Smoking.
- HPV exposure.
- Exposure to ionizing radiation.
- Arsenic exposure.
- Fair skin.
- Age older than 60 years.
- Male gender.
- Living at lower latitude and higher altitude.
- Nonhealing ulcers.
- Chronic or severe immunosuppression, including posttransplant immunosuppression, HIV, and long-term steroid use.
- Genetic syndromes, including Muir Torre, xeroderma pigmentosum, dystrophic epidermolysis bullosa, epidermodysplasia verruciformis, and oculocutaneous albinism.[4]

DIAGNOSIS

- The only sure method of making the diagnosis is a biopsy. Biopsy suspicious lesions (thickened, tender, indurated, ulcerated, or crusting) especially in sun-exposed areas.

CLINICAL FEATURES

SCC often presents as areas of persistent ulceration, crusting, hyperkeratosis, and erythema, especially on sun-damaged skin.

Less common types of SCC:

- Marjolin ulcer—SCC of the extremities found in chronic skin ulcers or burn scars. This is a more common risk in darker pigmented individuals (**Figure 171-3**).
- Erythroplasia of Queyrat—SCC in situ on the penis or vulva related to HPV infection (**Figure 171-4**). This can progress to invasive SCC of the penis (**Figure 171-5**).

TYPICAL DISTRIBUTION

SCC is found in all sun-exposed areas and on mucus membranes. The most common sites are:

- Face (**Figures 171-6** and **171-7**).
- Lower lip (**Figures 171-8** and **171-9**).
- Ears (**Figure 171-10**).
- Scalp (**Figures 171-1** and **171-11**).
- Extremities—arm—(**Figures 171-12** and **171-13**).

FIGURE 171-3 Marjolin ulcer (squamous cell carcinoma) arising in a burn that occurred years before on the face. (*Courtesy of Richard P Usatine, MD.*)

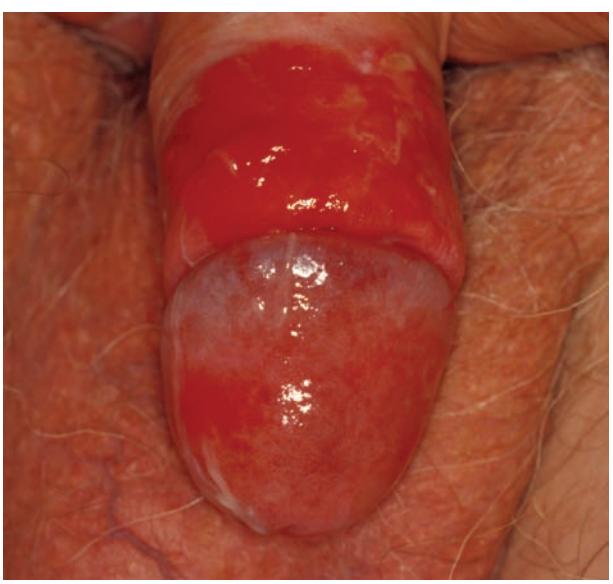

FIGURE 171-4 Erythroplasia of Queyrat (squamous cell carcinoma in situ) under the foreskin of an uncircumcised man. This is related to human papillomavirus infection as is cervical cancer. (*Courtesy of John Pfenninger, MD.*)

FIGURE 171-5 Squamous cell carcinoma of the glans penis. (*Courtesy of Jeff Meffert, MD.*)

- Hands (**Figure 171-14**).
- Fingers (**Figure 171-15**).
- Mucus membranes (**Figure 171-16**) (see Chapter 43, Oral Cancer).

BIOPSY

- Deep shave biopsy is adequate to make the diagnosis of most SCCs.
- Punch biopsy or incisional biopsy is an alternative for lesions that are pigmented or appear to be deeper.

FACTORS AFFECTING METASTATIC POTENTIAL OF CUTANEOUS SQUAMOUS CELL CARCINOMA[6]

The following factors are taken from "Multiprofessional guidelines for the management of the patient with primary cutaneous squamous cell carcinoma."[6]

SITE.

Tumor location influences prognosis: sites are listed in order of increasing metastatic potential.[2]

1. SCC arising at sun-exposed sites excluding lip and ear.
2. SCC of the lip (**Figures 171-8** and **171-9**).
3. SCC of the ear (**Figure 171-10**).
4. Tumors arising in non–sun-exposed sites (e.g., perineum, sacrum, sole of foot) (**Figures 171-4**, **171-5**, and **171-16**).
5. SCC arising in areas of radiation or thermal injury, chronic draining sinuses, chronic ulcers, chronic inflammation, or Bowen disease, such as the SCC arising in a burn site (**Figure 171-3**).

SIZE: DIAMETER.

Tumors larger than 2 cm in diameter are twice as likely to recur locally (15.2% vs. 7.4%), and 3 times as likely to metastasize (30.3% vs. 9.1%) as smaller tumors (**Figure 171-17**).

SIZE: DEPTH.

Tumors greater than 4 mm in depth (excluding surface layers of keratin) or extending down to the subcutaneous tissue (Clark level V) are more likely to recur and metastasize (metastatic rate 45.7%) compared with thinner tumors. Recurrence and metastases are less likely in tumors confined to the upper half of the dermis and less than 4 mm in depth (metastatic rate 6.7%).

HISTOLOGIC DIFFERENTIATION.

Poorly differentiated tumors have a poorer prognosis, with more than double the local recurrence rate and triple the metastatic rate of better differentiated SCC. Tumors with perineural involvement are more likely to recur and to metastasize.

HOST IMMUNOSUPPRESSION.

Tumors arising in patients who are immunosuppressed have a poorer prognosis. Host cellular immune response may be important both in determining the local invasiveness of SCC and the host's response to metastases. **Figures 171-16**, **171-17**, and **171-18** are SCCs in patients who are HIV-positive.

PREVIOUS TREATMENT AND TREATMENT MODALITY.

The risk of local recurrence depends upon the treatment modality. Locally recurrent disease itself is a risk factor for metastatic disease.

FIGURE 171-6 **A.** Squamous cell carcinoma on the nose of an 88-year-old woman. **B.** Subtle small squamous cell carcinoma on the nasal alae. Note that any crusting lesion on the face may be a squamous cell carcinoma no matter how small it is. (*Courtesy of Richard P. Usatine, MD.*)

FIGURE 171-7 **A.** Large cystic appearing squamous cell carcinoma on the face. Although this could have been a basal cell carcinoma, it definitely required a biopsy and excision. **B.** Small subtle invasive squamous cell carcinoma on the face that could have been overlooked or treated as an actinic keratosis. Any scaling lesion on the face that persists should be biopsied. (*Courtesy of Richard P. Usatine, MD.*)

FIGURE 171-8 Squamous cell carcinoma on the lower lip growing rapidly in a patient that was taking an immunosuppressive medication after a renal transplant. (*Courtesy of Richard P. Usatine, MD.*)

FIGURE 171-9 Squamous cell carcinoma showing ulceration on the lower lip of a man that was a smoker. (*Courtesy of Richard P. Usatine, MD.*)

FIGURE 171-10 Squamous cell carcinoma arising in an actinic keratosis on the helix of a 33-year-old woman. (*Courtesy of Richard P. Usatine, MD.*)

FIGURE 171-11 Squamous cell carcinoma on the shaven scalp of a 35-year-old man, which was formerly mistaken for a wart. (*Courtesy of Richard P. Usatine, MD.*)

FIGURE 171-12 Large squamous cell carcinoma on the leg of a homeless man. (*Courtesy of Richard P. Usatine, MD.*)

FIGURE 171-13 3 Large ulcerating squamous cell carcinoma on arm. (*Courtesy of Jonathan B. Karnes, MD.*)

FIGURE 171-14 Squamous cell carcinoma in situ on the thenar eminence of the hand. (*Courtesy of Richard P. Usatine, MD.*)

FIGURE 171-15 Two different appearing cases of squamous cell carcinoma on the finger. **A.** It took 2 shave biopsies to establish the correct diagnosis in this case. **B.** Squamous cell carcinoma in situ with human papillomavirus changes and pigment incontinence in a 35-year-old woman. The irregular hyperpigmented lesion on the proximal nailfold was originally suspicious for melanoma. (*Courtesy of Richard P. Usatine, MD.*)

FIGURE 171-17 Large squamous cell carcinoma on the arm of an human immunodeficiency virus-positive 51-year-old man. It grew to this size in 1 year and took 2 biopsies to get a definitive diagnosis. Differential diagnosis includes mycosis fungoides. (*Courtesy of Richard P. Usatine, MD.*)

FIGURE 171-16 Perianal invasive squamous cell carcinoma in an human immunodeficiency virus-positive man who had engaged in anal intercourse and was infected with human papillomavirus. The ulcerations were suspicious for invasive squamous cell carcinoma and not typical of condyloma acuminata.(*Courtesy of Richard P. Usatine, MD.*)

FIGURE 171-18 Squamous cell carcinoma invading the internal nasal structures in an human immunodeficiency virus-positive man who was afraid of having a biopsy done earlier. Patient referred to ear, nose, and throat specialist. (*Courtesy of Richard P. Usatine, MD.*)

Local recurrence rates are considerably less with Mohs micrographic surgery than with any other treatment modality.

DIFFERENTIAL DIAGNOSIS

- Actinic keratoses are precancers on sun-exposed areas, which can progress to SCC (see Chapter 166, Actinic Keratosis and Bowen Disease).
- Bowen disease is SCC in situ before it invades the basement membrane (see Chapter 166, Actinic Keratosis and Bowen Disease).
- Keratoacanthoma is a subtype of SCC that may resolve spontaneously, but is generally treated as a low risk SCC. **Figure 171-19** shows an invasive SCC resembling a lower-risk keratoacanthoma subtype (see Chapter 167, Keratoacanthoma).
- Basal cell carcinoma (BCC) cannot always be distinguished from SCC by clinical appearance alone. **Figure 171-17*A*** could be a BCC by appearance but was proven to be SCC by biopsy (see Chapter 170, Basal Cell Carcinoma).
- Merkel cell carcinoma (neuroendocrine carcinoma of the skin) is a rare aggressive malignancy. It is most commonly seen on the face of white elderly persons. It can resemble a SCC and the diagnosis is made on biopsy (**Figure 171-20**).
- Nummular eczema can usually be distinguished by the multiple coin-like shapes, transient nature, and pruritus (Chapter 145, Atopic Dermatitis).

FIGURE 171-19 Squamous cell carcinoma on the shoulder of an human immunodeficiency virus-positive man. Note that the pearly borders and telangiectasias resemble a basal cell carcinoma and the central crater suggests that this could be a keratoacanthoma. (*Courtesy of Richard P. Usatine, MD.*)

MANAGEMENT

The following recommendations are derived from the "Multiprofessional guidelines for the management of the patient with primary cutaneous squamous cell carcinoma." **Table 171-1** for a summary of treatment options.

Surgical resection for definitive treatment should include margins as given below:

- 4-mm margin—Should be adequate for well-defined, low-risk tumors less than 2 cm in diameter, such margins are expected to remove the primary tumor mass completely in 95% of cases.[5] SOR A
- 6-mm margin—Recommended for larger tumors, high-risk tumors, tumors extending into the subcutaneous tissue and those in high-risk locations (ear, lip, scalp, eyelids, nose).[5]

MOHS MICROGRAPHIC SURGERY

Frederick Mohs pioneered a technique for excising cutaneous tumors with immediate analysis of a continuous margin mapped to the clinical site. Mohs surgery offers superior cure rates compared with standard excision or destructive techniques, spares uninvolved tissue, and allows for reconstruction at the time of excision.

Mohs surgery may be considered for any continuous tumor, but is specifically indicated for lesions larger than 2 cm, lesions with ill-defined clinical borders, lesions with aggressive histologic subtypes, recurrent lesions, and lesions on or near the eye, nose, ear, mouth,

FIGURE 171-20 Merkel cell carcinoma on the lower lip of an elderly woman. This is an aggressive cancer with a high mortality rate. (*Courtesy of Jeff Meffert, MD.*)

TABLE 171-1 Summary of Treatment Options for Primary Cutaneous Squamous Cell Carcinoma

Treatment	Indications	Contraindications	Notes
Surgical excision	All resectable tumors	Where surgical morbidity is likely to be unreasonably high	Generally treatment of choice for SCC High-risk tumors need wide margins or histologic margin control
Mohs' micrographic surgery/excision with histologic control	High-risk tumors, recurrent tumors	Where surgical morbidity is likely to be unreasonably high	Treatment of choice for high-risk tumors
Radiotherapy	Nonresectable tumors	Where margins are ill-defined	
Curettage and cautery	Small, well-defined, low-risk tumors	High-risk tumors	Curettage may be helpful prior to surgical excision
Cryotherapy	Small, well-defined, low-risk tumors	High-risk tumors, recurrent tumors	Only suitable for experienced practitioners

Reprinted from Motley R, Kersey P, Lawrence C. Multiprofessional guidelines for the management of the patient with primary cutaneous squamous cell carcinoma. *BrJ Plast Surg.* 2003;56:85-91.

hair-bearing scalp, or chronic ulcers. Patients with chronic immunosuppression or genetic tumor syndromes may also benefit from Mohs surgery compared to standard excision.[4]

CURETTAGE AND ELECTRODESICCATION

Excellent cure rates have been reported in several series, and experience suggests that small (<1 cm), well-differentiated, primary, slow-growing tumors arising on sun-exposed sites can be removed by experienced physicians with electrodessication and curettage (EDC).[5]

The experienced clinician undertaking EDC can detect tumor tissue by its soft consistency, which may be of benefit in identifying invisible tumor extension and ensuring adequate treatment. Electrodesiccation is applied to the curetted wound and the curettage-cautery cycle then repeated twice. SOR C

CRYOSURGERY

Good short-term cure rates have been reported for small, histologically confirmed SCC treated by cryosurgery in experienced hands. Prior biopsy is necessary to establish the diagnosis histologically. There is great variability in the use of liquid nitrogen for cryotherapy. Start by drawing a 4- to 6-mm margin around the SCC and then use a total freeze time of 60 seconds. This can be divided up into two 30-second freezes with a thaw in between. Most patients prefer local anesthetic because these long freeze times are quite painful. SOR C

Cryosurgery and curettage and electrodesiccation are not appropriate for locally recurrent disease.

RADIOTHERAPY

Radiation therapy alone offers short- and long-term cure rates for SCC that are comparable with other treatments. It is recommended for lesions arising on the lip, nasal vestibule (and sometimes the outside of the nose), and ear. Certain very advanced tumors, where surgical morbidity would be unacceptably high, may also be best treated by radiotherapy. SOR C

ELECTIVE PROPHYLACTIC LYMPH NODE DISSECTION

Elective prophylactic lymph node dissection has been proposed for SCC on the lip that is greater than 6 mm in depth and for cutaneous SCC that is greater than 8 mm in depth, but evidence for this is weak. SOR C

PREVENTION AND SCREENING

- All skin cancer prevention starts with sun protection.
- There is good evidence from multiple randomized controlled trials (RCTs) that daily sunscreen use decreases the risk of developing sun-related SCCs.[7,8] SOR A In the longest RCT, sunscreen was applied regularly to the head, neck, hands, and forearms for 4.5 years with a decrease in SCC during the study period.[7] After cessation of the trial, the participants were followed for another 8 years and SCC tumor rates were significantly decreased, by almost 40%, during the entire follow-up period.[8]
- Sun protection should include sun avoidance, especially during peak hours of UV transmission, protective clothing, and sunscreen use.
- Indoor tanning is not safe and should be avoided.
- United States Preventive Services Task Force has not found sufficient evidence to recommend regular screening for any skin cancer in the general population.[9]
- Most experts believe that persons at high risk for SCC (including previous personal history of any skin cancer, high-risk family history and high-risk skin types with significant sun exposure, on immunosuppression after an organ transplant) should be screened regularly for skin cancer by a physician trained in such screening.
- Evidence for the value of self-screening is lacking but persons at high risk for skin cancer should also be encouraged to observe their own skin and to come in for evaluation if they see any suspicious changes or growths.

PROGNOSIS

Prognosis is excellent for small, thin lesions less than 2 mm thick that are removed with clear margins in immunocompetent patients. In these patients, the risk of metastasis is near zero. The risk of metastasis increases markedly with thicker lesions and lesions with thicknesses greater than 6 mm metastasize to the regional nodes 16% of the time.[10]

FOLLOW-UP

Patients should be seen at least yearly for skin examinations after the diagnosis and treatment of a SCC. The 3-year risk of recurrence of a new SCC after having a single SCC is 18%.[11]

PATIENT EDUCATION

Includes use of a hat and sunscreen on a regular basis with frequent follow-up for early recognition of new skin cancers.

PATIENT RESOURCES

- The Skin Cancer Foundation. *Squamous Cell Carcinoma*—**http://www.skincancer.org/skin-cancer-information/squamous-cell-carcinoma.**
- PubMed Health. *Squamous Cell Carcinoma*—**http://www.ncbi.nlm.nih.gov/pubmedhealth/PMH0001832/.**
- Skinsight. *Squamous Cell Carcinoma*—**http://www.skinsight.com/adult/squamousCellCarcinomaSCC.htm.**
- MedlinePlus. *Squamous Cell Carcinoma*—**http://www.nlm.nih.gov/medlineplus/ency/article/000829.htm.**

PROVIDER RESOURCES

- Medscape. *Head and Neck Cutaneous Squamous Cell Carcinoma*—**http://emedicine.medscape.com/article/1965430-overview.**
- Skinsight. *INFORMED: Melanoma and Skin Cancer Early Detection*—**http://www.skinsight.com/info/for_professionals/skin-cancer-detection-informed/skin-cancer-education.**
- Chapters and videos on diagnosing and surgically managing SCC can be found in the following book/DVD or electronic app: Usatine R, Pfenninger J, Stulberg D, Small R. *Dermatologic and Cosmetic Procedures in Office Practice*. Philadelphia, PA: Elsevier; 2012.

Information about smartphone and tablet apps of this resource can be viewed at **www.usatinemedia.com.**

REFERENCES

1. Lewis KG, Weinstock MA. Nonmelanoma skin cancer mortality (1988-2000): the Rhode Island follow-back study. *Arch Dermatol*. 2004;140(7):837-842.
2. Weinberg AS, Ogle CA, Shim EK. Metastatic cutaneous squamous cell carcinoma: an update. *Dermatol Surg*. 2007;33(8):885-899.
3. American Cancer Society. *Cancer Facts & Figures 2010*, http://www.cancer.org/research/cancerfactsfigures/cancerfactsfigures/cancer-facts-and-figures-2010, accessed June 1, 2012.
4. Bolognia JL, Jorizzo JL, Schaffer JV. *Dermatology*, 3rd ed. Philadelphia, PA: Saunders; 2012:2776.
5. Berg D, Otley CC. Skin cancer in organ transplant recipients: epidemiology, pathogenesis, and management. *J Am Acad Dermatol*. 2002;47(1):1-17; quiz 18-20.
6. Motley R, Kersey P, Lawrence C. British Association of Dermatologists, British Association of Plastic Surgeons. Multiprofessional guidelines for the management of the patient with primary cutaneous squamous cell carcinoma. *Br J Plast Surg*. 2003;56(2):85-91.
7. Green A, Williams G, Neale R, et al. Daily sunscreen application and betacarotene supplementation in prevention of basal-cell and squamous-cell carcinomas of the skin: a randomised controlled trial. *Lancet*. 1999;354:723-729. Erratum: *Lancet*. 1999;354:1038.
8. van der Pols JC, Williams GM, Pandeya N, Logan V, Green AC. Prolonged prevention of squamous cell carcinoma of the skin by regular sunscreen use. *Cancer Epidemiol Biomarkers Prev*. 2006;15(12):2546-2548.
9. Wolff T, Tai E, Miller T. *Screening for Skin Cancer: An Update of the Evidence for the U.S. Preventive Services Task Force*. Rockville, MD: Agency for Healthcare Research and Quality; 2009, http://www.ncbi.nlm.nih.gov/books/NBK34051/.
10. Brantsch KD, Meisner C, Schönfisch B, et al. Analysis of risk factors determining prognosis of cutaneous squamous-cell carcinoma: a prospective study. *Lancet Oncol*. 2008;9(8):713-720.
11. Marcil I, Stern RS. Risk of developing a subsequent nonmelanoma skin cancer in patients with a history of nonmelanoma skin cancer: a critical review of the literature and metaanalysis. *Arch Dermatol*. 2000;136(12):1524-1530.

172 MELANOMA

Jonathan B. Karnes, MD
Richard P. Usatine, MD

PATIENT STORIES

A 40-year-old woman noticed a new dark spot on her neck (**Figure 172-1**). On examination the spot was 8 mm in its longest diameter, was asymmetrical with irregular borders, and had variation in color. A scoop shave biopsy demonstrated melanoma in situ. The spot was excised with 0.5 cm margins and no residual tumor was found in the excised ellipse. She has a near 100% chance of complete cure.

The wife of a 73-year-old man noticed that a "mole" on his back was enlarging and bleeding. (**Figure 172-2**). It had been there for years. Even though a year earlier a doctor had told him not to worry about it, his wife sent him to have it rechecked. **Figure 172-2*B*** shows a close-up of the pigmented lesion showing ulceration and bleeding. An elliptical excision was performed and the tissue appeared to be a nodular melanoma with dark pigment into the subcutaneous fat (**Figure 172-2*C***). Histology revealed a nodular melanoma with a Breslow depth of 22 mm. The patient was referred to surgical and medical oncology. He underwent wide excision with 2-cm margins and a sentinel lymph node biopsy. The sentinel node was positive and further nodal dissection showed a total of another 4 axillary lymph nodes positive (1 on right and 3 on left). The lymph nodes on the left were black and enlarged. No distant metastases were found. Because more than 2 regional nodes were macroscopically positive, he was stage IIIC. He received radiation treatment to the original site and both axillae. Despite advances in targeted chemotherapy and immunotherapy, his prognosis was poor.

FIGURE 172-1 Melanoma in situ on the neck of a 40-year-old woman. Note the central regression. (*Courtesy of Richard P. Usatine, MD.*)

INTRODUCTION

Melanoma is the third most common skin cancer and the most deadly. The incidence of melanoma and the mortality from it are rising. Most lesions are found by clinicians on routine examination. When discovered early, surgical treatment is almost always curative. However, deeper lesions are prone to metastasize and have a much poorer prognosis. New therapies directed at the known gene changes in melanoma are beginning to show some promise, but widespread benefits of this research are still far off.

EPIDEMIOLOGY

- In 2012, an estimated 76,250 individuals will be diagnosed with melanoma of the skin and 9180 individuals will die from metastatic disease—or about 1 every hour.[1]
- Melanoma incidence has increased in every age group and in every thickness over the course of 1992 to 2006 among non-Hispanic whites, with death rates increasing in those older than age 65 years.[2]

- Incidence continues to increase worldwide at approximately 4% to 8% per year.[3]
- In the United States, the death rate for melanoma is decreasing among persons younger than age 65 years.[2]
- Deaths from thin melanomas account for more than 30% of total deaths.
- The lifetime risk of developing melanoma is 1 in 55 for men and 1 in 36 for women.[1]

RISK FACTORS

Risk factors can be broadly thought of as genetic risks, environmental risks, and phenotypic risks arising from a combination of genetic and environmental risks. For example, a fair-skinned child (genetic risk) who gets a sunburn (environmental) is much more likely to develop freckles (phenotypic) and melanoma.

ENVIRONMENTAL RISKS

- Exposure to sunlight.
  - History of sunburn doubles the risk of melanoma and is worse at a young age.
- Living closer to the equator.
- Indoor tanning.
- History of immunosuppression.
- Higher socioeconomic status (likely associated with more frequent opportunity for sunburns).

GENETIC RISKS

- Fair skin, blue or green eyes, red or blonde hair.
- Male sex.
- Melanoma in a first-degree relative.
- History of xeroderma pigmentosa or familial atypical mole melanoma syndrome.

PHENOTYPIC RISKS

- Many nevi.
- Multiple dysplastic nevi.
- Increased age.
- Personal history of any skin cancer.

DIAGNOSIS

CLINICAL FEATURES

Remember the *ABCDE* guidelines for diagnosing melanoma (**Figure 172-3**).[4]

A = *Asymmetry*. Most early melanomas are asymmetrical: a line through the middle will not create matching halves. Benign nevi are usually round and symmetrical.

B = *Border*. The borders of early melanomas are often uneven and may have scalloped or notched edges. Benign nevi have smoother, more even borders.

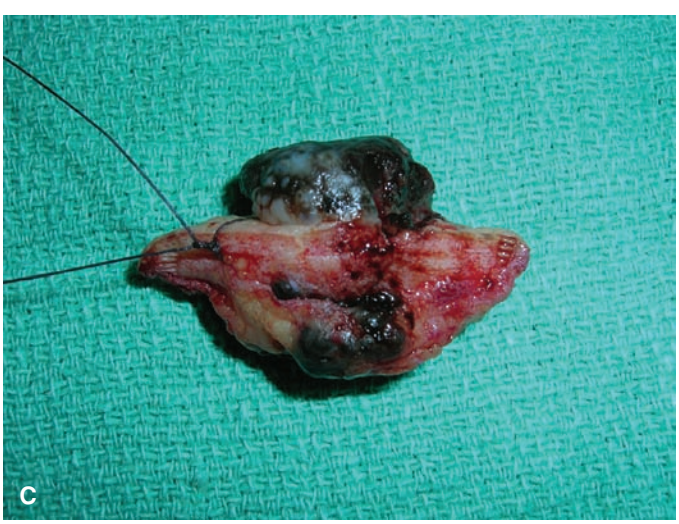

FIGURE 172-2 **A.** A 73-year-old man presents with bleeding "mole" on his back. Elliptical excision demonstrates this to be a nodular melanoma of 22-mm depth. **B.** Closeup of the nodular melanoma showing it to be thick with ulcerations and bleeding. **C.** Nodular melanoma after initial resection showing dark pigment into the subcutaneous fat. The Breslow depth is 22 mm with Clark level V. (*Courtesy of Richard P. Usatine, MD.*)

C = *Color* variation. Benign nevi are usually a single shade of brown. Melanomas are often in varied shades of brown, tan, or black, but may also exhibit red, white, or blue.

D = *Diameter* greater than or equal to 6 mm. Early melanomas tend to grow larger than most nevi. (Note: Congenital nevi are often large.)

E = *Evolving*. Any evolving or enlarging nevus should make you suspect melanoma. Evolving could be in size, shape, symptoms (itching, tenderness), surface (especially bleeding), and shades of color.

- A prospective controlled study compared 460 cases of melanoma with 680 cases of benign pigmented tumors and found significant differences for all individual ABCDE criteria ($p < 0.001$) between melanomas and benign nevi.[4]
- Sensitivity of each criterion: A 57%, B 57%, C 65%, D 90%, E 84%; specificity of each criterion: A 72%, B 71%, C 59%, D 63%, E 90%.[4]
- Sensitivity of ABCDE criteria varies depending upon the number of criteria needed: using 2 criteria it was 89.3%; with 3 criteria, it was 65.5%. Specificity was 65.3% using 2 criteria and 81% using 3.[4]
- The number of criteria present was different between benign nevi (1.24 ± 1.26) and melanomas (3.53 ± 1.53; $p < 0.001$). Unfortunately, no significant difference was found between melanomas and atypical nevi.[4]

There are 4 major categories of melanomas. With the exception of nodular melanoma, the growth patterns of the 3 other subtypes are characterized by a radial growth phase prior to dermal invasion. At the present time, the thickness of the lesion histologically regardless of the morphologic type is used to stage the tumor and assess prognosis. In the future, molecular analysis may allow more accurate risk stratification.[5] Here are the major categories of melanomas:

1. *Superficial spreading melanoma* is the most common type, representing 70% of all melanoma (**Figures 172-3** to **172-6**). This melanoma has the radial growth pattern before dermal invasion occurs. The first sign is the appearance of a flat macule or slightly raised discolored plaque that has irregular borders and is somewhat geometrical in form. The color varies, with areas of tan, brown, black, red, blue, or white. These lesions can arise in an older nevus. The melanoma can be seen almost anywhere on the body, but is most likely to occur on the trunk in men, the legs in women, and the upper back in both. Most melanomas found in the young are of the superficial spreading type.[5]
2. *Nodular melanoma* occurs in 15% to 30% of cases (**Figures 172-2**, **172-7** to **172-9**).[5] It is usually invasive at the time it is first diagnosed, and the malignancy is recognized when it becomes a bump. The color is most often black, but occasionally is blue, gray, white, brown, tan, red, or nonpigmented. The nodule in **Figure 172-9** is multicolored.
3. *Lentigo maligna melanoma* occurs in 4% to 15% of cutaneous melanoma.[4] It is similar to the superficial spreading type and appears as a flat or mildly elevated mottled tan, brown, or dark brown discoloration. This type of melanoma is found most often in the elderly and arises on chronically sun-exposed, damaged skin on the face, ears, arms, and upper trunk. These account for most melanomas on the face. The average age of onset is 65 years and it grows slowly over 5 to 20 years. The precursor lesion, lentigo maligna, goes on to melanoma in approximately 5% of cases. The in situ precursor lesion is usually larger than 3 cm in diameter and has existed for a minimum of 10 to 15 years (**Figures 172-10** and **172-11**) (see Chapter 168, Lentigo Maligna).[5]

FIGURE 172-3 Superficial spreading melanoma on the back with ABCDE features of melanoma. (*Courtesy of Richard P. Usatine, MD.*)

FIGURE 172-4 Superficial spreading melanoma near the areola. It is important to not mistake this for a seborrheic keratosis. Note the area of pigment regression near the top of the lesion. (*Courtesy of the University of Texas Health Sciences Center, Division of Dermatology.*)

FIGURE 172-5 Superficial spreading melanoma on the arm with depth of 0.25 mm. Note the pale pink coloration along with the black area with some erosion. (*Courtesy of Eric Kraus, MD.*)

FIGURE 172-6 Superficial spreading melanoma with multiple colors and ABCDE features of melanoma. (*Courtesy of Jonathan B. Karnes, MD.*)

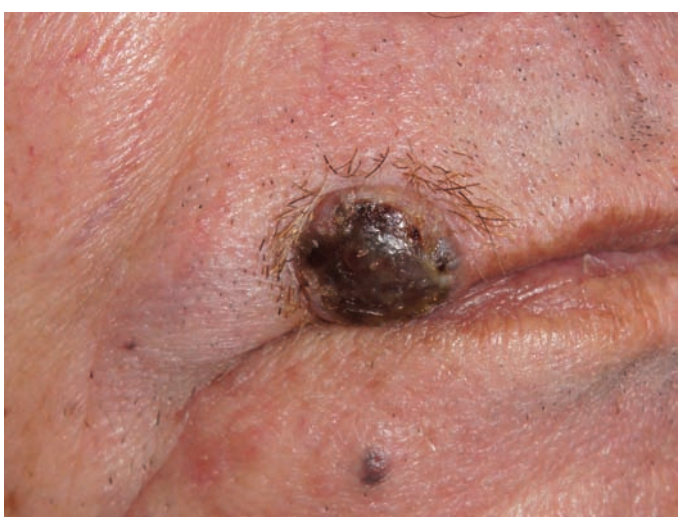

FIGURE 172-7 Thick nodular melanoma on the lip. (*Courtesy of Jonathan B. Karnes, MD.*)

FIGURE 172-8 Large nodular melanoma on the posterior helix of the ear. Depth was 8 mm. (*Courtesy of Jonathan B. Karnes, MD.*)

FIGURE 172-9 Raised, thick, nodular melanoma on the shoulder of a 37-year-old white woman with history of multiple sunburns from childhood. Note the multiple colors visible in the nodule. The Breslow depth is 8.5 mm with Clark level V. The sentinel node was negative and the patient underwent chemotherapy after wide excision. (*Courtesy of Richard P. Usatine, MD.*)

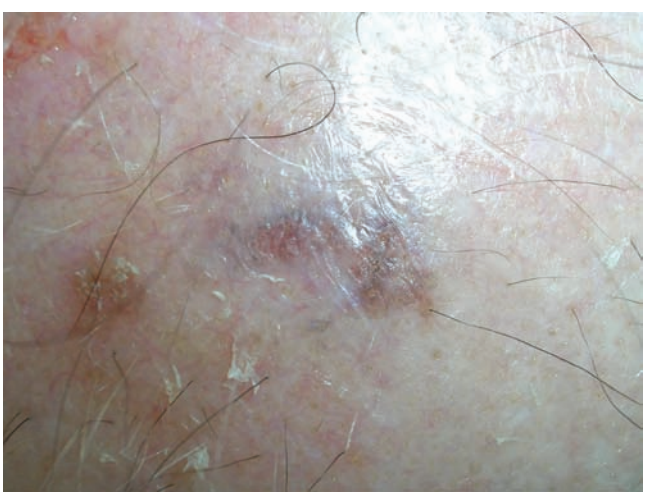

FIGURE 172-10 Lentigo maligna melanoma on the scalp of an 82-year-old man with a Breslow depth of 0.9 mm. This lesion was biopsied successfully with a scoop shave that completely cut under the lesion for full prognostic information. (*Courtesy Richard P. Usatine, MD.*)

FIGURE 172-11 Lentigo malignant melanoma presenting as a large pigmented area on the face of an elderly man. (*Courtesy of the Skin Cancer Foundation. For more information www.skincancer.org*)

4. *Acral lentiginous melanoma* is the least common subtype of melanoma (2% to 8%) cases in white people; however, it is the most frequent subtype found in African Americans (70%) and is also a frequent subtype in Asians (45%).[5] It may occur under the nail plate or on the soles or palms (**Figures 172-12** to **172-16**). This subtype often carries a worse prognosis because of delays in diagnosis. Subungual melanoma may manifest as diffuse nail discoloration or a longitudinal pigmented band within the nail plate. When subungual pigment spreads to the proximal or lateral nail fold, it is referred to as the Hutchinson sign, and is highly suggestive of acral lentiginous melanoma (**Figure 172-14**) (see Chapter 191, Pigmented Nail Disorders).

Less common types of melanomas include:

- *Amelanotic melanoma* (<5% of melanomas) is nonpigmented and appears pink or flesh-colored, often mimicking basal cell or squamous cell carcinoma or a ruptured hair follicle. Any of the 4 principal subtypes may present as an amelanotic variant, but nodular melanomas are highly represented. These may be intrinsically more aggressive and often present with a thicker Breslow depth than similarly pigmented melanomas (**Figures 172-17, 172-18** and **172-19**).[6]
- Other rare melanoma variants include (a) nevoid melanomas, (b) malignant blue nevus, (c) desmoplastic/spindled/neurotropic melanoma, (d) clear cell sarcoma (in fact a melanoma), (e) animal-type melanoma, (f) ocular melanoma, and (g) mucosal (lentiginous) melanoma.[5]

TYPICAL DISTRIBUTION

Melanoma occurs most commonly on the trunk in white males and the lower legs and back in white females, but may occur in any location where melanocytes exist. The most common site in African Americans, Hispanics, and Asians is the plantar foot, followed by the subungual, palmar, and mucosal sites.

DERMOSCOPY

Dermoscopy can be used to determine if a pigmented lesion has features suspicious for a melanoma, and it can also help determine when a biopsy is needed.[7] In a prospective study of 401 lesions evaluated for melanoma by experts in dermoscopy, the sensitivity of 66.6% with ABCDE criteria improved to 80%, and specificity rose from 79.3% to 89.1% (**Figure 172-20**).[7]

In a study of dermoscopy done by 60 physicians (35 general practitioners, 10 dermatologists, and 16 dermatology trainees) on unaided photos of 40 lesions using the ABCD rule, the Menzies method, a 7-point checklist, and pattern analysis, the sensitivity rose over the unaided eye.[8] The physicians were instructed in each of the dermoscopy methods using a CD-ROM. The unaided eye using a standard photo of the lesion was 61% sensitive and 85% specific with a 73% diagnostic accuracy. The dermoscopic photo increased sensitivity (68% for pattern analysis, 77% for the ABCD rule, 81% for the 7-point checklist, and 85% for the Menzies method). The specificity did not improve. Sensitivity is more important than specificity to avoid missing melanoma. Although the number of biopsies could increase with some drop in specificity, the biopsy itself is the most specific test to differentiate melanoma from benign pigmented lesions.[8]

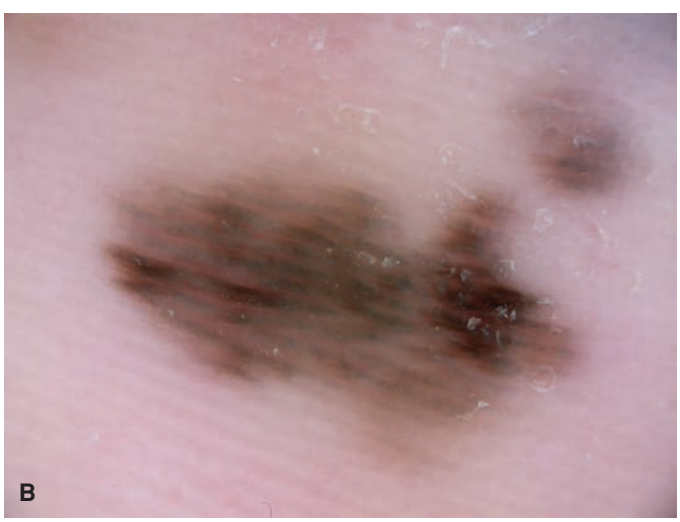

FIGURE 172-12 **A.** Acral lentiginous melanoma on the bottom of the foot where it went undetected for years. **B.** Dermoscopy showing the parallel ridge pattern typical of a melanoma on the sole. (*Courtesy Richard P. Usatine, MD.*)

FIGURE 172-13 Subungual melanoma in a white man showing hyperpigmentation of the nail and nail bed. (*Courtesy of the Skin Cancer Foundation. For more information www.skincancer.org*)

FIGURE 172-14 Acral lentiginous melanoma that started after trauma to the thumb which led to a delay in diagnosis. Note the destruction of the nail bed and the hyperpigmentation around the nail fold. (*Courtesy Journal of Family Practice and Adam Leight, MD.*)

FIGURE 172-15 Nodular and acral lentiginous melanoma of the foot in a 30-year-old black woman. There is ulceration and the depth was 5.5 mm. Sentinel node biopsy was positive for 2 of 2 nodes sampled. Clarke level IV and Stage IIIC (pT4b N2a MO). (*Courtesy of Richard P. Usatine, MD.*)

FIGURE 172-16 Acral lentiginous melanoma on the bottom of the foot where it went undetected for years. (*Courtesy of the University of Texas Health Sciences Center, Division of Dermatology.*)

FIGURE 172-17 Amelanotic melanoma on the arm of a middle-aged man with marked sun damage. Breslow depth was 1.5 mm. (*Courtesy of Jonathan B. Karnes, MD.*)

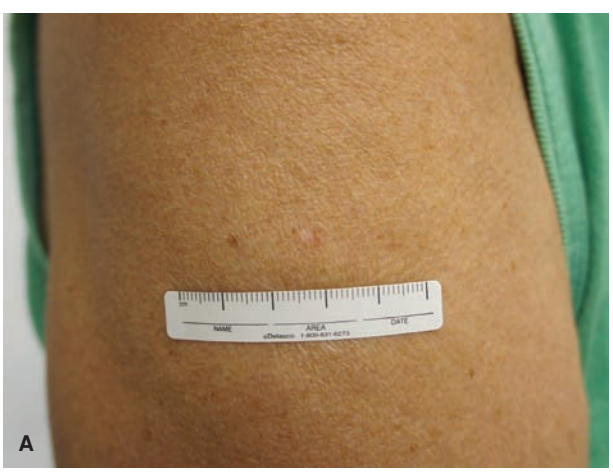

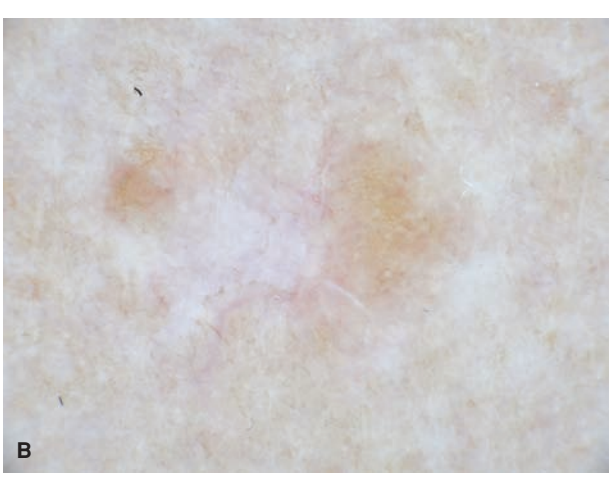

FIGURE 172-18 **A.** Amelanotic melanoma on the arm easily missed because of its small size and lack of dark pigmentation. **B.** Dermoscopy of the same melanoma showing white central area, peripheral pigment network, and linear vessels. (*Courtesy of Jonathan B. Karnes, MD.*)

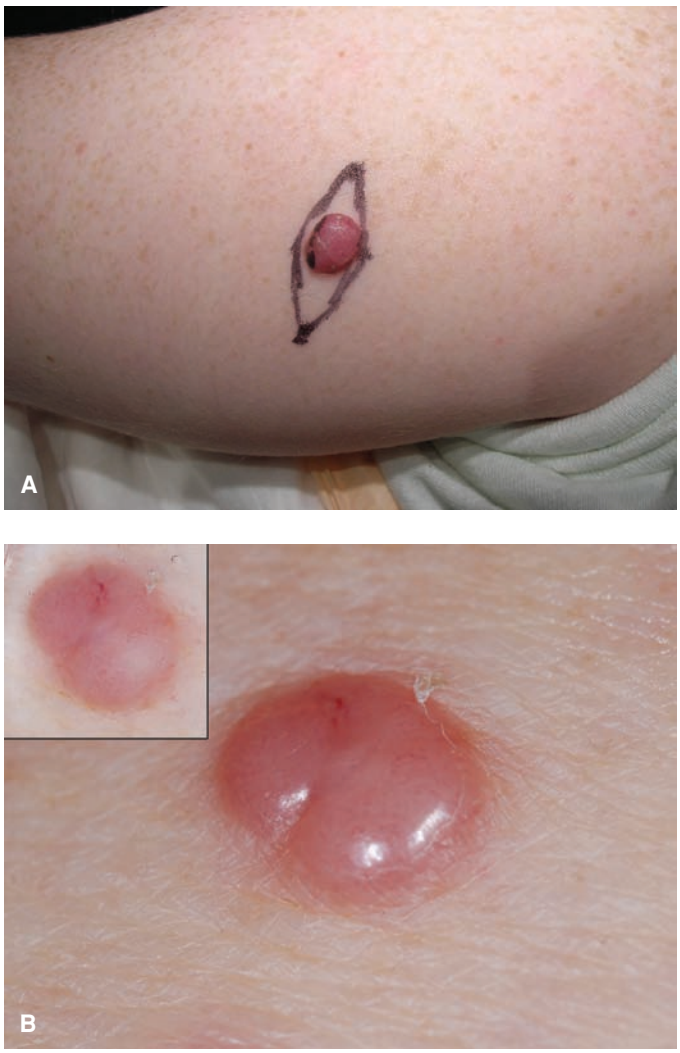

FIGURE 172-19 **A.** Amelanotic melanoma on the arm of a young woman prior to elliptical excision. The diagnosis was unexpected and shows the importance of excising suspicious lesions even when they are not pigmented. (*Courtesy of E.J. Mayeaux, Jr., MD.*) **B.** Amelanotic melanoma with a dermoscopy insert in upper corner. The use of the dermatoscope and the recognition of the abnormal vascular pattern lead to a high suspicion for amelanotic melanoma that was confirmed on excision. (*Courtesy of Ashfaq Marghoob, MD.*)

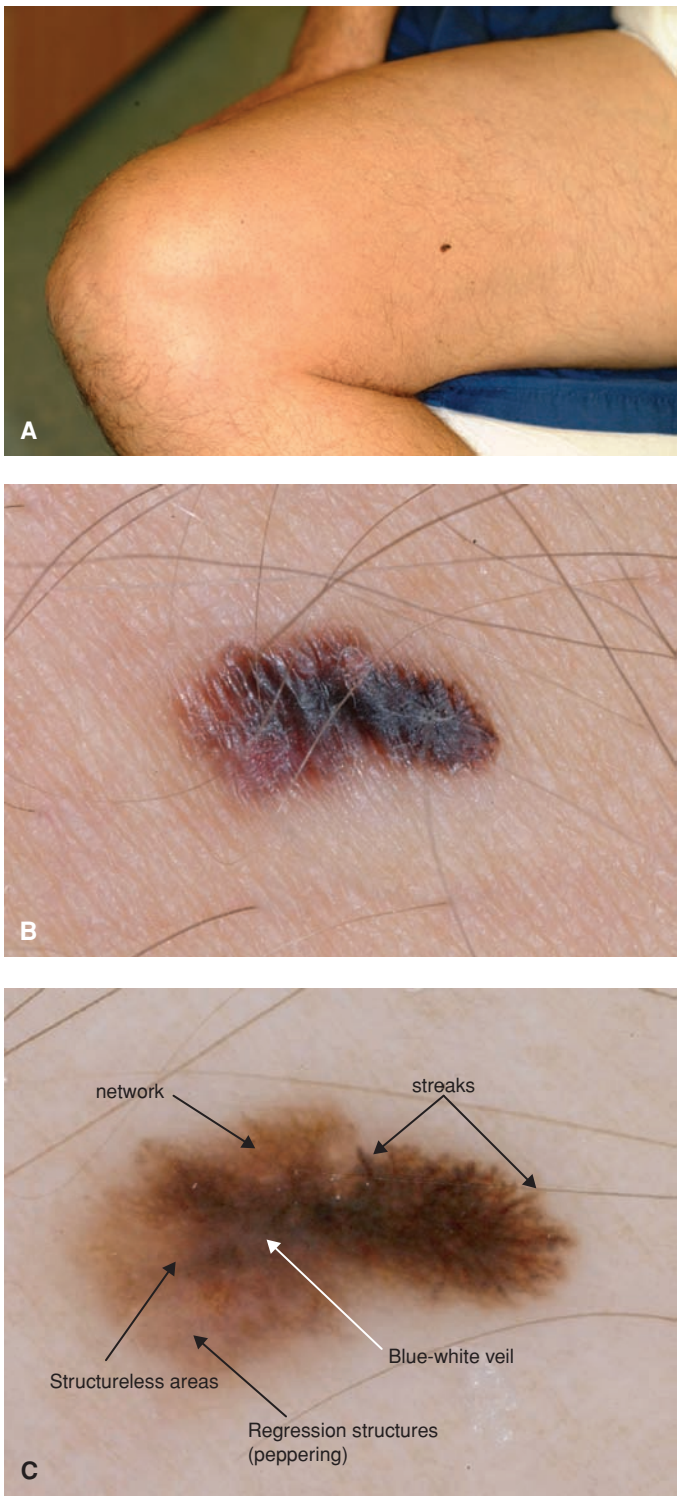

FIGURE 172-20 **A.** A melanoma on the leg that could be missed because of its small size (7-mm long). **B.** Closeup of that melanoma showing the asymmetry, irregular borders and a variation in color. **C.** Dermoscopy of a melanoma showing a blue-white veil, radial streaks, pigment network, structureless areas and regression structures with peppering. This early superficial-spreading melanoma was proven to be 0.55 mm at the time of excision. (*Courtesy of Ashfaq Marghoob, MD.*)

Accepted dermoscopic local features of melanoma include:

- Atypical network (includes branched-streaks).
- Streaks: pseudopods and radial streaming.
- Atypical dots and globules.
- Negative pigment network.
- Blotch (off center).
- Blue-white veil/peppering over macular areas (regression).
- Blue-white veil over raised areas.
- Vascular structures.
- Peripheral tan/brown structureless areas.

Figure 172-20 demonstrates a number of these features. See Appendix 3: Dermoscopy.

BIOPSY

A full-thickness skin biopsy remains the gold standard for diagnosing melanoma. Complete excisional biopsy with close margins (1 to 3 mm) is ideal for histologic diagnosis and tumor staging (**Box 172-1**). Although there is evidence that an incisional biopsy of a portion of a melanoma does not worsen the prognosis, this should only be performed when a lesion is too large to excise in the office. When the clinical impression differs markedly from the pathology report, discuss with the pathologist and share clinical photos if you haven't done so already. You may need to have the pathologist prepare "deeper sections" or "step sections"—meaning more slices from the same loaf of bread. Additionally, if the diagnosis of melanoma was expected and the result of an incisional biopsy does not meet the expectation, go forward with a complete excision or refer to a surgeon who can.

Despite strong opinions about biopsy technique, there is evidence that a saucerization (scoop or deep shave biopsy) leads to an accurate diagnosis and staging 97% of the time (**Figure 172-21**).[9] Still, a shallow shave biopsy may miss important staging information and may cause "upstaging" and unnecessary lymph node biopsy. However, for very large lesions, such as a suspected lentigo maligna, a broad scoop shave (saucerization) can often provide better tissue to the pathologist than a single or several punch biopsies (**Figure 172-10**).[10]

The impact of partial biopsy on histopathologic diagnosis of cutaneous melanoma has been studied extensively by Ng et al in Australia. They found increased odds of histopathologic misdiagnosis were associated with punch biopsy of part of the melanoma (odds ratio [OR] 16.6) and shallow shave biopsy (OR 2.6) compared with excisional biopsy (including saucerization). Punch biopsy of part of the melanoma was also associated with increased odds of misdiagnosis with an adverse outcome (OR 20).[11]

BOX 172-1 The National Comprehensive Cancer Network (NCCN) Melanoma Guidelines on the Principles of Biopsy State[12]

- Excisional biopsy (elliptical, punch [when whole lesion is small], or saucerization) with 1- to 3-mm margins is preferred. Avoid wider margins to permit accurate subsequent lymphatic mapping.
- The orientation of the biopsy should be planned with definitive wide excision in mind.
- Full-thickness incisional or punch biopsy of clinically thickest portion of the lesion is acceptable in certain anatomic areas (e.g., palm/sole, digit, face and ear) or for very large lesions.
- Shave biopsy (not saucerization or deep shave) may compromise pathologic diagnosis and complete assessment of Breslow thickness, but is acceptable when the index of suspicion is low.
- For lentigo maligna melanoma in situ, broad shave biopsy may help to optimize diagnosis.[12]

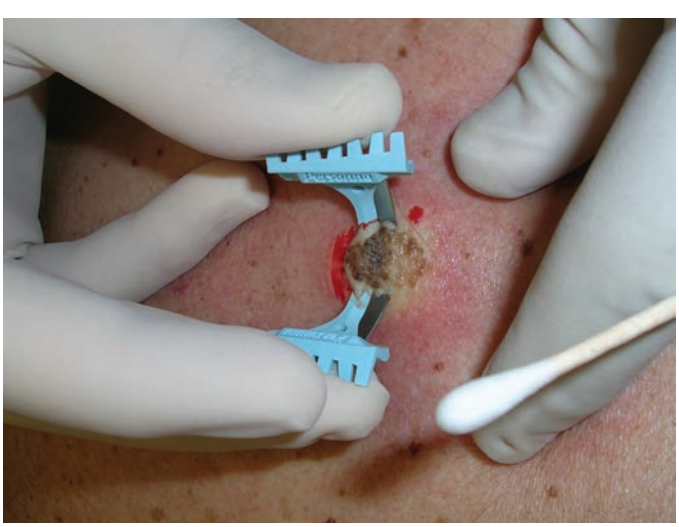

FIGURE 172-21 Saucerization (scoop or deep shave) of the entire pigmented lesion suspected to be a superficial spreading melanoma was performed successfully with a dermablade. Breslow's thickness was 0.6 mm and the patient then underwent a full surgical excision with 1-cm margins. (*Courtesy of Richard P. Usatine, MD.*)

DIFFERENTIAL DIAGNOSIS

Nevi of all types can mimic melanoma. Congenital nevi can be especially large and asymmetrical. Therefore, it is important to ask the patient if the pigmented area has been there from birth. Because some melanomas arise in congenital nevi, a changing congenital nevus needs to be biopsied to rule out melanoma.

- Dysplastic nevi, also called atypical moles, can mimic melanoma. When an atypical nevus is suspicious for melanoma, perform a full-thickness biopsy or a broad scoop shave for histology. Only the

less-suspicious dysplastic nevi should be followed with photography or serial exams (see Chapter 165, Dysplastic Nevus).

- Seborrheic keratoses (SKs) usually look like they are stuck-on with surface cracks and a verrucous (wart-like) appearance. These are benign and not precancerous. SKs can be darkly pigmented, asymmetrical with irregular borders and have varied colors. Perform a biopsy if the diagnosis is uncertain. Be careful to not mistake a lesion for a SK (**Figure 172-4**) (see Chapter 158, Seborrheic Keratosis).
- Solar lentigines often appear as light brown macules on the face and the dorsum of the hands. Many patients call them liver spots, but they have nothing to do with the liver. A large isolated solar lentigo on the face can mimic lentigo maligna melanoma. In this case, perform a broad scoop shave of the most suspicious area or the whole lesion.
- Dermatofibromas are fibrotic nodules that occur most frequently on the legs and arms. They can be any color from skin color to black and often have a brown halo surrounding them. A pinch test will produce a dimpling of the skin in most cases (see Chapter 160, Dermatofibroma).
- Pyogenic granulomas can resemble an amelanotic melanoma so always send the lesion to the pathologist to make sure that the clinical diagnosis is correct (**Figure 172-22**) (see Chapter 161, Pyogenic Granuloma).
- Pigmented basal cell carcinomas (BCCs) may resemble a melanoma. However, the pigment in the BCC is often scattered throughout the lesion, and it has other features of a BCC, such as a pearly appearance with a rolled border (**Figures 172-23** and **172-24**) (see Chapter 170, Basal Cell Carcinoma). Dermoscopy can be very helpful as a pigmented BCC has a number of specific dermoscopic structures to look for.

FIGURE 172-22 Thick ulcerated nodular melanoma on the back of a young woman that could be mistaken for a pyogenic granuloma or basal cell carcinoma. Most importantly, a full depth biopsy was performed. The melanoma depth was greater than 1 mm and the patient was sent for a complete excision with a sentinel node biopsy. (*Courtesy of Richard P. Usatine, MD.*)

MANAGEMENT

- Cutaneous melanoma is surgically treated with complete full skin-depth excision using margins determined by the Breslow depth. This depth is a measure of tumor thickness from the granular layer of the epidermis to the point of deepest invasion using an ocular micrometer.
- Current recommendations for excision margins range from 5 mm for in situ lesions to 1 to 2 cm for invasive lesions. A recent study showed significant benefit with a 9-mm margin on Mohs excision of melanoma in situ compared with 6-mm margins at a referral center.[13] **Table 172-1** for a comparison of world recommendations.[14] SOR A
- Mohs micrographic surgery, performed by specially trained physicians, may prove useful in completely removing subclinical tumor extension in certain subtypes of melanoma in situ, such as lentigo maligna, desmoplastic melanoma, and acral lentiginous melanoma in situ.[15]
- Sentinel lymph node biopsies are recommended for tumors of greater than or equal to 1 mm in depth and should be considered for thinner lesions with ulceration or more than 1 mitoses per mm^2. In the most recent guidelines, mitoses per mm^2 has replaced Clark levels to distinguish T1a from T1b tumors.[16]

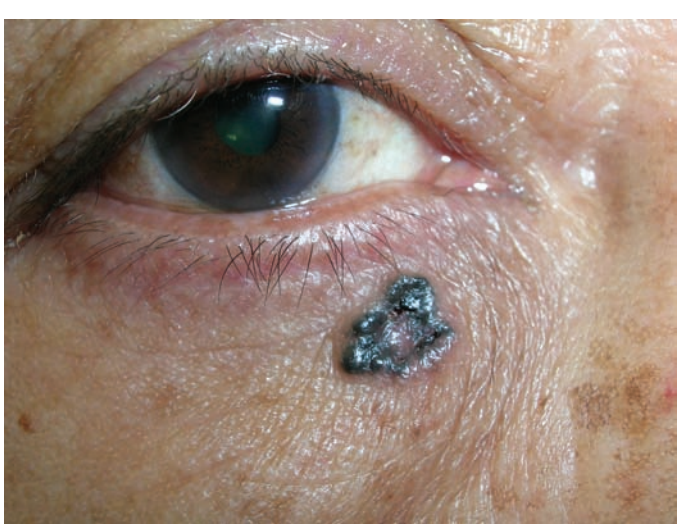

FIGURE 172-23 A pigmented basal cell carcinoma on the lower eyelid that has rolled pearly borders even though the color is black. A shave biopsy allowed a diagnosis of a basal cell carcinoma to be made. (*Courtesy of Richard P. Usatine, MD.*)

- Patients with advanced melanoma should be referred to medical oncology and may receive combination therapy with multiple chemotherapeutic agents and immunotherapy. Many trials are ongoing and 3 new drugs, including interferon 2α, vemurafenib, and ipilimumab, have been approved for use in advanced melanoma. Consideration should be given to consulting palliative care.
- Recently 2 new chemotherapeutic agents have been FDA approved for the treatment of metastatic melanoma (**Figure 172-25**). One, vemurafenib is a monoclonal antibody targeting the BRAF mutation expressed on many melanomas. Ipilimumab prevents dampening of the immune system by blocking a regulatory molecule CTLA-4. Both of these medications used in combination with dacarbazine have shown a small but significant increase in progression-free survival.[17]

PREVENTION AND SCREENING

- Melanoma prevention starts with sun protection.
- Until recently there is no proof that sunscreen helped to prevent melanoma. A recent study provides some evidence that sunscreen use does decrease the risk of invasive melanomas in adults.[18]
- Sun protection should include sun avoidance, protective clothing, and sunscreen.
- Indoor tanning is not safe and should be avoided.
- United States Preventive Services Task Force has not found sufficient evidence to recommend regular screening for melanoma or skin cancer in the general population.[19]
- Most experts believe that persons at high risk for melanoma (including previous personal history of melanoma, high-risk family history and high-risk skin types with significant sun exposure) should be screened regularly for melanoma by a physician trained in such screening.
- Evidence for the value of self-screening is lacking but persons at high risk for melanoma should also be encouraged to observe their own skin and to come in for evaluation if they see any suspicious changes or growths.

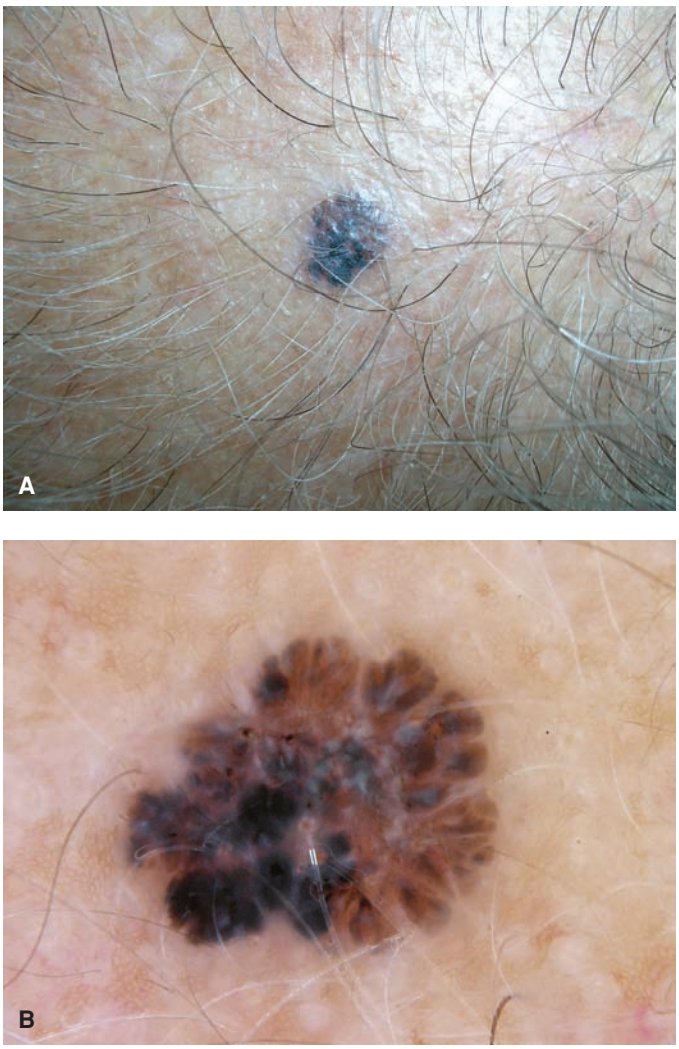

FIGURE 172-24 **A.** A pigmented basal cell carcinoma on the scalp mimicking a melanoma. **B.** Dermoscopy shows the typical maple leaf patterns of a pigmented basal cell carcinoma. A shave biopsy easily allowed for a diagnosis of a basal cell carcinoma to be made. (*Courtesy of Richard P. Usatine, MD.*)

TABLE 172-1 Currently Recommended Excision Margins for Primary Melanoma

	Excision Margin			
Tumor Thickness	UK MSG	WHO	Australian	Dutch MSG
In situ	2–5 mm	5 mm	5 mm	2 mm
<1 mm	1 cm	1 cm	1 cm	1 cm
1–2 mm	1–2 cm	1 cm*	1 cm	1 cm
2.1–4 mm	2–3 cm (2 cm preferred)	2 cm	1 cm	2 cm
>4 mm	2–3 cm	2 cm	2 cm	2 cm

*For melanomas thicker than 1.5 mm, recommended excision margin is 2 cm.

MSG, Melanoma Study Group; WHO, World Health Organization.

Source: Reprinted from Newton Bishop JA, et al. UK guidelines for the management of cutaneous melanoma. *British Journal of Plastic Surgery.* 2003;55(1):46-54. Copyright 2003, with permission from Elsevier.

PROGNOSIS

Prognosis depends upon tumor depth, mitotic rate, the presence of ulceration, positive lymph nodes, and metastases. In stage 0 disease surgical excision is almost always curative. Ten-year survival in patients by tumor thickness is almost 100% for in situ lesions, 92% for lesions less than 1 mm thick, 80% for lesions between 1 and 2 mm thick, 63% for lesions 2 to 4 mm thick, and 50% for lesions thicker than 4 mm. When accounting for nodal and distant metastasis, stage III disease carries a 39% to 70% 5-year survival depending on the number of nodal metastases, and stage IV disease carries a 32% to 62% 1-year survival rate.[16]

FOLLOW-UP

The need for follow-up is largely determined by the stage of the disease. The 2010 American Joint Committee on Cancer staging system is provided in **Table 172-2**. The prognosis is worsened by increasing depth, mitotic rate, presence of ulceration, positive lymph nodes, and metastases.

The follow-up for stages 0 and 1 cutaneous melanoma includes regular skin examinations by a physician trained in skin cancer screening. Total body photography may be of benefit in monitoring patients with multiple nevi. The rate of subsequent cutaneous melanomas among persons with a history of melanoma was found to be more than 10 times the rate of a first cutaneous melanoma and the highest incidence of recurrence was in the first 3 to 5 years after initial diagnosis.[20,21]

PATIENT EDUCATION

Advise patients who have had melanoma to avoid future sun exposure and monitor their skin for new and changing moles. Recommend a complete skin examination yearly by a physician trained to detect early melanoma.

PATIENT RESOURCES

- Medline Plus. *Melanoma*—**http://www.nlm.nih.gov/medlineplus/melanoma.html.**
- The Skin Cancer Foundation. *Melanoma*—**http://www.skincancer.org/skin-cancer-information/melanoma.**
- American Cancer Society. *Skin Cancer–Melanoma*—**http://www.cancer.org/cancer/skincancer-melanoma/index**.

PROVIDER RESOURCES

- Medscape. *Cutaneous Melanoma*—**http://emedicine.medscape.com/article/1100753.**
- National Cancer Institute. *Melanoma*—**http://www.cancer.gov/cancertopics/types/melanoma.**

FIGURE 172-25 Metastatic melanoma with dark black nodules scattered over the body and neck. (*Courtesy of Richard P. Usatine, MD.*)

TABLE 172-2A TNM Staging Categories for Cutaneous Melanoma

Classification	Thickness (mm)	Ulceration Status/Mitoses
T		
Tis	NA	NA
T1	≤1.00	a: Without ulceration and mitosis <1/mm^2 b: With ulceration or mitoses ≥1/mm^2
T2	1.01–2.00	a: Without ulceration b: With ulceration
T3	2.01–4.00	a: Without ulceration b: With ulceration
T4	>4.00	a: Without ulceration b: With ulceration
N	**No. of Metastatic Nodes**	**Nodal Metastatic Burden**
N0	0	NA
N1	1	a: Micrometastasis* b: Macrometastasis†
N2	2–3	a: Micrometastasis* b: Micrometastasis† c: In transit metastases/satellites without metastatic nodes
N3	4+ metastatic nodes, or matted nodes, or in transit metastates/satellites with metastatic nodes	
M	**Site**	**Serum LDH**
M0	No distant metastates	NA
M1a	Distant skin, subcutaneous, or nodal metastases	Normal
M1b	Lung metastases	Normal
M1c	All other visceral metastases Any distant metastasis	Normal Elevated

Abbreviation: NA, not applicable; LDH, lactate dehydrogenase.
*Micrometastases are diagnosed after sentinel lymph node biopsy.
†Macrometastases are defined as clinically detectable nodal metastases confirmed pathologically.

- Skinsight. *INFORMED: Melanoma and Skin Cancer Early Detection*—**http://www.skinsight.com/info/for_professionals/skin-cancer-detection-informed/skin-cancer-education**.
- Chapters and videos on diagnosing and surgically managing melanoma can be found in the following book/DVD or electronic application: Usatine R, Pfenninger J, Stulberg D, Small R. *Dermatologic and Cosmetic Procedures in Office Practice*. Philadelphia, PA: Elsevier; 2012.
- Information about smartphone and tablet apps of this resource can be viewed at **www.usatinemedia.com**.

TABLE 172-2B Anatomic Stage Groupings for Cutaneous Melanoma

	Clinical Staging*				Pathologic Staging†		
	T	N	M		T	N	M
0	Tis	N0	M0	0	Tis	N0	M0
IA	T1a	N0	M0	IA	T1a	N0	M0
IB	T1b	N0	M0	IB	T1b	N0	M0
	T2a	N0	M0		T2a	N0	M0
IIA	T2b	N0	M0	IIA	T2b	N0	M0
	T3a	N0	M0		T3a	N0	M0
IIB	T3b	N0	M0	IIB	T3b	N0	M0
	T4a	N0	M0		T4a	N0	M0
IIC	T4b	N0	M0	IIIC	T4b	N0	M0
III	Any T	N > N0	M0	IIIA	T1-4a	N1a	M0
					T1-4a	N2a	M0
				IIIB	T1-4b	N1a	M0
					T1-4b	N2a	M0
					T1-4a	N1b	M0
					T1-4a	N2b	M0
					T1-4a	N2c	M0
				IIIC	T1-4b	N1b	M0
					T1-4b	N2b	M0
					T1-4b	N2c	M0
					Any T	N3	M0
IV	Any T	Any N	M1	IV	Any T	Any N	M1

*Clinical staging includes microstaging of the primary melanoma and clinical/radiologic evaluation for metastases. By convention, it should be used after complete excision of the primary melanoma with clinical assessment for regional and distant metastases.
†Pathologic staging includes microstaging of the primary melanoma and pathologic information about the regional lymph nodes after partial (ie, sentinel node biopsy) or complete lymphadenectomy. Pathologic stage 0 or stage IA patients are the exception; they do not require pathologic evaluation of their lymph nodes.

REFERENCES

1. Siegel R, Naishadham D, Jemal A. Cancer statistics, 2012. *CA Cancer J Clin.* 2012;62(1):10-29.
2. Jemal A, Saraiya M, Patel P, et al. Recent trends in cutaneous melanoma incidence and death rates in the United States, 1992-2006. *J Am Acad Dermatol.* 2011;65(5 Suppl 1):S17-S25.e1-3.
3. Rigel DS. Trends in dermatology: melanoma incidence. *Arch Dermatol.* 2010;146(3):318.
4. Thomas L, Tranchand P, Berard F, Secchi T, Colin C, Moulin G. Semiological value of ABCDE criteria in the diagnosis of cutaneous pigmented tumors. *Dermatology*. 1998;197(1):11-17.
5. MD JLB, MD JLJ, MD RPR. *Dermatology e-dition: Text with Continually Updated Online Reference*, 2nd ed. St. Louis, MO: Mosby; 2007:2584.
6. Gualandri L, Betti R, Crosti C. Clinical features of 36 cases of amelanotic melanomas and considerations about the relationship between histologic subtypes and diagnostic delay. *J Eur Acad Dermatol Venereol.* 2009;23(3):283-287.
7. Benelli C, Roscetti E, Pozzo VD, Gasparini G, Cavicchini S. The dermoscopic versus the clinical diagnosis of melanoma. *Eur J Dermatol.* 1999;9(6):470-476.
8. Dolianitis C, Kelly J, Wolfe R, Simpson P. Comparative performance of 4 dermoscopic algorithms by nonexperts for the diagnosis of melanocytic lesions. *Arch Dermatol.* 2005;141(8):1008-1014.
9. Zager JS, Hochwald SN, Marzban SS, et al. Shave biopsy is a safe and accurate method for the initial evaluation of melanoma. *J Am Coll Surg.* 2011;212(4):454-460; discussion 460-462.

10. Dalton SR, Gardner TL, Libow LF, Elston DM. Contiguous lesions in lentigo maligna. *J Am Acad Dermatol.* 2005;52(5):859-862.
11. Ng JC, Swain S, Dowling JP, Wolfe R, Simpson P, Kelly JW. The impact of partial biopsy on histopathologic diagnosis of cutaneous melanoma: experience of an Australian tertiary referral service. *Arch Dermatol.* 2010;146(3):234-239.
12. Coit DG, Andtbacka R, Bichakjian CK, et al. NCCN Melanoma Panel. Melanoma. *J Natl Compr Canc Netw*. 2009;7(3):250-275.
13. Kunishige JH, Brodland DG, Zitelli JA. Surgical margins for melanoma in situ. *J Am Acad Dermatol.* 2012;66(3):438-444.
14. Lens MB, Dawes M, Goodacre T, Bishop JAN. Excision margins in the treatment of primary cutaneous melanoma: a systematic review of randomized controlled trials comparing narrow vs wide excision. *Arch Surg.* 2002;137(10):1101-1105.
15. Chang KH, Dufresne R, Cruz A, Rogers GS. The operative management of melanoma: where does Mohs surgery fit in? *Dermatol Surg.* 2011;37(8):1069-1079.
16. Balch CM, Gershenwald JE, Soong S-J, et al. Final version of 2009 AJCC melanoma staging and classification. *J Clin Oncol.* 2009;27(36):6199-6206.
17. Lee B, Mukhi N, Liu D. Current management and novel agents for malignant melanoma. *J Hematol Oncol.* 2012;5(1):3.
18. Green AC, Williams GM, Logan V, Strutton GM. Reduced melanoma after regular sunscreen use: randomized trial follow-up. *J Clin Oncol.* 2011;29(3):257-263.
19. Wolff T, Tai E, Miller T. *Screening for Skin Cancer: An Update of the Evidence for the U.S. Preventive Services Task Force*. Rockville, MD: Agency for Healthcare Research and Quality; 2009, http://www.ncbi.nlm.nih.gov/books/NBK34051/.
20. Tsao H, Atkins MB, Sober AJ. Management of cutaneous melanoma. *N Engl J Med.* 2004;351(10):998-1012.
21. Levi F, Randimbison L, Te V-C, La Vecchia C. High constant incidence rates of second cutaneous melanomas. *Int J Cancer.* 2005;117(5):877-879.

SECTION 13 INFILTRATIVE IMMUNOLOGIC

173 GRANULOMA ANNULARE

Melissa A. Muszynski, MD
Richard P. Usatine, MD

PATIENT STORY

A 39-year-old woman presents with raised rings on her right hand only. Not knowing the correct diagnosis, another physician prescribed topical steroids and antifungal medicines with no benefit. The diagnosis of granuloma annulare (GA) was made by the typical clinical appearance and the patient was offered intralesional steroids. Triamcinolone acetonide was injected as seen in **Figure 173-1, *A***. The patient noted improvement over the subsequent weeks, but within a month new lesions began to appear on her other hand (**Figure 173-1, *B***). Additional injections were provided and 1 month later the patient had regression of the treated lesions but had new lesions on the right arm (**Figure 173-2, *A***). At the next visit, the patient had new lesions on her feet as well (**Figure 173-2, *B***). The diagnosis of disseminated GA was made and systemic treatment was started.

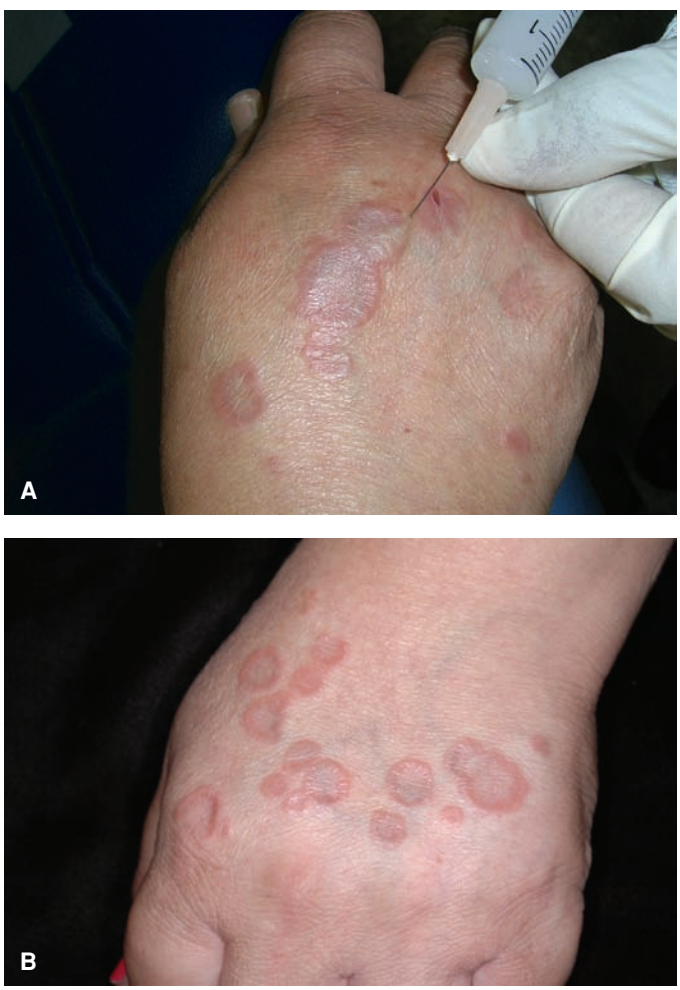

FIGURE 173-1 **A.** GA in a 42-year-old woman. Intralesional steroids were administered on the first visit with resolution of the injected lesions. **B.** Same patient months later with new annular lesions on the opposite hand. She requested additional injections. (*Courtesy of Richard P. Usatine, MD.*)

INTRODUCTION

GA is a common dermatologic condition that presents as small, light-red, dermal papules coalescing into annular plaques without scale. As in the above vignette, it is often mistaken as nummular eczema or tinea corporus. Distribution, pattern, and lack of scale are important diagnostic clues.

EPIDEMIOLOGY

- GA affects twice as many women as men.[1]
- The four presentations of GA are localized, disseminated/generalized, perforating, and subcutaneous.
- Of the four variations, the localized form is seen most often.[1]

ETIOLOGY AND PATHOPHYSIOLOGY

- Benign cutaneous, inflammatory disorder of unknown origin.[1]
- Disease may be self-limiting, but may persist for many years.
- Reported associations include diabetes mellitus, viral infections (including HIV), *Borrelia* and streptococcal infections, insect bites, lymphoma, tuberculosis, and trauma.[2,3]
- One proposed mechanism for GA is a delayed-type hypersensitivity reaction as a result of T-helper–type cell (Th)-1 lymphocytic

differentiation of macrophages. These macrophages become effector cells that express tumor necrosis factor (TNF)-α and matrix metalloproteinases. The activated macrophages are responsible for dermal collagen matrix degradation.[4]

- An association between high expression of gil-1 oncogene and granulomatous lesions of the skin, including GA, has been established.[5]

RISK FACTORS

The only identifiable risk factor is being a woman. There are several associations, but nothing has been shown to be causative.

DIAGNOSIS

CLINICAL FEATURES

Annular lesions have raised borders that are skin-colored to erythematous (**Figures 173-1** and **173-2**). The rings may become hyperpigmented or violaceous (**Figure 173-2, *B***). There is often a central depression within the ring. These lesions range from 2 mm to 5 cm. Although the classical appearance of GA is annular, the lesions may be arcuate instead of forming a complete ring (**Figure 173-3**). Most importantly, there should be no scaling as seen in tinea corporis (ringworm).

TYPICAL DISTRIBUTION

Each of the four types of GA has a different distribution. Localized and disseminated GA differ only in that disseminated lesions can spread to the trunk and neck and may be more pronounced in sun-exposed areas.[6]

- Localized—This is the most common form of GA affecting 75% of GA patients.[1] It typically presents as solitary lesions on the dorsal surfaces of extremities, especially of hands and feet (**Figure 173-4**).
- Disseminated or generalized—Adults are most affected by this form, which begins in the extremities and can spread to the trunk and neck (**Figures 173-5**).
- Perforating—Children and young adults present with 1 to hundreds of 1- to 4-mm annular papules that may coalesce to form a typical annular plaque. Although this form can appear anywhere on the body, it has an affinity for extremities, especially the hands and fingers.[7] The papules may exude a thick and creamy or clear and viscous fluid.
- Subcutaneous—These lesions present as rapidly growing, nonpainful, subcutaneous or dermal nodules on the extremities, scalp, and forehead. Subcutaneous GA mainly affects children, with a mean age of 3.9 years (**Figure 173-6**).[6] These lesions are often ill defined and less discrete.

LABORATORY STUDIES

Often a diagnosis of GA is made on clinical presentation alone, without the need for biopsy. Subcutaneous GA may be an exception, as the unusual appearance may be mistaken for a rheumatoid nodule. Histologic examination reveals an increase of mucin, which is a hallmark of GA. There is also a dense infiltrate of histiocytes in the mid-dermis and sparse perivascular lymphocytic infiltrate. The histiocytes are

FIGURE 173-2 **A.** Same patient as in **Figure 173-1** 1 month later with new crops of lesions on the arms and feet. She has disseminated GA. Note the central area of hypopigmentation secondary to a previous steroid intralesional steroid injection. **B.** Disseminated GA on the foot of the same patient. The rings are flatter and many are conjoined. (*Courtesy of Richard P. Usatine, MD.*)

FIGURE 173-3 GA on the elbow showing how the rings may not be complete. This patient is in her fifties and has had new crops of lesions over the past 10 years. (*Courtesy of Richard P. Usatine, MD.*)

either organized as palisading cells lining a collection of mucin or as a diffuse interstitial pattern. There are no signs of epidermal change.[3]

DIFFERENTIAL DIAGNOSIS

- Tinea corporis has a raised, scaling border and can present on any body surface. KOH preparation reveals hyphae with multiple branches (see Chapter 138, Tinea Corporis).
- Erythema annulare centrifugum has an affinity for thighs and legs. The diameter of these lesions can expand at a rate of 2 to 5 mm/day and may present with a trailing scale inside the advancing border.[2] Biopsy is helpful to differentiate this condition from GA (see Chapter 206, Erythema Annulare Centrifugum).
- Nummular eczema presents commonly on extremities, but is almost always associated with scaling plaques and intense itching (see Chapter 147, Hand Eczema).
- Pityriasis rosea often has oval lesions with a trailing collarette of scale. The lesions are minimally raised and have scale that is absent in GA (see Chapter 153, Pityriasis Rosea).
- Rheumatoid nodules may mimic appearance of subcutaneous GA. These nodules are often seen over the elbows, fingers, and other joints in a patient with joint pains and other clinical signs of arthritis (see Chapter 97, Rheumatoid Arthritis). Rheumatoid nodules have fibrin deposition on histologic examination, in contrast to mucin in GA.

FIGURE 173-4 One single large irregular annular lesion of GA. This ring is also incomplete. (*Courtesy of Richard P. Usatine, MD.*)

MANAGEMENT

The evidence for various treatments is at best small series of cases that are not randomized controlled trials. This disease is asymptomatic, and treatments only improve cosmetic appearance. Many patients may want intervention as diffuse lesions can cause psychological distress. Although GA will eventually resolve, some treatments may cause pigment change or atrophy that might be permanent. Several of the treatments below have shown promise, but these treatments may appear to work when in fact the resolution was natural.

Localized GA:

- In a retrospective study of children with localized GA (mean age: 8.6 years), 39 of 42 presented with complete clearance within 2 years. The average duration was 1 year. Researchers of this study consider most treatments unnecessary because of the self-limiting nature of this variation.[7] One treatment option is watchful waiting.[8] SOR B
- Intralesional corticosteroids can be injected into GA lesions with resolution of the area injected (**Figure 173-1**). Inject directly into the ring itself with 3 to 5 mg/mL triamcinolone acetonide (Kenalog) using a 27-gauge needle. SOR C A large completed ring may take 4 injections to reach 360 degrees of the circle. The major complications include hypopigmentation (**Figure 173-2, *A***) and skin atrophy at the injected sites.
- Cryotherapy was studied using nitrous oxide for 9 patients and liquid nitrogen for 22 patients. The results showed 80% clearing after a single freeze; however, 4 of 19 patients treated with liquid nitrogen developed atrophic scars when lesions were larger than

FIGURE 173-5 Disseminated GA in a middle-aged woman with diabetes. (*Courtesy of Richard P. Usatine, MD.*)

4 cm. All patients developed blisters.[9] Cryoatrophy may possibly be prevented by avoiding freeze thaw cycles greater than 10 seconds and not overlapping treatment areas.[10] SOR C

- A 53-year-old Hispanic woman with GA on the dorsal surface of both hands agreed to treatment with cryotherapy on the right hand and intralesional steroids on the left hand (**Figure 173-7**). Cryotherapy was performed using a 9- to 10-second freeze time and a single freeze. The intralesional injections were performed with a 30-gauge needle and 5 mg/mL triamcinolone (10 mg/mL diluted 1:1 with 1% lidocaine). During the treatment the patient rated the pain from cryotherapy as 9 out of 10 and intralesional steroid 2 out of 10. **Figure 173-7** shows the initial lesions and final results after 1 month. The patient was happy with the results of intralesional steroid and disappointed with the results of the cryotherapy. The lesion treated with cryotherapy did not resolve and spotted areas of hyperpigmentation and hypopigmentation occurred. Upon questioning, the patient states that the lesion treated with cryotherapy was painful for many days whereas she had no residual pain from the lesion treated with intralesional steroid. The patient then asked for the two remaining lesions on her right hand to be injected with steroid. Although this is a single case example, we could find no published studies of a head-to-head comparison between these commonly used methods for local treatment of GA.

Generalized/disseminated GA:

- This variant is more difficult to treat, and often has a longer duration than localized GA. Many treatments have been claimed to be effective, but the studies touting these treatments have small sample sizes and were not randomized.
- In 2009, Marcus et al. reported the successful treatment of 6 patients with a combination of rifampin 600 mg, ofloxacin 400 mg, and minocycline 100 mg. All patients had complete clearance after 3 to 5 months of treatment.[11]
- Successful treatment of 6 patients with GA was achieved with 100 mg of dapsone, once a day. Complete clearance in all patients took between 4 weeks and 3 months.[12] SOR C
- UVA1 phototherapy provided good or excellent results in 10 of 20 patients with disseminated GA. In patients with only a satisfactory treatment response, the disease reappeared soon after phototherapy was discontinued.[13] SOR C
- In a study of 4 patients, topical 5% imiquimod cream was effective when used once daily for an average of 2 months. After discontinuing treatment, 3 patients went an average of 12 months without recurrence; the fourth patient had remission 10 days after treatment stopped, but after an additional 6 weeks of applying cream once daily, he was lesion-free for 18 months.[14] SOR C
- Four patients were treated with twice-daily topical application of 0.1% tacrolimus ointment for 6 weeks; all reported improvement after 10 to 21 days. At treatment conclusion, two patients had complete clearance and the other two had marked improvement.[15] SOR C
- Treatment with 0.5 to 1 mg/kg of isotretinoin daily has produced some positive results across multiple small studies; however, because of the potential for adverse effects, this option should be reserved for the most severe, nonresponsive cases in patients who are at low risk for the adverse effects of isotretinoin.[16] SOR C

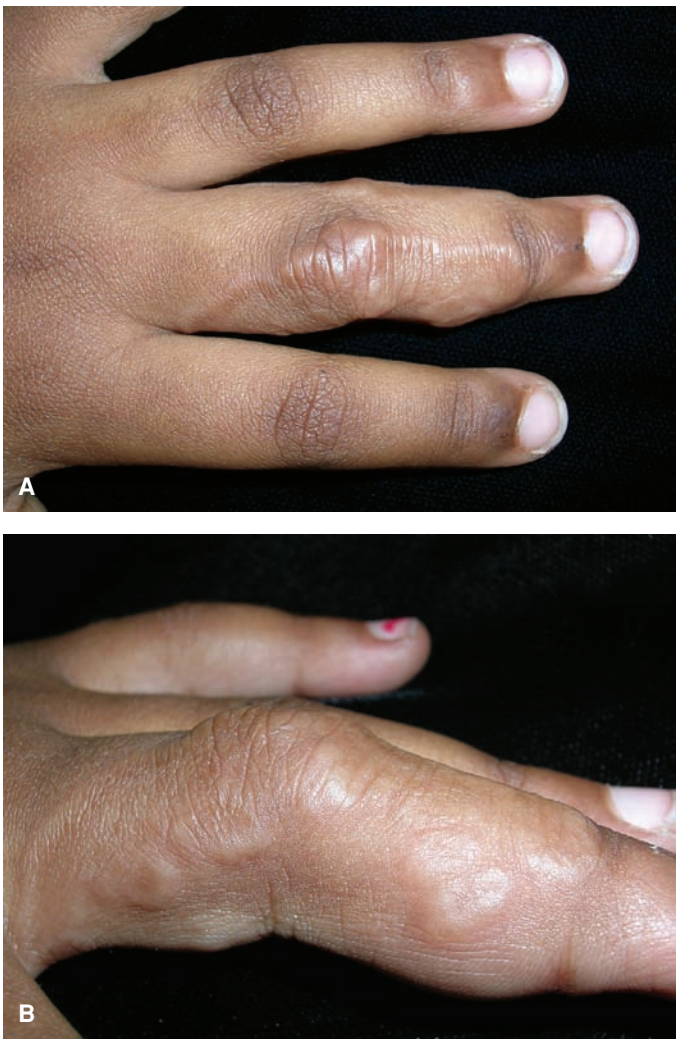

FIGURE 173-6 **A.** Subcutaneous GA in a 7-year-old girl showing one large ring on the dorsum of the finger with soft-tissue infiltration. **B.** Subcutaneous GA in a 7-year-old girl showing thickening of the involved finger along with the small annular patterns. Note the soft-tissue infiltration that has distorted the finger anatomy. (*Courtesy of Richard P. Usatine, MD.*)

FIGURE 173-7 **A.** GA on the dorsum of the right hand of a 53-year-old Hispanic woman. **B.** Cryotherapy of the largest annular lesion. **C.** Intralesional triamcinolone being injected with a 30-gauge needle of a different GA lesion on the left hand. **D.** One month later the lesion on the left hand treated with intralesional steroid has flattened and begun to fade while the lesion on the right hand continues to be elevated and now has areas of hyperpigmentation and hypopigmentation secondary to the cryotherapy. At the time of therapy the patient stated the injection hurt less than the cryotherapy. (*Courtesy of Richard P. Usatine, MD.*)

- Three patients were treated with vitamin E 400 IU daily and zileuton 2400 mg daily. All responded within 3 months with complete clinical clearing.[17] SOR C

Perforating, subcutaneous:

- Although we could find no specific data to inform the treatment of these less-common types of GA, treatments for both localized and disseminated GA could be applied based on clinical judgment along with patient's severity and preferences.

PROGNOSIS

In 50% of cases there is spontaneous resolution within 2 years; however, recurrence rate is as high as 40%.[18] Patients with skin of color may have postinflammatory hyperpigmentation once the papules and plaques resolve.

FOLLOW-UP

Follow-up visits should be offered to patients who want active treatment.

PATIENT EDUCATION

It is important to reassure patients that this disease is self-limiting. Despite a displeasing appearance, the best treatment may be to let lesions resolve naturally. Numerous individual case studies and treatments have been attempted without consistent success. Treatments may produce side effects that are equally as unwanted, but more permanent, than the GA.

PATIENT RESOURCES

- Skinsight. *Granuloma Annulare: Information for Adults*—**http://www.skinsight.com/adult/granulomaAnnulare.htm.**

PROVIDER RESOURCES

- Medscape. *Granuloma Annulare*—**http://emedicine.medscape.com/article/1123031.**

REFERENCES

1. Cyr PR. Diagnosis and management of granuloma annulare. *Am Fam Physician*. 2006;74(10):1729-1734.
2. Ghadially R, Garg A. *Granuloma Annulare*, http://emedicine.medscape.com/article/ 1123031-overview, accessed May 10, 2012.
3. Ko CJ, Glusac EJ, Shapiro PE. Noninfectious granulomas. In: Elder DE, ed. *Lever's Histopathology of the Skin*, 10th ed. Philadelphia, PA: Lippincott Williams & Wilkins; 2009:361-364.
4. Fayyazi A, Schweyer S, Eichmeyer B, et al. Expression of IFN-gamma, coexpression of TNF-alpha and matrix metalloproteinases and apoptosis of T lymphocytes and macrophages in granuloma annulare. *Arch Dermatol Res*. 2000;292:384-390.
5. Macaron NC, Cohen C, Chen SC, Arbiser JL. gli-1 Oncogene is highly expressed in granulomatous skin disorders, including sarcoidosis, granuloma annulare, and necrobiosis lipoidica diabeticorum. *Arch Dermatol*. 2005;141:259-262.
6. Habif TP. *Clinical Dermatology*, 4th ed. St Louis, MO: Mosby; 2004.
7. Smith MD, Downie JB, DiCostanzo D. Granuloma annulare. *Int J Dermatol*. 1997;36:326-333.
8. Martinón-Torres F, Martinón-Sánchez JM, Martinón-Sánchez F. Localized granuloma annulare in children: a review of 42 cases. *Eur J Pediatr*. 1999;158(10):866.
9. Blume-Peytavi U, Zouboulis CC, Jacobi H, et al. Successful outcome of cryosurgery in patients with granuloma annulare. *Br J Dermatol*. 1994;130(4):494-497.
10. Lebwohl MG, Berth-Jones M, Coulson I. *Treatment of Skin Disease, Comprehensive Therapeutic Strategies*, 2nd ed. St. Louis, MO: Mosby; 2006:251.
11. Marcus DV, Mahmoud BH, Hamzavi IH. Granuloma annulare treated with rifampin, ofloxacin, and minocycline combination therapy. *Arch Dermatol*. 2009;145(7):787-789.
12. Czarnecki DB, Gin D. The response of generalized granuloma annulare to Dapsone. *Acta Derm Venereol (Stockh)*. 1986;66:82-84.
13. Schnopp C, Tzaneva S, Mempel M, et al. UVA1 phototherapy for disseminated granuloma annulare. *Photodermatol Photoimmunol Photomed*. 2005;21(2):68-71.
14. Badavanis G, Monastirli A, Pasmatzi E, Tsambaos D. Successful treatment of granuloma annulare with imiquimod cream 5%: a report of four cases. *Acta Derm Venereol*. 2005;85(6):547-548.
15. Jain S, Stephens CJM. Successful treatment of disseminated granuloma annulare with topical tacrolimus. *Br J Dermatol*. 2004;150:1042-1043.
16. Looney M. Isotretinoin in the treatment of granuloma annulare. *Ann Pharmacother*. 2004;38(3):494-497.
17. Smith KJ, Norwood C, Skelton H. Treatment of disseminated granuloma annulare with a 5-lipoxygenase inhibitor and vitamin E. *Br J Dermatol*. 2002;146(4):667-670.
18. Reisenauer A, White KP, Korcheva V, White CR. Non-infectious granulomas. In: Bolognia JL, Jorizzo JL, Schaffer JV, eds. *Dermatology*, 2nd ed. Philadelphia, Elsevier: 2012.

174 PYODERMA GANGRENOSUM

E.J. Mayeaux, Jr., MD
Richard P. Usatine, MD

PATIENT STORY

A 32-year-old man was diagnosed with Crohn disease 10 years prior to his visit for these nonhealing leg ulcers (**Figure 174-1**). The patient experienced minor trauma to his lower leg 1 year ago and these ulcers developed (pathergy). Multiple treatments have been tried with partial success, but the ulcers persist.

FIGURE 174-1 Classic pyoderma gangrenosum on the leg of a 32-year-old man with Crohn disease. This ulcer started with minor trauma (pathergy) and has been there for 1 year. (*Courtesy of Richard P. Usatine, MD.*)

INTRODUCTION

Pyoderma gangrenosum (PG) is an uncommon ulcerative disease of the skin of unknown origin. It is a type of neutrophilic dermatosis.

EPIDEMIOLOGY

- PG occurs in approximately 1 person per 100,000 people each year.[1]
- No racial predilection is apparent.
- A slight female predominance may exist.
- Predominately occurs in fourth and fifth decade, but all ages may be affected.

ETIOLOGY AND PATHOPHYSIOLOGY

- Etiology is poorly understood.
- Pathergy (initiation at the site of trauma or injury) is a common process and it is estimated that 30% of patients with PG experienced pathergy.[1]
- Up to 50% of cases are idiopathic.[2]
- At least 50% of cases are associated with systemic diseases such as inflammatory bowel disease, hematologic malignancy, and arthritis.[2]
- It occurs in up to 5% of patients with ulcerative colitis and 2% of those with Crohn disease (**Figures 174-2** and **174-3**).[3,4]
- Biopsies usually show a polymorphonuclear cell infiltrate with features of ulceration, infarction, and abscess formation.

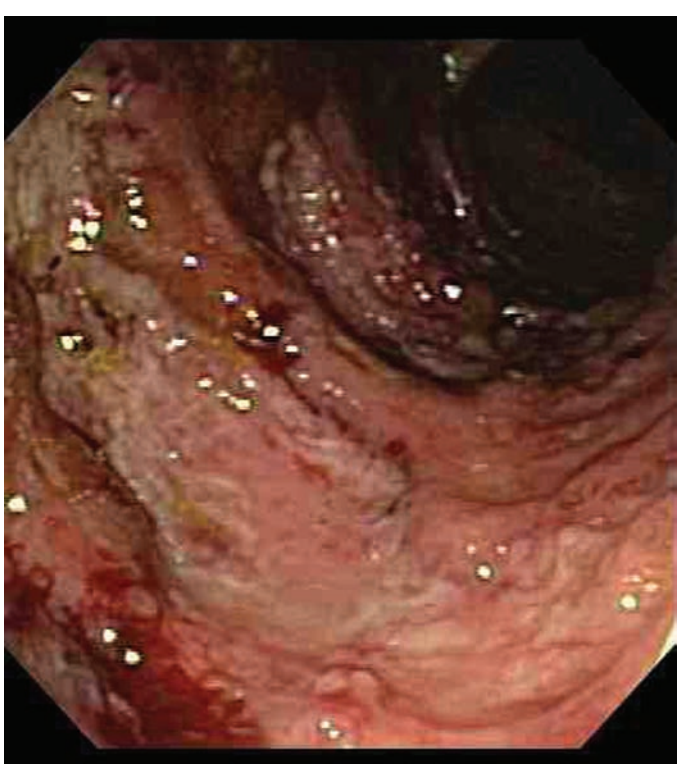

FIGURE 174-2 Friable inflamed mucosa of the colon in Crohn disease. (*Courtesy of Shashi Mittal, MD.*)

RISK FACTORS[2,5]

- Ulcerative colitis.
- Crohn disease.
- Polyarthritis (seronegative or seropositive).
- Hematologic diseases/disorders such as leukemia (predominantly myelocytic).

- Monoclonal gammopathies (primarily immunoglobulin A).
- Psoriatic arthritis and rheumatoid arthritis (**Figure 174-4**).
- Hepatic diseases (hepatitis and primary biliary cirrhosis).
- Immunologic diseases (lupus erythematosus and Sjögren syndrome).

DIAGNOSIS

CLINICAL FEATURES

- Typically PG presents with deep painful ulcer with a well-defined border, which is usually violet or blue. The color has also been described as the color of gun metal. The ulcer edge is often undermined and the surrounding skin is erythematous and indurated. It usually starts as a pustule with an inflammatory base, an erythematous nodule, or a hemorrhagic bulla on a violaceous base. The central area then undergoes necrosis to form a single ulcer.[5]
- The lesions are painful and the pain can be severe.[2] Patients may have malaise, arthralgia, and myalgia.
- Two main variants of PG exist: classic and atypical.[2]
  - Classic PG is characterized by a deep ulceration with a violaceous border that overhangs the ulcer bed.[2] These lesions of PG most commonly occur on the legs (**Figures 174-1** and **174-3** to **174-5**).[2]
  - Atypical PG has a vesiculopustular wet component (**Figures 174-8** and **174-9**). This is usually only at the border, is erosive or superficially ulcerated, and most often occurs on the dorsal surface of the hands, the extensor parts of the forearms, or the face.[2]
- Other variants:
  - Peristomal PG may occur around stoma sites. This form is often mistaken for a wound infection or irritation from the appliance.[6]
  - Vulvar or penile PG occurs on the genitalia and must be differentiated from ulcerative sexually transmitted diseases (STDs) such as chancroid and syphilis.[2]
  - Intraoral PG is known as pyostomatitis vegetans. Occurs primarily in patients with inflammatory bowel disease.[2]

TYPICAL DISTRIBUTION

- Most commonly seen on the legs and hands, but can occur on any skin surface including the genitalia, and around a stoma. PG can be seen on the scalp, head, and neck (**Figures 174-10** and **174-11**).

LABORATORY TESTING

- Complete blood count (CBC), urinalysis (UA), and liver function tests (LFTs) should be obtained. Order a hepatitis profile to rule out hepatitis.[2] Systemic disease markers may be elevated if associated conditions exist, that is, erythrocyte sedimentation rate (ESR), antinuclear antibody (ANA), and rheumatoid factor. Obtain rapid plasma reagin (RPR), protein electrophoresis, and skin cultures as indicated. Consider culturing the ulcer/erosion for bacteria, fungi, atypical *Mycobacteria*, and viruses.[2]
- If GI symptoms exist, perform or refer for colonoscopy to look for inflammatory bowel disease.

FIGURE 174-3 Classic pyoderma gangrenosum on the leg of a 35-year-old woman with Crohn disease. This ulcer started with minor trauma (pathergy) and has been there for 2 years. (*Courtesy of Richard P. Usatine, MD.*)

FIGURE 174-4 Pyoderma gangrenosum on the leg of a 56-year-old woman with rheumatoid arthritis. (*Courtesy of Richard P. Usatine, MD.*)

FIGURE 174-5 Pyoderma gangrenosum showing dusky red border with undermined edges. The surface appears purulent and necrotic. (*Courtesy of Jack Resneck, Sr., MD.*)

FIGURE 174-7 Partially healed pyoderma gangrenosum on the leg of a 29-year-old Hispanic woman. Note the areas of healed ulcerations and the dusky elevated borders. There remain 2 areas of active disease (*arrows*) with pain, erythema, swelling, and purulent discharge. The patient improved with dapsone. (*Courtesy of Richard P. Usatine, MD.*)

FIGURE 174-6 Pyoderma gangrenosum ulcer on the leg with purulent undermined edges and black eschar. (*Courtesy of Jeff Meffert, MD.*)

FIGURE 174-8 Atypical pyoderma gangrenosum with a vesiculopustular "juicy" component on the dorsal surface of the hand. Bulla were previously present before the ulcerations developed. (*Courtesy of Eric Kraus, MD.*)

BIOPSY

- Biopsy an active area of disease along with the border. A punch biopsy is preferred (4-mm punch is adequate). Although there are no specific pathologic signs of PG, the biopsy can be used to rule out other causes of ulcerative skin lesions.
- The pathologist may be able to confirm your clinical impression. Biopsy of the earliest lesions reveal a neutrophilic vascular reaction. Fully developed lesions exhibit dense neutrophilic infiltrate, and some lymphocytes and macrophages surrounding marked tissue necrosis. Ulceration, infarction of tissue, and abscess formation with fibrosing inflammation at the edge of the ulcer may be seen.[7]

DIFFERENTIAL DIAGNOSIS

- PG is sometimes a diagnosis of exclusion diagnosed with successful wound healing following immunosuppressant therapy.[8] When misdiagnosed it is often confused for vascular occlusive or venous disease, vasculitis, cancer, primary infection, drug-induced or exogenous tissue injury, and other inflammatory disorders.[9] Biopsy of a questionable lesion may be the only way to ultimately distinguish PG as the cause of ulcerative skin lesions.
- Ulcerative STDs, such as chancroid and syphilis, can resemble vulvar or penile PG. These STDs are more common than PG and should be diagnosed with appropriate tests, including RPR and bacterial culture for *Haemophilus ducreyi*. If these tests are negative, then PG should be considered. RPR should also be repeated in 2 weeks if it is initially negative at the start of a chancre—it takes some weeks to become positive and syphilis is easily treatable (see Chapter 216, Syphilis).
- Acute febrile neutrophilic dermatosis (Sweet syndrome) is a neutrophilic dermatosis like PG, but the patients are generally febrile with systemic symptoms (**Figure 174-12**). The diagnosis of Sweet syndrome is made when the patient fulfills 2 of 2 major criteria and 2 of 4 minor criteria. The 2 major criteria are (a) an abrupt onset of tender or painful erythematous plaques or nodules occasionally with vesicles, pustules, or bullae, and (b) predominantly neutrophilic infiltration in the dermis without leukocytoclastic vasculitis. Minor criteria include specific preceding or concurrent medical conditions, fever, abnormal lab values, including leukocytosis and an elevated sedimentation rate, and a rapid response to systemic steroids.
- Systemic vasculitis is perhaps the most difficult to differentiate, but history of minor trauma in the area preceding lesion formation (pathergy) and undermining of the violaceous border should lead one toward the diagnosis of PG.[9]
- Ecthyma is a type of impetigo in which ulcers form. Bacterial cultures will be positive and this disease should respond to cephalexin or other oral antibiotics (see Chapter 116, Impetigo).
- Spider bites from the black recluse spider can easily resemble PG when they ulcerate. The history of a spider bite can help differentiate this from PG.
- Sporotrichosis is a fungal infection that often starts from an injury while gardening with roses. It is usually on the arm or hand and can resemble PG. Use fungal culture to diagnose this when the history suggests this as the diagnosis. Oral antifungal medications can treat this (**Figure 174-13**).

FIGURE 174-9 Atypical pyoderma gangrenosum on the hands with violaceous borders that match the fingernail color. The lesions are "juicy" and resemble those seen in Sweet syndrome and have occurred at sites of minor trauma (pathergy). (*Courtesy of Jeff Meffert, MD.*)

FIGURE 174-10 Pyoderma gangrenosum on the scalp of a woman in Africa. (*Courtesy of Richard P. Usatine, MD.*)

FIGURE 174-11 Pyoderma gangrenosum on the face, neck, and chest of a child in Africa. The scarring has caused adhesions between the face, neck, and chest. (*Courtesy of Richard P. Usatine, MD.*)

FIGURE 174-13 Sporotrichosis (fungal infection) with the typical sporotrichoid spread up the arm from an inoculation of the hand. Note the ulcers that resemble pyoderma gangrenosum on the arm of this Panamanian child. (*Courtesy of Richard P. Usatine, MD.*)

FIGURE 174-12 Sweet syndrome is the eponym for acute febrile neutrophilic dermatosis. The lesion looks like pyoderma gangrenosum and occurs at sites of minor trauma (pathergy). However, this patient has a fever and is systemically ill. (*Courtesy of John Gonzalez, MD.*)

FIGURE 174-14 A large venous stasis ulcer on the lower leg not healing with intensive wound care and compression stockings. A punch biopsy on the edge was performed to make sure this was not pyoderma gangrenosum. (*Courtesy of Richard P. Usatine, MD.*)

- Squamous cell carcinoma with ulcerations may look like PG. Its diagnosis requires a biopsy. If the ulcer is on sun-exposed area, squamous cell carcinoma should be considered. A shave or punch biopsy can be used to diagnose this malignancy (see Chapter 171, Squamous Cell Carcinoma).
- Venous insufficiency ulcers are typically seen around the medial malleolus and the most severe of these ulcers resembles PG (**Figure 174-14**). The presence of signs and symptoms of venous insufficiency should help differentiate this from PG (see Chapter 52, Venous Stasis).
- Mycosis fungoides is a cutaneous T-cell lymphoma that can ulcerate and resemble PG. Use tissue biopsy to differentiate these two conditions (see Chapter 176, Mycosis Fungoides).

MANAGEMENT

NONPHARMACOLOGIC

- At each visit, measure and document the lesion's depth, length, and width to track treatment progression.[10]
- Surgical debridement is contraindicated as pathergy occurs in 25% to 50% of cases and surgery will make the lesions worse. SOR B

MEDICATIONS

- Patients frequently are in pain from the lesions, so treatment is aimed at pain relief as well as healing the skin lesions.
- Therapy directed at the underlying inflammatory bowel disease (IBD), when present, usually results in healing, although treatment with steroids is often necessary.[10] SOR B
- Topical medications are first-line therapy in cases of localized PG that are not severe. Start with potent corticosteroid ointments or tacrolimus ointment.[10,11] SOR B
- Small ulcers can be managed with topical steroid creams, silver sulfadiazine, or potassium iodide solution. SOR C
- Intralesional injections with corticosteroids are also an option.[10,11] SOR B
- Systemic treatment with oral corticosteroids, such as methylprednisolone (1 g/day IV for 3 days) or prednisone (0.5 to 1 mg/kg per day) or oral cyclosporine (e.g., 5 mg/kg per day) alone or together appears to be effective (in the absence of controlled trials) in many cases and should be considered first-line therapy.[6,11] SOR B Response is usually rapid, with stabilization of the PG within 24 hours.[12]
- In steroid-refractory PG associated with IBD, infliximab was effective in case series and a small placebo-controlled trial.[13,14] SOR B Other biologic therapies reported include alefacept, etanercept, efalizumab, and adalimumab.[10] SOR C
- To date, case reports have been published that show therapeutic efficacy of dapsone (100 mg/day), azathioprine (50 to 150 mg/day), 6-mercaptopurine, mycophenolate mofetil (1 to 2 g twice daily), cyclophosphamide (2 to 3 mg/kg per day), and tacrolimus (0.1 mg/kg per day).[11,15] SOR C

REFERRAL

In many cases, referral to a dermatologist is needed.

PROGNOSIS

- The prognosis of PG is generally good, but residual scarring is common (**Figure 174-11**) and recurrences may occur.
- Although many patients improve with initial immunosuppressive therapy, patients may follow a refractory course and require multiple therapies.

FOLLOW-UP

- All patients suspected of having PG need close and frequent follow-up to obtain a definitive diagnosis and treat this challenging condition.

PATIENT EDUCATION

- PG is a rare ulcerative skin condition that is poorly understood.
- A skin biopsy is needed to rule out other diagnoses.
- Most treatments are empirical and based on small studies.
- The risks and benefits of steroids and/or other immunosuppressive medications need to be explained.
- Surgical treatments are contraindicated.

PATIENT RESOURCES

- American Autoimmune Related Diseases Association, Inc. Tel: 800-598-4668—**http://www.aarda.org/.**
- Crohn's and Colitis Foundation of America. Tel: 800-932-2423—**http://www.ccfa.org.**

PROVIDER RESOURCES

- Medscape. *Pyoderma Gangrenosum*—**http://emedicine.medscape.com/article/1123821.**
- MayoClinic. *Pyoderma Gangrenosum*—**http://www.mayoclinic.com/health/pyoderma-gangrenosum/DS00723.**
- Wollina U. PG–a review. *Orphanet J Rare Dis.* 2007;2:19—**http://www.ncbi.nlm.nih.gov/pmc/articles/PMC1857704/.**

REFERENCES

1. Brooklyn T, Brooklyn T, Dunnill G, Probert C. Diagnosis and treatment of pyoderma gangrenosum. *BMJ*. 2006;333(7560):181-184.
2. Jackson JM, Callen JP. *Pyoderma Gangrenosum*. http://emedicine.medscape.com/article/1123821-overview. Accessed on March 30, 2012.
3. Mir-Madjlessi SH, Taylor JS, Farmer RG. Clinical course and evolution of erythema nodosum and pyoderma gangrenosum in chronic ulcerative colitis: a study of 42 patients. *Am J Gastroenterol*. 1985;80(8):615-620.

4. McCallum DI, Kinmont PD. Dermatological manifestations of Crohn's disease. *Br J Dermatol.* 1968;80(1):1-8.
5. Habif T. *Clinical Dermatology*, 4th ed. Philadelphia, PA: Mosby; 2004:653-654.
6. Keltz M, Lebwohl M, Bishop S. Peristomal pyoderma gangrenosum. *J Am Acad Dermatol.* 1992;27(2 Pt 2):360-364.
7. Su WP, Schroeter AL, Perry HO, Powell FC. Histopathologic and immunopathologic study of pyoderma gangrenosum. *J Cutan Pathol.* 1986;13(5):323-330.
8. Banga F, Schuitemaker N, Meijer P. Pyoderma gangrenosum after caesarean section: a case report. *Reprod Health*. 2006;3:9.
9. Weenig RH, Davis MD, Dahl PR, Su WP. Skin ulcers misdiagnosed as pyoderma gangrenosum. *N Engl J Med*. 2002;347(18): 1412-1418.
10. Miller J, Yentzer BA, Clark A, et al. Pyoderma gangrenosum: a review and update on new therapies. *J Am Acad Dermatol.* 2010; 62(4):646-654.
11. Reichrath J, Bens G, Bonowitz A, Tilgen W. Treatment recommendations for pyoderma gangrenosum: an evidence-based review of the literature based on more than 350 patients. *J Am Acad Dermatol*. 2005;53(2):273-283.
12. Chow RK, Ho VC. Treatment of pyoderma gangrenosum. *J Am Acad Dermatol*. 1996;34(6):1047-1060.
13. De la Morena F, Martín L, Gisbert JP, et al. Refractory and infected pyoderma gangrenosum in a patient with ulcerative colitis: response to infliximab. *Inflamm Bowel Dis.* 2007;13(4):509-510.
14. Brooklyn TN, Dunnill MG, Shetty A, et al. Infliximab for the treatment of pyoderma gangrenosum: a randomised, double blind, placebo controlled trial. *Gut.* 2006;55(4):505-509.
15. Eaton PA, Callen JP. Mycophenolate mofetil as therapy for pyoderma gangrenosum. *Arch Dermatol.* 2009;145(7):781-785.

175 SARCOIDOSIS

Yoon-Soo Cindy Bae-Harboe, MD
Khashayar Sarabi, MD
Amor Khachemoune, MD

PATIENT STORY

A 42-year-old man presents with "multiple bumps" that had been growing on his scalp, the back of the neck, and on preexisting scars (**Figure 175-1**). These lesions started developing slowly over a period of 1 year. The differential diagnosis of these lesions included cutaneous sarcoidosis, acne keloidalis nuchae, and pseudofolliculitis barbae. A punch biopsy was performed and the diagnosis of sarcoidosis was made.

FIGURE 175-1 Papular and annular lesions of sarcoid on the scalp and neck of a 42-year-old black man. (*Courtesy of Amor Khachemoune, MD.*)

INTRODUCTION

Sarcoidosis is a multisystem granulomatous disease most commonly involving the skin, lungs, lymph nodes, liver, and eyes. Patients of African descent are more commonly affected compared to white patients. Diagnosing cutaneous sarcoidosis is critical as 30% of these patients have been found to have systemic involvement. Diverse presentations of cutaneous sarcoidosis have been reported in addition to variants of specific sarcoidosis syndromes.

SYNONYMS

- Lupus pernio (cutaneous sarcoidosis).
- Darier-Roussy disease (subcutaneous sarcoidosis).
- Löfgren syndrome (erythema nodosum, hilar adenopathy, fever, arthritis).
- Heerfordt syndrome (parotid gland enlargement, uveitis, fever, cranial nerve palsy).

EPIDEMIOLOGY

- Cutaneous manifestations occur in approximately 25% of systemic sarcoidosis patients.
- The ratio between patients with only cutaneous sarcoid versus multisystem involvement is 1:3.
- Specific cutaneous involvement is seen most commonly in older, female patients of African descent (**Figures 175-2** and **175-3**).
- Common types are maculopapular, lupus pernio, cutaneous, or subcutaneous nodules, and infiltrative scars.
- Erythema nodosum (EN) occurs in 3% to 34% of patients with sarcoidosis and is the most common associated skin finding (see Chapter 178, Erythema Nodosum).
- Sarcoidosis-related EN is more prevalent in whites, especially Scandinavians. Irish and Puerto Rican females are also affected more often.

FIGURE 175-2 Lupus pernio in a 45-year-old black woman with sarcoid involving the nasal rim. (*Courtesy of Richard P. Usatine, MD.*)

- EN occurs between the second and fourth decades of life, more commonly in women.
- Nonspecific lesions of sarcoidosis reported, besides EN, include erythema multiforme, calcinosis cutis, prurigo, and lymphedema. Nail changes can include clubbing, onycholysis, subungual keratosis, and dystrophy, with or without underlying changes in the bone (cysts).

ETIOLOGY AND PATHOPHYSIOLOGY

- Sarcoidosis is a granulomatous disease with involvement of multiple organ systems with an unknown etiology.
- The typical findings in sarcoid lesions are characterized by the presence of circumscribed granulomas of epithelioid cells with little or no caseating necrosis, although fibrinoid necrosis is not uncommon.
- Granulomas are usually in the superficial dermis but may involve the thickness of dermis and extend to the subcutaneous tissue. These granulomas are referred to as "naked" because they only have a sparse lymphocytic infiltrate at their margins.

RISK FACTORS

- Positive family history.
- African descent.

DIAGNOSIS

CLINICAL FORMS OF DISEASE

Cutaneous involvement is either *specific* or *nonspecific*.

- Specific:
  - Typical noncaseating granulomas, no evidence of infection, foreign body, or other causes.
  - May be disfiguring, but almost always nontender and rarely ulcerate.
  - Maculopapular type is most common, red-brown or purplish, usually smaller than 1 cm, and found mostly on face, neck, upper back, and limbs (**Figure 175-4**).
  - Lupus pernio type are most distinctive lesions and present as purplish lesions resembling frostbites with shiny skin covering them, typically affecting nose, cheeks, ears, and lips and distal extremities (**Figures 175-2**, **175-3**, and **175-5**).
  - Lupus pernio may occur as a syndrome involving upper respiratory tract with pulmonary fibrosis, or be associated with chronic uveitis and bone cysts.
  - Annular or circinate type appear ribbon-like, with mild scaling and yellowish red in color, with centrifugal progression and central healing and depigmentation (**Figure 175-1**).
  - Plaque sarcoidosis is typically chronic, occurring over the forehead, extremities, and shoulders, but may heal without scarring (**Figure 175-6**).
  - Nodular cutaneous and subcutaneous plaques that are skin-colored or violaceous without epidermal involvement are typically seen in advanced systemic sarcoidosis (**Figure 175-7**).

FIGURE 175-3 Lupus pernio with red to violaceous sarcoid papules and plaques on the nose and lips. (*Courtesy of Amor Khachemoune, MD.*)

FIGURE 175-4 Maculopapular sarcoidosis on the leg of a 46-year-old white woman. (*Courtesy of Amor Khachemoune, MD.*)

- Areas of old scars that are damaged by trauma, radiation, surgery, or tattoo may also be infiltrated with sarcoid granulomas (**Figures 175-8** and **175-9**). Lesions may be tender and appear indurated with red or purple discoloration.

- Nonspecific:
  - EN lesions usually are not disfiguring, but tender to touch, especially when they occur with fever, polyarthralgias, and sometimes arthritis and acute iritis.
  - EN appears abruptly with warm, tender, reddish nodules on the lower extremities, most commonly the anterior tibial surfaces, ankles, and knees.
  - EN nodules are 1 to 5 cm, usually bilateral, and evolve through color stages: first bright red, then purplish, and lastly a bruise-like yellow or green appearance.
  - EN bouts occur with fatigue, fever, symmetrical polyarthritis, and skin eruptions that typically last 3 to 6 weeks with more than 80% of cases resolving within 2 years.[4]
  - EN is seen in the setting of Löfgren syndrome, appearing in conjunction with hilar lymphadenopathy (bilateral most often), and occasionally anterior uveitis and/or polyarthritis.
  - Löfgren syndrome is associated with right paratracheal lymph node involvement seen on x-ray.
  - Ulceration is typically not observed in EN, which heal without scarring.
  - Other nonspecific lesions of sarcoidosis include lymphedema, calcinosis cutis, prurigo, and erythema multiforme.
  - Nail changes seen in sarcoidosis include clubbing, onycholysis, and subungual keratosis.

FIGURE 175-5 Lupus pernio in a 48-year-old black man with sarcoid lesions on the nose and around the eyes. (*Courtesy of Richard P. Usatine, MD.*)

LABORATORY STUDIES

- Complete blood count (CBC) count with differential:
  - Leukopenia (5% to 10%) and/or thrombocytopenia may be seen.
  - Eosinophilia occurs in 24% of patients, and anemia occurs in 5% of patients.
  - Hypergammaglobulinemia (30% to 80%), positive rheumatoid factor, and decreased skin test reactivity.
  - Autoimmune hemolytic anemia and hypersplenism can occur in some patients, although rare.
  - Hypocapnia and hypoxemia may be present in certain patient populations, and may become worse with exercise.
- Serum calcium and 24-hour urine calcium levels:
  - Hypercalciuria has been found in 49% of patients in some studies, whereas 13% of patients had hypercalcemia.
  - Hypercalcemia occurs in sarcoidosis because of increased intestinal absorption of calcium that results from overproduction of a metabolite of vitamin D by pulmonary macrophages.
- Serum angiotensin-converting enzyme (ACE) level is elevated in 60% of patients:
  - Serum ACE levels are helpful in monitoring disease activity and treatment response. ACE is derived from epithelioid cells of the granulomas, therefore, it reflects granuloma load in the patient.
- Serum chemistries, such as alanine aminotransferase, aspartate aminotransferase, alkaline phosphatase, blood urea nitrogen (BUN), and creatinine levels. These levels may be elevated with hepatic and renal involvement.

FIGURE 175-6 Hypopigmented widespread cutaneous plaque sarcoidosis predominantly on the back of a black man. (*Courtesy of Eric Kraus, MD.*)

- Other—Elevated erythrocyte sedimentation rate, elevated antinuclear antibodies (30%), diabetes insipidus, and renal failure may be noted.

IMAGING STUDIES

- Chest x-ray (CXR):
  - Radiographic involvement is seen in almost 90% of patients. Chest radiography is used in staging the disease.
  - Stage I disease shows bilateral hilar lymphadenopathy (BHL). Stage II disease shows BHL plus pulmonary infiltrates. Stage III disease shows pulmonary infiltrates without BHL. Stage IV disease shows pulmonary fibrosis.
- CT of the thorax may demonstrate lymphadenopathy or granulomatous infiltration. Other findings may include small nodules with a bronchovascular and subpleural distribution, thickened interlobular septae, honeycombing, bronchiectasis, and alveolar consolidation.
- Pulmonary function tests—Evidence of both restrictive abnormalities and obstructive abnormalities may be found.

BIOPSY

- Punch biopsy is adequate to obtain a sample of skin that includes dermis.
- If EN nodules are deep, a biopsy should also include subcutaneous tissue.
- Biopsy specimens are sent for histologic examination, as well as stains and cultures to rule out infectious causes.

DIFFERENTIAL DIAGNOSIS

- Granulomatous skin disease (**Figure 175-10**).
  - Granuloma annulare (GA) is also a granulomatous skin disease, which appears in single or multiple rings in adults and children (see Chapter 173, Granuloma Annulare).
  - Rheumatoid nodules—These usually appear in the context of a diagnosed rheumatoid arthritis with joint disease present (see Chapter 97, Rheumatoid Arthritis).
  - Granulomatous mycosis fungoides—This is a type of cutaneous lymphoma with many clinical forms including granuloma formation (see Chapter 176, Mycosis Fungoides).
- Maculopapular type:
  - Lupus vulgaris—This is a type of cutaneous involvement with *Mycobacterium tuberculosis*.
  - Syringoma—These are small firm benign adnexal tumors usually appearing around the upper cheeks and lower eyelids.
  - Xanthelasma—These are the most common type of xanthomas. They are benign yellow macules, papules, or plaques often appearing on the eyelids. Approximately one half of the patients with xanthelasma have a lipid disorder (see Chapter 223, Hyperlipidemia).
  - Lichen planus—This is a very pruritic skin eruption with pink to violaceous papules and plaques. It may present in different body locations but the most common areas are the wrists and ankles (see Chapter 154, Lichen Planus).
  - Granulomatous rosacea—This is a variant of rosacea made of uniform papules involving the face.

FIGURE 175-7 Subcutaneous sarcoid (Darier-Roussy syndrome) in a patient with advanced systemic sarcoidosis. (*Courtesy of Amor Khachemoune, MD.*)

FIGURE 175-8 Sarcoidal plaque of the knee, which appeared after a trauma to the knee. (*Courtesy of Amor Khachemoune, MD.*)

FIGURE 175-9 Sarcoid on a heart-shaped homemade tattoo over the knee. (*Courtesy of Amor Khachemoune, MD.*)

- Acne keloidalis nuchae—This is commonly seen in dark-skinned patients. It presents with multiple perifollicular papules and nodules. The most common location is the back of the neck at the hairline (see Chapter 114, Pseudofolliculitis and Acne Keloidalis Nuchae).
- Pseudofolliculitis barbae—This is most commonly seen in patients with darker skin color, triggered by ingrown hair involving the beard area (see Chapter 114, Pseudofolliculitis and Acne Keloidalis Nuchae).

- Annular or circinate type of sarcoidosis (**Figure 175-11**):
- Granuloma annulare—Annular type (previously described above; see Chapter 173, Granuloma Annulare).
- Annular form of necrobiosis lipoidica—A granulomatous disease with areas of necrobiosis. This is usually seen on the pretibial areas of patients with diabetes. But not all patients have diabetes (see Chapter 222, Necrobiosis Lipoidica).
- These two entities may be differentiated histologically.
- Nodular cutaneous and subcutaneous type:
  - Morphea—Also known as localized scleroderma caused by excessive collagen deposition in the dermis or subcutaneous tissue leading to the formation of nodules (see Chapter 182, Scleroderma and Morphea).
  - Epidermal inclusion cyst—This is an encapsulated keratin-filled nodule of different sizes often found in the subcutaneous tissue. A central pore or punctum is often noted on examination of the overlying epidermis.
  - Lipoma—These are soft nodules of different sizes composed of mature fat cells and often found in the subcutaneous tissue.
  - Metastatic carcinoma—These nodular lesions often present in the context of a diagnosed primary carcinoma of other internal organs.
  - Foreign-body granuloma—This is usually localized to the area of introduction of the foreign body into the skin.

MANAGEMENT

- Cutaneous involvement of sarcoidosis is typically not life-threatening and, therefore, the major rationale for treatment is to prevent or minimize disfigurement. Cosmetic issues are particularly important on the face (**Figure 175-12 *A***). Also, the lesions can be painful.
- Corticosteroids are the mainstay of treatment.[1–5] SOR B
- Limited cutaneous disease responds to very high-potency topical corticosteroids, or intralesional triamcinolone repeated monthly.[3,4] SOR B
- Photochemotherapy (psoralen UVA) is successful in erythrodermic and hypopigmented lesions. SOR C
- Patients with lupus pernio may benefit from pulsed-dye or carbon dioxide laser treatments. SOR C
- Resistant lesions to topical therapy or large and diffuse lesions require prednisone.[2,5] SOR B
- To prevent complications from long-term treatment by steroids, hydroxychloroquine or chloroquine are used as steroid-sparing agents.[6] SOR C

FIGURE 175-10 Granulomatous plaques of biopsy proven sarcoidosis on the arm of a woman. She also has sarcoidosis of the lung. (*Courtesy of Richard P. Usatine, MD.*)

FIGURE 175-11 Violaceous sarcoidal papules coalescing into annular plaques on the back. (*Courtesy of Richard P. Usatine, MD.*)

- Other combinations that have been successful in chronic cutaneous disease and lung disease are methotrexate or azathioprine with low-dose prednisone.[5] SOR C
- Agents such as cyclophosphamide and cyclosporin are also used but with caution because of severe drug toxicity.[7] SOR C
- Infliximab, a tumor necrosis factor (TNF)-α monoclonal antibody has been found to be effective for severe cutaneous sarcoidosis with pulmonary involvement (**Figure 175-13**).[8] SOR C

REFERRAL

- A multidisciplinary approach is imperative in patients with systemic sarcoidosis.
- Patients with eye symptoms should be referred to an ophthalmologist (**Figure 175-12 *B***).
- Patients with lung involvement should be referred to a pulmonologist.
- Results from laboratory work-up may dictate appropriate referral.

PREVENTION AND SCREENING

As the cause remains to be elucidated, no preventative measures have been established.

Patients presenting with cutaneous sarcoidosis should be screened as clinically indicated.

PROGNOSIS

- Patients of African descent have more severe lung disease compared with white patients at presentation and an overall poorer long-term prognosis.[9]
- The presence of EN has been associated with a decreased frequency of respiratory involvement.[9]
- Lupus pernio, more commonly seen in patients of African descent, indicates a chronic disease course (**Figure 175-12** and **175-13**).[9]
- The prognostic value of cutaneous lesions alone remains unclear.[9]

FOLLOW-UP

Patients with cutaneous sarcoidosis should be worked up for systemic sarcoidosis. Regular follow-up is necessary.

PATIENT EDUCATION

Inform patients about the risk that systemic sarcoidosis can occur even if the skin is the only area currently involved.

PATIENT RESOURCES

- National Heart, Lung, and Blood Institute. *What Is Sarcoidosis?*—**http://www.nhlbi.nih.gov/health/dci/Diseases/sarc/sar_whatis.html.**

PROVIDER RESOURCE

- Medscape. *Dermatologic Manifestations of Sarcoidosis*—**http://emedicine.medscape.com/article/1123970.**

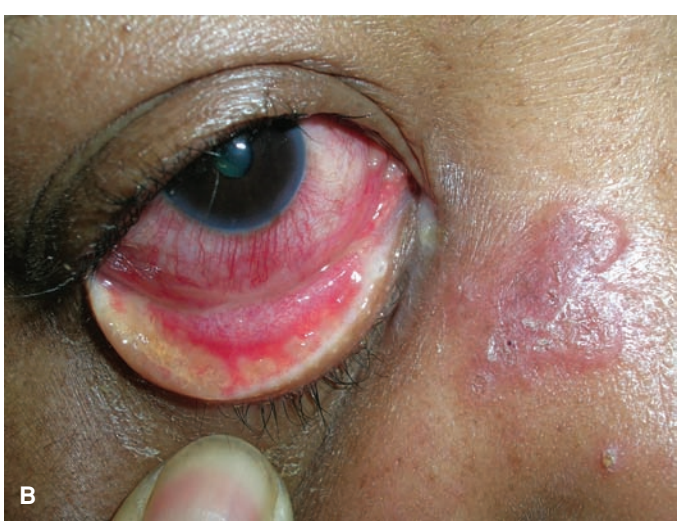

FIGURE 175-12 **A.** Sarcoidosis flare in a 50-year-old woman involving the face (lupus pernio), especially around the nose. **B.** Additionally she has sarcoidosis of the eye with involvement of the conjunctiva and infiltration of the inner lower eyelid. (*Courtesy of Richard P. Usatine, MD.*)

REFERENCES

1. Grutters JC, van den Bosch JM. Corticosteroid treatment in sarcoidosis. *Eur Respir J*. 2006;28(3):627-636.
2. English JC 3rd, Patel PJ, Greer KE. Sarcoidosis. *J Am Acad Dermatol*. 2001;44(5):725-743, quiz 744-746.
3. Khatri KA, Chotzen VA, Burrall BA. Lupus pernio: successful treatment with a potent topical corticosteroid. *Arch Dermatol*. 1995;131(5):617-618.
4. Yeager H, Sina B, Khachemoune A. Dermatologic disease. In: Baughman RP, ed. *Sarcoidosis*. New York, NY: Taylor & Francis; 2006:593-604.
5. Mosam A, Morar N. Recalcitrant cutaneous sarcoidosis: an evidence-based sequential approach. *J Dermatolog Treat*. 2004; 15(6):353-359.
6. Baughman RP. Infliximab for refractory sarcoidosis. *Sarcoidosis Vasc Diffuse Lung Dis*. 2001;18(1):70-74; erratum in: *Sarcoidosis Vasc Diffuse Lung Dis*. 2001;18(3):310.
7. Kouba DJ, Mimouni D, Rencic A, Nousari HC. Mycophenolate mofetil may serve as a steroid-sparing agent for sarcoidosis. *Br J Dermatol*. 2003;148(1):147-148.
8. Baughman RP, Judson MA, Teirstein AS, et al. Thalidomide for chronic sarcoidosis. *Chest*. 2002;122(1):227-232.
9. Heath CR, David J, Taylor SC. Sarcoidosis: are there differences in your skin of color patients? *J Am Acad Dermatol*. 2012;66(1):121.e1-e14.

FIGURE 175-13 47-year-old African-American woman with widespread cutaneous sarcoidosis on face (lupus pernio) trunk and extremities. She also has pulmonary involvement. Her sarcoidosis has improved since starting infliximab by IV infusion. (*Courtesy of Richard P. Usatine, MD.*)

176 CUTANEOUS T-CELL LYMPHOMA

Gina Chacon, MD
Anjeli Nayar, MD
Richard P. Usatine, MD

PATIENT STORY

A 52-year-old black woman presented with a 7-month history of a hypopigmented rash in a symmetric distribution on her upper thighs and arms (**Figures 176-1** and **176-2**). She had been from evacuated New Orleans following Hurricane Katrina. She had waded through polluted waters for hours before being rescued by a boat. Four days passed before she had access to a shower at which time she noticed a single erythematous spot the size of a silver dollar on her left thigh. Over the next several weeks, it faded to hypopigmented macules and plaques and eventually spread to both thighs and arms. The physical examination revealed no lymphadenopathy. A hematoxylin and eosin (H&E) stain of a full-thickness punch biopsy revealed "cerebriform" lymphocytes at the dermal–epidermal junction characteristic of mycosis fungoides (MF), a type of cutaneous T-cell lymphoma (CTCL). Her blood tests were essentially normal, and she was HIV-negative. The patient reported no improvement with topical high-potency generic steroid to affected areas and is currently receiving narrow-band UVB treatment twice weekly.

FIGURE 176-1 The hypopigmented patches of mycosis fungoides on the thighs of a 52-year-old black woman. This is the patch stage of the disease. Although this mimicked vitiligo, the distribution and appearance warranted a biopsy that provided a definitive diagnosis of mycosis fungoides. (*Courtesy of Richard P. Usatine, MD.*)

INTRODUCTION

CTCL clinically and biologically represent a heterogeneous group of non-Hodgkin lymphomas, with MF and Sézary syndrome being the most common subtypes.[1]

EPIDEMIOLOGY

- The annual incidence of CTCL in the United States has increased from 2.8 per 1 million (1973 to 1977) to 9.6 per 1 million (1998 to 2002) according to data from Criscione and Weinstock.[2]
- CTCL is a rare disease, with 1000 new cases per year in the United States, comprising approximately 0.5% of all non-Hodgkin lymphoma cases.[3,4]
- The two most common types of CTCL are MF (50% to 72%), which is generally indolent in behavior, and Sézary syndrome (1% to 3%), an aggressive leukemic form of the disease.[2]
- It is more common in African Americans than in whites, with an incidence ratio of 6:1.[3]
- It is more common in males, with a male-to-female ratio of 2:1.
- Median age at presentation is between 50 and 70 years,[2] although pediatric and young adult cases do occur.[1]

FIGURE 176-2 Hypopigmented patches on the arm of the woman in Figure 176-2 with mycosis fungoides. (*Courtesy of Richard P. Usatine, MD.*)

ETIOLOGY AND PATHOPHYSIOLOGY

- The exact etiology of CTCL is unknown, but environmental, infectious, and genetic causes have been suggested. CTCL is a malignant lymphoma of helper T cells that usually remain confined to skin and lymph nodes (LNs). MF is a specific type of CTCL named for the mushroom-like skin tumors seen in severe cases.[3]
- Human T-lymphocytic virus (HTLV) types 1 and 2, HIV-1, cytomegalovirus (CMV), Epstein-Barr virus (EBV), and *Borrelia burgdorferi* have been suggested, but unproven, infectious causes of MF.[4,5] Environmental exposure to Agent Orange may be responsible for some cases.[3] There is one case report of possible conjugal transmission of MF between a heterosexual couple who developed advanced MF within 14 months of one another.[5]
- MF and Sézary syndrome (SS) are associated with specific human leukocyte antigen (HLA) types (Aw31, Aw32, B8, Bw38, and DR5).[4] Genetic predisposition is also suggested by detection of HLA class II alleles DRB1*11 and DQB1*03 in association with sporadic and familial malignancy and familial clustering among Israeli Jews.[4,6]
- Metastasis, to the liver, spleen, lungs, GI tract, bone marrow, and the central nervous system (CNS) may occur via T-cell spread through the lymphatic system.[3,4]
- The reduction of T-cell receptor complexity contributes to immunosuppression in advanced MF and SS, and may manifest clinically as herpes simplex or zoster.[7] Death is usually secondary to systemic infection, especially from *Staphylococcus aureus* and *Pseudomonas aeruginosa*.
- Host antitumor immunity also deteriorates, and patients have an increased risk for secondary malignancies, including higher-grade non-Hodgkin lymphoma, Hodgkin disease, secondary melanoma, and colon cancer in addition to cardiopulmonary complications.[7]

DIAGNOSIS

CLINICAL FEATURES

- The most common initial presentation involves patches or scaly plaques with a persistent rash that is often pruritic and usually erythematous (**Figures 176-1** to **176-4**).[3] Patches may evolve to generalized, infiltrated plaques or to ulcerated, exophytic tumors (**Figures 176-5** and **176-6**).[4,8]
- Hypo- or hyperpigmented lesions, petechiae, poikiloderma (skin atrophy with telangiectasia), and alopecia with or without mucinosis are other findings. The folliculotropic variant of MF presents with spotty alopecia (**Figure 176-7**).
- A "premycotic" phase may precede definitive diagnosis for months to decades, which involves nonspecific, slightly scaling skin lesions that intermittently appear and may eventually resolve with topical steroids.
- SS is characterized by generalized exfoliative erythroderma, lymphadenopathy, and atypical Sézary cells in the peripheral blood. Diffuse infiltration of malignant T cells in SS may exaggerate facial lines, creating a leonine facies.[8]

FIGURE 176-3 Reticulated mycosis fungoides (MF). This netlike pattern of mycosis fungoides is also called *parapsoriasis variegata*. (*Courtesy of Heather Wickless, MD.*)

FIGURE 176-4 Plaque stage of mycosis fungoides (MF) on the arm of a 57-year-old nurse. She has had mycosis fungoides for 8 years and has intermittently been on chemotherapy. Recently, her mycosis fungoides has worsened and she was started on nitrogen mustard. (*Courtesy of E.J. Mayeaux, Jr., MD.*)

- "Invisible MF" describes pruritus without visible lesions but the skin biopsy is positive for monoclonal T-cell infiltrates.[4]

TYPICAL DISTRIBUTION

- Lesions may affect any skin surface, but typically initially develop on non–sun-exposed areas, such as the trunk below the waistline, flanks, breasts, inner thighs and arms, and the periaxillary areas (**Figure 176-8**).[9]
- If there is follicular involvement, lesions may be found on the face or scalp (**Figures 176-9** and **176-10**).
- MF occasionally presents as a refractory dermatosis of the palms or soles.

BIOPSY AND LABORATORY STUDIES

- A full-thickness punch biopsy of the lesion is the most important diagnostic tool. If the initial biopsy is negative but the rash persists, the biopsy should be repeated.[3] Topical treatments and systemic immunosuppressants should be discontinued 2 to 4 weeks before the biopsy.[10]
- If the LNs are palpable or lymphadenopathy is suspected, also known as "dermatopathic lymphadenitis," biopsies should be performed (**Figure 176-11**).[4]
- A bone marrow biopsy should be performed if there is proven nodal or blood involvement.
- Histology—The skin biopsy may reveal Pautrier microabscesses or an inflammatory cell band-like infiltrate lining the basal layer or in the upper dermis ("mononuclear epidermotropism"). Malignant lymphocytes have hyperchromatic and convoluted or "cerebriform" nuclei. Capillary dermal fibrosis may also be observed.[10]
- Radiography—A chest radiograph and CT scan of the abdomen and pelvis are recommended for advanced stages IIB to IIIB, or if visceral disease is suspected.[9] A combination of CT and positron emission tomography (PET) scans offers more sensitive detection of LN involvement than either imaging study alone.[4]
- Blood tests for infectious etiology—HIV test, HTLV type 1, EBV, CMV, as indicated by clinical history.
- Serology and blood tests—A complete blood cell count with differential, a buffy coat smear to screen for Sézary cells, lactic dehydrogenase and uric acid as markers for bulky or aggressive disease, and liver function tests to detect hepatic involvement should be measured. Progression of MF is associated with increased serum concentrations of immunoglobin (Ig) E and IgA.[4] Peripheral eosinophilia is an independent marker for poor prognosis and disease progression.[4,11]
- Flow cytometry—This test may be used to detect malignant clones and to quantify CD8+ lymphocytes to assess immunocompetence.
- Immunophenotyping may be used to support histology results.
- Polymerase chain reaction (PCR) and Southern blot testing are recommended to detect T-cell rearrangements, if histology and immunophenotyping results are equivocal and to detect abnormal cells in LNs.[4]
- The International Society for Cutaneous Lymphoma proposed criteria for diagnosing early "classic" MF by incorporating clinical;

FIGURE 176-5 Tumor stage of mycosis fungoides (MF). (*Courtesy of the University of Texas Health Sciences Center, Division of Dermatology.*)

FIGURE 176-6 Tumor stage of mycosis fungoides (MF) with large leg ulcers. (*Courtesy of the University of Texas Health Sciences Center, Division of Dermatology.*)

histopathologic; molecular biologic and immunopathologic features, including the presence of persistent or progressive patches or thin plaques in unexposed areas and/or poikiloderma; superficial lymphoid infiltrate, epidermotropism with spongiosis; lymphocytes with hyperchromatic and cerebriform nuclei; epidermal/dermal discordance between CD2, CD3, CD5, or CD7; and clonal T-cell receptor rearrangement.[10] The International Society for Cutaneous Lymphoma also proposed criteria for diagnosing SS with leukemic blood involvement including an absolute Sézary cell count of greater than 1000/mm^3, a CD4-to-CD8 ratio of 10 or greater, T-cell chromosomal abnormalities detected by Southern blot or PCR, increased circulation of T cells, and aberrant expression of pan T-cell markers as assessed by flow cytometry.[8]

DIFFERENTIAL DIAGNOSIS

- "Premycotic" period preceding diagnosis of MF may resemble parapsoriasis en plaque or nonspecific dermatitis.[4,10]
- MF with erythroderma must be distinguished from generalized atopic dermatitis, contact dermatitis, photodermatitis, drug eruptions, erythrodermic psoriasis, and idiopathic hyper-eosinophilic syndrome (see Chapter 156, Erythroderma).[4,8]
- Unilesional MF may resemble nummular eczema, lichen simplex chronicus, erythema chronicum migrans, tinea corporis, or digitate dermatosis (a variant of small plaque parapsoriasis).[10]
- Vitiligo typically involves discrete, hypopigmented macules on the hands and face that coalesce into larger areas.[3] However, some MF may mimic vitiligo as seen in (**Figures 176-1** and **176-2**). The distribution of the hypopigmented macules in this case is atypical for vitiligo and this prompted a biopsy that led to the diagnosis of MF (see Chapter 198, Vitiligo).
- Idiopathic guttate hypomelanosis is a benign condition involving smaller hypopigmented macules than those seen in MF.[3]
- In patients with HIV, histopathology; resembling MF may represent a reactive inflammatory condition instead. Nonepidermotrophic large T-cell cutaneous lymphoma and B-cell diffuse cutaneous lymphoma are more frequent complications than MF in these patients.[12]

MANAGEMENT

- The current treatments for CTCL can be divided into skin-directed therapy and systemic therapy. Of the skin-directed therapies, topical corticosteroids are widely used in all stages of CTCL in the hopes that they will help control the disease and palliate any cutaneous symptoms of itch.[15] SOR B
- For stage I disease localized to the skin, symptomatic treatment with emollients, antipruritics (Doxepin cream 5%) and topical high-potency steroids (clobetasol cream) on an outpatient basis are recommended.[9] SOR C Topical retinoids or topical chemotherapy (nitrogen mustard, bischloroethylnitrosourea, or carmustine) are treatment alternatives for localized disease and effective adjuvants in generalized disease.[3,9,13,14] SOR B

FIGURE 176-7 **A.** Folliculotropic variant of mycosis fungoides (MF) with visible alopecia in the eyebrow region of this 38-year-old man. **B.** Note the absence of hair growth in parts of the beard where there is follicular involvement. (*Courtesy of Richard P. Usatine, MD.*)

- Bexarotene 1% topical gel may be used if disease persists despite treatment or if other medication is not tolerated. When used in combination with psoralen-enhanced UV light (PUVA), bexarotene decreases the total UVA dosage needed and if used as maintenance therapy increases the duration of remission.[14] SOR C
- Alternatively, PUVA may also be used concurrently with interferon (IFN), 3 times weekly, or retinoids until skin lesions clear, then continued as maintenance therapy at a reduced frequency.[14] SOR C
- For a plaque recalcitrant to PUVA and retinoid combination therapy, 1 case study showed that imiquimod 5% topical cream effectively cleared the lesion.[7] SOR C
- UVA may also be enhanced with methoxsalen or Oxsoralen instead of psoralen.[9] SOR C
- Phototherapy is a safe, effective, and well-tolerated, first-line therapy in patients with early stage CTCL, with prolonged disease-free remissions being achieved. It suggests that narrowband UVB is at least as effective as PUVA for treatment of early stage MF.[15,16] SOR C
- Narrowband UVB light has proven effective in early MF and prolonging remission, although an optimal maintenance protocol still needs to be established.[17] SOR C
- The therapeutic effects of PUVA and UVB in immune-mediated skin diseases have been attributed to the direct apoptosis of lymphocytes, modification of cell surface receptors, and alteration in production of certain mediators.[15]
- Photodynamic therapy with 5-aminolevulinic acid (PDT-ALA) was found to effectively eradicate localized infiltrates better than topical steroids, but more studies are needed before it becomes standardized treatment.[13] SOR C
- In general, photodynamic therapy works via direct cytotoxicity, vascular damage, and immune host response.[8,18]
- Stage II disease involves the regional LNs and may be treated the same as for stage I. For stage IIB, the most recommended therapy is total-skin electron-beam therapy (EBT) followed by nitrogen mustard treatment for 6 or more months.[14] SOR C For disease relapse after EBT, PUVA may be used in combination with IFN or a systemic retinoid.[14] SOR C Other systemic therapies include fusion toxins, monoclonal antibody treatment, and single-agent chemotherapy.[9] For recalcitrant tumors, there is no evidence that combination systemic chemotherapy regimens offer superior survival outcome than single agents.[9,14] SOR C
- Stage III, or erythrodermic disease without extracutaneous disease or with limited LN involvement, should be treated with chemotherapy or photophoresis for 4 weeks.[14] SOR C Extracorporeal photochemotherapy involves irradiation of white blood cells with PUVA after leukophoresis before reinfusing the blood cells intravenously.[9] If the response is delayed, photophoresis may be combined with IFN or systemic retinoids.
- Stage IV extracutaneous disease should be treated with systemic chemotherapy. Although response rates are improved with combination chemotherapy, the response duration is less than 1 year. Regimens include cyclophosphamide, vincristine, and prednisone (CVP), CVP plus Adriamycin, CVP plus methotrexate, or

FIGURE 176-8 Mycosis fungoides (MF) causing hyperpigmented patches over the face, trunk, breasts, and upper extremities. (*Courtesy of Richard P. Usatine, MD.*)

FIGURE 176-9 Mycosis fungoides (MF) on the face with an ulcerated tumor under the nose. (*Courtesy of Richard P. Usatine, MD.*)

cyclophosphamide, vincristine, Adriamycin, and etoposide. Adjuvants treatments may include IFN, systemic retinoids, and photophoresis. Single-agent chemotherapy includes methotrexate, liposomal doxorubicin, gemcitabine, etoposide, cyclophosphamide, and purine analogs.[14] SOR C The patient should be referred to a dermatologist, and to medical and radiation oncologists.[3]

PROGNOSIS AND FOLLOW-UP

- Patient age and stage are the most important clinical prognostic factors.[19]
- Patients have a normal life expectancy, if diagnosed early during stage IA in which the patch or plaque is limited to less than 10% of the skin surface area.[3]
- MF and SS are otherwise difficult to cure and have a prognosis of 3.2 years for stage IIB cutaneous tumors, 4 to 6 years for stage III generalized erythroderma, and less than 1.5 years for stage IVA and stage IVB with LN and visceral involvement, respectively.[9]
- The patient should be monitored for development of secondary malignancies.

POTENTIAL COMPLICATIONS

- Infection, particularly from indwelling intravenous catheters or from lymph node biopsy sites.
- High-output cardiac failure.
- Anemia of chronic disorders.
- Edema.
- Secondary malignancies (e.g., skin cancer, melanoma).

PATIENT EDUCATION

- Avoid sun exposure, stay in a cool environment, and keep skin lubricated.
- See your physician if any new skin symptoms and signs appear or the medication is not working.
- Avoid smoking and second-hand smoke.

PATIENT RESOURCES

- Cutaneous Lymphoma Foundation. *About Cutaneous Lymphoma*—**http://www.clfoundation.org/about-cutaneous-lymphoma.**
- National Cancer Institute. *General Information About Mycosis Fungoides and the Sézary Syndrome*—**http://www.cancer.gov/cancertopics/pdq/treatment/mycosisfungoides/Patient.**

FIGURE 176-10 Facial predominance of this folliculotropic variant of mycosis fungoides (MF). Aside from the facial plaques, the only other area involved presented as alopecia in 1 area of the left forearm. (*Courtesy of Richard P. Usatine, MD.*)

FIGURE 176-11 Tumor stage of mycosis fungoides (MF) with a large posterior cervical node visible. (*Courtesy of Richard P. Usatine, MD.*)

PROVIDER RESOURCES

- National Cancer Institute. *Mycosis Fungoides and the Sézary Syndrome Treatment*—**http://www.cancer.gov/cancertopics/pdq/treatment/mycosisfungoides/HealthProfessional.**
- Skin Cancer Foundation. **http://www.skincancer.org.**
- American Cancer Society. **end_of_the_skype_highlightinghttp://www.cancer.org.**
- Medscape. *Cutaneous T-Cell Lymphoma*—**http://emedicine.medscape.com/article/209091.**

REFERENCES

1. Li JY, Horwitz S, Moskowitz A, et al. Management of cutaneous T cell lymphoma: new and emerging targets and treatment options. *Cancer Manag Res*. 2012;4:75-89.
2. Criscione VD, Weinstock MA. Incidence of cutaneous T-cell lymphoma in the United States, 1973-2002. *Arch Dermatol*. 2007;143(7):854-859.
3. Mahan RD, Usatine RP. Hurricane Katrina evacuee develops a persistent rash. *J Fam Pract*. 2007;56(6):454-457.
4. Hoppe RT, Kim YH. *Clinical manifestations, pathologic features, and diagnosis of mycosis fungoides*. Updated August 2, 2012. http://www.uptodate.com/contents/clinical-manifestations-pathologic-features-and-diagnosis-of-mycosis-fungoides?source=search_result&search=Hoppe+RT%2C+Kim+YH.+Clinical+Features%2C+Diagnosis%2C+and+Staging+of+Mycosis+Fungoides+and+S%C3%A9zary+Syndrome&selectedTitle=1~150. Accessed September 1, 2012.
5. Adriana N, Schmidt AN, Jason B, et al. Conjugal transformed mycosis fungoides: The unknown role of viral infection and environmental exposures in the development of cutaneous T-cell lymphoma. *J Am Acad Dermatol*. 2006;54(5):S202-S205.
6. Hodak E, Klein T, Gabay B, et al. Familial mycosis fungoides: report of 6 kindreds and a study of the HLA system. *J Am Acad Dermatol*. 2005;52(3):393-402.
7. Navi D, Huntley A. Imiquimod 5 percent cream and the treatment of cutaneous malignancy. *Dermatol Online J*. 2004;10(1):4.
8. Girardi M, Heald PW, Wilson LD. The pathogenesis of mycosis fungoides. *N Engl J Med*. 2004;350(19):1978-1988.
9. Pinter-Brown LC. Cutaneous T-Cell Lymphoma: Overview of CTCL. Updated May 17, 2011. http://emedicine.medscape.com/article/209091-overview. Accessed April 6, 2012.
10. Pimpinelli N, Olsen EA, Santucci M, et al. Defining early mycosis fungoides. *J Am Acad Dermatol*. 2005;53(6):1053-1063.
11. Querfeld C, Rosen ST, Guitart J, et al. Phase II trial of subcutaneous injections of human recombinant interleukin-2 for the treatment of mycosis fungoides and Sézary syndrome. *J Am Acad Dermatol*. 2007;56(4):580-583.
12. Honda KS. HIV and skin cancer. *Dermatol Clin*. 2006;24(4):521-530.
13. Blume JE, Oseroff AR. Aminolevulinic acid photodynamic therapy for skin cancers. *Dermatol Clin*. 2007;25(1):5-14.
14. Hoppe RT, Kim YH. *Treatment of Early Stage (IA to IIA) Mycosis Fungoides and Sézary Syndrome*. Updated February 23, 2012. http://www.uptodate.com/contents/treatment-of-advanced-stage-iib-to-iv-mycosis-fungoides-and-sezary-syndrome. UpToDate® www.uptodate.com. Accessed April 3, 2012.
15. Ahern K, Gilmore ES, Poligone B. Pruritus in cutaneous T-cell lymphoma: a review. *J Am Acad Dermatol*. 2012;26:1-9.
16. Ponte P, Serrao V, Apetato M. Efficacy of narrowband UVB vs. PUVA in patients with early-stage mycosis fungoides. *J Eur Acad Dermatol Venereol*. 2010;24(6):716-721.
17. Boztepe G, Sahin S, Ayhan M, et al. Narrowband ultraviolet B phototherapy to clear and maintain clearance in patients with mycosis fungoides. *J Am Acad Dermatol*. 2005;53(2):242-246.
18. Nayak CS. Photodynamic therapy in dermatology. *Indian J Dermatol Venereol Leprol*. 2005;71(3):155-160.
19. Suzuki SY, Ito K, Ito M, Kawai K. Prognosis of 100 Japanese patients with mycosis fungoides and Sézary syndrome. *J Dermatol Sci*. 2012;57(1):37-43.

SECTION 14 HYPERSENSITIVITY SYNDROMES

177 ERYTHEMA MULTIFORME, STEVENS-JOHNSON SYNDROME, AND TOXIC EPIDERMAL NECROLYSIS

Carolyn Milana, MD
Mindy A. Smith, MD, MS

PATIENT STORY

A 14-year-old boy presents to the emergency department with a 1-day history of fever associated with lip swelling and peeling (**Figure 177-1** ***A***). Within 48 hours he developed involvement of his ocular (**Figure 177-1** ***B***) and urethral mucosa along with an erythematous papular rash on his trunk that spread to his extremities. In **Figure 177-1** ***C*** target lesions can be seen on the back. He was diagnosed with Stevens-Johnson syndrome and admitted to the hospital.

FIGURE 177-1 Stevens-Johnson syndrome in a 14-year-old boy who received penicillin for pneumonia. **A.** Lips and mouth are involved. **B.** Eye involvement. (*continued*)

INTRODUCTION

Erythema multiforme (EM), Stevens-Johnson syndrome (SJS), and toxic epidermal necrolysis (TEN) are skin disorders thought to be types of hypersensitivity reactions (undesirable reactions produced by a normal immune system in a presensitized host) that occur in response to medication, infection, or illness. Both SJS and TEN are severe cutaneous reactions thought to describe the same disorder, only differing in severity (TEN more severe); however, there is debate as to whether these three fall into a spectrum of disease that includes EM.

SYNONYMS

- EM has also been called EM minor.
- SJS has been called EM major in the past but it is now thought to be a distinct entity different from all types of EM.
- TEN is also known as Lyell syndrome.

EPIDEMIOLOGY

- The incidence of EM has been estimated to range from 1 in 1000 persons to 1 in 10,000 persons.[1] The true incidence of the disease is unknown.[1]
- SJS and TEN are rare severe cutaneous reactions often caused by drugs. Reports of incidence vary from 1.2 to 6 per 1 million for SJS and from 0.4 to 1.2 per 1 million for TEN.[2–4]

- EM most commonly occurs between the ages of 10 and 30 years, with 20% of cases occurring in children and adolescents.[5]
- With respect to EM, males are affected slightly more often than females.[5]

ETIOLOGY AND PATHOPHYSIOLOGY

Numerous factors have been identified as causative agents for EM:

- Herpes simplex virus (HSV) I and HSV II are the most common causative agents, having been implicated in at least 60% of the cases (**Figure 177-2**).[6,7]
- The virus has been found in circulating blood,[8] as well as on skin biopsy of patients with EM minor.[6]

For SJS and TEN, the majority of cases are drug induced.

- Drugs most commonly known to cause SJS and TEN are sulfonamide antibiotics, allopurinol, NSAIDs, amine antiepileptic drugs (phenytoin and carbamazepine), and lamotrigine.[9]
- *Mycoplasma pneumoniae* has been identified as the most common infectious cause for SJS.[7]

Other less-common causative agents for EM, SJS, and TEN include:

- Infectious agents such as *Mycobacterium tuberculosis*, group A streptococci, hepatitis B, Epstein Barr virus, *Francisella tularensis*, *Yersinia*, enteroviruses, *Histoplasma*, *Coccidioides*.[1]
- Neoplastic processes, such as leukemia and lymphoma.[1]
- Antibiotics, such as penicillin, isoniazid, tetracyclines, cephalosporins, and quinolones.
- Anticonvulsants, such as phenobarbital and valproic acid.[1,7]
- Other drugs, including captopril, etoposide, aspirin, and allopurinol.
- Immunizations, such as Calmette-Guérin bacillus, diphtheria-tetanus toxoid, hepatitis B, measles-mumps-rubella, and poliomyelitis.[6]
- Other agents or triggers, including radiation therapy, sunlight, pregnancy, connective tissue disease, and menstruation.[1]

Although the pathogenesis of EM, SJS, and TEN remains unknown, recent studies show that it may be as a result of a host-specific cell-mediated immune response to an antigenic stimulus that activates cytotoxic T-cells and results in damage to keratinocytes.[6,9]

- The epidermal detachment (skin peeling) seen in SJS and TEN appears to result from epidermal necrosis in the absence of substantial dermal inflammation.

RISK FACTORS

- Recent evidence shows individuals with certain human leukocyte antigen (HLA) alleles may be predisposed to developing SJS/TEN when taking certain drugs.[2]
- Certain diseases, such as HIV/AIDS (**Figure 177-3**), malignancy, or autoimmune disease, also predispose individuals to SJS/TEN.[2,10]

FIGURE 177-1 (*Continued*) **C.** Target lesions on his back. (*Courtesy of Dan Stulberg, MD.*)

FIGURE 177-2 Erythema multiforme in a 43-year-old woman that recurs every time she breaks out with genital herpes. **A.** Target lesions on hand. **B.** Target lesions on elbow. (*Courtesy of Richard P. Usatine, MD.*)

FIGURE 177-3 Stevens-Johnson syndrome that evolved into toxic epidermal necrolysis in an human immunodeficiency virus-positive man with a CD4 of 6. He presented to the emergency department with fever and rash on face, eyes, and mouth. Chest x-ray suggested pneumonia, so he was started on azithromycin, ceftriaxone, and trimethoprim-sulfamethoxazole. He developed bulla on skin and a skin biopsy confirmed toxic epidermal necrolysis, possibly secondary to one of the antibiotics. He was transferred to a burn unit and given intravenous gammaglobulin 1 g/kg for 3 days. The patient survived. **A.** Oral lesions. **B.** Eye and facial involvement. **C.** Trunk and upper extremities involved so that greater than 30% of the skin was affected. (*Courtesy of Robert T. Gilson, MD.*)

DIAGNOSIS

CLINICAL FEATURES

In all of these conditions, there is a rapid onset of skin lesions. EM is a disease in which patients present with the following lesions:

- Classic lesions begin as red macules and expand centrifugally to become target-like papules or plaques with an erythematous outer border and central clearing (iris or bull's-eye lesions) (**Figures 177-4** to **177-7**). Target lesions, although characteristic, are not necessary to make the diagnosis. The center of the lesions should have some epidermal disruption, such as vesicles or erosions.
- Lesions can coalesce and form larger lesions up to 2 cm in diameter with centers that can become dusky purple or necrotic.
- Unlike urticarial lesions, the lesions of EM do not appear and fade; once they appear they remain fixed in place until healing occurs many days to weeks later.
- Patients are usually asymptomatic, although a burning sensation or pruritus may be present.
- Lesions typically resolve without any permanent sequelae within 2 weeks.
- Recurrent outbreaks are often associated with HSV infection (**Figure 177-2**).[6,7]

In both SJS and TEN, patients may have blisters that develop on dusky or purpuric macules. SJS is diagnosed when less than 10% of the body surface area is involved, SJS/TEN overlap when 10% to 30% is involved, and TEN when greater than 30% is involved.

- Lesions may become more widespread and rapidly progress to form areas of central necrosis, bullae, and areas of denudation (**Figure 177-1**).
- Fever higher than 39°C (102.2°F) is often present.
- In addition to skin involvement, there is involvement of at least 2 mucosal surfaces, such as the eyes, oral cavity, upper airway, esophagus, GI tract, or the anogenital mucosa (**Figures 177-1** and **177-3**).
- New lesions occur in crops and may take 4 to 6 weeks to heal.
- Large areas of epidermal detachment occur (**Figures 177-8** to **177-10**).
- Severe pain can occur from mucosal ulcerations but skin tenderness is minimal.
- Skin erosions lead to increased insensible blood and fluid losses, as well as an increased risk of bacterial superinfection and sepsis.
- These patients are at high risk for ocular complications that may lead to blindness. Additional risks include bronchitis, pneumonitis, myocarditis, hepatitis, enterocolitis, polyarthritis, hematuria, and acute tubular necrosis.

TYPICAL DISTRIBUTION

- The distribution of the rash in EM can be widespread.
- The distal extremities, including the palms and soles, are most commonly involved.
- Extensor surfaces are favored.

FIGURE 177-4 Erythema multiforme on the palm with target lesions that have a dusky red and white center. (*Courtesy of the University of Texas Health Sciences Center, Division of Dermatology.*)

FIGURE 177-5 Erythema multiforme with target lesions on the palms secondary to an outbreak of oral herpes. (*Courtesy of the University of Texas Health Sciences Center, Division of Dermatology.*)

FIGURE 177-6 Erythema multiforme with vesicles and blistering of the target lesions on the hand. (*Courtesy of the University of Texas Health Sciences Center, Division of Dermatology.*)

FIGURE 177-7 Erythema multiforme on the dorsum of the hand showing targets with small, eroded centers. There should be some epidermal erosion to diagnose erythema multiforme. (*Courtesy of the University of Texas Health Sciences Center, Division of Dermatology.*)

FIGURE 177-9 Toxic epidermal necrolysis with large areas of desquamation on the leg. (*Courtesy of the University of Texas Health Sciences Center, Division of Dermatology.*)

FIGURE 177-8 Toxic epidermal necrolysis with desquamation of skin on the hand. (*Courtesy of the University of Texas Health Sciences Center, Division of Dermatology.*)

FIGURE 177-10 Toxic epidermal necrolysis secondary to amoxicillin. **A.** Face with large areas of desquamation and loss of pigmentation. **B.** Skin detaching from leg in large sheets and bullae. (*Courtesy of Richard P. Usatine, MD.*)

- Oral lesions may be present, especially in SJS (**Figures 177-1** and **177-3**).
- Severe lesions with exfoliation and extensive mucosal lesions occur in SJS and TEN (**Figures 177-8** to **177-10**).

LABORATORY AND IMAGING

- There are no consistent laboratory findings with these conditions. The diagnosis is usually made based on clinical findings.
- Routine blood work may show leukocytosis, elevated liver transaminases, and an elevated erythrocyte sedimentation rate.
- In TEN, leukopenia may occur.

BIOPSY

- A cutaneous punch biopsy can be performed to confirm the diagnosis or to rule out other diseases.
- Histologic findings of EM will show a lymphocytic infiltrate at the dermal–epidermal junction. There is a characteristic vacuolization of the epidermal cells and necrotic keratinocytes within the epidermis.[1]

DIFFERENTIAL DIAGNOSIS

- Bullous pemphigoid—Can be either subacute or acute with tense widespread blisters that can occur after persistent urticaria; mucosal involvement is rare. Significant pruritus can be present. As with EM, SJS, and TEN, bullous pemphigoid can occur after certain exposures such as UV radiation, or certain drugs (Chapter 184, Bullous Pemphigoid).
- Urticaria—A skin reaction characterized by red wheals that are usually pruritic. Unlike EM, individual lesions rarely last more than 24 hours (Chapter 150, Urticaria and Angioedema).
- Kawasaki disease—Fever persists at least 5 days and there must be at least four of the following features[11]:
  - Changes in extremities—*Acute:* erythema of palms, soles; edema of hands and feet; or *subacute:* periungual peeling of fingers and toes in weeks 2 and 3.
  - Polymorphous exanthem.
  - Bilateral bulbar conjunctival injection without exudate.
  - Changes in lips and oral cavity—Erythema, lips cracking, strawberry tongue (see Chapter 34, Scarlet Fever and Strawberry Tongue), diffuse injection of oral and pharyngeal mucosae.
  - Cervical lymphadenopathy (>1.5 cm diameter), usually unilateral.
- Cutaneous vasculitis—Also caused by a hypersensitivity reaction, lesions are palpable papules or purpura. Blisters, hives, and necrotic ulcers can occur on the skin. Lesions are usually located on the legs, trunk, and buttocks (see Chapter 179, Vasculitis).
- Erythema annulare centrifugum—A hypersensitivity reaction caused by a variety of agents. Lesions look similar with erythematous papules of a few to several centimeters that enlarge and clear centrally and may be vesicular. Lesions tend to appear on the legs and thighs, but may occur on upper extremities, trunk, and face; palms and soles are spared (see Chapter 206, Erythema Annulare Centrifugum).
- Staphylococcal scalded skin syndrome—Rash may also follow a prodrome of malaise and fever but is macular, brightly erythematous, and initially involves the face, neck, axilla, and groin. Skin is markedly tender. Like SJS and TEN, large areas of the epidermis peel away. Unlike TEN, the site of the staphylococcal infection is usually extracutaneous (e.g., otitis media, pharyngitis) and not the skin lesions themselves (Chapter 116, Impetigo).

MANAGEMENT

EM:

- The treatment is mainly supportive. Symptomatic relief may be provided with topical emollients, systemic antihistamines, and acetaminophen. These do not, however, alter the course of the illness.
- The use of corticosteroids has not been well studied, but is thought to prolong the course or increase the frequency of recurrences in HSV-associated cases.[7]
- Prophylactic acyclovir has been used to control recurrent HSV-associated EM with some success.[7]

SJS and TEN:

- Treatment again, is mainly supportive and may require intensive care or placement in a burn unit. Early diagnosis is imperative so that triggering agents can be discontinued.
- Oral lesions can be managed with mouthwashes and glycerin swabs.
- Skin lesions should be cleansed with saline or Burow solution (aluminum acetate in water).
- IV fluids should be given to replace insensible losses.
- Daily examinations for secondary infections should occur and systemic antibiotics should be started as needed.
- Consultation with an ophthalmologist is important because of the high risk of ocular sequelae.
- Pharmacologic therapy is widely debated in the literature. Evidence suggests that intravenous immunoglobulin (IVIG) at doses of 2 to 3 g/kg can help shorten the course and improve outcome if started early in the course of the disease.[12]
- Systemic corticosteroids have been the mainstay of treatment for SJS/TEN. Recent evidence, however, suggests there may be an increase in morbidity and mortality when used for TEN.[12]
- Other agents that have been tried with limited success include thalidomide, tumor necrosis factor (TNF)-α inhibitors, cyclophosphamide, cyclosporine, and plasmapheresis.

PREVENTION

Screening populations known to carry HLA alleles prior to starting medications with higher risks for SJS/TEN has been suggested by some researchers.[2]

PROGNOSIS

- EM usually resolves spontaneously within 1 to 2 weeks.
- Recurrence of EM is common, especially when preceded by HSV infection.
- Prognosis is poorer for patients with SJS and TEN if they are older, have a large percentage of body surface area involved, or have intestinal or pulmonary involvement.
- Mortality for SJS/TEN can be predicted based on the severity of illness score for TEN.[13] One point is given for each of the following: serum blood urea nitrogen greater than 10 mmol/L; serum bicarbonate less than 20 mmol/L; serum glucose greater than 14 mmol/L; age older than 40 years; malignancy present; heart rate greater than 120 beats per minute; percentage of body surface area involved greater than 10%. Scores of 0 to 1 are associated with a mortality rate of 3.2% whereas scores of 5 or higher are associated with a mortality rate of 90%.
- For patients with SJS, mortality rates have been reported of 5% to 10% and up to 30% for TEN.[9,14]

FOLLOW-UP

- For uncomplicated cases, no specific follow-up is needed.
- For patients with EM major and any of the complications listed above, follow-up should be arranged with the appropriate specialist.

PATIENT EDUCATION

- If an offending drug is found to be the cause, it should be discontinued immediately.
- Patients with HSV-associated EM should be made aware of the risk of recurrence.

PATIENT RESOURCE

- Erythema multiforme—**http://www.nlm.nih.gov/medlineplus/ency/article/000851.htm.**

PROVIDER RESOURCES

- Medscape. *Erythema Multiforme*—**http://emedicine.medscape.com/article/1122915.**
- Medscape. *Stevens-Johnson Syndrome*—**http://emedicine.medscape.com/article/1197450.**

REFERENCES

1. Shaw JC. Erythema multiforme. In: Noble J, Green H, Levinson W, et al, eds. *Textbook of Primary Care Medicine*, 3rd ed. St. Louis, MO: Mosby; 2001:815-816.
2. Tan SK, Tay YK. Profile and Pattern of Stevens-Johnson syndrome and toxic epidermal necrolysis in a general hospital in Singapore: treatment outcomes. *Acta Derm Venereol.* 2012;92(1):62-66.
3. Finkelstein Y, Soon GS, Acuna P, et al. Recurrence and outcomes of Stevens-Johnson syndrome and toxic epidermal necrolysis in children. *Pediatrics.* 2011;128(4):723-728.
4. Del Pozzo-Magana BR, Lazo-Langner A, Carleton B. A systematic review of treatment of drug-induced Stevens-Johnson syndrome and toxic epidermal necrolysis in children. *J Popul Ther Clin Pharmacol.* 2011;18:e121-e133.
5. Plaza JA. *Erythema Multiforme*. Updated July 29, 2011. http://www.emedicine.com/derm/topic137.htm. Accessed January 2012.
6. Darmstadt GL. Erythema multiforme. In: Long S, Pickering L, Prober C, eds. *Principles and Practice of Pediatric Infectious Diseases*, 2nd ed. New York, NY: Churchill Livingstone; 2003:442-444.
7. Morelli JG, Vesiculobullous disorders. In: Behrman R, Kliegman RM, Jenson HB, eds. *Nelson Textbook of Pediatrics*, 19th ed. Philadelphia, PA: Saunders; 2011:2241-2249.
8. Weston WL. Herpes associated erythema multiforme. *J Invest Dermatol.* 2005;124(6):xv-xvi.
9. Chosidow OM, Stern RS, Wintroub BU. Cutaneous drug reactions. In: Kasper DL, Fauci AS, Longo DL, Braunwald EB, Hauser SL, Jameson JL, eds. *Harrison's Principles of Internal Medicine*, 16th ed. New York, NY: McGraw-Hill; 2005:318-324.
10. Sanmarkan AD, Tukaram S, Thappa DM, et al. Retrospective analysis of Stevens-Johnson syndrome and toxic epidermal necrolysis over a period of 10 years. *Indian J Dermatol.* 2011;56(1):25-29.
11. Newburger JW, Takahashi M, Gerber MA, et al. Diagnosis, treatment, and long-term management of Kawasaki disease: a statement for health professionals from the Committee on Rheumatic Fever, Endocarditis and Kawasaki Disease, Council on Cardiovascular Disease in the Young, American Heart Association. *Circulation* 2004;110(17):2747-2771.
12. Worswick S, Cotliar J. Stevens-Johnson syndrome and toxic epidermal necrolysis: a review of treatment options. *Dermatol Ther.* 2011;24(2):207-218.
13. Bastuji-Garin S, Fouchard N, Bertocchi M, et al. SCORTEN: a severity of illness score for toxic epidermal necrolysis. *J Invest Dermatol.* 2000;115(2):149-153.
14. The Stevens-Johnson syndrome/toxic epidermal necrolysis spectrum of disease. In: Habif T, ed. *Clinical Dermatology*, 4th ed. Philadelphia, Elsevier; 2004:627-631.

178 ERYTHEMA NODOSUM

E.J. Mayeaux, Jr., MD
Lucia Diaz, MD
Richard Paulis, MD

PATIENT STORY

A young woman presented to the office with several days of overall malaise, fever, and sore throat. At the time of presentation she noted some painful bumps on her lower legs, and denied trauma (**Figure 178-1**). No history of recent cough or change in bowel habits has been reported. The patient had no chronic medical problems, took no medications and had no known drug allergies. Her temperature was slightly elevated, but other vitals were normal. On examination, her oropharynx revealed tonsillar erythema and exudates. Bilateral lower extremities were spotted with slightly-raised, tender, erythematous nodules that varied in size from 2 to 6 cm. Rapid strep test was positive and she was diagnosed clinically with erythema nodosum (EN) secondary to group A β-hemolytic *Streptococcus*. She was treated with penicillin and NSAIDs, and was advised temporary bedrest. She experienced complete resolution of the EN within 4 weeks.

FIGURE 178-1 Erythema nodosum secondary to group A β-hemolytic *Streptococcus* in a young woman. (*Courtesy of Richard P. Usatine, MD.*)

INTRODUCTION

EN is a common inflammatory panniculitis characterized by ill-defined, erythematous patches with underlying tender, subcutaneous nodules. It is a reactive process caused by chronic inflammatory states, infections, medications, malignancies, and unknown factors.

SYNONYMS

Lofgren syndrome (with hilar adenopathy).

EPIDEMIOLOGY

- Erythema nodosum occurs in approximately 1 to 5 per 100,000 persons.[1] It is the most frequent type of septal panniculitis (inflammation of the septa of fat lobules in the subcutaneous tissue).[2]
- EN tends to occur more often in women, with a male-to-female ratio of 1:4.5 in the adult population, generally during the second and fourth decades of life (**Figures 178-1** to **178-3**).[3]
- In 1 study, an overall incidence of 54 million people worldwide was cited in patients older than 14 years of age.[4]
- In the childhood form, the female predilection is not seen.

FIGURE 178-2 EN in a middle-aged woman around the knee secondary to sarcoidosis. (*Courtesy of Richard P. Usatine, MD.*)

ETIOLOGY AND PATHOPHYSIOLOGY

- Most EN is idiopathic (**Figures 178-3** and **178-4**). Although the exact percentage is unknown, 1 study estimated that 55% of

EN is idiopathic.[5] This may be influenced by the fact that EN may precede the underlying illness. The distribution of etiologic causes may be seasonal.[6] Identifiable causes can be infectious, reactive, pharmacologic, or neoplastic.

- Histologic examination is most useful in defining EN. Defining characteristics of EN are a septal panniculitis without presence of vasculitis. That this pattern develops in certain areas of skin may be linked to local variations in temperature and efficient blood drainage.
- Septal panniculitis begins with polymorphonuclear cells infiltrating the septa of fat lobules in the subcutaneous tissue. It is thought that this is in response to existing immune complex deposition in these areas.[7] This inflammatory change consists of edema and hemorrhage which is responsible for the nodularity, warmth, and erythema.
- The infiltrate progresses from predominantly polymorphonuclear cells, to lymphocytes, and then histiocytes where fibrosis occurs around the lobules. There may be some necrosis though minimal as complete resolution without scarring is the typical course.
- The histopathologic hallmark of EN is the Miescher radial granuloma. This is a small, well-defined nodular aggregate of small histiocytes around a central stellate or banana-shaped cleft.

RISK FACTORS

- Group A β-hemolytic streptococcal pharyngitis has been linked to EN (**Figure 178-1**). A retrospective study of 129 cases of EN over several decades reports 28% had streptococcal infection.[5]
- Nonstreptococcal upper respiratory tract infections may also play a role.[1]
- Historically, tuberculosis (TB) was a common underlying illness with EN, but TB is now a rare cause of EN in developed countries. There are reports of EN occurring in patients receiving the bacille Calmette-Guérin vaccination.[8] In developed countries, sarcoidosis is more commonly found. One study estimates sarcoidosis as being the cause of 11% of EN cases (**Figure 178-2**).[5,7]
- EN occurs in 3% of all patients with coccidiomycosis,[9] and approximately 4% of patients with histoplasmosis.[10]
- EN is less frequently associated with other infections agents, including *Yersinia* gastroenteritis, *Salmonella*, *Campylobacter*, toxoplasmosis, syphilis, amebiasis, giardiasis, brucellosis, leprosy, *Chlamydia*, *Mycoplasma*, *Brucella*, hepatitis B (infection and vaccine), Epstein-Barr virus, and *Bartonella*.[4,11]
- When the EN rash occurs with hilar adenopathy, the entity is called Lofgren syndrome. Lofgren syndrome in TB represents primary infection. A more common cause of Lofgren syndrome is sarcoidosis.[7]
- The literature reports that EN is seen in patients with inflammatory bowel diseases. It is usually prominent around the time of GI flare-ups, but may occur before a flare. Most sources report a greater association between Crohn disease and EN than between ulcerative colitis and EN. Other chronic diseases associated with EN include Behçet disease and Sweet syndrome.[11]
- Some debate exists over causality from pregnancy and oral contraceptives in the occurrence of EN.

FIGURE 178-3 EN in a middle-aged woman with no known cause. These lesions are bright red, warm, and painful. (*Courtesy of Hanuš Rozsypal, MD.*)

FIGURE 178-4 EN on the arms and legs of unknown cause in a young man. (*Courtesy of Hanuš Rozsypal, MD.*)

- Besides oral contraceptives, medications implicated as causing EN are antibiotics including sulfonamides, penicillins, and bromides. However, the antibiotics may have been prescribed for the underlying infection that had caused EN.[11]
- Lymphomas, acute myelogenous leukemia, carcinoid tumor, and pancreatic carcinoma are associated with EN and should be considered in cases of persistent or recurrent EN.[11,12]

DIAGNOSIS

CLINICAL FEATURES

- The diagnosis is usually clinical.
- The lesions of EN are deep-seated nodules that may be more easily palpated than visualized.
- Lesions are initially firm, round or oval, and are poorly demarcated.
- Lesions may be bright red, warm, and painful (**Figure 178-3**).
- Lesions number from 1 to more than 10.5 and vary in size from 1 to 15 cm.
- Over their course, the lesions begin to flatten and change to a purplish color before eventually taking on the yellowish hue of a bruise.
- A characteristic of EN is the complete resolution of lesions with no ulceration or scarring.
- EN is associated with systemic occurrence of fever, malaise, and polyarthralgia sometime near eruption.

TYPICAL DISTRIBUTION

- Lesions appear on the anterior/lateral aspect of both lower extremities (**Figures 178-1** to **178-3**).
- Although lesions may appear in other regions such as the arms, absence in the lower legs is unusual (**Figure 178-4**).[1]
- Sarcoid, in particular, may present with lesions on the ankles and knees (**Figure 178-2**).
- Lesions may appear in dependent areas in bedridden patients.

LABORATORY TESTING

- Blood tests may help to identify the underlying cause. Typical tests include complete blood count, chemistries, liver function tests, and erythrocyte sedimentation rate. Erythrocyte sedimentation rate may be elevated.
- For suspected *Streptococcus* cases, rapid strep test or throat cultures are best during acute illness, whereas antistreptolysin O titers may be used in the convalescent phase.[4]
- In sarcoid, angiotensin-converting enzyme levels may be helpful but are not 100% sensitive.[2] A chest x-ray and/or skin biopsy of a suspected sarcoid lesion can help make this diagnosis (see Chapter 175, Sarcoidosis).

BIOPSY

- The diagnosis of EN is mostly made on physical examination. When the diagnosis is uncertain, a biopsy that includes subcutaneous fat is performed. This can be a deep punch biopsy or a deep incisional biopsy sent for standard histology. If a biopsy is needed,

this can be done by choosing a lesion not over a joint or vital structure and burying a 4-mm punch biopsy to the hilt.

DIFFERENTIAL DIAGNOSIS

- Cellulitis should be considered and not missed. These patients tend to be sicker and have more fever and systemic symptoms. EN tends to appear in multiple locations while cellulitis is usually in one localized area (see Chapter 120, Cellulitis).
- Nodular cutaneous and subcutaneous sarcoid is skin-colored or violaceous without epidermal involvement. The lack of surface involvement makes this resemble EN. Subcutaneous sarcoid may be seen in advanced systemic sarcoidosis that can also be the cause of EN. Skin biopsy is the best method to distinguish between these two conditions. Either way, treatment is directed toward the sarcoidosis (see Chapter 175, Sarcoidosis).
- Erythema induratum of Bazin is a lobular panniculitis that occurs on the posterior lower extremity of women with tendency of lesions to ulcerate with residual scarring.[7] This condition is typically caused by TB and is more chronic in nature than EN.[2]
- Erythema nodosum leprosum may occur in patients with leprosy and probably represent an immune complex or hypersensitivity reaction (**Figures 178-5** and **178-6**). Erythema nodosum leprosum is typically seen as a type 2 reaction to standard leprosy therapy.[13] It is more common in multibacillary lepromatous leprosy. Although the lesions often look like standard EN, the lesions may also ulcerate.
- An infectious panniculitis should also be considered in the differential, especially in immunocompromised patients. These lesions are often asymmetric and the patient may be febrile. If suspected, a punch biopsy of a lesion should be sent for tissue culture (bacteria, fungus, and *Mycobacteria*).

MANAGEMENT

- Look for and treat the underlying cause. There is limited evidence to guide treatment unless an underlying cause is found.

NONPHARMACOLOGIC

- Cool, wet compresses, elevation of the involved extremities, bedrest, gradient support stockings, or pressure bandages may help alleviate the pain.[11] SOR C

MEDICATIONS

- Treat the pain and discomfort of the nodules with NSAIDs and/or other analgesics.[14] SOR C
- The value of oral prednisone is controversial and should be avoided unless it is being used to treat the underlying cause (such as sarcoidosis) and if underlying infection, risk of bacterial dissemination or sepsis, and malignancy have been excluded.[1] SOR C
- Oral potassium iodide, which is contraindicated in pregnancy, led to resolution of EN in several small studies.[6,7] SOR B
- Colchicine, hydroxychloroquine, and dapsone have been used as well.[2,7] SOR C

FIGURE 178-5 Erythema nodosum leprosum (ENL) in a Texas man who acquired multibacillary leprosy from handling and eating armadillos. His ENL started when he started the antibacterial treatment.
A. Note the many subcutaneous nodules on his arms and legs.
B. Close-up of the ENL lesions. (*Courtesy of Richard P. Usatine, MD.*)

- There are a few case reports of EN treated with penicillin, erythromycin, adalimumab, etanercept, infliximab, mycophenolate mofetil, cyclosporine, thalidomide, and extracorporeal monocyte granulocytapheresis.[1,15,16] SOR C
- There is one case report of minocycline and tetracycline leading to EN improvement.[17] SOR C

PREVENTION

- Good hand washing and general health measures may prevent respiratory infections that may predispose to EN.

PROGNOSIS

- EN is usually self-limited or resolves with treatment of the underlying disorder.
- Patients may continue to develop nodules for a few weeks.
- The course depends on the etiology, but usually lasts only 6 weeks.
- Lesions completely resolve with no ulceration or scarring.
- Recurrences occur in 33% to 41% of cases, usually when the etiology is unknown.[16]

FOLLOW-UP

- Follow-up is needed to complete the work-up for an underlying cause and to make sure that the patient is responding to symptomatic treatment.

PATIENT EDUCATION

Reassure the patient that there is complete resolution in most cases within 3 to 6 weeks. Inform the patient that some EN outbreaks may persist for up to 12 weeks, and some cases are recurrent.[6]

PATIENT RESOURCES

- PubMed Health. *Erythema Nodosum*—**http://www.ncbi.nlm.nih.gov/pubmedhealth/PMH0001884/.**
- MedicineNet. *Erythema Nodosum*—**http://www.medicinenet.com/erythema_nodosum/article.htm.**

PROVIDER RESOURCES

- Medscape. *Erythema Nodosum*—**http://emedicine.medscape.com/article/1081633-overview.**
- Schwartz RA, Nervi SJ. Erythema nodosum: a sign of systemic disease. *Am Fam Physician*. 20071;75(5):695-700. Available at **http://www.aafp.org/afp/2007/0301/p695.html.**

FIGURE 178-6 Erythema nodosum leprosum (ENL) on the hand and arm of an Ethiopian woman being treated with three antileprosy drugs for multibacillary lepromatous leprosy. (*Courtesy of Richard P. Usatine, MD.*)

REFERENCES

1. Schwartz RA, Nervi SJ. Erythema nodosum: a sign of systemic disease. *Am Fam Physician.* 2007;75(5):695-700.
2. Atzeni F, Carrabba M, Davin JC, et al. Skin manifestations in vasculitis and erythema nodosum. *Clin Exp Rheumatol.* 2006;24 (1 Suppl 40):S60-S66.
3. Garcia-Porrua C, González-Gay MA, Vázquez-Caruncho M, et al. Erythema nodosum: etiologic and predictive factors erythema nodosum and erythema induratum in a defined population. *Arthritis Rheum.* 2000:43:584-592.
4. Gonzalez-Gay MA, Garcia-Porrua C, Pujol RM, Salvarani C. Erythema nodosum: a clinical approach. *Clin Exp Rheumatol.* 2001;19(4):365-368.
5. Cribier B, Caille A, Heid E, Grosshans E. Erythema nodosum and associated diseases. A study of 129 cases. *Int J Dermatol.* 1998; 37(9):667-672.
6. Hannuksela M. Erythema nodosum. *Clin Dermatol.* 1986;4(4):88-95.
7. Requena L, Requena C. Erythema nodosum. *Dermatol Online J.* 2002;8(1):4.
8. Fox MD, Schwartz RA. Erythema nodosum. *Am Fam Physician.* 1992;46(3):818-822.
9. Body BA. Cutaneous manifestations of systemic mycoses. *Dermatol Clin.* 1996;14:125-135.
10. Ozols II, Wheat LJ. Erythema nodosum in an epidemic of histoplasmosis in Indianapolis. *Arch Dermatol.* 1981;117:709-712.
11. Gilchrist H, Patterson JW. Erythema nodosum and erythema induratum (nodular vasculitis): diagnosis and management. *Dermatol Ther.* 2010;23(4):320-327.
12. Cho KH, Kim YG, Yang SG, et al. Inflammatory nodules of the lower legs: a clinical and histological analysis of 134 cases in Korea. *J Dermatol.* 1997;24:522-529.
13. Van Brakel WH, Khawas IB, Lucas SB. Reactions in leprosy: an epidemiological study of 386 patients in west Nepal. *Lepr Rev.* 1994;65(3):190-203.
14. Ubogy Z, Persellin RH. Suppression of erythema nodosum by indomethacin. *Acta Derm Venereol.* 1982;62:265.
15. Allen RA, Spielvogel RL. Erythema nodosum. In: Lebwohl MG, Heymann WR, Berth-Jones J, Coulson I, eds. *Treatment of Skin Disease*, 3rd ed. Philadelphia, PA: Saunders; 2010:223-225.
16. Gilchrist H, Patterson JW. Erythema nodosum and erythema induratum (nodular vasculitis): diagnosis and management. *Dermatol Ther.* 2010;23(4):320-327.
17. Davis MD. Response of recalcitrant erythema nodosum to tetracyclines. *J Am Acad Dermatol.* 2011;64(6):1211-1212.

179 VASCULITIS

E.J. Mayeaux, Jr., MD
Richard P. Usatine, MD

PATIENT STORY

A 21-year-old woman presented with a 3-day history of a painful purpuric rash on her lower extremities (**Figure 179-1** and **Figure 179-2**). The lesions had appeared suddenly, and the patient had experienced no prior similar episodes. The patient had been diagnosed with a case of pharyngitis earlier that week and was given a course of clindamycin. She had not experienced any nausea or vomiting, fever, abdominal cramping, or gross hematuria. Urine dipstick revealed blood in her urine, but no protein. The typical palpable purpura on the legs is consistent with Henoch-Schönlein purpura (HSP).

INTRODUCTION

Vasculitis refers to a group of disorders characterized by inflammation and damage in blood vessel walls. They may be limited to skin or may be a multisystem disorder. Cutaneous vasculitic diseases are classified according to the size (small versus medium to large vessel) and type of blood vessel involved (venule, arteriole, artery, or vein). Small- and medium-size vessels are found in the dermis and deep reticular dermis, respectively. The clinical presentation varies with the intensity of the inflammation, and the size and type of blood vessel involved.[1]

SYNONYMS

Hypersensitivity vasculitis is also known as leukocytoclastic vasculitis.

HSP is a type of leukocytoclastic vasculitis.

EPIDEMIOLOGY

- HSP (**Figure 179-1** to **Figure 179-3**) occurs mainly in children with an incidence of approximately 1 in 5000 children annually.[2] It results from immunoglobulin (Ig) A-containing immune complexes in blood vessel walls in the skin, kidney, and GI tract. HSP is usually benign and self-limiting, and tends to occur in the springtime. A streptococcal or viral upper respiratory infection often precedes the disease by 1 to 3 weeks. Prodromal symptoms include anorexia and fever. Most children with HSP also have joint pain and swelling with the knees and ankles being most commonly involved (**Figure 179-3**). In half of the cases there are recurrences, typically in the first 3 months. Recurrences are more common in patients with nephritis and are milder than the original episode. To make the diagnosis of HSP, establish the presence of 3 or more of the following:[3]
  - Palpable purpura
  - Bowel angina (pain)

FIGURE 179-1 Henoch-Schönlein purpura presenting as palpable purpura on the lower extremity. The visible sock lines are from lesions that formed where the socks exerted pressure on the legs. (*Courtesy of Richard P. Usatine, MD.*)

FIGURE 179-2 Close-up of palpable purpura from the patient in Figure 179-1. Some lesions look like target lesions but this is Henoch-Schönlein purpura and not erythema multiforme. (*Courtesy of Richard P. Usatine, MD.*)

- GI bleeding
- Hematuria
- Onset ≤20 years
- No new medications

- Some patients with systemic lupus erythematosus (SLE) (**Figure 179-4** and **Figure 179-5**), rheumatoid arthritis (RA), relapsing polychondritis, and other connective tissue disorders develop an associated necrotizing vasculitis. It most frequently involves the small muscular arteries, arterioles, and venules. The blood vessels can become blocked leading to tissue necrosis (**Figure 179-4** and **Figure 179-5**). The skin and internal organs may be involved.
- Leukocytoclastic vasculitis (**Figure 179-6** to **Figure 179-8**) is the most commonly seen form of small vessel vasculitis. Prodromal symptoms include fever, malaise, myalgia, and joint pain. The palpable purpura begins as asymptomatic localized areas of cutaneous hemorrhage that become palpable. Few or many discrete lesions are most commonly seen on the lower extremities but may occur on any dependent area. Small lesions itch and are painful, but nodules, ulcers, and bullae may be very painful. Lesions appear in crops, last for 1 to 4 weeks, and may heal with residual scarring and hyperpigmentation. Patients may experience 1 episode (drug reaction or viral infection) or multiple episodes (RA or SLE). The disease is usually self-limited and confined to the skin. To make the diagnosis, look for presence of 3 or more of the following:[4]
  - Age older than 16 years
  - Use of a possible offending drug in temporal relation to the symptoms
  - Palpable purpura
  - Maculopapular rash
  - Biopsy of a skin lesion showing neutrophils around an arteriole or venule
- Systemic manifestations of leukocytoclastic vasculitis may include kidney disease, heart, nervous system, GI tract, lungs, and joint involvement.

ETIOLOGY AND PATHOPHYSIOLOGY

- Vasculitis is defined as inflammation of the blood vessel wall. The mechanisms of vascular damage consist of either a humoral response, immune complex deposition, or cell-mediated T-lymphocyte response with granuloma formation.[5]
- Vasculitis induced injury to blood vessels may lead to increased vascular permeability, vessel weakening, aneurysm formation, hemorrhage, intimal proliferation, and thrombosis that result in obstruction and local ischemia.[5]
- Small-vessel vasculitis is initiated by hypersensitivity to various antigens (drugs, chemicals, microorganisms, and endogenous antigens), with formation of circulating immune complexes that are deposited in walls of postcapillary venules. The vessel-bound immune complexes activate complement, which attracts polymorphonuclear leukocytes. They damage the walls of small veins by release of lysosomal enzymes. This causes vessel necrosis and local hemorrhage.

FIGURE 179-3 Henoch-Schönlein purpura in an 11-year-old girl. **A.** In addition to the palpable purpura, this patient also had abdominal pain. Note how the seam of her jeans is visible in the purpuric pattern. **B.** She also had knee pain and swelling and was walking with a limp. (*Courtesy of Richard P. Usatine, MD.*)

FIGURE 179-4 Necrotizing vasculitis in a young Asian woman with systemic lupus erythematosus. The circulation to the fingertips was compromised and the woman was treated with high-dose intravenous steroids and intravenous immunoglobulins to prevent tissue loss. (*Courtesy of Richard P. Usatine, MD.*)

FIGURE 179-5 Vasculitis ulcer on the leg of a woman with systemic lupus erythematosus. (*Courtesy of Everett Allen, MD.*)

FIGURE 179-7 Very palpable purpura on the leg of a middle-aged woman with leukocytoclastic vasculitis. (*Courtesy of Eric Kraus, MD.*)

FIGURE 179-6 Leukocytoclastic vasculitis on the leg of a woman. (*Courtesy of Richard P. Usatine, MD.*)

FIGURE 179-8 Vasculitis on the abdomen of a middle-aged woman who also has the vasculitis on her legs. (*Courtesy of Everett Allen, MD.*)

- Small-vessel vasculitis most commonly affects the skin and rarely causes serious internal organ dysfunction, except when the kidney is involved. Small-vessel vasculitis is associated with leukocytoclastic vasculitis, HSP, essential mixed cryoglobulinemia, connective tissue diseases or malignancies, serum sickness and serum sickness-like reactions, chronic urticaria, and acute hepatitis B or C infection.
- Hypersensitivity (leukocytoclastic) vasculitis causes acute inflammation and necrosis of venules in the dermis. The term *leukocytoclastic vasculitis* describes the histologic pattern produced when leukocytes fragment.

RISK FACTORS

- Viral infections
- Autoimmune disorders
- Drug hypersensitivity
- Cocaine (adulterated with levamisole) (**Figure 179-9**) (Chapter 239, Cocaine for additional images and information)

DIAGNOSIS

- Initially, determining the extent of visceral organ involvement is more important than identifying the type of vasculitis, so that organs at risk of damage are not jeopardized by delayed or inadequate treatment. It is critical to distinguish vasculitis occurring as a primary autoimmune disorder from vasculitis secondary to infection, drugs, malignancy, or connective tissue disease such as SLE or RA.[5]

CLINICAL FEATURES

- Small-vessel vasculitis is characterized by necrotizing inflammation of small blood vessels, and may be identified by the finding of "palpable purpura." The lower extremities typically demonstrate "palpable purpura," varying in size from a few millimeters to several centimeters (**Figure 179-2**, **Figure 179-6**, **Figure 179-7**, and **Figure 179-10**). In its early stages leukocytoclastic vasculitis may not be palpable.
- The clinical features of HSP include nonthrombocytopenic palpable purpura mainly on the lower extremities and buttocks (**Figure 179-1**, **Figure 179-2**, and **Figure 179-3**), GI symptoms, arthralgia, and nephritis.

TYPICAL DISTRIBUTION

- Cutaneous vasculitis is found most commonly on the legs, but may be seen on the hands and abdomen (**Figure 179-3**, **Figure 179-8**, and **Figure 179-10**).

LABORATORY TESTING

- Laboratory evaluation is geared to finding the antigenic source of the immunologic reaction. Consider throat culture, antistreptolysin-*O* titer, erythrocyte sedimentation rate, platelets, complete blood count (CBC), serum creatinine, urinalysis, antinuclear antibody,

FIGURE 179-9 **A.** Cutaneous vasculitis of the ear caused by levamisole-adulterated cocaine. (*Courtesy of Jonathan Karnes, MD.*) **B.** Cutaneous vasculitis in a retiform (net-like) pattern caused by the use of levamisole-adulterated cocaine. This is called *retiform purpura.* (*Courtesy of John M. Martin IV, MD.*)

serum protein electrophoresis, circulating immune complexes, hepatitis B surface antigen, hepatitis C antibody, cryoglobulins, and rheumatoid factor. The erythrocyte sedimentation rate is almost always elevated during active vasculitis. Immunofluorescent studies are best done within the first 24 hours after a lesion forms. The most common immunoreactants present in and around blood vessels are IgM, C3, and fibrin. The presence of IgA in blood vessels of a child with vasculitis suggests the diagnosis of HSP.

- Basic laboratory analysis to assess the degree and types of organs affected should include serum creatinine, creatinine kinase, liver function studies, hepatitis serologies, urinalysis, and possibly chest x-ray and ECG.

BIOPSY

- The clinical presentation is so characteristic that a biopsy is generally unnecessary. In doubtful cases, a punch biopsy should be taken from an early active (nonulcerated) lesion or, if necessary, from the edge of an ulcer (**Figure 179-4**).

DIFFERENTIAL DIAGNOSIS

- Pigmented purpuric dermatosis is a capillaritis characterized by extravasation of erythrocytes in the skin with marked hemosiderin deposition. It is not palpable. Schamberg disease is a type of pigmented purpuric dermatosis found most often on the lower legs in older persons (**Figure 179-11** and **Figure 179-12**). It is described as a cayenne pepper-like appearance. Lichen aureus is a localized pigmented purpuric dermatosis seen in younger persons that may occur on the leg or in other parts of the body (**Figure 179-13**). The color may be yellow brown or golden brown. There is also a pigmented purpuric dermatosis of the Majocchi type that has an annular appearance with prominent elevated erythematous borders that may have telangiectasias (**Figure 179-14**). A dermatoscope can help to visualize the red or pink dots that represent inflamed capillaries in these conditions.
- Meningococcemia that presents with purpura in severely ill patients with central nervous system symptoms (**Figure 179-15** and **Figure 179-16**).
- Rocky Mountain spotted fever is a rickettsial infection that presents with pink to bright red, discrete 1- to 5-mm macules that blanch with pressure and may be pruritic. The lesions start distally and spread to the soles and palms (**Figure 179-17**).
- Malignancies, such as cutaneous T-cell lymphoma (mycosis fungoides) (Chapter 176, Mycosis Fungoides).
- Stevens-Johnson syndrome and toxic epidermal necrolysis (Chapter 177, Erythema Multiforme, Stevens-Johnson Syndrome, and Toxic Epidermal Necrolysis).
- Idiopathic thrombocytopenia purpura can be easily distinguished from vasculitis by measuring the platelet count. Also, the purpura is usually not palpable and the petechiae can be scattered all over the body (**Figure 179-18**).
- Wegener granulomatosis is an unusual multisystem disease characterized by necrotizing granulomatous inflammation and vasculitis of the respiratory tract, kidneys, and skin.

FIGURE 179-10 Leukocytoclastic vasculitis in a 26-year-old man. **A.** Palpable purpura on the lower leg. **B.** Involvement of the lower abdomen. (*Courtesy of Richard P. Usatine, MD.*)

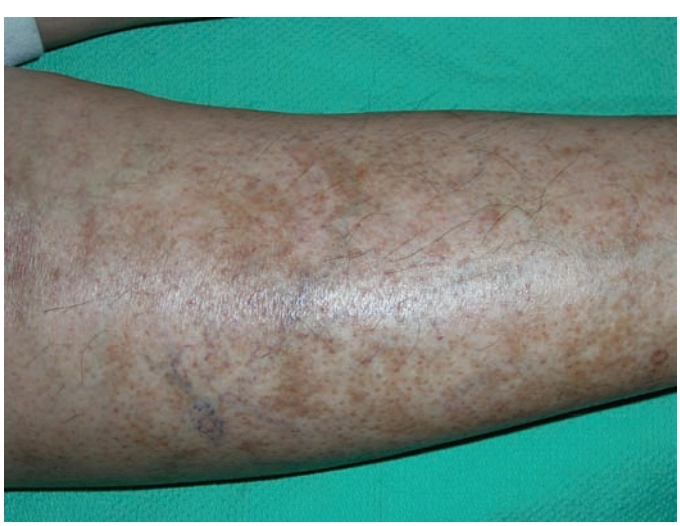

FIGURE 179-11 Schamberg disease (pigmented purpuric dermatosis) of the lower leg showing hemosiderin deposits and a cayenne pepper capillaritis. (*Courtesy of Richard P. Usatine, MD.*)

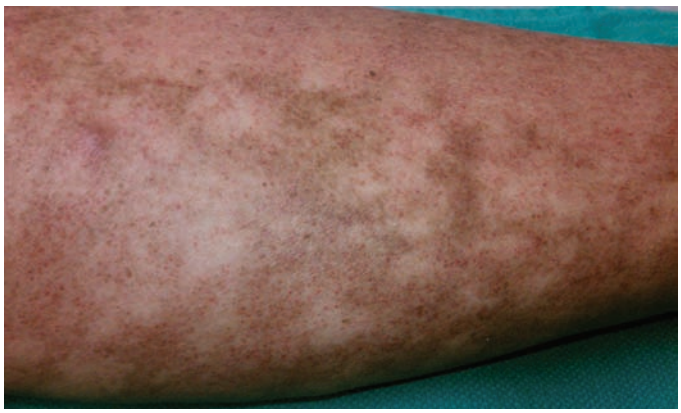

FIGURE 179-12 Schamberg disease with prominent petechiae and hemosiderin deposits. Note that this condition is not palpable. (*Courtesy of Richard P. Usatine, MD.*)

FIGURE 179-14 Pigmented purpuric dermatosis of the Majocchi type. Note the annular appearance and the prominent elevated erythematous borders. (*Courtesy of Suraj Reddy, MD.*)

FIGURE 179-13 Lichen aureus. **A.** On the leg of a 27-year-old woman. **B.** On the leg of a 16-year-old girl. (*Courtesy of Richard P. Usatine, MD.*)

- Churg-Strauss syndrome (allergic granulomatosis) that presents with a systemic vasculitis associated with asthma, transient pulmonary infiltrates, and hypereosinophilia.
- Cutaneous manifestations of cholesterol embolism, which are leg pain, livedo reticularis (blue-red mottling of the skin in a net-like pattern), and/or blue toes in the presence of good peripheral pulses.

MANAGEMENT

NONPHARMACOLOGIC

- The offending antigen should be identified and removed whenever possible. With a mild hypersensitivity vasculitis is due to a drug, discontinuing the offending drug may be all the treatment that is necessary. SOR C

MEDICATIONS

- An antihistamine might be used for itching. SOR C
- Oral prednisone is used to treat visceral involvement and more severe cases of vasculitis of the skin. Short courses of prednisone (60 to 80 mg/day) are effective and should be tapered slowly.[6,7] SOR B
- Colchicine (0.6 mg twice daily for 7 to 10 days) and dapsone (100 to 150 mg/day) may be used to inhibit neutrophil chemotaxis. SOR B They are tapered and discontinued when lesions resolve. Azathioprine, cyclophosphamide, and methotrexate have also been studied. SOR C
- In HSP and prolonged hypersensitivity vasculitis, treatment with nonsteroidal antiinflammatory drugs is usually preferred. Treatment with corticosteroids may be of more benefit in patients with more severe disease such as more pronounced abdominal pain and renal involvement.[8] SOR B Adding cyclophosphamide to the steroids may also be effective. SOR C Azathioprine also may be used.[9]

REFER OR HOSPITALIZE

- Refer or hospitalize with significant internal organ involvement or prolonged disease course.

PROGNOSIS

- In leukocytoclastic (hypersensitivity) vasculitis, the cutaneous lesions usually resolve without sequelae. Visceral involvement (such as kidney and lung) most commonly occurs in HSP, cryoglobulinemia and vasculitis associated with SLE.[10] Extensive internal organ involvement should prompt an investigation for coexistent medium-size vessel disease and referral to a rheumatologist.

FOLLOW-UP

- Relapses may occur, especially when the precipitating factor is an autoimmune disease. Regular monitoring is necessary.

PATIENT EDUCATION

- Reassure patients and parents that most cases of acute cutaneous vasculitis resolves spontaneously.

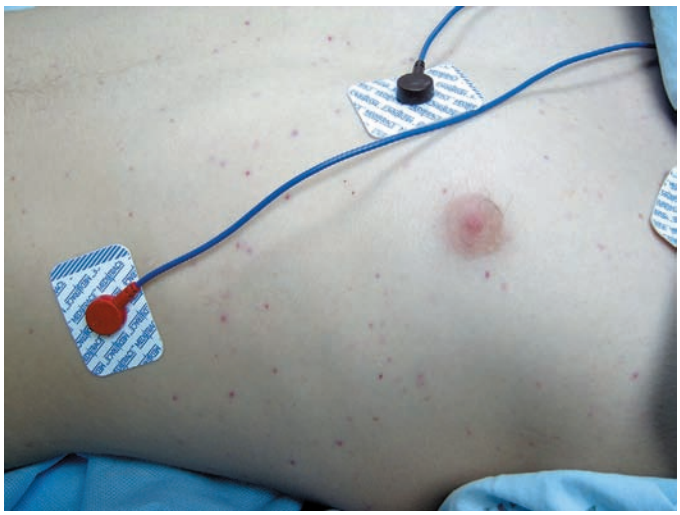

FIGURE 179-15 Petechiae of meningococcemia on the trunk of a hospitalized adolescent. (*Courtesy of Tom Moore, MD.*)

FIGURE 179-16 Petechiae, purpura, and acrocyanosis in a severely ill patient with meningococcemia. (*Courtesy of the University of Texas Health Sciences Center Division of Dermatology.*)

FIGURE 179-17 Rocky Mountain spotted fever with many petechiae visible around the original tick bite. This rickettsial disease looks similar to vasculitis. (*Courtesy of Tom Moore, MD.*)

PATIENT RESOURCES

- MedicineNet. *Vasculitis (Arteritis, Angiitis)*—**http://www.medicinenet.com/vasculitis/article.htm.**
- National Kidney and Urologic Diseases Information Clearinghouse. *Henoch-Schönlein Purpura*—**http://kidney.niddk.nih.gov/kudiseases/pubs/HSP/.**
- National Heart Blood and Lung Institute. *What Is Vasculitis?*—**http://www.nhlbi.nih.gov/health/dci/Diseases/vas/vas_whatis.html.**

PROVIDER RESOURCES

- Roane DW, Griger DR. An approach to diagnosis and initial management of systemic vasculitis. *Am Fam Physician* 1999:60:1421-1430—**http://www.aafp.org/afp/991001ap/1421.html.**
- Sharma P, Sharma S, Baltaro R, Hurley J. Systemic vasculitis. *Am Family Physician* 2011;83(5):556-565—**http://www.aafp.org/afp/2011/0301/p556.html.**

FIGURE 179-18 Petechiae and purpura in a patient with idiopathic thrombocytopenic purpura and a platelet count of 3000. Note that this purpura is not palpable. (*Courtesy of Richard P. Usatine, MD.*)

REFERENCES

1. Stone JH, Nousari HC. "Essential" cutaneous vasculitis: what every rheumatologist should know about vasculitis of the skin. *Curr Opin Rheumatol* 2001;13(1):23-34.
2. Gardner-Medwin JM, Dolezalova P, Cummins C, Southwood TR. Incidence of Henoch-Schönlein purpura, Kawasaki disease, and rare vasculitides in children of different ethnic origins. *Lancet* 2002;360(9341):1197-202.
3. Michel BA, Hunder GG, Bloch DA, Calabrese LH. Hypersensitivity vasculitis and Henoch-Schönlein purpura: a comparison between the 2 disorders. *J Rheumatol* 1992;19:721.
4. Calabrese LH, Michel BA, Bloch DA, et al. The American College of Rheumatology 1990 criteria for the classification of hypersensitivity vasculitis. *Arthritis Rheum* 1990;33:1108.
5. Sharma P, Sharma S, Baltaro R, Hurley J. Systemic vasculitis. *Am Fam Physician* 2011;83(5):556-565.
6. Martinez-Taboada VM, Blanco R, Garcia-Fuentes M, Rodriguez-Valverde V. Clinical features and outcome of 95 patients with hypersensitivity vasculitis. *Am J Med* 1997;102:186-191.
7. Sais G, Vidaller A, Jucgla A, et al. Colchicine in the treatment of cutaneous leukocytoclastic vasculitis. Results of a prospective, randomized controlled trial. *Arch Dermatol* 1995;131:1399-1402.
8. Weiss PF, Feinstein JA, Luan X, et al. Effects of corticosteroid on Henoch-Schonlein purpura: A systematic review. *Pediatrics* 2007;120:1079-1087.
9. Saulsbury FT. Henoch-Schönlein purpura. *Curr Opin Rheumatol* 2001;13:35-40.
10. Roane DW, Griger DR. An approach to diagnosis and initial management of systemic vasculitis. *Am Fam Physician* 1999;60:1421-1430.

SECTION 15 CONNECTIVE TISSUE DISEASE

180 LUPUS: SYSTEMIC AND CUTANEOUS

E.J. Mayeaux, Jr., MD

PATIENT STORY

A 39-year-old black woman presented to the clinic with 2 months of swelling of her upper lip and cheeks with new dark spots on her face (**Figure 180-1**). An antinuclear antibody (ANA) was positive at a 1:80 dilution. A homogeneous nuclear pattern was present as commonly seen in systemic lupus erythematosus (SLE) and drug-induced lupus. The punch biopsy of a facial lesion was consistent with chronic cutaneous lupus erythematosus (discoid lupus). The remainder of her laboratory tests were normal. The patient's facial lesions did not respond to topical steroids and hence she was started on a short course of systemic steroids. The improvement was seen 3 weeks later (**Figure 180-2**). Hyperpigmentation remained but erythema, swelling, and pruritus were gone. The patient did not meet criteria for SLE and it is possible to have discoid lupus with a positive ANA. Treatment with hydroxychloroquine was discussed.

FIGURE 180-1 Erythema, swelling, and hyperpigmentation on the cheeks and lips of a 39-year-old black woman as the initial presentation of chronic cutaneous lupus erythematosus. (*Courtesy of Richard P. Usatine, MD.*)

FIGURE 180-2 Hyperpigmented malar rash 3 weeks later; the patient was treated with oral and topical steroids. The erythema and swelling are now gone and patient is feeling better. (*Courtesy of Richard P. Usatine, MD.*)

INTRODUCTION

SLE is a chronic inflammatory disease that can affect many organs of the body including the skin, joints, kidneys, lungs, nervous system, and mucous membranes. Cutaneous lupus can occur in one of three forms: chronic cutaneous (discoid) lupus erythematosus, subacute cutaneous lupus erythematosus, and acute cutaneous lupus erythematosus.

SYNONYMS

- Chronic cutaneous lupus erythematosus = discoid lupus = DLE.
- Lupus profundus = lupus panniculitis.

EPIDEMIOLOGY

- In the United States, the prevalence of SLE plus incomplete SLE (disease only partially meeting diagnostic requirements for SLE) is 40 to 50 cases per 100,000 persons.[1] It is more common in women and patients with African ancestry.[1] Worldwide, the highest SLE prevalences have been reported in Italy, Spain, Martinique, and the United Kingdom Afro-Caribbean population, but it is rarely reported among blacks who live in Africa.[2]
- Discoid lupus erythematosus (DLE) develops in up to 25% of patients with SLE, but may also occur in the absence of any other clinical feature of SLE.[3] Patients with only DLE have a 5% to 10% risk of eventually developing SLE, which tends to follow a mild

course.[4] DLE lesions usually slowly expand with active inflammation at the periphery, and then to heal, leaving depressed central scars, atrophy, telangiectasias, and hypopigmentation.[5] The female-to-male ratio of DLE is 2:1.

ETIOLOGY AND PATHOPHYSIOLOGY

- One proposed mechanism for the etiology of SLE involves the development of autoantibodies that result from a defect in apoptosis. It has been determined that the specific defect involves the "find-me" (and adenosine triphosphate [ATP]/uridine triphosphate [UTP]) or "eat-me" (phosphatidylserine) signals that should be activated when red cell nuclei are extruded. With no apoptosis, the nuclei break down, causing inflammation and the development of autoimmunity.[6] Many of the signs and symptoms of lupus erythematosus (LE) are caused by the circulating immune complexes or by the direct effects of antibodies to cells.
- A genetic predisposition for SLE exists. The concordance rate in monozygotic twins is between 25% and 70%. If a mother has SLE, her daughter's risk of developing the disease is 1:40 and her son's risk is 1:250.
- The course of SLE is one of intermittent remissions punctuated by disease flares. Organ damage often progresses over time.
- Rarely, neonates may develop a lupus rush from acquired antibodies through transplacental transmission from mother if she has active SLE (**Figure 180-3**).

FIGURE 180-3 Neonatal lupus from acquired antibodies through transplacental transmission from the mother with active SLE. (*From Warner AM, Frey KA, Connolly S. Annular rash on a newborn. J Fam Pract. 2006;55(2):127-129. Reproduced with permission from Frontline Medical Communications.*)

RISK FACTORS

Precipitating factors for SLE include:

- Exposure to the sunlight (UV light, especially UVB).
- Infections.
- Stress.
- Trauma or surgery.
- Pregnancy (especially in the postpartum period).

Precipitating factors for cutaneous lupus include:

- Exposure to the sunlight (UV light, especially UVB).

DIAGNOSIS

CLINICAL FEATURES OF SYSTEMIC LUPUS ERYTHEMATOSUS

- SLE is a chronic, recurrent, potentially fatal inflammatory disorder that can be difficult to diagnose. It is an autoimmune disease involving multiple organ systems that is defined clinically with associated autoantibodies directed against cell nuclei. The disease has no single diagnostic sign or marker. Accurate diagnosis is important because treatment can reduce morbidity and mortality.[7]
- SLE most often presents with a mixture of constitutional symptoms including fatigue, fever, myalgia, anorexia, nausea, and weight loss. The mean length of time between onset of symptoms and diagnosis is 5 years.

- The disease is characterized by exacerbations and remissions as well as symptoms.
- The diagnosis of SLE is made if four or more of the manifestations mentioned below (and categorized in **Table 180-1**) are either present, serially or simultaneously, in the patient at the time of presentation or were present in the past. If two to three manifestations are present, some clinicians refer to the syndrome as "incomplete lupus."[8]
  - Arthralgias, which are often the initial complaint, are usually disproportionate to physical findings. The polyarthritis is symmetric, nonerosive, and usually nondeforming. In longstanding disease, rheumatoid-like deformities with swan-neck fingers are commonly seen.
  - A malar or butterfly rash is fixed erythema over the cheeks and bridge of the nose sparing the nasolabial folds (**Figures 180-2**, **180-4**, and **180-5**). It may also involve the chin and ears. More severe malar rashes may cause severe atrophy, scarring, and hypopigmentation (**Figure 180-5**).
  - Rash associated with photosensitivity to UV light.
  - A discoid rash consisting of erythematosus raised patches with adherent keratotic scaling and follicular plugging. Atrophic scarring may occur in older lesions.
  - Ulcers (usually painless) in the nose, mouth, or vagina are frequent complaints.
  - Pleuritis as evidenced by a convincing history of pleuritic pain or rub or evidence of pleural effusion.
  - Pericarditis as documented by ECG, rub, or evidence of pericardial effusion.
  - Renal disorder such as cellular casts or persistent proteinuria greater than 0.5 g/day or greater than 3+ if quantitation not performed.
  - Central nervous system (CNS) symptoms ranging from mild cognitive dysfunction to psychosis or seizures. Any region of CNS can be involved. Intractable headaches and difficulties with memory and reasoning are the most common features of neurologic disease in lupus patients.
  - Hematologic disorders such as hemolytic anemia, leukopenia ($<4000/mm^3$ total on two or more occasions), lymphopenia ($<1500/mm^3$ on two or more occasions), or thrombocytopenia ($<100,000/mm^3$ in the absence of precipitating drugs).
  - GI symptoms may include abdominal pain, diarrhea, and vomiting. Intestinal perforation and vasculitis are important diagnoses to exclude.
  - Vasculitis (**Figures 180-6** to **180-8**) can be severe and can include retinal vasculitis.
  - Immunologic disorders such as a positive antiphospholipid antibody, anti-DNA, anti-Smith antigen, or a false-positive serologic test for syphilis (known to be positive for at least 6 months and confirmed by a negative treponema specific test).
  - An abnormal titer of ANA at any point in time and in the absence of drugs associated with "drug-induced lupus."

CLINICAL FEATURES OF CUTANEOUS LUPUS

Cutaneous lupus can be divided up into three types:

1. Chronic cutaneous lupus (discoid lupus).
2. Subacute cutaneous lupus.
3. Acute cutaneous lupus, which is part of an SLE flare.

- Chronic cutaneous lupus (DLE) lesions are characterized by discrete, erythematous, slightly infiltrated papules or plaques covered by a

FIGURE 180-4 Malar rash in adolescent Hispanic girl with SLE. Note the relative sparing of the nasolabial fold. (*Courtesy of the University of Texas Health Sciences Center, Division of Dermatology.*)

FIGURE 180-5 Malar rash with severe atrophy, scarring, and hypopigmentation in a young woman with arthritis and other signs of more systemic lupus. (*Courtesy of Richard P. Usatine, MD.*)

well-formed adherent scale (**Figures 180-9** to **180-15**). As the lesion progresses, the scale often thickens and becomes adherent. Hypopigmentation develops in the central area and hyperpigmentation develops at the active border. Resolution of the active lesion results in atrophy and scarring. When they occur in the scalp, scarring alopecia often results (**Figures 180-12** and **180-15**). If the scale on the scalp is removed, it may leave a "carpet tack sign" from follicular plugging.

- Subacute cutaneous lupus occurs most commonly in sun-exposed areas. The lesions are erythematous with scale and distinct borders or they may be annular in shape (**Figure 180-16**). The photosensitivity that exists explains the distribution of the lesions. Fortunately, these lesions do not scar or itch, but they may heal with postinflammatory hyperpigmentation.
- Acute cutaneous lupus is the name given for the cutaneous manifestations of systemic lupus such as the malar rash. This malar rash is also called a butterfly rash (**Figure 180-4**). This rash may heal without scarring.
- Raynaud phenomenon, libido reticularis, and palmar erythema also occur in persons with lupus (**Figure 180-17**). All three of these conditions can be made worse by cold weather.

TYPICAL DISTRIBUTION

- Discoid lesions are most often seen on the face, neck, and scalp, but also occur on the ears, and, infrequently, on the upper torso.
- DLE lesions may be localized or widespread. Localized DLE occurs only in the head and neck area, whereas widespread DLE occurs anywhere. Patients with widespread involvement are more likely to develop SLE.
- Subacute cutaneous lupus lesions are most commonly found in the sun-exposed areas of the face, neck, and arms (**Figure 180-16**).
- Acute cutaneous lupus is generally seen in the malar rash distribution, although it can occur on other parts of the body.
- Lupus panniculitis, or lupus profundus, is a variant of LE that primarily affects subcutaneous fat. It usually involves the proximal extremities, trunk, breasts, buttocks, and face (**Figure 180-18**).

LABORATORY TESTING

- The American College of Rheumatology recommends ANA testing in patients who have two or more unexplained signs or symptoms that could be lupus. Elevation of the ANA titer to or above 1:80 is the most sensitive of the American College of Rheumatology diagnostic criteria. Although many patients may have a negative ANA titer early in the disease, more than 99% of SLE patients will eventually have an elevated ANA titer.[9] The ANA test is not specific for lupus, and the most common reason for a positive ANA test without SLE (usually at titers <1:80) is the presence of another connective tissue disease.
- Active SLE is often heralded by a rise in immunoglobulin (Ig) G anti–double-stranded DNA titers and/or a fall in complement levels.[10]
- Patients with only DLE generally have negative or low-titer ANA titers, and rarely have low titers of anti-Ro antibodies.[11]

BIOPSY

A biopsy is often needed to confirm the diagnosis, even when the pattern seems typical. A 4-mm punch biopsy should provide adequate

FIGURE 180-6 Necrotizing angiitis in a 28-year-old Japanese American woman with a severe lupus flare. Palpable purpura was evident on both feet and hands. (*Courtesy of Richard P. Usatine, MD.*)

FIGURE 180-7 Necrotizing angiitis on the hand of the patient in Figure 180-6 with lupus. (*Courtesy of Richard P. Usatine, MD.*)

FIGURE 180-8 Leukocytoclastic vasculitis on the foot of a 69-year-old woman with systemic lupus. (*Courtesy of Richard P. Usatine, MD.*)

tissue to the pathologist. Biopsy confirmation is particularly helpful before starting potentially toxic medications.

DIFFERENTIAL DIAGNOSIS

- Drug-induced lupus is a lupus-like syndrome most strongly associated with procainamide, hydralazine, isoniazid, chlorpromazine, methyldopa, and quinidine.
- Scleroderma presents with thickening of the skin and multisystem sclerosis (see Chapter 182, Scleroderma and Morphea).
- Actinic keratosis on the face may become confluent but lacks the systemic symptoms of lupus (see Chapter 166, Actinic Keratosis and Bowen Disease).
- Dermatomyositis presents with facial swelling, "heliotrope" rash around the eyes, Gottron papules and periungual erythema in the hands, and proximal muscular limb girdle weakness. It is often associated with internal malignancy (see Chapter 181, Dermatomyositis).
- Lichen planus produces a polygonal pruritic purple papular rash (see Chapter 154, Lichen Planus).
- Psoriasis demonstrates silver-white plaques that cover the elbows, knees, scalp, back, or vulva. There may also be nail and scalp involvement (see Chapter 152, Psoriasis).
- Rosacea is associated with midfacial skin erythema, papules, and pustules without the systemic symptoms of LE, and usually involves the nasolabial folds (see Chapter 113, Rosacea).
- Sarcoidosis may produce skin plaques but without the central clearing and atrophy of LE (see Chapter 175, Sarcoidosis).
- Syphilis may produce a plaque-like rash that can be confused with DLE. The short course of the disease and serologic testing can distinguish the diseases. However, lupus autoantibodies may produce a false-positive screening test for syphilis (see Chapter 216, Syphilis).

MANAGEMENT

NONPHARMACOLOGIC

- Because UV light can flair SLE, sunscreen use, preferably one that blocks both UVA and UVB, should be encouraged. SOR C

MEDICATIONS

- Conservative management for SLE with NSAIDs or cyclooxygenase-2 selective inhibitors are recommended for arthritis, arthralgias, and myalgias.[12] SOR B
- Antimalarial drugs (hydroxychloroquine [Plaquenil] 200 mg bid, maximum 6.5 mg/kg per day) most commonly for skin manifestations and for musculoskeletal complaints that do not adequately respond to NSAIDs. They may also prevent major damage to the kidneys and CNS and reduce the risk of disease flares.[13] SOR B
- Systemic glucocorticoids (1 to 2 mg/kg per day of prednisone or equivalent) alone or with immunosuppressive agents for patients with significant renal and CNS disease or any other organ-threatening manifestation.[14] SOR B Lower doses of glucocorticoids (prednisone 10 to 20 mg/day) for symptomatic relief of severe or unresponsive musculoskeletal symptoms. In severe, life-threatening

FIGURE 180-9 Discoid lupus in a middle-aged black man with hypopigmentation and scarring of the pinna. (*Courtesy of Richard P. Usatine, MD.*)

FIGURE 180-10 Discoid lupus on the face and scalp of a 56-year-old woman with hyperpigmented lesions that are indurated and atrophic. She also has similar lesions on the back and has scarring alopecia. (*Courtesy of Richard P. Usatine, MD.*)

FIGURE 180-11 Discoid lupus with hypopigmentation and scarring inside the pinna. (*Courtesy of E.J. Mayeaux, Jr., MD.*)

FIGURE 180-13 Severe discoid lupus in a malar distribution on the face of a 30-year-old woman. Note this chronic cutaneous lupus has caused permanent scarring. (*Courtesy of Richard P. Usatine, MD.*)

FIGURE 180-12 Discoid lupus with scarring alopecia and hypopigmentation on the scalp and face. (*Courtesy of E.J. Mayeaux, Jr., MD.*)

FIGURE 180-14 Chronic cutaneous lupus on the face of this Hispanic man with significant erythema and changes of skin coloration. (*Courtesy of Richard P. Usatine, MD.*)

FIGURE 180-15 Severe chronic cutaneous lupus with hyperpigmentation, hypopigmentation, and scarring alopecia. Sun-exposed areas of the face and neck are heavily involved. (*Courtesy of Richard P. Usatine, MD.*)

FIGURE 180-17 Palmar erythema in this young woman with SLE and an ANA of 1–640. (*Courtesy of Richard P. Usatine, MD.*)

FIGURE 180-16 Subacute cutaneous lupus in a 47-year-old woman in sun-exposed areas of the face and V-neck. This all started after hydrochlorothiazide was begun for hypertension. Diagnosis was biopsy proven and the differential diagnosis includes a photosensitivity reaction related to the hydrochlorothiazide. (*Courtesy of Richard P. Usatine, MD.*)

FIGURE 180-18 Lupus profundus showing localized atrophic changes of the arm secondary to the panniculitis. This young woman also has the lupus profundus on the face and other arm. The atrophy has been present for more than 1 year despite treatment. (*Courtesy of Richard P. Usatine, MD.*)

TABLE 180-1 American College of Rheumatology Criteria for Diagnosis of Systemic Lupus Erythematosus

Criterion	Definition
1. Malar rash	Fixed erythema, flat or raised, over the malar eminences, tending to spare the nasolabial folds
2. Discoid rash	Erythematosus-raised patches with adherent keratotic scaling and follicular plugging and later atrophic scarring
3. Photosensitivity	Skin rash as a result of unusual reaction to sunlight, by history or physician observation
4. Oral ulcers	Oral or nasopharyngeal ulceration, usually painless, observed by a physician
5. Arthritis	Nonerosive arthritis involving 2 or more peripheral joints, characterized by tenderness, swelling, or effusion
6. Serositis	Pleuritis—convincing history of pleuritic pain or rub heard by a physician or evidence of pleural effusion *or* pericarditis documented by ECG, rub, or evidence of pericardial effusion
7. Renal disorder	Persistent proteinuria greater than 0.5 g/day or greater than 3+ if quantitation not performed *or* red cell, hemoglobin, granular, tubular, or mixed cellular casts
8. Neurologic disorder	Seizures *or* psychosis—in the absence of offending drugs or known metabolic derangements (uremia, ketoacidosis, or electrolyte imbalance)
9. Hematologic disorder	Hemolytic anemia with reticulocytosis *or* leukopenia (<4,000/mm^3 on 2 or more occasions) *or* lymphopenia (<1,500/mm^3 on 2 or more occasions) *or* thrombocytopenia (<100,000/mm^3) in the absence of offending drugs
10. Immunologic disorders	Positive antiphospholipid antibody *or* anti-DNA antibody to native DNA in abnormal titer *or* anti-Smith antibody—presence of antibody to Smith nuclear antigen *or* false-positive serologic test for syphilis known to be positive for at least 6 months and confirmed by *Treponema pallidum* immobilization or fluorescent treponemal antibody absorption test
11. Antinuclear antibody	An abnormal titer of antinuclear antibody by immunofluorescence or an equivalent assay at any point in time and in the absence of drugs known to be associated with "drug-induced lupus" syndrome

SLE can be diagnosed if any 4 or more of the 11 criteria are present, serially or simultaneously, during any interval of observation. *Source:* Modified from Callahan LF, Pincus T. Mortality in the rheumatic diseases. *Arthritis Care Res.* 1995;8:229. Reproduced with permission of Wiley Inc.

situations, methylprednisolone bolus (1 g IV/day) can be given for 3 consecutive days.

- Immunosuppressive medications (e.g., methotrexate, cyclophosphamide, azathioprine, mycophenolate, or rituximab) are generally reserved for patients with significant organ involvement, or who have had an inadequate response to glucocorticoids. SOR B[15]
- Belimumab (10 mg/kg IV every 2 weeks for 3 doses then every 4 weeks) may be used in patients with active SLE who are not responding to standard therapy, such as NSAIDs, glucocorticoids, antimalarials, and/or immunosuppressives.[16]
- Patients with thrombosis, usually associated to the presence of antiphospholipid antibodies, require anticoagulation with warfarin, for a target international normalized ratio (INR) of 3:3.5 for arterial thrombosis and 2:3 for venous thrombosis.[17]
- DLE therapy includes corticosteroids (topical or intralesional) and antimalarials. SOR C Alternative therapies include auranofin, oral or topical retinoids, and immunosuppressive agents.

PREVENTION

- Avoiding precipitating factors may decrease exacerbations.

PROGNOSIS

- SLE can have a varied clinical course, ranging from a relatively benign illness to a rapidly progressive disease with organ failure and death. Most patients have a relapsing and remitting course.
- Poor prognostic factors for survival in SLE include:[18]
  - Renal disease (especially diffuse proliferative glomerulonephritis).
  - Hypertension.
  - Male sex.
  - Young age.
  - Older age at presentation.
  - Poor socioeconomic status.
  - Black race, which may primarily reflect low socioeconomic status.
  - Presence of antiphospholipid antibodies.
  - Antiphospholipid syndrome.
  - High overall disease activity.

FOLLOW-UP

- The patient should have regular follow-up appointments to monitor for and attempt to prevent end organ damage. Regular follow-up visits are needed to monitor medication benefits and side effects and to coordinate care of the whole person.

PATIENT EDUCATION

- Educate the patient on the necessity of protection from the sun, as UV exposure can cause lupus flares. They should use a sunscreen, preferably one that blocks both UVA and UVB, with a minimum skin protection factor (SPF) of 30.
- Because cigarette smoking may increase the risk of developing SLE and smokers generally have more active disease, smokers with SLE should be counseled to quit smoking.
- Have patients report any signs of superinfection in their rash, as this requires antibiotic therapy.
- If possible, avoid sulfa drugs, which are related to lupus flares.

PATIENT RESOURCES

- PubMed Health. *Systemic Lupus Erythematosus*—**http://www.ncbi.nlm.nih.gov/pubmedhealth/PMH0001471/.**
- Mayo Clinic. *Lupus*—**http://www.mayoclinic.com/health/lupus/DS00115.**
- Womenshealth.gov. *Lupus Fact Sheet*—**http://womenshealth.gov/publications/our-publications/fact-sheet/lupus.cfm.**
- Lupus Foundation—**http://www.lupus.org.**

PROVIDER RESOURCES

- Medscape. *Systemic Lupus Erythematosus (SLE)*—**http://emedicine.medscape.com/article/332244.**
- Medscape. *Discoid Lupus Erythematosus*—**http://emedicine.medscape.com/article/1065529.**

REFERENCES

1. Lawrence RC, Helmick CG, Arnett FC, et al. Estimates of the prevalence of arthritis and selected musculoskeletal disorders in the United States. *Arthritis Rheum.* 1998;41(5):778-799.
2. Danchenko N, Satia JA, Anthony MS. Epidemiology of systemic lupus erythematosus: a comparison of worldwide disease burden. *Lupus.* 2006;15(5):308-318.
3. Pistiner M, Wallace DJ, Nessim S, et al. Lupus erythematosus in the 1980s: a survey of 570 patients. *Semin Arthritis Rheum.* 1991;21(1):55-64.
4. Healy E, Kieran E, Rogers S. Cutaneous lupus erythematosus—a study of clinical and laboratory prognostic factors in 65 patients. *Ir J Med Sci.* 1995;164(2):113-115.
5. Rowell NR. Laboratory abnormalities in the diagnosis and management of lupus erythematosus. *Br J Dermatol.* 1971;84(3):210-216.
6. Nagata S, Hanayama R, Kawane K. Autoimmunity and the clearance of dead cells. *Cell.* 2010;140(5):619-630.
7. Gill JM, Quisel AM, Rocca PV, Walters DT. Diagnosis of systemic lupus erythematosus. *Am Fam Physician.* 2003;68(11):2179-2186.
8. Hochberg MC. Updating the American College of Rheumatology revised criteria for the classification of SLE [letter]. *Arthritis Rheum.* 1997;40(9):1725.
9. Tan EM, Cohen AS, Fries JF, et al. The 1982 revised criteria for the classification of systemic lupus erythematosus. *Arthritis Rheum.* 1982;25(11):1271-1277.
10. Kao AH, Navratil JS, Ruffing MJ, et al. Erythrocyte C3d and C4d for monitoring disease activity in systemic lupus erythematosus. *Arthritis Rheum.* 2010;62(3):837-844.
11. Provost TT. The relationship between discoid and systemic lupus erythematosus. *Arch Dermatol.* 1994;130(10):1308-1310.
12. Lander SA, Wallace DJ, Weisman MH. Celecoxib for systemic lupus erythematosus: case series and literature review of the use of NSAIDs in SLE. *Lupus.* 2002;11(6):340-347.
13. Fessler BJ, Alarcon GS, McGwin G Jr, et al; LUMINA Study Group. Systemic lupus erythematosus in three ethnic groups: XVI. Association of hydroxychloroquine use with reduced risk of damage accrual. *Arthritis Rheum.* 2005;52(5):1473-1480.
14. Parker BJ, Bruce IN. High dose methylprednisolone therapy for the treatment of severe systemic lupus erythematosus. *Lupus.* 2007;16(6):387-393.
15. Fortin PR, Abrahamowicz M, Ferland D, et al; Canadian Network For Improved Outcomes in Systemic Lupus. Steroid-sparing effects of methotrexate in systemic lupus erythematosus: a double-blind, randomized, placebo-controlled trial. *Arthritis Rheum.* 2008;59(12):1796-1804.
16. FDA news release. *FDA Approves Benlysta to Treat Lupus*. www.fda.gov/NewsEvents/Newsroom/PressAnnouncements/ucm246489.htm. Accessed February 18, 2012.
17. Erkan D, Lockshin MD. New treatments for antiphospholipid syndrome. *Rheum Dis Clin North Am.* 2006;32(1):129-148.
18. Cervera R, Khamashta MA, Font J, et al; European Working Party on Systemic Lupus Erythematosus. Morbidity and mortality in systemic lupus erythematosus during a 10-year period: a comparison of early and late manifestations in a cohort of 1,000 patients. *Medicine (Baltimore).* 2003;82(5):299-308.

181 DERMATOMYOSITIS

Margaret L. Burks, BA
Anna Allred, MD
Richard P. Usatine, MD

PATIENT STORY

A 55-year-old Hispanic woman presents to her family physician with a diffuse rash and increasing muscle weakness. The initial rash (without weakness) 2 months prior was thought to be a photosensitivity reaction to her new hydrochlorothiazide (HCTZ) prescription. She stopped the HCTZ and the rash initially improved with some topical corticosteroids. At the time of her current presentation, she had trouble getting up from a chair, walking, and lifting her arms over her head. The rash was prominent in sun-exposed areas, but was also seen in a shawl-like distribution in non–sun-exposed areas (**Figure 181-1**). Aside from her hypertension and obesity, the patient did not have any previous chronic medical conditions. She was afebrile with no other pertinent findings on physical exam.

This is a classic presentation of dermatomyositis with the typical rash and proximal muscle weakness. Close attention to the rash around her eyes demonstrates the pathognomonic heliotrope rash of dermatomyositis (**Figures 181-2** and **181-3**). Also the patient has Gottron papules on the fingers, seen best in this case over the proximal interphalangeal (PIP) joint of the third finger (**Figure 181-4**). There was periungual erythema and ragged cuticles. The scalp was red and scaly. Her neurologic exam was consistent with proximal myopathy. She also had some trouble swallowing bread; and dysphagia is not unusual in dermatomyositis. Laboratory tests showed mild elevations in muscle enzymes with the aspartate aminotransferase (AST) having the greatest elevation. In other cases, the creatine kinase (CK) can be very elevated.

The family physician started the patient on 60 mg of prednisone daily and topical steroids for the affected areas. The patient responded well to prednisone and 2 weeks later was feeling stronger and the rash was fading (**Figure 181-5**). After 4 weeks of 60 mg/day of prednisone she was started on 10 mg/wk of methotrexate in order to eventually taper her steroids. The patient has continued to do well, but the rash and muscle weakness tend to recur when her steroids are being tapered. The patient was sent for physical therapy and started on calcium and vitamin D supplementation to protect her from steroid-induced osteoporosis. She was also given 1 mg/day of folic acid to minimize the adverse effects of methotrexate. As dermatomyositis may be precipitated by an underlying malignancy, the physician screened the patient for internal cancers, especially ovarian cancer. Fortunately, the mammogram, Papanicolaou (Pap) smear, colonoscopy, transvaginal ultrasound for ovarian imaging, and abdominal/pelvic CT scans were all normal.

FIGURE 181-1 Initial presentation of dermatomyositis in a 55-year-old Hispanic woman. Prominent violaceous erythema with scale is visible on the chest, face, and arms. Deep-red erythema is especially visible on the side of the face. The scalp is red and scaling. (*Courtesy of Richard P. Usatine, MD.*)

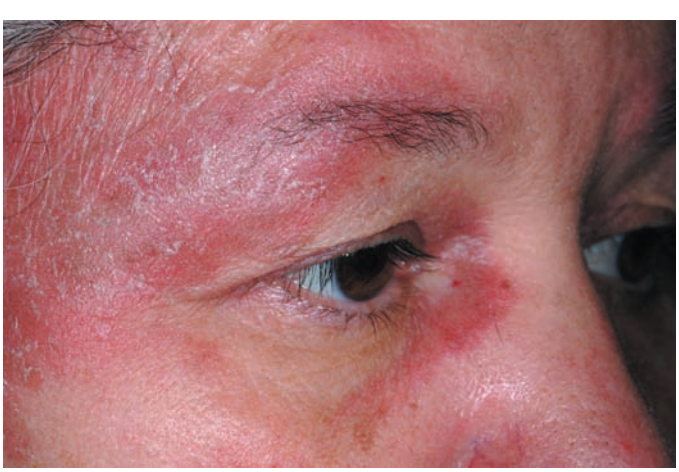

FIGURE 181-2 Close-up of the heliotrope (violaceous) rash around the eyes of the patient in **Figure 181-1**. (*Courtesy of Richard P. Usatine, MD.*)

INTRODUCTION

Dermatomyositis is a rare, idiopathic inflammatory disease involving the striated muscles and the skin. The disease is characterized by

progressive, symmetrical, proximal muscle weakness. Dermatologic manifestations may occur with or without muscular diseases and include the characteristic heliotrope rash (**Figures 181-2**, **181-3**, **181-5**, and **181-6**), "shawl sign," and Gottron papules of the PIP joints. Although primarily a disease of muscle and skin, dermatomyositis has a clear relationship with myocarditis and interstitial lung disease, as well as an increased risk of associated malignancy.

EPIDEMIOLOGY

- Annual incidence of 5 to 8.9 per 1 million population.[1]
- Seen more commonly in women.[1]
- Can affect any age; however, it is more common in children and older adults.[1]
- Thirty-five percent to 40% of patients with dermatomyositis also have interstitial lung disease. It is the most common internal organ manifestation of the disease and greatly affects morbidity and mortality.[1,2]
- Has been linked to malignancy in up to 15% to 24% of adults.[3]
- Cancers most commonly associated are breast, ovary, lung, and GI tract. The most common type of cancer is adenocarcinoma. Ovarian cancer is overrepresented in those patients with dermatomyositis and cancer. Cancer is not typically seen in children with dermatomyositis.
- In adults, the presence of anti-p155 autoantibodies has shown to be strongly associated with malignancy, with a 27-fold increase in odds.[4]

ETIOLOGY AND PATHOPHYSIOLOGY

- Dermatomyositis is considered an autoimmune disease of unknown etiology. Environmental exposure and infectious agents may play a role in disease pathogenesis.
- Dermatomyositis has been shown to be a microangiopathy that affects the skin and muscle. The muscle weakness and skin manifestations may be a result of activation and deposition of complement, which cause lysis of endomysial capillaries and muscle ischemia.

DIAGNOSIS

- Diagnosis includes 5 criteria: "definite" (skin findings plus any 3 of criteria 1 to 4), "probable" (skin findings plus 2 of any criteria 1 to 4), or "possible" (skin findings plus any 1 of criteria 1 to 4).[2,5,6]
  - Proximal symmetric muscle weakness that progresses over weeks to months.
  - Elevated serum levels of muscle enzymes (CK, AST, lactate dehydrogenase [LDH] and aldolase).
  - Abnormal electromyogram.

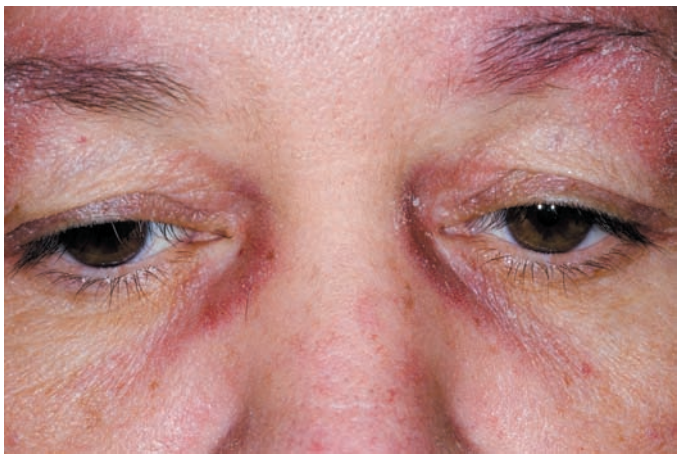

FIGURE 181-3 View showing the bilateral heliotrope rash of the patient in **Figure 181-1**. A pathognomonic sign of dermatomyositis. (*Courtesy of Richard P. Usatine, MD.*)

FIGURE 181-4 Hand involvement showing two Gottron papules over the knuckles (*arrows*) end erythematous nailfolds (periungual erythema) on the patient in **Figure 181-1**. (*Courtesy of Richard P. Usatine, MD.*)

- Abnormal muscle biopsy.
- Skin findings—Presence of cutaneous disease characteristic of dermatomyositis (heliotrope rash; Gottron papules are considered pathognomonic) (**Figures 181-2** to **181-8**). Nonpathognomonic manifestations include malar erythema, and periungual and cuticular changes (**Figure 181-9**).

- These criteria are still considered the "gold standard," although they are old (1975) and currently under critical review because of several limitations. The criteria do not include specific autoantibodies or MRI findings.[2,7,8]

Recent studies indicate that the dilated nailfold capillary loops (**Figure 181-10**) often seen in patients with dermatomyositis may help in earlier diagnosis and predicting patients with poor prognosis. Dilated nailfold capillary loops have shown promise in juvenile dermatomyositis as a marker for both skin and muscle disease activity to guide treatment. Some authors propose adding this finding to criteria for diagnosis.[9,10]

CLINICAL FEATURES

- Bilateral periorbital heliotrope erythema (pathognomonic) (**Figures 181-2**, **181-3**, **181-5**, and **181-6**) and scaling violaceous papular dermatitis in a patient complaining of proximal muscle weakness points to dermatomyositis.
- The patient may classically complain of difficulty climbing stairs, rising from a seat, or combing their hair. Notably the skin manifestations may precede, follow, or present simultaneously with muscle involvement; a patient may even have skin manifestations for longer than a year prior to developing muscle weakness.
- Hand involvement includes abnormal nailfolds and Gottron papules. "Moth-eaten" cuticles, also called the Samitz sign, are evidenced by periungual erythema and telangiectasias (**Figures 181-7** to **181-9**).
- Gottron papules, smooth, purple-to-red papules and plaques, are classically located over the knuckles and on the sides of fingers (**Figures 181-4**, **181-7**, and **181-8**). Plaques may be present over the knuckles instead of or in addition to papules. The papules are much more evident upon presentation of juvenile-onset dermatomyositis (**Figure 181-8**).
- Dysphagia can be present as a consequence of pharyngeal muscle involvement with risk of aspiration and pneumonia.
- Patients with concurrent interstitial lung disease may also present with fatigue, cough, dyspnea on exertion, and decreased exercise tolerance. Lung involvement usually appears following symptoms of myositis, although this is not always the case.[2]

TYPICAL DISTRIBUTION

- Face—The characteristic heliotrope rash occurs around the eyes. The color "heliotrope" is a pink-purple tint named after the color of the heliotrope flower. This color is best seen in **Figure 181-6**. The heliotrope rash can also be a dusky-red color as seen in **Figures 181-1** to **181-5**. This heliotrope rash is bilaterally symmetrical.

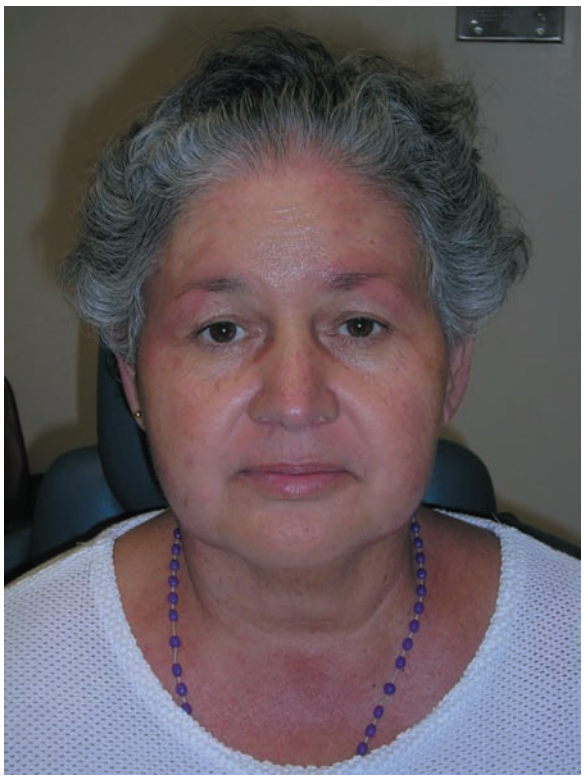

FIGURE 181-5 Patient improving after 2 weeks of oral prednisone. The heliotrope rash is still visible around the eyes and upper chest. The hairline erythema is from scalp involvement. (*Courtesy of Richard P. Usatine, MD.*)

FIGURE 181-6 Classic heliotrope rash around the eyes of this 19-year-old woman newly diagnosed with dermatomyositis. The color "heliotrope" is a pink-purple tint named after the color of the heliotrope flower. As expected, her heliotrope rash is bilaterally symmetrical. This rash resolved on prednisone and hydroxychloroquine. (*Courtesy of Richard P. Usatine, MD, and from Goodall J, Usatine RP. Skin rash and muscle weakness. J Fam Pract. 2005;54(10):864-868. Reproduced with permission from Frontline Medical Communications.*)

- Hands—There is usually hand involvement with Gottron papules (and plaques) and abnormal nailfolds and cuticles (**Figures 181-4** and **181-7** to **181-9**).
- Neck and upper trunk—A red or poikiloderma-type rash can be seen in a V-neck (**Figure 181-11**) or in a shawl distribution (**Figure 181-12**). Poikiloderma refers to hyperpigmentation of the skin demonstrating a variety of shades and associated with telangiectasias. The rash here can be scaling and look psoriasiform.
- Extremities may have erythematous plaques and papules with scale.
- Scalp is often involved with erythema and scale and appears similar to seborrhea or psoriasis.
- Sun-exposed areas are often involved and worsen with sun exposure. This is why so many of the skin findings are on the face and upper chest (**Figure 181-13**). However, patients rarely complain of sun sensitivity.

LABORATORY STUDIES AND DIAGNOSTIC TESTS

- Elevated muscle enzymes, evidence of inflammation on electromyography (EMG), and inflammatory infiltrates on muscle biopsy confirm the diagnosis of dermatomyositis. The following serum muscle enzymes can be drawn during the acute active phase and may be found to be elevated: CK, LDH, alanine aminotransferase, AST, and aldolase. Of note, it is necessary to measure all of the aforementioned enzymes as only one of them may be elevated.
- The diagnosis may be made with confidence in a patient with characteristic skin findings and elevated muscle enzymes. If the presentation is not straightforward, then EMG and muscle biopsy should be performed.
- The diagnosis can be supported with positive antibodies such as antinuclear antibody (ANA), anti-Mi-2, and anti-Jo-1. It is not necessary to order these antibodies to make the diagnosis of dermatomyositis. In fact, these myositis-specific antibodies are only positive in 30% of patients with dermatomyositis. Patients with anti-Mi-2 generally have a better overall prognosis.
- Other papulosquamous diseases, such as lichen planus and psoriasis, may be differentiated from dermatomyositis with a punch biopsy, but the histology of dermatomyositis is indistinguishable from cutaneous lupus erythematosus.
- Some experts recommend initial pulmonary function tests (PFTs), chest radiograph, and high-resolution CT to identify patients with interstitial lung disease early, regardless of presence or absence of respiratory symptoms.[11]
- PFTs demonstrate a restrictive pattern with presence of interstitial lung disease. Abnormal results must be confirmed by CT scan as PFT results may also reflect coexisting respiratory muscle weakness. Changes over time can be used to determine response to therapy, although intervals for testing are not clearly defined.[2]

BIOPSY

Muscle biopsy of dermatomyositis will show inflammatory cells around intramuscular blood vessels. Atrophic muscle fibers are seen around the periphery of muscle fascicles ("perifascicular atrophy").[1]

FIGURE 181-7 Hand involvement in the 19-year-old woman in **Figure 181-6** with Gottron papules over the finger joints. She has nailfold erythema and ragged cuticles (Samitz sign). (*Courtesy of Richard P. Usatine, MD, and from Goodall J, Usatine RP. Skin rash and muscle weakness. J Fam Pract. 2005;54(10):864-868. Reproduced with permission from Frontline Medical Communications.*)

FIGURE 181-8 Juvenile dermatomyositis in a young boy. Note how the erythematous papules and plaques are most prominent over the finger joints and spare the space between joints. This is a good example of Gottron papules being very visible in juvenile dermatomyositis. (*Courtesy of Richard P. Usatine, MD, and from Goodall J, Usatine RP. Skin rash and muscle weakness. J Fam Pract. 2005;54(10):864-868. Reproduced with permission from Frontline Medical Communications.*)

DIFFERENTIAL DIAGNOSIS

- Polymyositis is another form of inflammatory myopathy. It is distinguished from dermatomyositis by its lack of cutaneous involvement. Dermatomyositis can also occur without muscle involvement. This is called *dermatomyositis sine myositis* or *amyopathic dermatomyositis*.
- Polymorphous light eruption or other photosensitivity reactions may be mistaken for the dermatologic findings of dermatomyositis. As in the case of our patient, her cutaneous findings preceded her muscle weakness and the cutaneous findings were only in light-exposed areas. Therefore, it is essential in the management and follow-up with patients with suspected photosensitivity reactions to inquire about muscle weakness and to look for other signs of dermatomyositis. Examination of the hands and tests for muscle enzyme elevations might help to distinguish dermatomyositis from photosensitivity reactions (see Chapter 199, Photosensitivity).
- Hypothyroidism can cause a proximal myopathy just like polymyositis and dermatomyositis. Although hypothyroidism can cause a dermopathy, it does not resemble the skin findings of dermatomyositis. All patients with proximal muscle weakness should have a screening thyroid-stimulating hormone (TSH) to rule out hypothyroidism regardless of their skin findings (see Chapter 226, Goitrous Hypothyroidism).
- Rosacea causes an erythematous rash on the face as is often seen in dermatomyositis. Of course rosacea does not cause muscle weakness and the erythema of rosacea is generally confined to the face only (see Chapter 113, Rosacea).
- Steroid myopathy may develop as a side effect of systemic steroid therapy. The symptoms develop 4 to 6 weeks after starting oral steroids for dermatomyositis and other autoimmune diseases. Therefore if muscle weakness recurs after improving it could be from the steroids not the disease.
- Dermatomyositis-like reaction rarely may present with similar skin findings with initiation of the following medications and improvement with their discontinuation: penicillamine, NSAIDs, and carbamazepine.
- Overlap syndrome—The term *overlap* denotes that certain signs are seen in both dermatomyositis and other connective tissue diseases, such as scleroderma, rheumatoid arthritis, and lupus erythematosus. Scleroderma and dermatomyositis are the most commonly associated conditions and have been termed scleroderma-matomyositis or mixed connective disease. In mixed connective tissue disease, features of systemic lupus erythematosus (SLE), scleroderma, and polymyositis are evident, such as malar rash, alopecia, Raynaud phenomenon, waxy-appearing skin, and proximal muscle weakness.

MANAGEMENT

Given the autoimmune mechanism likely central to the disease process, treatment is geared toward the proximal muscle weakness and skin changes using immunosuppressive or immunomodulatory therapy. Treatment is nonspecific as the target antigen remains elusive.[4]

FIGURE 181-9 Dermatomyositis in a man showing cuticular changes that are thick, rough, and hyperkeratotic with telangiectasias. This moth-eaten appearance of the cuticles is called the Samitz sign. The hands also have the appearance of "mechanic's hands," another sign seen in dermatomyositis. (*Courtesy of the University of Texas Health Sciences Center, Division of Dermatology.*)

Cutaneous manifestations do not always parallel muscle disease in response to therapy. Clinical improvement should guide treatment regimen, and serum CK level should not be used as a sole guide for gauging responsiveness to therapy. Effective therapies for the myopathy are oral corticosteroids, immunosuppressant, biologic agents, and/or intravenous immunoglobulin. Effective therapies for the skin disease are sun protection, topical corticosteroids, antimalarials, methotrexate, and/or immunoglobulin. Drug therapy for dermatomyositis continues to be based on empirical rather than evidence-based practice because of lack of controlled trials.[12]

NONPHARMACOLOGIC

- Physical and/or occupational therapy to regain strength is highly recommended. Physical therapy will preserve muscle function and help to prevent atrophy and contractures.[13]
- In combination with exercise, oral creatine supplement was recently shown to improve muscle endurance and functionality in patients with dermatomyositis compared to placebo.[14]
- Photoprotection consisting of a broad-spectrum sunscreen, protective outerwear, and limiting sun exposure.[15–17] SOR B

TOPICAL TREATMENT

- Therapy of the skin disease begins with high-potency topical corticosteroids.[15,16,18] SOR B Triamcinolone ointment may be used for less-severe areas or on the face at first. Consider a short course of a very-high potency steroid, such as clobetasol, for more severe involvement not on the face.[5]
- Topical tacrolimus 0.1% is a useful adjunct in the treatment of refractory skin manifestations.[13] SOR B

ORAL TREATMENT

- First-line therapy for muscle disease is high-dose (1 mg/kg single daily dose) systemic corticosteroids, usually prednisone, with or without an immunosuppressive ("steroid-sparing") agent—methotrexate, cyclosporine, mycophenolate mofetil, or azathioprine.[3]
- Corticosteroids (either IV or oral) are also the first-line treatment for interstitial lung disease in patients with dermatomyositis. Approximately half of patients show response in respiratory symptoms. Refractory cases are treated with second-line calcineurin inhibitors (cyclosporine) or cyclophosphamide (oral or IV pulse), with or without corticosteroids. Methotrexate use is cautioned when there is coexisting lung disease, as it is a known cause of drug-induced interstitial lung disease.[2,19]
- Steroid taper (20% to 25% reduction monthly) should be initiated based on clinical responsiveness (increased muscle strength, energy) after 3 to 4 weeks on high-dose treatment.
- If no response by 3 months to oral high-dose steroids, another treatment approach should begin along with a reexamination of the diagnosis.[3,13] SOR B
- Methotrexate is effective in treating the muscular symptoms of childhood and adult refractory dermatomyositis as a steroid-sparing agent. Methotrexate significantly improves skin lesions as well.[20] SOR B

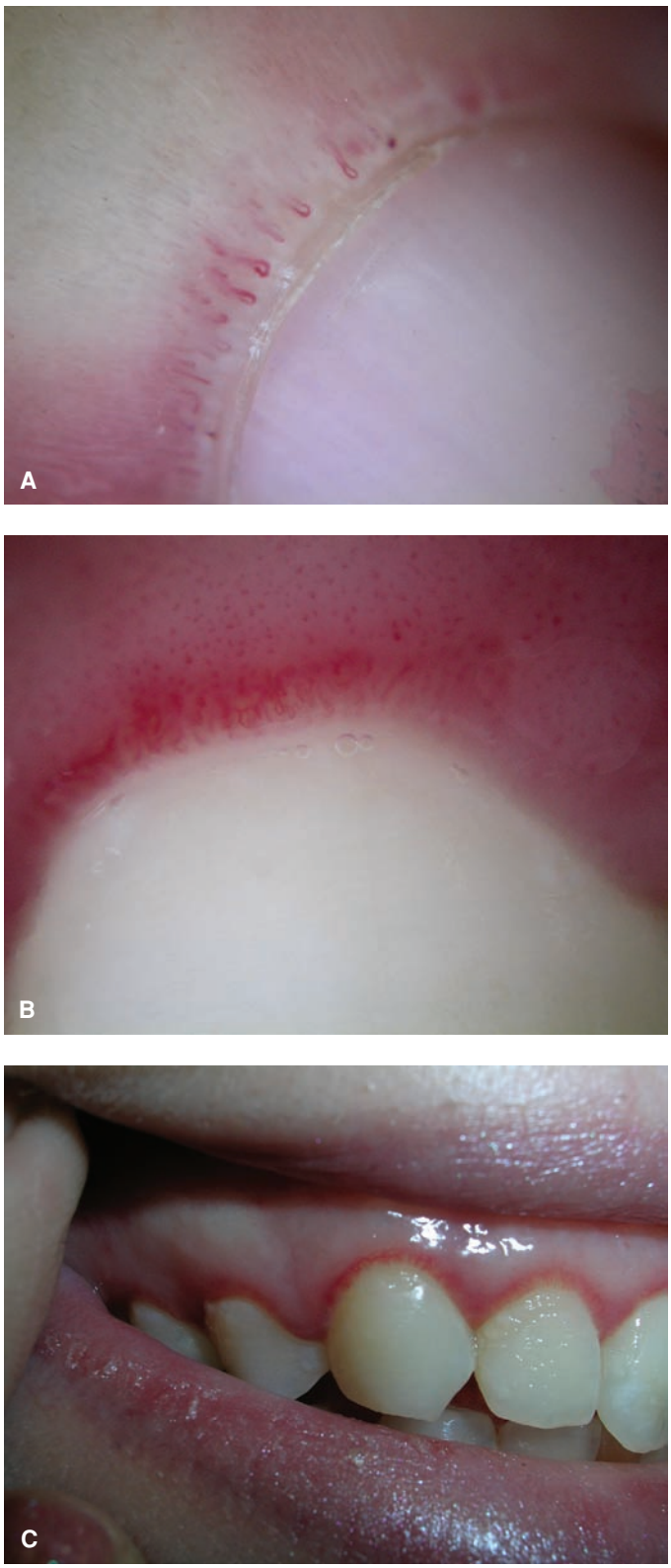

FIGURE 181-10 **A.** Dilated nailfold capillary loops visible with dermoscopy in a young woman with newly diagnosed dermatomyositis. **B.** She also had dilated capillary loops on the gingival borders of her teeth seen with dermoscopy. **C.** Marginal gingivitis in the same young woman with newly diagnosed dermatomyositis. The nailfold findings and gingival findings both resolved with treatment. (*Courtesy of Richard P. Usatine, MD.*)

- Methotrexate dosing starts at 10 to 15 mg/wk. The dose is then increased 2.5 mg/wk until a total dose of 15 to 25 mg/wk is reached. The total dose of methotrexate is also determined by how well the patient can tolerate this medication. Improvement is typically noted after 4 to 8 weeks of therapy.[13,18]
- Using methotrexate safely requires a number of precautions. All patients should have a purified protein derivative (PPD) placed or a quanta figure on gold assay performed to make sure that tuberculosis will not be activated. Patients with active liver disease, including hepatitis C and alcoholic cirrhosis, should receive alternative forms of therapy. Women should avoid becoming pregnant during therapy. Persons started on methotrexate should also be given 1 mg of folic acid daily to minimize the risk of side effects. The patient should be followed with regular laboratory testing, including complete blood counts and comprehensive metabolic profiles. Methotrexate should only be prescribed by doctors familiar with its risks and benefits.
- As the methotrexate dosage is increased, the dosage of prednisone should be tapered.
- Cyclosporine plus methotrexate has shown some benefit in the treatment of refractory juvenile and adult dermatomyositis.[13] SOR B Cyclosporine should cautiously be used with monitoring of blood pressure, renal function, liver function, and hematologic parameters.
- New data shows that methotrexate and cyclosporine both resulted in clinical improvement with no difference in efficacy or toxicity.[13]
- Azathioprine is commonly used in chronic inflammatory diseases as a steroid-sparing agent. It is usually administered up to 2 to 3 mg/kg per day. The combination of azathioprine and methotrexate may be more efficacious together with fewer side effects than when used alone. Azathioprine has been shown to have a slower clinical effect than methotrexate, but no difference was noted in efficacy.[13] Like all the other immunosuppressive agents, azathioprine must be used cautiously by physicians familiar with its risks.
- Tacrolimus has effects similar to cyclosporine, but has greater potency and is effective in refractory juvenile dermatomyositis.[13]
- Mycophenolate mofetil, an inhibitor of T- and B-cell proliferation, is a possible corticosteroid-sparing agent and affects both refractory cutaneous and muscular disease; however, concern regarding central nervous system (CNS) B-cell lymphoma and lack of controlled trials limits its use. It is also more costly than methotrexate or azathioprine.
- Cyclophosphamide is an alkylating agent that has been used sparingly in refractory cases of dermatomyositis. Lack of solid evidence of efficacy in dermatomyositis along with concerns that the agent may lead to later malignancies limits its use to severely refractory patients.
- Hydroxychloroquine is one option for a steroid-sparing agent, especially for the rash of dermatomyositis, that may be considered for young women with mild disease. SOR C Quinacrine and isotretinoin have shown promise in rashes that are unresponsive to hydroxychloroquine.[13]

FIGURE 181-11 Poikiloderma (erythema and mottled hyperpigmentation) on the neck of a 35-year-old Hispanic woman with dermatomyositis. The V-neck distribution is related to sun exposure. (*Courtesy of Richard P. Usatine, MD, and from Goodall J, Usatine RP. Skin rash and muscle weakness. J Fam Pract. 2005;54(10)864-868. Reproduced with permission from Frontline Medical Communications.*)

FIGURE 181-12 The shawl distribution of dermatomyositis. (*Courtesy of Richard P. Usatine, MD.*)

- Various combination therapies with two of the following agents have been studied, but are still empirical: azathioprine, cyclosporine, intramuscular methotrexate, and oral methotrexate.[17,18,21] SOR C
- Biologics, including tumor necrosis factor (TNF)-α inhibitors, are currently being tested for use in juvenile and adult dermatomyositis. Conflicting and discouraging initial results prompt the need for further clinical trials. Interferon-β, monoclonal complement antibodies, and anti–T-cell signaling drugs are currently under investigation.
- It is important to look at these medications' side-effect profile and monitor the patient accordingly during treatment. Patients must not get pregnant while on these medications and various labs need to be followed. A liver biopsy may be needed for patients taking methotrexate after a 1.5-g cumulative dose.

INTRAVENOUS TREATMENT

- Pulsed intravenous methylprednisolone has been advocated for severe disease (especially juvenile cases) and in refractory cases of myositis.[23] SOR C This treatment has also been recommended as first-line therapy for patients with associated interstitial lung disease.[1]
- In patients who are not responsive to traditional therapies, recent studies have found intravenous immunoglobulin (IVIG) to be an effective and relatively safe second-line therapy. Studies show improvement in muscle histology and cutaneous disease. Higher remission rates after 4 years are seen in patients receiving IVIG as part of therapy. IVIG is dosed 2 g/kg over 3 to 6 months with treatment for 2 to 5 consecutive days each month. High cost limits current use.[12,13] SOR C
- In one study, intravenous rituximab was shown to statistically increase long-term muscle strength in patients refractory to conventional therapy.[22] Thirteen patients were treated with rituximab 1000 mg IV, twice, with a 2-week interval, and followed for a median of 27 months. Patients experienced an increase in muscle strength and improvement in scores of disease activity, general health, functional ability, and health-related quality of life with sustained effect. Although rituximab is very expensive, these results are very promising for patients who are unresponsive to prednisone, methotrexate, and other conventional therapies.[22]

MALIGNANCY WORK-UP

- All patients with dermatomyositis, regardless of age, should undergo an age- and gender-relevant malignancy work-up beginning at the time of diagnosis. Cancer may be diagnosed before or after the diagnosis of dermatomyositis, but malignancy risk is highest at time of diagnosis or within 1 year. Some studies show an increased risk up to 5 years following diagnosis.[8,23]
- Screening should be performed with risks attributed to age, gender, ethnicity, and family history in mind.[24]
- For women newly diagnosed, a pelvic and transvaginal ultrasound, mammogram, CT thorax and abdomen, along with measurement of cancer antigen (CA)-125 level should be performed. Colonoscopy is recommended in patients older than age 50 years or with risk factors.[20]

FIGURE 181-13 A flare of dermatomyositis in a patient previously under control on medications now showing erythema on the lateral face, upper chest, and proximal arm. (*Courtesy of Richard P. Usatine, MD.*)

- For men, a testicular and prostate exam should be performed at diagnosis with colonoscopy if age older than 50 years.[25]
- If primary screening is negative, some experts recommend that a patient should be screened in 3 to 6 months and every 6 months up to 4 years following diagnosis. The value of surveillance of tumor markers such as CA-125 and CA-19-9 is debatable.[24,25]
- Given its suggestive high predictive value, some experts recommend more intensive and frequent screening for patients positive for the anti-p155 antibody.[4]
- In one study, conventional cancer screening (thoracoabdominal CT, mammography, gynecologic examination, ultrasound, and tumor marker analysis) and fluorodeoxyglucose-positron emission tomography (FDG-PET)/CT total-body screening had equivalent overall predictive values for diagnosing malignancy in patients with myositis.[26]

PROGNOSIS

Recent reports indicate that approximately 20% to 40% of patients treated achieve remission, although 80% of treated patients remained disabled. One study found the mortality ratio of patients with dermatomyositis to be 3-fold higher than the rest of the population. Cancer, lung, and cardiac complications are the most common cause of death. Poor prognostic indicators include older age, cardiac and lung involvement (interstitial lung disease [ILD]), and dysphagia. Certain antibodies have also been linked to higher mortality rates and greater risk of malignancy.[7]

FOLLOW-UP

The patients need very close and frequent follow-up to manage their medications and overall care, as well as continued surveillance for malignancy. High doses of steroids and steroid-sparing agents, such as methotrexate, have numerous potential side effects. The patients need to be closely followed with laboratory tests and careful titration of the toxic medicines used for treatment. Also the patients need physical therapy, periodic eye exams for cataracts and glaucoma, and specific supplements including calcium, vitamin D and folic acid to prevent some of the side effects of the strong medications being prescribed. Patients on long-term corticosteroids especially need efforts made to prevent and detect osteoporosis.

PATIENT EDUCATION

Discuss the importance of sun protection as sun exposure does make the cutaneous manifestations worse. Counseling about the serious nature of the disease and prognosis is important as many patients are left with residual weakness even after good disease control is obtained. Patients need to understand that the medications being used have many risks along with their benefits and need to report side effects to their physicians. Pregnancy prevention is needed for women of childbearing potential while on a number of the medications used to treat this disease.

PATIENT RESOURCES

- The Myositis Association. **www.myositis.org.**
- National Institute of Neurological Disorders and Stroke. *NINDS Dermatomyositis Information Page*—**www.ninds.nih.gov/disorders/dermatomyositis/dermatomyositis.htm.**

PROVIDER RESOURCES

- Medscape. *Dermatomyositis*—**http://emedicine.medscape.com/article/332783.**
- MedicineNet. *Polymyositis & Dermatomyositis*—**http://www.medicinenet.com/polymyositis/article.htm.**

REFERENCES

1. Robinson AB, Reed AM. Clinical features, pathogenesis and treatment of juvenile and adult dermatomyositis. *Nat Rev Rheumatol.* 2011;7(11):664-675.
2. Connors GR, Christopher-Stine L, Oddis CV, Danoff SK. Interstitial lung disease associated with the idiopathic inflammatory myopathies: what progress has been made in the past 35 years? *Chest.* 2010;138(6):1464-1474.
3. Dalakas MC. Immunotherapy of inflammatory myopathies: practical approach and future prospects. *Curr Treat Options Neurol.* 2011;13(3):311-323.
4. Trallero-Araguás E, Rodrigo-Pendás J, Selva-O'Callaghan A, et al. Usefulness of anti-p155 autoantibody for diagnosing cancer-associated dermatomyositis. *Arthritis Rheum.* 2012;64(2):523-532.
5. Bohan A, Peter JB. Polymyositis and dermatomyositis (first of two parts). *N Engl J Med.* 1975;292(7):344-347.
6. Bohan A, Peter JB. Polymyositis and dermatomyositis (second of two parts). *N Engl J Med.* 1975;292(8):403-407.
7. Marie I. Morbidity and mortality in adult polymyositis and dermatomyositis. *Curr Rheumatol Rep.* 2012;14(3):275-285.
8. Madan V, Chinoy H, Griffiths CE, Cooper RG. Defining cancer risk in dermatomyositis. Part I. *Clin Exp Dermatol.* 2009;34(4):451-455.
9. Schmeling H, Stevens S, Goia C, et al. Nailfold capillary density is importantly associated over time with muscle and skin disease activity in juvenile dermatomyositis. *Rheumatology.* 2011;50(5):885-893.
10. Selva-O'Callaghan A, Fonollosa-Pla V, Trallero-Araguás E, et al. Nailfold capillary microscopy in adults with inflammatory myopathy. *Semin Arthritis Rheum.* 2010;39(5):398-404.
11. Fathi M, Dastmalchi M, Rasmussen E, et al. Interstitial lung disease, a common manifestation of a newly diagnosed polymyositis and dermatomyositis. *Ann Rheum Dis.* 2004;63(3):297-301.
12. Wang DX, Shu XM, Tian XL, et al. Intravenous immunoglobulin therapy in adult patients with polymyositis/dermatomyositis: a systematic literature review. *Clin Rheumatol.* 2012;31(5):801-806.
13. Aggarwal R, Oddis CV. Therapeutic approaches in myositis. *Curr Rheumatol Rep.* 2011;13(3):182-191.
14. Chung Y, Alexanderson H, Pipitone N, et al. Creatine supplements in patients with idiopathic inflammatory myopathies who are clinically weak after conventional pharmacologic treatment: six-month, double-blind, randomized, placebo controlled trial. *Arthritis Rheum.* 2007;57(4):694-702.
15. Callen JP. Dermatomyositis: diagnosis, evaluation and management. *Minerva Med.* 2002;93(3):157-167.
16. Callen JP, Wortmann RL. Dermatomyositis. *Clin Dermatol.* 2006;24(5):363-373.
17. Choy EH, Isenberg DA. Treatment of dermatomyositis and polymyositis. *Rheumatology (Oxford).* 2002;41(1):7-13.
18. Habif T. *A Color Guide to Diagnosis and Therapy, Clinical Dermatology*, 4th ed. St. Louis, MO: Mosby; 2004.
19. Mimori T, Nakashima R, Hosono Y. Interstitial lung disease in myositis: clinical subsets, biomarkers, and treatment. *Curr Rheumatol Rep.* 2012;14(3):264-274.
20. Hornung T, Ko A, Tuting T, et al. Efficacy of low-dose methotrexate in the treatment of dermatomyositis skin lesions. *Clin Exp Dermatol.* 2011;37(2):139-142.
21. Choy EH, Hoogendijk JE, Lecky B, Winer JB. Immunosuppressant and immunomodulatory treatment for dermatomyositis and polymyositis. *Cochrane Database Syst Rev.* 2005;20(3):CD003643.
22. Mahler EA, Blom M, Voermans NC, et al. Rituximab treatment in patients with refractory inflammatory myopathies. *Rheumatology.* 2011;50(12):2206-2213.
23. Zahr ZA, Baer AN. Malignancy in myositis. *Curr Rheumatol Rep.* 2011;13(3):208-215.
24. Madan V, Chinoy H, Griffiths CE, Cooper RG. Defining cancer risk in dermatomyositis. Part II. Assessing diagnostic usefulness of myositis serology. *Clin Exp Dermatol.* 2009;34(5):561-565.
25. Titulaer MJ, Soffietti R, Dalmau J, et al; European Federation of Neurological Societies. Screening for tumors in paraneoplastic syndromes: report of an EFNS Task Force. *Eur J Neurol.* 2011;18(1):19-27.
26. Selva-O'Callaghan A, Grau JM, Gámez-Cenzano C, et al. Conventional cancer screening versus PET/CT in dermatomyositis/polymyositis. *Am J Med.* 2010;123(6):558-562.

182 SCLERODERMA AND MORPHEA

E.J. Mayeaux, Jr., MD

PATIENT STORY

A 35-year-old woman presented with areas of shiny tough skin in patches over her abdomen (**Figure 182-1**). The patient was otherwise in good health and was puzzled by this new condition. She feared that all her skin would become this way. The skin was slightly uncomfortable but not painful. A 3-mm punch biopsy confirmed the clinical suspicion of morphea or localized scleroderma. The patient was treated with topical clobetasol and calcipotriol with some improvement in skin quality and symptoms. An antinuclear antibody (ANA) test was positive, but she has not developed progressive systemic sclerosis.

FIGURE 182-1 Morphea on the abdomen in a 35-year-old woman. (*Courtesy of Richard P. Usatine, MD.*)

INTRODUCTION

Scleroderma (from the Greek *scleros*, to harden) is a term that describes the presence of thickened, hardened skin. It may affect only limited areas of the skin (morphea), most or all of the skin (scleroderma), or also involve internal organs (systemic sclerosis).

EPIDEMIOLOGY

- The prevalence rates of diseases that share scleroderma as a clinical feature are reported ranging from 4 to 253 cases per 1 million individuals.[1]
- Systemic sclerosis has an annual incidence of 1 to 2 per 100,000 individuals in the United States.[1] The peak onset is between the ages of 30 and 50 years.[1]
- In the United States, the incidence of morphea has been estimated at 25 cases per 1 million individuals per year.[1]
- Worldwide, there are higher rates in the United States and Australia than in Japan or Europe.[2]
- Pulmonary fibrosis and pulmonary arterial hypertension are the leading causes of death as a consequence of these diseases.[3]

ETIOLOGY AND PATHOPHYSIOLOGY

- The scleroderma disorders can be subdivided into three groups: localized scleroderma (morphea; **Figures 182-1** to **182-3**), systemic sclerosis (**Figures 182-4** to **182-9**), and other scleroderma-like disorders that are marked by the presence of thickened, sclerotic skin lesions.
- The most common vascular dysfunction associated with scleroderma is Raynaud phenomenon (**Figure 182-10**). Raynaud phenomenon is produced by arterial constriction in the digits. The

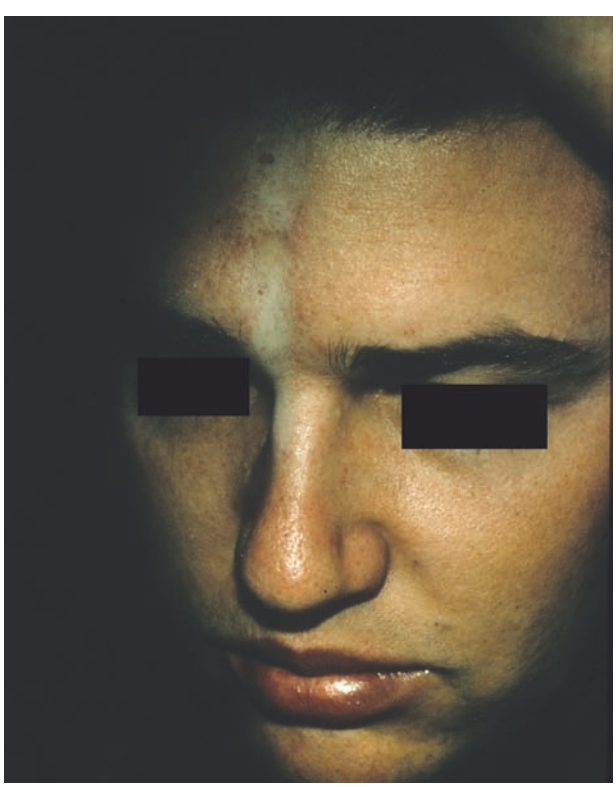

FIGURE 182-2 Linear morphea on the forehead called "en coup de sabre," meaning the blow of a sword. (*Courtesy of John Gonzalez, MD.*)

characteristic color changes progress from white pallor, to blue (acrocyanosis), to finally red (reperfusion hyperemia). Raynaud phenomenon generally precedes other disease manifestations, sometimes by years. Many patients develop progressive structural changes in their small blood vessels, which permanently impair blood flow, and can result in digital ulceration or infarction. Other forms of vascular injury include pulmonary artery hypertension, renal crisis, and gastric antral vascular ectasia.

- Systemic sclerosis is used to describe a systemic disease characterized by skin induration and thickening accompanied by variable tissue fibrosis and inflammatory infiltration in numerous visceral organs. Systemic sclerosis can be diffuse (DcSSc) or limited to the skin and adjacent tissues (limited cutaneous systemic sclerosis [LcSSc]).
- Patients with LcSSc usually have skin sclerosis restricted to the hands and, to a lesser extent, the face and neck. With time, some patients develop scleroderma of the distal forearm. They often display the CREST syndrome, which presents with Raynaud phenomenon (**Figure 182-10**), esophageal dysmotility, sclerodactyly (**Figures 182-4** to **182-7**), telangiectasias (**Figures 182-8** and **182-9**), and calcinosis cutis (**Figure 182-11**).
- Patients with DcSSc often present with sclerotic skin on the chest, abdomen, or upper arms and shoulders. The skin may take on a "salt-and-pepper" look (**Figure 182-12**). They are more likely to develop internal organ damage caused by ischemic injury and fibrosis than those with LcSSc or morphea.
- Almost 90% of patients with systemic sclerosis have some GI involvement,[4] although half of these patients may be asymptomatic. Any part of the GI tract may be involved. Potential signs and symptoms include dysphagia, choking, heartburn, cough after swallowing, bloating, constipation and/or diarrhea, pseudoobstruction, malabsorption, and fecal incontinency. Chronic gastroesophageal reflux and recurrent episodes of aspiration may contribute to the development of interstitial lung disease. Vascular ectasia in the stomach (often referred to as "water-melon stomach" on endoscopy) is common, and may lead to GI bleeding and anemia.
- Pulmonary involvement is seen in more than 70% of patients, usually presenting as dyspnea on exertion and a nonproductive cough. Fine "Velcro" rales may be heard at the lung bases with lung auscultation. Pulmonary vascular disease occurs in 10% to 40% of patients with systemic sclerosis, and is more common in patients with limited cutaneous disease. The risk of lung cancer is increased approximately 5-fold in patients with scleroderma.
- Autopsy data suggest that 60% to 80% of patients with DcSSc have evidence of kidney damage.[5] Some degree of proteinuria, a mild elevation in the plasma creatinine concentration, and/or hypertension are observed in as many as 50% of patients.[6] Severe renal disease develops in 10% to 15% of patients, most commonly in patients with DcSSc.
- Symptomatic pericarditis occurs in 7% to 20% of patients, which has a 5-year mortality rate of 75%.[7] Primary cardiac involvement includes pericarditis, pericardial effusion, myocardial fibrosis, heart failure, myocarditis associated with myositis, conduction disturbances, and arrhythmias.[8] Patchy myocardial fibrosis is

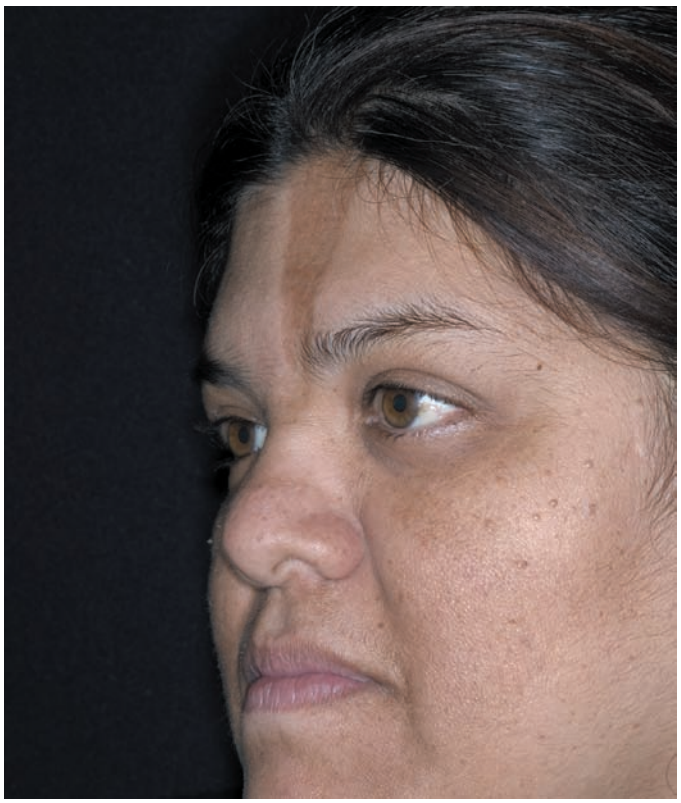

FIGURE 182-3 Linear morphea that started 3 years before on the forehead of a 41-year-old Hispanic woman. Another example of "en coup de sabre," meaning the blow of a sword. (*Courtesy of Richard P. Usatine, MD.*)

FIGURE 182-4 Scleroderma showing sclerodactyly with tight shiny skin over the fingers. (*Courtesy of Everett Allen, MD.*)

FIGURE 182-5 Sclerodactyly with tapering of the fingers and mottled hyperpigmentation. (*Courtesy of Jeffrey Meffert, MD.*)

FIGURE 182-6 Severe scleroderma with deformity of hands as a result of sclerodactyly leading to severe flexion contractures. (*Courtesy of Jeffrey Meffert, MD.*)

FIGURE 182-7 Scleroderma on the patient in **Figure 182-6** showing leg involvement with muscle atrophy. (*Courtesy of Jeffrey Meffert, MD.*)

FIGURE 182-8 Scleroderma with telangiectasias and digital necrosis of the hands. (*Courtesy of Everett Allen, MD.*)

FIGURE 182-9 Telangiectasias on the face of the patient in **Figure 182-8**. (*Courtesy of Everett Allen, MD.*)

FIGURE 182-10 Raynaud phenomenon with severe ischemia leading to the necrosis of the fingertips. (*Courtesy of Ricardo Zuniga-Montes, MD.*)

characteristic of systemic sclerosis, and is thought to result from recurrent vasospasm of small vessels. Arrhythmias are common and are most caused by fibrosis of the conduction system.

- Pulmonary vascular disease occurs in 10% to 40% of patients with scleroderma, and is more common in patients with limited cutaneous disease. It may occur in the absence of significant interstitial lung disease, generally a late complication, and is usually progressive. Severe pulmonary arterial hypertension, sometimes with pulmonale and right-sided heart failure or thrombosis of the pulmonary vessels may develop.
- Joint pain, immobility and contractures may develop, with contractures of the fingers being most common (**Figure 182-6**). Neuropathies and central nervous system involvement, including headache, seizures, stroke, vascular disease, radiculopathy, and myelopathy, occur.
- Scleroderma produces sexual dysfunction in men and women. In men, it is very frequently associated with erectile dysfunction.

DIAGNOSIS

CLINICAL FEATURES

- The diagnosis of systemic sclerosis and related disorders is based primarily upon the presence of characteristic clinical findings. Skin involvement is characterized by variable thickening and hardening of the skin. Skin pigmentary changes may occur, especially a salt-and-pepper appearance from spotty hypopigmentation (**Figure 182-12**). Other prominent skin manifestations include:
  - Pruritus and edema in the early stages.
  - Sclerodactyly (**Figures 182-4** to **182-6**).
  - Digital ulcers and pitting at the fingertips (**Figures 182-8** and **182-10**).
  - Telangiectasia (**Figures 182-8** and **182-9**).
  - Calcinosis cutis (**Figure 182-11**).
- The diagnosis of localized scleroderma (morphea) is suggested by the presence of typical skin thickening and hardening confined to one area (**Figures 182-1** to **182-3**). The diagnosis of systemic sclerosis is suggested by the presence of typical skin thickening and hardening (sclerosis) that is not confined to one area (i.e., not localized scleroderma). The combination of skin signs plus one or more of the typical systemic features supports the diagnosis of systemic sclerosis.
- The American College of Rheumatology criteria[9] for the diagnosis of systemic sclerosis requires one major criterion or two minor criteria:
  - The major criterion is typical sclerodermatous skin changes: tightness, thickening, and nonpitting induration, excluding the localized forms of scleroderma including:
    - Sclerodactyly—Above-indicated changes limited to fingers and toes. This can include sausage fingers with tuft resorption (**Figure 182-13**).
    - Proximal scleroderma—Above-indicated changes proximal to the metacarpophalangeal or metatarsophalangeal joints, affecting other parts of the extremities, face, neck, or trunk (thorax or abdomen) almost always including sclerodactyly (**Figure 182-14**).

FIGURE 182-11 Calcinosis over the elbow in a patient with CREST syndrome. (*Courtesy of Everett Allen, MD.*)

FIGURE 182-12 Scleroderma with mottled hypopigmentation. The skin may have a salt-and-pepper appearance as shown here. (*Courtesy of Ricardo Zuniga-Montes, MD.*)

FIGURE 182-13 Sclerodactyly and sausage fingers in a 56-year-old woman with scleroderma and CREST syndrome. Note how the fingers are shortened secondary to digital tuft resorption and loss of substance from finger pads. There is also a salt-and-pepper appearance to the skin on the dorsum of the hands. (*Courtesy of Richard P. Usatine, MD.*)

- Minor criteria:
  - Digital pitting scars or a loss of substance from the finger pad (**Figure 182-15**).
  - Bilateral finger or hand pitting edema.
  - Abnormal skin pigmentation: hyperpigmentation often with areas of punctate or patchy hypopigmentation (**Figure 182-12**).
  - Raynaud phenomenon.
  - Bibasilar pulmonary fibrosis (**Figure 182-14**).
  - Lower (distal) esophageal dysmotility.
  - Colonic sacculations: wide-mouthed diverticula of colon located along the antimesenteric border.

LABORATORY TESTING

- A positive ANA with a speckled, homogenous, or nucleolar staining pattern is common in scleroderma. Anticentromere antibodies are often associated with LcSSc. Anti-DNA topoisomerase I (Scl-70) antibodies are highly specific for both systemic sclerosis, and related interstitial lung and renal disease.[10] Although not very sensitive, anti-RNA polymerases I and III antibodies are specific for systemic sclerosis. Other testing for specific organ dysfunction is routinely done.
- The presence of characteristic autoantibodies, such as anticentromere, antitopoisomerase I (Scl-70), anti-RNA polymerase, or U3-RNP antibodies, is supportive of the diagnosis of systemic sclerosis.

IMAGING

All patients with systemic sclerosis should have a chest x-ray (CXR) and pulmonary function tests (PFTs) screening for pulmonary involvement. The most common types of pulmonary involvement are interstitial lung disease and pulmonary hypertension.

The diffusing capacity (as part of PFTs) is the most sensitive test for pulmonary disease in systemic sclerosis. High-resolution CT may be indicated for further evaluation of active pulmonary disease.

BIOPSY

- A punch biopsy can be used to diagnose morphea and scleroderma when the clinical diagnosis is not clear.

DIFFERENTIAL DIAGNOSIS

- Idiopathic occurrence of systemic sclerosis associated diseases such as Raynaud phenomenon, renal failure, and gastroesophageal reflux disease.
- Systemic lupus erythematosus (SLE) presents with systemic symptoms and a typical rash that may be scarring. ANA testing usually helps establish the diagnosis (see Chapter 180, Lupus: Systemic and Cutaneous).
- Discoid lupus erythematosus (DLE) presents as localized plaque lesion that eventually scar. Biopsy usually makes the diagnosis (see Chapter 180, Lupus: Systemic and Cutaneous).
- Myxedema is associated with hypothyroidism and is characterized by thickening and coarseness of the skin. Thyroid testing usually makes the diagnosis (see Chapter 226, Goitrous Hypothyroidism).

FIGURE 182-14 Proximal scleroderma on the face of a 56-year-old woman with scleroderma and CREST syndrome. Note the telangiectasias and a distinctive tightening of the skin around the lips. This patient also has pulmonary fibrosis as part of her progressive systemic sclerosis. (*Courtesy of Richard P. Usatine, MD.*)

FIGURE 182-15 Digital pitting scars and loss of substance from finger pads in this 27-year-old woman with scleroderma and sclerodactyly. (*Courtesy of Richard P. Usatine, MD.*)

- Lichen sclerosus when it occurs away from the genital area can resemble morphea. Although it most commonly affects the genital and perianal area, it can occur on the upper trunk, breasts, and upper arms. The plaques appear atrophic but a thin cigarette-paper crinkling appearance may help to differentiate it from morphea. A punch biopsy will lead to the correct diagnosis.
- Amyloidosis of the skin may result in thickening and stiffness of the skin. Skin biopsy reveals amyloid infiltration. Biopsy usually makes the diagnosis.
- Mycosis fungoides presents with purplish macules and plaques throughout the body. Biopsy usually makes the diagnosis (see Chapter 176, Mycosis Fungoides).

MANAGEMENT

NONPHARMACOLOGIC

- Localized scleroderma, including morphea, appears to soften with UVA light therapy.[11] SOR B
- For symptomatic therapy, skin lubrication, histamine 1 (H_1) and histamine 2 (H_2) blockers, oral doxepin, and low-dose oral glucocorticoids may be used to treat pruritus. SOR C
- Telangiectasias may be covered with foundation make-up or treated with laser therapy.

MEDICATIONS

- Treatment options for morphea include high-potency topical steroids such as clobetasol and topical calcipotriol.[12] SOR B
- Small localized lesions of morphea can be removed surgically. SOR C
- The combination of high-dose oral prednisone and low-dose oral methotrexate has been used successfully for scleroderma.[13] SOR B Methotrexate can be started at 7.5 mg PO weekly and titrated up as needed. Of course the long-term goal is to taper the prednisone while using the oral methotrexate as a steroid-sparing agent.
- Calcium channel blockers, prazosin, prostaglandin derivatives, dipyridamole, aspirin, and topical nitrates may help symptoms of Raynaud phenomenon.[14,15] SOR B Sildenafil (20 mg PO tid) has also been shown to be effective in patients with primary Raynaud phenomenon.[16] SOR B Patients should be advised to avoid cold, stress, nicotine, caffeine, and sympathomimetic decongestant medications. Acid-reducing agents may be used empirically for gastroesophageal reflux disease. Prokinetic agents, such as erythromycin, may be useful for patients with esophageal hypomotility. SOR C
- Unapproved therapies for skin disease include interferon-γ, mycophenolate mofetil (1 to 1.5 g PO bid), and cyclophosphamide (50 to 150 mg/day PO in a single AM dose). Extensive skin disease is being experimentally treated with D-penicillamine (250 to 1500 mg/day PO bid/tid on an empty stomach).[17] SOR B
- The mainstay of treatment of renal disease is control of blood pressure, with angiotensin-converting enzyme (ACE) inhibitors being

the first-line agent. SOR C Hemodialysis or peritoneal dialysis may be used as needed.

- Treatments of pulmonary hypertension associated with the systemic sclerosis being tested include the endothelin receptor antagonist bosentan (62.5 mg PO bid for 4 weeks, then increase to 125 mg PO bid), the phosphodiesterase-5 inhibitor sildenafil, and various prostacyclin analogs (e.g., epoprostenol, treprostinil, and iloprost). Pulmonary fibrosing alveolitis may be treated with cyclophosphamide.[18] SOR B
- Myositis may be treated with oral prednisone, methotrexate, and azathioprine (50 to 150 mg daily). Doses of prednisone greater than 40 mg/day are associated with a higher incidence of scleroderma renal crisis.[19] SOR B Arthralgias can be treated with acetaminophen and NSAIDs. SOR C
- Any patient on long-term oral prednisone needs to be monitored for osteoporosis and diabetes. Osteoporosis prevention should include weight-bearing exercise, calcium, vitamin D supplements, and yearly dual-energy x-ray absorptiometry (DEXA) scanning to determine when and if additional medications are needed.

REFERRAL

Patients with systemic sclerosis should be referred to a rheumatologist as this is a complicated disease that requires the use of toxic medications. Depending upon the complications, patients with scleroderma may also need referral to pulmonology, cardiology, and nephrology.

PROGNOSIS

- There is an increase in the risk of premature death with systemic sclerosis. Most deaths among these patients are a result of pulmonary fibrosis and/or pulmonary hypertension. Mortality also results from renal crisis, cardiac disease, infections, malignancies, and cardiovascular disease.[20]
- The prognosis for morphea is excellent as it only affects the skin. Although the appearance may be disturbing to the patient it is not life-threatening. If the morphea is extensive and over an extremity, it can affect function (**Figure 182-16**).

FIGURE 182-16 Localized morphea of the leg in this young girl. Although her disease is not systemic, the tightening of the skin around the knee does cause problems with knee movement and ambulation. (*Courtesy of Richard P. Usatine, MD.*)

FOLLOW-UP

- The patient with systemic sclerosis needs to be evaluated at least every 3 to 6 months to monitor disease activity and progression.

PATIENT EDUCATION

- Instruct the patient to avoid skin trauma (especially the fingers), cold exposure, and smoking. Make patients aware of potential complications and have them watch for signs of systemic disease occurrence or progression.

PATIENT RESOURCES

- American College of Rheumatology. *Scleroderma (Also Known as Systemic Sclerosis)*—**http://www.rheumatology.org/practice/clinical/patients/diseases_and_conditions/scleroderma.asp.**
- Scleroderma Foundation. **http://www.scleroderma.org/.**
- International Scleroderma Network. **http://www.sclero.org.**

PROVIDER RESOURCES

- National Institute of Arthritis and Musculoskeletal and Skin Diseases. *Handout on Health: Scleroderma*—**http://www.niams.nih.gov/Health_Info/Scleroderma/default.asp.**
- Medscape. *Scleroderma*—**http://emedicine.medscape.com/article/331864.**

REFERENCES

1. Lawrence RC, Helmick CG, Arnett FC, et al. Estimates of the prevalence of arthritis and selected musculoskeletal disorders in the United States. *Arthritis Rheum.* 1998;41(5):778-799.
2. Chifflot H, Fautrel B, Sordet C, et al. Incidence and prevalence of systemic sclerosis: a systematic literature review. *Semin Arthritis Rheum.* 2008;37(4):223-235.
3. Steen VD, Lucas M, Fertig N, Medsger TA Jr. Pulmonary arterial hypertension and severe pulmonary fibrosis in systemic sclerosis patients with a nucleolar antibody. *J Rheumatol.* 2007;34(11):2230-2235.
4. Akesson A, Wollheim FA. Organ manifestations in 100 patients with progressive systemic sclerosis: a comparison between the CREST syndrome and diffuse scleroderma. *Br J Rheumatol.* 1989;28(4):281-286.
5. Medsger TA Jr, Masi AT. Survival with scleroderma. II. A life-table analysis of clinical and demographic factors in 358 male U.S. veteran patients. *J Chronic Dis.* 1973;26(10):647-660.
6. Tuffanelli DL, Winkelmann RK. Systemic scleroderma, a clinical study of 727 cases. *Arch Dermatol.* 1961;84:359-371.
7. Janosik DL, Osborn TG, Moore TL, et al. Heart disease in systemic sclerosis. *Semin Arthritis Rheum.* 1989;19(3):191-200.
8. Byers RJ, Marshall DA, Freemont AJ. Pericardial involvement in systemic sclerosis. *Ann Rheum Dis.* 1997;56(6):393-394.
9. American Rheumatism Association Diagnostic and Therapeutic Criteria Committee. Preliminary criteria for the classification of systemic sclerosis (scleroderma). Subcommittee for scleroderma criteria of the American Rheumatism Association Diagnostic and Therapeutic Criteria Committee. *Arthritis Rheum.* 1980;23(5):581-590.
10. Reveille JD, Solomon DH. Evidence-based guidelines for the use of immunologic tests: Anticentromere, Scl-70, and nucleolar antibodies. *Arthritis Rheum.* 2003;49(3):399-412.
11. Kreuter A, Breuckmann F, Uhle A, et al. Low-dose UVA1 phototherapy in systemic sclerosis: effects on acrosclerosis. *J Am Acad Dermatol.* 2004;50(5):740-747.
12. Seyger MM, van den Hoogen FH, de Boo T, de Jong EM. Low-dose methotrexate in the treatment of widespread morphea. *J Am Acad Dermatol.* 1998;39(2 Pt 1):220-225.
13. Kreuter A, Gambichler T, Breuckmann F, et al. Pulsed high-dose corticosteroids combined with low-dose methotrexate in severe localized scleroderma. *Arch Dermatol.* 2005;141(7):847-852.
14. Thompson AE, Shea B, Welch V, et al. Calcium-channel blockers for Raynaud's phenomenon in systemic sclerosis. *Arthritis Rheum.* 2001;44(8):1841-1847.
15. Clifford PC, Martin MF, Sheddon EJ, et al. Treatment of vasospastic disease with prostaglandin E1. *Br Med J.* 1980;281(6247):1031-1034.
16. Fries R, Shariat K, von Wilmowsky H, Bohm M. Sildenafil in the treatment of Raynaud's phenomenon resistant to vasodilatory therapy. *Circulation.* 2005;112(19):2980-2985.
17. Falanga V, Medsger TA Jr. D-penicillamine in the treatment of localized scleroderma. *Arch Dermatol.* 1990;126(5):609-612.
18. Tashkin DP, Elashoff R, Clements PJ, et al. Cyclophosphamide versus placebo in scleroderma lung disease. *N Engl J Med.* 2006;354(25):2655-2666.
19. Steen VD, Medsger TA Jr. Case-control study of corticosteroids and other drugs that either precipitate or protect from the development of scleroderma renal crisis. *Arthritis Rheum.* 1998;41(9):1613-1619.
20. Tyndall AJ, Bannert B, Vonk M, et al. Causes and risk factors for death in systemic sclerosis: a study from the EULAR Scleroderma Trials and Research (EUSTAR) database. *Ann Rheum Dis.* 2010;69(10):1809-1815.

SECTION 16 BULLOUS DISEASE

183 OVERVIEW OF BULLOUS DISEASES

Richard P. Usatine, MD
Ana Treviño Sauceda, MD

PATIENT STORY

A 100-year-old black woman with diabetes was brought to the office by her family concerned about the large blister on her leg that started earlier that day (**Figure 183-1**). This large bulla appeared spontaneously without trauma and there was no surrounding erythema. The bulla contained clear fluid and there were no signs of infection. The bulla was drained with a sterile needle and no further bullae developed. The diagnosis is bullosis diabeticorum, a benign self-limited condition.

FIGURE 183-1 Bullosis diabeticorum on the lower leg of an older black woman with diabetes. This large bulla appeared spontaneously without trauma and there is no surrounding erythema. The bulla contained clear fluid and there was no infection. (*Courtesy of Richard P. Usatine, MD.*)

INTRODUCTION

Bullae are fluid-filled lesions on the skin that are larger than 5 mm in diameter. Bullous diseases are defined by the presence of bullae and vesicles (less than 5 mm in diameter). Bullous diseases are caused by many factors, including infections, bites, drug reactions, inflammatory conditions, and genetic and autoimmune diseases.

APPROACH TO THE DIAGNOSIS

The approach to a patient with a blistering disorder begins with a complete history and physical examination. To make the final diagnosis, laboratory investigations or tissue biopsies may be needed.

DIAGNOSIS

HISTORY

- How did the eruption present?
- Has it changed in morphology or location?
- Has it responded to any therapies?
- Are there any associated symptoms or aggravating factors?
- How has it impacted the patient's life?
- Does the patient have any chronic medical conditions?
- Does the patient take any medications?
- Does the patient have any significant family history?

PHYSICAL EXAMINATION

- Note the location of the eruption.
- Are the bullae flaccid or tense (**Figure 183-2**)?

- Are there other lesions present (erosions, excoriations, papules, wheals)?
- Is Nikolsky sign positive or negative? (Does the skin shear off when lateral pressure is applied to unblistered skin?)
- Is Asboe-Hansen sign positive or negative? (**Figure 183-3**) (Do the bullae extend to surrounding skin when vertical pressure is applied?) Sometimes the Asboe-Hansen sign is also attributed to Nikolsky and called a Nikolsky sign, too.
- Is the Darier sign positive or negative? (Do wheals form with rubbing of the skin?)
- Note the skin background (sun-exposed skin, postinflammatory hyperpigmentation, lichenification and scarring).
- Does the patient have lymphadenopathy or hepatosplenomegaly?

CLINICAL FEATURES

- Autoimmune.
  - In bullous pemphigoid, patients have large, tense bullae that primarily involve the trunk, groin, axilla, proximal extremities, and flexor surfaces (**Figures 183-2*A*** and **183-3**; Chapter 184, Bullous Pemphigoid).[1]
  - Pemphigus vulgaris is characterized by erosions and flaccid bullae that frequently involve the mouth (**Figure 183-4**; Chapter 185, Pemphigus). In fact, mucosal membrane involvement may be the initial presentation. If the skin is involved, then Nikolsky and Asboe-Hansen signs are positive.[1]
  - Pemphigus foliaceus presents with cutaneous erosions and never involves the mucosal membranes (**Figure 183-2*B***; Chapter 185, Pemphigus). Nikolsky and Asboe-Hansen signs are positive.[1]
  - Pemphigoid gestationis is a condition during pregnancy or during the postpartum period that can have a bullous component. The patient usually presents with urticarial papules and plaques with bullae developing around the umbilicus and extremities. The eruption eventually generalizes and involves the palms and soles. There usually is sparing of the face, scalp, and oral mucosa (**Figure 183-5**).[1]
  - Cicatricial pemphigoid involves the oral mucosa in 90% of cases and the conjunctiva in 66% of cases (**Figures 184-4** to **184-6** in Chapter 184, Bullous Pemphigoid). Patients frequently present with a desquamative gingivitis. Cutaneous lesions are seen in 25% of patients.[1]
  - Epidermolysis bullosa acquisita presents with trauma-induced blistering and erosions usually on the distal extremities (**Figure 183-6**). The patient should have background scarring, milia, and nail dystrophy. This usually affects elderly persons.
  - Epidermolysis bullosa simplex also has trauma-induced blistering that can involve the trunk and extremities. This is the most common form of epidermolysis bullosa and usually starts at birth or early childhood. The bullae are intraepidermal (**Figure 183-7**).
  - Dermatitis herpetiformis classically is a symmetrical, pruritic eruption that involves the extensor surfaces, scalp, and buttocks. The patient presents with pruritic vesicles and crusted papules with overlying excoriations (**Figures 186-11** and **186-12** in Chapter 186, Other Bullous Diseases).[1]
  - Linear immunoglobulin (Ig) A bullous dermatosis may produce a ring-like pattern of distribution and can occur in childhood (**Figure 183-10**). Patients may have mucous membrane involvement in up to 50% of cases.[1]

FIGURE 183-2 Comparison of the tense bullae seen in bullous pemphigoid and the more flaccid bullae seen in pemphigus. **A.** Tense bullae in bullous pemphigoid. **B.** Flaccid bulla on the leg of a patient with pemphigus foliaceous. (*Courtesy of Richard P. Usatine, MD.*)

FIGURE 183-3 Testing for Asboe-Hansen sign on the back of a patient with bullous pemphigoid. The bulla did not extend with vertical pressure so the sign was negative. (*Courtesy of Richard P. Usatine, MD.*)

FIGURE 183-4 Flaccid and partially crusted bulla on the breast of a 51-year-old woman with pemphigus vulgaris. She also has severe oral involvement with large mucosal erosions. (*Courtesy of Richard P. Usatine, MD.*)

FIGURE 183-5 Pemphigoid gestationis with bullae on the wrist. (*Courtesy of Richard P. Usatine, MD.*)

FIGURE 183-6 Epidermolysis bullosa acquisita in an elderly woman. Note the partially intact bulla over the knee along with other areas of erosions and hyperpigmentation. (*Courtesy of Richard P. Usatine, MD.*)

FIGURE 183-7 Large trauma-induced bulla on the leg of a 13-year-old girl with epidermolysis bullosa simplex. (*Courtesy of Richard P. Usatine, MD.*)

- Traumatic/Physical Stress.
  - Friction blisters form at sites of pressure and friction, frequently on the distal lower extremities.[1]
  - Bullosis diabeticorum is trauma-induced, painless blistering, frequently in an acral distribution, in individuals with diabetes mellitus (**Figure 183-11**).[1]
  - Postburn blistering occurs in the hours after the insult, such as is seen in severe second degree sunburns.[1] Blistering after cold injury can also occur rapidly (**Figure 183-12**).
  - Miliaria is caused by keratinous obstruction of the eccrine ducts in response to heat. Small superficial vesicles may involve the face, trunk, or extremities.[1]
- Metabolic.
  - Porphyria cutanea tarda (PCT) involves sun-exposed skin, particularly the dorsal hands, forearms, ears, and face. The patient will have associated milia, scarring, and background dyspigmentation. PCT has been associated with hepatitis C infection (**Figure 183-8**).[1]
- Immunologic.
  - Pityriasis lichenoides et varioliformis acuta usually presents as a papulonecrotic eruption but may have vesicles resembling varicella (**Figure 183-9**). It usually involves the anterior trunk, flexor surfaces of the upper extremities, and the axilla. The general health of the patient is unaffected, although most have lymphadenopathy. CD8 T-cells are the predominant cell-type in lesional skin.[1] It is seen more frequently in young men and can go on to become chronic.
  - Allergic-contact and irritant-contact dermatitis, if severe, can cause blistering. Special attention should be placed on the location and pattern of involvement. For example, linear vesicles and bullae would suggest a plant-induced dermatitis such as poison ivy, poison oak, or poison sumac (**Figure 183-13**). Blistering in the periumbilical area is consistent with nickel dermatitis. Involvement of the dorsal feet is frequently seen with footwear dermatitis; likewise, involvement of the dorsal hands is consistent with glove dermatitis (Chapter 146, Contact Dermatitis).[2]
- Drug.
  - Bullous drug eruptions may be localized to 2 mucosal surfaces with minimal cutaneous involvement or may be generalized involving all mucosal surfaces and a majority of the skin surface area. Nikolsky and Asboe-Hansen signs are positive on affected skin (see Section 14: Hypersensitivity Syndromes and Chapter 203, Cutaneous Drug Reactions).[1] Even fixed-drug eruptions can be bullous (**Figure 183-14**).
- Infections and Bites.
  - Bullous arthropod reaction can occur after an insect bite (**Figure 183-15**).[1]
  - Bacterial infections should be considered when evaluating a localized blistering eruption. Amongst these infections is bullous impetigo (**Figure 183-16**). When evaluating the extremities, vesiculation overlying cellulitis may be associated with the more severe staphylococcal and streptococcal infections, and a thorough evaluation should be conducted to rule out necrotizing fasciitis. As with most bacterial infections, the patient typically presents with fever and has an elevated white blood cell count.[2]

FIGURE 183-8 Porphyria cutanea tarda with a large bulla on the finger. (*Courtesy of Lewis Rose, MD.*)

FIGURE 183-9 Pityriasis lichenoides et varioliformis acuta in a young man showing erosions where vesicles and bullae had been previously. (*Courtesy of Richard P. Usatine, MD.*)

FIGURE 183-10 Bullae in a ring-like pattern in a young girl with IgA bullous dermatosis of childhood. (*Courtesy of Jack Resneck, Sr., MD.*)

FIGURE 183-11 Large intact bulla on the lower leg of a woman with diabetes. This is bullosis diabeticorum also known as a diabetic bulla. (*Courtesy of Richard P. Usatine, MD.*)

FIGURE 183-13 Bullae and vesicles on the extremity of a patient with poison ivy. Acute contact dermatitis can present with bulla and vesicles. (*Courtesy of Richard P. Usatine, MD.*)

FIGURE 183-12 Bullae the day after cryotherapy for warts. (*Courtesy of Richard P. Usatine, MD.*)

FIGURE 183-14 Bullous fixed-drug eruption on the ankle of a woman taking amoxicillin. She has had this reaction before in the same location while taking another penicillin antibiotic. Note the dusky color, annular erythema and the central bullae. (*Courtesy of Richard P. Usatine, MD.*)

- Herpes simplex viruses should always be considered when blistering of the mucosal surfaces is observed. Generalized blistering in the adult could be because of disseminated herpes and should prompt an evaluation for immunosuppression. Blistering in a dermatomal distribution is characteristic of herpes zoster (**Figures 183-17** and **183-18**).[2]
- Scabies, tinea, and *Candida* can also have bullous or pustular presentations in the classic sites of involvement.[2]

- Hydrostatic.
  - Edema blisters form from the osmotic pressure experienced during the third spacing of fluid. As such, patients usually have a diagnosis of heart failure, cirrhosis, or kidney failure.[1]
- Childhood.
  - Transient neonatal pustular melanosis (TNPM) are pustules or vesicles without associated erythema located in clusters on the forehead, posterior ears, chin, neck, upper chest, back, buttocks, abdomen, and thighs, that spontaneously heal leaving behind pigmented macules. TNPM affects up to 4% of term infants and is more commonly seen in the African American population (Chapter 110, Pustular Diseases of Childhood).[3]
  - Acropustulosis of infancy develops during the first few weeks to months of life and spontaneously remits at 2 to 3 years of age. In this condition, crops of vesicles and pustules involve palms and soles, causing pruritus (Chapter 110, Pustular Diseases of Childhood).[3]
  - Neonatal pemphigus occurs in neonates whose mothers have active pemphigus vulgaris (not pemphigus foliaceus). The patient is born with bullae that spontaneously resolve within 1 to 2 weeks.[3]
  - Epidermolysis bullosa simplex is a hereditary condition in which minimal friction or trauma causes vesicles, bullae, and erosions. The distal extremities are frequently involved (**Figure 183-19**).[4]
  - Congenital infections with herpes simplex virus usually present with vesicles. In addition, a vesicular eruption in the neonate could be caused by neonatal syphilis, which is the only form of syphilis with a vesicular presentation.[2]
  - Bullous mastocytosis is caused by mast cell accumulation in the skin. The bullous presentation is very rare, but may involve any area of the body. On examination, the Darier sign should be positive and dermatographism should be present. Work-up should be conducted to determine the presence of systemic involvement, which may include a mast cell leukemia. A good lymph node and abdominal examination is recommended to evaluate for lymphadenopathy and hepatosplenomegaly.[3]

LABORATORY STUDIES AND WORK-UP

If the clinical picture is not clear, various laboratory studies may assist the clinician in making the diagnosis. Some diagnoses should be confirmed by histology even if the diagnosis appears clear. For example, all cases of suspected pemphigus should be biopsied because the management will involve long-term use of potentially toxic medications and it is crucial to know exactly what you are treating. The information in Chapters 184, Bullous Pemphigoid, and 185: Pemphigus, will help you to decide which tests to use in some of the autoimmune blistering diseases. Consulting a dermatologist is very appropriate for many of the more rare and lethal conditions.

FIGURE 183-15 Bullous arthropod bites secondary to fire ants. (*From Lane K, Lumbang W. Pruritic blisters on legs and feet. J Fam Pract. 2008;57(3):177-180. Reproduced with permission from Frontline Medical Communications.*)

FIGURE 183-16 Bullous impetigo on the face of a child. Note the honey crusts, vesicles and bulla. (*Courtesy of Jack Resneck, Sr., MD.*)

- Direct fluorescent antibody test can be done on a scraping of a lesion if herpes simplex or varicella zoster is suspected. In many laboratories, a result can be obtained within 24 hours.
- Mineral oil scraping for scabies (Chapter 143, Scabies).
- KOH scraping for possible blistering tinea infections (such as bullous tinea pedis). See Section 5: Fungal.
- Genetic studies for suspected genetic defects; consider referral to geneticist.

BIOPSY

- One 4-mm punch biopsy for pathologic evaluation—Biopsy an established lesion including the edge of the blister. A shave biopsy is an alternative as long as the epidermis of the blister stays attached to the specimen.
- Biopsy for direct immunofluorescence (DIF)—Biopsy the perilesional skin and send the specimen in special Michel media or sterile saline and let the lab know to transfer it to Michel media when it arrives. The easiest way to do this is to take a shave biopsy that includes the bulla and the perilesional skin. Then cut the specimen in half and send the perilesional skin for DIF and the blister for standard pathology.
- Consider sending part of the biopsy for bacterial, fungal, and viral cultures and stains if infections are suspected and cultures and other less-invasive studies are not providing the diagnosis. Send the specimens in a sterile urine cup on top of a sterile gauze pad soaked with sterile saline.

FURTHER EVALUATIONS

Patients with cicatricial pemphigoid and toxic epidermal necrolysis need an ophthalmologic evaluation. Patients with several of the epidermolysis bullosa diseases and dermatitis herpetiformis need a gastroenterologic evaluation.

For possible paraneoplastic conditions, such as in epidermolysis bullosa acquisita and cicatricial pemphigoid, thorough cancer screening and studies targeting the patient's symptomatology are indicated.

REFERENCES

1. Bolognia JL, Jorizzo JL, Rapini RP. *Dermatology*. London, UK: Elsevier Health Sciences; 2003.
2. James WD, Berger TG, Elston DM. *Andrews' Diseases of the Skin: Clinical Dermatology*, 10th ed. Philadelphia, PA: Elsevier Health Sciences; 2005.
3. Schachner LA, Hansen RC. *Pediatric Dermatology*, 3rd ed. New York, NY: Mosby; 2003.
4. Spitz JL. *Genodermatoses: A Clinical Guide to Genetic Skin Disorders*. Philadelphia, PA: Lippincott Williams & Wilkins; 2004.

FIGURE 183-17 Herpes zoster with large bulla in a dermatomal pattern. (*Courtesy of Rose Walczak, MD.*)

FIGURE 183-18 Cluster of intact bullae and vesicles on an erythematous base in a young woman with herpes zoster in the axilla. (*Courtesy of Richard P. Usatine, MD.*)

FIGURE 183-19 Epidermolysis bullosa simplex in a teenage girl showing a large open bulla on the palm and scarring of the full hand and 5 fingers. (*Courtesy of Richard P. Usatine, MD.*)

184 BULLOUS PEMPHIGOID

Asad K. Mohmand, MD
Richard P. Usatine, MD

PATIENT STORY

A native of Panama was seen for extensive bullous disease that is classic for bullous pemphigoid (BP) (**Figure 184-1**). The presence of numerous intact bullae would make pemphigus very unlikely. The patient was treated with oral prednisone and began to respond quickly. The patient eventually had a good outcome.

INTRODUCTION

BP is an autoimmune blistering disease of older adults that may cause significant morbidity and a poor quality of life. The term *pemphigoid* refers to its similarity to the blisters seen in pemphigus. However, BP is usually less severe than pemphigus vulgaris and is not considered a life-threatening condition.

EPIDEMIOLOGY

- BP is the most frequent autoimmune blistering disease of the skin (and mucosa).
- It typically affects persons older than 65 years of age but can occur at any age.
- There is no racial or gender predilection (a recent British population study, however, suggested an increased prevalence in women).[1]
- Its incidence may be on the rise.[1]
- Although it is not considered life threatening, it has been associated with an increased risk of mortality (hazard ratio [HR] 2.3, 95% confidence interval [CI] 2 to 2.7).[1]

ETIOLOGY AND PATHOPHYSIOLOGY

- BP is a chronic autoimmune disorder of the skin.
- Immunoglobulin (Ig) G autoantibodies against BP180 antigen of the basement membrane protein are considered pathognomonic and can be found in up to 65% of patients.[2]
- Anti-BP230 antibodies are present in virtually all patients but are not considered pathognomonic.[3]
- Binding of antibodies to the basement membrane activates the complement system, leading to chemotaxis of inflammatory cells (eosinophils and mast cells), which release proteases. The subsequent degradation of hemidesmosomal proteins leads to blister formation.
- There are several morphologically distinct clinical presentations:
  - Generalized bullous form is the most common (**Figure 184-1**). Tense bullae occur on both erythematous and normal-appearing skin surfaces. The bullae usually heal without scarring.

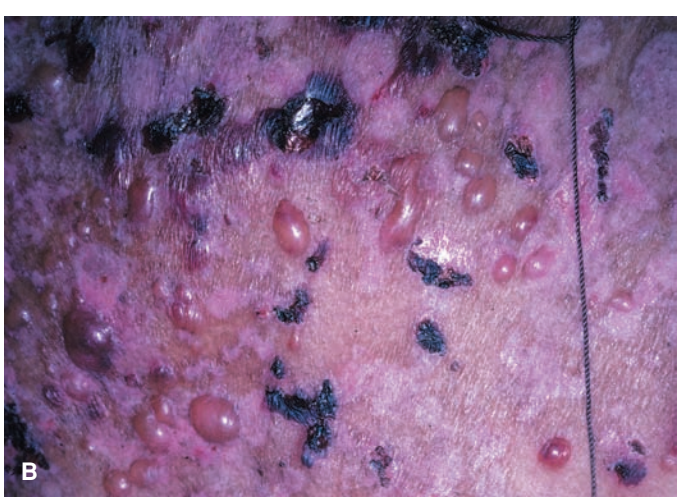

FIGURE 184-1 **A.** Extensive untreated bullous pemphigoid in a Panamanian woman. **B.** Close-up of intact bulla and dark crusts. (*Courtesy of Eric Kraus, MD.*)

- Localized form of BP is less common and is limited to a small area of involvement (**Figure 184-2**).
- Vesicular (also known as "eczematous") form is characterized by clusters of small tense blisters with an urticarial or erythematous base.
- Other forms are less common and include vegetative (intertriginous vegetating plaques), urticarial (without any bullae), nodular (resembling prurigo nodularis), acral (bullae on palms, soles, and face in children associated with vaccination), and generalized erythroderma (exfoliative lesions with or without vesicles/bullae).

- Pemphigoid gestationis is a variant of BP that occurs during or after pregnancy. Lesions resolve after delivery, but may recur with subsequent pregnancies, or in the nonpregnant state (Chapter 76, Pemphigoid Gestationis).[4]
- Drug-induced BP has been reported with drugs containing sulfhydryl groups, including penicillamine, furosemide, captopril, and sulfasalazine.

DIAGNOSIS

CLINICAL FEATURES

- Tense blisters that involve normal or inflamed skin or mucous membranes (**Figures 184-1** and **184-2**).
- Development of bullae is typically preceded by a prodromal phase characterized by intense pruritus with or without excoriations and eczematous (or urticarial) lesions. This phase can last for months, making early diagnosis difficult.[5]
- Nikolsky sign (wrinkling and sheet-like peeling of the skin when lateral pressure is applied to unblistered skin) is usually negative.[6] Asboe-Hansen sign will be negative too. Bulla will not extend to surrounding skin when vertical pressure is applied (**Figure 184-2B**).

TYPICAL DISTRIBUTION

- Flexure surfaces of the arms and legs.
- Lower abdomen and groin.
- Mucous membranes are involved in 10% to 25% of cases.

BIOPSY

Biopsy is required for establishing diagnosis and to differentiate BP from other conditions that can have a similar clinical presentation:

- A scoop shave or 4-mm punch biopsy from edge of an early blister including part of the normal-appearing skin for H and E staining shows a subepidermal blister and an eosinophil-rich mixed dermal inflammatory infiltrate. If the scoop shave contains sufficient perilesional skin, cut this off and send it for direct immunofluorescence (DIF).
- The skin from the scoop shave or a second 4-mm punch biopsy from perilesional skin, transported in Michel's medium for DIF. If Michel's transport medium is not available, send the specimen for DIF in sterile saline soaked gauze and alert the laboratory to transfer the specimen into Michel's medium ASAP. DIF demonstrates linear IgG and/or complement C3 deposits at the dermal–epidermal junction.

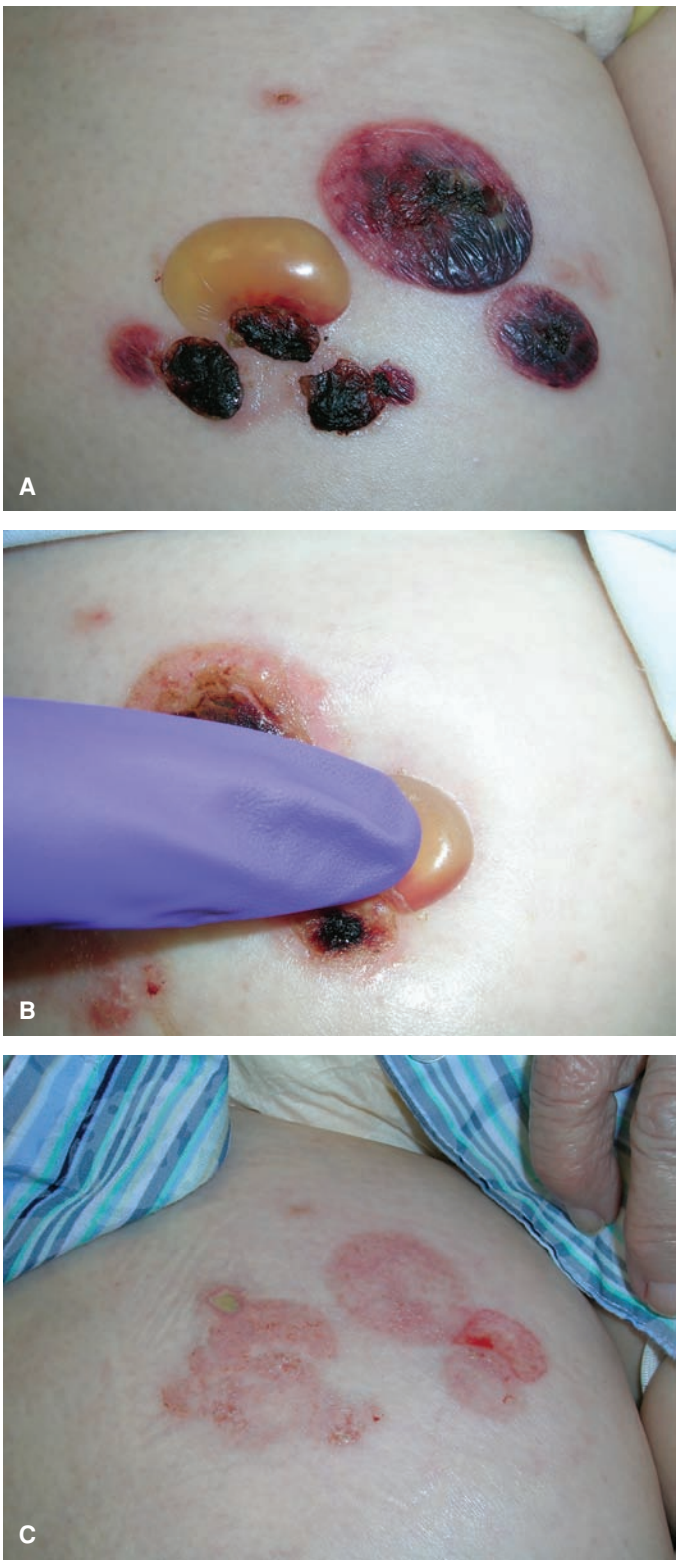

FIGURE 184-2 Localized bullous pemphigoid with large bulla on the thigh of this 91-year-old woman. Her biopsy for direct immunofluorescense demonstrated a linear band of igG at the dermal-epidermal junction. **A.** Bullae on the thigh. **B.** One week later there is a new bulla and the Asboe-Hansen sign is negative. **C.** One week later the bullae are healing as the bullous pemphigoid is being treated with clobetasol topically and the patient is taking doxycycline and niacin orally. (*Courtesy of Richard P. Usatine, MD.*)

- Alternatively, an enzyme-linked immunosorbent assay (ELISA) blood test for BP180 antibodies (and if negative, then ELISA for BP230 antibodies) can be performed for characterization of circulating antibodies.[7]

DIFFERENTIAL DIAGNOSIS

- Cicatricial pemphigoid (**Figures 184-4** to **184-6**)—Predominant mucosal involvement; lesions heal with prominent scarring; IgG localizes to blister floor on IDIF.
- Dermatitis herpetiformis—Grouped vesicles; extensor distribution (Chapter 186, Other Bullous Diseases).
- Epidermolysis bullosa acquisita—IgG localizes to blister floor on IDIF (Chapter 186, Other Bullous Diseases).
- Erythema multiforme—Targetoid lesions; linear IgG immunofluorescence is negative (Chapter 177, Erythema Multiforme, Stevens-Johnson Syndrome, and Toxic Epidermal Necrolysis).
- Linear IgA dermatosis—Usually drug-induced (e.g., vancomycin[8]); DIF demonstrates IgA deposits. Also called chronic bullous dermatosis of childhood (Chapter 183, Overview of Bullous Disease including **Figure 183-5**).

MANAGEMENT

The objectives of therapy in BP are to decrease the troublesome symptoms associated with the blistering lesions, resolve active lesions, and prevent recurrences.

- High-potency topical corticosteroids are considered first-line treatment for moderate to severe generalized disease (e.g., clobetasol).[9] SOR A Initial disease control and 1-year survival rates in extensive BP are better with topical approach when compared with oral prednisolone.[11]
- Oral corticosteroids.[9] SOR A
- Prednisone 0.5 to 0.75 mg/kg per day.[10]
- Increase dose until new blisters cease to develop.
- Reduce dose approximately10% every 2 to 3 weeks to reach dose of 15 to 20 mg/day.
- Adjuvant antibiotic treatment should be considered for all patients:
  - Tetracycline (1.5 to 2 g/day) with or without niacinamide (1.5 to 2 g/day).[12] SOR B Both tetracycline and niacinamide come in 500-mg capsules and may be taken 3 to 4 times daily. Niacinamide contains niacin (vitamin B_3) and is available over the counter. If tetracycline is not available, doxycycline 100 mg twice daily is an alternative.
  - Steroid-sparing drugs and adjuvant therapy for patients whose disease is not controlled with steroids and tetracycline:
  - Dapsone is an antineutrophilic antibiotic that is an alternative to tetracycline and doxycyline (**Figure 184-7**). Azathioprine 50 to 200 mg divided bid or tid (first-line adjuvant).[9] SOR B
  - Mycophenolate mofetil 0.5 to 2 g/day divided bid or tid (less hepatotoxic than azathioprine).[13] SOR C
  - Cyclophosphamide 1 to 5 mg/kg per day. SOR C

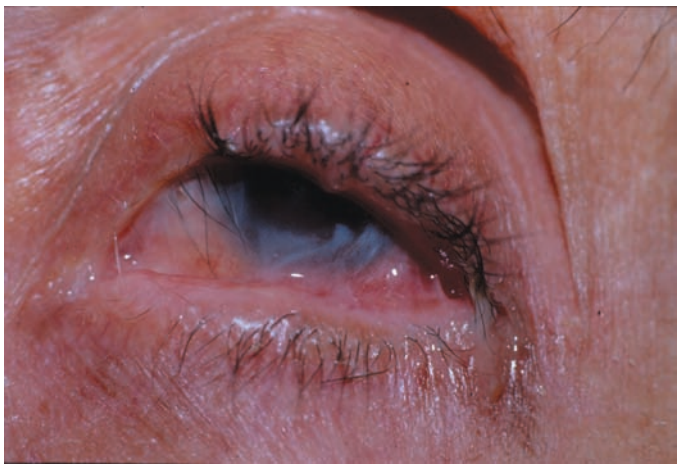

FIGURE 184-4 Cicatricial bullous pemphigoid of the eye, causing scarring and blindness. (*Courtesy of Eric Kraus, MD.*)

FIGURE 184-5 Cicatricial bullous pemphigoid with scarring connecting the lower lid to the cornea. (*Courtesy of Eric Kraus, MD.*)

FIGURE 184-6 Cicatricial bullous pemphigoid of the mouth showing gingivitis. More than 50% of cases of BP have oral involvement. (*Courtesy of Eric Kraus, MD.*)

- Disease resistant to combination of corticosteroids and steroid-sparing agents:
  - Intravenous immunoglobulin (IVIG) can produce a rapid and dramatic but very transient response; requires multiple cycles of IVIG. SOR C
  - Plasmapheresis can be considered for patients with severe resistant disease requiring high doses of systemic steroids to improve symptoms and reduce steroid dose.[14] SOR C
  - Case reports and small series of successful therapy of refractory BP with rituximab,[15] etanercept,[16] or omalizumab[17] have been published in the recent medical literature.
- Consultations
  - Dermatology consultation for recommending therapy based on extent of disease and for changes in therapy when required.
  - Nutrition consultation if patient is having difficulty maintaining weight.

FOLLOW-UP

- Ask patient about recurrent lesions, pruritus, and side effects from treatment.
- Perform periodic skin examinations looking for new lesions to adjust dose of prednisone and to monitor for lymphadenopathy and skin cancer in patients using immunosuppressive medications.
- Monitor for drug-specific laboratory abnormalities (e.g., glucose and triglycerides with steroid use; complete blood count [CBC], renal function, and liver function tests for azathioprine).
- Make sure patients do not run out of their medications because this can result in recurrent lesions (**Figure 184-8**).
- Adjust treatment if patient relapses (e.g., increase steroid dose or add an immunosuppressive agent).
- Taper steroids slowly (as above) after dissipation of disease flare.

PATIENT EDUCATION

- Avoid mechanical irritation, direct sun exposure, dental prostheses, extremes of temperature.
- Recommend high-protein, low-carbohydrate and low-fat diet; calcium and vitamin D supplementation for patients on corticosteroids.
- Provide information on wound care, stress-reduction, appropriate exercise, and side effects of medications.

PATIENT RESOURCES

- **http://www.patient.co.uk/showdoc/23069059/.**
- International Pemphigus & Pemphigoid Foundation—**http://www.pemphigus.org/wordpress/diseases/pemphigoid/.**

PROVIDER RESOURCES

- eMedicine—**http://emedicine.medscape.com/article/1062391.**

FIGURE 184-7 New onset bullous pemphigoid in a 65-year-old man with previous psoriasis. His bullous pemphigoid is currently controlled with dapsone. **A.** Bullae on abdomen with some psoriatic plaques visible. **B.** Tense bullae on leg. *(Courtesy of Richard P. Usatine, MD.)*

REFERENCES

1. Langan SM, Smeeth L, Hubbard R, et al. Bullous pemphigoid and pemphigus vulgaris—incidence and mortality in the UK: population based cohort study. *BMJ*. 2008;337:a180.
2. Zillikens D, Rose PA, Balding SD, et al. Tight clustering of extracellular BP180 epitopes recognized by bullous pemphigoid autoantibodies. *J Invest Dermatol*. 1997;109:573-579.
3. Yancey KB, Egan CA. Pemphigoid: clinical, histologic, immunopathologic, and therapeutic considerations. *JAMA*. 2000;284:350-356.
4. Kroumpouzos G, Cohen LM. Specific dermatoses of pregnancy: an evidence-based systematic review. *Am J Obstet Gynecol*. 2003;188(4):1083-1092.
5. Bingham EA, Burrows D, Sandford JC. Prolonged pruritus and bullous pemphigoid. *Clin Exp Dermatol*. 1984;9:564-570.
6. Habif TP. *Clinical Dermatology: A Color Guide to Diagnosis and Therapy*, 4th ed. St. Louis, MO: Mosby; 2004.
7. Schmidt E, Zillikens D. Modern diagnosis of auto-immune blistering skin diseases. *Autoimmun Rev*. 2010;10:84-89.
8. Kuechle MK, Stegemeir E, Maynard B, Gibson LE. Drug-induced linear IgA bullous dermatosis: report of six cases and review of the literature. *J Am Acad Dermatol*. 1994;30:187-192.
9. Khumalo N, Kirtschig G, Middleton P, et al. Interventions for bullous pemphigoid. *Cochrane Database Syst Rev*. 2003;(3):CD002292.
10. Kirtschig G, Middleton P, Bennett C, et al. Interventions for bullous pemphigoid. *Cochrane Database Syst Rev*. 2010;(10):CD002292. DOI: 10.1002/14651858.CD002292.pub3.
11. Joly P, Roujeau JC, Benichou J, et al. A comparison of oral and topical corticosteroids in patients with bullous pemphigoid. *N Engl J Med*. 2002;346:321-327.
12. Fivenson DP, Breneman DL, Rosen GB, et al. Nicotinamide and tetracycline therapy of bullous pemphigoid. *Arch Dermatol*. 1994;130(6):753-758.
13. Böhm M, Beissert S, Schwarz T, et al. Bullous pemphigoid treated with mycophenolate mofetil. *Lancet*. 1997;349(9051):541.
14. Mazzi G, Raineri A, Zanolli FA, et al. Plasmapheresis therapy in pemphigus vulgaris and bullous pemphigoid. *Transfus Apher Sci*. 2003;28(1):13-18.
15. Kasperkiewicz M, Shimanovich I, Ludwig RJ, et al. Rituximab for treatment-refractory pemphigus and pemphigoid: a case series of 17 patients. *J Am Acad Dermatol*. 2011;65(3):552-558.
16. Cusano F, Iannazzone SS, Riccio G, Piccirillo F. Coexisting bullous pemphigoid and psoriasis successfully treated with etanercept. *Eur J Dermatol*. 2010;20(4):520.
17. Fairley JA, Baum CL, Brandt DS, Messingham KA. Pathogenicity of IgE in autoimmunity: successful treatment of bullous pemphigoid with omalizumab. *J Allergy Clin Immunol*. 2009;123(3):704-705.

FIGURE 184-8 Recurrent bullous pemphigoid on the back of a 57-year-old man who ran out of his prednisone for a few days. (*Courtesy of Richard P. Usatine, MD.*)

185 PEMPHIGUS

Richard P. Usatine, MD
Shashi Mittal, MD

PATIENT STORY

A young man presented with painful blisters on his face and mouth (**Figure 185-1**). The patient was referred to dermatology that day. The dermatologist recognized likely pemphigus vulgaris (PV) and did shave biopsies for histopathology and direct immunofluorescence of facial vesicles/bullae to confirm the presumed diagnosis. The patient was started on 60 mg of prednisone daily until the pathology confirmed PV. Steroid-sparing therapy was then discussed and started in 2 weeks from presentation.

FIGURE 185-1 Pemphigus vulgaris on the face of a young man with mouth involvement. (*Courtesy of Eric Kraus, MD.*)

INTRODUCTION

Pemphigus is a rare group of autoimmune bullous diseases of skin and mucous membranes characterized by flaccid bulla and erosions. The three main types of pemphigus are PV (with the pemphigus vegetans variant), pemphigus foliaceous (with the pemphigus erythematosus variant), and paraneoplastic pemphigus. All types of pemphigus cause significant morbidity and mortality. Although pemphigus is not curable, it can be controlled with systemic steroids and immunosuppressive medications. These medications can be lifesaving, but also place pemphigus patients at risk for a number of complications. The word *pemphigus* is derived from the Greek word *pemphix,* which means bubble or blister.

EPIDEMIOLOGY

Epidemiology of the three major types of pemphigus:

- PV (**Figures 185-1** to **185-4**):
  - Most common form of pemphigus in the United States.
  - Annual incidence is 0.75 to 5 cases per 1 million population.[1]
  - Usually occurs between 30 and 50 years of age.[2]
  - Increased incidence in Ashkenazi Jews and persons of Mediterranean origin.[2]
  - Pemphigus vegetans is a variant form of PV (**Figures 185-5** and **185-6**).
- Pemphigus foliaceus (PF) (**Figures 185-7** to **185-10**): Superficial form of pemphigus.
  - More prevalent in Africa (**Figures 185-11** and **185-12**).[1]
  - Variant forms include pemphigus erythematosus (resembles the malar rash of lupus erythematosus) and fogo selvagem.
  - Fogo selvagem is an endemic form of PF seen in Brazil and affects teenagers and individuals in their twenties.[1]
- Paraneoplastic pemphigus (PNP)
  - Onset at age 60 years and older.
  - Associated with occult neoplasms commonly lymphoreticular.
  - Malignancies like non-Hodgkin lymphoma and chronic lymphocytic leukemia.

FIGURE 185-2 Pemphigus vulgaris on the back with crusted and intact bullae. Downward pressure on a bulla demonstrates a positive Asboe-Hansen sign with lateral spread of a fresh bullae. (*Courtesy of Eric Kraus, MD.*)

FIGURE 185-3 Pemphigus vulgaris involving the lips and palate of a 55-year-old woman. (*Courtesy of Dan Shaked, MD.*)

FIGURE 185-5 Pemphigus vegetans in the groin of a middle-aged woman. (*Courtesy of Eric Kraus, MD.*)

FIGURE 185-6 Pemphigus vegetans widespread over the external genitalia and buttocks. (*Courtesy of Eric Kraus, MD.*)

FIGURE 185-4 Severe fatal pemphigus vulgaris. (*Courtesy of Eric Kraus, MD.*)

FIGURE 185-7 Pemphigus foliaceous on the face of a black man. (*Courtesy of Jack Resneck, Sr., MD.*)

FIGURE 185-8 Pemphigus foliaceous on the back of a 55-year-old Hispanic woman. Note the absence of bulla and the corn flake crusting from the superficial erosions. (*Courtesy of Richard P. Usatine, MD.*)

FIGURE 185-10 Widespread pemphigus foliaceous. (*Courtesy of Eric Kraus, MD.*)

FIGURE 185-9 Pemphigus foliaceous with large erosions on the back and extremities of this patient. (*Courtesy of Eric Kraus, MD.*)

FIGURE 185-11 Pemphigus foliaceous on the trunk and arms of a woman in Africa. Some of the lesions appear annular but they are all superficial erosions within the epidermis. (*Courtesy of Richard P. Usatine, MD.*)

- Also associated with benign neoplasms such as thymoma and Castleman disease (angiofollicular lymph node hyperplasia).[2]

ETIOLOGY AND PATHOPHYSIOLOGY

- The basic abnormality in all three types of pemphigus is acantholysis, a process of separating keratinocytes from one another. This occurs as a result of autoantibody formation against desmoglein (the adhesive molecule that holds epidermal cells together). Separation of epidermal cells leads to formation of intraepidermal clefts, which enlarge to form bullae.[1]
- The mechanism that induces the production of these autoantibodies in most individuals is unknown. Yet PF may be triggered by drugs, most commonly thiol compounds like penicillamine, captopril, piroxicam, and others, like penicillin and imiquimod.[3] An environmental trigger in the presence of susceptible human leukocyte antigen (HLA) gene is suggested to induce autoantibodies in fogo selvagum.[1]
- The autoantibodies in pemphigus are usually directed against desmoglein 1 and 3 molecules (Dsg1 and Dsg3). Dsg1 is present predominantly in the superficial layers of the epidermis, whereas Dsg3 is expressed in deeper epidermal layers and in mucous membranes. As a result, clinical presentation depends on the antibody profile. In PV, a limited mucosal disease occurs when only anti-Dsg3 antibody is present, but extensive mucosal and cutaneous disease occurs when both anti-Dsg1 and Dsg3 antibodies are present. In PF, mucosal lesions are absent and the cutaneous lesions are superficial because of isolated anti-Dsg1 antibody.
- Patients with PNP demonstrate both anti-Dsg1 and Dsg3 antibodies. However, unlike PV, autoantibodies against plakin proteins (another adhesive molecule) are also observed in patients with PNP and these autoantibodies form a reliable marker for this type of pemphigus.

DIAGNOSIS

CLINICAL FEATURES

- Pemphigus vulgaris (**Figures 185-1** to **185-4**)—Classical lesions are flaccid bullae that rupture easily, creating erosions. Since bullae are short-lived, erosions are the more common presenting physical finding (**Figure 185-13**). Lesions are typically tender and heal with postinflammatory hyperpigmentation that resolves without scarring. A positive Asboe-Hansen or Nikolsky sign may be present, but neither sign is diagnostic. A positive Asboe-Hansen sign occurs when a bulla extends to surrounding skin while pressure is applied directly to the bulla. The Nikolsky sign is positive when skin shears off while lateral pressure is applied to unblistered skin during active disease. Sometimes the Asboe-Hansen sign is also attributed to Nikolsky and called a Nikolsky sign, too.
- Pemphigus vegetans is a variant of PV where healing is associated with vegetating proliferation of the epidermis (**Figures 185-5** and **185-6**).
- Pemphigus foliaceous: Multiple red, scaling, crusted, and pruritic lesions described as "corn flakes" are seen. Shallow erosions arise

FIGURE 185-12 Another case of pemphigus foliaceous in Africa. Pemphigus foliaceous is more prevalent in Africa. Note the hyperpigmentation of the healing lesions after treatment has begun. (*Courtesy of Richard P. Usatine, MD.*)

FIGURE 185-13 Pemphigus vulgaris involving the face and oral mucosa. The erosions are deeper than those seen in pemphigus foliaceous. The oral involvement points to pemphigus vulgaris. (*Courtesy of Richard P. Usatine, MD.*)

when crusts are removed, but intact blisters are rare as the disease is superficial (**Figures 185-7** to **185-12**).

- PNP (**Figure 185-14**)—Lesions are similar to PV, although lichen planus, morbilliform, or erythema multiforme-like lesions also may be seen in addition to blisters and erosions. Another distinctive feature is the presence of epithelial necrosis and lichenoid changes in the lesions. Pulmonary involvement secondary to acantholysis of bronchial mucosa is seen in 30% to 40% of cases of PNP.

TYPICAL DISTRIBUTION

- PV—Common mucosal site is oral mucosa, although any stratified squamous epithelium may be involved. Mucosal lesions may be followed by skin lesions after weeks to months usually on scalp, face, and upper torso. PV should be suspected if an oral ulcer persists beyond a month (**Figures 185-1**, **185-3**, and **185-15**).
- Pemphigus vegetans—Usually seen in intertriginous areas like the axilla, groin, and genital region (**Figures 185-5** and **185-6**).
- PF—Initially affects face and scalp, though may progress to involve chest and back (**Figures 185-7** to **185-12**). When the facial involvement in PF is in a lupus-like pattern, this is called pemphigus erythematosus (**Figure 185-16**).
- PNP—Common sites include oral mucosa and conjunctiva. (**Figure 185-14**) Columnar and transitional epithelia may also be involved besides stratified squamous epithelium.

LABORATORY STUDIES

- Circulating desmoglein antibodies levels may be measured in the blood using indirect immunofluorescence. This is usually not necessary unless the diagnosis is in question and further data are needed.
- Complete blood count and a comprehensive metabolic profile including liver function tests, creatinine, and glucose will be needed as a baseline, as all the systemic therapies have significant toxicities.
- Patients at risk for steroid-induced osteoporosis should have a dual-energy x-ray absorptiometry (DEXA) scan performed.

BIOPSY

- Skin biopsy is essential for accurate diagnosis. The depth of acantholysis and site of deposition of antibody complexes help differentiate pemphigus from other bullous diseases. Two specimens should be sent. Perform a shave of the edge of the bulla to include the surrounding normal appearing epidermis. This biopsy should be of the freshest lesion with an intact bulla, if possible. Cut the specimen in half and send the portion with the bulla in formalin for routine histopathology. The second half should be perilesional adjacent normal skin. This is sent on a gauze pad soaked in normal saline or Michel solution for direct immunofluorescence (DIF). Routine histopathology demonstrates suprabasal acantholysis and DIF shows antibody deposition in the intercellular spaces of the epidermis. The pattern of the DIF fluorescence is described as chicken wire (**Figure 185-17**).

DIFFERENTIAL DIAGNOSIS

- Bullous pemphigoid—Bullae are tense because they occur in the deeper subepidermal layer. Mucous membrane involvement is rare.

FIGURE 185-14 Paraneoplastic Pemphigus with severe erosions covering practically the entire mucosa of the oral cavity with partial sparing of the dorsum of the tongue. Lesions are extremely painful, interfering with adequate food intake. This patient had non-Hodgkin lymphoma as the underlying malignancy. (*Courtesy of Wolff K, and Johnson RA. Fitzpatrick's Color Atlas & Synopsis of Clinical Dermatology, Sixth Edition. New York: McGraw-Hill; 2009, Fig.18-19.*)

FIGURE 185-15 Pemphigus vulgaris involving the tongue and lips of a young woman. This is severely painful, making it difficult to eat or drink. (*Courtesy of Richard P. Usatine, MD.*)

Biopsy illustrates subepidermal acantholysis and immunoglobulin deposition along the basement membrane (Chapter 184, Bullous Pemphigoid).[3]

- Cicatricial pemphigoid—Also known as mucous membrane pemphigoid. Usually affects oral mucosa and conjunctiva. Lesions heal with scarring, which results in irreversible sequelae such as blindness, subglottic stenosis, and esophageal strictures.[3] Histology demonstrates antibody complexes in the basement membrane with submucosal infiltrate and prominent fibroblast proliferation (Chapter 184, Bullous Pemphigoid).
- Dermatitis herpetiformis—Herpes-like lesions in the form of grouped vesicles and erosions occur especially on the elbows and extensor surfaces. It is associated with gluten-induced enteropathy. Biopsy reveals neutrophilic microabscesses at the tips of dermal papillae with deposition of immunoglobulin (Ig) A antibody complexes. Blood tests for antigliadin and antiendomysial antibodies can help diagnose the gluten-induced enteropathy (Chapter 186, Other Bullous Diseases).
- Linear IgA dermatosis—Typical lesions are described as "string of pearls," which is an urticarial plaque surrounded by vesicles. Histologically, IgA antibodies are deposited in a linear fashion along the basement membrane (Chapter 183, Overview of Bullous Diseases).[5]
- Porphyria cutanea tarda—Bullae are seen on sun-exposed areas, especially on the dorsum of the hands. Histology shows antibody deposition in the capillary walls and dermoepidermal junction. Serum iron, ferritin, and transaminase levels are elevated as well as 24-hour urine porphyrins. Elevations in urine porphyrins are diagnostic (Chapter 186, Other Bullous Diseases).
- Hailey-Hailey disease (benign familial pemphigus)—A genodermatosis with crusted erosions and flaccid vesicles distributed in the intertriginous areas (**Figure 185-18**). It most closely resembles pemphigus vegetans clinically but has a completely different pathophysiology than true pemphigus. It is called benign because it is not life-threatening. A 4-mm punch biopsy is adequate to make this diagnosis as the histology is different than pemphigus.

FIGURE 185-16 Pemphigus erythematosus creating a lupus-like pattern of facial involvement. Note how the pemphigus foliaceous lesions involve the malar areas bilaterally. (*Courtesy of Richard P. Usatine, MD.*)

MANAGEMENT

Treatment of pemphigus should be undertaken in consultation with a dermatologist. Treatment is directed initially at disease control and remission followed by disease suppression. The goal is to eventually discontinue all medications and achieve complete remission. Unfortunately this goal is hard to achieve.

SYSTEMIC THERAPY

Corticosteroids

Oral steroids with a steroid-sparing adjuvant agent is the most effective treatment (two randomized controlled trials [RCTs]).[4,5] SOR B

- Treatment should begin with the corticosteroid.[4–6] SOR B Mild disease may be controlled with prednisone 40 mg/day but for rapidly progressive and extensive disease, a higher dose prednisone 60 to 80 mg/day is initiated. SOR C The dose may be increased by 50% every 1 to 2 weeks until disease activity is controlled. In most cases, a dose of approximately 60 mg of prednisone daily will need

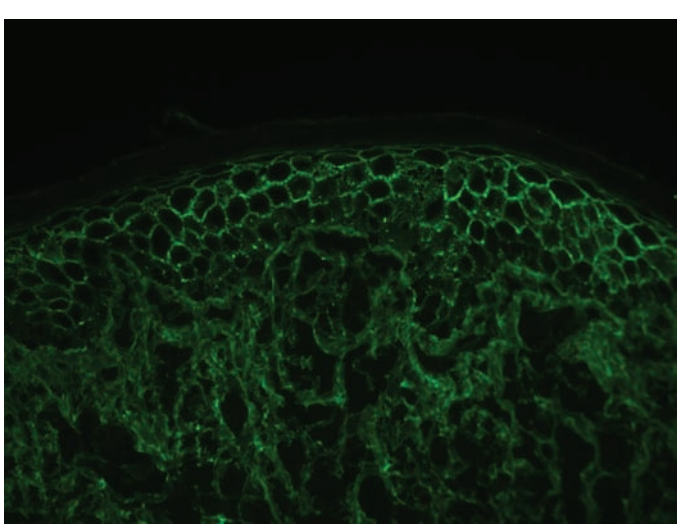

FIGURE 185-17 Direct immunofluorescence against immunoglobulin (Ig) G antibodies surrounding cells of the epidermis in a patient with pemphigus vulgaris. Note the chicken-wire appearance. (*Courtesy of Martin Fernandez, MD, and Richard P. Usatine, MD.*)

to be continued for at least 1 month. Once remission is induced, the dose is tapered by 25% every 1 to 2 weeks to the lowest dose needed to suppress recurrence of new lesions.[1]

- Pulse therapy with intravenous methylprednisolone 1 g/day for 5 days may be tried in severe cases in an attempt to decrease the cumulative dose of steroids, especially when high-dose oral steroids are ineffective.[6] SOR C
- High-dose and prolonged treatment with steroids can have serious side effects. Consequently, it is advisable to start adjuvant steroid-sparing therapy within 2 to 4 weeks of treatment. Adjuvant agents have a lag period of 4 to 6 weeks before they become effective, so starting them sooner allows for earlier steroid taper. They may be used alone to maintain remission after steroid withdrawal.

Adjuvant agents

- Adjuvant agents include azathioprine, cyclophosphamide, mycophenolate, dapsone, and intravenous immunoglobulin.[6–9] The efficacy of steroids have been shown to be enhanced when combined with a cytotoxic drug.[5]
- Azathioprine and mycophenolate mofetil (CellCept) are often the preferred adjuvants for PV.[6,8,10] SOR B
- Azathioprine was less effective than mycophenolate mofetil in achieving remission in one study with 40 participants (risk ratio 0.72; 95% confidence interval [CI] 0.52 to 0.99).[8,10] In 13 (72%) of 18 patients with pemphigus receiving oral methylprednisolone and azathioprine, complete remission was achieved after a mean of 74 (±127) days compared with 20 (95%) of 21 patients receiving oral methylprednisolone and mycophenolate in whom complete remission occurred after a mean of 91 (±113) days. A greater percentage of patients treated with azathioprine had adverse effects than those treated with mycophenolate.
- In one RCT open-label trial of four treatment regimens for PV, the most efficacious cytotoxic drug to reduce steroid was found to be azathioprine, followed by cyclophosphamide (IV pulse therapy), and mycophenolate mofetil.[5] SOR B
- Standard dosing for azathioprine is 50 mg a day. Standard dosing for mycophenolate is 1000 mg to 1500 mg twice daily. Azathioprine is significantly less expensive but patients may experience more side effects. Both are acceptable, widely used treatments for pemphigus.[4,5,8–10] SOR B
- Dapsone is an alternative adjuvant for pemphigus.[6] SOR C In one small study, 8 (73%) of 11 patients receiving dapsone versus 3 (30%) of 10 receiving placebo reached the primary outcome of a prednisone dosage of 7.5 mg/day or less. This was not statistically significant and only showed a trend to efficacy of dapsone as a steroid-sparing drug in maintenance-phase PV.[11]
- Intravenous immunoglobulin (IVIG) may be used as adjuvant therapy in refractory cases of pemphigus.[6,12–14] SOR B In one RCT, it was used as a 5-day cycle to treat pemphigus that was relatively resistant to systemic steroids. In this multicenter study of 61 patients with PV or foliaceous, there was a decrease in disease activity subsequent to the cycle of IVIG.[14] SOR B
- Rituximab is a chimeric monoclonal antibody against CD20 on B lymphocytes. It leads to depletion of pathogenic B cells for up to 12 months, resulting in a reduction of plasma cells secreting

FIGURE 185-18 Hailey-Hailey disease (benign familial pemphigus) with erythema and pustules in the axilla. This is not true pemphigus but resembles pemphigus vegetans. (*Courtesy of Jonathan B. Karnes, MD.*)

pathogenic autoantibodies. Rituximab is infused weekly for 4 consecutive weeks in addition to the standard immunosuppressive treatment. It has shown promise in several case reports and cohort studies in the treatment of PNP and refractory cases of PV and foliaceus.[15,16] SOR B

Treating and preventing complications of therapy

- Osteoporosis prevention—Long-term therapy with oral prednisone is a significant risk factor for osteoporosis. All patients should receive supplemental calcium and vitamin D based upon their age, gender, and normal dietary intake. A DEXA scan early in the course of the disease can be a helpful baseline. One study showed that alendronate therapy given to patients with immunobullous disease on long-term steroids resulted in statistically significant increases in bone mineral density at the lumbar spine and femoral neck.[17]
- Thrush is a common complication of high-dose steroids in pemphigus (**Figure 185-19**). This should be treated with oral fluconazole or another antifungal to prevent *Candida* esophagitis. If the patient is complaining of pain or difficulty swallowing, consider the diagnosis of *Candida* esophagitis and treat accordingly.
- Steroid-induced diabetes may also occur. This can be treated with metformin and monitoring of blood sugars and hemoglobin A_{1c}.

FIGURE 185-19 Thrush appearing in the mouth of a 50-year-old woman recently placed on oral prednisone for new-onset pemphigus vulgaris. Note the large erosion on the buccal mucosa and the adherent white *Candida* anterior to that and also on the tongue. KOH was positive and patient was treated with fluconazole. (*Courtesy of Richard P. Usatine, MD.*)

LOCAL THERAPY

- Solitary lesions may be treated with topical high-potency steroids, such as clobetasol, or with intralesional steroid injections, for example, 20 mg/mL triamcinolone acetonide. Isolated oral lesions may be treated with steroid paste, sprays, or lozenges.
- Normal saline compresses or bacteriostatic solutions such as potassium permanganate are useful in keeping lesions clean. Oral hygiene is crucial. Mouthwashes such as chlorhexidine 0.2% or 1:4 hydrogen peroxide may be used. Topical anesthetics may be used for pain.[6]

PROGNOSIS

Pemphigus is a chronic group of diseases that are potentially life-threatening. There is no cure and the long-term use of steroids and immunosuppressive drugs places the patients at risk for a number of complications including infections, sepsis, steroid-induced diabetes, and steroid-induced osteoporosis. Some patients will be lucky and go into remission while others will need systemic therapy for life. Complications of treatment have become the greatest source of morbidity and mortality in pemphigus.

FOLLOW-UP

Prolonged follow-up is needed for medication adjustment and to monitor disease activity and drug side effects.

PATIENT EDUCATION

- Educate patients regarding disease, complications, and side effects of medications.

- Advise patients on avoiding trauma to skin such as with contact sports. Similarly, oral lesions may be aggravated by nuts, spicy foods, chips, and dental plates and bridges.
- Instruct patients on wound care to prevent infections and relieve local discomfort.
- Provide information on support groups such as the International Pemphigus Pemphigoid Foundation.

PATIENT RESOURCES

- MedlinePlus. *Pemphigus*—**http://www.nlm.nih.gov/medlineplus/pemphigus.html.**
- Mayo Clinic. *Pemphigus*—**http://www.mayoclinic.com/health/pemphigus/DS00749.**
- International Pemphigus Pemphigoid Foundation—**http://www.pemphigus.org/.**

PROVIDER RESOURCES

- Medscape. *Pemphigus Vulgaris*—**http://emedicine.medscape.com/article/1064187.**
- Information on how to perform the appropriate biopsy can be found in Usatine R, Pfenninger J, Stulberg D, Small R. *Dermatologic and Cosmetic Procedures in Office Practice*. Philadelphia, PA: Elsevier; 2012. The text and the accompanying videos can also be purchased as an electronic application at: **http://www.usatinemedia.com.**

REFERENCES

1. Bystryn JC, Rudolph JL. Pemphigus. *Lancet.* 2005;366:61-73.
2. Ettlin DA. Pemphigus. *Dent Clin North Am.* 2005;49:107-1ix.
3. Bickle K, Roark TR, Hsu S. Autoimmune bullous dermatoses: a review. *Am Fam Physician.* 2002;65:1861-1870.
4. Beissert S, Mimouni D, Kanwar AJ, Solomons N, Kalia V, Anhalt GJ. Treating pemphigus vulgaris with prednisone and mycophenolate mofetil: a multicenter, randomized, placebo-controlled trial. *J Invest Dermatol.* 2010;130:2041-2048.
5. Chams-Davatchi C, Esmaili N, Daneshpazhooh M, et al. Randomized controlled open-label trial of four treatment regimens for pemphigus vulgaris. *J Am Acad Dermatol.* 2007;57:622-628.
6. Harman KE, Albert S, Black MM. Guidelines for the management of pemphigus vulgaris. *Br J Dermatol.* 2003;149:926-937.
7. Frew JW, Martin LK, Murrell DF. Evidence-based treatments in pemphigus vulgaris and pemphigus foliaceus. *Dermatol Clin.* 2011;29:599-606.
8. Martin LK, Werth VP, Villaneuva EV, Murrell DF. A systematic review of randomized controlled trials for pemphigus vulgaris and pemphigus foliaceus. *J Am Acad Dermatol.* 2011;64:903-908.
9. Singh S. Evidence-based treatments for pemphigus vulgaris, pemphigus foliaceus, and bullous pemphigoid: a systematic review. *Indian J Dermatol Venereol Leprol.* 2011;77:456-469.

10. Beissert S, Werfel T, Frieling U, et al. A comparison of oral methylprednisolone plus azathioprine or mycophenolate mofetil for the treatment of pemphigus. *Arch Dermatol.* 2006;142:1447-1454.

11. Werth VP, Fivenson D, Pandya AG, et al. Multicenter randomized, double-blind, placebo-controlled, clinical trial of dapsone as a glucocorticoid-sparing agent in maintenance-phase pemphigus vulgaris. *Arch Dermatol.* 2008;144:25-32.

12. Sami N, Qureshi A, Ruocco E, Ahmed AR. Corticosteroid-sparing effect of intravenous immunoglobulin therapy in patients with pemphigus vulgaris. *Arch Dermatol.* 2002;138:1158-1162.

13. Gurcan HM, Jeph S, Ahmed AR. Intravenous immunoglobulin therapy in autoimmune mucocutaneous blistering diseases: a review of the evidence for its efficacy and safety. *Am J Clin Dermatol.* 2010;11:315-326.

14. Amagai M, Ikeda S, Shimizu H, et al. A randomized double-blind trial of intravenous immunoglobulin for pemphigus. *J Am Acad Dermatol.* 2009;60:595-603.

15. Hertl M, Zillikens D, Borradori L, et al. Recommendations for the use of rituximab (anti-CD20 antibody) in the treatment of autoimmune bullous skin diseases. *J Dtsch Dermatol Ges.* 2008;6:366-373.

16. El Tal AK, Posner MR, Spigelman Z, Ahmed AR. Rituximab: a monoclonal antibody to CD20 used in the treatment of pemphigus vulgaris. *J Am Acad Dermatol.* 2006;55:449-459.

17. Tee SI, Yosipovitch G, Chan YC, et al. Prevention of glucocorticoid-induced osteoporosis in immunobullous diseases with alendronate: a randomized, double-blind, placebo-controlled study. *Arch Dermatol.* 2012;148:307-314.

186 OTHER BULLOUS DISEASES

Jimmy H. Hara, MD, FAAFP
Richard P. Usatine, MD

INTRODUCTION

There are a number of bullous diseases other than pemphigus and bullous pemphigoid that are important to recognize. Porphyria cutanea tarda is a porphyria that has no extracutaneous manifestations (**Figures 186-1** to **186-3**). Dystrophic epidermolysis bullosa belongs to a family of inherited diseases where blister formation can be caused by even minor skin trauma. PLEVA (pityriasis lichenoides et varioliformis acuta) is a minor cutaneous lymphoid dyscrasia that can appear suddenly and persist for weeks to months. Dermatitis herpetiformis is a recurrent eruption that is usually associated with gluten and diet-related enteropathies.

FIGURE 186-1 Porphyria cutanea tarda in a middle-aged woman. (*Courtesy of Lewis Rose, MD.*)

PORPHYRIA CUTANEA TARDA

PATIENT STORY

A middle-aged woman presented with tense blisters on the dorsum of her hand (**Figure 186-1**). One bulla was intact and the others had ruptured, showing erosions. Work-up showed elevated porphyrins in the urine (which fluoresced orange-red under a Wood lamp) and the patient was diagnosed with porphyria cutanea tarda.

EPIDEMIOLOGY

- Porphyria cutanea tarda (PCT) occurs mostly in middle-aged adults (typically 30 to 50 years of age) and is rare in children.
- It is especially likely to occur in women on oral contraceptives and in men on estrogen therapy for prostate cancer.[1]
- Alcohol, pesticides, and chloroquine have been implicated as chemicals that induce PCT.[1]
- PCT is equally common in both genders.
- There is an increased incidence of PCT in persons with hepatitis C (**Figures 186-2** and **186-3**).

FIGURE 186-2 Porphyria cutanea tarda in a man with hepatitis C. (*Courtesy of the University of Texas Health Sciences Center, Division of Dermatology.*)

ETIOLOGY AND PATHOPHYSIOLOGY

- The porphyrias are a family of illnesses caused by various metabolic derangements in the metabolism of porphyrin, the chemical backbone of hemoglobin. Whereas the other porphyrias (acute intermittent porphyria and variegate porphyria) are associated

with well-known systemic manifestations (abdominal pain, peripheral neuropathy, and pulmonary complications), PCT has no extracutaneous manifestations. Photosensitivity is seen (as with variegate porphyria). PCT is associated with a reduction in hepatic uroporphyrin decarboxylase.

RISK FACTORS

- Hepatitis C.
- Alcohol-induced liver injury.
- Hemochromatosis.[2]

DIAGNOSIS

CLINICAL FEATURES

The classic presentation is that of blistering (vesicles and tense bullae) on photosensitive "fragile skin" (similar to epidermolysis bullosa). Scleroderma-like heliotrope suffusion of the eyelids and face may be seen. As the blisters heal, the skin takes on an atrophic appearance. Hypertrichosis (especially on the cheeks and temples) is also common and may be the presenting feature.

TYPICAL DISTRIBUTION

Classically, the dorsa of the hands are affected (**Figures 186-1** to **186-3**). Facial suffusion (heliotrope) may be seen along with hypertrichosis of the cheeks and temples.

LABORATORY STUDIES

The diagnosis can be confirmed by the orange-red fluorescence of the urine when examined under a Wood lamp. Increased plasma iron may be seen (associated with increased hepatic iron in the Kupffer cells). Diabetes is said to occur in 25% of individuals.

- Twenty-four-hour urine collection for porphyrins—These will be elevated in PCT.
- Skin biopsy may help confirm PCT if the other information is not clear.
- Once the diagnosis is made, secondary causes of PCT should be investigated:
  - Serum for ferritin, iron, and iron-binding capacity to look for hemochromatosis.
  - Order liver function tests and if abnormal order tests for hepatitis B and C.
  - Consider α-fetoprotein and liver ultrasound if considering cirrhosis and/or hepatocellular carcinoma.
  - Order an HIV test if risk factors are present.

DIFFERENTIAL DIAGNOSIS

- The acral vesiculobullous lesions may suggest nummular or dyshidrotic eczema. In younger individuals, the acral blistering may suggest epidermolysis bullosa. The lesions may also suggest erythema multiforme bullosum. The heliotrope suffusion may suggest dermatomyositis and the atrophic changes may suggest systemic sclerosis.

FIGURE 186-3 Porphyria cutanea tarda in a man with hepatitis C and alcohol abuse. (*Courtesy of Richard P. Usatine, MD.*)

MANAGEMENT

- If the onset is associated with alcohol ingestion, estrogen therapy, or exposure to pesticides, reducing exposure is warranted.[2]
- Phlebotomy of 500 mL of blood weekly until the hemoglobin is decreased to 10 g is associated with biochemical and clinical remission within a year.[1]
- Low-dose chloroquine can help maintain remissions, whereas high-dose chloroquine can exacerbate the illness.[1]

FOLLOW-UP

- Periodic clinical follow-up until remission is achieved is necessary along with constant education and reinforcement of the need to avoid precipitants.

PATIENT EDUCATION

- Avoidance of potential precipitants (alcohol, estrogens, pesticides) and avoidance of excess sunlight exposure (to avoid hypersensitivity) are important. Avoidance of trauma and careful wound care is also necessary.

EPIDERMOLYSIS BULLOSA

PATIENT STORY

A 34-year-old pregnant woman presents with active blistering in her axilla and past history revealed that she lost her fingernails and toenails (**Figure 186-4***A*) as a young child. She was diagnosed as a child with recessive dystrophic epidermolysis bullosa. None of her children had been affected because her husband was neither affected nor a carrier (**Figure 186-4***B*). A topical steroid ointment helped relieve the pain and calm the blistering in her axilla.

EPIDEMIOLOGY

- Dystrophic epidermolysis bullosa belongs to a family of inherited diseases characterized by skin fragility and blister formation caused by minor skin trauma.[3] There are autosomal recessive and autosomal dominant types, the severity of this disease may vary widely. Onset is in childhood and in later years severe dystrophic deformities of hands and feet are characteristic (**Figure 186-5**). Malignant degeneration is common, especially squamous cell carcinoma, in sun-exposed areas.

FIGURE 186-4 **A.** Recessive dystrophic epidermolysis bullosa with loss of all her toenails as a young child. **B.** The same woman showing complete loss of her fingernails and the pregnant abdomen. Her daughter is touching the belly and does not have the disease and, therefore, has normal fingers. (*Courtesy of Richard P. Usatine, MD.*)

ETIOLOGY AND PATHOPHYSIOLOGY

- Dystrophic epidermolysis bullosa has vesiculobullous skin separation occurring at the sub-basal lamina level, as opposed to junctional epidermolysis bullosa, which blisters at the intralamina lucida layer, and epidermolysis bullosa simplex (**Figure 186-6**), which blisters at the intraepidermal layer.[4,5]

DIAGNOSIS

CLINICAL FEATURES

Acral skin fragility and blistering are the hallmark in childhood. Minor trauma can induce severe blistering. As the disease progresses initially, painful and ultimately debilitating dystrophic deformities are typical. Repeated blistering of the hands can lead to fusion of the fingers and the "mitten" deformity (**Figure 186-5**).

TYPICAL DISTRIBUTION

The typical distribution is acral (hands and feet), although blistering may extend proximally secondary to trauma.

LABORATORY STUDIES AND BIOPSY

There are no laboratory tests to confirm the diagnosis. A punch biopsy can provide adequate tissue for the dermatopathologist to differentiate between the different forms of epidermolysis bullosa: simplex, junctional, and dystrophic.

DIFFERENTIAL DIAGNOSIS

- Erythema multiforme bullosum may have a similar appearance, but the distribution is less apt to be limited to the distal extremities.
- The appearance of an acral blistering on fragile skin is also characteristic of PCT, but the age of onset of PCT is typically in middle age and not in childhood.
- The first appearance of the condition may be confused, with staphylococcal scalded skin syndrome (see Chapter 116, Impetigo).[6]

MANAGEMENT

Management is primarily prevention of trauma, careful wound care, and treatment of complicating infections. Other supportive measures such as pain management and nutritional support are often necessary. Screening the skin for squamous cell carcinoma is important in the dystrophic form.[4]

FOLLOW-UP

Periodic skin examinations should be done to help manage symptoms and screen for malignancy.

FIGURE 186-5 Severe recessive dystrophic epidermolysis bullosa in a 53-year-old Asian man. **A.** Complete loss of fingers from the disease on his hands. This is referred to as the mitten deformity. He has also had multiple squamous cell carcinomas excised from his hands. **B.** Similar foot deformities with loss of normal toes. (*Courtesy of Richard P. Usatine, MD.*)

PATIENT EDUCATION

Avoid trauma and come in early if there are any signs of infection or malignancy.

PITYRIASIS LICHENOIDES ET VARIOLIFORMIS ACUTA

PATIENT STORY

A 22-year-old man presented with a varicelliform eruption that he has had for 6 weeks (**Figure 186-7**). Initially, he was diagnosed with varicella and given a course of acyclovir. Then he was misdiagnosed with scabies and treated with permethrin. A correct diagnosis was made of PLEVA by clinical appearance and confirmed with biopsy. His skin lesions cleared with oral tetracycline.

EPIDEMIOLOGY

- PLEVA or Mucha-Habermann disease and pityriasis lichenoides chronica are maculopapular erythematous eruptions that can occur in crops of vesicles that can become hemorrhagic over a course of weeks to months (**Figures 186-7** and **186-8**).[7]
- There is a predilection for males in the second and third decades.
- PLEVA occurs in preschool and preadolescent children as well.[8]

ETIOLOGY AND PATHOPHYSIOLOGY

- PLEVA has traditionally been classified as a benign papulosquamous disease. However, there is increasing evidence that suggests that PLEVA should be considered a form of cutaneous lymphoid dyscrasia.[9] It may even, represent an indolent form of mycosis fungoides (see Chapter 176, Cutaneous T-Cell Lymphoma).

DIAGNOSIS

CLINICAL FEATURES

PLEVA occurs with crops of maculopapular and papulosquamous lesions that can vesiculate and form hemorrhagic vesicles (**Figures 186-7** and **186-8**). Although it resembles varicella, new crops of lesions continue to appear over weeks and months. It can be thought of as "chickenpox that lasts for weeks to months."

TYPICAL DISTRIBUTION

Lesions typically occur over the anterior trunk and flexural aspects of the proximal extremities. The face is spared.

FIGURE 186-6 A 12-year-old girl with the Dowling-Meara type of epidermolysis bullosa simplex. It is the most severe form with extensive, severe blistering over many areas of the body including, the **(A)** trunk, **(B)** extremities, and **(C)** the hands. (*Courtesy of Richard P, Usatine, MD.*)

LABORATORY STUDIES

There are no specific laboratory tests for PLEVA except biopsy.

BIOPSY

A punch biopsy is helpful in making the diagnosis. It may be necessary to differentiate PLEVA from lymphomatoid papulosis (see "Differential Diagnosis" below).

DIFFERENTIAL DIAGNOSIS

- Varicella—A varicella direct fluorescent antibody test can confirm acute varicella. If no viral testing was done and what appeared to be varicella persists, PLEVA should be considered (Chapter 123, Chickenpox).
- Pityriasis lichenoides chronica is the chronic form of PLEVA and can be distinguished from PLEVA by length of time and biopsy (**Figure 186-9**). It has a more low-grade clinical course than PLEVA and the lesions appear over a longer course of time.
- Erythema multiforme is a hypersensitivity syndrome in which target lesions are seen. The target lesions have epidermal disruption in the center with vesicles and/or erosions. Look for the target lesions to help differentiate this from PLEVA (see Section 14, Hypersensitivity Syndromes).
- Lymphomatoid papulosis presents in a manner similar to PLEVA with recurrent crops of pruritic papules at different stages of development that appear on the trunk and extremities. Although it has histologic features that suggest lymphoma, lymphomatoid papulosis alone is not fatal. It is important to differentiate this from PLEVA because these patients need to be worked up for coexisting malignancy. These patients tend to be older and a punch biopsy can make the diagnosis.
- Gianotti-Crosti syndrome (papular acrodermatitis of childhood) may resemble PLEVA but the lesions are usually acral in distribution (**Figure 186-10**).[5] The erythematous papules and vesicles are found on the extremities and sometimes on the face. It is a benign syndrome associated with many childhood viruses that may last 2 to 8 weeks.

MANAGEMENT

- UV A1 phototherapy has been deployed with some success.[10] Various reports suggest the efficacy of macrolides and tetracyclines, probably more for their antiinflammatory properties than for their antibacterial effects.

FOLLOW-UP

Needed only if the disease does not resolve.

PATIENT EDUCATION

This is usually a temporary disease but if it becomes chronic there are treatments that could help such as oral macrolides or tetracycline.

FIGURE 186-7 A 22-year-old man with pityriasis lichenoides et varioliformis acuta. His skin lesions cleared with oral tetracycline. (*Courtesy of Richard P, Usatine, MD.*)

FIGURE 186-8 A young woman with pityriasis lichenoides et varioliformis acuta. The individual lesions look like varicella but are unrelated to the varicella virus. (*Courtesy of David Anderson, MD.*)

DERMATITIS HERPETIFORMIS

PATIENT STORY

A young man with a past history of diarrhea and malabsorption carries a past diagnosis of gluten-induced enteropathy. Despite a gluten-free diet he continues to have a pruritic eruption on his shoulders, back, extremities and buttocks. (**Figures 186-11** and **186-12**). While the most likely diagnosis is dermatitis herpetiformis, a punch biopsy was performed to confirm this before starting the patient on oral dapsone.

EPIDEMIOLOGY

- Dermatitis herpetiformis is a chronic recurrent symmetric vesicular eruption that is usually associated with diet-related enteropathy.[11] It most commonly occurs in the 20 to 40 years of age group. Men are affected more often than women.

ETIOLOGY AND PATHOPHYSIOLOGY

- The disease is related to gluten and other diet-related antigens that cause the development of circulating immune complexes and their subsequent deposition in the skin. The term *herpetiformis* refers to the grouped vesicles that appear on extensor aspects of the extremities and trunk and is not a viral infection or related to the herpes viruses. The disease is characterized by the deposition of immunoglobulin (Ig) A along the tips of the dermal papillae. The majority of patients will also have blunting and flattening of jejunal villi, which leads to diarrhea even to the point of steatorrhea and malabsorption.

DIAGNOSIS

CLINICAL FEATURES

The clinical eruption is characterized by severe itching, burning, or stinging in the characteristic extensor distribution. Herpetiform vesicles and urticarial plaques may be seen. Because of the intense pruritus, characteristic lesions may be excoriated beyond recognition (**Figures 186-11** and **186-12**).

TYPICAL DISTRIBUTION

Classically, the lesions (or excoriations) are seen in the extensor aspects of the extremities, shoulders (**Figures 186-11**), lower back, and buttocks (**Figures 186-12**).

LABORATORY STUDIES

If the patient has gluten-induced enteropathy, antigliadin and antiendomysial antibodies may be present. A blood test for antigliadin antibody is a sensitive test for gluten-induced enteropathy.

BIOPSY

Diagnosis is confirmed by a punch biopsy. It is best to biopsy new crops of lesions. A standard histologic examination will show

FIGURE 186-9 Pityriasis lichenoides chronica is the chronic form of pityriasis lichenoides et varioliformis acuta that may persist for months to years. (*Courtesy of Richard P. Usatine, MD.*)

FIGURE 186-10 Gianotti-Crosti syndrome, "papular acrodermatitis of childhood," in a 7-month-old child. The acral eruption started just after a viral upper respiratory infection and involved the feet, lower legs, and buttocks. (*Courtesy of Richard P. Usatine, MD.*)

eosinophils and microabscesses of neutrophils in the dermal papillae and subepidermal vesicles. Direct immunofluorescence reveals deposits of IgA and complement within the dermal papillae.

DIFFERENTIAL DIAGNOSIS

- Scabies may have a similar appearance with pruritus, papules, and vesicles. If the lesions and distribution suggest scabies, it should be ruled out with skin scraping looking for the mite, feces, and eggs. If the scraping is negative, but the clinical appearance suggests scabies, empiric treatment with permethrin should be considered as well. If the lesions persist, consider a punch biopsy to look for dermatitis herpetiformis (Chapter 143, Scabies).
- Nummular and dyshidrotic eczema may also be diagnostic considerations, but response to steroids in eczema may be helpful in differentiation (Chapters 145, Atopic Dermatitis and 147, Hand Eczema).
- The classic differential for PCT is pseudoporphyria (caused by NSAIDs like Naprosyn), epidermolysis bullosa acquisita, and variegate porphyria.

MANAGEMENT

- With a gluten-free diet, 80% of patients will show improvement in the skin lesions (**Figure 186-12**). The degree of benefit is dependent upon the strictness of the diet.[11]
- A gluten-free diet may help the enteropathy and decrease the subsequent development of small bowel lymphoma.
- Dapsone at an initial dose of 100 to 200 mg daily with gradual reduction to a 25- to 50-mg maintenance level may be necessary indefinitely.[12]

FOLLOW-UP

Follow-up is needed to control the disease and monitor nutritional status.

PATIENT EDUCATION

Nutritional counseling is important for all patients with gluten-induced enteropathy. Persons with dermatitis herpetiformis and gluten-induced, enteropathy should not eat wheat and barley but can eat rice, oats and corn.

PATIENT RESOURCES

- MedlinePlus. *Porphyria*—**http://www.nlm.nih.gov/medlineplus/ency/article/001208.htm.**
- Genetics Home Reference. *Epidermolysis Bullosa Simplex*—**http://ghr.nlm.nih.gov/condition=epidermolysisbullosasimplex.**
- National Institute of Arthritis and Musculoskeletal and Skin Diseases. *Epidermolysis Bullosa*—**http://www.niams.nih.gov/Health_Info/Epidermolysis_Bullosa/default.asp.**

FIGURE 186-11 A young man with dermatitis herpetiformis and gluten-induced enteropathy. The daily vesicles that form are fragile and rapidly become small erosions. (*Courtesy of Richard P. Usatine, MD.*)

FIGURE 186-12 Dermatitis herpetiformis that has persisted even though he is on a strict gluten-free diet. The buttocks is a commonly involved area. His gastrointestinal symptoms have resolved on the gluten-free diet but his eruption has only improved with lack of full clearance. (*Courtesy of Richard P. Usatine, MD.*)

- PubMed Health. *Dermatitis Herpetiformis*—**http://www.ncbi.nlm.nih.gov/pubmedhealth/PMH0002451/.**
- DermNet NZ. *Pityriasis Lichenoides*—**http://dermnetnz.org/scaly/pityriasis-lichenoides.html.**

PROVIDER RESOURCES

- Medscape. *Porphyria Cutanea Tarda*—**http://emedicine.medscape.com/article/1103643.**
- Medscape. *Epidermolysis Bullosa*—**http://emedicine.medscape.com/article/1062939.**
- Medscape. *Dermatitis Herpetiformis*—**http://emedicine.medscape.com/article/1062640.**
- Medscape. *Pityriasis Lichenoides*—**http://emedicine.medscape.com/article/1099078.**

REFERENCES

1. Elder GH. Porphyria cutanea tarda and related disorders. In: Kadish K, Smith K, Guilard R, eds. *The Porphyrin Handbook*. Volume 14. San Diego, CA: Elsevier Science; 2003:67ff.
2. Jalil S, Grady JJ, Lee C, Anderson, KE. Associations among behavior-related susceptibility factors in porphyria cutanea tarda. *Clin Gastroenterol Hepatol.* 2010;8(3):297-302, 302e-1.
3. Horn HM, Tidman MJ. The clinical spectrum of epidermolysis bullosa. *Br J Dermatol.* 2002;146(2):267-274.
4. Fine JD, Johnson LB, Weiner M, et al. Epidermolysis bullosa and the risk of life-threatening cancers: the National EB Registry experience, 1986-2006. *J Am Acad Dermatol.* 2009;60(2):203-211.
5. Paller AS, Mancini AJ. Bullous diseases in children. In: Paller AS, Mancini AJ, eds. *Hurwitz's Clinical Pediatric Dermatology*, 3rd ed. Philadelphia, PA: Elsevier; 2006:345.
6. Patel GK, Finlay AY. Staphylococcal scalded skin syndrome: diagnosis and management. *Am J Clin Dermatol.* 2003;4(3):165-175.
7. Bowers S, Warshaw EM. Pityriasis lichenoides and its subtypes. *J Am Acad Dermatol.* 2006;55(4):557-572.
8. Ersoy-Evans S, Greco MF, Mancini AJ, et al. Pityriasis lichenoides in childhood: a retrospective review of 124 patients. *J Am Acad Dermatol.* 2007;56(2):205-210.
9. Magro C, Crowson AN, Kovatich A, Burns F. Pityriasis lichenoides: a clonal T-cell lymphoproliferative disorder. *Hum Pathol.* 2002;33(8):788-795.
10. Pinton PC, Capezzera R, Zane C, De Panfilis G. Medium-dose ultraviolet A1 therapy for pityriasis lichenoides et varioliformis acuta and pityriasis lichenoides chronica. *J Am Acad Dermatol.* 2002;47(3):410-414.
11. Patient.co.uk. *Dermatitis Herpetiformis*. http://www.patient.co.uk/showdoc/40001007/. Accessed October 7, 2007.
12. AGA Institute. AGA Institute Medical Position Statement on the Diagnosis and Management of Celiac Disease. *Gastroenterology*. 2006;131(6):1977-1980.

SECTION 17 HAIR AND NAIL CONDITIONS

187 ALOPECIA AREATA

Richard P. Usatine, MD
James W. Haynes, MD

PATIENT STORY

An 8-year-old Hispanic girl was brought to her physician by her mother, who noticed two bald spots on the back of her daughter's scalp while brushing her hair. The child had no itching or pain. The mother was more worried that her beautiful girl would become bald. The girl was pleased that the bald spots could be completely covered with her long hair, as she did not want anyone to see them. The child was otherwise healthy. When the mother lifted the hair in the back, two round areas of hair loss were evident (**Figure 187-1**). On close inspection, there was no scaling or scarring. The mother and child were reassured that alopecia areata (AA) is a condition in which the hair is likely to regrow without treatment. Neither of them wanted intralesional injections or topical therapies. During a well-child examination 1 year later, it was noted that the girl's hair had fully regrown.[1]

FIGURE 187-1 Alopecia areata in an 8-year-old girl. (*From Usatine R. Bald spots on a young girl. J Fam Pract. 2004;53(1):33-36. Reproduced with permission from Frontline Medical Communications.*)

INTRODUCTION

AA is a common disorder that causes patches of hair loss without inflammation or scarring. The areas of hair loss are often round and the scalp is often very smooth at the site of hair loss.

SYNONYMS

Alopecia totalis involves the whole scalp (**Figure 187-2**). Alopecia universalis (AU) involves the whole scalp, head, and body.

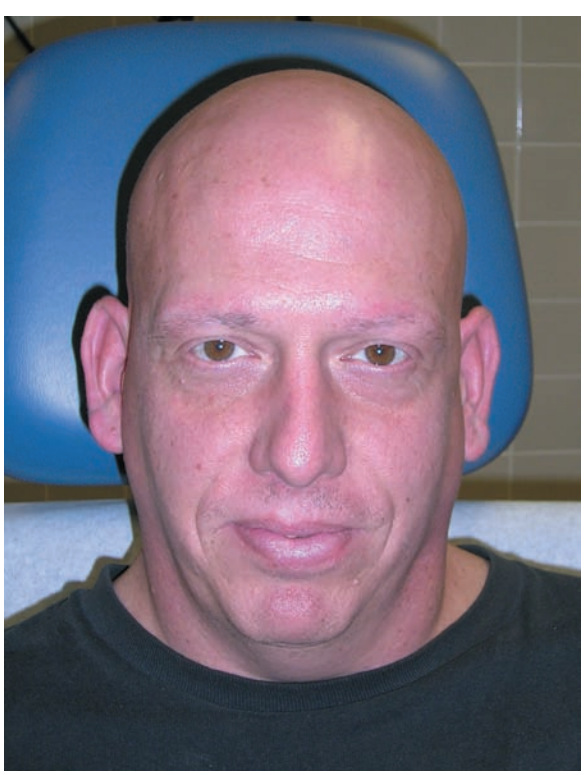

FIGURE 187-2 Alopecia totalis for more than 10 years in this adult man. (*Courtesy of Richard P. Usatine, MD.*)

EPIDEMIOLOGY

Alopecia affects approximately 0.2% of the population at any given time with approximately 1.7% of the population experiencing an episode during their lifetime.[2,3]

- Men and women are equally affected.
- Most patients are younger than age 40 years at disease onset, with the average age being 25 to 27 years.[2,4]

ETIOLOGY AND PATHOPHYSIOLOGY

- The etiology is unknown but experts presume that the AA spectrum of disorders is secondary to an autoimmune phenomenon involving antibodies, T cells, and cytokines.

RISK FACTORS

- Previous episode of AA
- Family history of AA—In one study, the estimated lifetime risks were 7.1% in siblings, 7.8% in parents, and 5.7% in offspring of patients with AA.[5]

DIAGNOSIS

CLINICAL FEATURES

- Sudden onset of 1 or more 1- to 4-cm areas of hair loss on the scalp (**Figures 187-1** and **187-3**). This can occur in the beard, eyebrows, or other areas of hair (**Figure 187-4**).
- The affected skin is smooth and may have short stubble hair growth.
- "Exclamation point" hairs are often noted (**Figure 187-5**). These hairs are characterized by proximal thinning while the distal portion remains of normal caliber.
- When hair begins to regrow, it often comes in as fine white hair (**Figure 187-6**).

TYPICAL DISTRIBUTION

- Scalp, beard, and eyebrows but can involve total-body hair loss.

LABORATORY STUDIES

- Typically, the diagnosis can be made with history and physical examination alone.
- Thyroid abnormalities, vitiligo, and pernicious anemia often accompany AA. Consequently, screening laboratory tests (e.g., thyroid-stimulating hormone, complete blood count [CBC]) may be helpful to look for thyroid disorders and anemia (**Figure 187-7**).

BIOPSY

Not needed unless the diagnosis is uncertain. Histology examination shows peribulbar lymphocytic infiltration, frequently including eosinophils and the above-mentioned (see "Clinical Features") "exclamation point" hairs.

DIFFERENTIAL DIAGNOSIS

- Trichotillomania—History of hair pulling; short, "broken" hairs are seen (see Chapter 188, Traction Alopecia and Trichotillomania).
- Telogen effluvium—Even distribution of hair loss; may be drug-induced (e.g., warfarin, β blockers, lithium) or occur after pregnancy (see Chapter 74, Skin Findings in Pregnancy).
- Anagen effluvium—History of drug use (e.g., antimitotic agents); even distribution of hair loss.
- Tinea capitis—Skin scaling and inflammation; KOH prep or fungal culture, if necessary (see Chapter 137, Tinea Capitis).
- Secondary syphilis—"Moth-eaten" appearance in beard or scalp; risk factors and rapid plasma reagin (RPR) will help distinguish (see Chapter 216, Syphilis).

FIGURE 187-3 Extensive alopecia areata for more than 6 months in an adult woman. (*Courtesy of Richard P. Usatine, MD.*)

FIGURE 187-4 Alopecia areata can be seen in the beard in this young man. (*Courtesy of Richard P. Usatine, MD.*)

FIGURE 187-5 Exclamation point hairs (*arrows*) can be seen in this case of alopecia areata. The hair is narrow at the base, short and wide at the end. (*Courtesy of Richard P. Usatine, MD.*)

- Lupus erythematosus—Skin scarring; antinuclear antibody (ANA) if clinical presentation compatible with this diagnosis (see Chapter 180, Lupus: Systemic and Cutaneous).
- Follicular mucinosis with or without mycosis fungoides can cause similar areas of hair loss to AA (**Figure 187-8**).

MANAGEMENT

- Many patients with AA will have significant comorbid anxiety and depression, so the management of psychological implications is paramount to successful management.
- Treatment for alopecia includes immune-modulating agents (e.g., corticosteroids, anthralin, psoralen plus ultraviolet A [PUVA]), contact sensitizers (e.g., dinitrochlorobenzene, squaric acid dibutyl ester, diphenylcyclopropenone), and biologic response modifiers (e.g., minoxidil).[6,7] SOR C
  - A commonly used treatment in patients older than 10 years of age with less than 50% scalp involvement is intralesional steroids (**Figure 187-9**). SOR B
    - In one randomized controlled trial (RCT), intralesional triamcinolone acetonide (10 mg/mL every 3 weeks) was better than betamethasone valerate foam in management of localized AA.[8] There was no satisfactory hair regrowth in the tacrolimus group.[8] Although 10 mg/mL triamcinolone is often used as treatment, there is a higher rate of scalp atrophy than when using 5 mg/mL. We recommend starting with 5 mg/mL and increasing to 10 mg/mL if needed and when the patient accepts the higher risk of atrophy.
    - Triamcinolone acetonide (Kenalog)—Dilute with sterile saline to 5 mg/mL. Inject with a 3-mL or 5-mL syringe and a 27- or 30-gauge needle. Inject into the dermis of the involved areas but not to exceed 4 mL per visit. Use 2.5 mg/mL for involved areas of the eyebrows or beard. SOR C
    - Skin atrophy can be reduced by injecting intradermally and limiting both the volume per site and the frequency of injections (4 to 6 weeks between injections). Do not reinject areas that show atrophy and in most cases, the atrophy will resolve spontaneously. SOR C
    - Because spontaneous regrowth can occur, steroid injections should be discontinued after 6 months if there is no response.
  - For patients younger than age 10 years, 5% minoxidil, midpotency topical steroids, and/or anthralin can be used. The combination of anthralin with topical steroids and/or minoxidil is a good choice for children and for those with extensive disease because of its easy use and effectiveness without skin irritation. SOR C
  - For patients with more than 50% of scalp involvement, topical immunotherapy with contact sensitizers may be an effective treatment.
    - Topical diphenylcyclopropenone (DPCP) is a contact immunotherapy that has some proven benefit with extensive AA. In one study, 56 patients with chronic, extensive AA (duration ranging from 1 to 10 years, involving 30% to 100% of the scalp) were treated with progressively higher concentrations of DPCP in a randomized crossover trial. Twenty-five of 56 patients had total hair regrowth at 6 months, and no relapse occurred in 60% of patients.[7] SOR B

FIGURE 187-6 New growth of white hair after 7 months of alopecia areata in this middle-age woman. (*Courtesy of Richard P. Usatine, MD.*)

FIGURE 187-7 A patient with alopecia areata who was hyperthyroid. He had symptoms of hyperthyroidism and his thyroid-stimulating hormone was low. (*Courtesy of Richard P. Usatine, MD.*)

- These contact sensitizers have potential severe side effects, including mutagenesis, blistering, hyperpigmentation, and scarring, and thus should be used by clinicians with significant experience with these agents or in consultation with a dermatologic specialist.
- Minoxidil, PUVA, and anthralin have been used with varying effectiveness and can be considered.

A Cochrane review in 2008 concluded that most trials have been reported poorly and are so small that any important clinical benefits are inconclusive.[9] They stated that considering the possibility of spontaneous remission (especially for those in the early stages of the disease) the options of not treating or wearing a wig are reasonable alternatives.[9]

- Hairpieces and transplantation may be used for those patients with unresponsive, recalcitrant disease.
- One RCT showed aromatherapy with topical essential oils to be a safe and effective treatment for AA.[10] SOR B

PATIENT EDUCATION AND PROGNOSIS

- Although spontaneous recovery usually occurs, the course of AA is unpredictable and often characterized by recurrent periods of hair loss and regrowth.
- Spontaneous long-term regrowth in alopecia totalis and AU is poor.
- Prognosis is worse if the alopecia persists longer than 1 year.

FOLLOW-UP

- Spontaneous recovery usually occurs within 6 to 12 months and the prognosis for total permanent regrowth with limited involvement (AA) is excellent.
- The regrown hair is usually of the same texture and color but may be fine and white at first (**Figure 187-5**).
- Ten percent of patients never regrow hair and advance to chronic disease. Clinicians should provide contact information to the National Alopecia Areata Foundation and offer follow-up in the office as necessary.
- Patients with a family history of AA, younger age at onset, coexisting immune disorders, nail dystrophy, atopy, and widespread hair loss have a poorer prognosis.[5]

PATIENT RESOURCES

- The National Alopecia Areata Foundation (**http://www.naaf.org/**) publishes a newsletter and can provide information regarding these support groups as well as hairpiece information.
- **http://www.niams.nih.gov/hi/topics/alopecia/ff_alopecia_areata.htm.**

PROVIDER RESOURCES

- **http://emedicine.medscape.com/article/1069931-overview.**

FIGURE 187-8 **A.** A rare occurrence of folliculotropic mycosis fungoides causing patches of hair loss on the arm and eyebrow. **B.** Before the red plaques appeared on the face, the hair loss was thought to be alopecia areata. Biopsy of a facial lesion demonstrated cutaneous T-cell lymphoma. (*Courtesy of Richard P. Usatine, MD.*)

REFERENCES

1. Usatine RP. Bald spots on a young girl. *J Fam Pract.* 2004;53:33-36.
2. Firooz A, Firoozabadi MR, Ghazisaidi B, Dowlati Y. Concepts of patients with alopecia areata about their disease. *BMC Dermatol.* 2005;5:1.
3. Springer K, Brown M, Stulberg DL. Common hair loss disorders. *Am Fam Physician.* 2003;68:93-102.
4. Choi HJ, Ihm CW. Acute alopecia totalis. *Acta Dermatovenerol Alp Panonica Adriat.* 2006;15:27-34.
5. Blaumeiser B, van der Goot I, Fimmers R, et al. Familial aggregation of alopecia areata [abstract]. *J Am Acad Dermatol.* 2006;54:627-632.
6. Price VH. Treatment of hair loss. *N Engl J Med.* 1999;341:964-973.
7. Cotellessa C, Peris K, Caracciolo E, et al. The use of topical diphenylcyclopropenone for the treatment of extensive alopecia areata. *J Am Acad Dermatol.* 2001;44:73-76.
8. Kuldeep C, Singhal H, Khare AK, et al. Randomized comparison of topical betamethasone valerate foam, intralesional triamcinolone acetonide and tacrolimus ointment in management of localized alopecia areata. *Int J Trichology.* 2011;3:20-24.
9. Delamere FM, Sladden MM, Dobbins HM, Leonardi-Bee J. Interventions for alopecia areata. *Cochrane Database Syst Rev.* 2008 Apr 16;(2):CD004413.
10. Hay IC, Jamieson M, Ormerod AD. Randomized trial of aromatherapy. Successful treatment for alopecia areata. *Arch Dermatol.* 1998;134:1349-1352.

FIGURE 187-9 Injecting alopecia areata with triamcinolone acetonide 5 mg/mL. (*Courtesy of Richard P. Usatine, MD.*)

188 TRACTION ALOPECIA AND TRICHOTILLOMANIA

E.J. Mayeaux, Jr., MD

PATIENT STORY

A 38-year-old woman was found to have hair thinning on the anterior scalp. She had long thick heavy hair that she always styled in a bun on the top of her head. She was concerned about the slow, steady loss of hair that she was experiencing. **Figure 188-1** shows the appearance of the thinned hair as a result of chronic traction. A 4-mm punch biopsy was performed to confirm the clinical impression and the histology was supportive of this diagnosis.

FIGURE 188-1 Traction alopecia from pulling the hair up in a tight bun. *(Courtesy of Richard P. Usatine, MD.)*

INTRODUCTION

Traction alopecia is hair loss caused by damage to the dermal papilla and hair follicle by constant pulling or tension over a long period. It often occurs in persons who wear tight braids, especially "cornrows" that lead to high tension, pulling, and breakage of hair. Trichotillomania (Greek for "hair-pulling madness") is a traction alopecia related to a compulsive disorder caused when patients pull on and pluck hairs, often creating bizarre patterns of hair loss.

EPIDEMIOLOGY

- The prevalence of traction alopecia (**Figures 188-1** and **188-2**) is unknown and varies by cultural hairstyle practices. It is most commonly seen in females and children.[1]
- The prevalence of trichotillomania (**Figures 188-3** to **188-6**) is also difficult to determine, but is estimated to be approximately 1.5% of males and 3.4% of females in the United States. The mean age of onset of trichotillomania is 8 years in boys and 12 years in girls, and it is the most common cause of childhood alopecia.[2]

ETIOLOGY AND PATHOPHYSIOLOGY

- Traction alopecia is seen in individuals who place chronic tension on the hair shafts with tight braids, heavy natural hair, use of hair prostheses, or chronic pulling (**Figures 188-1** and **188-2**).[1] It also occurs commonly in female athletes who pull their hair into tight ponytails.
- Chronic tension on the hair shaft seems to create inflammation within the hair follicle that eventually leads to cessation of hair growth. Because hair loss from traction alopecia may become permanent, prevention and early treatment are important.
- It is seen most frequently in black women who tightly braid or pull the hair into a hairstyle during youth and on into adulthood. May also be seen in individuals who wear hair prostheses or extensions for a prolonged period of time. It is also seen in Sikh men of India and Japanese women whose traditional hairstyles may pull and damage hair.

FIGURE 188-2 Traction alopecia in a young African American girl whose mom braids her hair tightly. *(Courtesy of Richard P. Usatine, MD.)*

- Trichotillomania is a subtype of traction alopecia manifested by chronic hair pulling (**Figures 188-3** to **188-6**) and sometimes hair eating (trichophagy), which can lead to a trichobezoar. It is classified as a psychiatric impulse-control disorder.[3]
- Trichotillomania may be a manifestation of the inability to cope with stress rather than more severe mental disorders.
- Children who exhibit trichotillomania may discontinue the hair pulling with parental support and maturity. Adults who exhibit trichotillomania, even though they are aware of the problem, may require psychiatric intervention to limit the behavior. The hair loss is initially reversible but may become permanent if the habits persist.

DIAGNOSIS

CLINICAL FEATURES

In patients with traction alopecia, there are decreased follicular ostia in the affected area coupled with decreased hair density. The hair loss usually occurs in the frontal and temporal areas but depends on the precipitating hairstyle (**Figures 188-1** and **188-2**). No scalp inflammation or scaling is typically visible. No pain or other discomfort is associated with the condition. Patients with trichotillomania often demonstrate short, broken hairs (**Figure 188-6**) without the presence of inflammation or skin scale early in the disease. The affected areas are not bald, but rather possess hairs of varying length. There may be telltale stubble of hairs too short to pull. The hair loss often follows bizarre patterns with incomplete areas of clearing. The scalp may appear normal or have areas of erythema and pustule formation. With chronic pulling, the hair loss becomes permanent (**Figure 188-4**). The patient may be observed pulling or twisting the hair by friends or family members.

TYPICAL DISTRIBUTION

Trichotillomania most commonly occurs on the scalp and can involve any area of the body that can be reached by the patient.[1] Traction alopecia can occur anywhere on the scalp, but is most commonly seen at the anterior hairline. This is the site where the hair is pulled back from the face into braids or a bun.

LABORATORY STUDIES

Laboratory tests are not needed to make the diagnosis. A hand lens can be used to examine the affected scalp for decreased follicular ostia, if desired. A scalp biopsy (4-mm punch biopsy) may be necessary to make the diagnosis and rule out other etiologies, especially in trichotillomania, because patients may not acknowledge the habit.

Hypothyroidism or hyperthyroidism may be associated with telogen effluvium or alopecia areata. It may be worth ordering a thyroid-stimulating hormone (TSH) if the history and physical exam are not completely convincing for self-induced hair loss.

DIFFERENTIAL DIAGNOSIS[1]

- Alopecia areata is characterized by the total absence of hair in an area and the presence of exclamation point hairs. These hairs are

FIGURE 188-3 Trichotillomania in an 11-year-old boy. Note the incomplete hair loss and unusual geometric pattern. He was receiving help and the hair is now growing in. *(Courtesy of Richard P. Usatine, MD.)*

FIGURE 188-4 Chronic hair loss in a 39-year-old woman with trichotillomania. *(Courtesy of E.J. Mayeaux, Jr., MD.)*

thinner in diameter closer to the scalp and thicker in diameter away from the scalp, creating the appearance of an exclamation point. Hairs are often white when they start to regrow (see Chapter 187, Alopecia Areata).

- Tinea capitis exhibits hairs broken off at the skin surface and the presence of scale and/or inflammation. Some varieties fluoresce when examined with a Wood light (UV light). Microscopy of a KOH preparation may detect the dermatophyte. Sometimes it is necessary to culture some hairs and scale to make this diagnosis (see Chapter 137, Tinea Capitis).
- Scarring alopecia (lichen planopilaris, folliculitis decalvans) is observed as loss of the follicular ostia and the absence of hairs. The scalp may appear scarred with changes in pigmentation (see Chapter 189, Scarring Alopecia).
- Telogen effluvium (postpregnancy hair loss) is associated with hair loss during the postpartum period and can happen after other stressful events such as surgery or severe illness (see Chapter 74, Skin Findings in Pregnancy). The hair loss is evenly distributed across the head and the hair is thinned all over rather than in patches as in traction alopecia.
- Androgenetic alopecia produces central thinning in women and temple and crown thinning in males. It should be considered in women with symptoms of hormonal abnormalities such as hirsutism, amenorrhea, or infertility.

FIGURE 188-5 Trichotillomania in his 17-year-old honors student who is currently taking four Advanced Placement courses simultaneously. *(Courtesy of Richard P. Usatine, MD.)*

MANAGEMENT

NONPHARMACOLOGIC

- Stop hairstyling practices that led to the traction alopecia. No tight braiding or buns should be worn.[1] SOR C
- For trichotillomania, open discussions with the patient, and the family, if appropriate, are important to understand the reason for the behavior. Many times there are secondary social or emotional issues that must be resolved before the trichotillomania ceases.
  - Cognitive behavioral treatment is the most effective treatment for trichotillomania.[1,3] SOR B
  - Cognitive-behavioral therapy usually is successful if the patient is recalcitrant to simple education.[5] SOR C

MEDICATIONS

- Topical corticosteroids can be used to decrease scalp inflammation if erythema or itching is present. SOR C
- Topical minoxidil is sometimes used to speed hair regrowth in the area. SOR C
- Fluoxetine hydrochloride (Prozac) 20 to 40 mg/day in adults or clomipramine (Anafranil) 25 to 250 mg/day in adults or a maximum of 3 mg/kg per day in children has had some success for alleviating compulsive hair pulling.[4–6] SOR B

Olanzapine (Zyprexa) has been studied for the treatment of trichotillomania in a 12-week, randomized, double-blind, placebo-controlled trial. A dose of 10 mg/day showed a significant decrease in the CGI-Severity of Illness scale in 85% of subjects.[7] SOR B

Methylphenidate also has showed limited efficacy in trichotillomania patients with comorbid attention deficit hyperactivity disorder (ADHD) in a 12-week study.[8] SOR B

PATIENT EDUCATION

Explain that in traction alopecia, current grooming practices are responsible for the hair loss and a new hairstyle must be selected. It is important to tell the patient that some of the hair loss may be permanent and no guarantee can be given regarding the amount of expected hair regrowth. Similar hair grooming practices should be avoided in the patient's children to prevent traction alopecia from occurring. Prevention is definitely the best treatment.

Explain that trichotillomania is a self-induced disease that can often resolve if the hair pulling or twisting is discontinued. Patients may exhibit hair pulling or twisting unconsciously when stressed or use it as a calming activity when relaxing or going to sleep. The underlying reasons for the behavior should be explored and discussed. Sometimes trichotillomania can be substituted with another behavior, such as playing with beads or rubbing a stone.

FOLLOW-UP

Specific follow-up is not required for traction alopecia but psychiatric/behavioral counseling follow-up is indicated for trichotillomania.

PATIENT RESOURCES

- Trichotillomania Support and Therapy Site. *Emphasis on Growth*—**http://www.trichotillomania.co.uk/.**
- WebMD. *Mental Health and Trichotillomania*—**http://www.webmd.com/anxiety-panic/guide/trichotillomania.**
- *Traction Alopecia: Causes and Treatment Options*—**http://www.traction-alopecia.com/.**
- National Organization for Rare Disorders, Inc. *Trichotillomania*—**http://www.kumed.com/healthwise/healthwise.aspx?DOCHWID=nord768.**
- MedlinePlus. *Trichotillomania*—**http://www.nlm.nih.gov/medlineplus/ency/article/001517.htm.**
- Mental Health America. *Trichotillomania*—**http://www.nmha.org/go/information/get-info/trichotillomania.**

PROVIDER RESOURCES

- *Trichotillomania*—**http://emedicine.medscape.com/article/1071854-overview.**
- *Traction Alopecia*—**http://www.emedicine.com/derm/topic895.htm.**

FIGURE 188-6 **A.** Trichotillomania in a 12-year-old girl undergoing much stress because of conflict in her family. **B.** Close-up of trichotillomania showing broken hairs, black dots, and excoriations. *(Courtesy of Richard P. Usatine, MD.)*

REFERENCES

1. Springer K, Brown M, Stulberg DL. Common hair loss disorders. *Am Fam Physician*. 2003;68:93-102, 107-108.
2. Messinger ML, Cheng TL. Trichotillomania. *Pediatr Rev*. 1999;20: 249-250.
3. Bloch MH, Landeros-Weisenberger A, Dombrowski P, et al. Systematic review: pharmacological and behavioral treatment for trichotillomania. *Biol Psychiatry*. 2007;62(8):839-846.
4. Christenson GA, Crow SJ. The characterization and treatment of trichotillomania. *J Clin Psychiatry*. 1996;57(Suppl 8):42-47.
5. Streichenwein SM, Thornby JI. A long-term, double-blind, placebo-controlled crossover trial of the efficacy of fluoxetine for trichotillomania. *Am J Psychiatry*. 1995;152:1192-1196.
6. Ninan PT, Rothbaum BO, Marsteller FA, et al. A placebo-controlled trial of cognitive-behavioral therapy and clomipramine in trichotillomania. *J Clin Psychiatry*. 2000;61:47-50.
7. Van Ameringen M, Mancini C, Patterson B, et al. A randomized, double-blind, placebo-controlled trial of olanzapine in the treatment of trichotillomania. *J Clin Psychiatry*. 2010;71(10):1336-1343.
8. Golubchik P, Sever J, Weizman A, Zalsman G. Methylphenidate treatment in pediatric patients with attention-deficit/hyperactivity disorder and comorbid trichotillomania: a preliminary report. *Clin Neuropharmacol*. 2011;34(3):108-110.

189 SCARRING ALOPECIA

Richard P. Usatine, MD

PATIENT STORY

A 32-year-old man presents with hair loss along with chronic pustular eruptions of his scalp. Previous biopsy has shown folliculitis decalvans. He has had many courses of antibiotics, but the hair loss continues to progress. The active pustular lesions are cultured and grow out methicillin-resistant *Staphylococcus aureus*. The patient is treated with trimethoprim-sulfamethoxazole twice daily and mupirocin to the nasal mucosa, twice daily for 5 days. Two weeks later, the pustular lesions are less prominent although the alopecia is permanent (**Figures 189-1** and **189-2**).

FIGURE 189-1 Folliculitis decalvans in a 32-year-old man. He has an active area of pustular lesions on the periphery with wide areas of scarring and hair loss. (*Courtesy of Richard P. Usatine, MD.*)

INTRODUCTION

Scarring alopecia is a group of inflammatory disorders in which there is permanent destruction of the pilosebaceous unit. Although it is mostly seen on the scalp, it can involve other areas, such as the eyebrows.

In primary cicatricial alopecia, the hair follicle is the primary target of destruction by inflammation. In secondary cicatricial alopecia, the follicular destruction is incidental to a nonfollicular process such as infection, tumor, burn, radiation, or traction.

SYNONYM

Cicatricial alopecia.

EPIDEMIOLOGY

Primary cicatricial alopecias are rare.

The annual incidence rate of lichen planopilaris (LPP) in 4 hair loss centers in the United States varied from 1.15% to 7.59% as defined by new biopsy-proven LPP—all new patients with hair loss seen over a 1-year period.[1]

PATHOPHYSIOLOGY

Scarring alopecia occurs when there is inflammation and destruction of the hair follicles leading to fibrous tissue formation.[2]

Hair loss in scarring alopecia is irreversible because the inflammatory infiltrate results in destruction of the hair follicle stem cells and the sebaceous glands.[3]

The inflammatory infiltrates are either predominantly lymphocytic, neutrophilic, or mixed. These differences are used to classify the scarring alopecias. See **Table 189-1**.

FIGURE 189-2 Same patient (**Figure 189-1**) showing permanent hair loss on the top of the head with some small active pustular lesions. (*Courtesy of Richard P. Usatine, MD.*)

TABLE 189-1 Classification of Cicatricial Alopecia

Lymphocytic	Lichen planopilaris (LPP) Frontal fibrosing alopecia (FFA) Central centrifugal cicatricial alopecia (CCCA) Discoid lupus erythematosus (DLE)*
Neutrophilic	Folliculitis decalvans Tufted folliculitis
Mixed	Dissecting cellulitis* Acne keloidalis nuchae*
End-stage	Nonspecific

*Not a primary cicatricial alopecia.
Source: Adapted from Olsen EA, Bergfeld WF, Cotsarelis G, et al.[4]

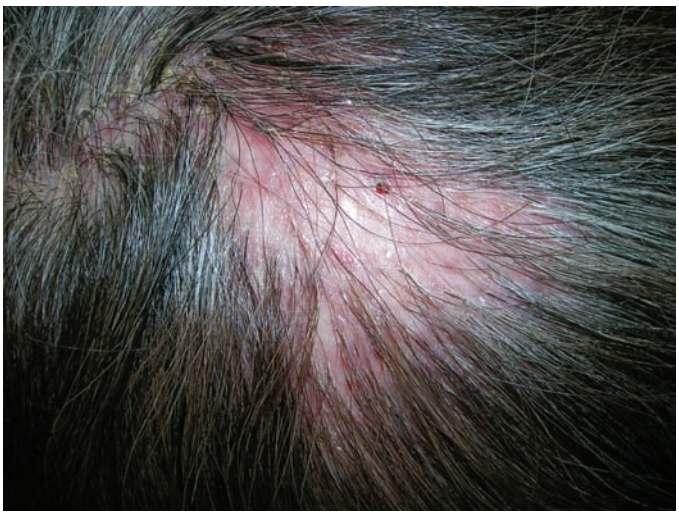

FIGURE 189-3 Lichen planopilaris in a 45-year-old woman causing hair loss with perifollicular scale. (*Courtesy of Richard P. Usatine, MD.*)

DIAGNOSIS

Scarring alopecias can vary by distribution and appearance. Most patients will need a biopsy to confirm the clinical impression and determine the specific type of alopecia.

CLINICAL PRESENTATION

- Hair loss with itching, pain, and/or burning of the scalp. Some cases are asymptomatic.

PHYSICAL EXAM

The "pull test" is used to see how active the hair loss is in general and in specific areas of the scalp. Always ask the patient if you can pull on the hair as part of your diagnosis.

- With the thumb and forefinger grasp approximately 30 to 40 hairs close to the scalp.
- Gently, but firmly, slide the fingers away from the scalp at a 90-degree angle along the entire length of the hair swatch. Do not tug or jerk.

Interpreting the pull test results:

- Negative pull test = 1 to 4 telogen hairs (small bulbs at bottom).
- Positive pull test = 5 or more hairs (including anagen hairs that have longer follicle sheath at the bottom of the hair).[5]

Forms of primary cicatricial alopecia include:

- LPP most commonly affects middle-age women. It mostly occurs on the frontal and parietal scalp and causes follicular hyperkeratosis, pruritus, perifollicular erythema, violaceous color of scalp, and scalp pain (**Figure 189-3**).[2] It may also affect other hair-bearing sites such as the groin and axilla.[2] Most patients with LPP do not have lichen planus even though the names are very similar.
- Central centrifugal scarring alopecia (CCCA) is a slowly progressive alopecia that begins in the vertex and advances to surrounding areas. It may be related to chemicals used on the hair, heat from hot combs, or chronic tension on the hair.[2] It is seen more commonly in African American women (**Figure 189-4**).

FIGURE 189-4 Central centrifugal scarring alopecia in a middle-age African American woman. Note how the vertex is most affected. Patient has used many hair chemicals, hot combs, and braids over the years. (*Courtesy of Richard P. Usatine, MD.*)

- Frontal fibrosing alopecia (FFA) presents with a progressive recession of the frontal hairline affecting particularly postmenopausal women. It is considered to be a variant of LPP on the basis of its clinical, histologic, and immunohistochemical features (**Figure 189-5**).[6]
- Folliculitis decalvans is a chronic painful neutrophilic bacterial folliculitis characterized by bogginess or induration of the scalp with pustules, erosions, crusts, and scale.[2] It is postulated that this results from an abnormal host response to *S. aureus*, which is often cultured from the lesions (**Figures 189-1** and **189-2**). In one case series, the disease ran a protracted course with temporary improvement while on antibiotic and flare-up of disease when antibiotics were stopped.[7]
- Tufted folliculitis can be considered to be a milder version of folliculitis decalvans with less surface area of the scalp involved and a better prognosis (**Figure 189-6**). However, these hair tufts can be seen in other types of scarring alopecias.

Secondary forms of scarring alopecia:

- Dissecting cellulitis presents with deep inflammatory nodules, primarily over the occiput, that progress to coalescing regions of boggy scalp.[1] Sinus tracts may form and *S. aureus* is frequently cultured from the inflamed lesions. When dissecting cellulitis occurs with acne conglobata and hidradenitis suppurativa, the syndrome is referred to as the follicular occlusion triad (**Figures 189-7** and **189-8**).
- Acne keloidalis nuchae (folliculitis keloidalis) presents with a chronic papular and pustular eruption at the nape of the neck. This can lead to scarring alopecia with large keloidal scarring. It is seen most commonly in men of color but also can be seen in women. It is often made worse by shaving the hair (see Chapter 114, Pseudofolliculitis and Acne Keloidalis Nuchae) (**Figure 189-9**).
- Discoid lupus erythematosus (DLE) presents with lesions that can be erythematous, atrophic, and/or hypopigmented. Scarring alopecia may be accompanied by follicular plugging on the scalp. Hypopigmentation may develop in the central area of the inflammatory lesions and hyperpigmentation may develop at the active border. The external ear and ear canal are often involved (**Figure 189-10**) (Chapter 180, Lupus: Systemic and Cutaneous).

LABORATORY STUDIES

If there is purulence, perform a bacterial culture. *S. aureus* and methicillin-resistant *S. aureus* are frequently seen in the neutrophilic alopecias. Consider obtaining various tests such as thyroid-stimulating hormone (TSH), serum iron level, complete blood count (CBC), and rapid plasma reagin (RPR) to rule out treatable causes of alopecia. Do a KOH smear and/or culture if tinea capitis is suspected.

BIOPSY

- Biopsy is almost always recommended to diagnose primary scarring alopecia.[5] Usually a single 4-mm punch biopsy for histology is adequate. Some dermatopathologists will prefer two 4-mm punch biopsies at the same time so that they may cut the specimens both tangentially and vertically for analysis. Discuss this with your dermatopathologist or pathologist. Make sure to biopsy at the margin of the active disease and include hair follicles in the specimen.

FIGURE 189-5 Frontal fibrosing alopecia with progressive recession of the frontal hairline in a postmenopausal African American woman. (*Courtesy of Richard P. Usatine, MD.*)

FIGURE 189-6 Tufted folliculitis showing multiple hairs growing from the same follicle along with purulence and hair loss. (*Courtesy of Richard P. Usatine, MD.*)

DIFFERENTIAL DIAGNOSIS

- Alopecia areata presents with hair loss and a very smooth scalp. The hair loss is usually in round punched-out patterns and the scalp otherwise appears normal (Chapter 187, Alopecia Areata).
- Androgenetic alopecia is the standard hair loss that males experience with aging. There are a number of male pattern types of hair loss. Women also get androgenic alopecia, but the pattern tends to be more diffuse and frontal. Both are treatable with topical minoxidil and oral finasteride.
- Drug-induced alopecia is from chemotherapy and other toxic drugs.
- Sarcoidosis of the scalp can resemble DLE, but treatment will be different, hence the importance of a biopsy diagnosis (see Chapter 175, Sarcoidosis).[8]
- Seborrheic dermatitis may cause some hair loss. The presence of scale on the scalp with minimal to no hair loss helps to differentiate this from scarring alopecia (see Chapter 151, Seborrheic Dermatitis).
- Secondary syphilis with moth-eaten alopecia is rare but should be considered. A highly positive RPR can easily make this diagnosis (see Chapter 216, Syphilis).
- Telogen effluvium is a type of nonscarring alopecia that occurs after childbirth or other traumatic events. The skin on the scalp appears normal.
- Tinea capitis presents with scale and hair loss. It is diagnosed by a positive KOH and/or fungal culture. Do not miss this diagnosis because it is much easier to treat than any of the scarring alopecias (see Chapter 137, Tinea Capitis).
- Trichotillomania is defined as self-induced hair loss caused by pulling at the hairs. The pattern of hair loss may be distinctive and the behavior may be discovered on history. The scalp appears normal and there is a distinctive pattern seen on biopsy (see Chapter 188, Traction Alopecia and Trichotillomania).
- Traction alopecia occurs when the hair is pulled too tight for braids or ponytails (see Chapter 188, Traction Alopecia and Trichotillomania).
- Various metabolic and nutritional problems can lead to alopecia. It is worth doing a CBC, ferritin, vitamin D 25-OH, and TSH to rule out iron deficiency, vitamin D deficiency, and hyper- or hypothyroidism.[5]

MANAGEMENT

- Scarring alopecias are such rare conditions that there are few randomized controlled trials available to guide therapy.
- One paradigm for treating primary scarring alopecia is to treat those containing predominantly lymphocytic infiltrates with immunomodulating agents and those with predominantly neutrophilic infiltrates with antimicrobial agents.[5,9] SOR C

Lymphocytic infiltrate predominates (LPP, CCCA, FFA). According to Price, treatment can be split into the following categories:[5]

- Tier 1—Start here with one of the two oral agents combined with topical/intralesional medications:

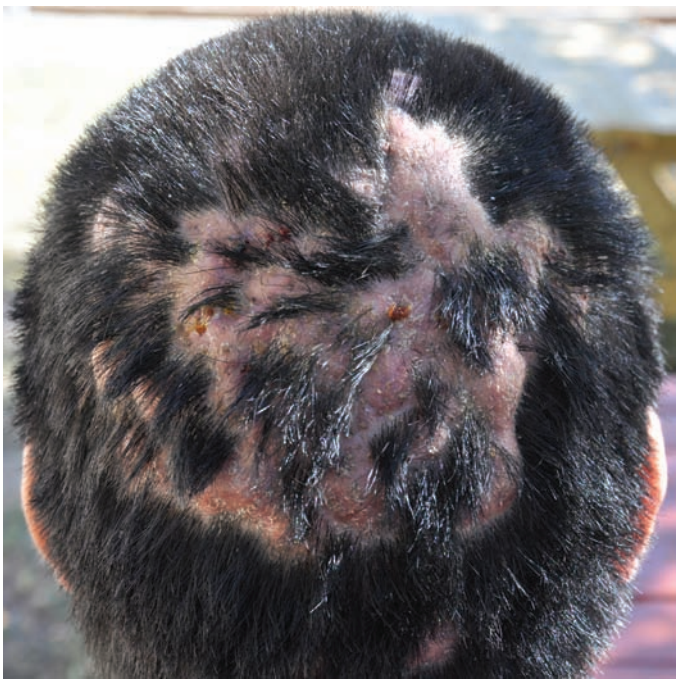

FIGURE 189-7 Dissecting cellulitis of the scalp in a young Hispanic man with many active sinus tracts and alopecia. (*Courtesy of Richard P. Usatine, MD.*)

FIGURE 189-8 Dissecting cellulitis of the scalp causing painful purulent nodules and sinus tracts leading to scarring alopecia. The patient also has severe hidradenitis suppurativa and therefore has two of three elements of the follicular occlusion triad (he does not have acne conglobata). The *arrow* points to one sinus tract. (*Courtesy of Richard P. Usatine, MD.*)

- Doxycycline 100 mg bid, or
- Hydroxychloroquine 200 mg bid.
- After 6 to 12 months, if symptoms and signs persist, move to tier 2.

- Tier 2
  - Mycophenolate mofetil 0.5 gm bid for 1 month, then 1 g bid for 5 months.
  - Cyclosporine 3 to 5 mg/kg per day, or 100 mg tid.[10]
  - Pioglitazone 15 mg daily.[11]
- Topical/intralesional medications:
  - Intralesional triamcinolone acetonide 10 mg/mL to inflamed, symptomatic sites (inject margins not bare center).
  - High-potency topical corticosteroids or topical tacrolimus or pimecrolimus.
  - Derma-Smoothe/FS scalp oil—Some patients prefer the oil-based vehicle on a dry scalp.

Studies that support this tiered approach for LPP include:

- In a retrospective review of 40 patients with LPP and its variant FFA, the investigators found that those treated with hydroxychloroquine daily had a 69% reduction in symptoms and signs after 6 months, and 89% improved after 12 months.[12] SOR B
- In another retrospective review of 16 patients with LPP treated with at least 6 months of mycophenolate mofetil in an open-label, single-center study, 5 of 12 patients were complete responders, 5 of 12 patients were partial responders, and 2 of 12 patients were treatment failures. Four patients withdrew from the trial because of adverse events.[13]
- In FFA the loss of eyebrows is common. Intralesional injection of triamcinolone acetonide showed regrowth response in 9 of 10 patients.[14]

Neutrophilic infiltrate predominates (folliculitis decalvans and tufted folliculitis):

- Start by culturing pustules and using oral antibiotics based upon the pathogens cultured.
- Powell et al. introduced a treatment regimen for patients with folliculitis decalvans that combines oral rifampicin 600 mg daily and oral clindamycin 300 mg bid together for 10 weeks.[15] SOR B Ten of the 18 patients responded well with no evidence of recurrence 2 to 22 months after 1 course of treatment, and 15 of the 18 responded after 2 or 3 courses.[15]
- For methicillin-sensitive *S. aureus* cephalexin 500 mg qid × 10 weeks with oral rifampin 600 mg × 10 days is an alternative treatment.
- For methicillin-resistant *S. aureus* (MRSA) treat with oral clindamycin 300 mg bid, or oral trimethoprim-sulfamethoxazole DS bid, or oral doxycycline 100 mg bid for 10 weeks combined with rifampin 600 mg × 10 days.[5]
- If the patient is a *S. aureus* carrier, add mupirocin ointment intranasally qd for 1 week, then monthly thereafter.[5] SOR C
- Dapsone at 75 to 100 mg/day for 4 to 6 months was well tolerated and rapidly effective in treating 2 cases of folliculitis decalvans. Long-term low-dose (25 mg/day) maintenance treatment avoided disease relapses. Paquet and Pierard chose dapsone because of its antimicrobial activity and its antiinflammatory action directed to the neutrophil metabolism.[16] SOR C

FIGURE 189-9 Acne keloidalis nuchae in a 45-year-old African American woman. Note the significant hair loss. Although acne keloidalis nuchae is more common in men, it can occur in women too. (*Courtesy of Richard P. Usatine, MD.*)

FIGURE 189-10 Chronic cutaneous lupus erythematosus showing scarring alopecia. Prominent hypopigmentation and skin atrophy are visible on the scalp and ear. (*Courtesy of Richard P. Usatine, MD.*)

Mixed infiltrates (dissecting cellulitis):

- Start by culturing any purulence and using oral antibiotics based upon the pathogens cultured.
- Just as for neutrophilic infiltrates, treat with oral clindamycin 300 mg bid, or oral trimethoprim-sulfamethoxazole DS bid, or oral doxycycline 100 mg bid for 10 weeks combined with rifampin 600 mg × 10 days.
- Isotretinoin may be effective in inducing a prolonged remission. Price suggests starting with 20 mg daily, to avoid a flare, and then slowly increase to 1 mg/kg per day for many months.[5] SOR C

Primary and secondary scarring alopecias:

- Imiquimod cream 5% was reported to cause regression of discoid lupus of the scalp and face in a single patient when applied to the lesions once a day 3 times a week. After 20 applications, Gul et al. reported that the lesions had regressed significantly.[17] SOR C
- Surgical excision of cicatricial alopecias includes excision and tissue expansion. Unfortunately, the outcomes have been disappointing to the patients and surgeons.[18] SOR C

FOLLOW-UP

Close follow-up is needed for patients put on oral agents. Monitoring for side effects is agent specific.

PATIENT EDUCATION

The following points are based upon information from the Cicatricial Alopecia Research Foundation **(http://www.carfintl.org/faq.html)**:

- The goal of treatment is to control scalp inflammation and stop the progression of the disease. Hair regrowth is not possible.
- Scarring alopecias often reactivate after a quiet period of 1 or more years. Patients should be encouraged to self-monitor for recurrence and to seek care early to prevent hair loss.
- It is safe to wash the hair with gentle hair products, if desired, even daily.
- When severe hair loss occurs, hats, scarves, hairpieces, and wigs may be used safely for cosmetic purposes.

PATIENT RESOURCES

- Cicatricial Alopecia Research Foundation—**http://www.carfintl.org/faq.html.**
- American Hair Loss Association—**http://www.americanhairloss.org/.**

PROVIDER RESOURCES

- **http://emedicine.medscape.com/article/1073559-overview.**
- Price V, Mirmirani P. *Cicatricial Alopecia: An Approach to Diagnosis and Management*. New York, NY: Springer; 2011.

REFERENCES

1. Ochoa BE, King LE Jr, Price VH. Lichen planopilaris: annual incidence in four hair referral centers in the United States. *J Am Acad Dermatol.* 2008;58:352-353.
2. Wolff K, Johnson RA, Suurmond D. *Fitzpatrick's Color Atlas & Synopsis of Clinical Dermatology*, 5th ed. New York, NY: McGraw-Hill; 2005.
3. Sperling LC, Cowper SE. The histopathology of primary cicatricial alopecia. *Semin Cutan Med Surg.* 2006;25:41-50.
4. Olsen EA, Bergfeld WF, Cotsarelis G, et al. Summary of North American Hair Research Society (NAHRS)-sponsored Workshop on Cicatricial Alopecia, Duke University Medical Center, February 10 and 11, 2001. *J Am Acad Dermatol.* 2003;48:103-110.
5. Price V, Mirmirani P. *Cicatricial Alopecia: An Approach to Diagnosis and Management*. New York, NY: Springer; 2011.
6. Moreno-Ramirez D, Camacho MF. Frontal fibrosing alopecia: a survey in 16 patients. *J Eur Acad Dermatol Venereol.* 2005;19:700-705.
7. Chandrawansa PH, Giam YC. Folliculitis decalvans—a retrospective study in a tertiary referred centre, over five years. *Singapore Med J.* 2003;44:84-87.
8. Henderson CL, Lafleur L, Sontheimer RD. Sarcoidal alopecia as a mimic of discoid lupus erythematosus. *J Am Acad Dermatol.* 2008;59:143-145.
9. Price VH. The medical treatment of cicatricial alopecia. *Semin Cutan Med Surg.* 2006;25:56-59.
10. Mirmirani P, Willey A, Price VH. Short course of oral cyclosporine in lichen planopilaris. *J Am Acad Dermatol.* 2003;49:667-671.
11. Mirmirani P, Karnik P. Lichen planopilaris treated with a peroxisome proliferator-activated receptor gamma agonist. *Arch Dermatol.* 2009;145:1363-1366.
12. Chiang C, Sah D, Cho BK, et al. Hydroxychloroquine and lichen planopilaris: efficacy and introduction of Lichen Planopilaris Activity Index scoring system. *J Am Acad Dermatol.* 2010;62:387-392.
13. Cho BK, Sah D, Chwalek J, et al. Efficacy and safety of mycophenolate mofetil for lichen planopilaris. *J Am Acad Dermatol.* 2010;62:393-397.
14. Donovan JC, Samrao A, Ruben BS, Price VH. Eyebrow regrowth in patients with frontal fibrosing alopecia treated with intralesional triamcinolone acetonide. *Br J Dermatol.* 2010;163:1142-1144.
15. Powell JJ, Dawber RP, Gatter K. Folliculitis decalvans including tufted folliculitis: clinical, histological and therapeutic findings. *Br J Dermatol.* 1999;140:328-333.
16. Paquet P, Pierard GE. [Dapsone treatment of folliculitis decalvans] [in French]. *Ann Dermatol Venereol.* 2004;131:195-197.
17. Gul U, Gonul M, Cakmak SK, et al. A case of generalized discoid lupus erythematosus: successful treatment with imiquimod cream 5%. *Adv Ther.* 2006;23:787-792.
18. Duteille F, Le FB, Hepner LD, Pannier M. The limitation of primary excision of cicatricial alopecia: a report of 63 patients. *Ann Plast Surg.* 2000;45:145-149.

190 NORMAL NAIL VARIANTS

E.J. Mayeaux, Jr., MD

PATIENT STORY

A 28-year-old man is in the office for a work physical and asks about the white streaks on his fingernail (**Figure 190-1**). He has had them on and off all of his adult life, but recently developed more of them and was concerned he may have a vitamin deficiency. He was reassured that this is a normal nail finding often associated with minor trauma.

FIGURE 190-1 Transverse striate leukonychia (transverse white streaks) in a healthy patient. Note that the lines do not extend all of the way to the lateral folds, which indicates a probable benign process. (*Courtesy of Richard P. Usatine, MD.*)

INTRODUCTION

The anatomy of the nail unit is shown in **Figure 190-2**. The nail unit includes the nail matrix, nail plate, nail bed, cuticle, proximal and lateral folds, and fibrocollagenous supportive tissues. The proximal matrix produces the superficial aspects of the plate, and the distal matrix the deeper portions. The nail plate is composed of hard and soft keratins, is formed via onychokeratinization, which is similar to hair sheath keratinization.[1] Most normal nail variants occur as a result of accentuation or disruption of normal nail formation.

SYNONYMS

- Leukonychia.
  - Transverse striate leukonychia.
  - Leukonychia punctata.
  - White nails.
- Longitudinal melanonychia (LM).
  - Racial melanonychia in African Americans.
- Nail hypertrophy and onychogryphosis (also known as onychogryposis).
  - Ram's horn nail.
  - Oyster-like deformity.
  - Lateral nail hypertrophy.
  - Thickened toenail.

EPIDEMIOLOGY

Melanonychia often involves several nails and is a more common occurrence in those patients with darker skin types. Among African Americans, benign melanonychia affects up to 77% of young adults and nearly 100% of those age 50 years or older. In the Japanese, LM affects 10% to 20% of adults.[1] Nail matrix nevi have been reported to represent approximately 12% of LM in adults and 48% in children.[2] The incidences of most other benign nail findings are not well established.

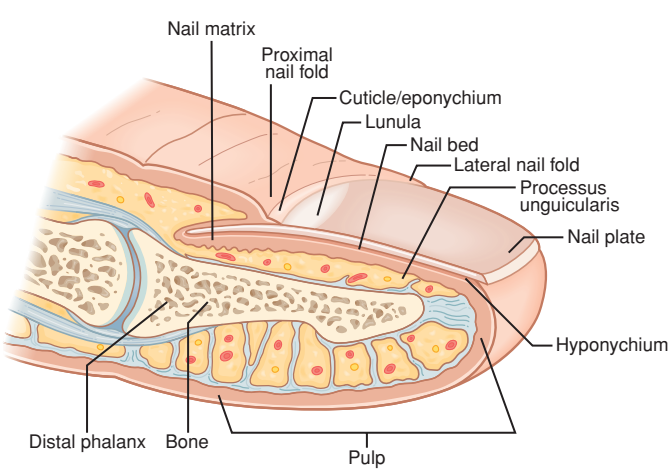

FIGURE 190-2 The anatomy of the nail unit. (*Courtesy of Usatine R, Pfenninger J, Stulberg D, Small R. Dermatologic and Cosmetic Procedures in Office Practice. Elsevier, Inc., Philadelphia. 2012.*)

ETIOLOGY AND PATHOPHYSIOLOGY

- *Leukonychia* represents benign, single or multiple, white spots or lines in the nails. Patchy patterns of partial, transverse white streaks (transverse striate leukonychia, see **Figure 190-1**) or spots (leukonychia punctata, **Figure 190-3**) are the most common patterns of leukonychia.[3] Leukonychia is common in children and becomes less frequent with age. Parents may fear that it represents a dietary deficiency, in particular a lack of calcium, but this concern is almost always unfounded.
- Most commonly, no specific cause for leukonychia can be found. It is usually the result of minor trauma to the nail cuticle or matrix and is the most commonly found nail condition in children.[4] When the lesions are caused by overly aggressive manicuring or nervous habit, behavior modification often is helpful. Leukonychia can also be an indirect manifestation of autoimmunity, including alopecia areata or thyroid disease. Histologically, the nail plate contains a greater number of nucleated cells that are associated with lack of cohesion between the corneocytes, producing reflective properties of the nail.
- Longitudinal melanonychia (LM) (**Figure 190-4**) represents a longitudinal pigmented band in the nail plate. Melanonychia is ultimately caused by melanocyte activation. Causes of nongenetic nail matrix melanocyte activation include drugs, inflammatory processes, trauma, mycosis, systemic diseases, and neoplasms (melanomas).[1] LM is often caused by lentigines, benign melanocytic hyperplasia, or nevus of the nail matrix. However, it must be differentiated from subungual melanoma (see Chapter 191, Pigmented Nail Disorders). Benign causes of LM produce melanocytic activation with bands that usually measure 3 to 5 mm or less in width, whereas melanoma tends to produce wider bands. Most lentigines and nevi display a band with a tan-to-brown hue. A benign nail band is generally relatively homogeneous with respect to color and color intensity and if it expands, tends to expand slowly.[1]
- *Nail hypertrophy and onychogryphosis* (ram's horn nail—lateral nail hypertrophy, **Figure 190-5**) is the development of opaque thickened nails with exaggerated upward, or lateral growth. It may be associated with age, fungal infections and trauma. It can cause pain with pressure.
- *Habit-tic deformity* (**Figures 190-6 and 190-7**) is caused by habitual picking of the proximal nail fold. The resulting inflammation induces the nail plate to be wavy and ridged, while its substance remains intact and hard.
- *Beau lines* are transverse linear depressions in the nail plate (**Figures 190-8 and 190-9**). They are thought to result from suppressed nail growth secondary to local trauma or severe illness.[5] They most commonly appear symmetrically in several or all nails and may have associated white lines. They usually grow out over several months. One may estimate the time since onset of systemic illness by measuring the distance from the Beau line to the proximal nail fold and applying the conversion factor of 6 to 10 days per millimeter of growth.[4]

FIGURE 190-3 Leukonychia punctata showing distinct punctate white spots and lines on the fingernails. *(Courtesy of Richard P. Usatine, MD.)*

FIGURE 190-4 Longitudinal melanonychia in multiple fingers in a young adult. These bands of translucent nail pigmentation in multiple fingers are typical of racial longitudinal melanonychia and not suspicious for melanoma. Note the dark pigment on the proximal nail folds represents a pseudo-Hutchinson sign. (*Courtesy of Richard P. Usatine, MD.)*

FIGURE 190-5 Onychogryphosis (ram's horn nail) is a type of lateral nail hypertrophy most frequently found in the toenails and often associated with onychomycosis. (*Courtesy of Richard P. Usatine, MD.)*

RISK FACTORS

- Leukonychia
  - Use of nail enamels, nail hardeners, or artificial nails as a result of trauma and allergic reactions.
  - Repetitive trauma from work, sports, or leisure activities.
- LM.
  - Race.
  - Age.
- Nail hypertrophy and onychogryphosis.
  - Age.
- Habit-tic deformity.
  - Psychological dysfunctions.
- Beau lines.
  - Severe illness.
  - High fever.

DIAGNOSIS

CLINICAL FEATURES

- All diagnoses of nail disorders should begin with a focused history and physical exam. It is especially important to ask about trauma and recent illnesses.

LABORATORY TESTING

- If renal disease is suspected, order a urinalysis and a serum creatinine.

IMAGING

- The use of nail plate or matrix dermoscopy has been proposed as a way to further define areas to biopsy in LM, but their accuracy in the diagnosis of subungual melanoma has not been established.[2] SOR C

BIOPSY

- Definitive diagnosis of a nail discoloration may be made with a biopsy of the nail or matrix. Patients with darker skin tones and multiple digits with translucent LM often need only be observed. A new dark line in a single nail should be biopsied. A 3-mm punch biopsy can be performed at the origin of the darkest part of a dark band. This usually involves reflecting the skin of the proximal nail fold back while performing a punch biopsy of the distal matrix. Histologic diagnosis of atypical melanocytic hyperplasia necessitates the complete removal of the lesion.[1] SOR C

DIFFERENTIAL DIAGNOSIS

- Pigmented lesions in the nail bed do not cause LM, only nail matrix lesions do. Nail bed lesions make spots under the nails but do not grow out as stripes. These are viewed through the nail as a grayish to brown or black spot.[6]
- The diagnosis of subungual melanoma must always be considered in patients with LM. A biopsy should be performed in an adult if the cause of LM is not apparent. Extension of pigmentation to the skin adjacent to the nail plate involving the nail folds or the

FIGURE 190-6 Habit-tic deformity of the thumbnail caused by a conscious or unconscious rubbing or picking of the proximal nails and nail folds. Horizontal grooves are formed proximally and move distally with fingernail growth. The thumbnails are most often affected. (*Courtesy of Richard P. Usatine, MD.*)

FIGURE 190-7 Habit-tic deformity of the large toenail in a man that walks barefoot often. He acknowledged that he picks at the nail and cuticle. (*Courtesy of Richard P. Usatine, MD.*)

FIGURE 190-8 Beau lines in the fingernails of a young boy that had erythema multiforme and exfoliation approximately 2 months prior to this visit. (*Courtesy of Richard P. Usatine, MD.*)

TABLE 190-1 Signs That Help Differentiate Local Trauma-Induced Nail Changes from Those Associated with Systemic Disease

Characteristic	Mees Lines (Figure 190-10)	Muehrcke Lines (Figure 190-11)	Beau lines (Figures 190-8 and 190-9)	Leukonychia (Figures 190-1 and 190-3)
Number of Nails involved	Tend to be single but may occur on several nails at once	Tend to occur on several nails at once	Appear symmetrically in several or all nails	Usually on 1 or 2 nails
Nail coverage	Spread transversely across the entire breadth of the nail	Spread across the entire breadth of the nail bed or plate, often disappear with nail plate pressure	Spread transversely across the entire breadth of the nail	Often do not span the entire breadth of the nail plate
Line shape	Tend to have contour similar to the distal lunula, with a rounded distal edge	White transverse lines that have contour similar to the distal lunula, with a rounded distal edge	Tend to have contour similar to the distal lunula, with a rounded distal edge	More linear and resemble the contour of the proximal nail fold
Nail surface changes	Absent	Absent	Usually depressed	Absent
Etiology	Fragmented nail plate structure as a result of a compromised nail matrix	Abnormality of the nail vascular bed	Suppressed nail growth	Disruption of nail plate formation
Associated conditions	History of a systemic insult correlated with the onset of the lines such as chemotherapy, heart failure, and heavy-metal poisoning	Chronic hypoalbuminemia (hepatic and renal disease)	History of a physiologic stressor such as surgery or a severe illness	History of physical trauma (often not identified)

FIGURE 190-9 Beau lines in the fingernails of a young girl who was hospitalized with pneumonia 4 months prior to this visit. (*Courtesy of Richard P. Usatine, MD.*)

FIGURE 190-10 Mee lines that spread transversely across the entire breadth of the nail and are somewhat rounded with a contour similar to the distal lunula. *(Courtesy of Jeffrey Meffert, MD.)*

fingertip is called Hutchinson sign, which is an important indicator of nail melanoma (see Chapter 191, Pigmented Nail Disorders).

- Hematoma may be confused with LM, but the color grows out with the nail plate, exhibiting a proximal border that reproduces the shape of the lunula. A hole punched in the nail plate allows for the visualization of the underlying nail bed and confirmation of the nature of the coloration.

- Mees and Muehrcke lines may be confused with leukonychia or Beau lines. Mees lines are multiple white transverse lines that begin in the nail matrix and extend completely across the nail plate (**Figure 190-10**). They are caused by heavy-metal poisoning or severe systemic insults. Muehrcke lines are white transverse lines that represent an abnormality of the nail vascular bed and may occur with chronic hypoalbuminemia or renal disease (**Figure 190-11**). In contrast to Beau lines, they are not grooved and they do not move with nail growth. **Table 190-1** lists the clinical signs that help differentiate local trauma-induced lesions from those associated with systemic disease.
  - Leukonychia must also be differentiated from localized white onychomycosis, half-and-half nails, which are white proximal nails and pink or brown distal nails seen in renal failure (**Figure 190-12**), and Terry nails, which are white proximal nails and reddened distal nails that are seen in liver cirrhosis.

- The differential diagnosis of habit-tic deformity includes several nail dystrophies. In median nail, dystrophy produces a distinctive longitudinal split in the center of the nail plate with several cracks projecting laterally. Chronic paronychia is a *Candida* induced inflammation of the proximal nail folds that may induce ripples that can mimic the habit-tic deformity. Chronic eczematous inflammation may produce similar changes. Onychomycosis, Beau lines, and psoriatic nail lesions may also appear similar to habit-tic deformity.[7]

Twenty-nail dystrophy (**Figure 190-13**) is an idiopathic nail dystrophy that starts in childhood and resolves slowly with age. The nails lose their luster and develop longitudinal striations. It often starts with the fingernails and then affects the toenails.

FIGURE 190-11 Muehrcke lines in a patient with chronic hypoalbuminemia from nephrotic syndrome. The white transverse lines extend across the full nail bed and represent an abnormality of the nail vascular bed. (*Courtesy of Wikimedia Commons and Lyrl at http://commons.wikimedia.org/wiki/File:Muehrcke%27s_lines.JPG*)

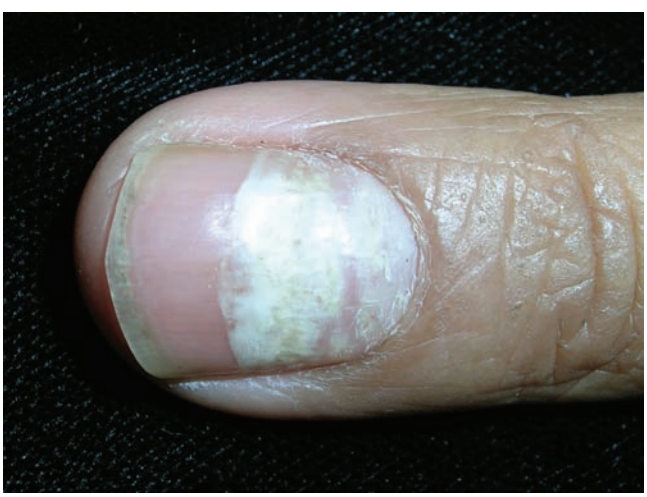

FIGURE 190-12 Half-and-half nail ("Lindsay nails") with the proximal portion of the nail being white and the distal portion pink. Note the sharp line of demarcation between the two halves. The patient had just started dialysis for renal failure. (*Courtesy of Richard P. Usatine, MD.*)

FIGURE 190-13 Twenty-nail dystrophy in a healthy 8-year-old girl. Note how all the fingernails are uniformly affected with longitudinal striations and loss of nail luster. Her skin is otherwise normal. (*Courtesy of Richard P. Usatine, MD.*)

MANAGEMENT

NONPHARMACOLOGIC

- Grinding of the nail at regular intervals is useful for onychogryphosis.

MEDICATIONS

- Fluoxetine has been reported as being helpful in the treatment of habit-tic deformity.[8] SOR C

SURGICAL

- Removal of the nail and ablation of the nail bed for onychogryphosis. SOR C

PATIENT RESOURCES

- *Melanonychia*—**http://www.diseasesatoz.com/melanonychia.htm.**
- Chiropods Web Site. *Thick Toenails (Onychogryphosis)*—**http://www.chiropods.co.uk/pages/gryphosis.htm.**

PROVIDER RESOURCES

- Emedicine. *Nail Surgery*—**http://www.emedicine.com/derm/topic818.htm.**
- Color pictures at Dermatlas.org—**http://www.dermatlas.com/derm/** and select body site: *nails (all)*.
- Medscape. *Melanonychia*—**http://emedicine.medscape.com/article/1375850-overview#showall.**
- Medscape Education. *Examining the Fingernails*—**http://www.medscape.org/viewarticle/571916_2.**
- DermnetNZ. *"Nail Diseases"*—**http://dermnetnz.org/hair-nails-sweat/nails.html.**

REFERENCES

1. Ruben B. Pigmented lesions of the nail unit: clinical and histopathologic features. *Semin Cutan Med Surg.* 2010;29:148-158.
2. Tosti A, Piraccini BM, de Farias DC. Dealing with melanonychia. *Semin Cutan Med Surg.* 2009;28:49-54.
3. Grossman M, Scher RK. Leukonychia. Review and classification. *Int J Dermatol*. 1990;29:535-541.
4. Baran R, Kechijian P. Diagnosis and management. *J Am Acad Dermatol*. 1989;21:1165-1175.
5. Daniel CR, Zaias N. Pigmentary abnormalities of the nails with emphasis on systemic diseases. *Dermatol Clin*. 1988;6:305-313.
6. Noronha PA, Zubkov B. Nails and nail disorders in children and adults. *Am Fam Physician*. 1997;55:2129-2140.
7. Farnell EA 4th. Bilateral thumbnail deformity. *J Fam Pract*. 2008;57(11):743-745.
8. Vittorio CC, Phillips KA. Treatment of habit-tic deformity with fluoxetine. *Arch Dermatol.* 1997;133(10):1203-1204.

191 PIGMENTED NAIL DISORDERS

E.J. Mayeaux, Jr., MD

PATIENT STORY

An African American medical student presented with a new dark band on her index finger for 1 year (**Figure 191-1**). The dark color and the lack of melanonychia in other fingers made this concerning. A biopsy of the nail matrix was performed and the result showed a benign nevus.

INTRODUCTION

Atypical pigmentation of the nail plate may result from many nonmalignant causes, such as longitudinal melanonychia (LM), inflammatory changes, benign melanocytic hyperplasia, nevi, drugs, and endocrine disorders. It may also result from development of subungual melanoma. The challenge for the clinician is separating the malignant from the nonmalignant sources.

LM is the most common cause and it represents a longitudinal pigmented band in the nail plate (**Figures 191-1 and 191-2**). It may involve of 1 or several digits, vary in color from light brown to black, vary in width (most range from 2 to 4 mm), and have sharp or blurred borders.

EPIDEMIOLOGY

- LM is more common in more darkly pigmented persons. It occurs in 77% of African Americans older than age 20 years and in almost 100% of those older than age 50 years.[1,2] It also occurs in 10% to 20% of persons of Japanese descent. LM is common in Hispanic and other dark-skinned groups. LM is unusual in whites, occurring in only approximately 1% of the population.[1]
- Melanoma is the seventh most common cause of cancer in patients in the United States. Subungual melanoma is a relatively rare tumor with reported incidences between 0.7% and 3.5% of all melanoma cases in the general population.[3]

ETIOLOGY AND PATHOPHYSIOLOGY

- LM originates in the nail matrix and results from increased deposition of melanin within the nail plate. This deposition may result from greater melanin synthesis or from an increase in the total number of melanocytes. Pigment clinically localized within the dorsal half of the nail plate indicates a proximal matrix origin, and pigment localized within the ventral nail plate indicates a distal matrix origin. Look at the distal edge of the nail in a cross-sectional view to see whether the pigment is dorsal or ventral (a dermatoscope may help).

FIGURE 191-1 Longitudinal melanonychia—a single dark band of nail pigment appearing in the matrix region and extended to the tip of the nail. This is concerning for melanoma. The widening of the band in the proximal nail shows that the melanocytic lesion in the matrix is growing. This young woman had a biopsy that showed a benign nevus. (*Courtesy of Richard P. Usatine, MD.*)

FIGURE 191-2 Close up of longitudinal melanonychia in a single finger. Note the color band is translucent. (*Courtesy of E.J. Mayeaux, Jr., MD.*)

- LM may also be caused by chronic trauma, especially in the great toes.
- Inflammatory changes accompanying skin diseases located in the nail unit, such as psoriasis, lichen planus, amyloidosis, and localized scleroderma, rarely may result in LM.
- Benign melanocytic hyperplasia (lentigo) is observed in 9% of the adult cases and 30% of the pediatric cases of single-biopsied LM.[4]
- Nevi represent 12% of LM in adults, but almost 50% of cases in children. A brown-black coloration is observed in two thirds of the cases and periungual pigmentation (benign pseudo-Hutchinson sign) in one third.
- Certain drugs may also cause LM, especially chemotherapeutic agents (**Figure 191-3**), and antimalarial drugs (mepacrine, amodiaquine, and chloroquine).
- Endocrine disorders, such as Addison disease, Cushing syndrome, hyperthyroidism, and acromegaly, can be responsible for LM.
- The diagnosis of subungual melanoma must always be considered in patients with LM (**Figures 191-4** and **191-5**). Separating benign from malignant lesions is often difficult. Both arise most often in the thumb or index fingers, and both are more common in dark-skinned persons.[5] A biopsy should be performed in an adult if the cause of LM is uncertain. **Table 191-1** lists diagnostic clues for subungual melanomas.
- Hutchinson sign is the extension of pigmentation to the skin adjacent to the nail plate involving the nail folds or the fingertip. It is an important indicator for nail melanoma (**Figures 191-4** to **191-6**).[6]
- Pseudo-Hutchinson sign is the presence of dark pigment around the proximal nail fold secondary to benign conditions such as racial melanosis and not melanoma (**Figure 191-7**). Another cause of

FIGURE 191-3 Melanonychia secondary to chemotherapy for metastatic penile cancer. (*Courtesy of Richard P. Usatine, MD.*)

TABLE 191-1 Diagnostic Clues That Indicate Longitudinal Melanonychia Is Suspicious for Subungual Melanoma

Hutchinson sign (melanoma until proven otherwise)
In a single digit
Sixth decade of life or later
Develops abruptly in a previously normal nail plate
Suddenly darkens or widens (change in the LM morphology)
Occurs in either the thumb, index finger, or great toe
History of digital trauma
Dark-skinned patient, particularly if the thumb or great toe is affected
Blurred, rather than sharp, lateral borders
Personal history of malignant melanoma
Increased risk for melanoma (e.g., familial atypical mole and melanoma [FAMM] syndrome)
Nail dystrophy, such as partial nail destruction or disappearance

FIGURE 191-4 Advanced acrolentiginous melanoma of the thumb with destruction of the nail plate and ulceration. Note the hyperpigmentation of the proximal nail fold (Hutchinson sign), which is strongly indicative of melanoma. (*Courtesy of Dr. Dubin at http://www.skinatlas.com.*)

pseudo-Hutchinson sign is a translucent cuticle below which the pigment of LM is visible. Trauma and drug-induced pigmentation can also produce a pseudo-Hutchinson sign.

- Subungual melanoma arises on the hand in 45% to 60% of cases, and most of those occur in the thumb (**Figures 191-4** to **191-6**).[4] On the foot, subungual melanoma usually occurs in the great toe.[5] The median age at which subungual melanoma is usually diagnosed is in the sixth and seventh decades. It appears with equal frequency in males and females.[5]

RISK FACTORS

Table 191-1 lists diagnostic clues that indicate an increased risk for the presence of subungual melanoma.

DIAGNOSIS

CLINICAL FEATURES

There is an ABCDEF mnemonic system that applies to subungual melanoma:

- In this system "A" stands for age (peak incidence being between the fifth to seventh decades) and African Americans, Asians, and Native Americans in whom subungual melanoma accounts for one third of melanoma cases.
- "B" stands for "brown to black" and with "breadth" of 3 mm or more.
- "C" stands for change in the nail band coloration or lack of change after adequate treatment.
- "D" stands for the digit most commonly involved.
- "E" stands for extension of the pigment onto the proximal and/or lateral nailfold (Hutchinson sign).
- "F" stands for family or personal history of dysplastic nevus or melanoma.

TYPICAL DISTRIBUTION

The digits used for grasping (thumb, index finger, and middle finger) are the most commonly involved in LM and melanoma, but either may be found in any finger or toe.

BIOPSY

Definitive diagnosis of a nail discoloration may be made with a biopsy of the nail matrix. Patients with darker skin color and multiple digits with translucent LM often need only be observed. Single dark lines in whites should always be biopsied. A 3-mm punch biopsy can be performed at the origin of the darkest part of a dark band within the nail matrix (**Figure 191-8**). Histologic diagnosis of atypical melanocytic hyperplasia necessitates the complete removal of the lesion.

DIFFERENTIAL DIAGNOSIS

- Pigmented lesions in the nail bed usually do not cause LM and are viewed through the nail as a grayish to brown or black spot.[7]

FIGURE 191-5 Acral lentiginous melanoma of the thumb with a very positive Hutchinson sign. Note how the pigmented band on the nail is greater than 3 mm in width. (*Courtesy of Robert T. Gilson, MD.*)

FIGURE 191-6 Acral lentiginous melanoma of the thumb with a very positive Hutchinson sign showing dark hyperpigmentation of the nail folds. Note how the light brown pigmented band on the nail is much greater than 3 mm in width. (*Courtesy of Ryan O'Quinn, MD.*)

- Subungual hematoma may be confused with LM, but the color grows out with the nail plate, exhibiting a proximal border that reproduces the shape of the lunula. A hole punched in the nail plate allows for the visualization of the underlying nail bed and confirmation of the nature of the coloration (see Chapter 196, Subungual Hematoma).

MANAGEMENT

NONPHARMACOLOGIC

No treatment is required for benign LM.

REFERRAL OR HOSPITALIZATION

Treatment of primary subungual melanomas includes amputation at the level of the interphalangeal joint for thumb lesions SOR B, the distal interphalangeal joint for fingers SOR C, and the metatarsophalangeal joint for toes.[8] For melanoma in situ, it may be possible to remove the full nail apparatus and save the digit. Regional lymph node dissection can help with establishment of disease stage. Chemotherapy is recommended for nodal or visceral metastases.

PROGNOSIS

The 5-year survival is approximately 74% for patients with stage I and 40% for patients with stage II disease. Prognostic variables negatively affecting survival include stage at diagnosis, deeper Clark level of invasion, African American race, and ulceration.[9]

FOLLOW-UP

Because LM may indicate an undiagnosed melanoma of the nail unit, regular monitoring is extremely important. Have the patient report any rapid changes in pigmentation of the nail plate or nail folds, and strongly consider biopsy in these individuals.

PATIENT RESOURCES

- Medscape. *Nail Diseases In Childhood*—**http://www.medscape.com/viewarticle/585158_8**.
- DermNet NZ. *Subungual Melanoma*—**http://dermnetnz.org/hair-nails-sweat/melanoma-nailunit.html.**

PROVIDER RESOURCES

- DermNet NZ. *Nail Diseases*—**http://dermnetnz.org/hair-nails-sweat/nails.html.**
- eMedicine. *Nail Surgery*—**http://www.emedicine.com/derm/topic818.htm.**
- Braun RP, Baran R, Le Gal FA, et al. Diagnosis and management of nail pigmentation. *J Am Acad Dermatol*. 2007;56[5]: 835–847.

FIGURE 191-7 Benign longitudinal melanonychia in a black person demonstrating pseudo-Hutchinson sign (dark pigment around the proximal nail fold secondary to racial melanosis and not melanoma). (*Courtesy of Richard P. Usatine, MD.*)

- Jellinek N. Nail matrix biopsy of longitudinal melanonychia: diagnostic algorithm including the matrix shave biopsy. *J Am Acad Dermatol*. 2007;56[5]:803–810.
- Usatine R. Nail procedures. In: Usatine R, Pfenninger J, Stulberg D, Small R, eds. *Dermatologic and Cosmetic Procedures in Office Practice*. Philadelphia, PA: Elsevier; 2012:216-228. The whole procedure depicted in **Figure 191-8** is described in detail.

REFERENCES

1. Baran R, Kechjijian P. Longitudinal melanonychia (melanonychia striata): diagnosis and management. *J Am Acad Dermatol*. 1989;21:1165-1175.
2. Ruben B. Pigmented lesions of the nail unit: clinical and histopathologic features. *Semin Cutan Med Surg*. 2010;29:148-158.
3. Finley RK, Driscoll DL, Blumenson LE, Karakousis CP. Subungual melanoma: an eighteen year review. *Surgery*. 1994;116:96-100.
4. Goettmann-Bonvallot S, André J, Belaich S, Longitudinal melanonychia in children: a clinical and histopathologic study of 40 cases. *J Am Acad Dermatol*. 1999;41:17-22.
5. Papachristou DN, Fortner JG. Melanoma arising under the nail. *J Surg Oncol*. 1982;21:219-222.
6. Mikhail GR. Hutchinson's sign. *J Dermatol Surg Oncol*. 1986;12:519-521.
7. Baran R, Perrin C. Linear melanonychia due to subungual keratosis of the nail bed: report of two cases. *Br J Dermatol*. 1999;140:730-733.
8. Moehrle M, Metzger S, Schippert W, et al. "Functional" surgery in subungual melanoma. *Dermatol Surg*. 2003;29(4):366-374.
9. O'Leary JA, Berend KR, Johnson JL, et al. Subungual melanoma: a review of 93 cases with identification of prognostic variables. *Clin Orthop Relat Res*. 2000;378:206-212.

FIGURE 191-8 **A.** The proximal nail fold is reflected back to perform a nail matrix biopsy in a young man with new onset of longitudinal melanonychia. The 3-mm punch is placed over the origin of the dark band at the distal matrix. **B.** The 3-mm punch now contains the specimen for pathology. The longitudinal melanonychia was caused by melanocytic hyperplasia. (*Courtesy of Richard P. Usatine, MD.*)

192 INGROWN TOENAIL

E.J. Mayeaux, Jr., MD

PATIENT STORY

A 14-year-old boy presents with a history of multiple ingrown nails of both great toes. Today his right big toe is swollen and painful (**Figure 192-1**). He has a 2-week history of pain, redness, and swelling of the lateral nail fold of the right great toe. Soaking the toe in Epsom salts has not helped. A partial nail removal after a digital block was successful. The nail matrix was also ablated with phenol to prevent recurrence of the ingrown nail.

FIGURE 192-1 Ingrown toenail of the lateral aspect of the right great toe showing inflammation and granulation tissue. (*Courtesy of Richard P. Usatine, MD.*)

INTRODUCTION

Onychocryptosis (ingrown toenails) is a common childhood and adult problem. Patients often seek treatment because of the significant levels of discomfort and disability associated with the condition.

SYNONYMS

Onychocryptosis, unguis incarnatus.

EPIDEMIOLOGY

The prevalence of onychocryptosis is unknown as many patients do not seek medical care and it is not a reportable disease. The toenails, especially the great toenail, are most commonly affected. Ingrown toenails at birth and in early childhood do occur, but are very rare.

ETIOLOGY AND PATHOPHYSIOLOGY

Onychocryptosis occurs when the lateral nail plate damages the lateral nail fold. The lateral edge of the nail plate penetrates and perforates the adjacent nailfold skin. Perforation of the lateral fold skin results in painful inflammation that manifests clinically as mild edema, erythema, and pain. In advanced stages, drainage, infection, and ulceration may be present. Hypertrophy of the lateral nail wall occurs, and granulation tissue forms over the nail plate and the nailfold during healing of the ulcerated skin.[1] It is a common affliction that can result from a variety of conditions that cause improper fit of the nail plate in the lateral nail groove (**Figure 192-1**).

RISK FACTORS[1]

- Genetic predisposition.
- Poor-fitting footwear.
- Excessive trimming of the lateral nail plate.
- Pincer nail deformity (**Figure 192-2**).
- Trauma.

FIGURE 192-2 The curved infolding of the lateral edges of the nail plate indicates this patient has a pincer nail, which predisposes to onychocryptosis. (*Courtesy of Richard P. Usatine, MD.*)

- Sports in which kicking or running is important.
- Hyperhidrosis.
- Anatomic features such as nailfold width.
- Congenital malalignment of the digit.
- Overcurvature of the nail plate.
- Onychomycosis and other diseases that result in abnormal changes in the nail plate.

DIAGNOSIS

CLINICAL FEATURES: HISTORY AND PHYSICAL

The diagnosis is based upon clinical appearance and rarely is difficult. Characteristic signs and symptoms include pain, edema, exudate, and granulation tissue (**Figure 192-1**).

TYPICAL DISTRIBUTION

The great toe is most commonly affected; fingers are rarely involved except when nail biting is present.

DIFFERENTIAL DIAGNOSIS

- Cellulitis—Presents with redness, pain, and swelling beyond the nail fold (see Chapter 120, Cellulitis).
- Paronychia—Presents with redness and abscess formation (pus) in a nail fold (see Chapter 194, Paronychia).

MANAGEMENT

The treatment of ingrown toenails depends upon the age of the patient and the severity of the lesion.

NONPHARMACOLOGIC

- Lesions characterized by minimal to moderate pain and no discharge can be treated conservatively with soaking the affected foot in warm water for 20 minutes, 3 times per day, and pushing the lateral nailfold away from the nail plate.[2] SOR C
  - Other palliative measures include cotton wedging underneath the lateral nail plate and trimming the lateral part of the nail plate below the area of nailfold irritation.
- Numerous alternative methods of conservative treatment have been described, including splints and commercially available devices. Devices that have shown promise include shape memory alloys (SMAs), either of a Cu-Al-Mn base or a Ni-Ti base.[3–5]

MEDICATIONS

- Although many elect to treat apparent infections with oral antibiotics, studies show the use of antibiotics does not decrease healing time or postprocedure morbidity in otherwise normal patients.[6] SOR A
- A medium- to high-potency topical corticosteroid can be applied after soaking to decrease inflammation, but is often unnecessary.

FIGURE 192-3 Status post partial nail avulsion procedure for an ingrown toenail. (*Courtesy of Richard P. Usatine, MD.*)

- If nail avulsion and/or matrix ablation is used, pain relievers for mild to moderate pain may be necessary.
- When placing digital blocks for surgical procedures, the best evidence indicates the use of lidocaine with epinephrine is equally safe and efficacious for anesthesia.[7]

SURGICAL

- Nonresponders to conservative therapy and patients with more severe lesions (substantial erythema, granulation tissue, and pus) need surgical therapy.[8,9] SOR C
- Surgical intervention involves partial or full nail plate avulsion. Usually it is only necessary to remove the part of the nail that is placing pressure on the lateral nailfold (**Figure 192-3**). SOR C
- Patients who develop recurrent ingrown toenails benefit from permanent nail ablation of the lateral nail matrix. This may be achieved with the combination of partial nail plate avulsion plus phenol matrixectomy, which can cut recurrence rates by 90% (**Figure 192-4**).[8–10] SOR A
- In a Cochrane Systematic Review of surgical treatments for ingrowing toenails nail avulsion with the use of phenol is more effective at preventing symptomatic recurrence than nail avulsion without the use of phenol.[10] Unfortunately the use of phenol does increase the risk of postoperative infection (by 5 times) compared with simple nail avulsion.[10] SOR A
- Chemical matricectomy is performed mainly by phenol (full-strength 88%), but 10% sodium hydroxide is another alternative. In a comparison study of the use of chemical matrixectomy for the treatment of ingrown toenails, the overall success rates were 95% for both phenol and sodium hydroxide.[11] SOR A
- One study found that partial nail avulsion with phenolization gave better results than partial avulsion with matrix excision.[12] Local antibiotics applied to the surgical site did not reduce signs of infection or recurrence. The use of phenol did not produce more signs of infection than matrix excision.[12] SOR B
- Electrosurgical ablation can be performed with electrosurgery units on the fulguration setting or using a special matrixectomy electrode with a high-frequency electrosurgical unit (**Figure 192-5**). SOR C

FIGURE 192-4 Phenol matrixectomy to destroy a portion of the nail matrix to prevent a recurrent ingrown toenail. Note the use of a tourniquet to decrease bleeding while applying the phenol with a twisting motion.

FOLLOW-UP

After surgical intervention, consider follow-up in 3 to 4 days to assess treatment and exclude cellulitis.

PATIENT EDUCATION

- Patients should be educated about proper nail trimming so as to minimize trauma to the lateral nailfold. The lateral nail plate should be allowed to grow well beyond the lateral nailfold before trimming horizontally.
- Patients should also be educated about the importance of avoiding shoes that are too tight over the toes to help minimize recurrences.

FIGURE 192-5 Use of electrosurgery to ablate the lateral nail matrix. This results in a narrower nail and a decreased likelihood of onychocryptosis recurrence. (*Courtesy of Richard P. Usatine, MD.*)

PATIENT RESOURCES

- Ingrown Toenails information at the familydoctor.org website—**http://familydoctor.org/online/famdocen/home/common/skin/disorders/208.html.**
- eMedicineHealth. *Ingrown Toenails*—**http://www.emedicinehealth.com/ingrown_toenails/article_em.htm.**

PROVIDER RESOURCES

- Medscape eMedicine. *Ingrown Nails*—**http://emedicine.medscape.com/article/909807.**
- Usatine R, Pfenninger J, Stulberg D, Small R. *Dermatologic and Cosmetic Procedures in Office Practice*. Philadelphia: Elsevier; 2012 (with DVD). The "Nail Procedures" chapter provides details, photographs, and videos of how to perform ingrown toenail surgeries. Available as an electronic app as well—**http://usatinemedia.com.**
- **http://itunes.apple.com/us/app/dermatologic-cosmetic-procedures/id479310808?ls=1&mt=8.**

REFERENCES

1. Siegle RJ, Swanson NA. Nail surgery: a review. *J Dermatol Surg Oncol.* 1982;8(8):659-666.
2. Connolly B, Fitzgerald RJ. Pledgets in ingrowing toenails. *Arch Dis Child*. 1988;63:71.
3. Nazari S. A simple and practical method in treatment of ingrown nails: splinting by flexible tube. *J Eur Acad Dermatol Venereol.* 2006;20(10):1302-1306.
4. Arai H. Formable acrylic treatment for ingrowing nail with gutter splint and sculptured nail. *Int J Dermatol.* 2004;43(10):759-765.
5. Ishibashi M, Tabata N, Suetake T, et al. A simple method to treat an ingrowing toenail with a shape-memory alloy device. *J Dermatolog Treat.* 2008;19(5):291-292.
6. Reyzelman AM, Trombello KA, Vayser DJ, et al. Are antibiotics necessary in the treatment of locally infected ingrown toenails? *Arch Fam Med.* 2000;9:930.
7. Altinyazar HC, Demirel CB, Koca R, Hosnuter M. Digital block with and without epinephrine during chemical matricectomy with phenol. *Dermatol Surg.* 2010;36(10):1568-1571.
8. Grieg JD, Anderson JH, Ireland AJ, Anderson JR. The surgical treatment of ingrowing toenails. *J Bone Joint Surg Br.* 1991;73:131.
9. Vaccari S, Dika E, Balestri R, et al. Partial excision of matrix and phenolic ablation for the treatment of ingrowing toenail: a 36-month follow-up of 197 treated patients. *Dermatol Surg.* 2010;36(8):1288-1293.
10. Rounding C, Bloomfield S. Surgical treatments for ingrowing toe-nails. *Cochrane Database Syst Rev.* 2005;(2):CD001541.
11. Bostanci S, Kocyigit P, Gurgey E. Comparison of phenol and sodium hydroxide chemical matricectomies for the treatment of ingrowing toenails. *Dermatol Surg.* 2007;33:680-685.
12. Bos AM, van Tilburg MW, van Sorge AA, Klinkenbijl JH. Randomized clinical trial of surgical technique and local antibiotics for ingrowing toenail. *Br J Surg.* 2007;94:292-296.

193 ONYCHOMYCOSIS

E.J. Mayeaux, Jr., MD

PATIENT STORY

A 29-year-old woman presents with thickened and discolored toenails for 1 year (**Figure 193-1**). She is embarrassed to wear sandals and wants treatment. The entire nail plates are involved and there is subungual keratosis. She did not realize that she had tinea pedis, but a fine scale was seen on the soles and sides of the feet indicative of tinea pedis in a moccasin distribution. A KOH scraping from the subungual debris was positive for hyphae. She has no history of liver disease or risk factors for liver disease. An oral antifungal was prescribed for 3 months.

FIGURE 193-1 Onychomycosis in all toenails of this 29-year-old woman. Note the nail plate thickening and discoloration along with the subungual keratosis. She also has tinea pedis in a moccasin distribution. *(Courtesy of Richard P. Usatine, MD.)*

INTRODUCTION

Onychomycosis is a term used to denote nail infections caused by any fungus, including dermatophytes, yeasts, and nondermatophyte molds. One, some, and occasionally all of the toenails and/or fingernails may be involved. Although most toenail onychomycosis is caused by dermatophytes, many cases of fingernail onychomycosis are caused by yeast. Onychomycosis may involve the nail plate and other parts of the nail unit, including the nail matrix.

SYNONYMS

Toenail fungus, tinea unguium, dermatophytosis of nails.

EPIDEMIOLOGY

- The incidence of onychomycosis has been reported to be 2% to 13% in North America.[1]
- Most patients (7.6%) only have toenail involvement and only 0.15% have fingernail involvement alone.[2]
- The prevalence of onychomycosis varies from 4% to 18%.[3,4]
- The disease is very common in adults, but may also occur in children.

ETIOLOGY AND PATHOPHYSIOLOGY

- Dermatophytes are responsible for most finger and toenail infections.
- Nonpathogenic fungi and *Candida* (in the rare syndrome of chronic mucocutaneous candidiasis) also can infect the nail plate (**Figure 193-2**).
- Dermatophytic onychomycosis (tinea unguium) occurs in three distinct forms: distal subungual, proximal subungual, and white superficial.
- The vast majority of distal and proximal subungual onychomycosis results from *Trichophyton rubrum* (**Figure 193-3**).

FIGURE 193-2 *Candida* infection of the skin and nails in an immunosuppressed patient with chronic mucocutaneous candidiasis. *(Courtesy of Richard P. Usatine, MD.)*

- White superficial onychomycosis is usually caused by *Trichophyton mentagrophytes*, although cases caused by *T. rubrum* have also been reported (**Figure 193-4**).
- Yeast onychomycosis is most common in the fingers caused by *Candida albicans*.

RISK FACTORS

- Tinea pedis.[5]
- Trauma predisposes to infection but can also cause a dysmorphic nail that can be confused for onychomycosis.[5]
- Older age.[5]
- Swimming.[5]
- Diabetes.[5]
- Living with family members who have onychomycosis.[5]
- Immunosuppression (**Figures 193-5** and **193-6**).[6]

DIAGNOSIS

CLINICAL FEATURES

- Distal subungual onychomycosis is the most common presentation.
- Distal subungual onychomycosis begins with a whitish, yellowish, or brownish discoloration of a distal corner of the nail, which gradually spreads to involve the entire width of the nail plate and extends slowly toward the cuticle. Keratin debris collecting between the nail plate and its bed is the cause of the discoloration (**Figures 193-1**, **193-3**, and **193-7**).
- Proximal subungual onychomycosis progresses in a manner similar to distal subungual onychomycosis but affects the nail in the vicinity of the cuticle first and extends distally. It usually occurs in individuals with a severely compromised immune system (**Figure 193-5**).
- White superficial onychomycosis appears as dull white spots on the surface of the nail plate (**Figure 193-4**). Eventually the whole nail plate may be involved. The white areas may be soft and can be lightly scraped to yield a chalky scale that may be examined or cultured.

TYPICAL DISTRIBUTION

- Nail infection may occur in a single digit but most often occurs simultaneously in multiple digits of the foot. Toenails and fingernails may be affected at the same time especially in patients that are immunocompromised (**Figures 193-5** and **193-6**).

LABORATORY TESTING

- KOH and culture—Clippings of nail plate and scrapings of subungual keratosis can be examined with KOH and microscopy and/or sent to the laboratory in a sterile container to be inoculated onto Sabouraud medium to culture.
- Dermatophyte test medium (DTM) culture is an alternative to Sabouraud medium culture. DTM is less expensive and can be

FIGURE 193-3 Severe toenail onychomycosis demonstrating subungual keratosis in the first nail and onychogryphosis (ram's horn nail) in the second nail because of the fungal infection. The culture grew *Trichophyton rubrum*. *(Courtesy of Richard P. Usatine, MD.)*

FIGURE 193-4 White superficial onychomycosis of the thumbnail. The culture was positive for *Trichophyton mentagrophytes*. *(Courtesy of Richard P. Usatine, MD.)*

performed in the physician's office, with results becoming available within 3 to 7 days. Dermatophyte growth is indicated by a change in the medium's color from yellow to red. It is important that DTM cultures be read in a timely fashion, as saprophytic organisms may grow over several weeks and cause a false-positive result. DTM does not identify the specific causative organism, but such identification is unnecessary as all dermatophyte infections are treated the same way. DTM cultures had good positive and negative correlation with culture on Sabouraud medium.[7]

- Clippings—Nail clippings may be sent to pathology in formalin to be examined with periodic acid-Schiff (PAS) stain for fungal elements. This can be more sensitive than KOH and culture.
- Comparison of diagnostic methods:
  - In a 2003 study by Weinberg et al, the sensitivities for onychomycosis detection were KOH 80%, Bx/PAS 92%, and culture 59%. The specificities were KOH 72%, Bx/PAS 72%, and culture 82%. The positive predictive values were KOH 88%, Bx/PAS 89.7%, and culture 90%. The negative predictive values were KOH 58%, Bx/PAS 77%, and culture 43%.[8]
  - In a 2007 study of the diagnosis of onychomycosis by Hsiao et al, the sensitivities of KOH, PAS, and culture were 87%, 81%, and 67%, respectively, and the negative predictive values of KOH, PAS, and culture were 50%, 40%, and 28%, respectively. One reason that the KOH may have done so well is that the nail specimen was immersed in 20% KOH in a test tube for 30 minutes or longer before looking under the microscope.[9]
  - KOH may be equivalent to PAS if done and read properly. It is less expensive and the results are available while the patient is in the office. PAS is a good second line if the KOH is negative and the suspicion for onychomycosis is still present.

DIFFERENTIAL DIAGNOSIS

- Nail trauma can cause a dysmorphic nail that is discolored and thickened. It is especially seen in the big toenail in runners. Ask about nail trauma before diagnosing onychomycosis. Although onychomycosis often starts in the big toenail, it usually spreads to other nails. Traumatic changes often present with only one nail involved.
- Psoriatic and lichen planus nail changes may easily be confused with onychomycosis, especially when the nail becomes thickened and discolored. Pitting of the nail plate surface, which is common in psoriasis, is not a feature of fungal infection. It is possible for a patient with psoriasis to get onychomycosis. Fungal studies can help determine if the changes are truly secondary to onychomycosis (see Chapter 195, Psoriatic Nails).
- Pseudomonal nail infection—Produces a blue-green tint to the nail plate (**Figure 193-8**).
- Leukonychia—White spots or bands that appear proximally and proceed out with the nail may be confused with white superficial onychomycosis (see Chapter 190, Normal Nail Variants).
- Habitual picking of the proximal nail fold—Induces the nail plate to be wavy and ridged, although its substance remains intact and hard (see Chapter 190, Normal Nail Variants).

FIGURE 193-5 Extensive onychomycosis involving all toenails in an HIV-positive man. His second toenail shows onychogryphosis (ram's horn nail) secondary to the fungal infection. *(Courtesy of Richard P. Usatine, MD.)*

FIGURE 193-6 Fungal infection involving 4 of 10 nails on the hands of the same HIV-positive man. *(Courtesy of Richard P. Usatine, MD.)*

FIGURE 193-7 Onychomycosis involving both thumbnails. *(Courtesy of Richard P. Usatine, MD.)*

MANAGEMENT

- Treating onychomycosis can be discouraging. Most topical creams and lotions do not penetrate the nail plate well and are of little value except in controlling inflammation at the nail folds.
- Surgical avulsion may be used to decrease pain caused by pressure on an elevated nail plate because of a dermatophytoma (a collection of dermatophytes and cellular debris under the nail plate). Recurrences are common in the absence of additional systemic or topical therapy with ciclopirox, as the infection typically involves the nail matrix and bed. SOR C
- There has been a resurgence of interest in phototherapy modalities for the treatment of onychomycosis. UV light therapy, near-infrared photoinactivation therapy, photodynamic therapy, and photothermal ablative therapy are being studied for treatment of onychomycosis.[10] Further studies are required to determine the clinical role of laser and light therapy in the treatment of onychomycosis. The Pinpointe FootLaser was approved for use to treat onychomycosis in February 2011. SOR C

FIGURE 193-8 *Pseudomonas* of the nail showing a blue-green discoloration. *(Courtesy of Richard P. Usatine, MD.)*

MEDICATIONS

- Oral therapy (**Table 193-1**) is no longer expensive now that terbinafine is generic and on many discounted drug lists.

TABLE 193-1 Common Treatments for Onychomycosis

Drug	Pediatric Dose	Adult Dose	Course	Toenail Cure Rate
Griseofulvin (Grifulvin V)	Microsize 15 to 20 mg/kg per day	500 mg po qd	4 to 9 months (f), 6 to 12 months (t)	60% ± 6%
Terbinafine (Lamisil)	10 to 20 kg: 62.5 mg/day 20 to 40 kg: 125 mg/day	250 mg po qd	6 weeks (f), 12 weeks (t)	76% ± 3%
Terbinafine (Lamisil) pulse*	—	250 mg bid 1 wk/mo	2 months (f), 3 months (t)	NR
Itraconazole (Sporanox)	—	200 mg daily	6 weeks (f), 12 weeks (t)	59% ± 5%
Itraconazole (Sporanox) pulse	<20 kg: 5 mg/kg per day for 1 wk/mo 20 to 40 kg: 100 mg daily for 1 wk/mo	200 mg bid or 5 mg/kg per day capsules for 1 wk/mo	2 months (f), 3 months (t)	63% ± 7%
Fluconazole (Diflucan)	3 to 6 mg/kg once a wk	150 mg once a wk	12 to 16 weeks (f), 18 to 26 weeks (t)	48% ± 5%
Ciclopirox 8% nail lacquer (Penlac)	—	Apply daily to nail and surrounding 5-mm skin	Up to 48 weeks	Approximately 7%

NR, Not recorded.
*Not indicated for treating onychomycosis by the FDA.
From: Harrell TK, Necomb WW, Replogle WH, et al. Onychomycosis: improved cure rates with itraconazole and terbinafine. *J Am Board Fam Pract*. 2000;13(4):268-273; Bell-Syer S, Porthouse J, Bigby M. Oral treatments for toenail onychomycosis. *Cochrane Database Syst Rev*. 2004;(2):CD004766. DOI: 10.1002/14651858. CD004766; Crawford F, Hart R, Bell-Syer S, et al. Topical treatments for fungal infections of the skin and nails of the foot. *Cochrane Database Syst Rev*. 1999;(3):CD001434. DOI: 10.1002/14651858. CD001434; Havu V, Heikkila H, Kuokkanen K, et al. A double-blind, randomized study to compare the efficacy and safety of terbinafine (Lamisil) with fluconazole (Diflucan) in the treatment of onychomycosis. *Br J Dermatol*. 2000;142(1):97-102.

- A Cochrane review found that the evidence suggests that terbinafine is more effective than griseofulvin and that terbinafine and itraconazole are more effective than no treatment.[11] SOR A
- Terbinafine dosing is 250 mg daily for 3 months for toenail onychomycosis and 2 months to treat fingernail involvement only.[11] SOR A
- Another Cochrane review found two trials of nail infections that did not provide any evidence of benefit for topical treatments (ciclopirox not included) compared with placebo.[12] SOR A
- Terbinafine has a preferable drug interaction profile, may have better long-term cure rates, and daily dosing may be the most effective treatment.[6,11] SOR A
- Itraconazole (Sporanox) has more drug interactions. Pulse dosing is as effective as daily dosing, but even with pulse dosing, therapy is more costly than terbinafine. Consider itraconazole if terbinafine does not effectively treat onychomycosis caused by fungus other than dermatophytes. SOR C
- Fluconazole (Diflucan) is not currently FDA approved for nail therapy and is not as effective as other oral therapies.[6,13] SOR B
- Ciclopirox 8% nail lacquer (Penlac) used daily (with weekly nail cleaning and filing) is an FDA-approved topical treatment for mild to moderate onychomycosis. A metaanalysis of 2 randomized controlled trials showed a clinical cure rate of 8% versus 1% for vehicle alone.[14] Such a low cure rate is disappointing, but a larger group of patients had some improvement without cure. This is one option for persons able to afford this topical treatment but who are not able to take oral antifungals.
- Amorolfine is a topical antifungal agent with activity against dermatophytes, yeasts, and fungi that is available over the counter in Australia and the United Kingdom, but is not approved for use in the United States. Amorolfine 5% nail lacquer has been used as monotherapy for the treatment of onychomycosis. It is applied once weekly after the surface of the nail is filed with a disposable file and wiped with alcohol. Once weekly application of amorolfine 5% nail lacquer for 6 months led to both clinical and mycologic cure in 38% and 46% of patients. It may also be used to increase cure rates when used in combination with oral antifungals.[15]

COMPLEMENTARY AND ALTERNATIVE THERAPY

- There are numerous complementary and alternative medicine (CAM) therapies described on the Internet, most of which have minimal or no evidence of clinical efficacy.
- Mentholated chest rub—There is minimal data on the efficacy of a mentholated chest rub (Vicks VapoRub) in the treatment of onychomycosis. In a series of 18 patients who applied the medication to affected nails daily for 48 weeks, 4 patients (22%) achieved both clinical and mycologic cure.[16] Although these products are unlikely to be harmful, additional studies that support their efficacy in onychomycosis are necessary before widespread use can be recommended.

PREVENTION

Patients should be educated about the use of appropriate footwear, especially in high-exposure areas such as communal bathing facilities and health clubs.

PROGNOSIS

The condition may persist indefinitely if left untreated.

In patients with diabetes or other immunocompromised states, onychomycosis may increase the risk of secondary bacterial infections.[17]

FOLLOW-UP

Routine monitoring of liver function tests during therapy is probably not necessary in patients without underlying liver disease. However, because the manufacturer of terbinafine recommends checking pretreatment serum aminotransferases and monitoring for potential symptoms of hepatotoxicity during treatment, many clinicians routinely obtain pretreatment and mid-therapy values.

PATIENT EDUCATION

Patients should be advised that with treatment, nails may not appear normal for up to 1 year. The normal nail must grow out as treatment progresses. The appearance of normal appearing nails at the proximal edge of the nail is an encouraging sign at the completion of therapy.

PATIENT RESOURCES

- eMedicineHealth. *Onychomycosis*—**http://www.emedicinehealth.com/onychomycosis/article_em.htm.**
- Familydoctor.org website. *Fungal Infections of Fingernails and Toenails*—**http://familydoctor.org/online/famdocen/home/common/infections/common/fungal/663.html.**
- MedicineNet. *Fungal Nails (Onychomycosis, Tinea Unguium)*—**http://www.medicinenet.com/fungal_nails/article.htm.**

PROVIDER RESOURCES

- Tosti A. *Onychomycosis*—**http://emedicine.medscape.com/article/1105828-overview.** Accessed November 25,2011.
- Roger P, Bassler M; American Family Physician. *Treating Onychomycosis*—**http://www.aafp.org/afp/20010215/663.html.** Accessed November 25,2011.
- Elewski BE. Onychomycosis: pathogenesis, diagnosis, and management. *Clin Microbiol Rev*. 1998;11[3]:415-429. **http://www.ncbi.nlm.nih.gov/pmc/articles/PMC88888/.** Accessed November 25,2011.
- DermNetNZ. *Fungal Nail Infections*—**http://dermnetnz.org/fungal/onychomycosis.html.** Accessed November 25,2011.
- Roberts DT, Taylor WD, Boyle J. Guidelines for treatment of onychomycosis. *Br J Dermatol*. 2003;148:402-410. **http://bad.org.uk/Portals/_Bad/Guidelines/Clinical%20Guidelines/Onychomycosis.pdf.** Accessed November 25,2011.

REFERENCES

1. Kemna ME, Elewski BE. A U.S. epidemiologic survey of superficial fungal diseases. *J Am Acad Dermatol.* 1996;35(4):539-542.
2. Gupta AK. Prevalence and epidemiology of onychomycosis in patients visiting physicians' offices: A multicenter Canadian survey of 15,000 patients. *J Am Acad Dermatol*. 2000;43:244.
3. Erbagci Z, Tuncel A, Zer Y, Balci I. A prospective epidemiologic survey on the prevalence of onychomycosis and dermatophytosis in male boarding school residents. *Mycopathologia*. 2005;159:347.
4. Sahin I, Kaya D, Parlak AH, et al. Dermatophytoses in forestry workers and farmers. *Mycoses*. 2005;48:260.
5. Sigurgeirsson B, Steingrímsson O. Risk factors associated with onychomycosis. *J Eur Acad Dermatol Venereol.* 2004;18:48.
6. Harrell TK, Necomb WW, Replogle WH, et al. Onychomycosis: improved cure rates with itraconazole and terbinafine. *J Am Board Fam Pract*. 2000;13(4):268-273.
7. Elewski BE, Leyden J, Rinaldi MG, Atillasoy E. Office practice-based confirmation of onychomycosis: a US nationwide prospective survey. *Arch Intern Med.* 2002;162:2133.
8. Weinberg JM, Koestenblatt EK, Tutrone WD, et al. Comparison of diagnostic methods in the evaluation of onychomycosis. *J Am Acad Dermatol*. 2003;49(2):193-197.
9. Hsiao YP, Lin HS, Wu TW, et al. A comparative study of KOH test, PAS staining and fungal culture in diagnosis of onychomycosis in Taiwan. *J Dermatol Sci*. 2007;45(2):138-140.
10. Bornstein E. A review of current research in light-based technologies for treatment of podiatric infectious disease states. *J Am Podiatr Med Assoc.* 2009;99(4):348-352.
11. Bell-Syer S, Porthouse J, Bigby M. Oral treatments for toenail onychomycosis. *Cochrane Database Syst Rev*. 2004;(2):CD004766. DOI: 10.1002/14651858. CD004766.
12. Crawford F, Hart R, Bell-Syer S, et al. Topical treatments for fungal infections of the skin and nails of the foot. *Cochrane Database Syst Rev*. 1999;(3):CD001434. DOI: 10.1002/14651858. CD001434.
13. Havu V, Heikkila H, Kuokkanen K, et al. A double-blind, randomized study to compare the efficacy and safety of terbinafine (Lamisil) with fluconazole (Diflucan) in the treatment of onychomycosis. *Br J Dermatol*. 2000;142(1):97-102.
14. Gupta AK, Joseph WS. Ciclopirox 8% nail lacquer in the treatment of onychomycosis of the toenails in the United States. *J Am Podiatr Med Assoc*. 2000;90(10):495-501.
15. Baran R, Kaoukhov A. Topical antifungal drugs for the treatment of onychomycosis: An overview of current strategies for monotherapy and combination therapy. *J Eur Acad Dermatol Venereol.* 2005;19:21.
16. Derby R, Rohal P, Jackson C, et al. Novel treatment of onychomycosis using over-the-counter mentholated ointment: a clinical case series. *J Am Board Fam Med.* 2011;24:69.
17. Bristow IR, Spruce MC. Fungal foot infection, cellulitis and diabetes: a review. *Diabet Med.* 2009;26:548.

194 PARONYCHIA

E.J. Mayeaux, Jr., MD

PATIENT STORY

A 41-year-old woman presented with a 3-day history of localized pain, redness, and tenderness of the lateral nailfold of the index finger. A small abscess had developed in the last 24 hours at the nail margin (**Figure 194-1**). After informed consent was given, a digital block was performed. This acute paronychia was treated with incision and drainage using a #11 scalpel (**Figure 194-2**). A significant amount of pus was drained. She soaked her finger four times daily as directed. Two days later the patient's finger was much better and the culture grew out *Staphylococcus aureus*. Draining the abscess was sufficient treatment.

FIGURE 194-1 Painful acute paronychia around the fingernail of a 41-year-old woman. Note the swelling and erythema with a small white-yellow area suggesting underlying purulence. (*Courtesy of Richard P. Usatine, MD.*)

INTRODUCTION

Paronychia is a localized, superficial infection or abscess of the nailfolds. It is one of the most common infections of the hand. Paronychia can be acute or chronic. Acute paronychia usually presents as an acutely painful abscess in the nailfold. Chronic paronychia is defined as being present for longer than 6 weeks' duration. It is a generalized red, tender, swelling of the proximal or lateral nailfolds. It is usually nonsuppurative and is more difficult to treat.

EPIDEMIOLOGY

Paronychia is the most common infection of the hand, representing 35% of all hand infections in the United States.[1]

ETIOLOGY AND PATHOPHYSIOLOGY

- Paronychial infections develop when a disruption occurs between the seal of the nailfold and the nail plate or the skin of a nailfold is disrupted and allows a portal of entry for invading organisms.[2]
- Acute paronychia is most commonly caused by *S. aureus*, followed by streptococci and *Pseudomonas* (**Figures 194-1** to **194-5**).[1]
- Chronic paronychia more likely results from chronic *Candida albicans* (95%) (**Figures 194-6** and **194-7**). Other rare causes include atypical *Mycobacteria* and Gram-negative rods. There is some evidence that chronic paronychia is at least partially an eczematous process and that *Candida* infection is a secondary phenomenon.[3]
- Untreated persistent chronic paronychia may cause horizontal ridging, undulations, and other changes to the nail plate (**Figures 194-6** and **194-7**).

FIGURE 194-2 Incision and drainage of the acute paronychia in the previous figure with a #11 scalpel. Note the exuberant pus draining from the incision. (*Courtesy of Richard P. Usatine, MD.*)

RISK FACTORS

- Acute paronychia commonly results from nail biting (**Figure 194-3**), finger sucking, aggressive manicuring (**Figure 194-6**), hang nails (**Figure 194-5**), trauma, and artificial nails.[2]
- Children are prone to acute paronychia through direct infection of fingers with mouth flora from finger sucking and nail biting.
- People at risk of developing chronic paronychia include those who are repeatedly exposed to liquid irritants or alkali, and those whose hands are chronically wet. People with occupations such as baker, bartender, housekeepers, and dishwashers are predisposed to developing chronic paronychia.
- Patients with diabetes mellitus, compromised immune systems, or a history of oral steroid use are at increased risk for paronychia. Retroviral therapy use, especially indinavir and lamivudine, may be associated with an increased incidence of paronychia.[4]

Sculptured (artificial) nail placement is associated with the development of paronychia.[1]

DIAGNOSIS

CLINICAL FEATURES

- Acute paronychia presents with localized pain and tenderness. The nailfold appears erythematous and inflamed, and a collection of pus usually develops (**Figures 194-1** to **194-5**). Granulation tissue may develop along the nailfold, and cellulitis may develop (**Figure 194-5**).
- Chronic paronychia is a red, tender, painful swelling of the proximal or lateral nailfolds. A small collection of pus or abscess may form but typically only redness and swelling are present. Eventually, the nail plates may become thickened and discolored, with pronounced horizontal ridges (**Figures 194-6** and **194-7**).[5]

DIFFERENTIAL DIAGNOSIS

- Mucus cyst, which presents as a painless swelling lateral and proximal to the nail plate (**Figure 194-8**). This can also cause changes in the nail morphology.
- Ingrown nail (onychocryptosis) is a condition in which the nail plate is too large for the nail bed. The pressure applied to the lateral nailfold causes a painful inflammation. Although this is sometimes called paronychia, it is different from the type of paronychia caused by an infection of the nailfold (see Chapter 192, Ingrown Toenail).
- Glomus tumor, which presents with constant severe pain, nail plate elevation, bluish-discoloration of the nail plate, and blurring of the lunula.
- Herpetic whitlow, which results from herpes simplex virus (HSV) infection presents with acute onset of vesicles or pustules, severe edema, erythema, and pain. Tzanck staining of vesicles will demonstrate multinucleated giant cells and viral culture will grow HSV (see Chapter 129, Herpes Simplex).

FIGURE 194-3 Acute paronychia from nail biting. Note abscess formation in the lateral nailfold that is extending into the proximal fold. (*Courtesy of E.J. Mayeaux, Jr., MD.*)

FIGURE 194-4 Acute paronychia of the great toe. Note extensive manicure of the nails, which may predispose to paronychia if the cuticle or nailfolds are disrupted. (*Courtesy of Jennifer P. Pierce, MD.*)

FIGURE 194-5 Acute paronychia with cellulitis of the skin of the fingertip and granulation tissue formation. This all started when the patient began manipulating a hang nail. (*Courtesy of Richard P. Usatine, MD.*)

- Felon—Paronychia must be distinguished from a felon, which is an infection of the digital pulp. It is characterized by severe pain, swelling, and erythema in the pad of the fingertip.
- Benign and malignant neoplasms, which may present early with redness and swelling should always be ruled out when chronic paronychia does not respond to conventional treatment.

MANAGEMENT

NONPHARMACOLOGIC

- Milder cases of acute paronychia without abscess formation may be treated with warm soaks for 20 minutes 3 to 4 times a day.[2] SOR C
- When an abscess or fluctuance is present, drainage is necessary.[7] SOR C It is performed with digital block anesthesia. The affected nailfold is incised with a scalpel with the blade parallel to the edge of the nail plate and the pus expressed (**Figure 194-2**). Warm soaks 4 times a day are initiated to keep the incision from sealing until all of the pus is gone.[8] Between soakings, an adhesive bandage can protect the nailfold. Antibiotic therapy is usually not necessary unless there is accompanying cellulitis. SOR C

MEDICATIONS

- Although antibiotics are not necessary for simple paronychia, addition of an oral antistaphylococcal agent (dicloxacillin 500 mg 3 times daily, cephalexin 500 mg 2 to 3 times daily for 7 to 10 days, erythromycin 333 to 500 mg 3 times daily, or azithromycin 500 mg on day 1 followed by 250 mg daily for 4 days) may be added for cases with coexisting cellulitis or that are unresponsive. SOR C
- Both children who suck their fingers and patients who bite their nails and who require antibiotics should be covered against anaerobes. Clindamycin and amoxicillin-clavulanate potassium are effective against most pathogens isolated from infections originating in the mouth.[6]
- Long-term treatment of chronic paronychia primarily involves avoiding predisposing factors such as prolonged exposure to water, nail trauma, and finger sucking. Treatment with topical antifungals (topical miconazole or ketoconazole) or a combination of topical steroids and an antifungal agent has been shown to be successful.[2,3] SOR B Oral antifungal therapy is usually not necessary.[2]

PREVENTION

- Trim hangnails to a semilunar smooth edge with a clean sharp nail plate trimmer. Trim toenails flush with the toe tip.
- Do not bite the nail plate or lateral nailfolds.
- Avoid prolonged hand exposure to moisture. If hand washing must be frequent, use antibacterial soap, thoroughly dry hands with a clean towel, and apply an antibacterial moisturizer. Use cotton glove liners under waterproof gloves to keep hands dry from sweat and condensation.
- Wear rubber or latex-free gloves when there is potential exposure to pathogens.
- Control diabetes mellitus.
- Keep fingernails clean.
- Moisturize the skin, don't let it become chafed and cracked.

FIGURE 194-6 Chronic paronychia. Note horizontal ridges on one side of the nail plate as a result of chronic inflammation. (*Courtesy of Richard P. Usatine, MD.*)

FIGURE 194-7 Chronic *Candida* paronychia causing a dysmorphic fingernail with horizontal ridging. (*Courtesy of Richard P. Usatine, MD.*)

PROGNOSIS

Although the nailfold should improve with treatment, some chronic nail plate changes may not resolve.

FOLLOW-UP

Patients can perform warm soaks 3 to 4 times per day and should have a follow-up examination several days after incision and drainage to assure the infection is resolving appropriately.

PATIENT EDUCATION

Educate patients on measures that may prevent or improve paronychia (above.)

PATIENT RESOURCES

- eMedicineHealth. *Paronychia (Nail Infection)*—**http://www.emedicinehealth.com/paronychia_nail_infection/article_em.htm.**
- Familydoctor.org. Paronychia information—**http://familydoctor.org/online/famdocen/home/common/skin/disorders/937.html.**

PROVIDER RESOURCES

- Rockwell PG. Acute and chronic paronychia. *Am Fam Physician.* 2001;63:1113-1116—**http://www.aafp.org/afp/20010315/1113.html.**
- Medscape. *Dermatologic Manifestations of Paronychia*—**http://emedicine.medscape.com/article/1106062.**

FIGURE 194-8 Digital mucus cyst presenting as a painless swelling of the nailfold in a young woman. Note the indented area of the nail caused by the pressure of the mucus cyst on the nail matrix. (*Courtesy of Richard P. Usatine, MD.*)

REFERENCES

1. Rockwell PG. Acute and chronic paronychia. *Am Fam Physician.* 2001;63(6):1113-1116.
2. Hochman LG. Paronychia: more than just an abscess. *Int J Dermatol.* 1995;34:385-386.
3. Tosti A, Piraccini BM, Ghetti E, Colombo MD. Topical steroids versus systemic antifungals in the treatment of chronic paronychia: an open, randomized double-blind and double dummy study. *J Am Acad Dermatol.* 2002;47:73.
4. Tosti A, Piraccini BM, D'Antuono A, et al. Paronychia associated with antiretroviral therapy. *Br J Dermatol.* 1999;140(6):1165-1168.
5. Canales FL, Newmeyer WL 3d, Kilgore ES. The treatment of felons and paronychias. *Hand Clin.* 1989;5:515-523.
6. Brook I. Aerobic and anaerobic microbiology of paronychia. *Ann Emerg Med.* 1990;19:994-996.
7. Keyser JJ, Littler JW, Eaton RG. Surgical treatment of infections and lesions of the perionychium. *Hand Clin.* 1990;6(1):137-153.
8. Zuber T, Mayeaux EJ Jr. *Atlas of Primary Care Procedures*. Philadelphia: Lippincott, Williams, & Wilkins; 2003:233-238.

195 PSORIATIC NAILS

E.J. Mayeaux, Jr., MD

PATIENT STORY

A 19-year-old man with a 4-year history of plaque psoriasis presents with nail abnormalities in several fingers (**Figure 195-1**). He is particularly concerned about the recently acquired greenish discoloration of his fifth digit.

FIGURE 195-1 Patient with nail psoriasis demonstrating the oil drop sign (second digit), nail pitting (second and third digit), onycholysis (second, fourth and fifth digit), and secondary pseudomonas infection (fifth digit). (*Courtesy of E.J. Mayeaux, Jr., MD.*)

INTRODUCTION

Psoriasis is a hereditary disorder of skin with numerous clinical expressions. It affects millions of people throughout the world.[1] Nail involvement is common and can have a significant cosmetic impact.

EPIDEMIOLOGY

- Nails are involved in 30% to 50% of psoriasis patients at any given time, and up to 90% develop nail changes over their lifetime.[1] In most cases, nail involvement coexists with cutaneous psoriasis, although the skin surrounding the affected nails need not be involved. Psoriatic nail disease without overt cutaneous disease occurs in 1% to 5% of psoriasis. Patients with nail involvement are thought to have a higher incidence of associated arthritis.[2]
- The most common nail change seen with psoriasis is nail plate pitting (**Figures 195-1** and **195-2**).

ETIOLOGY AND PATHOPHYSIOLOGY

- In psoriasis, parakeratotic cells within the stratum corneum of the nail matrix alters normal keratinization.[3] The proximal nail matrix forms the superficial portion of the nail plate, so that involvement in this part of the matrix results in pitting of the nail plate (**Figures 195-1** and **195-2**.) The pits may range in size from pinpoint depressions to large punched-out lesions. People without psoriasis can have nail pitting.
- Longitudinal matrix involvement produces longitudinal nail ridging or splitting (**Figure 195-2**). When transverse matrix involvement occurs, solitary or multiple "growth arrest" lines (Beau lines) may occur (see Chapter 190, Normal Nail Variants). Psoriatic involvement of the intermediate portion of the nail matrix leads to leukonychia and diminished nail plate integrity.
- Parakeratosis of the nail bed with thickening of the stratum corneum causes discoloration of the nail bed, producing the "salmon spot" or "oil drop" signs.[3]
- Desquamation of parakeratotic cells at the hyponychium leads to onycholysis, which may allow for bacteria and fungi infection.[4]

FIGURE 195-2 Nail psoriasis demonstrating nail pitting, onycholysis, oil drop sign, and longitudinal ridging. Nails held over the silvery plaque on the knee. (*Courtesy of Richard P. Usatine, MD.*)

RISK FACTORS

- Psoriasis of the skin.
- Psoriatic arthritis.
- Nail unit trauma.
- Generalized psoriasis flair.

DIAGNOSIS

CLINICAL FEATURES

- The diagnosis of nail psoriasis is usually straightforward when characteristic nail findings coexist with cutaneous psoriasis. Nail pitting and onycholysis are the most common findings (**Figure 195-3**).
- Nail psoriasis and onychomycosis are often indistinguishable by clinical examination alone. Psoriasis at the hyponychium produces subungual hyperkeratosis and distal onycholysis (**Figures 195-4** and **195-5**). Trauma may accentuate this process. Secondary microbial colonization by *Candida* or *Pseudomonas* organisms may occur (**Figures 195-1** and **195-5**).
- Nail bed psoriasis produces localized onycholysis which often appears like a drop of oil on a piece of paper (oil drop sign) (**Figures 195-2, 195-4**, and **195-5**). This same condition is also called the salmon patch sign.
- Extensive germinal matrix involvement may result in loss of nail integrity and transverse (horizontal) ridging (**Figure 195-6**).
- Psoriasis causes dermal vascular dilation and tortuosity, and in the nails is associated with splinter hemorrhages of the nail bed caused by foci of capillary bleeding. Extravasated blood becomes trapped between the longitudinal troughs of the nail bed and the overlying nail plate grows out distally along with the plate (**Figure 195-7**). The splinter hemorrhages of the psoriatic nail are analogous to the cutaneous Auspitz sign.

LABORATORY TESTING

- KOH preparation and fungal culture will usually provide an answer. However, it may be necessary to clip a portion of the nail plate and send it for fungal staining (periodic acid-Schiff [PAS] stain) if the first test results are not consistent with the clinical picture.[5] Psoriasis and onychomycosis can occur concomitantly.

BIOPSY

- Biopsy of the nail unit is rarely necessary unless a malignancy is suspected.

DIFFERENTIAL DIAGNOSIS

- Onychomycosis produces distal onycholysis and hyperkeratosis that appear identical to psoriasis and may coexist with it (see Chapter 193, Onychomycosis).
- Darier disease (keratosis follicularis) is an autosomal dominant disorder that results in abnormal keratinization and loss of adhesion

FIGURE 195-3 Nail pitting and onycholysis in a patient with psoriasis. (*Courtesy of Richard P. Usatine, MD.*)

FIGURE 195-4 Nail psoriasis with onycholysis and oil drop sign in a young woman. Note that end of the nail plates are no longer attached to the nail bed and there is a light brown discoloration where the nail loses its attachment. (*Courtesy of Richard P. Usatine, MD.*)

between epidermal cells. It typically presents in the second decade of life with hyperkeratotic, yellow-brown, greasy-appearing papules that coalesce into verrucous-like plaques in a seborrheic distribution. Nails may demonstrate red/white longitudinal stripes, subungual hyperkeratosis, and notching of the distal nail margins (**Figure 195-8**). The course of the illness is chronic and persistent.

- Alopecia areata also can produce pitting of the nails. As a general rule, pitting in psoriasis is more irregular and broader based; pitting in alopecia areata is more regular, shallow, and geometric and produces fine pits (see Chapter 187, Alopecia Areata).
- Neoplastic and dysplastic diseases may produce psoriasiform nail changes in a single nail. Bowen disease, squamous cell carcinoma, and verruca vulgaris may appear as an isolated subungual or periungual plaque, possibly with accompanying nail plate destruction. A biopsy can establish a definitive diagnosis.

FIGURE 195-5 Nail psoriasis with the oil drop sign proximal to the lighter onycholysis at the distal nail. (*Courtesy of Richard P. Usatine, MD.*)

MANAGEMENT

NONPHARMACOLOGIC

- Psoriatic nail disease is often persistent and refractory to treatment. There is insufficient evidence to recommend a standard treatment.
- The nails should be kept short, to avoid traumatic exacerbation of onycholysis and to avoid the accumulation of exogenous material under the nail.[3] SOR C
- Nail polish may be very helpful in concealing a range of nail unit changes.[6] SOR C
- Nail plate buffing may diminish surface imperfections.[6] SOR C

MEDICATIONS

- Unfortunately, specific evidence for systemic therapy in nail psoriasis is generally lacking. It should be considered in those with significant cutaneous involvement in addition to nail disease.
- One treatment option for nail psoriasis, especially with matrix involvement, is intralesional corticosteroid injection. Triamcinolone acetonide (0.4 mL, 10 mg/mL) is injected into the nail bed, matrix, or proximal fold following digital block, and then at 3-month intervals.[3,7] SOR A Subungual hyperkeratosis, ridging, and thickening respond better than pitting and onycholysis, with benefit sustained for at least 9 months.[7] Pain, periungual hypopigmentation, subungual hemorrhage and atrophy have been reported.[3]
- Nail bed disease, including subungual hyperkeratosis, distal onycholysis, and "oil drop" changes may also need the lateral nail folds injected close to the nail bed. Direct injection into the nail bed is prevented by the nail plate and extreme pain sensitivity of the hyponychial region. Atrophy and subungual hematoma formation are potential complications.
- One study found that topical 1% 5-fluorouracil solution or 5% cream applied twice daily to the matrix area for 6 months improved pitting and hyperkeratosis but worsened onycholysis.[3] SOR B
- Topical calcipotriol may be effective in reducing subungual hyperkeratosis.[3,8] SOR B

FIGURE 195-6 Nail psoriasis demonstrating onycholysis, pits, and transverse (horizontal) ridging. (*Courtesy of Richard P. Usatine, MD.*)

- Topical tazarotene improves onycholysis and nail pitting (if applied under occlusion) in those treated for 24 weeks.[3] SOR A
- In a single-blinded study, Feliciani et al found that combination therapy (oral cyclosporine and topical calcipotriol) was more effective than monotherapy (cyclosporine alone) on nail psoriasis.[9]
- Anthralin ointment 0.4% to 2.0%, applied and washed off after 30 minutes, is effective for onycholysis, subungual hyperkeratosis, and possibly pitting.[3] SOR B
- Narrow-band UVB and psoralen UVA (PUVA) phototherapy for 3 to 6 months is effective for cutaneous psoriasis but it's efficacy for nail psoriasis is poorly defined.[3]
- Acitretin, methotrexate, and cyclosporine are helpful for nail psoriasis.[3,10] SOR B
- Systemic retinoid therapy is often effective for pustular psoriasis, and early intervention is most likely to prevent chronic nail-associated scarring.

PREVENTION[11]

- Wearing gloves during wet work and during exposure to harsh materials may minimize trauma to the skin and nail unit.
- Trimming the nail short to minimize leverage at the free edge and resulting trauma.
- If dry skin or scaling develop, application of emollients may be helpful.
- Cosmetic manipulations of the nail risk exacerbating the disease due to minor trauma. Discretion and care should be exercised when trimming the cuticle and clearing subungual debris.

PROGNOSIS

- Psoriatic nail changes may be reversible because scarring typically does not occur. An exception to this may develop in severe cases of generalized pustular psoriasis.

FOLLOW-UP

- Follow-up can be combined with regular follow-ups for cutaneous psoriasis.

PATIENT EDUCATION

- Nail psoriasis is mainly a cosmetic problem. Nail polish or artificial nails can be used in some patients to conceal psoriatic pitting and onycholysis. When subungual hyperkeratosis becomes uncomfortable because of pressure exerted by footwear, the nail can be pared down to relieve the pressure.
- Patients should be instructed to trim nails back to the point of firm attachment with the nail bed to minimize further nail-bed and nail-plate disassociation. Wearing gloves while working may minimize trauma to the nails. Tell patients to avoid vigorous cleaning and scraping under the nails as this may break the skin where the nail is attached and lead to an infection.

FIGURE 195-7 Prominent splinter hemorrhages in the nail of a person with psoriasis. (*Courtesy of Richard P. Usatine, MD.*)

FIGURE 195-8 A woman with Darier disease (keratosis follicularis) demonstrating brittle nails with brown/white longitudinal stripes and notching of the distal nail plate. (*Courtesy of Richard P. Usatine, MD.*)

PATIENT RESOURCES

- National Psoriasis Foundation. *Hands, Feet and Nails*—**http://www.psoriasis.org/page.aspx?pid=445.**
- eMedicineHealth. *Nail Psoriasis*—**http://www.emedicinehealth.com/nail_psoriasis/article_em.htm.**

PROVIDER RESOURCES

- Medscape. *Nail Psoriasis: Overview of Nail Psoriasis*—**http://emedicine.medscape.com/article/1107949.**
- DermNet NZ. *Nail Psoriasis*—**http://dermnetnz.org/scaly/nail-psoriasis.html.**

REFERENCES

1. Jiaravuthisan MM, Sasseville D, Vender RB, et al. Psoriasis of the nail. Anatomy, pathology, clinical presentation, and a review of the literature on thereapy. *J Am Acad Dermatol.* 2007;57(1):1-27.
2. Noronha PA, Zubkov B. Nails and nail disorders in children and adults. *Am Fam Physician.* 1997;55(6):2129-2140.
3. Edwards F, de Berker D. Nail psoriasis: clinical presentation and best practice recommendations. *Drugs.* 2009;69(17):2351-2361.
4. Jiaravuthisan MM, Sasseville D, Vender RB, et al. Psoriasis of the nail: anatomy, pathology, clinical presentation, and a review of the literature on therapy. *J Am Acad Dermatol.* 2007;57(1):1-27.
5. Grammer-West NY, Corvette DM, Giandoni MB, Fitzpatrick JE. Clinical pearl: nail plate biopsy for the diagnosis of psoriatic nails. *J Am Acad Dermatol.* 1998;38(2 Pt 1):260-262.
6. de Berker D. Management of psoriatic nail disease. *Semin Cutan Med Surg.* 2009;28(1):39-43.
7. de Berker DA, Lawrence CM. A simplified protocol of steroid injection for psoriatic nail dystrophy. *Br J Dermatol.* 1998;138(1):90-95.
8. Tosti A, Piraccini BM, Cameli N, et al. Calcipotriol in nail psoriasis: a controlled double-blind comparison with betamethasone dipropionate and salicylic acid. *Br J Dermatol.* 1998;139(4):655-659.
9. Feliciani C, Zampetti A, Forleo P, et al. Nail psoriasis: combined therapy with systemic cyclosporine and topical calcipotriol. *J Cutan Med Surg.* 2004;8(2):122-125.
10. Cassell S, Kavanaugh AF. Therapies for psoriatic nail disease. A systematic review. *J Rheumatol.* 2006;33(7):1452-1456.
11. André J. Artificial nails and psoriasis. *J Cosmet Dermatol.* 2005;4(2):103-106.

196 SUBUNGUAL HEMATOMA

E.J. Mayeaux, Jr., MD

PATIENT STORY

A 22-year-old woman dropped an iron on her toe the day before she visited our free clinic. Her toe was painful at rest and worse when walking (**Figure 196-1**). This subungual hematoma needed to be drained and we did not have an electrocautery unit. A paperclip was bent open and held in a hemostat and heated with a torch. With some pressure it pierced the patient's nail plate and the blood spontaneously drained (**Figures 196-2** and **196-3**). This relieved the pressure and gave the patient immediate pain relief. The remaining old blood was drained with a little pressure on the proximal nail fold (**Figure 196-4**). Although we were concerned about a possible underlying fracture, the patient did not have health insurance and chose to postpone an x-ray. Her toe healed well and no radiographs were ever taken. (*Story by Richard P. Usatine, MD.*)

FIGURE 196-1 Acute subungual hematoma 1 day after dropping an iron on her toe. It was painful at rest and worse when walking. (*Courtesy of Richard P. Usatine, MD.*)

INTRODUCTION

Subungual hematoma (blood under the fingernail or toenail) is a common injury. It is typically caused by a blow to the distal phalanx (e.g., smashing with a tool, crush in a door jamb, stubbing one's toe). The blow causes bleeding of the nail matrix or bed with resultant subungual hematoma formation. Patients usually present because of throbbing pain associated with blue-black discoloration under the nail plate. Subungual hematomas may be simple (i.e., the nail and nail fold are intact) or accompanied by significant injuries to the nail fold and digit.[1] The patient may not be aware of the precipitating trauma, because it may have been minor and/or chronic (e.g., rubbing in a tight shoe).

EPIDEMIOLOGY

Subungual hematoma is a common childhood and adult injury.

ETIOLOGY AND PATHOPHYSIOLOGY

- The injury causes bleeding of the nail matrix and nail bed, which results in subungual hematoma formation (**Figures 196-1** to **196-5**).
- In most cases it grows out with the nail plate, exhibiting a proximal border that reproduces the shape of the lunula. Occasionally, a hematoma does not migrate because of repeated daily trauma. An extended, nonmigrating hematoma should be considered suspicious. Nail plate punch biopsy will often reveal the dark streak to be a subungual hematoma as the color lifts off with nail plate (**Figure 196-5**).
- Potential complications of subungual hematoma include onycholysis, nail deformity (usually splitting as in **Figure 196-6**), and infection. Complications are more likely to occur when presentation is delayed or there is an underlying fracture.[2]

FIGURE 196-2 A paperclip was held in a hemostat and heated with a torch to pierce the patient's nail plate in order to relieve the subungual hematoma. (*Courtesy of Richard P. Usatine, MD.*)

DIAGNOSIS

CLINICAL FEATURES

- Patients complain of throbbing pain and blue-black discoloration under the nail as the hematoma progresses. Pain is relieved immediately in most patients with simple nail trephination (**Figure 196-3**).

IMAGING

- If the mechanism of injury and clinical picture suggest a possible distal phalanx or distal interphalangeal (DIP) fracture, obtain a radiograph. SOR C

FIGURE 196-3 The hot paper clip formed a nice hole in the nail plate and the blood drained out spontaneously. This relieved the pressure and gave the patient immediate pain relief. (*Courtesy of Richard P. Usatine, MD.*)

DIFFERENTIAL DIAGNOSIS

- Nail bed nevus—Appears as a stable or slowly growing painless dark spot in the nail bed or matrix.
- Longitudinal melanonychia—Appears as painless pigmented bands that start in the matrix and extend the length of the nail (see Chapter 191, Pigmented Nail Disorders).
- Subungual melanoma—May start as a painless darkly pigmented band in the matrix and extend the length of the nail. It may be associated with pigment deposition in the proximal nail fold (Hutchinson sign) (see Chapter 191, Pigmented Nail Disorders).
- Splinter hemorrhages—Appears as reddish streaks in the nail bed and are seen in psoriasis more commonly than endocarditis (see Chapter 195, Psoriatic Nails).
- The diagnosis of child abuse must be considered in cases of chronic or frequently recurrent subungual hematomas in children.[3]

MANAGEMENT

NONPHARMACOLOGIC

- Subungual hematomas are treated with nail trephination, which removes the extravasated blood and relieves the pressure and resulting pain. Beyond 48 hours, most subungual hematomas have clotted and pain has decreased, so trephination is ineffective. SOR C

SURGERY

- Nail trephination is a painless procedure because there are no nerve endings in the nail plate that is perforated. The nail is perforated with a hot metal wire or steel paper clip (**Figures 196-2** to **196-4**), an electrocautery device, or by spinning a large-bore needle against the nail plate like a mechanical spade bit. This allows the collected blood to drain out (**Figures 196-3** and **196-4**). The hole must be large enough for continued drainage, which can continue for 24 to 36 hours. The puncture site should be kept covered with sterile gauze dressing while the wound drains, and the gauze should be changed daily.

MEDICATIONS

- The use of prophylactic antibiotics does not appear to improve outcomes in patients with subungual hematomas and intact nail folds.[4] SOR B

FIGURE 196-4 After the nail plate is pierced, the blood drains easily with a little pressure on the proximal nail fold. (*Courtesy of Richard P. Usatine, MD.*)

- Oral analgesia such as ibuprofen 10 mg/kg (maximum dose: 800 mg) every 6-8 hours may be used with more painful digits. SOR C

REFERRAL

- Some authors recommend removal of the nail with inspection instead of nail trephination when the hematoma involves more than 25% to 50% of the nail because of the increased likelihood of significant nail bed injury and fracture of the distal phalanx.[5,6] SOR C
- When deeper injuries are involved, nail plate removal after a digital block allows for nail bed repair.[7] SOR C

PROGNOSIS

The potential complications of a subungual hematoma include onycholysis (separation of the nail plate from the nail bed), nail deformity, nail loss, and infection. Complications are more likely to occur when care is delayed.

A retrospective analysis of 123 patients treated with simple trephination found that 85% of patients reported an excellent or very good outcome, 2% reported a poor outcome (nail splitting), and no correlation was found between outcome and size of the hematoma or the presence of fracture or infection.[2]

FOLLOW-UP

After trephination, instruct the patient to soak the affected digit in warm water several times per day for 2 days, and to keep the area dressed between soaks. Follow-up with any signs of reaccumulation of blood or infection.

PATIENT EDUCATION

- Potential complications of subungual hematoma and nail trephination should be discussed with the patient and/or the patient's parents or guardian.
- Inform the patient that residual discoloration usually slowly grows out with the nail.

PATIENT RESOURCES

- eMedicineHealth. *Subungual Hematoma*—**http://www.emedicinehealth.com/subungual_hematoma_bleeding_under_nail/article_em.htm.**
- HealthSquare. *Subungual Hematoma*—**http://www.healthcentral.com/symptoms/guide-154582–75.html.**
- WebMD. *Subungual Hematoma*—**http://www.webmd.com/skin-problems-and-treatments/bleeding-under-nail.**

PROVIDER RESOURCES

- American Family Physician. *Fingertip Injuries*—**http://www.aafp.org/afp/20010515/1961.html.**
- InteliHealth. *Nail Trauma*—**http://www.intelihealth.com/IH/ihtIH/WSIHW000/9339/25971.html.**

FIGURE 196-5 This persistent discoloration of the nail was found to be a subungual hematoma by nail plate biopsy using a punch biopsy instrument. (*Courtesy of E.J. Mayeaux, Jr., MD.*)

FIGURE 196-6 Split-nail deformity in a 6-year-old girl 1 year after her finger was closed in a car door and sutured in the emergency department. The matrix did not come together well and the nail will remain split (onychoschizia). (*Courtesy of Richard P. Usatine, MD.*)

REFERENCES

1. Roser SE, Gellman H. Comparison of nail bed repair versus nail trephination for subungual hematomas in children. *J Hand Surg Am.* 1999;24:1166-1170.
2. Meek S, White M. Subungual haematomas: is simple trephining enough? *J Accid Emerg Med.* 1998;15:269-271.
3. Gavin LA, Lanz MJ, Leung DY, Roesler TA. Chronic subungual hematomas: a presumed immunologic puzzle resolved with a diagnosis of child abuse. *Arch Pediatr Adolesc Med.* 1997;151:103-105.
4. Seaberg DC, Angelos WJ, Paris PM. Treatment of subungual hematomas with nail trephination: a prospective study. *Am J Emerg Med.* 1991;9:209-210.
5. Zook EG, Guy RJ, Russell RC. A study of nail bed injuries: causes, treatment, and prognosis. *J Hand Surg Am.* 1984;9:247-252.
6. Zacher JB. Management of injuries of the distal phalanx. *Surg Clin North Am.* 1984;64:747-760.
7. Hart RG, Kleinert HE. Fingertip and nail bed injuries. *Emerg Med Clin North Am.* 1993;11:755-765.

SECTION 18 PIGMENTARY AND LIGHT-RELATED CONDITIONS

197 MELASMA

E.J. Mayeaux, Jr., MD
Richard P. Usatine, MD

PATIENT STORY

A young Hispanic woman delivers a healthy baby boy. On the first postpartum day, she is sitting in the rocking chair after breastfeeding her son. Her doctor notes that she has melasma and asks her about it. She states that the hyperpigmented areas on her face have become darker during this pregnancy (**Figure 197-1**). She noted the dark spots started with her first pregnancy but they are worse this time. On physical examination, hyperpigmented patches are noted on the cheeks and upper lip (**Figure 197-2**). Although the patient hopes the pigment will fade, she does not want to treat the melasma at this time.

FIGURE 197-1 Melasma (chloasma) in the typical distribution in a woman that just gave birth to her second child. This is sometimes called the mask of pregnancy. (*Courtesy of Richard P. Usatine, MD.*)

INTRODUCTION

Melasma is an acquired hyperpigmentary disorder characterized by light- to dark-brown macules and patches occurring in the sun-exposed areas of the face and neck. It is most commonly caused by pregnancy or the use of sex steroid hormones, such as oral contraceptive pills.

SYNONYMS

Chloasma, mask of pregnancy.

EPIDEMIOLOGY

- It is a relatively common disorder that affects sun-exposed areas of skin, most commonly the face. It is believed to affect up to 75% of pregnant women.[1]
- It affects predominantly women (**Figures 197-1** to **197-3**), with men accounting for only 10% of all cases. It is particularly prevalent in women of Hispanic, East Asian, and Southeast Asian origin (skin types IV to VI) and who live in areas of intense UV radiation exposure.[1]
- Melasma caused by pregnancy usually regresses within a year, but areas of hyperpigmentation may never completely resolve.[2] It may increase with each subsequent pregnancy becoming more obvious.

ETIOLOGY AND PATHOPHYSIOLOGY

The major etiologic factors include genetic influences, exposure to UV radiation, and sex hormones.

- The precise cause of melasma has not been determined. Multiple factors have been implicated, including pregnancy, oral contraceptives, genetics, sun exposure, cosmetic use, thyroid dysfunction, and antiepileptic medications.[3,4]
- Women with melasma not related to pregnancy or oral contraceptive use may have hormonal alterations that are consistent with mild ovarian dysfunction.
- Melasma in men (**Figure 197-4**) shares the same clinical features as in women, but it is not known if hormonal factors play a role.[5]

Other factors associated with melasma include certain cosmetic ingredients (oxidized linoleic acid, salicylate, citral, preservatives) and certain antiepileptic drug. Some medications or topical preparations in combination with sun exposure worsen melasma.[1]

RISK FACTORS

A recent global survey of 324 women with melasma demonstrated that a combination of the known triggers, including pregnancy, hormonal birth control, family history, and sun exposure, affects onset of melasma.[6]

DIAGNOSIS

CLINICAL FEATURES

The diagnosis of melasma is based upon clinical appearance. Affected patients exhibit splotchy areas of hyperpigmented macules on the face (**Figures 197-1** to **197-4**). In natural light, epidermal melasma appears light to dark brown, and the dermal pattern is blue or gray.

Melasma is divided into four clinical types:

1. Epidermal type—The hyperpigmentation is usually light brown, and Wood's light enhances the color contrast between hyperpigmented areas and normal skin. It is the most common type, and it best responds to the use of depigmenting agents.
2. Dermal type—The hyperpigmentation is ashen or bluish-gray and exhibits no accentuation of color contrast under Wood's light. Depigmenting agents are generally not effective for this type.
3. Mixed type—The hyperpigmentation is usually dark brown, and Wood's light enhances the color contrast in some areas but not in others.
4. Indeterminate type—Presents in patients with darker complexions (skin types V to VI) and cannot be categorized under Wood's light.[1]

TYPICAL DISTRIBUTION

The lesion is found typically on sun-exposed areas. The three typical patterns of involvement are:

1. Centrofacial involving the cheeks, forehead, upper lip, nose, and chin.
2. Malar involving the cheeks and nose.
3. Mandibular involving the ramus of the mandible.

IMAGING

A Wood's light may be used to determine the type of melasma.[1] This does not change the choices of standard topical therapies.

FIGURE 197-2 Close-up of the melasma showing the hyperpigmented patches on cheeks and upper lip. (*Courtesy of Richard P. Usatine, MD.*)

FIGURE 197-3 A 39-year-old Hispanic woman with melasma seeking treatment. She is disturbed by this dark color on her face. Note the hyperpigmentation reaches the eyebrows but does not cover the upper lip. She has not been pregnant for years and is not taking hormonal contraceptives. (*Courtesy of Richard P. Usatine, MD.*)

BIOPSY

Histologically, there are an increased number of melanocytes, with the deposition of additional melanin and a background of solar elastosis. The two main histologic patterns are epidermal and dermal, depending on the skin layers involved.

DIFFERENTIAL DIAGNOSIS

- The facial rash of systemic lupus may be confused with melasma as they both can have a butterfly pattern. Melasma is hyperpigmented, whereas the lupus facial rash is usually inflammatory. An antinuclear antibody (ANA) test should be positive in systemic lupus erythematosus (SLE) and negative in melasma. False-positive antinuclear antibodies are usually low titer and the patient does not have other criteria for lupus (see Chapter 180, Lupus Erythematosus).
- Discoid lupus or cutaneous lupus can occur across the face but is usually seen with scarring. In this condition, the ANA is often negative (see Chapter 180, Lupus: Systemic and Cutaneous).
- Contact dermatitis will be inflamed in the acute stage but the postinflammatory hyperpigmentation could be confused with melasma (see Chapter 146, Contact Dermatitis).

FIGURE 197-4 Melasma in a man. (*Courtesy of Richard P. Usatine, MD.*)

MANAGEMENT

The treatment of melasma is challenging because treatment for melasma is generally unsatisfactory.[7] Numerous less-than-adequate treatment options exist, including topical agents and chemical peels. Melasma treatment is started only when the patient is disturbed by the hyperpigmentation. All patients can benefit from sun protection and this is always a good place to start.

It is important to give the patient realistic treatment goals. The treatments that follow may lighten the hyperpigmentation but do not generally remove all the hyperpigmentation.

Side effects of all topical treatments include contact dermatitis, depigmentation of surrounding normal skin, and postinflammatory hyperpigmentation. Tretinoin should not be used during pregnancy. Discontinue oral contraceptives or other estrogen/progesterone agents, if possible.

MEDICATIONS

- Hydroquinone is the main bleaching agent used to treat melasma.[7] SOR A It is available over the counter in 2% or 3% formulations (some including sunscreens). The prescription strength is 4% and is available with or without a sunscreen. Generic 4% hydroquinone comes in many sizes and formulations, so write the prescription to be flexible to avoid hassles for you and the patient. Although hydroquinone with sunscreen may be somewhat better than hydroquinone alone, a combination product has not been shown to be better than using these two topical agents together as two separate products. SOR C
- Hydroquinone is applied twice daily for up to 3 months with subsequent tapering to once daily. If the patient has not noticed a benefit by 3 months, the treatment should be stopped. SOR C

- Ochronosis—If the skin becomes darker with treatment, then the hydroquinone should be discontinued as there is a known side effect of hydroquinone, called ochronosis, that causes hyperpigmentation. Ochronosis only occurs in the treated area, but the hyperpigmentation can be permanent.[8]
- Hydroquinone can also cause a contact dermatitis, so it is a good idea for the patient to try it on a small area of skin before applying it to large areas of the face. Hydroquinone should be avoided on inflamed skin to avoid additional postinflammatory hyperpigmentation.
- Tretinoin 0.1% (Retin-A) cream is applied once daily at bedtime to lighten melasma. In two studies where tretinoin was compared to placebo, participants rated their melasma as significantly improved in one but not the other. In both studies, by other objective measures, tretinoin treatment significantly reduced the severity of melasma.[7] SOR A
- Combining tretinoin and hydroquinone is believed to potentiate their effects. SOR C
- There is a triple combination cream (Tri-Luma) containing 4% hydroquinone, retinoic acid, and fluocinolone (corticosteroid). It is used once daily before bed for a duration of 8 weeks. Studies show that it has a superior efficacy than hydroquinone monotherapy for melasma.[9,10] SOR A However, the side effect of skin irritation is very common and it is not recommended for long-term use.[9,10] Triple-combination cream was significantly more effective at lightening melasma than hydroquinone alone (relative risk [RR] 1.58) or when compared to the dual combinations of tretinoin and hydroquinone (RR 2.75).[7] SOR A
- Note that Tri-Luma is very expensive. Individual prescriptions for 4% hydroquinone, tretinoin cream, and a mild topical steroid cream can be given to keep the cost down. Desonide or 1% hydrocortisone are good options for the topical steroid. The steroid should not be used daily for longer than 8 weeks to avoid adverse effects.
- Azelaic acid (20%) was significantly more effective than 2% hydroquinone at lightening melasma but not better than 4% hydroquinone.[7] SOR A
- Kojic acid formulations, and α-hydroxy acids (such as glycolic acid) also have been used in the treatment of melasma. SOR C
- The adverse events most commonly reported with topical agents were mild and transient such as skin irritation, itching, burning, and stinging.[7] SOR A

SURGICAL PROCEDURES

- Chemical peels are one option for patients with moderate to severe melasma that has not responded to bleaching agents and are seeking further treatment. SOR C
- Dermabrasion treatment is one aggressive option.[11] SOR C
- Q-switched pigmentary lasers, intense pulsed light, and fractional laser treatments have some efficacy but can cause postinflammatory hyperpigmentation and relapses may occur so are usually not recommended.[12] SOR C

PREVENTION

Strict avoidance of sun exposure is important to prevent further hyperpigmentation. SOR C Broad-spectrum, high-protection-factor sunscreens (with UVB and UVA protection), such as titanium dioxide, micronized zinc oxide, Mexoryl, or avobenzone/Parsol, are essential.[13]

FOLLOW-UP

Follow-up is advisable when using bleaching agents. Long-term follow-up and reinforcement of limiting sun exposure can be accomplished during routine prevention visits.

PATIENT EDUCATION

- Provide the patient with realistic treatment goals.
- If the topical medications are irritating the skin, stop them and return for further evaluation.
- If after 3 months hydroquinone has not worked, stop it.
- If the skin is darkening rather than lightening, stop the medications and return for further evaluation.
- Bleaching agents are often not covered by insurance. The price of hydroquinone formulations can vary widely, so it helps to shop around when cost is a major concern.

PATIENT RESOURCES

- WebMD. *Skin Problems of Pregnancy*—**http://www.webmd.com/baby/skin-conditions-pregnancy.**
- American Pregnancy Association. *Skin Changes During Pregnancy*— **http://www.americanpregnancy.org/pregnancyhealth/skinchanges.html.**
- WebMD. *Cosmetic Procedures, Birthmarks, and Other Abnormal Skin Pigmentation*—**http://www.webmd.com/healthy-beauty/cosmetic-procedures-birthmarks.**
- WebMD. *Hyperpigmentation, Hypopigmentation, and Your Skin*—**http://www.webmd.com/skin-problems-and-treatments/guide/hyperpigmentation-hypopigmentation.**

PROVIDER RESOURCES

- American Academy of Family Physicians. *Common Hyperpigmentation Disorders in Adults: Part II*—**http://www.aafp.org/afp/20031115/1963.html.**
- Kang HY, Ortonne JP. What should be considered in treatment of melasma. *Ann Dermatol.* 2010;22(4):373-378—**http://pdf.medrang.co.kr/Aod/022/Aod022-04-01.pdf.**

REFERENCES

1. Rigopoulos D, Gregoriou S, Katsambas A. Hyperpigmentation and melasma. *J Cosmet Dermatol.* 2007;6:195-202.
2. Elling SV, Powell FC. Physiological changes in the skin during pregnancy. *Clin Dermatol.* 1997;15:35-43.
3. Grimes PE. Melasma. Etiologic and therapeutic considerations. *Arch Dermatol.* 1995;131:1453-1457.
4. Hassan I, Kaur I, Sialy R, Dash RJ. Hormonal milieu in the maintenance of melasma in fertile women. *J Dermatol.* 1998;25:510-512.
5. Vazquez M, Maldonado H, Benmaman C, Sanchez JL. Melasma in men. A clinical and histologic study. *Int J Dermatol.* 1988;27:25-27.
6. Ortonne JP, Arellano I, Berneburg M, et al. A global survey of the role of ultraviolet radiation and hormonal influences in the development of melasma. *J Eur Acad Dermatol Venereol.* 2009;23:1254-1262.
7. Rajaratnam R, Halpern J, Salim A, Emmett C. Interventions for melasma. *Cochrane Database Syst Rev.* 2010 Jul 7;(7):CD003583.
8. Ribas J, Schettini AP, Cavalcante Mde S. Exogenous ochronosis hydroquinone induced: a report of four cases. *An Bras Dermatol.* 2010;85(5):699-703.
9. Kang HY, Valerio L, Bahadoran P, Ortonne JP. The role of topical retinoids in the treatment of pigmentary disorders: an evidence-based review. *Am J Clin Dermatol.* 2009;10:251-260.
10. Taylor SC, Torok H, Jones T, et al. Efficacy and safety of a new triple-combination agent for the treatment of facial melasma. *Cutis.* 2003;72(1):67-72.
11. Kunachak S, Leelaudomlipi P, Wongwaisayawan S. Dermabrasion: a curative treatment for melasma. *Aesthetic Plast Surg.* 2001;25:114-117.
12. Kang HY, Ortonne J. What should be considered in treatment of melasma. *Ann Dermatol.* 2010;22:373-378.
13. Vazquez M, Sanchez JL. The efficacy of a broad-spectrum sunscreen in the treatment of chloasma. *Cutis.* 1983;32:92.

198 VITILIGO AND HYPOPIGMENTATION

Karen A. Hughes, MD, FAAFP
Richard P. Usatine, MD
Mindy A. Smith, MD, MS

PATIENT STORY

An 8-year-old Hispanic boy is brought in to the clinic by his mother, who is concerned about his pigment loss (**Figure 198-1**). He is starting to develop this vitiligo around the eyes, and his mother wants him to be treated. The child was started on a topical steroid, and the use of narrow band UVB was discussed if the steroid does not prove helpful. Realistic expectations of the treatments were provided to the mother and her son.

FIGURE 198-1 Vitiligo on the neck of an 8-year-old Hispanic boy. *(Courtesy of Richard P. Usatine, MD.)*

INTRODUCTION

Vitiligo is an acquired, progressive loss of pigmentation of the epidermis. The Vitiligo European Task Force defines nonsegmental vitiligo as "an acquired chronic pigmentation disorder characterized by white patches, often symmetrical, which usually increase in size with time, corresponding to a substantial loss of functioning epidermal and sometimes hair follicle melanocytes."[1] Segmental vitiligo is defined similarly except for a unilateral distribution that may totally or partially match a dermatome; occasionally more than one segment is involved.[1]

SYNONYMS

Vitiligo vulgaris.

EPIDEMIOLOGY

- Vitiligo occurs in approximately 0.5% to 2% of the worldwide population.[2,3]
- It can occur at any age but typically develops between the ages of 10 and 30 years.[2]
- Vitiligo has equal rates in men and women.[2]
- It occurs in all races but is more prominent in those with darker skin.

ETIOLOGY AND PATHOPHYSIOLOGY

- Autoimmune disease with destruction of melanocytes.
- Genetic component in approximately 30% of cases. Toll-like receptor genes were found to be associated with vitiligo in a population of Turkish patients.[4]
- Can trigger or worsen with illness, emotional stress, and/or skin trauma (Koebner phenomenon).

DIAGNOSIS

CLINICAL FEATURES

- Macular regions of depigmentation with scalloped, well-defined borders (**Figures 198-1 to 198-3**).
- Depigmented areas often coalesce over time to form larger areas (**Figures 198-4** and **198-5**).
- Depigmented areas are more susceptible to sunburn. Tanning of the normal surrounding skin makes the depigmented areas more obvious.
- There is no standardized method for assessing vitiligo; strategies include subjective clinical assessment, semiobjective assessment (e.g., Vitiligo Area Scoring Index [VASI] and point-counting methods), macroscopic morphologic assessment (e.g., visual, photographic in natural or UV light, computerized image analysis), micromorphologic assessment (e.g., confocal laser microscopy), and objective assessment (e.g., software-based image analysis, tristimulus colorimetry, spectrophotometry).[5] Authors of a literature review concluded that the VASI, the rule of 9, and Wood's lamp were the best techniques for assessing the degree of pigmentary lesions and measuring the extent and progression of vitiligo.[5]
- Conditions associated with vitiligo include thyroid disease and the presence of thyroid antibodies,[6,7] congenital nevi (in one study, 6.2% vs. 2.8% in those without vitiligo),[4] and halo nevi,[1] and possibly primary open-angle glaucoma (57% of patients in one case series).[8]

TYPICAL DISTRIBUTION

- Widespread, but generally seen first on the face, hands, arms, and genitalia (**Figure 198-6**).
- Depigmentation around body openings such as eyes, mouth, umbilicus, and anus is common (**Figure 198-7**). When the eyelashes are involved it is called *leukotrichia*.
- Vitiligo can be unilateral or bilateral; in one study, patients with unilateral vitiligo were younger and had an earlier age at onset while those with bilateral vitiligo were more likely to have light skin types and more commonly had associated autoimmune disease.[9]

LABORATORY AND IMAGING

- Evaluation for endocrine disorders such as hyper- or hypothyroidism (e.g., thyroid-stimulating hormone [TSH]) and diabetes mellitus (e.g., fasting blood sugar) is indicated, as vitiligo can be associated with these disorders.[10]
- Pernicious anemia and lupus erythematosus should be considered; obtain complete blood count (CBC) with indices and an antinuclear antibody (ANA).

BIOPSY

Not indicated unless the diagnosis is not clear and then a 4-mm punch biopsy will suffice.

DIFFERENTIAL DIAGNOSIS

- Pityriasis alba—Areas of decreased pigmentation with scaling and mild itching. Seen in young children and usually associated

FIGURE 198-2 Vitiligo on the hands of a Hispanic man. *(Courtesy of Richard P. Usatine, MD.)*

FIGURE 198-3 Vitiligo on the hands, knees, and feet of a black woman. *(Courtesy of Dan Stulberg, MD.)*

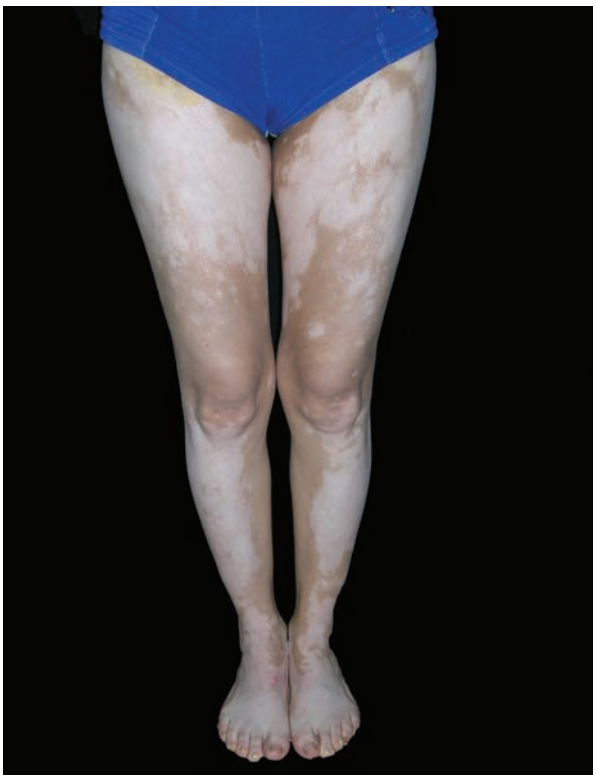

FIGURE 198-4 Vitiligo covering more than 50% of this young Hispanic woman's body. The patient is starting topical monobenzone to attempt to bleach the unaffected skin so that she has one matching skin color. *(Courtesy of Richard P. Usatine, MD.)*

FIGURE 198-6 Vitiligo on the penis of a 72-year-old man. *(Courtesy of Richard P. Usatine, MD.)*

FIGURE 198-5 This previously dark-skinned woman has only a few spots of pigment remaining on her arm because of the extensive vitiligo. Her father has the same condition. *(Courtesy of Richard P. Usatine, MD.)*

FIGURE 198-7 Vitiligo occurs commonly around the eye. **A.** Vitiligo with normal eyelashes. **B.** Vitiligo with leukotrichia. The loss of melanocytes has turned some of the eyelashes white. *(Courtesy of Richard P. Usatine, MD.)*

with eczema and improves with age (see Chapter 145, Atopic Dermatitis).

- Ash leaf spots—Lance-shaped macules of hypopigmentation, which remain stable in size and shape over time **(Figure 198-8)**. Often the earliest sign of tuberous sclerosis. More concerning if there are 3 or more present in one child.
- Halo nevus—Hypopigmentation confined to areas surrounding pigmented nevi that typically appear in adolescents and young adults (see Chapter 162, Nevus).
- Idiopathic guttate hypomelanosis—Confetti-like 2- to 5-mm areas of depigmentation predominantly on sun-exposed areas (**Figure 198-9**).
- Nevus depigmentosus is usually present at birth or starts in early childhood. There is a decreased number of melanosomes within a normal number of melanocytes. It typically has a serrated or jagged edge. Its presence at birth or early in childhood helps to differentiate it from vitiligo (**Figure 198-10**).
- Nevus anemicus—A congenital hypopigmented macule or patch that is stable in relative size and distribution. It occurs as a result of localized hypersensitivity to catecholamines and not a decrease in melanocytes. On diascopy (pressure with a glass slide) the skin is indistinguishable from the surrounding skin. Its presence from birth helps distinguish it from vitiligo (**Figure 198-11**).
- Hypomelanosis of Ito is a rare syndrome with hypopigmented whorls of skin present at birth along the Blaschko lines of development. This pattern may be accompanied by congenital abnormalities involving the eyes, or neurologic or renal systems. Its presence at birth helps distinguish it from vitiligo (**Figure 198-12**).

FIGURE 198-8 A hypopigmented patch on the abdomen of an infant in a shape that suggests an ash leaf. The child is otherwise healthy with no seizures or developmental delay but should be monitored for signs of tuberous sclerosis. This may be nothing more than a nevus depigmentosus *(Courtesy of Richard P. Usatine, MD.)*

MANAGEMENT

For assessing outcomes to treatment, the Vitiligo European Task Force suggests a system combining analysis of extent using percentage of body area involved (rule of 9), stage of disease based on cutaneous and hair pigmentation in **vitiligo** patches and staged 0 to 4 (with 0 representing normal pigment and 4 complete hair whitening) on the largest macule in each body region except hands and feet, and disease progression (spreading) assessed with Wood's lamp examination of the same largest macule in each body area.[1] An evaluation sheet can be found in the citation.[1]

NONPHARMACOLOGIC

- Addressing the psychological distress that this disfiguring skin disorder causes should be a primary focus as the clinical course is unpredictable and, in some cases, little can be done to modify the condition itself.
- Management of inciting factors such as illness, stress, and skin trauma may be useful. SOR C

MEDICATIONS

Topical treatments used for vitiligo include corticosteroids, immunomodulators, vitamin D analogs, and psoralens; these treatments had mixed outcomes based on a systematic review, with topical steroids having the highest rate of adverse events.[11] SOR B Ineffective topical agents include melagenina, topical phenylalanine, topical L-DOPA (levodopa), coal tar, anacarcin forte oil, and minoxidil.[12]

FIGURE 198-9 Idiopathic guttate hypomelanosis on the arm. This is usually seen in sun-exposed areas especially of the arms and legs. *(Courtesy of Richard P. Usatine, MD.)*

FIGURE 198-10 Nevus depigmentosus, present since birth, on the chest of this 4-month-old infant. Note the serrated or jagged edge. Vitiligo is not present at birth. *(Courtesy of Richard P. Usatine, MD.)*

FIGURE 198-12 Hypomelanosis of Ito is a rare syndrome with hypopigmented whorls of skin present at birth along the Blaschko lines of development. It is typically unilateral and extends down an extremity such as an arm. Note the whorls on the chest and upper arm. *(Courtesy of Richard P. Usatine, MD.)*

FIGURE 198-11 Nevus anemicus on the back of this woman, which has been there since birth. This is a congenital hypersensitivity to localized catecholamines. On diascopy the skin was indistinguishable from the surrounding skin. The irregular broken-up outline is seen in nevus anemicus and nevus depigmentosus. *(Courtesy of University of Texas Health Science Center Division of Dermatology.)*

FIGURE 198-13 Vitiligo, which spared the area under a ring; the patient has spotty return of pigment on hand with narrowband UVB treatment. *(Courtesy of Richard P. Usatine, MD.)*

- In a retrospective study of 101 children with vitiligo treated with moderate- to high-potency topical corticosteroids 64% (45/70) had repigmentation of the lesions, 24% (17/70) showed no change, and 11% (8/70) were worse than at the initial presentation.[13] SOR B Local steroid side effects were noted in 26% of patients at 81.7 ± 44 days of follow-up. Two children were given the diagnosis of steroid-induced adrenal suppression. Children with head and/or neck affected areas were eight times more likely to have an abnormal cortisol level compared with children who were affected in other body areas.[13] Therefore, a trial of topical steroids may be useful for patients with localized vitiligo that does not predominantly involve the head and neck. SOR C
- Based on several reviews, topical corticosteroids (potent or very potent) are the preferred drugs for localized vitiligo (<20% of skin area)[11,12]; a less-than-2-month trial is recommended.[12] SOR B
- Topical immunomodulators (tacrolimus, pimecrolimus) are an alternative for localized vitiligo and display comparable effectiveness with fewer side effects.[14] SOR B
- In a small case series (N = 6), various antitumor necrosis factor α agents (infliximab, etanercept, and adalimumab given according to treatment regimens used for psoriasis) were not effective for widespread nonsegmental vitiligo.[15]

COMPLEMENTARY AND ALTERNATIVE THERAPY

- Antioxidants may be useful adjunctive therapy.[11]

OTHER TREATMENT

- Use sunscreen to prevent burns to the depigmented areas and further trauma to unaffected skin, and to minimize contrast between these areas.[14] SOR A
- Bleaching the unaffected skin in patients with widespread depigmentation to reduce contrast with depigmented areas can improve cosmetic appearance.[14] SOR B A monobenzylether of hydroquinone 20% cream (Benoquin) is available by prescription to produce a permanent bleaching of the skin around the vitiligo. It is irreversible and makes the skin at higher risk for sunburn.

PROCEDURES

- Combination therapies are likely to be more effective than monotherapy, and most combinations include a form of phototherapy; narrow-band UVB appears to be the most effective with the fewest adverse effects **(Figure 198-13)**.[11,14] SOR B Psoralen UVA (PUVA) is the second-best choice. Authors of a Cochrane review concurred that majority of analyses showing statistically significant differences in treatment outcomes were from studies that assessed combination interventions including some form of light treatment.[16]
- Excimer laser is an alternative to UVB therapy, achieving good responses especially in localized vitiligo of the face, where the excimer laser may be superior to UVB therapy. By combining with topical immunomodulators, treatment response can be accelerated.[14] SOR B In one prospective study of 14 patients, repigmentation rates for once, twice, and thrice weekly treatment approached each other (60%, 79%, and 82%, respectively) at 12 weeks.[17] Although repigmentation occurred fastest with thrice weekly

treatment, the final repigmentation depends on the total number of treatments, not their frequency. SOR B

- No single therapy for vitiligo can be regarded as the most effective as the success of each treatment modality depends on the type and location of vitiligo. SOR B

PROGNOSIS

The course of vitiligo varies, but is usually progressive with periods of activity interspersed with times of inactivity.[18] Spontaneous repigmentation can occur but is rare.

- The face and neck respond best to all therapeutic approaches, while the acral areas are least responsive.[14] SOR B
- Vitiligo does not appear to be associated with adverse outcomes in pregnancy.[19]

FOLLOW-UP

- Counseling and emotional support are a mainstay of follow-up treatment.
- Trials of various combination therapies may be needed.

PATIENT EDUCATION

- Reassurance that this is a benign condition while acknowledging any psychological distress.
- Advise patients about the highly variable course of vitiligo with usually progressive periods of activity interspersed with times of inactivity.
- Inform patients about the multiple treatment options and possible need for prolonged or repeat treatment.

PATIENT RESOURCES

- National Institutes of Health. *Vitiligo*—**http://health.nih.gov/topic/Vitiligo.**
- National Organization for Albinism and Hypopigmentation—**http://www.healthfinder.gov/orgs/HR2242.htm.**
- National Vitiligo Foundation—**http://nvfi.org/index.php.**
- MedLine Plus. *Vitiligo*—**http://www.nlm.nih.gov/medlineplus/ency/article/003224.htm.**

PROVIDER RESOURCES

- Medscape. *Vitiligo*—**http://emedicine.medscape.com/article/1068962.**
- National Vitiligo Foundation. *A Handbook for Physicians*—**http://nvfi.org/pages/info_physician_handbook.php.**

REFERENCES

1. Taïeb A, Picardo M; VETF Members. The definition and assessment of vitiligo: a consensus report of the Vitiligo European Task Force. *Pigment Cell Res.* 2007;20(1):27-35.
2. Njoo MD, Westerhof W. Vitiligo: pathogenesis and treatment. *Am J Clin Dermatol.* 2001;2(3):167-181.
3. Krüger C, Schallreuter KU. A review of the worldwide prevalence of vitiligo in children/adolescents and adults. *Int J Dermatol.* 2012 Mar 27. doi: 10.1111/j.1365-4632.2011.05377.x. [Epub ahead of print].
4. Karaca N, Ozturk G, Gerceker BT, et al. TLR2 and TLR4 gene polymorphisms in Turkish vitiligo patients. *J Eur Acad Dermatol Venereol.* 2012 Mar 16. doi: 10.1111/j.1468-3083.2012.04514.x. [Epub ahead of print].
5. Alghamdi KM, Kumar A, Taïeb A, Ezzedine K. Assessment methods for the evaluation of vitiligo. *J Eur Acad Dermatol Venereol.* 2012 Mar 15. doi: 10.1111/j.1468-3083.2012.04505.x. [Epub ahead of print].
6. Schallreuter KU, Lemke R, Brandt O, et al. Vitiligo and other diseases: coexistence or true association? Hamburg study on 321 patients. *Dermatology.* 1994;188(4):269-275.
7. Hegedüs L, Heidenheim M, Gervil M, et al. High frequency of thyroid dysfunction in patients with vitiligo. *Acta Derm Venereol.* 1994;74(2):120-123.
8. Rogosić V, Bojić L, Puizina-Ivić N, et al. Vitiligo and glaucoma – an association or a coincidence? A pilot study. *Acta Dermatovenerol Croat.* 2010;18(1):21-26.
9. Barona MI, Arrunátegui A, Falabella R, Alzate A. An epidemiologic case-control study in a population with vitiligo. *J Am Acad Dermatol.* 1995;33(4):621-625.
10. Hacker SM. Common disorders of pigmentation: When are more than cosmetic cover-ups required? *Postgrad Med.* 1996;99(6):177-186.
11. Bacigalupi RM, Postolova A, Davis RS. Evidence-based, non-surgical treatments for vitiligo: a review. *Am J Clin Dermatol.* 2012 Mar 16. doi: 10.2165/11630540–000000000-00000. [Epub ahead of print].
12. Hossani-Madani AR, Halder RM. Topical treatment and combination approaches for vitiligo: new insights, new developments. *G Ital Dermatol Venereol.* 2010;145(1):57-78.
13. Kwinter J, Pelletier J, Khambalia A, Pope E. High-potency steroid use in children with vitiligo: a retrospective study. *J Am Acad Dermatol.* 2007;56(2):236-241.
14. Forschner T, Buchholtz S, Stockfleth E. Current state of vitiligo therapy—evidence-based analysis of the literature. *J Dtsch Dermatol Ges.* 2007;5(6):467-475.
15. Alghamdi KM, Khurrum H, Taieb A, Ezzedine K. Treatment of generalized vitiligo with anti-TNF-α agents. *J Drugs Dermatol.* 2012;11(4):534-539.
16. Whitton ME, Pinart M, Batchelor J, et al. Interventions for vitiligo. *Cochrane Database Syst Rev.* 2010;(1):CD003263.
17. Hofer A, Hassan AS, Legat FJ, et al. Optimal weekly frequency of 308-nm excimer laser treatment in vitiligo patients. *Br J Dermatol.* 2005;152(5):981-985.
18. Viles J, Monte D, Gawkrodger DJ. Vitiligo. *BMJ.* 2010;341:c3780.
19. Horev A, Weintraub AY, Sergienko R, et al. Pregnancy outcome in women with vitiligo. *Int J Dermatol.* 2011;50(9):1083-1085.

199 PHOTOSENSITIVITY

E.J. Mayeaux, Jr., MD

PATIENT STORY

A 50-year-old woman presented to the clinic with an abrupt onset of an intensely pruritic rash that extended over the dorsal aspect of both arms (**Figure 199-1**). The patient notes no new medicines and no recent exposures to any new chemicals. She acknowledged recent time spent outside in the sun. The plaques were photodistributed, with sparing of her watch area. A clinical diagnosis of polymorphous light eruption (PMLE) was made, and the patient was started on oral antihistamines and topical steroids. It was recommended that she minimize her sun exposure.

FIGURE 199-1 Polymorphous light eruption noted over dorsum of left forearm. Note absence of the lesion where the patient had been wearing her watch. (*From Wenner C, Lee A. A bright red pruritic rash on the forearms. J Fam Pract. 2007;56(8):627-629. Reproduced with permission from Frontline Medical Communications.*)

INTRODUCTION

Photosensitivity is an abnormal skin response to ultraviolet light that occurs on sun-exposed areas of the skin. There are three common types of photodermatitis:

- PMLE (**Figures 199-1** and **199-2**).
- Phototoxic eruptions (**Figures 199-3** to **199-7**).
- Photoallergic eruptions (**Figure 199-8**). **Table 199-1** compares key characteristics of phototoxic and photoallergic reactions.

UV light radiating from the sun may be categorized into UVA (wavelength 320 to 400 nm), UVB (290 to 320 nm), and UVC (200 to 290 nm). UVC is completely absorbed by the earth's ozone layer and thus does not play a role in photosensitivity. Photosensitivity may be induced by UVA, UVB, or visible light (400 to 760 nm). Longer wavelength light penetrates deeper into the skin. UVA penetrates through to the dermis, but UVB mainly penetrates and affects the epidermis.

Ultraviolet light has multiple effects on the skin. Notably, it causes DNA damage and has immunosuppressive effects on skin inflammatory cells increasing the risk of carcinogenesis. In patients with photosensitivity, it elicits an inflammatory response in the skin, leading to the development of a photodermatosis.

EPIDEMIOLOGY

- PMLE (**Figures 199-1** and **199-2**) may affect up to 10% of the population, with a predilection for females.[1] The prevalence increases in northern latitudes. Onset typically occurs within the first three decades of life, but may appear spontaneously at any age.
- The incidence of drug- and plant-induced phototoxic reactions in the United States is unknown. Phototoxic reactions are much more common than photoallergic reactions.

ETIOLOGY AND PATHOPHYSIOLOGY

PMLE is an idiopathic, delayed-type hypersensitivity reaction to UVA light and, to a lesser extent, UVB light (**Figures 199-1** and **199-2**). PMLE

FIGURE 199-2 Polymorphous light eruption on the arm of a young man. Note the sparing of the skin under his watchband. (*Courtesy of Richard P. Usatine, MD.*)

FIGURE 199-3 Severe phototoxic drug reaction secondary to hydrochlorothiazide use. (*Courtesy of Richard P. Usatine, MD.*)

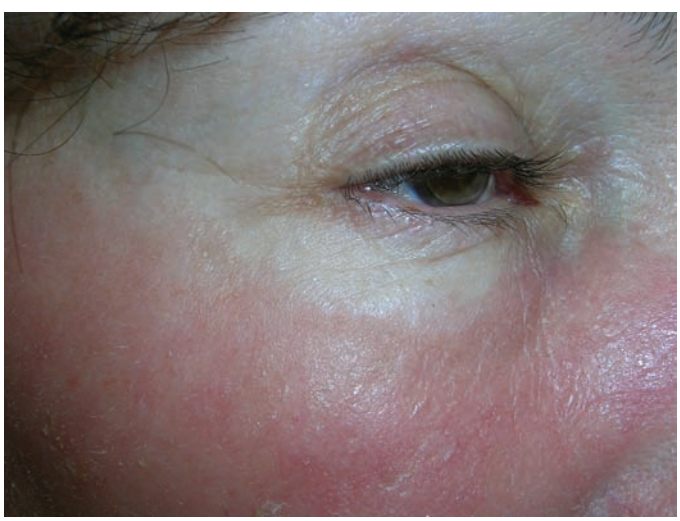

FIGURE 199-4 Phototoxic drug reaction secondary to ibuprofen. (*Courtesy of Richard P. Usatine, MD.*)

FIGURE 199-5 Phototoxic drug reaction secondary to treatment of vitiligo with oral psoralen and ultraviolet light (phytophotodermatitis). Note the bullae. (*Courtesy of Richard P. Usatine, MD.*)

FIGURE 199-6 Phytophotodermatitis in a woman, caused by lime juice and sun exposure on the beach. Note the hand print of her fiancé who had been squeezing limes into their tropical drinks. This contact occurred when they posed for a photograph. (*From Darby-Stewart AL, Edwards FD, Perry KJ. Hyperpigmentation and vesicles after beach vacation. Phytophotodermatitis. J Fam Pract. 2006;55(12):1050-1053. Reproduced with permission from Frontline Medical Communications.*)

FIGURE 199-7 Phytophotodermatitis visible on the arm, trunk, and leg caused by lime juice and sun exposure on the beach. Note the hyperpigmentation that occurs in conjunction with the erythema. (*From Darby-Stewart AL, Edwards FD, Perry KJ. Hyperpigmentation and vesicles after beach vacation. Phytophotodermatitis. J Fam Pract. 2006;55(12): 1050-1053. Reproduced with permission from Frontline Medical Communications.*)

is the most common photoeruption encountered in clinical practice. The reaction will remit spontaneously with time and absence of sun exposure, but occasionally it will last as long as sun exposure occurs. PMLE usually begins in the first three decades of life and occurs more commonly in women. The rash develops within hours to days after exposure to sunlight and lasts for several days to a week.

There is a broad range of degrees of photosensitivity with PMLE. Extremely sensitive individuals can tolerate only minutes of exposure, whereas many people have a low sensitivity and require prolonged exposure to sunlight before developing a reaction. It is a recurrent condition that persists for many years in most patients.[2]

Phototoxic reactions are the most common drug-induced photoeruptions (**Figures 199-3** to **199-7**). They are caused by absorption of ultraviolet rays by the causative drug, which releases energy and damages cell membranes, or, in the case of psoralens, DNA. The drugs that most frequently cause phototoxic reactions are NSAIDs, quinolones, tetracyclines, amiodarone, and the phenothiazines[3] (**Table 199-2**). Most of these drugs have at least one resonating double bond or an aromatic ring that can absorb radiant energy. Most compounds are activated by wavelengths within the UVA (320 to 400 nm) range, although some compounds have a peak absorption within the UVB or visible range.

Phytophotodermatitis are phototoxic reactions to psoralens, which are plant compounds found in limes, celery, figs, and certain drugs. They can cause dramatic inflammation and bullae where the psoralen comes into contact with the skin (**Figures 199-5** to **199-7**). The inflammation is frequently followed by hyperpigmentation.

Photoallergic eruptions are a lymphocyte-mediated reaction. Photoactivation of a drug or agent results in the development of a metabolite that can bind to proteins in the skin to form a complete antigen. The antigen is presented to lymphocytes by Langerhans cells, causing an inflammatory response and spongiotic dermatitis (eczema). The eruption is characterized by widespread eczema in the photodistribution areas such as the face, upper chest, arms, and back of hands (**Figure 199-8**). Most photoallergic reactions are caused by topical agents such as antibiotics and halogenated phenolic compounds added to soaps and fragrances.[4] Systemic photoallergens such as the phenothiazines, chlorpromazine, sulfa products, and NSAIDs can produce photoallergic reactions, although most of their photosensitive reactions are phototoxic (**Table 199-3**).

FIGURE 199-8 A photoallergic drug reaction characterized by widespread eczema in the photodistribution areas such as the face, upper chest, arms, and back of hands. A punch biopsy showed a spongiotic dermatitis (eczema). The exact photoallergen was not found. (*Courtesy of Richard P. Usatine, MD.*)

RISK FACTORS

Unprotected exposure to sunlight and the use of drugs associated with phototoxic and photoallergic eruptions are the main risk factors.

DIAGNOSIS

CLINICAL FEATURES

Most cases of photodermatitis can be diagnosed on the basis of the patient's history. Be sure to review the patient's medications for possible sources.

- The appearance of the PMLE varies from person to person but is consistent in a given patient. Erythematous pruritic papules, sometimes with vesicles, are most common (**Figures 199-1** and **199-2**).

TABLE 199-1 Characteristics of Phototoxic and Photoallergic Reactions

Feature	Phototoxic Reaction	Photoallergic Reaction
Incidence	High	Low
Amount of agent required for photosensitivity	Large	Small
Onset of reaction after exposure	Minutes to hours	24 to 72 hours
More than 1 exposure to agent required	No	Yes
Examination findings	Exaggerated sunburn	Dermatitis
Immunologically mediated	No	Yes

TABLE 199-2 Common Medications That Cause Phototoxic Reactions

Class	Medication
Antibiotics	Tetracyclines Fluoroquinolones Sulfonamides Griseofulvin
NSAIDs	Ketoprofen Ibuprofen Naproxen
Diuretics	Furosemide Hydrochlorothiazide
Retinoids	Isotretinoin Acitretin
Photodynamic therapy prophotosensitizers	5-Aminolevulinic acid Methyl-5-aminolevulinic acid Verteporfin Photofrin
Neuroleptic drugs	Phenothiazines Thioxanthenes (chlorprothixene and thiothixene) Other drugs Itraconazole 5-Fluorouracil (5-FU) Amiodarone Diltiazem Quinidine Coal tar
Sunscreens	Paraaminobenzoic acid (PABA)

Lesions may coalesce to form plaques. The rash typically involves the V of the neck and the arms, legs, or both. The face, which is exposed to sunlight in both summer and winter, tends to be spared. It tends to present in spring/summer, with the first significant UV exposure of the year. The rash typically develops 1 to 4 days after sun exposure.

- Phototoxic reaction occurs 2 to 6 hours after exposure to sunlight. The eruption typically appears as an exaggerated sunburn, with mild cases causing slight erythema and severe cases causing vesicles or bullae (**Figures 199-3** to **199-7**).
- Phytophotodermatitis reactions are asymmetric and localized to the area in which the plant psoralen was in contact with the skin. Accompanying hyperpigmentation is a good clue to a phytophotodermatitis reaction (**Figures 199-5** to **199-7**). Ask the patient if he or she had any contact with limes, celery, or figs. Squeezing lime juice into drinks is a particularly common cause of this reaction.
- Photoonycholysis phototoxicity reactions (sun-induced separation of the nail plate from the nail bed) have been reported with the use of tetracycline, psoralen, chloramphenicol, fluoroquinolones, oral contraceptives, quinine, and mercaptopurine. Photoonycholysis may be the only manifestation of phototoxicity in individuals with heavily pigmented skin.

TABLE 199-3 Common Substances That Cause Photoallergic Reactions

5-Fluorouracil (5-FU)
6-Methylcoumarin
Fragrances (6-methylcoumarin, musk, sandalwood oil)
NSAIDs (e.g., ketoprofen, diclofenac, piroxicam, celecoxib)
Sunscreens (benzophenones, cinnamates, dibenzoylmethanes)
Dapsone
Hormonal contraceptives
Hydrochlorothiazide
Antimicrobial agents (bithionol, chlorhexidine, hexachlorophene, fenticlor, Itraconazole)
Phenothiazines
Salicylates
Sulfonylureas (glipizide and glyburide)
Quinidine

- Photoallergic eruptions are characterized by widespread eczema in the photodistribution areas such as the face, upper chest, arms, and back of hands. They resemble allergic contact dermatitis, but the distribution is mostly limited to sun-exposed areas of the body (**Figure 199-8**).

TYPICAL DISTRIBUTION

- All photodermatitis reactions occur in sun-exposed areas, such as the face, ears, dorsal forearms, and V-area of the neck and upper chest.

LABORATORY TESTING

- Laboratory studies that may be helpful include antinuclear antibody (ANA), anti-Ro (SSA), and anti-La (SSB) titers to rule out lupus and porphyrin studies to exclude porphyria.
- Phototesting can be used to determine a patient's minimal erythema dose to light exposure and help to define the inciting spectrum of a photodermatosis (UVA versus UVB versus visible light). Phototesting involves irradiating the skin with varying doses of UVA, UVB, and visible light through an opaque screen with multiple openings.[5] Usually the test is performed on the back. The presence or absence of solar urticaria is recorded within the first hour and the minimal erythema dose is determined after 24 hours.
- Provocative phototesting involves irradiating normal-appearing previously affected skin with the suspected causative light, either by higher doses of UV light or by natural sunlight exposure.[5] Provocative phototesting is primarily used for suspected PMLE.

- Photopatch testing is useful when a topical photoallergen is suspected. It is performed by placing two identical sets of potential photoallergens on the patient's back and covering them. After 24 hours, one set is removed and that site is irradiated with UVA. The site is covered again. Twenty-four hours later, both the irradiated and control test sites are assessed for reactions. A reaction to a specific photoallergen in the irradiated site, but not the control site, indicates a photoallergy. A similar reaction in both sites suggests a contact dermatitis.[5]

BIOPSY

- Punch biopsy of PMLE demonstrates extensive spongiosis and edema of the dermis with a deep lymphohistiocytic infiltrate. In acute phototoxic reactions, necrotic keratinocytes are observed.

DIFFERENTIAL DIAGNOSIS

- Systemic lupus erythematosus (SLE)—Sunlight can precipitate a lupus rash. Serum ANA is usually positive (see Chapter 180, Lupus: Systemic and Cutaneous).
- Porphyria cutanea tarda reactions can also be precipitated by sunlight. It tends to present with vesicles or bullae in sun-exposed areas such as the back of the hands. The bullae generally do not have any surrounding erythema, and urine for porphyrins should be positive (see Chapter 186, Other Bullous Disease).
- Dermatomyositis may cause an erythematous or violaceous eruption in sun-exposed areas. If these cutaneous findings precede the muscle weakness it can appear to be a photosensitivity reaction such as PMLE or a phototoxic drug reaction. Therefore, it is essential in the management and follow-up of patients with suspected PMLE or other photosensitivity to inquire about muscle weakness and to look for other signs of dermatomyositis on the hands and/or through laboratory tests for muscle enzyme elevations (see Chapter 181, Dermatomyositis). The dermatomyositis patient story in Chapter 181 is one in which the initial rash was thought to be a photosensitivity reaction to a new hydrochlorothiazide (HCTZ) prescription.
- Contact dermatitis appears the same as photoallergic dermatitis but is usually not limited to sun-exposed areas (see Chapter 146, Contact Dermatitis).

MANAGEMENT

NONPHARMACOLOGIC

- The management of PMLE is aimed mainly at prevention. Patients who have mild disease should adopt a program of sun avoidance (see "Prevention" below). Broad spectrum (UVA and UVB blocking) sunscreen with a minimum sun protection factor (SPF) of 30 should be used whenever out of doors (**Table 199-4**).[6] However, the SPF value of a sunscreen describes its protection factor against sunburn, which is primarily caused by UVB. The SPF does not provide sufficient information on UVA protection.[7] SOR C Patients must use sunscreen liberally and frequently (reapply every 2 hours and after swimming) as an insufficiently thick application may reduce its effectiveness.[8] SOR B

TABLE 199-4 UV Blocking Characteristics or Sunscreens

Sunscreen	Blocks UVB	Blocks UVA
Aminobenzoic acid	X	
Avobenzone		X
Cinoxate	X	
Dioxybenzone	X	X
Ecamsule*		X
Ensulizole	X	
Homosalate	X	
Meradimate		X
Octocrylene	X	
Octinoxate	X	
Octisalate	X	
Oxybenzone	X	X
Padimate O	X	
Sulisobenzone	X	X
Titanium dioxide	X	X
Trolamine salicylate	X	
Zinc oxide	X	X
Drometrizole trisiloxane (Mexoryl XL)*	X	X
Methylene-bis-benzotriazolyl tetramethylbutylphenol (Tinosorb M)*	X	X
Bis-ethylhexyloxyphenol methoxyphenyl triazine (Tinosorb S)*		X

*Not available in the United States in 2012.

- Patients with severe PMLE can be desensitized in the spring with the use of phototherapy and maintained in the nonreactive state with weekly 1 hour unprotected exposure to sunlight. SOR C A course of psoralen and UVA radiation, or a course of narrow-band UVB, 3 times a week for 4 weeks provides protection.[9] SOR B These treatments may induce a typical rash or erythema but otherwise have no major adverse effects.
- Avoid tobacco products since they may make PMLE worse.[10] SOR B

MEDICATIONS

- Acute episodes of photodermatitis respond rapidly to topical and/or oral corticosteroids. Topical steroids should provide symptomatic relief and decrease the inflammation. For more severe reactions, a course of prednisone 30 mg daily for 5 to 7 days may be used.[11] SOR B

- Patients with acute drug-induced photodermatitis need to practice sun avoidance until well after the drug is discontinued. Topical and systemic corticosteroids may be used, especially with photoallergic reactions, but their efficacy is unproven. SOR C
- Nicotinamide was successful in 60% of 42 patients treated with 3 g/day orally for 2 weeks.[12] SOR B

PREVENTION

Sun protection is the primary preventative measure for patients with photosensitivity. Patients should avoid exposure to midday sun (between 10:00 AM and 3:00 PM). Protective clothing such as long sleeve shirts and broad rim hats should be worn while outdoors. Fabrics that are tightly woven, thick, and/or dark-colored are useful for protection.[14] Clothing treated with broad-spectrum UV absorbers is also helpful. Window film that blocks UV and some visible light can be applied to cars or homes.[15]

Sunscreen is important for daily use for patients with photosensitivity. Sunscreens are divided into chemical (organic) and physical (inorganic) products. Physical sunscreens block both UV and some visible light (see **Table 199-4**). Products containing avobenzone or ecamsule offer improved protection against UVA.

Physical blocker (inorganic) sunscreens, such as titanium dioxide and zinc oxide, work by reflecting and scattering UV and visible light. Older formulations were opaque making them cosmetically less acceptable to patients. Newer nonopaque, micronized formulations of titanium and zinc oxide have been developed but are less capable of scattering visible light and the longer wavelengths of UVA.

Chemical sunscreens may cause allergic contact dermatitis or photoallergic reactions in some patients. These patients should use titanium dioxide or zinc oxide sunscreens for protection.

PROGNOSIS

- Some patients with PMLE experience less-severe reactions with successive years, but they may also worsen over time without appropriate treatment.
- The prognosis is excellent with patients when the offending agent is removed. Complete resolution of the photosensitivity may take weeks to months. Patients with persistent light reactivity beyond this have a poorer prognosis.

FOLLOW-UP

- Follow-up is needed if the photosensitivity persists.

PATIENT EDUCATION

- Patients with any type of photodermatitis should apply strong broad-spectrum sunscreens daily and use protective clothing (hats and shirts that cover the arms and V-neck). The sunscreen should be water resistant and applied to exposed areas before sun exposure.[16] Sunscreens should be reapplied every 2 hours if there is continued sun exposure. Some of the most effective sunscreens contain stabilized avobenzone, Mexoryl, and/or titanium dioxide or zinc oxide to block UVA and UVB.
- Tell your patients that if they develop an allergy to one sunscreen, they should find another with different ingredients.
- It is important to avoid sunlight during the midday whenever possible.
- Explain to patients that phototoxic reactions may cause hyperpigmentation, which can take weeks to months to resolve. There is no guarantee that all the hyperpigmentation will go away.
- Avoid repeated rubbing and scratching, which can lead to skin thickening and chronic lichenification. Use the topical medications prescribed to treat the itching and to avoid lichenification.

PATIENT RESOURCES

- DermNet NZ. *Photosensitivity (Sun Allergy)*—**http://dermnetnz.org/reactions/photosensitivity.html.**
- The Skin Cancer Foundation. *Photosensitivity—A Reason To Be Even Safer in the Sun*—**http://www.skincancer.org/photosensitivity-a-reason-to-be-even-safer-in-the-sun.html.**

PROVIDER RESOURCES

- American Academy of Family Physicians. *Common Hyperpigmentation Disorders in Adults: Part I*—**http://www.aafp.org/afp/20031115/1955.html.**
- eMedicine. *Drug-Induced Photosensitivity*—**http://emedicine.medscape.com/article/1049648.**
- DermNet NZ. *Polymorphic Light Eruption*—**http://www.dermnetnz.org/reactions/pmle.html.**
- Darby-Stewart AL, Edwards FD, Perry KJ. Hyperpigmentation and vesicles after beach vacation. Phytophotodermatitis. *J Fam Pract.* 2006;55[12]:1050-1053.
- Phytophotodermatitis case report and review—**http://www.skinandaging.com/content/what-caused-this-rash-on-this-man%E2%80%99s-wrist-and-hand.**
- eMedicine. *Sunscreens and Photoprotection*—**http://emedicine.medscape.com/article/1119992.**

REFERENCES

1. Morison WL, Stern RS. Polymorphous light eruption: a common reaction uncommonly recognized. *Acta Derm Venereol.* 1982;62:237-240.
2. Hasan T, Ranki A, Jansen CT, Karvonen J. Disease associations in polymorphous light eruption: a long-term follow-up study of 94 patients. *Arch Dermatol.* 1998;134:1081-1085.
3. Stern RS, Shear NH. Cutaneous reactions to drugs and biological modifiers. In: Arndt KA, LeBoit PE, Robinson JK, Wintroub BU, eds. *Cutaneous Medicine and Surgery*. Vol. 1. Philadelphia, PA: Saunders; 1996:412.

4. Gonzalez E, Gonzalez S. Drug photosensitivity, idiopathic photodermatoses, and sunscreens. *J Am Acad Dermatol*. 1996;35:871-875.
5. Yashar SS, Lim HW. Classification and evaluation of photodermatoses. *Dermatol Ther.* 2003;16(1):1-7.
6. Dawe RS, Ferguson J. Diagnosis and treatment of chronic actinic dermatitis. *Dermatol Ther.* 2003;16:45-51.
7. Fourtanier A, Moyal D, Seité S. Sunscreens containing the broad-spectrum UVA absorber, Mexoryl SX, prevent the cutaneous detrimental effects of UV exposure: a review of clinical study results. *Photodermatol Photoimmunol Photomed.* 2008;24:164-174.
8. Faurschou A, Wulf HC. The relation between sun protection factor and amount of suncreen applied in vivo. *Br J Dermatol.* 2007;156:716-719.
9. Bilsland D, George SA, Gibbs NK, et al. A comparison of narrow band phototherapy (TL-01) and photochemotherapy (PUVA) in the management of polymorphic light eruption. *Br J Dermatol*. 1993;129:708-712.
10. Metelitsa AI, Lauzon GJ. Tobacco and the skin. *Clin Dermatol.* 2010;4:384-390.
11. Patel DC, Bellaney GJ, Seed PT, et al. Efficacy of short-course oral prednisolone in polymorphic light eruption: A randomized controlled trial. *Br J Dermatol*. 2000;143:828-831.
12. Neumann R, Rappold E, Pohl-Markl H. Treatment of polymorphous light eruption with nicotinamide: a pilot study. *Br J Dermatol.* 1986;115(1):77-80.
13. Ahmed RS, Suke SG, Seth V, et al. Impact of oral vitamin E supplementation on oxidative stress & lipid peroxidation in patients with polymorphous light eruption. *Indian J Med Res.* 2006;123(6):781-787.
14. Lautenschlager S, Wulf HC, Pittelkow MR. Photoprotection. *Lancet.* 2007; 370:528-537.
15. Dawe R, Russell S, Ferguson J. Borrowing from museums and industry: two photoprotective devices. *Br J Dermatol.* 1996;135:1016-1017.
16. Morison WL. Photosensitivity. *N Engl J Med*. 2004;350:1111-1117.

200 ERYTHEMA Ab IGNE

Amor Khachemoune, MD
Yoon-Soo Cindy Bae-Harboe, MD
Khashayar Sarabi, MD

PATIENT STORY

A 50-year-old woman presented to the office with bilateral erythematous lesions on the inner aspects of both of her lower extremities (**Figures 200-1** and **200-2**). The lesions started developing for the past 6 months. They became progressively more noticeable but stayed localized in the inner aspects of the lower extremities. She mentioned that she was using a hot-water bottle in the area involved to keep her warm at night when she was sleeping in bed. Although our working clinical diagnosis was erythema ab igne, clinical entities such as livedo reticularis, poikiloderma atrophicans vasculare, and acanthosis nigricans were also considered in the differential diagnosis. A skin biopsy was performed and confirmed the diagnosis of erythema ab igne. The patient was advised to abandon the hot-water bottle application to the skin. Over the course of 4 months her skin lesions started to clear with no further intervention.

FIGURE 200-1 Mottled or mesh-like pigmentary changes on the legs of a 50-year-old woman who slept with a hot-water bottle between her legs. (*From El-Ghandour A, Selim A, Khachemoune A. Bilateral lesions on the legs. J Fam Pract. 2007;56(1):37-39. Reproduced with permission from Frontline Medical Communications.*)

FIGURE 200-2 Close-up of legs in **Figure 200-1**. (*From El-Ghandour A, Selim A, Khachemoune A. Bilateral lesions on the legs. J Fam Pract. 2007; 56(1):37-39. Reproduced with permission from Frontline Medical Communications.*)

INTRODUCTION

Erythema ab igne is a rare condition caused by chronic exposure to heat (below the threshold for a thermal burn) from external heat sources. More specifically, prolonged use of hot-water bottles, heating pads, electric blankets, car seat warmers as well as exposure to open fires and laptops placed on the users' thighs or propped legs have all been reported to cause erythema ab igne. Affected skin is characterized by reticular pink colored and hyperpigmented mottled patches. Patients may complain of associated pruritus, paresthesias, or may be asymptomatic. Treatment is limited and patients are instructed to avoid triggers.

SYNONYMS

Chronic moderate heat dermatitis, chronic radiant heat dermatitis, toasted skin syndrome, fire stains, hot-water bottle rash, laptop thigh.

EPIDEMIOLOGY

- Rare disease.
- Women, in particular those who are overweight, are affected more often than men.

ETIOLOGY AND PATHOPHYSIOLOGY

- The skin findings form as a result of multiple exposures to an intense source of heat.

- Erythema ab igne has been noted for many years, and the sources of heat have changed over time. It used to be reported in women who stay for long periods of time in front of open fires, fireplaces, or furnaces to cook.[1–4] Most of the lesions were appearing on the medial side of the thigh and the lower leg in general.
- Currently, erythema ab igne is seen on different parts of the body, depending on what source of heat initiated the pathology, the angle of the heat radiation, the morphology of the skin, and the layers of clothing. Some of the modern-day examples are repeated application of hot-water bottles or heating pads to treat chronic pain, exposure to car heaters and furniture with internal heaters, the use of a laptop computer for long periods, and cooks and chefs who stand for long periods in the range of heat. Other causes include hot bricks, infrared lamps, and even microwave popcorn. Ultrasound physiotherapy was also reported as a cause of erythema ab igne. Recently, there was a reported case of frequent prolonged hot baths that caused the disease.[5]

RISK FACTORS

- Persistent exposure to heat.
- Occupations that involve chronic exposure to external heat sources (e.g., kitchen workers, silversmiths, jewelers, foundry workers).[6]

DIAGNOSIS

CLINICAL FEATURES

- Some patients have mild pruritus or burning sensation, but the majority of patients are asymptomatic.
- Skin lesions may not appear immediately after the exposure; it might take a period of 1 month to show up. Skin changes start as a reddish-brown pigmentation distributed as a mottled rash and are followed by skin atrophy (**Figures 200-1** to **200-3**).
- Telangiectasias with diffuse hyperpigmentation and subepidermal bullae may also develop.
- The rash appears mesh-like or net-like in the area exposed to the heat. The heat can be from fireplaces, heating pads, laptop computers, open fires, place heaters, and hot-water bottles (**Figures 200-1** to **200-7**).
- Malignant melanoma and various sarcomas are reported to arise in burn scars; however, those arising in areas of erythema ab igne have not been reported to date.

TYPICAL DISTRIBUTION

At the area of heat exposure, which is most often the legs or back (**Figure 200-4**).

LABORATORY STUDIES

None recommended.

SKIN BIOPSY

- In almost all cases, the diagnosis is based on the history and physical exam. Once the typical skin pattern is seen by the clinician, a few questions often will prompt the patient to recall the heat source.

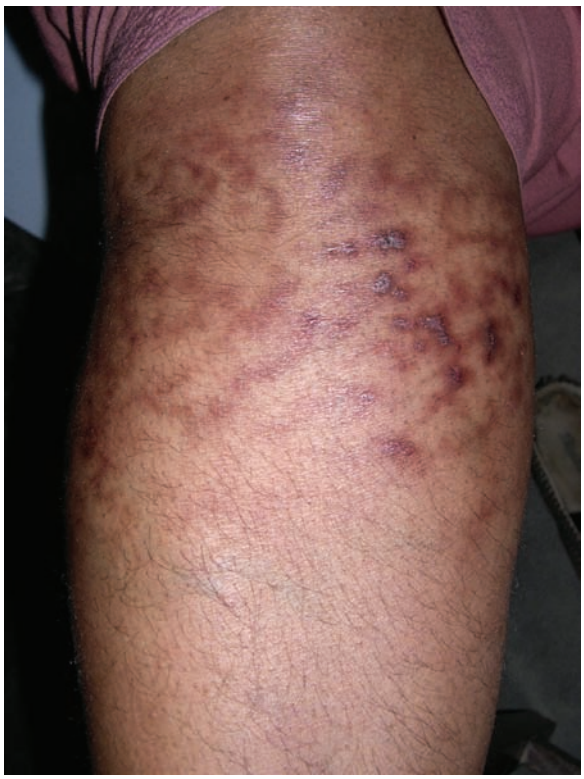

FIGURE 200-3 Mottled hyperpigmentation and hint of blistering and crusting on the anterior leg area in a 23-year-old woman who spent significant time close to a fireplace. (*Courtesy of Amor Khachemoune, MD.*)

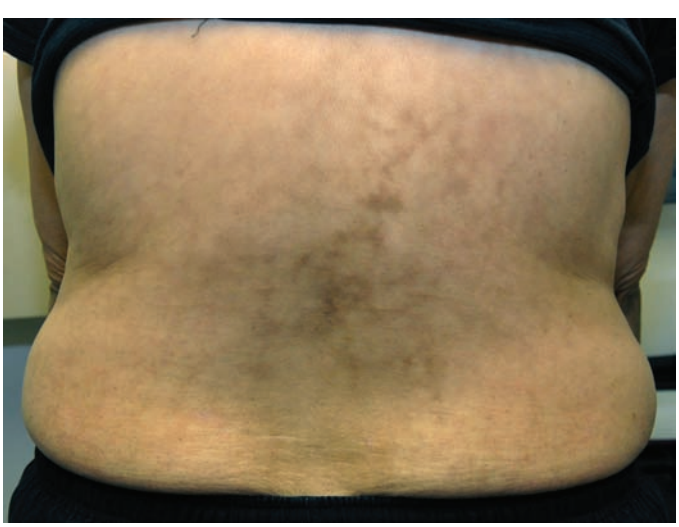

FIGURE 200-4 Erythema ab igne from the use of a heating pad in a woman with back pain. (*Courtesy of Richard P. Usatine, MD.*)

- In some rare cases, Markel cell carcinoma and squamous cell carcinomas have developed in areas of erythema ab igne.[7–9]
- If clinically warranted, a biopsy is performed to exclude the possibility of malignant transformation.
- Histopathology shows epidermal atrophy, subepidermal separation, and haziness of the dermoepidermal junction. Dilation of capillaries and connective tissue disintegration, elastosis, hemosiderin deposition, melanocytosis, and abundance of inflammatory cells are all seen in the dermis. Some of these lesions might progress to actinic keratosis, which could be a precursor for squamous cell carcinoma of the skin.

DIFFERENTIAL DIAGNOSIS

Erythema ab igne should be differentiated from other diseases with skin changes that mimic its presentation.

LIVEDO RETICULARIS

- Reticular cyanotic cutaneous discoloration surrounding pale central areas caused by dilation of capillary blood vessels and stagnation of blood (**Figure 200-8**).
- Occurs mostly on the legs, arms, and trunk and appears to be a purplish mottling of the skin.
- More pronounced in cold weather.
- Idiopathic condition that may be associated with systemic diseases such as systemic lupus erythematosus (SLE).

POIKILODERMA ATROPHICANS VASCULARE

- A variant of mycosis fungoides (cutaneous T-cell lymphoma) (see Chapter 176, Mycosis Fungoides).
- Circumscribed violaceous erythema.
- Occurs mostly in posterior shoulders, back, buttocks, V-shaped area of anterior neck and chest.
- May be asymptomatic or mildly pruritic.
- May remain stable in size or gradually increase.
- Numerous atypical lymphocytes are observed around dermal blood vessels, and some epidermotropism is observed.

CUTIS MARMORATA

- Net-like reticulated pink patches seen early usually seen in premature newborns.
- Improves with rewarming of the skin, worsens with cooling.

CUTIS MARMORATA TELANGIECTASIA CONGENITA

- Net-like reticulated pink patches.
- Persists despite rewarming.
- Genodermatosis usually associated with underlying limb atrophy.

ACANTHOSIS NIGRICANS

- Velvety, light-brown-to-black markings usually on the neck, under the arms, or in the groin (see Chapter 220, Acanthosis Nigricans).
- Most often associated with being overweight.

FIGURE 200-5 Erythema ab igne on the legs of a woman who was straddling a place heater to keep warm during the winter. (*Courtesy of Richard P. Usatine, MD.*)

FIGURE 200-6 Close-up of leg in **Figure 200-5** showing the net-like pattern on the medial leg. (*Courtesy of Richard P. Usatine, MD.*)

- More common in people with darker skin pigmentation.
- A disorder that may begin at any age and that may be inherited as a primary condition or associated with various underlying syndromes.
- Should be able to distinguish from erythema ab igne by the typical location around the neck and in the axilla.

MANAGEMENT

- The first goal of treatment is to identify the source of heat radiation to avoid further exposure. For mild lesions, no intervention is needed after the heat source is removed and the probability of full resolution is good.
- Topical retinoids, vitamin A derivatives, hydroquinone, and 5-fluorouracil have been prescribed to treat the abnormal skin pigmentation.[10] Laser therapy has been used to even out the skin color.[4,10] SOR C

PROGNOSIS

Prognosis is excellent for full resolution if the external heat source is removed or discontinued. However, the hyperpigmentation may remain and various treatments may not succeed in returning the skin to its normal pigmentation.

FOLLOW-UP

Follow-up visits are recommended if there are new changes to the skin after removing the source of heat. This is to diagnose and manage any malignant transformation.

PATIENT EDUCATION

Patients should avoid excessive and prolonged localized heat exposures (i.e., fireplaces, heating pads, laptop computers, and hot-water bottle applications).

There are many ways to shield the thighs from the heat of a laptop computer, from the use of pillows and blankets to the purchase of special devices manufactured for this purpose.

PATIENT RESOURCES

- Wikipedia. *Erythema Ab Igne*—**http://en.wikipedia.org/wiki/Erythema_ab_igne.**

PROVIDER RESOURCES

- Medscape. *Erythema Ab Igne*—**http://emedicine.medscape.com/article/1087535.**
- DermNet NZ. *Erythema Ab Igne*—**http://dermnetnz.org/vascular/erythema-ab-igne.html.**

FIGURE 200-7 Erythema ab igne on the legs of an Ethiopian woman who cooks over an open fire. (*Courtesy of Richard P. Usatine, MD.*)

FIGURE 200-8 Livedo reticularis in a 27-year-old woman with lupus. The mottled purple color gets worse when she is exposed to colder temperature. (*Courtesy of Richard P. Usatine, MD.*)

REFERENCES

1. Meffert JJ, Davis BM. Furniture-induced erythema ab igne. *J Am Acad Dermatol*. 1996;34(3):516-517.
2. Helm TN, Spigel GT, Helm KF. Erythema ab igne caused by a car heater. *Cutis*. 1997;59(2):81-82.
3. Bilic M, Adams BB. Erythema ab igne induced by a laptop computer. *J Am Acad Dermatol*. 2004;50(6):973-974.
4. El-Ghandour A, Selim A, Khachemoune A. Bilateral lesions on the legs. *J Fam Pract*. 2007;56(1):37-39.
5. Weber MB, Ponzio HA, Costa FB, Camini L. Erythema ab igne: a case report. *An Bras Dermatol*. 2005;80(2):187-188.
6. Runger TM. Disorders due to physical agents. In: Bolognia J, Jorizzo JL, Rapini RP, eds. *Dermatology*. Vol 2. London, UK: Mosby; 2003:1385-1409.
7. Jones CS, Tyring SK, Lee PC, Fine JD. Development of neuroendocrine (Merkel cell) carcinoma mixed with squamous cell carcinoma in erythema ab igne. *Arch Dermatol*. 1988;124(1):110-113.
8. Arrington JH 3rd, Lockman DS. Thermal keratoses and squamous cell carcinoma in situ associated with erythema ab igne. *Arch Dermatol*. 1979;115(10):1226-1228.
9. Hewitt JB, Sherif A, Kerr KM, Stankler L. Merkel cell and squamous cell carcinomas arising in erythema ab igne. *Br J Dermatol*. 1993;128(5):591-592.
10. Sahl WJ Jr, Taira JW. Erythema ab igne: treatment with 5-fluorouracil cream. *J Am Acad Dermatol*. 1992;27(1):109-110.

SECTION 19 VASCULAR

201 ACQUIRED VASCULAR SKIN LESIONS

Nathan Hitzeman, MD

PATIENT STORY

A 31-year-old woman presented with a new swelling on her lower lip. This was clinically recognized as a venous lake (**Figure 201-1**). The patient was bothered by its appearance and wanted it removed. She chose to have cryotherapy, which eradicated the venous lake. A closed-probe was used on a Cryogun for lesion compression while the freeze was applied using liquid nitrogen.

FIGURE 201-1 Venous lake on the lip of a young woman. This was eradicated with cryotherapy. (*Courtesy of Richard P. Usatine, MD.*)

INTRODUCTION

Acquired vascular lesions are common skin findings. They appear "vascular," or filled with blood. Acquired vascular lesions differ from congenital or hereditary vascular lesions in that they manifest months to years after birth.

EPIDEMIOLOGY

- Venous lakes are acquired vascular lesions of the face and ears.[1]
- Cherry angiomas are common vascular malformations that occur in many adults after the age of 30 years (**Figure 201-2**). Cherry angiomas sometimes proliferate during pregnancy.[1]
- Angiokeratomas, the most common form being angiokeratomas of the scrotum (Fordyce) or vulva, develop during adult years (**Figures 201-3** and **201-4**).[1]
- Glomangiomas, also known as glomuvenous malformations or glomus tumors, are a type of rare venous malformation (**Figure 201-5**). Most patients with glomangiomas are of Northern European descent and have a family history of similar lesions.[2]
- Cutaneous angiosarcomas are malignant vascular tumors most commonly found on the head and neck areas of elderly white men. These are rare but deadly (**Figure 201-6**).[3]

FIGURE 201-2 Large cherry angioma treated with shave excision and electrodesiccation of the base. (*Courtesy of Richard P. Usatine, MD.*)

ETIOLOGY AND PATHOPHYSIOLOGY

- Venous lakes are benign dilated vascular channels (**Figure 201-1**).
- Cherry angiomas are common benign vascular malformations (see **Figure 201-2**). They may increase during pregnancy. Several case reports have cited increased cherry angiomas after exposure to toxins.[4]
- Angiokeratomas are dilated superficial blood vessels that may be associated with increased venous pressure (such as in pregnant patients and patients with hemorrhoids)[1] (**Figures 201-3** and **201-4**).

- Glomangiomas are a distinct type of venous malformation caused by abnormal synthesis of the protein glomulin[2] (**Figure 201-5**). Lesions may be acquired or congenital.
- Cutaneous angiosarcomas are rare malignant vascular tumors thought to arise from vascular endothelium. Most arise spontaneously, but risk factors include radiation, chronic lymphedema, toxins, and certain familial syndromes. Elevation of several growth factors and cytokines has been associated with this malignancy (**Figures 201-6 and 201-7**).[3]

DIAGNOSIS

CLINICAL FEATURES

- Venous lakes are dark blue, slightly raised, and less than a centimeter in size. The lesions empty with firm compression. They may bleed with trauma.
- Cherry angiomas are deep red papules with a distinct cherry color.
- Angiokeratomas are multiple red-to-purple papules with associated hyperkeratosis. They may bleed easily with trauma.
- Glomangiomas are typically tender, blue-purple, partially compressible nodules with a cobblestone appearance.
- Cutaneous angiosarcomas present as progressively enlarging erythematous plaques.

TYPICAL DISTRIBUTION

- Venous lakes are found on the face and ears, particularly the vermilion border of the lips (**Figure 201-1**).
- Cherry angiomas favor the trunk but may occur on other parts of the body. Number of lesions ranges from several to hundreds.
- Angiokeratomas typically occur on the scrotum or vulva (**Figures 201-3** and **201-4**).
- Glomangiomas tend to occur on the extremities (**Figure 201-5**). Solitary glomangiomas often occur in the nail bed, especially in women. The number of lesions ranges from solitary to more than 100.[5]
- Cutaneous angiosarcomas often present on the head and neck areas (**Figures 201-6** and **201-7**).

LABORATORY STUDIES AND BIOPSY

- Diagnosis of venous lakes, cherry angiomas, and angiokeratomas is usually by history and physical examination alone. If these are removed surgically, it is still best to send them to pathology for confirmation of diagnosis. If the diagnosis is not clear clinically, a biopsy is warranted to rule out malignancy.
- Diascopy is a technique in which a microscope slide is used to compress a vascular lesion, allowing the clinician the ability to see the red or purple color of a vascular lesion blanch under pressure (**Figure 201-8**).
- Skin biopsy of glomangioma reveals distinct rows of glomus cells that surround distorted vascular channels.[2]
- Skin biopsy of cutaneous angiosarcoma reveals irregular vascular channels and atypical endothelial cells.[3]

DIFFERENTIAL DIAGNOSIS

- Melanoma lesions are irregularly shaped, usually pigmented lesions identified by the ABCDE guidelines discussed in Chapter 172, Melanoma. Unlike venous lakes, they do not change consistency with firm compression.

FIGURE 201-3 Angiokeratosis on the scrotum. Fordyce spots. (*Courtesy of Lewis Rose, MD.*)

FIGURE 201-4 Angiokeratosis on the vulva. This might be mistaken for a melanoma. (*Courtesy of Eric Kraus, MD.*)

FIGURE 201-5 Glomangiomas can be multiple or solitary. **A.** Large glomangiomas of the arm. (*Courtesy of Jack Resneck, Sr., MD.*) **B.** Solitary painful glomangioma on the leg of a young man. **C.** Small solitary painful glomangioma on the arm. These solitary glomangiomas were surgically resected. (*Courtesy of Richard P. Usatine, MD.*)

FIGURE 201-6 Angiosarcoma on the nose. A lesion like this requires an urgent biopsy. (*Courtesy of Amor Khachemoune, MD.*)

FIGURE 201-7 Angiosarcoma behind the ear and on the scalp of this 64-year-old man. (*Courtesy of Richard P. Usatine, MD.*)

FIGURE 201-8 Diascopy in which a microscope slide is being used to compress a vascular lesion. The red color of this vascular hemangioma is blanching under pressure. (*Courtesy of Richard P. Usatine, MD.*)

- Angiokeratomas typically occur on the scrotum or vulva and have a distinct appearance. They may bleed easily with trauma.
- Glomangiomas have a cobblestone appearance and are tender. Unlike venous lakes, these anomalies do not empty with compression.
- Cutaneous angiosarcomas present as progressively enlarging erythematous plaques that may resemble bruising, cellulitis, rosacea, or erysipelas. The head-tilt maneuver has been described to aid in its detection.[5] Having a patient lower his or her head below the level of the heart for 5 to 10 seconds will make the lesion more engorged and violaceous, thus confirming its vascular nature.

MANAGEMENT

OBSERVATION

- Patients can be reassured that venous lakes and most other acquired vascular lesions (with the exception of angiosarcomas) are benign lesions that develop during adult years.

SURGICAL

- Venous lakes, cherry angiomas, and other acquired vascular lesions can be eradicated by cryotherapy, electrodesiccation, sclerotherapy, intralesional bleomycin, intense pulsed light, and other laser modalities.[1,6–10] SOR C Compared with intense pulsed light, the Nd:YAG (neodymium:yttrium-aluminum-garnet) laser system may yield superior results in the treatment of benign vascular lesions.[11] SOR B Hyperpigmentation is the most common complication of treatment.
- When using cryotherapy to treat vascular lesions, it helps to compress the lesion at the same time as it is frozen. This can be done with a Cryogun that has a solid probe for compression. SOR C
- Cherry angiomas can be treated with light electrodesiccation using an electrosurgical instrument on a low setting without anesthesia. The tip of the instrument is lightly applied to the apex of the lesion while electrical current is engaged. The desired end point is "charring" of the lesion with minimal surrounding tissue destruction. SOR C
- Larger cherry angiomas can be removed with a shave excision after injecting with lidocaine and epinephrine. The base can be treated with electrodesiccation if needed. SOR C
- Isolated glomangiomas may be surgically excised. Sclerotherapy may be useful for multiple lesions or large segmental lesions.[12] SOR C
- Cutaneous angiosarcoma is best treated with excision and wide surgical margins, as the primary tumor is often more extensive than appears on examination. Postoperative radiotherapy is then used at the primary site and regional lymphatics. If inoperable, palliative chemotherapy may be considered.[3] SOR C

PATIENT EDUCATION

- When discussing any new lesions in sun-exposed areas, the clinician should take the opportunity to counsel patients on sunscreen use, avoiding direct sun during peak hours, and performing periodic skin examination.
- Patients should be fully informed about the risk of pigmentary changes and chance of recurrence if they elect for cosmetic removal of benign lesions. Avoidance of sunlight to the healing skin helps prevent a hyperpigmented scar.

FOLLOW-UP

None typically needed for benign lesions unless lesions recur or the patient is concerned about growth or changes to the lesions.

PATIENT RESOURCES

- MedlinePlus. *Cherry Angioma*—**http://www.nlm.nih.gov/medlineplus/ency/article/001441.htm.**
- SkinCancerNet (American Academy of Dermatology). *Skin Examinations*—**http://www.skincarephysicians.com/skincancernet/skin_examinations.html.**

PROVIDER RESOURCES

- Medscape. *Laser Treatment of Acquired and Congenital Vascular Lesions*—**http://emedicine.medscape.com/article/1120509.**

REFERENCES

1. Habif TP. Acquired vascular lesions. In: *Clinical Dermatology: A Color Guide to Diagnosis and Therapy*, 5th ed. Philadelphia, PA: Mosby; 2010:904-912, http:www.clinderm.com, accessed March 28, 2012.
2. Brauer JA, Anolik R, Tzu J, et al. Glomuvenous malformations (familial generalized multiple glomangiomas). *Dermatol Online J.* 2011;17(10):9, http://dermatology.cdlib.org/1710/2010-11/9_2010-11/article.html, accessed March 28, 2012.
3. Young RB, Brown NJ, Reed MW, et al. Angiosarcoma. *Lancet Oncol.* 2010;11(10):983-991, http://www.mdconsult.com/das/article/body/326552771-2/jorg=journal&source=&sp=23684736&sid=0/N/767926/s1470204510700231.pdf?issn=1470-2045, accessed March 28, 2012.
4. Hefazi M, Maleki M, Mahmoudi M, et al. Delayed complications of sulfur mustard poisoning in the skin and the immune system of Iranian veterans 16-20 years after exposure. *Int J Dermatol.* 2006;45(9):1025-1031.
5. Asgari MM, Cockerell CJ, Weitzul S. The head-tilt maneuver. *Arch Dermatol.* 2007;143:75-77.
6. Suhonen R, Kuflik EG. Venous lakes treated by liquid nitrogen cryosurgery. *Br J Dermatol.* 1997;137:1018-1019.
7. Hong SK, Lee HJ, Seo JK, et al. Reactive vascular lesions treated using ethanolamine oleate sclerotherapy [21 patient study, 5 of whom had venous lakes; 95% of patients had complete remission]. *Dermatol Surg.* 2010;36(7):1148-1152.
8. Sainsbury DC, Kessell G, Fall AJ, et al. Intralesional bleomycin injection treatment for vascular birthmarks: a 5-year experience at a single United Kingdom unit [164-patient study]. *Plast Reconstr Surg.* 2011;127(5):2031-2044.
9. Bernstein EF. The pulsed-dye laser for treatment of cutaneous conditions [17-page review article with before and after pics on using the pulsed laser]. *G Ital Dermatol Venereol.* 2009;144(5):557-572.
10. Bekhor PS. Long-pulsed Nd:YAG laser treatment of venous lakes: report of a series of 34 cases. *Dermatol Surg.* 2006;32:1151-1154.
11. Fodor L, Ramon Y, Fodor A, et al. A side-by-side prospective study of intense pulsed light and Nd:YAG laser treatment for vascular lesions. *Ann Plastic Surg.* 2006;56:164-170.
12. Parsi K, Kossard S. Multiple hereditary glomangiomas: Successful treatment with sclerotherapy. *Australas J Dermatol.* 2002;43:43.

202 HEREDITARY AND CONGENITAL VASCULAR LESIONS

Nathan Hitzeman, MD

PATIENT STORY

A 56-year-old woman has had recurrent nosebleeds starting in childhood and has visible telangiectasias on her lips and tongue (**Figure 202-1**). In early adulthood, she was diagnosed with hereditary hemorrhagic telangiectasias (HHTs) (Osler-Weber-Rendu syndrome) and was found to have an arteriovenous malformation (AVM) in the lung requiring surgical resection. She has led a normal productive life and has two children who have not inherited this condition. Her mom had recurrent epistaxis, but never had an AVM.

FIGURE 202-1 Hereditary hemorrhagic telangiectasias (Osler-Weber-Rendu syndrome) in a 56-year-old woman with recurrent nosebleeds and an arteriovenous malformation in the lung. (*Courtesy of Richard P. Usatine, MD.*)

INTRODUCTION

Hereditary and congenital vascular lesions range from the very common and benign stork bite (a variation of nevus flammeus) to rare but serious neurocutaneous syndromes. Childhood hemangiomas are covered separately in Chapter 109, Childhood Hemangiomas and Vascular Malformations.

EPIDEMIOLOGY

- HHT is an autosomal-dominant vascular disorder that affects one in several thousands of people (**Figure 202-1**). Certain populations in Europe and the United States have a higher prevalence of this disease.[1]
- Nevus flammeus, or port-wine stains, are congenital vascular malformations that occur in 0.1% to 0.3% of infants as developmental anomalies. They persist into adulthood (**Figure 202-2**).[2] They may be associated with rare syndromes such as Klippel-Trenaunay and Sturge-Weber syndromes (**Figure 202-3**).
- Maffucci syndrome is a rare, nonhereditary condition characterized by hemangiomas and enchondromas involving the hands, feet, and long bones (**Figure 202-4**).[3]

FIGURE 202-2 Large nevus flammeus or port-wine stain over the trunk of a 55-year-old man since birth. (*Courtesy of Casey Pollard, MD.*)

ETIOLOGY AND PATHOPHYSIOLOGY

- HHT is associated with mutations in two genes: endoglin on chromosome 9 (HHT type 1) and activin receptor-like kinase-1 on chromosome 12 (HHT type 2). These genes are involved in vascular development and repair. With the mutations, arterioles become dilated and connect directly with venules without a capillary in between. Although manifestations are not present at birth, telangiectasias later develop on the skin, mucous membranes, and GI tract. In addition, AVMs often develop in the hepatic (up to 70% of patients), pulmonary (5% to 300%), and cerebral circulations

(10% to 15%). Any of these lesions may become fragile and prone to bleeding.[1]

- Port-wine stains are vascular ectasias or dilations thought to arise from a deficiency of sympathetic nervous innervation to the blood vessels. Dilated capillaries are present throughout the dermis layer of the skin.
- The bone and vascular lesions of Maffucci syndrome exist at birth or develop during childhood. Progression usually does not occur after completion of puberty.

DIAGNOSIS

CLINICAL FEATURES

- HHT is diagnosed if three of the following four Curaçao criteria are met (and suspected if two are present):
  1. Recurrent spontaneous nosebleeds (the presenting sign in more than 90% of patients, often during childhood);
  2. Mucocutaneous telangiectasia (typically develops in the third decade of life);
  3. Visceral involvement (lungs, brain, liver, and colon); and/or
  4. An affected first-degree relative.[4]
- Port-wine stains are irregular red-to-purple patches that start out smooth in infancy but may hypertrophy and develop a cobblestone texture with age. Nuchal port-wine stains are associated with alopecia areata.[5] Klippel-Trenaunay syndrome is characterized by vascular malformations, venous varicosities, and soft-tissue hyperplasia. Patients with Sturge-Weber syndrome often have mental retardation, epilepsy, and eye problems.[2]
- The cobblestone deformity of the hands and feet in Maffucci syndrome is striking (**Figure 202-4**).

TYPICAL DISTRIBUTION

- HHT skin manifestations are few to numerous lesions on the tongue, lips, nasal mucosa, hands, and feet. However, any skin area or internal organ may be involved.
- Port-wine stains tend to affect the face and neck, although lesions may affect any body surface, including mucous membranes. Lesions of Klippel-Trenaunay syndrome tend to affect the lower extremities. A diagnosis of Sturge-Weber syndrome requires that a port-wine stain be present in the V1 trigeminal nerve distribution (aka ophthalmic branch). Patients with port-wine stains of the eyelids, bilateral trigeminal lesions (40% of patients with Sturge-Weber syndrome), and unilateral lesions involving all three divisions of the trigeminal nerve are particularly at risk of Sturge-Weber syndrome.[2]

LABORATORY STUDIES

- Check an annual complete blood count (CBC) and fecal occult blood in patients with HHT. They are at higher risk for iron-deficiency anemia because of recurrent nosebleeds and/or GI bleeding.
- Patients with benign-appearing port-wine stains, who lack other concerning symptoms, do not require laboratory testing (**Figure 202-5**).
- If Sturge-Weber syndrome is suspected, perform neuroimaging and glaucoma testing. Neuroimaging may reveal leptomeningeal malformations ipsilateral to the port-wine stain. An electroencephalogram

FIGURE 202-3 Port-wine stain, since birth, on the face of a man. Its distribution puts this patient at risk of Sturge-Weber syndrome. (*Courtesy of Richard P. Usatine, MD.*)

FIGURE 202-4 Hereditary hemangiomatosis, also called Maffucci syndrome. Note the cobblestone deformity of the foot. (*Courtesy of Tran Shellenberger, MD.*)

may reveal epilepsy. Elevated ocular pressures or visual field deficits may indicate glaucoma.

- Investigate the musculoskeletal system in persons with Maffucci syndrome. It is associated with various benign and malignant tumors of the bone and cartilage.[3]

DIFFERENTIAL DIAGNOSIS

- CREST (calcinosis, Raynaud phenomenon, esophageal involvement, sclerodactyly, and telangiectasia) syndrome and scleroderma usually have multiple telangiectasias as in HHT. Other clinical features and laboratory tests such as the antinuclear antibody (ANA) and skin biopsies can differentiate between these rheumatologic conditions and HHT (see Chapter 182, Scleroderma and Morphea).
- Port-wine stains are often isolated findings but may indicate underlying Klippel-Trenaunay or Sturge-Weber syndrome. Further investigations may be necessary when these syndromes are suspected.
- Glomangiomas are blue-purple, partially compressible nodules with a cobblestone appearance. These glomuvenous malformations may appear similar to Maffucci syndrome but lack the rheumatologic component (see Chapter 201, Acquired Vascular Skin Lesions).
- Salmon patches, also known as "stork bites" or "angel kisses" (present in 40% to 70% of newborns), are a type of nevus flammeus or port-wine stain. Salmon patches are pinker than purple but are true congenital vascular malformations, not hemangiomas. The angel kisses over the face tend to fade with time but the stork bites on the nape of the neck often persist, as seen in **Figure 202-6** (see Chapter 109, Childhood Hemangiomas and Vascular Malformations).[2]

MANAGEMENT

- HHT has no cure. Oral iron supplementation and transfusions are sometimes needed as a result of bleeding. Few randomized controlled trials exist regarding treatment of bleeding. Estrogen/progesterone supplementation for heavily transfusion-dependent patients decreases recurrent bleeding.[6] SOR B Case reports and uncontrolled studies regarding epistaxis treatment show some benefit from laser treatment, surgery, embolization, and topical therapy. SOR C Cauterization is not recommended because of complications from local tissue damage. Embolization procedures have been described for AVMs in the liver, lungs, and brain. Surgical resection of AVMs is sometimes done as a last resort when other measures fail.[1] In short, it is often best to do as little intervention as possible with HHT and, if any intervention is done, it is done with input from specialists experienced with this disease, as complications and recurrence are frequently encountered.
- Port-wine stains may be treated with makeup (see "Patient Resources" below). Pulsed-dye laser treatment is another option, albeit expensive. Laser treatments blanch most port-wine lesions to some degree, but complete resolution is difficult to achieve and the recurrence rate is high.[7] SOR C

FIGURE 202-5 Nevus flammeus or port-wine stain, since birth, on the arm of a 34-year-old woman. She has had no problems with this benign capillary malformation. (*Courtesy of Richard P. Usatine, MD.*)

FIGURE 202-6 Stork bite (salmon patch) that has persisted since birth in this 72-year-old woman. This benign capillary malformation is more visible now, caused by the hair loss from chemotherapy. (*Courtesy of Richard P. Usatine, MD.*)

- Patients with Maffucci syndrome often require multiple orthopedic surgeries for their enchondromatous deformities and for cosmetic purposes.[3,8]

PATIENT EDUCATION

- Whatever the vascular condition is, patients can benefit from reliable information about the current and future outlook for their condition.

FOLLOW-UP

- Patients with port-wine stains should have periodic skin checks, as other lesions may develop within the port-wine stains. Several case reports of basal cell cancers developing within port-wine stains have been described.[9]
- Patients with Sturge-Weber syndrome should have yearly eye examinations that include testing of intraocular pressures. SOR C
- Patients with Maffucci syndrome should be monitored closely for both skeletal and nonskeletal tumors, particularly of the brain and abdomen.[8] SOR C

PATIENT RESOURCES

- HHT Foundation International. Excellent patient information on HHT can be found at the Foundation's website—**http://www.hht.org.**
- Covermark. Port-wine stains are often psychologically detrimental. Cosmetic makeup may be purchased through Covermark—**http://www.covermark.com.**
- Dermablend is another effective cosmetic product for port-wine stains—**http://www.dermablend.com.**

PROVIDER RESOURCES

- Medscape. *Laser Treatment of Acquired and Congenital Vascular Lesions*—**http://emedicine.medscape.com/article/1120509.**

REFERENCES

1. Grand'Maison A. Hereditary hemorrhagic telangiectasia. *CMAJ*. 2009;180(8):833-835, http://www.ncbi.nlm.nih.gov/pmc/articles/PMC2665965/pdf/1800833.pdf. Accessed March 28, 2012.
2. Habif TP. Vascular tumors and malformations. In: *Clinical Dermatology: A Color Guide to Diagnosis and Therapy*, 5th ed. Philadelphia, PA: Mosby, 2010:891-903, http://www.clinderm.com, accessed March 28, 2012.
3. Jermann M, Eid K, Pfammatter T, Stahel R. Maffucci's syndrome. *Circulation*. 2001;104:1693.
4. Shovlin CL, Guttmacher AE, Buscarini E, et al. Diagnostic criteria for hereditary haemorrhagic telangiectasia (Rendu-Osler-Weber syndrome). *Am J Med Genet*. 2000;91:66-67.
5. Akhyani M, Farnaghi F, Seirafi H, et al. The association between nuchal nevus flammeus and alopecia areata: a case-control study. *Dermatology*. 2005;211(4):334-337.
6. Van Cutsem E, Rutgeerts P, Vantrappen G. Treatment of bleeding GI vascular malformations with oestrogen-progesterone. *Lancet*. 1990;335:953-955.
7. Lanigan SW, Taibjee SM. Recent advances in laser treatment of port-wine stains. *Br J Dermatol*. 2004;151(3):527-533.
8. Gupta N, Kabra M. Maffucci syndrome. *Indian Pediatr*. 2007;44(2):149-150.
9. Silapunt S, Goldberg LH, Thurber M, Friedman PM. Basal cell carcinoma arising in a port-wine stain. *Dermatol Surg*. 2004;30(9):1241-1245.

SECTION 20 OTHER SKIN DISORDERS

203 CUTANEOUS DRUG REACTIONS

Richard P. Usatine, MD
Anna Allred, MD
Mindy A. Smith, MD, MS

PATIENT STORY

A 20-year-old college student was seen for fatigue and an upper respiratory infection and started on amoxicillin for a sore throat. Six days later she broke out with a red rash all over her body (**Figure 203-1**). She went to see her family physician back home with the rash and lymphadenopathy. A monospot was drawn and found to be positive. This morbilliform rash (like measles) is typical of an amoxicillin drug eruption in a person with mononucleosis. Amoxicillin was stopped, and diphenhydramine was used for the itching.

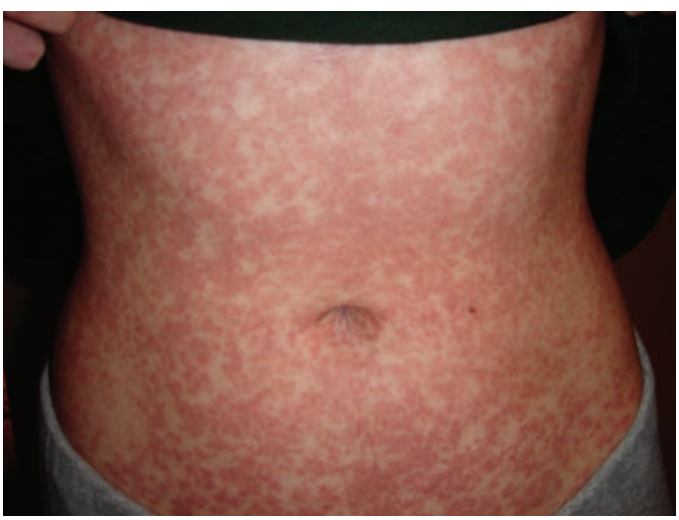

FIGURE 203-1 Amoxicillin rash in a young woman with mononucleosis. This is a morbilliform eruption. (*Courtesy of Richard P. Usatine, MD.*)

INTRODUCTION

Cutaneous drug reactions are skin manifestations of drug hypersensitivity. Drug hypersensitivity may be defined as symptoms or signs initiated by a drug exposure at a dose normally tolerated by nonhypersensitive persons.[1] Drug-induced adverse reactions are often classified as type A and type B. Type A reactions are common (80%) predictable side effects caused by a pharmacologic action of the drug, and type B reactions are uncommon (10% to 15%) and considered idiosyncratic, a result of individual predisposition (e.g., an enzyme defect).[2] Cutaneous drug reactions range from mild skin eruptions (e.g., exanthem, urticaria, and angioedema) to severe cutaneous drug reactions (SCARs), the latter category including Stevens-Johnson syndrome (SJS), toxic epidermal necrolysis (TEN), and drug reaction with eosinophilia and systemic symptoms (DRESS) or drug-induced hypersensitivity syndrome (DIHS).[3]

FIGURE 203-2 Maculopapular drug eruption in a 5-year-old boy with an upper respiratory infection started on amoxicillin for a questionable otitis media. Four days later he broke out with a red rash all over his face and body. This morbilliform rash (like measles) is typical of an amoxicillin drug eruption. (*Courtesy of Robert Tunks, MD.*)

SYNONYMS

Cutaneous adverse reactions, drug reactions, medication reactions, adverse effects to drugs, hypersensitivity reactions.

EPIDEMIOLOGY

- Cutaneous drug reactions are common complications of drug therapy occurring in 2% to 3% of hospitalized patients.[4]
- One study found that 45% of all adverse drug reactions were manifested in the skin.[4]

- Approximately 1 in 6 adverse drug reactions represents drug hypersensitivity, and are allergic or non–immune-mediated (pseudoallergic) reactions.[2]
- Maculopapular eruptions, also known as exanthematous drug eruptions, are the most frequent of all cutaneous drug reactions, representing 95% of skin reactions.[5] They are often confused with viral exanthems. This occurs most commonly with β-lactams such as amoxicillin, but also with barbiturates, gentamicin, isoniazid, phenytoin, sulfonamides, thiazides, and trimethoprim-sulfamethoxazole (**Figures 203-1** and **203-2**).
- Urticarial drug reactions are the second most common skin eruptions, representing approximately 5% of cutaneous drug reactions.[5] This reaction can result from any drug but commonly occurs with aspirin, penicillin, sulfa, angiotensin-converting enzyme (ACE) inhibitors, aminoglycosides, and blood products. Urticaria results from immunoglobulin (Ig) E reactions within minutes to hours of drug administration (**Figures 203-3** and **203-4**).
- Drug-induced hyperpigmentation occurs with antiarrhythmics (amiodarone), antibiotics (minocycline), NSAIDs, and chemotherapy agents (Adriamycin) (**Figure 203-5**).
- Warfarin-induced skin necrosis (WISN) is a rare but serious side effect predominantly seen in obese women and presents between days 3 and 6 of warfarin treatment. WISN is more common in those with thrombophilic abnormalities, given large loading doses (**Figure 203-6**).
- Fixed drug eruptions (FDEs) can occur with many medications, including phenolphthalein, doxycycline, ibuprofen, sulfonamide antibiotics, and barbiturates. FDEs are more commonly observed in men (**Figures 203-7** to **203-13**).
- Erythema multiforme (EM) and SJS can occur secondary to drug reactions (**Figures 203-14** to **203-16**). Incidence of SJS is estimated at 1.2 per 6 million people.[3]
- DRESS is also a severe adverse drug-induced reaction characterized by eosinophilia with liver involvement, fever, and lymphadenopathy. In a case series (N = 172), 44 drugs were associated with DRESS.[6] Also called DIHS, this syndrome is estimated to occur in 1 per 1000 to 1 per 10,000 exposures to antiepileptic drugs.[7]
- **Tables 203-1** and **203-2** list the most common medications associated with allergic cutaneous drug reactions and the rates of reactions found.[8]
- **Table 203-3** lists the frequency of various classes of drugs associated with an eruption (in cases with <4 suspected drugs) based on a 5-year study.[9]

ETIOLOGY AND PATHOPHYSIOLOGY

- Two mechanisms are responsible for cutaneous drug reactions—Immunologic, including all four types of hypersensitivity reactions, and, more commonly, nonimmunologic (pseudoallergic). Although the precise mechanism of immune stimulation is unknown, it may be triggered by drug-protein (hapten-carrier) complexes or through direct interaction with immune receptors (p-i concept).[2] The mechanism for pseudoallergic reactions is pathogenetically poorly defined.[2]

FIGURE 203-3 Urticarial drug eruption secondary to trimethoprim/sulfamethoxazole. (*Courtesy of Richard P. Usatine, MD.*)

FIGURE 203-4 Giant urticarial eruption (urticaria multiforme) in the patient in **Figure 203-3** with drug reaction to sulfa. (*Courtesy of Richard P. Usatine, MD.*)

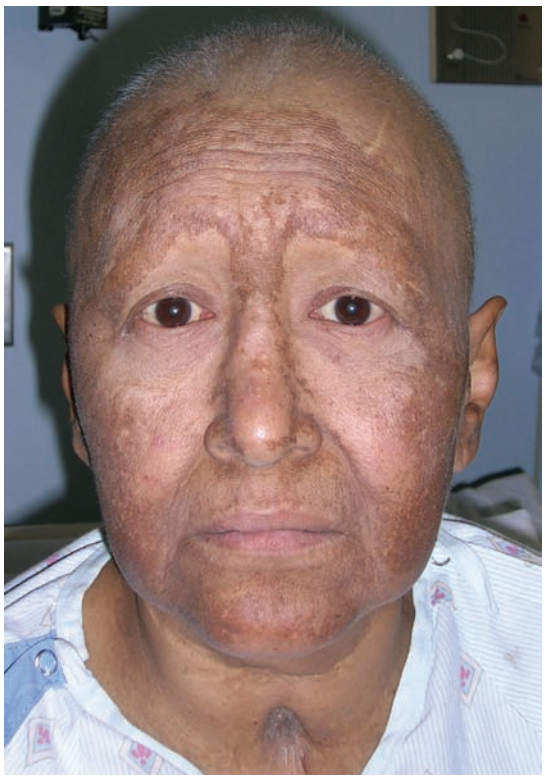

FIGURE 203-5 Facial hyperpigmentation secondary to Adriamycin. (*Courtesy of Richard P. Usatine, MD.*)

FIGURE 203-7 Annular appearing bullous fixed drug eruption with dusky center. (*Courtesy of Jeffrey Meffert, MD.*)

FIGURE 203-8 Hyperpigmented fixed drug eruption. (*Courtesy of Jeffrey Meffert, MD.*)

FIGURE 203-6 Coumadin necrosis with dark bullae on the arm of a woman just started on Coumadin. (*Courtesy of Eric Kraus, MD.*)

FIGURE 203-9 Fixed drug eruption to trimethoprim/sulfamethoxazole with hyperpigmented plaques in a 10-year-old boy. (*Courtesy of Richard P. Usatine, MD.*)

FIGURE 203-10 Fixed drug eruption to ibuprofen with violaceous and hyperpigmented macules and erosions on the penis. (*Courtesy of Richard P. Usatine, MD.*)

FIGURE 203-12 Third episode of fixed drug eruption to doxycycline. **A.** Note the lip and palatal involvement. **B.** Note how the finger lesion is similar to a target lesion in erythema multiforme. However, there is no central epithelial disruption in this target lesion. (*Courtesy of Richard P. Usatine, MD.*)

FIGURE 203-11 Bullous fixed drug eruptions. Bullous fixed drug eruption on the glans penis, a common location for these fixed drug eruptions. (*Courtesy of Jeffrey Meffert, MD.*)

FIGURE 203-13 Fixed drug eruption to hydrocodone seen on the scalp and neck of this 22-year-old man. (*Courtesy of Richard P. Usatine, MD.*)

FIGURE 203-15 Erythema multiforme showing target lesions on the palms. (*Courtesy of the University of Texas Health Sciences Center, Division of Dermatology.*)

FIGURE 203-14 Recurrent erythema multiforme secondary to repeated bouts of herpes simplex in this 43-year-old woman. (*Courtesy of Richard P. Usatine, MD.*)

FIGURE 203-16 Stevens-Johnson syndrome secondary to a sulfa antibiotic. (*Courtesy of Eric Kraus, MD.*)

TABLE 203-1 Allergic Cutaneous Reactions to Drugs Received by at Least 1000 Patients (Boston Collaborative Drug Surveillance Program)

Drug	Reactions, No.	Recipients, No.	Rate, %	95% Confidence Interval
Amoxicillin	63	1225	5.1	3.9 to 6.4
Ampicillin	215	4763	4.5	3.9 to 5.1
Cotrimoxazole (trimethoprim-sulfamethoxazole)	46	1235	3.7	2.7 to 4.8
Semisynthetic penicillins	41	1436	2.9	2.0 to 3.7
Red blood cells	67	3386	2.0	1.5 to 2.4
Penicillin G	68	4204	1.6	1.2 to 2.0
Cephalosporins	27	1781	1.5	0.9 to 2.1
Gentamicin	13	1277	1.0	0.5 to 1.6

- Hypersensitivity to NSAIDs is a nonimmunologic reaction that can be immediate (within hours after exposure) or delayed (more than 24 hours after administration).[1]
- WISN develops during the hypercoagulable state as a result of a more rapid fall in concentration of protein C compared to the other vitamin-K–dependent procoagulant factors. Thrombophilic abnormalities such as familial or acquired deficiency of protein C or S and antiphospholipid antibodies have been implicated in WISN (**Figure 203-6**).
- SJS/TEN is most commonly associated with penicillins and sulfonamide antibiotics but can also occur with anticonvulsants, NSAIDs, allopurinol, and corticosteroids. It is hypothesized that a specific human leukocyte antigen (HLA)-B molecule may present the drug or its metabolites to naïve CD8 cells resulting in clonal expansion of CD8 cytotoxic lymphocytes and induction of cytotoxic effector responses, resulting in apoptosis of keratinocytes.[10] This pathway is not likely to be specific to SJS.

RISK FACTORS

- Drug hypersensitivity reactions increase with the drug dose, duration, route of administration (topical > subcutaneous > intramuscular > oral > intravenous),[11] immune activation of the individual, and immunogenetic predisposition; they are also more frequent in women.[2] Multiple drug therapy may also increase risk.[11]
- Patients with the following HLAs are at higher risk for cutaneous drug reactions: HLA-B*1502 (confers a very high risk of carbamazepine-induced and other antiepileptic drug-induced SJS among people of southeastern Asian ethnicity); HLA-B*5801 (higher risk of allopurinol-induced severe cutaneous reactions); HLA-B*5701 (higher risk of abacavir [an antiretroviral drug] hypersensitivity reactions); HLA-B*3501, HLA-B*3505, HLA-B*1402, and HLA-Cw8 (nevirapine [an antiretroviral drug] sensitivity with rash; the latter two found in a Sardinian population); HLA-DRB1*0101 (nevirapine hypersensitivity rash with hepatitis).[2,6]

TABLE 203-2 Allergic Cutaneous Reactions to Drugs Received by at Least 1000 Patients

Drug	Reactions, No.	Recipients, No.	Rate,%	95% Confidence Interval
Fluoroquinolones	16	1015	1.6	0.8 to 2.3
Amoxicillin	40	3233	1.2	0.9 to 1.6
Augmentin	12	1000	1.2	0.5 to 1.9
Penicillins	63	5914	1.1	0.8 to 1.3
Nitrofurantoin	7	1085	0.6	0.2 to 1.1
Tetracycline	23	4981	0.5	0.3 to 0.7
Macrolides	5	1435	0.3	0.0 to 0.7

Source: Reprinted from van der Linden PDvan der Lei JVlug AEStricker BH Skin reactions to antibacterial agents in general practice. *J Clin Epidemiol.* 1998;(51)703-708. Copyright 1998, with permission from Elsevier.

TABLE 203-3 Frequency of various classes of drugs associated with an eruption (in cases with <4 suspected drugs)

Class of drug	No. of cases (N = 82)
Antibiotic	37
Antiepileptic	12
Phenytoin	9
Antiarrhythmic	6
Calcium ion inhibitors	3
Anticoagulant	5
Enoxaparin	2
Clopidogrel	2
Warfarin	1
Antifungal	4
Antigout	4
Proton pump inhibitors	4
ACE* inhibitors	3
Contrast	3
Diuretics	3
Anti-inflammatory	2
Antiretroviral (HIV)	2
Antiviral	2
Beta blockers	2
Chemotherapeutic	2
Other	11

*ACE, Angiotensin-converting enzyme.
Source: Gerson D, Sriganeshan V, Alexis JB. Cutaneous drug eruptions: a 5-year experience. *J Am Acad Dermatol*. 2008 Dec;59(6):995-9.

- Prior drug reaction may result in a faster recurrence on reexposure.[11]
- Concomitant illness, especially viral infections and autoimmune disorders.[11]

DIAGNOSIS

CLINICAL FEATURES AND TYPICAL DISTRIBUTION (THE MOST COMMON AND IMPORTANT DRUG ERUPTIONS)

- *Maculopapular*—These eruptions, red macules with papules, can occur any time after drug therapy is initiated (often 7 to 10 days) and last 1 to 2 weeks. The reaction usually starts on the upper trunk or head and neck then spreads symmetrically downward to limbs. The eruptions may become confluent in a symmetric, generalized distribution that spares the face (**Figure 203-1**). Mild desquamation is normal as the exanthematous eruption resolves.
- *Urticaria and angioedema*—Urticaria reactions present as circumscribed areas of blanching-raised erythema and edema of the superficial dermis (**Figures 203-3** and **203-4**). They may occur on any skin area and are usually transient, migratory, and pruritic. Angioedema represents a deeper reaction, with swelling usually around the lips and eyes (see Chapter 150, Urticaria and Angioedema).
- *Hyperpigmentation*—Drug-induced hyperpigmentation presents in many ways. Amiodarone causes a dusky red coloration that turns blue-gray with time in photo-exposed areas. Minocycline can cause a blue-gray color in acne lesions, on the gingiva and on the teeth. Phenytoin (Dilantin) and other hydantoins may cause melasma-like brown pigmentation on the face. Bleomycin can cause a streaking hyperpigmentation on the trunk and extremities. Adriamycin, as evident in the case above, can cause hyperpigmentation of the face and nails (**Figure 203-5**).
- *NSAIDs*—The cutaneous reactions to NSAID-associated drug hypersensitivity are urticaria, angioedema, or anaphylaxis.[1] These reactions can be caused by a single NSAID or multiple NSAIDs. There is also an NSAID-exacerbated urticaria and angioedema that occurs in patients with chronic idiopathic urticaria.
- *Warfarin-induced skin necrosis (WISN)*—It presents with sudden onset of painful localized skin lesion that is initially erythematous and/or hemorrhagic that becomes bullous, culminating in gangrenous necrosis (**Figure 203-6**). It develops more often in obese women in their 50s in areas with high subcutaneous fat content such as breasts, thighs, and buttocks. This is different from a warfarin bleed secondary to too much anticoagulation (**Figure 203-14**).
- *Fixed drug eruption (FDE)*—Presents with single or multiple sharply demarcated circular, violaceous or hyperpigmented plaques that may include a central blister (**Figures 203-8** to **203-13** and **203-17**). The lesion(s) appear after drug exposure and reappear exactly at the same site each time the drug is taken. The site resolves, leaving an area of macular hyperpigmentation (**Figure 203-8**). Lesions can occur anywhere including the hands and feet, but are commonly found on the penis (**Figures 203-10** and **203-11**). The eruption presents 30 minutes to 8 hours after drug administration. Bullous

FIGURE 203-17 Bullous fixed drug eruption with a dusky color and an annular pink border on the ankle. (*Courtesy of Richard P. Usatine, MD.*)

fixed drug eruptions occur when the lesion blisters and erodes, followed by desquamation and crusting (**Figures 203-7**, **203-11**, and **203-17**).

- *EM*—It presents with typical target or raised edematous papules distributed acrally. Most importantly, there should be some type of epidermal disruption with bullae or erosions within the target lesions (**Figures 203-14** and **203-15**). Severe EM becomes and more widespread epidermal detachment may occur involving less than 10% of total body surface area (see Chapter 177, Erythema Multiforme, Stevens-Johnson Syndrome, and Toxic Epidermal Necrolysis).
- *SJS*—It presents with erythematous or pruritic macules, widespread blisters on the trunk and face, and erosions of one or more mucous membranes (**Figure 203-16**). Atypical target lesions or widespread erythema, particularly in the upper chest and back, are potential early signs of both SJS and TEN.[11] Burning or painful skin can be a sign of increased severity. Epidermal detachment occurs and involves less than 30% of total body surface area.
- *Toxic epidermal necrolysis (TEN)*—It is on the most severe side of the SJS spectrum. EM is diagnosed when less than 10% of the body surface area is involved, SJS/TEN when 10% to 30% is involved, and toxic epidermal necrolysis when more than 30% is involved.
- *Drug reaction with eosinophilia and systemic symptoms (DRESS) or drug-induced hypersensitivity syndrome (DIHS)*—Infiltrated, palpable lesions are potential heralds of this disorder.[11] Central facial edema and erythema (**Figure 203-18**) and a maculopapular rash are seen along with high fever, generalized lymphadenopathy, and arthralgias. *Drug reaction with eosinophilia and systemic symptoms* can also cause an erythroderma (**Figure 203-19**). Latency between starting a drug and first signs of drug reaction with eosinophilia and systemic symptoms can be up to 12 weeks.[11]
- Drugs most commonly known to cause SJS and TEN are sulfonamide antibiotics, allopurinol, nonsteroidal antiinflammatory agents, amine antiepileptic drugs (phenytoin and carbamazepine), and lamotrigine (see Chapter 177, Erythema Multiforme, Stevens-Johnson Syndrome, and Toxic Epidermal Necrolysis).[12] Fifty percent of SJS/TEN cases have no identifiable cause.

LESS COMMON DRUG REACTIONS

- Acute generalized exanthematous pustulosis (AGEP)—is a type of drug eruption that results in clusters of small pustules along with erythematous skin (**Figure 203-20**). The patients are often febrile and the pustules are primarily non-follicular and sterile.
- Systemic drug-related intertriginous and flexural exanthema (SDRIFE)—is a type of drug eruption that causes erythema around the buttocks and genitalia along with intertriginous and flexural areas. If the pattern of erythema creates a red buttocks then it may also be called the baboon syndrome (**Figure 203-21**).

LABORATORY STUDIES

The diagnosis of drug eruptions is usually made based on history and physical examination.

- An FDE may be diagnosed by "provoking" the appearance of the lesion with an oral rechallenge with the suspected drug; however, this can be dangerous in bullous cases.

FIGURE 203-18 *Drug reaction with eosinophilia and systemic symptoms* on the face with facial swelling and erythema. This 40-year-old woman developed. *Drug reaction with eosinophilia and systemic symptoms* as a reaction to a new Dilantin prescription. (*Courtesy of Robert T. Gilson, MD.*)

FIGURE 203-19 *Drug reaction with eosinophilia and systemic symptoms* syndrome (drug reaction, eosinophilia, systemic symptoms). Erythroderma has persisted but the patient is feeling better after treatment and discharge from the hospital. (*Courtesy of Richard P. Usatine, MD.*)

- Severe reactions may need a complete blood count (CBC) with differential and comprehensive serum chemistry panel to look for systemic involvement and check hydration status.
- In more challenging cases, a skin biopsy may be helpful to confirm the diagnosis.
- Intradermal skin testing may be hazardous to patients, and patch tests are not useful.
- Skin biopsies are usually not required for diagnosis of WISN, but may aid in the diagnosis.
- Testing for thrombophilia (high platelet count) may also be done in WISN.
- Laboratory tests in patients with DRESS/DIHS may show atypical lymphocytes, eosinophilia, lymphocytopenia, and thrombocytopenia; liver abnormalities are often seen.

FIGURE 203-20 Acute generalized exanthematous pustulosis caused by a drug eruption. The clusters of small pustules with erythematous skin are seen on the buttocks. In this case the pustules and erythema covered major portions of the back and buttocks. (*Courtesy of Robert T. Gilson, MD.*)

DIFFERENTIAL DIAGNOSIS

- Viral exanthems look just like generalized maculopapular drug eruptions. Sometimes when a patient is given an antibiotic for an upper respiratory infection, the rash that ensues may be the viral exanthem rather than a drug eruption. The best way to avoid this confusion is only to use antibiotics when the evidence for bacterial infection is sufficient to justify the risks of a drug reaction. (See Section 4: Viral [Chapters 123 to 134] for more information on viral exanthems.)
- Urticarial reactions present as transient migratory circumscribed areas of blanching-raised erythema and edema of the superficial dermis. Patients experience itching. Identifying urticaria is easy compared with finding the precipitating factors. If there is a temporal association with starting a new drug, it is best to stop the drug (in most cases) and see if the urticaria resolves. (See Chapter 150, Urticaria and Angioedema.)
- EM presents with sudden onset of rapidly progressive, symmetrical, and cutaneus lesions with centripetal spread. The patient may have a burning sensation in affected areas but usually has no pruritus. EM is most often caused by a reaction to an infection such as herpes simplex virus (HSV) or mycoplasma but may be caused by a drug reaction. Careful history and physical examination can help differentiate between the possible causes (see Chapter 177, Erythema Multiforme, Stevens-Johnson Syndrome, and Toxic Epidermal Necrolysis).
- SJS and TEN present with generalized cutaneous lesion with blisters, fever, malaise, arthralgias, headache, sore throat, nausea, vomiting, and diarrhea. The patient may also have difficulty in eating, drinking, or opening his or her mouth secondary to erosion of oral mucous membranes (**Figure 203-16**). Not all SJS or TEN is secondary to drug exposure, but it is the job of the clinician to investigate this cause and stop any suspicious medications. SJS and TEN can be life-threatening (see Chapter 177, Erythema Multiforme, Stevens-Johnson Syndrome, and Toxic Epidermal Necrolysis).
- DRESS/DIHS can be distinguished by involvement of organs other than skin including liver (hepatitis in 50% to 70%), kidney (nephritis in 10%), and, more rarely, pneumonitis, colitis, myocarditis,

FIGURE 203-21 Systemic drug-related intertriginous and flexural exanthema. Because the pattern of erythema creates a red buttocks it may also be called the baboon syndrome. (*Courtesy of Robert T. Gilson, MD.*)

parotitis, meningitis, encephalitis, and pancreatitis; the pattern of organ involvement appears to depend on the drug trigger.[7,13] Some of the sequelae from DRESS/DHIS are strongly related to herpes virus reactivation.[7] A recurrence of symptoms at the third week is common. Diagnostic criteria have been proposed to include all of the following: maculopapular rash developing more than 3 weeks after drug exposure, prolonged clinical symptoms after drug discontinuation, fever (>38°C [100.4°F]), liver abnormalities or other organ involvement, leukocyte abnormalities (atypical lymphocytosis, leukocytosis, eosinophilia), lymphadenopathy, and human herpesvirus-6 reactivation.[13]

- Pityriasis rosea (PR) is a mysterious eruption of unknown etiology that could easily mimic a maculopapular drug eruption. Look and ask for the herald patch to help make the diagnosis of PR. In PR, look for the collarette scale and observe whether the eruption follows the skin lines (causing a Christmas tree pattern on the back). These features should help positively identify PR because there are no laboratory tests that are specific to PR or most drug eruptions (see Chapter 153, Pityriasis Rosea).
- Syphilis is the great imitator. Any generalized rash without a known etiology may be caused by secondary syphilis. A rapid plasma reagin (RPR) will always be positive in secondary syphilis and is easy to run (see Chapter 216, Syphilis).
- Bullous pemphigoid and pemphigus vulgaris can resemble a bullous drug eruption. Biopsies are the best way to diagnose these bullous diseases. Their clinical pictures are described in detail in Chapter 184, Bullous Pemphigoid, and Chapter 185, Pemphigus.
- Hematoma is a much more common complication of warfarin therapy and must be distinguished from WISN early to decrease permanent tissue damage; a high index of suspicion is needed and a very elevated international normalized ratio (INR) will confirm that bleeding is a result of overcoagulation (**Figure 203-22**).

FIGURE 203-22 Large bleed in the arm secondary to overcoagulation with Coumadin. The large hematoma was surgically evacuated to prevent neurovascular compromise to the arm. (*Courtesy of Richard P. Usatine, MD.*)

MANAGEMENT

NONPHARMACOLOGIC

- Discontinue the offending medication for all types of drug reactions whenever possible. Older patients with drug eruptions may be on multiple medications and may be very ill; however, efforts should be made to discontinue all nonessential medications.[5] SOR C
- Patients with maculopapular reactions may continue to be treated with the offending agent if it is essential for treating a serious underlying condition.[5]
- Maculopapular drug eruptions are not a precursor to severe reactions such as TEN.[5]
- Hyperpigmentation—Stop the drug if possible. In the case of Adriamycin-induced skin hyperpigmentation, the Adriamycin may be continued if it is the best chemotherapy for a life-threatening malignancy (**Figure 203-5**).
- Local wound care, debridement, and skin grafting may need to be performed to repair resultant disfigurement from necrosis.[14,15]

MEDICATIONS

- Maculopapular- and urticarial/angioedema-type drug reactions are treated with antihistamines. If the angioedema is causing airway compromise, epinephrine (10 mcg/kg intramuscular) and other treatments will be necessary.[5,13] SOR C Usually an H_1-blocker is started. In some cases of urticaria/angioedema, an H_2-blocker is added on for broader antihistamine effects (see Chapter 150, Urticaria and Angioedema).
- Diphenhydramine (Benadryl)—Adult dosing is 25 to 50 mg orally every 4 to 6 hours (nonprescription).
- Hydroxyzine (Atarax)—Adults receive 25 mg orally every 6 hours. Pediatric dose 0.5 to 1.0 mg/kg per day orally 4 times daily.[5]
- Loratadine (Claritin)—10 to 20 mg orally 1 time daily[5] (nonprescription).
- Any H_2-blocker can be used by prescription or nonprescription.
- Topical steroids such as triamcinolone or desonide may be used for symptomatic relief of pruritus.[5] SOR C
- Oral steroids have been used, but little benefit has been shown.[5] SOR C These are used in DRESS/DHIS.[13]
- FDEs are treated by discontinuing the drug and applying topical corticosteroids to the affected area.[4] SOR C

REFERRAL OR HOSPITALIZATION

Patients with WISN, SJS, TEN, and DRESS/DIHS are usually hospitalized.

- WISN treatment is generally supportive, including discontinuing the warfarin, admission to the hospital, and administration of vitamin K and fresh-frozen plasma.[14,15]
- Many clinicians recommend resuming heparin therapy if needed for the patient's underlying pathology that prompted the use of initial anticoagulation therapy.[14,15]
- SJS, TEN, DRESS/DIHS—Start with early diagnosis, rapid discontinuing of offending agent, intravenous fluid replacement, and placement in an intensive care unit (ICU) or burn unit (see Chapter 177, Erythema Multiforme, Steven-Johnson Syndrome, and Toxic Epidermal Necrolysis).[4,5] Liver transplant has been used in patients with DRESS.[13]
- Most experts and studies now agree that systemic corticosteroids should not be used.[4] SOR B
- Nutritional support, careful wound care, temperature control, and anticoagulation are recommended.[4] SOR C
- Daily skin samples should be sent for bacterial Gram stain and culture to monitor for developing infection.[4] SOR C

PREVENTION

- In the future, prevention may occur through screening for HLA associations and drug avoidance.[1]
- Avoid reexposure to the drug.
- Screening for HLA-B*1502 is advised by the U.S. FDA and Health Canada for patients of southeastern Asian ethnicity before carbamazepine therapy.[1]

PROGNOSIS

- Most cutaneous drug reactions resolve with discontinuation of the causative agent.
- Mortality, however, is high at 10% for SJS and DRESS/DHIS and 30% to 50% for TEN.[5,16] In a case series of patients with possible or probably DRESS, case fatality rate was 5% (9/172).[6]
- Some studies show the occurrence of autoimmune diseases, including type 1 diabetes mellitus, autoimmune thyroid disease, scleroderdmoid graft-versus-host disease (GVHD)-like lesions, and lupus erythematosus months to years after resolution of DIHS/DRESS.[7] Because of the long symptom-free interval in some patients, this relationship is questioned.

FOLLOW-UP

- Follow-up is most important when the case is severe or the diagnosis is uncertain. Clear-cut mild drug reactions may not need scheduled follow-up.
- Continued surveillance for autoimmune disorders may be warranted in patients following DRESS/DHIS.

PATIENT EDUCATION

- Most patients with drug eruptions recover fully without any complications. The patient should be warned that even after the responsible medication is stopped the eruptions may clear slowly or even worsen at first; the patient should be advised that the reaction may not resolve for 1 to 2 weeks.
- The patient should also be counseled that mild desquamation is normal as the exanthematous eruption resolves. Confirming the diagnosis of an FDE, especially lesions presenting on the glans, with a drug challenge may allay the patient anxiety about the venereal origin of the disease.
- The family should be counseled as to the genetic predisposition of some drug-induced eruptions.
- The patient should be advised to enroll in a medic alert program and to wear a bracelet detailing the allergy.

PATIENT RESOURCES

- MedlinePlus. *Drug Allergies*—**http://www.nlm.nih.gov/medlineplus/ency/article/000819.htm.**
- Mayo Clinic. *Stevens-Johnson Syndrome*—**http://www.mayoclinic.com/print/stevens-johnson-syndrome/DS00940/DSECTION=all&METHOD=print.**

PROVIDER RESOURCES

- **http://www.patient.co.uk/doctor/Drug-Eruptions.htm**
- **http://dermnetnz.org/reactions/drug-eruptions.html**
- Medscape. *Drug Eruptions*—**http://emedicine.medscape.com/article/1049474-overview.**

If the skin eruption is rare, serious, or unexpected, the drug reaction should be reported to the manufacturer and FDA.

REFERENCES

1. Sánchez-Borges M. NSAID hypersensitivity (respiratory, cutaneous, and generalized anaphylactic symptoms). *Med Clin North Am.* 2010;94(4):853-864.
2. Pichler WJ, Adam J, Daubner B, et al. Drug hypersensitivity reactions: pathomechanism and clinical symptoms. *Med Clin North Am.* 2010;94(4):645-664.
3. Phillips EJ, Chung WH, Mockenhaupt M, et al. Drug hypersensitivity: pharmacogenetics and clinical syndromes. *J Allergy Clin Immunol.* 2011;127(3 Suppl):S60-S66.
4. Nigen S, Knowles SR, Shear NH. Drug eruptions: approaching the diagnosis of drug-induced skin diseases. *J Drugs Dermatol.* 2003;2(3):278-299.
5. Habif T. *Skin Disease Diagnosis and Treatment*, 2nd ed. Philadelphia, PA: Mosby; 2005.
6. Cacoub P, Musette P, Descamps V, et al. The DRESS syndrome: a literature review. *Am J Med.* 2011;124(7):588-597.
7. Kano Y, Ishida T, Kazuhisa K, Shiohara T. Visceral involvements and long-term sequelae in drug-induced hypersensitivity syndrome. *Med Clin North Am.* 2010;94(4):743-759.
8. Bigby M. Rates of cutaneous reactions to drugs. *Arch Dermatol.* 2001;137(6):765-770.
9. Gerson D, Sriganeshan V, Alexis JB. Cutaneous drug eruptions: a 5-year experience. *J Am Acad Dermatol.* 2008 Dec;59(6):995-999.
10. Fernando SL, Broadfoot J. Prevention of severe cutaneous adverse drug reactions: the emerging value of pharmacogenetic screening. *CMAJ.* 2010;182(5):476-480.
11. Scherer K, Bircher AJ. Danger signs in drug hypersensitivity. *Med Clin North Am.* 2010;94(4):681-689.
12. Chosidow OM, Stern RS, Wintroub BU. Cutaneous drug reactions. In: Kasper DL, Fauci AS, Longo DL, Braunwald EB, Hauser SL, Jameson JL, eds. *Harrison's Principles of Internal Medicine*, 16th ed. New York, NY: McGraw-Hill; 2005:318-324.
13. Schnyder B. Approach to the patient with drug allergy. *Med Clin North Am.* 2010;94(4):665-679.
14. Alves DW, Chen IA. Warfarin-induced skin necrosis. *Hosp Physician.* 2002;38(8):39-42.
15. Stewart AJ, Penman ID, Cook MK, Ludlam CA. Warfarin-induced skin necrosis. *Postgrad Med J.* 1999;75:233-235.
16. Mockenhaupt M, Norgauer J. Cutaneous adverse drug reactions: Stevens-Johnson syndrome and toxic epidermal necrolysis. *Allergy Clin Immunol Int.* 2002;14:143-150.

204 KELOIDS

E.J. Mayeaux, Jr., MD
Richard P. Usatine, MD

PATIENT STORY

A 64-year-old black woman presents to the office with itching keloids on her chest (**Figure 204-1**). The horizontal keloid started during childhood when she was scratched by a branch of a tree. The vertical keloid is the result of bypass surgery 1 year ago. The lower portion of this area could be called a hypertrophic scar as it does not advance beyond the borders of the original surgery. The patient was happy to receive intralesional steroids to decrease her symptoms. Intralesional triamcinolone did, in fact, decrease the itching and flatten the vertical keloid.

FIGURE 204-1 Two keloids that cross the chest of a 64-year-old black woman. The horizontal keloid came from a scratch during childhood, and the vertical keloid is a result of open heart surgery. (*Courtesy of Richard P. Usatine, MD.*)

INTRODUCTION

Keloids are benign dermal fibroproliferative tumors that form in scar because of altered wound healing. They form as a result of overproduction of extracellular matrix and dermal fibroblasts that have a high mitotic rate.

SYNONYMS

Cheloid

EPIDEMIOLOGY

- Individuals with darker pigmentation are more likely to develop keloids. Sixteen percent of black persons reported having keloids in a random sampling.[1]
- Men and women are generally affected equally except that keloids are more common in young adult women—probably secondary to a higher rate of piercing the ears (**Figure 204-2**).[2]
- Highest incidence is in individuals ages 10 to 20 years.[2,3]

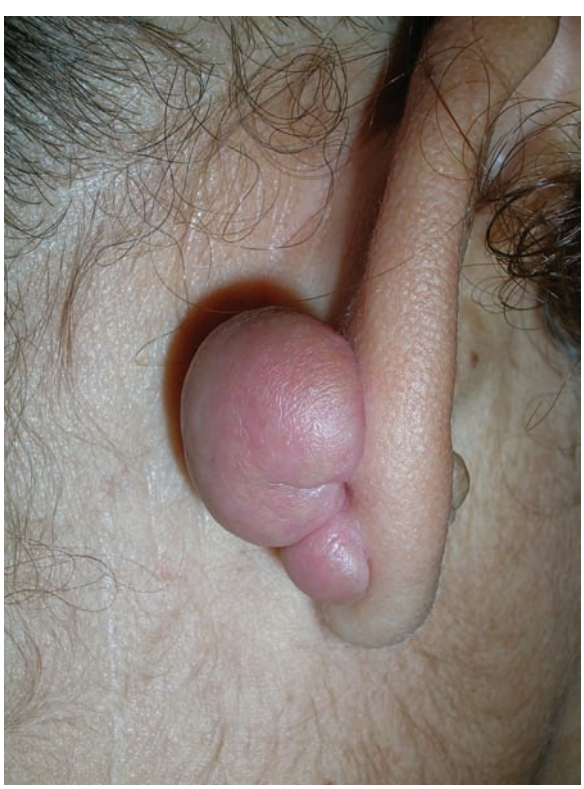

FIGURE 204-2 A keloid on the earlobe that started from piercing the ear. (*Courtesy of Richard P. Usatine, MD.*)

ETIOLOGY AND PATHOPHYSIOLOGY

- Keloids are dermal fibrotic lesions that are a variation of the normal wound-healing process in the spectrum of fibroproliferative disorders.
- Keloids are more likely to develop in areas of the body that are subjected to high skin tension such as over the sternum (**Figure 204-1**).
- These can occur even up to a year after the injury and will enlarge beyond the scar margin. Burns and other injuries can heal with a keloid in just one portion of the area injured (**Figure 204-3**).
- Wounds subjected to prolonged inflammation (acne cysts) are more likely to develop keloids.

RISK FACTORS[3]

- Darker skin pigmentation (African, Hispanic, or Asian ethnicity).
- A family history of keloids.
- Wound healing by secondary intention.
- Wounds subjected to prolonged inflammation.
- Sites of repeated trauma.
- Pregnancy.
- Body piercings (**Figure 204-4**).

DIAGNOSIS

CLINICAL FEATURES

- Some keloids present with pruritic pain or a burning sensation around the scar.
- Initially manifest as erythematous lesions devoid of hair follicles or other glandular tissue.
- Papules to nodules to large tuberous lesions (**Figure 204-5**).
- Range in consistency from soft and doughy to rubbery and hard. Most often, the lesions are the color of normal skin but can become brownish red or bluish and then pale as they age.[4]
- May extend in a claw-like fashion far beyond any slight injury.
- Lesions on neck, ears, and abdomen tend to become pedunculated.

TYPICAL DISTRIBUTION

- Anterior chest, shoulders, flexor surfaces of extremities, anterior neck, earlobes, and wounds that cross skin tension lines.

LABORATORY TESTING

- Biopsy is rarely needed to make a diagnosis because the clinical appearance is usually distinctive and clear.

DIFFERENTIAL DIAGNOSIS

- Hypertrophic scars can appear similar to keloids but are confined to the site of original injury.
- Acne keloidalis nuchae is an inflammatory disorder around hair follicles of the posterior neck that results in keloidal scarring (**Figure 204-6**). Although the scarring is similar to keloids the location and pathophysiology are unique. This process can also cause alopecia (Chapter 114, Pseudofolliculitis and Acne Keloidalis Nuchae).
- Dermatofibromas are common button-like dermal nodules usually found on the legs or arms. They may umbilicate when the surrounding skin is pinched. These often have a hyperpigmented halo around them and are less elevated than keloids (Chapter 160, Dermatofibroma).
- Dermatofibrosarcoma protuberans is a malignant version of the dermatofibroma. It usually presents as an atrophic, scar-like lesion developing into an enlarging firm and irregular nodular mass. If this is suspected, a biopsy is needed (Chapter 160, Dermatofibroma).

FIGURE 204-3 A keloid on the arm of a Hispanic woman burned accidentally by a hot iron at the age of 1 year. Most of the burn scar is not a keloid. The keloid is at the distal edge where the skin is raised nodular and pink. She has pruritus in that area. (*Courtesy of Richard P. Usatine, MD.*)

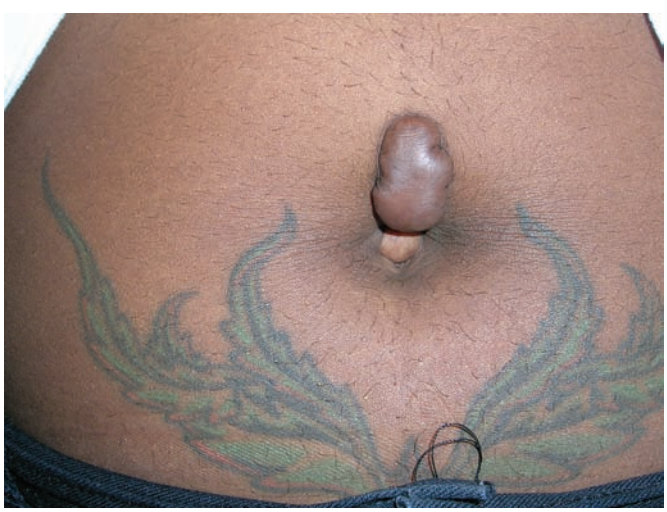

FIGURE 204-4 This keloid formed at the site of a belly button piercing in this young woman. (*Courtesy of Richard P. Usatine, MD.*)

FIGURE 204-5 Many keloids in a woman who develops keloids with even the most minor skin injuries. (*Courtesy of Richard P. Usatine, MD.*)

MANAGEMENT

- Patients frequently want keloids treated because of symptoms (pain and pruritus) and concerns about appearance.
- A 2006 systematic review of 396 studies and an accompanying metaanalysis of 36 articles concluded that no optimal evidence-based therapy exists and recommended choosing treatment based on cost and adverse effect profile.[5]

NONPHARMACOLOGIC

- Silicone gel sheeting as a treatment for hypertrophic and keloid scarring is supported by poor-quality trials susceptible to bias. There is only weak evidence of a benefit of silicone gel sheeting as prevention for abnormal scarring in high-risk individuals.[6,7] SOR B

MEDICATIONS

- Intralesional steroid injections—Intralesional injection of triamcinolone acetonide (10 to 40 mg/mL) may decrease pruritus, as well as decreasing size and flattening of keloids (**Figure 204-7**). SOR C This may be repeated monthly as needed.[5,8]
- Earlobe keloids can be treated with imiquimod 5% cream following tangential shave excision on both sides of the earlobe.[9,10] SOR B Patients were instructed to administer imiquimod 5% cream to the excision sites the night of the surgery and daily for 6 to 8 weeks postsurgery. Imiquimod 5% cream only temporarily prevented the recurrence of presternal keloids after excision.[11] SOR C
- Intralesional verapamil 2.5 mg/mL, bleomycin 1.5 IU/mL, and interferon α2b injections 1.5 million IU twice daily for 4 days are less-studied alternatives to corticosteroid treatment.[3] SOR C

COMPLEMENTARY AND ALTERNATIVE THERAPY

- No available evidence supports using nonprescription products such as Mederma and other creams, gels, and oils, to treat scars.[7] Limited clinical trials have failed to demonstrate lasting improvement of established keloids and hypertrophic scars with onion extract topical gel (e.g., Mederma) or topical vitamin E.[3] SOR B

SURGICAL

- Cryosurgery and intralesional triamcinolone have been used to treat smaller keloids (e.g., secondary to acne) with similar success to other therapies.[3,12] SOR B
- Combined cryosurgery and intralesional triamcinolone—The lesion is initially frozen with liquid nitrogen spray and allowed to thaw. Then it is injected with triamcinolone acetate (10 to 40 mg/mL). SOR C
- Earlobe keloids can be surgically excised with a shave or excisional technique and then injected with triamcinolone acetate (10 to 40 mg/mL) after hemostasis is obtained. The triamcinolone injection can be repeated in 1 month to decrease the chance of recurrence.[8] SOR B
- Keloids on the upper ear can be excised and the skin closed with sutures (**Figure 204-8**). SOR C
- Pulsed-dye laser treatment can be beneficial for keloids.[13] Combination treatment with pulsed-dye laser plus intralesional therapy

FIGURE 204-6 Acne keloidalis nuchae on the posterior neck of this young African-American man. (*Courtesy of Richard P. Usatine, MD.*)

FIGURE 204-7 Triamcinolone injected into this symptomatic keloid on the chest. Note how the keloid is blanching white, demonstrating that the steroid is properly injected into the body of the keloid. A Luer lock syringe is used to avoid the needle popping off during the injection under pressure and a 27-gauge needle is used to minimize patient discomfort. (*Courtesy of Richard P. Usatine, MD.*)

with corticosteroids and/or fluorouracil 50 mg/mL 2 to 3 times per week may be superior to either approach alone.[14] SOR C

- Keloids can be treated with cryosurgery alone or in combination with intralesional steroids. In one, small, controlled study, 10 patients with keloids were treated with intralesional steroid and cryosurgery vs. intralesional steroid or cryosurgery alone.[15] SOR B Patients were treated at least 3 times 4 weeks apart. Based upon keloid thickness, the keloids responded significantly better to combined cryosurgery and triamcinolone versus triamcinolone alone or cryotherapy alone. Pain intensity was significantly lowered with all treatment modalities. Pruritus was lowered only with the combined treatment and intralesional corticosteroid alone.[15]
- In another study, 20 patients with hypertrophic and keloidal scars received two 15-second cycles (total 30 seconds) of cryosurgery treatments once monthly for 12 months with intralesional injections of 10 to 40 mg/mL triamcinolone once monthly for 3 months.[16] SOR B Topical application of silicone gel was added 3 times daily for 12 months. The control group included 10 patients who received treatment with silicone sheeting only. After 1 year there was improvement in all the parameters, especially in terms of symptoms, cosmetic appearance, and associated signs, compared to baseline and compared to the control group.[16] SOR B
- Layton et al. reported that the intralesional injection of a steroid is helpful but cryotherapy is more effective (85% improvement in terms of flattening) for recent acne keloids located on the back.[17] Treatment with intralesional triamcinolone was beneficial, but the response to cryosurgery was significantly better in early, vascular lesions.[17] SOR B
- If the keloid is older and/or firmer, it may not respond to injection therapy as well as softer and newer lesions. It may help to pretreat the keloid with cryotherapy. It is not necessary to freeze a margin of normal tissue. After liquid nitrogen or another freezing modality is applied to the keloid, it is allowed to thaw and develop edema. This generally takes 1 to 2 minutes, which allows an easier introduction of intralesional steroids into the lesions. SOR C
- In one double-blind, clinical trial, 40 patients were randomized to receive intralesional triamcinolone (TAC) or a combination of TAC and 5-fluorouracil (5-FU).[18] Both groups received injections at weekly intervals for 8 weeks and lesions were assessed for erythema, pruritus, pliability, height, length, and width. Both groups showed an acceptable improvement in nearly all parameters, but these were more significant in the TAC plus 5-FU group ($P < 0.05$ for all except pruritus and percentage of itch reduction). Good-to-excellent improvement was reported by 20% of the patients receiving TAC alone and by 55% of the patients in the group receiving TAC plus 5-FU.[18] SOR B
- Earlobe keloids may be excised with a shave excision and injection of the base with steroid. It is hard to get much volume of steroid into the base of these keloids, so 40 mg/mL triamcinolone is preferred as the concentration for injection. SOR C Another option is to use radiofrequency electrosurgery technique with a pure cutting setting (and using steroid in the anesthetic).
- According to one article, simple excision of earlobe keloids can result in recurrence rates approaching 80%.[19] A randomized, prospective trial comparing steroid injections versus radiation therapy

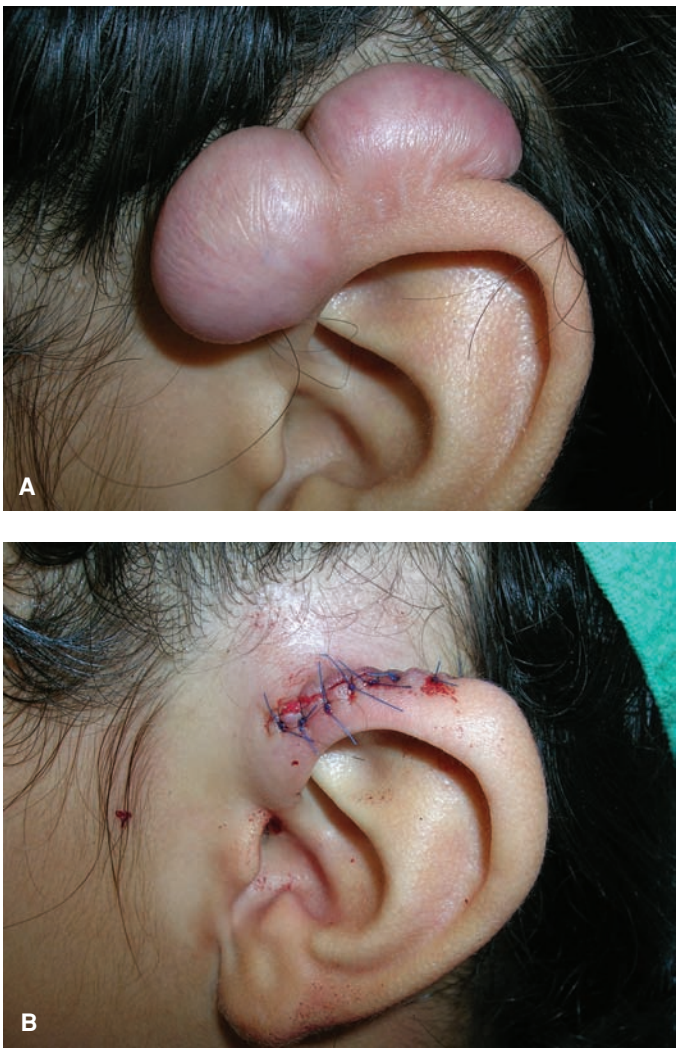

FIGURE 204-8 **A.** A large keloid has been present on the upper ear of this 14-year-old boy for more than 2 years, since he experienced trauma to this area. **B.** The keloid was excised in the office with local anesthetic and the defect sutured using 5-0 Prolene. The cosmetic result was excellent. (*Courtesy of Richard P. Usatine, MD.*)

found that 2 of 16 keloids (12.5%) recurred after surgery and radiation therapy, whereas 4 of 12 (33%) recurred after surgery and steroid injections. These results did not produce a statistically significant difference. No alteration of skin pigmentation, wound dehiscence, or chronic dermatitis was observed in any patient in either group.[19] Although radiation therapy was considered easy to obtain in this study, it is reasonable to use steroid injections in office practice.

PREVENTION

- Avoiding trauma, including surgical trauma, whenever possible may decrease keloids in susceptible individuals.

PROGNOSIS

- A 2006 systematic review of 396 studies and an accompanying metaanalysis of 36 articles concluded that any treatment gave patients an overall 70% (95% confidence interval, 49% to 91%) chance of improvement.[5]

FOLLOW-UP

- Follow-up is based on the chosen treatment. Follow-up for intralesional steroid injections is usually in 1 month.

PATIENT EDUCATION

- Advise patients to avoid local skin trauma, for example, ear piercing, body piercing, and tattoos, and to control inflammatory acne.

PATIENT RESOURCES

- MedlinePlus. *Keloids*—**http://www.nlm.nih.gov/medlineplus/ency/article/000849.htm.**
- Skinsight. *Keloid Information for Adults*—**http://www.skinsight.com/adult/keloid.htm.**

PROVIDER RESOURCES

- Medscape. *Keloid and Hypertrophic Scar* (Dermatology)—**http://emedicine.medscape.com/article/1057599.**
- Medscape. *Keloids* (Plastic Surgery)—**http://emedicine.medscape.com/article/1298013.**
- Usatine R, Pfenninger J, Stulberg D, Small R. Dermatologic and Cosmetic Procedures in Office Practice. Philadelphia, PA: Elsevier; 2012. Available as a text with DVD or electronic application. Contains details, photographs and videos on how to use cryosurgery and intralesional injections to treat keloids—**http://usatinemedia.com/Usatine_Media_LLC/DermProcedures_Overview.html.**

REFERENCES

1. Chike-Obi CJ, Cole PD, Brissett AE. Keloids: pathogenesis, clinical features, and management. *Semin Plast Surg*. 2009;23:178-184.
2. Alhady SM, Sivanantharajah K. Keloids in various races. A review of 175 cases. *Plast Reconstr Surg*. 1969;44(6):564-566.
3. Juckett G, Hartman-Adams H. Management of keloids and hypertrophic scars. *Am Fam Physician*. 2009;80(3):253-260.
4. Urioste SS, Arndt KA, Dover JS. Keloids and hypertrophic scars: review and treatment strategies. *Semin Cutan Med Surg*. 1999;18:159-171.
5. Leventhal D, Furr M, Reiter D. Treatment of keloids and hypertrophic scars: a meta-analysis and review of the literature. *Arch Facial Plast Surg*. 2006;8:362-368.
6. O'Brien L, Pandit A. Silicon gel sheeting for preventing and treating hypertrophic and keloid scars. *Cochrane Database Syst Rev*. 2006;(1):CD003826.
7. Williams CC, De Groote S. Clinical inquiry: what treatment is best for hypertrophic scars and keloids? *J Fam Pract*. 2011;60(12):757-758.
8. Shaffer JJ, Taylor SC, Cook-Bolden F. Keloidal scars: a review with a critical look at therapeutic options. *J Am Acad Dermatol*. 2002;46:S63.
9. Patel PJ, Skinner RB Jr. Experience with keloids after excision and application of 5% imiquimod cream. *Dermatol Surg*. 2006;32:462.
10. Stashower ME. Successful treatment of earlobe keloids with imiquimod after tangential shave excision. *Dermatol Surg*. 2006;32:380-386.
11. Malhotra AK, Gupta S, Khaitan BK, Sharma VK. Imiquimod 5% cream for the prevention of recurrence after excision of presternal keloids. *Dermatology*. 2007;215:63-65.
12. Layton AM, Yip J, Cunliffe WJ. A comparison of intralesional triamcinolone and cryosurgery in the treatment of acne keloids. *Br J Dermatol*. 1994;130:498-501.
13. Alster TS, Williams CM. Treatment of keloid sternotomy scars with 585 nm flashlamp-pumped pulsed-dye laser. *Lancet*. 1995;345:1198.
14. Asilian A, Darougheh A, Shariati F. New combination of triamcinolone, 5-fluorouracil, and pulsed-dye laser for treatment of keloid and hypertrophic scars. *Dermatol Surg*. 2006;32:907-915.
15. Yosipovitch G, Widijanti SM, Goon A, Chan YH, Goh CL. A comparison of the combined effect of cryotherapy and corticosteroid injections versus corticosteroids and cryotherapy alone on keloids: a controlled study. *J Dermatolog Treat*. 2001;12:87-89.
16. Boutli-Kasapidou F, Tsakiri A, Anagnostou E, Mourellou O. Hypertrophic and keloidal scars: an approach to polytherapy. *Int J Dermatol*. 2005;44:324-327.
17. Layton AM, Yip J, Cunliffe WJ. A comparison of intralesional triamcinolone and cryosurgery in the treatment of acne keloids. *Br J Dermatol*. 1994;130:498-501.
18. Darougheh A, Asilian A, Shariati F. Intralesional triamcinolone alone or in combination with 5-fluorouracil for the treatment of keloid and hypertrophic scars. *Clin Exp Dermatol*. 2009;34:219-223.
19. Sclafani AP, Gordon L, Chadha M, Romo T, III. Prevention of earlobe keloid recurrence with postoperative corticosteroid injections versus radiation therapy: a randomized, prospective study and review of the literature. *Dermatol Surg*. 1996;22:569-574.

205 GENODERMATOSES

Michael J. Babcock, MD
Richard P. Usatine, MD

PATIENT STORY

A 45-year-old black man presents with greasy scale over his face and large parts of his chest and back (**Figure 205-1**). A previous biopsy was diagnostic for Darier disease. His mother has the same condition. His sister has the full-blown disease. His brother has similar nail findings, but his skin is affected only behind the ears (**Figure 205-2**). The patient has suffered with this condition for his entire life and believes that he has been ostracized from normal social life because of his appearance and bad body odor. He suffers from depression and has used various substances to treat his pain. Topical steroids provide some help for the itching and scaling, but the patient is looking for a more effective treatment. The cost of oral retinoids is currently prohibitive, but an application has been put in for patient assistance to receive acitretin.

INTRODUCTION

There are more than 100 genetic syndromes with cutaneous manifestations that are referred to as genodermatoses. For example, there are disorders of pigmentation (albinism), cornification (the ichthyoses and Darier disease), vascularization (Sturge-Weber syndrome), connective tissue (Ehlers-Danlos syndrome), porphyrin metabolism, other errors of metabolism (phenylketonuria), the immune system (Wiskott-Aldrich syndrome), and DNA repair (ataxia-telangiectasia and xeroderma pigmentosa), to name a few. Some textbooks are dedicated to the topic of genodermatoses alone.[1] This chapter introduces the topic and illustrates a couple of genodermatoses. We have chosen two disorders of cornification as an introduction to the genodermatoses: Darier disease and X-linked ichthyosis.

EPIDEMIOLOGY

- Darier disease (keratosis follicularis)—1:30,000 to 1:100,000. Males and females are equally affected. Clinically becomes apparent near puberty.
- X-linked ichthyosis—1:2000 to 1:6000 males. Clinical lesions present typically during the first 1 to 2 months of life.

ETIOLOGY AND PATHOPHYSIOLOGY

- Darier disease—An abnormal calcium pump in the sarco-/endoplasmic reticulum, SERCA2, results from a gene mutation in the ATP2A2 gene. It is inherited in an autosomal-dominant fashion and results in abnormal epidermal differentiation.
- X-linked ichthyosis—A deletion of the steroid sulfatase gene results in keratinocyte retention by inhibiting degradation of the desmosome. It is inherited in an X-linked recessive manner.

FIGURE 205-1 Darier disease with greasy scales, hyperkeratotic and hyperpigmented papules and plaques in a seborrheic distribution involving the **(A)** face, neck, and chest, and **(B)** back, neck, ears, and scalp. Sunlight and heat make his disease worse. (*Courtesy of Richard P. Usatine, MD.*)

DIAGNOSIS

DARIER DISEASE

- Clinical features—Greasy, hyperkeratotic, yellowish-brown papules in a seborrheic distribution (**Figures 205-1** to **205-3**). The feet can be covered with hyperkeratotic plaques (**Figure 205-4**). The palms may have pits or keratotic papules, and the nails can have V-shaped nicking and alternating longitudinal red and white bands (**Figure 205-5**). The keratotic papules can be intensely malodorous such that it can interfere with normal social situations.
- Typical distribution—The clinical lesions involve skin in the seborrheic distribution (face, ears, scalp, upper chest, upper back, and groin) (**Figures 205-1** to **205-4**). The axilla and inframammary areas may be involved (**Figure 205-6**). In early, mild, or partially treated disease, only the skin behind the ears may be affected (**Figure 205-7**).[2] The nails are characteristically involved.
- Laboratories—Skin biopsy reveals the characteristic histopathology. A test for the ATP2A2 gene mutation can be performed.

X-LINKED ICHTHYOSIS

- Clinical features—Firm, adherent, fish-like brown scale noted early in the life of young affected boys whose mothers were carriers of the gene on their X chromosome (**Figures 205-8** and **205-9**). These boys have an increased incidence of cryptorchidism and are at an increased risk of testicular cancer, independent of the risk from cryptorchidism alone.[2,3] Often they are delivered by cesarian section because a placental sulfatase deficiency results in failure of labor progression. These patients can have corneal opacities on the Descemet membrane of the posterior capsule, which does not affect their vision.
- Typical distribution—Most of the body is involved, except for the typical sparing of the flexures, face, palms, and soles. The antecubital fossae are notably spared (**Figure 205-9**). There is an accentuation noted on the neck, giving these patients a characteristic "dirty neck" appearance.
- Tight skin over the fingers can be as a manifestation of X-linked ichthyosis (**Figure 205-10**).
- Laboratories—Increased levels of serum cholesterol sulfate levels (steroid sulfatase hydrolyses cholesterol sulfate). Steroid sulfatase activity can also be measured directly.

DIFFERENTIAL DIAGNOSIS

DARIER DISEASE[4]

- Hailey-Hailey disease (aka benign familial pemphigus)—Another genodermatosis with crusted erosions and flaccid vesicles distributed in the intertriginous areas as opposed to the greasy keratotic papules in the seborrheic distribution (**Figure 205-11**). A 4-mm punch biopsy is adequate to make this diagnosis.
- Grover disease—This presents sporadically as many small, pruritic, erythematous to reddish-brown hyperkeratotic papules on the trunk of older adults. These typically result from conditions that cause sweating or occlusion (like lying in a hospital bed) (Chapter 117, Folliculitis).

FIGURE 205-2 Darier disease present in three siblings. The brother on the left and the sister have the full blown disease. The sister's face cleared after 3 months of acitretin. The brother on the right has similar nail findings, but his skin is affected only behind the ears. As a family physician, I take care of all three siblings and their mother who also has the disease. (*Courtesy of Richard P. Usatine, MD.*)

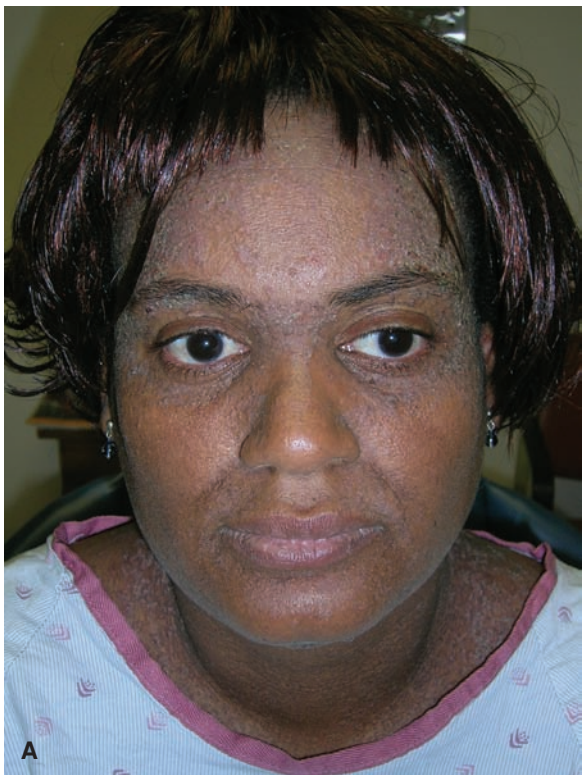

FIGURE 205-3 **A.** Darier disease with greasy, hyperkeratotic scaling plaques on the face of the 44-year-old woman (sister of the patient in **Figure 205-1**) with Darier disease prior to her use of acitretin. She is wearing a wig to cover the alopecia and plaques on her scalp. **B.** Close-up of the hyperkeratotic scaling plaques on the forehead, scalp, and ears. Note the seborrheic distribution. (*Courtesy of Richard P. Usatine, MD.*)

FIGURE 205-4 Thick hyperkeratotic plaque on the heel of the woman with Darier disease. (*Courtesy of Richard P. Usatine, MD.*)

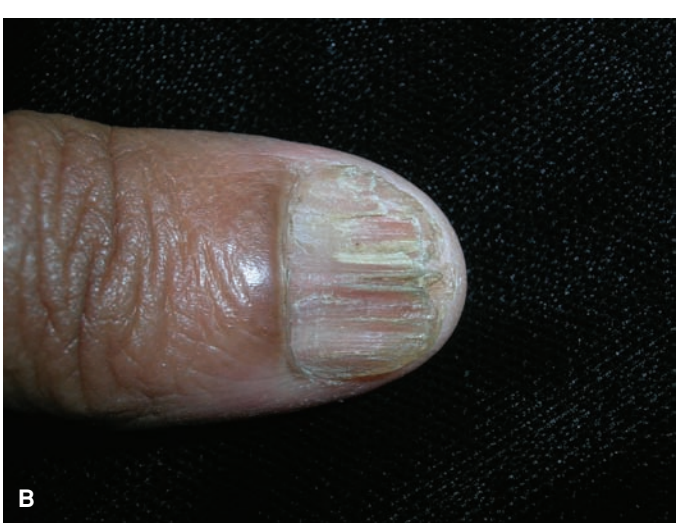

FIGURE 205-5 **A.** Typical nail findings in Darier disease showing longitudinal bands and longitudinal splitting. **B.** V-shaped nick at the free margin of the fingernail—the most pathognomonic nail finding in Darier disease. (*Courtesy of Richard P. Usatine, MD.*)

FIGURE 205-6 Darier disease with axillary and inframammary involvement in this 64-year-old woman. (*Courtesy of Richard P. Usatine, MD.*)

FIGURE 205-8 Heavy fish scale of X-linked ichthyosis on the legs of two affected brothers. (*Courtesy of Richard P. Usatine, MD.*)

FIGURE 205-7 Darier disease with hyperkeratotic papules behind the ear of this middle-aged white man. (*Courtesy of Richard P. Usatine, MD.*)

FIGURE 205-9 X-linked ichthyosis in two brothers showing sparing of the antecubital fossae of the arms amidst the heavy scales. (*Courtesy of Richard P. Usatine, MD.*)

- Seborrheic dermatitis—Erythematous patches and thin plaques with yellow greasy scale on the scalp, central face, and chest. This is rarely as severe as Darier disease (Chapter 151, Seborrheic Dermatitis).

X-LINKED ICHTHYOSIS

- Ichthyosis vulgaris—A relatively common condition that is inherited in an autosomal dominant manner (approximately 1 in 250 people affected). It presents in childhood with a fine adherent scale in similar distribution to X-linked ichthyosis (**Figure 205-12**). These patients frequently have hyperlinear palms, keratosis pilaris, and atopic dermatitis, which are not commonly associated with X-linked ichthyosis.
- Acquired ichthyosis does not occur until adulthood. It is not inherited and may be associated with some systemic disease. The time of onset is the key to diagnosis. The legs are often are most involved and the skin appears similar to fish-scales (**Figure 205-13**).
- Lamellar ichthyosis—A more severe and rare disorder that has a plate-like scale, which involves most of the body, including the face and flexures (**Figure 205-14**). These patients are typically born as a collodion baby (they have a thin translucent membrane that surrounds the baby at birth).
- Asteatotic eczema—Dry skin that has a "dried riverbed" or "cracked porcelain" appearance, which usually involves the lower extremities. There may be erythema and serous exudate associated with the cracks. It typically presents in the winter, improves during the rest of the year, and is also known as winter itch or eczema craquelé (Chapter 145, Atopic Dermatitis).
- Xerosis—Dry scaly skin most notably on legs without significant inflammation. This is very common compared with any ichthyosis.

FIGURE 205-10 This man has tight skin over the fingers as a manifestation of his X-linked ichthyosis. (*Courtesy of Richard P. Usatine, MD.*)

MANAGEMENT

- Darier disease is so rare that there are no randomized controlled trials to guide treatment.
- The intense malodor that accompanies the disease, as well as the facial involvement, often adversely affects the patient's quality of life; thus, treatment is often warranted. Mild-to-moderate disease can be treated by avoiding exacerbating factors (sunlight, heat, and occlusion) and with topical medications, SOR C but severe disease is best treated with oral retinoids. SOR C
- Topical retinoids (adapalene, tretinoin, or tazarotene) are effective in some patients, but their main limitation is irritation. Adapalene use may be effective in localized variants.[5] SOR C All retinoids are contraindicated in pregnancy.
- Topical corticosteroids may be of some help. Lower-potency topical corticosteroids should be used on the face, groin, and axillae to minimize side effects in these areas. SOR C
- Topical calcineurin inhibitors (pimecrolimus and tacrolimus) may also be helpful as noted in some case reports.[6,7] SOR C These do not have a risk of skin atrophy like steroids, but are generally more expensive and have a controversial black box warning.

FIGURE 205-11 Hailey-Hailey disease, also known as benign familial pemphigus, on the back of a 54-year-old man. This genodermatosis has a similar appearance to Darier disease and also occurs in a seborrheic distribution. (*Courtesy of Richard P. Usatine, MD.*)

- Systemic retinoids (acitretin or isotretinoin) are the most potent treatment and treatment of choice for severe disease.[8] SOR C They should only be prescribed by physicians who have experience with these medications. Patients on systemic retinoids require close monitoring and careful selection, as they are teratogenic (category X) and can cause hyperlipidemia, hypertriglyceridemia, mucous membrane dryness, alopecia, hepatotoxicity, and possible mood disturbances. Females must not get pregnant for at least 1 month after stopping isotretinoin and at least 3 years after stopping acitretin.
- Cyclosporine can be used for acute flares but should also only be prescribed by a physician who has experience with this medication. It should only be used temporarily and requires close follow-up for monitoring hypertension and nephrotoxicity. It is metabolized by the common cytochrome P450 3A4 system and has many medication interactions.
- Topical or oral antibiotics may be necessary for flares as they often are secondarily infected with bacteria. SOR C
- Laser, radiation, photodynamic, and gene therapy are newer treatment modalities that are being investigated.
- X-linked ichthyosis is rare and treatments are based on the clinical experience of experts rather than large studies.
- Frequent application of emollients, humectants, and keratinolytics are the mainstay of therapy. SOR C There are many effective nonprescription and prescription products that contain propylene glycol, urea, or lactic acid. Salicylic acid products should be used only on a limited body surface area, as systemic absorption has led to salicylate toxicity in some patients.
- Topical retinoids can be used, SOR C but systemic retinoids are rarely used.
- Refer to a urologist or ophthalmologist if testicular abnormality or corneal opacities are detected. SOR C
- Gene therapy has also been studied but has not yet become a viable treatment option.

FIGURE 205-12 Ichthyosis vulgaris starts in childhood and has a fine scale. (*Courtesy of Richard P. Usatine, MD.*)

FOLLOW-UP

- Darier disease—Follow-up is needed if patients are on oral retinoids to monitor patients' lipid panel and liver function tests approximately every 3 months. They should also be monitored for signs of secondary bacterial infection.
- X-linked ichthyosis—Monitoring for corneal opacities and for testicular cancer in men should be performed at follow-up visits.

PATIENT EDUCATION

DARIER DISEASE

- Avoid direct sunlight, heat, occlusion, and people acutely infected with herpes simplex virus (HSV) or varicella-zoster virus.
- Watch for signs of secondary cutaneous bacterial or viral infections.

X-LINKED ICHTHYOSIS

- Use daily moisturizers, especially in dry climates and in the winter.

FIGURE 205-13 Acquired ichthyosis starts in adulthood and is especially prominent on the legs. (*Courtesy of Richard P. Usatine, MD.*)

PATIENT RESOURCES

- There are patient advocacy groups for several genetic skin conditions. A quick search online can obtain their websites and contact information.
- The American Academy of Dermatology has a summer camp that is free of charge for children with skin conditions called Camp Discovery. Information can be found at **http://www.campdiscovery.org/.**

PROVIDER RESOURCES

- A helpful free online resource for the genodermatoses, or any genetic disease for that matter, is the Online Mendelian Inheritance of Man website at **http://www.omim.org.**
- For information on laboratories that perform rare genetic tests and clinics that perform prenatal diagnostic testing for certain conditions, see **http://www.genetests.org.**
- Skin Advocate is a free application for mobile devices that is provided by the Society of Investigative Dermatology. It lists contact information for various patient advocacy groups.

FIGURE 205-14 Lamellar ichthyosis is another genodermatosis that is more rare and severe than X-linked ichthyosis. **A.** Note the deep lines and severe dryness of the skin on the face of this girl with lamellar ichthyosis. **B.** Her arm is severely affected so that she cannot extend her elbow fully. (*Courtesy of Richard P. Usatine, MD.*)

REFERENCES

1. Spitz J. *Genodermatoses: A Clinical Guide to Genetic Skin Disorders*, 2nd ed. Philadelphia, PA: Lippincott Williams & Wilkins; 2005.
2. James W, Berger T, Elston D. *Andrews' Diseases of the Skin: Clinical Dermatology*, 11th ed. Amsterdam, The Netherlands: Elsevier; 2011.
3. Hazan C, Orlow S, Schagger J. X-linked recessive ichthyosis. *Dermatol Online J*. 2005;11(4):12.
4. Khachemoune A, Lockshin B. Chronic papules on the back and extremities. *J Fam Pract*. 2004;53(5):361-363.
5. Casals M, Campoy A, Aspiolea F, et al. Successful treatment of linear Darier's disease with topical adapalene. *J Eur Acad Dermatol Venerol*. 2009;23(2):237-238.
6. Pérez-Carmona L, Fleta-Asín B, Moreno-García-Del-Real C, et al. Successful treatment of Darier's disease with topical pimecrolimus. *Eur J Dermatol*. 2011;21(2):301-302.
7. Rubegni P, Poggiali S, Sbano P, et al. A case of Darier's disease successfully treated with topical tacrolimus. *J Eur Acad Dermatol Venereol*. 2006;20(1):84-87.
8. Bolognia J, Jorizzo J, Rapini R. *Dermatology*. London, UK: Mosby; 2003.

206 ERYTHEMA ANNULARE CENTRIFUGUM

Shehnaz Zaman Sarmast, MD
Richard P. Usatine, MD

PATIENT STORY

A 57-year-old farm worker presents with itchy red rings on his body that have come and gone for more than 13 years (**Figures 206-1** and **206-2**). The erythematous annular eruption was visible on his abdomen, legs, and arms. **Figure 206-2** shows the typical "trailing scale" of erythema annular centrifugum (EAC). A KOH preparation was negative for fungal elements and the patient was given the diagnosis of EAC. He recently began using paint thinner to "dry out the rash" and decrease the itching. Because topical steroids did not provide any relief for him in the past, we offered the option of using calcipotriol ointment. He chose to try the calcipotriol and stop using paint thinner.

FIGURE 206-1 Erythema annulare centrifugum with large erythematous rings on the trunk and legs of a 57-year-old man. (*Courtesy of Richard P. Usatine, MD. Reproduced with permission from Brand ME, Usatine RP. Persistent itchy pink rings. J Fam Pract. 2005;54(2):131-133. Reproduced with permission from Frontline Medical Communications.*)

INTRODUCTION

EAC is an uncommon inflammatory skin disease characterized by slowly migrating annular or configurate erythematous lesions.

SYNONYMS

Erythema gyratum perstans, erythema exudativum perstans, erythema marginatum perstans, erythema perstans, erythema figuratum perstans, erythema microgyratum perstans, and erythema simplex gyratum.

EPIDEMIOLOGY

- It may begin at any age (mean age of onset: 39.7 years), with no predilection for either sex.[1]
- The mean duration of skin condition is 2.8 years but may last between 4 weeks and 34 years.[2]

ETIOLOGY AND PATHOPHYSIOLOGY

- Unknown etiology and pathogenesis, but EAC has been associated with other medical conditions, such as fungal infections (in 72% of cases),[1] malignancy, and other systemic illness. Few case reports have reported the diagnosis of cancer 2 years after presentation of EAC.[2]
- Other infections identified as triggers for EAC include bacterial infections such as cystitis, appendicitis, and tuberculosis (TB); viral infections such as Epstein-Barr virus (EBV), molluscum contagiosum, and herpes zoster; and parasites, such as *Ascaris*.[2]

FIGURE 206-2 Erythema annulare centrifugum with conjoined rings on the thigh. *Arrow* pointing to "trailing scale," which appears as a white scaling line within the erythematous border. (*Courtesy of Richard P. Usatine, MD. Reproduced with permission from Brand ME, Usatine RP. Persistent itchy pink rings. J Fam Pract. 2005;54(2):131-133. Reproduced with permission from Frontline Medical Communications.*)

- Certain drugs, such as chloroquine, hydroxychloroquine, estrogen, cimetidine, penicillin, salicylates, piroxicam, hydrochlorothiazide, amitriptyline, lenalidomide, finasteride, and etizolam, can also trigger EAC.[2–6]
- Systemic diseases involving the liver, dysproteinemias, autoimmune disorders, HIV, and pregnancy are associated with EAC by various case reports.[2,7,8]
- Because injections of *Trichophyton*, *Candida,* tuberculin, and tumor extracts have been reported to induce EAC, a type IV hypersensitivity reaction is thought to be one possible mechanism for its development.[8]

DIAGNOSIS

CLINICAL FEATURES

- Large, scaly, erythematous plaques, which begin as papules and spread peripherally with a central clearing forming a "trailing" scale. The margins are indurated and may vary in width from 4 to 6 mm[1,2] (**Figures 206-1** to **206-4**).
- Pruritus is common but not always present.[2]
- Slowly progressing but may enlarge up to 2 to 5 mm/day.[2]
- Evaluation of a skin biopsy specimen by light microscopy reveals parakeratosis and spongiosis within the epidermis and a tightly cuffed lymphohistiocytic perivascular infiltrate with focal extravasation of erythrocytes in the papillary dermis.[10]

TYPICAL DISTRIBUTION

- Lesions typically found in lower extremities, particularly the thighs, but also can be found on trunk and face.[1,2]

LABORATORY STUDIES

- No specific laboratory tests are necessary to diagnose EAC, but laboratory tests may be obtained to rule out other common conditions. Consider a KOH prep to search for tinea corporis or cutaneous candidiasis. If the patient has been in an area with Lyme disease, consider *Borrelia* titers to rule out Lyme disease.[2,7]

BIOPSY

- If the diagnosis is uncertain, a punch biopsy can be performed to look for the typical histology of EAC, and a periodic acid-Schiff (PAS) stain can be performed on the specimen to look for fungal elements. Other diseases on the differential diagnosis, such as psoriasis, cutaneous lupus, and sarcoidosis, can be diagnosed with a punch biopsy.

DIFFERENTIAL DIAGNOSIS

- Pityriasis rosea has erythematous patch distributed on trunk and lower extremities, but these patches have distinctive collarette border and typically have a "herald patch" that appears first. Classically, the patches have a "Christmas tree" pattern in the back and, unlike EAC, last only 6 to 8 weeks[2] (see Chapter 153, Pityriasis Rosea).

FIGURE 206-3 Erythema annulare centrifugum on the arm with trailing scale. Note the largest ring is not a complete circle. (*Courtesy of Richard P. Usatine, MD.*)

FIGURE 206-4 Erythema annular centrifugum in the axilla of a 28-year-old man, which had repeatedly been mistaken for tinea corporis. The trailing scale is visible and a punch biopsy confirmed the diagnosis of erythema annular centrifugum. (*Courtesy of Richard P. Usatine, MD.*)

- Tinea corporis (ringworm) presents with one or multiple areas of annular plaques caused by a dermatophyte fungal infection. Tinea corporis often produces red scaling rings that resemble EAC. However, the scale in tinea corporis tends to lead with the erythema inside the ring and the scale on the outside (**Figure 206-5**). This is the opposite of the trailing scale seen with EAC (**Figure 206-6**). KOH prep shows branched hyphae with septae. Tinea corporis responds to antifungal treatment.[2] **Figure 206-4** shows a case of EAC that was mistaken for tinea corporis by a number of physicians (see Chapter 138, Tinea Corporis).
- Psoriatic plaques can be annular but do not have the trailing scale that is characteristic of EAC. Psoriasis will respond to steroid therapy[2] (see Chapter 152, Psoriasis).
- Erythema migrans seen in Lyme disease is a large annular rash with central clearing. The red ring in erythema migrans is usually smooth without the scale seen in EAC. Patients usually have other signs of infection, positive antibodies, and may have a history of tick bite (see Chapter 218, Lyme Disease).
- Erythema gyratum repens, which is typically seen in association with malignancies, has concentric rings but trailing scale is noted.
- Cutaneous lupus could present with annular or papulosquamous plaques, with or without scales, on sun-exposed areas. Patients with lupus generally have other systemic symptoms and positive antinuclear antibodies[9] (see Chapter 180, Lupus: Systemic and Cutaneous).
- Sarcoidosis may present with annular indurated papules and plaques, but they are more commonly found on the face. Patients may have other systemic manifestations of sarcoidosis. Sarcoidosis can effectively be treated with systemic corticosteroids[11] (see Chapter 175, Sarcoidosis).
- Mycosis fungoides, a type of cutaneous T cell lymphoma, can mimic EAC (Chapter 176, Cutaneous T Cell lymphoma).[12]

FIGURE 206-5 Tinea corporis with leading scale (arrows). The white scale is on the outside of the ring and the erythema is on the inside. KOH prep was positive. (*Courtesy of Richard P. Usatine, MD.*)

MANAGEMENT

- There is no proven treatment for EAC. Identifying and treating underlying medical conditions may help resolve the skin condition. Because EAC is seen in association with certain drugs, discontinuing the offending medication may resolve the problem.
- Topical corticosteroids have been traditionally used but there is little evidence to support their use. SOR C
- Case reports have reported benefits of using calcipotriol (Dovonex) daily for EAC.[13] Another case report described a good outcome for a patient with EAC being treated with calcipotriol and narrow-band UVB phototherapy.[14] Case reports have shown etanercept and metronidazole to be beneficial as well.[15,16]

FIGURE 206-6 Erythema annulare centrifugum on the buttocks and upper thigh showing trailing scale (arrows) inside the ring of erythema. KOH prep was negative. (*Courtesy of Richard P. Usatine, MD.*)

PROGNOSIS

The prognosis is excellent if there is no underlying disease and may resolve in an average of 11 months.[17] It often resolves with effective treatment of any underlying disorder. If EAC is associated with pregnancy, it should resolve soon after delivery. If EAC is associated with a malignancy, the prognosis depends on that of the malignancy. Even if it resolves, EAC may recur repeatedly over many years.

FOLLOW-UP

Follow-up depends on the type of treatment provided and patient's preferences.

PATIENT EDUCATION

- EAC is not contagious or malignant.
- Although the treatment might not work and the condition may recur, it is not dangerous and is confined to the skin only.

PROVIDER RESOURCES

- **http://emedicine.medscape.com/article/1122701-overview.**
- **http://www.patient.co.uk/doctor/Erythema-Annulare-Centrifugum.htm.**

REFERENCES

1. Kim KJ, Chang SE, Choi JH, et al. Clinicopathologic analysis of 66 cases of erythema annulare centrifugum. *J Dermatol.* 2002;29(2):61-67.
2. Brand ME, Usatine RP. Persistent itchy pink rings. *J Fam Pract.* 2005;54(2):131-133.
3. Garcia-Doval I, Pereiro C, Toribio J. Amitriptyline-induced erythema annulare centrifugum. *Cutis.* 1999;63(1):35-36.
4. Kuroda K, Yabunami H, Hisanaga Y. Etizolam-induced superficial erythema annulare centrifugum. *Clin Exp Dermatol.* 2002;27(1):34-36.
5. Tageja N, Giorgadze T, Zonder J. Dermatological complications following initiation of lenalidomide in a patient with chronic lymphocytic leukemia. *Intern Med J.* 2011;41(3):286-288.
6. Al Hammadi A, Asai Y, Patt M, Sasseville D. Erythema annulare centrifugum secondary to treatment of finasteride. *J Drugs Dermatol.* 2007;6(4):260-463.
7. Rosina P, Francesco S, Barba A. Erythema annulare centrifugum and pregnancy. *Int J Dermatol.* 2002;41(8):516-517.
8. Gonzalez-Vela MC, Gonzalez-Lopez MA, Val-Bernal JF, et al. Erythema annulare centrifugum in a HIV-positive patient. *Int J Dermatol.* 2006;45(12):1432-1435.
9. White JW. Gyrate erythema. *Dermatol Clin.* 1985;3:129-139.
10. Weyers W, Diaz-Cascajo C, Weyers I. Erythema annulare centrifugum: results of a clinicopathologic study of 73 patients. *Am J Dermatopathol.* 2003;25(6):451-462.
11. Hsu S, Le FH, Khoshevis MR. Differential diagnosis of annular lesions. *Am Fam Physician.* 2001;64(2):289-296.
12. Zackheim H, McCalmont T. Mycosis fungoides: the great imitator. *J Am Acad Dermatol.* 2002;47(6):914-918.

13. Gniadecki R. Case report: calcipotriol for erythema annulare centrifugum. British Association of Dermatologists. *Br J Dermatol.* 2002;146:317-319.

14. Reuter J, Braun-Falco M, Termeer C, Bruckner-Tuderman L. Erythema annulare centrifugum Darier: Successful therapy with topical calcitriol and 311 nm-ultraviolet B narrow band phototherapy [in German]. *Hautarzt*. 2007;58(2):146-148.

15. Minni J, Sarro R. A novel therapeutic approach to erythema annulare centrifugum. *J Am Acad Dermatol.* 2006;54(3 Suppl 2):S134-S135.

16. De Aloe G, Rubegni P, Risulo M, et al. Erythema annulare centrifugum successfully treated with metronidazole. *Clin Exp Dermatol.* 2005;30(5):583-584.

17. http://www.patient.co.uk/doctor/Erythema-Annulare-Centrifugum.htm. Accessed on October 23, 2011.

PART 14

PODIATRY

Strength of Recommendation (SOR)	Definition
A	Recommendation based on consistent and good-quality patient-oriented evidence.*
B	Recommendation based on inconsistent or limited-quality patient-oriented evidence.*
C	Recommendation based on consensus, usual practice, opinion, disease-oriented evidence, or case series for studies of diagnosis, treatment, prevention, or screening.*

*See Appendix A on pages 1447–1450 for further information.

207 CORN AND CALLUS

Naohiro Shibuya, DPM, MS
Javier La Fontaine, DPM, MS

PATIENT STORY

A 52-year-old man with diabetes and mild sensory neuropathy presented with callus under "the ball of his foot" for at least 5 years. He recently noticed that the callus had grown thicker as he gained weight. Sharp debridement of the callus was performed, and an offloading pad was placed (**Figure 207-1**). The patient walked out of the office with less pain and discomfort. He was encouraged to use a pumice stone gently after bathing. One important goal is to avoid an ulcer (**Figure 207-2**), which occurred in another patient who did not get care for his callus.

FIGURE 207-1 Typical callus under the first metatarsal head. An offloading device can alleviate pain caused by the callus. (*Courtesy of Naohiro Shibuya, DPM.*)

INTRODUCTION

Corns and calluses are localized, thickened epidermis, resulting from mechanical pressure or shearing force applied repeatedly on the same area. A callus is located on the plantar surface and "grows in." A corn in located on the dorsal surface or between digits and "grows out." An ulcer forms if the lesion penetrates the subcutaneous layer. Initial management includes removing the pressure by changing shoes or using pads followed by sharp debridement if needed.

SYNONYMS

Hyperkeratotic lesion, keratosis, heloma durum (hard corn) or heloma molle (soft corn), tyloma (callus), clavi (corns).

EPIDEMIOLOGY

In one population-based study, 20% of men and 40% of women reported corns or calluses.[1]

ETIOLOGY AND PATHOPHYSIOLOGY

Calluses and corns are caused by multiple factors:

- Mechanical pressure from abnormal biomechanics, underlying spur/exostosis, ill-fitting shoes, physiologic repetitive activities, and foot surgery or amputation that result in increased focal pressure at the distance site.[2]
- Shearing force from ill-fitting shoes, foot deformities (e.g., hammer toe and bunion), and physiologic repetitive activities.
- A foreign body in the foot or shoe.

FIGURE 207-2 Callus resulting in an underlying ulceration in a person with diabetes. A neglected callus in a high-risk patient can result in ulceration and infection. (*Courtesy of Naohiro Shibuya, DPM.*)

RISK FACTORS

- Bunion (**Figure 207-3**), hammer toe (**Figure 207-4**), flatfoot, high-arched (cavus) foot.
- Older age, fat pad atrophy.
- Smoking.
- Female gender.
- Genodermatoses with abnormal keratin formation (**Figure 207-5**).

DIAGNOSIS

The diagnosis of callus or corn formation is made clinically. Radiographic examination is helpful in identifying underlying bony pathology.

CLINICAL FEATURES

- Pain at site, especially with pressure.
- Prominent underlying bony structure or deformity of the foot (high arch, flatfoot, or bunion).
- Hard, slightly hyperpigmented or skin colored, well demarcated (**Figure 207-6**).
- Hard or soft nucleus.

TYPICAL DISTRIBUTION

- Callus (weight-bearing surface)—Under the metatarsal heads, plantar-medial hallux interphalangeal joint, distal tip of the digits, plantar heel, fifth metatarsal base, dorsolateral fifth digit, and nail folds.
- Corns (non–weight-bearing surface)—Dorsal proximal interphalangeal joints in patients with hammer-toe deformity (**Figure 207-4**), interdigital spaces, most commonly the fourth space (**Figure 207-7**).

IMAGING

- Dorsoplantar, lateral, and medial oblique weight-bearing plain radiographs, with a metal marker on the lesion may detect an exostosis (spur). Underlying deformities can also be assessed with plain radiographs.

DIFFERENTIAL DIAGNOSIS

Other painful hyperkeratotic lesions in the foot can be caused by the following:

- Plantar warts are common painful human papillomavirus (HPV) skin infections found on the sole of the foot. Black dots (thrombosed capillaries) and disruption of skin lines differentiate these warts from callus or corns (see Chapter 134, Planter Warts).
- Acrolentiginous melanoma can occur on the foot and become painful over time. These are usually pigmented with irregular borders and variations in color. If these are amelanotic they may be harder

FIGURE 207-3 Bunion resulting in callus on the side of the big toe and a corn between the first and second digit because of abnormal biomechanical pressure. (*Courtesy of Richard P. Usatine, MD.*)

FIGURE 207-4 Dorsal hard corn formed secondary to a hammer-toe deformity. (*Courtesy of Naohiro Shibuya, DPM.*)

to diagnose. Any unusual growth on the foot should be biopsied (see Chapter 172, Melanoma).

- Nonmelanoma skin cancers rarely occur on the foot and are more likely to be on the dorsum of the foot where there is more sun exposure. These cancers are hyperkeratotic and may ulcerate. If suspicious, a shave biopsy should be adequate for diagnosis (see Chapters 170, Basal Cell Carcinoma and 171, Squamous Cell Carcinoma).
- Porokeratosis is a deep, seeded callus that has been described as a "plugged sweat duct" and is not necessarily located in a weight-bearing area.
- Diseases with abnormal keratin production can cause painful and thick callus on the feet in the same areas such as the heels and under the metatarsal heads. **Figure 207-5** is an example of severely painful and hypertrophic callus on the heel of a patient with the genodermatosis of pachyonychia congenita.
- Surgical physiologic/hypertrophic scar can be easily identified by the surgical orientation of the incision and patient history.

MANAGEMENT

First, consider the following conservative measures:

- Suggest that the patient change shoes to something that puts less pressure on the area involved.
- Pad the foot to limit shearing force from shoes (**Figure 207-1**).
- Use interdigital spacers to relieve pressure (**Figure 207-8**).
- Incorporate offloading devices or "cutoffs" in custom-made orthoses to realign an underlying deformity to minimize abnormal biomechanics.
- Suggest the patient reduce activity level on the feet.
- Encourage the patient to stop smoking and offer assistance.

If conservative measures fail to work, consider these surgical options:

- Sharp debridement of the lesion provides instant temporary relief from pain and discomfort. Infiltration of a local anesthetic may be necessary before debridement of an extremely painful lesion, but most calluses and corns can be debrided without anesthesia. Perform sharp debridement with a #10 or #15 surgical blade. The #10 blade is especially good for large callus. Debride the lesion down to soft, nonkeratotic tissue and remove the hard nucleus (**Figure 207-9**)
- In a patient with recurring lesions, consider a surgical referral to a foot specialist to correct an underlying deformity or spur.
- Exostectomy of the prominent underlying bone can be done with a minimal incision technique.
- Consider prophylactic correction of the deformity and/or removal of exostosis in a high-risk patient (e.g., patients with diabetes who are immunocompromised and neuropathic) to reduce the risk of future ulceration and infection.
- Plastic procedures (e.g., excisional biopsy with primary closure or local flap) may be necessary in patients with a chronic lesion of idiopathic origin.

FIGURE 207-5 Pachyonychia congenita causes hard callus on the feet and other abnormal keratin papules seen on the legs in this young man. This genetic disease causes such painful thick calluses that it hurts to walk. (*Courtesy of Richard P. Usatine, MD.*)

FIGURE 207-6 Hard corn in a typical location on the dorsum of the fifth digit. (*Courtesy of Richard P. Usatine, MD.*)

FIGURE 207-7 Soft corn in the fourth interspace at the base of the fifth digit. (*Courtesy of Richard P. Usatine, MD.*)

PREVENTION

- Well-padded shoes and/or padded insoles can prevent hyperkeratotic lesion formation.
- Insoles made by Spenco or Doctor Scholl's can be an inexpensive start before purchasing customized orthotics.
- People with severe underlying deformity may benefit from customized orthotic and shoe management to relieve localized pressure in the foot.

PROGNOSIS

In healthy, younger patients, both conservative and surgical treatments have good prognosis. Severe peripherally neuropathic patients neglect repetitive painful stimuli, and they are prone to ulceration from untreated hyperkeratotic lesions. Surgical management by changing the biomechanics of the foot is often successful, but it can cause a "transfer lesion"—a new lesion developing distance from the original lesion.

FOLLOW-UP

- A healthy patient can be seen in an "as-needed" basis.
- A high-risk patient requires periodic follow-up and sharp debridement of the lesion are necessary to prevent development of a neurotrophic ulcer.
- If the patient develops an open lesion, obtain plain radiographs to rule out osteomyelitis and gas gangrene. An irregular, hyperpigmented, fast-growing lesion must be biopsied.

PATIENT EDUCATION

Conservative measures are effective in mild lesions. If conservative measures fail, surgical management is indicated to correct the underlying cause of the problem. Surgical correction can result in a "transferred lesion" by shifting the pressure point away from the original site.[3] Tell patients with neuropathy and/or their caregivers to examine the patient's feet daily for potential ulceration. An overlying hyperkeratotic lesion can mask an underlying ulcer. Drainage, maceration, and malodor are signs of underlying ulceration and infection.

PATIENT RESOURCE

- PubMed Health. *Corns and Calluses*—**http://www.ncbi.nlm.nih.gov/pubmedhealth/PMH0002212/.**

PROVIDER RESOURCE

- Medscape. *Corns*—**http://emedicine.medscape.com/article/1089807.**

FIGURE 207-8 A simple spacer can alleviate pain caused by the corn in the fourth interdigital space. (*Courtesy of Naohiro Shibuya, DPM.*)

FIGURE 207-9 A corn on the fifth digit was pared down with a sharp scalpel and the patient had immediate relief while walking. (*Courtesy of Richard P. Usatine, MD.*)

REFERENCES

1. Garrow AP, Silman AJ, Macfarlane GJ. The Cheshire Foot Pain and Disability Survey: a population survey assessing prevalence and associations. *Pain*. 2004;110(1-2):378-384.
2. Freeman DB. Corns and calluses resulting from mechanical hyperkeratosis. *Am Fam Physician*. 2002;65(11):2277-2280.
3. McGlamry ED, Banks AS. Lesser ray deformities, In: Downey MS, McGlamry MC, eds. *McGlamry's Comprehensive Textbook of Foot and Ankle Surgery*, 3rd ed, vol. 1. Philadelphia, PA: Lippincott Williams & Wilkins; 2001:253-372.

208 BUNION DEFORMITY

Naohiro Shibuya, DPM, MS
Javier La Fontaine, DPM, MS

PATIENT HISTORY

A healthy 34-year-old woman has had "bunion pain" for 5 years. Her custom-made orthoses alleviate 50% of her pain. On examination, she has severe lateral deviation of the hallux (**Figure 208-1**), a mildly dorsiflexed second digit, tenderness at the medial prominence, painless first metatarsophalangeal (MTP) range of motion, and a callus under the second metatarsal head. Radiographs (**Figure 208-2**) show medial angulation of the first metatarsal and lateral deviation of the hallux.

The patient was referred to podiatry for surgical correction of the bunion deformity. After surgery, she was placed in a short-leg cast for 6 weeks. She progressed to a regular shoe over the next month and was encouraged to use the custom-made orthoses for her flatfoot to prevent recurrence of the bunion.

FIGURE 208-1 Laterally deviated hallux resulting in a bunion (hallux abducto valgus deformity). (*Courtesy of Naohiro Shibuya, DPM.*)

INTRODUCTION

Bunion deformity is characterized by the presence of a medial prominence at the first MTP joint, caused by an abducted hallux and adducted first metatarsal. The deformity causes irritation in a tight shoe and pain in the MTP joint. Initial therapy can be conservative with correction of footwear and padding. Surgical procedures correct the misalignment, rather than shave the medial prominence.

SYNONYMS

Hallux valgus, hallux abducto valgus, metatarsus adductovarus.

EPIDEMIOLOGY

- The prevalence of bunions ranges from 2% to 50%.[1]
- It is far more common in women.

ETIOLOGY AND PATHOPHYSIOLOGY

Bunion deformities are caused by multiple factors:

- Genetic and hereditary factors.
- Abnormal biomechanics (limb length discrepancy, hypermobility/ligament laxity, flatfoot deformity, malaligned skeletal structures, and ankle equinus).[2]
- Neuromuscular diseases.
- Ill-fitting shoes.
- Trauma.
- Iatrogenic causes.

FIGURE 208-2 A weight-bearing dorsoplantar plain radiograph helps in assessing severity of the deformity and determining treatment plan. (*Courtesy of Naohiro Shibuya, DPM.*)

RISK FACTORS

- Flatfoot.
- Family history.
- Ligamentous laxity.

DIAGNOSIS

The diagnosis of hallux abducto valgus deformity is made clinically and radiographically.

CLINICAL FEATURES

- Laterally deviated hallux, erythema, edema.
- Tenderness on the medial eminence at the first MTP joint and pain through the first MTP joint range of motion.
- Associated signs—Hypermobility, flatfoot deformity, second MTP joint pain, pain under the second metatarsal head, overlapped second digit, decreased ankle dorsiflexion, concurrent gout, decreased first MTP joint range of motion, sesamoiditis, hyperkeratosis, and hammer toe deformity (see Chapter 209, Hammer Toe, Figure 209-4).

TYPICAL DISTRIBUTION

- Often bilateral (**Figure 208-3**).
- A unilateral bunion deformity is often caused by a limb length discrepancy (**Figure 208-4**).

IMAGING

- Weight-bearing plain radiographs are obtained in dorsoplantar, lateral, and medial oblique views (**Figure 208-2**).
- Lateral deviation of the hallux and medial deviation of the first metatarsal bone are noted in the dorsoplantar view.
- The first MTP joint narrowing, osteophyte formation, subchondral cysts, and sclerosis are indicative of osteoarthritis.
- The lateral view is useful in assessing elevation of the first metatarsal, dorsal spur formation at the first MTP joint, and hammer-toe deformity.

DIFFERENTIAL DIAGNOSIS

Pain and swelling around the first MTP joint may be caused by the following:

- Gout or pseudogout presents with acute pain with signs of inflammation and prior history of gout/pseudogout. Joint aspiration may be performed to rule out septic joint (see Chapter 100, Gout).
- Rheumatoid arthritis presents with pain, inflammation, and loss of range of motion and is often symmetrical. Radiographic evidence of other small pedal joint involvement is usually evident (see Chapter 97, Rheumatoid Arthritis).
- Septic joint presents with acute pain, loss of range of motion, and systemic signs and symptoms of infectious process.

FIGURE 208-3 Severe bilateral bunion deformities causing lateral deviations in the other digits. Note the onychomycosis and flaking skin from tinea pedis. (*Courtesy of Richard P. Usatine, MD.*)

FIGURE 208-4 A unilateral bunion deformity is often a result of limb length discrepancy. Note the prominent erythema around the first metatarsophalangeal joint of the left foot only. (*Courtesy of Naohiro Shibuya, DPM.*)

MANAGEMENT

Conservative measures and surgical treatments are described below.

CONSERVATIVE MEASURES

- Change to shoes with a wider toe box.
- Place a toe spacer in the first interdigital space to straighten the hallux and decrease the irritation caused by rubbing of the first and second digits.
- Pad the shoe to limit shearing force (**Figure 208-5**).
- Custom-made orthoses help slow progression of the deformity caused by biomechanical factors.
- Rest, NSAIDs, and ice may help an inflamed joint and/or shoe irritation.
- Physical therapy may help improve joint range of motion, reduce edema, or decrease nerve pain.

SURGICAL TREATMENT

- Consider surgical referral to a foot specialist for correction of the deformity.
- The tendon and ligament balancing procedure is used for minor, flexible deformities.
- Exostectomy may help patients who have no joint pain, but complain about extraarticular "bump pain."
- Osteotomy to realign the bony structure is indicated for moderate to severe deformities (**Figure 208-6**).
- Arthrodesis of the first MTP or metatarsocuneiform joint is indicated in a severe deformity.
- Adjunctive procedures (e.g., correction of hammer-toe deformities, flatfoot deformity, ankle equinus, and resection of the sesamoid bone) may be required for a positive long-term outcome.

FIGURE 208-5 Simple padding can alleviate shoe irritation from the bunion deformity. (*Courtesy of Naohiro Shibuya, DPM.*)

PREVENTION

- Treatment of underlying etiology, such as flatfoot can prevent progression of bunion deformity.
- Avoid shoes that push the hallux over in patients who are starting to develop a bunion.

PROGNOSIS

- The prognosis worsens as the deformity progresses.
- Function and quality of life can be affected in severe debilitating deformity. Surgical correction provides good prognosis in such patients.

FOLLOW-UP

The patient may be seen on an as-needed basis. Serial plain radiographs can be obtained to follow the progression of the deformity and arthritic changes in the first MTP joint.

FIGURE 208-6 Surgical correction is indicated if conservative measures fail. (*Courtesy of Naohiro Shibuya, DPM.*)

PATIENT EDUCATION

Conservative measures may or may not provide temporary relief and prevent progression of the deformity. Surgical management is necessary to correct the deformity. Surgical treatment will typically require 2 to 6 weeks of non–weight-bearing status postoperatively, depending on the procedure performed. More severe deformities will require a more extensive surgical approach and longer recovery period.

PATIENT RESOURCE

- PubMed Health. *Bunions*—**http://www.ncbi.nlm.nih.gov/pubmedhealth/PMH0002211/.**

PROVIDER RESOURCE

- Medscape. *Bunion*—**http://emedicine.medscape.com/article/1235796.**

REFERENCES

1. McGlamry ED, Banks AS. *McGlamry's Comprehensive Textbook of Foot and Ankle Surgery*, 3rd ed. vol 2. Philadelphia, PA: Lippincott Williams & Wilkins; 2001:66.
2. Chang TJ. *Master Techniques in Podiatric Surgery: The Foot and Ankle*. Philadelphia, PA: Lippincott Williams & Wilkins; 2005:560.

209 HAMMER TOE

Naohiro Shibuya, DPM, MS
Javier La Fontaine, DPM, MS

PATIENT HISTORY

A 44-year-old woman presented with pain in the ball of her left foot on weight-bearing. She works as a nurse and walks most of her 12-hour shift. Two months ago she noticed a new deformity of the second digit of her left foot (**Figure 209-1**). Her second digit was contracted with a nonreducible proximal interphalangeal joint and reducible metatarsophalangeal (MTP) joint. Her x-ray is seen in **Figure 209-2**.

She was referred to a podiatrist who diagnosed an acute isolated hammer-toe deformity. At the time of surgery a plantar plate rupture at the MTP joint was found. The podiatrist fused her proximal interphalangeal (PIP) joint and released her extensor tendon and dorsal capsule at the MTP joint to reduce the deformity. She began protective ambulation in a surgical shoe on postoperative day 3. An internal fixation wire, which was used to fixate the fusion site, was removed in 4 weeks. She returned to work and her regular activities within 6 weeks of the operation.

FIGURE 209-1 A plantar plate rupture at the metatarsophalangeal joint from overuse often causes an acute isolated hammer-toe deformity. (*Courtesy of Naohiro Shibuya, DPM.*)

INTRODUCTION

Hammer-toe deformity is a flexion contracture in the PIP joint of a pedal digit, resulting in plantar flexion of the middle phalanx at the PIP joint with dorsal angulation of the proximal phalanx at the MTP joint. Hammer toes are associated with imbalance of soft-tissue structures around the joints in the digits and are often progressive. Surgical correction is required when deformity interferes with function.

SYNONYMS

- Hammer toe, claw toe, and mallet toe describe similar digital contractures.
- Claw toe refers to progression of hammer toe to include extension of the MTP joint along with flexion in the PIP joint.
- Mallet toe has a digital contracture at the distal interphalangeal (DIP) joint.

EPIDEMIOLOGY

Hammer-toe deformity is the most common digital deformity, and it can affect up to 60% of adults. The second digit is most commonly affected.[1]

FIGURE 209-2 This lateral plain film shows dorsiflexion of the proximal phalanx at the metatarsophalangeal joint and plantarflexion of the middle phalanx at the proximal interphalangeal joint of the second digit. (*Courtesy of Naohiro Shibuya, DPM.*)

ETIOLOGY AND PATHOPHYSIOLOGY

A hammer toe is caused by multiple factors:

- Genetic and hereditary factors.

- Abnormal biomechanics (cavus or high-arch foot, flatfoot deformity, loss of intrinsic muscle function, and hypermobile first ray).
- Long metatarsal and/or digit.
- Systemic arthritidis.
- Neuromuscular diseases such as Charcot-Marie-Tooth disease (**Figure 209-3**).
- Ill-fitting shoes.
- Trauma.
- Iatrogenic causes.

RISK FACTORS

- High-arch foot type (cavus foot).
- Flatfeet.
- Bunion deformity (**Figure 209-4**).

DIAGNOSIS

The diagnosis of hammer-toe deformity is made clinically and radiographically.

CLINICAL FEATURES

- Pain and deformity in 1 or more of the lesser toes.
- Dorsiflexed proximal phalanx at the MTP joint and plantarflexed middle phalanx at the PIP joint of a lesser digit.
- Callus formation at the dorsal aspect of the PIP joint and/or distal aspect of the digit.
- Edema and tenderness on the plantar aspect of the lesser MTP joint(s).
- Associated signs—Cavus foot deformity, flatfoot deformity, bunion deformity, transverse deformity of the digits, decreased ankle dorsiflexion, and bowstringing of the extensor and/or flexor tendons.
- Evaluation of the digit in weight-bearing and non–weight-bearing conditions helps assess reducibility and rigidity of the deformity. In the case of predislocation syndrome (acute rupture or tear of the MTP joint capsule or plantar plate), the deformity may not be appreciated unless the foot is evaluated in the weight-bearing position.[2]

IMAGING

Obtain weight-bearing plain radiographs in dorsoplantar, lateral, and medial oblique views (**Figure 209-2**).

- Dorsal angulation and/or translation of the proximal phalanx on the metatarsal head with plantar angulation of the middle phalanx (lateral view).
- Degenerative changes in the digital joints and dislocation in the MTP joint.
- Transverse deformity and abnormal metatarsal length (dorsoplantar view).

FIGURE 209-3 Severe hammer-toe deformity caused by Charcot-Marie-Tooth disease, an autosomal dominant neuromuscular disease. (*Courtesy of Richard P. Usatine, MD.*)

FIGURE 209-4 Hammer-toe deformity caused by a bunion. (*Courtesy of Richard P. Usatine, MD.*)

DIFFERENTIAL DIAGNOSIS

Pain and swelling in the digit may be caused by the following:

- Gout or pseudogout presents with acute pain with signs of inflammation, and prior history of gout/pseudogout. Joint aspiration may be performed to rule out septic joint (see Chapter 100, Gout).
- Rheumatoid arthritis presents with pain, inflammation, and loss of range of motion and is often symmetrical. Radiographic evidence of other small foot joint involvement usually is evident (see Chapter 97, Rheumatoid Arthritis).
- Septic joint presents with acute pain, loss of range of motion, and systemic signs and symptoms of infectious process.
- Fractured toe caused by sudden trauma.
- Neuroma in the intermetatarsal space (Morton neuroma) with compression of the intermetatarsal nerves—Numbness and cramping of the innervated toes are the most common symptoms.

MANAGEMENT

Conservative measures and surgical treatment may be used to correct this condition. Note that a neglected hammer-toe deformity could result in ulceration in a patient with diabetes.

NONPHARMACOLOGIC

- Change shoes.
- Pad shoes to limit shearing force. A crest pad can be used to prevent painful callus formation at the distal tip of the digit (**Figure 209-5**).
- Splinting can be used in an early flexible hammer toe.
- Custom-made orthoses are helpful to slow down progression of the deformity if it is caused by biomechanical factors.
- Rest, NSAIDs, and ice help an inflamed joint and/or shoe irritation.

SURGICAL TREATMENT

- Consider surgical referral to a foot specialist to correct the deformity.
- Percutaneous tenotomy and/or capsulotomy are used for mild, flexible deformities.
- Resectional arthroplasty at the PIP joint may be beneficial for a more rigid deformity.
- Shortening osteotomy of the metatarsal is indicated in the deformities resulting from the long metatarsal.
- Arthrodesis (fusion) of the PIP joint and/or flexor tendon transfer is indicated for a severe deformity (**Figure 209-6**).
- Adjunctive procedures (e.g., correction of bunion, cavus foot, flatfoot deformities, and ankle equinus) may be necessary for a good long-term outcome.

PREVENTION

- Proper shoes with an adequate toe box and heel counter prevent excessive contracture of the digits.

FIGURE 209-5 A crest pad prevents painful callus formation at the distal tip of the digit. (*Courtesy of Naohiro Shibuya, DPM.*)

FIGURE 209-6 Proximal interphalangeal joint arthrodesis (fusion) is often used to correct hammer-toe deformity. (*Courtesy of Naohiro Shibuya, DPM.*)

- Controlling associated deformities, such as bunion and flatfoot deformities via orthotic management can prevent progression of hammer-toe deformity.

PROGNOSIS

- The prognosis worsens as the deformity progresses.
- Function and quality of life can be affected in severe debilitating deformity. Surgical correction provides good prognosis in such patients.

FOLLOW-UP

Periodic debridement of the calluses developed from the deformity may be sufficient in many of the patients if the deformity is not progressive. Serial plain radiographs can be obtained to follow the progression of the deformity and arthritic changes in the first MTP joint. In a high-risk, immunocompromised, neuropathic patient, prophylactic surgical correction of the deformity may be indicated.

PATIENT EDUCATION

Explain to patients that conservative measures may prevent progression of the deformity and provide temporary relief, but that surgical management is necessary to correct the deformity. Surgical treatment can require up to 4 to 6 weeks of non–weight-bearing status postoperatively in severe deformities. A less-involved surgical approach to correct a mild deformity can allow a patient to walk on the same day as the surgery. In many cases, fixation with a pin, small screw, or implant is necessary to correct the deformity.

PATIENT RESOURCE

- MedlinePlus. *Hammer Toe*—**http://www.nlm.nih.gov/medlineplus/ency/article/001235.htm.**

PROVIDER RESOURCE

- Medscape. *Hammertoe Deformity*—**http://emedicine.medscape.com/article/1235341.**

REFERENCES

1. McGlamry ED, Banks AS. *McGlamry's Comprehensive Textbook of Foot and Ankle Surgery*, 3rd ed. Philadelphia, PA: Lippincott Williams & Wilkins; 2001:66.
2. Yu GV, Judge MS, Hudson JR, Seidelmann FE. Predislocation syndrome. Progressive subluxation/dislocation of the lesser metatarsophalangeal joint. *J Am Podiatr Med Assoc.* 2002;92(4):182-199.

210 ISCHEMIC ULCER

Javier La Fontaine, DPM, MS
Naohiro Shibuya, DPM, MS

PATIENT STORY

A 58-year-old woman with uncontrolled type 2 diabetes, hypercholesterolemia, and tobacco use presented with a 2-month history of a nonhealing ulceration on her left foot (**Figure 210-1**). She believes this started after she stepped on a tack. She presented with the ulcer, loss of protective sensation, and a nonpalpable posterior tibial pulse. She began treatment in a wound care center. Arterial noninvasive studies showed severe vascular disease and she underwent revascularization. While in the hospital, she quit smoking and gained control of her diabetes. Her ulcer healed and she continues to take her diabetes medications and does not smoke.

FIGURE 210-1 A 38-year-old woman with type 2 diabetes and an ischemic ulcer on the first digit of the left foot. The base of the wound is gray in color with pink surrounding wound margins. (*Courtesy of Javier La Fontaine, DPM.*)

INTRODUCTION

Ulcerations occur from ongoing biomechanical forces or trauma and require normal blood flow to heal. Nonhealing ulcers are commonly a result of peripheral ischemia seen in patients with diabetes and other vascular diseases. Treatment includes local wound care and improvement or correction of underlying factors causing ischemia. Untreated ischemic ulcers become infected and may require amputation of the affected area.

SYNONYMS

Arterial ulcer.

EPIDEMIOLOGY

Of patients with diabetes, 15% to 25% will develop an ulcer at an annual incidence of 1% to 4%.[1]

ETIOLOGY AND PATHOPHYSIOLOGY

Microvascular dysfunction is an important component of the disease process that occurs in diabetic foot disease. The abnormalities observed in the endothelium in patients with diabetes are not well understood and evidence suggests that endothelial dysfunction could be involved in the pathogenesis of diabetic macroangiopathy and microangiopathy.[2] Microangiopathy is a functional disease where neuropathy and autoregulation of capillaries lead to poor perfusion of the tissues, especially at the wound base.

RISK FACTORS

- Diabetes for more than 10 years, especially with poor glycemic control and the presence of other macro- or microvascular complications.

- Peripheral vascular disease from any cause or other vascular risk factors, including dyslipidemia and tobacco use.
- Neuropathy caused by loss of protective sensation and as a sign of microvascular disease.
- History of a previous ischemic ulcer.

DIAGNOSIS

CLINICAL FEATURES

- Pain.
- Gray/yellow fibrotic base (**Figures 210-1** and **210-2**).
- Undermined skin margins.
- Punched-out appearance.
- Nonpalpable pulses.
- Associated trophic skin changes (e.g., absent pedal hair and thin shiny skin).

TYPICAL DISTRIBUTION

- Distal aspect of the toes.

IMAGING

- Noninvasive studies (e.g., arterial Doppler and pulse volume recordings) are important for baseline assessment of the patient's blood flow.[3]
- Radiographs may be necessary to rule out osteomyelitis.

DIFFERENTIAL DIAGNOSIS

- Neuropathic ulcer usually presents with beefy red wound base and hyperkeratosis at the skin margins (see Chapter 211, Neuropathic Ulcer).
- Infected wounds present with localized redness, edema, drainage, and warmness in any of the diabetic-type wounds with lack of systemic symptoms of infection.
- Gangrene usually is well-demarcated with black eschar in foot with vascular disease (see Chapter 213, Dry Gangrene).

MANAGEMENT

- Consider vascular surgery consultation to evaluate for revascularization.
- Carefully evaluate for a concomitant infection. Antibiotics are not indicated unless infection is present.
- Avoid aggressive debridement until optimization of blood flow occurs.
- Change dressings twice daily to evaluate the wound and keep a low bacterial load. Many advanced therapies can be added to accomplish the same goals.
- If the wound is plantar, offloading is important to prevent the wound from increasing in size.

FIGURE 210-2 A 57-year-old man with diabetes for 25 years with an ischemic ulcer of the third toe. A grayish base is a common finding in this type of ulcer. (*Courtesy of Javier La Fontaine, DPM.*)

PREVENTION

- In patients with diabetes, adequate glycemic control is essential. A yearly comprehensive foot examination should be performed.
- Smoking cessation.

PROGNOSIS

Prognosis of an ischemic ulcer depends on the possibility of revascularization. Many ulcers treated early heal. Untreated or inadequately treated ulcers lead to infection and amputation. Early recognition of underlying vascular disease is imperative for a successful outcome.

FOLLOW-UP

- Schedule weekly to biweekly visits to monitor the ulcer.
- Obtain serial radiographs every 4 weeks to monitor for the development of osteomyelitis.
- Closely monitor the patient every 3 to 4 months once healing has occurred. Patients who have had history of ulcerations are 36 times more likely to develop another ulcer.[5]

PATIENT EDUCATION

- Prevention measures, such as smoking cessation, are important to aid wound healing.[4]
- Promote successful treatment by encouraging adherence with use of offloading devices.
- Strive for normal glycemic control to optimize outcome for healing and surgical intervention.

REFERENCES

1. Singh N, Armstrong DG, Lipsky BA. Preventing foot ulcers in patients with diabetes. *JAMA*. 2005;293:217-228.
2. La Fontaine J, Allen M, Davis C, Harkless LB, Shireman PK. Current concepts in diabetic microvascular dysfunction. *J Am Podiatr Med Assoc*. 2006;96(3):245-252.
3. Sykes MT, Godsey JB. Vascular evaluation of the problem diabetic foot. *Clin Podiatr Med Surg*. 1998;15(1):49-82.
4. American Diabetes Association Guidelines. Preventive foot care in people with diabetes. *Diabetes Care*. 2000;23(Suppl 1):S55-S56.
5. Armstrong DG, Lavery LA, Harkless LB. Validation of a diabetic wound classification system. The contribution of depth, infection, and ischemia to risk of amputation. *Diabetes Care*. 1998;21(5):855-859.

211 NEUROPATHIC ULCER

Javier La Fontaine, DPM, MS
Naohiro Shibuya, DPM, MS

PATIENT STORY

A 57-year-old man with type 2 diabetes presented with history of a neuropathic ulceration to the right foot for 2 weeks (**Figure 211-1**). The patient recalled having a callus for several months. He noticed blood on his sock 3 days ago. He denied fever or chills, but his glucose has been running higher than normal. The patient demonstrated loss of protective sensation, but vascular status was intact. He was referred to a podiatrist who immediately offloaded his foot with a total contact cast. His ulcer healed in 1 month, and he was subsequently fitted with orthopedic shoes.

FIGURE 211-1 Neuropathic ulcer under the third metatarsal head of the right foot in a patient with diabetes. Note the red base with a white rim of hyperkeratotic tissue, a classical finding of this type of ulcer. (*Courtesy of Javier La Fontaine, DPM.*)

INTRODUCTION

Foot complications in patients with diabetes mellitus are common, costly, and impact quality of life. Neuropathic ulcers can lead to the most devastating outcome, which is an amputation. Eighty-five percent of all amputations related to diabetes are preceded by an ulcer. Prevention, early recognition, and treatment of foot ulcers are critical in avoiding amputations.

EPIDEMIOLOGY

- Of people with diabetes, 15% will experience a foot ulcer during their lifetime, and 15% of these will have osteomyelitis.[1]
- Neuropathy causes approximately 50% of diabetic foot ulcers.[2]
- The prevalence of neuropathic ulcer is 20% in patients with diabetic neuropathy.

ETIOLOGY AND PATHOPHYSIOLOGY

- Peripheral neuropathy is an important factor in the development of a diabetic foot ulcer.
- Neuropathy causes autonomic denervation of precapillary arterioles, leading to persistent vasodilation and chronic edema.
- Moderate pressure with repetitive trauma occurs in a particular site, often from poorly fitting footwear, which then leads to ulceration.

RISK FACTORS

- Diabetic neuropathy increases the risk of developing a foot ulcer by 70%.[3]
- Patients with pedal deformity combined with diabetic neuropathy are 12 times more likely to develop a foot ulcer.[3]
- Limited joint mobility, high level of activity, and poorly fitting footwear also increase the risk of the repetitive trauma that leads to ulceration.

DIAGNOSIS

The diagnosis of neuropathic ulceration is made clinically.

CLINICAL FEATURES

- A red, granular base (**Figures 211-1** and **211-2**).
- Surrounding hyperkeratosis with white, macerated margins (**Figures 211-1** and **211-2**).

TYPICAL DISTRIBUTION

- Foot ulcers are most common under the metatarsal heads, hallux, heel, or other weight-bearing areas.
- Foot ulcers can develop in any location of the foot such as the distal and plantar aspects of the toes (**Figures 211-1** and **211-2**).

LABORATORY STUDIES

- Cultures are only indicated if infection is suspected. Swab cultures are not reliable. Curettage of the base of the wound may be more reliable.

IMAGING

- Radiographs may identify a foreign body or underlying osteomyelitis.

BIOPSY

- A biopsy may be necessary to rule out a suspected malignancy.

DIFFERENTIAL DIAGNOSIS

- Ischemic ulcer presents in the dysvascular foot and may have black eschar at the wound base. Usually presents with pink to gray wound base (see Chapter 210, Ischemic Ulcer).
- Puncture wounds may become neuropathic ulcers in the presence of neuropathy.

MANAGEMENT

NONPHARMACOLOGIC

- Offloading pressure from the foot is the standard of care.
- Multiple devices (e.g., removable cast boot, surgical shoes, and wedge shoes) are used for offloading; however, a total contact cast is the gold standard.[4,5]
- Diabetic shoes should not be used as offloading devices for ulcerations.
- Serial tissue debridement should be performed weekly to biweekly to maintain minimal bacterial load, low pressure surrounding the ulcer, and a metabolically active wound base.

MEDICATIONS

- Oral antibiotics are not indicated unless infection is suspected.
- If no improvement in 4 weeks, the ulcer should be considered a chronic wound and adjunctive therapy such as topical growth factors and bioengineered skin products (i.e., Apligraf, Dermagraft, or Regranex) must be considered.

FIGURE 211-2 Neuropathic ulcers in the plantar aspect of both feet. Multiple amputations in this patient caused increased pressure in different areas of the feet, which, in combination with neuropathy, led to new ulcerations. (*Courtesy of Richard P. Usatine, MD.*)

REFERRAL

- Consider early referral to a podiatrist, wound care center, or physician with experience treating neuropathic ulcers.

PREVENTION

Patients need to understand the importance of checking their feet daily.

PROGNOSIS

Prognosis is good for patients with neuropathic ulcers as long as they adhere to the treatment plan. A neuropathic ulcer should heal in approximately 4 to 6 weeks once aggressive offloading therapy has been implemented.

FOLLOW-UP

- Weekly to biweekly visits are needed to monitor and treat the ulcer.
- Serial radiographs every 4 weeks may be necessary to monitor for the development of osteomyelitis.
- Closely monitor the patient every 3 to 4 months once healing is accomplished. Patients who have had history of ulcerations are 36 times more likely to develop another ulcer.[3]

PATIENT EDUCATION

- Tell patients that adherence with offloading devices is essential.
- Inform patients that control of blood sugar and blood pressure promotes healing.

PATIENT RESOURCES

- MedlinePlus. *Diabetes: Foot Ulcers*—**http://www.nlm.nih.gov/medlineplus/ency/patientinstructions/000077.htm.**
- FamilyDoctor. *Diabetic Neuropathy: What is a Total Contact Cast?*—**http://familydoctor.org/familydoctor/en/diseases-conditions/diabetic-neuropathy/treatment/what-is-a-total-contact-cast.html.**

PROVIDER RESOURCE

- Medscape. *Diabetic Ulcers*—**http://emedicine.medscape.com/article/460282.**

REFERENCES

1. Levin ME. Pathogenesis and general management of foot lesions in the diabetic patient. In: Bowker JH, Pfeifer MA, eds. *Levin and O'Neal's The Diabetic Foot*, 6th ed. St. Louis, MO: CV Mosby; 2001:219-260.
2. Reiber GE, Smith DG, Wallace C, et al. Effect of therapeutic footwear on foot reulceration in patients with diabetes: a randomized controlled trial. *JAMA*. 2002;287:2552-2558.
3. Armstrong DG, Lavery LA, Harkless LB. Validation of a diabetic wound classification system. The contribution of depth, infection, and ischemia to risk of amputation. *Diabetes Care*. 1998;21(5):855-859.
4. Lavery LA, Vela SA, Lavery DC, Quebedeaux TL. Reducing dynamic foot pressures in high-risk diabetic subjects with foot ulcerations. A comparison of treatments. *Diabetes Care*. 1996;19(8):818-821.
5. Fleischli JG, Lavery LA, Vela SA, Ashry H, Lavery DC. Comparison of strategies for reducing pressure at the site of neuropathic ulcers. *J Am Podiatr Med Assoc*. 1997;87(10):466-472.

212 CHARCOT ARTHROPATHY

Javier La Fontaine, DPM, MS
Naohiro Shibuya, DPM, MS

PATIENT STORY

A 62-year-old man with type 2 diabetes for 15 years presents with history of erythematous, hot, swollen right foot for 2 weeks (**Figure 212-1**). He is on multiple medications for management of his diabetes, but it is not successfully controlled. The patient does not recall any trauma to the foot. Three days ago, he noticed pain in his foot. He denies fever or chills. The radiograph of his foot (**Figure 212-2**) shows midfoot osteopenia, an early sign of acute Charcot arthropathy.

FIGURE 212-1 Charcot arthropathy in the right foot. Notice the swelling and discoloration compared to the contralateral side. (*Courtesy of Javier La Fontaine, DPM.*)

INTRODUCTION

Charcot arthropathy is an uncommon foot complication in patients with neuropathy. Patients often present with pain, swelling, and erythema, similar to the presentation with a foot infection. Patients may have a rockerbottom foot deformity. Radiographs confirm the diagnosis.

SYNONYMS

Charcot foot, Charcot neuroarthropathy.

EPIDEMIOLOGY

The incidence of Charcot arthropathy in diabetes ranges from 0.1% to 5%.[1]

ETIOLOGY AND PATHOPHYSIOLOGY

Charcot arthropathy is a gradual destruction of the joint in patients with neurosensory loss, most commonly seen in patients with diabetic neuropathy.[2] The pathogenesis is unknown. Proposed theories include:

- Neurotraumatic theory—Following sensory-motor neuropathy, the resulting sensory loss and muscle imbalance induces abnormal stress in the bones and joints of the affected limb, leading to bone destruction.
- Neurovascular theory—Following the development of autonomic neuropathy there is an increased blood flow to the extremity, resulting in osteopenia from a mismatch in bone reabsorption and synthesis.
- Stretching of the ligaments because of joint effusion may lead to joint subluxation.
- It is most likely that Charcot arthropathy involves all of the above mechanisms together.

FIGURE 212-2 Anterior–posterior view of same foot demonstrating midfoot osteopenia, an early sign of acute Charcot arthropathy. (*Courtesy of Javier La Fontaine, DPM.*)

RISK FACTORS

- Advanced peripheral neuropathy.
- Micro- or macrotrauma.
- Microangiopathy.
- Nephropathy.

DIAGNOSIS

The diagnosis of Charcot arthropathy is suspected based on the presentation and confirmed with imaging.

CLINICAL FEATURES

- Red, hot, swollen foot (**Figure 212-1**).
- Even with neurosensory loss, 71% of patients present with the chief complaint of pain.[3]
- Rockerbottom foot deformity is a classic finding of this entity (**Figure 212-3**).
- Patients may present with an open wound in the plantar aspect of the foot, which may complicate the diagnosis between Charcot arthropathy and infection.

IMAGING

Radiographs are imperative for diagnosis.

- Arch collapse within the joints of the midfoot (tarsometatarsal joints) (**Figure 212-4**).
- Erosions and cystic degeneration of the tarsometatarsal joints in Charcot arthropathy (**Figure 212-5**) may also be present.
- Bone scan and MRI may be ordered when infection is suspected, but are often inconclusive as cellulitis and osteomyelitis have similar findings.

CULTURE AND BIOPSY

- If osteomyelitis is suspected, bone cultures and bone biopsy are recommended. Cultures need to be taken during the bone biopsy so that the suspected infected bone can be visualized for accurate sampling. Send cultures for aerobic and anaerobic cultures as well as for acid-fast bacilli.

DIFFERENTIAL DIAGNOSIS

- Infections, including cellulitis and osteomyelitis, should be considered and treated if present (see Chapter 120, Cellulitis).
- Gouty arthropathy of the foot or ankle can resemble a Charcot foot (see Chapter 100, Gout).
- Acute trauma to the foot can cause swelling and erythema, but should be easy to distinguish by the history.
- Deep venous thrombosis in the leg will generally cause swelling that extends above the ankle.

FIGURE 212-3 Lateral view of the right foot demonstrating the classic rockerbottom deformity. (*Courtesy of Javier La Fontaine, DPM.*)

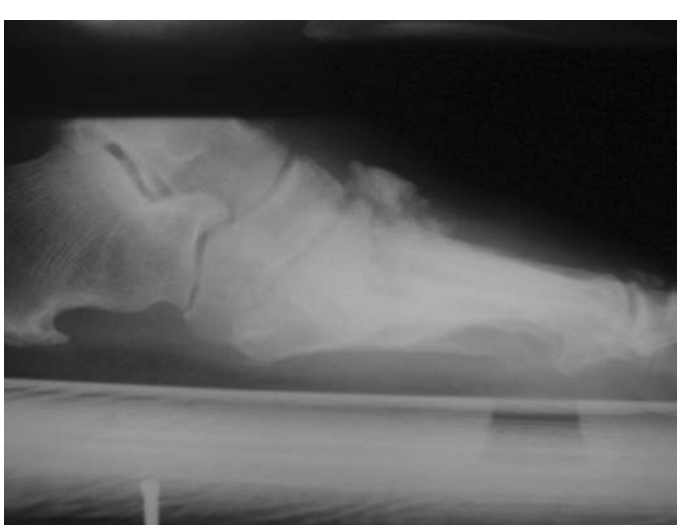

FIGURE 212-4 Lateral radiographic view of the left foot demonstrating the classic rockerbottom deformity in Charcot arthropathy with the arch collapsed at the tarsometatarsal joints. (*Courtesy of Javier La Fontaine, DPM.*)

MANAGEMENT

- Offloading of pressure from the foot is the standard of care. The total contact cast is most effective, and it covers the toes for protection. Other methods that are used include the removable cast boot, crutches, and the wheelchair.
- Diabetic shoes should not be used as offloading devices for Charcot arthropathy.
- Skin temperature assessment with infrared thermometry has been demonstrated to be successful in monitoring improvement.
- Prevention of rockerbottom deformities, plantar ulcers, and amputations is the major goal of the treatment. Untreated Charcot foot may lead to a rockerbottom foot, which in turn leads to increased plantar pressure in the neuropathic foot. This cascade will lead to an ulceration (**Figure 212-6**) and possible amputation.[3]
- The bones will take approximately 4 to 5 months to heal in presence of neuropathy.
- Oral antibiotics are not indicated unless infection is suspected.
- If deformity develops, custom-molded shoes and insoles must be ordered to prevent plantar ulcers that can lead to amputation.
- If the foot develops instability at the fracture sites, surgical reconstruction may be required.

FIGURE 212-5 Anterior–posterior radiograph of the right foot demonstrating erosion and cystic degeneration at the tarsometatarsal joints in Charcot arthropathy. (*Courtesy of Javier La Fontaine, DPM.*)

PREVENTION

- Control of blood glucose helps to prevent diabetic complications, including Charcot arthropathy.
- Appropriate footwear and foot care is essential to preventing many types of diabetic foot problems.

PROGNOSIS

Patients with history of Charcot arthropathy are always at risk to develop foot complications. The combination of severe foot deformity in presence of neuropathy places them at risk for more ulceration, and further amputation. Almost 50% of these patients will require complex foot surgery to fix the deformity.

FOLLOW-UP

- Weekly to biweekly visits to the podiatrist is needed.
- Serial radiographs every 4 weeks are required to monitor bone healing and deformity.
- Once healing is accomplished, it is imperative to continue monitoring the patient every 3 to 4 months. Patients who have had history of Charcot arthropathy are 36 times more likely to develop another ulcer and are at risk of amputation.[4]

FIGURE 212-6 Foot ulcer as a result of diabetic neuropathy and a Charcot foot. Note the collapse of the arch. (*Courtesy of Richard P. Usatine, MD.*)

PATIENT EDUCATION

- Tell the patient that all efforts should be made to control blood sugar and blood pressure to promote healing.
- Educate the patient to recognize the clinical signs of Charcot arthropathy.
- Educate patient to wear shoe gear prescribed by physician.
- Ensure that patients with Charcot arthropathy understand that adherence with offloading devices is essential.

PATIENT RESOURCE

- ePodiatry.com. *Charcot's Foot (Charcot's Arthropathy or Neuroarthropathy)*—**http://www.epodiatry.com/charcot-foot.htm.**

PROVIDER RESOURCES

- Medscape. *Charcot Arthropathy*—**http://emedicine.medscape.com/article/1234293.**
- Sommer TC, Lee TH. Charcot foot: the diagnostic dilemma. *Am Fam Physician*. 2001;64:1591-1598, **http://www.aafp.org/afp/20011101/1591.html.**

REFERENCES

1. Brodsky J, Rouse AM. Exostectomy for symptomatic bony prominences in diabetic Charcot feet. *Clin Orthop Relat Res*. 1993;296:21-26.
2. Fryksberg R. Osteoarthropathy. *Clin Podiatr Med Surg*. 1987;4(2):351-359.
3. Armstrong DG, Todd WF, Lavery LA, Harkless LB, Bushman TR. The natural history of acute Charcot's arthropathy in a diabetic foot specialty clinic. *J Am Podiatr Med Assoc*. 1997;87(6):272-278.
4. Levin ME. Pathogenesis and general management of foot lesions in the diabetic patient. In: Bowker JH, Pfeifer MA, eds. *Levin and O'Neal's The Diabetic Foot*, 6th ed. St. Louis, MO: Mosby; 2001:219-260.

213 DRY GANGRENE

Javier La Fontaine, DPM, MS
Naohiro Shibuya, DPM, MS

PATIENT STORY

A 36-year-old woman with type 1 diabetes presented with a 4-week history of a dry, black great toe and third toe on the right foot (**Figure 213-1**). She said that she noticed severe maceration between the first and second interspace approximately 6 weeks ago. Subsequently, the toes changed color and became very painful. Two days ago, she noticed a foul odor from both toes. The patient reported smoking since she was 13 years old. On physical examination, there were no palpable pulses in the right foot. The patient was admitted for IV antibiotics and revascularization was performed. Subsequently, the toes were partially amputated and the wounds healed without any complications. Her physicians attempted to help her to quit smoking without success.

FIGURE 213-1 Dry gangrene of the first and third toes in a 36-year-old woman with poorly controlled diabetes demonstrating the typical demarcation of the necrotic eschar from the normal tissue. (*Courtesy of Richard P. Usatine, MD.*)

INTRODUCTION

Dry gangrene develops following arterial obstruction and appears as dark brown/black dry tissue. Peripheral arterial disease is common in patients with diabetes and dry gangrene is most commonly seen on the toes. The nonviable tissue becomes black in color from the iron sulfide released by the hemoglobin in the lysed red blood cells.

SYNONYMS

Mummification necrosis.

EPIDEMIOLOGY

- Peripheral arterial disease (PAD) is a common finding in patients with diabetes. PAD is an important factor leading to lower-extremity amputation in patients with diabetes.[1]
- Thirty percent of diabetic patients with an absent pedal pulse will have some degree of coronary artery disease.[1]

ETIOLOGY AND PATHOPHYSIOLOGY

- PAD manifests in the lower extremity in two ways: macro- and microvascular diseases.
- The pattern of occlusion in the macrovascular tree is distal and multisegmental.[2]
- Multiple occlusions occur below the trifurcation of the popliteal artery into the anterior tibial artery, posterior tibial artery, and peroneal artery.

- Risk factors, such as hypercholesteremia, hyperlipidemia, and hypertension, are often associated with patients with PAD and, therefore, poor wound healing.[3,4]

RISK FACTORS

- Diabetes.
- Dyslipidemia.
- Smoking.
- Neuropathy.

DIAGNOSIS

CLINICAL FEATURES

- Dry, black eschar, which most commonly begins distally at the extremities (**Figures 213-1** and **213-2**).
- There is a clear demarcation between healthy tissue and necrotic tissue (**Figures 213-1** and **213-2**).
- Foul odor.
- Pain may be present.
- Trauma is the most common etiology.
- Nonpalpable pulses are common. Palpable pulses do not preclude the presence of limb-threatening ischemia. Also, the dorsalis pedis pulse is reported to be absent in 8% of healthy individuals, and the posterior tibial pulse is absent in 2% of the population.
- Smoking is commonly associated with this problem.
- Associated trophic skin changes (e.g., absent pedal hair and thin shiny skin).
- Indicators of vascular insufficiency include pallor upon elevation of the limb and rubor upon dependency, along with prolonged digital capillary filling time.

TYPICAL DISTRIBUTION

- Distal extremities, especially the toes.

IMAGING

- Even in the presence of a palpable pulse, noninvasive studies (e.g., arterial Doppler and pulse volume recordings) are important for baseline assessment of the patient's blood flow.
- Angiogram is required to evaluate the possibility of revascularization.
- Radiographs may be necessary to rule out osteomyelitis.

DIFFERENTIAL DIAGNOSIS

- Wet gangrene is an acute, urgent problem that is a caused by a severe infection in the dysvascular foot (**Figure 213-3**). Wet gangrene usually presents with cyanosis, purulence, foul odor, and systemic signs and symptoms of infection.

FIGURE 213-2 A 55-year-old man with type 2 diabetes presenting with dry gangrene of the third toe. Note a visible line of demarcation between the gangrene and normal tissue. The dry, black eschar is more distal than proximal. (*Courtesy of Javier La Fontaine, DPM.*)

FIGURE 213-3 A 53-year-old diabetic man with wet gangrene of the second and third toes of the right foot. This diagnosis should always be considered when evaluating the ischemic limb. Wet gangrene is an emergency caused by an infectious process with severe ischemia. (*Courtesy of Javier La Fontaine, DPM.*)

- Ischemic ulcer is an actual foot ulcer that usually presents with a pink to gray wound base (see Chapter 210, Ischemic Ulcer).
- Although diabetes is the most common cause of dry gangrene of the toes, severe frostbite and Buerger disease can also lead to dry gangrene by damage to the microvasculature.

MANAGEMENT

- Consult vascular surgery.
- Rule out wet gangrene. Wet gangrene is an emergent infectious process in combination with severe ischemia. Consequently, immediate debridement of infected tissue is required with antibiotics.
- Avoid amputation or debridement until optimization of blood flow occurs. This may require a vascular bypass procedure and/or interventional radiology for percutaneous angioplasty and stent placement.
- Antibiotics are not indicated for dry gangrene unless infection is suspected.

PREVENTION

- Smoking cessation.
- Diet and exercise to control blood sugar and lipids.
- Vascular examination at least on a yearly basis.

PROGNOSIS

Once dry gangrene has been established, gangrenous tissue will need to be amputated. On occasion, the toes will autoamputate. Successful revascularization must occur for the patient to heal. If the problem is addressed early and aggressive wound care is provided, most of the amputations heal. Because delaying revascularization increases the risk of infection, early and aggressive management of vascular disease is imperative for a successful outcome.

FOLLOW-UP

Closely monitor the patient for new gangrene or ulcers every 3 to 4 months once healing has occurred.

PATIENT EDUCATION

- Avoid trauma to the amputated site.
- Advise and assist patients to stop smoking to help the wound heal and prolong the survival of the revascularization procedure.

PATIENT RESOURCES

- MedicineNet. *Gangrene*—**http://www.medicinenet.com/gangrene/article.htm.**
- eMedicineHealth. *Gangrene*—**http://www.emedicinehealth.com/gangrene/article_em.htm.**

PROVIDER RESOURCES

- Medscape. *Toe Amputation*—**http://emedicine.medscape.com/article/1829931.**
- Medscape. *Gas Gangrene in Emergency Medicine*—**http://emedicine.medscape.com/article/782709.**

REFERENCES

1. American Diabetes Association Guidelines. Preventive foot care in people with diabetes. *Diabetes Care*. 2000;23(Suppl 1):S55-S56.
2. Sykes MT, Godsey JB. Vascular evaluation of the problem diabetic foot. *Clin Podiatr Med Surg*. 1998;15(1):49-82.
3. La Fontaine J, Allen M, Davis C, Harkless LB, Shireman PK. Current concepts in diabetic microvascular dysfunction. *J Am Podiatr Med Assoc*. 2006;96(3):245-252.
4. Tooke JE. A pathophysiological framework for the pathogenesis of diabetic microangiopathy. In: Tooke JE ed. *Diabetic Angiopathy*. New York, NY: Oxford University Press; 1999:187.

PART 15

INFECTIOUS DISEASES

Strength of Recommendation (SOR)	Definition
A	Recommendation based on consistent and good-quality patient-oriented evidence.*
B	Recommendation based on inconsistent or limited-quality patient-oriented evidence.*
C	Recommendation based on consensus, usual practice, opinion, disease-oriented evidence, or case series for studies of diagnosis, treatment, prevention, or screening.*

*See Appendix A on pages 1447–1450 for further information.

214 INTESTINAL WORMS AND PARASITES

Heidi Chumley, MD

PATIENT STORY

A parent brings in a 4-year-old boy suffering with anal itching. On examination the physician finds several excoriations around the anus and suspects pinworms. The physician then applies scotch tape to the perianal area and places the tape on a glass slide. Review of the slide demonstrates adult worms and ova of *Enterobius vermicularis* (pinworms) (**Figure 214-1**). The boy is treated with a single dose of chewable mebendazole and his symptoms resolve. The parent is told to repeat the mebendazole dose in 2 weeks to increase the long-term cure rate. If the scotch tape test were negative, the physician could choose to treat empirically as mebendazole is a very safe medication. Another option is to test again having the parent apply the scotch tape to the boy's perianal area first thing in the morning and bring that back to the office (the yield is higher in the morning).

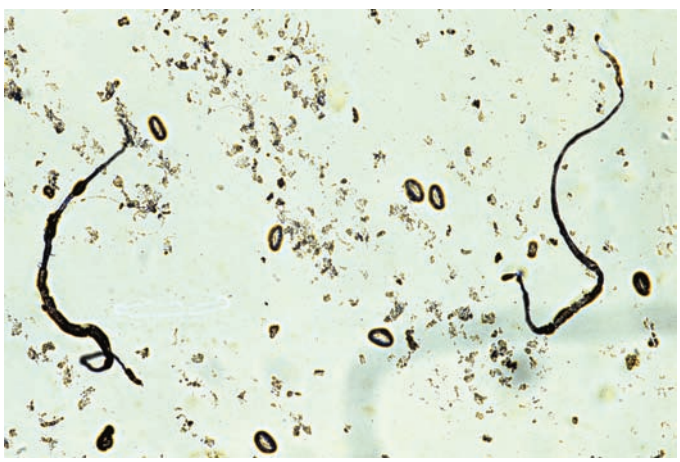

FIGURE 214-1 *Enterobius vermicularis* (pinworms and ova) seen under the microscope from a scotch tape specimen taken of the perianal region of a 4-year-old boy with anal itching. (*Courtesy of James L. Fishback, MD.*)

INTRODUCTION

Intestinal parasites are most common in places with warmer temperatures and high humidity, poor sanitation and unclean water, and a large number of individuals (especially children) living in close proximity. In general, the parasites are either asymptomatic or cause symptoms related to their presence in the GI tract. Several migrate through the lungs and can also cause pulmonary symptoms during the migration. Diagnoses are made by history of worms being seen by the patient or parents or by laboratory examination for ova and parasites in the stool.

EPIDEMIOLOGY

- Nematoda is the phylum that contains pinworms, hookworms, *Ascaris*, *Strongyloides*, and whipworms.
  - *E. vermicularis* (pinworm) is the most prevalent nematode in the United States. Populations at risk include preschool and school aged children, institutionalized persons, and household members of persons with pinworm infection[1] (**Figure 214-1**).
  - *Necator americanus* (hookworm) is found predominately in the Americas and Australia, and is the second most common nematode identified in stool studies in the United States[1] (**Figures 214-2** and **214-3**). *Ancylostoma duodenale* (hookworm) is found mostly in southern Europe, North Africa, the Middle East, and Asia.[1]
  - *Ascaris lumbricoides* is the largest and most common roundworm found in humans in the world; although less common in the United States, it is seen mostly in the rural southeast. It is found in tropical and subtropical areas, including the southeastern rural United States (**Figures 214-4** and **214-5**).[1]

FIGURE 214-2 *Necator americanus* (hookworm) larvae can penetrate the skin, travel through veins to the heart then lungs, climb the bronchial tree to the pharynx, are swallowed, and attach to intestine walls. (*Courtesy of James L. Fishback, MD.*)

- *Strongyloides stercoralis* is seen mostly in tropical and subtropical areas, but can be found in temperate areas, including the southern United States (**Figure 214-6**). It is more frequently found in rural areas, institutional settings, and lower socioeconomic groups.[1]
- *Trichuris trichiura* (whipworm) is the third most common roundworm found in humans worldwide. Infections are more frequent in areas with tropical weather and poor sanitation practices, and among children (**Figure 214-7**). It is estimated that 800 million people are infected worldwide. Trichuriasis occurs in the southern United States.[1]

- Cestodes (tapeworm) are a class in the phylum Platyhelminthes that contains *Taenia solium* (pork tapeworm).
  - *T. solium* is found worldwide where pigs and humans live in close proximity.
- Protozoa is the kingdom of one-celled organisms that includes *Giardia lamblia* and *Entamoeba histolytica*.
  - *G. lamblia (Giardia intestinalis)* is the most common parasite infection worldwide and the second most common in the United States (after pinworm), causing 2.5 million infections annually (**Figure 214-8**).[1]
  - *E. histolytica* is seen worldwide, with higher incidence in developing countries. In the United States, risk groups include men who have sex with men, travelers and recent immigrants, and institutionalized populations.[1]

ETIOLOGY AND PATHOPHYSIOLOGY

- Nematodes (roundworms).
  - *E. vermicularis* (pinworm) (**Figure 214-1**) is acquired through an oral route when hands that have contacted contaminated objects are placed in the mouth. Larvae hatch in the small intestine. Adults live in the cecum. The pregnant female goes to the perianal region at night to lay eggs.
  - *N. americanus* (hookworm) (**Figure 214-2**) larvae penetrate the skin, travel through veins to the heart and then to the lungs, climb the bronchial tree to the pharynx, and then are swallowed and attach to intestine walls (**Figure 214-3**).
  - When fertilized eggs of *A. lumbricoides* (**Figure 214-4**) are ingested, they hatch and the larvae enter the circulation through intestinal mucosa, travel to the lungs, climb to the pharynx, then are swallowed, and finally the adult *Ascaris* worms live in the small intestine.
  - *S. stercoralis* have both a free-living and parasitic cycle. In the parasitic cycle, larvae penetrate the skin, travel through the circulation to the lungs and are swallowed, and travel to the small intestine (**Figures 214-5** and **214-6**) to become adults. Adult females lay eggs, which become rhabditiform larvae, which can either become free living or can cause autoinfection by reentering the parasitic cycle or disseminating widely in the body.
  - *T. trichiura* (whipworm) (**Figure 214-7**) eggs are ingested and hatch in the small intestine; worms live in the cecum or colon.
  - Cestodes (tapeworms)—*T. solium* is acquired by ingesting undercooked contaminated pork. *Diphyllobothrium latum* is the fish tapeworm that is acquired by ingesting uncooked contaminated fresh-water fish.

FIGURE 214-3 Adult hookworm attached to the intestinal wall. (*Courtesy of Centers for Disease Control and Prevention.*)

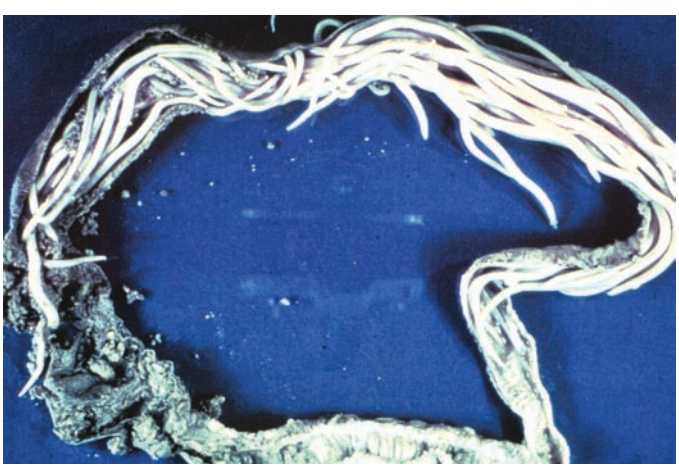

FIGURE 214-4 *Ascaris lumbricoides* in the resected bowel of a patient with bowel obstruction. (*Courtesy of James L. Fishback, MD.*)

FIGURE 214-5 *Ascaris lumbricoides* in the appendix after being removed from a young adult with acute appendicitis. (*Courtesy of James L. Fishback, MD.*)

- Protozoa.
  - *G. lamblia* cysts are ingested from contaminated water, food, or fomites and travel to the small intestine (**Figure 214-8**).
  - *E. histolytica* cysts or trophozoites are ingested from fecally contaminated food, water, or hands or from fecal contact during sexual practices; these then travel to the large intestine, where these either remain or travel through the bloodstream to the brain, liver, or lungs.

RISK FACTORS

- Endemic in developing countries with limited access to clean water.
- Living in an environment conducive to parasites (warm, humid climate) and parasitic transfer (crowded conditions, contaminated water supply, poor hygiene) dramatically raises the risk of parasitic infection.
- Household contacts or caretakers of persons with intestinal parasites are at risk for contracting the parasites.
- Children or others with poor hygiene are also at high risk.
- Immunocompromised patients, once infected, may have a more serious course.

DIAGNOSIS

CLINICAL FEATURES

- Nematodes.
  - *E. vermicularis* (pinworm)—Perianal pruritus is the most common; female genital tract irritation also reported; rarely abdominal pain or appendicitis; infants show irritability, but can be asymptomatic.[1]
  - *N. americanus* (hookworm)—Most commonly presents with iron-deficiency anemia.[1]
  - *A. lumbricoides*—Frequently asymptomatic; high numbers of worms can cause abdominal pain or intestinal obstruction. Cough, dyspnea, hemoptysis, or eosinophilic pneumonitis when in the lungs. Patients may cough up visible worms.
  - *S. stercoralis*—Frequently asymptomatic; eosinophilia; may cause abdominal pain or diarrhea, cough, shortness of breath, or hemoptysis when in the lungs; can disseminate in immunocompromised patients causing abdominal pain, distention, septicemia, shock, or death.
  - *T. trichiura* (whipworm)—Frequently asymptomatic; high number of worms can cause abdominal pain or intestinal obstruction, especially in children.
- Cestodes.
  - *T. solium*—Frequently asymptomatic; risk of developing cysticercosis with symptoms based on location of cysts in brain (e.g., seizures, focal neurologic signs, and death), eyes, heart, or spine.
- Protozoa.
  - *G. lamblia*—Diarrhea, nausea, emesis, abdominal bloating occurs 1 to 14 days after ingestion for up to 3 weeks, and can be asymptomatic.

FIGURE 214-6 *Strongyloides stercoralis* ova and parasite in stool. (*Courtesy of James L. Fishback, MD.*)

FIGURE 214-7 *Trichuris trichiura* (whipworm) egg in stool. (*Courtesy of James L. Fishback, MD.*)

- *E. histolytica*—Asymptomatic, intestinal symptoms (e.g., colitis and appendicitis), or extraintestinal (e.g., abscess in the liver or lungs, peritonitis, and skin or genital lesions).

LABORATORY TESTING

- Nematodes.
  - *E. vermicularis* (pinworm)—Microscopic identification of eggs (**Figure 214-1**) collected from perianal area; apply transparent adhesive tape to the unwashed perianal area at the time of presentation or in the morning and then place tape on slide.
  - *N. americanus* (hookworm)—Microscopic identification of eggs in the stool (**Figure 214-2**).
  - *A. lumbricoides*—Microscopic identification of eggs in the stool.
  - *S. stercoralis*—Microscopic identification of larvae in stool (**Figure 214-6**) or duodenal fluid; often requires several samples. Immunologic tests are useful when infection is suspected, but larvae are not seen in several samples. Immunologic tests do not differentiate from past or present infections.
  - *T. trichiura* (whipworm)—Microscopic identification of eggs in stool (**Figure 214-7**).
- Cestodes.
  - *T. solium*—Microscopic identification of eggs or proglottids in stool indicates taeniasis; presumed neurocysticercus diagnosed from Centers for Disease Control and Prevention (CDC)'s immunoblot assay.[1]
- Protozoa.
  - *G. lamblia*—Microscopic identification of cysts or trophozoites in stool or trophozoites in duodenal fluid or biopsy (**Figure 214-8**). Antigen tests and immunofluorescence are available.
  - *E. histolytica*—Microscopic identification of cysts or trophozoites in stool (difficult to distinguish from nonpathogens); antibody detection for extraintestinal disease; antigen detection can distinguish pathogenic and nonpathogenic infections.[1]

IMAGING

- Cestodes.
  - *T. solium*—MRI is typically used to identify brain cysts.

DIFFERENTIAL DIAGNOSIS

- Abdominal symptoms seen with several intestinal parasites can also be caused by the following:
  - Viral or bacterial infections—May present with acute onset of emesis and diarrhea often with fever.
  - Irritable bowel disease—Chronic symptoms of abdominal cramping with diarrhea or loose stools and/or constipation; usually no bloody stools, weight loss, or anemia.
  - Inflammatory bowel disease—Intermittent abdominal pain and bloody stools; diagnosis confirmed by colonoscopy with biopsy.
  - Iron-deficiency anemia seen with hookworms can be seen with blood loss from any site from one of many causes. Of course, iron deficiency can be seen with a diet deficient in iron without having hookworms.
  - GI blood loss can be seen with other infections or inflammation, polyps, or masses.

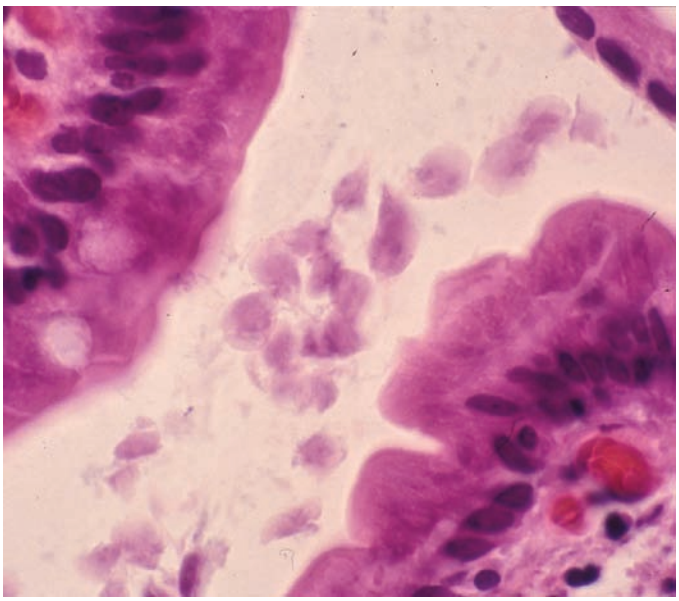

FIGURE 214-8 *Giardia lamblia* in a duodenal biopsy obtained by esophagogastroduodenoscopy in a patient with typical symptoms of chronic giardiasis (excessive flatulence and sulfurous belching) that failed to improve on metronidazole. (*Courtesy of Tom Moore, MD.*)

MANAGEMENT

MEDICATIONS

All medication doses are from *The Medical Letter*[2] and apply to adults and children unless specified.

- Nematodes
  - *E. vermicularis* (pinworm)—Pyrantel pamoate 11 mg/kg once (maximum 1 g), repeat in 2 weeks; or mebendazole 100 mg once, repeat in 2 weeks.
  - *N. americanus* (hookworm)—Albendazole 400 mg once; or mebendazole 100 mg twice a day for 3 days 500 mg once or pyrantel pamoate 11 mg/kg (maximum 1 g) for 3 days.
  - *A. lumbricoides*—Albendazole 400 mg once; alternate therapy mebendazole 500 mg once or ivermectin 150 to 200 mcg/kg po once.
  - *S. stercoralis*—Ivermectin 200 mcg/kg per day for 2 days; alternate therapy albendazole 400 mg bid for 7 days.
  - *T. trichiura* (whipworm)—Mebendazole 100 mg twice a day for 3 days or 500 mg once; alternate therapy albendazole 400 mg once a day for 3 days or ivermectin 0.2 mg/kg daily for 3 days.
- Cestodes
  - *T. solium*—Praziquantel 5 to 10 mg/kg once for intestinal stage; cysticercosis require seizure prophylaxis and steroids in conjunction with albendazole 400 mg bid (adults) or 15 mg/kg per day up to 400 mg bid (children) for 8 to 30 days; ophthalmologic examination for eye cysts is recommended.
- Protozoa
  - *G. lamblia*—Metronidazole 250 mg tid for 5 to 7 days (adults), 15 mg/kg per day divided tid for 5 to 7 days (children); or tinidazole 2 g once (adults), 50 mg/kg (maximum 2 g) once (children); or nitazoxanide 500 mg bid for 3 days (age >12 years), 100 mg bid for 3 days (age 1 to 3 years), 200 mg po bid for 3 days (age 4 to 11 years).
  - *E. histolytica*—Metronidazole 500 to 750 mg tid for 7 to 10 days (adults), 35 to 50 mg/kg per day divided in 3 doses for 7 to 10 days (children) or tinidazole 2 g once daily for 3 days (adults), 50 mg/kg per day in 3 doses up to 2 g for 3 days. Then iodoquinol 650 mg tid for 20 days (adults), 30 to 40 mg/kg per day up to 2 g in 3 doses for 20 days (children); or paromomycin 25 to 35 mg/kg per day in 3 doses for 7 days.

REFERRAL OR HOSPITALIZATION

Refer or hospitalize patients

- Who do not respond to initial therapy or have recurrent infections.
- Suspected of having cysticercosis.
- Experiencing severe abdominal symptoms suggesting obstruction or an acute abdomen.

PREVENTION

- Clean uncontaminated water for drinking and cooking—Use bottled water, chemically treated water, or boiled water in endemic areas.
- Good hygiene, especially hand washing.
- When travelling to endemic areas, drink bottled water when possible. Water can also be treated with chlorine, iodine, or boiled if bottled water is not available. Clean water should be used for brushing teeth. Avoid eating fresh salads washed in local water.
- Children in developing countries who are drinking contaminated water (and lack access to clean water) should be considered for deworming with albendazole every 3 to 6 months (see Chapter 7, Global Health Issues).

PROGNOSIS

Prognosis is excellent for most infections if adequate therapy and clean water is available.

FOLLOW-UP

Follow-up at completion of therapy.

PATIENT EDUCATION

Most intestinal parasites are asymptomatic and easily treatable. Avoid infecting others by practicing good hygiene, including hand washing.

PATIENT RESOURCE

- The Centers for Disease Control and Prevention division of parasitic diseases has information on many parasitic diseases—**http://www.cdc.gov/parasites.**

PROVIDER RESOURCES

- Centers for Disease Control and Prevention (CDC)—**http://www.cdc.gov/parasites.**
- The Medical Letter's "Drugs for Parasitic Infections" is available online at **www.medletter.com** for individual and institutional subscribers.

REFERENCES

1. Centers for Disease Control and Prevention. *Parasites*. http://www.cdc.gov/parasites. Accessed September 11, 2011.
2. The Medical Letter. Drugs for parasitic infections. Treatment guidelines. 2nd ed, 2010. http://secure.medicalletter.org/system/files/private/parasitic.pdf. Accessed September 11, 2011.

215 URETHRITIS IN MEN

Heidi Chumley, MD
Richard P. Usatine, MD

PATIENT STORY

A 24-year-old man presents to a skid row shelter clinic with 3 days of dysuria and penile discharge. A heavy purulent urethral discharge is seen (**Figure 215-1**). He admits to using crack cocaine and having multiple female sexual partners. He was diagnosed with gonococcal urethritis by clinical appearance and a urine specimen was sent for testing to confirm the gonorrhea and test for *Chlamydia*. He was treated with Ceftriaxone 250 mg IM for gonorrhea and 1 g of oral azithromycin for possible coexisting *Chlamydia*. He was offered and agreed to testing for other sexually transmitted diseases. He was told to inform his partners of the diagnosis. He was counseled about safe sex, and drug rehabilitation was recommended. On his 1-week follow-up visit, his symptoms were gone and he had no further discharge. His gonorrhea nucleic acid amplification test was positive and his *Chlamydia*, rapid plasma reagin (RPR), and HIV tests were negative. His case was reported to the Health Department for contact tracing.

FIGURE 215-1 A 24-year-old man with gonococcal urethritis and a heavy purulent urethral discharge. (*Courtesy of Richard P. Usatine, MD.*)

INTRODUCTION

Urethritis is urethral inflammation caused by infectious (gonococcal or chlamydial) or noninfectious causes (trauma or foreign bodies). Gonococcal and chlamydial infections in men occur most commonly between the ages of 20 and 24 years, and the prevalence is highest in black men. Diagnosis is suspected clinically, reinforced by an office urine test positive for leukocyte esterase, and confirmed by a urine nucleic acid amplification test. Treat for both gonorrhea and *Chlamydia* until one or both are ruled out by laboratory testing.

EPIDEMIOLOGY

- Worldwide, 151 million cases of gonococcal and nongonococcal urethritis are reported annually (**Figures 215-1** and **215-2**).[1]
- Urethritis of all types occurs in 4 million Americans each year.[1]
- The prevalence of gonorrhea in men was 94.1 per 100,000 population among men in the US in 2010. The rate was highest among those men aged 20–24 years (421.0 per 100,000 population). In 2010, gonorrhea rates remained highest among black men and women (432.5), which was 18.7 times the rate among whites (23.1 per 100,000 population). The rates among Hispanics (49.9) was 2.2 times those of whites.[2]
- The prevalence of *Chlamydia* in men in the US in 2010 was 233.7 cases per 100,000 males. Age-specific rates among men were highest in those aged 20–24 years (1,187.0 cases per 100,000 males).

FIGURE 215-2 Nongonococcal urethritis caused by *Chlamydia*. Note the discharge is more clear and less purulent than seen with gonorrhea. (*Courtesy of Seattle STD/HIV Prevention Training Center, University of Washington.*)

The rate of chlamydia among black men and women was more than eight times the rate among whites (1,167.5 and 138.7 cases per 100,000 population, respectively). The rate among Hispanics was 2.7 times the rate among whites.[2]

ETIOLOGY AND PATHOPHYSIOLOGY

- Urethritis is urethral inflammation caused by infectious or noninfectious causes.
- *Neisseria gonorrhoeae* and *Chlamydia trachomatis* are the most important infectious causes. When transmitted, they can cause other illnesses and complications in men (epididymitis, prostatitis, and reactive arthritis) and women (pelvic inflammatory disease and infertility).
- Other infectious agents include *Mycoplasma genitalium*, *Ureaplasma urealyticum*, *Trichomonas vaginalis*, herpes simplex viruses 1 and 2, adenovirus, and enteric bacteria.
- Noninfectious causes include trauma, foreign bodies, granulomas or unusual tumors, allergic reactions, or voiding dysfunction (any abnormal holding or voiding pattern not caused by an anatomical or a neurologic process).

DIAGNOSIS

CLINICAL FEATURES

Male patients with urethritis can be asymptomatic or present with urethral discharge, dysuria, or urethral pruritus.

Urethritis is diagnosed when one of the following is present:[3]

- Mucopurulent or purulent urethral discharge (**Figures 215-1** and **215-2**).
- First-void urine positive leukocyte esterase test ≥10 white blood cells (WBCs) per high-power field. (This can also be seen with a urinary tract infection [UTI]; however, the incidence of UTI in men younger than 50 years of age is approximately 50 per 100,000 per year, much lower than the incidence of gonococcal or chlamydial urethritis in this age group.)

LABORATORY TESTING

- Nucleic acid amplification test (NAAT) is the recommended test for screening asymptomatic at-risk men and testing symptomatic men.[3] Urine is a better specimen than urethral swab and does not hurt.[3,4]
- Gram stain of urethral secretions with ≥5 WBC per oil immersion field. (If Gram-negative intracellular diplococci are seen, gonococcal urethritis is present.) Gram stain will identify most cases; ≥5 WBCs are seen in 82% of *Chlamydia* and 94% of gonococcal infections.[5] Government regulations concerning in-office laboratory testing have severely curtailed the use of Gram stains in the office.
- Leukocyte esterase test on urine has a good negative predictive value (NPV) but poor positive predictive value (PPV) in a low-prevalence population (NPV 96.4% and PPV 35.4%).[6] Urethral culture is less commonly necessary when NAAT is available.
- Consider culture when tests for gonorrhea and *Chlamydia* are negative, or symptoms persist despite adequate treatment in a patient who is unlikely to have been reinfected by an untreated partner.

DIFFERENTIAL DIAGNOSIS

Dysuria in men can be caused by the following:[7]

- Infections in other sites or the urogenital tract—Cystitis, prostatitis with perineal pain or prostate tenderness, or epididymitis with scrotal pain.
- Penile lesions—Vesicles of herpes simplex, ulcers of syphilis, chancroid, or lymphogranuloma venereum, and glans irritation from balanitis.
- Mechanical causes—Obstruction from benign prostatic hyperplasia (BPH) causing inflammation without infection, trauma including catheterization, urethral strictures, or genitourinary cancers.
- Inflammatory conditions—Spondyloarthropathies, drug reactions, or autoimmune diseases.

MANAGEMENT

Treat patients who meet criteria for urethritis. Test patients with dysuria who do not meet criteria for urethritis, for *N. gonorrhoeae* and *C. trachomatis*, and treat if positive. Advise sex partners to be evaluated and treated.[2]

NONPHARMACOLOGIC

- Encourage safe-sex practices.

MEDICATIONS

- The 2010 CDC STD treatment guidelines recommend treating uncomplicated gonococcal urethritis with ceftriaxone 250 mg IM in a single dose plus treatment for *Chlamydia* with azithromcyin or doxycycline. Most gonococci in the United States are susceptible to doxycycline and azithromycin, so that routine cotreatment might also hinder the development of antimicrobial-resistant *N. gonorrhoeae*.[8] Avoid fluoroquinolones and oral cefixime as drug resistance is too high.[8,9] SOR A
- The 2010 CDC STD treatment guidelines recommend treating *Chlamydia* urethritis with azithromycin 1 g orally in a single dose or doxycycline 100 mg orally twice a day for 7 days.[10] SOR A
  Acceptable alternate regimens include:
  - Erythromycin base 500 mg 4 times a day for 7 days or erythromycin ethylsuccinate 800 mg 4 times a day for 7 days or ofloxacin 300 mg orally twice a day for 7 days or levofloxacin 500 mg orally once daily for 7 days.[10]
- For persistent urethritis, consider *Trichomonas vaginalis* as a possible cause—Culture and treat with a single dose of metronidazole 2 g.
- Consider expedited partner therapy (EPT). EPT is the delivery of medications or prescriptions by persons infected with a sexually transmitted disease (STD) to their sex partners without

clinical assessment of the partners. Legal status by state is available at **http://www.cdc.gov/std/ept/legal/default.htm.**

PREVENTION

Consider screening the following groups of men for *Chlamydia*, using urine NAAT for testing and screening.[2] Twelve percent of male patients with chlamydial and 5% with gonococcal infections had no Gram stain evidence of urethral inflammation.[5]

- Men attending an STD clinic.
- Men attending a national job training program.
- Men younger than 30 years of age who are military recruits.
- Men younger than 30 years of age entering jail.

PROGNOSIS

Gonococcal and chlamydial urethritis respond well to appropriate antibiotic therapy. Partners must be treated to avoid reinfection.

FOLLOW-UP

- Reevaluate patients with persistent or recurrent symptoms after treatment. Reexamine for evidence of urethral inflammation and retest for gonorrhea and *Chlamydia*.
- Routine test-of-cure laboratory examination is not recommended by the CDC for gonorrhea or chlamydia infections unless therapeutic compliance is in question, symptoms persist, or reinfection is suspected.[8,10]
- However, patients who have symptoms that persist after treatment of gonorrhea should be evaluated by culture for *N. gonorrhoeae*, and any gonococci isolated should be tested for antimicrobial susceptibility.[8]
- Consider chronic prostatitis if symptoms persist for more than 3 months.

PATIENT EDUCATION

The Centers for Disease Control and Prevention (CDC) recommends the following for patients diagnosed with gonorrhea or *Chlamydia*:[2]

- Return for evaluation if the symptoms persist or return after therapy is completed.
- Abstain from sexual intercourse until 7 days after starting therapy, symptoms have resolved, and sexual partners have been adequately treated.
- Undergo testing for other STDs, including HIV and syphilis.
- Advise sexual partners of the need for treatment and/or take medications directly to them using EPT.

PATIENT RESOURCES

- Centers for Disease Control and Prevention—**http://www.cdc.gov/std/Gonorrhea/STDFact-gonorrhea.htm.**
- Centers for Disease Control and Prevention—**http://www.cdc.gov/std/chlamydia/default.htm.**

PROVIDER RESOURCES

- The Centers for Disease Control and Prevention (CDC) website has the latest epidemiologic data and management recommendations—**http://www.cdc.gov/std/default.htm.**
- The newest CDC Treatment Guidelines are at **http://www.cdc.gov/std/treatment.**

REFERENCES

1. Terris MK. *Urethritis*. http://emedicine.medscape.com/article/438091. Accessed September 2, 2012.
2. U.S. Centers for Disease Control and Prevention. http://www.cdc.gov/std/stats10/chlamydia.htm. Accessed September 2, 2012.
3. Brill JR. Diagnosis and treatment of urethritis in men. *Am Fam Physician*. 2010;81(7):873-878.
4. Sugunendran H, Birley HD, Mallinson H, et al. Comparison of urine, first and second endourethral swabs for PCR based detection of genital *Chlamydia trachomatis* infection in male patients. *Sex Transm Infect*. 2001;77(6):423-426.
5. Geisler WM, Yu S, Hook EW III. Chlamydial and gonococcal infection in men without polymorphonuclear leukocytes on Gram stain: implications for diagnostic approach and management. *Sex Transm Dis*. 2005;32(10):630-634.
6. Bowden FJ. Reappraising the value of urine leukocyte esterase testing in the age of nucleic acid amplification. *Sex Transm Dis*. 1998;25(6):322-326.
7. Bremnor J, Sadovsky R. Evaluation of dysuria in adults. *Am Fam Physician*. 2002;65(8):1589-1596.
8. Centers for Disease Control and Prevention (CDC). *Sexually Transmitted Diseases Treatment Guidelines, 2010: Gonococcal-infections*. http://www.cdc.gov/std/treatment/2010/gonococcal-infections.htm. Accessed September 2, 2012.
9. Update to CDC's Sexually Transmitted Diseases Treatment Guidelines, 2010: Oral Cephalosporins No Longer a Recommended Treatment for Gonococcal Infections. *MMWR*. 2012;61(31):590-594. http://www.cdc.gov/mmwr/preview/mmwrhtml/mm6131a3.htm?s_cid=mm6131a3_w. Accessed September 2, 2012.
10. Centers for Disease Control and Prevention (CDC). *Sexually Transmitted Diseases Treatment Guidelines, 2010: Chlamydial Infections*. http://www.cdc.gov/std/treatment/2010/chlamydial-infections.htm. Accessed September 2, 2012.

216 SYPHILIS

Richard P. Usatine, MD
Heidi Chumley, MD

PATIENT STORY

A 39-year-old woman presents with a nonhealing ulcer over her upper lip for 1 week and a new-onset rash on her trunk (**Figures 216-1** and **216-2**). The ulcer on her upper lip was misdiagnosed as herpes simplex by the previous physician. Sexual history revealed that the patient had oral sex with a boyfriend who had a lesion on his penis and she suspected that he had been having sex with other women. The examining physician recognized the nonpainful ulcer and rash as a combination of primary and secondary (P&S) syphilis. An RPR (rapid plasma reagin) was drawn and the patient was treated immediately with IM benzathine penicillin. The RPR came back as 1:128 and the ulcer was healed within 1 week.

FIGURE 216-1 Primary syphilis with a chancre over the lip of a woman. (*Courtesy of Richard P. Usatine, MD.*)

INTRODUCTION

Syphilis, caused by *Treponema pallidum*, is a systemic disease characterized by multiple overlapping stages: primary syphilis (ulcer), secondary syphilis (skin rash, mucocutaneous lesions or lymphadenopathy), tertiary syphilis (cardiac or gummatous lesions), and early or late latent syphilis (positive serology without clinical manifestations). Neurosyphilis can occur at any stage. Diagnosis is made using treponemal and nontreponemal tests. Treatment is penicillin; the dose and duration depend on the stage.

SYNONYMS AND ACRONYMS

Lues is another word for syphilis.

Nontreponemal tests:

- VDRL—Venereal Disease Research Laboratory.
- RPR.

Treponemal tests:

- EIA—Enzyme immunoassay.
- TPPA—*T. pallidum* particle agglutination.
- FTA-ABS—Fluorescent treponemal antibody absorption.
- MHA-TP—Microhemagglutination assay for *T. pallidum*.

EPIDEMIOLOGY

- Primary and secondary (P&S) syphilis cases reported to CDC decreased from 13,997 in 2009 to 13,774 in 2010, a decrease of 1.6%. The rate of P&S syphilis in the US in 2010 (4.5 cases per 100,000 population) was 2.2% lower than the rate in 2009 (4.6 cases). This is the first overall decrease in P&S syphilis in 10 years.[1]

FIGURE 216-2 A nonpruritic rash of secondary syphilis on the abdomen of the patient shown in **Figure 216-1**. (*Courtesy of Richard P. Usatine, MD.*)

- The rate of P&S syphilis increased 1.3% among men (from 7.8 to 7.9 cases per 100,000 men) during 2009–2010. During this same period, the rate decreased 21.4% among women (from 1.4 to 1.1 cases per 100,000 women).[1]
- In 2010, the rate of P&S syphilis was highest among persons aged 20–24 years and 25–29 years (13.5 and 11.3 cases per 100,000 population, respectively).[1]
- The distribution of primary and secondary syphilis reported in 2010 differed by gender and sexual preferences: among men who have sex with women only (MSW), 35.8% had primary syphilis, and 64.2% had secondary syphilis. Among women, 16.0% had primary syphilis, and 84.0% had secondary syphilis. Among men who have sex with men (MSM), 25.0% had primary syphilis, and 75.0% had secondary syphilis.[1]
- Syphilis by races/ethnicities varied in 2010: Among women with P&S syphilis, 16.8% were white, 72.8% were black, 6.6% were Hispanic. Among MSW, 14.8% were white, 67.0% were black, 13.8% were Hispanic. Among MSM, 38.1% were white, 37.0% were black, 19.8% were Hispanic.[1]
- In 2008, 63% of the reported cases of P&S were in men who have sex with men (MSM).[2]
- HIV-infected patients were found to have syphilis rates of 62.3 per 1000 compared to 0.8 per 1000 in HIV-uninfected patients in a population study in California.[3]

ETIOLOGY AND PATHOPHYSIOLOGY

- Syphilis is caused by the spirochete *T. pallidum* and contracted through direct sexual contact with primary or secondary lesions. Congenital syphilis can be contracted across the placenta.

RISK FACTORS

- Sexual contact with a person with primary or secondary syphilis.
- MSM.
- Prostitution.
- Sex for drugs.
- HIV/AIDS.

DIAGNOSIS

CLINICAL FEATURES

- Primary syphilis is associated with a chancre—Usually a non-painful ulcer (**Figures 216-1**, **216-3**, and **216-4**). The presence of pain does not rule out syphilis, and the patient with a painful genital ulcer should be tested for both syphilis and herpes.
- Secondary syphilis occurs when the spirochetes become systemic and may present as a rash with protean morphologies, condyloma lata, and/or mucous patches (**Figures 216-2** and **216-5** to **216-11**).
- Tertiary syphilis may be visualized with gummas on the skin, but many of the manifestations are internal such as the cardiac and

FIGURE 216-3 A painless chancre at the location of treponemal entry. (*Courtesy of the Public Health Image Library, Centers for Disease Control and Prevention.*)

FIGURE 216-4 Primary syphilis with a large chancre on the glands of the penis. The multiple small surrounding ulcers are part of the syphilis and not a second disease. (*Courtesy of Richard P. Usatine, MD.*)

FIGURE 216-5 Papular squamous eruption on the hands of a woman with secondary syphilis. (*Courtesy of Richard P. Usatine, MD.*)

neurologic diseases that occur (e.g., aortitis, tabes dorsalis, and iritis). **Figure 216-12** shows a gumma of the scrotum.

- Neurosyphilis can occur at any stage. Clinical symptoms include cognitive dysfunction, vision or hearing loss, uveitis or iritis, motor or sensory abnormalities, cranial nerve palsies, or symptoms of meningitis.

TYPICAL DISTRIBUTION

- Primary syphilis is usually a single ulcer (chancre) that is not painful in the genital region (**Figures 216-3** and **216-4**). A chancre can be seen on the lip (**Figure 216-1**).
- Secondary syphilis may present with various eruptions on the trunk, palms, and soles (**Figures 216-2**, **216-5**, **216-6**, **216-8**, and **216-13**).
- Mucous patches are on the genitals or in the mouth (**Figures 216-7**, **216-9**, and **216-10**).

LABORATORY TESTING

- Serologic tests are either nontreponemal (RPR or VDRL), which measure anticardiolipin antibodies, or treponemal (EIA, TPPA, FTA-ABS, or MHA-TP), which measure antibodies to *T. pallidum*.
- There are two algorithms for laboratory testing currently in use around the world:
  1. Start with a low-cost nontreponemal test and confirm a positive result with a treponemal test.
  2. Start with the EIA treponemal test, followed by a nontreponemal test for confirmation.
- In 2008, the Centers for Disease Control and Prevention (CDC) recommended a treponemal EIA initially, with positive results followed by a nontreponemal test for confirmation, a strategy that detected an additional 3% of positive samples not identified in the nontreponemal–treponemal sequence.[4]
- A nontreponemal test is required for confirmation, as a treponemal EIA indicates exposure but not active infection.
- A positive EIA with a negative RPR can be a previous treated or untreated infection, a false positive, or early primary syphilis. In this case, retest with a second treponemal test.
- Dark-field microscopy is useful in evaluating moist cutaneous lesions, such as chancre, mucous patches, and condyloma lata (**Figure 216-14**).
- Test all patients with syphilis for HIV (**Figure 216-15**).
- Patients with syphilis who have any signs or symptoms suggesting neurologic disease including vision or hearing need a cerebrospinal fluid (CSF) exam, a slit-lamp ophthalmologic examination, and an otologic examination to determine if neurosyphilis is present.

DIFFERENTIAL DIAGNOSIS

- Herpes simplex—Most common cause of genital ulcers in the United States. These ulcers are painful and often start as vesicles (see Chapter 129, Herpes Simplex).

FIGURE 216-6 Papular squamous eruption on the foot of the woman in Figure 216-5, with secondary syphilis. (*Courtesy of Richard P. Usatine, MD.*)

FIGURE 216-7 Mucous patches on the labia of the woman in Figure 216-5, with secondary syphilis teeming with spirochetes. (*Courtesy of Richard P. Usatine, MD.*)

FIGURE 216-8 Pink macules on the feet and wrists of a man with secondary syphilis. (*Courtesy of Richard P. Usatine, MD.*)

FIGURE 216-9 Mucous patches on the penis and scrotum of the same man with secondary syphilis in **Figure 216-8**. (*Courtesy of Richard P. Usatine, MD.*)

FIGURE 216-12 Tertiary syphilis presenting as a swollen scrotum, which was diagnosed as a syphilitic gumma of the testicle. (*Courtesy of the Public Health Image Library, Centers for Disease Control and Prevention.*)

FIGURE 216-10 Oral lesion on the palate of the same man with secondary syphilis in **Figure 216-9**. (*Courtesy of Richard P. Usatine, MD.*)

FIGURE 216-13 Middle-age married man with diffuse eruption of secondary syphilis from neck to feet. The eruption remained undiagnosed for months as the patient denied any risk factors. His RPR was 1:256. (*Courtesy of Richard P. Usatine, MD.*)

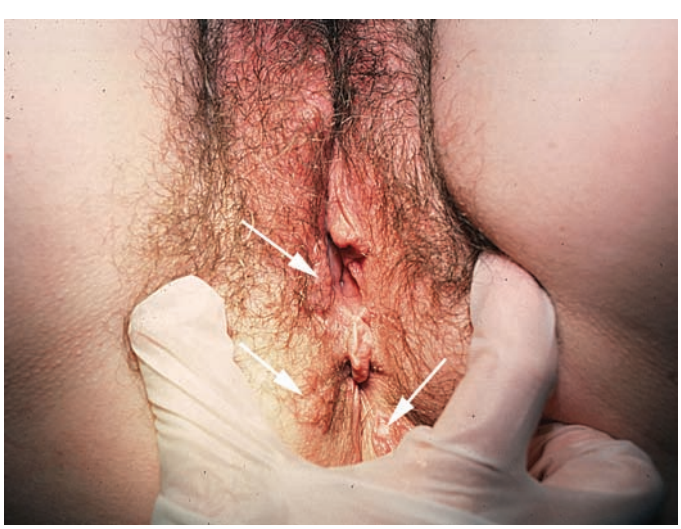

FIGURE 216-11 Condylomata lata (*arrows*) on the vulva of a woman with secondary syphilis. (*Courtesy of Richard P. Usatine, MD.*)

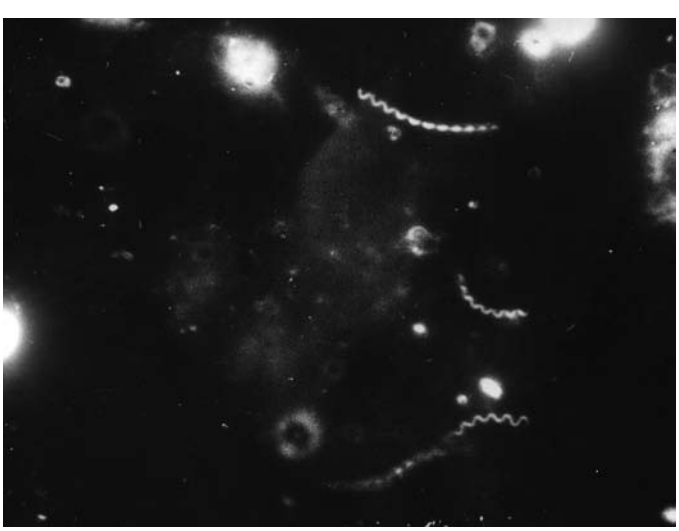

FIGURE 216-14 Live spirochetes of *T. pallidum* seen in a darkfield preparation. (*Courtesy of the Public Health Image Library, Centers for Disease Control and Prevention.*)

- Chancroid—Painful beefy red ulcers on the penis or vulva, less common than syphilis. Chancroid is also known to cause large painful inguinal adenopathy (bubo) (**Figures 216-16** and **216-17**).
- Drug eruptions—Can be on the genital area such as seen in a fixed drug eruption. Also whole-body drug eruptions can appear similar to secondary syphilis (see Chapter 203, Cutaneous Drug Reactions).
- Erythema multiforme—Can look like the rash of secondary syphilis but may have target lesions (see Chapter 177, Erythema Multiforme, Stevens-Johnson Syndrome, and Toxic Epidermal Necrolysis).
- Pityriasis rosea—A self-limited cutaneous eruption that often begins with a herald patch and may have a Christmas tree distribution on the back (see Chapter 153, Pityriasis Rosea).

FIGURE 216-15 Secondary syphilis in a 20-year-old woman with a history of injection drug use and multiple sexual partners. Her HIV test was also positive. (*Courtesy of Richard P. Usatine, MD.*)

FIGURE 216-16 Culture-proven indurated beefy chancroidal ulcers in an HIV positive man. (*Courtesy of Professor David Lewis.*)

FIGURE 216-17 Left-side inguinal bubo in a patient with a culture-proven chancroidal ulcer. (*Courtesy of Professor David Lewis.*)

MANAGEMENT

MEDICATIONS

Benzathine penicillin is the treatment of choice for all stages of syphilis. Dose and duration depend on stage. Treatment information below is from the CDC.[5]

- Primary, secondary, and early latent (immunocompetent and nonpregnant):
  - Adults: Benzathine penicillin G 2.4 million U IM one time.
  - Children older than 1 month with acquired primary or secondary: 50,000 U/kg IM up to 2.4 million U one time.
- Penicillin allergy:
  - Doxycycline 100 mg twice daily × 14 days or
  - Ceftriaxone 1 g IM/IV daily × 10 to 14 days (limited studies) or
  - Azithromycin 2 g single oral dose; however, azithromycin resistance has been documented in several areas of the United States. Use only when penicillin or doxycycline cannot be used. Do not use in MSM.
- Late latent syphilis or syphilis of unknown duration
  - Adults: Benzathine penicillin G 2.4 million U IM every week for 3 weeks.
  - Children: 50,000 U/kg IM (up to 2.4 million U) every week for 3 weeks.
- Penicillin allergy: Doxycycline 100 mg twice a day for 28 days (or tetracycline 500 mg 4 times a day for 28 days) are the only acceptable alternatives.
- For the management of congenital, tertiary, and neurosyphilis, see the *Sexually Transmitted Diseases Treatment Guidelines* published by the CDC in 2010: http://www.cdc.gov/std/treatment/2010/genital-ulcers.htm#syphilis.

REFERRAL OR HOSPITALIZATION

- Refer patients when the stage of syphilis is unclear. Consider referral to an infectious disease specialist in children younger than 1 month of age, pregnant women with a penicillin allergy, patients with tertiary or neurosyphilis, or patients who have failed treatment.

PREVENTION

Primary prevention: Safe sex practices—sexual transmission occurs when mucocutaneous syphilitic lesions are present.

Secondary prevention:

- Treat presumptively (regardless of serology) sexual partners who were exposed within 90 days of the partner's diagnosis of primary, secondary, or early latent syphilis.
- Consider presumptive treatment when exposure was greater than 90 days before partner's diagnosis if serology is unavailable or follow-up is uncertain.[5]

PROGNOSIS

When syphilis is recognized and appropriately treated, the prognosis is excellent.

FOLLOW-UP

Reexamine clinically and serologically at 6 and 12 months. Consider treatment failure if signs and/or symptoms persist or the nontreponemal test titer does not decline by 2 dilutions after 6 to 12 months of therapy. Fifteen percent will not achieve this decline in titer after 1 year.[5]

For treatment failures: Retest for HIV and perform a lumbar puncture for CSF analysis and treat for neurosyphilis if positive.

PATIENT EDUCATION

Condoms can prevent the spread of syphilis. Patients should be advised to get HIV testing and need to know that syphilis is a risk factor for the spread of HIV. HIV/AIDS is also a risk factor for acquiring syphilis (**Figure 216-18**). Patients should be advised of the importance of completing treatment and follow-up to prevent complications.

PATIENT RESOURCE

- Centers for Disease Control and Prevention (CDC). *Sexually Transmitted Diseases (STDs): Syphilis–CDC Fact Sheet*—**http://www.cdc.gov/std/syphilis/stdfact-syphilis.htm.**

PROVIDER RESOURCES

- **http://emedicine.medscape.com/article/22946.**
- The Centers for Disease Control and Prevention. *Sexually Transmitted Diseases Treatment Guidelines*—**http://www.cdc.gov/std/treatment/2010/toc.htm.** (Also available to download as an ebook for Apple iPad, iPhone, or iPod Touch—**http://www.cdc.gov/std/2010-ebook.htm.**)

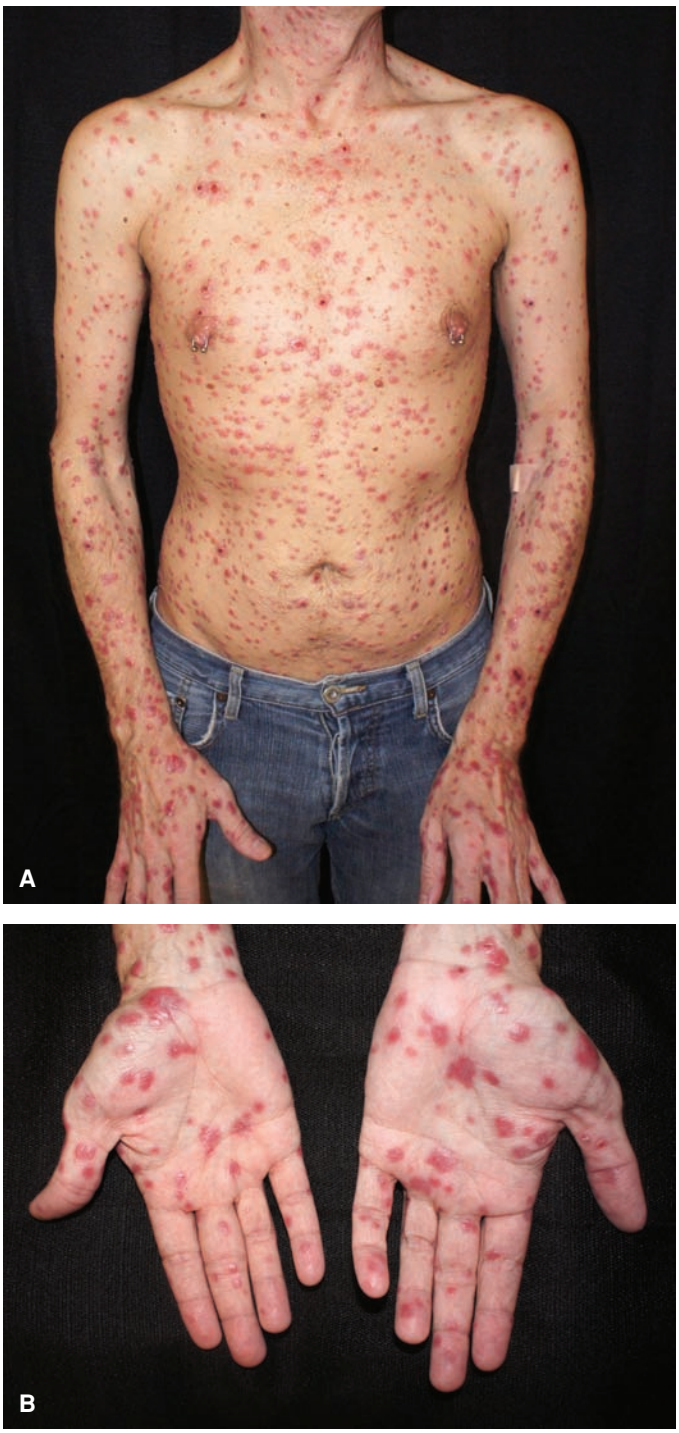

FIGURE 216-18 Secondary syphilis in a young man with known HIV/AIDS **A.** Impressive red papulosquamous eruption from head to toe is present. **B.** Close-up showing the palmar patches and plaques. (*Courtesy of Jonathan B. Karnes, MD.*)

REFERENCES

1. Centers for Disease Control and Prevention (CDC). *Sexually Transmitted Diseases Surveillance.* Syphilis. http://www.cdc.gov/std/stats10/Syphilis.htm. Accessed September 2, 2012.
2. Centers for Disease Control and Prevention (CDC). *Sexually Transmitted Diseases.* Syphilis. http://www.cdc.gov/std/syphilis/. Accessed September 2, 2012.
3. Horberg MA, Ranatunga DK, Quesenberry CP, et al. Syphilis epidemiology and clinical outcomes in HIV-infected and HIV-uninfected patients in Kaiser Permanente Northern California. *Sex Transm Dis.* 2010; 37(1):53-58.
4. Centers for Disease Control and Prevention (CDC). Syphilis testing algorithms using treponemal tests for initial screening—four laboratories, New York City, 2005-2006. *MMWR Morb Mortal Wkly Rep.* 2008;57(32):872-875.
5. Centers for Disease Control and Prevention (CDC). *Sexually Transmitted Diseases Treatment Guidelines, 2010: Diseases Characterized by Genital, Anal, or Perianal Ulcers*. http://www.cdc.gov/std/treatment/2010/genital-ulcers.htm#syphilis. Accessed September 23, 2011.

217 AIDS AND KAPOSI'S SARCOMA

Heidi Chumley, MD

PATIENT STORY

A 35-year-old gay man presented with papular lesions on his elbow (**Figure 217-1**). Shave biopsy demonstrated Kaposi's sarcoma (KS). He subsequently tested positive for HIV and began treatment with antiretroviral combination therapy. The KS resolved with topical alitretinoin gel treatment.

FIGURE 217-1 Several reddish-purple papular lesions of Kaposi's sarcoma on the elbow of a man with human immunodeficiency virus/acquired immuno deficiency syndrome. (*Courtesy of Heather Wickless, MD.*)

INTRODUCTION

In the United States, KS is most often seen in patients with AIDS and patients on immunosuppressants after organ transplantation. KS can also be classic (older Mediterranean men) or endemic (young men in sub-Saharan Africa). KS is caused by Kaposi's sarcoma-associates herpesvirus (KSHV), which promotes oncogenesis. KS cannot be cured, but treatment can result in improvement or disease stabilization. Current therapies improve the immune system or target KSHV. Therapies that modulate KSHV-mediated signaling are being studied.

EPIDEMIOLOGY

- KS can be classic (older Mediterranean men), endemic (young men in sub-Saharan Africa), epidemic (AIDS patients), or posttransplantation (organ recipients).[1]
- In the United States, 81.6% of KS is seen in patients with AIDS[2] (**Figure 217-1**).
- In HIV-positive patients, the prevalence is 7.2/1000 person years; 451 times higher than general population.[3]
- In transplant patients, the prevalence is 1.4/1000 person years; 128 times higher than general population.[3]
- The prevalence of classic KS in the general population of southern Italy is 2.5/100,000[4] (**Figure 217-2**).
- The male-to-female ratio for epidemic KS in the United States is approximately 50:1 but is falling as the prevalence of AIDS increases among women.[5] The male-to-female ratio has been approximately 10:1 for classic and endemic KS.
- KS is the most common malignancy seen in AIDS patients.

FIGURE 217-2 Classic Kaposi's sarcoma on the foot of an 88-year-old Italian man who does not have HIV/AIDS. These painful purple-red "growths" were present on his left foot for several years before diagnosis. (*Courtesy of John P. Welsh, MD, and Herbert B. Allen, MD.*)

ETIOLOGY AND PATHOPHYSIOLOGY

- KS is caused by KSHV, also known as human herpes virus 8 (HHV-8). KSHV acts through host cell signal transduction to activate multiple oncogenic pathways.[6]
- KS is an angioproliferative neoplasm, with abnormal proliferation of endothelial cells, myofibroblasts, and monocyte cells.

- Lesions often begin as papules or patches and progress to plaques as proliferation continues.
- Some lesions ulcerate (nodular stage), and lymphedema can occur.

RISK FACTORS

- Immunodeficiency as a consequence of AIDS.
- Immunosuppressants for solid-organ transplantation.

DIAGNOSIS

The diagnosis is often made clinically in a patient who has AIDS and a typical presentation of KS. In atypical presentations, diagnosis is made by biopsy.

CLINICAL FEATURES

- Cutaneous lesions are usually multifocal, papular, and reddish-purple in color (**Figures 217-1** and **217-2**).
- Plaques or fungating lesions can be seen on the lower extremities, including the soles of the feet (**Figure 217-3**).
  - Vascular-appearing papules on the feet and lower legs are typical of classic KS without AIDS (**Figure 217-4**).
- Oral cavity lesions can be flat or nodular and are red to purple in color (**Figure 217-5**).
- GI lesions can be asymptomatic or can cause abdominal pain, nausea, vomiting, bleeding, or weight loss.
- Pulmonary lesions can cause shortness of breath or may appear as infiltrates, nodules, or pleural effusions on chest radiographs.

TYPICAL DISTRIBUTION

AIDS-related KS[7]:

- Skin lesions are seen mainly on the lower extremities (**Figure 217-6**), face, and genitalia. Presence of skin lesions should prompt an oral examination as oral involvement may change prognosis and management.
- Lesions in the oral cavity are common (33%), typically seen on the palate or gingiva (**Figure 217-4**).
- GI involvement is noted in 40% of newly diagnosed KS in HIV patients at diagnosis and up to 80% in autopsy studies. GI lesions can occur without skin lesions.
- Pulmonary involvement is also common, and up to 15% may occur without skin lesions in patients with KS and HIV. A chest radiograph often demonstrates pulmonary involvement.
- Any organ can be involved.

LABORATORY TESTING

- Check an HIV test in any person with KS who is not known to be HIV-positive.
- CD4+ T lymphocyte count is an important prognostic indicator.

FIGURE 217-3 Kaposi's sarcoma on the foot in a man with AIDS in the 1990s. Note the purple color. (*From Usatine RP, Moy RL, Tobinick EL, Siegel DM. Skin Surgery: A Practical Guide. St. Louis, MO: Mosby; 1998.*)

FIGURE 217-4 Classic Kaposi's sarcoma on the foot of an 85-year-old Hispanic man from Mexico who is HIV-negative. He initially declined radiation and his lesions grew and multiplied over 3 years. Now he is receiving palliative radiation to improve his ability to walk. (*Courtesy of Richard P. Usatine, MD.*)

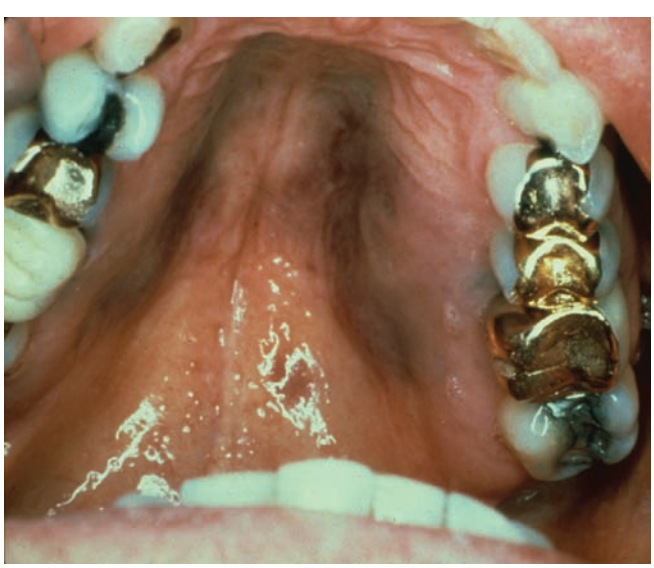

FIGURE 217-5 Early Kaposi's sarcoma on the palate. The color is abnormal but the lesion is still flat. (*Courtesy of Ellen Eisenberg, DMD.*)

IMAGING

Chest radiograph if there is pulmonary involvement. GI endoscopy if GI involvement if suspected.

BIOPSY

Often required for definitive diagnosis. If the lesions are nodular a simple shave biopsy should be sufficient. If the lesions are flat, a 4-mm punch biopsy should provide adequate tissue for diagnosis.

DIFFERENTIAL DIAGNOSIS

The diagnosis of KS requires a biopsy as several other lesions can mimic early KS.[7]

- Purpura—Bleeding under the skin caused by a variety of platelet, vascular, or coagulation disorders; usually not palpable and more widespread.
- Hematomas—Localized swelling usually from a break in a blood vessel; history of trauma and usually not palpable.
- Hemangiomas or angiomas—Benign growths of small blood vessels that blanch with pressure (Chapter 201, Acquired Vascular Skin Lesions).
- Dermatofibromas—Small, firm, red-to-brown nodules made up of hystiocytes and collagen deposits in the mid dermis, often seen on the legs; lesions are usually small (<6 mm) and dimple downward when compressed laterally (Chapter 160, Dermatofibroma).
- Bacillary angiomatosis—A systemic infectious disease caused by *Bartonella* species. Cutaneous lesions appear as scattered papules and nodules or an abscess. Bacillary angiomatosis may occur when the CD4 count is below 200 and is treated with antibiotics (**Figure 217-7**).

MANAGEMENT

KS is not curable, but treatments can reduce disease burden and slow progression (**Figure 217-8**).

MEDICATIONS

- In patients with HIV/AIDS, HAART (highly active antiretroviral therapy) therapy improves KS. Treat with antiretroviral drugs or refer to a physician with experience initiating and following antiretroviral therapy. Antiretroviral therapy inhibits HIV replication, decreases the response to KSHV, and has antiangiogenic activity. SOR A
- Avoid high-dose steroids, as they can severely aggravate KS, especially pulmonary KS.
- Consider KS-specific therapies:
  - Alitretinoin gel 0.1%—Patient applies gel to lesions 2 times a day, increasing to 3 to 4 times a day if tolerated, for 4 to 8 weeks (66% response rate).[8] SOR A
  - Liposomal doxorubicin 20 mg/m^2 every 3 weeks or liposomal daunorubicin 40 mg/m^2 every 2 weeks (50% response rate).[9] SOR A
  - Paclitaxel 100 mg/m^2 every 2 weeks or 135 mg/m^2 every 3 weeks; response rates 60% to 70% in patients who had failed a prior chemotherapy regiment.[10] SOR A Premedication with dexamethasone is recommended.[10]

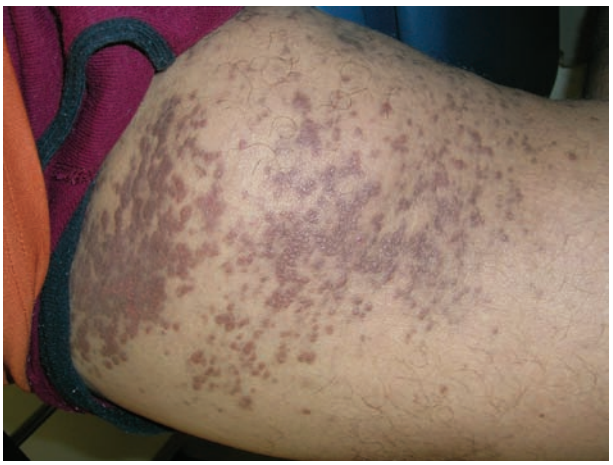

FIGURE 217-6 Kaposi's sarcoma in a 43-year-old man with HIV/AIDS already on antiretroviral therapy. He presented with a diffuse rash and lymphedema in the right leg. The initial biopsy was negative but a second biopsy demonstrated Kaposi's sarcoma. The right leg is significantly larger than the left leg due to the lymphedema. (*Courtesy of Richard P. Usatine, MD.*)

FIGURE 217-7 Cutaneous bacillary angiomatosis in a man with HIV/AIDS. (*From Usatine RP, Moy RL, Tobinick EL, Siegel DM. Skin Surgery: A Practical Guide. St. Louis, MO: Mosby; 1998.*)

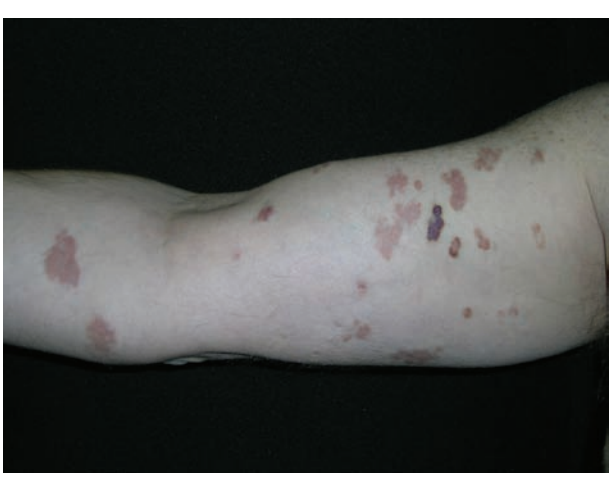

FIGURE 217-8 Kaposi's sarcoma on the arm of a 43-year-old man with HIV/AIDS. The patient is on antiretroviral therapy and has received radiation treatment for the Kaposi's sarcoma. The Kaposi's sarcoma is in remission but the discoloration has remained. Prior to treatment all of the patches on his arms were dark purple like the 1 remaining dark patch. (*Courtesy of Richard P. Usatine, MD.*)

- Interferon-α at 1 million U/day demonstrated the most benefit to patients with KS limited to the skin and CD4+ T-lymphocyte counts more than 200.[11]
- Intralesional vinblastine (70% response rate)[12] or radiation therapy (80% response rate) are also effective for skin lesions.[13] SOR A

- Classic and endemic KS are rare in the United States and are often treated with radiation or surgical excision.
- Removing immunosuppressants or radiation can treat transplant-related KS.

In addition to the medications that target KSHV, new therapies are undergoing study that target KSHV-mediating signaling.[6]

PROGNOSIS

- In severe disease requiring systemic therapy, 50% to 85% of patients will respond with either improvement or disease stability; however, the response lasts only 6 to 7 months before therapy has to be repeated. When therapy is repeated, the response times generally decrease.[6]
- Patients with AIDS-related KS have 5-year survival rates of greater than 80% when KS is the AIDS-defining illness and the CD4+ T-lymphocyte count is greater than 200. Survival rates fall to less than 10% when the patient is older than age 50 years and there is another AIDS-defining illness at the time of presentation.[14]

FOLLOW-UP

KS, particularly AIDS-related KS, is generally treated by physicians with advanced training in HIV/AIDS management and oncology. Follow-up is determined by disease progression and response to therapy.

PATIENT EDUCATION

- KS is not curable, but several treatments can result in regression of the lesions for a better cosmetic result.
- KS can affect most parts of the body, commonly the skin, oral cavity, GI tract, and lungs.
- During treatment, lesions typically flatten, shrink, and fade (**Figure 217-8**).
- Rarely, starting antiretroviral therapy may cause lesions to flare because of an inflammatory reaction as the immune system begins to recover (immune reconstitution).

PATIENT RESOURCE

- The National Cancer Institute. *Kaposi Sarcoma Treatment*—**http://www.cancer.gov/cancertopics/pdq/treatment/kaposis/patient/.**

PROVIDER RESOURCE

- The National Cancer Institute has information for health professionals—**http://www.cancer.gov/cancertopics/pdq/treatment/kaposis/HealthProfessional.**

REFERENCES

1. Alamartine E. Up-to-date epidemiological data and better treatment for Kaposi's sarcoma. *Transplantation*. 2005;80(12):1656-1567.
2. Shiels MS, Pfeiffer RM, Hall HI, et al. Proportions of Kaposi sarcoma, selected non-Hodgkin lymphomas, and cervical cancer in the United States occurring in persons with AIDS, 1980-2007. *JAMA*. 2011;305(14):1450-1459.
3. Serraino D, Piselli P, Angeletti C, et al. Kaposi's sarcoma in transplant and HIV-infected patients: An epidemiologic study in Italy and France. *Transplantation*. 2005;80(12):1699-1704.
4. Atzori L, Fadda D, Ferreli C, et al. Classic Kaposi's sarcoma in southern Sardinia, Italy. *Br J Cancer*. 2004;91(7):1261-1262.
5. Onyango JF, Njiru A. Kaposi's sarcoma in a Nairobi hospital. *East Afr Med J*. 2004;81(3):120-123.
6. Sullivan RJ, Pantanowitz L, Dezube B. Targeted therapy in Kaposi sarcoma. *BioDrugs*. 2009;23(2):69-75.
7. Cheung MC, Pantanowitz L, Dezube BJ. AIDS-related malignancies: emerging challenges in the era of highly active antiretroviral therapy. *Oncologist*. 2005;10(6):412-426.
8. Walmsley S, Northfelt DW, Melosky B, et al. Treatment of AIDS-related cutaneous Kaposi's sarcoma with topical alitretinoin (9-cis-retinoic acid) gel. Panretin Gel North American Study Group. *J Acquir Immune Defic Syndr*. 1999;22:235-246.
9. Cooley HD, Volberding P, Martin F, et al. Final results of a phase III randomized trial of pegylated liposomal doxorubicin versus liposomal daunorubicin in patients with AIDS-related Kaposi's sarcoma [abstract]. *Proc Am Soc Clin Oncol*. 2002;21:411a;1640.
10. Gill PS, Tulpule A, Espina BM, et al. Paclitaxel is safe and effective in the treatment of advanced AIDS related Kaposi's sarcoma. *J Clin Oncol*. 1999;17:1876-1883.
11. Krown SE, Li P, Von Roenn JH, et al. Efficacy of low-dose interferon with antiretroviral therapy in Kaposi's sarcoma: a randomized phase II AIDS Clinical Trials Group study. *J Interferon Cytokine Res*. 2002;22:295-303.
12. Boudreaux AA, Smith LL, Cosby CD, et al. Intralesional vinblastine for cutaneous Kaposi's sarcoma associated with acquired immunodeficiency syndrome. A clinical trial to evaluate efficacy and discomfort associated with infection. *J Am Acad Dermatol*. 1993;28:61-65.
13. Swift PS. The role of radiation therapy in the management of HIV-related Kaposi's sarcoma. *Hematol Oncol Clin North Am*. 1996;10:1069-1080.
14. Stebbing J, Sanitt A, Nelson M, et al. A prognostic index for AIDS-associated Kaposi's sarcoma in the era of highly active antiretroviral therapy. *Lancet*. 2006;367(9521):1495-1502.

218 LYME DISEASE

Thomas J. Corson, DO
Richard P. Usatine, MD
Heidi Chumley, MD

PATIENT STORY

On a warm, summer afternoon a 32-year-old woman presents having had low-grade fevers for 5 days and a rash. On physical examination, the physician notes a large, erythematous, annular patch with central clearing on her back (**Figure 218-1**). The patient states that the rash has gotten progressively larger during the last 3 days and she has had a recent onset of intermittent joint pain. She does not recall being bitten by an insect. She denies taking medications within the last month and has no known allergies. When asked about recent travel, she admits to a camping trip in eastern Massachusetts, which she returned from 4 days ago. The patient was diagnosed with Lyme borreliosis and started on doxycycline 100 mg twice daily for 14 days. She responded quickly to the antibiotics and never developed the persistent stage of Lyme disease.

FIGURE 218-1 A 32-year-old woman presents having had 5 days of low-grade fevers and the typical eruption of erythema migrans on her upper back. Note the expanding annular lesion with a target-like morphology. *(Courtesy of Thomas Corson, MD.)*

INTRODUCTION

Lyme disease is an infection caused by the spirochete *Borrelia burgdorferi*, transmitted via tick bite. Most cases of Lyme disease occur in the northeast United States between April and November. Patients experience flu-like symptoms and may develop the pathognomonic rash, erythema migrans. Lyme disease is prevented by avoiding exposure to the tick vector using insect repellent and protective clothing.

EPIDEMIOLOGY

- In 1977, clusters of patients in Old Lyme, Connecticut, began reporting symptoms originally thought to be juvenile rheumatoid arthritis.[1]
- In 1981, American entomologist, Dr. Willy Burgdorfer, isolated the infectious pathogen responsible for Lyme disease from the midgut of *Ixodes scapularis* (a.k.a., black-legged deer ticks) (**Figure 218-2**), which serve as the primary transmission vector in the United States.[1]
- It was identified as a bacterial spirochete and named *B. burgdorferi* in honor of its founder.
- Based on Centers for Disease Control and Prevention (CDC) data reported in 2007, Lyme disease (or Lyme borreliosis) is the most common tickborne illness in the United States, with an overall incidence of 7.9 per 100,000 persons.[2]
- In 2010, 94% of Lyme disease cases were reported from 12 states: Connecticut, Delaware, Maine, Maryland, Massachusetts, Minnesota,

FIGURE 218-2 The deer tick transmits the *Borrelia* spirochete. This is an unengorged female black-legged deer tick. The tick is tiny and can be undetected in its unengorged state. *(Courtesy of Thomas Corson, MD.)*

New Jersey, New Hampshire, New York, Pennsylvania, Virginia, and Wisconsin.[3]

- Patients living between Maryland and Maine accounted for 93% of all reported cases in the United States in 2005, with an overall incidence of 31.6 cases for every 100,000 persons.[2]
- More than 90% of cases report onset between April and November.[2]

ETIOLOGY AND PATHOPHYSIOLOGY

- *B. burgdorferi* begins to multiply in the midgut of *I. scapularis* ticks upon attaching to humans.
- Migration from midgut to salivary glands of ticks requires 24 to 48 hours.
- Prior to this migration, host infection rarely occurs.
- Common hosts include field mice, white-tailed deer, and household pets.
- Ticks must feed on infested hosts in order to infect humans.
- Thirty percent of infected patients do not recall being bitten.[4]
- Once a human is infected, disease progression is categorized into three stages: localized, disseminated, and persistent.

DIAGNOSIS

CLINICAL FEATURES

Localized (days to weeks)

Erythema migrans (formerly known as erythema chronicum migrans)

This pathognomonic finding occurs in roughly 68% of Lyme disease cases.[4] Described as a "bull's-eye" eruption (**Figures 218-1** and **218-3** to **218-6**), this nonpruritic, maculopapular lesion typically occurs near the site of infection. The erythematous perimeter migrates outward over several days while the central area clears. Multiple lesions in different sites can develop in some individuals (**Figures 218-3** and **218-4**). Erythema migrans can persist for 2 to 3 weeks if left untreated.

Flu-like symptoms

Roughly 67% of patients will develop flu-like symptoms that can include fever, myalgias, and lymphadenopathy. Symptoms usually subside within 7 to 10 days.

Disseminated (days to months)

Inflammatory arthritis

Typical onset occurs around 3 to 6 months after localized infection. Patients will often present with polyarticular, migratory joint pain with or without erythema, and swelling, which is exacerbated with

FIGURE 218-3 An 11-year-old girl with erythema migrans eruption on her shoulder. She is febrile and systemically ill. *(Courtesy of Jeremy Golding, MD.)*

FIGURE 218-4 Same 11-year-old girl in **Figure 218-3** with multiple erythema migrans eruptions on her legs. *(Courtesy of Jeremy Golding, MD.)*

motion. After more than 24 to 48 hours, these symptoms localize to one joint (especially knee, ankle, or wrist) and last approximately 1 week. Recurrence is common and usually happens every few months, but typically resolves within 10 years even without treatment.

Cranial nerve palsy

Bell palsy (seventh cranial nerve) is the most common neurologic manifestation of Lyme disease. However, nearly every cranial nerve has been reported to be involved. Facial nerve palsy is a lower motor neuron lesion that results in weakness of both the lower face and the forehead. Lasting up to 8 weeks, the resolution of symptoms is gradual and begins shortly after initial onset (see Chapter 233, Bell Palsy).

Atrioventricular blockade

Present in only 1% of patients with Lyme disease, syncope, lightheadedness, and dyspnea are classic symptoms consistent with atrioventricular (AV) dysfunction.[3] However, patients can be completely asymptomatic. The degree of Lyme-associated blockade varies so that symptoms are generally episodic. Most cases resolve spontaneously within 1 week.[4] Any patient with history and/or examination findings suspicious of Lyme disease should undergo ECG testing. Hospitalization and continuous monitoring are advisable for symptomatic patients, for patients with second- or third-degree AV block, as well as for those with first-degree heart block when the PR interval is prolonged to 30 or more milliseconds, because the degree of block may fluctuate and worsen very rapidly in such patients.[5]

Aseptic meningitis

Patients may present with complaints similar to bacterial meningitis (photophobia, nuchal rigidity, and headache), but symptoms are generally less severe in nature. This can also occur with or without concomitant cranial nerve palsy.[4]

Fatigue

A depressed level of activity as a result of fatigue is one of the most common complaints, affecting up to 80% of infected patients. Even after adequate treatment, symptoms consistent with chronic fatigue syndrome have developed in patients with known Lyme disease.

Persistent (longer than 1 year)

Chronic arthritis

Generally occurs in the knee, although other sites such as the shoulder, ankle, elbow, or wrist are not uncommon. Approximately 10% of patients with intermittent arthritis will progress to this stage.[4]

Chronic fatigue

Commonly misdiagnosed as fibromyalgia or chronic fatigue syndrome, patients develop debilitating malaise and myalgias that can persist for months or years after infection.

Meningoencephalitis

Symptoms vary from mild (memory loss, mood lability, irritability, or panic attacks) to severe (manic or psychotic episodes, paranoia, and obsessive/compulsive symptoms).[5]

FIGURE 218-5 A 12-year-old girl with erythema migrans eruption on her right arm. The annular border is somewhat raised and there is central clearing. *(Courtesy of Jeremy Golding, MD.)*

FIGURE 218-6 A 26-year-old man with erythema migrans eruption on right medial thigh. The central papule is the site of the bite, and there has not been much central clearing yet. *(Courtesy of Gil Shlamovitz, MD.)*

LABORATORY TESTING

Diagnosing Lyme disease is generally based on pertinent history findings and/or the presence of an erythema migrans lesion, especially in endemic areas. In cases where an erythema migrans lesion is absent, serologic testing may be warranted utilizing the following tests:

- Enzyme-linked immunosorbent assay (ELISA) (sensitivity: 94%, specificity: 97%)[6]—Used as a *screening* test in patients lacking physical signs of erythema migrans. Up to 50% of patients with early infection can have a false-negative result. If strong suspicion remains, convalescent titers should be obtained in 6 weeks.[6] Prior infection does not indicate immunity. Lyme titers may be falsely positive in patients with mononucleosis, periodontal disease, connective tissue disease, and other less common conditions.[7]
- Western blot (immunoglobulin [Ig] M and IgG for *B. burgdorferi*)—If ELISA test yields a positive result, Western blot test is used as a *confirmatory* test. IgM antibodies are detectable between 2 weeks and 6 months after inoculation. IgG may be present indefinitely after 6 weeks, despite appropriate antibiotic therapy. Once it is determined that a person is seropositive for Lyme disease, antibiotic therapy should be initiated promptly.

Empiric antibiotic therapy (no test necessary) should be considered in any of the following clinical presentations: presence of EM rash, flu-like symptoms (in absence of upper respiratory infection [URI] or GI symptoms) after known tick bite, Bell palsy in endemic areas, especially between June and September, and tick bites occurring during pregnancy.

Characteristic laboratory findings

- Complete blood count (CBC)—Leukocytosis (11,000 to 18,000/μL). Anemia and thrombocytopenia are rare.
- Elevated erythrocyte sedimentation rate (ESR) (>20 mm/h).
- Elevated γ-glutamyltransferase (GGT) and aspartate aminotransferase (AST).
- Cerebrospinal fluid—Pleocytosis and elevated protein levels if central nervous system (CNS) is involved. Spirochete antibodies may be detectable.
- Blood culture—Low yield; not recommended.
- Nerve conduction studies and EM—Useful in patients with paresthesias or radicular pain.
- ECG should be performed in all patients with history and physical examination suspicious for Lyme disease to detect AV block and arrhythmias.

DIFFERENTIAL DIAGNOSIS[8]

- Cellulitis—Spreads more rapidly than Lyme disease. Induration and tenderness are more common. Negative Lyme serologies (see Chapter 120, Cellulitis).

- Urticaria—Can resemble erythema migrans when the urticarial lesions are annular. Urticaria is generally more widespread and the wheals come and go over time whereas the lesion of EM is more fixed (see Chapter 150, Urticaria and Angioedema).
- Rocky Mountain spotted fever—Associated with *Dermacentor variabilis* (American dog) tick; rash is petechial and the spots are widely distributed over the body (see Chapter 179, Vasculitis, Figure 179-17). Patients often appear toxic.
- Cutaneous fungal infections—Usually pruritic and may be annular; associated with scaling, which is not characteristic of erythema migrans; and spreads slowly if at all. The similarity is that the annular appearance of tinea corporis can mimic EM (see Chapter 138, Tinea Corporis).
- Local reaction to tick bites—Tick bites may cause a local reaction in skin and do not expand with time; generally less than 2 cm in diameter, and are usually papular.
- Febrile viral illnesses (particularly enteroviruses during summer)—Rash, myalgias, arthralgias, and headache; GI symptoms; sore throat and/or cough. Perform Lyme serologic test in the absence of erythema migrans.
- Facial nerve palsy—May be bilateral in Lyme disease. This is uncommon in facial nerve palsy not associated with Lyme disease (see Chapter 233, Bell Palsy).
- Viral meningitis—Lymphocytic (aseptic) meningitis caused by viral infection generally results in transient illness that resolves within several days, usually after a monophasic course.
- Heart block—Idiopathic conduction system disease (sick sinus syndrome) can present with the same symptoms and signs as Lyme carditis. Use serologic testing and epidemiologic history to discriminate.
- Inflammatory arthritis (reactive arthritis, gout, pseudogout, and rheumatoid arthritis)—acute, large joint monoarticular or oligoarticular arthritis from multiple causes; may be indistinguishable from acute arthritis associated with Lyme disease at the time of presentation; joint fluid examination, and culture and x-ray may help distinguish from Lyme arthritis (see Chapter 95, Arthritis Overview).
- Peripheral neuropathy is more often associated with diabetes mellitus, peripheral vascular disease, endocrinopathies, and nerve root impingement syndromes. If Lyme disease is the cause, the serologies should be positive.
- Radiculoneuropathy—Dermatomal pain, sensory loss, and/or weakness in a limb or the trunk. Check serologies if Lyme disease is suspected.
- Encephalomyelitis—Focal inflammation of the brain or spinal cord. Check serologies if Lyme disease is suspected.

MANAGEMENT

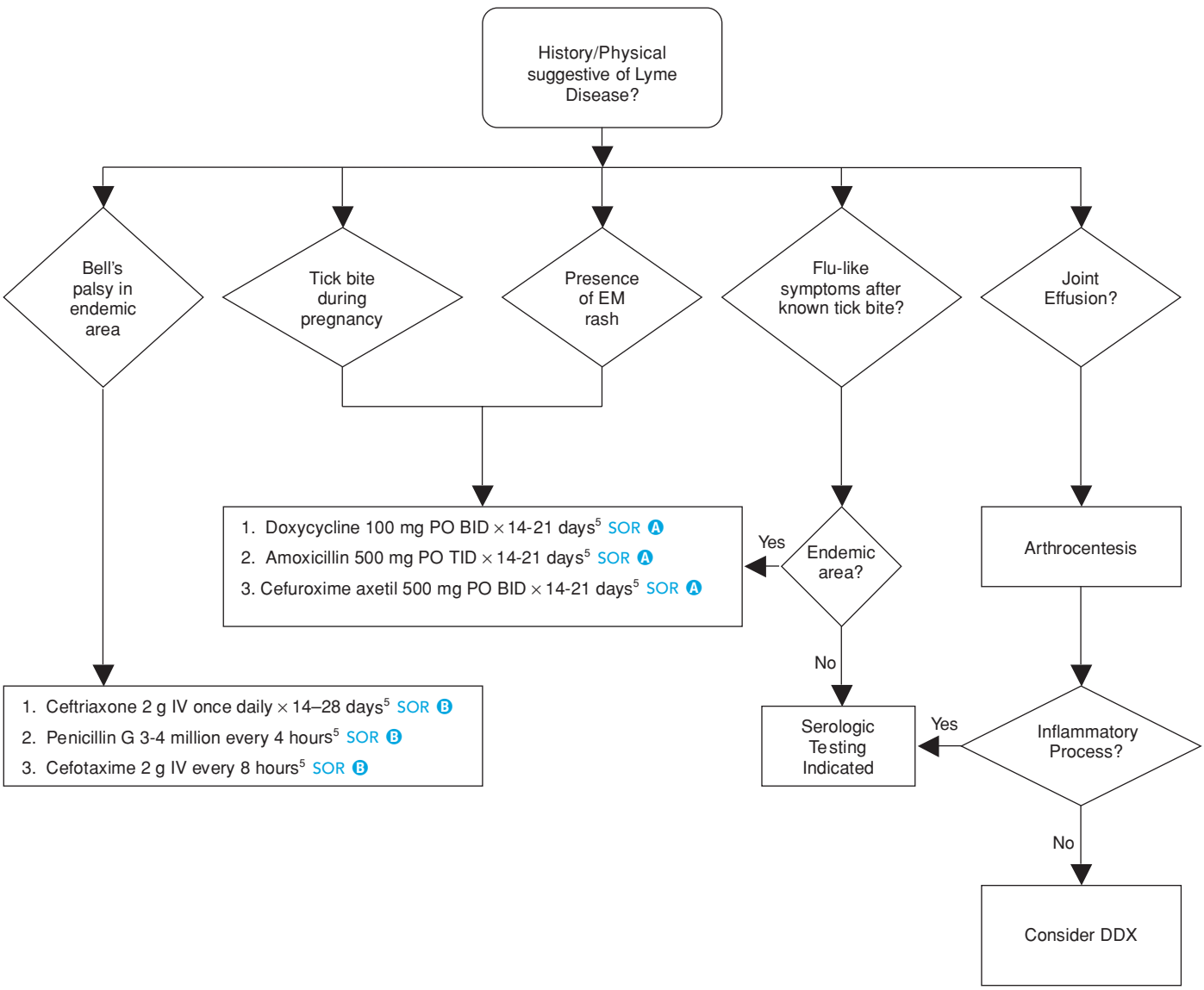
History/Physical suggestive of Lyme Disease?
Bell's palsy in endemic area
Tick bite during pregnancy
Presence of EM rash
Flu-like symptoms after known tick bite?
Joint Effusion?
1. Doxycycline 100 mg PO BID × 14-21 days[5] SOR A
2. Amoxicillin 500 mg PO TID × 14-21 days[5] SOR A
3. Cefuroxime axetil 500 mg PO BID × 14-21 days[5] SOR A
Yes
Endemic area?
Arthrocentesis
No
1. Ceftriaxone 2 g IV once daily × 14–28 days[5] SOR B
2. Penicillin G 3-4 million every 4 hours[5] SOR B
3. Cefotaxime 2 g IV every 8 hours[5] SOR B
Serologic Testing Indicated
Yes
Inflammatory Process?
No
Consider DDX

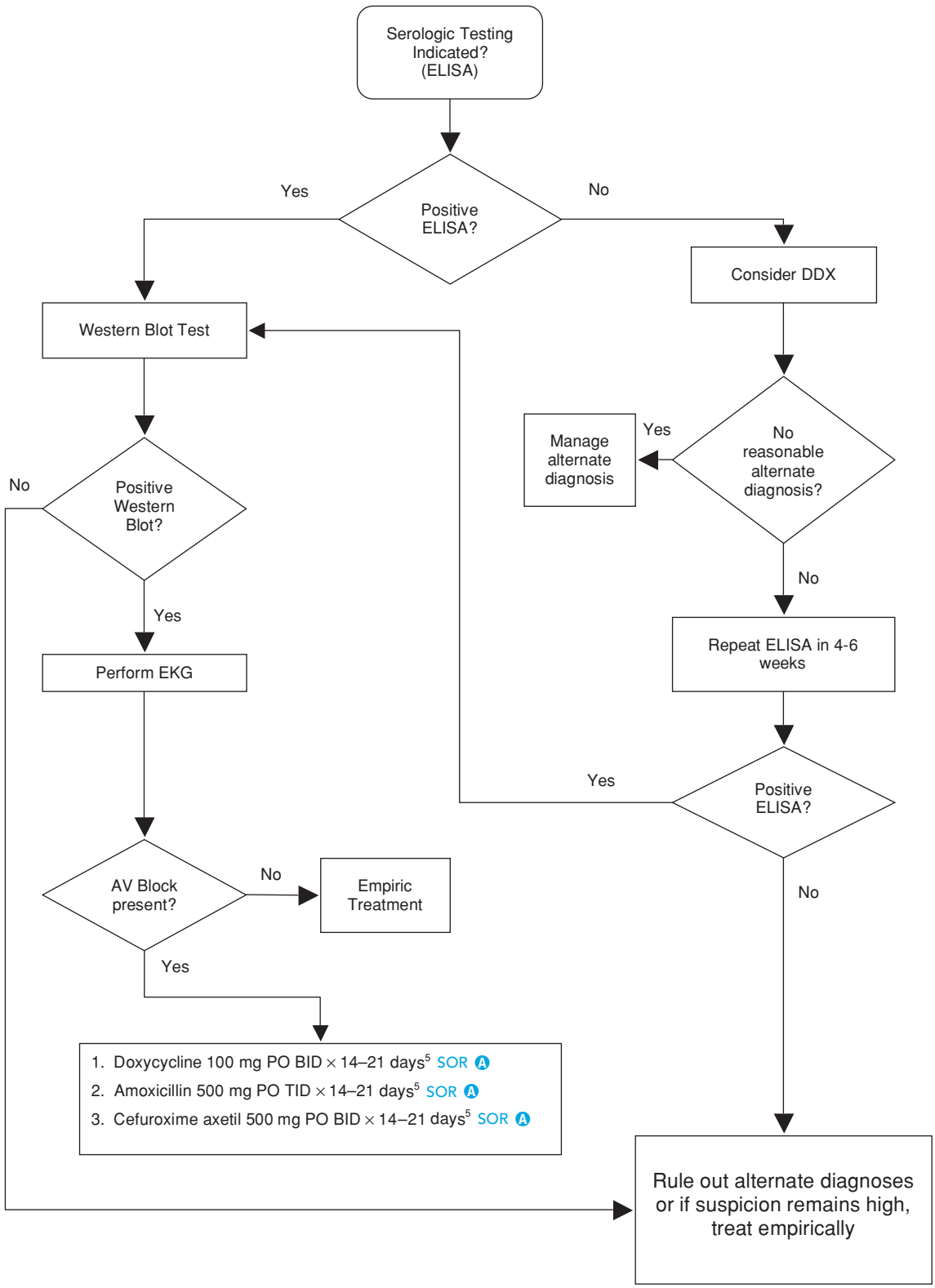
Serologic Testing Indicated? (ELISA)
Positive ELISA?
Yes
No
Consider DDX
Western Blot Test
Manage alternate diagnosis
Yes
No reasonable alternate diagnosis?
No
Positive Western Blot?
No
Yes
Perform EKG
Repeat ELISA in 4-6 weeks
Yes
Positive ELISA?
AV Block present?
No
Empiric Treatment
No
Yes
1. Doxycycline 100 mg PO BID × 14–21 days[5] SOR A
2. Amoxicillin 500 mg PO TID × 14–21 days[5] SOR A
3. Cefuroxime axetil 500 mg PO BID × 14–21 days[5] SOR A
Rule out alternate diagnoses or if suspicion remains high, treat empirically

MEDICATIONS

Localized:

- Adults—Doxycycline 100 mg twice a day (nonpregnant patients only) or amoxicillin 500 mg 3 times a day or cefuroxime 500 mg twice a day for 14 days.[5] SOR A
- Children—Amoxicillin 50 mg/kg divided 3 times a day up to 500 mg per dose or cefuroxime 30 mg/kg divided twice a day up to 500 mg per dose; older than 8 years of age—doxycycline 4 mg/kg divided twice a day up to 100 mg/dose.[5] SOR A

Meningitis or other neurologic manifestations:

- Adults—Ceftriaxone 2 g IV every day for 14 days; alternative therapy cefotaxime 2 g IV every 8 hours or penicillin G 18 to 24 million U every day divided into 6 daily doses for 14 days.[5] SOR B
- Children—Ceftriaxone 50 to 75 mg/kg IV up to a maximum of 2 g/day for 14 days; alternative therapy cefotaxime 150 to 200 mg/kg per day up to a maximum of 6 g/day, divided into 3 to 4 doses per day.[5] SOR B
- Doxycycline (oral) 100 to 200 mg twice a day for 10 to 28 days may be effective; consider for nonpregnant adults or children older than 8 years of age who are intolerant to β-lactam antibiotics.[5] SOR B
- Lyme carditis—Oral or IV antibiotics as above with hospitalization and continuous cardiac monitoring in patients with symptoms including syncope, shortness of breath, or chest pain, or in patients with AV block.[5] SOR B

Persistent Lyme disease

- Arthritis without neurologic disease—Doxycycline, amoxicillin, or cefuroxime; amoxicillin, cefuroxime in children younger than 8 years of age; medications at doses shown under early disease with therapy extended to 28 days.[5] SOR B If arthritis persists, treat for another 28 days with oral antibiotics or a 28-day regimen of IV antibiotics.
- Neurologic disease—IV therapy with ceftriaxone for 14 to 28 days.[5] SOR B

REFERRAL OR HOSPITALIZATION

- Symptomatic patients with Lyme carditis should be hospitalized with continuous cardiac monitoring.
- Consider referring patients in whom the diagnosis is unclear or who do not respond to initial therapy.

PREVENTION

- Avoid exposure to ticks by using protective clothing and tick repellant. If hiking in tick-infested areas check body daily for ticks and promptly remove any attached ticks.
- Prophylactic doxycycline (1 dose of 200 mg) is recommended only if the tick is identified as an adult or nymphal *I. scapularis* tick that has been attached for at least 36 hours; medication can be started within 72 hours of tick removal; local rate of infection of ticks with *B. burgdorferi* is at least 20%; and doxycycline is not contraindicated.[5]

PROGNOSIS

- Most patients respond to appropriate therapy with prompt resolution of symptoms within 4 weeks.
- Posttreatment Lyme disease syndrome (persistent or recurrent symptoms) occurs in 10% to 20% of patients despite appropriate treatment. Prolonged antibiotic treatment is not effective.[3] Most patients eventually feel completely well, but this can take months or years.
- True treatment failures are uncommon and prolonged oral or parenteral antibiotic courses are emphatically discouraged. In patients who continue to present with residual subjective symptoms, providers should seek alternate diagnoses and/or referral to an appropriate specialist.

FOLLOW-UP

Follow patients during antibiotic therapy through recovery.

PATIENT EDUCATION

Prevention is accomplished by reducing exposure to ticks. If you live in an area that has Lyme disease then use tick repellent, tick checks, and other simple measures to prevent tick bites. This is especially important during the high-risk months of April through November. Patients should know the early signs of Lyme disease so that they can get care early when it is most curable.

If a tick is found on the skin, remove it early using fine-tipped tweezers. See patient resources below.

PATIENT RESOURCES

- Centers for Disease Control and Prevention (CDC). *Lyme Disease*—**http://www.cdc.gov/lyme/.**
- Centers for Disease Control and Prevention (CDC). *Tick Removal*—**http://www.cdc.gov/lyme/removal/index.html.**

PROVIDER RESOURCE

- Centers for Disease Control and Prevention (CDC). *Lyme Disease*—**http://www.cdc.gov/lyme/.**

REFERENCES

1. Sternbach G, Dibble CL. Willy Burgdorfer: Lyme disease. *J Emerg Med.* 1996;14(5):631-634.
2. Centers for Disease Control and Prevention. Lyme disease—United States, 2003-2005. *MMWR Morb Mortal Wkly Rep.* 2007;56(23):573-576.
3. Centers for Disease Control and Prevention. *Lyme Disease*. http://www.cdc.gov/lyme/. Accessed January 22, 2012.

4. Meyerhoff JO. *Lyme Disease*. http://emedicine.medscape.com/article/330178. Accessed January 22, 2012.
5. Wormser GP, Dattwyler RJ, Shapiro ED, et al. The clinical assessment, treatment, and prevention of lyme disease, human granulocytic anaplasmosis, and babesiosis: clinical practice guidelines by the Infectious Diseases Society of America. *Clin Infect Dis.* 2006; 43(9):1089-1134.
6. *Lyme Disease Executive Summary*. http://www.harp.org/eng/kaiser-slymesummary.htm. Accessed January 22, 2012.
7. Columbia University Medical Center Lyme and Tick-Borne Diseases Research Center. http://www.columbia-lyme.org/index.html. Accessed January 22, 2012.
8. American College of Physicians. *Differential Diagnosis of Lyme Disease*. http://www.acponline.org/journals/news/jun07/critters.pdf. Accessed January 22, 2012.

This page intentionally left blank

PART 16

ENDOCRINE

Strength of Recommendation (SOR)	Definition
A	Recommendation based on consistent and good-quality patient-oriented evidence.*
B	Recommendation based on inconsistent or limited-quality patient-oriented evidence.*
C	Recommendation based on consensus, usual practice, opinion, disease-oriented evidence, or case series for studies of diagnosis, treatment, prevention, or screening.*

*See Appendix A on pages 1447–1450 for further information.

219 DIABETES OVERVIEW

Mindy A. Smith, MD, MS

PATIENT STORY

A 66-year-old man with obesity and mild hypertension controlled with a diuretic presents with increasing nocturia and excessive thirst. He has no other urinary symptoms and denies any visual problems. His mother had diabetes and died at age 85 years from a heart attack. His only other concern is a recurrent fungal infection on his feet. His blood pressure in the office today is 135/85 mm Hg and his finger stick blood sugar is 220 mg/dL. You explain that based on his elevated blood sugar, he has diabetes mellitus. Physical exam findings confirm the diagnosis of tinea pedis (**Figure 219-1**). A monofilament test demonstrates normal sensation in his feet. You order a fasting blood sugar, lipid profile, serum electrolytes, creatinine, and hemoglobin A_{1C}. You ask him to return next week for a more complete examination, review of his test results, and diabetes education. You ask him and his wife to consider meeting with a nutritionist, and briefly review treatment options, including diet, exercise, and metformin, as well as a possible need to improve his blood pressure control or switch to another agent. You suggest a nonprescription antifungal cream and will see if he needs additional treatment for his feet at follow-up. The patient is referred to an ophthalmologist who finds diabetic nonproliferative retinopathy (**Figure 219-2**).

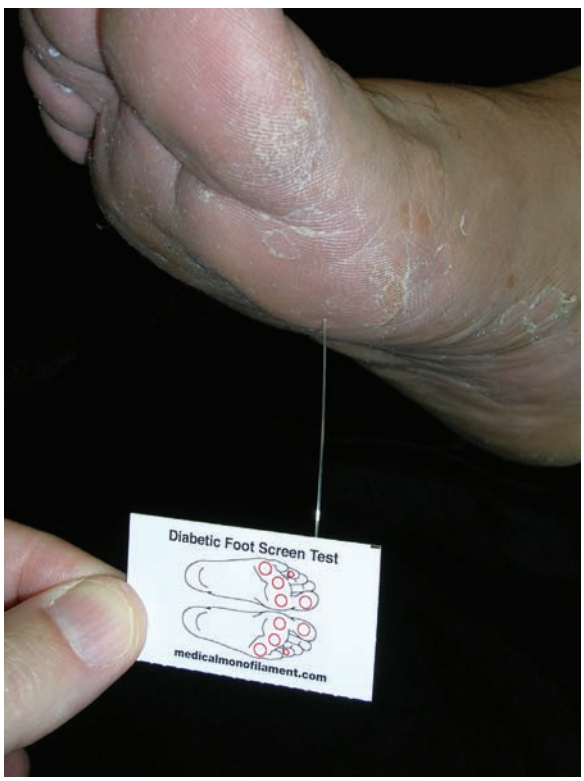

FIGURE 219-1 Patient with diabetes and tinea pedis being tested with a monofilament for sensation. (*Courtesy of Richard P. Usatine, MD.*)

INTRODUCTION

Diabetes is a group of disorders caused by a complex interaction between genetic susceptibility, environmental factors, and personal lifestyle choices that share the phenotype of hyperglycemia. Type 2 diabetes mellitus (DM) is a heterogeneous group of chronic disorders caused by a progressive insulin secretory defect and increased glucose production in the setting of insulin resistance.

EPIDEMIOLOGY[1]

- Prevalence—In the United States, 25.8 million adults and children (8.3% of the population), including 18.8 million who have been diagnosed, have diabetes. This includes about 1 in 400 children and adolescents and 26.9% of people age 65 years and older. Type 2 DM is the most common form, accounting for more than 90% of cases.
- Incidence—In the United States in 2010, there were 1.9 million new cases among individuals 19 years of age and older.
- Highest rates of diabetes are in non-Hispanic blacks (12.6%), followed by Hispanics (11.8%), Asian Americans (8.4%), and non-Hispanic whites (7.1%).

FIGURE 219-2 Nonproliferative diabetic retinopathy, with scattered intraretinal dot-blot and flame hemorrhages, along with macular exudates. Macular exudates can be related to diabetic macular edema, which accounts for a large portion of poor vision and disability secondary to diabetic retinopathy. (*Courtesy of Andrew Sanchez, COA.*)

- In 2007, total costs of diagnosed DM in the United States were $174 billion ($116 billion in direct medical costs).

ETIOLOGY AND PATHOPHYSIOLOGY

- Insulin resistance is attributed to obesity, inactivity, and genetic factors (including defects in β-cell function and insulin action).
- Initially, the pancreatic β cells increase insulin production to overcome insulin resistance and maintain euglycemia. Eventually, β cells fail, resulting in hyperglycemia.
- Other contributing factors include diseases of the pancreas (e.g., pancreatitis, hemochromatosis), infection (e.g., cytomegalovirus), and other endocrinopathies (e.g., hyperthyroidism [see Chapter 227, Graves Disease and Goiter] and acromegaly [see Chapter 228, Acromegaly]).
- Microvascular and macrovascular diseases may result from hyperglycemia or other metabolic changes.

RISK FACTORS[1-4]

- Obesity.*
- Red meat consumption (relative risk [RR] 1.51; 95% confidence interval [CI], 1.25, 1.83 for 50 g processed red meat/day).[5]
- Physical inactivity (also television viewing 2 h/day; odds ratio [OR] 1.20; 95% CI, 1.14 to 1.27).[6]*
- Nonwhite race.*
- First-degree relative with diabetes, hypertension, or myocardial infarction.*
- Prior gestational diabetes.*
- Impaired glucose tolerance (hazard ratio [HR] 13.2, 95% CI, 10.8 to 16.2).[7]
- Polycystic ovarian syndrome.
- Coronary heart disease, hypertension.*
- Smoking (OR [current smoker] 1.44; 95% CI, 1.31 to 1.58).
- Antipsychotic therapy for patients with schizophrenia or severe bipolar disease.*
- Previously identified glucose intolerance.*
- Prolonged use of oral corticosteroids.

*Risk factors used by the American Association of Clinical Endocrinologists (AACE) in making decisions for screening patients for DM (see below).[4]

Many risk models and scores have been developed to predict the development of DM.[8] Authors of a systematic review identified seven risk scores that had high potential for use in practice based on similar components and discriminatory properties.[4] One of these, the Framingham Offspring Study,[9] uses fasting plasma glucose levels, body mass index, high density lipoprotein cholesterol and triglyceride levels, parental history of diabetes and blood pressure to determine risk. Unfortunately, none of the models were developed on a cohort recruited prospectively, and no studies have demonstrated a reduction in incident DM using risk scoring and intervention.

DIAGNOSIS

The AACE guideline defines the diagnosis of diabetes as a fasting (8 or more hours of no caloric intake) glucose level 126 mg/dL or greater (≥7.0 mmol/L), *or* a 2-hour plasma glucose 200 mg/dL or greater (≥11.1 mmol/L) on a 75-g oral glucose tolerance test, *or* a random plasma glucose level of greater than 200 mg/dL with symptoms of diabetes, *or* a hemoglobin A_{1C} level of 6.5% or higher.[4] SOR A The same test should be repeated on a different day to confirm the diagnosis unless the patient has unequivocal hyperglycemia or severe metabolic stress. SOR C

CLINICAL FEATURES

- Many patients with type 2 DM are asymptomatic.
- Patients may report polydipsia, polyuria, and blurred vision.
- Funduscopic examination may reveal signs of retinopathy (hard exudates, hemorrhages) (**Figure 219-2**; see Chapter 20, Diabetic Retinopathy).
- Patients with diabetic neuropathy may have abnormalities on monofilament, vibration, and superficial pain testing.
- Skin changes in patients with DM include diabetic dermopathy in 15% to 40% of patients (**Figure 219-3**; see Chapter 221, Diabetic Dermopathy),[10] acanthosis nigricans in approximately one-third of patients (**Figure 219-4**; see Chapter 220, Acanthosis Nigricans),[11] diabetic foot ulcers (**Figure 219-5**; see Chapter 210, Ischemic Ulcer), and, uncommonly, necrobiosis lipoidica (**Figure 219-6**; see Chapter 222, Necrobiosis Lipoidica).
- Hyperlipidemia may result in eruptive xanthomas (**Figure 219-7**) or xanthelasma.
- Patients with DM of prolonged duration may also have Charcot joints (**Figure 219-8**; see Chapter 212, Charcot Joints).[12]

FIGURE 219-3 Diabetic dermopathy on the lower legs that is particularly prominent over the shins. (*Courtesy of Richard P. Usatine, MD.*)

LABORATORY TESTS

- The American Diabetes Association (ADA) recommends fasting plasma glucose as the preferred diagnostic test because of poor patient acceptance of the glucose tolerance test.[13] A value of 126 mg/dL or greater is diagnostic, although a second confirming test is recommended. Other tests that can be used for diagnosis are listed above.
- Hemoglobin A_{1C} is less sensitive to low levels of hyperglycemia than either the fasting plasma glucose or glucose tolerance tests and is not currently recommended by the ADA as a diagnostic test.
- A random capillary blood glucose may be a reasonable alternative. Compared with traditional criteria, a capillary blood glucose level of greater than 120 mg/dL has a sensitivity of 75% and specificity of 88% for the diagnosis of type 2 DM.[14]
- In cases where there is uncertainty regarding the diagnosis of type 1 or type 2 DM, glucagon-stimulated C-peptide, 2-hour postprandial urinary C-peptide-to-creatinine ratio, and 4-hour postprandial urinary C-peptide concentration can be used help distinguish between the types.

FIGURE 219-4 Acanthosis nigricans in a woman with type 2 diabetes and obesity. She is requesting that her skin tags be removed. (*Courtesy of Richard P. Usatine, MD.*)

MANAGEMENT

The primary treatment goals for the patient with DM are to aggressively control blood pressure (<130/80 mm Hg) and lower lipids (low-density lipoprotein [LDL] goal is <100 mg/dL) to improve cardiovascular and all-cause mortality. Reasonable blood glucose control (hemoglobin A_{1C} near 7%) is usually undertaken with metformin; this author believes that tight/strict control should no longer be stressed as it does not improve most outcomes and increases episodes of hypoglycemia. In the ADVANCE (Action in Diabetes and Vascular Disease: Preterax and Diamicron Modified-Release Controlled Evaluation) trial (N = 11,140), there were no differences seen in the rates of major macrovascular events or overall mortality between patients randomized to intense control (hemoglobin A_{1C} ≤6.5%) or standard control.[15] Furthermore, in the ACCORD (Action to Control Cardiovascular Risk in Diabetes) trial, intensive insulin therapy in patients with type 2 DM was associated with increased mortality in participants randomized to the very intensive glycemic control arm (hemoglobin A_{1C} <6%).[16] A recent metaanalysis of 14 trials also concluded that intensive control did not reduce all-cause mortality; data were insufficient to confirm a relative risk reduction for cardiovascular morbidity or mortality, composite microvascular complications, or retinopathy at a magnitude of 10%.[17] Intensive glycemic control increased the relative risk of severe hypoglycemia by 30%.[17]

In epidemiologic research, a hemoglobin A_{1C} level less than 7% is associated with the best outcomes and the ADA uses a hemoglobin A_{1C} of less than 7% as the benchmark for adequate control. The AACE recommends a glucose target of 6.5% or less in most nonpregnant adults if it can be achieved safely, as near-normal levels may prevent microvascular (e.g., retinopathy) complications.[4] SOR C

NONPHARMACOLOGIC

Diet and exercise interventions:

- Diet—Nutrition advice may be best delivered by a registered dietician familiar with DM. Guidelines from the ADA and AACE agree that the diet should contain carbohydrate from fruits, vegetables, whole grains, legumes, and low-fat milk, and be kept consistent on a day-to-day basis with respect to time and amount.[18] In otherwise healthy patients with DM, optimal diets include protein (15% to 20% of daily energy intake), fiber (25 to 50 g/day, with special emphasis on soluble fiber sources [7 to 13 g], to help to lower cholesterol), and dietary fat of less than 30% of daily energy intake.
- A Cochrane review of 11 randomized controlled trials (RCTs) concluded that a low-glycemic index diet improved glycemic control over a higher-glycemic index diet with fewer hypoglycemic episodes in one trial and fewer hyperglycemic episodes in another trial.[19]
- Daily consumption of vitamin D (500 IU as a fortified yogurt drink or supplement vs. placebo) improved glycemic control in one trial of patients with type 2 DM,[20] but not in another trial with patients with type 2 DM and normal vitamin D levels.[21] Vitamin D appears to have a positive effect on insulin resistance.[22]
- Weight-loss strategies for those who are overweight include diet, physical activity, and behavioral interventions. This combination can result in slight sustained weight loss (1.7 kg or 3.1% of baseline body weight) in comparison with usual care and lowers hemoglobin

FIGURE 219-5 Diabetic foot ulcer that has occurred at the amputation site. (*Courtesy of Richard P. Usatine, MD.*)

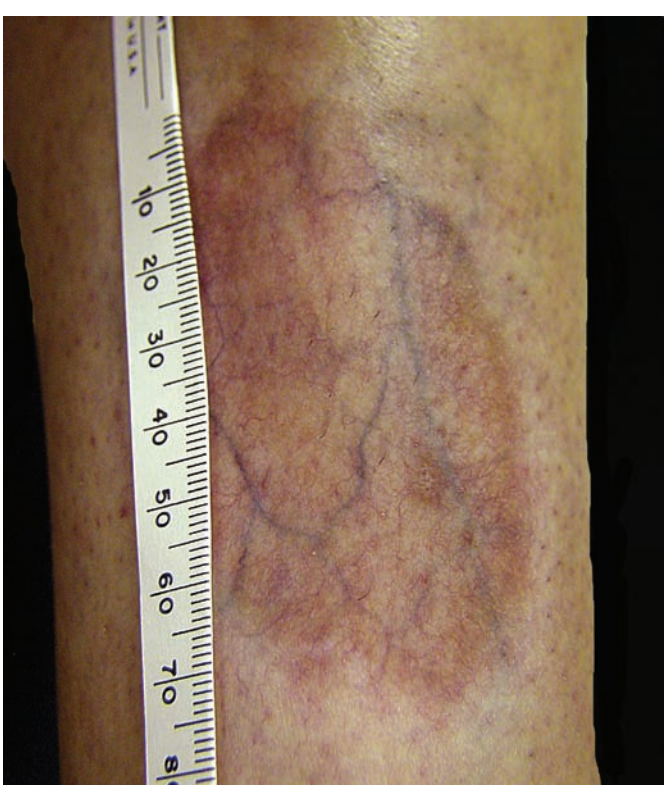

FIGURE 219-6 Necrobiosis lipoidica diabeticorum on the lower leg with typical findings of skin atrophy, yellow coloration, and prominent blood vessels. (*Courtesy of Richard P. Usatine, MD.*)

A_{1C}.[23] SOR A A more recent RCT (N = 593) found an intensive dietary intervention (dietary consultation every 3 months with monthly nurse support) reduced hemoglobin A_{1C} over the control group (actually had increased hemoglobin A_{1C}); the activity intervention did not confer additional benefit.[24]

- Even without weight loss, structured exercise (>150 min/wk) significantly improves glycemic control in patients with type 2 DM.[25] SOR A In this metaanalysis, a combination of dietary and exercise advice also lowered hemoglobin A_{1C}.[25] Individuals with type 2 DM are advised to get 30 to 90 min/day (AACE) or 90 to 150 min/wk (ADA) of exercise to improve glycemic control.[7,13]

Education, self-management, and self-monitoring interventions:

- Group-based diabetes education is associated with reductions in hemoglobin A_{1C}, systolic blood pressure, body weight, and the need for diabetic medications.[26] SOR A In another Cochrane review, use of a specialized diabetes nurse or case manager improved short-term glycemic control but not improve longer-term outcomes, such as hospital admission rates and quality of life.[27] Although one recent trial (N = 201) of behavioral support (video and five telephone sessions) for patients with poorly controlled DM did not show benefit on outcomes,[28] another trial (N = 222) using five educator-led group sessions for patients with poorly controlled DM did find improved glycemic control over the control group, although there were no differences in quality of life or frequency of diabetes self-care.[29]
- Authors of a Cochrane review of 12 trials on blood glucose self-monitoring in patients with type 2 DM not using insulin found a small effect of self-monitoring on glycemic control (reduced hemoglobin A_{1C}) that lasted up to 6 months after initiation but not at or beyond 12 months.[30] There was no evidence that self-monitoring affected patient satisfaction, general well-being, or general health-related quality of life. However, self-monitoring of glucose may be useful for assessing and preventing hypoglycemia and adjusting medications, medical nutrition therapy, and physical activity.[4]
- Structured goal setting was shown in a RCT (N = 87) to improve glycemic control up to 1-year postintervention.[31]

FIGURE 219-7 Eruptive xanthomas on the extremities and trunk of a young man with untreated type 2 diabetes and hyperlipidemia. (*Courtesy of Richard P. Usatine, MD.*)

MEDICATIONS

Agents that can be used for initial blood pressure control include diuretics, angiotensin-converting enzyme (ACE) inhibitors, and β blockers. The AACE considers ACE inhibitors or angiotensin II receptor blockers (ARBs) the preferred choice in patients with DM.[7] Combinations of medications may be needed. The blood pressure target is less than 130/80 mm Hg.[4,13] SOR C

- In one trial, an ACE inhibitor plus an ARB increased the risk of advancement to renal dialysis.[32]
- In the ACCORD trial of intensive blood pressure control in patients with type 2 DM (N = 4733), there were no additional cardiovascular benefits to targeting a systolic blood pressure of 120 mm Hg versus 140 mm Hg. Patients treated with intensive blood pressure lowering were more likely to experience serious adverse effects (3.3% vs. 1.3%).[33]
- In a subgroup analysis from another large blood pressure (BP) trial, progressively greater systolic BP reductions were associated with reduced risk for the primary outcome (pooled cardiovascular [CV]

FIGURE 219-8 Charcot feet bilaterally in a person with poorly controlled diabetes. Note the pronation of the feet with the abnormal bulging of the medial foot. X-rays showed abnormal tarsal bones secondary to diabetic neuropathy. (*Courtesy of Richard P. Usatine, MD.*)

death, nonfatal myocardial infarction or stroke, or hospitalized heart failure) only if the baseline systolic BP levels ranged from 143 to 155 mm Hg; there was no benefit in fatal or nonfatal CV outcomes by reducing systolic BP below 130 mm Hg.[34]

Agents used for glycemic control include metformin (biguanide that suppresses hepatic glucose production), sulfonylureas (e.g., glyburide that potentiates insulin secretion), glinides (e.g., nateglinide that potentiates insulin secretion), α-glucosidase inhibitors (e.g., acarbose that decreases intestinal carbohydrate absorption), thiazolidinediones (e.g., rosiglitazone that improves insulin sensitivity), incretin mimetic agent (Bydureon enhances insulin secretion and slows gastric emptying), and a dipeptidyl peptidase inhibitor (sitagliptin that improves glucagon-like peptide levels). Details on efficacy, dosing, and safety can be found elsewhere.[4]

- Of the oral hypoglycemic agents, only metformin and the sulfonylureas have been shown to decrease long-term vascular complications and only metformin decreases all-cause mortality (independently of its effect on glycemic control).[35,36] SOR A Monotherapy, although initially effective for many patients, fails to sustain control in approximately half of patients at 3 years.[37]
- Addition of a second oral agent should be considered when monotherapy does not provide adequate control, usually a sulfonylurea is added and is likely most cost-effective.[38] SOR C Sulfonylureas, glinides, and α-glucosidase inhibitors appear equal in effectiveness when added to metformin.[39] A thiazolidinedione also can be used, but there is concern about increased risk of myocardial infarction; data are conflicting.
- If dual therapy does not provide adequate control, options include adding a basal insulin analog (e.g., glargine or detemir), a thiazolidinedione, or dipeptidyl peptidase inhibitor. A metaanalysis of 18 trials did not find a clear difference in benefit between drug classes when adding a third agent for patients who were already on metformin and a sulfonylurea.[40] Bydureon, a once-weekly injection, although recently FDA approved, is costly and data are limited as this is so new. In the United Kingdom Prospective Diabetes Study (UKPDS) trial, the use of insulin therapy for patients with type 2 DM was not associated with decreased CV or all-cause mortality despite reductions in blood sugar.[41] A Cochrane review of six trials also did not find evidence of major clinical benefit for use of long-acting insulin analogues for patients with type 2 DM.[42] Finally, if insulin is added, continuing metformin if possible is advised as there is less weight gain associated with this combination.[43]
- Consultation with an endocrinologist is suggested if a third agent is needed and choice of agent should be made with consideration of the patient's age (decline in renal and cardiac function may preclude use of metformin, a thiazolidinedione, or long-acting sulfonylurea), weight (metformin, acarbose, exenatide, sitagliptin, and human amylin are more often associated with weight loss or maintenance), and comorbidities.[4] SOR C
- If further control is needed, options include discontinuing oral therapy and using combination insulin therapy.

Agents used for lipid control in patients whose lipids are not controlled by diet and exercise is usually achieved with statin therapy.[4] If the initial statin does not result in adequate control, the AACE recommend intensifying that statin to meet the LDL cholesterol goals.[4]

SOR A If the LDL goal cannot be met with high-dose statin therapy, there is no evidence to prove that adding other LDL-lowering drug classes will improve outcomes for people with DM.

Treatment of complications of DM is described in detail elsewhere.[4]

COMPLEMENTARY AND ALTERNATIVE THERAPY

- Several Chinese herbal medicines (e.g., Xianzhen Pian, Qidan Tongmai) show hypoglycemic effects in patients with type 2 DM but current evidence does not support widespread use.[44]
- In another Cochrane review of herbal mixtures, significant reductions in hemoglobin A_{1C}, fasting blood sugar or both were observed with Diabecon, Inolter, and Cogent db compared to placebo; however, small sample sizes precluded definite conclusions regarding efficacy.[45]

REFERRAL OR HOSPITALIZATION

- Consider referral for bariatric surgery for patients with DM who have a body mass index (BMI) of 35 kg/m^2 or more as this facilitates weight loss and improvement or reversal of hyperglycemia[4]; surgery has not yet been shown to decrease all-cause mortality or provide long-term benefit, and long-term risk is unknown. SOR A
- Consultation with a foot specialist is recommended for patients with DM and foot deformity, infected lesions, foot ulcers, or deformed nails or thick calluses.[4] SOR C
- Refer patients with diabetic retinopathy to an ophthalmologist for evaluation and treatment. SOR B
- Consider consultation with a vascular surgeon for patients with peripheral vascular disease. SOR C
- Patients with type 2 DM may require hospitalization for hyperglycemic crises (e.g., hyperosmolar hyperglycemic state, ketoacidosis).

PREVENTION AND SCREENING

Primary prevention is considered for patients who have prediabetes, defined by the AACE as the presence of impaired glucose tolerance (i.e., an oral glucose tolerance test glucose value of 140 to 199 mg/dL, 2 hours after ingesting 75 g of glucose and/or a fasting glucose value of 100 to 125 mg/dL).[4] Each year 3% to 10% of individuals with prediabetes will progress to type 2 DM.[46]

- Lifestyle changes that can prevent or at least delay type 2 DM in persons who have prediabetes include weight loss of 5% to 10% of body weight in overweight individuals and participation in moderate physical activity.[4,47,48] SOR A
- Smoking cessation should be encouraged; tobacco smoking increases the risk of macrovascular complications approximately 4% to 400% in adults with type 2 DM (see Chapter 236, Tobacco Addiction).
- Provide annual influenza immunization and pneumococcal vaccine as needed; repeat the pneumococcal vaccine at 5 years for patients with nephrotic syndrome, or chronic renal disease, or who are immunocompromised, or who are receiving the vaccine before age 65 years if 5 years has passed since the primary vaccine was given.[4]
- The AACE also recommends that metformin be considered for those with prediabetes who are younger patients at moderate to high risk for developing DM; for patients with additional cardiovascular disease risk factors including hypertension, dyslipidemia, or polycystic ovarian syndrome; for patients with a family history of DM in a first-degree relative; and/or for patients who are obese.[4] A recent RCT found pioglitazone effective in reducing the risk of conversion of impaired glucose tolerance to type 2 DM (annual incidence rate 2.1% vs. 7.6% with placebo), but was associated with significant weight gain and edema.[49]
- In a metaanalysis of lifestyle and pharmacologic interventions for the prevention or delay of DM in patients with impaired glucose tolerance, the number needed to treat to benefit was 6.4 for lifestyle (95% CI, 5.0 to 8.4), 10.8 for oral diabetes drugs (95% CI, 8.1 to 15.0), and 5.4 for orlistat (95% CI, 4.1 to 7.6).[50] SOR A
- Low-dose aspirin is recommended for patients with DM who have risk factors for CV disease and are older than age 40 years.[13]

Secondary prevention for micro- and macrovascular disease:

- Use of an ACE inhibitor or ARB can prevent progression of diabetic nephropathy.[51] SOR A
- Patients with DM should undergo a dilated comprehensive eye examination at diagnosis and annually.[13] SOR C Panretinal scatter photocoagulation reduces the risk of severe visual loss by more than 50% in eyes with high-risk characteristics, and immediate focal laser photocoagulation reduces the risk of moderate visual loss by at least 50% in patients with clinically significant macular edema.[52]
- Patients with DM should also undergo screening for peripheral neuropathy at diagnosis and annually, with inspection and assessment of pulses and sensation, using a monofilament and one additional sensory test (e.g., pinprick, vibration perception).[13] Patients with peripheral vascular disease, foot ulcers, or diabetic foot deformity should be considered for referral (as above) to prevent limb loss.
- As discussed above, patients with well-controlled BP, lipids, and good glycemic control have a lower risk of macrovascular and microvascular disease, and diabetic dermopathy.[4,10] For example, estimates for years of life saved with lipid lowering in patients with diabetes are 3 years to 3.4 years for men and 1.6 years to 2.4 years for women; greater increases than for patients without diabetes.[53]

The United States Preventive Services Task Force (USPSTF) recommends screening for type 2 DM in asymptomatic adults with sustained BP (either treated or untreated) greater than 135/80 mm Hg, SOR B but finds insufficient evidence to promote screening for asymptomatic adults with lower BP.[54]

- Screening for type 2 DM should be considered in the presence of risk factors for DM (see "Risk Factors" above) and for patients who have increased levels of triglycerides or low concentrations of high-density lipoprotein cholesterol.[4] SOR C
- All pregnant women should be screened for gestational DM at 24 to 28 weeks' gestation, using a 75-g (glucose), 2-hour oral glucose tolerance test.[4] SOR B There is currently a lack of consensus, however, on optimal screening; the American College of Obstetricians and Gynecologists recommends selective (risk-based) screening, the ADA recommends universal screening, and the USPSTF found insufficient evidence for or against screening.

PROGNOSIS

- Sustained elevation in fasting blood glucose levels and 2-hour post-load glucose testing, even when below the threshold for a diabetes diagnosis, is significantly associated with future CV events and mortality. Approximately 75% of patients with type 2 DM die of macrovascular complications, particularly CV disease.[4]
- Poorly controlled diabetes before conception and during the first trimester of pregnancy among women with type 1 DM can cause major birth defects in 5% to 10% of pregnancies and spontaneous abortions in 15% to 20% of pregnancies.[1]
- In 2007, diabetes was listed as the underlying cause on 71,382 death certificates and was listed as a contributing factor on an additional 160,022 death certificates.[1] Complications of diabetes contributing to death included heart disease (noted on 68% of death certificates among those age 65 years or older) and stroke (16%).
- Diabetes is the leading cause of new cases of blindness (4.4% have advanced diabetic retinopathy), kidney failure (48,374 people began treatment for end-stage renal disease in 2008), and nontraumatic lower-limb amputation (65,700 amputations in 2006).[1]

FOLLOW-UP

- Routine follow-up is recommended to continue to assist patients with risk factor reduction, adherence to treatment, screening for diabetes complications (including depression) and to provide ongoing support and guidance. Visit frequency depends on the patient's needs, recent changes in management, and severity of complications. The AACE recommends regular visits at least every 3 to 6 months to review and reinforce BP and blood glucose targets and management of ongoing risk factors (including alcohol and tobacco use).[4]
- The AACE also recommends contact within 1 week after a major modification of the treatment plan.[4] At each encounter, ask if the patient has experienced symptoms of hypoglycemia and educate the patient on appropriate recognition, prevention, and management. They also recommend the following:[4]
  - Goal setting for nutrition and physical activity regularly.
  - Monitor hemoglobin A_{1C} every 3 to 6 months, LDL or fasting lipid profile yearly (unless stable and with no change in medication), and microalbuminuria annually with serum creatinine if albuminuria is abnormal. If microalbuminuria testing is positive (>30 mg/g), repeat twice in the next 3 months. If two of three of these screening microalbuminuria tests are positive, the individual has microalbuminuria and interventions should be considered.[4] A negative finding should be followed yearly; a positive finding should be followed periodically to see if the interventions are effective in diminishing the albuminuria.
  - Remind the patient to schedule dilated ophthalmic exams with an optometrist or ophthalmologist.
  - Monitor foot exams annually or more frequently and educate the patient on appropriate recognition, prevention, and management of infections.

PATIENT EDUCATION

- Patient education includes information about DM (e.g., treatment options), primary and secondary prevention recommendations, and self-management.
- Recommended self-management activities include goal setting, incorporating nutrition management and physical activity into lifestyle, and prevention and early detection of complications (e.g., medication adherence, foot care).[4]

PATIENT RESOURCES

- ADA. Provides information and support—**http://www.diabetes.org/.**
- MedlinePlus. *Diabetes*—**http://www.nlm.nih.gov/medlineplus/diabetes.html.**

PROVIDER RESOURCES

- Handelsman Y, Mechanick JI, Blonde L, et al, AACE Task Force for Developing Diabetes Comprehensive Care Plan. AACE medical guidelines for clinical practice for developing a DM comprehensive care plan. *Endocr Pract*. 2011;17(Suppl 2):1-53.
- ADA. Standards of medical care in diabetes–2008. *Diabetes Care* 2008;31:S1-S108.
- Centers for Disease Control and Prevention. *Diabetes Public Health Resource*—**http://www.cdc.gov/diabetes/.**
- National Diabetes Information Clearing House. *Diabetes*—**http://diabetes.niddk.nih.gov/.**
- National Institute of Diabetes and Digestive and Kidney Diseases. **http://www2.niddk.nih.gov/.**

REFERENCES

1. Centers for Disease Control and Prevention. *Diabetes Fact Sheet (2011)*. http://www.cdc.gov/diabetes/pubs/pdf/ndfs_2011.pdf. Accessed March 2012.
2. Burchfiel CM, Hamman RF, Marshall JA, et al. Cardiovascular risk factors and impaired glucose tolerance: the San Luis Valley Diabetes Study. *Am J Epidemiol*. 1990;131(1):57-70.
3. Juonala M, Magnussen CG, Berenson GS, et al. Childhood adiposity, adult adiposity, and cardiovascular risk factors. *N Engl J Med*. 2011;365(20):1876-1885.
4. Handelsman Y, Mechanick JI, Blonde L, et al. AACE Task Force for Developing Diabetes Comprehensive Care Plan. American Association of Clinical Endocrinologists medical guidelines for clinical practice for developing a diabetes mellitus comprehensive care plan. *Endocr Pract*. 2011;17(Suppl 2):1-53.
5. Pan A, Sun Q, Bernstein AM, et al. Red meat consumption and risk of type 2 diabetes: 3 cohorts of US adults and an updated meta-analysis. *Am J Clin Nutr*. 2011;94(4):1088-1096.
6. Grøntved A, Hu FB. Television viewing and risk of type 2 diabetes, cardiovascular disease, and all-cause mortality: a meta-analysis. *JAMA*. 2011;305(23):2448-2455.

7. Yeboah J, Bertoni AG, Herrington DM, et al. Impaired fasting glucose and the risk of incident diabetes mellitus and cardiovascular events in an adult population: MESA (Multi-Ethnic Study of Atherosclerosis). *J Am Coll Cardiol.* 2011;58(2):140-146.
8. Noble D, Mathur R, Dent T, et al. Risk models and scores for type 2 diabetes: systematic review. *BMJ.* 2011;343:d7163. doi: 10.1136/bmj.d7163.
9. Wilson PW, Meigs JB, Sullivan L, et al. Prediction of incident diabetes mellitus in middle-aged adults: the Framingham Offspring Study. *Arch Intern Med.* 2007;167:1068-1074.
10. Sibbald RG, Landolt SJ, Toth D. Skin and diabetes. *Endocrinol Metab Clin North Am.* 1996;25(2):463-472.
11. Litonjua P, Pinero-Pilona A, Aviles-Santa L, et al. Prevalence of acanthosis nigricans in newly-diagnosed type 2 diabetes. *Endocr Pract.* 2004;10:101-106.
12. van der Ven A, Chapman CB, Bowker JH. Charcot neuroarthropathy of the foot and ankle. *J Am Acad Orthop Surg.* 2009;17(9):562-571.
13. American Diabetes Association. Standards of medical care in diabetes–2008. *Diabetes Care.* 2008;31:S1-S108.
14. Rolka DB, Narayan KM, Thompson TJ, et al. Performance of recommended screening tests for undiagnosed diabetes and dysglycemia. *Diabetes Care.* 2001;24:1899-1903.
15. Patel A, MacMahon S, Chalmers J, et al. The Advance Collaborative Group. Intensive blood glucose control and vascular outcomes in patients with type 2 diabetes. *N Engl J Med.* 2008; 358(24):2560-2572.
16. Gerstein HC, Miller ME, Byington, RP, et al. Action to Control Cardiovascular Risk in Diabetes Study Group. Effects of intensive glucose lowering in type 2 diabetes. *N Engl J Med.* 2008; 358:2545-2559.
17. Hemmingsen B, Lund SS, Gluud C, et al. Intensive glycaemic control for patients with type 2 diabetes: systematic review with meta-analysis and trial sequential analysis of randomised clinical trials. *BMJ.* 2011;343:d6898.
18. National Guideline Clearinghouse. *Guideline Synthesis: Nutritional Management of Diabetes Mellitus*. http://www.guideline.gov/syntheses/synthesis.aspx?id=36617&search=diabetes. Accessed August 2012.
19. Thomas D, Elliott EJ. Low glycaemic index, or low glycaemic load, diets for diabetes mellitus. *Cochrane Database Syst Rev.* 2009;(1):CD006296.
20. Nikooyeh B, Neyestani TR, Farvid M, et al. Daily consumption of vitamin D− or vitamin D + calcium-fortified yogurt drink improved glycemic control in patients with type 2 diabetes: a randomized clinical trial. *Am J Clin Nutr.* 2011;93(4):764-771.
21. Jorde R, Figenschau Y. Supplementation with cholecalciferol does not improve glycaemic control in diabetic subjects with normal serum 25-hydroxyvitamin D levels. *Eur J Nutr.* 2009;48(6):349-354.
22. Mitri J, Muraru MD, Pittas AG. Vitamin D and type 2 diabetes: a systematic review. *Eur J Clin Nutr.* 2011;65(9):1005-1015.
23. Norris SL, Zhang X, Avenell A, et al. Long-term non-pharmacological weight loss interventions for adults with type 2 diabetes mellitus. *Cochrane Database Syst Rev.* 2005;(3):CD004095.
24. Andrews RC, Cooper AR, Montgomery AA, et al. Diet or diet plus physical activity versus usual care in patients with newly diagnosed type 2 diabetes: the Early ACTID randomised controlled trial. *Lancet.* 2011;378(9786):129-139.
25. Umpierre D, Ribeiro PA, Kramer CK, et al. Physical activity advice only or structured exercise training and association with HbA1c levels in type 2 diabetes: a systematic review and meta-analysis. *JAMA.* 2011;305(17):1790-1799.
26. Deakin TA, McShane CE, Cade JE, Williams R. Group based training for self-management strategies in people with type 2 diabetes mellitus. *Cochrane Database Syst Rev.* 2005;(2):CD003417.
27. Loveman E, Royle P, Waugh N. Specialist nurses in diabetes mellitus. *Cochrane Database Syst Rev.* 2003;(2):CD003286.
28. Frosch DL, Uy V, Ochoa S, Mangione CM. Comparative effectiveness of goal setting in diabetes mellitus group clinics: randomized clinical trial. *Ann Intern Med.* 2011;171(22):2011-2017.
29. Weinger K, Beverly EA, Lee Y, et al. Quality of life, glucose monitoring, and frequency of diabetes self-care. *Arch Intern Med.* 2011; 171(22):1990-1999.
30. Malanda UL, Welschen LM, Riphagen II, et al. Self-monitoring of blood glucose in patients with type 2 diabetes mellitus who are not using insulin. *Cochrane Database Syst Rev.* 2012;(1):CD005060.
31. Naik AD, Palmer N, Petersen NJ, et al. Comparative effectiveness of goal setting in diabetes mellitus group clinics: randomized clinical trial. *Arch Intern Med.* 2011;171(5):453-459.
32. Mann JF, Schmieder RE, McQueen M, et al, for the ONTARGET investigators. Renal outcomes with telmisartan, ramipril, or both, in people at high vascular risk (the ONTARGET study): a multicentre, randomised, double-blind, controlled trial. *Lancet.* 2008; 372:547-553.
33. ACCORD Study Group, Cushman WC, Evans GW, Byington RP. Effects of intensive blood-pressure control in type 2 diabetes mellitus. *N Engl J Med.* 2010;362(17):1575-1585.
34. Redon J, Mancia G, Sleight P, et al. Safety and efficacy of low blood pressures among patients with diabetes: subgroup analyses from the ONTARGET (ONgoing Telmisartan Alone and in combination with Ramipril Global Endpoint Trial). *J Am Coll Cardiol.* 2012;59(1):74-83.
35. Inzucchi SE. Oral antihyperglycemic therapy for type 2 diabetes. Scientific review. *JAMA.* 2002;287:360-372.
36. Saenz A, Fernandez-Esteban I, Mataix A, et al. Metformin monotherapy for type 2 diabetes mellitus. *Cochrane Database Syst Rev.* 2005;(3):CD002966.
37. Turner RC, Cull CA, Frighi V, et al. Glycemic control with diet, sulfonylurea, metformin, or insulin in patients with type 2 diabetes mellitus: progressive requirement for multiple therapies (UKPDS 49). *JAMA.* 1999;281:2005-2012.
38. Klarenbach S, Cameron C, Singh S, Ur E. Cost-effectiveness of second-line antihyperglycemic therapy in patients with type 2 diabetes mellitus inadequately controlled on metformin. *CMAJ.* 2011;183(16):E1213-E1220.
39. Monami M, Lamanna C, Marchionni N, Mannucci E. Comparison of different drugs as add-on treatments to metformin in type 2

diabetes: a meta-analysis. *Diabetes Res Clin Pract.* 2008;79(2):196-203.

40. Gross JL, Kramer CK, Leitao CB, et al. Effect of antihyperglycemic agents added to metformin and a sulfonylurea on glycemic control and weight gain in type 2 diabetes: a network meta-analysis. *Ann Intern Med.* 2011;154(10):672-679.
41. Effect of intensive blood-glucose control with metformin on complications in overweight patients with type 2 diabetes (UKPDS 34). UK Prospective Diabetes Study (UKPDS) Group. *Lancet.* 1998;352(9131):854-865.
42. Horvath K, Jeitler K, Berghold A, et al. Long-acting insulin analogues versus NPH insulin (human isophane insulin) for type 2 diabetes mellitus. *Cochrane Database Syst Rev.* 2007;(2):CD005613.
43. Goudswaard AN, Furlong NJ, Valk GD, et al. Insulin monotherapy versus combinations of insulin with oral hypoglycaemic agents in patients with type 2 diabetes mellitus. *Cochrane Database Syst Rev.* 2004;(4):CD003418.
44. Liu JP, Zhang M, Wang W, Grimsgaard S. Chinese herbal medicines for type 2 diabetes mellitus. *Cochrane Database Syst Rev.* 2004;(3):CD003642.
45. Sridharan K, Mohan R, Ramaratnam S, Panneerselvam D. Ayurvedic treatments for diabetes mellitus. *Cochrane Database Syst Rev.* 2011;(12):CD008288.
46. Twigg SM, Kamp MC, Davis TM, et al. Prediabetes: a position statement from the Australian Diabetes Society and Australian Diabetes Educators Association. *Med J Aust.* 2007;186(9):461-465.
47. Lindström J, Ilanne-Parikka P, Peltonen M, et al, for the Finnish Diabetes Prevention Study Group. Sustained reduction in the incidence of type 2 diabetes by lifestyle intervention: follow-up of the Finnish Diabetes Prevention Study. *Lancet.* 2006;368(9548):1673-1679.
48. Tuomilehto J, Lindstrom J, Eriksson JG, et al. Prevention of type 2 diabetes mellitus by changes in lifestyle among subjects with impaired glucose tolerance. *N Engl J Med.* 2001;344(18):1343-1350.
49. DeFronzo RA, Tripathy D, Schwenke DC, et al. Pioglitazone for diabetes prevention in impaired glucose tolerance. *N Engl J Med.* 2011;364(12):1104-1115.
50. Gillies CL, Abrams KR, Lambert PC, et al. Pharmacological and lifestyle interventions to prevent or delay type 2 diabetes in people with impaired glucose tolerance: systematic review and meta-analysis. *BMJ.* 2007;334(7588):299.
51. Strippoli GFM, Craig ME, Craig JC, et al. Antihypertensive agents for preventing diabetic kidney disease. *Cochrane Database Syst Rev.* 2005;(4):CD004136.
52. Neubauer AS, Ulbig MW. Laser treatment in diabetic retinopathy. *Ophthalmologica.* 2007;221(2):95-102.
53. Grover SA, Coupal L, Zowall H, et al. Evaluating the benefits of treating dyslipidemia: the importance of diabetes as a risk factor. *Am J Med.* 2003;115(2):122-128.
54. U.S. Preventive Services Task Force. Screening for type 2 diabetes mellitus in adults: U.S. Preventive Services Task Force recommendation statement. *Ann Intern Med.* 2008;148(11):846-854.

220 ACANTHOSIS NIGRICANS

Mindy A. Smith, MD, MS

PATIENT STORY

An adolescent girl with obesity and recently diagnosed type II diabetes mellitus (DM) presents to her family physician with concerns about a "dirty area" under her arms and on her neck that "couldn't be cleaned" (**Figure 220-1**). She has irregular periods that often skip several months at a time. The physician makes the diagnosis of acanthosis nigricans.

FIGURE 220-1 Acanthosis nigricans in the left axilla of an overweight Hispanic 10-year-old girl. Note areas of dark velvety discoloration and pink filiform hypertrophy. (*Courtesy of Richard P. Usatine, MD.*)

INTRODUCTION

- Acanthosis nigricans (AN) is a localized form of hyperpigmentation that involves epidermal alteration. AN is usually associated with insulin resistance and is seen in patients with endocrine disorders (e.g., type II DM, Cushing syndrome, acromegaly), obesity, and polycystic ovary syndrome.

EPIDEMIOLOGY

- In a cross-sectional study conducted in a southwestern practice-based research network (N = 1133), AN was found in 17% of children and 21% of adults.[1]
- In 2 studies, AN was present in 36% of patients with newly diagnosed DM and 39% of children with obesity.[2,3]
- AN is sometimes associated with malignancy, primarily adenocarcinoma (60%) of the stomach, gallbladder, colon, ovary, pancreas, rectum, and uterus.[4,5]
- Although most cases are idiopathic, there are also genetic causes of AN.[5]
- A condition of hyperandrogenism (HA), insulin resistance (IR), and AN called HAIR-AN syndrome occurs in approximately 1% to 3% of women with HA.[6] This syndrome may also be seen in patients with autoimmune disorders like Hashimoto thyroiditis.
- AN can be an adverse effect from hormonal therapies.[7]

ETIOLOGY AND PATHOPHYSIOLOGY

- AN results from of long-term exposure of keratinocytes to insulin.
- Keratinocytes have insulin and insulin-like growth receptors on their surface and the pathogenesis of this condition may be linked to insulin binding to insulin-like growth receptors in the epidermis.
- Fibroblast growth factor receptor 3 (FGFR3) gene mutations should be considered in patients with coexistent AN and skeletal dysplasia.[8]

DIAGNOSIS

The diagnosis of AN is made clinically in a patient with or at risk for IR who has the characteristic lesions.

CLINICAL FEATURES

- AN ranges in appearance from diffuse streaky thickened brown velvety lesions to leathery verrucous papillomatous lesions (**Figures 220-1** to **220-9**).
- Women with HAIR-AN syndrome have evidence of virilization (e.g., increased body hair in male distribution, enlarged clitoris) in addition to AN.[6]

TYPICAL DISTRIBUTION

- Commonly located on the neck (**Figures 220-3** to **220-5**) or skin folds (i.e., axillae [**Figures 220-1**, **220-2**, and **220-9**], inframammary folds, groin, and perineum).
- Less often AN can be seen on the nipples or areolae, perineum, groin, and extensor surfaces of the legs.[5]
- Verrucous AN may affect the eyelids, lips, and buccal mucosa.[5]
- In patients with malignancy, the onset of AN can be abrupt and the distribution of lesions is more widespread and may include the palms and soles.[9]

BIOPSY

- May be needed in unusual cases.
- Histologic examination reveals hyperkeratosis and papillary hypertrophy, although the epidermis is only mildly thickened.[10]

DIFFERENTIAL DIAGNOSIS

Other hyperpigmented lesions that may be confused with AN include:

- Seborrheic keratosis (see Chapter 158, Seborrheic Keratosis)—Most commonly found on the trunk or the face; these lesions are more plaque-like with adherent, greasy scale and have a "stuck on" appearance.
- Pigmented actinic keratosis (see Chapter 166, Actinic Keratosis and Bowen Disease)—Usually in sun-exposed areas; the lesions can be macular or papular with dry, rough adherent scale.

MANAGEMENT

NONPHARMACOLOGIC

- Patients with AN are at higher risk of metabolic syndrome, and lipid screening should be considered along with consideration of testing for DM.
- Weight loss through diet and exercise helps reverse the process, probably by reducing both IR and compensatory hyperinsulinemia.

FIGURE 220-2 Acanthosis nigricans in the right axilla of a 25-year-old woman with type 2 diabetes. The skin appears velvety. (*Courtesy of Richard P. Usatine, MD.*)

FIGURE 220-3 Acanthosis nigricans on the neck of an obese Hispanic woman with type 2 diabetes. Note that multiple skin tags are also present. (*Courtesy of Richard P. Usatine, MD.*)

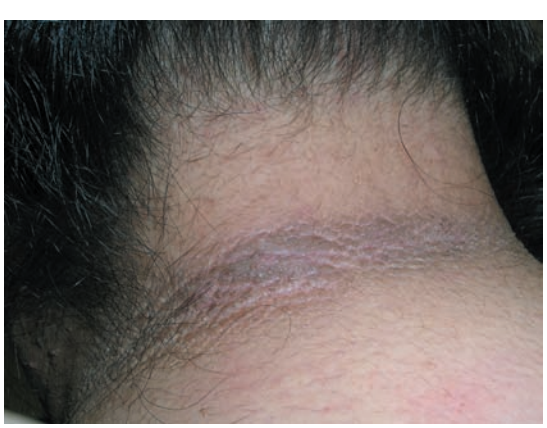

FIGURE 220-4 Acanthosis nigricans on the neck of an obese woman with type II diabetes. Note the hypertrophic thickening of the darker skin. (*Courtesy of Richard P. Usatine, MD.*)

MEDICATIONS

- Keratolytic agents (e.g., salicylic acid) can improve the cosmetic appearance. Other topical therapies, including 0.1% tretinoin cream (to lighten the lesion), combination tretinoin cream with 12% ammonium lactate cream, or topical vitamin D ointments,[11] may be useful.[5] SOR C
- Metformin[12] and octreotide have also been used to manage AN. SOR C

COMPLEMENTARY AND ALTERNATIVE THERAPY

- The use of omega-3-fatty acid and dietary fish oil supplementation has also been reported to improve AN.[13] SOR C

PROCEDURES

- Long-pulsed alexandrite laser therapy[14] and dermabrasion are alternative treatments.[5]
- Some patients have many skin tags within the area of acanthosis and request them to be removed (**Figure 220-9**). (See Chapter 157, Skin Tag for details on treatment.)

PROGNOSIS

- AN usually regresses when the underlying condition (e.g., diabetes, malignancy) is treated.[5]

PATIENT EDUCATION

- Patients who are overweight should be encouraged to lose weight through diet and exercise because weight loss often resolves this condition.

PATIENT RESOURCES

- **http://www.ncbi.nlm.nih.gov/pubmedhealth/PMH0001855/.**
- **http://www.nlm.nih.gov/medlineplus/ency/article/000852.htm.**

PROVIDER RESOURCE

- Diabetes Public Health Resource, National Center for Chronic Disease Prevention and Health Promotion of the Centers for Disease Control and Prevention—**http://www.cdc.gov/diabetes/news/docs/an.htm.**

REFERENCES

1. Kong AS, Williams RL, Smith M, et al. Acanthosis nigricans and diabetes risk factors: prevalence in young persons seen in southwestern US primary care practices. *Ann Fam Med.* 2007;5:202-208.
2. Litonjua P, Pinero-Pilona A, Aviles-Santa L, et al. Prevalence of acanthosis nigricans in newly-diagnosed type 2 diabetes. *Endocr Pract.* 2004;10:101-106.

FIGURE 220-5 Acanthosis nigricans on the neck of a 15-year-old boy with no obesity or diabetes. His mother has very prominent acanthosis nigricans. (*Courtesy of Richard P. Usatine, MD.*)

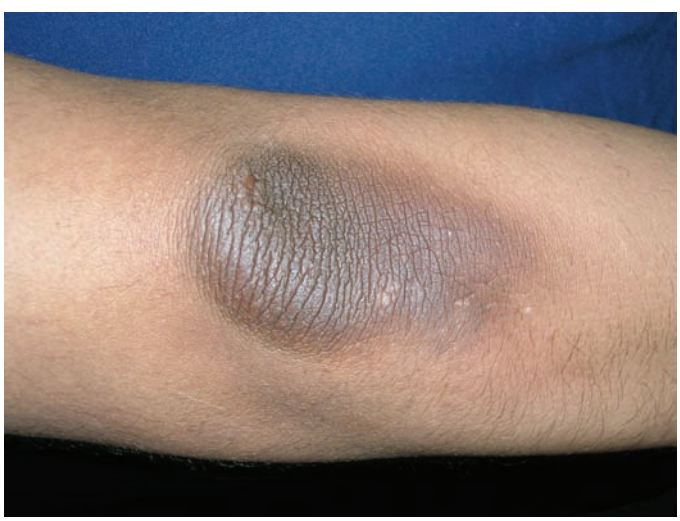

FIGURE 220-6 Acanthosis nigricans on the elbow of a young obese Hispanic woman. (*Courtesy of Richard P. Usatine, MD.*)

FIGURE 220-7 Acanthosis nigricans on the dorsum of the hand in a morbidly obese young man. Note the hyperpigmentation and tiny papules present. (*Courtesy of Richard P. Usatine, MD.*)

3. Miura N, Ikezaki A, Iwama S, et al. Genetic factors and clinical significance of acanthosis nigricans in obese Japanese children and adolescents. *Acta Paediatr.* 2006;95:170-175.
4. Rendon MI, Cruz PD, Sontheimer RD, Bergstresser PR. Acanthosis nigricans: a cutaneous marker of tissue resistance to insulin. *J Am Acad Dermatol.* 1989;29(3 pt 1):461-469.
5. Kapoor S. Diagnosis and treatment of acanthosis nigricans. *Skinmed.* 2010;8(3):161-164.
6. Elmer KB, George RM. HAIR-AN syndrome: a multisystem challenge. *Am Fam Physician.* 2001;63:2385-2390.
7. Downs AM, Kennedy CT. Somatotrophin-induced acanthosis nigricans. *Br J Dermatol.* 1999;141:390-391.
8. Blomberg M, Jeppesen EM, Skovby F, Benfeldt E. FGFR3 mutations and the skin: report of a patient with a FGFR3 gene mutation, acanthosis nigricans, hypochondroplasia and hyperinsulinemia and review of the literature. *Dermatology.* 2010;220(4):297-305.
9. Stulberg DL, Clark N. Hyperpigmented disorders in adults: part II. *Am Fam Physician.* 2003;68:1963-1968.
10. Sibbald RG, Landolt SJ, Toth D. Skin and diabetes. *Endocrinol Metab Clin North Am.* 1996;25(2):463-472.
11. Hermanns-Le T, Scheen A, Pierard GE. Acanthosis nigricans associated with insulin resistance: pathophysiology and management. *Am J Clin Dermatol.* 2004;5(3):199-203.
12. Wasniewska M, Arrigo T, Crisafulli G, et al. Recovery of acanthosis nigricans under prolonged metformin treatment in an adolescent with normal weight. *J Endocrinol Invest.* 2009;32:939-940.
13. Sheretz EF. Improved acanthosis nigricans with lipodystrophic diabetes during dietary fish oil supplementation. *Arch Dermatol.* 1988;124:1094-1096.
14. Rosenbach A, Ram R. Treatment of acanthosis nigricans of the axillae using a long-pulsed (5-msec) alexandrite laser. *Dermatol Surg.* 2004;30(8):1158-1160.

FIGURE 220-8 Acanthosis nigricans on the hand and wrist of a morbidly obese young man with widespread acanthosis. Note the texture of the skin along with the skin darkening. (*Courtesy of Richard P. Usatine, MD.*)

FIGURE 220-9 Acanthosis nigricans in the axilla of a man with type 2 diabetes. Note the many skin tags also present. (*Courtesy of Richard P. Usatine, MD.*)

221 DIABETIC DERMOPATHY

Mindy A. Smith, MD, MS

PATIENT STORY

A 60-year-old woman with diabetes mellitus (DM) for the past 10 years began to notice reddish-colored lesions on both anterior shins that turned brown over the past year (**Figure 221-1**). She reported no pain with the hyperpigmented areas but does have foot pain secondary to neuropathy. The patient is diagnosed with diabetic dermopathy, and she begins working with her physician on achieving better control of her diabetes.

FIGURE 221-1 Lesions of diabetic dermopathy (also called pigmented pretibial papules) on both lower extremities of a 60-year-old woman with diabetes. The skin appears atrophic and the lesions are flat and hyperpigmented. (*Courtesy of the University of Texas Health Sciences Center, Division of Dermatology.*)

INTRODUCTION

Diabetic dermopathy is a constellation of well-demarcated, hyperpigmented, atrophic depressions, macules, or papules located on the anterior surface of the lower legs that is usually found in patients with DM. It is the most common cutaneous marker of DM.

EPIDEMIOLOGY

- Diabetic dermopathy is found in 12.5% to 40% of patients and most often in the elderly. It is less common in women.[1]
- In a case series of 100 consecutive inpatients or outpatients in India with DM and skin lesions, diabetic dermopathy was found in 36%.[2] The incidence was much lower in a second case series of 500 patients attending a diabetes clinic in India, with only 0.2% diagnosed with diabetic dermopathy; the authors concluded that because the majority of patients were well controlled (fasting blood sugar <130 mg/mL in 60%), cutaneous signs of chronic hyperglycemia were decreased.[3]
- Sometimes seen in persons without DM, especially patients with circulatory compromise.

ETIOLOGY AND PATHOPHYSIOLOGY

The cause of diabetic dermopathy is unknown.

- Diabetic dermopathy may be related to mechanical or thermal trauma, especially in patients with neuropathy.
- Lesions have been classified as vascular because histology sections demonstrate red blood cell extravasation and capillary basement membrane thickening. In one study, patients with type 1 DM and diabetic dermopathy had marked reduction in skin blood flow at normal-appearing skin areas on the pretibial surface of the legs compared with type 1 control and nondiabetic control patients.[4]
- There is an association between diabetic dermopathy and the presence of retinopathy, nephropathy, and neuropathy.[5,6] In a Turkish study, women with diabetic dermopathy appeared to have a more severe sensorial neuropathy (e.g., loss of deep tendon reflexes,

superficial sensory loss, and the loss of vibration sense) than did patients without these skin lesions; a high prevalence of carpel tunnel syndrome (63.8%) was also found in these patients.[7]

DIAGNOSIS

CLINICAL FEATURES

The diagnosis is usually clinical. Lesions often begin as pink patches (0.5 to 1 cm), which become hyperpigmented with surface atrophy and fine scale (**Figures 221-1** to **221-4**).

TYPICAL DISTRIBUTION

Pretibial and lateral areas of the calf (**Figures 221-1** to **221-4**).

BIOPSY

Histology shows epidermal atrophy, thickened small superficial dermal blood vessels, increased epidermal melanin and hemorrhage with hemosiderin deposits. These findings are not all present in biopsy specimens; in an autopsy series, only 4 of 14 skin biopsies of diabetic dermopathy lesions showed moderate to severe wall thickening of arterioles or medium-sized arteries, 11 of 14 showed mild basement membrane thickening, and 9 of 14 had markedly increased epidermal melanin.[8]

DIFFERENTIAL DIAGNOSIS

Consider the following when evaluating patients with similar skin conditions:

- Early lesions of necrobiosis lipoidica diabeticorum—Erythematous papules or plaques beginning in the pretibial area, but become larger and darker with irregular margins and raised erythematous borders. Telangiectasias, atrophy, and yellow discoloration may be seen. The lesion may be painful (see Chapter 222, Necrobiosis Lipoidica).
- Schamberg disease (pigmented purpuric dermatosis) is a capillaritis that produces brown hemosiderin deposits along with visible pink-to-red spots like cayenne pepper on the lower extremities. It is not more common in diabetes but may resemble diabetic dermopathy. A biopsy could be used to distinguish between them (see Chapter 179, Vasculitis).
- Stasis dermatitis—The typical site is the medial aspect of the ankle. Early lesions are erythematous, scaly, and sometimes pruritic, becoming progressively hyperpigmented (see Chapter 52, Venous Stasis).
- Traumatic scars—There is no scale, lesions are permanent, and edema is not usually present.

MANAGEMENT

- There is no effective treatment.
- It is not known whether the lesions improve with better control of diabetes.
- One informal case report stated that patients may benefit from 15 to 25 mg chelated zinc daily for several weeks.[9] SOR C

FIGURE 221-2 Diabetic dermopathy on the leg showing pretibial hyperpigmentation and healed ulcers with hypopigmentation. There are also signs of erythema and fine scale. (*Courtesy of the University of Texas Health Sciences Center, Division of Dermatology.*)

FIGURE 221-3 Diabetic dermopathy on both lower extremities of a middle-age man with diabetes. The sparse hair is secondary to his vasculopathy. (*Courtesy of Dan Stulberg, MD.*)

PREVENTION

- It is possible that patients with well-controlled DM have a lower risk of diabetic dermopathy.

PROGNOSIS

- Lesions may resolve spontaneously.

PATIENT EDUCATION

- Reassure patients that the lesions are asymptomatic and may resolve spontaneously within 1 to 2 years, although new lesions may form.

PATIENT RESOURCE

- American Diabetes Association. *Skin Complications*—**http://www.diabetes.org/living-with-diabetes/complications/skin-complications.html?loc=DropDownLWD-skin.**

PROVIDER RESOURCE

- DermAtlas—**http://dermatlas.med.jhmi.edu/derm/result.cfm?Diagnosis=1070338873.**

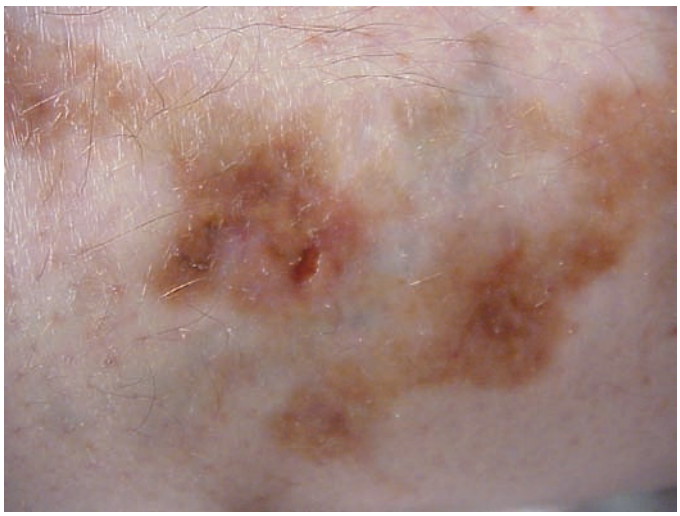

FIGURE 221-4 Close-up of diabetic dermopathy on the right leg showing atrophy, hyperpigmentation, a shallow ulcer, and fine scale. The hyperpigmentation is from hemosiderin deposition. *(Courtesy of Dan Stulberg, MD.)*

REFERENCES

1. Sibbald RG, Landolt SJ, Toth D. Skin and diabetes. *Endocrinol Metab Clin North Am.* 1996;25(2):463-472.
2. Goyal A, Raina S, Kaushal SS, et al. Pattern of cutaneous manifestations in diabetes mellitus. *Indian J Dermatol*. 2010;55(1):39-41.
3. Ragunatha S, Anitha B, Inamadar AC, et al. Cutaneous disorders in 500 diabetic patients attending diabetic clinic. *Indian J Dermatol*. 2011;56(2):160-164.
4. Brugler A, Thompson S, Turner S, et al. Skin blood flow abnormalities in diabetic dermopathy. *J Am Acad Dermatol.* 2011;65(3):559-563.
5. Shemer A, Bergnan R, Linn S, et al. Diabetic dermopathy and internal complications in diabetes mellitus. *Int J Dermatol.* 1998;37(2):113-115.
6. Abdollahi A, Daneshpazhooh M, Amirchaghmaghi E, et al. Dermopathy and retinopathy in diabetes: is there an association. *Dermatology*. 2007;214(2):133-136.
7. Kiziltan ME, Benbir G. Clinical and nerve conduction studies in female patients with diabetic dermopathy. *Acta Diabetol.* 2008;45(2):97-105.
8. McCash S, Emanuel PO. Defining diabetic dermopathy. *J Dermatol.* 2011;38(10):988-992.
9. DiabetesNet.com. *Skin Complications: Necrobiosis Lipoidica*. http://www.diabetesnet.com/diabetes_complications/diabetes_skin_changes.php. Accessed November 2011.

222 NECROBIOSIS LIPOIDICA

Mindy A. Smith, MD, MS

PATIENT STORY

A 30-year-old woman presents with discoloration on both lower legs. She has no personal history of diabetes; however, type 2 diabetes does run in her family. Visible inspection of the lesions is highly suggestive of necrobiosis lipoidica (NL) (**Figure 222-1**). There is hyperpigmentation, yellow discoloration, atrophy, and telangiectasias. The patient is not overweight and had no symptoms of diabetes. Her blood sugar at this visit is 142 after eating lunch 1 hour prior to testing. The following day, the patient's fasting blood sugar is 121, with a glycosylated hemoglobin of 6.1. The patient is informed of her borderline diabetes, and diet and exercise are prescribed. She is disturbed by her skin appearance and chooses to try a moderate-strength topical corticosteroid for treatment.

FIGURE 222-1 Necrobiosis lipoidica in a 30-year-old woman with impaired glucose tolerance (borderline diabetes). Note the brown pigmentation and prominent blood vessels. (*Courtesy of Suraj Reddy, MD.*)

INTRODUCTION

- NL is a chronic granulomatous skin condition with degenerative connective-tissue changes most often seen in patients with diabetes mellitus (DM). It was previously called *necrobiosis lipoidica diabeticorum* before the recognition of a significant minority of patients with NL who do not have DM.

EPIDEMIOLOGY

- NL is a rare condition that occurs in approximately 1% (0.3% to 2.3%) of patients with DM.[1–4]
- NL primarily affects women (80%), particularly those with type 1 DM, but it can occur with type 2 DM.[1,2] Approximately 75% of patients with NL have or will develop DM.[5]
- Average age of onset is 34 years.[1,2]
- In a study comparing young patients with type 1 DM (N = 212, ages 2 to 22 years) with sex- and age-matched control patients, most (68% vs. 26.5% of controls) had at least 1 cutaneous disorder, with 2.3% versus 0% of control patients having NL.[4]
- NL has also been reported in patients with Hashimoto thyroiditis.[3]
- Cases of familial NL not associated with DM have also been reported.[6]

ETIOLOGY AND PATHOPHYSIOLOGY

- The cause of NL remains unknown.
- Angiopathy leading to thrombosis and occlusion of the cutaneous vessels has been implicated in its etiology. However, microangiopathic changes are less common in lesions on areas other than the shins and, therefore, are not necessary for developing the lesions.[2] In addition, one study found that NL lesions exhibited significantly

higher blood flow rates than areas of unaffected skin close to the lesions.[7]

- Antibodies and C3 have been found at the dermal-epidermal junction, suggesting vasculitis.
- The presence of fibrin in these lesions associated with palisading histiocytes may indicate a delayed hypersensitivity reaction.
- In a study using focus-floating microscopy, a modified immunohistochemical technique was developed to detect *Borrelia* spirochetes. *Borrelia* was detected in 75% of NL lesions overall and 92.7% of inflammatory-rich (38 of 41) versus inflammatory-poor (4 of 15, 26.7%) cases.[8] The authors posit that these findings indicate a potential role for *Borrelia burgdorferi* or other similar strains in the development of or trigger for NL.

DIAGNOSIS

CLINICAL FEATURES

- The lesions begin as erythematous papules or plaques in the pretibial area and become larger and darker with irregular margins and raised erythematous borders (**Figures 222-1** to **222-4**). The lesion's center atrophies and turns yellow in color, appearing waxy (**Figures 222-3**, **222-4**, and **222-5*A***).
- There is often a prominent brown color or hyperpigmentation visible (**Figures 222-1** to **222-4**).
- The lesions may ulcerate (occurs in approximately one-third) and become painful (**Figure 222-5*B***).
- Telangiectasias and prominent blood vessels may be seen within the lesions (**Figures 222-1** to **222-4**).
- The yellow color may be because of lipid deposits or beta-carotene.

TYPICAL DISTRIBUTION

- The lesions are usually located on the shins (90%) (**Figures 222-1** to **222-4**).
- NL lesions have been reported on many skin areas, including the face, scalp, and penis.[9,10]

BIOPSY

- Biopsy is usually not needed as the clinical picture is usually clear. The dangers of a biopsy include delayed healing and infection in a patient who often has diabetes. The shin region of the leg is notorious for delayed healing even in healthy persons and so biopsy should be avoided in most cases.
- If the diagnosis is uncertain, a punch biopsy will show a thin atrophic epidermis with dermal granulomatous inflammation and obliterative endarteritis. The dermal change shows increased necrobiosis or degeneration of collagen with absence of elastic tissue.

DIFFERENTIAL DIAGNOSIS

NL may be confused with the following conditions:

- Erythema nodosum (EN) is an inflammatory panniculitis that occurs in the same areas (especially shins) as NL. These nodules are pink in color and the skin is smooth above them. The color and lack

FIGURE 222-2 Necrobiosis lipoidica in a patient with type 1 diabetes. Note the pink area at the site of a healed superficial ulcer. (*Courtesy of Amber Tully, MD.*)

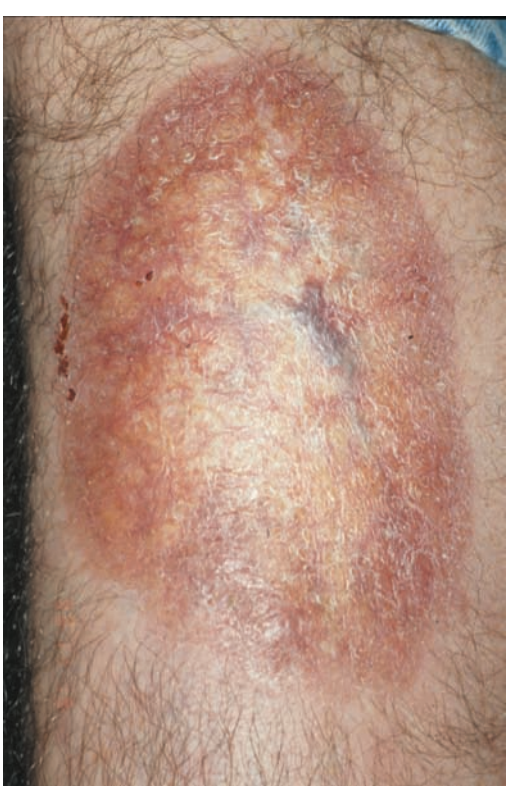

FIGURE 222-3 Necrobiosis lipoidica on the leg of a man with type 2 diabetes. Note the central atrophy and yellow discoloration with a well-demarcated brown border. (*Courtesy of the University of Texas Health Sciences Center, Division of Dermatology.*)

of epidermal changes should differentiate EN from NL (see Chapter 178, Erythema Nodosum).

- Granuloma annulare—Appears as asymmetric annular red plaques on the dorsum of the hands, extensor surface of the extremities, or posterior neck. They lack the yellow discoloration of NL. These lesions are so visibly like red raised rings that they should appear different from NL. If biopsy is needed, the presence of abundant mucin deposits helps to distinguish these lesions from NL (see Chapter 173, Granuloma Annulare).[2]
- Lichen simplex chronicus—A chronic pruritic eczematous lesion. The lesions are well-circumscribed plaques or papules with lichenified or thickened skin caused by chronic scratching or rubbing. Lesions are commonly located on the ankles, wrists, or posterior nuchal region. The prominent scale and lichenification should help differentiate these lesions from NL (see Chapter 145, Atopic Dermatitis).
- Sarcoidosis skin lesions—Including EN, maculopapular eruptions on the face, nose, back, and extremities; skin plaques that are often purple and raised; and broad macules with telangiectasias that are most commonly seen on the face or hands. Punch biopsy will distinguish between sarcoidosis and NL (see Chapter 175, Sarcoidosis).
- Stasis dermatitis—Occurs on the lower extremities secondary to venous incompetence and edema.[11] Affected patients are usually older, and the typical site is the medial aspect of the ankle. Early lesions are erythematous, scaly, and sometimes pruritic that progressively become hyperpigmented. These lesions are rarely well circumscribed, as seen in NL (see Chapter 52, Venous Stasis).

FIGURE 222-4 Multiple lesions of necrobiosis lipoidica in a young adult with type 1 diabetes. Note the central yellow discoloration and well-circumscribed brown borders. (*Courtesy of the University of Texas Health Sciences Center, Division of Dermatology.*)

MANAGEMENT

Evaluate patients not previously diagnosed with DM for diabetes. Even though glycemic control does not correlate with progression of these lesions, DM should be treated to decrease the risk of macro- and microvascular complications.

MEDICATIONS

Data on successful treatment is largely based on case reports. Necrobiosis lesions may respond to the following treatments:

- Local application of potent steroids or intralesional injections of 2.5 mg/mL of triamcinolone.[2] SOR C The major risk of these treatments includes increasing the existing atrophy, so patients should be informed of risks and benefits before initiating steroid treatments.
- Topical tacrolimus (0.1% ointment twice daily for 8 weeks followed by once daily for 8 weeks) was successful in a single case report.[12] SOR C
- Pentoxifylline (400 mg 2 to 3 times daily), an agent that improves blood flow and decreases red cell and platelet aggregation, was shown in 2 case reports to completely resolve the lesions at 8 weeks in one[3] and at 6-month follow-up in the other.[4] The latter patient continued therapy and remained in remission at a 2-year follow-up. SOR C
- Ulcerative NL has been reported to respond to tetracycline,[13] antimalarial agents (e.g., hydroxychloroquine),[14] clofazimine,[15] systemic steroids,[16] antiplatelet therapy,[17] and biologic agents (e.g., infliximab infusion, subcutaneous etanercept).[18,19] SOR C

REFERRAL

- Refer patients with intractable skin ulcers. In one study that included patients with NL, application of allogeneic cultured dermal substitute was successful in improving healing.[20]
- Topical photodynamic therapy may also be successful in treating refractory NL lesions; in 1 case series (N = 18), overall response rate was 39% with complete resolution in 1 patient and partial resolution in 6.[21] SOR C

PROGNOSIS

- Spontaneous resolution occurs in 10% to 20% of cases.
- In a study of patients with DM undergoing pancreatic transplantation (N = 11), all 5 patients with NL achieved resolution of NL following transplantation; 1 patient had recurrent NL associated with transplant rejection.[22] The single patient with NL who underwent kidney transplantation had persistent NL.

PATIENT EDUCATION

- Patients with NL without DM should be advised about the increased risk of developing the disease and counseled about symptoms and periodic surveillance.
- NL may resolve spontaneously and does respond to several treatments.

PATIENT RESOURCES

- American Diabetes Association—**http://www.diabetes.org.**
- American Diabetes Association. *Skin Complications*—**http://www.diabetes.org/living-with-diabetes/complications/skin-complications.html?loc=DropDownLWD-skin.**
- American Osteopathic College of Dermatology. *Necrobiosis Lipoidica Diabeticorum*—**http://www.aocd.org/skin/dermatologic_diseases/necrobiosis_lipoid.html.**

PROVIDER RESOURCE

- **http://emedicine.medscape.com/article/1103467-overview.**

FIGURE 222-5 **A.** Necrobiosis lipoidica on the leg of a woman with no diabetes. It was biopsy proven and treated. **B.** Worsening and ulcerations of necrobiosis lipoidica despite treatment with topical steroids. (*Courtesy of Richard P. Usatine, MD.*)

REFERENCES

1. Noz KC, Korstanje MJ, Vermeer BJ. Cutaneous manifestations of endocrine disorders: a guide for dermatologists. *Am J Clin Dermatol.* 2003;4(5):315-331.
2. Sibbald RG, Landolt SJ, Toth D. Skin and diabetes. *Endocrinol Metab Clin North Am.* 1996;25(2):463-472.
3. Ahmed K, Muhammad Z, Qayum I. Prevalence of cutaneous manifestations of diabetes mellitus. *J Ayub Med Coll Abbottabad.* 2009;21(2):76-79.
4. Pavlović MD, Milenković T, Dinić M, et al. The prevalence of cutaneous manifestations in young patients with type 1 diabetes. *Diabetes Care.* 2007;30(8):1964-1967.
5. O'Reilly K, Chu J, Meehan S, et al. Necrobiosis lipoidica. *Dermatol Online J.* 2011;17(10):18.

6. Roche-Gamón E, Vilata-Corell JJ, Velasco-Pastor M. Familial necrobiosis lipoidica not associated with diabetes. *Dermatol Online J.* 2007;13(3):26.
7. Ngo B, Wigington G, Hayes K, et al. Skin blood flow in necrobiosis lipoidica diabeticorum. *Int J Dermatol.* 2008;47(4):354-358.
8. Eisendle K, Baltaci M, Kutzner H, Zelger B. Detection of spirochaetal microorganisms by focus floating microscopy in necrobiosis lipoidica in patients from central Europe. *Histopathology.* 2008;52(7):877-884.
9. Lynch M, Callagy G, Mahon S, Murphy LA. Arcuate plaques of the face and scalp. Atypical necrobiosis lipoidica (ANL) of the face and scalp. *Clin Exp Dermatol.* 2010;35(7):799-800.
10. Alonso ML, Riós JC, González-Beato MJ, Herranz P. Necrobiosis lipoidica of the glans penis. *Acta Derm Venereol.* 2011;91(1):105-106.
11. Mistry N, Chih-Ho Hong H, Crawford RI. Pretibial angioplasia: a novel entity encompassing the clinical features of necrobiosis lipoidica and the histopathology of venous insufficiency. *J Cutan Med Surg.* 2011;15(1):15-20.
12. Patsatsi A, Kyriakou A, Sotiriadis D. Necrobiosis lipoidica: early diagnosis and treatment with tacrolimus. *Case Rep Dermatol.* 2011;3(1):89-93.
13. Mahé E, Zimmermann U. Significant improvement in ulcerative necrobiosis lipoidica with doxycycline. *Ann Dermatol Venereol.* 2011;138(10):686-688.
14. Durupt F, Dalle S, Debarbieux S, et al. Successful treatment of necrobiosis lipoidica with antimalarial agents. *Acta Derm Venereol.* 2009;89(6):651-652.
15. Benedix F, Geyer A, Lichte V, et al. Response of ulcerated necrobiosis lipoidica to clofazimine. *Acta Derm Venereol.* 2010;90(1): 104-106.
16. Tan E, Patel V, Berth-Jones J. Systemic corticosteroids for the outpatient treatment of necrobiosis lipoidica in a diabetic patient. *J Dermatolog Treat.* 2007;18(4):246-248.
17. Moore AF, Abourizk NN. Necrobiosis lipoidica: an important cutaneous manifestation of diabetes that may respond to antiplatelet therapy. *Endocr Pract.* 2008;14(7):947-948.
18. Hu SW, Bevona C, Winterfield L, et al. Treatment of refractory ulcerative necrobiosis lipoidica diabeticorum with infliximab: report of a case. *Arch Dermatol.* 2009;145(4):437-439.
19. Suárez-Amor O, Pérez-Bustillo A, Ruiz-González I, Rodríguez-Prieto MA. Necrobiosis lipoidica therapy with biologicals: an ulcerated case responding to etanercept and a review of the literature. *Dermatology.* 2010;221(2):117-121.
20. Taniguchi T, Amoh Y, Tanabe K, et al. Treatment of intractable skin ulcers caused by vascular insufficiency with allogeneic cultured dermal substitute: a report of eight cases. *J Artif Organs.* 2012;15(1): 77-82.
21. Berking C, Hegyi J, Arenberger P, et al. Photodynamic therapy of necrobiosis lipoidica—a multicenter study of 18 patients. *Dermatology.* 2009;218(2):136-139.
22. Souza AD, El-Azhary RA, Gibson LE. Does pancreas transplant in diabetic patients affect the evolution of necrobiosis lipoidica? *Int J Dermatol.* 2009;48(9):964-970.

223 HYPERLIPIDEMIA AND XANTHOMAS

Mindy A. Smith, MD, MS

PATIENT STORY

A 27-year-old Hispanic man reported new painful nonpruritic bumps, which started 6 months ago, over his entire body. The patient had not seen a physician for 10 months and had run out of his oral medicines for type 2 diabetes mellitus. His grandmother had a milder version of bumps like this years ago. The firm yellowish papules were present all over his body from the neck down (**Figures 223-1** to **223-3**). Laboratory evaluation revealed a random blood sugar of 203, a fasting triglyceride level greater than 7000 mg/dL, and total cholesterol greater than 700 mg/dL. High-density lipoproteins were 32 mg/dL, and there were no chylomicrons present. The patient was diagnosed with xanthomas, poorly controlled diabetes mellitus, and hyperlipidemia, and was started on metformin, gemfibrozil, and a β-hydroxy-β-methylglutaryl-coenzyme A (HMG-CoA)-reductase inhibitor.

FIGURE 223-1 Close-up of eruptive xanthomas on the arm of a 27-year-old man with untreated hyperlipidemia and diabetes.[1] (*Courtesy of Richard P. Usatine, MD.*)

INTRODUCTION

Hyperlipidemia refers to an elevated concentration of one or more of the measured serum lipid components (total cholesterol [TC], low-density lipid [LDL], high-density lipoprotein [HDL], and triglycerides [TGs]). Xanthomas are a skin manifestation of familial or severe secondary hyperlipidemia, although they can occur in patients with normal lipid levels. Hyperlipidemia is a major modifiable risk factor for cardiovascular disease.

EPIDEMIOLOGY

- During 2005 to 2006, 15.7% of adults in the United States had a high serum TC level.[1] The average cholesterol level of adults ages 20 to 74 years decreased from 222 mg/dL in 1959 to 1962 to 197 mg/dL in 2007 to 2008, reaching the *Healthy People 2010* goal.[2]
- An estimated 34% of the adult population had high LDL-C during 2005 to 2008 (LDL-C levels above the recommended goal levels or reported current use of cholesterol-lowering medication).[3]
- Among young adults (ages 12 to 19 years), 20.3% had abnormal lipids; boys are more likely than girls to have at least 1 lipid abnormality (24.3% vs. 15.9%, respectively).[4]
- Patients with homozygous familial hypercholesterolemia (FH) (1 in 1 million persons worldwide) present in childhood with cutaneous xanthomas on the hands, wrists, elbows, knees, heels, or buttocks.[5]

FIGURE 223-2 Eruptive xanthomas on the arm and trunk of the man in **Figure 223-1**. (*Courtesy of Richard P. Usatine, MD.*)

- Patients with heterozygous FH (1 in 500 persons worldwide) can present as adults with tendon xanthomas.

ETIOLOGY AND PATHOPHYSIOLOGY

- Lipoproteins are complexes of lipids and proteins essential for transporting cholesterol, TGs, and fat-soluble vitamins.
- Elevated levels can result from genetically based derangement of lipid metabolism and/or transport or from secondary causes such as diet, medical disorders (e.g., type 2 diabetes mellitus [DM], hypothyroidism, chronic kidney disease, cholestatic liver disease), cigarette smoking, obesity, or drugs (e.g., corticosteroids, estrogens, retinoids, high-dose β-blockers).
- Increased circulating LDL becomes incorporation into atherosclerotic plaques. These plaques can grow to block blood supply and oxygen delivery resulting in ischemia to vital organs. In addition, if the plaque ruptures, it can precipitate a clot, causing for example myocardial infarction.
- Elevated TG is an independent risk factor for coronary heart disease (CHD) and increases the risk of hepatomegaly, splenomegaly, hepatic steatosis, and pancreatitis. Contributing factors include obesity, physical inactivity, cigarette smoking, excess alcohol intake, medical diseases (e.g., type 2 DM, chronic renal failure, nephrotic syndrome), drugs (as above), and genetic disorders (e.g., familial combined hyperlipidemia).[6]
- Xanthomas are deposits of lipid in the skin or subcutaneous tissue, usually occurring as a consequence of primary or secondary hyperlipidemia. Xanthomas can also be seen in association with monoclonal gammopathy.[7] There are five basic types of xanthomas:
  - Eruptive xanthomas (also called tuberoeruptive) are the most common form. These appear as crops of yellow or hyperpigmented papules with erythematous halos in white persons (**Figures 223-1** to **223-3**), appearing hyperpigmented in black persons (**Figures 223-4** and **223-5**).
  - Tendon xanthomas are frequently seen on the Achilles and extensor finger tendons.
  - Plane xanthomas are flat and commonly seen on the palmar creases, face, upper trunk, and on scars.
  - Tuberous xanthomas are found most frequently on the hand or over large joints.
  - Xanthelasma are yellow papules found on the eyelids (**Figure 223-6**). Fifty percent of individuals with xanthelasmas have normal lipid profiles.

RISK FACTORS

Risk factors to consider for treatment decisions for patients with hyperlipidemia include:

- Type 2 DM.
- Family history of early CHD or familial hyperlipidemia.
- Cardiac risk factors (cigarette smoking, obesity, hypertension, or sedentary lifestyle).

FIGURE 223-3 Eruptive xanthomas covering most of the body of the man in **Figure 223-1**. (*Courtesy of Richard P. Usatine, MD.*)

FIGURE 223-4 Eruptive xanthomas on the elbows of a hyperlipidemic black man with type 2 diabetes. His triglycerides and total cholesterol levels were high.[1] (*Courtesy of Richard P. Usatine, MD. Previously published in the Western Journal of Medicine.*)

DIAGNOSIS

CLINICAL FEATURES

- Most patients with hyperlipidemia are asymptomatic.
- A very high TC level (>2000 mg/dL) may result in eruptive xanthomas or lipemia retinalis (white appearance of the retina; also seen with isolated high TG). Very high LDL may lead to the formation of tendinous xanthomas.
- Xanthomas manifest clinically as yellowish papules, nodules, or tumors (**Figure 223-1**).
- Eruptive xanthomas (**Figures 223-2** to **223-5**) begin as clusters of small papules on the elbows, knees, and buttocks that can grow to the size of grapes.
- There is a case report of a patient with normolipidemic xanthomatosis with lesions involving the bones and mucous membranes in addition to skin.[8]

TYPICAL DISTRIBUTION

Xanthomas are most commonly found in superficial soft tissues, such as skin and subcutis, or on tendon sheaths.

LABORATORY TESTING

- The National Cholesterol Education Program (NCEP) III recommends a fasting lipid profile (FLP) as the initial test[6]; alternatively patients may be tested initially with a random TC and HDL.
- If the TC is greater than 200 mg/dL or the HDL less than 40 mg/dL for men or less than 50 mg/dL for women, an FLP is obtained for LDL determination.[6] LDL cannot be determined if TG are greater than 400 mg/dL.
- If thyroid dysfunction is suspected, obtain a thyroid-stimulating hormone level to determine whether thyroid dysfunction is contributing to the lipid abnormalities.
- Other secondary causes to consider include anorexia nervosa, Cushing syndrome, hepatitis, nephrotic syndrome, renal failure, and systemic lupus erythematosus.
- If a statin is under consideration, a baseline creatine phosphokinase (CPK) is recommended before starting statin therapy.

BIOPSY

Biopsy is rarely needed and shows collections of lipid-filled macrophages.

DIFFERENTIAL DIAGNOSIS

Other skin papules that can be mistaken for xanthomas include the following:

- Gouty tophi—Deposits of monosodium urate that are usually firm and occasionally discharge a chalky material (**Figure 223-7**, see Chapter 100, Gout).
- Pseudoxanthoma elasticum—A disorder caused by abnormal deposits of calcium on the elastic fibers of the skin and eye.

FIGURE 223-5 Eruptive xanthomas on the knees in the patient in Figure 223-4. (*Courtesy of Richard P. Usatine, MD. Previously published in the Western Journal of Medicine.*)

FIGURE 223-6 Xanthelasma around the eyes (xanthoma palpebrarum); most often seen on the medial aspect of the eyelids, with upper lids being more commonly involved than lower lids. (*Courtesy of Richard P. Usatine, MD.*)

FIGURE 223-7 Ear gouty tophus in a young man with gout. (*Courtesy of Richard P. Usatine, MD.*)

- Molluscum contagiosum—Caused by a virus; lesions can be papular and widespread but generally have a central depression (see Chapter 130, Molluscum Contagiosum). The patient in **Figures 223-1** to **223-3** was originally misdiagnosed with molluscum.

MANAGEMENT

Management of patients with hyperlipidemia emphasizes reduction of cardiovascular risk factors (as noted above) and targets elevated LDL cholesterol for the goal of cholesterol-lowering therapy.[6] Optimal LDL is considered to be less than 100 mg/dL, near optimal LDL is 100 to 129 mg/dL, and high LDL is equal to or greater than 160 mg/dL. The Institute for Clinical Systems Improvement (ICSI) suggests consideration of a goal of less than 70 mg/dL for patients with established CHD, noncardiac atherosclerosis, or CHD equivalent.[9]

- The intensity of therapy should be based on the patient's risk status.[6] The recommended LDL goal is less than 160 for individuals with zero to 1 risk factor (or 10-year CHD risk of <10%), less than 130 mg/dL for 2 or more risk factors, and less than 100 mg/dL for those with CHD or CHD equivalents (e.g., DM or 10-year CHD risk of >20%).
- For those with 2 or more risk factors, a 10-year risk assessment is conducted using the Framingham scoring system (http://hp2010.nhlbihin.net/atpiii/calculator.asp) to help identify which individuals would benefit most from intensive treatment.
- For children with elevated lipids, diet is recommended as first-line treatment to achieve a TC of less than 215 mg/dL or an LDL of less than 155 mg/dL.[10] Referral to a pediatric endocrinologist or dietician may be beneficial.

NONPHARMACOLOGIC

- Smoking cessation should be encouraged and attempts actively supported; cessation lowers both cardiovascular risk and lipid levels. SOR A
- Patients should be encouraged to modify their risk factors through exercise and dietary changes. High cholesterol can be lowered through dietary changes. SOR A
- Patients who are overweight should be encouraged to reduce calories to achieve weight loss. SOR C
- Features of a lipid-lowering diet include reducing intake of total fats to 25% to 35% of total calories (provided trans fatty acids and saturated fats are kept low [<7% of total calories for saturated fats]), reducing cholesterol intake to less than 200 mg/day, and increasing fiber intake to 20 to 30 g/day (5 to 10 g/day of soluble fiber).[6] SOR C Authors of a Cochrane review, however, found no trials on long-term (>6 months) effects of a low-fat diet in patients with hyperlipidemia.[11]
- Similarly, of 11 small trials of dietary intervention identified by authors of a Cochrane review, only short-term outcomes were reported.[12] There were no differences between low-cholesterol diets and other dietary interventions (e.g., omega-3 fatty acids, soya proteins, plant sterols or plant stanols), with the exception of plant sterols lowering TC significantly more than a cholesterol-lowering diet.[12]

- Reducing saturated fat through fat modification diets reduces the risk of cardiovascular events by 14% (relative risk [RR] 0.86, 95% confidence interval [CI] 0.77 to 0.96).[13] SOR A This reduction in cardiovascular events was directly related to the degree of effect on serum total and LDL cholesterol and TGs. The strongest evidence was for trials of at least 2 years, duration and in studies of men (not of women). However, there were no clear effects of dietary fat changes on total mortality (RR 0.98, 95% CI 0.93 to 1.04) or cardiovascular mortality (RR 0.94, 95% CI 0.85 to 1.04).
- NCEP recommends beginning with lifestyle therapies and reassessing LDL after 6 weeks. If the LDL goal is not met, reinforce lifestyle change along with adding plant sterols and fiber; also consider dietician referral. If the LDL goal is not met at the next 6-week visit, consider medications.[6] Patients hospitalized for a coronary event or procedure should be discharged on drug therapy if their LDL is equal to or greater than 130 mg/dL.[6]
- Addition of plant sterols/stanols up to 2 g/day should be considered, particularly if the initial LDL goal is not met with diet modification and exercise. SOR B
- Treatment should also be initiated for patients with high TG (>200 to 499 mg/dL) or very high TG (≥500 mg/dL) beginning with weight reduction and exercise; for those with very high TGs, a very-low-fat diet is used (≤15% of calorie intake).
- Initial treatment of xanthomas should target the underlying hyperlipidemia (when present).

MEDICATIONS

In addition to primary interventions noted above, secondary therapy includes statins, niacin, fibric acids, ezetimibe, and a bile acid sequestrant.[6,9] The use of combination therapy has not been supported by outcome-based studies.

- Statins (HMG-CoA reductase inhibitors; lovastatin [20 to 80 mg], pravastatin [20 to 40 mg], simvastatin [20 to 80 mg], fluvastatin [20 to 80 mg], atorvastatin [10 to 80 mg], cerivastatin [0.4 to 0.8 mg]) are considered first-line for most patients. Evidence supports use of statins in patients with risk factors for CHD (lowers all-cause mortality [odds ratio (OR) 0.88, 95% CI 0.81 to 0.96], major coronary events [OR 0.70, 95% CI 0.61 to 0.81], and major cerebrovascular events [OR 0.81, 95% CI 0.71 to 0.93])[14] and in patients with CHD or CHD equivalent (reduces mortality risk from CHD and possibly overall mortality).[15] SOR A Number needed to treat (NNT) to prevent one additional death in patients with CHD is approximately 30 to 50. There do not appear to be important differences by type of statin.[16]
- Statin side effects include myopathy and increased liver enzymes; statins are associated with a small increase in the risk of developing DM (number needed to harm = 255).[17] The major contraindication is liver disease.
- Niacin (immediate release [crystalline] nicotinic acid [1.5 to 3 g], extended-release nicotinic acid [Niaspan] [1-2 g], sustained release) is considered a second-line agent to be used in combination with a statin if the LDL goal is not achieved with intensifying monotherapy or as first-line agent for patients with very high TG. Evidence supports reduction in major CHD events with niacin. SOR A Niacin is nonprescription.
- Niacin side effects include GI distress, flushing, hyperuricemia, hyperglycemia in patients with DM, and hepatotoxicity. Contraindications are chronic liver disease and severe gout; use with caution in patients with DM, hyperuricemia, peptic ulcer disease.
- Fibrates (gemfibrozil [600 mg bid], fenofibrate [200 mg], clofibrate [1000 mg bid]) is a second-line agent shown to reduce major CHD events but not overall mortality.[18] SOR A Fibrates can be used as primary therapy for very high TG. Side effects include dyspepsia, gallstones, myopathy, and unexplained non-CHD deaths. Contraindications are severe renal or hepatic disease.
- Bile acid sequestrants (cholestyramine [4 to 16 g], colestipol [5 to 20 g], colesevelam [2.6 to 3.8 g]) are second-line agents shown to reduce CHD mortality.[13] SOR A These drugs are considered first-line agents for children.[10] Side effects include GI distress, constipation, and decreased absorption of other drugs. Contraindications are dysbetalipoproteinemia or TG greater than 400 mg/dL.

Hypolipidemic drug treatment often results in regression of xanthomas. SOR C In patients with xanthomas associated with monoclonal gammopathy, hematologic remission following chemotherapy was associated with improvement in the xanthomas in several patients.[7]

COMPLEMENTARY AND ALTERNATIVE THERAPY

- Artichoke leaf extract, red yeast rice, and several Chinese herbal medicines (in particular Xuezhikang) lower cholesterol compared with placebo; data on patient-oriented outcomes are lacking.[19–21]
- It is not clear whether supplementing with omega-3 fatty acids reduces mortality when combined primary and secondary prevention data are analyzed. A 2006 metaanalysis failed to find a reduction in overall mortality or cardiovascular events.[22]
- Benefit is suggested for whole flaxseed and lignan, especially for women, but not for flaxseed oil.[23]
- In a randomized crossover trial, consuming walnuts (42.5 g walnuts/10.1 mJ) and fatty fish (113 g salmon, twice a week) in a healthy diet significantly lowered serum cholesterol and triglyceride concentrations, respectively.[24] In a metaanalysis, nut consumption (67 g) reduced lipid levels.[25]

SURGICAL PROCEDURES

- Between 1975 and 1983, a randomized controlled trial was conducted of primarily male patients following a first myocardial infarction (MI) (N = 838) of partial ileal bypass surgery or no surgery. The initial report found improved lipid patterns in patients in the intervention arm,[26] and a 25-year follow-up study found improved survival and cardiovascular disease-free survival in the surgery arm.[27]
- Xanthelasma lesions may be treated for cosmetic purposes. Methods of treatment include surgery, electrosurgery, cryotherapy, and laser therapy. In a case report of 24 patients, argon laser coagulation was well-tolerated and the cosmetic outcome was considered to be good in 85% of patients.[28] SOR C

When standard therapy fails, LDL apheresis has lowered lipid levels with subsequent regression of tendon xanthomas.[29] SOR C

REFERRAL

- Referral for nutritional counseling should be considered, especially if initial attempts at dietary control fail. Dietary advice has been shown to result in modest improvements in cardiovascular risk factors, such as blood pressure and total and LDL-cholesterol levels.[30] SOR A

PREVENTION AND SCREENING

- The United States Preventive Services Task Force (USPSTF) strongly recommends screening men age 35 years and older for lipid disorders.[31] SOR A There is strong evidence that drug therapy reduces CHD events and mortality in middle-aged men (ages 35 to 70 years) with abnormal lipids and a potential risk of CHD events greater than 1% per year. A Cochrane review confirmed reductions in all-cause mortality, major vascular events, and revascularizations with no cancer excess in 14 trials, 11 recruiting patients with risk factors.[32] In one metaanalysis, NNT for primary prevention in patients (primarily men) with risk factors was 173 to prevent 1 premature death, 81 to prevent 1 CHD event, and 245 to prevent 1 stroke.[14]
- The USPSTF strongly recommends screening women age 45 years and older if they are at increased risk for CHD.[31] SOR A The USPSTF also recommends screening men ages 20 to 35 years and women ages 20 to 45 years if they are at increased risk for CHD.[31] SOR B There is less direct evidence suggesting effectiveness of drug therapy in other adults, including men older than age 70 years and middle-aged and older women (age 45 years and older) with similar levels of risk.[33] In fact, in a metaanalysis of primary prevention trials including women, there was insufficient evidence of reduced risk of any clinical outcome in women.[34]
- Secondary prevention trials do show reductions in CHD mortality, CHD events, nonfatal MI, and revascularization for women that is similar to reductions seen for men and demonstrate decreased mortality for older men.[35]
- Retesting every 1 to 5 years is recommended by the USPSTF based on CHD risk.[31]
- Studies are not available to assess the efficacy of screening children and adolescents for dyslipidemia for delaying the onset and reducing the incidence of CHD-related events.

PROGNOSIS

- Based on observational data, each 30-mg/dL increase in LDL increases the relative risk of CHD by 30%.
- Use of strategies to lower elevated lipid levels will likely reduce CHD events and possibly overall mortality.
- With medical (diet or drugs) treatment of hyperlipidemia, many xanthomas and about half of xanthelasma resolve or improve. with surgical treatment, recurrence is uncommon.[36]

FOLLOW-UP

- NCEP recommends reassessing LDL approximately every 6 weeks until the LDL goal is met, then every 6 to 12 months.[6]
- It is not clear if monitoring liver enzymes in patients on statins is necessary.[37] Repeat a CPK if a patient experiences symptoms of myopathy. Statin therapy should be discontinued if the CPK is more than 10 times normal. For patients with myopathy and moderate or no CPK elevation, conduct weekly monitoring until symptoms improve or discontinue statins if there is worsening or failure to resolve.[38]

PATIENT EDUCATION

- Patients should be counseled about benefits and risks of screening.
- Lifestyle changes should be stressed as primary prevention for patients with hyperlipidemia.
- If persistent elevations in lipids continue despite lifestyle change, those with high risk or CHD should consider medications.
- Patients with hyperlipidemia and/or DM should be encouraged to establish and maintain good control of these diseases, as this often results in regression of xanthomas.

REFERENCES

1. Centers for Disease Control and Prevention. Schober SE, Carroll MD, Lacher DA, Hirsch R. High serum total cholesterol—an indicator for monitoring cholesterol lowering efforts: U.S. adults, 2005-2006. NCHS Data Brief. http://www.cdc.gov/nchs/data/databriefs/db02.pdf, accessed January 2012.
2. QuickStats: Average total cholesterol level among men and women aged 20-74 years—National Health and Nutrition Examination Survey, United States, 1959-1962 to 2007-2008. *MMWR* weekly. September 25, 2009;58(37):1045. http://www.cdc.gov/mmwr/preview/mmwrhtml/mm5837a9.htm, accessed September, 2012.
3. Vital signs: prevalence, treatment, and control of high levels of low-density lipoprotein cholesterol—United States, 1999-2002 and 2005-2008. *MMWR Morb Mortal Wkly Rep*. 2011;60(04):109-114, http://www.cdc.gov/mmwr/preview/mmwrhtml/mm6004a5.htm?s_cid=mm6004a5_w, accessed January 2012.
4. Prevalence of abnormal lipid levels among youths—United States, 1999-2006. *MMWR Morb Mortal Wkly Rep*. 2010;59(02):29-33, http://www.cdc.gov/mmwr/preview/mmwrhtml/mm5902a1.htm, accessed January 2012.
5. Rader DJ, Hobbs HH. Disorders of lipoprotein metabolism. In: Kasper DL, Braunwald E, Fauci AS, Hauser SL, Longo DL, Jameson JL, eds. *Harrison's Principles of Internal Medicine*. New York, NY: McGraw-Hill; 2005:2286-2298.
6. Third report of the National Cholesterol Education Program (NCEP) Expert Panel on Detection, Evaluation, and Treatment of High Blood Cholesterol in Adults. (Adult Treatment Panel III), Executive Summary. (NCEP/NHLBI., 2004-07-13). http://www.nhlbi.nih.gov/guidelines/cholesterol/index.htm, accessed January 2012.
7. Szalat R, Arnulf B, Karlin L, et al. Pathogenesis and treatment of xanthomatosis associated with monoclonal gammopathy. *Blood*. 2011;118(14):3777-3784.

8. Akasaka E, Matsuzaki Y, Kimura K, et al. Normolipidaemic xanthomatosis with systemic involvement of the skin, bone and pharynx. *Clin Exp Dermatol.* 2012;37(3):305-307.
9. Institute for Clinical Systems Improvement (ICSI). *Lipid Management in Adults*. Bloomington, MN: Institute for Clinical Systems Improvement (ICSI); 2009, http://www.guideline.gov/content.aspx?id=15530&search=hypercholesterolaemia, accessed January 2012.
10. Finnish Medical Society Duodecim. Diagnosis and treatment of childhood hypercholesterolaemia. In: *EBM Guidelines. Evidence-Based Medicine [Internet]*. Helsinki, Finland: Wiley Interscience; 2007, http://www.guideline.gov/content.aspx?id= 11034&searc= childhood+hypercholesterolaemia, accessed January 2011.
11. Smart NA, Marshall BJ, Daley M, et al. Low-fat diets for acquired hypercholesterolaemia. *Cochrane Database Syst Rev.* 2011;(2):CD007957.
12. Shafiq N, Singh M, Kaur S, Khosla P, Malhotra S. Dietary treatment for familial hypercholesterolaemia. *Cochrane Database Syst Rev.* 2010;(1):CD001918.
13. Hooper L, Summerbell CD, Thompson R, et al. Reduced or modified dietary fat for preventing cardiovascular disease. *Cochrane Database Syst Rev.* 2011;(7):CD002137.
14. Brugts JJ, Yetgin T, Hoeks SE, et al. The benefits of statins in people without established cardiovascular disease but with cardiovascular risk factors: meta-analysis of randomised controlled trials. *BMJ.* 2009;338:b2376.
15. Studer M, Briel M, Leimenstoll B, Glass TR, Bucher HC. Effect of different antilipidemic agents and diets on mortality: a systematic review. *Arch Intern Med.* 2005;165:725-730.
16. Zhou Z, Rahme E, Pilote L. Are statins created equal? Evidence from randomized trials of pravastatin, simvastatin, and atorvastatin for cardiovascular disease prevention. *Am Heart J.* 2006;151:273-281.
17. Sattar N, Preiss D, Murray HM, et al. Statins and risk of incident diabetes: a collaborative meta-analysis of randomised statin trials. *Lancet.* 2010;375:735-742.
18. Abourbih S, Filion KB, Joseph L, et al. Effect of fibrates on lipid profiles and cardiovascular outcomes: a systematic review. *Am J Med.* 2009;122:962.e1-8.
19. Wider B, Pittler MH, Thompson-Coon J, Ernst E. Artichoke leaf extract for treating hypercholesterolaemia. *Cochrane Database Syst Rev.* 2009;(4):CD003335.
20. Becker DJ, Gordon RY, Halbert SC, et al. Red yeast rice for dyslipidemia in statin-intolerant patients: a randomized trial. *Ann Intern Med.* 2009;150(12):830-839.
21. Liu ZL, Liu JP, Zhang AL, et al. Chinese herbal medicines for hypercholesterolemia. *Cochrane Database Syst Rev.* 2011;(7):CD008305.
22. Hooper L, Thompson RL, Harrison RA, et al. Risks and benefits of omega 3 fats for mortality, cardiovascular disease, and cancer: systematic review. *BMJ.* 2006;332:752-760.
23. Pan A, Yu D, Demark-Wahnefried W, et al. Meta-analysis of the effects of flaxseed interventions on blood lipids. *Am J Clin Nutr.* 2009;90(2):288-297.
24. Rajaram S, Haddad EH, Mejia A, Sabaté J. Walnuts and fatty fish influence different serum lipid fractions in normal to mildly hyperlipidemic individuals: a randomized controlled study. *Am J Clin Nutr.* 2009;89(5):1657S-1663S.
25. Sabaté J, Oda K, Ros E. Nut consumption and blood lipid levels: a pooled analysis of 25 intervention trials. *Arch Intern Med.* 2010;170(9):821-827.
26. Buchwald H, Varco RL, Matts JP, et al. Effect of partial ileal bypass surgery on mortality and morbidity from coronary heart disease in patients with hypercholesterolemia. Report of the Program on the Surgical Control of the Hyperlipidemias (POSCH). *N Engl J Med.* 1990;323(14):946-955.
27. Buchwald H, Rudser KD, Williams SE, et al. Overall mortality, incremental life expectancy, and cause of death at 25 years in the program on the surgical control of the hyperlipidemias. *Ann Surg.* 2010;251(6):1034-1040.
28. Basar E, Oguz H, Ozdemir H, et al. Treatment of xanthelasma palpebrarum with argon laser photocoagulation. Argon laser and xanthelasma palpebrarum. *Int Ophthalmol.* 2004;25(1):9-11.
29. Scheel AK, Schettler V, Koziolek M, et al. Impact of chronic LDL apheresis treatment on Achilles tendon affection in patients with severe familial hypercholesterolemia: a clinical and ultrasonographic 3-year follow-up study. *Atherosclerosis.* 2004;174(1):133-139.
30. Brunner E, Rees K, Ward K, Burke M, Thorogood M. Dietary advice for reducing cardiovascular risk. *Cochrane Database Syst Rev.* 2007;(4):CD002128.
31. United States Preventive Services Task Force. *Screening for Lipid Disorders in Adults. 2008*, http://www.uspreventiveservicestaskforce.org/uspstf/uspschol.htm, accessed January 2012.
32. Taylor F, Ward K, Moore THM, et al. Statins for the primary prevention of cardiovascular disease. *Cochrane Database Syst Rev.* 2011;(1):CD004816.
33. Pignone MP, Phillips CJ, Lannon CM, et al. *Screening for Lipid Disorders. April 2001*, http://www.uspreventiveservicestaskforce.org/uspstf08/lipid/lipides.pdf, accessed January 2012.
34. Grady D, Chaput L, Kristof M. *Systematic Review of Lipid Lowering Treatment to Reduce Risk of Coronary Heart Disease in Women*. Rockville, MD: Agency for Healthcare Research and Quality; 2003.
35. Helfand M, Carson S. *Screening for Lipid Disorders in Adults: Selective Update of 2001 US Preventive Services Task Force Review. June 2008*, http://www.ncbi.nlm.nih.gov/books/NBK33494/, accessed January 2011.
36. Fair KP. Xanthoma treatment and management. In: emedicine. Medscape. http://emedicine.medscape.com/article/1103971-treatment#a1128, accessed September 2012.
37. Cohen DE, Anania FA, Chalasani N; National Lipid Association Statin Safety Task Force Liver Expert Panel. An assessment of statin safety by hepatologists. *Am J Cardiol.* 2006;97:77C-81C.
38. Pasternak RC, Smith SC Jr, Bairey-Merz CN, et al; American College of Cardiology American Heart Association National Heart, Lung and Blood Institute. ACC/AHA/NHLBI clinical advisory on the use and safety of statins. *J Am Coll Cardiol.* 2002;40:567-572.

224 OBESITY

Mindy A. Smith, MD, MS

PATIENT STORY

Diane is a 35-year-old woman who has struggled with obesity for most of her life. Her current body mass index (BMI) is 36. She has tried "every kind of diet you can imagine" but has always gotten stuck after losing the first 10 pounds and gets discouraged. She is not currently exercising regularly. She is concerned about all the skin tags on her neck and wants them removed if possible. She and her husband are talking about having another baby and she would like to be in better shape before she attempts pregnancy. She wants to discuss risks of pregnancy considering her weight and asks for any advice that you can give her on how to successfully lose weight. You obtain a random blood sugar because of the acanthosis and obesity (**Figure 224-1**). The result is 150 mg/dL and you order a fasting blood sugar (FBS) before her next visit, at which time you will remove her skin tags. After discussing diet and exercise, you encourage her to pursue Weight Watchers or a similar program.

FIGURE 224-1 Neck circumference enlargement with acanthosis nigricans and many skin tags in a woman with obesity and impaired glucose tolerance. (*Courtesy of Richard P. Usatine, MD.*)

INTRODUCTION

Obesity is defined as a BMI greater than or equal to 30. BMI is calculated as weight in kilograms divided by height in meters squared, rounded to 1 decimal place.[1] Obesity in children is defined as a BMI greater than or equal to the age- and sex-specific 95th percentiles of the 2000 Centers for Disease Control and Prevention (CDC) growth charts. Adults with a BMI greater than 40 have substantially more serious health consequences, including heart disease and diabetes, and a reduced life expectancy.

EPIDEMIOLOGY

- Based on the National Health and Nutrition Examination Surveys, more than one-third of U.S. adults (35.7%) and 16.9% of children and adolescents are obese (2010).[1] Slightly more women than men are obese (35.8% vs. 35.5%), although obesity is more prevalent in boys than girls at ages 2 to 19 years (18.6% vs. 15%). The prevalence of obesity has dramatically increased over the past 20 years.
- At the 6-year follow-up of the Nurses' Health Study (NHS; a prospective cohort study of 50,277 women), 3757 (7.5%) women who had a BMI of less than 30 in 1992 became obese (BMI ≥30).[2]
- The medical care costs of obesity in the United States (2008 dollars) are approximately $147 billion.[3]

ETIOLOGY AND PATHOPHYSIOLOGY

Obesity is a complex problem involving genetics, health behaviors, environment, and sometimes medical diseases (see "Differential Diagnosis" below) or drugs (e.g., steroids, antidepressants). The

simplest explanation of obesity is an imbalance between intake (calories eaten) and output (physical activity).

GENETICS

The genetic contribution to interindividual variation in common obesity has been estimated at 40% to 70%.[4] Despite this relatively high heritability, the search for obesity susceptibility genes has been difficult. At least five variants in four candidate genes are associated with obesity-related traits. Although genome-wide linkage studies have been unable to pinpoint genetic loci for common obesity, high-density genome-wide association studies have discovered at least 15 previously unanticipated genetic loci associated with BMI and extreme obesity risk.[4] Genetic influences, however, cannot explain the recent increased prevalence in the rate of weight gain by age; rather significant changes in lifestyle factors are likely responsible.[5]

- Two GI "hormones" that appear to integrate into the brain may regulate appetite; these hormones—ghrelin (increases appetite) and obestatin (slows gastric emptying, blocking ghrelin action)—may also play a role in obesity. A metaanalysis concluded that obestatin and total and active ghrelin were significantly higher in normal weight subjects than those of obese groups.[6] It is not clear why this occurs but lower levels of ghrelin in obese subjects may be a response to hyperinsulinemia.

HEALTH BEHAVIORS

Lifestyle factors associated with obesity include physical activity level (low levels and associated behaviors such as television viewing), diet, and sleep.

- In the NHS, each 2-hour per day increment in TV watching was associated with a 23% (95% confidence interval [CI], 17% to 30%) and each 2-hour per day increment in sitting at work was associated with a 5% (95% CI, 0% to 10%) increase in obesity.[2]
- Based on second-wave interview data from the National Longitudinal Study of Adolescent Health (N = more than 14,000 adolescents), increasing levels of vigorous physical activities lowered the risk for obesity among all adolescents, while eating sufficient fruits and vegetables was inversely associated with adolescents' obesity.[5] As in the above study, sedentary lifestyle was associated with adolescents' obesity. However, in models based on race, low family socioeconomic status, and being sedentary were associated with overweight and obesity among whites and increased nighttime sleep hours was associated with obesity among African Americans.
- In one study, belief that obesity was inherited was associated with lower reported levels of physical activity and fruit and vegetable consumption while the belief that obesity was caused by lifestyle behaviors was associated with greater reported physical activity but not diet.[7]
- In a study of Latino men and women, men who did not exercise, rarely trimmed fat from meat, and ate fried foods the previous day were 16 pounds heavier than men with healthier habits.[8] Women who had limited exercise (<2.5 hours per week), watched television regularly, ate chips and snacks, and ate no fruit the previous day were 45 pounds heavier than women with healthier habits.

ENVIRONMENT

Factors that have been discussed include location of grocery stores versus fast-food restaurants and safe places to exercise in relation to home proximity. Research studies suggest that neighborhood residents who have better access to supermarkets and limited access to convenience stores tend to have healthier diets and lower levels of obesity.[9] Poor neighborhoods are often characterized by just the opposite. In fact, in one study, having the opportunity to move from a poor neighborhood to one with a lower level of poverty through housing vouchers was associated with modest reductions (4.6%) in the prevalence of extreme obesity and diabetes.[10]

RISK FACTORS

- Family history of obesity.
- Diet—High calorie, low fruits and vegetables,[11] snack foods, and fast-food consumption (obesity prevalence 24% of those going to fast-food restaurants less than once a week to 33% of those going 3 or more times per week).[12]
- Low levels of physical activity.

DIAGNOSIS

The diagnosis of obesity is based on a BMI greater than 30.

CLINICAL FEATURES

- Although elevated weight alone is a risk factor for the development of hypertension, diabetes mellitus (DM), and heart disease, increased waist circumference confers additional morbidity risk (**Figure 224-2**).[13]
- Neck circumference enlargement (**Figure 224-1**) along with increased BMI and waist circumference are significant risk factors for obstructive sleep apnea and metabolic syndrome.[14,15]
- There is a strong direct correlation between epicardial fat and abdominal visceral adiposity with evidence supporting a role for epicardial fat in the pathogenesis of coronary artery disease.[16]
- Nonalcoholic fatty liver disease (NAFLD) is present in 57% of overweight individuals attending outpatient clinics compared to 98% of nondiabetic obese patients and in contrast to 10% to 30% of adults in the general population (see Chapter 61, Liver Disorders).[17]
- Obesity is also associated with an increased risk of varicose veins (odds ratio [OR] 3.28; 95% CI 1.25 to 8.63) (see Chapter 52, Venous Stasis) (**Figure 224-3**).
- Skin conditions associated with obesity include acanthosis nigricans (**Figures 224-1** and **224-4**), eruptive xanthomas (**Figure 224-5**), hidradenitis suppurativa (**Figure 224-6**), and psoriasis (**Figure 224-2**). (see Chapters 115, Hidradenitis Suppurativa, 152, Psoriasis, 220, Acanthosis Nigricans, and 223, Hyperlipidemia).

LABORATORY TESTING

Although no specific tests are suggested for patients with obesity, assessing a patient's cardiovascular risk status in addition to BMI, waist circumference, and a patient's motivation to lose weight may

FIGURE 224-2 Central obesity in a man with extensive plaque psoriasis. (*Courtesy of Richard P. Usatine, MD.*)

FIGURE 224-3 Serpiginous varicose veins in a woman with obesity. (*Courtesy of Richard P. Usatine, MD.*)

be helpful in planning treatment.[13] Consider screening for DM and NAFLD.

DIFFERENTIAL DIAGNOSIS

The differential diagnosis of a patient with obesity includes the following medical conditions:

- Cushing syndrome—Caused by prolonged exposure to endogenous or exogenous glucocorticoids; in addition to truncal obesity, clinical features include moon facies, supraclavicular fat pads, buffalo hump, purple striae, proximal muscle weakness, and hirsutism. Diagnosis is confirmed with inappropriately high serum or urine cortisol levels.
- Polycystic ovary syndrome—Criteria include two of three of oligo-ovulation or anovulation, hyperandrogenism, and polycystic ovaries.
- Obesity is also a finding in many single-gene disorders such as Prader-Willi syndrome (abnormality of proximal arm of chromosome 15 with associated characteristics of obesity, hypotonia, mental retardation, short stature, hypogonadotropic hypogonadism, strabismus, and small hands and feet) and Bardet-Biedl syndrome (associated with truncal obesity, childhood-onset visual loss preceded by night blindness, and polydactyly).

FIGURE 224-4 Acanthosis nigricans in a 14-year-old Hispanic girl with obesity, insulin resistance, and a strong family history of type 2 diabetes. (*Courtesy of Richard P. Usatine, MD.*)

MANAGEMENT

The initial weight loss goal is to reduce body weight by approximately 10% from baseline over approximately 6 months.[13] Additional weight loss can be attempted if this goal is achieved.

NONPHARMACOLOGIC

- Dietary changes may be useful. In a metaanalysis of long-term weight loss strategies in adults, however, dietary/lifestyle therapy provides less than 5 kg weight loss after 2 to 4 years.[18] SOR A Commercial weight management services appear to be more effective and cheaper than primary care-based services led by specially trained staff (range: 4.4 kg [Weight Watchers] to 1.4 kg [general practice]).[19] SOR A
- Exercise should be encouraged and can result in small weight losses and improvement in cardiovascular risk factors; greater intensity exercise results in additional small weight loss (weighted mean difference [WMD] approximately −1.5 kg).[20,21] SOR A The addition of diet to exercise also increases weight loss (WMD −1 kg).
- Although data are limited, lifestyle interventions appear to reduce overweight in children.[22] SOR B
- Behavioral and cognitive-behavioral strategies are also effective (WMD −2.5 kg and −2.3 kg, respectively), but are most effective when used in combination with diet and exercise (WMD [added cognitive-behavioral strategies] −4.9 kg).[23] SOR A
- Behavioral strategies found to be effective include various forms of support, motivational interviewing, and reducing TV screen time.
- Both remote weight-loss support (study-specific website and e-mail) and in-person support during group and individual sessions

FIGURE 224-5 Eruptive xanthomas in a young man with untreated type 2 diabetes, hyperlipidemia and obesity. (*Courtesy of Richard P. Usatine, MD.*)

along with remote support resulted in greater sustained weight loss at 24 months than the control group (−4.6 kg, −5.1 kg, and −0.8 kg, respectively).[24]

- A program entitled "High Five for Kids," using motivational interviewing targeting television viewing, fast food, and sugar-sweetened beverage intake, was not effective in one randomized clinical trial (RCT) in reducing BMI at 1 year.[25]
- With respect to psychological interventions, of three interventions (usual care with quarterly primary care physician educational visits, brief lifestyle counseling, or enhanced brief lifestyle counseling including meal replacements) examined in adult patients with obesity, enhanced care was more effective than usual care for initial weight loss and sustained weight loss at 2 years (1.7 ± 0.7 and 4.6 ± 0.7 kg, respectively).[26] SOR B

MEDICATIONS

- In the 2005 systematic review by Douketis et al., pharmacologic therapy for obesity resulted in to 10-kg average weight loss after 1 to 2 years.[18] SOR A An older Cochrane review of orlistat, sibutramine, and rimonabant found more modest but significant weight reduction (2.9 to 4.7 kg); conclusions were limited by high attrition rates.[27]
- The National Heart, Lung, and Blood Institute (NHLBI) *Clinical Guideline* recommends consideration of drug therapy approved by the FDA for long-term use as an adjunct to diet and physical activity for patients with a BMI of 30 with no concomitant obesity-related risk factors or diseases, and for patients with a BMI of 27 with concomitant obesity-related risk factors or diseases. SOR B The American College of Physicians (ACP) guideline also recommends that pharmacologic therapy may be offered to patients with obesity who fail to achieve their weight loss goals through diet and exercise alone. However, they recommend a discussion of the drugs' side effects, the lack of long-term safety data, and the temporary nature of the weight loss achieved with medications before initiating therapy.[28]
- Medication options include sibutramine, orlistat, phentermine, diethylpropion, rimonabant, fluoxetine, bupropion, and phentermine/topiramate. Most weight loss occurs in the first 6 months of treatment.[29] Investigators conducting a phase III trial of phentermine/topiramate reported greater weight loss for two different strengths of the drug over placebo at 1 year (−8.1 kg [lower dose] and −10.2 kg [higher dose] and −1.4 kg [placebo]).[30]

COMPLEMENTARY AND ALTERNATIVE THERAPY

- A number of therapies have been proposed to assist in weight loss, including herbal and nonherbal food supplements, homeopathy, hypnotherapy, acupuncture, and acupressure.[31] Of these, only ephedra sinica and other ephedrine-containing dietary supplements had convincing evidence of small reductions in body weight over placebo.
- A systematic review of food supplements (e.g., guar gum, chromium, chitosan) for weight reduction by some of the same authors also failed to find evidence of a clinically relevant weight loss (WMDs in the range of no benefit to −1.7 kg) using these preparations.[32]

FIGURE 224-6 Hidradenitis suppurativa with significant scarring and sinus tract formation in an obese woman with a body mass index greater than 30. (*Courtesy of Richard P. Usatine, MD.*)

SURGERY

Surgical therapy provides approximately 25 to 75 kg of weight loss after 2 to 4 years.[18] According to the NHLBI guideline, weight loss surgery is an option for well-informed, carefully selected patients with clinically severe obesity (BMI 40 or 35 with comorbid conditions) when less-invasive methods of weight loss have failed and the patent is at high risk for obesity-associated morbidity or mortality.[13] SOR B The 2005 ACP guideline concurred and again added that a doctor–patient discussion of surgical options should include the long-term side effects (e.g., vitamin B_{12} deficiency, incisional hernia, possible need for reoperation, gastritis, gallbladder disease, and malabsorption).[28] In addition, they recommend that patients should be referred to high-volume centers with surgeons experienced in bariatric surgery.

Two types of surgical procedures (gastric banding and gastric bypass) are in current use; all induce substantial weight loss and serve to reduce weight-associated risk factors and comorbidities.

- In a Cochrane review, authors found that weight loss was greater from gastric bypass than vertical banded gastroplasty or adjustable gastric banding, but similar to isolated sleeve gastrectomy and banded gastric bypass.[33] Compared to other interventions available, surgery has produced the longest period of sustained weight loss.
- In a metaanalysis of 8 trials with more than 44,000 patients, the authors concluded that bariatric surgery (both gastric banding and gastric bypass) reduced long-term all-cause mortality (OR = 0.70; CI, 0.59 to 0.84), although the risk reduction was smaller in the larger studies; gastric bypass had a greater effect than banding on cardiovascular mortality.[34]
- In addition to reduced weight, a retrospective study of severely overweight patients with noninsulin-dependent diabetes who were referred for consideration of a gastric bypass procedure showed that patients undergoing the surgical procedure had a decrease in mortality rate for each year of follow-up compared to those who did not undergo the procedure because of personal preference or refusal of insurance payment.[35]
- Bariatric surgery was also found to be cost-effective compared to other treatments for obesity.[36] Authors identified several remaining questions to be answered, including the influence of surgery on quality of life, late complications leading to reoperation, duration of comorbidity remission, and resource use.
- Laparoscopic bariatric surgery may be safer than open surgery with respect to wound infection (relative risk [RR] 0.21; 95% CI, 0.07 to 0.65) and incisional hernia (RR 0.11; 95% CI, 0.03 to 0.35). Risks appear similar for reoperation, anastomotic leak, and all-cause mortality.[37]
- In one study, the rate of hospitalization in the year following gastric bypass surgery was more than double the rate in the preceding year (19.3% vs 7.9%). The most common reasons for admission prior to surgery were obesity-related problems (e.g., osteoarthritis, lower extremity cellulitis) and elective operation (e.g., hysterectomy). The most common reasons for admission after gastric bypass surgery were complications thought to be procedure related, such as ventral hernia repair and gastric revision.[38]
- In a study of 16,155 Medicare beneficiaries who underwent bariatric procedures (mean age: 47.7 years [standard deviation (SD): 11.3 years]; 75.8% women), the rates of 30-day, 90-day, and 1-year mortality were 2.0%, 2.8%, and 4.6%, respectively. After adjustment for sex and comorbidity index, the odds of death within 90 days were 5-fold greater for older Medicare beneficiaries (age 75 years or older; n = 136) than for those age 65 to 74 years (n = 1381; OR 5.0; 95% CI, 3.1 to 8.0). The odds of death at 90 days were 1.6 times higher (95% CI, 1.3 to 2.0) for patients of surgeons with less than the median surgical volume of bariatric procedures.[39]

REFERRAL

The Endocrine Society recommends that patients following bariatric surgery should receive care from a multidisciplinary team, including an experienced primary care physician, endocrinologist, or gastroenterologist. Primary providers should also consider enrolling patients postoperatively in a comprehensive program for nutrition and lifestyle management to prevent and detect nutritional deficiencies.[40]

PREVENTION AND SCREENING

- In one recent study, although a behavioral intervention (face-to-face visit; weekly mailed materials promoting appropriate weight gain, healthy eating, and exercise; individual weight gain graphs; and telephone-based feedback) was able to reduce the number of women with excessive weight gain in pregnancy by approximately 10%,[41] authors of a systematic review found insufficient quality data from four earlier trials to provide evidence-based recommendations.[42]
- A behavioral approach of lifestyle counseling from nurse practitioners was not effective compared with usual care in preventing weight gain in overweight or obese adults, although approximately 60% of patients in both groups achieved weight maintenance after 3 years.[43]
- Authors of a Cochrane review of 37 studies found strong evidence to support beneficial effects of child obesity prevention programs on BMI, particularly for programs targeting children age 6 to 12 years.[44] However, the overall effect was small (−0.15 kg/m^2 [95% CI, −0.21 to −0.09).
- The United States Preventive Services Task Force (USPSTF) recommends that clinicians screen children age 6 years and older for obesity and offer them or refer them to comprehensive, intensive behavioral interventions to promote improvement in weight status.[45] SOR B This recommendation is based in part on data showing that moderate- to high-intensity programs (>25 hours of contact with the child and/or the family over a 6-month period) improve weight status primarily in children with obesity.
- For adults, the USPSTF recommends that clinicians screen all adult patients for obesity and offer intensive counseling and behavioral interventions to promote sustained weight loss for obese adults.[46] SOR B Evidence, however, was insufficient to recommend for or against the use of moderate- or low-intensity counseling together with behavioral interventions to promote sustained weight loss in obese adults or use of counseling of any intensity and behavioral interventions to promote sustained weight loss in overweight adults.

PROGNOSIS

Obesity increases the risk in adults for the following:[13,47]

- Chronic health diseases such as coronary heart disease, type 2 DM, stroke, osteoarthritis, liver disease, and gallbladder disease.
- Cancers (i.e., endometrial, breast, colon, gallbladder).
- Cardiovascular risk factors such as hypertension and dyslipidemia.
- Sleep apnea and respiratory problems.
- Gynecologic problems (e.g., abnormal menses, infertility).

Overweight adolescents are also more susceptible than their leaner peers to hypertension, type 2 DM, dyslipidemia, lung problems (e.g., asthma, obstructive sleep apnea), orthopedic problems (e.g., genu varum, slipped capital femoral epiphysis), and nonalcoholic steatohepatitis.[48,49] Obese adolescents may also suffer from depression and low self-esteem.[49] In addition, more than half of obese adolescents remain overweight as young adults.[49]

Among pregnant women, obesity increases the risk for prenatal complications (gestational diabetes and hypertensive disorders),[50] intrapartum complications (cesarean section, induced preterm birth),[51] and stillbirth (OR 2.8; 95% CI, 1.5 to 5.3) and neonatal death (OR 2.6; 95% CI, 1.2 to 5.8) compared with women of normal weight.[52] In addition, women whose gestational weight gain is above the recommendations retain an additional 3 kg after 3 years and 4.7 kg on average after 15 or more years postpartum.[53]

Based on one metaanalysis, intentional weight loss did not confer benefit on all-cause mortality but may provide a small benefit for individuals classified as unhealthy (those with obesity-related risk factors).[54]

FOLLOW-UP

- The NHLBI recommends frequent contacts between the patient and provider to promote and monitor weight loss and weight maintenance therapies.[13] SOR C Although these programs can be conducted by a practitioner without specialization in weight loss, various health professionals with expertise are available and are often helpful.
- For children, health providers should calculate and plot BMI (or weight percentile) yearly and watch for excessive weight gain compared with linear growth, identify and track patients at risk of obesity based on risk factors, encourage and support breastfeeding, routinely promote healthy diets and levels of physical activity, and monitor changes in obesity-associated risk factors.[49]

PATIENT EDUCATION

- Advise patients to strive for a healthy lifestyle with a diet that is high in fruits and vegetables and to pursue daily physical activity. Maintaining normal weight and treating obstructive sleep apnea and diabetes may help prevent NAFLD.
- Weight loss can improve cardiovascular risk factors. Commercial weight-reduction programs may be most helpful.[19] The addition of cognitive-behavioral strategies may enhance weight loss.[23]
- For patients who are obese and fail to achieve their weight loss goals through diet and exercise alone, pharmacologic therapy can be considered, but pharmacologic therapy adds cost, can be associated with adverse effects, lacks long-term safety data, and weight loss may be temporary.
- Surgery is also an option for carefully selected patients with clinically severe obesity (BMI 40 or 35 with comorbid conditions) when less-invasive methods of weight loss have failed and the patient is at high risk for obesity-associated morbidity or mortality.

PATIENT RESOURCE

- Medline Plus. *Obesity*—**http://www.nlm.nih.gov/medlineplus/obesity.html.**

PROVIDER RESOURCES

- NHLBI. *Clinical Guidelines on the Identification, Evaluation, and Treatment of Overweight and Obesity in Adults* (1998 guideline, BMI calculator, tip sheet, evidence tables)—**http://www.nhlbi.nih.gov/guidelines/obesity/ob_home.htm.**
- Centers for Disease Control and Prevention. *Overweight and Obesity*—**http://www.cdc.gov/obesity/index.html.**

REFERENCES

1. Centers for Disease Control and Prevention. *Prevalence of Obesity in the United States, 2009-2010*. http://www.cdc.gov/nchs/data/databriefs/db82.pdf. Accessed March 2012.
2. Hu FB, Li TY, Colditz GA, et al. Television watching and other sedentary behaviors in relation to risk of obesity and type 2 diabetes mellitus in women. *JAMA*. 2003;289(14):1785-1791.
3. Finkelstein EA, Trogdon JG, Cohen JW, Dietz W. Annual medical spending attributable to obesity: payer- and service-specific estimates. *Health Aff*. 2009;28(5):w822-w831.
4. Loos RJ. Recent progress in the genetics of common obesity. *Br J Clin Pharmacol*. 2009;68(6):811-829.
5. Dodor BA, Shelley MC, Hausafus CO. Adolescents' health behaviors and obesity: does race affect this epidemic? *Nutr Res Pract*. 2010;4(6):528-534.
6. Zhang N, Yuan C, Li Z, et al. Meta-analysis of the relationship between obestatin and ghrelin levels and the ghrelin/obestatin ratio with respect to obesity. *Am J Med Sci*. 2011;341(1):48-55.
7. Wang C, Coups EJ. Causal beliefs about obesity and associated health behaviors: results from a population-based survey. *Int J Behav Nutr Phys Act*. 2010;7:19.
8. Hubert HB, Snider J, Winkleby MA. Health status, health behaviors, and acculturation factors associated with overweight and obesity in Latinos from a community and agricultural labor camp survey. *Prev Med*. 2005;50(6):642-651.
9. Larson NI, Story MT, Nelson MC. Neighborhood environments: disparities in access to healthy foods in the U.S. *Am J Prev Med*. 2009;36(1):74-81.

10. Ludwig J, Sanbonmastu L, Gennetian L, et al. Neighborhoods, obesity, and diabetes—a randomized social experiment. *N Engl J Med.* 2011;365(16):1509-1519.
11. Mozaffarian D, Hao T, Rimm EB, et al. Changes in diet and lifestyle and long-term weight gain in women and men. *N Engl J Med.* 2011;364(25):2392-2404.
12. Anderson B, Rafferty AP, Lyon-Callo S, et al. Fast-food consumption and obesity among Michigan adults. *Prev Chronic Dis.* 2011; Jul;8(4):A71.
13. National Heart Lung and Blood Institute. *Clinical Guidelines on the Identification, Evaluation, and Treatment of Overweight and Obesity in Adults*. http://www.nhlbi.nih.gov/guidelines/obesity/ob_home.htm. Accessed March 2012.
14. Soylu AC, Levent E, Sariman N, et al. Obstructive sleep apnea syndrome and anthropometric obesity indexes. *Sleep Breath.* 2011 Dec 3.
15. Onat A, Hergenc G, Yuksel H, et al. Neck circumference as a measure of central obesity: associations with metabolic syndrome and obstructive sleep apnea syndrome beyond waist circumference. *Clin Nutr.* 2009;28(1):46-51.
16. Rabkin SW. Epicardial fat: properties, function and relationship to obesity. *Obes Rev.* 2007;8(3):253-261.
17. Vernon G, Baranova A, Younossi ZM. Systematic review: the epidemiology and natural history of non-alcoholic fatty liver disease and non-alcoholic steatohepatitis in adults. *Aliment Pharmacol Ther.* 2011;34(3):274-285.
18. Douketis JD, Macie C, Thabane L, Williamson DF. Systematic review of long-term weight loss studies in obese adults: clinical significance and applicability to clinical practice. *Int J Obes (Lond).* 2005;29(10):1153-1167.
19. Jolly K, Lewis A, Beach J, et al. Comparison of range of commercial or primary care led weight reduction programmes with minimal intervention control for weight loss in obesity: Lighten Up randomised controlled trial. *BMJ.* 2011;343:d6500.
20. Shaw KA, Gennat HC, O'Rourke P, Del Mar C. Exercise for overweight or obesity. *Cochrane Database Syst Rev.* 2006; (4):CD003817.
21. Thorogood A, Mottillo S, Shimony A, et al. Isolated aerobic exercise and weight loss: a systematic review and meta-analysis of randomized controlled trials. *Am J Med.* 2011;124(8):747-755.
22. Oude Luttikhuis H, Baur L, Jansen H, Shrewsbury VA, et al. Interventions for treating obesity in children. *Cochrane Database Syst Rev.* 2009;(1):CD001872.
23. Shaw KA, O'Rourke P, Del Mar C, Kenardy J. Psychological interventions for overweight or obesity. *Cochrane Database Syst Rev.* 2005;(3):CD003818.
24. Appel LJ, Clark JM, Yeh HC, et al. Comparative effectiveness of weight-loss interventions in clinical practice. *N Engl J Med.* 2011;365(21):1959-1968.
25. Taveras EM, Gortmaker SL, Hohman KH, et al. Randomized controlled trial to improve primary care to prevent and manage childhood obesity: the High Five for Kids study. *Arch Pediatr Adolesc Med.* 2011;165(8):714-722.
26. Wadden TA, Volger S, Sarwer DB, et al. A two-year randomized trial of obesity treatment in primary care practice. *N Engl J Med.* 2011;365(21):1969-1979.
27. Padwal RS, Rucker D, Li SK, Curioni C, Lau DCW. Long-term pharmacotherapy for obesity and overweight. *Cochrane Database Syst Rev.* 2003;(4):CD004094.
28. Snow V, Barry P, Fitterman N, et al. Pharmacologic and surgical management of obesity in primary care: a clinical practice guideline from the American College of Physicians. *Ann Intern Med.* 2005;142(7):525-531.
29. Greenway FL, Caruso MK. Safety of obesity drugs. *Expert Opin Drug Saf.* 2005; 4(6):1083-1095.
30. Gadde KM, Allison DB, Ryan DH, et al. Effects of low-dose, controlled-release, phentermine plus topiramate combination on weight and associated comorbidities in overweight and obese adults (CONQUER): a randomised, placebo-controlled, phase 3 trial. *Lancet.* 2011;377(9774):1341-1352.
31. Pitter MH, Ernst E. Complementary therapies for reducing body weight: a systematic review. *Int J Obes (Lond).* 2005;29(9):1030-1038.
32. Onakpoya IJ, Wider B, Pittler MH, Ernst E. Food supplements for body weight reduction: as systematic review of systematic reviews. *Obesity (Silver Spring).* 2011;19(2):239-244.
33. Colquitt JL, Picot J, Loveman E, Clegg AJ. Surgery for obesity. *Cochrane Database Syst Rev.* 2009:(2):CD003641.
34. Pontiroli AE, Morabito A. Long-term prevention of mortality in morbid obesity through bariatric surgery. a systematic review and meta-analysis of trials performed with gastric banding and gastric bypass. *Ann Surg.* 2011;253(3):484-487.
35. MacDonald KG Jr, Long SD, Swanson MS, et al. The gastric bypass operation reduces the progression and mortality of non-insulin-dependent diabetes mellitus. *J Gastrointest Surg.* 1997; 1(3):213-220.
36. Picot J, Jones J, Colquitt JL, et al. The clinical effectiveness and cost-effectiveness of bariatric (weight loss) surgery for obesity: a systematic review and economic evaluation. *Health Technol Assess.* 2009;13(41):1-190.
37. Reoch J, Mottillo S, Shimony A, et al. Safety of laparoscopic vs open bariatric surgery: a systematic review and meta-analysis. *Arch Surg.* 2011;146(11):1314-1322.
38. Zingmond DS, McGory ML, Ko CY. Hospitalization before and after gastric bypass surgery. *JAMA.* 2005;294(15):1918-1924.
39. Flum DR, Salem L, Elrod JA, et al. Early mortality among Medicare beneficiaries undergoing bariatric surgical procedures. *JAMA.* 2005;294(15):1903-1908.
40. Heber D, Greenway FL, Kaplan LM, et al. Endocrine and nutritional management of the post-bariatric surgery patient: an Endocrine Society Clinical Practice Guideline. *J Clin Endocrinol Metab.* 2010;95(11):4823-4843.
41. Phelan S, Phipps MG, Abrams B, et al. Randomized trial of a behavioral intervention to prevent excessive gestational weight gain: the Fit for Delivery Study. *Am J Clin Nutr.* 2011;93(4):772-779.
42. Ronnberg AK, Nilsson K. Interventions during pregnancy to reduce excessive gestational weight gain: a systematic review

assessing current clinical evidence using the Grading of Recommendations, Assessment, Development and Evaluation (GRADE) system. *BJOG.* 2010;117(11):1327-1334.

43. ter Bogt NC, Bemelmans WJ, Beltman FW, et al. Preventing weight gain by lifestyle intervention in a general practice setting: three-year results of a randomized controlled trial. *Arch Intern Med.* 2011;171(4):306-313.
44. Waters E, de Silva-Sanigorski A, Hall BJ, et al. Interventions for preventing obesity in children. *Cochrane Database Syst Rev*. 2011 Dec 7;(12):CD001871
45. US Preventive Services Task Force, Barton M. Screening for obesity in children and adolescents: US Preventive Services Task Force recommendation statement. *Pediatrics.* 2010;125(2):361-367.
46. US Preventive Services Task Force. *Screening for Obesity in Adults*. http://www.uspreventiveservicestaskforce.org/uspstf/uspsobes.htm. Accessed March 2012.
47. Centers for Disease Control and Prevention. *Overweight and Obesity. Health Consequences*. http://www.cdc.gov/obesity/causes/health.html. Accessed March 2012.
48. Srinivasan SR, Bao W, Wattigney WA, Berenson GS. Adolescent overweight is associated with adult overweight and related multiple cardiovascular risk factors: the Bogalusa Heart Study. *Metabolism.* 1996;45(2):235-240.
49. American Academy of Pediatrics. Committee on Nutrition. Prevention of pediatric overweight and obesity. *Pediatrics.* 2003;112(2):424-430.
50. Arendas K, Qiu Q, Gruslin A. Obesity in pregnancy: preconceptional to postpartum consequences. *J Obstet Gynaecol Can.* 2008;30(6):477-488.
51. McDonald SD, Han Z, Mulla S, et al. Obesity is associated with fatal coronary heart disease independently of traditional risk factors and deprivation. *BMJ.* 2010;341:c3428.
52. Kristensen J, Vestergaard M, Wisborg K, et al. Pre-pregnancy weight and the risk of stillbirth and neonatal death. *BJOG.* 2005;112(4):403-408.
53. Nehring I, Schmoll S, Beverlein A, et al. Gestational weight gain and long-term postpartum weight retention: a meta-analysis. *Am J Clin Nutr.* 2011;94(5):1225-1231.
54. Harrington M, Gibson S, Cottrell RC. A review and meta-analysis of the effect of weight loss on all-cause mortality risk. *Nutr Res Rev.* 2009;22(1):93-108.

225 OSTEOPOROSIS AND OSTEOPENIA

Mindy Smith, MD, MS

PATIENT STORY

An 83-year-old woman accompanied by her 56-year-old daughter presents to the office with severe upper back pain over the past 2 days. Her medical problems include hypothyroidism, for which she is on replacement medication, and mild hypertension, which is controlled with a diuretic. She has known osteopenia and was taking calcium and vitamin D but had not tolerated a bisphosphonate. Physical examination reveals moderate thoracic kyphosis and tenderness over several lower thoracic vertebrae. A plain radiograph demonstrates a vertebral compression fractures (**Figure 225-1A**). The daughter asks about management options for pain and prevention of future fractures and also about screening for herself. As there was a suggestion of multiple compression fractures a CT was ordered to better visualize the fractures (**Figure 225-1B**).

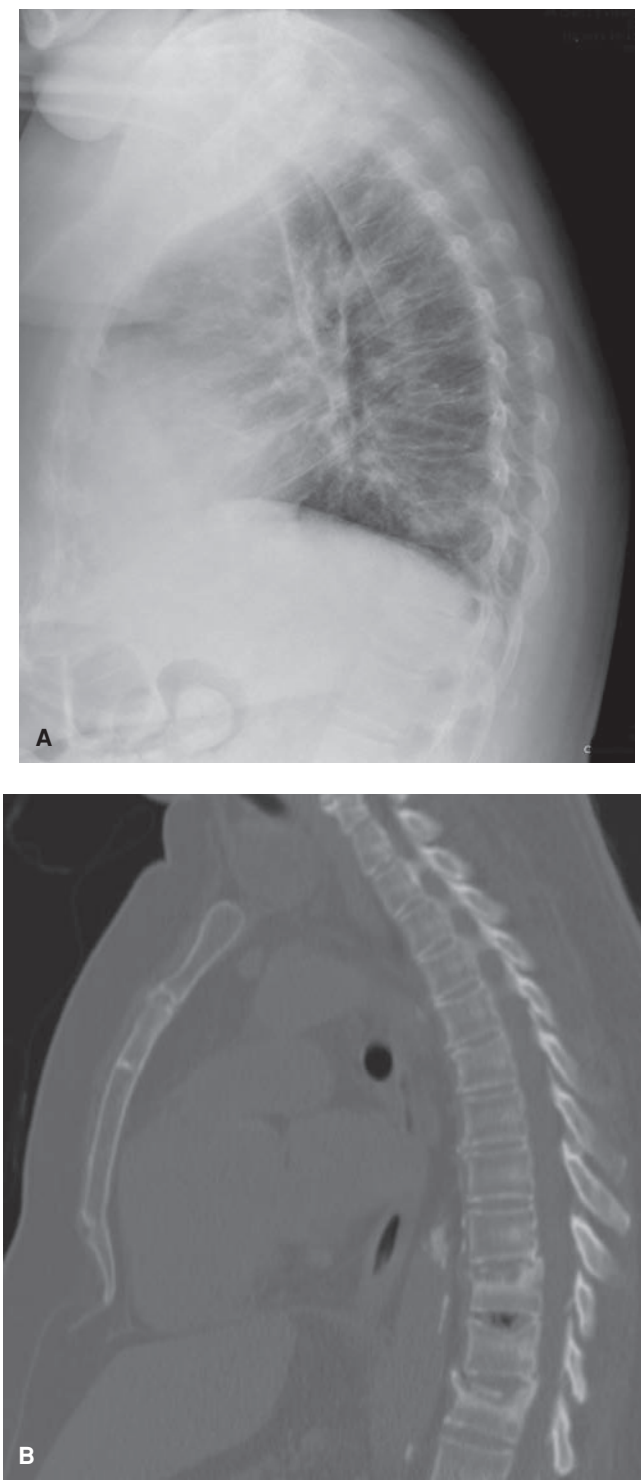

FIGURE 225-1 Osteoporosis-related thoracic vertebral compression fractures in an 83-year-old woman with kyphosis. **A.** Lower thoracic vertebral compression fractures seen on the lateral plain radiograph. **B.** Same fractures visualized more clearly on a lateral CT of the spine. (*Courtesy of Rebecca Loredo-Hernandez, MD.*)

INTRODUCTION

- Osteoporosis is a skeletal disorder characterized by low bone mineral density (BMD) ≤2.5 standard deviations (SD) of the mean for a gender-matched young white adult and compromised bone strength predisposing a person to fracture from minimal trauma.
- Osteopenia is defined as a BMD measurement of between 1.0 and 2.5 SD below the gender-matched young white adult mean. The World Health Organization also defines osteoporosis as a history of fragility fractures and osteopenia.[1]

EPIDEMIOLOGY

- Approximately 12 million Americans older than age 50 years are have osteopenia.[2]
- Half of all postmenopausal women will have an osteoporosis-related fracture in their lifetime; 25% will experience a vertebral deformity and 15% will suffer a hip fracture.[2]
- Low BMD at the femoral neck (T-score of −2.5 or below) is found in 21% of postmenopausal white women,16% of postmenopausal Mexican American women, and 10% of postmenopausal African American women.[3]
- About 1 in 5 older men are at risk of an osteoporosis-related fracture.[2]
- Vertebral fractures can cause severe pain and lead to 150,000 hospital admissions per year in the United States.
- Following a hip fracture, more than 30% of men and approximately 17% of women die within 1 year and more than half are unable to return to independent living.[3]

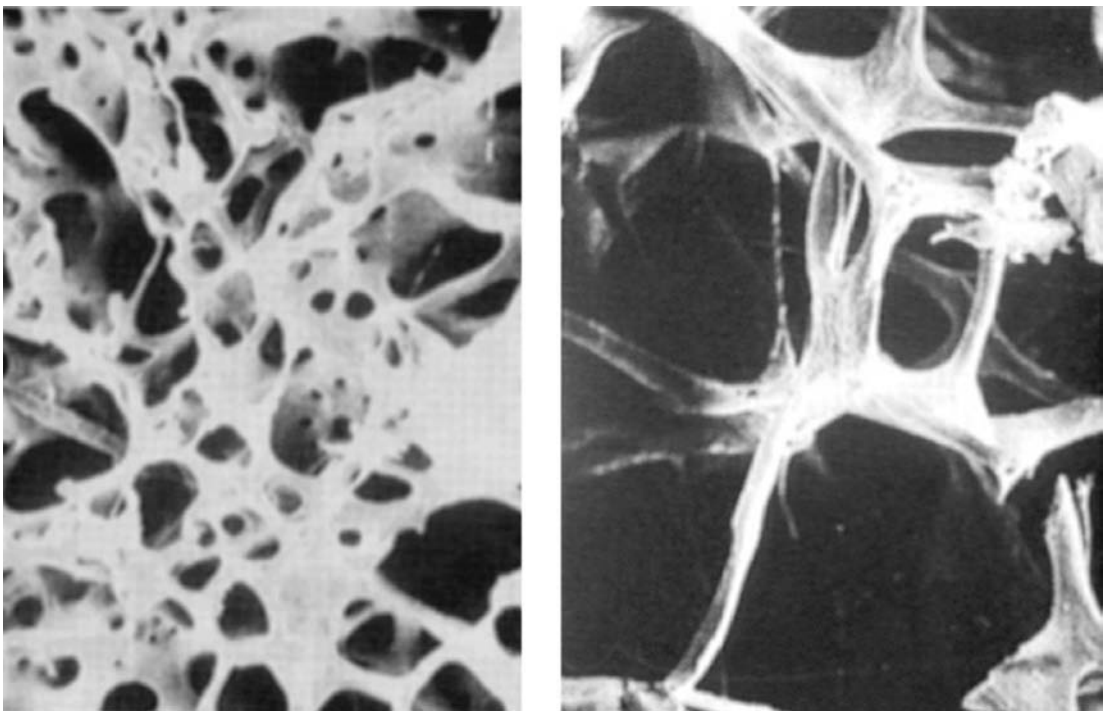

FIGURE 225-2 Normal trabecular bone (*left*) compared with trabecular bone murmur patient with osteoporosis (*right*). The loss of mass in osteoporosis these bones more susceptible to breakage. (*Printed with permission from Barrett KE, Barman SM, Boitano S, et al. Ganong's Review of Medical Physiology, 23rd ed. Philadelphia, McGraw-Hill Medical; 2009.*)

ETIOLOGY AND PATHOPHYSIOLOGY

- Primary osteoporosis is either a result of aging changes or menopause.
  - Usually affects those older than age 70 years.
  - Proportionate loss of cortical and trabecular bone density (**Figure 225-2**). Bone mass peaks at approximately age 30 years and declines thereafter. This bone loss can lead to an increase in vertebral, hip, and radius fractures.
  - In the 15 years following menopause, there is a disproportionate loss of trabecular bone. This can lead to an increase in fractures of the vertebrae, distal forearm, and ankle.
- Secondary osteoporosis is a result of medical conditions or medications (**Table 225-1**). Long-term oral prednisone used to treat a number of autoimmune diseases is a major contributing cause of secondary osteoporosis (**Figure 225-3**).

RISK FACTORS

- See **Table 225-1**.
- Previous low-trauma fracture.[4] Other risk factors for an osteoporosis-related fracture include advanced age, low BMD, low body mass index (BMI), and starred items in **Table 225-1**.[3]
- There are many validated clinical decision rules that can help identify patients who are at higher-than-average risk of fracture.[5,6]

TABLE 225-1 Factors Associated with Osteoporosis

Genetic factors White or Asian ethnicity Family history of osteoporosis* Low body weight (<127 pounds)* Late menarche or early menopause	**Medications (commonly used)** Systemic corticosteroids*, antiepileptic drugs, proton pump inhibitors, chemotherapy, diuretics producing calciuria, GnRH agonist or antagonist, heparin, extended tetracycline use
Nutritional factors Low intake of calcium or vitamin D High animal protein intake Low protein intake	**Lifestyle factors** Sedentary Excessive exercise Current smoking or alcohol use (>2 U/day)*
Medical disorders Endocrine disorders (e.g., hyperthyroidism, hyperparathyroidism, diabetes mellitus type 1, Cushing disease, hypogonadism) Hematologic disorders (e.g., multiple myeloma, anemia (hemolytic, pernicious), lymphoma, leukemia) GI disorders (e.g., malabsorption syndromes, chronic liver disease) Renal disorders (e.g., chronic renal failure) Rheumatologic disorders (e.g., rheumatoid arthritis, ankylosing spondylitis) Other disorders (e.g., anorexia, osteogenesis imperfecta)	

Abbreviations: GnRH, Gonadotropin-releasing hormone.
*Also risk factors for osteoporosis-related fractures.
Sources: Kaplan-Machlis B, Bors KP, Brown SR. Osteoporosis. In: Smith MA, Shimp LA, eds. *Twenty Common Problems in Women's Health Care*. New York, NY: McGraw Hill; 2000; Osteoporosis. In: Ebell MH, Ferenchik G, Smith MA, et al, eds. *Essential Evidence Plus*. Hoboken, NJ: John Wiley; 2009; Watts NB, Bilezikian JP, Camacho PM, et al. American Association of Clinical Endocrinologists medical guidelines for clinical practice for the prevention and treatment of postmenopausal osteoporosis: 2010 edition. *Endocr Pract*. 2010;16(Suppl 3):1-37.

An extensively validated online tool developed by the World Health Organization, the Fracture Risk Assessment (FRAX) (http://www.shef.ac.uk/FRAX/), can be used to estimate 10-year risk for fractures for women and men based on easily obtainable clinical information, such as age, BMI, parental fracture history, and tobacco and alcohol use.

DIAGNOSIS

CLINICAL FEATURES

- Height loss (>1 cm or >0.8 inch) can alert the clinician to osteoporosis.
- Kyphosis and cervical lordosis (dowager's hump).
- Acute pain is often the first symptom from a fracture, usually of the vertebrae (vertebral body collapse), hip or forearm, especially occurring after minor trauma. Pain may also be elicited from palpation over spinous processes and paraspinous muscle spasm may be noted.
- Osteoporosis may be identified on x-ray done for another purpose.

TYPICAL DI.STRIBUTION

- Fractures caused by menopausal osteoporosis typically occur in thoracic vertebrae, distal forearm, and ankle; occasionally there is loss of teeth.
- Fractures caused by senile osteoporosis are in the vertebrae, hip, and radius.

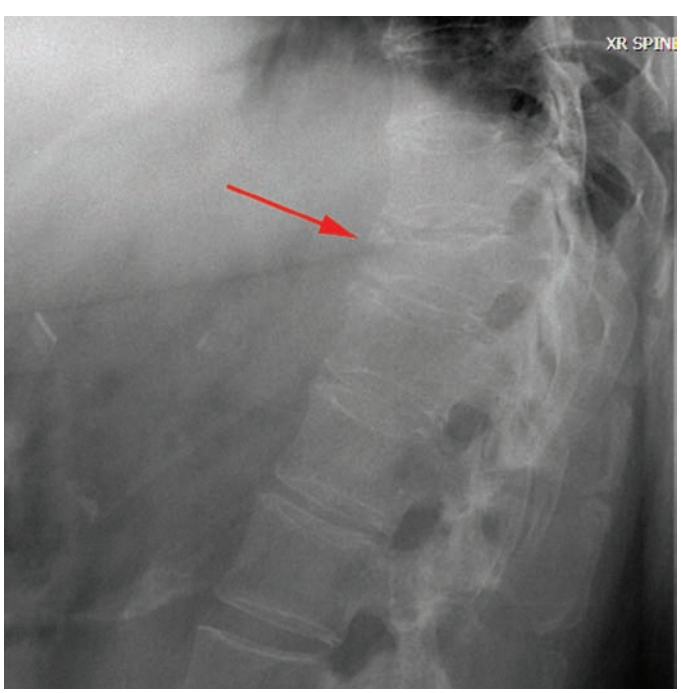

FIGURE 225-3 Wedge compression fracture of T11 vertebra in a postmenopausal woman on long-term prednisone for dermatomyositis. The patient presented with acute back pain. (*Courtesy of Richard P. Usatine, MD.*)

LABORATORY TESTING

- Laboratory testing is recommended for women with osteoporosis to identify secondary causes including a complete blood cell count (for anemia or malignancy), serum chemistry (calcium, phosphorus, total protein, albumin, liver enzymes, alkaline phosphatase, creatinine, and electrolytes), 24-hour urine collection (calcium, sodium, and creatinine excretion to identify calcium malabsorption or hypercalciuria), and serum 25-hydroxyvitamin D.[3]
- Other laboratory tests may be indicated for patients with suspected secondary causes (e.g., serum thyrotropin, erythrocyte sedimentation rate, testosterone, acid–base studies).[3,4]
- Central dual-energy x-ray absorptiometry (DEXA) measurement of BMD is the accepted gold standard for diagnosis (T-score less than or equal to −2.5 in the spine, femoral neck or hip in the absence of fracture) (**Figures 225-4** and **225-5**).
- Additional imaging with X-ray can confirm osteoporosis-related fracture (**Figures 225-1** and **225-3**).
- The presence of a hip or vertebral fracture in the absence of other bone conditions can also be considered osteoporosis.[3] Two types of

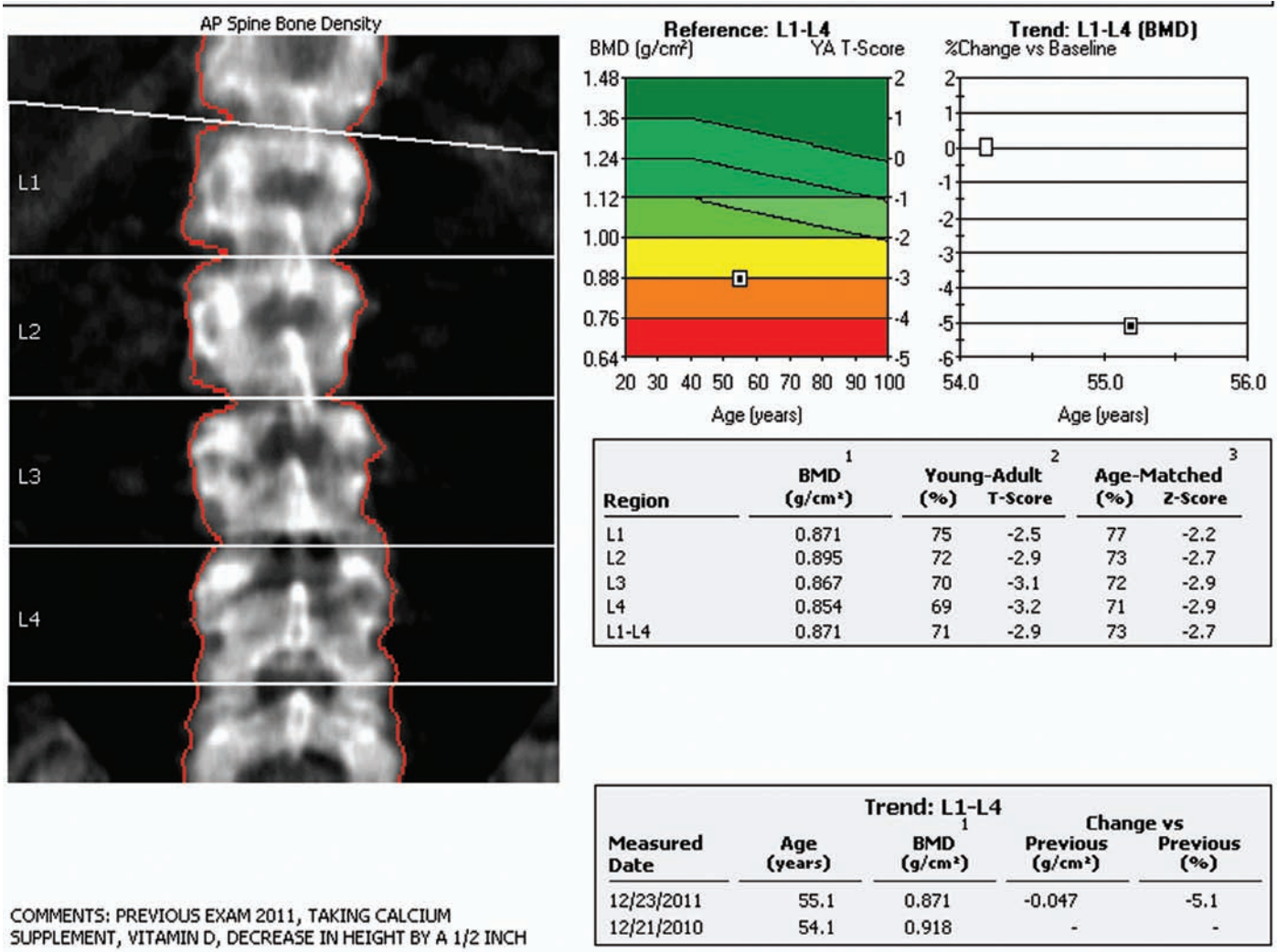

Region	BMD[1] (g/cm²)	Young-Adult[2] (%)	Young-Adult[2] T-Score	Age-Matched[3] (%)	Age-Matched[3] Z-Score
L1	0.871	75	-2.5	77	-2.2
L2	0.895	72	-2.9	73	-2.7
L3	0.867	70	-3.1	72	-2.9
L4	0.854	69	-3.2	71	-2.9
L1-L4	0.871	71	-2.9	73	-2.7

Trend: L1-L4

Measured Date	Age (years)	BMD[1] (g/cm²)	Change vs Previous (g/cm²)	Change vs Previous (%)
12/23/2011	55.1	0.871	-0.047	-5.1
12/21/2010	54.1	0.918	-	-

FIGURE 225-4 Dual-energy x-ray absorptiometry bone density scan showing osteoporosis in the vertebral spine showing 5% loss of vertebral bone density in 1 year. (*Courtesy of Richard P. Usatine, MD.*)

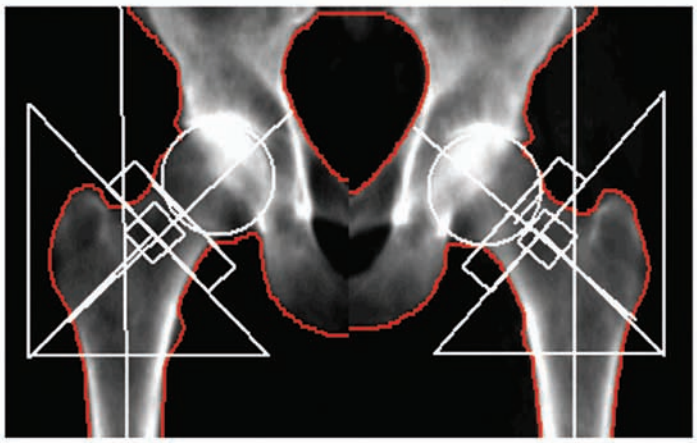

Region	BMD[1,6] (g/cm²)	Young-Adult[2,7] (%)	Young-Adult[2,7] T-Score	Age-Matched[3] (%)	Age-Matched[3] Z-Score
Neck					
Left	0.720	67	-2.7	78	-1.5
Right	0.712	67	-2.8	78	-1.6
Mean	0.716	67	-2.7	78	-1.6
Difference	0.008	1	0.1	1	0.1
Total					
Left	0.740	68	-2.7	76	-1.8
Right	0.741	68	-2.7	76	-1.8
Mean	0.740	68	-2.7	76	-1.8
Difference	0.001	0	0.0	0	0.0

Trend: Total Mean

Measured Date	Age (years)	BMD[1,6] (g/cm²)	Change vs Previous (g/cm²)	Change vs Previous (%)
12/23/2011	55.1	0.740	0.010	1.4
12/21/2010	54.1	0.730	-	-

FIGURE 225-5 Dual-energy x-ray absorptiometry bone density scan showing osteoporosis of the hips with 2% gain of bone density in 1 year. (*Courtesy of Richard P. Usatine, MD.*)

hip fractures related to osteoporosis are femoral neck fractures (**Figure 225-6**) and intertrochanteric fractures.

DIFFERENTIAL DIAGNOSIS

Thoracic kyphosis of recent onset in adults can also be caused by:

- Degenerative arthritis of the spine—Pain and swelling in other joints, morning stiffness.
- Ankylosing spondylitis—Male gender, night pain, and limited motion in sacroiliac joints, uveitis.
- Tuberculosis (TB) and other infections of the spine—History of TB, positive cultures, X-ray showing joint destruction (Chapter 54, Tuberculosis).
- Cancer—History of cancer, imaging distinguishes.

FIGURE 225-6 Femoral neck fracture (*arrow*) in an elderly woman with osteoporosis. The woman fell on her left hip when coming out of the shower. (*Courtesy of Rebecca Loredo-Hernandez, MD.*)

MANAGEMENT

NONPHARMACOLOGIC

- Identify and treat secondary causes (see **Table 225-1**).
- Dietary advice includes adequate calcium, vitamin D, and protein intake.[3] SOR B
- Recommend regular weight-bearing exercise.[3] Institute for Clinical Systems Improvement (ICSI) notes that 3 components of an exercise program are needed for strong bone health: impact exercise (e.g., jogging, brisk walking, stair climbing), strengthening exercise with weights, and balance training such as Tai Chi or dancing.[4]
- Encourage smoking cessation and moderate alcohol use (<3 drinks per day).[3] SOR B
- Hip protectors may reduce hip fractures in the nursing home.[7] SOR B
- Address other risk factors for falling (e.g., low vision, gait disturbance, use of sedatives) and consider referral for physical or occupational therapy, if indicated.

MEDICATIONS

- Calcium (1200 mg/day from diet plus supplement) and vitamin D (at least 800 IU/day).[8,9] SOR A One study found that a single large dose of vitamin D (100,000 IU given orally every 4 months) over 5 years reduced fractures in elderly British women (NNT = 20).[10]
- Women with osteoporosis or previous hip or spine fractures should receive medication therapy, beginning with a bisphosphonate.[3,4] Women should also be considered for medication if they have a T-score of between −1.0 and −2.5, if FRAX major osteoporotic fracture probability is equal to or greater than 20%, or hip fracture probability is equal to or greater than 3%.[3]
- First-line agents include alendronate, risedronate, and zoledronic acid. SOR A Based on a Cochrane review of 11 studies, use of alendronate prevented hip (absolute risk reduction [ARR] 1%), vertebral (ARR 6%), and nonvertebral fractures (ARR 2%).[11] Potential side effects of bisphosphonates include rare atypical femoral shaft fracture (0.13% in the subsequent year for women with at least 5 years of treatment)[12] and jaw osteonecrosis (0.7 per 100,000 patient-years with oral bisphosphonate therapy).[13]
- Other drug therapies approved by the U.S. Food and Drug Administration to reduce fractures include parathyroid hormone (PTH, teriparatide [e.g., Forteo]), raloxifene (a selective estrogen receptor modulator [SERM]), and estrogen (women only). The ICSI recommends PTH as a first-line agent for patients with the highest fracture risk. Second-line agents recommended by American Association of Clinical Endocrinologists (AACE) are ibandronate and raloxifene.[3] Choice of second-line medications should be based on the patient's clinical situation, preferences, and the tradeoff between benefits and harms. AACE recommends against combination therapy. SOR B
- The first-line agents listed above for treatment of osteoporosis have been approved for use in men as well as women; however, data are limited for men, especially for fracture reduction. In a randomized controlled trial (RCT) of 265 men on glucocorticoid therapy, both risedronate and zoledronic acid prevented bone loss in the prevention population while zoledronic acid increased BMD slightly

more than risedronate (4.7% vs. 3.3% lumbar spine and 1.8% vs. 0.2% total hip, respectively) in the treatment group.[14]

- Denosumab is a human monoclonal antibody that inhibits osteoclast mediated bone resorption; denosumab was shown to reduce new vertebral fractures in women with multiple and/or severe prevalent vertebral fractures (ARR 9.1%) and hip fractures in subjects age 75 years or older (ARR 1.4%). Both denosumab and zoledronic acid appear to reduce fracture risk in men with castration-resistant prostate cancer metastatic to bone and denosumab and toremifene (a SERM) reduced osteoporotic fracture risk in men on androgen-deprivation treatment.[15] Denosumab has not been compared with bisphosphonates or other interventions. AACE considers this a first-line agent but it is very expensive.[3] SOR A Risks of treatment include endocarditis, cancer, and skin rash.
- Nasal calcitonin may preserve BMD and reduce new vertebral fractures; this drug also has an analgesic effect for some women with painful acute vertebral fractures.[16] AACE recommends calcitonin as a last line of therapy for treatment of osteoporosis.[3]

COMPLEMENTARY AND ALTERNATIVE THERAPY

- Limited data support use of phytoestrogens, synthetic isoflavones such as ipriflavone or natural progesterone cream for prevention or treatment of osteoporosis. A 2-year multicenter, randomized trial of ipriflavone showed some effect on total body BMD but no significant effect on regional bone density at common fracture sites.[17]

REFERRAL

- AACE recommends referral of patients to a clinical endocrinologist if a patient with a normal BMD sustains a low-trauma fracture, has recurrent fractures or continued bone loss despite therapy, has unexpectedly severe osteoporosis or unusual features, or has a complicating condition (e.g., renal failure).[3] SOR C

PREVENTION AND SCREENING

- The AACE guideline recommends adequate calcium and vitamin D intake to reduce bone loss.[3] SOR A Maintaining an active lifestyle SOR B, smoking cessation SOR B, limiting alcohol intake SOR B, and limiting caffeine intake SOR C are also recommended.
- The United States Preventive Services Task Force (USPSTF) and AACE recommend screening for osteoporosis for women 65 years of age and older and for younger women whose fracture risk is the same as or greater than that of a 65-year-old white woman who has no additional risk factors (9.3% risk over 10 years).[2]
- Screening should be done with DEXA of the hip or lumbar spine or quantitative ultrasonography of the calcaneus; appropriate cutoffs for diagnosis and treatment using ultrasound, however, have not been established. Other guidelines have similar risk-based recommendations, although the age of initial assessment (all adults, adults age 50 years, or postmenopausal women) differs and the groups do not recommend use of ultrasound for screening.[18]
- Bisphosphonate therapy should be considered in patients starting glucocorticoid therapy planned for over 3 months and those on chronic glucocorticoid therapy if their T-score is less than −1.0.[19]

FOLLOW-UP

- Repeat DEXA (same machine if possible) every 1 to 2 years until findings are stable and then continue with follow-up DEXA every 2 years or less (**Figures 225-4** and **225-5**).[3,4]
- Consider discontinuation of a bisphosphonates after 4 to 5 years of stability or after 10 years of stability for high-risk patients.[3] Reinstitute treatment if BMD declines substantially, bone turnover markers increase, or a fracture occurs.

PATIENT EDUCATION

- Encourage home-based fall prevention by removing throw rugs, reducing clutter in high traffic areas, increasing lighting, use of safety step stools and safety hand rails in the bathroom, and walking aids.
- Encourage healthy lifestyle and diet.

PATIENT RESOURCES

- MedlinePlus. *Osteoporosis*—**http://www.nlm.nih.gov/medlineplus/osteoporosis.html.**
- MedlinePlus. *Kyphosis*—**http://www.nlm.nih.gov/medlineplus/ency/article/001240.htm.**
- Osteoporosis Foundation—**http://www.nof.org/.**

PROVIDER RESOURCES

- **http://www.niams.nih.gov/Health_Info/Bone/default.asp.**
- **https://www.aace.com/sites/default/files/OsteoGuidelines2010.pdf.**
- The FRAX tool has been developed by the World Health Organization (WHO) to evaluate fracture risk of patients. It can be very helpful in making treatment choices: **http://www.shef.ac.uk/FRAX/.** It is also available as an iTunes app.

REFERENCES

1. The WHO Study Group. *Assessment of Fracture Risk and Its Application to Screening for Postmenopausal Osteoporosis*. Technical Report Series. No. 843. Geneva, Switzerland: World Health Organization; 1994.
2. U.S. Preventive Services Task Force. Screening for osteoporosis: U.S. Preventive Services Task Force Recommendation Statement. *Ann Intern Med.* 2011;154(5):356-364.
3. Watts NB, Bilezikian JP, Camacho PM, et al. American Association of Clinical Endocrinologists medical guidelines for clinical

practice for the prevention and treatment of postmenopausal osteoporosis: 2010 edition. *Endocr Pract*. 2010;16(Suppl 3): 1-37. https://www.aace.com/sites/default/files/OsteoGuidelines2010.pdf. Accessed October 2011.

4. Institute for Clinical Systems Improvement (ICSI). Diagnosis and treatment of osteoporosis http://www.guideline.gov/content.aspx?id=13190&search=osteoporosis. Accessed October 2011.
5. Kanis JA, Borgstrom F, De Laet C, et al. Assessment of fracture risk. *Osteoporos Int*. 2005;16:581-589.
6. Mauck KF, Cuddihy MT, Atkinson EJ, Melton LJ 3rd. Use of clinical prediction rules in detecting osteoporosis in a population-based sample of postmenopausal women. *Arch Intern Med*. 2005; 165:530-536.
7. Sawka AM, Boulos P, Beattie K, et al. Hip protectors decrease hip fracture risk in elderly nursing home residents: a bayesian meta-analysis. *J Clin Epidemiol*. 2007;60:336-344.
8. Bischoff-Ferrari HA, Willett WC, Wong JB, et al. Prevention of nonvertebral fractures with oral vitamin D dose dependency. A meta-analysis of randomized controlled trials. *Arch Intern Med*. 2009;169(6):551-561.
9. Avenell A, Gillespie WJ, Gillespie LD, O'Connell D. Vitamin D and vitamin D analogues for preventing fractures associated with involutional and post-menopausal osteoporosis. *Cochrane Database Syst Rev*. 2009;(2):CD000227.
10. Trivedi DP, Doll R, Khaw KT. Effect of four monthly oral vitamin D3 (cholecalciferol) supplementation on fractures and mortality in men and women living in the community: randomised double blind controlled trial. *BMJ*. 2003;326:469-472.
11. Wells GA, Cranney A, Peterson J, et al. Alendronate for the primary and secondary prevention of osteoporotic fractures in postmenopausal women (Cochrane Review). *Cochrane Database Syst Rev*. 2008;(1):CD001155.
12. Park-Wyllie LY, Mamdani MM, Juurlink DN, et al. Bisphosphonate use and the risk of subtrochanteric or femoral shaft fractures in older women. *JAMA*. 2011;305:783-789.
13. Ruggiero SL, Dodson TB, Assael LA, et al. Association of Oral and Maxillofacial Surgeons. American Association of Oral and Maxillofacial Surgeons position paper on bisphosphonate-related osteonecrosis of the jaws. *J Oral Maxillofac Surg*. 2009; 67(5 Suppl): 2-12.
14. Sambrook PN, Roux C, Devogelaer JP, et al. Bisphosphonate and glucocorticoid osteoporosis in men: results of a randomized controlled trial comparing zoledronic acid with risedronate. *Bone*. 2012;50(1):289-295.
15. Saylor PJ, Lee RJ, Smith MR. Emerging therapies to prevent skeletal morbidity in men with prostate cancer. *J Clin Oncol*. 2011;29(27):3705-3714.
16. Chesnut CH, Silverman S, Andriano K, et al. A randomized trial of nasal spray salmon calcitonin in postmenopausal women with established osteoporosis: the prevent recurrence of osteoporotic fractures study. *Am J Med*. 2000;109:267-276.
17. Wong WW, Lewis RD, Steinberg FM, et al. Soy isoflavone supplementation and bone mineral density in menopausal women: a 2-y multicenter clinical trial. *Am J Clin Nutr*. 2009; 90(5):1433-1439.
18. Guideline synthesis. Screening and Risk Assessment for Osteoporosis in Postmenopausal Women. http://www.guideline.gov/syntheses/synthesis.aspx?id=35128. Accessed October 2012.
19. Recommendations for the prevention and treatment of glucocorticoid-induced osteoporosis: 2001 update. American College of Rheumatology Ad Hoc Committee on Glucocorticoid-Induced Osteoporosis. *Arthritis Rheum*. 2001;44:1496-1503.

226 GOITROUS HYPOTHYROIDISM

Mindy A. Smith, MD, MS

PATIENT STORY

A 55-year-old woman presented with a several-month history of fatigue and weight gain. She reported that she felt puffy and swollen. She had difficulty buttoning the top button of her blouse because her neck was so large, but she reported no neck pain. Review of systems was positive for constipation, dry skin, and cold intolerance. On physical examination, a large goiter was found (**Figure 226-1**). Laboratory testing revealed an elevated thyroid-stimulating hormone (TSH) and a low free thyroxine (FT_4) level confirming hypothyroidism. The patient was started on levothyroxine.

FIGURE 226-1 Goiter that extends approximately 2 cm forward when viewed from the patient's side. (*Courtesy of Dan Stulberg, MD.*)

INTRODUCTION

- Goiter is a spectrum of changes in the thyroid gland ranging from diffuse enlargement to nodular enlargement depending on the cause. In the United States, the most common etiology of goiter with normal thyroid function or transient dysfunction is thyroiditis.
- Hypothyroidism is a condition caused by lack of thyroid hormone and usually develops as a result of thyroid failure from intrinsic thyroid disease. The most common cause of goitrous hypothyroidism is chronic lymphocytic (Hashimoto) thyroiditis.
- Subclinical thyroid disease refers to a patient with no or minimal thyroid-related symptoms but abnormal laboratory values (elevated TSH and thyroxine level within the normal range).

EPIDEMIOLOGY

- Worldwide, goiter is the most common endocrine disorder with rates of 4% to 15% in areas of adequate iodine intake and more than 90% where there is iodine deficiency.[1] Endemic goiter is defined as goiter that affects more than 5% of the population (**Figures 226-2** and **226-3**).
- Most goiters are not associated with thyroid dysfunction.
- The prevalence of goitrous hypothyroidism varies from 0.7% to 4% of the population.
- Subclinical hypothyroidism is present in 3% to 10% of population groups and in 10% to 18% of elderly persons.[2,3]
- The female-to-male ratio of goiter is 3:1, and 6:1 for goitrous hypothyroidism.
- The annual incidence of autoimmune hypothyroidism is 4 in 1000 women and 1 in 1000 men, with a mean age at diagnosis of 60 years.[4]

FIGURE 226-2 Massive goiter in an Ethiopian woman who lives in an endemic area for goiters. Many adults have large goiters in Ethiopia where there is little iodine in their diets. (*Courtesy of Richard P. Usatine, MD.*)

ETIOLOGY AND PATHOPHYSIOLOGY

Contributing factors for goiter are:

- Iodine deficiency or excess (**Figures 226-2** and **226-3**).
- TSH stimulation.
- Drugs, including lithium, amiodarone, and α-interferon.
- Autoimmunity/heredity.

Hypothyroidism may be caused by disease of the thyroid gland itself (e.g., Hashimoto thyroiditis), radioiodine thyroid ablation, thyroidectomy, high-dose head and neck radiation therapy, and medications (as above), or, rarely, by pituitary or hypothalamic disorders (e.g., tumors, inflammatory conditions, infiltrative diseases, infections, pituitary surgery, pituitary radiation therapy, and head trauma).[2]

- Hashimoto thyroiditis is caused by thyroid peroxidase (TPO) antibodies.
- Human leukocyte antigen-D related (HLA-DR) and cytotoxic T-lymphocyte antigen 4 (CTLA-4) are the best-documented genetic risk factors for this disorder.[4]
- There is marked lymphocytic infiltration of the thyroid in Hashimoto thyroiditis; the infiltrate is composed of activated CD4+ and CD8+ T cells, as well as B cells.
- Thyroid destruction in Hashimoto thyroiditis is believed to be primarily mediated by CD8+ cytotoxic T cells.

FIGURE 226-3 Goiter developing in a 12-year-old girl in an endemic area for goiters. (*Courtesy of Richard P. Usatine, MD.*)

RISK FACTORS

Risk factors for hypothyroidism include:[2]

- Symptoms of thyroid hormone deficiency.
- Goiter.
- Personal or family history of thyroid disease.
- Personal treatment of thyroid disease.
- History of autoimmune disease, especially diabetes mellitus.
- High-dose head and neck radiation therapy.

Myxedema coma usually occurs in elderly patients with untreated or inadequately treated hypothyroidism who develop a precipitating event, such as myocardial infarction, stroke, sepsis, or prolonged cold exposure.[2]

DIAGNOSIS

CLINICAL FEATURES

The history can be the key to the diagnosis:

- A painful neck mass is usually a form of thyroiditis.
- Large goiters are easily visible before palpating the neck (**Figures 226-1** to **226-5**).
- Asymmetric goiters can shift the trachea away from the midline (**Figure 226-6**).

Common signs and symptoms of hypothyroidism are:

- Fatigue and/or weakness.
- Dry and cool skin.
- Diffuse hair loss or thinning of the lateral eyebrows.
- Difficulty concentrating.
- Puffy face/hands/feet from myxedema (**Figure 226-7**).
- Bradycardia.
- Delayed deep tendon reflex relaxation.
- Weight gain despite poor appetite.
- Constipation.
- The most useful signs for diagnosing hypothyroidism are puffiness (likelihood ratio positive [LR+] 16.2) and delayed ankle reflex (LR+ 11.8).[5]

Clues to a central cause of hypothyroidism include a history of pituitary/hypothalamic surgery or radiation, headache, visual field defects, or ophthalmoplegia.[2]

Physical examination maneuvers that help detect goiter are:[6]

- Neck extension.
- Observation from the side.
- Palpation by locating the isthmus first.
- Having the patient swallow.
- Myxedema coma

LABORATORY STUDIES

Laboratory tests include an erythrocyte sedimentation rate (ESR) if thyroiditis is suspected, and TSH (elevated in hypothyroidism and subclinical disease) and FT_4 levels (low in hypothyroidism).

- In acute granulomatous thyroiditis, ESR is greater than 50 (LR+ 95) and the TSH and FT_4 are usually normal.
- In primary hypothyroidism, the TSH is greater than 10 mU/L (LR+ 16) and FT_4 is less than 8 (LR+ 11).
- The presence of antibodies to TPO and thyroglobulin help establish the diagnosis of Hashimoto thyroiditis but is unnecessary for treatment. TPO antibodies will be positive in 90% to 95% of patients.[4]
- In pituitary causes of hypothyroidism (central hypothyroidism), the TSH may be normal or elevated but FT_4 will be low.[2]
- In the future, reference limits may need to change as TSH distribution and reference limits have been shown to shift to higher concentrations with age and are unique for different racial/ethnic groups.[7]

DIFFERENTIAL DIAGNOSIS

Goiter presenting as a painful neck mass is most commonly caused by subacute granulomatous (de Quervain) thyroiditis (likely viral) or hemorrhage into a thyroid cyst or adenoma. Other causes include the following:

- Painful Hashimoto thyroiditis—Hypothyroidism with the presence of antibodies helps to confirm this diagnosis.

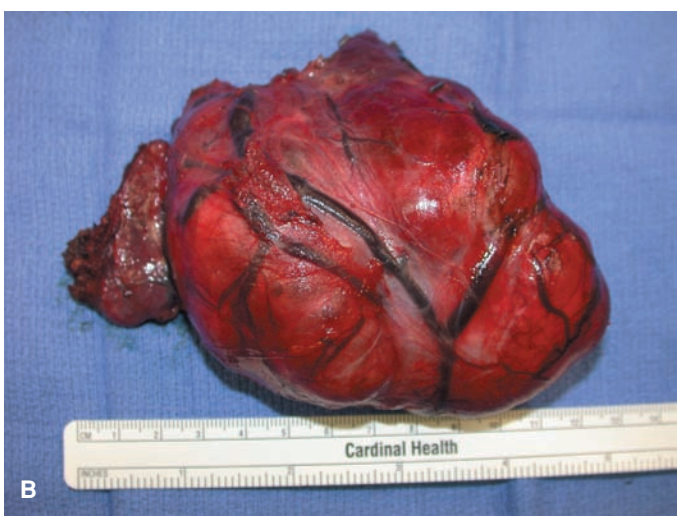

FIGURE 226-4 **A.** A 36-year-old woman with large goiter. **B.** The resected goitrous thyroid gland. (*Courtesy of Frank Miller, MD.*)

FIGURE 226-5 Massive multinodular goiter before surgery. (*Courtesy of Frank Miller, MD.*)

- Infected thyroglossal duct or branchial cleft cyst—Mass palpates as cystic and may be fluctuant; focal (e.g., erythema and warmth) and systemic symptoms of infection (e.g., fever) may be present. Even a noninfected thyroglossal duct cyst can be confused for an enlarged thyroid (**Figure 226-8**).
- Acute suppurative thyroiditis (microbial)—Focal (e.g., erythema and warmth) and systemic symptoms of infection (e.g., fever) are usually present.
- Thyroid carcinoma—Hard mass within thyroid gland (**Figure 226-9**).

Painless goiter and hypothyroidism are most often caused by Hashimoto thyroiditis, but may also be caused by the following:

- Environmental goitrogens (e.g., excess iodine, foods such as cassava, cabbage, and soybeans).
- Iodine deficiency.
- Pharmacologic inhibition (rare)—Drugs include lithium, amiodarone, and interferon-α.

Painless goiter and hyperthyroidism may be caused by the following:

- Graves disease (common, 0.5% to 2.5% of the population)—Symptoms of nervousness, fatigue, weight loss, heat intolerance, palpitations, and exophthalmus (Chapter 227, Graves Disease and Goiter).
- Postpartum thyroiditis (2% to 16% within 3 to 6 months of delivery)—Recent delivery.
- Toxic nodular goiter (uncommon)—Usually in the elderly; thyroid gland feels nodular (**Figure 226-4**) and thyroid scan shows multiple foci of increased uptake.

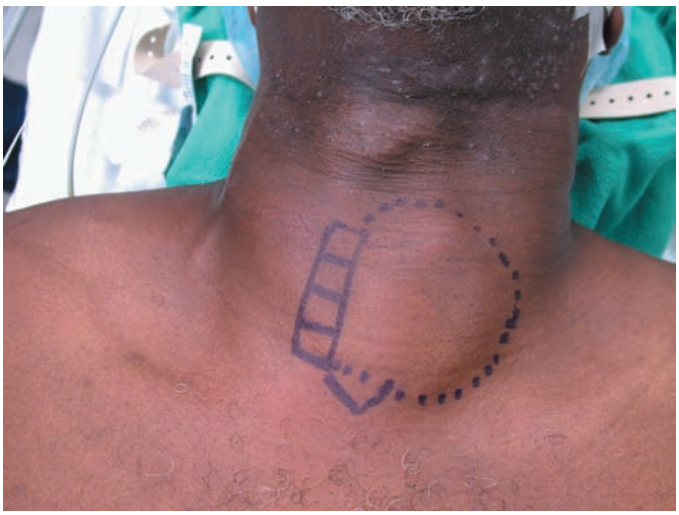

FIGURE 226-6 Asymmetric multinodular goiter causing trachea to deviate from the midline prior to resection. (*Courtesy of Frank Miller, MD.*)

MANAGEMENT

NONPHARMACOLOGIC

- For nonendemic goiter, identify and remove goitrogens.

MEDICATIONS

Patients with endemic goiter should be provided with iodine.

For nonendemic goiter, also consider the following:

- TSH suppression with levothyroxine (1 to 2.2 mg/kg per day) (variable but limited effect on goiter size and can cause hyperthyroidism).[8] SOR B
- Radioactive iodine treatment if enough functioning tissue is present. SOR C

Treat patients with acute microbial thyroiditis with antibiotics against the most common pathogens (i.e., *Staphylococcus aureus, Streptococcus pyogenes,* and *Streptococcus pneumoniae*). Alternative agents, used for 7 to 10 days, include: SOR C

- Amoxicillin/clavulanate (500 mg 3 times daily),
- A first- or second-generation cephalosporin (e.g., cephalexin 500 mg 4 times daily), and
- Penicillinase-resistant penicillin (e.g., dicloxacillin 500 mg 4 times daily).

FIGURE 226-7 Myxedema of the face with puffiness around the eye. (*Courtesy of the University of Texas Health Sciences Center, Division of Dermatology.*)

In patients with subacute thyroiditis:

- Oral corticosteroids can reduce pain and swelling. SOR C
- Symptoms of hyperthyroidism can be treated with β-blockers or calcium channel blockers.[9] SOR B
- Symptoms of hypothyroidism can be treated with levothyroxine.[8] SOR B

Patients with Hashimoto thyroiditis and low FT4 are treated with levothyroxine as follows:

- Younger patients start with 50 to 100 mcg/day increasing by 25 to 50 mcg/day at 6- to 8-week intervals until the TSH is normal (approximately 1.6 mcg/kg per day of levothyroxine).[2,8] SOR B
- Older patients or those with cardiac disease start with 25 mcg/day and increase by 12.5 to 25 mcg/day every 6 to 8 weeks to normalize the TSH (approximately 1 mcg/kg per day of levothyroxine). SOR C
- Dosing in the evening appears to normalize the laboratory values more effectively, but in one study, did not influence symptoms or quality of life.[2,10]

A Cochrane review of 12 small randomized controlled trials (RCTs) determined that treatment of subclinical hypothyroidism did not improve survival or decrease cardiovascular morbidity.[11]

- Patients with subclinical hypothyroidism should be considered for treatment if they have symptoms of thyroid deficiency, are at high likelihood of progression to hypothyroidism (e.g., TSH >10 mIU/L), or are pregnant.[2,3]
- For patients with TSH levels of 5 to 10 mIU/L, other factors to consider in a treatment decision include presence of goiter, bipolar disorder or depression, infertility or ovulatory dysfunction, presence of antithyroid antibodies, young age, patient preference, and possibly hyperlipidemia.[3]
- A dose of 50 to 75 mcg/day is usually sufficient for those with subclinical hypothyroidism. SOR C

REFERRAL

- Large goiters that impinge upon the trachea or do not respond to medications may be treated with surgery (**Figure 226-4**).
- Subtotal thyroidectomy can be considered for nodular goiters but recurrence rates can be high.[12] SOR A
- Consultation with an endocrinologist may be helpful if the diagnosis is uncertain and for patients with central hypothyroidism, severe hypothyroidism (i.e., myxedema coma), or coexisting cardiovascular disease.[2]
- Patients with myxedema coma should be hospitalized in an intensive care unit; without treatment, mortality approaches 100%.

PREVENTION AND SCREENING

- There is insufficient evidence to support screening for hypothyroidism in pregnant and nonpregnant patients[13]; however, pregnant women with subclinical hypothyroidism are more likely to have placental abruption (three-fold increase) and preterm delivery

FIGURE 226-8 Thyroglossal duct cyst in the midline superior to the thyroid. (*Courtesy of Frank Miller, MD.*)

FIGURE 226-9 A 93-year-old woman with thyroid cancer that went untreated for 3 years. Two large firm masses are visible in the neck. (*Courtesy of Dustin Williams, MD.*)

(two-fold increase) and their infants are at higher risk for intraventricular hemorrhage and respiratory distress syndrome.[14] Authors of a literature review found a single intervention trial demonstrating a decrease in preterm delivery among thyroid antibody-positive women treated with levothyroxine.[15]

- One expert panel recommended TSH testing in women with symptoms of thyroid dysfunction, personal or family history of thyroid disease, an abnormal thyroid gland on palpation, or type 1 diabetes mellitus or other autoimmune disorders.[16] In support of this approach, a clinical trial of universal screening versus case finding did not demonstrate a difference in adverse outcomes; however, treatment of women with thyroid dysfunction identified by screening a low-risk group was associated with a lower rate of adverse outcomes.[17]

PROGNOSIS

- In the most extensive community survey on goiter (Whickham, England), goiter was present in 15.5% of the population.[1] At the 20-year follow-up, 20% of women and 5% of men no longer had goiter and 4% of women and no men had acquired a goiter.
- Suppression of TSH with levothyroxine effectively reduces the goiter of Hashimoto thyroiditis and should be continued indefinitely. In one study, withdrawal of medication after 1 year resulted in only 11.4% remaining euthyroid.[18]
- Large goiter, TSH greater than 10 mU/L, and a family history of thyroid disease are associated with failure to recover normal thyroid function and treatment should continue indefinitely.
- In patients with subclinical hypothyroidism, progression to clinically overt hypothyroidism is 2.6% each year if TPO antibodies are absent, and 4.3% if they are present.[19]

FOLLOW-UP

- TSH should be rechecked approximately 6 to 8 weeks after initiation of levothyroxine therapy and again in 4 to 6 months if normal, and annually thereafter unless otherwise clinically indicated.[20] SOR C
- Although the need for thyroid replacement is lifelong, dose requirements may change over time. Thyroxine dose may need to be increased during pregnancy (20% to 40%), with use of estrogens, or in situations of weight gain, malabsorption, *Helicobacter pylori*-related gastritis and atrophic gastritis and with use of some medications. Requirements may decrease with increased age, androgen use, reactivation of Graves disease, or the development of autonomous thyroid nodules.[2]
- There is some evidence that use of ultrasound can help predict progression to overt hypothyroidism in patients with subclinical hypothyroidism[21]; in one study, patients with TPO antibodies and/or ultrasound abnormalities had a greater progression to overt disease than those without either finding (31.2% vs. 9.5% at 3 years).[22]
- The frequency of other autoimmune disease is increased in patients with Hashimoto thyroiditis (14.3% in one study), including rheumatoid

arthritis, pernicious anemia, systemic lupus erythematosus, Addison disease, celiac disease, and vitiligo, and increased monitoring should be considered.[23]

PATIENT RESOURCES

- Booklet from the American Thyroid Association: **http://www.thyroid.org/patients/brochures/Hypothyroidism%20_web_booklet.pdf.**
- Web-based resources: **http://www.nlm.nih.gov/medlineplus/thyroiddiseases.html.**

PROVIDER RESOURCE

- Baskin HJ, Cobin RH, Duick DS, et al; American Association of Clinical Endocrinologists. American Association of Clinical Endocrinologists medical guidelines for clinical practice for the evaluation and treatment of hyperthyroidism and hypothyroidism. *Endocr Pract*. 2002;8(6):457-469.

REFERENCES

1. Wang C, Crapo LM. The epidemiology of thyroid disease and implications for screening. *Endocrinol Metab Clin North Am.* 1997;26(1):189-218.
2. McDermott MT. In the clinic. Hypothyroidism. *Ann Intern Med.* 2009;151(11):ITC61.
3. Fatourechi V. Subclinical hypothyroidism: an update for primary care physicians. *Mayo Clin Proc.* 2009;84(1):65-71.
4. Jameson JL, Weetman AP. Disorders of the thyroid gland. In: Kasper DL, Braunwald E, Fauci AS, Hauser SL, Longo DL, Jameson JL, eds. *Harrison's Principles of Internal Medicine*, 16th ed. New York, NY: McGraw-Hill; 2005:2109-2113.
5. Zulewski H, Müller B, Exer P, et al. Estimation of tissue hypothyroidism by a new clinical score: Evaluation of patients with various grades of hypothyroidism and controls. *J Clin Endocrinol Metab.* 1997;82:771-776.
6. Siminoski K. Does this patient have a goiter? *JAMA.* 1995;273(10):813-819.
7. Surks MI, Boucai L. Age- and race-based serum thyrotropin reference limits. *J Clin Endocrinol Metab.* 2010;95(2):496-502.
8. Zelmanovitz F, Genro S, Gross JL. Suppressive therapy with levothyroxine for solitary thyroid nodules: A double-blind controlled clinical study and cumulative meta-analyses. *J Clin Endocrinol Metab.* 1998;3:3881-3885.
9. Singer PA, Cooper DS, Levy EG, et al. Treatment guideline for patients with hyperthyroidism and hypothyroidism. *JAMA.* 1995;273(10):808-812.
10. Bolk N, Visser TJ, Nijman J, et al. Effects of evening vs morning levothyroxine intake: a randomized double-blind crossover trial. *Ann Intern Med.* 2010;170(22):1996-2003.
11. Villar HCCE, Saconato H, Valente O, Atallah ÁN. Thyroid hormone replacement for subclinical hypothyroidism. *Cochrane Database Syst Rev.* 2007;(3):CD003419.
12. Rojdmark J, Jarhult J. High long term recurrence rate after subtotal thyroidectomy for nodular goitre. *Eur J Surg.* 1995;161:725-727.
13. United States Preventive Services Task Force. *Screening for Thyroid Disease*. http://www.uspreventiveservicestaskforce.org/uspstf/uspsthyr.htm. Accessed November 2011.
14. Casey BM, Dashe JS, Spong CY, et al. Perinatal significance of isolated maternal hypothyroxinemia identified in the first half of pregnancy. *Obstet Gynecol.* 2007;109:1129-1135.
15. Stagnaro-Green A. Material thyroid disease and preterm delivery. *J Clin Endocrinol Metab*. 2009;94(1):21-25.
16. Surks MI, Ortiz E, Daniels GH, et al. Subclinical thyroid disease: scientific review and guidelines for diagnosis and management. *JAMA.* 2004;291:228-238.
17. Negro R, Schwartz A, Gismondi R, et al. Universal screening versus case finding for detection and treatment of thyroid hormonal dysfunction during pregnancy. *J Clin Endocrinol Metab.* 2010;95(4):1699-1707.
18. Comtois R, Faucher L, Lafleche L. Outcome of hypothyroidism cause by Hashimoto's thyroiditis. *Arch Intern Med.* 1995;155(13):1404-1408.
19. Vanderpump MP, Tunbridge WM, French JM, et al. The incidence of thyroid disorders in the community: a twenty-year follow-up of the Whickham Survey. *Clin Endocrinol (Oxf).* 1995;43(1):55-68.
20. Wirsing N, Hamilton A. How often should you follow up on a patient with newly diagnosed hypothyroidism? *J Fam Pract*. 2009;58(1):40-41.
21. Shin DY, Kim EK, Lee EJ. Role of ultrasonography in outcome prediction in subclinical hypothyroid patients treated with levothyroxine. *Endocr J.* 2010;57(1):15-22.
22. Rosário PW, Bessa B, Valadão MM, Purisch S. Natural history of mild subclinical hypothyroidism: prognostic value of ultrasound. *Thyroid.* 2009;19(1):9-12.
23. Boelaert K, Newby PR, Simmonds MJ, et al. Prevalence and relative risk of other autoimmune diseases in subjects with autoimmune thyroid disease. *Am J Med.* 2010;123(2):183.e1-e9.

227 GRAVES' DISEASE AND GOITER

Mindy A. Smith, MD, MS

PATIENT STORY

A 32-year-old woman presents with fatigue and "eye strain" (**Figure 227-1**). She had been working as a secretary and noticed difficulty focusing her eyes. She said she was anxious and was having difficulty writing. She reported that her sister was taking medication for "thyroid trouble." A low thyroid-stimulating hormone (TSH) and an elevated free thyroxin level (T_4) were found on laboratory testing, and the patient was diagnosed with Graves disease (GD). Her thyroid scan showed an enlarged thyroid with increased uptake (**Figure 227-2**). The patient chose radioactive iodine (RAI) as her treatment and her symptoms resolved. One year later she required levothyroxine treatment.

FIGURE 227-1 This patient displays the following common findings of Graves disease: Lid retraction and mild proptosis (exophthalmus), particularly evident on the left eye, and goiter. (*Courtesy of Dan Stulberg, MD.*)

INTRODUCTION

GD is an autoimmune thyroid disorder characterized by circulating antibodies that stimulate the TSH receptor and resulting in hyperthyroidism.[1]

SYNONYMS

Thyrotoxicosis (clinical state resulting from inappropriately high thyroid hormone levels); hyperthyroidism (thyrotoxicosis caused by elevated synthesis and secretion of thyroid hormone).

EPIDEMIOLOGY

- GD is a common disorder affecting 0.5% to 1.2% of the population.
- There is a female-to-male ratio of 5 to 10:1.
- Among patients with hyperthyroidism, 60% to 80% have GD; younger patients (younger than age 64 years) with hyperthyroidism are more likely to have GD than are older patients with hyperthyroidism.
- Graves ophthalmopathy (see "Clinical Features" below) occurs in more than 80% of patients within 18 months of diagnosis of GD. The ophthalmopathy is clinically apparent in 30% to 50% of patients.[2]
- Goiter is present in 90% of patients younger than age 50 years (vs. 75% in older patients with GD).[1]
- Untreated hyperthyroidism can lead to osteoporosis, atrial fibrillation, cardiomyopathy, and congestive heart failure; thyrotoxicosis (thyroid storm) has an associated mortality rate of 20% to 50%.[3]



FIGURE 227-2 Nuclear scan of the thyroid in Graves disease showing increased uptake (61%). (*Courtesy of Michael Freckleton, MD.*)

ETIOLOGY AND PATHOPHYSIOLOGY

- The hyperthyroidism of GD results from circulating immunoglobulin (Ig) G antibodies that stimulate the TSH receptor.[2] These

antibodies are synthesized in the thyroid gland, bone marrow, and lymph nodes. Activation of the TSH receptor stimulates follicular hypertrophy and hyperplasia causing thyroid enlargement (goiter) and an increase in thyroid hormone production with an increased fraction of triiodothyronine (T_3) relative to T_4 (from approximately 20% to up to 30%).[2]

- The etiology is seen as a combination of genetic (human leukocyte antigen-D related [HLA-DR] and cytotoxic T-lymphocyte antigen 4 [CTLA-4] polymorphisms) and environmental factors, including physical and emotional stress (e.g., infection, childbirth, life events).[2] In addition, insulin-like growth factor-1 receptor (IGF-1R)-bearing fibroblasts and B-cells exhibiting the IGF-1R(+) phenotype may be involved in the connective tissue manifestations.[4] Siblings have higher incidence of both GD and Hashimoto thyroiditis (Chapter 226, Goitrous Hypothyroidism).
- The ophthalmopathy is believed to result from an autoimmune response directed toward an antigen shared by the thyroid and the eye's orbit. There is infiltration of the extraocular muscles by activated T cells, which release cytokines, activating fibroblasts (fibrosis can lead to diplopia) and increasing the synthesis of glycosaminoglycans (water trapping causes swelling).[2]

FIGURE 227-3 This 37-year-old woman has Graves disease and a loud bruit over her enlarged hyperactive thyroid gland. She was thyrotoxic at this time. (*Courtesy of Richard P. Usatine, MD.*)

RISK FACTORS

- Family history of thyroid disease, especially in maternal relatives.
- Smoking (a strong risk factor for Graves ophthalmopathy).

DIAGNOSIS

There are several guidelines available for the diagnosis and management of thyroid disease in provider resources on page 1360.

CLINICAL FEATURES

Symptoms depend on the severity of thyrotoxicosis, duration of disease, and age (findings are more subtle in the elderly). More than half of patients diagnosed with GD have these common symptoms:

- Nervousness.
- Fatigue.
- Weight loss.
- Heat intolerance.
- Palpitations.

Signs of disease include:

- Tachycardia (atrial fibrillation is common in patients >50 years of age).[2]
- Goiter—Listening over the goiter with a stethoscope may reveal a thyroid bruit (**Figure 227-3**).
- Resting tremor.
- Hyperreflexia
- Flushing and temporal wasting (**Figure 227-4**).

FIGURE 227-4 Visible flushed skin and temporal wasting in this thyrotoxic woman with new-onset Graves disease. (*Courtesy of Richard P. Usatine, MD.*)

- Skin and nail changes include:
  - Warm, erythematous, moist skin (from increased peripheral circulation).
  - Palmer erythema.
  - Pretibial myxedema—Occurring in a small percentage of patients (0.5% to 4%), it consists of nonpitting scaly thickening and induration of the skin usually on the anterior shin and dorsa of the feet (**Figures 227-5** and **227-6**).[5] It can also appear as a few well-demarcated pink, flesh-colored, or purple-brown papules or nodules.
  - Nails are soft and shiny and may develop onycholysis (distal separation of the nail plate from the underlying nail bed).
- Eye involvement may occur before hyperthyroidism (in 20% of patients) and gradually progresses with only mild discomfort (a gritty sensation with increased tearing is the earliest manifestation). The eye findings in GD[1,2] are:
  - Lid retraction (drawing back of the eyelid allowing more sclera to be visible) (**Figures 227-1** and **227-7**).
  - Frank proptosis (displacement of the eye in the anterior direction); occurs in one-third (**Figures 227-1** and **227-7**).
  - It is possible to have unilateral eye involvement with Graves ophthalmopathy (**Figure 227-8**).
  - Extraocular muscle dysfunction (e.g., diplopia).
  - Corneal exposure keratitis or ulcer.
  - Periorbital edema, chemosis, and scleral injection.

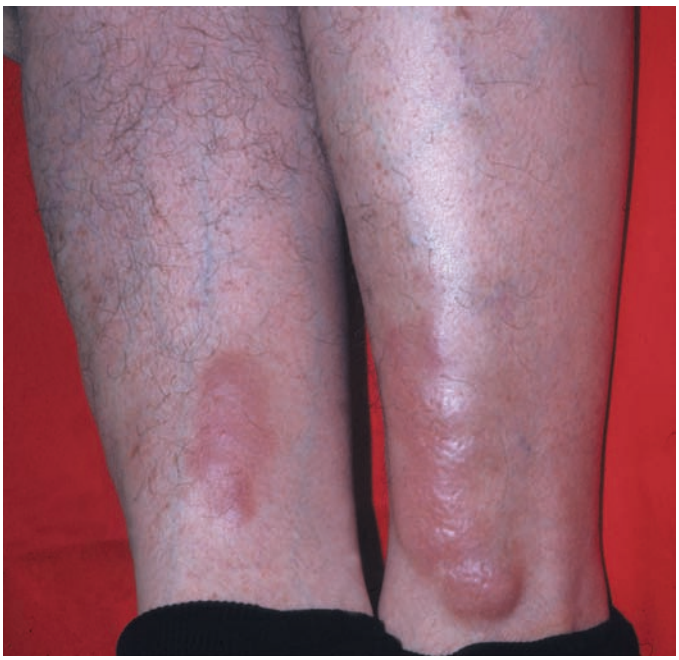

FIGURE 227-5 Early bilateral pretibial myxedema in a patient with Graves eye disease. These asymmetrical erythematous plaques and nodules are firm and nonpitting. (*Courtesy of the University of Texas Health Sciences Center, Division of Dermatology.*)

LABORATORY TESTING AND IMAGING

- With typical symptoms, you can confirm the diagnosis of GD with a low or undetectable sensitive assay for TSH and an elevated free T_4 level.
- The presence of TSH receptor antibodies (present in 70% to 100% of patients at diagnosis) has a positive and negative likelihood ratio of 247 and 0.01, respectively.[6] These antibodies are not usually required for diagnosis.
- If the clinical picture is uncertain or there is thyroid nodularity, obtain a RAI scan and uptake.[7] Elevated uptake (>30%) and a homogeneous pattern on scan are diagnostic (**Figure 227-2**).

DIFFERENTIAL DIAGNOSIS

Other causes of hyperthyroidism:

- Autonomous functioning nodule—This is an uncommon cause of thyrotoxicosis (present in 1.6% to 9% of patients with hyperthyroidism),[8] and most nodules do not cause hyperthyroidism. These present as a discrete swelling in an otherwise normal thyroid gland, and thyroid scan would show a discrete nodule.
- Toxic multinodular goiter—More common cause of hyperthyroidism in the elderly; thyroid scan shows multiple foci of increased uptake.
- Thyrotropin-secreting pituitary adenoma (rare)—Adenomas may cause visual disturbance (in the absence of exophthalmus), and other hormonal stimulation may occur (e.g., elevated serum prolactin).
- Thyroiditis—May be painless or painful, short duration, low update on RAI scan.
- Exogenous thyroid hormone ingestion—History of overdosage of prescribed or acquired thyroid medication.

FIGURE 227-6 Pretibial myxedema in a patient with Graves ophthalmopathy. Hair follicles are prominent, giving a peau d'orange appearance. (*Courtesy of the University of Texas Health Sciences Center, Division of Dermatology.*)

The differential diagnoses for the eye findings include the following:

- Metastatic disease to the extraocular muscles.
- Pseudotumor—This condition's rapid onset and pain differentiate it from Graves ophthalmopathy.

MANAGEMENT

- Three options are available to treat the hyperthyroidism: antithyroid drugs, RAI therapy, and surgery, as discussed below.[1,2] SOR A

NONPHARMACOLOGIC

- Supportive measures for eye symptoms include dark glasses, artificial tears, propping up the head and taping the eyelids closed at night.

MEDICATIONS

- Symptoms of hyperthyroidism can be controlled with β-adrenergic blockers (e.g., propranolol, 10 to 40 mg bid–qid) or calcium channel blockers (e.g., diltiazem, 30 to 90 mg bid). SOR B Authors of a recent guideline recommend β-adrenergic blockage in elderly patients with symptomatic disease, those who are thyrotoxic with cardiovascular disease or a resting heart rate greater than 90 beats/min, and prior to RAI treatment in patients with GD at risk for complications of extreme hyperthyroidism (e.g., highly symptomatic).[7]
- Antithyroid drugs (methimazole 10 to 20 mg/day or propylthiouracil [PTU], 100 to 200 mg every 8 hours). Potential side effects of these medications include rash, joint pain, liver inflammation, and, rarely, agranulocytosis.[2] Baseline liver enzymes and complete blood count (CBC) (including white blood cells (WBCs) and differential) is recommended.[7] Methimazole is preferred except in patients during the first trimester of pregnancy, those being treated for thyroid storm, or for those who have reactions to methimazole.[7]
- The drug dose may be reduced after the patient is euthyroid (typically PTU 50 to 100 mg/day and methimazole 2.5 to 10 mg/day).
- Antithyroid drugs are preferred during pregnancy and can be considered in patients with mild disease, small goiter, and lower antibody levels. Pretreatment with methimazole prior to RAI is suggested for patients with GD who are at high risk for complications of extreme hyperthyroidism.[7] They are also used more commonly as primary treatment in Europe and Asia.
- The optimal duration of titrated antithyroid drug therapy is 12 to 18 months to minimize relapse.[7,9] SOR A
- In a randomized controlled trial (RCT) of 159 patients with mild Graves orbitopathy who were given selenium (100 mcg twice daily), pentoxifylline (600 mg twice daily), or placebo (twice daily) orally for 6 months, selenium significantly improved quality of life, reduced ocular involvement, and slowed progression of the disease compared to the other treatments.[10]
- Patients with severe (and possibly moderate) Graves orbitopathy are usually treated with a 12-week course of high-dose intravenous glucocorticoid pulses (total <8 g of methylprednisolone); approximately 80% of patients respond to this regimen.[11,12] Liver failure is a serious but rare side effect.

FIGURE 227-7 Bilateral exophthalmus that has been present for 5 years since patient was diagnosed with Graves disease. Although the radioactive iodine returned her thyroid function to normal, the exophthalmus continues to bother the patient. (*Courtesy of Richard P. Usatine, MD.*)

FIGURE 227-8 Woman with unilateral Graves ophthalmopathy and vitiligo. There is a strong association between autoimmune thyroid diseases and vitiligo. (*Courtesy of Richard P. Usatine, MD.*)

RADIOTHERAPY

- RAI—It is the most commonly prescribed treatment in the United States, but is contraindicated in pregnancy or with breastfeeding and should be used with caution in patients with cardiovascular disease.
- RAI may also be used after initial treatment with antithyroid drugs; these drugs should be discontinued for 3 to 7 days before treatment.[2]
- The half-life of iodine-131 is about 1 week; however, it is recommended that women not attempt pregnancy for 6 to 12 months after RAI treatment.
- RAI may cause painful thyroid inflammation for a few weeks in approximately 1% of patients; this condition can be treated with nonsteroidal antiinflammatory agents, β-blockers, and possibly steroids.[3] Approximately 5% of patients with toxic nodular goiter treated with RAI develop GD.[3]
- In addition, radiation-induced thyroiditis can aggravate ophthalmopathy. This side effect can be minimized by early levothyroxine replacement and prednisone (60 to 80 mg/day starting at the time of RAI treatment and tapering, after 2 to 4 weeks, over the next 3 to 12 months).[13] One author believed that moderate to severe ophthalmopathy was a contraindication for RAI.[3]

SURGICAL TREATMENT

- Near-total to total thyroidectomy by a high-volume thyroid surgeon is recommended for patients with GD.[7]
- Indications for surgery are very large goiters, presence of suspicious nodules, pregnant women requiring high doses of antithyroid drugs, and allergy or failure of other therapies.
- In most cases for patients with GD, pretreatment with methimazole until euthyroid is recommended prior to surgery and levothyroxine is started following surgery.[7]
- Following surgery, small remnants of thyroid tissue (<4 g) result in rates of hypothyroidism of greater than 50% and large remnants (>8 g) have higher rates of recurrent hyperthyroidism (15%).
- With respect to the eye findings, most symptoms except for proptosis improve with control of the hyperthyroidism. In one study, 64% of the patients spontaneously improved, 22% stabilized, and 14% progressed.[13]

REFERRAL

- Patients with significant eye symptoms or clinical findings should be referred to an ophthalmologist.
- Treatment options for the persistent severe ophthalmopathy include high-dose systemic steroids (40 to 80 mg/day), orbital radiotherapy, and orbital decompression surgery.[14] SOR B

PROGNOSIS

- With use of antithyroid medications, symptoms improve in 3 to 4 weeks; weight gain (about 4.5 kg) often occurs as metabolism normalizes.[2] Remission rates following antithyroid drugs vary from 37% to 70% and occur within 6 to 8 weeks.

- Following RAI, 50% to 75% of patients become euthyroid after 5 to 8 weeks, but 50% to 90% of patients with GD eventually become hypothyroid (10% to 20% in year 1 and 5% per year afterward). Retreatment with radioiodine may be needed in 14% of patients with GD, 10% to 30% of patients with toxic adenoma, and 6% to 18% of patients with toxic nodular goiter.[3]
- In a RCT comparing GD treatments, relapse rates were higher among patients who received antithyroid drugs (approximately 40% [range: 34% (elderly) to 42% (young)]) versus patients following RAI (21%) and surgery (5% [3% (young) to 8% (elderly)]).[15]

FOLLOW-UP

- The goals of therapy are to resolve hyperthyroid symptoms and to restore the euthyroid state. Close follow-up is needed in the initial treatment period; medications for symptoms of hyperthyroidism may be withdrawn slowly following treatment.
- Antithyroid drug dosages may be reduced after the patient is euthyroid (typically PTU 50 to 100 mg/day and methimazole 2.5 to 10 mg/day), but drugs should be continued for 12 to 18 months to minimize relapse. SOR A
- Following treatment with RAI, most patients eventually become hypothyroid (20% within the first year) and so periodic monitoring of thyroid function is important. Follow-up within the first 1 to 2 months (free T_4 and T_3) is recommended and then at 4 to 6 weeks if hyperthyroidism continues; consider retreatment with RAI if there is minimal response at 3 months or hyperthyroidism persists at 6 months.[7]
- Following surgery, patients may become hypothyroid or have a recurrence of hyperthyroidism, depending on the size of the remnant remaining; patients should be monitored with periodic blood tests and for symptoms. For those with GD following surgery and levothyroxine, a TSH is recommended at 6 to 8 weeks postoperation.[7]
- An in-office exophthalmometer can be used to track changes in eye prominence over time.[2]
- Patients with GD are at high risk for development of other autoimmune disease; in one cross-sectional study in the United Kingdom of patients attending a thyroid clinic, the frequency of another autoimmune disorder (e.g., rheumatoid arthritis [3.15%], pernicious anemia, systemic lupus erythematosus, Addison disease, celiac disease, and vitiligo) was 9.67% in patients with GD.[16]

PATIENT EDUCATION

- Patients should be told that the goals of therapy are to resolve the symptoms of thyroid excess and to restore the thyroid function to normal.
- The treatment choices should be discussed, as each has advantages and disadvantages; treatment should be individualized.
- Regardless of the therapy chosen, long-term follow-up is needed to monitor thyroid status; there is a high risk of becoming hypothyroid in the future or to relapse again into hyperthyroidism. Patients should be made aware of symptoms to watch for and to report any recurrent symptoms.
- Following RAI, patients should avoid intimate contact (including kissing) and contact with children for 5 days; avoid contact with pregnant women for 10 days (maintain distance of approximately 6 feet); limit close contact with other adults to 2 hours for 5 days; sit while voiding and flush twice with the lid closed; not share toothbrushes, utensils, dishes, towels, or clothes, and wash these separately.[3]
- Ophthalmopathy usually runs its own course independent of the thyroid function. Additional treatment may be needed in consultation with an ophthalmologist.
- Smoking cessation may have a beneficial effect on the course of ophthalmopathy.
- Siblings and children should be made aware of their increased risk of developing thyroid disease or associated disorders and should monitor themselves for symptoms.

PATIENT RESOURCES

- Booklets from the American Thyroid Association—**http://www.thyroid.org/patients/brochures.html.**
- National Library of Medicine—**http://www.nlm.nih.gov/medlineplus/thyroiddiseases.html.**
- National Graves' Disease Foundation—**http://www.ngdf.org.**

PROVIDER RESOURCES

- Bahn RS, Burch HB, Cooper DS, et al. Hyperthyroidism and other causes of thyrotoxicosis: management guidelines of the American Thyroid Association and the American Association of Clinical Endocrinologists. *Thyroid.* 2011;21(6):593-641.
- Stagnaro-Green A, Abalovich M, Alexander E, et al. American Thyroid Association Taskforce on thyroid disease during pregnancy and postpartum. *Thyroid.* 2011;21(10):1081-1125.

REFERENCES

1. Jameson JL, Weetman AP. Disorders of the thyroid gland. In: Kasper DL, Braunwald E, Fauci AS, Hauser SL, Longo DL, Jameson JL, eds. *Harrison's Principles of Internal Medicine*, 16th ed. New York, NY: McGraw-Hill; 2005:2109-2113.
2. Brent GA. Graves' disease. *N Engl J Med.* 2008;358(24):2594-2605.
3. Ross DS. Radioiodine therapy for hyperthyroidism. *N Engl J Med.* 2011;364:542-550.
4. Douglas RS, Naik V, Hwang CJ, et al. B cells from patients with Graves' disease aberrantly express the IGF-1 receptor: implications for disease pathogenesis. *J Immunol.* 2008;181(8):5768-5774.
5. Jabbour SA. Cutaneous manifestations of endocrine disorders. *Am J Clin Dermatol.* 2003;4(5):315-331.
6. Costagliola S, Marganthaler NG, Hoermann R, et al. Second generation assay for thyrotropin receptor antibodies has superior diagnostic sensitivity for Graves' disease. *J Clin Endocrinol Metab.* 1999;84:90-97.

7. Bahn RS, Burch HB, Cooper DS, et al. Hyperthyroidism and other causes of thyrotoxicosis: management guidelines of the American Thyroid Association and the American Association of Clinical Endocrinologists. *Thyroid.* 2011;21(6):593-641.
8. Siegel RD, Lee SL. Toxic nodular goiter—toxic adenoma and toxic multinodular goiter. *Endocrinol Metab Clin North Am.* 1998;27(1):151-166.
9. Abraham P, Avenell A, Watson W, et al. Antithyroid drug regimen for treating Graves' hyperthyroidism. *Cochrane Database Syst Rev.* 2005;2:CD003420.
10. Marcocci C, Kahaly GJ, Krassas GE, et al. Selenium and the course of mild Graves' orbitopathy. *N Engl J Med.* 2011;364(20):1920-1931.
11. Zang S, Ponto KA, Kahaly GJ. Clinical review: Intravenous glucocorticoids for Graves' orbitopathy: efficacy and morbidity. *J Clin Endocrinol Metab.* 2011;96(2):320-332.
12. Bartalena L, Baldeschi L, Dickinson AJ, et al. Consensus statement of the European Group on Graves' Orbitopathy (EUGOGO) on management of Graves' orbitopathy. *Thyroid.* 2008;18(3):333-346.
13. Kaplan MM, Meier DA, Dworkin HJ. Treatment of hyperthyroidism with radioactive iodine. *Endocrinol Metab Clin North Am.* 1998;27(1):205-222.
14. Boulos PR, Hardy I. Thyroid-associated orbitopathy: a clinicopathologic and therapeutic review. *Curr Opin Ophthalmol.* 2004;15(5):389-400.
15. Törring O, Tallstedt L, Wallin G, et al. Graves' hyperthyroidism: treatment with antithyroid drugs, surgery, or radioiodine—a prospective, randomized study. *J Clin Endocrinol Metab.* 1996;81:2986-2993.
16. Boelaert K, Newby PR, Simmonds MJ, et al. Prevalence and relative risk of other autoimmune diseases in subjects with autoimmune thyroid disease. *Am J Med.* 2010;123(2):183.e1-e9.

228 ACROMEGALY

Mindy A Smith, MD, MS

PATIENT'S STORY

A 60-year-old man presents to his family physician with severe headache and weakness (**Figure 228-1**). He also noted enlargement of his hands (**Figure 228-2**), which made him remove his wedding ring when it became too tight, and feet (his shoe size had increased). He said his voice seemed to be deeper and his hands feel doughy and sweaty. Laboratory testing reveals an elevated insulin-like growth factor (IGF)-I, and there is a failure of growth hormone (GH) suppression following an oral glucose load confirming the diagnosis of acromegaly. Computed tomography (CT) scan of the head demonstrates a pituitary adenoma.

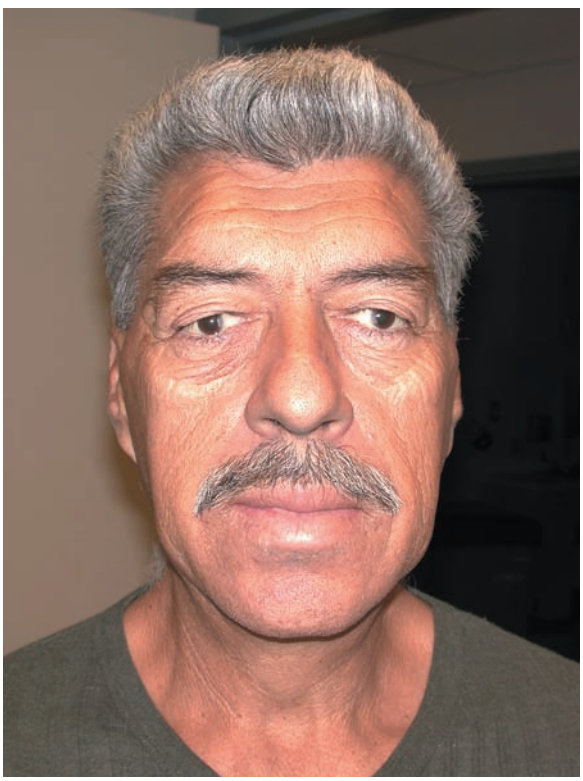

FIGURE 228-1 A 60-year-old man with acromegaly. Note the coarse facial features and moderate prognathism (protrusion of the lower jaw). (*Courtesy of Richard P. Usatine, MD.*)

INTRODUCTION

Acromegaly is a condition of excessive linear and organ growth usually caused by autonomous GH hypersecretion from a pituitary tumor.

EPIDEMIOLOGY

- Rare (5/1,000,000 adults)[1]
- Most typically caused by a pituitary somatotrope macroadenoma. It may also be caused by growth hormone-releasing hormone (GHRH) excess from lesions of the pancreas, lung, or ovaries, or from a chest or abdominal carcinoid tumor.
- The disorder is usually sporadic, but may be familial (<5%) and has been associated with other endocrine tumors (e.g., multiple endocrine neoplasia type I).[1]
- In a Spanish multicenter epidemiologic study, the reported mean age at diagnosis was 45 years.[2]
- The occurrence of GH hypersecretion in children and adolescents, prior to epiphyseal closure, causes gigantism.

ETIOLOGY AND PATHOPHYSIOLOGY

- The clinical signs and symptoms of acromegaly result from GH excess that stimulates linear and organ growth (through IGF-I), soft-tissue swelling, and chondrocyte action.
- Acromegaly is also associated with insulin resistance and an increased risk of cardiovascular disease; the latter appears to be a result of pressure-related arterial and left ventricular stiffening rather than atherosclerotic disease.[3]
- An increased risk for several cancers among these patients may be a result of the proliferative and antiapoptotic activity associated with increased circulating levels of IGF-I.

DIAGNOSIS

The diagnosis of acromegaly is established by documenting autonomous GH hypersecretion and by pituitary imaging.

CLINICAL FEATURES

The clinical manifestations of acromegaly are often subtle and may not be noticed for many years. Gigantism occurs if excessive GH exposure occurs *before* closure of the epiphyses; acromegaly develops *after* closure of the epiphyses. Clinical features of acromegaly include[1]:

- Soft-tissue swelling resulting in hand and foot enlargement (**Figure 228-2**).
- Kyphoscoliosis and skeletal hyperostosis.
- Coarse facial features and a large fleshy nose (**Figures 228-1** and **228-3**).
- Frontal bossing.
- Jaw malocclusion and overbite.
- Hyperhidrosis and oily skin.
- Other common features are deep voice (soft-tissue swelling of vocal cords), arthropathy, carpel tunnel syndrome, kyphosis, proximal muscle weakness, and fatigue; patients may complain of headache and visual field defects (expanding tumor), paresthesias, and sexual dysfunction.[1]
- Associated medical conditions include sleep apnea (60%), coronary heart disease (20% to 90% depending on duration and associated hypertension), and diabetes mellitus (25%). There also appears to be an increase in intracranial aneurysms.[4]
- In one study (N = 55), approximately two-thirds of women had anovulatory cycles; some believed related to elevated hormone levels.[5]

LABORATORY AND IMAGING

- An elevated total serum IGF-I concentration (age and gender matched) is extremely useful in the diagnosis of acromegaly.[6] Lack of standardization and normative data, however, have hampered diagnosis and monitoring.
- Failure of GH suppression to less than 1 mcg/L within 1 to 2 hours of an oral glucose load (75 g) can confirm the diagnosis, although 20% of patients exhibit a paradoxical increase in GH. Failure to suppress GH levels may also be seen in patients with diabetes, renal or hepatic failure, and obesity, and in those receiving estrogen replacement and in pregnant women.[1]
- A single measure of GH is not helpful because of its pulsatile secretion.
- Another associated laboratory abnormality is elevated prolactin (30% of patients).

MANAGEMENT

The Acromegaly Consensus Group recommends a team approach, including an experienced surgeon, endocrinologist with pituitary expertise, and a physician with radiotherapy experience.[7] Treatment is usually surgical followed by medication (usually a somatostatin

FIGURE 228-2 The man in **Figure 228-1** with acromegaly producing hands that are large and doughy with widened fingers. (*Courtesy of Richard P. Usatine, MD.*)

receptor ligand [SRL]) if the disease is not controlled. If initial medical treatment (following dose titration) fails to normalize GH and IGF-I, patients with tumor mass on magnetic resonance imaging (MRI) may consider radiation therapy while those without a mass effect may be tried on combination medical therapy.[7]

MEDICATIONS

There are 3 types of medications used in the treatment of patients with acromegaly: SRLs, a GH receptor antagonist, and a dopamine agonist. Although GH reduction may alleviate symptoms, attempts to normalize levels of both GH and its target growth factor (i.e., IGF-I) should be made because persistent secretion of either pose significant long-term health risks.

- There is insufficient evidence to support presurgical treatment with SRLs.[7]
- Somatostatin analogs are first-line therapy for those with nonsurgically resectable tumors; after surgery if normalization of GH and IGF-I does not occur; or during radiation treatment until control is achieved by that therapy (can take several years).
  - Long-acting somatostatin depot formulations, octreotide LAR and lanreotide Autogel, are available and appear equivalent. Patients should be treated with the same dose for 3 months before reassessment and dose titration if needed.[7]
  - Side effects are injection pain, sinus bradycardia, and symptoms related to suppression of GI motility and secretion (nausea, abdominal pain, diarrhea, and flatulence); gallstones or sludge occur in 30%, but few develop cholecystitis.[1]
- Subcutaneous pegvisomant is the available GH receptor antagonist for acromegaly. It is indicated for patients with persistent IGF-I elevations despite other treatment, as an adjunct to SRLs, or possibly as monotherapy; supporting data are lacking.[7]
  - Side effects include injection site pain and lipohypertrophy. Elevated liver enzymes are seen in approximately 5% to 25% of patients (usually transient) and should be monitored.
- Of the dopamine agonists, only cabergoline is effective (limited) at suppressing GH hypersecretion.[7]
  - Considered for patients preferring oral medication, patients following surgery with markedly elevated prolactin along with elevated GH and IGF-I, and as an adjunct to SRLs when failed response to maximum dose.[7]
  - Common side effects are GI (nausea, constipation), psychiatric and central nervous system (sleep disturbance, vertigo, depression), and cardiovascular (hypertension, peripheral edema); cardiac valve abnormalities have been reported in patients with Parkinson disease (who usually use high doses).

PROCEDURES

- Surgical resection (adenomectomy via transsphenoidal approach) is the cornerstone of treatment for intrasellar microadenomas, noninvasive macroadenomas, and when the tumor is causing compression symptoms.[7]
- Radiation therapy, conventional and stereotactic procedures, is also effective in decreasing GH levels but takes 10 to 15 years to work and carries a risk of hypopituitarism (>50%). It is considered

FIGURE 228-3 **A.** A 26-year-old attractive woman prior to acromegaly changes. **B.** Facial changes 20 years later in the same woman. Note the coarse facial features with large nose, lips, and chin. Protrusion of the lower jaw is visible. (*Courtesy of Vernon Burke, DMD.*)

third-line therapy.[7] Radiation has been used in an attempt to discontinue medical therapy.
  - Five-year remission rates from gamma knife radiotherapy (after surgical debulking) are between 29% and 60%.[7]
  - Conventional radiotherapy has potential risks of second tumors (approximately 1% intracranial) and cerebrovascular events, but long-term data are lacking.[7]

PROGNOSIS

- After surgical resection, 70% to 95% of patients with microadenomas and 40% to 68% of patients with macroadenomas have normalization of IGF-I.[6,7]
  - Irradiation of adenomas results in attenuation of IGF-I secretion in more than 60% of subjects after 10 to 15 years.[7]
  - Less than half of patients (44%) receiving somatostatin analogs achieve normal IGF-I levels, and a third achieve normal GH levels.[7]
- An MRI following surgery demonstrating a hypotense MRI signal in the remaining tumor may be useful in predicting good response to subsequent somatostatin analog treatment.[8]
- In the past, patients with acromegaly had a 10-year reduction in life span because of cardiac (heart failure, arrhythmia), cerebrovascular, metabolic (diabetes, osteoporosis), and respiratory (airway obstruction from macroglossia and hypertrophied mucosal tissues, sleep apnea) disease; radiotherapy may also increase the mortality rate.[1] Both IGF-I and GH levels correlate with mortality and normalizing these levels (IGF-I to age/sex standards and GH <2.5 ng/mL) appear to normalize the life span.[7]
- Successful pregnancy appears to occur in women with acromegaly,[5] although one case series found cases of gestation diabetes and gestational hypertension in women with uncontrolled disease; symptomatic (e.g., visual field defect, headache) enlargement of GH-secreting pituitary macroadenomas occurred in a few women.[9]

FOLLOW-UP

- Identification and treatment of comorbidities should be pursued. An initial colonoscopy and echocardiogram is recommended.[7]
- The Acromegaly Consensus Group defines optimal disease control (i.e., posttreatment remission of acromegaly) as IGF-I level (determined by a reliable standardized assay) in the age-adjusted normal range, and a GH level less than 1 g/L from a random GH measurement, using an ultrasensitive assay.[6] In patients who are controlled, monitor levels every 6 months.
- Based on a cohort study of patients hospitalized for acromegaly (Denmark 1977–1993; Sweden 1965–1993) linked to tumor registry data for up to 28 years of follow-up, individuals with acromegaly have higher rates of small intestine, colon, rectal, kidney, and bone cancer.[10] The researchers also found that these patients had elevated rates for cancers of the brain and thyroid that may be related to pituitary irradiation.
- Monitoring treatment success postoperatively or following radiation therapy includes:

- Measurement of GH and IGF-I levels. The consensus group suggest that optimal disease control (i.e., posttreatment remission of acromegaly) is now defined as IGF-I level (determined by a reliable standardized assay) in the age-adjusted normal range and a GH level less than 1 g/L from a random GH measurement.[6]
- Postoperative magnetic resonance imaging (MRI) 3 to 4 months postsurgery and 3 to 6 months following medical therapy, and yearly for those who remain uncontrolled. There is no consensus on frequency of continued MRI once remission is achieved.[7]
- Full pituitary function should be measured 3 months after surgery and periodically for those receiving radiotherapy.[7]

PATIENT EDUCATION

- Patients should be advised that untreated, one's life span is decreased by an average of 10 years. Survival improves greatly if GH and IGF-I can be normalized.
- Patients should consider increased surveillance for colorectal cancer and encouraged to actively manage comorbid conditions.

PATIENT RESOURCE

- National Endocrine and Metabolic Diseases Information Service. *Acromegaly*—**http://www.endocrine.niddk.nih.gov/pubs/acro/acro.aspx.**

PROVIDER RESOURCE

- Medscape. *Acromegaly*—**http://emedicine.medscape.com/article/116366.**

REFERENCES

1. Melmed S. Acromegaly pathogenesis and treatment. *J Clin Invest.* 2009;119(11):3189-3202.
2. Mestron A, Webb SM, Astorga R, et al. Epidemiology, clinical characteristics, outcome, morbidity and mortality in acromegaly based on the Spanish Acromegaly Registry (Registro Espanol de Acromegalia, REA). *Eur J Endocrinol.* 2004;151(4):439-446.
3. Paisley AN, Banerjee M, Rezai M, et al. Changes in arterial stiffness but not carotid intimal thickness in acromegaly. *J Clin Endocrinol Metab.* 2011;96(5):1486-1492.
4. Manara R, Maffei P, Citton V, et al. Increased rate of intracranial saccular aneurysms in acromegaly: an MR angiography study and review of the literature. *J Clin Endocrinol Metab.* 2011;96(5):1292-1300.
5. Grynberg M, Salenave S, Young J, Chanson P. Female gonadal function before and after treatment of acromegaly. *J Clin Endocrinol Metab.* 2010;95(10):4518-4525.
6. Giustina A, Chanson P, Bronstein MD, et al. Acromegaly Consensus Group. A consensus on criteria for cure of acromegaly. *J Clin Endocrinol Metab.* 2010;95(7):3141-3148.
7. Melmed S, Colao A, Barkan A, et al. Guidelines for acromegaly management: an update. *J Clin Endocrinol Metab.* 2009;94:1509-1517.
8. Puig-Domingo M, Resmini E, Gomez-Anson B, et al. Magnetic resonance imaging as a predictor of response to somatostatin analogs in acromegaly after surgical failure. *J Clin Endocrinol Metab.* 2010;95(11):4973-4978.
9. Caron P, Broussaud S, Bertherat J, et al. Acromegaly and pregnancy: a retrospective multicenter study of 59 pregnancies in 46 women. *J Clin Endocrinol Metab.* 2010;95(10):4680-4687.
10. Baris D, Gridley G, Ron E, et al. Acromegaly and cancer risk: a cohort study in Sweden and Denmark. *Cancer Causes Control.* 2002;13(5):395-400.

PART 17

NEUROLOGY

Strength of Recommendation (SOR)	Definition
A	Recommendation based on consistent and good-quality patient-oriented evidence.*
B	Recommendation based on inconsistent or limited-quality patient-oriented evidence.*
C	Recommendation based on consensus, usual practice, opinion, disease-oriented evidence, or case series for studies of diagnosis, treatment, prevention, or screening.*

*See Appendix A on pages 1447–1450 for further information.

229 HEADACHE

Heidi Chumley, MD

PATIENT STORY

A 35-year-old woman presented to the office to discuss her migraines. She has episodic unilateral throbbing headaches accompanied by nausea, photophobia, and phonophobia. She used to have a migraine about every 3 months, but is now having one almost every 2 weeks. As this frequency interferes with her life, prophylactic therapy is discussed. She accepts and her migraine frequency decreases dramatically.

INTRODUCTION

More than 77% of adults experience headaches during their lifetime. Headaches are either primary or secondary and the presence or absence of red flags is useful to distinguish dangerous causes of secondary headaches. The most common primary headaches are tension, migraine, and chronic daily headaches. Medication overuse can complicate headache therapy. Treatment and prognosis is dependent on type of headache.

EPIDEMIOLOGY

- Lifetime prevalence estimated to be greater than 77% in adults.[1]
- Fifty-three percent of adults (61% of women and 45% of men), and 53% of children have had a headache in the past year.[1] Elderly adults have a lower rate of headaches with 36% reporting a headache in the past year.
- Episodic tension-type headache (TTH) prevalence is 62.6% in adults and 15.9% in children.[1]
- Chronic (>15 days per month) TTH has a prevalence of 3.3% in adults and 0.9% in children.[1]
- Migraine has a prevalence of 14.7% in adults (8% in men, 17.6% in women) and 9.2% in children.[1]
- Chronic daily headache has lifetime prevalence of 4% to 5%.[2]
- Medication overuse contributes to daily headache in approximately 1% of adults in the general population.[1]
- Cluster headache has a lifetime prevalence of 0.2% to 0.3%.[1]

ETIOLOGY AND PATHOPHYSIOLOGY

- TTH etiology is uncertain, but likely caused by activation of peripheral afferent neurons in head and neck muscles.[3]
- Migraine headache is thought to be caused by central sensory processing dysfunction, which is genetically influenced.[4] Nociceptive input from the meningeal vessels is abnormally modulated in the dorsal raphe nucleus, locus coeruleus, and nucleus raphe magnus. This activation can be seen on positron emission tomography (PET) scan during an acute attack (**Figure 229-1**).

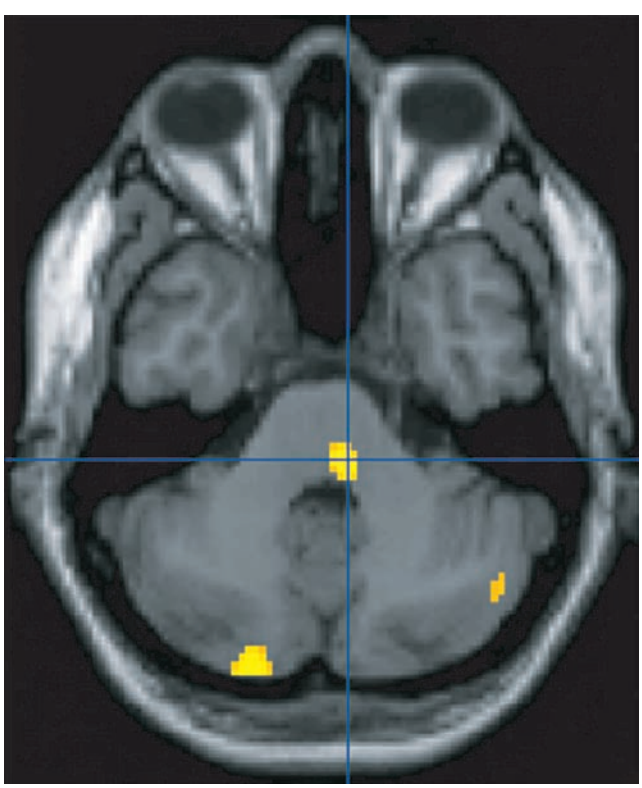

FIGURE 229-1 Imaging has helped clarify the etiology of migraine disorder. This positron emission tomography image shows activation in the dorsolateral pons, which includes the noradrenergic locus coeruleus, an area that modulates nociceptive input from the meningeal vessels. (*With permission from Longo D, Fauci A, Kasper D, Hauser S, Jameson J, Loscalzo J, eds. Harrison's Principles of Internal Medicine, 18th ed. New York, NY: McGraw-Hill; 2011:116, Figure 14-2B.*)

- Cluster headache is caused by trigeminal activation with hypothalamic involvement, but the inciting mechanism is unknown.[5]

RISK FACTORS

- For migraines—Family history.
- For medication overuse headache—Regular use of any medication used to treat acute headaches, most commonly simple analgesics and triptans.

DIAGNOSIS

CLINICAL FEATURES

- Red flags for dangerous secondary cause—Sudden onset; persistent headache with nausea, vomiting; worsening pattern; history of cancer, HIV, or systemic illness (fever, rash, etc); focal neurologic signs or seizures; vision changes; papilledema; headache worsened by Valsalva, exertion, or position changes; new headache during pregnancy or postpartum; new headache after age 55 years.[2,3,6]
- Episodic TTH—At least 10 episodes of bilateral, mild to moderate, pressure (nonpulsating) type pain without nausea or vomiting, not aggravated by exertion, and rare photophobia or phonophobia, occurring less than 15 days per month.[7]
- Migraine headache—At least 5 episodes of unilateral, pulsating, moderate-to-severe headache lasting 4 to 72 hours, aggravated by physical activity, accompanied by nausea or emesis or photophobia and phonophobia.[7]
- Chronic daily headache (CDH)—A primary headache 15 or more days per month, for 4 or more hours per day, for 3 months.[2] Four types of CDH:
  - Chronic migraine—Episodic migraines increase in frequency while associated symptoms decrease; resembles tension headache with occasional typical migraine; often accompanied by medication overuse.[2]
  - Chronic TTH—Bilateral, nonpulsating, without nausea. Photophobia or phonophobia can be present.[2]
  - New daily persistent headache—Abrupt onset of daily headache in patient without a history of a headache disorder; patient often remembers exactly where and when the headaches started.[2]
  - Hemicrania continua—Chronic unilateral pain with exacerbations, often associated with ipsilateral autonomic features.[2]
- Medication overuse headache—Accompanies one of the CDHs; acute medications, such as triptans or opiates are taken more than 10 days a month, or analgesics more than 15 days a month, for more than 3 months.[7]
- Cluster headache—The most common type of trigeminal autonomic cephalalgias; can be episodic or chronic; sharp stabbing unilateral pain in trigeminal distribution, lasting 15 minutes to 3 hours, with ipsilateral autonomic features[2] (**Figure 229-2**).
- Sinus headache—Purulent nasal discharge, co-onset of sinusitis, headache localized to facial and cranial areas.

FIGURE 229-2 Lacrimation, ptosis, and lid edema seen in cluster headache. (*Courtesy of The International Headache Society, http://ihs-classification.org/en/. Copyright www.ihs-classification.org; Copyright (2012) Prof. Hartmut Göbel, Germany, www.schmerzklinik.de.*)

TYPICAL DISTRIBUTION

- Tension headaches are typically bilateral (**Figure 229-3**).
- Migraine and cluster headaches are typically unilateral.

LABORATORY TESTING

- Generally not indicated.
- May be used when a secondary cause, such as infection is suspected.

IMAGING

- Generally not indicated.
- MRI when red flags are present.

DIFFERENTIAL DIAGNOSIS

- Common primary headaches include episodic TTH, migraine, and chronic daily headache.
- Secondary causes of headache are uncommon and include systemic illnesses/infections, brain masses, subarachnoid hemorrhage (**Figure 229-4**), or increased intracranial pressure.
- Medication overuse headache is predominately seen with a primary headache, but may also accompany a secondary headache.

MANAGEMENT

Episodic TTH:

- Acute therapy.
  - Aspirin 500 to 1000 mg is the most effective treatment for acute episode. NSAIDs are more effective than acetaminophen.[3]
  - Avoid opiates.
  - Limit acute medications to less than 3 times a week to reduce the risk of medication overuse headache.[3]
- Consider preventive therapy if headaches occur once a week.
  - Amitriptyline 75 to 150 mg a day is the most effective medication.[3]
  - Biofeedback may be effective.[3]
  - Acupuncture may be helpful.[3]

Migraine headache:

- Use a stepped approach to treat acute migraine episodes.
  - Start with simple analgesics. Aspirin and ibuprofen are often effective.[8]
  - Add an antiemetic or try butorphanol nasal spray or an oral opiate combination.[8]
  - Reserve migraine-specific agents such as triptans for patients who fail the above therapies.[8]
- Consider prophylaxis for patients whose migraines have a negative impact on their lives or to decrease risk of developing medication overuse headache when frequency requires use of simple analgesics more than 15 days a month or use of opioids, triptans, or combination analgesics more than 10 days a month.
  - Amitriptyline (before bedtime starting with 10 or 25 mg and titrate up as needed and tolerated), divalproex sodium 500 to

FIGURE 229-3 Woman with daily tension-type headache. This is a primary headache. (*Courtesy of Wikimedia Commons and Shanghai killer whale at http://commons.wikimedia.org/wiki/File:Tension-headache.jpg*)

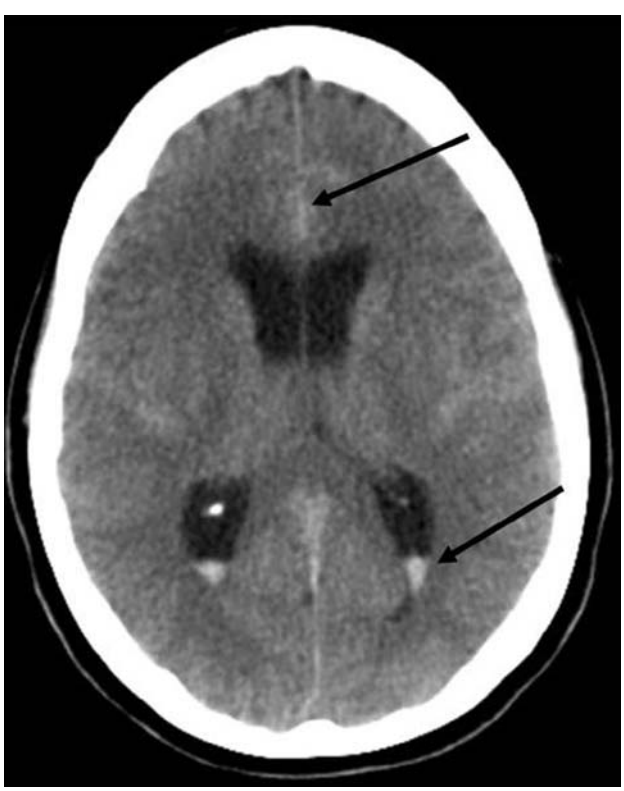

FIGURE 229-4 Sudden onset of a thunderclap headache prompted imaging that showed diffuse subarachnoid hemorrhage with associated ventricular hemorrhage. Top arrow indicates blood in interhemispheric fissure. Bottom arrow indicates blood in lateral ventricle. (*Courtesy of James Anderson, MD, Department of Radiology, Oregon Health & Science University.*)

1500 mg daily, topiramate 100 mg daily, venlafaxine 150 mg daily, and multiple β-blockers have each demonstrated 50% reduction in migraine frequency.[9]
  - Riboflavin 400 mg daily, coenzyme Q10 300 mg daily, butterbur 50 mg twice daily have each demonstrated 50% reduction in migraine frequency.[9]
  - Magnesium citrate 600 mg daily also reduces migraine frequency and has an A rating in pregnancy.[9]
- Cognitive behavioral therapy, biofeedback, stress management, and lifestyle modification may also be useful.[8]
- Acupuncture may provide additional benefit.[10]

CDH:

- Tricyclic antidepressants significantly reduce the number of days with TTH compared to placebo.[11] Amitriptyline taken before bedtime starting with 10 or 25 mg and titrate up as needed and tolerated.
- Acupuncture may be beneficial in chronic TTHs.[12]

Cluster headache:

- Acute episode:
  - Inhaled high-flow oxygen 10 to 15 L per minute.[5]
  - Sumatriptan 6 mg subcutaneously; contraindicated in pregnancy, lactation, coronary artery disease, stroke, peripheral artery disease.[5]
- Several agents may be effective for prophylactic therapy including verapamil or topiramate.[5]
- Refer refractory patients for evaluations for other medical or surgical therapies.

Medication overuse headaches:

- Educate patients that chronic medication use is contributing to their daily headaches.[13]
- Abruptly stop (when safe) or taper the overused medication.[13]
- Inpatient withdrawal is recommended for patients overusing opiates, benzodiazepines, or barbiturates.[13]
- Start prophylactic therapy with topiramate 100 to 200 mg daily prior to initiating withdrawal or as soon as possible after withdrawal has been initiated.[13]

REFERRAL

- Refer patients when the diagnosis is unclear or response to therapy is inadequate.
- Consider referral for medication overuse headaches as these are difficult to treat.

PREVENTION

- Closely monitor use of medications for acute episodes. Advise patients to limit simple analgesics to less than 15 days per month and triptans, opiates, and combination medications to less than 10 days per month.
- Appropriately prescribe preventive therapies to reduce frequency of headaches and avoid development of CDHs.

PROGNOSIS

- Tension headaches—Favorable; 45% of adults with frequent episodic or chronic TTHs experienced remission before 3 years.[3]
- Cluster headaches—Unknown; ranges from total remission to chronic form.[5]

FOLLOW-UP

- Dangerous causes of secondary headaches require immediate evaluation and management.
- Frequency of follow-up for primary headaches is determined by type and severity of headache and response to therapy.

PATIENT EDUCATION

Advise patients to limit frequency of acute medications to less than 2 to 3 times a week to reduce the risk of medication overuse headache.

PATIENT RESOURCES

National headache foundation has information for patients on many topics including:

- *Migraine*—**http://www.headaches.org/education/Headache_Topic_Sheets/Migraine.**
- *Medication Overuse Headache*—**http://www.headaches.org/education/Headache_Topic_Sheets/Analgesic_Rebound.**
- *Cluster Headache*—**http://www.headaches.org/education/Headache_Topic_Sheets/Cluster_Headaches.**
- *New Daily Persistent Headache*—**http://www.headaches.org/education/Headache_Topic_Sheets/New_Daily_Persistent_Headache.**

PROVIDER RESOURCES

- The Institute for Clinical Systems Improvement has a comprehensive guideline on the diagnosis and treatment of headache—**http://www.icsi.org/guidelines_and_more/gl_os_prot/other_health_care_conditions/headache/headache__diagnosis_and_treatment_of__guideline_.html.**
- The International Headache Society has a searchable website to assist with headache classification using ICHD-II criteria—**http://ihs-classification.org/en/02_klassifikation/.**

REFERENCES

1. Stovner LJ, Andree C. Prevalence of headache in Europe: a review for the Eurolight project. *J Headache Pain.* 2010;11(4):289-299.
2. Bigal ME, Lipton RB. The differential diagnosis of chronic daily headaches: an algorithmic-based approach. *J Headache Pain.* 2007;8(5):263-272.
3. Loder E, Rizzoli P. Tension-type headache. *BMJ.* 2008:336(7635):88-92.
4. Sprenger T, Goadsby PJ. Migraine pathogenesis and state of pharmacological treatment options. *BMC Med.* 2009;7:71.
5. Leroux E, Ducros A. Cluster headache. *Orphanet J Rare Dis.* 2008;3:20.
6. Chandana SR, Mowa S, Arora M, Singh T. Primary brain tumors in adults. *Am Fam Physician.* 2008;77(10):1423-1430.
7. Headache Classification Subcommittee of the International Headache Society. The International Classification of Headache Disorders: 2nd edition. *Cephalalgia.* 2004;24 Suppl 1:9-160.
8. Buse DC, Rupnow MFT, Lipton RB. Assessing and managing all aspects of migraine: migraine attacks, migraine-related functional impairment, common comorbidities, and quality of life. *Mayo Clin Proc.* 2009;84(5):422-435.
9. Pringsheim T, Davenport WJ, Becker WJ. Prophylaxis of migraine headache. *CMAJ.* 2010;182(7):E269-E276.
10. Linde K, Allais G, Brinkhaus B, et al. Acupuncture for migraine prophylaxis. *Cochrane Database Syst Rev.* 2009 Jan 21;(1):CD001218.
11. Jackson JL, Shimeall W, Sessums L, et al. Tricyclic antidepressants and headaches: systematic review and meta-analysis. *BMJ.* 2010;341:c5222.
12. Linde K, Allais G, Brinkhaus B, et al. Acupuncture for tension-type headache. *Cochrane Database Syst Rev.* 2009 Jan 21;(1):CD007587.
13. Evers S, Jensen R. Treatment of medication overuse headache—guideline of the EFNS headache panel. *Eur J Neurol.* 2011;18(9):1115-1121.

230 CEREBRAL VASCULAR ACCIDENT

Heidi Chumley, MD

PATIENT STORY

A 65-year-old hypertensive black man presented to the emergency department with onset of right face, arm, and hand paralysis, and difficulty communicating. Rapid diagnostic testing using MRI revealed an ischemic infarct in the left middle cerebral artery (**Figure 230-1**). He was evaluated by a stroke response team and was found to be a candidate for tissue plasminogen activator (TPA). After the stroke, he was treated with aspirin, antihypertensives, and cholesterol-lowering medication. He recovered 80% of his neurologic deficit over the next 3 months. **Figure 230-2** is a noncontrast CT image of this patient 2 weeks later.

FIGURE 230-1 Acute left middle cerebral artery infarct on MRI of a 65-year-old hypertensive man. The MRI demonstrates increased signal intensity (*arrows*). Abnormalities in MRI occur before those seen on CT during ischemic strokes. (*Courtesy of Chen MYM, Pope TL, Ott DJ. Basic Radiology. New York, NY: McGraw-Hill; 2004:338.*)

INTRODUCTION

Cerebral vascular accidents or strokes are common, especially in older populations. Most strokes are ischemic or hemorrhagic. Risk factors include hypertension, smoking, diabetes mellitus, and atrial fibrillation. Thirty-day mortality for a first stroke is greater than 20%.

SYNONYMS

Stroke.

EPIDEMIOLOGY

- Cerebral vascular accidents (CVAs) affect approximately 700,000 people per year in the United States, most being older than age 65 years.[1]
- Ischemic (66%) and hemorrhagic (10%) strokes account for most strokes.[1]
- Prevalence of stroke and mortality are higher in blacks than in whites. Prevalence is 753 versus 424 per 100,000 and mortality is 95.8 versus 73.7 per 100,000 for black and white men, respectively.[1]

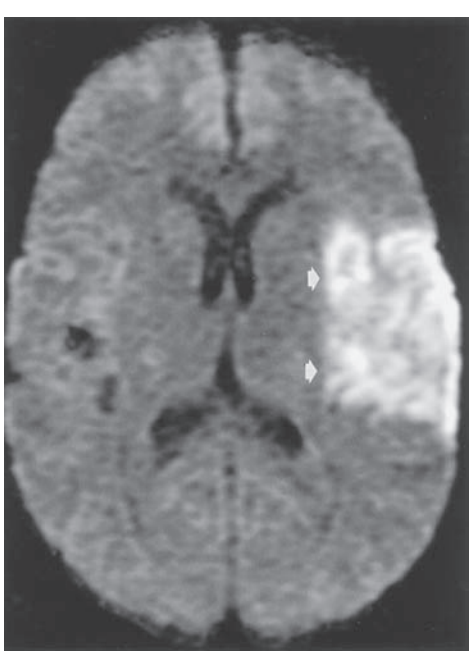

FIGURE 230-2 Noncontrast CT image of a subacute left middle cerebral artery infarct (*arrows*). This was done 2 weeks after the stroke in the same patient as previous figure. CT findings occur later than MRI findings in ischemic strokes. (*Courtesy of Chen MYM, Pope TL, Ott DJ. Basic Radiology. New York, NY: McGraw-Hill; 2004:338.*)

ETIOLOGY AND PATHOPHYSIOLOGY

- CVAs are typically classified into cardioembolic (15% to 22%), large vessel (10% to 12%), small vessel (15% to 18%), other known cause (2% to 4%), and undetermined cause (46% to 51%).[2]
- Ischemic CVAs occur when atherosclerosis progresses to a plaque, which ruptures acutely. Each step of this process is mediated by inflammation.[3]

- Hemorrhagic CVAs occur when vessels bleed into the brain, usually as the result of elevated blood pressure.
- Other known causes of CVAs include inflammatory disorders (giant cell arteritis, systemic lupus erythematosus [SLE], polyarteritis nodosa, granulomatous angiitis, syphilis, and AIDS), fibromuscular dysplasia, drugs (cocaine, amphetamines, and heroin), hematologic disorders (thrombocytopenia, polycythemia, and sickle cell), and hypercoagulable states.

RISK FACTORS

- Hypertension (HTN)—The predominant risk factor for more than 50% of all strokes. Prehypertension (blood pressure in the range of 130 to 139/85 to 89) carries a hazard ratio of 2.5 for women and 1.6 for men.[4]
- Cigarette smoking carries a hazard ratio of 1.62 for ischemic stroke and 2.56 for hemorrhagic stroke.[5]
- Type 2 diabetes mellitus (DM) increases the risk of having a stroke six-fold.[4]
- Black patients at ages 45 and 65 are 2.9 and 1.66 times more likely to have a stroke compared to white patients.[6]
- Atrial fibrillation increases the risk of stroke. The CHADS2 (congestive heart failure [CHF], HTN, age >75, DM, stroke) scoring system (see below) separates patients into low risk (stroke rate 1% to 1.5% per year), moderate risk (2.5%), high risk (4%), and very high risk (7%).[4]
- Body mass index (BMI) greater than 30 carries a hazard ratio of 1.45 for ischemic stroke but does not increase the risk of hemorrhagic stroke.[5]

DIAGNOSIS

Diagnosis of CVA must be made expediently to minimize mortality and morbidity.

CLINICAL FEATURES

- History of risk factors, including older age, HTN, cigarette smoking, type 2 DM, or previous transient ischemic attack (TIA) or stroke.
- Acute onset of neurologic signs and symptoms based on the site of the CVA (see "Typical Distribution" below).

TYPICAL DISTRIBUTION

TIA or stroke can occur in any area of the brain; common areas with typical symptoms include the following:

- Middle cerebral artery is the most common ischemic site (**Figure 230-3**):
  - Superior branch occlusion causes contralateral hemiparesis and sensory deficit in face, hand, and arm, and an expressive aphasia if the lesion is in the dominant hemisphere.
  - Inferior branch occlusion causes a homonymous hemianopia, impairment of contralateral graphesthesia and stereognosis, anosognosia and neglect of the contralateral side, and a receptive aphasia if the lesion is in the dominant hemisphere.

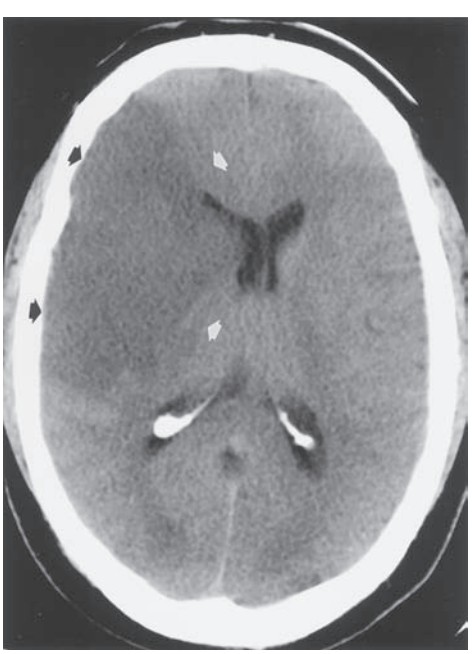

FIGURE 230-3 CT image of right middle cerebral artery infarct; the hypodense (darker) area (*arrows*) indicates the infarct. The midline structures are shifted to the left. (*Courtesy of Chen MYM, Pope TL, Ott DJ. Basic Radiology. New York, NY: McGraw-Hill; 2004:335.*)

- Internal carotid artery (approximately 20% of ischemic strokes) occlusion causes contralateral hemiplegia, hemisensory deficit, and homonymous hemianopia; aphasia is also present with dominant hemisphere involvement.
- Posterior cerebral artery occlusion causes a homonymous hemianopia affecting the contralateral visual field.

LABORATORY TESTING (INCLUDE ANCILLARY TESTING)

These tests may be helpful in the context of an acute stroke, particularly when the cause of the stroke is not immediately evident:

- Complete blood count (CBC) for thrombocytosis or polycythemia.
- Erythrocyte sedimentation rate (ESR) for diseases such as giant cell arteritis or SLE.
- Testing for syphilis using a treponemal enzyme immunoassay (EIA), with positive results confirmed by a nontreponemal test (Venereal Disease Research Laboratory [VDRL]).
- Serum glucose to eliminate hypoglycemia as the cause of the neurologic symptoms.

IMAGING

CT or MRI can distinguish ischemic from hemorrhagic and localize the lesion (**Figure 230-4**).

FIGURE 230-4 Hemorrhagic stroke. CT image demonstrates bleeding in the right basal ganglia (*large black arrow*) and into the ventricles (*small black arrows*). Blood appears white on the CT scan. The *white arrows* illustrate midline shift. (*Courtesy of Chen MYM, Pope TL, Ott DJ. Basic Radiology. New York, NY: McGraw-Hill; 2004:337.*)

DIFFERENTIAL DIAGNOSIS

Other causes of acute neurologic dysfunction include the following:

- TIA—This precursor to a CVA can appear identical; however, no lesion is seen on imaging, and symptoms resolve within 48 hours.
- Multiple sclerosis—Multiple anatomically distinct neurologic signs and symptoms that occur over time and resolve; vision is often affected. MRI findings should help to distinguish multiple sclerosis from CVA.
- Brain mass—More common presentation is headache or seizure; however, may present with focal neurologic signs based on location. CT or MRI will help to diagnose a brain mass and differentiate this from stroke.
- Migraines—Throbbing, unilateral headache with photophobia, and nausea; hemiparesis or aphasia may be part of the aura.
- Vertigo from benign positional vertigo or acute labyrinthitis—Can mimic a CVA in the posterior circulation; however, symptoms such as dysarthria, dysphagia, and diplopia are typically absent.
- Hypoglycemia—Confused state is similar to large stroke syndromes but is easily differentiated by a blood glucose measurement.

MANAGEMENT

ACUTE STROKE (WITHIN THE FIRST 3 HOURS)

- Rapidly evaluate or consult specialists to identify candidates for TPA. Odds for a favorable 3-month outcome for TPA compared to no TPA are 2.8 (95% confidence interval [CI], 1.8 to 4.5) for 0 to 90 minutes, 1.6 (95% CI, 1.1 to 2.2) for 91 to 180 minutes.[7] SOR A

- Favorable outcomes at 90 days poststroke have also been demonstrated when TPA is given up to 4.5 hours after the onset of symptoms.[8] SOR B
- Currently, only 3% of patients who meet the criteria receive TPA.[4]
- Preliminary studies cautioned about using TPA in community settings; recent studies, however, indicate several options to improve outcomes, including telephone consultation with a regional stroke center.[9]
- Acutely elevated blood pressure should not be aggressively treated in most cases.

After stabilization, treat ischemic strokes with antithrombotic, antihypertensives, statins, and lifestyle changes.

- Prescribe 81-mg or 325-mg aspirin for secondary stroke prevention in patients with prior ischemic stroke or TIA (relative risk [RR] reduction 28%; number needed to treat [NNT] to prevent 1 stroke per year = 77).[4] SOR A
- Lower blood pressure (RR reduction 28%; NNT to prevent 1 stroke per year = 51).[4] Current data demonstrate that thiazide-type diuretic and angiotensin-converting enzyme inhibitor (ACEI) (or angiotensin receptor blocker [ARB]) may provide additional risk reduction beyond blood pressure (BP) control and should be used first. ACEI and ARB may not be as effective as monotherapy in black populations.[4] SOR A
- Lower low-density lipoprotein (LDL) cholesterol to less than 100 mg/dL for patients with a prior stroke or who are at high risk of stroke using a statin (RR reduction 25%; NNT to prevent 1 stroke per year = 57).[4] SOR A
- Assist patients to stop smoking (RR reduction 33%; NNT to prevent 1 stroke per year = 43).[4] SOR A
- Advise patients to adopt a healthy lifestyle by eating more fruits and vegetables, losing weight, and maintaining a physical exercise program. SOR B

Consider the following to further decrease morbidity and mortality:

- Avoid indwelling urinary catheters to reduce the risk of urinary tract infection.
- Encourage early ambulation to reduce the risk of a deep venous thrombosis.
- Use antiembolism stockings to reduce the risk of a deep venous thrombosis.
- Consider a swallowing study to identify patients at risk of aspiration.

SPECIAL SITUATIONS

- Hemorrhagic stroke:
  - Acutely—Do not aggressively lower BP. Some authorities recommend lowering BP only when mean arterial pressure (MAP) is more than 130 mm Hg (MAP = [(2 × diastolic BP) + systolic BP]/3).
  - After the hemorrhagic stroke is over, treat BP aggressively; modest decreases (12/5 mm Hg) from one of many classes of hypertensive drugs lower recurrent stroke risk by 50% to 75%.[4]
- Nonvalvular atrial fibrillation (AF)—Use the CHADS2 scoring system to identify patients with AF who can be managed with aspirin or should be anticoagulated with coumadin.[4]
- The CHADS/CHADS2 scoring table is shown below:[2]

C: Congestive heart failure	= 1 point
H: HTN (or treated HTN)	= 1 point
A: Age >75 years	= 1 point
D: Diabetes	= 1 point
S: Prior TIA or stroke	= 2 points

  - For 0 to 1 point, use aspirin; 2 points, weigh risk of bleeding, adequacy of follow-up versus benefit; 3 or greater, use warfarin if at all possible.
- Patients with symptomatic carotid stenosis: Refer for carotid endarterectomy patients with 70% to 99% carotid stenosis (without near-occlusion) with ipsilateral focal neurologic signs (absolute risk reduction [ARR] 16.0%).[10] Consider referring symptomatic patients with moderate stenosis of 50% to 69% (ARR 4.6%).[10] SOR A
- Patients with asymptomatic carotic artery stenosis greater than 60%. Consider referral for carotid endarterectomy in patients younger than the age of 75 years (NNT = 20 to prevent 1 stroke in 5 years).[4]

PREVENTION

- Address modifiable risk factors: Control HTN, high cholesterol and DM; stop smoking; and maintain a healthy body weight.
- The United States Preventive Services Task Force (USPSTF) recommends the use of aspirin for women ages 55 to 79 when the potential benefit of reduction in ischemic strokes outweighs the potential harm of an increase in GI hemorrhage.[11]
- The USPSTK found the evidence insufficient to recommend for or against the use of aspirin for stroke reduction in men.[11]

PROGNOSIS

CVA prognosis varies based on size and location of ischemia or hemorrhage, time to TPA administration (for ischemic stroke), and availability of aggressive poststroke rehabilitation.

- The 30-day mortality rate after a first or second stroke is 22% and 41%, respectively.[4]
- Five-year observed survival is 40% to 68% for stroke.[12]

FOLLOW-UP

- Patients with symptoms of an acute stroke should be hospitalized, evaluated immediately for appropriateness of TPA and treatment of reversible causes, and managed, if possible, in a stroke unit or using the "best practices" associated with these units.
- After a stroke and rehabilitation, patients should be followed at regular intervals to evaluate risk reduction strategies.

PATIENT EDUCATION

Educate patients who have had a stroke about the high risk of having a second stroke, the high morbidity and mortality associated with a recurrent stroke, and the need for lifestyle modifications and medications to reduce this risk.

PATIENT RESOURCES

- The National Stroke Association has patient information including signs of a stroke and *HOPE: The Stroke Recovery Guide*—**http://www.stroke.org.**
- The Internet Stroke Center has a section for patients and families with patient education about signs of a stroke and living after a stroke—**http://www.strokecenter.org.**
- The National Institute of Neurologic Diseases and Stroke has written and auditory patient information in English and Spanish—**http://www.ninds.nih.gov.**

PROVIDER RESOURCES

- The Internet Stroke Center has a large collection of stroke scales and clinical assessment tools, a neurology image library, listings of professional resources, and evidence-based diagnosis and management strategies—**http://www.strokecenter.org.**
- Guidelines for early management of adults with ischemic stroke from the American Heart Association and other partners—**http://stroke.ahajournals.org/content/38/5/1655.full.**

REFERENCES

1. Stansbury JP, Jia H, Williams LS, et al. Ethnic disparities in stroke: epidemiology, acute care, and postacute outcomes [see comment] [review] [91 refs]. *Stroke.* 2005;36(2):374-386.
2. Schneider AT, Kissela B, Woo D, et al. Ischemic stroke subtypes: a population-based study of incidence rates among blacks and whites. *Stroke.* 2004;35(7):1552-1556.
3. Elkind MS. Inflammation, atherosclerosis, and stroke [review] [72 refs]. *Neurologist.* 2006;12(3):140-148.
4. Sanossian N, Ovbiagele B. Multimodality stroke prevention [review] [179 refs]. *Neurologist.* 2006;12(1):14-31.
5. Zhang Y, Tuomilehto J, Jousilahti P, et al. Lifestyle factors on the risks of ischemic and hemorrhagic stroke. *Arch Intern Med.* 2011;171(20):1811-1818.
6. Howard G, Cushman M, Kissela BM, et al; REasons for Geographic And Racial Differences in Stroke (REGARDS) Investigators. Traditional risk factors as the underlying cause of racial disparities in stroke: lessons from the half-full (empty?) glass. *Stroke.* 2011;42(12):3369-3375.
7. Tonarelli SB, Hart RG. What's new in stroke? The top 10 for 2004/05 [review] [25 refs]. *J Am Geriatr Soc.* 2006;54(4):674-679.
8. Maiser SJ, Georgiadis AL, Suri MF, et al. Intravenous recombinant tissue plasminogen activator administered after 3 h following onset of ischaemic stroke: a metaanalysis. *Int J Stroke.* 2011;6(1):25-32.
9. Frey JL, Jahnke HK, Goslar PW, et al. TPA by telephone: extending the benefits of a comprehensive stroke center. *Neurology.* 2005;64(1):154-156.
10. Rerkasem K, Rothwell PM. Carotid endarterectomy for symptomatic carotid stenosis. *Cochrane Database Syst Rev.* 2011;13(4):CD001081.
11. United States Preventive Services Task Force, *Aspirin for the Prevention of Cardiovascular Disease: Recommendation Statement,* AHRQ Publication No. 09-05129-EF-2. Rockville, MD: Agency for Healthcare Research and Quality; 2009. http://www.ahrq.gov/clinic/uspstf09/aspirincvd/aspcvdrs.htm. Accessed September 2, 2012.
12. Askoxylakis V, Thieke C, Pleger ST, et al. Long-term survival of cancer patients compared to heart failure and stroke: a systematic review. *BMC Cancer.* 2010;10:105.

231 SUBDURAL HEMATOMA

Heidi Chumley, MD

PATIENT STORY

A 34-year-old driver was hit from behind at approximately 25 mph. He hit his head, but did not lose consciousness and did not seek care. Approximately 12 hours later, he developed a headache and confusion, and was taken to the emergency department by a family member. He was found to have an acute subdural hematoma (**Figure 231-1**). He was hospitalized, and a neurosurgeon was consulted for surgical management.

INTRODUCTION

Subdural hematomas (SHs) can occur at any age, but are most common in infants and older adults. Most SHs are caused by trauma. Symptoms are generally nonspecific such as irritability or poor feeding in infants and confusion or headaches in adults. Treatment is prompt consultation with a neurosurgeon.

EPIDEMIOLOGY

- SHs occur at all ages. In adults, SHs are more common in men.[1]
- Eight percent of asymptomatic newborns can have an SH.[2]
- Twenty-four of 100,000 infants ages 0 to 1 year in United Kingdom population studies.[3]
- Less than 1 in 100,000 adults per year have a traumatic SH.[1]
- Forty-two of 100,000 hospitalizations for adult patients.[4]
- Cost is $1.6 billion per year in 2007 dollars.[4]
- Mortality rates in treated older adults are approximately 8% for patients younger than age 65 years and 33% for patients older than age 65 years.[5]

ETIOLOGY AND PATHOPHYSIOLOGY

- Most SHs are caused by trauma, either accidental or intentional, from a direct injury to the head or shaking injury in an infant.
- Falls, motor vehicle accidents, and assault are the most common causes of traumatic SH.[1]
- SHs have been reported from chronic jarring from rapid walking in older patients and can occur during a nontraumatic birth.
- Motion of the brain within the skull causes a shearing force to the cortical surface and interhemispheric bridging veins.[3]
- This force tears the weakest bridging veins as they cross the subdural space, resulting in an acute SH as seen in **Figure 231-1**.[3]
- Three days to 3 weeks after the injury, the body breaks down the blood in an SH; water is drawn into the collection causing hemodilution, which appears less white and more gray on noncontrast CT.[3]
- If the hematoma fails to resolve, the collection has an even higher content of water and appears darker on a noncontrast CT; it may

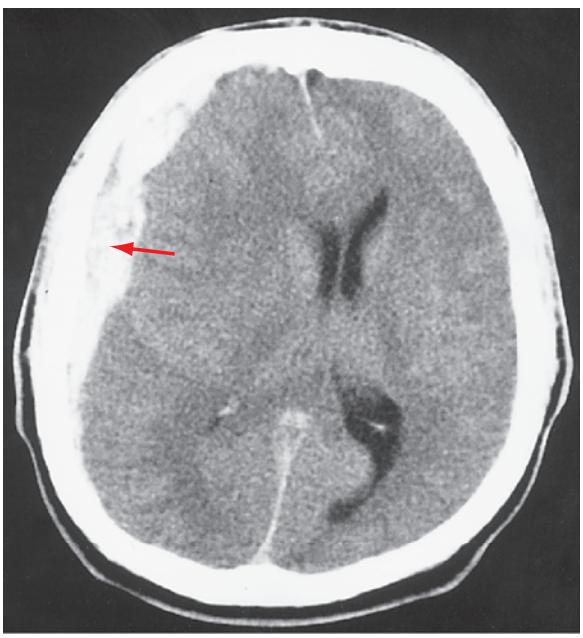

FIGURE 231-1 CT scan of an acute subdural hematoma (*arrow*) seen as a hyperdense clot with an irregular border. There is a midline shift from the mass effect of the accumulated blood. (*Courtesy of Kasper DL, Braunwald E, Fauci, AS, Hauser SL, Longo DL, Jameson JL. Harrison's Principles of Internal Medicine, 16th ed. New York, NY: McGraw-Hill; 2005:2450.*)

have fresh bleeding or may calcify (chronic SH; **Figure 231-2**).[3] This is often of the same color as brain parenchyma on noncontrast CT.

- Nontraumatic causes reported in the literature include spontaneous bleeding because of bleeding disorders or anticoagulation, meningitis, and complications of neurologic procedures, including spinal anesthesia.

RISK FACTORS

Increased mortality is seen in patients:

- Older than 80 years of age.[4]
- With lower income.[4]
- With acquired clotting abnormalities.[4,6]
- Who experienced trauma.[4]
- With a higher APACHE (Acute physiology, Age, and Chronic Health Evaluation) III score on presentation.[6]

DIAGNOSIS

The clinical features are often nonspecific, making the diagnosis difficult in the absence of known trauma.

- Infants may present with drowsiness, irritability, poor tone, poor feeding, or new seizures.[3]
- Older adults may present with headaches, confusion, subtle changes in mental status, gait disturbances, hemiparesis, or other focal neurologic signs.[7]

TYPICAL DISTRIBUTION

SHs by definition occur in the subdural space, most commonly seen in the parietal region.

IMAGING

Acute SHs are seen easily on a noncontrast CT scan (**Figure 231-1**). Subacute and chronic SHs (**Figure 231-2**) can be similar in color to the brain parenchyma and may be easier to see on a contrast CT or an MRI.

DIFFERENTIAL DIAGNOSIS

Other causes of nonspecific symptoms seen with SH can be differentiated by neuroimaging and include the following:

- Infections such as sepsis or meningitis—Fever, elevated white blood cells, positive blood cultures, and cerebral spinal fluid consistent with meningitis.
- Hemorrhagic (**Figure 231-3**) or ischemic stroke or transient ischemic attacks—Consider risk factors for stroke such as hypertension, diabetes, atrial fibrillation, and smoking (see Chapter 230, Cerebral Vascular Accident).
- Dementia or depression—Less acute onset, advanced age, and other symptoms consistent with depression.
- Primary or metastatic brain neoplasms—History of cancer and risk factors for cancer.

FIGURE 231-2 CT scan of chronic bilateral subdural hematomas. As subdural hematomas age, these become isodense gray and then hypodense (darker gray to black) compared to the brain. Some resolving blood is still visible on the left (*arrows*). (*Courtesy of Kasper DL, Braunwald E, Fauci, AS, Hauser SL, Longo DL, Jameson JL. Harrison's Principles of Internal Medicine, 16th ed. New York, NY: McGraw-Hill; 2005:2450.*)

FIGURE 231-3 Hemorrhagic stroke seen on CT. The CT image demonstrates bleeding in the right basal ganglia (*large black arrow*) into the ventricles (*small black arrows*) with midline shift (*white arrows*). (*Courtesy of Chen MYM, Pope TL Jr., Ott, DJ. Basic Radiology. New York, NY: McGraw-Hill; 2004:337.*)

Other causes of intracranial bleeding can also be differentiated by neuroimaging and include the following:

- Epidural hematoma (**Figure 231-4**)—Well-defined biconvex bright white density that resembles the shape of the lens of the eye.
- Subarachnoid hemorrhage (**Figure 231-5**)—Bright white blood outlines cerebral sulci.
- Hemorrhage in brain parenchyma—Bright white lesion apart from dura.

MANAGEMENT

Most SHs are managed surgically, and there is little evidence about conservative management.

- Determine the Glasgow Coma Scale in patients with serious head trauma and consider airway protection in patients with a score less than 12.
- Obtain an urgent noncontrast CT scan on any patient suspected of having an SH.
- If the noncontrast CT scan is nonrevealing, obtain a contrast CT or MRI, particularly if the traumatic event occurred 2 to 3 days prior.
- Emergently refer patients with an SH and deteriorating neurologic status or evidence of brain edema or midline shift to a hospital with neurosurgeons.
- Consult a neurosurgeon expediently in patients with an SH and stable focal neurologic signs.
- Consider neurosurgical consultation in asymptomatic patient or patients with only a headache and a small acute SH without brain edema or midline shift. These patients may be followed by serial CT scans without surgical treatment, but this should be done in consultation with experts in CT interpretation and management of SHs.[7] SOR C
- Evaluate any infant with an SH for child abuse or neglect.[3] SOR C

PREVENTION

- Follow safety measures that reduce motor vehicle accidents, and falls in the elderly.
- Use recommended protective gear for sports and recreational activities and follow guidelines for return to play after a head injury.
- Carefully evaluate the risks and benefits of chronic use of antiplatelet and anticoagulation medications.

PROGNOSIS

- In-hospital mortality for acute SH is 12%.[4,5]
- In-hospital mortality for traumatic SH is 26%.[1]
- Best predictor of in-hospital mortality is neurologic status on admission.[8]

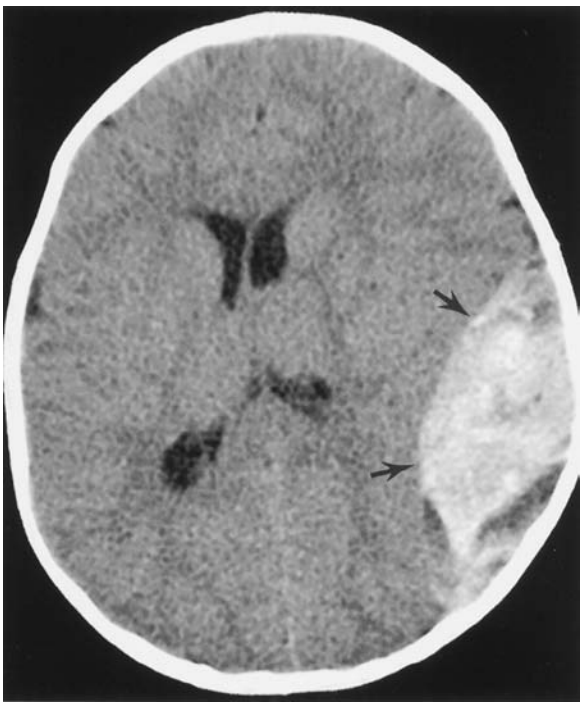

FIGURE 231-4 This head CT demonstrates an epidural hematoma, with the typical biconvex appearance (*arrows*). Note how the biconvex appearance resembles the lens of an eye. (*Courtesy of Chen MYM, Pope TL Jr., Ott, DJ. Basic Radiology. New York, NY: McGraw-Hill; 2004:346.*)

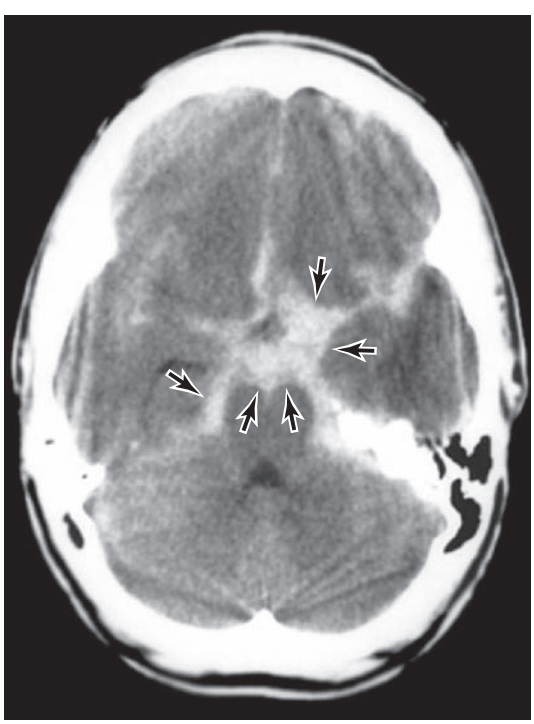

FIGURE 231-5 A subarachnoid hemorrhage appears as areas of high density (more white like bone rather than the darker gray of brain tissue) in the subarachnoid space (*arrows*). (*Courtesy of Aminoff MJ, Greenberg DA, Simon RP. Clinical Neurology, 6th ed. New York, NY: McGraw-Hill; 2005:77.*)

- In patients older than age 65 years, the mortality rate for chronic SH remains elevated until 1 year after diagnosis independent of treatment.[8]

FOLLOW-UP

- Follow-up is determined by severity of SH and type of treatment.
- Ideally, follow-up is conducted jointly between the neurosurgeon and primary care physician to ensure resolution of the SH and maximal return of function, especially in elderly patients.

PATIENT EDUCATION

- Advise patients to seek medical care immediately for head trauma, which can cause several emergencies including an SH.
- Discuss with parents or guardians the need for a thorough evaluation for child abuse and neglect in infants with an SH.

PATIENT RESOURCE

- MedlinePlus. *Subdural Hematoma*—**http://www.nlm.nih.gov/medlineplus/ency/article/000713.htm.**

PROVIDER RESOURCES

- *Head Injury. Triage, Assessment, Investigation and Early Management of Head Injury in Infants, Children and Adults*—**http://www.guidelines.gov/content.aspx?id=11468.**
- *Glasgow Coma Scale Calculator*—**www.mdcalc.com/glasgow-coma-scale-score.**

REFERENCES

1. Tallon JM, Ackroyd-Stolarz S, Darim Sa, Clarke DB. The epidemiology of surgically treated acute subdural and epidural hematomas in patients with head injuries: a population-based study. *Can J Surg.* 2008;51(5):339-345.
2. Whitby EH, Griffiths PD, Rutter S, et al. Frequency and natural history of subdural haemorrhages in babies and relation to obstetric factors [see comment]. *Lancet.* 2004;363(9412):846-851.
3. Minns RA. Subdural haemorrhages, haematomas, and effusions in infancy [comment] [review] [9 refs]. *Arch Dis Child.* 2005;90(9):883-884.
4. Frontera JA, Egorova N, Moskowittz AJ. National trend in prevalence, cost, and discharge disposition after subdural hematoma from 1998-2007. *Crit Care Med.* 2011;39(7):119-125.
5. Munro PT, Smith RD, Parke TR. Effect of patients' age on management of acute intracranial haematoma: prospective national study. *BMJ.* 2002;325(7371):1001.
6. Bershad EM, Farhadi S, Suri MF, et al. Coagulopathy and inhospital deaths in patients with acute subdural hematoma. *J Neurosurg.* 2008;109(4):664-669.
7. Karnath B. Subdural hematoma. Presentation and management in older adults. *Geriatrics.* 2004;59(7):18-23.
8. Miranda LB, Braxton E, Hobbs J, Quigley MR. Chronic subdural hematoma in the elderly: not a benign disease. *J Neurosurg.* 2011;114(1):72-76.

232 NORMAL PRESSURE HYDROCEPHALUS

Heidi Chumley, MD

PATIENT STORY

A 68-year-old man presented with a gradual onset of difficulty with his gait, increased urinary incontinence, and difficulty with his memory during the past several months. His gait was wide-based and slow, with decreased step height and length. His Mini Mental State Examination was consistent with impaired cognition. As part of his workup, he had a noncontrast head CT, which demonstrated dilated ventricles (**Figure 232-1**) without extensive cortical atrophy. He had normal cell counts and opening pressure on a spinal tap. He was diagnosed with normal pressure hydrocephalus (NPH) and referred to a neurosurgeon to be evaluated for a ventricular shunt. The patient had the shunt placed (**Figure 232-2**). His gait and urinary incontinence improved. Unfortunately, his cognitive impairments did not improve as is often the case.

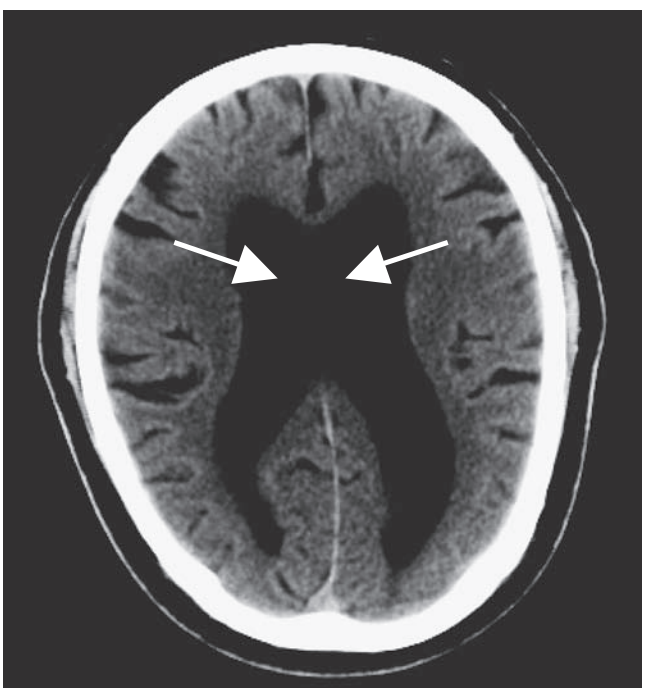

FIGURE 232-1 Noncontrast CT demonstrates enlarged lateral ventricles (*white arrows*) without significant cerebral atrophy. (*Courtesy of Reginald Dusing, MD.*)

FIGURE 232-2 Noncontrast CT shows ventricular shunt (*red arrow*) in place. Lateral ventricles remain enlarged after shunting (*white arrows*). (*Courtesy of Reginald Dusing, MD.*)

INTRODUCTION

NPH can be idiopathic or secondary to meningitis, subarachnoid hemorrhage, or head trauma, and is caused by impaired reabsorption of spinal fluid. Patients present with gait abnormalities, urinary incontinence, and/or cognitive impairment. Diagnosis is confirmed by radiographic evidence and a normal opening pressure on lumbar puncture.

EPIDEMIOLOGY

- Prevalence—1 in 250 in those older than age 65 years; determined in a door-to-door survey in Germany.[1]
- Incidence—1 to 2/100,000 population per year; determined by number of surgeries in Sweden.[2]
- Most common between the ages of 60 to 70 years.
- Five percent of dementias are caused by NPH.[3]

ETIOLOGY AND PATHOPHYSIOLOGY

- Cerebral spinal fluid (CSF) is produced by the choroid plexus, circulates through the ventricles, exits into the subarachnoid space, and is reabsorbed by the arachnoid granulations at the top of the brain.[3]
- NPH is thought to be due to impaired reabsorption and can be idiopathic or secondary to meningitis, subarachnoid hemorrhage, or head trauma.

DIAGNOSIS

NPH is a clinical diagnosis based on signs and symptoms, CSF studies, radiographic imaging, and a clinical response to ventriculoperitoneal (VP) shunting.

CLINICAL FEATURES

Classic triad is gait disturbance, urinary incontinence, and cognitive impairment:

- Gait disturbances typically occur first—Wide-based stance; slow, shuffling steps; difficulty with initiation.[3]
- Urinary incontinence usually with urgency; abnormal detrusor contractions on urodynamic studies.[3]
- Cognitive impairment—Difficulty with attention and concentration (digit span, arithmetic) with sparing of orientation and general memory.[4]

LABORATORY TESTING

- CSF had normal cell counts and opening pressure less than 200 mm Hg.[3]
- High-volume spinal tap (removal of 30 to 66 cc of CSF) or prolonged CSF drainage (3 to 5 days via an indwelling catheter) followed by clinical improvement can be helpful in selecting patients more likely to respond to VP shunting.[5]
- Continuous monitoring of intracranial pressure demonstrates characteristic waves of NPH; however, this is done only in specialized centers.

IMAGING

- Enlarged ventricles without substantial cerebral atrophy can be seen on CT or MRI.
- Cisternography, a nuclear medicine test, can demonstrate impaired clearing of CSF from the lateral ventricles at 48 hours (**Figure 232-3**), which is useful in predicting which patients respond to shunting[6]

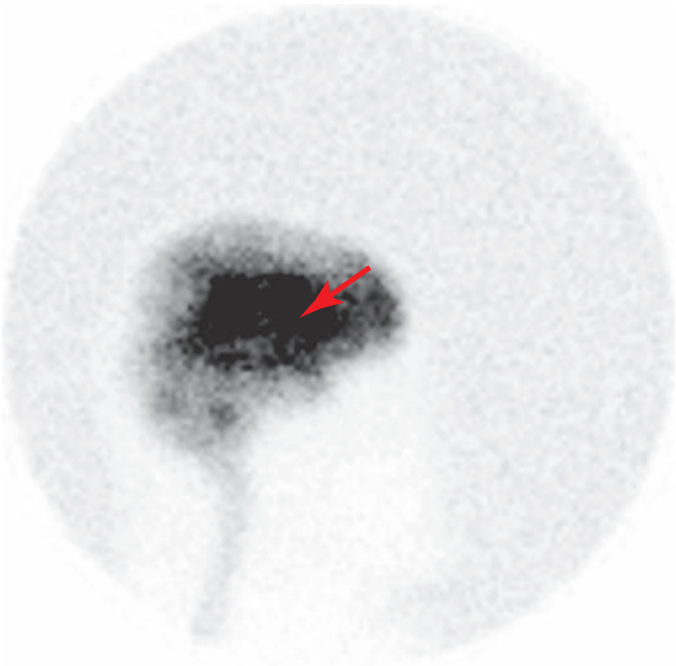

FIGURE 232-3 Lateral view on cisternography demonstrates increased uptake in the lateral ventricle (*red arrow*). In this nuclear medicine study, indium is injected into the cerebral spinal fluid at the lower lumbar spine and a scan is done 48 hours later. Normally, the indium-tagged spinal fluid has been reabsorbed at 48 hours, and the lateral ventricle does not have increased uptake. (*Courtesy of Reginald Dusing, MD.*)

DIFFERENTIAL DIAGNOSIS

- Alzheimer disease—Impaired orientation and memory, which are often spared in NPH; cortical atrophy.
- Parkinson disease—Tremor and rigidity in addition to bradykinesia and gait disturbances; normal neuroimaging.
- Chronic alcoholism—History of alcohol use, memory and learning difficulties; cortical atrophy.
- Multiinfarct dementia, atherosclerotic disease, subdural hematomas, and tumors—Identifiable on neuroimaging.
- Intracranial infections or carcinomatous meningitis—Abnormal CSF findings.

- Hypothyroidism—Has other symptoms such as fatigue, weakness, dry and cool skin, diffuse hair loss, cold intolerance, constipation, and difficulty concentrating. The thyroid-stimulating hormone (TSH) is elevated and there is no urinary incontinence (see Chapter 226, Goitrous Hypothyroidism).

MANAGEMENT

Refer to a neurosurgeon to evaluate for VP shunting (**Figure 232-2**).

- VP shunting is the only known effective treatment (**Figure 232-2**). In larger retrospective studies, 39% to 75% of patients demonstrated improvement by 24 months.[5,7]
- The risks of VP shunting can be substantial; moderate to severe complications occurred in 28% of patients in one study[7]; more recent reviews report a 6% complication rate.[8]
- Repetitive lumbar punctures may be considered in patients who cannot undergo surgery.[9]

PROGNOSIS

- In one study, patients demonstrated improvements in gait (81.1%), urinary incontinence (55.9%), and dementia (64.4%) after surgery. Surgical complications occurred in approximately 6% of patients.[8]
- Favorable prognostic factors include—Gait abnormality as the presenting or dominant symptom, symptoms less than 6 months prior to treatment, and an identified cause (i.e., because of head trauma).[10]
- Poor prognostic factors include—Dementia preceding gait abnormality or dementia for more than 2 years.[10]

FOLLOW-UP

Long-term multidisciplinary follow-up can facilitate gait and bladder retraining and early recognition of signs of shunt malfunction including vomiting, headache, fever, or seizures.

PATIENT EDUCATION

Advise patients that improvements from VP shunting:

- Do not occur for all patients.
- Appear slowly over several months.
- May last several years.
- Are more likely to involve gait disturbances rather than cognitive deficits.

Advise patients to inform any healthcare provider they see about their VP shunt.

PATIENT RESOURCES

- eMedicineHealth. *Normal Pressure Hydrocephalus*—**http://www.emedicinehealth.com/normal_pressure_hydrocephalus/article_em.htm.**
- The National Institute of Neurologic Disorders and Stroke. *Normal Pressure Hydrocephalus Information Page*—**http://www.ninds.nih.gov/disorders/normal_pressure_hydrocephalus/normal_pressure_hydrocephalus.htm.**

PROVIDER RESOURCE

- Medscape. *Normal Pressure Hydrocephalus*—**http://emedicine.medscape.com/article/1150924.**

REFERENCES

1. Trenkwalder C, Schwarz J, Gebhard J, et al. Starnberg trial on epidemiology of Parkinsonism and hypertension in the elderly. Prevalence of Parkinson's disease and related disorders assessed by a door-to-door survey of inhabitants older than 65 years. *Arch Neurol.* 1995;52(10):1017-1022.
2. Tisell M, Hoglund M, Wikkelso C. National and regional incidence of surgery for adult hydrocephalus in Sweden. *Acta Neurol Scand.* 2005;112(2):72-75.
3. Verrees M, Selman WR. Management of normal pressure hydrocephalus [summary for patients in *Am Fam Physician*. 2004;70(6):1085-1086; PMID: 15456117]. *Am Fam Physician.* 2004;70(6):1071-1078.
4. Ogino A, Kazui H, Miyoshi N, et al. Cognitive impairment in patients with idiopathic normal pressure hydrocephalus. *Dement Geriatr Cogn Disord.* 2006;21(2):113-119.
5. McGirt MJ, Woodworth G, Coon AL, et al. Diagnosis, treatment, and analysis of long-term outcomes in idiopathic normal-pressure hydrocephalus. *Neurosurgery.* 2005;57(4):699-705; discussion 699-705.
6. Algin O, Hakyemez B, Ocakoglu G, Parlak M. MR cisternography: is it useful in the diagnosis of normal-pressure hydrocephalus and the selection of "good shunt responders"? *Diagn Interv Radiol.* 2011;17(2):105-11.
7. Vanneste J, Augustijn P, Dirven C, et al. Shunting normal-pressure hydrocephalus: Do the benefits outweigh the risks? A multicenter study and literature review [review] [46 refs]. *Neurology.* 1992;42(1):54-59.
8. Cage TA, Auguste KI, Wrensch M, et al. Self-reported functional outcome after surgical intervention in patients with idiopathic normal pressure hydrocephalus. *J Clin Neurosci.* 2011;18(5):649-54.
9. Lim TS, Yong SW, Moon SY. Repetitive lumbar punctures as treatment for normal pressure hydrocephalus. *Eur Neurol.* 2009;62(5):293-7.
10. Siraj S. An overview of normal pressure hydrocephalus and its importance: how much do we really know? *J Am Med Dir Assoc.* 2011;12(1):19-21.

233 BELL'S PALSY

Heidi Chumley, MD

PATIENT STORY

Five years ago, a young woman awoke with the inability to move the left side of her face. She was pregnant at that time. On examination it was found that she had absent brow furrowing, weak eye closure, and dropping of her mouth angle (**Figure 233-1**). She was diagnosed with Bell's palsy and was provided eye lubricants and guidance on keeping her left eye moist. Her physician discussed the available evidence about treatment with steroids. She chose not to take the steroids because of her pregnancy.

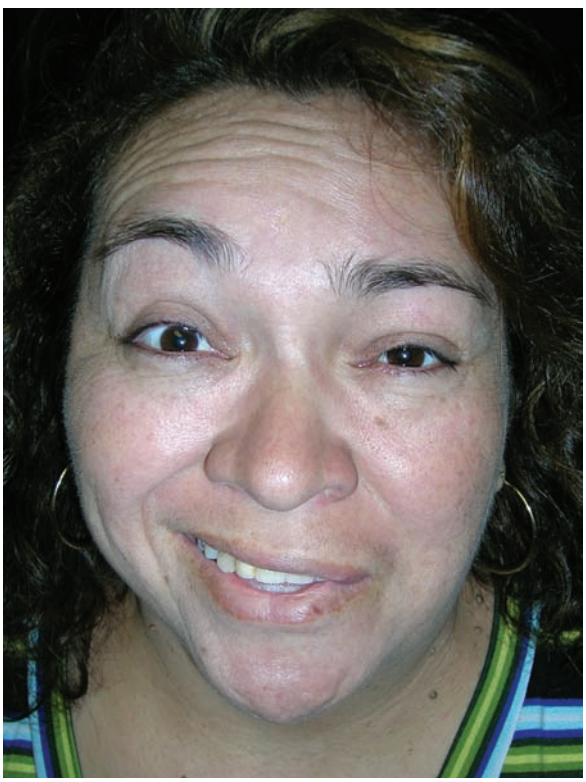

FIGURE 233-1 Bell's palsy with loss of brow furrowing and dropped angle of the mouth on the affected left side of her face demonstrated during a request to smile and raise her eyebrows. The Bell's palsy has been present for 5 years and the patient is being evaluated by ear, nose, and throat (ENT) for surgery to restore facial movement. (*Courtesy of Richard P. Usatine, MD.*)

INTRODUCTION

Bell's palsy is an idiopathic paralysis of the facial nerve resulting in loss of brow furrowing, weak eye closure, and dropped angle of mouth. Treatment is oral steroids as soon after the onset of symptoms as possible. Most patients have a full recovery within 6 months.

SYNONYMS

Idiopathic facial paralysis.

EPIDEMIOLOGY

- In a Canadian study, incidence was 13.1 to 15.2/100,000 adults.[1]
- In a study of United States military members, the incidence was 42.77/100,000, with higher incidence in females, blacks, and Hispanics; arid climate and cold months were independent predictors of risk with adjusted relative risk ratios of 1.34 and 1.31, respectively.[2]
- Women who develop Bell's palsy in pregnancy have a 5-fold increased risk over national average of preeclampsia or gestational hypertension.[3]
- Seventy percent of cases of acute peripheral facial nerve palsy are idiopathic (Bell's palsy); 30% have known etiologic factors such as trauma, diabetes mellitus, polyneuritis, tumors, or infections such as herpes zoster, leprosy (**Figure 233-2**) or *Borrelia*.[4]

FIGURE 233-2 Bell's palsy secondary to leprosy. The hypopigmented patches on his back are further signs of the leprosy. (*Courtesy of Richard P. Usatine, MD.*)

ETIOLOGY AND PATHOPHYSIOLOGY

- Etiology of Bell's palsy is currently unknown and under debate; the prevailing theory suggests a viral etiology from the herpes family.
- The facial nerve becomes inflamed, resulting in nerve compression.
- Compression of the facial nerve compromises muscles of facial expression, taste fibers to the anterior tongue, pain fibers, and secretory fibers to the salivary and lacrimal glands.

- This is a lower motor neuron lesion; the upper and lower portions of the face are affected (**Figure 233-1**). In upper motor neuron lesions (e.g., cortical stroke), the upper third of the face is spared, while the lower two-thirds are affected as a result of the bilateral innervation of the orbicularis, frontalis, and corrugator muscles, which allows sparing of upper face movement.

DIAGNOSIS

CLINICAL FEATURES

- Weakness of all facial muscles on the affected side—Loss of brow furrowing, weak eye closure, and dropped angle of mouth.
- Postauricular pain.
- Dry eyes.
- Involuntary tearing.
- Hyperacusis.
- Altered tastes.

LABORATORY TESTING

Laboratory testing is not usually indicated:

- Herpes virus titers are not usually helpful.
- Consider serologic tests for Lyme disease in endemic areas.
- Consider testing for diabetes mellitus in patients with risk factors.

IMAGING

- Consider MRI to look for a space-occupying lesion with atypical presentations.

DIFFERENTIAL DIAGNOSIS

- Upper motor neuron diseases including stroke—Normal brow furrowing, eye closure, and blinking.
- Space-occupying lesion—Symptoms are dependent on the location of the mass; consider with an isolated facial nerve palsy that does not affect all three branches of the facial nerve.
- Lyme disease—Occurs in endemic area with skin rash, joint inflammation, and flu-like symptoms. Bell's palsy is the most common neurologic manifestation of Lyme disease (see Chapter 218, Lyme Disease).
- Suppurative ear disease—Ear pain, abnormal tympanic membrane, and more common in children.
- Facial nerve damage from microvascular disease—Most commonly in diabetes mellitus.
- Facial nerve damage from trauma—History of trauma differentiates this from Bell's palsy that is idiopathic or from an infectious etiology.
- Isolated third nerve palsy—Manifestations include diplopia and drooping of the upper eyelid (ptosis) (**Figure 233-3**). The affected eye may deviate out and down in straight-ahead gaze; adduction is slow and cannot proceed past the midline. Upward gaze is

FIGURE 233-3 Ptosis from an isolated third nerve palsy in a patient with diabetes. Note the symmetry of the facial creases, which would be absent in Bell's palsy. This patient would also have abnormal eye movements. The eye would deviate down and out, adduction would not pass the midline, and upward gaze would be impaired. (*Courtesy of Richard P. Usatine, MD.*)

impaired. When downward gaze is attempted, the superior oblique muscle causes the eye to adduct. The pupil may be normal or dilated; its response to direct or consensual light may be sluggish or absent (efferent defect). Pupil dilation (mydriasis) may be an early sign.

MANAGEMENT

NONPHARMACOLOGIC

- Provide eye protection with artificial tears, lubricants, or closing of the eyelid. SOR C

MEDICATIONS

- New data and a Cochrane systematic review supports treating patients with systemic corticosteroids. Steroids significantly decrease a patient's risk for incomplete recovery from 33% to 23%, risk ratio 0.71.[5] SOR A
  - Dosing of steroids in the studies analyzed within the Cochrane review varied from oral methylprednisolone 1 mg/kg daily for 10 days, and then gradually withdrawn for another 3 to 5 days to prednisone given as a single dose of 60 mg daily for 5 days, followed by a dose reduced by 10 mg, per day, with a total treatment of 10 days. One trial used high-dose prednisolone given intravenously.
- A Cochrane systematic review does not support using antiviral medications. There is no significant benefit from acyclovir or valacyclovir when compared to placebo. Antivirals are less likely than steroids to produce complete recovery.[6] SOR A

COMPLEMENTARY AND ALTERNATIVE THERAPY

Acupuncture has been studied; the data, however, is inadequate to determine the efficacy.[7]

REFERRAL

- In longstanding facial paralysis, consider referral to an ear, nose, and throat (ENT) surgeon or plastic surgeon with experience in treating Bell's palsy with surgery. It is possible to restore some facial movement with specialized surgical procedures including regional muscle transfer and microvascular free tissue transfer.[8] SOR C

PROGNOSIS

Seventy-seven percent of patients treated with systemic steroids have complete recovery of facial motor function in 6 months.

FOLLOW-UP

Consider seeing patients in 2 to 3 weeks to evaluate recovery and to reconsider diagnosis if there has been no recovery, particularly in children.

PATIENT EDUCATION

- Most patients recover spontaneously. Steroid treatment improves a patient's chance of complete recovery.
- Ninety-five percent of children recover; 70% recover within 3 weeks.

PATIENT RESOURCES

- The American Academy of Family Physicians has written and auditory information in English and in Spanish—**http://www.familydoctor.org.**
- FamilyDoctor.org. *Bell's Palsy Overview*—**http://familydoctor.org/familydoctor/en/diseases-conditions/bells-palsy.html.**
- The National Institute of Neurologic Disorders and Stroke has written and auditory patient information in English and Spanish—**http://www.ninds.nih.gov/disorders/bells/bells.htm.**

PROVIDER RESOURCES

- The Cochrane Collaborative contains updated systematic reviews of steroid and/or antiviral treatment of Bell palsy at **http://onlinelibrary.wiley.com/doi/10.1002/14651858.CD001942.pub4/full.**
- **http://onlinelibrary.wiley.com/doi/10.1002/14651858.CD001869.pub4/full.**

REFERENCES

1. Morris AM, Deeks SL, Hill MD, et al. Annualized incidence and spectrum of illness from an outbreak investigation of Bell's palsy. *Neuroepidemiology*. 2002;21(5):255-261.
2. Campbell KE, Brundage JF. Effects of climate, latitude, and season on the incidence of Bell's palsy in the US Armed Forces, October 1997 to September 1999. *Am J Epidemiol*. 2002;156(1):32-39.
3. Shmorgun D, Chan WS, Ray JG. Association between Bell's palsy in pregnancy and pre-eclampsia. *QJM*. 2002;95(6):359-362.
4. Berg T, Jonsson L, Engstrom M. Agreement between the Sunnybrook, House-Brackmann, and Yanagihara facial nerve grading systems in Bell's palsy. *Otol Neurotol*. 2004;25(6):1020-1026.
5. Salinas RA, Alvarez G, Daly F, Ferreira J. Corticosteroids for Bell's palsy (idiopathic facial paralysis). *Cochrane Database Syst Rev*. 2010;(3):CD001942.
6. Lockhart P, Daly F, Pitkethly M, et al. Antiviral treatment for Bell's palsy (idiopathic facial paralysis.) *Cochrane Database Syst Rev*. 2009;(4):CD001869.
7. Chen N, Zhou M, He L, et al. Acupuncture for Bell's palsy. *Cochrane Database Syst Rev*. 2010;(8):CD002914.
8. Chuang DC. Free tissue transfer for the treatment of facial paralysis. *Facial Plast Surg*. 2008;24(2):194-203.

234 NEUROFIBROMATOSIS

Heidi Chumley, MD

PATIENT STORY

A 44-year-old Hispanic man has neurofibromatosis type 1 (NF-1). He has typical features of NF-1, including eight café-au-lait spots, axillary freckling, and neurofibromas all over his body (**Figures 234-1** to **234-4**). He states that he is used to having the NF and it does not currently affect his work or life. He is happily married but never had children. No intervention is necessary at this time other than recommending yearly visits to his family physician and ophthalmologist.

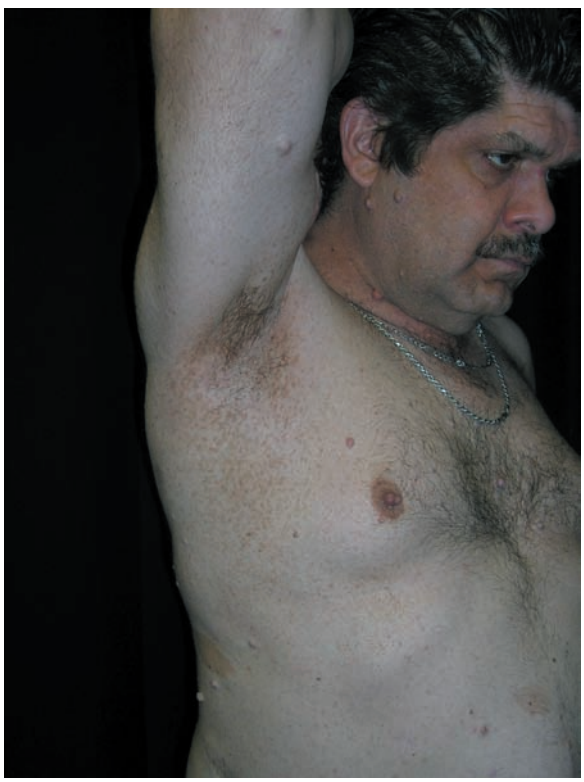

FIGURE 234-1 A 44-year-old Hispanic man with neurofibromatosis type 1 showing all the typical findings including neurofibromas, café-au-lait spots, and axillary freckling. (*Courtesy of Richard P. Usatine, MD.*)

INTRODUCTION

NF-1 is a common autosomal dominant disorder that predisposes to tumor formation. Café-au-lait spots are often the first clinical sign. Other clinical signs include neurofibromas, axillary or inguinal freckling, optic gliomas, Lisch nodules, and sphenoid bone dysplasia. Treatment at present is early recognition and monitoring for complications such as cognitive dysfunction, scoliosis or other orthopedic problems, tumor pressure on vital structures, or malignant transformation.

EPIDEMIOLOGY

- NF-1 is relatively common—Birth incidence is 1 in 3000 and prevalence in the general population is 1 in 5000.[1]
- Autosomal-dominant inheritance; however, up to 50% of cases are sporadic.[1]
- Diagnosis is typically made during childhood.

ETIOLOGY AND PATHOPHYSIOLOGY

- Mutations in the NF-1 gene (on the long arm of chromosome 17) result in loss of function of neurofibromin, which helps keep protooncogene ras (which increases tumorigenesis) in an inactive form.
- Loss of neurofibromin results in increased protooncogene ras activity in neurocutaneous tissues, leading to tumorigenesis.[1]

RISK FACTORS

A first-degree relative with NF-1.

DIAGNOSIS

For a diagnosis of NF-1, patients need to have at least 2 of the following:[2]

1. Two or more neurofibromas (**Figures 234-1** to **234-6**) or one or more plexiform neurofibromas (**Figure 234-7**).

FIGURE 234-2 Close-up of neurofibromas on the back of the man in Figure 234-1. These are soft and round. (*Courtesy of Richard P. Usatine, MD.*)

2. Six or more café-au-lait spots, 0.5 cm or larger before puberty and 1.5 cm or larger after puberty (**Figures 234-3** and **234-4**).
3. Axillary or inguinal freckling (**Figures 234-1** and **234-4**).
4. Optic glioma.
5. Two or more Lisch nodules (melanotic iris hamartomas) (**Figure 234-8**).
6. Dysplasia of the sphenoid bone or dysplasia/thinning of long bone cortex.
7. A first-degree relative with NF-1.

CLINICAL FEATURES

History and physical:

- Ninety-five percent have café-au-lait macules, mostly before the age of 1 year.
- Ninety percent have axillary or inguinal freckling (**Figures 234-1** and **234-4**).
- Eighty-one percent have cognitive dysfunction manifest as learning disorder, attention deficit hyperactivity disorder, or mild cognitive impairment.[3]
- Nerve sheath, intracranial, or spinal tumors.
- Cutaneous or subcutaneous neurofibromas (**Figures 234-1** to **234-6**).
- Other bony pathology, including dysplasia of the sphenoid or long bones, scoliosis, or short stature.
- Eye abnormalities, including Lisch nodules or early glaucoma (**Figure 234-7**).

LABORATORY TESTING

- Genetic testing for couples considering having children.

IMAGING

- Although not typically used for diagnosis, imaging may be needed if tumor compression of vital structures is suspected.

DIFFERENTIAL DIAGNOSIS

NF-1 is the predominant cause of café-au-lait spots, which can also be seen in the following cases:

- Normal childhood—13% to 27% of children younger than 10 years of age have at least 1 spot.
- Neurofibromatosis type 2 (NF-2)—Vestibular schwannomas, family history of NF-2, meningioma, glioma, schwannoma, juvenile posterior subcapsular lenticular opacities, or juvenile cortical cataracts.
- Tuberous sclerosis—Angiofibromas (skin-colored telangiectatic papules most commonly in the nasolabial folds, cheek, or chin; **Figure 234-9**) and hypopigmented ovoid or ash leaf-shaped macules.
- McCune-Albright syndrome—Fibrous dysplasia of bone and endocrine gland hyperactivity.
- Fanconi anemia—Decreased production of all blood cells, short stature, upper limb anomalies, genital changes, skeletal anomalies,

FIGURE 234-3 Large café-au-lait spot on the back of the man in **Figure 234-1**. Café-au-lait spots are ovoid hyperpigmented macules, 10 to 40 mm in diameter, with smooth borders. (*Courtesy of Richard P. Usatine, MD.*)

FIGURE 234-4 Close-up of axillary freckling (Crow sign) with large café-au-lait spot on arm. (*Courtesy of Richard P. Usatine, MD.*)

FIGURE 234-5 A man with neurofibromatosis covered with neurofibromas. (*Courtesy of Jack Resneck, Sr., MD.*)

eye/eyelid anomalies, kidney malformations, ear anomalies/deafness, and GI/cardiopulmonary malformations.

- Segmental NF—Cutaneous neurofibromas limited to specific dermatome(s); very rare.
- Bloom syndrome—Growth delay and short stature, increased risk of cancer, telangiectatic erythema on the face, cheilitis, narrow face, prominent nose, large ears, and long limbs.
- Ataxia telangiectasia—Progressive neurologic impairment, cerebellar ataxia, immunodeficiency, impaired organ maturation, ocular and cutaneous telangiectasia, and a predisposition to malignancy.
- Proteus syndrome—Very rare condition with hamartomatous and multisystem involvement. Joseph Merrick (also known as "the elephant man") is now, in retrospect, thought by clinical experts to have had Proteus syndrome and not NF.

MANAGEMENT

Management focuses on early recognition and treatment of manifestations.

- Evaluate children twice a year and adults annually. SOR C
- Screen for cognitive impairment and refer early for intervention. SOR C
- Screen for scoliosis and treat accordingly.
- Refer patients annually for ophthalmologic evaluation.
- Consider treatment or referral for treatment of café-au-lait spots if desired by the patient. Topical vitamin D_3 analogs (calcipotriene [Dovonex]) and laser therapy independently may improve the appearance of café-au-lait spots.[4,5] SOR B One small study suggests that intense pulsed light–radio frequency (IPL-RF) in combination with topical application of vitamin D_3 ointment may lighten small-pigmented lesions in patients with NF-1.[6] SOR B Although calcipotriene is approved for use in psoriasis, it can be prescribed off-label to patients disturbed by their hyperpigmented macules.[4,6] SOR B
- Examine other undiagnosed first-degree relatives. SOR C
- Surgical excision of tumors is required for tumors pressing on vital structures (i.e., spinal cord impingement) or when characteristics such as rapid enlargement are worrisome for malignant transformation.

PROGNOSIS

- Clinical manifestations are variable leading to difficulty in prognosis.
- There is a 10% lifetime risk of developing a malignant peripheral nerve sheath tumor.

FOLLOW-UP

- Primary care evaluation biannually for children; annually for adults, including monitoring of blood pressure.

FIGURE 234-6 Neurofibromatosis in a 62-year-old black woman. Note how large some the neurofibromas can become. (*Courtesy of Richard P. Usatine, MD.*)

FIGURE 234-7 Plexiform neurofibroma on the thenar eminence feels like a bag of worms in this man with neurofibromatosis. It is a benign tumor of the peripheral nerve sheath and is most often asymptomatic. (*Courtesy of Richard P. Usatine, MD.*)

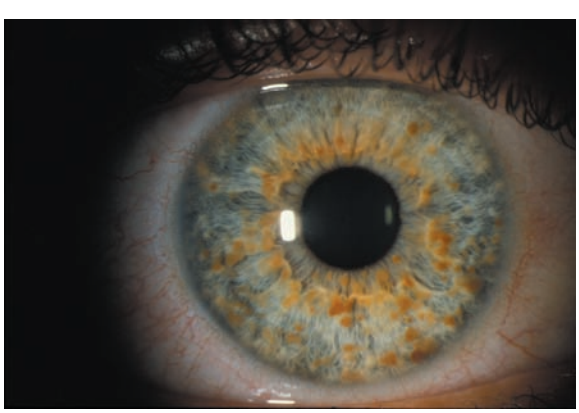

FIGURE 234-8 Lisch nodules (melanotic hamartomas of the iris) are clear yellow-to-brown, dome-shaped elevations that project from the surface of this blue iris. These hamartomas are the most common type of ocular involvement in neurofibromatosis type 1 and do not affect vision. (*Courtesy of Paul Comeau.*)

- Ophthalmologic examination annually for children and adults for early detection of optic gliomas and glaucoma. Neurofibromas and plexiform neuromas can occur on the eyelids. Neurofibromas on the eyelids usually are not a problem (**Figure 234-10**) but a plexiform neuroma can present with ptosis and need surgical intervention.
- Genetic counseling for patients with NF-1 considering having children.

PATIENT RESOURCES

- Neurofibromatosis, Inc. has a variety of patient education materials, information about local support groups, ongoing clinical trials, and camp New Friends for children with NF—**http://www.nfinc.org.**
- The National Institute of Neurological Diseases and Stroke has patient information at its *Neurofibromatosis Information Page*—**http://www.ninds.nih.gov/disorders/NF/NF.htm.**

PROVIDER RESOURCE

- Neurofibromatosis, Inc. has a variety of resources including NF specialists by location—**http://www.nfinc.org.**

FIGURE 234-9 Angiofibromas (previously called adenoma sebaceum) on the face of a patient with tuberous sclerosis. The patient was originally thought to have neurofibromatosis. He also has epilepsy and cognitive impairment, which accompanies with tuberous sclerosis. (*Courtesy of Natalie Norman, MD.*)

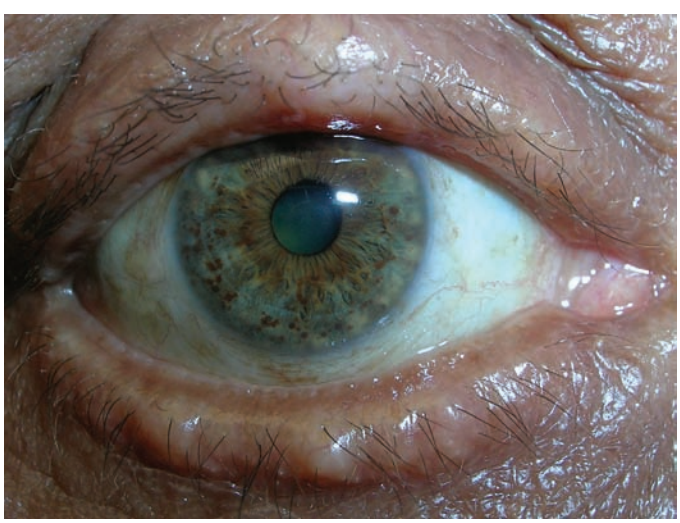

FIGURE 234-10 Neurofibromas on the lower lid with Lisch nodules (dark brown spots) on the iris of this 64-year-old man with neurofibromatosis type 1. (*Courtesy of Richard P. Usatine, MD.*)

REFERENCES

1. Yohay K. Neurofibromatosis types 1 and 2 [review] [65 refs]. *Neurologist*. 2006;12(2):86-93.
2. Hirsch NP, Murphy A, Radcliffe JJ. Neurofibromatosis: clinical presentations and anaesthetic implications [review] [114 refs]. *Br J Anaesth*. 2001;86(4):555-564.
3. Hyman SL, Shores A, North KN. The nature and frequency of cognitive deficits in children with neurofibromatosis type 1. *Neurology*. 2005;65(7):1037-1044.
4. Nakayama J, Kiryu H, Urabe K, et al. Vitamin D3 analogues improve café au lait spots in patients with von Recklinghausen's disease: experimental and clinical studies. *Eur J Dermatol*. 1999;9(3):202-206.
5. Shimbashi T, Kamide R, Hashimoto T. Long-term follow-up in treatment of solar lentigo and café-au-lait macules with Q-switched ruby laser. *Aesthetic Plast Surg*. 1997;21(6):445-448.
6. Yoshida Y, Sato N, Furumura M, Nakayama J. Treatment of pigmented lesions of neurofibromatosis 1 with intense pulsed-radio frequency in combination with topical application of vitamin D_3 ointment. *J Dermatol*. 2007;34(4):227-230.

PART 18

SUBSTANCE ABUSE

Strength of Recommendation (SOR)	Definition
A	Recommendation based on consistent and good-quality patient-oriented evidence.*
B	Recommendation based on inconsistent or limited-quality patient-oriented evidence.*
C	Recommendation based on consensus, usual practice, opinion, disease-oriented evidence, or case series for studies of diagnosis, treatment, prevention, or screening.*

*See Appendix A on pages 1447–1450 for further information.

235 SUBSTANCE ABUSE DISORDER

Richard P. Usatine, MD
Heidi Chumley, MD
Kelli Hejl, MA

PATIENT STORY

A 21-year-old mother and her 4 children are being seen in a free clinic within a homeless shelter for various health reasons (**Figure 235-1**). The woman is currently clean and sober, but has a long history of cocaine use and addiction (**Figure 235-2**). Her children span the ages of 3 months to 5 years. She was recently living with her mother after the birth of her youngest child, but was kicked out of her mother's home when she went out to use cocaine once again. The patient gave written consent to the photograph and when she was shown the image on the digital camera she noted how depressed she looked. She asked for us to tell the viewers of this photograph that these can be the consequences of drug abuse—being depressed, homeless, and a single mom.

FIGURE 235-1 A cocaine-addicted mother with her children in a homeless shelter. Her drug addiction resulted in their homelessness. (*Courtesy of Richard P. Usatine, MD.*)

INTRODUCTION

Addiction occurs when substance use has altered brain function to an extent that an individual loses a degree of control over his or her behaviors. Addiction is an epigenetic phenomenon. Many genes influence the brain functions that affect behavior and genetic variants. These genes differ in their susceptibility to environmental conditions, which trigger the changes in brain circuitry, and contribute to the development of addiction. Addiction must be recognized and treated as a chronic illness with an interprofessional team and social support.

EPIDEMIOLOGY

- An estimated 69.6 million Americans age 12 years or older were current users of a tobacco product in 2010. This represents 27.4% of the population in that age range. In addition, 58.3 million persons (23% of the population) were current cigarette smokers, 13.2 million (5.2%) smoked cigars, 8.9 million (3.5%) used smokeless tobacco, and 2.2 million (0.8%) smoked tobacco in pipes.[1]
- An estimated 22.6 million Americans age 12 years or older were current illicit drug users in 2010. This represents 8.9% of the population in that age range.[1]
- Marijuana was the most commonly used illicit drug (17.4 million users) (**Figures 235-3** and **235-4**). It was used by 76.8% of current illicit drug users. Among current illicit drug users, 60.1% used only marijuana, 16.7% used marijuana and another illicit drug, and the remaining 23.2% used only an illicit drug other than marijuana.[1]
- There were 1.5 million persons who were current cocaine users in 2010.[1]

FIGURE 235-2 Purified cocaine. (*Courtesy of DEA.*)

- There were 353,000 persons who were current methamphetamine users in 2010 (**Figure 235-5**).[1]
- Hallucinogens were used by 1.2 million persons (0.5%) in 2010, including 695,000 (0.3%) who had used Ecstasy (**Figure 235-6**).[1]
- In 2010, 140,000 persons used heroin for the first time (**Figure 235-7**).[1]
- There were 9 million people age 12 years or older (3.6%) who were current users of illicit drugs other than marijuana in 2010. Most (7 million, 2.7%) used psychotherapeutic drugs (including prescription drugs) nonmedically. Of these, 5.1 million used pain relievers, 2.2 million used tranquilizers, 1.1 million used stimulants and 374,000 used sedatives.[1]
- Among persons who used pain relievers nonmedically in the past 12 months, 55% reported that the source of the drug the was from a friend or relative for free. Another 17.3% reported that they got the drug from a physician. Only 4.4% obtained the pain relievers from a drug dealer or other stranger, and only 0.4% reported buying the drug on the Internet.[1]

FIGURE 235-3 Home-grown marijuana plant. (*Courtesy of DEA.*)

ASSOCIATION WITH CIGARETTE AND ALCOHOL USE

- In 2010, the rate of current illicit drug use was 8.5 times higher among youths age 12 to 17 years who smoked cigarettes in the past month (52.9%) than it was among youths who did not smoke cigarettes in the past month (6.2%).[1]
- Past month illicit drug use was also associated with the level of past month alcohol use. Among youths age 12 to 17 years in 2010 who were heavy drinkers (i.e., drank 5 or more drinks on the same occasion [i.e., at the same time or within a couple of hours] on each of 5 or more days in the past 30 days), 70.6% were also current illicit drug users, which was higher than among nondrinkers (5.1%).[1]

FIGURE 235-4 Marijuana ready to be smoked. (*Courtesy of DEA.*)

ETIOLOGY AND PATHOPHYSIOLOGY

- "Drug addiction is a brain disease. Although initial drug use might be voluntary, drugs of abuse have been shown to alter gene expression and brain circuitry, which in turn affect human behavior. Once addiction develops, these brain changes interfere with an individual's ability to make voluntary decisions, leading to compulsive drug craving, seeking and use."[2]
- Addiction is a polygenic disorder. Many genes have direct or indirect influences on neurotransmitters, drug metabolic pathways and behavioral patterns. For example, variants of receptors for dopamine or opiates influences perceived reward.[3]
- Epigenetic mechanisms, external influences that trigger changes in gene expression, are believed to play a role through modulation of reward and emotion.[3] As such, both genetics and environment/learned behaviors can increase a person's risk for substance abuse.
- Family, twin, and adoption studies convincingly demonstrate that genes play an important role in the development of alcohol dependence, with heritability estimates in the range of 50% to 60% for both men and women. Important genes include those involved in alcohol metabolism, and those involved in γ-aminobutyric acid



FIGURE 235-5 Methamphetamine ice with pipe. (*Courtesy of DEA.*)

(GABA), endogenous opioid, dopaminergic, cholinergic, and serotonergic transmission.[4]

- Several drinking behaviors, including alcohol dependence, history of blackouts, age at first drunkenness, and level of response to alcohol are associated with single-nucleotide polymorphisms (SNPs) within 1 of 4 GABA receptor genes on chromosome 5q.[5]
- Comorbid mental health issues and chronic pain disorders are highly prevalent among persons with substance abuse disorders. Commonly, a person begins using drugs to self-treat feelings of depression and symptoms of pain.
- The medical consequences of addiction are far reaching and very costly to society. Cardiovascular disease, stroke, cancer, HIV/AIDS, hepatitis, and lung disease can all be increased by drug abuse. Some of these effects occur when drugs are used at high doses or after prolonged use. Some consequences occur after just 1 use.[2]
- Classes of substances that are frequently abused and involved in addiction include:
  - Depressants—Alcohol, sedatives, hypnotics, opioids, and anxiolytics.
  - Stimulants—Cocaine, amphetamines, and nicotine.
  - Hallucinogens—Cannabis, phencyclidine (PCP), and lysergic acid diethylamide (LSD).
  - Toxic inhalants.
- The onset of drug effects is approximately:
  - Seven to 10 seconds for inhaling or smoking.
  - Fifteen to 30 seconds for intravenous injection.
  - Three to 5 minutes for intramuscular or subcutaneous injection.
  - Three to 5 minutes for intranasal use (snorting).

FIGURE 235-6 Ecstasy tablets used at raves where people dance all night long and some collapse in dehydration. (*Courtesy of DEA.*)

RISK FACTORS

- Family history.
- Personal history of prior addiction.

DIAGNOSIS

It helps to make the distinction between substance abuse and substance dependence to understand how to provide help for the patient.

DSM-IV CRITERIA FOR SUBSTANCE ABUSE[6]

Substance abuse is defined by the *Diagnostic and Statistical Manual of Mental Disorders, 4th edition* (DSM-IV) as a maladaptive pattern of substance use leading to clinically significant impairment or distress, as manifested by 1 (or more) of the following, occurring within a 12-month period:

- Recurrent substance use resulting in a failure to fulfill major role obligations at work, school, or home (such as repeated absences or poor work performance related to substance use; substance-related absences, suspensions, or expulsions from school; or neglect of children or household).
- Recurrent substance use in situations in which it is physically hazardous (such as driving an automobile or operating a machine when impaired by substance use).

FIGURE 235-7 Black tar heroin for injection. (*Courtesy of DEA.*)

- Recurrent substance-related legal problems (such as arrests for substance-related disorderly conduct).
- Continued substance use despite having persistent or recurrent social or interpersonal problems caused or exacerbated by the effects of the substance (e.g., arguments with spouse about consequences of intoxication and physical fights).

DSM-IV CRITERIA FOR SUBSTANCE DEPENDENCE[6]

A maladaptive pattern of substance use leading to clinically significant impairment or distress, as manifested by 3 (or more) of the following, occurring at any time in the same 12-month period:

- Substance is often taken in larger amounts or over a longer period than intended.
- Persistent desire or unsuccessful efforts to cut down or control substance use.
- A great deal of time is spent in activities necessary to obtain the substance (e.g., visiting multiple physicians or driving long distances), to use the substance (e.g., chain smoking), or to recover from its effects.
- Important social, occupational, or recreational activities are given up or reduced because of substance abuse.
- Continued substance use despite knowledge of having a persistent or recurrent psychological or physical problem that is caused or exacerbated by use of the substance.

Tolerance, as defined by either:

- Need for markedly increased amounts of the substance in order to achieve intoxication or desired effect; or
- Markedly diminished effect with continued use of the same amount.

Withdrawal, as manifested by either:

- Characteristic withdrawal syndrome for the substance; or
- The same (or closely related) substance is taken to relieve or avoid withdrawal symptoms.

CLINICAL FEATURES VISIBLE WITH SUBSTANCE ABUSE

- With intoxication, the following signs may be visible:
  - Via stimulants—Dilated pupils and increase in blood pressure, respiratory rate, pulse, and body temperature.
  - Via depressants—Decrease in blood pressure, respiratory rate, pulse, and body temperature. Opioids produce pinpoint pupils. Alcohol intoxication produces dilated pupils.
  - Withdrawal develops with decline of substance in the central nervous system (CNS). Withdrawal reactions vary by the substance used. Alcohol withdrawal is one of the most deadly and dangerous types of withdrawal.

LABORATORY TESTING

- All injection-drug users and persons engaged in high-risk sexual activities should be screened for HIV (with consent), hepatitis B and hepatitis C, and syphilis (rapid plasma reagin [RPR]).
- Women should have Papanicolaou (Pap) smears performed and be screened for chlamydia and gonorrhea based on age, risk factors and previous history of screening.

- Men or women who have multiple sex partners or use sex to obtain drugs are at high risk for sexually transmitted diseases (STDs) and should be tested.
- Homeless, HIV-positive, and previously incarcerated patients should be screened for tuberculosis using a purified protein derivative (PPD) test.
- ECG is warranted if there are any cardiac symptoms or if the physical examination reveals signs of cardiac disease.
- Urine screen for common drugs of abuse may reveal other drugs not admitted to in the history. Most laboratories can differentiate prescription from nonprescription drugs (i.e., opiates) upon request. Substances have different physiologic half-lives in the body and show up for varying amounts of time in the urine. Marijuana has a long excretion half-life and may be detectable for 1 month after its use. Other substances may last for only days.

DIFFERENTIAL DIAGNOSIS

Substance abuse disorders coexist with and complicate the course and treatment of numerous psychiatric conditions.

- Mood/anxiety disorders—Especially depression, bipolar affective disorder, panic disorder, and generalized anxiety disorder. Persons with addictions can develop the symptoms of these disorders from the drugs of abuse. However, mood and anxiety disorders can predate the use of drugs, and some of the motivation for drug use can stem from the desire to self-treat these psychological conditions. It is best to evaluate persons when they are off the drugs whenever possible.
- Schizophrenia—Although drugs can cause temporary psychosis and paranoia, if these symptoms persist after the drugs are stopped for some time, consider schizophrenia and other causes of psychosis.
- Personality disorders—These are a complicated set of disorders that can coexist and be confused with substance abuse disorder. An addict may appear to have an antisocial personality disorder when committing crimes to get money for expensive drugs. It is best to not use this diagnosis unless the behaviors continue when the person is off the drugs.

MANAGEMENT

- Recognize addiction (referred to as dependence in the DSM-IV criteria). One simple mnemonic device is the "three C's of addiction":
  - **C**ompulsion to use.
  - Lack of **C**ontrol.
  - **C**ontinued use despite adverse consequences.
- Use the "5 *A*s"—Ask, Advise, Assess, Assist, and Arrange—to help smokers who are willing to quit. This model can be applied to any substance of abuse.[7]
- Offer counseling and pharmacotherapy to aid your patients to quit smoking.
- Use the CAGE[7] questionnaire when asking about alcohol use:
  - Cut down (Have you ever felt you should *cut* down on your drinking?).
  - Annoyed (Have people *annoyed* you by criticizing your drinking?).
  - Guilty (Have you ever felt bad or *guilty* about your drinking?).
  - Eye opener (Have you ever had a drink first thing in the morning to steady your nerves or get rid of a hangover (eye-opener)?).

Interpreting the results: 1 positive suggests at risk, 2 positives suggest abuse, and 3 or 4 positives suggest dependence. This is just a screening tool, and further evaluation is always needed.

- Recommend the 12-step programs to your patients. These have been very effective for millions of people worldwide.
- Refer to substance abuse programs. Such programs include hospital- and community-based programs. Some programs include detoxification and others require the patient to have gone through detoxification before starting the program. There are residential treatment units, outpatient programs, and ongoing self-help programs. Learn about the programs in your community and work with them.
- When prescribing opioid analgesics for chronic pain consider the outcomes in 4 domains, or the "4 *A*s." Is the patient:
  - Receiving adequate Analgesia?
  - Experiencing improvements in Activities of daily life?
  - Experiencing any Adverse effects?
  - Demonstrating Aberrant medication-taking behaviors that may be linked to addiction?[8]
- When patients are exhibiting aberrant drug-taking behaviors, consider the following:
  - They may have an addiction.
  - They may not be getting adequate pain relief taking the drug as prescribed.
  - They may have a comorbid mental illness.
  - They may intend to distribute pain medications illegally.[9]
- Help your patients acknowledge that they have a problem and offer them help in a nonjudgmental manner.
- Enlist family members to help whenever the patient gives your permission to do so.
- Demonstrate genuine concern and care; suspend judgment and you will have a higher chance of succeeding to help your patients overcome addiction.
- Advanced brain imaging and genetic tests are helping us to understand the physiologic basis of addiction and will ultimately provide us with better treatments for the medical disease of addiction.

PERSONS IN RECOVERY

- Be careful how you prescribe medications to persons in recovery. A "simple" prescription for hydrocodone (Vicodin) postoperatively can start a recovered person down the road of active addiction.
- Avoid giving opioids and benzodiazepines whenever there are good alternatives. Use NSAIDs for pain if possible. Use selective serotonin reuptake inhibitors (SSRIs), other antidepressants, or buspirone for anxiety if a medication is needed.
- If an opioid is needed, work with the patient to monitor the amount and manner of use. Involving a third person or sponsor to help meter out the dose may prevent relapse.
- Be upfront and honest about a shared goal to avoid relapse.

FOLLOW-UP

- Follow-up is critical to the treatment of all types of substance abuse. Substance abuse is a chronic condition (similar to hypertension or diabetes mellitus) and requires ongoing intervention to maintain sobriety.
- The frequency and intensity of follow-up depends on the substance, the addiction, and the patient.
- Do not give up on patients who relapse because it often takes more than 1 attempt before long-term cessation can be achieved.

PATIENT EDUCATION

Explain to patients that addiction is a disease and not a failing of their moral character. Inform patients about the existing treatment programs in their community and offer them names and phone numbers so that they may get help. If your patient is not ready for help today, give the numbers and names for tomorrow. Speak about the value of 12-step programs because these are effective and everyone can afford a 12-step program (they are free). There are 12-step programs in the community for everyone, including nonsmokers and agnostics.

PATIENT RESOURCES

- Alcoholics Anonymous (AA)—meetings and the Big Book are free. The Big Book is online for free in three languages. **http://www.alcoholics-anonymous.org/.**
- Narcotics Anonymous (NA)—meetings are free. The "Basic Text" costs $10; it is similar to the AA big book, but the language is more up to date and readable. **http://www.na.org/index.htm.**
- Cocaine Anonymous (CA)—meetings are free. Their first book "Hope, Faith and Courage: Stories from the Fellowship of Cocaine Anonymous" was published in 1994 and sells for $10. **http://www.ca.org/.**
- Crystal Meth Anonymous (12-step meetings). **http://www.crystalmeth.org/.**

PROVIDER RESOURCES

- The National Institute on Drug Abuse (NIDA). *Medical Consequences of Drug Abuse*—**http://www.nida.nih.gov/consequences/.**
- Substance Abuse and Mental Health Services Administration. **http://www.samhsa.gov/.**
- Drug Enforcement Agency. *Multi-Media Library* (includes many images of illegal drugs)—**http://www.usdoj.gov/dea/multimedia.html.**

REFERENCES

1. Substance Abuse and Mental Health Services Administration, *Results from the 2010 National Survey on Drug Use and Health: Summary of National Findings*, NSDUH Series H-41, HHS Publication No. (SMA) 11-4658. Rockville, MD: Substance Abuse and Mental Health Services Administration; 2011. Report online at: http://www.samhsa.gov/data/NSDUH/2k10NSDUH/2k10Results.pdf.
2. The National Institute on Drug Abuse (NIDA). *Medical Consequences of Drug Abuse*. http://www.nida.nih.gov/consequences/. Accessed April 24, 2012.
3. Baler RD, Volkow ND. Addiction as a systems failure: focus on adolescence and smoking. *J Am Acad Child Adolesc Psychiatry*. 2011; 50(4):329-339.
4. Dick DM, Bierut LJ. The genetics of alcohol dependence. *Curr Psychiatry Rep*. 2006;8:151-157.
5. Dick DM, Plunkett J, Wetherill LF, et al. Association between GABRA1 and drinking behaviors in the collaborative study on the genetics of alcoholism sample. *Alcohol Clin Exp Res*. 2006;30(7): 1101-1110.
6. The American Psychiatric Association. *Diagnostic and Statistical Manual of Mental Disorders*, 4th ed (DSM-IV). Washington, DC: American Psychiatric Association, 1994.
7. Fiore MC, Bailey WC, Cohen SJ, et al. *Treating Tobacco Use and Dependence. Quick Reference Guide for Clinicians*. Rockville, MD: U.S. Department of Health and Human Services, Public Health Service; 2000.
8. Ewing JA. Detecting alcoholism: the CAGE questionnaire. *JAMA*. 1984;252(14):1905-1907.
9. Passik SD, Kirsh KL, Whitcomb L, et al. A new tool to assess and document pain outcomes in chronic pain patients receiving opioid therapy. *Clin Ther*. 2004;26(4):552-561.

236 TOBACCO ADDICTION

Carlos Roberto Jaén, MD, PhD, MS

PATIENT STORY

A 55-year-old woman presents for follow-up of hypertension. She has been smoking 1.5 packs of cigarettes per day since her late teens and reports that she is now ready to stop smoking. She realizes that smoking is bad for her health and does not like how smoking causes more wrinkles on the face (**Figure 236-1**). She has tried unsuccessfully to stop smoking on 3 different occasions using nicotine replacement therapy (patches and gum) and bupropion. She has no history of a psychiatric or seizure disorder. She would like to try stopping smoking using varenicline. She is also willing to return for 4 follow-up sessions at weekly intervals. She agrees to call a stop smoking telephone helpline (1-800-QUIT NOW) for counseling help. The patient tolerates the varenicline well and is able to stop successfully without any adverse effects. Two years after treatment she continues to be abstinent and very glad of this outcome. The clinician used elements of the "5 A's" model for treating tobacco use and dependence to successfully help this patient quit smoking. (**Table 236-1**)

FIGURE 236-1 55-year-old woman with premature wrinkling from years of heavy smoking. Note the numerous lines around her mouth and lips. (*Courtesy of Richard P. Usatine, MD.*)

INTRODUCTION

Half of all deaths (more than 440,000) in the United States are attributed to tobacco addiction, including those caused by passive smoking. Tobacco addiction is a chronic disease, often developed during adolescence and early adulthood, that requires ongoing assessment and repeated intervention. There are effective treatments that can significantly increase rates of long-term abstinence. There are also effective preventive interventions that can prevent the initiation of tobacco use and reduce its prevalence among youth.

SYNONYMS

Tobacco use and dependence, tobacco use disorder, nicotine addiction, tobacco dependence.

EPIDEMIOLOGY

- Among adults who become daily smokers, nearly all first use of cigarettes occurs by 18 years of age (88%), with 99% of first use by 26 years of age.[1]
- Almost 1 in 4 high school seniors is a current (in the past 30 days) cigarette smoker, compared with 1 in 3 young adults and 1 in 5 adults. Approximately 1 in 10 high school senior males is a current smokeless tobacco user, and approximately 1 in 5 high school senior males is a current cigar smoker.[1]
- Significant disparities in tobacco use remain among young people nationwide. The prevalence of cigarette smoking is highest among American Indians and Alaska Natives, followed by whites and Hispanics, and then Asians and blacks. The prevalence of cigarette smoking is also higher among lower socioeconomic status youth.[1]

- The latest data show the use of smokeless tobacco is increasing among white high school males, and cigar smoking may be increasing among black high school females.[1]
- Concurrent use of multiple tobacco products is prevalent among youth. Among those who use tobacco, nearly one-third of high school females and more than one-half of high school males report using more than 1 tobacco product in the last 30 days.[1]
- Persons with psychiatric diagnoses have much higher rates of smoking than the general population.[2]
- Persons with mental illness and/or substance abuse consume 44% of all cigarettes sold in the United States, despite being only 22% of the population.[2]

ETIOLOGY AND PATHOPHYSIOLOGY

- The evidence on the mechanisms by which smoking causes disease indicates that there is no risk-free level of exposure to tobacco smoke.[3]
- Inhaling the complex chemical mixture of combustion compounds in tobacco smoke causes adverse health outcomes, particularly cancer and cardiovascular and pulmonary diseases, through mechanisms that include DNA damage, inflammation, and oxidative stress.[3]
- There is sufficient evidence to infer that a causal relationship exists between active smoking and (a) impaired lung growth during childhood and adolescence; (b) early onset of decline in lung function during late adolescence and early adulthood; (c) respiratory signs and symptoms in children and adolescents, including coughing, phlegm, wheezing, and dyspnea; and (d) asthma-related symptoms (e.g., wheezing) in childhood and adolescence.[1]
- The evidence is suggestive but not sufficient to conclude that smoking by adolescents and young adults is *not* associated with significant weight loss, contrary to young people's belief.[1]
- Through multiple defined mechanisms, the risk and severity of many adverse health outcomes caused by smoking are directly related to the duration and level of exposure to tobacco smoke.[3]
- Sustained use and long-term exposures to tobacco smoke are caused by the powerfully addicting effects of tobacco products, which are mediated by diverse actions of nicotine and perhaps other compounds, at multiple types of nicotinic receptors in the brain.[3]
- Nicotine stimulates the release of multiple neurotransmitters, including dopamine, norepinephrine, acetylcholine, glutamate, serotonin, β-endorphin, and γ-aminobutyric acid.[4]
- Low levels of exposure, including exposures to secondhand tobacco smoke, lead to a rapid and sharp increase in endothelial dysfunction and inflammation, which are implicated in acute cardiovascular events and thrombosis.[3]
- There is insufficient evidence that product modification strategies to lower emissions of specific toxicants in tobacco smoke reduce risk for the major adverse health outcomes.[3]

RISK FACTORS

Given their developmental stage, adolescents and young adults are uniquely susceptible to social and environmental influences to use tobacco.

TABLE 236-1 The "5 A's" Model for Treating Tobacco Use and Dependence

Ask about tobacco use.	Identify and document tobacco use status for every patient at every visit.
Advise to quit.	In a clear, strong, and personalized manner, urge every tobacco user to quit.
Assess willingness to make a quit attempt.	Is the tobacco user willing to make a quit attempt at this time?
Assist in quit attempt.	For the patient willing to make a quit attempt, offer medication and provide or refer for counseling or additional treatment to help the patient quit. For patients unwilling to quit at the time, provide interventions designed to increase future quit attempts.
Arrange followup.	For the patient willing to make a quit attempt, arrange for followup contacts, beginning within the first week after the quit date. For patients unwilling to make a quit attempt at the time, address tobacco dependence and willingness to quit at next clinic visit.

From: Treating Tobacco Use and Dependence: 2008 Update. US Department of Health and Human Services; 2008. http://www.ahrq.gov/clinic/tobacco/treating_tobacco_use08.pdf

- Socioeconomic factors and educational attainment influence the development of youth smoking behavior. The adolescents most likely to begin to use tobacco and progress to regular use are those who have lower academic achievement.[1]
- The evidence is sufficient to conclude that there is a causal relationship between peer group social influences and the initiation and maintenance of smoking behaviors during adolescence.[1]
- Affective processes play an important role in youth smoking behavior, with a strong association between youth smoking and negative affect.[1]
- The evidence is suggestive that tobacco use is a heritable trait, more so for regular use than for onset. The expression of genetic risk for smoking among young people may be moderated by small-group and larger social–environmental factors.[1]

DIAGNOSIS

CLINICAL FEATURES

- History—Most tobacco users express a desire to stop using tobacco but report repeated failures in their attempts. All patients should be asked if they use tobacco and should have their tobacco use status documented on a regular basis. Evidence shows that clinic screening systems, such as expanding the vital signs to include tobacco use status, or the use of other reminder systems, such as chart stickers or computer prompts, significantly increase rates of clinician intervention.[5] SOR A
- Physical—Individuals with tobacco addiction may easily be detected by:
  - Distinctive odor of tobacco smoke.
  - Smoker's cough.
  - Raspy or hoarse voice (see Chapter 36, The Larynx [Hoarseness])
  - Pack of cigarettes in the front pocket of the shirt.
  - Wrinkles in excess of what would be expected for their age (**Figure 236-2**).
- *Smoker's face* is described as:
  - "Lines or wrinkles on the face, typically radiating at right angles from the upper and lower lips or corners of the eyes, deep lines on the cheeks, or numerous shallow lines on the cheeks and lower jaw." (**Figure 236-2**.)
  - "A subtle gauntness of the facial features with prominence of the underlying bony contours."[6]
- The oral cavity of smokers often shows signs of prolonged exposure to tobacco in the form:
  - Yellow and brown teeth (**Figures 236-3** to **236-5**).
  - Angular cheilitis (**Figure 236-3**) (see Chapter 32, Angular Cheilitis).
  - Gingivitis and periodontitis (**Figure 236-4**) (see Chapter 39, Gingivitis and Periodontal Disease).
- There may be other serious conditions within the oral cavity such as:
  - Leukoplakia—A pre-malignant condition (**Figure 236-5**) (see Chapter 42, Leukoplakia).
  - Nicotine stomatitis (**Figure 236-6**).

FIGURE 236-2 **Smoker's face** described as "one or more of the following: (a) lines or wrinkles on the face, typically radiating at right angles from the upper and lower lips or corners of the eyes, deep lines on the cheeks, or numerous shallow lines on the cheeks and lower jaw. (b) A subtle gauntness of the facial features with prominence of the underlying bony contours.[6] (*Courtesy of Usatine R, Moy R, Tobinick E, Siegel D. Skin Surgery: A Practical Guide. St. Louis, MO: Mosby; 1998.*)

FIGURE 236-3 Angular cheilitis and tobacco staining of the tongue from chewing tobacco. (*Courtesy of Richard P. Usatine, MD.*)

FIGURE 236-4 Tobacco staining teeth and periodontitis from smoking tobacco. (*Courtesy of Richard P. Usatine, MD.*)

- Squamous cell carcinoma (**Figures 236-7** and **236-8**) (see Chapter 43, Oral Cancer).

- Withdrawal symptoms—Symptoms associated with tobacco addiction withdrawal include a dysphoric or depressed mood, insomnia, irritability, frustration or anger, anxiety, difficulty concentrating, restlessness, decreased heart rate, and increased appetite or weight gain.[7] None of the withdrawal symptoms are life-threatening, as they can be with other drugs like alcohol and opiates. Their intensity peaks during the first week and most last no more than 2 to 4 weeks following abstinence.[8]
- Complications—Continuing use of tobacco causes multiple cancers and the development and/or exacerbation of multiple chronic diseases as summarized in **Figure 236-9**.
- Emphysema may significantly impair lung function and lead to death (see Chapter 56, Chronic Obstructive Pulmonary Disease). Centrilobular emphysema occurs with carbon deposits in the destroyed lung tissue.

FIGURE 236-5 Leukoplakia on the buccal mucosa and gingiva in a tobacco smoker. Although much of the leukoplakia is on the bite line, the risk of squamous cell carcinoma of the oral cavity must be assessed with appropriate biopsies. (*Courtesy of Richard P. Usatine, MD.*)

LABORATORY TESTING

- Some specialized assessments of individual and environmental attributes provide information for tailoring treatment and may predict quitting success. Specialized assessments refer to the use of formal instruments (e.g., questionnaires, clinical interviews, or physiologic indices such as carbon monoxide, serum nicotine/cotinine levels, and/or pulmonary function) that may be associated with cessation outcome. In addition, clinicians may find other assessments relevant to medication use and specific populations when selecting treatment. The use of biochemical confirmation (use of biologic samples, such as expired air, saliva, urine, or blood, to measure tobacco-related compounds, such as nicotine, cotinine, and carboxyhemoglobin) is particularly useful to verify abstinence during pregnancy treatment where reports of deception have been documented.[5] Variables targeted by specialized assessments that predict treatment success include:
  - High motivation;
  - Readiness to change in the next month;
  - Moderate to high self-efficacy (confidence in his or her ability to stop using tobacco successfully); and
  - Supportive social network.
- Variables associated with lower abstinence rates include:
  - High nicotine dependence;
  - Psychiatric comorbidity and substance use (particularly elevated depressive symptoms, schizophrenia, and current alcohol abuse);
  - High stress level; and
  - Exposure to other smokers.[5]

IMAGING

There are currently no practical clinical applications for imaging studies that are helpful when treating individuals with tobacco addiction. Experimentally several MRI, functional MRI, and positron emission tomography (PET) scan studies provide helpful clues as to mechanisms of actions of tobacco addiction.[3]

FIGURE 236-6 Nicotine stomatitis over the hard palate from smoking tobacco. (*From Rizzolo D, Chiodo TA. Lesion on the hard palate. J Fam Pract, 2008;57(1):33-35. Reproduced with permission from Frontline Medical Communications.*)

MANAGEMENT

The combination of counseling and medication is more effective for smoking cessation than either medication or counseling alone. Therefore, whenever feasible and appropriate, both counseling and medication should be provided to patients trying to stop smoking.[5] SOR A

NONPHARMACOLOGIC (COUNSELING INTERVENTIONS)

- Minimal interventions lasting less than 3 minutes increase overall tobacco abstinence rates. Every tobacco user should be offered at least a minimal intervention, whether or not he or she is referred to an intensive intervention.[5] SOR A
- Two types of counseling and behavioral therapies result in higher abstinence rates: (a) providing smokers with practical counseling (problem-solving skills/skills training), and (b) providing support and encouragement as part of treatment. These types of counseling elements should be included in smoking cessation interventions.[5] SOR B
- There is a strong dose–response relationship between the session length of person-to-person contact and successful treatment outcomes. Intensive interventions are more effective than less-intensive interventions and should be used whenever possible.[5] SOR A
- Proactive telephone counseling, group counseling, and individual counseling formats are effective and should be used in smoking cessation interventions.[5] SOR A
- Person-to-person treatment delivered for 4 or more sessions appears especially effective in increasing abstinence rates. Therefore, if feasible, clinicians should strive to meet 4 or more times with individuals quitting tobacco use.[5] SOR A
- Motivational interviewing for smokers not willing to make an attempt to stop tobacco use:
  - Motivational intervention techniques appear to be effective in increasing a patient's likelihood of making a future quit attempt. Therefore, clinicians should use motivational techniques to encourage smokers who are not currently willing to quit to consider making a quit attempt in the future.[5] SOR B
  - The four general principles that underlie motivational intervention are: (a) *express empathy,* (b) *develop discrepancy,* (c) *roll with resistance,* and (d) *support self-efficacy* (**Table 236-2**). Motivational intervention researchers have found that having patients use their own words to commit to change is more effective than clinician exhortations, lectures, or arguments for quitting, which tend to increase rather than lessen patient resistance to change.[5]

MEDICATIONS

Clinicians should encourage all patients attempting to quit to use effective medications for tobacco dependence treatment, except where contraindicated or for specific populations for which there is insufficient evidence of effectiveness (e.g., pregnant women, smokeless tobacco users, light smokers, and adolescents).[5] SOR A

- In the United States, there are 7 FDA-approved medications for treating tobacco use and these first-line medications should be recommended: bupropion SR (Zyban), nicotine gum, nicotine inhaler, nicotine

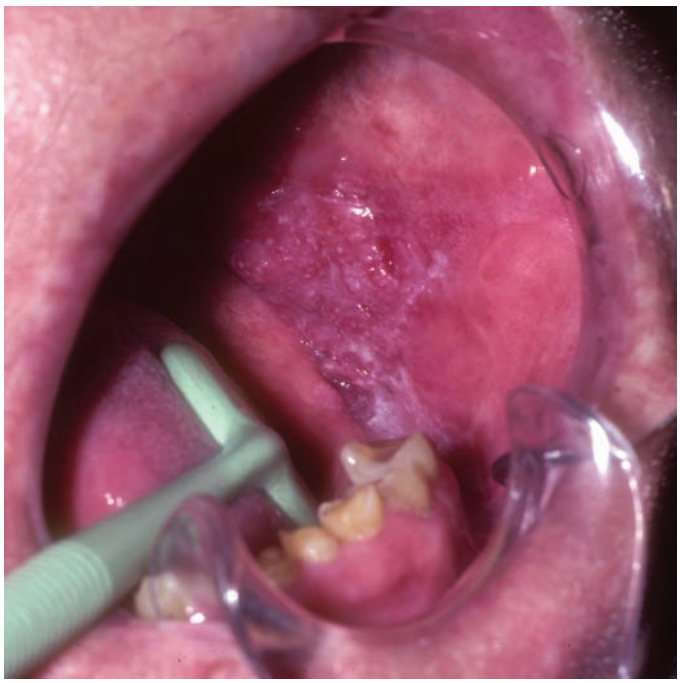

FIGURE 236-7 Squamous cell carcinoma of buccal mucosa in a man that used chewing tobacco along with smoking. (*Courtesy of Richard P. Usatine, MD.*)

FIGURE 236-8 Squamous cell carcinoma of the lip inner lip in a cigar smoker. (*Courtesy of Gerald Ferritti, DDS.*)

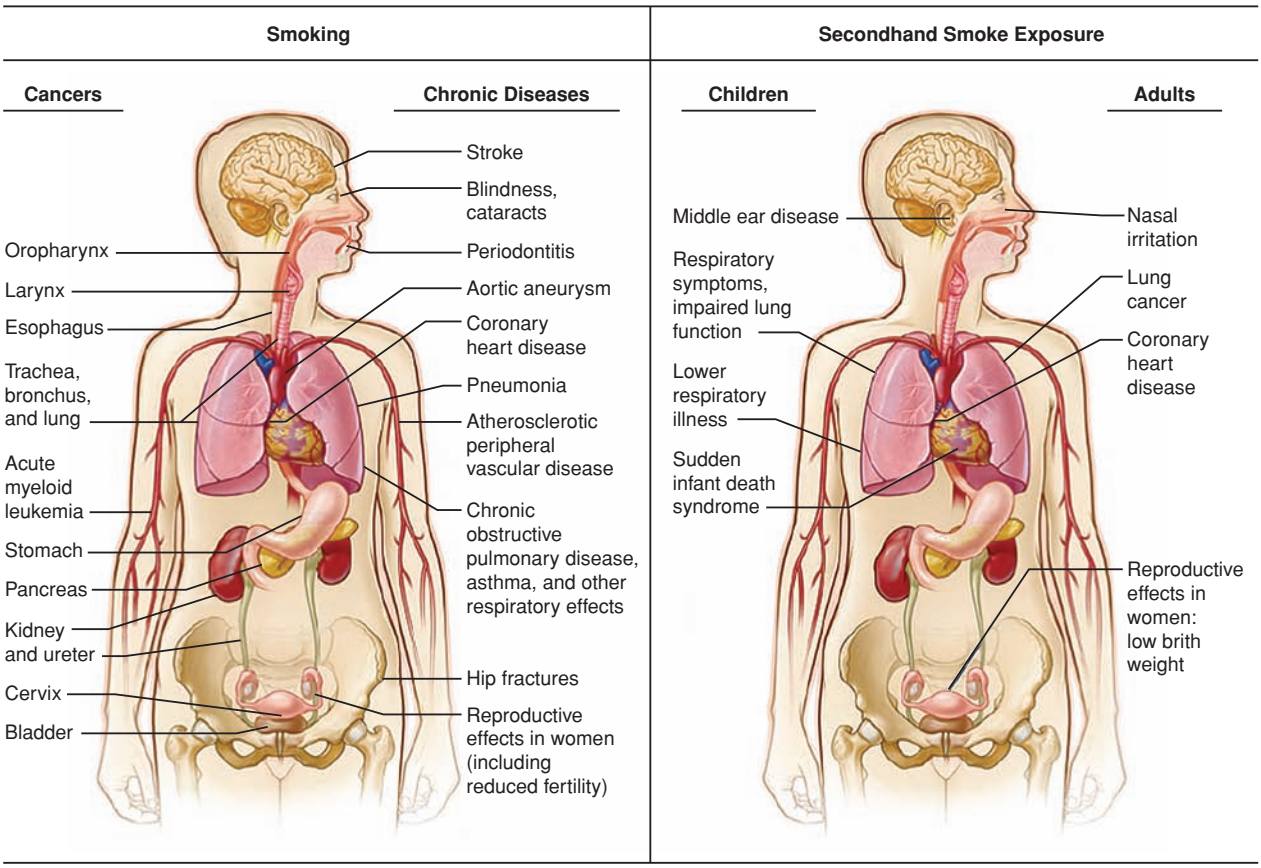

Source: **USDHHS 2004. 2006.**

FIGURE 236-9 Health consequences causally linked to smoking and second hand smoking. (*From U.S. Department of Health and Human Services. How Tobacco Smoke Causes Disease: The Biology and Behavioral Basis for Smoking-Attributable Disease: A Report of the Surgeon General. Atlanta, GA: U.S. Department of Health and Human Services, Centers for Disease Control and Prevention, National Center for Chronic Disease Prevention and Health Promotion, Office on Smoking and Health; 2010.*)

lozenge, nicotine nasal spray, nicotine patch, and varenicline (Chantix). Dosing guidelines for these 7 meds are found in **Table 236-3**.

- The clinician should consider the first-line medications shown to be more effective than the nicotine patch alone: 2 mg/day varenicline or the combination of long-term nicotine patch use + ad libitum nicotine replacement therapy (NRT).[5]
- Certain combinations of first-line medications have been shown to be effective smoking cessation treatments. Therefore, clinicians should consider using these combinations of medications with their patients who are willing to quit. Effective combination medications are:
  - Long-term (>14 weeks) nicotine patch + other NRT (gum and spray).
  - The nicotine patch + the nicotine inhaler.
  - The nicotine patch + bupropion SR.[5] SOR A
- There is a strong relationship between the number of sessions of counseling combined with medication and the likelihood of successful smoking cessation. Therefore, to the extent possible, clinicians should provide multiple counseling sessions, in addition to medication, to their patients who are trying to quit smoking.[5] SOR A

COMPLEMENTARY AND ALTERNATIVE THERAPY

- Acupuncture—A metaanalysis of 5 studies did not show effectiveness of acupuncture as a tobacco use treatment. There is also lack

TABLE 236-2 Motivational Interviewing Strategies

Express empathy.	• Use open-ended questions to explore: ◦ The importance of addressing smoking or other tobacco use (e.g., "How important do you think it is for you to quit smoking?") ◦ Concerns and benefits of quitting (e.g„ "What might happen if you quit?") • Use reflective listening to seek shared understanding: ◦ Reflect words or meaning (e.g., "So you think smoking helps you to maintain your weight"). ◦ Summarize (e.g., "What I have heard so far is that smoking is something you enjoy. On the other hand, your boyfriend hates your smoking, and you are worried you might develop a serious disease."). • Normalize feelings and concerns (e.g., "Many people worry about managing without cigarettes."). • Support the patient's autonomy and right to choose or reject change (e.g., "I hear you saying you are not ready to quit smoking right now. I'm here to help you when you are ready.").
Develop discrepancy.	• Highlight the discrepancy between the patient's present behavior and expressed priorities, values, and goals (e.g., "It sounds like you are very devoted to your family. How do you think your smoking is affecting your children?"). • Reinforce and support "change talk" and "commitment" language: ◦ "So, you realize how smoking is affecting your breathing and making it hard to keep up with your kids." ◦ "It's great that you are going to quit when you get through this busy time at work." • Build and deepen commitment to change: ◦ "There are effective treatments that will ease the pain of quitting, including counseling and many medication options." ◦ "We would like to help you avoid a stroke like the one your father had."
Roll with resistance.	• Back off and use reflection when the patient expresses resistance: ◦ "Sounds like you are feeling pressured about your smoking." • Express empathy: ◦ "You are worried about how you would manage withdrawal symptoms." • Ask permission to provide information: ◦ "Would you like to hear about some strategies that can help you address that concern when you quit?"
Support self-efficacy.	• Help the patient to identify and build on past successes: ◦ "So you were fairly successful the last time you tried to quit." • Offer options for achievable small steps toward change: ◦ Call the quitline (1–800-QUIT-NOW) for advice and information. ◦ Read about quitting benefits and strategies. ◦ Change smoking patterns (e.g., no smoking in the home). ◦ Ask the patient to share his or her ideas about quitting strategies.

From: Treating Tobacco Use and Dependence: 2008 Update. US Department of Health and Human Services; 2008. http:// www.ahrq.gov/clinic/tobacco/treating_tobacco_use08.pdf

of scientific evidence for the effectiveness of electrostimulation or laser acupuncture for the treatment of tobacco addiction.[5]

- Hypnotherapy—There is insufficient evidence to recommend hypnotherapy as an effective treatment for tobacco addiction.[5]
- Novel tobacco products—There is insufficient evidence to determine whether novel tobacco products reduce individual and population health risks. The evidence indicates that changing cigarette designs over the last 5 decades, including filtered, low-tar, and "light" variations, have not reduced overall disease risk among smokers and may have hindered prevention and cessation efforts. The overall health of the public could be harmed if the introduction of novel tobacco products encourages tobacco use among people who would otherwise be unlikely to use a tobacco product or delays cessation among persons who would otherwise quit using tobacco altogether.[3]

REFERRAL

For patients who are unsuccessful with therapies available in primary care, it is reasonable to refer them to a tobacco-cessation specialist. These specialists typically provide intensive tobacco interventions. Specialists are not defined by their professional affiliation or by the field in which they trained. Rather, specialists view tobacco dependence treatment as a primary professional role. Specialists possess the skills, knowledge, and training to provide effective interventions across a range of intensities, and often are affiliated with programs offering intensive treatment interventions or services.

TABLE 236-3 Pharmacologic Product Guide: FDA-Approved Medications for Smoking Cessationw

	Nicotine Replacement Therapy (NRT) Formulations						
	Gum	Lozenge	Transdermal Patch	Nasal Spray	Oral Inhaler	Bupropion SR	Varenicline
Product	**Nicorette,[1] Generic** OTC 2 mg, 4 mg original, cinnamon, fruit, mint, orange	**Nicorette Lozenge,[1] Nicorette Mini Lozenge,[1] Generic** OTC 2 mg, 4 mg cherry, mint	**NicoDerm CQ,[1] Generic** OTC (NicoDerm CQ, generic) Rx (generic) 7 mg, 14 mg, 21 mg (24-hour release)	**Nicotrol NS[2]** Rx Metered spray 0.5 mg nicotine in 50 mcL aqueous nicotine solution	**Nicotrol Inhaler[2]** Rx 10 mg cartridge delivers 4 mg inhaled nicotine vapor	**Zyban,[1] Generic** Rx 150 mg sustained-release tablet	**Chantix[2]** Rx 0.5 mg, 1 mg tablet
Precautions	• Recent (≤2 weeks) myocardial infarction • Serious underlying arrhythmias • Serious or worsening angina pectoris • Temporomandibular joint disease • Pregnancy[3] and breastfeeding • Adolescents (<18 years)	• Recent (≤2 weeks) myocardial infarction • Serious underlying arrhythmias • Serious or worsening angina pectoris • Pregnancy[3] and breastfeeding • Adolescents (<18 years)	• Recent (≤2 weeks) myocardial infarction • Serious underlying arrhythmias • Serious or worsening angina pectoris • Pregnancy[3] (Rx formulations, category D) and breastfeeding • Adolescents (<18 years)	• Recent (≤2 weeks) myocardial infarction • Serious underlying arrhythmias • Serious or worsening angina pectoris • Underlying chronic nasal disorders (rhinitis, nasal polyps, sinusitis) • Severe reactive airway disease • Pregnancy[3] (category D) and breastfeeding • Adolescents (<18 years)	• Recent ≤2 weeks) myocardial infarction • Serious underlying arrhythmias • Serious or worsening angina pectoris • Bronchospastic disease • Pregnancy[3] (category D) and breastfeeding • Adolescents (<18 years)	• Concomitant therapy with medications or medical conditions known to lower the seizure threshold • Severe hepatic cirrhosis • Pregnancy[3] (category C) and breastfeeding • Adolescents (<18 years) **Warning:** • BLACK-BOXED WARNING for neuropsychiatric symptoms[4] **Contraindications:** • Seizure disorder • Concomitant bupropion (e.g., Wellbutrin) therapy • Current or prior diagnosis of bulimia or anorexia nervosa • Simultaneous abrupt discontinuation of alcohol or sedatives/benzodiazepines • MAO inhibitor therapy in previous 14 days	• Severe renal impairment (dosage adjustment is necessary) • Pregnancy[3] (category C) and breastfeeding • Adolescents (<18 years) **Warnings:** • BLACK-BOXED WARNING for neuropsychiatric symptoms[4] • Cardiovascular adverse events in patients with existing cardiovascular disease

(continued)

TABLE 236-3 Pharmacologic Product Guide: FDA-Approved Medications for Smoking Cessation (*Continued*)

	Nicotine Replacement Therapy (NRT) Formulations						
	Gum	**Lozenge**	**Transdermal Patch**	**Nasal Spray**	**Oral Inhaler**	**Bupropion SR**	**Varenicline**
Dosing	*≥25 cigarettes/day:* 4 mg *<25 cigarettes/day:* 2 mg Weeks 1–6: 1 piece q 1–2 hours Weeks 7–9: 1 piece q 2–4 hours Weeks 10–12: 1 piece q 4-8 hours • Maximum, 24 pieces/day • Chew each piece slowly • Park between cheek and gum when peppery or tingling sensation appears (~15–30 chews) • Resume chewing when tingle fades • Repeat chew/park steps until most of the nicotine is gone (tingle does not return: generally 30 min) • Park in different areas of mouth • No food or beverages 15 minutes before or during use • Duration: up to 12 weeks	*1st cigarette ≤30 minutes after waking:* 4 mg *1st cigarette >30 minutes after waking:* 2 mg Weeks 1–6: 1 lozenge q 1–2 hours Weeks 7–9: 1 lozenge q 2–4 hours Weeks 10–12: 1 lozenge q 4–8 hours • Maximum, 20 lozenges/day • Allow to dissolve slowly (20–30 minutes for standard: 10 minutes for mini) • Nicotine release may cause a warm, tingling sensation • Do not chew or swallow • Occasionally rotate to different areas of the mouth • No food or beverages 15 minutes before or during use • Duration: up to 12 weeks	*>10 cigarettes/day:* 21 mg/day × 4 weeks (generic) 6 weeks (NicoDerm CQ) 14 mg/day × 2 weeks 7 mg/day × 2 weeks *≤10 cigarettes/day:* 14 mg/day × 6 weeks 7 mg/day × 2 weeks • May wear patch for 16 hours if patient experiences sleep disturbances (remove at bedtime) • Duration: 8–10 weeks	1–2 doses/hour (8–40 doses/day) One dose = 2 sprays (one in **each** nostril): each spray delivers 0.5 mg of nicotine to the nasal mucosa • Maximum – 5 doses/hour or – 40 doses/day • For best results, initially use at least 8 doses/day • Do not sniff, swallow, or inhale through the nose as the spray is being administered • Duration: 3–6 months	6–16 cartridges/day Individualize dosing: initially use 1 cartridge q 1–2 hours • Best effects with continuous puffing for 20 minutes • Initially use at least 6 cartridges/day • Nicotine in cartridge is depleted after 20 minutes of active puffing • Inhale into back of throat or puff in short breaths • Do NOT inhale into the lungs (like a cigarette) but "puff" as if lighting a pipe • Open cartridge retains potency for 24 hours • No food or beverages 15 minutes before or during use • Duration: 3–6 months	150 mg po q AM × 3 days, then 150 mg po bid • Do not exceed 300 mg/day • Begin therapy 1–2 weeks **prior** to quit date • Allow at least 8 hours between doses • Avoid bedtime dosing to minimize insomnia • Dose tapering is not necessary • Can be used safely with NRT • Duration: 7–12 weeks, with maintenance up to 6 months in selected patients	Days 1–3: 0.5 mg po q AM Days 4–7: 0.5 mg po bid Weeks 2–12: 1 mg po bid • Begin therapy 1 week **prior** to quit date • Take dose after eating and with a full glass of water • Dose tapering is not necessary • Duration: 12 weeks: an additional 12-week course may be used in selected patients
Adverse Effects	• Mouth/jaw soreness • Hiccups • Dyspepsia • Hypersalivation • Effects associated with incorrect chewing technique: – Lightheadedness – Nausea/vomiting – Throat and mouth irritation	• Nausea • Hiccups • Cough • Heartburn • Headache • Flatulence • Insomnia	• Local skin reactions (erythema, pruritus, burning) • Headache • Sleep disturbances (insomnia, abnormal/vivid dreams); associated with nocturnal nicotine absorption	• Nasal and/or throat irritation (hot, peppery, or burning sensation) • Rhinitis • Tearing • Sneezing • Cough • Headache	• Mouth and/or throat irritation • Cough • Headache • Rhinitis • Dyspepsia • Hiccups	• Insomnia • Dry mouth • Nervousness/difficulty concentrating • Rash • Constipation • Seizures (risk is 0.1%) • Neuropsychiatric symptoms (rare; see PRECAUTIONS)	• Nausea • Sleep disturbances (insomnia, abnormal/vivid dreams) • Constipation • Flatulence • Vomiting • Neuropsychiatric symptoms (rare; see PRECAUTIONS)

Advantages	• Might satisfy oral cravings • Might delay weight gain • Patients can titrate therapy to manage withdrawal symptoms • Variety of flavors are available	• Might satisfy oral cravings • Might delay weight gain • Easy to use and conceal • Patients can titrate therapy to manage withdrawal symptoms • Variety of flavors are available	• Provides consistent nicotine levels over 24 hours • Easy to use and conceal • Once daily dosing associated with fewer compliance problems	• Patients can titrate therapy to rapidly manage withdrawal symptoms	• Patients can titrate therapy to manage withdrawal symptoms • Mimics hand-to-mouth ritual of smoking (could also be perceived as a disadvantage)	• Easy to use; oral formulation might be associated with fewer compliance problems • Might delay weight gain • Can be used with NRT • Might be beneficial in patients with depression	• Easy to use; oral formulation might be associated with fewer compliance problems • Offers a new mechanism of action for patients who have failed other agents
Disadvantages	• Need for frequent dosing can compromise compliance • Might be problematic for patients with significant dental work • Patients must use proper chewing technique to minimize adverse effects • Gum chewing may not be socially acceptable	• Need for frequent dosing can compromise compliance • Gastrointestinal side effects (nausea, hiccups, heartburn) might be bothersome	• Patients cannot titrate the dose to acutely manage withdrawal symptoms • Allergic reactions to adhesive might occur • Patients with dermatologic conditions should not use the patch	• Need for frequent dosing can compromise compliance • Nasal/throat irritation may be bothersome • Patients must wait 5 minutes before driving or operating heavy machinery • Patients with chronic nasal disorders or severe reactive airway disease should not use the spray	• Need for frequent dosing can compromise compliance • Initial throat or mouth irritation can be bothersome • Cartridges should not be stored in very warm conditions or used in very cold conditions • Patients with underlying bronchospastic disease must use with caution	• Seizure risk is increased • Several contraindications and precautions preclude use in some patients (see PRECAUTIONS) • Patients should be monitored for potential neuropsychiatric symptoms[4] (see PRECAUTIONS)	• May induce nausea in up to one third of patients • Patients should be monitored for potential neuropsychiatric symptoms[4] (see PRECAUTIONS)
Cost/Day[5]	2 mg or 4 mg: $2.25–$4.41 (9 pieces)	2 mg or 4 mg: $2.61–$4.95 (9 pieces)	$1.87–$3.52 (1 patch)	$4.43 (8 doses)	$7.68 (6 cartridges)	$3.62–$7.46 (2 tablets)	$5.38–$6.20 (2 tablets)

[1]Marketed by GlaxoSmithKline.
[2]Marketed by Pfizer.
[3]The U.S. Clinical Practice Guideline states that pregnant smokers should be encouraged to quit without medication based on insufficient evidence of effectiveness and theoretical concerns with safety. Pregnant smokers should be offered behavioral counseling interventions that exceed minimal advice to quit.
[4]In July 2009, the FDA mandated that the prescribing information for all bupropion- and varenicline-containing products include a black-boxed warning highlighting the risk of serious neuropsychiatric symptoms, including changes in behavior, hostility, agitation, depressed mood, suicidal thoughts and behavior, and attempted suicide. Clinicians should advise patients to stop taking varenicline or bupropion SR and contact a healthcare provider immediately if they experience agitation, depressed mood, and any changes in behavior that are not typical of nicotine withdrawal, or if they experience suicidal thoughts or behavior. If treatment is stopped due to neuropsychiatric symptoms, patients should be monitored until the symptoms resolve.
[5]Average wholesale price from Medi-Span Electronic Drug File. Indianapolis, IN: Wolters Kluwer Health, July 2011.
Abbreviations: MAO, monoamine oxidase; NRT, nicotine replacement therapy; OTC, over-the-counter (non-prescription product); Rx, prescription product.
For complete prescribing information, please refer to the manufacturers' package inserts.
Copyright © 1999–2011. The Regents of the University of California. All rights reserved. Updated July 10, 2011.

PREVENTION

The simple fact is that we cannot end the tobacco epidemic without focusing our efforts on young people. Nearly 100% of adults who smoke every day started smoking when they were age 26 years or younger, so prevention is the key to success. The tobacco industry spends almost $10 billion a year to market its products, half of all movies for children younger than age 13 years contain scenes of tobacco use, and images and messages normalize tobacco use in magazines, on the Internet, and at retail stores frequented by youth. With a quarter of all high school seniors and a third of all young adults smoking, and with progress in reducing prevalence slowing dramatically, the time for action is now.[1]

- Advertising and promotional activities by tobacco companies have been shown to cause the onset and continuation of smoking among adolescents and young adults.[1]
- The evidence is sufficient to conclude that there is a causal relationship between depictions of smoking in the movies and the initiation of smoking among young people.[1]
- The evidence is sufficient to conclude that mass media campaigns, comprehensive community programs, and comprehensive statewide tobacco control programs can prevent the initiation of tobacco use and reduce its prevalence among youth.[1]
- The evidence is sufficient to conclude that increases in cigarette prices reduce the initiation, prevalence, and intensity of smoking among youth and young adults.[1]
- The evidence is sufficient to conclude that school-based programs with evidence of effectiveness, containing specific components, can produce at least short-term effects and reduce the prevalence of tobacco use among school-age youth.[1] One tobacco-free education program for kids from the American Academy of Family Physicians (AAFP) is *Tar Wars*: http://www.tarwars.org/online/tarwars/home.html.

FIGURE 236-10 Smoking addiction is a killer. (*Courtesy of Nerilicon, CagleCartoons.com, Mexico City, Mexico.*)

PROGNOSIS

- Young individuals progress from smoking occasionally to smoking every day.
- Each day across the United States more than 3800 youths younger than 18 years of age start smoking. Of every 3 young smokers, only 1 will quit, and 1 of those remaining smokers will die from tobacco-related causes. Most of these young people never considered the long-term health consequences associated with tobacco use when they started smoking; and nicotine, a highly addictive drug, causes many to continue smoking well into adulthood, often with deadly consequences (**Figure 236-10**).[1]
- Those with serious mental illnesses die, on average, 25 years earlier than the general population, with most deaths related to tobacco-related diseases such as heart disease, diabetes, and chronic lung disease.[2]

FOLLOW-UP

- All patients who receive a tobacco dependence intervention should be assessed for abstinence at the completion of treatment and

during subsequent contacts.[1] Abstinent patients should have their quitting success acknowledged, and the clinician should offer to assist the patient with problems associated with quitting.[2] Patients who have relapsed should be assessed to determine whether they are willing to make another quit attempt. SOR C

PATIENT RESOURCES

- **1–800-QUIT NOW**—This free telephone quit line service refers callers to their own state's quit line via this national routing number. In some counties free nicotine patches are available to callers.
- The American Legacy Foundation's Became an EX Program—**http://www.becomeanex.org/.**

The EX Plan is a free quit smoking program that helps you re-learn life without cigarettes. Before you actually stop smoking, they'll show you how to deal with the very things that trip up so many people when they try to stop smoking. So you'll be more prepared to stop and stay off tobacco.

- Office on Smoking and Health at the Centers for Disease Control and Prevention. *Smoking & Tobacco Use*—**http://www.cdc.gov/tobacco.**

The Smoking and Tobacco Use website of the Centers for Disease Control and Prevention (CDC) provides tobacco use data and statistics; information about the health effects of smoking, smokeless tobacco products, and secondhand smoke; resources for tobacco cessation and youth smoking prevention; and products and materials that can help motivate behavior change. Visitors to the CDC website can find links to clinician and patient resources, such as a quit guideline.

PROVIDER RESOURCES

- *Treating Tobacco Use and Dependence 2008 Update*. Excellent clinical practice guideline. **http://www.ahrq.gov/clinic/tobacco/treating_tobacco_use08.pdf**
- American Academy of Family Physicians' Tobacco Cessation Program. **http://www.askandact.org.**

The American Academy of Family Physicians' (AAFP) tobacco cessation program, "Ask and Act," encourages family physicians to ASK their patients about tobacco use, then ACT to help them quit. Through the Ask and Act program, AAFP members have access to a variety of free resources to help patients quit using tobacco, such as a quit smoking prescription pad and a wallet card with quitline information.

- American Academy of Family Physicians. *Pharmacologic Product Guide: FDA-Approved Medications*—**http://www.aafp.org/online/etc/medialib/aafp_org/documents/clinical/pub_health/askact/prescribguidelines.Par.0001.File.tmp/PRESCRIBINGGUIDE2010.pdf.**

This is an excellent guide to pharmacologic intervention that summarizes precautions, dosing, adverse effects, advantages, disadvantages and costs for the 7 FDA-approved medications for treatment of tobacco addiction.

- Smoking Cessation Leadership Center. **http://smokingcessationleadership.ucsf.edu.**

The Smoking Cessation Leadership Center aims to increase smoking cessation rates and increase the number of health professionals

who help smokers quit. The site not only provides tobacco cessation resources for providers to pass on to patients, it also offers a variety of tools, materials, and training courses aimed toward improving the delivery of tobacco cessation intervention in clinical settings. 1–800-QUIT-NOW cards can be ordered online at this website, which provides telephone cessation resources for all 50 states in the United States.

- Nicotine and Tobacco Dependence Website. **http://www.nicotineandtobaccodependence.com/.**

A companion to the book *Nicotine and Tobacco Dependence* (Peterson, Vander Werg and Jaén, 2011), it provides book owners with easy-to-print forms, including a Nicotine and Tobacco Dependence Intake Form; Minnesota Nicotine Withdrawal Scale-Revised (MSW-R); Decisional Balance Exercise; Tobacco Use Diary; Physical, Behavioral, and Psychologic Strategies to Quit Tobacco; and a Sample Treatment Manual for 8 sessions for intensive tobacco treatment.

- American Academy of Family Physicians. *Tar Wars*—**http://www.tarwars.org/online/tarwars/home.html.**

This is a tobacco-free education program for kids from the AAFP involving classroom presentations and poster contests.

REFERENCES

1. U.S. Department of Health and Human Services. *Preventing Tobacco Use Among Youth and Young Adults: A Report of the Surgeon General*. Atlanta, GA: U.S. Department of Health and Human Services, Centers for Disease Control and Prevention, National Center for Chronic Disease Prevention and Health Promotion, Office on Smoking and Health; 2012. http://www.surgeongeneral.gov/library/preventing-youth-tobacco-use/index.html.
2. Schroeder SA. A 51-year-old woman with bipolar disorder who wants to quit smoking. *JAMA*. 2009;301(5):522-531.
3. U.S. Department of Health and Human Services. *How Tobacco Smoke Causes Disease: The Biology and Behavioral Basis for Smoking-Attributable Disease: A Report of the Surgeon General*. Atlanta, GA: U.S. Department of Health and Human Services, Centers for Disease Control and Prevention, National Center for Chronic Disease Prevention and Health Promotion, Office on Smoking and Health; 2010. http://www.surgeongeneral.gov/library/tobaccosmoke/.
4. Benowitz NL. Clinical pharmacology of nicotine: implications for understanding, preventing, and treating tobacco addiction. *Clin Pharmacol Ther*. 2008;83(4):531-541.
5. Fiore MC, Jaén CR, Baker TB, et al. *Treating Tobacco Use and Dependence: 2008 Update. Clinical Practice Guideline*. Rockville, MD: U.S. Department of Health and Human Services, Public Health Service; 2008.
6. Model D. Smoker's face. An underrated clinical sign? *Br Med J (Clin Res Ed)*. 1985;291(6511):1760-1762.
7. American Psychiatric Association. *Diagnostic and Statistical Manual of Mental Disorders, Fourth Edition, Text Revision (DSM-IV-TR)*. Arlington, VA: American Psychiatric Publishing; 2000.
8. Peterson AL, Vander Weg MW, Jaén CR. *Advances in Psychotherapy—Evidence-Based Practice. Vol. 21. Nicotine and Tobacco Dependence*. Cambridge, MA: Hogrefe; 2011.

237 ALCOHOLISM (ALCOHOL USE DISORDER)

Mark L. Willenbring, MD

PATIENT STORY

Theresa is a 39-year-old, white, single woman who presents with insomnia and depression. After exploring the presenting symptoms, her physician reviews some screening questions about potentially related problems. In response to a question about heavy drinking in the past year, Theresa responds that she is drinking about 2 bottles (10 drinks) of wine nightly. She acknowledges going over limits repeatedly and a persistent desire to quit or cut down, as well as continuing to drink in spite of hangovers and nausea in the morning. She denies withdrawal symptoms, driving while intoxicated, job or serious relationship problems, but admits that her social activities have decreased over the past year because she spends her evening drinking alone. No one else knows she is struggling with drinking. Her depression and insomnia started after her drinking increased about 2 years ago.

INTRODUCTION

Excessive drinking of alcohol is a common behavior encountered in primary care, yet few clinicians feel prepared to address it. Most clinicians are unclear about the best way to screen for heavy drinking and lack confidence in how to address it. Physicians often lack the knowledge and skill to screen and evaluate excessive drinking, let alone address it other than suggesting a referral to an addiction counselor or treatment program. Regrettably, few patients are appropriate for or accept referral to a counselor or program. Fortunately, research over the past 20 years has provided evidence-based, efficient ways to screen, evaluate, and treat heavy drinking in primary care.

SYNONYMS (TERMINOLOGY)

Heavy drinking refers to drinking in excess of low-risk guidelines (see below).

Alcohol dependence (alcoholism) is a disorder of compulsive drinking associated with impaired control over intake, such as repeatedly exceeding self-defined limits, a persistent desire to quit or cut down and difficulty doing so, and continued use despite adverse consequences.

The terms *alcohol use disorder, alcohol dependence*, and *alcoholism* can be used interchangeably.

EPIDEMIOLOGY

- In any given year, approximately 30% of U.S. adults 18 years of age and older exceed the National Institute on Alcohol Abuse and Alcoholism (NIAAA) low-risk drinking guidelines at least once (**Figures 237-1** and **237-2**).[1] The low-risk drinking limits for

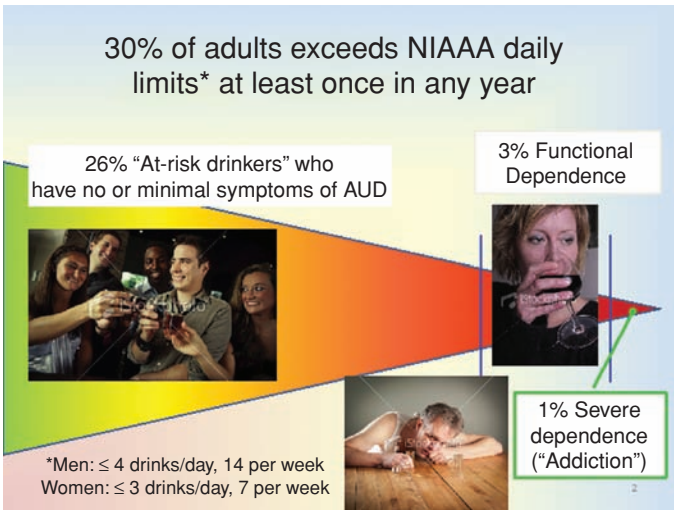

FIGURE 237-1 Spectrum of alcohol use disorder. (*Courtesy of Mark L. Willenbring, MD.*)

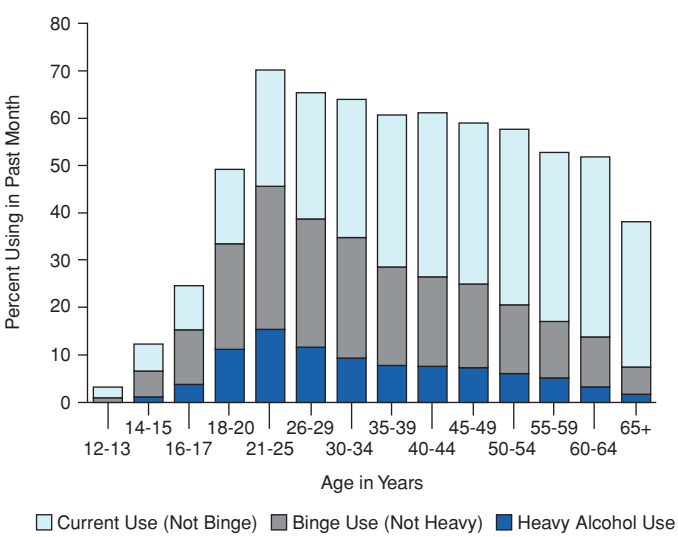

FIGURE 237-2 Past month use of alcohol among U.S. residents over age 12. Category definitions: *Current (past month) use*—at least 1 drink in the past 30 days; *binge use*—5 or more drinks on the same occasion (i.e., at the same time or within a couple of hours of each other) on at least 1 day in the past 30 days; *heavy use*—5 or more drinks on the same occasion on each of 5 or more days in the past 30 days.

healthy adult women is defined as drinking no more than 3 drinks in any day and 7 drinks in any week, and for men, no more than 4 drinks in any day and 14 drinks in any week.

- A drink refers to 12 oz of beer, 5 oz of wine or 1.5 oz of spirits, each of which contains about 14 g of absolute ethanol.[1] Within that group, the frequency varies from occasional to daily or near daily, and the amount of drinking varies from 5 to more than 20 drinks daily. Most excessive drinkers who exceed the limits (72%) do not meet diagnostic criteria for an alcohol use disorder and are considered at-risk drinkers.[1]
- At-risk drinkers are analogous to asymptomatic patients with hyperlipidemia or hypertension: they do not currently have a disorder (other than the risk factor) but are at elevated risk for developing one if the risk factor is not decreased. Reduction in excessive drinking significantly reduces risk of developing an alcohol use disorder, liver disease, or social problems.[2]
- Approximately 4% of adults meet *Diagnostic and Statistical Manual of Mental Disorders, 4th Edition* (DSM-IV) criteria for alcohol dependence in any year.[3] Three-quarters of them have functional alcohol dependence, which is characterized by a predominance of "internal symptoms" of impaired control such as going over limits and persistent desire to quit or cut down and a limited course. People with functional alcohol dependence have a single episode, lasting on average 3 to 4 years, usually with resolution of the episode and no recurrence. A quarter of those with dependence, 1% of the general population in any year, have recurrent alcohol dependence, demonstrating an average of 5 episodes over a period of years to decades.[4]
- Thus, there are 3 categories of heavy drinkers the primary care provider is apt to encounter (**Box 237-1**):
  1. At-risk drinkers (the predominant group);
  2. Functional alcohol dependence; and
  3. Recurrent, more severe alcohol dependence.

ETIOLOGY AND PATHOPHYSIOLOGY

Alcohol use disorder is a heritable disease: Approximately 50% of the risk is genetic, while environmental factors account for the remainder, the most clearly established factor being early childhood abuse or neglect.[5,6] Multigenerational alcohol dependence often appears in the early to mid-teens, but functional alcohol dependence can begin at any age.[7]

RISK FACTORS

The most important risk factors are:

- Family history of alcohol dependence,[8] and
- Early life stress in the form of early childhood abuse or neglect.[9]

Other risk factors include:

- An early history of externalizing personality factors, such as:
  - Extroversion
  - Attention deficit disorder
  - Oppositional defiant disorder
  - Conduct disorder
- Antisocial and borderline personality disorders among adults[10]

BOX 237-1 Common Presentations of 3 Categories of Excessive Drinkers*

Diagnosis of Alcohol Use Disorder	
Category	**Common Presentation**
At-risk drinkers	None or driving while drinking only (no DWI)
Functional alcohol use disorder	• "Internal symptoms" of impaired control – Going over limits repeatedly – Desire to cut down/quit without success – Use despite "internal" problems associated with drinking (e.g., hangover, nausea) – Drinking and driving (no DWI) • Usually 2 to 4 criteria positive (out of 11)* • No legal, job, or serious interpersonal problems • Maximum drinks about 5 to 8 per drinking day • Single episode lasting 3 to 4 years on average, no recurrence
Severe recurrent alcohol use disorder	• "Internal" symptoms of impaired control (above) plus – Spending a lot of time drinking – Giving up non-drinking activities – Physical withdrawal and morning drinking – Serious medical complications (e.g. liver disease) • Usually >5 criteria positive • "External" symptoms of dysfunction – Social and family disruption – Problems with job, school, parenting – Legal problems (e.g. DWI) • Maximum drinks about 10 to 24 per drinking day • Recurrent episodes over years to decades (average of 5)

*The approach of proposed DSM-V diagnosis (combining DSM-IV abuse and dependence criteria is used here).[15] (*Courtesy of Mark Willenbring, MD.*)

Onset of drinking before the age of 14 years markedly increases risk for later development of alcohol dependence, especially for adolescents with a positive family history.[11]

DIAGNOSIS

CLINICAL FEATURES

- Contrary to common belief, heavy drinkers are very likely to answer questions about their drinking honestly, provided the questions are skillful. Asking about quantity and frequency ("On any single occasion during the past 3 months, have you had more than 5 drinks containing alcohol?") is most likely to elicit an informative answer, whereas any question that suggests even the possibility of moral judgment (e.g., "How much do you drink?") is less likely to yield helpful answers. **Box 237-2** for the specific screening question recommended by the NIAAA.
- Most heavy drinkers are not symptomatic. Thus, they do not have alcohol-related symptoms. They can only be detected through screening for quantity and frequency of drinking. Screening focused on symptoms of alcohol use disorder, such as the well-known CAGE ("Have you ever tried to cut down on your drinking? Have you ever felt annoyed by criticism of your drinking? Have you ever felt guilty about your drinking? Have you ever had a morning eye-opener?"), will not detect asymptomatic at-risk drinkers, and it

BOX 237-2 Screening question recommended by the National Institute on Alcohol Abuse and Alcoholism (NIAAA)

How many times in the past year have you had…
- 5 or more drinks in a day? (for men)
- 4 or more drinks in a day? (for women)

One standard drink is equivalent to 12 oz of beer, 5 oz of wine, or 1.5 oz of 80-proof spirits.

Source: http://www.niaaa.nih.gov/guide.

performs poorly compared to almost all other methods.[12] It is important to inquire about quantity and frequency of drinking in order to identify at-risk drinkers and patients with functional alcohol dependence. The AUDIT (Alcohol Use Disorders Identification Test) (**Figure 237-3**) is the gold standard for a written questionnaire; it only takes about 3 minutes to complete and is easy to score. A score of 8 or more for men or 4 or more for women suggests excessive drinking.[1]

- Current diagnostic criteria are based on the DSM-IV.[13] DSM-IV specifies 2 types of alcohol use disorder: abuse and dependence. However, since that manual was published, research on the epidemiology of alcohol use disorders and clustering of clinical signs and symptoms has failed to confirm the differentiation of these 2 disorders. Current research supports instead the presence of a single disorder that includes the criteria of both abuse and dependence under DSM-IV into a single dimensional diagnosis.[14] The proposed criteria for the next edition, DSM-V, currently under consideration, have a single disorder, alcohol use disorder. The presence of any 2 of 11 criteria (**Box 237-3**) is enough to establish a diagnosis, where the number of criteria met are highly correlated with severity of the disorder.[15] Although there may be some minor modifications, it is almost certain that in the final version, there will be a single diagnostic category. Note that serious medical, social or personal complications of heavy drinking, such as employment or school problems, serious family or marital disruptions or legal problems are not required for a diagnosis. DSM-IV alcohol dependence criteria are usually among the earliest to occur, while most abuse criteria such as serious interpersonal, vocational or legal problems only occur among a relatively small group of the most severely affected.[16] Thus, in this chapter the terms *alcohol use disorder* (AUD) and *alcohol dependence* are used interchangeably.
- According to NIAAA, healthy adult men should not drink in excess of 4 standard U.S. drinks in any day, or 14 in any week, and adult women should not exceed 3 drinks in any day and 7 in any week.[1] Low-risk drinking limits may be less for certain groups, such as adults older than age 65 years, or in the presence of medical illnesses, such as liver disease. Women who are pregnant or are trying to become pregnant should be advised to abstain completely.
- Drinking in excess of these limits is considered unhealthy, placing heavy drinkers at elevated risk for developing AUD and associated complications such as liver disease.[17] Approximately 30% of U.S. adults age 18 years and older drink in excess of low-risk limits at least once in any year. About 4 of 5 of them do not meet diagnostic criteria for a disorder, and are considered to be "at-risk" for developing one.[1] In other words, this group has an asymptomatic risk factor similar to hypertension or hyperlipidemia. At-risk drinkers are typically unaware that their drinking constitutes a health risk. This does not reflect "denial" but rather the lack of information available to the public about what constitutes high-risk drinking or how to measure consumption. For example, how many standard U.S. drinks are in a 7 oz. martini? (Depending on the specific way it is mixed, the answer is about 4.) It is much easier to obtain dietary information about food than information about alcohol content in a beverage.
- Patients with functional alcohol dependence are aware of struggling with their alcohol consumption, but lack serious life consequences at this time. Most are open to changing their drinking, but they

BOX 237-3 Alcohol Use Disorder

Proposed DSM-V (*Updated April 30, 2012*)

A. A problematic pattern of alcohol use leading to clinically significant impairment or distress.
B. Two (or more) of the following occurring within a 12-month period:
   1. Alcohol is often taken in larger amounts or over a longer period than was intended
   2. There is a persistent desire or unsuccessful effort to cut down or control alcohol use
   3. A great deal of time is spent in activities necessary to obtain alcohol, use the substance, or recover from its effects
   4. Recurrent alcohol use resulting in a failure to fulfill major role obligations at work, school, or home (e.g., repeated absences or poor work performance related to alcohol use; substance-related absences, suspensions, or expulsions from school; neglect of children or household)
   5. Continued alcohol use despite having persistent or recurrent social or interpersonal problems caused or exacerbated by the effects of the substance
   6. Important social, occupational, or recreational activities are given up or reduced because of alcohol use
   7. Recurrent alcohol use in situations in which it is physically hazardous (e.g., driving an automobile or operating a machine when impaired by substance use
   8. Alcohol use is continued despite knowledge of having a persistent or recurrent physical or psychological problem that is likely to have been caused or exacerbated by the substance
   9. Tolerance, as defined by either or both of the following:
      a. A need for markedly increased amounts of alcohol to achieve intoxication or desired effect
      b. Markedly diminished effect with continued use of the same amount of the substance
   10. Withdrawal, as manifested by either of the following:
      a. The characteristic withdrawal syndrome for alcohol (refer to Criteria A and B of the criteria set for Withdrawal)
      b. The same (or a closely related) substance is taken to relieve or avoid withdrawal symptoms
   11. Craving or a strong desire or urge to use alcohol

AUDIT

PATIENT: Because alcohol use can affect your health and can interfere with certain medications and treatments, it is important that we ask some questions about your use of alcohol. Your answers will remain confidential, so please be honest.

For each question in the chart below, place an X in one box that best describes your answer.

NOTE: In the U.S., a single drink serving contains about 14 grams of ethanol or "pure" alcohol. Although the drinks below are different sizes, each one contains the same amount of pure alcohol and counts as a single drink:

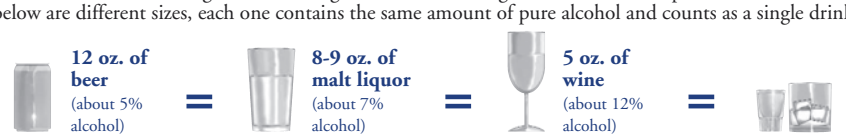

Questions	0	1	2	3	4	
1. How often do you have a drink containing alcohol?	Never	Monthly or less	2 to 4 times a month	2 to 3 times a week	4 or more times a week	
2. How many drinks containing alcohol do you have on a typical day when you are drinking?	1 or 2	3 or 4	5 or 6	7 to 9	10 or more	
3. How often do you have 5 or more drinks on one occasion?	Never	Less than monthly	Monthly	Weekly	Daily or almost daily	
4. How often during the last year have you found that you were not able to stop drinking once you had started?	Never	Less than monthly	Monthly	Weekly	Daily or almost daily	
5. How often during the last year have you failed to do what was normally expected of you because of drinking?	Never	Less than monthly	Monthly	Weekly	Daily or almost daily	
6. How often during the last year have you needed a first drink in the morning to get yourself going after a heavy drinking session?	Never	Less than monthly	Monthly	Weekly	Daily or almost daily	
7. How often during the last year have you had a feeling of guilt or remorse after drinking?	Never	Less than monthly	Monthly	Weekly	Daily or almost daily	
8. How often during the last year have you been unable to remember what happened the night before because of your drinking?	Never	Less than monthly	Monthly	Weekly	Daily or almost daily	
9. Have you or someone else been injured because of your drinking?	No		Yes, but not in the last year		Yes, during the last year	
10. Has a relative, friend, doctor, or other health care worker been concerned about your drinking or suggested you cut down?	No		Yes, but not in the last year		Yes, during the last year	
					Total	

Note: This questionnaire (the AUDIT) is reprinted with permission from the World Health Organization. To reflect drink serving sizes in the United States (14g of pure alcohol), the number of drinks in question 3 was changed from 6 to 5. A free AUDIT manual with guidelines for use in primary care settings is available online at *www.who.org*.

Excerpted from NIH Publication No. 07-3769 **National Institute on Alcohol and Alcoholism** *www.niaaa.nih.gov/guide*

FIGURE 237-3 The AUDIT questionnaire. Scores are added to determine the total. Positive screens are indicated by total scores ≥8 in men and ≥4 in women. Higher scores indicate more severe alcohol involvement. Scores >16 suggest the possibility of alcohol dependence.[1,39]

may need to be identified through screening, rather than presenting with this problem.

- Patients with more severe, recurrent alcohol dependence often present with intoxication, withdrawal, or medical complications of heavy drinking, such as liver disease or pancreatitis. If these disorders are present, they demonstrate the expected physical manifestations. Like other patients with chronic, treatment-refractory illness, they have a chronic course, with periodic relapses or even with ongoing chronic illness.

TYPICAL DISTRIBUTION

- In a given year, 30% of the adult U.S. population engages in unhealthy drinking at least once (**Figure 237-1**). In an average primary care practice, approximately 10% to 15% of outpatients are heavy drinkers.

LABORATORY TESTING

- The most sensitive way to detect heavy drinking is to ask about the frequency of heavy drinking. Use of a written questionnaire such as the AUDIT can be helpful (**Figure 237-3**).[18]
- The most sensitive but least specific laboratory test is γ-glutamyltransferase (GGT). Carbohydrate-deficient transferrin provides similar sensitivity but better specificity but is not widely available.[19]
- Other transaminases such as aspartate aminotransferase (AST) and alanine aminotransferase (ALT) are less sensitive, and require hepatic cell destruction before they are elevated. Thus, they are not very sensitive for detecting heavy drinking but they may be helpful in following patients who have elevated values at baseline.

IMAGING

- There are no imaging tests that detect heavy drinking itself. Abdominal ultrasound is often helpful in evaluating alcoholic liver disease.

DIFFERENTIAL DIAGNOSIS

- It is important to distinguish between AUD and asymptomatic at-risk drinking. AUD is characterized by preoccupation with and impaired control over drinking.

MANAGEMENT

Box 237-4: Clinical Prevention and Treatment of Alcohol Use Disorder.

NONPHARMACOLOGIC

- Brief counseling and advice to reduce drinking is effective for at-risk drinking, resulting in 15% to 20% reduction in drinking for at least 1 year.[2]
- Alcohol dependence requires either more intensive counseling and/or antirelapse medications. The relationship between intensity and setting (inpatient, residential, or outpatient) is complex. Most studies show no difference in 1-year outcomes based on intensity or

BOX 237-4 Clinical Prevention and Treatment of Alcohol Use Disorder

Category	Management
At-risk drinkers Goal: risk reduction	• Brief counseling to quit or cut down • Hand patients *Rethinking Drinking* booklet • Repeated counseling increases effectiveness
Functional alcohol use disorder Goal: long-term abstinence or low-risk drinking (e.g., recovery)	• Antirelapse medications – Naltrexone (oral, injection) – Topiramate (Topamax) – Disulfiram (Antabuse) • Brief behavioral support (medication management) • Recommend Alcoholics Anonymous • Offer referral to addiction specialist especially if fails to respond to primary care treatment
Severe recurrent alcohol use disorder Goals: • Reduce frequency, severity and length of relapses • Treat complications • Slow the rate of deterioration • Aim for full recovery but recognize it may not be achieved	• Offer referral to addiction specialist • Recommend Alcoholics Anonymous • Medications – Treat withdrawal if needed – Antirelapse medications • Care coordination • Integrate medical, psychiatric, addiction treatment • Treatment for as long as needed; usually years to decades

setting.[20] For example, in a highly controlled, well-done study, 174 persons with alcoholism were randomly assigned to partial hospital treatment or extended inpatient rehabilitation after inpatient evaluation and/or detoxification. The outpatient group attended daily Monday through Friday therapy alongside the group that was assigned to 6 months of psychiatric inpatient hospitalization. The study found no additional benefit to extended hospitalization.[21]

- However, there are circumstances that make providing structured sober housing important: among people who are homeless, those who cannot stop drinking while living independently, and people with significant coexisting psychiatric illness.[20] The degree of housing structure required, however, is relatively independent of the intensity or type of treatment given. Some patients require a great deal of housing structure but very few treatment services, whereas others are stably housed but require intensive and prolonged treatment. Thus it makes sense to uncouple housing structure from treatment decisions, as there is no apparent benefit to having patients stay in a facility overnight while they are receiving treatment services.
- Increasingly, treatment for recurrent AUD (dependence) is being conceptualized as management of a chronic illness.[22] A recent study found that continued care that included primary care management as well as continued access to specialty addiction care resulted in improved outcomes and reduced costs.[23]
- Long-term regular medical follow up that simply attends to drinking and encourages abstinence is effective for reducing drinking among patients with medical complications such as liver cirrhosis or pancreatitis.[24]

MEDICATIONS

- Several antirelapse medications are available for alcohol dependence. Their average efficacy is similar to that for selective serotonin reuptake inhibitor (SSRI) antidepressants in treating depression.[25,26]
- Naltrexone 50 mg daily or as needed for each drinking occasion reduces relapse rates and quantity of drinking per occasion. It reduces craving for alcohol and the reward or "kick" an individual experiences when first beginning a drinking episode. This reduces the compulsive quality of drinking, making it easier to stop before a full relapse occurs. Its effectiveness is determined by genetic factors; it is most effective among northern Europeans and least likely to be effective among African Americans. In the author's experience, naltrexone 25 to 50 mg as needed per drinking occasion may help at-risk drinkers reduce excessive alcohol use, especially in social situations. Approximately 10% of patients will experience nausea. Patients should be warned that usual doses of oral opioids such as hydrocodone will not work because of the opioid blockade, so naltrexone should be stopped at least 3 days prior to elective procedures. In emergencies the blockade can be overridden, but the therapeutic index is reduced. Although initially quite concerning, in practice this has not proved to be a significant problem. Naltrexone also is available in a long-acting injectable formulation that only requires monthly administration.
- Disulfiram 250 mg daily acts by blocking the breakdown of ethanol, resulting in increased levels of acetaldehyde, which causes an adverse flushing reaction. The disulfiram-ethanol reaction is thus dose related; a small amount of alcohol such as might exist in wine

vinegar, for example, might cause mild facial flushing, whereas drinking several glasses of wine or beer, or several ounces of distilled spirits, will cause a more severe reaction. Disulfiram-ethanol reactions may be very unpleasant but are unlikely to be harmful in the absence of preexisting ischemic heart disease. Reactions can occur up to several days after discontinuation, so patients should be warned. Some patients will not develop a disulfiram-ethanol reaction at the standard dose and require 500 mg daily. Disulfiram therapy is the most effective for maintaining abstinence, because any significant alcohol use will cause a reaction. It works best when administration is monitored by a family member, roommate, or friend. The most common side effect is a metallic taste. Less common are peripheral neuropathy, optical neuritis, and delirium or psychosis. A rare but serious idiosyncratic risk is that of fulminant hepatitis, often leading to liver failure and death.

- Topiramate is thought to work by normalizing the γ-aminobutyric acid (GABA)-glutamate imbalance that occurs with severe alcohol dependence. It both reduces desire to drink and the reward that occurs with drinking. Because of side effects, it is important to start at a low dose, for example, 25 mg before bedtime, and ramp up slowly over 4 to 8 weeks to a target dose of 200 to 800 mg daily. The most distressing side effect is cognitive dysfunction, best described as difficulty with word finding. Perioral paresthesias are common but reversible. Because of induction of renal tubular acidosis topiramate increases excretion of calcium, thus increasing the risk for renal calculi, especially in patients with a previous history.
- Acamprosate is licensed for alcohol dependence by the FDA but the last 3 large multisite trials demonstrated no effectiveness.[27–29] It is expensive and must be taken 3 times a day. If it is effective at all, it would be in very severe dependence with a history of physical withdrawal.

COMPLEMENTARY AND ALTERNATIVE THERAPY

- No complementary/alternative therapies have proven efficacy in alcohol dependence.
- Unfortunately, some treatment programs continue to offer "nutritional therapy," treatment guided by single-photon emission computed tomography (SPECT) scans, acupuncture and other unproven therapies, but there is no evidence of their effectiveness.
- 12-Step community support groups such as Alcoholics Anonymous (AA) help some patients with severe alcohol dependence. People who affiliate and stay with AA have better outcomes than those who do not.

REFER OR HOSPITALIZE

- Alcohol withdrawal is best managed in the hospital for patients with histories of alcohol withdrawal seizures or delirium, or who have medical conditions that might destabilize during withdrawal, such as ischemic heart disease or fragile diabetes.
- Alcohol withdrawal delirium requires hospitalization, usually in an intensive care unit.
- Most patients will not accept a referral to an addiction rehab program, but will accept treatment by their primary care physician. Patients who are naïve to rehab programs may benefit from referral. However, rehab programs tend to offer the same programming no matter how many times an individual has been exposed to it. There is no reason to believe that repeated exposure to the same type of program improves outcomes. If an addiction medical specialist is available, referral for patients not responding to initial primary care management is indicated.
- Inpatient psychiatric hospitalization conferred no added benefit compared with outpatient treatment, but might inpatient treatment might be useful for patients who are unable to abstain for the 4 to 8 weeks necessary for outpatient treatment.[30] Sober housing coupled with an outpatient treatment program can also be beneficial for some.
- Antirelapse medication along with medical management is as effective as high-quality addiction counseling for more functional patients with alcohol dependence.[31]
- Patients with severe recurrent alcohol dependence with medical comorbidities fare best with long-term regular medical management, which includes discussion of alcohol consumption and its relationship to medical conditions, as well as encouragement to abstain. When sustained over 1 to 2 years, such medical management results in a substantial proportion of patients who are abstinent.[32]
- The presence of severe psychiatric conditions such as psychosis, mania, or severe depression with suicidal ideation requires referral to a psychiatrist or hospital. Long-term comanagement by primary care physicians and psychiatrists is likely to be necessary.

PREVENTION

- Most heavy drinkers are asymptomatic, but are drinking at a rate that puts them at increased risk for developing alcohol addiction (dependence) and associated medical and social complications. These "at-risk" drinkers respond well to brief counseling by physicians, resulting in significant reductions in heavy drinking. This finding is based on extensive research, such that the U.S. Prevention Task Force has rated screening and brief counseling to be a "B" recommendation, which also have been determined to be cost-effective.[33] Because the prevalence of at-risk drinking is so high (26% of U.S. adults in any given year), the potential public health impact of broad implementation of screening and brief counseling is large.
- The NIAAA has published a guide to help physicians with screening, assessment and brief counseling techniques (**Figure 237-4**). There is also an online continuing medical education (CME) activity available. This online training uses 4 video case series, along with advanced interactive educational techniques, to improve physicians' skills and knowledge (available at http://www.niaaa.nih.gov/publications/clinical-guides-and-manuals/niaaa-clinicians-guide-online-training). CME credit is available and it has been approved by the American Academy of Family Physicians.
- *Rethinking Drinking*, available as a booklet and online, is an educational tool for at-risk drinkers (available at http://rethinkingdrinking.niaaa.nih). This publication takes the drinker through a process of increasing awareness of drinking, deciding whether to change and what the drinking goal is, and developing a plan to implement change. Using this publication substantially enhances the value while decreasing the time it takes to counsel a patient to reduce or stop drinking.

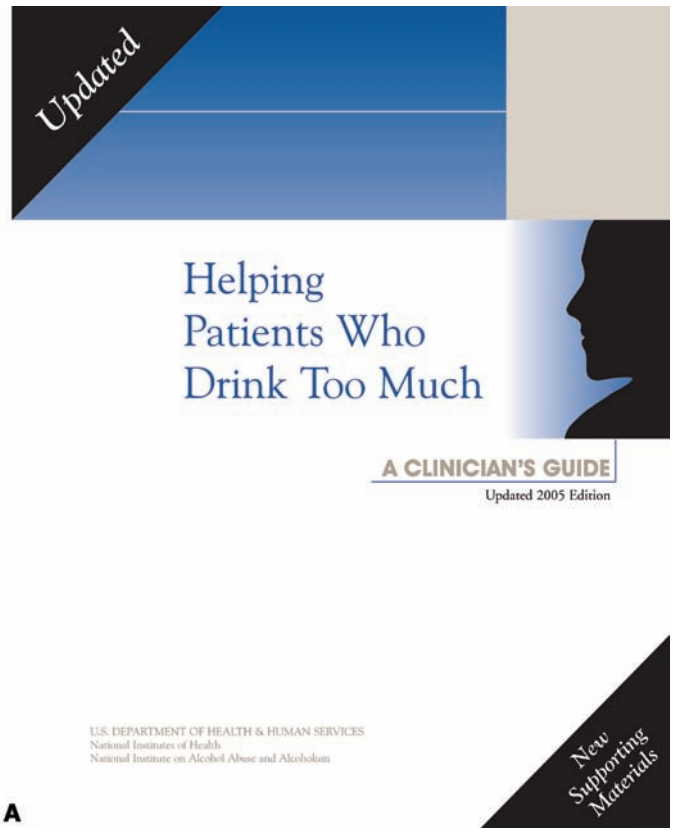

A

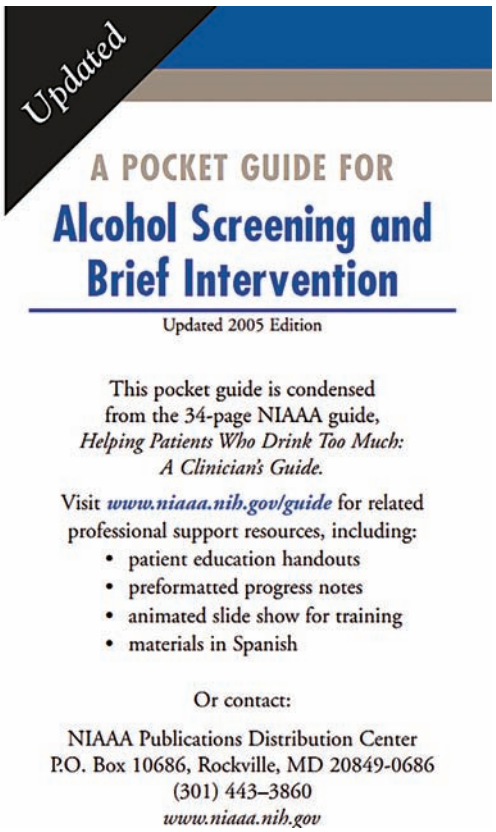

B

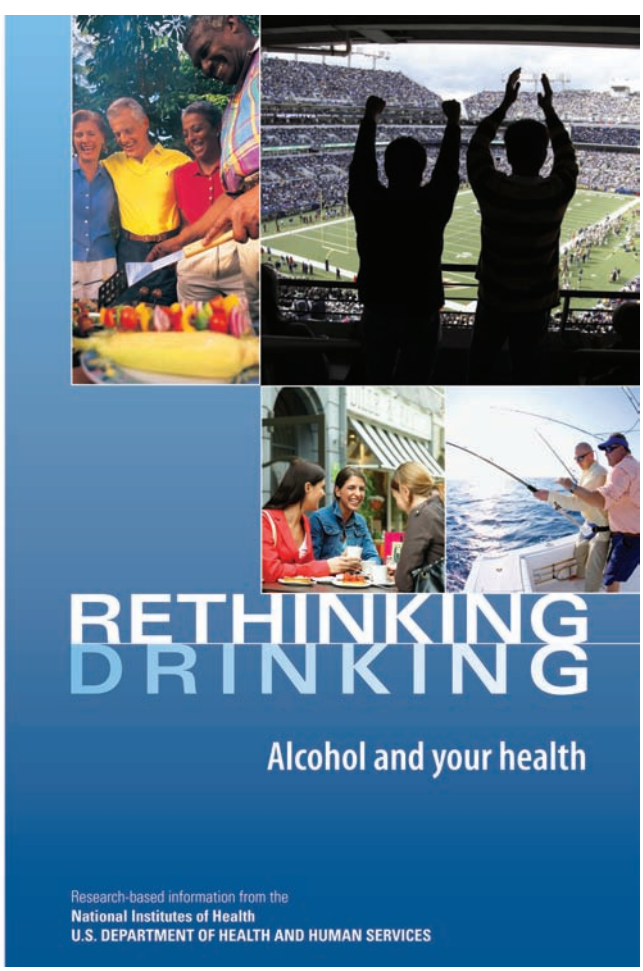

C

FIGURE 237-4 A. *Clinician's Guide* and (B) *Pocket Guide* versions are available from the National Institute on Alcohol Abuse and Alcoholism. These *Guides* provide physicians with the tools needed to screen for excessive alcohol use, diagnose alcohol use disorder, and provide the appropriate counseling and pharmacotherapy to their patients. A companion video case studies training program offers physicians the opportunity to see the *Guides*' principles put into action, and includes CME credits. Both are available at http://www.niaaa.nih.gov/guide. C. *Rethinking Drinking* is a booklet for excessive drinkers that physicians can hand out to patients who drink excessively. It greatly reduces the time required for counseling about excessive drinking. It is available from the National Institute on Alcohol Abuse and Alcoholism. A companion website has additional features (http://rethinkingdrinking.niaaa.nih.gov).

PROGNOSIS

- Most at-risk drinkers eventually reduce their drinking or abstain, and do not develop an AUD or other complications of heavy drinking.
- Nearly three-fourths of people who have an episode where they meet criteria for an AUD experience remission of the disorder (either through abstaining or reducing drinking to low-risk levels) after a few years. Once remitted, the AUD generally does not recur, and 20 years after onset, fewer than 10% still meet full diagnostic criteria for a disorder (**Figure 237-5**).[4]
- Those with recurrent or chronic dependence have an average of 5 episodes over a period of decades. However, many eventually do remit. Almost all patients who enter rehab programs have severe recurrent dependence.[7] Rehab outcomes are very similar across different programs.[34] In the first year following an episode of rehab, roughly one-third of patients will be in stable recovery (approximately 25% will abstain and 10% will be in nonabstinent recovery, defined as engaging in no high-risk drinking and having no alcohol-related problems,) a third will not respond and will remain in stable nonrecovery, and the remainder will show variability (**Figure 237-6**).
- Patients with moderate-severe, recurrent dependence usually must make multiple quit attempts over several years before long-term abstinence is established.[35]
- Recent research suggests that heavy drinking in mid-life tends to persist over time and may be resistant to available treatment approaches.[36] Consequently, repeated and ongoing efforts to support change are often required. It is helpful under these circumstances to think in terms of "quit attempts," much like is used for smoking cessation.
- A minority of patients have chronic dependence or periodic relapses for many years, and as is true with all chronic illnesses, some will die of the disease and its medical complications, in spite of availability of all available current treatments and motivated effort by the patient. The science of behavior change is in its infancy, so much of what we do is non-specific and modestly effective.

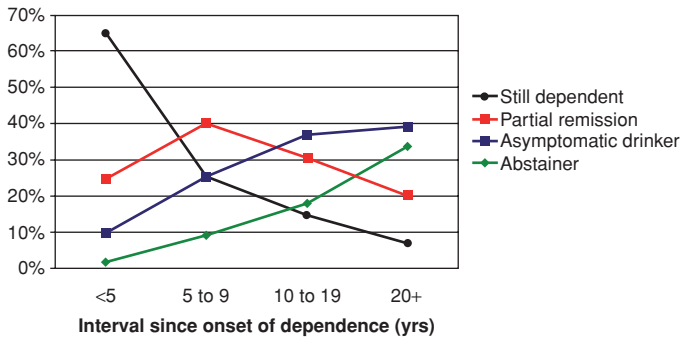

FIGURE 237-5 Course of alcohol dependence over time. At time zero, 100% of subjects were dependent.[33] (*Courtesy of Mark Willenbring, MD.*)

FOLLOW-UP

- *At-risk drinkers:* Although a single brief counseling session has significant efficacy, the effect may be magnified by repeated counseling. For this reason, it is best to inquire about drinking quantity and frequency at each follow-up visit and to reinforce advice about low-risk drinking limits.
- *Patients with alcohol dependence:* Approach this group of patients with the same attitude you adopt for smoking cessation. Most people require multiple quit attempts before achieving lasting remission, so it is important to anticipate the possibility of recurrence, and to plan for it if it occurs. Let the patient know that you won't be angry or disappointed with them if recurrence occurs. In fact, if they have a relapse to heavy drinking, that is exactly when they should seek care; a relapse is similar to an asthma attack or an increase in chest pain from ischemic heart disease. Exacerbations or recurrences of chronic illnesses are common and can be managed.

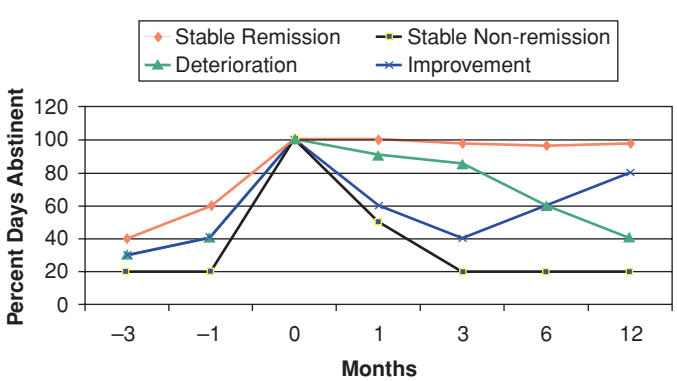

FIGURE 237-6 Course of alcohol dependence before and after treatment. Many patients reduce drinking significantly before entering treatment.[37] After treatment, about a third of patients will be in stable recovery for the following 12 months, a third will be in stable nonrecovery, and the remainder will fluctuate between recovery and nonrecovery.[38] (*Courtesy of Mark Willenbring, MD.*)

The goal is to seek care quickly if a recurrence occurs and to keep relapses infrequent, short and to reduce their severity. If withdrawal is a concern, it can generally be managed on an outpatient basis.[37] Reevaluate pharmacotherapy and behavioral approaches. Support learning from the recurrence: How did it happen? What could prevent the next one? Address guilt and shame and encourage patients to minimize time spent on this relapse and to look to the future and get right back on track.

- For patients with functional alcohol dependence consider referral to an addiction medicine or psychiatry specialist.
- For patients with complex chronic addiction, treat complications, recruit social and environmental resources (family, community, etc.) as indicated, and provide support.

PATIENT EDUCATION

- A patient handbook is available from the NIAAA. Titled *Rethinking Drinking* (**Figure 237-4**), it takes patients through a scientifically based process of education, evaluation of their drinking and decision-making regarding whether to change it. Free copies of the printed version are available from the Institute and it is also available on the Internet—**http://rethinkingdrinking.niaaa.nih.com**.
- General principles in approaching patients
  - Heavy drinking and AUDs are similar to other common complex diseases such as diabetes: they have about a 50:50 combination of genetic and environmental etiologies.
  - Alcohol dependence occurs when the brain changes after exposure to large doses of alcohol, causing an impairment of control over intake. In all but mild cases, this is irreversible and good control over drinking will always be problematic. Thus, abstinence is the best and easiest approach for most people.
  - Acknowledge that friends and family may take a long time to trust an individual in early recovery, as most have been disappointed numerous times in the past.
  - Emphasize that slips and relapses are common and encourage patients to keep trying in spite of them.

PATIENT RESOURCES

- The National Institute on Alcohol Abuse and Alcoholism—**http://www.niaaa.nih.gov.**
- *Rethinking Drinking*, a booklet for people who wish to consume alcohol—**http://rethinkingdrinking.niaaa.nih.gov.**
- Faces and Voices of Recovery—**http://www.facesandvoicesofrecovery.org/.**
- Alcoholics Anonymous—**http://www.aa.org.**

PROVIDER RESOURCES

- *Helping Patients Who Drink Too Much: A Clinician's Guide*—**http://www.niaaa.nih.gov/publications/clinical-guides-and-manuals/helping-patients-who-drink-too-much-clinicians-guide.**

REFERENCES

1. *Helping Patients Who Drink Too Much: A Clinician's Guide*. Bethesda, MD: National Institutes of Health; 2007.
2. Whitlock EP, Polen MR, Green CA, Orleans T, Klein J. Behavioral counseling interventions in primary care to reduce risky/harmful alcohol use by adults: a summary of the evidence for the U.S. Preventive Services Task Force. *Ann Intern Med* 2004;140(7):557-568, I564.
3. Grant BF, Dawson DA, Stinson FS, Chou SP, Dufour MC, Pickering RP. The 12-month prevalence and trends in DSM-IV alcohol abuse and dependence: United States, 1991-1992 and 2001-2002. *Drug Alcohol Depend* 2004;74(3):223-234.
4. Hasin DS, Stinson FS, Ogburn E, Grant BF. Prevalence, correlates, disability, and comorbidity of DSM-IV alcohol abuse and dependence in the United States: results from the national epidemiologic survey on alcohol and related conditions. *Arch Gen Psychiatry* 2007;64(7):830-842.
5. Dick DM, Bierut LJ. The genetics of alcohol dependence. *Curr Psychiatry Rep* 2006;8(2):151-157.
6. Enoch M-A. The influence of gene-environment interactions on the development of alcoholism and drug dependence. *Curr Psychiatry Rep* 2012;14(2):150-158.
7. Moss HB, Chen CM, Yi Hy. Subtypes of alcohol dependence in a nationally representative sample. *Drug Alcohol Depend* 2007;91(2-3):149-158.
8. Lynskey MT, Agrawal A, Heath AC. Genetically informative research on adolescent substance use: methods, findings, and challenges. *J Am Acad Child Adolesc Psychiatry* 2010;49(12):1202-1214.
9. Enoch M-A. The role of early life stress as a predictor for alcohol and drug dependence. *Psychopharmacology (Berl)* 2011;214(1):17-31.
10. Chartier KG, Hesselbrock MN, Hesselbrock VM. Development and vulnerability factors in adolescent alcohol use. *Child Adolesc Psychiatr Clin N Am* 2010;19(3):493-504.
11. Hingson RW, Heeren T, Winter MR. Age of alcohol-dependence onset: associations with severity of dependence and seeking treatment. *Pediatrics* 2006;118(3):e755-e763.
12. Rubinsky AD, Kivlahan DR, Volk RJ, Maynard C, Bradley KA. Estimating risk of alcohol dependence using alcohol screening scores. *Drug Alcohol Depend* 2010;108(1-2):29-36.
13. American Psychiatric Association. *Diagnostic and Statistical Manual of Psychiatric Disorders, Fourth Edition, Text Revision*. Washington, DC: American Psychiatric Publishing; 2000.
14. Hasin DS, Beseler CL. Dimensionality of lifetime alcohol abuse, dependence and binge drinking. *Drug Alcohol Depend* 2009;101(1-2):53-61.
15. American Psychiatric Association. Proposed Revisions/Substance Use and Addictive Disorders. http://www.dsm5.org/ProposedRevision/Pages/SubstanceUseandAddictiveDisorders.aspx, accessed August 10, 2012.
16. Saha TD, Chou SP, Grant BF. Toward an alcohol use disorder continuum using item response theory: results from the National Epidemiologic Survey on Alcohol and Related Conditions. *Psychol Med* 2006;36(7):931-941.
17. Dawson DA, Grant BF, Li TK. Quantifying the risks associated with exceeding recommended drinking limits. *Alcohol Clin Exp Res* 2005;29(5):902-908.
18. Boschloo L, Vogelzangs N, Smit JH, et al. The performance of the Alcohol Use Disorder Identification Test (AUDIT) in detecting alcohol abuse and dependence in a population of depressed or anxious persons. *J Affect Disord* 2010;126(3):441-446.
19. Hock B, Schwarz M, Limmer C, et al. Validity of carbohydrate-deficient transferrin (%CDT), gamma-glutamyltransferase (gamma-GT) and mean corpuscular erythrocyte volume (MCV) as biomarkers for chronic alcohol abuse: A study in patients with alcohol dependence and liver disorders of non-alcoholic and alcoholic origin. *Addiction* 2005;100(10):1477-1486.
20. Finney JW, Hahn AC, Moos RH. The effectiveness of inpatient and outpatient treatment for alcohol abuse: the need to focus on mediators and moderators of setting effects. *Addiction* 1996;91(12):1773-1796.
21. Longabaugh R, McCrady B, Fink E, et al. Cost effectiveness of alcoholism treatment in partial vs inpatient settings. Six-month outcomes. *J Stud Alcohol* 1983;44(6):1049-1071.
22. McLellan AT, Lewis DC, O'Brien CP, Kleber HD. Drug dependence, a chronic medical illness: implications for treatment, insurance, and outcomes evaluation. *JAMA* 2000;284(13):1689-1695.
23. Parthasarathy S, Chi FW, Mertens JR, Weisner C. The role of continuing care in 9-year cost trajectories of patients with intakes into an outpatient alcohol and drug treatment program. *Med Care* 2012;50(6):540-546.
24. Willenbring ML, Olson DH. A randomized trial of integrated outpatient treatment for medically ill alcoholic men. *Arch Intern Med* 1999;159(16):1946-1952.
25. Bouza C, Angeles M, Munoz A, Amate JM. Efficacy and safety of naltrexone and acamprosate in the treatment of alcohol dependence: a systematic review. *Addiction* 2004;99(7):811-828.
26. Johnson BA, Rosenthal N, Capece J, et al. Topiramate for the treatment of alcohol dependence: results from a multi-site trial. *Alcohol Clin Exp Res* 2007;31(s2):261A-261A.
27. Anton RF, O'Malley SS, Ciraulo DA, et al. Combined pharmacotherapies and behavioral interventions for alcohol dependence: the COMBINE study: a randomized controlled trial. *JAMA* 2006;295(17):2003-2017.
28. Mason BJ, Goodman AM, Chabac S, Lehert P. Effect of oral acamprosate on abstinence in patients with alcohol dependence in a double-blind, placebo-controlled trial: the role of patient motivation. *J Psychiatr Res* 2006;40(5):383-393.
29. Mann KF, Lemenager KF, Smolka M, & the Project PREDICT Research Group. Craving subtypes as predictors for treatment response: results from the PREDICT Study. *Alcohol Clin Exp Res* 2008;32(Suppl 1a):281A.
30. Fink EB, Longabaugh R, McCrady BM, et al. Effectiveness of alcoholism treatment in partial versus inpatient settings: twenty-four month outcomes. *Addict Behav* 1985;10(3):235-248.
31. O'Malley SS, Rounsaville BJ, Farren C, et al. Initial and maintenance naltrexone treatment for alcohol dependence using

primary care vs specialty care: a nested sequence of 3 randomized trials. *Arch Intern Med* 2003;163(14):1695-1704.

32. Willenbring ML, Olson DH, Bielinski J. Integrated outpatient treatment for medically ill alcoholic men: results from a quasi-experimental study. *J Stud Alcohol* 1995;56(3):337-343.
33. Solberg LI, Maciosek MV, Edwards NM. Primary care intervention to reduce alcohol misuse. ranking its health impact and cost effectiveness. *Am J Prev Med* 2008;34(2).
34. Miller WR, Walters ST, Bennett ME. How effective is alcoholism treatment in the United States? *J Stud Alcohol* 2001;62(2):211-220.
35. Dawson DA, Grant BF, Stinson FS, Chou PS, Huang B, Ruan WJ. Recovery from DSM-IV alcohol dependence: United States, 2001-2002. *Addiction* 2005;100(3):281-292.
36. Delucchi KL, Kline Simon AH, Weisner C. Remission from alcohol and other drug problem use in public and private treatment samples over seven years. *Drug Alcohol Depend* 2012;124(1-2):57-62.
37. Hayashida M, Alterman AI, McLellan AT, et al. Comparative effectiveness and costs of inpatient and outpatient detoxification of patients with mild-to-moderate alcohol withdrawal syndrome. *N Engl J Med* 1989;320(6):358-365.

238 METHAMPHETAMINE

Michelle Rowe, DO
Andrew D. Schechtman, MD

PATIENT STORY

A 40-year-old woman with diabetes comes to the clinic with blood sugar in the 400s because she ran out of insulin a few weeks ago. She appears poorly groomed and has nicotine stains on her fingertips. Excoriated lesions (**Figure 238-1**) are noted on her forearms and face. She reports no itching at this moment, but when asked confirms that she regularly smokes methamphetamine. The diagnosis of her skin condition is meth mites. She acknowledges that she picks at her skin when she is high on meth. The physician asks her if she wants help to get off the meth so she can care for her health and well-being. She breaks down in tears and says that her craving for meth is very strong, but she is willing to try something because she knows the meth is ruining her body and life.

FIGURE 238-1 A 40-year-old woman with sores on her arm caused by picking at her skin while using methamphetamine. Also called meth mites, although there are no mites. (*Courtesy of Andrew Schechtman, MD.*)

INTRODUCTION

Methamphetamine is a powerfully addictive stimulant that can be smoked, snorted, or injected. Methamphetamine can be produced by using common household products and pseudoephedrine. There is a worldwide epidemic of methamphetamine abuse and addiction.

SYNONYMS

Meth, crank, ice, and crystal.

EPIDEMIOLOGY

- Worldwide, compared to other drugs of abuse, only marijuana is used more often than amphetamine/methamphetamine.[1]
- The lifetime prevalence ("ever-used") rate for methamphetamine was 2.1% for 12th graders in the 2011 Monitoring the Future study, which surveys 50,000 students in 8th, 10th, and 12th grades in 420 schools nationwide annually. This has decreased from 1999, when the lifetime prevalence for methamphetamine use in 12th graders was 8.2%. For comparison, marijuana/hashish had a lifetime prevalence in 12th graders of 45.5% and 49.7% in 2011 and 1999, respectively.[2]
- Stimulants (methamphetamine and amphetamine) accounted for 9.6% of nationwide emergency department visits involving use of illicit drugs in 2009, with the highest incidence in those from 18 to 44 years old.[3]
- Methamphetamine use is associated with white or Native American race; residence in the west or south; having an ever-incarcerated father; marijuana, cocaine, intravenous drug use; and men who have sex with men (MSM).[4]

- Analysis of methamphetamine found in workforce drug testing done nationwide in 2010 by Quest Diagnostics showed the highest rates of use in western and midwestern states, with relative sparing of eastern states. Highest prevalence (more than twice the national average) was found in Hawaii, Arkansas, Oklahoma, Nevada, California, Wyoming, Utah, and Arizona.[5]
- Methamphetamine is a Schedule II stimulant with legitimate medical uses, including the treatment of narcolepsy and attention deficit hyperactivity disorder.
- Methamphetamine is known on the street as meth, crank, ice (**Figure 238-2**), and crystal. It is abused by smoking, injecting, snorting, or oral ingestion. Smoking or injecting the drug gives an intense, short-lived "flash" or rush. Snorting or oral ingestion creates euphoria but no rush.
- Methamphetamine can be manufactured from inexpensive, readily available chemicals using recipes easily found on the Internet and in books (**Figure 238-3**).
- Common household and industrial chemicals used to make methamphetamine include pseudoephedrine and ephedrine (cold tablets), red phosphorus (matches/road flares), iodine (teat dip or flakes/crystal), methanol (gasoline additives), muriatic acid (used in swimming pools), anhydrous ammonia (farm fertilizer), sodium hydroxide (lye), sulfuric acid (drain cleaner), toluene (brake cleaner), and ether (engine starter).[7]
- The "meth laboratory," the site of small-scale methamphetamine production (**Figure 238-4**), brings with it many hazards, including exposure to toxic chemicals for the meth cooks themselves, their children, and law enforcement, medical, and fire personnel entering the laboratory in the course of their duties. Explosions and fires at meth laboratories are common. Improper disposal of the toxic chemicals used in the laboratories frequently leads to environmental contamination.[8]
- Effects of methamphetamine, such as euphoria, increased libido, and impaired judgment, may lead to increased high-risk sexual behaviors, such as unprotected sexual intercourse and contact with multiple sexual partners. As a result, methamphetamine users are at increased risk of contracting sexually transmitted infections, including HIV.

FIGURE 238-2 Methamphetamine in its ice format. (*Courtesy of DEA.*)

ETIOLOGY AND PATHOPHYSIOLOGY

- Methamphetamine acts as a central nervous system stimulant by blocking presynaptic reuptake of dopamine, norepinephrine, and serotonin.
- Compared to amphetamines, methamphetamine has an increased ability to cross the blood–brain barrier and has a prolonged half-life (10 to 12 hours). This leads to faster-onset, more intense, and longer-lasting effects when compared to amphetamine.
- Intended effects of methamphetamine use include euphoria, increased energy, a heightened sense of alertness, and increased libido.
- Unintended effects include increased heart rate, blood pressure, and body temperature; headaches; nausea; anxiety; aggression; paranoia; visual and auditory hallucinations; insomnia; tremors; and cardiac arrhythmias.



FIGURE 238-3 One of many books by Uncle Fester that can be purchased on the Internet. The information to manufacture methamphetamine is readily available. (*Reproduced with permission from Uncle Fester, www.unclefesterbooks.com.*)

- With chronic abuse, neurologic manifestations include confusion, poor concentration, depression, paranoia, and psychosis. Weight loss and dental decay can occur. The face and body become atrophic and gaunt, making the chronic methamphetamine user appear older than their stated age.
- Methamphetamine users may experience formication, the hallucination that bugs are crawling under the skin. The skin excoriations resulting from picking at the imagined bugs are known as "meth mites" (**Figures 238-1**, **238-5**, and **238-6**).
- The rampant dental caries and gingivitis commonly seen in methamphetamine users is known as "meth mouth" (**Figures 238-7** and **238-8**). The causes of meth mouth are multiple. Vasoconstriction leads to decreased saliva production and dry mouth, which often result in consumption of large amounts of sugar-containing beverages. Methamphetamine users often neglect their oral hygiene when preoccupied with obtaining and using the drug. Methamphetamine-induced bruxism also damages the teeth. Neglect of early symptoms and lack of access to or failure to seek dental care often lead to unsalvageable teeth that can only be extracted.[9-11]

FIGURE 238-4 A methamphetamine laboratory with visible toxic and flammable substances.

DIAGNOSIS

ACUTE INTOXICATION

This can lead to tachycardia, hypertension, chest pain, hyperthermia, diaphoresis, mydriasis, agitation, irritability, hypervigilance, paranoia, hallucinations, and tremor.

CHRONIC USE

Chronic use of methamphetamine can cause violent behavior, anxiety, depression, confusion, insomnia, and psychotic symptoms (paranoia, auditory hallucinations, delusions, and formication).[12,13]

WITHDRAWAL SYMPTOMS

Withdrawal symptoms include drug cravings, depressed mood, disturbed sleep patterns, increased appetite, and fatigue.

COMPLICATIONS

Complications arising from using methamphetamine include neurologic (seizures, stroke caused by intracerebral hemorrhage or vasospasm), cardiovascular (myocardial ischemia or infarction, dilated cardiomyopathy, and cardiac arrhythmias), hyperthermia (potentially fatal), rhabdomyolysis, consequences of injection drug abuse (skin infections and abscesses, endocarditis), and high-risk sexual behavior increasing risks of contracting sexually transmitted infections including hepatitis B, hepatitis C, and HIV.

LABORATORY STUDIES

- Urine drug screening is commonly done with immunoassays. These tests are highly cross-reactive and may give false-positive results for methamphetamine or amphetamine caused by the presence of other sympathomimetic amines such as pseudoephedrine or ephedrine. Unexpected positive results on a screening test can be confirmed

FIGURE 238-5 A 19-year-old woman with sores on her arms from picking at her skin while using methamphetamine. Also called meth mites. (*Courtesy of Richard P. Usatine, MD.*)

with more specific tests such as gas chromatography/mass spectrometry (GC/MS) and stereospecific chromatography.[14] One limitation of urine drug testing for methamphetamine is that the drug may only be detectable for up to 3 days after use. Hair testing is available and remains positive for up to 90 days after drug use.

- Methamphetamine users are at increased risk of sexually transmitted diseases and diseases transmitted through the use of shared needles. Consider screening for HIV, hepatitides B and C, and other sexually transmitted infections.
- For patients with signs and symptoms of acute intoxication, consider excluding complications of methamphetamine abuse by ordering creatinine phosphokinase (CK), complete blood count (CBC), and chem panel. If chest pain is present, cardiac enzymes and ECG are indicated.

DIFFERENTIAL DIAGNOSIS

ACUTE METHAMPHETAMINE INTOXICATION

- Intoxication with other substances causing sympathetic stimulation and/or altered mental status (cocaine, ecstasy, phencyclidine [PCP], theophylline, aspirin, monoamine oxidase inhibitors, serotonin syndrome).
- Psychiatric disorders (bipolar disorder, panic attack, and schizophrenia).
- Hyperthyroidism and thyroid storm (see Chapter 227, Graves Disease and Goiter).

METHAMPHETAMINE-INDUCED SKIN LESIONS (METH MITES)

- Scabies—Burrows may be present; located on wrists, fingers, genital region, and spares face; very pruritic. Family members may be infected too (see Chapter 143, Scabies).
- Atopic dermatitis—Persistent pruritus (pruritus from meth stops after acute intoxication clears). In most cases there is a long history of the dermatitis before the meth use had begun (see Chapter 145, Atopic Dermatitis).
- Contact dermatitis is pruritic but is generally localized to the area in which the contact allergen has touched the skin. A good history should allow this to be differentiated from meth mites (see Chapter 146, Contact Dermatitis).
- Neurodermatitis and prurigo nodularis—Persistent complaints of severe pruritus. In many ways, these are similar to meth mites in that the stimulus to scratch is from the brain not just the skin. Absence of meth use should be present in these self-inflicted dermatoses to distinguish them from meth mites (see Chapter 149, Self-Inflicted Dermatoses).

MANAGEMENT

- Acute methamphetamine intoxication is treated with supportive measures. Sedation with haloperidol, droperidol, or benzodiazepines (diazepam and lorazepam) can be used for agitated patients. Methamphetamine-induced cardiac ischemia is treated with

FIGURE 238-6 Postinflammatory hyperpigmentation in a young woman who has picked at her skin while addicted to methamphetamine. (*Courtesy of Richard P. Usatine, MD.*)

FIGURE 238-7 Methamphetamine mouth (meth mouth) in a 42-year-old woman with 20 years of methamphetamine use. The meth has completely destroyed her teeth. (*Courtesy of Richard P. Usatine, MD.*)

oxygen, nitrates, and β blockers. Seizures and rhabdomyolysis are treated in the standard fashion.[15] SOR B

- There are no medications with proven efficacy for treatment of methamphetamine withdrawal. Mirtazapine and modafinil have shown some benefit in preliminary studies.[16] SOR C

Treatment of methamphetamine dependence and addiction is challenging. Inpatient detoxification may be required initially, followed by a long-term program of behavioral interventions. SOR C

- Refer patients to 12-step programs, which are valuable and free. Crystal Meth Anonymous is a 12-step program modeled on the 12 steps of Alcoholics Anonymous and the White Book of Narcotics Anonymous. If Crystal Meth Anonymous meetings are not available, any 12-step program can be of help in recovery and maintaining sobriety. SOR B
- The Matrix model, a behavioral treatment method initially developed for treatment of cocaine addiction, has been used successfully to treat methamphetamine addiction. It consists of a 16-week program, including group and individual therapy, relapse prevention, family involvement, participation in a 12-step program or other spiritual group, and weekly drug testing.[17] SOR C

In the context of outpatient behavioral treatment programs, providing small incentives for drug-free urine samples can help promote abstinence. One study found that 19% of incentivized patients achieved 12 weeks of continuous abstinence whereas only 5% of non-incentivized patients did so (number needed to treat [NNT] = 7.1) at a cost of only $2.42 per day per participant.[18] SOR B

- Although there currently are no FDA-approved medications to help treat methamphetamine dependence, several medications under study have shown favorable early results, including modafinil, bupropion, and naltrexone. SOR B "Replacement" therapy using low-dose stimulants, similar to the way methadone and nicotine are used for opioid and nicotine dependence, respectively, has also shown some benefit.[19]
- Methamphetamine-related skin excoriation should heal without treatment if the picking behavior stops. However, postinflammatory hyperpigmentation may never resolve (**Figure 238-6**). Antibiotic treatment with an antistaphylococcal agent, such as cephalexin or dicloxacillin, is indicated if the excoriations become infected. If methicillin-resistant *Staphylococcus* aureus (MRSA) is suspected, choose an antibiotic that covers MRSA (see Chapter 116, Impetigo).
- Referral for dental care is indicated for patients with gingivitis and dental caries caused by chronic methamphetamine use. Recommend daily use of a soft-bristled toothbrush and dental floss for treatment and prevention of oral pathology. SOR A Rinsing with a chlorhexidine-containing mouthwash may be a reasonable alternative for patients who find it too painful to floss. SOR C (see Chapter 39, Gingivitis and Periodontal Disease and Chapter 45, Adult Dental Caries).

FIGURE 238-8 "Meth mouth" in a 17-year-old man actively using methamphetamine. (*Courtesy of Michelle Rowe, MD.*)

FOLLOW-UP

- Methamphetamine users who have recently quit are at high risk of relapse. Close follow-up is indicated to identify relapses and to reinitiate treatment.

- Maintenance of abstinence can be aided by participation in an outpatient treatment program and 12-step programs.
- Methamphetamine-induced skin lesions should heal when the picking behavior ceases. Resolution is unlikely if methamphetamine abuse continues.

PATIENT EDUCATION

- Encourage patients to stop using methamphetamine. Offer referral to a treatment program in the community.
- Inform patients that methamphetamine use carries risks of heart attack, stroke, and death that can result from a single dose. There is no safe level of methamphetamine use.
- Counsel patients who have sex while using methamphetamine that this combination increases the likelihood of unsafe sexual practices and their risk of getting a sexually transmitted infection.
- Advise users who inject methamphetamine to use clean needles and to avoid sharing needles to decrease their risk of contracting hepatitis B, hepatitis C, and HIV.

PATIENT RESOURCES

- Crystal Meth Anonymous (12-step meetings)—**http://www.crystalmeth.org/.**
- Substance Abuse & Mental Health Services Administration (SAMHSA). *Substance Abuse Treatment Facility Locator*—**http://www.findtreatment.samhsa.gov/.**
- ADA Division of Communications; Journal of the American Dental Association; ADA Division of Scientific Affairs. For the dental patient…methamphetamine use and oral health. *J Am Dent Assoc.* 2005;136(10):1491, **http://www.ada.org/sections/professionalResources/pdfs/patient_55.pdf.**
- PBS. *Frontline: the Meth Epidemic: How Meth Destroys the Body*—**http://www.pbs.org/wgbh/pages/frontline/meth/body/.**

PROVIDER RESOURCES

- National Institute on Drug Abuse—**http://www.nida.nih.gov/DrugPages/Methamphetamine.html.**
- American Society of Addiction Medicine: Research & Treatment—**http://www.asam.org/research-treatment/treatment.**

REFERENCES

1. United Nations Office of Drugs and Crime (UNODC). *2010 World Drug Report*. Vienna, Austria: UNODC; 2010, http://www.unodc.org/unodc/en/data-and-analysis/WDR-2010.html, accessed April 3, 2012.
2. Monitoring the Future. *Trends in Lifetime Prevalence of Use of Various Drugs for Eight, Tenth and Twelfth Graders*, http://monitoringthefuture.org/data/11data/pr11t1.pdf, accessed April 3, 2012.

3. Substance Abuse and Mental Health Services Administration, Drug Abuse Warning Network. *2009: National Estimates of Drug-Related Emergency Department Visits*. HHS Publication No. (SMA) 11-4659, DAWN Series D-35. Rockville, MD: Substance Abuse and Mental Health Services Administration; 2011.
4. Iritani BJ, Hallfors DD, Bauer DJ. Crystal methamphetamine use among young adults in the USA. *Addiction.* 2007;102:1102-1113.
5. Quest Diagnostics. *Press Release:* "Hawaii, Arkansas and Oklahoma Lead the Nation for Methamphetamine Use in the Workforce, Reveals Quest Diagnostics Drug Testing Index(TM): Five-year Data Suggest Methamphetamine's National Decline Has Halted and That the Drug's Stronghold May Be Moving Eastward." Madison, NJ: PRNewswire; Sept. 2, 2011, http://ir.questdiagnostics.com/phoenix.zhtml?c=82068&p=irol-newsArticle_pf&ID=1603058&highlight=, accessed April 3, 2012.
7. Lynn Police Department. *The Ingredients of Meth*, http://www.lynnpolice.org/ingredients_of_meth.htm, accessed April 3, 2012.
8. Lineberry TW, Bostwick JM. Methamphetamine abuse: a perfect storm of complications. *Mayo Clin Proc.* 2006;81(1):77-84.
9. American Dental Association. *Methamphetamine Use (Meth Mouth)*, http://www.ada.org/2711.aspx, accessed April 3, 2012.
10. Klasser G, Epstein J. Methamphetamine and its impact on dental care. *J Can Dent Assoc.* 2005;71(10):759-762.
11. Shaner JW, Kimmes N, Saini T, Edwards P. "Meth mouth": rampant caries in methamphetamine abusers. *AIDS Patient Care STDS.* 2006;20(3):146-150.
12. Rawson RA, Condon TP. Why do we need an Addiction supplement focused on methamphetamine? *Addiction.* 2007;102 (Suppl 1):1-4.
13. Cruickshank CC, KR Dyer. A review of the clinical pharmacology of methamphetamine. *Addiction.* 2009;104:1085-1099.
14. Gourlay DL, Heit HA, Caplan YH. Urine drug testing in clinical practice. California Academy of Family Physicians Monograph Edition 4, 2010, http://www.familydocs.org/files/UDTmonograph _for_web.pdf, accessed April 3, 2012.
15. Richard J. *Methamphetamine Toxicity*, http://emedicine.medscape.com/article/820918, accessed April 3, 2012.
16. Pennay AE, Lee NK. Putting the call out for more research: The poor evidence base for treating methamphetamine withdrawal. *Drug Alcohol Rev.* 2011;30:216-222.
17. Rawson RA, Marinelli-Casey P, Anglin MD, et al. A multisite comparison of psychosocial approaches for the treatment of methamphetamine dependence. *Addiction.* 2004;99:708-717.
18. Petry NM, Peirce JM, Stitzer ML, et al. Effect of prize-based incentives on outcomes in stimulant abusers in outpatient psychosocial treatment programs: A National Drug Abuse Treatment Clinical Trials Network Study. *Arch Gen Psychiatry.* 2005;62(10):1148-1156.
19. Karila L, Weinstein W, Aubin HJ, et al. Pharmacological approaches to methamphetamine dependence: a focused review. *Br J Clin Pharmacol.* 2010;69(6):578-592.

239 COCAINE

Heidi Chumley, MD
Mindy A. Smith, MD, MS

PATIENT STORY

A 26-year-old man is brought into the emergency department in status epilepticus by his "friends," who promptly flee the scene. His seizures spontaneously cease, and he is noted to have an altered mental status. IV access is obtained and he is stabilized. A urine toxicology screen is positive for cocaine and his creatinine phosphokinase is markedly elevated. He is admitted for cocaine-induced seizures and rhabdomyolysis. He survives the hospitalization and consents to a photograph of his eyes before discharge. **Figure 239-1** shows the bilateral subconjunctival hemorrhages that occurred during his seizures. The patient states that he understands the gravity of the situation and will enter a drug rehabilitation program when he leaves the hospital.

FIGURE 239-1 Bilateral subconjunctival hemorrhages after severe cocaine-induced seizures in a young man. This patient also developed rhabdomyolysis and was hospitalized. (*Courtesy of Beau Willison, MD.*)

INTRODUCTION

Cocaine use is common, and 5% to 6% of users develop dependence within the first year of use. Acutely intoxicated patients have increased heart rates, blood pressures, temperatures, and, initially, respiratory rates; mood changes, involuntary movements; and dilated pupils. Chronic addiction can be treated with a comprehensive program, although only one-third of patients will become and remain abstinent.

SYNONYMS

Cocaine is also called blow, C, coke, crack, flake, and snow.

EPIDEMIOLOGY

- Based on the National Comorbidity Survey Replication (NCS-R) using interviews with a nationally representative sample of 9282 English-speaking respondents ages 18 years and older (conducted in 2001 to 2003), the cumulative incidence of cocaine use was 16%.[1]
- Similar numbers were reported from the National Survey on Drug Use and Health in 2005:[2]
  - Of Americans ages 12 years and older, 13.8% reported lifetime cocaine use in 2005.[2]
  - A total of 33.7 million Americans ages 12 years and older reported lifetime use of cocaine, and 7.9 million reported using crack cocaine.[2]
  - An estimated 2.4 million Americans reported current use of cocaine (682,000 of whom reported using crack).[2]
  - Of the estimated 860,000 new users of cocaine in 2005, most were age 18 years or older, with the average age of first use being 20 years.[2]

- The percentage of youth ages 12 to 17 years reporting lifetime use of cocaine was 2.3%, and among young adults ages 18 to 25 years the rate was 15.1%.[2]

- For both male and female cocaine users, the estimated risk for developing cocaine dependence, based on data from the NCS-R, was 5% to 6% within the first year after first use.[3] Thereafter, the estimated risk decreased from the peak value, with a somewhat faster decline for females in the next 3 years after first use.
- Females may be more susceptible to crack/cocaine dependence; in a study of 152 individuals (37% female) in a residential substance-use treatment program, females evidenced greater use of crack/cocaine (current and lifetime heaviest) and were significantly more likely to show crack/cocaine dependence than males.[4]
- In one study, siblings of cocaine-dependent individuals had an elevated risk of developing cocaine dependence (relative risk [RR] = 1.71).[5]

FIGURE 239-2 Cocaine in a powder form used for snorting and injecting. (*Courtesy of the Drug Enforcement Agency.*)

ETIOLOGY AND PATHOPHYSIOLOGY

- Cocaine is a stimulant and local anesthetic that causes potent vasoconstriction.
- It produces its stimulant effects by causing increasing synaptic concentration of monoamine neurotransmitters (i.e., dopamine, norepinephrine, and serotonin).[6]
- Similar to other local anesthetics, cocaine blocks the generation and conduction of electrical impulses in excitable tissues (e.g., neurons and cardiac muscle) blocking the voltage-gated fast sodium channels in the cell membrane and abolishing the ability of the tissue to generate an action potential.[7]
- Effects are seen following oral, intranasal (as a powder [**Figure 239-2**]), IV, and inhalation administration (as crack cocaine [**Figure 239-3**], coca paste, and free-base).

RISK FACTORS

- Family history/genetic predisposition
- In a study of inner-city incarcerated male adolescents (23% of whom had used cocaine or crack in the month before arrest and 32% of whom had used cocaine at least once), current cocaine/crack users were more likely to have the following characteristics:[8]
  - Alcohol, marijuana, and intranasal heroin use.
  - Multiple previous arrests.
  - To be out of school.
  - To be psychologically distressed.
  - To have been sexually molested as a child.
  - To have substance-abusing parents.
  - To have frequent sex with girls, to be gay or bisexual, and to engage in anal intercourse.
- Among those who died from an accidental drug overdose in New York City, those dying from cocaine-only versus opiates were more likely to be male, black or Hispanic, have alcohol detected at autopsy, and to be of older age.[9]

FIGURE 239-3 Crack cocaine used for smoking. (*Courtesy of the Drug Enforcement Agency.*)

DIAGNOSIS

CLINICAL FEATURES

- Acute effects occur within 3 to 5 minutes with intranasal administration (8 to 10 seconds with free base) and last approximately 1 hour, after which there is an abrupt disappearance of the effects.[6] When used IV or smoked as crack cocaine, the onset of action is immediate and the peak effect occurs 3 to 5 minutes later, lasting for 20 to 30 minutes.[7]
  - The acute effects include:[6,7]
    - Elevated heart rate, increased blood pressure, and usually increased temperature.
    - Increased respiratory rate and/or dyspnea followed by decreased respiratory rate.
    - Mood changes including enhanced mood/euphoria, hyperactivity, irritability and anxiety, excessive talking, and long periods without eating or sleeping.
    - Involuntary movements (e.g., tremors, chorea, and dystonic reactions).
  - Additional findings on physical examination can include:
    - Dilated pupils, nystagmus, and/or retinal hemorrhages.
    - Nasal septum perforation (**Figure 239-4**), epistaxis, and/or cerebrospinal fluid (CSF) rhinorrhea.
    - Wheezing, rales, and/or pneumothorax.
    - Absent bowel sounds (mesenteric ischemia) and/or right upper quadrant tenderness (hepatic necrosis).
    - Skin tracks from intravenous use (**Figure 239-5**).
    - Multiple areas of atrophic skin scars are from skin popping—injecting cocaine directly into the skin without finding a vein for intravenous injections (**Figure 239-6**).
  - Acute effects may be altered by concomitant use of other drugs or alcohol.
- Adverse effects of cocaine use can include:[6]
  - Respiratory depression that may result in death.
  - Cardiac arrhythmias, chest pain, and myocardial infarction (MI).
  - Neurologic symptoms, including headache, tonic-clonic seizures, ischemic or hemorrhagic stroke, and subarachnoid hemorrhage.
  - Myalgias and rhabdomyolysis.
  - Severe pulmonary disease (e.g., alveolar hemorrhage and pulmonary edema) and hepatic necrosis caused by crack cocaine.
  - Exacerbation of existing hypertension, cardiac, and cerebrovascular disease.
  - Recurrent diabetic ketoacidosis.[10]
- Cutaneous vasculitis secondary to levamisole-adulterated cocaine has been reported many times in the literature.[11-15] This type of vasculitis presents with ear purpura (**Figure 239-7**), retiform (like a net) purpura (**Figure 239-8**) of the trunk or extremities, neutropenia, and positive tests for perinuclear antineutrophil cytoplasmic antibody (P-ANCA).[11] A 2010 U.S. report found that more than 77% of seized cocaine in the United States is contaminated with levamisole.[13] This cutaneous vasculitis may also present on the nose or face (**Figure 239-9**).
- Chronic cocaine use is associated with decreased libido and impaired reproductive function.[1]

FIGURE 239-4 Shining a light through a hole in the nasal septum caused by 10 years of snorting cocaine. (*Courtesy of Richard P. Usatine, MD.*)

FIGURE 239-5 An injection track along the vein of a young woman in recovery from IV cocaine use and addiction. (*Courtesy of Richard P. Usatine, MD.*)

- In men, cocaine can cause impotence and gynecomastia.
- In women, cocaine can cause galactorrhea, amenorrhea, and infertility.
- In pregnant women, crack cocaine is associated with an increase in placental abruption, miscarriage, and congenital malformation.

- Protracted use can cause paranoid ideation and visual and auditory hallucinations. Severe depression can follow recovery from cocaine intoxication (called "crashing").[1]
- Withdrawal from chronic cocaine use can cause depression, insomnia, and anorexia.

LABORATORY STUDIES

- Urine toxicology screen (using immunoassays) for commonly abused drugs (e.g., cocaine, marijuana, and opiates) is the gold standard.
  - Cocaine may be detected in the urine for 24 hours after use and the metabolite of cocaine, benzoylecgonine, may be detected as long as 60 hours after a single use.[7]
  - In chronic cocaine users, benzoylecgonine may be detected for up to 22 days.[7]
  - A rapid urine test, OnTrak Testcup-5, was reported in a manufacturer-supported study to be accurate and reproducible for marijuana, cocaine, and heroin.[16]
- Saliva and hair tests are also available but may not be as accurate for all drugs of interest.
- All injection-drug users should be screened for human immunodeficiency virus (HIV) (with consent) and hepatitides B and C.
- If there is a history of multiple sexual partners, unsafe sex and/or sex for drugs, cocaine users should be screened for sexually transmitted diseases (STDs). This might include *Chlamydia*, gonorrhea, hepatitides B and C, HIV (with consent), and syphilis (**Figure 239-10**).
- In an unconscious patient and in patients denying cocaine use, the following laboratory tests can be considered to rule out other diseases with similar symptoms:[7]
  - Serum glucose, magnesium, and phosphorus.
  - Serum electrolytes.
- Laboratory tests that can be completed to detect or monitor acute complications of cocaine overdose include:[7]
  - Arterial blood gas (respiratory acidosis or alkalosis).
  - Blood urea nitrogen (BUN) and/or creatinine (renal infarction).
  - Creatinine kinase (CK) (rhabdomyolysis) and isoenzyme of creatine kinase (CK-MB) (MI).
  - Liver function tests (liver necrosis).
  - Urine dipstick (rhabdomyolysis).

IMAGING AND OTHER TESTS

- Plain films of the abdomen (supine and upright) can be useful in the diagnosis of body packing or stuffing of cocaine (swallowing or inserting packets of cocaine into a body orifice), but false-negative results may occur. Serial abdominal roentgenograms may be useful in detecting the passage of drug packages.[7]
- A chest x-ray and head CT can be considered for respiratory and neurologic symptoms, respectively.

FIGURE 239-6 Multiple areas of atrophic skin scarring from skin popping cocaine. Note how the scars are depressed and relatively round. Some cocaine addicts inject the cocaine directly into the skin rather than look for a vein for intravenous injections. (*Courtesy of Richard P. Usatine, MD.*)

FIGURE 239-7 Cutaneous vasculitis of the ear caused by levamisole-adulterated cocaine. (*Courtesy of Robert T. Gilson, MD.*)

DIFFERENTIAL DIAGNOSIS

- Adrenal hyperplasia or adenoma—Produces excess cortisol, causing signs and symptoms of Cushing syndrome, including hypertension and emotional changes (ranging from irritability to severe depression and psychosis). Distinguishing features are increased body weight with adipose deposition in the upper face ("moon" facies) and interscapular area ("buffalo" hump), hirsutism, violaceous cutaneous striae, and proximal myopathy. A 24-hour urine test for free cortisol or overnight dexamethasone suppression test is recommended for diagnosis.
- Hyperthyroidism—In addition to tachycardia and nervousness/agitation, patients can report fatigue, weight loss, and heat intolerance. Exophthalmus and pretibial myxedema may be seen, and laboratory testing reveals a low or undetectable thyroid-stimulating hormone (TSH) and an elevated free thyroxin level (T_4) (see Chapter 227, Graves Disease and Goiter).
- Delirium—Defined as a state of confusion accompanied by agitation, hallucinations, tremor, and illusions, delirium can be caused by drug toxicity or withdrawal, seizure, head injury, systemic infections, metabolic disorders, or a chronic dementing condition. The history, physical examination, and laboratory tests (many noted above) can help to identify the etiology.
- Hypoglycemia—Low blood sugar most commonly caused by taking insulin or oral drugs used to treat diabetes mellitus. Symptoms include confusion, fatigue, seizures, and loss of consciousness. Autonomic responses to hypoglycemia include palpitations, sweating, tremor, and anxiety. Laboratory testing for serum glucose will document the condition, and symptoms resolve with administration of oral or IV glucose.
- Meningitis—Acute infection within the subarachnoid space presenting within hours or days with fever, headache, and stiff neck (more than 90% of patients); additional potential signs are change in mental status (e.g., confusion and decreased consciousness), seizures, increased intracranial pressure, and stroke. The appearance of a rash/petechiae can aid in the diagnosis (meningococcemia). Diagnosis is made with examination of the CSF following lumbar puncture (LP).
- Encephalitis—Acute infection of the central nervous system that involves the brain parenchyma usually caused by viruses. The clinical features include fever, altered level of consciousness, and focal (e.g., aphasia, ataxia, hemiparesis, and involuntary movements) or diffuse (e.g., agitation, hallucinations, and personality change) symptoms. Diagnosis is established with examination of the CSF following LP.

MANAGEMENT

MANAGEMENT OF ACUTE OVERDOSE

- Acute overdose is a medical emergency best managed in the intensive care unit because of the hyperadrenergic state and seizures.
  - Hyperthermia and severe psychomotor agitation are the most immediately life-threatening complications of cocaine poisoning.[7] Temperatures as high as 45.6°C (114°F) have

FIGURE 239-8 Cutaneous vasculitis in a retiform (net-like) pattern caused by the use of levamisole-adulterated cocaine. This is also called retiform purpura. (*Courtesy of University of Texas Health Science Center San Antonio, Division of Dermatology.*)

FIGURE 239-9 Cutaneous vasculitis of the nose secondary to the use of levamisole-adulterated cocaine. (*Courtesy of Robert T. Gilson, MD.*)

been recorded. Rapid physical cooling with sponging, fans, ice baths, and cooling blankets can be used and gastric or peritoneal lavage with iced saline is considered if persistent.

- IV diazepam up to 0.5 mg/kg given over 8 hours is used to control psychomotor agitation and seizures.
  - Hypertension may also respond to benzodiazepines. β-Blockers should not be used in the setting of cocaine toxicity (except to control ventricular arrhythmia, as below) because they may result in unopposed alpha effects of cocaine.[7]
  - Avoid the use of neuroleptic agents because they can interfere with heat dissipation and, perhaps, lower the seizure threshold.[7]
  - Avoid physical restraints if possible. Benzodiazepines are safe to use as a pharmacologic restraint.[7]
- Propranolol (0.5 to 1 mg IV) can be used to control ventricular arrhythmia.
  - Perform defibrillation in all patients with pulseless ventricular tachycardia.[7]
  - Consider electrical cardioversion in all unstable patients.[7]
  - Beta-blockers should not be used in cocaine-induced cardiac ischemia.[17] Nitroglycerin may be used for cocaine-induced cardiac ischemia or infarct.[7]
  - Monitor for rhabdomyolysis and provide rapid fluid resuscitation as needed.[7]
  - Check a pregnancy test on women of childbearing years as 6% of emergency room patients may have an unrecognized pregnancy.[7]
- Administer activated charcoal to alert patients with oral ingestions of cocaine (i.e., body stuffers and body packers) to reduce absorption. Whole-bowel irrigation may be used to reduce transit time in these patients.[7]
- Medical providers should be prepared to manage multiple drug effects, especially heroin.

MANAGEMENT OF CHRONIC ADDICTION

- Cognitive-behavioral therapy is effective in the treatment of cocaine-dependent outpatients.[18]
- There is no current evidence supporting the clinical use of carbamazepine, antidepressants, dopamine agonists, disulfiram, mazindol, phenytoin, nimodipine, lithium, and NeuRecover-SA in the treatment of cocaine dependence.[19]
- Antidepressant medication exerts a modest beneficial effect for patients with combined depressive and substance-use disorders, but should be used as part of a program to directly target the addiction.[20]
- The cocaine vaccine elicits an immune response that binds cocaine, creating an immune complex that is too large to cross the blood–brain barrier. In early phase II trials, 57% of subjects remained abstinent at 6 months. The immunologic treatment of substance use disorders is an exciting new approach that needs further study.[21]

REFERRAL

- Referral to specialists may be needed to assist patients with upper respiratory tract (e.g., CSF rhinorrhea and nasal septum perforation) or ophthalmologic complications (e.g., central retinal artery occlusion).
- Following withdrawal from chronic cocaine use, patients may benefit from individual, group, and/or family therapy and peer assistance.[6]

FIGURE 239-10 Secondary syphilis in a man who was involved in unsafe sex while addicted to cocaine. The papulonodular eruption is an unusual presentation of secondary syphilis that was diagnosed with a skin biopsy and confirmed with an rapid plasma reagin titer of 1:512. The specific treponemal blood test was also positive. (*Courtesy of Richard P. Usatine, MD.*)

PROGNOSIS

- Cocaine addiction is difficult to treat.
- Of patients enrolled in cocaine addiction programs, 42% do not complete treatment.[22]
- One-third of patients treated for cocaine addiction remain abstinent.[22] Some comprehensive therapy programs have demonstrated abstinence rates at 1 year of up to 58%.[23]
  - Of 131 persons addicted to crack cocaine, 107 were able to be followed for 12-years: 43 (33%) were crack-free for at least 12 months, 22 (17%) continued to use, 13 (10%) were imprisoned, 2 (1.5%) were lost to follow-up, and 27 (20.5%) were deceased.[24]

FOLLOW-UP

- Patients and their families may need ongoing support, home healthcare, and physical and occupational therapy to address long-term neurologic and cardiovascular complications of cocaine including anoxic encephalopathy, stroke, intracerebral hemorrhage, congestive heart failure, and cardiomyopathy.
- Physicians should closely monitor and assist patients in managing depression, insomnia, and anorexia that may follow cessation of chronic cocaine use.[6]
- Among individuals leaving residential detoxification, chronic pain is a common problem and is associated independently with long-term substance use after detoxification; management of pain may improve long-term outcomes.[25]

PATIENT EDUCATION

- Encourage patients to quit cocaine use and offer assistance.
- Recommend 12-step programs including cocaine anonymous.
- Patients should be made aware of the potential complications associated with use of cocaine, including its powerful psychologically addictive properties.
- Instruct patients about seeking help in the emergency department for any of the following:[26]
  - A brisk nosebleed that does not stop after 10 minutes of direct pressure.
  - Facial pain or headache with a fever.
  - Severe chest pain, difficulty breathing, or shortness of breath.
  - If pregnant, vaginal bleeding or premature labor pains.
  - Significant swelling, pain, redness, and red lines leading from the injection site and accompanied by fever.
  - Severe abdominal pain, persistent vomiting, and vomiting blood.
  - If you think that one of your packets you have swallowed or stuffed in a body orifice (vagina and rectum) is leaking or has broken.
- Instruct IV drug users who continue to use not to reuse or share needles or syringes; cleaning the skin before injection can also decrease risk of infection. Harm reduction programs exist that help addicts obtain and maintain clean needles and syringes.

PATIENT RESOURCES

- eMedicineHealth. *Cocaine Abuse*—**http://www.emedicinehealth.com/cocaine_abuse/article_em.htm.**
- The Substance Abuse and Mental Health Services Administration (SAMHSA) provides an on-line resource for locating drug and alcohol abuse treatment programs—**http://findtreatment.samhsa.gov/TreatmentLocator/faces/quickSearch.jspx.**
- The SAMHSA referral helpline in English and Spanish is: **1-800-662-HELP.**
- National Institute on Drug Abuse. *Preventing Drug Abuse among Children and Adolescents (In Brief)* [for parents]—**http://www.drugabuse.gov/prevention/prevopen.html.**
- Cocaine Anonymous (CA). Meetings are free. "Hope, Faith and Courage: Stories from the Fellowship of Cocaine Anonymous" now has a new second volume to go with the first volume – both can be ordered online—**http://www.ca.org/.**

PROVIDER RESOURCES

- National Institute on Drug Abuse. *Cocaine*—**http://www.nida.nih.gov/drugpages/cocaine.html.**
- MedlinePlus. *Cocaine*—**http://www.nlm.nih.gov/medlineplus/cocaine.html.**
- U.S. Drug Enforcement Administration. *Cocaine*—**http://www.usdoj.gov/dea/concern/cocaine.html.**

REFERENCES

1. Degenhardt L, Chiu WT, Sampson N, et al. Epidemiological patterns of extra-medical drug use in the United States: evidence from the National Comorbidity Survey Replication, 2001-2003. *Drug Alcohol Depend.* 2007;90(2-3):210-223.
2. National Survey on Drug Use and Health. Substance Abuse and Mental Health Services Administration. http://www.samhsa.gov, accessed May 14, 2012.
3. Wagner FA, Anthony JC. Male–female differences in the risk of progression from first use to dependence upon cannabis, cocaine, and alcohol. *Drug Alcohol Depend.* 2007;86(2-3):191-198.
4. Lejuez CW, Bornovalova MA, Reynolds EK, et al. Risk factors in the relationship between gender and crack/cocaine. *Exp Clin Psychopharmacol.* 2007;15(2):165-175.
5. Bierut LJ, Dinwiddie SH, Begleiter H, et al. Familial transmission of substance dependence: Alcohol, marijuana, cocaine, and habitual smoking: a report from the Collaborative Study on the Genetics of Alcoholism. *Arch Gen Psychiatry.* 1998;55(11):982-988.
6. Mendelson JH, Mello NK. Cocaine and other commonly abused drugs. In: Kasper DL, Braunwald E, Fauci AS, Hauser SL, Longo DL, Jameson JL eds. *Harrison's Principles of Internal Medicine*, 16th ed. New York, NY: McGraw-Hill; 2005:2570-2573.
7. Burnett LB. *Cocaine Toxicity in Emergency Medicine Treatment and Management*. http://emedicine.medscape.com/article/813959, updated Mar 19, 2010, accessed May 14, 2012.
8. Kang SY, Magura S, Shapiro JL. Correlates of cocaine/crack use among inner-city incarcerated adolescents. *Am J Drug Alcohol Abuse.* 1994;20(4):413-429.
9. Bernstein KT, Bucciarelli A, Piper TM, et al. Cocaine- and opiate-related fatal overdose in New York City, 1990-2000. *BMC Public Health.* 2007;7:31.
10. Nyenwe EA, Loganathan RS, Blum S, et al. Active use of cocaine: an independent risk factor for recurrent diabetic ketoacidosis in a city hospital. *Endocr Pract.* 2007;13(1):22-29.
11. Chung C, Tumeh PC, Birnbaum R, et al. Characteristic purpura of the ears, vasculitis, and neutropenia—a potential public health epidemic associated with levamisole-adulterated cocaine. *J Am Acad Dermatol.* 2011;65:722-725.
12. Gross RL, Brucker J, Bahce-Altuntas A, et al. A novel cutaneous vasculitis syndrome induced by levamisole-contaminated cocaine. *Clin Rheumatol.* 2011;30:1385-1392.
13. Gulati S, Donato AA. Lupus anticoagulant and ANCA associated thrombotic vasculopathy due to cocaine contaminated with levamisole: a case report and review of the literature. *J Thromb Thrombolysis.* 2012;34(1):7-10.
14. Jenkins J, Babu K, Hsu-Hung E, et al. ANCA-positive necrotizing vasculitis and thrombotic vasculopathy induced by levamisole-adulterated cocaine: a distinctive clinicopathologic presentation. *J Am Acad Dermatol.* 2011;65:e14-e16.
15. Larocque A, Hoffman RS. Levamisole in cocaine: unexpected news from an old acquaintance. *Clin Toxicol (Phila).* 2012;50:231-241.
16. Yacoubian GS Jr, Wish ED, Choyka JD. A comparison of the OnTrak Testcup-5 to laboratory urinalysis among arrestees. *J Psychoactive Drugs.* 2002;34(3):325-329.
17. Sen A, Fairbairn T, Levy F. Best evidence topic report. Beta-blockers in cocaine induced acute coronary syndrome. *Emerg Med J.* 2006;23(5):401-402.
18. Carroll KM, Onken LS. Behavioral therapies for drug abuse. *Am J Psychiatry.* 2005;162(8):1452-1460.
19. de Lima MS, de Oliveira Soares BG, Reisser AA, Farrell M. Pharmacological treatment of cocaine dependence: a systematic review. *Addiction.* 2002;97(8):931-949.
20. Nunes EX, Levin FR. Treatment of depression in patients with alcohol or other drug dependence: a meta-analysis. *JAMA.* 2004;291(15):1887-1896.
21. Shorter D, Kosten TR. Novel pharmacotherapeutic treatments for cocaine addiction. *BMC Med.* 2001,9:119.
22. Dutra L, Stathopoulou G, Basden SL, et al. A meta-analytic review of psychosocial interventions for substance use disorders. *Am J Psychiatry.* 2008;165:179-187.
23. Secades-Villa R, García-Rodríguez O, García-Fernández G, et al. Community reinforcement approach plus vouchers among cocaine-dependent outpatients: twelve-month outcomes. *Psychol Addict Behav.* 2011;25(1):174-179.
24. Dias AC, Araujo MR, Laranjeira R. Evolution of drug use in a cohort of treated crack cocaine users. *Rev Saude Publica.* 2011;45(5):938-948.
25. Larson MJ, Paasche-Orlow M, Cheng DM, et al. Persistent pain is associated with substance use after detoxification: A prospective cohort analysis. *Addiction.* 2007;102(5):752-760.
26. Dryden-Edwards R. http://www.emedicinehealth.com/cocaine_abuse/article_em.htm, accessed May 14, 2012.

240 INJECTION-DRUG USE

Heidi Chumley, MD
Richard P. Usatine, MD

PATIENT STORY

A 23-year-old woman is seen for her intake physical in a residential treatment program for women recovering from substance abuse. She has not injected heroin for two days now, but her tracks are still visible (**Figure 240-1**). Her parents were both addicted to heroin, and she admits to having been born addicted to heroin herself. She began using heroin on her own in her early teens and has been on and off heroin since that time. She acknowledges a history of physical and sexual abuse as a child. She has had many suicide attempts and has cut herself with a knife across her arm many times. She has traded sex for money to buy heroin. Her 2 children are in foster care after having been removed by Child Protective Services. She is an attractive young woman looking for help and is thankful to have been admitted to this program. She does not know whether she has acquired hepatitis B, hepatitis C, or HIV, but wants to be tested.

FIGURE 240-1 A 23-year-old woman with visible tracks on her arms from intravenous heroin use. She also has visible scars from self-mutilation with a knife. (*Courtesy of Richard P. Usatine, MD.*)

INTRODUCTION

Injection-drug use affects millions of people across the world. Combinations of genetic, environmental, and behavioral factors influence risk of drug use and addiction. People who inject drugs often have other medical and psychiatric diagnoses, as well as social, legal, and vocational problems. Comprehensive management includes acute treatment and continuing care. Relapse is common, but involvement in a treatment program improves outcomes.

EPIDEMIOLOGY

- An estimated 16 million people inject drugs worldwide, based on data from 148 countries. The largest numbers of injectors are in China, the United States, and Russia.[1]
- In the United States, injection-drug use among persons ages 15 to 29 years increased from 96 (1996) to 116 (2002) per 10,000 persons.[2]
- From 2000 to 2002, 1.5% of the U.S. population older than the age of 12 years reported injection-drug use at any time; 0.19% reported injection-drug use within the last year—440,000 persons.[3]
- Prevalence was highest in persons ages 35 to 49 years (3.5%); higher in men than women (2.0% vs. 1.0%); and higher in whites (1.7%) than African Americans (0.8%) or Hispanics (0.8%).[3]
- In 2002, the mean age of injection-drug users (IDUs) was 36 years compared to 21 years in 1979.[3]
- Needle sharing is common. In the previous 3 months, 46% of IDUs lent a person a used syringe[4] and 54% injected with a used syringe.[5]
- There were 27,8371–278,371 meant? substance-abuse treatment admissions for injection-drug use (14.2% of all admissions reported

to Substance Abuse and Mental Health Services Administration's [SAMHSA] *Treatment Episode Data Set for 2009*).[6]

- The most commonly injected drug is heroin. Amphetamines, buprenorphine, benzodiazepines, cocaine, and barbiturates also are injected.[7]
- HIV prevalence among IDUs is estimated to be 20% to 40%.[1]
- The 2009 Monitoring the Future Survey showed that 2.5% of 12th-grade boys in the United States were using anabolic steroids (**Figure 240-2**).[8]
- Anabolic steroid abuse among athletes may range between 1% and 6%.[8]
- Some adolescents abuse steroids as part of a pattern of high-risk behaviors. These adolescents also take risks such as drinking and driving, carrying a gun, driving a motorcycle without a helmet, and abusing other illicit drugs.[8]

FIGURE 240-2 A high school athlete used injectable anabolic steroids for muscle building and developed a large abscess in his buttocks. This photograph was taken 2 months after the original abscess was drained and the wound is healing by secondary intention. (*Courtesy of William Rodney, MD.*)

ETIOLOGY AND PATHOPHYSIOLOGY

- Drug use disorders are thought to be a result of combinations of multiple factors, including genetic, environmental, and individual risk-conferring behaviors.[9]
- Drug use alters the brain's structure and function. These changes persist after drug use stops.[10]
- Most injecting drug users inject drugs intravenously, but subcutaneous injection (skin-popping) also is common.[7]
- Injected, snorted, or smoked heroin causes an almost immediate "rush" or brief period of euphoria that wears off very quickly, terminating in a "crash." The user then experiences an intense craving to use more heroin to stop the crash and bring back the euphoria. The cycle of euphoria, crash, and craving—repeated several times a day—leads to a cycle of addiction.
- A heroin overdose can lead to death from respiratory depression, coma, and pulmonary edema. Death from the direct effects of cocaine is usually associated with cardiac dysrhythmias and conduction disturbances, leading to myocardial infarction and stroke.[7]
- Anabolic steroids can lead to early heart attacks, strokes, liver tumors, kidney failure, and serious psychiatric problems. In addition, because steroids are often injected, users who share needles or use nonsterile techniques when they inject steroids are at risk of contracting dangerous infections, such as HIV/AIDS and hepatitis B and hepatitis C (**Figure 240-2**).[8]

RISK FACTORS

- Family history.

DIAGNOSIS

CLINICAL FEATURES

Heroin use produces the following clinical appearances:

- Pinpoint pupils and no response of pupils to light.
- A rush of pleasurable feelings.
- Cessation of physical pain.

- Lethargy and drowsiness.
- Slurred speech.
- Shallow breathing.
- Sweating.
- Vomiting.
- A drop in body temperature.
- Sleepiness.
- Loss of appetite.

Cocaine (by injection) can produce the following signs, symptoms, and adverse effects:

- Dilated pupils.
- Hyperactivity.
- Euphoria.
- Irritability and anxiety.
- Excessive talking.
- Depression or excessive sleeping.
- Long periods without eating or sleeping.
- Weight loss.
- Dry mouth and nose.
- Paranoia.
- Cardiac—arrhythmias, chest pain, myocardial infarction (MI), and congestive heart failure (CHF).
- Strokes and seizures.
- Respiratory failure.

COMPLICATIONS OF INJECTING DRUG USE

- Local problems—Abscess (**Figures 240-2** and **240-3**; see Chapter 121, Abscess), cellulitis, septic thrombophlebitis, local induration, necrotizing fasciitis, gas gangrene, pyomyositis, mycotic aneurysm, compartmental syndromes, and foreign bodies (e.g., broken needle parts) in local areas.[2]
  - IDUs are at higher risk of getting methicillin-resistant *Staphylococcus aureus* (MRSA) skin infections that the patient may think are spider bites (**Figure 240-4**).
  - Some IDUs give up trying to inject into their veins and put the cocaine directly into the skin. This causes local skin necrosis that produces round atrophic scars (**Figure 240-5**).
- IDUs are at risk for contracting systemic infections, including HIV and hepatitis B or hepatitis C.
  - Injecting drug users are at risk of endocarditis, osteomyelitis (**Figures 240-6** and **240-7**), and an abscess of the epidural region. These infections can lead to long hospitalizations for intravenous antibiotics. The endocarditis that occurs in IDUs involves the right-sided heart valves (see Chapter 50, Bacterial Endocarditis).[2] They are also at risk of septic emboli to the lungs, group A β-hemolytic streptococcal septicemia, septic arthritis, and candidal and other fungal infections.

LABORATORY TESTING

- All IDUs should be screened for HIV (with consent), hepatitis B, and hepatitis C.

FIGURE 240-3 A 32-year-old woman with type 1 diabetes developed large abscesses all over her body secondary to injection of cocaine and heroin. Her back shows the large scars remaining after the healing of these abscesses. (*Courtesy of Richard P. Usatine, MD.*)

FIGURE 240-4 A young woman with methicillin-resistant *Staphylococcus aureus* infection from injection-drug use. Track visible on hand with pustule from methicillin-resistant *Staphylococcus aureus*. (*Courtesy of Richard P. Usatine, MD.*)

- If there is a history of high-risk sexual behavior, screen for syphilis (rapid plasma reagin [RPR]), chlamydia and gonorrhea.
- Purified protein derivative (PPD) test to screen for tuberculosis (especially if the patient is homeless or HIV-positive).
- Urine screen for common drugs of abuse may reveal other drugs not admitted to in the history.
- ECG is warranted if there are any cardiac symptoms or if the physical examination reveals signs of cardiac disease.

DIFFERENTIAL DIAGNOSIS

- Injection-drug use and dependence may be hidden problems. The differential diagnosis will differ based on the presenting complaints.

MANAGEMENT

- Drug-abuse therapy is cost-effective. For example, 1 year of methadone maintenance therapy is approximately $4700 compared to 1 year of imprisonment, which costs $18,400.[10,11]
- Every $1 invested in addiction treatment saves $12 in health, legal, and theft costs.[10]

NONPHARMACOLOGIC

- Recognize addiction as a chronic illness that requires a comprehensive approach during the treatment phase (e.g., residential/outpatient treatment) and continuing care (e.g., drug-abuse monitoring, booster sessions, and reevaluation of treatment needs).[10]
- Identify and address associated medical and psychiatric diagnoses, as well as social, legal, and work-related problems. Coexisting psychiatric illnesses are common.[10]
- For criminal justice-involved drug abusers and addicts, use this opportunity to engage individuals in treatment. Research supports the efficacy of combining criminal justice sanctions and drug-abuse treatment.[10]
- Test IDUs for HIV/AIDS, and hepatitis B and hepatitis C. Consider testing for tuberculosis and other infectious diseases as indicated.[10]
- Consider medically assisted detoxification to minimize withdrawal symptoms.
- Recommend an appropriate length of time for treatment. Most patients need at least 3 months to stop using drugs.[10]
- Encourage patients to engage in individual or group behavioral therapies and assist patients in finding programs that meet their individual needs.[10]
- Advise patients to join a self-help group, such as Narcotics Anonymous (NA) or Cocaine Anonymous (CA), which are based on the 12-step model. Most drug-addiction treatment programs encourage patients to participate in a self-help group during and after formal treatment.[6]

MEDICATIONS

- For opioid addiction, consider a methadone maintenance program.
  - Opioid replacement therapy reduces injecting drug use and thus reduces the mortality and morbidity associated with injecting

FIGURE 240-5 A young woman in residential treatment program with multiple scars from skin popping cocaine. She gave up trying to inject into her veins and put the cocaine directly into the skin. Note how the local skin necrosis caused round atrophic scars. (*Courtesy of Richard P. Usatine, MD.*)

FIGURE 240-6 A 24-year-old woman with an 8-year history of injection-drug use. She has a large deep linear scar from osteomyelitis of the ulnar bone and smaller round scars from skin popping. A track is also visible above the deep scar. (*Courtesy of Richard P. Usatine, MD.*)

drug use, including the transmission of HIV and hepatitis C virus (HCV).[7]

- Opioid replacement combined with counseling, medical and psychiatric care, employment assistance, and family services is superior to opioid replacement alone.[10]

- Buprenorphine, a partial opioid agonist, is also used for opioid detoxification and for opioid replacement therapy.[7,10] In the United States, physicians who wish to prescribe buprenorphine must take a certification course.
- Naltrexone, a long-acting synthetic opioid antagonist, blocks opioid receptors, thereby preventing the effects of opioids. Treatment is initiated after patients have been opioid-free for several days to prevent a severe withdrawal.[10]
- Treating criminal justice-involved drug abusers and addicts—Drug abusers may come into contact with the criminal justice system earlier than with other health or social systems. Thus, the period of involvement with the criminal justice system may offer an opportunity to engage individuals in a treatment that can shorten a pattern of drug abuse and related crime. Research supports the efficacy of combining criminal justice sanctions and drug-abuse treatment.[11]
- Drug-abuse treatment is less expensive than alternatives, such as not treating addicts or incarcerating them. The average cost for 1 full year of methadone maintenance treatment is approximately $4700 per patient, whereas 1 full year of imprisonment costs approximately $18,400 per person. According to several conservative estimates, every $1 invested in addiction treatment programs yields up to $7 in savings, much of which results from reduced drug-related crime and criminal justice costs.[11] Although methadone maintenance is not as desirable as full abstinence, the comparative costs are in favor of drug treatment over incarceration.
- Recovery from drug addiction has two key components: treatment and continuing care. The clinical practices that make up the treatment phase (e.g., residential/outpatient treatment) must be followed up by management of the disorder over time (e.g., drug-abuse monitoring, booster sessions, and reevaluation of treatment needs).[11]
- Research shows that treatment must last, on average, at least 3 months to produce stable behavior change.[11] This accounts for the existence of 90-day residential treatment programs.
- A comprehensive assessment is the first step in the treatment process, and includes identifying individual strengths to facilitate treatment and recovery. In addition, drug abuse cannot be treated in isolation from related issues and potential threats, such as criminal behavior, mental health status, physical health, family functioning, employment status, homelessness, and HIV/AIDS.[11]
- Treatments that utilize cognitive behavioral therapies, residential treatment, contingency management, and medications have demonstrated effectiveness in reducing drug abuse and criminal behavior.[11]
- Medications are a key treatment component for drug abusers and can stabilize the brain and help return it to normal functioning. Methadone and buprenorphine are effective in helping individuals

FIGURE 240-7 The other arm of the woman in Figure 240-6 with deep scar from osteomyelitis secondary to injecting drugs that destroyed the bones in her left forearm. Her arm is deformed and poorly functional. (*Courtesy of Richard P. Usatine, MD.*)

addicted to heroin or other opiates reduce their drug abuse. Naltrexone is also an effective medication for some opiate-addicted patients and those with concurrent alcohol dependence.[11]

- Family and friends can play critical roles in motivating individuals with drug problems to enter and stay in treatment. Family therapy is important, especially for adolescents. Involvement of a family member in an individual's treatment program can strengthen and extend the benefits of the program.[11]
- Buprenorphine (Subutex or, in combination with naloxone, Suboxone) is demonstrated to be a safe and acceptable addiction treatment. Congress passed the Drug Addiction Treatment Act (DATA 2000), permitting qualified physicians to prescribe narcotic medications (Schedules III to V) for the treatment of opioid addiction. This legislation created a major paradigm shift by allowing access to opiate treatment in a medical setting rather than limiting it to specialized drug treatment clinics. Approximately 10,000 physicians have taken the training needed to prescribe these 2 medications, and nearly 7000 have registered as potential providers.
- Methadone and levo-α-acetyl methadol (LAAM) have more gradual onsets of action and longer half-lives than heroin. Patients stabilized on these medications do not experience the heroin rush. Both medications wear off much more slowly than heroin, so there is no sudden crash, and the brain and body are not exposed to the marked fluctuations seen with heroin use. Maintenance treatment with methadone or LAAM markedly reduces the desire for heroin.
- If an individual maintained on adequate, regular doses of methadone (once a day) or LAAM (several times per week) tries to take heroin, the euphoric effects of heroin will be significantly blocked. According to research, patients undergoing maintenance treatment do not suffer the medical abnormalities and behavioral destabilization that rapid fluctuations in drug levels cause in heroin addicts.

PREVENTION AND SCREENING

- The United States Preventive Services Task Force concluded that there is insufficient evidence to screen for illicit drug use in adolescents, adults, or pregnant women, but advises clinicians to be alert for sign and symptoms of drug use.[12]
- Accurate and reliable office screening instruments include CRAFFT (adolescent drug use/misuse), and the ASSIST, CAGE-AID, and DAST (adults with drug misuse).[12]

PROGNOSIS

- Most patients who enter and remain in treatment stop injecting drugs and see improvements in their work, relationships, and psychological functioning.[10]
- Forty percent to 60% of patients relapse.[10]
- Drug injectors who do not enter treatment are up to 6 times more likely to become infected with HIV than are injectors who enter and remain in treatment. Drug users who enter and continue in treatment reduce activities that can spread disease, such as sharing injection equipment and engaging in unprotected sexual activity. Participation in treatment also presents opportunities for screening, counseling, and referral for additional services. The best drug-abuse treatment programs provide HIV counseling and offer HIV testing to their patients.[10]

FOLLOW-UP

- Follow-up is important for the treatment of IDUs. Addiction is a chronic (and relapsing) condition and requires long-term follow-up. Your intervention and caring attitude can help the patient to overcome addiction and to live a sober and drug-free life. Do not give up on patients who relapse because it often takes more than one attempt before long-term cessation can be achieved. The frequency and intensity of follow-up depend upon the substance, the addiction, and the patients and their complications.

PATIENT EDUCATION

- For patients who are not ready to stop their injecting drug use there are harm-reduction and counseling programs that can be helpful. Encourage patients to use clean and sterile needles and not to share their needles with anyone. Bleach can be used to clean and sterilize needles and prevent the spread of HIV and hepatitis.
- Refer continuing drug users to needle exchange programs that exist to help IDUs use clean needles and avoid infectious diseases. These programs can also be helpful if they give out condoms to encourage safe sex.
- Encourage patients to get help to become drug-free and abstinent. There is no safe level of injecting drug use.
- Explain to patients that addiction is a disease and not a failing of their moral character.
- Inform patients about the existing treatment programs in their community and offer them names and phone numbers so that they may get help.
- If your patient is not ready for help today, give the numbers and names for tomorrow.
- Speak about the value of 12-step programs including NA and CA because everyone can afford a 12-step program. There are 12-step programs in the community for everyone including nonsmokers and agnostics.

PATIENT RESOURCES

- Narcotics Anonymous. Provides information about meetings and literature in more than 40 different languages. **http://www.na.org/.**
- Cocaine Anonymous. Provides information about meetings and other resources. **http://www.ca.org/.**

PROVIDER RESOURCES

- OpioidRisk. *Substance Abuse Assessment Tools* (screening instruments for adults including the ASSIST, CAGE-AID, and DAST are available)—**http://www.opioidrisk.com/node/773.**
- The Center for Adolescent Substance Abuse Research. *The CRAFFT Screening Tool*—**http://www.ceasar-boston.org/clinicians/crafft.php.**
- The National Institute on Drug Abuse. *Medical Consequences of Drug Abuse*—**http://www.nida.nih.gov/consequences/.**
- Substance Abuse and Mental Health Services Administration. *Substance Abuse Treatment Facility Locator* (information on treatment programs in the United States)—**http://www.findtreatment.samhsa.gov.**

REFERENCES

1. Mathers BM, Degenhardt L, Phillips B, et al. Global epidemiology of injecting drug use and HIV among people who inject drugs: a systematic review. *Lancet.* 2008;372(9651):1733-1745.
2. Chatterjee A, Tempalski B, Pouget ER, et al. Changes in the prevalence of injection drug use among adolescents and young adults in large U.S. metropolitan areas. *AIDS Behav.* 2011;15(7):1570-1578.
3. Armstrong GL. Injection drug users in the United States, 1979-2002: an aging population. *Arch Intern Med.* 2007;167(2):166-173.
4. Golub ET, Strathdee SA, Bailey SL, et al; DUIT Study Team. Distributive syringe sharing among young adult injection drug users in five U.S. cities. *Drug Alcohol Depend.* 2007;91 Suppl 1:S30-S38.
5. Bailey SL, Ouellet LJ, Mackesy-Amiti ME, et al. DUIT Study Team. Perceived risk, peer influences, and injection partner type predict receptive syringe sharing among young adult injection drug users in five U.S. cities. *Drug Alcohol Depend.* 2007;91 Suppl 1:S18-S29.
6. Substance Abuse and Mental Health Services Administration. *Treatment Episode Data Set (TEDS). 1999-2009.* (National Admission to Substance Abuse Treatment Services, DASIS Series: S-56, HHS Publication No. 9SMA 11-4646.) Rockville, MD: Substance Abuse and Mental Health Services Administration; 2011.
7. Baciewicz GJ. *Injecting Drug Use*. Updated December 15, 2011. http://www.emedicine.com/med/topic586.htm. Accessed April 16, 2012.
8. Johnston LD, O'Malley PM, Bachman JG, Schulenberg JE. *Monitoring the Future: National Results on Adolescent Drug Use: Overview of Key Findings, 2009*. (NIH Publication No. 10-7583). Bethesda, MD: National Institute on Drug Abuse.
9. Schulden JD, Thomas YF, Compton W. Substance abuse in the United States: findings from recent epidemiologic studies. *Curr Psychiatry Rep.* 2009;11(5):353-359.
10. National Institute on Drug Abuse. *Principles of Drug Addiction Treatment: A Research Based Guide*, 2nd ed. (NIH Publication No. 09-4180, revised April 2009.) Bethesda, MD: National Institutes of Health and U.S. Department of Health and Human Services; 2009.
11. *Principles of Drug Abuse Treatment for Criminal Justice Populations—A Research-Based Guide*. http://www.drugabuse.gov/drugpages/cj.html. Accessed May 6, 2012.
12. U.S. Preventive Services Task Force. *Screening for Illicit Drug Use*. http://www.uspreventiveservicestaskforce.org. Accessed April 16, 2012.

This page intentionally left blank

APPENDIX

Strength of Recommendation (SOR)	Definition
A	Recommendation based on consistent and good-quality patient-oriented evidence.*
B	Recommendation based on inconsistent or limited-quality patient-oriented evidence.*
C	Recommendation based on consensus, usual practice, opinion, disease-oriented evidence, or case series for studies of diagnosis, treatment, prevention, or screening.*

*See Appendix A on pages 1447–1450 for further information.

APPENDIX A INTERPRETING EVIDENCE-BASED MEDICINE

Mindy A. Smith, MD, MS

"Evidence-based medicine—is this something new?" asked my father, incredulously. "What were you practicing before?"

Like my father, our patients assume that we provide recommendations to them based on scientific evidence. The idea that there might not be relevant evidence or that we might not have access to that evidence has not even occurred to most of them. This is certainly not to imply that such evidence is the be-all and end-all of medical practice or that our patients would follow such recommendations blindly—rather, for me, it is a starting point from which to begin rational testing or outline a possible therapeutic plan.

The first time that I recall the term *evidence-based medicine* (EBM) being discussed was in the early 1990s.[1,2] It seemed that we would need to develop skills in evaluating the published literature and determining its quality, validity, and relevance to the care of our patients. As a teacher and researcher, I was intrigued by the challenges of critically appraising articles and teaching this newfound skill to others. As a clinician, however, I was most interested in answering clinical questions and doing so in a compressed time frame. I need rapid access to tools or sources that provided summary answers to those questions tagged to information about the quantity and quality of the evidence and the consistency of information across studies.

There seemed to be many systems for rating literature but few that met the needs of the busy practitioner trying to make sense of individual clinical trials and the hundreds of both evidence-based and consensus-based guidelines that seemed to spring up overnight. In 2004, the editors of the U.S. family medicine and primary care journals and the Family Practice Inquiries Network published a paper on a unified taxonomy called *Strength of Recommendation* (SOR) Taxonomy that seemed to fit the bill (**Figure A-1**).[3] This taxonomy made use of existing systems for judging study quality while incorporating the concept of patient-oriented (e.g., mortality, morbidity, symptom improvement) rather than disease-oriented (e.g., change in blood pressure, blood chemistry) outcomes as most relevant. A SOR A recommendation is one based on consistent, good-quality patient-oriented evidence; SOR B is a recommendation based on inconsistent or limited-quality patient-oriented evidence; and SOR C is a recommendation based on consensus, usual practice, opinion, disease-oriented evidence, or case series (**Figure A-1** and **A-2**).

In this book, we made a commitment to search for patient-oriented evidence to support the information that we provide in each of the chapter sections (i.e., epidemiology, etiology and pathophysiology, risk factors, diagnosis, differential diagnosis, management, prevention, prognosis, and follow-up) and to provide a SOR rating for that evidence whenever possible. The bulleted format within these divisions would allow the practitioner to quickly find answers to their clinical questions while providing some direction about how confident we were that a recommendation had high-quality patient-oriented evidence to support it.

For example, a practitioner caring for a patient with severe chronic obstructive pulmonary disease (COPD) and frequent exacerbations who is already taking a combination long-acting β-agonist with an inhaled glucocorticoid asks, "What other options are available to reduce exacerbations?" This information can be found in the Management section of Chapter 56: Chronic Obstructive Pulmonary Disease, under Medications. Although the Global Initiative for Chronic Obstructive Lung Disease does not recommend mucolytics for routine use, authors of a Cochrane review, based on strong evidence SOR A, concluded that these medications produce a small decrease in the frequency of exacerbations (0.5 fewer exacerbations/year) and in disability days.[4] Tiotropium (a long-acting anticholinergic) also reduces exacerbations and improves symptoms, but a recent metaanalysis concluded that mortality was increased with use of this medication SOR A.[5] Theophylline also reduces exacerbations SOR B but is associated with nausea. The physician armed with this information can discuss the options with this patient and explore potential benefits and risks. Particularly in difficult cases where there are multiple options, the clinician's experience and the patient preferences are important aspects of shared decision making. One definition of EBM is "The integration of best research evidence with clinical expertise and patient values."[6]

Several other concepts are used throughout the book that can assist practitioners in using evidence-based information and explaining that information to patients. Risk reductions from medical treatments are often presented in relative terms—the *relative risk reduction* (RRR) or the difference in the percentage of adverse outcomes between the intervention group and the control group divided by the percentage of adverse outcomes in the control group. These numbers are often large and use of them not only causes us to overestimate the importance of a treatment but misses its clinical relevance. A more meaningful term is the *absolute risk reduction* (ARR)—the risk difference between the two groups. This number can then be used to obtain a *number needed to treat* (NNT)—the number of patients that would need to be treated (over the same time as used in the treatment trial) to prevent 1 bad outcome or produce 1 good outcome. This is calculated as 100% divided by the ARR. NNT is more easily understood by us and our patients. See the NNT example in **Box A-1**.

In the above case, for example, the patient might ask how risky it could be to add tiotropium. As written in the chapter, the difference in death with use of this medication was 0.8% (2.4% vs. 1.6% on placebo) making the number needed to harm (NNH) over 1 year to be equal to 124 (for every 124 patients treated, 1 additional death might occur in 1 year).

Another term that is used in this book is the *likelihood ratio* (LR). This number, based on the sensitivity and specificity of a diagnostic

BOX A-1 NNT Example

If a new drug was released for the treatment of postherpetic neuralgia and a randomized controlled trial found that the 70% of the treated group reported significant pain control (based on the defined end point) and 20% of the placebo group reported significant pain control this would produce an absolute risk reduction (ARR) of 50%. In this case the NNT would be 100%/50% = 2. On average, only 2 patients would need to be treated for 1 patient to receive the defined pain control benefit. If the ARR was only 10% (30% of the intervention group and 20% of the control group benefitted), then the NNT = 10 or 10 patients would need treatment on average for 1 to receive benefit.

Figure A-1

How recommendations are graded for strength, and underlying individual studies are rated for quality

In general, only key recommendations for readers require a grade of the "Strength of Recommendation." Recommendations should be based on the highest quality evidence available. For example, vitamin E was found in some cohort studies (level 2 study quality) to have a benefit for cardiovascular protection, but good-quality randomized trials (level 1) have not confirmed this effect. Therefore, it is preferable to base clinical recommendations in a manuscript on the level 1 studies.

Strength of recommendation	Definition
A	Recommendation based on consistent and good-quality patient-oriented evidence.*
B	Recommendation based on inconsistent or limited-quality patient-oriented evidence.*
C	Recommendation based on consensus, usual practice, opinion, disease-oriented evidence,* or case series for studies of diagnosis, treatment, prevention, or screening

Use the following scheme to determine whether a study measuring patient-oriented outcomes is of good or limited quality, and whether the results are consistent or inconsistent between studies.

	Type of Study		
Study quality	**Diagnosis**	**Treatment/prevention/ screening**	**Prognosis**
Level 1— good-quality patient-oriented evidence	Validated clinical decision rule SR/meta-analysis of high-quality studies High-quality diagnostic cohort study†	SR/meta-analysis of RCTs with consistent findings High-quality individual RCT‡ All-or-none study§	SR/meta-analysis of good-quality cohort studies Prospective cohort study with good follow-up
Level 2— limited-quality patient-oriented evidence	Unvalidated clinical decision rule SR/meta-analysis of lower-quality studies or studies with inconsistent findings Lower-quality diagnostic cohort study or diagnostic case-control study§	SR/meta-analysis lower-quality clinical trials or of studies with inconsistent findings Lower-quality clinical trial‡ or prospective cohort study Cohort study Case-control study	SR/meta-analysis of lower-quality cohort studies or with inconsistent results Retrospective cohort study with poor follow-up Case-control study Case series
Level 3— other evidence	Consensus guidelines, extrapolations from bench research, usual practice, opinion, other evidence disease-oriented evidence (intermediate or physiologic outcomes only), or case series for studies of diagnosis, treatment, prevention, or screening		

Consistency across studies	
Consistent	Most studies found similar or at least coherent conclusions (coherence means that differences are explainable); ***or*** If high-quality and up-to-date systematic reviews or meta-analyses exist, they support the recommendation
Inconsistent	Considerable variation among study findings and lack of coherence; ***or*** If high-quality and up-to-date systematic reviews or meta-analyses exist, they do not find consistent evidence in favor of the recommendation

*Patient-oriented evidence measures outcomes that matter to patients: morbidity, mortality, symptom improvement, cost reduction, and quality of life. Disease-oriented evidence measures intermediate, physiologic, or surrogate end points that may or may not reflect improvements in patient outcomes (ie, blood pressure, blood chemistry, physiologic function, and pathologic findings).

† High-quality diagnostic cohort study: cohort design, adequate size, adequate spectrum of patients, blinding, and a consistent, well-defined reference standard.

‡ High-quality RCT: allocation concealed, blinding if possible, intention-to-treat analysis, adequate statistical power, adequate follow-up (greater than 80 percent).

§ In an all-or-none study, the treatment causes a dramatic change in outcomes, such as antibiotics for meningitis or surgery for appendicitis, which precludes study in a controlled trial.

SR, systematic review; RCT, randomized controlled trial

FIGURE A-1 With permission from Ebell MH, Siwek J, Weiss BD, et al. Simplifying the language of evidence to improve patient care: Strength of recommendation taxonomy (SORT). *J. Fam Pract* 2004;53(2):110–120. Dowden Health Media.

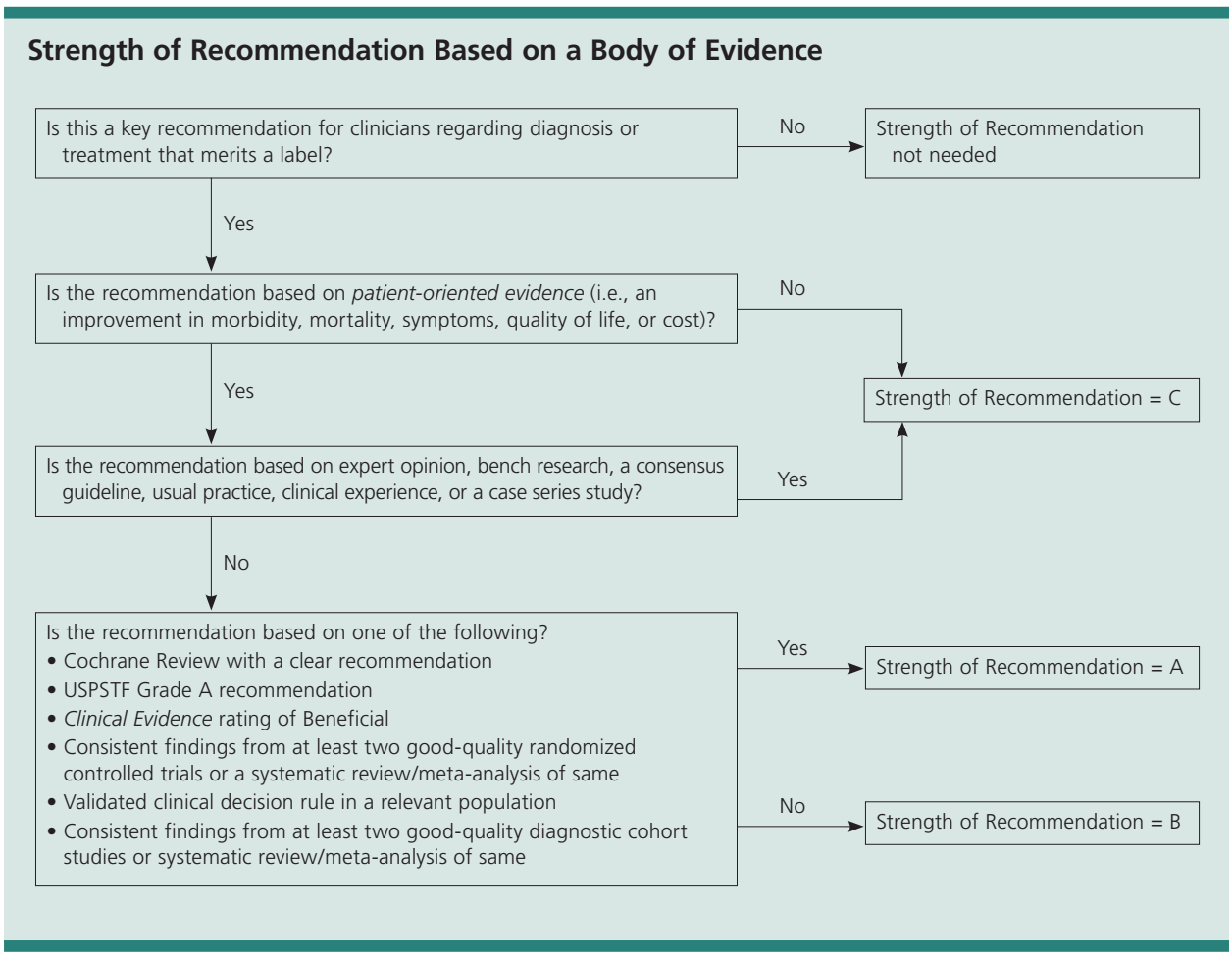

FIGURE A-2 Assigning a Strength-of-Recommendation grade based on a body of evidence. (USPSTF = U.S. Preventive Services Task Force.) (With permission from Ebell MH, Siwek J, Weiss BD, et al. Simplifying the language of evidence to improve patient care: Strength of recommendation taxonomy (SORT). *J. Fam Pract* 2004;53(2):110–120. Dowden Health Media.)

test, is used to determine the probability of a patient with a positive test (LR+) having the disease or the probability of the patient with a negative test (LR−) not having the disease in question. The LR is defined as the likelihood that a given test result would be expected in a patient with the target disorder compared to the likelihood that that same result would be expected in a patient without the target disorder.[6] The number obtained for the LR+ [Sensitivity/(100 − Specificity)] or the LR− [(100 − Sensitivity)/Specificity] can be multiplied by the pretest probability of disease to determine the posttest probability of disease. A nomogram (one can be found by visiting the website mentioned in reference 6) can be used to more easily work with these numbers to convert a pretest probability into a posttest probability. A LR+ over 10 is considered strong evidence to rule in disease while a LR− of less than 0.1 is strong evidence to rule out disease.

We both are privileged and cursed with practicing medicine in an information-rich environment. We have designed our *Color Atlas* to link evidence to clinical recommendations so that we can provide our patients the best science available. When the evidence is lacking, we make that clear and encourage you to engage in frank and honest discussions that lead to the shared responsibility for decisions. Our patients are justified in expecting science along with humanism—can we give them anything less?

REFERENCES

1. Evidence-Based Medicine Working Group. Evidence-based medicine. A new approach to teaching the practice of medicine. *JAMA* 1992;268:2420-2425.
2. Shaughnessy AF, Slawson DC, Bennett JH. Becoming an information master: a guidebook to the medical information jungle. *J Fam Pract* 1994;39:489-499.
3. Ebell MA, Siwek J, Weiss BD, et al. Strength of Recommendation Taxonomy (SORT): a patient-centered approach to grading evidence in the medical literature. *J Fam Pract* 2004 Feb; 53(2): 111-120.
4. Poole P, Black PN. Mucolytic agents for chronic bronchitis or chronic obstructive pulmonary disease. *Cochrane Database Syst Rev* 2010;(2):CD001287.
5. Singh S, Loke YK, Enright PL, Furberg CD. Mortality associated with tiotropium mist inhaler in patients with chronic obstructive pulmonary disease: systematic review and meta-analysis of randomised controlled trials. *BMJ* 2011;342:d3215.
6. Center for Evidence-Based Medicine. http://www.cebm.net/index.aspx?o=1162, accessed June 30, 2008.

APPENDIX B GUIDE FOR THE USE OF TOPICAL AND INTRALESIONAL CORTICOSTEROIDS

TABLE B-1 Corticosteroid Potency Chart

Generic Name	U.S. Trade Name and Strength
Class 1—Superpotent	
Betamethasone dipropionate*	Diprolene lotion/gel/ointment, 0.05%
Clobetasol propionate*	Temovate cream/emollient base cream/gel/ointment, 0.05%;
	Clobex ointment/lotion/shampoo/spray aerosol, 0.05%;
	Cormax ointment/solution 0.05%;
	Olux foam aerosol 0.05%
Diflorasone diacetate	Psorcon or ApexiCon ointment, 0.05%
Halobetasol propionate	Ultravate cream/ointment, 0.05%
Fluocinonide	Vanos cream 0.1%
Flurandrenolide	Cordran Tape 4 mcg/cm^2
Class 2—Potent	
Amcinonide	Cyclocort or Amcort ointment, 0.1%
Betamethasone dipropionate	Diprosone ointment/augmented cream 0.05%
Desoximetasone	Topicort cream/ointment, 0.25%; gel, 0.05%
Diflorasone diacetate	ApexiCon cream/ointment, 0.05%
	Florone ointment, 0.05%; Psorcon cream/ointment, 0.05%
Fluocinonide	Lidex cream/ointment/gel/solution, Fluone cream, 0.05%
Halcinonide	Halog cream/ointment/cream/solution, 0.1%
Triamcinolone acetonide	Kenalog ointment, 0.5%
Class 3—Upper Mid-Strength	
Amcinonide	Amcort cream//lotion 0.1%; Cyclocort cream 0.1%
Betamethasone dipropionate†	Diprosone cream or hydrophilic emollient, 0.05%
Betamethasone valerate†	Valisone or Betatrex ointment, 0.1%; Luxiq foam, 0.12%
	Generic cream/ointment/lotion, 0.1%
Diflorasone diacetate†	Maxiflor, Florone, Psorcon cream, 0.05%
Diflorasone diacetate	Generic cream/ointment, 0.05%
Fluticasone propionate†	Cutivate ointment 0.005%
Fluocinonide†	Lidex-E cream, aqueous emollient, 0.05%
Mometasone furoate†	Elocon cream/ointment, 0.1%
Triamcinolone acetonide	Kenalog ointment 0.5%
	Aristocort cream 0.05%, ointment, 0.1%
Class 4—Mid-Strength	
Clocortolone pivalate	Cloderm cream, 0.1%
Desoximetasone	Topicort LP cream, 0.05%
Fluocinolone acetonide†	Synalar-HP, Synalar ointment, 0.025%
Flurandrenolide	Cordran ointment, 0.05%
Hydrocortisone valerate	Westcort ointment, 0.2%
Mometasone furoate†	Elocon cream, lotion, solution 0.1%
	Momexin cream, 0.1%
Triamcinolone acetonide	Kenalog cream, ointment, spray 0.1%
	Kenonel cream 0.1%

(*continued*)

TABLE B-1 Corticosteroid Potency Chart (*Continued*)

Generic Name	U.S. Trade Name and Strength
Class 5—Lower Mid-Strength	
Betamethasone dipropionate	Diprosone lotion, 0.05%
Betamethasone valerate	Valisone, Beta-Val, Betatrex cream, 0.1%
Desonide	DesOwen Tridesilon ointment, 0.05%
	Desonate gel 0.05%
Fluocinolone acetonide	Synalar cream, 0.025%
Flurandrenolide	Cordran cream, lotion, 0.05%
Fluticasone propionate	Cutivate cream, lotion, solution, 0.05%
	Cortizone 10 lotion, spray, 0.1%
Hydrocortisone butyrate	Locoid cream, ointment, 0.1%
Hydrocortisone probutate	Pandel cream 0.1%
Hydrocortisone valerate	Westcort cream, 0.2%
Prednicarbate	Dermatop emollient cream, ointment, 0.1%
	Kenalog lotion, 0.1%, ointment 0.025%
Triamcinolone acetonide‡	
Class 6—Mild	
Alclometasone dipropionate†	Aclovate cream/ointment, 0.05%
Betamethasone valerate	Valisone or Beta-Val lotion, 0.1%
Desonide	DesOwen cream, lotion, 0.05%
	Tridesilon cream 0.05%
	LoKara lotion 0.05%
	Verdeso foam 0.05%
Fluocinolone acetonide	Synalar cream/solution, 0.01%; Capex shampoo, Derma-Smoothe oil, 0.01%
Triamcinolone acetonide	Aristocort cream, 0.1%
	Kenalog cream, lotion, 0.025%
Class 7—Least Potent	
Hydrocortisone§	Hytone, Cortate, Unicort, other nonprescription cream/lotion/foam 0.5% to 2.5%

*New Zealand Class 1, United Kingdom, Germany, and the Netherlands Class IV.
†New Zealand Class 2, United Kingdom, Germany, and the Netherlands Class III.
‡New Zealand Class 3, United Kingdom, Germany, and the Netherlands Class II.
§New Zealand Class 4, United Kingdom, Germany, and the Netherlands Class I.

TABLE B-2 Grams of Topical Medication Needed Based on Body Area*

Body Area	Grams of Medicine Needed for Daily Application for 1 Week
Face and neck	7.5
Trunk	30
One arm	7.5
One leg	15
Hands and feet	7.5
Whole body	90

*Multiply the amount by the number of times a day the medication is to be applied and the number of weeks of prescribed usage. Then choose the nearest higher volume available. For children divide the number by approximately 2 based on the child's size.

TABLE B-3 Common Side Effects of Topical Corticosteroids

Skin atrophy	Most common adverse effect Epidermal thinning may begin after only a few days Dermal thinning usually takes several weeks to develop Usually reversible within 2 months after stopping the corticosteroid
Telangiectasia	Most often occurs on the face, neck, and upper chest Tends to decrease when steroid discontinued, but may be irreversible
Striae	Usually occur around flexures (groin, axillary, and inner thigh areas) Usually permanent, but may fade with time
Purpura	Frequently occurs after minimal trauma Attributed to loss of perivascular supporting tissue in the dermis
Hypopigmentation	Reversible upon discontinuing the corticosteroid
Acneform eruptions	Particularly common on the face, especially with the "potent" and "very potent" corticosteroids Usually reversible
Fine hair growth	Reversible upon discontinuation of the corticosteroid
Infections	May worsen viral, bacterial, or fungal skin infections May cause tinea incognito
Hypothalamic–pituitary–adrenal axis suppression	Rare with topicals >30 g/week of "very potent" corticosteroids should be limited to 3 to 4 weeks Children (>10 g/week) and elderly are at higher risk because of thinner skin

TABLE B-4 Intralesional Steroids—Concentrations for Injection

Condition	Concentration of Triamcinolone Acetonide Solution (mg/mL)
Acne (**Figure B-1**)	2 to 2.5
Alopecia areata (**Figure B-2**)	5 to 10
Granuloma annulare	5 to 10
Psoriasis	5 to 10
Hypertrophic lichen planus	5 to 10
Prurigo nodularis	10
Hidradenitis suppurativa	10
Keloids and hypertrophic scars (**Figure B-3**)	10 to 40

Use a 27-gauge or 30-gauge needle when injecting intralesional steroids to minimize pain. Steroid dilutions can be made with sterile saline for injection. This is also less painful than diluting steroid with lidocaine. A Luer-Lok syringe is helpful to avoid the needle from popping off during the injection. For further information on performing intralesional injections see Usatine R, Pfenninger J, Stulberg D, Small R. Dermatologic and Cosmetic Procedures in Office Practice. Philadelphia, PA: Elsevier; 2012. This text and accompanying videos can also be purchased as an electronic application at **http://www.usatinemedia.com**.

FIGURE B-1 Injecting painful cystic acne with 2 mg/mL triamcinolone using a 30-gauge needle. (*Courtesy of Richard P. Usatine, MD.*)

FIGURE B-2 Injecting alopecia areata with 5 mg/mL triamcinolone using a 27-gauge needle on a Luer-Lok syringe. (*Courtesy of Richard P. Usatine, MD.*)

FIGURE B-3 Injecting a hypertrophic scar with 10 mg/mL triamcinolone using a 27-gauge needle on a Luer-Lok syringe. (*Courtesy of Richard P. Usatine, MD.*)

APPENDIX C DERMOSCOPY

Ashfaq A. Marghoob, MD
Natalia Jaimes, MD
Richard P. Usatine, MD

Dermoscopy allows the clinician to visualize structures below the level of the stratum corneum. These structures are not routinely discernible without dermoscopy. The presence or absence of specific dermoscopic structures, their location and their distribution can assist the clinician in making a diagnosis or at least in narrowing the differential diagnosis.

The major goal of dermoscopy is to differentiate benign from malignant lesions on the skin so that one is less likely to miss a skin cancer (higher sensitivity) and less likely to perform unnecessary biopsies (higher specificity). Together, this will increase your diagnostic accuracy.

There are 3 major types of dermatoscopes:

1. Polarized
2. Nonpolarized
3. Hybrid, which combines a polarized mode with a nonpolarized mode in one dermatoscope.

Because some structures are better seen under polarized light and others best seen without polarization is helpful to purchase a hybrid dermatoscope. Dermatoscopes are currently manufactured by 3Gen, Welch Allyn, Canfield and Heine (**Figures C-1** and **C-2**). A number of dermatoscopes work well while attached to the iPhone for easy image capture and full screen images that can be shown to the patients.

FIGURE C-1 An assortment of polarized and hybrid dermatoscopes from 3Gen. (*Courtesy of Richard P. Usatine, MD* and *3Gen, San Juan Capistrano, CA.*)

FIGURE C-2 Nonpolarized contact dermatoscopes from Heine and Welch-Allyn. (*Courtesy of Heine, Herrsching, Germany, and Welch Allyn, Skaneateles Falls, NY.*)

Dermoscopic diagnosis is based on the 2-step dermoscopy algorithm described in **Figure C-3**.

Step 1 requires the observer to decide whether the lesion in question is of melanocytic origin (contains melanocytes and therefore could be a melanoma). If the lesion is deemed to be a melanocytic lesion then the observer proceeds to step 2. In this phase of the evaluation, the observer needs to decide whether the lesion is a benign nevus or a melanoma. However, if during step 1 analysis the lesion does not display any features of a melanocytic lesion then the observer needs to decide if the lesion possesses any criteria for a basal cell carcinoma, seborrheic keratosis, hemangioma, or dermatofibroma. If the lesion does not display any structures common to the aforementioned lesions then the lesion is considered nondescript or featureless. The index of suspicion needs to remain high for all featureless lesions as amelanotic melanoma can present as a completely structureless lesion. These featureless lesions sometimes do reveal blood vessels and, if present, their morphology can often help in narrowing the differential diagnosis.

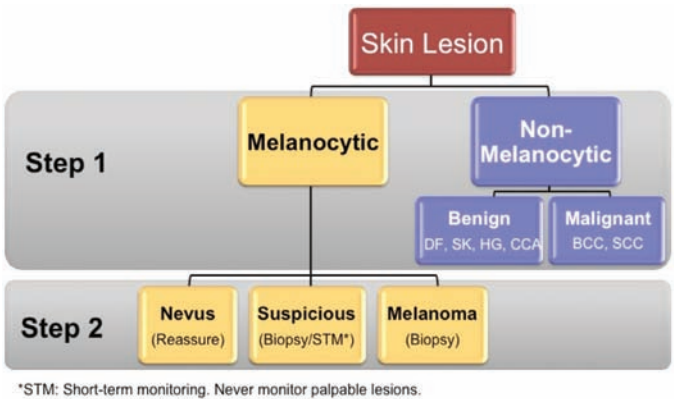

FIGURE C-3 Two-step diagnostic procedure requires separating all lesions into melanocytic or nonmelanocytic as step 1. *BCC*, Basal cell carcinoma; *CCA*, clear-cell acanthoma; *DF*, dermatofibroma; *HG*, hemangioma; *SCC*, squamous cell carcinoma; *SK*, seborrheic keratosis.

STEP 1 – LEVEL 1

A melanocytic lesion usually will display one of the following structures:

a. Pigment network (**Figure C-4**).
b. Negative network (**Figure C-5**).
c. Streaks (**Figure C-6**).
d. Homogeneous blue pigmentation (**Figure C-7**).
e. Aggregated globules (**Figure C-8**).
f. Pseudonetwork (facial skin) (**Figure C-9**).
g. Parallel pigment pattern (acral lesions) (**Figure C-10**).
h. There is one exception to including lesions with pigment network in the melanocytic category; that is, the dermatofibroma in which the pattern trumps the network (**Figure C-11**).

FIGURE C-4 Pigment network tells us this benign nevus is a melanocytic lesion in step 1 of the 2-step algorithm; that is, it contains melanocytes. (*Copyright of Ashfaq Marghoob, MD.*)

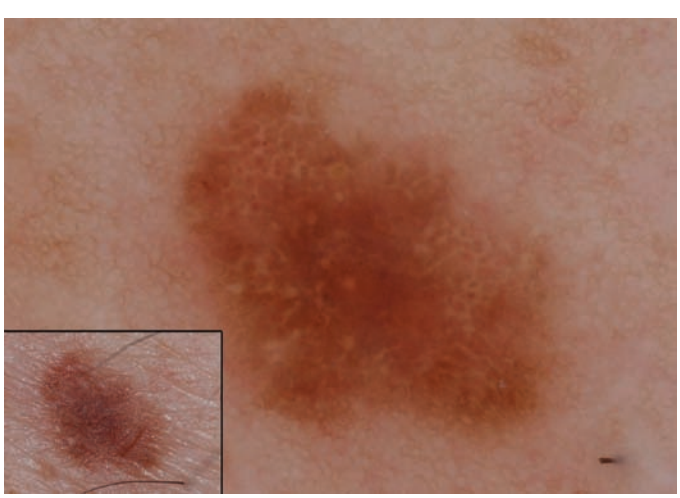

FIGURE C-5 Negative network inform us that this microinvasive melanoma is a melanocytic lesion. The negative network consists of dark, elongated and curved globular structures surrounded by relative hypopigmentation. (*Copyright of Ashfaq Marghoob, MD.*)

This lesion does not display any of the structures commonly seen in melanocytic lesions (i.e., network, streaks, globules). It also does not have any features of a basal cell carcinoma, seborrheic keratosis, dermatofibroma, or hemangioma. Thus, this is a featureless lesion. However, it does display many irregular tortuous blood vessels, which may be a sign of neoangiogenesis. The possibility of melanoma needs to be entertained for such featureless lesion.

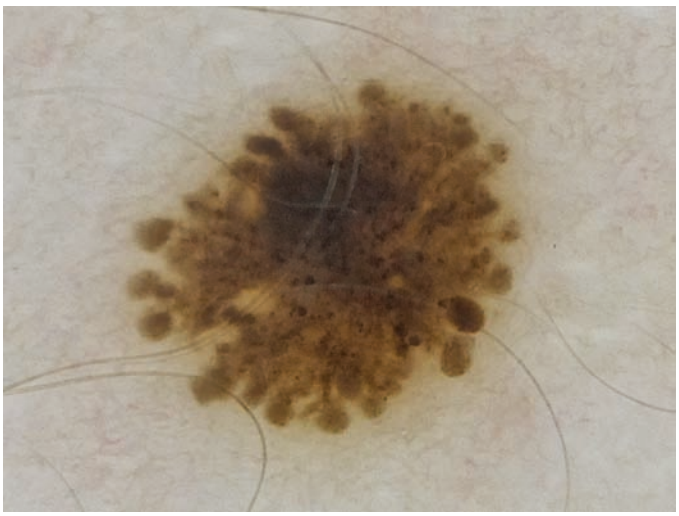

FIGURE C-6 Streaks of the pseudopod type inform us that this is a melanocytic lesion. The 360-degree symmetry is typical in a Spitz nevus. (*Copyright of Ashfaq Marghoob, MD.*)

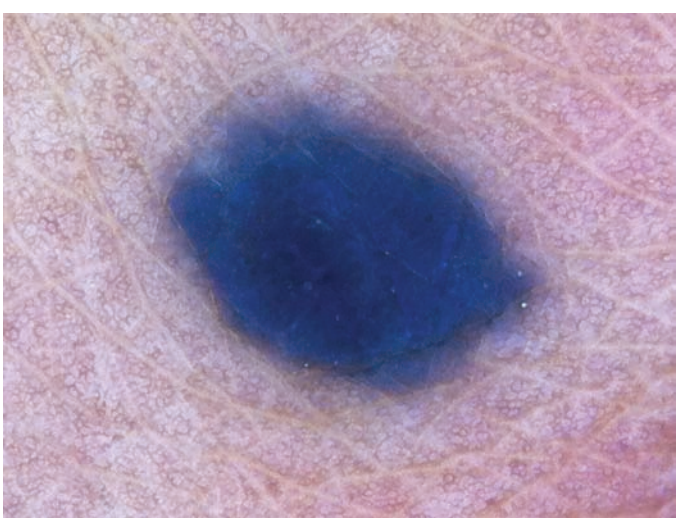

FIGURE C-7 Homogeneous blue pigmentation is a feature of a melanocytic lesion of the blue nevus type. (*Courtesy of Richard P. Usatine, MD.*)

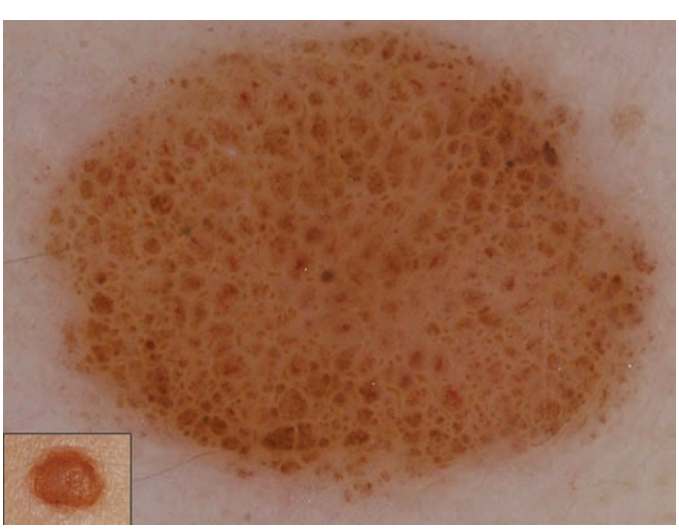

FIGURE C-8 Aggregated globules inform us that this benign nevus is melanocytic. (*Courtesy of Ashfaq Marghoob, MD.*)

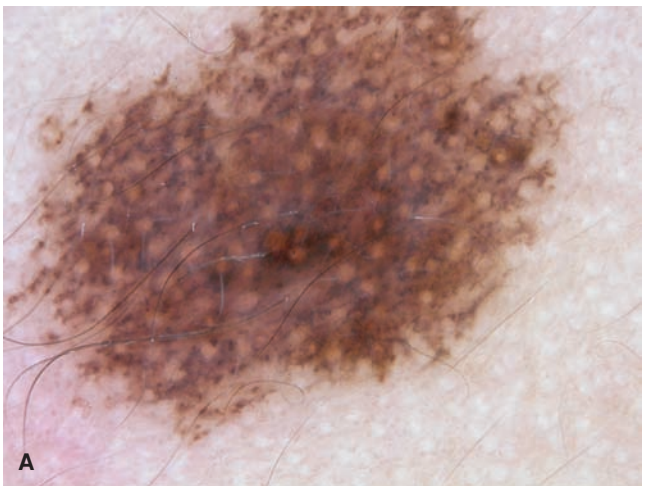

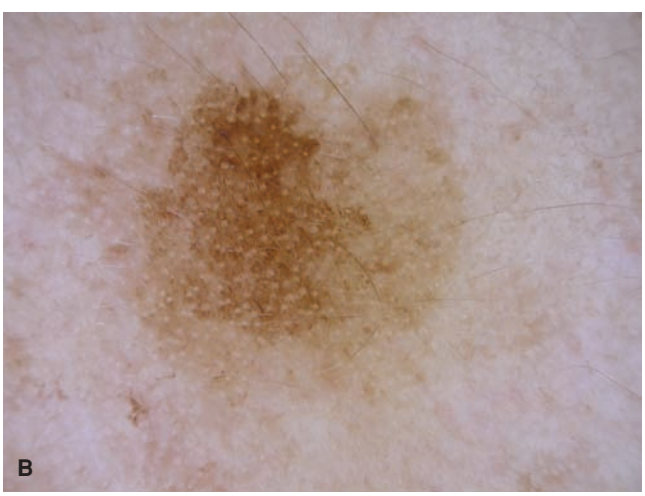

FIGURE C-9 Pseudonetwork is the net-like pattern made by white adnexal openings on the face within any pigmented lesion. **A.** Pseudonetwork pattern is seen on the face in this congenital nevus that is melanocytic. **B.** Although this solar lentigo also has a pseudonetwork pattern created by white adnexal openings it is not melanocytic. It does have a typical moth-eaten border found in solar lentigines and seborrheic keratoses. (*Courtesy of Richard P. Usatine, MD.*)

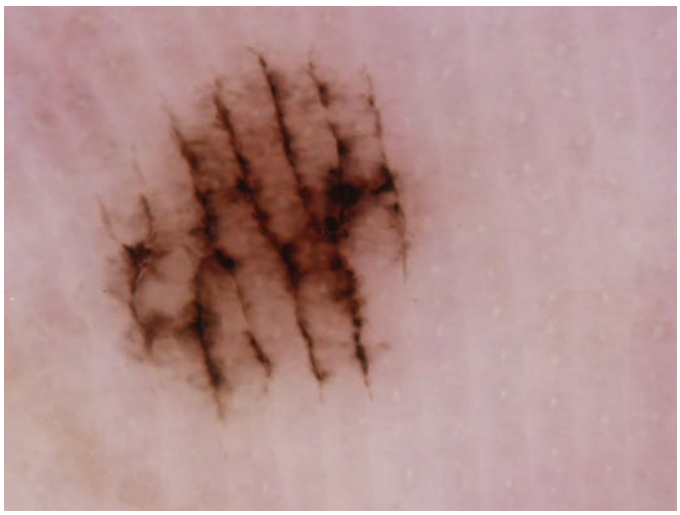

FIGURE C-10 Nevus on the sole of the foot showing parallel network pigment in the furrows (valleys) rather than the ridges. Note the white eccrine gland openings on the ridges which are wider than the furrows. (*Courtesy of Richard P. Usatine, MD.*)

FIGURE C-11 Pattern trumps network in this dermatofibroma. Although this appears to have peripheral network, the central stellate scar makes this a dermatofibroma, which is not a melanocytic lesion. (*Courtesy of Richard P. Usatine, MD.*)

STEP 2

- If the lesion is deemed to be of melanocytic origin, then one needs to decide whether the lesion is a benign nevus or a melanoma.

Nevi tend to manifest one of the following 10 benign patterns (**Figure C-12**)

1. Diffuse reticular (**Figure C-13**)
2. Patchy reticular (**Figure C-14**)
3. Peripheral reticular with central hypopigmentation (**Figure C-15**)
4. Peripheral reticular with central hyperpigmentation (**Figure C-16**)
5. Homogeneous (**Figure C-17**)
6. Peripheral globules/starburst (**Figure C-18**)
7. Peripheral reticular with central globules (**Figure C-19**)
8. Globular (**Figure C-20**)
9. Two-component (**Figure C-21**)
10. Symmetric multicomponent (note this pattern should be interpreted with caution and a biopsy is probably warranted for dermoscopic novices) (**Figure C-22**)



FIGURE C-12 Benign nevi tend to adhere to 1 of 10 recurrent patterns. Melanoma is a melanocytic lesion that deviates from the 10 benign patterns.

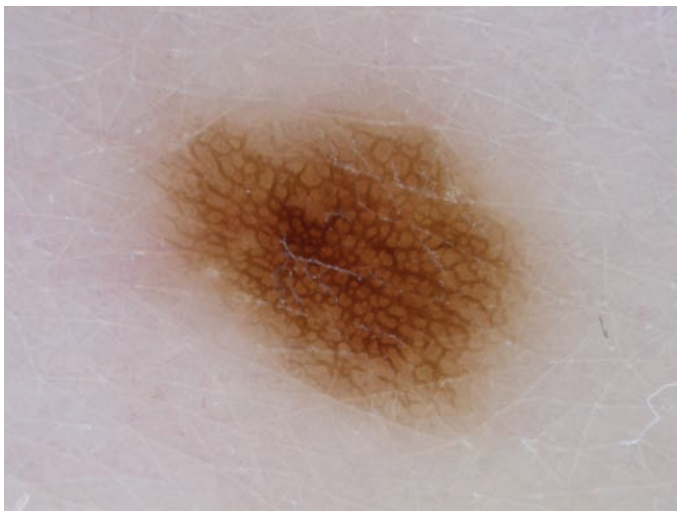

FIGURE C-13 Diffuse reticular pattern in a benign nevus. Note the regular line thickness and the fading of the lines at the periphery. (*Courtesy of Richard P. Usatine, MD.*)

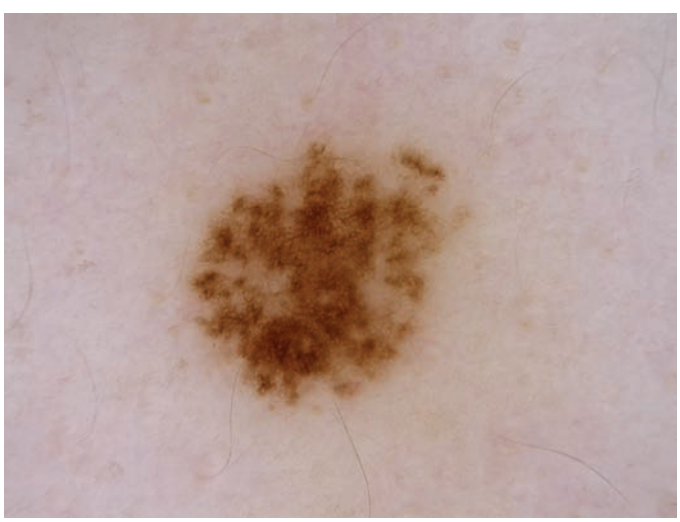

FIGURE C-14 Patchy reticular pattern in a benign nevus. (*Courtesy of Richard P. Usatine, MD.*)

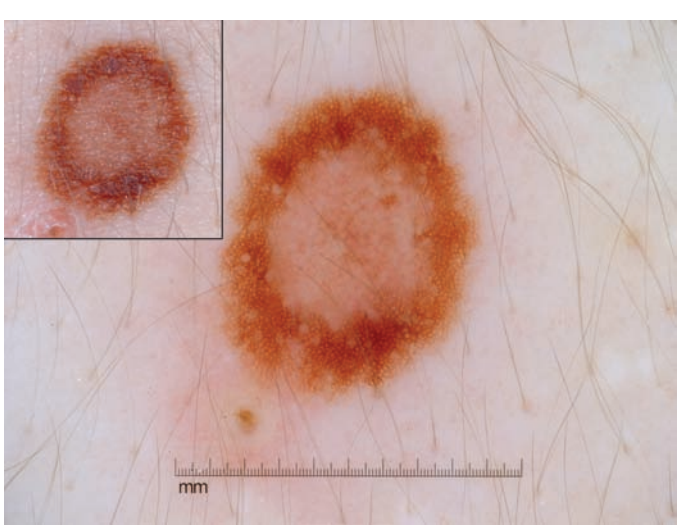

FIGURE C-15 Peripheral reticular pattern with central hypopigmentation in a benign nevus. (*Copyright of Ashfaq Marghoob, MD.*)

FIGURE C-16 Peripheral network with a central hyperpigmentation in this benign nevus. The central hyperpigmentation may also be called a typical blotch. (*Copyright of Ashfaq Marghoob, MD.*)

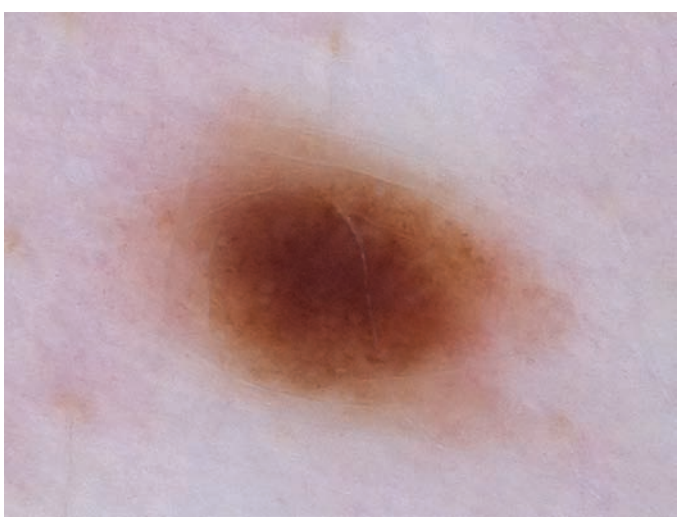

FIGURE C-17 Homogeneous pattern with a brown coloration in a benign nevus. The color may be brown, pink, or blue. (*Courtesy of Richard P. Usatine, MD.*)

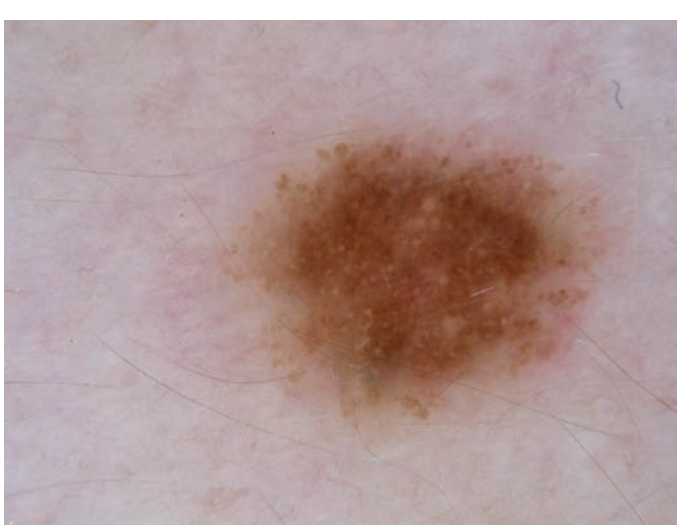

FIGURE C-18 Peripheral globules that are symmetrically placed are visible in this benign nevus. (*Copyright of Ashfaq Marghoob, MD.*)

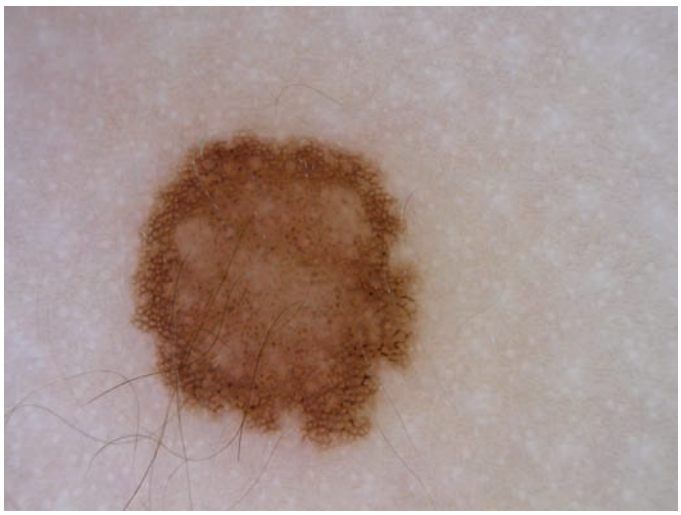

FIGURE C-19 Peripheral reticular pattern with central globules in this benign congenital nevus. (*Courtesy of Richard P. Usatine, MD.*)

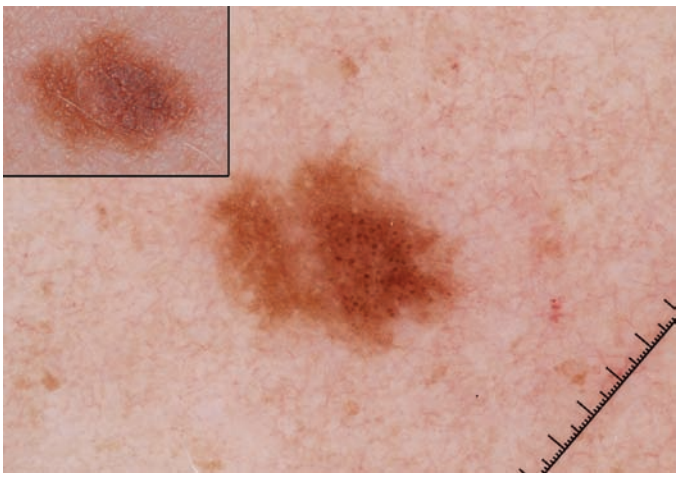

FIGURE C-21 Two-component pattern with globules on the right and a strictly reticular pattern on the left. (*Copyright of Ashfaq Marghoob, MD.*)

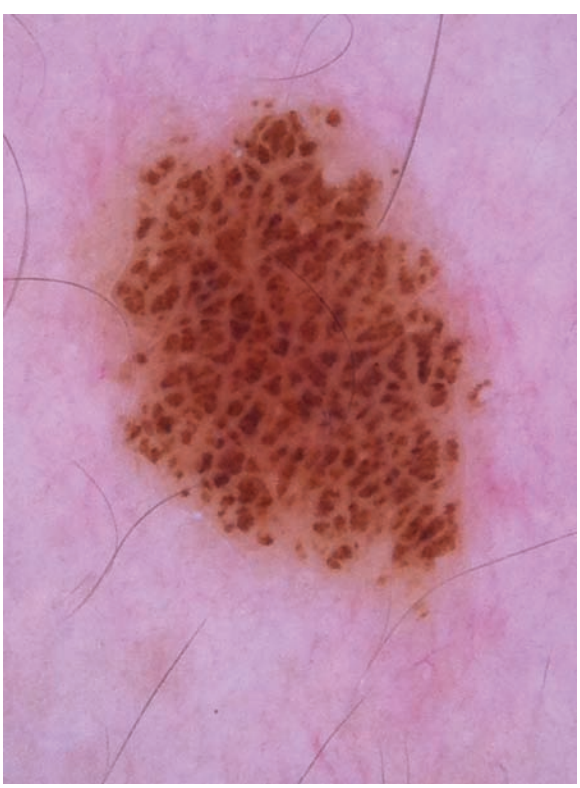

FIGURE C-20 Globular pattern in a benign nevus. Note this globules have a cobblestone pattern but other globules may be rounded. (*Courtesy of Richard P. Usatine, MD.*)

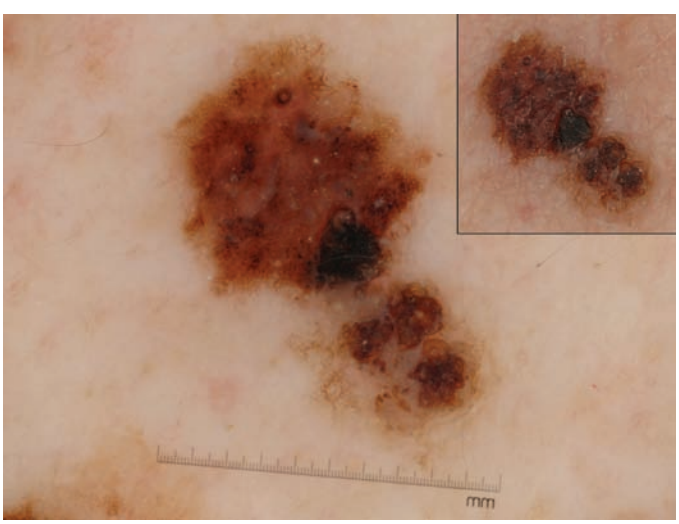

FIGURE C-22 Symmetric multicomponent pattern. Although this turned out to be a benign nevus, only the most experienced dermoscopist could afford to call this benign without a biopsy. (*Copyright of Ashfaq Marghoob, MD.*)

In contrast, melanomas tend to deviate from the benign pattern described above. Furthermore, the structures in a melanoma are often distributed in an asymmetric fashion. Most melanomas will also reveal one or more of the melanoma specific structures (**Figure C-23**).

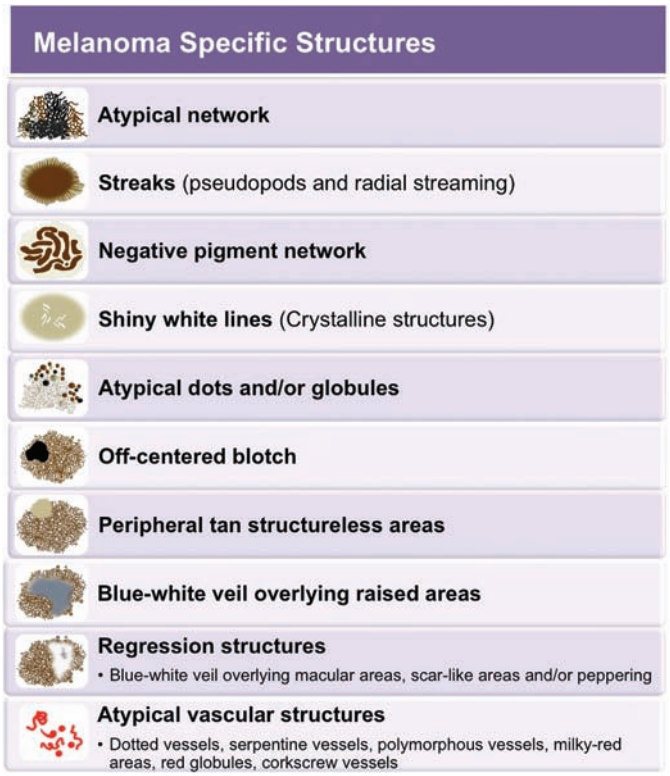

FIGURE C-23 Melanoma-specific structures.

MELANOMA-SPECIFIC STRUCTURES

1. Atypical network (**Figure C-24**)
2. Streaks (pseudopods and radial streaming) (**Figure C-25**)
3. Negative pigment network (**Figure C-26**)
4. Shiny white lines (crystalline structures) (**Figure C-27**)
5. Atypical dots and or globules (**Figure C-28**)
6. Off-center blotch (**Figure C-29**)
7. Peripheral tan structureless areas (**Figure C-30**)
8. Blue-white veil overlying raised areas (**Figure C-31**)
9. Regression structures (blue-white veil overlying macular areas, scar-like areas, and/or peppering) (**Figure C-32**)
10. Atypical vascular structures (dotted vessels, serpentine vessels, polymorphous vessels, milky red areas, red globules, corkscrew vessels) (**Figure C-33**)

Note that melanoma on the soles or palms may present with a parallel ridge pattern (**Figure C-34**).

On the face, with rhomboidal structures (**Figure C-35**).

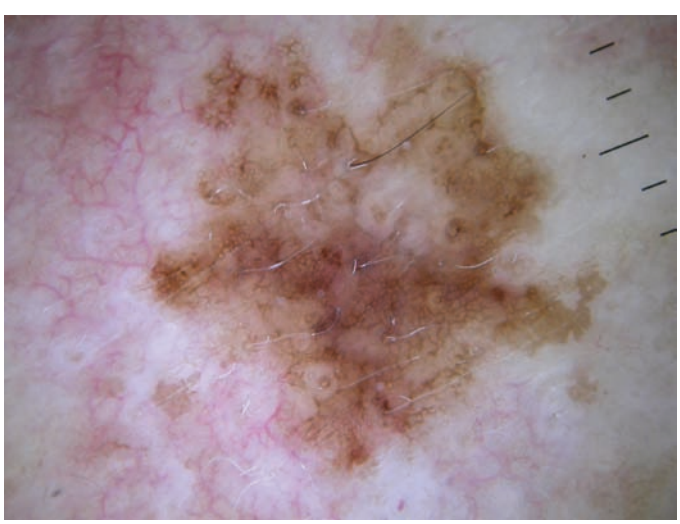

FIGURE C-24 Atypical network can be seen in this suspicious melanocytic lesion. (*Courtesy of Richard P. Usatine, MD.*)

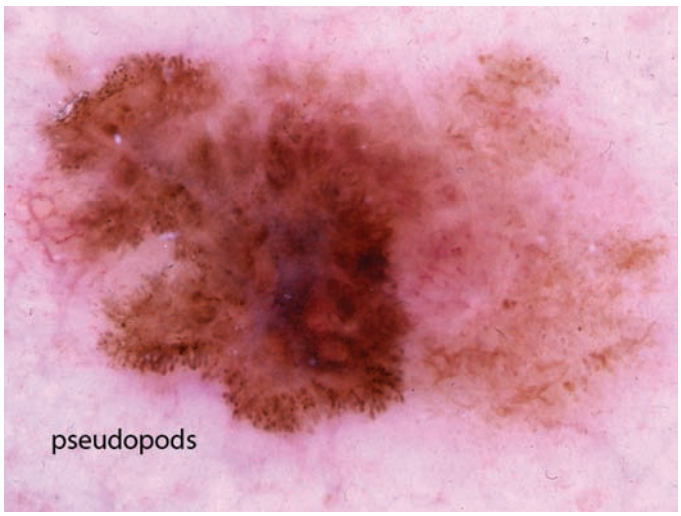

FIGURE C-25 Pseudopods can be seen in this melanoma. Pseudopods are streaks with radial streaming, a melanoma-specific structure. (*Copyright of Ashfaq Marghoob, MD.*)

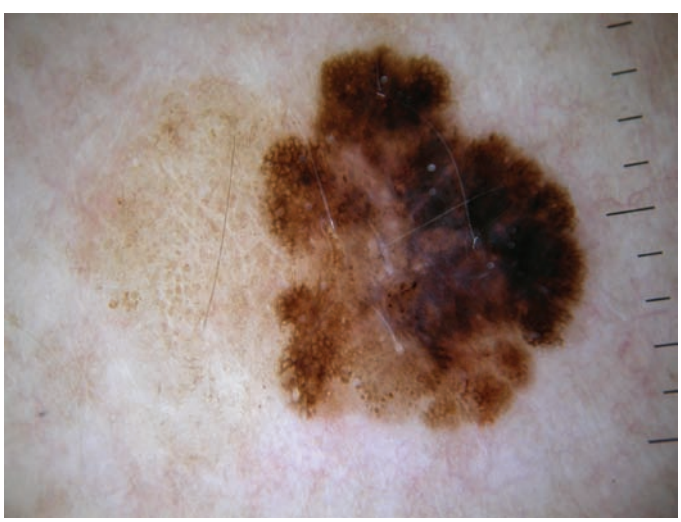

FIGURE C-26 Negative pigment network can be seen on the left side of this melanoma. (*Courtesy of Richard P. Usatine, MD.*)

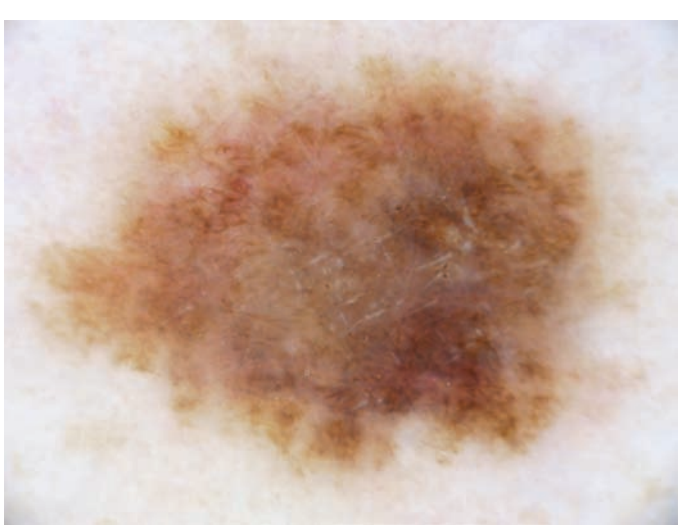

FIGURE C-27 Shiny white lines are visible in this melanoma. Shiny white lines are also called chrysalis or crystalline structures. (*Copyright of Ashfaq Marghoob, MD.*)

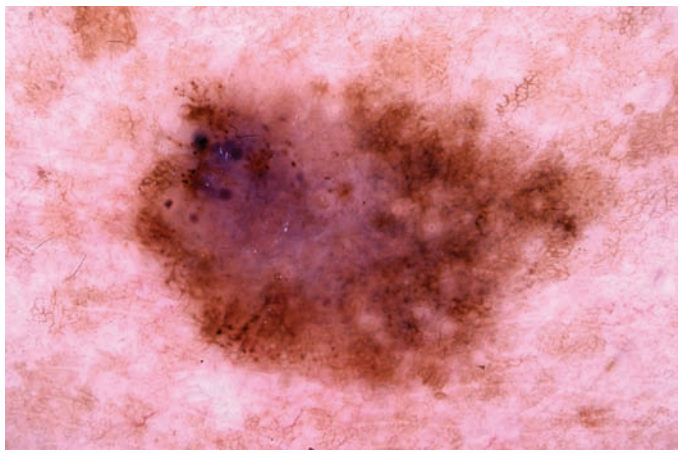

FIGURE C-28 Atypical dots and globules are seen in this melanoma. The dots and globules are peripheral and not symmetrically placed. A blue white veil is also visible. (*Copyright of Ashfaq Marghoob, MD.*)

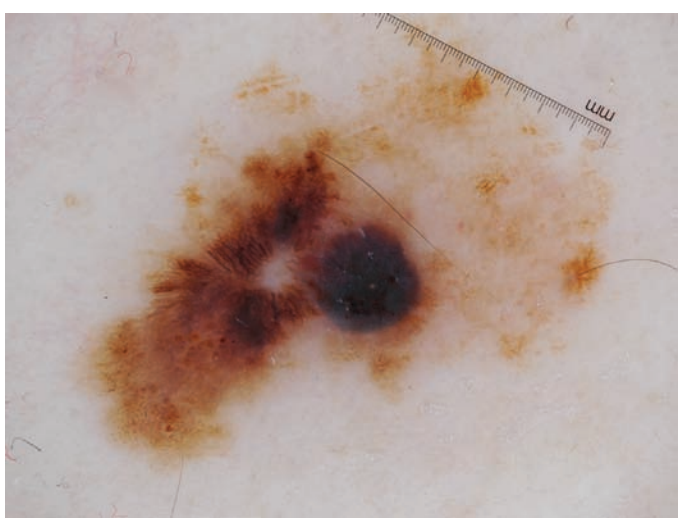

FIGURE C-29 Off-centered blotch in a melanoma. Note the blue-white veil, atypical globules, atypical network, and the peripheral tan structureless areas. (*Copyright of Ashfaq Marghoob, MD.*)

FIGURE C-30 Peripheral tan structureless areas are visible on the bottom left portion of this melanoma (*arrow*). Note that there is also negative network visible. (*Copyright of Ashfaq Marghoob, MD.*)

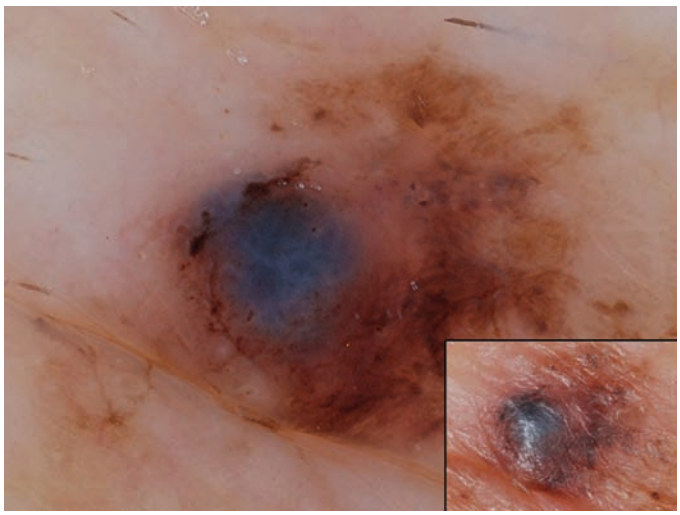

FIGURE C-31 Blue-white veil overlying raised area in a melanoma. (*Copyright of Ashfaq Marghoob, MD.*)

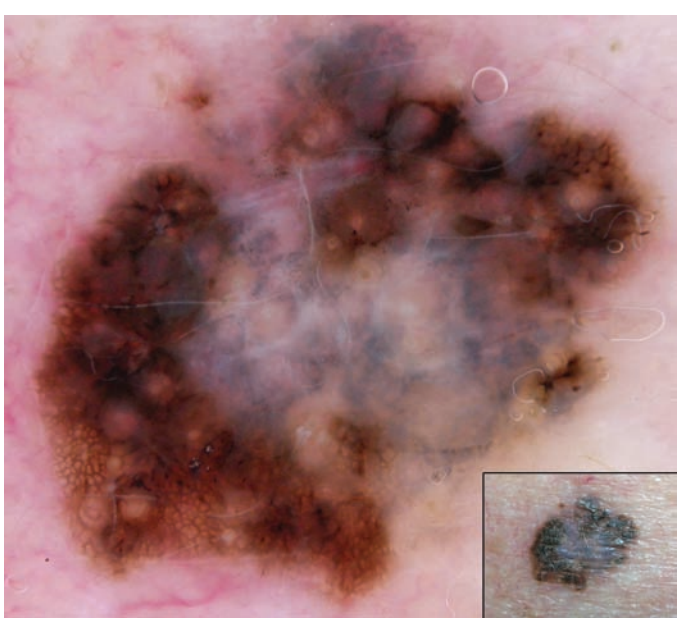

FIGURE C-32 Regression structures visible in this melanoma-in-situ. The regression structures consist of blue-white veil overlying macular areas and "peppering." (*Courtesy of Richard P. Usatine, MD.*)

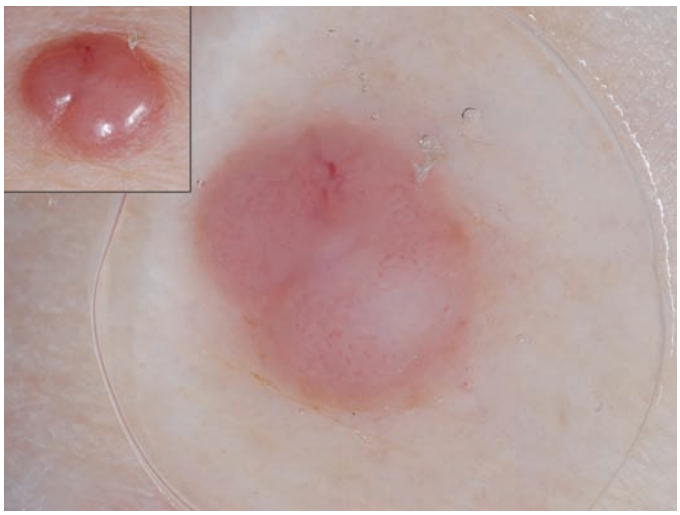

FIGURE C-33 Atypical vascular structures can be seen in this amelanotic nodular melanoma. Dotted and serpentine vessels are visible. (*Copyright of Ashfaq Marghoob, MD.*)

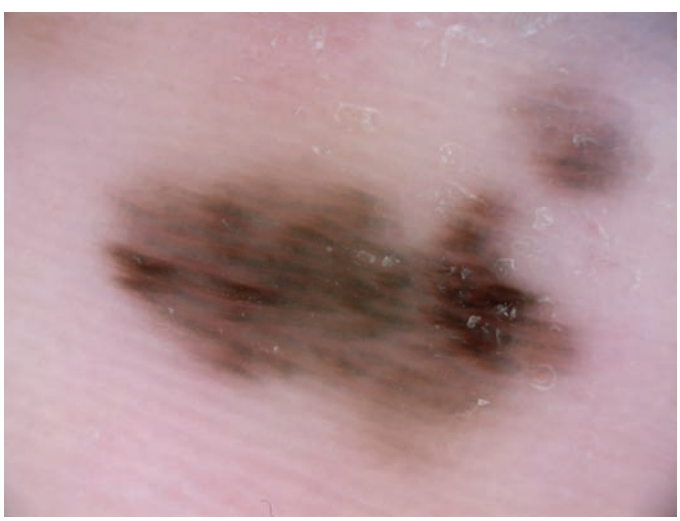

FIGURE C-34 Acrolentiginous melanoma on the foot with a parallel ridge pattern. (*Courtesy of Richard P. Usatine, MD.*)

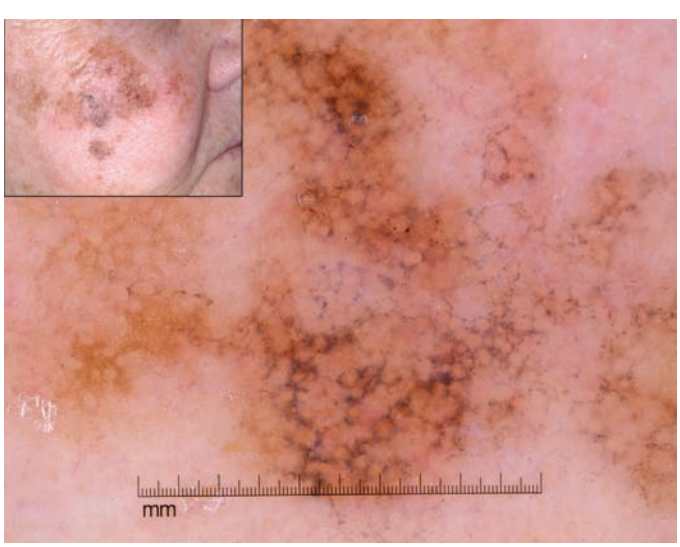

FIGURE C-35 Lentigo maligna on the face with rhomboidal structures. (*Copyright of Ashfaq Marghoob, MD.*)

STEP 2 FOR MELANOCYTIC LESIONS

Three possible pathways (**Figure C-36**):

1. The lesion adheres to one of the benign nevus patterns (**Figures C-13** to **C-22**). Reassure the patient that the lesion is a benign nevus.
2. The lesion:
   A. Adheres to one of the benign nevus patterns but also displays at least one of the melanoma specific structures.
   B. Does not adhere to one of the benign nevus patterns and does not have any of the melanoma specific structures.

   This is an indeterminate or suspicious lesion. The choices include: Perform a biopsy now or perform short-term mole monitoring with dermoscopic photographs and a 3-month followup. (Caveat: Do not monitor a raised lesion because a nodular melanoma can grow quickly with a worsened prognosis in a short time.)
3. The lesion deviates from the benign nevus patterns and has at least one melanoma specific structure (**Figures C-24** to **C-33**).

Biopsy this lesion as a suspected melanoma (see Chapter 172, Melanoma).

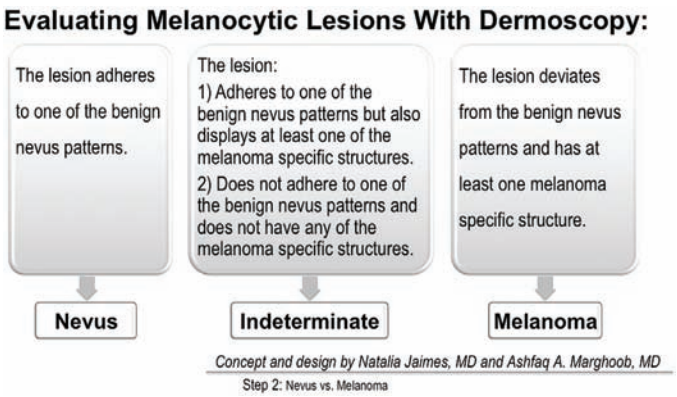

FIGURE C-36 Evaluating melanocytic lesions with dermoscopy.

STEP 1 FOR NONMELANOCYTIC TUMORS

If the lesion is not of melanocytic origin then one needs to look for structures seen in:

- Dermatofibromas
- Basal cell carcinomas
- Seborrheic keratoses
- Hemangiomas

DERMATOFIBROMA

a. Peripheral delicate fine network (**Figure C-37**)
b. Central scar-like area (**Figure C-37**)
c. Blood vessels within the scar-like area (**Figure C-38**)
d. Ring-like globular structures (**Figure C-39**)

FIGURE C-37 Peripheral delicate fine network with a central scar-like area are visible in this typical dermatofibroma. (*Courtesy of Richard P. Usatine, MD.*)

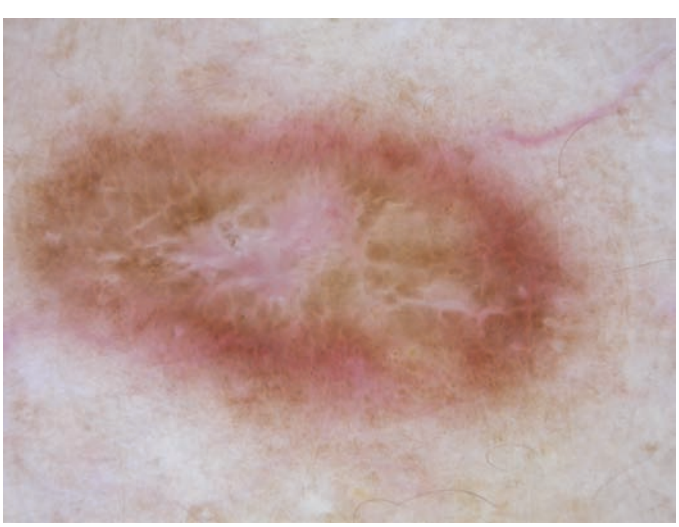

FIGURE C-38 Blood vessels are visible in the scar-like area of the dermatofibroma. (*Courtesy of Richard P. Usatine, MD.*)

FIGURE C-39 Ring like globular structures are visible in the central scar-like area of the dermatofibroma. (*Courtesy of Ashfaq Marghoob, MD.*)

BASAL CELL CARCINOMA

a. Arborizing vessels (**Figure C-40**)
b. Spoke-wheel-like structures/concentric structures (**Figure C-41**)
c. Leaf-like areas (**Figure C-42**)
d. Large blue-gray ovoid nest (**Figure C-41**)
e. Multiple blue-gray globules (**Figure C-42**)
f. Ulceration (**Figure C-43**)
g. Shiny white structures (crystalline structures) (**Figure C-43**)

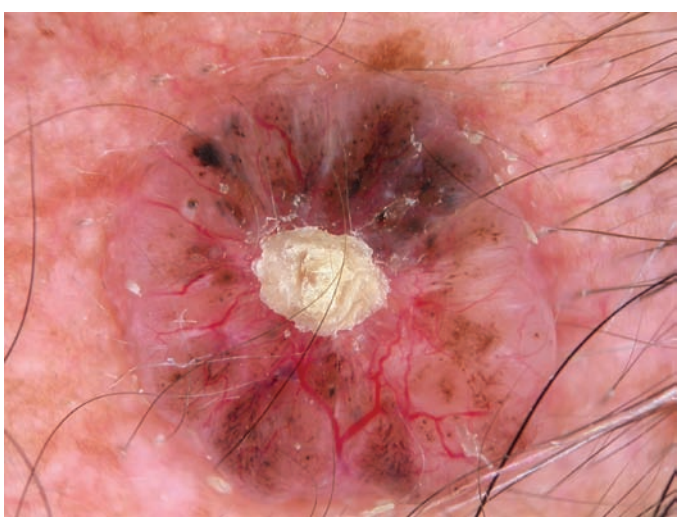

FIGURE C-40 Arborizing blood vessels like branching trees in a basal cell carcinoma. (*Courtesy of Richard P. Usatine, MD.*)

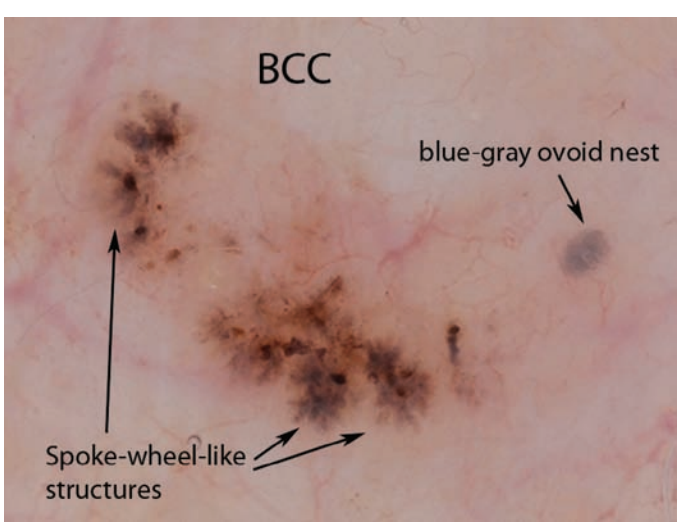

FIGURE C-41 Spoke-wheel-like structures and isolated blue-gray ovoid nest on the left of this basal cell carcinoma. (*Copyright of Ashfaq Marghoob, MD.*)

BASAL CELL CARCINOMA

a. Arborizing vessels (**Figure C-40**)
b. Spoke-wheel-like structures/concentric structures (**Figure C-41**)
c. Leaf-like areas (**Figure C-42**)
d. Large blue-gray ovoid nest (**Figure C-41**)
e. Multiple blue-gray globules (**Figure C-42**)
f. Ulceration (**Figure C-43**)
g. Shiny white structures (crystalline structures) (**Figure C-43**)

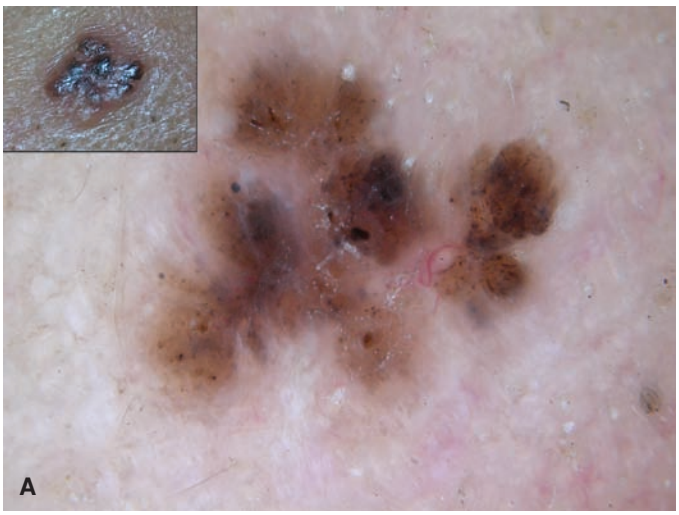

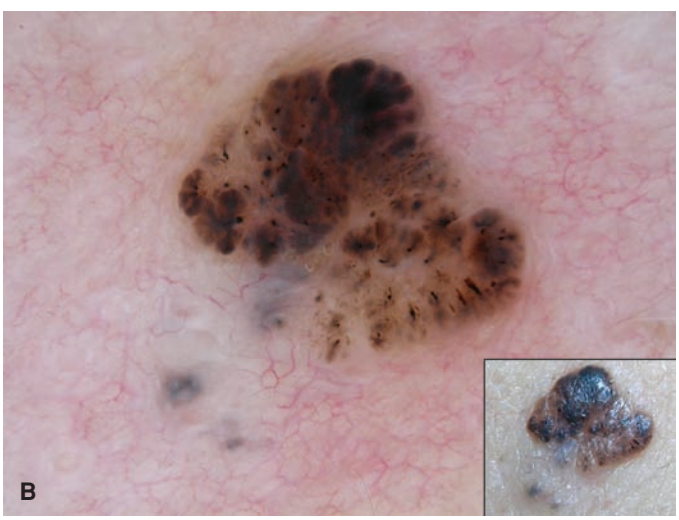

FIGURE C-42 **A.** Leaf-like structures in a pigmented basal cell carcinoma. **B.** Leaf-like structures and blue-gray ovoid nest in bottom left hand corner. (*Courtesy of Richard P. Usatine, MD.*)

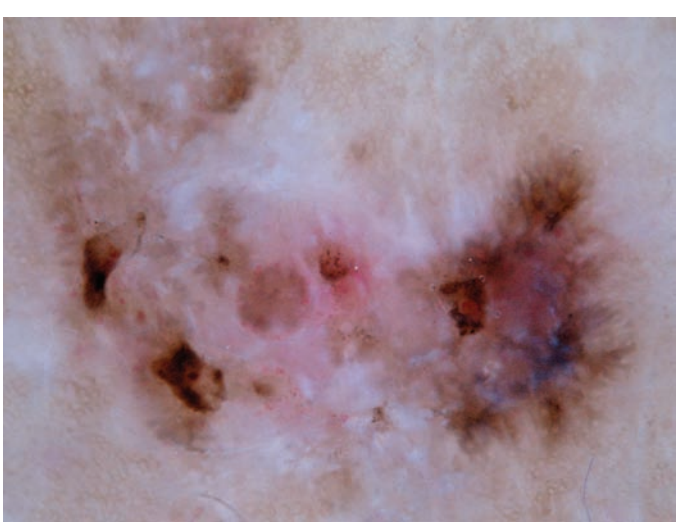

FIGURE C-43 Shiny white structures visible in this basal cell carcinoma. Also called chrystalline and chrysalis structures. (*Copyright of Ashfaq Marghoob, MD.*)

SEBORRHEIC KERATOSIS

a. Multiple (greater than 2) milia-like cysts (**Figure C-44**)

b. Comedo-like openings (**Figure C-45**)

c. Gyri and sulci (fat finger-like structures) (**Figure C-46**) and cerebriform (**Figure C-47**)

d. Fingerprint-like structures (**Figure C-48**)

e. Moth-eaten borders (**Figure C-48**)

f. Additional features: sharp demarcation; negative wobble sign (the lesion slides).

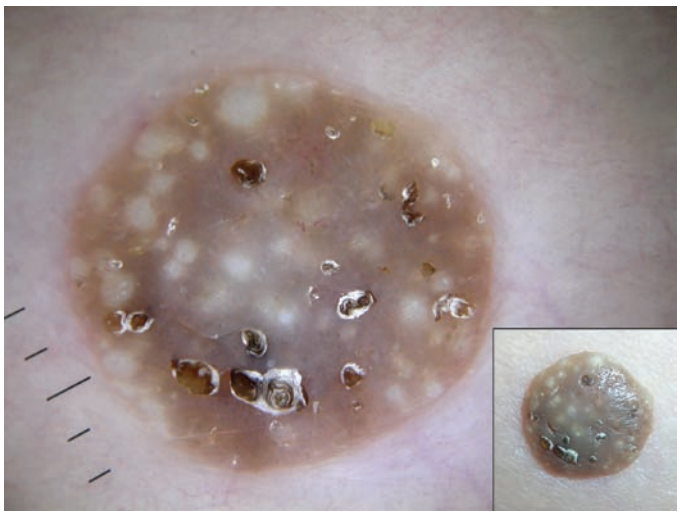

FIGURE C-44 Seborrheic keratosis with milia-like cysts and comedo-like openings. (*Copyright of Richard P. Usatine, MD.*)

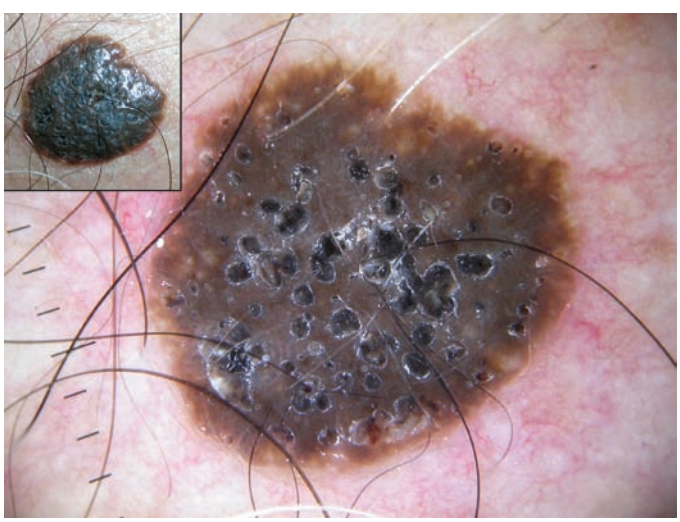

FIGURE C-45 Many comedone-like openings are visible in this seborrheic keratosis. (*Courtesy of Richard P. Usatine, MD.*)

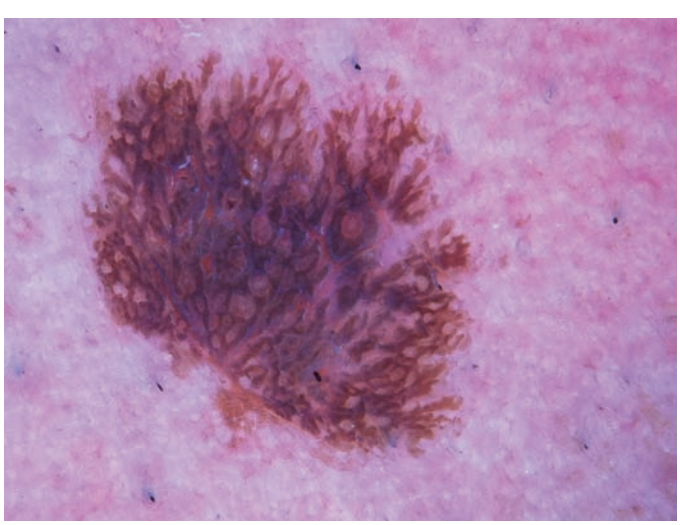

FIGURE C-46 Fat fingers are visible in this seborrheic keratosis. (*Courtesy of Richard P. Usatine, MD.*)

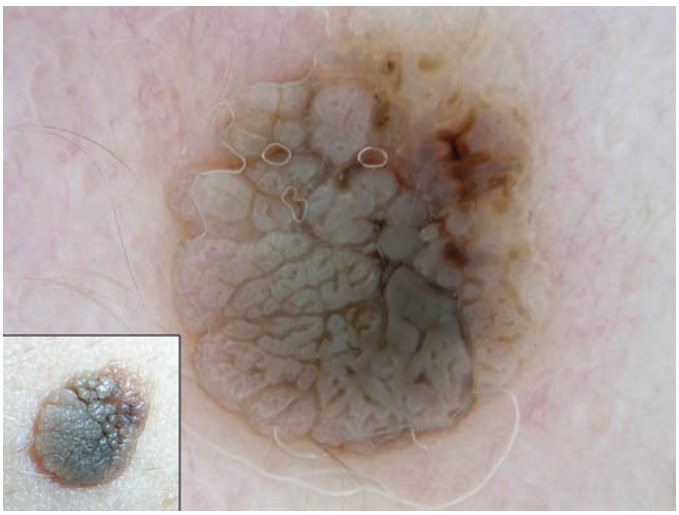

FIGURE C-47 Cerebriform seborrheic keratosis with gyri and sulci. (*Courtesy of Richard P. Usatine, MD.*)

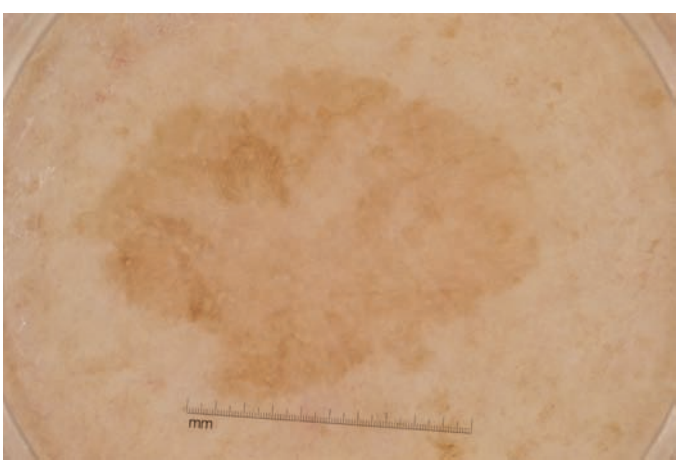

FIGURE C-48 Note the moth-eaten borders and fingerprint-like structures visible in this early seborrheic keratosis forming from any solar lentigo. (*Copyright of Ashfaq Marghoob, MD.*)

HEMANGIOMA

a. Red lacunae (**Figure C-49**)

b. Blue lacunae (**Figure C-50**)

c. Black lacunae = angiokeratoma (**Figure C-51**)

FIGURE C-49 Hemangioma showing red lacunae (lakes or lagoons of sharply demarcated vascular tissue). (*Courtesy of Richard P. Usatine, MD.*)

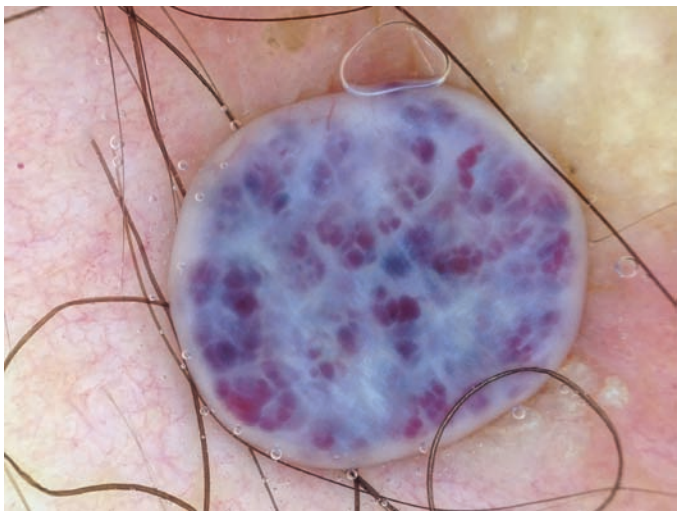

FIGURE C-50 Hemangioma with red and blue lacunae. (*Copyright of Ashfaq Marghoob, MD.*)

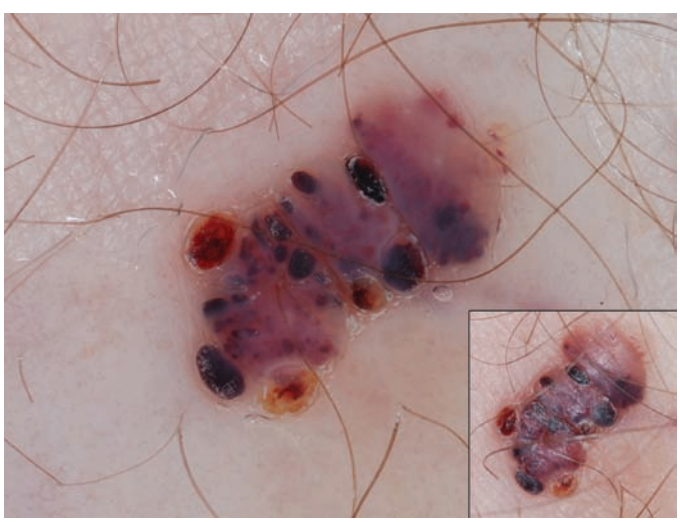

FIGURE C-51 Angiokeratoma showing purple and black lacunae. (*Copyright of Ashfaq Marghoob, MD.*)

Note that dermoscopy can be helpful in detecting the scabies mite without having to scrape and use the microscope (**Figure C-52**; see Chapter 143, Scabies).

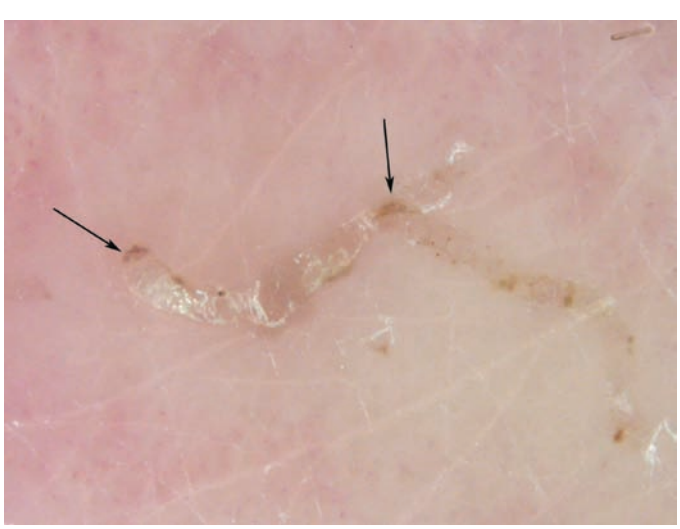

FIGURE C-52 Scabies mites (arrows) visible at the end of 2 intersecting burrows. The head and legs are most visible and resemble arrowheads pointing away from the burrows. (*Courtesy of Richard P. Usatine, MD.*)

VASCULAR STRUCTURES

Levels 5 and 6 (**Figures C-53** and **C-54**) in step 1 involve evaluating vascular structures in nonmelanocytic and melanocytic tumors. For further information about this more advanced steps see the resources below.

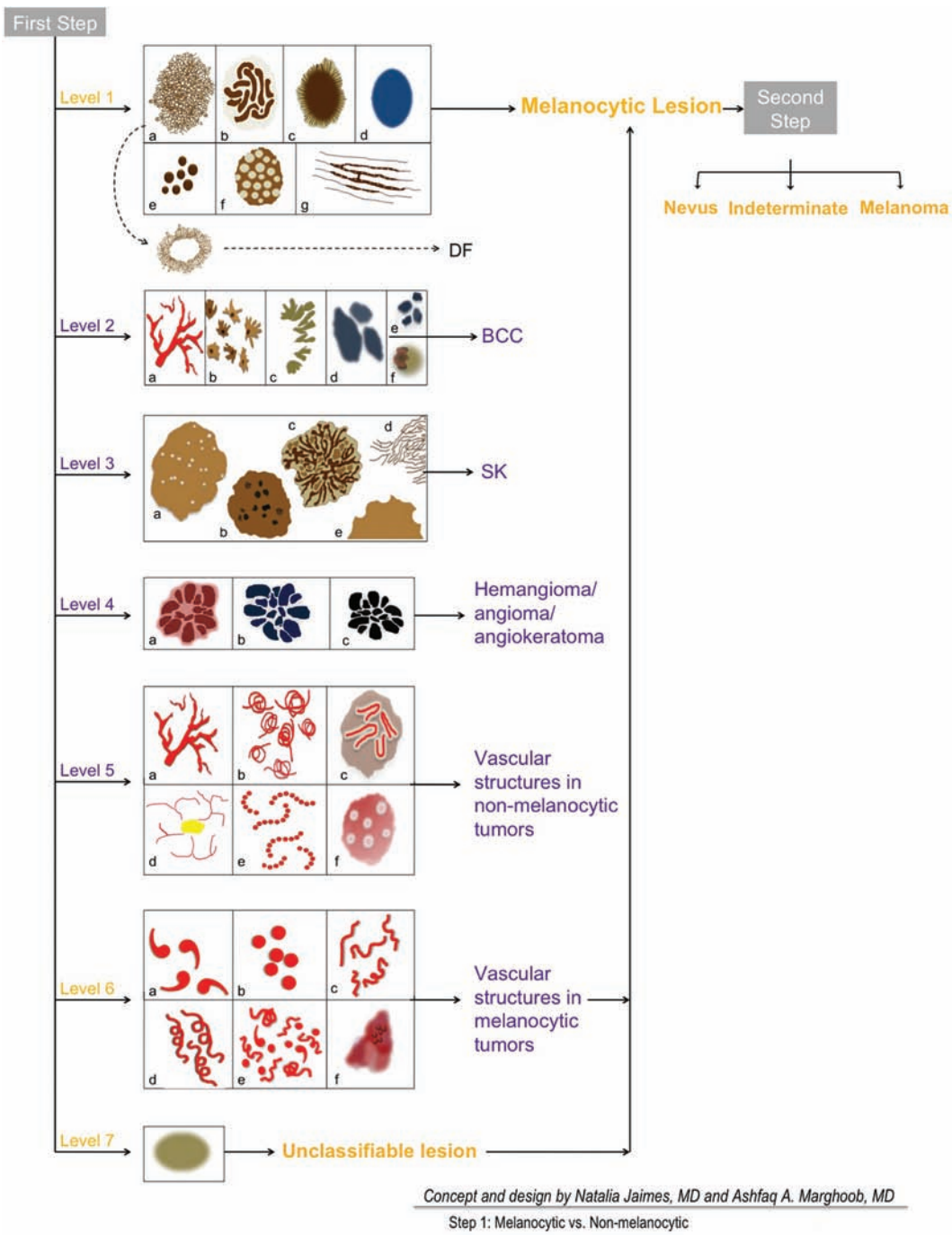

FIGURE C-53 Seven levels are part of the 2-step algorithm. See Figure C-54 for an explanation of the letters and structures in this flow diagram.

Step 1: Melanocytic versus Non-melanocytic lesions						
Level 1: Melanocytic lesions	**Level 2: Basal cell carcinoma (BCC)**	**Level 3: Seborrheic keratosis (SK)**	**Level 4: Hemangioma (HG)/ angioma/ angiokeratoma**	**Level 5: Blood vessels in non-melanocytic tumors***	**Level 6: Blood vessels in melanocytic tumors***	**Level 7: Unclassifiable lesions**
a. Pigment network* b. Negative network c. Streaks d. Homogeneous blue pigmentation e. Aggregated globules f. Pseudonetwork (Facial skin) g. Parallel pigment pattern (Acral lesions) h. * Exception to pigment network: Dermatofibroma (DF)	a. Arborizing vessels b. Spoke wheel-like structures / concentric structures c. Leaf-like areas d. Large blue-gray ovoid nests e. Multiple blue-gray globules f. Ulceration g. Additional clues: Shiny white structures	a. Multiple (>2) milia-like cysts b. Comedo-like opening c. Gyri and sulci (Fat finger-like structures) d. Fingerprint-like structures e. Moth-eaten borders f. Additional features: sharp demarcation; negative wobble sign: the lesion slides	a. Red lacunae b. Blue lacunae c. Black lacunae	**Morphology** a. Arborizing vessels b. Glomerular vessels c. Hairpin vessels with white halo **Arrangement** d. Crown e. Serpiginous or string of pearls f. "Strawberry" pattern g. Focal clusters at the periphery **Distribution** • Focal • Diffuse • Central • Peripheral • Random ***Usually seen in** a. BCC b. Squamous cell carcinoma (SCC) c. SK/ Keratoacanthoma d. Sebaceous hyperplasia (SH) e. Clear cell acanthoma (CCA) f. Actinic keratosis	**Morphology** a. Comma vessels b. Dotted vessels c. Serpentine vessels (linear irregular) d. Corkscrew vessels e. Polymorphous vessels f. Milky-red area **Distribution** • Focal • Diffuse • Central • Peripheral • Random ***Usually in:** a. Intradermal nevi b – f .Melanoma	**None of the structures from levels 1 to 6 are noted**

Concept and design by Natalia Jaimes, MD and Ashfaq A. Marghoob, MD

Step 1: Melanocytic vs. Non-melanocytic

FIGURE C-54 Explanation of the flow diagram in figure C-53.

RESOURCES TO LEARN MORE DERMOSCOPY

Dermoscopy. Website from Italy that includes a free dermoscopy tutorial—http://www.dermoscopy.org/

International Dermoscopy Society, http://www.dermoscopy-ids.org/.

Johr R, Stolz W. *Dermoscopy: An Illustrated Self-Assessment Guide*. New York, NY: McGraw-Hill; 2010, with an interactive app: see www.usatinemedia.com.

Malvehy J, Puig S, Braun, RP, Marghoob, AA, Kopf AW. *Handbook of Dermoscopy*. London, UK: Taylor & Francis; 2006.

Marghoob AA, Braun R, Kopf AW, eds. *Atlas of Dermoscopy*. London, UK: Parthenon Publishing; 2004.

Marghoob A, Braun R, Kopf A. *Interactive CD-ROM of Dermoscopy*. London, UK: Informa Healthcare; 2007.

Marghoob A, Usatine R. Dermoscopy. In: Usatine R, Pfenninger J, Stulberg D, Small R, eds. *Dermatologic and Cosmetic Procedures in Office Practice*. Philadelphia, PA: Elsevier; 2012.

The American Academy of Family Physicians (AAFP) yearly fall scientific assembly now offers a dermoscopy workshop taught by the authors of this chapter.

Also every summer the AAFP sponsors a course on "Skin Problems and Diseases" that includes a dermoscopy workshop taught by the authors of this chapter.

Note: In this index, the letters "f" and "t" denote figures and tables, respectively.

A

ABCDE guidelines, for melanoma, 949–950, 1009–1010, 1010f
Abdominal aortic aneurysm, *vs.* kidney stones, 427
Abdominal circumference (AC), fetal, on second trimester ultrasound, 478–480, 479f
Abdominal infections. *See also specific types*
  vs. bacterial endocarditis, 290
Abortion, 17
  first trimester ultrasound for, 475–477
  medical, 21
  patient education on, 22
  surgical, 21, 22
Abruptio placentae, ultrasound for
  second trimester, 479
  third trimester, 482
Abscess, 698–700
  breast, 546–549
  definition of, 698
  diagnosis of, 698f–700f, 699
  differential diagnosis of
    vs. acne cysts, 699
    vs. cellulitis, 699
    vs. epidermal inclusion cyst, 699, 700f
    vs. furuncles and carbuncles, 699
    vs. hemorrhoids, 416, 416f
    vs. hidradenitis suppurativa, 699
  epidemiology of, 698
  etiology and pathophysiology of, 698, 698f, 699f
  follow-up of, 700
  management of, 699–700, 699f
  patient education on, 700
  patient story of, 698, 698f
  peritonsillar, in pharyngitis, 214, 214f
  tuboovarian, 20
Absolute risk reduction (ARR), 1448
Abstinence periodic sexual, 13t
Abuse
  child physical, 82–87 (*See also* Child physical abuse)
  intimate partner, 95–100 (*See also* Intimate partner violence (IPV))
  sexual
    adult, 102–107 (*See also* Sexual assault, adult)
    child, 89–93 (*See also* Sexual abuse, child)
  substance (*See* Substance abuse disorder; *specific drugs*)
Acantholysis, in pemphigus, 1112, 1113
Acanthosis nigricans, 922, 922f, 1310–1313
  definition of, 1310
  with diabetes, 1302, 1302f
  diagnosis of, 858f, 1310f–1313f, 1311
  differential diagnosis of
    vs. actinic keratosis, pigmented, 1311
    vs. erythema ab igne, 1200–1201
    vs. seborrheic keratosis, 1311
  epidemiology of, 1310
  etiology and pathophysiology of, 1310
  management of, 1311–1312, 1313f
  with obesity, 1329, 1329f, 1331, 1332f
  patient education on, 1312
  patient story of, 1310, 1310f
  prognosis in, 1312
Accessory ossicles
  vs. apophysis, 613
  vs. metatarsal fracture, 613
Access to health care, universal, 39–41, 39f–42f
Accidents
  epidemiology of, 26
  on mortality, 26
  motor vehicle, on mortality, 26
Acetowhite changes on colposcopy
  of high-grade lesions, 535–536, 535f, 537f
  of low-grade disease, 530–533, 530f, 531f
Acidosis, metabolic, *vs.* heart failure, 278
Acne, neonatal, 630–634. *See also* Skin changes, normal pediatric
  definition of, 630, 630f
  diagnosis of, 630f, 632
  differential diagnosis of
    vs. miliaria, 633, 633f
    vs. neonatal pustular melanosis, 633
  etiology and pathophysiology of, 631
  management of, 634
  parent education on, 634
  prognosis in, 634
Acne conglobata, *vs.* acne vulgaris, 652, 653f
Acne cysts, *vs.* abscess, 699
Acne fulminans, *vs.* acne vulgaris, 652, 654f. *See also* Acne vulgaris
Acne inversa, 671–674, 671f–675f. *See also* Hidradenitis suppurativa
Acne keloidalis, 680, 681f, 682f
Acne keloidalis nuchae, 665–669, 681, 681f, 682f
  diagnosis of, 665f–667f, 666
  differential diagnosis of
    vs. acne vulgaris, 652, 667
    vs. folliculitis, 667
    vs. impetigo, 667
    vs. keloids, 1225, 1226f
    vs. sarcoidosis, 1039
    vs. self-inflicted dermatoses, 860
  epidemiology of, 665, 666f, 667f
  etiology and pathophysiology of, 665–666
  follow-up for, 669
  management of, 667–668
  patient education on, 669
  patient story of, 665, 665f
  prevention of, 668
  prognosis in, 668
  risk factors for, 666
  scarring alopecia in, 1140, 1141f
Acne neonatorum, 630–634. *See also* Acne, neonatal
Acne rosacea, 659–664. *See also* Rosacea
Acne vulgaris, 651–657
  diagnosis of, 652, 653f
  differential diagnosis of
    vs. acne conglobata, 652, 653f
    vs. acne fulminans, 652, 654f
    vs. acne keloidalis nuchae, 652, 667
    vs. actinic comedones, 654, 655f
    vs. folliculitis, 652, 684
    vs. pseudofolliculitis, 667
    vs. rosacea, 652, 655f, 661
  epidemiology of, 651
  etiology and pathophysiology of, 651, 652f, 653f

Acne vulgaris (*Continued*)
follow-up of, 657
fundamentals of, 651
management of, 654–657
combination therapies in, 656
complementary and alternative therapy in, 655, 656f
cortisone injection for, 1453f
intense pulsed light and photodynamic therapy in, 657
medication cost in, 657
medications in, 654–655, 656f
therapy by severity in, 653f, 654f, 655–656
patient education on, 657
patient story of, 651, 651f, 652f
Acquired ichthyosis, *vs.* X-linked ichthyosis, 1233, 1234f
Acquired immunodeficiency syndrome (AIDS). *See also* Human immunodeficiency virus (HIV) infection
death from, 27
Kaposi sarcoma in, 1285–1288 (*See also* Kaposi sarcoma)
on mortality, 26
Acrochordon. *See* Skin tag (acrochordon)
Acrodermatitis enteropathica, 648, 648f
from zinc deficiency, 62–63, 63f
Acrolentiginous melanoma, 1012, 1012f, 1153f. *See also* Melanoma
vs. corns and calluses, 1243–1244
dermoscopy of, 1464f
Acromegaly, 1360–1364
acanthosis nigricans in (*See* Acanthosis nigricans)
diagnosis of, 1360f–1362f, 1361
epidemiology of, 1360
etiology and pathophysiology of, 1360
follow-up of, 1363–1364
management of, 1361–1363
patient education on, 1364
patient story of, 1360, 1361f, 1362f
prognosis in, 1363
Acromioclavicular (AC) separation, 602, 603f
vs. clavicle fracture, 602, 602t, 603f
Acropustulosis, 642–644
diagnosis of, 642f, 643–644, 643f
differential diagnosis of
vs. cutaneous candidiasis, 644
vs. erythema toxicum neonatorum, 644
vs. hand, foot, and mouth disease, 644
vs. herpes, 644
vs. impetigo, 644
vs. psoriasis, pustular, 644
vs. scabies, 644
vs. varicella, 644
epidemiology of, 642
etiology and pathophysiology of, 642–643
fundamentals of, 642
of infancy, 1102
vs. scabies, 821, 821f
management of, 644
patient education on, 644
patient story on, 642, 642f
prognosis and follow-up of, 644
Actinic cheilitis, 969–975, 969f. *See also* Actinic keratosis
Actinic comedones, *vs.* acne vulgaris, 654, 655f
Actinic keratosis, 969–975, 999, 999f
diagnosis of, 969f–971f, 970
differential diagnosis of
vs. acanthosis nigricans, 1311
vs. basal cell carcinoma, 972
vs. basal cell carcinoma, superficial, 995
vs. common warts, 751
vs. eczema, nummular, 970, 972
vs. keratoacanthomas, 978
vs. lupus erythematosus, 1072
vs. seborrheic keratosis, 929, 972
vs. squamous cell carcinoma, 1005
epidemiology of, 969
etiology and pathophysiology of, 969–970
follow-up of, 975
fundamentals of, 687, 969
management of, 972–973, 972f, 972t, 973f
patient education on, 975
patient story of, 969, 969f
prevention of, 974
prognosis in, 975
risk factors for, 970
squamous cell carcinoma from, 999, 1002f, 1003f, 1005
Actinic superficial folliculitis, 682
Actinobacillus bacterial endocarditis, 288
Active empathic listening, 9
Acute angle-closure glaucoma. *See* Glaucoma, acute-angle closure
Acute febrile neutrophilic dermatosis, *vs.* pyoderma gangrenosum, 1031, 1032f
Acute generalized exanthematous pustulosis (AGEP), 1219, 1220f
Acute necrotizing ulcerative gingivitis, 236–238, 237f
Acute otitis media (AOM), 170–176
diagnosis of, 172–173
differential diagnosis of, 173–174, 174f–177f
vs. bullous myringitis, 173, 175f
vs. cholesteatoma, 173, 174f
vs. chronic suppurative otitis media, 173
vs. foreign body, ear, 173, 186
vs. mastoiditis, 173, 176f
vs. otalgia, referred, 173
vs. otitic barotrauma, 173
vs. otitis externa, 173, 182
vs. otitis media with effusion, 173
vs. tympanic membrane perforation, traumatic, 173, 177f
epidemiology of, 170–171
etiology and pathophysiology of, 171
follow-up for, 176
fundamentals of, 170
management of, 174–175
patient education on, 177
patient story of, 170, 170f
prevention of, 176, 177f, 178f
prognosis in, 176
risk factors for, 171
Addiction, 1392. *See also* Substance abuse disorder; *specific types*
drug, 26
etiology and pathophysiology of, 1393–1394
risk factors for, 1394
tobacco, 1398–1409 (*See also* Tobacco addiction)
Adenocarcinoma
cervical, 541–544, 541f–543f (*See also* Cervical cancer)
lung, 355–363 (*See also* Lung cancer)
mouth, 254, 256f (*See also* Oropharyngeal cancer)
Adenoid cystic carcinoma, *vs.* squamous cell carcinoma, 207, 207f
Adenoma sebaceum, *vs.* neurofibromatosis, 1388, 1390f
Adenomatous polyp, 393–397. *See also* Colon polyps

Adenomatous polyposis coli *(APC)* gene mutation, 393, 395, 396
Adenovirus
conjunctivitis from, 126–129
urethritis in men from, 1275–1277
Adnexal masses, large uterine, 20
Adrenal adenoma, *vs.* cocaine abuse, 1435
Adrenal hyperplasia, *vs.* cocaine abuse, 1435
Adriamycin, reactions from, 1211–1222, 1213f. *See also* Drug reactions, cutaneous
Adult education, peer-to-peer, 55
Advance care planning, 29–30
Advance directives, 29–30
Advocacy, for universal access to health care, 39–41, 39f–42f
Age-related macular degeneration (AMD), 155–158
diagnosis of, 155f, 156–157, 156f
differential diagnosis of, 157
vs. cataract, 157
vs. diabetic retinopathy, 157
vs. glaucoma, 157
epidemiology of, 155
etiology and pathophysiology of, 155–156
fundamentals of, 155
management of, 157
patient education on, 158
patient story of, 155, 155f
prevention of, 158
prognosis and follow-up of, 158
risk factors for, 156
AIDS, 1285–1288. *See also* Kaposi sarcoma
Airway obstruction, *vs.* asthma, 326
Albendazole, 59
Alcohol abuse. *See also* Substance abuse disorder
chronic, *vs.* normal pressure hydrocephalus, 1381
on mortality, 26
substance abuse and, 1393
Alcohol dependence. *See* Alcoholism
Alcohol disorder. *See* Alcoholism
Alcohol elimination, in pregnancy, 23
Alcoholic hepatitis, 377–384. *See also* Liver disease
Alcoholism, 1411–1423
diagnosis of
clinical features in, 1413–1416, 1413t, 1414b, 1415f
imaging in, 1416
laboratory testing in, 1415f, 1416
typical distribution of, 1411f, 1416
differential diagnosis of, 1416
epidemiology of, 1411–1412, 1411f
etiology and pathophysiology of, 1412
follow-up of, 1420–1421
fundamentals of, 1411
liver disease from, 377–384 (*See also* Liver disease)
management of, 1416–1418, 1416t
complementary and alternative therapy in, 1418
medications in, 1417–1418
nonpharmacologic, 1416–1417
referral and hospitalization in, 1418
patient education on, 1419f, 1423
patient story of, 1411
prevention of, 1416t, 1418, 1419f
prognosis in, 1420, 1420f
risk factors for, 1412–1413
terminology for, 1411
Alkaptonuria, eye manifestations, 120
Allergens. *See also specific types and disorders*
in hand eczema, 845
Allergic contact dermatitis, 834–841. *See also* Contact dermatitis
Allergic dermatitis. *See also* Contact dermatitis
vs. scarlet fever, 210
Allergic granulomatosis, *vs.* vasculitis, 1068
Allergic reaction. *See also* Hypersensitivity syndromes
contact (*See* Contact dermatitis)
differential diagnosis of
vs. cellulitis, 694, 696f
vs. fifth disease, 730
Allergic rhinitis, *vs.* sinusitis, 200
Allergic shiners, 85
Allergic triad, 324, 324f
Alopecia
drug-induced, *vs.* scarring alopecia, 1141
postpartum, 464, 464f
Alopecia, androgenetic
differential diagnosis of
vs. scarring alopecia, 1141
vs. traction hair loss and trichotillomania, 1135
in pregnancy, 464
Alopecia, scarring, 1138–1143
classification of, 1138, 1139t
diagnosis of, 1138f–1141f, 1139–1140
differential diagnosis of
vs. alopecia areata, 1141
vs. androgenetic alopecia, 1141
vs. drug-induced alopecia, 1141
vs. metabolic and nutritional problems, 1141
vs. sarcoidosis of scalp, 1141
vs. seborrheic dermatitis, 1141
vs. syphilis, secondary, 1141
vs. telogen effluvium, 1141
vs. tinea capitis, 785, 1141
vs. tractional alopecia, 1135, 1141
vs. trichotillomania, 1135, 1141
epidemiology of, 1138
follow-up of, 1143
fundamentals of, 1138
management of, 1141–1143
pathophysiology of, 1138
patient education on, 1143
patient story of, 1138, 1138f
Alopecia areata, 1128–1132
diagnosis of, 1128f–1131f, 1129
differential diagnosis of
vs. anagen effluvium, 1129
vs. follicular mucinosis, 1130, 1131f
vs. lupus erythematosus, 1130
vs. psoriatic nails, 1172
vs. scarring alopecia, 1141
vs. syphilis, secondary, 1129
vs. telogen effluvium, 1129
vs. tinea capitis, 785, 1129
vs. tractional alopecia, 1134–1135
vs. trichotillomania, 1129, 1134–1135
epidemiology of, 1128
etiology and pathophysiology of, 1128
follow-up of, 1129f, 1131
fundamentals of, 1128

Alopecia areata (*Continued*)
management of, 1130–1131, 1132f, 1454f
patient education on, 1131
patient story of, 1128, 1128f
prognosis in, 1131
risk factors for, 1129
Alopecia totalis, 1128, 1128f
Alopecia universalis, 1128
α_1-Antitrypsin deficiency, COPD from, 335, 337, 340f
Alpha Home, 48f
Alzheimer disease, *vs.* normal pressure hydrocephalus, 1381
Amelanotic melanoma, 1012, 1013f, 1014f. *See also* Melanoma
differential diagnosis of
vs. common warts, 751
vs. Paget disease of external genitalia, 516
vs. plantar warts, 767
vs. pyogenic granuloma, 941–943, 942f
nodular, dermoscopy of, 1464f
Amenorrhea
conditions with, 20
in pregnancy (*See* Pregnancy)
Aminoglycosides, reactions from, 1211–1222
Amiodarone, reactions from, 1211–1222
Amoxicillin, reactions from, 1211–1222, 1211f
Amphetamine. *See* Injection-drug use; Methamphetamine; Substance abuse disorder
Ampicillin, reactions from, 1216t
Amyloidosis of skin, *vs.* scleroderma, 1094
Anabolic steroid abuse, injection. *See also* Injection-drug use; Substance abuse disorder
diagnosis of, 1441–1442, 1441f–1443f
epidemiology of, 1440, 1440f
etiology and pathophysiology of, 1440, 1440f
Anaerobic vaginosis, 494–497. *See also* Bacterial vaginosis (BV)
Anagen effluvium, *vs.* alopecia areata, 1129
Anal bruising, in child sexual abuse, 91
Anal fissure
vs. child sexual abuse, 92
vs. colon polyps, 395–396
vs. hemorrhoids, 416, 416f
Anal laceration, in child sexual abuse, 91, 91f
Anal tumor. *See also* Colon cancer
vs. hemorrhoids, 416
Ancylostoma braziliense, 823. *See also* Cutaneous larva migrans
Ancylostoma caninum, 823. *See also* Cutaneous larva migrans
Androgenetic alopecia
differential diagnosis of
vs. scarring alopecia, 1141
vs. traction hair loss and trichotillomania, 1135
in pregnancy, 464
Aneuploidy, first trimester ultrasound for, 476
"Angel's kisses," 638, 1209f. *See also* Hemangioma, childhood
vs. childhood hemangioma, 638, 638f
vs. vascular lesions, hereditary and congenital, 1209, 1209f
Angioedema, 863–869
definition of, 863
diagnosis of, 864–865, 864f, 867f, 868f
in drug-related angioedema, 1212f, 1218
differential diagnosis of, *vs.* mast cell releasability syndromes, 864f–866f, 866
epidemiology of, 863
etiology and pathophysiology of, 863–864, 865f
follow-up of, 869
hereditary, 864, 865f
management of, 866–869
patient education on, 869
Angiofibroma
vs. nasal polyps, 195
vs. neurofibromatosis, 1388, 1390f
Angiokeratoma, 1203–1206, 1204f
cutaneous (*See* Vascular lesions, acquired)
diagnosis of, dermoscopy in, 1469, 1470f
Angioma
cherry, 1203–1206, 1203f
vs. Kaposi sarcoma, 1287
spider, in pregnancy, 462–463
Angiosarcoma, 1203–1206, 1205f
cutaneous (*See* Vascular lesions, acquired)
differential diagnosis of
vs. childhood hemangioma, 638
vs. vascular lesions, acquired adult, 1206
Angiotensin-converting enzyme (ACE) inhibitors, reactions from, 1211–1222
Angle-closure glaucoma, 139–142, 140f. *See also* Glaucoma, acute-angle closure
Angular cheilitis, 203–205, 203f–205f, 777, 778, 778f
differential diagnosis of
vs. herpes simplex, 204
vs. impetigo, 204
from smoking, 1400, 1400f
Angular cheilosis, 203–205, 203f–205f
Angular stomatitis, 203–205, 203f–205f
Ankylosing spondylitis, 580–583
diagnosis of, 580f, 581, 581f
imaging in, 566
typical distribution in, 563
differential diagnosis of
vs. arthritis, 568t
vs. back pain, 587
vs. herniated disc, 582
vs. kidney diseases, 582
vs. lumbar strain or muscle spasm, 581
vs. osteoarthritis, 582
vs. osteoporosis and osteopenia, 1342
vs. pancreatitis, 582
vs. psoriatic spondyloarthritis, 582, 582f
vs. spondyloarthritides, other, 582
vs. vertebral fracture, 582
epidemiology of, 580
etiology and pathophysiology of, 580
follow-up of, 582–583
fundamentals of, 580
management of, 582
patient education on, 583
patient story on, 580, 580f
prognosis in, 582
risk factors for, 580
uveitis in, 135, 136
Anogenital irritation/bleeding. *See also* Rectal bleeding
vs. child sexual abuse, 92, 93f
Anogenital warts. *See* Warts, genital
Anterior cruciate ligament (ACL) tear, 619–624. *See also* Knee soft tissue injuries
Anterior drawer test, 621
Anterior uveitis, from zoster ophthalmicus, 718–722, 718f
Antiarrhythmics, reactions from, 1211–1222

Antibiotics, reactions from, 1211–1222
Anxiety, *vs.* heart failure, 278
Anxiety disorder
after sexual assault, 107
vs. substance abuse disorder, 1396
Aortic aneurysm, abdominal, *vs.* kidney stones, 427
Aphthous stomatitis, 244–248. *See also* Aphthous ulcer
vs. hand, foot, and mouth disease, 733
Aphthous ulcer, 244–248, 244f, 245f
diagnosis of, 245–246, 245f
differential diagnosis of, 246, 246f
vs. Behçet's syndrome, 245f, 246, 246f
vs. candidiasis, 246
vs. erosive lichen planus, 246
vs. erythema multiforme, 246
vs. gingivostomatitis, 246
vs. hand, foot, and mouth disease, 246
vs. herpangina, 246
vs. herpes simplex virus, 246
vs. lichen planus, erosive, 246
vs. oral cancer, 246
epidemiology of, 244
etiology and pathophysiology of, 244–245
fundamentals and synonyms for, 244
management of, 246–248
patient education on, 248
patient story of, 244, 244f, 245f
prevention of, 248
risk factors for, 245
Apophysis, 613
Appendicitis
vs. colon cancer, 400
vs. kidney stones, 427
Areola
benign lichenoid keratosis of, 559, 560f
eczema of, *vs.* Paget disease of breast, 559, 559f
Arsenic toxicity, *vs.* pitted keratolysis, 687
Arterial spiders, in pregnancy, 462–463
Arterial ulcers, *vs.* venous insufficiency, 296
Arteriogram, coronary, 268, 268f
Arteriovenous malformation, *vs.* childhood hemangioma, 638
Arthritis, 562–568. *See also specific types*
diagnosis of
clinical features in, 563
imaging in, 566, 568f
laboratory testing in, 565–566
typical distribution in, 563–565, 563f–567f
differential diagnosis of
vs. bursitis, 566
vs. fibromyalgia, 566
vs. inflammatory myopathy or myositis, 566
vs. knee soft tissue injuries, 622
vs. osteoporosis and osteopenia, 1342
vs. polymyalgia rheumatica, 566
vs. tendinitis, 566
epidemiology of, 562
etiology and pathophysiology of
autoimmune, 562
crystalline, 563
in fibromyalgia, 563
noninflammatory, 562, 563f
postinfectious (reactive), 563
septic, 563
follow-up for, 567
fundamentals of, 562
gouty, 590–594 (*See also* Gout)
inflammatory
from Lyme disease, 1290–1291
vs. Lyme disease, 1293
management of, 566–567
osteoarthritis, 569–573, 569f–571f (*See also* Osteoarthritis)
patient education on, 567
patient story on, 562, 562f
prognosis in, 567
psoriatic (*See* Psoriatic arthritis)
reactive (*See* Reactive arthritis)
rheumatoid, 575–579, 575f–578f (*See also* Rheumatoid arthritis)
types of, comparison of, 568t
Arthropod bites
vs. pyoderma gangrenosum, 1031
vs. scabies, 821
Arthropod reaction, bullous, 1100, 1102f
Artificial hip, 616f
Asboe-Hansen sign, 1098, 1100, 1112
in pemphigus vulgaris, 1112
Ascaris, global health problem of, 59–60
Ascaris duodenale, 1270–1274
Ascaris lumbricoides, 1270–1274, 1271f
Ash leaf spots, *vs.* vitiligo, 1187, 1187f
Aspergillus niger, otitis externa from, 180
Aspirin
drug reactions from, 1211–1222
mouth burn from, *vs.* leukoplakia, 251
Asteatotic dermatitis, *vs.* nummular eczema, 854
Asteatotic eczema, *vs.* X-linked ichthyosis, 1233
Asthma, 320–331
diagnosis of, 323–326
clinical features in, 323–324, 324f, 325f
imaging in, 325–326, 327f
laboratory testing in, 321f, 324–325, 325f, 326f, 326t
differential diagnosis of
vs. airway obstruction, 326
vs. bronchitis, chronic, 326
vs. chronic obstructive pulmonary disease, 326, 338
vs. congestive heart failure, 327
vs. cough, drug-induced, 327
vs. pneumonia, 303, 304, 326
vs. tuberculosis, 326
vs. upper airway disease, 326
epidemiology of, 320–322
etiology and pathophysiology of, 322–323
follow-up of, 321f, 331
fundamentals of, 320
management of
medications in, 321f, 328–330
nonpharmacologic, 327–328, 328f
referral in, 330
patient education on, 331
patient story of, 320, 321f, 322t
pneumonia with, 301
prevention and screening in, 330
prognosis in, 330–331
risk factors for, 323
severity of, 325, 326t

Asylum seekers, 41–44, 42f, 43f
Ataxia telangiectasia, *vs.* neurofibromatosis, 1389
Atelectasis, in asthma, 326, 327f
Atherosclerotic disease, coronary heart disease from, 268–270, 268f, 269f
Athlete's foot, 799–804. *See also* Tinea pedis
Atlases, on internet, 3–4, 4t
Atopic dermatitis, 826–833
  cutaneous infection susceptibility with, 827, 827f, 828f
  definition of, 826
  diagnosis of, 826f–832f, 827, 831
  differential diagnosis of
    vs. contact dermatitis, 831, 836f, 839
    vs. dermatophyte infection, 831
    vs. dyshidrotic eczema, 831
    vs. eczema, nummular, 854
    vs. impetigo, 677, 679f
    vs. lichen simplex chronicus, 831
    vs. methamphetamine abuse, 1427
    vs. psoriasis, 831
    vs. scabies, 820, 831
    vs. seborrheic dermatitis, 831
    vs. self-inflicted dermatoses, 860
  eczema herpeticum with, 827, 827f
  eczema vaccinatum with, 827, 828f
  epidemiology of, 826, 827f
  etiology and pathophysiology of, 826–827, 827f, 828f
  eye findings in, 827, 831f
  follow-up of, 833
  hand (*See* Eczema, hand)
  impetigo with, 827
  keratoconus with, 827, 831f
  management of, 831–832, 833f, 833t
  patient education on, 833
  patient story of, 826, 826f
Atopic eczema, 826–833, 826f–833f. *See also* Atopic dermatitis
Atopic eruption of pregnancy, 463, 464, 464f
Atopic hand dermatitis. *See* Eczema, hand
Atopic triad, 324, 324f, 827, 831, 832f
Atrial fibrillation, cerebral vascular accident with, 1372
Atrioventricular blockage, from Lyme disease, 1291
At-risk drinkers, 1412, 1413t
Atrophic cervical epithelium
  colposcopy and diagnosis of, 527, 527f
  management of, 528
Atrophic vaginal epithelium
  colposcopy and diagnosis of, 527, 527f
  management of, 528
Atrophic vaginitis, 489–492
  diagnosis of, 489f, 490–491, 490f
  differential diagnosis of
    vs. contact dermatitis, 491
    vs. lichen sclerosus et atrophicus, 491, 491f
    vs. sexually transmitted diseases, 491
    vs. vaginal coinfection, 491
    vs. vulvovaginal lichen planus, 491
  epidemiology of, 489
  etiology and pathophysiology of, 489–490, 489f
  follow-up of, 492
  fundamentals of, 489
  management of, 491–492
  patient education on, 492
  patient story of, 489, 489f
  risk factors for, 490
Atypical moles. *See* Dysplastic nevus
Atypical nevus, 963–967, 963f–967f. *See also* Dysplastic nevus
AUDIT questionnaire, 1414, 1415f, 1416
Augmentin, reactions from, 1216t
Auspitz sign, 882
Autosensitization, tinea pedis, 799, 799f, 800
Autosomal-dominant polycystic kidney disease (ADPKD), 436–439. *See also* Polycystic kidneys
Avulsion fracture, metatarsal, 611–614. *See also* Metatarsal fracture
Axillary freckling, in neurofibromatosis, 1387, 1387f, 1388f

B

Baboon syndrome, 1219, 1220f
Baby bottle caries, 257–260. *See also* Caries, early childhood
Bacillary angiomatosis
  vs. Kaposi sarcoma, 1287, 1287f
  vs. pyogenic granuloma, 943
Back pain, 585–588
  diagnosis of, 586
  differential diagnosis of
    vs. abdominal pathology, 587
    vs. ankylosing spondylitis, 587
    vs. herniated disc, 587, 587f
    vs. malignancy, 587
    vs. osteoporotic vertebral fracture, 586, 586f
    vs. spinal infection/abscess, 587
    vs. spinal stenosis, 587
  epidemiology of, 585
  etiology and pathophysiology of, 585
  follow-up of, 588
  fundamentals of, 585
  management of, 587–588
  patient education on, 588
  patient story of, 585, 585f
  prevention of, 588
  prognosis in, 588
  risk factors for, 585–586
Bacterial endocarditis, 287–291. *See also* Endocarditis, bacterial
Bacterial folliculitis, 680–684, 680f–682f. *See also* Folliculitis
Bacterial infections. *See also specific bacteria and infections*
  blistering eruption from, 1100, 1102f
  differential diagnosis of
    vs. hidradenitis suppurativa, 672
    vs. intestinal worms and parasites, 1273
Bacterial vaginosis (BV), 485–487, 487t, 494–497
  after sexual assault, 105
  diagnosis of, 485f, 486f, 495–496, 495f, 496f
  differential diagnosis of
    vs. Candida vaginitis, 496
    vs. Candida vulvovaginitis, 501
    vs. chlamydia, 496
    vs. chlamydia cervicitis, 511
    vs. gonorrhea, 496
    vs. Trichomonas, 496, 506
  epidemiology of, 494
  etiology and pathophysiology of, 495
  follow-up of, 497
  fundamentals of, 494
  management of, 496–497, 497t
  patient education on, 497

patient story of, 494, 494f, 495f
prevention of, 497
risk factors for, 495
Bacteriuria, with urinary tract infection, 421
Bacteroides
necrotizing fasciitis from, 702
otitis externa from, 180
Balanitis, *Candida,* 777–780
diagnosis of, 777–778
differential diagnosis of, 778
epidemiology of, 777, 777f
etiology and pathophysiology of, 777
management of, 778–780
patient education on, 780
patient story of, 777, 777f
risk factors for, 777
Balanitis circinata, in reactive arthritis, 910–914, 911f. *See also* Reactive arthritis
Barbiturates
abuse of (*See* Injection-drug use; Substance abuse disorder)
drug reactions from, 1211–1222
Bardet-Biedl syndrome, obesity in, 1332
Barotrauma, otitic, *vs.* acute otitis and otitis media with effusion, 173
Barton fracture, 605–609, 607f. *See also* Radius fracture, distal
Basal cell carcinoma (BCC), 989–997
dermoscopy of
arborizing vessels in, 1466, 1466f
concentric structures in, 1466, 1466f
in diagnosis, 1466, 1467f
large blue-gray ovoid nest in, 1466, 1466f
leaf-like areas in, 1466, 1467f
in pigmented basal cell carcinoma, 1466, 1467f
shiny white structures in, 1466, 1467f
spoke-wheel-like structures in, 1466, 1466f
ulceration in, 1466, 1467f
diagnosis of, 989f–995f, 991, 995
differential diagnosis of
vs. actinic keratosis, 972
vs. Bowen disease, 972
vs. hordeolum and chalazion, 115
vs. melanoma, 1016, 1016f, 1017f
vs. molluscum contagiosum, 745
for nodular BCC
vs. fibrous papule of face, 995
vs. intradermal (dermal) nevi, 989f, 995, 995f
vs. keratoacanthoma, 995
vs. sebaceous hyperplasia, 995, 996f
vs. trichepithelioma/trichoblastoma/trichilemmoma, 995
for sclerosing BCC, *vs.* scars, 996
vs. sebaceous hyperplasia, 933, 933f
vs. seborrheic keratosis, 929, 930f
vs. skin tag, 924
vs. squamous cell carcinoma, 1005, 1005f
for superficial BCC
vs. actinic keratoses, 995
vs. benign lichenoid keratosis, 996
vs. Bowen disease, 995
vs. discoid lupus erythematosus, 996
vs. eczema, nummular, 996
epidemiology of, 989, 989f–991f
etiology and pathophysiology of, 989, 992f
follow-up of, 997
fundamentals of, 989
management of, 996, 996f, 997f
of mouth (*See* Oropharyngeal cancer)
patient education on, 997
patient story of, 989, 989f
prevention and screening for, 997
prognosis in, 997
risk factors for, 991
Basal nevus syndrome, *vs.* pitted keratolysis, 687
BATHE method, 10
Bathing trunk nevus, 953–956, 955f
Beau lines, 1146, 1147f, 1148f
in psoriatic nails, 1170
Becker nevus, 948, 948f. *See also* Nevus, benign
vs. congenital nevi, 956
Behçet disease (syndrome)
differential diagnosis of
vs. aphthous ulcer, 245f, 246, 246f
vs. herpes simplex virus, 739, 739f
uveitis in, 136
Bell palsy, 1383–1386
diagnosis of, 1384
differential diagnosis of
vs. facial nerve damage, 1384
vs. Lyme disease, 1293, 1384
vs. space-occupying lesion, 1384
vs. suppurative ear disease, 1384
vs. third nerve palsy, isolated, 1384–1385, 1384f
vs. upper motor neuron diseases, 1384
epidemiology of, 1383, 1383f
etiology and pathophysiology of, 1383–1384, 1383f
follow-up of, 1385
from Lyme disease, 1291, 1294f
management of, 1385
patient education on, 1386
patient story of, 1383, 1383f
prognosis in, 1385
Benign familial pemphigus, *vs.* pemphigus vegetans, 1114, 1115f
Benign fibrous histiocytoma, 935–938. *See also* Dermatofibroma
Benign intracranial hypertension, 151–154. *See also* Papilledema
Benign juvenile melanoma, 946, 947f. *See also* Nevus, benign
Benign lichenoid keratosis, *vs.* basal cell carcinoma, superficial, 996
Benign migratory glossitis, 232–235. *See also* Geographic tongue
Benign nevus. *See* Nevus, benign; *specific types*
Benign prostatic hyperplasia (BPH), *vs.* prostate cancer, 457
Benzodiazepine abuse. *See* Injection-drug use; Substance abuse disorder
Bereavement follow-up, 34
β-lactams, reactions from, 1211–1222
Beta-chorionic gonadotropin (B-HCG), 19
Biliary colic
vs. kidney stones, 427
vs. peptic ulcer disease, 368
Biometric measurements, fetal, ultrasound for
first trimester, 475–477, 475f–477f
second trimester, 478–481, 478f–481f
Biophysical profile (BPP), on third trimester ultrasound, 483–484
Biparietal diameter (BPD), on ultrasound
first trimester, 477, 477f
second trimester, 478, 478f, 480
third trimester, 483f
Birthing, 22. *See also* Pregnancy
maternal mortality in, 17–18
patient education on, 22–23, 22f

Bismuth subsalicylate ingestion, black tongue from, 229
Bite trauma in mouth, *vs.* lichen planus, 907
Black hairy tongue, 228–230, 228f, 229f
differential diagnosis of
vs. candidiasis, oral, 229
vs. hairy leukoplakia, 229, 230f
Blackheads, 652. *See also* Acne vulgaris
vs. acne vulgaris, 654, 655f
Black heel, *vs.* plantar warts, 767
Black recluse spider bite, *vs.* pyoderma gangrenosum, 1031
Black warts, *vs.* plantar warts, 767
Bladder cancer, 448–452
definition of, 448
diagnosis of, 448f, 449–450, 449f
differential diagnosis of, 450
epidemiology of, 448
etiology and pathophysiology of, 448–449, 448f, 449f
follow-up for, 451–452
management of, 450–451, 451t
patient education on, 452
patient story of, 448, 448f
prevention and screening for, 423, 451
prognosis in, 451, 451t
risk factors for, 449
Bleeding. *See specific types and sites*
Bleeding disorders. *See also specific types*
vs. child abuse, 85
Blepharitis, red eye in, 163, 165, 166f, 167f
Blindness
from *Chlamydia trachomatis,* 69–70, 69f
from diabetic retinopathy, 143–145
from glaucoma, 139–142
Blisters. *See also* Bullous diseases
friction, 1100
vs. tinea pedis, 801
Blood products, reactions from, 1211–1222
Bloody show, 18
Bloom syndrome, *vs.* neurofibromatosis, 1389
Blow. *See* Cocaine abuse
Blue nevus, 946, 947f. *See also* Nevus, benign
dermoscopic diagnosis of, 1457f
Blue rubber bleb nevus syndrome, *vs.* childhood hemangioma, 638
Blum, Dr. Alan, 9f, 29
Body lice, 809–814, 810f. *See also* Lice
Bone mineral density (BMD)
in osteopenia, 1338
in osteoporosis, 1338
Bone tumors, *vs.* knee soft tissue injuries, 622
Borrelia burgdorferi, 1289–1296, 1289f. *See also* Lyme disease
Bouchard nodes, 563f, 569, 569f, 570
Bourne toxemic rash of pregnancy, 467–470, 467f–469f. *See also* Pruritic urticarial papules and plaques of pregnancy (PUPPP)
Bowen disease, 969–975
diagnosis of, 970, 970f, 971f
differential diagnosis of
vs. basal cell carcinoma, 972, 995
vs. eczema, nummular, 970, 972
vs. lichen planus, 906
vs. Paget disease of breast, 559
vs. seborrheic keratosis, 972
vs. squamous cell carcinoma, 1005
epidemiology of, 969
etiology and pathophysiology of, 969–970
follow-up of, 975
fundamentals of, 687, 969
management of, 973–974, 974t, 975f
patient education on, 975
prevention of, 974
prognosis in, 975
risk factors for, 970
Brain cancer, *vs.* subdural hematoma, 1377
Brain mass, *vs.* cerebral vascular accident, 1373
Brain parenchyma hemorrhage, *vs.* subdural hematoma, 1378
Branchial cleft cyst, *vs.* goitrous hypothyroidism, 1349
BRCA mutation, 552, 555
Breast abscess, 546–549
vs. breast cancer, 554
definition of, 546, 546f
diagnosis of, 546f, 547
differential diagnosis of
vs. Paget disease of breast, 547
vs. tinea corporis, 547
distribution of, typical, 547
epidemiology of, 546
etiology and pathophysiology of, 546
follow-up of, 549
management of, 548, 548f
patient education on, 549
patient story of, 546, 546f
risk factors for, 546–547
Breast areola, benign lichenoid keratosis of, 559, 560f
Breast cancer, 551–556
diagnosis of, 553, 553f, 554f
differential diagnosis of
vs. breast abscess, 554
vs. cyst, benign, 553–554
vs. ductal ectasia with inflammation, 554
vs. fibroadenoma, 553
vs. leukemia in breast, 554
vs. mastalgia, bilateral, 554
vs. mastitis, 554
vs. nipple discharge, 554
epidemiology of, 551, 551f–554f
etiology and pathophysiology of, 551–552
follow-up of, 555, 555f
management of, 554–555
patient education on, 556
patient story of, 551, 551f
prevention of, 555
risk factors for, 552
Breast cyst, benign, *vs.* breast cancer, 553–554
Breastfeeding, 21, 22f
HIV on, 53
Breathiness, 220–225. *See also* Hoarseness
British Thoracic Society (BTS) rule, 304
Bronchitis, chronic
vs. asthma, 326
vs. chronic obstructive pulmonary disease, 338
Bronchoalveolar carcinoma, 355–363. *See also* Lung cancer
Bronchopneumonia, 303, 303f, 305f
Bruises, in child abuse, 82, 82f, 83f, 85, 85f, 86f
Buerger disease, dry gangrene from, 1265–1267, 1265f, 1266f
Bulimia, *vs.* dental caries, 264, 264f
Bullosis diabeticorum, 1097f, 1100, 1101f

Bullous arthropod reaction, 1100, 1102f
Bullous diseases, 1097–1103. *See also specific diseases*
diagnosis of, 1097–1103
approach to, 1097
biopsy in, 1103
clinical features in, 1098–1102
autoimmune, 1097f–1100f, 1098
childhood, 1102, 1103f
drug, 1100, 1101f
hydrostatic (edema blisters), 1102
immunologic, 1100, 1100f, 1101f
infections and bites, 1100–1102, 1102f, 1103f
metabolic (porphyria cutanea tarda), 1100, 1100f
traumatic/physical stress, 1100, 1101f
further evaluations in, 1103
history in, 1097
laboratory studies and work-up in, 1102–1103
physical examination in, 1097–1098, 1098f, 1099f
differential diagnosis of
vs. herpes zoster, 714
vs. zoster ophthalmicus, 720
fundamentals of, 1097
patient story of, 1097, 1097f
Bullous drug eruptions, 1100, 1101f
fixed, 1213f, 1214f, 1218, 1219, 1221
Bullous impetigo, 1100, 1102f
Bullous mastocytosis, 1102
Bullous myringitis, *vs.* acute otitis and otitis media with effusion, 173, 175f
Bullous pemphigoid, 1098, 1098f, 1099f, 1104–1108
diagnosis of, 1104f, 1105–1106, 1105f
differential diagnosis of
vs. cicatricial pemphigoid, 1106, 1106f
vs. cutaneous drug reactions, 1221
vs. dermatitis herpetiformis, 1106
vs. epidermolysis bullosa acquisita, 1106
vs. erythema multiforme, 1106
vs. hypersensitivity syndromes, 1054
vs. impetigo, 677
vs. linear AgA dermatosis, 1106, 1106f
vs. pemphigoid gestationis, 473
vs. pemphigus, 1113–1114
epidemiology of, 1104
etiology and pathophysiology of, 1104–1105, 1104f, 1105f
follow-up of, 1107, 1108f
fundamentals of, 1104
management of, 1106–1107
patient education on, 1107
patient story of, 1104, 1104f
Bunion, callus from, 1243, 1243f
Bunion deformity, 1247–1250
diagnosis of, 1247f, 1248, 1248f
differential diagnosis of
vs. gout or pseudogout, 1248
vs. rheumatoid arthritis, 1248
vs. septic joint, 1248
epidemiology of, 1247
etiology and pathophysiology of, 1247
follow-up for, 1249
fundamentals of, 1247
management of, 1249, 1249f
patient education on, 1250
patient story of, 1247, 1247f
prevention of, 1249
prognosis in, 1249
Buprenorphine abuse. *See* Injection-drug use; Substance abuse disorder
Burns, from child abuse, 84, 85, 85f
Bursa, hemorrhage into, *vs.* olecranon bursitis, 598
Bursitis
differential diagnosis of
vs. arthritis, 566
vs. osteoarthritis, 571
olecranon, 596–599, 596f–598f (*See also* Olecranon bursitis)
Buschke-Lowenstein tumor
vs. condylomata acuminata, 763f
vs. genital warts, 762

C

C. *See* Cocaine abuse
Café-au-lait spots, 923f
vs. congenital nevi, 956
in neurofibromatosis, 1387–1390, 1387f, 1388f
CAGE questionnaire, 1413–1414
Cain, Jeff, 39–41, 40f–42f
Calcium pyrophosphate dihydrate disease (CPPD) diagnosis
imaging in, 566
typical distribution in, 565
Calluses, 1242–1245
diagnosis of, 1243
differential diagnosis of
vs. acrolentiginous melanoma, 1243–1244
vs. genodermatosis of pachyonychia congenita, 1244, 1244f
vs. plantar warts, 767, 767f, 1243
vs. porokeratosis, 1244
vs. scar, 1244
vs. skin cancer, nonmelanoma, 1244
epidemiology of, 1242
etiology and pathophysiology of, 1242
fundamentals of, 1242
management of, 1242f, 1244
patient education on, 1245
patient story of, 1242, 1242f
prevention of, 1245
prognosis and follow-up of, 1245
risk factors for, 1243, 1243f, 1244f
Cancer. *See also specific types*
death from, 27
epidemiology of, 26
Candib, Lucy, 41–44, 42f, 43f
Candida albicans, 777–780, 777f–780f. *See also* Candidiasis
angular cheilitis from, 203, 203f
paronychia from, 1166–1169, 1168f
vs. pharyngitis, 216
Candida diaper dermatitis, 646–650, 646f, 648f. *See also* Diaper rash
Candida glabrata vulvovaginitis, 500. *See also Candida* vulvovaginitis
Candida infection (candidiasis), dermal, 771–776. *See also* Fungal infections, cutaneous
bullous presentation of, 1102
contact hand dermatitis from, 845f
diagnosis of, 845–846
differential diagnosis of
vs. aphthous ulcer, 246
vs. hand eczema, 845f, 847
vs. psoriasis, 888

Candida infection (candidiasis) (*Continued*)
vs. pustular diseases of childhood, 644
vs. tinea cruris, 796
folliculitis from, 681
hand dermatitis from, 845
microscopic appearance of, 778, 779f
onychomycosis from, 1160–1161, 1160f
vulvovaginal, 485–486, 487t
Candida vaginitis. *See also Candida* vulvovaginitis
vs. Trichomonas vaginitis, 506
Candida vulvovaginitis, 499–503
cutaneous, 485–486, 487t
diagnosis of, 499f, 500–501, 500f
differential diagnosis of
vs. bacterial vaginosis, 496, 501
vs. Chlamydia, 501
vs. cytolytic vaginosis, 501–502
vs. Döderlein's cytolysis, 501–502
vs. gonorrhea, 501
vs. Paget disease of external genitalia, 516
vs. trichomoniasis, 501
vs. vulvar intraepithelial neoplasia, 521
epidemiology of, 499
etiology and pathophysiology of, 499f, 500, 500f
follow-up of, 503
fundamentals of, 499
management of, 502, 502t
patient education on, 503
patient story of, 499, 499f, 500f
prevention of, 502
prognosis in, 503
risk factors for, 500
Candidiasis, 499–503, 777–780
chronic, 780, 780f
definition of, 777
diagnosis of, 777–778, 777f–779f
differential diagnosis of
vs. erythrasma, 690, 778
vs. intertrigo, 778, 779f, 780f
vs. inverse psoriasis, 778, 780f
vs. leukoplakia, 251
vs. seborrhea, 778, 873
vs. tinea corporis/cruris, 778, 780f
epidemiology of, 777
etiology and pathophysiology of, 777
mammary (nipple), 777–780, 777f, 778f
management of, 778–780, 778f
patient education on, 780
patient story of, 777, 777f
risk factors for, 777
Candidiasis, mucocutaneous (thrush), 771–776, 773f, 777–780, 777f, 778f
angular cheilitis from, 203, 203f, 204
differential diagnosis of
vs. black hairy tongue, 229, 230f
vs. lichen planus, 907
vs. pharyngitis, 216
management of, 775t, 780
patient education on, 780
Canker sores, 244–248. *See also* Aphthous ulcer
Carbuncles, *vs.* abscess, 699
Carcinoma. *See also specific types*
metastatic, *vs.* sarcoidosis, 1039
Carcinoma of the cervix, 535–539. *See also* Cervical intraepithelial neoplasia II/III (CIN II/III); Colposcopy, of high-grade lesions
Carcinomatous meningitis, *vs.* normal pressure hydrocephalus, 1381
Cardiac tamponade, acute, with pericardial effusion, 282
Cardiac tumors, *vs.* bacterial endocarditis, 290
Cardiobacterium bacterial endocarditis, 288
Cardiomegaly
heart failure, 277–280, 277f–279f (*See also* Heart failure)
pericardial effusion, 281f
Cardiovascular disease. *See also specific types*
epidemiology of, 26
Careers in medicine, disparity in, 49–50, 49f, 50f
Caries, 257
Caries, adult, 262–266, 262f
diagnosis of, 263–264
differential diagnosis of, 264
vs. bulimia, 264, 264f
vs. fluorosis, 264
vs. staining, 264
vs. tooth abrasion, 264
vs. tooth attrition, 264
vs. tooth erosion, 264
vs. tooth trauma, 264
epidemiology of, 262, 262f
etiology and pathophysiology of, 263
follow-up of, 265
fundamentals of, 262
management of, 264–265
patient education on, 265–266
patient story of, 262, 262f
prevention and screening for, 265
prognosis in, 265
risk factors for, 263
Caries, early childhood, 257–260
definition of, 257, 257f, 258f
diagnosis of, 257f, 258–259, 258f
epidemiology of, 257–258
etiology and pathophysiology of, 258
fluoride for, 259t, 260, 260f
follow-up for, 259
fundamentals of, 257
management of, 259, 259t
patient education on, 260, 260f
patient story of, 257, 257f
risk factors for, 258
Caring, 10
Cash, Crystal, 49–51, 49f, 50f
Casts, urinary, 420–423, 421f–423f. *See also* Urinary sediment
Cataract, *vs.* age-related macular degeneration, 157
Catarrh, spring, 128
Cavitated lesions, 262–266. *See also* Caries, adult
Cavities, dental. *See* Caries
Cellulitis, 693–697
breast, 546, 546f
definition of, 693
diagnosis of, 693–694, 693f–696f
differential diagnosis of
vs. abscess, 699
vs. allergic reactions, 694, 696f
vs. Charcot arthropathy, 1262
vs. erythema nodosum, 1059

vs. gout, 593, 694
vs. knee soft tissue injuries, 622
vs. Lyme disease, 1292
vs. necrotizing fasciitis, 694, 704
vs. thrombophlebitis, 694
vs. venous stasis and venous stasis dermatitis, 694, 694f
dissecting, scarring alopecia from, 1140, 1141f
epidemiology of, 693
etiology and pathophysiology of, 693, 693f–695f
follow-up of, 697
management of, 694–697
patient education on, 697
patient story of, 693, 693f
Central centrifugal scarring alopecia (CCSA), 1139, 1139f. *See also* Alopecia, scarring
Cephalic index, on second trimester ultrasound, 480
Cephalosporins, reactions from, 1216t
Cerebral vascular accident (CVA), 1371–1375
diagnosis of, 1372–1373, 1372f, 1373f
differential diagnosis of
vs. brain mass, 1373
vs. hypoglycemia, 1373
vs. migraine headache, 1373
vs. multiple sclerosis, 1373
vs. transient ischemic attack, 1373
vs. vertigo, 1373
epidemiology of, 1371
etiology and pathophysiology of, 1371–1372
follow-up of, 1374
fundamentals of, 1371
management of, 1373–1374
patient education on, 1375
patient story of, 1371, 1371f
prevention of, 1374
prognosis in, 1374
risk factors for, 1372
Cervical atrophy
colposcopy and diagnosis of, 527, 527f
management of, 528
Cervical cancer, 541–544
colposcopy of, 541–545, 541f–543f (*See also* Colposcopy, of high-grade lesions)
diagnosis of, 541f–543f, 542–543
differential diagnosis of, 543
epidemiology of, 541, 541f–543f
etiology and pathophysiology of, 542
follow-up of, 544–545
patient education on, 545
prevention of, 544
prognosis in, 544
staging and management of, 543, 544t
Cervical dysplasia, colposcopy of, 530–533, 530f–532f. *See also* Cervical intraepithelial neoplasia I (CIN I)
Cervical epithelium, atrophic
colposcopy and diagnosis of, 527, 527f
management of, 528
Cervical erosion (ectropion)
colposcopy and diagnosis of, 525, 525f, 526, 528f
management of, 528
Cervical intraepithelial neoplasia I (CIN I)
vs. cervical intraepithelial neoplasia II/III, 538
CIN II/III and, 536, 537, 538
colposcopy of, 530–533, 530f–532f
human papillomavirus (HPV) and, 530
Cervical intraepithelial neoplasia II/III (CIN II/III), 535–539, 535f–538f
diagnosis of, 535f–538f, 536–537
differential diagnosis of
vs. cervical intraepithelial neoplasia I, 538
vs. human papillomavirus, 538
vs. nonmalignant inflammatory lesions, 537–538
vs. trichomoniasis and *Chlamydia,* 537–538
epidemiology of, 535
etiology and pathophysiology of, 535–536
follow-up of, 539
management of, 538
patient education on, 539
patient story of, 535, 535f
prevention of, 538–539
prognosis in, 539
risk factors for, 536
Cervical length, on second trimester ultrasound, 478f, 479, 480, 481f
Cervical os, third trimester ultrasound of, 484f
Cervical polyp
colposcopy and diagnosis of, 527, 528f
management of, 528, 528f
Cervical transformation zone, 525
Cervicitis
colposcopy of, 527, 527f, 528f
management of, 528
Cestodes, 1270–1274
CHADS/CHADS2 scoring table, 1374
Chadwick sign, 19
Chalazion, 114–117
diagnosis of, 115, 115f, 116f
differential diagnosis of
vs. basal cell carcinoma, 115
vs. hydrocystoma, 115, 116f
vs. molluscum contagiosum, 115
vs. sebaceous cell carcinoma, 115
vs. xanthelasma, 115
epidemiology of, 114–115
fundamentals of, 114
management of, 116
patient education on, 117
patient story of, 114, 114f
prevention of, 116
prognosis and follow-up for, 116
risk factors for, 115
Chancroid
vs. herpes simplex virus, 739
vs. pyoderma gangrenosum, 1031
vs. syphilis, 1282, 1282f
Charcot arthropathy, 1261–1264
definition of, 1261
in diabetes, 1302, 1304f
diagnosis of, 1261f–1263f, 1262
differential diagnosis of, 1262
epidemiology of, 1261
etiology and pathophysiology of, 1261
management of, 1263, 1263f
patient education on, 1264
patient story of, 1261, 1261f
prevention of, 1263
prognosis and follow-up of, 1263
risk factors for, 1262

Charcot-Marie-Tooth disease, hammer toe from, 1252, 1252f
Chauffeur's fracture, 605–609, 607f. *See also* Radius fracture, distal
Cheilitis
actinic, 969–975, 969f (*See also* Actinic keratosis)
angular, 203–205, 203f–205f, 777, 778, 778f
differential diagnosis of
vs. herpes simplex, 204
vs. impetigo, 204
from smoking, 1400, 1400f
with atopic dermatitis, 827
Cheloids, 1224–1228. *See also* Keloids
Chemical burn of mouth, *vs.* leukoplakia, 251
Cherry angioma, 1203–1206, 1203f. *See also* Vascular lesions, acquired
Cherry hemangioma, *vs.* pyogenic granuloma, 943, 943f
Chest pain, differential diagnosis of, 270
Chickenpox, 707–711. *See also* Herpes zoster
definition of, 707
diagnosis of, 708–709, 710f, 711f
differential diagnosis of
vs. dermatitis herpetiformis, 709
vs. erythema toxicum neonatorum, 633
vs. herpes simplex, 709
vs. impetigo, 709
vs. insect bites, 709
vs. pemphigus and bullous pemphigoid, 709
epidemiology of, 707, 707f, 708f
etiology and pathophysiology of, 707–708, 708f–710f
follow-up of, 710
with impetigo, 710f
management of, 709–710
patient education on, 710
patient story of, 707, 707f
prevention of, 710
Childhood hemangioma. *See* Hemangioma, childhood
Child physical abuse, 82–87
diagnosis of, 83–85, 84f, 85f
differential diagnosis of, 85, 85f, 86f
vs. Mongolian spots, 633
epidemiology of, 83
follow-up for, 86
identification of, 83
management of, 86
patient education on, 86
patient stories on, 82, 82f–84f
risk factors for, 83
Child Protective Services. *See* Child physical abuse
Child sexual abuse, 89–93
diagnosis of, 89f–92f, 90–91
differential diagnosis of
vs. anal fissure, 92
vs. anogenital irritation/bleeding, 92, 93f
vs. genital irritation/bleeding, 93f
vs. labial adhesion, 92, 93f
vs. leukorrhea, 92
vs. lichen sclerosus et atrophicus, 92, 92f
vs. phimosis, 92
vs. pinworm infestation, 92
vs. straddle injury, 91
vs. vaginitis, 92
vs. vulvar dermatitis, 91
vs. vulvovaginitis, 91
epidemiology of, 89
etiology and pathophysiology of, 90
management of, 92–93
patient story of, 89, 89f, 90f
Chlamydia cervicitis, 509–512
diagnosis of, 510–511, 510f, 511f
differential diagnosis of
vs. bacterial vaginosis, 511
vs. cervical intraepithelial neoplasia II/III, 537–538
vs. gonorrhea, 511
vs. trichomoniasis, 511
epidemiology of, 509
etiology and pathophysiology of, 510
follow-up of, 512
fundamentals of, 509
management of, 511–512, 512t
patient education on, 512
patient story of, 509, 509f
prevention of, 512
prognosis in, 512
risk factors for, 510
Chlamydial pelvic inflammatory disease, with reactive arthritis, 910–914, 912f, 913f. *See also* Reactive arthritis
Chlamydia trachomatis, 509–512. *See also Chlamydia* cervicitis
after sexual assault, 105, 106
blindness from, 69–70, 69f
conjunctivitis from, 126–129
differential diagnosis of
vs. bacterial vaginosis, 496
vs. Candida vulvovaginitis, 501
vs. Trichomonas vaginitis, 506
epidemiology of, 509
urethritis in men from, 1275–1277, 1275f
Chloasma, 19, 19f
Choice, supporting, 10
Cholecystitis, *vs.* gallstones, 389
Cholelithiasis
vs. hydronephrosis, 432
vs. kidney stones, 427
Cholera, 57–59
water and sanitation in, 55–56, 55f, 56f
Cholestatic disease, 377–384. *See also* Liver disease
Cholesteatoma, *vs.* acute otitis and otitis media with effusion, 173, 174f
Cholesterol embolism, *vs.* vasculitis, 1068
Cholesterol stones, 386, 387, 388. *See also* Gallstones
Chondrodermatitis nodularis chronica helicis. *See* Chondrodermatitis nodularis helicis
Chondrodermatitis nodularis helicis, 189–192
diagnosis of, 189f, 190, 190f
differential diagnosis of, 190–191
vs. skin cancer, 189f, 190
vs. squamous cell carcinoma of skin, 190
epidemiology of, 189
etiology and pathophysiology of, 190
follow-up and patient education on, 191
management of, 191, 192f
patient story of, 189, 189f, 190f
Chordoma, *vs.* nasal polyps, 194
Chorioretinitis, 135
Choroiditis, 135
Chromophobic tumors, renal cell, 442. *See also* Renal cell carcinoma

Chronic cutaneous lupus erythematosus. *See* Discoid lupus erythematosus (DLE)
Chronic daily headache, 1366–1370
diagnosis of, 1367
epidemiology of, 1366
management of, 1369
prevention of, 1369
Chronic obstructive pulmonary disease (COPD), 334–343
α_1-antitrypsin deficiency in, 335, 337, 340f
clubbing in, 292–294, 293f
diagnosis of, 336–337
clinical features in, 335t, 336, 336b
imaging in, 334f, 337, 337f–340f
laboratory testing in, 337
differential diagnosis of, 337–338
vs. asthma, 326, 338
vs. chronic bronchitis, 338
vs. heart failure, 278, 338
vs. lung cancer, 338, 359
vs. pneumonia, 338
vs. tuberculosis, 338
epidemiology of, 26, 334–335, 335t
etiology and pathophysiology of, 335
follow-up for, 342–343
fundamentals of, 334
management of, 338–342
complementary and alternative therapy in, 342
GOLD, 338, 341t
medications in
for acute exacerbation, 341–342
for stable COPD, 339–341
for symptomatic relief, 339–341
nonpharmacologic, 338–339
referral in, 342
surgery in, 342
patient education on, 343
patient story of, 334, 334f
prevention and screening for, 342
prognosis in, 342
risk factors for, 335–336
severity of, GOLD grade, 334–335, 335t
Chronic suppurative otitis media (CSOM)
vs. acute otitis and otitis media with effusion, 173
vs. ear foreign body, 186
vs. otitis externa, 181f, 182
Churg–Strauss syndrome, *vs.* vasculitis, 1068
Cicatricial alopecia, 1138–1143. *See also* Alopecia, scarring
Cicatricial pemphigoid, 1098, 1099f, 1103
vs. pemphigus, 1114
Cigarettes. *See* Smoking
Ciliary flush, 135, 135f, 136f
Cirrhosis, 377–384. *See also* Liver disease
Clark nevus, 963–967, 963f–967f. *See also* Dysplastic nevus
Clavi, 1242–1245. *See also* Corns
Clavicular fracture, 601–604
diagnosis of, 601–602, 602t
differential diagnosis of
vs. acromioclavicular separation, 602, 602t, 603f
vs. pseudoarthrosis of clavicle, 602
vs. sternoclavicular dislocation, 602
epidemiology of, 601
etiology and pathophysiology of, 601
follow-up of, 604
fundamentals of, 601
management of, 601f, 602–603, 602t
patient education on, 604
patient story of, 601, 601f
prognosis in, 603–604
Clear cell carcinoma, renal cell, 441. *See also* Renal cell carcinoma
Clinical evidence. *See also specific disorders*
educating patients on, 11
Closed-angle glaucoma, 164t
Clostridial myonecrosis, *vs.* necrotizing fasciitis, 704
Clubbing, 292–294, 292f, 293f
Cluster headache, 1366–1370
diagnosis of, 1367–1368, 1367f
etiology and pathophysiology of, 1367
management of, 1369
prognosis in, 1370
vs. sinusitis, 200
Cocaine abuse, 1431–1437. *See also* Injection-drug use; Substance abuse disorder
addiction and, 1392
death from, 26
diagnosis of, 1433–1434, 1433f–1435f, 1441–1442
differential diagnosis of
vs. adrenal hyperplasia/adenoma, 1435
vs. delirium, 1435
vs. encephalitis, 1435
vs. hyperthyroidism, 1435
vs. hypoglycemia, 1435
vs. meningitis, 1435
epidemiology of, 1392, 1431–1432
etiology and pathophysiology of, 1432, 1432f
follow-up of, 1437
forms of, 1432, 1432f
fundamentals of, 1431
injection, 1439–1444
diagnosis of, 1441–1442
differential diagnosis of, 1442
epidemiology of, 1439–1440
etiology and pathophysiology of, 1440
follow-up of, 1444
fundamentals of, 1439
management of, 1442–1444
patient education on, 1444
prevention and screening for, 1444
prognosis in, 1444
risk factors for, 1440
management of, 1435–1436
patient education on, 1437
patient story of, 1392, 1392f, 1431, 1431f
prevalence of, 26
prognosis in, 1437
risk factors for, 1432
Coccidiomycosis
erythema nodosum in, 1057
vs. tuberculosis, 314
Coining, 85, 87f
Coke. *See* Cocaine abuse
Cold sores, *vs.* angular cheilitis, 204
Colic, biliary
vs. kidney stones, 427
vs. peptic ulcer disease, 368

Colitis
ischemic *vs.* ulcerative, 409, 410f
vs. kidney stones, 427
NSAID-induced, 409
ulcerative, 405–412 (*See also* Inflammatory bowel disease (IBD); Ulcerative colitis (UC))
Collateral ligament injuries, 619–624. *See also* Knee soft tissue injuries
Colles fracture, 605–609, 605f. *See also* Radius fracture, distal
Colon cancer, 399–403
diagnosis of, 399f, 400, 402f, 403f
differential diagnosis of
vs. appendicitis, 400
vs. colon polyp, 396, 401
vs. diverticula, 401
vs. diverticulitis, 400
vs. gastrointestinal infection, 401
vs. hemorrhoids, 401
vs. inflammatory bowel disease, 400
vs. vascular colonic ectasias, 401
epidemiology of, 399
etiology and pathophysiology of, 399–400
follow-up of, 402–403
fundamentals of, 399
management of, 401
patient education on, 403
patient story of, 399, 399f
prevention and screening for, 399f, 401–402, 402f, 403f
prognosis in, 402
risk factors for, 400
Colonic ectasias, vascular, *vs.* colon polyps, 396
Colon infection. *See specific types*
Colon polyps, 393–397
definition of, 393
diagnosis of, 393f, 394–395, 395f, 396f
differential diagnosis of, 395–396
vs. anal fissure, 395–396
vs. colon cancer, 396
vs. diverticula, 396
vs. gastrointestinal infection, 395
vs. hemorrhoids, 395–396
vs. inflammatory bowel disease, 396
vs. rectal bleeding, 395–396
vs. vascular colonic ectasias, 396
epidemiology of, 393
etiology and pathophysiology of, 393–394
follow-up of, 397
management of, 396, 396f
patient education on, 397
patient story of, 393, 393f
prevention of, 396–397
prognosis in, 397
risk factors for, 394
Colposcope, 525, 525f
Colposcopy
of cervical cancer, 541–545
diagnosis in, 541f–543f, 542–543
differential diagnosis of, 543
epidemiology in, 541, 541f–543f
etiology and pathophysiology in, 542
follow-up in, 544–545
fundamentals of, 541
patient education in, 545
patient story of, 541, 541f
prevention in, 544
prognosis in, 544
staging and management in, 543, 544t
definition of, 525
of high-grade lesions, 535–539
diagnosis of, 535f–538f, 536–537
epidemiology of, 535
etiology and pathophysiology of, 535–536
follow-up in, 539
management in, 538
patient education on, 539
patient story of, 535, 535f
prevention in, 538–539
risk factors for, 536
indications for, 525, 541
of low-grade disease, 530–533
diagnosis of, 530f–532f, 531
differential diagnosis of, 531–532
epidemiology of, 530
etiology and pathophysiology of, 530–531, 530f–532f
follow-up of, 533
fundamentals of, 530
management of, 532
patient education on, 533
patient story of, 530, 530f
prevention of, 532
normal and noncancerous findings on, 525–528
diagnosis of, 526–527, 526f–528f
differential diagnosis of, 527
epidemiology of, 525–526, 526f
etiology and pathophysiology of, 525f, 526, 526f
follow-up of, 528
management of, 527–528
patient education on, 528
patient story of, 525, 525f
Columnar epithelium, cervical, 526, 526f
Combination contraceptive patch, 15, 16f
Comedonal acne, 651–657, 653f. *See also* Acne vulgaris
Comedonal nevus, 948, 949f
Commissural cheilitis, 203–205, 203f–205f
Common River, 49f, 53, 54f
Common warts, 749–754. *See also* Warts, common
Community-acquired pneumonia, 300–308, 300f, 301f, 303f–306f. *See also* Pneumonia
Compound nevi, 946, 946f, 947f, 948–949. *See also* Nevus, benign
Condoms, 13t
Condylar split fracture, lateral, 621, 622f
Condyloma lata, *vs.* genital warts, 762
Condylomata acuminata. *See* Warts, genital
Congenital dermal melanocytosis, 630–634. *See also* Mongolian spots
Congenital heart disease, clubbing in, 292–294, 292f, 293f
Congenital nevus. *See* Nevus, congenital
Congestive heart failure, 277–280, 277f–279f. *See also* Heart failure
Conjunctival foreign body irritation, red eye in, 165f
Conjunctival melanoma, 118–121, 119f, 120f
Conjunctival melanosis, 118–121, 119f
Conjunctival nevus, 118–121, 118f, 126f
Conjunctival pigmentation, 118–121
Conjunctival squamous cell carcinoma, 111
Conjunctivitis, 126–129

allergic, 126–129
diagnosis of, 126f–128f, 127
differential diagnosis of, 127–128, 128f
vs. acute-angle closure glaucoma, 128
vs. corneal foreign body/abrasion, 124
vs. corneal ulceration, 128, 128f
vs. episcleritis, 127, 133
vs. herpetic keratitis, 128, 128f
vs. iritis, 127, 137
vs. pterygium, 111
vs. scleritis, 127, 133
vs. uveitis, 127, 137
vs. zoster ophthalmicus, 720
epidemiology of, 126
etiology and pathophysiology of, 126–127, 126f
follow-up and return to school in, 129
foreign body, 128, 129f
giant papillary, 128, 128f
gonococcus, 126–129, 127f
management of, 128–129
patient education on, 129
patient story of, 126, 126f
prevention of, 129
with reactive arthritis, 910, 911, 912f
red eye in, 163–168, 163f, 164t, 165f
bacterial, 165f
giant papillary, 165f
trachoma, 128, 129f
vernal (allergic, warm weather), 128
viral, 163, 163f
from zoster ophthalmicus, 719, 720
Connective tissue disorders. *See also specific types*
differential diagnosis of
vs. bacterial endocarditis, 290
vs. osteoarthritis, 571
vs. rheumatoid arthritis, 577
Contact dermatitis, 834–841, 1100, 1101f
allergic, 834
vs. impetigo, 677
diagnosis of
clinical features in, 834f, 835, 836f–838f, 838
history in, 834f–838f, 835
laboratory studies in, 838, 838f, 849t
differential diagnosis of
vs. atopic dermatitis, 831, 836f, 839
vs. atrophic vaginitis, 491
vs. cutaneous larva migrans, 824
vs. dyshidrotic eczema, 839
vs. eczema, nummular, 854
vs. erythrasma, 691
vs. fungal infections, 837f, 839
vs. immediate IgE contact reaction, 839
vs. melasma, 1181
vs. methamphetamine abuse, 1427
vs. otitis externa, 182
vs. pemphigoid gestationis, 473
vs. photodermatitis, 1195
vs. scabies, 820, 839
vs. scarlet fever, 210
vs. seborrheic dermatitis, 873
vs. self-inflicted dermatoses, 860
vs. tattoo dye allergy, 839, 839f
vs. tinea cruris, 796
vs. tinea pedis, 801, 802f
epidemiology, 834, 834f
etiology and pathophysiology of, 834–835
follow-up of, 841
hand, 843–849 (*See also* Eczema, hand)
irritant, 834
management of, 839–841, 840f
patient education on, 841
patient story of, 834, 834f
Contact lens
conjunctivitis from, 127, 127f
giant papillary conjunctivitis from, 128, 128f
keratitis from, 128
Contraception, 12–16. *See also* Family planning; *specific types*
choice of, 12–14, 13t
emergency, 20–21
epidemiology of, 12
follow-up with, 15
options in, 12–14, 13t
new, 12f, 13t, 14–15, 14f–16f
patient education on, 15
patient story of, 12
risks, benefits, and barriers to, 12
with smoking, 13
Contraceptive patch, 13t
Contraceptive patch, combination, 15, 16f
Control, supporting, 10
Copper-containing intrauterine device (IUD), 13t, 14–15
Cornea, 122
Corneal foreign body/abrasion, 122–125
diagnosis of, 123, 123f
differential diagnosis of, 123–124
vs. conjunctivitis, 124
vs. corneal ulceration, 124, 124f
vs. glaucoma, acute angle-closure, 124
vs. iritis, 123
vs. keratitis, 124
vs. uveitis, 123
epidemiology of, 122
etiology and pathophysiology of, 122
follow-up for, 125
management of, 122f, 123f, 124
metallic, 123, 123f
patient education on, 125
patient story of, 122, 122f
prevention of, 124
risk factors for, 123
wood chip, 122, 122f
Corneal ulceration
differential diagnosis of
vs. conjunctivitis, 128, 128f
vs. corneal foreign body/abrasion, 124, 124f
vs. scleritis and episcleritis, 133
vs. uveitis and iritis, 137
red eye in, 165, 166f
Corns, 1242–1245
diagnosis of, 1243, 1243f, 1244f
differential diagnosis of
vs. acrolentiginous melanoma, 1243–1244
vs. genodermatosis of pachyonychia congenita, 1244, 1244f
vs. plantar warts, 767, 767f, 1243

Corns (*Continued*)
vs. porokeratosis, 1244
vs. scar, 1244
vs. skin cancer, nonmelanoma, 1244
epidemiology of, 1242
etiology and pathophysiology of, 1242
fundamentals of, 1242
management of, 1244, 1245f
patient education on, 1245
prevention of, 1245
prognosis and follow-up of, 1245
risk factors for, 1243, 1243f
Coronary artery disease (CAD), 268–270, 268f, 269f
vs. costochondritis, 270
vs. gastroesophageal reflux, 270
vs. herpes zoster, 715
vs. pericarditis, 270
vs. pneumothorax, 270
Coronary heart disease (CHD), 268–270, 268f, 269f
Corticosteroids, topical and intralesional
dose of, by body area, 1452t
generic and trade names for, 1451t–1452t
infection technique for, 1453f, 1454f
injection concentrations of, 1453t
side effects of, common, 1453t
Corynebacterium, pitted keratolysis from, 686
Corynebacterium minutissimum, erythrasma from, 689, 689f
Corynebacterium vaginosis (vaginalis, vaginitis), 494–497. *See also* Bacterial vaginosis (BV)
Costochondritis, *vs.* coronary artery disease, 270
Cough, drug-induced, *vs.* asthma, 327
Coumadin (warfarin)
drug reactions from, 1211–1222 (*See also* Drug reactions, cutaneous)
diagnosis of, 1213f, 1218, 1221f
epidemiology of, 1212, 1213f
etiology and pathophysiology of, 1216
warfarin-induced skin necrosis from, 1211–1222 (*See also* Warfarin-induced skin necrosis)
Cowden's disease, gingival overgrowth from, 240, 240f
Coxsackievirus
A16, *vs.* pharyngitis, 216, 216f
hand, foot, and mouth disease, 732–734, 732f, 733f
Crab lice, 809–814, 810f, 812f. *See also* Lice
Crack (cocaine). *See* Cocaine abuse; Substance abuse disorder
Cradle cap, 871–876, 873f, 874f
Cranial nerve palsy. *See also* Bell palsy
from Lyme disease, 1291, 1294f
Crank. *See* Methamphetamine
Creeping eruption, 823–825, 823f, 824f
CREST syndrome, 1090, 1090f–1093f
vs. vascular lesions, 1209
Crohn disease, 405–412. *See also* Inflammatory bowel disease (IBD)
colon mucosa in, 1028f
vs. peptic ulcer disease, 368
pyoderma gangrenosum with, 1028–1034, 1028f, 1029f
Cross-cultural events, patient encounters as, 9
Crown-to-rump length, 19, 19f
on first trimester ultrasound, 476–477, 476f
Crow sign, in neurofibromatosis, 1387, 1387f, 1388f
Cryotherapy, blistering after, 1100, 1101f
Crystal. *See* Methamphetamine
Cup-to-disc ratio
in glaucoma, 139, 139f, 140, 140f
normal, 140, 140f
Cushing syndrome, *vs.* obesity, 1332
Cusp prolapse, *vs.* bacterial endocarditis, 290
Cutaneous angiokeratomas, 1205f. *See also* Vascular lesions, acquired
Cutaneous drug reactions. *See* Drug reactions, cutaneous
Cutaneous fungal infections. *See* Fungal infections, cutaneous
Cutaneous horn, 985–986, 985f–987f
vs. keratoacanthomas, 978
Cutaneous larva migrans, 823–825, 823f, 824f
differential diagnosis of
vs. contact dermatitis, 824
vs. cutaneous fungal infections, 824
vs. erythema chronicum migrans of Lyme disease, 824
vs. phytophotodermatitis, 824
vs. tinea corporis, 791
Cutaneous lupus erythematosus, chronic. *See* Discoid lupus erythematosus (DLE)
Cutaneous T-cell lymphoma (CTCL), 1042–1047. *See also* Mycosis fungoides
classification of, 1042
complications of, potential, 1047
diagnosis of, 1042f–1047f, 1043–1045
differential diagnosis of
vs. dermatitis, 1045
vs. idiopathic guttate hypomelanosis, 1045
vs. parapsoriasis, 1043f, 1045
vs. psoriasis, 888
vs. reactive inflammation in HIV, 1045
vs. vasculitis, 1066
vs. vitiligo, 1042f, 1045
epidemiology of, 1042
etiology and pathophysiology of, 1043
follow-up of, 1047
management of, 1045–1047
patient education on, 1047
patient story of, 1042, 1042f
prognosis in, 1047
Cutaneous tuberculosis, 74, 76f
Cutaneous vasculitis, 1062–1069. *See also* Vasculitis
vs. hypersensitivity syndromes, 1054
Cutis marmorata
vs. erythema ab igne, 1200
vs. erythema toxicum neonatorum, 634, 634f
Cutis marmorata telangiectasia congenita, *vs.* erythema ab igne, 1200
Cutting, self-, after sexual assault, 104, 104f
Cyst. *See also specific types*
simple, *vs.* polycystic kidneys, 438
Cystic disease, acquired, *vs.* polycystic kidneys, 438
Cystitis
hematuria in, 421, 423
management of, 423
urinary sediment in, 420–423
white blood cell casts in, 422, 422f
Cytolytic vaginosis, *vs. Candida* vulvovaginitis, 501–502
Cytomegalovirus (CMV), *vs.* pharyngitis, 216

D

Dactylitis, 911f
Dancer fracture, 611–614. *See also* Metatarsal fracture
Dandruff, *vs.* lice, 811
Daniel Hale Williams Prep School for Medicine, 50, 50f

Darier disease, 1229–1234
diagnosis of, 1229f–1233f, 1230
differential diagnosis of
vs. Grover disease, 1230
vs. Hailey-Hailey disease, 1230, 1233f
vs. psoriatic nails, 1171–1172, 1173f
vs. seborrheic dermatitis, 1233
epidemiology of, 1229
etiology and pathophysiology of, 1229
follow-up of, 1234
management of, 1233–1234
patient education on, 1234
patient story of, 1229, 1229f, 1230f
Darier-Roussy disease, 1035–1040, 1038f. *See also* Sarcoidosis
Darier sign, 864, 865f, 1102
Date rape. *See* Sexual assault, adult
DaVinci robot, for prostate cancer surgery, 458, 458f
Death. *See* End of life
Decay, dental, 262–266
Deconditioning, *vs.* heart failure, 278
Deep hemangiomas of infancy, 636–640. *See also* Hemangioma, childhood
Deep venous thrombosis (DVT)
vs. Charcot arthropathy, 1262
diagnostic strategy for, 347f
epidemiology of, 345
pulmonary embolus from, 345
Degenerative arthritis of spine, *vs.* osteoporosis and osteopenia, 1342
Delirium, *vs.* cocaine abuse, 1435
Delusions of parasitosis, *vs.* self-inflicted dermatoses, 860–861
Dementia
death from, 27
differential diagnosis of
vs. normal pressure hydrocephalus, 1381
vs. subdural hematoma, 1377
end of life, patient story of, 25
Dennie-Morgan lines, with atopic dermatitis, 827, 829f
Dental caries. *See* Caries
Dental cavities, 262–266. *See also* Caries
Dental decay, 262–266. *See also* Caries
Dental pain, *vs.* sinusitis, 200
Depo-Provera, 13t, 14
Depression
after intimate partner violence, 96, 97, 99
after sexual assault, 102, 104, 107
vs. subdural hematoma, 1377
de Quervain tenosynovitis, *vs.* distal radius fracture, 606
Dermal melanocytosis, 630–634. *See also* Mongolian spots
Dermal nevi, 946, 946f, 947f, 949. *See also* Nevus, benign
Dermatitis. *See also specific types*
differential diagnosis of
vs. cutaneous T-cell lymphoma, 1045
vs. lichen planus, 906
nummular, 851–854 (*See also* Eczema, nummular)
perioral, 661, 664f
vs. seborrheic dermatitis, 873
Dermatitis herpetiformis, 1098, 1103, 1125–1126, 1126f
vs. eczema, nummular and dyshidrotic, 1126
vs. pemphigoid gestationis, 473
vs. pemphigus, 1114
vs. scabies, 1126
Dermatitis syphiloides posterosiva, 648
Dermatofibroma, 935–938
dermoscopy of, 1458f, 1465, 1465f, 1466f
blood vessels within scar-like area in, 1465, 1465f
central scar-like area in, 1465, 1465f
peripheral delicate fine network in, 1465, 1465f
ring-like globular structures in, 1465, 1466f
diagnosis of, 935–936, 936f–937f
differential diagnosis of
vs. dermatofibrosarcoma protuberans, 936, 938f
vs. epidermal inclusion cyst, 937
vs. hypertrophic scar, 937
vs. Kaposi sarcoma, 1287
vs. keloids, 1225
vs. malignant fibrous histiocytoma, 936
vs. melanoma, 1016
vs. molluscum contagiosum, 745
vs. neurofibroma, 937
vs. pigmented seborrheic keratosis, 937
vs. pseudosarcomatous dermatofibrosarcoma, 936
etiology and pathophysiology of, 935
fundamentals of, 935
management of, 937
patient education on, 937
patient story of, 935, 935f
in pregnancy, 463
prognosis in, 937
Dermatofibrosarcoma protuberans
vs. dermatofibroma, 936, 938f
vs. keloids, 1225
Dermatomyositis, 1079–1087
diagnosis of, 1079f–1086f, 1080–1082
differential diagnosis of
vs. drug reaction, 1083
vs. hypothyroidism, 1083
vs. lupus erythematosus, 1074
vs. photodermatitis, 1195
vs. photosensitivity reactions, 1083
vs. polymorphous light eruption, 1083
vs. polymyositis, 1083
vs. porphyria cutanea tarda, 1120
vs. rosacea, 1083
vs. steroid myopathy, 1083
epidemiology of, 1080
etiology and pathophysiology of, 1080
follow-up of, 1087
fundamentals of, 1079–1080
management of, 1083–1087
intravenous treatment in, 1086
malignancy work-up in, 1086–1087
nonpharmacologic, 1084
oral treatment in, 1084–1086
overview of, 1083–1084
topical treatment in, 1084
overlap syndrome in, 1083
patient education on, 1087
patient story of, 1079, 1079f–1081f
prognosis in, 1087
Dermatophid reaction, in tinea pedis, 799, 799f, 800
Dermatophilus congolensis, pitted keratolysis from, 686
Dermatophytes, 771–776. *See also* Fungal infections, cutaneous; *specific types*
vs. atopic dermatitis, 831

Dermatophytic onychomycosis, 1160–1164. *See also* Onychomycosis
Dermatophytosis
  vs. erythrasma, 690
  of nails, 1160–1164 (*See also* Onychomycosis)
Dermatoses, self-inflicted, 856–862. *See also* Self-inflicted dermatoses
Dermatosis papulosa nigra, 927, 928f
Dermoid tumor, *vs.* nasal polyps, 194
Dermoscopes, 1455, 1455f
Dermoscopy, 1455–1471
  applications and goals of, 1455
  seven levels of, 1471f
  step 1, level 1, melanocytic lesions, 1456–1458
    aggregated globules, 1456, 1457f
    dermatofibroma, 1456, 1458f
    homogeneous blue pigmentation, 1456, 1457f
    negative network, 1456, 1456f
    parallel pigment pattern (acral lesions), 1456, 1458f
    pigment network, 1456, 1456f
    pseudonetwork (facial skin), 1456, 1458f
    streaks, 1456, 1457f
  step 1, nonmelanocytic tumors, 1465–1471
    basal cell carcinoma
      arborizing vessels, 1466, 1466f
      concentric structures, 1466, 1466f
      large blue-gray ovoid nest, 1466, 1466f
      leaf-like areas, 1466, 1467f
      shiny white structures, 1466, 1467f
      spoke-wheel-like structures, 1466, 1466f
      ulceration, 1466, 1467f
    dermatofibromas
      blood vessels within scar-like area, 1465, 1465f
      central scar-like area, 1465, 1465f
      peripheral delicate fine network, 1465, 1465f
      ring-like globular structures, 1465, 1466f
    hemangioma
      black lacunae (angiokeratoma), 1469, 1470f
      blue lacunae, 1469, 1470f
      red lacunae, 1469, 1469f
    scabies mite, 1470, 1470f
    seborrheic keratosis
      cerebriform, 1468, 1469f
      comedo-like openings, 1468, 1468f
      gyri and sulci, 1468, 1468f
      moth-eaten borders, 1468, 1469f
      multiple milia-like cysts, 1468, 1468f
      negative wobble sign, 1468
      sharp demarcation, 1468
    vascular structures, 1471, 1471f
  step 2, 1459–1465
    benign nevi patterns, 1459–1461, 1459f
      diffuse reticular, 1459, 1459f, 1460f
      globular, 1459, 1459f, 1461f
      homogeneous, 1459, 1459f, 1460f
      patchy reticular, 1459, 1459f, 1460f
      peripheral globules/starburst, 1459, 1459f, 1460f
      peripheral reticular with central globules, 1459, 1459f, 1461f
      peripheral reticular with central hyperpigmentation, 1459, 1459f, 1460f
      peripheral reticular with central hypopigmentation, 1459, 1459f, 1460f
      symmetric multicomponent, 1459, 1459f, 1461f
      two-component, 1459, 1459f, 1461f
    melanocytic lesions, pathways in, 1465, 1465f
    melanoma-specific structures, 1462–1465
      atypical dots and/or globules, 1462, 1462f, 1463f
      atypical network, 1462, 1462f
      atypical vascular structures, 1462, 1462f, 1464f
      blue-white veil overlying raised areas, 1462, 1462f, 1464f
      negative pigment network, 1462, 1462f, 1463f
      off-center blotch, 1462, 1462f, 1463f
      parallel ridge pattern, 1462, 1462f, 1464f
      peripheral tan structureless areas, 1462, 1462f, 1463f
      regression structures, 1462, 1462f, 1464f
      rhomboidal structures (face), 1462, 1462f, 1464f
      shiny white lines (crystalline structures), 1462, 1462f, 1463f
      streaks, 1462, 1462f, 1463f
  two-step algorithm for, 1456, 1456f
Diabetes mellitus (DM), 1300–1307
  acanthosis nigricans in, 1302, 1302f, 1310–1313, 1310f–1313f (*See also* Acanthosis nigricans)
  acrochordons in, 922, 922f, 923, 1312, 1313f (*See also* Skin tag (acrochordon))
  Charcot arthropathy in, 1261–1264, 1261f–1263f, 1302, 1304f (*See also* Charcot arthropathy)
  diabetic dermopathy in, 1302, 1302f, 1314–1316, 1314f–1317f (*See also* Diabetic dermopathy)
  diagnosis of, 1272f–1274f, 1300f, 1302
  dry gangrene in, 1265–1267, 1265f, 1266f
  epidemiology of, 26, 1300–1301
  etiology and pathophysiology of, 1301
  follow-up in, 1307
  foot ulcers in
    ischemic, 1255–1257, 1255f, 1256f, 1302, 1303f
    neuropathic, 1258–1260, 1258f, 1259f
    vs. venous insufficiency ulcers, 296
  fundamentals of, 1300
  management of, 1303–1306
    complementary and alternative therapy in, 1306
    diet and exercise interventions in, 1303–1304
    education in, 1304
    goals of, 1303
    medications in, 1304–1306
    referral or hospitalization in, 1306
    self-management and -monitoring interventions in, 1304
  necrobiosis lipoidica in, 1302, 1303f, 1317–1320, 1317f–1320f (*See also* Necrobiosis lipoidica; Necrobiosis lipoidica (NL))
  patient education in, 1307
  patient story of, 1300, 1300f
  peripheral arterial disease and dry gangrene in, 1265
  prevention and screening in, 1306
  prognosis in, 1307
  psoriasis in, 892
  risk factors for, 1301
  xanthoma and xanthelasma in, 1302, 1304f, 1322–1327, 1322f–1324f (*See also* Xanthomas)
Diabetic dermopathy, 1314–1316
  diagnosis of, 1302, 1302f, 1314f–1316f, 1315
  differential diagnosis of
    vs. necrobiosis lipoidica, 1315
    vs. Schamberg disease, 1315
    vs. stasis dermatitis, 1315
    vs. traumatic scars, 1315
  epidemiology of, 1314
  etiology and pathophysiology of, 1314–1315
  fundamentals of, 1314
  management of, 1315

patient story of, 1314, 1314f
prevention of, 1316
prognosis and patient education in, 1316
Diabetic retinopathy, 143–145
diagnosis of, 143f, 144, 144f
differential diagnosis of
vs. age-related macular degeneration, 157
vs. HIV retinopathy, 144
vs. hypertensive retinopathy, 144
vs. hyphema, 160
epidemiology of, 143
etiology and pathophysiology of, 143–144, 143f, 144f
follow-up and patient education on, 145
management of, 144–145, 145f
nonproliferative
diagnosis of, 1302
management of, 1303–1306
patient story of, 1300, 1300f
prognosis in, 1307
patient story of, 143, 143f
prevention of, 145
proliferative *vs.* nonproliferative, 143, 143f–144f
risk factors for, 144
Diagnosis. *See also specific disorders*
dermoscopy in (*See* Dermoscopy)
images in, 2
internal image banks for, 3
senses in, 2
using images for, 3–4
Diaper dermatitis, 646–650. *See also* Diaper rash
secondary, 648
Diaper rash, 646–650
definition of, 646
diagnosis of, 647–648, 647f, 648f
differential diagnosis of, 648
epidemiology of, 646, 646f, 647f
etiology and pathophysiology of, 647, 647f
follow-up of, 650
management of, 648–649
patient (parent) education on, 650
patient story of, 646, 646f
prevention of, 649
prognosis in, 650
risk factors for, 647
Diaphragm with spermicide, 13t
Diaphyseal stress fracture, *vs.* metatarsal fracture, 612
Diet, on mortality, 26
DIHS. *See* DRESS/DIHS
"Dinner fork" deformity, 605–609. *See also* Radius fracture, distal
Diphtheria, *vs.* pharyngitis, 217
Diphyllobothrium latum, 1270–1274
Disabilities, caring for those with, 44–46, 44f, 46f
Disc herniation
vs. ankylosing spondylitis, 582
vs. back pain, 587, 587f
Discoid eczema. *See* Eczema, nummular
Discoid hand dermatitis, 844f, 845
Discoid lupus erythematosus (DLE), 1070–1078
diagnosis of, 1072–1074, 1072f, 1074f–1076f
biopsy in, 1073–1074
laboratory testing in, 1073
typical distribution in, 1073, 1076f
differential diagnosis of
vs. actinic keratosis, 1074
vs. basal cell carcinoma, superficial, 996
vs. dermatomyositis, 1074
vs. drug-induced lupus, 1074
vs. leukoplakia, 251
vs. lichen planus, 1074
vs. melasma, 1181
vs. osteoarthritis, 571
vs. psoriasis, 1074
vs. rosacea, 1074
vs. sarcoidosis, 1074
vs. scleroderma, 1074, 1093
vs. syphilis, 1074
epidemiology of, 1070–1071
etiology and pathophysiology of, 1071
follow-up of, 1078
management of, 1074, 1077, 1141–1143
patient education on, 1078
prevention of, 1077
prognosis in, 1078
risk factors for, 1071
scarring alopecia in, 1140, 1142f
Dissecting cellulitis, scarring alopecia from, 1140, 1141f. *See also* Alopecia, scarring
Distal radius fracture. *See* Radius fracture, distal
Diverticula
vs. colon cancer, 401
vs. colon polyps, 396
Diverticulitis
vs. colon cancer, 400
vs. kidney stones, 427
Doctor–patient reciprocity, 9
Doctor–patient relationship, 8–11
good
benefits of, 10
essentials of, 10
humor in, 8
language for increasing patient power in, 10
maximizing patient education effectiveness in, 11
patient story in, 8
skills for building of, 10
what patients want from their physician in, 8
what physicians want from and for patients in, 9, 9f
Doctors Without Borders, 38–39
patient stories from, 37, 37f
Döderlein's cytolysis, *vs. Candida* vulvovaginitis, 501–502
Domestic violence, 95–100. *See also* Intimate partner violence (IPV)
Double decidual sign, 19
Dowling-Meara epidermolysis bullosa simplex, 1121–1123, 1123f
Doxycycline, reactions from, 1211–1222, 1214f
DRESS/DIHS
diagnosis of, 1219, 1219f
differential diagnosis of, 1220–1221
epidemiology of, 1212
Drink, 1412
Drinking, heavy, 1411–1423. *See also* Alcoholism
Drospirenone, 14
Drug abuse or addiction. *See* Substance abuse disorder; *specific drugs*
Drug eruptions. *See* Drug reactions, cutaneous
Drug-induced alopecia, *vs.* scarring alopecia, 1141
Drug-induced bullous pemphigoid, 1104–1108. *See also* Bullous pemphigoid

Drug-induced gingival overgrowth (DIGO), 240–243, 240f, 241f. *See also* Gingival overgrowth
Drug-induced liver disease, 377–384. *See also* Liver disease
Drug-induced lupus, *vs.* lupus erythematosus, 1074
Drug-induced photosensitivity, 1191–1196, 1192f. *See also* Photodermatitis; Photosensitivity
Drug reactions, cutaneous, 1211–1222
  bullous drug eruptions, 1100, 1101f
  diagnosis of, 1211f–1215f, 1218–1220
  differential diagnosis of
    vs. bullous pemphigoid, 1221
    vs. dermatomyositis, 1083
    for DRESS/DIHS, 1220–1221
    for erythema multiforme, 1220
    vs. hematoma, warfarin, 1221, 1221f
    vs. herpes simplex virus, 739
    vs. pemphigoid gestationis, 473
    vs. pemphigus vulgaris, 1221
    vs. pityriasis rosea, 1221
    vs. pruritic urticarial papules and plaques of pregnancy, 468
    vs. Stevens-Johnson syndrome, 1215f, 1220
    vs. syphilis, 1282
    vs. syphilis, secondary, 1221
    for toxic epidermal necrolysis, 1220
    for urticarial reactions, 1220
    vs. viral exanthemas, 1220
  epidemiology of, 1211–1212, 1211f–1215f, 1216t, 1217t
  erythroderma from, 915–921 (*See also* Erythroderma)
  etiology and pathophysiology of, 1212, 1213f, 1216
  follow-up of, 1222
  fundamentals of, 1211
  management of, 1221–1222
  patient education on, 1222
  patient story of, 1211, 1211f
  pityriasis rosea from, 897
  prevention of, 1222
  prognosis in, 1222
  risk factors for, 1216–1218
Drumstick fingers, 292–294, 292f, 293f
Drusen
  in age-related macular degeneration, 155–158, 155f, 156f
  diseases with, 157
  optic disc, 153
Dry gangrene, 1265–1267, 1265f, 1266f
Dry mouth, dental caries with, 263, 265
Dry skin. *See* Xerosis
Ductal ectasia with inflammation, *vs.* breast cancer, 554
Dupuytren disease (contractures), 625–628
  diagnosis of, 626
  differential diagnosis of
    vs. ganglion cysts and palmar nodules, 627
    vs. hand tumors, 627
    vs. rheumatoid arthritis, 627
    vs. trigger finger and stenosing tenosynovitis, 626
  epidemiology of, 625, 625f
  etiology and pathophysiology of, 625–626
  fundamentals of, 625
  management of, 627
  patient education on, 627–628
  patient story of, 625, 625f
  prognosis and follow-up in, 627
  risk factors for, 626
Dust mite control, 328, 328f
Dye allergy, tattoo, *vs.* contact dermatitis, 839, 839f
Dyscoria, 160f
Dyshidrotic eczema, 843–849. *See also* Eczema, hand
  vs. atopic dermatitis, 831
  vs. contact dermatitis, 839
  vs. dermatitis herpetiformic, 1126
  vs. tinea pedis, 801, 802f
Dysphonia, 220–225. *See also* Hoarseness
Dysplastic nevus, 963–967. *See also* Nevus, dysplastic
Dyspnea scale, MMRC, 336, 336b
Dystrophic epidermolysis bullosa, 1121–1123, 1121f–1123f
  vs. erythema multiforme bullosum, 1122

E

Ear foreign body, 185–187
  ant, 186f
  beach sand, 186f
  bead, 185, 185f
  crayon piece, 185f
  differential diagnosis of
    vs. acute otitis and otitis media with effusion, 173, 186
    vs. chronic suppurative otitis media, 186
    vs. otitis externa, 182, 186
Early childhood caries (ECC), 257–260. *See also* Caries, early childhood
Ecstasy, 1394f. *See also* Substance abuse disorder
  epidemiology of, 1393, 1394f
  prevalence of use of, 26
Ecthyma, *vs.* pyoderma gangrenosum, 1031
Ectopic pregnancy, 20
  first trimester ultrasound for, 475–477
Ectropion
  colposcopy and diagnosis of, 525, 525f, 526, 528f
  management of, 528
Eczema, 826–833, 826f–833f. *See also* Atopic dermatitis
  of areola, *vs.* Paget disease of breast, 559, 559f
  asteatotic, *vs.* X-linked ichthyosis, 1233
  differential diagnosis of, *vs.* porphyria cutanea tarda, 1120
  discoid, 851–854 (*See also* Eczema, nummular)
  dyshidrotic, 843–849 (*See also* Eczema, hand)
    vs. atopic dermatitis, 831
    vs. contact dermatitis, 839
    vs. dermatitis herpetiformis, 1126
    vs. tinea pedis, 801, 802f
  microbial, 851–854 (*See also* Eczema, nummular)
  orbicular, 851–854 (*See also* Eczema, nummular)
  as photoallergic drug reaction, 1191–1196, 1193f
Eczema, hand, 843–849
  allergens in, 845
  atopic, 843, 844f
  chronic vesicular, 843, 845f
  contact, 843, 843f, 845f
  definition of, 843
  diagnosis of, 843f–846f, 845–846
  differential diagnosis of
    vs. Candida, 845f, 847
    vs. cutaneous fungal infections, 845f, 847
    vs. knuckle pads, 847
    vs. psoriasis, 847
    vs. tinea manus, 847, 847f
  dyshidrotic (pompholyx), 843–849, 844f
  endogenous, 845

epidemiology of, 843
etiology and pathophysiology of, 843–845, 843f–846f
exogenous, 845
follow-up of, 849
frictional, 843, 844f
hyperkeratotic, 843, 844f
infectious, 845, 845f
management of, 847–849, 848t, 849t
nummular, 843, 844f (*See also* Eczema, nummular)
patient education on, 848t
patient story of, 843, 843f
rubber allergens in, 845
Eczema, nummular, 851–854
diagnosis of, 852, 852f, 853f
differential diagnosis of
vs. actinic keratosis and Bowen disease, 970, 972
vs. asteatotic dermatitis, 854
vs. atopic dermatitis, 854
vs. basal cell carcinoma, superficial, 996
vs. contact dermatitis, 854
vs. dermatitis herpetiformis, 1126
vs. granuloma annulare, 1024
vs. lichen simplex chronicus, 854
vs. mycosis fungoides, 854
vs. pityriasis rosea, 899
vs. psoriasis, 854, 888
vs. self-inflicted dermatoses, 861
vs. squamous cell carcinoma, 1005
vs. tinea corporis, 791, 852–854
epidemiology of, 851
etiology and pathophysiology of, 851–852
follow-up of, 854
fundamentals of, 851
hand, 844f, 845 (*See also* Eczema, hand)
management of, 854
patient education on, 854
patient story of, 851, 851f
Eczema herpeticum
with atopic dermatitis, 827, 827f
vs. impetigo, 677, 677f
Eczematous dermatitis, *vs.* lichen planus, 906
Eczema vaccinatum, with atopic dermatitis, 827, 828f
Edema. *See also specific types*
scalp, on third trimester ultrasound, 482, 483f
Edema blisters, 1102
Education, family, end of life, 33–34
Education, patient. *See also specific disorders*
on child abuse, 86
context for, 10
end of life, 33–34
on family planning, 15
maximizing effectiveness of, 11
on pregnancy and birthing, 22–23, 22f
Effusion
otitis media with, 170–178 (*See also* Otitis media with effusion (OME))
pericardial, 281–285 (*See also* Pericardial effusion)
pleural
in heart failure, 278f
vs. pericardial effusion, 283–284, 284f
Eikenella bacterial endocarditis, 288
Embolus
cholesterol, *vs.* vasculitis, 1068
deep venous (*See* Deep venous thrombosis (DVT))
pulmonary, 345–352 (*See also* Pulmonary embolus)
Embryo, on first trimester ultrasound, 475–477, 475f–477f
Embryonic disc, on first trimester ultrasound, 476
Emergency contraceptives (ECs), 20–21
Empathy, expressing, 10
Emphysema, 334–343. *See also* Chronic obstructive pulmonary disease (COPD)
Encephalitis, *vs.* cocaine abuse, 1435
Encephalomyelitis
vs. Lyme disease, 1293
postinfectious, 724, 726
"En coupe de sabre," in linear morphea, 1089f, 1090f
Endocarditis, bacterial, 287–291
diagnosis of, 287f–289f, 288–289
differential diagnosis of, 289–290
vs. abdominal infections, 290
vs. cardiac tumors, 290
vs. connective tissue disorders, 289
vs. cusp prolapse, 290
vs. fever of unknown origin, 289
vs. intra-abdominal infections, 290
vs. Lamb excrescences, 290
vs. myxomatous changes, 290
vs. noninfective vegetations, 290
vs. rheumatoid arthritis, 577
epidemiology of, 287
etiology and pathophysiology of, 288f
follow-up for, 290
fundamentals of, 287
management of, 290
patient education on, 291
patient story of, 287, 287f, 288f
prevention of, 290
prognosis in, 290
Endocervical polyp
colposcopy and diagnosis of, 527, 528f
management of, 528, 528f
End of life, 25–34
clinical features of, 28
diagnosis of, 27–28
epidemiology of, 26
etiology and pathophysiology of, 26–27
follow-up in, 32–33
management of, 28–33
advance directives in, 29–30
hospice care and services in, 30–31, 30f
important factors in, 29
pain management in, 32
palliative care in, 30, 31–32
patient and family/caregiver discussions in, 29
primary care provider role in, 29, 29f
principles of, 28–29, 29f
P-SPIKES approach in, 28–29
social needs in, 32–33
spiritual needs in, 33
symptom control in, 32
patient and family education on, 33–34
patient story of, 25
physical changes in, 33–34
processes in, 33
End-stage renal disease, death from, 27
Entamoeba histolytica, 1270–1274

Enterobacter folliculitis, 681
Enterobacteriaceae necrotizing fasciitis, 702
Enterobius vermicularis, 1270–1274, 1270f
Enterococcus bacterial endocarditis, 288
Entropion, red eye in, 163, 165
Eosinophilic folliculitis, 682, 682f
Epicondylitis, *vs.* olecranon bursitis, 598
Epidermal cyst, *vs.* hidradenitis suppurativa, 672
Epidermal hyperplasia, in melanocytic nevi, *vs.* skin tag, 923
Epidermal inclusion cyst
  vs. abscess, 699, 700f
  vs. dermatofibroma, 937
  vs. sarcoidosis, 1039
Epidermal nevus. *See* Nevus, epidermal
Epidermolysis bullosa, 1121–1123, 1121f–1123f
  vs. porphyria cutanea tarda, 1120, 1122
Epidermolysis bullosa acquisita, 1098, 1099f
Epidermolysis bullosa simplex, 1098, 1099f, 1103, 1103f
  in children, 1102
Epidermophyton, 771. *See also* Fungal infections, cutaneous; Tinea
Epidermophyton floccosum, 799
Epidural hematoma, *vs.* subdural hematoma, 1378, 1378f
Epiglottitis, *vs.* pharyngitis, 217
Episcleritis, 131–136, 133f
  diagnosis of, 132–133, 133f
  differential diagnosis of, 133
    vs. acute-angle closure glaucoma, 133
    vs. conjunctivitis, 127, 133
    vs. corneal ulceration, 133
    vs. iritis, 133, 137
    vs. keratitis, 133
    vs. uveitis, 133, 137
  epidemiology of, 131
  etiology and pathophysiology of, 132
  fundamentals of, 131
  management of, 134
  patient education on, 134
  prognosis and follow-up for, 134
  red eye in, 163–168, 164t, 166f
Episodic tension-type headache, 1366–1370
  diagnosis of, 1367–1368
  epidemiology of, 1366
  etiology and pathophysiology of, 1366
  management of, 1368
  prognosis in, 1370
Epithelial cysts, 525, 526f
  management of, 527
Epithelial keratitis, from zoster ophthalmicus, 718–722, 718f
Epithelium, cervical, 526, 526f
  atrophic
    diagnosis of, 527, 527f
    management of, 528
Erosio interdigitalis blastomycetica, 845, 845f
Eruptive lingual papillitis, *vs.* strawberry tongue, 210
Eruptive xanthomas, 1322f–1324f, 1323
Erysipelas, 693, 695f. *See also* Cellulitis
Erythema ab igne, 1198–1201
  diagnosis of, 1198f–1201f, 1199–1200
  differential diagnosis of
    vs. acanthosis nigricans, 1200–1201
    vs. cutis marmorata, 1200
    vs. cutis marmorata telangiectasia congenita, 1200
    vs. livedo reticularis, 1200, 1201f
    vs. poikiloderma atrophicans vasculare, 1200
  epidemiology of, 1198
  etiology and pathophysiology of, 1198–1199
  follow-up of, 1201
  fundamentals of, 1198
  management of, 1201
  patient education on, 1201
  patient story of, 1198, 1198f
  prognosis in, 1201
  risk factors for, 1199
Erythema annulare centrifugum (EAC), 1236–1239
  definition of, 1236
  diagnosis of, 1236f, 1237, 1237f
  differential diagnosis of
    vs. erythema gyratum repens, 1238
    vs. erythema migrans, 1238
    vs. granuloma annulare, 1024
    vs. hypersensitivity syndromes, 1054
    vs. lupus, cutaneous, 1238
    vs. Lyme disease, 1238
    vs. mycosis fungoides, 1238
    vs. pityriasis rosea, 1237
    vs. psoriatic plaques, 1238
    vs. sarcoidosis, 1238
    vs. tinea corporis, 791, 792f, 1238, 1238f
  epidemiology of, 1236
  etiology and pathophysiology of, 1236–1237
  follow-up of, 1239
  management of, 1238
  patient education on, 1239
  patient story of, 1236, 1236f
  prognosis in, 1238
Erythema chronicum migrans of Lyme disease. *See also* Lyme disease
  vs. cutaneous larva migrans, 824
  vs. erythema annulare centrifugum, 1238
Erythema exudativum perstans, 1236–1239, 1236f–1238f. *See also* Erythema annulare centrifugum
Erythema figuratum perstans, 1236–1239, 1236f–1238f. *See also* Erythema annulare centrifugum
Erythema gyratum perstans, 1236–1239, 1236f–1238f. *See also* Erythema annulare centrifugum
Erythema gyratum repens, *vs.* erythema annulare centrifugum, 1238
Erythema induratum, *vs.* necrotizing fasciitis, 704–705
Erythema induratum of Bazin, *vs.* erythema nodosum, 1059
Erythema infectiosum (fifth disease), 728–731, 728f–730f. *See also* Fifth disease (erythema infectiosum)
Erythema marginatum perstans, 1236–1239, 1236f–1238f. *See also* Erythema annulare centrifugum
Erythema microgyratum perstans, 1236–1239, 1236f–1238f. *See also* Erythema annulare centrifugum
Erythema migrans, 1289f–1291f, 1290
  vs. erythema annulare centrifugum, 1238
Erythema multiforme (EM), 1049–1055
  diagnosis of, 1050f, 1052–1054, 1052f, 1053f
  differential diagnosis of
    vs. aphthous ulcer, 246
    vs. bullous pemphigoid, 1054
    vs. cutaneous drug reactions, 1220
    vs. cutaneous vasculitis, 1054
    vs. erythema annulare centrifugum, 1054
    vs. hand, foot, and mouth disease, 734

vs. Kawasaki disease, 1054
vs. pemphigoid gestationis, 473
vs. pityriasis lichenoides et varioliformis acuta, 1124
vs. pruritic urticarial papules and plaques of pregnancy, 468
vs. syphilis, 1282
vs. urticaria, 866, 866f, 1054
from drugs (*See also* Drug reactions, cutaneous)
diagnosis of, 1215f, 1219
differential diagnosis of, 1220
epidemiology of, 1212
epidemiology of, 1049–1050
etiology and pathophysiology of, 1050, 1050f
follow-up of, 1055
fundamentals of, 1049
management of, 1054
patient education on, 1055
prevention of, 1054
prognosis in, 1055
risk factors for, 1050
Erythema multiforme bullosum
vs. dystrophic epidermolysis bullosa, 1122
vs. porphyria cutanea tarda, 1120
Erythema nodosum, 1056–1060. *See also* Sarcoidosis
definition of, 1056
diagnosis of, 1056f, 1057f, 1058–1059
differential diagnosis of
vs. cellulitis, 1059
vs. erythema induratum of Bazin, 1059
vs. erythema nodosum leprosum, 1059, 1059f, 1060f
vs. necrobiosis lipoidica, 1318–1319
vs. nodular cutaneous/subcutaneous sarcoid, 1059
vs. panniculitis, infectious, 1060
vs. sarcoidosis, 1059
epidemiology of, 1056, 1056f, 1057f
etiology and pathophysiology of, 1056–1057, 1057f
follow-up of, 1060
management of, 1059–1060
patient education on, 1060
patient story of, 1056, 1056f
prevention of, 1060
prognosis in, 1060
risk factors for, 1056f, 1057–1058
Erythema nodosum leprosum, *vs.* erythema nodosum, 1059, 1059f, 1060f
Erythema perstans, 1236–1239, 1236f–1238f. *See also* Erythema annulare centrifugum
Erythema simplex gyratum, 1236–1239, 1236f–1238f. *See also* Erythema annulare centrifugum
Erythematotelangiectatic rosacea, 660, 661f–662f. *See also* Rosacea
Erythema toxicum neonatorum (ETN), 630–634
definition of, 630, 632f
diagnosis of, 632–633, 632f
differential diagnosis of, 633–634
vs. chickenpox, 633
vs. cutis marmorata, 634, 634f
vs. folliculitis, 633
vs. harlequin color change, 634
vs. miliaria, 633, 633f
vs. neonatal lupus, 634, 634f
vs. neonatal pustular melanosis, 633
vs. pustular diseases of childhood, 644
vs. scarlet fever, 210
epidemiology of, 631
etiology and pathophysiology of, 631
management of, 634
parent education on, 634
prognosis in, 634
Erythrasma, 689–692
definition of, 689
diagnosis of, 689f–691f, 690
differential diagnosis of
vs. candidiasis, 690
vs. candidiasis, mucocutaneous, 778
vs. contact dermatitis, 691
vs. dermatophytosis, 690
vs. intertrigo, 691
vs. psoriasis, 690
vs. tinea corporis, 791
vs. tinea cruris, 796, 797f
epidemiology of, 689
etiology and pathophysiology of, 689, 689f
follow-up of, 691
management of, 691
patient education on, 692
patient story of, 689, 689f
prognosis in, 691
risk factors for, 689
Erythroderma, 915–921
diagnosis of, 919–920
differential diagnosis of, 920
epidemiology of, 915
etiology and pathophysiology of, 915f–921f, 916–919, 916t
follow-up of, 921
fundamentals of, 915
management of, 920
patient education on, 920–921
patient story of, 915, 915f
Erythrodermic psoriasis, 915–921, 915f–917f. *See also* Erythroderma; Psoriasis
Erythroleukoplakia, 249–252, 251f. *See also* Leukoplakia
in oropharyngeal cancer, 254, 254f
Erythroplakia, 249–252, 251f. *See also* Leukoplakia
diagnosis of, 250, 251f
differential diagnosis of, 251
vs. geographic tongue, 233
vs. leukoplakia, 249
epidemiology of, 249
etiology and pathophysiology of, 249–250
follow-up for, 252
fundamentals of, 249
management of, 251
in oropharyngeal cancer, 253f, 254
patient education on, 252
prevention and screening for, 251
prognosis in, 251
risk factors for, 250
Erythroplasia of Queyrat, 969–975, 970f, 1000, 1000f. *See also* Actinic keratosis; Squamous cell carcinoma
Escherichia coli
folliculitis from, 681
mastitis from, 546
pneumonia from, 301
Esophageal cancer, *vs.* gastric cancer, 374
Esophagitis, *vs.* gastric cancer, 374

Essure tubal occlusion device, 14f, 15, 15f
Estimated date of delivery (EDD), 18–19, 483
Estimated fetal weight (EFW), 478, 478f–481f
Estimated gestational age (EGA), ultrasound for
first trimester, 475–477, 475f–477f
second trimester, 478–481, 478f–481f
third trimester, 482–484, 482f, 483f
Estrogen-containing contraceptives, smoking with, 13
Estrogen deficiency, postmenopause, 489–491
Etonogestrel implant, 13t, 14f, 15
Evidence, 1448
Evidence-based medicine
definition of, 1448
history of, 1448
interpreting, 1448–1450, 1449f, 1450f
Exanthem, viral
vs. cutaneous drug reactions, 1220
vs. pruritic urticarial papules and plaques of pregnancy, 469
vs. scarlet fever, 210
Exanthematous drug eruptions, 1211–1222. *See also* Drug reactions, cutaneous
diagnosis of, 1211f, 1218
epidemiology of, 1211f, 1212
Exercise, on mortality, 26
Exophthalmos, Graves, 1353–1358. *See also* Graves disease and goiter
Extramammary Paget disease, 514–517. *See also* Paget disease of external genitalia
Eyelid ecchymosis, 160, 160f
Eye trauma (hyphema), 159–162. *See also* Hyphema

F

Face, on second trimester ultrasound, 479f, 480, 480f
Facial nerve damage, *vs.* Bell palsy, 1384
Facial nerve palsy
in Bell palsy (*See* Bell palsy)
isolated, 1384
vs. Bell palsy, 1384f
Failure to thrive
from child abuse, 84
vs. child abuse, 85
end of life, 27
False vocal cords, 220
Falx cerebri, on second trimester ultrasound, 479f, 481f
Familial atypical mole and melanoma (FAMM) syndrome, 963–967. *See also* Dysplastic nevus
Familial hypercholesterolemia, 1322–1323
Family physicians, pregnancy care delivery and outcomes of, 18
Family planning, 12–16
contraceptive choice in, 12–14, 13t
contraceptive options in, 12–14, 13t
contraceptive options in, new, 12f, 13t, 14–15, 14f–16f
epidemiology of, 12
follow-up in, 15
patient education on, 15
patient story of, 12
Fanconi anemia, *vs.* neurofibromatosis, 1388–1389
Felon
vs. herpes simplex virus, 739
vs. paronychia, 1168
Female sterilization, 13t
Femoral neck fracture, 615–617, 615f–617f
Femur length (FL), on second trimester ultrasound, 478, 479f, 480
Fertility, 18
Fertility awareness, 13t
Fetal biometric measurements, ultrasound for
first trimester, 475–477, 476f, 477f
second trimester, 478–481, 478f–481f
Fetal maturity, on third trimester ultrasound, 483
Fetal pole, 19, 477
Fever of unknown origin, *vs.* bacterial endocarditis, 289
Fibroadenoma, *vs.* breast cancer, 553
Fibroepithelial polyps, 922–924, 922f, 923f. *See also* Skin tag (acrochordon)
Fibromyalgia
vs. arthritis, 566
vs. osteoarthritis, 571
vs. rheumatoid arthritis, 577
Fibrosarcoma, infantile, *vs.* childhood hemangioma, 638
Fibrous histiocytoma
benign, 935–938
malignant, *vs.* dermatofibroma, 936
Fibrous papule
vs. basal cell carcinoma, nodular, 995
vs. pyogenic granuloma, 943, 943f
vs. sebaceous hyperplasia, 933
Fifth disease (erythema infectiosum), 728–731
diagnosis of, 728f–730f, 729–730
differential diagnosis of
vs. allergic-hypersensitivity reaction, 730
vs. Lyme disease, 730
vs. measles, 730
vs. rheumatic fever, 730
epidemiology of, 728
etiology and pathophysiology of, 728–729, 729f
fundamentals of, 728
management of, 730
patient education on, 731
patient story of, 728, 728f
prevention of, 730
prognosis in, 730
risk factors for, 729
Fifth metatarsal fracture, 611–614, 611f
Fifth metatarsal tuberosity avulsion fracture, 611–614, 611f
Fifth metatarsal tuberosity fracture, 611–614. *See also* Metatarsal fracture
Fingernail clubbing, 292–294, 292f, 293f
Fire ants, bullous bites from, 1100, 1102f
First trimester obstetrical ultrasound, 475–477, 475f–477f
Fish tapeworm, 1270–1274
Fissured tongue, *vs.* geographic tongue, 233, 234f
Fixed drug eruptions (FDE), 1211–1222. *See also* Drug reactions, cutaneous
diagnosis of, 1213f–1215f, 1218–1220
epidemiology of, 1212, 1213f–1215f
Flake. *See* Cocaine abuse
Flat warts, 755–758. *See also* Warts, flat
Fluid–air interface, in liver disease, 380, 381f
Fluorescein, for corneal foreign body/abrasion, 123, 123f
Fluoride, for early childhood caries, 259t, 260, 260f
Fluoroquinolones, reactions from, 1216t
Folic acid supplements, in pregnancy, 23
Follicular mucinosis, *vs.* alopecia areata, 1130, 1131f
Folliculitis, 680–684
definition of, 680

diagnosis of, 680f, 683
differential diagnosis of
vs. acne keloidalis nuchae, 667
vs. acne vulgaris, 652, 684
vs. erythema toxicum neonatorum, 633
vs. Grover disease, 683, 683f
vs. herpes zoster, 715
vs. impetigo, 677, 684
vs. keratosis pilaris, 684
vs. miliaria, 684
vs. pseudofolliculitis, 667
epidemiology of, 680, 680f–683f
etiology and pathophysiology of, 680–683, 680f–684f
acne keloidalis, 681, 681f, 682f
acne keloidalis nuchae, 681, 681f, 682f
actinic superficial, 683
bacterial or staphylococcus, 680f–682f, 681
eosinophilic, 682f, 683
folliculitis decalvans, 681, 682f
fungal, 681, 683f
gram-negative, 681
MRSA, 680, 682f
noninfectious, 680
parasitic, 681
Pityrosporum, 681, 683f
pseudofolliculitis barbae, 680, 681, 681f, 684
Pseudomonas ("hot tub"), 680f, 681
staphylococcus, 681
tufted folliculitis, 681, 682f
viral, 681–683
follow-up of, 684
management of, 680f, 683f, 684
patient education on, 684
patient story of, 680, 680f
Folliculitis, *Pityrosporum,* 681, 682f, 683f, 806, 807f
diagnosis of, 807f
vs. tinea versicolor, 806, 807f
Folliculitis, tufted, 681, 682f
scarring alopecia in, 1138–1143 (*See also* Alopecia, scarring)
diagnosis of, 1140, 1140f
management of, 1141–1143
Folliculitis decalvans, 681, 682f. *See also* Folliculitis
scarring alopecia in, 1138–1143 (*See also* Alopecia, scarring)
diagnosis of, 1138f, 1140
management of, 1141–1143
patient story of, 1138, 1138f
Folliculitis keloidalis. *See* Acne keloidalis nuchae
Food dye, *vs.* strawberry tongue, 210
Foot dermatitis, with atopic dermatitis, 827
Forchheimer spots, 209
Fordyce spots, *vs.* measles, 725
Foreign body, ear, 185–187
vs. acute otitis and otitis media with effusion, 173
ant, 186f
beach sand, 186f
bead, 185, 185f
crayon piece, 185f
differential diagnosis of
vs. acute otitis and otitis media with effusion, 173
vs. acute otitis media, 186
vs. chronic suppurative otitis media, 186
vs. otitis externa, 182, 186
Foreign body, eye
conjunctival
conjunctivitis from, 128, 129f
irritation from, red eye in, 165f
corneal, 122–125
Foreign body granuloma, *vs.* sarcoidosis, 1039
Fourchette, posterior, from child sexual abuse, 91
Fournier gangrene, 702, 704, 704f
Fractures. *See also specific types*
from child abuse
clinical features of, 84, 84f
follow-up for, 86
patient stories on, 82, 82f, 84f
vs. child abuse, 85
Fragrances, contact dermatitis from, 834, 835, 836f
Friction blisters, 1100
vs. tinea pedis, 801
Frontal fibrosing alopecia, 1140, 1140f
Frostbite, dry gangrene from, 1265–1267, 1265f, 1266f
Functional alcohol use disorder, 1412, 1413t. *See also* Alcoholism
Functional dyspepsia, *vs.* peptic ulcer disease, 368
Fungal folliculitis, 681, 683f
Fungal infections, cutaneous, 771–776. *See also specific types*
diagnosis of, 771–774, 771f–774f, 774t, 775t
differential diagnosis of
vs. contact dermatitis, 837f, 839
vs. cutaneous larva migrans, 824
vs. hand eczema, 845f, 847
vs. Lyme disease, 1293
epidemiology of, 771
fundamentals of, 771
management of, 774–776, 775t
pathophysiology of, 771, 771f–773f
patient story of, 771, 771f
Fungal respiratory infections, *vs.* tuberculosis, 314
Furuncle, *vs.* abscess, 699
Future Doctors of America Club, 50, 50f
Future of Family Medicine (FFM) initiative, on physician–patient relationship, 8–9

G

Gallbladder sludge, 386, 387
Gallstone ileus, 388f
Gallstones, 386–391
diagnosis of, 386f, 387–388, 388f–390f
differential diagnosis of
vs. cholecystitis, 389
vs. hepatitis, 389
vs. pancreatitis, 389
vs. peptic ulcer disease, 389
epidemiology of, 386
etiology and pathophysiology of, 387
follow-up of, 390
fundamentals of, 386
intrahepatic cholestasis of pregnancy and, 464
management of, 389–390
patient education on, 390–391
patient story of, 386, 386f
prognosis in, 390
risk factors for, 387
Ganglion cysts, *vs.* Dupuytren disease, 627

Gangrene
dry, 1265–1267, 1265f, 1266f
vs. ischemic ulcer of foot, 1256
necrotizing fasciitis with, 702–706, 704f
wet, 1266, 1266f
wet *vs.* dry, 1266, 1266f
Gardnerella vaginalis, 494–497
Gardnerella vaginalis vaginitis, 485–487, 486f
Gardnerella vaginosis, 494–497. *See also* Bacterial vaginosis (BV)
Gastric cancer, 371–375
definition of, 371
diagnosis of, 371f, 372–374, 373f
differential diagnosis of
vs. esophageal cancer, 374
vs. esophagitis, 374
vs. gastritis, chronic, 374
vs. nonulcer dyspepsia, 374
vs. peptic ulcer disease, 368, 374
epidemiology of, 371
etiology and pathophysiology of, 371–372
follow-up of, 375
management of, 374
patient education on, 375
patient story of, 371, 371f
prevention of, 374–375
prognosis in, 375
risk factors for, 372
Gastric ulcers, 366–369, 366f, 367f. *See also* Peptic ulcer disease (PUD)
Gastritis, chronic, *vs.* gastric cancer, 374
Gastroesophageal reflux (GERD)
vs. coronary artery disease, 270
vs. laryngopharyngeal reflux, 221
vs. peptic ulcer disease, 368
Gastrointestinal infection. *See also specific types*
vs. colon cancer, 401
vs. colon polyps, 395
Gender, on second trimester ultrasound, 479f, 480, 481f
Genital herpes, 735–742. *See also* Herpes simplex virus (HSV)
Genital irritation/bleeding. *See also* Rectal bleeding
vs. child sexual abuse, 92, 93f
Genital warts, 759–765. *See also* Warts, genital
Genodermatoses, 1229–1234
callus from, 1243, 1244, 1244f
diagnosis of, 1229f–1235f, 1230
differential diagnosis of
vs. Grover disease, 1230
vs. Hailey-Hailey disease, 1230, 1233f
vs. seborrheic dermatitis, 1233
epidemiology of, 1229
etiology and pathophysiology of, 1229
follow-up of, 1234
management of, 1233–1234
patient education on, 1234
patient story of, 1229, 1229f, 1230f
Gentamicin, reactions from, 1211–1222, 1216t
Geographic stomatitis, 232–235. *See also* Geographic tongue
Geographic tongue, 232–235
diagnosis of, 232f, 233, 233f
differential diagnosis of
vs. erythroplakia or leukoplakia, 233
vs. fissured tongue, 233, 234f
vs. lichen planus, 233, 233f
vs. psoriasis, 233, 234f
vs. reactive arthritis, 233
epidemiology of, 232
etiology and pathophysiology of, 232
follow-up of, 234
fundamentals of, 232
management of, 234, 235f
patient education on, 234
patient story of, 232, 232f
Gestational age, on ultrasound
first trimester, 475–477, 475f–477f
second trimester, 478–481, 478f–481f
third trimester, 482–484, 482f, 483f
Gestational sac, 19
on first trimester ultrasound, 476
Ghon complex, 311, 311f, 314
Ghrelin, 1330
Gianotti-Crosti syndrome, *vs.* pityriasis lichenoides et varioliformis acuta, 1124, 1125f
Giant condyloma, *vs.* genital warts, 762, 763f
Giant papillary conjunctivitis, 128, 128f
red eye in, 165f
Giant urticaria, 866f
Giardia lamblia, 1270–1274, 1273f
Gigantism, 1360–1364. *See also* Acromegaly
Gingival fibromatosis, hereditary, 240–243
Gingival hyperplasia, 240–242. *See also* Gingival overgrowth
vs. gingivitis, 238
vs. pyogenic granuloma, 241f
Gingival overgrowth, 240–242, 240f
diagnosis of, 241
differential diagnosis of
vs. gingivitis, generalized, 241
vs. gingivitis, pregnancy, 241
vs. leukemia, 242
vs. pregnancy tumor, 241–242
vs. pyogenic granuloma, 241–242
epidemiology of, 240
etiology and pathophysiology of, 240–241
fundamentals and synonyms for, 240
management of, 242
patient education and follow-up of, 242
patient story of, 240, 240f
prevention of, 242
risk factors for, 241
Gingivitis, 236–238
acute necrotizing ulcerative, 236–238, 237f
diagnosis of, 236f, 237, 237f
differential diagnosis of, 238
vs. gingival overgrowth, 241
epidemiology of, 236, 237f
etiology and pathophysiology of, 236–237, 236f, 237f
fundamentals of, 236
management of, 238
patient education and follow-up in, 238
patient story of, 236, 236f
prevention of, 238
risk factors for, 237
from smoking, 1400
Gingivostomatitis, herpes, 735–742, 737f. *See also* Herpes simplex virus (HSV)
vs. aphthous ulcer, 246

vs. pharyngitis, 216
Glaucoma, 139–142
differential diagnosis of
vs. age-related macular degeneration, 157
vs. optic disc cupping, 140f, 141
vs. zoster ophthalmicus, 720
red eye in, 163, 164t, 165
Glaucoma, acute-angle closure, 139–142, 140f
diagnosis of, 140, 140f
differential diagnosis of, 141
vs. conjunctivitis, 128
vs. corneal foreign body/abrasion, 124
vs. scleritis and episcleritis, 133
vs. uveitis and iritis, 137
epidemiology of, 139
etiology and pathophysiology of, 139–140
management of, 141
patient education on, 142
prevention of, 141
prognosis and follow-up for, 141
red eye in, 163, 164t, 165
risk factors for, 140
Glaucoma, angle-closure, 139–142, 140f
red eye in, 164t
Glaucoma, open-angle
vs. age-related macular degeneration, 157
primary, 139–142
Gleason grade and score, prostate cancer, 454–455, 455f
Glioblastoma, *vs.* nasal polyps, 194
Global health, 53–76
behavioral changes in, long-term, 55
cholera in, 57–59
Common River community story in, 49f, 53, 54f
definition of, 53–55
epidemiology of, 55
ethical dilemmas in, 53–55, 55f
eye diseases in, trachoma, 69–70, 69f
vs. international health, 53
intestinal parasites in, 59–60
malnutrition in, 60–61, 60f, 71f
marasmus in, 60–61, 60f, 70f
Mycobacterium in
leprosy, 72–74, 73f, 74f
tuberculosis and HIV, 74–75, 75f, 76f
peer-to-peer adult education in, 55
skin diseases in, infectious, 70–71, 70f– 72f
trust in local health care providers in, 55, 55f
typhoid fever in, 56–57
vector borne diseases in, 64–69 (*See also specific diseases*)
leishmaniasis, 67–69, 67f–69f
malaria, 64–66, 65f
prevention of, 69
prognosis in, 69
water and sanitation in, 55–56, 55f, 56f
preventing contaminated-water–borne diseases in, 59, 59f
Globe (eye) injury, red eye in, 167f
Glomangiomas, 1203–1206, 1205f. *See also* Vascular lesions, acquired
vs. vascular lesions, 1209
Glomus tumor, *vs.* paronychia, 1167
Gluten-induced enteropathy, dermatitis herpetiformis with, 1125–1126, 1126f
Goals, 4–5
Goiter, from iodine deficiency, 63–64, 64f
Goiter and Graves disease, 1353–1358, 1353f–1356f. *See also* Graves disease and goiter
Goitrogens, environmental, *vs.* goitrous hypothyroidism, 1349
Goitrous hypothyroidism, 1346–1352
diagnosis of, 1346f–1349f, 1347–1348
differential diagnosis of
vs. branchial cleft cyst, 1349
vs. environmental goitrogens, 1349
vs. Graves disease, 1349
vs. Hashimoto thyroiditis, 1348, 1349
vs. iodine deficiency, 1349
vs. postpartum thyroiditis, 1349
vs. suppurative thyroiditis, acute, 1349
vs. thyroglossal duct cyst, 1349, 1350f
vs. thyroid cancer, 1349, 1350f
vs. toxic nodular goiter, 1348f, 1349
epidemiology of, 1346, 1346f, 1347f
etiology and pathophysiology of, 1346f, 1347, 1347f
follow-up for, 1351–1352
fundamentals of, 1346
management of, 1349–1350
patient story of, 1346, 1346f
prevention and screening for, 1350–1351
prognosis in, 1351
risk factors for, 1347
subacute granulomatous thyroiditis in, 1348
Gonococcal arthritis
diagnosis of, typical distribution in, 563
vs. reactive arthritis, 913
Gonococcal conjunctivitis, 126–129, 127f. *See also* Conjunctivitis
Gonococcal urethritis, in men, 1275–1277, 1275f
Gonococcus. *See* Gonorrhea *(Neisseria gonorrhoeae)*
Gonorrhea *(Neisseria gonorrhoeae)*
after sexual assault, 105, 106
differential diagnosis of
vs. bacterial vaginosis, 496
vs. *Candida* vulvovaginitis, 501
vs. *Chlamydia* cervicitis, 511
vs. *Trichomonas* vaginitis, 506
urethritis in men from, 1275–1277, 1275f
Gottron's papules, in dermatomyositis, 1079, 1080, 1080f, 1081, 1082, 1082f
Gout, 590–594
diagnosis of, 590f–592f, 591–593
imaging in, 566
typical distribution in, 563, 565f, 566f
differential diagnosis of
vs. bunion deformity, 1248
vs. cellulitis, 593, 694
vs. Charcot arthropathy, 1262
vs. hammer toe, 1253
vs. knee soft tissue injuries, 622
vs. olecranon bursitis, 598
vs. pseudogout, 593
vs. rheumatic arthritis, 593
vs. septic arthritis, 593
vs. xanthomas, 1324, 1324f
epidemiology of, 590
etiology and pathophysiology of, 590–591
follow-up of, 594
fundamentals of, 590
management of, 593–594

Gout (*Continued*)
patient education on, 594
patient story of, 590, 590f, 591f
prevention of, 594
prognosis in, 594
risk factors for, 591
tophaceous, diagnosis of, 563, 566f
Gouty arthritis, 590–594, 590f–592f. *See also* Gout
Gram-negative folliculitis, 681
Granular casts, 420–423, 423f. *See also* Urinary sediment
Granuloma, pyogenic. *See* Pyogenic granuloma
Granuloma annulare, 1022–1027
definition of, 1022
diagnosis of, 1022f–1025f, 1023–1024
differential diagnosis of
vs. eczema, nummular, 1024
vs. erythema annulare centrifugum, 1024
vs. necrobiosis lipoidica, 1319
vs. pityriasis rosea, 1024
vs. rheumatoid nodules, 1024
vs. sarcoidosis, 1038
vs. tinea corporis, 1024
epidemiology of, 1022
etiology and pathophysiology of, 1022–1023
follow-up of, 1027
management of, 1024–1027
for generalized/disseminated disease, 1025–1027
for localized disease, 1022f, 1023f, 1024–1025, 1026f
for perforating, subcutaneous disease, 1027
patient education on, 1027
patient story of, 1022, 1022f, 1023f
prognosis in, 1027
risk factors for, 1023
Granuloma gluteale infantum, 648
Granuloma gravidarum, 464, 465, 465f
Granuloma inguinale
vs. hidradenitis suppurativa, 672
vs. vulvar intraepithelial neoplasia, 521
Granulomatous rosacea, *vs.* sarcoidosis, 1038
Granulomatous thyroiditis, subacute, 1347
Graves disease and goiter, 1353–1358
with amenorrhea, 20
diagnosis of, 1353f–1356f, 1354–1355
differential diagnosis of
vs. autonomous functioning nodule, 1355
vs. cocaine abuse, 1435
vs. goiter of hypothyroidism, 1349
vs. metastatic disease (ocular muscles), 1356
vs. pseudotumor (eye), 1356
vs. thyroid hormone overdose, 1355
vs. thyroiditis, 1355
vs. thyrotropin-secreting pituitary adenoma, 1355
vs. toxic multinodular goiter, 1355
epidemiology of, 1353
etiology and pathophysiology of, 1353–1354
follow-up of, 1358
fundamentals of, 1353
management of, 1356–1357
patient education on, 1358
patient story of, 1353, 1353f
prognosis in, 1357–1358
risk factors for, 1354
Grief follow-up, 34
Group A β-hemolytic streptococcus (GABHS)
cellulitis from, 693
impetigo from, 676–679 (*See also* Impetigo)
perianal dermatitis from, 646–650, 646f, 647f (*See also* Diaper rash)
pharyngitis from, 213–218 (*See also* Pharyngitis)
erythema nodosum from, 1056, 1056f, 1057
Group A streptococcus, scarlet fever and strawberry tongue from, 208–209
Grover disease
vs. Darier disease, 1230
vs. folliculitis, 683, 683f
Guttate psoriasis. *See* Psoriasis

H

Habit-tic deformity, 1146, 1147f, 1149
Haemophilus bacterial endocarditis, 288
Haemophilus influenzae
acute otitis media from, 171
conjunctivitis from, 126–129
pneumonia from, 301
sinusitis from, 198
Haemophilus vaginalis, 494–497. *See also* Bacterial vaginosis (BV)
Haemophilus vaginitis, 494–497. *See also* Bacterial vaginosis (BV)
Hailey-Hailey disease
vs. Darier disease, 1230, 1233f
vs. pemphigus vegetans, 1114, 1115f
Hair, in pregnancy, 463–464, 464f
HAIR-AN syndrome, 1310
Hair casts, *vs.* lice, 811
Hairy leukoplakia
vs. black hairy tongue, 229, 230f
vs. leukoplakia, 251
Hairy tongue, black, 228–230, 228f, 229f
vs. candidiasis, oral, 229
vs. hairy leukoplakia, 229, 230f
Half-and-half nail, 1149, 1149f
Hallucinogens. *See also* Substance abuse disorder; *specific types*
epidemiology of, 1393
Hallux abducto valgus deformity, 1247–1250, 1247f–1249f. *See also* Bunion deformity
Hallux valgus, 1247–1250, 1247f–1249f. *See also* Bunion deformity
Halo nevus, 945f, 946. *See also* Nevus, benign
vs. vitiligo, 1187
Hammer toe, 1251–1254
callus from, 1243, 1243f
diagnosis, 1251f, 1252
differential diagnosis of
vs. fractured toe, 1253
vs. gout and pseudogout, 1253
vs. rheumatoid arthritis, 1253
vs. septic joint, 1253
epidemiology of, 1251
etiology and pathophysiology of, 1251–1252, 1252f
follow-up for, 1254
fundamentals of, 1251
imaging of, 1251f, 1252
management of, 1253–1254, 1253f
patient education on, 1254
patient story of, 1251, 1251f
prognosis in, 1254
risk factors for, 1252, 1252f
Hand, foot, and mouth disease (HFMD), 732–734, 732f, 733f
vs. aphthous stomatitis, 733
vs. aphthous ulcer, 246

vs. chickenpox, 733
vs. erythema multiforme, 734
vs. herpes simplex, 734
vs. pustular diseases of childhood, 644
Hand dermatitis, 843–849. *See also* Eczema, hand
with atopic dermatitis, 827
Hand eczema, 843–849. *See also* Eczema, hand
Hands, on second trimester ultrasound, 480, 480f
Hand tumors, *vs.* Dupuytren disease, 627
Hansen disease, 72–74, 73f, 74f. *See also* Leprosy
Harlequin color change, *vs.* erythema toxicum neonatorum, 634
Hart line, 521
Hashimoto thyroiditis, *vs.* goitrous hypothyroidism, 1348, 1349
Head, on second trimester ultrasound, 478, 478f, 480
Headache, 1366–1370
diagnosis of, 1367–1368, 1368f
differential diagnosis of
vs. sinusitis, 200
vs. subarachnoid hemorrhage, 1368, 1368f
epidemiology of, 1366
etiology and pathophysiology of, 1366–1367, 1366f
follow-up in, 1370
fundamentals of, 1366
management of, 1368–1369
patient education on, 1370
patient story of, 1366
prevention of, 1369
prognosis in, 1370
risk factors for, 1367
Head circumference (HC), fetal, 478, 478f, 480
Head lice, 809–814, 810f, 811f. *See also* Lice
HEADSS, 89
Healthcare associated pneumonia, 300. *See also* Pneumonia
Health insurance reform, 39
Hearing aid, otitis externa with, 182f. *See also* Otitis externa
Heart block, *vs.* Lyme disease, 1293
Heart disease. *See also specific types*
coronary, 268–270, 268f, 269f
death from, 27
epidemiology of, 26
Heart failure, 277–280
diagnosis of, 277f–279f, 278
differential diagnosis of, 278
vs. anxiety, 278
vs. asthma, 327
vs. chronic obstructive pulmonary disease, 278, 338
vs. deconditioning, 278
vs. metabolic acidosis, 278
vs. neuromuscular weakness, 278
vs. pericardial effusion, 284f
vs. pneumonia, 278
vs. pulmonary embolus, 350
epidemiology of, 277
etiology and pathophysiology of, 277–278
follow-up of, 280
fundamentals of, 277
management of, 278–280
patient education on, 280
patient story of, 277, 277f
pericardial effusion in, 283–284, 284f
prognosis in, 280
Heart motion, fetal, 482, 483f
Heart rate, fetal, 483, 483f
Heat rash. *See* Miliaria
Heavy drinking, 1411–1423. *See also* Alcoholism
Heberden nodes, 563f, 569, 569f, 570, 570f
Heerfordt syndrome, 1035–1040. *See also* Sarcoidosis
Hegar sign, 19
Helicobacter pylori
colon polyps and, 394
peptic ulcer disease from, 366–369, 366f, 367f (*See also* Peptic ulcer disease (PUD))
Heloma durum, 1242–1245. *See also* Corns
Heloma molle, 1242–1245. *See also* Corns
Hemangioma
dermoscopy of, 1469, 1469f, 1470f
black lacunae (angiokeratoma), 1469, 1470f
blue lacunae, 1469, 1470f
red lacunae, 1469, 1469f
differential diagnosis of
vs. Kaposi sarcoma, 1287
vs. nasal polyps, 194
vascular, 1205f
Hemangioma, childhood, 636–640
diagnosis of, 636f–639f, 637–638
differential diagnosis of
vs. angiosarcoma, 638
vs. arteriovenous malformation, 638
vs. blue rubber bleb nevus syndrome, 638
vs. fibrosarcoma, infantile, 638
vs. Maffucci syndrome, 638
vs. salmon patch, 638, 638f
vs. stork bite, 638, 638f
epidemiology of, 636
etiology and pathophysiology of, 636–637, 637f
follow-up of, 640
fundamentals of, 636
management of, 637f, 638–640, 639f
patient education on, 640
patient story of, 636, 636f
topical therapy for, new, 640
Hematoma
vs. Kaposi sarcoma, 1287
nail, *vs.* nail variants, normal, 1149
subgaleal, *vs.* child abuse, 85, 86f
warfarin, *vs.* cutaneous drug reactions, 1221, 1221f
Hematoma, subdural, 1376–1379
diagnosis of, 1376f, 1377, 1377f
differential diagnosis of
vs. brain cancer, 1377
vs. brain parenchyma hemorrhage, 1378
vs. dementia or depression, 1377
vs. epidural hematoma, 1378, 1378f
vs. infections (sepsis, meningitis), 1377
vs. stroke, 1377, 1377f
vs. subarachnoid hemorrhage, 1378, 1378f
epidemiology of, 1376
etiology and pathophysiology of, 1376–1377, 1376f, 1377f
follow-up of, 1379
fundamentals of, 1376
management of, 1378
patient education on, 1379
patient story of, 1376, 1376f
prevention of, 1378
prognosis in, 1378–1379
risk factors for, 1377

Hematoma, subungual, 1175–1177
diagnosis of, 1176
differential diagnosis of
vs. longitudinal melanonychia, 1154, 1176
vs. nail bed nevus, 1176
vs. splinter hemorrhage, 1176
vs. subungual melanoma, 1176
epidemiology of, 1175
etiology and pathophysiology of, 1175, 1175f–1177f
follow-up of, 1177
fundamentals of, 1175
management of, 1175f, 1176–1177, 1176f
patient education on, 1177
patient story of, 1175, 1175f, 1176f
prognosis in, 1177
Hematuria, 420–423
bladder cancer, 448–452, 448f (*See also* Bladder cancer)
diagnosis of, 421f, 422–423, 422f
differential diagnosis of, 428
epidemiology of, 420
etiology and pathophysiology of, 420f, 421, 421f
management of, 423
patient story of, 420, 420f
prevention and screening in, 423
in renal cell carcinoma, 441–446 (*See also* Renal cell carcinoma)
risk factors for cancer with, 421
Hemochromatosis
in liver disease, 377–384 (*See also* Liver disease)
vs. rheumatoid arthritis, 577
Hemorrhage. *See specific types*
Hemorrhagic stroke, *vs.* subdural hematoma, 1377, 1377f
Hemorrhoidal varicosities, in pregnancy, 463, 464, 465
Hemorrhoids, 414–418
definition of, 414
diagnosis of, 414f, 415, 415f
differential diagnosis of
vs. anal fissure, 416, 416f
vs. anal tumor, 416
vs. colon cancer, 401
vs. colon polyps, 395–396
vs. condyloma acuminata, 416
vs. inflammatory bowel disease, 416
vs. perirectal abscess, 416, 416f
vs. rectal infection, 416, 416f
vs. rectal prolapse, 416
epidemiology of, 414
etiology and pathophysiology of, 414–415
follow-up of, 418
management of, 416–418
patient education on, 418
patient story of, 414, 414f
in pregnancy, 463, 464
prognosis in, 418
risk factors for, 415
Hemosiderin deposition, lipodermatosclerosis with, 296, 296f, 297f
Henoch-Schönlein purpura (HSP), 1062–1069, 1062f, 1063f. *See also* Vasculitis
vs. urticaria, 866, 867f
Hepatic. *See also* Liver
Hepatic artery, 378
Hepatic dysfunction, 377–384. *See also* Liver disease
Hepatic failure, 377–384. *See also* Liver disease
Hepatitis, 377–384. *See also* Liver disease
alcoholic, 377–384 (*See also* Liver disease)
differential diagnosis of, *vs.* gallstones, 389
Hepatitis A, 378
Hepatitis B, 378
Hepatitis B vaccination, after sexual assault, 106
Hepatitis C, 378
Hepatitis D, 378
Hepatitis E, 378
Hepatocellular disease, 377–384. *See also* Liver disease
Hepatocytes, 378–379
Herald patch, 896, 897, 897f, 898f
Hereditary angioedema, 864, 865f
Hereditary gingival fibromatosis, 240–242. *See also* Gingival overgrowth
Hereditary hemangiomatosis, 1207–1210, 1208f. *See also* Vascular lesions, hereditary and congenital
Hereditary hemorrhagic telangiectasias (HHTs), 1207–1210, 1207f. *See also* Vascular lesions, hereditary and congenital
Hereditary nonpolyposis colorectal cancer (HNPCC), 395
Herniated disc
vs. ankylosing spondylitis, 582
vs. back pain, 587, 587f
Heroin, 1394f
black tar, 1394f
Heroin abuse. *See also* Substance abuse disorder
epidemiology of, 1393, 1394f
Heroin abuse, injection, 1439–1444. *See also* Injection-drug use
diagnosis of, 1440–1442, 1440f–1443f
epidemiology of, 1393, 1394f, 1439–1440
etiology and pathophysiology of, 1440
follow-up of, 1444
fundamentals of, 1439
management of, 1442–1444
overdose in, 1440
patient education on, 1444
patient story of, 1439, 1439f
prevention and screening for, 1444
prognosis in, 1444
risk factors for, 1440
Herpangina
vs. aphthous ulcer, 246
vs. pharyngitis, 216, 216f
Herpes gestationis, 471–474, 471f–473f. *See also* Pemphigoid gestationis
Herpes gingivostomatitis, 735–742, 737f. *See also* Herpes simplex virus (HSV)
vs. pharyngitis, 216
Herpes labialis, 735–742. *See also* Herpes simplex virus (HSV)
Herpes simplex virus (HSV), 735–742
blistering from, 1102
congenital, 1102
diagnosis of, 735f–738f, 738–739
differential diagnosis of
vs. angular cheilitis, 204
vs. aphthous ulcer, 246
vs. Behçet's disease, 739, 739f
vs. chancroid, 739
vs. drug eruption, 739
vs. felon, 739
vs. hand, foot, and mouth disease, 734
vs. herpes zoster, 715
vs. impetigo, 677
vs. paronychia, 739

vs. pustular diseases of childhood, 644
vs. syphilis, 739, 1280
epidemiology of, 735, 735f–737f
etiology and pathophysiology of, 735–736, 737f
follow-up of, 742
management of, 739–741, 740t, 741t
patient education on, 742
patient story of, 735, 735f
prevention of, 740t, 741–742
risk factors for, 736
urethritis in men from, 1275–1277
Herpes simplex virus 1 (HSV1)
from child abuse, 90, 92f
differential diagnosis of
vs. Paget disease of external genitalia, 516
vs. vulvar intraepithelial neoplasia, 521
Herpes simplex virus 2 (HSV2)
vs. Paget disease of external genitalia, 516
vs. vulvar intraepithelial neoplasia, 521
Herpes zoster, 712–716
blistering from, 1102, 1103f
definition of, 712, 712f
diagnosis of, 713f–715f, 714
differential diagnosis of
vs. coronary artery disease, 715
vs. folliculitis, 715
vs. hand, foot, and mouth disease, 733
vs. herpes simplex, 715
vs. insect bites, 714
vs. molluscum contagiosum, 714
vs. pemphigus, 714
vs. scabies, 714
epidemiology of, 712
etiology and pathophysiology of, 712–713, 713f
follow-up of, 716
management of, 715, 715t, 716t
patient education on, 716
patient story of, 712, 712f
prevention of, 715
risk factors for, 713–714
Herpes zoster oticus, 713, 713f
Herpetic folliculitis, 681–683
Herpetic keratitis, *vs.* conjunctivitis, 128, 128f
Herpetic whitlow, 735–742, 737f
vs. paronychia, 1167
Heterotopic pregnancies, 20
Hidradenitis suppurativa, 671–674
diagnosis of, 671f–674f, 672
differential diagnosis of
vs. abscess, 699
vs. bacterial infections, 672
vs. epidermal cysts, 672
vs. granuloma inguinale, 672
vs. lymphogranuloma venereum, 672
vs. Paget disease of external genitalia, 516
epidemiology of, 671
etiology and pathophysiology of, 671, 672f–674f
follow-up of, 674
fundamentals of, 671
management of, 672–674
with obesity, 1331, 1333f
patient education on, 674
patient story of, 671, 671f
in pregnancy, 463
risk factors for, 672
High-grade squamous intraepithelial lesions (HGSIL), 535–539, 535f–538f. *See also* Cervical intraepithelial neoplasia I (CIN I)
Hip fracture, 615–617, 615f–617f
Hippocratic nails (fingers), 292–294, 292f, 293f
Hirsutism, in pregnancy, 464
Histiocytoma, fibrous
benign, 935–938
malignant, *vs.* dermatofibroma, 936
Histoplasmosis, *vs.* tuberculosis, 314, 317f
Hives, 863–869. *See also* Urticaria
HIV retinopathy, *vs.* diabetic retinopathy, 144
HLA-B27 positive, uveitis and iritis with, 135–137
Hoarseness, 220–225
diagnosis of, 222–223
differential diagnosis of, 220f, 223, 223f–225f
epidemiology of, 220–221
etiology and pathophysiology of, 220f, 221–222
follow-up for, 225
fundamentals of, 220
management of, 223–224
patient education on, 225
patient story of, 220
synonyms and definitions in, 220, 220f
Homeless, caring for, 46–49, 48f, 49f
Home pregnancy kits, 19, 22
Homicide, epidemiology of, 26
Homogenous leukoplakia, 249–252, 249f–251f. *See also* Leukoplakia
Hookworms, 823, 1270–1274, 1270f, 1271f. *See also* Cutaneous larva migrans
global health problem of, 59–60
Hordeolum, 114–117
diagnosis of, 115, 115f, 116f
differential diagnosis of, 115, 115f, 116f
vs. basal cell carcinoma, 115
vs. hydrocystoma, 115, 116f
vs. molluscum contagiosum, 115
vs. sebaceous cell carcinoma, 115
vs. xanthelasma, 115
epidemiology of, 114
fundamentals of, 114
management of, 115–116
patient education on, 117
patient story of, 114, 114f
prevention of, 116
prognosis and follow-up for, 116
risk factors for, 115
Hormonal vaginal ring, 12, 12f, 14
Horn, cutaneous, 985–986, 985f–987f
Hospice care and services, 30–31, 30f. *See also* End of life
prevalence of, 26
Hot flashes, in premature menopause, 20
"Hot tub" folliculitis, 680, 680f, 681
Human immunodeficiency virus (HIV) infection. *See also* Acquired immunodeficiency syndrome (AIDS)
angular cheilitis with, 204, 205f
from child sexual abuse, 91, 93
death from, 27
on mortality, 26
prophylaxis against

Human immunodeficiency virus (HIV) infection (*Continued*)
after child sexual abuse, 93
postexposure, 106
reactive inflammation in, *vs.* cutaneous T-cell lymphoma, 1045
skin viral infections with, 71
tuberculosis co-infection with, global, 74–75, 75f, 76f
Humanism Fellowship, 48, 48f
Humanitarian emergency, 37, 37f, 38–39
patient stories of, 37, 37f
Human papillomavirus (HPV), 749. *See also* Warts, genital
in cervical cancer, 541, 542
cervical intraepithelial neoplasia from, 530
differential diagnosis of
vs. cervical cancer, 543
vs. cervical intraepithelial neoplasia II/III, 538
vs. nonmalignant inflammatory lesions, 531
vs. vulvar intraepithelial neoplasia, 521
maternal, and juvenile onset recurrent respiratory papillomatosis, 221
in oropharyngeal cancer, 254 (*See also* Oropharyngeal cancer)
with squamous intraepithelial lesions
high-grade, 535
low-grade, 530–533 (*See also* Cervical intraepithelial neoplasia I (CIN I))
warts from
common, 749–754, 749f–753f
flat, 755–758, 755f, 756f (*See also* Warts, flat)
genital, 759–765 (*See also* Warts, genital)
plantar, 766–769, 766f–768f (*See also* Warts, plantar)
Humerus, third trimester ultrasound of, 482f, 483
Humor, in patient–physician relationship, 8
Hurt-Insult-Threat-Scream (HITS), 97
Hutchinson fracture, 605–609, 607f. *See also* Radius fracture, distal
Hutchinson sign
in acral lentiginous melanoma, 1012, 1013f
pigmented nail from, 1152, 1152f, 1153f
definition of, 1152, 1152f, 1153f
pseudo-, 1152, 1154f
in zoster ophthalmicus, 719, 719f, 720f
Hyaline cell casts, 420–423, 422f. *See also* Urinary casts
Hydrocephalus, normal pressure, 1380–1382, 1380f, 1381f
Hydrocodone, reactions from, 1215f
Hydrocystoma, *vs.* hordeolum and chalazion, 115, 116f
Hydrogen peroxide–producing *Lactobacillus,* vaginal, 495
Hydronephrosis, 430–434
definition of, 430
diagnosis of, 430f, 431–432, 432f
differential diagnosis of
vs. cholelithiasis, 432
vs. pyelonephritis, 432
epidemiology of, 430, 430f
etiology and pathophysiology of, 430–431
management of, 432–433
patient education on, 434
patient story of, 430, 430f
prevention and screening of, 433
prognosis and follow-up for, 434
Hydrops fetalis, on third trimester ultrasound, 482, 483f
Hydroureter, 430f, 432
Hymen
in child sexual abuse, 89–92, 89f–91f
normal, 89, 89f
Hyperglycemia, diabetic retinopathy from, 143–145
Hyperhidrosis, in pregnancy, 463
Hyperkeratosis of the tongue, 228–230, 228f, 229f
Hyperkeratotic lesions, 1242–1245. *See also* Calluses; Corns
Hyperlipidemia, 1322–1327. *See also* Xanthomas
definition of, 1322
diagnosis of, 1324
epidemiology of, 1322–1323
etiology and pathophysiology of, 1323
follow-up of, 1327
fundamentals of, 1322
management of, 1325–1327
patient education on, 1327
patient story of xanthomas in, 1322, 1322f, 1323f
prevention and screening for, 1327
prognosis in, 1327
Hyperpigmentation, drug-induced. *See also* Drug reactions, cutaneous
diagnosis of, 1213f, 1218
epidemiology of, 1212, 1213f
Hyperplastic polyp, 393–397. *See also* Colon polyps
Hypersensitivity syndromes, 1049–1055
diagnosis of, 1049f–1053f, 1052–1054
differential diagnosis of
vs. bullous pemphigoid, 1054
vs. cutaneous vasculitis, 1054
vs. erythema annulare centrifugum, 1054
vs. fifth disease, 730
vs. Kawasaki disease, 1054
vs. staphylococcal scalded skin syndrome, 1054
vs. urticaria, 1054
epidemiology of, 1049
etiology and pathophysiology of, 1050, 1050f
follow-up of, 1055
fundamentals of, 1049
management of, 1054
patient education on, 1055
patient story of, 1049, 1049f, 1050f
prevention of, 1054
prognosis in, 1055
risk factors for, 1050
Hypersensitivity vasculitis, 1062–1069. *See also* Vasculitis
Hypertension, 272–276
benign intracranial, 151–154 (*See also* Papilledema)
cerebral vascular accident with, 1372
diagnosis of, 272f–274f, 273–274
differential diagnosis of, 274
epidemiology of, 273
etiology and pathophysiology of, 273, 273f
follow-up of, 276
fundamentals of, 272–273
idiopathic intracranial, papilledema from, 151–154, 151f, 152f (*See also* Papilledema)
management of, 275
patient education on, 276
patient story of, 272, 272f
prevention of, 275
prognosis of, 275–276
pulmonary
in chronic obstructive pulmonary disease, 335, 337
with pulmonary embolus, 348, 350, 350f, 352
risk factors for, 273
white coat, 274
Hypertensive retinopathy, 147–150. *See also* Retinopathy, hypertensive
vs. diabetic retinopathy, 144
diagnosis of, 273f

Hyperthyroidism, 1353–1358. *See also* Graves disease and goiter
with amenorrhea, 20
Hypertriglyceridemia, 1323
Hypertrophic scars
cortisone injection of, 1454f
differential diagnosis of
vs. dermatofibroma, 937
vs. keloids, 1225
Hyperuricemia
in gout, 591
medications in, 591, 594
Hyphema, 159–162
diagnosis of, 159f, 160, 160f
differential diagnosis of, 160–161
epidemiology of, 159
etiology and pathophysiology of, 159
fundamentals of, 159
management of, 161
patient education on, 162
patient story of, 159, 159f
prevention of, 162
prognosis and follow-up for, 162
red eye in, 165, 167f
Hypoglycemia
vs. cerebral vascular accident, 1373
vs. cocaine abuse, 1435
Hypomelanosis of Ito, *vs.* vitiligo, 1187, 1187f
Hypopigmentation. *See* Vitiligo; *specific disorders*
Hypopyon
red eye in, 165, 167f
in uveitis, 136, 136f
Hypothyroidism
definition of, 1346
differential diagnosis of
vs. dermatomyositis, 1083
vs. normal pressure hydrocephalus, 1382
goitrous, 1346–1352, 1346f–1349f (*See also* Goitrous hypothyroidism)
Hysteroscopic tubal occlusion, 14f, 15, 15f

I

Ibuprofen, reactions from, 1211–1222, 1214f
Ice. *See* Methamphetamine
Ichthyosis
acquired, 1233, 1234f
with atopic dermatitis, 827, 830f
lamellar, 1233, 1235f
X-linked (*See* X-linked ichthyosis)
Ichthyosis vulgaris, *vs.* X-linked ichthyosis, 1233, 1234f
Idiopathic guttate hypomelanosis
vs. cutaneous T-cell lymphoma, 1045
vs. vitiligo, 1187, 1187f
Idiopathic intracranial hypertension (IIH), papilledema from, 151–154, 151f, 152f. *See also* Papilledema
Idiopathic thrombocytopenic purpura, *vs.* cutaneous vasculitis, 1066, 1069f
Id reaction, tinea pedis, 799, 799f, 800
IgA bullous dermatosis, 1098, 1100f
Ileus, gallstone, 388f
Images. *See also specific disorders*
for building patient–physician relationship, 4
for diagnosis, 2–5, 2f, 3f, 4t
on internet, 3–4, 4t
internet sources for, 3–4, 4t
taken your own, 4
Immediate IgE contact reaction, *vs.* contact dermatitis, 839
Impetiginization, 677, 679f
Impetigo, 676–679
with atopic dermatitis, 827
with chickenpox, 710f
diagnosis of, 676–677, 676f–679f
differential diagnosis of
vs. acne keloidalis nuchae, 667
vs. allergic contact dermatitis, 677
vs. angular cheilitis, 204
vs. atopic dermatitis, 677, 679f
vs. bullous pemphigoid, 677
vs. eczema herpeticum, 675f, 677, 677f
vs. folliculitis, 677, 684
vs. herpes simplex virus, 677
vs. insect bites, 677, 678f
vs. pemphigus vulgaris, 677
vs. pseudofolliculitis, 667
vs. pustular diseases of childhood, 644
vs. scabies, 677, 821, 821f
vs. second degree burn, 677, 679f
vs. staphylococcal scalded skin syndrome, 677, 679f
vs. sunburn, 677, 679f
vs. tinea corporis, 677
epidemiology of, 676
etiology and pathophysiology of, 676
follow-up of, 679
fundamentals of, 676
as global health problem, 71, 71f, 72f
management of, 677–679
patient education on, 679
patient story of, 676, 676f
prevention on, 679
Implanon, 14f, 15
Implantation, fertilized egg, 18
Inactivity, physical, on mortality, 26
Inclusion cyst, epidermal
vs. abscess, 699, 700f
vs. dermatofibroma, 937
vs. sarcoidosis, 1039
Infectious mononucleosis
vs. pharyngitis, 215f, 216
tonsillar exudate in, 215f
Inflammation. *See specific disorders*
Inflammatory acne, 651–657, 653f. *See also* Acne vulgaris
Inflammatory arthritis
from Lyme disease, 1290–1291
vs. Lyme disease, 1293
Inflammatory bowel disease (IBD), 405–412
diagnosis of, 406–409
clinical features in, 406–408, 409f
endoscopy and imaging in, 405f, 408–409, 408f–410f
laboratory tests in, 408
typical distribution in, 405f, 408
differential diagnosis of
vs. colon cancer, 400
vs. colon infections, 409
vs. colon polyps, 396
vs. hemorrhoids, 416
vs. infections, 409

Inflammatory bowel disease (IBD) (*Continued*)
vs. ischemic colitis, 409, 410f
vs. kidney stones, 427
vs. NSAID colitis, 409
epidemiology of, 405
etiology and pathophysiology of, 405–406
follow-up of, 412
fundamentals of, 405
management of, 409–411
medication in, 409–411
surgery in, 411
patient education on, 412
patient story of, 405, 405f
prognosis in, 411–412
risk factors for, 406
Inflammatory breast cancer (IBC), 551–555, 553f. *See also* Breast cancer
Inflammatory linear verrucous epidermal nevus, 958–962, 959f. *See also* Nevus, epidermal
Inflammatory myopathy, *vs.* arthritis, 566
Influenza virus sinusitis, 198
Ingrown toenail, 1156–1158
definition of, 1156
diagnosis of, 1156f, 1257
differential diagnosis of
vs. cellulitis, 1157
vs. paronychia, 1157, 1167
etiology and pathophysiology of, 1156, 1156f
follow-up of, 1158
management of, 1157–1158, 1157f, 1158f
patient education on, 1158
patient story of, 1156, 1156f
risk factors for, 1156–1157, 1156f, 1257
Injection-drug use, 1439–1444. *See also* Substance abuse disorder; *specific drugs*
complications of, 1441
diagnosis of, 1440–1442, 1440f–1443f
cocaine, 1441–1442
complications in, 1440f–1443f, 1441
heroin, 1440–1442
laboratory testing in, 1441–1442
differential diagnosis of, 1442
epidemiology of, 1439–1440, 1440f
etiology and pathophysiology of, 1440, 1440f
follow-up of, 1444
fundamentals of, 1439
management of, 1442–1444
patient education on, 1444
patient story of, 1439, 1439f
prevention and screening for, 1444
prognosis in, 1444
risk factors for, 1440
Injury. *See also specific types*
eye
globe (eye), red eye in, 167f
retinal pigment epithelial, 155–156
from intimate partner violence, 95–100 (*See also* Intimate partner violence (IPV))
intracranial
from child abuse, 84, 85
vs. child abuse, 85
knee soft tissue, 619–624 (*See also* Knee soft tissue injuries)
Lisfranc, 613
on mortality, 26
from sexual abuse
adult, 102–107 (*See also* Sexual assault, adult)
child, 89–93 (*See also* Sexual abuse, child)
straddle, *vs.* child sexual abuse, 91
Insect bites
vs. herpes zoster, 714
vs. impetigo, 677, 678f
vs. urticaria, 866
Instructional directives, 29–30
Insulin resistance
in diabetes mellitus, 1300 (*See also* Diabetes mellitus)
etiology and pathophysiology of, 1301
vitamin D on, 1303
Internally displaced persons, 38
International health, 53
Internet, images on, 3–4, 4t
Interstitial pneumonia, 304, 306f, 307f
Intertriginous vegetating plaques, 1105
Intertrigo
vs. candidiasis, 778, 779f, 780f
vs. erythrasma, 691
vs. tinea cruris, 796
Intertrochanteric fracture, 615–617, 617f
Interview, patient-centered, 10
Intestinal worms and parasites, 1270–1274
diagnosis of, 1270f–1273f, 1272–1273
differential diagnosis of
vs. GI blood loss, 1273
vs. infections, 1273
vs. inflammatory bowel disease, 1273
vs. iron-deficiency anemia, 1273
vs. irritable bowel disease, 1273
epidemiology of, 1270–1271, 1270f–1273f
etiology and pathophysiology of, 1270f–1273f, 1271–1272
follow-up of, 1274
global health problem of, 59–60
management of, 1274
patient education on, 1274
patient story of, 1270, 1270f
prevention of, 1274
prognosis with, 1274
risk factors for, 1272
water and sanitation in, 55–56, 55f, 56f
Intimate partner violence (IPV), 95–100
child witnesses of, 95
definition of, 95
diagnosis of, 95f, 96–97, 97f
epidemiology of, 95–96
follow-up of, 99
management of, 97–98, 97f, 98f
patient education on, 99–100
patient story of, 95, 95f
prognosis in, 99
risk factors for, 96
screening and prevention of, 98–99
Intra-abdominal infections. *See also specific infections*
vs. bacterial endocarditis, 290
Intraarticular fractures, *vs.* knee soft tissue injuries, 621, 622f
Intracranial bleeding, *vs.* child abuse, 85
Intracranial injury
from child abuse, 84, 85
vs. child abuse, 85

Intracranial pressure, increased
etiology of, 153
papilledema from, 151–154, 151f, 152f
Intradermal melanocytic nevus, 946, 946f, 947f
Intradermal nevi, 946, 946f, 947f, 949
Intrahepatic cholestasis of pregnancy
epidemiology of, 463
etiology and pathophysiology of, 464
management of, 465
patient story of, 462, 462f
risk factors for, 464
Intrauterine device (IUD)
copper-containing, 13t, 14–15
levonorgestrel, 12, 12f, 13t, 14–15
Invasive squamous cell cancer, of cervix, 541–545, 541f–543f. *See also* Cervical cancer
Inverse psoriasis, 2, 3f. *See also* Psoriasis
diagnosis of, 878f, 879, 880f
differential diagnosis of
vs. candidiasis, 778, 780f
vs. tinea cruris, 796, 797f
distribution of, 880f, 884, 885f
management of, 880f, 893
Iodine, Lugol's, 530, 531, 532f
Iodine deficiency, 63–64, 64f
vs. goitrous hypothyroidism, 1349
Iridocyclitis, 135
Iris, melanotic hamartomas of, in neurofibromatosis, 1387–1390, 1390f
Iritis, 135–137
differential diagnosis of
vs. acute-angle closure glaucoma, 137
vs. conjunctivitis, 127, 137
vs. corneal foreign body/abrasion, 123
vs. corneal ulceration, 2
vs. episcleritis, 2, 133
vs. keratitis, 2
vs. scleritis, 133, 136–137
red eye in, 163–168, 164t, 167f
traumatic, 135, 135f
from zoster ophthalmicus, 718–722, 718f
Iron deficiency, 63
Iron-deficiency anemia, from hookworms, 1273
Irritable bowel disease, *vs.* intestinal worms and parasites, 1273
Irritant contact dermatitis, 834–841. *See also* Contact dermatitis
Irritant diaper dermatitis, 646–650, 647f. *See also* Diaper rash
Ischemic colitis, *vs.* ulcerative colitis, 409, 410f
Ischemic stroke, *vs.* subdural hematoma, 1377
Ischemic ulcer, of foot, 1255–1257, 1255f, 1256f, 1302, 1303f
vs. dry gangrene, 1267
vs. neuropathic ulcer, 1256, 1259
Isoniazid, reactions from, 1211–1222

J

Jaccoud arthropathy, 564f
Jacquemier sign, 464
Jacquet's diaper dermatitis, 648
Janeway lesions, 287–291, 289f. *See also* Endocarditis, bacterial
Joint sepsis, *vs.* olecranon bursitis, 598
Jones fracture, 611–614, 612f
Junctional nevi, 946f, 948
Juvenile nevi, 946, 946f. *See also* Nevus, benign
Juvenile polyp, 393–397. *See also* Colon polyps
Juvenile rheumatoid arthritis, *vs.* knee soft tissue injuries, 622
Juvenile transformation zone, persistent, 528f
colposcopy and diagnosis of, 525, 525f, 526, 528f
management of, 528
Juvenile xanthogranuloma, *vs.* hyphema, 161

K

Kala-azar, 67–69, 67f–69f. *See also* Leishmaniasis
Kaposi sarcoma, 1285–1288
diagnosis of, 1285f–1287f, 1286–1287
differential diagnosis of
vs. bacillary angiomatosis, 1287, 1287f
vs. dermatofibroma, 1287
vs. hemangioma and angioma, 1287
vs. hematoma, 1287
vs. purpura, 1287
epidemiology of, 1285, 1285f
etiology and pathophysiology of, 1285–1286
follow-up of, 1288
fundamentals of, 1285
management of, 1287–1288, 1287f
patient education on, 1288
patient story of, 1285, 1285f
prognosis in, 1288
risk factors for, 1286
Kawasaki disease
diagnosis of, 209
differential diagnosis of
vs. hypersensitivity syndromes, 1054
vs. scarlet fever, 209, 210, 210f
Kayser-Fleischer ring, 380, 382f
Keloids, 1224–1228
diagnosis of, 1225, 1225f
differential diagnosis of
vs. acne keloidalis, 1225, 1226f
vs. dermatofibromas, 1225
vs. dermatofibrosarcoma protuberans, 1225
vs. hypertrophic scars, 1225
epidemiology of, 1224, 1224f
etiology and pathophysiology of, 1224, 1224f
fundamentals of, 1224
management of, 1226–1228, 1226f, 1227f
patient education on, 1228
patient story of, 1224, 1224f
in pregnancy, 463
prevention of, 1228
prognosis and follow-up for, 1228
risk factors for, 1225
Keratitis
differential diagnosis of
vs. conjunctivitis, 128, 128f
vs. corneal foreign body/abrasion, 124
vs. scleritis and episcleritis, 133
vs. uveitis and iritis, 137
herpetic, 128, 128f
vs. conjunctivitis, 128, 128f
red eye in, 163–168, 164t, 166f
from zoster ophthalmicus, 718–722, 718f
Keratoacanthoma, 977–980
diagnosis of, 977f–979f, 978
differential diagnosis of
vs. actinic keratosis, 978

Keratoacanthoma (*Continued*)
vs. basal cell carcinoma, nodular, 995
vs. common warts, 751
vs. cutaneous horn, 978
vs. squamous cell carcinoma, 978, 1005, 1005f
epidemiology of, 977
etiology and pathophysiology of, 977–978
follow-up of, 980
fundamentals of, 977
management of, 978–980
patient education on, 980
patient story of, 977, 977f
prognosis in, 980
Keratoconus, with atopic dermatitis, 827, 831f
Keratoderma, *vs.* tinea pedis, 801, 802f
Keratoderma climactericum, *vs.* tinea pedis, 801, 802f
Keratoses, seborrheic. *See* Seborrheic keratosis
Keratosis, 1242–1245. *See also* Calluses; Corns
Keratosis follicularis, *vs.* psoriatic nails, 1171–1172, 1173f
Keratosis pilaris
with atopic dermatitis, 827, 830f
vs. folliculitis, 684
Keratotic melanocytic nevus, *vs.* skin tag, 923–924
Kidney. *See also* Renal
Kidney failure, unexplained, 432
Kidney stones, 425–428
diagnosis of, 425f–427f, 426–427
differential diagnosis of
vs. abdominal aortic aneurysm, 427
vs. appendicitis, 427
vs. cholelithiasis, 427
vs. colitis, 427
vs. diverticulitis, 427
vs. gynecologic conditions, 427
vs. peptic ulcer disease, 427
vs. urinary tract infection, 428
vs. urologic disorders, 427
epidemiology of, 425
etiology and pathophysiology of, 425–426
follow-up of, 428
fundamentals of, 425
management of, 427f, 428
patient education on, 428
patient story of, 425, 425f, 426f
with polycystic kidneys, 437 (*See also* Polycystic kidneys)
prevention of, 428
prognosis in, 428
risk factors for, 426
Kingella bacterial endocarditis, 288
"Kissing warts," 749, 750f
Klebsiella folliculitis, 681
Klippel-Trenaunay, port-wine stains in, 1208, 1209
Knee anatomy, 619f
Knee fracture
vs. knee soft tissue injury, 621, 622f
patellar, 621, 622f
Knee soft tissue injuries, 619–624
diagnosis of, 619f–621f, 620–621
differential diagnosis of
vs. arthritis, 622
vs. gout or pseudogout, 622
vs. infections, 622, 623f
vs. intraarticular fractures, 621, 622f
vs. juvenile rheumatoid arthritis, 622
vs. malignant tumors, 622
vs. osteoarthritis, 622
vs. patellar dislocation, 622
vs. reactive arthritis, 622
vs. rheumatoid arthritis, 622
vs. septic arthritis, 622, 623f
epidemiology of, 619, 619f
etiology and pathophysiology of, 620
follow-up of, 623
fundamentals of, 619
management of, 622–623
patient education on, 624
patient story of, 619, 619f
prevention of, 623
prognosis in, 623
risk factors for, 620
Knuckle pads, 847
Koebner phenomenon, 882, 884f
in lichen planus, 901f, 902
Koilocytosis, 535
Koplik spots, 724, 724f, 725
KPS, 27
Kwashiorkor, 60–61, 60f, 61f
Kyphosis. *See also* Osteoporosis and osteopenia
thoracic, 1338–1344
Kytococcus sedentarius, pitted keratolysis from, 686

L

Labial adhesion, *vs.* child sexual abuse, 92, 93f
Labial melanotic macules, *vs.* nevus, benign, 950, 950f
Labia minora micropapillae, *vs.* vulvar intraepithelial neoplasia, 521
Labor, 18, 21–22
Lachman test, 619, 621
Lacrimal ducts, plugged, *vs.* mastitis, 547
Lactobacillus, hydrogen peroxide–producing, vaginal, 495
Lamb excrescences, *vs.* bacterial endocarditis, 290
Lamellar ichthyosis, *vs.* X-linked ichthyosis, 1233, 1235f
Language, positive, 10
Laryngeal cancer
hoarseness in, 220–225 (*See also* Hoarseness)
from squamous cell carcinoma, 223f
Laryngeal papillomatosis, 220–225, 224f. *See also* Hoarseness
Laryngeal polyp, 220–225, 225f. *See also* Hoarseness
Laryngitis, 220–225. *See also* Hoarseness
Laryngopharyngeal reflux, 220–225, 223f. *See also* Hoarseness
vs. gastroesophageal reflux, 221
Larynx, 220–225. *See also* Hoarseness
normal, 220f
Lateral condylar split fracture, 621, 622f
Latrines, pit, in Ethiopia, 55–56, 56f, 57f
Ledderhose disease, 625–628. *See also* Dupuytren disease (contractures)
Left portal vein, on third trimester ultrasound, 482f
Legionella pneumonia, 301
Legler, Jim, 8f
Leiomyoma
in pregnancy, 463
uterine, 20
Leishmaniasis, 67–69
diagnosis of, 67–68, 66f–69f
differential diagnosis of, 68
epidemiology of, 67

etiology and pathophysiology of, 67
fundamentals of, 67
management of, 68–69
risk factors for, 67
Lentiginous nevus. *See* Nevus, benign
Lentigo maligna, 981–984
definition of, 981
diagnosis of, 981f, 982–983, 982f
dermoscopy in, 1464f
differential diagnosis of
vs. lentigo maligna melanoma, 982, 982f, 983
vs. seborrheic keratosis, 982, 983
vs. solar lentigo, 982, 982f, 983, 983f
epidemiology of, 981
etiology and pathophysiology of, 981, 981f, 982f
follow-up of, 984
management of, 983–984
patient education on, 984
patient story of, 981, 981f
prevention of, 984
prognosis in, 984
risk factors for, 982
Lentigo maligna melanoma, 1010, 1011f. *See also* Melanoma
diagnosis of, 982–983, 982f
epidemiology of, 981
etiology and pathophysiology of, 982, 982f
vs. lentigo maligna, 982, 982f, 983
risk factors for, 982
Leprosy, 72–74
diagnosis of, 73, 73f, 74f
differential diagnosis of, 73
epidemiology of, 73
etiology and pathophysiology of, 73, 73f, 74f
fundamentals of, 71, 73
management of, 73–74
patient story of, 71, 72, 73f
risk factors for, 73
Lesser-Trélat sign, 927, 927f
Leukemia
in breast, *vs.* breast cancer, 554
vs. gingival overgrowth, 242
Leukocytoclastic vasculitis, 1062–1069, 1064f, 1066f. *See also* Vasculitis
Leukonychia
diagnosis of, 1146f, 1147, 1148t
differential diagnosis of
vs. Mee lines, 1148f, 1148t, 1149
vs. Muehrcke lines, 1148t, 1149, 1149f
vs. onychomycosis, 1162
vs. trauma-induced lesions, 1148t
epidemiology of, 1145
etiology and pathophysiology of, 1146
management of, 1149
risk factors for, 1147
Leukonychia punctata
diagnosis of, 1147, 1148t
epidemiology of, 1145
etiology and pathophysiology of, 1146, 1146f
management of, 1149
risk factors for, 1147
Leukoplakia, 249–252, 249f–251f
of cervix on colposcopy, 536, 536f
diagnosis of, 249f, 250, 250f
differential diagnosis of, 251
vs. aspirin/chemical burn, 251
vs. black hairy tongue, 229, 230f
vs. candidosis, 251
vs. discoid lupus, 251
vs. erythroplakia, 249
vs. geographic tongue, 233
vs. hairy leukoplakia, 251
vs. lichenoid lesion, 251
vs. lichen planus, 251, 907
vs. linea alba, 251
vs. morsicatio, 251, 251f
vs. nicotine stomatitis, 251, 251f
vs. oropharyngeal cancer, 256f
vs. Paget disease of external genitalia, 516
vs. snuff patch, 251
vs. white sponge nevus, 251
epidemiology of, 249
etiology and pathophysiology of, 249–250
follow-up for, 252
fundamentals of, 249
management of, 251
oropharyngeal cancer and, 254, 254f, 256f
patient education on, 252
patient story of, 249, 249f
prevention and screening for, 251
prognosis in, 251
risk factors for, 250
from smoking, 1400, 1401f
Leukorrhea, *vs.* child sexual abuse, 92
Levonorgestrel EE pills, 14
Levonorgestrel intrauterine device (IUD), 12, 12f, 13t, 14–15
Lice, 809–814
diagnosis of, 809f–812f, 810–811
differential diagnosis of
vs. dandruff, hair casts, and debris, 811
vs. scabies, 811–812
epidemiology of, 809, 809f
etiology and pathophysiology of, 810
follow-up of, 813
fundamentals of, 810
global health problem of, 70, 71
management of, 812–813
patient education on, 814
patient story of, 809, 809f
prevention of, 813
Lichen aureus, *vs.* vasculitis, 1066, 1067f
Lichen nuchae, 857, 858f, 859f
Lichenoid keratosis
vs. basal cell carcinoma, superficial, 996
vs. Paget disease of breast, 559, 560f
Lichenoid lesion, *vs.* leukoplakia, 251
Lichen planopilaris
epidemiology of, 1138
scarring alopecia in, 1139, 1139f (*See also* Alopecia, scarring)
Lichen planus, 901–908
diagnosis of, 901f–906f, 902, 906
differential diagnosis of
vs. aphthous ulcer, 246
vs. atrophic vaginitis, 491
vs. bite trauma in mouth, 907
vs. Bowen disease, 906

Lichen planus (*Continued*)
vs. eczematous dermatitis, 906
vs. epidermal nevus and nevus sebaceous, 961, 961f
vs. flat warts, 756
vs. geographic tongue, 233, 233f
vs. leukoplakia, 251, 907
vs. lichen simplex chronicus, 906
vs. lupus erythematosus, 1074
vs. lupus erythematosus, chronic cutaneous, 906
vs. onychomycosis, 1162
vs. pityriasis rosea, 906
vs. prurigo nodularis, 907
vs. psoriasis, 888, 906, 907
vs. sarcoidosis, 1038
vs. stasis dermatitis, 906
vs. syphilis, 907
vs. thrush, 907
vs. vulvar intraepithelial neoplasia, 521
epidemiology of, 901
etiology and pathophysiology of, 901
follow-up of, 908
fundamentals of, 901
management of, 907–908
patient education on, 908
patient story of, 901, 901f, 902f
prognosis in, 908
risk factors for, 901
Lichen sclerosis, 522f
vs. morphea, 1094
vs. vulvar intraepithelial neoplasia, 521, 522f
Lichen sclerosus et atrophicus, vulvar
vs. atrophic vaginitis, 491, 491f
vs. child sexual abuse, 92, 92f
vs. Paget disease of external genitalia, 516, 516f
Lichen simplex chronicus, 856–862, 858f, 859f. *See also* Self-inflicted dermatoses
vs. atopic dermatitis, 831
vs. eczema, nummular, 854
vs. lichen planus, 906
vs. necrobiosis lipoidica, 1319
vs. psoriasis, 888
vs. vulvar intraepithelial neoplasia, 521
Lichen striatus, *vs.* epidermal nevus and nevus sebaceous, 961, 961f
Life support, withdrawal of, 34
Likelihood ratio (LR), 1448–1450
Lindsay nails, 1149, 1149f
Linea alba
darkening of, in pregnancy, 463, 463f
vs. leukoplakia, 251
Linea nigra, 19, 463, 463f
Linear ecchymosis, from child abuse, 84, 84f
Linear immunoglobulin A (IgA) dermatosis
bullous, 1098, 1100f
vs. pemphigus, 1114
Linear immunoglobulin (Ig) M dermatosis, of pregnancy, 467–470, 467f–469f
Lingual papillitis, *vs.* strawberry tongue, 210
Lingua villosa nigra, 228–230, 228f, 229f
Lip cancer, 253–256. *See also* Oropharyngeal cancer
Lip licking, perlèche from, 203, 204f
Lipodermatosclerosis, with hemosiderin deposition, 296, 296f, 297f
Lipoma, *vs.* sarcoidosis, 1039
Lipoproteins, 1323
Lisch nodules, in neurofibromatosis, 1387–1390, 1390f
Lisfranc injury, *vs.* metatarsal fracture, 613
Listening, active empathic, 9
Livedo reticularis, *vs.* erythema ab igne, 1200, 1201f
Liver disease, 377–384. *See also* Hepatic entries; *specific types*
diagnosis of, 379–382
biopsy in, 382
clinical features of, 379–380, 380f, 381f
imaging in, 382
laboratory testing for, 380–381, 383t
epidemiology of, 377–378
etiology and pathophysiology of, 378–379
follow-up of, 384
fundamentals of, 377
management of, 382–384
patient education on, 384
patient story of, 377, 377f
prevention and screening of, 384
prognosis in, 384
risk factors for, 379
Liver fibrosis, 377–384. *See also* Liver disease
Living wills, 29–30
Lobar pneumonia, 300f, 301f, 303, 303f, 304f
Lobullary capillary hemangioma, 940–944. *See also* Pyogenic granuloma
Locally advanced breast cancer, 551–555, 553f, 554f. *See also* Breast cancer
Löfgren syndrome, 1035–1040. *See also* Sarcoidosis
erythema nodosum in, 1056–1061 (*See also* Erythema nodosum)
Longitudinal melanonychia (LM), 1146, 1146f, 1151–1155
diagnosis of, 1152t, 1153, 1154f, 1155f
differential diagnosis of
vs. hematoma, 1149
vs. pigmented lesions, 1147, 1153
vs. subungual hematoma, 1154, 1176
vs. subungual melanoma, 1147, 1149
epidemiology of, 1151
etiology and pathophysiology of, 1151–1152, 1151f, 1152f
follow-up of, 1154
fundamentals of, 1151
management of, 1154
patient story of, 1151, 1151f
prognosis in, 1154
Lordosis, 1338–1344. *See also* Osteoporosis and osteopenia
Low back pain, 585–588. *See also* Back pain
Low-grade squamous intraepithelial lesion (LGSIL), 530–533, 530f–532f
Lues. *See* Syphilis
Lugol's iodine, 530, 531, 532f
Lumbar muscle spasm, *vs.* ankylosing spondylitis, 581
Lumbar strain, *vs.* ankylosing spondylitis, 581
Lung. *See also* Pulmonary
Lung cancer, 355–363
diagnosis of, 355f, 356–358, 356f, 358f–360f
differential diagnosis of
vs. chronic obstructive pulmonary disease, 338, 359
vs. pneumonia, 359
epidemiology of, 355
etiology and pathophysiology of, 355–356
follow-up of, 362
fundamentals of, 355
management of, 359–362, 360t
complementary and alternative therapy in, 361
medications in, 361

nonpharmacologic, 360
staging in, 359, 360t
surgery and radiation in, 361–362
patient education on, 362–363
patient story of, 355, 355f, 356f
prevention of, 362
prognosis in, 362
risk factors for, 356
Lung transplantation, for COPD, 342
Lung volume reduction surgery (LVRS), for COPD, 342
Lupus
cutaneous, *vs.* erythema annulare centrifugum, 1238
neonatal, 1071, 1071f
vs. erythema toxicum neonatorum, 634, 634f
Lupus erythematosus. *See also* Discoid lupus erythematosus (DLE); Systemic lupus erythematosus (SLE)
vs. alopecia areata, 1130
Lupus panniculitis, distribution of, 1073, 1076f
Lupus pernio, 1035–1040, 1035f, 1036f. *See also* Sarcoidosis
Lupus profundus. *See* Systemic lupus erythematosus (SLE)
Lupus vulgaris, *vs.* sarcoidosis, 1038
Lyme disease, 1289–1296
diagnosis of, 1290–1292
clinical features in, 1289f–1291f, 1290–1291
laboratory testing in, 1292
typical distribution in, 563
differential diagnosis of
vs. cellulitis, 1292
vs. cutaneous larva migrans, 824
vs. encephalomyelitis, 1293
vs. erythema annulare centrifugum, 1238
vs. facial nerve (Bell) palsy, 1293, 1384
vs. fifth disease, 730
vs. fungal infections, cutaneous, 1293
vs. heart block, 1293
vs. inflammatory arthritis, 1293
vs. peripheral neuropathy, 1293
vs. radiculoneuropathy, 1293
vs. Rocky Mountain spotted fever, 1293
vs. tick bite local reaction, 1293
vs. urticaria, 1293
vs. viral meningitis, 1293
epidemiology of, 1289–1290, 1289f
etiology and pathophysiology of, 1290
follow-up of, 1296
fundamentals of, 1289
management of, 1294f–1295f, 1296
patient education on, 1296
patient story of, 1289, 1289f
prevention of, 1296
prognosis in, 1296
Lymphadenitis, tuberculous, 74, 76f
Lymphoma, cutaneous T-cell. *See* Cutaneous T-cell lymphoma
Lymphomatoid papulosis, *vs.* pityriasis lichenoides et varioliformis acuta, 1123
Lympogranuloma venereum, *vs.* hidradenitis suppurativa, 672

M

Macrolides, reactions from, 1216t
Macular degeneration, age-related. *See* Age-related macular degeneration (AMD)
Macular-type blue nevi. *See* Mongolian spots
Maculopapular eruptions, drug-related, 1211–1222. *See also* Drug reactions, cutaneous
diagnosis of, 1211f, 1218
epidemiology of, 1211f, 1212
Maffucci syndrome, 1207–1210, 1208f. *See also* Vascular lesions, hereditary and congenital
vs. childhood hemangioma, 638
Malaria, 64–66
clinical presentation of, 64–65
diagnosis of, 65, 65f
differential diagnosis of, 65
epidemiology and geographic distribution of, 64
fundamentals of, 64
management of, 65–66
meningitis from, 66f
prevention of, 66
Malassezia. *See also* Fungal infections, cutaneous; *Pityrosporum*
seborrheic dermatitis from, 872
Malassezia furfur, 805, 807f. *See also* Fungal infections, cutaneous; *Pityrosporum*
Male sterilization, 13t
Malignant fibrous histiocytoma, *vs.* dermatofibroma, 936
Malignant melanoma
of mouth (*See* Oropharyngeal cancer)
vs. Paget disease of breast, 559, 559f
vs. seborrheic keratosis, 929
Malnutrition
from child abuse, 84
childhood, global problem of, 60–61, 60f, 61f
Mammary candidiasis, 777–780, 777f, 778f
Mammogram, screening
breast cancer on, 551, 551f, 552f
Paget disease of breast on, 557
Marasmus, 60–61, 60f
Marijuana, 26, 1392, 1393f. *See also* Substance abuse disorder
Marjolin ulcer, 1000, 1000f. *See also* Squamous cell carcinoma
Mask of pregnancy, 1179–1182, 1179f–1181f. *See also* Melasma
Mastalgia, bilateral, *vs.* breast cancer, 554
Mast cell releasability syndromes, *vs.* urticaria and angioedema, 864f–866f, 866
Mastitis, 546–549
definition of, 546, 546f
diagnosis of, 546f, 547, 547f
differential diagnosis of
vs. lacrimal duct plugging, 547
vs. Paget disease of breast, 547
vs. tinea corporis, 547
epidemiology of, 546
etiology and pathophysiology of, 546
follow-up of, 549
infectious, *vs.* breast cancer, 554
management of, 548
patient education on, 549
patient story of, 546, 546f
risk factors for, 546–547
Mastoiditis, *vs.* acute otitis and otitis media with effusion, 173, 176f
McCune Albright syndrome, *vs.* neurofibromatosis, 1388
McMurray test, 619, 621
Measles, 723–726
diagnosis of, 725
differential diagnosis of, 725–726
vs. fifth disease, 730
vs. Fordyce spots, 725
vs. upper respiratory trace infections, 725
epidemiology of, 723

Measles (*Continued*)
etiology and pathophysiology of, 723–725, 723f–725f
follow-up of, 726
fundamentals of, 723
management of, 726
patient education on, 726
patient story of, 723, 723f
prevention of, 726
prognosis in, 726
risk factors for, 725
Médecins sans Frontières, 38–39
patient stories from, 37, 37f
Medical careers, disparity in, 49–50, 49f, 50f
Medical school, minorities in, 49–50, 50f
Medicare Hospice Benefit (MHB), 30–31
Medication overuse headache, 1366–1370
diagnosis of, 1367
epidemiology of, 1367
management of, 1369
patient education on, 1370
risk factors for, 1367
Mee lines, 1148f, 1148t, 1149
Megaureter, in children, 431, 432, 434
Meibomian gland, blockage or infection of, 114, 114f
Melanocytic atypia, 963–967, 963f–967f. *See also* Dysplastic nevus
Melanocytic lesions, dermoscopy of
aggregated globules in, 1456, 1457f
dermatofibroma in, 1456, 1458f
homogeneous blue pigmentation in, 1456, 1457f
negative network in, 1456, 1456f
parallel pigment pattern (acral lesions) in, 1456, 1458f
pathways in, 1465, 1465f
pigment network in, 1456, 1456f
pseudonetwork (facial skin) in, 1456, 1458f
streaks in, 1456, 1457f
Melanocytic nevus, 945–951. *See also* Nevus, benign
differential diagnosis of
vs. dysplastic nevus, 965
vs. Mongolian spots, 633
vs. skin tag, 923–924
intradermal, 946, 946f, 947f
Melanocytosis, oculodermal, 120, 121f
Melanoma, 1008–1020
in acquired nevus, 955f
amelanotic (*See* Amelanotic melanoma)
benign juvenile, 946, 947f
conjunctival, 118–121, 119f, 120f
dermoscopy of, 1012, 1014f, 1015, 1462–1465 (*See also* Dermoscopy)
atypical dots and/or globules, 1462, 1462f, 1463f
atypical network, 1462, 1462f
atypical vascular structures, 1462, 1462f, 1464f
blue-white veil overlying raised areas, 1462, 1462f, 1464f
negative pigment network, 1462, 1462f, 1463f
off-center blotch, 1462, 1462f, 1463f
parallel ridge pattern, 1462, 1462f, 1464f
peripheral tan structureless areas, 1462, 1462f, 1463f
regression structures, 1462, 1462f, 1464f
rhomboidal structures (face), 1462, 1462f, 1464f
shiny white lines (crystalline structures), 1462, 1462f, 1463f
streaks, 1462, 1462f, 1463f
diagnosis of, 1008f–1017f, 1009–1015
biopsy in, 1011f, 1015, 1015f
clinical features and categories of, 1009–1012
distribution in, 1012
differential diagnosis of
vs. basal cell carcinoma, pigmented, 1016, 1016f, 1017f
vs. congenital neva, 1010, 1015
vs. dermatofibromas, 1016
vs. dysplastic nevus, 965, 1015–1016
vs. hyphema, 161
vs. nevus, benign, 949–950
vs. pyogenic granuloma, 1016, 1016f
vs. seborrheic keratosis, 928f, 929, 930f, 1010f, 1016
vs. solar lentigines, 1016
vs. vascular lesions, acquired, 1204
epidemiology of, 1008–1009
follow-up of, 1018, 1020t
fundamentals of, 1008
malignant (*See* Malignant melanoma)
management of, 1016–1017, 1017t, 1018f
mouth, 254 (*See also* Oropharyngeal cancer)
patient education on, 1018
patient story of, 1008, 1008f, 1009f
prevention and screening for, 1017
prognosis in, 1018
staging of, 1018, 1018f, 1019t, 1020t
Melanoma, subungual
diagnosis of, 1152t, 1153, 1153f, 1155f
differential diagnosis of
vs. nail variants, normal, 1147, 1149
vs. subungual hematoma, 1176
epidemiology of, 1151
etiology and pathophysiology of, 1152–1153, 1152f, 1152t, 1153f
follow-up of, 1154
fundamentals of, 1151
management of, 1154
prognosis in, 1154
Melanosis
acquired
primary, 118–121, 119f
secondary, 120
conjunctival, 118–121, 119f
eye
physiologic (racial), 118–121, 119f
primary acquired, 118–121, 119f
Melanotic hamartomas of iris, in neurofibromatosis, 1387–1390, 1390f
Melasma, 19, 19f, 1179–1182
definition of, 1179
diagnosis of, 1179f–1181f, 1180–1181
differential diagnosis of
vs. contact dermatitis, 1181
vs. discoid lupus erythematosus, 1181
vs. systemic lupus erythematosus, 1181
epidemiology of, 1179, 1179f, 1180f
etiology and pathophysiology of, 1179–1180, 1181f
follow-up of, 1182
management of, 1181–1182
patient education on, 1182
patient story of, 1179, 1179f, 1180f
prevention of, 1182
Meningitis. *See also* Malaria
differential diagnosis of
vs. cerebral malaria, 66f
vs. cocaine abuse, 1435

vs. Lyme disease, 1293
vs. normal pressure hydrocephalus, 1381
vs. subdural hematoma, 1377
from Lyme disease, 1291
from malaria, 66f
Meningococcemia
vs. cutaneous vasculitis, 1066
vs. vasculitis, 1068f
Meningoencephalitis, from Lyme disease, 1291
Meningoencephalocele, *vs.* nasal polyps, 194, 195
Meniscal tear, 619–624, 621f. *See also* Knee soft tissue injuries
Menopause, 489
atrophic vaginitis in, 489–492 (*See also* Atrophic vaginitis)
definition of, 20
premature, with amenorrhea, 20
Menzies method, 1012
Merkel cell carcinoma, *vs.* squamous cell carcinoma, 1005, 1005f
Metabolic acidosis, *vs.* heart failure, 278
Metal, contact dermatitis from, 834, 835, 835f, 836f
Metatarsal fracture, 611–614, 611f
diagnosis of, 611f, 612, 612f
differential diagnosis of, 612f
vs. accessory ossicles, 613
vs. apophysis, 613
vs. diaphyseal stress fracture, 612
vs. Lisfranc injury, 613
epidemiology of, 611, 611f
etiology and pathophysiology of, 611–612
follow-up of, 613
fundamentals of, 611
management of, 613
patient education in, 614
patient story of, 611, 611f
prognosis in, 613
Metatarsus adductovarus, 1247–1250, 1247f–1249f. *See also* Bunion deformity
Meth. *See* Methamphetamine
Methamphetamine abuse, 1424–1429. *See also* Substance abuse disorder
death from, 26
diagnosis of, 1426–1427
differential diagnosis of
vs. atopic dermatitis, 1427
vs. contact dermatitis, 1427
vs. neurodermatitis, 1427
vs. prurigo nodularis, 1427
vs. scabies, 1427
epidemiology of, 26, 1393, 1393f, 1424–1425, 1425f, 1426f
etiology and pathophysiology of, 1424f, 1425–1426, 1426f–1428f
follow-up for, 1428–1429
fundamentals of, 1424
ice form of, 1393f, 1425f
management of, 1427–1428, 1427f
meth lab production of, 1425, 1425f, 1426f
patient education on, 1429
patient story of, 1424, 1424f
Methicillin-resistant *Staphylococcus aureus* (MRSA)
abscess from, 698–700, 699f
cellulitis from, 693
folliculitis from, 680, 682f (*See also* Folliculitis)
impetigo from, 676–679 (*See also* Impetigo)
necrotizing fasciitis from, 703
pneumonia from, 301
Meth lab(oratory), 1425, 1425f, 1426f
Meth mites, 1424, 1424f, 1426, 1426f, 1427, 1427f
Meth mouth, 1426, 1427f, 1428f
Microaneurysms, eye
in diabetic retinopathy, 143–144, 143f
in hypertensive retinopathy, 147–150 (*See also* Retinopathy, hypertensive)
Microbial agents. *See also specific agents and disorders*
on mortality, 27
Micrococcus. See Kytococcus sedentarius
Micronutrient deficiencies, global, 61–64
iodine, 63–64, 64f
iron, 63
vitamin A, 61–62, 62f
zinc, 62–63, 63f
Micropapillae of inner labia minora, *vs.* vulvar intraepithelial neoplasia, 521
Micropapillomatosis of vulva, *vs.* genital warts, 762
Microsporum, 771. *See also* Fungal infections, cutaneous; Tinea
tinea capitis from, 782–786, 784f, 785f
Microsporum canis, 784f
tinea capitis from, 782–786
Middle-ear effusion (MEE)
in acute otitis media, 170–178 (*See also* Acute otitis media (AOM))
diagnosis of, 166–167, 170f–172f
patient education on, 177
Middle-ear inflammation, diagnosis of, 170f, 172, 172f
Migraine headache, 1366–1370
diagnosis of, 1367–1368
differential diagnosis of
vs. cerebral vascular accident, 1373
vs. sinusitis, 200
epidemiology of, 1366
etiology and pathophysiology of, 1366, 1366f
management of, 1368–1369
patient story of, 1366
risk factors for, 1367
Migratory glossitis, benign, 232–235. *See also* Geographic tongue
Milia, newborn, 630–634
definition of, 630, 630f
diagnosis of, 630f, 631–632
differential diagnosis of
vs. miliaria, 633, 633f
vs. neonatal pustular melanosis, 633
vs. sebaceous hyperplasia, 933, 933f
epidemiology of, 630
etiology and pathophysiology of, 631
management of, 634
parent education on, 634
patient story of, 630, 630f
prognosis in, 634
Miliaria, 633, 633f, 1100
differential diagnosis of
vs. folliculitis, 684
vs. milia, newborn, 633, 633f
neonatal, 633, 633f
in pregnancy, 463
Miliary pneumonia, 304. *See also* Tuberculosis (TB)
Milk spots, 630–634. *See also* Milia, newborn
Minocycline
black tongue from, 229
drug reactions from, 1211–1222
Minority physicians, 49–50, 50f
Mirena intrauterine device, 12, 12f, 14–15

Miscarriage, after intimate partner violence victims, 99
Mixed connective disease, 1083. *See also* Dermatomyositis; Scleroderma
MMRC Dyspnea Scale, 336, 336b
Modified British Medical Research Council (MMRC) Dyspnea Scale, 336, 336b
Mohs surgery, 1005–1006, 1006t
Moles, 945–951. *See also* Nevus, benign
Molluscum contagiosum, 743–746
  diagnosis of, 744–745, 744f–746f
  differential diagnosis of
    vs. basal cell carcinoma, 745
    vs. dermatofibroma, 745
    vs. genital warts, 745, 762
    vs. herpes zoster, 714
    vs. hordeolum and chalazion, 115
    vs. scabies, 745
    vs. sebaceous hyperplasia, 933
    vs. vulvar intraepithelial neoplasia, 521
    xanthoma, 1325
  epidemiology of, 743, 743f–745f
  etiology and pathophysiology of, 743–744
  folliculitis from, 681–683
  follow-up of, 746
  fundamentals of, 743
  management of, 745–746, 746f
  patient education on, 746
  patient story of, 743, 743f
  prevention of, 746
  prognosis in, 746
  risk factors for, 744, 744f, 745f
Mongolian spots, 630–634
  definition of, 630, 631f
  diagnosis of, 631f, 632
  differential diagnosis of
    vs. bruising of child abuse, 633
    vs. congenital melanocytic nevi, 633
  epidemiology of, 631
  etiology and pathophysiology of, 631
  management of, 634
  parent education on, 634
  prognosis in, 634
Moniliasis, 499–503. *See also Candida* vulvovaginitis
Monoarticular inflammatory arthritis, 563. *See also* Arthritis
Monoarticular noninflammatory arthritis, 563. *See also* Arthritis
Mononucleosis, infectious
  vs. pharyngitis, 215f, 216
  tonsillar exudate in, 215f
Monosodium urate crystal deposition, 590, 591, 591f
Montgomery tubercles, 463, 463f
Mood disorder, *vs.* substance abuse disorder, 1396
Moraxella catarrhalis
  acute otitis media from, 171
  sinusitis from, 198
Morbillivirus, 723. *See also* Measles
Morbus Dupuytren, 625–628. *See also* Dupuytren disease (contractures)
Morphea, 1089–1095
  definition of, 1089
  diagnosis of, 1089f, 1090f, 1092–1093, 1095f
  differential diagnosis of, 1093–1094
  epidemiology of, %1089
  etiology and pathophysiology of, 1089–1092, 1089f, 1090f
  follow-up of, 1095
  management of, 1094–1095
  patient education on, 1095
  patient story of, 1089, 1089f, 1090f
  prognosis in, 1095, 1095f
  vs. sarcoidosis, 1039
Morsicatio, *vs.* leukoplakia, 251, 251f
Morton neuroma, *vs.* hammer toe, 1253
Mosaic wart, 766–769, 766f–768f. *See also* Warts, plantar
Motivational interviewing, for smoking cessation, 1402, 1404t
Motor vehicle accidents, on mortality, 26
MRSA. *See* Methicillin-resistant *Staphylococcus aureus* (MRSA)
Mucha-Habermann disease, 1123–1124, 1124f. *See also* Pityriasis lichenoides et varioliformis acuta (PLEVA)
Mucinous retention cysts, 525, 526f, 527
Mucopyocele, 199f, 200f
Mucormycosis sinusitis, 198, 198f
Mucus cyst, *vs.* paronychia, 1167, 1169f
Muehrcke lines, 1148t, 1149, 1149f
Multiinfarct dementia, *vs.* normal pressure hydrocephalus, 1381
Multiple sclerosis, *vs.* cerebral vascular accident, 1373
Murine typhus, erythroderma with, 915–921, 919f. *See also* Erythroderma
Mutans streptococci, dental caries from, 258, 263
Mycobacterium infection, in global health
  leprosy, 72–74, 73f, 74f (*See also* Leprosy)
  tuberculosis and HIV in, 74–75, 75f
Mycobacterium tuberculosis
  pneumonia from, 301
  tuberculosis from, 310, 311f
Mycoplasma genitalium urethritis, in men, 1275–1277
Mycosis fungoides. *See also* Cutaneous T-cell lymphoma
  differential diagnosis of
    vs. eczema, nummular, 854
    vs. erythema annulare centrifugum, 1238
    vs. pyoderma gangrenosum, 1033
    vs. sarcoidosis, 1038
    vs. scleroderma, 1094, 1144
  erythroderma with, 915–921, 919f (*See also* Erythroderma)
  folliculotropic, 1130, 1131f
Myoma, uterine, 20
Myositis, *vs.* arthritis, 566
Myringitis, bullous, *vs.* acute otitis and otitis media with effusion, 173, 175f
Myringotomy, 175
Myrmecia, 766–769, 766f–768f. *See also* Warts, plantar
Myxedema
  in hypothyroidism, 1348
  pretibial, in Graves disease, 1355, 1355f
  vs. scleroderma, 1093
Myxedema coma, 1347. *See also* Goitrous hypothyroidism
  in hypothyroidism, 1349f
Myxomatous changes, *vs.* bacterial endocarditis, 290

N

Nabothian cyst
  colposcopy and diagnosis of, 525, 526f, 527, 527f
  management of, 527
Naegele's rule, 19
Nail bed nevus, *vs.* subungual hematoma, 1176
Nail disorders, patient story of, 1151f
Nail disorders, pigmented, 1151–1155
  diagnosis of, 1152t, 1153, 1154f, 1155f
  differential diagnosis of
    vs. longitudinal melanonychia, 1153
    vs. subungual hematoma, 1154

epidemiology of, 1151
etiology and pathophysiology of, 1151–1153, 1151f–1154f
follow-up of, 1154
fundamentals of, 1151
management of, 1154
patient story of, 1151
prognosis in, 1154
treatment of, 1154
Nail fold picking, *vs.* onychomycosis, 1162
Nail hypertrophy, 1145, 1146, 1146f
Nail psoriasis. *See* Psoriasis
Nail splitting, 1177, 1177f
Nail trauma, 1175–1177, 1175f–1178f. *See also* Hematoma, subungual
vs. onychomycosis, 1162
Nail unit, 1145, 1145f
Nail variants, normal, 1145–1149. *See also specific types*
Beau lines, 1146, 1147f, 1148f
diagnosis of, 1147, 1148t
differential diagnosis of
vs. half-and-half nails, 1149, 1149f
vs. hematoma, 1149
vs. Mee and Muehrcke lines, 1148f, 1148t, 1149
vs. pigmented lesions of nail bed, 1147
vs. subungual melanoma, 1147, 1149
vs. twenty-nail dystrophy, 1149, 1149f
epidemiology of, 1145
etiology and pathophysiology of, 1145f–1148f, 1146–1147
fundamentals of, 1145
habit-tic deformity, 1146, 1147f, 1149
half-and-half nail (Lindsay nails), 1149, 1149f
leukonychia, 1145, 1145f, 1146
leukonychia punctata, 1145, 1145f, 1146f
longitudinal melanonychia, 1146, 1146f
management of, 1149
onychogryphosis, 1145, 1146, 1146f
patient story of, 1145, 1145f
risk factors for, 1147
transverse striate leukonychia, 1145, 1145f
Napkin dermatitis, 646–650. *See also* Diaper rash
Nasal polyps, 193–195, 193f, 194f
differential diagnosis of
vs. angiofibroma, 195
vs. chordoma, 194
vs. dermoid tumor, 194
vs. glioblastoma, 194
vs. hemangioma, 194
vs. meningoencephalocele, 194, 195
vs. nasopharyngeal carcinoma, 194
vs. neuroblastoma, 195
vs. papilloma, 194
vs. pyogenic granuloma, 194
vs. rhabdomyosarcoma, 194
Nasopharyngeal carcinoma, *vs.* nasal polyps, 194
Necator americanus, 1270–1274, 1270f, 1271f
Neck infections, deep, *vs.* pharyngitis, 217
Necrobiosis lipoidica (NL), 1317–1320
diagnosis of, 1302, 1303f, 1317f–1320f, 1318
differential diagnosis of
vs. diabetic dermopathy, 1315
vs. erythema nodosum, 1318–1319
vs. granuloma annulare, 1319
vs. lichen simplex chronicus, 1319
vs. sarcoidosis, 1039, 1319
vs. stasis dermatitis, 1319
epidemiology of, 1317
etiology and pathophysiology of, 1317–1318
fundamentals of, 1317
management of, 1319–1320
patient education on, 1320
patient story of, 1317, 1317f
prognosis in, 1320
Necrobiosis lipoidica diabeticorum. *See* Necrobiosis lipoidica (NL)
Necrotizing fasciitis, 702–706
diagnosis of, 702f–704f, 703–704
differential diagnosis of
vs. cellulitis, 694, 704
vs. clostridial myonecrosis, 704
vs. erythema induratum, 704–705
vs. pyomyositis, 704
vs. streptococcal or staphylococcal toxic shock syndrome, 705
epidemiology of, 702
etiology and pathophysiology of, 702–703, 703f
fundamentals of, 702
management of, 705–706
patient education on, 706
patient story of, 702, 702f
prognosis and follow-up for, 706
risk factors for, 703
saltwater variant, 703, 703f
Neisseria gonorrhoeae infection. *See* Gonorrhea *(Neisseria gonorrhoeae)*
Nematodes, 1270–1274, 1270f–1272f. *See also* Intestinal worms and parasites
global health problem of, 59–60
Neomycin contact dermatitis, 834, 835, 836f
Neonatal acne, 630–634, 630f, 651–657, 652f. *See also* Acne vulgaris; Skin changes, normal pediatric
definition of, 630, 630f
diagnosis of, 630f, 632
differential diagnosis of
vs. miliaria, 633, 633f
vs. neonatal pustular melanosis, 633
etiology and pathophysiology of, 631
management of, 634
parent education on, 634
prognosis in, 634
Neonatal lupus, 1071, 1071f
vs. erythema toxicum neonatorum, 634, 634f
Neonatal pemphigus, 1102
Neonatal pustular melanosis, 633
Neonatal syphilis, 1102
Neovascularization, eye, *vs.* hyphema, 160
Nephrolithiasis, 425–428. *See also* Kidney stones
vs. ankylosing spondylitis, 582
Neuroblastoma, *vs.* nasal polyps, 195
Neurodermatitis, 856–862, 856f–858f. *See also* Self-inflicted dermatoses
vs. methamphetamine abuse, 1427
Neurodermatitis circumscripta, 856–862. *See also* Self-inflicted dermatoses
Neuroendocrine carcinoma of skin, *vs.* squamous cell carcinoma, 1005, 1005f
Neurofibroma
differential diagnosis of
vs. dermatofibroma, 937
vs. skin tag, 923, 923f
with neurofibromatosis, 1388f
in pregnancy, 463
Neurofibromatosis, with neurofibroma, 1388f

Neurofibromatosis type 1 (NF-1), 1387–1390
diagnosis of, 1387–1388, 1387f–1389f
differential diagnosis of
vs. ataxia telangiectasia, 1389
vs. Bloom syndrome, 1389
vs. Fanconi anemia, 1388–1389
vs. McCune Albright syndrome, 1388
vs. neurofibromatosis type 2, 1388
vs. Proteus syndrome, 1389
vs. segmental neurofibromatosis, 1389
vs. tuberous sclerosis (angiofibroma), 1388, 1390f
epidemiology of, 1387
etiology and pathophysiology of, 1387
follow-up of, 1389–1390
fundamentals of, 1387
management of, 1389
patient story of, 1387, 1387f
prognosis in, 1389
risk factors for, 1387
Neurologic disease, death from, 27
Neuromuscular weakness, *vs.* heart failure, 278
Neuropathic ulcer of foot, 1258–1260, 1258f, 1259f
vs. ischemic ulcer of foot, 1256, 1259
Neurotic excoriation, 856–862, 856f–858f. *See also* Self-inflicted dermatoses
Nevus. *See also specific types*
with architectural disorder, 963–967, 963f–967f (*See also* Dysplastic nevus)
atypical *vs.* benign, 949–950
differential diagnosis of
nail bed, *vs.* subungual hematoma, 1176
white sponge, *vs.* leukoplakia, 251
Nevus, benign, 945–951. *See also specific types*
dermoscopy of patterns of, 1459–1461, 1459f
diffuse reticular, 1459, 1459f, 1460f
globular, 1459, 1459f, 1461f
homogeneous, 1459, 1459f, 1460f
patchy reticular, 1459, 1459f, 1460f
peripheral globules/starburst, 1459, 1459f, 1460f
peripheral reticular with central globules, 1459, 1459f, 1461f
peripheral reticular with central hyperpigmentation, 1459, 1459f, 1460f
peripheral reticular with central hypopigmentation, 1459, 1459f, 1460f
symmetric multicomponent, 1459, 1459f, 1461f
two-component, 1459, 1459f, 1461f
diagnosis of, 946f, 948–949
differential diagnosis of
vs. dysplastic or atypical nevi, 949–950
vs. labial melanotic macules, 950, 950f
vs. melanomas, 949–950
vs. seborrheic keratoses, 950
vs. vulvar intraepithelial neoplasia, 521
epidemiology of, 945
etiology and pathophysiology of, 945f–950f, 946
eye
conjunctival, 118–121, 118f, 126f
scleral, 118–121, 118f
follow-up of, 951
fundamentals of, 945
management of, 950
patient education on, 951
patient story of, 945, 945f
prevention of, 950–951
prognosis in, 951
Nevus, congenital, 953–956
definition of, 953
diagnosis of, 953f–955f, 954–956
dermoscopy in, 1458f
differential diagnosis of
vs. Becker nevus, 956
vs. café-au-lait spots, 956
vs. melanoma, 1010, 1015
vs. Mongolian spots, 633
epidemiology of, 953–954
etiology and pathophysiology of, 954
follow-up of, 956
management of, 955f, 956
melanoma arising in (*See* Melanoma)
patient education on, 956
patient story of, 953, 953f
Nevus, dysplastic, 963–967
diagnosis of, 963f–965f, 964–965
differential diagnosis of
vs. melanocytic nevi, 965
vs. melanoma, 965, 1015–1016
epidemiology of, 963–964
etiology and pathophysiology of, 963f, 964
follow-up of, 966–967, 966f, 967f
fundamentals of, 963
management of, 965–966, 966f
patient education on, 967
patient story of, 963, 963f, 964f
prevention of, 966
prognosis in, 966
Nevus, epidermal, 948, 958–962
diagnosis of, 958f–960f, 959–961
differential diagnosis of
vs. lichen planus, 961
vs. lichen striatus, 961, 961f
vs. linear lichen planus, 961f
vs. linear porokeratosis, 961
vs. syringoma, 961, 961f
epidemiology of, 958, 959f
etiology and pathophysiology of, 959
follow-up of, 962
management of, 961–962
patient story of, 958, 958f
prognosis in, 962
Nevus, melanocytic, 945–951. *See also* Nevus, benign
differential diagnosis of
vs. dysplastic nevus, 965
vs. Mongolian spots, 633
vs. skin tag, 923–924
intradermal, 946, 946f, 947f
Nevus, Spitz, 946, 947f. *See also* Nevus, benign
dermoscopy of, 1457f
Nevus anemicus, 948, 949f
vs. vitiligo, 1188f
Nevus comedonicus, 948, 950f
Nevus depigmentosus, 948, 949f
vs. vitiligo, 1187, 1188f
Nevus flammeus, 1207–1210, 1207f–1209f. *See also* Vascular lesions, hereditary and congenital
Nevus of Ota, 120, 121f, 946, 948f
Nevus sebaceous, 958–962
diagnosis of, 958f, 959–961, 960f

differential diagnosis of
vs. lichen planus, 961f
vs. lichen striatus, 961, 961f
vs. linear lichen planus, 961
vs. linear porokeratosis, 961
vs. syringoma, 961, 961f
epidemiology of, 958–959, 960f
etiology and pathophysiology of, 959, 959f, 960f
follow-up of, 962
management of, 961–962
prognosis in, 962
Nevus spilus, 946, 947f, 954, 954f. *See also* Nevus, benign
Nexplanon sterilization, 15
Nickel contact dermatitis, 834, 835, 835f, 836f. *See also* Contact dermatitis
Nicotine addiction, 1398–1409. *See also* Tobacco addiction
Nicotine stomatitis, 1400, 1401f
vs. leukoplakia, 251, 251f
Nikolsky sign, 1098, 1100, 1112
in pemphigus vulgaris, 1112
Nipple adenoma, *vs.* Paget disease of breast, 559
Nipple candidiasis, 777–780, 777f, 778f
Nipple discharge, *vs.* breast cancer, 554
Nitrofurantoin, reactions from, 1216t
Nits. *See* Lice
Nodular cutaneous sarcoid, *vs.* erythema nodosum, 1059
Nodular leukoplakia, 249–252, 249f–251f. *See also* Leukoplakia
Nodular melanoma, 1009f, 1010, 1011f. *See also* Melanoma
Nodular subcutaneous sarcoid, *vs.* erythema nodosum, 1059
Nodule. *See also* Morphology index
Lisch, 1387–1390, 1390f
palmar, 627
rheumatoid arthritis, 1024
thyroid, autonomous functioning, 1355
vocal cord, 220–225, 224f (*See also* Hoarseness)
Nomogram, 1448, 1450
Nonalcoholic fatty liver disease (NAFLD), 377, 379, 381, 382, 384. *See also* Liver disease
with obesity, 1331
Noncontact sexual abuse, 102
Nongonococcal urethritis, in men, 1275–1277, 1275f
Nonhomogenous leukoplakia, 249–252, 249f–251f. *See also* Leukoplakia
Noninfective vegetations, *vs.* bacterial endocarditis, 290
Nonmelanocytic tumors, dermoscopy of, 1465–1471. *See also specific tumors*
basal cell carcinoma, 1466, 1466f, 1467f
dermatofibromas
blood vessels within scar-like area, 1465, 1465f
central scar-like area, 1465, 1465f
peripheral delicate fine network, 1465, 1465f
ring-like globular structures, 1465, 1466f
hemangioma, 1469, 1469f, 1470f
seborrheic keratosis, 1468, 1468f, 1469f
Non-neoplastic hamartoma, 393–397. *See also* Colon polyps
Nonsteroidal antiinflammatory drugs (NSAIDs)
colitis from, 409
drug reactions to, 1211–1222, 1214f (*See also* Drug reactions, cutaneous)
diagnosis of, 1218
etiology and pathophysiology of, 1216
peptic ulcer disease from, 366–369, 366f, 367f (*See also* Peptic ulcer disease (PUD))
risk factors for GI events from, 571, 573t
Nonulcer dyspepsia
vs. gastric cancer, 374
vs. peptic ulcer disease, 368
Normal pressure hydrocephalus, 1380–1382, 1380f, 1381f
differential diagnosis of
vs. alcoholism, chronic, 1381
vs. Alzheimer disease, 1381
vs. carcinomatous meningitis, 1381
vs. hypothyroidism, 1382
vs. intracranial infections, 1381
vs. multiinfarct dementia, 1381
vs. Parkinson disease, 1381
Number needed to harm (NNH), 1448
Number needed to treat (NNT), 1448, 1448b
Nummular dermatitis, 851–854. *See also* Eczema, nummular
Nummular eczema. *See* Eczema, nummular
Nummular hand dermatitis, 844f, 845
Nurse's late-onset prurigo, 467–470, 467f–469f. *See also* Pruritic urticarial papules and plaques of pregnancy (PUPPP)
Nursing bottle caries, 257–260. *See also* Caries, early childhood
NuvaRing, 12, 12f, 14

O

Obesity, 1329–1335
acanthosis nigricans in, 1310–1313, 1329, 1329f, 1331, 1332f (*See also* Acanthosis nigricans)
central, 1331, 1331f
cerebral vascular accident with, 1372
definition of, 1329
diagnosis of, 1329f, 1331–1332, 1331f–1333f
differential diagnosis of
in Bardet-Biedl syndrome, 1332
vs. Cushing syndrome, 1332
in genetic disorders, 1332
vs. polycystic ovary syndrome, 1332
in Prader-Willi syndrome, 1332
epidemiology of, 1329
etiology and pathophysiology of, 1329–1331
complexity of, 1329
environment in, 1331
genetics in, 1330
health behaviors in, 1330
follow-up for, 1335
hidradenitis suppurativa with, 1331, 1333f
management of, 1332–1334
complementary and alternative therapy in, 1333
medications in, 1333
nonpharmacologic, 1332–1333
referral in, 1334
surgery in, 1334
patient education on, 1335
patient story of, 1329, 1329f
prevention and screening for, 1334
prognosis in, 1335
psoriasis in, plaque, 1331, 1331f
risk factors for, 1331
skin tag in, 1329, 1329f
varicose veins in, 1331, 1331f
xanthoma with, 1322–1327, 1322f–1324f, 1331, 1332f (*See also* Xanthomas)
Obestatin, 1330
Obstructive acne, 651–657, 653f. *See also* Acne vulgaris
Obstructive liver disease, 378. *See also* Liver disease

Occupational skin diseases. *See* Contact dermatitis
Ocular herpes zoster, 718–722. *See also* Zoster ophthalmicus
Ocular rosacea, 660, 663f. *See also* Rosacea
  red eye in, 164t, 165, 166f
Oculodermal melanocytosis, 120, 121f
Oil drop sign, in psoriatic nails, 1170, 1170f–1172f
Oil seed, 630–634. *See also* Milia, newborn
Olecranon bursitis, 596–599
  diagnosis of, 596f–598f, 597
  differential diagnosis of, 598
    vs. epicondylitis, 598
    vs. gout or pseudogout, 598
    vs. hemorrhage into bursa, 598
    vs. rheumatoid arthritis, 598
    vs. septic joint, 598
    vs. ulnar nerve entrapment, 598
  epidemiology of, 596
  etiology and pathophysiology of, 596
  follow-up of, 599
  fundamentals of, 596
  from gout, 563, 567f
  management of, 598–599, 598f
  patient education on, 599
  patient story of, 596, 596f
  prognosis in, 599
  risk factors for, 597
Onychocryptosis, 1156–1158
  definition of, 1156
  diagnosis of, 1156f, 1257
  differential diagnosis of
    vs. cellulitis, 1157
    vs. paronychia, 1157, 1167
  etiology and pathophysiology of, 1156, 1156f
  follow-up of, 1158
  management of, 1157–1158, 1157f, 1158f
  patient education on, 1158
  patient story of, 1156, 1156f
  risk factors for, 1156–1157, 1156f, 1257
Onychogryphosis, 1145, 1146, 1146f, 1161f, 1162f
Onychomycosis, 771–776, 1160–1164
  diagnosis of, 1160f–1162f, 1161–1162
  differential diagnosis of
    vs. habitual nail fold picking, 1162
    vs. leukonychia, 1162
    vs. lichen planus nail changes, 1162
    vs. nail trauma, 1162
    vs. pseudomonal nail infection, 1162, 1163f
    vs. psoriatic nails, 1162, 1171
  epidemiology of, 1160
  etiology and pathophysiology of, 1160–1161, 1160f, 1161f
  fundamentals of, 1160
  management of, 1163–1164, 1163t
  patient story of, 1160, 1160f
  prevention of, 1164
  risk factors for, 1161
  with tinea pedis, 799, 800, 801
Onychoschizia, 1177, 1177f
Open-angle glaucoma
  vs. age-related macular degeneration, 157
  primary, 139–142
Oppression, recognition of, 10
Optic disc cupping, 139f, 140, 140f
  in glaucoma, 139f, 140, 140f, 141
  vs. glaucoma, 140f, 141
  normal, 140, 140f
Optic disc drusen, 153
Optic nerve atrophy, in glaucoma, 139f, 140, 140f
Optic neuropathies, 153
Oral cancer, *vs.* aphthous ulcer, 246
Oral contraceptive pills (OCPs)
  ethinyl estradiol, 13t, 14
  ethinyl estradiol with drospirenone, 14
  extended regimens of, 14
  traditional, 13t
  use of, 12
Oral lesions, from child abuse, 84
Orbicular eczema, 851–854. *See also* Eczema, nummular
Orolabial herpes, 735–742. *See also* Herpes simplex virus (HSV)
Oropharyngeal cancer, 253–256
  diagnosis of, 253f–256f, 254
  differential diagnosis of, 255, 256f
  epidemiology of, 253
  etiology and pathophysiology of, 253–254
  follow-up of, 255
  fundamentals of, 253
  management of, 255
  patient education and follow-up of, 255
  patient story of, 253, 253f
  prognosis in, 255
  risk factors for, 254
Ortho Evra, 15, 16f
Osler nodes, 287–291, 289f. *See also* Endocarditis, bacterial
Osler-Weber-Rendu syndrome, 1207–1210, 1207f. *See also* Vascular lesions, hereditary and congenital
Ossicles, accessory, *vs.* metatarsal fracture, 613
Osteoarthritis, 569–573
  definition of, 569
  diagnosis of, 569f–571f, 570
    clinical features in, 581
    imaging in, 566, 581f, 582f
    laboratory testing in, 581
    typical distribution in, 563, 563f, 581
  differential diagnosis of
    vs. ankylosing spondylitis, 582
    vs. bursitis, 571
    vs. connective tissue diseases, 571
    vs. fibromyalgia, 571
    vs. knee soft tissue injuries, 622
    vs. lupus, 571
    vs. other arthritis and ankylosing spondylitis, 568t
    vs. polyarticular gout, 571
    vs. polymyalgia rheumatica, 571
    vs. reactive arthritis, 571
    vs. rheumatoid arthritis, 571, 572f
    vs. scleroderma, 571
    vs. seronegative spondyloarthropathies, 571
  epidemiology of, 569
  etiology and pathophysiology of, 569–570
  follow-up for, 573
  management of, 571–573, 572t
  patient education on, 573
  patient story in, 569, 569f
  risk factors for, 570
  risk factors for GI events from NSAIDs for, 571, 573t

Osteogenesis imperfecta, *vs.* child abuse, 85
Osteomyelitis
vs. Charcot arthropathy, 1262
vs. knee soft tissue injuries, 622
Osteoporosis and osteopenia, 1338–1344
definition of, 1338
diagnosis of, 1338f, 1340–1342, 1340f–1342f
differential diagnosis of
vs. ankylosing spondylitis, 1342
vs. cancer, 1342
vs. degenerative arthritis of spine, 1342
vs. tuberculosis, 1342
epidemiology of, 1338
etiology and pathophysiology of, 1339, 1339f, 1340f, 1340t
follow-up of, 1341f, 1342f, 1344
management of, 1340t, 1343–1344
patient education on, 1344
patient story of, 1338, 1338f
prevention and screening for, 1344
risk factors for, 1339–1340, 1340t
Osteoporotic vertebral fracture, *vs.* back pain, 586, 586f
Otalgia, referred, *vs.* acute otitis and otitis media with effusion, 173
Otitic barotrauma, *vs.* acute otitis and otitis media with effusion, 173
Otitis externa, 180–184
diagnosis of, 180f–183f, 181–182
differential diagnosis of, 181f, 182
vs. acute otitis and otitis media with effusion, 173
vs. acute otitis media with perforated tympanic membrane, 182
vs. chronic suppurative otitis media, 181f, 182
vs. contact dermatitis, 182
vs. foreign body, ear, 182, 186
vs. otomycosis, 182
vs. tympanic membrane perforation, acute otitis media with, 182
epidemiology of, 180
etiology and pathophysiology of, 180
follow-up for, 183
with hearing aid, 182f
management of, 182–183
patient education on, 184
patient story of, 180, 180f, 181f
prevention of, 183
prognosis in, 183
risk factors for, 181
Otitis media, acute. *See* Acute otitis media (AOM)
Otitis media with effusion (OME), 170–178
diagnosis of, 170f, 172–173, 172f, 173f
differential diagnosis of, 173, 174f–177f
vs. bullous myringitis, 173, 175f
vs. cholesteatoma, 173, 174f
vs. chronic suppurative otitis media, 173
vs. foreign body, 173
vs. mastoiditis, 173, 176f
vs. otalgia, referred, 173
vs. otitic barotrauma, 173
vs. otitis externa, 173
vs. otitis media, 173
vs. tympanic membrane perforation, traumatic, 173, 177f
epidemiology of, 170–171
etiology and pathophysiology of, 171
follow-up for, 176
fundamentals of, 170
management of, 174–175
patient education on, 177
patient story of, 170, 170f
prevention of, 176, 177f, 178f
prognosis in, 176
risk factors for, 171
Otomycosis, *vs.* otitis externa, 182
Ottawa ankle rules, 611, 613, 614

P

Paget disease of breast, 557–560
diagnosis of, 557f, 558–559, 558f
differential diagnosis of
vs. benign lichenoid keratoses, 559, 560f
vs. Bowen disease, 559
vs. eczema of areola, 559, 559f
vs. mastitis and breast abscess, 547
vs. nipple adenoma, 559
vs. seborrheic keratoses, 559
vs. superficial spreading malignant melanoma, 559, 559f
epidemiology of, 557
etiology and pathophysiology of, 557–558, 557f
management of, 559
patient education on, 559–560
patient story of, 546f, 557
prognosis in, 559
Paget disease of external genitalia, 514–517
diagnosis of, 514–515, 514f–516f
differential diagnosis of
vs. amelanotic melanoma of vulva, 516
vs. *Candida* vulvovaginitis, 516
vs. condylomata acuminata, 516
vs. herpes simplex virus 1, 516
vs. herpes simplex virus 2, 516
vs. hidradenitis suppurativa, 516
vs. leukoplakia, 516
vs. lichen sclerosus et atrophicus, vulvar, 516, 516f
vs. squamous cell carcinoma of vulva, 516
epidemiology of, 514, 515f
follow-up of, 517
fundamentals of, 514
management of, 516–517
patient story of, 514, 514f
prognosis in, 517
risk factors of, 514
Paget disease of the scrotum, 514–517. *See also* Paget disease of external genitalia
Paget disease of the vulva, 514–517. *See also* Paget disease of external genitalia
Pain management. *See also specific disorders*
end of life, 32
Pain reliever addiction, 1393
Palliative care, 29f, 30, 31–32. *See also* End of life
Palliative Performance Scale (PPS), 27
Palmar erythema, in pregnancy, 463
Palmar fibromatosis, 625–628. *See also* Dupuytren disease (contractures)
Palmar hyperlinearity, with atopic dermatitis, 827
Palmar nodules, *vs.* Dupuytren disease, 627
Palmar-plantar (palmoplantar) psoriasis. *See* Psoriasis
Palmoplantar eczema, 843–849. *See also* Eczema, hand
Palmoplantar keratoderma, *vs.* plantar warts, 767–768, 769f, 770f
Palmoplantar warts, 766–769, 766f–768f. *See also* Warts, plantar

Pancreatitis
vs. ankylosing spondylitis, 582
vs. gallstones, 389
Panniculitis
erythema nodosum, 1056–1061 (*See also* Erythema nodosum)
infectious, *vs.* erythema nodosum, 1060
Panuveitis, 136
Papanicolaou (Pap) smear, 525, 526f
Papanicolaou (Pap) smear abnormalities
colposcopy in
of high-grade lesions, 535–539
of low-grade disease, 530–533, 530f–532f
epidemiology of, 530, 535
Papillary carcinoma, renal cell, 441. *See also* Renal cell carcinoma
Papilledema, 151–154
diagnosis of, 151f, 152–153, 152f
differential diagnosis of, 153
epidemiology of, 151
etiology and pathophysiology of, 151–152
fundamentals of, 151
management of, 153–154
patient education on, 154
patient story of, 151, 151f
prevention of, 154
prognosis and follow-up in, 154
risk factors for, 152
Papilloma, *vs.* nasal polyps, 194
Papillomatosis
laryngeal, 220–225, 224f
micropapillomatosis of vulva, 762
recurrent respiratory, 224f
hoarseness in, 220–225 (*See also* Hoarseness)
maternal HPV infection and juvenile onset of, 221
Papular acrodermatitis of childhood, *vs.* pityriasis lichenoides et varioliformis acuta, 1124, 1125f
Papulopustular rosacea, 659f–660f, 660, 662f–663f. *See also* Rosacea
Parainfluenza virus sinusitis, 198
Parakeratosis, in psoriatic nails, 1170
Paramyxoviridae, 723. *See also* Measles
Paraneoplastic pemphigus (PNP), 1109–1117
diagnosis of, 1112–1113, 1113f
differential diagnosis of, 1113–1114
epidemiology of, 1109
etiology and pathophysiology of, 1112
follow-up of, 1116
management of, 1114–1116
patient education on, 1116–1117
prognosis in, 1116
Parapsoriasis, *vs.* cutaneous T-cell lymphoma, 1043f, 1045
Parapsoriasis variegata, 1043f, 1045
Parasites. *See* Intestinal worms and parasites; *specific types*
Parasitic folliculitis, 681
Parasitosis delusions, *vs.* self-inflicted dermatoses, 860–861
Parkinson disease, *vs.* normal pressure hydrocephalus, 1381
Paronychia, 1166–1169
diagnosis of
acute, 1166f, 1167, 1167f
chronic, 1167, 1168f
differential diagnosis of
vs. felon, 1168
vs. glomus tumor, 1167
vs. herpes simplex virus, 739
vs. herpetic whitlow, 1167
vs. ingrown nail, 1167
vs. mucus cyst, 1167, 1169f
vs. neoplasms, 1168
epidemiology of, 1166
etiology and pathophysiology of, 1166, 1166f–1168f
fundamentals of, 1166
management of, 1168
patient education on, 1169
patient story of, 1166, 1166f
prevention of, 1168
prognosis and follow-up of, 1169
risk factors for, 1167, 1167f, 1168f
Paronychia congenita
callus from, 1243, 1244, 1244f
vs. corns and calluses, 1244, 1244f
Parvovirus B19, in fifth disease, 728–731, 729f. *See also* Fifth disease (erythema infectiosum)
Pasteurella multocida cellulitis, 693
Pastia's lines, 208f, 209
Patch
combination contraceptive, 15, 16f
contraceptive, 13t
Patellar dislocation, *vs.* knee soft tissue injuries, 622
Patellar fracture, 622f
vs. knee soft tissue injuries, 621, 622f
Pathergy, 1028, 1029f
Patient
education of (*See* Education, patient; *specific disorders*)
learning from, 9
what physicians want from and for, 9, 9f
Patient-centered interview, 10
Patient–physician relationship, images for building trust in, 4
Patient story, 8. *See also specific topics*
Pautrier microabscess, 1044
Pearly penile papules, *vs.* genital warts, 762, 763f
Pediculus humanus capitis, 809–814, 810f
Pediculus humanus corporis, 809–814, 810f
Peer-to-peer adult education, 55
Pelvic inflammatory disease (PID), after *Chlamydia* infection, 509
Pemphigoid gestationis, 471–474. *See also* Bullous pemphigoid
definition of, 471
diagnosis of, 471f–473f, 472
differential diagnosis of, 473
vs. bullous pemphigoid, 473
vs. contact dermatitis, 473
vs. dermatitis herpetiformis, 473
vs. drug reaction, 473
vs. erythema multiforme, 473
vs. pruritic urticarial papules and plaques of pregnancy, 468, 473
vs. urticaria, 473, 866
epidemiology of, 471
etiology and pathophysiology of, 471–472
follow-up of, 473–474
management of, 473
patient education on, 474
patient story of, 471, 471f–473f
prognosis in, 473
risk factors for, 472
Pemphigus, 1109–1117
diagnosis of, 1112–1113, 1114f
differential diagnosis of

vs. bullous pemphigoid, 1113–1114
vs. cicatricial pemphigoid, 1114
vs. dermatitis herpetiformis, 1114
vs. Hailey-Hailey disease, 1114, 1115f
vs. herpes zoster, 714
vs. linear IgA dermatosis, 1114
vs. pemphigus vegetans, 1114, 1115f
vs. porphyria cutanea tarda, 1114
vs. zoster ophthalmicus, 720
epidemiology of, 1109, 1111
etiology and pathophysiology of, 1112
follow-up of, 1116
fundamentals of, 1109
management of, 1114–1116, 1116f
patient education on, 1116–1117
patient story of, 1109, 1109f
prognosis in, 1116
Pemphigus foliaceous, 1098, 1098f, 1109–1117
diagnosis of, 1110f–1112f, 1112–1113, 1114f
differential diagnosis of, 1113–1114
epidemiology of, 1109, 1110f–1112f
etiology and pathophysiology of, 1112
follow-up of, 1116
management of, 1114–1116, 1116f
patient education on, 1116–1117
prognosis in, 1116
Pemphigus vegetans. *See also* Pemphigus vulgaris
diagnosis of, 1110f, 1112
distribution of, 1113
fundamentals of, 1109
vs. Hailey-Hailey disease, 1114, 1115f
Pemphigus vulgaris, 1098, 1098f, 1099f, 1109–1117
black tongue from, 229f
diagnosis of, 1109f, 1110f, 1112–1113, 1113f
differential diagnosis of, 1113–1114
vs. cutaneous drug reactions, 1221
vs. impetigo, 677
epidemiology of, 1109, 1109f, 1110f
etiology and pathophysiology of, 1112
follow-up of, 1116
fundamentals of, 1109
management of, 1114–1116, 1116f
neonatal, 1102
patient education on, 1116–1117
patient story of, 1109, 1109f
prognosis in, 1116
Penicillin, reactions from, 1211–1222, 1216t
Penile pyoderma gangrenosum, 1029. *See also* Pyoderma gangrenosum
Penis, on second trimester ultrasound, 479f, 480
Peptic ulcer disease (PUD), 366–369
definition of, 366
diagnosis of, 366f, 367–368, 367f
differential diagnosis of
vs. biliary colic, 368
vs. Crohn's disease, 368
vs. functional dyspepsia, 368
vs. gallstones, 389
vs. gastric cancer, 368, 374
vs. gastroesophageal reflux, 368
vs. kidney stones, 427
vs. nonulcer dyspepsia, 368
epidemiology of, 366, 366f
etiology and pathophysiology of, 366–367, 366f, 367f
follow-up for, 369
management of, 368–369
patient education on, 369
patient story of, 366
prevention of, 369
prognosis in, 369
risk factors for, 367
Peptostreptococcus
necrotizing fasciitis from, 702
otitis externa from, 180
Perfume, contact dermatitis from, 843f
Perianal dermatitis, childhood, 646–650, 646f, 647f. *See also* Diaper rash
Perianal Paget disease, 514–517. *See also* Paget disease of external genitalia
Perianal pseudoverrucous papules, 648
Pericardial effusion, 281–285
diagnosis of, 281f, 282–283, 283f
differential diagnosis of
vs. heart failure, 283–284, 284f
vs. pericarditis, 284
vs. pleural effusion, 284
epidemiology of, 281
etiology and pathophysiology of, 281
follow-up for, 285
fundamentals of, 281
in heart failure, 283–284, 283f, 284f
management of, 284–285
patient education on, 285
patient story of, 281, 281f
prognosis in, 285
risk factors in, 282
"water-bottle" heart in, 281f
Pericarditis
vs. coronary artery disease, 270
vs. pericardial effusion, 284
Perinuclear cytoplasmic vacuolization, 535
Periodontal anatomy, healthy, 236, 236f
Periodontal disease (periodontitis), 236–238
diagnosis of, 236f, 237, 237f
differential diagnosis of, 238
epidemiology of, 236, 237f
etiology and pathophysiology of, 236–237, 236f, 237f
fundamentals of, 236
management of, 238
patient education and follow-up in, 238
prevention of, 238
risk factors for, 237
smoking and, 1400, 1400f
Perioral dermatitis, 661, 664f
Peripheral arterial disease, with diabetes and dry gangrene, 1265
Peripheral neuropathy, *vs.* Lyme disease, 1293
Peripheral photocoagulation, for diabetic retinopathy, 144f, 145, 145f
Perirectal abscess, *vs.* hemorrhoids, 416, 416f
Peristomal pyoderma gangrenosum, 1029. *See also* Pyoderma gangrenosum
Peritonsillar abscess, in pharyngitis, 214, 214f
Perlèche, 203–205, 203f–205f, 777, 778, 778f
Persistent juvenile transformation zone
colposcopy and diagnosis of, 525, 525f, 526, 528f
management of, 528
Personality disorders. *See also specific types*
vs. substance abuse disorder, 1396
Petroleum products, contact dermatitis from, 840f

Pharyngitis, 213–218
diagnosis of, 213f–216f, 214–216
differential diagnosis of
vs. cytomegalovirus, 216
vs. diphtheria, 217
vs. epiglottitis, 217
vs. gingivostomatitis, herpes, 216
vs. herpangina/coxsackievirus, 216, 216f
vs. infectious mononucleosis, 215f, 216
vs. neck infections, deep, 217
vs. oral *Candida* (thrush), 216
vs. sexually transmitted infections, 216
vs. supraglottitis, 217
epidemiology of, 213
etiology and pathophysiology of, 213–214, 213f, 214f
follow-up for, 218
fundamentals of, 213
management of, 217–218
patient education on, 218
patient story of, 213, 213f
prognosis in, 218
risk factors for, 214
Phenolphthalein, reactions from, 1211–1222
Phenytoin, reactions from, 1211–1222
Phimosis, *vs.* child sexual abuse, 92
Photoallergic drug reactions, 1191–1196, 1193f
eczema as, 1191–1196, 1193f
Photoallergic eruptions, 1191–1196, 1193f, 1194t. *See also* Photodermatitis; Photosensitivity
Photocoagulation, for diabetic retinopathy, 144f, 145, 145f
Photodermatitis
prevention of, 1195t, 1196
prognosis in, 1196
risk factors for, 1193
types of, 1191
UV light in, 1191
Photography
digital, 4
of patients, 4
Photoonycholysis phototoxicity reactions, 1191–1196
Photosensitivity, 1191–1196
diagnosis of, 1191f–1193f, 1193–1195
differential diagnosis of
vs. contact dermatitis, 1195
vs. dermatomyositis, 1083, 1195
vs. porphyria cutanea tarda, 1195
vs. systemic lupus erythematosus, 1195
epidemiology of, 1191, 1191f
etiology and pathophysiology of, 1186t, 1187t, 1191–1193, 1191f–1193f, 1194t
follow-up of, 1196
management of, 1195–1196
patient education on, 1196
patient story of, 1191, 1191f
Phototoxic drug reactions, 1191–1196, 1192f
Phototoxic reactions. *See* Photodermatitis; Photosensitivity
Phthirus pubis, 809–814, 810f
Phymatous rosacea, 660, 660f–661f. *See also* Rosacea
Physical abuse
child, 82–87 (*See also* Child physical abuse)
intimate partner, 95–100 (*See also* Intimate partner violence (IPV))
Physical inactivity, on mortality, 26
Physical violence, 95
Physician
desires for patients of, 9, 9f
what patients want from, 8
Physician orders for life-sustaining treatment (POL ST) Paradigm task force, 29
Physiologic melanosis, eye, 118–121, 119f
Phytophotodermatitis, 1191–1196, 1192f. *See also* Photodermatitis; Photosensitivity
vs. cutaneous larva migrans, 824
Pigmented basal cell carcinoma, dermoscopy of, 1466, 1467f
Pigmented lesions of nail bed, *vs.* normal nail variants, 1147
Pigmented nail disorders, 1151–1155
Pigmented pretibial papules, 1314–1316, 1314f–1316f. *See also* Diabetic dermopathy
Pigmented purpuric dermatosis
vs. diabetic dermopathy, 1315
vs. vasculitis, 1066, 1066f, 1067f
Pigmented purpuric dermatosis of Majocchi type, *vs.* vasculitis, 1066, 1067f
Pigmented stones, 387, 388. *See also* Gallstones
Piles, 414–418. *See also* Hemorrhoids
Pincer nail, 1156, 1156f
Pinguecula, *vs.* pterygium, 111, 112f
Pink eye, 126–129. *See also* Conjunctivitis
Pinworm infestation, 1270–1274, 1270f
vs. child sexual abuse, 92
Pit latrines, in Ethiopia, 55–56, 56f, 57f
Pitted keratolysis, 686–688
definition of, 686
diagnosis of, 686–687, 686f, 687f
differential diagnosis of
vs. arsenic toxicity, 687
vs. basal nevus syndrome, 687
vs. planar warts, 687
vs. tinea pedis, 801, 802f
epidemiology of, 686
etiology and pathophysiology of, 686
follow-up of, 687–688
management of, 687
patient education on, 688
patient story of, 686, 686f
Pituitary adenoma
somatrotrope, acromegaly from, 1360–1364 (*See also* Acromegaly)
thyrotropin-secreting, *vs.* Graves disease and goiter, 1355
Pityriasis alba
with atopic dermatitis, 827, 830f
differential diagnosis of
vs. tinea versicolor, 806
vs. vitiligo, 1185–1187
Pityriasis lichenoides chronica, 1123–1124, 1125f
Pityriasis lichenoides et varioliformis acuta (PLEVA), 1100, 1100f, 1123–1124, 1124f
differential diagnosis of
vs. erythema multiforme, 1124
vs. Gianotti-Crosti syndrome, 1124, 1125f
vs. lymphomatoid papulosis, 1123
vs. papular acrodermatitis of childhood, 1124, 1125f
vs. pityriasis lichenoides chronica, 1124, 1125f
vs. varicella, 1124
Pityriasis rosea, 896–900
diagnosis of, 897–899, 897f–900f
differential diagnosis of

vs. cutaneous drug reactions, 1221
vs. eczema, nummular, 899
vs. erythema annulare centrifugum, 1237
vs. granuloma annulare, 1024
vs. guttate psoriasis, 899
vs. lichen planus, 906
vs. psoriasis, 888
vs. syphilis, 1282
vs. syphilis, secondary, 899
vs. tinea corporis, 899
vs. tinea versicolor, 806, 899
epidemiology of, 896
etiology and pathophysiology of, 896–897
follow-up of, 900
fundamentals of, 896
management of, 899
patient education on, 900
patient story of, 896, 896f, 897f
Pityriasis versicolor. *See* Tinea versicolor
Pityrosporum, 771–776, 805, 807f. *See also* Fungal infections, cutaneous
seborrhea from, 771, 774t, 805, 872
tinea versicolor from, 771, 774t
Pityrosporum folliculitis, 681, 682f, 683f, 806, 807f
diagnosis of, 807f
vs. tinea versicolor, 806, 807f
Pityrosporum orbiculare, 805
Pityrosporum ovale, 805
Pivot shift test, 621
Placenta, on ultrasound
second trimester, 478–481, 478f–481f
third trimester, 482–484, 482f–484f
Placenta previa, third trimester ultrasound of, 482, 484, 484f
Plane warts, 755–758. *See also* Warts, flat
Plane xanthomas, 1323
Plantar hyperlinearity, with atopic dermatitis, 827
Plantar warts, 766–769. *See also* Warts, plantar
Plaque, coronary, 269
Plaque psoriasis. *See* Psoriasis
Plasmodium falciparum, 64–66, 65f. *See also* Malaria
Plasmodium malariae, 64–66. *See also* Malaria
Plasmodium ovale, 64–66. *See also* Malaria
Plasmodium vivax, 64–66, 65f. *See also* Malaria
Pleural effusion
heart failure, 278f
vs. pericardial effusion, 284
PLEVA. *See* Pityriasis lichenoides et varioliformis acuta (PLEVA)
Plumber's itch, 823–825, 823f, 824f
Pneumococcal conjugate vaccination, 307
Pneumococcal polysaccharide vaccination, 307
Pneumonia, 300–308
bronchopneumonia, 303, 303f, 305f
definition and types of, 300
diagnosis of, 302–304
clinical features in, 302
history in, 302
imaging in, 300f, 301f, 303–304, 303f–306f
laboratory studies in, 302–303
differential diagnosis of
vs. asthma, 303, 304, 326
vs. chronic obstructive pulmonary disease, 338
vs. heart failure, 278
vs. lung cancer, 359
vs. pulmonary embolus, 304, 350
vs. tuberculosis, 314
vs. upper respiratory illness, 304
epidemiology of, 300
etiology and pathophysiology of, 301
follow-up of, 307–308
interstitial, 304, 306f, 307f
lobar, 300f, 301f, 303, 303f, 304f
management of, 304–307
hospitalization in, 306
medications in, 305–306
nonpharmacologic, 304–305
outpatient treatment criteria in, 304
miliary, 304 (*See also* Tuberculosis (TB))
patient education in, 308
patient story of, 300, 300f, 301f
prevention of, 307
prognosis in, 307
risk factors for, 301
Pneumothorax
vs. coronary artery disease, 270
vs. pulmonary embolus, 350
Podagra, 591, 591f. *See also* Gout
Poikiloderma, 1082, 1085f
Poikiloderma atrophicans vasculare, *vs.* erythema ab igne, 1200
Poisoning, on mortality, 27
Poison ivy/oak, contact dermatitis from, 834, 835, 836f, 837f, 1101f
POL ST (physician orders for life-sustaining treatment) Paradigm task force, 29
Polyarticular gout
vs. osteoarthritis, 571
vs. rheumatoid arthritis, 577
Polyarticular inflammatory arthritis, 563. *See also* Arthritis
Polyarticular noninflammatory arthritis, 563. *See also* Arthritis
Polycystic kidneys, 436–439
diagnosis of, 436f, 437–438, 437f
differential diagnosis of
vs. acquired cystic disease, 438
vs. simple cyst, 438
vs. tuberous sclerosis, 438
epidemiology of, 436
etiology and pathophysiology of, 436–437, 437f
follow-up of, 439
fundamentals of, 436
kidney stones with, 437 (*See also* Kidney stones)
management of, 438
patient education on, 439
patient story of, 436, 436f
prognosis in, 438
Polycystic ovary syndrome, *vs.* obesity, 1332
Polymorphic eruption of pregnancy, 467–470, 467f–469f
Polymorphous light eruption (PMLE), 1191–1196, 1191f. *See also* Photodermatitis; Photosensitivity
vs. dermatomyositis, 1083
Polymyalgia rheumatica
vs. arthritis, 566
vs. osteoarthritis, 571
vs. rheumatoid arthritis, 577
Polymyositis, *vs.* dermatomyositis, 1083
Polyp
colon (*See* Colon polyps)
laryngeal, 220–225, 225f (*See also* Hoarseness)
nasal, 193–195, 193f, 194f (*See also* Nasal polyps)

Pompholyx, 843–849. *See also* Eczema, hand
Pork tapeworm, 1270–1274
Porokeratosis
  vs. corns and calluses, 1244
  vs. epidermal nevus and nevus sebaceous, 961
Porphyria cutanea tarda (PCT), 1100, 1100f, 1119–1121, 1119f, 1120f
  vs. eczema, 1120
  vs. epidermolysis bullosa, 1122
  vs. erythema multiforme bullosum, 1120
  vs. pemphigus, 1114
  vs. photodermatitis, 1195
  vs. systemic sclerosis, 1120
Portal vein, 378
  on third trimester ultrasound, 482f
Port-wine stains, 1207–1210, 1207f–1209f. *See also* Vascular lesions, hereditary and congenital
  in Klippel-Trenaunay syndrome, 1208, 1209
  in Sturge-Weber syndrome, 1208, 1209
  vs. vascular lesions, hereditary and congenital adult, 1209
Postburn blistering, 1100, 1101f
Postcholecystectomy syndrome, 390
Postherpetic neuralgia (PHN), 712–716
  etiology and pathophysiology of, 712–713, 713f
  management of, 715, 716t
  prevention of, 715
  risk factors for, 714
Postinfectious encephalomyelitis, 724, 726
Postpartum thyroiditis, *vs.* goitrous hypothyroidism, 1349
Postscabies syndrome, 642
Posttraumatic stress disorder (PTSD), after sexual assault, 104, 107
Pott disease, from tuberculosis, 312, 312f
Prader-Willi syndrome, obesity in, 1332
Preauricular tags, 189–191
  diagnosis of, 190, 191f
  differential diagnosis of, 190–191
  epidemiology of, 189
  etiology and pathophysiology of, 190
  follow-up and patient education on, 191
  management of, 191
Pregnancy, 17–23
  atopic eruption of, 463, 464, 464f
  definition of, 18
  diagnosis of, 18–19
  differential diagnosis of, 20
  ectopic, 20
  epidemiology of, 17–18
  etiology and pathophysiology of, 18
  home pregnancy kits for, 19, 22
  intrahepatic cholestasis of
    epidemiology of, 463
    etiology and pathophysiology of, 464
    management of, 465
    patient story of, 462, 462f
    risk factors for, 464
  management of, 21–22
  mask of, 1179–1182, 1179f–1181f (*See also* Melasma)
  maternal mortality in, 17–18
  patient education on, 22–23, 22f
  patient story of, 17, 17f
  planned, 17
  planning for, 22–23
  prevention of, 22 (*See also* Family planning)
  prurigo of, 463
  from rape, 107
  skin findings in, 462–466, 462f–465f (*See also* Skin, in pregnancy)
  tubal, 510
  unplanned (unintended), 17
Pregnancy epulis, 464, 465, 465f
Pregnancy tests, 19
Pregnancy tumor, 464, 465, 465f
  vs. gingival overgrowth, 241–242
Premature menopause, with amenorrhea, 20
Prenatal care, 21
Presbyphonia, 222, 224
Prickly heat (miliaria), 633, 633f, 1100
  differential diagnosis of
    vs. folliculitis, 684
    vs. milia, newborn, 633, 633f
  neonatal, 633, 633f
  in pregnancy, 463
Primary acquired melanosis (PAM), 118–121, 119f
Progestin-only oral contraceptive pills, 13t
Prostate cancer, 453–459
  diagnosis of, 455–457
  differential diagnosis of
    vs. atypical glands on biopsy, 457
    vs. benign prostatic hyperplasia, 457
    vs. prostatic intraepithelial neoplasia, 457
    vs. prostatitis, 457
  epidemiology of, 453, 453f, 454f
  etiology and pathophysiology of, 454–455, 455f
  fundamentals of, 453
  management of, 457–458, 458f
  patient education on, 459
  patient story of, 453, 453f
  prevention of, 458
  prognosis in, 458
  risk factors for, 455
Prostate zones, 455, 455f
Prostatic intraepithelial neoplasia, *vs.* prostate cancer, 457
Prostatitis, *vs.* prostate cancer, 457
Prosthetic parity, 39–41, 41f, 42f
Prosthetic valve endocarditis, 288. *See also* Endocarditis, bacterial
Protein–calorie malnutrition, 60–61, 60f
Proteus folliculitis, 681
Proteus syndrome, *vs.* neurofibromatosis, 1389
Protozoa, 1270–1274, 1273f
Proxy designations, 29
Prurigo nodularis, 856–862, 859f, 860f. *See also* Self-inflicted dermatoses
  vs. lichen planus, 907
  vs. methamphetamine abuse, 1427
Prurigo of pregnancy, 463, 464, 464f
Pruritic urticarial papules and plaques of pregnancy (PUPPP), 467–470
  definition of, 467
  diagnosis of, 467f–469f, 468
  differential diagnosis of
    vs. drug reaction, 468
    vs. erythema multiforme, 468
    vs. pemphigoid gestationis, 468, 473
    vs. scabies, 469
    vs. urticaria, 866, 867f
    vs. viral exanthem, 469
  epidemiology of, 467
  etiology and pathophysiology of, 467–468

management of, 469
patient education on, 469–470
patient story of, 467, 467f
prognosis and follow-up for, 469
risk factors for, 468
Pruritus, urticaria and angioedema, 863–869
Pruritus gravidarum, 462f, 464
epidemiology of, 463
etiology and pathophysiology of, 464
management of, 465
patient story of, 462, 462f
risk factors for, 464
PSA screening, 456
Pseudoarthrosis of clavicle, *vs.* clavicle fracture, 602
Pseudofolliculitis, 665–669
diagnosis of, 665f, 666, 666f
differential diagnosis of
vs. acne vulgaris, 667
vs. folliculitis, 667
vs. impetigo, 667
epidemiology of, 665, 667f
etiology and pathophysiology of, 665–666
follow-up for, 669
management of, 667–668
patient education on, 669
patient story of, 665, 665f
prevention of, 668
prognosis in, 668
risk factors for, 666
Pseudofolliculitis barbae, 680–684, 681, 681f. *See also* Folliculitis; Pseudofolliculitis
vs. sarcoidosis, 1039
Pseudofolliculitis pubis, 665–669. *See also* Pseudofolliculitis
Pseudogout
vs. bunion deformity, 1248
vs. gout, 593
vs. hammer toe, 1253
vs. knee soft tissue injuries, 622
vs. olecranon bursitis, 598
Pseudo-Hutchinson sign, 1152–1153, 1154f
Pseudo-Jones fracture., 611–614. *See also* Metatarsal fracture
Pseudomonal nail infection, *vs.* onychomycosis, 1162, 1163f
Pseudomonas, paronychia from, 1166–1169, 1166f, 1167f
Pseudomonas aeruginosa
folliculitis from, 680, 680f, 681
otitis externa from, 180, 180f
pneumonia from, 301
Pseudopapilledema, 153
Pseudopregnancy, 20
Pseudosarcomatous dermatofibrosarcoma, *vs.* dermatofibroma, 936
Pseudotumor cerebri, 151–154. *See also* Papilledema
Pseudotumor of eye, *vs.* Graves disease and goiter, 1356
Pseudoverrucous papules, perianal, 648
Pseudoxanthoma elasticum, *vs.* xanthomas, 1324
Psoriasis, 878–894
with diabetes mellitus, 892
diagnosis of, 879–887
disease severity in, 887
erythrodermic, 879, 881f
guttate, 879, 880f
imaging in, 887, 887f
inverse, 878f, 879, 880f
laboratory studies in, 887, 889f
nail changes in, 3, 3f, 879, 881f
palmar-plantar, 879, 880f
plaque, 878f, 879, 879f
psoriatic arthritis, 879, 881f
pustular, 879, 881f
scalp, 879, 879f
differential diagnosis of
vs. atopic dermatitis, 831
vs. candidiasis, cutaneous, 888
vs. cutaneous T-cell lymphoma, 888
vs. eczema, nummular, 854, 888
vs. erythema annulare centrifugum, 1238
vs. erythrasma, 690
vs. geographic tongue, 233, 234f
vs. hand eczema, 847
vs. lichen planus, 888, 906, 907
vs. lichen simplex chronicus, 888
vs. lupus erythematosus, 1074
vs. pityriasis rosea, 888, 899
vs. pustular diseases of childhood, 644
vs. reactive arthritis, 888–889
vs. seborrheic dermatitis, 873, 888
vs. syphilis, secondary, 888
vs. tinea capitis, 785
vs. tinea corporis, 791, 792f, 883f, 888
vs. tinea cruris, 883f, 888
vs. tinea pedis, 801, 804f
vs. vulvar intraepithelial neoplasia, 521
distribution of, 879, 882–887, 882t
erythrodermic psoriasis, 9f, 884
guttate, 882, 884, 884f, 885f
inverse, 880f, 884, 885f
nail, 881f, 887
palmar-plantar, 884, 885f, 886f
plaque, 878f, 879f, 882, 882f–884f
psoriatic arthritis, 881f, 887, 887f
pustular, 884, 886f, 887
scalp, 879f, 882
epidemiology of, 878
erythrodermic, 915–921, 915f–917f
etiology and pathophysiology of, 878
follow-up of, 894
fundamentals of, 878
management of
biologic agents in, 892–893, 892t, 893t
general, 889
methotrexate *vs.* biologic agents in, 893
phototherapy in, 891–892
systemic, 883f, 889f, 891t, 892
topical treatments in, 880f, 889–890, 890f, 890t
topic vehicle choice in, 889
management of, by type
erythrodermic/generalized, 886f, 894
guttate, 884f, 893
inverse, 880f, 894
palmar-plantar, 894
plaque, 891t, 893
pustular, 893–894
scalp, 893
patient education on, 894, 894t
patient story of, 878, 878f

Psoriasis (*Continued*)
plaque
vs. erythema annulare centrifugum, 1238
with obesity, 1331, 1331f
prognosis in, 894
pustular, *vs.* pustular diseases of childhood, 644
risk factors for, 879, 879t
Psoriasis, inverse, 2, 3f. *See also* Psoriasis
diagnosis of, 878f, 879, 880f
differential diagnosis of
vs. candidiasis, 778, 780f
vs. tinea cruris, 796, 797f
distribution of, 880f, 884, 885f
management of, 880f, 893
Psoriatic arthritis
arthritis mutilans, 565t
asymmetric, 564f, 565t, 568t
diagnosis of, 879, 881f
imaging in, 562f, 566
typical distribution in, 563, 564f–565f, 565t, 881f, 887, 887f
differential diagnosis of
vs. other arthritis and ankylosing spondylitis, 568t
vs. reactive arthritis, 913
distal interphalangeal predominant, 565t
patient story on, 562, 562f
spondylitis, 565t
swan-neck deformities in, 582f
symmetric, 565t
types of, 565t
Psoriatic nails, 564f, 565t, 568t, 1170–1173
definition of, 1170
diagnosis of, 1170f–1173f, 1171
differential diagnosis of
vs. alopecia areata, 1172
vs. Darier disease, 1171–1172, 1173f
vs. onychomycosis, 1162, 1171
epidemiology of, 1170, 1170f
etiology and pathophysiology of, 1170, 1170f
follow-up of, 1173
management of, 1172–1173
patient education on, 1173
patient story of, 1170, 1170f
prevention of, 1173
prognosis in, 1173
risk factors for, 1171
Psoriatic spondyloarthritis, *vs.* ankylosing spondylitis, 582, 582f
P-SPIKES approach, 28–29
Psychotherapeutic drug abuse, 1393. *See also* Substance abuse disorder
Pterygium, 110–112
diagnosis of, 111, 111f, 112f
differential diagnosis of, 112f
vs. conjunctivitis, 111
vs. pinguecula, 111, 112f
vs. squamous cell carcinoma of conjunctiva, 111
epidemiology of, 110
etiology and pathophysiology of, 110
management of, 111–112
nasal, 110, 110f, 112f
patient education on, 112
patient story of, 110, 110f
prevention of, 112, 112f
prognosis and follow-up in, 112
red eye in, 165, 167f
risk factors for, 111
Pubic lice, 809–814, 810f. *See also* Lice
Puffiness, myxedema in hypothyroidism, 1348, 1349f
Pulmonary disease. *See also* Lung entries
death from, 27
Pulmonary embolus, 345–352
definition of, 345
diagnosis of, 347–350
clinical features in, 348
history and physical exam in, 345f, 347
imaging in, 345f, 347f, 349–350, 349f–350f
laboratory studies and ECG in, 347f, 348–349
strategy in, 347–348, 347f
differential diagnosis of, 350
vs. heart failure, 350
vs. pneumonia, 304, 350
vs. pneumothorax, 350
epidemiology of, 345
etiology and pathophysiology of, 345–346, 345f
follow-up for, 352
management of, 350–352
medication in, 350–351
nonpharmacologic, 350
referral or hospitalization in, 351–352
surgery and procedures in, 351
patient education on, 352
patient story of, 345, 345f
prevention of, 352
prognosis in, 352
risk factors for, 346
Pulmonary function tests
abbreviations for, 322t
for asthma, 321f, 325, 325f, 326f
Pulmonary hypertension
in chronic obstructive pulmonary disease, 335, 337
with pulmonary embolus, 348, 350, 350f, 352
Pulsus paradoxus, 324
Puncture wound, neuropathic ulcer from, 1259
Purpura, *vs.* Kaposi sarcoma, 1287
Pustular diseases of childhood, 642–644
differential diagnosis of
vs. cutaneous candidiasis, 644
vs. erythema toxicum neonatorum, 644
vs. hand, foot, and mouth disease, 644
vs. herpes, 644
vs. impetigo, 644
vs. psoriasis, pustular, 644
vs. scabies, 644
vs. varicella, 644
epidemiology of, 642
etiology and pathophysiology of, 642–643
fundamentals of, 642
management of, 644
patient education on, 644
patient story on, 642, 642f
prognosis and follow-up of, 644
Pustular psoriasis. *See* Psoriasis
Pyelonephritis
differential diagnosis of
vs. ankylosing spondylitis, 582
vs. hydronephrosis, 432

management of, 423
white blood cell casts in, 421, 422, 422f
Pyloric ulcers, 366–369, 366f, 367f. *See also* Peptic ulcer disease (PUD)
Pyoderma faciale, 661, 664f
vs. acne vulgaris, 654, 655f
Pyoderma gangrenosum, 1028–1034
diagnosis of, 1028f–1032f, 1029–1031
differential diagnosis of
vs. acute febrile neutrophilic dermatosis, 1031, 1032f
vs. black recluse spider bite, 1031
difficulties in, 1031
vs. ecthyma, 1031
vs. mycosis fungoides, 1033
vs. sporotrichosis, 1031, 1032f
vs. squamous cell carcinoma, 1033
vs. systemic vasculitis, 1031
vs. ulcerative STDs, 1031
vs. venous insufficiency ulcers, 1033, 1033f
epidemiology of, 1028
etiology and pathophysiology of, 1028
follow-up of, 1034
fundamentals of, 1028
management of, 1033
patient education on, 1034
patient story of, 1028, 1028f
prognosis in, 1034
risk factors for, 1028–1029
Pyogenic granuloma, 940–944
diagnosis of, 940f–942f, 941
differential diagnosis of
vs. amelanotic melanoma, 941–943, 942f
vs. bacillary angiomatosis, 943
vs. cherry hemangioma, 941, 942f, 943, 943f
vs. fibrous papule of nose, 943, 943f
vs. gingival overgrowth, 241–242, 241f
vs. melanoma, 1016, 1017f
vs. nasal polyps, 194
epidemiology of, 940
etiology and pathophysiology of, 940
follow-up of, 944
fundamentals of, 940
on gums, 241–242, 241f
in pregnancy, 464, 465f
management of, 943
patient education on, 944
patient story of, 940, 940f
in pregnancy, 464, 465f
prognosis in, 943–944
risk factors for, 941
Pyomyositis, *vs.* necrotizing fasciitis, 704
Pyostomatitis vegetans, 1029. *See also* Pyoderma gangrenosum
Pyuria
diagnosis of, 422–423
epidemiology of, 420
etiology and pathophysiology of, 421, 421f, 422f
management of, 423
urinary sediment in, 420–423
with urinary tract infection, 421, 421f

R

Racial melanosis, eye, 118–121, 119f
Radicular syndrome, 586
Radiculoneuropathy, *vs.* Lyme disease, 1293
Radius fracture, 608, 608t
Radius fracture, distal, 605–609
classification of, 608, 608t
diagnosis of, 605f–607f, 606
differential diagnosis of
vs. de Quervain tenosynovitis, 606
vs. scaphoid fracture, 606
epidemiology of, 605
etiology and pathophysiology of, 605–606
follow-up of, 609
fundamentals of, 605
management of, 608, 608f, 608t, 609f
patient education on, 609
patient story of, 605, 605f, 606f
prevention of, 608
prognosis of, 609
risk factors for, 606
Ramsay Hunt syndrome, 713, 713f. *See also* Herpes zoster
Ram's horn nail, 1145, 1146, 1146f, 1161f, 1162f
Rape. *See* Sexual assault, adult
Raspiness, 220–225. *See also* Hoarseness
Raynaud phenomenon, 1089–1090, 1091f
Reactive arthritis, 910–914
from *Chlamydia,* 510
with conjunctivitis, 910, 911, 912f
diagnosis of, 910f–913f, 911–913
differential diagnosis of
vs. geographic tongue, 233
vs. gonococcal arthritis, 913
vs. knee soft tissue injuries, 622
vs. osteoarthritis, 571
vs. psoriasis, 888–889
vs. psoriatic arthritis, 913
vs. reactive arthropathy, 913
vs. rheumatoid arthritis, 577, 913
vs. spondyloarthropathies, 913
epidemiology of, 910
etiology and pathophysiology of, 911
follow-up of, 914
fundamentals of, 910
management of, 913
patient education on, 914
patient story of, 910, 910f–913f
prognosis in, 914
risk factors for, 911
Reactive arthropathy, *vs.* reactive arthritis, 913
Reactive inflammation in HIV, *vs.* cutaneous T-cell lymphoma, 1045
Rectal bleeding. *See also specific disorders*
in colon cancer, 399–403
vs. colon polyps, 395–396
in hemorrhoids, 414–418
in inflammatory bowel disease, 405–412
Rectal infection, *vs.* hemorrhoids, 416, 416f
Rectal prolapse, *vs.* hemorrhoids, 416
Recurrent aphthous ulcer, 244–248, 244f, 245f. *See also* Aphthous ulcer
Recurrent respiratory papillomatosis (RRP), 224f
hoarseness in, 220–225 (*See also* Hoarseness)
maternal HPV infection and juvenile onset of, 221
Red blood cell casts, 420–423, 421f. *See also* Urinary sediment
Red eye, 163–168, 164t
differential diagnosis of, 164t, 165, 165f–167f

Red eye (*Continued*)
epidemiology of, 163
etiology and pathophysiology of, 163
follow-up of, 168
fundamentals of, 163, 163t
management of, 165, 168
patient education on, 168
patient story of, 163, 163f
prognosis in, 168
Red food dye, *vs.* strawberry tongue, 210
Referred otalgia, *vs.* otitis media, 173
Refugees, 37, 37f, 38–39, 41–44, 42f, 43f
patient stories of, 37, 37f
Reiter's syndrome. *See* Reactive arthritis
Relapsing polychondritis
scleritis and episcleritis with, 132, 134
vasculitis in, 1063 (*See also* Vasculitis)
Relative risk reduction (RRR), 1448
Renal. *See also* Kidney
Renal artery stenosis, angiogram of, 273, 273f
Renal calculus, 425–428. *See also* Kidney stones
Renal cell carcinoma, 441–446
definition of, 441
diagnosis of, 441f, 442–443, 442f
differential diagnosis of, 443
epidemiology of, 441
etiology and pathophysiology of, 441–442
follow-up of, 445–446
management of, 443–445, 444t
patient education on, 446
patient story of, 441, 441f
prognosis in, 446
risk factors for, 442
stages of, 444t
Renal disease, end-stage, death from, 27
Renal failure, unexplained, 432
Renal stone, 425–428. *See also* Kidney stones
Respect, for patient, 10
Retinal necrosis, from zoster ophthalmicus, 719
Retinal pigment epithelial (RPE) injury, 155–156
Retinoblastoma, *vs.* hyphema, 161
Retinopathy, diabetic, 143–145, 143f–145f
vs. age-related macular degeneration, 157
vs. HIV retinopathy, 144
vs. hypertensive retinopathy, 144
Retinopathy, hypertensive, 147–150
diagnosis of, 148
differential diagnosis of, 148
vs. diabetic retinopathy, 144
epidemiology of, 147
etiology and pathophysiology of, 147, 147f, 148f
follow-up of, 150
fundamentals of, 147
management of, 149
patient education on, 150
patient story of, 147, 147f
prevention of, 149
prognosis in, 149
Reverse Colles fracture, 605–609, 606f. *See also* Radius fracture, distal
Rhabdomyosarcoma, *vs.* nasal polyps, 194
Rheumatic fever, *vs.* fifth disease, 730
Rheumatoid arthritis, 575–579
diagnosis of, 575f–578f
clinical features in, 576
imaging in, 566, 577, 578f
laboratory testing in, 576
typical distribution in, 563, 564f, 575f–577f, 576
differential diagnosis of
vs. ankylosing spondylitis, 568t
vs. arthritis, other, 568t
vs. bunion deformity, 1248
vs. connective tissue disorders, 577
vs. Dupuytren disease, 626
vs. endocarditis, infectious, 577
vs. fibromyalgia, 577
vs. gout, 593
vs. hammer toe, 1253
vs. hemochromatosis, 577
vs. knee soft tissue injuries, 622
vs. neuroma, 1253
vs. olecranon bursitis, 598
vs. osteoarthritis, 571, 572f
vs. polyarticular gout, 577
vs. polymyalgia rheumatica, 577
vs. reactive arthritis, 577, 913
vs. seronegative spondyloarthropathies, 577
epidemiology of, 575
etiology and pathophysiology of, 575
follow-up for, 579
fundamentals of, 575
management of, 577–578
patient education on, 579
patient story of, 575, 575f, 576f
prognosis in, 578
risk factors for, 575
scleritis with, 131–134, 131f
vasculitis in, 1063 (*See also* Vasculitis)
Rheumatoid nodules, 563, 564f
vs. granuloma annulare, 1024
vs. sarcoidosis, 1038
Rhinocerebral mucormycosis, sinusitis from, 198, 198f
Rhinophyma, 660, 660f–661f
Rhinophymatous rosacea, 660, 660f–661f. *See also* Rosacea
Rhinosinusitis, 197–202. *See also* Sinusitis
Rhinovirus sinusitis, 198
Rhus dermatitis, 834, 835, 836f, 837f, 1101f. *See also* Contact dermatitis
Rickets, *vs.* child abuse, 85
Ring, vaginal, 13t
hormonal, 12, 12f, 14
Rockerbottom foot deformity, 1261–1264, 1262f
Rocky Mountain spotted fever (RMSF)
vs. Lyme disease, 1293
vs. vasculitis, 1066, 1068f
Rosacea, 659–664
diagnosis of, 659f–663f, 660–661
differential diagnosis of
vs. acne vulgaris, 652, 655f, 661
vs. dermatomyositis, 1083
vs. lupus erythematosus, 1074
vs. sarcoidosis, 661
vs. seborrheic dermatitis, 661, 873
vs. systemic lupus erythematosus, 661, 663f, 667, 1074
epidemiology of, 659, 660f
etiology and pathophysiology of, 659–660, 660f–662f

follow-up for, 662
fundamentals of, 659
management of, 661–662, 663f
ocular, 663f
red eye in, 164t, 165, 166f
patient education on, 662
patient story of, 659, 659f, 660f
risk factors for, 660
with syringoma, 934f
Rosacea fulminans, 661, 664f
vs. acne vulgaris, 654, 655f
Roth spots, 287–291, 287f, 288f. *See also* Endocarditis, bacterial
Roundworm, 1270–1274, 1271f
Rubber allergens, in hand eczema, 845

S

SAFE Kit, 105
Safety plan, 97–98
Salivary gland tumors, 254. *See also* Oropharyngeal cancer
Salmonella typhi, 56–57
Salmon patch, 1209f. *See also* Hemangioma, childhood
diagnosis of, 638f
differential diagnosis of
vs. childhood hemangioma, 638, 638f
vs. vascular lesions, hereditary and congenital, 1209, 1209f
Salmon spot, in psoriatic nails, 1170, 1170f–1172f
Salvation Army
free clinic of, 39f
transitional housing village of, 39f
Samitz sign, 1081, 1082f, 1083f
Sanitation, in world health, 55–56, 55f, 56f
Saphenous varicosities, in pregnancy, 463, 464
Sarcoidosis, 1035–1040
annular (circinate), 1035f, 1036, 1039, 1039f
definition of, 1035
diagnosis of, 1035f–1038f, 1036–1038
differential diagnosis of
vs. acne keloidalis nuchae, 1039
vs. carcinoma, metastatic, 1039
vs. epidermal inclusion cyst, 1039
vs. erythema annulare centrifugum, 1238
vs. erythema nodosum, 1059
vs. foreign body granuloma, 1039
vs. granuloma annulare, 1038, 1039
vs. granulomatous rosacea, 1038
vs. lichen planus, 1038
vs. lipoma, 1039
vs. lupus erythematosus, 1074
vs. lupus vulgaris, 1038
vs. morphea, 1039
vs. mycosis fungoides, granulomatous, 1038
vs. necrobiosis lipoidica, 1039, 1319
vs. pseudofolliculitis barbae, 1039
vs. rheumatoid nodules, 1038
vs. rosacea, 661
vs. scarring alopecia, scalp, 1141
vs. syringoma, 1038
vs. xanthelasma, 1038
epidemiology of, 1035–1036, 1035f, 1036f
erythema nodosum in, 1056–1060, 1056f
etiology and pathophysiology of, 1036
follow-up of, 1040
granulomas, 1036, 1039f
lupus pernio, 1035f, 1036, 1036f
maculopapular, 1036, 1036f
management of, 1039–1040, 1040f
nodular and subcutaneous, 1036, 1038f
patient education on, 1040
patient story of, 1035, 1035f
plaque, 1036, 1037f–1039f
prevention and screening for, 1040
prognosis in, 1040
risk factors for, 1036
Scabies, 815–822
bullous presentation of, 1102
diagnosis of, 816, 816f–819f, 820
dermoscopy of mite in, 1470, 1470f
differential diagnosis of, 821f
vs. acropustulosis, 644
vs. acropustulosis of infancy, 821, 821f
vs. arthropod bites, 821
vs. atopic dermatitis, 820, 831
vs. contact dermatitis, 820, 839
vs. dermatitis herpetiformis, 1126
vs. herpes zoster, 714
vs. impetigo, 677, 821, 821f
vs. lice, 811–812
vs. methamphetamine abuse, 1427
vs. molluscum contagiosum, 745
vs. pruritic urticarial papules and plaques of pregnancy, 469
vs. seborrheic dermatitis, 820–821
vs. self-inflicted dermatoses, 861
epidemiology of, 815
etiology and pathophysiology of, 815–816, 815f–817f
follow-up of, 822
as global health problem, 70, 70f, 71, 71f
management of, 821–822
patient education on, 822
patient story of, 815, 815f, 816f
prevention of, 822
prognosis in, 822
risk factors for, 816
Scalp edema, on third trimester ultrasound, 482, 483f
Scalp hair, in pregnancy, 463–464, 464f
Scalp psoriasis. *See* Psoriasis
Scaphoid fracture, *vs.* distal radius fracture, 606
Scar. *See also* Alopecia, scarring
vs. basal cell carcinoma, sclerosis, 996
vs. corns and calluses, 1244
vs. dermatofibroma, 937
vs. diabetic dermopathy, 1315
Scar, hypertrophic. *See also* Keloids
cortisone injection of, 1454f
differential diagnosis of
vs. dermatofibroma, 937
vs. keloids, 1225
Scarlatiniform rash, 208–212, 208f, 209f, 213, 213f
Scarlet fever, 208–212
diagnosis of, 208f, 209, 209f
differential diagnosis of
vs. allergic dermatitis, 210
vs. contact dermatitis, 210
vs. erythema toxicum, 210
vs. Kawasaki disease, 210, 210f

Scarlet fever (*Continued*)
vs. staphylococcal scalded skin syndrome, 210
vs. viral exanthem, 210
epidemiology of, 208, 208f, 209f
etiology and pathophysiology of, 208–209
follow-up for, 211
management of, 210–211
patient education on, 211–212
patient story of, 208, 208f
prognosis in, 211
rash in, 213, 213f
strawberry tongue in, 208, 209f
Scarring alopecia, 1138–1143. *See also* Alopecia, scarring
Schamberg disease, *vs.* diabetic dermopathy, 1315
Schamberg disease, *vs.* vasculitis, 1066, 1066f, 1067f
Schamroth sign, 293, 293f
Schechtman, Andrew, 37, 37f, 38–39
Schiller's test, 530, 531, 532f
Schistosomiasis, 59–60
Schizophrenia, *vs.* substance abuse disorder, 1396
Scleral nevus, 118–121, 118f
Scleral pigmentation, 118–121
Scleritis, 131–134
with autoimmune diseases, 131, 132, 132f
diagnosis of, 131f, 132–133, 132f
differential diagnosis of, 133
vs. acute-angle closure glaucoma, 133
vs. conjunctivitis, 127, 133
vs. corneal ulceration, 133
vs. iritis, 133, 136–137
vs. keratitis, 133
vs. uveitis, 133, 136–137
epidemiology of, 131
etiology and pathophysiology of, 132, 132f
fundamentals of, 131
management of, 134
patient education on, 134
patient story of, 131, 131f
prognosis and follow-up for, 134
red eye in, 163–168, 164t, 166f
Scleroderma, 1089–1095
definition of, 1089
diagnosis of, 1089f–1093f, 1092–1093, 1095f
differential diagnosis of
vs. amyloidosis of skin, 1094
vs. discoid lupus erythematosus, 1093
vs. lichen sclerosis, 1094
vs. lupus erythematosus, 1074
vs. mycosis fungoides, 1094
vs. myxedema, 1093
vs. osteoarthritis, 571
vs. systemic lupus erythematosus, 1093
vs. systemic sclerosis–associated diseases, 1093
epidemiology of, 1089
etiology and pathophysiology of, 1089–1092, 1089f–1093f
follow-up of, 1095
management of, 1094–1095
patient education on, 1095
prognosis in, 1095
Sclerodermatomyositis, 1083. *See also* Dermatomyositis; Scleroderma
Screening mammogram
breast cancer on, 551, 551f, 552f
Paget disease of breast on, 557
Scrofula, 74, 76f
Scrofuloderma, from tuberculosis, 312, 312f, 313f
Scrotum
angiokeratosis of, 1203–1206, 1204f
Paget disease of, 514–517 (*See also* Paget disease of external genitalia)
Sebaceous cell carcinoma, *vs.* hordeolum and chalazion, 115
Sebaceous hyperplasia, 931–934
diagnosis of, 931f, 932–933, 932f
differential diagnosis of
vs. basal cell carcinoma, nodular, 933, 933f, 995, 996f
vs. fibrous papule of face, 933
vs. milia, 933, 933f
vs. molluscum contagiosum, 933
vs. syringoma, 933, 933f
vs. vulvar intraepithelial neoplasia, 521
vs. xanthoma, 933
epidemiology of, 931
etiology and pathophysiology of, 931–932
follow-up of, 934
fundamentals of, 931
management of, 933–934
patient story of, 931, 931f
risk factors for, 932
Seborrhea (seborrheic dermatitis), 871–876
diagnosis of, 871f–875f, 872–873
differential diagnosis of
vs. atopic dermatitis, 831
vs. candidiasis, 778, 873
vs. contact (allergic) dermatitis, 873
vs. Darier disease, 1233
vs. dermatitis, perioral, 873
vs. nutritional deficiency, 873
vs. otitis externa from, 176, 181f
vs. psoriasis, 873, 888
vs. rosacea, 661, 873
vs. scabies, 820–821
vs. scarring alopecia, 1141
vs. seborrhea, 888
vs. systemic lupus erythematosus with butterfly rash, 873
vs. tinea capitis, 785, 873
vs. tinea versicolor, 873
etiology and pathophysiology of, 872
Pityrosporum in, 771, 774t, 805
follow-up of, 876
fundamentals of, 871
management of, 873–876
patient education on, 876
patient story of, 871, 871f
risk factors for, 872
of scalp (dandruff), 871–876
Seborrheic keratosis, 926–930
dermoscopy of
cerebriform, 1468, 1469f
comedo-like openings, 1468, 1468f
gyri and sulci, 1468, 1468f
moth-eaten borders, 1468, 1469f
multiple milia-like cysts, 1468, 1468f
negative wobble sign, 1468
sharp demarcation, 1468
diagnosis of, 926f–929f, 927–929
differential diagnosis of

vs. acanthosis nigricans, 1311
vs. actinic keratosis, 929, 972
vs. basal cell carcinoma, 929, 930f
vs. Bowen disease, 972
vs. condylomata acuminata, 763f
vs. dermatofibroma, 937
vs. lentigo maligna, 982, 982f, 983
vs. malignant melanoma, 929
vs. melanoma, 928f, 929, 930f, 1010f, 1016
vs. nevus, benign, 950
vs. Paget disease of breast, 559
vs. solar lentigo, 928f, 929
vs. warts, 929
vs. warts, common, 750
vs. warts, flat, 756
vs. warts, genital, 762
epidemiology of, 926
etiology and pathophysiology of, 926–927, 927f
follow-up of, 930
fundamentals of, 926
management of, 929
patient education on, 930
patient story of, 126f, 926, 926f
Second hand smoke, 1399, 1403f
Second trimester obstetrical ultrasound, 478–481, 478f–481f
Sedative abuse, 1393. *See also* Substance abuse disorder
Sediment, urinary, 420–423. *See also* Urinary sediment
Segmental neurofibromatosis, *vs.* neurofibromatosis, 1389
Self-disclosure, 10
Self-inflicted dermatoses, 856–862
diagnosis of, 856f–860f, 857, 860
differential diagnosis of
vs. acne keloidalis nuchae, 860
vs. atopic dermatitis, 860
vs. contact dermatitis, 860
vs. eczema, nummular, 861
vs. parasitosis, delusions of, 860–861
vs. scabies, 861
epidemiology of, 856f–860f, 857
etiology and pathophysiology of, 857
follow-up of, 862
fundamentals and types of, 856
management of, 861–862
patient education on, 856f, 857f, 862
patient story of, 856, 856f
Senses, in diagnosis, 2
Sepsis, brain, *vs.* subdural hematoma, 1377
Septic arthritis
differential diagnosis of
vs. gout, 593
vs. knee soft tissue injuries, 622, 623f
distribution of, 565, 567f
Septic joint
vs. bunion deformity, 1248
vs. hammer toe, 1253
Seronegative spondyloarthropathies
differential diagnosis of
vs. osteoarthritis, 571
vs. rheumatoid arthritis, 577
scleritis and episcleritis with, 132, 134
Seven-year itch, 815–822. *See also* Scabies
Severe recurrent alcohol use disorder, 1412, 1413t. *See also* Alcoholism
Sex, on second trimester ultrasound, 479f, 480, 481f
Sexual abstinence, periodic, 13t
Sexual abuse, child, 89–93. *See also* Child sexual abuse
Sexual abuse, noncontact, 102
Sexual assault, adult, 102–107
diagnosis of, 102f, 104, 104f
epidemiology of, 102–103
etiology and pathophysiology of, 103
follow-up for, 107
by intimate partners, 95, 96, 97 (*See also* Intimate partner violence (IPV))
management of, 105–106
patient education on, 107
patient stories on, 102, 102f
prevention of, 106–107
prognosis in, 107
Sexually transmitted infections (STIs)
after sexual assault, 105–106
from child abuse, 91, 92f, 93
differential diagnosis of
vs. atrophic vaginitis, 491
vs. pyoderma gangrenosum, 1031
on mortality, 26
Sexual violence, 102. *See also* Intimate partner violence (IPV); Sexual assault, adult
Sézary syndrome, 1042–1047. *See also* Cutaneous T-cell lymphoma; Mycosis fungoides
Sheehan's syndrome, with amenorrhea, 20
Shiners, allergic, 85
Shingles, 712–716. *See also* Herpes zoster
Shoes, contact dermatitis from, 835, 837f
Sinus headache, 1367. *See also* Headache
Sinusitis, 197–202
diagnosis of, 197f–200f, 198–199
differential diagnosis of
vs. allergic rhinitis, 200
vs. cluster headache, 200
vs. dental pain, 200
vs. migraine headache, 200
vs. squamous cell carcinoma, 200
vs. temporal arteritis, 200
vs. trigeminal neuralgia, 200
vs. upper respiratory tract infection, 200
epidemiology of, 197
etiology and pathophysiology of, 197–198
follow-up for, 202
fundamentals of, 197
management of, 200–201
patient education on, 202
patient story of, 197, 197f
prevention of, 201
prognosis in, 202
Skin, in pregnancy, 462–466
categories of, 462
epidemiology of, 462–463
etiology and pathophysiology of, 462f–465f, 463–464
follow-up of, 465
management of, 465
patient education on, 466
patient story on, 462, 462f
risk factors in, 464
synonyms for, 462

Skin cancer. *See also* Melanoma; *specific types*
vs. chondrodermatitis nodularis helicis, 189f, 190
vs. corns and calluses, 1244
diagnosis of (*See* Dermoscopy)
Skin care for infants, routine, 649
Skin changes, normal pediatric, 630–634
definitions of, 630f–632f
diagnosis of, 630f–632f, 631–633
differential diagnosis of, 633–634, 634f
epidemiology of, 630–631
etiology and pathophysiology of, 631
fundamentals of, 630
management of, 634
parent education on, 634
patient story of, 630, 630f
prognosis in, 634
Skin discoloration, *vs.* child abuse, 85
Skin diseases, infectious. *See also specific types*
epidemiology of, 70
fungal infections, 71, 72f
impetigo and bacterial infections, 71, 71f, 72f
lice, 70, 71
scabies, 70, 71f
viral infections, 71
Skin popping, 1440, 1442f
Skin tag (acrochordon), 922–924
definition of, 922
in diabetes mellitus, 922, 922f, 923, 1312, 1313f
diagnosis of, 922f, 923, 924f
differential diagnosis of
vs. basal cell carcinoma, 924
vs. common warts, 750
vs. keratotic melanocytic nevus, 923–924
vs. neurofibroma, 923, 923f
vs. wart, 923
epidemiology of, 922
etiology and pathophysiology of, 922–923, 922f, 923f
follow-up of, 924, 924f
management of, 924, 924f
in obesity, 1329, 1329f
patient education on, 924
patient story of, 922
in pregnancy, 463
Skin tag, preauricular, 189–191
diagnosis of, 190, 191f
differential diagnosis of, 190–191
epidemiology of, 189
etiology and pathophysiology of, 190
follow-up and patient education on, 191
management of, 191
Skin tape, contact dermatitis from, 835, 837f
Slapped cheek disease, 728–731, 728f–730f. *See also* Fifth disease (erythema infectiosum)
Sleep disorders, after sexual assault, 107
Slit lamp examination, of corneal foreign body/abrasion, 122, 122f, 123, 124
Small-vessel vasculitis, 1062–1069. *See also* Vasculitis
Smith fracture, 605–609, 606f, 608f, 609f. *See also* Radius fracture, distal
Smoker's face, 1398f, 1400, 1400f
Smoking. *See* Tobacco addiction
Smoking cessation
counseling for, 1402, 1404t
motivational interviewing for, 1402, 1404t
in pregnancy, 23
Snow. *See* Cocaine abuse
Snuff patch, *vs.* leukoplakia, 251
Social justice, 37–50
access and advocacy in, 39–41, 39f–42f
careers in medicine, disparity in, 49–50, 49f, 50f
caring clinician stories in, 37
disabilities in, caring for those with, 44–46, 44f, 46f
Doctors Without Borders in, 37, 37f, 38–39
homeless in, caring for, 46–49, 48f, 49f
patient stories on, 37, 37f
prosthetic parity in, 39–41, 41f, 42f
refugees and asylum seekers in, 41–44, 42f, 43f
uninsured in, caring for, 39–40, 39f
Solar keratosis, 969–975. *See also* Actinic keratosis
Solar lentigo
dermoscopy in, 1458f, 1469f
differential diagnosis of
vs. lentigo maligna, 982, 982f, 983, 983f
vs. melanoma, 1016
vs. seborrheic keratosis, 928f, 929
Space-occupying lesion, *vs.* Bell palsy, 1384
Speckled leukoplakia, 249–252, 249f–251f. *See also* Leukoplakia
Spermicide, 13t
Sperm viability, 18
Spider angiomas, in pregnancy, 462–463
Spider bites
vs. pyoderma gangrenosum, 1031
vs. scabies, 821
Spider nevi, in pregnancy, 462–463
Spider telangiectasias, in pregnancy, 462–463
Spinal infection/abscess, *vs.* back pain, 587
Spinal stenosis, *vs.* back pain, 587
Spine. *See also specific disorders*
on third trimester ultrasound, 482f
Spitz nevus, 946, 947f. *See also* Nevus, benign
dermoscopy of, 1457f
Splinter hemorrhage, *vs.* subungual hematoma, 1176
Spondylitis, 565t
Spondyloarthritides. *See also specific types*
vs. ankylosing spondylitis, 582, 582f
Spondyloarthropathies, *vs.* reactive arthritis, 913
Spongiotic dermatitis, as photoallergic drug reaction, 1193, 1193f
Spontaneous venous pulsations (SVPs), 151, 152
Sporotrichosis, *vs.* pyoderma gangrenosum, 1031, 1032f
Spring catarrh, 128
Squamocolumnar junction (SCJ), cervical, 525f–527f, 526
Squamous cell carcinoma, 999–1007
diagnosis of, 999f–1005f, 1000–1005
biopsy in, 999f, 1001
clinical features in, 1000, 1000f
metastatic potential of, 1000f, 1001, 1002f–1004f, 1005
typical distribution in, 999f–1005f, 1000–1001
differential diagnosis of
vs. actinic keratosis, 1005
vs. adenoid cystic carcinoma, 207, 207f
vs. basal cell carcinoma, 1005, 1005f
vs. Bowen disease, 1005
vs. chondrodermatitis nodularis helicis, 190
vs. eczema, nummular, 1005
vs. keratoacanthoma, 978, 1005, 1005f
vs. Merkel cell carcinoma, 1005, 1005f

vs. pyoderma gangrenosum, 1033
vs. sinusitis, 200
vs. torus palatinus, 206
vs. warts, common, 751, 752f
vs. warts, flat, 756
vs. warts, plantar, 767
epidemiology of, 999
follow-up of, 1007
in immunosuppressed, 999–1001, 1004f, 1006
laryngeal cancer from, 223f
hoarseness in, 220–225 (*See also* Hoarseness)
lung, 355–363, 355f, 356f (*See also* Lung cancer)
management of, 1005–1006, 1006t
of mouth, in oropharyngeal cancer, 253–256, 253f–255f (*See also* Oropharyngeal cancer)
pathophysiology of, 999–1000
patient education on, 1007
patient story of, 999, 999f
prevention and screening for, 1006
prognosis in, 1007
risk factors for, 1000
of skin, in situ, 969–975 (*See also* Bowen disease)
from smoking, 1401, 1402f
of vulva, *vs.* Paget's disease of vulva, 516
Squamous epithelium, cervical, 526, 526f
Squamous intraepithelial lesion, low-grade, 530–533, 530f–532f
Squamous metaplasia, cervical, 526f, 527
Staghorn calculi, 426
Standard Sexual Assault Forensic Evidence (SAFE) Kit, 105
Staphylococcal scalded skin syndrome
vs. hypersensitivity syndromes, 1054
vs. impetigo, 677, 679f
vs. scarlet fever, 210
Staphylococcal toxic shock syndrome, *vs.* necrotizing fasciitis, 705
Staphylococcus aureus infections. *See also specific diseases*
atopic dermatitis, 826
bacterial endocarditis, 288, 290
cellulitis, 693, 695f
hand dermatitis, 845
hordeolum, 114
impetigo, 676–679 (*See also* Impetigo)
mastitis, 546
necrotizing fasciitis, 703
otitis externa, 180
paronychia, 1166–1167, 1166f, 1167f
pneumonia, 301
Staphylococcus epidermis bacterial endocarditis, 288, 290
Staphylococcus folliculitis, 680, 681, 682f
Staphylococcus pneumoniae sinusitis, 197
Stasis dermatitis
vs. diabetic dermopathy, 1315
vs. lichen planus, 906
vs. necrobiosis lipoidica, 1319
Status asthmaticus, 324
Stenosing tenosynovitis, *vs.* Dupuytren disease, 626
Stenosis, coronary artery, 268–269, 268f, 269f
Sterilization
female, 13t
male, 13t
nexplanon, 15
Sternoclavicular dislocation, *vs.* clavicle fracture, 602
Steroid abuse, anabolic. *See also* Injection-drug use; Substance abuse disorder
diagnosis of, 1441–1442
differential diagnosis of, 1442
epidemiology of, 1440, 1440f
etiology and pathophysiology of, 1440, 1440f
Steroid-induced acneiform eruption, 661, 664f
Steroid myopathy, *vs.* dermatomyositis, 1083
Stevens-Johnson syndrome (SJS), 1049–1055
diagnosis of, 1049f–1051f, 1052–1054, 1215f, 1219
differential diagnosis of, 1215f, 1220
vs. bullous pemphigoid, 1054
vs. vasculitis, 1066
epidemiology of, 1049, 1212
etiology and pathophysiology of, 1050, 1216
follow-up of, 1055
fundamentals of, 1049
management of, 1054
patient education on, 1055
patient story of, 1049, 1049f, 1050f
prevention of, 1054
prognosis in, 1055
risk factors for, 1050
Stimulant abuse, 1393. *See also* Injection-drug use; Substance abuse disorder
S-to-D ratio, 482
Stomach, on third trimester ultrasound, 482f
Stomach cancer. *See* Gastric cancer
Stomatitis. *See also* Gingivostomatitis; Pyostomatitis vegetans
angular, 203–205, 203f–205f
aphthous, 244–248 (*See also* Aphthous ulcer)
geographic, 232–235 (*See also* Geographic tongue)
nicotine, 1400, 1401f
vs. leukoplakia, 251, 251f
viral, *vs.* strawberry tongue, 210
Stones
gallbladder, 386–391 (*See also* Gallstones)
kidney, 425–428 (*See also* Kidney stones)
Stork bite, 1209f. *See also* Hemangioma, childhood
diagnosis of, 638f
differential diagnosis of
vs. childhood hemangioma, 638, 638f
vs. vascular lesions, hereditary and congenital, 1209, 1209f
Straddle injury, *vs.* child sexual abuse, 91
Strawberry cervix, 504–507, 527, 527f. *See also Trichomonas* vaginitis
Strawberry hemangioma, 636–640, 636f, 637f, 639f. *See also* Hemangioma, childhood
Strawberry tongue, 208–212, 209f
vs. eruptive lingual papillitis, 210
vs. red food dye, 210
vs. stomatitis, viral, 210
Strength of Recommendation (SOR) Taxonomy, 1448, 1449f, 1450f
Streptococcal toxic shock syndrome, *vs.* necrotizing fasciitis, 705
Streptococcus
mastitis from, 546
paronychia from, 1166–1167, 1166f, 1167f
scarlet fever and strawberry tongue from, 208–212, 208f, 209f
Streptococcus bovis bacterial endocarditis, 288
Streptococcus mutans, dental caries from, 258, 263
Streptococcus pneumoniae
acute otitis media from, 171
pneumonia from, 301
Streptococcus pyogenes necrotizing fasciitis, 702–706. *See also* Necrotizing fasciitis
Stress fracture, metatarsal, 611–614

Stretch marks, in pregnancy
epidemiology of, 462
etiology and pathophysiology of, 463, 464f
management of, 465
risk factors for, 465
Striae distensae
epidemiology of, 462
etiology and pathophysiology of, 463, 464f
management of, 465
risk factors for, 464
Striae gravidarum
epidemiology of, 462
etiology and pathophysiology of, 463, 464f
management of, 465
risk factors for, 465
Stroke, 1371–1375. *See also* Cerebral vascular accident (CVA)
death from, 27
hemorrhagic, *vs.* subdural hematoma, 1377, 1377f
ischemic, *vs.* subdural hematoma, 1377
Stromal keratitis, from zoster ophthalmicus, 718–722
Strongyloides stercoralis, 1270–1274, 1272f
in global health, 59–60
Struvite kidney stones, 425–428. *See also* Kidney stones
Stucco keratosis, 927, 929f
Sturge-Weber syndrome, port-wine stains in, 1208, 1209
Stye. *See* Hordeolum
Subacute granulomatous thyroiditis, 1347
Subacute sclerosing panencephalitis, 724–725
Subarachnoid hemorrhage
vs. headache, 1368, 1368f
vs. subdural hematoma, 1378, 1378f
Subclinical thyroid disease, 1346
Subconjunctival hemorrhage, 160, 160f
red eye in, 163, 164t, 165, 166f
Subdural hematoma, 1376–1379, 1376f–1378f. *See also* Hematoma, subdural
Subgaleal hematoma, *vs.* child abuse, 85, 86f
Substance abuse disorder, 1392–1397. *See also* Injection-drug use; *specific substances*
addiction and, 1392
cigarette and alcohol use and, 1393
diagnosis of, 1394–1396
differential diagnosis of
vs. anxiety disorder, 1396
vs. mood disorder, 1396
vs. personality disorders, 1396
vs. schizophrenia, 1396
epidemiology of, 1392–1393, 1392f–1394f
etiology and pathophysiology of, 1393–1394
follow-up of, 1397
management of, 1396
on mortality, 26
patient education on, 1397
patient story of, 1392, 1392f
risk factors for, 1394
Subtrochanteric fracture, 615–617
Subungual hematoma, 1175–1177. *See also* Hematoma, subungual
Suicide
attempted, after sexual assault, 104, 104f, 107
epidemiology of, 26
Sulfa antibiotics
drug reactions from, 1211–1222, 1212f, 1213f
Stevens-Johnson syndrome from, 1214f, 1215f
Sulfonamides, reactions from, 1211–1222
Sunburn, blistering after, 1100
Sununguial hematoma. *See* Hematoma, subungual
Sununguial melanoma. *See* Melanoma, subungual
Superficial capillary malformations, *vs.* childhood hemangioma, 638, 639f
Superficial hemangiomas of infancy, 636–640. *See also* Hemangioma, childhood
Superficial spreading (malignant) melanoma, 1010, 1010f, 1011f. *See also* Melanoma
vs. Paget disease of breast, 559, 559f
Suppurative ear disease, *vs.* Bell palsy, 1384
Suppurative thyroiditis, *vs.* goitrous hypothyroidism, 1349
Supraglottitis, *vs.* pharyngitis, 217
Swab test, 510, 510f
Swan-neck deformities
in lupus erythematosus, 564f
in psoriatic arthritis, 582f
Sweet syndrome, *vs.* pyoderma gangrenosum, 1031, 1032f
Syndesmophytes, 580, 580f, 581
Syphilis, 1278–1283
diagnosis of, 1278f–1283f, 1279–1280
differential diagnosis of
vs. chancroid, 1282, 1282f
vs. drug eruptions, 1282
vs. erythema multiforme, 1282
vs. herpes simplex, 1280
vs. lupus erythematosus, 1074
vs. pityriasis rosea, 1282
epidemiology of, 1278–1279
etiology and pathophysiology of, 1279
follow-up of, 1283
fundamentals of, 1278
management of, 1282
neonatal, 1102
patient education on, 1283, 1283f
patient story of, 1278, 1278f
prevention of, 1283
primary *vs.* secondary, 1278–1279
prognosis in, 1283
risk factors for, 1279
tertiary, 1279–1280, 1281f
Syphilis, secondary, 1278–1283. *See also* Syphilis
diagnosis of, 1278f–1283f, 1279–1280
differential diagnosis of
vs. alopecia areata, 1129
vs. cutaneous drug reactions, 1221
vs. herpes simplex, 739
vs. lichen planus, 907
vs. pityriasis rosea, 899
vs. psoriasis, 888
vs. pyoderma gangrenosum, 1031
vs. scarring alopecia, 1141
vs. seborrheic dermatitis, 873
vs. tinea versicolor, 806
vs. vulvar intraepithelial neoplasia, 521
epidemiology of, 1278–1279
etiology and pathophysiology of, 1279
follow-up of, 1283
management of, 1282
patient education on, 1283, 1283f
patient story of, 1278, 1278f
prevention of, 1283
prognosis in, 1283

risk factors for, 1279
Syringocystadenoma papilliferum, 960f, 962
Syringoma
differential diagnosis of
vs. epidermal nevus and nevus sebaceous, 961, 961f
vs. sarcoidosis, 1038
vs. sebaceous hyperplasia, 933, 933f
with rosacea, 934f
Systemic drug-related intertriginous and flexural exanthema (SDRIFE), 1219, 1220f
Systemic lupus erythematosus (SLE), 1070–1078
cutaneous vasculitis in, 1063f, 1064f
diagnosis of, 1077t
biopsy in, 1074
butterfly (malar) rash in, 1070, 1070f, 1072, 1072f, 1073, 1077t
clinical presentation in, 1070f, 1071–1072, 1073f
imaging in, 566
laboratory testing in, 1073
typical distribution in, 563, 564f, 1073, 1076f
differential diagnosis of
vs. actinic keratosis, 1074
vs. alopecia areata, 1130
vs. dermatomyositis, 1074
vs. drug-induced lupus, 1074
vs. lichen planus, 1074
vs. melasma, 1181
vs. photodermatitis, 1195
vs. psoriasis, 1074
vs. rosacea, 661, 1074
vs. sarcoidosis, 1074
vs. scleroderma, 1074, 1093
vs. seborrheic dermatitis, 873
vs. syphilis, 1074
epidemiology of, 1070
etiology and pathophysiology of, 1071
follow-up of, 1078
fundamentals of, 1070
management of, 1074, 1077
patient education on, 1078
patient story of, 1070, 1070f
prevention of, 1077
prognosis in, 1078
risk factors for, 1071
scleritis and episcleritis with, 132, 132f
vasculitis in, 1063 (*See also* Vasculitis)
Systemic sclerosis, 1089–1095
definition of, 1089
diagnosis of, 1090f–1093f, 1092–1093
epidemiology of, 1089
etiology and pathophysiology of, 1089–1092, 1090f–1092f
follow-up of, 1095
management of, 1094–1095
patient education on, 1095
vs. porphyria cutanea tarda, 1120
prognosis in, 1095, 1095f
Systemic vasculitis, *vs.* pyoderma gangrenosum, 1031

T

Taenia solium, 1270–1274
Tags
preauricular, 189–191
diagnosis of, 190, 191f
differential diagnosis of, 190–191
epidemiology of, 189
etiology and pathophysiology of, 190
follow-up and patient education on, 191
management of, 191
skin, 922–924 (*See also* Skin tag (acrochordon))
Tape, skin, contact dermatitis from, 835, 837f
Tapeworm, 1270–1274
Tattoo dye allergy, *vs.* contact dermatitis, 839, 839f
T-cell lymphoma
cutaneous (*See* Cutaneous T-cell lymphoma; Mycosis fungoides)
erythroderma with, 916t, 918
Teeth. *See* Tooth (teeth)
Telogen effluvium
differential diagnosis of
vs. alopecia areata, 1129
vs. scarring alopecia, 1141
vs. tractional alopecia and trichotillomania, 1135
postpartum, 464, 464f
Temporal arteritis, *vs.* sinusitis, 200
Tendon xanthomas, 1323
Tetracycline, reactions from, 1216t
Thiazides, reactions from, 1211–1222
Third nerve palsy
in Bell palsy, 1383–1386 (*See also* Bell palsy)
isolated, *vs.* Bell palsy, 1384–1385, 1384f
Third trimester obstetrical ultrasound, 482–484, 482f, 483f
Thoracic back pain, 585–588. *See also* Back pain
Thoracic kyphosis, 1338–1344. *See also* Osteoporosis and osteopenia
Thrombophlebitis, *vs.* cellulitis, 694
Thrush (oral candidiasis), 771–776, 773f, 777–780, 777f, 778f
angular cheilitis from, 203, 203f, 204, 205f
differential diagnosis of
vs. black hairy tongue, 229, 230f
vs. lichen planus, 907
vs. pharyngitis, 216
management of, 775t, 780
patient education on, 780
Thyroglossal duct cyst, *vs.* goitrous hypothyroidism, 1349, 1350f
Thyroid cancer, *vs.* goitrous hypothyroidism, 1349, 1350f
Thyroid disease. *See also specific types*
subclinical, 1346
Thyroid hormone overdose, *vs.* Graves disease and goiter, 1355
Thyroiditis
acute suppurative, *vs.* goitrous hypothyroidism, 1349
vs. Graves disease and goiter, 1355
Thyroid nodule, autonomous functioning, *vs.* Graves disease and goiter, 1355
Thyrotoxicosis, 1353–1358. *See also* Graves disease and goiter
Thyrotropin-secreting pituitary adenoma, *vs.* Graves disease and goiter, 1355
Tick bite local reaction, *vs.* Lyme disease, 1293
Tinea. *See also specific types*
vs. atopic dermatitis, 831
bullous presentation of, 1102
hand dermatitis from, 845
Tinea barbae, *vs.* tinea capitis, 785, 786f
Tinea capitis, 771–776, 782–786
diagnosis of, 771–774, 772f, 782f–785f, 783–785
differential diagnosis of
vs. alopecia areata, 785, 1129
vs. psoriasis, scalp, 785
vs. scarring alopecia, 785, 1141
vs. seborrhea of scalp (dandruff), 785

Tinea capitis (*Continued*)
vs. seborrheic dermatitis, 873
vs. tinea barbae, 785, 786f
vs. tractional alopecia, 785, 785f, 1135
vs. trichotillomania, 785, 1135
epidemiology of, 782, 782f–784f
etiology and pathophysiology of, 782
folliculitis from, 681
follow-up of, 786
fundamentals of, 782
as global health problem, 71, 72f, 75f
management of, 785–786
pathophysiology of, 771
patient education on, 786
patient story of, 782, 782f
prevention of, 786
prognosis in, 786
risk factors for, 783
Tinea corporis, 771–776, 788–793
definition of, 788
diagnosis of, 771–774, 771f, 772f, 774t, 775t, 788f–792f, 789
differential diagnosis of
vs. breast abscess, 547
vs. candidiasis, 778, 780f
vs. cutaneous larva migrans, 791
vs. eczema, nummular, 791, 852–854
vs. erythema annulare centrifugum, 791, 792f, 1238, 1238f
vs. erythrasma, 791
vs. granuloma annulare, 1024
vs. impetigo, 677
vs. mastitis, 547
vs. pityriasis rosea, 899
vs. psoriasis, 791, 792f, 883f, 888
vs. tinea versicolor, 806
epidemiology of, 788
etiology and pathophysiology of, 788
follow-up of, 793
management of, 774–776, 775t, 788f–790f, 791–793
pathophysiology of, 771
patient education on, 793
patient story of, 771, 771f, 788, 788f
prevention of, 793
risk factors for, 788–789
Tinea cruris, 771–776, 795–798
diagnosis of, 771–774, 772f–774f, 774t, 775t, 795f–797f, 796
differential diagnosis of
vs. contact dermatitis, 796
vs. cutaneous candidiasis, 796
vs. erythrasma of groin, 796, 797f
vs. intertrigo, 796
vs. inverse psoriasis, 796, 797f
vs. mucocutaneous candidiasis, 778
vs. psoriasis, 883f, 888
vs. vulvar intraepithelial neoplasia, 521
etiology and pathophysiology of, 795
management of, 774–776, 775t, 776t, 797f, 798
pathophysiology of, 771
patient education on, 798
patient story of, 795, 795f
risk factors for, 795
Tinea faciei, 8f, 771–776, 788–793. *See also* Tinea corporis
diagnosis of, 755t, 771–774, 771f, 775t
management of, 774–776, 775t
pathophysiology of, 771
patient story of, 771f
Tinea incognito, 800, 801f, 802f
Tinea manus, 771–776, 772, 773f
vs. hand eczema, 847, 847f
Tinea pedis, 799–804
in diabetes, 1300, 1300f
diagnosis of, 799f–801f, 800, 1160, 1160f
differential diagnosis of
vs. contact dermatitis, 801, 802f
vs. dyshidrotic eczema, 801, 802f
vs. friction blisters, 801
vs. keratoderma, 801, 802f
vs. pitted keratolysis, 801, 802f
vs. psoriasis, 801, 804f
epidemiology of, 799
etiology and pathophysiology of, 799
fundamentals of, 799
inflammatory, 799
interdigital, 799, 800, 800f, 802f
management of, 801–804, 803t
moccasin, 799, 800, 800f, 803t
patient education on, 804
patient story of, 799, 799f
risk factors for, 799–800
ulcerative, 800, 801f
Tinea unguium, 1160–1164. *See also* Onychomycosis
Tinea versicolor, 771–776, 805–808
definition of, 805
diagnosis of, 771–774, 773f, 774t, 775t, 805f–807f, 806
differential diagnosis of
vs. pityriasis alba, 806
vs. pityriasis rosea, 806, 899
vs. *Pityrosporum* folliculitis, 806, 807f
vs. seborrheic dermatitis, 873
vs. syphilis, secondary, 806
vs. tinea corporis, 806
vs. vitiligo, 806, 806f
epidemiology of, 805
etiology and pathophysiology of, 805
Pityrosporum in, 771, 774t
follow-up of, 808
management of, 774–776, 775t, 806–808
pathophysiology of, 771
patient education on, 808
patient story of, 805, 805f
prevention of, 808
Tobacco addiction, 1398–1409
chronic obstructive pulmonary disease from, 334, 335
diagnosis of
clinical features in, 1400–1401, 1400f–1403f
imaging in, 1401
laboratory testing in, 1401
epidemiology of, 1392, 1398–1399
on episcleritis and scleritis recovery, 134
with estrogen-containing contraceptives, 13
etiology and pathophysiology of, 1399
follow-up for, 1408–1409
fundamentals of, 1398
management of, 1402–1407
5 A's model in, 1399t

complementary and alternative therapy in, 1404
medications in, 1402–1403, 1405t–1407t
motivational interviewing in, 1402, 1404t
referral in, 1404
on mortality, 26
patient story of, 1398
prevention of, 1408
prognosis in, 1408, 1408f
risk factors for, 1399–1400
substance abuse and, 1393
Toe fracture, *vs.* hammer toe, 1253
Toenail fungus, 1160–1164. *See also* Onychomycosis
Tooth (teeth)
abrasion of, *vs.* dental caries, 264
attrition of, of *vs.* dental caries, 264
decay of
adult, 262–266 (*See also* Caries, adult)
early childhood, 257–260 (*See also* Caries, early childhood)
demineralization *vs.* remineralization of, 263
erosion of, *vs.* dental caries, 264
staining of, *vs.* dental caries, 264
trauma to, *vs.* dental caries, 264
Tophaceous gout, 563, 566f, 590–594, 590f–592f. *See also* Gout
Torus mandibularis, *vs.* torus palatinus, 206f, 207
Torus palatinus, 206–207, 206f
vs. squamous cell carcinoma of palate, 206
vs. torus mandibularis, 206f, 207
Toxic agents. *See also specific agents*
on mortality, 27
Toxic epidermal necrolysis (TEN), 1049–1055
diagnosis of, 1052–1054, 1053f, 1219
differential diagnosis of
vs. bullous pemphigoid, 1054
vs. cutaneous drug reactions, 1220
vs. vasculitis, 1066
epidemiology of, 1049
etiology and pathophysiology of, 1050, 1216
follow-up of, 1055
fundamentals of, 1049–1055
management of, 1054
patient education on, 1055
prevention of, 1054
prognosis in, 1055
risk factors for, 1050
Toxic erythema of pregnancy, 467–470, 467f–469f
Toxic multinodular goiter, *vs.* Graves disease and goiter, 1355
Toxic nodular goiter, *vs.* goitrous hypothyroidism, 1348f, 1349
Toxicodendron (Rhus) dermatitis, 834, 835, 836f, 837f, 1101f. *See also* Contact dermatitis
Trabecular bone
normal, 1339, 1339f
osteoporotic, 1339, 1339f (*See also* Osteoporosis and osteopenia)
Trachoma, 69–70, 69f, 70f
Traction alopecia, 1133–1136
diagnosis of, 1133f, 1134
differential diagnosis of
vs. alopecia areata, 1134–1135
vs. androgenic alopecia, 1135
vs. scarring alopecia, 1135, 1141
vs. telogen effluvium, 1135
vs. tinea capitis, 785, 785f, 1135
epidemiology of, 1133, 1133f
etiology and pathophysiology of, 1133–1134, 1133f
follow-up of, 1136
management of, 1135
patient education on, 1136
patient story of, 1133, 1133f
Tranquilizer abuse. *See also* Substance abuse disorder
epidemiology of, 1393
Transformation zone, 526f, 557
atypical, 530–531, 530f–532f
persistent juvenile, 528f
colposcopy and diagnosis of, 525, 525f, 526, 528f
management of, 528
Transient acantholytic dermatosis, *vs.* folliculitis, 683, 683f
Transient ischemic attack (TIA), *vs.* cerebral vascular accident, 1373
Transient neonatal pustular melanosis (TNPM), 642–644, 1102
diagnosis of, 642f, 643–644, 643f
differential diagnosis of
vs. cutaneous candidiasis, 644
vs. erythema toxicum neonatorum, 644
vs. hand, foot, and mouth disease, 644
vs. herpes, 644
vs. impetigo, 644
vs. psoriasis, pustular, 644
vs. varicella, 644
epidemiology of, 642
etiology and pathophysiology of, 642–643
fundamentals of, 642
management of, 644
patient education on, 644
prognosis and follow-up of, 644
Transitional cell carcinoma, of bladder, 448–452, 449f. *See also* Bladder cancer
Transplantation, lung, for COPD, 342–343
Transrectal ultrasound (TRUS), 456
Transvaginal ultrasound, 19, 19f
Transverse striate leukonychia, 1145, 1145f, 1146
Transverse striate punctata, 1146
Trench mouth, 236–238, 237f
Treponema pallidum infection. *See* Syphilis
Trichepithelioma, *vs.* nodular basal cell carcinoma, 995
Trichilemmoma, *vs.* nodular basal cell carcinoma, 995
Trichoblastoma, *vs.* nodular basal cell carcinoma, 995
Trichomonas cervicitis, colposcopy of, 527, 527f
Trichomonas vaginalis
urethritis in men from, 1275–1277
vaginitis from, 485–487, 486f, 487t, 504–507 (*See also Trichomonas* vaginitis; Vaginitis)
Trichomonas vaginitis, 485–487, 486f, 487t, 504–507
diagnosis of, 504–506f, 505–506, 506f
differential diagnosis of
vs. bacterial vaginosis, 496, 506
vs. Candida vaginitis, 506
vs. Chlamydia, 506
vs. gonorrhea, 506
epidemiology of, 504
etiology and pathophysiology of, 504–505
follow-up of, 507
fundamentals of, 504
management of, 506–507
patient education on, 507
patient story of, 504, 504f, 505f
prevention of, 507
risk factors for, 505

Trichomoniasis
after sexual assault, 105, 106
differential diagnosis of
vs. Candida vulvovaginitis, 501
vs. cervical intraepithelial neoplasia II/III, 537–538
vs. Chlamydia cervicitis, 511
Trichophagy, 1134
Trichophyton, 771. *See also* Fungal infections, cutaneous; Tinea
tinea capitis from, 782–786, 782f, 784f
Trichophyton mentagrophytes, 799
onychomycosis from, 1161, 1161f
Trichophyton rubrum, 799
diagnosis of, 773f, 774, 774f
management of, 776
onychomycosis from, 1160, 1161f
Trichophyton tonsurans, tinea capitis from, 782–786, 782f, 784f
Trichotillomania, 1133–1136
diagnosis of, 1134, 1134f–1136f
differential diagnosis of
vs. alopecia areata, 1129, 1134–1135
vs. androgenic alopecia, 1135
vs. scarring alopecia, 1135, 1141
vs. telogen effluvium, 1135
vs. tinea capitis, 785, 1135
epidemiology of, 1133, 1134f–1136f
etiology and pathophysiology of, 1133–1134, 1134f–1136f
follow-up of, 1136
management of, 1135–1136
patient education on, 1136
Trichuris trichiura, 1270–1274, 1272f
Trigeminal nerve
sensory distribution of, 720, 720f
zoster ophthalmicus in, 718–722, 719f, 720f (*See also* Zoster ophthalmicus)
Trigeminal neuralgia
vs. sinusitis, 200
vs. zoster ophthalmicus, 720
Trigger finger, *vs.* Dupuytren disease, 626
Triglycerides, high, 1323
Trimethoprim/sulfamethoxazole, reactions from, 1211–1222, 1212f, 1213f. *See also* Drug reactions, cutaneous
T.R.U.E. Test, 838, 838f, 849t
Tubal occlusion, hysteroscopic, 14f, 15, 15f
Tubal pregnancy, 510
Tuberculosis (TB), 310–318
cutaneous, 74, 76f
diagnosis of, 312–314
biopsy in, 314
clinical features in, 312, 312f, 313f
imaging in, 310f, 311f, 313f–316f, 314
laboratory and ancillary testing in, 311f, 313
skin testing and rapid testing in, 312–313
differential diagnosis of
vs. asthma, 326
vs. chronic obstructive pulmonary disease, 338
vs. coccidiomycosis, 314
vs. histoplasmosis, 314, 317f
vs. osteoporosis and osteopenia, 1342
vs. pneumonia, 311, 314
vs. respiratory infections, fungal, 314
epidemiology of, 310
erythema nodosum in, 1057
etiology and pathophysiology of, 311, 311f
follow-up of, 317–318
fundamentals of, 310
HIV and, in global health, 74–76, 75f, 76f
management of, 314–317
medications in, 315–317
nonpharmacologic, 315
patient education on, 318
patient story of, 310, 310f, 311f
prevention of, 317
prognosis in, 317
risk factors for, 311–312
Tuberculous lymphadenitis, 75, 76f
Tuberoeruptive xanthomas, 1322f–1324f, 1323
Tuberous sclerosis, 442f
vs. neurofibromatosis, 1388, 1390f
vs. polycystic kidneys, 438
Tuberous xanthomas, 1323
Tuboovarian abscesses (TOAs), 20
Tufted folliculitis, 681, 682f
scarring alopecia in, 1138–1143 (*See also* Alopecia, scarring)
diagnosis of, 1140, 1140f
management of, 1141–1143
Twenty-nail dystrophy, 1149, 1149f
Twin pregnancy, third trimester ultrasound for, 483
Two-foot, one-hand syndrome, 772, 773f, 847, 847f
Tyloma, 1242–1245. *See also* Calluses
Tympanic membrane
in acute otitis media, 170, 170f
normal, 173f
in otitis media with effusion, 170, 170f
Tympanic membrane perforation
vs. acute otitis and otitis media with effusion, 173, 177f
acute otitis media with, *vs.* otitis externa, 182
Tympanosclerosis, 176, 178f
Tympanostomy tube insertion, 175, 176, 177f
Tyndall effect, 946, 947f
Typhoid fever, 56–57
water and sanitation in, 55–56, 55f, 56f
Typhus, murine, erythroderma with, 915–921, 919f

U

Ulcer. *See also* Morphology index; *specific disorders*
aphthous, 244–248 (*See also* Aphthous ulcer; *specific ulcers*)
corneal, red eye in, 165, 166f
foot
ischemic, 1255–1257, 1255f, 1256f, 1302, 1303f
neuropathic, 1258–1260, 1258f, 1259f
vs. venous insufficiency, 296
gastric/peptic, 366–369, 366f, 367f (*See also* Peptic ulcer disease (PUD))
Marjolin, 1000, 1000f
pyloric, 366–369, 366f, 367f
venous stasis, 296, 297f
Ulcerative colitis (UC), 405–412. *See also* Inflammatory bowel disease (IBD)
follow-up of, 412
patient education on, 412
prognosis in, 411–412
surgery for, 411
Ulnar nerve entrapment, *vs.* olecranon bursitis, 598
Ultrasound, in pregnancy
transvaginal, 19, 19f
Ultrasound, obstetrical
first trimester, 475–477, 475f–477f

second trimester, 478–481, 478f–481f
third trimester, 482–484, 482f, 483f
3D, 483, 484f
4D, 483
Uncinaria stenocephala, 823
Unguis incarnatus, 1156–1158, 1156f–1158f
Uninsured, 39
caring for, 39–40, 39f
Unintended (unplanned) pregnancy, 17
Upper airway disease. *See also specific diseases*
vs. asthma, 326
Upper motor neuron diseases. *See also specific diseases*
vs. Bell palsy, 1384
Upper respiratory tract infections
vs. measles, 725
vs. pneumonia, 304
vs. sinusitis, 200
Ureaplasma urealyticum urethritisin men, 1275–1277
Ureteral stones, 425–428, 432f. *See also* Kidney stones
Ureterolithiasis, 425–428, 432f. *See also* Kidney stones
Urethritis, in men, 1275–1277, 1275f
Uric acid kidney stones, 425–428. *See also* Kidney stones
Urinary casts, 420–423
Urinary sediment, 420–423
applications of, 420
diagnosis of
clinical features of, 422
laboratory testing and imaging of, 421f, 422–423, 422f
epidemiology of, 420–421
etiology and pathophysiology of, 421, 421f–423f
management of, 423
patient story of, 420, 420f
prevention and screening for, 423
risk factors for, 421–422
Urinary tract infection
bacteriuria with, 421
vs. kidney stones, 428
pyuria with, 421, 421f
Urinary tract stone, 425–428. *See also* Kidney stones
Urolithiasis, 425–428. *See also* Kidney stones
Urticaria, 863–869
definition of, 863
diagnosis of, 863f–867f, 864–865
differential diagnosis of
vs. erythema multiforme, 866, 866f, 1054
vs. hypersensitivity syndromes, 1054
vs. insect bites, 866
vs. Lyme disease, 1293
vs. mast cell releasability syndromes, 864–866f, 866
vs. pemphigoid gestationis, 473, 866
vs. pruritic urticarial papules and plaques of pregnancy, 866, 867f
vs. urticarial vasculitis, 866, 867f
epidemiology of, 863
etiology and pathophysiology of, 863–864, 864f–867f
follow-up of, 869
giant, 866f
management of, 866–869
patient education on, 869
patient story of, 863, 863f
Urticarial drug reactions. *See also* Drug reactions, cutaneous; *specific drugs*
diagnosis of, 1212f, 1218
differential diagnosis of, 1220
epidemiology of, 1212, 1212f
etiology and pathophysiology of, 1212, 1216
management of, 1221–1222
risk factors for, 1216–1218
Urticarial drugs reactions
diagnosis of, 1218
Urticarial vasculitis, 1062–1069, 1062f, 1063f. *See also* Vasculitis
vs. urticaria, 866, 867f
Urticaria pigmentosa, 863–869, 864, 865f, 867f
Usatine, Richard, 46–49, 48f, 49f
Uterine cervix. *See also* Cervical entries
invasive cancer of, 541–545, 541f–543f (*See also* Cervical cancer; Colposcopy, of high-grade lesions)
Uterine leiomyomas, 20
Uteroplacental insufficiency, third trimester ultrasound of, 482
Uveal tract, 135
Uveitis, 135–137
acute anterior, with corneal endothelial white cell aggregates, 135, 135f
in ankylosing spondylitis, 581
anterior, from zoster ophthalmicus, 718–722, 718f
differential diagnosis of
vs. acute-angle closure glaucoma, 137
vs. conjunctivitis, 127, 137
vs. corneal foreign body/abrasion, 123
vs. corneal ulceration, 137
vs. episcleritis, 133, 137
vs. keratitis, 137
vs. scleritis, 133, 136–137
hypopyon in, 136, 136f
idiopathic intermediate, 136, 136f
perilimbic injection in, 135f, 136, 136f
posterior synechiae in, 135f, 136, 137, 137f
red eye in, 163–168, 164t, 167f
UV light, 1191

V

Vaccination
hepatitis B, after sexual assault, 106
pneumococcal conjugate, 307
pneumococcal polysaccharide, 307
against pneumonia pathogens, 307
Vaginal bacteriosis, 494–497. *See also* Bacterial vaginosis (BV)
Vaginal bleeding, ultrasound for
first trimester, 475–477
second trimester, 479
third trimester, 482, 484, 484f
Vaginal discharge, 485–487, 485f–487f, 487t
Vaginal dryness, 489
Vaginal epithelium, atrophic
colposcopy and diagnosis of, 527, 527f
management of, 528
Vaginal ring, 13t
hormonal, 12, 12f, 14
Vaginitis, 485–487, 494–497. *See also* Bacterial vaginosis (BV)
atrophic, 489–492 (*See also* Atrophic vaginitis)
Candida (*See Candida* vulvovaginitis)
diagnosis of, 485f–487f, 486–487, 487t
differential diagnosis of
vs. atrophic vaginitis, 491
vs. child sexual abuse, 92
epidemiology of, 485
etiology and pathophysiology of, 485–486, 485f, 486f

Vaginitis (*Continued*)
fundamentals of, 485
management of, 487
patient story of, 485, 485f
Trichomonas, 504–507 (*See also Trichomonas* vaginitis)
yeast, 499–503 (*See also Candida* vulvovaginitis)
Vaginocervicitis
colposcopy of, 527, 527f
management of, 528
Valgus stress test, 620, 621
Varicella-zoster virus (VZV), 707f–710f, 712–716. *See also* Herpes zoster
chickenpox from, 707–710, 707f–711f (*See also* Chickenpox)
differential diagnosis of
vs. pityriasis lichenoides et varioliformis acuta (PLEVA), 1124
vs. pustular diseases of childhood, 644
Varicose veins, 295–298, 295f–297f. *See also* Venous insufficiency
with obesity, 1331, 1331f
Varicosities, in pregnancy, 463, 464
Varus stress test, 620, 621
Vascular colonic ectasias
vs. colon cancer, 401
vs. colon polyps, 396
Vascular lesions, acquired, 1203–1206
diagnosis of, 1203f–1205f, 1204
differential diagnosis of
vs. angiokeratomas, 1206
vs. glomangiomas, 1206
vs. melanoma, 1204
epidemiology of, 1203, 1203f–1205f
etiology and pathophysiology of, 1203–1204, 1203f–1205f
follow-up of, 1206
fundamentals of, 1203
management of, 1206
patient education on, 1206
patient story of, 1203, 1203f
Vascular lesions, hereditary and congenital, 1207–1210
diagnosis of, 1208–1209, 1208f, 1209f
differential diagnosis of
vs. childhood hemangioma, 638, 639f
vs. CREST, 1209
vs. glomangioma, 1209
vs. port-wine stains, 1209
vs. salmon patches, 1209, 1209f
epidemiology of, 1207, 1207f, 1208f
etiology and pathophysiology of, 1207–1208
follow-up of, 1210
fundamentals of, 1207
management of, 1209–1210
patient education on, 1210
patient story of, 1207, 1207f
Vascular malformations, childhood, 636–640. *See also* Hemangioma, childhood
Vascular structures, dermoscopy of, 1471, 1471f
Vasculitis, 1062–1069. *See also specific types*
diagnosis of, 1062f–1066f, 1065–1066
differential diagnosis of
vs. cholesterol embolism, 1068
vs. Churg–Strauss syndrome, 1068
vs. cutaneous T-cell lymphoma, 1066
vs. idiopathic thrombocytopenic purpura, 1066, 1069f
vs. lichen aureus, 1066, 1067f
vs. meningococcemia, 1066, 1068f
vs. pigmented purpuric dermatosis, 1066, 1066f, 1067f
vs. pigmented purpuric dermatosis of Majocchi type, 1066, 1067f
vs. Rocky Mountain spotted fever, 1066, 1068f
vs. Schamberg disease, 1066, 1066f, 1067f
vs. Stevens-Johnson syndrome, 1066
vs. toxic epidermal necrolysis, 1066
vs. venous insufficiency, 296
vs. Wegener granulomatosis, 1066
epidemiology of, 1062–1063, 1062f–1064f
etiology and pathophysiology of, 1063–1065
follow-up of, 1068
fundamentals of, 1062
in Henoch-Schönlein purpura, 1062–1069, 1062f, 1063f
vs. urticaria, 866, 867f
management of, 1068
patient education on, 1068
patient story of, 1062, 1062f
prognosis in, 1068
risk factors for, 1065, 1065f
Vector borne diseases, 64–69. *See also specific diseases*
leishmaniasis, 67f–69f, 68–69
malaria, 64–66, 65f
prevention of, 68
prognosis in, 68
Vegetations, noninfective, *vs.* bacterial endocarditis, 290
Venice Family Clinic, 47
Venous insufficiency, 295–298
diagnosis of, 296, 297f
differential diagnosis of
vs. arterial ulcers, 296
vs. diabetic ulcers, 296
vs. pyoderma gangrenosum, 1033, 1033f
vs. vasculitides, 296
epidemiology of, 295
etiology and pathophysiology of, 295–296, 295f–297f
follow-up of, 297
fundamentals of, 295
management of, 296–297
patient education on, 296f, 297f, 298
patient story of, 295, 295f
prevention of, 297
prognosis in, 297
risk factors for, 296
Venous lake, 1203–1206, 1203f. *See also* Vascular lesions, acquired
Venous pulsations, spontaneous, 151, 152
Venous stasis, 1032, 1033f
vs. cellulitis, 694, 694f
ulcer from, 296, 297f
Vernal conjunctivitis, 128
Verrucae, 749–754, 749f–753f
Verruca plana, 755–758, 755f, 756f. *See also* Warts, flat
Verruca plana juvenilis, 755–758, 755f, 756f. *See also* Warts, flat
Verruca plantaris, 766–769, 766f–768f. *See also* Warts, plantar
Verruca vulgaris, 749–754, 749f–753f
Verrucous leukoplakia, 249–252, 249f–251f. *See also* Leukoplakia
Vertebral fracture
vs. ankylosing spondylitis, 582
osteoporotic, *vs.* back pain, 586, 586f
Vertigo, *vs.* cerebral vascular accident, 1373
Vestibule tear, in child sexual abuse, 90f, 91
Vibrio cholerae, 57–59
Vibrio vulnificus

cellulitis from, 693, 695f
necrotizing fasciitis from, 703, 703f
Villous polyp, 393–397. *See also* Colon polyps
Vincent's disease, 236–238, 237f
Violence
intimate partner, 95–100 (*See also* Intimate partner violence (IPV))
physical, 95
prevention–intervention programs for, 106
sexual, 102 (*See also* Sexual assault, adult)
Viral exanthem
vs. cutaneous drug reactions, 1220
vs. pruritic urticarial papules and plaques of pregnancy, 469
vs. scarlet fever, 210
Viral hepatitis, 377–384. *See also* Liver disease
Viridans streptococcus bacterial endocarditis, 288
Vision loss
age-related macular degeneration in, 155–158 (*See also* Age-related macular degeneration (AMD))
blindness in
from *Chlamydia trachomatis,* 69–70, 69f
from diabetic retinopathy, 143–145
from glaucoma, 139–142
Vitamin A deficiency, 61–62, 62f
Vitamin B deficiency, angular cheilitis from, 203
Vitamin D deficiency, rickets from, 85
Vitiligo, 1184–1190
diagnosis of, 1184f–1186f, 1185
differential diagnosis of
vs. ash leaf spots, 1187, 1187f
vs. cutaneous T-cell lymphoma, 1042f, 1045
vs. halo nevus, 1187
vs. idiopathic guttate hypomelanosis, 1187, 1187f, 1188f
vs. nevus anemicus, 1187, 1188f
vs. nevus depigmentosus, 1187, 1188f
vs. pityriasis alba, 1185–1187
vs. tinea versicolor, 806, 806f
epidemiology of, 1184
etiology and pathophysiology of, 1184
follow-up of, 1190
fundamentals of, 1184
management of, 1187–1190
patient education on, 1190
patient story of, 1184, 1184f
prognosis in, 1190
Vitiligo vulgaris. *See* Vitiligo
Vocal cord nodules, 220–225, 224f. *See also* Hoarseness
Vocal cord paresis and paralysis, 222, 223f, 224
Vocal cords, false, 220, 220f
Vocal strain, 220–225. *See also* Hoarseness
Vulvar angiokeratosis, 1203–1206, 1204f
Vulvar cancer. *See also specific types*
epidemiology of, 519
vs. vulvar intraepithelial neoplasia, 519
Vulvar dermatitis, *vs.* child sexual abuse, 92
Vulvar intraepithelial neoplasia (VIN), 519–522
diagnosis of, 519f–521f, 520–521
differential diagnosis of
vs. Candida vulvovaginitis, 521
vs. condylomata acuminata, 521
vs. granuloma inguinale, 521
vs. herpes simplex virus, 521
vs. human papillomavirus, 521
vs. lichen planus, 521
vs. lichen sclerosus, 521, 522f
vs. lichen simplex chronicus, 521
vs. micropapillae of inner labia minora, 521
vs. molluscum contagiosum, 521
vs. nevus, benign, 521
vs. psoriasis, 521
vs. sebaceous hyperplasia, 521
vs. syphilis, secondary, 521
vs. tinea cruris, 521
epidemiology of, 519
etiology and pathophysiology of, 519–520
follow-up of, 522
management of, 522
patient education on, 522
patient story of, 519, 519f
prevention of, 522
prognosis in, 522
risk factors for, 520
Vulvar pyoderma gangrenosum, 1029. *See also* Pyoderma gangrenosum
Vulvar varicosities, in pregnancy, 463, 464, 465
Vulvovaginal candidiasis. *See Candida* vulvovaginitis
Vulvovaginal lichen planus, *vs.* atrophic vaginitis, 491
Vulvovaginitis
Candida, 499–503 (*See also Candida* vulvovaginitis)
vs. child sexual abuse, 92

W

Warfarin, drug reactions from, 1211–1222. *See also* Drug reactions, cutaneous
diagnosis of, 1213f, 1218, 1221f
epidemiology of, 1212, 1213f
etiology and pathophysiology of, 1216
Warfarin-induced skin necrosis (WISN), 1211–1222. *See also* Drug reactions, cutaneous
diagnosis of, 1213f, 1218, 1221f
epidemiology of, 1212, 1213f
etiology and pathophysiology of, 1216
Warm weather conjunctivitis, 128
Warts. *See also specific types*
differential diagnosis of
vs. seborrheic keratosis, 929
vs. skin tag, 923
mosaic, 766–769, 766f–768f (*See also* Warts, plantar)
Warts, common, 749–754
diagnosis of, 749f–751f, 750
differential diagnosis of
vs. actinic keratosis, 751
vs. amelanotic melanoma, 751
vs. keratoacanthoma, 751
vs. seborrheic keratosis, 750
vs. skin tag, 750
vs. squamous cell carcinoma, 751, 752f
epidemiology of, 749, 749f, 750f
etiology and pathophysiology of, 749–750, 750f
follow-up of, 754
fundamentals of, 749
management of, 751–753, 752f, 753f
patient education on, 754
patient story of, 749, 749f
prevention of, 753
prognosis in, 753–754
risk factors for, 750

Warts, flat, 755–758
diagnosis of, 755f, 756, 756f
differential diagnosis of
vs. lichen planus, 756
vs. seborrheic keratosis, 756
vs. squamous cell carcinoma, 756
epidemiology of, 755, 755f, 756f
etiology and pathophysiology of, 755
follow-up of, 758
fundamentals of, 755, 755f
management of, 756–758, 757t
patient education on, 758
patient story of, 755, 755f
prevention of, 758
risk factors for, 755, 755f, 756f
Warts, genital (condylomata acuminata), 759–765
diagnosis of, 759f–763f, 760
differential diagnosis of
vs. Buschke-Lowenstein tumor, 762, 763f
vs. condyloma lata, 762, 763f
vs. hemorrhoids, 416
vs. malignant neoplasms, 762
vs. micropapillomatosis of vulva, 762
vs. molluscum contagiosum, 745, 762
vs. Paget disease of external genitalia, 516
vs. pearly penile papules, 762, 763f
vs. seborrheic keratosis, 762, 763f
vs. vulvar intraepithelial neoplasia, 521
epidemiology of, 759
etiology and pathophysiology of, 759
follow-up for, 764
fundamentals of, 759
giant, 762, 763f
management of, 762–764, 764t
patient education on, 764–765
patient story of, 759, 759f
prevention of, 762–764
prognosis with, 764
risk factors for, 760, 760f
Warts, plantar, 766–769
definition of, 766
diagnosis of, 767, 767f, 768f
differential diagnosis of
vs. amelanotic melanoma, 767
vs. black heel, 767
vs. black warts, 767
vs. corns and calluses, 767, 767f, 1243
vs. palmoplantar keratoderma, 767–768, 769f, 770f
vs. pitted keratolysis, 687
vs. squamous cell carcinoma, 767
epidemiology of, 766
etiology and pathophysiology of, 766, 766f–768f
management of, 768–769
patient education on, 769
patient story of, 766, 766f
prevention of, 769
prognosis and follow-up for, 769
risk factors for, 766
Water
contaminated, preventing diseases from, 59, 59f
in world health, 55–56
Wegener's granulomatosis
scleritis and episcleritis with, 132, 132f, 134
vs. vasculitis, 1066
Wet gangrene, 1266, 1266f
Wheel-a-thon, 46f
"Whiff test," 486–487, 487t
Whipworm, 1270–1274, 1272f
White blood cell casts, 420–423, 422f. *See also* Urinary sediment
White coat hypertension, 274
Whiteheads, 652. *See also* Acne vulgaris
White sponge nevus, *vs.* leukoplakia, 251
Wickham lines, 902, 902f, 904f
Wife-battering, 95–100. *See also* Intimate partner violence (IPV)
child witnesses of, 95
Wilson disease, liver disease from, 378, 380, 381, 382f, 383t. *See also* Liver disease
Withdrawal
as birth control, 13t
of life-sustaining treatment, 34
Woman Abuse Screening Tool (WAST), 97
Woodard, Laurie, 44–46, 44f, 46f
Wood chip, in cornea, 122, 122f
World health. *See* Global health
Worms, intestinal, 1270–1274. *See also* Intestinal worms and parasites
Wound infection. *See also specific types*
vs. ischemic ulcer of foot, 1256

X

Xanthelasma, 1323, 1324f, 1325f
vs. hordeolum and chalazion, 115
vs. sarcoidosis, 1038
Xanthomas, 1322–1327
in diabetes mellitus, 1302, 1304f
diagnosis of, 1322f–1324f, 1324
differential diagnosis of
vs. gouty tophi, 1324, 1324f
vs. molluscum contagiosum, 1325
vs. pseudoxanthoma elasticum, 1324
vs. sebaceous hyperplasia, 933, 933f
epidemiology of, 1322–1323
eruptive, 1322–1327, 1322f–1324f
etiology and pathophysiology of, 1322f–1324f, 1323
follow-up of, 1327
fundamentals of, 1322
management of, 1325–1327
with obesity, 1331, 1332f
patient education on, 1327
patient story of, 1322, 1322f, 1323f
prevention and screening for, 1327
prognosis in, 1327
risk factors for, 1323
Xerophthalmia, from vitamin A deficiency, 61–62, 62f
Xerosis
with atopic dermatitis, 827, 831f
vs. X-linked ichthyosis, 1233
Xerostomia, dental caries with, 263, 265
X-linked ichthyosis, 1229–1234
diagnosis of, 1230, 1232f, 1233f
differential diagnosis of
vs. acquired ichthyosis, 1233, 1234f
vs. asteatotic eczema, 1233
vs. ichthyosis vulgaris, 1233, 1234f
vs. lamellar ichthyosis, 1233, 1235f

vs. xerosis, 1233
epidemiology of, 1229
etiology and pathophysiology of, 1229
follow-up of, 1234
management of, 1233–1234
patient education on, 1234

Y

Yeast infection, 499–503. *See also Candida* vulvovaginitis
Yeast onychomycosis, 1161
Yeast vaginitis, 499–503. *See also Candida* vulvovaginitis
Yolk sac, on first trimester ultrasound, 476, 476f

Z

Zinc deficiency, 62–63, 63f
acrodermatitis enteropathica from, 648, 648f
vs. seborrheic dermatitis, 873
Zoster. *See* Herpes zoster
Zoster ophthalmicus, 718–722
diagnosis of, 718f–720f, 720
differential diagnosis of
vs. abrasions, traumatic, 720
vs. conjunctivitis, 720
vs. glaucoma, 720
vs. pemphigus, 720
vs. trigeminal neuralgia, 720
epidemiology of, 718
etiology and pathophysiology of, 718–719, 718f–720f
follow-up of, 722
fundamentals of, 718
management of, 721
patient education on, 722
patient story of, 718, 718f
prevention of, 721
prognosis in, 721–722
risk factors for, 719

Note: In this index, the letters "f" and "t" denote figures and tables, respectively.

A

Abscess and microabscess, 698–700, 698f–700f
- acne conglobata, 652, 653f
- breast abscess, 546–549, 546f, 548f, 553
- breast cellulitis, 546, 546f
- caries, early childhood, 258
- cellulitis, 693–697, 693f, 696f
- dermatitis herpetiformis, 1114, 1125–1126
- endocarditis, bacterial, 287–291
- *Entamoeba histolytica,* 1270–1274
- hemorrhoids, 414–418, 414f–416f
- hidradenitis suppurativa, 516, 671–674, 672f, 674f, 1333f
- injection-drug use, 1439–1444, 1440f, 1441f
- lung cancer, 355–363
- mycosis fungoides, 1042–1047
- paronychia, 739, 1166–1169, 1166f–1168f
- peritonsillar pharyngitis, 213–218, 214f
- pneumonia, 303, 304f
- pyoderma gangrenosum, 1028–1034
- scarlet fever, 211
- sinusitis, 197–202, 198f, 200f
- tuboovarian abscess, 20

Acetowhite changes, colposcopy
- cervical cancer, 541–545, 541f
- high-grade cervical lesions, 535–536, 535f, 537f
- low-grade cervical lesions, 530–533, 530f, 531f
- vulvar intraepithelial neoplasm, 520, 520f

Alopecia
- acne keloidalis nuchae, 665–669
- alopecia areata, 1128–1131, 1128f–1132f, 1141
- alopecia totalis, 1128, 1128f
- alopecia universalis, 1128
- androgenetic alopecia, 1141
- dermatitis, seborrheic, 1141
- discoid lupus erythematosus, 1070–1078, 1075f, 1076f
- drug-induced alopecia, 1141
- erythroderma, 915–921
- folliculitis decalvans, 680–684, 682f
- lichen planus, 901–908
- mixed connective tissues disease, 1083
- mycosis fungoides, 1042–1047, 1045f
- postpartum, 464, 464f
- sarcoidosis of scalp, 1141
- scarring alopecia, 666, 667f, 1135, 1138–1143, 1138f–1142f
- syphilis, secondary, 1141
- telogen effluvium, 464, 464f, 1141
- tinea, 772, 772f
- tinea capitis, 772f, 782–786, 783f, 1141
- traction alopecia, 1141
- traction hair loss, 1133–1136, 1133f
- trichotillomania, 1133–1136, 1134f–1136f, 1141

Annular lesion
- basal cell carcinoma, 990f
- bullous fixed drug eruption, 1211–1222, 1213f
- erythema annulare centrifugum, 1054, 1236–1239, 1236f–1238f
- erythema chronicum migrans of Lyme disease, 824
- erythema multiforme, 866
- granuloma annulare, 789, 792f, 1022–1027, 1022f–1026f
- lichen planus, 901–908
- linear porokeratosis, 961
- Lyme disease, 1289–1296, 1289f–1291f
- pigmented purpuric dermatosis, Majocchi type, 1066, 1067f
- pityriasis rosea, 896–900, 897f, 900f
- psoriasis, 878–894, 883f
- reactive arthritis, 910–914, 910f, 911f
- sarcoidosis, 1035–1040, 1035f, 1039f
- tinea, 771f, 778, 780f
- tinea barbae, 785, 786f
- tinea capitis, 782–786, 784f
- tinea corporis, 771–776, 771f, 788–793, 788f–791f, 852, 888
- tinea cruris, 888
- tinea faciei, 771–776, 771f, 772
- urticaria, 863–869, 866f

Atrophy
- atrophic vaginitis, 485, 486, 489–492, 489f, 490f
- basal cell carcinoma, 989–997, 991f
- cervical atrophy, 527, 527f, 528
- cocaine abuse, 1431–1437, 1434f
- cortical/cerebral, normal pressure hydrocephalus, 1380–1382, 1380f
- corticosteroids, 1453t
- diabetic dermopathy, 1302f, 1314–1316, 1314f–1316f
- filiform papillae, geographic tongue, 232f, 233, 233f, 235f
- gastritis, chronic, 372, 374
- lichen planus, 901–908, 904f
- lichen sclerosus et atrophicus, 92, 92f, 491, 521, 522f
- lupus
  - chronic cutaneous lupus erythematosus, 1140, 1142f
  - systemic lupus erythematosus, 1070–1078, 1072f
- muscle, scleroderma, 1089–1095, 1091f
- mycosis fungoides, 1042–1047
- necrobiosis lipoidica, 1303f, 1315, 1317–1320, 1318f–1321f
- optic, hyphema, 162
- optic nerve, glaucoma, 139–142
- porphyria cutanea tarda, 1119–1121
- retina, age-related macular degeneration, 156, 157f
- skin tag, 922–924
- testicular, liver disease, 380
- tubular, polycystic kidneys, 436–439
- vaginal epithelium, 527, 527f, 528
- vulvar intraepithelial neoplasia, 520, 521f

B

Bite, sexual assault, 105

Black dots
- nevus
  - congenital nevus, 953–956, 953f–955f
  - nevus spilus, 946, 947f, 953–956, 954f
- tinea capitis, 782–786, 783f
- wart
  - common, 749–754
  - plantar, 766–769, 766f–768f

Blanching
- angioma, 1287
- drug reactions, cutaneous, 1211–1222
- erythema toxicum neonatorum, 630–634
- hemangioma, 1287
  - childhood, 636–640
- measles, 723–726
- Rocky Mountain spotted fever, 1066, 1068f

scarlet fever, 208–212
vascular lesions, adult acquired, 1204, 1205f
Bulla, 1097–1103, 1097f–1103f
acropustulosis of infancy, 1102
acute febrile neutrophilic dermatosis, 1031, 1032f
arthropod reaction, 1100, 1102f
bacterial infections, 1100, 1102f
bullosis diabeticorum, 1097, 1097f, 1100, 1101f
bullous fixed drug eruption, 1214f, 1218f
bullous mastocytosis, 1102
bullous myringitis, 173, 175f
bullous pemphigoid, 1098, 1098f, 1099f, 1104–1107, 1104f–1108f
Candida, 1102
cellulitis, 693–697, 695f
chronic obstructive pulmonary disorder, 334–343, 339f
cicatricial pemphigoid, 1098, 1099f, 1103
coumadin necrosis, 1213f
cryotherapy, 1100, 1101f
dermatitis
allergic contact dermatitis, 1100, 1101f
contact dermatitis, 834–841, 834f, 835f, 839f, 1100, 1101f
dermatitis herpetiformis, 1098, 1103, 1125–1126
irritant contact dermatitis, 1100, 1101f
diaper rash, 646–650
drug eruptions, 1100, 1101f
drug reactions, cutaneous, 1211–1222, 1214f
eczema
hand, 843–849
nummular, 888
edema blisters, 1102
epidermolysis bullosa, 1121–1123, 1121f, 1123f
epidermolysis bullosa acquisita, 1098, 1099f
epidermolysis bullosa simplex, 1098, 1099f, 1103
in children, 1102
erythema ab igne, 1198–1201
erythema multiforme, 866, 1049–1055, 1052f, 1211–1222
fixed drug eruption, 1211–1222, 1213f
friction blisters, 801, 1100
herpes
herpes simplex virus, 715, 1102, 1103f
herpes simplex virus, congenital, 1102
herpes zoster, 712–716, 712f–715f
hypersensitivity syndromes, 1049–1055
IgA bullous dermatosis, 1098, 1100f
impetigo, 644, 667, 676–679, 676f
insect bites, 714
lichen planus, 901–908
linear IgA bullous dermatosis, 1098, 1100f
miliaria, 1100
necrotizing fasciitis, 694, 702–706, 702f, 703f
neonatal pemphigus, 1102
pemphigoid gestationis, 469, 471–474, 472f, 473f, 866, 1098, 1099f
pemphigus, 714, 1109–1117, 1109f, 1111f
pemphigus foliaceus, 1098, 1098f
pemphigus vulgaris, 1098, 1098f, 1099f
photosensitivity, 1191–1196, 1192f
pityriasis lichenoides et varioliformis acuta, 1100, 1100f, 1123–1124, 1124f
pompholyx, hand, 843–849, 845f
porphyria cutanea tarda, 1100, 1100f, 1114, 1119–1121, 1120f
postburn blistering, 1100, 1101f
pyoderma gangrenosum, 1028–1034
scabies, 1102
sexually transmitted infections, ulcerative, 1031
Stevens–Johnson syndrome, 1049–1055, 1049f, 1211–1222, 1215f
sunburn, 1100
tinea, 1102
tinea pedis, 799–804, 799f, 801f
toxic epidermal necrolysis, 1049–1055, 1051f
transient neonatal pustular melanosis, 1102
vasculitis, 1062–1069
cutaneous, 1054
zoster ophthalmicus, 718–722, 718f–720f
Burrow
cutaneous larva migrans, 791, 823–825, 823f, 824f
scabies, 644, 677, 811, 815–822, 816f–819f, 831, 861, 1427

C

Callous formation (callus)
calluses and corns, 767, 1242–1245, 1242f–1245f
child physical abuse, 84, 84f, 86
hammer toe, 1251–1254, 1251f–1253f
wart, plantar, 687, 766–769
Cancer. *See* Tumor and cancer
Cavitation, lung
lung cancer, 355–363
pneumonia, 300–308, 304f
tuberculosis, 310–318, 310f, 313f, 316f
Central clearing
erythema annulare centrifugum, 1055, 1236–1239, 1236f–1238f
erythema multiforme, 1049–1055, 1050f, 1052f, 1053f
erythrasma, 689–692, 691f
fungal infections, cutaneous, 771–776, 771f, 824
Lyme disease, 730, 1289–1296, 1289f–1291f
pityriasis rosea, 896–900, 897f
psoriasis, 878–894, 883f
systemic lupus erythematosus, 1070–1078
tinea, 690, 771–776, 771f, 772f, 774t
tinea corporis, 788–793, 788f–791f, 806, 888
tinea cruris, 888
tinea faciei, 771f, 772
Chancre, syphilis, 739, 1278–1283, 1278f, 1279f
Chancroid, chancroid, 739, 1282, 1282f
Comedone
acne
acne vulgaris, 651–657, 653f, 655f, 656f, 661, 667, 684
neonatal acne, 630–634, 630f, 631, 632, 651–657, 652f
actinic comedones, 654, 655f
Consolidation, pulmonary
lung cancer, 355–363, 359f
pneumonia, 300–308, 300f, 301f, 303f–305f
sarcoidosis, 1038
tuberculosis, 310–318, 310f, 314f
Corneal clouding
acute angle closure glaucoma, 124, 128, 133, 137, 139–142, 140f, 165
keratitis, 166f
ocular rosacea, 164t
zoster ophthalmicus, 718–722, 718f
Cotton wool spots
bacterial endocarditis (Roth spot), 287–291, 287f, 288f
diabetic retinopathy, 143–145, 157
HIV retinopathy, 144
hypertensive retinopathy, 144, 147–150, 147f, 148f, 274, 274f
papilledema, 151–154, 152f

Crust
acne
acne fulminans, 652, 654f
acne keloidalis nuchae, 665–670
actinic keratosis, 971f, 973f
basal cell carcinoma, 989–997, 993f
Bowen disease, 971f
bullous impetigo, 1102f
bullous pemphigoid, 1104–1107, 1104f
chickenpox, 633, 707–710, 707f–710f
dermatitis
atopic dermatitis, 826–833, 828f, 833f
contact dermatitis, 182, 834–841
dermatitis herpetiformis, 1098
seborrheic dermatitis, 820
diaper rash, 646–650
eczema
hand, 843–849
nummular, 851–854, 852f, 853f
erythema ab igne, 1198–1201, 1199f
eyelash
ocular rosacea, 663f
red eye, 163
folliculitis, 680–684
folliculitis decalvans, 1138f, 1140
from 5-FU for actinic keratosis, 972, 973f
Hailey-Hailey disease, 1114, 1115f, 1230, 1233f
herpes
herpes simplex virus, 715, 735–742, 735f, 738f
herpes zoster, skin, 712–716
impetigo, 71, 71f, 72f, 204, 644, 667, 676–679, 676f–679f, 684, 709
MRSA skin infection, 695
otitis externa, 180–184, 180f
pemphigus foliaceous, 1109–1117, 1110f–1112f
pemphigus vulgaris, 1098, 1099f, 1109–1117, 1109f
pseudofolliculitis barbae, 665–670
psoriasis, scalp, 785
pyogenic granuloma, 940–944
scabies, 644, 815–822, 815f, 816f
squamous cell carcinoma, 999–1007, 999f–1004f
tinea capitis, 782–786, 783f, 784f
zoster ophthalmicus, 718–722, 719f
Cyst
acne vulgaris, 651–657, 651f, 699
bone, lupus pernio, 1036
breast, benign, 553–554
bunion deformity, 1247–1250, 1247f–1249f
chronic obstructive pulmonary disease, 334–343, 338f, 339f
dermoid tumor, 194
Entamoeba histolytica, 1270–1274
epidermal, 672
epidermal inclusion, 699, 700f, 937, 1039
Giardia lamblia, 1270–1274, 1273f
gout, 590–594
hidradenitis suppurativa, 671–674, 674f, 675f
hydrocystoma, 115, 116f
milia, 630–634, 630f, 933, 933f
Nabothian, 526f, 527, 527f
non-neoplastic hamartoma, 394, 395
polycystic kidneys, 436–439, 436f, 437f
renal cell carcinoma, 441–446
seborrheic keratosis, 926f, 927f
subchondral, osteoarthritis, 571f
Taenia solium, 1270–1274
thyroglossal duct, 1349, 1350f
vocal cord, 220–225

D

Dermatographism
bullous mastocytosis, 1102
urticaria, 864, 864f
urticaria pigmentosa, 863–869
Desquamation
acne vulgaris, 651–657
black hairy tongue, 228
bullous impetigo, 677f
cicatricial pemphigoid, 1098
cytolytic vaginosis, 501
drug reactions, cutaneous, 1211–1222
eczema, hand, 844
folliculitis, 681
nasal polyps, 193
pompholyx, hand, 843–849
psoriasis
erythrodermic, 878–894, 886f
psoriatic nails, 1170–1173
pustular, 878–894
scarlet fever, 208–212
strawberry tongue, 208–212
toxic epidermal necrolysis, 1049–1055, 1053f
vaginitis, 485–487
Drusen
age-related macular degeneration, 155–158, 155f, 156f
optic disc, 153

E

Ecchymosis
cellulitis, 693–697, 695f
coining, 85, 87f
eyelid, 160, 160f
knee trauma, 621
necrotizing fasciitis, 702–706
physical abuse, child, 84, 84f
sexual assault, adult, 105
Erosion
arthrithis
cartilage, osteoarthritis, 569–573, 569f–571f
periarticular, psoriatic arthritis, 562, 562f
rheumatoid arthritis, 575–579, 578f
bony, sinusitis, 197–202, 199f
Candida infection (thrush), 1116, 1116f
Charcot arthropathy, 1261–1264, 1263f, 1304f
drug reactions, cutaneous, 1214f
epidermolysis bullosa simplex, 1102
erythema multiforme, 865, 866, 1049–1055, 1053f, 1211–1222
fixed drug eruption, 1214f
folliculitis decalvans, 1138f, 1140
Hailey-Hailey disease, 1114, 1115f, 1230, 1233f
leishmaniasis, 67–69, 67f–69f
lichen planus, 901–908, 904f
neurotic excoriations, 843–849, 856f–858f
paraneoplastic pemphigus, 1109–1117, 1113f
pemphigus, 1109–1117, 1111f

pemphigus foliaceous, 1109–1117, 1111f
pemphigus vulgaris, 1109–1117, 1112f
pityriasis lichenoides et varioliformis, 1100, 1100f
porphyria cutanea tarda, 1119–1121, 1119f
pyoderma granuloma, 1028–1034, 1030f
Stevens–Johnson syndrome, 1049–1055, 1211–1222
tooth
bulimia, 264, 264f
caries, adult, 262–266
toxic epidermal necrolysis, 1049–1055
Eschar
dry gangrene, 1265–1267, 1265f, 1266f
gangrene, 1256
ischemic ulcer, foot, 1256, 1259
necrotizing fasciitis, 702–706, 704f
pyoderma gangrenosum, 1020, 1028–1034
Excoriation
anal fissure, 92
atopic eruption of pregnancy, 463, 464, 464f
Candida vulvovaginitis, 499–503
cutaneous larva migrans, 823–825, 823f
dermatitis
atopic dermatitis, 826–833, 829f
contact dermatitis, 182, 834f–839f, 840f
dermatitis herpetiformis, 1098, 1125–1126, 1126f
eczematous dermatitis, 906
eczema, nummular, 851–854, 851f, 853f
epidermolysis bullosa, 1121–1123, 1123f
hemorrhoid, 414–418
intrahepatic cholestasis of pregnancy, 462–466, 462f
lice, 809–814, 809f
lichen simplex chronicus, 906
liver disease, 380
methamphetamine, 1424–1429, 1424f, 1426f, 1427f
molluscum contagiosum, 743–746
neurotic, 856f–858f
pinworm, 92
scabies, 745
Exfoliation
bullous pemphigoid, 1105
erythroderma, 915–921, 915f–921f
psoriasis, 884, 886f
Sézary syndrome, 1043
staphylococcal scalded skin syndrome, 677, 679f
Stevens-Johnson syndrome, 1049–1055
toxic epidermal necrolysis, 1049–1055, 1053f
Exostosis
calluses and corns, 1242–1245
ear, cold water swimmer, 186f
torus mandibularis, 206–207, 206f
torus palatinus, 206–207, 206f

F

Fissure
angular cheilitis, 203–205, 203f–205f
anorectal, 92, 395–396, 401, 416, 416f
sexual abuse, child, 92
Candida vulvovaginitis, 499–503
dental caries
adult, 262–266
early childhood, 257–260, 257f
dermatitis
atopic dermatitis, 826–833
contact dermatitis, 834–841, 834f, 840f
eczema, hand, 843–849
fissured tongue, 233, 234f
lung, pneumonia, 303f
scabies, 815–822, 815f
tinea pedis, 799–804, 800f
Follicles, trachoma of eye, 69–70, 69f, 70f
Fracture
ankylosing spondylitis, 580–583
clavicle, 601–604, 601f–603f, 602t
hip, 615–617, 615f–617f
intimate partner violence, 95–100, 97
lateral condylar split, 621, 622f
metatarsal, 611–614, 611f, 612f
patellar, 621, 622f
physical abuse, child, 82, 82f, 84f, 86
radius, distal, 605–609, 605f–609f, 608t
vertebral, osteoporotic, 586, 586f

G

Goiter
goitrous hypothyroidism, 1346–1352, 1346f–1349f
Graves disease, 1353–1358, 1353f–1356f
toxic multinodular goiter, 1355

H

Hyperkeratosis
acanthosis nigricans, 1302f, 1310–1312, 1310f–1313f, 1329f, 1332f
angiokeratoma, 1203–1206, 1204f
breast
benign lichenoid keratosis, 559, 559f
seborrheic keratosis, 559
bunion deformity, 1247–1250, 1247f–1249f
cervical intraepithelial neoplasia II/III, 536
corns and calluses, 1242–1245, 1242f–1245f
cutaneous horn, 985–986, 985f–987f
Darier disease, 1171–1172, 1173f, 1229–1234, 1229f–1232f
eczema, hand, 844f
genodermatoses, 1229–1234
leukoplakia, 249–252, 250f
lichen planopilaris, 1139
lichen planus, 901–908
neuropathic ulcer of foot, 1256, 1258–1260, 1258f, 1259f
nicotine stomatitis, 251f
onychomycosis, 1171
palmoplantar keratoderma, 767–768, 769f, 770f
psoriatic nails, 1170–1173, 1170f–1173f
squamous cell carcinoma, 999–1007, 999f–1004f
wart, plantar, 766–769, 766f–768f
Hyperpigmentation
acanthosis nigricans, 1302f, 1310–1312, 1310f–1313f, 1329f, 1332f
acne vulgaris, 651–657, 656f
acropustolosis, 642–644
acropustulosis, 642f, 643f
angiokeratoma, 1203–1206, 1204f
basal cell carcinoma, 989–997, 990f
pigmented, 1016, 1016f, 1017f
cafe au lait spot, 923f
neurofibromatosis, 1387–1390, 1387f, 1388f
chloasma, pregnancy, 19, 19f

Hyperpigmentation (*Continued*)
conjunctival, 118–121, 118f–121f
corns and calluses, 1242–1245, 1242f–1245f
Darier disease, 1229–1234, 1229f–1232f
dermatitis
acrodermatitis enteropathica, 62–63, 63f
atopic dermatitis, 826–833, 829f, 832f
contact dermatitis, 834–841, 836f
phytophotodermatitis, 824
seborrheic dermatitis, 871–876, 873f
stasis dermatitis, 1315
dermatofibroma, 935–938, 935f–938f, 1225
dermatomyositis, 1079–1087, 1085f
diabetic dermopathy, 1302f, 1314–1316, 1314f–1316f
drug reactions, cutaneous, 1211–1222, 1213f–1215f
eczema, hand, 843–849
erythema ab igne, 1198–1201, 1198f–1201f
erythema toxicum neonatorum, 210, 630–634, 632f
fixed drug eruption, 1213f, 1218f
folliculitis, 680f–683f
genodermatoses, 1229–1234, 1229f–1235f
glomangioma, 1203–1206, 1205f
granuloma annulare, 1022–1027, 1022f–1026f
Grover disease, 683, 683f
hemangioma, childhood, 636–640, 636f–639f
hidradenitis suppurativa, 671–674, 672f–675f
ichthyosis
acquired, 1233, 1234f
ichthyosis vulgaris, 1233, 1234f
lamellar, 1233, 1235f
X-linked, 1229–1234, 1232f, 1233f
intertrigo, 778, 779f
labial melanocytic macule, 950, 950f
lentigo maligna, 981–984, 981f, 982f
lice, 809–814
lichen planus, 901–908, 901f–906f
longitudinal melanonychia, 1146, 1146f, 1151–1154
lupus
discoid lupus erythematosus, 1070–1078, 1074f
systemic lupus erythematosus, 1070–1078, 1072f, 1076f
measles, 723–726, 723f–725f
melanoma, 1008–1020, 1008f–1016f
lentigo maligna, 981f
superficial spreading, of breast, 559, 559f
melasma, 1179–1182, 1179f–1181f
methamphetamine, 1424–1429, 1424f, 1426f, 1427f
mycosis fungoides, 1042–1047, 1043f–1046f
necrobiosis lipoidica, 1303f, 1317–1320, 1317f–1320f
neurofibromatosis, 1387–1390, 1387f–1389f
nevus
benign nevus, 945–951, 945f–950f
dysplastic nevus, 963–967, 963f–967f
pemphigus, 1109–1117, 1109f–1115f
pemphigus foliaceous, 1109–1117, 1110f–1112f
photosensitivity, 1191–1196, 1191f–1193f
pigmented nail disorders, 1151–1154, 1151f–1155f
pigmented purpuric dermatosis, Majocchi type, 1066, 1067f
pitted keratolysis, 686–688, 687f
pityriasis rosea, 896–900, 896f–899f
pregnancy, 462, 463, 463f, 464
pseudofolliculitis barbae, 665–669, 665f, 666f, 667f
Pseudomonas, nail, 1162, 1163f
psoriasis, 878–894, 878f–890f
inverse, 778, 780f, 796, 797f
scarlet fever, 208–212, 208f
Schamberg disease, 1066, 1066f, 1067f, 1315
scleral, 118–121, 118f–121f
scleroderma, 1089–1095, 1091f, 1092f
scrofula, 74, 76f
seborrheic keratosis, 926–930, 926f–929f, 950
self-inflicted dermatoses, 856–862, 856f–860f
solar lentigo, 928f, 929, 982, 982f
tinea, 772, 772f, 778, 780f
tinea corporis, 771f, 772, 772f, 788–793, 788f–791f
tinea cruris, 795–798, 795f–797f
tinea faciei, 771f
tinea incognito, 788–793, 790f
tinea versicolor, 805–808, 807f
transient neonatal pustular melanosis, 642–644
urticarial pigmentosa, 865f, 866
vasculitis, 1062–1069, 1062f–1067f
urticarial, 866
vulvar intraepithelial neoplasia, 519–522, 519f
xanthoma, 1304f, 1322–1327, 1322f–1324f, 1332f
Hypertrophy, linear porokeratosis, 961
Hypopigmentation
ash leaf spots, 1187, 1187f
corticosteroids, 1453t
dermatitis, seborrheic, 871–876, 875f
hemangioma, childhood, 636–640
hypomelanosis of Ito, 1187, 1188f
idiopathic guttate hypomelanosis, 1187, 1187f
lichen sclerosus et atrophicus, vulvar, 92, 92f
lupus
discoid lupus erythematosus, 1070–1078, 1074f, 1075f
discoid lupus erythematosus, scarring alopecia, 1140, 1142f
systemic lupus erythematosus, 1070–1078, 1072f
mycosis fungoides, 1042–1047, 1042f
nevus
dysplastic nevus, 963–967
halo nevus, 1187
nevus anemicus, 1187, 1188f
nevus depigmentosus, 1187, 1188f
pityriasis alba, asthma, 324, 325f
pregnancy, 462, 463, 464f, 465
psoriasis, 878–894, 879f, 883f, 884f
sarcoidosis, 1035–1040, 1037f
scarring alopecia, 785
scleroderma, 1089–1095, 1092f
self-inflicted dermatoses, 856–862, 856f–860f
tinea, 772, 773f
tinea corporis, 772, 773f
tinea versicolor, 771–776, 805–808, 805f, 806f
tuberous sclerosis, 1388, 1390f
vitiligo, 1184–1190, 1184f–1188f

J

Jaundice
end of life, 33
gastric cancer, 371–375
hepatitis, 389
liver disease, 377–384, 377f, 380f–382f, 383t

L
Lace-like rash, fifth disease, 728–731, 728f
Laceration
intimate partner violence, 95–100, 97f
physical abuse, child, 82–86
sexual abuse, child, 89–93, 91f
sexual assault, adult, 105
Lichenification
bullous diseases, 1098
dermatitis
acrodermatitis enteropathica, 62–63, 63f
atopic dermatitis, 826–833, 829f
contact dermatitis, 819f
eczematous dermatitis, 906
eczema
hand, 843–849
nummular, 851–854, 853f
lichen simplex chronicus, 856–862, 858f, 859f, 888, 906
paraneoplastic pemphigus, 1109–1117
self-inflicted dermatoses, 856–862, 858f, 859f

M
Macule
ash leaf spots, 1187, 1187f
Bowen disease, 906
candidiasis, 777–780
chickenpox, 633
drug reactions, cutaneous, 1214f
erythema chronicum migrans of Lyme disease, 824
erythema multiforme, 1049–1055, 1052f, 1053f
erythema toxicum neonatorum, 630–634, 632f, 644
fixed drug eruptions, 1213f, 1214f, 1218f
Forchheimer spots, 209
fungal infections, cutaneous, 824
gonococcal arthritis, 913
hand, foot, and mouth disease, 644, 732–734, 732f, 733f
hemangioma, childhood, 636–640
idiopathic guttate hypomelanosis, 1045
labial melanotic macule, 950, 950f
maculopapular eruptions, drug, 1211–1222, 1211f
melasma, 1179–1182, 1179f–1181f
Mongolian spots, 630–634, 631f, 632
mycosis fungoides, 1042–1047, 1042f, 1094
nevus
atypical nevus, 950
Becker nevus, 956
benign nevus, 946f
congenital nevus, 953–956
dysplastic nevus, 950, 963–967, 963f–967f
junctional nevus, 946, 946f, 948
nevus anemicus, 948, 949f, 1187, 1188f
nevus depigmentosus, 1187, 1188f
Paget disease of external genitalia, 514–517, 514f, 515f
pigmented seborrheic keratosis, 937
pityriasis rosea, 896–900
psoriasis, 878–894, 880f, 888f
guttate, 899
Rocky Mountain spotted fever, 1066, 1068f
scarlet fever, 208–212
solar lentigines, 1016
staphylococcal scalded skin syndrome, 1054
Stevens–Johnson syndrome, 1049–1055, 1211–1222
superficial spreading melanoma, 1008–1020, 1010f
syphilis, 806, 907, 1278–1283, 1280f
tinea versicolor, 805–808, 806f
toxic epidermal necrolysis, 1049–1055
transient neonatal pustular melanosis, 642–644, 643f, 1102
vitiligo, 1045
xanthelasma, 1038
zoster ophthalmicus, 718–722
Maculopapular lesion
DRESS/DIHS, 1211–1222, 1219f
DRESS syndrome, 1211–1222, 1219f
drug reactions, cutaneous, 1211–1222, 1211f
lice, 809–814, 809f
Lyme disease, 1289–1296, 1289f–1291f
maculopapular eruptions, drug, 1211–1222, 1211f
measles, 723–726, 723f–725f
pityriasis lichenoides et varioliformis acuta, 1123–1124, 1124f
sarcoidosis, 1035–1040, 1036f, 1319
vasculitis, leukocytoclastic, 1062–1068, 1064f
viral exanthema, 210, 1215f
Microaneurysm (eye)
diabetic retinopathy, 143–144, 143f, 157
hypertensive retinopathy, 147–150, 147f, 274, 274f
Morbilliform
drug reactions, cutaneous, 1211–1222, 1211f
measles, 723–726, 723f–725f
paraneoplastic pemphigus, 1113
Mosaic
cervical cancer, 542–543
cervical intraepithelial neoplasia II/III, 537, 538f
cutaneous horn, 985–987
wart, plantar, 766–769, 766f, 767f

N
Nail changes
arsenic toxicity, 687
bacterial endocarditis, 287–291, 287f
Beau lines, 1146, 1147f, 1148f
candidiasis, 777–780
clubbing, 292–294, 292f, 293f
Darier disease, 1171–1172, 1173f, 1229–1234, 1231f
dermatomyositis, 1079–1087, 1080f, 1082f, 1084f
erythroderma, 915–921
Graves disease and goiter, 1353–1358
habit-tic deformity, 1146, 1147f, 1149
half-and-half nail, 1149, 1149f
ingrown toenail, 1156–1158, 1156f–1158f
leukonychia, 1145, 1145f, 1146, 1146f, 1162
leukonychia punctata, 1145, 1146, 1146f
lichen planus, 901–908, 905f, 1162
Lindsay nails, 1149, 1149f
longitudinal melanonychia, 1146, 1146f, 1151–1154, 1151f–1155f
Mee lines, 1148f, 1148t, 1149
melanoma
acral lentiginous, 1008–1020, 1012f, 1013f
subungual, 1151–1154, 1152f–1154f
mucus cyst, 1167, 1169f
Muehrcke lines, 1148t, 1149, 1149f
onychocryptosis, 1156–1158, 1156f–1158f
onychogryphosis, 1145, 1146, 1146f, 1161f, 1162f
onychomycosis, 1160–1164, 1160f–1162f
onychoschizia, 1177, 1177f

Nail changes (*Continued*)
paronychia, 1166–1169, 1166f–1168f
photoonycholysis phototoxicity reactions, 1194
pincer nail, 1156, 1156f
proximal nail fold habitual picking, 1162
pseudo-Hutchinson sign, 1153
Pseudomonas of nail, 1162, 1163f
psoriasis, 2, 3f, 878–894, 881f
inverse, 2, 3f, 796, 797f
psoriatic nails, 878–894, 881f, 1162, 1170–1173, 1170f–1173f
reactive arthritis, 910–914, 912f
sarcoidosis, 1035, 1037
subungual hematoma, 1175–1177, 1175f–1177f
transverse striate leukonychia, 1145, 1145f, 1146
trauma, 1162
twenty-nail dystrophy, 1149, 1149f
Nail pitting, psoriasis and psoriatic arthritis, 690
Nodule
acne
acne conglobata, 652, 653f
acne keloidalis nuchae, 652, 665f, 666f, 1039, 1225, 1226f
acne vulgaris, 651–657, 651f, 653f, 684
acute febrile neutrophilic dermatosis, 1031, 1032f
angiosarcoma, 638
autonomous functioning, thyroid, 1355
basal cell carcinoma, 989f, 990f
nodular, 933, 933f, 989–997
blue rubber bleb nevus syndrome, 638
Bouchard nodes, 563f
carcinoma, metastatic, 1039
cervical intraepithelial neoplasia II/III, 537
chalazion, 114–117, 115f
chondrodermatitis nodularis helicis, 189–192, 189f, 190f, 192f
cutaneous horn, 985–986
dermatofibroma, 745, 935–938, 935f–938f, 1016, 1225, 1287
dermatofibrosarcoma, 1225
diaper rash, 646–650, 647f
dissecting folliculitis, 1140, 1141f
Dupuytren's disease, 625–628
endocarditis, bacterial, 289, 289f
epidermal inclusion cyst, 1039
erythema induratum, 704
erythema nodosum, 1056–1060, 1056f, 1057f
erythema nodosum leprosum, 1059, 1059f, 1060f
folliculitis, 633
glomangioma, 1203–1206, 1205f, 1209
granuloma
granuloma annulare, 1022–1027
granuloma gluteale infantum, 648
juvenile xanthogranuloma, 161
pyoderma granuloma, 1028–1034
pyogenic granuloma, 940–944, 940f–942f
Graves disease and goiter, 1353–1358, 1355f
Heberden nodes, 563f
hemangioma, childhood, 636–640, 636f–639f
hidradenitis suppurativa, 671–674, 671f–675f, 1333f
hordeolum, 114–117, 114f, 115f
Kaposi's sarcoma, 1285–1288
keloids, 1224–1228, 1224f, 1225f, 1227f
keratoacanthoma, 977–980, 977f–979f
leishmaniasis, 67–69, 67f–69f
lipoma, 1039
Lisch, neurofibromatosis, 1387–1390, 1390f, 1391f
lung cancer, 355–363, 355f, 356f, 358f, 360t
lupus pernio, 1035–1040
melanoma, 1011f, 1016f, 1018f
in acquired nevus, 955f, 956
amelanotic, 1012
nodular, 1008–1020, 1009f, 1011f, 1013f
Merkel cell carcinoma, 1005, 1005f
morphea, 1039
Osler nodes, 289, 289f
pinguecula, 111, 112f
preauricular tag, 189–191, 191f
prurigo nodularis, 827, 856–862, 859f, 860f, 907
pseudofolliculitis barbae, 665–669, 665f, 666f
rheumatoid arthritis, 563, 564f, 575–579, 577f, 578f, 1024, 1038
rosacea fulminans, 661, 664f
sarcoidosis, 1035–1040, 1038f
scabies, 815–822, 818f
syphilis, secondary, 1436f
toxic multinodular goiter, 1355
toxic nodular goiter, 1349f, 1350
tuberculosis, 310–318, 311f, 315f, 316f
vasculitis, 1062–1069
vocal cord, 220–225, 224f
xanthoma, 933, 1304f, 1322–1327, 1322f

P

Papule
acanthosis nigricans, 1302f, 1310–1312, 1312f
acne
acne keloidalis nuchae, 652, 665–669, 665f, 666f, 1039
acne rosacea, 652, 655f
acne vulgaris, 651–657, 651f, 652f, 655f, 684
neonatal acne, 630–634, 630f
acropustulosis, 642–644, 642f, 643f
angioedema, 863–869, 865f
angiokeratoma, 1203–1206, 1204f
arteriovenous malformation, 638
arthrithis
gonococcal arthritis, 911
keratoderma blennorrhagicum, reactive arthritis, 910–914, 910f
reactive arthritis, 910f
atopic eruption of pregnancy, 463, 464, 464f
bacillary angiomatosis, 943, 943f, 1287, 1287f
Bowen disease, 906
cherry angiomas, 1203–1206, 1203f
cherry hemangioma, 943, 943f
chickenpox, 633, 707–710
cutaneous candidiasis, 644
Darier disease, 1171–1172, 1229–1234, 1232f
dermatitis
allergic contact dermatitis, 677
atopic dermatitis, 826–833, 826f–833f
dermatitis herpetiformis, 709, 1098
papular acrodermatitis of childhood, 1124, 1125f
seborrheic dermatitis, 661, 820
dermatomyositis, 1074, 1079–1087, 1080f, 1082f
dermatosis papulosa nigra, 927, 928f
diabetic dermopathy, 1314f–1316f
diaper rash, 646–650, 646f, 648f
drug eruptions, 739

eczema
hand, 843–849, 844f
nummular, 851–854, 851f–853f
erythema annulare centrifugum, 1054, 1236–1239, 1237f
erythema multiforme, 1049–1055, 1211–1222
erythema toxicum neonatorum, 630–634, 632f
fibrous papule of face, 933, 995
fibrous papule of nose, 943, 943f
folliculitis, 652, 680–684, 680f–683f
Gianotti–Crosti syndrome, 1124, 1125f
granuloma
granuloma annulare, 791, 792f, 1022–1027
granulomatous rosacea, 1038
juvenile xanthogranuloma, 161
pyogenic granuloma, 464, 465f, 940–944, 940f–942f
Graves disease and goiter, 1353–1358, 1355f
Grover disease, 683, 683f, 1230
Hailey-Hailey disease, 1230, 1233f
hand, foot, and mouth disease, 644
Kaposi's sarcoma, 1285–1288, 1285f, 1286f
keloids, 1224–1228
keratosis pilaris, 684, 830f
lichen planus, 901–908, 901f–906f, 1038
lichen striatus, 961, 961f
linear lichen planus, 961, 961f
lupus
discoid lupus erythematosus, 1070–1078, 1074f, 1075f
lupus pernio, 1035–1040, 1036f
systemic lupus erythematosus, 661
Lyme disease, 1289–1296, 1289f–1291f
lymphomatoid papulosis, 1124, 1125f
maculopapular eruptions, 1211f
maculopapular eruptions, drug, 1211–1222
measles, 723–726, 723f–725f
milia, 630–634, 630f
miliaria, 684
molluscum contagiosum, 521, 714, 743–746, 743f–746f, 762, 933
Montgomery's tubercles, 463, 463f
necrobiosis lipoidica, 1315, 1317–1320, 1318f
nevus
atypical nevus, 950
dysplastic nevus, 950
nevus sebaceous, 958–962, 958f, 959f, 960f
Spitz nevus, 946, 947f
papular pruritic eruption, 75f
pearly penile papules, 762, 763f
pemphigoid gestationis, 471–474, 471f, 1098, 1099f
perianal pseudoverrucous papules, 648
photosensitivity, 1191–1196, 1191f
Pityrosporum folliculitis, 806, 807f
pompholyx, hand, 843–849
pregnancy, 464, 465f
pruritic urticarial papules and plaques of pregnancy, 467–470, 467f–469f, 473, 866, 867f
pseudofolliculitis barbae, 665–669, 665f, 666f
psoriasis, 878–894, 886f
pyoderma gangrenosum, 1028–1034
rosacea, 659–664, 659f, 660f, 662f, 663f, 1074
rosacea fulminans, 661, 664f
sarcoidosis, 1035–1040, 1035f–1040f, 1238
scabies, 815–822, 817f–819f, 821f, 831, 1126
scarlet fever, 208–212, 208f, 209f
sebaceous hyperplasia, 931–934, 995, 996f
skin tag, 750, 922–924, 922f
Stevens-Johnson syndrome, 1049–1055, 1049f
syphilis, 907, 1278–1283, 1283f
syphilis, secondary, 1436f
syringoma, 961, 961f
tinea pedis, 799–804, 799f
tuberous sclerosis, 1388, 1390f
urticaria, 863–869, 865f
vasculitis, cutaneous, 1054
vulvar intraepithelial neoplasia, 519–522, 519f
wart
common, 749–754, 749f–753f
flat, 755–758, 755f, 756f
genital, 759–765
xanthelasma, 1038, 1323, 1324f
xanthoma, 933, 1304f, 1322–1327, 1322f–1324f, 1332f
zoster ophthalmicus, 718–722, 718f–720f
Patch
acrodermatitis enteropathica, 62–63, 63f
angiosarcoma, 638
basal cell carcinoma, superficial, 989–997
Candida
Candida vulvovaginitis, 499–503, 499f
candidiasis, 777–780, 777f–780f
diabetic dermopathy, 1314–1316
eczema, nummular, 851–854, 852f, 970, 972
erythema chronicum migrans of Lyme disease, 824
erythema multiforme, 246
erythrasma, 689–692, 689f–691f
erythroderma, 915–921
erythroplakia, 249–252, 251f
eye, pinguecula, 111
hairy leukoplakia, oral, 229, 230f
hemangioma, infantile, 639f
Kaposi's sarcoma, 1285–1288, 1286f, 1287f
lentigo maligna, 981–984, 981f, 982f
lentigo maligna melanoma, 981f, 982f
leukoplakia, 249–252, 249f, 250f, 907, 1400, 1401f
lichen sclerosus, 521
lichen sclerosus et atrophicus, 521, 522f
lichen simplex chronicus, 831
melasma, 1179–1182, 1179f–1181f
Mongolian spots, 630–634, 631f, 632
mycosis fungoides, 854, 1042–1047, 1042f, 1043f
nevus
Becker nevus, 948, 948f
nevus anemicus, 948, 949f
nevus depigmentosus, 1187, 1188f
oral cancer, 253–256
Paget disease of external genitalia, 514–517, 514f, 515f
pityriasis alba, 806
pityriasis alba, asthma, 324, 325f
pityriasis rosea, 806, 888, 896–900, 897f–900f, 906, 1237, 1282
port-wine stain, 1207–1210, 1207f–1209f
psoriasis, 878–894, 880f
salmon patch, 638, 638f, 1209, 1209f
solar lentigo, 982, 983f
syphilis, 1278–1283, 1278f–1281f, 1283f
systemic lupus erythematosus, 1070–1078, 1072f, 1076f
tinea versicolor, 805–808, 806f

Pearly
basal cell carcinoma, 115, 745, 972, 989–997, 989f, 990f
nodular, 933, 933f
pigmented, 1016, 1016f, 1017f
chondrodermatitis nodularis, 189f, 190f
fibrous papule of face, 995, 995f
keratoacanthoma, 977–980, 977f–979f, 995, 995f
lice (nits), 809–814, 811f
milia, 630–634, 933, 933f
molluscum contagiosum, 743–746, 743f–746f
pearly penile papules, 762, 763f
sebaceous hyperplasia, 931–934, 931f, 932f
squamous cell carcinoma, 999–1007, 1005f
trichoepithelioma/trichoblastoma/trichilemmoma, 995, 995f
Petechia
atrophic vaginitis, 489–492
cellulitis, 693–697, 695f
cervical, colposcopy of, 527, 527f
idiopathic thrombocytopenic purpura, 1066, 1069f
measles, 723–726
meningococcemia, 1068f, 1435
mycosis fungoides, 1042–1047
oral, child, 84
pharyngitis, 213–218, 215f
physical abuse, child, 84
Rocky Mountain spotted fever, 1068f, 1293
scarlet fever (Forchheimer spots), 208–212
Schamberg disease, 1066, 1067f
sexual abuse, child, 91
Trichomonas cervicitis, 527, 527f
Pink eye, conjunctivitis, 126–129, 126f–129f
Pit
Darier disease, 1229–1234, 1230, 1231f
dental caries
adult, 262–266
early childhood, 257–260, 257f
nail, psoriasis and psoriatic arthritis, 2, 3f, 831, 878–894, 881f, 1170–1173, 1170f–1173f
pitted keratolysis, 686–688, 686f, 687f, 801, 802f
scleroderma, 1089–1095, 1091f, 1093f
Plaque
fixed drug eruption, 1211–1222, 1213f
Plaque, coronary, coronary artery disease, 268–270, 268f, 269f, 1371
Plaque, dental
caries
adult, 262–266, 262f
early childhood, 257–260
gingival overgrowth, 240–242
gingivitis and periodontal disease, 236–238, 236f, 237f
Plaque, oral
Candida, 216, 229, 230f, 246
gingival overgrowth, 240–242
leukoplakia, 249–252, 249f, 250f
Plaque, skin
acne keloidalis nuchae, 665–669
actinic keratosis, pigmented, 929
acute febrile neutrophilic dermatosis, 1031
angioedema, 863–869
angiosarcoma, 638
arthrithis
balanitis circinata with reactive arthritis, 910–914, 911f
keratoderma blennorrhagicum, reactive arthritis, 910–914, 910f
psoriatic arthritis, 582, 582f
reactive arthritis, 910–914, 910f–912f
basal cell carcinoma, superficial, 989–997
Bowen disease, 906, 1171
Candida
Candida, cutaneous, 644
candidiasis, 777–780, 777f–780f
cutaneous candidiasis, 644
diaper rash, *Candida,* 646–650
cervical cancer, 541f, 542
cervical intraepithelial neoplasia II/III, 536, 536f
cutaneous angiosarcoma, 1203–1206, 1205f
cutaneous T-cell lymphoma, 888
Darier disease, 1171–1172, 1229–1234, 1229f–1232f
dermatitis
atopic dermatitis, 826–833, 829f
dermatitis herpetiformis, 1125–1126, 1126f
seborrheic dermatitis, 871–876, 871f–874f, 888, 1233
dermatomyositis, 1079–1087, 1080f, 1082f
eczema
hand, 843–849, 844f
nummular, 791, 851–854, 852f, 888, 1023, 1024
erythema annulare centrifugum, 1236–1239, 1236f–1238f
erythema multiforme, 1049–1055
erythrasma, 689–692, 689f–691f
erythroderma, 915–921, 917f
fixed drug eruption, 1211–1222, 1218f
folliculotropic mycosis fungoides, 1130, 1131f
fungal infection, cutaneous, 824
Gottron papules, 1079–1087, 1080f, 1082f
granuloma annulare, 1022–1027
Graves disease and goiter, 1353–1358, 1355f
hemangioma, childhood, 636–640, 636f, 637f
impetigo, 676–679, 676f–679f, 821
intertriginous vegetating plaques, 1106
Kaposi's sarcoma, 1285–1288
leukoplakia, 516
lice, 809–814
lichen planus, 901–908, 901f–906f, 1038
lichen sclerosus, 1094
lichen simplex chronicus, 854, 856–862, 858f, 859f
linear IgA dermatosis, 1114
linear porokeratosis, 961
lupus
discoid lupus erythematosus, 1070–1078, 1074f, 1075f, 1093
lupus pernio, 1036f
melanoma, 1008–1020, 1011f, 1020t
superficial spreading, 1008–1020, 1011f, 1020t
mycosis fungoides, 854, 1042–1047, 1043f, 1094
necrobiosis lipoidica, 1315, 1317–1320, 1317f–1319f
Paget disease of external genitalia, 514–517, 516f
pemphigoid gestationis, 471–474, 1098
photosensitivity, 1191–1196, 1191f
pityriasis rosea, 896–900
pruritic urticarial papules and plaques of pregnancy, 467–470, 467f–469f, 866, 867f
psoriasis, 234, 234f, 690, 791, 792f, 831, 854, 878–894, 878f, 879f, 882f, 883f, 1074
inverse, 2f, 3f
obesity, 1331f
plaque, 1170f
psoriatic arthritis, 582, 582f

rhinophymatous rosacea, 659–664, 661f, 666f
sarcoidosis, 661, 1035–1040, 1036f–1039f, 1074, 1238
seborrheic keratosis, 926–930
solar lentigo, 928f, 929
squamous cell carcinoma, 1171
tinea corporis, 888
tinea cruris, 795–798, 795f–797f, 888
urticaria, 863–869, 866f, 867f
urticaria pigmentosa, 863–869, 866f, 867f
verruca vulgaris, 1171
vulvar intraepithelial neoplasia, 519–522, 519f
wart, plantar, 766–769, 766f–768f
xanthelasma, 115, 1038
Polyp
atrophic vaginitis, 489–492, 489f
cervical and endocervical, colposcopy, 527, 528, 528f
colon, 393–397, 393f, 395f, 396f, 399, 401, 402, 403
juvenile, 394, 395
laryngeal, 220–225, 225f
nasal, 193–195, 193f, 194f, 324
skin tag, 922–924, 922f–924f
vocal cord, 220–225
Punctation
cervical cancer, 542
cervical lesions
high-grade, 537, 537f, 542
low-grade, 530–533, 531f
Purpura
cocaine abuse, 1431–1437, 1435f
corticosteroids, 1453t
Henoch-Schönlein purpura, 866, 867f
hepatitis, 380
idiopathic thrombocytopenic purpura, 1069f
meningococcemia, 1066, 1068f
necrotizing angiitis, systemic lupus erythematosis, 1070–1078, 1072f, 1076f
purpura, 1287
vasculitis, 1062–1069, 1062f–1066f
cutaneous, 1054
Pustule
acne
acne keloidalis nuchae, 652, 1140, 1141f
acne rosacea, 652, 655f
acne vulgaris, 651–657, 651f, 653f, 684
neonatal acne, 630–634, 630f
acropustulosis, 642–644, 642f, 643f
acropustulosis of infancy, 821, 821f, 1102
acute febrile neutrophilic dermatosis, 1031
arthrithis
keratoderma blennorrhagicum, reactive arthritis, 910–914, 910f
reactive arthritis, 910–914, 910f
Candida, 1102
candidiasis, cutaneous, 644
chickenpox, 633, 707–710, 707f–709f
diaper rash, 646–650, 648f
erythroderma, 915–921, 917f
folliculitis, 680–684, 680f–683f, 714
folliculitis decalvans and tufted folliculitis, 1138–1143, 1138f
herpes
herpes zoster, 712–716, 712f–715f
herpes zoster ophthalmicus, 718–722, 718f–720f
herpetic whitlow, 1167
impetigo, 667, 676–679, 684
injection-drug use, 1439–1444, 1441f
insect bites, 714
neonatal pustular melanosis, 633
pseudofolliculitis barbae, 665–669, 666f
psoriasis, 878–894, 880f, 881f, 886f, 888f, 889f
pustular, 644
pyoderma granuloma, 1028–1034
rosacea, 659–664, 659f, 660f, 662f, 1074
rosacea fulminans, 661, 664f
sarcoidosis, 1038f
scabies, 70, 70f, 71, 71f, 714, 815–822, 818f, 821f, 1102
syphilis, 907
systemic lupus erythematosus, 661
tinea, 1102
tinea corporis, 789f
transient neonatal pustular melanosis, 642–644, 643f, 1102
Pustules
acute generalized exanthematous pustulosis, 1219, 1220f

R

Red eye, 163–168, 164t
blepharitis, 165, 167f, 663f
conjunctivitis, 124, 126–129, 126f–129f, 163–168, 164t
corneal ulcerations, 124f, 163–168, 166f
entropion, 165
episcleritis, 131–134, 133f, 163–168, 164t, 166f
glaucoma, 139–142, 140f, 163–168, 164t
globe injury, traumatic, 167f
hyphema, 159–162, 159f, 160f, 167f
hypopyon, 165
iritis, 135–137, 135f–137f, 163–168, 164t, 167f
keratitis, 163–168, 164t, 166f
ocular rosacea, 163–168, 166f
pterygium, 165, 167f
scleritis, 131–134, 131f, 132f, 163–168, 164t, 166f
subconjunctival hemorrhage, 160, 160f, 163–168, 164t, 166f
uveitis, 135–137, 135f–137f, 163–168, 164t, 167f
Reticular
cervical intraepithelial neoplasia III, 535
cutis marmorata, 634f
erythema ab igne, 1198–1201, 1198f–1201f
fifth disease, 728–731, 730f
lichen planus, 233, 756, 901–908, 902f, 904f
livedo reticularis, 1200, 1201f
cholesterol embolism, 1068
lupus, 1073
nevus
benign nevus, 945–951, 1461, 1461f–1463f
congenital nevus, 953–956
pregnancy, areola, 463

S

Scale
acropustolosis, 642–644
actinic keratosis, 969f–971f, 973f, 995, 1311
basal cell carcinoma, 990f
nodular, 989–997
blepharitis, 167f
Bowen disease, 906
Candida, 796, 845, 845f
Darier disease, 1229–1234, 1229f–1232f

Scale (*Continued*)
dermatitis
atopic dermatitis, 826–833, 826f–833f
contact dermatitis, 819f, 834f–839f, 840f
dermatitis, perioral, 661, 664f
seborrheic dermatitis, 820, 871–876, 871f, 872f, 874f, 875f, 1141
stasis dermatitis, 1315
dermatofibroma, 935–938, 937f
dermatomyositis, 1079–1087, 1079f
diabetic dermopathy, 1314–1316, 1314f–1316f
diaper rash, 646–650, 646f, 648f
eczema
areola, 559, 559f
asteatotic, 1233
dyshidrotic, 801, 802f, 831, 839
hand, 843–849, 845, 845f
nummular, 851–854, 853f, 970, 972, 1024
erythema annulare centrifugum, 791, 792f, 1024, 1236–1239, 1236f–1238f
erythrasma, 689–692, 690f
erythroderma, 915–921
folliculitis decalvans, 1138f, 1140
fungal infections, cutaneous, 824
Grover disease, 683, 683f
ichthyosis
acquired, 831f, 1233, 1234f
ichthyosis vulgaris, 1233, 1234f
lamellar, 1233, 1235f
X-linked, 1229–1234, 1232f, 1233f
keratosis, 926–930, 927f
lichen planopilaris, 1139f
lichen planus, scalp, 901–906
lichen simplex chronicus, 856–862, 858f, 859f
lupus
chronic cutaneous lupus erythematosus, 906
discoid lupus erythematosus, 996, 1070–1078, 1074f, 1075f
discoid lupus erythematosus, scarring alopecia, 1140, 1142f
neonatal lupus, 634
mycosis fungoides, 1042–1047, 1042f, 1043f
onychomycosis, 1160–1164, 1160f–1162f
Paget disease of breast, 557–560, 557f, 558f
pemphigus foliaceous, 1109–1117, 1110f–1112f
pigmented seborrheic keratosis, 937
pityriasis rosea, 896–900, 896f–898f, 1024
psoriasis, 791, 792f, 878–894, 878f–880f, 882f, 883f, 885f, 906
plantar, 804f
scalp, 785
reactive arthritis, 910–914, 911f, 912f
scabies, 70, 70f, 71, 71f, 644
seborrhea, 785, 785f
scalp, 785
seborrheic keratosis, 1311
tinea, 771–776, 771f, 774t
tinea capitis, 782–786, 782f, 784f, 1141
tinea corporis, 677, 789f, 852, 1238, 1238f
tinea cruris, 795–798, 795f–797f
tinea manus, 847
tinea pedis, 799–804, 800f
tinea versicolor, 805–808, 806f, 899
transient neonatal pustular melanosis, 642–644
xerosis, 1233

Scar
acne
acne conglobata, 652, 653f
acne keloidalis nuchae, 682f
acne vulgaris, 651–657, 651f
cicatricial bullous pemphigoid, 1106, 1106f
cicatricial pemphigoid, 1114
cocaine abuse, 1431–1437, 1434f
conjunctival, in red eye, 168
corneal, zoster ophthalmicus, 718–722, 718f
dermatofibrosarcoma, 1225
epidermolysis bullosa acquisita, 1098
epidermolysis bullosa simplex, 1103f
erythema induratum of Bazin, 1059
folliculitis, 680–684, 681f, 682f
granuloma gluteale infantum, 648
herpes zoster, skin, 712–716, 712f
hidradenitis suppurativa, 671–674, 672f–675f, 1333f
hypertrophic scarring, 668f, 937
injection-drug use, 1439–1444, 1439f, 1441f–1443f
keloids, 1224–1228, 1224f–1227f
lupus
discoid lupus, 1181
discoid lupus erythematosus, 1070–1078, 1074f–1076f, 1093
systemic lupus erythematosus, 661, 1070–1078, 1072f, 1093
porphyria cutanea tarda, 1100
scarring alopecia, 666, 667f, 785, 1135, 1138–1143, 1138f–1142f
scleroderma, 1089–1095, 1093f
self-inflicted dermatoses, 856–862, 856f, 858f
subretinal, age-related macular degeneration, 156, 157f
vasculitis, 1062–1069
Stone
gallstones, 386–391, 386f, 388f–390f
kidney stones, 425–428, 425f–427f
polycystic kidneys, 437

T

Target lesion
erythema multiforme, 468, 471f, 734, 866, 866f, 1049–1055, 1050f, 1052f, 1053f, 1124, 1282
Stevens–Johnson syndrome, 1049–1055, 1050f
Telangiectasia
ataxia telangiectasia, 1389
basal cell carcinoma, 115
nodular, 933, 933f, 989–997, 994f
Bloom syndrome, 1389
corticosteroids, 1453t
CREST syndrome, 1209
dermatitis, seborrheic, 661
dermatomyositis, 1079–1087, 1082f, 1083f
discoid lupus erythematosus, 1070–1078
erythema ab igne, 1198–1201
hemangioma, childhood, 636–640, 636f–639f
hereditary hemorrhagic telangiectasias, 1207–1210, 1207f
hydrocystoma, 116f
keratoacanthoma, 977–980, 977f–979f, 995
necrobiosis lipoidica, 1303f, 1315, 1317–1320, 1317f–1320f
nevus
benign nevus, 945–951
dermal nevus, 947f, 949, 995, 995f
rosacea, 659–664, 660f–663f
rosacea fulminans, 652

scleroderma, 1089–1095, 1091f, 1092f
sebaceous hyperplasia, 931–934, 931f, 932f, 995, 996f
squamous cell carcinoma, 999–1007, 1005f
tuberous sclerosis, 1388
Tracks, skin
cocaine abuse, 1431–1437, 1433f
cutaneous larva migrans, 823–825, 823f, 824f
heroin, IV, 1439, 1439f
injection-drug use, 1439–1444, 1439f, 1441f, 1442f
Tracts, sinus
acne conglobata, 652, 653f
hidradenitis suppurativa, 671–674, 672f, 675f, 1333f
Trauma
eye, 165, 166f, 167f
corneal, 122–125, 122f–124f
globe injury, 165, 167f
hyphema, 159–162, 159f, 160f, 165, 167f
subconjunctival hemorrhage, 164t, 165, 166f
uveitis and iritis, 135–137, 135f, 165, 167f
without hyphema, 160, 160f
head
normal pressure hydrocephalus, 1380–1382, 1380f, 1381f
subdural hematoma, 1376–1379, 1376f–1378f
intimate partner violence, 95–100, 95f–98f
nail, 1146, 1146f–1148f, 1148t, 1149
Beau lines, 1146, 1147f, 1148f
leukonychia, 1145f, 1146, 1148t
nail hypertrophy, 1145, 1146, 1146f
onychogryphosis, 1145, 1146, 1146f
onychoschizia, 1177, 1177f
pseudo-Hutchinson's sign, 1153, 1154f
subungual hematoma, 1175–1177, 1175f–1177f
physical abuse, child, 82–87, 82f–86f
sexual abuse, child, 89–93, 89f–92f, 89f–93f
Tumor and cancer
actinic keratosis, 969–975, 969f–971f, 973f
adenoid cystic carcinoma, 207, 207f
angiosarcoma, 1203–1206
basal cell carcinoma, nodular, 933, 933f
bladder cancer, 448–452, 448f, 449f, 451t
breast
Bowen disease, 559
breast cancer, 551–556, 551f–555f
Burschke-Lowenstein, 762, 763f
cervical cancer, colposcopy, 541–545, 541f–543f, 544t
cervical intraepithelial neoplasia II/III, 535–539, 535f–538f
colon cancer, 399–403, 399f, 402f, 403f
cutaneous angiosarcoma, 1205f
dermatofibrosarcoma protuberans, 936
endocrine, acromegaly from, 1360–1364, 1360f–1362f
glomus (glomangioma), 1167, 1203–1206, 1205f, 1209
malignant fibrous histiocytoma, 936
melanoma, 1008–1020, 1008f–1018f
acral lentiginous, of foot, 1243–1244
subungual, 1151–1154
superficial spreading, of breast, 559, 559f
mycosis fungoides, 1042–1047, 1043f, 1044f
neurofibroma, 937
neurofibromatosis, 1387–1390, 1387f–1390f
oral cancer, 253–256, 253f–256f
pigmented nail disorders, 1151–1154, 1152f–1154f
prostate cancer, 453–459, 453f–455f, 458f
pseudosarcomatous dermatofibrosarcoma, 936
renal cell carcinoma, 441–446, 441f, 442f, 444t
squamous cell carcinoma, tobacco, 1401, 1402f
syringoma, 933, 933f
thyroid cancer, 1349, 1350f
vascular type, pregnancy, 464, 465f
xanthoma, 933, 1304f, 1322–1327

U

Ulcer
acute necrotizing ulcerative gingivitis, 236–238, 237f
aphthous, 244–248, 244f, 245f
aphthous stomatitis, 733
basal cell carcinoma, 989–997, 992f–995f
Behçet syndrome, 245f, 246, 246f, 739, 739f
cancer, oral, 246
cervical cancer, 541f, 542, 543f
cervical intraepithelial neoplasia II/III, 537, 542
chancroid, 739
Charcot arthropathy, 1261–1264, 1262f, 1263f, 1304f
conjunctival, conjunctivitis, 126–129, 126f–129f
corneal, 124f, 166f
Graves disease and goiter, 1353–1358
diabetic dermopathy, 1302f, 1314–1316, 1314f–1316f
diabetic foot, 1300–1307, 1303f
erythema multiforme, 246
gastric cancer, 371–375, 373f
hand, foot, and mouth disease, 732–734, 733f
herpangina, 246
herpes simplex virus, 246, 521, 735–742, 735f–737f, 740f
impetigo, 676–679, 677f–679f
inflammatory bowel disease, 405–412, 405f, 408f, 409f
ischemic ulcer of foot, 1255–1257, 1255f, 1256f
Kaposi's sarcoma, 1285–1288
leishmaniasis, 67–69, 67f–69f
lichen planus, 901–908
lichen planus, erosive, 246
Marjolin, 1000, 1000f
mycosis fungoides, 1042–1047, 1044f–1047f
necrobiosis lipoidica, 1317–1320, 1318f, 1320f
neuropathic, of foot, 1258–1260, 1258f, 1259f, 1263f
neurotic excoriations, 856f–858f
Paget disease of breast, 557–560, 557f, 558f
pemphigus vulgaris, 1109–1117, 1109f, 1110f, 1113f
peptic ulcer disease, 366–369, 366f, 367f, 374, 389
pyoderma gangrenosum, 1028–1034, 1030f
scabies, 70, 70f, 71
scleroderma, 1089–1095, 1091f
scrofula, 74, 76f
sporotrichosis, 1031, 1032f
squamous cell carcinoma, 999–1007, 1000f–1005f
Stevens–Johnson syndrome, 1215f
syphilis, 739, 907, 1278–1283, 1278f, 1279f, 1282f
vasculitis, 1062–1069, 1064f
cutaneous, 1054
venous insufficiency, 295–298, 297f, 1033, 1033f
vulvar intraepithelial neoplasia, 519–522, 520f
Ulcerdermatitis
chondrodermatitis nodularis, 189–192
contact dermatitis, 801, 802f

Umbilication
dermatofibroma, 1225
molluscum contagiosum, 115, 521, 714, 743–746, 743f–746f, 762, 933
sebaceous hyperplasia, 931–934, 931f, 932f

V

Verrucous
acanthosis nigricans, 1302f, 1310–1312, 1329f, 1332f
condyloma acuminata, 416, 516, 521
leishmaniasis, 67–69, 67f
leukoplakia, 249–252
linear porokeratosis, 961
nevus
benign nevus, 945–951
congenital nevus, 953–956, 953f
epidermal nevus, 958–962, 958f–960f
nevus sebaceous, 958–962, 958f, 960f
pigmented seborrheic keratosis, 937
sebaceous hyperplasia, 931–934, 931f, 934f
seborrheic keratosis, 926–930, 928f, 972, 1016
vulvar intraepithelial neoplasia, 519–522, 519f
wart
common, 749–754, 749f–753f
flat, 755–758, 755f, 756f
genital, 759–765, 759f–763f, 764f
plantar, 766–769, 766f–768f

Vesicle
acropustulosis, 642–644, 642f, 643f
acropustulosis of infancy, 821, 1102
acute febrile neutrophilic dermatosis, 1031
arthropod bite, 1100, 1102f
bullous diseases, 1097
bullous impetigo, 1100
bullous pemphigoid, 1104–1107
chickenpox, 633, 707–710, 707f–711f
dermatitis
allergic contact dermatitis, 677
atopic dermatitis, 826–833, 826f–833f
contact dermatitis, 210, 824, 834–841, 834f–839f, 1100, 1101f
dermatitis herpetiformis, 1098, 1114, 1125–1126, 1126f
papular acrodermatitis of childhood, 1124, 1125f
perioral, 661, 664f
phytophotodermatitis, 824
diaper rash, 646–650
eczema
dyshidrotic, 801, 802f, 831
hand, 843–849, 845f
nummular, 851–854, 851f–853f, 888
epidermolysis bullosa, 1121–1123, 1123f
epidermolysis bullosa simplex, 1102
erythema multiforme, 866, 1049–1055, 1052f
erythema toxicum neonatorum, 630–634, 632f, 644
Gianotti–Crosti syndrome, 1124, 1125f
Hailey-Hailey disease, 1114, 1115f, 1230, 1233f
hand, foot, and mouth disease, 644, 732–734, 732f
herpangina/coxsackievirus infection, 216, 216f
herpes
herpes simplex virus, 521, 644, 709, 715, 735–742, 735f–737f, 1280
herpes simplex virus, congenital, 1100
herpes zoster, skin, 712–716, 712f–715f
herpetic whitlow, 1167
impetigo, 644, 676–679, 676f, 677f
infantile acropustulosis, 821, 821f
insect bites, 714
lichen planus, 901–908
linear IgA dermatosis, 1114
miliaria, 684, 1100
necrotizing fasciitis, 702–706
neonatal pustular melanosis, 633
Paget disease of breast, 557–560
pemphigoid gestationis, 471–474
pemphigus, 1109–1117
pharyngitis, 213–218
photosensitivity, 1191–1196, 1191f–1193f
pityriasis lichenoides et varioliformis acuta, 1100, 1100f, 1123–1124, 1124f
pompholyx, hand, 843–849, 845f
porphyria cutanea tarda, 1119–1121, 1120f
pyoderma granuloma, 1028–1034
scabies, 644, 811
syphilis, neonatal, 1100
tinea corporis, 852
tinea pedis, 799–804, 799f, 801f
transient neonatal pustular melanosis, 1100
zoster ophthalmicus, 718–722, 718f–720f

W

Wheal
erythema toxicum neonatorum, 210, 630–634, 632f
pruritic urticarial papules and plaques of pregnancy, 867f
urticaria, 863–869, 863f–868f, 1054

Note: In this index, the letters "f" and "t" denote figures and tables, respectively.

A

Abdomen
- ashleaf spots, 1187, 1187f
- atopic eruption of pregnancy, 463, 464, 464f
- bullous pemphigoid, 1104–1107, 1104f, 1107f
- colon cancer, 399–403, 399f, 402f, 403f
- contact dermatitis, 834–841, 835f–837f
- cutaneous larva migrans, 823–825
- Darier disease, 1229–1234, 1232f
- diaper rash, 646–650
- drug reactions, cutaneous, 1211–1222, 1211f, 1212f
- eczema, nummular, 851–854, 853f
- epidermolysis bullosa, 1121–1123, 1123f
- fetus, third trimester ultrasound, 482–484, 482f
- gallstones, 386–391, 386f, 388f–390f
- gastric cancer, 371–375, 371f, 373f
- hirsutism, pregnancy, 464
- hydronephrosis, 430–434, 430f, 432f
- impetigo, 676–679, 678f
- keloids, 1224–1228, 1225f
- kidney stones, 425–428, 425f–427f
- lice, 809–814, 809f
- linea nigra, pregnancy, 463, 463f
- liver disease, 377–384, 377f, 380f–382f, 381f
- molluscum contagiosum, 743–746, 744f
- morphea, 1089–1095, 1089f
- necrotizing fasciitis, 702–706, 703f
- pemphigoid gestationis, 471–474, 471f–473f
- peptic ulcer disease, 366–369, 366f, 367f
- physical abuse, child, 82–87
- pityriasis rosea, 896–900, 896f, 897f, 899f
- polycystic kidney disease, 436–439, 436f, 437f
- pruritic urticarial papules and plaques of pregnancy, 467–470, 467f, 468f
- psoriasis, 878–894, 883f, 884f, 886f, 1331f
  - inverse, 2, 3f
- renal cell carcinoma, 441–446, 441f, 442f, 444t
- scabies, 815–822, 819f, 821f
- scleroderma, 1089–1095
- scrofula, tuberculosis with HIV, 74, 76f
- seborrheic keratosis, 926–930
- skin tag, 922–924
- stretch marks, pregnancy, 462, 463, 464f, 465
- syphilis, 1278–1283, 1278f
- tinea, 771–776, 772f
- tinea corporis, 772f, 1238, 1238f
- tinea cruris, 795–798, 796f
- tinea versicolor, 805–808, 807f
- transient neonatal pustular melanosis, 642–644, 1102
- vasculitis, 1054, 1062–1069, 1065f

Ankles. *See also* Lower extremities
- arthritis
  - gonococcal, 562–568
  - rheumatoid, 575–579
- calcium pyrophosphate dihydrate disease, 565
- dermatitis
  - atopic dermatitis, 826–833, 829f
  - contact dermatitis, 834–841, 834f
- dermatosis papulosa nigra, 927
- fifth disease (erythema infectiosum), 728–731
- gout, 563, 590–594
- lichen planus, 901–908, 901f
- lichen simplex chronicus, 856–862, 858f
- Lyme disease, 1289–1296
- neurotic excoriations, 856–862, 856f
- scabies, 815–822, 817f–819f, 821f
- stucco keratosis, 927, 929f

Anus and perianal region
- bleeding, 92
- cellulitis, 693–697, 695f
- colon cancer, 399–403, 399f, 402f, 403f
- *Enterobius vermicularis,* 1270–1274, 1270f
- erythrasma, 689–692, 689f–691f, 796, 797f
- fissure, 92
- hemangioma, childhood, 636–640, 639f
- hemorrhoids and fissures, 414–418, 414f–416f
- irritation, 92
- laceration, 91, 91f, 92
- lichen sclerosus et atrophicus, 92, 92f, 491, 491f, 522f
- Paget disease of external genitalia, 514–517, 515f
- pinworms, 1270–1274, 1270f
- sexual abuse, child, 89–93, 91, 91f, 92
- sexual assault, adult, 102–107
- squamous cell carcinoma, 999–1007, 1004f
- *Trichuris trichiura,* 1270–1274, 1272f
- vitiligo, 1184–1190
- vulvar intraepithelial neoplasia, 519–522
- wart, genital, 759–765, 761f

Appendix
- *Ascaris lumbricoides,* 1270–1274, 1271f
- roundworms, 1270–1274, 1271f

Arms. *See* Upper extremities

Axilla
- acanthosis nigricans, 1310–1312, 1310f, 1311f, 1313f, 1332f
- bullous pemphigoid, 1098
- Darier disease, 1229–1234, 1232f
- dermatitis
  - contact dermatitis, 834–841, 836f
  - seborrheic dermatitis, 871–876
- erythema annulare centrifugum, 791, 792f, 1236–1239, 1237f
- erythrasma, 689–692, 689f–691f, 796, 797f
- folliculitis, 680–684, 682f
- Hailey-Hailey disease, 1114, 1115f
- hidradenitis suppurativa, 671–674, 671f, 672f, 675f, 1331, 1333f
- lice, 809–814
- MRSA folliculitis, 680–684, 682f
- neurofibromatosis, 1387–1390, 1387f, 1388f
- Pastia's lines, 208f, 209
- pemphigus, benign familial, 1115f
- physical abuse, child, 82, 83f
- pityriasis lichenoides chronica, 1124, 1125f
- psoriasis, 878–894, 881f
  - inverse, 878–894, 878f
- scabies, 815–822, 818f
- scarlet fever, 208–212, 208f, 213
- skin tag, 922–924
  - pregnancy, 463
- staphylococcal scalded skin syndrome, 210, 1054
- tinea, 771–776, 771f
- tinea corporis, 771f, 788–793, 790f
- tinea incognito, 788–793, 790f

B
Back
acne
acne fulminans, 651–657, 654f
acne vulgaris, 651–657
acute generalized exanthematous pustulosis, 1219, 1220f
angioedema, 863–869, 867f
ankylosing spondylitis, 563, 580–583, 580f
back pain, 585–588, 585f–587f
basal cell carcinoma, 989–997, 990f
bullous pemphigoid, 1098, 1099f, 1104–1107, 1108f
chickenpox, 707–710, 707f, 710f
cutaneous horn, 985–986, 987f
Darier disease, 1229–1234, 1229f, 1232f
dermatitis herpetiformis, 1125–1126
dermatofibroma, 935–938, 937f
ecchymoses, coining, 85, 87f
erythema ab igne, 1198–1201, 1199f
erythroderma, 915–921, 921f
folliculitis, 680–684, 680f–682f
Grover disease, 683, 683f
Hailey-Hailey disease, 1233, 1233f
hemangioma, childhood, 636–640
herniated disc, 587, 587f
herpes zoster, 712–716, 712f, 714f
hirsutism, pregnancy, 464
impetigo, 71, 71f, 676–679
injection-drug abuse, 1439–1444, 1441f
keloids, 1224–1228, 1225f
lice, 809–814
lichen planus, 901–908, 902f, 903f
linear IgA bullous dermatosis, 1098, 1100f
Lyme disease, 1289–1296, 1289f
measles, 723–726, 723f
melanoma, 1008–1020, 1009f, 1010f, 1016f
molluscum contagiosum, 743–746, 746f
Mongolian spots, 630–634, 631f
neurofibromatosis, 1387–1390, 1387f–1389f
neurotic excoriations, 856–862
nevus
Becker nevus, 948, 948f, 956
benign nevi, 945–951, 945f
compound nevus, benign, 946, 946f
dysplastic nevus, 963–967, 966f, 967f
halo nevi, 945f, 946
nevus anemicus, 1187, 1188f
osteoarthritis, 569–573, 571f
osteoporosis and osteopenia, 1338–1344, 1338f–1341f, 1340t
pemphigus foliaceous, 1109–1117, 1111f, 1112f
pemphigus vulgaris, 1109–1117, 1109f
physical abuse, child, 82–87, 86f, 87f
pityriasis lichenoides et varioliformis acuta, 1100, 1100f, 1123–1124, 1124f
pityriasis rosea, 896–900, 896f, 898f
Pityrosporum folliculitis, 806, 807f
poikiloderma atrophicans vasculare, 1200
Pott disease, tuberculosis, 310–318
prurigo nodularis, 856–862, 860f
psoriasis, 878–894, 879f, 881f, 883f
sarcoidosis, 1035–1040, 1037f, 1039f
seborrheic keratosis, 926–930, 927f
self-inflicted dermatoses, 856–862, 859f, 860f
skin tag, 922–924
Stevens-Johnson syndrome, 1049–1055, 1050f, 1211–1222
stretch marks, pregnancy, 462, 463, 464f, 465
tinea corporis, 788–793, 790f, 791f
tinea versicolor, 805–808, 806f
transient neonatal pustular melanosis, 1102
vertebral fracture, osteoporotic, 586, 586f
xanthoma, 1322–1327, 1323f, 1332f
Bladder
bladder cancer, 448–452, 448f, 449f, 451t
hydronephrosis, 430–434, 430f, 432f
kidney stones, 425–428, 425f–427f
Paget disease of external genitalia, 514–517
urinary sediment, 420–423, 420f–423f
Blood vessels
cerebral vascular accident, 1371–1375, 1371f–1373f
coronary artery disease, 268–270, 268f, 269f
dermoscopy of, 1471, 1471f
headache, 1366–1370, 1366f–1368f
leukocytoclastic vasculitis, lupus, 1072, 1073f
migraine headache, 200
telangiectasia
hereditary hemorrhagic telangiectasias, 1207–1210, 1207f
spider telangiectasias, pregnancy, 462–463, 465
temporal arteritis, 200
vascular ectasia, scleroderma, 1090
vascular lesions
acquired, 1203–1206, 1203f–1205f
hereditary and congenital, 1207–1210, 1207f–1209f
vasculitis, 1062–1069, 1062f–1064f
cutaneous, 1054
urticarial, 866, 867f, 868f
venous distension, pregnancy, 464
venous insufficiency, 295–298, 295f–297f, 1331, 1331f
venous lakes, 1203–1206, 1203f
venous pulsations, spontaneous, 151, 152
venous stasis, 296, 297f, 694, 694f, 1032, 1033f
Bones
injection-drug abuse, 1439–1444, 1442f, 1443f
lung cancer metastases, 355–363
osteoporosis and osteopenia, 1338–1344, 1338f–1342f, 1340t
Brain
bacterial endocarditis, 287–291
bladder cancer metastases, 448–452
cerebral vascular accident, 1371–1375, 1371f–1373f
Entamoeba histolytica, 1270–1274
fetus, second trimester ultrasound, 479f, 481f
lung cancer metastases, 355–363
methamphetamine, 1424–1429
normal pressure hydrocephalus, 1380–1382, 1380f, 1381f
renal cell carcinoma metastases, 441–446
subdural hematoma, 1376–1379, 1376f–1378f
substance abuse disorder, 1392–1397
Taenia solium, 1270–1274
traumatic brain injury, intimate partner violence, 97
Breasts
abscess, 546–549, 546f, 548f, 698–700
acanthosis nigricans, 1310–1312
areola
benign lichenoid keratosis, 559, 560f
eczema, 559, 559f
breastfeeding, 21, 22f

bullous pemphigoid, 1104–1107, 1104f
cancer, 551–556, 551f–555f
candidiasis, 777–780, 778f, 779f
contact dermatitis, 778f, 834–841, 836f
erythrasma, 689–692, 689f–691f, 796, 797f
gynecomastia, liver disease, 380, 381f
hidradenitis suppurativa, 671–674, 673f, 675f
hyperpigmentation, pregnancy, 463
keloids, 1224–1228, 1224f
mastitis, 546–549, 546f, 547f
melanoma, 1008–1020, 1010f, 1011f
superficial spreading, 559, 559f
Montgomery tubercles, 463, 463f
mycosis fungoides, 1042–1047, 1045f
nevus
benign nevi, 945–951
dysplastic nevus, 963–967
Paget disease of breast, 557–560, 557f, 558f
Paget disease of external genitalia, 514–517
pemphigus foliaceous, 1109–1117, 1111f
pemphigus vulgaris, 1098, 1098f, 1099f
pregnancy, 19
psoriasis, 878–894, 1331f
erythrodermic, 915–921, 917f
inverse, 2, 2f, 3f, 778, 780f, 878–894, 878f
scabies, 70, 71, 71f
sebaceous hyperplasia, 931–934
seborrheic keratosis, 926–930, 929f
sexual violence, 102
skin tag, pregnancy, 463
stretch marks, pregnancy, 462, 463, 464f, 465
tinea, 780f
tinea cruris, 795–798
tinea versicolor, 805–808, 807f
warfarin-induced skin necrosis, 1211–1222
Buttocks
abscess, 698–700
acute generalized exanthematous pustulosis, 1219, 1220f
cutaneous larva migrans, 823–825, 823f
dermatitis
acrodermatitis enteropathica, 62–63, 63f, 648, 648f
dermatitis herpetiformis, 1098
diaper dermatitis, 646–650, 646f–648f
dermatofibroma, 935–938, 936f
erythema annulare centrifugum, 1236–1239, 1237f, 1238f
erythrasma, 689–692, 689f–691f, 796, 797f
erythroderma, 915–921
folliculitis, 680–684
hand, foot, and mouth disease, 732–734
herpes simplex, 735–742, 736f, 738f
hidradenitis suppurativa, 671–674, 673f, 674f
impetigo, 71, 72f, 676–679
injection-drug use, 1439–1444, 1440f
lichen planus, 901–908, 903f
molluscum contagiosum, 743–746
Mongolian spots, 630–634, 631f
necrotizing fasciitis, 702–706, 704f
nevus
benign nevi, 945–951
cellular blue nevus, 946
dysplastic nevus, 963–967
pemphigus vegetans, 1109–1117, 1111f
physical abuse, child, 82, 82f, 84, 86f
pityriasis rosea, 896–900, 896f
poikiloderma atrophicans vasculare, 1200
psoriasis, 878–894, 881f, 883f
erythrodermic, 915–921, 916f
sarcoidosis, 1035–1040, 1037f
stretch marks, pregnancy, 462, 463, 464f, 465
systemic drug-related intertriginous and flexural exanthema, 1219, 1220f
transient neonatal pustular melanosis, 1102
vasculitis, 1062–1069
cutaneous, 1054
warfarin-induced skin necrosis, 1211–1222
xanthoma, 1322–1327, 1323f, 1332f

C

Cervix
atrophic vaginitis, 489–492, 489f
bacterial vaginosis, 494–497, 496f
Candida vulvovaginitis, 499–503, 499f
cervical cancer, 541–545, 541f–543f, 544t
cervical intraepithelial neoplasia I, 530–533, 530f–532f
cervical intraepithelial neoplasia III, 535–539, 535f–538f
Chlamydia cervicitis, 509–512, 509f
colposcopy
cervical cancer, 541–545, 541f–543f, 544t
high-grade lesions, 535–539, 535f–538f
low-grade lesions, 530–533, 530f–532f
normal and noncancerous findings, 525–528, 525f–528f
condyloma, 530, 531f
herpes simplex, 735–742
leukoplakia, colposcopy, 536, 536f
pregnancy and birth, 17–23
second trimester imaging, 478–481, 480, 481f
strawberry, 504–507, 504f–506f, 527, 527f
third trimester ultrasound, 482–484, 484f
Trichomonas vaginitis, 504–507, 504f–506f
vaginitis, 485–487, 485f–487f, 487t
Chest
acne
acne fulminans, 651–657, 654f
acne vulgaris, 651–657
asthma, 324
atopic triad with asthma, 323, 324f
bullous pemphigoid, 1104–1107, 1107f
candidiasis, 780f
chickenpox, 707–710, 707f, 708f, 710f
chronic obstructive pulmonary disease, 334–343, 334f, 335t, 337f–340f, 341t
Darier disease, 1229–1234, 1229f
dermatitis herpetiformis, 1125–1126, 1126f
dermatomyositis, 1079–1087, 1079f, 1081f, 1085f, 1086f
discoid lupus erythematosus, 1076f
erythroderma, 915–921, 919f–921f
folliculitis, 680–684, 683f
hemangioma, childhood, 636–640
herpes zoster, 712–716, 714f, 715f
histoplasmosis, 314, 317f
hypomelanosis of Ito, 1187, 1188f
ichthyosis, X-linked, 1229–1234, 1232f
intimate partner violence, 95–100
Kaposi sarcoma, 1285–1288, 1287f
keloids, 1224–1228, 1224f, 1226f
keratoacanthomas, 977–980, 979f

Chest (*Continued*)
leprosy, 72–74, 74f
lice, 809–814
lung cancer, 355–363, 355f, 356f, 358f–360f
measles, 723–726, 723f–725f
miliaria, 633f
neurofibromatosis, 1387–1390, 1388f
nevus
dysplastic nevus, 963–967, 965f
epidermal nevus, 958–962, 959f, 960f
nevus comedonicus, 948, 950f
nevus depigmentosus, 1187, 1188f
papular pruritic eruption, 75f
pemphigus foliaceous, 1109–1117, 1111f
photosensitivity, 1191–1196, 1192f, 1193f
physical abuse, child, 82–87, 82f, 84f
pityriasis lichenoides chronica, 1124, 1125f
pityriasis lichenoides et varioliformis acuta, 1123–1124, 1124f
pityriasis rosea, 896–900, 897f–899f
Pityrosporum folliculitis, 681, 683f
poikiloderma atrophicans vasculare, 1200
pulmonary embolus, 345–352, 345f, 347f, 349f–350f
pyoderma gangrenosum, 1028–1034, 1032f
scarlet fever, 208–212
scleroderma, 1089–1095
sebaceous hyperplasia, 931–934
skin tag, pregnancy, 463
spider telangiectasias, pregnancy, 462–463, 465
Stevens-Johnson syndrome, 1049–1055, 1049f, 1051f, 1211–1222
syphilis, secondary, 1278–1283, 1436f
tinea, 771–776, 773f
tinea corporis, 788–793, 790f
tinea versicolor, 773f, 805–808, 805f–807f
transient neonatal pustular melanosis, 642–644, 1102
Colon
colon cancer, 399–403, 399f, 402f, 403f
colon polyp, 393–397, 393f, 395f, 396f
gastric cancer, 371–375
inflammatory bowel disease, 405–412, 405f, 408f, 409f
ischemic colitis, 409, 410f
pyoderma gangrenosa Crohn disease, 1028, 1028f
Trichuris trichiura, 1270–1274, 1272f

E

Ears. *See also* Tympanic membrane
actinic keratosis, 969–975
acute otitis media, 170–178, 170f, 172f, 177f, 178f
basal cell carcinoma, 989–997
Bowen disease, 969–975
bullous myringitis, 173, 175f
cholesteatoma, 173, 174f
cocaine, 1431–1437, 1434f
cutaneous horn, 985–986, 985f
Darier disease, 1229–1234, 1232f
dermatitis
chondrodermatitis nodularis helicis, 189–191, 189f, 190f, 192f
seborrheic dermatitis, 871–876, 874f
dermatosis papulosa nigra, 927, 928f, 929f
discoid lupus erythematosus, 1070–1078, 1074f, 1075f
foreign bodies, 185–187, 185f, 186f
gouty tophi, 1324, 1324f
herpes zoster oticus, 712–716, 714f
keloids, 1224–1228, 1224f, 1227f
keratoacanthomas, 977–980, 979f
lupus pernio, 1035–1040
mastoiditis, 173, 176f
melanoma, 1008–1020, 1011f
lentigo maligna, 981–984, 982f
nevus sebaceous, 958–962, 960f
otitis externa, 180–184, 180f–183f
otitis media with effusion, 170–178, 170f, 171f
pemphigus vulgaris, 1109–1117, 1110f
physical abuse, child, 85, 85f
porphyria cutanea tarda, 1100
preauricular tag, 189–191, 191f
psoriasis, 878–894, 885f
squamous cell carcinoma, 999–1007, 1003f
suppurative ear disease, 1384
transient neonatal pustular melanosis, 1102
tympanosclerosis, 176, 178f
vasculitis, 1062–1069, 1065f
venous lakes, 1203–1206
Elbows. *See also* Upper extremities
calcium pyrophosphate dihydrate disease, 565
CREST syndrome, 1089–1095, 1092f
dermatitis, atopic, 826–833, 828f, 829f
gout, 590–594, 592f
granuloma annulare, 1022–1027, 1023f
Lyme disease, 1289–1296
olecranon bursitis, 596–599, 596f–598f
rheumatoid arthritis, 562–568, 564f, 575–579
sarcoidosis, 1035–1040, 1038f
xanthoma, 1322–1327, 1322f, 1323f
Esophagus
CREST syndrome, 1209
oropharyngeal cancer, 253–256
Stevens-Johnson syndrome, 1049–1055
toxic epidermal necrolysis, 1049–1055
varices, liver disease, 377, 377f
Extremities. *See also* Lower extremities; Upper extremities; *specific locations*
abscess, 698–700, 699f, 700f
acanthosis nigricans, 1310–1312, 1312f, 1313f
bullous pemphigoid, 1104–1107, 1104f, 1105f, 1107f
cellulitis, 693–697, 693f–695f
chickenpox, 707–710, 707f–711f
cutis marmorata, 634, 634f
dermatitis herpetiformis, 1125–1126, 1126f
dermatomyositis, 1079–1087, 1079f, 1080f, 1082f, 1083f, 1085f, 1086f
epidermal inclusion cyst, 699, 700f
epidermal nevus, 958–962
erythema annulare centrifugum, 1054, 1236–1239, 1236f, 1237f
erythema multiforme, 1049–1055, 1050f, 1052f, 1053f
erythema nodosum, 1056–1060, 1056f–1060f
erythema toxicum neonatorum, 630–634
fifth disease (erythema infectiosum), 728–731, 728f, 730f
folliculitis, 680–684
friction blisters, 1100
Gianotti-Crosti syndrome, 1124, 1125f
granuloma annulare, 1022–1027, 1022f–1026f
herpes zoster, 712–716, 713f, 714f
Kawasaki disease, 210, 1054
lichen striatus, 961, 961f
linear lichen planus, 961, 961f
lupus pernio, 1035–1040

Marjolin ulcer, 1000
measles, 723–726
Mongolian spots, 630–634
mycosis fungoides, 1042–1047
pityriasis lichenoides chronica, 1124, 1125f
pityriasis lichenoides et varioliformis acuta, 1123–1124, 1124f
pityriasis rosea, 867f, 896–900, 899f
Pityrosporum folliculitis, 681, 683f
pruritic urticarial papules and plaques of pregnancy, 467–470, 468f, 469f
psoriasis, 878–894, 878f, 880f–890f
sarcoidosis, 1035–1040, 1037f–1039f
scarlet fever, 208–212, 209f
scleroderma, 1089–1095, 1090f–1093f, 1095f
self-inflicted dermatoses, 856–862, 856f–860f
squamous cell carcinoma, 999–1007, 1003f, 1004f
Stevens-Johnson syndrome, 1049–1055, 1051f
syphilis, 1278–1283, 1282f
toxic epidermal necrolysis, 1049–1055, 1053f
urticaria, 863–869, 863f, 865f, 867f
vasculitis, cutaneous, 1054

Eyelids and eyebrows
actinic keratosis, 970f
Bell palsy, 1383–1386, 1383f
blepharitis, 163, 165, 166f, 167f
chalazion, 114–117, 115f
cherry angioma, 1203–1206, 1203f
corneal foreign body, 122–125, 122f–124f
dermatitis
atopic dermatitis, 826–833, 828f–830f, 832f, 833f
seborrheic dermatitis, 871–876, 871f, 873f, 874f
dermatosis papulosa nigra, 927, 928f
ecchymosis, 160, 160f
entropion, 163, 165
Goldenhar syndrome, 189
Graves disease and goiter, 1353–1358, 1353f, 1356f
hemangioma, childhood, 636–640, 637f–639f
hordeolum, 114–117, 115f
lichen planus, 901–908
lupus pernio, 1035–1040, 1037f
milia, 933, 933f
molluscum contagiosum, 743–746, 745f
nevus
angel's kiss (nevus flammeus), 638, 638f
nevus flammeus, 1207–1210, 1208f
red eye, 163–168, 163f, 164t, 165f–167f, 165f–167rf
rosacea, 659–664, 659f, 663f
sarcoidosis, 1035–1040, 1040f
skin tag, 922–924, 922f, 924f
syringoma, 933f
third nerve palsy, isolated, 1384–1385, 1384f
tinea, 771–776, 771f
toxic epidermal necrolysis, 1049–1055, 1053f
trachoma, 69–70, 69f, 70f
xanthelasma, 1323, 1324f
zoster ophthalmicus, 718–722, 718f–720f

Eyes and periorbital region
age-related macular degeneration, 155–158, 155f–157f
angioedema, 863–869, 864f, 865f
atopic triad with asthma, 323, 324f
bacterial endocarditis, 287–291, 287f, 288f
basal cell carcinoma, 989–997, 990f, 991f, 994f
Bell palsy, 1383–1386, 1383f
blepharitis, 163, 165, 166f, 167f
cellulitis, 693–697, 695f
cestodes, 1270–1274
chalazion, 114–117, 115f
cicatricial bullous pemphigoid, 1104–1107, 1106f
cocaine, 1431–1437, 1431f
conjunctivitis, 126–129, 126f–129f, 163–168, 163f, 164t, 165f
conjunctivitis, reactive arthritis, 910–914, 912f
corneal foreign body and abrasions, 122–125, 122f–124f
corneal ulcerations, 124, 124f, 165, 166f
dermatitis, atopic, 826–833, 828f–830f, 832f, 833f
dermatomyositis, 1079–1087, 1085f, 1086f
drug reactions, cutaneous, 1211–1222
entropion, 163, 165
episcleritis, 131–134, 133f, 163–168, 164t, 166f
glaucoma, 139–142, 139f, 140f, 163, 164t, 165
globe injury, 167f
Goldenhar syndrome, 189
Graves disease and goiter, 1353–1358, 1353f, 1356f
hordeolum, 7f, 114–117, 114f, 115f
hyphema (eye trauma), 159–162, 159f, 160f, 165, 167f
hypopyon, 136, 136f, 165, 167f
intimate partner violence, 95–100, 95f, 98f
Kawasaki disease, 210, 210f, 1054
Kayser-Fleischer rings, liver disease, 380, 382f
keratitis, 163–168, 164t, 166f
Lisch nodules, 1387–1390, 1389f, 1390f
liver disease, 377, 382f
melanoma, 118–121, 119f, 120f
conjunctival, 118–121, 119f, 120f
melanosis, 118–121, 119f
molluscum contagiosum, 743–746, 744f, 745f
myxedema, goitrous hypothyroidism, 1346–1352, 1349f
neurofibromatosis, 1387–1390, 1390f
nevus
conjunctival, 118–121, 118f
epidermal nevus, 958–962
nevus flammeus, 1207–1210, 1208f
nevus of Ota, 120, 121f, 946, 948f
scleral, 118–121, 118f
papilledema, 139–142, 151–154, 151f, 152f
physical abuse, child, 82–87, 83f, 84f, 86f
pigmentation, 118–121, 118f–121f
conjunctival, 118–121, 118f–120f
scleral, 118–121, 118f, 119f, 121f
pseudoxanthoma elasticum, 1323
pterygium, 110–112, 110f–112f, 165, 167f
red eye, 163–168, 163f, 164t, 165f–167f
retinopathy
diabetic, 143–145, 143f–145f, 1300, 1300f
hypertensive, 147–150, 147f, 148f, 274, 274f
rosacea, 164t, 165, 166f, 659–664, 659f
Roth spots, 287–291, 287f, 288f
sarcoidosis, 1035–1040, 1040f
scleral and conjunctival pigmentation, 118–121, 118f–121f
scleral icterus, liver disease, 377, 377f
scleritis, 131–134, 131f, 132f, 163–168, 164t, 166f
Stevens-Johnson syndrome, 1049–1055, 1049f, 1051f
subconjunctival hemorrhage, 160, 160f, 163, 164t, 165, 166f
Taenia solium, 1270–1274
third nerve palsy, isolated, 1384–1385, 1384f
trachoma, 69–70, 69f, 70f

Eyes and periorbital region (*Continued*)
uveitis and iritis, 135–137, 135f–137f, 163–168, 164t, 167f
vitiligo, 1184–1190, 1186f
xanthelasma, 1323, 1324f
xerophthalmia, 61–62, 62f
zoster ophthalmicus, 718–722, 718f–720f

F

Face. *See also* Lips; Nose
abscess, 698–700, 698f
acne
acne conglobata, 651–657, 653f
acne fulminans, 651–657, 654f
acne keloidalis nuchae, 665–669
acne vulgaris, 651–657, 651f–656f
neonatal acne, 630–634, 630f, 651–657, 652f
acneiform eruption, steroid-induced, 661, 664f
acromegaly, 1360–1364, 1363f
acropustulosis, 642–644
actinic keratosis, 969–975, 970f, 973f
angioedema, 863–869, 864f, 865f, 868f
angiofibroma, 1388, 1390f
angiosarcoma, 1203–1206, 1205f
atopic triad with asthma, 323, 324f
basal cell carcinoma, 989–997, 989f–997f
nodular, 933, 933f
Bell palsy, 1383–1386, 1383f
Bowen disease, 969–975
bullous impetigo, 1100, 1102f
bullous pemphigoid, 1104f
acral, 1105
cellulitis, 693–697, 695f
cerebral vascular accident, 1371–1375
chickenpox, 707–710, 707f–709f
CREST syndrome, 1089–1095, 1093f
cutaneous horn, 985–986, 985f, 987f
Darier disease, 1229–1234, 1229f–1232f
dermatitis
acrodermatitis enteropathica, 62–63, 63f
atopic dermatitis, 679f, 826–833, 826f–830f, 832f, 833f
atopic dermatitis, asthma, 324, 324f, 325f
dermatitis, 661, 664f
seborrheic dermatitis, 871–876, 871f–875f
dermatomyositis, 1079–1087, 1079f–1081f, 1086f
dermatosis papulosa nigra, 927, 928f
DRESS syndrome, 1211–1222, 1219f
drug reactions, cutaneous, 1211–1222, 1211f–1213f
eczema, nummular, 851–854, 852f
epidermal inclusion cyst, 937
erysipelas, 693–697, 695f
erythema annulare centrifugum, 1054, 1236–1239
erythema toxicum neonatorum, 630–634, 632f
erythroderma, 915–921, 919f
facial nerve damage
microvascular, 1384
traumatic, 1384
fetus, second trimester ultrasound, 479f, 480, 480f
fifth disease (erythema infectiosum), 728–731, 728f, 729f
folliculitis, 680–684
Gianotti-Crosti syndrome, 1124
hemangioma
cherry, 943, 943f
childhood, 636–640, 636f–639f
herpes zoster, 712–716, 713f
hirsutism, pregnancy, 464
hypertension, 272–276, 272f–274f
ichthyosis, lamellar, 1233, 1235f
impetigo, 676–679, 676f–679f, 1102f
intimate partner violence, 95–100, 95f, 98f
Kaposi sarcoma, 1285–1288
keratoacanthomas, 977–980, 977f, 979f
kwashiorkor, 60–61, 60f, 61f
leishmaniasis, 66–68, 66f, 68f
leprosy, 72–74, 73f
lichen planus, 901–908, 904f
lupus
discoid lupus erythematosus, 1070–1078, 1074f–1076f, 1075f
lupus pernio, 1035–1040, 1035f, 1036f, 1037f
neonatal lupus, 634, 634f
systemic lupus erythematosus, 661, 1070–1078, 1072f
Lyme disease, 1289–1296, 1384
Marjolin ulcer, 1000, 1000f
measles, 723–726, 723f–725f
melanoma, 1008–1020, 1011f
lentigo maligna, 981–984, 981f, 982f, 1011f
in situ, 930f
melasma, 1179–1182, 1179f–1181f
Merkel cell carcinoma, 1005, 1005f
methamphetamine, 1424–1429, 1427f
milia, 933, 933f
newborn, 630–634, 630f
miliaria, 1100
molluscum contagiosum, 743–746, 743f–746f
morphea, 1089f, 1090f
mycosis fungoides, 1042–1047, 1045f–1047f
myxedema, goitrous hypothyroidism, 1346–1352, 1349f
nevus
benign nevi, 945–951, 947f, 948f
blue nevus, 946, 947f
dermal nevus, 946, 946f, 947f
epidermal nevus, 958–962, 958f
intradermal nevus, 989f, 995, 995f
nevus depigmentosus, 948, 949f
nevus flammeus, 1207–1210, 1208f
nevus of Ota, 946, 948f
nevus sebaceous, 958–962
Spitz nevus, 946, 947f
papular pruritic eruption, 75f
paraneoplastic pemphigus, 1109–1117, 1113f
pemphigoid gestationis, 471–474
pemphigus erythematosus, 1109–1117, 1114f
pemphigus foliaceous, 1109–1117, 1110f, 1111f, 1115f
pemphigus vulgaris, 1109–1117, 1109f, 1110f, 1112f
photosensitivity, 1191–1196, 1192f, 1193f
physical abuse, child, 82–87, 83f–86f
pityriasis alba, 827, 830f
pityriasis alba, asthma, 323, 325f
porphyria cutanea tarda, 1100, 1119–1121
pruritic urticarial papules and plaques of pregnancy, 467–470
pseudofolliculitis, 665–669, 665f–667f
psoriasis, 878–894, 880f, 885f
pyoderma faciale, 652, 655f, 656, 661, 664f
pyoderma gangrenosum, 1028–1034, 1032f

pyogenic granuloma, 940–944, 940f, 941f
rosacea, 659–664, 659f–663f
rosacea fulminans, 652, 655f, 656, 661, 664f
sarcoidosis, 1035–1040, 1035f, 1040f
scarlet fever, 208–212, 209f
scleroderma, 1089–1095, 1091f, 1093f
sebaceous hyperplasia, 931–934, 931f, 932f, 934f, 995, 996f
seborrheic keratosis, 926–930, 928f–929f, 1311
skin tag, pregnancy, 463
smoker's, 1398, 1398f, 1399, 1400f
solar lentigo, 983f, 1016
space-occupying lesion, 1384
spider angioma, liver disease, 380, 380f
spider telangiectasias, pregnancy, 462–463, 465
squamous cell carcinoma, 999–1007
staphylococcal scalded skin syndrome, 1054
Stevens-Johnson syndrome, 1049–1055, 1049f, 1051f, 1211–1222, 1215f
subdural hematoma, 1376–1379, 1376f–1378f
systemic sclerosis, 1089–1095
third nerve palsy, isolated, 1384–1385, 1384f
tinea, 771–776, 771f
tinea corporis, 788–793
tinea faciei, 771f, 788–793, 789f
tinea versicolor, 805–808
toxic epidermal necrolysis, 1049–1055, 1053f
transient neonatal pustular melanosis, 642–644, 1102
vasculitis, 1062–1069, 1065f
venous insufficiency, 295–298, 295f–297f
venous lakes, 1203–1206, 1203f
vitiligo, 1184–1190, 1186f
wart, flat, 755–758, 755f, 756f
xanthoma, 1322–1327
zoster ophthalmicus, 718–722, 718f–720f
Feet. *See also* Lower extremities
abscess, 698–700
acromegaly, 1360–1364
acropustulosis, 642–644, 642f
arsenic toxicity, 687
arthritis
gonococcal, 562–568
psoriatic, 562–568
reactive, 910f–912f
reactive, with chlamydia, 910–914
reactive, with dactylitis, 911f
reactive, with keratoderma blennorhagicum, 910–914, 910f, 912f
rheumatoid, 575–579, 575f, 576f
arthropod bites, bullous, 1100, 1102f
bacterial endocarditis, 289f
bunion deformity, 1247–1250, 1247f–1249f
cellulitis, 693–697, 693f, 694f
Charcot arthropathy, 1261–1264, 1261f–1263f, 1302, 1304f
contact dermatitis, 801, 802f, 834–841, 1100
corns and calluses, 1242–1245, 1243f–1245f
cutaneous larva migrans, 823–825, 823f
Darier disease, 1229–1234, 1231f
dermatosis papulosa nigra, 927
diabetic, 1302, 1303f
diabetic neuropathy, 1263f
diaphyseal fracture, 611–614
Jones, 612f
stress, 611–614
drug reactions, cutaneous, 1211–1222, 1218f
eczema
dyshidrotic, 801, 802f
nummular, 851–854, 853f
epidermolysis bullosa, 1121–1123, 1121f, 1122f
erythema toxicum neonatorum, 630–634
erythroderma, 915–921
fire ant bite, 1100, 1102f
Gianotti-Crosti syndrome, 1124, 1125f
gout, podagra, 590–594, 591f
granuloma annulare, 1022–1027, 1023f
Graves disease and goiter, 1353–1358
hammer toe, 1243f, 1251–1254
hand, foot, and mouth disease, 644, 732–734, 732f
hereditary hemangiomatosis, 1207–1210, 1208f
hereditary hemorrhagic telangiectasias, 1207–1210
ischemic ulcer, 1255–1257, 1256f
Kaposi sarcoma, 1285–1288, 1285f, 1286f
Kawasaki disease, 1054
keratoderma climactericum, 801, 802f
leishmaniasis, 67–69, 68f
lichen planus, 901–908, 901f, 903f, 905f
lupus
leukocytoclasic vasculitis, 1072, 1073f
necrotizing angiitis, 1072, 1073f
systemic lupus erythematosus, 1070–1078
melanoma, 1008–1020, 1013f
acral lentiginous, 1008–1020, 1012f, 1013f, 1243–1244
meningococcemia, 1066, 1068f
metatarsal fracture, 611–614
fifth metatarsal, 611–614, 611f
Jones, 612f
mycosis fungoides, 1042–1047
neuropathic ulcer, 1258–1260, 1258f, 1259f
nevus
basal cell nevus syndrome, 687
dysplastic nevus, 963–967
onychomycosis, 1160–1164, 1160f–1162f
palmoplantar keratoderma, 767–768, 769f, 770f
paronychia congenita, 1244, 1244f
pitted keratolysis, 686–688, 686f, 687f, 801, 802f
porokeratosis, 1244
psoriasis, 878–894, 885f, 886f, 888f
plantar, 801, 804f
Rock Mountain spotted fever, 1066
scabies, 70, 70f, 71, 817f–819f, 821f
skin cancer, nonmelanoma, 1244
staphylococcal scalded skin syndrome, 677, 679f
stucco keratosis, 927, 929f
syphilis, 899, 1278–1283, 1280f
tinea cruris, 795–798
tinea incognito, 801, 802f
tinea pedis, 799–804, 799f–801f
two-foot, one-hand syndrome, 773f
vitiligo, 1184–1190, 1185f, 1186f
wart
common, 749–754, 750f
plantar, 687, 1243
Feet, dorsum of
acropustolosis, 642–644, 642f
contact dermatitis, 834–841, 1100
dysplastic nevus, 963–967
granuloma annulare, 1022–1027, 1023f

Feet, dorsum of (*Continued*)
hammer toe, 1251–1254, 1251f–1253f
hand, foot, and mouth disease, 644
Feet, soles of
acanthosis nigricans, 1310–1312
acropustulosis, 642–644
acropustulosis of infancy, 821, 1102
arsenic toxicity, 687
bacterial endocarditis, 287–291, 289f
basal cell nevus syndrome, 687
corns and calluses, 1242–1245, 1242f
cutaneous larva migrans, 823–825, 823f
Darier disease, 1229–1234
dermatitis, chronic vesicular, 846
erythema multiforme, 1049–1055
erythema toxicum neonatorum, 630–634
hand, foot, and mouth disease, 732–734, 732f
Kaposi sarcoma, 1285–1288, 1286f
Kawasaki disease, 210, 1054
keratoderma climactericum, 801, 802f
lichen planus, 901–908
melanoma, 1008–1020, 1013f
acral lentiginous, 1008–1020, 1012f, 1013f
mycosis fungoides, 1042–1047
neuropathic ulcer, 1258–1260, 1258f, 1259f
palmoplantar keratoderma, 767–768, 769f, 770f
paronychia congenita, 1244, 1244f
pemphigoid gestationis, 471–474, 1098
pitted keratolysis, 801, 802f
pompholyx, 846
psoriasis, 878–894, 886f, 888f
plantar, 801, 804f
reactive arthritis, 910–914, 910f
Rocky Mountain spotted fever, 1066
scabies, 70, 70f, 71, 815–822, 817f, 818f, 821f
syphilis, 806, 899, 1278–1283, 1280f
tinea pedis, 799–804, 800f, 801f
wart, plantar, 687, 766–769, 766f, 767f, 1243
Femur
fetus
first trimester ultrasound, 477
second trimester ultrasound, 478, 479f, 480
fracture, 615–617, 615f–617f
Fingers. *See also* Hands; Upper extremities
acute febrile neutrophilic dermatosis, 1031, 1032f
arthritis
gouty, 565f, 590–594
osteoarthritis, 563, 563f, 569–573, 569f, 570f
psoriatic, 562–568, 562f, 564f, 565f, 582, 582f
rheumatoid, 562–568, 564f, 571, 572f, 575–579
cellulitis, 693–697, 693f
clubbing, 292–294, 292f, 293f
contact dermatitis, 834–841, 834f, 835f
CREST syndrome, 1089–1095, 1092f
Darier disease, 1229–1234
dermatomyositis, 1079–1087, 1080f, 1082f, 1083f
drug reactions, cutaneous, 1211–1222, 1214f
Dupuytren disease, 625–628, 625f, 626f
epidermolysis bullosa simplex, 1098, 1103f
erythema multiforme, 1049–1055, 1215f
erythroderma, 915–921, 918f
ezema, hand, 843–849, 843f–847f
gout, 563, 566f, 590–594, 590f–592f
granuloma
granuloma annulare, 1022–1027, 1025f
pyogenic granuloma, 940–944, 942f
pyogenic granuloma, pregnancy, 464, 465f
habit-tic deformity, 1146, 1147f, 1149
ichthyosis, X-linked, 1229–1234, 1232f
leishmaniasis, 67–69, 68f
melanoma, 1008–1020, 1012f, 1013f
acral lentiginous, 1008–1020, 1013f, 1151–1154, 1152f, 1153f
morphea, 1089–1095
mucus cyst, 1167, 1169f
onychomycosis, 1160–1164, 1160f–1162f
palmoplantar keratoderma, 767–768, 769f, 770f
paronychia, 1166–1169, 1166f–1168f
porphyria cutanea tarda, 1100, 1100f
Pseudomonas, nail, 1162, 1163f
psoriasis, 878–894, 887f
psoriatic arthritis, 562–568, 562f, 564f, 565f, 582, 582f
scabies, 815–822, 815f, 817f–819f, 821f
scleroderma, 1089–1095, 1090f–1093f
squamous cell carcinoma, 999–1007, 1004f
tinea pedis, 799–804, 799f
two-foot, one-hand syndrome, 772, 773f
wart
common, 749–754, 749f–753f
plantar, 766–769, 768f
xanthoma, tendon, 1322–1327

G

Gallbladder
gallbladder sludge, 386, 387
gallstone ileus, 388f
gallstones, 386–391, 386f, 388f–390f
Genitalia. *See also specific types*
acrodermatitis enteropathica, 648, 648f
diaper rash, 646–650, 646f–648f
dysplastic nevus, 963–967
Kaposi sarcoma, 1285–1288
lice, 70, 71
pseudofolliculitis, 665–669
systemic drug-related intertriginous and flexural exanthema, 1219, 1220f
Groin
acanthosis nigricans, 1200–1201, 1310–1312
bullous pemphigoid, 1104–1107
dermatitis, seborrheic, 871–876
erythrasma, 689–692, 690f, 691f
folliculitis, 680–684
pemphigus vegetans, 1109–1117
psoriasis, 878–894, 885f, 886f
skin tag, pregnancy, 463
staphylococcal scalded skin syndrome, 1054
tinea cruris, 772f, 795–798

H

Hair. *See also* Scalp
acne keloidalis nuchae, 1140, 1141f
alopecia
alopecia areata, 1128–1131, 1128f–1132f, 1141
alopecia universalis, 1128
androgenetic alopecia, 1141
drug-induced, 1141

frontal fibrosing, 1140, 1140f
scarring, 1138–1143, 1138f–1142f
traction, 785, 785f, 1141
Becker nevus, 948, 948f, 956
dermatitis, seborrheic, 1141
discoid lupus erythematosus, 1140, 1142f
dissecting cellulitis, 1140, 1141f
folliculitis, 680–684, 680f–683f
folliculitis decalvans, 680–684, 682f, 1138f, 1140, 1140f
folliculotropic mycosis fungoides, 1130, 1130f
hirsutism, pregnancy, 464
lice, 809–814, 811f, 812f
lichen planopilaris, 1138, 1139f
lichen planus, 901–908
physical abuse, child, 85, 86f
pregnancy, 464, 464f
sarcoidosis of scalp, 1141
syphilis, secondary, 1141, 1278–1283
telogen effluvium, 1141
telogen effluvium, postpartum, 464, 464f
tinea, 771–776, 772f
tinea barbae, 785, 786f
tinea capitis, 782–786, 782f–785f, 1141
traction hair loss, 1133–1136, 1133f
trichotillomania, 1133–1136, 1134f–1136f, 1141
tufted folliculitis, 1140, 1140f
Hands. *See also* Fingers; Upper extremities
abscess, 698–700, 699f
acanthosis nigricans, 1310–1312, 1312f, 1313f
acromegaly, 1360–1364, 1362f
acropustulosis, 642–644, 643f
acropustulosis of infancy, 821, 821f
actinic keratosis, 969–975, 969f, 971f
acute febrile neutrophilic dermatosis, 1031, 1032f
ankylosing spondylitis, 580–583
arthritis
gonococcal, 562–568
gouty, 565f, 590–594
osteoarthritis, 569–573, 569f, 570f
psoriatic, 562–568, 562f, 564f, 565f, 582, 582f, 878–894, 881f
rheumatoid, 562–568, 564f, 571, 572f, 575–579, 575f–578f
septic, 565
bacterial endocarditis, 287–291, 289f
Bowen disease, 969–975
calcium pyrophosphate dihydrate disease, 565
cellulitis, 693–697, 693f
cerebral vascular accident, 1371–1375
CREST syndrome, 1089–1095, 1092f
cutaneous horn, 985–986, 986f
Darier disease, 1229–1234, 1231f
dermatitis
atopic dermatitis, 826–833, 829f
contact dermatitis, 834–841, 834f, 840f, 1100
dermatitis herpetiformis, 1125–1126, 1126f
dermatomyositis, 1079–1087, 1080f, 1082f, 1083f
drug reactions, cutaneous, 1211–1222, 1214f
Dupuytren disease, 625–628, 625f, 626f
eczema
hand, 843–849, 843f–847f
nummular, 851–854, 852f
epidermolysis bullosa, 1121–1123, 1121f, 1123f
epidermolysis bullosa acquisita, 1098
epidermolysis bullosa simplex, 1098, 1103f
erythema multiforme, 1049–1055, 1050f, 1052f, 1053f, 1215f
erythema nodosum leprosum, 1059, 1060f
erythema toxicum neonatorum, 630–634
erythroderma, 915–921, 918f
fetus, second trimester ultrasound, 480, 480f
fifth disease (erythema infectiosum), 728–731, 730f
Gianotti-Crosti syndrome, 1124
gout, 563, 566f, 590–594, 590f–592f
granuloma
granuloma annulare, 791, 792f, 1022–1027, 1022f, 1024f–1026f
pyogenic granuloma, 940–944, 942f
pyogenic granuloma, pregnancy, 464, 465f
hand, foot, and mouth disease, 644, 732–734, 732f
hereditary hemorrhagic telangiectasias, 1207–1210
herpetic whitlow, 735–742, 737f
ichthyosis
lamellar, 1233, 1235f
X-linked, 1229–1234, 1232f, 1233f
impetigo, 676–679, 677f
injection-drug abuse, 1439–1444, 1441f
intimate partner violence, 95–100
Jaccoud arthropathy, 564f
Kawasaki disease, 210, 1054
keratoacanthomas, 977–980
leishmaniasis, 67–69, 68f
leprosy, 72–74, 73f, 74f
lichen planus, 901–908, 906f
lupus
necrotizing angiitis with lupus, 1072, 1073f
systemic lupus erythematosus, 563, 564f, 1070–1078, 1076f
melanoma, 1008–1020, 1012f, 1013f
acral lentiginous, 1008–1020, 1013f
subungual, 1151–1154, 1152f, 1153f, 1155f
morphea, 1089–1095
mucus cyst, 1167, 1169f
neurofibromatosis, 1387–1390, 1389f
nevus
blue nevus, 946
dysplastic nevus, 963–967, 965f
onychomycosis, 1160–1164, 1160f–1162f
palmar erythema, pregnancy, 463, 465
palmoplantar keratoderma, 767–768, 769f, 770f
papular pruritic eruption, 71f
paronychia, 1166–1169, 1166f–1168f
pemphigus foliaceous, 1109–1117, 1111f
photosensitivity, 1191–1196, 1191f–1193f
pityriasis lichenoides et varioliformis acuta, 1123–1124, 1124f
pompholyx, 843–849, 844f
porphyria cutanea tarda, 1100, 1100f, 1119–1121, 1119f, 1120f
psoriasis, 878–894, 880f, 881f, 885f–887f
psoriatic arthritis, 562–568, 562f, 564f, 565f, 582, 582f, 878–894, 881f
pyoderma gangrenosum, 1028–1034, 1030f, 1031f
radius fracture, 608t
distal, 605–609, 605f–609f
Raynaud phenomenon, 1089–1090, 1091f
scabies, 70, 71, 71f, 815–822, 815f, 817f–819f, 821f
scarlet fever, 208–212, 209f
scleroderma, 1089–1095, 1090f–1093f
self-inflicted dermatoses, 856–862, 858f
solar lentigo, 1016

Hands (*Continued*)
spider telangiectasias, pregnancy, 462–463, 465
sporotrichosis, 1031, 1032f
squamous cell carcinoma, 999–1007, 1003f, 1004f
syphilis, 1278–1283, 1279f, 1283f
tinea, 771–776, 773f
tinea pedis, 799–804, 799f
toxic epidermal necrolysis, 1049–1055, 1053f
two-foot, one-hand syndrome, 772, 773f
vasculitis, 1062–1069, 1063f
vitiligo, 1184–1190, 1185f, 1188f
wart
common, 749–754, 749f, 750f, 753f
flat, 755–758
plantar, 766–769, 768f
xanthoma, tuberous, 1322–1327
Hands, dorsum of. *See also* Hands; Upper extremities
acropustolosis, 642–644, 643f
actinic keratosis, 969–975, 969f, 971f
blue nevus, 946
Bowen disease, 969–975
dermatitis
contact dermatitis, 834–841, 1100
dermatitis herpetiformis, 1125–1126, 1126f
eczema
hand, 843–849, 843f–846f
nummular, 851–854, 852f
granuloma annulare, 1022–1027, 1022f, 1024f–1026f
hand, foot, and mouth disease, 644
porphyria cutanea tarda, 1100, 1119–1121, 1119f, 1120f
pyoderma gangrenosum, 1028–1034, 1030f
solar lentigo, 1016
two-foot, one-hand syndrome, 772, 773f
wart
common, 749–754, 749f, 750f, 753f
flat, 755–758
Hands, palms of
acanthosis nigricans, 1310–1312
acral lentiginous melanoma, 1008–1020
acropustulosis, 642–644
acropustulosis of infancy, 821, 1102
arsenic toxicity, 687
bacterial endocarditis, 287–291, 289f
Darier disease, 1229–1234
Dupuytren disease, 625–628, 625f, 626f
eczema, hand, 843–849, 844f, 845f
erythema, liver disease, 380, 380f
erythema multiforme, 1049–1055, 1052f, 1211–1222, 1215f
erythema toxicum neonatorum, 630–634
erythroderma, 915–921
Graves disease and goiter, 1353–1358
hand, foot, and mouth disease, 732–734, 732f
Kawasaki disease, 210, 1054
lichen planus, 901–908, 906f
mycosis fungoides, 1042–1047
nevus
basal cell nevus syndrome, 687
dysplastic nevus, 963–967, 965f
palmoplantar keratoderma, 767–768, 769f, 770f
pemphigoid gestationis, 471–474, 1098
psoriasis, 878–894, 881f, 885f
reactive arthritis, 910–914
Rock Mountain spotted fever, 1066
scabies, 815–822, 817f
scarlet fever, 208–212
syphilis, 806, 899, 1278–1283, 1279f, 1283f
systemic lupus erythematosus, 1070–1078, 1076f
vasculitis, 1062–1069, 1063f
wart, plantar, 766–769, 768f
Head
abscess, 698–700
allergic rhinitis, 200
alopecia
alopecia areata, 1128–1131, 1128f–1132f
alopecia universalis, 1128
angiosarcoma, 1203–1206, 1205f
fetus
first trimester ultrasound, 475–477, 475f–477f
second trimester, 478, 478f–480f, 480
folliculotropic mycosis fungoides, 1130, 1130f
headache, 1366–1370, 1366f–1368f
cluster, 200
migraine, 200
hydrops fetalis, 482, 483f
intimate partner violence, 95–100, 97f
lice, 70, 71
lichen planopilaris, 1138, 1139f
neonatal lupus, 634, 634f
psoriasis, 878–894, 879f
salmon patches, 1209, 1209f
squamous cell carcinoma, 200, 999–1007, 999f, 1003f
temporal arteritis, 200
tinea capitis, 772f, 782–786
trigeminal neuralgia, 200
upper respiratory tract infection, 200
Heart
anabolic steroids, 1439–1444
bacterial endocarditis, 287–291, 287f–289f
cestodes, 1270–1274, 1272f
cocaine, 1431–1437
coronary artery disease, 268–270, 268f, 269f
fetus, third trimester ultrasound, 482, 483, 483f
finger clubbing and, 292–294, 292f, 293f
heart failure, 277–280, 277f–279f
hookworms, 1270–1274, 1270f, 1271f
Lyme disease, 1289–1296
methamphetamine, 1424–1429
Necator americanus, 1270–1274, 1270f, 1271f
pericardial effusion, 281–285, 281f, 283f, 284f
substance abuse disorder, 1392–1397
Taenia solium, 1270–1274, 1272f
Hips
ankylosing spondylitis, 563, 580f, 581f
arthritis, 562–568
osteoarthritis, 569–573, 571f
fracture, 615–617, 615f–617f
osteoporosis and osteopenia, 1338–1344, 1340t, 1342f

I

Inframammary area. *See* Breasts
Inguinal area
acanthosis nigricans, 1310–1312
balanitis circinata, reactive arthritis, 910–914, 911f
Darier disease, 1229–1234

hidradenitis suppurativa, 671–674, 673f–675f
molluscum contagiosum, 743–746
neurofibromatosis, 1387–1390, 1387f, 1388f
pemphigus vegetans, 1109–1117, 1111f
psoriasis, 878–894, 885f, 886f
inverse, 796, 797f
scabies, 815–822
scrofula, tuberculosis with HIV, 74, 76f
scrofuloderma, tuberculosis, 310–318, 313f
tinea cruris, 795–798, 795f–797f

J

Joints. *See also specific joints*
arthritis, 562–568, 562f–568f, 565t, 568t
bursitis, 566, 571
olecranon bursitis, 566f–598f, 596–599
septic, 598, 1248, 1253

K

Kidneys
anabolic steroids, 1439–1444
bacterial endocarditis, septic embolic, 288
gout, 590–594
hydronephrosis, 430–434, 430f, 432f
kidney stones, 425–428, 425f–427f
polycystic kidneys, 436–439, 436f, 437f
renal cell carcinoma, 441–446, 441f, 442f, 444t
scleroderma, 1089–1095
tuberculosis, 310–317
urinary sediment, 420–423
vasculitis, 1062–1069

Knees. *See also* Lower extremities
anatomy, 619f
anterior cruciate ligament tear, 619–624, 619f
arthritis
gonococcal, 562–568
osteoarthritis, 563, 563f, 568f, 569–573, 570f
psoriatic, 562–568, 564f
rheumatoid, 575–579
septic, 565, 567f, 622, 623f
calcium pyrophosphate dihydrate disease, 565
dermatitis, atopic, 826–833, 826f, 828f, 831f
fifth disease (erythema infectiosum), 728–731
gout, 563, 590–594
lateral condylar split fracture, 621, 622f
lichen simplex chronicus, 856–862
Lyme disease, 563, 1289–1296, 1290f
meniscal tear, 619–624, 621f
olecranon bursitis, 563, 567f
patellar fracture, 621, 622f
psoriasis, 878–894, 882f, 883f, 890f, 1170f
psoriatic arthritis, 562–568, 564f
sarcoidosis, 1035–1040, 1038f
soft tissue injuries, 619–624, 619f, 621f, 622f
systemic lupus erythematosus, 563
wart, flat, 755–758, 755f
xanthoma, 1322–1327, 1324f

L

Labia, genital
adhesions, 92, 93f
lichen planus, 901–908
sexual abuse, child, 89–93
squamous cell carcinoma, 999–1007
straddle injury, 91
syphilis, 1278–1283, 1280f
vulvar intraepithelial neoplasia, 519–522, 519f, 520f
wart, genital, 759–765

Labia, orofacial. *See* Lips

Large intestines
Ascaris lumbricoides, 1270–1274, 1271f
Entamoeba histolytica, 1270–1274
inflammatory bowel disease, 405–412, 405f, 408f, 409f
roundworms, 1270–1274, 1271f
Trichuris trichiura, 1270–1274, 1272f

Larynx
hoarseness, 220–225, 220f, 223–225f
laryngopharyngeal reflux, 220–225, 223f
larynx, 220–225, 220f
normal, 220, 220f
oropharyngeal cancer, 253–256
polyps, hoarseness, 220–225, 225f
recurrent respiratory papillomatosis, 220–225, 224f
squamous cell carcinoma, 220–225, 223f
vocal cord nodules and polyps, 220–225, 224f

Legs. *See* Lower extremities

Lips. *See also* Face
actinic cheilitis, 969–975, 969f
angioedema, 863–869, 864f, 865f
basal cell carcinoma, 989–997
Bell palsy, 1383–1386, 1383f
cherry hemangioma, 943, 943f
drug reactions, cutaneous, 1211–1222
hand, foot, and mouth disease, 732–734, 733f
hereditary hemorrhagic telangiectasias, 1207–1210
herpes simplex, 735–742, 737f
intimate partner violence, 95–100, 95f
Kawasaki disease, 1054
lichen planus, 901–906, 904f
lupus pernio, 1035–1040, 1036f
melanoma, 1008–1020, 1011f
melanotic macule, 950, 950f
melasma, 1179–1182, 1179f
Merkel cell carcinoma, 1005, 1005f
milia, newborn, 630–634
oropharyngeal cancer, 253–256, 255f
paraneoplastic pemphigus, 1109–1117, 1113f
pemphigus vulgaris, 1109–1117, 1109f, 1110f, 1112f
pyogenic granuloma, 940–944, 940f
squamous cell carcinoma, 999–1007, 1002f, 1401, 1402f
Stevens-Johnson syndrome, 1049–1055, 1049f, 1051f
syphilis, 1278–1283, 1278f
toxic epidermal necrolysis, 1049–1055, 1053f
venous lakes, 1203–1206, 1203f

Liver
alcoholism, 1411–1421
anabolic steroids, 1439–1444
bladder cancer, 448–452
cutaneous T-cell lymphoma (mycosis fungoides), 1042–1047
Entamoeba histolytica, 1270–1274, 1271f
fetus, second trimester, 480
gastric cancer metastases, 371–374
hepatomegaly, liver disease, 380
intrahepatic cholestasis of pregnancy, 462, 462f, 463f, 464, 465

Liver (*Continued*)
liver disease, 377–384, 377f, 380f–382f
lung cancer metastases, 355–363
polycystic kidneys, 436–439, 437f
renal cell carcinoma metastases, 441–446
substance abuse disorder, 1392–1397
Lower extremities. *See also* Ankles; Extremities; Feet; Knees
actinic keratosis, 969–975
arthritis
osteoarthritis, 568f–570f, 569–573
reactive, 910–914, 910f–912f
reactive, with chlamydia, 910–914
reactive, with conjunctivitis, 910–914, 910f–912f
rheumatoid, 575–579, 575f–578f
ascending lymphangitis, 695f
atopic eruption of pregnancy, 463, 464, 464f
Bowen disease, 969–975, 971f, 975f
bullosis diabeticorum, 1097, 1097f
bullous pemphigoid, 1098, 1098f, 1104–1107, 1105f, 1107f
cellulitis, 693–697, 693f–695f
chickenpox, 707–710, 709f
cutaneous larva migrans, 823–825, 823f, 824f
dermatitis
acrodermatitis enteropathica, 62–63, 63f
atopic dermatitis, 826–833, 826f–831f
contact dermatitis, 834–841, 836f, 837f, 1100, 1101f
erythroderma atopic dermatitis, 915–921, 917f
dermatofibroma, 935–938, 935f–938f
diabetic dermopathy, 671–674, 674f, 1302, 1302f, 1314–1316, 1314f–1316f
diaper rash, 646–650
DRESS syndrome, 1211–1222, 1219f
drugs reactions, cutaneous, 1211–1222, 1213f
eczema
asteatotic, 1233
nummular, 851–854, 851f, 853f
epidermolysis bullosa acquisita, 1098, 1099f
erythema ab igne, 1198–1201, 1198f–1201f
erythema annulare centrifugum, 1236–1239, 1236f, 1237f
erythema induratum of Bazin, 1059
erythema nodosum, 1056–1060, 1056f, 1057f, 1059f, 1060f
fetus, first trimester ultrasound, 477
friction blisters, 1100
gangrene, dry, 1265–1267, 1265f, 1266f
Gianotti-Crosti syndrome, 1124, 1125f
glomangioma, 1203–1206, 1205f
granuloma
granuloma annulare, 1022–1027, 1023f, 1024f
pyogenic granuloma, 940–944, 942f
Graves disease and goiter, 1353–1358, 1355f
herpes zoster, 712–716, 714f
hirsutism, pregnancy, 464
ichthyosis
acquired, 830f, 1233, 1234f
ichthyosis vulgaris, 1233, 1234f
X-linked, 1229–1234, 1232f
idiopathic thrombocytopenic purpura, 1066, 1069f
impetigo, 676–679, 676f, 678f, 679f
Kaposi sarcoma, 1285–1288, 1285f, 1286f
keloids, 1224–1228
leishmaniasis, 67–69, 68f
lice, 809–814
lichen aureus, 1066, 1067f
lichen planus, 901–908, 901f, 903f
livedo reticularis, 1200, 1201f
Lyme disease, 1289–1296, 1290f, 1291f
melanoma, 1008–1020, 1014f
meningococcemia, 1066, 1068f
miliaria, 1100
molluscum contagiosum, 743–746
morphea, 1089–1095
mycosis fungoides, 1042–1047
necrobiosis lipoidica, 1302, 1303f, 1317–1320, 1317f–1320f
necrotizing fasciitis, 702–706, 702f–704f
nevus
blue nevus, 946
nevus flammeus, 1207–1210
nevus spilus, 946, 947f
Paget disease of external genitalia, 514–517
pemphigoid gestationis, 1098
pemphigus foliaceous, 1109–1117, 1111f
physical abuse, child, 85–88, 85f, 86f
pigmented purpuric dermatosis, Majocchi type, 1066, 1067f
pityriasis lichenoides et varioliformis acuta, 1123–1124, 1124f
pityriasis rosea, 896–900, 899f
pneumococcal vaccine allergic reaction, 694, 696f
pruritic urticarial papules and plaques of pregnancy, 467–470, 469f
psoriasis, 878–894, 882f, 883f, 885f, 886f, 890f
erythrodermic, 915–921, 916f, 917f
pyoderma gangrenosum, 1028–1034, 1028f–1031f
Crohn disease, 1028, 1029f
Rocky Mountain spotted fever, 1068f
sarcoidosis, 1035–1040, 1036f, 1038f
scabies, 70, 70f, 71
Schamberg disease, 1066, 1066f, 1067f
scleroderma, 1089–1095, 1091f, 1095f
scrofuloderma, tuberculosis, 310–318, 313f
seborrheic keratosis, 926–930, 929f
self-inflicted dermatoses, 856–862, 856f–860f
squamous cell carcinoma, 999–1007, 1003f
staphylococcal scalded skin syndrome, 677, 679f
stretch marks, pregnancy, 462, 463, 464f, 465
syphilis, 1278–1283, 1282f
tinea, 771–776, 773f
tinea corporis, 788–793, 790f, 791f
toxic epidermal necrolysis, 1049–1055, 1053f
transient neonatal pustular melanosis, 642–644, 1102
vasculitis, 1062–1069, 1062f–1064f
cutaneous, 1054
urticarial, 866, 867f, 868f
venous insufficiency, 295–298, 295f–297f
venous stasis, 694, 694f, 1032, 1033f
vitiligo, 1184–1190, 1185f, 1186f
warfarin-induced skin necrosis, 1211–1222
wart
common, 749–754, 750f
flat, 755–758, 755f
Lungs
Ascaris lumbricoides, 1270–1274, 1271f
asthma, 321–331, 321f, 322t, 324f–328f
bladder cancer, 448–452
chronic obstructive pulmonary disease, 334–343, 334f, 335t, 337f–340f, 341t
finger clubbing, 292–294, 293f

Entamoeba histolytica, 1270–1274
fetus, third trimester ultrasound, 483
histoplasmosis, 314, 317f
injection-drug use, 1439–1444
Kaposi sarcoma, 1285–1288
lung cancer, 355–363, 355f, 356f, 358f–360f
finger clubbing, 292–294
Necator americanus, 1270–1274, 1270f
pneumonia, 300–308, 300f, 301f, 303f–306f
pulmonary embolus, 345–352, 345f, 347f, 349f–350f
renal cell carcinoma metastases, 441–446
scleroderma, 1089–1095
Strongyloides stercoralis, 1270–1274, 1272f
substance abuse disorder, 1392–1397
Trichuris trichiura, 1270–1274, 1272f
tuberculosis, 310–317, 310f, 311f, 313f–316f

M

Mons pubis
diaper rash, 646–650, 646f
hidradenitis suppurativa, 671–674, 674f
Mouth and oral cavity. *See also* Teeth and gums; Tongue
acneiform eruption, steroid-induced, 661, 664f
adenoid cystic carcinoma, 207, 207f
angioedema, 863–869, 864f, 865f
angular cheilitis, 203–205, 203f–205f, 777–780, 778f, 1400, 1400f
aphthous ulcer, 244–248, 244f, 245f
Behçet syndrome, 245f, 246, 246f
Bell palsy, 1383–1386, 1383f
black hairy tongue, 228–230, 228f, 229f
Candida
candidiasis, oral, 229
thrush, 216, 773f, 777–780, 777f, 778f, 1116, 1116f
caries
adult, 262–266, 262f
early childhood, 257–260, 257f, 258f, 259t, 260f
cicatricial bullous pemphigoid, 1104–1107, 1106f
cytomegalovirus, 216
dental abscess, 698–700, 698f
dermatitis, 661, 664f
atopic dermatitis, 826–833, 827f–829f
diphtheria, 217
drug reactions, cutaneous, 1211–1222, 1214f
dry (xerostomia), 265
epiglottitis, 217
erythroplakia, 249–252, 251f
gingivitis, 236–238, 236f
hand, foot, and mouth disease, 732–734, 733f
herpangina/coxsackievirus, 216, 216f
herpes
herpes gingivostomatitis, 216
herpes simplex, 735–742, 737f, 740f
impetigo, 676–679, 676f, 677f, 679f
infectious mononucleosis, 215f, 216
intimate partner violence, 95–100, 95f
Kaposi sarcoma, 1285–1288, 1286f
Kawasaki disease, 1054
leukoplakia, 249–252, 249f–251f
smoking, 1400, 1401f
lichen planus, 901–908, 904f
methamphetamine, 1424–1429, 1427f, 1428f
morsicatio, 251, 251f
nicotine stomatitis, 251, 251f, 1400, 1401f
oropharyngeal cancer, 253–256, 253f–256f
paraneoplastic pemphigus, 1109–1117, 1113f
pemphigus vulgaris, 1098, 1098f–1110f, 1109–1117, 1112f, 1114f
periodontal disease, 236–238, 236f, 237f
perlèche, 778, 778f
pharyngitis, 213–218, 213f–216f
pyoderma gangrenosum, 1028–1034
pyogenic granuloma, 940–944
reactive arthritis, chlamydia, 910–914, 913f
sebaceous hyperplasia, 931–934
squamous cell cancer, 253–256, 253f–255f, 1401, 1402f
Stevens-Johnson syndrome, 1049–1055, 1049f, 1051f
supraglottitis, 217
syphilis, 1278–1283, 1281f
systemic lupus erythematosus, 1070–1078
torus mandibularis, 206–207, 206f
torus palatinus, 206–207, 206f
vitiligo, 1184–1190
wart, flat, 755–758, 756f

N

Nails and nail bed
ankylosing spondylitis, 580–583
arsenic toxicity, 687
bacterial endocarditis, 287–291, 287f
Beau lines, 1146, 1147f, 1148f
candidiasis, 777–780
clubbing, 292–294, 292f, 293f
Darier disease, 1171–1172, 1173f, 1229–1234, 1231f
dermatomyositis, 1079–1087, 1080f, 1082f, 1084f
drug eruptions, cutaneous, 1211–1222
erythroderma, 915–921
glomangioma, 1203–1206
Graves disease and goiter, 1353–1358
habit-tic deformity, 1146, 1147f, 1149
half-and-half nails, 1149, 1149f
leukonychia, 1145, 1145f, 1146, 1146f
leukonychia punctata, 1145, 1146, 1146f
lichen planus, 901–908, 905f
longitudinal melanonychia, 1146, 1146f, 1151–1155, 1151f–1155f
Mee lines, 1148f, 1148t, 1149
melanoma
acral lentiginous, 1008–1020
subungual, 1151–1155, 1152f, 1153f, 1155f
mucus cyst, 1167, 1169f
Muehrcke lines, 1148t, 1149, 1149f
nail hypertrophy, 1145, 1146, 1146f
normal variants, 1145–1149, 1145f–1149f, 1148t
onychocryptosis, 1156–1158, 1156f–1158f
onychogryphosis, 1145, 1146, 1146f, 1161f, 1162f
onychomycosis, 1160–1164, 1160f–1162f
onychoschizia, 1177, 1177f
paronychia, 1166–1169, 1166f–1168f
photoonycholysis phototoxicity reactions, 1194
pigmented nail disorders, 1151–1155, 1151f–1155f
pincer nail, 1156, 1156f
Pseudomonas, nail, 1162, 1163f
psoriasis, 2, 3f, 878–894, 881f
inverse, 796, 797f
psoriatic nails, 564f, 565t, 568t, 1170–1173, 1170f–1173f
reactive arthritis, 910–914, 912f

Nails and nail bed (*Continued*)
sarcoidosis, 1035–1040
subungual hematoma, 1175–1177, 1175f–1177f
transverse striate leukonychia, 1145, 1145f, 1146
twenty-nail dystrophy, 1149, 1149f
Neck
abscess, 698–700, 698f, 699f
acanthosis nigricans, 922f, 1200–1201, 1302, 1302f, 1310–1312, 1311f, 1312f, 1329f
acne
acne keloidalis nuchae, 665–669, 665f, 666f, 681, 681f, 682f, 1140, 1225, 1226f
acne vulgaris, 651–657, 651f, 653f
actinic superficial folliculitis, 683
angiosarcoma, 1203–1206
basal cell carcinoma, 989–997, 994f
café-au-lait spot, 923f
cellulitis, 693–697, 696f
Darier disease, 1229–1234, 1229f
dermatitis
atopic dermatitis, 826–833, 827f–829f, 833f
seborrheic dermatitis, 871–876
dermatomyositis, 1079–1087, 1085f, 1086f
DRESS syndrome, 1211–1222, 1219f
drug reactions, cutaneous, 1211–1222, 1211f, 1215f, 1219f
epidermal inclusion cyst, 937
folliculitis, 680–684, 681f, 682f
goiter, iodine deficiency, 63–64, 64f
goitrous hypothyroidism, 1346–1352, 1346f–1349f
granuloma
granuloma annulare, 1022–1027
pyogenic granuloma, 940–944
Graves disease and goiter, 1353–1358, 1353f, 1354f
herpes zoster, 712–716, 713f
impetigo, 676–679, 678f
infections, deep neck, 217
keloids, 1224–1228
lice, 809–814
lichen nuchae, 857, 858f, 859f
lichen simplex chronicus, 856–862, 858f, 859f
lupus
discoid lupus erythematosus, 1070–1078, 1074f
neonatal lupus, 634
mass, 222
measles, 723–726, 723f, 725f
melanoma, 1008–1020, 1008f
lentigo maligna, 981–984
mycosis fungoides, 1042–1047, 1043f, 1045f, 1047f
neurofibroma, 923, 923f
nevus
benign nevi, 945–951
epidermal nevus, 958–962, 959f
nevus anemicus, 948, 949f
nevus flammeus, 1207–1210
photosensitivity, 1191–1196
pityriasis rosea, 896–900, 898f
poikiloderma atrophicans vasculare, 1200
postinfectious encephalomyelitis, 724
pseudofolliculitis, 665–669, 665f–667f
pseudofolliculitis barbae, 665f–667f, 680, 681f
psoriasis, 878–894, 879f, 880f, 885f
pyoderma gangrenosum, 1028–1034, 1032f
salmon patch, 638, 638f
salmon patches, 1209, 1209f
sarcoidosis, 1035–1040, 1035f
scleroderma, 1089–1095
scrofula, tuberculosis with HIV, 74, 76f
scrofuloderma, tuberculosis, 310–318, 312f
self-inflicted dermatoses, 856–862, 858f, 859f
skin tag, 922–924, 922f, 1329f
pregnancy, 463
spider telangiectasias, pregnancy, 462–463, 465
staphylococcal scalded skin syndrome, 210, 1054
stork bite, 638, 638f
thyroglossal duct cyst, 1349, 1350f
thyroid cancer, 1349, 1350f
toxic nodular goiter, 1348f, 1349
transient neonatal pustular melanosis, 642–644, 1102
vitiligo, 1184–1190, 1184f
wart, flat, 755–758, 756f
Nose. *See also* Face
acne, neonatal, 630–634, 630f
acromegaly, 1360–1364, 1363f
angiofibroma, 1388, 1390f
angiosarcoma, 1203–1206, 1205f
basal cell carcinoma, 989–997, 989f, 993f
cocaine, 1431–1437, 1433f, 1435f
dermatitis, seborrheic, 871–876, 871f–875f
fibrous papule of nose, 943, 943f
folliculitis, 680–684
hereditary hemorrhagic telangiectasias, 1207–1210
leishmaniasis, 67–69, 67f, 69f
lupus
discoid lupus erythematosus, 1070–1078, 1074f–1076f
lupus pernio, 1035–1040, 1035f, 1036f
systemic lupus erythematosus, 1070–1078
melanoma, 1008–1020
amelanotic, 942f
lentigo maligna, 981–984
pyogenic, 943f
melasma, 1179–1182, 1179f
milia, 630–634, 630f
nasal polyps, 193–195, 193f, 194f
nevus
intradermal nevus, 989f, 995, 995f
Spitz nevus, 946, 947f
pemphigus erythematosus, 1098
pemphigus vulgaris, 1109–1117, 1109f
pregnancy, hyperpigmentation, 19, 19f
pyogenic granuloma, 940–944, 941f
rhinophyma, 660, 660f, 661f
rosacea, 659–664, 659f–661f, 663f
sarcoidosis, 1035–1040, 1040f
sebaceous hyperplasia, 931–934
squamous cell carcinoma, 999–1007, 1001f, 1004f
toxic epidermal necrolysis, 1049–1055, 1053f
zoster ophthalmicus, 718–722, 719f, 720f

P

Palate, hard. *See* Mouth and oral cavity
Palms. *See* Hands, palms of
Penis
acrodermatitis enteropathica, 648, 648f
Behçet syndrome, 739, 739f

Bowen disease of penis, 969–975, 970f
candidiasis, 777–780, 777f
caught in zipper, 92
drug reactions, cutaneous, 1211–1222, 1214f
erythroplasia of Queyrat, 1000, 1000f
fetus, second trimester ultrasound, 479f, 480, 481f
herpes simplex, 735–742, 735f
lichen planus, 901–908, 905f
molluscum contagiosum, 743–746, 745f, 746f
phimosis, 92
psoriasis, 878–894, 883f
pyoderma gangrenosum, 1028–1034
reactive arthritis, 910–914, 911f
scabies, 815–822, 818f
squamous cell carcinoma, 999–1007, 1000f
syphilis, 1278–1283, 1279f, 1281f, 1282f
tinea cruris, 795–798, 795f, 796f
ulcer, Behçet syndrome, 246, 246f
urethritis, 1275–1277, 1275f
vitiligo, 1184–1190, 1186f
wart, genital, 759–765, 760f–763f, 765f
Perianal region. *See* Anus and perianal region
Perineum
acanthosis nigricans, 1310–1312
Paget disease of external genitalia, 514–517
vulvar intraepithelial neoplasia, 519–522
Periorbital region. *See* Eyes and periorbital region
Prostate, prostate cancer, 453–459, 453f–455f, 458f

S

Sacrum. *See also* Back
dermatitis herpetiformis, 1125–1126
Mongolian spots, 630–634
transient neonatal pustular melanosis, 642–644
Scalp. *See also* Hair
acne keloidalis nuchae, 665–669, 665f–668f, 1140, 1141f
acropustulosis, 642–644
actinic keratosis, 969–975, 971f
alopecia
alopecia areata, 1128–1131, 1128f–1132f, 1141
alopecia totalis, 1128, 1128f
alopecia universalis, 1128
androgenetic alopecia, 1141
drug-induced, 1141
frontal fibrosing, 1140, 1140f
scarring, 1138–1143, 1138f–1142f
traction, 1141
angiosarcoma, 1203–1206, 1205f
basal cell carcinoma, 989–997, 993f
Bowen disease, 969–975
cutaneous horn, 985–986
Darier disease, 1229–1234
dermatits
dermatitis herpetiformis, 1098
seborrheic dermatitis, 820–821, 871–876, 873f, 874f, 1141
dermatomyositis, 1079–1086, 1079–1087, 1079f, 1081
dissecting cellulitis, 1140, 1141f
erythroderma, 915–921
folliculitis decalvans, 680–684, 682f, 1138f, 1140, 1140f
folliculotropic mycosis fungoides, 1130, 1130f
granuloma annulare, 1022–1027
hemangioma, childhood, 636–640
hydrops fetalis, 482, 483f
lice, 809–814, 811f
lichen planopilaris, 1138, 1139f
lichen planus, 901–908
lupus
discoid lupus erythematosus, 1070–1078, 1074f–1076f, 1140, 1142f
neonatal lupus, 634, 634f
melanoma, 1008–1020, 1011f
acral lentiginous, 1016, 1017f
lentigo maligna, 981–984, 1011f
milia, newborn, 630–634
molluscum contagiosum, 743–746, 744f
mycosis fungoides, 1042–1047
nevus
benign nevi, 945–951
dysplastic nevus, 963–967
nevus sebaceous, 958–962, 958f, 960f
pemphigus foliaceous, 1109–1117, 1111f
pemphigus vulgaris, 1109–1117, 1110f
psoriasis, 878–894, 879f, 880f
pyoderma gangrenosum, 1028–1034, 1032f
reactive arthritis, 910–914, 910f
sarcoidosis, 1035–1040, 1035f, 1141
seborrhea, tinea versicolor, 805–808
squamous cell carcinoma, 999–1007, 999f, 1003f
syphilis, secondary, 1141, 1278–1283
telogen effluvium, 1141
tinea, 771–776, 772f
tinea capitis, 71, 72f, 75f, 772f, 782–786, 782f–785f, 1141
traction hair loss, 1133–1136, 1133f
trichotillomania, 1133–1136, 1134f–1136f, 1141
tufted folliculitis, 680–684, 682f, 1140, 1140f
Scrotum
angiokeratoma, 1203–1206, 1204f
Candida, cutaneous, 796
lichen planus, 901–908
lichen simplex chronicus, 856–862
neonatal pustular melanosis, 642–644, 643f
Paget disease of external genitalia, 514–517, 515f, 516f
scabies, 815–822, 818f
syphilis, 1278–1283, 1281f
tinea cruris, 795–798, 795f, 796f
wart, genital, 759–765
Shoulders
acne
acne fulminans, 651–657, 654f
acne vulgaris, 651–657
acromioclavicular separation, 602, 602t, 603f
actinic superficial folliculitis, 682
ankylosing spondylitis, 563
Becker nevus, 948, 948f, 956
clavicle fracture, 601–604, 601f–603f, 602t
dermatitis herpetiformis, 1125–1126
keloids, 1224–1228, 1225f
Lyme disease, 1289–1296, 1290f
melanoma, 1008–1020, 1011f
Mongolian spots, 630–634
Pityrosporum folliculitis, 681, 683f
poikiloderma atrophicans vasculare, 1200
psoriasis, 878–894, 880f
sarcoidosis, 1035–1040, 1037f
scleroderma, 1089–1095

Shoulders (*Continued*)
squamous cell carcinoma, 999–1007, 1005f
tinea corporis, 788–793, 788f
tinea versicolor, 805–808, 806f
Sinuses
headache, 200
mucopyocele, 199f, 200f
sinusitis, 197–202, 197f–200f
squamous cell carcinoma, 200
Small intestines
Entamoeba histolytica, 1270–1274
Giardia lamblia, 1270–1274, 1273f
Trichuris trichiura, 1270–1274, 1272f
Soles. *See* Feet, soles of
Spine
ankylosing spondylitis, 580–583, 580f, 581f
arthritis
osteoarthritis, 562–568
psoriatic, 562–568
fetus
first trimester ultrasound, 475–477, 476f
second trimester ultrasound, 478f
third trimester ultrasound, 482–484, 482f
psoriatic arthritis, 562–568
Taenia solium, 1270–1274
Stomach
fetus
second trimester ultrasound, 479f
third trimester ultrasound, 482–484, 482f
gastric cancer, 371–375, 371f, 373f
peptic ulcer disease, 366–369, 366f, 367f
vascular ectasia, scleroderma, 1090

T

Teeth and gums. *See also* Mouth and oral cavity
bulimia, 264, 264f
caries
adult, 262–266, 262f
early childhood, 257–260, 257f, 258f, 259t, 260f
cicatricial bullous pemphigoid, 1104–1107, 1106f
dental pain, 200
gingival overgrowth, 240–242, 240f, 241f
gingivitis, 236–238, 236f
granuloma
pyogenic granuloma, 241–242, 241f
pyogenic granuloma, pregnancy, 464, 465f
hand, foot, and mouth disease, 732–734
intimate partner violence, 95–100
leukoplakia from smoking, 1400, 1401f
lichen planus, 901–908, 904f
methamphetamines, 1424–1429, 1427f, 1428f
minocycline drug reaction, 1218
periodontal disease, 236–238, 236f, 237f
smoking, 1400, 1400f
smoking-related periodontitis, 1400, 1400f
tobacco staining, 1400, 1400f
Thighs. *See* Lower extremities
Throat
larynx (hoarseness), 220–225, 220f, 223f–225f
pharyngitis, 213–218, 213f–216f
scarlet fever, 208–212
upper respiratory tract infection, 200
Thyroid gland
goitrous hypothyroidism, 1346–1352, 1346f–1349f
Graves disease and goiter, 1353–1358, 1353f–1356f
hyperthyroidism, 20
Toes. *See also* Feet; Lower extremities
arthritis
reactive, 910–914, 910f–912f
rheumatoid, 575–579, 575f, 576f
bunion deformity, 1247–1250, 1247f–1249f
cellulitis, 693–697, 693f, 694f
Charcot arthropathy, 1261–1264, 1261f–1263f, 1302, 1304f
contact dermatitis, 834–841, 837f
corns and calluses, 1242–1245, 1243f–1245f
cutaneous larva migrans, 823–825, 823f
Darier disease, 1229–1234
diabetic neuropathy, 1263f
diaphyseal fracture (Jones), 611–614, 612f
diaphyseal stress fracture, 611–614
eczema
dyshidrotic, 801, 802f
nummular, 851–854, 853f
epidermolysis bullosa, 1121–1123
erythrasma, 689–692
erythroderma, 915–921
gangrene
dry, 1265–1267, 1265f, 1266f
wet, 1266, 1266f
gout, 563
gout (podagra), 590–594, 591f
granuloma annulare, 1022–1027
hammer toe, 1251–1254, 1251f–1253f
hand, foot, and mouth disease, 732–734, 732f
ischemic ulcer, 1255–1257, 1255f, 1256f
Kaposi sarcoma, 1285–1288, 1286f
keratoderma climactericum, 801, 802f
leishmaniasis, 67–69, 68f
lichen planus, 901–908, 905f
melanoma, 1008–1020
subungual, 1151–1154
melanoma, acral lentiginous, 1008–1020, 1013f
meningococcemia, 1066, 1068f
metatarsal fracture, 611–614
fifth metatarsal, 611–614, 611f
necrotizing fasciitis, 702–706, 703f
neuropathic ulcer, 1258–1260, 1258f, 1259f
onychocryptosis, 1156–1158, 1156f–1158f
onychogryphosis, 1145, 1146, 1161f, 1162f
onychomycosis, 1160–1164, 1160f–1162f
paronychia, 1166–1169, 1167f
pitted keratolysis, 686–688, 686f, 687f
Pseudomonas, nail, 1162, 1163f
psoriasis, 878–894
plantar, 801, 804f
scabies, 815–822, 817f, 819f, 821f
subungual hematoma, 1175–1177, 1175f, 1176f
syphilis, 1278–1283, 1280f
tinea, 771–776, 773f
tinea cruris, 795–798
tinea incognito, 801, 802f
tinea pedis, 799–804, 799f–801f
two-foot, one-hand syndrome, 772, 773f
wart, plantar, 766–769, 766f, 767f

Tongue. *See also* Mouth
aphthous ulcer, 244–248, 244f
Bell palsy, 1383–1386
bismuth subsalicylate ingestion, 229
black hairy tongue, 228–230, 228f
candidiasis, 229
erythroplakia, 249–252, 251f
fissured tongue, 233, 234f
geographic tongue, 232–235, 232f–235f
hand, foot, and mouth disease, 732–734
hereditary hemorrhagic telangiectasias, 1207–1210, 1207f
herpes simplex, 735–742
leukoplakia, 249–252, 249f–251f
lichen planus, 233, 233f, 901–908, 904f
minocycline ingestion, 229
oral hairy leukoplakia, 229, 230f
oropharyngeal cancer, 253–256, 254f, 255f
pemphigus vulgaris, 229f, 1109–1117
psoriasis, 233, 234f
reactive arthritis, 233, 910–914
squamous cell carcinoma, 253–256, 254f, 255f
strawberry tongue, 208–212, 209f
tobacco staining, 1400, 1400f
Total body
abscess, 698–700, 698f–700f
alcoholism, 1411–1421
alopecia
alopecia areata, 1128–1131, 1128f–1132f
alopecia universalis, 1128
bullous mastocytosis, 1102
bullous pemphigoid, 1104–1107, 1104f–1108f
cellulitis, 693–697, 693f–696f
chickenpox, 707–710, 707f–711f
contact dermatitis, 834–841, 834f–840f
cutaneous horn, 985–986, 985f–987f
Darier disease, 1229–1234, 1229f–1232f
dermatofibroma, 935–938, 935f–938f
drug reactions, cutaneous, 1211–1222
erythema multiforme, 1049–1055, 1211–1222
erythema toxicum neonatorum, 630–634, 632f
erythroderma, 915–921, 915f–921f
folliculitis, 680–684, 680f–683f
harlequin color change, 634
hemangioma, childhood, 636–640, 636f–639f
hereditary hemorrhagic telangiectasias, 1207–1210
ichthyosis, X-linked, 1229–1234, 1232f, 1233f
kwashiorkor, 60–61, 60f, 61f
lice, 70, 71
lupus
discoid lupus erythematosus, 1074f–1076f
systemic lupus erythematosus, 1070–1078
marasmus, 60–61, 60f, 61f, 70f
melanoma, 1008–1020, 1009f–1018f
milia, 630–634, 630f
molluscum contagiosum, 743–746, 743f–746f
mycosis fungoides, 1042–1047, 1042f–1047f
nevus
benign nevi, 945–951, 945f–950f
congenital nevi, 953–956, 953f–955f
pemphigus foliaceous, 1109–1117, 1110f, 1111f, 1112f
psoriasis, 881f, 886f
erythrodermic, 915–921, 917f
pyoderma gangrenosum, 1028–1034, 1028f–1033f
Stevens-Johnson syndrome, 1211–1222
syphilis, 1281f, 1282f
tinea corporis, 788–793, 788f–792f
toxic epidermal necrolysis, 1211–1222
urticaria, 863–869, 863f–868f
venous insufficiency, 295–298, 295f–297f
Trunk
acne fulminans, 651–657, 654f
acropustulosis, 642–644
angioedema, 863–869, 863f–867f
atopic triad, 323, 324f
bullous pemphigoid, 1104–1107, 1107f
cherry angioma, 1203–1206
contact dermatitis, 834–841, 836f
cutis marmorata, 634, 634f
Darier disease, 1229–1234, 1229f, 1232f
dermatomyositis, 1079–1087
drug reactions, cutaneous, 1211–1222, 1211f–1213f
eczema, nummular, 851–854, 853f
epidermal inclusion cyst, 937
epidermolysis bullosa, 1121–1123, 1123f
erythema annulare centrifugum, 1054, 1236–1239, 1236f
erythema toxicum neonatorum, 630–634, 632f
erythroderma, 915–921, 919f–921f
fifth disease (erythema infectiosum), 728–731, 728f
folliculitis, 680–684
granuloma
granuloma annulare, 1022–1027
pyogenic granuloma, 940–944
Grover disease, 1230
harlequin color change, 634
herpes zoster, 712–716, 715f
ichthyosis, X-linked, 1229–1234, 1232f
impetigo, 71, 71f, 72f, 676–679, 677f, 678f
Kaposi sarcoma, 1285–1288, 1287f
keloids, 1224–1228, 1224f–1226f
keratoacanthomas, 977–980, 978f, 979f
leprosy, 72–74, 74f
lice, 809–814, 809f, 810f
linear IgA bullous dermatosis, 1098, 1100f
livedo reticularis, 1200
measles, 723–726, 723f–725f
melanoma, 1008–1020, 1009f–1011f
meningococcemia, 1066, 1068f
molluscum contagiosum, 743–746, 744f
neurofibromatosis, 1387–1390, 1387f–1389f
nevus
epidermal nevus, 958–962, 959f, 960f
halo nevi, 945f, 946
nevus comedonicus, 948, 950f
nevus flammeus, 1207–1210, 1207f
papular pruritic eruption, 75f
pemphigus foliaceous, 1109–1117, 1111f
pemphigus vulgaris, 1109–1117, 1109f
photosensitivity, 1192f, 1193f
physical abuse, child, 82–87, 82f–84f
pityriasis lichenoides chronica, 1124, 1125f
pityriasis lichenoides et varioliformis acuta, 1100, 1100f, 1123–1124, 1124f
psoriasis, 878–894, 879f, 883f, 884f, 886f, 1331f
erythrodermic, 915–921, 915f, 916f, 917f

Trunk (*Continued*)
pyoderma gangrenosum, 1028–1034, 1032f
sarcoidosis, 1035–1040, 1037f
scarlet fever, 208–212, 208f
scrofula, tuberculosis with HIV, 74, 76f
seborrheic keratosis, 926–930, 927f, 1311
skin tag, 922–924, 923f
Stevens-Johnson syndrome, 1049–1055, 1050f, 1051f, 1211–1222
syphilis, 1278–1283, 1278f
syphilis, secondary, 1278–1283, 1436f
tinea corporis, 791f, 1238, 1238f
transient neonatal pustular melanosis, 1102
urticaria, 863–869, 863f–867f
vasculitis, cutaneous, 1054
xanthoma, 1302, 1304f, 1322–1327, 1322f, 1323f
Tympanic membrane. *See also* Ears
acute otitis media, 170–178, 170f, 172f, 177f, 178f
normal, 173f
otitis media with effusion, 170–178, 170f, 171f
traumatic perforation, 173, 176, 177f
tympanosclerosis, 176, 178f

U

Umbilicus
pemphigoid gestationis, 471–474, 471f–473f, 1098
psoriasis, inverse, 2, 3f
Upper extremities. *See also* Extremities; Fingers; Hands
acanthosis nigricans, 1200–1201, 1310–1312, 1312f, 1313f
acromegaly, 1360–1364, 1362f
acropustulosis of infancy, 821, 821f
actinic keratosis, 969–975, 969f, 971f
acute febrile neutrophilic dermatosis, 1031, 1032f
arthritis
osteoarthritis, 569–573, 569f, 570f
rheumatoid, 562–568, 564f, 577f
atopic eruption of pregnancy, 463, 464, 464f
atopic triad with asthma, 323, 324f
basal cell carcinoma, 989–997, 990f
Bowen disease, 969–975, 971f
bullous pemphigoid, 1098, 1098f
cellulitis, 693–697, 693f
cerebral vascular accident, 1371–1375
cocaine, 1431–1437, 1433f–1435f
cutaneous horn, 985–986, 986f
dermatits
atopic dermatitis, 826–833, 826f, 828f–831f
contact dermatitis, 834–841, 834f, 835f, 837f–840f, 1100, 1101f
dermatitis herpetiformis, 1125–1126, 1126f
dermatofibroma, 935–938
dermatomyositis, 1079–1087, 1079f, 1080f, 1082f, 1083f, 1085f, 1086f
dermatosis papulosa nigra, 927
DRESS syndrome, 1211–1222, 1219f
drugs reactions, cutaneous, 1211–1222, 1213f–1215f, 1221f
eczema, nummular, 851–854, 851f–853f
epidermolysis bullosa, 1121–1123, 1123f
epidermolysis bullosa acquisita, 1098
epidermolysis bullosa simplex, 1098, 1103f
erythema annulare centrifugum, 1054
erythema multiforme, 1049–1055, 1050f, 1052f, 1053f, 1215f
erythema nodosum, 1056–1060, 1057f–1060f, 1059f
erythema toxicum neonatorum, 630–634
erythroderma, 915–921, 918f, 919f, 921f
fifth disease (erythema infectiosum), 728–731, 728f, 730f
glomangioma, 1203–1206, 1205f
granuloma
granuloma annulare, 791, 792f, 1022–1027, 1022f–1026f
pyogenic granuloma, 940–944, 942f
hemangioma, childhood, 636–640, 638f
herpes zoster, 712–716, 714f
hidradenitis suppurativa, 331, 671–674, 1333f
hirsutism, pregnancy, 464
hypomelanosis of Ito, 1187, 1188f
ichthyosis
ichthyosis vulgaris, 1233, 1234f
lamellar, 1233, 1235f
X-linked, 1229–1234, 1232f, 1233f
idiopathic guttate hypomelanosis, 1187, 1187f
impetigo, 676–679
injection-drug abuse, 1439–1444, 1439f, 1441f–1443f
Kaposi sarcoma, 1285–1288, 1285f, 1287f
keloids, 1224–1228, 1225f
keratoacanthomas, 977–980
keratosis pilaris, 830f
leishmaniasis, 67–69, 68f
leprosy, 72–74, 74f
lichen planus, 901–908, 901f, 904f, 906f
linear IgA bullous dermatosis, 1098, 1100f
livedo reticularis, 1200
Lyme disease, 1289–1296, 1290f, 1291f
melanoma, 1008–1020, 1010f, 1013f, 1014f
methamphetamine, 1424–1429, 1424f, 1426f
miliaria, 1100
molluscum contagiosum, 743–746, 745f
morphea, 1089–1095
mycosis fungoides, 1042–1047
necrotizing fasciitis, 702–706
nevus
benign nevi, 945–951
blue nevus, 946
junctional nevi, 946, 946f
nevus flammeus, 1207–1210, 1208f, 1209f
nevus spilus, 946, 947f
papular pruritic eruption, 75f
pemphigoid gestationis, 1098, 1099f
pemphigus foliaceous, 1109–1117, 1111f
photosensitivity, 1191–1196, 1191f–1193f
physical abuse, child, 85–88
pityriasis alba, 827, 830f
pityriasis lichenoides chronica, 1124, 1125f
pityriasis lichenoides et varioliformis acuta, 1100, 1123–1124
pityriasis rosea, 867f, 896–900, 899f, 900f
Pityrosporum folliculitis, 681, 683f
porphyria cutanea tarda, 1100, 1100f
pruritic urticarial papules and plaques of pregnancy, 467–470, 468f
psoriasis, 878–894, 878f, 880f, 883f, 885f, 886f, 889f
erythrodermic, 915–921, 915f, 917f
with Koebner phenomenon, 882, 884f
pyoderma gangrenosum, 1028–1034, 1030f, 1031f
sarcoidosis, 1035–1040, 1037f–1039f
scabies, 70, 71, 71f
scleroderma, 1089–1095, 1090f–1093f
seborrheic keratosis, 926–930
self-inflicted dermatoses, 856–862, 856f–859f
spider telangiectasias, pregnancy, 462–463, 465

sporotrichosis, 1031, 1032f
squamous cell carcinoma, 999–1007, 1003f, 1004f
Stevens-Johnson syndrome, 1049–1055, 1051f
stretch marks, pregnancy, 462, 463, 464f, 465
syphilis, 1278–1283, 1281f–1283f
systemic lupus erythematosus, 563, 564f, 1070–1078, 1076f
tinea corporis, 788–793, 790f, 791f
tinea incognito, 788–793, 790f
tinea versicolor, 773f, 805–808
toxic epidermal necrolysis, 1049–1055, 1053f
vasculitis, 1062–1069, 1063f
vitiligo, 638f, 1184–1190, 1186f, 1188f
xanthoma, 1302, 1304f, 1322–1327, 1322f, 1323f, 1332f
Ureter
hydroureter, 430f, 432
megaureter, children, 431, 432, 434
ureteral stones, 425–428, 432f
urinary sediment, 420f–423f
Urethra
hydronephrosis, 430–434, 430f, 432f
urethritis, 1275–1277, 1275f
Uterus
adnexal mass, 20
cancer of, invasive, 541–545, 541f–543f
enlarged, 20
hysterosalpingogram of, 15
intrauterine devices, 12, 12f, 13t, 14–15
myoma, 20
pregnancy and birth, 17–23
ultrasound of, in pregnancy
first trimester, 475–477, 475f–477f
second trimester, 478–481, 478f–481f
third trimester, 482–484, 482f, 483f
uterine leiomyomas, 20
uteroplacental insufficiency, 482

V
Vagina
atrophic vaginitis, 489–492, 489f
bacterial vaginosis, 494–497, 494f–496f
Candida vulvovaginitis, 499–503, 499f
herpes simplex virus, 735–742
lichen planus, 901–908
lichen sclerosus et atrophicus, 491, 491f
pregnancy and birth, 17–23
pregnancy ultrasound
first trimester, 475–477, 475f–477f
second trimester, 478–481
third trimester, 482–484, 482f–484f
sexual abuse, child, 89–93
sexual assault, adult, 102–107, 102f
systemic lupus erythematosus, 1070–1078
Trichomonas vaginitis, 504–507, 504f–506f
vaginitis, 485–487, 485f–487f, 487t
venous distension, pregnancy, 464
wart, genital, 759–765
Vulva
angiokeratoma, 1203–1206, 1204f
atrophic vaginitis, 489–492, 490f
Candida
Candida vulvovaginitis, 499–503, 499f
candidiasis, 777–780
condyloma, 1279, 1281f
condyloma lata, 1279, 1281f
dermatitis, vular, 91
erythroplasia of Queyrat, 1000
herpes simplex virus, 91, 92f, 735–742, 736f
child, 90, 92f
hidradenitis suppurativa, 671–674, 674f
leukorrhea, 92
lichen planus, 901–908
lichen sclerosus et atrophicus, 92, 92f, 491, 491f, 516, 516f
lichen simplex chronicus, 856–862
Paget disease of external genitalia, 514–517, 514f
pregnancy and birth, 17–23
pyoderma gangrenosum, 1028–1034
sebaceous hyperplasia, 931–934
sexual abuse, child, 89–93, 92f
syphilis, 1278–1283, 1281f
Trichomonas vaginitis, 504–507
venous distension, pregnancy, 464
vulvar intraepithelial neoplasia, 519–522, 519f–521f
vulvovaginitis, 92
wart, genital, 759–765, 759f, 760f, 763f

W
Wrists
acanthosis nigricans, 1310–1312, 1313f
acropustulosis of infancy, 821, 821f
arthritis
gonococcal, 562–568
rheumatoid, 575–579, 578f
calcium pyrophosphate dihydrate disease, 565
dermatitis, atopic, 826–833, 829f
eczema, hand, 843–849, 844f–846f
fifth disease (erythema infectiosum), 728–731
lichen planus, 901–908, 901f, 906f
lichen simplex chronicus, 856–862
pemphigoid gestationis, 471–474, 471f, 1098, 1099f
radius fracture, distal, 605–609, 605f–609f
radius fractures, 608t
scabies, 815–822, 815f, 817f, 819f, 821f, 1424–1429, 1426f
syphilis, 1278–1283, 1280f
systemic lupus erythematosus, 563, 564f
xanthoma, 1322–1327

This page intentionally left blank

TOPIC INDEX

Note: In this index, the letters "f" and "t" denote figures and tables, respectively.

A
Abscess, 698
Acanthosis Nigricans, 1310
Acne Keloidalis Nuchae, 665
Acne Vulgaris, 651
Acquired Vascular Skin Lesions, 1203
Acromegaly, 1360
Actinic Keratosis, 969
Acute Otitis Media, 170
Age-Related Macular Degeneration, 155
AIDS, 1285
Alcoholism (Alcohol Use Disorder), 1411
Alopecia areata, 1128
Angioedema, 863
Angular Cheilitis, 203
Ankylosing Spondylitis, 580
Aphthous Ulcer, 244
Arthritis, 562
Asthma, 320
Atopic Dermatitis, 826
Atrophic Vaginitis, 489

B
Back Pain, 585
Bacterial Endocarditis, 287
Bacterial Vaginosis, 494
Basal Cell Carcinoma, 989
Bell Palsy, 1383
Benign Nevi, 945, 1459
Birth, 17
Black Hairy Tongue, 228
Bladder Cancer, 448
Bowen Disease, 969
Breast Abscess, 546
Breast Cancer, 551
Bullous Diseases, 1097
Bullous Pemphigoid, 1104
Bunion Deformity, 1247

C
Callus, 1242
Candida Vulvovaginitis, 499
Candidiasis, 777
Caries
  Adult, 262
  Early Childhood, 257
Cellulitis, 693
Cerebral Vascular Accident, 1371
Chalazion, 114
Charcot Arthropathy, 1261
Chickenpox, 707
Child Physical Abuse, 82
Child Sexual Abuse, 89
Childhood Hemangiomas, 636
Chlamydia Cervicitis, 509
Chondrodermatitis Nodularis Helicis, 189
Chronic Obstructive Pulmonary Disease, 334
Clavicular Fracture, 601
Clubbing, 292
Cocaine, 1431
Colon Cancer, 399
Colon Polyps, 393
Colposcopy - Normal and Noncancerous Findings, 525
Colposcopy of Cervical Cancer, 541
Colposcopy of High-Grade Lesions, 535
Colposcopy of Low-Grade Lesions, 530
Common Warts, 749
Congenital Nevi, 953
Congenital Vascular Lesions, 1207
Conjunctivitis, 126
Contact Dermatitis, 834
Corneal Abrasion, 122
Corneal Foreign Body, 122
Corns, 1242
Coronary Artery Disease, 268
Corticosteroids, Topical and Intralesional, 1451
Cutaneous Drug Reactions, 1211
Cutaneous Horn, 985
Cutaneous Larva Migrans, 823
Cutaneous T-Cell Lymphoma, 1042

D
Dermatofibroma, 935
Dermatomyositis, 1079
Dermoscopy, 1455
Diabetes, 1300
Diabetic Dermopathy, 1314
Diabetic Retinopathy, 143
Diaper Rash, 646
Distal Radius Fracture, 605
Doctor—Patient Relationship, 8
Dry Gangrene, 1265

Strength of Recommendation (SOR)	Definition
A	Recommendation based on consistent and good-quality patient-oriented evidence.*
B	Recommendation based on inconsistent or limited-quality patient-oriented evidence.*
C	Recommendation based on consensus, usual practice, opinion, disease-oriented evidence, or case series for studies of diagnosis, treatment, prevention, or screening.*

*See Appendix A on pages 1447–1450 for further information.

Dupuytren Disease, 625
Dysplastic Nevus, 963

E
Ear Foreign Body, 185
End of Life, 25
Epidermal Nevus, 958
Episcleritis, 131
Erythema Ab Igne, 1198
Erythema Annulare Centrifugum, 1236
Erythema Multiforme, 1049
Erythema Nodosum, 1056
Erythrasma, 689
Erythroderma, 915
Evidence-Based Medicine (EBM), 1448
Eye Trauma, 159

F
Family Planning, 12
Fifth Disease, 728
First Trimester Obstetrical Ultrasound, 475
Flat Warts, 755
Folliculitis, 680
Foreign Body, Ear, 185
Fungal Infections, 771

G
Gallstones, 386
Gangrene, Dry, 1265
Gastric Cancer, 371
Genital Warts, 759
Genodermatoses, 1229
Geographic Tongue, 232
Gingival Overgrowth, 240
Gingivitis, 236
Glaucoma, 139
Global Health, 53
Goitrous Hypothyroidism, 1346
Gout, 590
Granuloma Annulare, 1022
Graves Disease and Goiter, 1353

H
Hammer Toe, 1251
Hand Eczema, 843
Hand, Foot, and Mouth Disease, 732
Headache, 1366
Heart Failure, 277
Hemangiomas, Childhood, 636
Hemorrhoids, 414
Hereditary and Congenital Vascular Lesions, 1207
Herpes Simplex, 735
Hidradenitis Suppurativa, 671
Hip Fracture, 615
Hoarseness, 220
Hordeolum, 114
Hydrocephalus, Normal Pressure, 1380
Hydronephrosis, 430
Hyperlipidemia, 1322
Hypertension, 272
Hypertensive Retinopathy, 147
Hyphema, 159
Hypopigmentation, 1184

I
Impetigo, 676
Inflammatory Bowel Disease, 405
Ingrown Toenail, 1156
Injection-Drug Use, 1439
Intestinal Worms and Parasites, 1270
Intimate Partner Violence, 95
Iritis, 135
Ischemic Ulcer, 1255

K
Kaposi Sarcoma, 1285
Keloids, 1224
Keratoacanthoma, 977
Kidney Stones, 425
Knee, 619

L
Larynx (Hoarseness), 220
Lentigo Maligna, 981
Leukoplakia, 249
Lice, 809
Lichen Planus, 901
Liver Disease, 377
Lung Cancer, 355
Lupus: Systemic and Cutaneous, 1070
Lyme Disease, 1289

M
Mastitis, 546
Measles, 723
Melanoma, 1008
Melasma, 1179
Metatarsal Fracture, 611
Methamphetamine, 1424
Molluscum Contagiosum, 743
Morphea, 1089

N
Nail Variants, Normal, 1145
Nasal Polyps, 193
Necrobiosis Lipoidica, 1317
Necrotizing Fasciitis, 702
Neurofibromatosis, 1387
Neuropathic Ulcer, 1258
Nevus Sebaceous, 958
Normal Pressure Hydrocephalus, 1380
Nummular Eczema, 851

O
Obesity, 1329
Obstetrical Ultrasound
  First Trimester, 475
  Second Trimester, 478
  Third Trimester, 482
Olecranon Bursitis, 596
Onychomycosis, 771
Oropharyngeal Cancer, 253
Osteoarthritis, 569

(continued on next page)

Osteopenia, 1338
Osteoporosis, 1338
Otitis Externa, 180
Otitis Media with Effusion, 170
Otitis Media, Acute, 170

P
Paget Disease of the Breast, 557
Paget Disease of the External Genitalia, 514
Papilledema, 151
Paronychia, 1166
Pemphigoid gestationis, 471
Pemphigus, 1109
Peptic Ulcer Disease, 366
Perianal Dermatitis, 646
Pericardial Effusion, 281
Periodontal Disease, 236
Pharyngitis, 213
Photosensitivity, 1191
Physical Abuse, Child, 82
Pigmented Nail Disorders, 1151
Pitted Keratolysis, 686
Pityriasis Rosea, 896
Plantar Warts, 766
Pneumonia, 300
Polycystic Kidneys, 436
Preauricular Tags, 189
Pregnancy, 17
Prostate Cancer, 453
Pruritic Urticarial Papules and Plaques of Pregnancy, 467
Pseudofolliculitis, 665
Psoriasis, 878
Psoriatic Nails, 1170
Pterygium, 110
Pulmonary Embolus, 345
Pustular Diseases of Childhood, 642
Pyoderma Gangrenosum, 1028
Pyogenic Granuloma, 940

R
Radius Fracture, Distal, 605
Reactive Arthritis, 910
Red Eye, 163
Renal Cell Carcinoma, 441
Rheumatoid Arthritis, 575
Rosacea, 659

S
Sarcoidosis, 1035
Scabies, 815
Scarlet Fever, 208
Scarring Alopecia, 1138
Scleral Pigmentation, 118
Scleritis, 131
Scleroderma, 1089
Sebaceous Hyperplasia, 931
Seborrheic Dermatitis, 871
Seborrheic Keratosis, 926
Second Trimester Obstetrical Ultrasound, 478
Self-Inflicted Dermatoses, 856
Sexual Abuse, Child, 89
Sexual Assault, Adult, 102
Sinusitis, 197
Skin Changes
  Normal Childhood, 630
  Pregnancy, 462
Skin Tag, 922
Social Justice, 37
Squamous Cell Carcinoma, 999
Stevens-Johnson Syndrome, 1049
Strawberry Tongue, 208
Subdural Hematoma, 1376
Substance Abuse Disorder, 1392
Subungual Hematoma, 1175
Syphilis, 1278

T
Third Trimester Obstetrical Ultrasound, 482
Tinea Capitis, 782
Tinea Corporis, 788
Tinea Cruris, 795
Tinea Pedis, 799
Tinea Versicolor, 805
Tobacco Addiction, 1398
Torus Palatinus, 206
Toxic Epidermal Necrolysis, 1049
Traction Alopecia, 1133
Trichomonas Vaginitis, 504
Trichotillomania, 1133
Tuberculosis, 310

U
Urethritis in Men, 1275
Urinary sediment, 420
Urticaria, 863
Uveitis, 135

V
Vaginitis, 485
Vascular Lesions, Hereditary and Congenital, 1207
Vascular Malformations, Childhood, 636
Vascular Skin Lesions, Acquired, 1203
Vasculitis, 1062
Venous Insufficiency, 295
Vitiligo, 1184
Vulvar Intraepithelial Neoplasia, 519

X
Xanthomas, 1322

Z
Zoster, 712
Zoster Ophthalmicus, 718